


UC-NRLF



C 3 037 426

LESTER SAWYER YALE MEDICAL SCHOOL


UNIVERSITY OF CALIFORNIA
MEDICAL CENTER LIBRARY
SAN FRANCISCO



GIFT OF
LESTER J. SAWYER, M.D.



Digitized by the Internet Archive
in 2007 with funding from
Microsoft Corporation



ANATOMY
OF
THE HUMAN BODY

BY

HENRY GRAY, F.R.S.

FELLOW OF THE ROYAL COLLEGE OF SURGEONS; LECTURER ON ANATOMY AT ST. GEORGE'S
HOSPITAL MEDICAL SCHOOL, LONDON

TWENTIETH EDITION

THOROUGHLY REVISED AND RE-EDITED

BY

WARREN H. LEWIS, B.S., M.D.

PROFESSOR OF PHYSIOLOGICAL ANATOMY, JOHNS HOPKINS UNIVERSITY, BALTIMORE, MD.

Illustrated with 1247 Engravings



LEA & FEBIGER
PHILADELPHIA AND NEW YORK

COPYRIGHT
LEA & FEBIGER
1918

PRINTED IN U. S. A.

QM23
G77
1918

THE FIRST EDITION OF THIS WORK
WAS DEDICATED TO
SIR BENJAMIN COLLINS BRODIE, BART., F.R.S., D.C.L.
IN ADMIRATION OF
HIS GREAT TALENTS
AND IN REMEMBRANCE OF
MANY ACTS OF KINDNESS SHOWN TO THE ORIGINAL
AUTHOR OF THE BOOK
FROM AN
EARLY PERIOD OF HIS PROFESSIONAL CAREER

6727

PREFACE TO THE TWENTIETH EDITION.

SINCE the publication of the first English edition of this work in 1858 and the first American edition in 1859 great advances in the subject of Anatomy have been made, especially in microscopic anatomy and the anatomy of the embryo. This knowledge was embodied from time to time in the successive editions until finally considerable portions of the text, sometimes sections, were devoted to these subjects. However, the main text has always remained primarily a descriptive anatomy of the human body.

In the present edition the special sections on embryology and histology have been distributed among the subjects under which they naturally belong. New matter on physiological anatomy, laws of bone architecture, the mechanics and variations of muscles have been added, occupying much of the space formerly devoted to the sections on applied anatomy.

The sections on the ductless glands and the nervous system have been largely rewritten. In the latter a more rational presentation of the sympathetic nervous system has been achieved through the use of diagrams and descriptions based on physiological and pharmacological work. The central connections of the spinal and cranial nerves are also emphasized.

Illustrations have been added wherever important points could be made more clear, and throughout the work colored pictures have been even more extensively used than heretofore. In this respect special mention might be made of the central nervous system and the section on the muscles. In the section on Syndesmology six illustrations are used from Quain's *Anatomy* through the courtesy of the publishers, Messrs. Longmans, Green & Company, of London.

The use of the B. N. A. nomenclature in English has been retained practically unchanged in this edition and important references to the literature have been added at the end of each section.

As a practical work on the subject for the student, Gray's *Anatomy* has always been recognized and appreciated. The plan originally formulated, which has proved so successful, has been adhered to as much as possible. It is interesting to note that although Henry Gray saw only the first edition, much of the original text persists and many of his illustrations are still in use. Bearing this in mind it has been the endeavor of the Editor to supply only such changes as advances in the science made necessary in order that this work may reflect the latest accessions to anatomical knowledge.

CONTENTS.

EMBRYOLOGY.

<p style="text-align: center;"><i>The Animal Cell.</i></p> <p>Cytoplasm 35</p> <p>Nucleus 36</p> <p>Reproduction of Cells 36</p> <p style="padding-left: 20px;">Prophase 36</p> <p style="padding-left: 20px;">Metaphase 36</p> <p style="padding-left: 20px;">Anaphase 36</p> <p style="padding-left: 20px;">Telophase 38</p> <p style="text-align: center;"><i>The Ovum.</i></p> <p>Yolk 39</p> <p>Germinal Vesicle 40</p> <p>Coverings of the Ovum 40</p> <p>Maturation of the Ovum 40</p> <p style="text-align: center;"><i>The Spermatozoön 42</i></p> <p style="text-align: center;"><i>Fertilization of the Ovum 44</i></p> <p style="text-align: center;"><i>Segmentation of the Fertilized Ovum.</i></p> <p>The Primitive Streak; Formation of the Mesoderm 47</p> <p style="padding-left: 20px;">Ectoderm 47</p> <p style="padding-left: 20px;">Entoderm 49</p> <p style="padding-left: 20px;">Mesoderm 49</p> <p style="text-align: center;"><i>The Neural Groove and Tube 50</i></p> <p style="text-align: center;"><i>The Notochord 52</i></p>	<p style="text-align: center;"><i>The Primitive Segments 52</i></p> <p style="text-align: center;"><i>Separation of the Embryo 53</i></p> <p style="text-align: center;"><i>The Yolk-sac 54</i></p> <p style="text-align: center;"><i>Development of the Fetal Membranes and Placenta.</i></p> <p>The Allantois 54</p> <p>The Amnion 56</p> <p>The Umbilical Cord and Body-stalk 57</p> <p>Implantation or Imbedding of the Ovum 58</p> <p>The Decidua 59</p> <p>The Chorion 60</p> <p>The Placenta 62</p> <p style="padding-left: 20px;">Fetal Portion 62</p> <p style="padding-left: 20px;">Maternal Portion 63</p> <p style="padding-left: 20px;">Separation of the Placenta 64</p> <p style="text-align: center;"><i>The Branchial Region.</i></p> <p>The Branchial or Visceral Arches and Pharyngeal Pouches 65</p> <p style="padding-left: 20px;">The Nose and Face 67</p> <p style="padding-left: 20px;">The Limbs 71</p> <p style="text-align: center;"><i>Development of the Body Cavities 72</i></p> <p style="text-align: center;"><i>The Form of the Embryo at Different Stages of its Growth 74</i></p>
---	--

OSTEOLOGY.

<p>Long Bones 79</p> <p>Short Bones 79</p> <p>Flat Bones 79</p> <p>Irregular Bones 80</p> <p>Surfaces of Bones 80</p> <p style="text-align: center;">DEVELOPMENT OF THE SKELETON.</p> <p>The Skeleton 80</p> <p style="padding-left: 20px;">The Vertebral Column 80</p> <p style="padding-left: 20px;">The Ribs 82</p> <p style="padding-left: 20px;">The Sternum 83</p> <p style="padding-left: 20px;">The Skull 83</p> <p style="text-align: center;">BONE.</p> <p>Structure and Physical Properties 86</p> <p style="padding-left: 20px;">Periosteum 87</p> <p style="padding-left: 20px;">Marrow 87</p> <p style="padding-left: 20px;">Vessels and Nerves of Bone 88</p> <p style="padding-left: 20px;">Minute Anatomy 89</p> <p style="padding-left: 20px;">Chemical Composition 91</p> <p style="padding-left: 20px;">Ossification 91</p> <p style="padding-left: 40px;">Intramembranous Ossification 91</p> <p style="padding-left: 40px;">Intercartilaginous Ossification 93</p> <p style="text-align: center;">THE VERTEBRAL COLUMN.</p> <p style="text-align: center;"><i>General Characteristics of a Vertebra.</i></p> <p>The Cervical Vertebrae 97</p> <p style="padding-left: 20px;">The First Cervical Vertebra 99</p> <p style="padding-left: 20px;">The Second Cervical Vertebra 100</p> <p style="padding-left: 20px;">The Seventh Cervical Vertebra 101</p>	<p>The Thoracic Vertebra 102</p> <p style="padding-left: 20px;">The First Thoracic Vertebra 104</p> <p style="padding-left: 20px;">The Ninth Thoracic Vertebra 104</p> <p style="padding-left: 20px;">The Tenth Thoracic Vertebra 104</p> <p style="padding-left: 20px;">The Eleventh Thoracic Vertebra 104</p> <p style="padding-left: 20px;">The Twelfth Thoracic Vertebra 104</p> <p>The Lumbar Vertebrae 104</p> <p style="padding-left: 20px;">The Fifth Lumbar Vertebra 106</p> <p>The Sacral and Coccygeal Vertebrae 106</p> <p style="padding-left: 20px;">The Sacrum 106</p> <p style="padding-left: 20px;">The Coccyx 111</p> <p>Ossification of the Vertebral Column 111</p> <p style="text-align: center;"><i>The Vertebral Column as a Whole.</i></p> <p>Curves 114</p> <p>Surfaces 114</p> <p>Vertebral Canal 116</p> <p style="text-align: center;">THE THORAX.</p> <p>Boundaries 117</p> <p>The Sternum 119</p> <p style="padding-left: 20px;">Manubrium 120</p> <p style="padding-left: 20px;">Body 120</p> <p style="padding-left: 20px;">Xiphoid Process 121</p> <p>The Ribs 123</p> <p style="padding-left: 20px;">Common Characteristics of the Ribs 123</p> <p style="padding-left: 20px;">Peculiar Ribs 125</p> <p style="padding-left: 40px;">First Rib 125</p> <p style="padding-left: 40px;">Second Rib 125</p> <p style="padding-left: 40px;">Tenth Rib 126</p> <p style="padding-left: 40px;">Eleventh and Twelfth Ribs 126</p> <p>The Costal Cartilages 127</p>
---	---

THE SKULL.

The Cranial Bones.

The Occipital Bone	129
The Squama	129
Lateral Parts	131
Basilar Parts	132
Angles	132
The Parietal Bone	133
The Frontal Bone	135
Squama	135
Orbital or Horizontal Part	137
The Temporal Bone	138
The Squama	139
Mastoid Portion	141
Petrous Portion	142
Tympanic Part	145
Styloid Process	145
The Sphenoid Bone	147
Body	147
The Great Wings	149
The Small Wings	151
Pterygoid Processes	151
The Sphenoidal Conchæ	152
Ethmoid bone	153
Cribriform plate	153
Perpendicular Plate	154
Labyrinth or Lateral Mass	154
Sutural or Wormian Bones	156

The Facial Bones.

The Nasal Bones	156
The Maxillæ (Upper Jaw)	157
The Maxillary Sinus or Antrum of High- more	160
The Zygomatic Process	161
The Frontal Process	161
The Alveolar Process	161
The Palatine Process	162
Changes Produced in the Maxilla by Age	163
The Lacrimal Bone	163
The Zygomatic Bone	164
The Palatine Bone	166
The Horizontal Part	167
The Vertical Part	167
The Pyramidal Process or Tuberosity	168
The Orbital Process	168
The Sphenoidal Process	169
The Inferior Nasal Concha	169
The Vomer	170
The Mandible (Lower Jaw)	172
Changes Produced in the Mandible by Age	175
The Hyoid Bone	177

The Exterior of the Skull.

Norma Verticalis	178
Norma Basalis	179
Norma Lateralis	182
The Temporal Fossa	183
The Infratemporal Fossa	184
The Pterygopalatine Fossa	185
Norma Occipitalis	185
Norma Frontalis	185
The Orbits	188

The Interior of the Skull.

Inner Surface of the Skull-cap	189
Under Surface of the Base of the Skull	190
The Anterior Fossa	190
The Middle Fossa	190
The Posterior Fossa	192
The Nasal Cavity	194
Anterior Nasal Aperture	196
Differences in the Skull Due to Age	196
Sexual Differences in the Skull	197
Craniology	197

THE EXTREMITIES.

The Bones of the Upper Extremity.

The Clavicle	200
Lateral Third	200
Medial Two-thirds	201
The Sternal Extremity	202
The Acromial Extremity	202
The Scapula	202
The Spine	203
The Acromion	203
The Coracoid Process	207
The Humerus	209
Upper Extremity	209
The Head	209
The Anatomical Neck	209
The Greater Tubercle	209
The Lesser Tubercle	209
The Body or Shaft	209
The Lower Extremity	212
The Ulna	214
The Upper Extremity	214
The Olecranon	214
The Coronoid Process	214
The Semilunar Notch	215
The Radial Notch	215
The Body or Shaft	215
The Lower Extremity	218
The Radius	219
The Upper Extremity	219
The Body or Shaft	219
The Lower Extremity	220

The Hand.

The Carpus	221
Common Characteristics of the Carpals	221
Bones of the Proximal Row	221
The Navicular Bone	221
The Lunate Bone	224
The Triangular Bone	224
The Pisiform Bone	225
Bones of the Distal Row	225
The Greater Multangular Bone	225
The Lesser Multangular Bone	225
The Capitate Bone	226
The Hamate Bone	227
The Metacarpus	227
Common Characteristics of the Meta- carpal Bones	227
Characteristics of the Individual Meta- carpal Bones	228
The First Metacarpal Bone	228
The Second Metacarpal Bone	228
The Third Metacarpal Bone	228
The Fourth Metacarpal Bone	228
The Fifth Metacarpal Bone	228
The Phalanges of the Hand	230
Ossification of the Bones of the Hand	230

The Bones of the Lower Extremity.

The Hip Bone	231
The Ilium	231
The Body	231
The Ala	232
The Ischium	234
The Body	234
The Superior Ramus	235
The Inferior Ramus	235
The Pubis	236
The Body	236
The Superior Ramus	236
The Inferior Ramus	237
The Acetabulum	237
The Obturator Foramen	237
The Pelvis	238
The Greater or False Pelvis	238
The Lesser or True Pelvis	239
Axes	240
Position of the Pelvis	241
Differences between Male and Female Pelvis	241
Abnormalities	242

The Femur	242	The Tarsus—	
The Upper Extremity	243	The Talus	266
The Head	243	The Cuboid Bone	269
The Neck	243	The Navicular Bone	270
The Trochanters	244	The First Cuneiform Bone	270
The Body or Shaft	246	The Second Cuneiform Bone	271
The Lower Extremity	247	The Third Cuneiform Bone	271
The Architecture of the Femur	248	The Metatarsus	272
The Patella	255	Common Characteristics of the Meta-	
The Tibia	256	tarsal Bones	272
The Upper Extremity	256	Characteristics of the Individual Meta-	
The Body or Shaft	257	tarsal Bones	272
The Lower Extremity	259	The First Metatarsal Bone	272
The Fibula	260	The Second Metatarsal Bone	273
The Upper Extremity or Head	260	The Third Metatarsal Bone	274
The Body or Shaft	260	The Fourth Metatarsal Bone	274
The Lower Extremity or Lateral		The Fifth Metatarsal Bone	274
Malleolus	262	The Phalanges of the Foot	275
<i>The Foot.</i>		Ossification of the Bones of the Foot	275
The Tarsus	263	Comparison of the Bones of the Hand and	
The Calcaneus	263	Foot	276
		The Sesamoid Bones	277

SYNDESMOLOGY.

Bone	279	Articulations of the Vertebral Column—	
Hyaline Cartilage	279	Articulations of Vertebral Arches—	
Articular Cartilage	280	The Ligamentum Nuchæ	290
Costal Cartilage	281	The Interspinal Ligaments	291
White Fibrocartilage	281	The Intertransverse Ligaments	291
Interarticular Fibrocartilages	281	Articulation of the Atlas with the Epistro-	
Connecting Fibrocartilages	282	pheus or Axis	292
Circumferential Fibrocartilages	282	The Articular Capsules	292
Stratiform Fibrocartilages	282	The Anterior Atlantoaxial Ligament	293
Ligaments	282	The Posterior Atlantoaxial Ligament	293
The Articular Capsules	282	The Transverse Ligament of the Atlas	293
Mucous Sheaths	283	Articulations of the Vertebral Column with	
Bursæ Mucosæ	283	the Cranium	295
DEVELOPMENT OF THE JOINTS	283	Articulation of the Atlas with the	
CLASSIFICATION OF JOINTS		Occipital Bone	295
Synarthrosis	284	The Articular Capsules	295
Sutura	284	The Anterior Atlantooccipital Mem-	
Schindylesis	284	brane	295
Gomphosis	284	The Posterior Atlantooccipital Mem-	
Synchondrosis	284	brane	296
Amphiarthrosis	285	The Lateral Ligaments	296
Diarthrosis	285	Ligaments Connecting the Axis with the	
Ginglimus	285	Occipital Bone	296
Trochoid	285	The Membrana Tectoria	296
Condylloid	286	The Alar Ligaments	296
Articulation by Reciprocal Reception	286	Articulation of the Mandible	297
Enarthrosis	286	The Articular Capsule	297
Arthrodia	286	The Temporomandibular Ligament	297
THE KIND OF MOVEMENT ADMITTED IN JOINTS.		The Sphenomandibular Ligament	297
Gliding Movement	286	The Articular Disk	298
Angular Movement	286	The Stylomandibular Ligament	298
Circumduction	286	Costovertebral Articulations	299
Rotation	287	Articulations of the Heads of the Ribs	299
Ligamentous Action of Muscles	287	The Articular Capsule	299
ARTICULATIONS OF THE TRUNK.		The Radiate Ligament	299
Articulations of the Vertebral Column	287	The Interarticular Ligament	300
Articulations of Vertebral Bodies	287	Costotransverse Articulations	300
The Anterior Longitudinal Liga-		The Articular Capsule	301
ment	287	The Anterior Costotransverse Liga-	
The Posterior Longitudinal Liga-		ment	301
ment	288	The Posterior Costotransverse Liga-	
The Intervertebral Fibrocartilages		ment	301
Structure	289	The Ligament of the Neck of the	
Articulations of Vertebral Arches	289	Rib	302
The Articular Capsules	290	The Ligament of the Tubercle of	
The Ligamenta Flava	290	the Rib	302
The Supraspinal Ligament	290	Sternocostal Articulations	302
		The Articular Capsules	302
		The Radiate Sternocostal Ligaments	302
		The Intervertebral Sternocostal Liga-	
		ment	303
		The Costoxiphoid Ligaments	304
		Interchondral Articulations	304
		Costochondral Articulations	304
		Articulation of the Manubrium and Body of	
		the Sternum	304
		Mechanism of the Thorax	304

Articulation of the Vertebral Column with the Pelvis	306	Intercarpal Articulations—	
The Iliolumbar Ligament	306	Articulations of the Proximal Row of Carpa Bones—	
Articulations of the Pelvis	306	The Dorsal Ligaments	328
Sacroiliac Articulation	306	The Volar Ligaments	328
The Anterior Sacroiliac Ligament	307	The Interosseous Ligaments	328
The Posterior Sacroiliac Ligament	307	Articulations of the Distal Row of Carpal Bones	329
The Interosseous Sacroiliac Ligament	308	The Dorsal Ligaments	329
Ligaments Connecting the Sacrum and Ischium	309	The Volar Ligaments	329
The Sacrotuberous Ligament	309	The Interosseous Ligaments	329
The Sacrospinous Ligament	309	Articulations of the Two Rows of Carpal Bones with Each Other	329
Sacrococcygeal Symphysis	309	The Volar Ligaments	329
The Anterior Sacrococcygeal Ligament	309	The Dorsal Ligaments	329
The Posterior Sacrococcygeal Ligament	309	The Collateral Ligaments	329
The Lateral Sacrococcygeal Ligament	310	Carpometacarpal Articulations	330
The Interarticular Ligaments	310	Carpometacarpal Articulation of the Thumb	330
The Pubic Symphysis	310	Articulations of the Other Four Metacarpal Bones with the Carpus	331
The Anterior Pubic Ligament	310	The Dorsal Ligaments	331
The Posterior Pubic Ligament	310	The Volar Ligaments	331
The Superior Pubic Ligament	310	The Interosseous Ligaments	331
The Arcuate Pubic Ligament	310	Intermetacarpal Articulations	331
The Interpubic Fibrocartilaginous Lamina	311	The Transverse Metacarpal Ligament	331
Mechanism of the Pelvis	311	Metacarpophalangeal Articulations	332
		The Volar Ligaments	332
		The Collateral Ligaments	332
		Articulations of the Digits	333
ARTICULATIONS OF THE UPPER EXTREMITY.		ARTICULATIONS OF THE LOWER EXTREMITY.	
Sternoclavicular Articulation	313	Coxal Articulation or Hip-joint	333
The Articular Capsule	313	The Articular Capsule	334
The Anterior Sternoclavicular Ligament	313	The Iliofemoral Ligament	335
The Posterior Sternoclavicular Ligament	313	The Pubocapsular Ligament	335
The Interclavicular Ligament	314	The Ischiocapsular Ligament	335
The Costoclavicular Ligament	314	The Ligamentum Teres Femoris	336
The Articular Disk	314	The Glenoidal Labrum	336
Acromioclavicular Articulation	315	The Transverse Acetabular Ligament	336
The Articular Capsule	315	The Knee-joint	339
The Superior Acromioclavicular Ligament	315	The Articular Capsule	340
The Inferior Acromioclavicular Ligament	315	The Ligamentum Patellae	340
The Articular Disk	315	The Oblique Popliteal Ligament	340
The Coracoclavicular Ligament	315	The Tibial Collateral Ligament	341
The Trapezoid Ligament	315	The Fibular Collateral Ligament	341
The Conoid Ligament	315	The Cruciate Ligaments	342
The Ligaments of the Scapula	316	The Anterior Cruciate Ligament	342
The Coracoclavicular Ligament	316	The Posterior Cruciate Ligament	342
The Superior Transverse Ligament	317	The Menisci	342
The Inferior Transverse Ligament	317	The Medial Meniscus	343
Humeral Articulation or Shoulder-joint	317	The Lateral Meniscus	343
The Articular Capsule	317	The Transverse Ligament	343
The Coracohumeral Ligament	318	The Coronary Ligaments	343
Glenohumeral Ligaments	318	Bursæ	345
The Transverse Humeral Ligament	319	Articulations between the Tibia and Fibula	347
The Glenoidal Labrum	319	Tibiofibular Articulation	348
Bursæ	319	The Articular Capsule	348
Elbow-joint	321	The Anterior Ligament	348
The Anterior Ligament	321	The Posterior Ligament	348
The Posterior Ligament	322	Interosseous Membrane	348
The Ulnar Collateral Ligament	322	Tibiofibular Syndesmosis	348
The Radial Collateral Ligament	322	The Anterior Ligament	348
The Posterior Ligament	322	The Posterior Ligament	348
The Radial Collateral Ligament	322	The Inferior Transverse Ligament	349
Radioulnar Articulation	324	The Interosseous Ligament	349
Proximal Radioulnar Articulation	324	Talocrural Articulation or Ankle-joint	349
The Annular Ligament	324	The Articular Capsule	350
The Interosseous Membrane	325	The Deltoid Ligament	350
Middle Radioulnar Union	325	The Anterior Talofibular Ligament	351
The Oblique Cord	325	The Posterior Talofibular Ligament	351
The Interosseous Membrane	325	The Calcaneofibular Ligament	351
Distal Radioulnar Articulation	325	Intertarsal Articulations	352
The Volar Radioulnar Ligament	325	Talocalcaneal Articulation	352
The Dorsal Radioulnar Ligament	325	The Articular Capsule	352
The Articular Disk	325	The Anterior Talocalcaneal Ligament	352
Radiocarpal Articulation or Wrist-joint	327	The Posterior Talocalcaneal Ligament	352
The Volar Radiocarpal Ligament	327	The Lateral Talocalcaneal Ligament	352
The Dorsal Radiocarpal Ligament	328	The Medial Talocalcaneal Ligament	353
The Ulnar Collateral Ligament	328		
The Radial Collateral Ligament	328		
Intercarpal Articulations	328		
Articulations of the Proximal Row of Carpal Bones	328		

Intertarsal Articulations—	Intertarsal Articulations—
Talocalcaneal Articulation—	Cuboideonavicular Articulation—
The Interosseous Talocalcaneal Ligament	The Plantar Ligament
353	357
Talocalcaneonavicular Articulation	The Interosseous Ligament
353	357
The Articular Capsule	Intercuneiform and Cuneocuboid Articulation
354	357
The Dorsal Talonavicular Ligament	The Dorsal Ligaments
354	357
Calcaneocuboid Articulation	The Plantar Ligaments
354	357
The Articular Capsule	The Interosseous Ligaments
354	357
The Dorsal Calcaneocuboid Ligament	Tarsometatarsal Articulations
354	358
The Bifurcated Ligament	The Dorsal Ligaments
354	358
The Long Plantar Ligament	The Plantar Ligaments
354	358
The Plantar Calcaneocuboid Ligament	The Interosseous Ligaments
354	358
The Ligaments Connecting the Calcaneus and Navicular	Intermetatarsal Articulations
355	358
The Plantar Calcaneonavicular Ligament	The Dorsal Ligaments
355	358
Cuneonavicular Articulation	The Plantar Ligaments
356	358
The Dorsal Ligaments	The Interosseous Ligaments
356	358
The Plantar Ligaments	The Transverse Metatarsal Ligament
356	359
Cuboideonavicular Articulation	Metatarsophalangeal Articulations
356	359
The Dorsal Ligament	The Plantar Ligaments
357	359
	The Collateral Ligaments
	359
	Articulations of the Digits
	359
	Arches of the Foot
	360

MYOLOGY.

MECHANICS OF MUSCLE.	
The Direction of Muscle Pull	363
The Action of Muscle Pull on Tendon	364
The Strength of Muscles	364
The Work Accomplished by Muscles	365
The Action of Muscles on Joints	368
DEVELOPMENT OF THE MUSCLES.	
The Ventro-lateral Muscles of the Neck	371
Muscles of the Shoulder Girdle and Arm	371
The Muscles of the Leg	372
The Muscles of the Head	372
Striped or Voluntary Muscle	373
Vessels and Nerves of Striped Muscle	376
TENDONS, APONEUROSES, AND FASCÆ.	
Tendons	376
Aponeuroses	376
Fasciæ	376
THE FASCIÆ AND MUSCLES OF THE HEAD.	
<i>The Muscles of the Scalp.</i>	
The Skin of the Scalp	378
The Superficial Fasciæ	378
Epicraniius	378
Occipitalis	379
Frontalis	379
Galea Aponeurotica	380
<i>The Muscles of the Eyelid.</i>	
Orbicularis Oculi	380
Corrugator	381
<i>The Muscles of the Nose.</i>	
Procerus	382
Nasalis	382
Depressor Septi	382
Dilator Naris Posterior	382
Dilator Naris Anterior	382
<i>The Muscles of the Mouth.</i>	
Quadratus Labii Superioris	383
Caninus	383
Zygomaticus	383
Mentalis	383
Quadratus Labii Inferioris	383
Triangularis	383
Buccinator	384
Pterygomandibular Raphé	384
Orbicularis Oris	384
Risorius	385
<i>The Muscles of Mastication.</i>	
Parotidomasseteric Fasciæ	385
Masseter	385
Temporal Fasciæ	386
Temporalis	386
Pterygoideus Externus	386
Pterygoideus Internus	387
THE FASCIÆ AND MUSCLES OF THE ANTERO-LATERAL REGION OF THE NECK.	
<i>The Superficial Cervical Muscle.</i>	
Superficial Fasciæ	387
Platysma	388
Variations	388
<i>The Lateral Cervical Muscles.</i>	
The Fasciæ Colli	388
Sternocleidomastoideus	390
Variations	390
Triangles of the Neck	390
<i>The Supra- and Infrahyoid Muscles.</i>	
Digastricus	391
Variations	391
Stylohyoideus	392
Variations	392
The Stylohyoid Ligament	392
Mylohyoideus	393
Variations	393
Geniohyoideus	393
Sternohyoideus	393
Variations	393
Sternothyroideus	393
Variations	394
Thyrohyoideus	394
Omohyoideus	394
Variations	394
<i>The Anterior Vertebral Muscles.</i>	
Longus Colli	394
Longus Capitis	395
Rectus Capitis Anterior	395
Rectus Capitis Lateralis	395

The Lateral Vertebral Muscles.

Scalenus Anterior	396
Scalenus Medius	396
Scalenus Posterior	396
Variations	396

THE FASCIAE AND MUSCLES OF THE TRUNK.

The Deep Muscles of the Back.

The Lumbodorsal Fascia	397
Splenius Capitis	397
Splenius Cervicis	397
Variations	397
Sacrospinalis	397
Iliocostalis Lumborum	399
Iliocostalis Dorsi	399
Iliocostalis Cervicis	399
Longissimus Dorsi	399
Longissimus Cervicis	399
Longissimus Capitis	399
Spinalis Dorsi	399
Spinalis Cervicis	400
Spinalis Capitis	400
Semispinalis Dorsi	400
Semispinalis Cervicis	400
Semispinalis Capitis	400
Multifidus	400
Rotatores	400
Interspinales	400
Extensor Coccygis	401
Intertransversarii	401

The Suboccipital Muscles.

Rectus Capitis Posterior Major	401
Rectus Capitis Posterior Minor	401
Obliquus Capitis Inferior	402
Obliquus Capitis Superior	402
The Suboccipital Triangle	402

The Muscles of the Thorax.

Intercostal Fascia	402
Intercostales	403
Intercostales Externi	403
Variations	403
Intercostales Interni	403
Subcostales	403
Transversus Thoracis	403
Levatores Costarum	403
Serratus Posterior Superior	404
Variations	404
Serratus Posterior Inferior	404
Variations	404
Diaphragm	404
Medial Lumbocostal Arch	404
Lateral Lumbocostal Arch	405
The Crura	405
The Central Tendon	406
Openings in the Diaphragm	406
Variations	406
Mechanism of Respiration	407

The Muscles and Fasciæ of the Abdomen.

The Antero-lateral Muscles of the Abdomen	408
The Superficial Fascia	408
Obliquus Externus Abdominis	409
Aponeurosis of the Obliquus Externus Abdominis	410
Subcutaneous Inguinal Ring	410
The Intererural Fibers	410
The Inguinal Ligament	411
The Lacunar Ligament	412
The Reflected Inguinal Ligament	412
Ligament of Cooper	412
Variations	412
Obliquus Internus Abdominis	412
Variations	414
Cremaster	414
Transversus Abdominis	414

The Antero-lateral Muscles of the Abdomen—

Transversus Abdominis—	
Variations	414
Inguinal Aponeurotic Falx	414
Rectus Abdominis	415
Pyramidalis	416
Variations	417
The Linea Alba	417
The Linea Semilunares	417
The Transversalis Fascia	418
The Abdominal Inguinal Ring	418
The Inguinal Canal	418
Extraperitoneal Connective Tissue	418
The Deep Crural Arch	419
The Posterior Muscles of the Abdomen	419
The Fascia Covering the Quadratus Lumborum	419
Quadratus Lumborum	420
Variations	420

The Muscles and Fasciæ of the Pelvis.

Pelvic Fascia	420
Levator Ani	422
Coccygeus	424

The Muscles and Fasciæ of the Perineum.

Muscles of the Anal Region	424
The Superficial Fascia	424
The Deep Fascia	425
Ischiorectal Fossa	425
The Corrugator Cutis Ani	425
Sphincter Ani Externus	425
Sphincter Ani Internus	426
The Muscles of the Urogenital Region in the Male	426
Superficial Fascia	426
The Central Tendinous Point of the Perineum	427
Transversus Perinæi Superficialis	427
Variations	427
Bulbocavernosus	428
Ischiocavernosus	428
The Deep Fascia	428
Transversus Perinæi Profundus	429
Sphincter Urethræ Membranacæ	429
The Muscles of the Urogenital Region in the Female	430
Transversus Perinæi Superficialis	430
Bulbocavernosus	430
Ischiocavernosus	430
Transversus Perinæi Profundus	431

THE FASCIA AND MUSCLES OF THE UPPER EXTREMITY.

The Muscles Connecting the Upper Extremity to the Vertebral Column.

Superficial Fascia	432
Deep Fascia	432
Trapezius	432
Variations	432
Latissimus Dorsi	432
Variations	434
Rhomboideus Major	434
Rhomboideus Minor	434
Variations	435
Levator scapulæ	435
Variations	435

The Muscles Connecting the Upper Extremity to the Anterior and Lateral Thoracic Walls.

Superficial Fascia	435
Pectoralis Major	436
Variations	437
Coracoacromioclavicular Fascia	437
Pectoralis Minor	438
Variations	438
Subclavius	438
Variations	438
Serratus Anterior	438
Variations	439

The Muscles and Fasciæ of the Shoulder.

Deep Fascia	439
Deltoides	439
Variations	440
Subscapular Fascia	440
Subscapularis	440
Supraspinatus Fascia	440
Supraspinatus	440
Infraspinatus Fascia	441
Infraspinatus	441
Teres Minor	441
Variations	442
Teres Major	442

The Muscles and Fasciæ of the Arm.

Brachial Fascia	442
Coracobrachialis	443
Variations	443
Biceps Brachii	443
Variations	444
Brachialis	444
Variations	444
Triceps Brachii	444
Variations	445

The Muscles and Fasciæ of the Forearm.

Antibrachial Fascia	445
The Volar Antibrachial Muscles	445
The Superficial Group	446
Pronator Teres	446
Variations	446
Flexor Carpi Radialis	446
Variations	446
Palmaris Longus	446
Variations	446
Flexor Carpi Ulnaris	447
Variations	447
Flexor Digitorum Sublimis	448
Variations	448
The Deep Group	448
Flexor Digitorum Profundus	448
Fibrous Sheaths of the Flexor	
Tendons	448
Variations	449
Flexor Pollicis Longus	449
Variations	449
Pronator Quadratus	449
Variations	450
The Dorsal Antibrachial Muscles	451
The Superficial Group	451
Brachioradialis	451
Variations	451
Extensor Carpi Radialis Longus	452
Extensor Carpi Radialis Brevis	452
Variations	452
Extensor Digitorum Communis	452
Variations	454
Extensor Digiti Quinti Proprius	454
Variations	454
Extensor Carpi Ulnaris	454
Variations	454
Anconæus	454
The Deep Group	454
Supinator	454
Abductor Pollicis Longus	455
Variations	455
Extensor Pollicis Brevis	455
Variations	455
Extensor Pollicis Longus	455
Extensor Indicis Proprius	456
Variations	456

The Muscles and Fasciæ of the Hand.

Volar Carpal Ligament	456
Transverse Carpal Ligament	456
The Mucous Sheaths of the Tendons on the	
Front of the Wrist	457
Dorsal Carpal Ligament	458
The Mucous Sheaths of the Tendons on the	
Back of the Wrist	459
Palmar Aponeurosis	460

Superficial Transverse Ligament of the

Fingers	461
The Lateral Volar Muscles	461
Abductor Pollicis Brevis	461
Opponens Pollicis	461
Flexor Pollicis Brevis	461
Adductor Pollicis (Obliquus)	462
Adductor Pollicis (Transversus)	462
Variations	462
The Medial Volar Muscles	462
Palmaris Brevis	463
Abductor Digiti Quinti	463
Flexor Digiti Quinti Brevis	464
Opponens Digiti Quinti	464
Variations	464
The Intermediate Muscles	464
Lumbricales	464
Variations	464
Interossei	464
Interossei Dorsales	464
Interossei Volares	465

THE MUSCLES AND FASCLE OF THE LOWER EXTREMITY.

The Muscles and Fasciæ of the Iliac Region.

The Fascia Covering the Psoas and Iliacus	466
Psoas Major	467
Psoas Minor	467
Iliacus	467
Variations	467

The Muscles and Fasciæ of the Thigh.

The Anterior Femoral Muscles	467
Superficial Fascia	468
Deep Fascia	468
The Fossa Ovalis	469
Sartorius	470
Variations	470
Quadriceps Femoris	470
Rectus Femoris	470
Vastus Lateralis	470
Vastus Medialis	471
Vastus Intermedius	471
Articularis Genu	471
The Medial Femoral Muscles	471
Gracilis	471
Pectineus	472
Adductor Longus	472
Adductor Brevis	473
Adductor Magnus	473
Variations	474
The Muscles of the Gluteal Region	474
Glutæus Maximus	474
Bursæ	474
Glutæus Medius	474
Variations	475
Glutæus Minimus	475
Variations	475
Piriformis	476
Variations	476
Tensor Fasciæ Late	476
Obturator Membrane	477
Obturator Internus	477
Gemelli	477
Gemellus Superior	477
Gemellus Inferior	477
Quadratus Femoris	477
Obturator Externus	477
The Posterior Femoral Muscles	478
Biceps Femoris	478
Variations	479
Semitendinosus	479
Semimembranosus	479
Variations	479

The Muscles and Fasciæ of the Leg.

The Anterior Crural Muscles	480
Deep Fascia	480
Tibialis Anterior	480
Variations	480

The Anterior Crural Muscles—		The Mucous Sheaths of the Tendons Around	
Extensor Hallucis Longus	481	the Ankle	489
Variations	481	<i>The Muscles and Fasciæ of the Foot.</i>	
Extensor Digitorum Longus	481	The Dorsal Muscle of the Foot	490
Variations	482	Extensor Digitorum Brevis	490
Peronæus Tertius	482	Variations	490
The Posterior Crural Muscles	482	The Plantar Muscles of the Foot	490
The Superficial Group	482	Plantar Aponeurosis	490
Gastrocnemius	482	The First Layer	491
Variations	483	Abductor Hallucis	491
Soleus	483	Variations	491
Variations	483	Flexor Digitorum Brevis	491
Tendo Calcaneus	483	Variations	492
Plantaris	483	Fibrous Sheaths of the Flexor	
The Deep Group	483	Tendons	492
Deep Transverse Fascia	483	Abductor Digiti Quinti	492
Popliteus	484	Variations	492
Variations	485	The Second Layer	493
Flexor Hallucis Longus	485	Quadratus Plantæ	493
Variations	485	Variations	493
Flexor Digitorum Longus	485	Lumbricales	493
Variations	485	Variations	493
Tibialis Posterior	485	The Third Layer	493
The Lateral Crural Muscles	486	Flexor Hallucis Brevis	493
Peronæus Longus	486	Variations	493
Peronæus Brevis	486	Adductor Hallucis	493
Variations	487	Variations	494
<i>The Fasciæ Around the Ankle.</i>		Flexor Digiti Quinti Brevis	494
Transverse Crural Ligament	488	The Fourth Layer	495
Cruciate Crural Ligament	488	Interossei	495
Lacinate Ligament	489	Interossei Dorsales	495
Peroneal Retinacula	489	Interossei Plantares	495

ANGIOLOGY.

Structure of Arteries	498	THE THORACIC CAVITY.	
Capillaries	499	The Cavity of the Thorax	524
Sinusoids	501	The Upper Opening of the Thorax	524
Structure of Veins	591	The Lower Opening of the Thorax	524
THE BLOOD.		<i>The Pericardium.</i>	
General Composition of the Blood	503	Structure of the Pericardium	525
Blood Corpuscles	503	<i>The Heart.</i>	
Colored or Red Corpuscles	503	Size	526
Colorless Corpuscles or Leukocytes	504	Component Parts	526
DEVELOPMENT OF THE VASCULAR SYSTEM.		Right Atrium	528
Further Development of the Heart	508	Sinus Venarum	528
The Valves of the Heart	514	Auricula	528
Further Development of the Arteries	515	Right Ventricle	531
The Anterior Ventral Aortæ	516	Left Atrium	533
The Aortic Arches	516	Auricula	533
The Dorsal Aortæ	517	Left Ventricle	535
Further Development of the Veins	518	Ventricular Septum	535
The Visceral Veins	518	Structure of the Heart	535
The Parietal Veins	520	The Cardiac Cycle and the Actions of the	
Inferior Vena Cava	520	Valves	538
Venous Sinuses of the Dura Mater	522	<i>Peculiarities in the Vascular System in the</i>	
		<i>Fetus.</i>	
		Fetal Circulation	540
		Changes in the Vascular System at Birth	542

THE ARTERIES.

The Pulmonary Artery	543	Branches of the Ascending Aorta—	
Relations	545	The Coronary Arteries	546
THE AORTA.		Right Coronary Artery	546
<i>The Ascending Aorta.</i>		Left Coronary Artery	547
Relations	546	Peculiarities	547
Branches	546	<i>The Arch of the Aorta.</i>	
		Relations	547
		Peculiarities	548

Branches	548
Peculiarities	548
The Innominate Artery	548
Relations	549
Branches	549
Thyreoidea Ima	549
Collateral Circulation	549

THE ARTERIES OF THE HEAD AND NECK.

The Common Carotid Artery.

Relations	549
Peculiarities	551
Collateral Circulation	551
The External Carotid Artery	551
Relations	552
Branches	552
Superior Thyroid Artery	552
Relations	552
Branches	552
Lingual Artery	553
Relations	553
Branches	553
External Maxillary Artery	553
Relations	554
Branches	554
Peculiarities	556
Occipital Artery	556
Course and Relations	556
Branches	556
Posterior Auricular Artery	557
Branches	557
Ascending Pharyngeal Artery	557
Branches	558
Superficial Temporal Artery	558
Relations	558
Branches	558
Internal Maxillary Artery	559
Branches	560
The Triangles of the Neck	562
Anterior Triangle	563
Inferior Carotid or Muscular Tri- angle	563
Superior Carotid or Carotid Tri- angle	564
Submaxillary or Digastric Tri- angle	564
Suprahyoid Triangle	565
Posterior Triangle	565
Occipital Triangle	565
Subclavian Triangle	565
The Internal Carotid Artery	566
Course and Relations	567
Cervical Portion	567
Petrous Portion	567
Cavernous Portion	567
Cerebral Portion	567
Peculiarities	567
Branches	568
Caroticotympanic	568
Artery of the Pterygoid Canal	568
Cavernous	568
Hypophyseal	568
Semilunar	568
Anterior Meningeal	568
Ophthalmic artery	568
Branches	568
Anterior Cerebral Artery	571
Branches	571
Middle Cerebral Artery	572
Branches	573
Posterior Communicating Artery	573
Anterior Choroidal Artery	574

The Arteries of the Brain.

The Ganglionic System	575
The Cortical Arterial System	575

THE ARTERIES OF THE UPPER EXTREMITY.

The Subclavian Artery.

First Part of the Right Subclavian Artery	576
Relations	576
First Part of the Left Subclavian Artery	577
Relations	577
Second and Third Parts of the Subclavian Artery	577
Relations	577
Relations	577
Peculiarities	577
Collateral Circulation	578
Branches	578
Vertebral Artery	578
Relations	578
Branches	579
Thyrocervical Trunk	581
Branches	581
Peculiarities	583
Internal Mammary Artery	584
Relations	584
Branches	584
The Costocervical Trunk	585

The Axilla.

Boundaries	585
Contents	586
The Axillary Artery	586
Relations	586
Collateral Circulation	587
Branches	587
The Highest Thoracic Artery	587
The Thoracoacromial Artery	588
The Lateral Thoracic Artery	588
The Subscapular Artery	588
The Posterior Humeral Circumflex Artery	589
The Anterior Humeral Circumflex Artery	589
Peculiarities	589
The Brachial Artery	589
Relations	589
The Anticubital Fossa	589
Peculiarities	590
Collateral Circulation	590
Branches	590
The Arteria Profunda Brachii	591
The Nutrient Artery	591
The Superior Ulnar Collateral Artery	591
The Inferior Ulnar Collateral Artery	592
Muscular Branches	592
The Anastomosis Around the Elbow-joint	592
The Radial Artery	592
Relations	592
Peculiarities	594
Branches	594
Radial Recurrent Artery	594
Muscular	594
Volar Carpal	594
Superficial Volar	594
Dorsal Carpal	594
Arteria Princeps Pollicis	595
Arteria Volaris Indicis Radialis	595
Deep Volar Arch	595
Volar Metacarpal Arteries	595
Perforating	595
Recurrent	595
The Ulnar Artery	595
Relations	595
Peculiarities	596
Branches	596
Anterior Ulnar Recurrent Artery	596
Posterior Ulnar Recurrent Artery	596
Common Interosseous Artery	596
Muscular	598
Volar Carpal	598
Dorsal Carpal	598
Deep Volar	598
Superficial Volar	598
Relations	598

THE ARTERIES OF THE TRUNK.

<i>The Descending Aorta.</i>	
The Thoracic Aorta	598
Relations	599
Peculiarities	599
Branches	600
Pericardial	600
Bronchial	600
Esophageal	600
Mediastinal	600
Intercostal Arteries	600
Branches	601
Subcostal Arteries	601
Superior Phrenic	601
The Abdominal Aorta	602
Relations	603
Collateral Circulation	603
Branches	603
The Celiac Artery	603
Relations	603
The Superior Mesenteric Artery	606
Branches	607
The Inferior Mesenteric Artery	609
Branches	610
The Middle Suprarenal Arteries	610
The Renal Arteries	610
The Internal Spermatic Arteries	611
The Ovarian Arteries	611
The Inferior Phrenic Arteries	612
The Lumbar Arteries	612
The Middle Sacral Artery	613
<i>The Common Iliac Arteries.</i>	
Peculiarities	614
Collateral Circulation	614
The Hypogastric Artery	614
Relations	614
Peculiarities	615
Collateral Circulation	615
Branches	615
Superior Vesical Artery	615
Middle Vesical Artery	615
Inferior Vesical Artery	615
Middle Hemorrhoidal Artery	615
Uterine Artery	615
Vaginal Artery	616
Obturator Artery	616
Branches	616
Peculiarities	617
Internal Pudendal Artery	617
Relations	618
Peculiarities	618
Branches	618
Inferior Gluteal Artery	620
Branches	620
Lateral Sacral Arteries	621
Superior Gluteal Artery	622
The External Iliac Artery	622
Relations	622
Collateral Circulation	622
Branches	622
Inferior Epigastric Artery	623
Branches	623
Peculiarities	623
Deep Iliac Circumflex Artery	623

THE ARTERIES OF THE LOWER EXTREMITY.

<i>The Femoral Artery.</i>	
The Femoral Sheath	625
The Femoral Triangle	626
The Adductor Canal	627
Relations of the Femoral Artery	627
Peculiarities of the Femoral Artery	629
Collateral Circulation	629
Branches	629
Superficial Epigastric Artery	629
Superficial Iliac Circumflex Artery	629
Superficial External Pudendal Artery	629
Deep External Pudendal Artery	629
Muscular	629
Profunda Femoris Artery	629
Relations	630
Peculiarities	630
Branches	630
Highest Genicular Artery	631
The Popliteal Fossa	631
Boundaries	631
Contents	632
The Popliteal Artery	632
Relations	632
Peculiarities	633
Branches	633
Superior Muscular	633
Sural Arteries	633
Cutaneous Branches	633
Superior Genicular Arteries	633
Middle Genicular Artery	633
Inferior Genicular Arteries	633
The Anastomosis Around the Knee-joint	634
The Anterior Tibial Artery	634
Relations	635
Peculiarities	635
Branches	635
Posterior Tibial Recurrent Artery	635
Fibular Artery	635
Anterior Tibial Recurrent Artery	635
Muscular Branches	635
Anterior Medial Malleolar Artery	635
Anterior Lateral Malleolar Artery	635
The Arteria Dorsalis Pedis	636
Relations	636
Peculiarities	636
Branches	637
Lateral Tarsal Artery	637
Medial Tarsal Artery	637
Arcuate Artery	637
Deep Plantar Artery	637
The Posterior Tibial Artery	637
Relations	637
Peculiarities	638
Branches	638
Peroneal Artery	638
Peculiarities	638
Branches	638
Nutrient Artery	638
Muscular Branches	639
Posterior Medial Malleolar Artery	639
Communicating Branch	639
Medial Calcaneal	639
Medial Plantar Artery	639
Lateral Plantar Artery	639
Branches	640

THE VEINS.

THE PULMONARY VEINS	642	The Veins of the Exterior of the Head and Face—	
THE SYSTEMIC VEINS.		The Supraorbital Vein	645
<i>The Veins of the Heart.</i>		The Angular Vein	645
Coronary Sinus	642	The Anterior Facial Vein	645
Tributaries	642	Tributaries	645
<i>The Veins of the Head and Neck.</i>		The Superficial Temporal Vein	645
The Veins of the Exterior of the Head and Face	644	Tributaries	645
The Frontal Vein	644	The Pterygoid Plexus	645
		The Internal Maxillary Vein	646
		The Posterior Facial Vein	646
		The Posterior Auricular Vein	646
		The Occipital Vein	646

The Veins of the Neck 646
 The External Jugular Vein 646
 Tributaries 647
 The Posterior External Jugular Vein 647
 The Anterior Jugular Vein 647
 The Internal Jugular Vein 648
 Tributaries 648
 The Vertebral Vein 649
 Tributaries 650
 The Diploic Veins 651
 The Veins of the Brain 652
 The Cerebral Veins 652
 The External Veins 652
 The Superior Cerebral Vein 652
 The Middle Cerebral Vein 652
 The Inferior Cerebral Vein 652
 The Internal Cerebral Veins 653
 The Great Cerebral Vein 653
 The Cerebellar Veins 653
 The Sinuses of the Dura Mater. Ophthalmic
 Veins and Emissary Veins 654
 The Superior Sagittal Sinus 654
 The Inferior Sagittal Sinus 655
 The Straight Sinus 655
 The Transverse Sinuses 657
 The Occipital Sinus 658
 The Confluence of the Sinuses 658
 The Cavernous Sinuses 658
 The Ophthalmic Veins 658
 The Superior Ophthalmic Vein 659
 The Inferior Ophthalmic Vein 659
 The Intercavernous Sinuses 659
 The Superior Petrosal Sinus 659
 The Inferior Petrosal Sinus 659
 The Basilar Plexus 660
 The Emissary Veins 660

*The Veins of the Upper Extremity and
 Thorax.*
 The Superficial Veins of the Upper Extremity 660
 Digital Veins 660
 The Cephalic Vein 661
 The Accessory Cephalic Vein 662
 The Basilic Vein 662
 The Median Antibrachial Vein 662
 The Deep Veins of the Upper Extremity 663
 Deep Veins of the Hand 663
 Deep Veins of the Forearm 663
 The Brachial Veins 663
 The Axillary Vein 663
 The Subclavian Vein 664
 Tributaries 664
 The Veins of the Thorax 664
 The Innominate Veins 664
 The Right Innominate Vein 664
 The Left Innominate Vein 666
 Tributaries 666
 Peculiarities 666
 The Internal Mammary Veins 666
 The Inferior Thyroid Veins 666
 The Highest Intercostal Vein 666
 The Superior Vena Cava 666
 Relations 667
 The Azygos Vein 667
 Tributaries 667
 The Hemiazygos Veins 667

The Veins of the Thorax—
 The Azygos Vein—
 The Accessory Hemiazygos
 Veins 667
 The Bronchial Veins 667
 The Veins of the Vertebral Column 667
 The External Vertebral Venous Plexuses 668
 The Internal Vertebral Venous Plexuses 668
 The Basivertebral Veins 668
 The Intervertebral Veins 669
 The Veins of the Medulla Spinalis 669

*The Veins of the Lower Extremity, Abdomen,
 and Pelvis.*
 The Superficial Veins of the Lower Extremity 669
 The Dorsal Digital Veins 669
 The Great Saphenous Vein 669
 Tributaries 670
 The Small Saphenous Vein 670
 The Deep Veins of the Lower Extremity 671
 The Plantar Digital Veins 671
 The Posterior Tibial Veins 672
 The Anterior Tibial Veins 672
 The Popliteal Vein 672
 The Femoral Vein 672
 The Deep Femoral Vein 672
 The Veins of the Abdomen and Pelvis 672
 The External Iliac Vein 672
 Tributaries 672
 The Hypogastric Veins 673
 Tributaries 673
 The Hemorrhoidal Plexus 676
 The Pudendal Plexus 676
 The Vesical Plexus 676
 The Dorsal Veins of the Penis 676
 The Uterine Plexuses 676
 The Vaginal Plexuses 677
 The Common Iliac Veins 677
 The Middle Sacral Veins 677
 Peculiarities 677
 The Inferior Vena Cava 677
 Relations 678
 Peculiarities 678
 Applied Anatomy 678
 Tributaries 678
 Lumbar Veins 678
 Spermatc Veins 678
 Ovarian Veins 679
 Renal Veins 679
 Suprarenal Veins 679
 Inferior Phrenic Veins 679
 Hepatic Veins 680

THE PORTAL SYSTEM OF VEINS.

The Portal Vein 681
 Tributaries 681
 The Lienal Vein 681
 Tributaries 681
 The Superior Mesenteric Vein 682
 Tributaries 682
 The Coronary Vein 682
 The Pyloric Vein 682
 The Cystic Vein 682
 The Parumbilical Veins 682

THE LYMPHATIC SYSTEM.

The Development of the Lymphatic Vessels 683
 Lymphatic Capillaries 684
 Distribution 684
 Lymphatic Vessels 687
 Structure of Lymphatic Vessels 687
 The Lymph Glands 688
 Structure of Lymph Glands 688
 Hemolymph Nodes 690
 Lymph 690

 THE THORACIC DUCT.
 The Cisterna Chyli 691
 Tributaries 691
 The Right Lymphatic Duct 691
 Tributaries 692

THE LYMPHATICS OF THE HEAD, FACE, AND NECK.

The Lymph Glands of the Head 692
 The Occipital Glands 692
 The Posterior Auricular Glands 693
 The Anterior Auricular Glands 693
 The Parotid Glands 693
 The Facial Glands 694
 The Deep Facial Glands 694
 The Lingual Glands 694
 The Retropharyngeal Glands 694
 The Lymphatic Vessels of the Scalp 694
 The Lymphatic Vessels of the Auricula
 and External Acoustic Meatus 694
 The Lymphatic Vessels of the Face 695

The Lymph Glands of the Head—		The Lymphatic Vessels of the Abdomina and Pelvic Viscera—	
The Lymphatic Vessels of the Nasal Cavities	695	The Lymphatic Vessels of the Subdia- phragmatic Portions of the Digestive Tube	710
The Lymphatic Vessels of the Mouth . .	695	The Lymphatic Vessels of the Stomach .	710
The Lymphatic Vessels of the Palatine Tonsil	695	The Lymphatic Vessels of the Duodenum .	710
The Lymphatic Vessels of the Tongue . .	696	The Lymphatic Vessels of the Jejunum and Ileum	710
The Lymph Glands of the Neck	697	The Lymphatic Vessels of the Vermiform Process and Cecum	710
The Submaxillary Glands	697	The Lymphatic Vessels of the Colon . .	711
The Submental or Suprahyoid Glands . .	697	The Lymphatic Vessels of the Anus, Anal Canal, and Rectum	711
The Superficial Cervical Glands	697	The Lymphatic Vessels of the Liver . .	711
The Anterior Cervical Glands	697	The Lymphatic Vessels of the Gall- bladder	711
The Deep Cervical Glands	697	The Lymphatic Vessels of the Pancreas .	711
The Lymphatic Vessels of the Skin and Muscles of the Neck	698	The Lymphatic Vessels of the Spleen and Suprarenal Glands	711
THE LYMPHATICS OF THE UPPER EXTREMITY.		The Lymphatic Vessels of the Urinary Organs	
The Lymph Glands of the Upper Extremity .	699	The Lymphatic Vessels of the Kidney	712
The Superficial Lymph Glands	699	The Lymphatic Vessels of the Ureter . .	712
The Deep Lymph Glands	699	The Lymphatic Vessels of the Bladder	712
The Axillary Glands	699	The Lymphatic Vessels of the Prostate	713
The Lymphatic Vessels of the Upper Extremity	700	The Lymphatic Vessels of the Urethra	713
The Superficial Lymphatic Vessels . . .	700	The Lymphatic Vessels of the Repro- ductive Organs	713
The Deep Lymphatic Vessels	701	The Lymphatic Vessels of the Testes	713
THE LYMPHATICS OF THE LOWER EXTREMITY.		The Lymphatic Vessels of the Ductus Deferens	713
The Lymph Glands of the Lower Extremity .	701	The Lymphatic Vessels of the Ovary . .	714
The Anterior Tibial Gland	701	The Lymphatic Vessels of the Uterine Tube	714
The Popliteal Glands	701	The Lymphatic Vessels of the Uterus	714
The Inguinal Glands	702	The Lymphatic Vessels of the Vagina	714
The Lymphatic Vessels of the Lower Extremity	703	THE LYMPHATICS OF THE THORAX.	
The Superficial Lymphatic Vessels . . .	703	The Parietal Lymph Glands	715
The Deep Lymphatic Vessels	703	The Sternal Glands	715
THE LYMPHATICS OF THE ABDOMEN AND PELVIS.		The Intercostal Glands	715
The Lymph Glands of the Abdomen and Pelvis	703	The Diaphragmatic Glands	715
The Parietal Glands	703	The Superficial Lymphatic Vessels of the Thoracic Wall	715
The External Iliac Glands	703	The Lymphatic Vessels of the Mamma . .	715
The Common Iliac Glands	704	The Deep Lymphatic Vessels of the Thoracic Wall	716
The Epigastric Glands	704	The Visceral Lymph Glands	717
The Iliac Circumflex Glands	704	The Anterior Mediastinal Glands	717
The Hypogastric Glands	704	The Posterior Mediastinal Glands	717
The Sacral Glands	704	The Tracheobronchial Glands	717
The Lumbar Glands	705	The Lymphatic Vessels of the Thoracic Viscera	718
The Lymphatic Vessels of the Abdomen and Pelvis	706	The Lymphatic Vessels of the Heart . .	718
The Superficial Vessels	706	The Lymphatic Vessels of the Lungs . .	718
The Deep Vessels	706	The Lymphatic Vessels of the Pleura . .	719
The Lymphatic Vessels of the Perineum and External Genitals	706	The Lymphatic Vessels of the Thymus . .	719
The Visceral Glands	706	The Lymphatic Vessels of the Eso- phagus	719
The Gastric Glands	706	NEUROLOGY.	
The Hepatic Glands	706	STRUCTURE OF THE NERVOUS SYSTEM.	
The Pancreaticocolic Glands	706	Neuroglia	722
The Superior Mesenteric Glands	709	Nerve Cells	722
The Mesenteric Glands	709	Nerve Fibers	724
The Ileocolic Glands	709	Wallerian Degeneration	727
The Mesocolic Glands	709	Non-medullated Fibers	728
The Inferior Mesenteric Glands	710	Structure of the Peripheral Nerves and Ganglia	728
The Lymphatic Vessels of the Abdominal and Pelvic Viscera	710	Origins and Terminations of Nerves . . .	729
		Ganglia	730
		Neuron Theory	732
		Fasciculi, Tracts or Fiber Systems	732
		DEVELOPMENT OF THE NERVOUS SYSTEM.	
		The Medulla Spinalis	733
		The Spinal Nerves	735
		The Brain	736

NEUROLOGY.

STRUCTURE OF THE NERVOUS SYSTEM.		Ganglia		730
Neuroglia	722	Neuron Theory	732	
Nerve Cells	722	Fasciculi, Tracts or Fiber Systems	732	
Nerve Fibers	724	DEVELOPMENT OF THE NERVOUS SYSTEM.		
Wallerian Degeneration	727	The Medulla Spinalis	733	
Non-medullated Fibers	728	The Spinal Nerves	735	
Structure of the Peripheral Nerves and Ganglia	728	The Brain	736	
Origins and Terminations of Nerves . . .	729			

The Brain—
 The Hind-brain or Rhombencephalon 738
 The Mid-brain or Mesencephalon 741
 The Fore-brain or Prosencephalon 741
 The Diencephalon 742
 The Telencephalon 743
 The Commissures 746
 Fissures and Sulci 747
 The Cranial Nerves 748

THE SPINAL CORD OR MEDULLA SPINALIS.

Enlargements 751
 Fissures and Sulci 752
 The Anterior Median Fissure 752
 The Posterior Median Sulcus 752
 The Internal Structure of the Medulla Spinalis 753
 The Gray Substance 753
 Structure of the Gray Substance 755
 The White Substance 758
 Nerve Fasciculi 759
 Roots of the Spinal Nerves 764
 The Anterior Nerve Root 764
 The Posterior Root 764

THE BRAIN OR ENCEPHALON.

General Considerations and Divisions 766
 The Hind-brain or Rhombencephalon.
 The Medulla Oblongata 767
 The Anterior Median Fissure 767
 The Posterior Median Fissure 767
 Internal Structure of the Medulla Oblongata 775
 The Cerebrospinal Fasciculi 775
 Gray Substance of the Medulla Oblongata 779
 Inferior Peduncle 782
 Formatio Reticularis 784
 The Pons 785
 Structure 785
 The Cerebellum 788
 Lobes of the Cerebellum 788
 Internal Structure of the Cerebellum 791
 The White Substance 791
 Projection Fibres 791
 The Gray Substance 794
 Microscopic Appearance of the Cortex 794
 The Fourth Ventricle 797
 Angles 797
 Lateral Boundaries 797
 Choroid Plexuses 798
 Openings in the Roof 798
 Rhomboid Fossa 798

The Mid-brain or Mesencephalon.

The Cerebral Peduncles 800
 Structure of the Cerebral Peduncles 801
 The Gray Substance 802
 The White Substance 803
 The Corpora Quadrigemina 805
 Structure of the Corpora Quadrigemina 806
 The Cerebral Aqueduct 806

The Fore-brain or Prosencephalon.

The Diencephalon 807
 The Thalamencephalon 808
 Structure 810
 Connections 810
 The Metathalamus 811
 The Epithalamus 812
 The Hypothalamus 812
 The Optic Chiasma 814
 The Optic Tracts 814
 The Third Ventricle 815
 The Interpeduncular Fossa 816
 The Telencephalon 817

The Cerebral Hemispheres 817
 The Longitudinal Cerebral Fissure 818
 The Surfaces of the Cerebral Hemispheres 818
 The Lateral Cerebral Fissure 819
 The Central Sulcus 819
 The Parietooccipital Fissure 820
 The Calcarine Fissure 820
 The Cingulate Sulcus 820
 The Collateral Fissure 820
 The Sulcus Circularis 821
 The Lobes of the Hemispheres 821
 The Frontal Lobe 821
 The Parietal Lobe 822
 The Occipital Lobe 823
 The Temporal Lobe 823
 The Insula 825
 The Limbic Lobe 825
 The Rhinencephalon 826
 The Olfactory Lobe 826
 The Interior of the Cerebral Hemispheres 827
 The Corpus Callosum 828
 The Lateral Ventricles 829
 The Fornix 838
 The Interventricular Foramen 840
 The Anterior Commissure 840
 The Septum Pellucidum 840
 The Choroid Plexus of the Lateral Ventricle 840
 Structure of the Cerebral Hemispheres 842
 Structure of the Cerebral Cortex 845
 Special Types of Cerebral Cortex 847
 Weight of Encephalon 848
 Cerebral Localization 849

Composition and Central Connections of the Spinal Nerves.

The Intrinsic Spinal Reflex Paths 850
 Sensory Pathways from the Spinal Cord to the Brain 851

Composition and Central Connections of the Cranial Nerves.

The Hypoglossal Nerve 855
 The Accessory Nerve 855
 The Vagus Nerve 855
 The Glossopharyngeal Nerve 856
 The Acoustic Nerve 857
 The Vestibular Nerve 860
 The Facial Nerve 861
 The Abducens Nerve 861
 The Trigeminal Nerve 862
 The Trochlear Nerve 863
 The Oculomotor Nerve 863
 The Optic Nerve 864
 The Olfactory Nerves 866

Pathways from the Brain to the Spinal Cord.

The Motor Tract 870

The Meninges of the Brain and Medulla Spinalis.

The Dura Mater 872
 The Cranial Dura Mater 872
 Processes 873
 Structure 875
 The Spinal Dura Mater 875
 Structure 876
 The Arachnoid 876
 The Cranial Part 876
 The Spinal Part 876
 Structure 876
 The Subarachnoid Cavity 876
 The Subarachnoid Cisternæ 876
 The Arachnoid Villi 878
 Structure 878
 The Pia Mater 878
 The Cranial Pia Mater 879
 The Spinal Pia Mater 879
 The Ligamentum Denticulatum 880

<i>The Cerebrospinal Fluid</i>	880	<i>The Ganglion Nodosum—</i>	
THE CRANIAL NERVES.		The Meningeal Branch	911
<i>The Olfactory Nerves</i>	881	The Auricular Branch	911
<i>The Optic Nerve.</i>		The Pharyngeal Branch	911
The Optic Chiasma	883	The Superior Laryngeal Nerve	912
The Optic Tract	884	The Recurrent Nerve	912
<i>The Oculomotor Nerve</i>	884	The Superior Cardiac Branches	912
<i>The Trochlear Nerve</i>	885	The Inferior Cardiac Branches	912
<i>The Trigeminal Nerve.</i>		The Anterior Bronchial Branches	913
The Semilunar Ganglion	886	The Posterior Bronchial Branches	913
The Ophthalmic Nerve	887	The Esophageal Branches	913
The Lacrimal Nerve	887	The Gastric Branches	913
The Frontal Nerve	887	The Celiac Branches	913
The Nasociliary Nerve	888	The Hepatic Branches	913
The Ciliary Ganglion	888	<i>The Accessory Nerve.</i>	
The Maxillary Nerve	889	The Cranial Part	913
Branches	889	The Spinal Part	913
The Middle Meningeal Nerve	889	<i>The Hypoglossal Nerve.</i>	
The Zygomatic Nerve	889	Branches of Communication	915
The Sphenopalatine	890	Branches of Distribution	916
The Posterior Superior Alveolar	890	The Meningeal Branches	916
The Middle Superior Alveolar	891	The Descending Ramus	916
The Anterior Superior Alveolar	891	The Thyrohyoid Branch	916
The Inferior Palpebral	891	The Muscular Branches	916
The External Nasal	891	THE SPINAL NERVES.	
The Superior Labial	891	Nerve Roots	916
The Sphenopalatine Ganglion	891	The Anterior Root	916
The Mandibular Nerve	893	The Posterior Root	916
Branches	894	The Spinal Ganglia	917
The Nervus Spinosus	894	Structure	917
The Internal Pterygoid Nerve	894	Connections with Sympathetic	920
The Masseteric Nerve	894	Structure	920
The Deep Temporal Nerves	895	Divisions of the Spinal Nerves	921
The Buccinator Nerve	895	The Posterior Divisions	921
The External Pterygoid Nerve	895	The Cervical Nerves	921
The Auriculotemporal Nerve	895	The Thoracic Nerves	923
The Lingual Nerve	895	The Lumbar Nerves	924
The Inferior Alveolar Nerve	896	The Sacral Nerves	924
The Otic Ganglion	897	The Coccygeal Nerve	925
The Submaxillary Ganglion	898	The Anterior Divisions	925
Trigeminal Nerve Reflexes	899	The Cervical Nerves	925
<i>The Abducent Nerve</i>	899	The Cervical Plexus	925
<i>The Facial Nerve.</i>		Great Auricular Nerve	926
The Greater Superficial Petrosal Nerve	903	Cutaneous Cervical Nerve	927
The Nerve to the Stapedius	904	Supraclavicular Nerves	928
The Chorda Tympani Nerve	904	Communicantes Cervicales	928
The Posterior Auricular Nerve	905	Phrenic Nerve	928
The Digastric Branch	905	The Brachial Plexus	930
The Stylohyoid Branch	905	Relations	931
The Temporal Branches	905	Dorsal Scapular Nerve	932
The Zygomatic Branches	905	Suprascapular Nerve	932
The Buccal Branches	905	Nerve to Subclavius	933
The Mandibular Branch	905	Long Thoracic Nerve	933
The Cervical Branch	905	Anterior Thoracic Nerves	933
<i>The Acoustic Nerve.</i>		Subscapular Nerves	933
The Cochlear Nerve	906	Thoracodorsal Nerve	934
The Vestibular Nerve	906	Axillary Nerve	934
<i>The Glossopharyngeal Nerve.</i>		Musculocutaneous Nerve	935
The Superior Ganglion	908	Medial Antibrachial Cuta- neous Nerve	937
The Petrous Ganglion	908	Medial Brachial Cuta- neous Nerve	937
The Tympanic Nerve	909	Median Nerve	938
The Carotid Branches	909	Ulnar Nerve	939
The Pharyngeal Branches	909	Radial Nerve	943
The Muscular Branches	909	The Thoracic Nerves	944
The Tonsillar Branches	909	First Thoracic Nerve	945
The Lingual Branches	909	Upper Thoracic Nerves	945
<i>The Vagus Nerve.</i>		Lower Thoracic Nerves	948
The Jugular Ganglion	911	The Lumbosacral Plexus	948
The Ganglion Nodosum	911	The Lumbar Nerves	948
		The Lumbar Plexus	949
		Iliohypogastric Nerve	950
		Ilioinguinal Nerve	952
		Genitofemoral Nerve	953
		Lateral Femoral Cuta- neous Nerve	953
		Obturator Nerve	953

Divisions of the Spinal Nerves—
 The Anterior Divisions—
 The Lumbosacral Plexus—
 The Lumbar Nerves—
 The Lumbar Plexus—
 Accessory Obturator Nerve 955
 Femoral Nerve 955
 Saphenous Nerve 956
 The Sacral and Coccygeal Nerves 957
 The Sacral Plexus 957
 Relations 957
 Nerve to Quadratus Femoris and Gemellus Inferior 957
 Nerve to Obturator Internus and Gemellus Superior 958
 Nerve to Piriformis 959
 Superior Gluteal Nerve 959
 Inferior Gluteal Nerve 959
 Posterior Femoral Cutaneous Nerve 959
 Sciatic Nerve 960
 Tibial Nerve 960
 Lateral Plantar Nerve 963
 Common Peroneal Nerve 964
 Deep Peroneal Nerve 965
 Superficial Peroneal Nerve 966
 The Pudendal Plexus 966
 Perforating Cutaneous Nerve 967
 Pudendal Nerve 967
 Anococcygeal Nerve 968

THE SYMPATHETIC NERVES.

The Cranial Sympathetics 970
 The Sacral Sympathetics 973
 The Thoracolumbar Sympathetics 974
 The Sympathetic Trunks 976
 Connections with the Spinal Nerves 976
 Development 977

The Cephalic Portion of the Sympathetic System.
 The Internal Carotid Plexus 977
 The Cavernous Plexus 978

The Cervical Portion of the Sympathetic System.
 The Superior Cervical Ganglion 978
 Branches 978
 The Middle Cervical Ganglion 979
 Branches 979
 The Inferior Cervical Ganglion 980
 Branches 981

The Thoracic Portion of the Sympathetic System.
 The Greater Splanchnic Nerve 981
 The Lesser Splanchnic Nerve 981
 The Lowest Splanchnic Nerve 981

The Abdominal Portion of the Sympathetic System 982

The Pelvic Portion of the Sympathetic System 984

The Great Plexuses of the Sympathetic System.
 The Cardiac Plexus 984
 The Celiac Plexus 985
 Phrenic Plexus 985
 Hepatic Plexus 986
 Lienal Plexus 986
 Superior Gastric Plexus 987
 Suprarenal Plexus 987
 Renal Plexus 987
 Spermatic Plexus 987
 Superior Mesenteric Plexus 987
 Abdominal Aortic Plexus 987
 Inferior Mesenteric Plexus 987
 The Hypogastric Plexus 987
 The Pelvic Plexuses 987
 The Middle Hemorrhoidal Plexus 988
 The Vesical Plexus 988
 The Prostatic Plexus 988
 The Vaginal Plexus 989
 The Uterine Plexus 989

THE ORGANS OF THE SENSES AND THE COMMON INTEGUMENT.

THE PERIPHERAL ORGANS OF THE SPECIAL SENSES.

The Organs of Taste.
 Structure 991
The Organ of Smell.
 The External Nose 992
 Structure 992
 The Nasal Cavity 994
 The Lateral Wall 994
 The Medial Wall 995
 The Mucous Membrane 996
 Structure 996
 The Accessory Sinuses of the Nose 998
 The Frontal Sinuses 998
 The Ethmoidal Air Cells 998
 The Sphenoidal Sinuses 998
 The Maxillary Sinus 999
The Organ of Sight.
 Development 1001
 The Tunics of the Eye 1005
 The Fibrous Tunic 1005
 The Sclera 1005
 Structure 1006
 The Cornea 1006
 Structure 1007

The Tunics of the Eye—
 The Vascular Tunic 1009
 The Choroid 1009
 Structure 1010
 The Ciliary Body 1010
 Structure 1011
 The Iris 1012
 Structure 1013
 Membrana Pupillaris 1014
 The Retina 1014
 Structure 1015
 The Refracting Media 1018
 The Aqueous Humor 1018
 The Vitreous Body 1018
 The Crystalline Lens 1019
 Structure 1020
 The Accessory Organs of the Eye 1021
 The Ocular Muscles 1021
 Levator Palpebræ Superioris 1021
 The Recti 1022
 Obliquus Oculi Superior 1022
 Obliquus Oculi Inferior 1023
 The Fascia Bulb 1024
 The Orbital Fascia 1025
 The Eyebrows 1025
 The Eyelids 1025
 The Lateral Palpebral Commis-
 sure 1025
 The Eyelashes 1025
 Structure of the Eyelids 1025
 The Tarsal Glands 1026

The Accessory Organs of the Eye—		The Internal Ear or Labyrinth—	
Structure of the Tarsal Glands	1026	The Osseous Labyrinth—	
The Conjunctiva	1026	The Vestibule	1047
The Palpebral Portion	1027	The Bony Semicircular Canals	1049
The Bulbar Portion	1027	The Cochlea	1050
The Lacrimal Apparatus	1028	The Membranous Labyrinth	1051
The Lacrimal Gland	1028	The Utricle	1051
Structure	1028	The Sacculæ	1052
The Lacrimal Ducts	1028	The Semicircular Ducts	1052
The Lacrimal Sac	1028	Structure	1052
Structure	1029	The Ductus Cochlearis	1054
The Nasolacrimal Duct	1029	The Basilar Membrane	1056
		The Spiral Organ of Corti	1056
<i>The Organ of Hearing.</i>		Hair Cells	1057
Development	1029	<i>Peripheral Terminations of Nerves of General</i>	
The External Ear	1033	<i>Sensations.</i>	
The Auricula or Pinna	1033	Free Nerve-endings	1059
Structure	1034	Special End-organs	1059
The External Acoustic Meatus	1036	End-bulbs of Krause	1060
Relations	1037	Tactile Corpuscles of Grandry	1060
The Middle Ear or Tympanic Cavity	1037	Pacinian Corpuscles	1060
The Tegumental Wall or Roof	1038	Corpuscles of Golgi and Mazzoni	1061
The Jugular Wall or Floor	1038	Tactile Corpuscles of Wagner and Meissner	1061
The Membranous or Lateral Wall	1038	Corpuscles of Ruffini	1061
The Tympanic Membrane	1039	Neurotendinous Spindles	1061
Structure	1039	Neuromuscular Spindles	1061
The Labyrinthine or Medial Wall	1040		
The Mastoid or Posterior Wall	1042	THE COMMON INTEGUMENT.	
The Carotid or Anterior Wall	1042	The Epidermis, Cuticle, or Scarf Skin	1062
The Auditory Tube	1042	The Corium, Cutis Vera, Dermis, or True	
The Auditory Ossicles	1044	Skin	1065
The Malleus	1044	Development	1066
The Incus	1044		
The Stapes	1045	<i>The Appendages of the Skin.</i>	
Articulations of the Auditory Ossicles	1045	The Nails	1066
Ligaments of the Ossicles	1045	The Hairs	1067
The Muscles of the Tympanic Cavity	1046	The Sebaceous Glands	1069
The Tensor Tympani	1046	The Sudoriferous or Sweat Glands	1070
The Stapedius	1046		
The Internal Ear or Labyrinth	1047		
The Osseous Labyrinth	1047		

SPLANCHNOLOGY.

THE RESPIRATORY APPARATUS.		<i>The Pleuræ.</i>	
Development	1071	Reflections of the Pleura	1088
<i>The Larynx.</i>		Pulmonary Ligament	1090
The Cartilages of the Larynx	1073	Structure of Pleura	1090
The Thyroid Cartilage	1073	<i>The Mediastinum.</i>	
The Cricoid Cartilage	1074	Superior Mediastinum	1090
The Arytenoid Cartilage	1075	Anterior Mediastinum	1092
The Corniculate Cartilages	1075	Middle Mediastinum	1092
The Cuneiform Cartilages	1075	Posterior Mediastinum	1093
The Epiglottis	1075	<i>The Lungs.</i>	
Structure	1076	The Apex of the Lungs	1094
The Ligaments of the Larynx	1076	The Base of the Lungs	1094
The Extrinsic Ligaments	1076	Surfaces of the Lungs	1094
The Intrinsic Ligaments	1077	Borders of the Lungs	1096
The Interior of the Larynx	1078	Fissures and Lobes of the Lungs	1096
The Ventricular Folds	1079	The Root of the Lung	1097
The Vocal Folds	1079	Divisions of the Bronchi	1097
The Ventricle of the Larynx	1080	Structure of the Lungs	1098
The Rima Glottidis	1080		
The Muscles of the Larynx	1081	THE DIGESTIVE APPARATUS.	
Cricothyreoideus	1081	The Digestive Tube	1100
Cricocarytænoideus Posterior	1082	The Development of the Digestive	
Cricocarytænoideus Lateralis	1082	Tube	1101
Arytænoideus	1082	The Mouth	1101
Thyreocarytænoideus	1083	The Salivary Glands	1102
<i>The Trachea and Bronchi.</i>		The Tongue	1102
Relations	1084	The Palatine Tonsils	1103
The Right Bronchus	1085	The Further Development of the	
The Left Bronchus	1085	Digestive Tube	1103
Structure	1086	The Rectum and Anal Canal	1108

The Mouth.

The Vestibule of the Mouth	1110
The Mouth Cavity Proper	1110
Structure	1110
The Lips	1111
The Labial Glands	1111
The Cheeks	1112
Structure	1112
The Gums	1112
The Palate	1112
The Hard Palate	1112
The Soft Palate	1112
The Teeth	1112
General Characteristics	1114
The Permanent Teeth	1115
The Canine Teeth	1117
The Premolar or Bicuspid Teeth	1118
The Molar Teeth	1118
The Deciduous Teeth	1118
Structure of the Teeth	1118
Development of the Teeth	1121
Development of the Deciduous Teeth	1122
Development of the Permanent Teeth	1124
Eruption of the Teeth	1124
The Tongue	1125
The Root of the Tongue	1125
The Apex of the Tongue	1125
The Dorsum of the Tongue	1125
The Papillæ of the Tongue	1126
The Muscles of the Tongue	1128
Genioglossus	1129
Hyoglossus	1129
Chondroglossus	1130
Styloglossus	1130
Longitudinalis Linguae Superior	1130
Longitudinalis Linguae Inferior	1130
Transversus Linguae	1130
Verticalis Linguae	1131
Structure of the Tongue	1131
Glands of the Tongue	1131
The Salivary Glands	1132
The Parotid Gland	1132
Structures within the Gland	1134
The Parotid Duct	1134
Structure	1134
The Submaxillary Gland	1135
The Submaxillary Duct	1135
The Sublingual Gland	1136
Structure of the Salivary Gland	1136
Accessory Glands	1137

The Fauces.

The Glossopalatine Arch	1137
The Pharyngopalatine Arch	1137
The Palatine Tonsils	1137
Structure	1139
The Palatine Aponeurosis	1139
The Muscles of the Palate	1139
Levator Veli Palatini	1139
Tensor Veli Palatini	1139
Musculus Uvulæ	1139
Glossopalatinus	1139
Pharyngopalatinus	1139

The Pharynx.

The Nasal Part of the Pharynx	1141
The Oral Part of the Pharynx	1142
The Laryngeal Part of the Pharynx	1142
The Muscles of the Pharynx	1142
Constrictor Pharyngis Inferior	1142
Constrictor Pharyngis Medius	1142
Constrictor Pharyngis Superior	1142
Stylopharyngeus	1142
Salpingopharyngeus	1142
Structure of the Pharynx	1143

The Esophagus.

Relations	1145
Structure	1146

The Abdomen.

Boundaries of the Abdomen	1147
The Apertures in the Walls of the Abdomen	1147
Regions of the Abdomen	1147
The Peritoneum	1149
Vertical Dispositions of the Main Peritoneal Cavity	1150
Vertical Disposition of the Omental Bursa	1152
Horizontal Disposition of the Peritoneum	1153
In the Pelvis	1153
In the Lower Abdomen	1154
In the Upper Abdomen	1155
The Omenta	1156
The Mesenteries	1157
The Peritoneal Recesses or Fossæ	1158
The Duodenal Fossæ	1159
The Cecal Fossæ	1160
The Intersigmoid Fossa	1161

The Stomach.

Openings of the Stomach	1161
Curvatures of the Stomach	1162
Surfaces of the Stomach	1162
Component Parts of the Stomach	1163
Position of the Stomach	1163
Interior of the Stomach	1164
Pyloric Valve	1164
Structure of the Stomach	1164
The Gastric Glands	1166

The Small Intestine.

The Duodenum	1169
Relations	1169
The Jejunum and Ileum	1170
Meckel's Diverticulum	1172
Structure	1172

The Large Intestine.

The Cecum	1177
The Vermiform Process or Appendix	1178
Structure	1179
The Colic Valve	1179
The Colon	1180
The Ascending Colon	1180
The Transverse Colon	1180
The Descending Colon	1181
The Iliac Colon	1182
The Sigmoid Colon	1182
The Rectum	1183
Relations of the Rectum	1184
The Anal Canal	1184
Structure of the Colon	1184

The Liver.

Surfaces of the Liver	1188
Fossæ of the Liver	1191
Lobes of the Liver	1191
Ligaments of the Liver	1192
Fixation of the Liver	1193
Development of the Liver	1193
Structure of the Liver	1195
Excretory Apparatus of the Liver	1197
The Hepatic Duct	1197
The Gall-bladder	1197
Relations	1197
Structure	1198
The Common Bile Duct	1198
Structure	1199

The Pancreas.

Relations	1200
The Pancreatic Duct	1202
Development of the Pancreas	1202
Structure	1203

THE UROGENITAL APPARATUS.			
<i>Development of the Urinary and Generative Organs</i>			
The Pronephros and Wolffian Duct	1205	The Prostate 1251	
The Mesonephros, Müllerian Duct, and Genital Gland	1205	Structure 1253	
The Müllerian Ducts	1206	The Bulbourethral Glands 1253	
Genital Glands	1207	Structure 1253	
The Ovary	1207	<i>The Female Genital Organs.</i>	
The Testis	1210	The Ovaries 1254	
Descent of the Ovaries	1211	The Epoöphoron 1255	
The Metanephros and the Permanent Kidney	1211	The Paroöphoron 1255	
The Urinary Bladder	1212	Structure 1255	
The Prostate	1213	Vesicular Ovarian Follicles 1256	
External Organs of Generation	1213	Discharge of the Ovum 1256	
The Urethra	1215	Corpus Luteum 1256	
<i>The Urinary Organs.</i>		The Uterine Tube 1257	
The Kidneys 1215		Structure 1257	
Relations 1215		The Uterus 1258	
Surfaces 1215		The Body 1259	
Borders 1218		The Cervix 1259	
Extremities 1219		The Interior of the Uterus 1260	
Fixation of the Kidney 1220		The Cavity of the Body 1260	
General Structure of the Kidney 1220		The Canal of the Cervix 1260	
The Ureters 1225		The Ligaments of the Uterus 1260	
The Ureter Proper 1226		Structure 1262	
Structure 1227		The Vagina 1264	
Variations 1227		Relations 1264	
The Urinary Bladder 1227		Structure 1264	
The Empty Bladder 1227		The External Organs 1264	
The Distended Bladder 1228		The Mons Pubis 1265	
The Bladder in the Child 1229		The Labia Majora 1265	
The Female Bladder 1230		The Labia Minora 1265	
The Ligaments of the Bladder 1231		The Clitoris 1266	
The Interior of the Bladder 1231		The Vestibule 1266	
Structure 1232		The Bulb of the Vestibule 1266	
Abnormalities 1233		The Greater Vestibular Glands 1266	
The Male Urethra 1234		The Mammae 1267	
The Prostatic Portion 1234		The Mammary Papilla or Nipple 1267	
The Membranous Portion 1235		Development 1267	
The Cavernous Portion 1235		Structure 1267	
Structure 1235		THE DUCTLESS GLANDS.	
Congenital Defects 1235		<i>The Thyroid Gland.</i>	
The Female Urethra 1236		Development 1270	
Structure 1236		Structure 1271	
<i>The Male Genital Organs.</i>		<i>The Parathyroid Glands.</i>	
The Testes and their Coverings 1236		Development 1272	
The Scrotum 1237		Structure 1273	
The Intercrural Fascia 1238		<i>The Thymus.</i>	
The Cremaster Muscle 1238		Development 1273	
The Infundibuliform Fascia 1239		Structure 1274	
The Tunica Vaginalis 1239		<i>The Hypophysis Cerebri.</i>	
The Inguinal Canal 1239		Development 1276	
The Spermatic Cord 1239		<i>The Pineal Body.</i>	
Structure of the Spermatic Cord 1239		Structure 1277	
The Testes 1240		<i>The Chromophil and Cortical Systems.</i>	
The Epididymis 1242		Development 1277	
Appendages of the Testis and Epididymis 1242		The Suprarenal Glands 1278	
The Tunica Vaginalis 1242		Development 1278	
The Tunica Albuginea 1242		Relations 1278	
The Tunica Vasculosa 1243		Accessory Suprarenals 1279	
Structure 1243		Structure 1279	
Peculiarities 1245		Glomus Caroticum 1281	
The Ductus Deferens 1245		Glomus Coccygeum 1281	
The Ductuli Aberrantes 1246		<i>The Spleen.</i>	
Paradidymis 1246		Development 1282	
Structure 1246		Relation 1282	
The Vesiculæ Seminales 1246		Structure 1283	
Structure 1247			
The Ejaculatory Ducts 1247			
Structure 1247			
The Penis 1247			
The Corpora Caverosa Penis 1248			
The Corpus Caverosum Urethræ 1248			
Structure of the Penis 1250			

SURFACE ANATOMY AND SURFACE MARKINGS.

<i>Surface Anatomy of the Head and Neck.</i>		<i>Surface Markings of the Abdomen.</i>	
The Bones	1287	Bony Landmarks	1315
The Joints and Muscles	1288	Muscles	1315
The Arteries	1290	Surface Lines	1315
<i>Surface Markings of Special Regions of the Head and Neck.</i>		Stomach	1317
The Cranium	1291	Duodenum	1319
The Scalp	1291	Small Intestine	1319
Bony Landmarks	1291	Cecum and Vermiform Process	1319
The Brain	1292	Ascending Colon	1319
Vessels	1294	Transverse Colon	1319
The Face	1294	Descending Colon	1320
External Maxillary Artery	1294	Iliac Colon	1320
Trigeminal Nerve	1295	Liver	1320
Parotid Gland	1295	Pancreas	1320
The Nose	1296	Spleen	1320
The Mouth	1296	Kidneys	1320
The Eye	1299	Ureters	1321
The Ear	1300	Vessels	1321
The Tympanic Antrum	1301	Nerves	1322
The Neck	1301	<i>Surface Anatomy of the Perineum.</i>	
Muscles	1302	Skin	1322
Arteries	1302	Bones	1322
Veins	1303	Muscles and Ligaments	1322
Nerves	1303	<i>Surface Markings of the Perineum.</i>	
Submaxillary Gland	1303	Rectum and Anal Canal	1322
<i>Surface Anatomy of the Back.</i>		Male Urogenital Organs	1323
Bones	1303	Female Urogenital Organs	1323
Muscles	1304	<i>Surface Anatomy of the Upper Extremity.</i>	
<i>Surface Markings of the Back.</i>		Skin	1325
Bony Landmarks	1305	Bones	1326
Medulla Spinalis	1306	Articulations	1327
Spinal Nerves	1307	Muscles	1327
<i>Surface Anatomy of the Thorax.</i>		Arteries	1331
Bones	1307	Veins	1331
Muscles	1307	Nerves	1331
Mamma	1308	<i>Surface Markings of the Upper Extremity.</i>	
<i>Surface Markings of the Thorax.</i>		Bony Landmarks	1331
Bony Landmarks	1308	Articulations	1331
Diaphragm	1309	Muscles	1332
Surface Lines	1309	Mucous Sheaths	1334
Pleurae	1309	Arteries	1334
Lungs	1310	Nerves	1335
Trachea	1311	<i>Surface Anatomy of the Lower Extremity.</i>	
Esophagus	1311	Skin	1336
Heart	1311	Bones	1336
Arteries	1312	Articulations	1338
Veins	1312	Muscles	1338
<i>Surface Anatomy of the Abdomen.</i>		Arteries	1341
Skin	1313	Veins	1342
Bones	1313	Nerves	1342
Muscles	1313	<i>Surface Markings of the Lower Extremity.</i>	
Vessels	1313	Bony Landmarks	1342
Viscera	1313	Articulations	1343
		Muscles	1343
		Mucous Sheaths	1343
		Arteries	1343
		Veins	1346
		Nerves	1346

ANATOMICAL BIBLIOGRAPHY.

INDEXES.

- Anatomical Bibliography of the Concilium Bibliographicum.
Bibliographic Service; Wistar Institute of Anatomy, 1917- .
Bibliographie Anatomique, 1893- .
Index Medicus, 1879- .
Index Catalogue of the Library of the Surgeon-General's Office, U. S. Army,
1880- .
Jahresberichte über die Fortschritte der Anatomie und Physiologie, 1856-1894.
Jahresberichte über die Fortschritte der Anatomie und Entwicklungsgeschichte,
1895- .

JOURNALS.

- The Anatomical Record, 1906- .
The American Journal of Anatomy, 1901- .
Anatomische Hefte, 1892- .
Anatomischer Anzeiger, 1886- .
Archives d'Anatomie Microscopique, 1897- .
Archiv für Anatomie und Physiologie, 1795- .
Archiv für Entwicklungsmechanik der Organismen, 1894- .
Archiv für Mikroskopische Anatomie, 1865- .
Archivo Italiano di Anatomia e di Embriologia, 1902- .
Biological Bulletin, 1900- .
Brain, 1878- .
Bibliographie Anatomique, 1893- .
Contributions to Embryology, Carnegie Institution of Washington, 1914- .
Comptes Rendus de l'Association des Anatomistes, 1899- .
Gegenbaur's Morphologisches Jahrbuch, 1876- .
International Monatschrift für Anatomie und Histologie, 1884- .
The Journal of Anatomy and Physiology, 1867- .
Journal of Comparative Neurology, 1891- .
Journal de l'Anatomie et de Physiologie, etc., 1864- .
Journal of Experimental Zoölogy, 1904- .
Journal of Morphology, 1887- .
Le Nevraxe, 1900- .
Morphologische Arbeiten, 1892-1898.
Petrus Camper Nederlandsche Bijdragen tot de Anatomie, 1902- .
Proceedings of the Royal Society, Series B.
Quarterly Journal of Microscopical Science, 1853- .
Zeitschrift für Morphologie und Anthropologie, 1899- .
Zeitschrift für Wissenschaftliche Mikroskopie, 1884- .

ANATOMY OF THE HUMAN BODY.

INTRODUCTION.

THE term *human anatomy* comprises a consideration of the various structures which make up the human organism. In a restricted sense it deals merely with the parts which form the fully developed individual and which can be rendered evident to the naked eye by various methods of dissection. Regarded from such a standpoint it may be studied by two methods: (1) the various structures may be separately considered—**systematic anatomy**; or (2) the organs and tissues may be studied in relation to one another—**topographical** or **regional anatomy**.

It is, however, of much advantage to add to the facts ascertained by naked-eye dissection those obtained by the use of the microscope. This introduces two fields of investigation, viz., the study of the minute structure of the various component parts of the body—**histology**—and the study of the human organism in its immature condition, *i. e.*, the various stages of its intrauterine development from the fertilized ovum up to the period when it assumes an independent existence—**embryology**. Owing to the difficulty of obtaining material illustrating all the stages of this early development, gaps must be filled up by observations on the development of lower forms—**comparative embryology**, or by a consideration of adult forms in the line of human ancestry—**comparative anatomy**. The direct application of the facts of human anatomy to the various pathological conditions which may occur constitutes the subject of **applied anatomy**. Finally, the appreciation of structures on or immediately underlying the surface of the body is frequently made the subject of special study—**surface anatomy**.

SYSTEMATIC ANATOMY.—The various systems of which the human body is composed are grouped under the following headings:

1. **Osteology**—the bony system or skeleton.
2. **Syndesmology**—the articulations or joints.
3. **Myology**—the muscles. With the description of the muscles it is convenient to include that of the fasciæ which are so intimately connected with them.
4. **Angiology**—the vascular system, comprising the heart, bloodvessels, lymphatic vessels, and lymph glands.
5. **Neurology**—the nervous system. The organs of sense may be included in this system.
6. **Splanchnology**—the visceral system. Topographically the viscera form two groups, viz., the thoracic viscera and the abdomino-pelvic viscera. The heart, a thoracic viscus, is best considered with the vascular system. The rest

of the viscera may be grouped according to their functions: (a) the **respiratory apparatus**; (b) the **digestive apparatus**; and (c) the **urogenital apparatus**. Strictly speaking, the third subgroup should include only such components of the urogenital apparatus as are included within the abdomino-pelvic cavity, but it is convenient to study under this heading certain parts which lie in relation to the surface of the body, *e. g.*, the testes and the external organs of generation.

For descriptive purposes, the body is supposed to be in the erect posture, with the arms hanging by the sides and the palms of the hands directed forward. The *median plane* is a vertical antero-posterior plane, passing through the center of the trunk. This plane will pass approximately through the sagittal suture of the skull, and hence any plane parallel to it is termed a *sagittal plane*. A vertical plane at right angles to the median plane passes, roughly speaking, through the central part of the coronal suture or through a line parallel to it; such a plane is known as a *frontal plane* or sometimes as a *coronal plane*. A plane at right angles to both the median and frontal planes is termed a *transverse plane*.

The terms *anterior* or *ventral*, and *posterior* or *dorsal*, are employed to indicate the relation of parts to the front or back of the body or limbs, and the terms *superior* or *cephalic*, and *inferior* or *caudal*, to indicate the relative levels of different structures; structures nearer to or farther from the median plane are referred to as *medial* or *lateral* respectively.

The terms *superficial* and *deep* are strictly confined to descriptions of the relative depth from the surface of the various structures; *external* and *internal* are reserved almost entirely for describing the walls of cavities or of hollow viscera. In the case of the limbs the words *proximal* and *distal* refer to the relative distance from the attached end of the limb.

EMBRYOLOGY.

THE term **Embryology**, in its widest sense, is applied to the various changes which take place during the growth of an animal from the egg to the adult condition: it is, however, usually restricted to the phenomena which occur before birth. Embryology may be studied from two aspects: (1) that of **ontogeny**, which deals only with the development of the individual; and (2) that of **phylogeny**, which concerns itself with the evolutionary history of the animal kingdom.

In vertebrate animals the development of a new being can only take place when a female germ cell or **ovum** has been fertilized by a male germ cell or **spermatozoön**. The ovum is a nucleated cell, and all the complicated changes by which the various tissues and organs of the body are formed from it, after it has been fertilized, are the result of two general processes, viz., **segmentation** and **differentiation** of cells. Thus, the fertilized ovum undergoes repeated segmentation into a number of cells which at first closely resemble one another, but are, sooner or later, differentiated into two groups: (1) **somatic cells**, the function of which is to build up the various tissues of the body; and (2) **germinal cells**, which become imbedded in the sexual glands—the ovaries in the female and the testes in the male—and are destined for the perpetuation of the species.

Having regard to the main purpose of this work, it is impossible, in the space available in this section, to describe fully, or illustrate adequately, all the phenomena which occur in the different stages of the development of the human body. Only the principal facts are given, and the student is referred for further details to one or other of the text-books¹ on human embryology.

THE ANIMAL CELL.

All the tissues and organs of the body originate from a microscopic structure (the **fertilized ovum**), which consists of a soft jelly-like material enclosed in a membrane and containing a vesicle or small spherical body inside which are one or more denser spots. This may be regarded as a complete cell. All the solid tissues consist largely of cells essentially similar to it in nature but differing in external form.

In the higher organisms a cell may be defined as “a nucleated mass of protoplasm of microscopic size.” Its two essentials, therefore, are: a soft jelly-like material, similar to that found in the ovum, and usually styled **cytoplasm**, and a small spherical body imbedded in it, and termed a **nucleus**. Some of the unicellular protozoa contain no nuclei but granular particles which, like true nuclei, stain with basic dyes. The other constituents of the ovum, viz., its limiting membrane and the denser spot contained in the nucleus, called the **nucleolus**, are not essential to the type cell, and in fact many cells exist without them.

Cytoplasm (*protoplasm*) is a material probably of variable constitution during life, but yielding on its disintegration bodies chiefly of proteid nature. Lecithin and cholesterin are constantly found in it, as well as inorganic salts, chief among

¹ Manual of Human Embryology, Keibel and Mall; Handbuch der vergleichenden und experimentellen Entwicklungslehre der Wirbeltiere, Oskar Hertwig; Lehrbuch der Entwicklungsgeschichte, Bonnet; The Physiology of Reproduction, Marshall.

which are the phosphates and chlorides of potassium, sodium, and calcium. It is of a semifluid, viscid consistence, and probably colloidal in nature. The living cytoplasm appears to consist of a homogeneous and structureless ground-substance in which are embedded granules of various types. The **mitochondria** are the most constant type of granule and vary in form from granules to rods and threads. Their function is unknown. Some of the granules are proteid in nature and probably essential constituents; others are fat, glycogen, or pigment granules, and are regarded as adventitious material taken in from without, and hence are styled cell-inclusions or **paraplasm**. When, however, cells have been "fixed" by reagents a fibrillar or granular appearance can often be made out under a high power of the microscope. The fibrils are usually arranged in a network or reticulum, to which the term **spongioplasm** is applied, the clear substance in the meshes being termed **hyaloplasm**. The size and shape of the meshes of the spongioplasm vary in different cells and in different parts of the same cell. The relative amounts of spongioplasm and hyaloplasm also vary in different cells, the latter preponderating in the young cell and the former increasing at the expense of the hyaloplasm as the cell grows. Such appearances in fixed cells are no indication whatsoever of the existence of

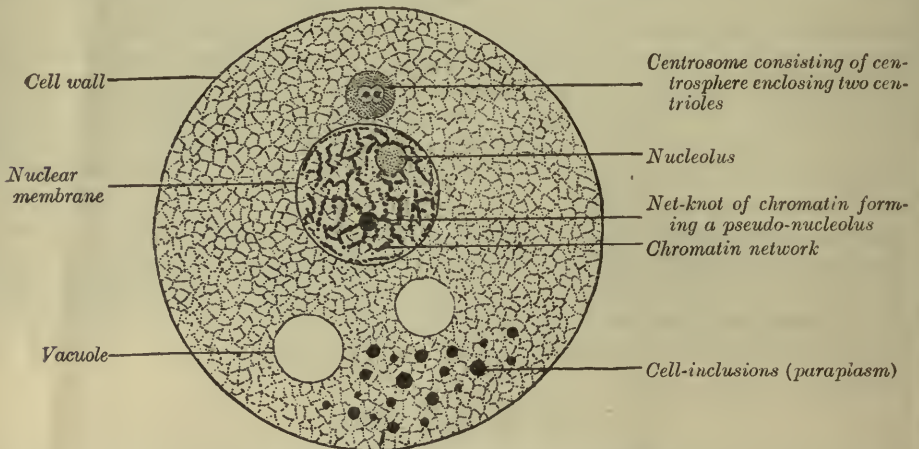


FIG. 1.—Diagram of a cell. (Modified from Wilson.)

similar structures in the living, although there must have been something in the living cell to give rise to the fixed structures. The peripheral layer of a cell is in all cases modified, either by the formation of a definite **cell membrane** as in the ovum, or more frequently in the case of animal cells, by a transformation, probably chemical in nature, which is only recognizable by the fact that the surface of the cell behaves as a semipermeable membrane.

Nucleus.—The nucleus is a minute body, imbedded in the protoplasm, and usually of a spherical or oval form, its size having little relation to that of the cell. It is surrounded by a well-defined wall, the **nuclear membrane**; this encloses the **nuclear substance** (*nuclear matrix*), which is composed of a homogeneous material in which is usually embedded one or two nucleoli. In fixed cells the nucleus seems to consist of a clear substance or **karyoplasm** and a network or **karyomitome**. The former is probably of the same nature as the hyaloplasm of the cell, but the latter, which forms also the wall of the nucleus, differs from the spongioplasm of the cell substance. It consists of fibers or filaments arranged in a reticular manner. These filaments are composed of a homogeneous material known as **linin**, which stains with acid dyes and contains embedded in its substance particles which have a strong affinity for basic dyes. These basophil granules have been named **chromatin**

or **basichromatin** and owe their staining properties to the presence of nucleic acid. Within the nuclear matrix are one or more highly refracting bodies, termed **nucleoli**, connected with the nuclear membrane by the nuclear filaments. They are regarded as being of two kinds. Some are mere local condensations ("net-knots") of the chromatin; these are irregular in shape and are termed **pseudo-nucleoli**; others are distinct bodies differing from the pseudo-nucleoli both in nature and chemical composition; they may be termed **true nucleoli**, and are usually found in resting cells. The true nucleoli are oxyphil, *i. e.*, they stain with acid dyes.

Most living cells contain, in addition to their protoplasm and nucleus, a small particle which usually lies near the nucleus and is termed the **centrosome**. In the middle of the centrosome is a minute body called the **centriole**, and surrounding this is a clear spherical mass known as the **centrosphere**. The protoplasm surrounding the centrosphere is frequently arranged in radiating fibrillar rows of granules, forming what is termed the **attraction sphere**.

Reproduction of Cells.—Reproduction of cells is effected either by **direct** or by **indirect division**. In reproduction by **direct division** the nucleus becomes constricted in its center, assuming an hour-glass shape, and then divides into two. This is followed by a cleavage or division of the whole protoplasmic mass of the cell; and thus two daughter cells are formed, each containing a nucleus. These daughter cells are at first smaller than the original mother cell; but they grow, and the process may be repeated in them, so that multiplication may take place rapidly. **Indirect division** or **karyokinesis** (*karyomitosis*) has been observed in all the tissues—generative cells, epithelial tissue, connective tissue, muscular tissue, and nerve tissue. It is possible that cell division may always take place by the indirect method.

The process of indirect cell division is characterized by a series of complex changes in the nucleus, leading to its subdivision; this is followed by cleavage of the cell protoplasm. Starting with the nucleus in the quiescent or **resting stage**, these changes may be briefly grouped under the four following phases (Fig. 2).

1. **Prophase.**—The nuclear network of chromatin filaments assumes the form of a twisted *skein* or *spirem*, while the nuclear membrane and nucleolus disappear. The convoluted skein of chromatin divides into a definite number of V-shaped segments or **chromosomes**. The number of chromosomes varies in different animals, but is constant for all the cells in an animal of any given species; in man the number is given by Flemming and Duesberg as twenty-four.¹ Coincidentally with or preceding these changes the centriole, which usually lies by the side of the nucleus, undergoes subdivision, and the two resulting centrioles, each surrounded by a centrosphere, are seen to be connected by a spindle of delicate achromatic fibers the **achromatic spindle**. The centrioles move away from each other—one toward either extremity of the nucleus—and the fibrils of the achromatic spindle are correspondingly lengthened. A line encircling the spindle midway between its extremities or **poles** is named the **equator**, and around this the V-shaped chromosomes arrange themselves in the form of a star, thus constituting the **mother star** or **monaster**.

2. **Metaphase.**—Each V-shaped chromosome now undergoes longitudinal cleavage into two equal parts or **daughter chromosomes**, the cleavage commencing at the apex of the V and extending along its divergent limbs.

3. **Anaphase.**—The daughter chromosomes, thus separated, travel in opposite directions along the fibrils of the achromatic spindle toward the centrioles, around which they group themselves, and thus two star-like figures are formed, one at either pole of the achromatic spindle. This constitutes the **diaster**. The daughter chromosomes now arrange themselves into a *skein* or *spirem*, and eventually form the network of chromatin which is characteristic of the resting nucleus.

4. **Telophase.**—The cell protoplasm begins to appear constricted around the equator of the achromatic spindle, where double rows of granules are also sometimes seen. The constriction deepens and the original cell gradually becomes divided into two new cells, each with its own nucleus and centrosome, which assume the ordinary positions occupied by such structures in the resting stage. The nuclear membrane and nucleolus are also differentiated during this phase.

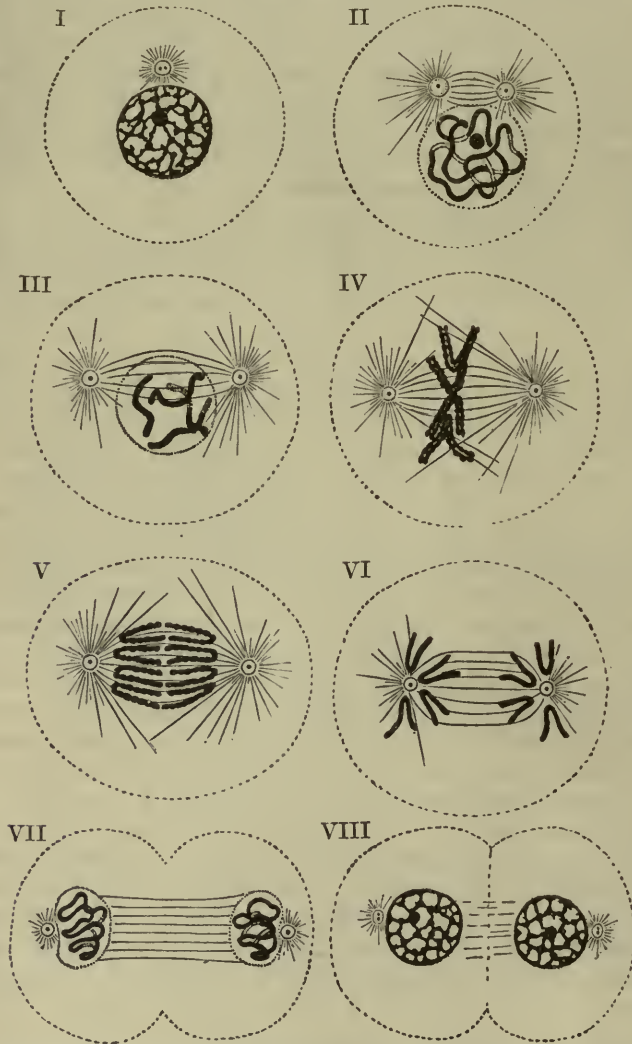


FIG. 2.—Diagram showing the changes which occur in the centrosomes and nucleus of a cell in the process of mitotic division. (Schäfer.) I to III, prophase; IV, metaphase; V and VI, anaphase; VII and VIII, telophase.

THE OVUM.

The ova are developed from the primitive germ cells which are imbedded in the substance of the ovaries. Each primitive germ cell gives rise, by repeated divisions, to a number of smaller cells termed **oögonia**, from which the **ova** or **primary oöcytes** are developed.

Human ova are extremely minute, measuring about 0.2 mm. in diameter, and are enclosed within the egg follicles of the ovaries; as a rule each follicle contains

a single ovum, but sometimes two or more are present.¹ By the enlargement and subsequent rupture of a follicle at the surface of the ovary, an ovum is liberated and conveyed by the uterine tube to the cavity of the uterus. Unless it be fertilized it undergoes no further development and is discharged from the uterus, but if fertilization take place it is retained within the uterus and is developed into a new being.

In appearance and structure the ovum (Fig. 3) differs little from an ordinary cell, but distinctive names have been applied to its several parts; thus, the cell substance is known as the **yolk** or **oöplasm**, the nucleus as the **germinal vesicle**, and the nucleolus as the **germinal spot**. The ovum is enclosed within a thick, trans-




FIG. 3.—Human ovum examined fresh in the liquor folliculi. (Waldeyer.) The zona pellucida is seen as a thick clear girdle surrounded by the cells of the corona radiata. The egg itself shows a central granular deutoplasmic area and a peripheral clear layer, and encloses the germinal vesicle, in which is seen the germinal spot.

parent envelope, the **zona striata** or **zona pellucida**, adhering to the outer surface of which are several layers of cells, derived from those of the follicle and collectively constituting the **corona radiata**.

Yolk.—The yolk comprises (1) the **cytoplasm** of the ordinary animal cell with its spongioplasm and hyaloplasm; this is frequently termed the **formative yolk**; (2) the **nutritive yolk** or **deutoplasm**, which consists of numerous rounded granules of fatty and albuminoid substances imbedded in the cytoplasm. In the mammalian ovum the nutritive yolk is extremely small in amount, and is of service in nourish-

ing the embryo in the early stages of its development only, whereas in the egg of the bird there is sufficient to supply the chick with nutriment throughout the whole period of incubation. The nutritive yolk not only varies in amount, but in its mode of distribution within the egg; thus, in some animals it is almost uniformly distributed throughout the cytoplasm; in some it is centrally placed and is surrounded by the cytoplasm; in others it is accumulated at the lower pole of the ovum, while the cytoplasm occupies the upper pole. A **centrosome** and **centriole** are present and lie in the immediate neighborhood of the nucleus.

Germinal Vesicle.—The germinal vesicle or nucleus is a large spherical body which at first occupies a nearly central position, but becomes eccentric as the growth of the ovum proceeds. Its structure is that of an ordinary cell-nucleus, viz., it consists of a reticulum or karyomitome, the meshes of which are filled with karyoplasm, while connected with, or imbedded in, the reticulum are a number of chromatin masses or chromosomes, which may present the appearance of a skein or may assume the form of rods or loops. The nucleus is enclosed by a delicate nuclear membrane, and contains in its interior a well-defined nucleolus or germinal spot.

Coverings of the Ovum.—The **zona striata** or **zona pellucida** (Fig. 3) is a thick membrane, which, under the higher powers of the microscope, is seen to be radially striated. It persists for some time after fertilization has occurred, and may serve for protection during the earlier stages of segmentation. It is not yet determined whether the **zona striata** is a product of the cytoplasm of the ovum or of the cells of the **corona radiata**, or both.

The **corona radiata** (Fig. 3) consists of two or three strata of cells; they are derived from the cells of the follicle, and adhere to the outer surface of the **zona striata** when the ovum is set free from the follicle; the cells are radially arranged around the **zona**, those of the innermost layer being columnar in shape. The cells of the **corona radiata** soon disappear; in some animals they secrete, or are replaced by, a layer of adhesive protein, which may assist in protecting and nourishing the ovum.

The phenomena attending the discharge of the ova from the follicles belong more to the ordinary functions of the ovary than to the general subject of embryology, and are therefore described with the anatomy of the ovaries.¹

Maturation of the Ovum.—Before an ovum can be fertilized it must undergo a process of **maturation** or **ripening**. This takes place previous to or immediately after its escape from the follicle, and consists essentially of an unequal subdivision of the ovum (Fig. 4) first into two and then into four cells. Three of the four cells are small, incapable of further development, and are termed **polar bodies** or **polocytes**, while the fourth is large, and constitutes the **mature ovum**. The process of maturation has not been observed in the human ovum, but has been carefully studied in the ova of some of the lower animals, to which the following description applies.

It was pointed out on page 37 that the number of chromosomes found in the nucleus is constant for all the cells in an animal of any given species, and that in man the number is probably twenty-four. This applies not only to the somatic cells but to the primitive ova and their descendants. For the purpose of illustrating the process of maturation a species may be taken in which the number of nuclear chromosomes is four (Fig. 5). If an ovum from such be observed at the beginning of the maturation process it will be seen that the number of its chromosomes is apparently reduced to two. In reality, however, the number is doubled, since each chromosome consists of four granules grouped to form a **tetrad**. During the metaphase (see page 37) each tetrad divides into two **dyads**, which are equally

¹ See description of the ovary on a future page.

distributed between the nuclei of the two cells formed by the first division of the ovum. One of the cells is almost as large as the original ovum, and is named the **secondary oöcyte**; the other is small, and is termed the **first polar body**. The

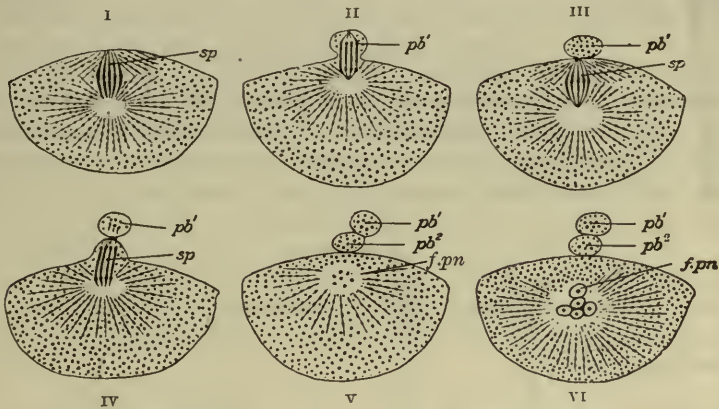


FIG. 4.—Formation of polar bodies in *Asterias glacialis*. (Slightly modified from Hertwig.) In I the polar spindle (*sp*) has advanced to the surface of the egg. In II a small elevation (*pb*¹) is formed which receives half of the spindle. In III the elevation is constricted off, forming the first polar body (*pb*¹), and a second spindle is formed. In IV is seen a second elevation which in V has been constricted off as the second polar body (*pb*²). Out of the remainder of the spindle (*f.pn* in VI) the female pronucleus is developed.

secondary oöcyte now undergoes subdivision, during which each dyad divides and contributes a single chromosome to the nucleus of each of the two resulting cells.

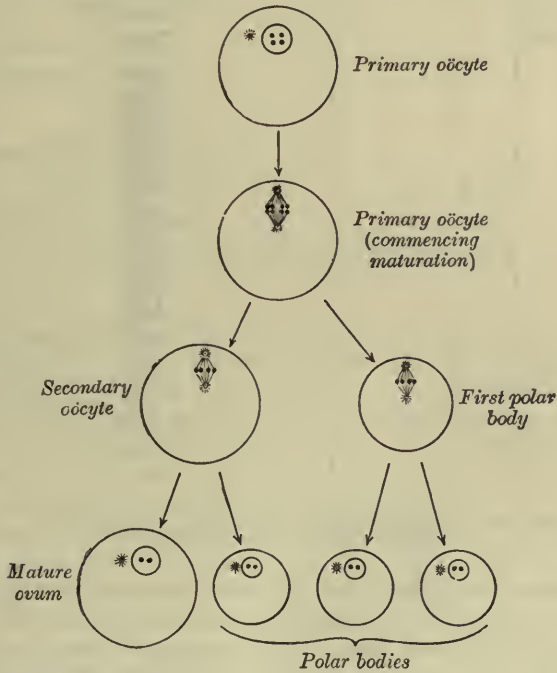


FIG. 5.—Diagram showing the reduction in number of the chromosomes in the process of maturation of the ovum.

This second division is also unequal, producing a large cell which constitutes the **mature ovum**, and a small cell, the **second polar body**. The first polar body frequently divides while the second is being formed, and as a final result four cells

are produced, viz., the mature ovum and three polar bodies, each of which contains two chromosomes, *i. e.*, one-half the number present in the nuclei of the somatic cells of members of the same species. The nucleus of the mature ovum is termed the **female pronucleus**.

THE SPERMATOZOÖN.

The **spermatozoa** or **male germ cells** are developed in the testes and are present in enormous numbers in the seminal fluid. Each consists of a small but greatly modified cell. The human spermatozoön possesses a **head**, a **neck**, a **connecting piece** or **body**, and a **tail** (Fig. 6).

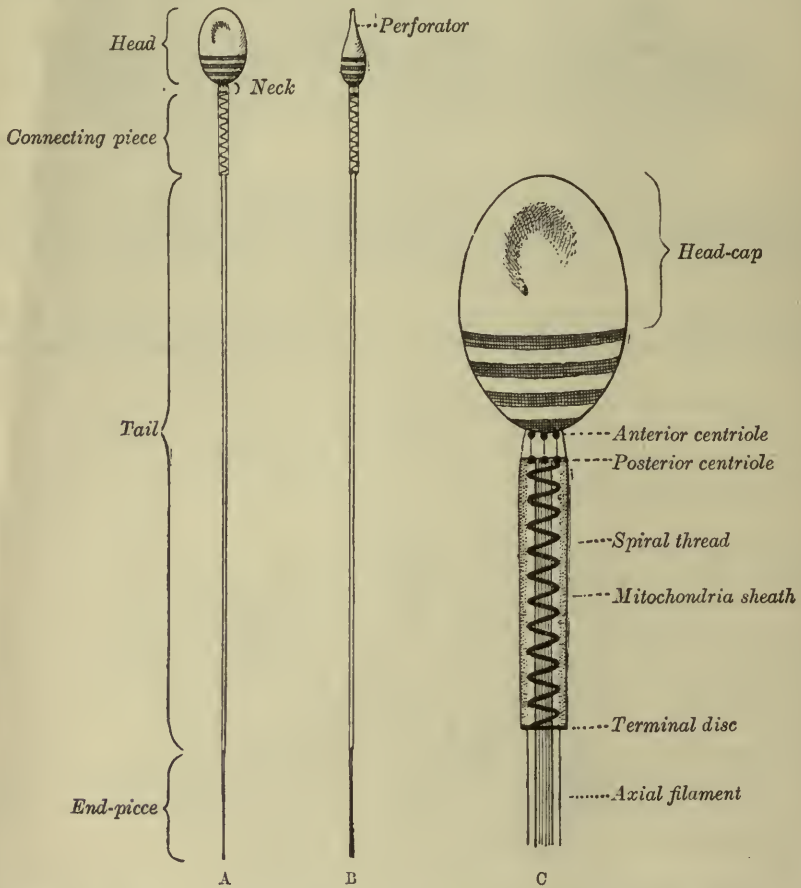


FIG. 6.—Human spermatozoön. Diagrammatic. A. Surface view. B. Profile view. In C the head, neck, and connecting piece are more highly magnified.

The **head** is oval or elliptical, but flattened, so that when viewed in profile it is pear-shaped. Its anterior two-thirds are covered by a layer of modified protoplasm, which is named the **head-cap**. This, in some animals, *e. g.*, the salamander, is prolonged into a barbed spear-like process or **perforator**, which probably facilitates the entrance of the spermatozoön into the ovum. The posterior part of the head exhibits an affinity for certain reagents, and presents a transversely striated appearance, being crossed by three or four dark bands. In some animals a central rod-like filament extends forward for about two-thirds of the length of the head, while in others a rounded body is seen near its center. The head contains a mass of

chromatin, and is generally regarded as the nucleus of the cell surrounded by a thin envelope.

The **neck** is less constricted in the human spermatozoön than in those of some of the lower animals. The **anterior centriole**, represented by two or three rounded particles, is situated at the junction of the head and neck, and behind it is a band of homogeneous substance.

The **connecting piece** or **body** is rod-like, and is limited behind by a *terminal disk*. The **posterior centriole** is placed at the junction of the body and neck and, like the anterior, consists of two or three rounded particles. From this centriole an **axial filament**, surrounded by a sheath, runs backward through the body and tail. In the body the sheath of the axial filament is encircled by a **spiral thread**, around which is an envelope containing mitochondria granules, and termed the **mitochondria sheath**.

The **tail** is of great length, and consists of the axial thread or filament, surrounded by its sheath, which may contain a spiral thread or may present a striated appearance. The terminal portion or **end-piece** of the tail consists of the axial filament only.

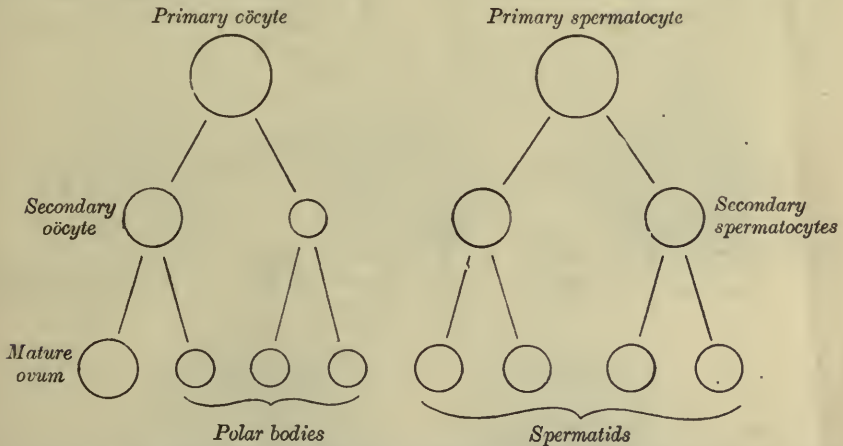


FIG. 7.—Scheme showing analogies in the process of maturation of the ovum and the development of the spermatids (young spermatozoa).

Krause gives the length of the human spermatozoön as between 52μ and 62μ , the head measuring 4 to 5μ , the connecting piece 6μ , and the tail from 41μ to 52μ .

By virtue of their tails, which act as propellers, the spermatozoa are capable of free movement, and if placed in favorable surroundings, *e. g.*, in the female passages, will retain their vitality and power of fertilizing for several days. In certain animals, *e. g.*, bats, it has been proved that spermatozoa retained in the female passages for several months are capable of fertilizing.

The spermatozoa are developed from the primitive germ cells which have become imbedded in the testes, and the stages of their development are very similar to those of the maturation of the ovum. The primary germ cells undergo division and produce a number of cells termed **spermatogonia**, and from these the **primary spermatocytes** are derived. Each primary spermatocyte divides into two **secondary spermatocytes**, and each secondary spermatocyte into two **spermatids** or young spermatozoa; from this it will be seen that a primary spermatocyte gives rise to *four* spermatozoa. On comparing this process with that of the maturation of the ovum (Fig. 7) it will be observed that the primary spermatocyte gives rise to two cells, the secondary spermatocytes, and the primary oöcyte to two cells, the secondary oöcyte and the first polar body. Again, the two secondary sperma-

toocytes by their subdivision give origin to four spermatozoa, and the secondary oöcyte and first polar body to four cells, the mature ovum and three polar bodies. In the development of the spermatozoa, as in the maturation of the ovum, there is a reduction of the nuclear chromosomes to one-half of those present in the primary spermatocyte. But here the similarity ends, for it must be noted that the four spermatozoa are of equal size, and each is capable of fertilizing a mature ovum, whereas the three polar bodies are not only very much smaller than the mature ovum but are incapable of further development, and may be regarded as abortive ova.

FERTILIZATION OF THE OVUM.

Fertilization consists in the union of the spermatozöon with the mature ovum (Fig. 8). Nothing is known regarding the fertilization of the human ovum, but

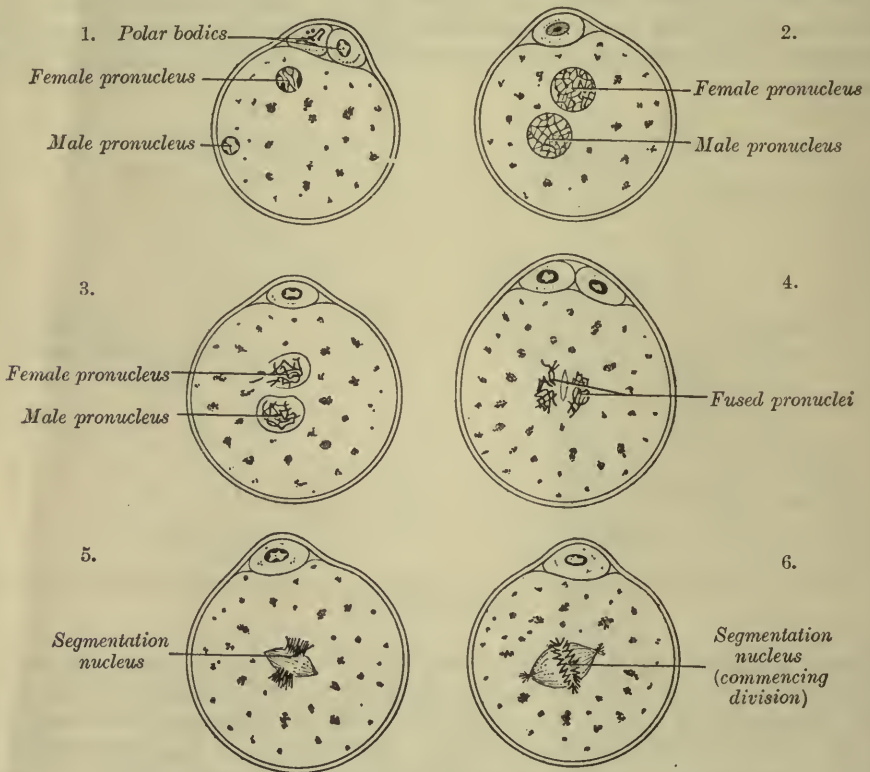


FIG. 8.—The process of fertilization in the ovum of a mouse. (After Sobotta.)

the various stages of the process have been studied in other mammals, and from the knowledge so obtained it is believed that fertilization of the human ovum takes place in the lateral or ampullary part of the uterine tube, and the ovum is then conveyed along the tube to the cavity of the uterus—a journey probably occupying seven or eight days and during which the ovum loses its corona radiata and zona striata and undergoes segmentation. Sometimes the fertilized ovum is arrested in the uterine tube, and there undergoes development, giving rise to a *tubal pregnancy*; or it may fall into the abdominal cavity and produce an *abdominal pregnancy*. Occasionally the ovum is not expelled from the follicle when the latter ruptures, but is fertilized within the follicle and produces what is known as an *ovarian pregnancy*. Under normal conditions only one spermatozöon enters the yolk and takes part in the process of fertilization. At the point where the sperma

tozoön is about to pierce, the yolk is drawn out into a conical elevation, termed the **cone of attraction**. As soon as the spermatozoön has entered the yolk, the peripheral portion of the latter is transformed into a membrane, the **vitelline membrane** which prevents the passage of additional spermatozoa. Occasionally a second spermatozoön may enter the yolk, thus giving rise to a condition of *polyspermy*: when this occurs the ovum usually develops in an abnormal manner and gives rise to a monstrosity. Having pierced the yolk, the spermatozoön loses its tail, while its head and connecting piece assume the form of a nucleus containing a cluster of chromosomes. This constitutes the **male pronucleus**, and associated with it there are a centriole and centrosome. The male pronucleus passes more deeply into the yolk, and coincidentally with this the granules of the cytoplasm surrounding it become radially arranged. The male and female pronuclei migrate toward each other, and, meeting near the center of the yolk, fuse to form a new nucleus, the **segmentation nucleus**, which therefore contains both male and female nuclear substance; the former transmits the individualities of the male ancestors, the latter those of the female ancestors, to the future embryo. By the union of the male and female pronuclei the number of chromosomes is restored to that which is present in the nuclei of the somatic cells.

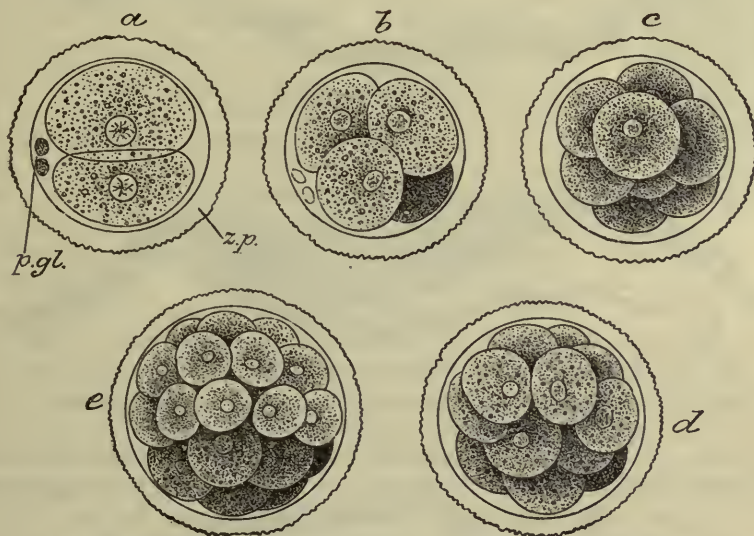


FIG. 9.—First stages of segmentation of a mammalian ovum. Semidiagrammatic. (From a drawing by Allen Thomson.) z.p. Zona striata. p.gl. Polar bodies. a. Two-cell stage. b. Four-cell stage. c. Eight-cell stage. d, e. Morula stage.

SEGMENTATION OF THE FERTILIZED OVUM.

The early segmentation of the human ovum has not yet been observed, but judging from what is known to occur in other mammals it may be regarded as certain that the process starts immediately after the ovum has been fertilized, *i. e.*, while the ovum is in the uterine tube. The segmentation nucleus exhibits the usual mitotic changes, and these are succeeded by a division of the ovum into two cells of nearly equal size.¹ The process is repeated again and again, so that

¹ In the mammalian ova the nutritive yolk or deutoplasm is small in amount and uniformly distributed throughout the cytoplasm; such ova undergo complete division during the process of segmentation, and are therefore termed *holoblastic*. In the ova of birds, reptiles, and fishes where the nutritive yolk forms by far the larger portion of the egg, the cleavage is limited to the formative yolk, and is therefore only *partial*; such ova are termed *meroblastic*. Again, it has been observed, in some of the lower animals, that the pronuclei do not fuse but merely lie in apposition. At the commencement of the segmentation process the chromosomes of the two pronuclei group themselves around the equator of the spindle, and then divide; an equal number of male and female chromosomes travel to the opposite poles of the spindle, and thus the male and female pronuclei contribute equal shares of chromatin to the nuclei of the two cells which result from the subdivision of the fertilized ovum.

the two cells are succeeded by four, eight, sixteen, thirty-two, and so on, with the result that a mass of cells is found within the zona striata, and to this mass the term **morula** is applied (Fig. 9). The segmentation of the mammalian ovum may not take place in the regular sequence of two, four, eight, etc., since one of the two first formed cells may subdivide more rapidly than the other, giving rise to a three- or a five-cell stage. The cells of the morula are at first closely aggregated, but soon they become arranged into an outer or peripheral layer, the **trophoblast**, which

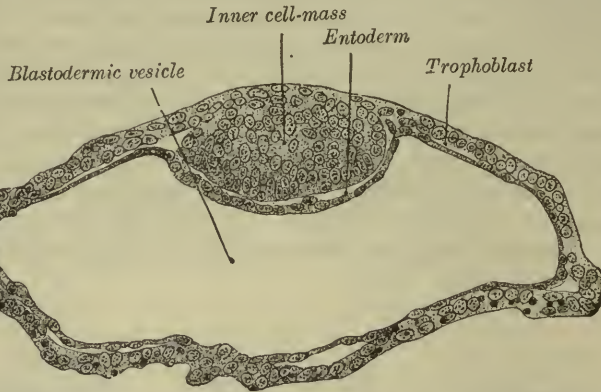


FIG. 10.—Blastodermic vesicle of *Vespertilio murinus*. (After van Beneden.)

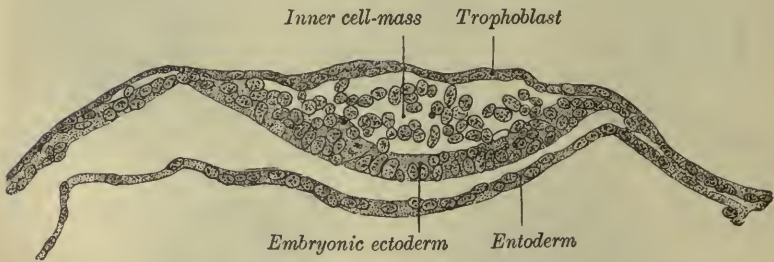


FIG. 11.—Section through embryonic disk of *Vespertilio murinus*. (After van Beneden.)

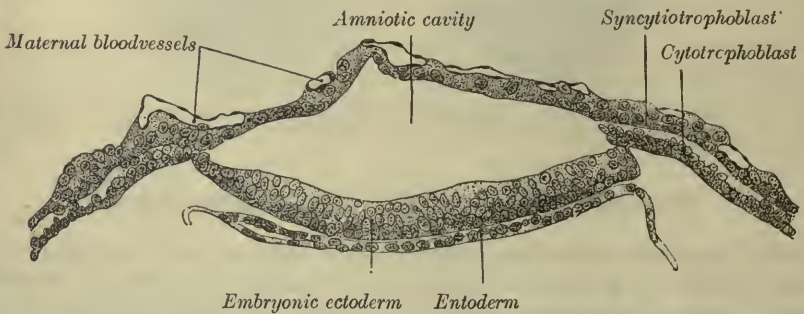


FIG. 12.—Section through embryonic area of *Vespertilio murinus* to show the formation of the amniotic cavity. (After van Beneden.)

does not contribute to the formation of the embryo proper, and an **inner cell-mass**, from which the embryo is developed. Fluid collects between the trophoblast and the greater part of the inner cell-mass, and thus the morula is converted into a vesicle, the **blastodermic vesicle** (Fig. 10). The inner cell-mass remains in contact, however, with the trophoblast at one pole of the ovum; this is named the **embryonic pole**, since it indicates the situation where the future embryo will be developed. The cells of the trophoblast become differentiated into two strata: an

outer, termed the **syncytium** or **syncytiotrophoblast**, so named because it consists of a layer of protoplasm studded with nuclei, but showing no evidence of subdivision into cells; and an inner layer, the **cytotrophoblast** or **layer of Langhans**, in which the cell outlines are defined. As already stated, the cells of the trophoblast do not contribute to the formation of the embryo proper; they form the ectoderm of the chorion and play an important part in the development of the placenta. On the deep surface of the inner cell-mass a layer of flattened cells, the **entoderm**, is differentiated and quickly assumes the form of a small sac, the **yolk-sac**. Spaces appear between the remaining cells of the mass (Fig. 11), and by the enlargement and coalescence of these spaces a cavity, termed the **amniotic cavity** (Fig. 12), is gradually developed. The floor of this cavity is formed by the **embryonic disk** composed of a layer of prismatic cells, the **embryonic ectoderm**, derived from the inner cell-mass and lying in apposition with the entoderm.

The Primitive Streak; Formation of the Mesoderm.—The embryonic disk becomes oval and then pear-shaped, the wider end being directed forward. Near the narrow, posterior end an opaque streak, the **primitive streak** (Figs. 13 and 14), makes its appearance and extends along the middle of the disk for about one-half of its length; at the anterior end of the streak there is a knob-like thickening termed **Hensen's knot**. A shallow groove, the **primitive groove**, appears on the surface of the streak, and the anterior end of this groove communicates by means of an aperture, the **blastophore**, with the yolk-sac. The primitive streak is produced by a thickening of the axial part of the ectoderm, the cells of which multiply, grow downward, and blend with those of the subjacent entoderm (Fig. 15). From the sides of the primitive streak a third layer of cells, the **mesoderm**, extends lateralward between the ectoderm and entoderm; the caudal end of the primitive streak forms the cloacal membrane.

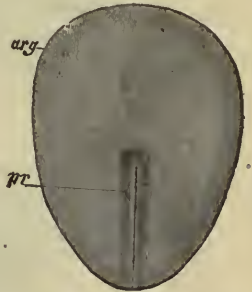


FIG. 13.—Surface view of embryo of a rabbit. (After Kölliker.) *arg.* Embryonic disk. *pr.* Primitive streak.

The extension of the mesoderm takes place throughout the whole of the embryonic and extra-embryonic areas of the ovum, except in certain regions. One of these is seen immediately in front of the neural tube. Here the mesoderm extends forward in the form of two crescentic masses, which meet in the middle line so as to enclose behind them an area which is devoid of mesoderm. Over this area the ectoderm and entoderm come into direct contact with each other and constitute a thin membrane, the **buccopharyngeal membrane**, which forms a septum between the primitive mouth and pharynx. In front of the buccopharyngeal area, where the lateral crescents of mesoderm fuse in the middle line, the pericardium is afterward developed, and this region is therefore designated the **pericardial area**. A second region where the mesoderm is absent, at least for a time, is that immediately in front of the pericardial area. This is termed the **proamniotic area**, and is the region where the **proamnion** is developed; in man, however, a proamnion is apparently never formed. A third region is at the hind end of the embryo where the ectoderm and entoderm come into apposition and form the **cloacal membrane**.

The blastoderm now consists of three layers, named from without inward: ectoderm, mesoderm, and entoderm; each has distinctive characteristics and gives rise to certain tissues of the body.¹

Ectoderm.—The ectoderm consists of columnar cells, which are, however, somewhat flattened or cubical toward the margin of the embryonic disk. It forms the whole of the nervous system, the epidermis of the skin, the lining cells of the sebaceous,

¹ The mode of formation of the germ layers in the human ovum has not yet been observed; in the youngest known human ovum (viz., that described by Bryce and Teacher), all three layers are already present and the mesoderm is split into its two layers. The extra-embryonic celom is of considerable size, and scattered mesodermal strands are seen stretching between the mesoderm of the yolk-sac and that of the chorion.

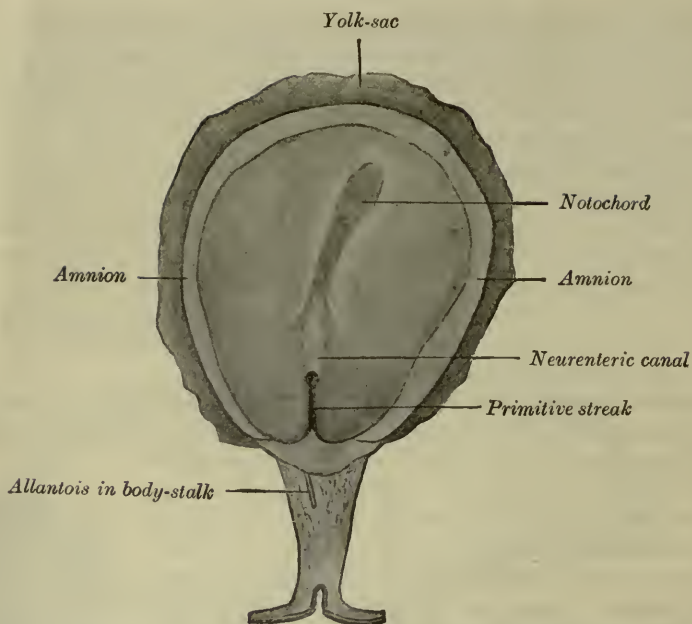


FIG. 14.—Surface view of embryo of *Hylobates concolor*. (After Selenka.) The amnion has been opened to expose the embryonic disk.

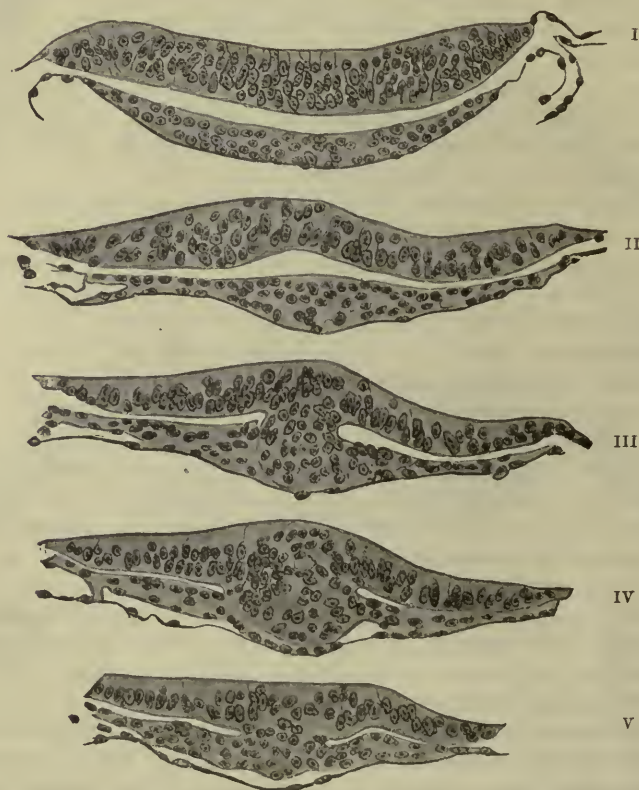


FIG. 15.—Series of transverse sections through the embryonic disk of *Tarsius*. (After Hubrecht.) Section *I* passes through the disk, in front of Hensen's knot and shows only the ectoderm and entoderm. Sections *II*, *III*, and *IV* pass through Hensen's knot, which is seen in *V* tapering away into the primitive streak. In *III*, *IV*, and *V* the mesoderm is seen springing from the keel-like thickening of the ectoderm, which in *III* and *IV* is observed to be continuous into the entoderm.

sudoriferous, and mammary glands, the hairs and nails, the epithelium of the nose and adjacent air sinuses, and that of the cheeks and roof of the mouth. From it also are derived the enamel of the teeth, and the anterior lobe of the hypophysis cerebri, the epithelium of the cornea, conjunctiva, and lacrimal glands, and the neuro-epithelium of the sense organs.

Entoderm.—The entoderm consists at first of flattened cells, which subsequently become columnar. It forms the epithelial lining of the whole of the digestive tube excepting part of the mouth and pharynx and the terminal part of the rectum (which are lined by involutions of the ectoderm), the lining cells of all the glands which open into the digestive tube, including those of the liver and pancreas,

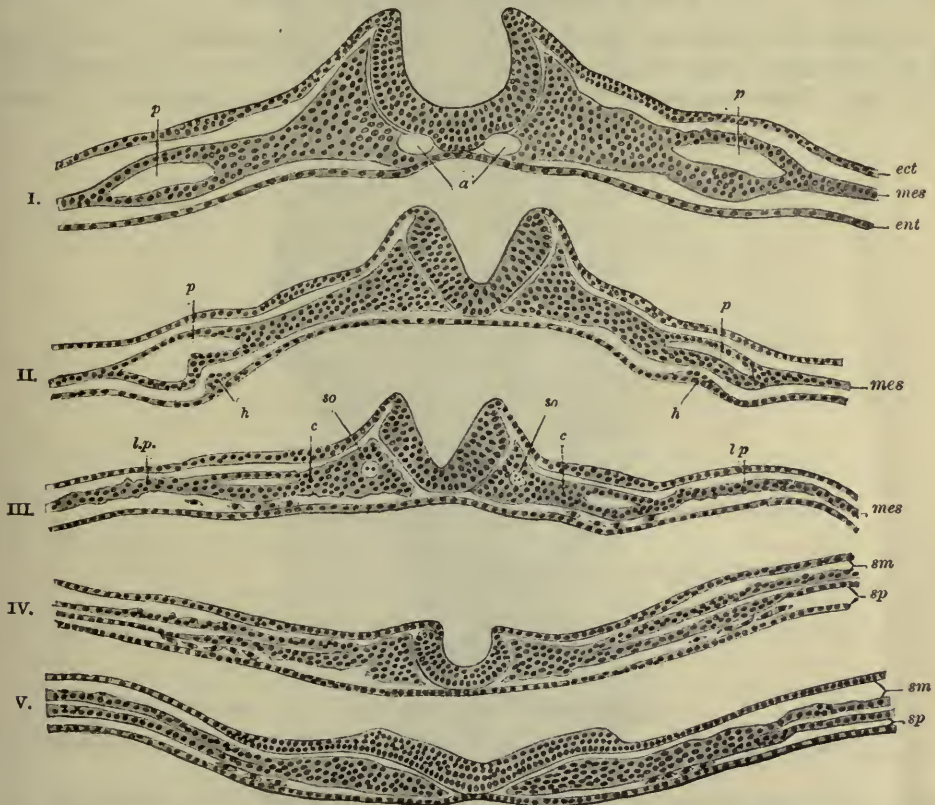


FIG. 16.—A series of transverse sections through an embryo of the dog. (After Bonnet.) Section I is the most anterior. In V the neural plate is spread out nearly flat. The series shows the uprising of the neural folds to form the neural canal. *a*. Aortæ. *c*. Intermediate cell mass. *ect*. Ectoderm. *ent*. Entoderm. *h, h*. Rudiments of endothelial heart tubes. In III, IV, and V the scattered cells represented between the entoderm and splanchnic layer of mesoderm are the vasoformative cells which give origin in front, according to Bonnet, to the heart tubes, *h*; *l.p.* Lateral plate still undivided in I, II, and III; in IV and V split into somatic (*sm*) and splanchnic (*sp*) layers of mesoderm. *mes*. Mesoderm. *p*. Pericardium. *so*. Primitive segment.

the epithelium of the auditory tube and tympanic cavity, of the trachea, bronchi, and air cells of the lungs, of the urinary bladder and part of the urethra, and that which lines the follicles of the thyroid gland and thymus.

Mesoderm.—The mesoderm consists of loosely arranged branched cells surrounded by a considerable amount of intercellular fluid. From it the remaining tissues of the body are developed. The endothelial lining of the heart and blood-vessels and the blood corpuscles are, however, regarded by some as being of entodermal origin.

As the mesoderm develops between the ectoderm and entoderm it is separated into lateral halves by the neural tube and notochord, presently to be described. A

longitudinal groove appears on the dorsal surface of either half and divides it into a medial column, the **paraxial mesoderm**, lying on the side of the neural tube, and a lateral portion, the **lateral mesoderm**. The mesoderm in the floor of the groove connects the paraxial with the lateral mesoderm and is known as the **intermediate cell-mass**; in it the genito-urinary organs are developed. The lateral mesoderm splits into two layers, an outer or **somatic**, which becomes applied to the inner surface of the ectoderm, and with it forms the **somatopleure**; and an inner or **splanchnic**, which adheres to the entoderm, and with it forms the **splanchnopleure** (Fig. 16). The space between the two layers of the lateral mesoderm is termed the **celom**.

THE NEURAL GROOVE AND TUBE.

In front of the primitive streak two longitudinal ridges, caused by a folding up of the ectoderm, make their appearance, one on either side of the middle line (Fig. 16). These are named the **neural folds**; they commence some little distance

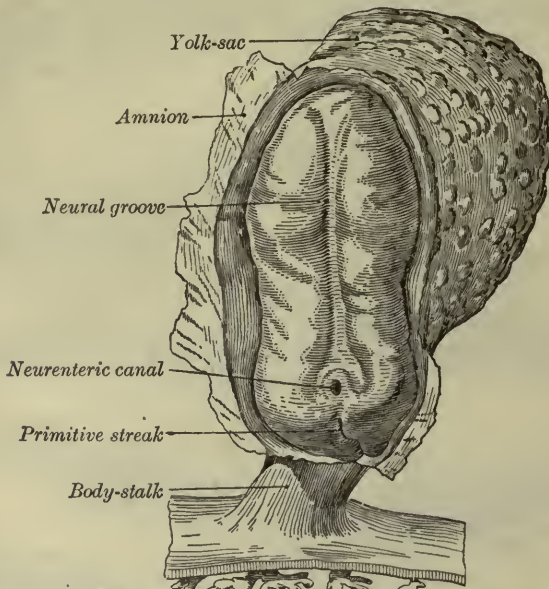


FIG. 17.—Human embryo—length, 2 mm. Dorsal view, with the amnion laid open. $\times 30$. (After Graf Spee.)

behind the anterior end of the embryonic disk, where they are continuous with each other, and from there gradually extend backward, one on either side of the anterior end of the primitive streak. Between these folds is a shallow median groove, the **neural groove** (Figs. 16, 17). The groove gradually deepens as the neural folds become elevated, and ultimately the folds meet and coalesce in the middle line and convert the groove into a closed tube, the **neural tube** or **canal** (Fig. 18), the ectodermal wall of which forms the rudiment of the nervous system. After the coalescence of the neural folds over the anterior end of the primitive streak, the blastopore no longer opens on the surface but into the closed canal of the neural tube, and thus a transitory communication, the **neurenteric canal**, is established between the neural tube and the primitive digestive tube. The coalescence of the neural folds occurs first in the region of the hind-brain, and from there extends forward and backward; toward the end of the third week the front opening (anterior neuropore) of the tube finally closes at the anterior end of the future brain, and forms a recess which is in contact, for a time, with the overlying ectoderm; the hinder part of the neural groove presents for a time a rhomboidal shape, and to this

expanded portion the term *sinus rhomboidalis* has been applied (Fig. 18). Before the neural groove is closed a ridge of ectodermal cells appears along the prominent margin of each neural fold; this is termed the **neural crest** or **ganglion ridge**, and from it the spinal and cranial nerve ganglia and the ganglia of the sympathetic nervous system are developed. By the upward growth of the mesoderm the neural tube is ultimately separated from the overlying ectoderm.

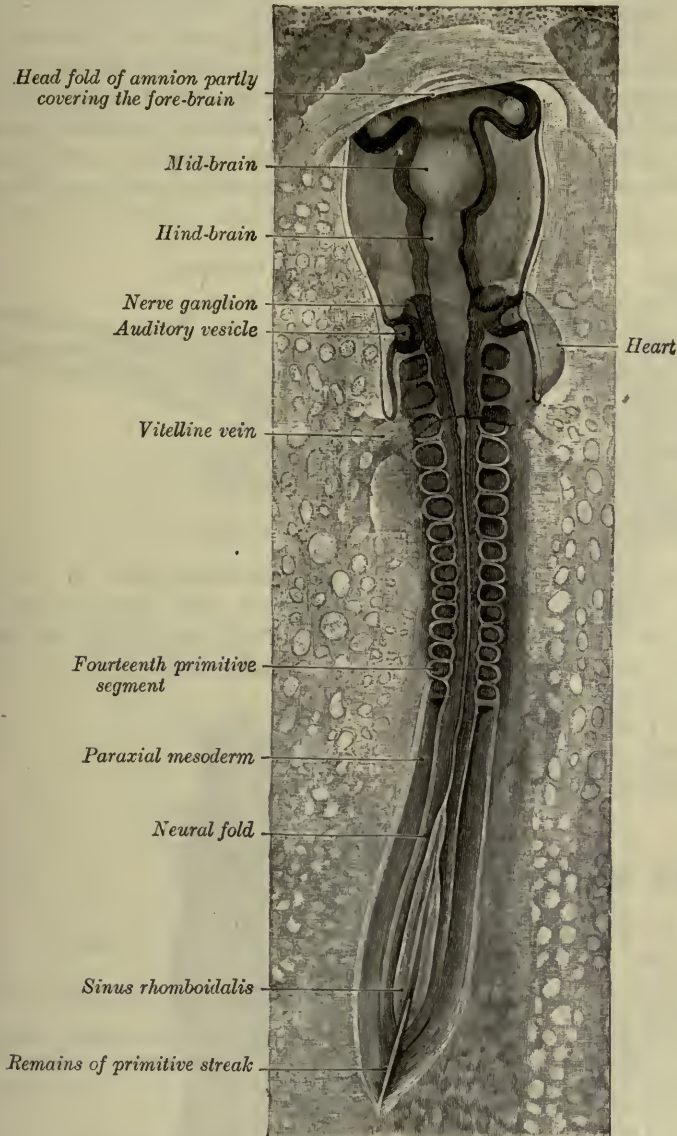


FIG. 18.—Chick embryo of thirty-three hours' incubation, viewed from the dorsal aspect. $\times 30$.
(From Duval's "Atlas d'Embryologie.")

The cephalic end of the neural groove exhibits several dilatations, which, when the tube is closed, assume the form of three vesicles; these constitute the three primary cerebral vesicles, and correspond respectively to the future **fore-brain** (*prosencephalon*), **mid-brain** (*mesencephalon*), and **hind-brain** (*rhombencephalon*) (Fig. 18). The walls of the vesicles are developed into the nervous tissue and neuroglia of the brain, and their cavities are modified to form its ventricles. The remainder

of the tube forms the **medulla spinalis** or **spinal cord**; from its ectodermal wall the nervous and neuroglial elements of the medulla spinalis are developed while the cavity persists as the central canal.

THE NOTOCHORD.

The notochord (Fig. 19) consists of a rod of cells situated on the ventral aspect of the neural tube; it constitutes the foundation of the axial skeleton, since around it the segments of the vertebral column are formed. Its appearance synchronizes with that of the neural tube. On the ventral aspect of the neural groove an axial thickening of the entoderm takes place; this thickening assumes the appearance of a furrow—the **chordal furrow**—the margins of which come into contact, and so convert it into a solid rod of cells—the **notochord**—which is then separated from the entoderm. It extends throughout the entire length of the future vertebral

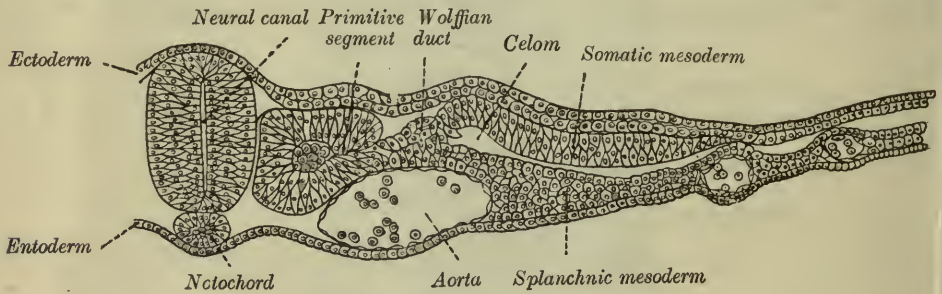


FIG. 19.—Transverse section of a chick embryo of forty-five hours' incubation. (Balfour.)

column, and reaches as far as the anterior end of the mid-brain, where it ends in a hook-like extremity in the region of the future dorsum sellæ of the sphenoid bone. It lies at first between the neural tube and the entoderm of the yolk-sac, but soon becomes separated from them by the mesoderm, which grows medialward and surrounds it. From the mesoderm surrounding the neural tube and notochord, the skull and vertebral column, and the membranes of the brain and medulla spinalis are developed.

THE PRIMITIVE SEGMENTS.

Toward the end of the second week transverse segmentation of the paraxial mesoderm begins, and it is converted into a series of well-defined, more or less cubical masses, the **primitive segments** (Figs. 18, 19, 20), which occupy the entire length of the trunk on either side of the middle line from the occipital region of the head. Each segment contains a central cavity—**myocœl**—which, however, is soon filled with angular and spindle-shaped cells.

The primitive segments lie immediately under the ectoderm on the lateral aspect of the neural tube and notochord, and are connected to the lateral mesoderm by the **intermediate cell-mass**. Those of the trunk may

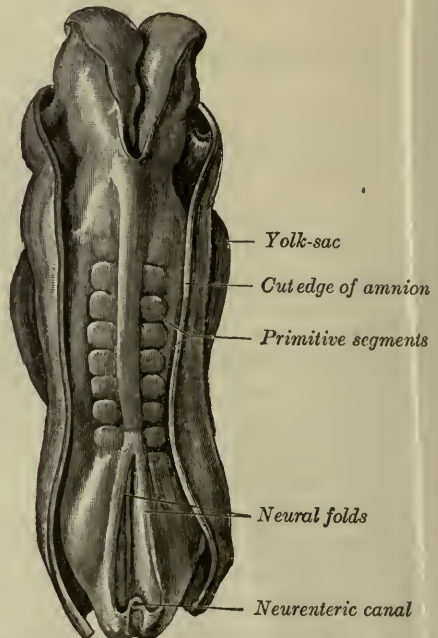


FIG. 20.—Dorsum of human embryo, 2.11 mm. in length. (After Eternod.)

be arranged in the following groups, viz.: cervical 8, thoracic 12, lumbar 5, sacral 5, and coccygeal from 5 to 8. Those of the occipital region of the head are usually described as being four in number. In mammals primitive segments of the head can be recognized only in the occipital region, but a study of the lower vertebrates leads to the belief that they are present also in the anterior part of the head, and that altogether nine segments are represented in the cephalic region.

SEPARATION OF THE EMBRYO.

The embryo increases rapidly in size, but the circumference of the embryonic disk, or line of meeting of the embryonic and amniotic parts of the ectoderm, is of relatively slow growth and gradually comes to form a constriction between the embryo and the greater part of the yolk-sac. By means of this constriction, which corresponds to the future umbilicus, a small part of the yolk-sac is enclosed within the embryo and constitutes the primitive digestive tube.

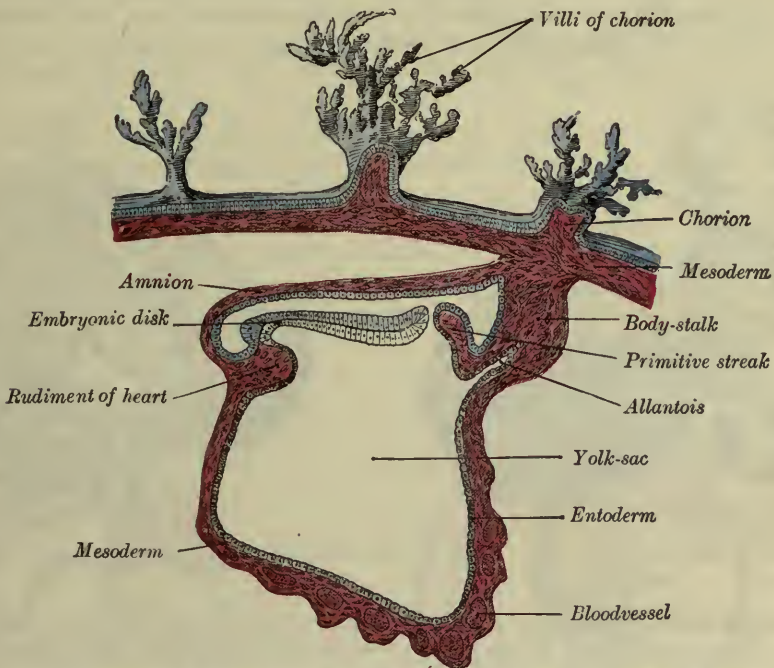


FIG. 21.—Section through the embryo which is represented in Fig. 17. (After Graf Spee.)

The embryo increases more rapidly in length than in width, and its cephalic and caudal ends soon extend beyond the corresponding parts of the circumference of the embryonic disk and are bent in a ventral direction to form the **cephalic** and **caudal folds** respectively (Figs. 26 and 27). The cephalic fold is first formed, and as the proamniotic area (page 47) lying immediately in front of the pericardial area (page 47) forms the anterior limit of the circumference of the embryonic disk, the forward growth of the head necessarily carries with it the posterior end of the pericardial area, so that this area and the buccopharyngeal membrane are folded back under the head of the embryo which now encloses a diverticulum of the yolk-sac named the **fore-gut**. The caudal end of the embryo is at first connected to the chorion by a band of mesoderm called the **body-stalk**, but with the formation of the caudal fold the body-stalk assumes a ventral position; a diverticulum of the yolk-sac extends into the tail fold and is termed the **hind-gut**. Between the fore-gut

and the hind-gut there exists for a time a wide opening into the yolk-sac, but the latter is gradually reduced to a small pear-shaped sac (sometimes termed the **umbilical vesicle**), and the channel of communication is at the same time narrowed and elongated to form a tube called the **vitelline duct**.

THE YOLK-SAC.

The yolk-sac (Figs. 22 and 23) is situated on the ventral aspect of the embryo; it is lined by entoderm, outside of which is a layer of mesoderm. It is filled with fluid, the **vitelline fluid**, which possibly may be utilized for the nourishment of the embryo during the earlier stages of its existence. Blood is conveyed to the wall of the sac by the primitive aortæ, and after circulating through a wide-meshed capillary plexus, is returned by the vitelline veins to the tubular heart of the embryo. This constitutes the **vitelline circulation**, and by means of it nutritive material is absorbed from the yolk-sac and conveyed to the embryo. At the end of the fourth week the yolk-sac presents the appearance of a small pear-shaped vesicle (umbilical vesicle) opening into the digestive tube by a long narrow tube, the **vitelline duct**. The vesicle can be seen in the after-birth as a small, somewhat oval-shaped body

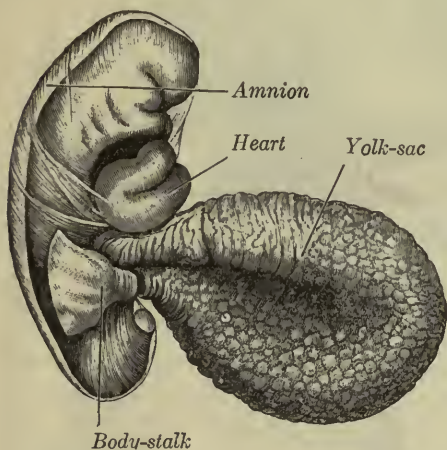


FIG. 22.—Human embryo of 2.6 mm. (His.)

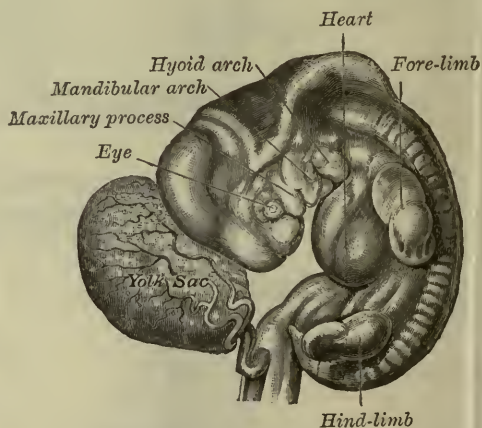


FIG. 23.—Human embryo from thirty-one to thirty-four days. (His.)

whose diameter varies from 1 mm. to 5 mm.; it is situated between the amnion and the chorion and may lie on or at a varying distance from the placenta. As a rule the duct undergoes complete obliteration during the seventh week, but in about three per cent. of cases its proximal part persists as a diverticulum from the small intestine, **Meckel's diverticulum**, which is situated about three or four feet above the ileocolic junction, and may be attached by a fibrous cord to the abdominal wall at the umbilicus. Sometimes a narrowing of the lumen of the ileum is seen opposite the site of attachment of the duct.

DEVELOPMENT OF THE FETAL MEMBRANES AND THE PLACENTA.

The Allantois (Figs. 25 to 28).—The allantois arises as a tubular diverticulum of the posterior part of the yolk-sac; when the hind-gut is developed the allantois is carried backward with it and then opens into the cloaca or terminal part of the hind-gut: it grows out into the body-stalk, a mass of mesoderm which lies below and around the tail end of the embryo. The diverticulum is lined by entoderm and covered by mesoderm, and in the latter are carried the allantoic or umbilical vessels.

In reptiles, birds, and many mammals the allantois becomes expanded into a vesicle which projects into the extra-embryonic celom. If its further development be traced in the bird, it is seen to project to the right side of the embryo, and, gradually expanding, it spreads over its dorsal surface as a flattened sac between the amnion and the serosa, and extending in all directions, ultimately surrounds the yolk. Its outer wall becomes applied to and fuses with the serosa, which lies immediately inside the shell membrane. Blood is carried to the allantoic sac by

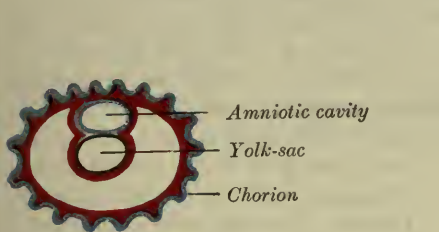


FIG. 24.—Diagram showing earliest observed stage of human ovum.

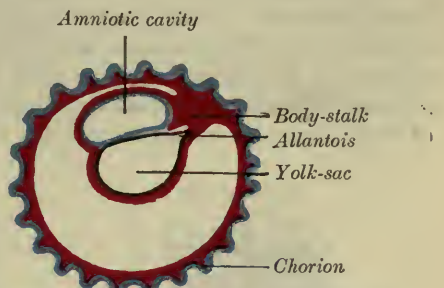


FIG. 25.—Diagram illustrating early formation of allantois and differentiation of body-stalk.

the two allantoic or umbilical arteries, which are continuous with the primitive aortæ, and after circulating through the allantoic capillaries, is returned to the primitive heart by the two umbilical veins. In this way the allantoic circulation, which is of the utmost importance in connection with the respiration and nutrition of the chick, is established. Oxygen is taken from, and carbonic acid is given up to the atmosphere through the egg-shell, while nutritive materials are at the same time absorbed by the blood from the yolk.

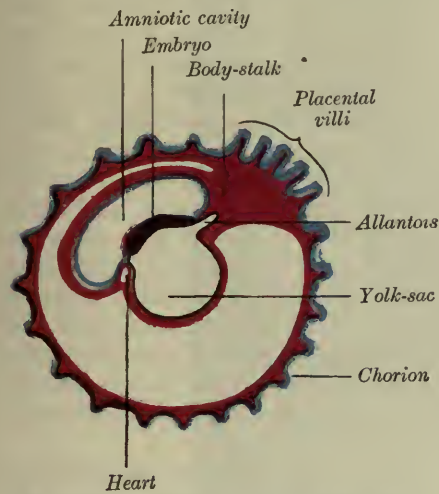


FIG. 26.—Diagram showing later stage of allantoic development with commencing constriction of the yolk-sac.

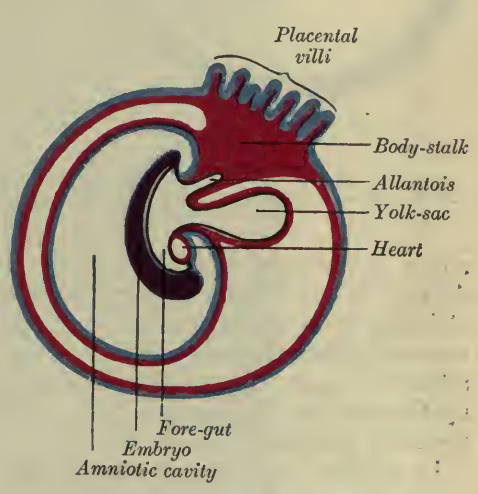


FIG. 27.—Diagram showing the expansion of amnion and delimitation of the umbilicus.

In man and other primates the nature of the allantois is entirely different from that just described. Here it exists merely as a narrow, tubular diverticulum of the hind-gut, and never assumes the form of a vesicle outside the embryo. With the formation of the amnion the embryo is, in most animals, entirely separated from the chorion, and is only again united to it when the allantoic mesoderm spreads over and becomes applied to its inner surface. The human embryo, on the other hand, as was pointed out by His, is never wholly separated from the chorion, its

tail end being from the first connected with the chorion by means of a thick band of mesoderm, named the **body-stalk** (Bauchstiel); into this stalk the tube of the allantois extends (Fig. 21).

The Amnion.—The amnion is a membranous sac which surrounds and protects the embryo. It is developed in reptiles, birds, and mammals, which are hence called "Amniota;" but not in amphibia and fishes, which are consequently termed "Anamnia."

In the human embryo the earliest stages of the formation of the amnion have not been observed; in the youngest embryo which has been studied the amnion was already present as a closed sac (Figs. 24 and 32), and, as indicated on page 46, appears in the inner cell-mass as a cavity. This cavity is roofed in by a single stratum of flattened, ectodermal cells, the **amniotic ectoderm**, and its floor consists of the prismatic ectoderm of the embryonic disk—the continuity between the

roof and floor being established at the margin of the embryonic disk.

Outside the amniotic ectoderm is a thin layer of mesoderm, which is continuous with that of the somatopleure and is connected by the body-stalk with the mesodermal lining of the chorion.

When first formed the amnion is in contact with the body of the embryo, but about the fourth or fifth week fluid (*liquor amnii*) begins to accumulate within it. This fluid increases in quantity and causes the amnion to expand and ultimately to adhere to the inner surface of the chorion, so that the extra-embryonic part of the celom is obliterated. The liquor amnii increases in quantity up to the sixth or seventh month of pregnancy, after which it diminishes somewhat; at the end of preg-

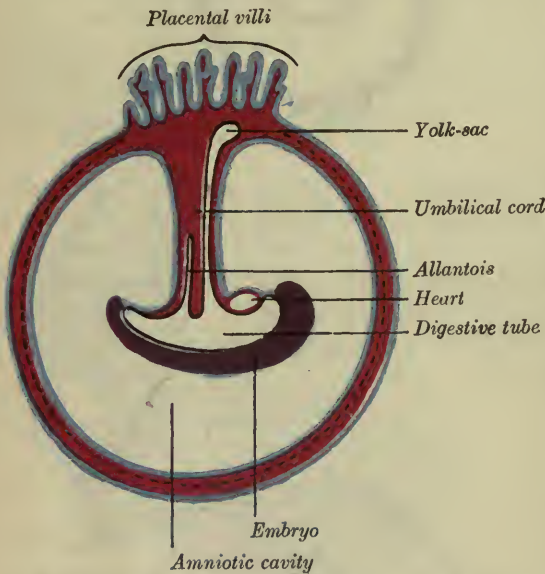


FIG. 28.—Diagram illustrating a later stage in the development of the umbilical cord.

nancy it amounts to about 1 liter. It allows of the free movements of the fetus during the later stages of pregnancy, and also protects it by diminishing the risk of injury from without. It contains less than 2 per cent. of solids, consisting of urea and other extractives, inorganic salts, a small amount of protein, and frequently a trace of sugar. That some of the liquor amnii is swallowed by the fetus is proved by the fact that epidermal debris and hairs have been found among the contents of the fetal alimentary canal.

In reptiles, birds, and many mammals the amnion is developed in the following manner: At the point of constriction where the primitive digestive tube of the embryo joins the yolk-sac a reflection or folding upward of the somatopleure takes place. This, the **amniotic fold** (Fig. 29), first makes its appearance at the cephalic extremity, and subsequently at the caudal end and sides of the embryo, and gradually rising more and more, its different parts meet and fuse over the dorsal aspect of the embryo, and enclose a cavity, the **amniotic cavity**. After the fusion of the edges of the amniotic fold, the two layers of the fold become completely separated, the inner forming the **amnion**, the outer the **false amnion** or **serosa**. The space between the amnion and the serosa constitutes the extra-embryonic celom, and for a time communicates with the embryonic celom.

The Umbilical Cord and Body-stalk.—The umbilical cord (Fig. 28) attaches the fetus to the placenta; its length at full time, as a rule, is about equal to the

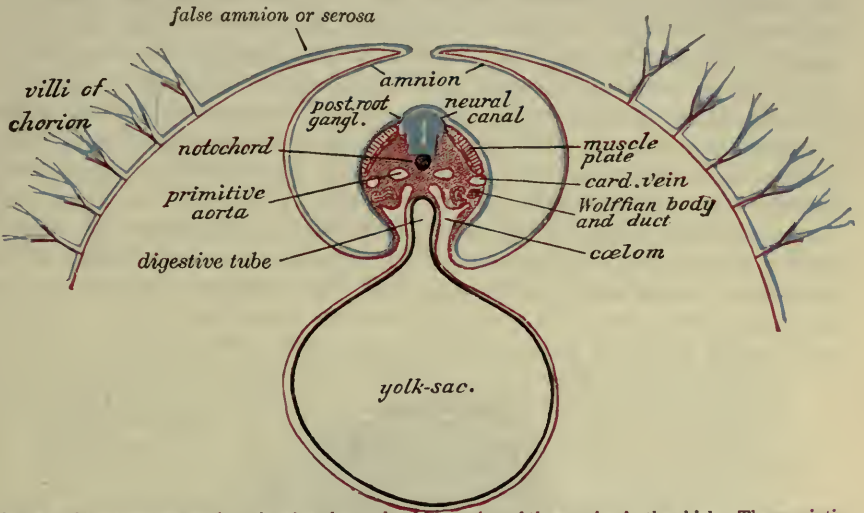


FIG. 29.—Diagram of a transverse section, showing the mode of formation of the amnion in the chick. The amniotic folds have nearly united in the middle line. (From Quain's Anatomy.) Ectoderm, blue; mesoderm, red; endoderm and notochord, black.

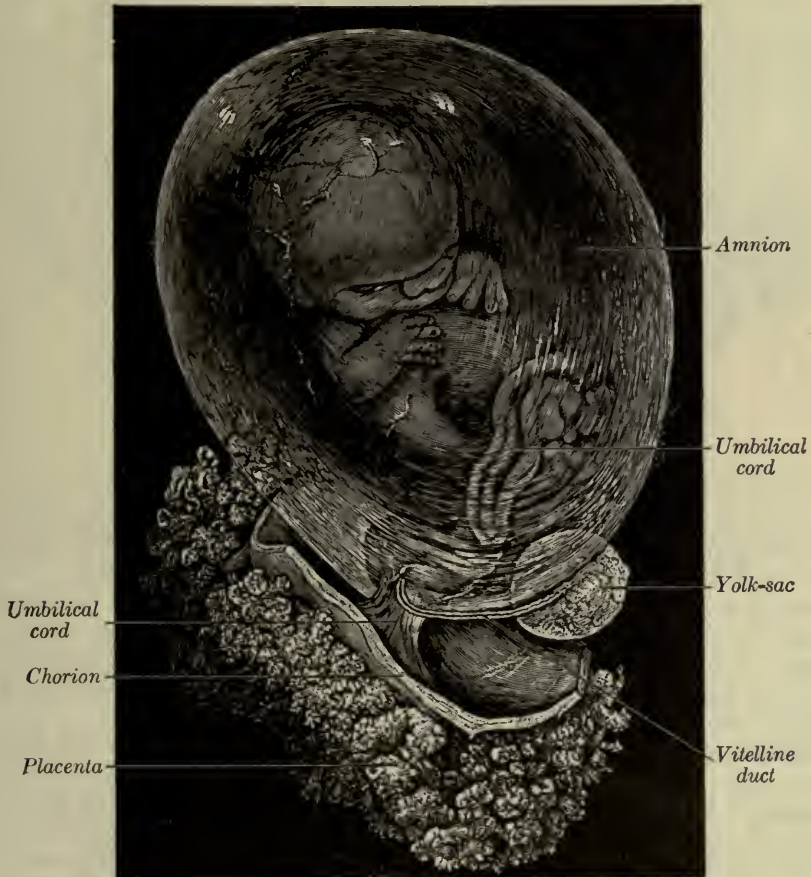

FIG. 30.—Fetus of about eight weeks, enclosed in the amnion. Magnified a little over two diameters. (Drawn from stereoscopic photographs lent by Prof. A. Thomson, Oxford.)

length of the fetus, *i. e.*, about 50 cm., but it may be greatly diminished or increased. The rudiment of the umbilical cord is represented by the tissue which connects the rapidly growing embryo with the extra-embryonic area of the ovum. Included in this tissue are the body-stalk and the vitelline duct—the former containing the allantoic diverticulum and the umbilical vessels, the latter forming the communication between the digestive tube and the yolk-sac. The body-stalk is the posterior segment of the embryonic area, and is attached to the chorion. It consists of a plate of mesoderm covered by thickened ectoderm on which a trace of the neural groove can be seen, indicating its continuity with the embryo. Running through its mesoderm are the two umbilical arteries and the two umbilical veins, together with the canal of the allantois—the last being lined by entoderm (Fig. 31). Its dorsal surface is covered by the amnion, while its ventral surface is bounded by the extra-embryonic celom, and is in contact with the vitelline duct and yolk-sac. With the rapid elongation of the embryo and the formation of the tail fold, the body stalk comes to lie on the ventral surface of the embryo (Figs. 27 and 28), where

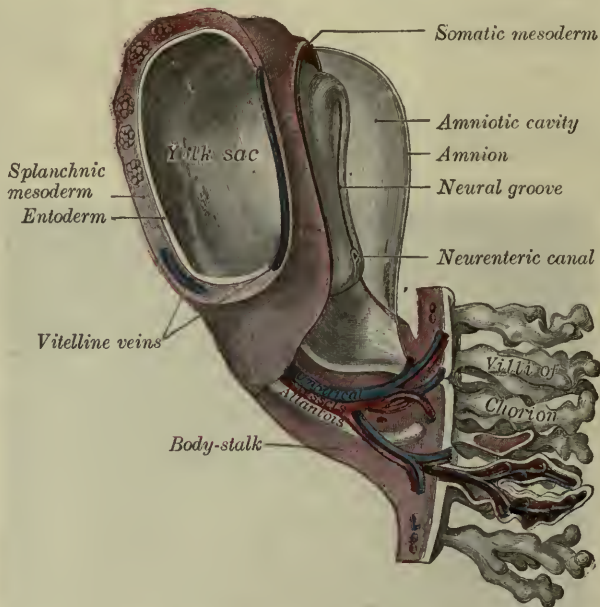


FIG. 31.—Model of human embryo 1.3 mm. long. (After Eternod.)

its mesoderm blends with that of the yolk-sac and the vitelline duct. The lateral leaves of somatopleure then grow round on each side, and, meeting on the ventral aspect of the allantois, enclose the vitelline duct and vessels, together with a part of the extra-embryonic celom; the latter is ultimately obliterated. The cord is covered by a layer of ectoderm which is continuous with that of the amnion, and its various constituents are enveloped by embryonic gelatinous tissue, **jelly of Wharton**. The vitelline vessels and duct, together with the right umbilical vein, undergo atrophy and disappear; and thus the cord, at birth, contains a pair of umbilical arteries and one (the left) umbilical vein.

Implantation or Imbedding of the Ovum.—As described (page 44), fertilization of the ovum occurs in the lateral or ampullary end of the uterine tube and is immediately followed by segmentation. On reaching the cavity of the uterus the segmented ovum adheres like a parasite to the uterine mucous membrane, destroys the epithelium over the area of contact, and excavates for itself a cavity in the mucous membrane in which it becomes imbedded. In the ovum described by

Bryce and Teacher¹ the point of entrance was visible as a small gap closed by a mass of fibrin and leucocytes; in the ovum described by Peters² the opening was covered by a mushroom-shaped mass of fibrin and blood-clot (Fig. 32), the narrow stalk of which plugged the aperture in the mucous membrane. Soon, however, all trace of the opening is lost and the ovum is then completely surrounded by the uterine mucous membrane.

The structure actively concerned in the process of excavation is the trophoblast of the ovum, which possesses the power of dissolving and absorbing the uterine tissues. The trophoblast proliferates rapidly and forms a network of branching processes which cover the entire ovum and invade and destroy the maternal tissues and open into the maternal bloodvessels, with the result that the spaces in the trophoblastic network are filled with maternal blood; these spaces communicate freely with one another and become greatly distended and form the **intervillous space**.

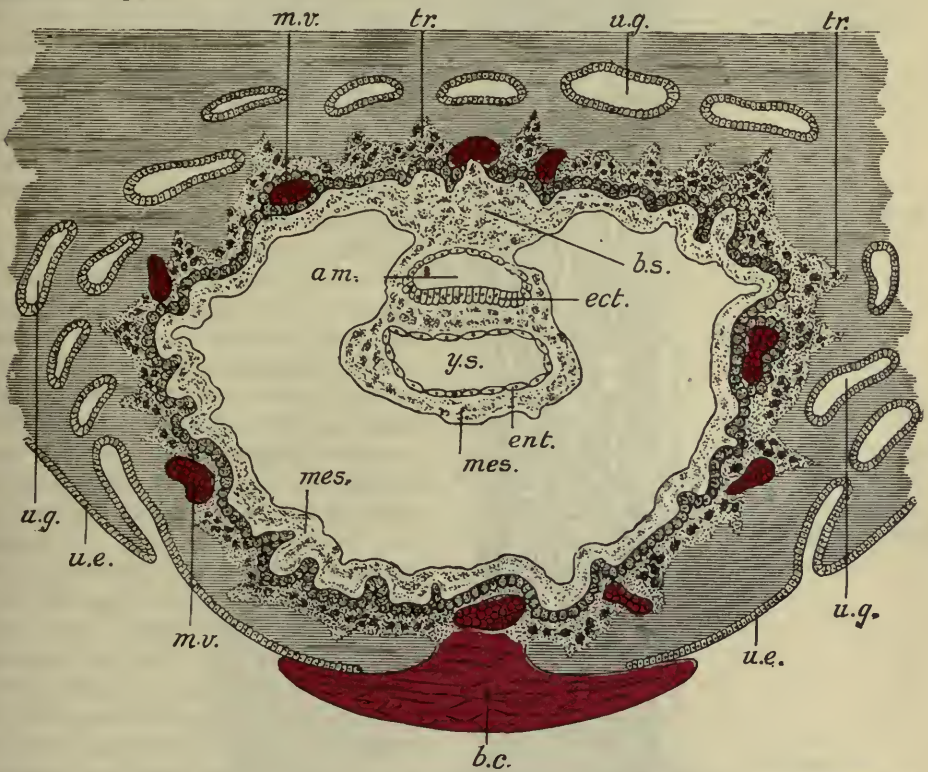


FIG. 32.—Section through ovum imbedded in the uterine decidua. Semi-diagrammatic. (After Peters.) *am.* Amniotic cavity. *b.c.* Blood-clot. *b.s.* Body-stalk. *ect.* Embryonic ectoderm. *ent.* Entoderm. *mes.* Mesoderm. *m.v.* Maternal vessels. *tr.* Trophoblast. *u.e.* Uterine epithelium. *u.g.* Uterine glands. *y.s.* Yolk-sac.

The Decidua.—Before the fertilized ovum reaches the uterus, the mucous membrane of the body of the uterus undergoes important changes and is then known as the **decidua**. The thickness and vascularity of the mucous membrane are greatly increased; its glands are elongated and open on its free surface by funnel-shaped orifices, while their deeper portions are tortuous and dilated into irregular spaces. The interglandular tissue is also increased in quantity, and is crowded with large round, oval, or polygonal cells, termed **decidual cells**. These changes are well advanced by the second month of pregnancy, when the mucous membrane consists of the following strata (Fig. 33): (1) **stratum compactum**, next

¹ Contribution to the study of the early development and imbedding of the human ovum, 1908.

² Die Einbettung des menschlichen Eies, 1899.

the free surface; in this the uterine glands are only slightly expanded, and are lined by columnar cells; (2) **stratum spongiosum**, in which the gland tubes are greatly dilated and very tortuous, and are ultimately separated from one another by only a small amount of interglandular tissue, while their lining cells are flattened or cubical; (3) a thin **unaltered or boundary layer**, next the uterine muscular fibers, containing the deepest parts of the uterine glands, which are not dilated, and are lined with columnar epithelium;

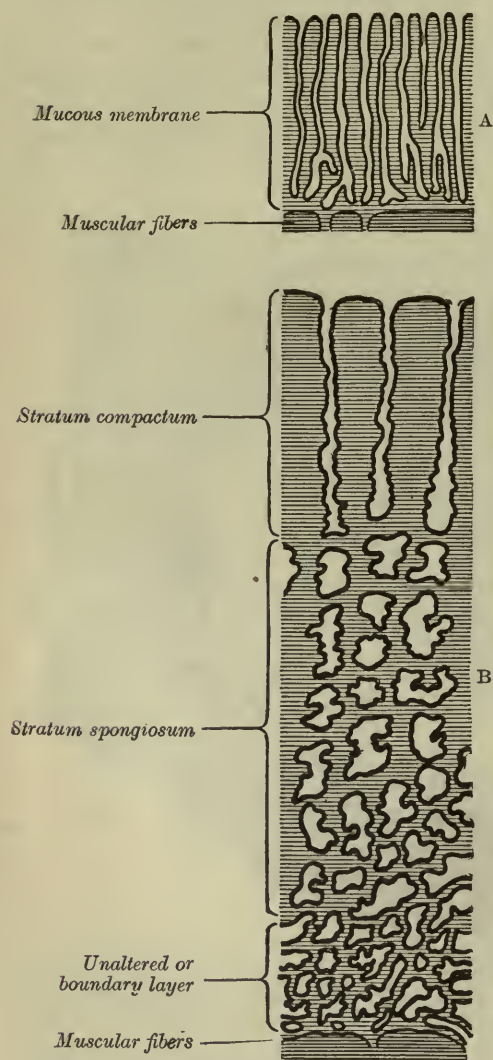


FIG. 33.—Diagrammatic sections of the uterine mucous membrane: *A*, The non-pregnant uterus. *B*, The pregnant uterus, showing the thickened mucous membrane and the altered condition of the uterine glands. (Kundrat and Engelmann.)

it is from this epithelium that the epithelial lining of the uterus is regenerated after pregnancy. Distinctive names are applied to different portions of the decidua. The part which covers in the ovum is named the **decidua capsularis**; the portion which intervenes between the ovum and the uterine wall is named the **decidua basalis** or **decidua placentalis**; it is here that the placenta is subsequently developed. The part of the decidua which lines the remainder of the body of the uterus is known as the **decidua vera** or **decidua parietalis**.

Coincidentally with the growth of the embryo, the decidua capsularis is thinned and extended (Fig. 34) and the space between it and the decidua vera is gradually obliterated, so that by the third month of pregnancy the two are in contact. By the fifth month of pregnancy the decidua capsularis has practically disappeared, while during the succeeding months the decidua vera also undergoes atrophy, owing to the increased pressure. The glands of the stratum compactum are obliterated, and their epithelium is lost. In the stratum spongiosum the glands are compressed and appear as slit-like fissures, while their epithelium undergoes degeneration. In the unaltered or boundary layer, however, the glandular epithelium retains a columnar or cubical form.

The Chorion (Figs. 23 to 28).—The chorion consists of two layers: an outer formed by the primitive ectoderm or trophoblast, and an inner by the somatic mesoderm; with this latter the amnion is in contact. The trophoblast is made up of an internal layer of cubical or prismatic cells, the **cytotrophoblast** or **layer of Langhans**, and an external layer of richly nucleated protoplasm devoid of cell boundaries, the **syncytiotrophoblast**. It undergoes rapid proliferation and forms numerous processes, the **chorionic villi**, which invade and destroy the uterine decidua and at the same time absorb from it nutritive materials for the growth

of the embryo. The chorionic villi are at first small and non-vascular, and consist of trophoblast only, but they increase in size and ramify, while the mesoderm, carrying branches of the umbilical vessels, grows into them, and in this way they are vascularized. Blood is carried to the villi by the branches of the umbilical

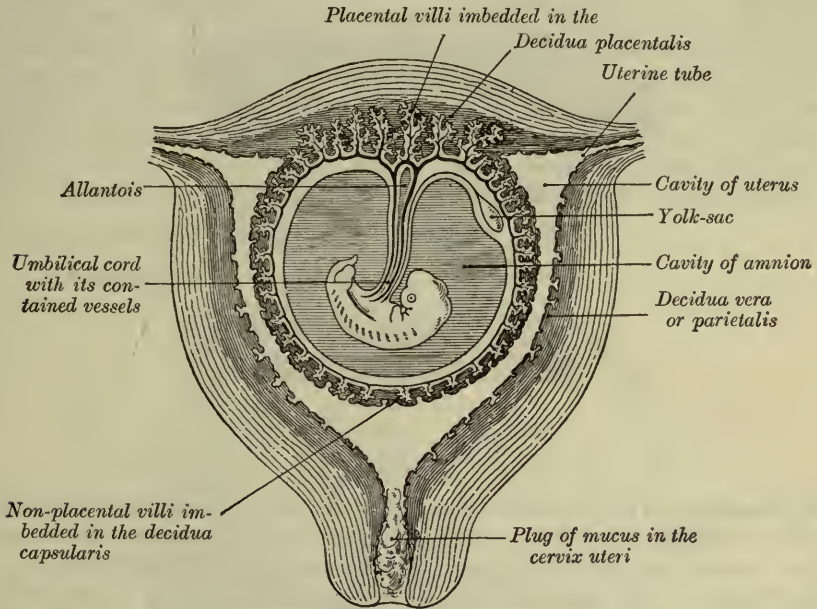


FIG. 34.—Sectional plan of the gravid uterus in the third and fourth month. (Modified from Wagner.)

arteries, and after circulating through the capillaries of the villi, is returned to the embryo by the umbilical veins. Until about the end of the second month of pregnancy the villi cover the entire chorion, and are almost uniform in size (Fig. 25), but after this they develop unequally. The greater part of the chorion

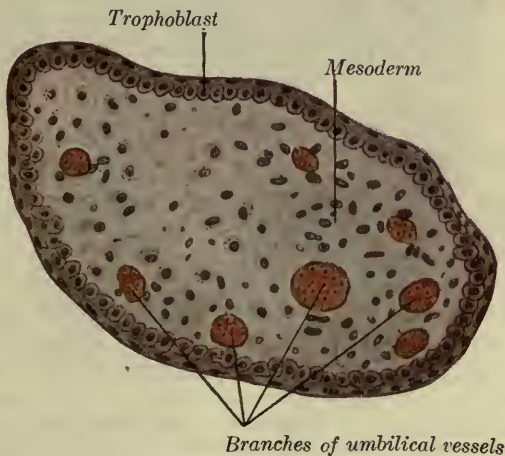


FIG. 35.—Transverse section of a chorionic villus.

is in contact with the decidua capsularis (Fig. 34), and over this portion the villi, with their contained vessels, undergo atrophy, so that by the fourth month scarcely a trace of them is left, and hence this part of the chorion becomes smooth, and is named the **chorion laeve**; as it takes no share in the formation of the placenta, it

is also named the non-placental part of the chorion. On the other hand, the villi on that part of the chorion which is in contact with the decidua placentalis increase greatly in size and complexity, and hence this part is named the **chorion frondosum** (Fig. 28).

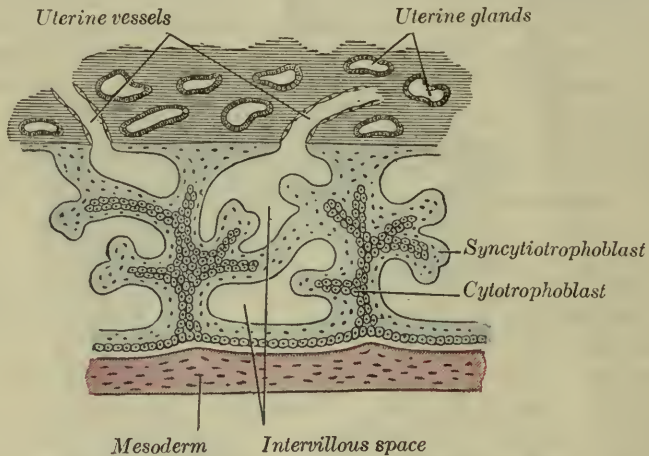


FIG. 36.—Primary chorionic villi. Diagrammatic. (Modified from Bryce.)

The Placenta.—The placenta connects the fetus to the uterine wall, and is the organ by means of which the nutritive, respiratory, and excretory functions of the fetus are carried on. It is composed of **fetal** and **maternal** portions.

Fetal Portion.—The fetal portion of the placenta consists of the villi of the chorion frondosum; these branch repeatedly, and increase enormously in size. These greatly ramified villi are suspended in the intervillous space, and are bathed

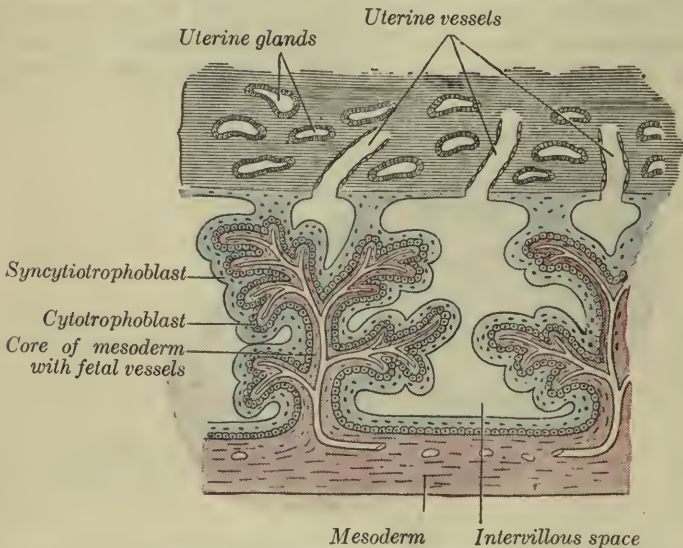


FIG. 37.—Secondary chorionic villi. Diagrammatic. (Modified from Bryce.)

in maternal blood, which is conveyed to the space by the uterine arteries and carried away by the uterine veins. A branch of an umbilical artery enters each villus and ends in a capillary plexus from which the blood is drained by a tributary of the umbilical vein. The vessels of the villus are surrounded by a thin layer of mesoderm consisting of gelatinous connective tissue, which is covered by two

strata of ectodermal cells derived from the trophoblast: the deeper stratum, next the mesodermic tissue, represents the cytotrophoblast or layer of Langhans; the superficial, in contact with the maternal blood, the syncytiotrophoblast (Figs. 36 and 37). After the fifth month the two strata of cells are replaced by a single layer of somewhat flattened cells.

Maternal Portion.—The maternal portion of the placenta is formed by the decidua placentalis containing the intervillous space. As already explained, this space is produced by the enlargement and intercommunication of the spaces in the trophoblastic network. The changes involve the disappearance of the greater portion of the stratum compactum, but the deeper part of this layer persists and is condensed to form what is known as the **basal plate**. Between this plate and the uterine muscular fibres are the stratum spongiosum and the boundary layer;

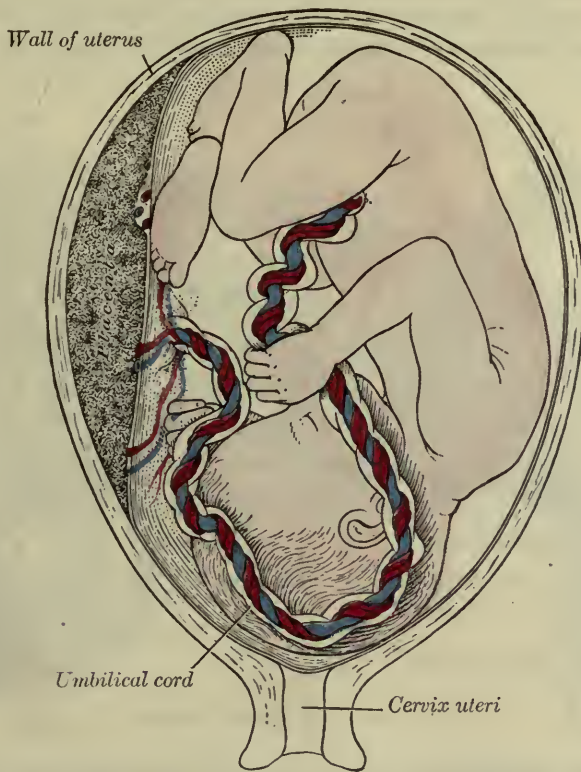

FIG. 38.—Fetus in utero, between fifth and sixth months.

through these and the basal plate the uterine arteries and veins pass to and from the intervillous space. The endothelial lining of the uterine vessels ceases at the point where they terminate in the intervillous space which is lined by the syncytiotrophoblast. Portions of the stratum compactum persist and are condensed to form a series of septa, which extend from the basal plate through the thickness of the placenta and subdivide it into the lobules or **cotyledons** seen on the uterine surface of the detached placenta.

The fetal and maternal blood currents traverse the placenta, the former passing through the bloodvessels of the placental villi and the latter through the intervillous space (Fig. 39). The two currents do not intermingle, being separated from each other by the delicate walls of the villi. Nevertheless, the fetal blood is able to absorb, through the walls of the villi, oxygen and nutritive materials from the

maternal blood, and give up to the latter its waste products. The blood, so purified, is carried back to the fetus by the umbilical vein. It will thus be seen that the placenta not only establishes a mechanical connection between the mother and the fetus, but subserves for the latter the purposes of nutrition, respiration, and excretion. In favor of the view that the placenta possesses certain selective powers may be mentioned the fact that glucose is more plentiful in the maternal than in the fetal blood. It is interesting to note also that the proportion of iron, and of lime and potash, in the fetus is increased during the last months of pregnancy. Further, there is evidence that the maternal leucocytes may migrate into the fetal blood, since leucocytes are much more numerous in the blood of the umbilical vein than in that of the umbilical arteries.

The placenta is usually attached near the fundus uteri, and more frequently on the posterior than on the anterior wall of the uterus. It may, however, occupy a lower position and, in rare cases, its site is close to the orificium internum uteri, which it may occlude, thus giving rise to the condition known as *placenta previa*.

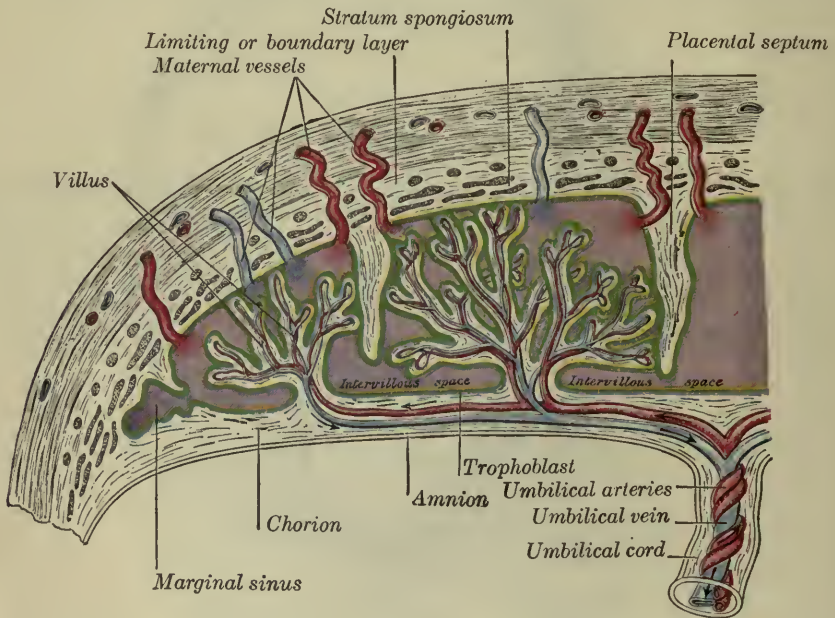


FIG. 39.—Scheme of placental circulation.

Separation of the Placenta.—After the child is born, the placenta and membranes are expelled from the uterus as the *after-birth*. The separation of the placenta from the uterine wall takes place through the stratum spongiosum, and necessarily causes rupture of the uterine vessels. The orifices of the torn vessels are, however, closed by the firm contraction of the uterine muscular fibers, and thus *postpartum hemorrhage* is controlled. The epithelial lining of the uterus is regenerated by the proliferation and extension of the epithelium which lines the persistent portions of the uterine glands in the unaltered layer of the decidua.

The expelled placenta appears as a discoid mass which weighs about 450 gm. and has a diameter of from 15 to 20 cm. Its average thickness is about 3 cm., but this diminishes rapidly toward the circumference of the disk, which is continuous with the membranes. Its uterine surface is divided by a series of fissures into lobules or *cotyledons*, the fissures containing the remains of the septa which extended between the maternal and fetal portions. Most of these septa end in irregular or pointed processes; others, especially those near the edge of the placenta, pass

through its thickness and are attached to the chorion. In the early months these septa convey branches of the uterine arteries which open into the intervillous space on the surfaces of the septa. The fetal surface of the placenta is smooth, being closely invested by the amnion. Seen through the latter, the chorion presents a mottled appearance, consisting of gray, purple, or yellowish areas. The umbilical cord is usually attached near the center of the placenta, but may be inserted anywhere between the center and the margin; in some cases it is inserted into the membranes, *i. e.*, the **velamentous insertion**. From the attachment of the cord the larger branches of the umbilical vessels radiate under the amnion, the veins being deeper and larger than the arteries. The remains of the vitelline duct and yolk-sac may be sometimes observed beneath the amnion, close to the cord, the former as an attenuated thread, the latter as a minute sac.

On section, the placenta presents a soft, spongy appearance, caused by the greatly branched villi; surrounding them is a varying amount of maternal blood giving the dark red color to the placenta. Many of the larger villi extend from the chorionic to the decidual surface, while others are attached to the septa which separate the cotyledons; but the great majority of the villi hang free in the intervillous space.

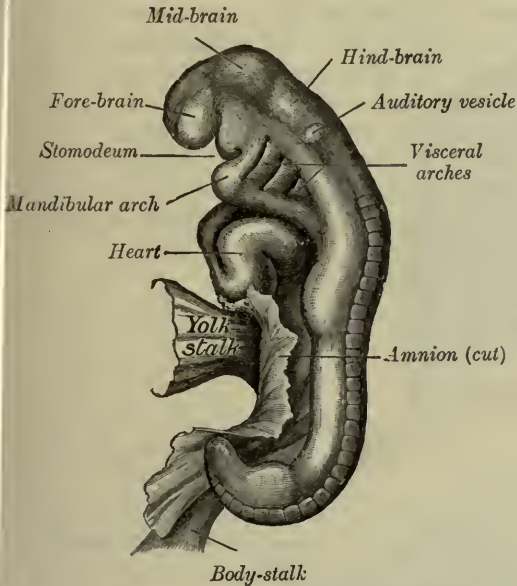


FIG. 40.—Embryo between eighteen and twenty-one days. (His.)

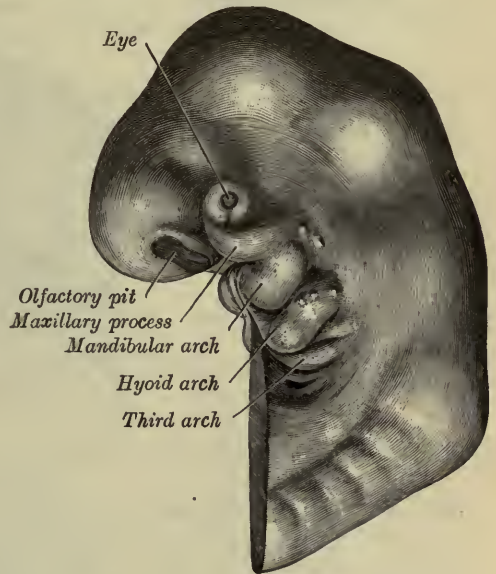


FIG. 41.—Head end of human embryo, about the end of the fourth week. (From model by Peter.)

THE BRANCHIAL REGION.

The Branchial or Visceral Arches and Pharyngeal Pouches.—In the lateral walls of the anterior part of the fore-gut five *pharyngeal pouches* appear (Fig. 42); each of the upper four pouches is prolonged into a dorsal and a ventral diverticulum. Over these pouches corresponding indentations of the ectoderm occur, forming what are known as the **branchial or outer pharyngeal grooves**. The intervening mesoderm is pressed aside and the ectoderm comes for a time into contact with the entodermal lining of the fore-gut, and the two layers unite along the floors of the grooves to form thin **closing membranes** between the fore-gut and the exterior. Later the mesoderm again penetrates between the entoderm and the ectoderm. In gill-bearing animals the closing membranes disappear, and the grooves become

complete clefts, the **gill-clefts**, opening from the pharynx on to the exterior; perforation, however, does not occur in birds or mammals. The grooves separate a series of rounded bars or arches, the **branchial** or **visceral arches**, in which thickening of the mesoderm takes place (Figs. 40 and 41). The dorsal ends of these arches are attached to the sides of the head, while the ventral extremities ultimately meet in the middle line of the neck. In all, six arches make their appearance, but of these only the first four are visible externally. The first arch is named the **mandibular**, and the second the **hyoid**; the others have no distinctive names. In each arch a cartilaginous bar, consisting of right and left halves, is developed, and with each of these there is one of the primitive aortic arches.

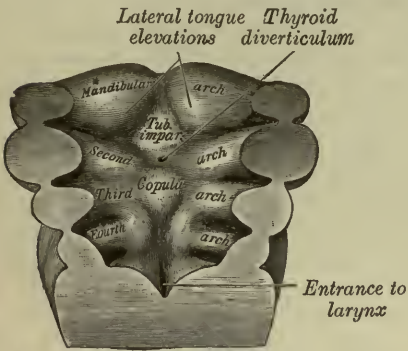


FIG. 42.—Floor of pharynx of embryo shown in Fig. 40.

The **mandibular arch** lies between the first branchial groove and the stomodeum; from it are developed the lower lip, the mandible, the muscles of mastication, and the anterior part of the tongue. Its cartilaginous bar is formed by what are known as **Meckel's cartilages** (right and left) (Fig. 43); above this the **incus** is developed. The dorsal end of each cartilage is connected with the ear-capsule and is ossified to form the **malleus**; the ventral ends meet each other in the region of the **symphysis menti**, and are usually regarded as undergoing ossification to form that portion of the mandible which contains the incisor teeth. The intervening part of the cartilage disappears; the portion immediately adjacent to the malleus is replaced by fibrous membrane, which constitutes the **spheno-mandibular ligament**,

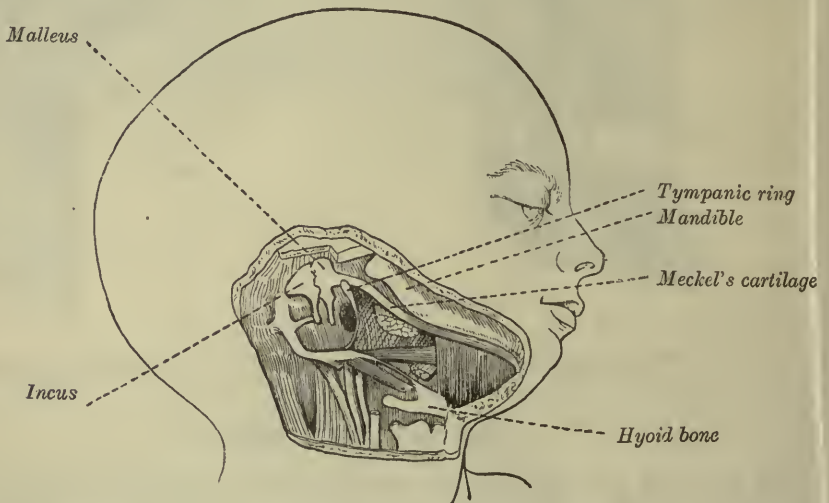


FIG. 43.—Head and neck of a human embryo eighteen weeks old, with Meckel's cartilage and hyoid bar exposed. (After Kölliker.)

while from the connective tissue covering the remainder of the cartilage the greater part of the mandible is ossified. From the dorsal ends of the mandibular arch a triangular process, the **maxillary process**, grows forward on either side and forms the cheek and lateral part of the upper lip. The **second** or **hyoid arch** assists in forming the side and front of the neck. From its cartilage are developed the **styloid process**, **stylohyoid ligament**, and **lesser cornu of the hyoid bone**. The stages prob-

ably arises in the upper part of this arch. The cartilage of the **third arch** gives origin to the greater cornu of the hyoid bone. The ventral ends of the second and third arches unite with those of the opposite side, and form a transverse band, from which the body of the hyoid bone and the posterior part of the tongue are developed. The ventral portions of the cartilages of the **fourth and fifth arches** unite to form the thyroid cartilage; from the cartilages of the **sixth arch** the cricoid and arytenoid cartilages and the cartilages of the trachea are developed. The mandibular and hyoid arches grow more rapidly than those behind them, with the result that the latter become, to a certain extent, telescoped within the former, and a deep depression, the **sinus cervicalis**, is formed on either side of the neck. This sinus is bounded in front by the hyoid arch, and behind by the thoracic wall; it is ultimately obliterated by the fusion of its walls.

From the first branchial groove the concha auriculæ and external acoustic meatus are developed, while around the groove there appear, on the mandibular and hyoid arches, a number of swellings from which the auricula or pinna is formed. The first pharyngeal pouch is prolonged dorsally to form the auditory tube and the tympanic cavity; the closing membrane between the mandibular and hyoid arches

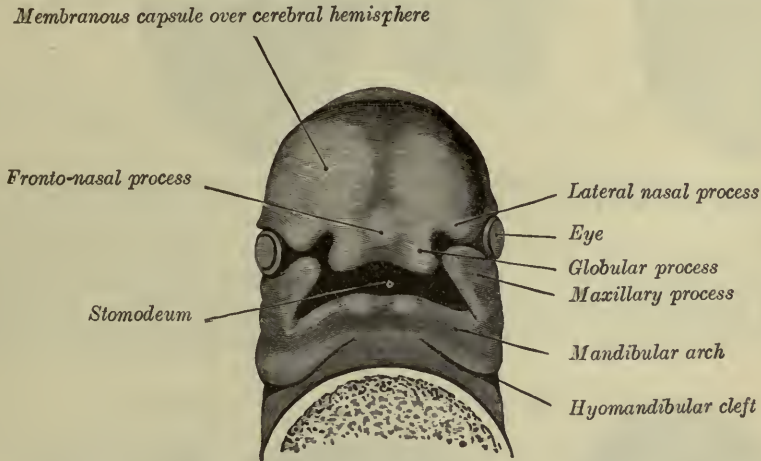


FIG. 44.—Under surface of the head of a human embryo about twenty-nine days old. (After His.)

is invaded by mesoderm, and forms the tympanic membrane. No traces of the second, third, and fourth branchial grooves persist. The inner part of the second pharyngeal pouch is named the **sinus tonsillaris**; in it the tonsil is developed, above which a trace of the sinus persists as the supratonsillar fossa. The fossa of Rosenmüller or lateral recess of the pharynx is by some regarded as a persistent part of the second pharyngeal pouch, but it is probably developed as a secondary formation. From the third pharyngeal pouch the thymus arises as an entodermal diverticulum on either side, and from the fourth pouches small diverticula project and become incorporated with the thymus, but in man these diverticula probably never form true thymus tissue. The parathyroids also arise as diverticula from the third and fourth pouches. From the fifth pouches the ultimobranchial bodies originate and are enveloped by the lateral prolongations of the median thyroid rudiment; they do not, however, form true thyroid tissue, nor are any traces of them found in the human adult.

The Nose and Face.—During the third week two areas of thickened ectoderm, the **olfactory areas**, appear immediately under the fore-brain in the anterior wall of the stomodeum, one on either side of a region termed the **fronto-nasal process** (Fig. 44). By the upgrowth of the surrounding parts these areas are converted into pits,

the olfactory pits, which indent the fronto-nasal process and divide it into a medial and two lateral nasal processes (Fig. 45). The rounded lateral angles of the medial process constitute the globular processes of His. The olfactory pits form

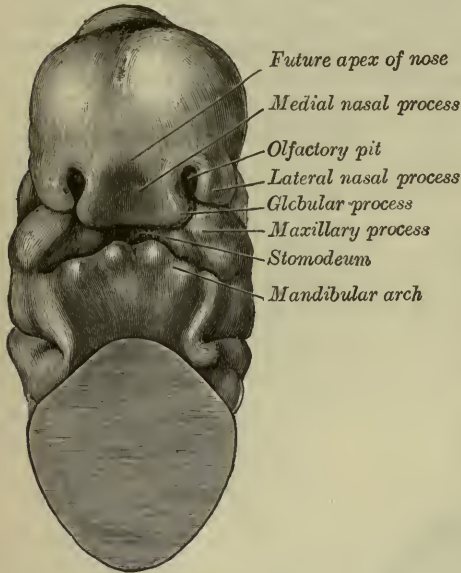


FIG. 45.—Head end of human embryo of about thirty to thirty-one days. (From model by Peters.)

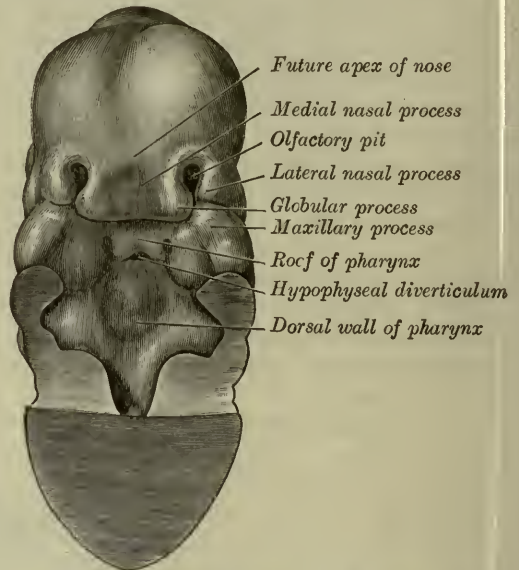


FIG. 46.—Same embryo as shown in Fig. 45, with front wall of pharynx removed.

the rudiments of the nasal cavities, and from their ectodermal lining the epithelium of the nasal cavities, with the exception of that of the inferior meatuses, is derived. The globular processes are prolonged backward as plates, termed the nasal laminae: these laminae are at first some distance apart, but, gradually approach-




FIG. 47.—Head of a human embryo of about eight weeks, in which the nose and mouth are formed. (His.)

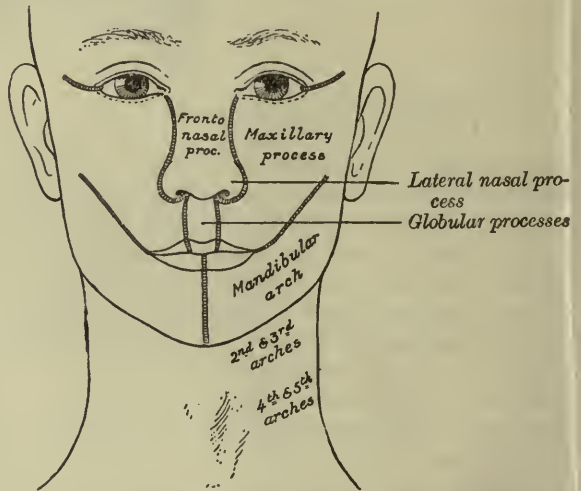


FIG. 48.—Diagram showing the regions of the adult face and neck related to the fronto-nasal process and the branchial arches.

ing, they ultimately fuse and form the nasal septum; the processes themselves meet in the middle line, and form the premaxillae and the philtrum or central part of the upper lip (Fig. 48). The depressed part of the medial nasal process

between the globular processes forms the lower part of the nasal septum or *columella*; while above this is seen a prominent angle, which becomes the future apex (Figs. 45, 46), and still higher a flat area, the future bridge, of the nose. The lateral nasal processes form the alæ of the nose.

Continuous with the dorsal end of the mandibular arch, and growing forward from its cephalic border, is a triangular process, the **maxillary process**, the ventral extremity of which is separated from the mandibular arch by a > shaped notch

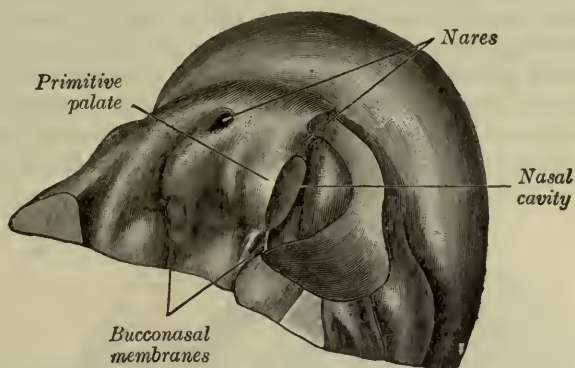


FIG. 49.—Primitive palate of a human embryo of thirty-seven to thirty-eight days. (From model by Peters.)
On the left side the lateral wall of the nasal cavity has been removed.

(Fig. 44). The maxillary process forms the lateral wall and floor of the orbit, and in it are ossified the zygomatic bone and the greater part of the maxilla; it meets with the lateral nasal process, from which, however, it is separated for a time by a groove, the **naso-optic furrow**, that extends from the furrow encircling the eyeball to the olfactory pit. The maxillary processes ultimately fuse with the lateral nasal and globular processes, and form the lateral parts of the upper lip

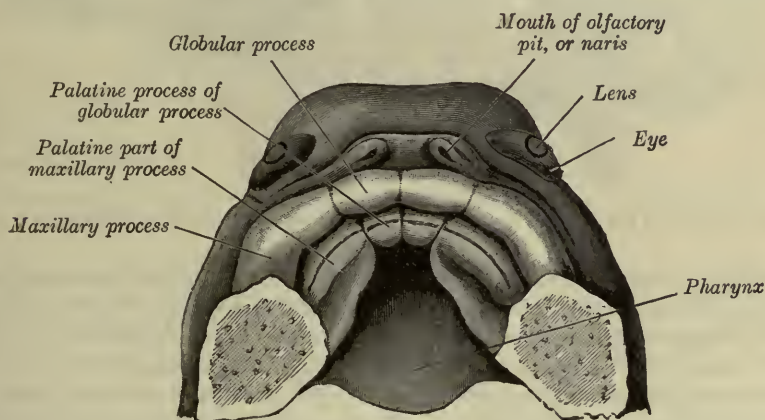


FIG. 50.—The roof of the mouth of a human embryo, aged about two and a half months, showing the mode of formation of the palate. (His.)

and the posterior boundaries of the nares (Figs. 47, 48). From the third to the fifth month the nares are filled by masses of epithelium, on the breaking down and disappearance of which the permanent openings are produced. The maxillary process also gives rise to the lower portion of the lateral wall of the nasal cavity. The roof of the nose and the remaining parts of the lateral wall, viz., the ethmoidal labyrinth, the inferior nasal concha, the lateral cartilage, and the lateral crus of the alar cartilage, are developed in the lateral nasal process. By the fusion of the

maxillary and nasal processes in the roof of the stomodeum the **primitive palate** (Fig. 49) is formed, and the olfactory pits extend backward above it. The posterior end of each pit is closed by an epithelial membrane, the **bucco-nasal membrane**, formed by the apposition of the nasal and stomodeal epithelium. By the rupture of these membranes the **primitive choanæ** or openings between the olfactory pits and the stomodeum are established. The floor of the nasal cavity is completed by the development of a pair of shelf-like **palatine processes** which extend medialward from the maxillary processes (Figs. 50 and 51); these coalesce with each other in the middle line, and constitute the entire palate, except a small part in front which is formed by the premaxillary bones. Two apertures persist for a time between the palatine processes and the premaxillæ and represent the permanent channels which in the lower animals connect the nose and mouth. The union of the parts which form the palate commences in front, the premaxillary and palatine processes joining in the eighth week, while the region of the future hard palate

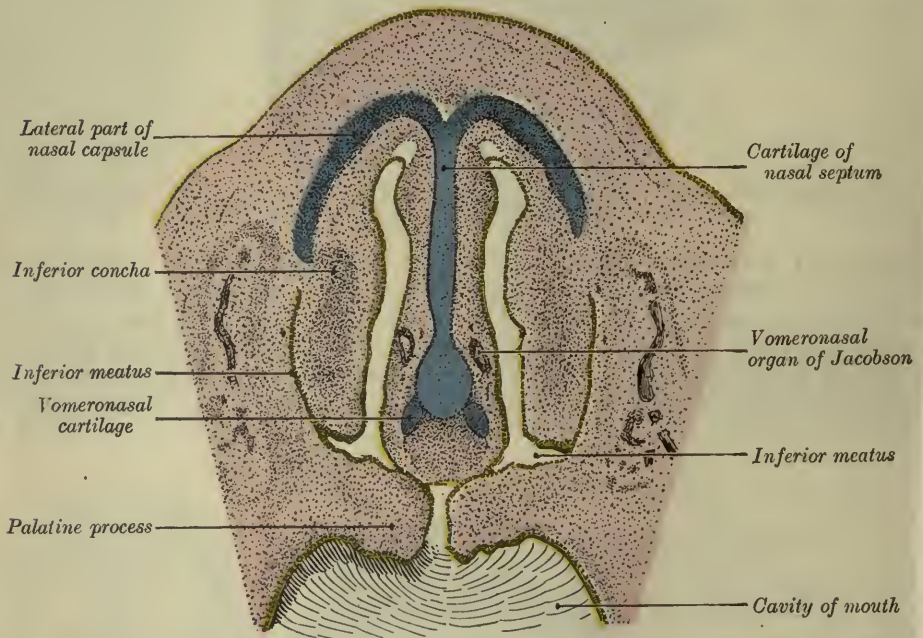


FIG. 51.—Frontal section of nasal cavities of a human embryo 28 mm. long. (Kollmann.)

is completed by the ninth, and that of the soft palate by the eleventh week. By the completion of the palate the **permanent choanæ** are formed and are situated a considerable distance behind the primitive choanæ. The deformity known as cleft palate results from a non-union of the palatine processes, and that of hare-lip through a non-union of the maxillary and globular processes (see page 199). The nasal cavity becomes divided by a vertical septum, which extends downward and backward from the medial nasal process and nasal laminae, and unites below with the palatine processes. Into this septum a plate of cartilage extends from the under aspect of the ethmoid plate of the chondrocranium. The anterior part of this cartilaginous plate persists as the septal cartilage of the nose and the medial crus of the alar cartilage, but the posterior and upper parts are replaced by the vomer and perpendicular plate of the ethmoid. On either side of the nasal septum, at its lower and anterior part, the ectoderm is invaginated to form a blind pouch or diverticulum, which extends backward and upward into the nasal septum and is supported by a curved plate of cartilage. These pouches form the rudiments of

the vomero-nasal organs of Jacobson, which open below, close to the junction of the premaxillary and maxillary bones.

The Limbs.—The limbs begin to make their appearance in the third week as small elevations or buds at the side of the trunk (Fig. 52). Prolongations from the muscle- and cutis-plates of several primitive segments extend into each bud, and carry with them the anterior divisions of the corresponding spinal nerves. The nerves supplying the limbs indicate the number of primitive segments which contribute to their formation—the upper limb being derived from seven, viz., fourth cervical to second thoracic inclusive, and the lower limb from ten, viz., twelfth thoracic to fourth sacral inclusive. The axial part of the mesoderm of the limb-bud becomes condensed and converted into its cartilaginous skeleton, and by the ossification of this the bones of the limbs are formed. By the sixth week the three chief divisions of the limbs are marked off by furrows—the upper into arm, forearm, and hand; the lower into thigh, leg, and foot (Fig. 53). The limbs are at first directed backward nearly parallel to the long axis of the trunk,

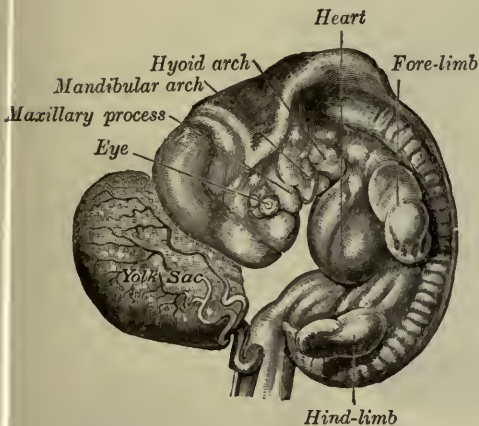


FIG. 52.—Human embryo from thirty-one to thirty-four days. (His.)

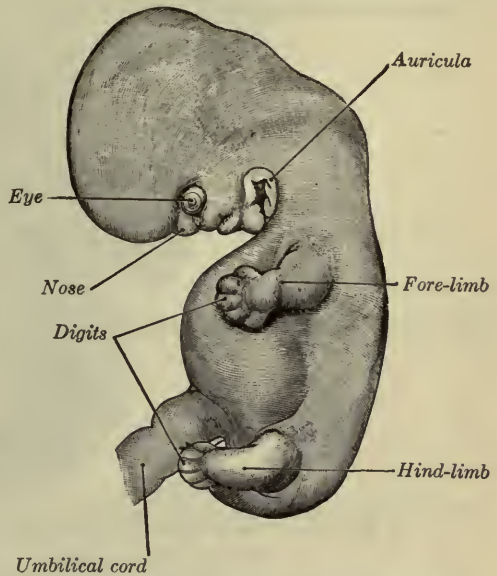


FIG. 53.—Embryo of about six weeks. (His.)

and each presents two surfaces and two borders. Of the surfaces, one—the future *flexor* surface of the limb—is directed ventrally; the other, the *extensor* surface, dorsally; one border, the *preaxial*, looks forward toward the cephalic end of the embryo, and the other, the *postaxial*, backward toward the caudal end. The lateral epicondyle of the humerus, the radius, and the thumb lie along the preaxial border of the upper limb; and the medial epicondyle of the femur, the tibia, and the great toe along the corresponding border of the lower limb. The preaxial part is derived from the anterior segments, the postaxial from the posterior segments of the limb-bud; and this explains, to a large extent, the innervation of the adult limb, the nerves of the more anterior segments being distributed along the preaxial (radial or tibial), and those of the more posterior along the postaxial (ulnar or fibular) border of the limb. The limbs next undergo a rotation or torsion through an angle of 90° around their long axes the rotation being effected almost entirely at the limb girdles. In the upper limb the rotation is outward and forward; in the lower limb, inward and backward. As a consequence of this rotation the preaxial (radial)

border of the fore-limb is directed lateralward, and the preaxial (tibial) border of the hind-limb is directed medialward; thus the flexor surface of the fore-limb is turned forward, and that of the hind-limb backward.

DEVELOPMENT OF THE BODY CAVITIES.

In the human embryo described by Peters the mesoderm outside the embryonic disk is split into two layers enclosing an extra-embryonic cœlom; there is no trace of an intra-embryonic cœlom. At a later stage four cavities are formed within the embryo, viz., one on either side within the mesoderm of the pericardial area, and one in either lateral mass of the general mesoderm. All these are at first independent of each other and of the extra-embryonic celom, but later they become continuous. The two cavities in the general mesoderm unite on the ventral aspect of the gut and form the pleuro-peritoneal cavity, which becomes continuous with the remains of the extra-embryonic celom around the umbilicus; the two cavities in the pericardial area rapidly join to form a single pericardial cavity, and this from two lateral diverticula extend caudalward to open into the pleuro-peritoneal cavity (Fig. 54).

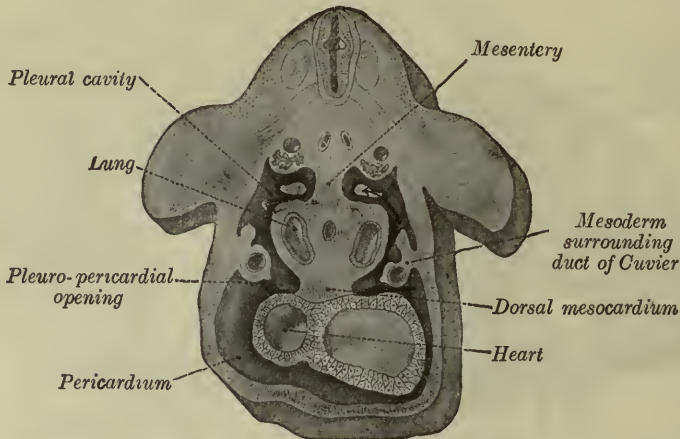


FIG. 54.—Figure obtained by combining several successive sections of a human embryo of about the fourth week (From Kollmann.) The upper arrow is in the pleuroperitoneal opening, the lower in the pleuropericardial.

Between the two latter diverticula is a mass of mesoderm containing the ducts of Cuvier, and this is continuous ventrally with the mesoderm in which the umbilical veins are passing to the sinus venosus. A septum of mesoderm thus extends across the body of the embryo. It is attached in front to the body-wall between the pericardium and umbilicus; behind to the body-wall at the level of the second cervical segment; laterally it is deficient where the pericardial and pleuro-peritoneal cavities communicate, while it is perforated in the middle line by the fore-gut. This partition is termed the **septum transversum**, and is at first a bulky plate of tissue. As development proceeds the dorsal end of the septum is carried gradually caudalward, and when it reaches the fifth cervical segment muscular tissue with the phrenic nerve grows into it. It continues to recede, however, until it reaches the position of the adult diaphragm on the bodies of the upper lumbar vertebræ. The liver buds grow into the septum transversum and undergo development there.

The lung buds meantime have grown out from the fore-gut, and project laterally into the forepart of the pleuro-peritoneal cavity; the developing stomach and liver are imbedded in the septum transversum; caudal to this the intestines project into the back part of the pleuro-peritoneal cavity (Fig. 55). Owing to the descent of

the dorsal end of the septum transversum the lung buds come to lie above the septum and thus pleural and peritoneal portions of the pleuro-peritoneal cavity (still, however, in free communication with one another) may be recognized; the pericardial cavity opens into the pleural part.

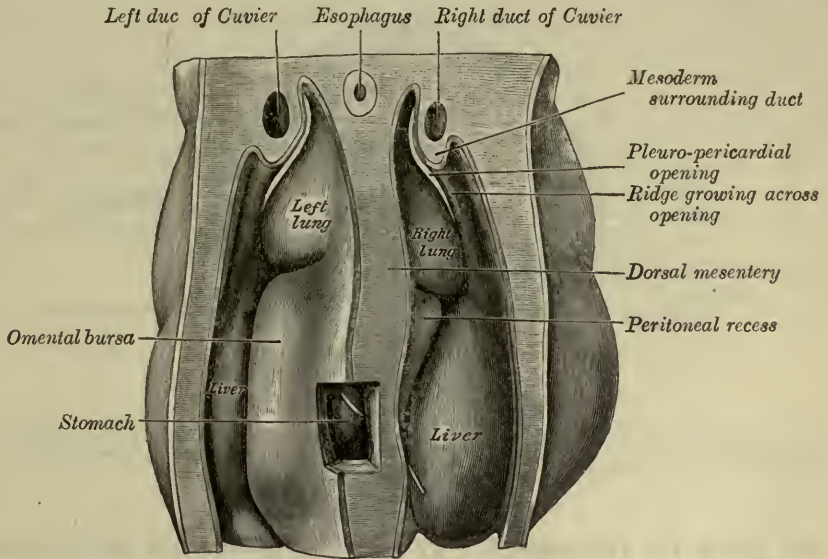


FIG. 55.—Upper part of celom of human embryo of 6.8 mm., seen from behind. (From model by Piper.)

The ultimate separation of the permanent cavities from one another is effected by the growth of a ridge of tissue on either side from the mesoderm surrounding

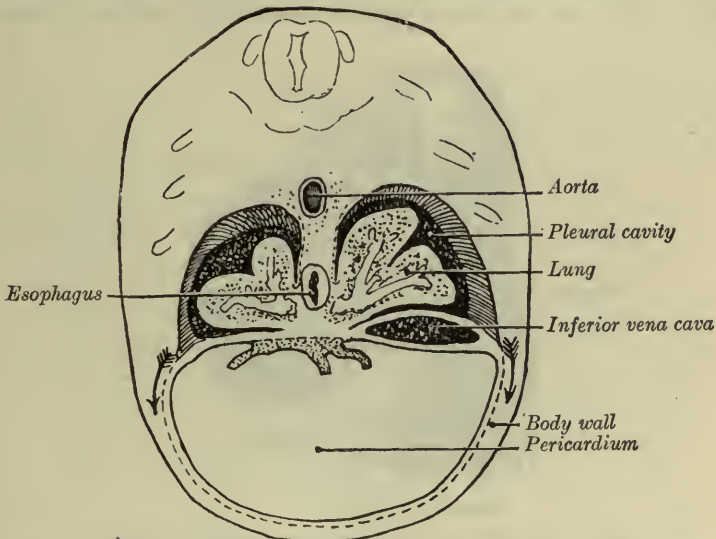


FIG. 56.—Diagram of transverse section through rabbit embryo. (After Keith.)

the duct of Cuvier (Figs. 54, 55). The front part of this ridge grows across and obliterates the pleuro-pericardial opening; the hinder part grows across the pleuro-peritoneal opening.

With the continued growth of the lungs the pleural cavities are pushed forward

in the body-wall toward the ventral median line, thus separating the pericardium from the lateral thoracic walls (Fig. 53). The further development of the peritoneal cavity has been described with the development of the digestive tube (page 168 *et seq.*).

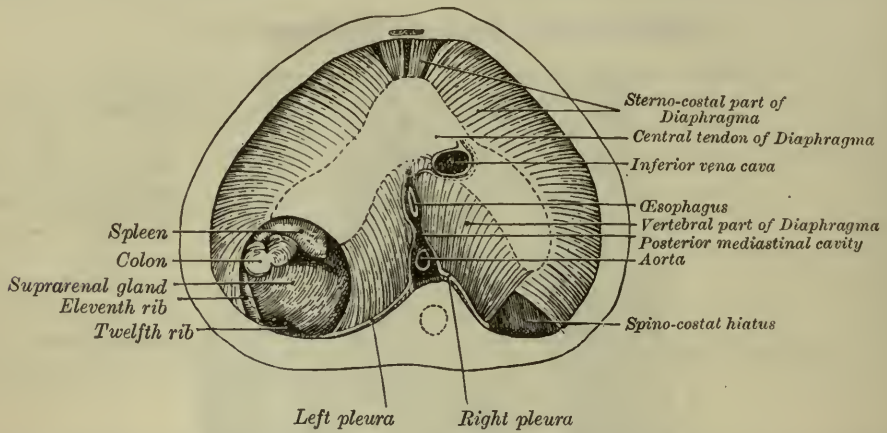


FIG. 57.—The thoracic aspect of the diaphragm of a newly born child in which the communication between the peritoneum and pleura has not been closed on the left side; the position of the opening is marked on the right side by the spinocostal hiatus. (After Keith.)

THE FORM OF THE EMBRYO AT DIFFERENT STAGES OF ITS GROWTH.

First Week.—During this period the ovum is in the uterine tube. Having been fertilized in the upper part of the tube, it slowly passes down, undergoing segmentation, and reaches the uterus. Peters¹ described a specimen, the age of which he reckoned as from three to four days. It was imbedded in the decidua on the posterior wall of the uterus and enveloped by a decidua capsularis, the central part of which, however, consisted merely of a layer of fibrin. The ovum was in the form of a sac, the outer wall of which consisted of a layer of trophoblast; inside this

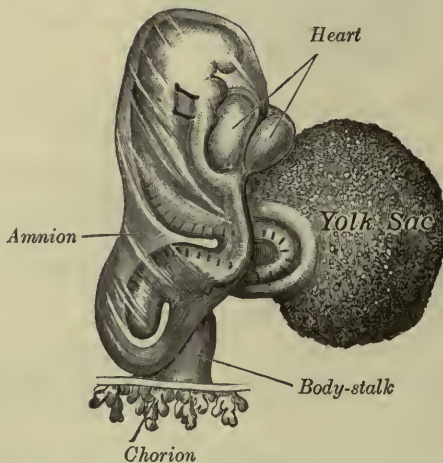


FIG. 58.—Human embryo about fifteen days old. (His.)

was a thin layer of mesoderm composed of round, oval, and spindle-shaped cells. Numerous villous processes—some consisting of trophoblast only, others possessing a core of mesoderm—projected from the surface of the ovum into the surrounding decidua. Inside this sac the rudiment of the embryo was found in the form of a patch of ectoderm, covered by a small but com-

¹ Die Einbettung des menschlichen Eies, 1899.

pletely closed amnion. It possessed a minute yolk-sac and was surrounded by mesoderm, which was connected by a band to that lining the trophoblast (Fig. 32).¹

Second Week.—By the end of this week the ovum has increased considerably in size, and the majority of its villi are vascularized. The embryo has assumed a definite form, and its cephalic and caudal extremities are easily distinguished. The neural folds are partly united. The embryo

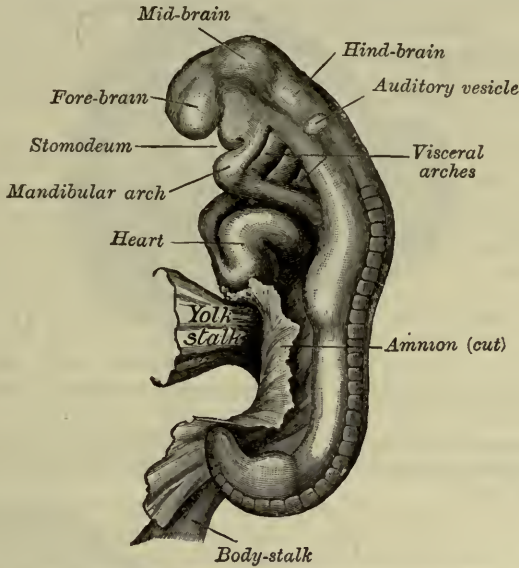


FIG. 59.—Human embryo between eighteen and twenty-one days old. (His.)

is more completely separated from the yolk-sac, and the paraxial mesoderm is being divided into the primitive segments (Fig. 58).

Third Week.—By the end of the third week the embryo is strongly curved, and the primitive segments number about thirty. The primary divisions of the brain are visible, and the optic

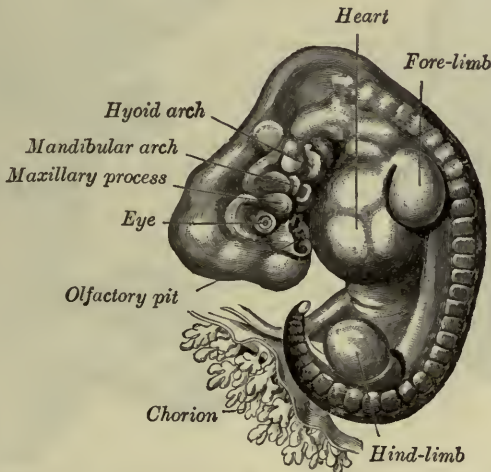


FIG. 60.—Human embryo, twenty-seven to thirty days old. (His.)

and auditory vesicles are formed. Four branchial grooves are present: the stomodeum is well-marked, and the bucco-pharyngeal membrane has disappeared. The rudiments of the limbs are seen as short buds, and the Wolffian bodies are visible (Fig. 59).

¹ Bryce and Teacher (*Early Development and Imbedding of the Human Ovum*, 1908) have described an ovum which they regard as thirteen to fourteen days old. In it the two vesicles, the amnion and yolk-sac, were present, but there was no trace of a layer of embryonic ectoderm. They are of opinion that the age of Peters' ovum has been understated, and estimate it as between thirteen and one-half and fourteen and one-half days.

Fourth Week.—The embryo is markedly curved on itself, and when viewed in profile is almost circular in outline. The cerebral hemispheres appear as hollow buds, and the elevations which form the rudiments of the auricula are visible. The limbs now appear as oval flattened projections (Fig. 60).

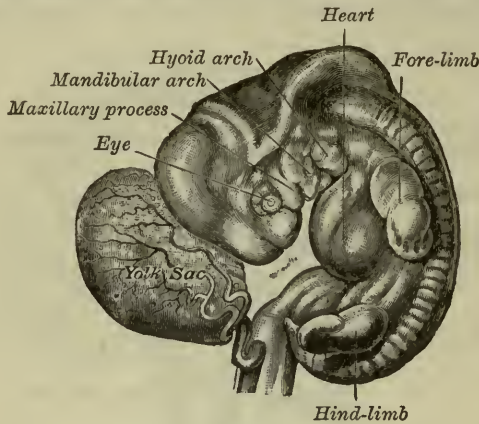


FIG. 61.—Human embryo, thirty-one to thirty-four days old. (His.)

Fifth Week.—The embryo is less curved and the head is relatively of large size. Differentiation of the limbs into their segments occurs. The nose forms a short, flattened projection. The cloacal tubercle is evident (Fig. 61).

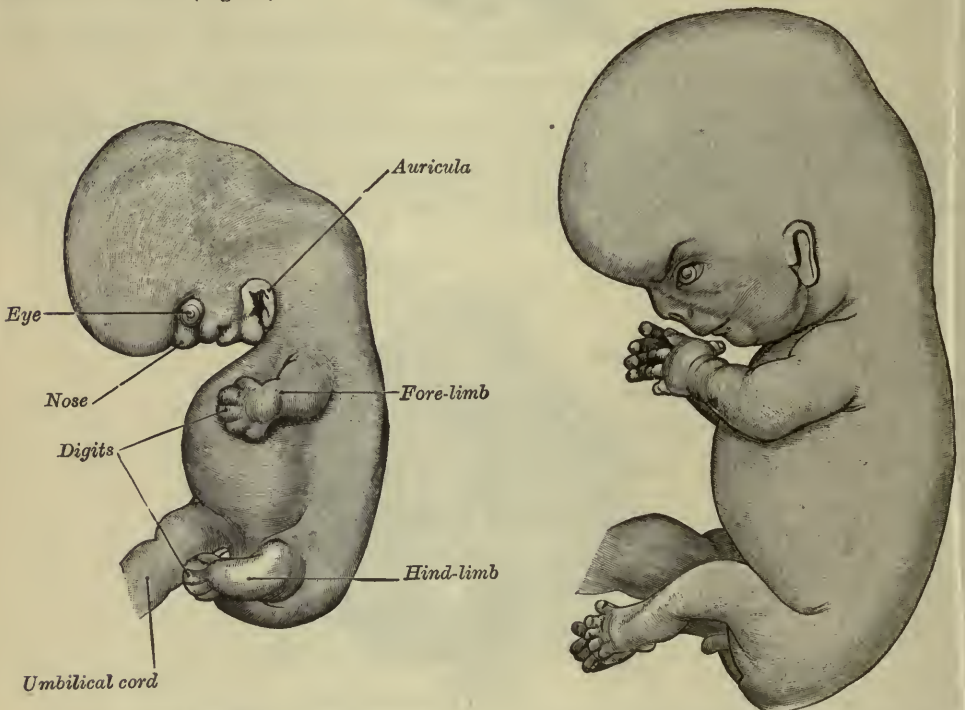


FIG. 62.—Human embryo of about six weeks. (His.)

FIG. 63.—Human embryo about eight and a half weeks old. (His.)

Sixth Week.—The curvature of the embryo is further diminished. The branchial grooves—except the first—have disappeared, and the rudiments of the fingers and toes can be recognized (Fig. 62).

Seventh and Eighth Weeks.—The flexure of the head is gradually reduced and the neck is somewhat lengthened. The upper lip is completed and the nose is more prominent. The nostrils

are directed forward and the palate is not completely developed. The eyelids are present in the shape of folds above and below the eye, and the different parts of the auricula are distinguishable. By the end of the second month the fetus measures from 28 to 30 mm. in length (Fig. 63).

Third Month.—The head is extended and the neck is lengthened. The eyelids meet and fuse, remaining closed until the end of the sixth month. The limbs are well-developed and nails appear on the digits. The external generative organs are so far differentiated that it is possible to distinguish the sex. By the end of this month the length of the fetus is about 7 cm., but if the legs be included it is from 9 to 10 cm.

Fourth Month.—The loop of gut which projected into the umbilical cord is withdrawn within the fetus. The hairs begin to make their appearance. There is a general increase in size so that by the end of the fourth month the fetus is from 12 to 13 cm. in length, but if the legs be included it is from 16 to 20 cm.

Fifth Month.—It is during this month that the first movements of the fetus are usually observed. The eruption of hair on the head commences, and the *vernix caseosa* begins to be deposited. By the end of this month the total length of the fetus, including the legs, is from 25 to 27 cm.

Sixth Month.—The body is covered by fine hairs (*lanugo*) and the deposit of *vernix caseosa* is considerable. The papillæ of the skin are developed and the free border of the nail projects from the corium of the dermis. Measured from vertex to heels, the total length of the fetus at the end of this month is from 30 to 32 cm.

Seventh Month.—The pupillary membrane atrophies and the eyelids are open. The testis descends with the vaginal sac of the peritoneum. From vertex to heels the total length at the end of the seventh month is from 35 to 36 cm. The weight is a little over three pounds.

Eighth Month.—The skin assumes a pink color and is now entirely coated with *vernix caseosa*, and the lanugo begins to disappear. Subcutaneous fat has been developed to a considerable extent, and the fetus presents a plump appearance. The total length, *i. e.*, from head to heels, at the end of the eighth month is about 40 cm., and the weight varies between four and one-half and five and one-half pounds.

Ninth Month.—The lanugo has largely disappeared from the trunk. The umbilicus is almost in the middle of the body and the testes are in the scrotum. At full time the fetus weighs from six and one-half to eight pounds, and measures from head to heels about 50 cm.

BIBLIOGRAPHY.

- BROMAN: Normale und abnorme Entwicklung des Menschen, 1911.
 BRYCE, TEACHER and KERR: Contributions to the Study of the Early Development and Imbedding of the Human Ovum, 1908.
 HERTWIG, O.: Handbuch der Vergleichenden und Experimentellen Entwicklungslehre der Wirbeltiere, 1906.
 HIS, W.: Anatomie menschlicher Embryonen, 1883-1885.
 HOCHSTETTER, F.: Bilder der äusseren Körperform einiger menschlicher Embryonen aus den beiden ersten Monaten der Entwicklung, 1907.
 KEIBEL and ELZE: Normentafel zur Entwicklungsgeschichte des Menschen, 1908.
 KEIBEL and MALL: Manual of Human Embryology, 1910-1912.
 KOLLMANN, J.: Handatlas der Entwicklungsgeschichte des Menschen, 1907.
 KOLLMANN, J.: Lehrbuch der Entwicklungsgeschichte des Menschen, 1898.
 MALL: Contribution to the Study of the Pathology of the Human Embryo, Jour. of Morph., 1908. See also contributions to Embryology of the Carnegie Institution of Washington.
 MALL: Development of the Human Cœlom, Jour. of Morph., 1897.
 PETERS, H.: Ueber die Einbettung des menschlichen Eies und das früheste bisher bekannte menschliche Placentationsstadium, 1899.

OSTEOLOGY.

THE general framework of the body is built up mainly of a series of bones, supplemented, however, in certain regions by pieces of cartilage; the bony part of the framework constitutes the **skeleton**.

In the skeleton of the adult there are 206 distinct bones, as follows:—

Axial	{	Vertebral column	26	
		Skull	22	
Skeleton	{	Hyoid bone	1	
		Ribs and sternum	25	
			—	74
Appendicular	{	Upper extremities	64	
Skeleton	{	Lower extremities	62	
			—	126
Auditory ossicles			6	
			—	
		Total		206

The patellæ are included in this enumeration, but the smaller sesamoid bones are not reckoned.

Bones are divisible into four classes: *Long, Short, Flat, and Irregular*.

Long Bones.—The long bones are found in the limbs, and each consists of a body or shaft and two extremities. The **body**, or **diaphysis** is cylindrical, with a central cavity termed the **medullary canal**; the wall consists of dense, compact tissue of considerable thickness in the middle part of the body, but becoming thinner toward the extremities; within the medullary canal is some cancellous tissue, scanty in the middle of the body but greater in amount toward the ends. The *extremities* are generally expanded, for the purposes of articulation and to afford broad surfaces for muscular attachment. They are usually developed from separate centers of ossification termed **epiphyses**, and consist of cancellous tissue surrounded by thin compact bone. The medullary canal and the spaces in the cancellous tissue are filled with marrow. The long bones are not straight, but curved, the curve generally taking place in two planes, thus affording greater strength to the bone. The bones belonging to this class are: the **clavicle, humerus, radius, ulna, femur, tibia, fibula, metacarpals, metatarsals, and phalanges**.

Short Bones.—Where a part of the skeleton is intended for strength and compactness combined with limited movement, it is constructed of a number of short bones, as in the **carpus** and **tarsus**. These consist of cancellous tissue covered by a thin crust of compact substance. The **patellæ**, together with the other sesamoid bones, are by some regarded as short bones.

Flat Bones.—Where the principal requirement is either extensive protection or the provision of broad surfaces for muscular attachment, the bones are expanded into broad, flat plates, as in the **skull** and the **scapula**. These bones are composed of two thin layers of compact tissue enclosing between them a variable quantity of cancellous tissue. In the cranial bones, the layers of compact tissue are familiarly known as the **tables of the skull**; the outer one is thick and tough; the inner is thin, dense, and brittle, and hence is termed the **vitreous table**. The intervening

cancellous tissue is called the **diploë**, and this, in certain regions of the skull, becomes absorbed so as to leave spaces filled with air (*air-sinuses*) between the two tables. The flat bones are: the **occipital, parietal, frontal, nasal, lacrimal, vomer, scapula, os coxæ** (*hip bone*), **sternum, ribs**, and, according to some, the **patella**.

Irregular Bones.—The irregular bones are such as, from their peculiar form, cannot be grouped under the preceding heads. They consist of cancellous tissue enclosed within a thin layer of compact bone. The irregular bones are: the **vertebræ, sacrum, coccyx, temporal, sphenoid, ethmoid, zygomatic, maxilla, mandible, palatine, inferior nasal concha, and hyoid**.

Surfaces of Bones.—If the surface of a bone be examined, certain eminences and depressions are seen. These eminences and depressions are of two kinds: articular and non-articular. Well-marked examples of **articular eminences** are found in the heads of the humerus and femur; and of **articular depressions** in the glenoid cavity of the scapula, and the acetabulum of the hip bone. **Non-articular eminences** are designated according to their form. Thus, a broad, rough, uneven elevation is called a **tuberosity, protuberance, or process**; a small, rough prominence, a **tubercle**; a sharp, slender pointed eminence, a **spine**; a narrow, rough elevation, running some way along the surface, a **ridge, crest, or line**. *Non-articular depressions* are also of variable form, and are described as **fossæ, pits, depressions, grooves, furrows, fissures, notches**, etc. These non-articular eminences and depressions serve to increase the extent of surface for the attachment of ligaments and muscles, and are usually well-marked in proportion to the muscularity of the subject. A short perforation is called a **foramen**, a longer passage a **canal**.

DEVELOPMENT OF THE SKELETON.

The Skeleton.—The skeleton is of mesodermal origin, and may be divided into (a) that of the trunk (**axial skeleton**), comprising the vertebral column, skull, ribs, and sternum, and (b) that of the limbs (**appendicular skeleton**).

The Vertebral Column.—The notochord (Fig. 19) is a temporary structure and forms a central axis, around which the segments of the vertebral column are developed.¹ It is derived from the entoderm, and consists of a rod of cells, which lies on the ventral aspect of the neural tube and reaches from the anterior end of the mid-brain to the extremity of the tail. On either side of it is a column of paraxial mesoderm which becomes subdivided into a number of more or less cubical segments, the **primitive segments** (Figs. 19 and 20). These are separated from one another by **intersegmental septa** and are arranged symmetrically on either side of the neural tube and notochord: to every segment a spinal nerve is distributed. At first each segment contains a central cavity, the **myocœl**, but this is soon filled with a core of angular and spindle-shaped cells. The cells of the segment become differentiated into three groups, which form respectively the **cutis-plate or dermatome, the muscle-plate or myotome, and the sclerotome** (Fig. 64). The **cutis-plate** is placed on the lateral and dorsal aspect of the myocœl, and from it the true skin of the corresponding segment is derived; the **muscle-plate** is situated on the medial side of the cutis-plate and furnishes the muscles of the segment. The cells of the **sclerotome** are largely derived from those forming the core of the myocœl, and lie next the notochord. Fusion of the individual sclerotomes in an antero-posterior direction soon takes place, and thus a continuous strand of cells, the **sclerotogenous layer**, is formed along the ventro-lateral aspects of the neural tube. The cells of this layer proliferate rapidly, and extending medialward surround the notochord; at the same time they grow backward on the lateral aspects of the neural tube and eventually surround it, and thus the notochord and neural tube are enveloped

¹ In the amphioxus the notochord persists and forms the only representative of a skeleton in that animal.

by a continuous sheath of mesoderm; which is termed the **membranous vertebral column**. In this mesoderm the original segments are still distinguishable, but each is now differentiated into two portions, an anterior, consisting of loosely arranged cells, and a posterior, of more condensed tissue (Fig. 65, *A* and *B*). Between the two portions the rudiment of the intervertebral fibrocartilage is laid down (Fig. 65, *C*). Cells from the posterior mass grow into the intervals between the myotomes (Fig. 65, *B* and *C*) of the corresponding and succeeding segments, and extend both dorsally and ventrally; the dorsal extensions surround the neural tube and represent the future vertebral arch, while the ventral extend into the body-wall as the costal processes. The hinder part of the posterior mass joins the anterior mass of the succeeding segment to form the vertebral body. Each vertebral body is there-

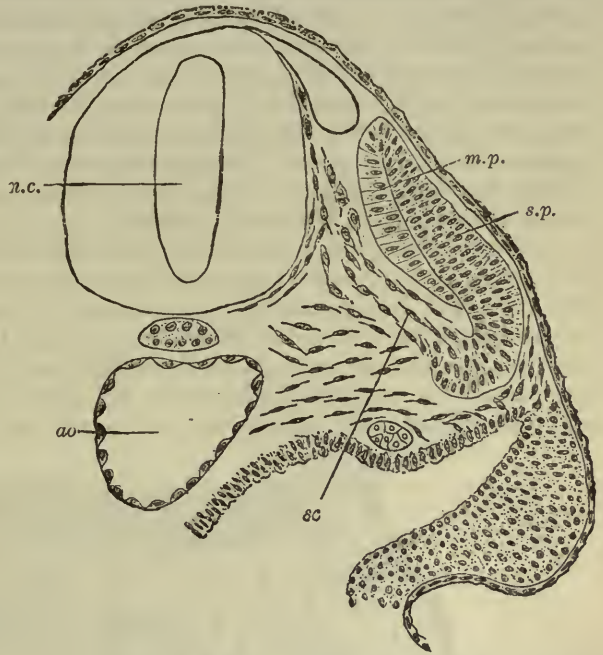


FIG. 64.—Transverse section of a human embryo of the third week to show the differentiation of the primitive segment. (Kollmann.) *ao.* Aorta. *m.p.* Muscle-plate. *n.c.* Neural canal. *sc.* Sclerotome. *s.p.* cutis-plate.

fore a composite of two segments, being formed from the posterior portion of one segment and the anterior part of that immediately behind it. The vertebral

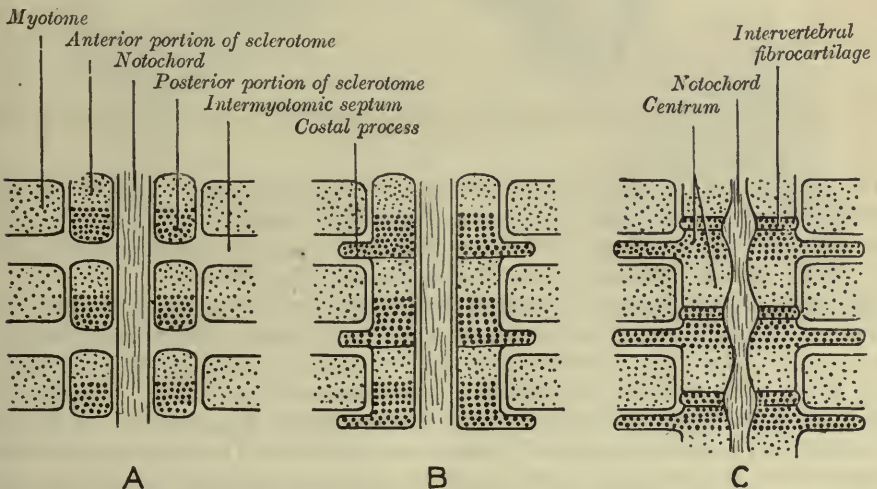


FIG. 65.—Scheme showing the manner in which each vertebral centrum is developed from portions of two adjacent segments.

and costal arches are derivatives of the posterior part of the segment in front of the intersegmental septum with which they are associated.

This stage is succeeded by that of the **cartilaginous vertebral column**. In the fourth week two cartilaginous centers make their appearance, one on either side of the notochord; these extend around the notochord and form the body of the cartilaginous vertebra. A second pair of cartilaginous foci appear in the lateral parts of the vertebral bow, and grow backward on either side of the neural tube to form the cartilaginous vertebral arch, and a separate cartilaginous center appears for each costal process. By the eighth week the cartilaginous arch has fused with the body, and in the fourth month the two halves of the arch are joined on the dorsal aspect of the neural tube. The spinous process is developed from the junction of the two halves of the vertebral arch. The transverse process grows out from the vertebral arch behind the costal process.

In the upper cervical vertebræ a band of mesodermal tissue connects the ends of the vertebral arches across the ventral surfaces of the intervertebral fibrocartilages. This is termed the **hypochordal bar** or **brace**; in all except the first it is transitory and disappears by fusing with the fibrocartilages. In the atlas, however, the entire bow persists and undergoes chondrification; it develops into the anterior arch of the bone, while the cartilage representing the body of the atlas forms the dens or odontoid process which fuses with the body of the second cervical vertebra.

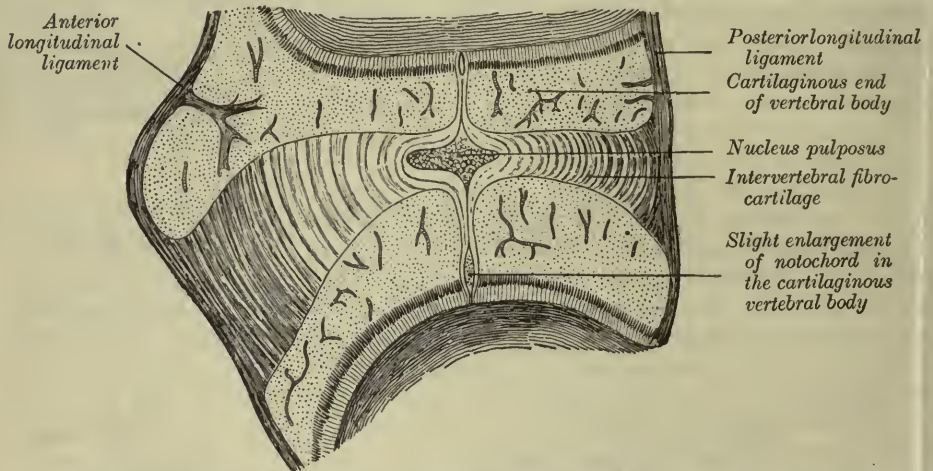


FIG. 66.—Sagittal section through an intervertebral fibrocartilage and adjacent parts of two vertebræ of an advanced sheep's embryo. (Kölliker.)

The portions of the notochord which are surrounded by the bodies of the vertebræ atrophy, and ultimately disappear, while those which lie in the centers of the intervertebral fibrocartilages undergo enlargement, and persist throughout life as the central **nucleus pulposus** of the fibrocartilages (Fig. 66).

The Ribs.—The ribs are formed from the ventral or costal processes of the primitive vertebral bows, the processes extending between the muscle-plates. In the *thoracic region* of the vertebral column the costal processes grow lateralward to form a series of arches, the **primitive costal arches**. As already described, the transverse process grows out behind the vertebral end of each arch. It is at first connected to the costal process by continuous mesoderm, but this becomes differentiated later to form the costotransverse ligament; between the costal process and the tip of the transverse process the costotransverse joint is formed by absorption. The costal process becomes separated from the vertebral bow by the development of the costocentral joint. In the *cervical vertebræ* (Fig. 67) the transverse process forms the posterior boundary of the foramen transversarium, while the costal process corresponding to the head and neck of the rib fuses with the

body of the vertebra, and forms the antero-lateral boundary of the foramen. The distal portions of the primitive costal arches remain undeveloped; occasionally the arch of the seventh cervical vertebra undergoes greater development, and by the formation of costovertebral joints is separated off as a rib. In the *lumbar region* the distal portions of the primitive costal arches fail; the proximal portions fuse with the transverse processes to form the transverse processes of descriptive anatomy. Occasionally a movable rib is developed in connection with the first lumbar vertebra. In the *sacral region* costal processes are developed only in connection with the upper three, or it may be four, vertebræ; the processes of adjacent segments fuse with one another to form the lateral parts of the sacrum. The *coccygeal vertebræ* are devoid of costal processes.

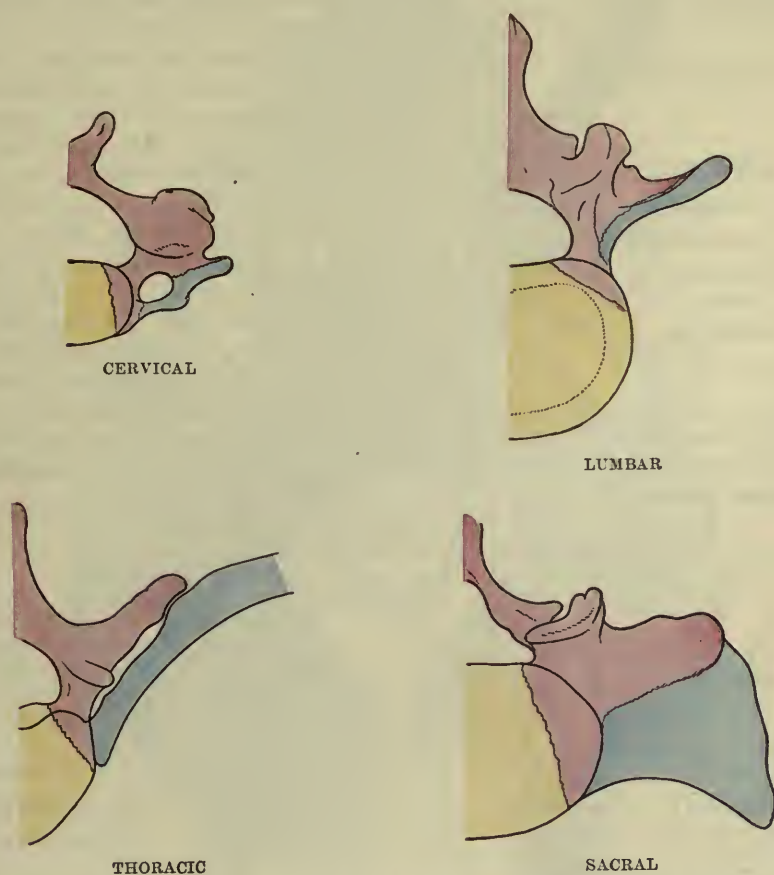


FIG. 67.—Diagrams showing the portions of the adult vertebræ derived respectively from the bodies, vertebral arches, and costal processes of the embryonic vertebræ. The bodies are represented in yellow, the vertebral arches in red, and the costal processes in blue.

The Sternum.—The ventral ends of the ribs become united to one another by a longitudinal bar termed the **sternal plate**, and opposite the first seven pairs of ribs these sternal plates fuse in the middle line to form the manubrium and body of the sternum. The xiphoid process is formed by a backward extension of the sternal plates.

The Skull.—Up to a certain stage the development of the skull corresponds with that of the vertebral column; but it is modified later in association with the expansion of the brain-vesicles, the formation of the organs of smell, sight, and hearing, and the development of the mouth and pharynx.

The notochord extends as far forward as the anterior end of the mid-brain, and becomes partly surrounded by mesoderm (Fig. 68). The posterior part of this mesodermal investment corresponds with the basilar part of the occipital bone, and shows a subdivision into four segments, which are separated by the roots of the hypoglossal nerve. The mesoderm then extends over the brain-vesicles, and thus the entire brain is enclosed by a mesodermal investment, which is termed the **membranous cranium**. From the inner layer of this the bones of the skull and the membranes of the brain are developed; from the outer layer the muscles, bloodvessels, true skin, and subcutaneous tissues of the scalp. In the shark and dog-fish this membranous cranium undergoes complete chondrification, and forms the cartilaginous skull or **chondrocranium** of these animals. In mammals, on the other hand, the process of chondrification is limited to the base of the skull—the roof and sides being covered in by membrane. Thus the bones of the base of the skull are preceded by cartilage, those of the roof and sides by membrane. The posterior part of the base of the skull is developed around the notochord, and exhibits a segmented condition analogous to that of the vertebral column, while the anterior part arises in front of the notochord and shows no regular segmentation. The base of the skull may therefore be divided into (a) a **chordal or vertebral**, and (b) a **prechordal or prevertebral** portion.

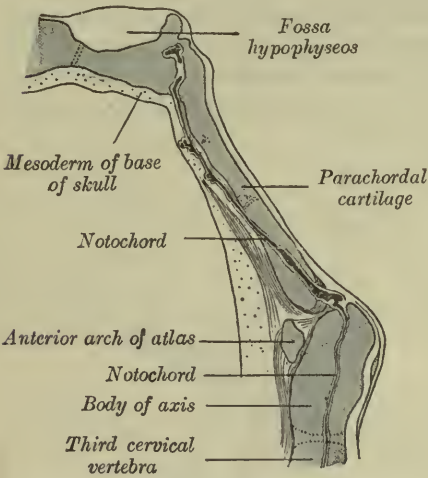


FIG. 68.—Sagittal section of cephalic end of notochord. (Keibel.)

The posterior part of the base of the skull is developed around the notochord, and exhibits a segmented condition analogous to that of the vertebral column, while the anterior part arises in front of the notochord and shows no regular segmentation. The base of the skull may therefore be divided into (a) a **chordal or vertebral**, and (b) a **prechordal or prevertebral** portion.

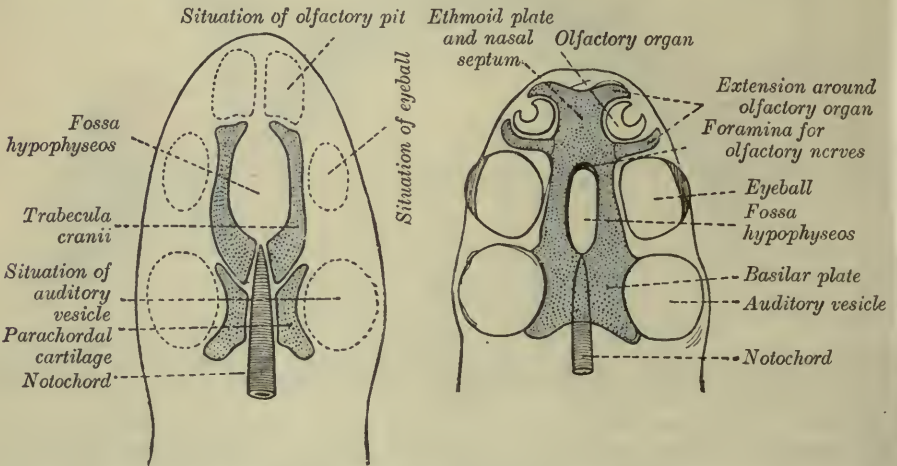


FIG. 69.—Diagrams of the cartilaginous cranium. (Wiedersheim.)

In the lower vertebrates two pairs of cartilages are developed, viz., a pair of parachordal cartilages, one on either side of the notochord; and a pair of prechordal cartilages, the **trabeculae cranii**, in front of the notochord (Fig. 66). The **parachordal cartilages** (Fig. 69) unite to form a basilar plate, from which the cartilaginous part of the occipital bone and the basi-sphenoid are developed. On the lateral aspects of the parachordal cartilages the auditory vesicles are situated,

and the mesoderm enclosing them is soon converted into cartilage, forming the **cartilaginous ear-capsules**. These cartilaginous ear-capsules, which are of an oval shape, fuse with the sides of the basilar plate, and from them arise the petrous and mastoid portions of the temporal bones. The **trabeculae cranii** (Fig. 69) are two curved bars of cartilage which embrace the hypophysis cerebri; their posterior ends soon unite with the basilar plate, while their anterior ends join to form the **ethmoidal plate**, which extends forward between the fore-brain and the olfactory pits. Later the trabeculae meet and fuse below the hypophysis, forming the floor

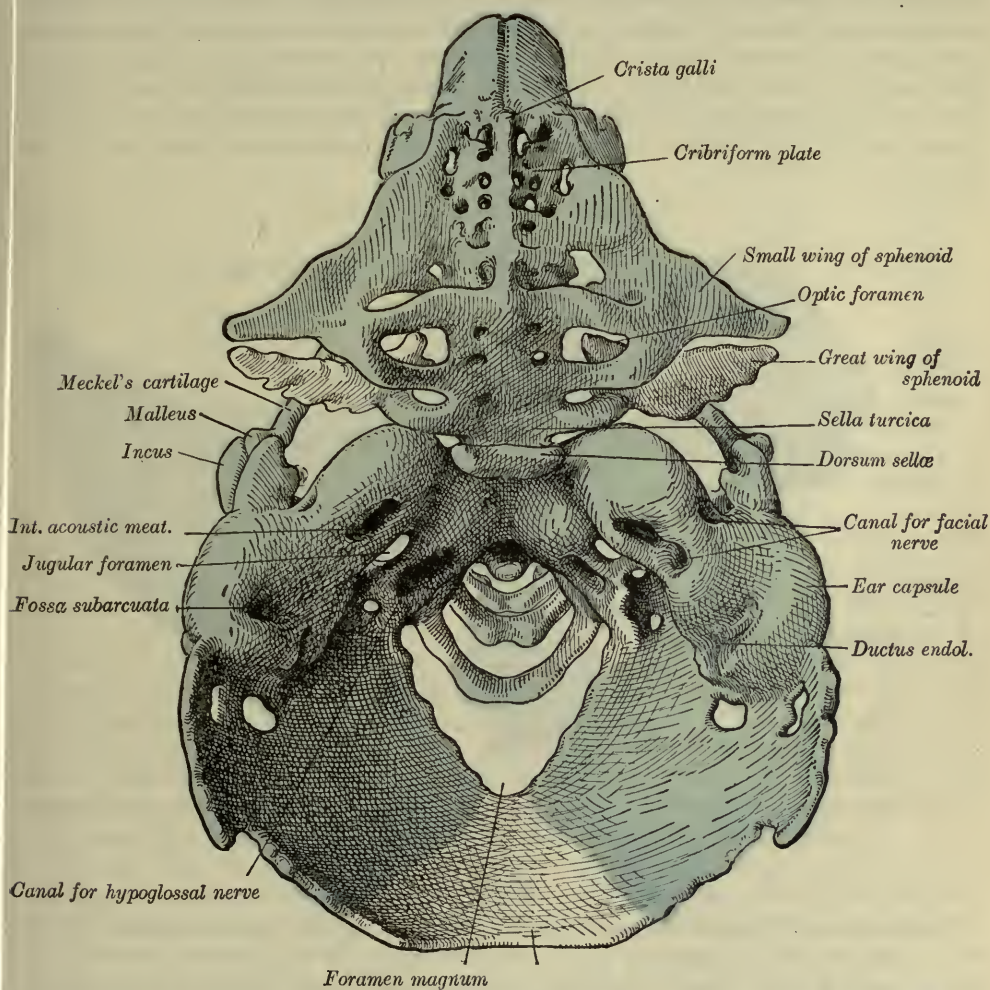


FIG. 70.—Model of the chondrocranium of a human embryo, 8 cm. long. (Hertwig.) The membrane bones are not represented.

of the fossa hypophyseos and so cutting off the anterior lobe of the hypophysis from the stomodeum. The median part of the ethmoidal plate forms the bony and cartilaginous parts of the nasal septum. From the lateral margins of the trabeculae cranii three processes grow out on either side. The anterior forms the ethmoidal labyrinth and the lateral and alar cartilages of the nose; the middle gives rise to the small wing of the sphenoid, while from the posterior the great wing and lateral pterygoid plate of the sphenoid are developed (Figs. 70, 71). The bones of the vault are of membranous formation, and are termed **dermal** or **covering bones**. They are partly developed from the mesoderm of the membranous

cranium, and partly from that which lies outside the entoderm of the fore-gut. They comprise the upper part of the occipital squama (interparietal), the squamæ and tympanic parts of the temporals, the parietals, the frontal, the vomer, the medial pterygoid plates, and the bones of the face. Some of them remain distinct throughout life, *e. g.*, parietal and frontal, while others join with the bones of the chondrocranium, *e. g.*, interparietal, squamæ of temporals, and medial pterygoid plates.

Recent observations have shown that, in mammals, the basi-cranial cartilage, both in the chordal and prechordal regions of the base of the skull, is developed as a single plate which extends from behind forward. In man, however, its posterior part shows an indication of being developed from two chondrifying centers which fuse rapidly in front and below. The anterior and posterior thirds of the cartilage surround the notochord, but its middle third lies on the dorsal aspect of the notochord, which in this region is placed between the cartilage and the wall of the pharynx.

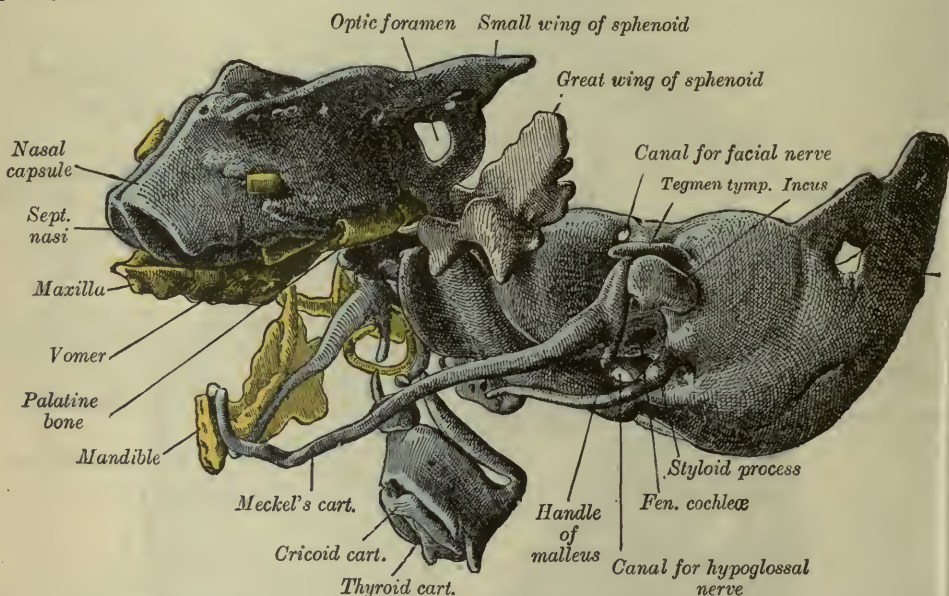


FIG. 71.—The same model as shown in Fig. 70 from the left side. Certain of the membrane bones of the right side are represented in yellow. (Hertwig.)

BONE

Structure and Physical Properties.—Bone is one of the hardest structures of the animal body; it possesses also a certain degree of toughness and elasticity. Its color, in a fresh state, is pinkish-white externally, and deep red within. On examining a section of any bone, it is seen to be composed of two kinds of tissue, one of which is dense in texture, like ivory, and is termed **compact tissue**; the other consists of slender fibers and lamellæ, which join to form a reticular structure; this, from its resemblance to lattice-work, is called **cancellous tissue**. The compact tissue is always placed on the exterior of the bone, the cancellous in the interior. The relative quantity of these two kinds of tissue varies in different bones, and in different parts of the same bone, according as strength or lightness is requisite. Close examination of the compact tissue shows it to be extremely porous, so that the difference in structure between it and the cancellous tissue depends merely upon the different amount of solid matter, and the size and number of spaces in each; the cavities are small in the compact tissue and the solid matter between

them abundant, while in the cancellous tissue the spaces are large and the solid matter is in smaller quantity.

Bone during life is permeated by vessels, and is enclosed, except where it is coated with articular cartilage, in a fibrous membrane, the **periosteum**, by means of which many of these vessels reach the hard tissue. If the periosteum be stripped from the surface of the living bone, small bleeding points are seen which mark the entrance of the periosteal vessels; and on section during life every part of the bone exudes blood from the minute vessels which ramify in it. The interior of each of the long bones of the limbs presents a cylindrical cavity filled with marrow and lined by a highly vascular areolar structure, called the **medullary membrane**.

THE STRENGTH OF BONE COMPARED WITH OTHER MATERIALS

Substance.	Weight in pounds per cubic foot.	Ultimate strength. Pounds per square inch.		
		Tension.	Compression.	Shear.
Medium steel	490	65,000	60,000	40,000
Granite	170	1,500	15,000	2,000
Oak, white	46	12,500 ¹	7,000 ¹	4,000 ²
Compact bone (low)	119	13,200 ¹	18,000 ¹	11,800 ²
Compact bone (high)	17,700 ¹	24,000 ¹	7,150 ¹

Periosteum.—The periosteum adheres to the surface of each of the bones in nearly every part, but not to cartilaginous extremities. When strong tendons or ligaments are attached to a bone, the periosteum is incorporated with them. It consists of two layers closely united together, the outer one formed chiefly of connective tissue, containing occasionally a few fat cells; the inner one, of elastic fibers of the finer kind, forming dense membranous networks, which again can be separated into several layers. In young bones the periosteum is thick and very vascular, and is intimately connected at either end of the bone with the epiphysial cartilage, but less closely with the body of the bone, from which it is separated by a layer of soft tissue, containing a number of **granular corpuscles** or **osteoblasts**, by which ossification proceeds on the exterior of the young bone. Later in life the periosteum is thinner and less vascular, and the osteoblasts are converted into an epithelioid layer on the deep surface of the periosteum. The periosteum serves as a nidus for the ramification of the vessels previous to their distribution in the bone; hence the liability of bone to exfoliation or necrosis when denuded of this membrane by injury or disease. Fine nerves and lymphatics, which generally accompany the arteries, may also be demonstrated in the periosteum.

Marrow.—The marrow not only fills up the cylindrical cavities in the bodies of the long bones, but also occupies the spaces of the cancellous tissue and extends into the larger bony canals (Haversian canals) which contain the bloodvessels. It differs in composition in different bones. In the bodies of the long bones the marrow is of a *yellow* color, and contains, in 100 parts, 96 of fat, 1 of areolar tissue and vessels, and 3 of fluid with extractive matter; it consists of a basis of connective tissue supporting numerous bloodvessels and cells, most of which are fat cells but some are "marrow cells," such as occur in the red marrow to be immediately described. In the flat and short bones, in the articular ends of the long bones, in the bodies of the vertebræ, in the cranial diploë, and in the sternum and ribs the marrow is of a *red* color, and contains, in 100 parts, 75 of water, and 25 of solid matter consisting of cell-globulin, nucleoprotein, extractives, salts, and only a small proportion of fat. The red marrow consists of a small quantity of connective tissue, bloodvessels, and numerous cells (Fig. 72), some few of which are fat cells,

¹ Indicates stresses with the grain, *i. e.*, when the load is parallel to the long axis of the material, or parallel to the direction of the fibers of the material.

² Indicates unit-stresses across the grain, *i. e.*, at right angles to the direction of the fibers of the material.

but the great majority are roundish nucleated cells, the true "marrow cells" of Kölliker. These marrow cells proper, or **myelocytes**, resemble in appearance lymphoid corpuscles, and like them are ameboid; they generally have a hyaline protoplasm, though some show granules either oxyphil or basophil in reaction. A number of eosinophil cells are also present. Among the marrow cells may be seen smaller cells, which possess a slightly pinkish hue; these are the **erythroblasts** or **normoblasts**, from which the red corpuscles of the adult are derived, and which may be regarded as descendants of the nucleated colored corpuscles of the embryo. **Giant cells** (*myeloplaxes*, *osteoclasts*), large, multinucleated, protoplasmic masses, are also to be found in both sorts of adult marrow, but more particularly in red marrow. They were believed by Kölliker to be concerned in the absorption of bone matrix, and hence the name which he gave to them—*osteoclasts*. They excavate in the bone small shallow pits or cavities, which are named **Howship's foveolæ**, and in these they are found lying.

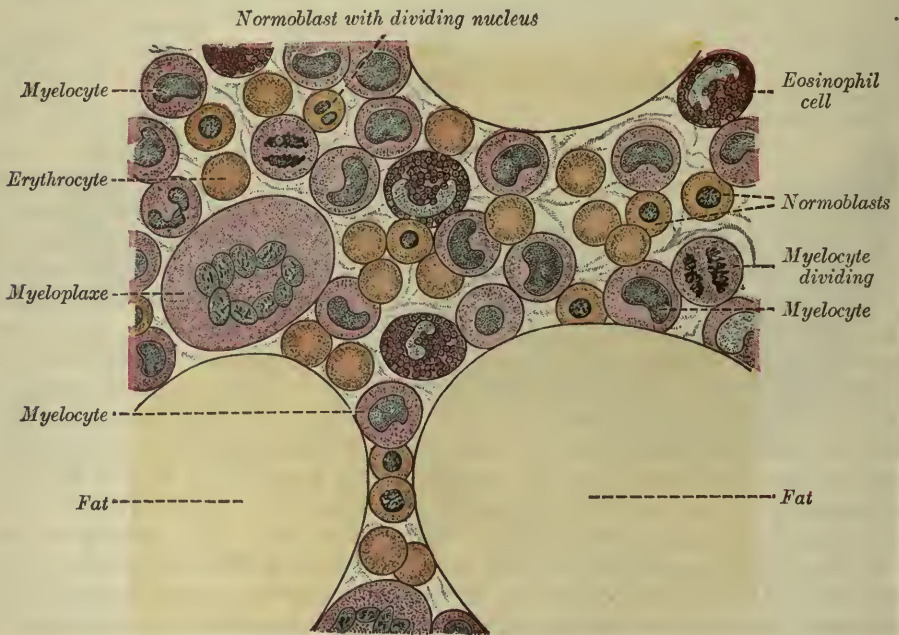

FIG. 72.—Human bone marrow. Highly magnified.

Vessels and Nerves of Bone.—The bloodvessels of bone are very numerous. Those of the compact tissue are derived from a close and dense network of vessels ramifying in the periosteum. From this membrane vessels pass into the minute orifices in the compact tissue, and run through the canals which traverse its substance. The cancellous tissue is supplied in a similar way, but by less numerous and larger vessels, which, perforating the outer compact tissue, are distributed to the cavities of the spongy portion of the bone. In the long bones, numerous apertures may be seen at the ends near the articular surfaces; some of these give passage to the arteries of the larger set of vessels referred to; but the most numerous and largest apertures are for some of the veins of the cancellous tissue, which emerge apart from the arteries. The marrow in the body of a long bone is supplied by one large artery (or sometimes more), which enters the bone at the nutrient foramen (situated in most cases near the center of the body), and perforates obliquely the compact structure. The *medullary* or *nutrient* artery, usually accompanied by one or two veins, sends branches upward and downward, which ramify in the medullary membrane, and give twigs to the adjoining canals. The ramifications of this

vessel anastomose with the arteries of the cancellous and compact tissues. In most of the flat, and in many of the short spongy bones, one or more large apertures are observed, which transmit to the central parts of the bone vessels corresponding to the nutrient arteries and veins. The **veins** emerge from the long bones in three places (Kölliker): (1) one or two large veins accompany the artery; (2) numerous large and small veins emerge at the articular extremities; (3) many small veins pass out of the compact substance. In the flat cranial bones the veins are large, very numerous, and run in tortuous canals in the diploic tissue, the sides of the canals being formed by thin lamellæ of bone, perforated here and there for the passage of branches from the adjacent cancelli. The same condition is also found in all cancellous tissue, the veins being enclosed and supported by osseous material, and having exceedingly thin coats. When a bone is divided, the vessels remain patulous, and do not contract in the canals in which they are contained. **Lymphatic vessels**, in addition to those found in the periosteum, have been traced by Cruikshank into the substance of bone, and Klein describes them as running in the Haversian canals. **Nerves** are distributed freely to the periosteum, and accompany the nutrient arteries into the interior of the bone. They are said by Kölliker to be most numerous in the articular extremities of the long bones, in the vertebræ, and in the larger flat bones.

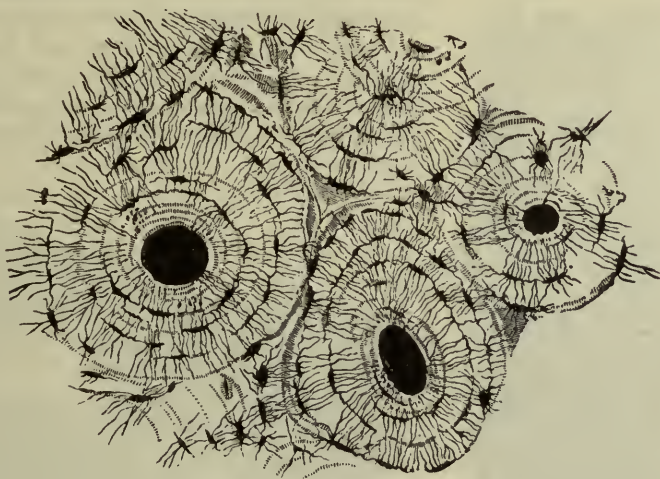

FIG. 73.—Transverse section of compact tissue bone. Magnified. (Sharpey.)

Minute Anatomy.—A transverse section of dense bone may be cut with a saw and ground down until it is sufficiently thin.

If this be examined with a rather low power the bone will be seen to be mapped out into a number of circular districts each consisting of a central hole surrounded by a number of concentric rings. These districts are termed **Haversian systems**; the central hole is an **Haversian canal**, and the rings are layers of bony tissue arranged concentrically around the central canal, and termed **lamellæ**. Moreover, on closer examination it will be found that between these lamellæ, and therefore also arranged concentrically around the central canal, are a number of little dark spots, the **lacunæ**, and that these lacunæ are connected with each other and with the central Haversian canal by a number of fine dark lines, which radiate like the spokes of a wheel and are called **canaliculi**. Filling in the irregular intervals which are left between these circular systems are other lamellæ, with their lacunæ and canaliculi running in various directions, but more or less curved (Fig. 73); they are termed **interstitial lamellæ**. Again, other lamellæ, found on the surface of the bone, are arranged parallel to its circumference; they are termed **circum-**

ferential, or by some authors **primary** or **fundamental lamellæ**, to distinguish them from those laid down around the axes of the Haversian canals, which are then termed **secondary** or **special lamellæ**.

The **Haversian canals**, seen in a transverse section of bone as round holes at or about the center of each Haversian system, may be demonstrated to be true canals if a longitudinal section be made (Fig. 74). It will then be seen that the canals run parallel with the longitudinal axis of the bone for a short distance and then branch and communicate. They vary considerably in size, some being as much as 0.12 mm. in diameter; the average size is, however, about 0.05 mm. Near the medullary cavity the canals are larger than those near the surface of the bone. Each canal contains one or two bloodvessels, with a small quantity of delicate connective tissue and some nerve filaments. In the larger ones there are also lymphatic vessels, and cells with branching processes which communicate, through the canaliculi, with the branched processes of certain bone cells in the substance of the bone. Those canals near the surface of the bone open upon it by minute orifices, and those near the medullary cavity open in the same way into this space, so that the whole of the bone is permeated by a system of bloodvessels running through the bony canals in the centers of the Haversian systems.

The **lamellæ** are thin plates of bony tissue encircling the central canal, and may be compared, for the sake of illustration, to a number of sheets of paper pasted one over another around a central hollow cylinder. After macerating a piece of bone in dilute mineral acid, these lamellæ may be stripped off in a

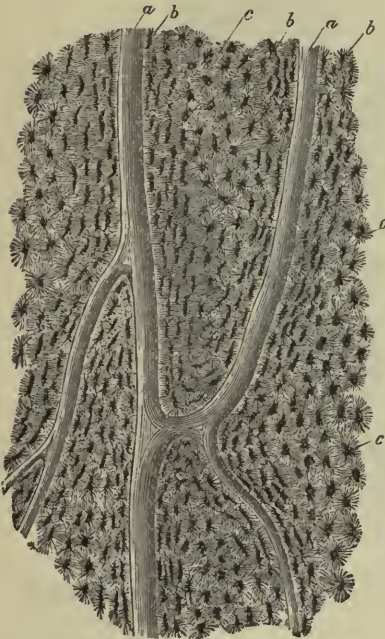


FIG. 74.—Section parallel to the surface from the body of the femur. $\times 100$. *a*, Haversian canals; *b*, lacunæ seen from the side; *c*, others seen from the surface in lamellæ, which are cut horizontally.

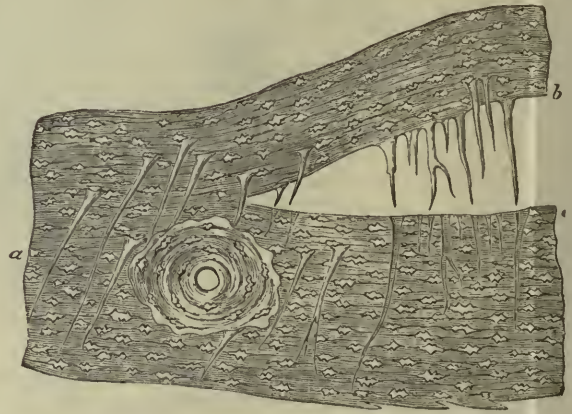


FIG. 75.—Perforating fibers, human parietal bone, decalcified. (H. Müller.) *a*, perforating fibers *in situ*; *b*, fibres drawn out of their sockets; *c*, sockets.

longitudinal direction as thin films. If one of these be examined with a high power of the microscope, it will be found to be composed of a finely reticular structure, made up of very slender transparent fibers, decussating obliquely; and coalescing at the points of intersection; these fibers are composed of fine fibrils identical with those of white connective tissue. The intercellular matrix between the fibers is impregnated by calcareous deposit which the acid dissolves. In many places the various lamellæ may be seen to be held together by tapering fibers, which run obliquely through them, pinning or bolting them together; they were first described by Sharpey, and were named by him **perforating fibers** (Fig. 75).

The **Lacunæ** are situated between the lamellæ, and consist of a number of oblong

spaces. In an ordinary microscopic section, viewed by transmitted light, they appear as fusiform opaque spots. Each lacuna is occupied during life by a branched cell, termed a **bone-cell** or **bone-corpuscle**, the processes from which extend into the canaliculi (Fig. 76).

The **Canaliculi** are exceedingly minute channels, crossing the lamellæ and connecting the lacunæ with neighboring lacunæ and also with the Haversian canal. From the Haversian canal a number of canaliculi are given off, which radiate from it, and open into the first set of lacunæ between the first and second lamellæ. From these lacunæ a second set of canaliculi is given off; these run outward to the next series of lacunæ, and so on until the periphery of the Haversian system is reached; here the canaliculi given off from the last series of lacunæ do not communicate with the lacunæ of neighboring Haversian systems, but after passing outward for a short distance form loops and return to their own lacunæ. Thus every part of an Haversian system is supplied with nutrient fluids derived from the vessels in the Haversian canal and distributed through the canaliculi and lacunæ.

The **bone cells** are contained in the lacunæ, which, however, they do not completely fill. They are flattened nucleated branched cells, homologous with those of connective tissue; the branches, especially in young bones, pass into the canaliculi from the lacunæ.

In thin plates of bone (as in the walls of the spaces of cancellous tissue) the Haversian canals are absent, and the canaliculi open into the spaces of the cancellous tissue (medullary spaces), which thus have the same function as the Haversian canals.

Chemical Composition.—Bone consists of an animal and an earthy part intimately combined together.

The animal part may be obtained by immersing a bone for a considerable time in dilute mineral acid, after which process the bone comes out exactly the same shape as before, but perfectly flexible, so that a long bone (one of the ribs, for example) can easily be tied in a knot. If now a transverse section is made (Fig. 77) the same general arrangement of the Haversian canals, lamellæ, lacunæ, and canaliculi is seen.

The earthy part may be separately obtained by calcination, by which the animal matter is completely burnt out. The bone will still retain its original form, but it will be white and brittle, will have lost about one-third of its original weight, and will crumble down with the slightest force. The earthy matter is composed chiefly of calcium phosphate, about 58 per cent. of the weight of the bone, calcium carbonate about 7 per cent., calcium fluoride and magnesium phosphate from 1 to 2 per cent. each and sodium chloride less than 1 per cent.; they confer on bone its hardness and rigidity, while the animal matter (*ossein*) determines its tenacity.

Ossification.—Some bones are preceded by membrane, such as those forming the roof and sides of the skull; others, such as the bones of the limbs, are preceded by rods of cartilage. Hence two kinds of ossification are described: the **intramembranous** and the **intracartilaginous**.

INTRAMEMBRANOUS OSSIFICATION.—In the case of bones which are developed in membrane, no cartilaginous mould precedes the appearance of the bony tissue. The membrane which occupies the place of the future bone is of the nature of connective tissue, and ultimately forms the periosteum; it is composed of fibers and granular cells in a matrix. The peripheral portion is more fibrous, while, in the

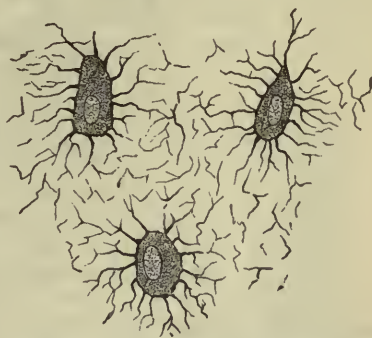

FIG. 76.—Nucleated bone cells and their processes, contained in the bone lacunæ and their canaliculi respectively. From a section through the vertebra of an adult mouse. (Klein and Noble Smith.)

interior the cells or *osteoblasts* predominate; the whole tissue is richly supplied with bloodvessels. At the outset of the process of bone formation a little network of spicules is noticed radiating from the point or center of ossification. These rays consist at their growing points of a network of fine clear fibers and granular

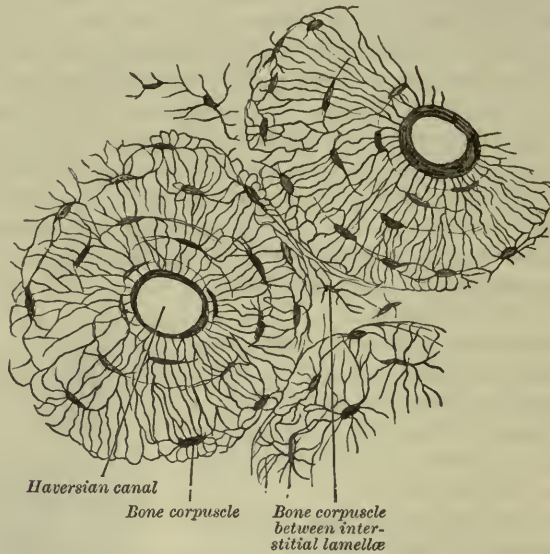


FIG. 77.—Transverse section of body of human fibula, decalcified. $\times 250$.

corpuscles with an intervening ground substance (Fig. 78). The fibers are termed **osteogenetic fibers**, and are made up of fine fibrils differing little from those of white fibrous tissue. The membrane soon assumes a dark and granular appearance from the deposition of calcareous granules in the fibers and in the intervening matrix,

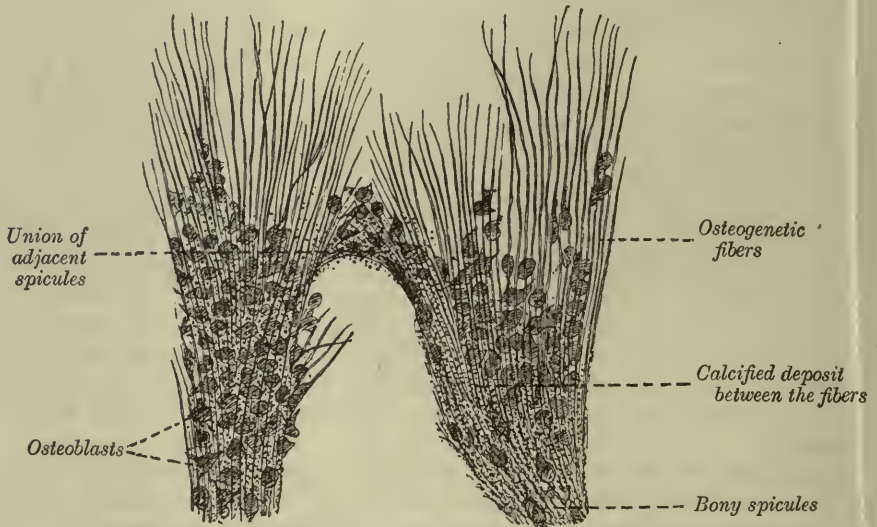


FIG. 78.—Part of the growing edge of the developing parietal bone of a fetal cat. (After J. Lawrence.)

and in the calcified material some of the granular corpuscles or osteoblasts are enclosed. By the fusion of the calcareous granules the tissue again assumes a more transparent appearance, but the fibers are no longer so distinctly seen. The involved osteoblasts form the corpuscles of the future bone, the spaces in

which they are enclosed constituting the lacunæ. As the osteogenetic fibers grow out to the periphery they continue to calcify, and give rise to fresh bone spicules. Thus a network of bone is formed, the meshes of which contain the bloodvessels and a delicate connective tissue crowded with osteoblasts. The bony trabeculæ thicken by the addition of fresh layers of bone formed by the osteoblasts on their surface, and the meshes are correspondingly encroached upon. Subsequently, successive layers of bony tissue are deposited under the periosteum and around the larger vascular channels which become the Haversian canals, so that the bone increases much in thickness.

INTERCARTILAGINOUS OSSIFICATION.—Just before ossification begins the mass is entirely cartilaginous, and in a long bone, which may be taken as an example, the process commences in the center and proceeds toward the extremities, which for some time remain cartilaginous. Subsequently a similar process commences in one or more places in those extremities and gradually extends through them. The extremities do not, however, become joined to the body of the bone by bony tissue until growth has ceased; between the body and either extremity a layer of cartilaginous tissue termed the **epiphysial cartilage** persists for a definite period.

The first step in the ossification of the cartilage is that the cartilage cells, at the point where ossification is commencing and which is termed a **center of ossification**, enlarge and arrange themselves in rows (Fig. 79). The matrix in which they are imbedded increases in quantity, so that the cells become further separated from each other. A deposit of calcareous material now takes place in this matrix, between the rows of cells, so that they become separated from each other by longitudinal columns of calcified matrix, presenting a granular and opaque appearance. Here and there the matrix between two cells of the same row also becomes calcified, and transverse bars of calcified substance stretch across from one calcareous column to another. Thus there are longitudinal groups of the cartilage cells enclosed in oblong cavities, the walls of which are formed of calcified matrix which cuts off all nutrition from the cells; the cells, in consequence, atrophy, leaving spaces called the **primary areolæ**.

At the same time that this process is going on in the center of the solid bar of cartilage, certain changes are taking place on its surface. This is covered by a very vascular membrane, the **perichondrium**, entirely similar to the embryonic connective tissue already described as constituting the basis of membrane bone; on the inner surface of this—that is to say, on the surface in contact with the cartilage—are gathered the formative cells, the **osteoblasts**. By the agency of these cells a thin layer of bony tissue is formed between the peri-

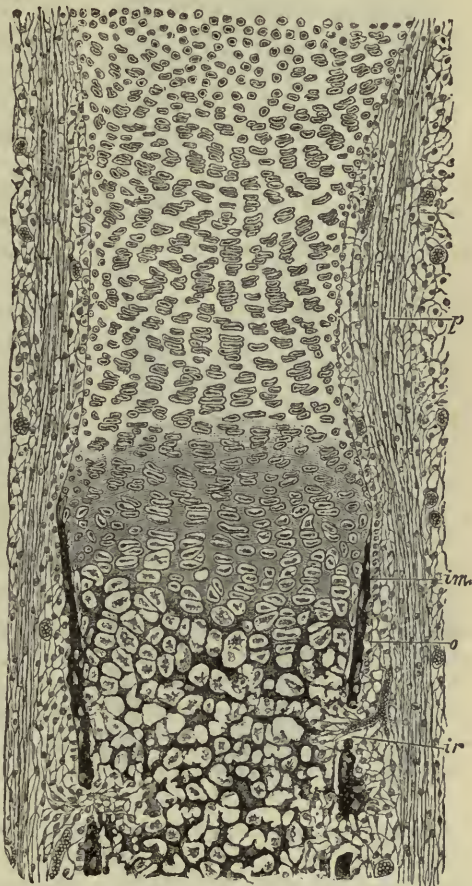


FIG. 79.—Section of fetal bone of cat. *ir*, Irruption of the subperiosteal tissue. *p*, Fibrous layer of the periosteum. *o*, Layer of osteoblasts. *im*, Subperiosteal bony deposit. (From Quain's "Anatomy," E. A. Schäfer.)

chondrium and the cartilage, by the *intramembranous* mode of ossification just described. There are then, in this first stage of ossification, two processes going on simultaneously: in the center of the cartilage the formation of a number of oblong spaces, formed of calcified matrix and containing the withered cartilage cells, and on the surface of the cartilage the formation of a layer of true membrane bone. The second stage consists in the prolongation into the cartilage of processes of the deeper or osteogenetic layer of the perichondrium, which has now become periosteum (Fig. 79, *ir*). The processes consist of bloodvessels and cells—osteoblasts, or bone-formers, and osteoclasts, or bone-destroyers. The latter are similar to the giant cells (myeloplaxes) found in marrow, and they excavate passages through the new-formed bony layer by absorption, and pass through it into the calcified matrix (Fig. 80). Wherever these processes come in contact with the calcified walls of the primary areolæ they absorb them, and thus cause a fusion of the original cavities and the formation of larger spaces, which are termed the **secondary areolæ** or **medullary spaces**. These secondary spaces become filled with embryonic marrow, consisting of osteoblasts and vessels, derived, in the manner described above, from the osteogenetic layer of the periosteum (Fig. 80).

Thus far there has been traced the formation of enlarged spaces (secondary areolæ), the perforated walls of which are still formed by calcified cartilage matrix, containing an embryonic marrow derived from the processes sent in from the osteogenetic layer of the periosteum, and consisting of bloodvessels and osteoblasts. The walls of these secondary areolæ are at this time of only inconsiderable thickness, but they become thickened by the deposition of layers of true bone on their surface. This process takes place in the following manner: Some of the osteoblasts of the embryonic marrow, after undergoing rapid division, arrange themselves as an epithelioid layer on the surface of the wall of the space (Fig. 81). This layer of osteoblasts forms a bony stratum, and thus the wall of the space becomes gradually covered with a layer of

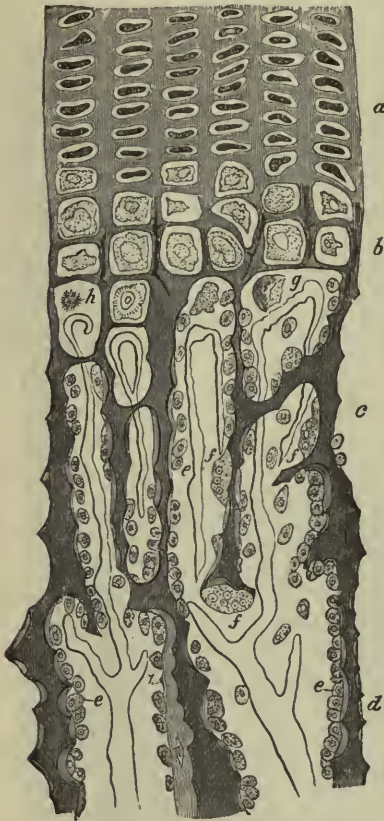

FIG. 80.—Part of a longitudinal section of the developing femur of a rabbit. *a*. Flattened cartilage cells. *b*. Enlarged cartilage cells. *c*, *d*. Newly formed bone. *e*. Osteoblasts. *f*. Giant cells or osteoclasts. *g*, *h*. Shrunken cartilage cells. (From "Atlas of Histology," Klein and Noble Smith.)

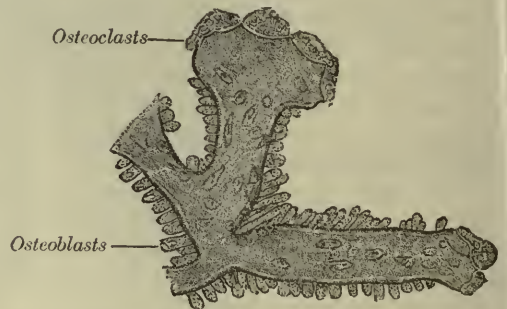


FIG. 81.—Osteoblasts and osteoclasts on trabecula of lower jaw of calf embryo. (Kölliker.)

true osseous substance in which some of the bone-forming cells are included as bone corpuscles. The next stage in the process consists in the removal of these primary bone spicules by the osteoclasts. One of these giant cells may be found lying in a Howship's foveola at the free end of each spicule. The removal of the

primary spicules goes on *pari passu* with the formation of permanent bone by the periosteum, and in this way the medullary cavity of the body of the bone is formed.

This series of changes has been gradually proceeding toward the end of the body of the bone, so that in the ossifying bone all the changes described above may be seen in different parts, from the true bone at the center of the body to the hyaline cartilage at the extremities.

While the ossification of the cartilaginous body is extending toward the articular ends, the cartilage immediately in advance of the osseous tissue continues to grow until the length of the adult bone is reached.

During the period of growth the articular end, or epiphysis, remains for some time entirely cartilaginous, then a bony center appears, and initiates in it the process of intracartilaginous ossification; but this process never extends to any great distance. The epiphysis remains separated from the body by a narrow cartilaginous layer for a definite time. This layer ultimately ossifies, the distinction between body and epiphysis is obliterated, and the bone assumes its completed form and shape. The same remarks also apply to such processes of bone as are separately ossified, *e. g.*, the trochanters of the femur. The bones therefore continue to grow until the body has acquired its full stature. They increase in length by ossification continuing to extend behind the epiphysial cartilage, which goes on growing in advance of the ossifying process. They increase in circumference by deposition of new bone, from the deeper layer of the periosteum, on their external surface, and at the same time an absorption takes place from within, by which the medullary cavities are increased.

The permanent bone formed by the periosteum when first laid down is cancellous in structure. Later the osteoblasts contained in its spaces become arranged in the concentric layers characteristic of the Haversian systems, and are included as bone corpuscles.

The number of ossific centers varies in different bones. In most of the short bones ossification commences at a single point near the center, and proceeds toward the surface. In the long bones there is a central point of ossification for the body or diaphysis: and one or more for each extremity, the epiphysis. That for the body is the first to appear. The times of union of the epiphyses with the body vary inversely with the dates at which their ossifications began (with the exception of the fibula) and regulate the direction of the nutrient arteries of the bones. Thus, the nutrient arteries of the bones of the arm and forearm are directed toward the elbow, since the epiphyses at this joint become united to the bodies before those at the opposite extremities. In the lower limb, on the other hand, the nutrient arteries are directed away from the knee: that is, upward in the femur, downward in the tibia and fibula; and in them it is observed that the upper epiphysis of the femur, and the lower epiphyses of the tibia and fibula, unite first with the bodies. Where there is only one epiphysis, the nutrient artery is directed toward the other end of the bone; as toward the acromial end of the clavicle, toward the distal ends of the metacarpal bone of the thumb and the metatarsal bone of the great toe, and toward the proximal ends of the other metacarpal and metatarsal bones.

Parsons¹ groups epiphyses under three headings, *viz.*: (1) **pressure epiphyses**, appearing at the articular ends of the bones and transmitting "the weight of the body from bone to bone;" (2) **traction epiphyses**, associated with the insertion of muscles and "originally sesamoid structures though not necessarily sesamoid bones;" and (3) **atavistic epiphyses**, representing parts of the skeleton, which at one time formed separate bones, but which have lost their function, "and only appear as separate ossifications in early life."

¹ Jour. of Anat. and Phys., vols. xxxviii, xxxix, and xlii.

THE VERTEBRAL COLUMN (COLUMNA VERTEBRALIS; SPINAL COLUMN).

The vertebral column is a flexuous and flexible column, formed of a series of bones called *vertebræ*.

The *vertebræ* are thirty-three in number, and are grouped under the names *cervical*, *thoracic*, *lumbar*, *sacral*, and *coccygeal*, according to the regions they occupy; there are seven in the cervical region, twelve in the thoracic, five in the lumbar, five in the sacral, and four in the coccygeal.

This number is sometimes increased by an additional vertebra in one region, or it may be diminished in one region, the deficiency often being supplied by an additional vertebra in another. The number of cervical *vertebræ* is, however, very rarely increased or diminished.

The *vertebræ* in the upper three regions of the column remain distinct throughout life, and are known as *true* or *movable* *vertebræ*; those of the sacral and coccygeal regions, on the other hand, are termed *false* or *fixed* *vertebræ*, because they are united with one another in the adult to form two bones—five forming the upper bone or *sacrum*, and four the terminal bone or *coccyx*.

With the exception of the first and second cervical, the true or movable *vertebræ* present certain common characteristics which are best studied by examining one from the middle of the thoracic region.

GENERAL CHARACTERISTICS OF A VERTEBRA.

A typical vertebra consists of two essential parts—viz., an anterior segment, the *body*, and a posterior part, the *vertebral* or *neural arch*; these enclose a foramen, the *vertebral foramen*. The vertebral arch consists of a pair of *pedicles* and a pair of *laminæ*, and supports seven processes—viz., four *articular*, two *transverse*, and one *spinous*.

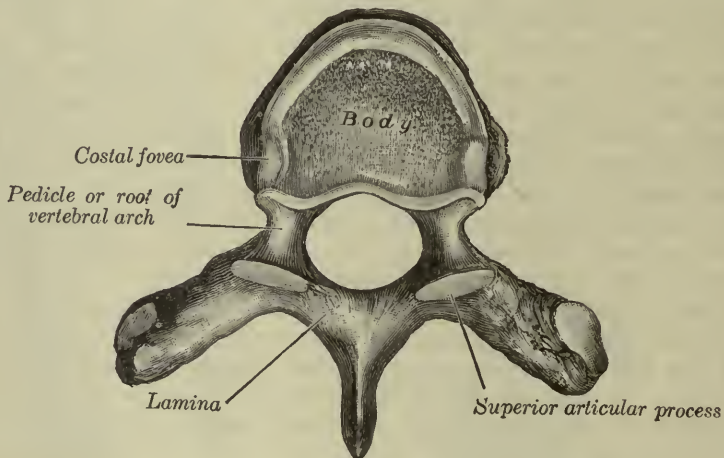


FIG. 82.—A typical thoracic vertebra, viewed from above.

When the *vertebræ* are articulated with each other the bodies form a strong pillar for the support of the head and trunk, and the vertebral foramina constitute a canal for the protection of the *medulla spinalis* (*spinal cord*), while between every pair of *vertebræ* are two apertures, the *intervertebral foramina*, one on either side, for the transmission of the spinal nerves and vessels.

Body (*corpus vertebrae*).—The body is the largest part of a vertebra, and is more or less cylindrical in shape. Its upper and lower surfaces are flattened and

rough, and give attachment to the intervertebral fibrocartilages, and each presents a rim around its circumference. In front, the body is convex from side to side and concave from above downward. Behind, it is flat from above downward and slightly concave from side to side. Its anterior surface presents a few small apertures, for the passage of nutrient vessels; on the posterior surface is a single large, irregular aperture, or occasionally more than one, for the exit of the basi-vertebral veins from the body of the vertebra.

Pedicles (*radices arci vertebræ*).—The pedicles are two short, thick processes, which project backward, one on either side, from the upper part of the body, at the junction of its posterior and lateral surfaces. The concavities above and below the pedicles are named the **vertebral notches**; and when the vertebræ are articulated, the notches of each contiguous pair of bones form the intervertebral foramina, already referred to.

Laminæ.—The laminæ are two broad plates directed backward and medialward from the pedicles. They fuse in the middle line posteriorly, and so complete the posterior boundary of the vertebral foramen. Their upper borders and the lower parts of their anterior surfaces are rough for the attachment of the ligamenta flava.

Processes.—**Spinous Process** (*processus spinosus*).—The spinous process is directed backward and downward from the junction of the laminæ, and serves for the attachment of muscles and ligaments.

Articular Processes.—The articular processes, two superior and two inferior, spring from the junctions of the pedicles and laminæ. The superior project upward, and their articular surfaces are directed more or less backward; the inferior project downward, and their surfaces look more or less forward. The articular surfaces are coated with hyaline cartilage.

Transverse Processes (*processus transversi*).—The transverse processes, two in number, project one at either side from the point where the lamina joins the pedicle, between the superior and inferior articular processes. They serve for the attachment of muscles and ligaments.

Structure of a Vertebra (Fig. 83).—The body is composed of cancellous tissue, covered by a thin coating of compact bone; the latter is perforated by numerous orifices, some of large size for the passage of vessels; the interior of the bone is traversed by one or two large canals, for the reception of veins, which converge toward a single large, irregular aperture, or several small apertures, at the posterior part of the body. The thin bony lamellæ of the cancellous tissue are more pronounced in lines perpendicular to the upper and lower surfaces and are developed in response to greater pressure in this direction (Fig. 83). The arch and processes projecting from it have thick coverings of compact tissue.

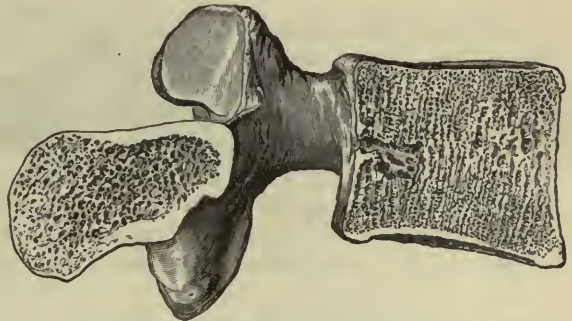


FIG. 83.—Sagittal section of a lumbar vertebra.

The Cervical Vertebræ (Vertebræ Cervicales).

The cervical vertebræ (Fig. 84) are the smallest of the true vertebræ, and can be readily distinguished from those of the thoracic or lumbar regions by the presence of a foramen in each transverse process. The first, second, and seventh present exceptional features and must be separately described; the following characteristics are common to the remaining four.

The body is small, and broader from side to side than from before backward. The anterior and posterior surfaces are flattened and of equal depth; the former

is placed on a lower level than the latter, and its inferior border is prolonged downward, so as to overlap the upper and forepart of the vertebra below. The **upper surface** is concave transversely, and presents a projecting lip on either side; the **lower surface** is concave from before backward, convex from side to side, and presents laterally shallow concavities which receive the corresponding projecting lips of the subjacent vertebra. The **pedicles** are directed lateralward and backward, and are attached to the body midway between its upper and lower borders, so that the superior vertebral notch is as deep as the inferior, but it is, at the same time,

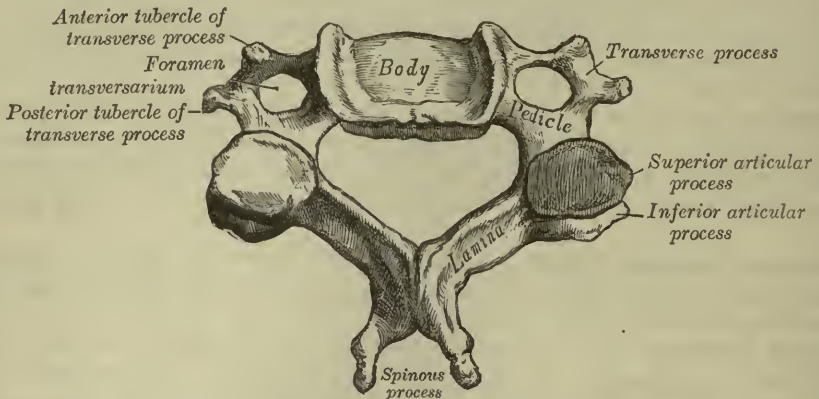


FIG. 84.—A cervical vertebra.

narrower. The **laminae** are narrow, and thinner above than below; the **vertebral foramen** is large, and of a triangular form. The **spinous process** is short and bifid, the two divisions being often of unequal size. The **superior and inferior articular processes** on either side are fused to form an articular pillar, which projects lateralward from the junction of the pedicle and lamina. The articular facets are flat and of an oval form: the superior look backward, upward, and slightly medialward; the inferior forward, downward, and slightly lateralward. The **transverse processes** are each pierced by the **foramen transversarium**, which, in the upper six

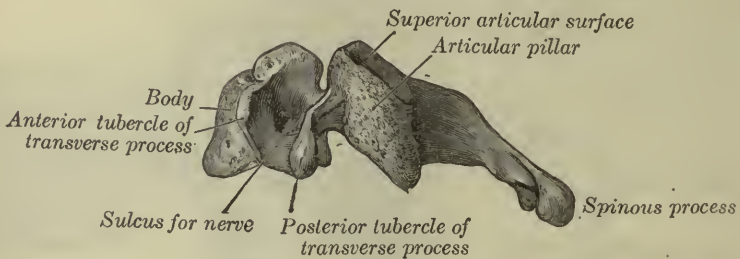


FIG. 85.—Side view of a typical cervical vertebra.

vertebrae, gives passage to the vertebral artery and vein and a plexus of sympathetic nerves. Each process consists of an anterior and a posterior part. The **anterior** portion is the homologue of the rib in the thoracic region, and is therefore named the **costal process** or **costal element**; it arises from the side of the body, is directed lateralward in front of the foramen, and ends in a tubercle, the **anterior tubercle**. The **posterior** part, the true transverse process, springs from the vertebral arch behind the foramen, and is directed forward and lateralward; it ends in a flattened vertical tubercle, the **posterior tubercle**. These two parts

are joined, outside the foramen, by a bar of bone which exhibits a deep sulcus on its upper surface for the passage of the corresponding spinal nerve.¹

First Cervical Vertebra.—The first cervical vertebra (Fig. 86) is named the *atlas* because it supports the globe of the head. Its chief peculiarity is that it has no body, and this is due to the fact that the body of the atlas has fused with that of the next vertebra. Its other peculiarities are that it has no spinous process, is ring-like, and consists of an anterior and a posterior arch and two lateral masses. The **anterior arch** forms about one-fifth of the ring: its anterior surface is convex, and presents at its center the **anterior tubercle** for the attachment of the Longus colli muscles; posteriorly it is concave, and marked by a smooth, oval or circular facet (*fovea dentis*), for articulation with the odontoid process (*dens*) of the axis. The upper and lower borders respectively give attachment to the anterior atlanto-occipital membrane and the anterior atlantoaxial ligament; the former connects it with the occipital bone above, and the latter with the axis below. The **posterior arch** forms about two-fifths of the circumference of the ring: it ends behind in the **posterior tubercle**, which is the rudiment of a spinous process and gives origin to the Recti capitis posteriores minores. The diminutive size of this process prevents any interference with the movements between the atlas and the skull. The posterior part of the arch presents above and behind a rounded edge for

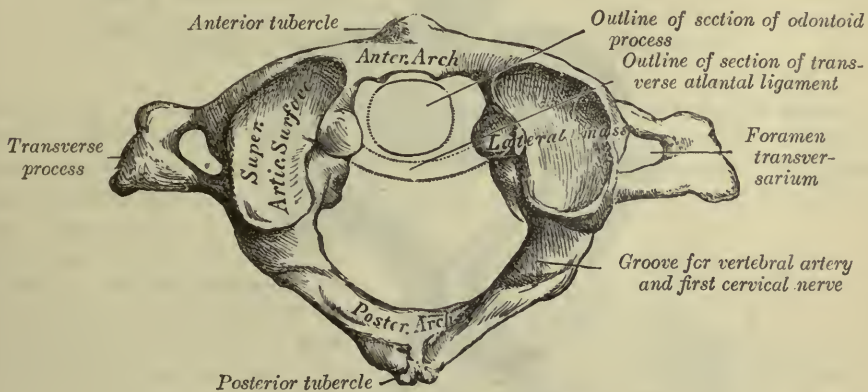


FIG. 86.—First cervical vertebra, or atlas.

the attachment of the posterior atlantoöccipital membrane, while immediately behind each superior articular process is a groove (*sulcus arteriæ vertebralis*), sometimes converted into a foramen by a delicate bony spiculum which arches backward from the posterior end of the superior articular process. This groove represents the superior vertebral notch, and serves for the transmission of the vertebral artery, which, after ascending through the foramen in the transverse process, winds around the lateral mass in a direction backward and medialward; it also transmits the suboccipital (first spinal) nerve. On the under surface of the posterior arch, behind the articular facets, are two shallow grooves, the **inferior vertebral notches**. The lower border gives attachment to the posterior atlantoaxial ligament, which connects it with the axis. The **lateral masses** are the most bulky and solid parts of the atlas, in order to support the weight of the head. Each carries two articular facets, a superior and an inferior. The **superior facets** are of large size, oval, concave, and approach each other in front, but diverge behind: they are directed upward, medialward, and a little backward, each forming a cup for the corresponding condyle of the occipital bone, and are admirably adapted to the nodding movements of the head. Not infrequently they are

¹ The *costal element* of a cervical vertebra not only includes the portion which springs from the side of the body, but the anterior and posterior tubercles and the bar of bone which connects them (Fig. 67).

partially subdivided by indentations which encroach upon their margins. The **inferior articular facets** are circular in form, flattened or slightly convex and directed downward and medialward, articulating with the axis, and permitting the rotatory movements of the head. Just below the medial margin of each superior facet is a small tubercle, for the attachment of the transverse atlantal ligament which stretches across the ring of the atlas and divides the vertebral foramen into two unequal parts—the anterior or smaller receiving the odontoid process of the axis, the posterior transmitting the medulla spinalis and its membranes. This part of the vertebral canal is of considerable size, much greater than is required for the accommodation of the medulla spinalis, and hence lateral displacement of the atlas may occur without compression of this structure. The **transverse processes** are large; they project lateralward and downward from the lateral masses, and serve for the attachment of muscles which assist in rotating the head. They are long, and their anterior and posterior tubercles are fused into one mass; the foramen transversarium is directed from below, upward and backward.

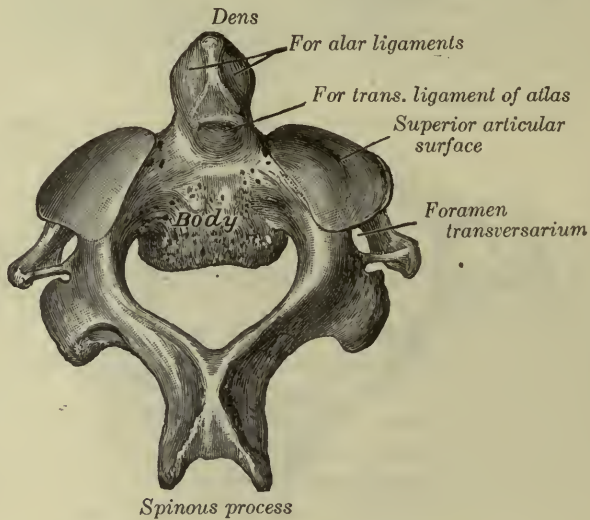


FIG. 87.—Second cervical vertebra, or epistropheus, from above.

Second Cervical Vertebra.—The second cervical vertebra (Fig. 87 and 88) is named the **epistropheus** or **axis** because it forms the pivot upon which the first vertebra, carrying the head, rotates. The most distinctive characteristic of this bone is the strong odontoid process which rises perpendicularly from the upper surface of the body. The **body** is deeper in front than behind, and prolonged downward anteriorly so as to overlap the upper and fore part of the third vertebra. It presents in front a median longitudinal ridge, separating two lateral depressions for the attachment of the Longus colli muscles. Its under surface is concave from before backward and convex from side to side. The **dens** or **odontoid process** exhibits a slight constriction or neck, where it joins the body. On its anterior surface is an oval or nearly circular facet for articulation with that on the anterior arch of the atlas. On the back of the neck, and frequently extending on to its lateral surfaces, is a shallow groove for the transverse atlantal ligament which retains the process in position. The **apex** is pointed, and gives attachment to the apical odontoid ligament; below the apex the process is somewhat enlarged, and presents on either side a rough impression for the attachment of the alar ligament; these ligaments connect the process to the occipital bone. The internal structure

of the odontoid process is more compact than that of the body. The **pedicles** are broad and strong, especially in front, where they coalesce with the sides of the body and the root of the odontoid process. They are covered above by the superior articular surfaces. The **laminae** are thick and strong, and the vertebral

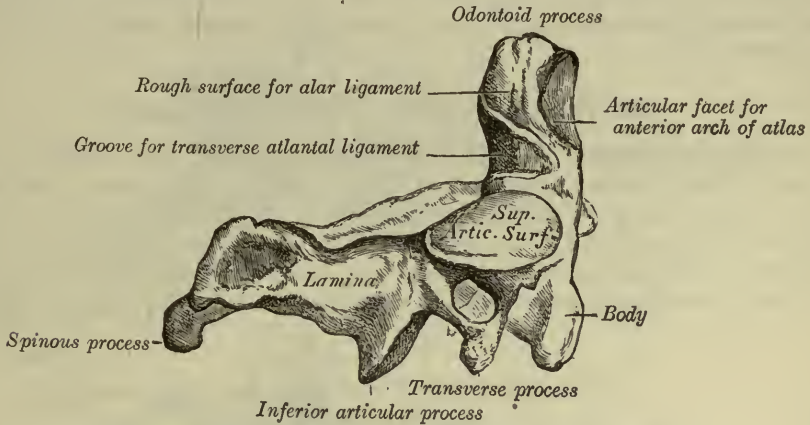


FIG. 88.—Second cervical vertebra, epistropheus, or axis, from the side.

foramen large, but smaller than that of the atlas. The **transverse processes** are very small, and each ends in a single tubercle; each is perforated by the foramen transversarium, which is directed obliquely upward and lateralward. The **superior articular surfaces** are round, slightly convex, directed upward and lateralward, and are supported on the body, pedicles, and transverse processes. The **inferior articular surfaces** have the same direction as those of the other cervical vertebræ. The **superior vertebral notches** are very shallow, and lie behind the articular processes; the **inferior** lie in front of the articular processes, as in the other cervical vertebræ. The **spinous process** is large, very strong, deeply channelled on its under surface, and presents a bifid, tuberculated extremity.

The Seventh Cervical Vertebra (Fig. 89).—The most distinctive characteristic of this vertebra is the existence of a long and prominent spinous process, hence the name **vertebra prominens**. This process is thick, nearly horizontal in direction, not bifurcated, but terminating in a tubercle to which the lower end of the ligamentum nuchæ is attached. The **transverse processes** are of considerable size, their posterior roots are large and prominent, while the anterior are small and faintly marked; the upper surface of each has usually a shallow sulcus for the eighth spinal nerve, and its extremity seldom presents more than a trace of bifurcation. The foramen

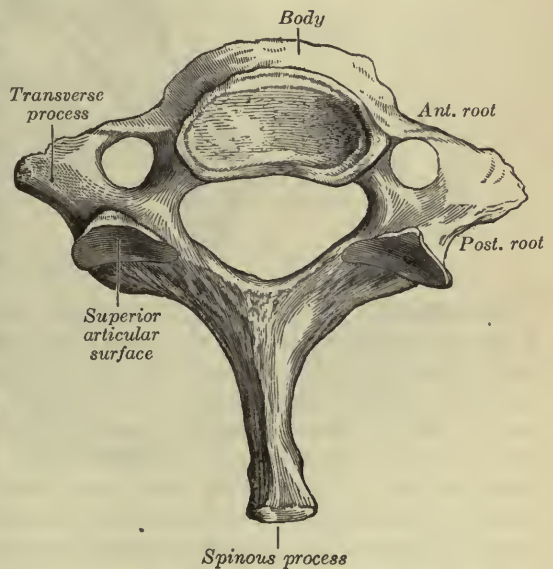


FIG. 89.—Seventh cervical vertebra.

transversarium may be as large as that in the other cervical vertebræ, but is generally smaller on one or both sides; occasionally it is double, sometimes it is absent. On the left side it occasionally gives passage to the vertebral artery; more frequently the vertebral vein traverses it on both sides; but the usual arrangement is for both artery and vein to pass in front of the transverse process, and not through the foramen. Sometimes the anterior root of the transverse process attains a large size and exists as a separate bone, which is known as a **cervical rib**.

The Thoracic Vertebræ (Vertebræ Thoracales).

The **thoracic vertebræ** (Fig. 90) are intermediate in size between those of the cervical and lumbar regions; they increase in size from above downward, the upper vertebræ being much smaller than those in the lower part of the region. They are distinguished by the presence of facets on the sides of the bodies for articulation with the heads of the ribs, and facets on the transverse processes of all, except the eleventh and twelfth, for articulation with the tubercles of the ribs.

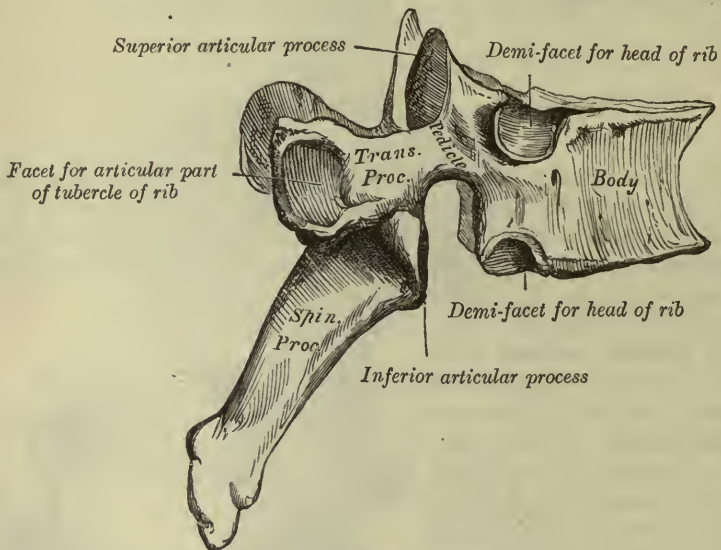


FIG. 90.—A thoracic vertebra.

The **bodies** in the middle of the thoracic region are heart-shaped, and as broad in the antero-posterior as in the transverse direction. At the ends of the thoracic region they resemble respectively those of the cervical and lumbar vertebræ. They are slightly thicker behind than in front, flat above and below, convex from side to side in front, deeply concave behind, and slightly constricted laterally and in front. They present, on either side, two costal demi-facets, one above, near the root of the pedicle, the other below, in front of the inferior vertebral notch; these are covered with cartilage in the fresh state, and, when the vertebræ are articulated with one another, form, with the intervening intervertebral fibrocartilages, oval surfaces for the reception of the heads of the ribs. The **pedicles** are directed backward and slightly upward, and the inferior vertebral notches are of large size, and deeper than in any other region of the vertebral column. The **laminæ** are broad, thick, and imbricated—that is to say, they overlap those of subjacent vertebræ like tiles on a roof. The **vertebral foramen** is small, and of a circular form. The **spinous process** is long, triangular on coronal section, directed obliquely downward, and ends in a tuberculated extremity. These processes

overlap from the fifth to the eighth, but are less oblique in direction above and below. The **superior articular processes** are thin plates of bone projecting upward from the junctions of the pedicles and laminae; their articular facets are practically flat, and are directed backward and a little lateralward and upward. The **inferior articular processes** are fused to a considerable extent with the laminae,

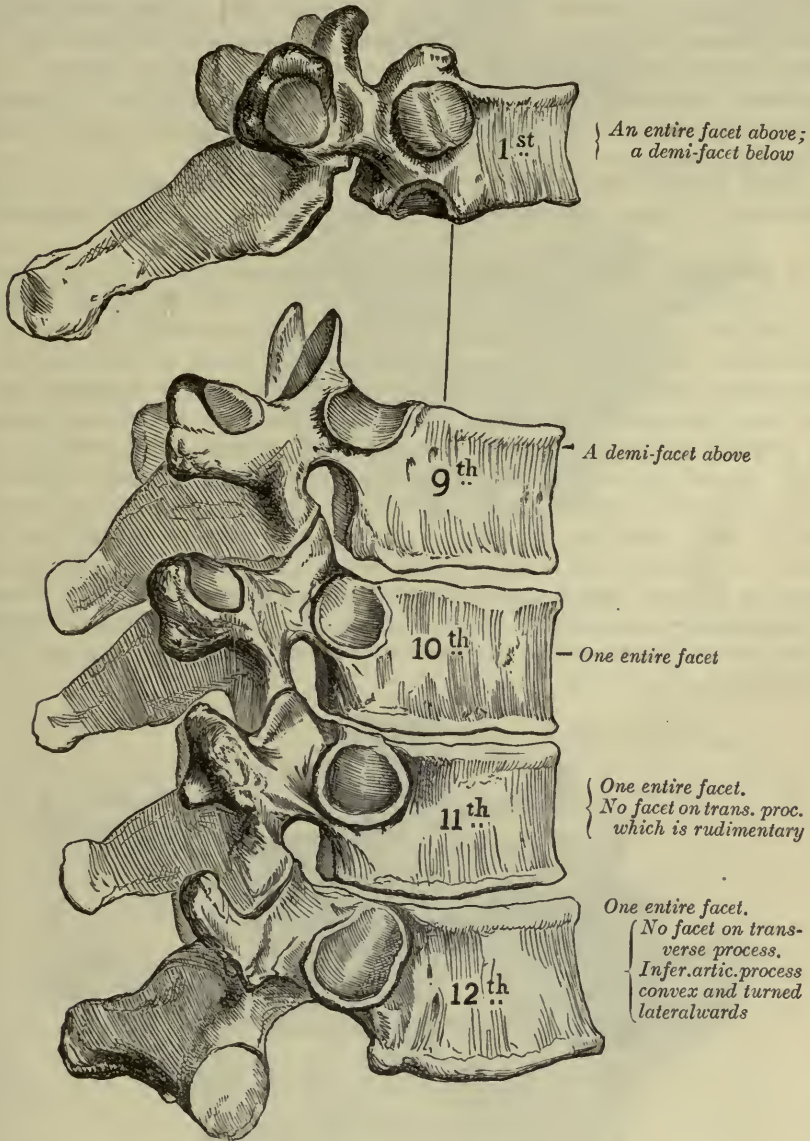


FIG. 91.—Peculiar thoracic vertebræ.

and project but slightly beyond their lower borders; their facets are directed forward and a little medialward and downward. The **transverse processes** arise from the arch behind the superior articular processes and pedicles; they are thick, strong, and of considerable length, directed obliquely backward and lateralward, and each ends in a clubbed extremity, on the front of which is a small, concave surface, for articulation with the tubercle of a rib.

The *first, ninth, tenth, eleventh, and twelfth* thoracic vertebræ present certain peculiarities, and must be specially considered (Fig. 91).

The **First Thoracic Vertebra** has, on either side of the **body**, an entire articular facet for the head of the first rib, and a demi-facet for the upper half of the head of the second rib. The body is like that of a cervical vertebra, being broad transversely; its upper surface is concave, and lipped on either side. The **superior articular surfaces** are directed upward and backward; the **spinous process** is thick, long, and almost horizontal. The **transverse processes** are long, and the upper vertebral notches are deeper than those of the other thoracic vertebræ.

The **Ninth Thoracic Vertebra** may have no demi-facets below. In some subjects however, it has two demi-facets on either side; when this occurs the tenth has only demi-facets at the upper part.

The **Tenth Thoracic Vertebra** has (except in the cases just mentioned) an entire articular facet on either side, which is placed partly on the lateral surface of the pedicle.

In the **Eleventh Thoracic Vertebra** the **body** approaches in its form and size to that of the lumbar vertebræ. The articular facets for the heads of the ribs are of large size, and placed chiefly on the pedicles, which are thicker and stronger in this and the next vertebra than in any other part of the thoracic region. The **spinous process** is short, and nearly horizontal in direction. The **transverse processes** are very short, tuberculated at their extremities, and have no articular facets.

The **Twelfth Thoracic Vertebra** has the same general characteristics as the eleventh, but may be distinguished from it by its inferior articular surfaces being convex and directed lateralward, like those of the lumbar vertebræ; by the general form of the body, laminae, and spinous process, in which it resembles the lumbar vertebræ; and by each transverse process being subdivided into three elevations, the superior, inferior, and lateral tubercles: the superior and inferior correspond to the mammillary and accessory processes of the lumbar vertebræ. Traces of similar elevations are found on the transverse processes of the tenth and eleventh thoracic vertebræ.

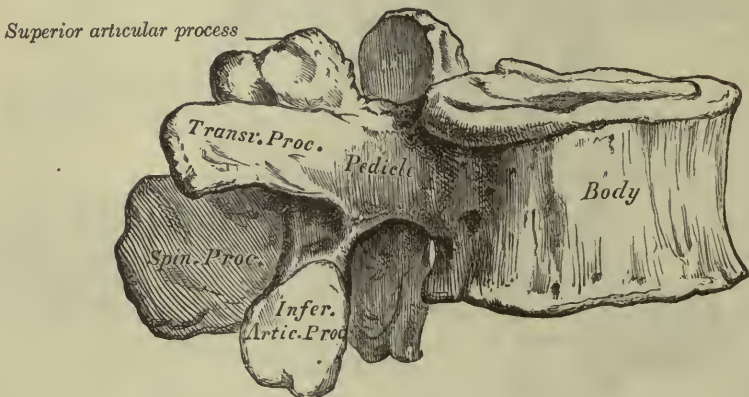


FIG. 92.—A lumbar vertebra seen from the side.

The Lumbar Vertebræ (Vertebræ Lumbales).

The **lumbar vertebræ** (Figs. 92 and 93) are the largest segments of the movable part of the vertebral column, and can be distinguished by the absence of a foramen in the transverse process, and by the absence of facets on the sides of the body.

The **body** is large, wider from side to side than from before backward, and a little thicker in front than behind. It is flattened or slightly concave above and

below, concave behind, and deeply constricted in front and at the sides. The pedicles are very strong, directed backward from the upper part of the body;

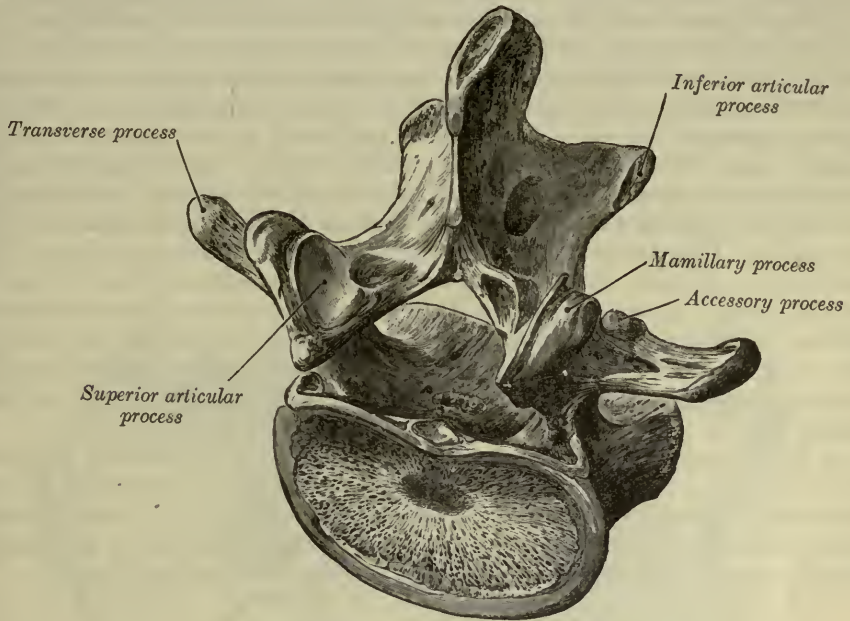


FIG. 93.—A lumbar vertebra from above and behind.

consequently, the inferior vertebral notches are of considerable depth. The laminae are broad, short, and strong; the vertebral foramen is triangular, larger

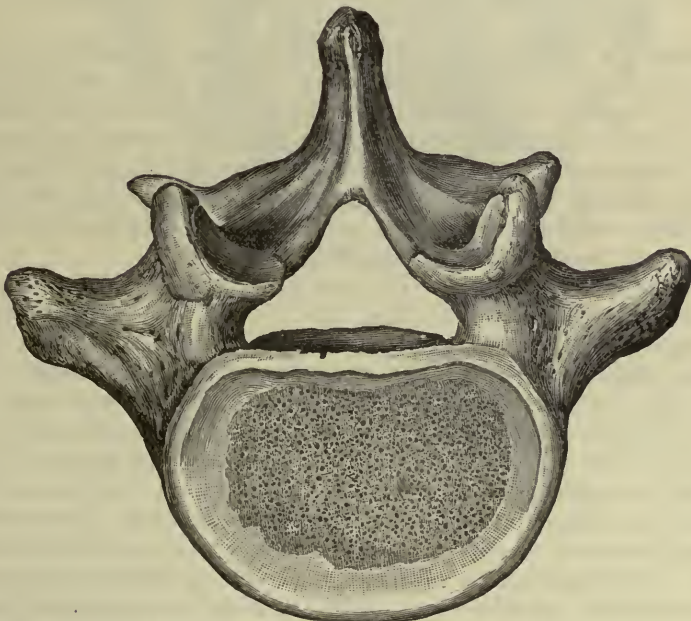


FIG. 94.—Fifth lumbar vertebra, from above.

than in the thoracic, but smaller than in the cervical region. The spinous process is thick, broad, and somewhat quadrilateral; it projects backward and ends in

a rough, uneven border, thickest below where it is occasionally notched. The **superior** and **inferior articular processes** are well-defined, projecting respectively upward and downward from the junctions of pedicles and laminae. The facets on the superior processes are concave, and look backward and medialward; those on the inferior are convex, and are directed forward and lateralward. The former are wider apart than the latter, since in the articulated column the inferior articular processes are embraced by the superior processes of the subjacent vertebra. The **transverse processes** are long, slender, and horizontal in the upper three lumbar vertebrae; they incline a little upward in the lower two. In the upper three vertebrae they arise from the junctions of the pedicles and laminae, but in the lower two they are set farther forward and spring from the pedicles and posterior parts of the bodies. They are situated in front of the articular processes instead of behind them as in the thoracic vertebrae, and are homologous with the ribs. Of the three tubercles noticed in connection with the transverse processes of the lower thoracic vertebrae, the superior one is connected in the lumbar region with the back part of the superior articular process, and is named the **mammillary process**; the inferior is situated at the back part of the base of the transverse process, and is called the **accessory process** (Fig. 93).

The **Fifth Lumbar Vertebra** (Fig. 94) is characterized by its body being much deeper in front than behind, which accords with the prominence of the sacro-vertebral articulation; by the smaller size of its spinous process; by the wide interval between the inferior articular processes; and by the thickness of its transverse processes, which spring from the body as well as from the pedicles.

The Sacral and Coccygeal Vertebrae.

The **sacral** and **coccygeal vertebrae** consist at an early period of life of nine separate segments which are united in the adult, so as to form two bones, five entering into the formation of the sacrum, four into that of the coccyx. Sometimes the coccyx consists of five bones; occasionally the number is reduced to three.

The Sacrum (*os sacrum*).—The sacrum is a large, triangular bone, situated in the lower part of the vertebral column and at the upper and back part of the pelvic cavity, where it is inserted like a wedge between the two hip bones; its upper part or base articulates with the last lumbar vertebra, its apex with the coccyx. It is curved upon itself and placed very obliquely, its base projecting forward and forming the **prominent sacrovertebral angle** when articulated with the last lumbar vertebra; its central part is projected backward, so as to give increased capacity to the pelvic cavity.

Pelvic Surface (*facies pelvina*).—The pelvic surface (Fig. 95) is concave from above downward, and slightly so from side to side. Its middle part is crossed by four **transverse ridges**, the positions of which correspond with the original planes of separation between the five segments of the bone. The portions of bone intervening between the ridges are the bodies of the sacral vertebrae. The body of the first segment is of large size, and in form resembles that of a lumbar vertebra; the succeeding ones diminish from above downward, are flattened from before backward, and curved so as to accommodate themselves to the form of the sacrum, being concave in front, convex behind. At the ends of the ridges are seen the **anterior sacral foramina**, four in number on either side, somewhat rounded in form, diminishing in size from above downward, and directed lateralward and forward; they give exit to the anterior divisions of the sacral nerves and entrance to the lateral sacral arteries. Lateral to these foramina are the **lateral parts of the sacrum**, each consisting of five separate segments at an early period of life; in the adult, these are blended with the bodies and with each other. Each lateral part is tra-

versed by four broad, shallow grooves, which lodge the anterior divisions of the sacral nerves, and are separated by prominent ridges of bone which give origin to the Piriformis muscle.

If a sagittal section be made through the center of the sacrum (Fig. 99), the bodies are seen to be united at their circumferences by bone, wide intervals being left centrally, which, in the fresh state, are filled by the intervertebral fibrocartilages. In some bones this union is more complete between the lower than the upper segments.

Dorsal Surface (*facies dorsalis*).—The dorsal surface (Fig. 96) is convex and narrower than the pelvic. In the middle line it displays a crest, the **middle sacral crest**, surmounted by three or four tubercles, the rudimentary spinous processes

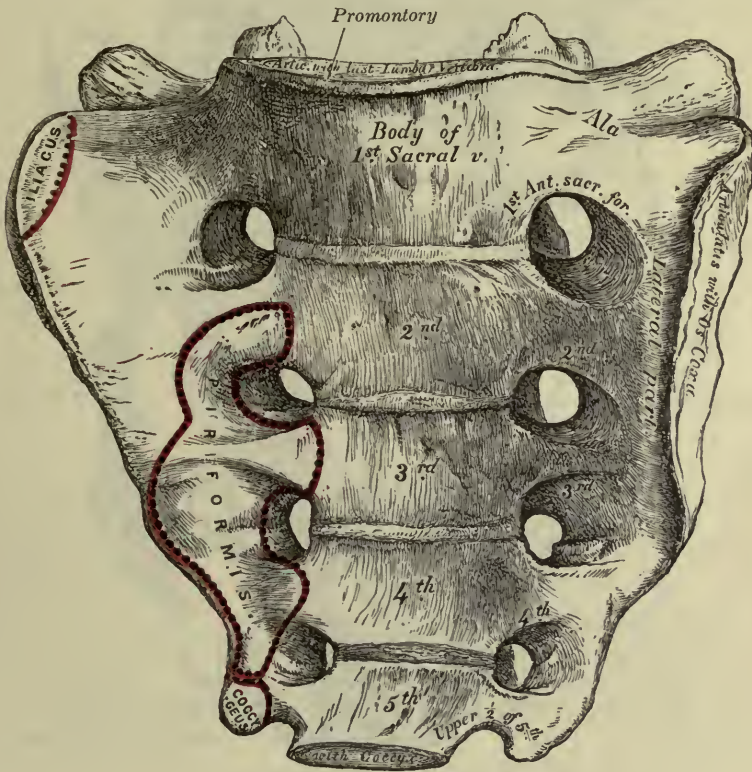


FIG. 95.—Sacrum, pelvic surface.

of the upper three or four sacral vertebræ. On either side of the middle sacral crest is a shallow groove, the **sacral groove**, which gives origin to the Multifidus, the floor of the groove being formed by the united laminae of the corresponding vertebræ. The laminae of the fifth sacral vertebra, and sometimes those of the fourth, fail to meet behind, and thus a hiatus or deficiency occurs in the posterior wall of the sacral canal. On the lateral aspect of the sacral groove is a linear series of tubercles produced by the fusion of the articular processes which together form the indistinct **sacral articular crests**. The articular processes of the first sacral vertebra are large and oval in shape; their facets are concave from side to side, look backward and medialward, and articulate with the facets on the inferior processes of the fifth lumbar vertebra. The tubercles which represent the inferior articular processes of the fifth sacral vertebra are prolonged downward as rounded

processes, which are named the **sacral cornua**, and are connected to the cornua of the coccyx. Lateral to the articular processes are the four **posterior sacral foramina**; they are smaller in size and less regular in form than the anterior, and transmit the posterior divisions of the sacral nerves. On the lateral side of the posterior sacral foramina is a series of tubercles, which represent the transverse processes of the sacral vertebræ, and form the **lateral crests** of the sacrum. The transverse tubercles of the first sacral vertebra are large and very distinct; they, together with the transverse tubercles of the second vertebra, give attachment to the horizontal parts of the posterior sacroiliac ligaments; those of the third vertebra give attachment to the oblique fasciculi of the posterior sacroiliac ligaments; and those of the fourth and fifth to the sacrotuberous ligaments.

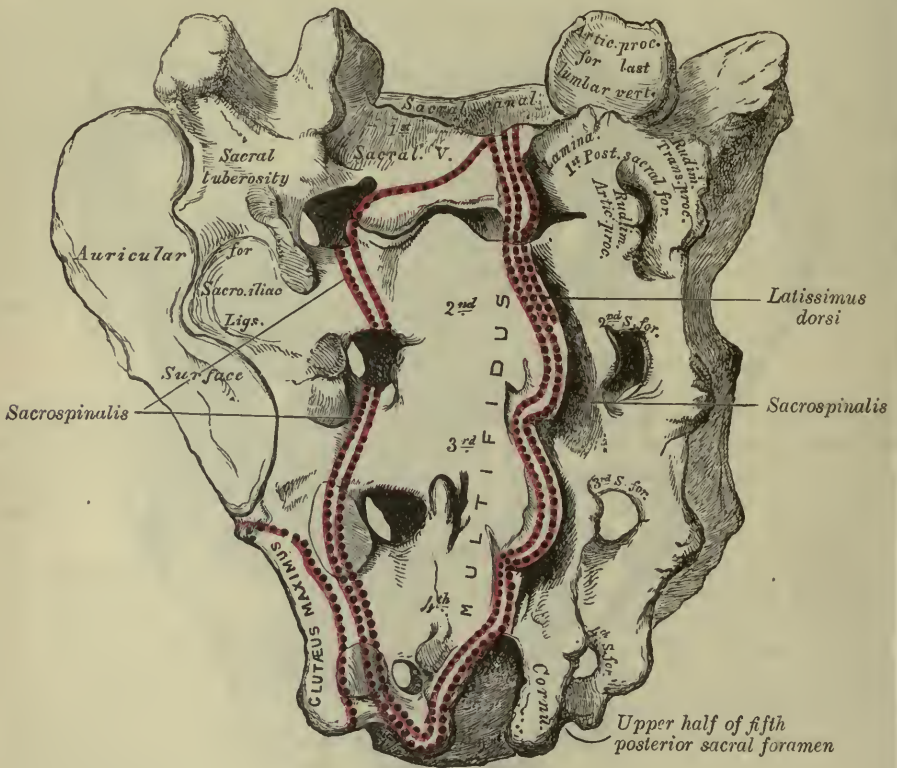


FIG. 96.—Sacrum, dorsal surface.

Lateral Surface.—The lateral surface is broad above, but narrowed into a thin edge below. The upper half presents in front an ear-shaped surface, the **auricular surface**, covered with cartilage in the fresh state, for articulation with the ilium. Behind it is a rough surface, the **sacral tuberosity**, on which are three deep and uneven impressions, for the attachment of the posterior sacroiliac ligament. The lower half is thin, and ends in a projection called the **inferior lateral angle**; medial to this angle is a notch, which is converted into a foramen by the transverse process of the first piece of the coccyx, and transmits the anterior division of the fifth sacral nerve. The thin lower half of the lateral surface gives attachment to the sacrotuberous and sacrospinous ligaments, to some fibers of the *Glutæus maximus* behind, and to the *Coccygeus* in front.

Base (basis oss. sacri).—The base of the sacrum, which is broad and expanded, is directed upward and forward. In the middle is a large oval articular surface,

the upper surface of the body of the first sacral vertebra, which is connected with the under surface of the body of the last lumbar vertebra by an intervertebral

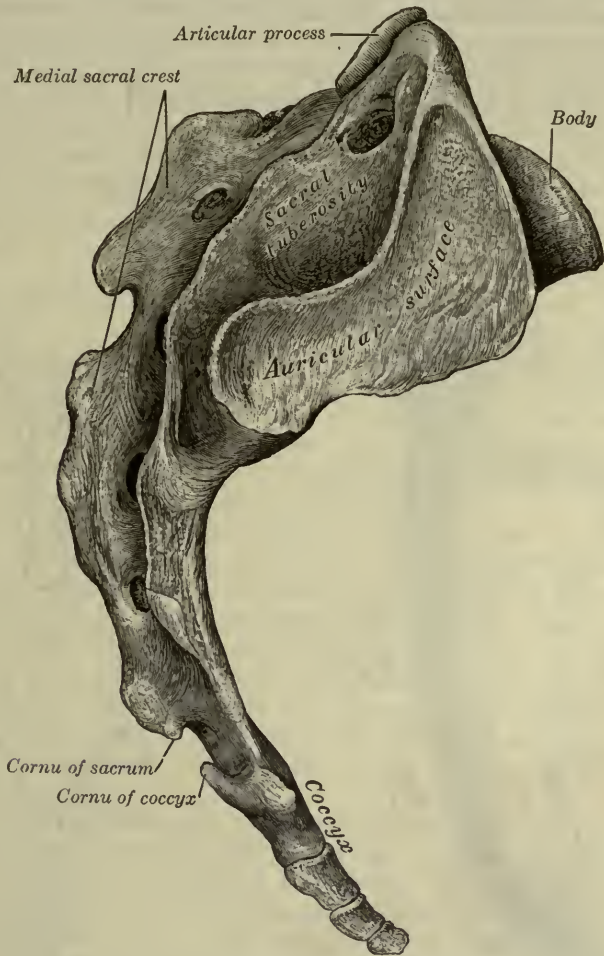

FIG. 97.—Lateral surfaces of sacrum and coccyx.

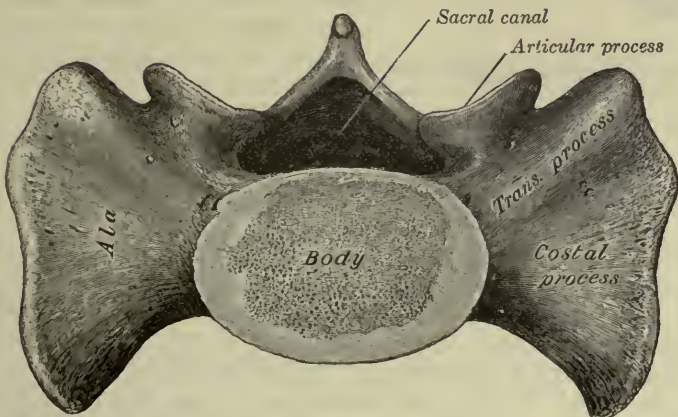
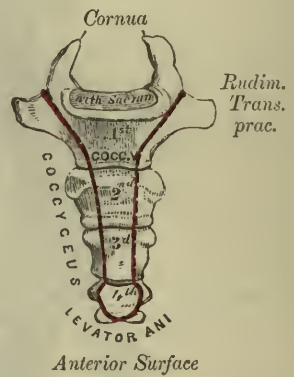


FIG. 98.—Base of sacrum.

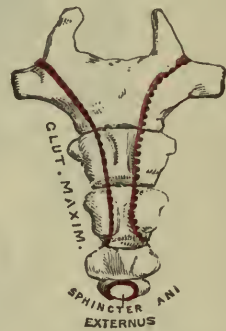
fibrocartilage. Behind this is the large triangular orifice of the sacral canal, which is completed by the laminæ and spinous process of the first sacral vertebra. The superior articular processes project from it on either side; they are oval, concave, directed backward and medialward, like the superior articular processes of a lumbar vertebra. They are attached to the body of the first sacral vertebra and to the alæ by short thick pedicles; on the upper surface of each pedicle is a vertebral notch, which forms the lower part of the foramen between the last lumbar and first sacral vertebræ. On either side of the body is a large triangular surface, which supports the Psoas major and the lumbosacral trunk, and in the articulated pelvis is continuous with the iliac fossa. This is called the *ala*; it is slightly concave

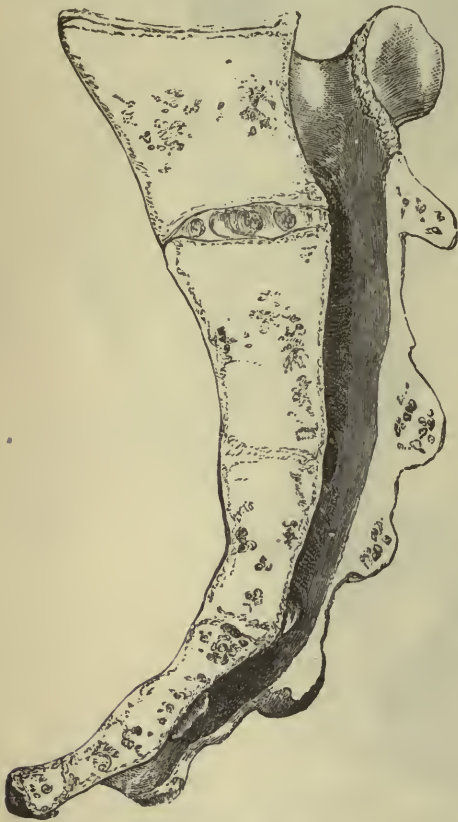

FIG. 99.—Median sagittal section of the sacrum.



Anterior Surface



Posterior surface

FIG. 100.—Coccyx.

from side to side, convex from before backward, and gives attachment to a few of the fibers of the Iliacus. The posterior fourth of the ala represents the transverse process, and its anterior three-fourths the costal process of the first sacral segment.

Apex (*apex oss. sacri*).—The apex is directed downward, and presents an oval facet for articulation with the coccyx.

Vertebral Canal (*canalis sacralis; sacral canal*).—The vertebral canal (Fig. 99) runs throughout the greater part of the bone; above, it is triangular in form; below, its posterior wall is incomplete, from the non-development of the laminæ and spinous processes. It lodges the sacral nerves, and its walls are perforated by the anterior and posterior sacral foramina through which these nerves pass out.

Structure.—The sacrum consists of cancellous tissue enveloped by a thin layer of compact bone.

Articulations.—The sacrum articulates with *four* bones; the last lumbar vertebra above, the coccyx below, and the hip bone on either side.

Differences in the Sacrum of the Male and Female.—In the female the sacrum is shorter and wider than in the male; the lower half forms a greater angle with the upper; the upper half is nearly straight, the lower half presenting the greatest amount of curvature. The bone is also directed more obliquely backward; this increases the size of the pelvic cavity and renders the sacrovertebral angle more prominent. In the male the curvature is more evenly distributed over the whole length of the bone, and is altogether greater than in the female.

Variations.—The sacrum, in some cases, consists of six pieces; occasionally the number is reduced to four. The bodies of the first and second vertebræ may fail to unite. Sometimes the uppermost transverse tubercles are not joined to the rest of the ala on one or both sides, or the sacral canal may be open throughout a considerable part of its length, in consequence of the imperfect development of the laminæ and spinous processes. The sacrum, also, varies considerably with respect to its degree of curvature.

The Coccyx (*os coccygis*).—The coccyx (Fig. 100) is usually formed of four rudimentary vertebræ; the number may however be increased to five or diminished to three. In each of the first three segments may be traced a rudimentary body and articular and transverse processes; the last piece (sometimes the third) is a mere nodule of bone. All the segments are destitute of pedicles, laminæ, and spinous processes. The first is the largest; it resembles the lowest sacral vertebra, and often exists as a separate piece; the last three diminish in size from above downward, and are usually fused with one another.

Surfaces.—The **anterior surface** is slightly concave, and marked with three transverse grooves which indicate the junctions of the different segments. It gives attachment to the anterior sacrococcygeal ligament and the Levatores ani, and supports part of the rectum. The **posterior surface** is convex, marked by transverse grooves similar to those on the anterior surface, and presents on either side a linear row of tubercles, the rudimentary articular processes of the coccygeal vertebræ. Of these, the superior pair are large, and are called the **coccygeal cornua**; they project upward, and articulate with the cornua of the sacrum, and on either side complete the foramen for the transmission of the posterior division of the fifth sacral nerve.

Borders.—The **lateral borders** are thin, and exhibit a series of small eminences, which represent the transverse processes of the coccygeal vertebræ. Of these, the first is the largest; it is flattened from before backward, and often ascends to join the lower part of the thin lateral edge of the sacrum, thus completing the foramen for the transmission of the anterior division of the fifth sacral nerve; the others diminish in size from above downward, and are often wanting. The borders of the coccyx are narrow, and give attachment on either side to the sacrotuberous and sacrospinous ligaments, to the Coccygeus in front of the ligaments, and to the Glutæus maximus behind them.

Base.—The base presents an oval surface for articulation with the sacrum.

Apex.—The apex is rounded, and has attached to it the tendon of the Sphincter ani externus. It may be bifid, and is sometimes deflected to one or other side.

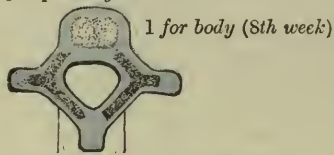
Ossification of the Vertebral Column.—Each cartilaginous vertebra is ossified from three primary centers (Fig. 101), two for the vertebral arch and one for the body.¹ Ossification of the vertebral arches begins in the upper cervical vertebræ about the seventh or eighth week of fetal life, and gradually extends down the column. The ossific granules first appear in the situations where the transverse processes afterward project, and spread backward to the spinous process forward into the pedicles, and lateralward into the transverse and articular processes. Ossification of the bodies begins about the eighth week in the lower thoracic region, and subsequently extends upward and downward along the column. The center for the body does not give rise to the whole of the body of the adult vertebra, the postero-lateral portions of which are ossified by extensions from the vertebral arch centers. The body of the vertebra during the first few years of life shows, therefore,

¹ A vertebra is occasionally found in which the body consists of two lateral portions—a condition which proves that the body is sometimes ossified from *two* primary centers, one on either side of the middle line.

two synchondroses, **neurocentral synchondroses**, traversing it along the planes of junction of the three centers (Fig. 102). In the thoracic region, the facets for the heads of the ribs lie behind the neurocentral synchondroses and are ossified from the centers for the vertebral arch.

FIG. 101.—Ossification of a vertebra

By 3 primary centers

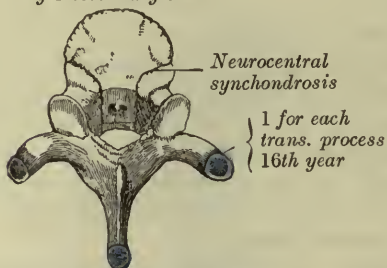


1 for body (8th week)

1 for each vertebral arch (7th or 8th week)

FIG. 102.

By 3 secondary centers



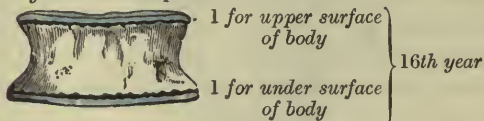
Neurocentral synchondrosis

1 for each trans. process
16th year

1 for spinous process (16th year)

FIG. 103.

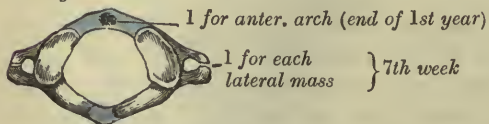
By 2 additional plates



1 for upper surface of body
1 for under surface of body
16th year

FIG. 104.—Atlas.

By 3 centers

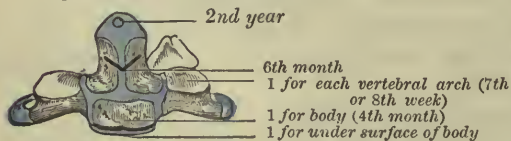


1 for anter. arch (end of 1st year)

1 for each lateral mass
7th week

FIG. 105.—Axis.

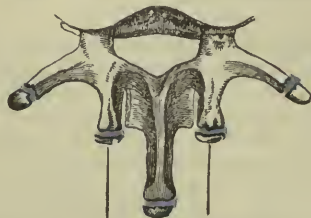By 7 centers



2nd year

6th month
1 for each vertebral arch (7th or 8th week)
1 for body (4th month)
1 for under surface of body

FIG. 106.—Lumbar vertebra.



2 additional centers for mammillary processes

the neurocentral synchondroses and are ossified from the centers for the vertebral arch. At birth the vertebra consists of three pieces, the body and the halves of the vertebral arch. During the first year the halves of the arch unite behind, union taking place first in the lumbar region and then extending upward through the thoracic and cervical regions. About the third year the bodies of the upper cervical vertebrae are joined to the arches on either side; in the lower lumbar vertebrae the union is not completed until the sixth year. Before puberty, no other

Additional centers for costal elements*

At birth

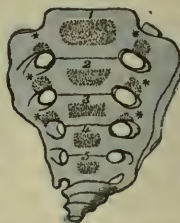

FIG. 107

At 4½ yrs.

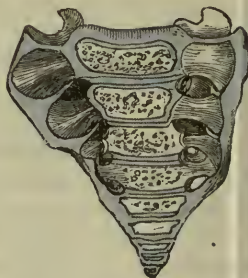

FIG. 108

Two epiphysial plates for each lateral surface*

At 25th year

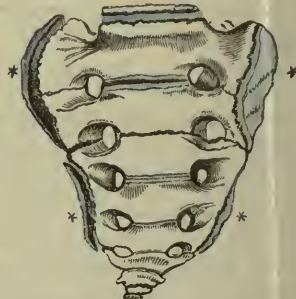

FIG. 107-109.—Ossification of the sacrum.

Exceptional cases

changes occur, excepting a gradual increase of these primary centers, the upper and under surfaces of the bodies and the ends of the transverse and spinous processes being cartilaginous.

About the sixteenth year (Fig. 102), five secondary centers appear, one for the tip of each transverse process, one for the extremity of the spinous process, one for the upper and one for the lower surface of the body (Fig. 103). These fuse with the rest of the bone about the age of twenty-five.

Exceptions to this mode of development occur in the first, second, and seventh cervical vertebræ, and in the lumbar vertebræ.

Atlas.—The atlas is usually ossified from *three* centers (Fig. 104). Of these, one appears in each lateral mass about the seventh week of fetal life, and extends backward; at birth, these portions of bone are separated from one another behind by a narrow interval filled with cartilage. Between the third and fourth years they unite either directly or through the medium of a separate center developed in the cartilage. At birth, the anterior arch consists of cartilage; in this a separate center appears about the end of the first year after birth, and joins the lateral masses from the sixth to the eighth year—the lines of union extending across the anterior portions of the superior articular facets. Occasionally there is no separate center, the anterior arch being formed by the forward extension and ultimate junction of the two lateral masses; sometimes this arch is ossified from two centers, one on either side of the middle line.

Epistropheus or Axis.—The axis is ossified from *five* primary and *two* secondary centers (Fig. 105). The body and vertebral arch are ossified in the same manner as the corresponding parts in the other vertebræ, viz., one center for the body, and two for the vertebral arch. The centers for the arch appear about the seventh or eighth week of fetal life, that for the body about the fourth or fifth month. The dens or odontoid process consists originally of a continuation upward of the cartilaginous mass, in which the lower part of the body is formed. About the sixth month of fetal life, two centers make their appearance in the base of this process: they are placed laterally, and join before birth to form a conical bilobed mass deeply cleft above; the interval between the sides of the cleft and the summit of the process is formed by a wedge-shaped piece of cartilage. The base of the process is separated from the body by a cartilaginous disk, which gradually becomes ossified at its circumference, but remains cartilaginous in its center until advanced age. In this cartilage, rudiments of the lower epiphysial lamella of the atlas and the upper epiphysial lamella of the axis may sometimes be found. The apex of the odontoid process has a separate center which appears in the second and joins about the twelfth year; this is the upper epiphysial lamella of the atlas. In addition to these there is a secondary center for a thin epiphysial plate on the under surface of the body of the bone.

The Seventh Cervical Vertebra.—The anterior or costal part of the transverse process of this vertebra is sometimes ossified from a separate center which appears about the sixth month of fetal life, and joins the body and posterior part of the transverse process between the fifth and sixth years. Occasionally the costal part persists as a separate piece, and, becoming lengthened lateralward and forward, constitutes what is known as a *cervical rib*. Separate ossific centers have also been found in the costal processes of the fourth, fifth, and sixth cervical vertebræ.

Lumbar Vertebræ.—The lumbar vertebræ (Fig. 106) have each *two* additional centers, for the mammillary processes. The transverse process of the first lumbar is sometimes developed as a separate piece, which may remain permanently ununited with the rest of the bone, thus forming a lumbar rib—a peculiarity, however, rarely met with.

Sacrum (Figs. 107 to 110).—The *body* of each sacral vertebra is ossified from a primary center and *two* epiphysial plates, one for its upper and another for its under surface, while each vertebral arch is ossified from two centers.

The anterior portions of the *lateral parts* have *six* additional centers, two for each of the first three vertebræ; these represent the costal elements, and make their appearance above and lateral to the anterior sacral foramina (Figs. 107, 108).

On each *lateral surface* two epiphysial plates are developed (Figs. 109, 110): one for the auricular surface, and another for the remaining part of the thin lateral edge of the bone.¹

PERIODS OF OSSIFICATION.—About the eighth or ninth week of fetal life, ossification of the central part of the body of the first sacral vertebra commences, and is rapidly followed by deposit of ossific matter in the second and third; ossification does not commence in the bodies of the lower two segments until between the fifth and eighth months of fetal life. Between the sixth

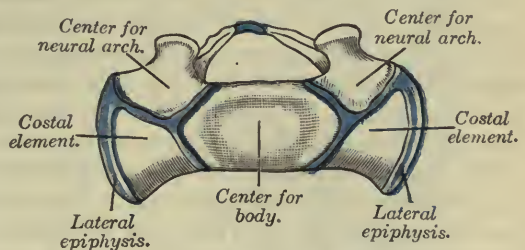


FIG. 110.—Base of young sacrum.

¹ The ends of the spinous processes of the upper three sacral vertebræ are sometimes developed from separate epiphyses, and Fawcett (Anatomischer Anzeiger, 1907, Band xxx) states that a number of epiphysial nodules may be seen in the sacrum at the age of eighteen years. These are distributed as follows: One for each of the mammillary processes of the first sacral vertebra; twelve—six on either side—in connection with the costal elements (two each for the first and second and one each for the third and fourth) and eight for the transverse processes—four on either side—one each for the first, third, fourth, and fifth. He is further of opinion that the lower part of each lateral surface of the sacrum is formed by the extension and union of the third and fourth "costal" and fourth and fifth "transverse" epiphyses.

and eighth months ossification of the vertebral arches takes place; and about the same time the costal centers for the lateral parts make their appearance. The junctions of the vertebral arches with the bodies take place in the lower vertebræ as early as the second year, but are not effected in the uppermost until the fifth or sixth year. About the sixteenth year the epiphysial plates for the upper and under surfaces of the bodies are formed; and between the eighteenth and twentieth years, those for the lateral surfaces make their appearance. The bodies of the sacral vertebræ are, during early life, separated from each other by intervertebral fibrocartilages, but about the eighteenth year the two lowest segments become united by bone, and the process of bony union gradually extends upward, with the result that between the twenty-fifth and thirtieth years of life all the segments are united. On examining a sagittal section of the sacrum, the situations of the intervertebral fibrocartilages are indicated by a series of oval cavities (Fig. 99).

Coccyx.—The coccyx is ossified from *four* centers, one for each segment. The ossific nuclei make their appearance in the following order: in the first segment between the first and fourth years; in the second between the fifth and tenth years; in the third between the tenth and fifteenth years; in the fourth between the fourteenth and twentieth years. As age advances, the segments unite with one another, the union between the first and second segments being frequently delayed until after the age of twenty-five or thirty. At a late period of life, especially in females, the coccyx often fuses with the sacrum.

THE VERTEBRAL COLUMN AS A WHOLE.

The vertebral column is situated in the median line, as the posterior part of the trunk; its average length in the male is about 71 cm. Of this length the cervical part measures 12.5 cm., the thoracic about 28 cm., the lumbar 18 cm., and the sacrum and coccyx 12.5 cm. The female column is about 61 cm. in length.

Curves.—Viewed laterally (Fig. 111), the vertebral column presents several curves, which correspond to the different regions of the column, and are called cervical, thoracic, lumbar, and pelvic. The **cervical** curve, convex forward, begins at the apex of the odontoid process, and ends at the middle of the second thoracic vertebra; it is the least marked of all the curves. The **thoracic** curve, concave forward, begins at the middle of the second and ends at the middle of the twelfth thoracic vertebra. Its most prominent point behind corresponds to the spinous process of the seventh thoracic vertebra. The **lumbar** curve is more marked in the female than in the male; it begins at the middle of the last thoracic vertebra, and ends at the sacrovertebral angle. It is convex anteriorly, the convexity of the lower three vertebræ being much greater than that of the upper two. The **pelvic** curve begins at the sacrovertebral articulation, and ends at the point of the coccyx; its concavity is directed downward and forward. The thoracic and pelvic curves are termed **primary** curves, because they alone are present during fetal life. The cervical and lumbar curves are compensatory or **secondary**, and are developed after birth, the former when the child is able to hold up its head (at three or four months), and to sit upright (at nine months), the latter at twelve or eighteen months, when the child begins to walk.

The vertebral column has also a slight **lateral** curvature, the convexity of which is directed toward the right side. This may be produced by muscular action, most persons using the right arm in preference to the left, especially in making long-continued efforts, when the body is curved to the right side. In support of this explanation it has been found that in one or two individuals who were left-handed, the convexity was to the left side. By others this curvature is regarded as being produced by the aortic arch and upper part of the descending thoracic aorta—a view which is supported by the fact that in cases where the viscera are transposed and the aorta is on the right side, the convexity of the curve is directed to the left side.

Surfaces.—**Anterior Surface.**—When viewed from in front, the width of the bodies of the vertebræ is seen to increase from the second cervical to the first thoracic; there is then a slight diminution in the next three vertebræ; below this there is again a gradual and progressive increase in width as low as the sacrovertebral angle. From this point there is a rapid diminution, to the apex of the coccyx.

Posterior Surface.—The posterior surface of the vertebral column presents in the median line the spinous processes. In the cervical region (with the exception of the second and seventh vertebræ) these are short and horizontal, with bifid extremities. In the upper part of the thoracic region they are directed obliquely downward; in the middle they are almost vertical, and in the lower part they are nearly horizontal. In the lumbar region they are nearly horizontal. The spinous processes are separated by considerable intervals in the lumbar region, by narrower intervals in the neck, and are closely approximated in the middle of the thoracic region. Occasionally one of these processes deviates a little from the median line—a fact to be remembered in practice, as irregularities of this sort are attendant also on fractures or displacements of the vertebral column. On either side of the spinous processes is the **vertebral groove** formed by the laminae in the cervical and lumbar regions, where it is shallow, and by the laminae and transverse processes in the thoracic region, where it is deep and broad; these grooves lodge the deep muscles of the back. Lateral to the vertebral grooves are the articular processes, and still more laterally the transverse processes. In the thoracic region, the transverse processes stand backward, on a plane considerably behind that of the same processes in the cervical and lumbar regions. In the cervical region, the transverse processes are placed in front of the articular processes, lateral to the pedicles and between the intervertebral foramina. In the thoracic region they are posterior to the pedicles, intervertebral foramina, and articular processes. In the lumbar region they are in front of the articular processes, but behind the intervertebral foramina.

Lateral Surfaces.—The lateral surfaces are separated from the posterior surface by the articular processes in the cervical and lumbar regions, and by the transverse processes in the thoracic region. They present, in front, the sides of the bodies of the vertebræ, marked in the thoracic region by the facets for articulation with the heads of the ribs. More posteriorly are the intervertebral foramina, formed by the juxtaposition of the vertebral notches, oval in

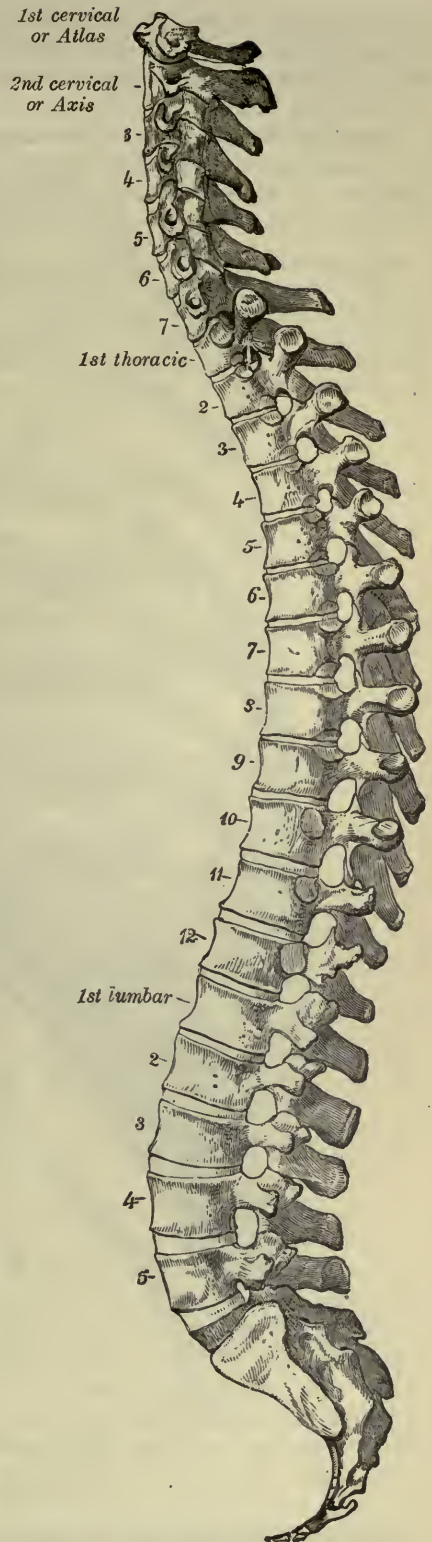


FIG. 111.—Lateral view of the vertebral column.

shape, smallest in the cervical and upper part of the thoracic regions, and gradually increasing in size to the last lumbar. They transmit the spinal nerves and are situated between the transverse processes in the cervical region, and in front of them in the thoracic and lumbar regions.

Vertebral Canal.—The vertebral canal follows the different curves of the column; it is large and triangular in those parts of the column which enjoy the greatest freedom of movement, viz., the cervical and lumbar regions; and is small and rounded in the thoracic region, where motion is more limited.

Abnormalities.—Occasionally the coalescence of the laminae is not completed, and consequently a cleft is left in the arches of the vertebræ, through which a protrusion of the spinal membranes (dura mater and arachnoid), and generally of the medulla spinalis itself, takes place, constituting the malformation known as *spina bifida*. This condition is most common in the lumbosacral region, but it may occur in the thoracic or cervical region, or the arches throughout the whole length of the canal may remain incomplete.

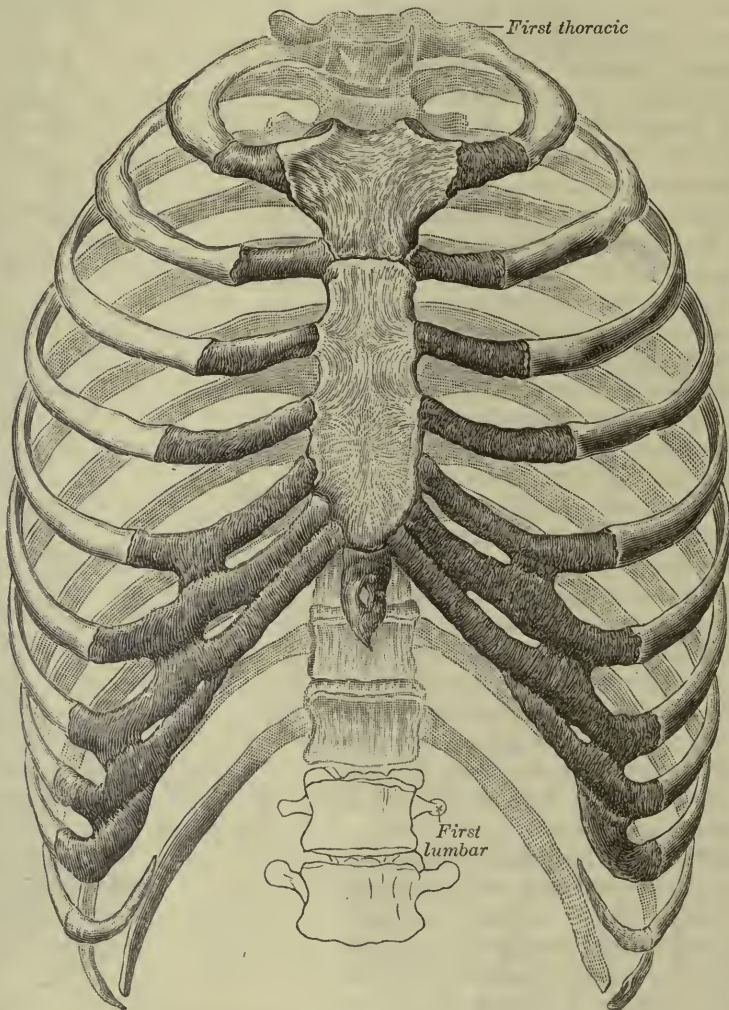


FIG. 112.—The thorax from in front. (Spalteholz.)

THE THORAX.

The skeleton of the **thorax** or **chest** (Figs. 112, 113, 114) is an osseo-cartilaginous cage, containing and protecting the principal organs of respiration and circulation.

It is conical in shape, being narrow above and broad below, flattened from before backward, and longer behind than in front. It is somewhat reniform on transverse section on account of the projection of the vertebral bodies into the cavity.

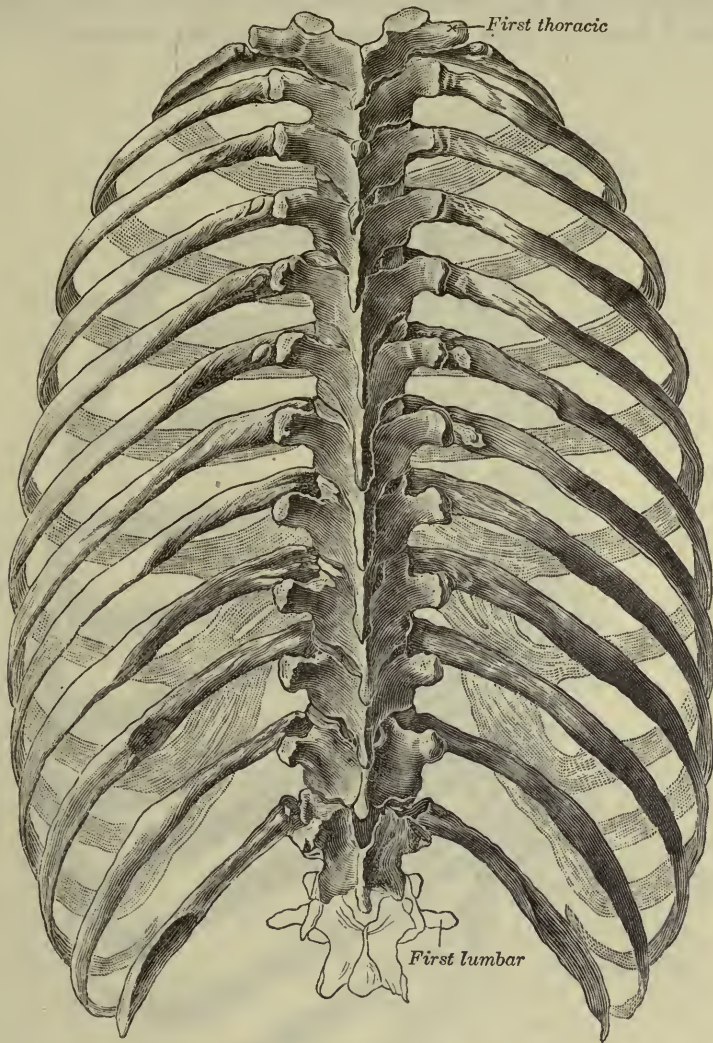


FIG. 113.—The thorax from behind. (Spalteholz.)

Boundaries.—The **posterior surface** is formed by the twelve thoracic vertebræ and the posterior parts of the ribs. It is convex from above downward, and presents on either side of the middle line a deep groove, in consequence of the lateral and backward direction which the ribs take from their vertebral extremities to their angles. The **anterior surface**, formed by the sternum and costal cartilages, is flattened or slightly convex, and inclined from above downward and forward. The **lateral surfaces** are convex; they are formed by the ribs, separated from each other by the intercostal spaces, eleven in number, which are occupied by the Intercostal muscles and membranes.

The **upper opening** of the thorax is reniform in shape, being broader from side to side than from before backward. It is formed by the first thoracic vertebra behind, the upper margin of the sternum in front, and the first rib on either side.

It slopes downward and forward, so that the anterior part of the opening is on a lower level than the posterior. Its antero-posterior diameter is about 5 cm., and its transverse diameter about 10 cm. The lower opening is formed by the twelfth thoracic vertebra behind, by the eleventh and twelfth ribs at the sides, and in front by the cartilages of the tenth, ninth, eighth, and seventh ribs, which ascend on either side and form an angle, the *subcostal angle*, into the apex of which the

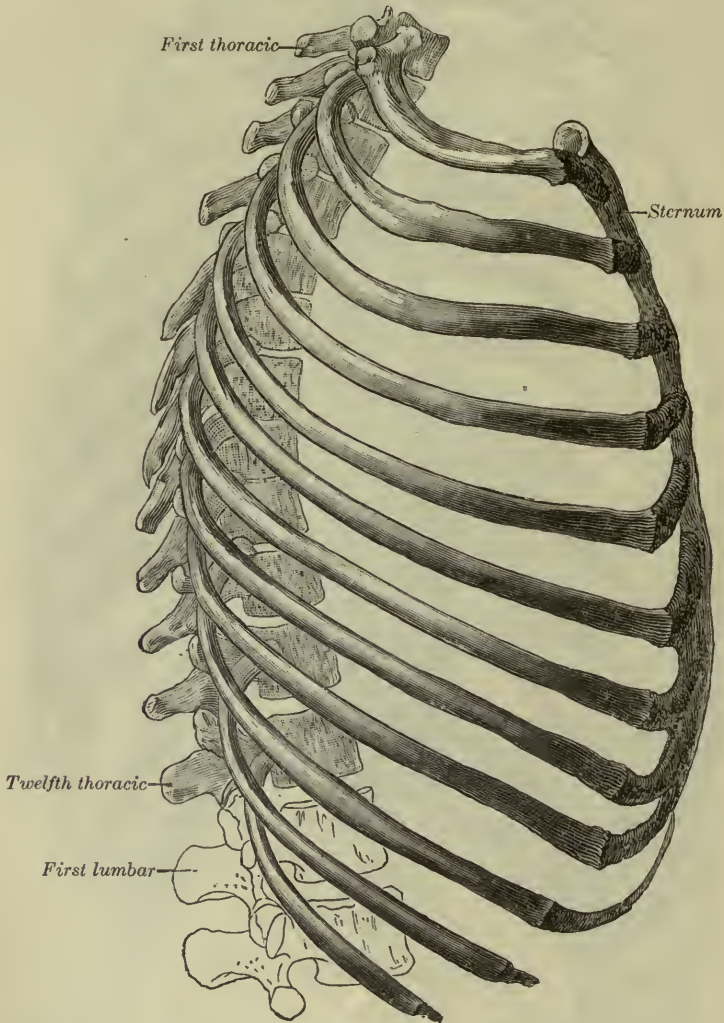


FIG. 114.—The thorax from the right. (Spalteholz.)

xiphoid process projects. The lower opening is wider transversely than from before backward, and slopes obliquely downward and backward, it is closed by the diaphragm which forms the floor of the thorax.

The thorax of the female differs from that of the male as follows: 1. Its capacity is less. 2. The sternum is shorter. 3. The upper margin of the sternum is on a level with the lower part of the body of the third thoracic vertebra, whereas in the male it is on a level with the lower part of the body of the second. 4. The upper ribs are more movable, and so allow a greater enlargement of the upper part of the thorax.

The Sternum (Breast Bone).

The **sternum** (Figs. 115 to 117) is an elongated, flattened bone, forming the middle portion of the anterior wall of the thorax. Its upper end supports the clavicles, and its margins articulate with the cartilages of the first seven pairs

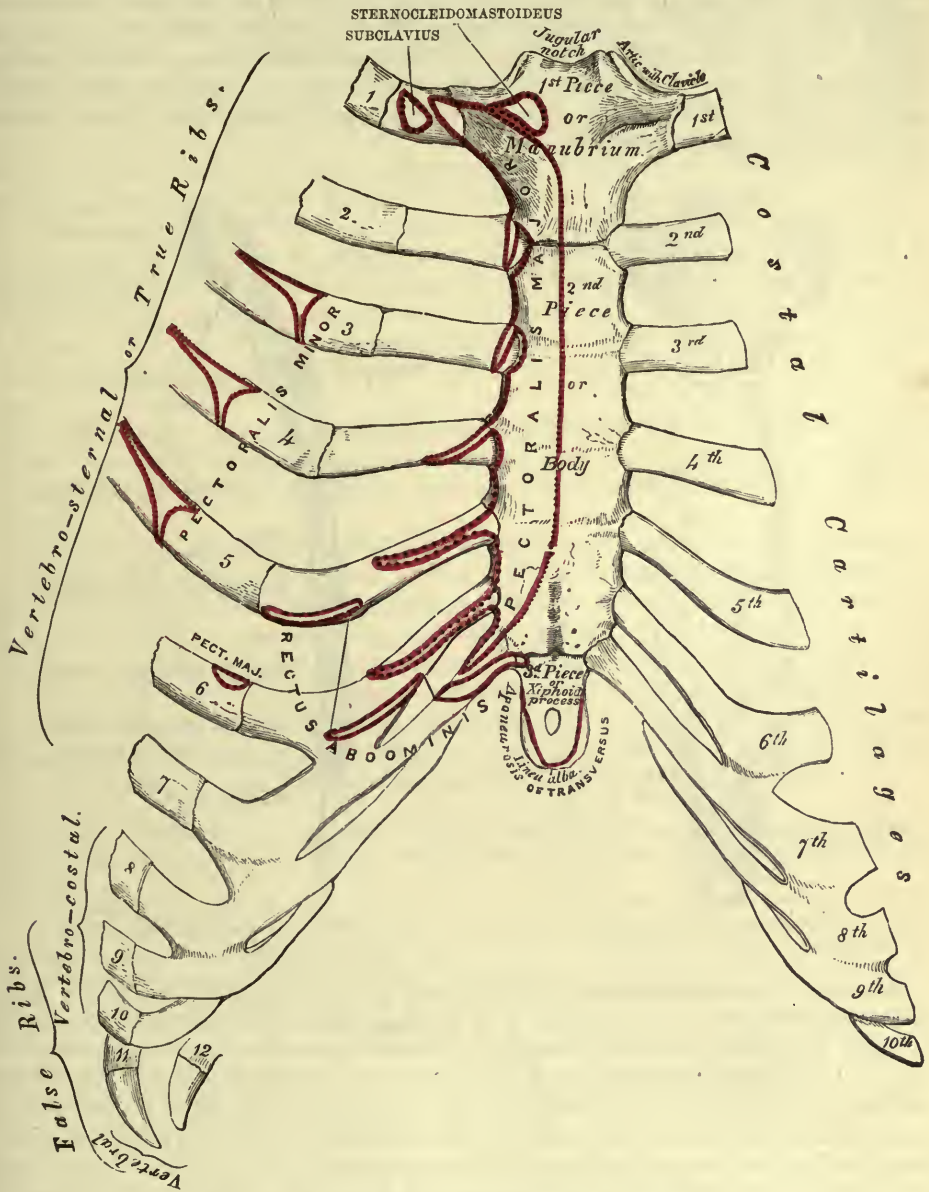


FIG. 115.—Anterior surface of sternum and costal cartilages.

of ribs. It consists of three parts, named from above downward, the **manubrium**, the **body** or **gladiolus**, and the **xiphoid process**; in early life the body consists of four segments or *sternebrae*. In its natural position the inclination of the bone is oblique from above, downward and forward. It is slightly convex in front and concave

behind; broad above, becoming narrowed at the point where the manubrium joins the body, after which it again widens a little to below the middle of the body, and then narrows to its lower extremity. Its average length in the adult is about 17 cm., and is rather greater in the male than in the female.

Manubrium (*manubrium sterni*).—The manubrium is of a somewhat quadrangular form, broad and thick above, narrow below at its junction with the body.

Surfaces.—Its **anterior surface**, convex from side to side, concave from above downward, is smooth, and affords attachment on either side to the sternal origins of the Pectoralis major and Sternocleidomastoideus. Sometimes the ridges limiting the attachments of these muscles are very distinct. Its **posterior surface**, concave and smooth, affords attachment on either side to the Sternohyoideus and Sternothyroideus.

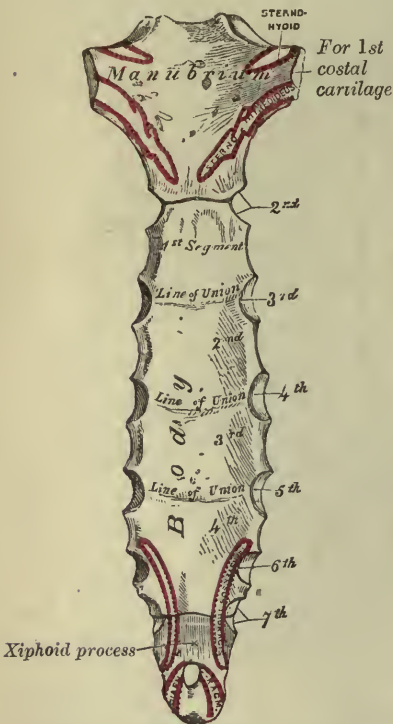


FIG. 116.—Posterior surface of sternum.

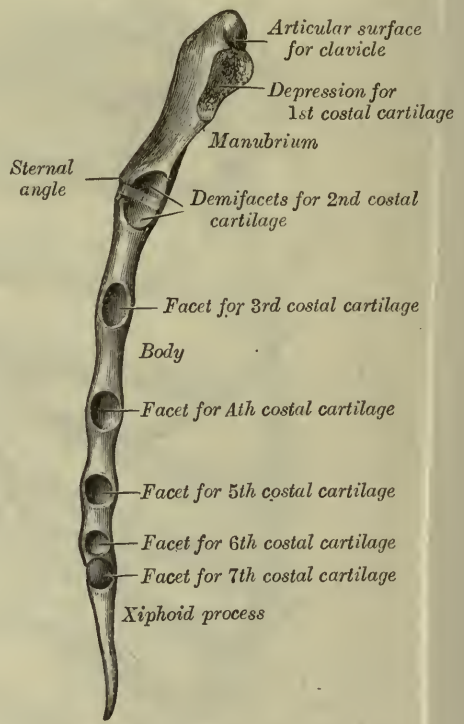


FIG. 117.—Lateral border of sternum.

Borders.—The **superior border** is the thickest and presents at its center the **jugular** or **presteral notch**; on either side of the notch is an oval articular surface, directed upward, backward, and lateralward, for articulation with the sternal end of the clavicle. The **inferior border**, oval and rough, is covered in a fresh state with a thin layer of cartilage, for articulation with the body. The **lateral borders** are each marked above by a depression for the first costal cartilage, and below by a small facet, which, with a similar facet on the upper angle of the body, forms a notch for the reception of the costal cartilage of the second rib. Between the depression for the first costal cartilage and the demi-facet for the second is a narrow, curved edge, which slopes from above downward and medialward.

Body (*corpus sterni; gladiolus*).—The body, considerably longer, narrower, and thinner than the manubrium, attains its greatest breadth close to the lower end.

Surfaces.—Its **anterior surface** is nearly flat, directed upward and forward, and marked by three transverse ridges which cross the bone opposite the third,

fourth, and fifth articular depressions.¹ It affords attachment on either side to the sternal origin of the Pectoralis major. At the junction of the third and fourth pieces of the body is occasionally seen an orifice, the **sternal foramen**, of varying size and form. The **posterior surface**, slightly concave, is also marked by three transverse lines, less distinct, however, than those in front; from its lower part, on either side, the Transversus thoracis takes origin.

Borders.—The **superior border** is oval and articulates with the manubrium, the junction of the two forming the **sternal angle** (*angulus Ludovici*²). The **inferior border** is narrow, and articulates with the xiphoid process. Each **lateral border** (Fig. 117), at its superior angle, has a small facet, which with a similar facet on the manubrium, forms a cavity for the cartilage of the second rib; below this are four angular depressions which receive the cartilages of the third, fourth, fifth, and sixth ribs, while the inferior angle has a small facet, which, with a corresponding one on the xiphoid process, forms a notch for the cartilage of the seventh rib. These articular depressions are separated by a series of curved interarticular intervals, which diminish in length from above downward, and correspond to the intercostal spaces. Most of the cartilages belonging to the true ribs, as will be seen from the foregoing description, articulate with the sternum at the lines of junction of its primitive component segments. This is well seen in many of the lower animals, where the parts of the bone remain ununited longer than in man.

Xiphoid Process (*processus xiphoideus; ensiform or xiphoid appendix*).—The xiphoid process is the smallest of the three pieces: it is thin and elongated, cartilaginous in structure in youth, but more or less ossified at its upper part in the adult.

Surfaces.—Its **anterior surface** affords attachment on either side to the anterior costoxiphoid ligament and a small part of the Rectus abdominis; its **posterior surface**, to the posterior costoxiphoid ligament and to some of the fibers of the diaphragm and Transversus thoracis, its **lateral borders**, to the aponeuroses of the abdominal muscles. Above, it articulates with the lower end of the body, and on the front of each superior angle presents a facet for part of the cartilage of the seventh rib; below, by its pointed extremity, it gives attachment to the linea alba. The xiphoid process varies much in form; it may be broad and thin, pointed, bifid, perforated, curved, or deflected considerably to one or other side.

Structure.—The sternum is composed of highly vascular cancellous tissue, covered by a thin layer of compact bone which is thickest in the manubrium between the articular facets for the clavicles.

Ossification.—The sternum originally consists of two cartilaginous bars, situated one on either side of the median plane and connected with the cartilages of the upper nine ribs of its own side. These two bars fuse with each other along the middle line to form the cartilaginous sternum which is ossified from six centers: one for the manubrium, four for the body, and one for the xiphoid process (Fig. 118). The ossific centers appear in the intervals between the articular depressions for the costal cartilages, in the following order: in the manubrium and first piece of the body, during the sixth month; in the second and third pieces of the body, during the seventh month of fetal life; in its fourth piece, during the first year after birth; and in the xiphoid process, between the fifth and eighteenth years. The centers make their appearance at the upper parts of the segments, and proceed gradually downward.³ To these may be added the occasional existence of two small episternal centers, which make their appearance one on either side of the jugular notch; they are probably vestiges of the episternal bone of the monotremata and lizards. Occasionally some of the segments are formed from more than one center, the number and position of which vary (Fig. 120). Thus, the first piece may have two, three, or even six centers. When two are

¹ Paterson (The Human Sternum, 1904), who examined 524 specimens, points out that these ridges are altogether absent in 26.7 per cent.; that in 69 per cent. a ridge exists opposite the third costal attachment; in 39 per cent. opposite the fourth; and in 4 per cent. only, opposite the fifth.

² Named after the French surgeon Antoine Louis, 1723-1792. The Latin name *angulus Ludovici* is not infrequently mistranslated into English as "the angle of Ludwig."

³ Out of 141 sterna between the time of birth and the age of sixteen years, Paterson (*op. cit.*) found the fourth or lowest center for the body present only in thirty-eight cases—i. e., 26.9 per cent.

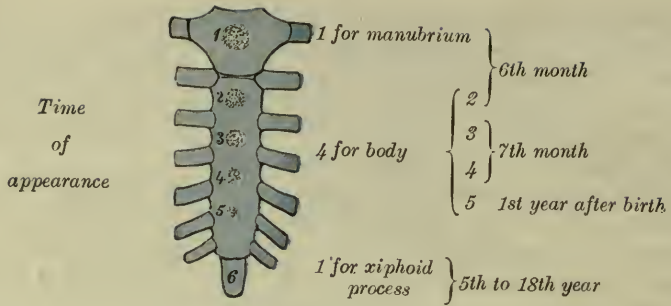


FIG. 118.—Ossification of the sternum.

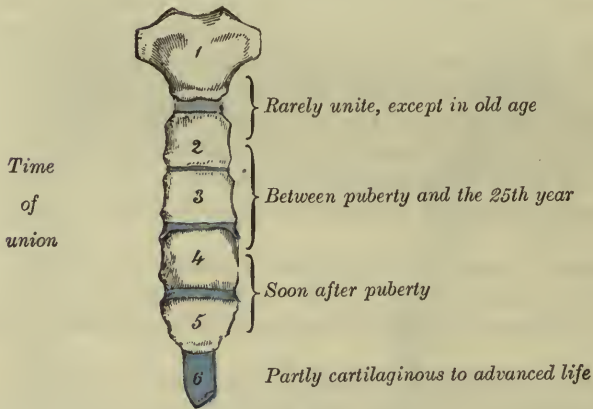


FIG. 119

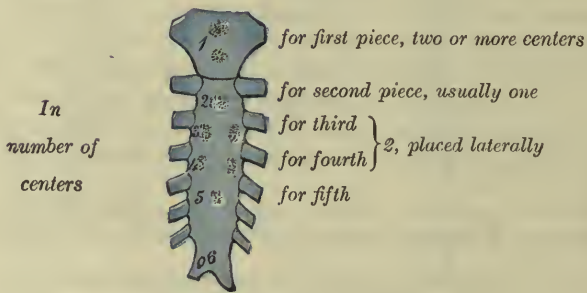


FIG. 120.—Peculiarities.

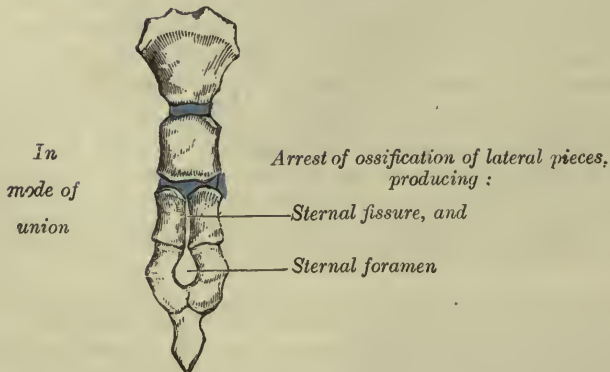


FIG. 121

present, they are generally situated one above the other, the upper being the larger; the second piece has seldom more than one; the third, fourth, and fifth pieces are often formed from two centers placed laterally, the irregular union of which explains the rare occurrence of the sternal foramen (Fig. 121), or of the vertical fissure which occasionally intersects this part of the bone constituting the malformation known as *fissura sterni*; these conditions are further explained by the manner in which the cartilaginous sternum is formed. More rarely still the upper end of the sternum may be divided by a fissure. Union of the various centers of the body begins about puberty, and proceeds from below upward (Fig. 119); by the age of twenty-five they are all united. The xiphoid process may become joined to the body before the age of thirty, but this occurs more frequently after forty; on the other hand, it sometimes remains ununited in old age. In advanced life the manubrium is occasionally joined to the body by bone. When this takes place, however, the bony tissue is generally only superficial, the central portion of the intervening cartilage remaining unossified.

Articulations.—The sternum articulates on either side with the clavicle and upper seven costal cartilages.

The Ribs (Costæ).

The ribs are elastic arches of bone, which form a large part of the thoracic skeleton. They are twelve in number on either side; but this number may be increased by the development of a cervical or lumbar rib, or may be diminished to eleven. The first seven are connected behind with the vertebral column, and in front, through the intervention of the costal cartilages, with the sternum (Fig. 115); they are called **true** or **vertebro-sternal ribs**.¹ The remaining five are **false ribs**; of these, the first three have their cartilages attached to the cartilage of the rib above (**vertebro-chondral**): the last two are free at their anterior extremities and are termed **floating** or **vertebral ribs**. The ribs vary in their direction, the upper ones being less oblique than the lower; the obliquity reaches its maximum at the ninth rib, and gradually decreases from that rib to the twelfth. The ribs are situated one below the other in such a manner that spaces called **intercostal spaces** are left between them. The length of each space corresponds to that of the adjacent ribs and their cartilages; the breadth is greater in front than behind, and between the upper than the lower ribs. The ribs increase in length from the first to the seventh, below which they diminish to the twelfth. In breadth they decrease from above downward; in the upper ten the greatest breadth is at the sternal extremity.

Common Characteristics of the Ribs (Figs. 122, 123).—A rib from the middle of the series should be taken in order to study the common characteristics of these bones.

Each rib has two extremities, a **posterior** or **vertebral**, and an **anterior** or **sternal**, and an intervening portion—the **body** or **shaft**.

Posterior Extremity.—The **posterior** or **vertebral extremity** presents for examination a head, neck, and tubercle.

The **head** is marked by a kidney-shaped articular surface, divided by a horizontal crest into two facets for articulation with the depression formed on the bodies of two adjacent thoracic vertebræ; the upper facet is the smaller; to the crest is attached the interarticular ligament.

The **neck** is the flattened portion which extends lateralward from the head; it is about 2.5 cm. long, and is placed in front of the transverse process of the lower of the two vertebræ with which the head articulates. Its **anterior surface** is flat and smooth, its **posterior** rough for the attachment of the ligament of the neck, and perforated by numerous foramina. Of its two borders the **superior** presents a rough crest (*crista colli costæ*) for the attachment of the anterior costotransverse ligament; its **inferior border** is rounded. On the posterior surface at the junction of the neck and body, and nearer the lower than the upper border, is an eminence

¹ Sometimes the eighth rib cartilage articulates with the sternum; this condition occurs more frequently on the right than on the left side.

—the **tubercle**; it consists of an articular and a non-articular portion. The *articular portion*, the lower and more medial of the two, presents a small, oval surface for

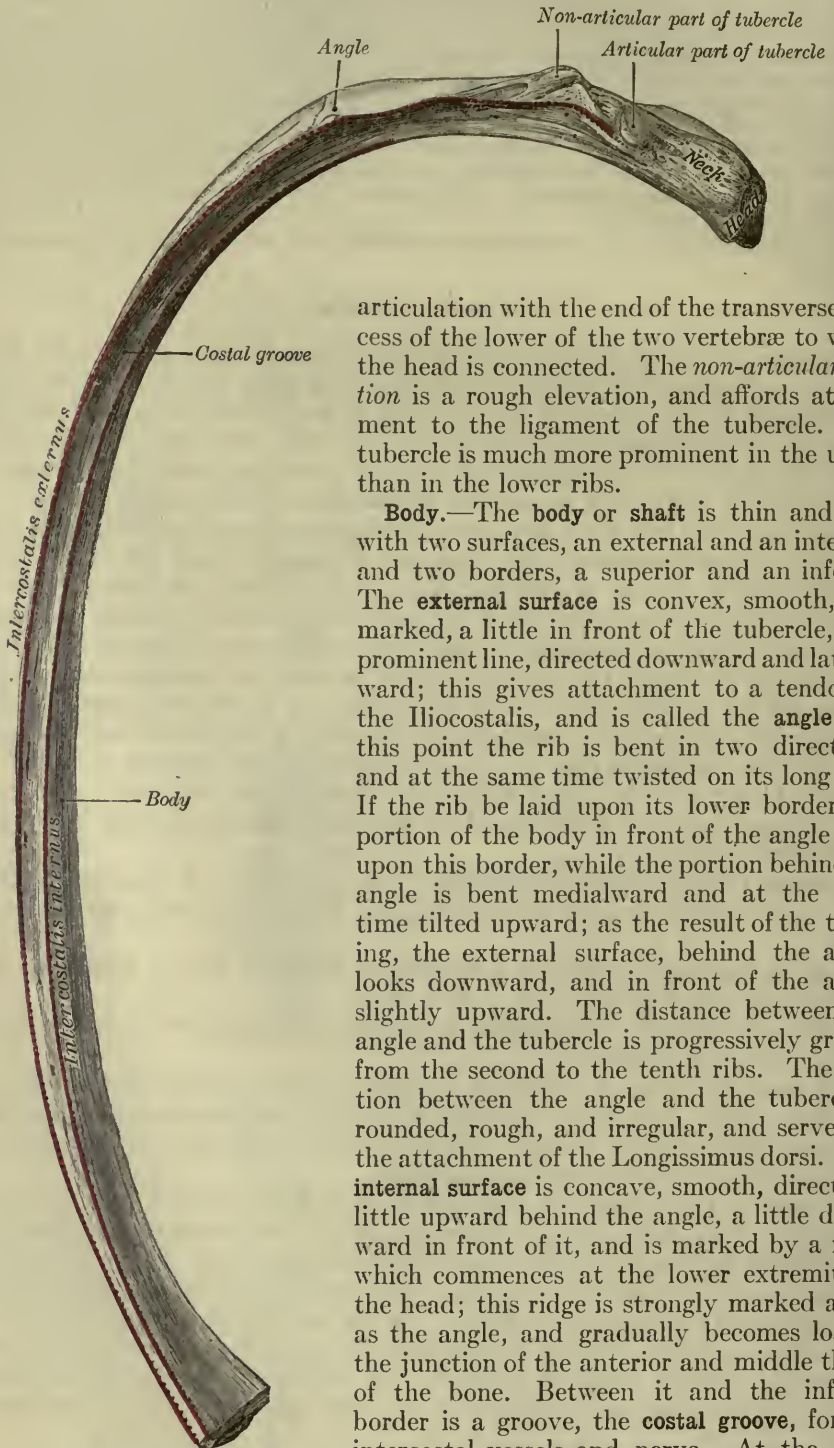


FIG. 122.—A central rib of the left side. Inferior aspect.

articulation with the end of the transverse process of the lower of the two vertebræ to which the head is connected. The *non-articular portion* is a rough elevation, and affords attachment to the ligament of the tubercle. The tubercle is much more prominent in the upper than in the lower ribs.

Body.—The **body** or **shaft** is thin and flat, with two surfaces, an external and an internal; and two borders, a superior and an inferior. The **external surface** is convex, smooth, and marked, a little in front of the tubercle, by a prominent line, directed downward and lateralward; this gives attachment to a tendon of the *Iliocostalis*, and is called the **angle**. At this point the rib is bent in two directions, and at the same time twisted on its long axis. If the rib be laid upon its lower border, the portion of the body in front of the angle rests upon this border, while the portion behind the angle is bent medialward and at the same time tilted upward; as the result of the twisting, the external surface, behind the angle, looks downward, and in front of the angle, slightly upward. The distance between the angle and the tubercle is progressively greater from the second to the tenth ribs. The portion between the angle and the tubercle is rounded, rough, and irregular, and serves for the attachment of the *Longissimus dorsi*. The **internal surface** is concave, smooth, directed a little upward behind the angle, a little downward in front of it, and is marked by a ridge which commences at the lower extremity of the head; this ridge is strongly marked as far as the angle, and gradually becomes lost at the junction of the anterior and middle thirds of the bone. Between it and the inferior border is a groove, the **costal groove**, for the intercostal vessels and nerve. At the back part of the bone, this groove belongs to the

inferior border, but just in front of the angle, where it is deepest and broadest, it is on the internal surface. The superior edge of the groove is rounded and serves for the attachment of an *Intercostalis internus*; the inferior edge corresponds to the lower margin of the rib, and gives attachment to an *Intercostalis externus*. Within the groove are seen the orifices of numerous small foramina for nutrient vessels which traverse the shaft obliquely from before backward. The **superior border**, thick and rounded, is marked by an external and an internal lip, more distinct behind than in front, which serve for the attachment of *Intercostales externus* and *internus*. The **inferior border** is thin, and has attached to it an *Intercostalis externus*.

Anterior Extremity.—The **anterior or sternal extremity** is flattened, and presents a porous, oval, concave depression, into which the costal cartilage is received.

Peculiar Ribs.—The first, second, tenth, eleventh, and twelfth ribs present certain variations from the common characteristics described above, and require special consideration.

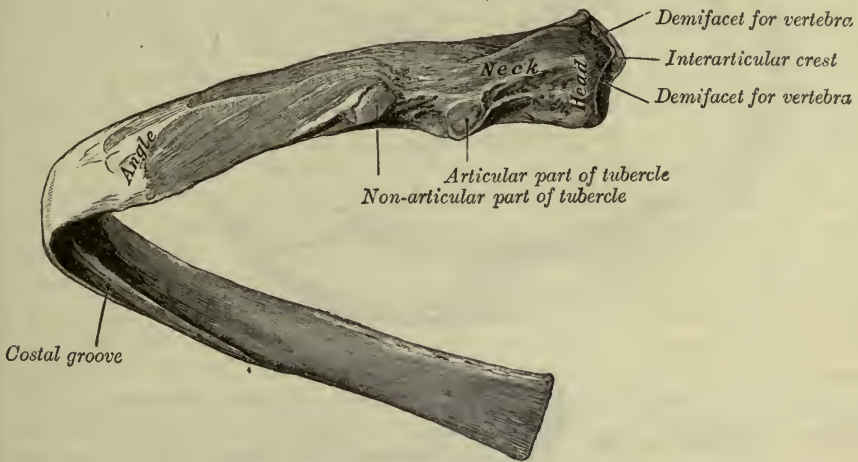


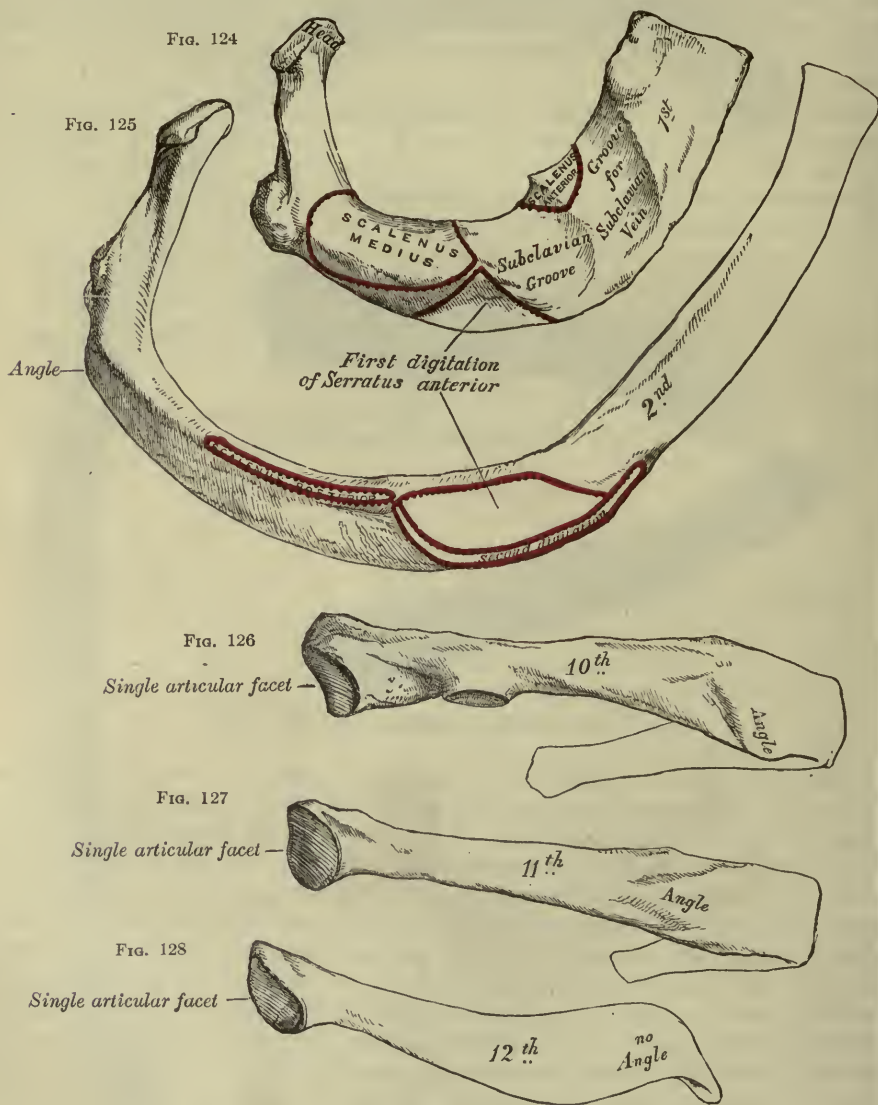
FIG. 123.—A central rib of the left side, viewed from behind.

First Rib.—The first rib (Fig. 124) is the most curved and usually the shortest of all the ribs; it is broad and flat, its surfaces looking upward and downward, and its borders inward and outward. The **head** is small, rounded, and possesses only a single articular facet, for articulation with the body of the first thoracic vertebra. The **neck** is narrow and rounded. The **tubercle**, thick and prominent, is placed on the outer border. There is *no angle*, but at the tubercle the rib is slightly bent, with the convexity upward, so that the head of the bone is directed downward. The **upper surface** of the body is marked by two shallow grooves, separated from each other by a slight ridge prolonged internally into a tubercle, the **scalene tubercle**, for the attachment of the *Scalenus anterior*; the anterior groove transmits the subclavian vein, the posterior the subclavian artery and the lowest trunk of the brachial plexus.¹ Behind the posterior groove is a rough area for the attachment of the *Scalenus medius*. The **under surface** is smooth, and destitute of a costal groove. The **outer border** is convex, thick, and rounded, and at its posterior part gives attachment to the first digitation of the *Serratus anterior*; the **inner border** is concave, thin, and sharp, and marked about its center by the scalene tubercle. The **anterior extremity** is larger and thicker than that of any of the other ribs.

Second Rib.—The second rib (Fig. 125) is much longer than the first, but has a very similar curvature. The non-articular portion of the **tubercle** is occasionally

¹ *Anat. Anzeiger*, 1910, Band xxxvi.

only feebly marked. The **angle** is slight, and situated close to the tubercle. The **body** is not twisted, so that both ends touch any plane surface upon which it may be laid; but there is a bend, with its convexity upward, similar to, though smaller than that found in the first rib. The body is not flattened horizontally like that of the first rib. Its **external surface** is convex, and looks upward and a little outward; near the middle of it is a rough eminence for the origin of the lower part of the



FIGS. 124 TO 128.—Peculiar ribs.

first and the whole of the second digitation of the Serratus anterior; behind and above this is attached the Scalenus posterior. The **internal surface**, smooth, and concave, is directed downward and a little inward: on its posterior part there is a short costal groove.

Tenth Rib.—The tenth rib (Fig. 126) has only a single articular facet on its head.

Eleventh and Twelfth Ribs.—The eleventh and twelfth ribs (Figs. 127 and 128) have each a single articular facet on the head, which is of rather large size; they

have *no necks or tubercles*, and are pointed at their anterior ends. The eleventh has a slight angle and a shallow costal groove. The twelfth has neither; it is much shorter than the eleventh, and its head is inclined slightly downward. Sometimes the twelfth rib is even shorter than the first.

Structure.—The ribs consist of highly vascular cancellous tissue, enclosed in a thin layer of compact bone.

Ossification.—Each rib, with the exception of the last two, is ossified from *four* centers; a primary center for the body, and three epiphysial centers, one for the head and one each for the articular and non-articular parts of the tubercle. The eleventh and twelfth ribs have each only *two* centers, those for the tubercles being wanting. Ossification begins near the angle toward the end of the second month of fetal life, and is seen first in the sixth and seventh ribs. The epiphyses for the head and tubercle make their appearance between the sixteenth and twentieth years, and are united to the body about the twenty-fifth year. Fawcett¹ states that “in all probability there is usually no epiphysis on the non-articular part of the tuberosity below the sixth or seventh rib.

The Costal Cartilages (*Cartilagine Costales*).

The **costal cartilages** (Fig. 115) are bars of hyaline cartilage which serve to prolong the ribs forward and contribute very materially to the elasticity of the walls of the thorax. The first seven pairs are connected with the sternum; the next three are each articulated with the lower border of the cartilage of the preceding rib; the last two have pointed extremities, which end in the wall of the abdomen. Like the ribs, the costal cartilages vary in their length, breadth, and direction. They increase in length from the first to the seventh, then gradually decrease to the twelfth. Their breadth, as well as that of the intervals between them, diminishes from the first to the last. They are broad at their attachments to the ribs, and taper toward their sternal extremities, excepting the first two, which are of the same breadth throughout, and the sixth, seventh, and eighth, which are enlarged where their margins are in contact. They also vary in direction: the first descends a little, the second is horizontal, the third ascends slightly, while the others are angular, following the course of the ribs for a short distance, and then ascending to the sternum or preceding cartilage. Each costal cartilage presents two surfaces, two borders, and two extremities.

Surfaces.—The **anterior surface** is convex, and looks forward and upward: that of the first gives attachment to the costoclavicular ligament and the Subclavius muscle; those of the first six or seven at their sternal ends, to the Pectoralis major. The others are covered by, and give partial attachment to, some of the flat muscles of the abdomen. The **posterior surface** is concave, and directed backward and downward; that of the first gives attachment to the Sternothyroideus, those of the third to the sixth inclusive to the Transversus thoracis, and the six or seven inferior ones to the Transversus abdominis and the diaphragm.

Borders.—Of the two borders the **superior** is concave, the **inferior** convex; they afford attachment to the Intercostales interni: the upper border of the sixth gives attachment also to the Pectoralis major. The inferior borders of the sixth, seventh, eighth, and ninth cartilages present heel-like projections at the points of greatest convexity. These projections carry smooth oblong facets which articulate respectively with facets on slight projections from the upper borders of the seventh, eighth, ninth, and tenth cartilages.

Extremities.—The **lateral end** of each cartilage is continuous with the osseous tissue of the rib to which it belongs. The **medial end** of the first is continuous with the sternum; the medial ends of the six succeeding ones are rounded and are received into shallow concavities on the lateral margins of the sternum. The medial ends of the eighth, ninth, and tenth costal cartilages are pointed, and are connected each with the cartilage immediately above. Those of the eleventh and twelfth are pointed and free. In old age the costal cartilages are prone to undergo superficial ossification.

¹ Journal of Anatomy and Physiology. vol. xlv.

Cervical ribs derived from the seventh cervical vertebra (page 83) are of not infrequent occurrence, and are important clinically because they may give rise to obscure nervous or vascular symptoms. The cervical rib may be a mere epiphysis articulating only with the transverse process of the vertebra, but more commonly it consists of a defined head, neck, and tubercle, with or without a body. It extends lateralward, or forward and lateralward, into the posterior triangle of the neck, where it may terminate in a free end or may join the first thoracic rib, the first costal cartilage, or the sternum.¹ It varies much in shape, size, direction, and mobility. If it reach far enough forward, part of the brachial plexus and the subclavian artery and vein cross over it, and are apt to suffer compression in so doing. Pressure on the artery may obstruct the circulation so much that arterial thrombosis results, causing gangrene of the finger tips. Pressure on the nerves is commoner, and affects the eighth cervical and first thoracic nerves, causing paralysis of the muscles they supply, and neuralgic pains and paresthesia in the area of skin to which they are distributed: no oculopupillary changes are to be found.

The *thorax* is frequently found to be altered in shape in certain diseases.

In *ricketts*, the ends of the ribs, where they join the costal cartilages, become enlarged, giving rise to the so-called "rickety rosary," which in mild cases is only found on the internal surface of the thorax. Lateral to these enlargements the softened ribs sink in, so as to present a groove passing downward and lateralward on either side of the sternum. This bone is forced forward by the bending of the ribs, and the antero-posterior diameter of the chest is increased. The ribs affected are the second to the eighth, the lower ones being prevented from falling in by the presence of the liver, stomach, and spleen; and when the abdomen is distended, as it often is in ricketts, the lower ribs may be pushed outward, causing a transverse groove (Harrison's sulcus) just above the costal arch. This deformity or forward projection of the sternum, often asymmetrical, is known as *pigeon breast*, and may be taken as evidence of active or old ricketts except in cases of primary spinal curvature. In many instances it is associated in children with obstruction in the upper air passages, due to enlarged tonsils or adenoid growths. In some ricketty children or adults, and also in others who give no history or further evidence of having had ricketts, an opposite condition obtains. The lower part of the sternum and often the xiphoid process as well are deeply depressed backward, producing an oval hollow in the lower sternal and upper epigastric regions. This is known as *funnel breast* (German, *Trichterbrust*); it never appears to produce the least disturbance of any of the vital functions. The *phthisical chest* is often long and narrow, and with great obliquity of the ribs and projection of the scapulæ. In *pulmonary emphysema* the chest is enlarged in all its diameters, and presents on section an almost circular outline. It has received the name of the *barrel-shaped chest*. In severe cases of *lateral curvature of the vertebral column* the thorax becomes much distorted. In consequence of the rotation of the bodies of the vertebræ which takes place in this disease, the ribs opposite the convexity of the dorsal curve become extremely convex behind, being thrown out and bulging, and at the same time flattened in front, so that the two ends of the same rib are almost parallel. Coincidentally with this the ribs on the opposite side, on the concavity of the curve, are sunk and depressed behind, and bulging and convex in front.

THE SKULL.

The *skull* is supported on the summit of the vertebral column, and is of an oval shape, wider behind than in front. It is composed of a series of flattened or irregular bones which, with one exception (the mandible), are immovably jointed together. It is divisible into two parts: (1) the *cranium*, which lodges and protects the brain, consists of eight bones, and (2) the *skeleton of the face*, of fourteen, as follows:

Skull, 22 bones	Cranium, 8 bones	Occipital.
		Two Parietals.
		Frontal.
		Two Temporals.
		Sphenoidal.
		Ethmoidal.
	Face, 14 bones	Two Nasals.
		Two Maxillæ.
		Two Lacrimals.
		Two Zygomatics.
		Two Palatines.
		Two Inferior Nasal Conchæ.
		Vomer.
		Mandible.

¹ W. Thorburn, *The Medical Chronicle*, Manchester, 1907, 4th series, xiv, No. 3

In the Basle nomenclature, certain bones developed in association with the nasal capsule, viz., the inferior nasal conchæ, the lacrimals, the nasals, and the vomer, are grouped as cranial and not as facial bones.

The hyoid bone, situated at the root of the tongue and attached to the base of the skull by ligaments, is described in this section.

THE CRANIAL BONES (OSSA CRANII).

The Occipital Bone (Os Occipitale).

The occipital bone (Figs. 129, 130), situated at the back and lower part of the cranium, is trapezoid in shape and curved on itself. It is pierced by a large oval aperture, the *foramen magnum*, through which the cranial cavity communicates with the vertebral canal.

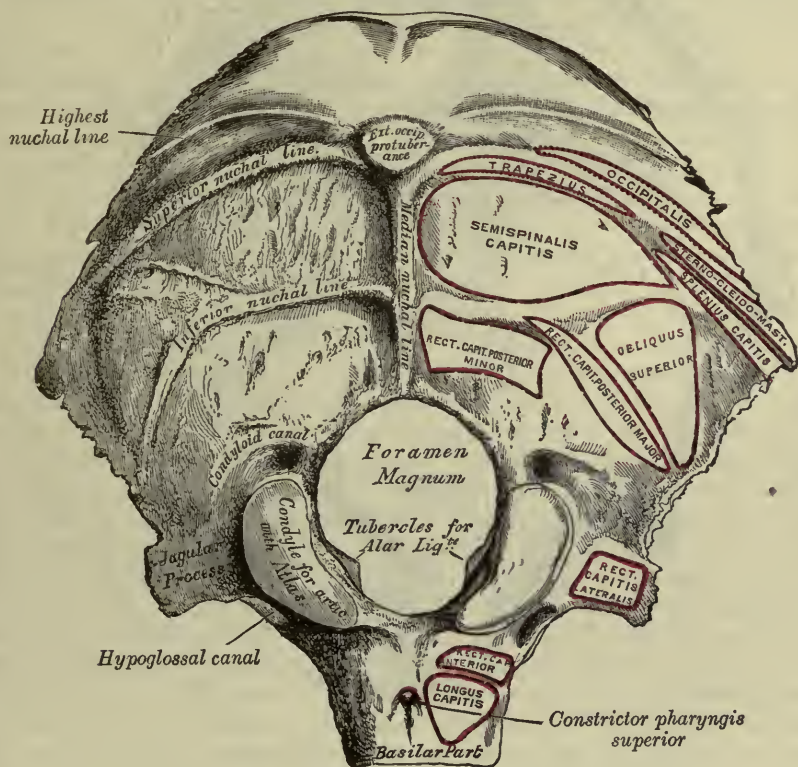


FIG. 129.—Occipital bone. Outer surface.

The curved, expanded plate behind the foramen magnum is named the *squama*; the thick, somewhat quadrilateral piece in front of the foramen is called the *basilar part*, whilst on either side of the foramen is the *lateral portion*.

The Squama (*squama occipitalis*).—The squama, situated above and behind the foramen magnum, is curved from above downward and from side to side.

Surfaces.—The **external surface** is convex and presents midway between the summit of the bone and the foramen magnum a prominence, the **external occipital protuberance**. Extending lateralward from this on either side are two curved lines, one a little above the other. The upper, often faintly marked, is named the **highest nuchal line**, and to it the galea aponeurotica is attached. The lower

is termed the **superior nuchal line**. That part of the squama which lies above the highest nuchal lines is named the **planum occipitale**, and is covered by the Occipitalis muscle; that below, termed the **planum nuchale**, is rough and irregular for the attachment of several muscles. From the external occipital protuberance a ridge or crest, the **median nuchal line**, often faintly marked, descends to the foramen magnum, and affords attachment to the ligamentum nuchæ; running from the middle of this line across either half of the nuchal plane is the **inferior nuchal line**. Several muscles are attached to the outer surface of the squama, thus: the superior nuchal line gives origin to the Occipitalis and Trapezius, and insertion to the Sternocleidomastoideus and Splenius capitis; into the surface between

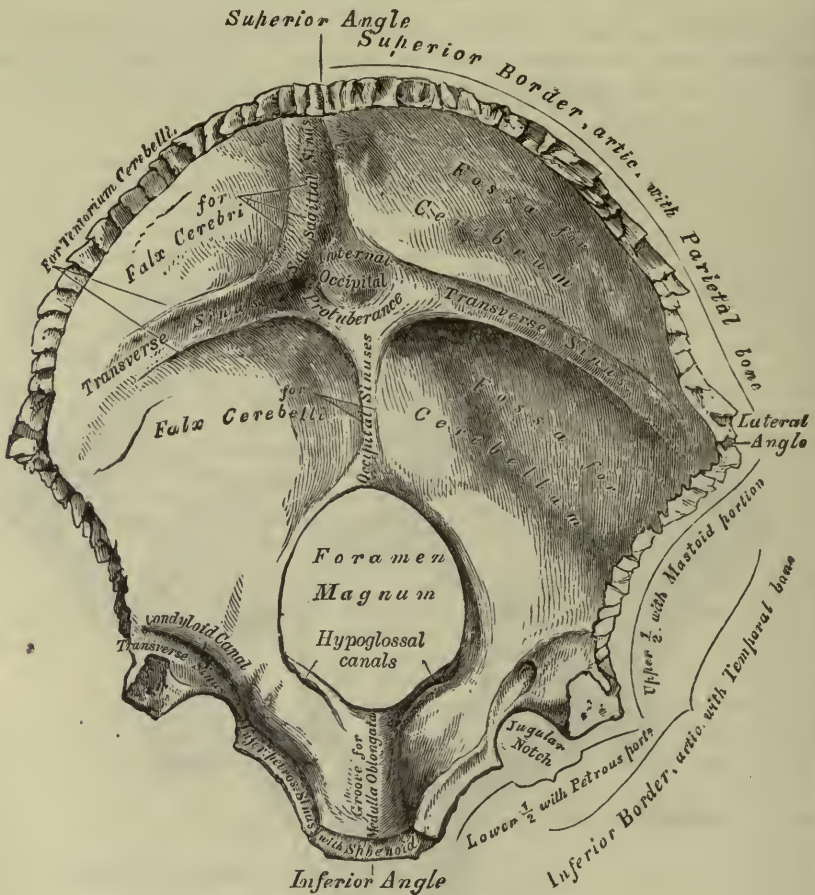


FIG. 130.—Occipital bone. Inner surface.

the superior and inferior nuchal lines the Semispinalis capitis and the Obliquus capitis superior are inserted, while the inferior nuchal line and the area below it receive the insertions of the Recti capitis posteriores major and minor. The posterior atlantooccipital membrane is attached around the postero-lateral part of the foramen magnum, just outside the margin of the foramen.

The internal surface is deeply concave and divided into four fossæ by a **cruciate eminence**. The upper two fossæ are triangular and lodge the occipital lobes of the cerebrum; the lower two are quadrilateral and accommodate the hemispheres of the cerebellum. At the point of intersection of the four divisions of the cruciate eminence is the **internal occipital protuberance**. From this protuberance the upper division of the cruciate eminence runs to the superior angle of the bone, and on

one side of it (generally the right) is a deep groove, the **sagittal sulcus**, which lodges the hinder part of the superior sagittal sinus; to the margins of this sulcus the falx cerebri is attached. The lower division of the cruciate eminence is prominent, and is named the **internal occipital crest**; it bifurcates near the foramen magnum and gives attachment to the falx cerebelli; in the attached margin of this falx is the occipital sinus, which is sometimes duplicated. In the upper part of the internal occipital crest, a small depression is sometimes distinguishable; it is termed the **vermian fossa** since it is occupied by part of the vermis of the cerebellum. Transverse grooves, one on either side, extend from the internal occipital protuberance to the lateral angles of the bone; those grooves accommodate the transverse sinuses, and their prominent margins give attachment to the tentorium cerebelli. The groove on the right side is usually larger than that on the left, and is continuous with that for the superior sagittal sinus. Exceptions to this condition are, however, not infrequent; the left may be larger than the right or the two may be almost equal in size. The angle of union of the superior sagittal and transverse sinuses is named the **confluence of the sinuses** (*torcular Herophili*¹), and its position is indicated by a depression situated on one or other side of the protuberance.

Lateral Parts (*pars lateralis*).—The lateral parts are situated at the sides of the foramen magnum; on their under surfaces are the **condyles** for articulation with the superior facets of the atlas. The condyles are oval or reniform in shape, and their anterior extremities, directed forward and medialward, are closer together than their posterior, and encroach on the basilar portion of the bone; the posterior extremities extend back to the level of the middle of the foramen magnum. The articular surfaces of the condyles are convex from before backward and from side to side, and look downward and lateralward. To their margins are attached the capsules of the atlantoöccipital articulations, and on the medial side of each is a rough impression or tubercle for the alar ligament. At the base of either condyle the bone is tunnelled by a short canal, the **hypoglossal canal** (*anterior condyloid foramen*). This begins on the cranial surface of the bone immediately above the foramen magnum, and is directed lateralward and forward above the condyle. It may be partially or completely divided into two by a spicule of bone; it gives exit to the hypoglossal or twelfth cerebral nerve, and entrance to a meningeal branch of the ascending pharyngeal artery. Behind either condyle is a depression, the **condyloid fossa**, which receives the posterior margin of the superior facet of the atlas when the head is bent backward; the floor of this fossa is sometimes perforated by the **condyloid canal**, through which an emissary vein passes from the transverse sinus. Extending lateralward from the posterior half of the condyle is a quadrilateral plate of bone, the **jugular process**, excavated in front by the **jugular notch**, which, in the articulated skull, forms the posterior part of the jugular foramen. The jugular notch may be divided into two by a bony spicule, the **intra-jugular process**, which projects lateralward above the hypoglossal canal. The under surface of the jugular process is rough, and gives attachment to the Rectus capitis lateralis muscle and the lateral atlantoöccipital ligament; from this surface an eminence, the **paramastoid process**, sometimes projects downward, and may be of sufficient length to reach, and articulate with, the transverse process of the atlas. Laterally the jugular process presents a rough quadrilateral or triangular area which is joined to the jugular surface of the temporal bone by a plate of cartilage; after the age of twenty-five this plate tends to ossify.

The **upper surface** of the lateral part presents an oval eminence, the **jugular tubercle**, which overlies the hypoglossal canal and is sometimes crossed by an oblique groove for the glossopharyngeal, vagus, and accessory nerves. On the

¹ The columns of blood coming in different directions were supposed to be pressed together at this point (*torcular*, a wine press).

upper surface of the jugular process is a deep groove which curves medialward and forward and is continuous with the jugular notch. This groove lodges the terminal part of the transverse sinus, and opening into it, close to its medial margin, is the orifice of the condyloid canal.

Basilar Part (*pars basilaris*).—The basilar part extends forward and upward from the foramen magnum, and presents *in front* an area more or less quadrilateral in outline. In the young skull this area is rough and uneven, and is joined to the body of the sphenoid by a plate of cartilage. By the twenty-fifth year this cartilaginous plate is ossified, and the occipital and sphenoid form a continuous bone.

Surfaces.—On its **lower surface**, about 1 cm. in front of the foramen magnum, is the **pharyngeal tubercle** which gives attachment to the fibrous raphé of the pharynx. On either side of the middle line the Longus capitis and Rectus capitis anterior are inserted, and immediately in front of the foramen magnum the anterior atlantoöccipital membrane is attached.

The **upper surface** presents a broad, shallow groove which inclines upward and forward from the foramen magnum; it supports the medulla oblongata, and near the margin of the foramen magnum gives attachment to the membrana tectoria. On the lateral margins of this surface are faint grooves for the inferior petrosal sinuses.

Foramen Magnum.—The foramen magnum is a large oval aperture with its long diameter antero-posterior; it is wider behind than in front where it is encroached upon by the condyles. It transmits the medulla oblongata and its membranes, the accessory nerves, the vertebral arteries, the anterior and posterior spinal arteries, and the membrana tectoria and alar ligaments.

Angles.—The **superior angle** of the occipital bone articulates with the occipital angles of the parietal bones and, in the fetal skull, corresponds in position with the **posterior fontanelle**. The **inferior angle** is fused with the body of the sphenoid. The **lateral angles** are situated at the extremities of the grooves for the transverse sinuses: each is received into the interval between the mastoid angle of the parietal and the mastoid part of the temporal.

Borders.—The **superior borders** extend from the superior to the lateral angles: they are deeply serrated for articulation with the occipital borders of the parietals, and form by this union the **lambdoidal suture**. The **inferior borders** extend from the lateral angles to the inferior angle; the upper half of each articulates with the mastoid portion of the corresponding temporal, the lower half with the petrous part of the same bone. These two portions of the inferior border are separated from one another by the jugular process, the notch on the anterior surface of which forms the posterior part of the jugular foramen.

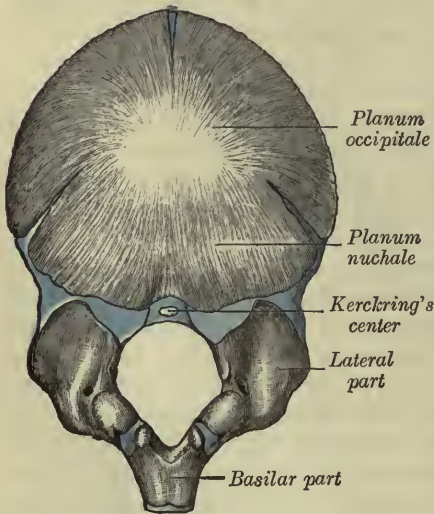


FIG. 131.—Occipital bone at birth.

Structure.—The occipital, like the other cranial bones, consists of two compact lamellæ, called the *outer* and *inner tables*, between which is the cancellous tissue or diploë; the bone is especially thick at the ridges, protuberances, condyles, and anterior part of the basilar part; in the inferior fossæ it is thin, semitransparent, and destitute of diploë.

Ossification (Fig. 131).—The planum occipitale of the squama is developed in membrane, and may remain separate throughout life when it constitutes the *interparietal* bone; the rest of

the bone is developed in cartilage. The number of nuclei for the planum occipitale is usually given as four, two appearing near the middle line about the second month, and two some little distance from the middle line about the third month of fetal life. The planum nuchale of the squama is ossified from two centers, which appear about the seventh week of fetal life and soon unite to form a single piece. Union of the upper and lower portions of the squama takes place in the third month of fetal life. An occasional center (Kerckring) appears in the posterior margin of the foramen magnum during the fifth month; this forms a separate ossicle (sometimes double) which unites with the rest of the squama before birth. Each of the lateral parts begins to ossify from a single center during the eighth week of fetal life. The basilar portion is ossified from two centers, one in front of the other; these appear about the sixth week of fetal life and rapidly coalesce. Mall¹ states that the planum occipitale is ossified from two centers and the basilar portion from one. About the fourth year the squama and the two lateral portions unite, and about the sixth year the bone consists of a single piece. Between the eighteenth and twenty-fifth years the occipital and sphenoid become united, forming a single bone.

Articulations.—The occipital articulates with *six* bones: the two parietals, the two temporals, the sphenoid, and the atlas.

The Parietal Bone (Os Parietale).

The **parietal bones** form, by their union, the sides and roof of the cranium. Each bone is irregularly quadrilateral in form, and has two surfaces, four borders, and four angles.

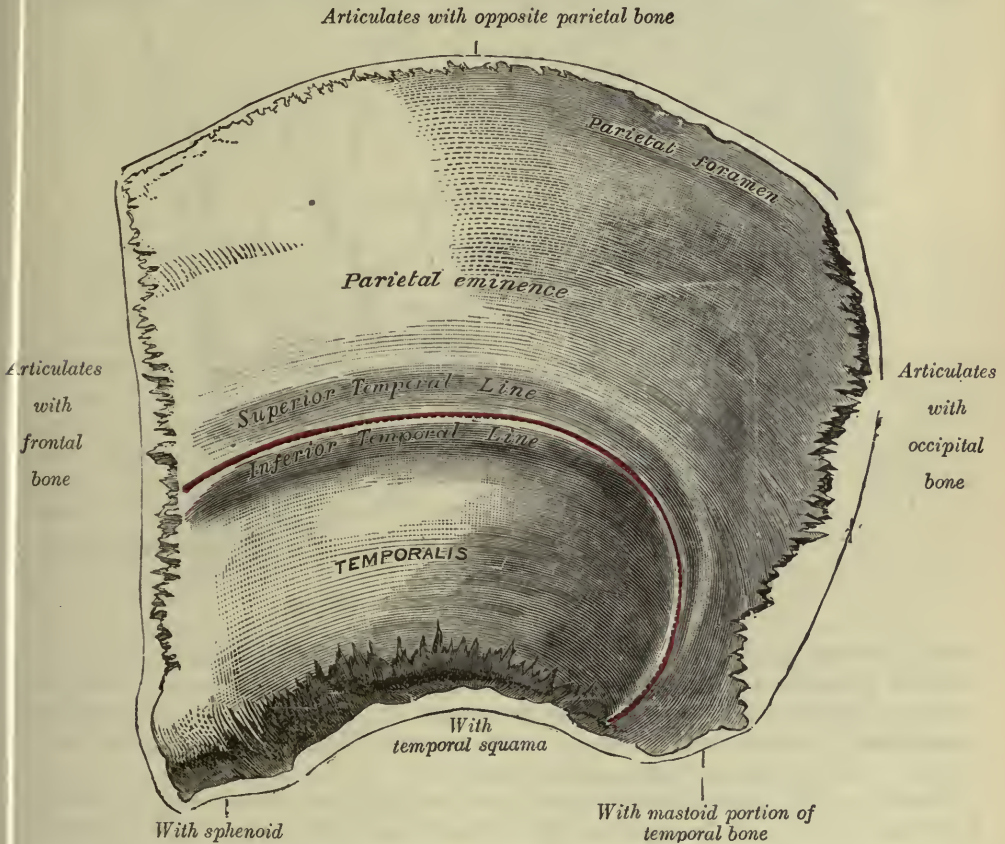


FIG. 132.—Left parietal bone. Outer surface.

Surfaces.—The **external surface** (Fig. 132) is convex, smooth, and marked near the center by an eminence, the **parietal eminence** (*tuber parietale*), which indicates the point where ossification commenced. Crossing the middle of the bone in an

¹ American Journal of Anatomy, 1906, vol. v.

arched direction are two curved lines, the **superior and inferior temporal lines**; the former gives attachment to the temporal fascia, and the latter indicates the upper limit of the muscular origin of the Temporalis. Above these lines the bone is covered by the galea aponeurotica; below them it forms part of the temporal fossa, and affords attachment to the Temporalis muscle. At the back part and close to the upper or sagittal border is the **parietal foramen**, which transmits a vein to the superior sagittal sinus, and sometimes a small branch of the occipital artery; it is not constantly present, and its size varies considerably.

The **internal surface** (Fig. 133) is concave; it presents depressions corresponding to the cerebral convolutions, and numerous furrows for the ramifications of the middle meningeal vessel;¹ the latter run upward and backward from the sphenoidal angle, and from the central and posterior part of the squamous border. Along the upper margin is a shallow groove, which, together with that on the opposite

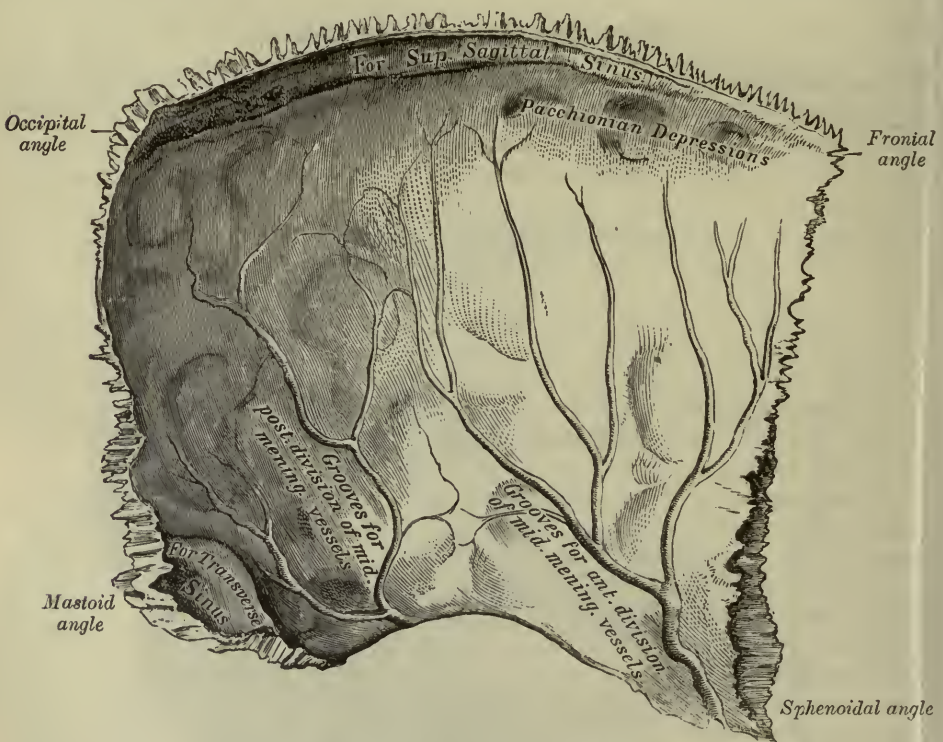

FIG. 133.—Left parietal bone. Inner surface.

parietal, forms a channel, the **sagittal sulcus**, for the superior sagittal sinus; the edges of the sulcus afford attachment to the falx cerebri. Near the groove are several depressions, best marked in the skulls of old persons, for the **arachnoid granulations** (*Pacchionian bodies*). In the groove is the internal opening of the parietal foramen when that aperture exists.

Borders.—The **sagittal border**, the longest and thickest, is dentated and articulates with its fellow of the opposite side, forming the sagittal suture. The **squamous border** is divided into three parts: of these, the anterior is thin and pointed, bevelled at the expense of the outer surface, and overlapped by the tip of the great wing of the sphenoid; the middle portion is arched, bevelled at the expense of the outer surface, and overlapped by the squama of the temporal; the posterior part is thick and serrated for articulation with the mastoid portion of the temporal. The

¹ Journal of Anatomy and Physiology, 1912, vol. xlvii

frontal border is deeply serrated, and bevelled at the expense of the outer surface above and of the inner below; it articulates with the frontal bone, forming one-half of the **coronal suture**. The **occipital border**, deeply denticulated, articulates with the occipital, forming one-half of the **lambdoidal suture**.

Angles.—The **frontal angle** is practically a right angle, and corresponds with the point of meeting of the sagittal and coronal sutures; this point is named the **bregma**; in the fetal skull and for about a year and a half after birth this region is membranous, and is called the **anterior fontanelle**. The **sphenoidal angle**, thin and acute, is received into the interval between the frontal bone and the great wing of the sphenoid. Its inner surface is marked by a deep groove, sometimes a canal, for the anterior divisions of the middle meningeal artery. The **occipital angle** is rounded and corresponds with the point of meeting of the sagittal and lambdoidal sutures—a point which is termed the **lambda**; in the fetus this part of the skull is membranous, and is called the **posterior fontanelle**. The **mastoid angle** is truncated; it articulates with the occipital bone and with the mastoid portion of the temporal, and presents on its inner surface a broad, shallow groove which lodges part of the transverse sinus. The point of meeting of this angle with the occipital and the mastoid part of the temporal is named the **asterion**.

Ossification.—The parietal bone is ossified in membrane from a single center, which appears at the parietal eminence about the eighth week of fetal life. Ossification gradually extends in a radial manner from the center toward the margins of the bone; the angles are consequently the parts last formed, and it is here that the fontanelles exist. Occasionally the parietal bone is divided into two parts, upper and lower, by an antero-posterior suture.

Articulations.—The parietal articulates with *five* bones: the opposite parietal, the occipital, frontal, temporal, and sphenoid.

The Frontal Bone (Os Frontale).

The **frontal bone** resembles a cockle-shell in form, and consists of two portions—a **vertical** portion, the **squama**, corresponding with the region of the forehead; and an **orbital** or **horizontal** portion, which enters into the formation of the roofs of the orbital and nasal cavities.

Squama (*squama frontalis*).—**Surfaces.**—The **external surface** (Fig. 134) of this portion is convex and usually exhibits, in the lower part of the middle line, the remains of the **frontal** or **metopic suture**; in infancy this suture divides the bone into two, a condition which may persist throughout life. On either side of this suture, about 3 cm. above the supraorbital margin, is a rounded elevation, the **frontal eminence** (*tuber frontale*). These eminences vary in size in different individuals, are occasionally unsymmetrical, and are especially prominent in young skulls; the surface of the bone above them is smooth, and covered by the galea aponeurotica. Below the frontal eminences, and separated from them by a shallow groove, are two arched elevations, the **superciliary arches**; these are prominent medially, and are joined to one another by a smooth elevation named the **glabella**. They are larger in the male than in the female, and their degree of prominence depends to some extent on the size of the frontal air sinuses;¹ prominent ridges are, however, occasionally associated with small air sinuses. Beneath each superciliary arch is a curved and prominent margin, the **supraorbital margin**, which forms the upper boundary of the base of the orbit, and separates the squama from the orbital portion of the bone. The lateral part of this margin is sharp and prominent, affording to the eye, in that situation, considerable protection from injury; the medial part is rounded. At the junction of its medial and intermediate thirds is

¹ Some confusion is occasioned to students commencing the study of anatomy by the name "sinus" having been given to two different kinds of space connected with the skull. It may be as well, therefore, to state here that the "sinuses" in the interior of the cranium which produce the grooves on the inner surfaces of the bones are venous channels which convey the blood from the brain, while the "sinuses" external to the cranial cavity (the frontal, sphenoidal, ethmoidal, and maxillary) are hollow spaces in the bones themselves; they communicate with the nasal cavities and contain air.

a notch, sometimes converted into a foramen, the **supraorbital notch or foramen**, which transmits the supraorbital vessels and nerve. A small aperture in the upper part of the notch transmits a vein from the diploë to join the supraorbital vein. The supraorbital margin ends laterally in the **zygomatic process**, which is strong and prominent, and articulates with the zygomatic bone. Running upward and backward from this process is a well-marked line, the **temporal line**, which divides into the **upper and lower temporal lines**, continuous, in the articulated skull, with the corresponding lines on the parietal bone. The area below and behind the temporal line forms the anterior part of the temporal fossa, and gives origin to the Temporalis muscle. Between the supraorbital margins the squama projects downward to a level below that of the zygomatic processes; this portion is known as the **nasal part** and presents a rough, uneven interval, the **nasal notch**, which articulates

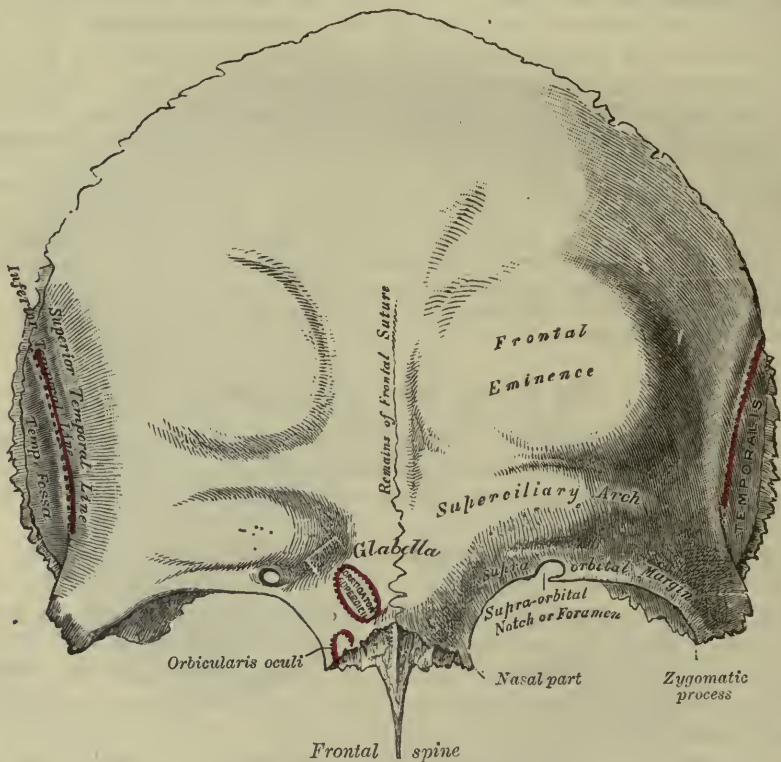


FIG. 134.—Frontal bone. Outer surface.

on either side of the middle line with the nasal bone, and laterally with the frontal process of the maxilla and with the lacrimal. The term **nasion** is applied to the middle of the frontonasal suture. From the center of the notch the **nasal process** projects downward and forward beneath the nasal bones and frontal processes of the maxillæ, and supports the bridge of the nose. The nasal process ends below in a sharp **spine**, and on either side of this is a small grooved surface which enters into the formation of the roof of the corresponding nasal cavity. The spine forms part of the septum of the nose, articulating in front with the crest of the nasal bones and behind with the perpendicular plate of the ethmoid.

The **internal surface** (Fig. 135) of the squama is concave and presents in the upper part of the middle line a vertical groove, the **sagittal sulcus**, the edges of which unite below to form a ridge, the **frontal crest**; the sulcus lodges the superior sagittal sinus, while its margins and the crest afford attachment to the falx cerebri.

The crest ends below in a small notch which is converted into a foramen, the **foramen cecum**, by articulation with the ethmoid. This foramen varies in size in different subjects, and is frequently impervious; when open, it transmits a vein from the nose to the superior sagittal sinus. On either side of the middle line the bone presents depressions for the convolutions of the brain, and numerous small furrows for the anterior branches of the middle meningeal vessels. Several small, irregular fossæ may also be seen on either side of the sagittal sulcus, for the reception of the arachnoid granulations.

Orbital or Horizontal Part (*pars orbitalis*).—This portion consists of two thin triangular plates, the **orbital plates**, which form the vaults of the orbits, and are separated from one another by a median gap, the **ethmoidal notch**.

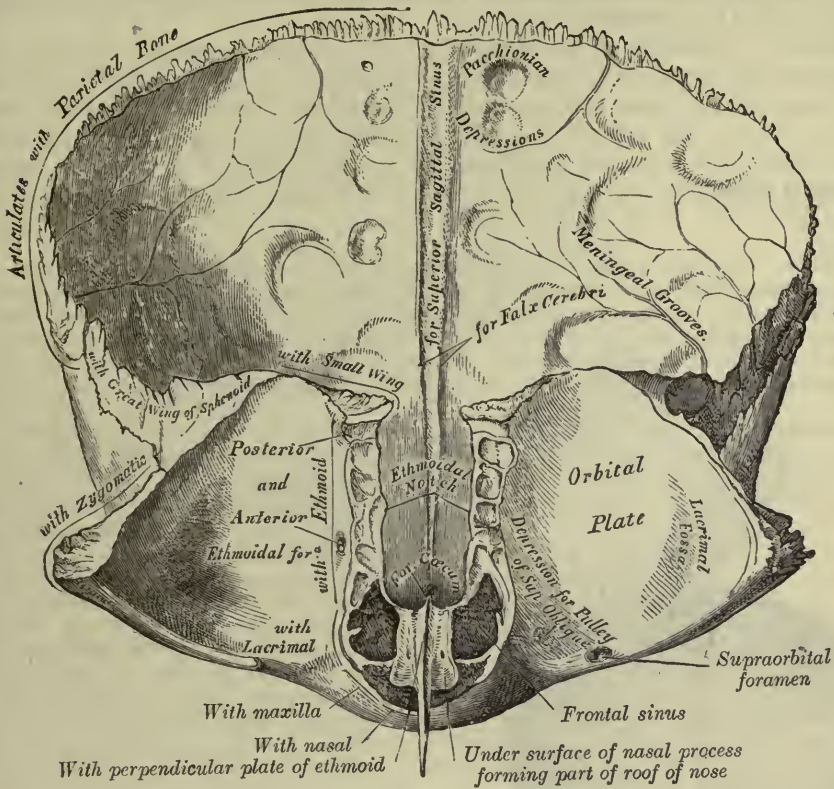


FIG. 135.—Frontal bone. Inner surface.

Surfaces.—The **inferior surface** (Fig. 135) of each orbital plate is smooth and concave, and presents, laterally, under cover of the zygomatic process, a shallow depression, the **lacrimal fossa**, for the lacrimal gland; near the nasal part is a depression, the **fovea trochlearis**, or occasionally a small **trochlear spine**, for the attachment of the cartilaginous pulley of the *Obliquus oculi superior*. The **superior surface** is convex, and marked by depressions for the convolutions of the frontal lobes of the brain, and faint grooves for the meningeal branches of the ethmoidal vessels.

The **ethmoidal notch** separates the two orbital plates; it is quadrilateral, and filled, in the articulated skull, by the cribriform plate of the ethmoid. The margins of the notch present several half-cells which, when united with corresponding half-cells on the upper surface of the ethmoid, complete the ethmoidal air cells. Two grooves cross these edges transversely; they are converted into the **anterior**

and **posterior ethmoidal canals** by the ethmoid, and open on the medial wall of the orbit. The anterior canal transmits the nasociliary nerve and anterior ethmoidal vessels, the posterior, the posterior ethmoidal nerve and vessels. In front of the ethmoidal notch, on either side of the frontal spine, are the openings of the **frontal air sinuses**. These are two irregular cavities, which extend backward, upward, and lateralward for a variable distance between the two tables of the skull; they are separated from one another by a thin bony septum, which often deviates to one or other side, with the result that the sinuses are rarely symmetrical. Absent at birth, they are usually fairly well-developed between the seventh and eighth years, but only reach their full size after puberty. They vary in size in different persons, and are larger in men than in women.¹ They are lined by mucous membrane, and each communicates with the corresponding nasal cavity by means of a passage called the **frontonasal duct**.

Borders.—The border of the **squama** is thick, strongly serrated, bevelled at the expense of the inner table above, where it rests upon the parietal bones, and at the expense of the outer table on either side, where it receives the lateral pressure of those bones; this border is continued below into a triangular, rough surface, which articulates with the great wing of the sphenoid. The **posterior borders of the orbital plates** are thin and serrated, and articulate with the small wings of the sphenoid.

Structure.—The squama and the zygomatic processes are very thick, consisting of diploic tissue contained between two compact laminae; the diploic tissue is absent in the regions occupied by the frontal air sinuses. The orbital portion is thin, translucent, and composed entirely of compact bone; hence the facility with which instruments can penetrate the cranium through this part of the orbit; when the frontal sinuses are exceptionally large they may extend backward for a considerable distance into the orbital portion, which in such cases also consists of only two tables.

Ossification (Fig. 136).—The frontal bone is ossified in membrane from *two primary* centers, one for each half, which appear toward the end of the second month of fetal life, one above each supraorbital margin. From each of these centers ossification extends upward to form the corresponding half of the squama, and backward to form the orbital plate. The spine is

ossified from a pair of *secondary* centers, on either side of the middle line; similar centers appear in the nasal part and zygomatic processes. At birth the bone consists of two pieces, separated by the frontal suture, which is usually obliterated, except at its lower part, by the eighth year, but occasionally persists throughout life. It is generally maintained that the development of the frontal sinuses begins at the end of the first or beginning of the second year, but Onodi's researches indicate that development begins at birth. The sinuses are of considerable size by the seventh or eighth year, but do not attain their full proportions until after puberty.

Articulations.—The frontal articulates with *twelve* bones: the sphenoid, the ethmoid, the two parietals, the two nasals, the two maxillae, the two lacrimals, and the two zygomatics.

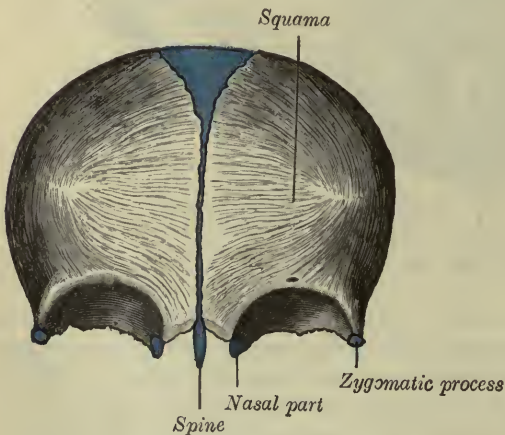


FIG. 136.—Frontal bone at birth.

The Temporal Bone (Os Temporale).

The **temporal bones** are situated at the sides and base of the skull. Each consists of five parts, viz., the **squama**, the **petrous**, **mastoid**, and **tympanic parts**, and the **styloid process**.

¹ Aldren Turner (*The Accessory Sinuses of the Nose*, 1901) gives the following measurements for a sinus of average size: height, $1\frac{1}{4}$ inches; breadth, 1 inch; depth from before backward, 1 inch.

The Squama (*squama temporalis*).—The squama forms the anterior and upper part of the bone, and is scale-like, thin, and translucent.

Surfaces.—Its **outer surface** (Fig. 137) is smooth and convex; it affords attachment to the Temporalis muscle, and forms part of the temporal fossa; on its hinder part is a vertical groove for the middle temporal artery. A curved line, the **temporal line**, or **supramastoid crest**, runs backward and upward across its posterior part; it serves for the attachment of the temporal fascia, and limits the origin of the Temporalis muscle. The boundary between the squama and the mastoid portion of the bone, as indicated by traces of the original suture, lies about 1 cm. below this line. Projecting from the lower part of the squama is a long, arched process, the **zygomatic process**. This process is at first directed lateralward, its two surfaces looking upward and downward; it then appears as if twisted inward

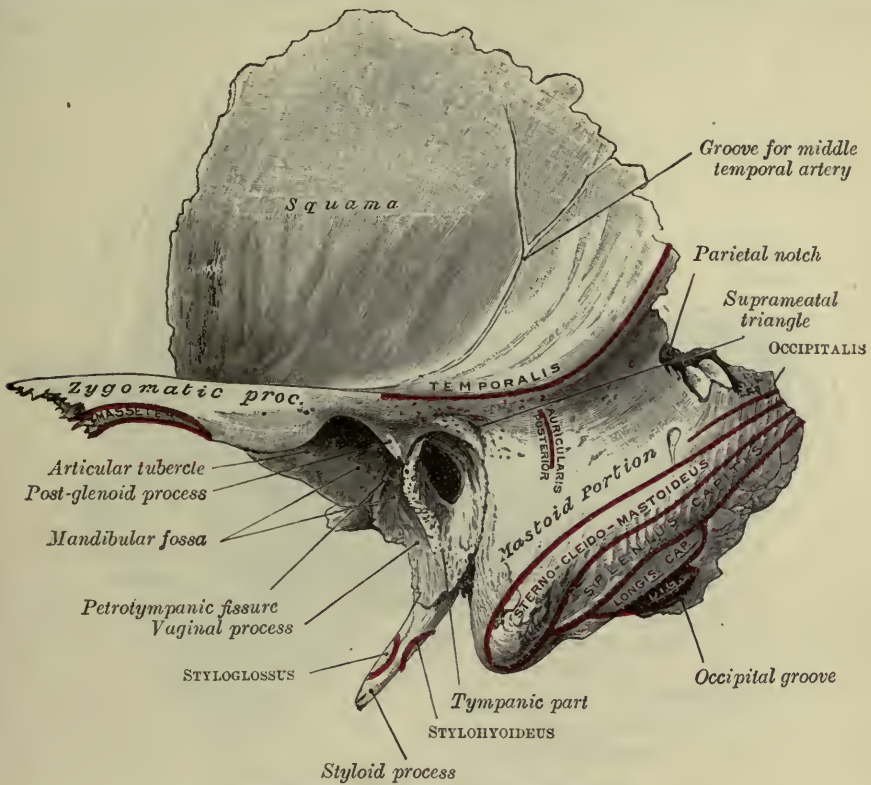


FIG. 137.—Left temporal bone. Outer surface.

upon itself, and runs forward, its surfaces now looking medialward and lateralward. The superior border is long, thin, and sharp, and serves for the attachment of the temporal fascia; the inferior, short, thick, and arched, has attached to it some fibers of the Masseter. The lateral surface is convex and subcutaneous; the medial is concave, and affords attachment to the Masseter. The anterior end is deeply serrated and articulates with the zygomatic bone. The posterior end is connected to the squama by two roots, the **anterior** and **posterior roots**. The posterior root, a prolongation of the upper border, is strongly marked; it runs backward above the external acoustic meatus, and is continuous with the temporal line. The anterior root, continuous with the lower border, is short but broad and strong; it is directed medialward and ends in a rounded eminence, the **articular tubercle** (*eminentia articularis*). This tubercle forms the front boundary of the mandibular fossa,

and in the fresh state is covered with cartilage. In front of the articular tubercle is a small triangular area which assists in forming the infratemporal fossa; this area is separated from the outer surface of the squama by a ridge which is continuous behind with the anterior root of the zygomatic process, and in front, in the articulated skull, with the infratemporal crest on the great wing of the sphenoid. Between the posterior wall of the external acoustic meatus and the posterior root of the zygomatic process is the area called the **suprameatal triangle** (Macewen), or **mastoid fossa**, through which an instrument may be pushed into the tympanic antrum. At the junction of the anterior root with the zygomatic process is a projection for the attachment of the temporomandibular ligament; and behind the anterior root is an oval depression, forming part of the mandibular fossa, for the reception of the condyle of the mandible. The **mandibular fossa** (*glenoid fossa*)

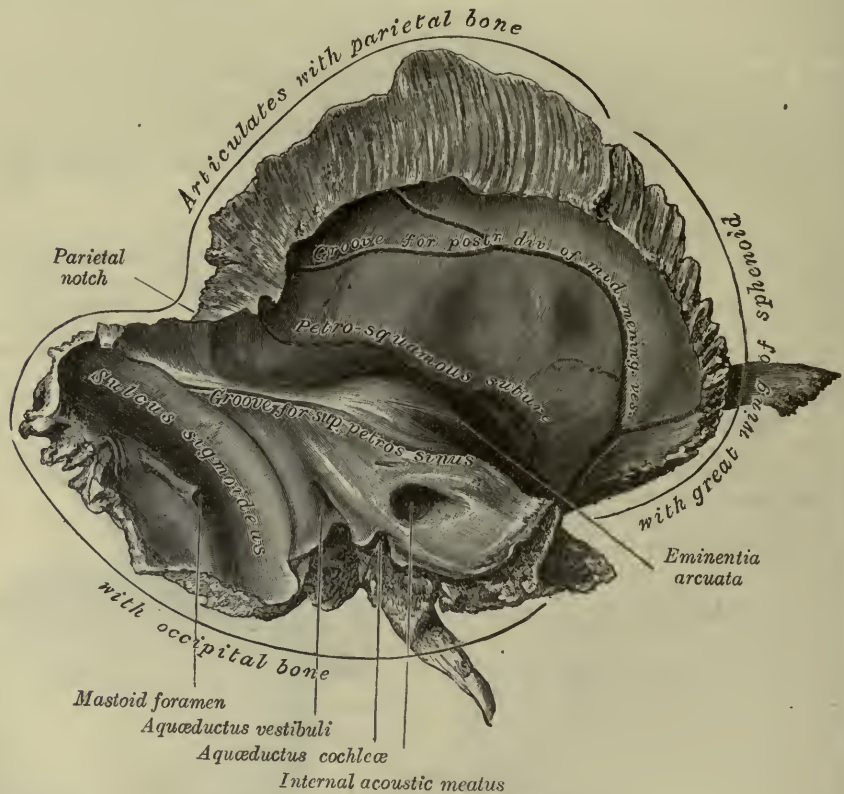


FIG. 138.—Left temporal bone. Inner surface.

is bounded, in front, by the articular tubercle; behind, by the tympanic part of the bone, which separates it from the external acoustic meatus; it is divided into two parts by a narrow slit, the **petrotympanic fissure** (*Glaserian fissure*). The anterior part, formed by the squama, is smooth, covered in the fresh state with cartilage, and articulates with the condyle of the mandible. Behind this part of the fossa is a small conical eminence; this is the representative of a prominent tubercle which, in some mammals, descends behind the condyle of the mandible, and prevents its backward displacement. The posterior part of the mandibular fossa, formed by the tympanic part of the bone, is non-articular, and sometimes lodges a portion of the parotid gland. The petrotympanic fissure leads into the middle ear or tympanic cavity; it lodges the anterior process of the malleus, and transmits the tympanic branch of the internal maxillary artery. The chorda

tympani nerve passes through a canal (*canal of Huguier*), separated from the anterior edge of the petrotympanic fissure by a thin scale of bone and situated on the lateral side of the auditory tube, in the retiring angle between the squama and the petrous portion of the temporal.

The **internal surface** of the squama (Fig. 138) is concave; it presents depressions corresponding to the convolutions of the temporal lobe of the brain, and grooves for the branches of the middle meningeal vessels.

Borders.—The **superior border** is thin, and bevelled at the expense of the internal table, so as to overlap the squamous border of the parietal bone, forming with it the squamosal suture. Posteriorly, the superior border forms an angle, the **parietal notch**, with the mastoid portion of the bone. The **antero-inferior border** is thick, serrated, and bevelled at the expense of the inner table above and of the outer below, for articulation with the great wing of the sphenoid.

Mastoid Portion (*pars mastoidea*).—The mastoid portion forms the posterior part of the bone.

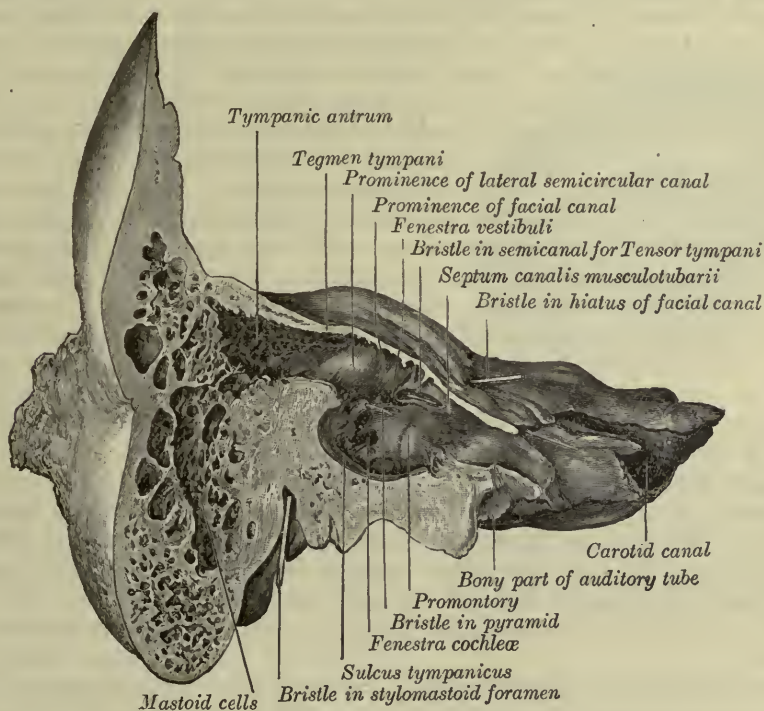


FIG. 139.—Coronal section of right temporal bone.

Surfaces.—Its **outer surface** (Fig. 137) is rough, and gives attachment to the Occipitalis and Auricularis posterior. It is perforated by numerous foramina; one of these, of large size, situated near the posterior border, is termed the **mastoid foramen**; it transmits a vein to the transverse sinus and a small branch of the occipital artery to the dura mater. The position and size of this foramen are very variable; it is not always present; sometimes it is situated in the occipital bone, or in the suture between the temporal and the occipital. The mastoid portion is continued below into a conical projection, the **mastoid process**, the size and form of which vary somewhat; it is larger in the male than in the female. This process serves for the attachment of the Sternocleidomastoideus, Splenius capitis, and Longissimus capitis. On the medial side of the process is a deep groove, the **mastoid notch** (*digastric fossa*), for the attachment of the Digastricus; medial to this is a shallow furrow, the **occipital groove**, which lodges the occipital artery.

The **inner surface** of the mastoid portion presents a deep, curved groove, the **sigmoid sulcus**, which lodges part of the transverse sinus; in it may be seen the opening of the mastoid foramen. The groove for the transverse sinus is separated from the innermost of the mastoid air cells by a very thin lamina of bone, and even this may be partly deficient.

Borders.—The **superior border** of the mastoid portion is broad and serrated, for articulation with the mastoid angle of the parietal. The **posterior border**, also serrated, articulates with the inferior border of the occipital between the lateral angle and jugular process. Anteriorly the mastoid portion is fused with the descending process of the squama above; below it enters into the formation of the external acoustic meatus and the tympanic cavity.

A section of the mastoid process (Fig. 139) shows it to be hollowed out into a number of spaces, the **mastoid cells**, which exhibit the greatest possible variety as to their size and number. At the upper and front part of the process they are large and irregular and contain air, but toward the lower part they diminish in size, while those at the apex of the process are frequently quite small and contain marrow; occasionally they are entirely absent, and the mastoid is then solid throughout. In addition to these a large irregular cavity is situated at the upper and front part of the bone. It is called the **tympanic antrum**, and must be distinguished from the mastoid cells, though it communicates with them. Like the mastoid cells it is filled with air and lined by a prolongation of the mucous membrane of the tympanic cavity, with which it communicates. The tympanic antrum is bounded above by a thin plate of bone, the **tegmen tympani**, which separates it from the middle fossa of the base of the skull; below by the mastoid process; laterally by the squama just below the temporal line, and medially by the lateral semicircular canal of the internal ear which projects into its cavity. It opens in front into that portion of the tympanic cavity which is known as the **attic** or **epitympanic recess**. The tympanic antrum is a cavity of some considerable size at the time of birth; the mastoid air cells may be regarded as diverticula from the antrum, and begin to appear at or before birth; by the fifth year they are well-marked, but their development is not completed until toward puberty.

Petrous Portion (*pars petrosa* [*pyramis*]).—The petrous portion or pyramid is pyramidal and is wedged in at the base of the skull between the sphenoid and occipital. Directed medialward, forward, and a little upward, it presents for examination a base, an apex, three surfaces, and three angles, and contains, in its interior, the essential parts of the organ of hearing.

Base.—The base is fused with the internal surfaces of the squama and mastoid portion.

Apex.—The apex, rough and uneven, is received into the angular interval between the posterior border of the great wing of the sphenoid and the basilar part of the occipital; it presents the anterior or internal orifice of the carotid canal, and forms the postero-lateral boundary of the foramen lacerum.

Surfaces.—The **anterior surface** forms the posterior part of the middle fossa of the base of the skull, and is continuous with the inner surface of the squamous portion, to which it is united by the **petrosquamous suture**, remains of which are distinct even at a late period of life. It is marked by depressions for the convolutions of the brain, and presents six points for examination: (1) near the center, an **eminence** (*eminentia arcuata*) which indicates the situation of the superior semicircular canal; (2) in front of and a little lateral to this eminence, a depression indicating the position of the tympanic cavity: here the layer of bone which separates the tympanic from the cranial cavity is extremely thin, and is known as the **tegmen tympani**; (3) a shallow groove, sometimes double, leading lateralward and backward to an oblique opening, the **hiatus of the facial canal**, for the passage of the greater superficial petrosal nerve and the petrosal branch of the middle men-

ingeal artery; (4) lateral to the hiatus, a smaller opening, occasionally seen, for the passage of the lesser superficial petrosal nerve; (5) near the apex of the bone, the termination of the carotid canal, the wall of which in this situation is deficient in front; (6) above this canal the shallow **trigeminal impression** for the reception of the semilunar ganglion.

The **posterior surface** (Fig. 138) forms the front part of the posterior fossa of the base of the skull, and is continuous with the inner surface of the mastoid portion. Near the center is a large orifice, the **internal acoustic meatus**, the size of which varies considerably; its margins are smooth and rounded, and it leads into a short canal, about 1 cm. in length, which runs lateralward. It transmits the facial and acoustic nerves and the internal auditory branch of the basilar artery. The lateral end of the canal is closed by a vertical plate, which is divided by a horizontal crest, the **crista falciformis**, into two unequal portions (Fig. 140). Each portion is further subdivided by a vertical ridge into an anterior and a posterior part. In the portion beneath the crista falciformis are three sets of foramina;

one group, just below the posterior part of the crest, situated in the **area cribrosa media**, consists of several small openings for the nerves to the sacculæ; below and behind this area is the **foramen singulare**, or opening for the nerve to the posterior semicircular duct; in front of and below the first is the **tractus spiralis foraminosus**, consisting of a number of small spirally arranged openings, which encircle the **canalis centralis cochleæ**; these openings together with this central canal transmit the nerves to the cochlea. The portion above the crista falciformis presents behind, the **area cribrosa superior**, pierced by a series of small openings, for the passage of the nerves to the utricle and the superior and lateral semicircular ducts, and, in front, the **area facialis**, with one large opening, the commencement of the canal for the facial nerve (**aquæductus Fallopii**). Behind the internal acoustic meatus is a small slit almost hidden by a thin plate of bone, leading to a canal, the **aquæductus vestibuli**, which transmits the ductus endolymphaticus together with a small artery and vein. Above and between these two openings is an irregular depression which lodges a process of the dura mater and transmits a small vein; in the infant this depression is represented by a large fossa, the **subarcuate fossa**, which extends backward as a blind tunnel under the superior semicircular canal.

The **inferior surface** (Fig. 141) is rough and irregular, and forms part of the exterior of the base of the skull. It presents eleven points for examination: (1) near the apex is a rough surface, quadrilateral in form, which serves partly for the attachment of the Levator veli palatini and the cartilaginous portion of the auditory tube, and partly for connection with the basilar part of the occipital bone through the intervention of some dense fibrous tissue; (2) behind this is the large circular aperture of the **carotid canal**, which ascends at first vertically, and then, making a bend, runs horizontally forward and medialward; it transmits into the cranium the internal carotid artery, and the carotid plexus of nerves; (3) medial to the opening for the carotid canal and close to its posterior border, in front of the jugular fossa, is a triangular depression; at the apex of this is a small opening, the

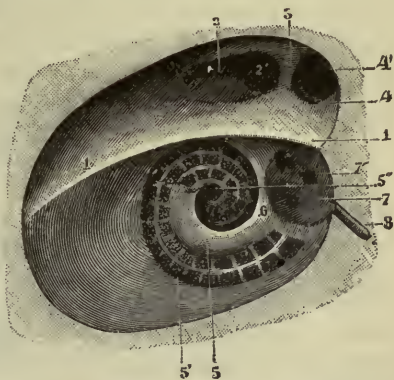


FIG. 140.—Diagrammatic view of the fundus of the right internal acoustic meatus. (Testut.) 1. Crista falciformis. 2. Area facialis, with (2'') internal opening of the facial canal. 3. Ridge separating the area facialis from the area cribrosa superior. 4. Area cribrosa superior, with (4'') openings for nerve filaments. 5. Anterior inferior cribriform area, with (5'') the tractus spiralis foraminosus, and (5'') the canalis centralis of the cochlea. 6. Ridge separating the tractus spiralis foraminosus from the area cribrosa media. 7. Area cribrosa media, with (7'') orifices for nerves to sacculæ. 8. Foramen singulare.

aquæductus cochleæ, which lodges a tubular prolongation of the dura mater establishing a communication between the perilymphatic space and the subarachnoid space, and transmits a vein from the cochlea to join the internal jugular; (4) behind these openings is a deep depression, the **jugular fossa**, of variable depth and size in different skulls; it lodges the bulb of the internal jugular vein; (5) in the bony ridge dividing the carotid canal from the jugular fossa is the small **inferior tympanic canaliculus** for the passage of the tympanic branch of the glossopharyngeal nerve; (6) in the lateral part of the jugular fossa is the **mastoid canaliculus** for the entrance of the auricular branch of the vagus nerve; (7) behind the jugular fossa is a quadrilateral area, the **jugular surface**, covered with cartilage in the fresh state, and articulating with the jugular process of the occipital bone; (8) extending backward from the carotid canal is the **vaginal process**, a sheath-like plate of bone, which divides

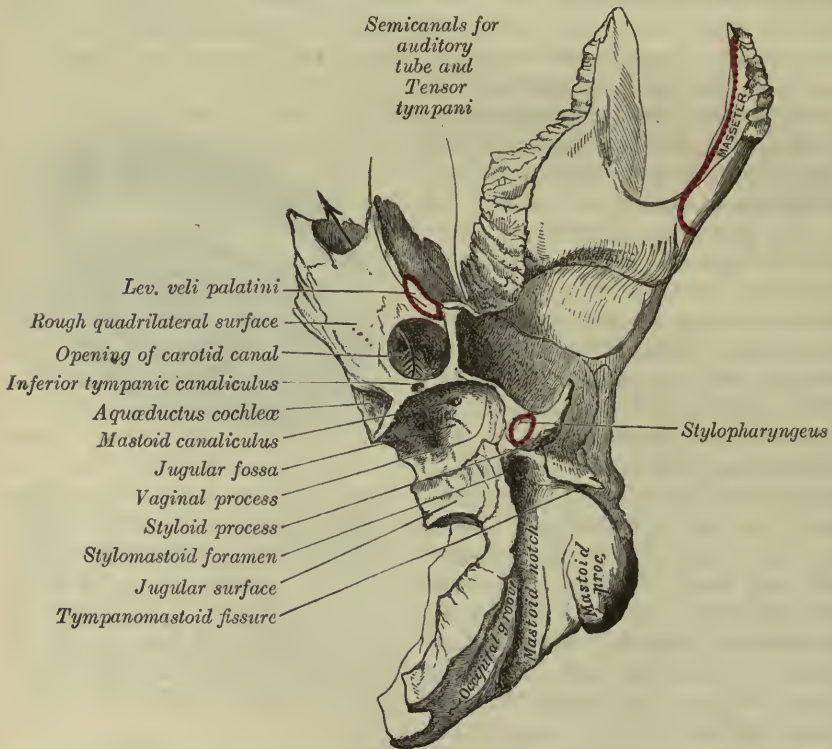


FIG. 141.—Left temporal bone. Inferior surface.

behind into two laminae; the lateral lamina is continuous with the tympanic part of the bone, the medial with the lateral margin of the jugular surface; (9) between these laminae is the **styloid process**, a sharp spine, about 2.5 cm. in length; (10) between the styloid and mastoid processes is the **stylomastoid foramen**; it is the termination of the facial canal, and transmits the facial nerve and stylomastoid artery; (11) situated between the tympanic portion and the mastoid process is the **tympanomastoid fissure**, for the exit of the auricular branch of the vagus nerve.

Angles.—The **superior angle**, the longest, is grooved for the superior petrosal sinus, and gives attachment to the tentorium cerebelli; at its medial extremity is a notch, in which the trigeminal nerve lies. The **posterior angle** is intermediate in length between the superior and the anterior. Its medial half is marked by a sulcus, which forms, with a corresponding sulcus on the occipital bone, the channel for the inferior petrosal sinus. Its lateral half presents an excavation—the **jugular fossa**—which, with the jugular notch on the occipital, forms the

jugular foramen; an eminence occasionally projects from the center of the fossa, and divides the foramen into two. The **anterior angle** is divided into two parts—a lateral joined to the squama by a suture (*petrosquamous*), the remains of which are more or less distinct; a medial, free, which articulates with the spinous process of the sphenoid.

At the angle of junction of the petrous part and the squama are two canals, one above the other, and separated by a thin plate of bone, the **septum canalis musculotubarii** (*processus cochleariformis*); both canals lead into the tympanic cavity. The upper one (*semicanalis m. tensoris tympani*) transmits the Tensor tympani, the lower one (*semicanalis tubæ auditivæ*) forms the bony part of the auditory tube.

The tympanic cavity, auditory ossicles, and internal ear, are described with the organ of hearing.

Tympanic Part (*pars tympanica*).—The tympanic part is a curved plate of bone lying below the squama and in front of the mastoid process.

Surfaces.—Its **postero-superior surface** is concave, and forms the anterior wall, the floor, and part of the posterior wall of the bony external acoustic meatus. Medially, it presents a narrow furrow, the **tympanic sulcus**, for the attachment of the tympanic membrane. Its **antero-inferior surface** is quadrilateral and slightly concave; it constitutes the posterior boundary of the mandibular fossa, and is in contact with the retromandibular part of the parotid gland.

Borders.—Its **lateral border** is free and rough, and gives attachment to the cartilaginous part of the external acoustic meatus. Internally, the tympanic part is fused with the petrous portion, and appears in the retreating angle between it and the squama, where it lies below and lateral to the orifice of the auditory tube. Posteriorly, it blends with the squama and mastoid part, and forms the anterior boundary of the tympanomastoid fissure. Its **upper border** fuses laterally with the back of the postglenoid process, while medially it bounds the petro-tympanic fissure. The medial part of the **lower border** is thin and sharp; its lateral part splits to enclose the root of the styloid process, and is therefore named the **vaginal process**. The central portion of the tympanic part is thin, and in a considerable percentage of skulls is perforated by a hole, the **foramen of Huschke**.

The **external acoustic meatus** is nearly 2 cm. long and is directed inward and slightly forward: at the same time it forms a slight curve, so that the floor of the canal is convex upward. In sagittal section it presents an oval or elliptical shape with the long axis directed downward and slightly backward. Its anterior wall and floor and the lower part of its posterior wall are formed by the tympanic part; the roof and upper part of the posterior wall by the squama. Its inner end is closed, in the recent state, by the tympanic membrane; the upper limit of its outer orifice is formed by the posterior root of the zygomatic process, immediately below which there is sometimes seen a small spine, the **suprameatal spine**, situated at the upper and posterior part of the orifice.

Styloid Process (*processus styloideus*).—The styloid process is slender, pointed, and of varying length; it projects downward and forward, from the under surface of the temporal bone. Its proximal part (*tympanohyal*) is ensheathed by the vaginal process of the tympanic portion, while its distal part (*stylohyal*) gives attachment to the stylohyoid and stylomandibular ligaments, and to the Styloglossus, Stylohyoideus, and Stylopharyngeus muscles. The stylohyoid ligament extends from the apex of the process to the lesser cornu of the hyoid bone, and in some instances is partially, in others completely, ossified.

Structure.—The structure of the squama is like that of the other cranial bones: the mastoid portion is spongy, and the petrous portion dense and hard.

Ossification.—The temporal bone is ossified from *eight* centers, exclusive of those for the internal ear and the tympanic ossicles, viz., one for the squama including the zygomatic process, one for

the tympanic part, four for the petrous and mastoid parts, and two for the styloid process. Just before the close of fetal life (Fig. 142) the temporal bone consists of three principal parts: 1. The *squama* is ossified in membrane from a single nucleus, which appears near the root of the zygomatic process about the second month. 2. The *petromastoid* part is developed from four centers, which make their appearance in the cartilaginous ear capsule about the fifth or sixth month. One (*prootic*) appears in the neighborhood of the eminentia arcuata, spreads in front and above the internal acoustic meatus and extends to the apex of the bone; it forms part of the

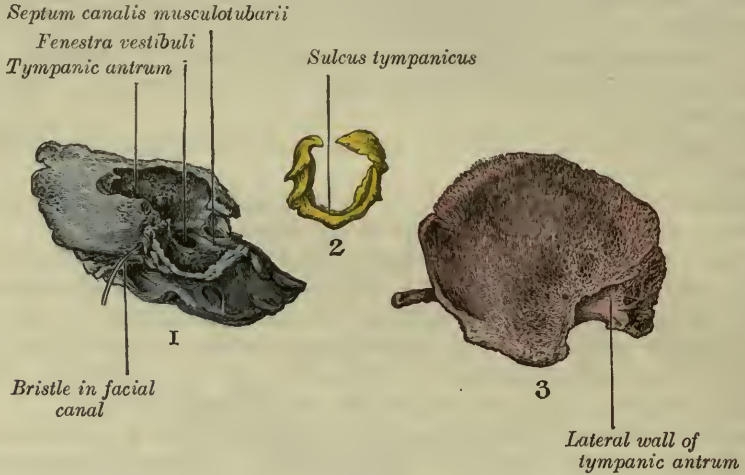


FIG. 142.—The three principal parts of the temporal bone at birth. 1. Outer surface of petromastoid part. 2. Outer surface of tympanic ring. 3. Inner surface of squama.

cochlea, vestibule, superior semicircular canal, and medial wall of the tympanic cavity. A second (*opisthotic*) appears at the promontory on the medial wall of the tympanic cavity and surrounds the fenestra cochleae; it forms the floor of the tympanic cavity and vestibule, surrounds the carotid canal, invests the lateral and lower part of the cochlea, and spreads medially below the internal acoustic meatus. A third (*plerotic*) roofs in the tympanic cavity and antrum; while the fourth

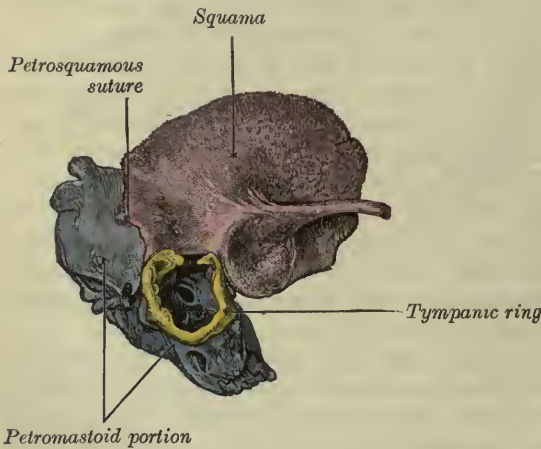


FIG. 143.—Temporal bone at birth. Outer aspect.

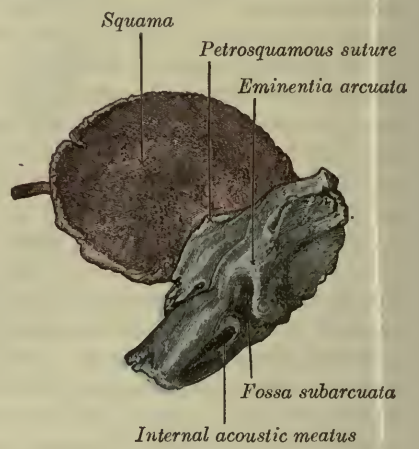


FIG. 144.—Temporal bone at birth. Inner aspect.

(*epiotic*) appears near the posterior semicircular canal and extends to form the mastoid process (Vrolik). 3. The *tympanic ring* is an incomplete circle, in the concavity of which is a groove, the tympanic sulcus, for the attachment of the circumference of the tympanic membrane. This ring expands to form the tympanic part, and is ossified in membrane from a single center which appears about the third month. The *styloid process* is developed from the proximal part of the cartilage of the second branchial or hyoid arch by two centers: one for the proximal part, the *tympanohyal*, appears before birth; the other, comprising the rest of the process, is named the

stylohyal, and does not appear until after birth. The tympanic ring unites with the squama shortly before birth; the petromastoid part and squama join during the first year, and the tympanohyal portion of the styloid process about the same time (Figs. 143, 144). The stylohyal does not unite with the rest of the bone until after puberty, and in some skulls never at all.

The chief subsequent changes in the temporal bone apart from increase in size are: (1) The tympanic ring extends outward and backward to form the tympanic part. This extension does not, however, take place at an equal rate all around the circumference of the ring, but occurs most rapidly on its anterior and posterior portions, and these outgrowths meet and blend, and thus, for a time, there exists in the floor of the meatus a foramen, the *foramen of Huschke*; this foramen is usually closed about the fifth year, but may persist throughout life. (2) The mandibular fossa is at first extremely shallow, and looks lateralward as well as downward; it becomes deeper and is ultimately directed downward. Its change in direction is accounted for as follows. The part of the squama which forms the fossa lies at first below the level of the zygomatic process. As, however, the base of the skull increases in width, this lower part of the squama is directed horizontally inward to contribute to the middle fossa of the skull, and its surfaces therefore come to look upward and downward; the attached portion of the zygomatic process also becomes everted, and projects like a shelf at right angles to the squama. (3) The mastoid portion is at first quite flat, and the stylo-mastoid foramen and rudimentary styloid process lie immediately behind the tympanic ring. With the development of the air cells the outer part of the mastoid portion grows downward and forward to form the mastoid process, and the styloid process and stylo-mastoid foramen now come to lie on the under surface. The descent of the foramen is necessarily accompanied by a corresponding lengthening of the facial canal. (4) The downward and forward growth of the mastoid process also pushes forward the tympanic part, so that the portion of it which formed the original floor of the meatus and contained the foramen of Huschke is ultimately found in the anterior wall. (5) The fossa subarcuata becomes filled up and almost obliterated.

Articulations.—The temporal articulates with *five* bones: occipital, parietal, sphenoid, mandible and zygomatic.

The Sphenoid Bone (*Os Sphenoidale*).

The **sphenoid bone** is situated at the base of the skull in front of the temporals and basilar part of the occipital. It somewhat resembles a bat with its wings extended, and is divided into a median portion or body, two great and two small wings extending outward from the sides of the body, and two pterygoid processes which project from it below.

Body (*corpus sphenoidale*).—The body, more or less cubical in shape, is hollowed out in its interior to form two large cavities, the **sphenoidal air sinuses**, which are separated from each other by a septum.

Surfaces.—The **superior surface** of the body (Fig. 145) presents in front a prominent spine, the **ethmoidal spine**, for articulation with the cribriform plate of the ethmoid; behind this is a smooth surface slightly raised in the middle line, and grooved on either side for the olfactory lobes of the brain. This surface is bounded behind by a ridge, which forms the anterior border of a narrow, transverse groove, the **chiasmatic groove** (*optic groove*), above and behind which lies the optic chiasma; the groove ends on either side in the **optic foramen**, which transmits the optic nerve and ophthalmic artery into the orbital cavity. Behind the chiasmatic groove is an elevation, the **tuberculum sellæ**; and still more posteriorly, a deep depression, the **sella turcica**, the deepest part of which lodges the hypophysis cerebri and is known as the **fossa hypophyseos**. The anterior boundary of the sella turcica is completed by two small eminences, one on either side, called the **middle clinoid processes**, while the posterior boundary is formed by a square-shaped plate of bone, the **dorsum sellæ**, ending at its superior angles in two tubercles, the **posterior clinoid processes**, the size and form of which vary considerably in different individuals. The posterior clinoid processes deepen the sella turcica, and give attachment to the tentorium cerebelli. On either side of the dorsum sellæ is a notch for the passage of the abducent nerve, and below the notch a sharp process, the **petrosal process**, which articulates with the apex of the petrous portion of the temporal bone, and forms the medial boundary of the foramen lacerum.

Behind the dorsum sellæ is a shallow depression, the **clivus**, which slopes obliquely backward, and is continuous with the groove on the basilar portion of the occipital bone; it supports the upper part of the pons.

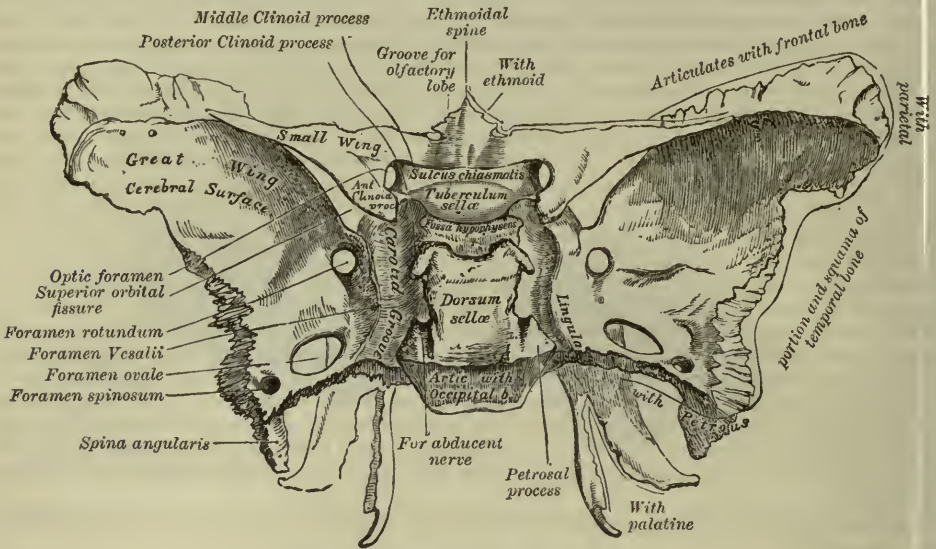


Fig. 145.—Sphenoid bone. Upper surface.

The **lateral surfaces** of the body are united with the great wings and the medial pterygoid plates. Above the attachment of each great wing is a broad groove, curved something like the italic letter *f*; it lodges the internal carotid artery and the cavernous sinus, and is named the **carotid groove**. Along the posterior part

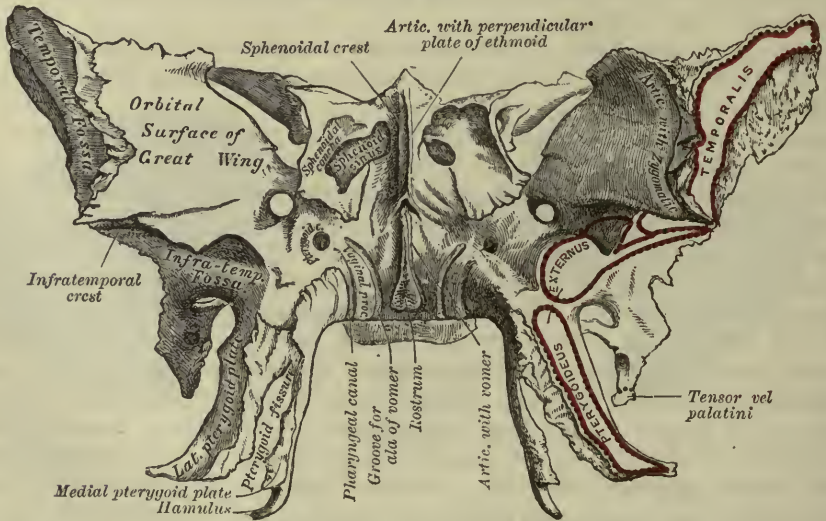


Fig. 146.—Sphenoid bone. Anterior and inferior surfaces.

of the lateral margin of this groove, in the angle between the body and great wing, is a ridge of bone, called the **lingula**.

The **posterior surface**, quadrilateral in form (Fig. 147), is joined, during infancy and adolescence, to the basilar part of the occipital bone by a plate of cartilage.

Between the eighteenth and twenty-fifth years this becomes ossified, ossification commencing above and extending downward.

The **anterior surface** of the body (Fig. 146) presents, in the middle line, a vertical crest, the **sphenoidal crest**, which articulates with the perpendicular plate of the ethmoid, and forms part of the septum of the nose. On either side of the crest is an irregular opening leading into the corresponding **sphenoidal air sinus**. These sinuses are two large, irregular cavities hollowed out of the interior of the body of the bone, and separated from one another by a bony septum, which is commonly bent to one or the other side. They vary considerably in form and size,¹ are seldom symmetrical, and are often partially subdivided by irregular bony laminae. Occasionally, they extend into the basilar part of the occipital nearly as far as the foramen magnum. They begin to be developed before birth, and are of a considerable size by the age of six. They are partially closed, in front and below, by two thin, curved plates of bone, the **sphenoidal conchæ** (see page 152), leaving in the articulated skull a round opening at the upper part of each sinus by which it com-

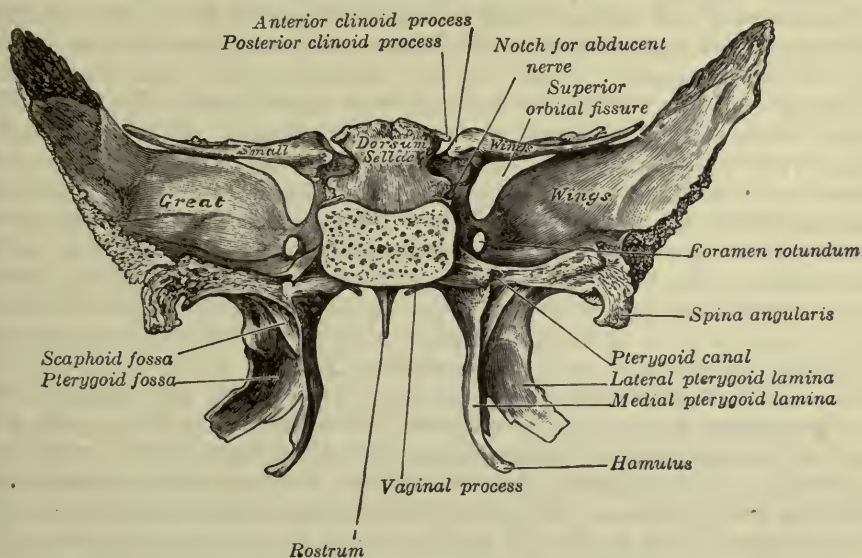


FIG. 147.—Sphenoid bone. Upper and posterior surfaces.

municates with the upper and back part of the nasal cavity and occasionally with the posterior ethmoidal air cells. The lateral margin of the anterior surface is serrated, and articulates with the lamina papyracea of the ethmoid, completing the posterior ethmoidal cells; the lower margin articulates with the orbital process of the palatine bone, and the upper with the orbital plate of the frontal bone.

The **inferior surface** presents, in the middle line, a triangular spine, the **sphenoidal rostrum**, which is continuous with the sphenoidal crest on the anterior surface, and is received in a deep fissure between the alæ of the vomer. On either side of the rostrum is a projecting lamina, the **vaginal process**, directed medialward from the base of the medial pterygoid plate, with which it will be described.

The **Great Wings** (*alæ magnæ*).—The great wings, or **ali-sphenoids**, are two strong processes of bone, which arise from the sides of the body, and are curved upward, lateralward, and backward; the posterior part of each projects as a triangular process which fits into the angle between the squama and the petrous

¹ Aldren Turner (*op. cit.*) gives the following as their average measurements: vertical height, $\frac{1}{8}$ inch; antero-posterior depth, $\frac{1}{3}$ inch; transverse breadth, $\frac{3}{4}$ inch.

portion of the temporal and presents at its apex a downwardly directed process, the *spina angularis* (*sphenoidal spine*).

Surfaces.—The superior or cerebral surface of each great wing (Fig. 145) forms part of the middle fossa of the skull; it is deeply concave, and presents depressions for the convolutions of the temporal lobe of the brain. At its anterior and medial part is a circular aperture, the *foramen rotundum*, for the transmission of the maxillary nerve. Behind and lateral to this is the *foramen ovale*, for the transmission of the mandibular nerve, the accessory meningeal artery, and sometimes the lesser superficial petrosal nerve.¹ Medial to the foramen ovale, a small aperture, the *foramen Vesalii*, may occasionally be seen opposite the root of the pterygoid process; it opens below near the scaphoid fossa, and transmits a small vein from the cavernous sinus. Lastly, in the posterior angle, near to and in front of the spine, is a short canal, sometimes double, the *foramen spinosum*, which transmits the middle meningeal vessels and a recurrent branch from the mandibular nerve.

The lateral surface (Fig. 146) is convex, and divided by a transverse ridge, the *infratemporal crest*, into two portions. The superior or temporal portion, convex from above downward, concave from before backward, forms a part of the temporal fossa, and gives attachment to the Temporalis; the inferior or infratemporal, smaller in size and concave, enters into the formation of the infratemporal fossa, and, together with the infratemporal crest, affords attachment to the Pterygoideus externus. It is pierced by the foramen ovale and foramen spinosum, and at its posterior part is the *spina angularis*, which is frequently grooved on its medial surface for the chorda tympani nerve. To the *spina angularis* are attached the sphenomandibular ligament and the Tensor veli palatini. Medial to the anterior extremity of the infratemporal crest is a triangular process which serves to increase the attachment of the Pterygoideus externus; extending downward and medialward from this process on to the front part of the lateral pterygoid plate is a ridge which forms the anterior limit of the infratemporal surface, and, in the articulated skull, the posterior boundary of the pterygomaxillary fissure.

The orbital surface of the great wing (Fig. 146), smooth, and quadrilateral in shape, is directed forward and medialward and forms the posterior part of the lateral wall of the orbit. Its upper serrated edge articulates with the orbital plate of the frontal. Its inferior rounded border forms the postero-lateral boundary of the inferior orbital fissure. Its medial sharp margin forms the lower boundary of the superior orbital fissure and has projecting from about its center a little tubercle which gives attachment to the inferior head of the Rectus lateralis oculi; at the upper part of this margin is a notch for the transmission of a recurrent branch of the lacrimal artery. Its lateral margin is serrated and articulates with the zygomatic bone. Below the medial end of the superior orbital fissure is a grooved surface, which forms the posterior wall of the pterygopalatine fossa, and is pierced by the foramen rotundum.

Margin (Fig. 145).—Commencing from behind, that portion of the circumference of the great wing which extends from the body to the spine is irregular. Its medial half forms the anterior boundary of the foramen lacerum, and presents the posterior aperture of the pterygoid canal for the passage of the corresponding nerve and artery. Its lateral half articulates, by means of a synchondrosis, with the petrous portion of the temporal, and between the two bones on the under surface of the skull, is a furrow, the *sulcus tubæ*, for the lodgement of the cartilaginous part of the auditory tube. In front of the spine the circumference presents a concave, serrated edge, bevelled at the expense of the inner table below, and of the outer table above, for articulation with the temporal squama. At the tip of the great wing is a triangular portion, bevelled at the expense of the

¹ The lesser superficial petrosal nerve sometimes passes through a special canal (*canaliculus innominatus* of Arnold) situated medial to the foramen spinosum.

internal surface, for articulation with the sphenoidal angle of the parietal bone; this region is named the **pterion**. Medial to this is a triangular, serrated surface, for articulation with the frontal bone; this surface is continuous medially with the sharp edge, which forms the lower boundary of the superior orbital fissure, and laterally with the serrated margin for articulation with the zygomatic bone.

The Small Wings (*alæ parvæ*).—The small wings or **orbito-sphenoids** are two thin triangular plates, which arise from the upper and anterior parts of the body, and, projecting lateralward, end in sharp points (Fig. 145).

Surfaces.—The **superior surface** of each is flat, and supports part of the frontal lobe of the brain. The **inferior surface** forms the back part of the roof of the orbit, and the upper boundary of the **superior orbital fissure**. This fissure is of a triangular form, and leads from the cavity of the cranium into that of the orbit: it is bounded *medially* by the body; *above*, by the small wing; *below*, by the medial margin of the orbital surface of the great wing; and is completed *laterally* by the frontal bone. It transmits the oculomotor, trochlear, and abducent nerves, the three branches of the ophthalmic division of the trigeminal nerve, some filaments from the cavernous plexus of the sympathetic, the orbital branch of the middle meningeal artery, a recurrent branch from the lacrimal artery to the dura mater, and the ophthalmic vein.

Borders.—The **anterior border** is serrated for articulation with the frontal bone. The **posterior border**, smooth and rounded, is received into the lateral fissure of the brain; the medial end of this border forms the **anterior clinoid process**, which gives attachment to the tentorium cerebelli; it is sometimes joined to the middle clinoid process by a spicule of bone, and when this occurs the termination of the groove for the internal carotid artery is converted into a foramen (*carotico-clinoid*). The small wing is connected to the body by two roots, the upper thin and flat, the lower thick and triangular; between the two roots is the **optic foramen**, for the transmission of the optic nerve and ophthalmic artery.

Pterygoid Processes (*processus pterygoidei*).—The pterygoid processes, one on either side, descend perpendicularly from the regions where the body and great wings unite. Each process consists of a medial and a lateral plate, the upper parts of which are fused anteriorly; a vertical sulcus, the **pterygopalatine groove**, descends on the front of the line of fusion. The plates are separated below by an angular cleft, the **pterygoid fissure**, the margins of which are rough for articulation with the pyramidal process of the palatine bone. The two plates diverge behind and enclose between them a V-shaped fossa, the **pterygoid fossa**, which contains the Pterygoideus internus and Tensor veli palatini. Above this fossa is a small, oval, shallow depression, the **scaphoid fossa**, which gives origin to the Tensor veli palatini. The anterior surface of the pterygoid process is broad and triangular near its root, where it forms the posterior wall of the pterygopalatine fossa and presents the anterior orifice of the pterygoid canal.

Lateral Pterygoid Plate.—The **lateral pterygoid plate** is broad, thin, and everted; its **lateral surface** forms part of the medial wall of the infratemporal fossa, and gives attachment to the Pterygoideus externus; its **medial surface** forms part of the pterygoid fossa, and gives attachment to the Pterygoideus internus.

Medial Pterygoid Plate.—The medial pterygoid plate is narrower and longer than the lateral; it curves lateralward at its lower extremity into a hook-like process, the **pterygoid hamulus**, around which the tendon of the Tensor veli palatini glides. The **lateral surface** of this plate forms part of the pterygoid fossa, the **medial surface** constitutes the lateral boundary of the choana or posterior aperture of the corresponding nasal cavity. Superiorly the medial plate is prolonged on to the under surface of the body as a thin lamina, named the **vaginal process**, which articulates in front with the sphenoidal process of the palatine and behind this with the ala of the vomer. The angular prominence between the posterior margin

of the vaginal process and the medial border of the scaphoid fossa is named the **pterygoid tubercle**, and immediately above this is the posterior opening of the pterygoid canal. On the under surface of the vaginal process is a furrow, which is converted into a canal by the sphenoidal process of the palatine bone, for the transmission of the pharyngeal branch of the internal maxillary artery and the pharyngeal nerve from the sphenopalatine ganglion. The pharyngeal aponeurosis is attached to the entire length of the posterior edge of the medial plate, and the Constrictor pharyngis superior takes origin from its lower third. Projecting backward from near the middle of the posterior edge of this plate is an angular process, the **processus tubarius**, which supports the pharyngeal end of the auditory tube. The anterior margin of the plate articulates with the posterior border of the vertical part of the palatine bone.

The Sphenoidal Conchæ (*conchæ sphenoidales; sphenoidal turbinated processes*).—The sphenoidal conchæ are two thin, curved plates, situated at the anterior and lower part of the body of the sphenoid. An aperture of variable size exists in the anterior wall of each, and through this the sphenoidal sinus opens into the nasal cavity. Each is irregular in form, and tapers to a point behind, being broader and thinner in front. Its upper surface is concave, and looks toward the cavity of the sinus; its under surface is convex, and forms part of the roof of the corresponding nasal cavity. Each bone articulates in front with the ethmoid, laterally with the palatine; its pointed posterior extremity is placed above the vomer, and is received between the root of the pterygoid process laterally and the rostrum of the sphenoid medially. A small portion of the sphenoidal concha sometimes enters into the formation of the medial wall of the orbit, between the lamina papyracea of the ethmoid in front, the orbital plate of the palatine below, and the frontal bone above.

Ossification.—Until the seventh or eighth month of fetal life the body of the sphenoid consists of two parts, viz., one in front of the tuberculum sellæ, the *presphenoid*, with which the small wings are continuous; the other, comprising the sella turcica and dorsum sellæ, the *postsphenoid*, with which are associated the great wings, and pterygoid processes. The greater part of the bone is ossified in cartilage. There are fourteen centers in all, *six* for the presphenoid and *eight* for the postsphenoid.

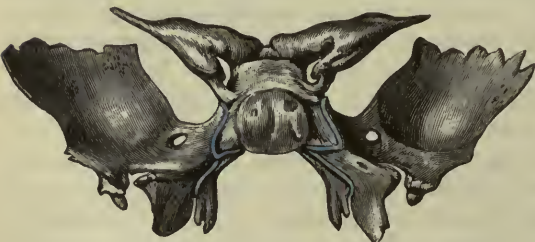

FIG. 148.—Sphenoid bone at birth. Posterior aspect.

a center which makes its appearance about the fifth month;¹ at birth they consist of small triangular laminae, and it is not until the third year that they become hollowed out and cone-shaped; about the fourth year they fuse with the labyrinths of the ethmoid, and between the ninth and twelfth years they unite with the sphenoid.

Postsphenoid.—The first ossific nuclei are those for the great wings (ali-sphenoids)². One makes its appearance in each wing between the foramen rotundum and foramen ovale about the eighth week. The orbital plate and that part of the sphenoid which is found in the temporal fossa, as well as the lateral pterygoid plate, are ossified in membrane (Fawcett)³. Soon after, the centers for the postsphenoid part of the body appear, one on either side of the sella turcica, and become blended together about the middle of fetal life. Each medial pterygoid plate (with the exception of its hamulus) is ossified in membrane, and its center probably appears about the ninth or tenth week; the hamulus becomes chondrified during the third month, and almost at once undergoes

¹ According to Cleland, each sphenoidal concha is ossified from four centers.

² Mall, *Am. Jour. Anat.*, 1906, states that the pterygoid center appears first in an embryo fifty-seven days old.

³ *Journal of Anatomy and Physiology*, 1910, vol. xlv.

ossification (Fawcett).¹ The medial joins the lateral pterygoid plate about the sixth month. About the fourth month a center appears for each lingula and speedily joins the rest of the bone.

The presphenoid is united to the postsphenoid about the eighth month, and at birth the bone is in three pieces (Fig. 148): a central, consisting of the body and small wings, and two lateral, each comprising a great wing and pterygoid process. In the first year after birth the great wings and body unite, and the small wings extend inward above the anterior part of the body, and, meeting with each other in the middle line, form an elevated smooth surface, termed the *jugum sphenoidale*. By the twenty-fifth year the sphenoid and occipital are completely fused. Between the pre- and postsphenoid there are occasionally seen the remains of a canal, the *canalis cranio-pharyngeus*, through which, in early fetal life, the hypophyseal diverticulum of the buccal ectoderm is transmitted.

The sphenoidal sinuses are present as minute cavities at the time of birth (Onodi), but do not attain their full size until after puberty.

Intrinsic Ligaments of the Sphenoid.—The more important of these are: the *pterygospinous*, stretching between the spina angularis and the lateral pterygoid plate (see *cervical fascia*); the *interclinoid*, a fibrous process joining the anterior to the posterior clinoid process; and the *caroticoclinoid*, connecting the anterior to the middle clinoid process. These ligaments occasionally ossify.

Articulations.—The sphenoid articulates with *twelve* bones: four single, the vomer, ethmoid, frontal, and occipital; and four paired, the parietal, temporal, zygomatic, and palatine.²

The Ethmoid Bone (Os Ethmoidale).

The **ethmoid bone** is exceedingly light and spongy, and cubical in shape; it is situated at the anterior part of the base of the cranium, between the two orbits, at the roof of the nose, and contributes to each of these cavities. It consists of four parts: a **horizontal** or **cribriform plate**, forming part of the base of the cranium; a **perpendicular plate**, constituting part of the nasal septum; and two **lateral masses** or **labyrinths**.

Cribriform Plate (*lamina cribrosa; horizontal lamina*).—The cribriform plate (Fig. 149) is received into the ethmoidal notch of the frontal bone and roofs in the nasal cavities. Projecting upward from the middle line of this plate is a thick, smooth, triangular process, the **crista galli**, so called from its resemblance to a cock's comb. The long thin posterior border of the crista galli serves for the attachment of the falx cerebri:

Its anterior border, short and thick, articulates with the frontal bone, and presents two small projecting *alæ*, which are received into corresponding depressions in the frontal bone and complete the foramen cecum. Its sides are smooth, and sometimes bulging from the presence of a small air sinus in the interior. On either side of the crista galli, the cribriform plate is narrow and deeply grooved; it supports the olfactory bulb and is perforated by foramina for the passage of the olfactory nerves. The foramina in the middle of the groove are small and transmit the nerves to the

roof of the nasal cavity; those at the medial and lateral parts of the groove are larger—the former transmit the nerves to the upper part of the nasal septum, the latter those to the superior nasal concha. At the front part of the cribriform

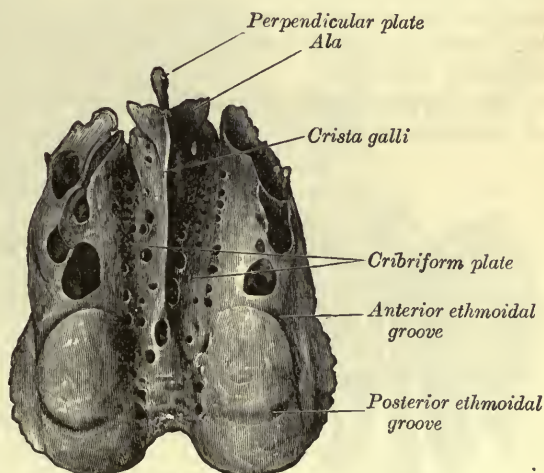


FIG. 149.—Ethmoid bone from above.

¹ Anatomischer Anzeiger, March, 1905.

It also sometimes articulates with the tuberosity of the maxilla (see page 159).

plate, on either side of the crista galli, is a small fissure which is occupied by a process of dura mater. Lateral to this fissure is a notch or foramen which transmits the nasociliary nerve; from this notch a groove extends backward to the anterior ethmoidal foramen.

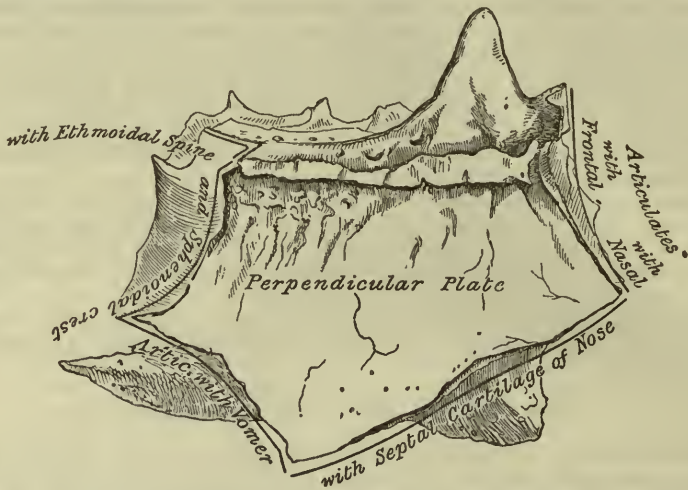


FIG. 150.—Perpendicular plate of ethmoid. Shown by removing the right labyrinth.

Perpendicular Plate (*lamina perpendicularis*; *vertical plate*).—The perpendicular plate (Figs. 150, 151) is a thin, flattened lamina, polygonal in form, which descends from the under surface of the cribriform plate, and assists in forming the septum of the nose; it is generally deflected a little to one or other side. The **anterior border** articulates with the spine of the frontal bone and the crest of the nasal bones. The **posterior border** articulates by its upper half with the sphenoidal crest, by its lower with the vomer. The **inferior border** is thicker than the posterior, and serves for the attachment of the septal cartilage of the nose. The surfaces of the plate are smooth, except above, where numerous grooves and canals are seen; these lead from the medial foramina on the cribriform plate and lodge filaments of the olfactory nerves.

The **Labyrinth** or **Lateral Mass** (*labyrinthus ethmoidalis*) consists of a number of thin-walled cellular cavities, the **ethmoidal cells**, arranged in three groups, *anterior, middle, and posterior*, and interposed between two vertical plates of bone; the lateral plate forms part of the orbit, the medial, part of the corresponding nasal cavity. In the disarticulated bone many of these cells are opened into, but when the bones are articulated, they are closed in at every part, except where they open into the nasal cavity.

Surfaces.—The **upper surface** of the labyrinth (Fig. 149) presents a number of half-broken cells, the walls of which are completed, in the articulated skull, by the edges of the ethmoidal notch of the frontal bone. Crossing this surface are

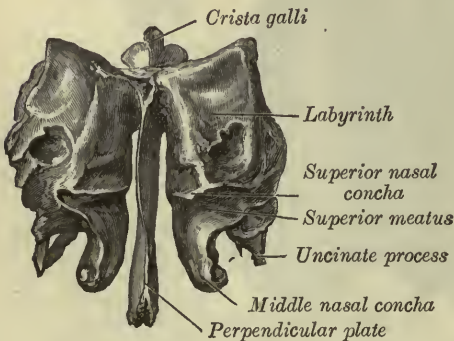


FIG. 151.—Ethmoid bone from behind.

two grooves, converted into canals by articulation with the frontal; they are the **anterior** and **posterior ethmoidal canals**, and open on the inner wall of the orbit. The **posterior surface** presents large irregular cellular cavities, which are closed in

by articulation with the sphenoidal concha and orbital process of the palatine. The **lateral surface** (Fig. 152) is formed of a thin, smooth, oblong plate, the **lamina papyracea** (*os planum*), which covers in the middle and posterior ethmoidal cells

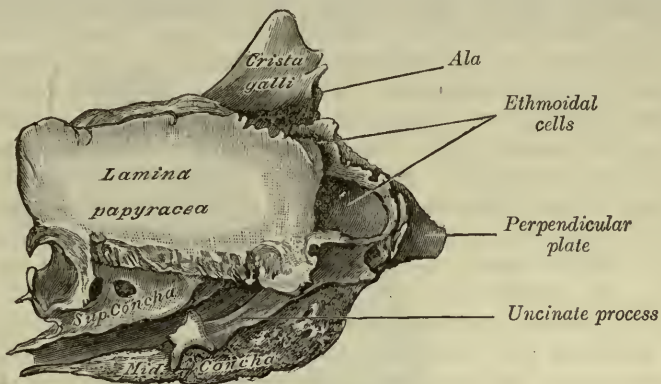


FIG. 152.—Ethmoid bone from the right side.

and forms a large part of the medial wall of the orbit; it articulates above with the orbital plate of the frontal bone, below with the maxilla and orbital process of the palatine, in front with the lacrimal, and behind with the sphenoid.

In front of the lamina papyracea are some broken air cells which are overlapped and completed by the lacrimal bone and the frontal process of the maxilla. A

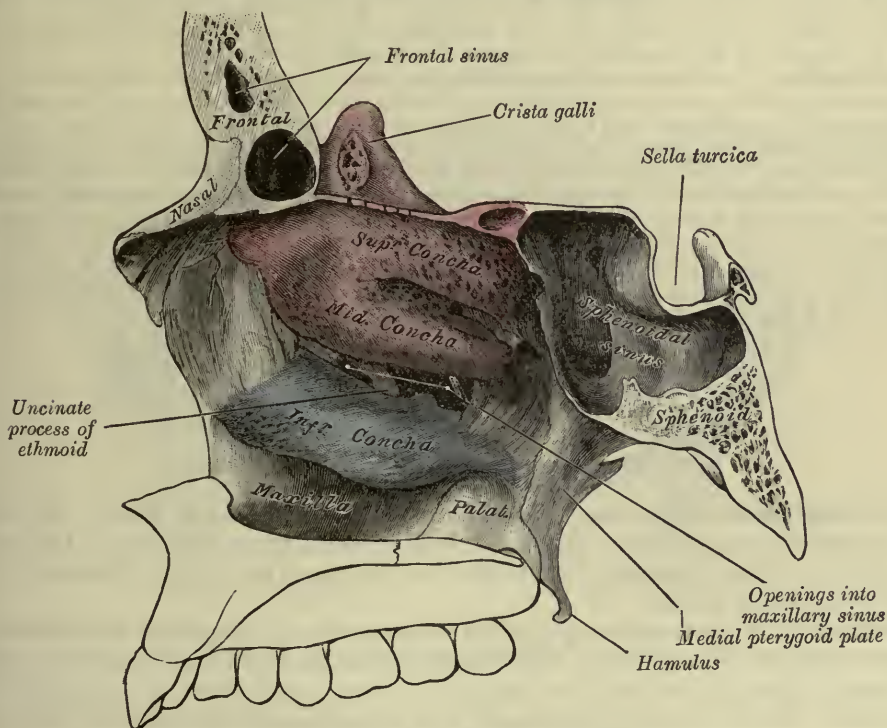


FIG. 153.—Lateral wall of nasal cavity, showing ethmoid bone in position.

curved lamina, the **uncinate process**, projects downward and backward from this part of the labyrinth; it forms a small part of the medial wall of the maxillary sinus, and articulates with the ethmoidal process of the inferior nasal concha.

The **medial surface** of the labyrinth (Fig. 153) forms part of the lateral wall of the corresponding nasal cavity. It consists of a thin lamella, which descends from the under surface of the cribriform plate, and ends below in a free, convoluted margin, the **middle nasal concha**. It is rough, and marked above by numerous grooves, directed nearly vertically downward from the cribriform plate; they lodge branches of the olfactory nerves, which are distributed to the mucous membrane covering the superior nasal concha. The back part of the surface is subdivided by a narrow oblique fissure, the **superior meatus** of the nose, bounded above by a thin, curved plate, the **superior nasal concha**; the posterior ethmoidal cells open into this meatus. Below, and in front of the superior meatus, is the convex surface of the middle nasal concha; it extends along the whole length of the medial surface of the labyrinth, and its lower margin is free and thick. The lateral surface of the middle concha is concave, and assists in forming the **middle meatus** of the nose. The middle ethmoidal cells open into the central part of this meatus, and a sinuous passage, termed the **infundibulum**, extends upward and forward through the labyrinth and communicates with the anterior ethmoidal cells, and in about 50 per cent. of skulls is continued upward as the frontonasal duct into the frontal sinus.

Ossification.—The ethmoid is ossified in the cartilage of the nasal capsule by *three* centers: one for the perpendicular plate, and one for each labyrinth.

The labyrinths are first developed, ossific granules making their appearance in the region of the lamina papyracea between the fourth and fifth months of fetal life, and extending into the conchæ. At birth, the bone consists of the two labyrinths, which are small and ill-developed. During the first year after birth, the perpendicular plate and crista galli begin to ossify from a single center, and are joined to the labyrinths about the beginning of the second year. The cribriform plate is ossified partly from the perpendicular plate and partly from the labyrinths. The development of the ethmoidal cells begins during fetal life.

Articulations.—The ethmoid articulates with *fifteen* bones: four of the cranium—the frontal, the sphenoid, and the two sphenoidal conchæ; and eleven of the face—the two nasals, two maxillæ, two lacrimals, two palatines, two inferior nasal conchæ, and the vomer.

Sutural or Wormian¹ Bones.—In addition to the usual centers of ossification of the cranium, others may occur in the course of the sutures, giving rise to irregular, isolated bones, termed *sutural* or *Wormian bones*. They occur most frequently in the course of the lambdoidal suture, but are occasionally seen at the fontanelles, especially the posterior. One, the *pterion ossicle*, sometimes exists between the sphenoidal angle of the parietal and the great wing of the sphenoid. They have a tendency to be more or less symmetrical on the two sides of the skull, and vary much in size. Their number is generally limited to two or three; but more than a hundred have been found in the skull of an adult hydrocephalic subject.

THE FACIAL BONES (OSSA FACIEI).

The Nasal Bones (Ossa Nasalia).

The **nasal bones** are two small oblong bones, varying in size and form in different individuals; they are placed side by side at the middle and upper part of the face, and form, by their junction, "the bridge" of the nose (Fig. 190). Each has two surfaces and four borders.

Surfaces.—The **outer surface** (Fig. 155) is concavoconvex from above downward, convex from side to side; it is covered by the Procerus and Compressor naris, and perforated about its center by a foramen, for the transmission of a small vein. The **inner surface** (Fig. 156) is concave from side to side, and is traversed from above downward, by a groove for the passage of a branch of the nasociliary nerve.

Borders.—The **superior border** is narrow, thick, and serrated for articulation with the nasal notch of the frontal bone. The **inferior border** is thin, and gives attach-

¹ Ole Worm, Professor of Anatomy at Copenhagen, 1624–1639, was erroneously supposed to have given the first detailed description of these bones.

ment to the lateral cartilage of the nose; near its middle is a notch which marks the end of the groove just referred to. The lateral border is serrated, bevelled at the expense of the inner surface above, and of the outer below, to articulate with the frontal process of the maxilla. The medial border, thicker above than

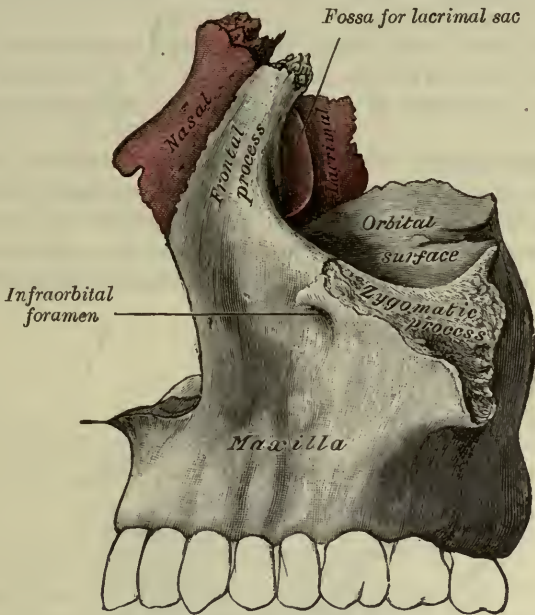


FIG. 154.—Articulation of nasal and lacrimal bones with maxilla.

below, articulates with its fellow of the opposite side, and is prolonged behind into a vertical crest, which forms part of the nasal septum: this crest articulates, from above downward, with the spine of the frontal, the perpendicular plate of the ethmoid, and the septal cartilage of the nose.

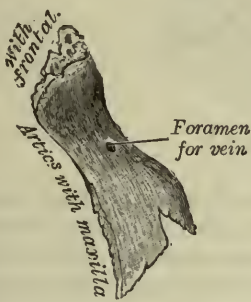


FIG. 155.—Right nasal bone. Outer surface.

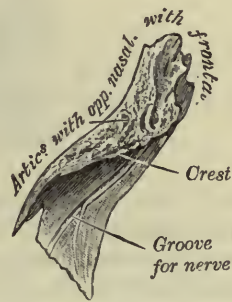

FIG. 156.—Right nasal bone. Inner surface.

Ossification.—Each bone is ossified from *one* center, which appears at the beginning of the third month of fetal life in the membrane overlying the front part of the cartilaginous nasal capsule.

Articulations.—The nasal articulates with four bones: two of the cranium, the frontal and ethmoid, and two of the face, the opposite nasal and the maxilla.

The Maxillæ (Upper Jaw).

The maxillæ are the largest bones of the face, excepting the mandible, and form, by their union, the whole of the upper jaw. Each assists in forming the

boundaries of three cavities, viz., the roof of the mouth, the floor and lateral wall of the nose and the floor of the orbit; it also enters into the formation of two fossæ, the infratemporal and pterygopalatine, and two fissures, the inferior orbital and pterygomaxillary.

Each bone consists of a body and four processes—zygomatic, frontal, alveolar, and palatine.

The Body (*corpus maxillæ*).—The body is somewhat pyramidal in shape, and contains a large cavity, the **maxillary sinus** (*antrum of Highmore*). It has four surfaces—an anterior, a posterior or infratemporal, a superior or orbital, and a medial or nasal.

Surfaces.—The **anterior surface** (Fig. 157) is directed forward and lateralward. It presents at its lower part a series of eminences corresponding to the positions of the roots of the teeth. Just above those of the incisor teeth is a depression, the **incisive fossa**, which gives origin to the *Depressor alæ nasi*; to the alveolar border below the fossa is attached a slip of the *Orbicularis oris*; above and a little

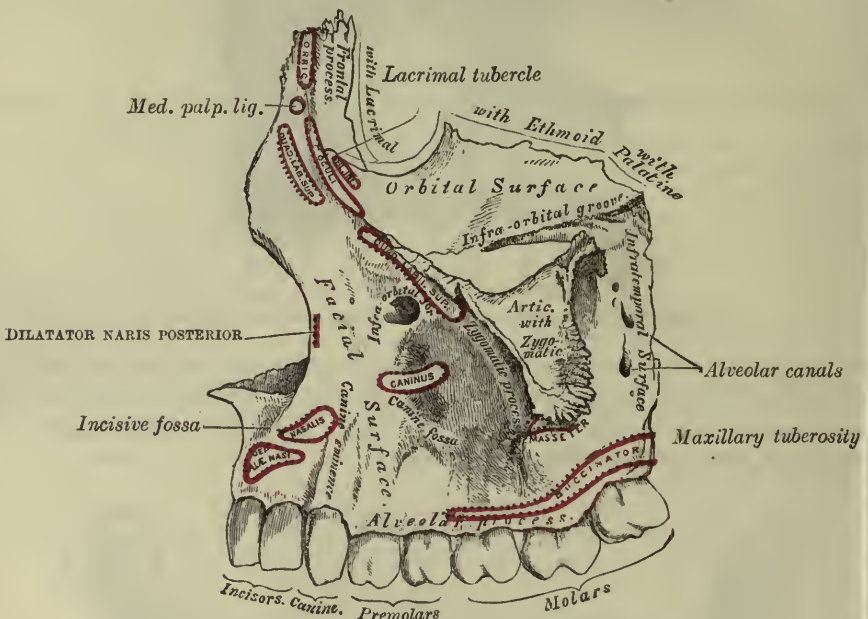


FIG. 157.—Left maxilla. Outer surface.

lateral to it, the *Nasalis* arises. Lateral to the incisive fossa is another depression, the **canine fossa**; it is larger and deeper than the incisive fossa, and is separated from it by a vertical ridge, the **canine eminence**, corresponding to the socket of the canine tooth; the canine fossa gives origin to the *Caninus*. Above the fossa is the **infraorbital foramen**, the end of the infraorbital canal; it transmits the infraorbital vessels and nerve. Above the foramen is the margin of the orbit, which affords attachment to part of the *Quadratus labii superioris*. Medially, the anterior surface is limited by a deep concavity, the **nasal notch**, the margin of which gives attachment to the *Dilatator naris posterior* and ends below in a pointed process, which with its fellow of the opposite side forms the **anterior nasal spine**.

The **infratemporal surface** (Fig. 157) is convex, directed backward and lateralward, and forms part of the infratemporal fossa. It is separated from the anterior surface by the zygomatic process and by a strong ridge, extending upward from the socket of the first molar tooth. It is pierced about its center by the apertures of the **alveolar canals**, which transmit the posterior superior alveolar vessels and nerves. At the lower part of this surface is a rounded eminence, the **maxillary**

tuberosity, especially prominent after the growth of the wisdom tooth; it is rough on its lateral side for articulation with the pyramidal process of the palatine bone and in some cases articulates with the lateral pterygoid plate of the sphenoid. It gives origin to a few fibers of the Pterygoideus internus. Immediately above this is a smooth surface, which forms the anterior boundary of the pterygopalatine fossa, and presents a groove, for the maxillary nerve; this groove is directed lateralward and slightly upward, and is continuous with the infraorbital groove on the orbital surface.

The **orbital surface** (Fig. 157) is smooth and triangular, and forms the greater part of the floor of the orbit. It is bounded *medially* by an irregular margin which in front presents a notch, the **lacrimal notch**; behind this notch the margin articulates with the lacrimal, the lamina papyracea of the ethmoid and the orbital process of the palatine. It is bounded *behind* by a smooth rounded edge which forms the anterior margin of the inferior orbital fissure, and sometimes articulates at its lateral extremity with the orbital surface of the great wing of the sphenoid.

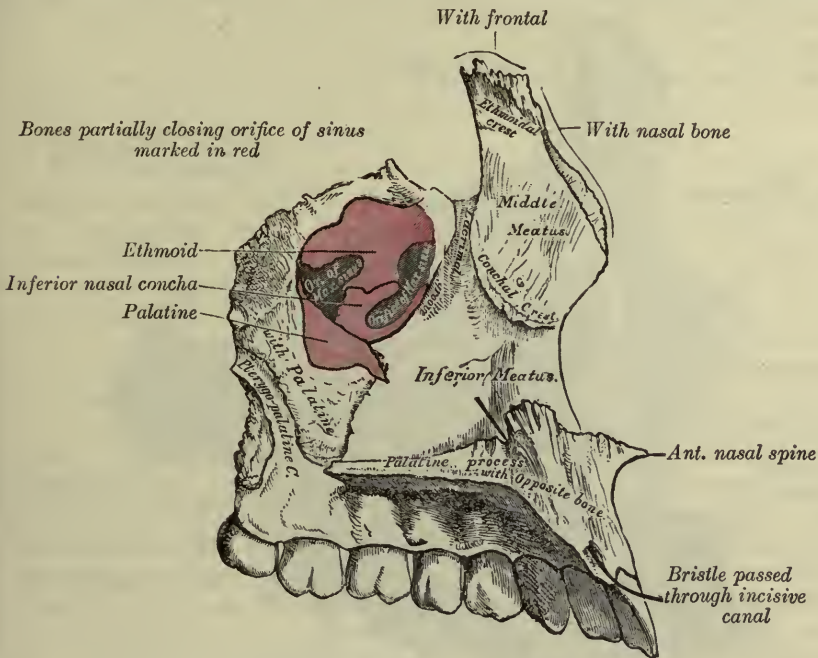


FIG. 158.—Left maxilla. Nasal surface.

It is limited *in front* by part of the circumference of the orbit, which is continuous medially with the frontal process, and laterally with the zygomatic process. Near the middle of the posterior part of the orbital surface is the **infraorbital groove**, for the passage of the infraorbital vessels and nerve. The groove begins at the middle of the posterior border, where it is continuous with that near the upper edge of the infratemporal surface, and, passing forward, ends in a canal, which subdivides into two branches. One of the canals, the **infraorbital canal**, opens just below the margin of the orbit; the other, which is smaller, runs downward in the substance of the anterior wall of the maxillary sinus, and transmits the anterior superior alveolar vessels and nerve to the front teeth of the maxilla. From the back part of the infraorbital canal, a second small canal is sometimes given off; it runs downward in the lateral wall of the sinus, and conveys the middle alveolar nerve to the premolar teeth. At the medial and forepart of the orbital surface, just lateral to the lacrimal groove, is a depression, which gives origin to the Obliquus oculi inferior.

The **nasal surface** (Fig. 158) presents a large, irregular opening leading into the maxillary sinus. At the upper border of this aperture are some broken air cells, which, in the articulated skull, are closed in by the ethmoid and lacrimal bones. Below the aperture is a smooth concavity which forms part of the inferior meatus of the nasal cavity, and behind it is a rough surface for articulation with the perpendicular part of the palatine bone; this surface is traversed by a groove, commencing near the middle of the posterior border and running obliquely downward and forward; the groove is converted into a canal, the **pterygopalatine canal**, by the palatine bone. In front of the opening of the sinus is a deep groove, the **lacrimal groove**, which is converted into the nasolacrimal canal, by the lacrimal bone and inferior nasal concha; this canal opens into the inferior meatus of the nose and transmits the nasolacrimal duct. More anteriorly is an oblique ridge, the **conchal crest**, for articulation with the inferior nasal concha. The shallow concavity above this ridge forms part of the atrium of the middle meatus of the nose, and that below it, part of the inferior meatus.

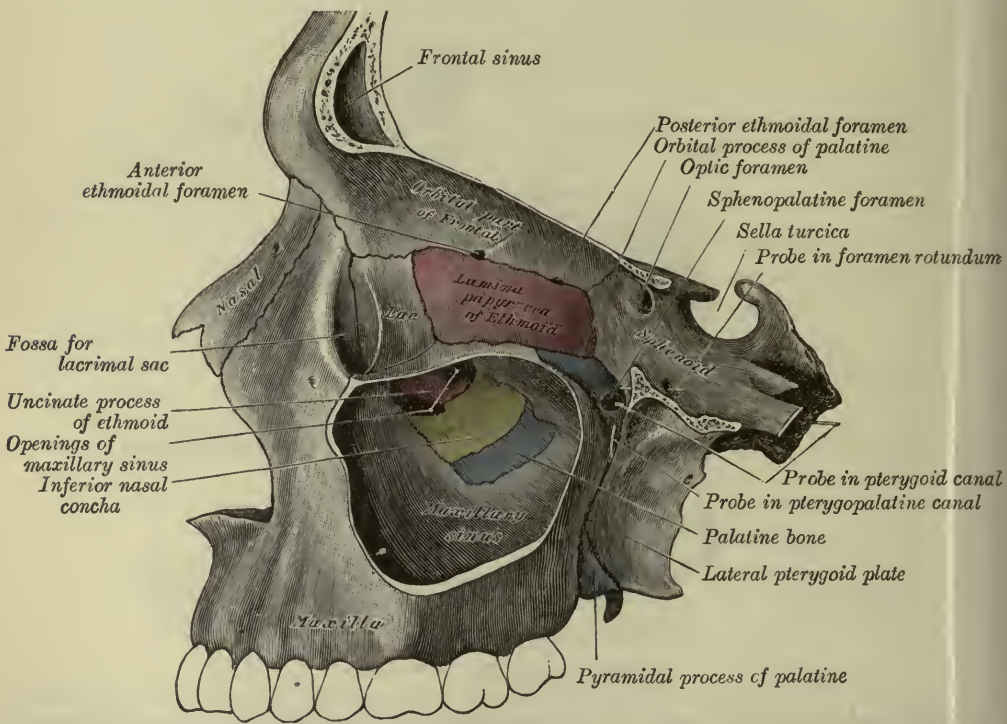


FIG. 159.—Left maxillary sinus opened from the exterior.

The Maxillary Sinus or Antrum of Highmore (*sinus maxillaris*).—The maxillary sinus is a large pyramidal cavity, within the body of the maxilla: its **apex**, directed lateralward, is formed by the zygomatic process; its **base**, directed medialward, by the lateral wall of the nose. Its walls are everywhere exceedingly thin, and correspond to the nasal orbital, anterior, and infratemporal surfaces of the body of the bone. Its **nasal wall**, or **base**, presents, in the disarticulated bone, a large, irregular aperture, communicating with the nasal cavity. In the articulated skull this aperture is much reduced in size by the following bones: the uncinat process of the ethmoid above, the ethmoidal process of the inferior nasal concha below, the vertical part of the palatine behind, and a small part of the lacrimal above and in front (Figs. 158, 159); the sinus communicates with the middle meatus

of the nose, generally by two small apertures left between the above-mentioned bones. In the fresh state, usually only one small opening exists, near the upper part of the cavity; the other is closed by mucous membrane. On the **posterior wall** are the **alveolar canals**, transmitting the posterior superior alveolar vessels and nerves to the molar teeth. The **floor** is formed by the alveolar process of the maxilla, and, if the sinus be of an average size, is on a level with the floor of the nose; if the sinus be large it reaches below this level.

Projecting into the floor of the antrum are several conical processes, corresponding to the roots of the first and second molar teeth;¹ in some cases the floor is perforated by the fangs of the teeth. The infraorbital canal usually projects into the cavity as a well-marked ridge extending from the roof to the anterior wall; additional ridges are sometimes seen in the posterior wall of the cavity, and are caused by the alveolar canals. The size of the cavity varies in different skulls, and even on the two sides of the same skull.²

The Zygomatic Process (*processus zygomaticus; malar process*).—The zygomatic process is a rough triangular eminence, situated at the angle of separation of the anterior, zygomatic, and orbital surfaces. *In front* it forms part of the anterior surface; *behind*, it is concave, and forms part of the infratemporal fossa; *above*, it is rough and serrated for articulation with the zygomatic bone; while *below*, it presents the prominent arched border which marks the division between the anterior and infratemporal surfaces.

The Frontal Process (*processus frontalis; nasal process*).—The frontal process is a strong plate, which projects upward, medialward, and backward, by the side of the nose, forming part of its lateral boundary. Its *lateral surface* is smooth, continuous with the anterior surface of the body, and gives attachment to the Quadratus labii superioris, the Orbicularis oculi, and the medial palpebral ligament. Its *medial surface* forms part of the lateral wall of the nasal cavity; at its upper part is a rough, uneven area, which articulates with the ethmoid, closing in the anterior ethmoidal cells; below this is an oblique ridge, the **ethmoidal crest**, the posterior end of which articulates with the middle nasal concha, while the anterior part is termed the **agger nasi**; the crest forms the upper limit of the atrium of the middle meatus. The *upper border* articulates with the frontal bone and the *anterior* with the nasal; the *posterior border* is thick, and hollowed into a groove, which is continuous below with the lacrimal groove on the nasal surface of the body: by the articulation of the medial margin of the groove with the anterior border of the lacrimal a corresponding groove on the lacrimal is brought into continuity, and together they form the **lacrimal fossa** for the lodgement of the lacrimal sac. The lateral margin of the groove is named the **anterior lacrimal crest**, and is continuous below with the orbital margin; at its junction with the orbital surface is a small tubercle, the **lacrimal tubercle**, which serves as a guide to the position of the lacrimal sac.

The Alveolar Process (*processus alveolaris*).—The alveolar process is the thickest and most spongy part of the bone. It is broader behind than in front, and excavated into deep cavities for the reception of the teeth. These cavities are eight in number, and vary in size and depth according to the teeth they contain. That for the canine tooth is the deepest; those for the molars are the widest, and are subdivided into minor cavities by septa; those for the incisors are single, but deep and narrow. The Buccinator arises from the outer surface of this process, as far forward as the first molar tooth. When the maxillæ are articulated with each other, their alveolar processes together form the **alveolar arch**; the center of the anterior margin of this arch is named the **alveolar point**.

¹ The number of teeth whose roots are in relation with the floor of the antrum is variable. The sinus "may extend so as to be in relation to all the teeth of the true maxilla, from the canine to the *dens sapientie*." (Salter.)

² Aldren Turner (*op. cit.*) gives the following measurements as those of an average sized sinus: vertical height opposite first molar tooth, $1\frac{1}{2}$ inch; transverse breadth, 1 inch; and antero-posterior depth, $1\frac{1}{4}$ inch.

The Palatine Process (*processus palatinus; palatal process*).—The palatine process, thick and strong, is horizontal and projects medialward from the nasal surface of the bone. It forms a considerable part of the floor of the nose and the roof of the mouth and is much thicker in front than behind. Its *inferior surface* (Fig. 160) is concave, rough and uneven, and forms, with the palatine process of the opposite bone, the anterior three-fourths of the hard plate. It is perforated by numerous foramina for the passage of the nutrient vessels; is channelled at the back part of its lateral border by a groove, sometimes a canal, for the transmission of the descending palatine vessels and the anterior palatine nerve from the sphenopalatine ganglion; and presents little depressions for the lodgement of the palatine glands. When the two maxillæ are articulated, a funnel-shaped opening, the **incisive foramen**, is seen in the middle line, immediately behind the incisor teeth. In this opening the orifices of two lateral canals are visible; they are named the

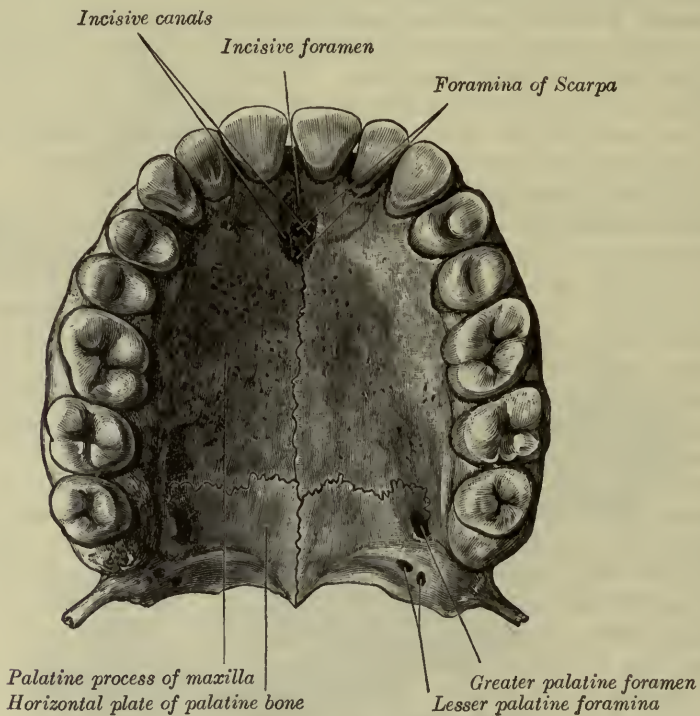


FIG. 160.—The bony palate and alveolar arch.

incisive canals or **foramina of Stenson**; through each of them passes the terminal branch of the descending palatine artery and the nasopalatine nerve. Occasionally two additional canals are present in the middle line; they are termed the **foramina of Scarpa**, and when present transmit the nasopalatine nerves, the left passing through the anterior, and the right through the posterior canal. On the under surface of the palatine process, a delicate linear suture, well seen in young skulls, may sometimes be noticed extending lateralward and forward on either side from the incisive foramen to the interval between the lateral incisor and the canine tooth. The small part in front of this suture constitutes the **premaxilla** (*os incisivum*), which in most vertebrates forms an independent bone; it includes the whole thickness of the alveolus, the corresponding part of the floor of the nose and the anterior nasal spine, and contains the sockets of the incisor teeth. The *upper surface* of the palatine process is concave from side to side, smooth, and forms the greater part of the floor of the nasal cavity. It presents, close to its medial margin, the

upper orifice of the incisive canal. The *lateral border* of the process is incorporated with the rest of the bone. The *medial border* is thicker in front than behind, and is raised above into a ridge, the **nasal crest**, which, with the corresponding ridge of the opposite bone, forms a groove for the reception of the vomer. The front part of this ridge rises to a considerable height, and is named the **incisor crest**; it is prolonged forward into a sharp process, which forms, together with a similar process of the opposite bone, the **anterior nasal spine**. The *posterior border* is serrated for articulation with the horizontal part of the palatine bone.

Ossification.—The maxilla is ossified in membrane. Mall¹ and Fawcett² maintain that it is ossified from *two* centers only, one for the maxilla proper and one for the premaxilla. These centers appear during the sixth week of fetal life and unite in the beginning of the third month, but the suture between the two portions persists on the palate until nearly middle life. Mall states that the frontal process is developed from both centers. The maxillary sinus appears as a shallow groove on the nasal surface of the bone about the fourth month of fetal life, but does not reach its full size until after the second dentition. The maxilla was formerly described as ossifying from six centers, viz., one, the *orbitonasal*, forms that portion of the body of the bone which lies medial to the infraorbital canal, including the medial part of the floor of the orbit and the lateral wall of the nasal cavity; a second, the *zygomatic*, gives origin to the portion which lies lateral to the infraorbital canal, including the zygomatic process; from a third, the *palatine*, is developed the palatine process posterior to the incisive canal together with the adjoining part of the nasal wall; a fourth, the *premaxillary*, forms the incisive bone which carries the incisor

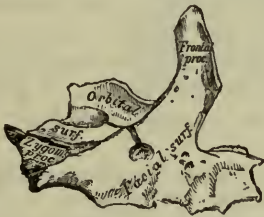

FIG. 161.—Anterior surface of maxilla at birth.

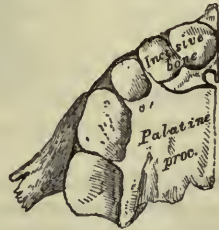

FIG. 162.—Inferior surface of maxilla at birth.

teeth and corresponds to the premaxilla of the lower vertebrates;³ a fifth, the *nasal*, gives rise to the frontal process and the portion above the canine tooth; and a sixth, the *infravomerine*, lies between the palatine and premaxillary centers and beneath the vomer; this center, together with the corresponding center of the opposite bone, separates the incisive canals from each other.

Articulations.—The maxilla articulates with *nine* bones: two of the cranium, the frontal and ethmoid, and seven of the face, viz., the nasal, zygomatic, lacrimal, inferior nasal concha, palatine, vomer, and its fellow of the opposite side. Sometimes it articulates with the orbital surface, and sometimes with the lateral pterygoid plate of the sphenoid.

CHANGES PRODUCED IN THE MAXILLA BY AGE.

At birth the transverse and antero-posterior diameters of the bone are each greater than the vertical. The frontal process is well-marked and the body of the bone consists of little more than the alveolar process, the teeth sockets reaching almost to the floor of the orbit. The maxillary sinus presents the appearance of a furrow on the lateral wall of the nose. In the adult the vertical diameter is the greatest, owing to the development of the alveolar process and the increase in size of the sinus. In old age the bone reverts in some measure to the infantile condition; its height is diminished, and after the loss of the teeth the alveolar process is absorbed, and the lower part of the bone contracted and reduced in thickness.

The Lacrimal Bone (Os Lacrimale).

The **lacrimal bone**, the smallest and most fragile bone of the face, is situated at the front part of the medial wall of the orbit (Fig. 164). It has two surfaces and four borders.

¹ American Journal of Anatomy, 1906, vol. v.

² Journal of Anatomy and Physiology, 1911, vol. xlv.

³ Some anatomists believe that the premaxillary bone is ossified by two centers (see page 299).

Surfaces.—The lateral or orbital surface (Fig. 163) is divided by a vertical ridge, the posterior lacrimal crest, into two parts. In front of this crest is a longitudinal groove, the lacrimal sulcus (*sulcus lacrimalis*), the inner margin of which unites with the frontal process of the maxilla, and the lacrimal fossa is thus completed. The upper part of this fossa lodges the lacrimal sac, the lower part, the nasolacrimal duct. The portion behind the crest is smooth, and forms part of the medial wall of the orbit. The crest, with a part of the orbital surface immediately behind it, gives origin to the lacrimal part of the Orbicularis oculi and ends below in a small, hook-like projection, the lacrimal hamulus, which articulates with the lacrimal tubercle of the maxilla, and completes the upper orifice of the lacrimal canal; it sometimes exists as a separate piece, and is then called the lesser lacrimal bone.

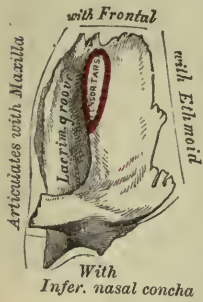

FIG. 163.—Left lacrimal bone. Orbital surface. Enlarged.

The medial or nasal surface presents a longitudinal furrow, corresponding to the crest on the lateral surface. The area in front of this furrow forms part of the middle meatus of the nose; that behind it articulates with the ethmoid, and completes some of the anterior ethmoidal cells.

Borders.—Of the four borders the anterior articulates with the frontal process of the maxilla; the posterior with the lamina papyracea of the ethmoid; the superior with the frontal bone. The inferior is divided by the lower edge of the posterior lacrimal crest into two parts: the posterior part articulates with the orbital plate of the maxilla; the anterior is prolonged downward as the descending process, which articulates with the lacrimal process of the inferior nasal concha, and assists in forming the canal for the nasolacrimal duct.

Ossification.—The lacrimal is ossified from a single center, which appears about the twelfth week in the membrane covering the cartilaginous nasal capsule.

Articulations.—The lacrimal articulates with four bones: two of the cranium, the frontal and ethmoid, and two of the face, the maxilla and the inferior nasal concha.

The Zygomatic Bone (*Os Zygomaticum*; Malar Bone).

The zygomatic bone is small and quadrangular, and is situated at the upper and lateral part of the face: it forms the prominence of the cheek, part of the lateral wall and floor of the orbit, and parts of the temporal and infratemporal fossæ (Fig. 164). It presents a malar and a temporal surface; four processes, the frontosphenoidal, orbital, maxillary, and temporal; and four borders.

Surfaces.—The malar surface (Fig. 165) is convex and perforated near its center by a small aperture, the zygomaticofacial foramen, for the passage of the zygomaticofacial nerve and vessels; below this foramen is a slight elevation, which gives origin to the Zygomaticus.

The temporal surface (Fig. 166), directed backward and medialward, is concave, presenting medially a rough, triangular area, for articulation with the maxilla, and laterally a smooth, concave surface, the upper part of which forms the anterior boundary of the temporal fossa, the lower a part of the infratemporal fossa. Near the center of this surface is the zygomaticotemporal foramen for the transmission of the zygomaticotemporal nerve.

Processes.—The frontosphenoidal process is thick and serrated, and articulates with the zygomatic process of the frontal bone. On its orbital surface, just within the orbital margin and about 11 mm. below the zygomaticofrontal suture is a tubercle of varying size and form, but present in 95 per cent. of skulls (Whitnall¹).

¹ Journal of Anatomy and Physiology, vol. xlv. The structures attached to this tubercle are: (1) the check ligament of the Rectus lateralis; (2) the lateral end of the aponeurosis of the Levator palpebræ superioris; (3) the suspensory ligament of the eye (Lockwood); and (4) the lateral extremities of the superior and inferior tarsi.

The orbital process is a thick, strong plate, projecting backward and medialward from the orbital margin. Its *antero-medial surface* forms, by its junction with the orbital surface of the maxilla and with the great wing of the sphenoid, part of the floor and lateral wall of the orbit. On it are seen the orifices of two canals,

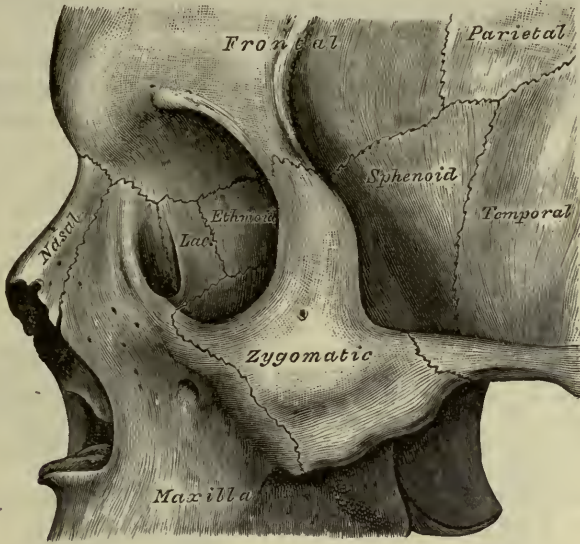


FIG. 164.—Left zygomatic bone in situ.

the *zygomatico-orbital foramina*; one of these canals opens into the temporal fossa, the other on the malar surface of the bone; the former transmits the zygomatico-temporal, the latter the zygomaticofacial nerve. Its *postero-lateral surface*, smooth and convex, forms parts of the temporal and infratemporal fossæ. Its *anterior margin*, smooth and rounded, is part of the circumference of the orbit. Its *superior*

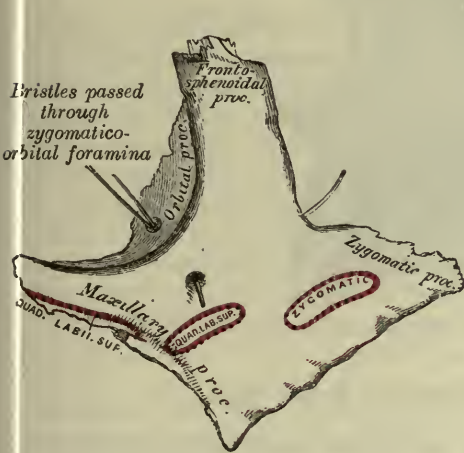

FIG. 165.—Left zygomatic bone. Malar surface.

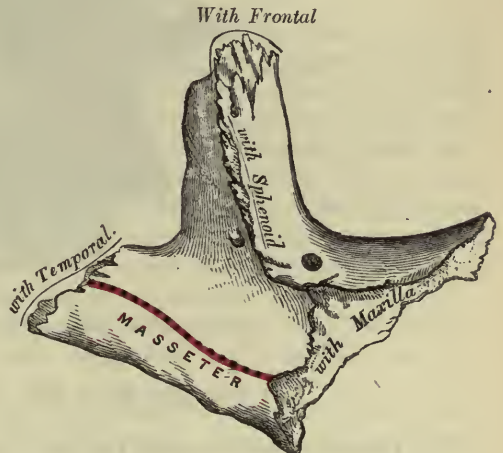


FIG. 166.—Left zygomatic bone. Temporal surface.

margin, rough, and directed horizontally, articulates with the frontal bone behind the zygomatic process. Its *posterior margin* is serrated for articulation, with the great wing of the sphenoid and the orbital surface of the maxilla. At the angle of junction of the sphenoidal and maxillary portions, a short, concave, non-articular

part is generally seen; this forms the anterior boundary of the inferior orbital fissure: occasionally, this non-articular part is absent, the fissure then being completed by the junction of the maxilla and sphenoid, or by the interposition of a small sutural bone in the angular interval between them. The **maxillary process** presents a rough, triangular surface which articulates with the maxilla. The **temporal process**, long, narrow, and serrated, articulates with the zygomatic process of the temporal.

Borders.—The **antero-superior** or **orbital border** is smooth, concave, and forms a considerable part of the circumference of the orbit. The **antero-inferior** or **maxillary border** is rough, and bevelled at the expense of its inner table, to articulate with the maxilla; near the orbital margin it gives origin to the *Quadratus labii superioris*. The **postero-superior** or **temporal border**, curved like an italic letter *f*, is continuous above with the commencement of the temporal line, and below with the upper border of the zygomatic arch; the temporal fascia is attached to it. The **postero-inferior** or **zygomatic border** affords attachment by its rough edge to the *Masseter*.

Ossification.—The zygomatic bone is generally described as ossifying from three centers—one for the malar and two for the orbital portion; these appear about the eighth week and fuse about the fifth month of fetal life. Mall describes it as being ossified from one center which appears just beneath and to the lateral side of the orbit. After birth, the bone is sometimes divided by a horizontal suture into an upper larger, and a lower smaller division. In some quadrumana the zygomatic bone consists of two parts, an orbital and a malar.

Articulations.—The zygomatic articulates with *four* bones: the frontal, sphenoidal, temporal, and maxilla.

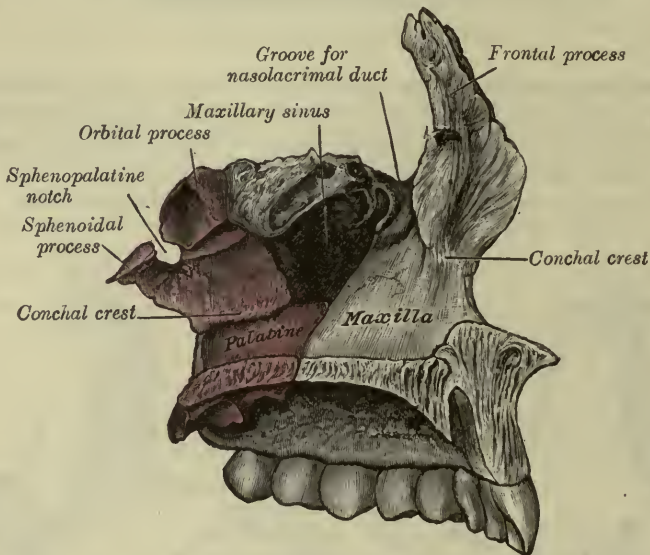


FIG. 167.—Articulation of left palatine bone with maxilla.

The Palatine Bone (*Os Palatinum*; Palate Bone).

The **palatine bone** is situated at the back part of the nasal cavity between the maxilla and the pterygoid process of the sphenoid (Fig. 167). It contributes to the walls of three cavities: the floor and lateral wall of the nasal cavity, the roof of the mouth, and the floor of the orbit; it enters into the formation of two fossæ, the **pterygopalatine** and **pterygoid fossæ**; and one fissure, the **inferior orbital fissure**. The palatine bone somewhat resembles the letter *L*, and consists of a horizontal and a vertical part and three outstanding processes—viz., the pyramidal

process, which is directed backward and lateralward from the junction of the two parts, and the orbital and sphenoidal processes, which surmount the vertical part, and are separated by a deep notch, the sphenopalatine notch.

The Horizontal Part (*pars horizontalis*; *horizontal plate*) (Figs. 168, 169).—The horizontal part is quadrilateral, and has two surfaces and four borders.

Surfaces.—The **superior surface**, concave from side to side, forms the back part of the floor of the nasal cavity. The **inferior surface**, slightly concave and rough, forms, with the corresponding surface of the opposite bone, the posterior fourth of the hard palate. Near its posterior margin may be seen a more or less marked transverse ridge for the attachment of part of the aponeurosis of the Tensor veli palatini.

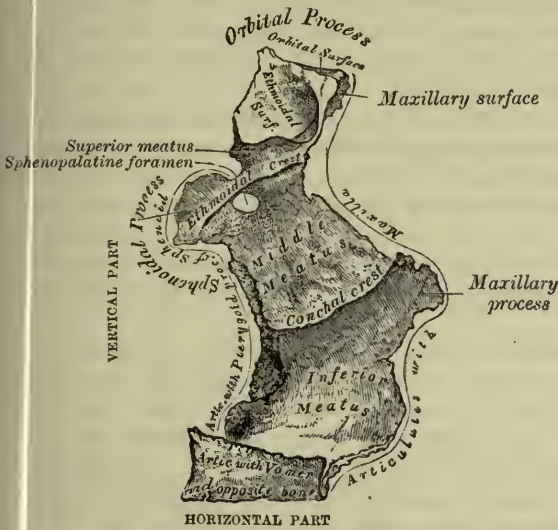


FIG. 168.—Left palatine bone. Nasal aspect. Enlarged.

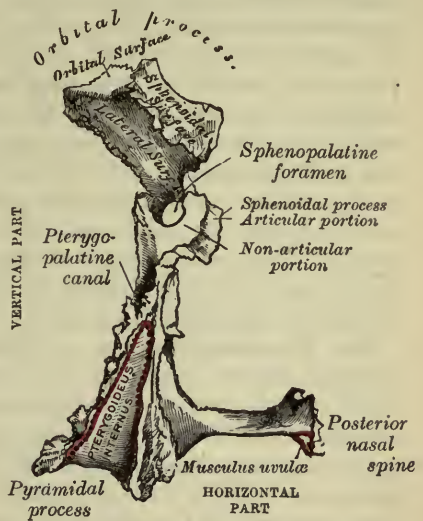


FIG. 169.—Left palatine bone. Posterior aspect. Enlarged.

Borders.—The **anterior border** is serrated, and articulates with the palatine process of the maxilla. The **posterior border** is concave, free, and serves for the attachment of the soft palate. Its medial end is sharp and pointed, and, when united with that of the opposite bone, forms a projecting process, the **posterior nasal spine** for the attachment of the Musculus uvulae. The **lateral border** is united with the lower margin of the perpendicular part, and is grooved by the lower end of the pterygopalatine canal. The **medial border**, the thickest, is serrated for articulation with its fellow of the opposite side; its superior edge is raised into a ridge, which, united with the ridge of the opposite bone, forms the **nasal crest** for articulation with the posterior part of the lower edge of the vomer.

The Vertical Part (*pars perpendicularis*; *perpendicular plate*) (Figs. 168, 169).—The vertical part is thin, of an oblong form, and presents two surfaces and four borders.

Surfaces.—The **nasal surface** exhibits at its lower part a broad, shallow depression, which forms part of the inferior meatus of the nose. Immediately above this is a well-marked horizontal ridge, the **conchal crest**, for articulation with the inferior nasal concha; still higher is a second broad, shallow depression, which forms part of the middle meatus, and is limited above by a horizontal crest less prominent than the inferior, the **ethmoidal crest**, for articulation with the middle nasal concha. Above the ethmoidal crest is a narrow, horizontal groove, which forms part of the superior meatus.

The **maxillary surface** is rough and irregular throughout the greater part of its extent, for articulation with the nasal surface of the maxilla; its upper and back part is smooth where it enters into the formation of the pterygopalatine fossa; it is also smooth in front, where it forms the posterior part of the medial wall of the maxillary sinus. On the posterior part of this surface is a deep vertical groove, converted into the **pterygopalatine canal**, by articulation with the maxilla; this canal transmits the descending palatine vessels, and the anterior palatine nerve.

Borders.—The **anterior border** is thin and irregular; opposite the conchal crest is a pointed, projecting lamina, the **maxillary process**, which is directed forward, and closes in the lower and back part of the opening of the maxillary sinus. The **posterior border** (Fig. 169) presents a deep groove, the edges of which are serrated for articulation with the medial pterygoid plate of the sphenoid. This border is continuous above with the sphenoidal process; below it expands into the pyramidal process. The **superior border** supports the orbital process in front and the sphenoidal process behind. These processes are separated by the **sphenopalatine notch**, which is converted into the **sphenopalatine foramen** by the under surface of the body of the sphenoid. In the articulated skull this foramen leads from the pterygopalatine fossa into the posterior part of the superior meatus of the nose, and transmits the sphenopalatine vessels and the superior nasal and nasopalatine nerves. The **inferior border** is fused with the lateral edge of the horizontal part, and immediately in front of the pyramidal process is grooved by the lower end of the pterygopalatine canal.

The Pyramidal Process or Tuberosity (*processus pyramidalis*).—The pyramidal process projects backward and lateralward from the junction of the horizontal and vertical parts, and is received into the angular interval between the lower extremities of the pterygoid plates. On its **posterior surface** is a smooth, grooved, triangular area, limited on either side by a rough articular furrow. The furrows articulate with the pterygoid plates, while the grooved intermediate area completes the lower part of the pterygoid fossa and gives origin to a few fibers of the Pterygoideus internus. The anterior part of the **lateral surface** is rough, for articulation with the tuberosity of the maxilla; its posterior part consists of a smooth triangular area which appears, in the articulated skull, between the tuberosity of the maxilla and the lower part of the lateral pterygoid plate, and completes the lower part of the infratemporal fossa. On the **base** of the pyramidal process, close to its union with the horizontal part, are the lesser palatine foramina for the transmission of the posterior and middle palatine nerves.

The Orbital Process (*processus orbitalis*).—The orbital process is placed on a higher level than the sphenoidal, and is directed upward and lateralward from the front of the vertical part, to which it is connected by a constricted neck. It presents five surfaces, which enclose an air cell. Of these surfaces, three are articular and two non-articular. The articular surfaces are: (1) the **anterior** or **maxillary**, directed forward, lateralward, and downward, of an oblong form, and rough for articulation with the maxilla; (2) the **posterior** or **sphenoidal**, directed backward, upward, and medialward; it presents the opening of the air cell, which usually communicates with the sphenoidal sinus; the margins of the opening are serrated for articulation with the sphenoidal concha; (3) the **medial** or **ethmoidal**, directed forward, articulates with the labyrinth of the ethmoid. In some cases the air cell opens on this surface of the bone and then communicates with the posterior ethmoidal cells. More rarely it opens on both surfaces, and then communicates with the posterior ethmoidal cells and the sphenoidal sinus. The non-articular surfaces are: (1) the **superior** or **orbital**, directed upward and lateralward; it is triangular in shape, and forms the back part of the floor of the orbit; and (2) the **lateral**, of an oblong form, directed toward the pterygopalatine fossa; it is separated

from the orbital surface by a rounded border, which enters into the formation of the inferior orbital fissure.

The Sphenoidal Process (*processus sphenoidalis*).—The sphenoidal process is a thin, compressed plate, much smaller than the orbital, and directed upward and medialward. It presents three surfaces and two borders. The **superior surface** articulates with the root of the pterygoid process and the under surface of the sphenoidal concha, its medial border reaching as far as the ala of the vomer; it presents a groove which contributes to the formation of the pharyngeal canal. The **medial surface** is concave, and forms part of the lateral wall of the nasal cavity. The **lateral surface** is divided into an articular and a non-articular portion: the former is rough, for articulation with the medial pterygoid plate; the latter is smooth, and forms part of the pterygopalatine fossa. The **anterior border** forms the posterior boundary of the sphenopalatine notch. The **posterior border**, serrated at the expense of the outer table, articulates with the medial pterygoid plate.

The orbital and sphenoidal processes are separated from one another by the **sphenopalatine notch**. Sometimes the two processes are united above, and form between them a complete foramen (Fig. 168), or the notch may be crossed by one or more spicules of bone, giving rise to two or more foramina.

Ossification.—The palatine bone is ossified in membrane from a single center, which makes its appearance about the sixth or eighth week of fetal life at the angle of junction of the two parts of the bone. From this point ossification spreads medialward to the horizontal part, downward into the pyramidal process, and upward into the vertical part. Some authorities describe the bone as ossifying from four centers: one for the pyramidal process and portion of the vertical part behind the pterygopalatine groove; a second for the rest of the vertical and the horizontal parts; a third for the orbital, and a fourth for the sphenoidal process. At the time of birth the height of the vertical part is about equal to the transverse width of the horizontal part, whereas in the adult the former measures about twice as much as the latter.

Articulations.—The palatine articulates with *six* bones: the sphenoid, ethmoid, maxilla, inferior nasal concha, vomer, and opposite palatine.

The Inferior Nasal Concha (Concha Nasalis Inferior; Inferior Turbinated Bone).

The **inferior nasal concha** extends horizontally along the lateral wall of the nasal cavity (Fig. 170) and consists of a lamina of spongy bone, curled upon itself like a scroll. It has two surfaces, two borders, and two extremities.

The **medial surface** (Fig. 171) is convex, perforated by numerous apertures, and traversed by longitudinal grooves for the lodgement of vessels. The **lateral surface** is concave (Fig. 172), and forms part of the inferior meatus. Its **upper border** is thin, irregular, and connected to various bones along the lateral wall of the nasal cavity. It may be divided into three portions: of these, the anterior articulates with the conchal crest of the maxilla; the posterior with the conchal crest of the palatine; the middle portion presents three well-marked processes, which vary much in their size and form. Of these, the anterior or **lacrimal process** is small and pointed and is situated at the junction of the anterior fourth with the posterior three-fourths of the bone: it articulates, by its apex, with the descending process of the lacrimal bone, and, by its margins, with the groove on the back of the frontal process of the maxilla, and thus assists in forming the canal for the nasolacrimal duct. Behind this process a broad, thin plate, the **ethmoidal process**, ascends to join the uncinatè process of the ethmoid; from its lower border a thin lamina, the **maxillary process**, curves downward and lateralward; it articulates with the maxilla and forms a part of the medial wall of the maxillary sinus. The **inferior border** is free, thick, and cellular in structure, more especially in the middle of the bone. Both **extremities** are more or less pointed, the posterior being the more tapering.

Ossification.—The inferior nasal concha is ossified from a single center, which appears about the fifth month of fetal life in the lateral wall of the cartilaginous nasal capsule.

Articulations.—The inferior nasal concha articulates with *four* bones: the ethmoid, maxilla, lacrimal, and palatine.

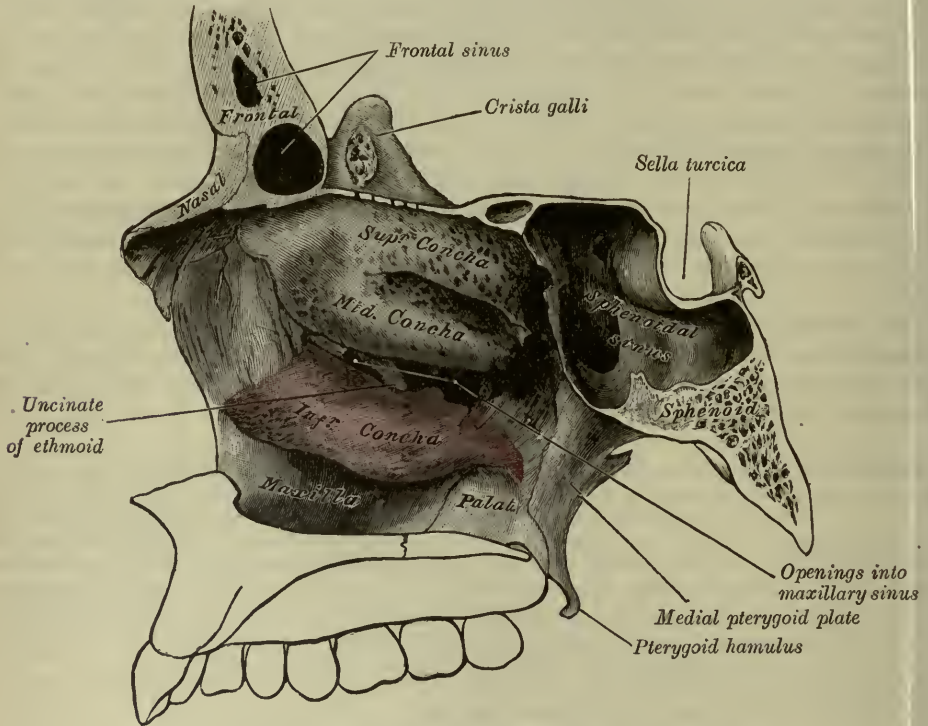


FIG. 170.—Lateral wall of right nasal cavity showing inferior concha *in situ*.

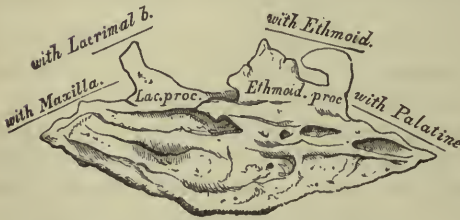

FIG. 171.—Right inferior nasal concha. Medial surface.

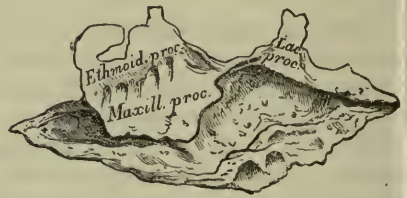


FIG. 172.—Right inferior nasal concha. Lateral surface.

The Vomer.

The **vomer** is situated in the median plane, but its anterior portion is frequently bent to one or other side. It is thin, somewhat quadrilateral in shape, and forms the hinder and lower part of the nasal septum (Fig. 173); it has two surfaces and four borders. The **surfaces** (Fig. 174) are marked by small furrows for blood-vessels, and on each is the **nasopalatine groove**, which runs obliquely downward and forward, and lodges the nasopalatine nerve and vessels. The **superior border**, the thickest, presents a deep furrow, bounded on either side by a horizontal projecting ala of bone; the furrow receives the rostrum of the sphenoid, while the margins of the *alæ* articulate with the vaginal processes of the medial pterygoid plates of the sphenoid behind, and with the sphenoidal processes of the palatine bones in front. The **inferior border** articulates with the crest formed by the maxillæ

and palatine bones. The **anterior border** is the longest and slopes downward and forward. Its upper half is fused with the perpendicular plate of the ethmoid; its lower half is grooved for the inferior margin of the septal cartilage of the nose. The **posterior border** is free, concave, and separates the choanæ. It is thick and bifid above, thin below.

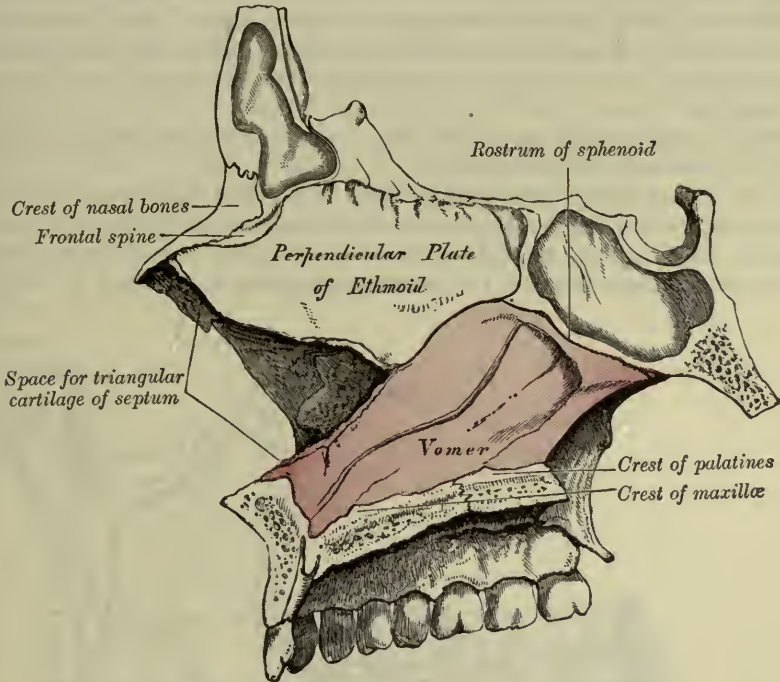


FIG. 173.—Median wall of left nasal cavity showing vomer *in situ*.

Ossification.—At an early period the septum of the nose consists of a plate of cartilage, the *ethmovomerine cartilage*. The postero-superior part of this cartilage is ossified to form the perpendicular plate of the ethmoid; its antero-inferior portion persists as the septal cartilage, while the vomer is ossified in the membrane covering its postero-inferior part. Two ossific centers, one on either side of the middle line, appear about the eighth week of fetal life in this part of the membrane, and hence the vomer consists primarily of two lamellæ. About the third month

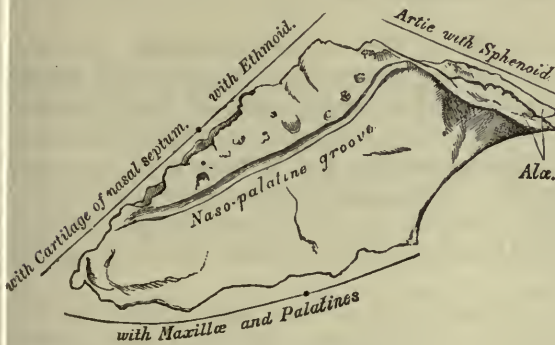

FIG. 174.—The vomer.




FIG. 175.—Vomer of infant.

these unite below, and thus a deep groove is formed in which the cartilage is lodged. As growth proceeds, the union of the lamellæ extends upward and forward, and at the same time the intervening plate of cartilage undergoes absorption. By the age of puberty the lamellæ are almost completely united to form a median plate, but evidence of the bilaminar origin of the bone is seen in the everted alæ of its upper border and the groove on its anterior margin.

Articulations.—The vomer articulates with *six* bones: two of the cranium, the sphenoid and ethmoid; and four of the face, the two maxillæ and the two palatine bones; it also articulates with the septal cartilage of the nose.

The Mandible (Mandibula; Inferior Maxillary Bone; Lower Jaw).

The **mandible**, the largest and strongest bone of the face, serves for the reception of the lower teeth. It consists of a curved, horizontal portion, the **body**, and two perpendicular portions, the **rami**, which unite with the ends of the body nearly at right angles.

The Body (*corpus mandibulæ*).—The body is curved somewhat like a horseshoe, and has two surfaces and two borders.

Surfaces.—The **external surface** (Fig. 176) is marked in the median line by a faint ridge, indicating the **symphysis** or line of junction of the two pieces of which the bone is composed at an early period of life. This ridge divides below and encloses a triangular eminence, the **mental protuberance**, the base of which is de-

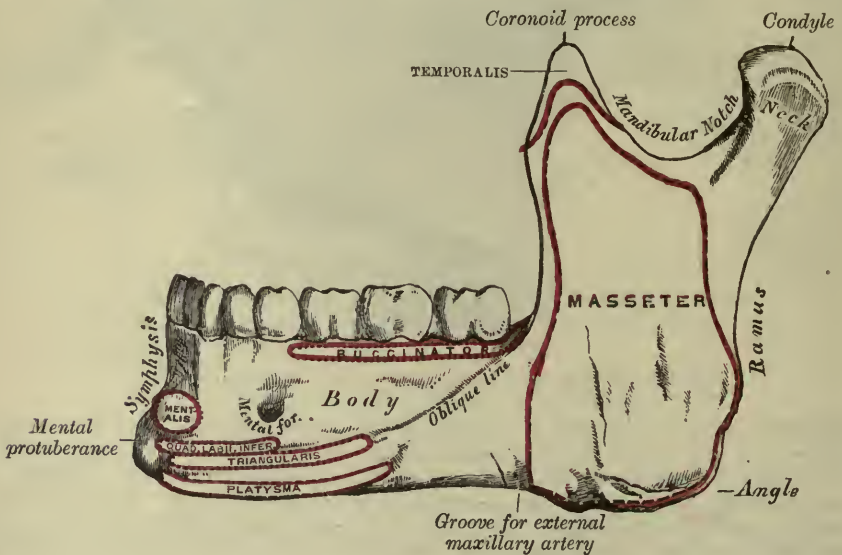


FIG. 176.—Mandible. Outer surface. Side view.

pressed in the center but raised on either side to form the **mental tubercle**. On either side of the symphysis, just below the incisor teeth, is a depression, the **incisive fossa**, which gives origin to the Mentalis and a small portion of the Orbicularis oris. Below the second premolar tooth, on either side, midway between the upper and lower borders of the body, is the **mental foramen**, for the passage of the mental vessels and nerve. Running backward and upward from each mental tubercle is a faint ridge, the **oblique line**, which is continuous with the anterior border of the ramus; it affords attachment to the Quadratus labii inferioris and Triangularis; the Platysma is attached below it.

The **internal surface** (Fig. 177) is concave from side to side. Near the lower part of the symphysis is a pair of laterally placed spines, termed the **mental spines**, which give origin to the Genioglossi. Immediately below these is a second pair of spines, or more frequently a median ridge or impression, for the origin of the Geniohyoidei. In some cases the mental spines are fused to form a single eminence, in others they are absent and their position is indicated merely by an irregularity of the surface. Above the mental spines a median foramen and furrow are sometimes seen; they mark the line of union of the halves of the bone. Below the mental

spines, on either side of the middle line, is an oval depression for the attachment of the anterior belly of the Digastricus. Extending upward and backward on either side from the lower part of the symphysis is the **mylohyoid line**, which gives origin to the Mylohyoideus; the posterior part of this line, near the alveolar margin, gives attachment to a small part of the Constrictor pharyngis superior, and to the pterygomandibular raphé. Above the anterior part of this line is a smooth triangular area against which the sublingual gland rests, and below the hinder part, an oval fossa for the submaxillary gland.

Borders.—The **superior or alveolar border**, wider behind than in front, is hollowed into cavities, for the reception of the teeth; these cavities are sixteen in number, and vary in depth and size according to the teeth which they contain. To the outer lip of the superior border, on either side, the Buccinator is attached as far forward as the first molar tooth. The **inferior border** is rounded, longer than the superior, and thicker in front than behind; at the point where it joins the lower border of the ramus a shallow groove; for the external maxillary artery, may be present.

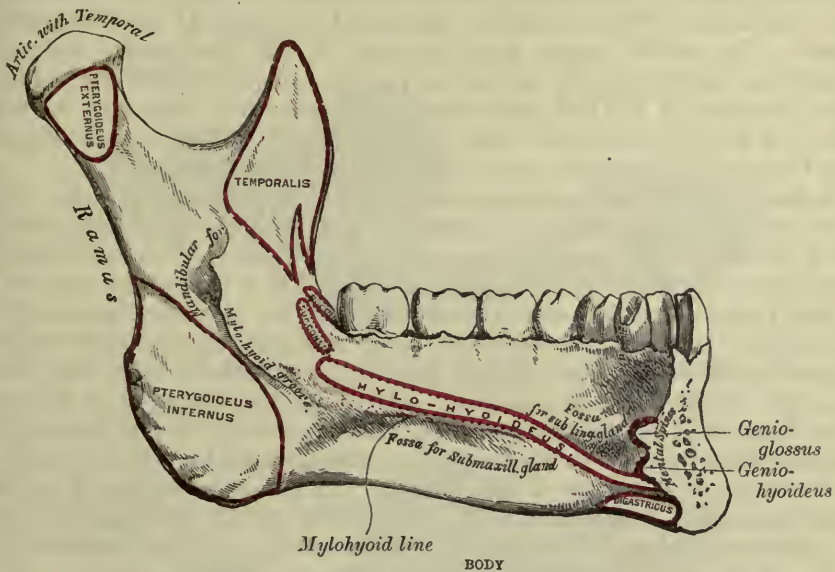


FIG. 177.—Mandible. Inner surface. Side view.

The Ramus (*ramus mandibulæ; perpendicular portion*).—The ramus is quadrilateral in shape, and has two surfaces, four borders, and two processes.

Surfaces.—The **lateral surface** (Fig. 176) is flat and marked by oblique ridges at its lower part; it gives attachment throughout nearly the whole of its extent to the Masseter. The **medial surface** (Fig. 177) presents about its center the oblique **mandibular foramen**, for the entrance of the inferior alveolar vessels and nerve. The margin of this opening is irregular; it presents in front a prominent ridge, surmounted by a sharp spine, the **lingula mandibulæ**, which gives attachment to the sphenomandibular ligament; at its lower and back part is a notch from which the **mylohyoid groove** runs obliquely downward and forward, and lodges the mylohyoid vessels and nerve. Behind this groove is a rough surface, for the insertion of the Pterygoideus internus. The **mandibular canal** runs obliquely downward and forward in the ramus, and then horizontally forward in the body, where it is placed under the alveoli and communicates with them by small openings. On arriving at the incisor teeth, it turns back to communicate with the mental foramen, giving off two small canals which run to the cavities containing the incisor teeth.

In the posterior two-thirds of the bone the canal is situated nearer the internal surface of the mandible; and in the anterior third, nearer its external surface. It contains the inferior alveolar vessels and nerve, from which branches are distributed to the teeth. The **lower border** of the ramus is thick, straight, and continuous with the inferior border of the body of the bone. At its junction with the posterior border is the **angle of the mandible**, which may be either inverted or everted and is marked by rough, oblique ridges on each side, for the attachment of the Masseter laterally, and the Pterygoideus internus medially; the stylo-mandibular ligament is attached to the angle between these muscles. The **anterior border** is thin above, thicker below, and continuous with the oblique line. The **posterior border** is thick, smooth, rounded, and covered by the parotid gland. The **upper border** is thin, and is surmounted by two processes, the **coronoid** in front and the **condyloid** behind, separated by a deep concavity, the **mandibular notch**.

The **Coronoid Process** (*processus coronoideus*) is a thin, triangular eminence, which is flattened from side to side and varies in shape and size. Its *anterior border* is convex and is continuous below with the anterior border of the ramus; its *posterior border* is concave and forms the anterior boundary of the mandibular notch. Its *lateral surface* is smooth, and affords insertion to the Temporalis and Masseter. Its *medial surface* gives insertion to the Temporalis, and presents a ridge which begins near the apex of the process and runs downward and forward to the inner side of the last molar tooth. Between this ridge and the anterior border is a grooved triangular area, the upper part of which gives attachment to the Temporalis, the lower part to some fibers of the Buccinator.

The **Condyloid Process** (*processus condyloideus*) is thicker than the coronoid, and consists of two portions: the **condyle**, and the constricted portion which supports it, the **neck**. The **condyle** presents an articular surface for articulation with the articular disk of the temporomandibular joint; it is convex from before backward and from side to side, and extends farther on the posterior than on the anterior surface. Its long axis is directed medialward and slightly backward, and if prolonged to the middle line will meet that of the opposite condyle near the anterior margin of the foramen magnum. At the lateral extremity of the condyle is a small tubercle for the attachment of the temporomandibular ligament. The **neck** is flattened from before backward, and strengthened by ridges which descend from the forepart and sides of the condyle. Its posterior surface is convex; its anterior presents a depression for the attachment of the Pterygoideus externus.

The **mandibular notch**, separating the two processes, is a deep semilunar depression, and is crossed by the masseteric vessels and nerve.

Ossification.—The mandible is ossified in the fibrous membrane covering the outer surfaces of Meckel's cartilages. These cartilages form the cartilaginous bar of the mandibular arch (see p. 66), and are two in number, a right and a left. Their proximal or cranial ends are connected with the ear capsules, and their distal extremities are joined to one another at the symphysis by mesodermal tissue. They run forward immediately below the condyles and then, bending downward, lie in a groove near the lower border of the bone; in front of the canine tooth they incline upward to the symphysis. From the proximal end of each cartilage the malleus and incus, two of the bones of the middle ear, are developed; the next succeeding portion, as far as the lingula, is replaced by fibrous tissue, which persists to form the sphenomandibular ligament. Between the lingula and the canine tooth the cartilage disappears, while the portion of it below and behind the incisor teeth becomes ossified and incorporated with this part of the mandible.

Ossification takes place in the membrane covering the outer surface of the ventral end of Meckel's cartilage (Figs. 178 to 181), and each half of the bone is formed from a single center which appears, near the mental foramen, about the sixth week of fetal life. By the tenth week the portion of Meckel's cartilage which lies below and behind the incisor teeth is surrounded and invaded by the membrane bone. Somewhat later, accessory nuclei of cartilage make their appearance, viz., a wedge-shaped nucleus in the condyloid process and extending downward through the ramus; a small strip along the anterior border of the coronoid process; and smaller nuclei in the front part of both alveolar walls and along the front of the lower border of the bone. These accessory nuclei possess no separate ossific centers, but are invaded by the surrounding membrane

bone and undergo absorption. The inner alveolar border, usually described as arising from a separate ossific center (*splenic center*), is formed in the human mandible by an ingrowth from the main mass of the bone. At birth the bone consists of two parts, united by a fibrous symphysis, in which ossification takes place during the first year.

The foregoing description of the ossification of the mandible is based on the researches of Low¹ and Fawcett,² and differs somewhat from that usually given.

Articulations.—The mandible articulates with the *two* temporal bones.

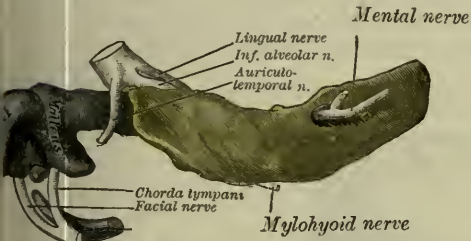


FIG. 178.—Mandible of human embryo 24 mm. long. Outer aspect. (From model by Low.)

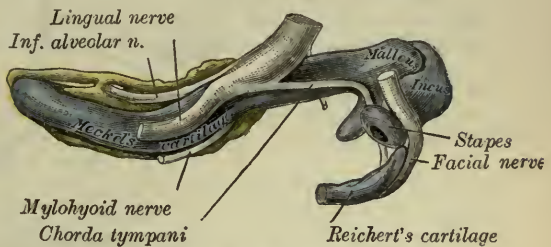


FIG. 179.—Mandible of human embryo 24 mm. long. Inner aspect. (From model by Low.)

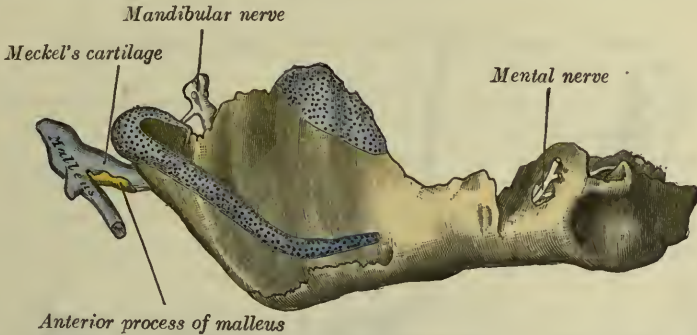


FIG. 180.—Mandible of human embryo 95 mm. long. Outer aspect. Nuclei of cartilage stippled. (From model by Low.)

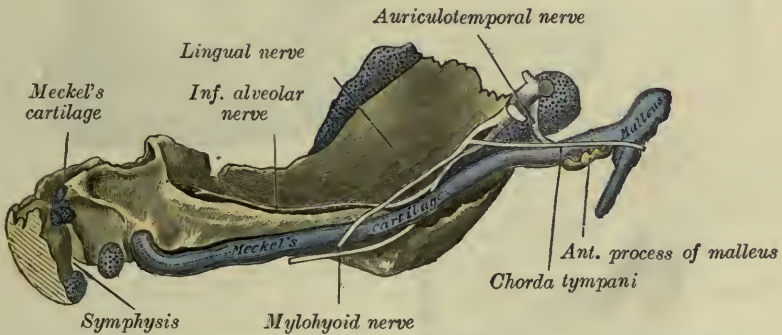


FIG. 181.—Mandible of human embryo 95 mm. long. Inner aspect. Nuclei of cartilage stippled. (From model by Low.)

CHANGES PRODUCED IN THE MANDIBLE BY AGE.

At birth (Fig. 182) the body of the bone is a mere shell, containing the sockets of the two incisor, the canine, and the two deciduous molar teeth, imperfectly partitioned off from one another. The mandibular canal is of large size, and runs near the lower border of the bone; the mental foramen opens beneath the socket of the first deciduous molar tooth. The angle is obtuse (175°), and the condyloid portion is nearly in line with the body. The coronoid process is of comparatively large size, and projects above the level of the condyle.

¹ Proceedings of the Anatomical and Anthropological Society of the University of Aberdeen, 1905, and Journal of Anatomy and Physiology, vol. xiv.

² Journal of the American Medical Association, September 2, 1905.

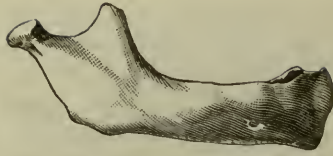


FIG. 182.—At birth.

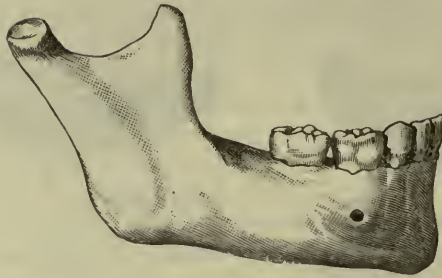

FIG. 183.—In childhood.

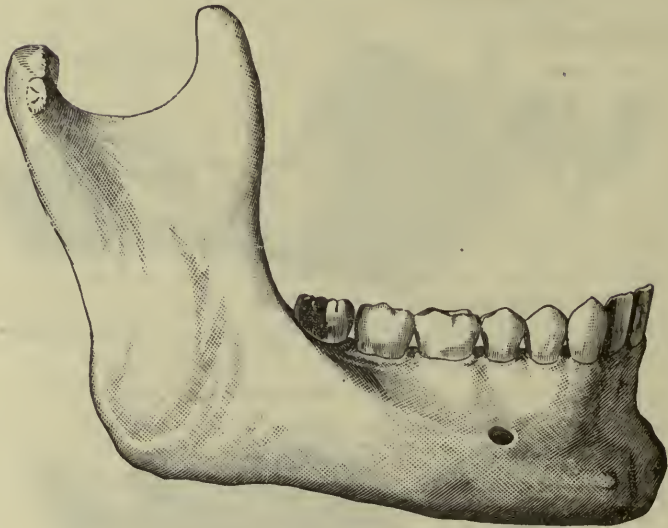
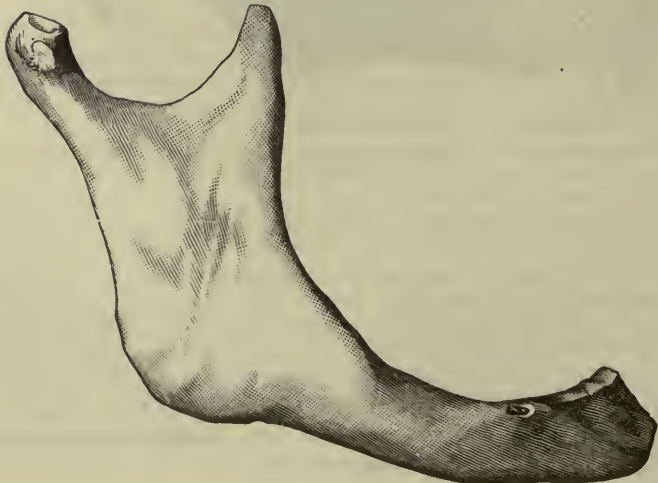

FIG. 184.—In the adult.

FIG. 185.—In old age.
Side view of the mandible at different periods of life.

After birth (Fig. 183) the two segments of the bone become joined at the symphysis, from below upward, in the first year; but a trace of separation may be visible in the beginning of the second year, near the alveolar margin. The body becomes elongated in its whole length, but more especially behind the mental foramen, to provide space for the three additional teeth developed in this part. The depth of the body increases owing to increased growth of the alveolar part, to afford room for the roots of the teeth, and by thickening of the subdental portion which enables the jaw to withstand the powerful action of the masticatory muscles; but the alveolar portion is the deeper of the two, and, consequently, the chief part of the body lies above the oblique line. The mandibular canal, after the second dentition, is situated just above the level of the mylohyoid line; and the mental foramen occupies the position usual to it in the adult. The angle becomes less obtuse, owing to the separation of the jaws by the teeth; about the fourth year it is 140° .

In the adult (Fig. 184) the alveolar and subdental portions of the body are usually of equal depth. The mental foramen opens midway between the upper and lower borders of the bone, and the mandibular canal runs nearly parallel with the mylohyoid line. The ramus is almost vertical in direction, the angle measuring from 110° to 120° .

In old age (Fig. 185) the bone becomes greatly reduced in size, for with the loss of the teeth the alveolar process is absorbed, and, consequently, the chief part of the bone is below the oblique line. The mandibular canal, with the mental foramen opening from it, is close to the alveolar border. The ramus is oblique in direction, the angle measures about 140° , and the neck of the condyle is more or less bent backward.

The Hyoid Bone (Os Hyoideum; Lingual Bone).

The **hyoid bone** is shaped like a horseshoe, and is suspended from the tips of the styloid processes of the temporal bones by the stylohyoid ligaments. It consists of five segments, viz., a **body**, two **greater cornua**, and two **lesser cornua**.

The Body or Basihyal (*corpus oss. hyoidei*).—The body or central part is of a quadrilateral form. Its **anterior surface** (Fig. 186) is convex and directed forward and upward. It is crossed in its upper half by a well-marked transverse ridge with a slight downward

convexity, and in many cases a vertical median ridge divides it into two lateral halves. The portion of the vertical ridge above the transverse line is present in a majority of specimens, but the lower portion is evident only in rare cases. The anterior surface gives insertion to the Geniohyoideus in the greater part of its extent both above and below the transverse ridge; a portion of the origin of the Hyoglossus notches the lateral

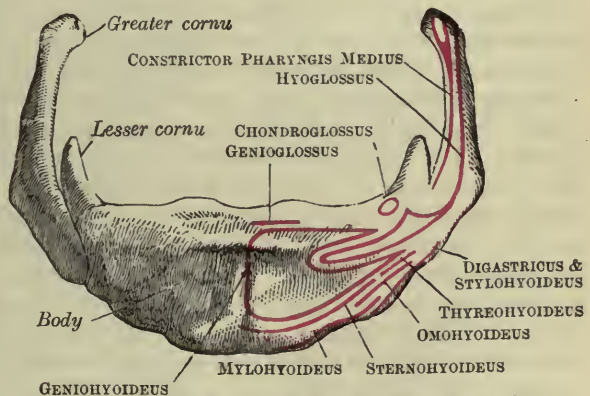


Fig. 186.—Hyoid bone. Anterior surface. Enlarged.

margin of the Geniohyoideus attachment. Below the transverse ridge the Mylohyoideus, Sternohyoideus, and Omohyoideus are inserted. The **posterior surface** is smooth, concave, directed backward and downward, and separated from the epiglottis by the hyothyroid membrane and a quantity of loose areolar tissue; a bursa intervenes between it and the hyothyroid membrane. The **superior border** is rounded, and gives attachment to the hyothyroid membrane and some aponeurotic fibers of the Genioglossus. The **inferior border** affords insertion medially to the Sternohyoideus and laterally to the Omohyoideus and occasionally a portion of the Thyreohyoideus. It also gives attachment to the Levator glandulæ thyreoideæ, when this muscle is present. In early life the **lateral borders** are connected to the greater cornua by sychondroses; after middle life usually by bony union.

The Greater Cornua or Thyrohyals (*cornua majora*).—The greater cornua project backward from the lateral borders of the body; they are flattened from above downward and diminish in size from before backward; each ends in a tubercle to which is fixed the lateral hyothyroid ligament. The **upper surface** is rough close to its lateral border, for muscular attachments: the largest of these are the origins of the Hyoglossus and Constrictor pharyngis medius which extend along the whole length of the cornu; the Digastricus and Stylohyoideus have small insertions in front of these near the junction of the body with the cornu. To the **medial border** the hyothyroid membrane is attached, while the anterior half of the **lateral border** gives insertion to the Thyreohyoideus.

The Lesser Cornua or Ceratohyals (*cornua minora*).—The lesser cornua are two small, conical eminences, attached by their bases to the angles of junction between the body and greater cornua. They are connected to the body of the bone by fibrous tissue, and occasionally to the greater cornua by distinct diarthrodial joints, which usually persist throughout life, but occasionally become ankylosed.

The lesser cornua are situated in the line of the transverse ridge on the body and appear to be morphological continuations of it (Parsons¹). The apex of each cornu gives attachment to the stylohyoid ligament;² the Chondroglossus rises from the medial side of the base.

Ossification.—The hyoid is ossified from *six* centers: two for the body, and one for each cornu. Ossification commences in the greater cornua toward the end of fetal life, in the body shortly afterward, and in the lesser cornua during the first or second year after birth.

THE EXTERIOR OF THE SKULL.

The skull as a whole may be viewed from different points, and the views so obtained are termed the **normæ** of the skull; thus, it may be examined from above (**norma verticalis**), from below (**norma basalis**), from the side (**norma lateralis**), from behind (**norma occipitalis**), or from the front (**norma frontalis**).

Norma Verticalis.—When viewed from above the outline presented varies greatly in different skulls; in some it is more or less oval, in others more nearly circular. The surface is traversed by three sutures, viz.: (1) the **coronal sutures**, nearly transverse in direction, between the frontal and parietals; (2) the **sagittal sutures**, medially placed, between the parietal bones, and deeply serrated in its anterior two-thirds; and (3) the upper part of the **lambdoidal suture**, between the parietals and the occipital. The point of junction of the sagittal and coronal suture is named the **bregma**, that of the sagittal and lambdoid sutures, the **lambda**; they indicate respectively the positions of the anterior and posterior fontanelles in the fetal skull. On either side of the sagittal suture are the **parietal eminence** and **parietal foramen**—the latter, however, is frequently absent on one or both sides. The skull is often somewhat flattened in the neighborhood of the parietal foramina, and the term **obelion** is applied to that point of the sagittal suture which is on a level with the foramina. In front is the **glabella**, and on its lateral aspects are the **superciliary arches**, and above these the **frontal eminences**. Immediately above the glabella may be seen the remains of the **frontal suture**; in a small percentage of skulls this suture persists and extends along the middle line to the bregma. Passing backward and upward from the zygomatic processes of the frontal bone are the **temporal lines**, which mark the upper limits of the temporal fossæ. The zygomatic arches may or may not be seen projecting beyond the anterior portions of these lines.

¹ See article on "The Topography and Morphology of the Human Hyoid Bone," by F. G. Parsons, *Journal of Anatomy and Physiology*, vol. xliii.

² These ligaments in many animals are distinct bones, and in man may undergo partial ossification.

Norma Basalis (Fig. 187).—The inferior surface of the base of the skull, exclusive of the mandible, is bounded in front by the incisor teeth in the maxillæ; behind,

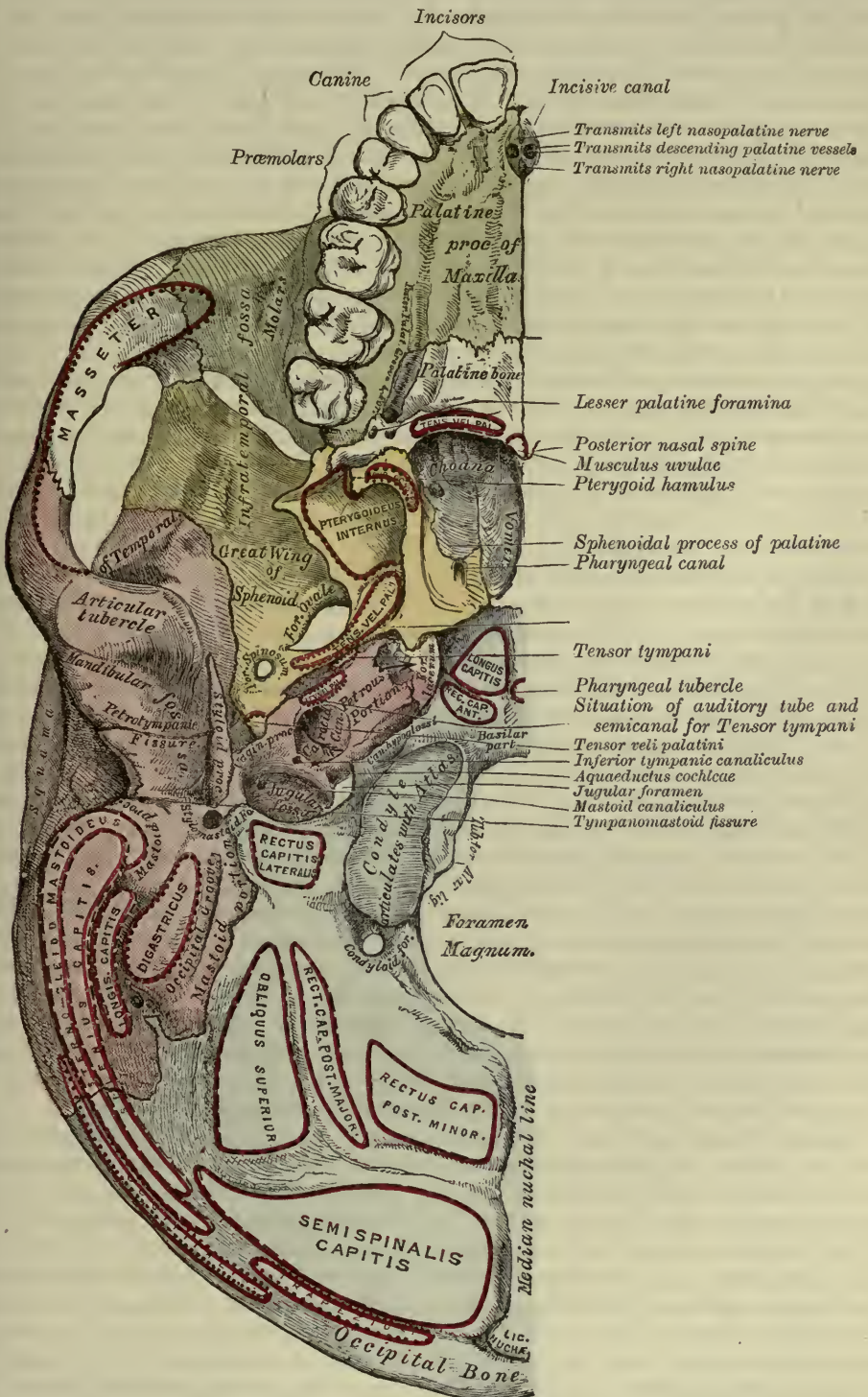


FIG. 187.—Base of skull. Inferior surface.

by the superior nuchal lines of the occipital; and laterally by the alveolar arch, the lower border of the zygomatic bone, the zygomatic arch and an imaginary line extending from it to the mastoid process and extremity of the superior nuchal line of the occipital. It is formed by the palatine processes of the maxillæ and palatine bones, the vomer, the pterygoid processes, the under surfaces of the great wings, spinous processes, and part of the body of the sphenoid, the under surfaces of the squamæ and mastoid and petrous portions of the temporals, and the under surface of the occipital bone. The anterior part or hard palate projects below the level of the rest of the surface, and is bounded in front and laterally by the alveolar arch containing the sixteen teeth of the maxillæ. Immediately behind the incisor teeth is the **incisive foramen**. In this foramen are two lateral apertures, the openings of the **incisive canals** (*foramina of Stenson*) which transmit the anterior branches of the descending palatine vessels, and the nasopalatine nerves. Occasionally two additional canals are present in the incisive foramen; they are termed the **foramina of Scarpa** and are situated in the middle line; when present they transmit the nasopalatine nerves. The vault of the hard palate is concave, uneven, perforated by numerous foramina, marked by depressions for the palatine glands, and traversed by a crucial suture formed by the junction of the four bones of which it is composed. In the young skull a suture may be seen extending on either side from the incisive foramen to the interval between the lateral incisor and canine teeth, and marking off the os incisivum or premaxillary bone. At either posterior angle of the hard palate is the **greater palatine foramen**, for the transmission of the descending palatine vessels and anterior palatine nerve; and running forward and medialward from it a groove, for the same vessels and nerve. Behind the posterior palatine foramen is the **pyramidal process of the palatine bone**, perforated by one or more **lesser palatine foramina**, and marked by the commencement of a transverse ridge, for the attachment of the tendinous expansion of the Tensor veli palatini. Projecting backward from the center of the posterior border of the hard palate is the **posterior nasal spine**, for the attachment of the Musculus uvulæ. Behind and above the hard palate are the **choanæ**, measuring about 2.5 cm. in their vertical and 1.25 cm. in their transverse diameters. They are separated from one another by the vomer, and each is bounded above by the body of the sphenoid, below by the horizontal part of the palatine bone, and laterally by the medial pterygoid plate of the sphenoid. At the superior border of the vomer may be seen the expanded alæ of this bone, receiving between them the rostrum of the sphenoid. Near the lateral margins of the alæ of the vomer, at the roots of the pterygoid processes, are the **pharyngeal canals**. The pterygoid process presents near its base the **pterygoid canal**, for the transmission of a nerve and artery. The medial pterygoid plate is long and narrow; on the lateral side of its base is the **scaphoid fossa**, for the origin of the Tensor veli palatini, and at its lower extremity the **hamulus**, around which the tendon of this muscle turns. The lateral pterygoid plate is broad; its lateral surface forms the medial boundary of the infratemporal fossa, and affords attachment to the Pterygoideus externus.

Behind the nasal cavities is the basilar portion of the occipital bone, presenting near its center the **pharyngeal tubercle** for the attachment of the fibrous raphé of the pharynx, with depressions on either side for the insertions of the Rectus capitis anterior and Longus capitis. At the base of the lateral pterygoid plate is the **foramen ovale**, for the transmission of the mandibular nerve, the accessory meningeal artery, and sometimes the lesser superficial petrosal nerve; behind this are the **foramen spinosum** which transmits the middle meningeal vessels, and the prominent **spina angularis** (*sphenoidal spine*), which gives attachment to the sphenomandibular ligament and the Tensor veli palatini. Lateral to the spina angularis is the **mandibular fossa**, divided into two parts by the **petrotympanic fissure**; the anterior portion, concave, smooth, bounded in front by the **articular tubercle**,

serves for the articulation of the condyle of the mandible; the posterior portion, rough and bounded behind by the tympanic part of the temporal, is sometimes occupied by a part of the parotid gland. Emerging from between the laminae of the vaginal process of the tympanic part is the **styloid process**; and at the base of this process is the **stylomastoid foramen**, for the exit of the facial nerve, and entrance of the stylomastoid artery. Lateral to the stylomastoid foramen, between the tympanic part and the mastoid process, is the **tympanomastoid fissure**, for the auricular branch of the vagus. Upon the medial side of the mastoid process is the **mastoid notch** for the posterior belly of the Digastricus, and medial to the notch, the **occipital groove** for the occipital artery. At the base of the medial pterygoid plate is a large and somewhat triangular aperture, the **foramen lacerum**, bounded in front by the great wing of the sphenoid, behind by the apex of the petrous portion of the temporal bone, and medially by the body of the sphenoid and basilar portion of the occipital bone; it presents in front the posterior orifice of the **pterygoid canal**; behind, the aperture of the **carotid canal**. The lower part of this opening is filled up in the fresh state by a fibrocartilaginous plate, across the upper or cerebral surface of which the internal carotid artery passes. Lateral to this aperture is a groove, the **sulcus tubæ auditivæ**, between the petrous part of the temporal and the great wing of the sphenoid. This sulcus is directed lateralward and backward from the root of the medial pterygoid plate and lodges the cartilaginous part of the auditory tube; it is continuous behind with the canal in the temporal bone which forms the bony part of the same tube. At the bottom of this sulcus is a narrow cleft, the **petrosphenoidal fissure**, which is occupied, in the fresh condition, by a plate of cartilage. Behind this fissure is the under surface of the petrous portion of the temporal bone, presenting, near its apex, the quadrilateral rough surface, part of which affords attachment to the Levator veli palatini; lateral to this surface is the orifice of the **carotid canal**, and medial to it, the depression leading to the **aquæductus cochleæ**, the former transmitting the internal carotid artery and the carotid plexus of the sympathetic, the latter serving for the passage of a vein from the cochlea. Behind the carotid canal is the **jugular foramen**, a large aperture, formed in front by the petrous portion of the temporal, and behind by the occipital; it is generally larger on the right than on the left side, and may be subdivided into three compartments. The anterior compartment transmits the inferior petrosal sinus; the intermediate, the glossopharyngeal, vagus, and accessory nerves; the posterior, the transverse sinus and some meningeal branches from the occipital and ascending pharyngeal arteries. On the ridge of bone dividing the carotid canal from the jugular foramen is the **inferior tympanic canaliculus** for the transmission of the tympanic branch of the glossopharyngeal nerve; and on the wall of the jugular foramen, near the root of the styloid process, is the **mastoid canaliculus** for the passage of the auricular branch of the vagus nerve. Extending forward from the jugular foramen to the foramen lacerum is the **petrooccipital fissure** occupied, in the fresh state, by a plate of cartilage. Behind the basilar portion of the occipital bone is the **foramen magnum**, bounded laterally by the occipital condyles, the medial sides of which are rough for the attachment of the alar ligaments. Lateral to each condyle is the **jugular process** which gives attachment to the Rectus capitis lateralis muscle and the lateral atlantooccipital ligament. The foramen magnum transmits the medulla oblongata and its membranes, the accessory nerves, the vertebral arteries, the anterior and posterior spinal arteries, and the ligaments connecting the occipital bone with the axis. The mid-points on the anterior and posterior margins of the foramen magnum are respectively termed the **basion** and the **opisthion**. In front of each condyle is the canal for the passage of the hypoglossal nerve and a meningeal artery. Behind each condyle is the **condyloid fossa**, perforated on one or both sides by the condyloid canal, for the transmission of a vein from the transverse sinus. Behind the foramen magnum

is the **median nuchal line** ending above at the **external occipital protuberance**, while on either side are the **superior and inferior nuchal lines**; these, as well as the surfaces of bone between them, are rough for the attachment of the muscles which are enumerated on pages 129 and 130.

Norma Lateralis (Fig. 188).—When viewed from the side the skull is seen to consist of the cranium above and behind, and of the face below and in front. The cranium is somewhat ovoid in shape, but its contour varies in different cases and depends largely on the length and height of the skull and on the degree of prominence of the superciliary arches and frontal eminences. Entering into its formation are the frontal, the parietal, the occipital, the temporal, and the great wing of the

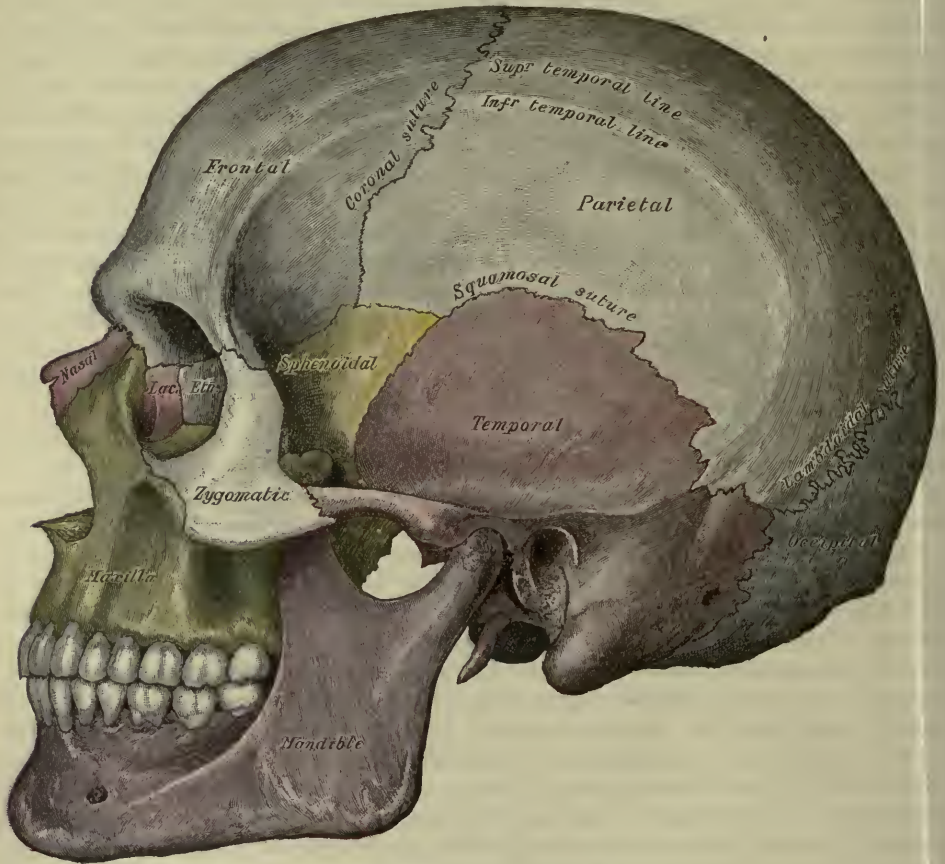


FIG. 188.—Side view of the skull.

sphenoid. These bones are joined to one another and to the zygomatic by the following sutures: the **zygomaticotemporal** between the zygomatic process of the temporal and the temporal process of the zygomatic; the **zygomaticofrontal** uniting the zygomatic bone with the zygomatic process of the frontal; the sutures surrounding the great wing of the sphenoid, viz., the **sphenozygomatic** in front, the **sphenofrontal** and **sphenoparietal** above, and the **sphenosquamosal** behind. The sphenoparietal suture varies in length in different skulls, and is absent in those cases where the frontal articulates with the temporal squama. The point corresponding with the posterior end of the sphenoparietal suture is named the **pterion**; it is situated about 3 cm. behind, and a little above the level of the zygomatic process of the frontal bone.

The **squamosal suture** arches backward from the pterion and connects the temporal squama with the lower border of the parietal: this suture is continuous behind with the short, nearly horizontal **parietomastoid suture**, which unites the mastoid process of the temporal with the region of the mastoid angle of the parietal. Extending from above downward and forward across the cranium are the **coronal** and **lambdoidal sutures**; the former connects the parietals with the frontal, the latter, the parietals with the occipital. The lambdoidal suture is continuous below with the **occipitomastoid suture** between the occipital and the mastoid portion of the temporal. In or near the last suture is the **mastoid foramen**, for the transmission of an emissary vein. The point of meeting of the parietomastoid, occipitomastoid, and lambdoidal sutures is known as the **asterion**. Immediately above the orbital margin is the **superciliary arch**, and, at a higher level, the **frontal eminence**. Near the center of the parietal bone is the **parietal eminence**. Posteriorly is the **external occipital protuberance**, from which the superior nuchal line may be followed forward to the mastoid process. Arching across the side of the cranium are the **temporal lines**, which mark the upper limit of the temporal fossa.

The Temporal Fossa (*fossa temporalis*).—The temporal fossa is bounded above and behind by the temporal lines, which extend from the zygomatic process of the frontal bone upward and backward across the frontal and parietal bones, and then curve downward and forward to become continuous with the supramastoid crest and the posterior root of the zygomatic arch. The point where the upper temporal line cuts the coronal suture is named the **stephanion**. The temporal fossa is bounded in front by the frontal and zygomatic bones, and opening on the back of the latter is the **zygomaticotemporal foramen**. *Laterally* the fossa is limited by the zygomatic arch, formed by the zygomatic and temporal bones; *below*, it is separated from the infratemporal fossa by the **infratemporal crest** on the great wing of the sphenoid, and by a ridge, continuous with this crest, which is carried backward across the temporal squama to the anterior root of the zygomatic process. In front and below, the fossa communicates with the orbital cavity through the **inferior orbital** or **sphenomaxillary fissure**. The floor of the fossa is deeply concave in front and convex behind, and is formed by the zygomatic, frontal, parietal, sphenoid, and temporal bones. It is traversed by vascular furrows; one, usually well-marked, runs upward above and in front of the external acoustic meatus, and lodges the middle temporal artery. Two others, frequently indistinct, may be observed on the anterior part of the floor, and are for the anterior and posterior deep temporal arteries. The temporal fossa contains the Temporalis muscle and its vessels and nerves, together with the zygomaticotemporal nerve.

The **zygomatic arch** is formed by the zygomatic process of the temporal and the temporal process of the zygomatic, the two being united by an oblique suture; the tendon of the Temporalis passes medial to the arch to gain insertion into the coronoid process of the mandible. The zygomatic process of the temporal arises by two roots, an anterior, directed inward in front of the mandibular fossa, where it expands to form the articular tubercle, and a posterior, which runs backward above the external acoustic meatus and is continuous with the supramastoid crest. The upper border of the arch gives attachment to the temporal fascia; the lower border and medial surface give origin to the Masseter.

Below the posterior root of the zygomatic arch is the elliptical orifice of the **external acoustic meatus**, bounded in front, below, and behind by the tympanic part of the temporal bone; to its outer margin the cartilaginous segment of the external acoustic meatus is attached. The small triangular area between the posterior root of the zygomatic arch and the postero-superior part of the orifice is termed the **suprameatal triangle**, on the anterior border of which a small spinous process, the **suprameatal spine**, is sometimes seen. Between the tympanic part and the articular tubercle is the **mandibular fossa**, divided into two parts by the

petrotympanic fissure. The anterior and larger part of the fossa articulates with the condyle of the mandible and is limited behind by the external acoustic meatus; the posterior part sometimes lodges a portion of the parotid gland. The styloid process extends downward and forward for a variable distance from the lower part of the tympanic part, and gives attachment to the Styloglossus, Stylohyoideus, and Stylopharyngeus, and to the stylohyoid and stylomandibular ligaments. Projecting downward behind the external acoustic meatus is the mastoid process, to the outer surface of which the Sternocleidomastoideus, Splenius capitis, and Longissimus capitis are attached.

The Infratemporal Fossa (*fossa infratemporalis*; *zygomatic fossa*) (Fig. 189).—The infratemporal fossa is an irregularly shaped cavity, situated below and medial to the zygomatic arch. It is bounded, in *front*, by the infratemporal surface of the maxilla

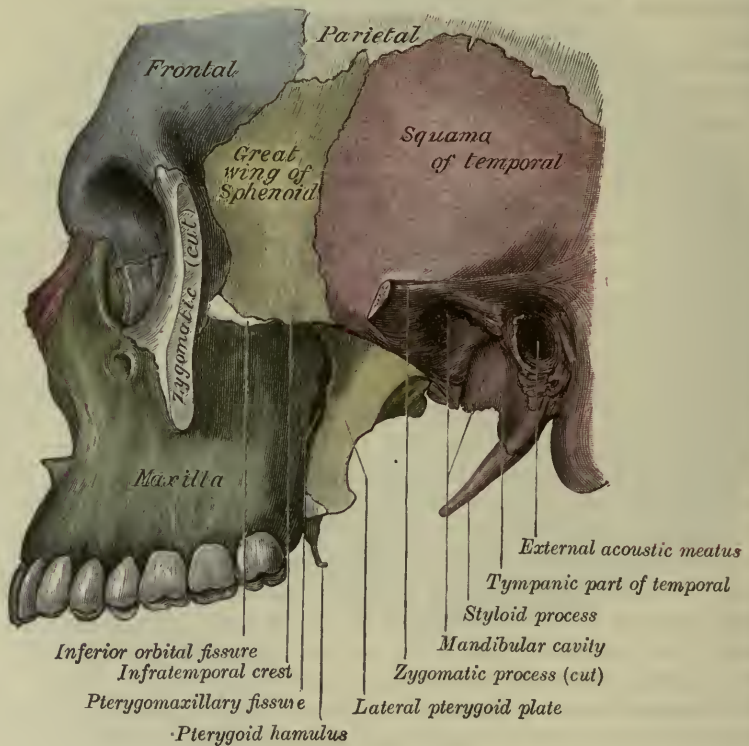


FIG. 189.—Left infratemporal fossa.

and the ridge which descends from its zygomatic process; *behind*, by the articular tubercle of the temporal and the spina angularis of the sphenoid; *above*, by the great wing of the sphenoid below the infratemporal crest, and by the under surface of the temporal squama; *below*, by the alveolar border of the maxilla; *medially*, by the lateral pterygoid plate. It contains the lower part of the Temporalis, the Pterygoidei internus and externus, the internal maxillary vessels, and the mandibular and maxillary nerves. The foramen ovale and foramen spinosum open on its roof, and the alveolar canals on its anterior wall: At its upper and medial part are two fissures, which together form a T-shaped fissure, the horizontal limb being named the inferior orbital, and the vertical one the pterygomaxillary.

The **inferior orbital fissure** (*fissura orbitalis inferior*; *sphenomaxillary fissure*), horizontal in direction, opens into the lateral and back part of the orbit. It is bounded *above* by the lower border of the orbital surface of the great wing of the

sphenoid; *below*, by the lateral border of the orbital surface of the maxilla and the orbital process of the palatine bone; *laterally*, by a small part of the zygomatic bone;¹ *medially*, it joins at right angles with the pterygomaxillary fissure. Through the inferior orbital fissure the orbit communicates with the temporal, infratemporal, and pterygopalatine fossæ; the fissure transmits the maxillary nerve and its zygomatic branch, the infraorbital vessels, the ascending branches from the sphenopalatine ganglion, and a vein which connects the inferior ophthalmic vein with the pterygoid venous plexus.

The **pterygomaxillary fissure** is vertical, and descends at right angles from the medial end of the preceding; it is a triangular interval, formed by the divergence of the maxilla from the pterygoid process of the sphenoid. It connects the infratemporal with the pterygopalatine fossa, and transmits the terminal part of the internal maxillary artery.

The Pterygopalatine Fossa (*fossa pterygopalatina; sphenomaxillary fossa*).—The pterygopalatine fossa is a small, triangular space at the angle of junction of the inferior orbital and pterygomaxillary fissures, and placed beneath the apex of the orbit. It is bounded *above* by the under surface of the body of the sphenoid and by the orbital process of the palatine bone; *in front*, by the infratemporal surface of the maxilla; *behind*, by the base of the pterygoid process and lower part of the anterior surface of the great wing of the sphenoid; *medially*, by the vertical part of the palatine bone with its orbital and sphenoidal processes. This fossa communicates with the orbit by the inferior orbital fissure, with the nasal cavity by the sphenopalatine foramen, and with the infratemporal fossa by the pterygomaxillary fissure. Five foramina open into it. Of these, three are on the posterior wall, viz., the **foramen rotundum**, the **pterygoid canal**, and the **pharyngeal canal**, in this order downward and medialward. On the medial wall is the **sphenopalatine foramen**, and below is the superior orifice of the **pterygopalatine canal**. The fossa contains the maxillary nerve, the sphenopalatine ganglion, and the terminal part of the internal maxillary artery.

Norma Occipitalis.—When viewed from behind the cranium presents a more or less circular outline. In the middle line is the posterior part of the **sagittal suture** connecting the parietal bones; extending downward and lateralward from the hinder end of the sagittal suture is the deeply serrated **lambdoidal suture** joining the parietals to the occipital and continuous below with the **parietomastoid** and **occipitomastoid sutures**; it frequently contains one or more sutural bones. Near the middle of the occipital squama is the **external occipital protuberance** or **inion**, and extending lateralward from it on either side is the superior nuchal line, and above this the faintly marked highest nuchal line. The part of the squama above the inion and highest lines is named the **planum occipitale**, and is covered by the Occipitalis muscle; the part below is termed the **planum nuchale**, and is divided by the median nuchal line which runs downward and forward from the inion to the foramen magnum; this ridge gives attachment to the ligamentum nuchæ. The muscles attached to the planum nuchale are enumerated on p. 130. Below and in front are the mastoid processes, convex laterally and grooved medially by the mastoid notches. In or near the occipitomastoid suture is the **mastoid foramen** for the passage of the mastoid emissary vein.

Norma Frontalis (Fig. 190).—When viewed from the front the skull exhibits a somewhat oval outline, limited *above* by the frontal bone, *below* by the body of the mandible, and *laterally* by the zygomatic bones and the mandibular rami. The upper part, formed by the frontal squama, is smooth and convex. The lower part, made up of the bones of the face, is irregular; it is excavated laterally by the orbital cavities, and presents in the middle line the **anterior nasal aperture** leading to the

¹ Occasionally the maxilla and the sphenoid articulate with each other at the anterior extremity of this fissure; the zygomatic is then excluded from it.

nasal cavities, and below this the transverse slit between the upper and lower dental arcades. *Above*, the **frontal eminences** stand out more or less prominently, and beneath these are the **superciliary arches**, joined to one another in the middle by the **glabella**. On and above the glabella a trace of the **frontal suture** sometimes persists; beneath it is the frontonasal suture, the mid-point of which is termed the **nasion**. Behind and below the frontonasal suture the frontal articulates with the frontal process of the maxilla and with the lacrimal. Arching transversely below the superciliary arches is the upper part of the margin of the orbit, thin and promi-

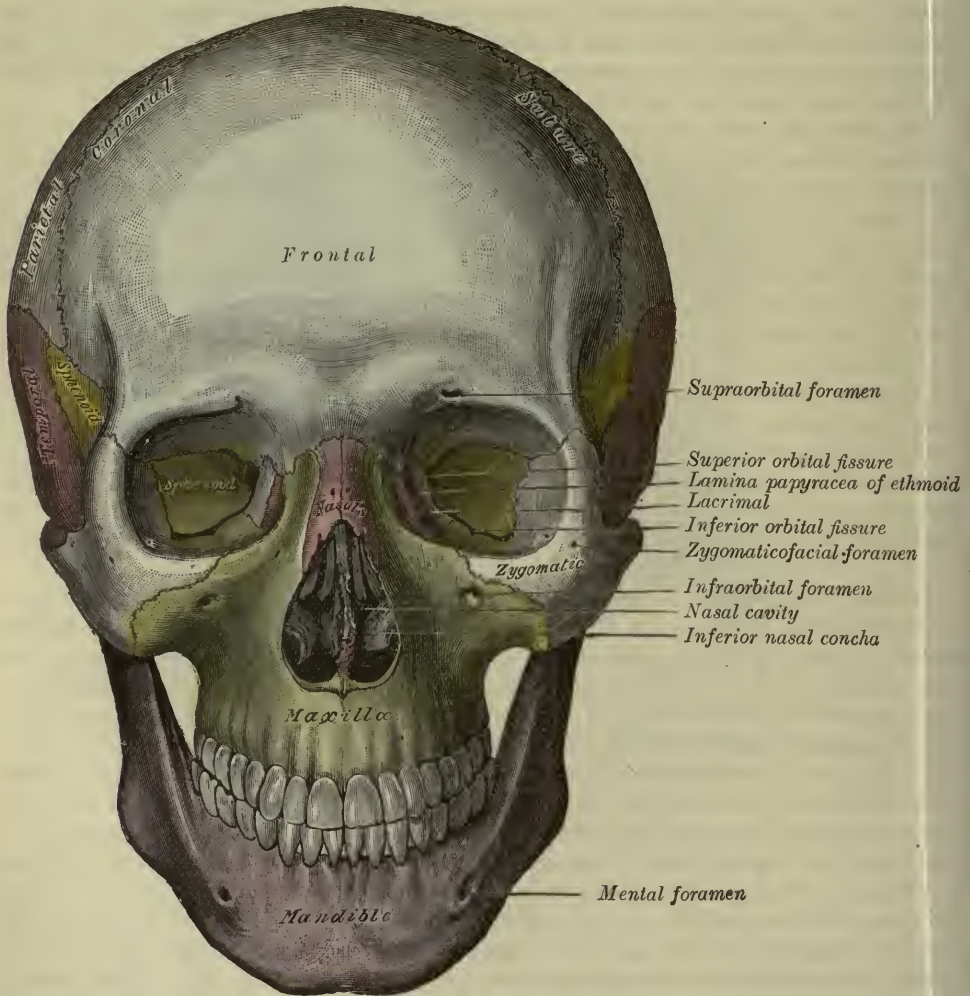


FIG. 190.—The skull from the front.

nent in its lateral two-thirds, rounded in its medial third, and presenting, at the junction of these two portions, the **supraorbital notch or foramen** for the supra-orbital nerve and vessels. The supraorbital margin ends laterally in the zygomatic process which articulates with the zygomatic bone, and from it the temporal line extends upward and backward. Below the frontonasal suture is the bridge of the nose, convex from side to side, concavo-convex from above downward, and formed by the two nasal bones supported in the middle line by the perpendicular plate of the ethmoid, and laterally by the frontal processes of the maxillæ which are prolonged upward between the nasal and lacrimal bones and form the lower and

medial part of the circumference of each orbit. Below the nasal bones and between the maxillæ is the anterior aperture of the nose, pyriform in shape, with the narrow end directed upward. Laterally this opening is bounded by sharp margins, to which the lateral and alar cartilages of the nose are attached; *below*, the margins are thicker and curve medialward and forward to end in the **anterior nasal spine**. On looking into the nasal cavity, the bony septum which separates the nasal cavities presents, in front, a large triangular deficiency; this, in the fresh state, is filled up by the cartilage of the nasal septum; on the lateral wall of each nasal cavity the anterior part of the inferior nasal concha is visible. Below and lateral to the anterior nasal aperture are the anterior surfaces of the maxillæ, each perforated, near the lower margin of the orbit, by the **infraorbital foramen** for the

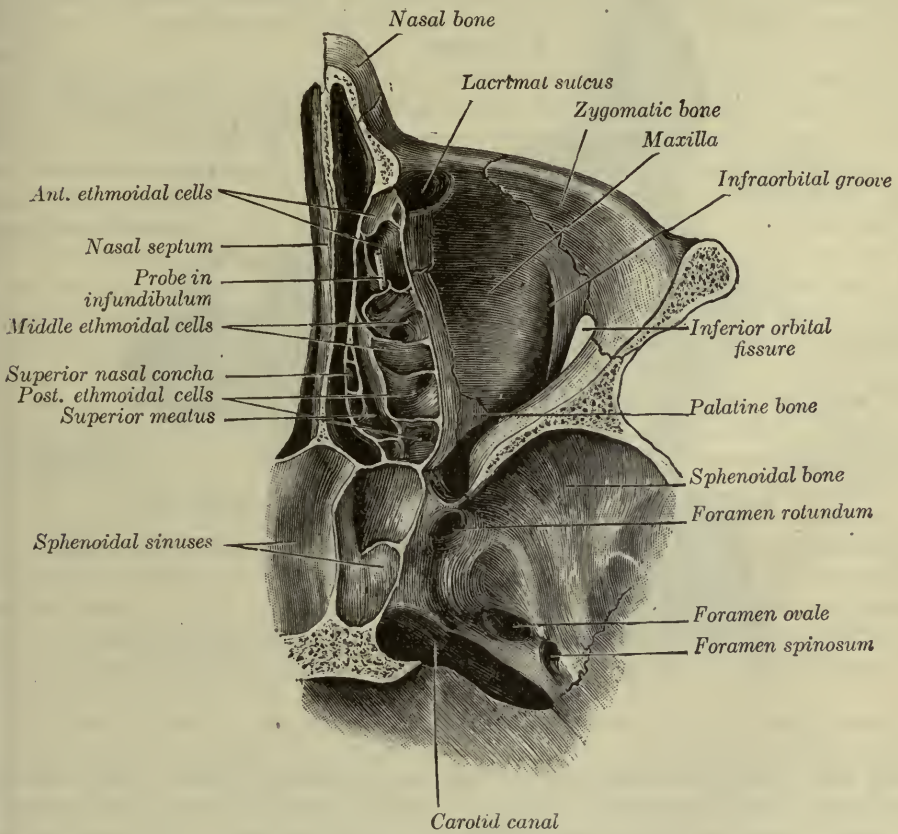


FIG. 191.—Horizontal section of nasal and orbital cavities.

passage of the infraorbital nerve and vessels. Below and medial to this foramen is the canine eminence separating the incisive from the canine fossa. Beneath these fossæ are the alveolar processes of the maxillæ containing the upper teeth, which overlap the teeth of the mandible in front. The zygomatic bone on either side forms the prominence of the cheek, the lower and lateral portion of the orbital cavity, and the anterior part of the zygomatic arch. It articulates medially with the maxilla, behind with the zygomatic process of the temporal, and above with the great wing of the sphenoid and the zygomatic process of the frontal; it is perforated by the **zygomaticofacial foramen** for the passage of the zygomaticofacial nerve. On the body of the mandible is a median ridge, indicating the position of the symphysis; this ridge divides below to enclose the mental protuberance, the lateral angles of which constitute the mental tubercles. Below the incisor teeth

is the **incisive fossa**, and beneath the second premolar tooth the **mental foramen** which transmits the mental nerve and vessels. The oblique line runs upward from the mental tubercle and is continuous behind with the anterior border of the ramus. The posterior border of the ramus runs downward and forward from the condyle to the angle, which is frequently more or less everted.

The Orbits (*orbitæ*) (Fig. 190).—The orbits are two quadrilateral pyramidal cavities, situated at the upper and anterior part of the face, their bases being directed forward and lateralward, and their apices backward and medialward, so that their long axes, if continued backward, would meet over the body of the sphenoid. Each presents for examination a **roof**, a **floor**, a **medial** and a **lateral wall**, a **base**, and an **apex**.

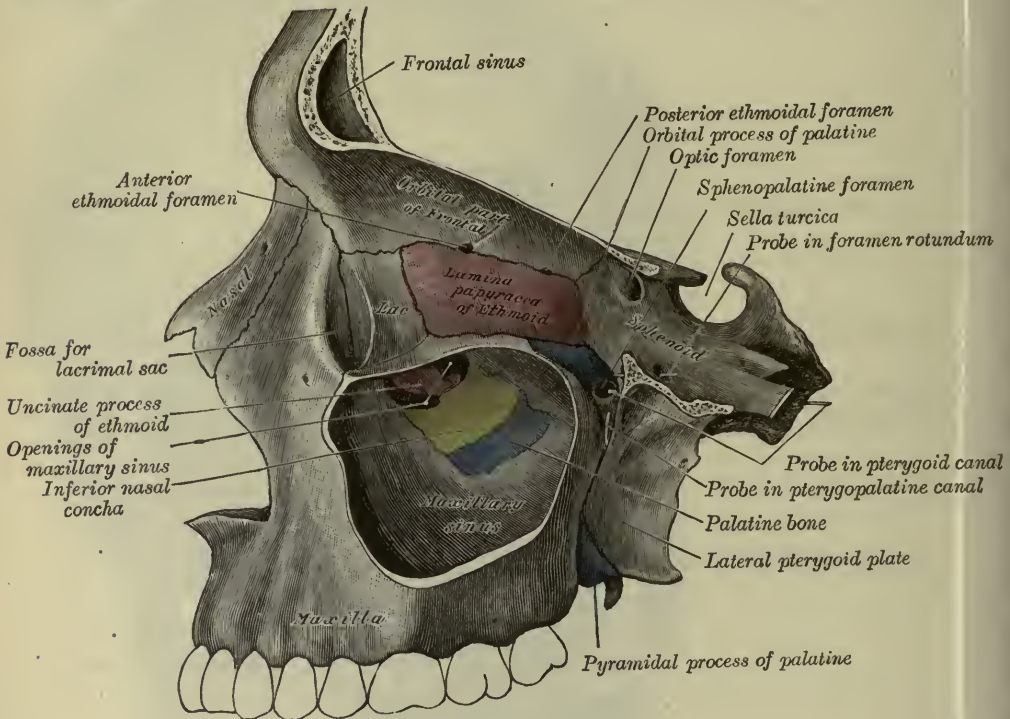


FIG. 192.—Medial wall of left orbit.

The **roof** is concave, directed downward, and slightly forward, and formed in *front* by the orbital plate of the frontal; *behind* by the small wing of the sphenoid. It presents *medially* the **trochlear fovea** for the attachment of the cartilaginous pulley of the *Obliquus oculi superior*; *laterally*, the **lacrimal fossa** for the lacrimal gland; and *posteriorly*, the suture between the frontal bone and the small wing of the sphenoid.

The **floor** is directed upward and lateralward, and is of less extent than the roof; it is formed chiefly by the orbital surface of the maxilla; in *front* and *laterally*, by the orbital process of the zygomatic bone, and *behind* and *medially*, to a small extent, by the orbital process of the palatine. At its medial angle is the upper opening of the nasolacrimal canal, immediately to the lateral side of which is a depression for the origin of the *Obliquus oculi inferior*. On its lateral part is the suture between the maxilla and zygomatic bone, and at its posterior part that between the maxilla and the orbital process of the palatine. Running forward near the middle of the floor is the **infraorbital groove**, ending in front in the **infraorbital canal** and transmitting the **infraorbital nerve** and vessels.

The **medial wall** (Fig. 192) is nearly vertical, and is formed from before backward by the frontal process of the maxilla, the lacrimal, the lamina papyracea of the ethmoid, and a small part of the body of the sphenoid in front of the optic foramen. Sometimes the sphenoidal concha forms a small part of this wall (see page 152). It exhibits three vertical sutures, viz., the lacrimomaxillary, lacrimoethmoidal, and sphenoeethmoidal. In front is seen the **lacrimal groove**, which lodges the lacrimal sac, and behind the groove is the **posterior lacrimal crest**, from which the lacrimal part of the Orbicularis oculi arises. At the junction of the medial wall and the roof are the frontomaxillary, frontolacrimal, frontoethmoidal, and sphenofrontal sutures. The point of junction of the anterior border of the lacrimal with the frontal is named the **dacryon**. In the frontoethmoidal suture are the **anterior and posterior ethmoidal foramina**, the former transmitting the nasociliary nerve and anterior ethmoidal vessels, the latter the posterior ethmoidal nerve and vessels.

The **lateral wall**, directed medialward and forward, is formed by the orbital process of the zygomatic and the orbital surface of the great wing of the sphenoid; these are united by the sphenozygomatic suture which terminates below at the front end of the inferior orbital fissure. On the orbital process of the zygomatic bone are the orbital tubercle (Whitnall) and the orifices of one or two canals which transmit the branches of the zygomatic nerve. Between the roof and the lateral wall, near the apex of the orbit, is the **superior orbital fissure**. Through this fissure the oculomotor, the trochlear, the ophthalmic division of the trigeminal, and the abducent nerves enter the orbital cavity, also some filaments from the cavernous plexus of the sympathetic and the orbital branches of the middle meningeal artery. Passing backward through the fissure are the ophthalmic vein and the recurrent branch from the lacrimal artery to the dura mater. The lateral wall and the floor are separated posteriorly by the **inferior orbital fissure** which transmits the maxillary nerve and its zygomatic branch, the infraorbital vessels, and the ascending branches from the sphenopalatine ganglion.

The **base** of the orbit, quadrilateral in shape, is formed *above* by the supra-orbital arch of the frontal bone, in which is the **supraorbital notch or foramen** for the passage of the supraorbital vessels and nerve; *below* by the zygomatic bone and maxilla, united by the zygomaticomaxillary suture; laterally by the zygomatic bone and the zygomatic process of the frontal joined by the zygomaticofrontal suture; medially by the frontal bone and the frontal process of the maxilla united by the frontomaxillary suture.

The **apex**, situated at the back of the orbit, corresponds to the optic foramen¹ a short, cylindrical canal, which transmits the optic nerve and ophthalmic artery.

It will thus be seen that there are nine openings communicating with each orbit, viz., the optic foramen, superior and inferior orbital fissures, supraorbital foramen, infraorbital canal, anterior and posterior ethmoidal foramina, zygomatic foramen, and the canal for the nasolacrimal duct.

THE INTERIOR OF THE SKULL.

Inner Surface of the Skull-cap.—The inner surface of the skull-cap is concave and presents depressions for the convolutions of the cerebrum, together with numerous furrows for the lodgement of branches of the meningeal vessels. Along the middle line is a longitudinal groove, narrow in front, where it commences at the frontal crest, but broader behind; it lodges the superior sagittal sinus, and its margins afford attachment to the falx cerebri. On either side of it are several

¹ Some anatomists describe the apex of the orbit as corresponding with the medial end of the superior orbital fissure. It seems better, however, to adopt the statement in the text, since the ocular muscles take origin around the optic foramen, and diverge from it to the bulb of the eye.

depressions for the arachnoid granulations, and at its back part, the openings of the **parietal foramina** when these are present. It is crossed, in front, by the **coronal suture**, and behind by the **lambdaoidal**, while the **sagittal** lies in the medial plane between the parietal bones.

Upper Surface of the Base of the Skull (Fig. 193).—The upper surface of the base of the skull or floor of the cranial cavity presents three fossæ, called the **anterior**, **middle**, and **posterior cranial fossæ**.

Anterior Fossa (*fossa cranii anterior*).—The floor of the anterior fossa is formed by the orbital plates of the frontal, the cribriform plate of the ethmoid, and the small wings and front part of the body of the sphenoid; it is limited behind by the posterior borders of the small wings of the sphenoid and by the anterior margin of the chiasmatic groove. It is traversed by the **frontoethmoidal**, **sphenoethmoidal**, and **sphenofrontal sutures**. Its lateral portions roof in the orbital cavities and support the frontal lobes of the cerebrum; they are convex and marked by depressions for the brain convolutions, and grooves for branches of the meningeal vessels. The central portion corresponds with the roof of the nasal cavity, and is markedly depressed on either side of the crista galli. It presents, in and near the median line, from before backward, the commencement of the **frontal crest** for the attachment of the falx cerebri; the **foramen cecum**, between the frontal bone and the crista galli of the ethmoid, which usually transmits a small vein from the nasal cavity to the superior sagittal sinus; behind the foramen cecum, the **crista galli**, the free margin of which affords attachment to the falx cerebri; on either side of the crista galli, the **olfactory groove** formed by the cribriform plate, which supports the olfactory bulb and presents foramina for the transmission of the olfactory nerves, and in front a slit-like opening for the nasociliary nerve. Lateral to either olfactory groove are the internal openings of the **anterior** and **posterior ethmoidal foramina**; the anterior, situated about the middle of the lateral margin of the olfactory groove, transmits the anterior ethmoidal vessels and the nasociliary nerve; the nerve runs in a groove along the lateral edge of the cribriform plate to the slit-like opening above mentioned; the posterior ethmoidal foramen opens at the back part of this margin under cover of the projecting lamina of the sphenoid, and transmits the posterior ethmoidal vessels and nerve. Farther back in the middle line is the **ethmoidal spine**, bounded behind by a slight elevation separating two shallow longitudinal grooves which support the olfactory lobes. Behind this is the anterior margin of the chiasmatic groove, running lateralward on either side to the upper margin of the optic foramen.

The Middle Fossa (*fossa cranii media*).—The middle fossa, deeper than the preceding, is narrow in the middle, and wide at the sides of the skull. It is bounded in *front* by the posterior margins of the small wings of the sphenoid, the anterior clinoid processes, and the ridge forming the anterior margin of the chiasmatic groove; *behind*, by the superior angles of the petrous portions of the temporals and the dorsum sellæ; *laterally* by the temporal squamæ, sphenoidal angles of the parietals, and great wings of the sphenoid. It is traversed by the **squamosal**, **sphenoparietal**, **sphenosquamosal**, and **sphenopetrosal sutures**.

The middle part of the fossa presents, in *front*, the **chiasmatic groove** and **tuberculum sellæ**; the chiasmatic groove ends on either side at the **optic foramen**, which transmits the optic nerve and ophthalmic artery to the orbital cavity. Behind the optic foramen the **anterior clinoid process** is directed backward and medialward and gives attachment to the tentorium cerebelli. Behind the tuberculum sellæ is a deep depression, the **sella turcica**, containing the **fossa hypophyseos**, which lodges the hypophysis, and presents on its anterior wall the **middle clinoid processes**. The sella turcica is bounded posteriorly by a quadrilateral plate of bone, the **dorsum sellæ**, the upper angles of which are surmounted by the **posterior clinoid processes**: these afford attachment to the tentorium cerebelli, and below each is a notch for

the abducent nerve. On either side of the sella turcica is the **carotid groove**, which is broad, shallow, and curved somewhat like the italic letter *f*. It begins behind

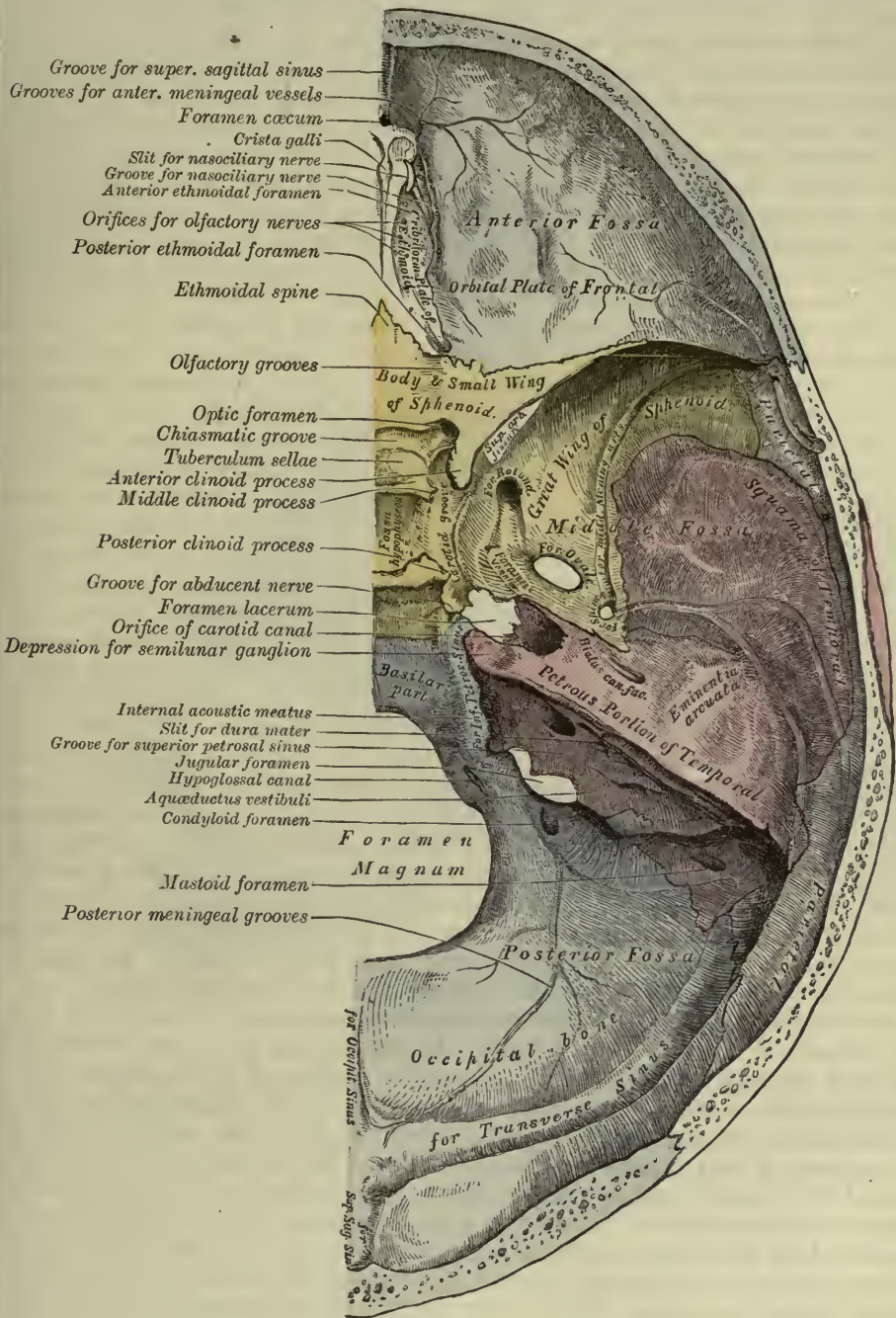


FIG. 193.—Base of the skull. Upper surface.

at the foramen lacerum, and ends on the medial side of the anterior clinoid process, where it is sometimes converted into a foramen (*carotico-clinoid*) by the union of the anterior with the middle clinoid process; posteriorly, it is bounded laterally

by the **lingula**. This groove lodges the cavernous sinus and the internal carotid artery, the latter being surrounded by a plexus of sympathetic nerves.

The lateral parts of the middle fossa are of considerable depth, and support the temporal lobes of the brain. They are marked by depressions for the brain convolutions and traversed by furrows for the anterior and posterior branches of the middle meningeal vessels. These furrows begin near the foramen spinosum, and the anterior runs forward and upward to the sphenoidal angle of the parietal, where it is sometimes converted into a bony canal; the posterior runs lateralward and backward across the temporal squama and passes on to the parietal near the middle of its lower border. The following apertures are also to be seen. In front is the **superior orbital fissure**, bounded above by the small wing, below, by the great wing, and medially, by the body of the sphenoid; it is usually completed laterally by the orbital plate of the frontal bone. It transmits to the orbital cavity the oculomotor, the trochlear, the ophthalmic division of the trigeminal, and the abducent nerves, some filaments from the cavernous plexus of the sympathetic, and the orbital branch of the middle meningeal artery; and from the orbital cavity a recurrent branch from the lacrimal artery to the dura mater, and the ophthalmic veins. Behind the medial end of the superior orbital fissure is the **foramen rotundum**, for the passage of the maxillary nerve. Behind and lateral to the foramen rotundum is the **foramen ovale**, which transmits the mandibular nerve, the accessory meningeal artery, and the lesser superficial petrosal nerve.¹ Medial to the foramen ovale is the **foramen Vesalii**, which varies in size in different individuals, and is often absent; when present, it opens below at the lateral side of the scaphoid fossa, and transmits a small vein. Lateral to the foramen ovale is the **foramen spinosum**, for the passage of the middle meningeal vessels, and a recurrent branch from the mandibular nerve. Medial to the foramen ovale is the **foramen lacerum**; in the fresh state the lower part of this aperture is filled up by a layer of fibrocartilage, while its upper and inner parts transmit the internal carotid artery surrounded by a plexus of sympathetic nerves. The nerve of the pterygoid canal and a meningeal branch from the ascending pharyngeal artery pierce the layer of fibrocartilage. On the anterior surface of the petrous portion of the temporal bone are seen the eminence caused by the projection of the superior semicircular canal; in front of and a little lateral to this a depression corresponding to the roof of the tympanic cavity; the groove leading to the **hiatus of the facial canal**, for the transmission of the greater superficial petrosal nerve and the petrosal branch of the middle meningeal artery; beneath it, the smaller groove, for the passage of the lesser superficial petrosal nerve; and, near the apex of the bone, the depression for the semilunar ganglion and the orifice of the carotid canal.

The Posterior Fossa (*fossa cranii posterior*).—The posterior fossa is the largest and deepest of the three. It is formed by the dorsum sellæ and clivus of the sphenoid, the occipital, the petrous and mastoid portions of the temporals, and the mastoid angles of the parietal bones; it is crossed by the **occipitomastoid** and the **parietomastoid sutures**, and lodges the cerebellum, pons, and medulla oblongata. It is separated from the middle fossa in and near the median line by the dorsum sellæ of the sphenoid and on either side by the superior angle of the petrous portion of the temporal bone. This angle gives attachment to the tentorium cerebelli, is grooved for the superior petrosal sinus, and presents at its medial end a notch upon which the trigeminal nerve rests. The fossa is limited behind by the grooves for the transverse sinuses. In its center is the **foramen magnum**, on either side of which is a rough tubercle for the attachment of the alar ligaments; a little above this tubercle is the canal, which transmits the hypoglossal nerve and a meningeal branch from the ascending pharyngeal artery. In front of the foramen magnum

¹ See footnote, page 150.

the basilar portion of the occipital and the posterior part of the body of the sphenoid form a grooved surface which supports the medulla oblongata and pons; in the young skull these bones are joined by a synchondrosis. This grooved surface is separated on either side from the petrous portion of the temporal by the **petro-occipital fissure**, which is occupied in the fresh state by a plate of cartilage; the fissure is continuous behind with the jugular foramen, and its margins are grooved for the inferior petrosal sinus. The **jugular foramen** is situated between the lateral part of the occipital and the petrous part of the temporal. The anterior portion of this foramen transmits the inferior petrosal sinus; the posterior portion, the transverse sinus and some meningeal branches from the occipital and ascending pharyngeal arteries; and the intermediate portion, the glossopharyngeal, vagus, and accessory nerves. Above the jugular foramen is the **internal acoustic meatus**, for the facial and acoustic nerves and internal auditory artery; behind and lateral

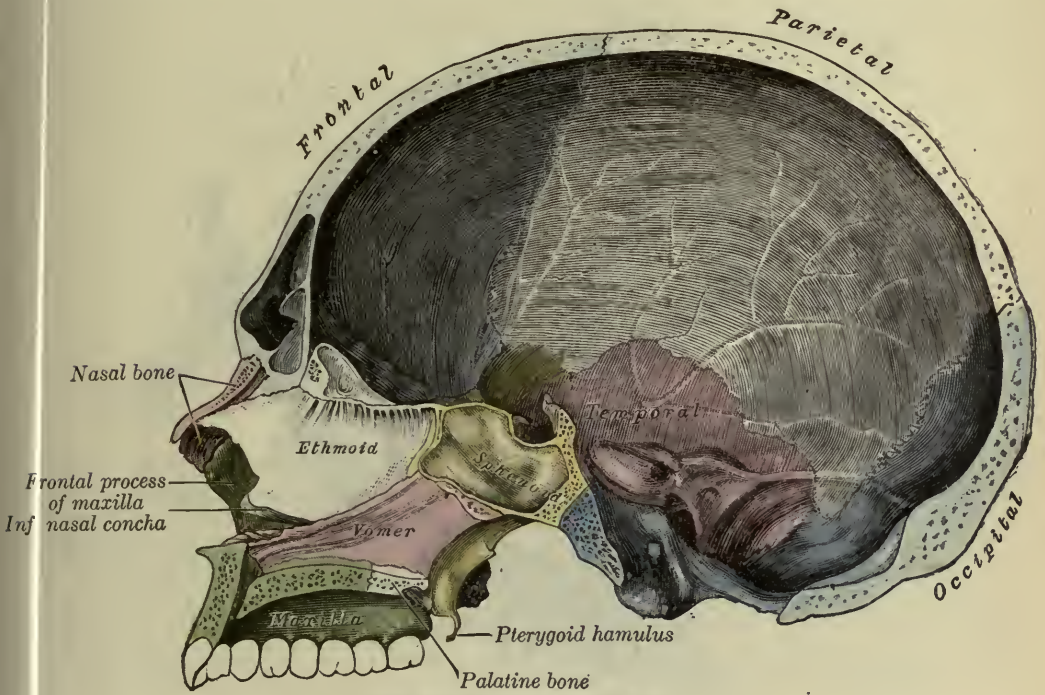


FIG. 194.—Sagittal section of skull.

to this is the slit-like opening leading into the aquæductus vestibuli, which lodges the ductus endolymphaticus; while between these, and near the superior angle of the petrous portion, is a small triangular depression, the remains of the fossa sub-arcuata, which lodges a process of the dura mater and occasionally transmits a small vein. Behind the foramen magnum are the **inferior occipital fossæ**, which support the hemispheres of the cerebellum, separated from one another by the **internal occipital crest**, which serves for the attachment of the falx cerebelli, and lodges the occipital sinus. The posterior fossæ are surmounted by the deep grooves for the **transverse sinuses**. Each of these channels, in its passage to the jugular foramen, grooves the occipital, the mastoid angle of the parietal, the mastoid portion of the temporal, and the jugular process of the occipital, and ends at the back part of the jugular foramen. Where this sinus grooves the mastoid portion of the temporal, the orifice of the **mastoid foramen** may be seen; and, just previous to its termination, the **condyloid canal** opens into it; neither opening is constant.

The Nasal Cavity (*cavum nasi*; *nasal fossa*).—The nasal cavities are two irregular spaces, situated one on either side of the middle line of the face, extending from the base of the cranium to the roof of the mouth, and separated from each other by a thin vertical septum. They open on the face through the pear-shaped **anterior nasal aperture**, and their posterior openings or **choanæ** communicate, in the fresh state, with the nasal part of the pharynx. They are much narrower above than below, and in the middle than at their anterior or posterior openings: their depth, which is considerable, is greatest in the middle. They communicate with the frontal, ethmoidal, sphenoidal, and maxillary sinuses. Each cavity is bounded by a **roof**, a **floor**, a **medial** and a **lateral wall**.

The **roof** (Figs. 195, 196) is horizontal in its central part, but slopes downward in front and behind; it is formed in *front* by the nasal bone and the spine of the frontal; in the *middle*, by the cribriform plate of the ethmoid; and *behind*,

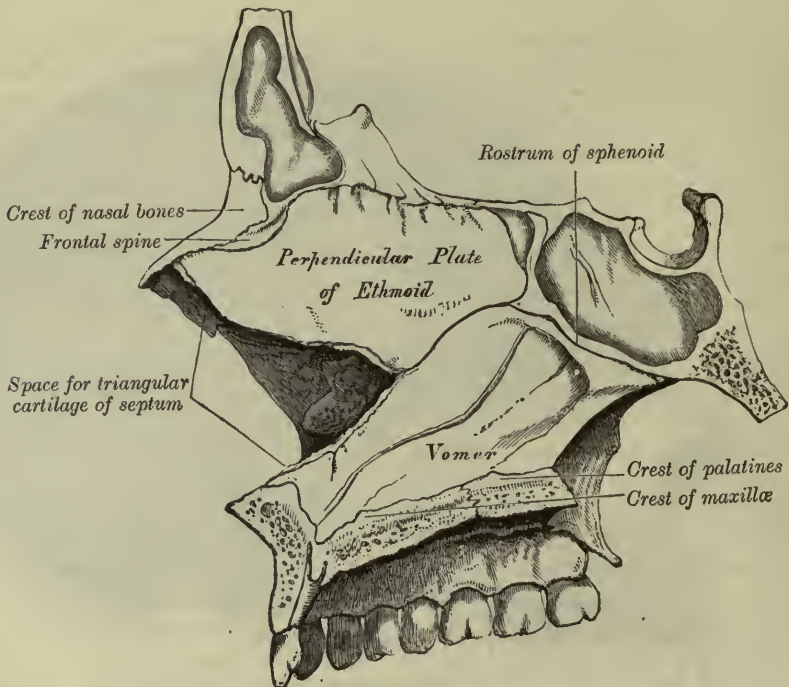


FIG. 195.—Medial wall of left nasal fossa.

by the body of the sphenoid, the sphenoidal concha, the ala of the vomer and the sphenoidal process of the palatine bone. In the cribriform plate of the ethmoid are the foramina for the olfactory nerves, and on the posterior part of the roof is the opening into the sphenoidal sinus.

The **floor** is flattened from before backward and concave from side to side. It is formed by the palatine process of the maxilla and the horizontal part of the palatine bone; near its anterior end is the opening of the incisive canal.

The **medial wall** (*septum nasi*) (Fig. 195), is frequently deflected to one or other side, more often to the left than to the right. It is formed, in *front*, by the crest of the nasal bones and frontal spine; in the *middle*, by the perpendicular plate of the ethmoid; *behind*, by the vomer and the rostrum of the sphenoid; *below*, by the crest of the maxillæ and palatine bones. It presents, in front, a large, triangular notch, which receives the cartilage of the septum; and behind, the free edge of the vomer. Its surface is marked by numerous furrows for vessels

and nerves and by the grooves for the nasopalatine nerve, and is traversed by sutures connecting the bones of which it is formed.

The lateral wall (Fig. 196) is formed, in front, by the frontal process of the maxilla and by the lacrimal bone; in the middle, by the ethmoid, maxilla, and inferior nasal concha; behind, by the vertical plate of the palatine bone, and the medial pterygoid plate of the sphenoid. On this wall are three irregular antero-posterior passages, termed the superior, middle, and inferior meatuses of the nose. The **superior meatus**, the smallest of the three, occupies the middle third of the lateral wall. It lies between the superior and middle nasal conchæ; the **spheno-palatine foramen** opens into it behind, and the **posterior ethmoidal cells** in front. The sphenoidal sinus opens into a recess, the **sphenoethmoidal recess**, which is placed above and behind the superior concha. The **middle meatus** is situated between the middle and inferior conchæ, and extends from the anterior to the posterior end of

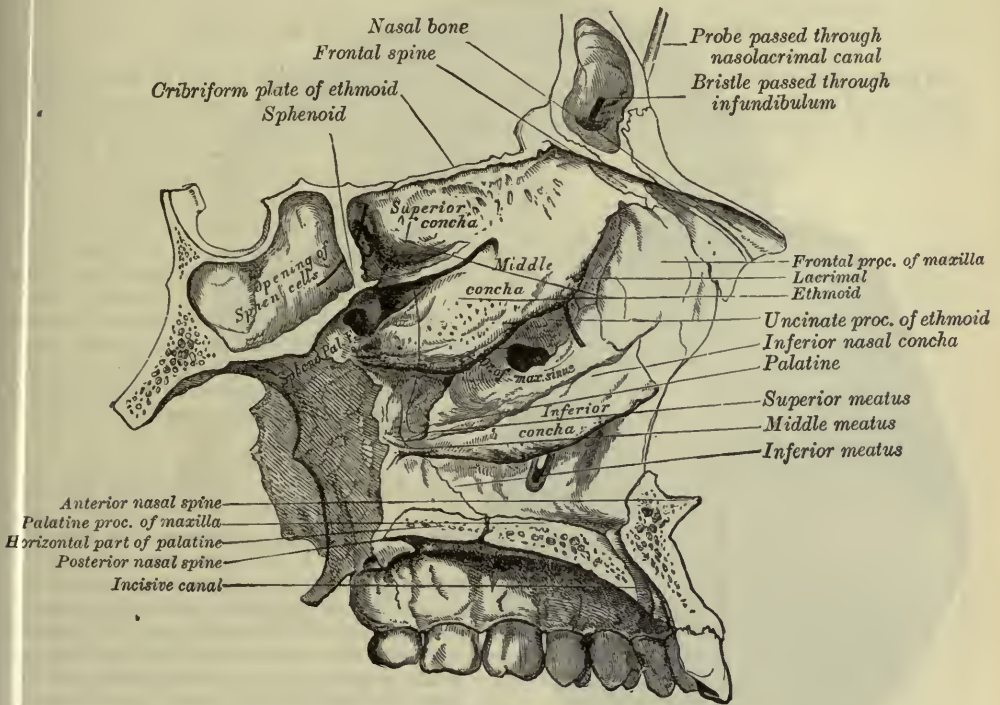


FIG. 196.—Roof, floor, and lateral wall of left nasal cavity.

the latter. The lateral wall of this meatus can be satisfactorily studied only after the removal of the middle concha. On it is a curved fissure, the **hiatus semilunaris**, limited below by the edge of the uncinatè process of the ethmoid and above by an elevation named the **bulla ethmoidalis**; the middle ethmoidal cells are contained within this bulla and open on or near to it. Through the hiatus semilunaris the meatus communicates with a curved passage termed the **infundibulum**, which communicates in front with the anterior ethmoidal cells and in rather more than fifty per cent. of skulls is continued upward as the **frontonasal duct** into the frontal air-sinus; when this continuity fails, the frontonasal duct opens directly into the anterior part of the meatus. Below the bulla ethmoidalis and hidden by the uncinatè process of the ethmoid is the opening of the maxillary sinus (**ostium maxillare**); an accessory opening is frequently present above the posterior part of the inferior nasal concha. The **inferior meatus**, the largest of the three, is the space between the inferior concha and the floor of the nasal cavity. It extends almost the entire

length of the lateral wall of the nose, is broader in front than behind, and presents anteriorly the lower orifice of the nasolacrimal canal.

The **Anterior Nasal Aperture** (Fig. 181) is a heart-shaped or pyriform opening, whose long axis is vertical, and narrow end upward; in the recent state it is much contracted by the lateral and alar cartilages of the nose. It is bounded *above* by the inferior borders of the nasal bones; *laterally* by the thin, sharp margins which separate the anterior from the nasal surfaces of the maxillæ; and *below* by the same borders, where they curve medialward to join each other at the anterior nasal spine.

The **choanæ** are each bounded *above* by the under surface of the body of the sphenoid and ala of the vomer; *below*, by the posterior border of the horizontal part of the palatine bone; *laterally*, by the medial pterygoid plate; they are separated from each other by the posterior border of the vomer.

DIFFERENCES IN THE SKULL DUE TO AGE.

At birth the skull is large in proportion to the other parts of the skeleton, but its facial portion is small, and equals only about one-eighth of the bulk of the cranium as compared with one-half in the adult. The frontal and parietal eminences are prominent, and the greatest width of the skull is at the level of the latter; on the other hand, the glabella, superciliary arches, and mastoid processes are not developed. Ossification of the skull bones is not completed, and many of them, *e. g.*, the occipital, temporals, sphenoid, frontal, and mandible, consist of more than one piece. Unossified membranous intervals, termed *fontanelles*, are seen at the angles of the parietal bones; these fontanelles are six in number: two, an anterior and a posterior, are situated in the middle line, and two, an antero-lateral and a postero-lateral, on either side.

The *anterior* or *bregmatic fontanelle* (Fig. 197) is the largest, and is placed at the junction of the sagittal, coronal, and frontal sutures; it is lozenge-shaped, and measures about 4 cm. in its antero-posterior and 2.5 cm. in its transverse diameter. The *posterior fontanelle* is triangular in form and is situated at the junction of the sagittal and lambdoidal sutures. The *lateral fontanelles* (Fig. 198) are small, irregular in shape, and correspond respectively with the sphenoidal and mastoid angles of the parietal bones. An additional fontanelle is sometimes seen in the sagittal suture at the region of the obelion. The fontanelles are usually closed by the growth and extension of the bones which surround them, but sometimes they are the sites of separate ossific centers which develop into sutural bones. The posterior and lateral fontanelles are obliterated within a month or two after birth, but the anterior is not completely closed until about the middle of the second year.

The smallness of the face at birth is mainly accounted for by the rudimentary condition of the maxillæ and mandible, the non-eruption of the teeth, and the small size of the maxillary air sinuses and nasal cavities. At birth the nasal cavities lie almost entirely between the orbits, and the lower border of the anterior nasal aperture is only a little below the level of the orbital floor. With the eruption of the deciduous teeth there is an enlargement of the face and jaws, and these changes are still more marked after the second dentition.

The skull grows rapidly from birth to the seventh year, by which time the foramen magnum and petrous parts of the temporals have reached their full size and the orbital cavities are only a little smaller than those of the adult. Growth is slow from the seventh year until the approach

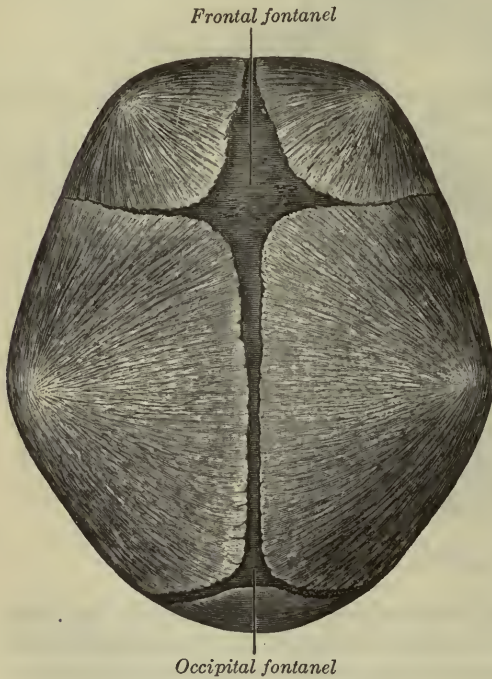


FIG. 197.—Skull at birth, showing frontal and occipital fonticuli.

of puberty, when a second period of activity occurs: this results in an increase in all directions, but it is especially marked in the frontal and facial regions, where it is associated with the development of the air sinuses.

Obliteration of the sutures of the vault of the skull takes place as age advances. This process may commence between the ages of thirty and forty, and is first seen on the inner surface, and some ten years later on the outer surface of the skull. The dates given are, however, only approximate, as it is impossible to state with anything like accuracy the time at which the sutures are closed. Obliteration usually occurs first in the posterior part of the sagittal suture, next in the coronal, and then in the lambdoidal.

In old age the skull generally becomes thinner and lighter, but in a small proportion of cases it increases in thickness and weight, owing to an hypertrophy of the inner table. The most striking feature of the old skull is the diminution in the size of the maxillæ and mandible consequent on the loss of the teeth and the absorption of the alveolar processes. This is associated with a marked reduction in the vertical measurement of the face and with an alteration in the angles of the mandible.

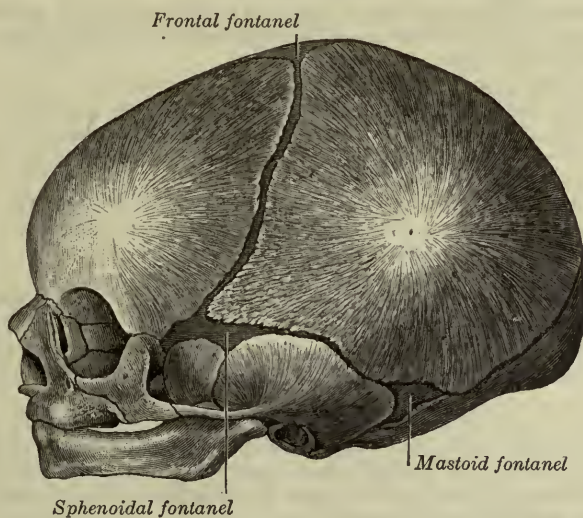


FIG. 198.—Skull at birth, showing sphenoidal and mastoid fonticuli.

SEXUAL DIFFERENCES IN THE SKULL.

Until the age of puberty there is little difference between the skull of the female and that of the male. The skull of an adult female is, as a rule, lighter and smaller, and its cranial capacity about 10 per cent. less, than that of the male. Its walls are thinner and its muscular ridges less strongly marked; the glabella, superciliary arches, and mastoid processes are less prominent, and the corresponding air sinuses are small or rudimentary. The upper margin of the orbit is sharp, the forehead vertical, the frontal and parietal eminences prominent, and the vault somewhat flattened. The contour of the face is more rounded, the facial bones are smoother, and the maxillæ and mandible and their contained teeth smaller. From what has been said it will be seen that more of the infantile characteristics are retained in the skull of the adult female than in that of the adult male. A well-marked male or female skull can easily be recognized as such, but in some cases the respective characteristics are so indistinct that the determination of the sex may be difficult or impossible.

CRANIOLOGY.

Skulls vary in size and shape, and the term craniology is applied to the study of these variations. The capacity of the cranial cavity constitutes a good index of the size of the brain which it contained, and is most conveniently arrived at by filling the cavity with shot and measuring the contents in a graduated vessel. Skulls may be classified according to their capacities as follows:

1. *Microcephalic*, with a capacity of less than 1350 c.cm.—*e. g.*, those of native Australians and Andaman Islanders.
2. *Mesocephalic*, with a capacity of from 1350 c.cm. to 1450 c.cm.—*e. g.*, those of African negroes and Chinese.
3. *Megacephalic*, with a capacity of over 1450 c.cm.—*e. g.*, those of Europeans, Japanese, and Eskimos.

In comparing the shape of one skull with that of another it is necessary to adopt some definite position in which the skulls should be placed during the process of examination. They should be so placed that a line carried through the lower margin of the orbit and upper margin of the external acoustic meatus is in the horizontal plane. The normæ of one skull can then be compared with those of another, and the differences in contour and surface form noted. Further, it is necessary that the various linear measurements used to determine the shape of the skull should be made between definite and easily localized points on its surface. The principal points may be divided into two groups: (1) those in the median plane, and (2) those on either side of it.

The Points in the Median Plane are the:

Mental Point. The most prominent point of the chin.

Alveolar Point or *Prosthion.* The central point of the anterior margin of the upper alveolar arch.

Subnasal Point. The middle of the lower border of the anterior nasal aperture, at the base of the anterior nasal spine.

Nasion. The central point of the frontonasal suture.

Glabella. The point in the middle line at the level of the superciliary arches.

Ophryon. The point in the middle line of the forehead at the level where the temporal lines most nearly approach each other.

Bregma. The meeting point of the coronal and sagittal sutures.

Obelion. A point in the sagittal suture on a level with the parietal foramina.

Lambda. The point of junction of the sagittal and lambdoidal sutures.

Occipital Point. The point in the middle line of the occipital bone farthest from the glabella.

Inion. The external occipital protuberance.

Opisthion. The mid-point of the posterior margin of the foramen magnum.

Basion. The mid-point of the anterior margin of the foramen magnum.

The Points on Either Side of the Median Plane are the:

Gonion. The outer margin of the angle of the mandible.

Dacryon. The point of union of the antero-superior angle of the lacrimal with the frontal bone and the frontal process of the maxilla.

Stephanion. The point where the temporal line intersects the coronal suture.

Pterion. The point where the great wing of the sphenoid joins the sphenoidal angle of the parietal.

Auricular Point. The center of the orifice of the external acoustic meatus.

Asterion. The point of meeting of the lambdoidal, mastoöccipital, and mastoparietal sutures.

The *horizontal circumference* of the cranium is measured in a plane passing through the glabella (Turner) or the ophryon (Flower) in front, and the occipital point behind; it averages about 50 cm. in the female and 52.5 cm. in the male.

The *occipitofrontal* or *longitudinal arc* is measured from the nasion over the middle line of the vertex to the opisthion: while the *basinasal length* is the distance between the basion and the nasion. These two measurements, plus the antero-posterior diameter of the foramen magnum, represent the *vertical circumference* of the cranium.

The *length* is measured from the glabella to the occipital point, while the *breadth* or greatest transverse diameter is usually found near the external acoustic meatus. The proportion of breadth to length $\frac{\text{breadth} \times 100}{\text{length}}$ is termed the *cephalic index* or *index of breadth*.

The *height* is usually measured from the basion to the bregma, and the proportion of height to length $\frac{(\text{height} \times 100)}{\text{length}}$ constitutes the *vertical* or *height index*.

In studying the face the principal points to be noticed are the proportion of its length and breadth, the shape of the orbits and of the anterior nasal aperture, and the degree of projection of the jaws.

The *length of the face* may be measured from the ophryon or nasion to the chin, or, if the mandible be wanting, to the alveolar point; while its *width* is represented by the distance between the zygomatic arches. By comparing the length with the width of the face, skulls may be divided into two groups; *dolichofacial* or *leptoprosope* (long faced) and *brachyfacial* or *chemoprosope* (short faced).

The *orbital index* signifies the proportion which the orbital height bears to the orbital width, thus:

$$\frac{\text{orbital height} \times 100}{\text{orbital width}}$$

The *nasal index* expresses the proportion which the width of the anterior nasal aperture bears to the height of the nose, the latter being measured from the nasion to the lower margin of the nasal aperture, thus:

$$\frac{\text{nasal width} \times 100}{\text{nasal height}}$$

The degree of projection of the jaws is determined by the *gnathic* or *alveolar index*, which represents the proportion between the basalveolar and basinasal lengths, thus:

$$\frac{\text{basialveolar length} \times 100}{\text{basinasal length}}$$

The following table, modified from that given by Duckworth,¹ illustrates how these different indices may be utilized in the classification of skulls:

Index.	Classification.	Nomenclature.	Examples.
1. Cephalic	Below 75 Between 75 and 80 Above 80	Dolichocephalic Mesaticephalic Brachycephalic	Kaffirs and Native Australians. Europeans and Chinese. Mongolians and Andamans.
2. Orbital	Below 84 Between 84 and 89 Above 89	Microseme Mesoseme Megaseme	Tasmanians and Native Australians. Europeans. Chinese and Polynesians.
3. Nasal	Below 48 Between 48 and 53 Above 53	Leptorhine Mesorhine Platyrrhine	Europeans. Japanese and Chinese. Negroes and Native Australians.
4. Gnathic	Below 98 Between 98 and 103 Above 103	Orthognathous Mesognathous Prognathous	Europeans. Chinese and Japanese. Native Australians.

The chief function of the skull is to protect the brain, and therefore those portions of the skull which are most exposed to external violence are thicker than those which are shielded from injury by overlying muscles. Thus, the skull-cap is thick and dense, whereas the temporal squamæ, being protected by the temporales muscles, and the inferior occipital fossæ, being shielded by the muscles at the back of the neck, are thin and fragile. Fracture of the skull is further prevented by its elasticity, its rounded shape, and its construction of a number of secondary elastic arches, each made up of a single bone. The manner in which vibrations are transmitted through the bones of the skull is also of importance as regards its protective mechanism, at all events as far as the base is concerned. In the vault, the bones being of a fairly equal thickness and density, vibrations are transmitted in a uniform manner in all directions, but in the base, owing to the varying thickness and density of the bones, this is not so; and therefore in this situation there are special buttresses which serve to carry the vibrations in certain definite directions. At the front of the skull, on either side, is the ridge which separates the anterior from the middle fossa of the base; and behind, the ridge or buttress which separates the middle from the posterior fossa; and if any violence is applied to the vault, the vibrations would be carried along these buttresses to the sella turcica, where they meet. This part has been termed the "center of resistance," and here there is a special protective mechanism to guard the brain. The subarachnoid cavity at the base of the brain is dilated, and the cerebrospinal fluid which fills it acts as a water cushion to shield the brain from injury. In like manner, when violence is applied to the base of the skull, as in falls upon the feet, the vibrations are carried backward through the occipital crest, and forward through the basilar part of the occipital and body of the sphenoid to the vault of the skull.

In connection with the bones of the face a common malformation is *cleft palate*. The cleft usually starts posteriorly, and its most elementary form is a bifid uvula; or the cleft may extend through the soft palate; or the posterior part of the whole of the hard palate may be involved, the cleft extending as far forward as the incisive foramen. In the severest forms, the cleft extends through the alveolus and passes between the incisive or premaxillary bone and the rest of the maxilla; that is to say, between the lateral incisor and canine teeth. In some instances, the cleft runs between the central and lateral incisor teeth; and this has induced some anatomists to believe that the premaxillary bone is developed from two centers (Fig. 199) and not from one, as was stated on p. 163. The medial segment, bearing a central incisor, is called an *endognathion*; the lateral segment, bearing the lateral incisor, is called a *mesognathion*. The cleft may affect one or both sides; if the latter, the central part is frequently displaced forward and remains united to the septum of the nose, the deficiency in the alveolus being complicated with a cleft

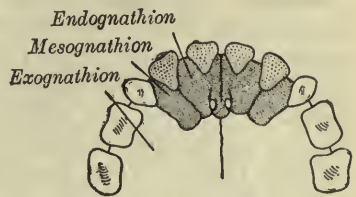

FIG. 199.—The premaxilla and its sutures. (After Albrecht.)

¹ Morphology and Anthropology, by W. L. H. Duckworth, M.A., Cambridge University Press.

in the lip (hare-lip). On examining a cleft palate in which the alveolus is not implicated, the cleft will generally appear to be in the median line, but occasionally is unilateral and in some cases bilateral. To understand this it must be borne in mind that three processes are concerned in the formation of the palate—the palatine processes of the two maxillæ, which grow in horizontally and unite in the middle line, and the ethmovomerine process, which grows downward from the base of the skull and frontonasal process to unite with the palatine processes in the middle line. In those cases where the palatine processes fail to unite with each other and with the medial process, the cleft of the palate is median; where one palatine process unites with the medial septum, the other failing to do so, the cleft in the palate is unilateral. In some cases where the palatine processes fail to meet in the middle, the ethmovomerine process grows downward between them and thus produces a bilateral cleft. Occasionally there may be a hole in the middle line of the hard palate, the anterior part of the hard and the soft palate being perfect; this is rare, because, as a rule, the union of the various processes progresses from before backward, and therefore the posterior part of the palate is more frequently defective than the anterior.

THE EXTREMITIES.

The bones by which the upper and lower limbs are attached to the trunk constitute respectively the shoulder and pelvic girdles. The **shoulder girdle** or **girdle of the superior extremity** is formed by the scapulæ and clavicles, and is imperfect in front and behind. In front, however, it is completed by the upper end of the sternum, with which the medial ends of the clavicles articulate. Behind, it is widely imperfect, the scapulæ being connected to the trunk by muscles only. The **pelvic girdle** or **girdle of the inferior extremity** is formed by the hip bones, which articulate with each other in front, at the symphysis pubis. It is imperfect behind, but the gap is filled in by the upper part of the sacrum. The pelvic girdle, with the sacrum, is a complete ring, massive and comparatively rigid, in marked contrast to the lightness and mobility of the shoulder girdle.

THE BONES OF THE UPPER EXTREMITY (OSSA EXTREMITATIS SUPERIORIS).

The Clavicle (Clavicula; Collar Bone).

The **clavicle** (Figs. 200, 201) forms the anterior portion of the shoulder girdle. It is a long bone, curved somewhat like the italic letter *f*, and placed nearly horizontally at the upper and anterior part of the thorax, immediately above the first rib. It articulates medially with the manubrium sterni, and laterally with the acromion of the scapula.¹ It presents a double curvature, the convexity being directed forward at the sternal end, and the concavity at the scapular end. Its lateral third is flattened from above downward, while its medial two-thirds is of a rounded or prismatic form.

Lateral Third.—The lateral third has two surfaces, an upper and a lower; and two borders, an anterior and a posterior.

Surface.—The **upper surface** is flat, rough, and marked by impressions for the attachments of the Deltoideus in front, and the Trapezius behind; between these impressions a small portion of the bone is subcutaneous. The **under surface** is flat. At its posterior border, near the point where the prismatic joins with the flattened portion, is a rough eminence, the **coracoid tuberosity** (*conoid tubercle*); this, in the natural position of the bone, surmounts the coracoid process of the scapula, and gives attachment to the conoid ligament. From this tuberosity an oblique ridge, the **oblique** or **trapezoid ridge**, runs forward and lateralward, and afford attachment to the trapezoid ligament.

¹ The clavicle acts especially as a fulcrum to enable the muscles to give lateral motion to the arm. It is accordingly absent in those animals whose fore-limbs are used only for progression, but is present for the most part in animals whose anterior extremities are clawed and used for prehension, though in some of them—as, for instance, in a large number of the carnivora—it is merely a rudimentary bone suspended among the muscles, and not articulating with either the scapula or sternum.

Borders.—The **anterior border** is concave, thin, and rough, and gives attachment to the *Deltoideus*. The **posterior border** is convex, rough, thicker than the anterior, and gives attachment to the *Trapezius*.

Medial Two-thirds.—The medial two-thirds constitute the prismatic portion of the bone, which is curved so as to be convex in front, concave behind, and is marked by three borders, separating three surfaces.

Borders.—The **anterior border** is continuous with the anterior margin of the flat portion. Its lateral part is smooth, and corresponds to the interval between the attachments of the *Pectoralis major* and *Deltoideus*; its medial part forms the lower boundary of an elliptical surface for the attachment of the clavicular portion

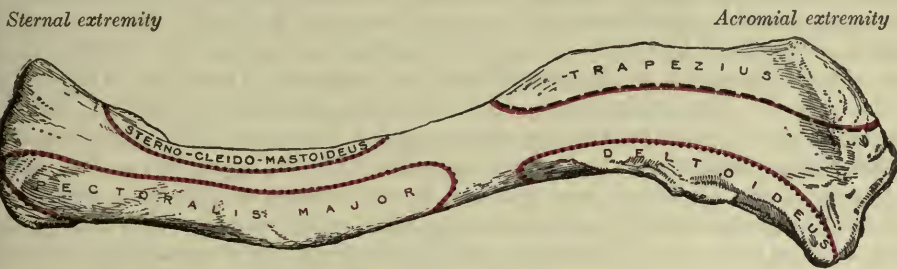

FIG. 200.—Left clavicle. Superior surface.

of the *Pectoralis major*, and approaches the posterior border of the bone. The **superior border** is continuous with the posterior margin of the flat portion, and separates the anterior from the posterior surface. Smooth and rounded laterally, it becomes rough toward the medial third for the attachment of the *Sternocleidomastoideus*, and ends at the upper angle of the sternal extremity. The **posterior or subclavian border** separates the posterior from the inferior surface, and extends from the coracoid tuberosity to the costal tuberosity; it forms the posterior boundary of the groove for the *Subclavius*, and gives attachment to a layer of cervical fascia which envelops the *Omohyoideus*.

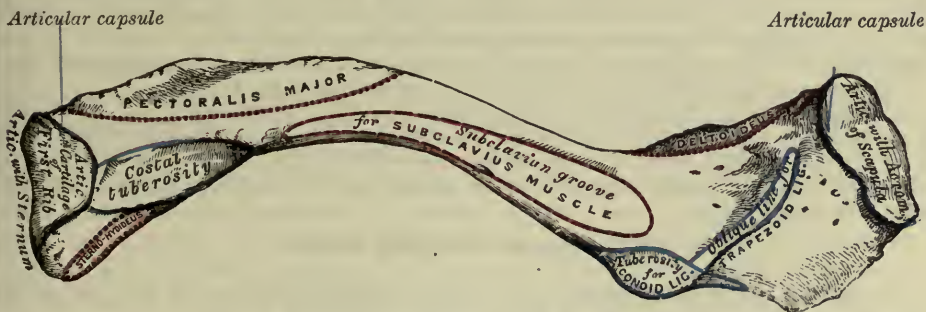


FIG. 201.—Left clavicle. Inferior surface.

Surfaces.—The **anterior surface** is included between the superior and anterior borders. Its lateral part looks upward, and is continuous with the superior surface of the flattened portion; it is smooth, convex, and nearly subcutaneous, being covered only by the *Platysma*. Medially it is divided by a narrow subcutaneous area into two parts: a lower, elliptical in form, and directed forward, for the attachment of the *Pectoralis major*; and an upper for the attachment of the *Sternocleidomastoideus*. The **posterior or cervical surface** is smooth, and looks backward toward the root of the neck. It is limited, above, by the superior border; below, by the subclavian border; medially, by the margin of the sternal extremity; and laterally, by the coracoid tuberosity. It is concave medio-laterally,

and is in relation, by its lower part, with the transverse scapular vessels. This surface, at the junction of the curves of the bone, is also in relation with the brachial plexus of nerves and the subclavian vessels. It gives attachment, near the sternal extremity, to part of the Sternohyoideus; and presents, near the middle, an oblique foramen directed lateralward, which transmits the chief nutrient artery of the bone. Sometimes there are two foramina on the posterior surface, or one on the posterior and another on the inferior surface. The **inferior** or **subclavian surface** is bounded, in front, by the anterior border; behind, by the subclavian border. It is narrowed medially, but gradually increases in width laterally, and is continuous with the under surface of the flat portion. On its medial part is a broad rough surface, the **costal tuberosity** (*rhomboid impression*), rather more than 2 cm. in length, for the attachment of the costoclavicular ligament. The rest of this surface is occupied by a groove, which gives attachment to the Subclavius; the coracoclavicular fascia, which splits to enclose the muscle, is attached to the margins of the groove. Not infrequently this groove is subdivided longitudinally by a line which gives attachment to the intermuscular septum of the Subclavius.

The Sternal Extremity (*extremitas sternalis; internal extremity*).—The sternal extremity of the clavicle is triangular in form, directed medialward, and a little downward and forward; it presents an articular facet, concave from before backward, convex from above downward, which articulates with the manubrium sterni through the intervention of an articular disk. The lower part of the facet is continued on to the inferior surface of the bone as a small semi-oval area for articulation with the cartilage of the first rib. The circumference of the articular surface is rough, for the attachment of numerous ligaments; the upper angle gives attachment to the articular disk.

The Acromial Extremity (*extremitas acromialis; outer extremity*).—The acromial extremity presents a small, flattened, oval surface directed obliquely downward, for articulation with the acromion of the scapula. The circumference of the articular facet is rough, especially above, for the attachment of the acromioclavicular ligaments.

In the female, the clavicle is generally shorter, thinner, less curved, and smoother than in the male. In those persons who perform considerable manual labor it becomes thicker and more curved, and its ridges for muscular attachment are prominently marked.

Structure.—The clavicle consists of cancellous tissue, enveloped by a compact layer, which is much thicker in the intermediate part than at the extremities of the bone.

Ossification.—The clavicle begins to ossify before any other bone in the body; it is ossified from *three* centers—viz., two primary centers, a medial and a lateral, for the body,¹ which appear during the fifth or sixth week of fetal life; and a secondary center for the sternal end, which appears about the eighteenth or twentieth year, and unites with the rest of the bone about the twenty-fifth year.

The Scapula (Shoulder Blade).

The **scapula** forms the posterior part of the shoulder girdle. It is a flat, triangular bone, with two surfaces, three borders, and three angles.

Surfaces.—The **costal** or **ventral surface** (Fig. 202) presents a broad concavity, the **subscapular fossa**. The medial two-thirds of the fossa are marked by several oblique ridges, which run lateralward and upward. The ridges give attachment to the tendinous insertions, and the surfaces between them to the fleshy fibers, of the Subscapularis. The lateral third of the fossa is smooth and covered by the fibers of this muscle. The fossa is separated from the vertebral border by smooth triangular areas at the medial and inferior angles, and in the interval between these by a narrow ridge which is often deficient. These triangular areas and the intervening ridge afford attachment to the Serratus anterior. At the upper part of the fossa is a transverse depression, where the bone appears to be bent on itself

¹ Mall, American Journal of Anatomy, vol. v; Fawcett, Journal of Anatomy and Physiology, vol. xlvii.

along a line at right angles to and passing through the center of the glenoid cavity, forming a considerable angle, called the **subscapular angle**; this gives greater strength to the body of the bone by its arched form, while the summit of the arch serves to support the spine and acromion.

The **dorsal surface** (Fig. 203) is arched from above downward, and is subdivided into two unequal parts by the spine; the portion above the spine is called the **supraspinatous fossa**, and that below it the **infraspinatous fossa**.

The **supraspinatous fossa**, the smaller of the two, is concave, smooth, and broader at its vertebral than at its humeral end; its medial two-thirds give origin to the Supraspinatus.

The **infraspinatous fossa** is much larger than the preceding; toward its vertebral margin a shallow concavity is seen at its upper part; its center presents a prominent convexity, while near the axillary border is a deep groove which runs from the upper toward the lower part. The medial two-thirds of the fossa give origin to the Infraspinatus; the lateral third is covered by this muscle.

The dorsal surface is marked near the axillary border by an elevated ridge, which runs from the lower part of the glenoid cavity, downward and backward to the vertebral border, about 2.5 cm. above the inferior angle. The ridge serves for the attachment of a fibrous septum, which separates the Infraspinatus from the Teres major and Teres minor. The surface between the ridge and the axillary border is narrow in the upper two-thirds of its extent, and is crossed near its center by a groove for the passage of the scapular circumflex vessels; it affords attachment to the Teres minor. Its lower third presents a broader, somewhat triangular surface, which gives origin to the Teres major, and over which the Latissimus dorsi glides; frequently the latter muscle takes origin by a few fibers from this part. The broad and narrow portions above alluded to are separated by an oblique line, which runs from the axillary border, downward and backward, to meet the elevated ridge: to it is attached a fibrous septum which separates the Teres muscles from each other.

The Spine (*spina scapulae*).—The spine is a prominent plate of bone, which crosses obliquely the medial four-fifths of the dorsal surface of the scapula at its upper part, and separates the supra- from the infraspinatous fossa. It begins at the vertical border by a smooth, triangular area over which the tendon of insertion of the lower part of the Trapezius glides, and, gradually becoming more elevated, ends in the acromion, which overhangs the shoulder-joint. The spine is triangular, and flattened from above downward, its apex being directed toward the vertebral border. It presents two surfaces and three borders. Its **superior surface** is concave; it assists in forming the supraspinatous fossa, and gives origin to part of the Supraspinatus. Its **inferior surface** forms part of the infraspinatous fossa, gives origin to a portion of the Infraspinatus, and presents near its center the orifice of a nutrient canal. Of the three borders, the **anterior** is attached to the dorsal surface of the bone; the **posterior**, or **crest of the spine**, is broad, and presents two lips and an intervening rough interval. The Trapezius is attached to the superior lip, and a rough tubercle is generally seen on that portion of the spine which receives the tendon of insertion of the lower part of this muscle. The Deltoides is attached to the whole length of the inferior lip. The interval between the lips is subcutaneous and partly covered by the tendinous fibers of these muscles. The **lateral border**, or **base**, the shortest of the three, is slightly concave; its edge, thick and round, is continuous above with the under surface of the acromion, below with the neck of the scapula. It forms the medial boundary of the **great scapular notch**, which serves to connect the supra- and infraspinatous fossæ.

The Acromion.—The acromion forms the summit of the shoulder, and is a large, somewhat triangular or oblong process, flattened from behind forward, projecting at first lateralward, and then curving forward and upward, so as to overhang the

glenoid cavity. Its **superior surface**, directed upward, backward, and lateralward, is convex, rough, and gives attachment to some fibers of the *Deltoides*, and in the rest of its extent is subcutaneous. Its **inferior surface** is smooth and concave. Its **lateral border** is thick and irregular, and presents three or four tubercles for the tendinous origins of the *Deltoides*. Its **medial border**, shorter than the lateral, is concave, gives attachment to a portion of the *Trapezius*, and presents about its center a small, oval surface for articulation with the acromial end of the clavicle.

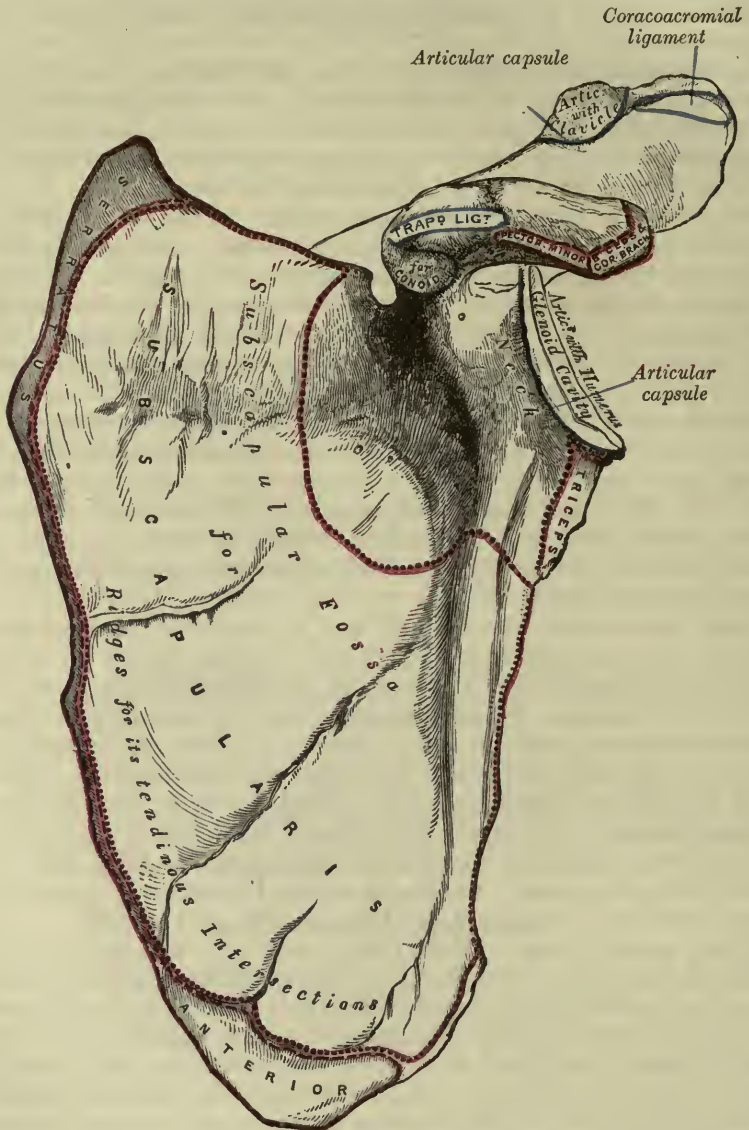


FIG. 202.—Left scapula. Costal surface.

Its **apex**, which corresponds to the point of meeting of these two borders in front, is thin, and has attached to it the coracoacromial ligament.

Borders.—Of the *three* borders of the scapula, the **superior** is the shortest and thinnest; it is concave, and extends from the medial angle to the base of the coracoid process. At its lateral part is a deep, semicircular notch, the **scapular notch**,

formed partly by the base of the coracoid process. This notch is converted into a foramen by the superior transverse ligament, and serves for the passage of the suprascapular nerve; sometimes the ligament is ossified. The adjacent part of the superior border affords attachment to the Omohyoideus. The axillary border

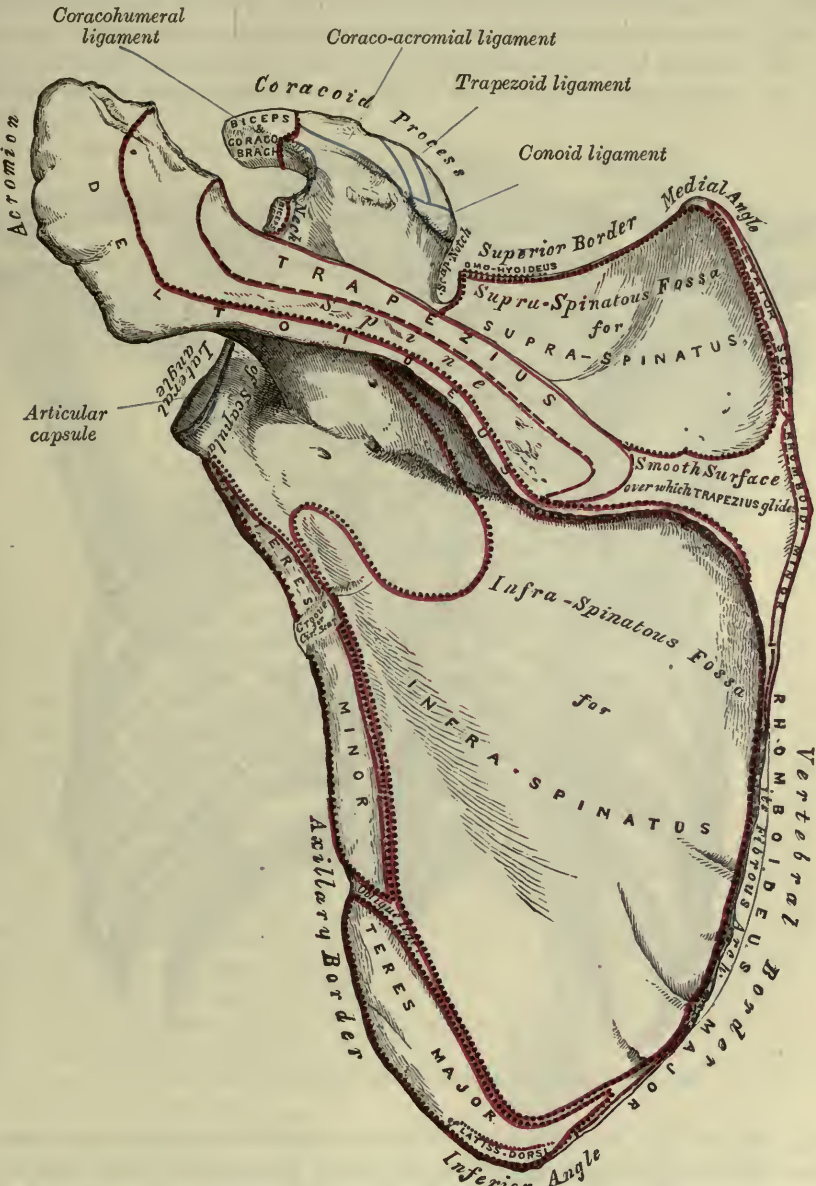


FIG. 203.—Left scapula. Dorsal surface.

is the thickest of the three. It begins above at the lower margin of the glenoid cavity, and inclines obliquely downward and backward to the inferior angle. Immediately below the glenoid cavity is a rough impression, the **infraglenoid tuberosity**, about 2.5 cm. in length, which gives origin to the long head of the Triiceps brachii; in front of this is a longitudinal groove, which extends as far as the

lower third of this border, and affords origin to part of the Subscapularis. The inferior third is thin and sharp, and serves for the attachment of a few fibers of the Teres major behind, and of the Subscapularis in front. The **vertebral border** is the longest of the three, and extends from the medial to the inferior angle. It is arched, intermediate in thickness between the superior and the axillary borders, and the portion of it above the spine forms an obtuse angle with the part below. This border presents an anterior and a posterior lip, and an intermediate narrow area. The anterior lip affords attachment to the Serratus anterior; the posterior lip, to the Supraspinatus above the spine, the Infraspinatus below; the area

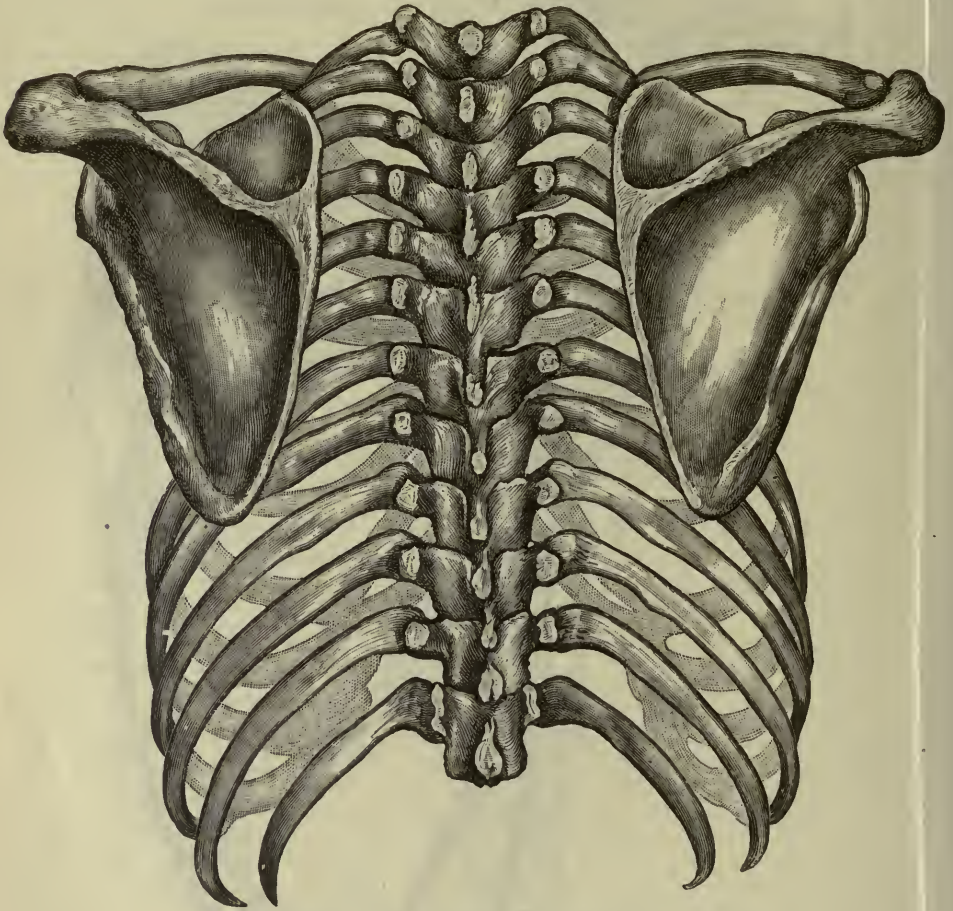


FIG. 204.—Posterior view of the thorax and shoulder girdle. (Morris.)

between the two lips, to the Levator scapulæ above the triangular surface at the commencement of the spine, to the Rhomboideus minor on the edge of that surface, and to the Rhomboideus major below it; this last is attached by means of a fibrous arch, connected above to the lower part of the triangular surface at the base of the spine, and below to the lower part of the border.

Angles.—Of the *three* angles, the **medial**, formed by the junction of the superior and vertebral borders, is thin, smooth, rounded, inclined somewhat lateralward, and gives attachment to a few fibers of the Levator scapulæ. The **inferior angle**, thick and rough, is formed by the union of the vertebral and axillary borders; its dorsal surface affords attachment to the Teres major and frequently to a few

fibers of the *Latissimus dorsi*. The **lateral angle** is the thickest part of the bone, and is sometimes called the head of the scapula. On it is a shallow pyriform, articular surface, the **glenoid cavity**, which is directed lateralward and forward and articulates with the head of the humerus; it is broader below than above and its vertical diameter is the longest. The surface is covered with cartilage in the fresh state; and its margins, slightly raised, give attachment to a fibrocartilaginous structure, the **glenoid labrum**, which deepens the cavity. At its apex is a slight elevation, the **supraglenoid tuberosity**, to which the long head of the *Biceps brachii* is attached. The **neck** of the scapula is the slightly constricted portion which surrounds the head; it is more distinct below and behind than above and in front.

The Coracoid Process (*processus coracoideus*).—The coracoid process is a thick curved process attached by a broad base to the upper part of the neck of the scapula; it runs at first upward and medialward; then, becoming smaller, it changes its direction, and projects forward and lateralward.

The ascending portion, flattened from before backward, presents in front a smooth concave surface, across which the *Subscapularis* passes. The horizontal portion is flattened from above downward; its upper surface is convex and irregular, and gives attachment to the *Pectoralis minor*; its under surface is smooth; its medial and lateral borders are rough; the former gives attachment to the *Pectoralis minor* and the latter to the coracoacromial ligament; the apex is embraced by the conjoined tendon of origin of the *Coracobrachialis* and short head of the *Biceps brachii* and gives attachment to the coracoclavicular fascia. On the medial part of the root of the coracoid process is a rough impression for the attachment of the conoid ligament; and running from it obliquely forward and lateralward, on to the upper surface of the horizontal portion, is an elevated ridge for the attachment of the trapezoid ligament.

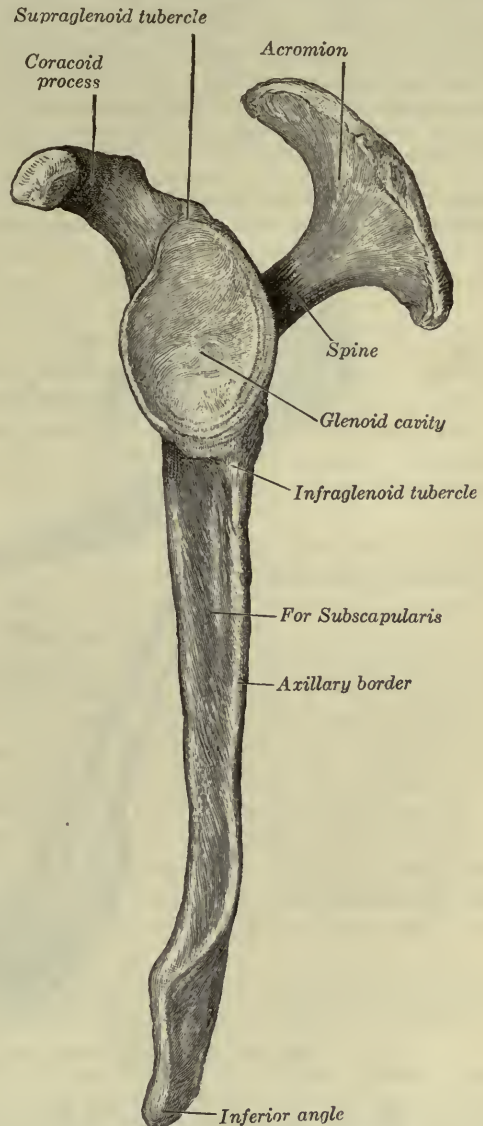


FIG. 205.—Left scapula. Lateral view.

Structure.—The head, processes, and the thickened parts of the bone, contain cancellous tissue; the rest consists of a thin layer of compact tissue. The central part of the supraspinatus

fossa and the upper part of the infraspinatus fossa, but especially the former, are usually so thin as to be semitransparent; occasionally the bone is found wanting in this situation, and the adjacent muscles are separated only by fibrous tissue.

Ossification (Fig. 206).—The scapula is ossified from *seven* or more centers: one for the body, two for the coracoid process, two for the acromion, one for the vertebral border, and one for the inferior angle.

Ossification of the body begins about the second month of fetal life, by the formation of an irregular quadrilateral plate of bone, immediately behind the glenoid cavity. This plate extends so as to form the chief part of the bone, the spine growing up from its dorsal surface about the third month. At birth, a large part of the scapula is osseous, but the glenoid cavity, the coracoid process, the acromion, the vertebral border, and the inferior angle are cartilaginous. From the fifteenth to the eighteenth month after birth, ossification takes place in the middle of the coracoid process, which as a rule becomes joined with the rest of the bone about the fifteenth year. Between the fourteenth and twentieth years, ossification of the remaining parts takes place in quick succession, and usually in the following order; first, in the root of the coracoid process, in the form of a broad scale; secondly, near the base of the acromion; thirdly, in the inferior angle and contiguous part of the vertebral border; fourthly, near the extremity of the acromion; fifthly, in the vertebral border. The base of the acromion is formed by an extension from the spine; the two separate nuclei of the acromion unite, and then join with the extension from the spine. The upper third

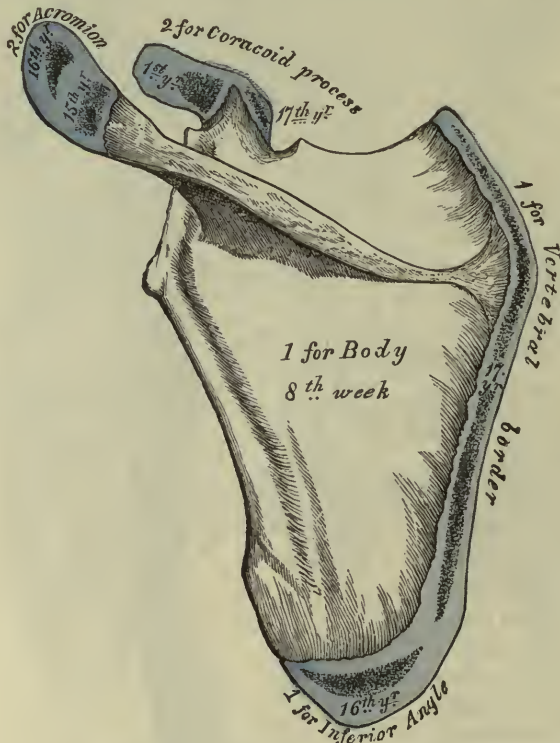


FIG. 206.—Plan of ossification of the scapula. From seven centers.

of the glenoid cavity is ossified from a separate center (subcoracoid), which makes its appearance between the tenth and eleventh years and joins between the sixteenth and the eighteenth. Further, an epiphysial plate appears for the lower part of the glenoid cavity, while the tip of the coracoid process frequently presents a separate nucleus. These various epiphyses are joined to the bone by the twenty-fifth year. Failure of bony union between the acromion and spine sometimes occurs, the junction being effected by fibrous tissue, or by an imperfect articulation; in some cases of supposed fracture of the acromion with ligamentous union, it is probable that the detached segment was never united to the rest of the bone.

The Humerus (Arm Bone).

The humerus (Figs. 207, 208) is the longest and largest bone of the upper extremity; it is divisible into a **body** and **two extremities**.

Upper Extremity.—The upper extremity consists of a large rounded *head* joined to the body by a constricted portion called the **neck**, and two eminences, the **greater** and **lesser tubercles**.

The Head (*caput humeri*).—The head, nearly hemispherical in form,¹ is directed upward, medialward, and a little backward, and articulates with the glenoid cavity of the scapula. The circumference of its articular surface is slightly constricted and is termed the **anatomical neck**, in contradistinction to a constriction below the tubercles called the **surgical neck** which is frequently the seat of fracture. Fracture of the anatomical neck rarely occurs.

The **Anatomical Neck** (*collum anatomicum*) is obliquely directed, forming an obtuse angle with the body. It is best marked in the lower half of its circumference; in the upper half it is represented by a narrow groove separating the head from the tubercles. It affords attachment to the articular capsule of the shoulder-joint, and is perforated by numerous vascular foramina.

The Greater Tubercle (*tuberculum majus; greater tuberosity*).—The greater tubercle is situated lateral to the head and lesser tubercle. Its upper surface is rounded and marked by three flat impressions: the highest of these gives insertion to the Supraspinatus; the middle to the Infraspinatus; the lowest one, and the body of the bone for about 2.5 cm. below it, to the Teres minor. The lateral surface of the greater tubercle is convex, rough, and continuous with the lateral surface of the body.

The Lesser Tubercle (*tuberculum minus; lesser tuberosity*).—The lesser tubercle, although smaller, is more prominent than the greater: it is situated in front, and is directed medialward and forward. Above and in front it presents an impression for the insertion of the tendon of the Subscapularis.

The tubercles are separated from each other by a deep groove, the **intertubercular groove** (*bicipital groove*), which lodges the long tendon of the Biceps brachii and transmits a branch of the anterior humeral circumflex artery to the shoulder-joint. It runs obliquely downward, and ends near the junction of the upper with the middle third of the bone. In the fresh state its upper part is covered with a thin layer of cartilage, lined by a prolongation of the synovial membrane of the shoulder-joint; its lower portion gives insertion to the tendon of the Latissimus dorsi. It is deep and narrow above, and becomes shallow and a little broader as it descends. Its lips are called, respectively, the **crests of the greater and lesser tubercles** (*bicipital ridges*), and form the upper parts of the anterior and medial borders of the body of the bone.

The Body or Shaft (*corpus humeri*).—The body is almost cylindrical in the upper half of its extent, prismatic and flattened below, and has three borders and three surfaces.

Borders.—The **anterior border** runs from the front of the greater tubercle above to the coronoid fossa below, separating the antero-medial from the antero-lateral surface. Its upper part is a prominent ridge, the crest of the greater tubercle; it serves for the insertion of the tendon of the Pectoralis major. About its center it forms the anterior boundary of the deltoid tuberosity; below, it is smooth and rounded, affording attachment to the Brachialis.

The **lateral border** runs from the back part of the greater tubercle to the

¹ Though the head is nearly hemispherical in form, its margin, as Humphry has shown, is by no means a true circle. Its greatest diameter is, from the top of the intertubercular groove in a direction downward, medialward, and backward. Hence it follows that the greatest elevation of the arm can be obtained by rolling the articular surface in this direction—that is to say, obliquely upward, lateralward, and forward.

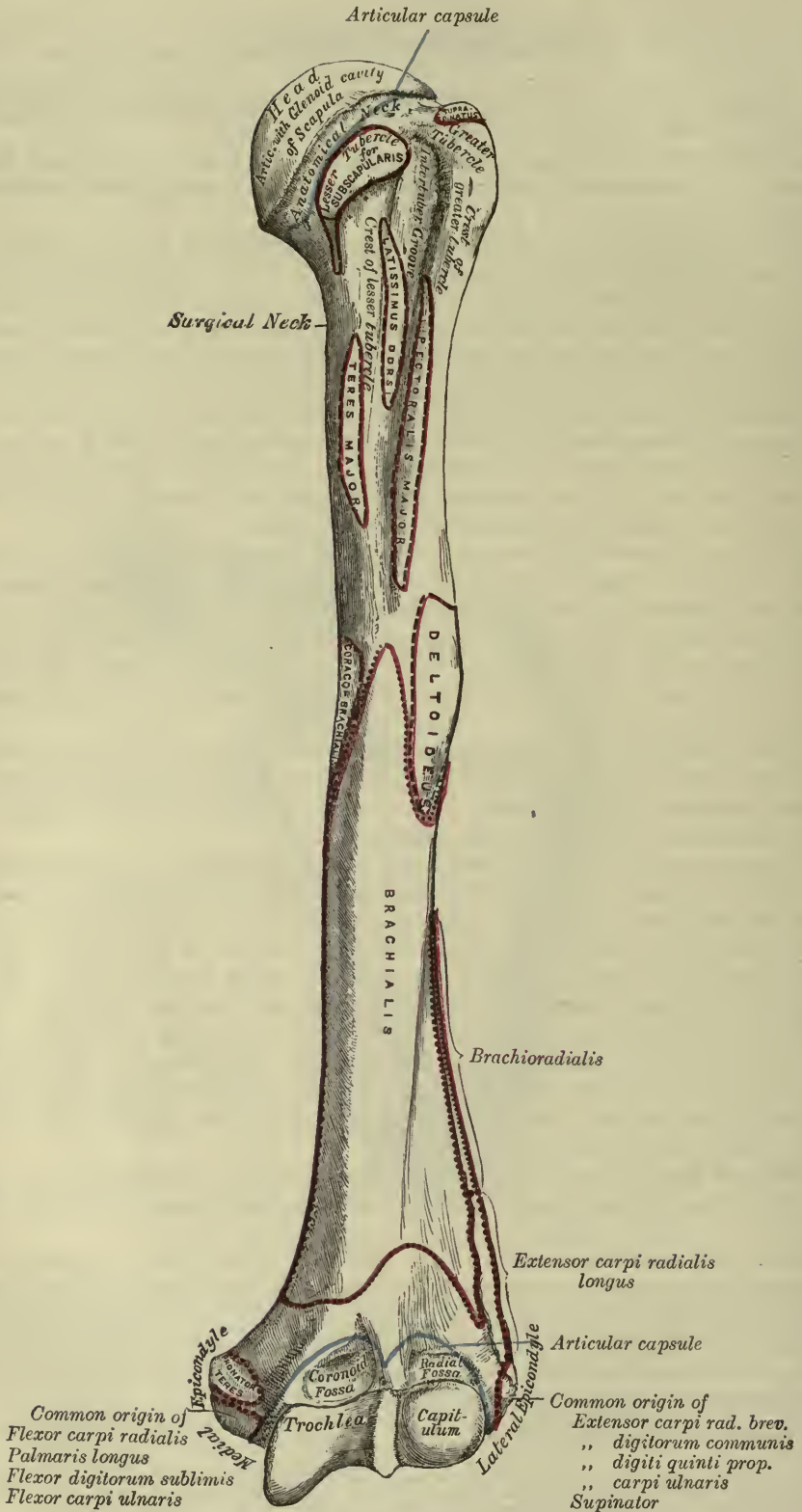


FIG. 207.—Left humerus. Anterior view.

lateral epicondyle, and separates the antero-lateral from the posterior surface. Its upper half is rounded and indistinctly marked, serving for the attachment of the lower part of the insertion of the *Teres minor*, and below this giving origin to the lateral head of the *Triceps brachii*; its center is traversed by a broad but shallow oblique depression, the **radial sulcus** (*musculospiral groove*). Its lower part forms a prominent, rough margin, a little curved from behind forward, the **lateral supracondylar ridge**, which presents an anterior lip for the origin of the *Brachioradialis* above, and *Extensor carpi radialis longus* below, a posterior lip for the *Triceps brachii*, and an intermediate ridge for the attachment of the lateral intermuscular septum.

The **medial border** extends from the lesser tubercle to the medial epicondyle. Its upper third consists of a prominent ridge, the **crest of the lesser tubercle**, which gives insertion to the tendon of the *Teres major*. About its center is a slight impression for the insertion of the *Coracobrachialis*, and just below this is the entrance of the nutrient canal, directed downward; sometimes there is a second nutrient canal at the commencement of the radial sulcus. The inferior third of this border is raised into a slight ridge, the **medial supracondylar ridge**, which becomes very prominent below; it presents an anterior lip for the origins of the *Brachialis* and *Pronator teres*, a posterior lip for the medial head of the *Triceps brachii*, and an intermediate ridge for the attachment of the medial intermuscular septum.

Surfaces.—The **antero-lateral surface** is directed lateralward above, where it is smooth, rounded, and covered by the *Deltoides*; forward and lateralward below, where it is slightly concave from above downward, and gives origin to part of the *Brachialis*. About the middle of this surface is a rough, triangular elevation, the **deltoid tuberosity** for the insertion of the *Deltoides*; below this is the **radial sulcus**, directed obliquely from behind, forward, and downward, and transmitting the radial nerve and profunda artery.

The **antero-medial surface**, less extensive than the antero-lateral, is directed medialward above, forward and medialward below; its upper part is narrow, and forms the floor of the intertubercular groove which gives insertion to the tendon of the *Latissimus dorsi*; its middle part is slightly rough for the attachment of some of

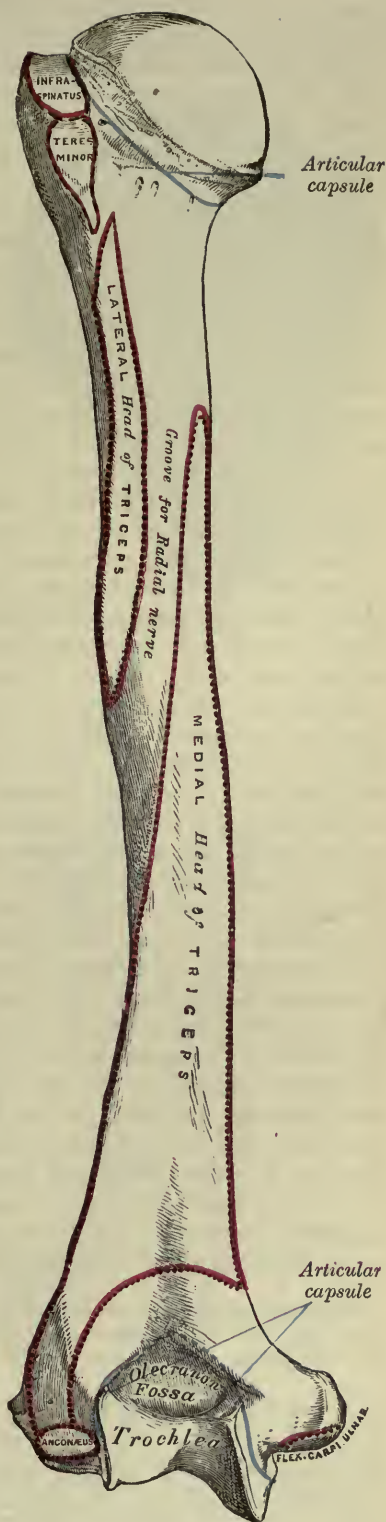


FIG. 208.—Left humerus. Posterior view.

the fibers of the tendon of insertion of the Coracobrachialis; its lower part is smooth, concave from above downward, and gives origin to the Brachialis.¹

The **posterior surface** appears somewhat twisted, so that its upper part is directed a little medialward, its lower part backward and a little lateralward. Nearly the whole of this surface is covered by the lateral and medial heads of the Triceps brachii, the former arising above, the latter below the radial sulcus.

The Lower Extremity.—The lower extremity is flattened from before backward, and curved slightly forward; it ends below in a broad, articular surface, which is divided into two parts by a slight ridge. Projecting on either side are the lateral and medial epicondyles. The **articular surface** extends a little lower than the epicondyles, and is curved slightly forward; its medial extremity occupies a lower level than the lateral. The lateral portion of this surface consists of a smooth, rounded eminence, named the **capitulum of the humerus**; it articulates with the cup-shaped depression on the head of the radius, and is limited to the front and lower part of the bone. On the medial side of this eminence is a shallow groove, in which is received the medial margin of the head of the radius. Above the front part of the capitulum is a slight depression, the **radial fossa**, which receives the anterior border of the head of the radius, when the forearm is flexed. The medial portion of the articular surface is named the **trochlea**, and presents a deep depression between two well-marked borders; it is convex from before backward, concave from side to side, and occupies the anterior, lower, and posterior parts of the extremity. The lateral border separates it from the groove which articulates with the margin of the head of the radius. The medial border is thicker, of greater length, and consequently more prominent, than the lateral. The grooved portion of the articular surface fits accurately within the semilunar notch of the ulna; it is broader and deeper on the posterior than on the anterior aspect of the bone, and is inclined obliquely downward and forward toward the medial side. Above the front part of the trochlea is a small depression, the **coronoid fossa**, which receives the coronoid process of the ulna during flexion of the forearm. Above the back part of the trochlea is a deep triangular depression, the **olecranon fossa**, in which the summit of the olecranon is received in extension of the forearm. These fossæ are separated from one another by a thin, transparent lamina of bone, which is sometimes perforated by a **supratrochlear foramen**; they are lined in the fresh state by the synovial membrane of the elbow-joint, and their margins afford attachment to the anterior and posterior ligaments of this articulation. The **lateral epicondyle** is a small, tuberculated eminence, curved a little forward, and giving attachment to the radial collateral ligament of the elbow-joint, and to a tendon common to the origin of the Supinator and some of the Extensor muscles. The **medial epicondyle**, larger and more prominent than the lateral, is directed a little backward; it gives attachment to the ulnar collateral ligament of the elbow-joint, to the Pronator teres, and to a common tendon of origin of some of the Flexor muscles of the forearm; the ulnar nerve runs in a groove on the back of this epicondyle. The epicondyles are continuous above with the supracondylar ridges.

Structure.—The extremities consist of cancellous tissue, covered with a thin, compact layer (Fig. 209); the body is composed of a cylinder of compact tissue, thicker at the center than toward the extremities, and contains a large medullary canal which extends along its whole length.

¹ A small, hook-shaped process of bone, the *supracondylar process*, varying from 2 to 20 mm. in length, is not infrequently found projecting from the antero-medial surface of the body of the humerus 5 cm. above the medial epicondyle. It is curved downward and forward, and its pointed end is connected to the medial border, just above the medial epicondyle, by a fibrous band, which gives origin to a portion of the Pronator teres; through the arch completed by this fibrous band the median nerve and brachial artery pass, when these structures deviate from their usual course. Sometimes the nerve alone is transmitted through it, or the nerve may be accompanied by the ulnar artery, in cases of high division of the brachial. A well-marked groove is usually found behind the process, in which the nerve and artery are lodged. This arch is the homologue of the supracondyloid foramen found in many animals, and probably serves in them to protect the nerve and artery from compression during the contraction of the muscles in this region.

Ossification (Figs. 210, 211).—The humerus is ossified from *eight* centers, one for each of the following parts: the body, the head, the greater tubercle, the lesser tubercle, the capitulum, the trochlea, and one for each epicondyle. The center for the body appears near the middle of the bone in the eighth week of fetal life, and soon extends toward the extremities. At birth the humerus is ossified in nearly its whole length, only the extremities remaining cartilaginous. During the first year, sometimes before birth, ossification commences in the head of the bone, and during the third year the center for the greater tubercle, and during the fifth that for the lesser tubercle, make their appearance. By the sixth year the centers for the head and tubercles have joined, so as to form a single large epiphysis, which fuses with the body about the twentieth year. The lower end of the humerus is ossified as follows. At the end of the second year ossification begins in the capitulum, and extends medialward, to form the chief part of the articular end of the bone; the center for the medial part of the trochlea appears about the age of twelve. Ossification begins in the medial epicondyle about the fifth year, and in the lateral about the thirteenth or fourteenth year. About the sixteenth or seventeenth year, the lateral epicondyle and both portions of the articulating surface, having already joined, unite with the body, and at the eighteenth year the medial epicondyle becomes joined to it.

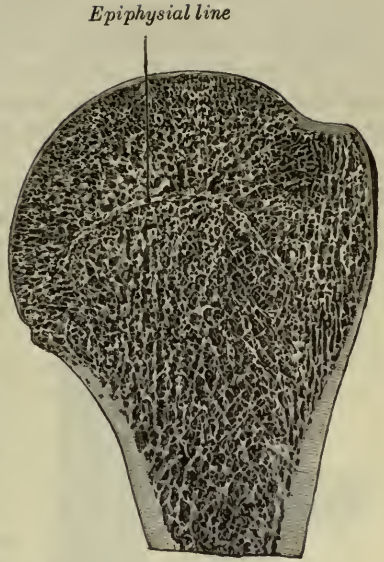


FIG. 209.—Longitudinal section of head of left humerus.

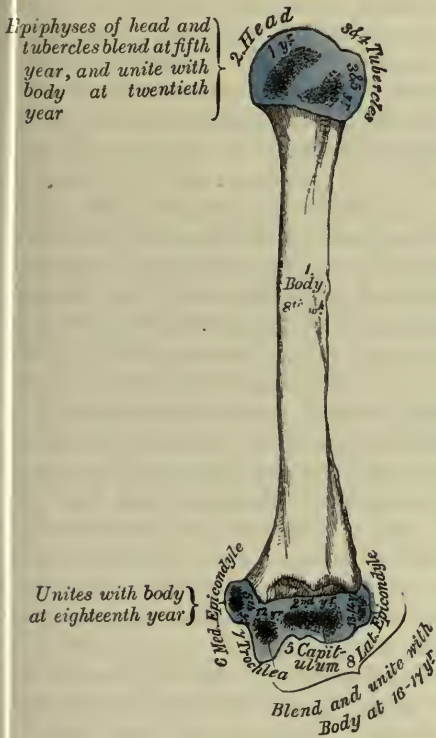


FIG. 210.—Plan of ossification of the humerus.

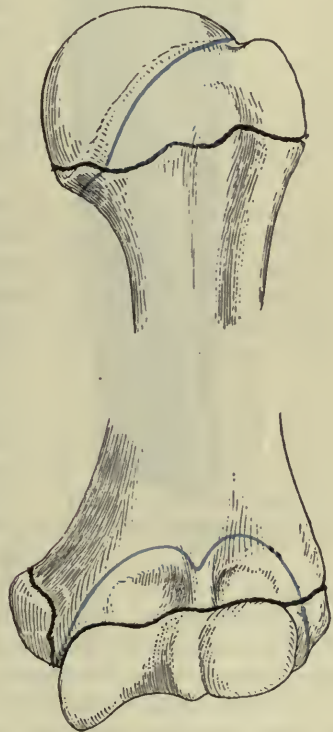

FIG. 211.—Epiphysial lines of humerus in a young adult. Anterior aspect. The lines of attachment of the articular capsules are in blue.

The Ulna (Elbow Bone).¹

The **ulna** (Figs. 212, 213) is a long bone, prismatic in form, placed at the medial side of the forearm, parallel with the radius. It is divisible into a **body** and **two extremities**. Its upper extremity, of great thickness and strength, forms a large part of the elbow-joint; the bone diminishes in size from above downward, its lower extremity being very small, and excluded from the wrist-joint by the interposition of an articular disk.

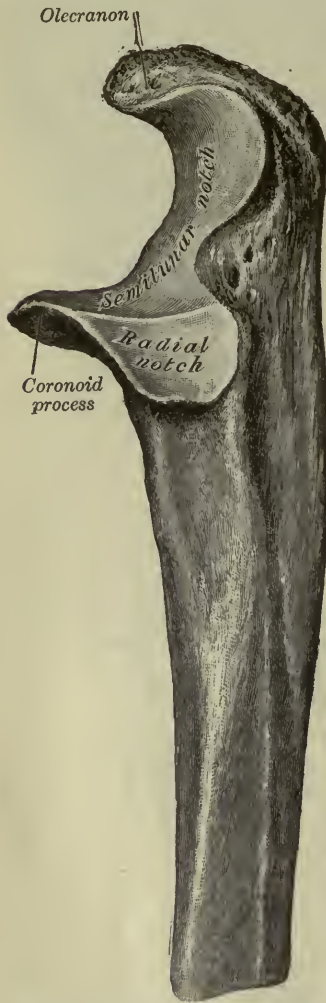


FIG. 212.—Upper extremity of left ulna.
Lateral aspect.

The Upper Extremity (*proximal extremity*) (Fig. 212).—The upper extremity presents two curved processes, the **olecranon** and the **coronoid process**; and two concave, articular cavities, the **semilunar** and **radial notches**.

The Olecranon (*olecranon process*).—The olecranon is a large, thick, curved eminence, situated at the upper and back part of the ulna. It is bent forward at the summit so as to present a prominent lip which is received into the olecranon fossa of the humerus in extension of the forearm. Its **base** is contracted where it joins the body and the narrowest part of the upper end of the ulna. Its **posterior surface**, directed backward, is triangular, smooth, subcutaneous, and covered by a bursa. Its **superior surface** is of quadrilateral form, marked behind by a rough impression for the insertion of the Triceps brachii; and in front, near the margin, by a slight transverse groove for the attachment of part of the posterior ligament of the elbow-joint. Its **anterior surface** is smooth, concave, and forms the upper part of the semilunar notch. Its **borders** present continuations of the groove on the margin of the superior surface; they serve for the attachment of ligaments, viz., the back part of the ulnar collateral ligament medially, and the posterior ligament laterally. From the medial border a part of the Flexor carpi ulnaris arises; while to the lateral border the Anconæus is attached.

The Coronoid Process (*processus coronoideus*).—The coronoid process is a triangular eminence projecting forward from the upper and front part of the ulna. Its **base** is continuous with the body of the bone, and of considerable strength. Its **apex** is pointed, slightly curved upward, and in flexion of the forearm is received into the coronoid

fossa of the humerus. Its **upper surface** is smooth, concave, and forms the lower part of the semilunar notch. Its **antero-inferior surface** is concave, and marked by a rough impression for the insertion of the Brachialis. At the junction of this surface with the front of the body is a rough eminence, the **tuberosity of the ulna**, which gives insertion to a part of the Brachialis; to the lateral border of this tuberosity the oblique cord is attached. Its **lateral surface** presents a narrow, oblong, articular depression, the **radial notch**. Its **medial surface**, by its prominent,

¹ In the anatomical position, the forearm is placed in extension and supination with the palm looking forward and the thumb on the outer side.

free margin, serves for the attachment of part of the ulnar collateral ligament. At the front part of this surface is a small rounded eminence for the origin of one head of the Flexor digitorum sublimis; behind the eminence is a depression for part of the origin of the Flexor digitorum profundus; descending from the eminence is a ridge which gives origin to one head of the Pronator teres. Frequently, the Flexor pollicis longus arises from the lower part of the coronoid process by a rounded bundle of muscular fibers.

The Semilunar Notch (*incisura semilunaris; greater sigmoid cavity*).—The semilunar notch is a large depression, formed by the olecranon and the coronoid process, and serving for articulation with the trochlea of the humerus. About the middle of either side of this notch is an indentation, which contracts it somewhat, and indicates the junction of the olecranon and the coronoid process. The notch is concave from above downward, and divided into a medial and a lateral portion by a smooth ridge running from the summit of the olecranon to the tip of the coronoid process. The medial portion is the larger, and is slightly concave transversely; the lateral is convex above, slightly concave below.

The Radial Notch (*incisura radialis; lesser sigmoid cavity*).—The radial notch is a narrow, oblong, articular depression on the lateral side of the coronoid process; it receives the circumferential articular surface of the head of the radius. It is concave from before backward, and its prominent extremities serve for the attachment of the annular ligament.

The Body or Shaft (*corpus ulnæ*).—The body at its upper part is prismatic in form, and curved so as to be convex behind and lateralward; its central part is straight; its lower part is rounded, smooth, and bent a little lateralward. It tapers gradually from above downward, and has three borders and three surfaces.

Borders.—The **volar border** (*margo volaris; anterior border*) begins above at the prominent medial angle of the coronoid process, and ends below in front of the styloid process. Its upper part, well-defined, and its middle portion, smooth and rounded, give origin to the Flexor digitorum profundus; its lower fourth serves for the origin of the Pronator quadratus. This border separates the volar from the medial surface.

The **dorsal border** (*margo dorsalis; posterior border*) begins above at the apex of the triangular subcutaneous surface at the back part of the olecranon, and ends below at the back of the styloid process; it is well-marked in the upper three-fourths, and gives attachment to an aponeurosis which affords a common origin to the Flexor carpi ulnaris, the Extensor carpi ulnaris, and the Flexor digitorum profundus; its lower fourth is smooth and rounded. This border separates the medial from the dorsal surface.

The **interosseous crest** (*crista interossea; external or interosseous border*) begins above by the union of two lines, which converge from the extremities of the radial notch and enclose between them a triangular space for the origin of part of the Supinator; it ends below at the head of the ulna. Its upper part is sharp, its lower fourth smooth and rounded. This crest gives attachment to the interosseous membrane, and separates the volar from the dorsal surface.

Surfaces.—The **volar surface** (*facies volaris; anterior surface*), much broader above than below, is concave in its upper three-fourths, and gives origin to the Flexor digitorum profundus; its lower fourth, also concave, is covered by the Pronator quadratus. The lower fourth is separated from the remaining portion by a ridge, directed obliquely downward and medialward, which marks the extent of origin of the Pronator quadratus. At the junction of the upper with the middle third of the bone is the nutrient canal, directed obliquely upward.

The **dorsal surface** (*facies dorsalis; posterior surface*) directed backward and lateralward, is broad and concave above; convex and somewhat narrower in the middle; narrow, smooth, and rounded below. On its upper part is an oblique

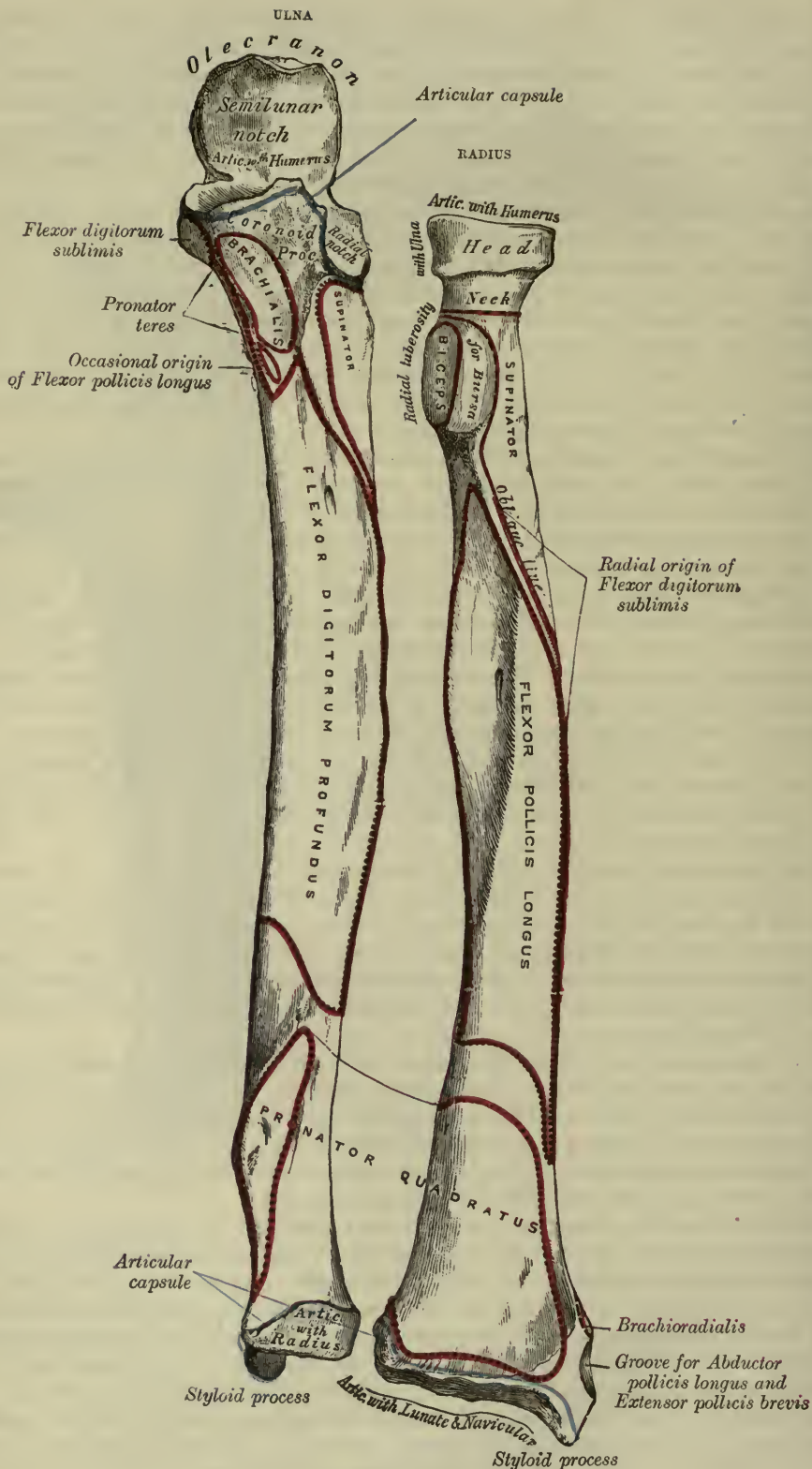


FIG. 213.—Bones of left forearm. Anterior aspect.

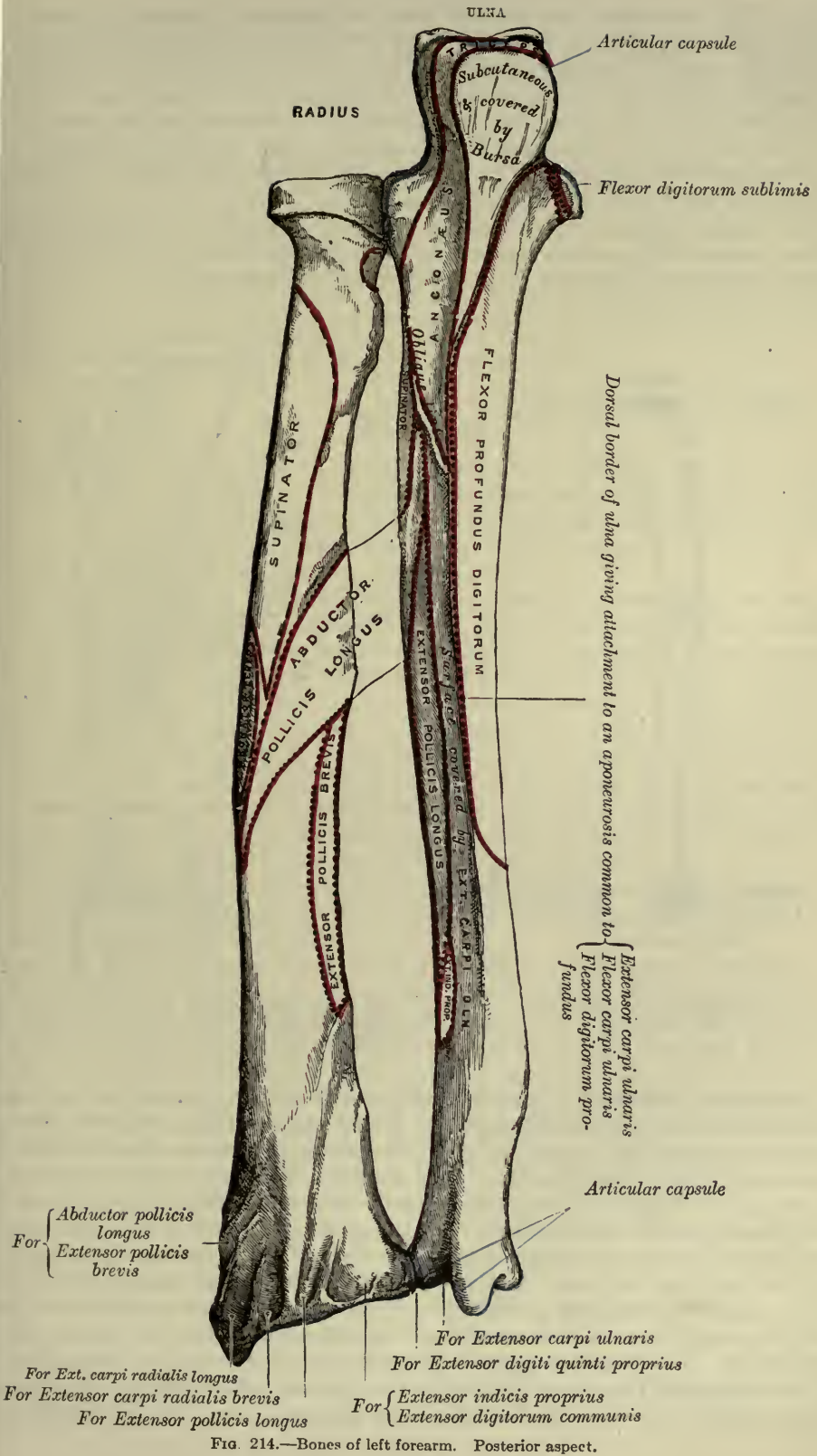


FIG. 214.—Bones of left forearm. Posterior aspect.

ridge, which runs from the dorsal end of the radial notch, downward to the dorsal border; the triangular surface above this ridge receives the insertion of the Anconæus, while the upper part of the ridge affords attachment to the Supinator. Below this surface is subdivided by a longitudinal ridge, sometimes called the **perpendicular line**, into two parts: the medial part is smooth, and covered by the Extensor carpi ulnaris; the lateral portion, wider and rougher, gives origin from above downward to the Supinator, the Abductor pollicis longus, the Extensor pollicis longus, and the Extensor indicis proprius.

The **medial surface** (*facies medialis; internal surface*) is broad and concave above, narrow and convex below. Its upper three-fourths give origin to the Flexor digitorum profundus; its lower fourth is subcutaneous.

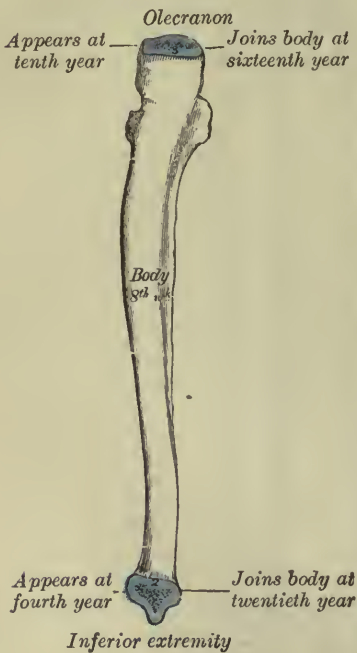


FIG. 215.—Plan of ossification of the ulna. From three centers.

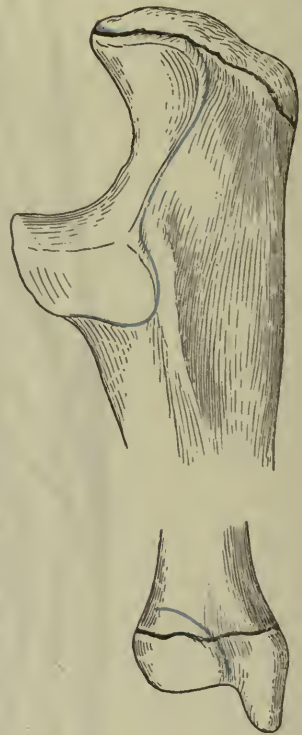


FIG. 216.—Epiphysal lines of ulna in a young adult. Lateral aspect. The lines of attachment of the articular capsules are in blue.

The Lower Extremity (*distal extremity*).—The lower extremity of the ulna is small, and presents two eminences; the lateral and larger is a rounded, articular eminence, termed the head of the ulna; the medial, narrower and more projecting, is a non-articular eminence, the styloid process. The **head** presents an articular surface, part of which, of an oval or semilunar form, is directed downward, and articulates with the upper surface of the triangular articular disk which separates it from the wrist-joint; the remaining portion, directed lateralward, is narrow, convex, and received into the ulnar notch of the radius. The **styloid process** projects from the medial and back part of the bone; it descends a little lower than the head, and its rounded end affords attachment to the ulnar collateral ligament of the wrist-joint. The head is separated from the styloid process by a depression for the attachment of the apex of the triangular articular disk, and behind, by a shallow groove for the tendon of the Extensor carpi ulnaris.

Structure.—The long, narrow medullary cavity is enclosed in a strong wall of compact tissue which is thickest along the interosseous border and dorsal surface. At the extremities the compact layer thins. The compact layer is continued onto the back of the olecranon as a plate of close spongy bone with lamellæ parallel. From the inner surface of this plate and the compact layer below it trabeculæ arch forward toward the olecranon and coronoid and cross other trabeculæ, passing backward over the medullary cavity from the upper part of the shaft below the coronoid. Below the coronoid process there is a small area of compact bone from which trabeculæ curve upward to end obliquely to the surface of the semilunar notch which is coated with a thin layer of compact bone. The trabeculæ at the lower end have a more longitudinal direction.

Ossification (Figs. 215, 216).—The ulna is ossified from *three* centers: one each for the body, the inferior extremity, and the top of the olecranon. Ossification begins near the middle of the body, about the eighth week of fetal life, and soon extends through the greater part of the bone. At birth the ends are cartilaginous. About the fourth year, a center appears in the middle of the head, and soon extends into the styloid process. About the tenth year, a center appears in the olecranon near its extremity, the chief part of this process being formed by an upward extension of the body. The upper epiphysis joins the body about the sixteenth, the lower about the twentieth year.

Articulations.—The ulna articulates with the humerus and radius.

The Radius.

The **radius** (Figs. 213, 214) is situated on the lateral side of the ulna, which exceeds it in length and size. Its upper end is small, and forms only a small part of the elbow-joint; but its lower end is large, and forms the chief part of the wrist-joint. It is a long bone, prismatic in form and slightly curved longitudinally. It has a body and two extremities.

The Upper Extremity (*proximal extremity*).—The upper extremity presents a head, neck, and tuberosity. The **head** is of a cylindrical form, and on its upper surface is a shallow cup or fovea for articulation with the capitulum of the humerus. The circumference of the head is smooth; it is broad medially where it articulates with the radial notch of the ulna, narrow in the rest of its extent, which is embraced by the annular ligament. The head is supported on a round, smooth, and constricted portion called the **neck**, on the back of which is a slight ridge for the insertion of part of the Supinator. Beneath the neck, on the medial side, is an eminence, the **radial tuberosity**; its surface is divided into a posterior, rough portion, for the insertion of the tendon of the Biceps brachii, and an anterior, smooth portion, on which a bursa is interposed between the tendon and the bone.

The Body or Shaft (*corpus radii*).—The body is prismoid in form, narrower above than below, and slightly curved, so as to be convex lateralward. It presents three borders and three surfaces.

Borders.—The **volar border** (*margo volaris; anterior border*) extends from the lower part of the tuberosity above to the anterior part of the base of the styloid process below, and separates the volar from the lateral surface. Its upper third is prominent, and from its oblique direction has received the name of the **oblique line of the radius**; it gives origin to the Flexor digitorum sublimis and Flexor pollicis longus; the surface above the line gives insertion to part of the Supinator. The middle third of the volar border is indistinct and rounded. The lower fourth is prominent, and gives insertion to the Pronator quadratus, and attachment to the dorsal carpal ligament; it ends in a small tubercle, into which the tendon of the Brachioradialis is inserted.

The **dorsal border** (*margo dorsalis; posterior border*) begins above at the back of the neck, and ends below at the posterior part of the base of the styloid process; it separates the posterior from the lateral surface. It is indistinct above and below, but well-marked in the middle third of the bone.

The **interosseous crest** (*crista interossea; internal or interosseous border*) begins above, at the back part of the tuberosity, and its upper part is rounded and indistinct; it becomes sharp and prominent as it descends, and at its lower part divides into two ridges which are continued to the anterior and posterior margins of the ulnar notch. To the posterior of the two ridges the lower part of the interosseous

membrane is attached, while the triangular surface between the ridges gives insertion to part of the Pronator quadratus. This crest separates the volar from the dorsal surface, and gives attachment to the interosseous membrane.

Surface.—The **volar surface** (*facies volaris; anterior surface*) is concave in its upper three-fourths, and gives origin to the Flexor pollicis longus; it is broad and flat in its lower fourth, and affords insertion to the Pronator quadratus. A prominent ridge limits the insertion of the Pronator quadratus below, and between this and the inferior border is a triangular rough surface for the attachment of the volar radiocarpal ligament. At the junction of the upper and middle thirds of the volar surface is the nutrient foramen, which is directed obliquely upward.

The **dorsal surface** (*facies dorsalis; posterior surface*) is convex, and smooth in the upper third of its extent, and covered by the Supinator. Its middle third is broad, slightly concave, and gives origin to the Abductor pollicis longus above, and the Extensor pollicis brevis below. Its lower third is broad, convex, and covered by the tendons of the muscles which subsequently run in the grooves on the lower end of the bone.

The **lateral surface** (*facies lateralis; external surface*) is convex throughout its entire extent. Its upper third gives insertion to the Supinator. About its center is a rough ridge, for the insertion of the Pronator teres. Its lower part is narrow, and covered by the tendons of the Abductor pollicis longus and Extensor pollicis brevis.

The Lower Extremity.—The lower extremity is large, of quadrilateral form, and provided with two articular surfaces—one below, for the carpus, and another at the medial side, for the ulna. The carpal articular surface is triangular, concave, smooth, and divided by a slight antero-posterior ridge into two parts. Of these, the lateral, triangular, articulates with the navicular bone; the medial, quadrilateral, with the lunate bone. The articular surface for the ulna is called the **ulnar notch** (*sigmoid cavity*) of the radius; it is narrow, concave, smooth, and articulates with the head of the ulna. These two articular surfaces are separated by a prominent ridge, to which the base of the triangular articular disk is attached; this disk separates the wrist-joint from the distal radioulnar articulation. This end of the bone has three non-articular surfaces—volar, dorsal, and lateral. The **volar surface**, rough and irregular, affords attachment to the volar radiocarpal ligament. The **dorsal surface** is convex, affords attachment to the dorsal radiocarpal ligament, and is marked by three grooves. Enumerated from the lateral side, the first groove is broad, but shallow, and subdivided into two by a slight ridge; the lateral of these two transmits the tendon of the Extensor carpi radialis longus, the medial the tendon of the Extensor carpi radialis brevis. The second is deep but narrow, and bounded laterally by a sharply defined ridge; it is directed obliquely from above downward and lateralward, and transmits the tendon of the Extensor pollicis longus. The third is broad, for the passage of the tendons of the Extensor indicis proprius and Extensor digitorum communis. The **lateral surface** is prolonged obliquely downward into a strong, conical projection, the **styloid process**, which gives attachment by its base to the tendon of the Brachioradialis, and by its apex to the radial collateral ligament of the wrist-joint. The lateral surface of this process is marked by a flat groove, for the tendons of the Abductor pollicis longus and Extensor pollicis brevis.

Structure.—The long narrow medullary cavity is enclosed in a strong wall of compact tissue which is thickest along the interosseous border and thinnest at the extremities except over the cup-shaped articular surface (fovea) of the head where it is thickened. The trabeculae of the spongy tissue are somewhat arched at the upper end and pass upward from the compact layer of the shaft to the fovea capituli; they are crossed by others parallel to the surface of the fovea. The arrangement at the lower end is somewhat similar.

Ossification (Figs. 217, 218).—The radius is ossified from *three* centers: one for the body, and one for either extremity. That for the body makes its appearance near the center of the bone, during the eighth week of fetal life. About the end of the second year, ossification commences

in the lower end; and at the fifth year, in the upper end. The upper epiphysis fuses with the body at the age of seventeen or eighteen years, the lower about the age of twenty. An additional center sometimes found in the radial tuberosity, appears about the fourteenth or fifteenth year.

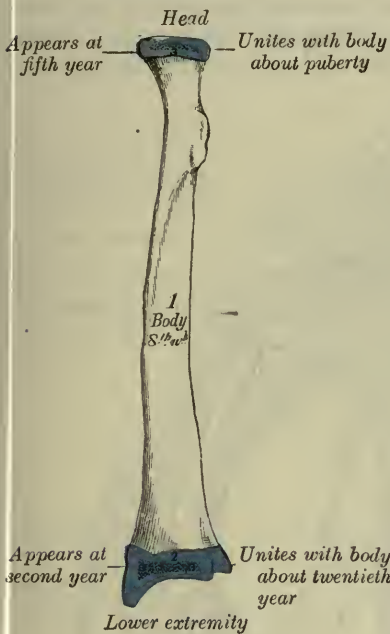

FIG. 217.—Plan of ossification of the radius. From three centers.




FIG. 218.—Epiphysal lines of radius in a young adult. Anterior aspect. The line of attachment of the articular capsule of the wrist-joint is in blue.

THE HAND.

The skeleton of the hand (Figs. 219, 220) is subdivided into three segments: the carpus or wrist bones; the metacarpus or bones of the palm; and the phalanges or bones of the digits.

The Carpus (Ossa Carpi).

The carpal bones, eight in number, are arranged in two rows. Those of the proximal row, from the radial to the ulnar side, are named the navicular, lunate, triangular, and pisiform; those of the distal row, in the same order, are named the greater multangular, lesser multangular, capitate, and hamate.

Common Characteristics of the Carpal Bones.—Each bone (excepting the pisiform) presents six surfaces. Of these the *volar* or *anterior* and the *dorsal* or *posterior* surfaces are rough, for ligamentous attachment; the dorsal surfaces being the broader, except in the navicular and lunate. The *superior* or *proximal*, and *inferior* or *distal* surfaces are articular, the superior generally convex, the inferior concave; the *medial* and *lateral* surfaces are also articular where they are in contact with contiguous bones, otherwise they are rough and tuberculated. The structure in all is similar, viz., cancellous tissue enclosed in a layer of compact bone.

Bones of the Proximal Row (upper row).—**The Navicular Bone** (*os naviculare manus*; *scaphoid bone*) (Fig. 221).—The navicular bone is the largest bone of the proximal row, and has received its name from its fancied resemblance to a boat. It is situated at the radial side of the carpus, its long axis being from above downward, lateralward, and forward. The *superior surface* is convex, smooth, of triangular shape, and artic-

ulates with the lower end of the radius. The **inferior surface**, directed downward, lateralward, and backward, is also smooth, convex, and triangular, and is divided by a slight ridge into two parts, the lateral articulating with the greater multangular, the medial with the lesser multangular. On the **dorsal surface** is a narrow, rough groove, which runs the entire length of the bone, and serves for the attachment of ligaments. The **volar surface** is concave above, and elevated at its lower and lateral part into a rounded projection, the **tubercle**, which is directed forward

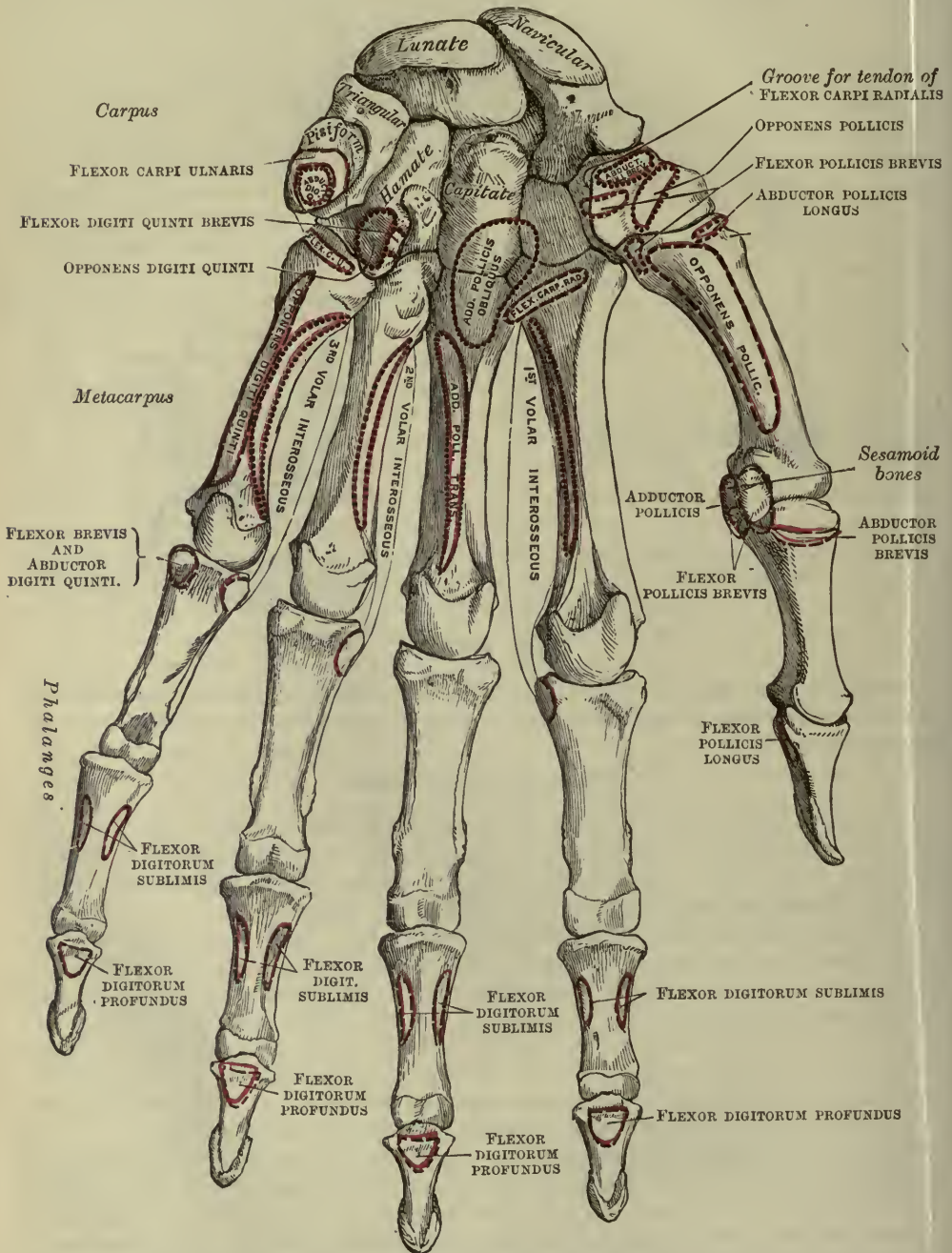


FIG. 219.—Bones of the left hand. Volar surface.

and gives attachment to the transverse carpal ligament and sometimes origin to a few fibers of the Abductor pollicis brevis. The lateral surface is rough and narrow, and gives attachment to the radial collateral ligament of the wrist. The medial surface presents two articular facets; of these, the superior or smaller is flattened of semilunar form, and articulates with the lunate bone; the inferior or larger is concave, forming with the lunate a concavity for the head of the capitate bone.

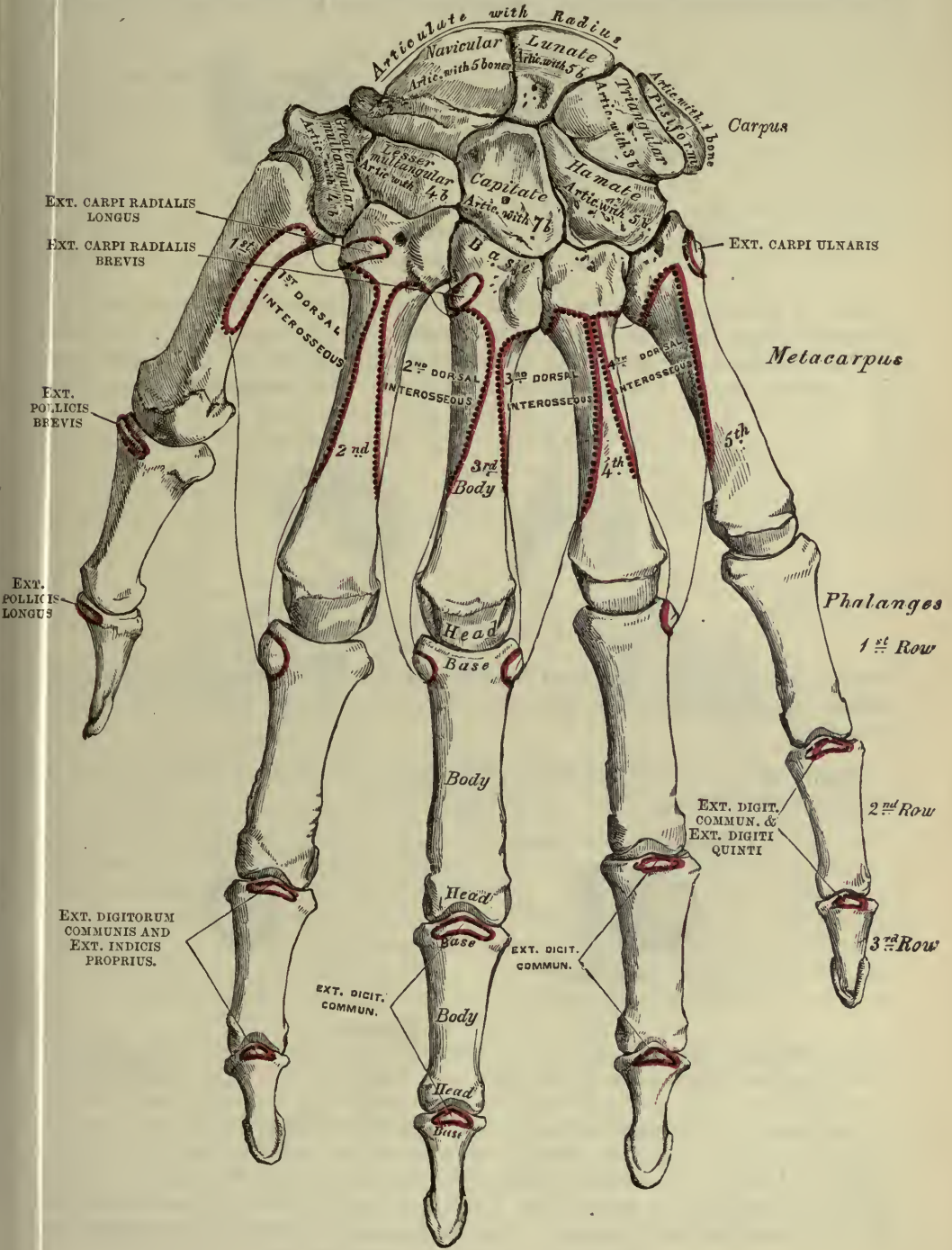


FIG. 220.—Bones of the left hand. Dorsal surface.

Articulations.—The navicular articulates with *five* bones: the radius proximally, greater and lesser multangulars distally, and capitate and lunate medially.

The Lunate Bone (*os lunatum*; *semilunar bone*) (Fig. 222).—The lunate bone may be distinguished by its deep concavity and crescentic outline. It is situated in the center of the proximal row of the carpus, between the navicular and triangular. The **superior surface**, convex and smooth, articulates with the radius. The **inferior surface** is deeply concave, and of greater extent from before backward than trans-

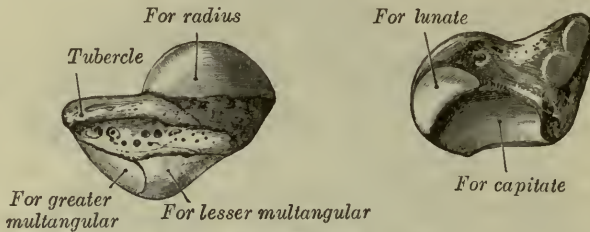


FIG. 221.—The left navicular bone.

versely: it articulates with the head of the capitate, and, by a long, narrow facet (separated by a ridge from the general surface), with the hamate. The **dorsal and volar surfaces** are rough, for the attachment of ligaments, the former being the broader, and of a somewhat rounded form. The **lateral surface** presents a

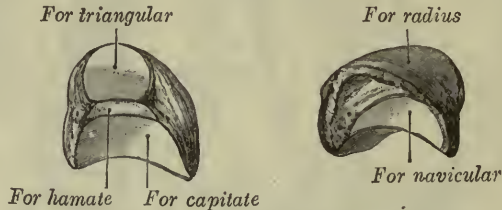

FIG. 222.—The left lunate bone.

narrow, flattened, semilunar facet for articulation with the navicular. The **medial surface** is marked by a smooth, quadrilateral facet, for articulation with the triangular.

Articulations.—The lunate articulates with *five* bones: the radius proximally, capitate and hamate distally, navicular laterally, and triangular medially.

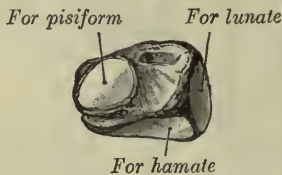


FIG. 223.—The left triangular bone.



FIG. 224.—The left pisiform bone.

The Triangular Bone (*os triquetrum*; *cuneiform bone*) (Fig. 223).—The triangular bone may be distinguished by its pyramidal shape, and by an oval isolated facet for articulation with the pisiform bone. It is situated at the upper and ulnar side of the carpus. The **superior surface** presents a medial, rough, non-articular portion, and a lateral convex articular portion which articulates with the triangular articular disk of the wrist. The **inferior surface**, directed lateralward, is concave, sinuously curved, and smooth for articulation with the hamate. The **dorsal surface** is rough for the attachment of ligaments. The **volar surface** presents, on its medial part,

an oval facet, for articulation with the pisiform; its lateral part is rough for ligamentous attachment. The **lateral surface**, the base of the pyramid, is marked by a flat, quadrilateral facet, for articulation with the lunate. The **medial surface**, the summit of the pyramid, is pointed and roughened, for the attachment of the ulnar collateral ligament of the wrist.

Articulations.—The triangular articulates with *three* bones: the lunate laterally, the pisiform in front, the hamate distally; and with the triangular articular disk which separates it from the lower end of the ulna.

The Pisiform Bone (*os pisiforme*) (Fig. 224).—The pisiform bone may be known by its small size, and by its presenting a single articular facet. It is situated on a plane anterior to the other carpal bones and is spheroidal in form. Its **dorsal surface** presents a smooth, oval facet, for articulation with the triangular: this facet approaches the superior, but not the inferior border of the bone. The **volar surface** is rounded and rough, and gives attachment to the transverse carpal ligament, and to the Flexor carpi ulnaris and Abductor digiti quinti. The **lateral and medial surfaces** are also rough, the former being concave, the latter usually convex.

Articulation.—The pisiform articulates with *one* bone, the triangular.

Bones of the Distal Row (lower row).—The **Greater Multangular Bone (*os multangulum majus; trapezium*)** (Fig. 225).—The greater multangular bone may be distinguished by a deep groove on its volar surface. It is situated at the radial side of the carpus, between the navicular and the first metacarpal bone. The **superior surface** is directed upward and medialward; medially it is smooth, and articulates with the navicular; laterally it is rough and continuous with the lateral surface. The **inferior surface** is oval, concave from side to side, convex from before backward, so as to form a saddle-shaped surface for articulation with the base

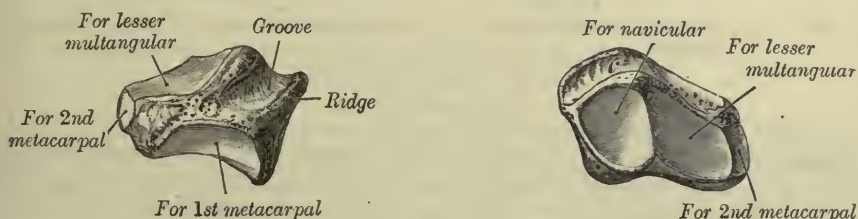


FIG. 225.—The left greater multangular bone.

of the first metacarpal bone. The **dorsal surface** is rough. The **volar surface** is narrow and rough. At its upper part is a deep groove, running from above obliquely downward and medialward; it transmits the tendon of the Flexor carpi radialis, and is bounded laterally by an oblique ridge. This surface gives origin to the Opponens pollicis and to the Abductor and Flexor pollicis brevis; it also affords attachment to the transverse carpal ligament. The **lateral surface** is broad and rough, for the attachment of ligaments. The **medial surface** presents two facets; the upper, large and concave, articulates with the lesser multangular; the lower, small and oval, with the base of the second metacarpal.

Articulations.—The greater multangular articulates with *four* bones: the navicular proximally, the first metacarpal distally, and the lesser multangular and second metacarpal medially.

The Lesser Multangular Bone (*os multangulum minus; trapezoid bone*) (Fig. 226).—The lesser multangular is the smallest bone in the distal row. It may be known by its wedge-shaped form, the broad end of the wedge constituting the dorsal, the narrow end the volar surface; and by its having four articular facets touching each other, and separated by sharp edges. The **superior surface**, quadrilateral,

smooth, and slightly concave, articulates with the navicular. The **inferior surface** articulates with the proximal end of the second metacarpal bone; it is convex from side to side, concave from before backward and subdivided by an elevated ridge into two unequal facets. The **dorsal and volar surfaces** are rough for the attachment of ligaments, the former being the larger of the two. The **lateral surface**, convex and smooth, articulates with the greater multangular. The **medial surface** is concave and smooth in front, for articulation with the capitate; rough behind, for the attachment of an interosseous ligament.

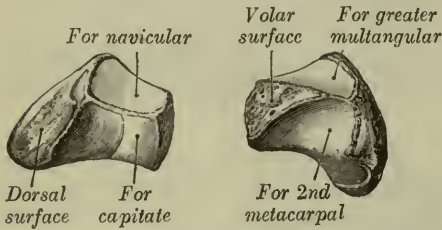


FIG. 226.—The left lesser multangular bone.

Articulations.—The lesser multangular articulates with *four* bones: the navicular proximally, second metacarpal distally, greater multangular laterally, and capitate medially.

The Capitate Bone (*os capitatum*; *os magnum*) (Fig. 227).—The capitate bone is the largest of the carpal bones, and occupies the center of the wrist. It presents, above, a rounded portion or head, which is received into the concavity formed by

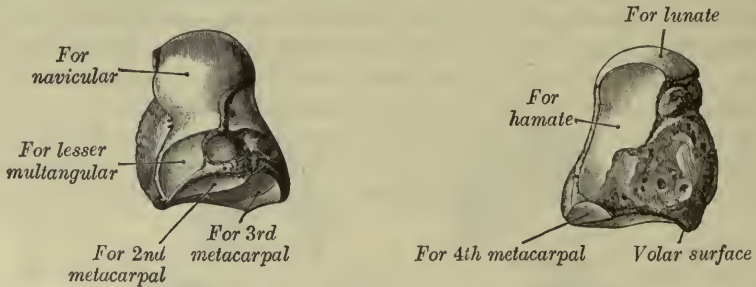


FIG. 227.—The left capitate bone.

the navicular and lunate; a constricted portion or neck; and below this, the body. The **superior surface** is round, smooth, and articulates with the lunate. The **inferior surface** is divided by two ridges into three facets, for articulation with the second, third, and fourth metacarpal bones, that for the third being the largest. The **dorsal surface** is broad and rough. The **volar surface** is narrow, rounded, and rough, for the attachment of ligaments and a part of the Adductor pollicis obliquus.

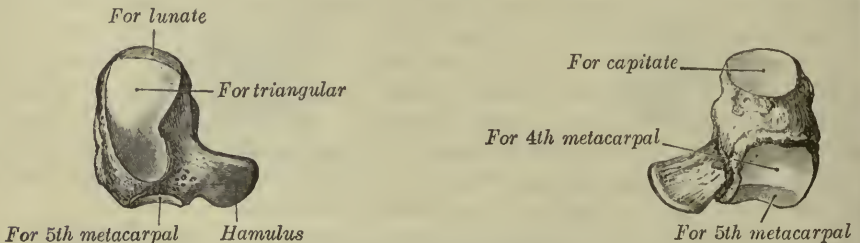


FIG. 228.—The left hamate bone.

The **lateral surface** articulates with the lesser multangular by a small facet at its anterior inferior angle, behind which is a rough depression for the attachment of an interosseous ligament. Above this is a deep, rough groove, forming part of the neck, and serving for the attachment of ligaments; it is bounded superiorly by a smooth, convex surface, for articulation with the navicular. The **medial**

surface articulates with the hamate by a smooth, concave, oblong facet, which occupies its posterior and superior parts; it is rough in front, for the attachment of an interosseous ligament.

Articulations.—The capitate articulates with *seven* bones: the navicular and lunate proximally, the second, third, and fourth metacarpals distally, the lesser multangular on the radial side, and the hamate on the ulnar side.

The Hamate Bone (*os hamatum; unciform bone*) (Fig. 228).—The hamate bone may be readily distinguished by its wedge-shaped form, and the hook-like process which projects from its volar surface. It is situated at the medial and lower angle of the carpus, with its base downward, resting on the fourth and fifth metacarpal bones, and its apex directed upward and lateralward. The **superior surface**, the apex of the wedge, is narrow, convex, smooth, and articulates with the lunate. The **inferior surface** articulates with the fourth and fifth metacarpal bones, by concave facets which are separated by a ridge. The **dorsal surface** is triangular and rough for ligamentous attachment. The **volar surface** presents, at its lower and ulnar side, a curved, hook-like process, the **hamulus**, directed forward and lateralward. This process gives attachment, by its apex, to the transverse carpal ligament and the Flexor carpi ulnaris; by its medial surface to the Flexor brevis and Opponens digiti quinti; its lateral side is grooved for the passage of the Flexor tendons into the palm of the hand. It is one of the four eminences on the front of the carpus to which the transverse carpal ligament of the wrist is attached; the others being the pisiform medially, the oblique ridge of the greater multangular and the tubercle of the navicular laterally. The **medial surface** articulates with the triangular bone by an oblong facet, cut obliquely from above, downward and medialward. The **lateral surface** articulates with the capitate by its upper and posterior part, the remaining portion being rough, for the attachment of ligaments.

Articulations.—The hamate articulates with *five* bones: the lunate proximally, the fourth and fifth metacarpals distally, the triangular medially, the capitate laterally.

The Metacarpus.

The **metacarpus** consists of five cylindrical bones which are numbered from the lateral side (*ossa metacarpalia I-V*); each consists of a body and two extremities.

Common Characteristics of the Metacarpal Bones.—The **Body** (*corpus; shaft*).—The body is prismoid in form, and curved, so as to be convex in the longitudinal direction behind, concave in front. It presents three surfaces: medial, lateral, and dorsal. The **medial** and **lateral surfaces** are concave, for the attachment of the Interossei, and separated from one another by a prominent anterior ridge. The **dorsal surface** presents in its distal two-thirds a smooth, triangular, flattened area which is covered in the fresh state, by the tendons of the Extensor muscles. This surface is bounded by two lines, which commence in small tubercles situated on either side of the digital extremity, and, passing upward, converge and meet some distance above the center of the bone and form a ridge which runs along the rest of the dorsal surface to the carpal extremity. This ridge separates two sloping surfaces for the attachment of the Interossei dorsales. To the tubercles on the digital extremities are attached the collateral ligaments of the metacarpophalangeal joints.

The **Base or Carpal Extremity** (*basis*) is of a cuboidal form, and broader behind than in front: it articulates with the carpus, and with the adjoining metacarpal bones; its **dorsal** and **volar surfaces** are rough, for the attachment of ligaments.

The **Head or Digital Extremity** (*capitulum*) presents an oblong surface markedly convex from before backward, less so transversely, and flattened from side to side; it articulates with the proximal phalanx. It is broader, and extends farther up-

ward, on the volar than on the dorsal aspect, and is longer in the antero-posterior than in the transverse diameter. On either side of the head is a tubercle for the attachment of the collateral ligament of the metacarpophalangeal joint. The **dorsal surface**, broad and flat, supports the Extensor tendons; the **volar surface** is grooved in the middle line for the passage of the Flexor tendons, and marked on either side by an articular eminence continuous with the terminal articular surface.

Characteristics of the Individual Metacarpal Bones.—The **First Metacarpal Bone** (*os metacarpale I; metacarpal bone of the thumb*) (Fig. 229) is shorter and

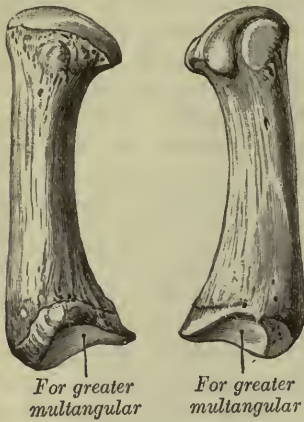


FIG. 229.—The first metacarpal. (Left.)

stouter than the others, diverges to a greater degree from the carpus, and its volar surface is directed toward the palm. The **body** is flattened and broad on its dorsal surface, and does not present the ridge which is found on the other metacarpal bones; its volar surface is concave from above downward. On its radial border is inserted the Opponens pollicis; its ulnar border gives origin to the lateral head of the first Interosseus dorsalis. The **base** presents a concavo-convex surface, for articulation with the greater multangular; it has no facets on its sides, but on its radial side is a tubercle for the insertion of the Abductor pollicis longus. The **head** is less convex than those of the other metacarpal bones, and is broader from side to side than from before backward. On its volar surface are two articular eminences, of which the lateral is the larger, for the two sesamoid bones in the tendons of the Flexor pollicis brevis.

The Second Metacarpal Bone (*os metacarpale II; metacarpal bone of the index finger*) (Fig. 230) is the longest, and its base the largest, of the four remaining bones. Its **base** is prolonged upward and medialward, forming a prominent ridge. It presents four articular facets: three on the upper surface and one on the ulnar side. Of the facets on the upper surface the intermediate is the largest and is concave from side to side, convex from before backward for articulation with the lesser multangular; the lateral is small, flat and oval for articulation with the greater multangular; the medial, on the summit of the ridge, is long and narrow for articulation with the capitate. The facet on the ulnar side articulates with the third metacarpal. The Extensor carpi radialis longus is inserted on the dorsal surface and the Flexor carpi radialis on the volar surface of the base.

The Third Metacarpal Bone (*os metacarpale III; metacarpal bone of the middle finger*) (Fig. 231) is a little smaller than the second. The dorsal aspect of its **base** presents on its radial side a pyramidal eminence, the **styloid process**, which extends upward behind the capitate; immediately distal to this is a rough surface for the attachment of the Extensor carpi radialis brevis. The carpal articular facet is concave behind, flat in front, and articulates with the capitate. On the radial side is a smooth, concave facet for articulation with the second metacarpal, and on the ulnar side two small oval facets for the fourth metacarpal.

The Fourth Metacarpal Bone (*os metacarpale IV; metacarpal bone of the ring finger*) (Fig. 232) is shorter and smaller than the third. The **base** is small and quadrilateral; its superior surface presents two facets, a large one medially for articulation with the hamate, and a small one laterally for the capitate. On the radial side are two oval facets, for articulation with the third metacarpal; and on the ulnar side a single concave facet, for the fifth metacarpal.

The Fifth Metacarpal Bone (*os metacarpale V; metacarpal bone of the little finger*) (Fig. 233) presents on its **base** one facet on its superior surface, which is concavo-

convex and articulates with the hamate, and one on its radial side, which articulates with the fourth metacarpal. On its ulnar side is a prominent tubercle for the insertion of the tendon of the Extensor carpi ulnaris. The dorsal surface of the body

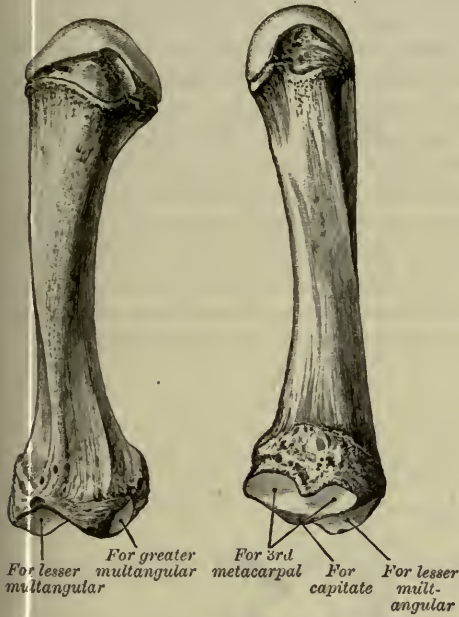


FIG. 230.—The second metacarpal. (Left.)

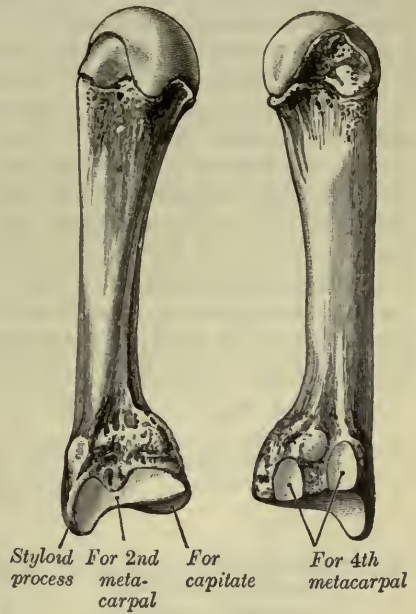


FIG. 231.—The third metacarpal. (Left.)

is divided by an oblique ridge, which extends from near the ulnar side of the base to the radial side of the head. The lateral part of this surface serves for the attachment of the fourth Interosseus dorsalis; the medial part is smooth, triangular, and covered by the Extensor tendons of the little finger.

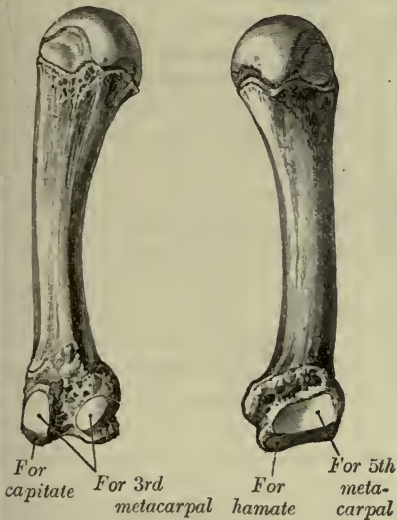


FIG. 232.—The fourth metacarpal. (Left.)

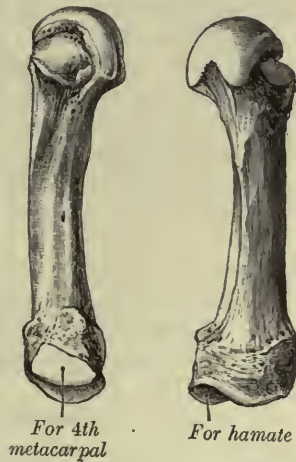

FIG. 233.—The fifth metacarpal. (Left.)

Articulations.—Besides their phalangeal articulations, the metacarpal bones articulate as follows: the first with the greater multangular; the second with the greater multangular, lesser multangular, capitate and third metacarpal; the third with the capitate and second and fourth metacarpals; the fourth with the capitate, hamate, and third and fifth metacarpals; and the fifth with the hamate and fourth metacarpal.

The Phalanges of the Hand (Phalanges Digitorum Manus).

The **phalanges** are fourteen in number, three for each finger, and two for the thumb. Each consists of a body and two extremities. The **body** tapers from above downward, is convex posteriorly, concave in front from above downward, flat from side to side; its sides are marked by rough ridges which give attachment to the fibrous sheaths of the Flexor tendons. The **proximal extremities** of the bones of the first row present oval, concave articular surfaces, broader from side to side than from before backward. The **proximal extremity** of each of the bones of the second and third rows presents a double concavity separated by a median ridge. The **distal extremities** are smaller than the proximal, and each ends in two condyles separated by a shallow groove; the articular surface extends farther on the volar than on the dorsal surface, a condition best marked in the bones of the first row.

The **ungual phalanges** are convex on their dorsal and flat on their volar surfaces; they are recognized by their small size, and by a roughened, elevated surface of a horseshoe form on the volar surface of the distal extremity of each which serves to support the sensitive pulp of the finger.

CARPUS
 One center for each bone :
 All cartilaginous at birth

METACARPALS OF FINGERS
 Two centers for each bone :
 One for body
 One for head

PHALANGES
 Two centers for each bone :
 One for body
 One for proximal
 extremity

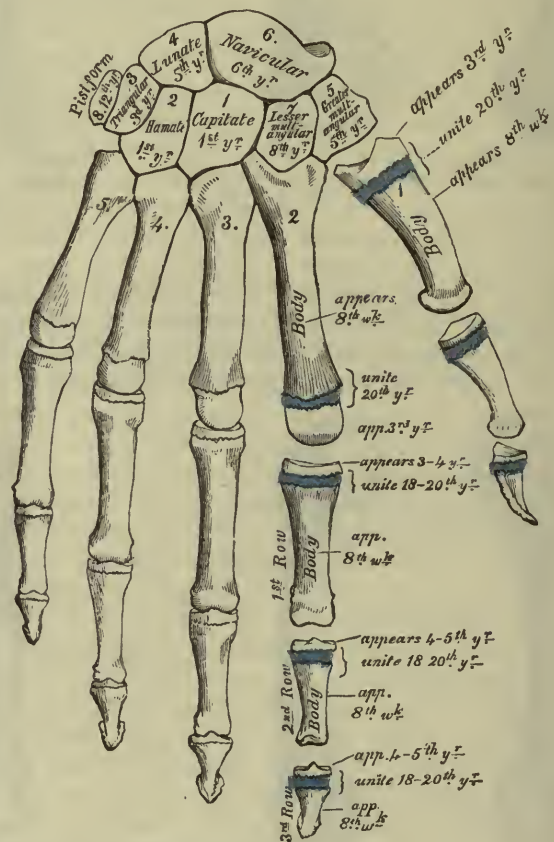


FIG. 234.—Plan of ossification of the hand.

Articulations.—In the four fingers the phalanges of the first row articulate with those of the second row and with the metacarpals; the phalanges of the second row with those of the first and third rows, and the ungual phalanges with those of the second row. In the thumb, which has only two phalanges, the first phalanx articulates by its proximal extremity with the metacarpal bone and by its distal with the ungual phalanx.

Ossification of the Bones of the Hand.—The **carpal bones** are each ossified from a single center, and ossification proceeds in the following order (Fig. 234): in the capitate and hamate, during

the first year, the former preceding the latter; in the triangular, during the third year; in the lunate and greater multangular, during the fifth year, the former preceding the latter; in the navicular, during the sixth year; in the lesser multangular, during the eighth year; and in the pisiform, about the twelfth year

Occasionally an additional bone, the *os centrale*, is found on the back of the carpus, lying between the navicular, lesser multangular, and capitate. During the second month of fetal life it is represented by a small cartilaginous nodule, which usually fuses with the cartilaginous navicular. Sometimes the styloid process of the third metacarpal is detached and forms an additional ossicle.

The **metacarpal bones** are each ossified from *two* centers: one for the body and one for the distal extremity of each of the second, third, fourth, and fifth bones; one for the body and one for the base of the first metacarpal bone.¹ The first metacarpal bone is therefore ossified in the same manner as the phalanges, and this has led some anatomists to regard the thumb as being made up of three phalanges, and not of a metacarpal bone and two phalanges. Ossification commences in the middle of the body about the eighth or ninth week of fetal life, the centers for the second and third metacarpals being the first, and that for the first metacarpal, the last, to appear; about the third year the distal extremities of the metacarpals of the fingers, and the base of the metacarpal of the thumb, begin to ossify; they unite with the bodies about the twentieth year.

The **phalanges** are each ossified from *two* centers: one for the body, and one for the proximal extremity. Ossification begins in the body, about the eighth week of fetal life. Ossification of the proximal extremity commences in the bones of the first row between the third and fourth years, and a year later in those of the second and third rows. The two centers become united in each row between the eighteenth and twentieth years.

In the ungual phalanges the centers for the bodies appear at the distal extremities of the phalanges, instead of at the middle of the bodies, as in the other phalanges. Moreover, of all the bones of the hand, the ungual phalanges are the first to ossify.

THE BONES OF THE LOWER EXTREMITY (OSSA EXTREMITATIS INFERIORIS).

The Hip Bone (Os Coxæ; Innominate Bone).

The **hip bone** is a large, flattened, irregularly shaped bone, constricted in the center and expanded above and below. It meets its fellow on the opposite side in the middle line in front, and together they form the sides and anterior wall of the pelvic cavity. It consists of three parts, the **ilium**, **ischium**, and **pubis**, which are distinct from each other in the young subject, but are fused in the adult; the union of the three parts takes place in and around a large cup-shaped articular cavity, the **acetabulum**, which is situated near the middle of the outer surface of the bone. The **ilium**, so-called because it supports the flank, is the superior broad and expanded portion which extends upward from the acetabulum. The **ischium** is the lowest and strongest portion of the bone; it proceeds downward from the acetabulum, expands into a large tuberosity, and then, curving forward, forms, with the pubis, a large aperture, the **obturator foramen**. The **pubis** extends medialward and downward from the acetabulum and articulates in the middle line with the bone of the opposite side: it forms the front of the pelvis and supports the external organs of generation.

The **Ilium** (*os ilii*).—The ilium is divisible into two parts, the **body** and the **ala**; the separation is indicated on the internal surface by a curved line, the **arcuate line**, and on the external surface by the margin of the acetabulum.

The **Body** (*corpus oss. ilii*).—The body enters into the formation of the acetabulum, of which it forms rather less than two-fifths. Its **external surface** is partly articular, partly non-articular; the articular segment forms part of the lunate surface of the acetabulum, the non-articular portion contributes to the acetabular fossa. The **internal surface** of the body is part of the wall of the lesser pelvis and gives origin to some fibers of the Obturator internus. Below, it is continuous with the pelvic surfaces of the ischium and pubis, only a faint line indicating the place of union.

¹ Allen Thomson demonstrated the fact that the first metacarpal bone is often developed from three centers: that is to say, there is a separate nucleus for the distal end, forming a distinct epiphysis visible at the age of seven or eight years. He also stated that there are traces of a proximal epiphysis in the second metacarpal bone, *Journal of Anatomy and Physiology*, 1869.

The Ala (ala oss. ili).—The ala is the large expanded portion which bounds the greater pelvis laterally. It presents for examination two surfaces—an external and an internal—a crest, and two borders—an anterior and a posterior. The **external surface** (Fig. 235), known as the **dorsum ili**, is directed backward and lateralward behind, and downward and lateralward in front. It is smooth, convex in front,

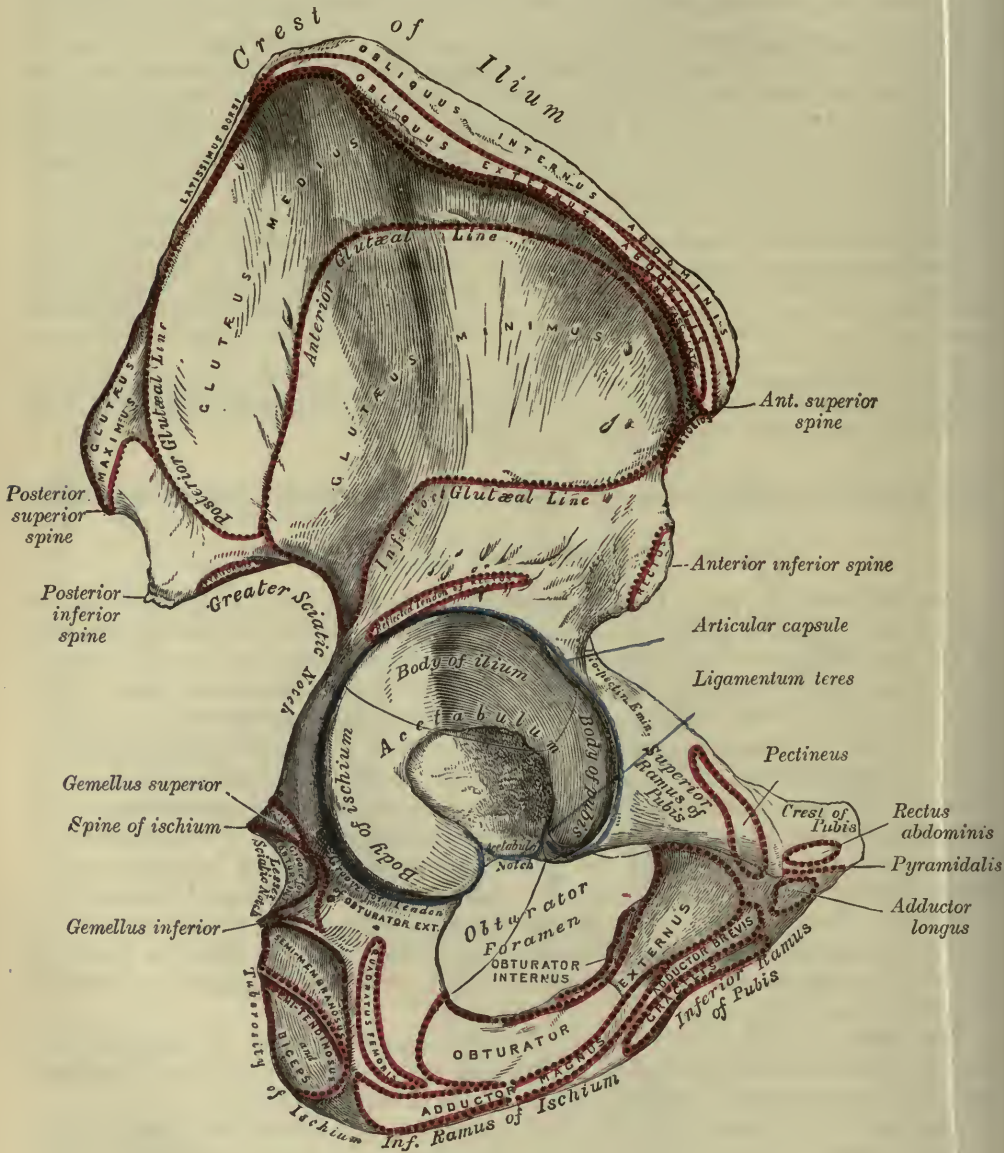


FIG. 235.—Right hip bone. External surface.

deeply concave behind; bounded above by the crest, below by the upper border of the acetabulum, in front and behind by the anterior and posterior borders. This surface is crossed in an arched direction by three lines—the posterior, anterior, and inferior gluteal lines. The **posterior gluteal line** (*superior curved line*), the shortest of the three, begins at the crest, about 5 cm. in front of its posterior extremity; it is at first distinctly marked, but as it passes downward to the upper part of the

greater sciatic notch, where it ends, it becomes less distinct, and is often altogether lost. Behind this line is a narrow semilunar surface, the upper part of which is rough and gives origin to a portion of the *Glutæus maximus*; the lower part is smooth and has no muscular fibers attached to it. The **anterior gluteal line** (*middle curved line*), the longest of the three, begins at the crest, about 4 cm. behind its anterior extremity, and, taking a curved direction downward and backward, ends

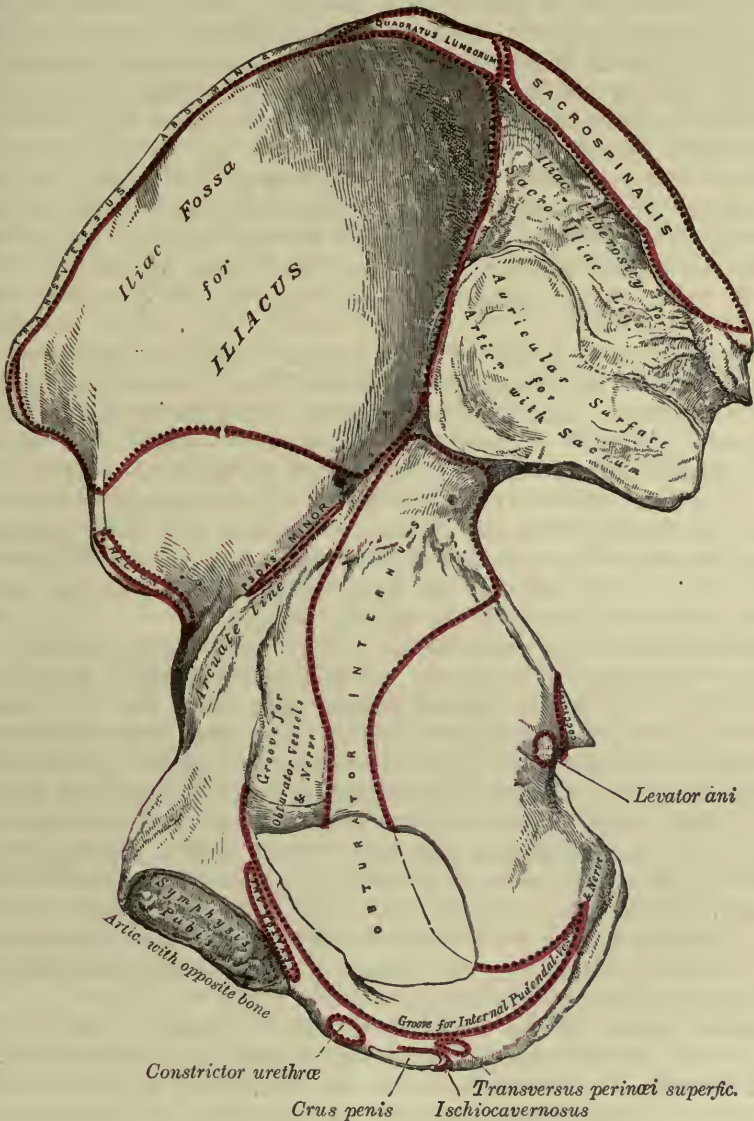


FIG. 236.—Right hip bone. Internal surface.

at the upper part of the greater sciatic notch. The space between the anterior and posterior gluteal lines and the crest is concave, and gives origin to the *Glutæus medius*. Near the middle of this line a nutrient foramen is often seen. The **inferior gluteal line** (*inferior curved line*), the least distinct of the three, begins in front at the notch on the anterior border, and, curving backward and downward, ends near the middle of the greater sciatic notch. The surface of bone included

between the anterior and inferior gluteal lines is concave from above downward, convex from before backward, and gives origin to the *Glutæus minimus*. Between the inferior gluteal line and the upper part of the acetabulum is a rough, shallow groove, from which the reflected tendon of the *Rectus femoris* arises.

The **internal surface** (Fig. 236) of the ala is bounded above by the crest, below, by the arcuate line; in front and behind, by the anterior and posterior borders. It presents a large, smooth, concave surface, called the **iliac fossa**, which gives origin to the *Iliacus* and is perforated at its inner part by a nutrient canal; and below this a smooth, rounded border, the **arcuate line**, which runs downward, forward, and medialward. Behind the iliac fossa is a rough surface, divided into two portions, an anterior and a posterior. The **anterior surface** (*auricular surface*), so called from its resemblance in shape to the ear, is coated with cartilage in the fresh state, and articulates with a similar surface on the side of the sacrum. The posterior portion, known as the **iliac tuberosity**, is elevated and rough, for the attachment of the posterior sacroiliac ligaments and for the origins of the *Sacrospinalis* and *Multifidus*. Below and in front of the auricular surface is the **preauricular sulcus**, more commonly present and better marked in the female than in the male; to it is attached the pelvic portion of the anterior sacroiliac ligament.

The **crest** of the ilium is convex in its general outline but is sinuously curved, being concave inward in front, concave outward behind. It is thinner at the center than at the extremities, and ends in the **anterior and posterior superior iliac spines**. The surface of the crest is broad, and divided into external and internal lips, and an intermediate line. About 5 cm. behind the anterior superior iliac spine there is a prominent tubercle on the outer lip. To the external lip are attached the *Tensor fasciæ latæ*, *Obliquus externus abdominis*, and *Latissimus dorsi*, and along its whole length the fascia lata; to the intermediate line the *Obliquus internus abdominis*; to the internal lip, the fascia iliaca, the *Transversus abdominis*, *Quadratus lumborum*, *Sacrospinalis*, and *Iliacus*.

The **anterior border** of the ala is concave. It presents two projections, separated by a notch. Of these, the uppermost, situated at the junction of the crest and anterior border, is called the **anterior superior iliac spine**; its outer border gives attachment to the fascia lata, and the *Tensor fasciæ latæ*; its inner border, to the *Iliacus*; while its extremity affords attachment to the inguinal ligament and gives origin to the *Sartorius*. Beneath this eminence is a notch from which the *Sartorius* takes origin and across which the lateral femoral cutaneous nerve passes. Below the notch is the **anterior inferior iliac spine**, which ends in the upper lip of the acetabulum; it gives attachment to the straight tendon of the *Rectus femoris* and to the iliofemoral ligament of the hip-joint. Medial to the anterior inferior spine is a broad, shallow groove, over which the *Iliacus* and *Psoas major* pass. This groove is bounded medially by an eminence, the **iliopectineal eminence**, which marks the point of union of the ilium and pubis.

The **posterior border** of the ala, shorter than the anterior, also presents two projections separated by a notch, the **posterior superior iliac spine** and the **posterior inferior iliac spine**. The former serves for the attachment of the oblique portion of the posterior sacroiliac ligaments and the *Multifidus*; the latter corresponds with the posterior extremity of the auricular surface. Below the posterior inferior spine is a deep notch, the **greater sciatic notch**.

The Ischium (*os ischii*).—The ischium forms the lower and back part of the hip bone. It is divisible into three portions—a **body** and **two rami**.

The Body (*corpus oss. ischii*).—The body enters into and constitutes a little more than two-fifths of the acetabulum. Its **external surface** forms part of the lunate surface of the acetabulum and a portion of the acetabular fossa. Its **internal surface** is part of the wall of the lesser pelvis; it gives origin to some fibers of the

Obturator internus. Its anterior border projects as the **posterior obturator tubercle**; from its posterior border there extends backward a thin and pointed triangular eminence, the **ischial spine**, more or less elongated in different subjects. The external surface of the spine gives attachment to the Gemellus superior, its internal surface to the Coccygeus, Levator ani, and the pelvic fascia; while to the pointed extremity the sacrospinous ligament is attached. Above the spine is a large notch, the **greater sciatic notch**, converted into a foramen by the sacrospinous ligament; it transmits the Piriformis, the superior and inferior gluteal vessels and nerves, the sciatic and posterior femoral cutaneous nerves, the internal pudendal vessels, and nerve, and the nerves to the Obturator internus and Quadratus femoris. Of these, the superior gluteal vessels and nerve pass out above the Piriformis, the other structures below it. Below the spine is a smaller notch, the **lesser sciatic notch**; it is smooth, coated in the recent state with cartilage, the surface of which presents two or three ridges corresponding to the subdivisions of the tendon of the Obturator internus, which winds over it. It is converted into a foramen by the sacrotuberous and sacrospinous ligaments, and transmits the tendon of the Obturator internus, the nerve which supplies that muscle, and the internal pudendal vessels and nerve.

The Superior Ramus (*ramus superior oss. ischii; descending ramus*).—The superior ramus projects downward and backward from the body and presents for examination three surfaces: external, internal, and posterior. The **external surface** is quadrilateral in shape. It is bounded *above* by a groove which lodges the tendon of the Obturator externus; *below*, it is continuous with the inferior ramus; in *front* it is limited by the posterior margin of the obturator foramen; *behind*, a prominent margin separates it from the posterior surface. In front of this margin the surface gives origin to the Quadratus femoris, and anterior to this to some of the fibers of origin of the Obturator externus; the lower part of the surface gives origin to part of the Adductor magnus. The **internal surface** forms part of the bony wall of the lesser pelvis. In *front* it is limited by the posterior margin of the obturator foramen. *Below*, it is bounded by a sharp ridge which gives attachment to a falciform prolongation of the sacrotuberous ligament, and, more anteriorly, gives origin to the Transversus perinæi and Ischioavernosus. *Posteriorly* the ramus forms a large swelling, the **tuberosity of the ischium**, which is divided into two portions: a lower, rough, somewhat triangular part, and an upper, smooth, quadrilateral portion. The lower portion is subdivided by a prominent longitudinal ridge, passing from base to apex, into two parts; the outer gives attachment to the Adductor magnus, the inner to the sacrotuberous ligament. The upper portion is subdivided into two areas by an oblique ridge, which runs downward and outward; from the upper and outer area the Semimembranosus arises; from the lower and inner, the long head of the Biceps femoris and the Semitendinosus.

The Inferior Ramus (*ramus inferior oss. ischii; ascending ramus*).—The inferior ramus is the thin, flattened part of the ischium, which ascends from the superior ramus, and joins the inferior ramus of the pubis—the junction being indicated in the adult by a raised line. The **outer surface** is uneven for the origin of the Obturator externus and some of the fibers of the Adductor magnus; its **inner surface** forms part of the anterior wall of the pelvis. Its **medial border** is thick, rough, slightly everted, forms part of the outlet of the pelvis, and presents two ridges and an intervening space. The ridges are continuous with similar ones on the inferior ramus of the pubis: to the outer is attached the deep layer of the superficial perineal fascia (*fascia of Colles*), and to the inner the inferior fascia of the urogenital diaphragm. If these two ridges be traced downward, they will be found to join with each other just behind the point of origin of the Transversus perinæi; here the two layers of fascia are continuous behind the posterior border of the muscle. To the intervening space, just in front of the point of junction of the ridges, the

Transversus perinæi is attached, and in front of this a portion of the crus penis vel clitoridis and the Ischiocavernosus. Its **lateral border** is thin and sharp, and forms part of the medial margin of the obturator foramen.

The Pubis (*os pubis*).—The pubis, the anterior part of the hip bone, is divisible into a **body**, a **superior** and an **inferior ramus**.

The Body (*corpus oss. pubis*).—The body forms one-fifth of the acetabulum, contributing by its **external surface** both to the lunate surface and the acetabular fossa. Its **internal surface** enters into the formation of the wall of the lesser pelvis and gives origin to a portion of the Obturator internus.

The Superior Ramus (*ramus superior oss. pubis; ascending ramus*).—The superior ramus extends from the body to the median plane where it articulates with its fellow of the opposite side. It is conveniently described in two portions, viz., a medial flattened part and a narrow lateral prismoid portion.

The **Medial Portion** of the superior ramus, formerly described as the body of the pubis, is somewhat quadrilateral in shape, and presents for examination two surfaces and three borders. The **anterior surface** is rough, directed downward and outward, and serves for the origin of various muscles. The Adductor longus arises from the upper and medial angle, immediately below the crest; lower down, the Obturator externus, the Adductor brevis, and the upper part of the Gracilis take origin. The **posterior surface**, convex from above downward, concave from side to side, is smooth, and forms part of the anterior wall of the pelvis. It gives origin to the Levator ani and Obturator internus, and attachment to the puboprostatic ligaments and to a few muscular fibers prolonged from the bladder. The **upper border** presents a prominent tubercle, the **pubic tubercle** (*pubic spine*), which projects forward; the inferior crus of the **subcutaneous inguinal ring** (*external abdominal ring*), and the **inguinal ligament** (*Poupart's ligament*) are attached to it. Passing upward and lateralward from the pubic tubercle is a well-defined ridge, forming a part of the pectineal line which marks the brim of the lesser pelvis: to it are attached a portion of the **inguinal falx** (*conjoined tendon of Obliquus internus and Transversus*), the **lacunar ligament** (*Gimbernat's ligament*), and the **reflected inguinal ligament** (*triangular fascia*). Medial to the pubic tubercle is the **crest**, which extends from this process to the medial end of the bone. It affords attachment to the inguinal falx, and to the Rectus abdominis and Pyramidalis. The point of junction of the crest with the medial border of the bone is called the **angle**; to it, as well as to the symphysis, the superior crus of the subcutaneous inguinal ring is attached. The **medial border** is articular; it is oval, and is marked by eight or nine transverse ridges, or a series of nipple-like processes arranged in rows, separated by grooves; they serve for the attachment of a thin layer of cartilage, which intervenes between it and the interpubic fibrocartilaginous lamina. The **lateral border** presents a sharp margin, the **obturator crest**, which forms part of the circumference of the obturator foramen and affords attachment to the obturator membrane.

The **Lateral Portion** of the ascending ramus has three surfaces: superior, inferior, and posterior. The **superior surface** presents a continuation of the pectineal line, already mentioned as commencing at the pubic tubercle. In front of this line, the surface of bone is triangular in form, wider laterally than medially, and is covered by the Pectineus. The surface is bounded, laterally, by a rough eminence, the **iliopectineal eminence**, which serves to indicate the point of junction of the ilium and pubis, and below by a prominent ridge which extends from the acetabular notch to the pubic tubercle. The **inferior surface** forms the upper boundary of the obturator foramen, and presents, laterally, a broad and deep, oblique groove, for the passage of the obturator vessels and nerve; and medially, a sharp margin, the **obturator crest**, forming part of the circumference of the obturator foramen, and giving attachment to the obturator membrane. The **posterior surface** consti-

tutes part of the anterior boundary of the lesser pelvis. It is smooth, convex from above downward, and affords origin to some fibers of the Obturator internus.

The Inferior Ramus (*ramus inferior oss. pubis; descending ramus*).—The inferior ramus is thin and flattened. It passes lateralward and downward from the medial end of the superior ramus; it becomes narrower as it descends and joins with the inferior ramus of the ischium below the obturator foramen. Its **anterior surface** is rough, for the origin of muscles—the Gracilis along its medial border, a portion of the Obturator externus where it enters into the formation of the obturator foramen, and between these two, the Adductores brevis and magnus, the former being the more medial. The **posterior surface** is smooth, and gives origin to the Obturator internus, and, close to the medial margin, to the Constrictor urethræ. The **medial border** is thick, rough, and everted, especially in females. It presents two ridges, separated by an intervening space. The ridges extend downward, and are continuous with similar ridges on the inferior ramus of the ischium; to the external is attached the fascia of Colles, and to the internal the inferior fascia of the urogenital diaphragm. The **lateral border** is thin and sharp, forms part of the circumference of the obturator foramen, and gives attachment to the obturator membrane.

The Acetabulum (*cotyloid cavity*).—The acetabulum is a deep, cup-shaped, hemispherical depression, directed downward, lateralward, and forward. It is formed medially by the pubis, above by the ilium, laterally and below by the ischium; a little less than two-fifths is contributed by the ilium, a little more than two-fifths by the ischium, and the remaining fifth by the pubis. It is bounded by a prominent uneven rim, which is thick and strong above, and serves for the attachment of the **glenoidal labrum** (*cotyloid ligament*), which contracts its orifice, and deepens the surface for articulation. It presents below a deep notch, the **acetabular notch**, which is continuous with a circular non-articular depression, the **acetabular fossa**, at the bottom of the cavity: this depression is perforated by numerous apertures, and lodges a mass of fat. The notch is converted into a foramen by the transverse ligament; through the foramen nutrient vessels and nerves enter the joint; the margins of the notch serve for the attachment of the ligamentum teres. The rest of the acetabulum is formed by a curved articular surface, the **unate surface**, for articulation with the head of the femur.

The Obturator Foramen (*foramen obturatum; thyroid foramen*).—The obturator foramen is a large aperture, situated between the ischium and pubis. In the male it is large and of an oval form, its longest diameter slanting obliquely from before backward; in the female it is smaller, and more triangular. It is bounded by a thin, uneven margin, to which a strong membrane is attached, and presents, superiorly, a deep groove, the **obturator groove**, which runs from the pelvis obliquely medialward and downward. This groove is converted into a canal by a ligamentous band, a specialized part of the obturator membrane, attached to two tubercles: one, the **posterior obturator tubercle**, on the medial border of the ischium, just in front of the acetabular notch; the other, the **anterior obturator tubercle**, on the obturator crest of the superior ramus of the pubis. Through the canal the obturator vessels and nerve pass out of the pelvis.

Structure.—The thicker parts of the bone consist of cancellous tissue, enclosed between two layers of compact tissue; the thinner parts, as at the bottom of the acetabulum and center of the iliac fossa, are usually semitransparent, and composed entirely of compact tissue.

Ossification (Fig. 237).—The hip bone is ossified from *eight* centers: *three* primary—one each for the ilium, ischium, and pubis; and *five* secondary—one each for the crest of the ilium, the anterior inferior spine (said to occur more frequently in the male than in the female), the tuberosity of the ischium, the pubic symphysis (more frequent in the female than in the male), and one or more for the Y-shaped piece at the bottom of the acetabulum. The centers appear in the following order: in the lower part of the ilium, immediately above the greater sciatic notch, about the eighth or ninth week of fetal life; in the superior ramus of the ischium, about the third month;

in the superior ramus of the pubis, between the fourth and fifth months. At birth, the three primary centers are quite separate, the crest, the bottom of the acetabulum, the ischial tuberosity, and the inferior rami of the ischium and pubis being still cartilaginous. By the seventh or eighth year, the inferior rami of the pubis and ischium are almost completely united by bone. About the thirteenth or fourteenth year, the three primary centers have extended their growth into the bottom of the acetabulum, and are there separated from each other by a Y-shaped portion of cartilage, which now presents traces of ossification, often by two or more centers. One of these, the *os acetabuli*, appears about the age of twelve, between the ilium and pubis, and fuses with them about the age of eighteen; it forms the pubic part of the acetabulum. The ilium and ischium then become joined, and lastly the pubis and ischium, through the intervention of this Y-shaped portion. At about the age of puberty, ossification takes place in each of the remaining portions, and they join with the rest of the bone between the twentieth and twenty-fifth years. Separate centers are frequently found for the pubic tubercle and the ischial spine, and for the crest and angle of the pubis.

Articulations.—The hip bone articulates with its fellow of the opposite side, and with the sacrum and femur.

By eight centers { Three primary (Ilium, Ischium, and Pubis)
Five secondary

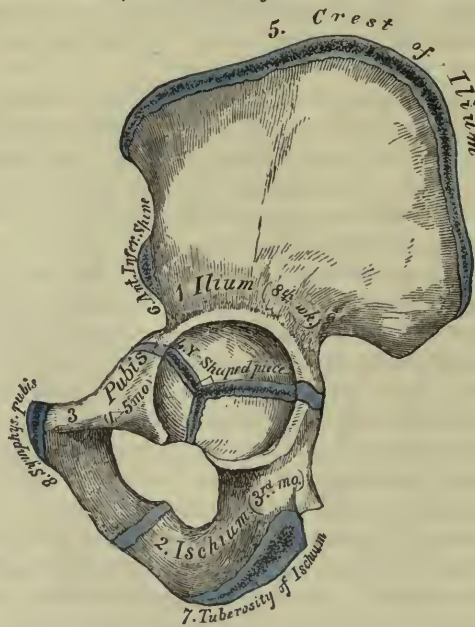


FIG. 237.—Plan of ossification of the hip bone. The three primary centers unite through a Y-shaped piece about puberty. Epiphyses appear about puberty, and unite about twenty-fifth year.

The Pelvis.

The **pelvis**, so called from its resemblance to a basin, is a bony ring, interposed between the movable vertebræ of the vertebral column which it supports, and the lower limbs upon which it rests; it is stronger and more massively constructed than the wall of the cranial or thoracic cavities, and is composed of four bones: the two **hip bones** laterally and in front and the **sacrum** and **coccyx** behind.

The pelvis is divided by an oblique plane passing through the prominence of the sacrum, the arcuate and pectineal lines, and the upper margin of the symphysis pubis, into the greater and the lesser pelvis. The circumference of this plane is termed the **linea terminalis** or **pelvic brim**.

The Greater or False Pelvis (*pelvis major*).—The greater pelvis is the expanded portion of the cavity situated above and in front of the pelvic brim. It is bounded on either side by the ilium; in *front* it is incomplete, presenting a wide interval between the anterior borders of the ilia, which is filled up in the fresh state by

the parietes of the abdomen; behind is a deep notch on either side between the ilium and the base of the sacrum. It supports the intestines, and transmits part of their weight to the anterior wall of the abdomen.

The Lesser or True Pelvis (*pelvis minor*).—The lesser pelvis is that part of the pelvic cavity which is situated below and behind the pelvic brim. Its bony walls are more complete than those of the greater pelvis. For convenience of description, it is divided into an **inlet** bounded by the superior circumference, and **outlet** bounded by the inferior circumference, and a **cavity**.

The Superior Circumference.—The superior circumference forms the brim of the pelvis, the included space being called the **superior aperture** or **inlet** (*apertura pelvis [minoris] superior*) (Fig. 238). It is formed laterally by the pectineal and arcuate lines, in front by the crests of the pubes, and behind by the anterior margin of the base of the sacrum and sacrovertebral angle. The superior aperture is somewhat heart-shaped, obtusely pointed in front, diverging on either side, and encroached upon behind by the projection forward of the promontory of the sacrum. It has three principal diameters: antero-posterior, transverse, and oblique. The **antero-posterior** or **conjugate diameter** extends from the sacrovertebral angle to the sym-

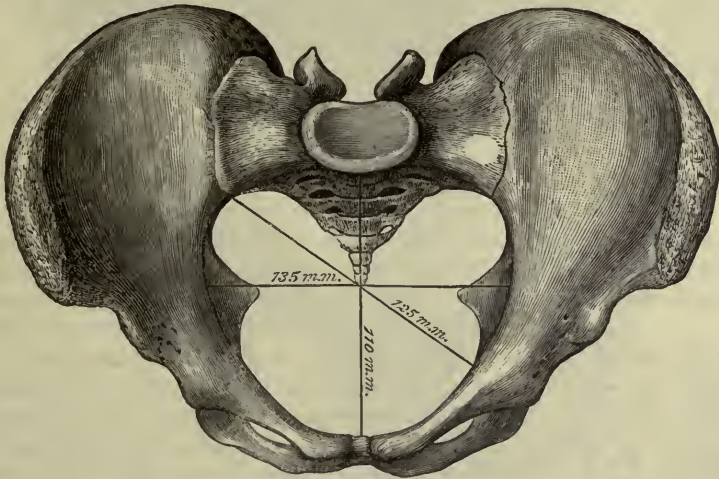


FIG. 238.—Diameters of superior aperture of lesser pelvis (female).

physis pubis; its average measurement is about 110 mm. in the female. The **transverse diameter** extends across the greatest width of the superior aperture, from the middle of the brim on one side to the same point on the opposite; its average measurement is about 135 mm. in the female. The **oblique diameter** extends from the iliopectineal eminence of one side to the sacroiliac articulation of the opposite side; its average measurement is about 125 mm. in the female.

The **cavity** of the lesser pelvis is bounded in front and below by the pubic symphysis and the superior rami of the pubes; above and behind, by the pelvic surfaces of the sacrum and coccyx, which, curving forward above and below, contract the superior and inferior apertures of the cavity; laterally, by a broad, smooth, quadrangular area of bone, corresponding to the inner surfaces of the body and superior ramus of the ischium and that part of the ilium which is below the arcuate line. From this description it will be seen that the cavity of the lesser pelvis is a short, curved canal, considerably deeper on its posterior than on its anterior wall. It contains, in the fresh subject, the pelvic colon, rectum, bladder, and some of the organs of generation. The rectum is placed at the back of the pelvis, in the curve of the sacrum and coccyx; the bladder is in front, behind the pubic symphysis. In the female the uterus and vagina occupy the interval between these viscera.

The Lower Circumference.—The lower circumference of the pelvis is very irregular; the space enclosed by it is named the **inferior aperture** or **outlet** (*apertura pelvis [minoris] inferior*) (Fig. 239), and is bounded behind by the point of the coccyx, and laterally by the ischial tuberosities. These eminences are separated by three notches: one in front, the **pubic arch**, formed by the convergence of the inferior

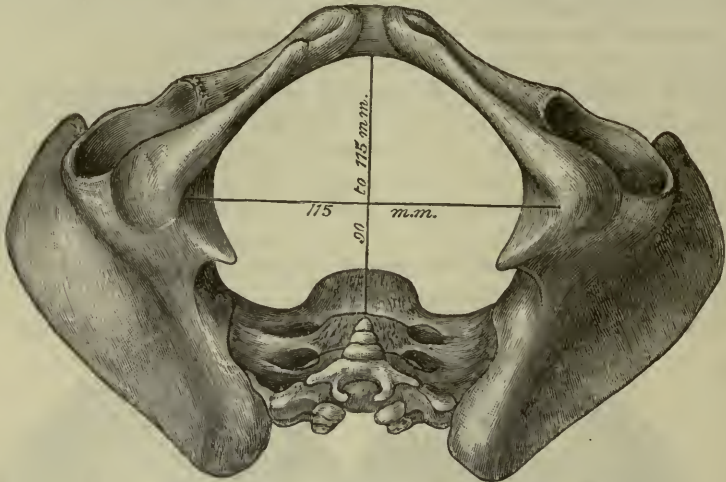


FIG. 239.—Diameters of inferior aperture of lesser pelvis (female).

rami of the ischium and pubis on either side. The other notches, one on either side, are formed by the sacrum and coccyx behind, the ischium in front, and the ilium above; they are called the **sciatic notches**; in the natural state they are converted into foramina by the sacrotuberous and sacrospinous ligaments. When the ligaments are *in situ*, the inferior aperture of the pelvis is lozenge-shaped, bounded, in front, by the pubic arcuate ligament and the inferior rami of the pubes and ischia; laterally, by the ischial tuberosities; and behind, by the sacrotuberous ligaments and the tip of the coccyx.

The diameters of the outlet of the pelvis are two, antero-posterior and transverse. The **antero-posterior diameter** extends from the tip of the coccyx to the lower part of the pubic symphysis; its measurement is from 90 to 115 mm. in the female. It varies with the length of the coccyx, and is capable of increase or diminution, on account of the mobility of that bone. The **transverse diameter**, measured between the posterior parts of the ischial tuberosities, is about 115 mm. in the female.¹

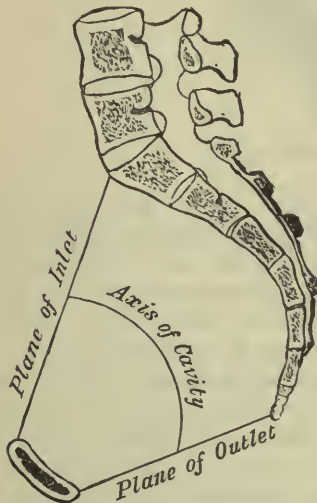

FIG. 240.—Median sagittal section of pelvis.

Axes (Fig. 240).—A line at right angles to the plane of the superior aperture at its center would, if prolonged, pass through the umbilicus above and the middle of the coccyx below; the axis of the superior aperture is therefore directed downward and backward. The axis of the inferior aperture, produced upward, would touch the base of the sacrum, and is also directed downward, and slightly backward. The axis of the cavity—*i. e.*, an axis at right angles to a series of planes between those of the superior and inferior apertures

¹ The measurements of the pelvis given above are fairly accurate, but different figures are given by various authors no doubt due mainly to differences in the physique and stature of the population from whom the measurements have been taken.

—is curved like the cavity itself: this curve corresponds to the concavity of the sacrum and coccyx, the extremities being indicated by the central points of the superior and inferior apertures. A knowledge of the direction of these axes serves to explain the course of the fetus in its passage through the pelvis during parturition.

Position of the Pelvis (Fig. 240).—In the erect posture, the pelvis is placed obliquely with regard to the trunk: the plane of the superior aperture forms an angle of from 50° to 60° , and that of the inferior aperture one of about 15° with the horizontal plane. The pelvic surface of the symphysis pubis looks upward and backward, the concavity of the sacrum and coccyx downward and forward. The position of the pelvis in the erect posture may be indicated by holding it so that the anterior superior iliac spines and the front of the top of the symphysis pubis are in the same vertical plane.

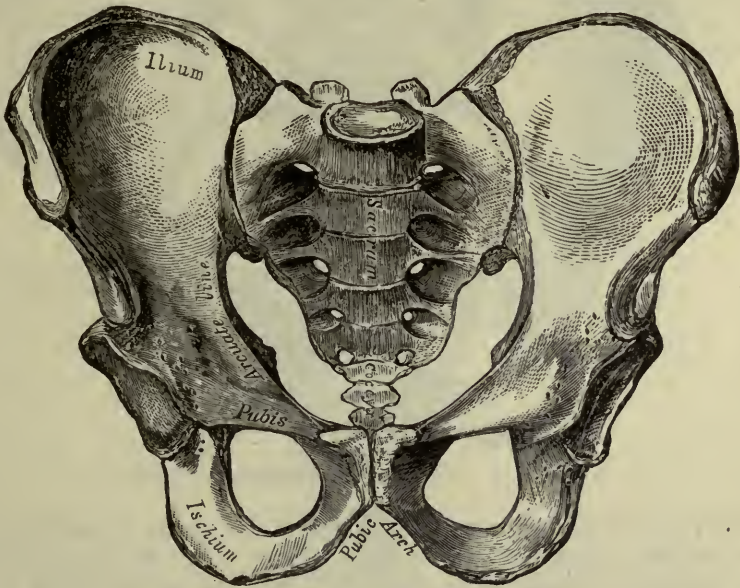


FIG. 241.—Male pelvis.

Differences between the Male and Female Pelves.—The *female* pelvis (Fig. 242) is distinguished from that of the *male* (Fig. 241) by its bones being more delicate and its depth less. The whole pelvis is less massive, and its muscular impressions are slightly marked. The ilia are less sloped, and the anterior iliac spines more widely separated; hence the greater lateral prominence of the hips. The preauricular sulcus is more commonly present and better marked. The superior aperture of the lesser pelvis is larger in the female than in the male; it is more nearly circular, and its obliquity is greater. The cavity is shallower and wider; the sacrum is shorter wider, and its upper part is less curved; the obturator foramina are triangular in shape and smaller in size than in the male. The inferior aperture is larger and the coccyx more movable. The sciatic notches are wider and shallower, and the spines of the ischia project less inward. The acetabula are smaller and look more distinctly forward (Derry¹). The ischial tuberosities and the acetabula are wider apart, and the former are more everted. The pubic symphysis is less deep, and the pubic arch is wider and more rounded than in the male, where it is an angle rather than an arch.

¹ Journal of Anatomy and Physiology, vol. xliii.

The size of the pelvis varies not only in the two sexes, but also in different members of the same sex, and does not appear to be influenced in any way by the height of the individual. Women of short stature, as a rule, have broad pelvis. Occasionally the pelvis is equally contracted in all its dimensions, so much so that all its diameters measure 12.5 mm. less than the average, and this even in well-formed women of average height. The principal divergences, however, are found at the superior aperture, and affect the relation of the antero-posterior to the transverse diameter. Thus the superior aperture may be elliptical either in a transverse or an antero-posterior direction, the transverse diameter in the former, and the antero-posterior in the latter, greatly exceeding the other diameters; in other instances it is almost circular.

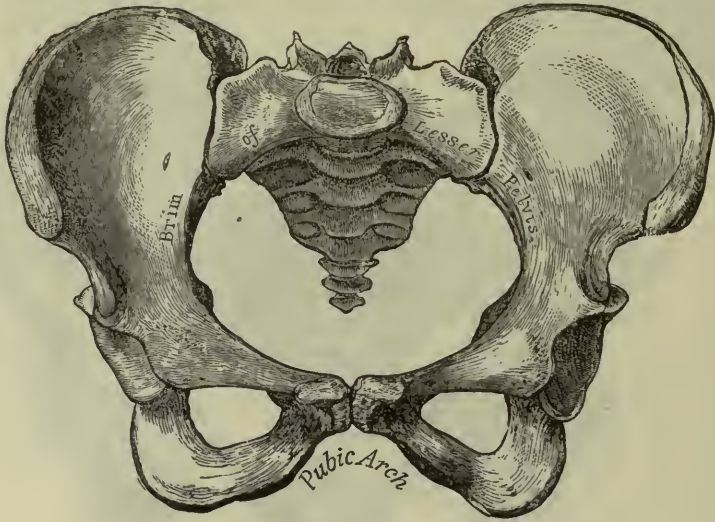


FIG. 242.—Female pelvis.

In the fetus, and for several years after birth, the pelvis is smaller in proportion than in the adult, and the projection of the sacrovertebral angle less marked. The characteristic differences between the male and female pelvis are distinctly indicated as early as the fourth month of fetal life.

Abnormalities.—There is arrest of development in the bones of the pelvis in cases of extroversion of the bladder; the anterior part of the pelvic girdle is deficient, the superior rami of the pubes are imperfectly developed, and the symphysis is absent. “The pubic bones are separated to the extent of from two to four inches, the superior rami shortened and directed forward, and the obturator foramen diminished in size, narrowed, and turned outward. The iliac bones are straightened out more than normal. The sacrum is very peculiar. The lateral curve, instead of being concave; is flattened out or even convex, with the iliosacral facets turned more outward than normal, while the vertical curve is straightened.”¹

The Femur (Thigh Bone).

The femur (Figs. 244, 245), the longest and strongest bone in the skeleton, is almost perfectly cylindrical in the greater part of its extent. In the erect posture it is not vertical, being separated above from its fellow by a considerable interval, which corresponds to the breadth of the pelvis, but inclining gradually downward and medialward, so as to approach its fellow toward its lower part, for the purpose of bringing the knee-joint near the line of gravity of the body. The degree of this inclination varies in different persons, and is greater in the female than in the male,

¹ Wood, Heath's Dictionary of Practical Surgery, i, 426.

on account of the greater breadth of the pelvis. The femur, like other long bones, is divisible into a **body** and **two extremities**.

The Upper Extremity (*proximal extremity*, Fig. 243).—The upper extremity presents for examination a **head**, a **neck**, a **greater** and a **lesser trochanter**.

The Head (*caput femoris*).—The head which is globular and forms rather more than a hemisphere, is directed upward, medialward, and a little forward, the greater part of its convexity being above and in front. Its surface is smooth, coated with cartilage in the fresh state, except over an ovoid depression, the **fovea capitis femoris**, which is situated a little below and behind the center of the head, and gives attachment to the ligamentum teres.

The Neck (*collum femoris*).—The neck is a flattened pyramidal process of bone, connecting the head with the body, and forming with the latter a wide angle opening medialward. The angle is widest in infancy, and becomes lessened during growth, so that at puberty it forms a gentle curve from the axis of the body of the bone. In the adult, the neck forms an angle of about 125° with the body, but this varies in inverse proportion to the development of the pelvis and the stature. In

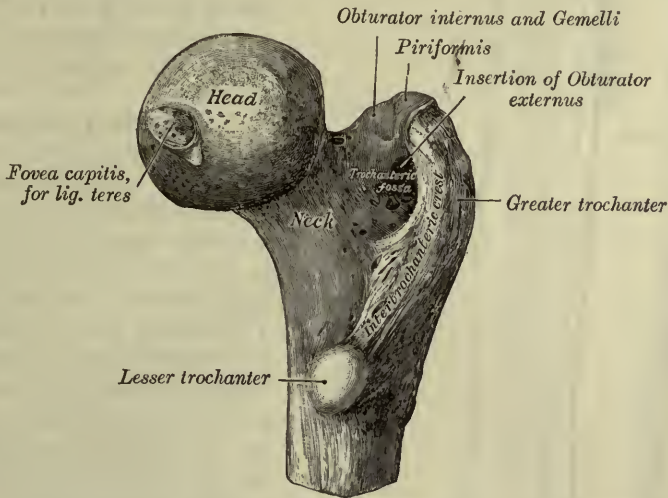


FIG. 243.—Upper extremity of right femur viewed from behind and above.

the female, in consequence of the increased width of the pelvis, the neck of the femur forms more nearly a right angle with the body than it does in the male. The angle decreases during the period of growth, but after full growth has been attained it does not usually undergo any change, even in old age; it varies considerably in different persons of the same age. It is smaller in short than in long bones, and when the pelvis is wide. In addition to projecting upward and medialward from the body of the femur, the neck also projects somewhat forward; the amount of this forward projection is extremely variable, but on an average is from 12° to 14° .

The neck is flattened from before backward, contracted in the middle, and broader laterally than medially. The vertical diameter of the lateral half is increased by the obliquity of the lower edge, which slopes downward to join the body at the level of the lesser trochanter, so that it measures one-third more than the antero-posterior diameter. The medial half is smaller and of a more circular shape. The **anterior surface** of the neck is perforated by numerous vascular foramina. Along the upper part of the line of junction of the anterior surface with the head is a shallow groove, best marked in elderly subjects; this

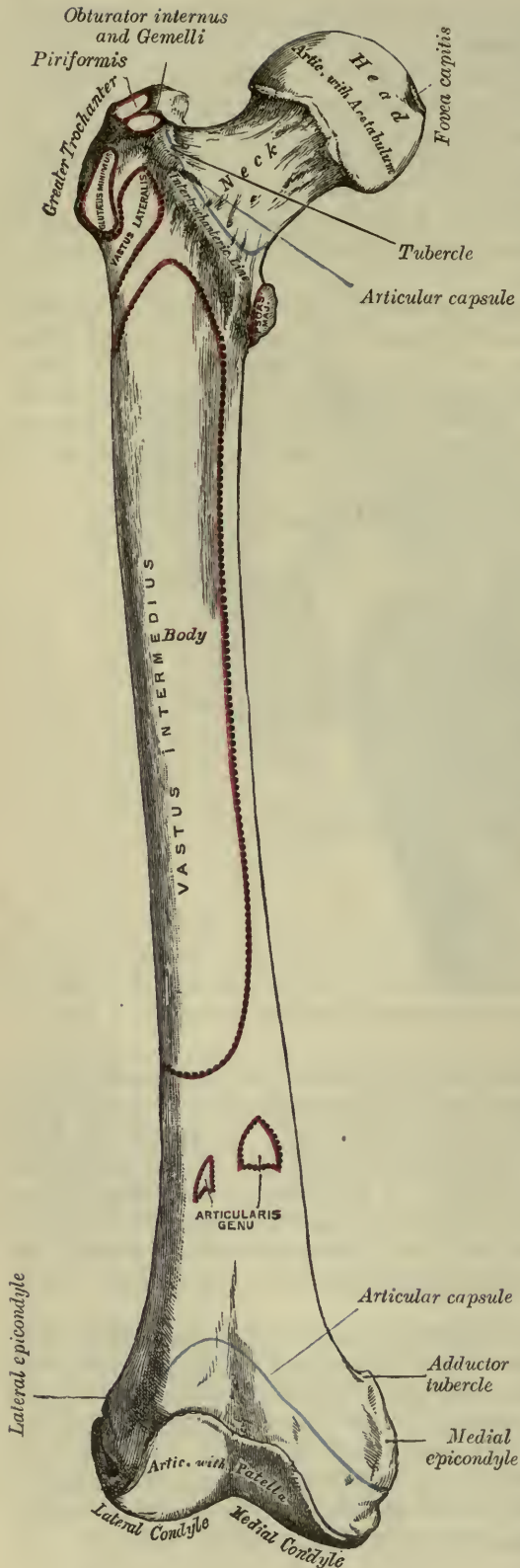


FIG. 244.—Right femur. Anterior surface.

groove lodges the orbicular fibers of the capsule of the hip-joint. The **posterior surface** is smooth, and is broader and more concave than the anterior: the posterior part of the capsule of the hip-joint is attached to it about 1 cm. above the intertrochanteric crest. The **superior border** is short and thick, and ends laterally at the greater trochanter; its surface is perforated by large foramina. The **inferior border**, long and narrow, curves a little backward, to end at the lesser trochanter.

The Trochanters.—The trochanters are prominent processes which afford leverage to the muscles that rotate the thigh on its axis. They are two in number, the greater and the lesser.

The **Greater Trochanter** (*trochanter major; great trochanter*) is a large, irregular, quadrilateral eminence, situated at the junction of the neck with the upper part of the body. It is directed a little lateralward and backward, and, in the adult, is about 1 cm. lower than the head. It has two surfaces, four borders. The **lateral surface**, quadrilateral in form, is broad, rough, convex, and marked by a diagonal impression, which extends from the postero-superior to the antero-inferior angle, and serves for the insertion of the tendon of the *Glutæus medius*. Above the impression is a triangular surface, sometimes rough for part of the tendon of the same muscle, sometimes smooth for the interposition of a bursa between the tendon and the bone. Below and behind the diagonal impression is a smooth, triangular surface, over which the tendon of the *Glutæus maximus* plays, a bursa being interposed. The **medial surface**, of much less extent than the lateral, presents at its base a deep depression, the **trochanteric fossa** (*digital fossa*), for the insertion of the tendon of the *Obturator externus*, and above and in front of this an impression for the insertion of the *Obtura-*

tor internus and Gemelli. The **superior border** is free; it is thick and irregular, and marked near the center by an impression for the insertion of the Piriformis. The **inferior border** corresponds to the line of junction of the base of the trochanter with the lateral surface of the body; it is marked by a rough, prominent, slightly curved ridge, which gives origin to the upper part of the Vastus lateralis. The **anterior border** is prominent and somewhat irregular; it affords insertion at its lateral part to the Glutæus minimus. The **posterior border** is very prominent and appears as a free, rounded edge, which bounds the back part of the trochanteric fossa.

The **Lesser Trochanter** (*trochanter minor; small trochanter*) is a conical eminence, which varies in size in different subjects; it projects from the lower and back part of the base of the neck. From its apex three well-marked borders extend; two of these are above—a **medial** continuous with the lower border of the neck, a **lateral** with the intertrochanteric crest; the **inferior border** is continuous with the middle division of the linea aspera. The **summit** of the trochanter is rough, and gives insertion to the tendon of the Psoas major.

A prominence, of variable size, occurs at the junction of the upper part of the neck with the greater trochanter, and is called the **tubercle of the femur**; it is the point of meeting of five muscles: the Glutæus minimus laterally, the Vastus lateralis below, and the tendon of the Obturator internus and two Gemelli above. Running obliquely downward and medialward from the tubercle is the **intertrochanteric line** (*spiral line of the femur*); it winds around the medial side of the body of the bone, below the lesser tro-

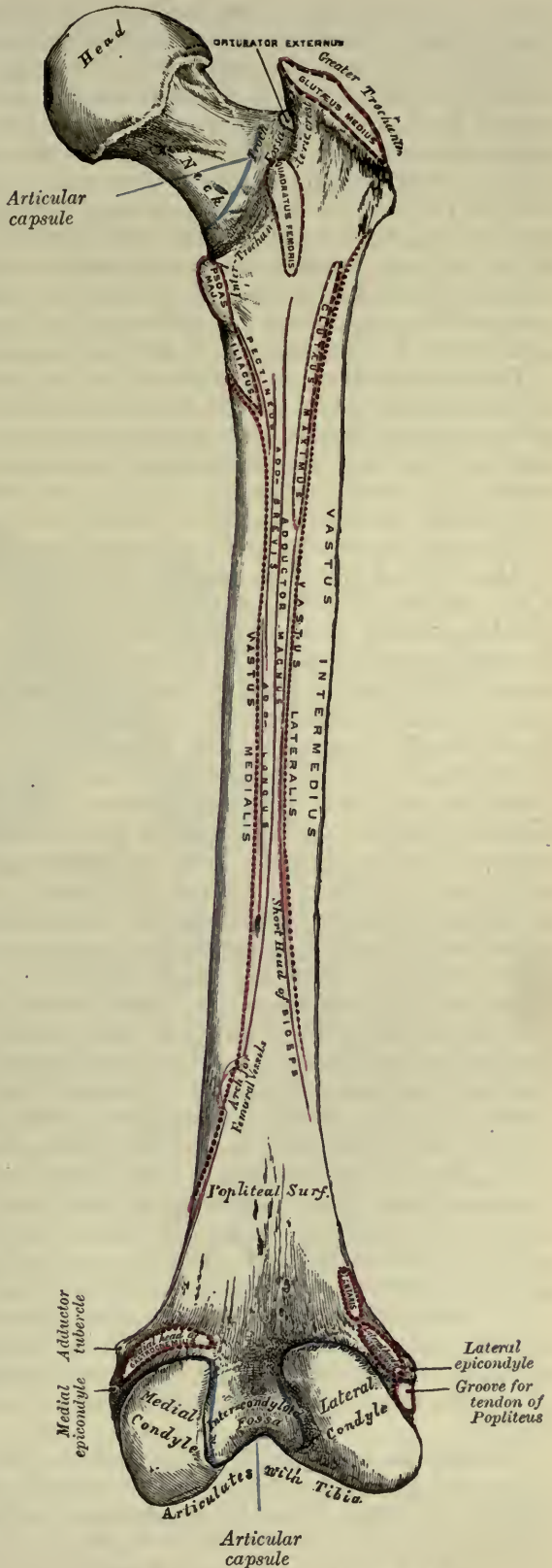


FIG. 245.—Right femur. Posterior surface.

chanter, and ends about 5 cm. below this eminence in the *linea aspera*. Its upper half is rough, and affords attachment to the iliofemoral ligament of the hip-joint; its lower half is less prominent, and gives origin to the upper part of the *Vastus medialis*. Running obliquely downward and medialward from the summit of the greater trochanter on the posterior surface of the neck is a prominent ridge, the **intertrochanteric crest**. Its upper half forms the posterior border of the greater trochanter, and its lower half runs downward and medialward to the lesser trochanter. A slight ridge is sometimes seen commencing about the middle of the intertrochanteric crest, and reaching vertically downward for about 5 cm. along the back part of the body: it is called the **linea quadrata**, and gives attachment to the *Quadratus femoris* and a few fibers of the *Adductor magnus*. Generally there is merely a slight thickening about the middle of the intertrochanteric crest, marking the attachment of the upper part of the *Quadratus femoris*.

The Body or Shaft (*corpus femoris*).—The body, almost cylindrical in form, is a little broader above than in the center, broadest and somewhat flattened from before backward below. It is slightly arched, so as to be convex in front, and concave behind, where it is strengthened by a prominent longitudinal ridge, the **linea aspera**. It presents for examination three borders, separating three surfaces. Of the borders, one, the *linea aspera*, is posterior, one is medial, and the other, lateral.

The **linea aspera** (Fig. 245) is a prominent longitudinal ridge or crest, on the middle third of the bone, presenting a medial and a lateral lip, and a narrow rough, intermediate line. Above, the *linea aspera* is prolonged by three ridges. The lateral ridge is very rough, and runs almost vertically upward to the base of the greater trochanter. It is termed the **gluteal tuberosity**, and gives attachment to part of the *Glutæus maximus*: its upper part is often elongated into a roughened crest, on which a more or less well-marked, rounded tubercle, the **third trochanter**, is occasionally developed. The intermediate ridge or **pectineal line** is continued to the base of the lesser trochanter and gives attachment to the *Pectineus*; the medial ridge is lost in the intertrochanteric line; between these two a portion of the *Iliacus* is inserted. Below, the *linea aspera* is prolonged into two ridges, enclosing between them a triangular area, the **popliteal surface**, upon which the popliteal artery rests. Of these two ridges, the lateral is the more prominent, and descends to the summit of the lateral condyle. The medial is less marked, especially at its upper part, where it is crossed by the femoral artery. It ends below at the summit of the medial condyle, in a small tubercle, the **adductor tubercle**, which affords insertion to the tendon of the *Adductor magnus*.

From the **medial lip** of the *linea aspera* and its prolongations above and below, the *Vastus medialis* arises; and from the **lateral lip** and its upward prolongation, the *Vastus lateralis* takes origin. The *Adductor magnus* is inserted into the *linea aspera*, and to its lateral prolongation above, and its medial prolongation below. Between the *Vastus lateralis* and the *Adductor magnus* two muscles are attached—viz., the *Glutæus maximus* inserted above, and the short head of the *Biceps femoris* arising below. Between the *Adductor magnus* and the *Vastus medialis* four muscles are inserted: the *Iliacus* and *Pectineus* above; the *Adductor brevis* and *Adductor longus* below. The *linea aspera* is perforated a little below its center by the nutrient canal, which is directed obliquely upward.

The other two *borders* of the femur are only slightly marked: the **lateral border** extends from the antero-inferior angle of the greater trochanter to the anterior extremity of the lateral condyle; the **medial border** from the intertrochanteric line, at a point opposite the lesser trochanter, to the anterior extremity of the medial condyle.

The **anterior surface** includes that portion of the shaft which is situated between the lateral and medial borders. It is smooth, convex, broader above and below than in the center. From the upper three-fourths of this surface the *Vastus intermedius* arises; the lower fourth is separated from the muscle by the intervention

of the synovial membrane of the knee-joint and a bursa; from the upper part of it the *Articularis genu* takes origin. The **lateral surface** includes the portion between the lateral border and the *linea aspera*; it is continuous above with the corresponding surface of the greater trochanter, below with that of the lateral condyle: from its upper three-fourths the *Vastus intermedius* takes origin. The **medial surface** includes the portion between the medial border and the *linea aspera*; it is continuous above with the lower border of the neck, below with the medial side of the medial condyle: it is covered by the *Vastus medialis*.

The Lower Extremity (*distal extremity*), (Fig. 246).—The lower extremity, larger than the upper, is somewhat cuboid in form, but its transverse diameter is greater than its antero-posterior; it consists of two oblong eminences known as the **condyles**. In front, the condyles are but slightly prominent, and are separated from one another by a smooth shallow articular depression called the **patellar surface**; behind, they project considerably, and the interval between them forms a deep notch, the **intercondyloid fossa**. The **lateral condyle** is the more prominent and is the broader both in its antero-posterior and transverse diameters, the **medial condyle** is the longer and, when the femur is held with its body perpendicular, projects to a lower

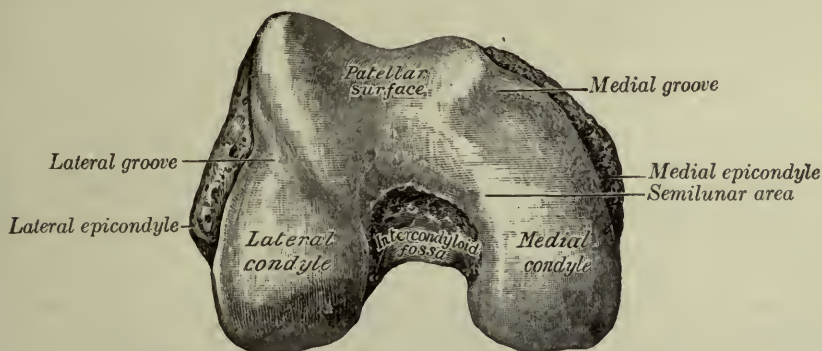


FIG. 246.—Lower extremity of right femur viewed from below.

level. When, however, the femur is in its natural oblique position the lower surfaces of the two condyles lie practically in the same horizontal plane. The condyles are not quite parallel with one another; the long axis of the lateral is almost directly antero-posterior, but that of the medial runs backward and medialward. Their opposed surfaces are small, rough, and concave, and form the walls of the intercondyloid fossa. This fossa is limited above by a ridge, the **intercondyloid line**, and below by the central part of the posterior margin of the patellar surface. The posterior cruciate ligament of the knee-joint is attached to the lower and front part of the medial wall of the fossa and the anterior cruciate ligament to an impression on the upper and back part of its lateral wall. Each condyle is surmounted by an elevation, the epicondyle. The **medial epicondyle** is a large convex eminence to which the tibial collateral ligament of the knee-joint is attached. At its upper part is the adductor tubercle, already referred to, and behind it is a rough impression which gives origin to the medial head of the *Gastrocnemius*. The **lateral epicondyle**, smaller and less prominent than the medial, gives attachment to the fibular collateral ligament of the knee-joint. Directly below it is a small depression from which a smooth well-marked groove curves obliquely upward and backward to the posterior extremity of the condyle. This groove is separated from the articular surface of the condyle by a prominent lip across which a second, shallower groove runs vertically downward from the depression. In the fresh state these grooves are covered with cartilage. The *Popliteus* arises from the depression; its tendon lies in the oblique groove when the knee is flexed and in the vertical

groove when the knee is extended. Above and behind the lateral epicondyle is an area for the origin of the lateral head of the Gastrocnemius, above and to the medial side of which the Plantaris arises.

The **articular surface** of the lower end of the femur occupies the anterior, inferior, and posterior surfaces of the condyles. Its front part is named the **patellar surface** and articulates with the patella; it presents a median groove which extends downward to the intercondyloid fossa and two convexities, the lateral of which is broader, more prominent, and extends farther upward than the medial. The lower and posterior parts of the articular surface constitute the **tibial surfaces** for articulation with the corresponding condyles of the tibia and menisci. These surfaces are separated from one another by the intercondyloid fossa and from the patellar surface by faint grooves which extend obliquely across the condyles. The lateral groove is the better marked; it runs lateralward and forward from the front part of the intercondyloid fossa, and expands to form a triangular depression. When the knee-joint is fully extended, the triangular depression rests upon the anterior portion of the lateral meniscus, and the medial part of the groove comes into contact with the medial margin of the lateral articular surface of the tibia in front of the lateral tubercle of the tibial intercondyloid eminence. The medial groove is less distinct than the lateral. It does not reach as far as the intercondyloid fossa and therefore exists only on the medial part of the condyle; it receives the anterior edge of the medial meniscus when the knee-joint is extended. Where the groove ceases laterally the patellar surface is seen to be continued backward as a semilunar area close to the anterior part of the intercondyloid fossa; this semilunar area articulates with the medial vertical facet of the patella in forced flexion of the knee-joint. The tibial surfaces of the condyles are convex from side to side and from before backward. Each presents a double curve, its posterior segment being an arc of a circle, its anterior, part of a cycloid.¹

The Architecture of the Femur.—Koch² by mathematical analysis has “shown that in every part of the femur there is a remarkable adaptation of the inner structure of the bone to the mechanical requirements due to the load on the femur-head. The various parts of the femur taken together form a single mechanical structure wonderfully well-adapted for the efficient, economical transmission of the loads from the acetabulum to the tibia; a structure in which every element contributes its modicum of strength in the manner required by theoretical mechanics for maximum efficiency.” “The internal structure is everywhere so formed as to provide in an efficient manner for all the internal stresses which occur due to the load on the femur-head. Throughout the femur, with the load on the femur-head, the bony material is arranged in the paths of the maximum internal stresses, which are thereby resisted with the greatest efficiency, and hence with maximum economy of material.” “The conclusion is inevitable that the inner structure and outer form of the femur are governed by the conditions of maximum stress to which the bone is subjected normally by the preponderant load on the femur-head; that is, by the body weight transmitted to the femur-head through the acetabulum.” “The femur obeys the mechanical laws that govern other elastic bodies under stress; the relation between the computed internal stresses due to the load on the femur-head, and the internal structure of the different portions of the femur is in very close agreement with the theoretical relations that should exist between stress and structure for maximum economy and efficiency; and, therefore, it is believed that the following laws of bone structure have been demonstrated for the femur:

“1. The inner structure and external form of human bone are closely adapted to the mechanical conditions existing at every point in the bone.

“2. The inner architecture of normal bone is determined by definite and exact requirements of mathematical and mechanical laws to produce a maximum of strength with a minimum of material.”

The Inner Architecture of the Upper Femur.—“The spongy bone of the upper femur (to the lower limit of the lesser trochanter) is composed of two distinct systems of trabeculae arranged in curved paths: one, which has its origin in the medial (inner) side of the shaft and curving upward

¹ A *cycloid* is a curve traced by a point in the circumference of a wheel when the wheel is rolled along in a straight line.

² The Laws of Bone Architecture. Am. Jour. of Anat., 21, 1917. The following paragraphs are taken almost verbatim from Koch's article in which we have the first correct mathematical analysis of the femur in support of the theory of the functional form of bone proposed by Wolff and also by Roux.

in a fan-like radiation to the opposite side of the bone; the other, having origin in the lateral (outer) portion of the shaft and arching upward and medially to end in the upper surface of the greater trochanter, neck and head. These two systems intersect each other at right angles.

"A. *Medial (Compressive) System of Trabeculae*.—As the compact bone of the medial (inner) part of the shaft nears the head of the femur it gradually becomes thinner and finally reaches the articular surface of the head as a very thin layer. From a point at about the lower level of the

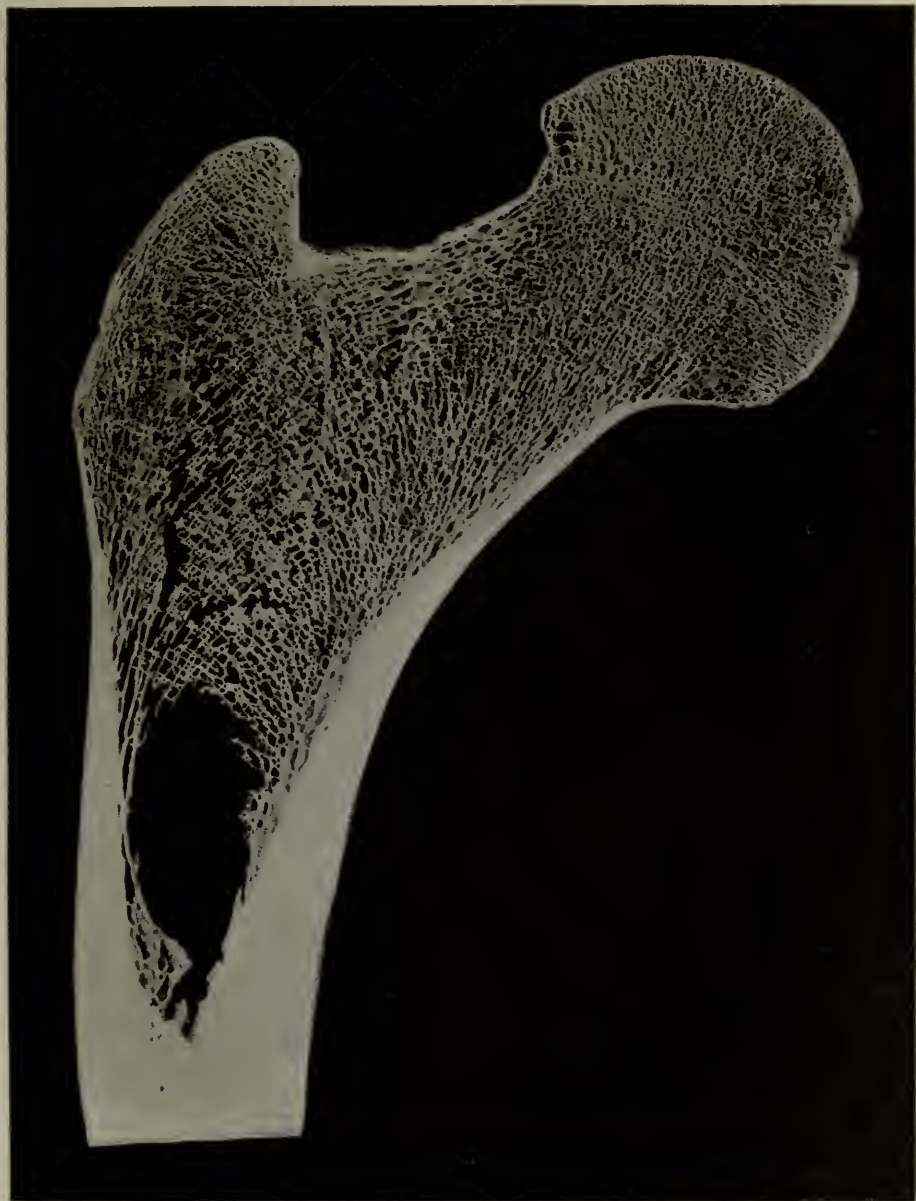


FIG. 247.—Frontal longitudinal midsection of upper femur.

lesser trochanter, $2\frac{1}{2}$ to 3 inches from the lower limit of the articular surface of the head, the trabeculae branch off from the shaft in smooth curves, spreading radially to cross to the opposite side in two well-defined groups: a lower, or secondary group, and an upper, or principal group.

"a. *The Secondary Compressive Group*.—This group of trabeculae leaves the inner border of the shaft beginning at about the level of the lesser trochanter, and for a distance of almost 2 inches along the curving shaft, with which the separate trabeculae make an angle of about 45 degrees.

They curve outwardly and upwardly to cross in radiating smooth curves to the opposite side. The lower filaments end in the region of the greater trochanter: the adjacent filaments above these pursue a more nearly vertical course and end in the upper portion of the neck of the femur. The trabeculae of this group are thin and with wide spaces between them. As they traverse the space between the medial and lateral surfaces of the bone they cross at right angles the system of curved trabeculae which arise from the lateral (outer) portion of the shaft. (Figs. 247 and 249.)

"*b. The Principal Compressive Group.*—This group of trabeculae (Figs. 247 and 249) springs from the medial portion of the shaft just above the group above-described, and spreads upward and in slightly radial smooth curved lines to reach the upper portion of the articular surface of the head of the femur. These trabeculae are placed very closely together and are the thickest ones seen in the upper femur. They are a prolongation of the shaft from which they spring in straight

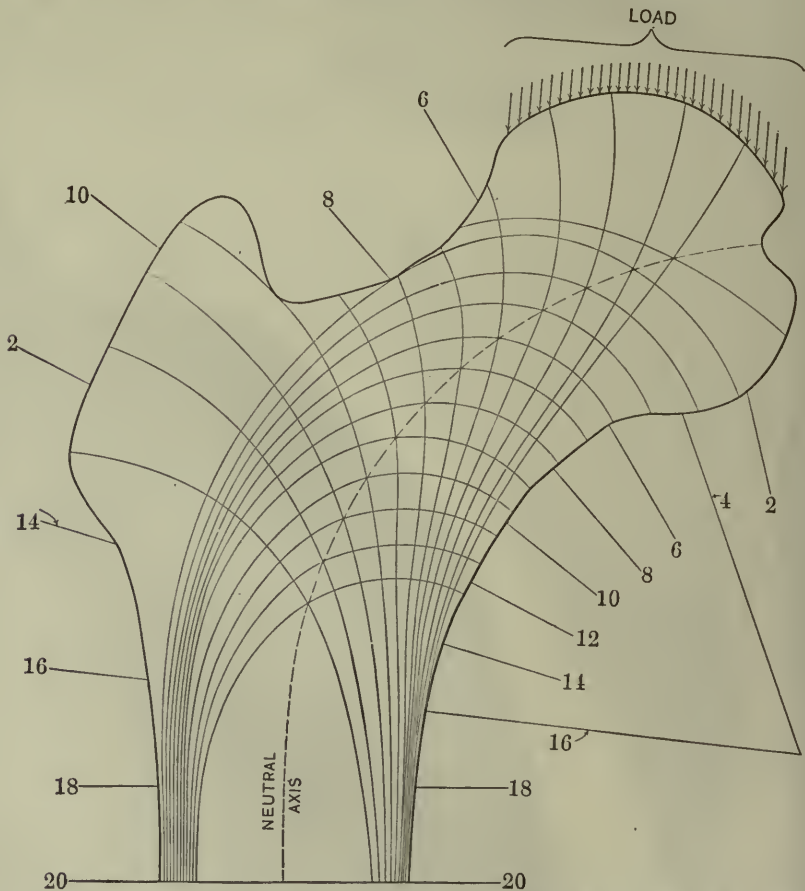


FIG. 248.—Diagram of the lines of stress in the upper femur, based upon the mathematical analysis of the right femur. These result from the combination of the different kinds of stresses at each point in the femur. (After Koch.)

lines which gradually curve to meet at right-angles the articular surface. There is no change as they cross the epiphyseal line. They also intersect at right-angles the system of lines which rise from the lateral side of the femur.

"This system of principal and secondary compressive trabeculae corresponds in position and in curvature with the lines of maximum compressive stress, which were traced out in the mathematical analysis of this portion of the femur. (Figs. 247 and 250.)

"*B. Lateral (Tensile) System of Trabeculae.*—As the compact bone of the outer portion of the shaft approaches the greater trochanter it gradually decreases in thickness. Beginning at a point about 1 inch below the level of the lower border of the greater trochanter, numerous thin trabeculae are given off from the outer portion of the shaft. These trabeculae lie in three distinct groups.

"*c. The Greater Trochanter Group.*—These trabeculae rise from the outer part of the shaft just below the greater trochanter and rise in thin, curving lines to cross the region of the greater trochanter and end in its upper surface. Some of these filaments are poorly defined. This group



FIG. 249. — Frontal longitudinal midsection of left femur. Taken from the same subject as the one that was analyzed and shown in Figs. 248 and 250. $\frac{1}{3}$ of natural size. (After Koch.)

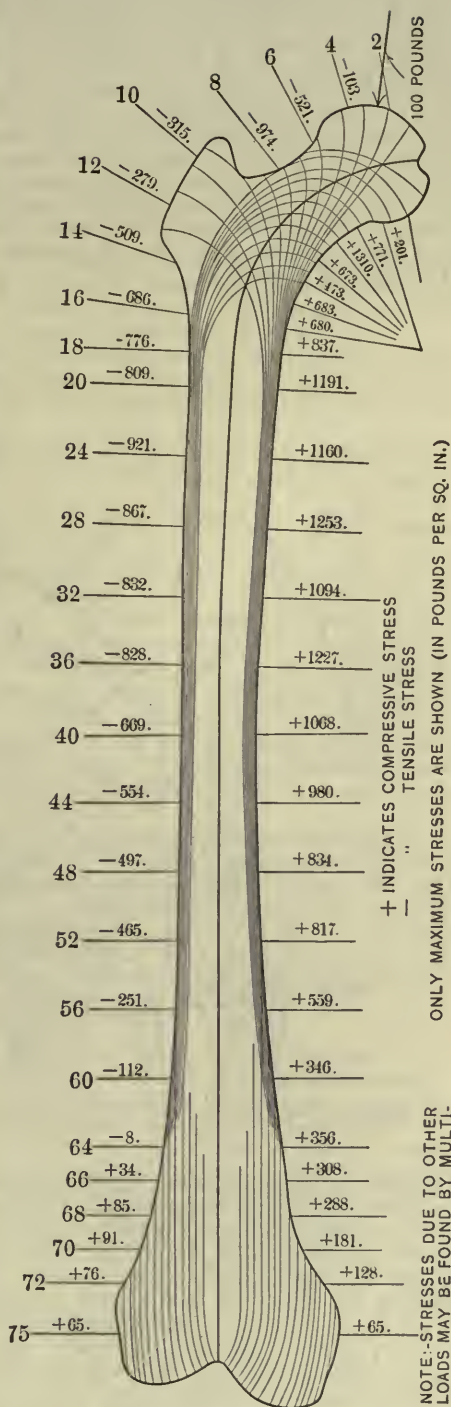


FIG. 250. — Diagram of the computed lines of maximum stress in the normal femur. The section numbers 2, 4, 6, 8, etc., show the positions of the transverse sections analyzed. The amounts of the maximum tensile and compressive stress at the various sections are given for a load of 100 pounds on the femur-head. For the standing position ("at attention") these stresses are multiplied by 0.6, for walking by 1.6 and for running by 3.2. (After Koch.)

intersects the trabeculae of group (a) which rise from the opposite side. The trabeculae of this group evidently carry small stresses, as is shown by their slenderness.

"d. *The Principal Tensile Group.*—This group springs from the outer part of the shaft immediately below group c, and curves convexly upward and inward in nearly parallel lines across the neck of the femur and ends in the inferior portion of the head. These trabeculae are somewhat thinner and more widely spaced than those of the principal compressive group (b). All the trabeculae of this group cross those of groups (a) and (b) at right angles. This group is the most important of the lateral system (tensile) and, as will be shown later, the greatest tensile stresses of the upper femur are carried by the trabeculae of this group.

"e. *The Secondary Tensile Group.*—This group consists of the trabeculae which spring from the outer side of the shaft and lie below those of the preceding group. They curve upward and medially across the axis of the femur and end more or less irregularly after crossing the midline, but a number of these filaments end in the medial portion of the shaft and neck. They cross at right angles the trabeculae of group (a).

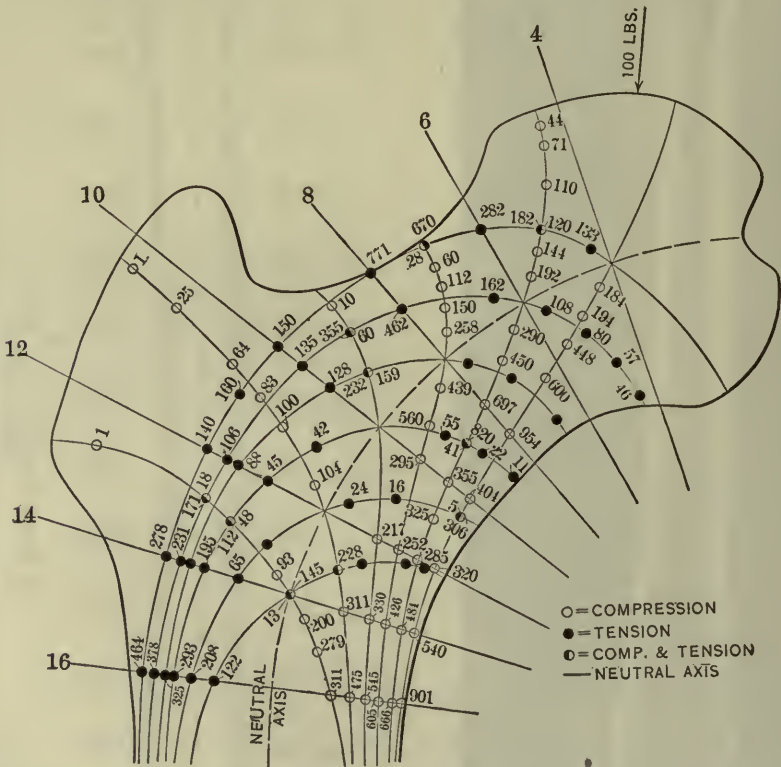


FIG. 251.—Intensity of the maximum tensile and compressive stresses in the upper femur. Computed for the load of 100 pounds on the right femur. Corresponds to the upper part of Fig. 250. (After Koch.)

"In general, the trabeculae of the tensile system are lighter in structure than those of the compressive system in corresponding positions. The significance of the difference in thickness of these two systems is that the thickness of the trabeculae varies with the intensity of the stresses at any given point. Comparison of Fig. 247 with Fig. 251 will show that the trabeculae of the compressive system carry heavier stresses than those of the tensile system in corresponding positions. For example, the maximum tensile stress at section 8 (Fig. 251) in the outermost fiber is 771 pounds per square inch, and at the corresponding point on the compressive side the compressive stress is 954 pounds per square inch. Similar comparisons may be made at other points, which confirm the conclusion that the thickness and closeness of spacing of the trabeculae varies in proportion to the intensity of the stresses carried by them.

"It will be seen that the trabeculae lie exactly in the paths of the maximum tensile and compressive stresses (compare Figs. 247, 248 and 251), and hence these trabeculae carry these stresses in the most economical manner. This is in accordance with the well-recognized principle of mechanics that the most direct manner of transmitting stress is in the direction in which the stress acts.

"Fig. 249 shows a longitudinal frontal section through the left femur, which is the mate of the right femur on which the mathematical analysis was made. In this midsection the system of tensile trabeculae, which rises from the lateral (outer) part of the shaft and crosses over the central area to end in the medial portion of the shaft, neck and head, is clearly shown. This figure also shows the compressive system of trabeculae which rises on the medial portion of the shaft and crosses the central area to end in the head, neck and greater trochanter. By comparing the position of these two systems of trabeculae shown in Fig. 249 with the lines of maximum and minimum stresses shown in Figs. 248 and 250 it is seen that the tensile system of trabeculae corresponds exactly with the position of the lines of maximum and minimum tensile stresses which were determined by mathematical analysis. In a similar manner, the compressive system of trabeculae in Fig. 249 corresponds exactly with the lines of maximum and minimum compressive stresses computed by mathematical analysis.

"The amount of vertical shear varies almost uniformly from a maximum of 90 pounds (90 per cent. of the load on the femur-head) midway between sections 4 and 6, to a minimum of -5.7 pounds at section 18" (Fig. 251). There is a gradual diminution of the spongy bone from section 6 to section 18 parallel with the diminished intensities of the vertical shear.

1. The trabeculae of the upper femur, as shown in frontal sections, are arranged in two general systems, compressive and tensile, which correspond in position with the lines of maximum and minimum stresses in the femur determined by the mathematical analysis of the femur as a mechanical structure.

2. The thickness and spacing of the trabeculae vary with the intensity of the maximum stresses at various points in the upper femur, being thickest and most closely spaced in the regions where the greatest stresses occur.

3. The amount of bony material in the spongy bone of the upper femur varies in proportion to the intensity of the shearing force at the various sections.

4. The arrangement of the trabeculae in the positions of maximum stresses is such that the greatest strength is secured with a minimum of material.

Significance of the Inner Architecture of the Shaft.—1. Economy for resisting shear. The shearing stresses are at a minimum in the shaft. "It is clear that a minimum amount of material will be required to resist the shearing stresses." As horizontal and vertical shearing stresses are most efficiently resisted by material placed near the neutral plane, in this region a minimum amount of material will be needed near the neutral axis. In the shaft there is very little if any material in the central space, practically the only material near the neutral plane being in the compact bone, but lying at a distance from the neutral axis. This conforms to the requirement of mechanics for economy, as a minimum of material is provided for resisting shearing stresses where these stresses are a minimum.

2. Economy for resisting bending moment. "The bending moment increases from a minimum at section 4 to a maximum between sections 16 and 18, then gradually decreases almost uniformly to 0 near section 75." "To resist bending moment stresses most effectively the material should be as far from the neutral axis as possible." It is evident that the hollow shaft of the femur is an efficient structure for resisting bending moment stresses, all of the material in the shaft being relatively at a considerable distance from the neutral axis. It is evident that the hollow shaft provides efficiently for resisting bending moment not only due to the load on the femur-head, but from any other loads tending to produce bending in other planes.

3. Economy for resisting axial stress.

The inner architecture of the shaft is adapted to resist in the most efficient manner the combined action of the minimal shearing forces and the axial and maximum bending stresses.

The structure of the shaft is such as to secure great strength with a relatively small amount of material.

The Distal Portion of the Femur.—In frontal section (Fig. 249) in the distal 6 inches of the femur "there are to be seen two main systems of trabeculae, a longitudinal and a transverse system. The trabeculae of the former rise from the inner wall of the shaft and continue in perfectly straight lines parallel to the axis of the shaft and proceed to the epiphyseal line, whence they continue in more or less curved lines to meet the articular surface of the knee-joint at right angles at every point. Near the center there are a few thin, delicate, longitudinal trabeculae which spring from the longitudinal trabeculae just described, to which they are joined by fine transverse filaments that lie in planes parallel to the sagittal plane.

"The trabeculae of the transverse system are somewhat lighter in structure than those of the longitudinal system, and consist of numerous trabeculae at right angles to the latter.

"As the distal end of the femur is approached the shaft gradually becomes thinner until the articular surface is reached, where there remains only a thin shell of compact bone. With the gradual thinning of the compact bone of the shaft, there is a simultaneous increase in the amount of the spongy bone, and a gradual flaring of the femur which gives this portion of the bone a gradually increasing gross area of cross-section.

"There is a marked thickening of the shell of bone in the region of the intercondyloid fossa where the anterior and posterior crucial ligaments are attached. This thickened area is about

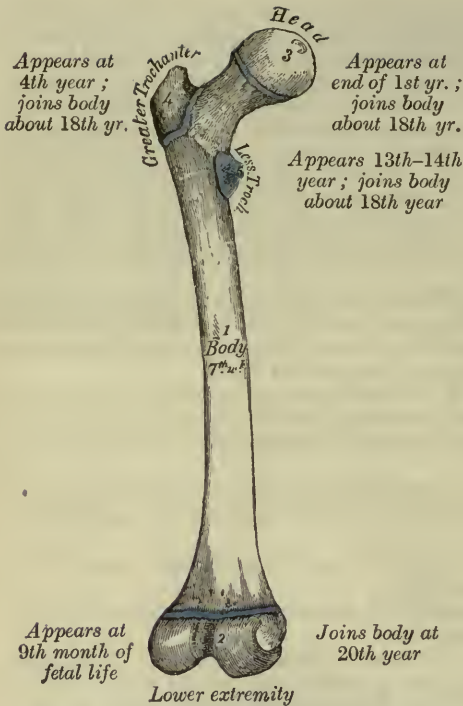


FIG. 252.—Plan of ossification of the femur. From five centers.

0.4 inch in diameter and consists of compact bone from which a number of thick trabeculae pass at right angles to the main longitudinal system. The inner structure of the bone is here evidently adapted to the efficient distribution of the stresses arising from this ligamentary attachment.

“Near the distal end of the femur the longitudinal trabeculae gradually assume curved paths and end perpendicularly to the articular surface at every point. Such a structure is in accordance with the principles of mechanics, as stresses can be communicated through a frictionless joint only in a direction perpendicular to the joint surface at every point.

“With practically no increase in the amount of bony material used, there is a greatly increased stability produced by the expansion of the lower femur from a hollow shaft of compact bone to a structure of much larger cross-section almost entirely composed of spongy bone.

“Significance of the Inner Architecture of the Distal Part of the Femur.—The function of the lower end of the femur is to transmit through a hinged joint the loads carried by the femur. For stability the width of the bearing on which the hinge action occurs should be relatively large. For economy of material the expansion of the end bearing should be as lightly constructed as is consistent with proper strength. In accordance with the principles of mechanics. . . . ,

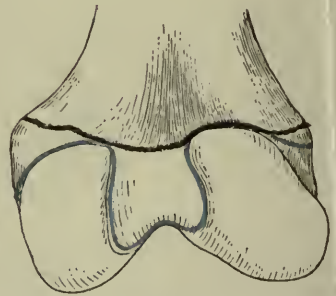
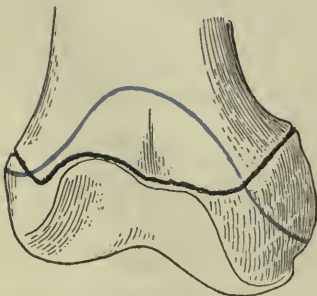
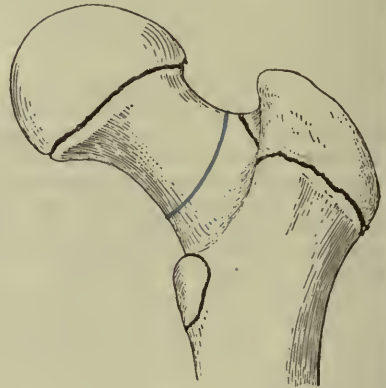
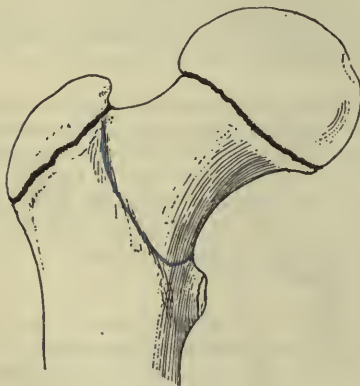


FIG. 253.—Epiphysal lines of femur in a young adult. Anterior aspect. The lines of attachment of the articular capsules are in blue.

FIG. 254.—Epiphysal lines of femur in a young adult. Posterior aspect. The lines of attachment of the articular capsules are in blue.

the most efficient manner in which stresses are transmitted is by the arrangement of the resisting material in lines parallel to the direction in which the stresses occur and in the paths taken by the stresses. Theoretically the most efficient manner to attain these objects would be to prolong the innermost filaments of the bone as straight lines parallel to the longitudinal axis of the bone, and gradually to flare the outer shell of compact bone outward, and continuing to give off filaments of bone parallel to the longitudinal axis as the distal end of the femur is approached. These filaments should be well-braced transversely and each should carry its proportionate part of the total load, parallel to the longitudinal axis, transmitting it eventually to the articular surface, and in a direction perpendicular to that surface."

Referring to Fig. 249, it is seen that the large expansion of the bone is produced by the gradual transition of the hollow shaft of compact bone to cancellated bone, resulting in the production of a much larger volume. The trabeculae are given off from the shaft in lines parallel to the longitudinal axis, and are braced transversely by two series of trabeculae at right angles to each other, in the same manner as required theoretically for economy.

Although the action of the muscles exerts an appreciable effect on the stresses in the femur, it is relatively small and very complex to analyze and has not been considered in the above analysis.

Ossification (Figs. 252, 253, 254).—The femur is ossified from five centers: one for the body, one for the head, one for each trochanter, and one for the lower extremity. Of all the long bones, except the clavicle, it is the first to show traces of ossification; this commences in the middle of the body, at about the seventh week of fetal life, and rapidly extends upward and downward. The centers in the epiphyses appear in the following order: in the lower end of the bone, at the ninth month of fetal life (from this center the condyles and epicondyles are formed); in the head, at the end of the first year after birth; in the greater trochanter, during the fourth year; and in the lesser trochanter, between the thirteenth and fourteenth years. The order in which the epiphyses are joined to the body is the reverse of that of their appearance; they are not united until after puberty, the lesser trochanter being first joined, then the greater, then the head, and, lastly, the inferior extremity, which is not united until the twentieth year.

The Patella (Knee Cap).

The **patella** (Figs. 255, 256) is a flat, triangular bone, situated on the front of the knee-joint. It is usually regarded as a sesamoid bone, developed in the tendon of the Quadriceps femoris, and resembles these bones (1) in being developed in a tendon; (2) in its center of ossification presenting a knotty or tuberculated outline; (3) in being composed mainly of dense cancellous tissue. It serves to protect the front of the joint, and increases the leverage of the Quadriceps femoris by making it act at a greater angle. It has an anterior and a posterior surface three borders, and an apex.

Surfaces.—The **anterior surface** is convex, perforated by small apertures for the passage of nutrient vessels, and marked by numerous rough, longitudinal striae. This surface is covered, in the recent state, by an expansion from the tendon of the Quadriceps femoris, which is continuous below with the superficial fibers of the ligamentum patellae. It is separated from the integument by a bursa. The **posterior surface** presents above a smooth, oval, articular area, divided into two facets by a vertical ridge; the ridge corresponds to the groove on the patellar surface of the femur, and the facets to the medial and lateral parts of the same surface; the lateral facet is the broader and deeper. Below the articular surface is a rough, convex, non-articular area, the lower half of which gives attachment to the ligamentum patellae; the upper half is separated from the head of the tibia by adipose tissue.

Borders.—The **base** or superior border is thick, and sloped from behind, downward, and forward: it gives attachment to that portion of the Quadriceps femoris



FIG. 255.—Right patella.
Anterior surface.



FIG. 256.—Right patella.
Posterior surface.

which is derived from the Rectus femoris and Vastus intermedius. The **medial** and **lateral borders** are thinner and converge below: they give attachment to those portions of the Quadriceps femoris which are derived from the Vasti lateralis and medialis.

Apex.—The apex is pointed, and gives attachment to the ligamentum patellæ.

Structure.—The patella consists of a nearly uniform dense cancellous tissue, covered by a thin compact lamina. The cancelli immediately beneath the anterior surface are arranged parallel with it. In the rest of the bone they radiate from the articular surface toward the other parts of the bone.

Ossification.—The patella is ossified from a single center, which usually makes its appearance in the second or third year, but may be delayed until the sixth year. More rarely, the bone is developed by two centers, placed side by side. Ossification is completed about the age of puberty.

Articulation.—The patella articulates with the femur.

The Tibia (Shin Bone).

The **tibia** (Figs. 258, 259) is situated at the medial side of the leg, and, excepting the femur, is the longest bone of the skeleton. It is prismoid in form, expanded above, where it enters into the knee-joint, contracted in the lower third, and again enlarged but to a lesser extent below. In the male, its direction is vertical, and parallel with the bone of the opposite side; but in the female it has a slightly oblique direction downward and lateralward, to compensate for the greater obliquity of the femur. It has a **body** and **two extremities**.

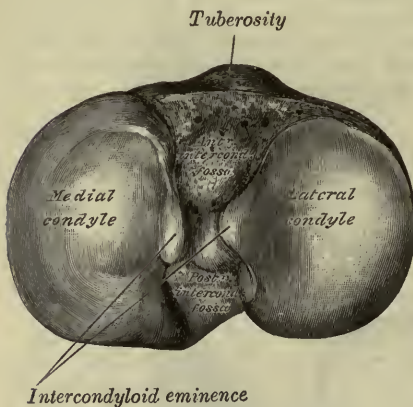


FIG. 257.—Upper surface of right tibia.

The Upper Extremity (*proximal extremity*).

—The upper extremity is large, and expanded into two eminences, the **medial** and **lateral condyles**. The **superior articular surface** presents two smooth articular facets (Fig. 257). The medial facet, oval in shape, is slightly concave from side to side, and from before backward. The lateral, nearly circular, is concave from side to side, but slightly convex from before backward, especially at its posterior part, where it is prolonged on to the posterior surface for a short distance. The central portions of these facets articulate with the condyles of the femur, while their peripheral portions support the menisci of the knee-joint, which here intervene between the two bones. Between the articular facets, but nearer the posterior than the anterior aspect of the bone, is the **intercondyloid eminence** (*spine of tibia*), surmounted on either side by a prominent tubercle, on to the sides of which the articular facets are prolonged; in front of and behind the intercondyloid eminence are rough depressions for the attachment of the anterior and posterior cruciate ligaments and the menisci. The **anterior surfaces** of the condyles are continuous with one another, forming a large somewhat flattened area; this area is triangular, broad above, and perforated by large vascular foramina; narrow below where it ends in a large oblong elevation, the **tuberosity of the tibia**, which gives attachment to the ligamentum patellæ; a bursa intervenes between the deep surface of the ligament and the part of the bone immediately above the tuberosity. *Posteriorly*, the condyles are separated from each other by a shallow depression, the **posterior intercondyloid fossa**, which gives attachment to part of the posterior cruciate ligament of the knee-joint. The **medial condyle** presents posteriorly a deep transverse groove, for the insertion of the tendon of

the Semimembranosus. Its *medial surface* is convex, rough, and prominent; it gives attachment to the tibial collateral ligament. The **lateral condyle** presents posteriorly a flat articular facet, nearly circular in form, directed downward, backward, and lateralward, for articulation with the head of the fibula. Its *lateral surface* is convex, rough, and prominent in front: on it is an eminence, situated on a level with the upper border of the tuberosity and at the junction of its anterior and lateral surfaces, for the attachment of the iliotibial band. Just below this a part of the Extensor digitorum longus takes origin and a slip from the tendon of the Biceps femoris is inserted.

The Body or Shaft (*corpus tibiæ*).

—The body has three borders and three surfaces.

Borders.—The **anterior crest** or border, the most prominent of the three, commences above at the tuberosity, and ends below at the anterior margin of the medial malleolus. It is sinuous and prominent in the upper two-thirds of its extent, but smooth and rounded below; it gives attachment to the deep fascia of the leg.

The **medial border** is smooth and rounded above and below, but more prominent in the center; it begins at the back part of the medial condyle, and ends at the posterior border of the medial malleolus; its upper part gives attachment to the tibial collateral ligament of the knee-joint to the extent of about 5 cm., and insertion to some fibers of the Popliteus; from its middle third some fibers of the Soleus and Flexor digitorum longus take origin.

The **interosseous crest** or **lateral border** is thin and prominent, especially its central part, and gives attachment to the interosseous membrane; it commences above in front of the fibular articular facet, and




FIG. 258.—Bones of the right leg. Anterior surface.

bifurcates below, to form the boundaries of a triangular rough surface, for the attachment of the interosseous ligament connecting the tibia and fibula.

Surfaces.—The **medial surface** is smooth, convex, and broader above than below; its upper third, directed forward and medialward, is covered by the aponeurosis derived from the tendon of the Sartorius, and by the tendons of the Gracilis and Semitendinosus, all of which are inserted nearly as far forward as the anterior crest; in the rest of its extent it is subcutaneous.

The **lateral surface** is narrower than the medial; its upper two-thirds present a shallow groove for the origin of the Tibialis anterior; its lower third is smooth, convex, curves gradually forward to the anterior aspect of the bone, and is covered by the tendons of the Tibialis anterior, Extensor hallucis longus, and Extensor digitorum longus, arranged in this order from the medial side.

The **posterior surface** (Fig. 259) presents, at its upper part, a prominent ridge, the **popliteal line**, which extends obliquely downward from the back part of the articular facet for the fibula to the medial border, at the junction of its upper and middle thirds; it marks the lower limit of the insertion of the Popliteus, serves for the attachment of the fascia covering this muscle, and gives origin to part of the Soleus, Flexor digitorum longus, and Tibialis posterior. The triangular area, above this line, gives insertion to the Popliteus. The middle third of the posterior surface is divided by a vertical ridge into two parts; the ridge begins at the popliteal line and is well-marked above, but indistinct below; the medial and broader portion gives origin to the Flexor digitorum longus, the lateral and narrower to part of the Tibialis posterior. The

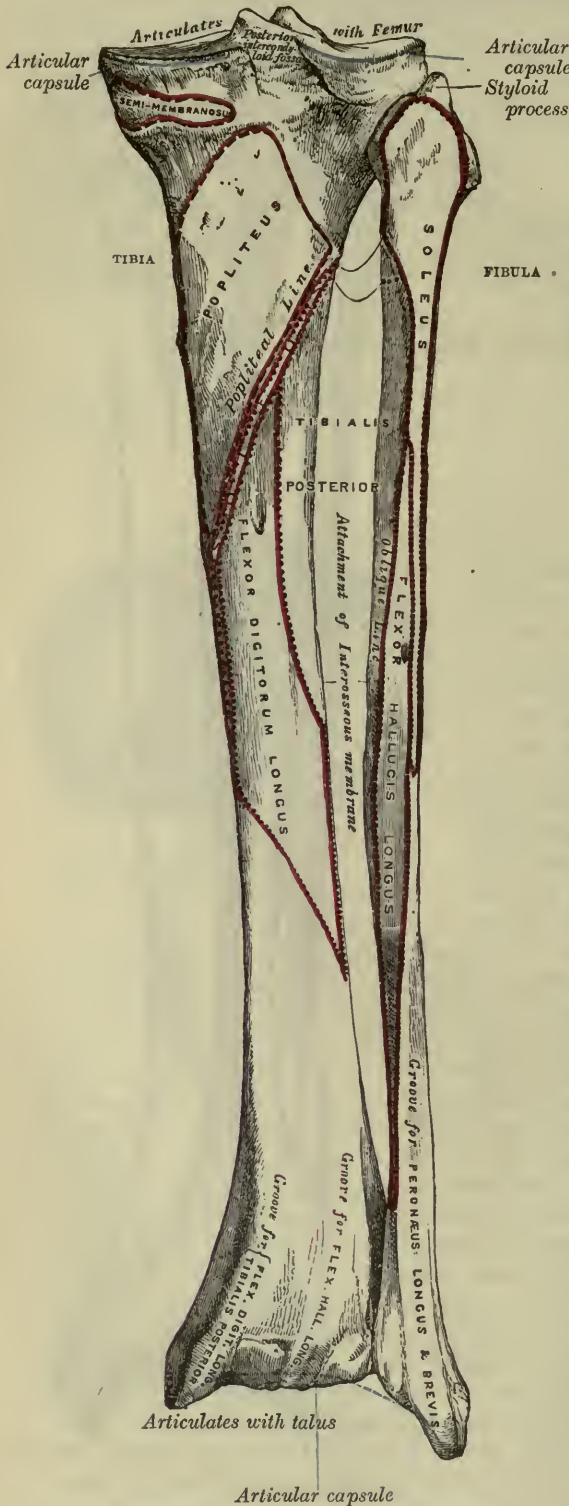


FIG. 259.—Bones of the right leg. Posterior surface.

remaining part of the posterior surface is smooth and covered by the Tibialis posterior, Flexor digitorum longus, and Flexor hallucis longus. Immediately below the popliteal line is the **nutrient foramen**, which is large and directed obliquely downward.

The Lower Extremity (*distal extremity*).—The lower extremity, much smaller than the upper, presents five surfaces; it is prolonged downward on its medial side as a strong process, the **medial malleolus**.

Surfaces.—The **inferior articular surface** is quadrilateral, and smooth for articulation with the talus. It is concave from before backward, broader in front than behind, and traversed from before backward by a slight elevation, separating two depressions. It is continuous with that on the medial malleolus.



FIG. 260.—Plan of ossification of the tibia. From three centers.

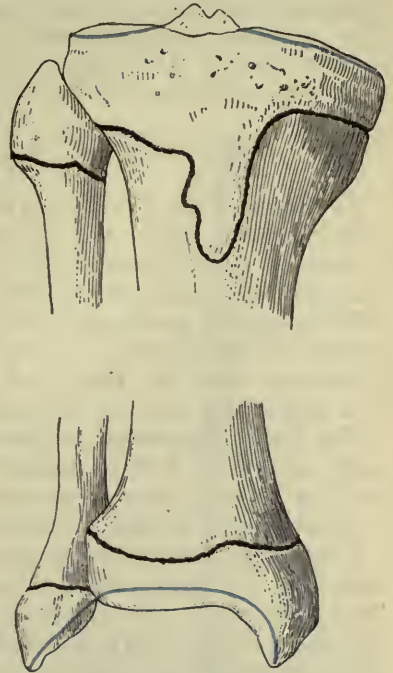


FIG. 261.—Epiphysal lines of tibia and fibula in a young adult. Anterior aspect.

The **anterior surface** of the lower extremity is smooth and rounded above, and covered by the tendons of the Extensor muscles; its lower margin presents a rough transverse depression for the attachment of the articular capsule of the ankle-joint.

The **posterior surface** is traversed by a shallow groove directed obliquely downward and medialward, continuous with a similar groove on the posterior surface of the talus and serving for the passage of the tendon of the Flexor hallucis longus.

The **lateral surface** presents a triangular rough depression for the attachment of the inferior interosseous ligament connecting it with the fibula; the lower part of this depression is smooth, covered with cartilage in the fresh state, and articulates with the fibula. The surface is bounded by two prominent borders, continuous above with the interosseous crest; they afford attachment to the anterior and posterior ligaments of the lateral malleolus.

The **medial surface** is prolonged downward to form a strong pyramidal process, flattened from without inward—the **medial malleolus**. The *medial surface* of this process is convex and subcutaneous; its *lateral or articular surface* is smooth and slightly concave, and articulates with the talus; its *anterior border* is rough, for

the attachment of the anterior fibers of the deltoid ligament of the ankle-joint; its *posterior border* presents a broad groove, the **malleolar sulcus**, directed obliquely downward and medialward, and occasionally double; this sulcus lodges the tendons of the Tibialis posterior and Flexor digitorum longus. The *summit* of the medial malleolus is marked by a rough depression behind, for the attachment of the deltoid ligament.

Structure.—The structure of the tibia is like that of the other long bones. The compact wall of the body is thickest at the junction of the middle and lower thirds of the bone.

Ossification.—The tibia is ossified from *three* centers (Figs. 260, 261): one for the body and one for either extremity. Ossification begins in the center of the body, about the seventh week of fetal life, and gradually extends toward the extremities. The center for the upper epiphysis appears before or shortly after birth; it is flattened in form, and has a thin tongue-shaped process in front, which forms the tuberosity (Fig. 260); that for the lower epiphysis appears in the second year. The lower epiphysis joins the body at about the eighteenth, and the upper one joins about the twentieth year. Two additional centers occasionally exist, one for the tongue-shaped process of the upper epiphysis, which forms the tuberosity, and one for the medial malleolus.

The Fibula (Calf Bone).

The **fibula** (Figs. 258, 259) is placed on the lateral side of the tibia, with which it is connected above and below. It is the smaller of the two bones, and, in proportion to its length, the most slender of all the long bones. Its upper extremity is small, placed toward the back of the head of the tibia, below the level of the knee-joint, and excluded from the formation of this joint. Its lower extremity inclines a little forward, so as to be on a plane anterior to that of the upper end; it projects below the tibia, and forms the lateral part of the ankle-joint. The bone has a **body** and **two extremities**.

The Upper Extremity or Head (*capitulum fibulæ; proximal extremity*).—The upper extremity is of an irregular quadrate form, presenting above a flattened articular surface, directed upward, forward, and medialward, for articulation with a corresponding surface on the lateral condyle of the tibia. On the lateral side is a thick and rough prominence continued behind into a pointed eminence, the **apex** (*styloid process*), which projects upward from the posterior part of the head. The prominence, at its upper and lateral part, gives attachment to the tendon of the Biceps femoris and to the fibular collateral ligament of the knee-joint, the ligament dividing the tendon into two parts. The remaining part of the circumference of the head is rough, for the attachment of muscles and ligaments. It presents in front a tubercle for the origin of the upper and anterior fibers of the Peronæus longus, and a surface for the attachment of the anterior ligament of the head; and behind, another tubercle, for the attachment of the posterior ligament of the head and the origin of the upper fibers of the Soleus.

The Body or Shaft (*corpus fibulæ*).—The body presents four borders—the antero-lateral, the antero-medial, the postero-lateral, and the postero-medial; and four surfaces—anterior, posterior, medial, and lateral.

Borders.—The **antero-lateral border** begins above in front of the head, runs vertically downward to a little below the middle of the bone, and then curving somewhat lateralward, bifurcates so as to embrace a triangular subcutaneous surface immediately above the lateral malleolus. This border gives attachment to an intermuscular septum, which separates the Extensor muscles on the anterior surface of the leg from the Peronæi longus and brevis on the lateral surface.

The **antero-medial border**, or **interosseous crest**, is situated close to the medial side of the preceding, and runs nearly parallel with it in the upper third of its extent, but diverges from it in the lower two-thirds. It begins above just beneath the head of the bone (sometimes it is quite indistinct for about 2.5 cm. below the head), and ends at the apex of a rough triangular surface immediately above the

articular facet of the lateral malleolus. It serves for the attachment of the interosseous membrane, which separates the Extensor muscles in front from the Flexor muscles behind.

The **postero-lateral border** is prominent; it begins above at the apex, and ends below in the posterior border of the lateral malleolus. It is directed lateralward above, backward in the middle of its course, backward, and a little medialward below, and gives attachment to an aponeurosis which separates the Peronæi on the lateral surface from the Flexor muscles on the posterior surface.

The **postero-medial border**, sometimes called the **oblique line**, begins above at the medial side of the head, and ends by becoming continuous with the interosseous crest at the lower fourth of the bone. It is well-marked and prominent at the upper and middle parts of the bone. It gives attachment to an aponeurosis which separates the Tibialis posterior from the Soleus and Flexor hallucis longus.

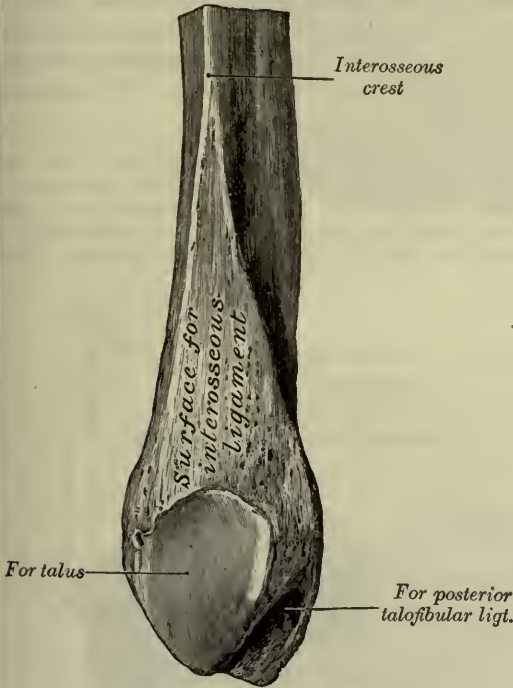


FIG. 262.—Lower extremity of right fibula. Medial aspect.



FIG. 263.—Plan of ossification of the fibula. From three centers.

Surfaces.—The **anterior surface** is the interval between the antero-lateral and antero-medial borders. It is extremely narrow and flat in the upper third of its extent; broader and grooved longitudinally in its lower third; it serves for the origin of three muscles: the Extensor digitorum longus, Extensor hallucis longus, and Peronæus tertius.

The **posterior surface** is the space included between the postero-lateral and the postero-medial borders; it is continuous below with the triangular area above the articular surface of the lateral malleolus; it is directed backward above, backward and medialward at its middle, directly medialward below. Its upper third is rough, for the origin of the Soleus; its lower part presents a triangular surface, connected to the tibia by a strong interosseous ligament; the intervening part of the surface is covered by the fibers of origin of the Flexor hallucis longus. Near the middle of this surface is the nutrient foramen, which is directed downward.

The **medial surface** is the interval included between the antero-medial and the postero-medial borders. It is grooved for the origin of the Tibialis posterior.

The **lateral surface** is the space between the antero-lateral and postero-lateral borders. It is broad, and often deeply grooved; it is directed lateralward in the upper two-thirds of its course, backward in the lower third, where it is continuous with the posterior border of the lateral malleolus. This surface gives origin to the *Peronæi longus* and *brevis*.

The Lower Extremity or Lateral Malleolus (*malleolus lateralis*; *distal extremity*; *external malleolus*).—The lower extremity is of a pyramidal form, and somewhat flattened from side to side; it descends to a lower level than the medial malleolus. The **lateral surface** is convex, subcutaneous, and continuous with the triangular, subcutaneous surface on the lateral side of the body. The **medial surface** (Fig. 262) presents in front a smooth triangular surface, convex from above downward, which articulates with a corresponding surface on the lateral side of the talus. Behind and beneath the articular surface is a rough depression, which gives attachment to the posterior talofibular ligament. The **anterior border** is thick and rough, and marked below by a depression for the attachment of the anterior talofibular ligament. The **posterior border** is broad and presents the shallow **malleolar sulcus**, for the passage of the tendons of the *Peronæi longus* and *brevis*. The **summit** is rounded, and give attachment to the calcaneofibular ligament.

Ossification.—The fibula is ossified from *three* centers (Fig. 263): one for the body, and one for either end. Ossification begins in the body about the eighth week of fetal life, and extends toward the extremities. At birth the ends are cartilaginous. Ossification commences in the lower end in the second year, and in the upper about the fourth year. The lower epiphysis, the first to ossify, unites with the body about the twentieth year; the upper epiphysis joins about the twenty-fifth year.

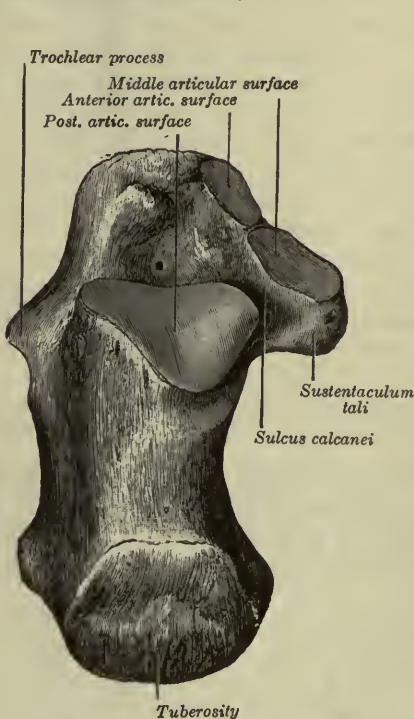


FIG. 264.—Left calcaneus, superior surface.

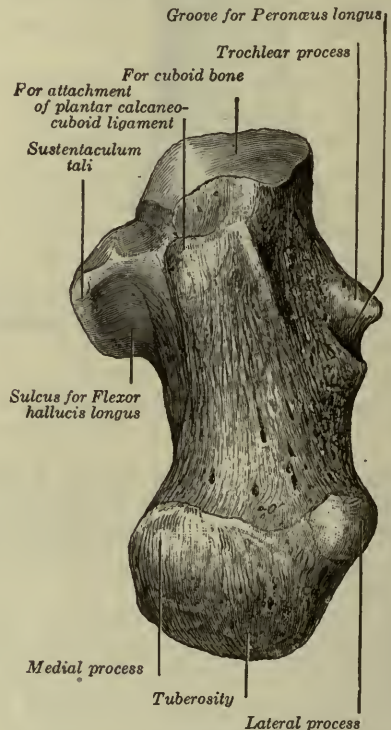


FIG. 265.—Left calcaneus, inferior surface.

THE FOOT.

The skeleton of the foot (Figs. 268 and 269) consists of three parts: the **tarsus**, **metatarsus**, and **phalanges**.

The Tarsus (Ossa Tarsi).

The tarsal bones are seven in number, viz., the calcaneus, talus, cuboid, navicular, and the first, second, and third cuneiforms.

The Calcaneus (*os calcis*) (Figs. 264 to 267).—The calcaneus is the largest of the tarsal bones. It is situated at the lower and back part of the foot, serving to transmit the weight of the body to the ground, and forming a strong lever for the muscles of the calf. It is irregularly cuboidal in form, having its long axis directed forward and lateralward; it presents for examination six surfaces.

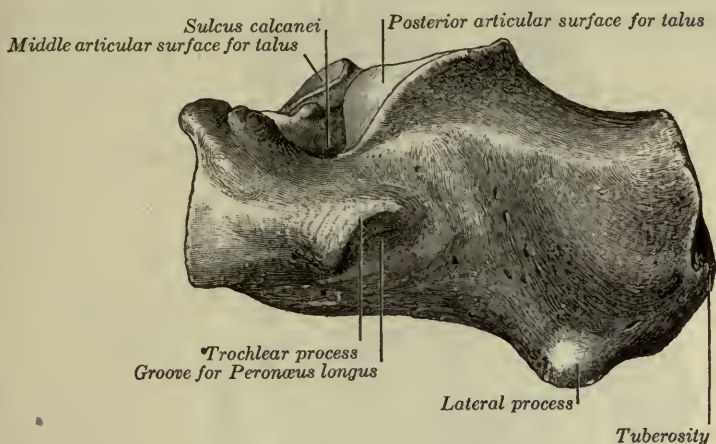


FIG. 266.—Left calcaneus, lateral surface.

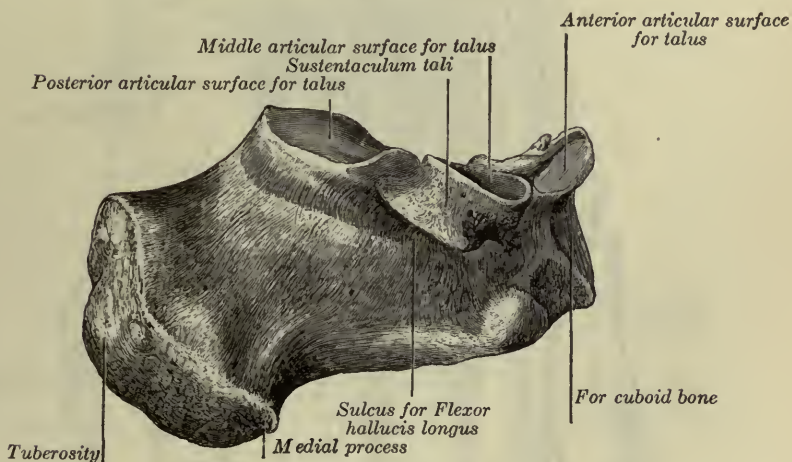


FIG. 267.—Left calcaneus, medial surface.

Surfaces.—The **superior surface** extends behind on to that part of the bone which projects backward to form the heel. This varies in length in different individuals, is convex from side to side, concave from before backward, and supports a mass of fat placed in front of the tendo calcaneus. In front of this area is a large usually somewhat oval-shaped facet, the **posterior articular surface**, which looks upward and forward; it is convex from behind forward, and articulates with the posterior calcaneal facet on the under surface of the talus. It is bounded anteriorly by a deep depression which is continued backward and medialward in the form of a groove, the **calcaneal sulcus**. In the articulated foot this sulcus lies below a similar one on the under surface of the talus, and the two form a canal (**sinus tarsi**) for the

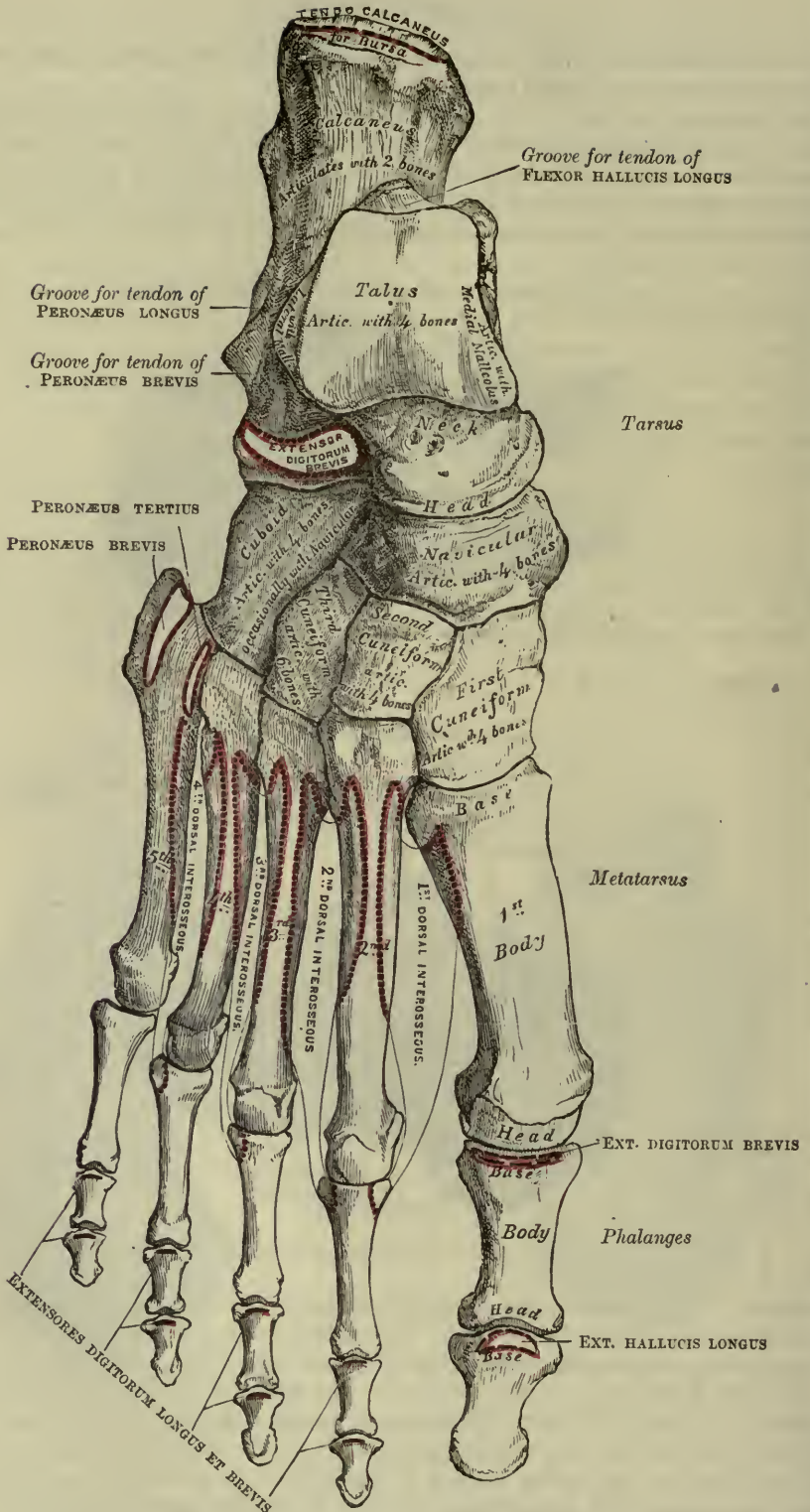


FIG. 268.—Bones of the right foot. Dorsal surface.

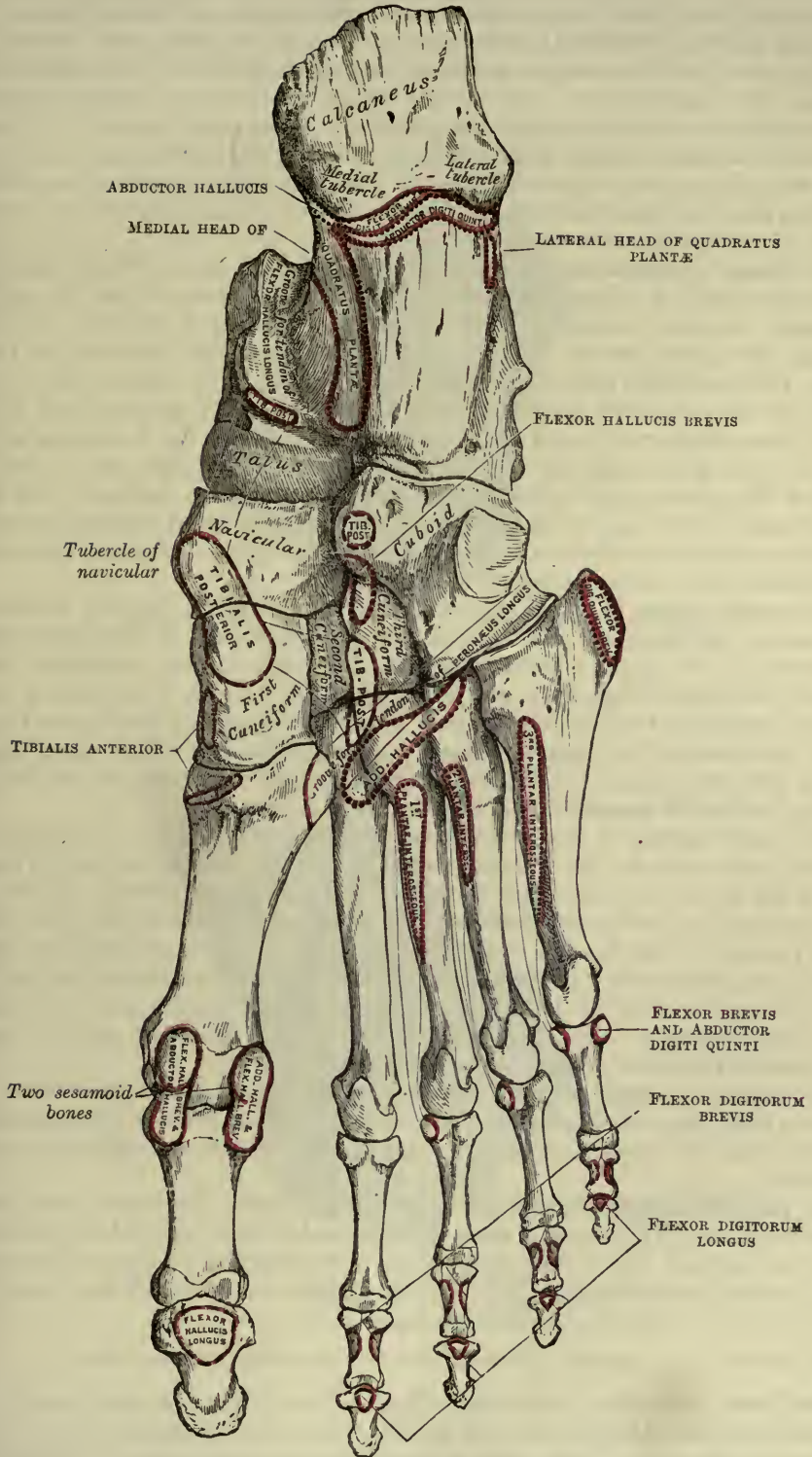


FIG. 269.—Bones of the right foot. Plantar surface.

lodgement of the interosseous talocalcaneal ligament. In front and to the medial side of this groove is an elongated facet, concave from behind forward, and with its long axis directed forward and lateralward. This facet is frequently divided into two by a notch: of the two, the posterior, and larger is termed the **middle articular surface**; it is supported on a projecting process of bone, the **sustentaculum tali**, and articulates with the middle calcaneal facet on the under surface of the talus; the **anterior articular surface** is placed on the anterior part of the body, and articulates with the anterior calcaneal facet on the talus. The upper surface, anterior and lateral to the facets, is rough for the attachment of ligaments and for the origin of the *Extensor digitorum brevis*.

The **inferior or plantar surface** is uneven, wider behind than in front, and convex from side to side; it is bounded posteriorly by a transverse elevation, the **calcaneal tuberosity**, which is depressed in the middle and prolonged at either end into a process; the **lateral process**, small, prominent, and rounded, gives origin to part of the *Abductor digiti quinti*; the **medial process**, broader and larger, gives attachment, by its prominent medial margin, to the *Abductor hallucis*, and in front to the *Flexor digitorum brevis* and the plantar aponeurosis; the depression between the processes gives origin to the *Abductor digiti quinti*. The rough surface in front of the processes gives attachment to the long plantar ligament, and to the lateral head of the *Quadratus plantæ*; while to a prominent tubercle nearer the anterior part of this surface, as well as to a transverse groove in front of the tubercle, is attached the plantar calcaneocuboid ligament.

The **lateral surface** is broad behind and narrow in front, flat and almost subcutaneous; near its center is a tubercle, for the attachment of the calcaneofibular ligament. At its upper and anterior part, this surface gives attachment to the lateral talocalcaneal ligament; and in front of the tubercle it presents a narrow surface marked by two oblique grooves. The grooves are separated by an elevated ridge, or tubercle, the **trochlear process** (*peroneal tubercle*), which varies much in size in different bones. The **superior groove** transmits the tendon of the *Peronæus brevis*; the **inferior groove**, that of the *Peronæus longus*.

The **medial surface** is deeply concave; it is directed obliquely downward and forward, and serves for the transmission of the plantar vessels and nerves into the sole of the foot; it affords origin to part of the *Quadratus plantæ*. At its upper and forepart is a horizontal eminence, the **sustentaculum tali**, which gives attachment to a slip of the tendon of the *Tibialis posterior*. This eminence is concave above, and articulates with the middle calcaneal articular surface of the talus; below, it is grooved for the tendon of the *Flexor hallucis longus*; its anterior margin gives attachment to the plantar calcaneonavicular ligament, and its medial, to a part of the deltoid ligament of the ankle-joint.

The **anterior or cuboid articular surface** is of a somewhat triangular form. It is concave from above downward and lateralward, and convex in a direction at right angles to this. Its medial border gives attachment to the plantar calcaneonavicular ligament.

The **posterior surface** is prominent, convex, wider below than above, and divisible into three areas. The lowest of these is rough, and covered by the fatty and fibrous tissue of the heel; the middle, also rough, gives insertion to the *tendo calcaneus* and *Plantaris*; while the highest is smooth, and is covered by a bursa which intervenes between it and the *tendo calcaneus*.

Articulations.—The calcaneus articulates with two bones: the talus and cuboid.

The Talus (*astragalus*; *ankle bone*) (Figs. 270 to 273).—The talus is the second largest of the tarsal bones. It occupies the middle and upper part of the tarsus, supporting the tibia above, resting upon the calcaneus below, articulating on either side with the malleoli, and in front with the navicular. It consists of a **body**, a **neck**, and a **head**

The Body (*corpus tali*).—The superior surface of the body presents, behind, a smooth trochlear surface, the **trochlea**, for articulation with the tibia. The trochlea is broader in front than behind, convex from before backward, slightly concave from side to side: in front it is continuous with the upper surface of the neck of the bone.

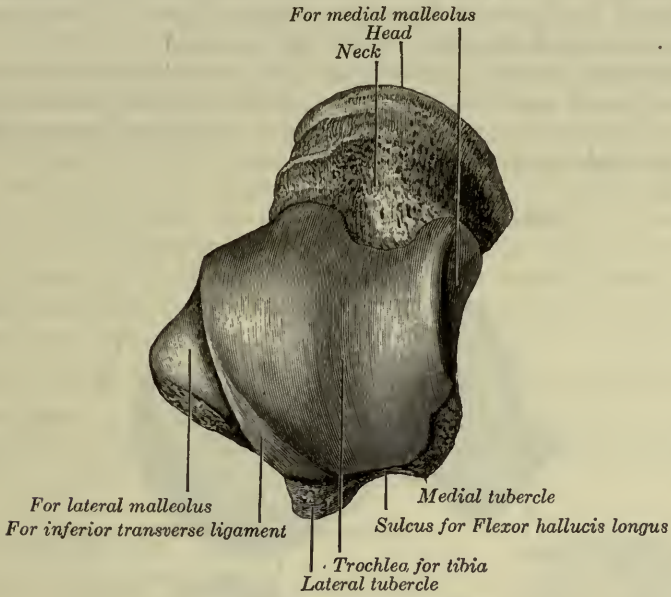


FIG. 270.—Left talus, from above.

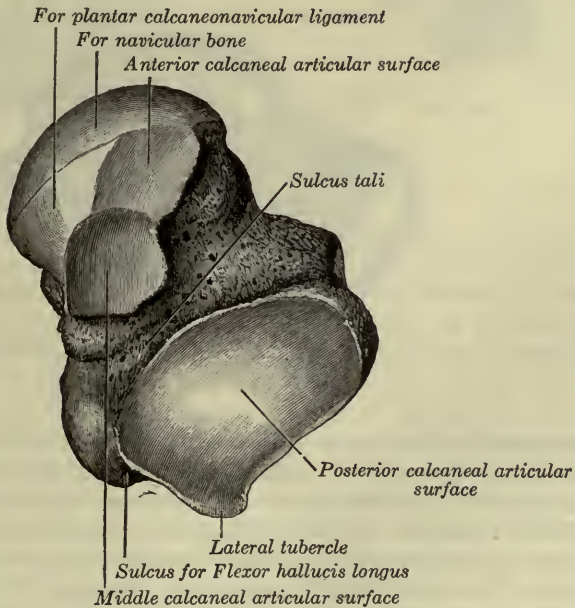


FIG. 271.—Left talus, from below.

The **inferior surface** presents two articular areas, the posterior and middle calcaneal surfaces, separated from one another by a deep groove, the **sulcus tali**. The groove runs obliquely forward and lateralward, becoming gradually broader and deeper in front: in the articulated foot it lies above a similar groove upon the upper surface of the calcaneus, and forms, with it, a canal (**sinus tarsi**) filled

up in the fresh state by the interosseous talocalcaneal ligament. The **posterior calcaneal articular surface** is large and of an oval or oblong form. It articulates with the corresponding facet on the upper surface of the calcaneus,¹ and is deeply concave in the direction of its long axis which runs forward and lateralward at an angle of about 45° with the median plane of the body. The **middle calcaneal articular surface** is small, oval in form and slightly convex; it articulates with the upper surface of the sustentaculum tali of the calcaneus.

The **medial surface** presents at its upper part a pear-shaped articular facet for the medial malleolus, continuous above with the trochlea; below the articular surface is a rough depression for the attachment of the deep portion of the deltoid ligament of the ankle-joint.

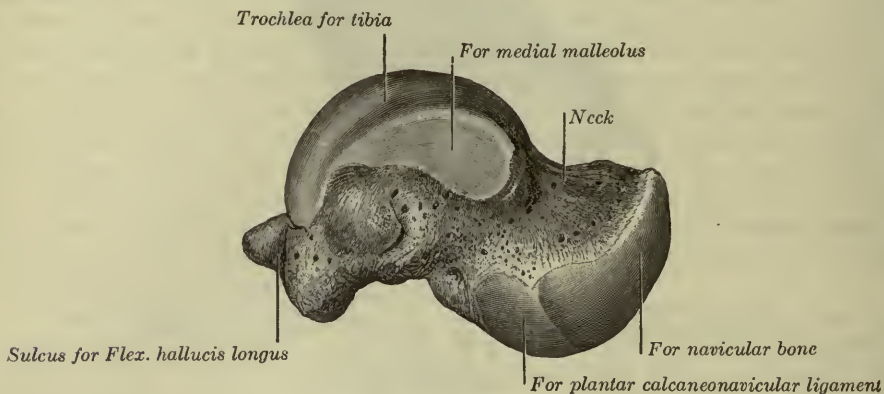


FIG. 272.—Left talus, medial surface.

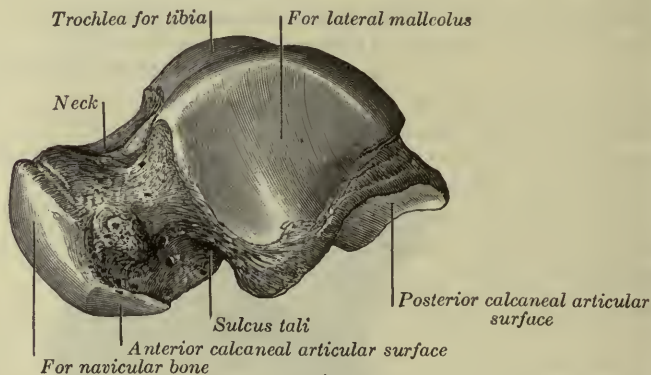


FIG. 273.—Left talus, lateral surface.

The **lateral surface** carries a large triangular facet, concave from above downward, for articulation with the lateral malleolus; its anterior half is continuous above with the trochlea; and in front of it is a rough depression for the attachment of the anterior talofibular ligament. Between the posterior half of the lateral border of the trochlea and the posterior part of the base of the fibular articular surface is a triangular facet (Fawcett²) which comes into contact with the transverse inferior tibiofibular ligament during flexion of the ankle-joint; below the base of this facet is a groove which affords attachment to the posterior talofibular ligament.

The **posterior surface** is narrow, and traversed by a groove running obliquely

¹ Sewell (*Journal of Anatomy and Physiology*, vol. xxxviii) pointed out that in about 10 per cent. of bones a small triangular facet, continuous with the posterior calcaneal facet, is present at the junction of the lateral surface of the body with the posterior wall of the sulcus tali.

² *Edinburgh Medical Journal*, 1895.

downward and medialward, and transmitting the tendon of the Flexor hallucis longus. Lateral to the groove is a prominent tubercle, the **posterior process**, to which the posterior talofibular ligament is attached; this process is sometimes separated from the rest of the talus, and is then known as the **os trigonum**. Medial to the groove is a second smaller tubercle.

The Neck (*collum tali*).—The neck is directed forward and medialward, and comprises the constricted portion of the bone between the body and the oval head. Its **upper and medial surfaces** are rough, for the attachment of ligaments; its **lateral surface** is concave and is continuous below with the deep groove for the interosseous talocalcaneal ligament.

The Head (*caput tali*).—The head looks forward and medialward; its **anterior articular or navicular surface** is large, oval, and convex. Its **inferior surface** has two facets, which are best seen in the fresh condition. The medial, situated in front of the middle calcaneal facet, is convex, triangular, or semi-oval in shape, and rests on the plantar calcaneonavicular ligament; the lateral, named the **anterior calcaneal articular surface**, is somewhat flattened, and articulates with the facet on the upper surface of the anterior part of the calcaneus.

Articulations.—The talus articulates with *four* bones: tibia, fibula, calcaneus, and navicular.

The Cuboid Bone (*os cuboideum*) (Figs. 274, 275).—The cuboid bone is placed on the lateral side of the foot, in front of the calcaneus, and behind the fourth and fifth metatarsal bones. It is of a pyramidal shape, its base being directed medialward.

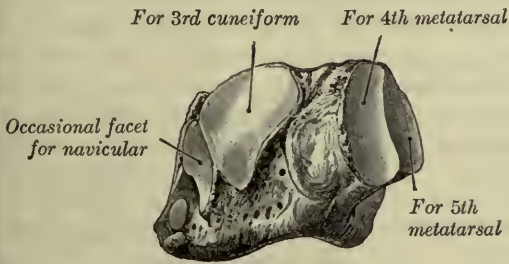


FIG. 274.—The left cuboid. Antero-medial view.

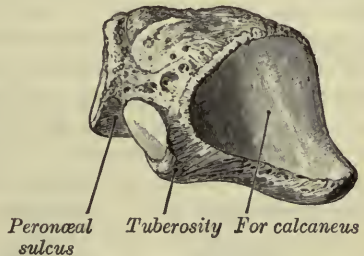


FIG. 275.—The left cuboid. Postero-lateral view.

Surfaces.—The **dorsal surface**, directed upward and lateralward, is rough, for the attachment of ligaments. The **plantar surface** presents in front a deep groove, the **peroneal sulcus**, which runs obliquely forward and medialward; it lodges the tendon of the Peronæus longus, and is bounded behind by a prominent ridge, to which the long plantar ligament is attached. The ridge ends laterally in an eminence, the **tuberosity**, the surface of which presents an oval facet; on this facet glides the sesamoid bone or cartilage frequently found in the tendon of the Peronæus longus. The surface of bone behind the groove is rough, for the attachment of the plantar calcaneocuboid ligament, a few fibers of the Flexor hallucis brevis, and a fasciculus from the tendon of the Tibialis posterior. The **lateral surface** presents a deep notch formed by the commencement of the peroneal sulcus. The **posterior surface** is smooth, triangular, and concavo-convex, for articulation with the anterior surface of the calcaneus; its infero-medial angle projects backward as a process which underlies and supports the anterior end of the calcaneus. The **anterior surface**, of smaller size, but also irregularly triangular, is divided by a vertical ridge into two facets: the medial, quadrilateral in form, articulates with the fourth metatarsal; the lateral, larger and more triangular, articulates with the fifth. The **medial surface** is broad, irregularly quadrilateral, and presents at its middle and upper part a smooth oval facet, for articulation with the third

cuneiform; and behind this (occasionally) a smaller facet, for articulation with the navicular; it is rough in the rest of its extent, for the attachment of strong interosseous ligaments.

Articulations.—The cuboid articulates with *four* bones: the calcaneus, third cuneiform, and fourth and fifth metatarsals; occasionally with a fifth, the navicular.

The Navicular Bone (*os naviculare pedis; scaphoid bone*) (Figs. 276, 277).—The navicular bone is situated at the medial side of the tarsus, between the talus behind and the cuneiform bones in front.

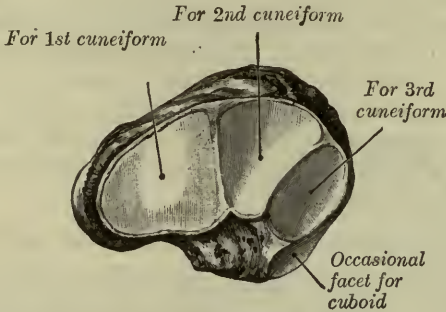


FIG. 276.—The left navicular. Antero-lateral view.

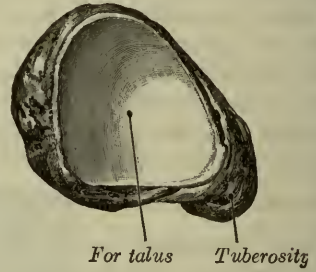


FIG. 277.—The left navicular. Postero-medial view.

Surfaces.—The **anterior surface** is convex from side to side, and subdivided by two ridges into three facets, for articulation with the three cuneiform bones. The **posterior surface** is oval, concave, broader laterally than medially, and articulates with the rounded head of the talus. The **dorsal surface** is convex from side to side, and rough for the attachment of ligaments. The **plantar surface** is irregular, and also rough for the attachment of ligaments. The **medial surface** presents a rounded

tuberosity, the lower part of which gives attachment to part of the tendon of the Tibialis posterior. The **lateral surface** is rough and irregular for the attachment of ligaments, and occasionally presents a small facet for articulation with the cuboid bone.

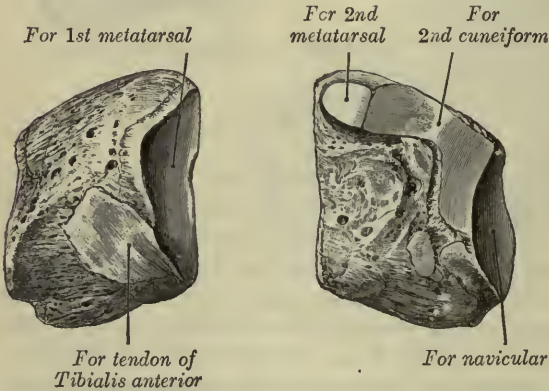


FIG. 278.—The left first cuneiform. Antero-medial view.

FIG. 279.—The left first cuneiform. Postero-lateral view.

Articulations.—The navicular articulates with *four* bones: the talus and the three cuneiforms; occasionally with a fifth, the cuboid.

The First Cuneiform Bone (*os cuneiform primum; internalcuneiform*) (Figs. 278, 279).—The first cuneiform bone is the largest of

the three cuneiforms. It is situated at the medial side of the foot, between the navicular behind and the base of the first metatarsal in front.

Surfaces.—The **medial surface** is subcutaneous, broad, and quadrilateral; at its anterior plantar angle is a smooth oval impression, into which part of the tendon of the Tibialis anterior is inserted; in the rest of its extent it is rough for the attachment of ligaments. The **lateral surface** is concave, presenting, along its superior and posterior borders a narrow L-shaped surface, the vertical limb and posterior part of the horizontal limb of which articulate with the second cuneiform, while the anterior part of the horizontal limb articulates with the second metatarsal

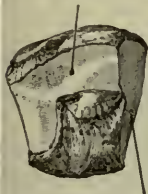bone: the rest of this surface is rough for the attachment of ligaments and part of the tendon of the *Peronæus longus*. The **anterior surface**, kidney-shaped and much larger than the posterior, articulates with the first metatarsal bone. The **posterior surface** is triangular, concave, and articulates with the most medial and largest of the three facets on the anterior surface of the navicular. The **plantar surface** is rough, and forms the base of the wedge; at its back part is a tuberosity for the insertion of part of the tendon of the *Tibialis posterior*. It also gives insertion in front to part of the tendon of the *Tibialis anterior*. The **dorsal surface** is the narrow end of the wedge, and is directed upward and lateralward; it is rough for the attachment of ligaments.

Articulations.—The first cuneiform articulates with *four* bones: the navicular, second cuneiform, and first and second metatarsals.

The Second Cuneiform Bone (*os cuneiforme secundum; middle cuneiform*) (Figs. 280, 281).—The second cuneiform bone, the smallest of the three, is of very regular wedge-like form, the thin end being directed downward. It is situated between the other two cuneiforms, and articulates with the navicular behind, and the second metatarsal in front.

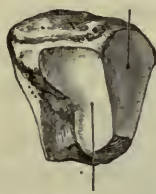Surfaces.—The **anterior surface**, triangular in form, and narrower than the posterior, articulates with the base of the second metatarsal bone. The **posterior surface**, also triangular, articulates with the intermediate facet on the anterior surface of the navicular. The **medial surface** carries an L-shaped articular facet, running along the superior and posterior borders, for articulation with the first cuneiform, and is rough in the rest of its extent for the attachment of ligaments. The **lateral surface** presents posteriorly a smooth facet for articulation with the third cuneiform bone. The **dorsal surface** forms the base of the wedge; it is quadrilateral and rough for the attachment of ligaments. The **plantar surface**, sharp and tuberculated, is also rough for the attachment of ligaments, and for the insertion of a slip from the tendon of the *Tibialis posterior*.

For 1st cuneiform



For 2nd metatarsal

For navicular



For 3rd cuneiform

FIG. 280.—The left second cuneiform. Antero-medial view.

FIG. 281.—The left second cuneiform. Postero-lateral view.

Articulations.—The second cuneiform articulates with *four* bones: the navicular, first and third cuneiforms, and second metatarsal.

The Third Cuneiform Bone (*os cuneiforme tertium; external cuneiform*) (Figs. 282, 283).—The third cuneiform bone, intermediate in size between the two preceding, is wedge-shaped, the base being uppermost. It occupies the center of the front row of the tarsal bones, between the second cuneiform medially, the cuboid laterally, the navicular behind, and the third metatarsal in front.

Surfaces.—The **anterior surface**, triangular in form, articulates with the third metatarsal bone. The **posterior surface** articulates with the lateral facet on the anterior surface of the navicular, and is rough below for the attachment of ligamentous fibers. The **medial surface** presents an anterior and a posterior articular facet, separated by a rough depression: the anterior, sometimes divided, articulates with the lateral side of the base of the second metatarsal bone; the posterior skirts the posterior border, and articulates with the second cuneiform; the rough depression gives attachment to an interosseous ligament. The **lateral surface** also presents two articular facets, separated by a rough non-articular area; the anterior facet, situated at the superior angle of the bone, is small and semi-oval in shape, and articulates with the medial side of the base of the fourth metatarsal bone;

the posterior and larger one is triangular or oval, and articulates with the cuboid; the rough, non-articular area serves for the attachment of an interosseous ligament. The three facets for articulation with the three metatarsal bones are continuous with one another; those for articulation with the second cuneiform and navicular are also continuous, but that for articulation with the cuboid is usually separate. The **dorsal surface** is of an oblong form, its postero-lateral angle being prolonged backward. The **plantar surface** is a rounded margin, and serves for the attachment of part of the tendon of the Tibialis posterior, part of the Flexor hallucis brevis, and ligaments.

Articulations.—The third cuneiform articulates with *six* bones: the navicular, second cuneiform, cuboid, and second, third, and fourth metatarsals.

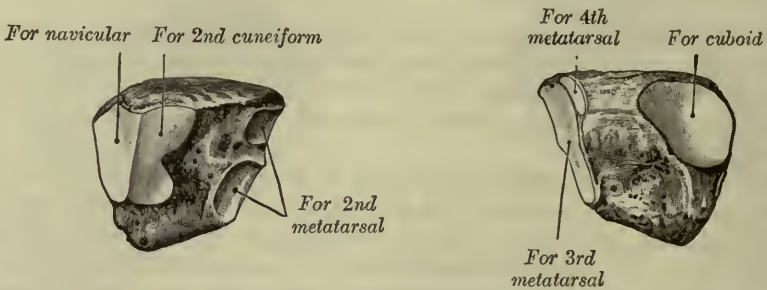


FIG. 282.—The left third cuneiform. Postero-medial view.

FIG. 283.—The third left cuneiform. Antero-lateral view.

The Metatarsus.

The **metatarsus** consists of five bones which are numbered from the medial side (*ossa metatarsalia* I.–V.); each presents for examination a **body** and **two extremities**.

Common Characteristics of the Metatarsal Bones.—The body is prismoid in form, tapers gradually from the tarsal to the phalangeal extremity, and is curved longitudinally, so as to be concave below, slightly convex above. The **base** or **posterior extremity** is wedge-shaped, articulating proximally with the tarsal bones, and by its sides with the contiguous metatarsal bones: its dorsal and plantar surfaces are rough for the attachment of ligaments. The **head** or **anterior extremity** presents a convex articular surface, oblong from above downward, and extending farther backward below than above. Its sides are flattened, and on each is a depression, surmounted by a tubercle, for ligamentous attachment. Its plantar surface is grooved antero-posteriorly for the passage of the Flexor tendons, and marked on either side by an articular eminence continuous with the terminal articular surface.

Characteristics of the Individual Metatarsal Bones.—The **First Metatarsal Bone** (*os metatarsale I*; *metatarsal bone of the great toe*) (Fig. 284).—The first metatarsal bone is remarkable for its great thickness, and is the shortest of the metatarsal bones. The **body** is strong, and of well-marked prismoid form. The **base** presents, as a rule, no articular facets on its sides, but occasionally on the lateral side there is an oval facet, by which it articulates with the second metatarsal. Its proximal articular surface is of large size and kidney-shaped; its circumference is grooved, for the tarsometatarsal ligaments, and medially gives insertion to part of the tendon of the Tibialis anterior; its plantar angle presents a rough oval prominence for the insertion of the tendon of the Peronæus longus. The **head** is large; on its plantar surface are two grooved facets, on which glide sesamoid bones; the facets are separated by a smooth elevation.

The Second Metatarsal Bone (*os metatarsale II*) (Fig. 285).—The second metatarsal bone is the longest of the metatarsal bones, being prolonged backward

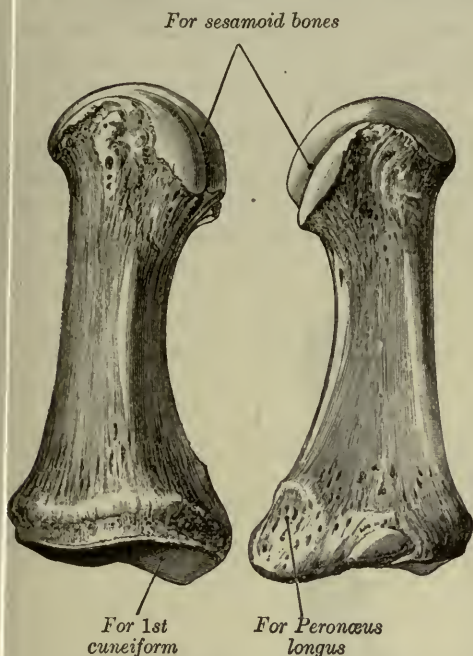


FIG. 284.—The first metatarsal. (Left.)

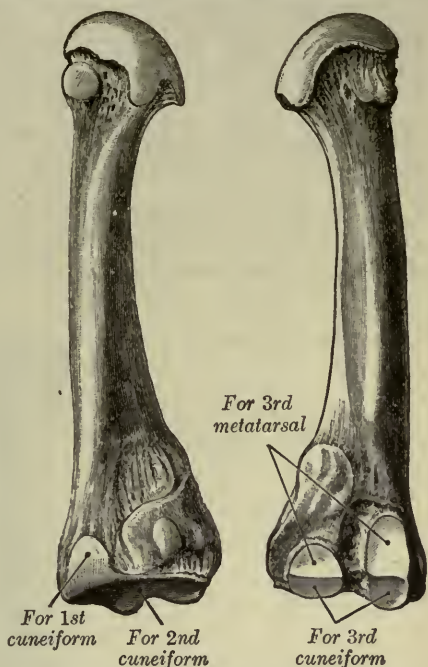


FIG. 285.—The second metatarsal. (Left.)

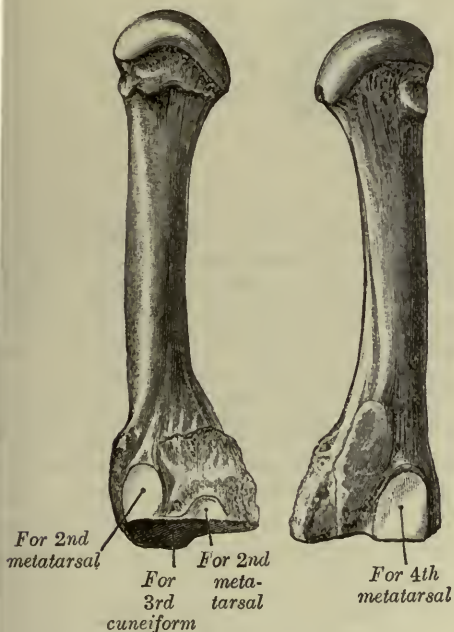


FIG. 286.—The third metatarsal. (Left.)

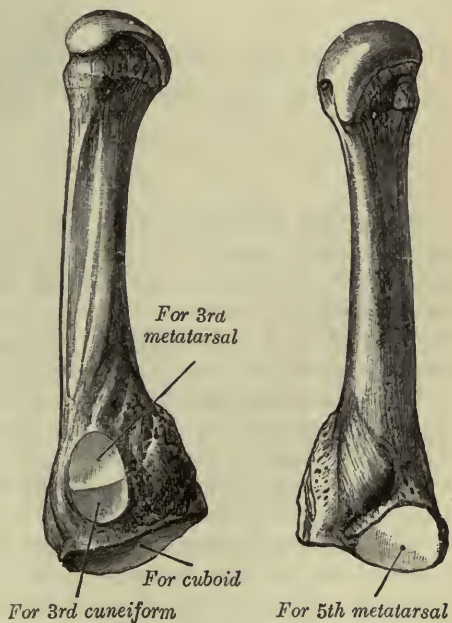


FIG. 287.—The fourth metatarsal. (Left.)

into the recess formed by the three cuneiform bones. Its base is broad above, narrow and rough below. It presents four articular surfaces: one behind, of a triangular form, for articulation with the second cuneiform; one at the upper part

of its medial surface, for articulation with the first cuneiform; and two on its lateral surface, an upper and lower, separated by a rough non-articular interval. Each of these lateral articular surfaces is divided into two by a vertical ridge; the two anterior facets articulate with the third metatarsal; the two posterior (sometimes continuous) with the third cuneiform. A fifth facet is occasionally present for articulation with the first metatarsal; it is oval in shape, and is situated on the medial side of the body near the base.

The Third Metatarsal Bone (*os metatarsale III*) (Fig. 286).—The third metatarsal bone articulates proximally, by means of a triangular smooth surface, with the third cuneiform; medially, by two facets, with the second metatarsal; and laterally, by a single facet, with the fourth metatarsal. This last facet is situated at the dorsal angle of the base.

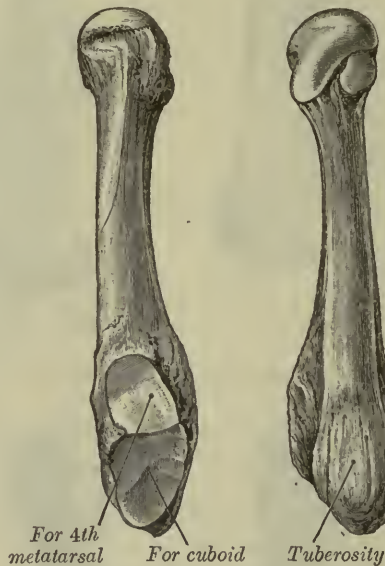

FIG. 288.—The fifth metatarsal. (Left.)

The Fourth Metatarsal Bone (*os metatarsale IV*) (Fig. 287).—The fourth metatarsal bone is smaller in size than the preceding; its base presents an oblique quadrilateral surface for articulation with the cuboid; a smooth facet on the medial side, divided by a ridge into an anterior portion for articulation with the third metatarsal, and a posterior portion for articulation with the third cuneiform; on the lateral side a single facet, for articulation with the fifth metatarsal.

The Fifth Metatarsal Bone (*os metatarsale V*) (Fig. 288).—The fifth metatarsal bone is recognized by a rough eminence, the **tuberosity**, on the lateral side of its base. The base articulates behind, by a triangular surface cut obliquely in a transverse direction, with the cuboid; and medially, with the fourth metatarsal. On the medial part of its dorsal surface is inserted the tendon of the *Peronæus tertius* and on the dorsal surface of the tuberosity that of the *Peronæus brevis*. A strong band of the plantar aponeurosis connects the projecting part of the tuberosity with the lateral process of the tuberosity of the calcaneus. The plantar surface of the base is grooved for the tendon of the *Abductor digiti quinti*, and gives origin to the *Flexor digiti quinti brevis*.

Articulations.—The base of each metatarsal bone articulates with one or more of the tarsal bones, and the head with one of the first row of phalanges. The first metatarsal articulates with the first cuneiform, the second with all three cuneiforms, the third with the third cuneiform, the fourth with the third cuneiform and the cuboid, and the fifth with the cuboid.

The Phalanges of the Foot (Phalanges Digitorum Pedis).

The **phalanges** of the foot correspond, in number and general arrangement, with those of the hand; there are two in the great toe, and three in each of the other toes. They differ from them, however, in their size, the bodies being much reduced in length, and, especially in the first row, laterally compressed.

First Row.—The **body** of each is compressed from side to side, convex above, concave below. The **base** is concave; and the **head** presents a trochlear surface for articulation with the second phalanx.

Second Row.—The phalanges of the second row are remarkably small and short, but rather broader than those of the first row.

The **ungual phalanges**, in form, resemble those of the fingers; but they are smaller and are flattened from above downward; each presents a broad base for articulation with the corresponding bone of the second row, and an expanded distal extremity for the support of the nail and end of the toe.

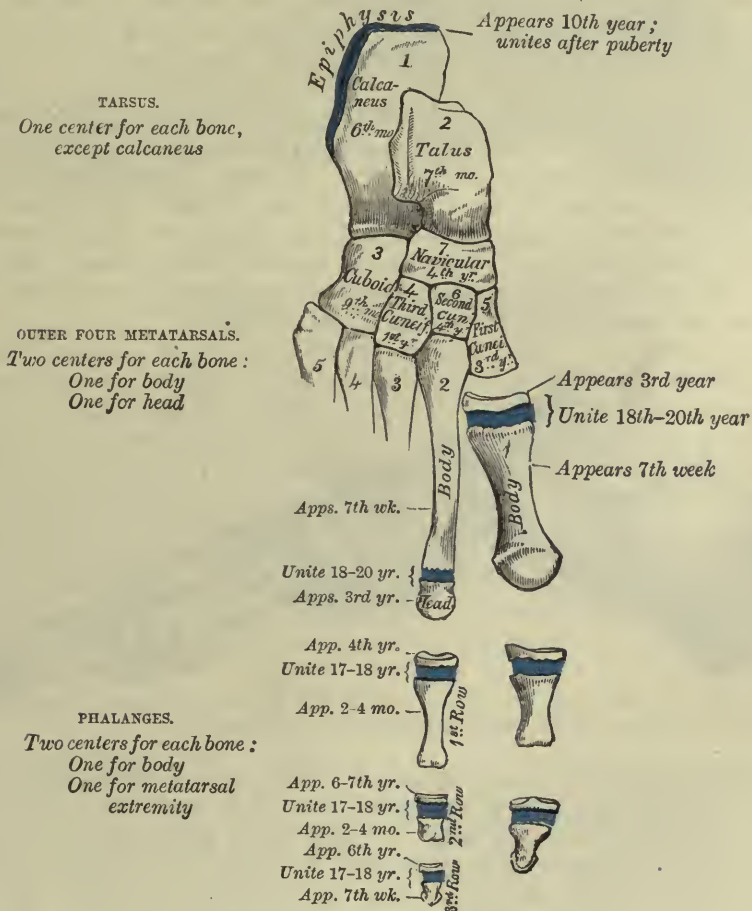


FIG. 289.—Plan of ossification of the foot.

Articulations.—In the second, third, fourth, and fifth toes the phalanges of the first row articulate behind with the metatarsal bones, and in front with the second phalanges, which in their turn articulate with the first and third: the unguinal phalanges articulate with the second.

Ossification of the Bones of the Foot (Fig. 289).—The **tarsal bones** are each ossified from a **single center**, excepting the calcaneus, which has an epiphysis for its posterior extremity. The centers make their appearance in the following order: calcaneus at the sixth month of fetal life;

talus, about the seventh month; cuboid, at the ninth month; third cuneiform, during the first year; first cuneiform, in the third year; second cuneiform and navicular, in the fourth year. The epiphysis for the posterior extremity of the calcaneus appears at the tenth year, and unites with the rest of the bone soon after puberty. The posterior process of the talus is sometimes ossified from a separate center, and may remain distinct from the main mass of the bone, when it is named the *os trigonum*.

The **metatarsal bones** are each ossified from *two* centers: one for the body, and one for the head, of the second, third, fourth, and fifth metatarsals; one for the body, and one for the base, of the first metatarsal.¹ Ossification commences in the center of the body about the ninth week, and extends toward either extremity. The center for the base of the first metatarsal appears about the third year; the centers for the heads of the other bones between the fifth and eighth years; they join the bodies between the eighteenth and twentieth years.

The **phalanges** are each ossified from *two* centers: one for the body, and one for the base. The center for the body appears about the tenth week, that for the base between the fourth and tenth years; it joins the body about the eighteenth year.

Comparison of the Bones of the Hand and Foot.

The hand and foot are constructed on somewhat similar principles, each consisting of a proximal part, the carpus or the tarsus, a middle portion, the metacarpus, or the metatarsus, and a terminal portion, the phalanges. The proximal part consists of a series of more or less cubical bones which allow a slight amount of gliding on one another and are chiefly concerned in distributing forces transmitted to or from the bones of the arm or leg. The middle part is made up of slightly movable long bones which assist the carpus or tarsus in distributing forces and also give greater breadth for the reception of such forces. The separation of the individual bones from one another allows of the attachments of the Interossei and protects the dorsi-palmar and dorsi-plantar vascular anastomoses. The terminal portion is the most movable, and its separate elements enjoy a varied range of movements, the chief of which are flexion and extension.

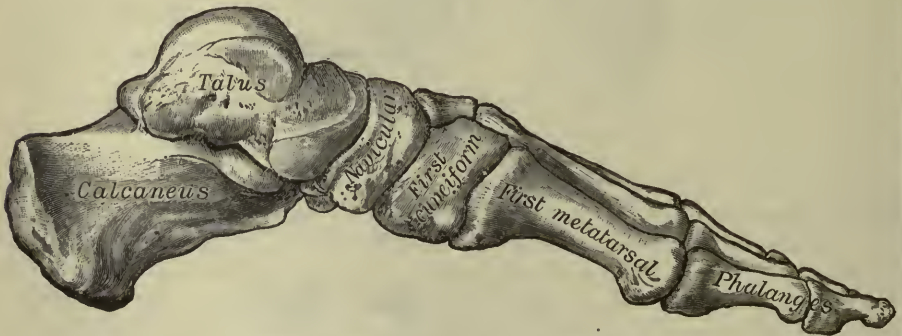

FIG. 290.—Skeleton of foot. Medial aspect.

The function of the hand and foot are, however, very different, and the general similarity between them is greatly modified to meet these requirements. Thus the foot forms a firm basis of support for the body in the erect posture, and is therefore more solidly built up and its component parts are less movable on each other than those of the hand. In the case of the phalanges the difference is readily noticeable; those of the foot are smaller and their movements are more limited than those of the hand. Very much more marked is the difference between the metacarpal bone of the thumb and the metatarsal bone of the great toe. The metacarpal bone of the thumb is constructed to permit of great mobility, is directed at an acute angle from that of the index finger, and is capable of a considerable range

¹ As was noted in the first metacarpal (see footnote, page 231), so in the first metatarsal, there is often a second epiphysis for its head.

of movements at its articulation with the carpus. The metatarsal bone of the great toe assists in supporting the weight of the body, is constructed with great solidity, lies parallel with the other metatarsals, and has a very limited degree of mobility. The carpus is small in proportion to the rest of the hand, is placed in line with the forearm, and forms a transverse arch, the concavity of which constitutes a bed for the Flexor tendons and the palmar vessels and nerves. The tarsus forms a considerable part of the foot, and is placed at right angles to the leg, a position which is almost peculiar to man, and has relation to his erect posture. In order to allow of their supporting the weight of the body with the least expenditure of material the tarsus and a part of the metatarsus are constructed in a series of arches (Figs. 290, 291), the disposition of which will be considered after the articulations of the foot have been described.

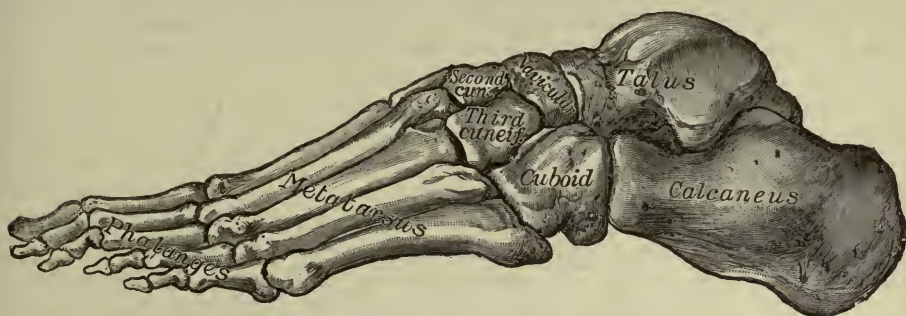

FIG. 291.—Skeleton of foot. Lateral aspect.

The Sesamoid Bones (*Ossa Sesamoidea*).

Sesamoid bones are small more or less rounded masses embedded in certain tendons and usually related to joint surfaces. Their functions probably are to modify pressure, to diminish friction, and occasionally to alter the direction of a muscle pull. That they are not developed to meet certain physical requirements in the adult is evidenced by the fact that they are present as cartilaginous nodules in the fetus, and in greater numbers than in the adult. They must be regarded, according to Thilenius, as integral parts of the skeleton phylogenetically inherited.¹ Physical necessities probably come into play in selecting and in regulating the degree of development of the original cartilaginous nodules. Nevertheless, irregular nodules of bone may appear as the result of intermittent pressure in certain regions, *e. g.*, the "rider's bone," which is occasionally developed in the Adductor muscles of the thigh.

Sesamoid bones are invested by the fibrous tissue of the tendons, except on the surfaces in contact with the parts over which they glide, where they present smooth articular facets.

In the upper extremity the sesamoid bones of the joints are found only on the palmar surface of the hand. Two, of which the medial is the larger, are constant at the metacarpophalangeal joint of the thumb; one is frequently present in the corresponding joint of the little finger, and one (or two) in the same joint of the index finger. Sesamoid bones are also found occasionally at the metacarpophalangeal joints of the middle and ring fingers, at the interphalangeal joint of the thumb and at the distal interphalangeal joint of the index finger.

In the lower extremity the largest sesamoid bone of the joints is the patella, developed in the tendon of the Quadriceps femoris. On the plantar aspect of the foot, two, of which the medial is the larger, are always present at the metatar-

¹ Morpholog. Arbeiten, 1906, v, 309.

sophalangeal joint of the great toe; one sometimes at the metatarsophalangeal joints of the second and fifth toes, one occasionally at the corresponding joint of the third and fourth toes, and one at the interphalangeal joint of the great toe.

Sesamoid bones apart from joints are seldom found in the tendons of the upper limb; one is sometimes seen in the tendon of the *Biceps brachii* opposite the radial tuberosity. They are, however, present in several of the tendons of the lower limb, viz., one in the tendon of the *Peronæus longus*, where it glides on the cuboid; one, appearing late in life, in the tendon of the *Tibialis anterior*, opposite the smooth facet of the first cuneiform bone; one in the tendon of the *Tibialis posterior*, opposite the medial side of the head of the talus; one in the lateral head of the *Gastrocnemius*, behind the lateral condyle of the femur; and one in the tendon of the *Psoas major*, where it glides over the pubis. Sesamoid bones are found occasionally in the tendon of the *Glutæus maximus*, as it passes over the greater trochanter, and in the tendons which wind around the medial and lateral malleoli.

SYNDESMOLOGY.

THE bones of the skeleton are joined to one another at different parts of their surfaces, and such connections are termed **Joints** or **Articulations**. Where the joints are *immovable*, as in the articulations between practically all the bones of the skull, the adjacent margins of the bones are almost in contact, being separated merely by a thin layer of fibrous membrane, named the **sutural ligament**. In certain regions at the base of the skull this fibrous membrane is replaced by a layer of cartilage. Where *slight movement* combined with great strength is required, the osseous surfaces are united by tough and elastic **fibrocartilages**, as in the joints between the vertebral bodies, and in the interpubic articulation. In the *freely movable* joints the surfaces are completely separated; the bones forming the articulation are expanded for greater convenience of mutual connection, covered by **cartilage** and enveloped by **capsules** of fibrous tissue. The cells lining the interior of the fibrous capsule form an imperfect membrane—the **synovial membrane**—which secretes a lubricating fluid. The joints are strengthened by strong fibrous bands called **ligaments**, which extend between the bones forming the joint.

Bone.—Bone constitutes the fundamental element of all the joints. In the long bones, the extremities are the parts which form the articulations; they are generally somewhat enlarged; and consist of spongy cancellous tissue with a thin coating of compact substance. In the flat bones, the articulations usually take place at the edges; and in the short bones at various parts of their surfaces. The layer of compact bone which forms the joint surface, and to which the articular cartilage is attached, is called the **articular lamella**. It differs from ordinary bone tissue in that it contains no Haversian canals, and its lacunæ are larger and have no canaliculi. The vessels of the cancellous tissue, as they approach the articular lamella, turn back in loops, and do not perforate it; this layer is consequently denser and firmer than ordinary bone, and is evidently designed to form an unyielding support for the articular cartilage.

Cartilage.—Cartilage is a non-vascular structure which is found in various parts of the body—in adult life chiefly in the joints, in the parietes of the thorax, and in various tubes, such as the trachea and bronchi, nose, and ears, which require to be kept permanently open. In the fetus, at an early period, the greater part of the skeleton is cartilaginous; as this cartilage is afterward replaced by bone, it is called **temporary**, in contradistinction to that which remains unossified during the whole of life, and is called **permanent**.

Cartilage is divided, according to its minute structure, into **hyaline cartilage**, **white fibrocartilage**, and **yellow** or **elastic fibrocartilage**.

Hyaline Cartilage.—Hyaline cartilage consists of a gristly mass of a firm consistence, but of considerable elasticity and pearly bluish color. Except where it coats the articular ends of bones, it is covered externally by a fibrous membrane, the **perichondrium**, from the vessels of which it imbibes its nutritive fluids, being itself destitute of bloodvessels. It contains no nerves. Its intimate structure is very simple. If a thin slice be examined under the microscope, it will be found to consist of cells of a rounded or bluntly angular form, lying in groups of two or more in a granular or almost homogeneous matrix (Fig. 292). The cells, when arranged in groups of two or more, have generally straight outlines where they are in contact

with each other, and in the rest of their circumference are rounded. They consist of clear translucent protoplasm in which fine interlacing filaments and minute granules are sometimes present; imbedded in this are one or two round nuclei, having the usual intranuclear network. The cells are contained in cavities in the matrix, called **cartilage lacunæ**; around these the matrix is arranged in concentric lines, as if it had been formed in successive portions around the cartilage cells. This constitutes the so-called **capsule of the space**. Each lacuna is generally

occupied by a single cell, but during the division of the cells it may contain two, four, or eight cells.

The matrix is transparent and apparently without structure, or else presents a dimly granular appearance, like ground glass. Some observers have shown that the matrix of hyaline cartilage, and especially of the articular variety, after prolonged maceration, can be broken up into fine fibrils.

These fibrils are probably of the same nature, chemically, as the white fibers of connective tissue. It is believed by some histologists that the matrix is permeated by a number of fine channels, which connect the lacunæ with each other, and that these canals communicate with the lymphatics of the perichondrium, and thus the structure is permeated by a current of nutrient fluid.

Articular cartilage, costal cartilage, and temporary cartilage are all of the hyaline variety. They present differences in the size, shape, and arrangement of their cells.

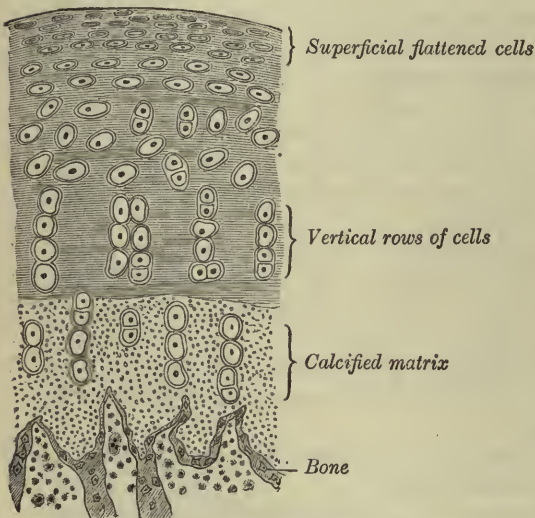


FIG. 293.—Vertical section of articular cartilage.

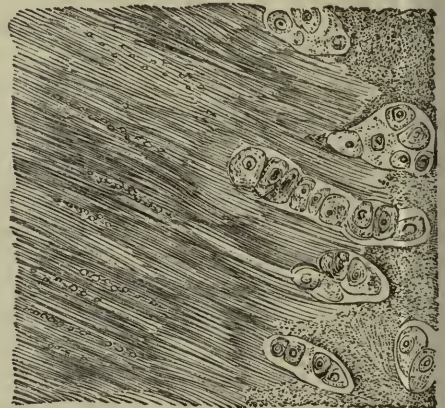

FIG. 294.—Costal cartilage from a man, aged seventy-six years, showing the development of fibrous structure in the matrix. In several portions of the specimen two or three generations of cells are seen enclosed in a parent cell wall. Highly magnified.

In **Articular Cartilage** (Fig. 293), which shows no tendency to ossification, the matrix is finely granular; the cells and nuclei are small, and are disposed parallel to the surface in the superficial part, while nearer to the bone they are arranged in vertical rows. Articular cartilages have a tendency to split in a vertical direction; in disease this tendency becomes very manifest. The free surface of articular cartilage, where it is exposed to friction, is not covered by perichondrium, although a layer of connective tissue continuous with that of the synovial membrane can be

traced in the adult over a small part of its circumference, and here the cartilage cells are more or less branched and pass insensibly into the branched connective tissue corpuscles of the synovial membrane. Articular cartilage forms a thin incrustation upon the joint surfaces of the bones, and its elasticity enables it to break the force of concussions, while its smoothness affords ease and freedom of movement. It varies in thickness according to the shape of the articular surface on which it lies; where this is convex the cartilage is thickest at the center, the reverse being the case on concave articular surfaces. It appears to derive its nutriment partly from the vessels of the neighboring synovial membrane and partly from those of the bone upon which it is implanted. Toynbee has shown that the minute vessels of the cancellous tissue as they approach the articular lamella dilate and form arches, and then return into the substance of the bone.

In **Costal Cartilage** the cells and nuclei are large, and the matrix has a tendency to fibrous striation, especially in old age (Fig. 294). In the thickest parts of the costal cartilages a few large vascular channels may be detected. This appears, at first sight, to be an exception to the statement that cartilage is a non-vascular tissue, but is not so really, for the vessels give no branches to the cartilage substance itself, and the channels may rather be looked upon as involutions of the perichondrium. The xiphoid process and the cartilages of the nose, larynx, and trachea (except the epiglottis and corniculate cartilages of the larynx, which are composed of elastic fibrocartilage) resemble the costal cartilages in microscopic characteristics. The arytenoid cartilage of the larynx shows a transition from hyaline cartilage at its base to elastic cartilage at the apex.

The hyaline cartilages, especially in adult and advanced life, are prone to calcify—that is to say, to have their matrix permeated by calcium salts without any appearance of true bone. The process of calcification occurs frequently, in such cartilages as those of the trachea and in the costal cartilages, where it may be succeeded by conversion into true bone.

White Fibrocartilage.—White fibrocartilage consists of a mixture of white fibrous tissue and cartilaginous tissue in various proportions; to the former of these constituents it owes its flexibility and toughness, and to the latter its elasticity. When examined under the microscope it is found to be made up of fibrous connective tissue arranged in bundles, with cartilage cells between the bundles; the cells to a certain extent resemble tendon cells, but may be distinguished from them by being surrounded by a concentrically striated area of cartilage matrix and by being less flattened (Fig. 295). The white fibrocartilages admit of arrangement into four groups—**interarticular, connecting, circumferential, and stratiform.**

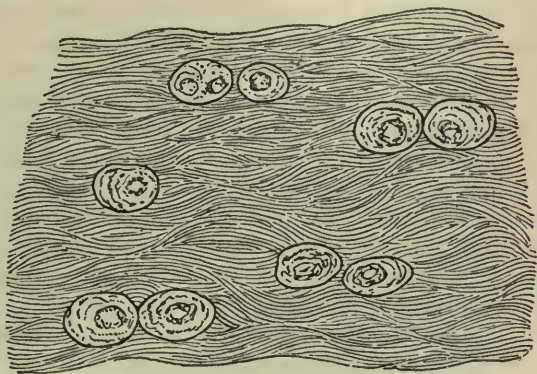


Fig. 295.—White fibrocartilage from an intervertebral fibrocartilage.

1. The **Interarticular Fibrocartilages** (*menisci*) are flattened fibrocartilaginous plates, of a round, oval, triangular, or sickle-like form, interposed between the articular cartilages of certain joints. They are free on both surfaces, usually thinner toward the center than at the circumference, and held in position by the attachment of their margins and extremities to the surrounding ligaments. The synovial membranes of the joints are prolonged over them. They are found in the temporomandibular, sternoclavicular, acromioclavicular, wrist, and knee

joints—*i. e.*, in those joints which are most exposed to violent concussion and subject to frequent movement. Their uses are to obliterate the intervals between opposed surfaces in their various motions; to increase the depths of the articular surfaces and give ease to the gliding movements; to moderate the effects of great pressure and deaden the intensity of the shocks to which the parts may be subjected. Humphry has pointed out that these interarticular fibrocartilages serve an important purpose in increasing the varieties of movement in a joint. Thus in the knee joint there are two kinds of motion, *viz.*, angular movement and rotation, although it is a hinge joint, in which, as a rule, only one variety of motion is permitted; the former movement takes place between the condyles of the femur and the interarticular cartilages, the latter between the cartilages and the head of the tibia. So, also, in the temporomandibular joint, the movements of opening and shutting the mouth take place between the fibrocartilage and the mandible, the grinding movement between the mandibular fossa and the fibrocartilage, the latter moving with the mandible.

2. The **Connecting Fibrocartilages** are interposed between the bony surfaces of those joints which admit of only slight mobility, as between the bodies of the vertebræ. They form disks which are closely adherent to the opposed surfaces. Each disk is composed of concentric rings of fibrous tissue, with cartilaginous laminae interposed, the former tissue predominating toward the circumference, the latter toward the center.

3. The **Circumferential Fibrocartilages** consist of rims of fibrocartilage, which surround the margins of some of the articular cavities, *e. g.*, the glenoidal labrum of the hip, and of the shoulder; they serve to deepen the articular cavities and to protect their edges.

4. The **Stratiform Fibrocartilages** are those which form a thin coating to osseous grooves through which the tendons of certain muscles glide. Small masses of fibrocartilage are also developed in the tendons of some muscles, where they glide over bones, as in the tendons of the Peronæus longus and Tibialis posterior.

The distinguishing feature of cartilage chemically is that it yields on boiling a substance called **chondrin**, very similar to gelatin, but differing from it in several of its reactions. It is now believed that chondrin is not a simple body, but a mixture of gelatin with mucinoid substances, chief among which, perhaps, is a compound termed **chondro-mucoid**.

Ligaments.—Ligaments are composed mainly of bundles of **white fibrous tissue** placed parallel with, or closely interlaced with one another, and present a white, shining, silvery appearance. They are pliant and flexible, so as to allow perfect freedom of movement, but strong, tough, and inextensible, so as not to yield readily to applied force. Some ligaments consist entirely of **yellow elastic tissue**, as the ligamenta flava which connect together the laminae of adjacent vertebræ, and the ligamentum nuchæ in the lower animals. In these cases the elasticity of the ligament is intended to act as a substitute for muscular power.

The Articular Capsules.—The articular capsules form complete envelopes for the freely movable joints. Each capsule consists of two strata—an **external** (*stratum fibrosum*) composed of white fibrous tissue, and an **internal** (*stratum synoviale*) which is a secreting layer, and is usually described separately as the synovial membrane.

The **fibrous capsule** is attached to the whole circumference of the articular end of each bone entering into the joint, and thus entirely surrounds the articulation.

The **synovial membrane** invests the inner surface of the fibrous capsule, and is reflected over any tendons passing through the joint cavity, as the tendon of the Popliteus in the knee, and the tendon of the Biceps brachii in the shoulder. It is composed of a thin, delicate, connective tissue, with branched connective-tissue corpuscles. Its secretion is thick, viscid, and glairy, like the white of an egg, and

is hence termed **synovia**. In the fetus this membrane is said, by Toynbee, to be continued over the surfaces of the cartilages; but in the adult such a continuation is wanting, excepting at the circumference of the cartilage, upon which it encroaches for a short distance and to which it is firmly attached. In some of the joints the synovial membrane is thrown into folds which pass across the cavity; they are especially distinct in the knee. In other joints there are flattened folds, subdivided at their margins into fringe-like processes which contain convoluted vessels. These folds generally project from the synovial membrane near the margin of the cartilage, and lie flat upon its surface. They consist of connective tissue, covered with endothelium, and contain fat cells in variable quantities, and, more rarely, isolated cartilage cells; the larger folds often contain considerable quantities of fat.

Closely associated with synovial membrane, and therefore conveniently described in this section, are the mucous sheaths of tendons and the mucous bursæ.

Mucous sheaths (*vaginæ mucosæ*) serve to facilitate the gliding of tendons in fibroösseous canals. Each sheath is arranged in the form of an elongated closed sac, one layer of which adheres to the wall of the canal, and the other is reflected upon the surface of the enclosed tendon. These sheaths are chiefly found surrounding the tendons of the Flexor and Extensor muscles of the fingers and toes as they pass through fibroösseous canals in or near the hand and foot.

Bursæ mucosæ are interposed between surfaces which glide upon each other. They consist of closed sacs containing a minute quantity of clear viscid fluid, and may be grouped, according to their situations, under the headings *subcutaneous*, *submuscular*, *subfacial*, and *subtendinous*.

DEVELOPMENT OF THE JOINTS.

The mesoderm from which the different parts of the skeleton are formed shows at first no differentiation into masses corresponding with the individual bones. Thus continuous cores of mesoderm form the axes of the limb-buds and a continuous column of mesoderm the future vertebral column. The first indications of the bones and joints are circumscribed condensations of the mesoderm; these condensed parts become chondrified and finally ossified to form the bones of the skeleton. The intervening non-condensed portions consist at first of undifferentiated mesoderm, which may develop in one of three directions. It may be converted into fibrous tissue as in the case of the skull bones, a synarthrodial joint being the result, or it may become partly cartilaginous, in which case an amphiarthrodial joint is formed. Again, it may become looser in texture and a cavity ultimately appear in its midst; the cells lining the sides of this cavity form a synovial membrane and thus a diarthrodial joint is developed.

The tissue surrounding the original mesodermal core forms fibrous sheaths for the developing bones, *i. e.*, periosteum and perichondrium, which are continued between the ends of the bones over the synovial membrane as the capsules of the joints. These capsules are not of uniform thickness, so that in them may be recognized especially strengthened bands which are described as ligaments. This, however, is not the only method of formation of ligaments. In some cases by modification of, or derivations from, the tendons surrounding the joint, additional ligamentous bands are provided to further strengthen the articulations.

In several of the movable joints the mesoderm which originally existed between the ends of the bones does not become completely absorbed—a portion of it persists and forms an articular disk. These disks may be intimately associated in their development with the muscles surrounding the joint, *e. g.*, the menisci of the knee-joint, or with cartilaginous elements, representatives of skeletal structures, which are vestigial in human anatomy, *e. g.*, the articular disk of the sternoclavicular joint.

CLASSIFICATION OF JOINTS.

The articulations are divided into three classes: **synarthroses** or immovable, **amphiarthroses** or slightly movable, and **diarthroses** or freely movable, joints.

Synarthroses (*immovable articulations*).—Synarthroses include all those articulations in which the surfaces of the bones are in almost direct contact, fastened together by intervening connective tissue or hyaline cartilage, and in which there is no appreciable motion, as in the joints between the bones of the skull, excepting those of the mandible. There are four varieties of synarthrosis: **sutura**, **schindylesis**, **gomphosis**, and **synchondrosis**.

Sutura.—Sutura is that form of articulation where the contiguous margins of the bones are united by a thin layer of fibrous tissue; it is met with only in the skull (Fig. 296). When the margins of the bones are connected by a series of processes, and indentations interlocked together, the articulation is termed a **true suture** (*sutura vera*); and of this there are three varieties: *sutura dentata*, *serrata*, and *limbosa*. The margins of the bones are not in direct contact, being separated by a thin layer of fibrous tissue, continuous externally with the pericranium, internally with the dura mater. The **sutura dentata** is so called from the tooth-like form of the projecting processes, as in the suture between the parietal bones. In the

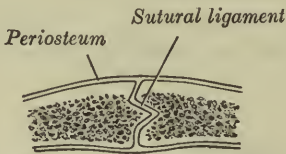


FIG. 296.—Section across the sagittal suture.

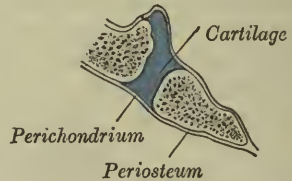


FIG. 297.—Section through occipitosphenoid synchondrosis of an infant.

sutura serrata the edges of the bones are serrated like the teeth of a fine saw, as between the two portions of the frontal bone. In the **sutura limbosa**, there is besides the interlocking, a certain degree of bevelling of the articular surfaces, so that the bones overlap one another, as in the suture between the parietal and frontal bones. When the articulation is formed by roughened surfaces placed in apposition with one another, it is termed a **false suture** (*sutura notha*), of which there are two kinds: the **sutura squamosa**, formed by the overlapping of contiguous bones by broad bevelled margins, as in the squamosal suture between the temporal and parietal, and the **sutura harmonia**, where there is simple apposition of contiguous rough surfaces, as in the articulation between the maxillæ, or between the horizontal parts of the palatine bones.

Schindylesis.—Schindylesis is that form of articulation in which a thin plate of bone is received into a cleft or fissure formed by the separation of two laminae in another bone, as in the articulation of the rostrum of the sphenoid and perpendicular plate of the ethmoid with the vomer, or in the reception of the latter in the fissure between the maxillæ and between the palatine bones.

Gomphosis.—Gomphosis is articulation by the insertion of a conical process into a socket; this is not illustrated by any articulation between bones, properly so called, but is seen in the articulations of the roots of the teeth with the alveoli of the mandible and maxillæ.

Synchondrosis.—Where the connecting medium is cartilage the joint is termed a synchondrosis (Fig. 297). This is a temporary form of joint, for the cartilage is converted into bone before adult life. Such joints are found between the epiphyses and bodies of long bones, between the occipital and the sphenoid at, and for some years after, birth, and between the petrous portion of the temporal and the jugular process of the occipital.

Amphiarthroses (*slightly movable articulations*).—In these articulations the contiguous bony surfaces are either connected by broad flattened disks of fibrocartilage, of a more or less complex structure, as in the articulations between the bodies of the vertebræ; or are united by an interosseous ligament, as in the inferior tibiofibular articulation. The first form is termed a **symphysis** (Fig. 298), the second a **syndesmosis**.




FIG. 298.—Diagrammatic section of a symphysis.

Diarthroses (*freely movable articulations*).

—This class includes the greater number of the joints in the body. In a diarthrodial joint the contiguous bony surfaces are covered with articular cartilage, and connected by ligaments lined by synovial membrane (Fig. 299). The joint may be divided, completely or incompletely, by an articular disk or meniscus, the periphery of which is continuous with the fibrous capsule while its free surfaces are covered by synovial membrane (Fig. 300).

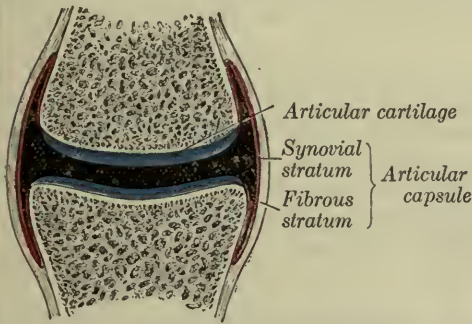


FIG. 299.—Diagrammatic section of a diarthrodial joint.

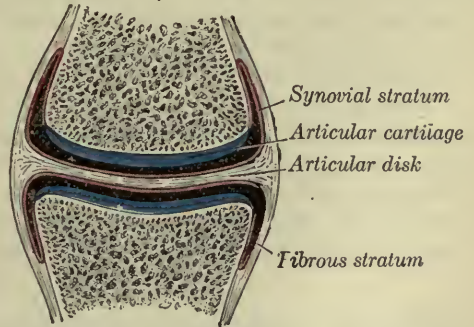


FIG. 300.—Diagrammatic section of a diarthrodial joint, with an articular disk.

The varieties of joints in this class have been determined by the kind of motion permitted in each. There are two varieties in which the movement is uniaxial, that is to say, all movements take place around one axis. In one form, the **ginglymus**, this axis is, practically speaking, transverse; in the other, the **trochoid** or **pivot-joint**, it is longitudinal. There are two varieties where the movement is biaxial, or around two horizontal axes at right angles to each other, or at any intervening axis between the two. These are the **condyloid** and the **saddle-joint**. There is one form where the movement is polyaxial, the **enarthrosis** or **ball-and-socket joint**; and finally there are the **arthrodia** or **gliding joints**.

Ginglymus or Hinge-joint.—In this form the articular surfaces are moulded to each other in such a manner as to permit motion only in one plane, forward and backward, the extent of motion at the same time being considerable. The direction which the distal bone takes in this motion is seldom in the same plane as that of the axis of the proximal bone; there is usually a certain amount of deviation from the straight line during flexion. The articular surfaces are connected together by strong collateral ligaments, which form their chief bond of union. The best examples of ginglymus are the interphalangeal joints and the joint between the humerus and ulna; the knee- and ankle-joints are less typical, as they allow a slight degree of rotation or of side-to-side movement in certain positions of the limb.

Trochoid or Pivot-joint (*articulatio trochoidea; rotary joint*).—Where the movement is limited to rotation, the joint is formed by a pivot-like process turning within

a ring, or a ring on a pivot, the ring being formed partly of bone, partly of ligament. In the proximal radioulnar articulation, the ring is formed by the radial notch of the ulna and the annular ligament; here, the head of the radius rotates within the ring. In the articulation of the odontoid process of the axis with the atlas the ring is formed in front by the anterior arch, and behind by the transverse ligament of the atlas; here, the ring rotates around the odontoid process.

Condylod Articulatio (*articulatio ellipsoidea*).—In this form of joint, an ovoid articular surface, or condyle, is received into an elliptical cavity in such a manner as to permit of flexion, extension, adduction, abduction, and circumduction, but no axial rotation. The wrist-joint is an example of this form of articulation.

Articulatio by Reciprocal Reception (*articulatio sellaris; saddle-joint*).—In this variety the opposing surfaces are reciprocally concavo-convex. The movements are the same as in the preceding form; that is to say, flexion, extension, adduction, abduction, and circumduction are allowed; but no axial rotation. The best example of this form is the carpometacarpal joint of the thumb.

Enarthrosis (*ball-and-socket joints*).—Enarthrosis is a joint in which the distal bone is capable of motion around an indefinite number of axes, which have one common center. It is formed by the reception of a globular head into a cup-like cavity, hence the name "ball-and-socket." Examples of this form of articulation are found in the hip and shoulder.

Arthrodia (*gliding joints*) is a joint which admits of only gliding movement; it is formed by the apposition of plane surfaces, or one slightly concave, the other slightly convex, the amount of motion between them being limited by the ligaments or osseous processes surrounding the articulation. It is the form present in the joints between the articular processes of the vertebræ, the carpal joints, except that of the capitate with the navicular and lunate, and the tarsal joints with the exception of that between the talus and the navicular.

THE KINDS OF MOVEMENT ADMITTED IN JOINTS.

The movements admissible in joints may be divided into four kinds: **gliding** and **angular movements**, **circumduction**, and **rotation**. These movements are often, however, more or less combined in the various joints, so as to produce an infinite variety, and it is seldom that only one kind of motion is found in any particular joint.

Gliding Movement.—Gliding movement is the simplest kind of motion that can take place in a joint, one surface gliding or moving over another without any angular or rotatory movement. It is common to all movable joints; but in some, as in most of the articulations of the carpus and tarsus, it is the only motion permitted. This movement is not confined to plane surfaces, but may exist between any two contiguous surfaces, of whatever form.

Angular Movement.—Angular movement occurs only between the long bones, and by it the angle between the two bones is increased or diminished. It may take place: (1) forward and backward, constituting flexion and extension; or (2) toward and from the median plane of the body, or, in the case of the fingers or toes, from the middle line of the hand or foot, constituting adduction and abduction. The strictly ginglymoid or hinge-joints admit of flexion and extension only. Abduction and adduction, combined with flexion and extension, are met with in the more movable joints; as in the hip, the shoulder, the wrist, and the carpometacarpal joint of the thumb.

Circumduction.—Circumduction is that form of motion which takes place between the head of a bone and its articular cavity, when the bone is made to circumscribe a conical space; the base of the cone is described by the distal end of the bone,

the apex is in the articular cavity; this kind of motion is best seen in the shoulder- and hip-joints.

Rotation.—Rotation is a form of movement in which a bone moves around a central axis without undergoing any displacement from this axis; the axis of rotation may lie in a separate bone, as in the case of the pivot formed by the odontoid process of the axis vertebræ around which the atlas turns; or a bone may rotate around its own longitudinal axis, as in the rotation of the humerus at the shoulder-joint; or the axis of rotation may not be quite parallel to the long axis of the bone, as in the movement of the radius on the ulna during pronation and supination of the hand, where it is represented by a line connecting the center of the head of the radius above with the center of the head of the ulna below.

Ligamentous Action of Muscles.—The movements of the different joints of a limb are combined by means of the long muscles passing over more than one joint. These, when relaxed and stretched to their greatest extent, act as elastic ligaments in restraining certain movements of one joint, except when combined with corresponding movements of the other—the latter movements being usually in the opposite direction. Thus the shortness of the hamstring muscles prevents complete flexion of the hip, unless the knee-joint is also flexed so as to bring their attachments nearer together. The uses of this arrangement are threefold: (1) It coördinates the kinds of movements which are the most habitual and necessary, and enables them to be performed with the least expenditure of power. (2) It enables the short muscles which pass over only one joint to act upon more than one. (3) It provides the joints with ligaments which, while they are of very great power in resisting movements to an extent incompatible with the mechanism of the joint, at the same time spontaneously yield when necessary.

The articulations may be grouped into those of the trunk, and those of the upper and lower extremities.

ARTICULATIONS OF THE TRUNK.

These may be divided into the following groups, viz.:

- | | |
|--|--|
| I. Of the Vertebral Column. | VI. Of the Cartilages of the Ribs with the Sternum, and with Each Other. |
| II. Of the Atlas with the Axis. | VII. Of the Sternum. |
| III. Of the Vertebral Column with the Cranium. | VIII. Of the Vertebral Column with the Pelvis. |
| IV. Of the Mandible. | IX. Of the Pelvis. |
| V. Of the Ribs with the Vertebræ. | |

I. Articulations of the Vertebral Column.

The articulations of the vertebral column consist of (1) a series of amphiarthrodial joints between the vertebral bodies, and (2) a series of diarthrodial joints between the vertebral arches.

1. **Articulations of Vertebral Bodies** (*intercentral ligaments*).—The articulations between the bodies of the vertebræ are amphiarthrodial joints, and the individual vertebræ move only slightly on each other. When, however, this slight degree of movement between the pairs of bones takes place in all the joints of the vertebral column, the total range of movement is very considerable. The ligaments of these articulations are the following:

The Anterior Longitudinal. The Posterior Longitudinal.
The Intervertebral Fibrocartilages.

The Anterior Longitudinal Ligament (*ligamentum longitudinale anterius; anterior common ligament*) (Figs. 301, 312).—The anterior longitudinal ligament is a broad and strong band of fibers, which extends along the anterior surfaces of the bodies of the vertebræ, from the axis to the sacrum. It is broader below than above,

thicker in the thoracic than in the cervical and lumbar regions, and somewhat thicker opposite the bodies of the vertebræ than opposite the intervertebral fibrocartilages. It is attached, above, to the body of the axis, where it is continuous with the anterior atlantoaxial ligament, and extends down as far as the upper part of the front of the sacrum. It consists of dense longitudinal fibers, which are intimately adherent to the intervertebral fibrocartilages and the prominent margins of the vertebræ, but not to the middle parts of the bodies. In the latter situation the ligament is thick and serves to fill up the concavities on the anterior surfaces, and to make the front of the vertebral column more even. It is composed of several layers of fibers, which vary in length, but are closely interlaced with each other. The most superficial fibers are the longest and extend between four or five vertebræ. A second, subjacent set extends between two or three vertebræ; while a third set, the shortest and deepest, reaches from one vertebra to the next. At the sides of the bodies the ligament consists of a few short fibers which pass from one vertebra to the next, separated from the concavities of the vertebral bodies by oval apertures for the passage of vessels.

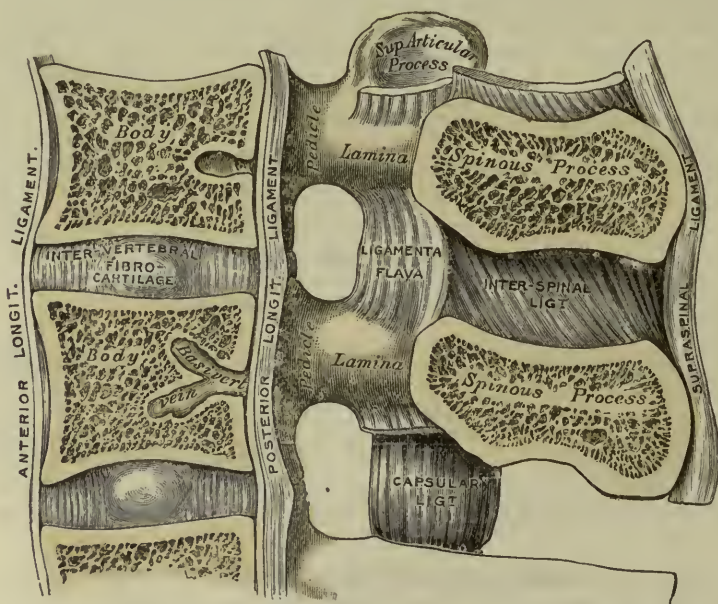


FIG. 301.—Median sagittal section of two lumbar vertebræ and their ligaments.

The Posterior Longitudinal Ligament (*ligamentum longitudinale posterius; posterior common ligament*) (Figs. 301, 302).—The posterior longitudinal ligament is situated within the vertebral canal, and extends along the posterior surfaces of the bodies of the vertebræ, from the body of the axis, where it is continuous with the *membrana tectoria*, to the sacrum. It is broader above than below, and thicker in the thoracic than in the cervical and lumbar regions. In the situation of the intervertebral fibrocartilages and contiguous margins of the vertebræ, where the ligament is more intimately adherent, it is broad, and in the thoracic and lumbar regions presents a series of dentations with intervening concave margins; but it is narrow and thick over the centers of the bodies, from which it is separated by the *basivertebral veins*. This ligament is composed of smooth, shining, longitudinal fibers, denser and more compact than those of the anterior ligament, and consists of superficial layers occupying the interval between three or four vertebræ, and deeper layers which extend between adjacent vertebræ.

The Intervertebral Fibrocartilages (*fibrocartilaginee intervertebrales; intervertebral disks*) (Figs. 301, 313).—The intervertebral fibrocartilages are interposed between the adjacent surfaces of the bodies of the vertebræ, from the axis to the sacrum, and form the chief bonds of connection between the vertebræ. They vary in shape, size, and thickness, in different parts of the vertebral column. In *shape* and *size* they correspond with the surfaces of the bodies between which they are placed, except in the cervical region, where they are slightly smaller from side to side than the corresponding bodies. In *thickness* they vary not only in the different regions of the column, but in different parts of the same fibrocartilage; they are thicker in front than behind in the cervical and lumbar regions, and thus contribute to the anterior convexities of these parts of the column; while they are of nearly uniform thickness in the thoracic region, the anterior concavity of this part of the column being almost entirely owing to the shape of the vertebral bodies. The intervertebral fibrocartilages constitute about one-fourth of the length of the vertebral column, exclusive of the first two vertebræ; but this amount is not equally distributed between the various bones, the cervical and lumbar portions having, in proportion to their length, a much greater amount than the thoracic region, with the result that these parts possess greater pliancy and freedom of movement. The intervertebral fibrocartilages are adherent, by their surfaces, to thin layers of hyaline cartilage which cover the upper and under surfaces of the bodies of the vertebræ; in the lower cervical vertebræ, however, small joints lined by synovial membrane are occasionally present between the upper surfaces of the bodies and the margins of the fibrocartilages on either side. By their circumferences the intervertebral fibrocartilages are closely connected in front to the anterior, and behind to the posterior, longitudinal ligaments. In the thoracic region they are joined laterally, by means of the interarticular ligaments, to the heads of those ribs which articulate with two vertebræ.

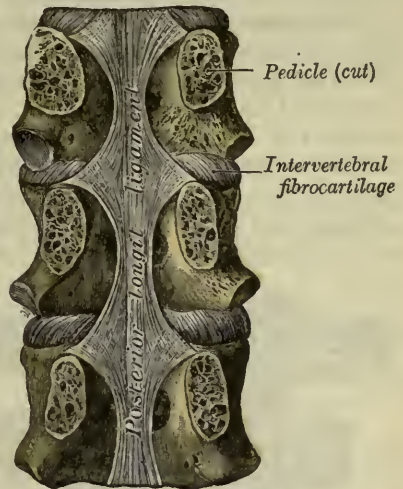


FIG. 302.—Posterior longitudinal ligament, in the thoracic region.

Structure of the Intervertebral Fibrocartilages.—Each is composed, at its circumference, of laminae of fibrous tissue and fibrocartilage, forming the *annulus fibrosus*; and, at its center, of a soft, pulpy, highly elastic substance, of a yellowish color, which projects considerably above the surrounding level when the disk is divided horizontally. This pulpy substance (*nucleus pulposus*), especially well-developed in the lumbar region, is the remains of the notochord. The laminae are arranged concentrically; the outermost consist of ordinary fibrous tissue, the others of white fibrocartilage. The laminae are not quite vertical in their direction, those near the circumference being curved outward and closely approximated; while those nearest the center curve in the opposite direction, and are somewhat more widely separated. The fibers of which each lamina is composed are directed, for the most part, obliquely from above downward, the fibers of adjacent laminae passing in opposite directions and varying in every layer; so that the fibers of one layer are directed across those of another, like the limbs of the letter X. This laminar arrangement belongs to about the outer half of each fibrocartilage. The pulpy substance presents no such arrangement, and consists of a fine fibrous matrix, containing angular cells united to form a reticular structure.

The intervertebral fibrocartilages are important shock absorbers. Under pressure the highly elastic nucleus pulposus becomes flatter and broader and pushes the more resistant fibrous laminae outward in all directions.

2. Articulations of Vertebral Arches.—The joints between the articular processes of the vertebræ belong to the arthrodial variety and are enveloped by

capsules lined by synovial membranes; while the laminae, spinous and transverse processes are connected by the following ligaments:

The Ligamenta Flava.
The Supraspinal.

The Ligamentum Nuchæ.
The Interspinal.

The Intertransverse.

The Articular Capsules (*capsulae articulares; capsular ligaments*) (Fig. 301).—The articular capsules are thin and loose, and are attached to the margins of the articular processes of adjacent vertebræ. They are longer and looser in the cervical than in the thoracic and lumbar regions.

The Ligamenta Flava (*ligamenta subflava*, Fig. 303).—The ligamenta flava connect the laminae of adjacent vertebræ, from the axis to the first segment of the sacrum. They are best seen from the interior of the vertebral canal; when looked at from the outer surface they appear short, being overlapped by the laminae. Each ligament consists of two lateral portions which commence one on either side of the roots of the articular processes, and extend backward to the point where the laminae meet to form the spinous process; the posterior margins of the two portions are in contact and to a certain extent united, slight intervals being left for the passage of small vessels. Each consists of yellow elastic tissue, the fibers of which, almost

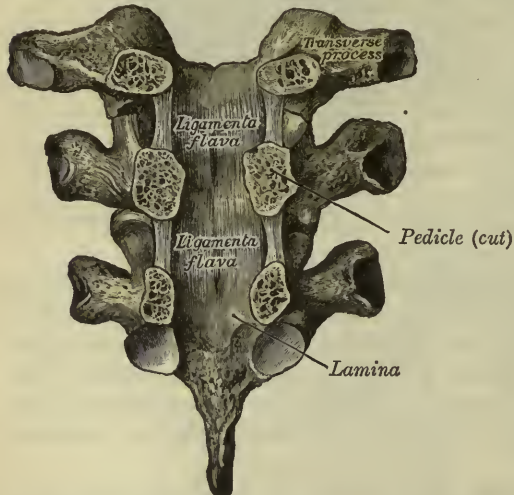


FIG. 303.—Vertebral arches of three thoracic vertebræ viewed from the front.

perpendicular in direction, are attached to the anterior surface of the lamina above, some distance from its inferior margin, and to the posterior surface and upper margin of the lamina below. In the cervical region the ligaments are thin, but broad and long; they are thicker in the thoracic region, and thickest in the lumbar region. Their marked elasticity serves to preserve the upright posture, and to assist the vertebral column in resuming it after flexion.

The Supraspinal Ligament (*ligamentum supraspinale; supraspinous ligament*) (Fig. 301).—The supraspinal ligament is a strong fibrous cord, which connects together the apices of the spinous processes from

the seventh cervical vertebra to the sacrum; at the points of attachment to the tips of the spinous processes fibrocartilage is developed in the ligament. It is thicker and broader in the lumbar than in the thoracic region, and intimately blended, in both situations, with the neighboring fascia. The most superficial fibers of this ligament extend over three or four vertebræ; those more deeply seated pass between two or three vertebræ; while the deepest connect the spinous processes of neighboring vertebræ. Between the spinous processes it is continuous with the interspinal ligaments. It is continued upward to the external occipital protuberance and median nuchal line, as the ligamentum nuchæ.

The Ligamentum Nuchæ.—The ligamentum nuchæ is a fibrous membrane, which, in the neck, represents the supraspinal ligaments of the lower vertebræ. It extends from the external occipital protuberance and median nuchal line to the spinous process of the seventh cervical vertebra. From its anterior border a fibrous lamina is given off, which is attached to the posterior tubercle of the atlas, and to the spinous processes of the cervical vertebræ, and forms a septum between the muscles

on either side of the neck. In man it is merely the rudiment of an important elastic ligament, which, in some of the lower animals, serves to sustain the weight of the head.

The Interspinal Ligaments (*ligamenta interspinalia*; *interspinous ligaments*) (Fig. 301).—The interspinal ligaments thin and membranous, connect adjoining spinous processes and extend from the root to the apex of each process. They meet the ligamenta flava in front and the supraspinal ligament behind. They are narrow and elongated in the thoracic region; broader, thicker, and quadrilateral in form in the lumbar region; and only slightly developed in the neck.

The Intertransverse Ligaments (*ligamenta intertransversaria*).—The intertransverse ligaments are interposed between the transverse processes. In the cervical region they consist of a few irregular, scattered fibers; in the thoracic region they are rounded cords intimately connected with the deep muscles of the back; in the lumbar region they are thin and membranous.

Movements.—The movements permitted in the vertebral column are: *flexion*, *extension*, *lateral movement*, *circumduction*, and *rotation*.

In **flexion**, or movement forward, the anterior longitudinal ligament is relaxed, and the intervertebral fibrocartilages are compressed in front; while the posterior longitudinal ligament, the ligamenta flava, and the inter- and supraspinal ligaments are stretched, as well as the posterior fibers of the intervertebral fibrocartilages. The interspaces between the laminae are widened, and the inferior articular processes glide upward, upon the superior articular processes of the subjacent vertebræ. Flexion is the most extensive of all the movements of the vertebral column, and is freest in the lumbar region.

In **extension**, or movement backward, an exactly opposite disposition of the parts takes place. This movement is limited by the anterior longitudinal ligament, and by the approximation of the spinous processes. It is freest in the cervical region.

In **lateral movement**, the sides of the intervertebral fibrocartilages are compressed, the extent of motion being limited by the resistance offered by the surrounding ligaments. This movement may take place in any part of the column, but is freest in the cervical and lumbar regions.

Circumduction is very limited, and is merely a succession of the preceding movements.

Rotation is produced by the twisting of the intervertebral fibrocartilages; this, although only slight between any two vertebræ, allows of a considerable extent of movement when it takes place in the whole length of the column, the front of the upper part of the column being turned to one or other side. This movement occurs to a slight extent in the cervical region, is freer in the upper part of the thoracic region, and absent in the lumbar region.

The extent and variety of the movements are influenced by the shape and direction of the articular surfaces. In the *cervical* region the upward inclination of the superior articular surfaces allows of free flexion and extension. Extension can be carried farther than flexion; at the upper end of the region it is checked by the locking of the posterior edges of the superior atlantal facets in the condyloid fossæ of the occipital bone; at the lower end it is limited by a mechanism whereby the inferior articular processes of the seventh cervical vertebra slip into grooves behind and below the superior articular processes of the first thoracic. Flexion is arrested just beyond the point where the cervical convexity is straightened; the movement is checked by the apposition of the projecting lower lips of the bodies of the vertebræ with the shelving surfaces on the bodies of the subjacent vertebræ. Lateral flexion and rotation are free in the cervical region; they are, however, always combined. The upward and medial inclinations of the superior articular surfaces impart a rotatory movement during lateral flexion, while pure rotation is prevented by the slight medial slope of these surfaces.

In the **thoracic region**, notably in its upper part, all the movements are limited in order to reduce interference with respiration to a minimum. The almost complete absence of an upward inclination of the superior articular surfaces prohibits any marked flexion, while extension is checked by the contact of the inferior articular margins with the laminae, and the contact of the spinous processes with one another. The mechanism between the seventh cervical and the first thoracic vertebræ, which limits extension of the cervical region, will also serve to limit flexion of the thoracic region when the neck is extended. Rotation is free in the thoracic region: the superior articular processes are segments of a cylinder whose axis is in the mid-ventral line of the vertebral bodies. The direction of the articular facets would allow of free lateral flexion, but this movement is considerably limited in the upper part of the region by the resistance of the ribs and sternum.

In the **lumbar region** flexion and extension are free. Flexion can be carried farther than extension, and is possible to just beyond the straightening of the lumbar curve; it is, therefore, greatest at the lowest part where the curve is sharpest. The inferior articular facets are not in close appo-

sition with the superior facets of the subjacent vertebræ, and on this account a considerable amount of lateral flexion is permitted. For the same reason a slight amount of rotation can be carried out, but this is so soon checked by the interlocking of the articular surfaces that it is negligible.

The principal muscles which produce *flexion* are the Sternocleidomastoideus, Longus capitis, and Longus colli; the Scaleni; the abdominal muscles and the Psoas major. *Extension* is produced by the intrinsic muscles of the back, assisted in the neck by the Splenius, Semispinales dorsi and cervicis, and the Multifidus. *Lateral motion* is produced by the intrinsic muscles of the back by the Splenius, the Scaleni, the Quadratus lumborum, and the Psoas major, the muscles of one side only acting; and *rotation* by the action of the following muscles of one side only, viz., the Sternocleidomastoideus, the Longus capitis, the Scaleni, the Multifidus, the Semispinalis capitis, and the abdominal muscles.

II. Articulation of the Atlas with the Epistropheus or Axis (Articulatio Atlantoepistrophica).

The articulation of the atlas with the axis is of a complicated nature, comprising no fewer than four distinct joints. There is a pivot articulation between the odontoid process of the axis and the ring formed by the anterior arch and the transverse ligament of the atlas (see Fig. 306); here there are two joints: one between the posterior surface of the anterior arch of the atlas and the front of the odontoid process; the other between the anterior surface of the ligament and the back of the process. Between the articular processes of the two bones there is on either side an arthro-dial or gliding joint. The ligaments connecting these bones are:

Two Articular Capsules.
The Anterior Atlantoaxial.

The Posterior Atlantoaxial.
The Transverse.

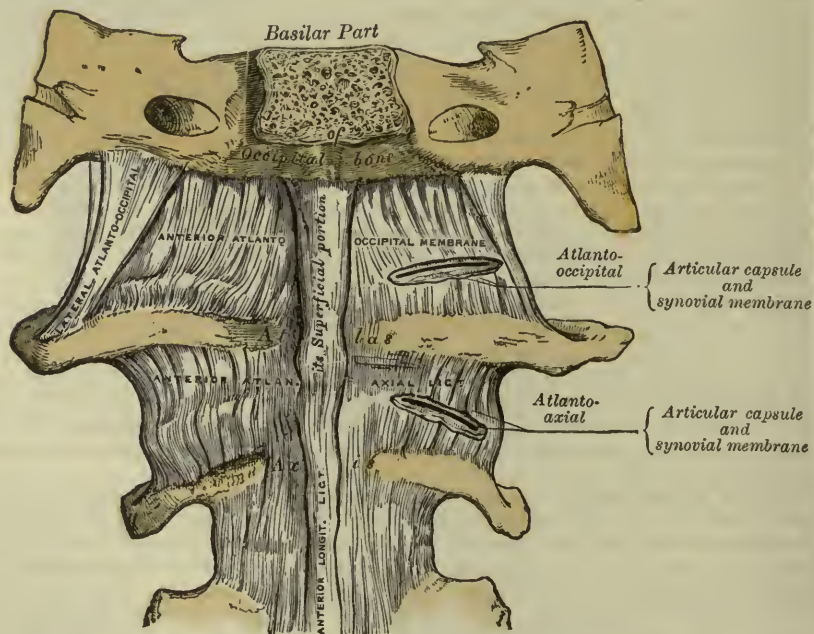


FIG. 304.—Anterior atlanto-occipital membrane and atlantoaxial ligament.

The Articular Capsules (*capsulæ articulares; capsular ligaments*).—The articular capsules are thin and loose, and connect the margins of the lateral masses of the atlas with those of the posterior articular surfaces of the axis. Each is strengthened at its posterior and medial part by an **accessory ligament**, which is attached

below to the body of the axis near the base of the odontoid process, and above to the lateral mass of the atlas near the transverse ligament.

The Anterior Atlantoaxial Ligament (Fig. 304).—This ligament is a strong membrane, fixed, *above*, to the lower border of the anterior arch of the atlas; *below*, to the front of the body of the axis. It is strengthened in the middle line by a

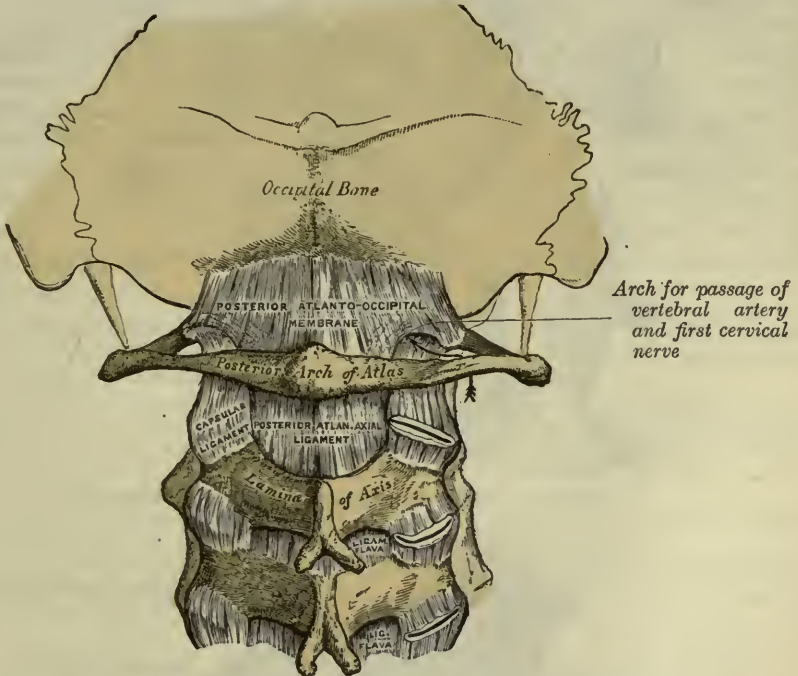


FIG. 305.—Posterior atlantoöccipital membrane and atlantoaxial ligament.

rounded cord, which connects the tubercle on the anterior arch of the atlas to the body of the axis, and is a continuation upward of the anterior longitudinal ligament. The ligament is in relation, in front, with the Longi capitis.

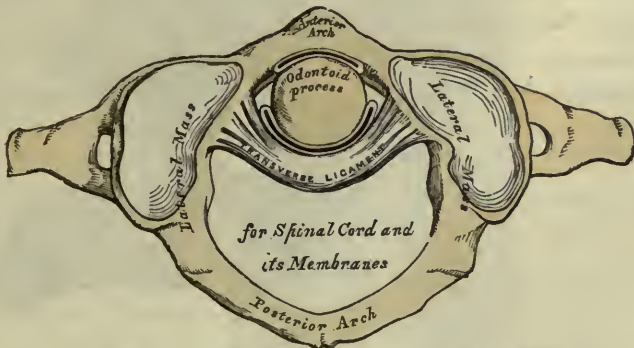


FIG. 306.—Articulation between odontoid process and atlas.

The Posterior Atlantoaxial Ligament (Fig. 305).—This ligament is a broad, thin membrane attached, *above*, to the lower border of the posterior arch of the atlas; *below*, to the upper edges of the laminae of the axis. It supplies the place of the ligamenta flava, and is in relation, *behind*, with the Obliqui capitis inferiores.

The Transverse Ligament of the Atlas (*ligamentum transversum atlantis*) (Figs. 306, 307, 308).—The transverse ligament of the atlas is a thick, strong band, which

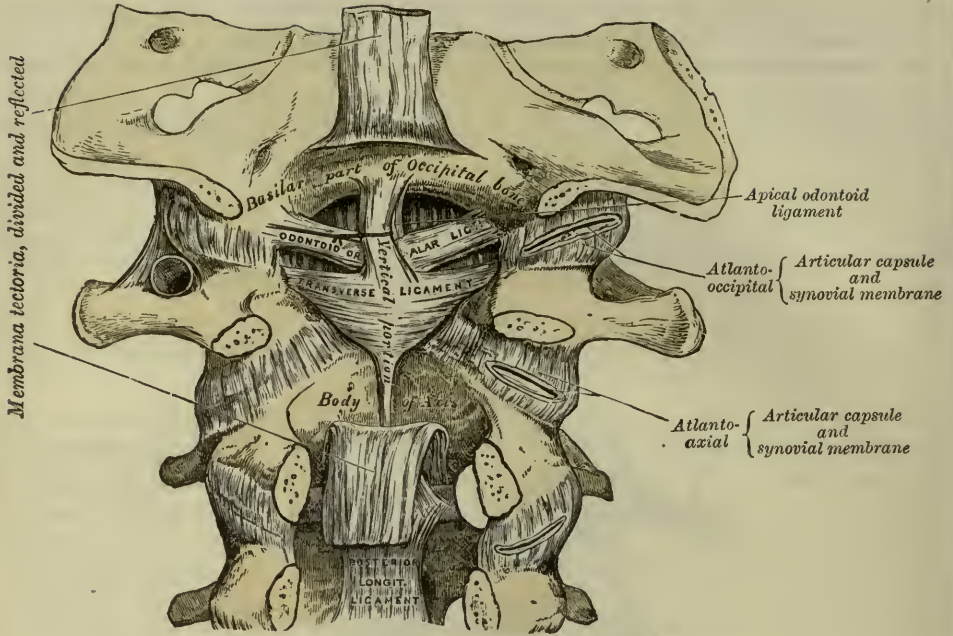


FIG. 307.—Membrana tectoria, transverse, and alar ligaments.

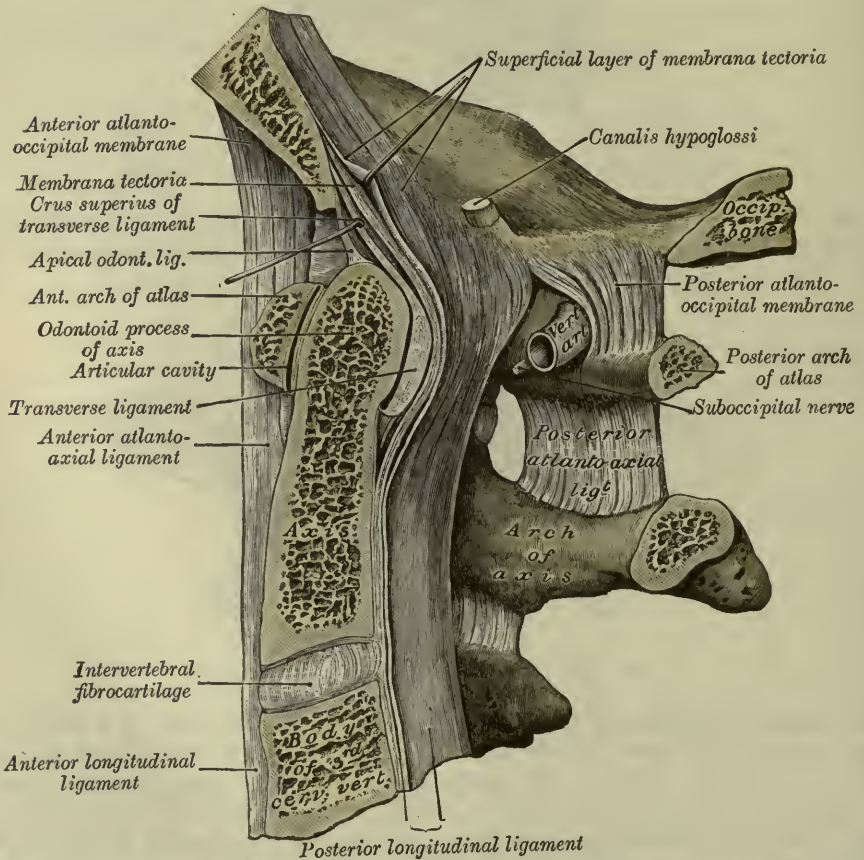


FIG. 308.—Median sagittal section through the occipital bone and first three cervical vertebrae. (Spalteholz.)

arches across the ring of the atlas, and retains the odontoid process in contact with the anterior arch. It is concave in front, convex behind, broader and thicker in the middle than at the ends, and firmly attached on either side to a small tubercle on the medial surface of the lateral mass of the atlas. As it crosses the odontoid process, a small fasciculus (*crus superius*) is prolonged upward, and another (*crus inferius*) downward, from the superficial or posterior fibers of the ligament. The former is attached to the basilar part of the occipital bone, in close relation with the membrana tectoria; the latter is fixed to the posterior surface of the body of the axis; hence, the whole ligament is named the **cruciate ligament of the atlas**. The transverse ligament divides the ring of the atlas into two unequal parts: of these, the posterior and larger serves for the transmission of the medulla spinalis and its membranes and the accessory nerves; the anterior and smaller contains the odontoid process. The neck of the odontoid process is constricted where it is embraced posteriorly by the transverse ligament, so that this ligament suffices to retain the odontoid process in position after all the other ligaments have been divided.

Synovial Membranes.—There is a synovial membrane for each of the four joints; the joint cavity between the odontoid process and the transverse ligament is often continuous with those of the atlantoöccipital articulations.

Movements.—The opposed articular surfaces of the atlas and axis are not reciprocally curved; both surfaces are convex in their long axes. When, therefore, the upper facet glides forward on the lower it also descends; the fibers of the articular capsule are relaxed in a vertical direction, and will then permit of movement in an antero-posterior direction. By this means a shorter capsule suffices and the strength of the joint is materially increased.¹

This joint allows the rotation of the atlas (and, with it, the skull) upon the axis, the extent of rotation being limited by the alar ligaments.

The principal muscles by which these movements are produced are the Sternocleidomastoideus and Semispinalis capitis of one side, acting with the Longus capitis, Splenius, Longissimus capitis, Rectus capitis posterior major, and Obliqui capitis superior and inferior of the other side.

III. Articulations of the Vertebral Column with the Cranium.

The ligaments connecting the vertebral column with the cranium may be divided into two sets: those uniting the atlas with the occipital bone, and those connecting the axis with the occipital bone.

Articulation of the Atlas with the Occipital Bone (*articulatio atlantoöccipitalis*).

—The articulation between the atlas and the occipital bone consists of a pair of condyloid joints. The ligaments connecting the bones are:

Two Articular Capsules.	The Posterior Atlantoöccipital membrane.
The Anterior Atlantoöccipital membrane.	Two Lateral Atlantoöccipital.

The Articular Capsules (*capsulæ articulares; capsular ligaments*).—The articular capsules surround the condyles of the occipital bone, and connect them with the articular processes of the atlas: they are thin and loose.

The Anterior Atlantoöccipital Membrane (*membrana atlantoöccipitalis anterior; anterior atlantoöccipital ligament*) (Fig. 304).—The anterior atlantoöccipital membrane is broad and composed of densely woven fibers, which pass between the anterior margin of the foramen magnum above, and the upper border of the anterior arch of the atlas below; laterally, it is continuous with the articular capsules; in front, it is strengthened in the middle line by a strong, rounded

¹ Corner ("The Physiology of the Atlanto-axial Joints," Journal of Anatomy and Physiology, vol. xli) states that the movements which take place at these articulations are of a complex nature. The first part of the movement is an eccentric or asymmetrical one; the atlanto-axial joint of the side to which the head is moved is fixed, or practically fixed, by the muscles of the neck, and forms the center of the movement, while the opposite atlantal facet is carried downward and forward on the corresponding axial facet. The second part of the movement is centric and symmetrical, the odontoid process forming the axis of the movement.

cord, which connects the basilar part of the occipital bone to the tubercle on the anterior arch of the atlas. This membrane is in relation in *front* with the *Recti capitis anteriores*, *behind* with the alar ligaments.

The Posterior Atlantoöccipital Membrane (*membrana atlantoöccipitalis posterior; posterior atlantoöccipital ligament*) (Fig. 305).—The posterior atlantoöccipital membrane, broad but thin, is connected above, to the posterior margin of the foramen magnum; below, to the upper border of the posterior arch of the atlas. On either side this membrane is defective below, over the groove for the vertebral artery, and forms with this groove an opening for the entrance of the artery and the exit of the suboccipital nerve. The free border of the membrane, arching over the artery and nerve, is sometimes ossified. The membrane is in relation, *behind*, with the *Recti capitis posteriores minores* and *Obliqui capitis superiores*; in *front*, with the *dura mater* of the vertebral canal, to which it is intimately adherent.

The Lateral Ligaments.—The lateral ligaments are thickened portions of the articular capsules, reinforced by bundles of fibrous tissue, and are directed obliquely upward and medialward; they are attached above to the jugular processes of the occipital bone, and below, to the bases of the transverse processes of the atlas.

Synovial Membranes.—There are two synovial membranes: one lining each of the articular capsules. The joints frequently communicate with that between the posterior surface of the odontoid process and the transverse ligament of the atlas.

Movements.—The movements permitted in this joint are (a) flexion and extension, which give rise to the ordinary forward and backward nodding of the head, and (b) slight lateral motion to one or other side. *Flexion* is produced mainly by the action of the *Longi capitis* and *Recti capitis anteriores*; *extension* by the *Recti capitis posteriores major* and *minor*, the *Obliquus superior*, the *Semispinalis capitis*, *Splenius capitis*, *Sternocleidomastoideus*, and upper fibers of the *Trapezius*. The *Recti laterales* are concerned in the *lateral movement*, assisted by the *Trapezius*, *Splenius capitis*, *Semispinalis capitis*, and the *Sternocleidomastoideus* of the same side, all acting together.

Ligaments Connecting the Axis with the Occipital Bone.—

The *Membrana Tectoria*.

Two Alar.

The Apical Odontoid.

The *Membrana Tectoria* (*occipitoaxial ligament*) (Figs. 307, 308).—The *membrana tectoria* is situated within the vertebral canal. It is a broad, strong bands which covers the odontoid process and its ligaments, and appears to be a prolongation upward of the posterior longitudinal ligament of the vertebral column. It is fixed, below, to the posterior surface of the body of the axis, and, expanding as it ascends, is attached to the basilar groove of the occipital bone, in front of the foramen magnum, where it blends with the cranial *dura mater*. Its anterior surface is in relation with the transverse ligament of the atlas, and its posterior surface with the *dura mater*.

The Alar Ligaments (*ligamenta alaria; odontoid ligaments*) (Fig. 307).—The alar ligaments are strong, rounded cords, which arise one on either side of the upper part of the odontoid process, and, passing obliquely upward and lateralward, are inserted into the rough depressions on the medial sides of the condyles of the occipital bone. In the triangular interval between these ligaments is another fibrous cord, the **apical odontoid ligament** (Fig. 308), which extends from the tip of the odontoid process to the anterior margin of the foramen magnum, being intimately blended with the deep portion of the anterior atlantoöccipital membrane and superior crus of the transverse ligament of the atlas. It is regarded as a rudimentary intervertebral fibrocartilage, and in it traces of the notochord may persist. The alar ligaments limit rotation of the cranium and therefore receive the name of **check ligaments**.

In addition to the ligaments which unite the atlas and axis to the skull, the *ligamentum nuchæ* (page 290) must be regarded as one of the ligaments connecting the vertebral column with the cranium.

IV. Articulation of the Mandible (*Articulatio Mandibularis*; *Temporomandibular Articulation*).

This is a ginglymo-arthrodial joint; the parts entering into its formation on either side are: the anterior part of the mandibular fossa of the temporal bone and the articular tubercle above; and the condyle of the mandible below. The ligaments of the joint are the following:

The Articular Capsule.

The Temporomandibular.

The Stylomandibular.

The Sphenomandibular.

The Articular Disk.

The Articular Capsule (*capsula articularis*; *capsular ligament*).—The articular capsule is a thin, loose envelope, attached above to the circumference of the mandibular fossa and the articular tubercle immediately in front; below, to the neck of the condyle of the mandible.

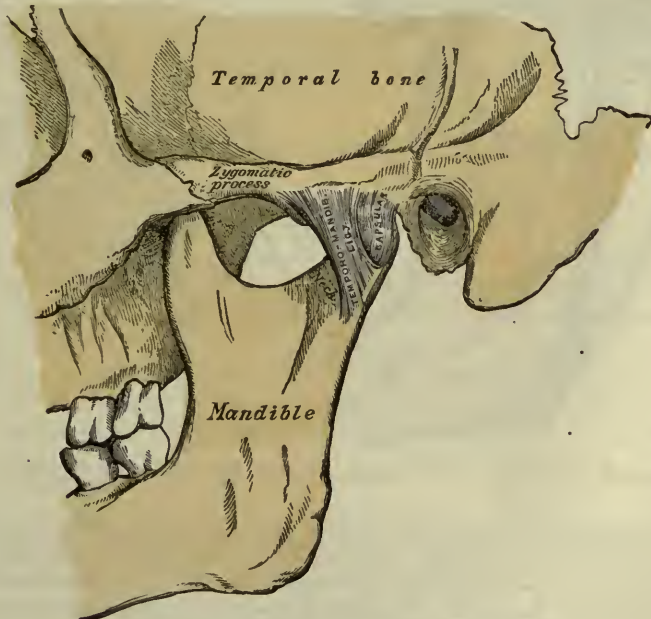


FIG. 309.—Articulation of the mandible. Lateral aspect.

The Temporomandibular Ligament (*ligamentum temporomandibulare*; *external lateral ligament*) (Fig. 309).—The temporomandibular ligament consists of two short, narrow fasciculi, one in front of the other, attached, above, to the lateral surface of the zygomatic arch and to the tubercle on its lower border; below, to the lateral surface and posterior border of the neck of the mandible. It is broader above than below, and its fibers are directed obliquely downward and backward. It is covered by the parotid gland, and by the integument.

The Sphenomandibular Ligament (*ligamentum sphenomandibulare*; *internal lateral ligament*) (Fig. 310).—The sphenomandibular ligament is a flat, thin band which is attached above to the spina angularis of the sphenoid bone, and, becoming broader as it descends, is fixed to the lingula of the mandibular foramen. Its lateral surface is in relation, above, with the Pterygoideus externus; lower down, it is separated from the neck of the condyle by the internal maxillary vessels; still lower, the inferior alveolar vessels and nerve and a lobule of the parotid gland lie between it and the ramus of the mandible. Its medial surface is in relation with the Pterygoideus internus.

The Articular Disk (*discus articularis*; *interarticular fibrocartilage*; *articular meniscus*) (Fig. 311).—The articular disk is a thin, oval plate, placed between the condyle of the mandible and the mandibular fossa. Its upper surface is concavo-convex from before backward, to accommodate itself to the form of the mandibular fossa and the articular tubercle. Its under surface, in contact with the condyle, is concave. Its circumference is connected to the articular capsule; and in front to the tendon of the Pterygoideus externus. It is thicker at its periphery, especially behind, than at its center. The fibers of which it is composed have a concentric arrangement, more apparent at the circumference than at the center. It divides the joint into two cavities, each of which is furnished with a synovial membrane.

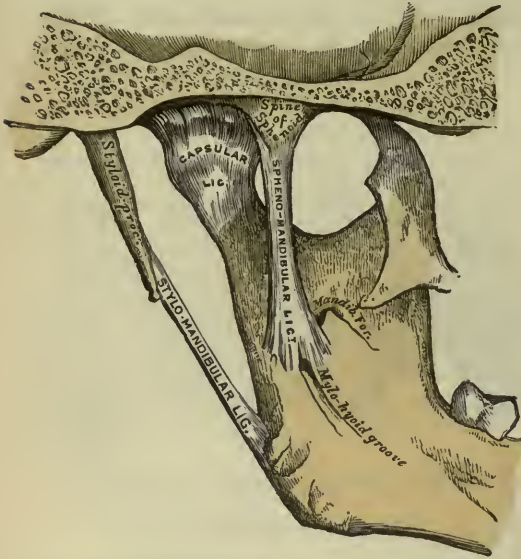

FIG. 310.—Articulation of the mandible. Medial aspect.

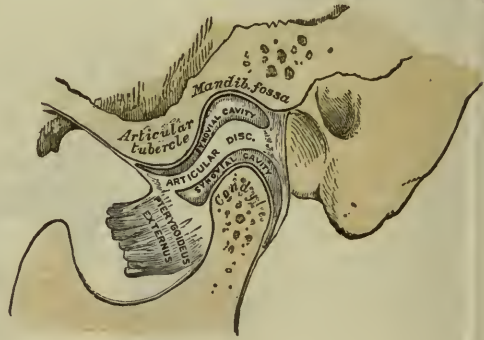

FIG. 311.—Sagittal section of the articulation of the mandible.

The Synovial Membranes.—The synovial membranes, two in number, are placed one above, and the other below, the articular disk. The upper one, the larger and looser of the two, is continued from the margin of the cartilage covering the mandibular fossa and articular tubercle on to the upper surface of the disk. The lower one passes from the under surface of the disk to the neck of the condyle, being prolonged a little farther downward behind than in front. The articular disk is sometimes perforated in its center, and the two cavities then communicate with each other.

The Stylomandibular Ligament (*ligamentum stylomandibulare*); *stylomaxillary ligament* (Fig. 310).—The stylomandibular ligament is a specialized band of the cervical fascia, which extends from near the apex of the styloid process of the temporal bone to the angle and posterior border of the ramus of the mandible, between the Masseter and Pterygoideus internus. This ligament separates the parotid from the submaxillary gland, and from its deep surface some fibers of the Styloglossus take origin. Although classed among the ligaments of the temporomandibular joint, it can only be considered as accessory to it.

The **nerves** of the temporomandibular joint are derived from the auriculotemporal and masseteric branches of the mandibular nerve, the **arteries** from the superficial temporal branch of the external carotid.

Movements.—The movements permitted in this articulation are extensive. Thus, the mandible may be depressed or elevated, or carried forward or backward; a slight amount of side-to-side movement is also permitted. It must be borne in mind that there are two distinct joints in this articulation—one between the condyle and the articular disk, and another between the disk and the mandibular fossa. When the mouth is but slightly opened, as during ordinary conversation,

the movement is confined to the lower of the two joints. On the other hand, when the mouth is opened more widely, both joints are concerned in the movement; in the lower joint the movement is of a hinge-like character, the condyle moving around a transverse axis on the disk, while in the upper joint the movement is of a gliding character, the disk, together with the condyle, gliding forward on to the articular tubercle, around an axis which passes through the mandibular foramina. These two movements take place simultaneously, the condyle and disk move forward on the eminence, and at the same time the condyle revolves on the disk. In shutting the mouth the reverse action takes place; the disk glides back, carrying the condyle with it, and this at the same time moves back to its former position. When the mandible is carried horizontally forward, as in protruding the lower incisor teeth in front of the upper, the movement takes place principally in the upper joint, the disk and the condyle gliding forward on the mandibular fossa and articular tubercle. The grinding or chewing movement is produced by one condyle, with its disk, gliding alternately forward and backward, while the other condyle moves simultaneously in the opposite direction; at the same time the condyle undergoes a vertical rotation on the disk. One condyle advances and rotates, the other condyle recedes and rotates, in alternate succession.

The mandible is *depressed* by its own weight, assisted by the Platysma, the Digastricus, the Mylohyoideus, and the Geniohyoideus. It is *elevated* by the Masseter, Pterygoideus internus, and the anterior part of the Temporalis. It is drawn *forward* by the simultaneous action of the Pterygoidei internus and externus, the superficial fibers of the Masseter and the anterior fibers of the Temporalis; and *backward* by the deep fibers of the Masseter and the posterior fibers of the Temporalis. The grinding movement is caused by the alternate action of the Pterygoidei of either side.

V. Costovertebral Articulations (Articulationes Costovertebrales).

The articulations of the ribs with the vertebral column may be divided into two sets, one connecting the heads of the ribs with the bodies of the vertebræ, another uniting the necks and tubercles of the ribs with the transverse processes.

1. **Articulations of the Heads of the Ribs** (*articulationes capitulorum; costocentral articulations*) (Fig. 312).—These constitute a series of gliding or arthro-dial joints, and are formed by the articulation of the heads of the typical ribs with the facets on the contiguous margins of the bodies of the thoracic vertebræ and with the intervertebral fibrocartilages between them; the first, tenth, eleventh, and twelfth ribs each articulate with a single vertebra. The ligaments of the joints are:

The Articular Capsule.

The Radiate.

The Interarticular.

The Articular Capsule (*capsula articularis; capsular ligament*).—The articular capsule surrounds the joint, being composed of short, strong fibers, connecting the head of the rib with the circumference of the articular cavity formed by the intervertebral fibrocartilage and the adjacent vertebræ. It is most distinct at the upper and lower parts of the articulation; some of its upper fibers pass through the intervertebral foramen to the back of the intervertebral fibrocartilage, while its posterior fibers are continuous with the ligament of the neck of the rib.

The Radiate Ligament (*ligamentum capituli costæ radiatum; anterior costovertebral or stellate ligament*).—The radiate ligament connects the anterior part of the head of each rib with the side of the bodies of two vertebræ, and the intervertebral fibrocartilage between them. It consists of three flat fasciculi, which are attached to the anterior part of the head of the rib, just beyond the articular surface. The superior fasciculus ascends and is connected with the body of the vertebra above; the inferior one descends to the body of the vertebra below; the middle one, the smallest and least distinct, is horizontal and is attached to the intervertebral fibrocartilage. The radiate ligament is in relation, in *front*, with the thoracic ganglia of the sympathetic trunk, the pleura, and, on the right side, with the azygos vein; *behind*, with the interarticular ligament and synovial membranes.

In the case of the first rib, this ligament is not divided into three fasciculi, but its fibers are attached to the body of the last cervical vertebra, as well as to that of the first thoracic. In the articulations of the heads of the tenth, eleventh, and twelfth ribs, each of which articulates with a single vertebra, the triradiate arrange-

ment does not exist; but the fibers of the ligament in each case are connected to the vertebra above, as well as to that with which the rib articulates.

The Interarticular Ligament (*ligamentum capituli costæ interarticulare*).—The interarticular ligament is situated in the interior of the joint. It consists of a short band of fibers, flattened from above downward, attached by one extremity to the crest separating the two articular facets on the head of the rib, and by the other to the intervertebral fibrocartilage; it divides the joint into two cavities. In the joints of the first, tenth, eleventh, and twelfth ribs, the interarticular ligament does not exist; consequently, there is but one cavity in each of these articulations. This ligament is the homologue of the **ligamentum conjugale** present in some mammals, and uniting the heads of opposite ribs, across the back of the intervertebral fibrocartilage.

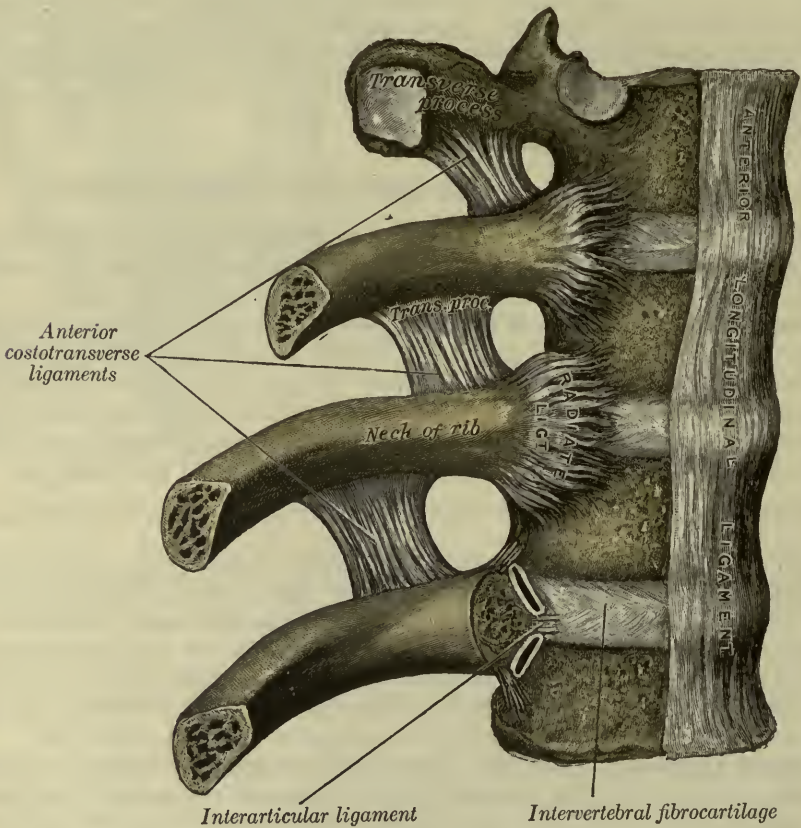


FIG. 312.—Costovertebral articulations. Anterior view.

Synovial Membranes.—There are two synovial membranes in each of the articulations where an interarticular ligament exists, one above and one below this structure; but only one in those joints where there are single cavities.

2. Costotransverse Articulations (*articulationes costotransversariæ*) (Fig. 313).—The articular portion of the tubercle of the rib forms with the articular surface on the adjacent transverse process an arthrodial joint.

In the eleventh and twelfth ribs this articulation is wanting.

The ligaments of the joint are:

- | | |
|--|--------------------------------------|
| The Articular Capsule. | The Posterior Costotransverse. |
| The Anterior Costotransverse. | The Ligament of the Neck of the Rib. |
| The Ligament of the Tubercle of the Rib. | |

The Articular Capsule (*capsula articularis; capsular ligament*).—The articular capsule is a thin membrane attached to the circumferences of the articular surfaces, and lined by a synovial membrane.

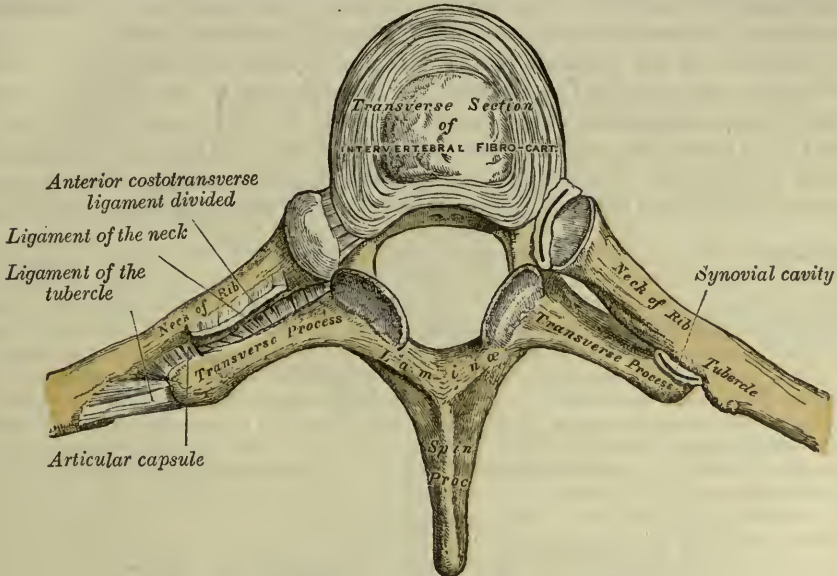


FIG. 313.—Costotransverse articulation. Seen from above.

The Anterior Costotransverse Ligament (*ligamentum costotransversarium anterius; anterior superior ligament*).—The anterior costotransverse ligament is attached below to the sharp crest on the upper border of the neck of the rib, and passes obliquely upward and lateralward to the lower border of the transverse process immediately above. It is in relation, in front, with the intercostal vessels and nerves; its medial border is thickened and free, and bounds an aperture which transmits the posterior branches of the intercostal vessels and nerves; its lateral border is continuous with a thin aponeurosis, which covers the *Intercostalis externus*.

The first rib has no anterior costotransverse ligament. A band of fibers, the **lumbocostal ligament**, in series with the anterior costotransverse ligaments, connects the neck of the twelfth rib to the base of the transverse process of the first lumbar vertebra; it is merely a thickened portion of the posterior layer of the lumbodorsal fascia.

The Posterior Costotransverse Ligament (*ligamentum costotransversarium posterius*).—The posterior costotransverse ligament is a feeble band which is attached below to the neck of the rib and passes upward and medialward to the base of the transverse process and lateral border of the inferior articular process of the vertebra above.

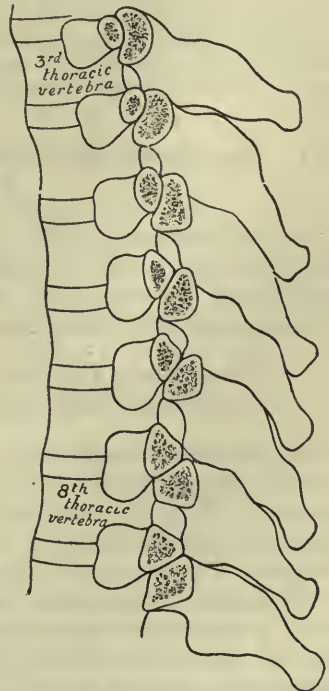


FIG. 314.—Section of the costotransverse joints from the third to the ninth inclusive. Contrast the concave facets on the upper with the flattened facets on the lower transverse processes.

The posterior costotransverse ligament is a feeble band which is attached below to the neck of the rib and passes upward and medialward to the base of the transverse process and lateral border of the inferior articular process of the vertebra above.

The Ligament of the Neck of the Rib (*ligamentum colli costæ; middle costotransverse or interosseous ligament*).—The ligament of the neck of the rib consists of short but strong fibers, connecting the rough surface on the back of the neck of the rib with the anterior surface of the adjacent transverse process. A rudimentary ligament may be present in the case of the eleventh and twelfth ribs.

The Ligament of the Tubercle of the Rib (*ligamentum tuberculi costæ; posterior costotransverse ligament*).—The ligament of the tubercle of the rib is a short but thick and strong fasciculus, which passes obliquely from the apex of the transverse process to the rough non-articular portion of the tubercle of the rib. The ligaments attached to the upper ribs ascend from the transverse processes; they are shorter and more oblique than those attached to the inferior ribs, which descend slightly.

Movements.—The heads of the ribs are so closely connected to the bodies of the vertebræ by the radiate and interarticular ligaments that only slight gliding movements of the articular surfaces on one another can take place. Similarly, the strong ligaments binding the necks and tubercles of the ribs to the transverse processes limit the movements of the costotransverse joints to slight gliding, the nature of which is determined by the shape and direction of the articular surfaces (Fig. 314). In the upper six ribs the articular surfaces on the tubercles are oval in shape and convex from above downward; they fit into corresponding concavities on the *anterior surfaces* of the transverse processes, so that upward and downward movements of the tubercles are associated with rotation of the rib neck on its long axis. In the seventh, eighth, ninth, and tenth ribs the articular surfaces on the tubercles are flat, and are directed obliquely downward, medialward, and backward. The surfaces with which they articulate are placed on the *upper margins* of the transverse processes; when, therefore, the tubercles are drawn up they are at the same time carried backward and medialward. The two joints, costocentral and costotransverse, move simultaneously and in the same directions, the total effect being that the neck of the rib moves as if on a single joint, of which the costocentral and costotransverse articulations form the ends. In the upper six ribs the neck of the rib moves but slightly upward and downward; its chief movement is one of rotation around its own long axis, rotation backward being associated with depression, rotation forward with elevation. In the seventh, eighth, ninth, and tenth ribs the neck of the rib moves upward, backward, and medialward, or downward, forward, and lateralward; very slight rotation accompanies these movements.

VI. Sternocostal Articulations (Articulationes Sternocostales; Costosternal Articulations) (Fig. 315).

The articulations of the cartilages of the true ribs with the sternum are arthrodiar joints, with the exception of the first, in which the cartilage is directly united with the sternum, and which is, therefore, a synarthrodial articulation. The ligaments connecting them are:

The Articular Capsules.
The Radiate Sternocostal.

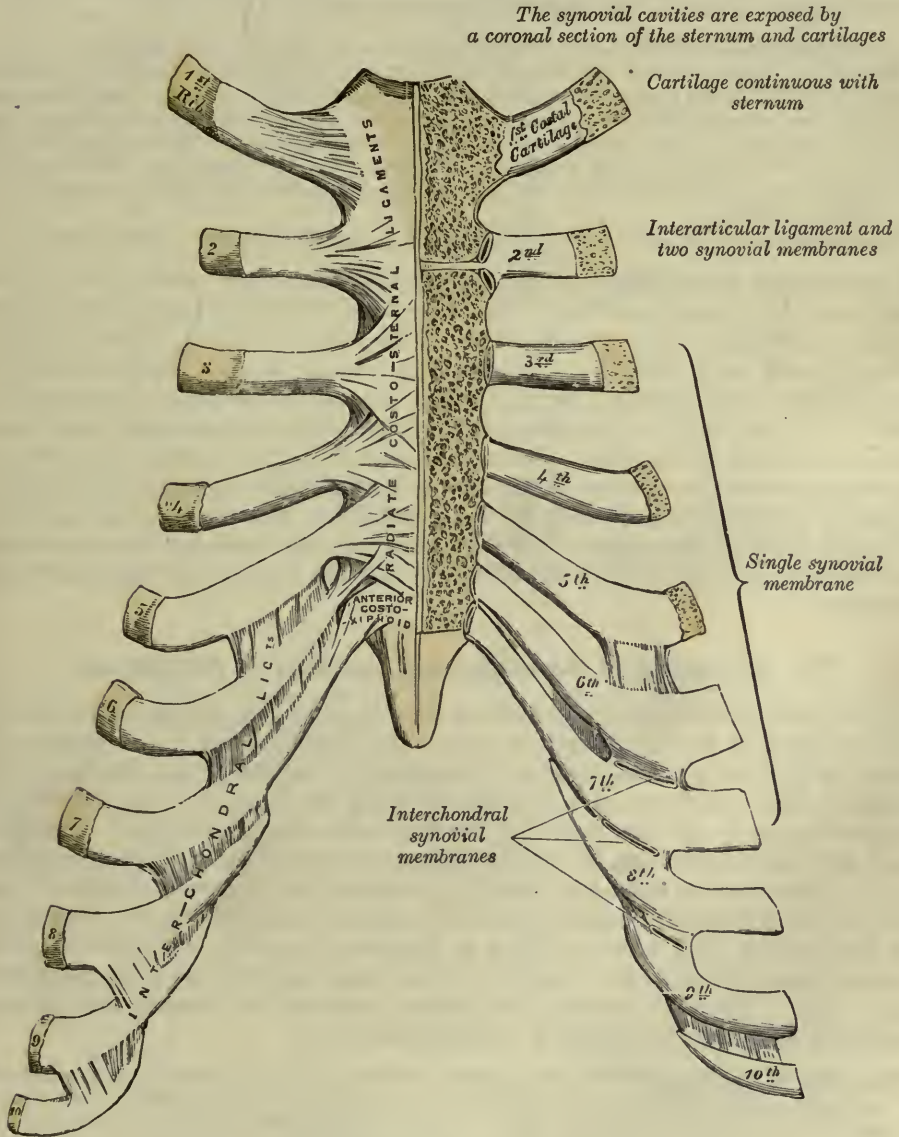
The Interarticular Sternocostal.
The Costoxiphoid.

The Articular Capsules (*capsulæ articulares; capsular ligaments*).—The articular capsules surround the joints between the cartilages of the true ribs and the sternum. They are very thin, intimately blended with the radiate sternocostal ligaments, and strengthened at the upper and lower parts of the articulations by a few fibers, which connect the cartilages to the side of the sternum.

The Radiate Sternocostal Ligaments (*ligamenta sternocostalia radiata; chondrosternal or sternocostal ligaments*).—These ligaments consist of broad and thin membranous bands that radiate from the front and back of the sternal ends of the cartilages of the true ribs to the anterior and posterior surfaces of the sternum. They are composed of fasciculi which pass in different directions. The **superior fasciculi** ascend obliquely, the **inferior fasciculi** descend obliquely, and the **middle fasciculi** run horizontally. The superficial fibers are the longest; they intermingle with the fibers of the ligaments above and below them, with those of the opposite side, and in front with the tendinous fibers of origin of the Pectoralis major, form-

ing a thick fibrous membrane (**membrana sterni**) which envelops the sternum. This is more distinct at the lower than at the upper part of the bone.

The Interarticular Sternocostal Ligament (*ligamentum sternocostale interarticulare; interarticular chondrosternal ligament*).—This ligament is found constantly only between the second costal cartilages and the sternum. The cartilage of the *second*



rib is connected with the sternum by means of an interarticular ligament, attached by one end to the cartilage of the rib, and by the other to the fibrocartilage which unites the manubrium and body of the sternum. This articulation is provided with two synovial membranes. Occasionally the cartilage of the *third* rib is connected with the first and second pieces of the body of the sternum by an interarticular ligament. Still more rarely, similar ligaments are found in the other four

joints of the series. In the lower two the ligament sometimes completely obliterates the cavity, so as to convert the articulation into an amphiarthrosis.

The Costoxiphoid Ligaments (*ligamenta costoxiphoides; chondroxiphoid ligaments*).—These ligaments connect the anterior and posterior surfaces of the seventh costal cartilage, and sometimes those of the sixth, to the front and back of the xiphoid process. They vary in length and breadth in different subjects; those on the back of the joint are less distinct than those in front.

Synovial Membranes.—There is no synovial membrane between the first costal cartilage and the sternum, as this cartilage is directly continuous with the manubrium. There are two in the articulation of the second costal cartilage and generally one in each of the other joints; but those of the sixth and seventh sternocostal joints are sometimes absent; where an interarticular ligament is present, there are two synovial cavities. After middle life the articular surfaces lose their polish, become roughened, and the synovial membranes apparently disappear. In old age, the cartilages of most of the ribs become continuous with the sternum, and the joint cavities are consequently obliterated.

Movements.—Slight gliding movements are permitted in the sternocostal articulations.

Interchondral Articulations (*articulationes interchondrales; articulations of the cartilages of the ribs with each other*) (Fig. 315).—The contiguous borders of the sixth, seventh, and eighth, and sometimes those of the ninth and tenth, costal cartilages articulate with each other by small, smooth, oblong facets. Each articulation is enclosed in a thin **articular capsule**, lined by **synovial membrane** and strengthened laterally and medially by ligamentous fibers (**interchondral ligaments**) which pass from one cartilage to the other. Sometimes the fifth costal cartilages, more rarely the ninth and tenth, articulate by their lower borders with the adjoining cartilages by small oval facets; more frequently the connection is by a few ligamentous fibers.

Costochondral Articulations.—The lateral end of each costal cartilage is received into a depression in the sternal end of the rib, and the two are held together by the periosteum.

VII. Articulation of the Manubrium and Body of the Sternum.

The manubrium is united to the body of the sternum either by an amphiarthrodial joint—a piece of fibrocartilage connecting the segments—or by a diarthrodial joint, in which the articular surface of each bone is clothed with a lamina of cartilage. In the latter case, the cartilage covering the body is continued without interruption on to the cartilages of the facets for the second ribs. Rivington found the diarthrodial form of joint in about one-third of the specimens examined by him, Maisonneuve more frequently. It appears to be rare in childhood, and is formed, in Rivington's opinion, from the amphiarthrodial form, by absorption. The diarthrodial joint seems to have no tendency to ossify, while the amphiarthrodial is more liable to do so, and has been found ossified as early as thirty-four years of age. The two segments are further connected by **anterior and posterior intersternal ligaments** consisting of longitudinal fibers.

Mechanism of the Thorax.—Each rib possesses its own range and variety of movements, but the movements of all are combined in the respiratory excursions of the thorax. Each rib may be regarded as a lever the fulcrum of which is situated immediately outside the costotransverse articulation, so that when the body of the rib is elevated the neck is depressed and *vice versa*; from the disproportion in length of the arms of the lever a slight movement at the vertebral end of the rib is greatly magnified at the anterior extremity.

The anterior ends of the ribs lie on a lower plane than the posterior; when therefore the body of the rib is elevated the anterior extremity is thrust also forward. Again, the middle of the body of the rib lies in a plane below that passing through the two extremities, so that when the body is elevated relatively to its ends it is at the same time carried outward from the median plane of the thorax. Further, each rib forms the segment of a curve which is greater than that of the rib immediately above, and therefore the elevation of a rib increases the transverse diameter of the thorax in the plane to which it is raised. The modifications of the rib movements at their vertebral ends have already been described (page 302). Further modifications result from the

attachments of their anterior extremities, and it is convenient therefore to consider separately the movements of the ribs of the three groups—vertebrosternal, vertebrochondral, and vertebral.

Vertebrosteral Ribs (Figs. 316, 317).—The first rib differs from the others of this group in that its attachment to the sternum is a rigid one; this is counterbalanced to some extent by the fact that its head possesses no interarticular ligament, and is therefore more movable. The first pair of ribs with the manubrium sterni move as a single piece, the anterior portion being elevated by rotatory movements at the vertebral extremities. In normal quiet respiration the movement of this arc is practically *nil*; when it does occur the anterior part is raised and carried forward, increasing the antero-posterior and transverse diameters of this region of the chest. The movement of the second rib is also slight in normal respiration, as its anterior extremity is fixed to the manubrium, and prevented therefore from moving upward. The sternocostal articulation, however, allows the middle of the body of the rib to be drawn up, and in this way the transverse thoracic diameter is increased. Elevation of the third, fourth, fifth, and sixth ribs raises and thrusts forward their anterior extremities, the greater part of the movement being effected by the rotation of the rib neck backward. The thrust of the anterior extremities carries forward and upward the body of the sternum, which moves on the joint

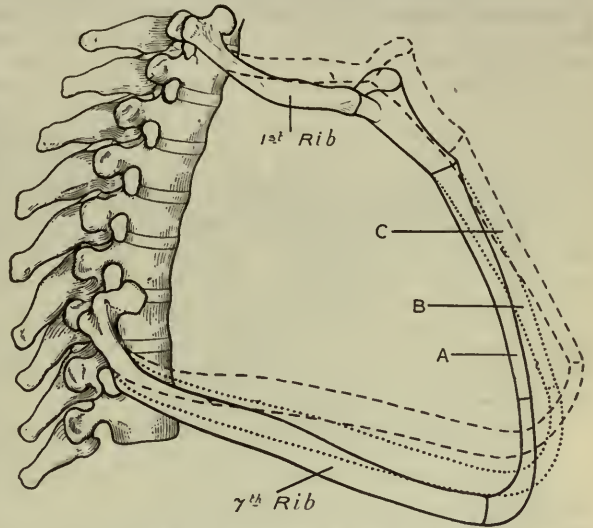


FIG. 316.—Lateral view of first and seventh ribs in position, showing the movements of the sternum and ribs in A, ordinary expiration; B, quiet inspiration; C, deep inspiration.

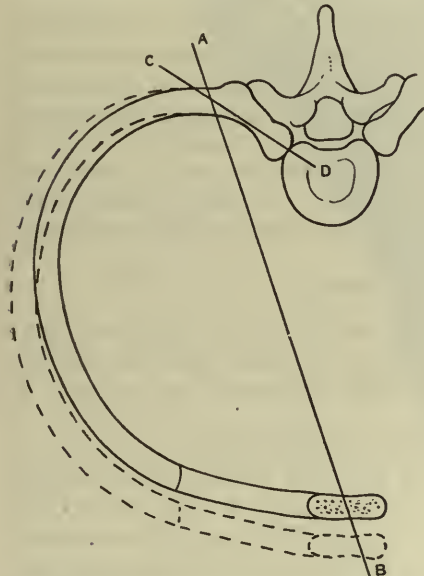


FIG. 317.—Diagram showing the axes of movement (A B and C D) of a vertebrosteral rib. The interrupted lines indicate the position of the rib in inspiration.

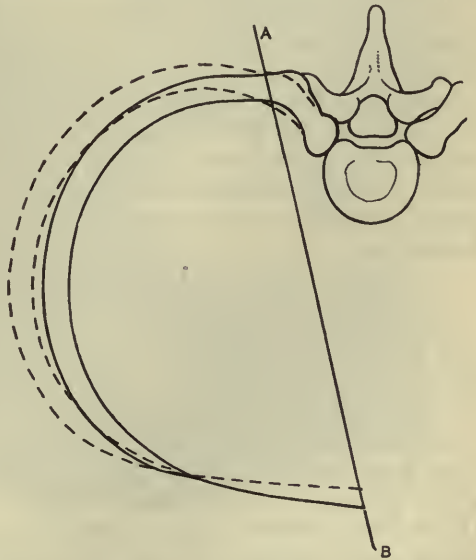


FIG. 318.—Diagram showing the axis of movement (A B) of a vertebrochondral rib. The interrupted lines indicate the position of the rib in inspiration.

between it and the manubrium, and thus the antero-posterior thoracic diameter is increased. This movement is, however, soon arrested, and the elevating force is then expended in raising the middle part of the body of the rib and everting its lower border; at the same time the

costochondral angle is opened out. By these latter movements a considerable increase in the transverse diameter of the thorax is effected.

Vertebrochondral Ribs (Fig. 318).—The seventh rib is included with this group, as it conforms more closely to their type. While the movements of these ribs assist in enlarging the thorax for respiratory purposes, they are also concerned in increasing the upper abdominal space for viscera displaced by the action of the diaphragm. The costal cartilages articulate with one another, so that each pushes up that above it, the final thrust being directed to pushing forward and upward the lower end of the body of the sternum. The amount of elevation of the anterior extremities is limited on account of the very slight rotation of the rib neck. Elevation of the shaft is accompanied by an outward and backward movement; the outward movement everts the anterior end of the rib and opens up the subcostal angle, while the backward movement pulls back the anterior extremity and counteracts the forward thrust due to its elevation; this latter is most noticeable in the lower ribs, which are the shortest. The total result is a considerable increase in the transverse and a diminution in the median antero-posterior diameter of the upper part of the abdomen; at the same time, however, the lateral antero-posterior diameters of the abdomen are increased.

Vertebral Ribs.—Since these ribs have free anterior extremities and only costocentral articulations with no interarticular ligaments, they are capable of slight movements in all directions. When the other ribs are elevated these are depressed and fixed to form points of action for the diaphragm.

VIII. Articulation of the Vertebral Column with the Pelvis.

The ligaments connecting the fifth lumbar vertebra with the sacrum are similar to those which join the movable segments of the vertebral column with each other—viz.: 1. The continuation downward of the anterior and posterior longitudinal ligaments. 2. The intervertebral fibrocartilage, connecting the body of the fifth lumbar to that of the first sacral vertebra and forming an amphiarthrodial joint. 3. Ligamenta flava, uniting the laminae of the fifth lumbar vertebra with those of the first sacral. 4. Capsules connecting the articular processes and forming a double arthrodia. 5. Inter- and supraspinal ligaments.

On either side an additional ligament, the **iliolumbar**, connects the pelvis with the vertebral column.

The Iliolumbar Ligament (*ligamentum iliolumbale*) (Fig. 319).—The iliolumbar ligament is attached above to the lower and front part of the transverse process of the fifth lumbar vertebra. It radiates as it passes lateralward and is attached by two main bands to the pelvis. The lower bands run to the base of the sacrum, blending with the anterior sacroiliac ligament; the upper is attached to the crest of the ilium immediately in front of the sacroiliac articulation, and is continuous above with the lumbodorsal fascia. In *front*, it is in relation with the Psoas major; *behind*, with the muscles occupying the vertebral groove; *above*, with the Quadratus lumborum.

IX. Articulations of the Pelvis.

The ligaments connecting the bones of the pelvis with each other may be divided into four groups: 1. Those connecting the sacrum and ilium. 2. Those passing between the sacrum and ischium. 3. Those uniting the sacrum and coccyx. 4. Those between the two pubic bones.

1. **Sacroiliac Articulation** (*articulatio sacroiliaca*).—The sacroiliac articulation is an amphiarthrodial joint, formed between the auricular surfaces of the sacrum and the ilium. The articular surface of each bone is covered with a thin plate of cartilage, thicker on the sacrum than on the ilium. These cartilaginous plates are in close contact with each other, and to a certain extent are united together by irregular patches of softer fibrocartilage, and at their upper and posterior part by fine interosseous fibers. In a considerable part of their extent, especially in advanced life, they are separated by a space containing a synovia-like fluid, and hence the joint presents the characteristics of a diarthrosis. The ligaments of the joint are:

The Anterior Sacroiliac.

The Posterior Sacroiliac.

The Interosseous.

various directions. The upper part (**short posterior sacroiliac ligament**) is nearly horizontal in direction, and passes from the first and second transverse tubercles on the back of the sacrum and to the tuberosity of the ilium. The lower part (**long posterior sacroiliac ligament**) is oblique in direction; it is attached by one extremity

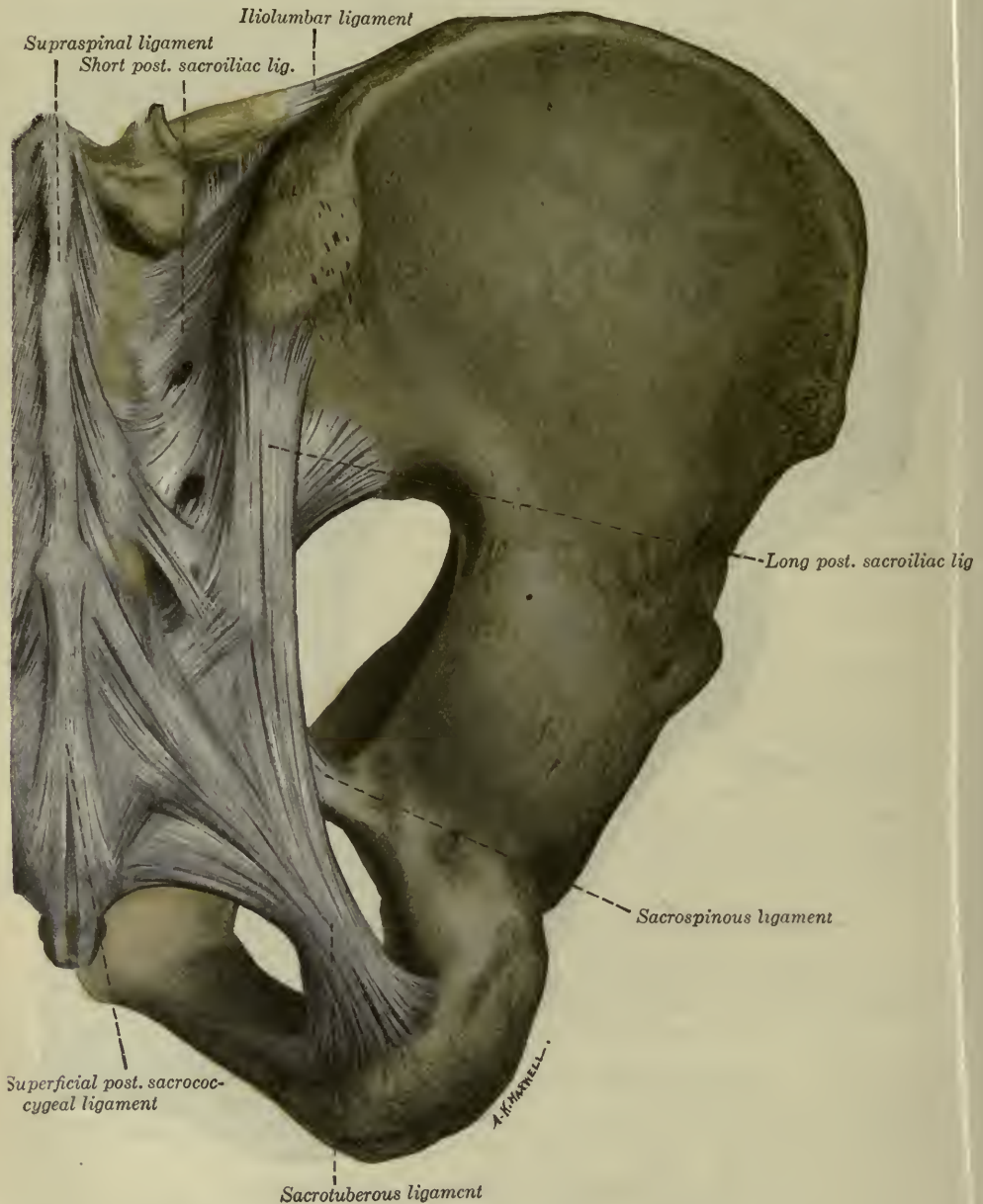

FIG. 320.—Articulations of pelvis. Posterior view. (Quain.)

to the third transverse tubercle of the back of the sacrum, and by the other to the posterior superior spine of the ilium.

The Interosseous Sacroiliac Ligament (*ligamentum sacroiliacum interosseum*).—This ligament lies deep to the posterior ligament, and consists of a series of short, strong fibers connecting the tuberosities of the sacrum and ilium.

2. Ligaments Connecting the Sacrum and Ischium (Fig. 320).

The Sacrotuberous.

The Sacrospinous.

The Sacrotuberous Ligament (*ligamentum sacrotuberosum; great or posterior sacrosciatic ligament*).—The sacrotuberous ligament is situated at the lower and back part of the pelvis. It is flat, and triangular in form; narrower in the middle than at the ends; attached by its broad base to the posterior inferior spine of the ilium, to the fourth and fifth transverse tubercles of the sacrum, and to the lower part of the lateral margin of that bone and the coccyx. Passing obliquely downward, forward, and lateralward, it becomes narrow and thick, but at its insertion into the inner margin of the tuberosity of the ischium, it increases in breadth, and is prolonged forward along the inner margin of the ramus, as the **falciform process**, the free concave edge of which gives attachment to the obturator fascia; one of its surfaces is turned toward the perineum, the other toward the Obturator internus. The lower border of the ligament is directly continuous with the tendon of origin of the long head of the Biceps femoris, and by many is believed to be the proximal end of this tendon, cut off by the projection of the tuberosity of the ischium.

Relations.—The *posterior surface* of this ligament gives origin, by its whole extent, to the Glutæus maximus. Its *anterior surface* is in part united to the sacrospinous ligament. Its *upper border* forms, above, the posterior boundary of the greater sciatic foramen, and, below, the posterior boundary of the lesser sciatic foramen. Its *lower border* forms part of the boundary of the perineum. It is pierced by the coccygeal nerve and the coccygeal branch of the inferior gluteal artery.

The Sacrospinous Ligament (*ligamentum sacrospinosum; small or anterior sacrosciatic ligament*).—The sacrospinous ligament is thin, and triangular in form; it is attached by its apex to the spine of the ischium, and medially, by its broad base, to the lateral margins of the sacrum and coccyx, in front of the sacrotuberous ligament with which its fibers are intermingled.

Relations.—It is in relation, *anteriorly*, with the Coccygeus muscle, to which it is closely connected; *posteriorly*, it is covered by the sacrotuberous ligament, and crossed by the internal pudendal vessels and nerve. Its *upper border* forms the lower boundary of the greater sciatic foramen; its *lower border*, part of the margin of the lesser sciatic foramen.

These two ligaments convert the sciatic notches into foramina. The **greater sciatic foramen** is bounded, in *front and above*, by the posterior border of the hip bone; *behind*, by the sacrotuberous ligament; and *below*, by the sacrospinous ligament. It is partially filled up, in the recent state, by the Piriformis which leaves the pelvis through it. Above this muscle, the superior gluteal vessels and nerve emerge from the pelvis; and below it, the inferior gluteal vessels and nerve, the internal pudendal vessels and nerve, the sciatic and posterior femoral cutaneous nerves, and the nerves to the Obturator internus and Quadratus femoris make their exit from the pelvis. The **lesser sciatic foramen** is bounded, in *front*, by the tuberosity of the ischium; *above*, by the spine of the ischium and sacrospinous ligament; *behind*, by the sacrotuberous ligament. It transmits the tendon of the Obturator internus, its nerve, and the internal pudendal vessels and nerve.

3. **Sacrococcygeal Symphysis** (*symphysis sacrococcygea; articulation of the sacrum and coccyx*).—This articulation is an amphiarthrodial joint, formed between the oval surface at the apex of the sacrum, and the base of the coccyx. It is homologous with the joints between the bodies of the vertebræ, and is connected by similar ligaments. They are:

The Anterior Sacrococcygeal.

The Lateral Sacrococcygeal.

The Posterior Sacrococcygeal.

The Interposed Fibrocartilage.

The Interarticular.

The Anterior Sacrococcygeal Ligament (*ligamentum sacrococcygeum anterius*).—This consists of a few irregular fibers, which descend from the anterior surface of the sacrum to the front of the coccyx, blending with the periosteum.

The Posterior Sacrococcygeal Ligament (*ligamentum sacrococcygeum posterius*).—This is a flat band, which arises from the margin of the lower orifice of the sacral

canal, and descends to be inserted into the posterior surface of the coccyx. This ligament completes the lower and back part of the sacral canal, and is divisible into a short deep portion and a longer superficial part. It is in relation, behind, with the *Glutæus maximus*.

The Lateral Sacrococcygeal Ligament (*ligamentum sacrococcygeum laterale; inter-transverse ligament*).—The lateral sacrococcygeal ligament exists on either side and connects the transverse process of the coccyx to the lower lateral angle of the sacrum; it completes the foramen for the fifth sacral nerve.

A disk of **fibrocartilage** is interposed between the contiguous surfaces of the sacrum and coccyx; it differs from those between the bodies of the vertebræ in that it is thinner, and its central part is firmer in texture. It is somewhat thicker in front and behind than at the sides. Occasionally the coccyx is freely movable on the sacrum, most notably during pregnancy; in such cases a synovial membrane is present.

The **Interarticular Ligaments** are thin bands, which unite the cornua of the two bones.

The different segments of the coccyx are connected together by the extension downward of the anterior and posterior sacrococcygeal ligaments, thin annular disks of fibrocartilage being interposed between the segments. In the adult male, all the pieces become ossified together at a comparatively early period; but in the female, this does not commonly occur until a later period of life. At more advanced age the joint between the sacrum and coccyx is obliterated.

Movements.—The movements which take place between the sacrum and coccyx, and between the different pieces of the latter bone, are forward and backward; they are very limited. Their extent increases during pregnancy.

4. **The Pubic Symphysis** (*symphysis ossium pubis; articulation of the pubic bones*) (Fig. 321).—The articulation between the pubic bones is an amphiarthrodial joint, formed between the two oval articular surfaces of the bones. The ligaments of this articulation are:

The Anterior Pubic.

The Superior Pubic.

The Posterior Pubic.

The Arcuate Pubic.

The Interpubic Fibrocartilaginous Lamina.

The Anterior Pubic Ligament (Fig. 319).—The anterior pubic ligament consists of several superimposed layers, which pass across the front of the articulation. The superficial fibers pass obliquely from one bone to the other, decussating and forming an interlacement with the fibers of the aponeuroses of the *Obliqui externi* and the medial tendons of origin of the *Recti abdominis*. The deep fibers pass transversely across the symphysis, and are blended with the fibrocartilaginous lamina.

The Posterior Pubic Ligament.—The posterior pubic ligament consists of a few thin, scattered fibers, which unite the two pubic bones posteriorly.

The Superior Pubic Ligament (*ligamentum pubicum superius*).—The superior pubic ligament connects together the two pubic bones superiorly, extending laterally as far as the pubic tubercles.

The Arcuate Pubic Ligament (*ligamentum arcuatum pubis; inferior pubic or subpubic ligament*).—The arcuate pubic ligament is a thick, triangular arch of ligamentous fibers, connecting together the two pubic bones below, and forming the upper boundary of the pubic arch. *Above*, it is blended with the interpubic fibrocartilaginous lamina; *laterally*, it is attached to the inferior rami of the pubic bones; *below*, it is free, and is separated from the fascia of the urogenital diaphragm by an opening through which the deep dorsal vein of the penis passes into the pelvis.

The Intertubercular Fibrocartilaginous Lamina (*lamina fibrocartilaginea interpubica; interpubic disk*).—The intertubercular fibrocartilaginous lamina connects the opposed surfaces of the pubic bones. Each of these surfaces is covered by a thin layer of hyaline cartilage firmly joined to the bone by a series of nipple-like processes which accurately fit into corresponding depressions on the osseous surfaces. These opposed cartilaginous surfaces are connected together by an intermediate lamina of fibrocartilage which varies in thickness in different subjects. It often contains a cavity in its interior, probably formed by the softening and absorption of the fibrocartilage, since it rarely appears before the tenth year of life and is not lined by synovial membrane. This cavity is larger in the female than in the male, but it is very doubtful whether it enlarges, as was formerly supposed, during pregnancy. It is most frequently limited to the upper and back part of the joint; it occasionally reaches to the front, and may extend the entire length of the cartilage. It may be easily demonstrated when present by making a coronal section of the symphysis pubis near its posterior surface (Fig. 321).

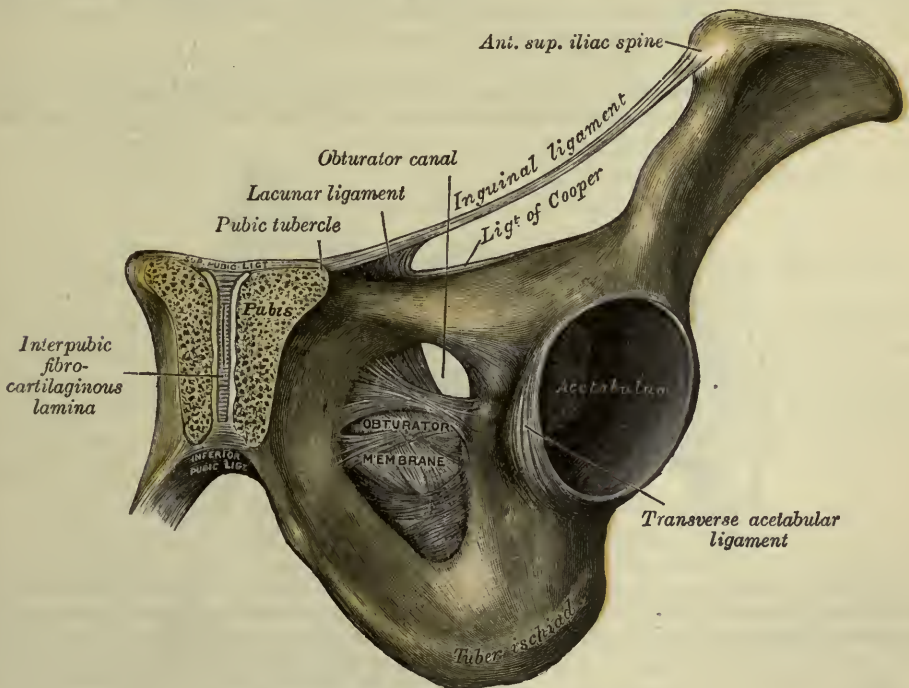


FIG. 321.—Symphysis pubis exposed by a coronal section.

Mechanism of the Pelvis.—The pelvic girdle supports and protects the contained viscera and affords surfaces for the attachments of the trunk and lower limb muscles. Its most important mechanical function, however, is to transmit the weight of the trunk and upper limbs to the lower extremities.

It may be divided into two arches by a vertical plane passing through the acetabular cavities; the posterior of these arches is the one chiefly concerned in the function of transmitting the weight. Its essential parts are the upper three sacral vertebrae and two strong pillars of bone running from the sacroiliac articulations to the acetabular cavities. For the reception and diffusion of the weight each acetabular cavity is strengthened by two additional bars running toward the pubis and ischium. In order to lessen concussion in rapid changes of distribution of the weight, joints (sacroiliac articulations) are interposed between the sacrum and the iliac bones; an accessory joint (pubic symphysis) exists in the middle of the anterior arch. The sacrum forms the summit of the posterior arch; the weight transmitted falls on it at the lumbosacral articulation and, theoretically, has a component in each of two directions. One component of the force is expended in driving the sacrum downward and backward between the iliac bones, while the other thrusts the upper end of the sacrum downward and forward toward the pelvic cavity.

The movements of the sacrum are regulated by its form. Viewed as a whole, it presents the shape of a wedge with its base upward and forward. The first component of the force is there-

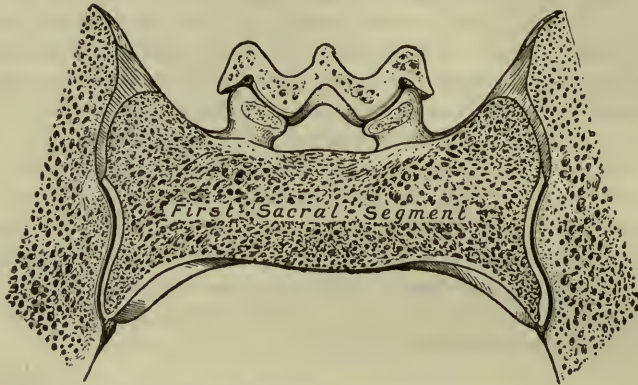


FIG. 322.—Coronal section of anterior sacral segment.

fore acting against the resistance of the wedge, and its tendency to separate the iliac bones is resisted by the sacroiliac and iliolumbar ligaments and by the ligaments of the pubic symphysis.

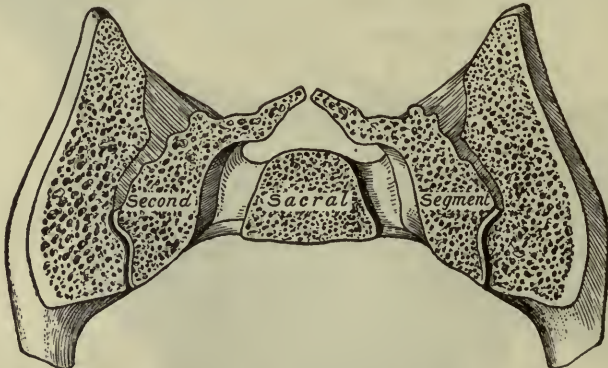


FIG. 323.—Coronal section of middle sacral segment.

If a series of coronal sections of the sacroiliac joints be made, it will be found possible to divide the articular portion of the sacrum into three segments: anterior, middle, and posterior. In the **anterior segment** (Fig. 322), which involves the first sacral vertebra, the articular surfaces show slight sinuosities and are almost parallel to one another; the distance between their dorsal margins is, however, slightly greater than that between their ventral margins.

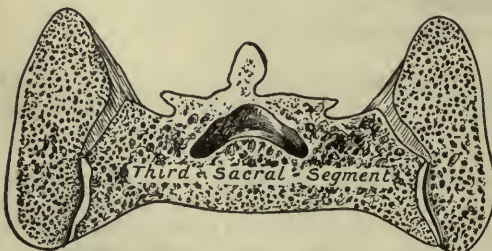

FIG. 324.—Coronal section of posterior sacral segment.

This segment therefore presents a slight wedge shape with the truncated apex downward. The **middle segment** (Fig. 323) is a narrow band across the centers of the articulations. Its dorsal width is distinctly greater than its ventral, so that the segment is more definitely wedge-shaped, the truncated apex being again directed downward. Each articular surface presents in the center a marked concavity from above downward, and into this a corresponding convexity of the iliac articular surface fits, forming an interlocking mechanism. In the **posterior segment** (Fig. 324) the ventral width is greater than the dorsal, so that the wedge form is the reverse of those of the other segments—*i. e.*, the truncated apex is directed upward. The articular surfaces are only slightly concave.

Dislocation downward and forward of the sacrum by the second component of the force applied to it is prevented therefore by the middle segment, which interposes the resistance of its wedge

shape and that of the interlocking mechanism on its surfaces; a rotatory movement, however, is produced by which the anterior segment is tilted downward and the posterior upward; the axis of this rotation passes through the dorsal part of the middle segment. The movement of the anterior segment is slightly limited by its wedge form, but chiefly by the posterior and interosseous sacroiliac ligaments; that of the posterior segment is checked to a slight extent by its wedge form, but the chief limiting factors are the sacrotuberous and sacrospinous ligaments. In all these movements the effect of the sacroiliac and iliolumbar ligaments and the ligaments of the symphysis pubis in resisting the separation of the iliac bones must be recognized.

During pregnancy the pelvic joints and ligaments are relaxed, and capable therefore of more extensive movements. When the fetus is being expelled the force is applied to the front of the sacrum. Upward dislocation is again prevented by the interlocking mechanism of the middle segment. As the fetal head passes the anterior segment the latter is carried upward, enlarging the antero-posterior diameter of the pelvic inlet; when the head reaches the posterior segment this also is pressed upward against the resistance of its wedge, the movement only being possible by the laxity of the joints and the stretching of the sacrotuberous and sacrospinous ligaments.

ARTICULATIONS OF THE UPPER EXTREMITY.

The articulations of the Upper Extremity may be arranged as follows:

- | | |
|----------------------------------|-------------------------|
| I. Sternoclavicular. | VI. Wrist. |
| II. Acromioclavicular. | VII. Intercarpal. |
| III. Shoulder. | VIII. Carpometacarpal. |
| IV. Elbow. | IX. Intermetacarpal. |
| V. Radioulnar. | X. Metacarpophalangeal. |
| XI. Articulations of the Digits. | |

I. Sternoclavicular Articulation (*Articulatio Sternoclavicularis*) (Fig. 325).

The sternoclavicular articulation is a double arthrodial joint. The parts entering into its formation are the sternal end of the clavicle, the upper and lateral part of the manubrium sterni, and the cartilage of the first rib. The articular surface of the clavicle is much larger than that of the sternum, and is invested with a layer of cartilage,¹ which is considerably thicker than that on the latter bone. The ligaments of this joint are:

- | | |
|---------------------------------|----------------------|
| The Articular Capsule. | The Interclavicular. |
| The Anterior Sternoclavicular. | The Costoclavicular. |
| The Posterior Sternoclavicular. | The Articular Disk. |

The Articular Capsule (*capsula articularis; capsular ligament*).—The articular capsule surrounds the articulation and varies in thickness and strength. In front and behind it is of considerable thickness, and forms the anterior and posterior sternoclavicular ligaments; but above, and especially below, it is thin and partakes more of the character of areolar than of true fibrous tissue.

The Anterior Sternoclavicular Ligament (*ligamentum sternoclaviculare anterior*).—The anterior sternoclavicular ligament is a broad band of fibers, covering the anterior surface of the articulation; it is attached *above* to the upper and front part of the sternal end of the clavicle, and, passing obliquely downward and medialward, is attached below to the front of the upper part of the manubrium sterni. This ligament is covered by the sternal portion of the Sternocleidomastoideus and the integument; *behind*, it is in relation with the capsule, the articular disk, and the two synovial membranes.

The Posterior Sternoclavicular Ligament (*ligamentum sternoclaviculare posterius*).—The posterior sternoclavicular ligament is a similar band of fibers, covering the posterior surface of the articulation; it is attached above to the upper and back

¹ According to Bruch, the sternal end of the clavicle is covered by a tissue which is fibrous rather than cartilaginous in structure.

part of the sternal end of the clavicle, and, passing obliquely downward and medialward, is fixed below to the back of the upper part of the manubrium sterni. It is in relation, in *front*, with the articular disk and synovial membranes; *behind*, with the Sternohyoideus and Sternothyreoides.

The Interclavicular Ligament (*ligamentum interclaviculare*).—This ligament is a flattened band, which varies considerably in form and size in different individuals, it passes in a curved direction from the upper part of the sternal end of one clavicle to that of the other, and is also attached to the upper margin of the sternum. It is in relation, in *front*, with the integument and Sternocleidomastoidei; *behind*, with the Sternothyreidei.

The Costoclavicular Ligament (*ligamentum costoclaviculare; rhomboid ligament*).—This ligament is short, flat, strong, and rhomboid in form. Attached below to the upper and medial part of the cartilage of the first rib, it ascends obliquely backward and lateralward, and is fixed above to the costal tuberosity on the under surface of the clavicle. It is in relation, in *front*, with the tendon of origin of the Subclavius; *behind*, with the subclavian vein.

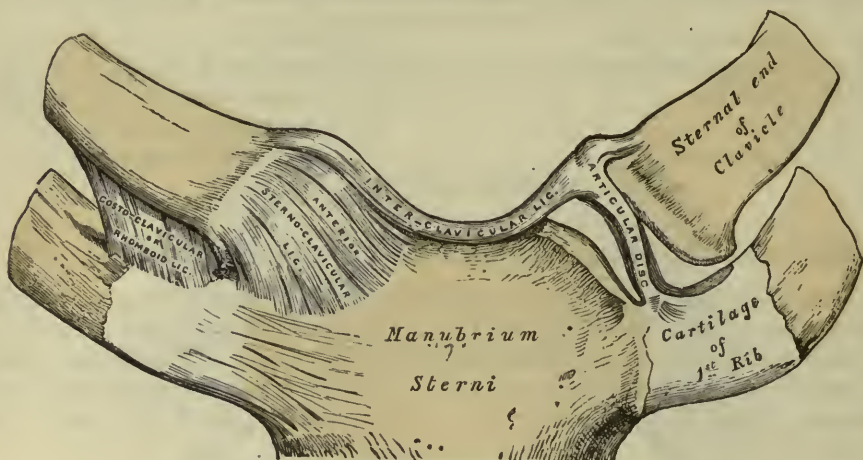

FIG. 325.—Sternoclavicular articulation. An terior view.

The Articular Disk (*discus articularis*).—The articular disk is flat and nearly circular, interposed between the articulating surfaces of the sternum and clavicle. It is attached, *above*, to the upper and posterior border of the articular surface of the clavicle; *below*, to the cartilage of the first rib, near its junction with the sternum; and by its circumference to the interclavicular and anterior and posterior sternoclavicular ligaments. It is thicker at the circumference, especially its upper and back part, than at its center. It divides the joint into two cavities, each of which is furnished with a synovial membrane.

Synovial Membranes.—Of the two synovial membranes found in this articulation, the lateral is reflected from the sternal end of the clavicle, over the adjacent surface of the articular disk, and around the margin of the facet on the cartilage of the first rib; the medial is attached to the margin of the articular surface of the sternum and clothes the adjacent surface of the articular disk; the latter is the larger of the two.

Movements.—This articulation admits of a limited amount of motion in nearly every direction—upward, downward, backward, forward, as well as circumduction. When these movements take place in the joint, the clavicle in its motion carries the scapula with it, this bone gliding on the outer surface of the chest. This joint therefore forms the center from which all movements of the supporting arch of the shoulder originate, and is the only point of articulation of the shoulder girdle with the trunk. The movements attendant on elevation and depression of the shoulder take place between the clavicle and the articular disk, the bone rotating upon the ligament on an axis drawn from before backward through its own articular facet; when the shoulder is moved forward and backward, the clavicle, with the articular disk rolls to and fro on the

articular surface of the sternum, revolving, with a sliding movement, around an axis drawn nearly vertically through the sternum; in the circumduction of the shoulder, which is compounded of these two movements, the clavicle revolves upon the articular disk and the latter, with the clavicle, rolls upon the sternum.¹ Elevation of the shoulder is limited principally by the costoclavicular ligament; depression, by the interclavicular ligament and articular disk. The muscles which raise the shoulder are the upper fibers of the Trapezius, the Levator scapulae, and the clavicular head of the Sternocleidomastoideus, assisted to a certain extent by the Rhomboidei, which pull the vertebral border of the scapula backward and upward and so raise the shoulder. The depression of the shoulder is principally effected by gravity assisted by the Subclavius, Pectoralis minor and lower fibers of the Trapezius. The shoulder is drawn backward by the Rhomboidei and the middle and lower fibers of the Trapezius, and forward by the Serratus anterior and Pectoralis minor.

II. Acromioclavicular Articulation (Articulatio Acromioclavicularis; Scapulo-clavicular Articulation) (Fig. 326).

The acromioclavicular articulation is an arthrodial joint between the acromial end of the clavicle and the medial margin of the acromion of the scapula. Its ligaments are:

The Articular Capsule.	The Articular Disk.	
The Superior Acromioclavicular.	The Coracoclavicular	{ Trapezoid and Conoid.
The Inferior Acromioclavicular.		

The Articular Capsule (*capsula articularis; capsular ligament*).—The articular capsule completely surrounds the articular margins, and is strengthened above and below by the superior and inferior acromioclavicular ligaments.

The Superior Acromioclavicular Ligament (*ligamentum acromioclaviculare*).—This ligament is a quadrilateral band, covering the superior part of the articulation, and extending between the upper part of the acromial end of the clavicle and the adjoining part of the upper surface of the acromion. It is composed of parallel fibers, which interlace with the aponeuroses of the Trapezius and Deltoideus; below, it is in contact with the articular disk when this is present.

The Inferior Acromioclavicular Ligament.—This ligament is somewhat thinner than the preceding; it covers the under part of the articulation, and is attached to the adjoining surfaces of the two bones. It is in relation, above, in rare cases with the articular disk; below, with the tendon of the Supraspinatus.

The Articular Disk (*discus articularis*).—The articular disk is frequently absent in this articulation. When present, it generally only partially separates the articular surfaces, and occupies the upper part of the articulation. More rarely, it completely divides the joint into two cavities.

The Synovial Membrane.—There is usually only one synovial membrane in this articulation, but when a complete articular disk is present, there are two.

The Coracoclavicular Ligament (*ligamentum coracoclaviculare*) (Fig. 326).—This ligament serves to connect the clavicle with the coracoid process of the scapula. It does not properly belong to this articulation, but is usually described with it, since it forms a most efficient means of retaining the clavicle in contact with the acromion. It consists of two fasciculi, called the **trapezoid** and **conoid ligaments**.

The Trapezoid Ligament (*ligamentum trapezoideum*), the anterior and lateral fasciculus, is broad, thin, and quadrilateral: it is placed obliquely between the coracoid process and the clavicle. It is attached, below, to the upper surface of the coracoid process; above, to the oblique ridge on the under surface of the clavicle. Its anterior border is free; its posterior border is joined with the conoid ligament, the two forming, by their junction, an angle projecting backward.

The Conoid Ligament (*ligamentum conoideum*), the posterior and medial fasciculus, is a dense band of fibers, conical in form, with its base directed upward. It is

¹ Humphry, On the Human Skeleton, page 402.

attached by its apex to a rough impression at the base of the coracoid process, medial to the trapezoid ligament; above, by its expanded base, to the coracoid tuberosity on the under surface of the clavicle, and to a line proceeding medialward from it for 1.25 cm. These ligaments are in relation, in *front*, with the Subclavius and Deltoideus; *behind*, with the Trapezius.

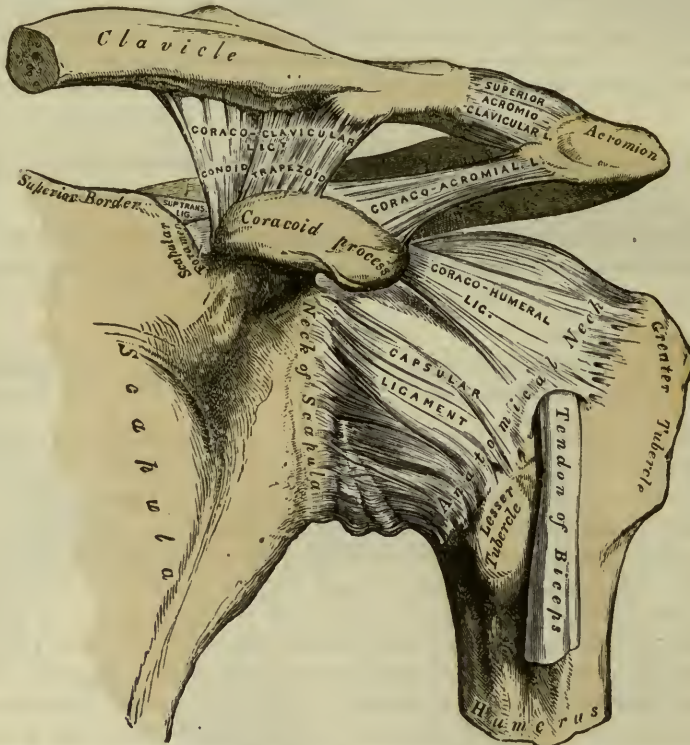


FIG. 326.—The left shoulder and acromioclavicular joints, and the proper ligaments of the scapula.

Movements.—The movements of this articulation are of two kinds: (1) a gliding motion of the articular end of the clavicle on the acromion; (2) rotation of the scapula forward and backward upon the clavicle. The extent of this rotation is limited by the two portions of the coraco-clavicular ligament, the trapezoid limiting rotation forward, and the conoid backward.

The acromioclavicular joint has important functions in the movements of the upper extremity. It has been well pointed out by Humphry, that if there had been no joint between the clavicle and scapula, the circular movement of the scapula on the ribs (as in throwing the shoulders backward or forward) would have been attended with a greater alteration in the direction of the shoulder than is consistent with the free use of the arm in such positions, and it would have been impossible to give a blow straight forward with the full force of the arm; that is to say, with the combined force of the scapula, arm, and forearm. "This joint," as he happily says, "is so adjusted as to enable either bone to turn in a hinge-like manner upon a vertical axis drawn through the other, and it permits the surfaces of the scapula, like the baskets in a roundabout swing, to look the same way in every position, or nearly so." Again, when the whole arch formed by the clavicle and scapula rises and falls (in elevation or depression of the shoulder), the joint between these two bones enables the scapula still to maintain its lower part in contact with the ribs.

THE LIGAMENTS OF THE SCAPULA.

The ligaments of the scapula (Fig. 326) are:

Coracoacromial, Superior and Inferior Transverse.

The Coracoacromial Ligament (*ligamentum coracoacromiale*).—This ligament is a strong triangular band, extending between the coracoid process and the acromion.

It is attached, by its apex, to the summit of the acromion just in front of the articular surface for the clavicle; and by its broad base to the whole length of the lateral border of the coracoid process. This ligament, together with the coracoid process and the acromion, forms a vault for the protection of the head of the humerus. It is in relation, *above*, with the clavicle and under surface of the Deltoides; *below*, with the tendon of the Supraspinatus, a bursa being interposed. Its lateral border is continuous with a dense lamina that passes beneath the Deltoides upon the tendons of the Supraspinatus and Infraspinatus. The ligament is sometimes described as consisting of two marginal bands and a thinner intervening portion, the two bands being attached respectively to the apex and the base of the coracoid process, and joining together at the acromion. When the Pectoralis minor is inserted, as occasionally is the case, into the capsule of the shoulder-joint instead of into the coracoid process, it passes between these two bands, and the intervening portion of the ligament is then deficient.

The Superior Transverse Ligament (*ligamentum transversum scapulae superioris; transverse or suprascapular ligament*).—This ligament converts the scapular notch into a foramen. It is a thin and flat fasciculus, narrower at the middle than at the extremities, attached by one end to the base of the coracoid process, and by the other to the medial end of the scapular notch. The suprascapular nerve runs through the foramen; the transverse scapular vessels cross over the ligament. The ligament is sometimes ossified.

The Inferior Transverse Ligament (*ligamentum transversum scapulae inferioris; spinoglenoid ligament*).—This ligament is a weak membranous band, situated behind the neck of the scapula and stretching from the lateral border of the spine to the margin of the glenoid cavity. It forms an arch under which the transverse scapular vessels and suprascapular nerve enter the infraspinatous fossa.

III. Humeral Articulation or Shoulder-joint (Articulatio Humeri) (Fig. 326).

The shoulder-joint is an enarthrodial or ball-and-socket joint. The bones entering into its formation are the hemispherical head of the humerus and the shallow glenoid cavity of the scapula, an arrangement which permits of very considerable movement, while the joint itself is protected against displacement by the tendons which surround it. The ligaments do not maintain the joint surfaces in apposition, because when they alone remain the humerus can be separated to a considerable extent from the glenoid cavity; their use, therefore, is to limit the amount of movement. The joint is protected above by an arch, formed by the coracoid process, the acromion, and the coracoacromial ligament. The articular cartilage on the head of the humerus is thicker at the center than at the circumference, the reverse being the case with the articular cartilage of the glenoid cavity. The ligaments of the shoulder are:

The Articular Capsule.

The Coracohumeral.

The Glenohumeral.

The Transverse Humeral.

The Glenoidal Labrum.¹

The Articular Capsule (*capsula articularis; capsular ligament*) (Fig. 327).—The articular capsule completely encircles the joint, being attached, above, to the circumference of the glenoid cavity beyond the glenoidal labrum; below, to the anatomical neck of the humerus, approaching nearer to the articular cartilage above than in the rest of its extent. It is thicker above and below than elsewhere, and is so remarkably loose and lax, that it has no action in keeping the bones in contact, but allows them to be separated from each other more than 2.5 cm., an

¹ The long tendon of origin of the biceps brachii also acts as one of the ligaments of this joint. See the observations on page 287, on the function of the muscles passing over more than one joint.

evident provision for that extreme freedom of movement which is peculiar to this articulation. It is strengthened, *above*, by the Supraspinatus; *below*, by the long head of the Triceps brachii; *behind*, by the tendons of the Infraspinatus and Teres minor; and in *front*, by the tendon of the Subscapularis. There are usually three openings in the capsule. One anteriorly, below the coracoid process, establishes a communication between the joint and a bursa beneath the tendon of the Subscapularis. The second, which is not constant, is at the posterior part, where an opening sometimes exists between the joint and a bursal sac under the tendon of the Infraspinatus. The third is between the tubercles of the humerus, for the passage of the long tendon of the Biceps brachii.

The Coracohumeral Ligament (*ligamentum coracohumerale*).—This ligament is a broad band which strengthens the upper part of the capsule. It arises from the lateral border of the coracoid process, and passes obliquely downward and lateralward to the front of the greater tubercle of the humerus, blending with the

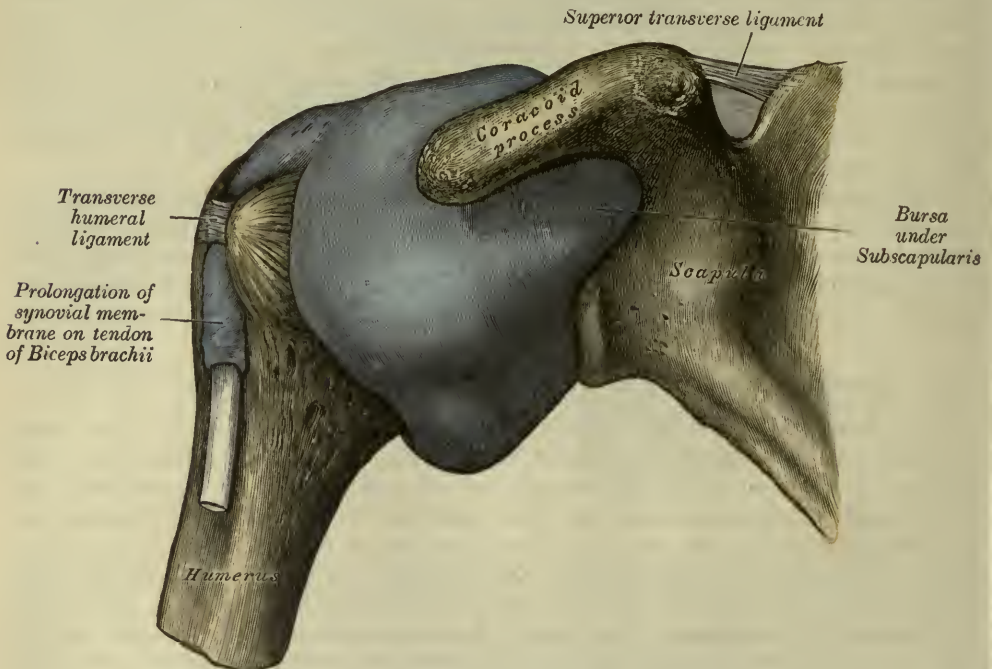


FIG. 327.—Capsule of shoulder-joint (distended). Anterior aspect.

tendon of the Supraspinatus. This ligament is intimately united to the capsule by its hinder and lower border; but its anterior and upper border presents a free edge, which overlaps the capsule.

Glenohumeral Ligaments.—In addition to the coracohumeral ligament, three supplemental bands, which are named the **glenohumeral ligaments**, strengthen the capsule. These may be best seen by opening the capsule at the back of the joint and removing the head of the humerus. One on the medial side of the joint passes from the medial edge of the glenoid cavity to the lower part of the lesser tubercle of the humerus. A second at the lower part of the joint extends from the under edge of the glenoid cavity to the under part of the anatomical neck of the humerus. A third at the upper part of the joint is fixed above to the apex of the glenoid cavity close to the root of the coracoid process, and passing downward along the medial edge of the tendon of the Biceps brachii, is attached below to a small depression above the lesser tubercle of the humerus. In addition to

these, the capsule is strengthened in front by two bands derived from the tendons of the Pectoralis major and Teres major respectively.

The Transverse Humeral Ligament (Fig. 327) is a broad band passing from the lesser to the greater tubercle of the humerus, and always limited to that portion of the bone which lies above the epiphysial line. It converts the intertubercular groove into a canal, and is the homologue of the strong process of bone which connects the summits of the two tubercles in the musk ox.

The Glenoidal Labrum (*labrium glenoidale; glenoid ligament*) is a fibrocartilaginous rim attached around the margin of the glenoid cavity. It is triangular on section, the base being fixed to the circumference of the cavity, while the free edge is thin and sharp. It is continuous above with the tendon of the long head of the Biceps brachii, which gives off two fasciculi to blend with the fibrous tissue of the labrum. It deepens the articular cavity, and protects the edges of the bone.

Synovial Membrane.—The synovial membrane is reflected from the margin of the glenoid cavity over the labrum; it is then reflected over the inner surface of the capsule, and covers the lower part and sides of the anatomical neck of the humerus as far as the articular cartilage on the head of the bone. The tendon of the long head of the Biceps brachii passes through the capsule and is enclosed in a tubular sheath of synovial membrane, which is reflected upon it from the summit of the glenoid cavity and is continued around the tendon into the intertubercular groove as far as the surgical neck of the humerus (Fig. 327). The tendon thus traverses the articulation, but it is not contained within the synovial cavity.

Bursæ.—The bursæ in the neighborhood of the shoulder-joint are the following: (1) A constant bursa is situated between the tendon of the Subscapularis muscle and the capsule; it communicates with the synovial cavity through an opening in the front of the capsule; (2) a bursa which occasionally communicates with the joint is sometimes found between the tendon of the Infraspinatus and the capsule; (3) a large bursa exists between the under surface of the Deltoideus and the capsule, but does not communicate with the joint; this bursa is prolonged under the acromion and coraco-acromial ligament, and intervenes between these structures and the capsule; (4) a large bursa is situated on the summit of the acromion; (5) a bursa is frequently found between the coracoid process and the capsule; (6) a bursa exists beneath the Coracobrachialis; (7) one lies between the Teres major and the long head of the Triceps brachii; (8) one is placed in front of, and another behind, the tendon of the Latissimus dorsi.

The **muscles** in relation with the joint are, *above*, the Supraspinatus; *below*, the long head of the Triceps brachii; in *front*, the Subscapularis; *behind*, the Infraspinatus and Teres minor; *within*, the tendon of the long head of the Biceps brachii. The Deltoideus covers the articulation in front, behind, and laterally.

The **arteries** supplying the joint are articular branches of the anterior and posterior humeral circumflex, and transverse scapular.

The **nerves** are derived from the axillary and suprascapular.

Movements.—The shoulder-joint is capable of every variety of movement, flexion, extension, abduction, adduction, circumduction, and rotation. The humerus is *flexed* (drawn forward) by the Pectoralis major, anterior fibers of the Deltoideus, Coracobrachialis, and when the forearm is flexed, by the Biceps brachii; *extended* (drawn backward) by the Latissimus dorsi, Teres major, posterior fibers of the Deltoideus, and, when the forearm is extended, by the Triceps brachii; it is *abducted* by the Deltoideus and Supraspinatus; it is *adducted* by the Subscapularis, Pectoralis major, Latissimus dorsi, and Teres major, and by the weight of the limb; it is *rotated outward* by the Infraspinatus and Teres minor; and it is *rotated inward* by the Subscapularis, Latissimus dorsi, Teres major, Pectoralis major, and the anterior fibers of the Deltoideus.

The most striking peculiarities in this joint are: (1) The large size of the head of the humerus in comparison with the depth of the glenoid cavity, even when this latter is supplemented by the glenoidal labrum. (2) The looseness of the capsule of the joint. (3) The intimate connection of the capsule with the muscles attached to the head of the humerus. (4) The peculiar relation of the tendon of the long head of the Biceps brachii to the joint.

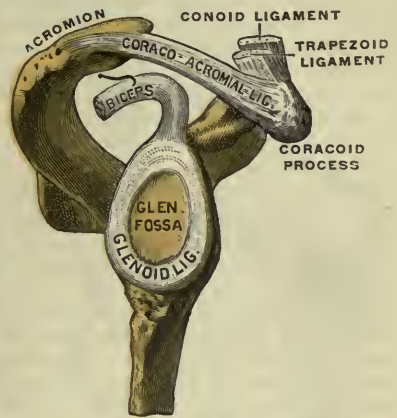


FIG. 328.—Glenoid fossa of right side.

It is in consequence of the relative sizes of the two articular surfaces, and the looseness of the articular capsule, that the joint enjoys such free movement in all directions. When these movements of the arm are arrested in the shoulder-joint by the contact of the bony surfaces, and by the tension of the fibers of the capsule, together with that of the muscles acting as accessory ligaments, the arm can be carried considerably farther by the movements of the scapula, involving, of course, motion at the acromio- and sternoclavicular joints. These joints are therefore to be regarded as accessory structures to the shoulder-joint (see pages 314 and 316). The extent of the scapular movements is very considerable, especially in extreme elevation of the arm, a movement best accomplished when the arm is thrown somewhat forward and outward, because the margin of the head of the humerus is by no means a true circle; its greatest diameter is from the intertubercular groove, downward, medialward, and backward, and the greatest elevation of the arm can be obtained by rolling its articular surface in the direction of this measurement. The great width of the central portion of the humeral head also allows of very free horizontal movement when the arm is raised to a right angle, in which movement the arch formed by the acromion, the coracoid process and the coracoacromial ligament, constitutes a sort of supplemental articular cavity for the head of the bone.

The looseness of the capsule is so great that the arm will fall about 2.5 cm. from the scapula when the muscles are dissected from the capsule, and an opening made in it to counteract the atmospheric pressure. The movements of the joint, therefore, are not regulated by the capsule so much as by the surrounding muscles and by the pressure of the atmosphere, an arrangement which "renders the movements of the joint much more easy than they would otherwise have been, and permits a swinging, pendulum-like vibration of the limb when the muscles are at rest" (Humphry). The fact, also, that in all ordinary positions of the joint the capsule is not put on the stretch, enables the arm to move freely in all directions. Extreme movements are checked by the tension of appropriate portions of the capsule, as well as by the interlocking of the bones. Thus it is said that "abduction is checked by the contact of the great tuberosity with the upper edge of the glenoid cavity; adduction by the tension of the coracohumeral ligament" (Beaunis et Bouchard). Cleland¹ maintains that the limitations of movement at the shoulder-joint are due to the structure of the joint itself, the glenoidal labrum fitting, in different positions of the elevated arm, into the anatomical neck of the humerus.

The scapula is capable of being moved upward and downward, forward and backward, or, by a combination of these movements, circumducted on the wall of the chest. The muscles which *raise* the scapula are the upper fibers of the Trapezius, the Levator scapulae, and the Rhomboidei; those which *depress* it are the lower fibers of the Trapezius, the Pectoralis minor, and, through the clavicle, the Subclavius. The scapula is drawn *backward* by the Rhomboidei and the middle and lower fibers of the Trapezius, and *forward* by the Serratus anterior and Pectoralis minor, assisted, when the arm is fixed, by the Pectoralis major. The mobility of the scapula is very considerable, and greatly assists the movements of the arm at the shoulder-joint. Thus, in raising the arm from the side, the Deltoides and Supraspinatus can only lift it to a right angle with the trunk, the further elevation of the limb being effected by the Trapezius and Serratus anterior moving the scapula on the wall of the chest. This mobility is of special importance in ankylosis of the shoulder-joint, the movements of this bone compensating to a very great extent for the immobility of the joint.

Cathcart² has pointed out that in abducting the arm and raising it above the head, the scapula rotates throughout the whole movement with the exception of a short space at the beginning and at the end; that the humerus moves on the scapula not only while passing from the hanging to the horizontal position, but also in travelling upward as it approaches the vertical above; that the clavicle moves not only during the second half of the movement but in the first as well, though to a less extent—*i. e.*, the scapula and clavicle are concerned in the first stage as well as in the second; and that the humerus is partly involved in the second as well as chiefly in the first.

The intimate union of the tendons of the Supraspinatus, Infraspinatus, Teres minor and Subscapularis with the capsule, converts these muscles into elastic and spontaneously acting ligaments of the joint.

The peculiar relations of the tendon of the long head of the Biceps brachii to the shoulder-joint appear to subservise various purposes. In the first place, by its connection with both the shoulder and elbow the muscle harmonizes the action of the two joints, and acts as an elastic ligament in all positions, in the manner previously discussed (see page 287). It strengthens the upper part of the articular cavity, and prevents the head of the humerus from being pressed up against the acromion, when the Deltoides contracts; it thus fixes the head of the humerus as the center of motion in the glenoid cavity. By its passage along the intertubercular groove it assists in steadying the head of the humerus in the various movements of the arm. When the arm is raised from the side it assists the Supraspinatus and Infraspinatus in rotating the head of the humerus in the glenoid cavity. It also holds the head of the bone firmly in contact with the glenoid cavity, and prevents its slipping over its lower edge, or being displaced by the action of the Latissimus dorsi and Pectoralis major, as in climbing and many other movements.

¹ Journal of Anatomy and Physiology, 1867, i, 85.

² Ibid., 1884, vol. xviii.

IV. Elbow-joint (*Articulatio Cubiti*) (Figs. 329, 330).

The elbow-joint is a ginglymus or hinge-joint. The trochlea of the humerus is received into the semilunar notch of the ulna, and the capitulum of the humerus articulates with the fovea on the head of the radius. The articular surfaces are connected together by a **capsule**, which is thickened medially and laterally, and, to a less extent, in front and behind. These thickened portions are usually described as distinct ligaments under the following names:

The Anterior.
The Posterior.

The Ulnar Collateral.
The Radial Collateral.

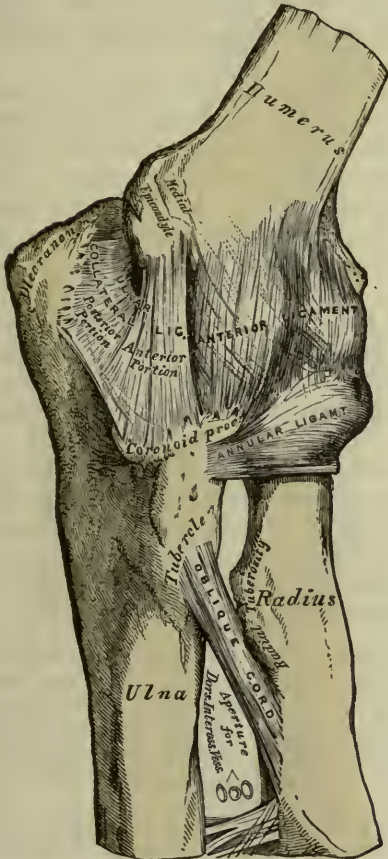


FIG. 329.—Left elbow-joint, showing anterior and ulnar collateral ligaments.

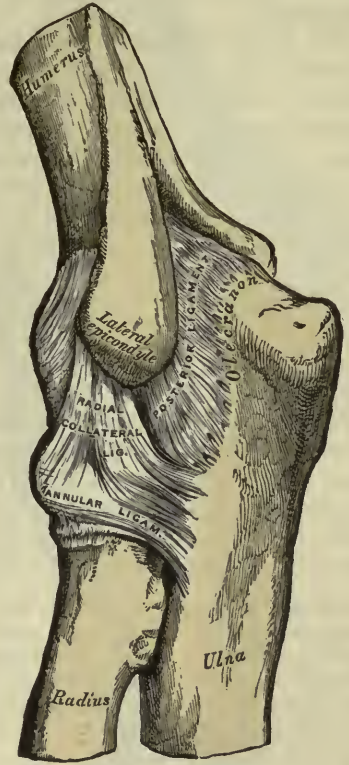


FIG. 330.—Left elbow-joint, showing posterior and radial collateral ligaments.

The Anterior Ligament (Fig. 329).—The anterior ligament is a broad and thin fibrous layer covering the anterior surface of the joint. It is attached to the *front* of the medial epicondyle and to the front of the humerus immediately above the coronoid and radial fossæ; *below*, to the anterior surface of the coronoid process of the ulna and to the annular ligament (page 324), being continuous on either side with the collateral ligaments. Its superficial fibers pass obliquely from the medial epicondyle of the humerus to the annular ligament. The middle fibers, vertical in direction, pass from the upper part of the coronoid depression and become partly blended with the preceding, but are inserted mainly into the anterior surface of the coronoid process. The deep or transverse set intersects these at right angles. This ligament is in relation, in *front*, with the Brachialis, except at its most lateral part.

The Posterior Ligament (Fig. 330).—This posterior ligament is thin and membranous, and consists of transverse and oblique fibers. *Above*, it is attached to the humerus immediately behind the capitulum and close to the medial margin of the trochlea, to the margins of the olecranon fossa, and to the back of the lateral epicondyle some little distance from the trochlea. *Below*, it is fixed to the upper and lateral margins of the olecranon, to the posterior part of the annular ligament, and to the ulna behind the radial notch. The transverse fibers form a strong band which bridges across the olecranon fossa; under cover of this band a pouch of synovial membrane and a pad of fat project into the upper part of the fossa when the joint is extended. In the fat are a few scattered fibrous bundles, which pass from the deep surface of the transverse band to the upper part of the fossa. This ligament is in relation, *behind*, with the tendon of the Triceps brachii and the Anconæus.

The Ulnar Collateral Ligament (*ligamentum collaterale ulnare; internal lateral ligament*) (Fig. 329).—This ligament is a thick triangular band consisting of two portions, an anterior and posterior united by a thinner intermediate portion. The **anterior portion**, directed obliquely forward, is attached, *above*, by its apex, to the front part of the medial epicondyle of the humerus; and, *below*, by its broad base to the medial margin of the coronoid process. The **posterior portion**, also of triangular form, is attached, *above*, by its apex, to the lower and back part of the medial epicondyle; *below*, to the medial margin of the olecranon. Between these two bands a few intermediate fibers descend from the medial epicondyle to blend with a *transverse band* which bridges across the notch between the olecranon and the coronoid process. This ligament is in relation with the Triceps brachii and Flexor carpi ulnaris and the ulnar nerve, and gives origin to part of the Flexor digitorum sublimis.

The Radial Collateral Ligament (*ligamentum collaterale radiale; external lateral ligament*) (Fig. 330).—This ligament is a short and narrow fibrous band, less distinct than the ulnar collateral, attached, *above*, to a depression below the lateral epicondyle of the humerus; *below*, to the annular ligament, some of its most posterior fibers passing over that ligament, to be inserted into the lateral margin of the ulna. It is intimately blended with the tendon of origin of the Supinator.

Synovial Membrane (Figs. 331, 332).—The synovial membrane is very extensive. It extends from the margin of the articular surface of the humerus, and lines the coronoid, radial and olecranon fossæ on that bone; it is reflected over the deep surface of the capsule and forms a pouch between the radial notch, the deep surface of the annular ligament, and the circumference of the head of the radius. Projecting between the radius and ulna into the cavity is a crescentic fold of synovial membrane, suggesting the division of the joint into two; one the humeroradial, the other the humeroulnar.

Between the capsule and the synovial membrane are three masses of fat: the largest, over the olecranon fossa, is pressed into the fossa by the Triceps brachii during the flexion; the second, over the coronoid fossa, and the third, over the radial fossa, are pressed by the Brachialis into their respective fossæ during extension.

The **muscles** in relation with the joint are, in *front*, the Brachialis; *behind*, the Triceps brachii and Anconæus; *laterally*, the Supinator, and the common tendon of origin of the Extensor muscles; *medially*, the common tendon of origin of the Flexor muscles, and the Flexor carpi ulnaris.

The **arteries** supplying the joint are derived from the anastomosis between the profunda and the superior and inferior ulnar collateral branches of the brachial, with the anterior, posterior, and interosseous recurrent branches of the ulnar, and the recurrent branch of the radial. These vessels form a complete anastomotic network around the joint.

The **nerves** of the joint are a twig from the ulnar, as it passes between the medial condyle and the olecranon; a filament from the musculocutaneous, and two from the median.

Movements.—The elbow-joint comprises three different portions—viz., the joint between the ulna and humerus, that between the head of the radius and the humerus, and the proximal radioulnar articulation, described below. All these articular surfaces are enveloped by a common synovial membrane, and the movements of the whole joint should be studied together. The combination of the movements of flexion and extension of the forearm with those of pronation and supination of the hand, which is ensured by the two being performed at the same joint, is essential to the accuracy of the various minute movements of the hand.

The portion of the joint between the ulna and humerus is a simple hinge-joint, and allows of movements of flexion and extension only. Owing to the obliquity of the trochlea of the humerus, this movement does not take place in the antero-posterior plane of the body of the humerus. When the forearm is extended and supinated, the axes of the arm and forearm are not in the same line; the arm forms an obtuse angle with the forearm, the hand and forearm being directed lateralward. During flexion, however, the forearm and the hand tend to approach the middle line of the body, and thus enable the hand to be easily carried to the face. The accurate adaptation of the trochlea of the humerus, with its prominences and depressions, to the semilunar notch of the ulna, prevents any lateral movement. *Flexion* is produced by the action of the Biceps brachii and Brachialis, assisted by the Brachioradialis and the muscles arising from the medial condyle of the humerus; *extension*, by the Triceps brachii and Anconæus, assisted by the Extensors of the wrist, the Extensor digitorum communis, and the Extensor digiti quinti proprius.

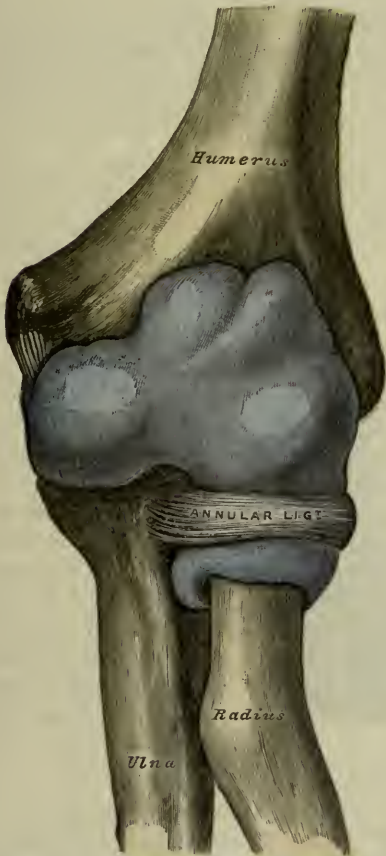

FIG. 331.—Capsule of elbow-joint (distended).
Anterior aspect.

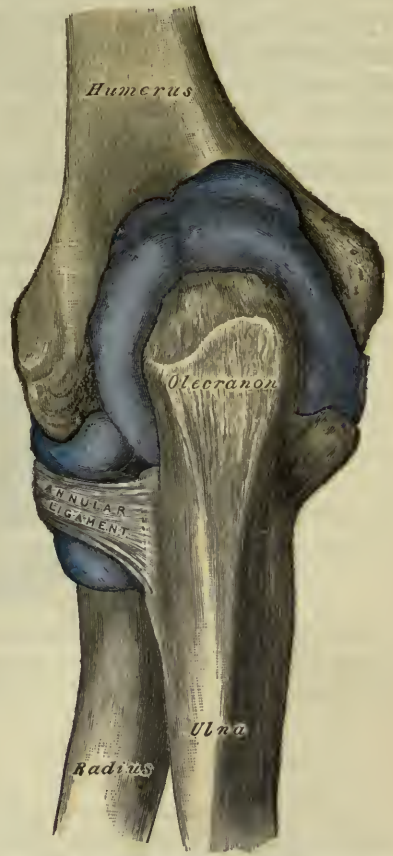

FIG. 332.—Capsule of elbow-joint (distended).
Posterior aspect.

The joint between the head of the radius and the capitulum of the humerus is an arthroïdial joint. The bony surfaces would of themselves constitute an enarthrosis and allow of movement in all directions, were it not for the annular ligament, by which the head of the radius is bound to the radial notch of the ulna, and which prevents any separation of the two bones laterally. It is to the same ligament that the head of the radius owes its security from dislocation, which would otherwise tend to occur, from the shallowness of the cup-like surface on the head of the radius. In fact, but for this ligament, the tendon of the Biceps brachii would be liable to pull the head of the radius out of the joint. The head of the radius is not in complete contact with the capitulum of the humerus in all positions of the joint. The capitulum occupies only the anterior and inferior surfaces of the lower end of the humerus, so that in complete extension a part of the radial head can be plainly felt projecting at the back of the articulation. In full flexion the movement of the radial head is hampered by the compression of the surrounding soft parts, so that the freest rotatory movement of the radius on the humerus (pronation and supination) takes place in semiflexion, in which position the two articular surfaces are in most intimate

contact. Flexion and extension of the elbow-joint are limited by the tension of the structures on the front and back of the joint; the limitation of flexion is also aided by the soft structures of the arm and forearm coming into contact.

In any position of flexion or extension, the radius, carrying the hand with it, can be rotated in the proximal radioulnar joint. The hand is directly articulated to the lower surface of the radius only, and the ulnar notch on the lower end of the radius travels around the lower end of the ulna. The latter bone is excluded from the wrist-joint by the articular disk. Thus, rotation of the head of the radius around an axis passing through the center of the radial head of the humerus imparts circular movement to the hand through a very considerable arc.

V. Radioulnar Articulations (*Articulatio Radioulnaris*).

The articulation of the radius with the ulna is effected by ligaments which connect together the extremities as well as the bodies of these bones. The ligaments may, consequently, be subdivided into three sets: 1, those of the proximal radioulnar articulation; 2, the middle radioulnar ligaments; 3, those of the distal radioulnar articulation.

Proximal Radioulnar Articulation (*articulatio radioulnaris proximalis; superior radioulnar joint*).—This articulation is a trochoid or pivot-joint between the circumference of the head of the radius and the ring formed by the radial notch of the ulna and the *annular ligament*.

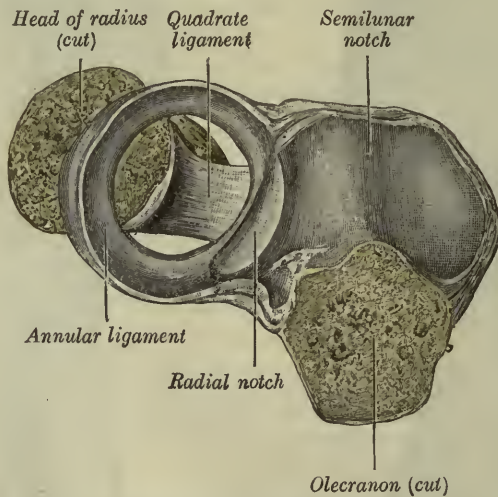


FIG. 333.—Annular ligament of radius, from above. The head of the radius has been sawn off and the bone dislodged from the ligament.

The Annular Ligament (*ligamentum annulare radii; orbicular ligament*) (Fig. 333).—This ligament is a strong band of fibers, which encircles the head of the radius, and retains it in contact with the radial notch of the ulna. It forms about four-fifths of the osseo-fibrous ring, and is attached to the anterior and posterior margins of the radial notch; a few of its lower fibers are continued around below the cavity and form at this level a complete fibrous ring. Its upper border blends with the anterior and posterior ligaments of the elbow, while from its lower border a thin loose membrane passes to be attached to the neck of the radius; a thickened band which extends from the inferior border of the annular ligament below the radial notch to the neck of the radius is known as the **quadrate ligament**. The **superficial surface** of the annular ligament is strengthened by the radial collateral ligament of the elbow, and affords origin to part of the Supinator. Its **deep surface** is smooth, and lined by synovial membrane, which is continuous with that of the elbow-joint.

Movements.—The movements allowed in this articulation are limited to rotatory movements of the head of the radius within the ring formed by the annular ligament and the radial notch of the ulna; rotation forward being called *pronation*; rotation backward, *supination*. Supination is performed by the Biceps brachii and Supinator, assisted to a slight extent by the Extensor muscles of the thumb. Pronation is performed by the Pronator teres and Pronator quadratus.

Middle Radioulnar Union.—The shafts of the radius and ulna are connected by the Oblique Cord and the Interosseous Membrane.

The Oblique Cord (*chorda obliqua*; *oblique ligament*) (Fig. 329).—The oblique cord is a small, flattened band, extending downward and lateralward, from the lateral side of the tubercle of the ulna at the base of the coronoid process to the radius a little below the radial tuberosity. Its fibers run in the opposite direction to those of the interosseous membrane. It is sometimes wanting.

The Interosseous Membrane (*membrana interossea antebrachii*).—The interosseous membrane is a broad and thin plane of fibrous tissue descending obliquely downward and medialward, from the interosseous crest of the radius to that of the ulna; the lower part of the membrane is attached to the posterior of the two lines into which the interosseous crest of the radius divides. It is deficient above, commencing about 2.5 cm. beneath the tuberosity of the radius; is broader in the middle than at either end; and presents an oval aperture a little above its lower margin for the passage of the volar interosseous vessels to the back of the forearm. This membrane serves to connect the bones, and to increase the extent of surface for the attachment of the deep muscles. Between its upper border and the oblique cord is a gap, through which the dorsal interosseous vessels pass. Two or three fibrous bands are occasionally found on the dorsal surface of this membrane; they descend obliquely from the ulna toward the radius, and have consequently a direction contrary to that of the other fibers. The membrane is in relation, in *front*, by its upper three-fourths, with the Flexor pollicis longus on the radial side, and with the Flexor digitorum profundus on the ulnar, lying in the interval between which are the volar interosseous vessels and nerve; by its lower fourth with the Pronator quadratus; *behind*, with the Supinator, Abductor pollicis longus, Extensor pollicis brevis, Extensor pollicis longus, Extensor indicis proprius; and, near the wrist, with the volar interosseous artery and dorsal interosseous nerve.

Distal Radioulnar Articulation (*articulatio radioulnaris distalis*; *inferior radioulnar joint*).—This is a pivot-joint formed between the head of the ulna and the ulnar notch on the lower end of the radius. The articular surfaces are connected together by the following ligaments:

The Volar Radioulnar.

The Dorsal Radioulnar.

The Articular Disk.

The Volar Radioulnar Ligament (*anterior radioulnar ligament*) (Fig. 334).—This ligament is a narrow band of fibers extending from the anterior margin of the ulnar notch of the radius to the front of the head of the ulna.

The Dorsal Radioulnar Ligament (*posterior radioulnar ligament*) (Fig. 335).—This ligament extends between corresponding surfaces on the dorsal aspect of the articulation.

The Articular Disk (*discus articularis*; *triangular fibrocartilage*) (Fig. 336).—The articular disk is triangular in shape, and is placed transversely beneath the head of the ulna, binding the lower ends of the ulna and radius firmly together. Its periphery is thicker than its center, which is occasionally perforated. It is attached by its apex to a depression between the styloid process and the head of the ulna; and by its base, which is thin, to the prominent edge of the radius, which separates the ulnar notch from the carpal articular surface. Its margins are united to the ligaments of the wrist-joint. Its **upper surface**, smooth and concave, articulates with the head of the ulna, forming an arthrodial joint; its **under surface**, also con-

cave and smooth, forms part of the wrist-joint and articulates with the triangular bone and medial part of the lunate. Both surfaces are clothed by synovial membrane; the upper, by that of the distal radioulnar articulation, the under, by that of the wrist.

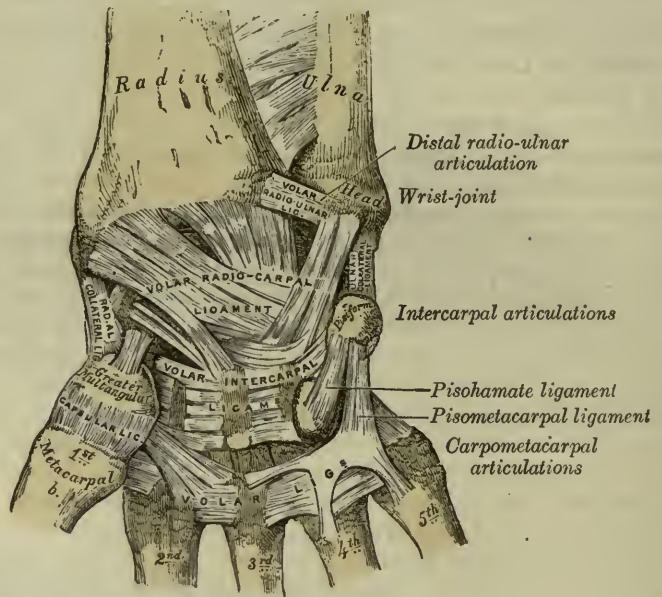


FIG. 334.—Ligaments of wrist. Anterior view

Synovial Membrane (Fig. 336).—The synovial membrane of this articulation is extremely loose, and extends upward as a recess (*recessus sacciformis*) between the radius and the ulna.

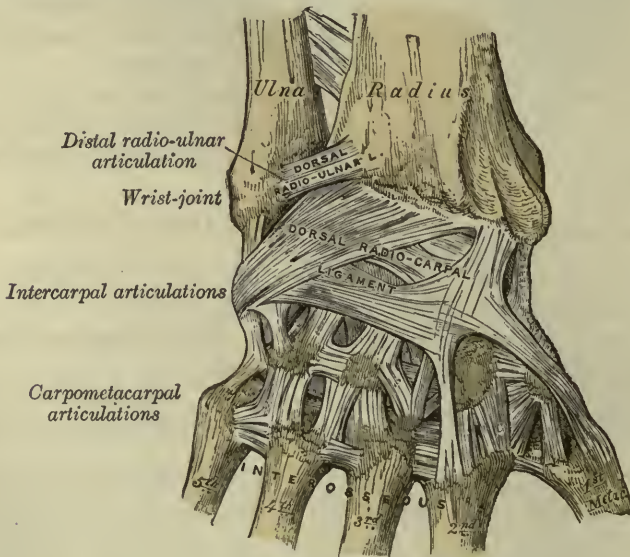


FIG. 335.—Ligaments of wrist. Posterior view.

Movements.—The movements in the distal radioulnar articulation consist of rotation of the lower end of the radius around an axis which passes through the center of the head of the ulna. When the radius rotates forward, *pronation* of the forearm and hand is the result; and when backward, *supination*. It will thus be seen that in pronation and supination the radius describes the

segment of a cone, the axis of which extends from the center of the head of the radius to the middle of the head of the ulna. In this movement the head of the ulna is not stationary, but describes a curve in a direction opposite to that taken by the head of the radius. This, however, is not to be regarded as a rotation of the ulna—the curve which the head of this bone describes is due to a combined antero-posterior and rotatory movement, the former taking place almost entirely at the elbow-joint, the latter at the shoulder-joint.

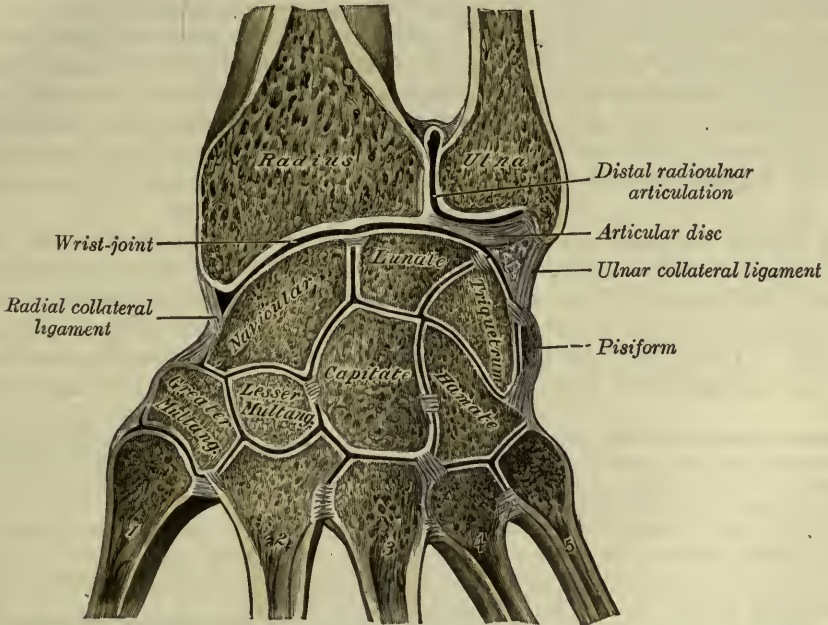


FIG. 336.—Vertical section through the articulations at the wrist, showing the synovial cavities.

VI. Radiocarpal Articulation or Wrist-joint (*Articulatio Radiocarpea*) (Figs. 334, 335).

The wrist-joint is a condyloid articulation. The parts forming it are the lower end of the radius and under surface of the articular disk above; and the navicular, lunate, and triangular bones below. The articular surface of the radius and the under surface of the articular disk form together a transversely elliptical concave surface, the **receiving cavity**. The superior articular surfaces of the navicular, lunate, and triangular form a smooth convex surface, the **condyle**, which is received into the concavity. The joint is surrounded by a capsule, strengthened by the following ligaments:

The Volar Radiocarpal.

The Dorsal Radiocarpal.

The Ulnar Collateral.

The Radial Collateral.

The Volar Radiocarpal Ligament (*ligamentum radiocarpeum volare; anterior ligament*) (Fig. 334).—This ligament is a broad membranous band, attached above to the anterior margin of the lower end of the radius, to its styloid process, and to the front of the lower end of the ulna; its fibers pass downward and medialward to be inserted into the volar surfaces of the navicular, lunate, and triangular bones, some being continued to the capitate. In addition to this broad membrane, there is a rounded fasciculus, superficial to the rest, which reaches from the base of the styloid process of the ulna to the lunate and triangular bones. The ligament is perforated by apertures for the passage of vessels, and is in relation, in *front*, with the tendons of the Flexor digitorum profundus and Flexor pollicis

longus; *behind*, it is closely adherent to the anterior border of the articular disk of the distal radioulnar articulation.

The Dorsal Radiocarpal Ligament (*ligamentum radiocarpeum dorsale; posterior ligament*) (Fig. 335).—The dorsal radiocarpal ligament less thick and strong than the volar, is attached, *above*, to the posterior border of the lower end of the radius; its fibers are directed obliquely downward and medialward, and are fixed, *below*, to the dorsal surfaces of the navicular, lunate, and triangular, being continuous with those of the dorsal intercarpal ligaments. It is in relation, *behind*, with the Extensor tendons of the fingers; in *front*, it is blended with the articular disk.

The Ulnar Collateral Ligament (*ligamentum collaterale carpi ulnare; internal lateral ligament*) (Fig. 334).—The ulnar collateral ligament is a rounded cord, attached above to the end of the styloid process of the ulna, and dividing below into two fasciculi, one of which is attached to the medial side of the triangular bone, the other to the pisiform and transverse carpal ligament.

The Radial Collateral Ligament (*ligamentum collaterale carpi radiale; external lateral ligament*) (Fig. 335).—The radial collateral ligament extends from the tip of the styloid process of the radius to the radial side of the navicular, some of its fibers being prolonged to the greater multangular bone and the transverse carpal ligament. It is in relation with the radial artery, which separates the ligament from the tendons of the Abductor pollicis longus and Extensor pollicis brevis.

Synovial Membrane (Fig. 336).—The synovial membrane lines the deep surfaces of the ligaments above described, extending from the margin of the lower end of the radius and articular disk above to the margins of the articular surfaces of the carpal bones below. It is loose and lax, and presents numerous folds, especially behind.

The wrist-joint is covered in front by the Flexor, and behind by the Extensor tendons.

The **arteries** supplying the joint are the volar and dorsal carpal branches of the radial and ulnar, the volar and dorsal metacarpals, and some ascending branches from the deep volar arch.

The **nerves** are derived from the ulnar and dorsal interosseous.

Movements.—The movements permitted in this joint are flexion, extension, abduction, adduction, and circumduction. They will be studied with those of the carpus, with which they are combined.

VII. Intercarpal Articulations (Articulationes Intercarpeæ; Articulations of the Carpus).

These articulations may be subdivided into three sets:

1. The Articulations of the Proximal Row of Carpal Bones.
2. The Articulations of the Distal Row of Carpal Bones.
3. The Articulations of the Two Rows with each Other.

Articulations of the Proximal Row of Carpal Bones.—These are arthrodiar joints. The navicular, lunate, and triangular are connected by dorsal, volar, and interosseous ligaments.

The Dorsal Ligaments (*ligamenta intercarpea dorsalia*).—The dorsal ligaments, two in number, are placed transversely behind the bones of the first row; they connect the navicular and lunate, and the lunate and triangular.

The Volar ligaments (*ligamenta intercarpea volaria; palmar ligaments*).—The volar ligaments, also two, connect the navicular and lunate, and the lunate and triangular; they are less strong than the dorsal, and placed very deeply behind the Flexor tendons and the volar radiocarpal ligament.

The Interosseous Ligaments (*ligamenta intercarpea interossea*) (Fig. 336).—The interosseous ligaments are two narrow bundles, one connecting the lunate with the navicular, the other joining it to the triangular. They are on a level with the superior surfaces of these bones, and their upper surfaces are smooth, and form part of the convex articular surface of the wrist-joint.

The ligaments connecting the pisiform bone are the articular capsule and the two volar ligaments.

The **articular capsule** is a thin membrane which connects the pisiform to the triangular; it is lined by synovial membrane.

The two **volar ligaments** are strong fibrous bands; one, the **pisohamate ligament**; connects the pisiform to the hamate, the other, the **pisometacarpal ligament**, joins the pisiform to the base of the fifth metacarpal bone (Fig. 334). These ligaments are, in reality, prolongations of the tendon of the Flexor carpi ulnaris.

Articulations of the Distal Row of Carpal Bones.—These also are arthrodioid joints; the bones are connected by dorsal, volar, and interosseous ligaments.

The Dorsal Ligaments (*ligamenta intercarpea dorsalia*).—The dorsal ligaments, three in number, extend transversely from one bone to another on the dorsal surface, connecting the greater with the lesser multangular, the lesser multangular with the capitate, and the capitate with the hamate.

The Volar Ligaments (*ligamenta intercarpea volaria; palmar ligaments*).—The volar ligaments, also three, have a similar arrangement on the volar surface.

The Interosseous Ligaments (*ligamenta intercarpea interossea*).—The three interosseous ligaments are much thicker than those of the first row; one is placed between the capitate and the hamate, a second between the capitate and the lesser multangular, and a third between the greater and lesser multangulars. The first is much the strongest, and the third is sometimes wanting.

Articulations of the Two Rows of Carpal Bones with Each Other.—The joint between the navicular, lunate, and triangular on the one hand, and the second row of carpal bones on the other, is named the **midcarpal joint**, and is made up of three distinct portions: in the center the head of the capitate and the superior surface of the hamate articulate with the deep cup-shaped cavity formed by the navicular and lunate, and constitute a sort of ball-and-socket joint. On the radial side the greater and lesser multangulars articulate with the navicular, and on the ulnar side the hamate articulates with the triangular, forming gliding joints.

The ligaments are: volar, dorsal, ulnar and radial collateral.

The Volar Ligaments (*ligamenta intercarpea volaria; anterior or palmar ligaments*).—The volar ligaments consist of short fibers, which pass, for the most part, from the volar surfaces of the bones of the first row to the front of the capitate.

The Dorsal Ligaments (*ligamenta intercarpea dorsalia; posterior ligaments*).—The dorsal ligaments consist of short, irregular bundles passing between the dorsal surfaces of the bones of the first and second rows.

The Collateral Ligaments (*lateral ligaments*).—The collateral ligaments are very short; one is placed on the radial, the other on the ulnar side of the carpus; the former, the stronger and more distinct, connects the navicular and greater multangular, the latter the triangular and hamate; they are continuous with the collateral ligaments of the wrist-joint. In addition to these ligaments, a slender interosseous band sometimes connects the capitate and the navicular.

Synovial Membrane.—The synovial membrane of the carpus is very extensive (Fig. 336), and bounds a synovial cavity of very irregular shape. The upper portion of the cavity intervenes between the under surfaces of the navicular, lunate, and triangular bones and the upper surfaces of the bones of the second row. It sends two prolongations upward—between the navicular and lunate, and the lunate and triangular—and three prolongations downward between the four bones of the second row. The prolongation between the greater and lesser multangulars, or that between the lesser multangular and capitate, is, owing to the absence of the interosseous ligament, often continuous with the cavity of the carpometacarpal joints, sometimes of the second, third, fourth, and fifth metacarpal bones, sometimes of the second and third only. In the latter condition the joint between the hamate and the fourth and fifth metacarpal bones has a separate synovial membrane. The synovial cavities of these joints are prolonged for a short distance between the bases of the metacarpal bones. There is a separate synovial membrane between the pisiform and triangular.

Movements.—The articulation of the hand and wrist considered as a whole involves four articular surfaces: (a) the inferior surfaces of the radius and articular disk; (b) the superior surfaces of the navicular, lunate, and triangular, the pisiform having no essential part in the movement of the hand; (c) the S-shaped surface formed by the inferior surfaces of the navicular, lunate, and triangular; (d) the reciprocal surface formed by the upper surfaces of the bones of the second row. These four surfaces form two joints: (1) a proximal, the wrist-joint proper; and (2) a distal, the mid-carpal joint.

1. The wrist-joint proper is a true condyloid articulation, and therefore all movements but rotation are permitted. Flexion and extension are the most free, and of these a greater amount of extension than of flexion is permitted, since the articulating surfaces extend farther on the dorsal than on the volar surfaces of the carpal bones. In this movement the carpal bones rotate on a transverse axis drawn between the tips of the styloid processes of the radius and ulna. A certain amount of adduction (or ulnar flexion) and abduction (or radial flexion) is also permitted. The former is considerably greater in extent than the latter on account of the shortness of the styloid process of the ulna, abduction being soon limited by the contact of the styloid process of the radius with the greater multangular. In this movement the carpus revolves upon an antero-posterior axis drawn through the center of the wrist.¹ Finally, circumduction is permitted by the combined and consecutive movements of adduction, extension, abduction, and flexion. No rotation is possible, but the effect of rotation is obtained by the pronation and supination of the radius on the ulna. The movement of *flexion* is performed by the Flexor carpi radialis, the Flexor carpi ulnaris, and the Palmaris longus; *extension* by the Extensores carpi radiales longus and brevis and the Extensor carpi ulnaris; *adduction* (ulnar flexion) by the Flexor carpi ulnaris and the Extensor carpi ulnaris; and *abduction* (radial flexion) by the Abductor pollicis longus, the Extensors of the thumb, and the Extensores carpi radiales longus and brevis and the Flexor carpi radialis. When the fingers are extended, flexion of the wrist is performed by the Flexores carpi radialis and ulnaris and extension is aided by the Extensor digitorum communis. When the fingers are flexed, flexion of the wrist is aided by the Flexores digitorum sublimis and profundus, and extension is performed by the Extensores carpi radiales and ulnaris.

2. The chief movements permitted in the mid-carpal joint are flexion and extension and a slight amount of rotation. In flexion and extension, which are the movements most freely enjoyed, the greater and lesser multangulars on the radial side and the hamate on the ulnar side glide forward and backward on the navicular and triangular respectively, while the head of the capitate and the superior surface of the hamate rotate in the cup-shaped cavity of the navicular and lunate. Flexion at this joint is freer than extension. A very trifling amount of rotation is also permitted, the head of the capitate rotating around a vertical axis drawn through its own center, while at the same time a slight gliding movement takes place in the lateral and medial portions of the joint.

VIII. Carpometacarpal Articulations (Articulationes Carpometacarpeæ).

Carpometacarpal Articulation of the Thumb (*articulatio carpometacarpea pollicis*).

—This is a joint of reciprocal reception between the first metacarpal and the greater multangular; it enjoys great freedom of movement on account of the configuration of its articular surfaces, which are saddle-shaped. The joint is surrounded by a capsule, which is thick but loose, and passes from the circumference of the base of the metacarpal bone to the rough edge bounding the articular surface of the greater multangular; it is thickest laterally and dorsally, and is lined by synovial membrane.

Movements.—In this articulation the movements permitted are flexion and extension in the plane of the palm of the hand, abduction and adduction in a plane at right angles to the palm, circumduction, and opposition. It is by the movement of opposition that the tip of the thumb is brought into contact with the volar surfaces of the slightly flexed fingers. This movement is effected through the medium of a small sloping facet on the anterior lip of the saddle-shaped articular surface of the greater multangular. The Flexor muscles pull the corresponding part of the articular surface of the metacarpal bone on to this facet, and the movement of opposition is then carried out by the Adductors.

Flexion of this joint is produced by the Flexores pollicis longus and brevis, assisted by the Opponens pollicis and the Adductor pollicis. Extension is effected mainly by the abductor pollicis longus, assisted by the Extensores pollicis longus and brevis. Adduction is carried out by the Adductor; abduction mainly by the Abductores pollicis longus and brevis, assisted by the Extensors.

¹ H. M. Johnston (Journal of Anatomy and Physiology, vol. xli) maintains that a ulnar and radial flexion only slight lateral movement occurs at the radiocarpal joint, and that in complete flexion and extension of the hand there is a small degree of ulnar flexion at the radiocarpal joint.

Articulations of the Other Four Metacarpal Bones with the Carpus (*articulationes carpometacarpeæ*).—The joints between the carpus and the second, third, fourth, and fifth metacarpal bones are arthrodial. The bones are united by dorsal, volar, and interosseous ligaments.

The Dorsal Ligaments (*ligamenta carpometacarpea dorsalia*).—The dorsal ligaments, the strongest and most distinct, connect the carpal and metacarpal bones on their dorsal surfaces. The second metacarpal bone receives two fasciculi, one from the greater, the other from the lesser multangular; the third metacarpal receives two, one each from the lesser multangular and capitate; the fourth two, one each from the capitate and hamate; the fifth receives a single fasciculus from the hamate, and this is continuous with a similar ligament on the volar surface, forming an incomplete capsule.

The Volar Ligaments (*ligamenta carpometacarpea volaria; palmar ligaments*).—The volar ligaments have a somewhat similar arrangement, with the exception of those of the third metacarpal, which are three in number: a lateral one from the greater multangular, situated superficial to the sheath of the tendon of the Flexor carpi radialis; and intermediate one from the capitate; and a medial one from the hamate.

The Interosseous Ligaments.—The interosseous ligaments consist of short, thick fibers, and are limited to one part of the carpometacarpal articulation; they connect the contiguous inferior angles of the capitate and hamate with the adjacent surfaces of the third and fourth metacarpal bones.

Synovial Membrane.—The synovial membrane is a continuation of that of the intercarpal joints. Occasionally, the joint between the hamate and the fourth and fifth metacarpal bones has a separate synovial membrane.

The synovial membranes of the wrist and carpus (Fig. 336) are thus seen to be five in number. The *first* passes from the lower end of the ulnar to the ulnar notch of the radius, and lines the upper surface of the articular disk. The *second* passes from the articular disk and the lower end of the radius above, to the bones of the first row below. The *third*, the most extensive, passes between the contiguous margins of the two rows of carpal bones, and sometimes, in the event of one of the interosseous ligaments being absent, between the bones of the second row to the carpal extremities of the second, third, fourth, and fifth metacarpal bones. The *fourth* extends from the margin of the greater multangular to the metacarpal bone of the thumb. The *fifth* runs between the adjacent margins of the triangular and pisiform bones. Occasionally the fourth and fifth carpometacarpal joints have a separate synovial membrane.

Movements.—The movements permitted in the carpometacarpal articulations of the fingers are limited to slight gliding of the articular surfaces upon each other, the extent of which varies in the different joints. The metacarpal bone of the little finger is most movable, then that of the ring finger; the metacarpal bones of the index and middle fingers are almost immovable.

IX. Intermetacarpal Articulations (*Articulationes Intermetacarpeæ; Articulationes of the Metacarpal Bones with Each Other*).

The bases of the second, third, fourth and fifth metacarpal bones articulate with one another by small surfaces covered with cartilage, and are connected together by dorsal, volar, and interosseous ligaments.

The **dorsal** (*ligamenta basium oss. metacarp. dorsalia*) and **volar ligaments** (*ligamenta basium oss. metacarp. volaria; palmar ligaments*) pass transversely from one bone to another on the dorsal and volar surfaces. The **interosseous ligaments** (*ligamenta basium oss. metacarp. interossea*) connect their contiguous surfaces, just distal to their collateral articular facets.

The **synovial membrane** for these joints is continuous with that of the carpometacarpal articulations.

The Transverse Metacarpal Ligament (*ligamentum capitulorum [oss. metacarpalium] transversum*) (Fig. 337).—This ligament is a narrow fibrous band, which runs across the volar surfaces of the heads of the second, third, fourth and fifth metacarpal bones, connecting them together. It is blended with the volar (glenoid)

ligaments of the metacarpophalangeal articulations. Its volar surface is concave where the Flexor tendons pass over it; behind it the tendons of the Interossei pass to their insertions.

X. Metacarpophalangeal Articulations (Articulationes Metacarpophalangeæ; Metacarpophalangeal Joints) (Figs. 337, 338).

These articulations are of the condyloid kind, formed by the reception of the rounded heads of the metacarpal bones into shallow cavities on the proximal ends of the first phalanges, with the exception of that of the thumb, which presents more of the characters of a ginglymoid joint. Each joint has a volar and two collateral ligaments.

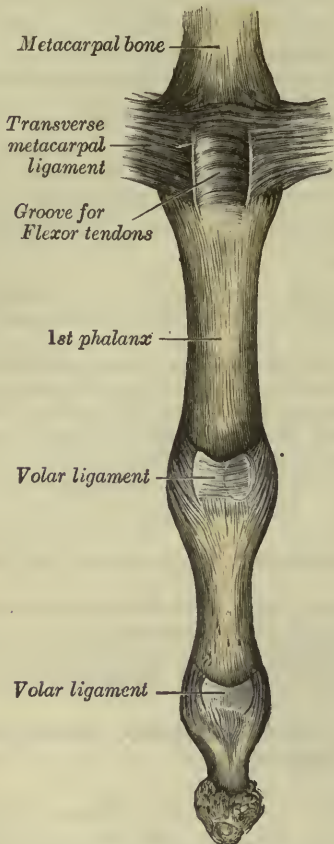


FIG. 337.—Metacarpophalangeal articulation and articulations of digit. Volar aspect.

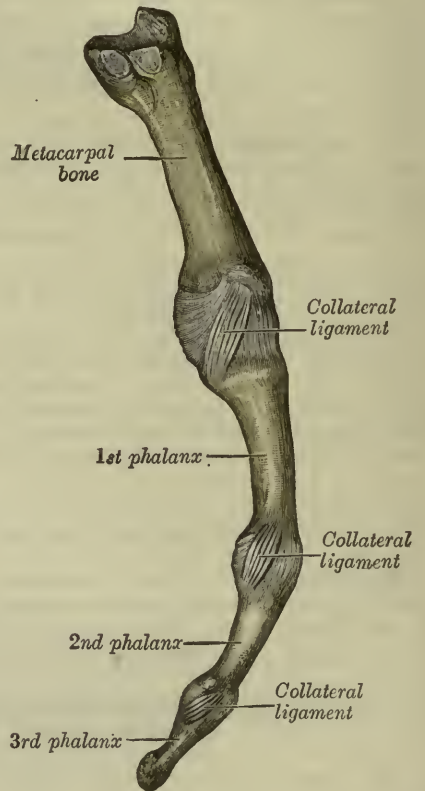


FIG. 338.—Metacarpophalangeal articulation and articulations of digit. Ulnar aspect.

The Volar Ligaments (*glenoid ligaments of Cruveilhier; palmar or vaginal ligaments*).—The volar ligaments are thick, dense, fibrocartilaginous structures, placed upon the volar surfaces of the joints in the intervals between the collateral ligaments, to which they are connected; they are loosely united to the metacarpal bones, but are very firmly attached to the bases of the first phalanges. Their volar surfaces are intimately blended with the transverse metacarpal ligament, and present grooves for the passage of the Flexor tendons, the sheaths surrounding which are connected to the sides of the grooves. Their deep surfaces form parts of the articular facets for the heads of the metacarpal bones, and are lined by synovial membranes.

The Collateral Ligaments (*ligamenta collateralia; lateral ligaments*).—The collateral ligaments are strong, rounded cords, placed on the sides of the joints;

each is attached by one extremity to the posterior tubercle and adjacent depression on the side of the head of the metacarpal bone, and by the other to the contiguous extremity of the phalanx.

The dorsal surfaces of these joints are covered by the expansions of the Extensor tendons, together with some loose areolar tissue which connects the deep surfaces of the tendons to the bones.

Movements.—The movements which occur in these joints are flexion, extension, adduction, abduction, and circumduction; the movements of abduction and adduction are very limited, and cannot be performed when the fingers are flexed.

XI. Articulations of the Digits (*Articulationes Digitorum Manus*; **Interphalangeal Joints**) (Figs. 337, 338).

The interphalangeal articulations are hinge-joints; each has a volar and two collateral ligaments. The arrangement of these ligaments is similar to those in the metacarpophalangeal articulations. The Extensor tendons supply the place of posterior ligaments.

Movements.—The only movements permitted in the interphalangeal joints are flexion and extension; these movements are more extensive between the first and second phalanges than between the second and third. The amount of flexion is very considerable, but extension is limited by the volar and collateral ligaments.

Muscles Acting on the Joints of the Digits.—Flexion of the metacarpophalangeal joints of the fingers is effected by the *Flexores digitorum sublimis* and *profundus*, *Lumbricales*, and *Interossei*, assisted in the case of the little finger by the *Flexor digiti quinti brevis*. Extension is produced by the *Extensor digitorum communis*, *Extensor indicis proprius*, and *Extensor digiti quinti proprius*.

Flexion of the interphalangeal joints of the fingers is accomplished by the *Flexor digitorum profundus* acting on the proximal and distal joints and by the *Flexor digitorum sublimis* acting on the proximal joints. Extension is effected mainly by the *Lumbricales* and *Interossei*, the long Extensors having little or no action upon these joints.

Flexion of the metacarpophalangeal joint of the thumb is effected by the *Flexores pollicis longus* and *brevis*; extension by the *Extensores pollicis longus* and *brevis*. Flexion of the interphalangeal joint is accomplished by the *Flexor pollicis longus*, and extension by the *Extensor pollicis longus*.

ARTICULATIONS OF THE LOWER EXTREMITY.

The articulations of the Lower Extremity comprise the following:

- | | |
|----------------------------------|----------------------------|
| I. Hip. | V. Intertarsal. |
| II. Knee. | VI. Tarsometatarsal. |
| III. Tibiofibular. | VII. Intermetatarsal. |
| IV. Ankle. | VIII. Metatarsophalangeal. |
| IX. Articulations of the Digits. | |

I. Coxal Articulation or Hip-joint (*Articulatio Coxæ*).

This articulation is an enarthrodial or ball-and-socket joint, formed by the reception of the head of the femur into the cup-shaped cavity of the acetabulum. The articular cartilage on the head of the femur, thicker at the center than at the circumference, covers the entire surface with the exception of the *fovea capitis femoris*, to which the *ligamentum teres* is attached; that on the acetabulum forms an incomplete marginal ring, the *lunate surface*. Within the *lunate surface* there is a circular depression devoid of cartilage, occupied in the fresh state by a mass of fat, covered by *synovial membrane*. The ligaments of the joint are:

- | | |
|---------------------------|-------------------------------|
| The Articular Capsule. | The Pubocapsular. |
| The Iliofemoral. | The Ligamentum Teres Femoris. |
| The Ischiocapsular. | The Glenoidal Labrum. |
| The Transverse Acetabular | |

The Articular Capsule (*capsula articularis*; *capsular ligament*) (Figs. 339, 340).—The articular capsule is strong and dense. *Above*, it is attached to the margin of the acetabulum 5 to 6 mm. beyond the glenoidal labrum behind; but in *front*, it is attached to the outer margin of the labrum, and, opposite to the notch where the margin of the cavity is deficient, it is connected to the transverse ligament, and by a few fibers to the edge of the obturator foramen. It surrounds the neck of the femur, and is attached, in *front*, to the intertrochanteric line; *above*, to the base of the neck; *behind*, to the neck, about 1.25 cm. above the intertrochanteric crest; *below*, to the lower part of the neck, close to the lesser trochanter. From its femoral attachment some of the fibers are reflected upward along the neck as longitudinal bands, termed *retinacula*. The capsule is much thicker at the upper and forepart of the joint, where the greatest amount of resistance is required;

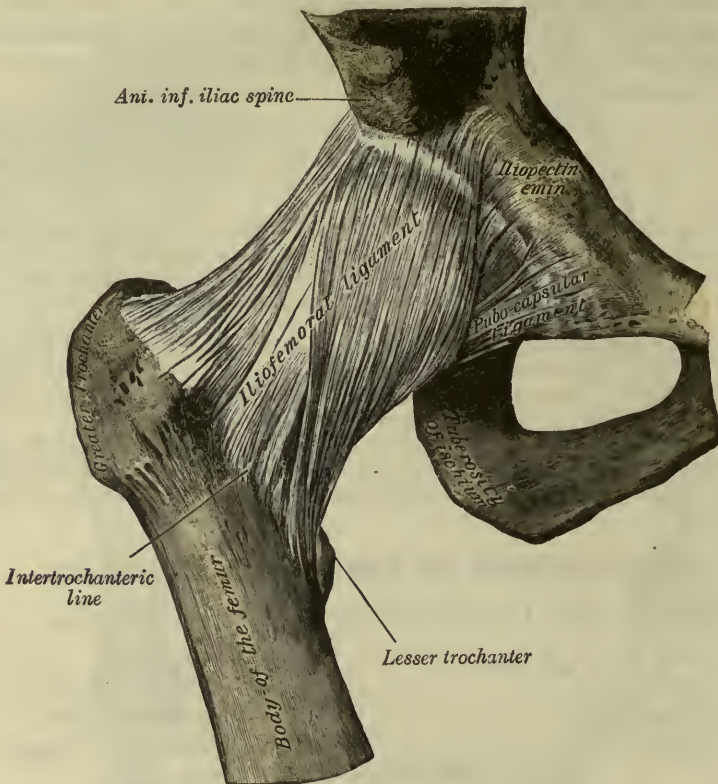


FIG. 339.—Right hip-joint from the front. (Spalteholz.)

behind and below, it is thin and loose. It consists of two sets of fibers, circular and longitudinal. The circular fibers, *zona orbicularis*, are most abundant at the lower and back part of the capsule (Fig. 342), and form a sling or collar around the neck of the femur. Anteriorly they blend with the deep surface of the iliofemoral ligament, and gain an attachment to the anterior inferior iliac spine. The longitudinal fibers are greatest in amount at the upper and front part of the capsule, where they are reinforced by distinct bands, or accessory ligaments, of which the most important is the iliofemoral ligament. The other accessory bands are known as the *pubocapsular* and the *ischiocapsular* ligaments. The external surface of the capsule is rough, covered by numerous muscles, and separated in front from the Psoas major and Iliacus by a bursa, which not infrequently communicates by a circular aperture with the cavity of the joint.

The Iliofemoral Ligament (*ligamentum iliofemorale*; *Y-ligament*; *ligament of Bigelow*) (Fig. 339).—The iliofemoral ligament is a band of great strength which lies in front of the joint; it is intimately connected with the capsule, and serves to strengthen it in this situation. It is attached, *above*, to the lower part of the anterior inferior iliac spine; *below*, it divides into two bands, one of which passes downward and is fixed to the lower part of the intertrochanteric line; the other is directed downward and lateralward and is attached to the upper part of the same line. Between the two bands is a thinner part of the capsule. In some cases there is no division, and the ligament spreads out into a flat triangular band which is attached to the whole length of the intertrochanteric line. This ligament is frequently called the Y-shaped ligament of Bigelow; and its upper band is sometimes named the **iliotrochanteric ligament**.

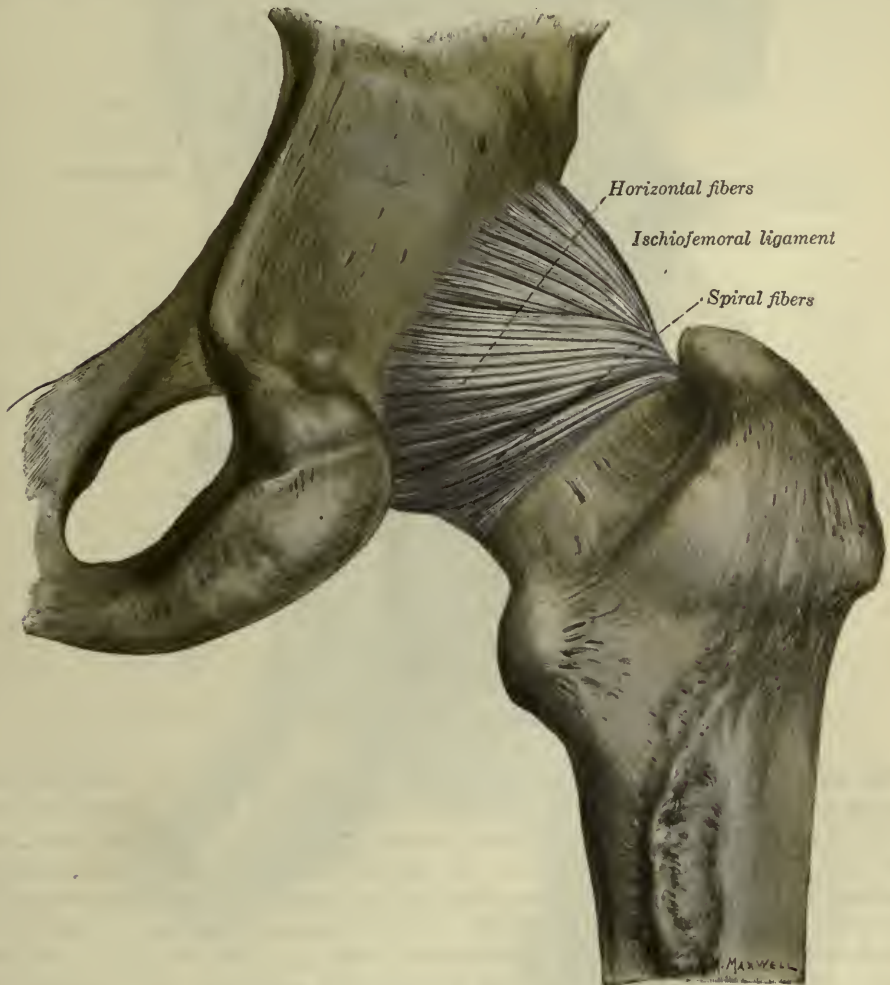

FIG. 340.—The hip-joint from behind. (Quain.)

The Pubocapsular Ligament (*ligamentum pubocapsulare*; *pubofemoral ligament*).—This ligament is attached, *above*, to the obturator crest and the superior ramus of the pubis; *below*, it blends with the capsule and with the deep surface of the vertical band of the iliofemoral ligament.

The Ischiocapsular Ligament (*ligamentum ischiocapsulare*; *ischiocapsular band*; *ligament of Bertin*).—The ischiocapsular ligament consists of a triangular band of strong fibers, which spring from the ischium below and behind the acetabulum, and blend with the circular fibers of the capsule (Fig. 340).

The Ligamentum Teres Femoris (Fig. 341).—The ligamentum teres femoris is a triangular, somewhat flattened band implanted by its apex into the antero-superior part of the fovea capitis femoris; its base is attached by two bands, one into either side of the acetabular notch, and between these bony attachments it blends with the transverse ligament. It is ensheathed by the synovial membrane, and varies greatly in strength in different subjects; occasionally only the synovial fold exists, and in rare cases even this is absent. The ligament is made tense when the thigh is semiflexed and the limb then adducted or rotated outward; it is, on the other hand, relaxed when the limb is abducted. It has, however, but little influence as a ligament.

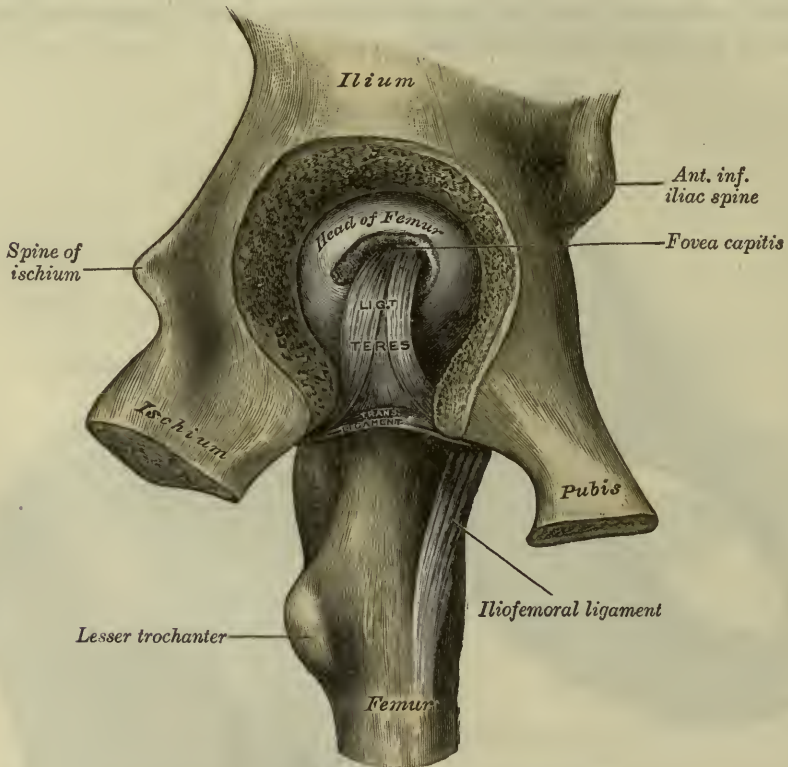


FIG. 341.—Left hip-joint, opened by removing the floor of the acetabulum from within the pelvis.

The Glenoidal Labrum (*labrum glenoidale*; *cotyloid ligament*).—The glenoidal labrum is a fibrocartilaginous rim attached to the margin of the acetabulum, the cavity of which it deepens; at the same time it protects the edge of the bone, and fills up the inequalities of its surface. It bridges over the notch as the **transverse ligament**, and thus forms a complete circle, which closely surrounds the head of the femur and assists in holding it in its place. It is triangular on section, its base being attached to the margin of the acetabulum, while its opposite edge is free and sharp. Its two surfaces are invested by synovial membrane, the external one being in contact with the capsule, the internal one being inclined inward so as to narrow the acetabulum, and embrace the cartilaginous surface of the head of the femur. It is much thicker above and behind than below and in front, and consists of compact fibers.

The Transverse Acetabular Ligament (*ligamentum transversum acetabuli*; *transverse ligament*).—This ligament is in reality a portion of the glenoidal labrum, though differing from it in having no cartilage cells among its fibers. It consists of strong,

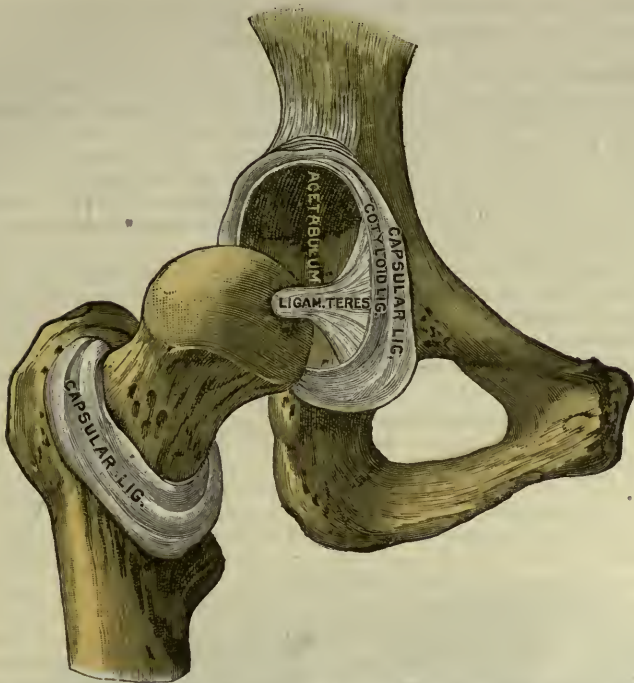


FIG. 342.—Hip-joint, front view. The capsular ligament has been largely removed.

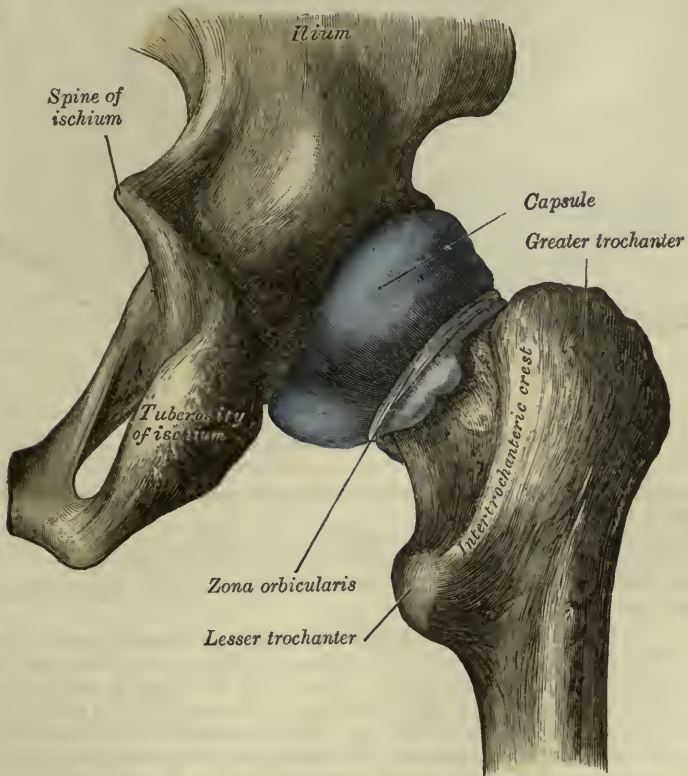


FIG. 343.—Capsule of hip-joint (distended). Posterior aspect.

flattened fibers, which cross the acetabular notch, and convert it into a foramen through which the nutrient vessels enter the joint.

Synovial Membrane (Fig. 343).—The synovial membrane is very extensive. Commencing at the margin of the cartilaginous surface of the head of the femur, it covers the portion of the neck which is contained within the joint; from the neck it is reflected on the internal surface of the capsule, covers both surfaces of the glenoidal labrum and the mass of fat contained in the depression at the bottom of the acetabulum, and ensheathes the ligamentum teres as far as the head of the femur. The joint cavity sometimes communicates through a hole in the capsule between the vertical band of the iliofemoral ligament and the pubocapsular ligament with a bursa situated on the deep surfaces of the Psoas major and Iliacus.

The **muscles** in relation with the joint are, in *front*, the Psoas major and Iliacus, separated from the capsule by a bursa; *above*, the reflected head of the Rectus femoris and Glutæus minimus, the latter being closely adherent to the capsule; *medially*, the Obturator externus and Pectineus; *behind*, the Piriformis, Gemellus superior, Obturator internus, Gemellus inferior, Obturator externus, and Quadratus femoris (Fig. 344).

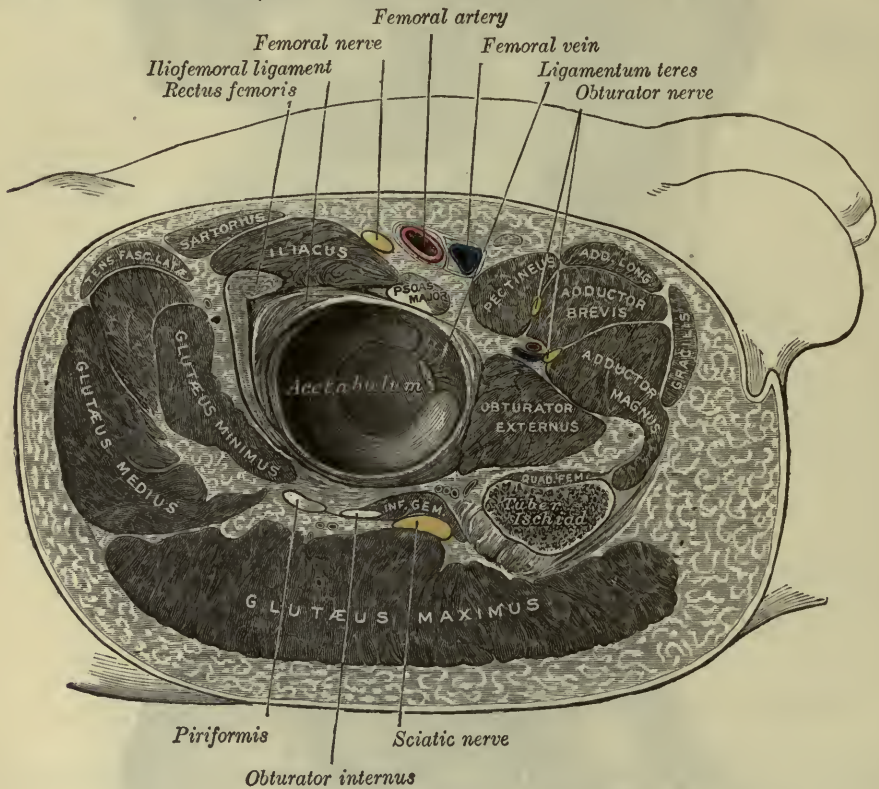


FIG. 344.—Structures surrounding right hip-joint.

The **arteries** supplying the joint are derived from the obturator, medial femoral circumflex, and superior and inferior gluteals.

The **nerves** are articular branches from the sacral plexus, sciatic, obturator, accessory obturator, and a filament from the branch of the femoral supplying the Rectus femoris.

Movements.—The movements of the hip are very extensive, and consist of flexion, extension, adduction, abduction, circumduction, and rotation.

The length of the neck of the femur and its inclinations to the body of the bone have the effect of converting the angular movements of flexion, extension, adduction, and abduction partially into rotatory movements in the joint. Thus when the thigh is flexed or extended, the head of the femur, on account of the *medial* inclination of the neck, rotates within the acetabulum with only a slight amount of gliding to and fro. The *forward* slope of the neck similarly affects the movements of adduction and abduction. Conversely rotation of the thigh which is permitted by the *upward* inclination of the neck, is not a simple rotation of the head of the femur in the acetabulum, but is accompanied by a certain amount of gliding.

The hip-joint presents a very striking contrast to the shoulder-joint in the much more complete mechanical arrangements for its security and for the limitation of its movements. In the shoulder, as has been seen, the head of the humerus is not adapted at all in size to the glenoid cavity, and is hardly restrained in any of its ordinary movements by the capsule. In the hip-joint, on the contrary, the head of the femur is closely fitted to the acetabulum for an area extending over nearly half a sphere, and at the margin of the bony cup it is still more closely embraced by the glenoid labrum, so that the head of the femur is held in its place by that ligament even when the fibers of the capsule have been quite divided. The iliofemoral ligament is the strongest of all the ligaments in the body, and is put on the stretch by any attempt to extend the femur beyond a straight line with the trunk. That is to say, this ligament is the chief agent in maintaining the erect position without muscular fatigue; for a vertical line passing through the center of gravity of the trunk falls behind the centers of rotation in the hip-joints, and therefore the pelvis tends to fall backward, but is prevented by the tension of the iliofemoral ligaments. The security of the joint may be provided for also by the two bones being directly united through the ligamentum teres; but it is doubtful whether this ligament has much influence upon the mechanism of the joint. When the knee is flexed, flexion of the hip-joint is arrested by the soft parts of the thigh and abdomen being brought into contact, and when the knee is extended, by the action of the hamstring muscles; extension is checked by the tension of the iliofemoral ligament; adduction by the thighs coming into contact; adduction with flexion by the lateral band of the iliofemoral ligament and the lateral part of the capsule; abduction by the medial band of the iliofemoral ligament and the pubocapsular ligament; rotation outward by the lateral band of the iliofemoral ligament; and rotation inward by the ischiocapsular ligament and the hinder part of the capsule. The muscles which *flex* the femur on the pelvis are the Psoas major, Iliacus, Rectus femoris, Sartorius, Pectineus, Adductores longus and brevis, and the anterior fibers of the Glutæi medius and minimus. *Extension* is mainly performed by the Glutæus maximus, assisted by the hamstring muscles and the ischial head of the Adductor magnus. The thigh is *adducted* by the Adductores magnus, longus, and brevis, the Pectineus, the Gracilis, and lower part of the Glutæus maximus, and *abducted* by the Glutæi medius and minimus, and the upper part of the Glutæus maximus. The muscles which *rotate* the thigh *inward* are the Glutæus minimus and the anterior fibers of the Glutæus medius, the Tensor fasciæ latæ and the Iliacus and Psoas major; while those which rotate it *outward* are the posterior fibers of the Glutæus medius, the Piriformis, Obturatores externus and internus, Gemelli superior and inferior, Quadratus femoris, Glutæus maximus, the Adductores longus, brevis, and magnus, the Pectineus, and the Sartorius.

II. The Knee-joint (Articulatio Genu).

The knee-joint was formerly described as a ginglymus or hinge-joint, but is really of a much more complicated character. It must be regarded as consisting of three articulations in one: two condyloid joints, one between each condyle of the femur and the corresponding meniscus and condyle of the tibia; and a third between the patella and the femur, partly arthrodial, but not completely so, since the articular surfaces are not mutually adapted to each other, so that the movement is not a simple gliding one. This view of the construction of the knee-joint receives confirmation from the study of the articulation in some of the lower mammals, where, corresponding to these three subdivisions, three synovial cavities are sometimes found, either entirely distinct or only connected together by small communications. This view is further rendered probable by the existence in the middle of the joint of the two cruciate ligaments, which must be regarded as the collateral ligaments of the medial and lateral joints. The existence of the patellar fold of synovial membrane would further indicate a tendency to separation of the synovial cavity into two minor sacs, one corresponding to the lateral and the other to the medial joint.

The bones are connected together by the following ligaments:

The Articular Capsule.
The Ligamentum Patellæ.
The Oblique Popliteal.
The Tibial Collateral.
The Fibular Collateral.

The Anterior Cruciate.
The Posterior Cruciate.
The Medial and Lateral Menisci.
The Transverse.
The Coronary.

The Articular Capsule (*capsula articularis; capsular ligament*) (Fig. 345).—The articular capsule consists of a thin, but strong, fibrous membrane which is strengthened in almost its entire extent by bands inseparably connected with it. Above and in front, beneath the tendon of the Quadriceps femoris, it is represented only by the synovial membrane. Its chief strengthening bands are derived from the fascia lata and from the tendons surrounding the joint. In front, expansions from the Vasti and from the fascia lata and its iliotibial band fill in the intervals between the anterior and collateral ligaments, constituting the **medial** and **lateral patellar retinacula**. Behind the capsule consists of vertical fibers which arise from the condyles and from the sides of the intercondyloid fossa of the femur;

the posterior part of the capsule is therefore situated on the sides of and in front of the cruciate ligaments, which are thus excluded from the joint cavity. Behind the cruciate ligaments is the oblique popliteal ligament which is augmented by fibers derived from the tendon of the Semimembranosus. Laterally, a prolongation from the iliotibial band fills in the interval between the oblique popliteal and the fibular collateral ligaments, and partly covers the latter. Medially, expansions from the Sartorius and Semimembranosus pass upward to the tibial collateral ligament and strengthen the capsule.

The Ligamentum Patellæ (*anterior ligament*) (Fig. 345).—The ligamentum patellæ is the central portion of the common tendon of the Quadriceps femoris, which is continued from the patella to the tuberosity of the tibia. It is a strong, flat, ligamentous band, about 8 cm. in length, attached, *above*, to the apex and adjoining margins of the patella and the rough depression on its posterior surface; *below*, to the tuberosity of the tibia; its superficial fibers are continuous over the front of the patella with those of the tendon of the Quadriceps femoris. The medial and lateral portions of the tendon of the Quadriceps pass down on either side of the patella, to be inserted into the upper extremity of the tibia on either side of the tuberosity; these portions merge into the capsule, as stated above,

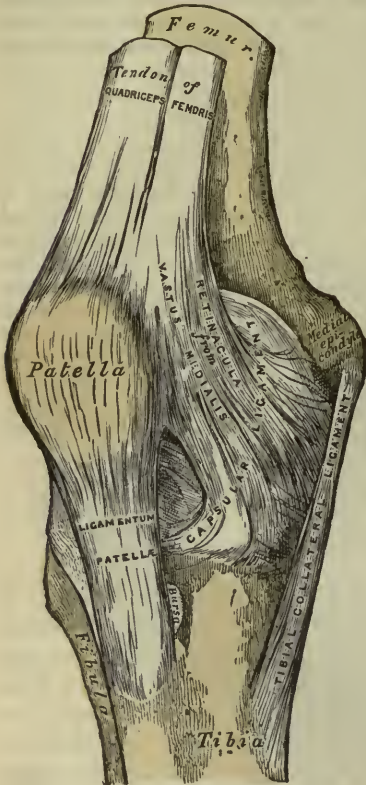


FIG. 345.—Right knee-joint. Anterior view.

forming the medial and lateral patellar retinacula. The posterior surface of the ligamentum patellæ is separated from the synovial membrane of the joint by a large infrapatellar pad of fat, and from the tibia by a bursa.

The Oblique Popliteal Ligament (*ligamentum popliteum obliquum; posterior ligament*) (Fig. 346).—This ligament is a broad, flat, fibrous band, formed of fasciculi separated from one another by apertures for the passage of vessels and nerves. It is attached above to the upper margin of the intercondyloid fossa and posterior surface of the femur close to the articular margins of the condyles, and below to the posterior margin of the head of the tibia. Superficial to the main part of the ligament is a strong fasciculus, derived from the tendon of the Semimembranosus and passing from the back part of the medial condyle of the tibia obliquely upward and lateralward to the back part of the lateral condyle of the femur. The oblique popliteal ligament forms part of the floor of the popliteal fossa, and the popliteal artery rests upon it.

The Tibial Collateral Ligament (*ligamentum collaterale tibiale; internal lateral ligament*) (Fig. 345).—The tibial collateral is a broad, flat, membranous band, situated nearer to the back than to the front of the joint. It is attached, *above*, to the medial condyle of the femur immediately below the adductor tubercle; *below*, to the medial condyle and medial surface of the body of the tibia. The fibers of the posterior part of the ligament are short and incline backward as they descend; they are inserted into the tibia above the groove for the Semimembranosus. The anterior part of the ligament is a flattened band, about 10 cm. long, which inclines forward as it descends. It is inserted into the medial surface of the body of the tibia about 2.5 cm. below the level of the condyle. It is crossed, at its lower part, by the tendons of the Sartorius, Gracilis, and Semitendinosus, a bursa being interposed. Its deep surface covers the inferior medial genicular vessels and nerve and the anterior portion of the tendon of the Semimembranosus, with which it is connected by a few fibers; it is intimately adherent to the medial meniscus.

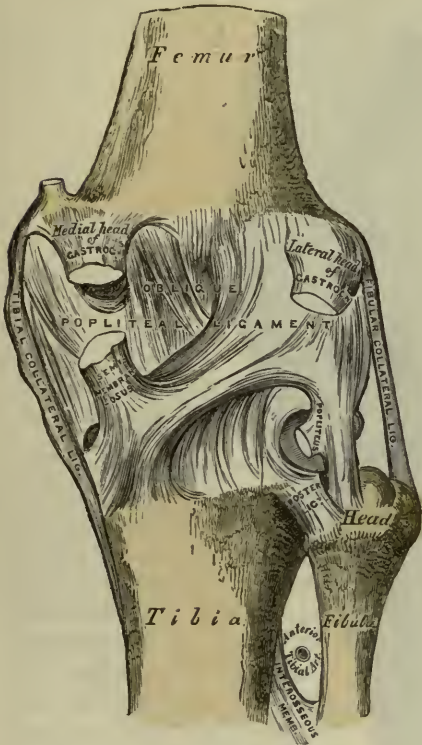


FIG. 346.—Right knee-joint. Posterior view.

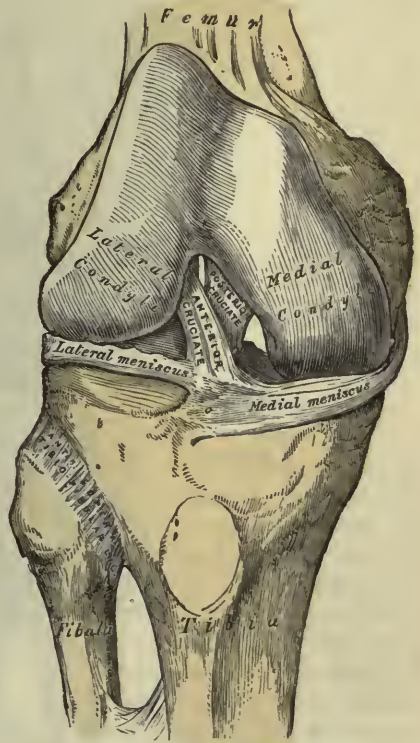


FIG. 347.—Right knee-joint, from the front, showing interior ligaments.

The Fibular Collateral Ligament (*ligamentum collaterale fibulare; external lateral or long external lateral ligament*) (Fig. 348).—The fibular collateral is a strong, rounded, fibrous cord, attached, *above*, to the back part of the lateral condyle of the femur, immediately above the groove for the tendon of the Popliteus; *below*, to the lateral side of the head of the fibula, in front of the styloid process. The greater part of its lateral surface is covered by the tendon of the Biceps femoris; the tendon, however, divides at its insertion into two parts, which are separated by the ligament. Deep to the ligament are the tendon of the Popliteus, and the inferior lateral genicular vessels and nerve. The ligament has no attachment to the lateral meniscus.

An inconstant bundle of fibers, the **short fibular collateral ligament**, is placed behind and parallel with the preceding, attached, *above*, to the lower and back part of the lateral condyle of the femur; *below*, to the summit of the styloid process of the fibula. Passing deep to it are the tendon of the Popliteus, and the inferior lateral genicular vessels and nerve.

The Cruciate Ligaments (*ligamenta cruciata genu; crucial ligaments*).—The cruciate ligaments are of considerable strength, situated in the middle of the joint, nearer to its posterior than to its anterior surface. They are called *cruciate* because they cross each other somewhat like the lines of the letter X; and have received the names **anterior** and **posterior**, from the position of their attachments to the tibia.

The Anterior Cruciate Ligament (*ligamentum cruciatum anterius; external crucial ligament*) (Fig. 347) is attached to the depression in front of the intercondyloid eminence of the tibia, being blended with the anterior extremity of the lateral meniscus; it passes upward, backward, and lateralward, and is fixed into the medial and back part of the lateral condyle of the femur.

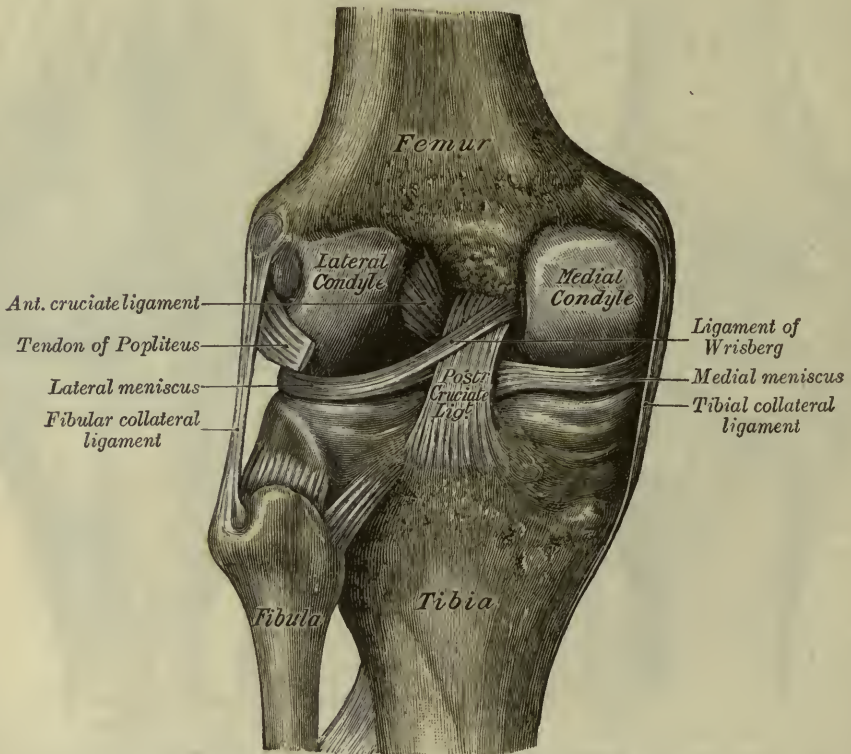


FIG. 348.—Left knee-joint from behind, showing interior ligaments.

The Posterior Cruciate Ligament (*ligamentum cruciatum posterius; internal crucial ligament*) (Fig. 348) is stronger, but shorter and less oblique in its direction, than the anterior. It is attached to the posterior intercondyloid fossa of the tibia, and to the posterior extremity of the lateral meniscus; and passes upward, forward, and medialward, to be fixed into the lateral and front part of the medial condyle of the femur.

The Menisci (*semilunar fibrocartilages*) (Fig. 349).—The menisci are two crescentic lamellæ, which serve to deepen the surfaces of the head of the tibia for articulation with the condyles of the femur. The peripheral border of each meniscus is thick, convex, and attached to the inside of the capsule of the joint; the opposite border

is thin, concave, and free. The upper surfaces of the menisci are concave, and in contact with the condyles of the femur; their lower surfaces are flat, and rest upon the head of the tibia; both surfaces are smooth, and invested by synovial membrane. Each meniscus covers approximately the peripheral two-thirds of the corresponding articular surface of the tibia.

The **medial meniscus** (*meniscus medialis*; *internal semilunar fibrocartilage*) is nearly semicircular in form, a little elongated from before backward, and broader behind than in front; its anterior end, thin and pointed, is attached to the anterior intercondyloid fossa of the tibia, in front of the anterior cruciate ligament; its posterior end is fixed to the posterior intercondyloid fossa of the tibia, between the attachments of the lateral meniscus and the posterior cruciate ligament.

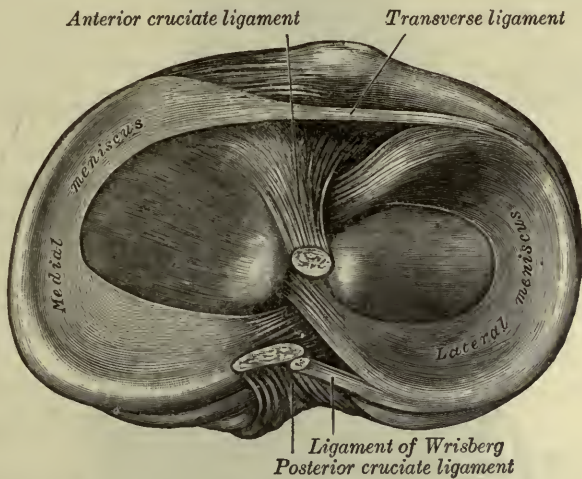


FIG. 349.—Head of right tibia seen from above, showing menisci and attachments of ligaments.

The **lateral meniscus** (*meniscus lateralis*; *external semilunar fibrocartilage*) is nearly circular and covers a larger portion of the articular surface than the medial one. It is grooved laterally for the tendon of the Popliteus, which separates it from the fibular collateral ligament. Its anterior end is attached in front of the intercondyloid eminence of the tibia, lateral to, and behind, the anterior cruciate ligament, with which it blends; the posterior end is attached behind the intercondyloid eminence of the tibia and in front of the posterior end of the medial meniscus. The anterior attachment of the lateral meniscus is twisted on itself so that its free margin looks backward and upward, its anterior end resting on a sloping shelf of bone on the front of the lateral process of the intercondyloid eminence. Close to its posterior attachment it sends off a strong fasciculus, the **ligament of Wrisberg** (Figs. 348, 349), which passes upward and medialward, to be inserted into the medial condyle of the femur, immediately behind the attachment of the posterior cruciate ligament. Occasionally a small fasciculus passes forward to be inserted into the lateral part of the anterior cruciate ligament. The lateral meniscus gives off from its anterior convex margin a fasciculus which forms the transverse ligament.

The Transverse Ligament (*ligamentum transversum genu*).—The transverse ligament connects the anterior convex margin of the lateral meniscus to the anterior end of the medial meniscus; its thickness varies considerably in different subjects, and it is sometimes absent.

The **coronary ligaments** are merely portions of the capsule, which connect the periphery of each meniscus with the margin of the head of the tibia.

Synovial Membrane.—The synovial membrane of the knee-joint is the largest and most extensive in the body. Commencing at the upper border of the patella, it forms a large cul-de-sac beneath the Quadriceps femoris (Figs. 350, 351) on the lower part of the front of the femur, and frequently communicates with a bursa interposed between the tendon and the front of the femur. The pouch of synovial membrane between the Quadriceps and front of the femur is supported, during the movements of the knee, by a small muscle, the Articularis genu, which is inserted into it. On either side of the patella, the synovial membrane extends beneath the aponeuroses of the Vasti, and more especially beneath that of the Vastus medialis. Below the patella it is separated from the ligamentum patellæ by a considerable quantity of fat, known as

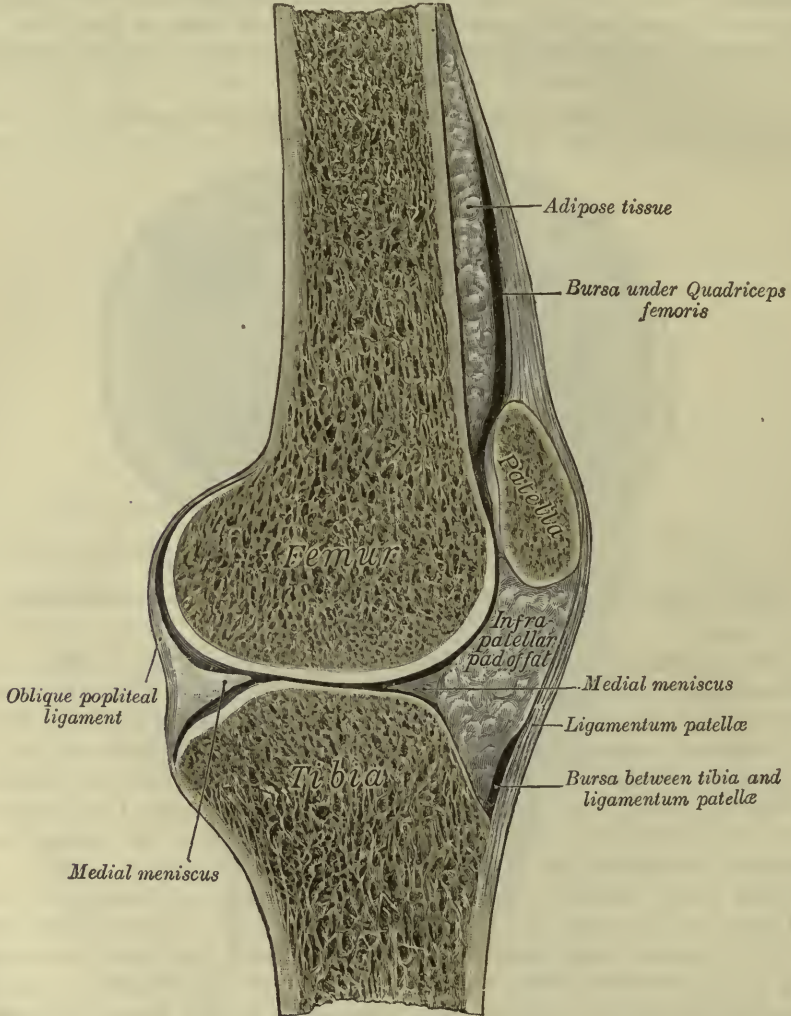


FIG. 350.—Sagittal section of right knee-joint.

the **infrapatellar pad**. From the medial and lateral borders of the articular surface of the patella, reduplications of the synovial membrane project into the interior of the joint. These form two fringe-like folds termed the **alar folds**; below, these folds converge and are continued as a single band, the **patellar fold** (*ligamentum mucosum*), to the front of the intercondyloid fossa of the femur. On either side of the joint, the synovial membrane passes downward from the femur, lining the capsule to its point of attachment to the menisci; it may then be traced over the upper surfaces of these to their free borders, and thence along their under surfaces to the tibia (Figs. 351, 352). At the back part of the lateral meniscus it forms a cul-de-sac between the groove on its surface and the tendon of the Popliteus; it is reflected across the front of the cruciate ligaments, which are therefore situated outside the synovial cavity.

Bursæ.—The bursæ near the knee-joint are the following: In front there are *four* bursæ: a large one is interposed between the patella and the skin, a small one between the upper part of the tibia and the ligamentum patellæ, a third between the lower part of the tuberosity of the tibia and the skin, and a fourth between the anterior surface of the lower part of the femur and the deep surface of the Quadriceps femoris, usually communicating with the knee-joint. Laterally there are four bursæ: (1) one (which sometimes communicates with the joint) between the lateral head of the Gastrocnemius and the capsule; (2) one between the fibular collateral ligament and the tendon of the Biceps; (3) one between the fibular collateral ligament and the tendon of the Popliteus (this is sometimes only an expansion from the next bursa); (4) one between the tendon of the Popliteus and the lateral condyle of the femur, usually an extension from the synovial membrane of the joint. Medially, there are five bursæ: (1) one between the medial head of the Gastrocnemius and the capsule; this sends a prolongation between the tendon of the

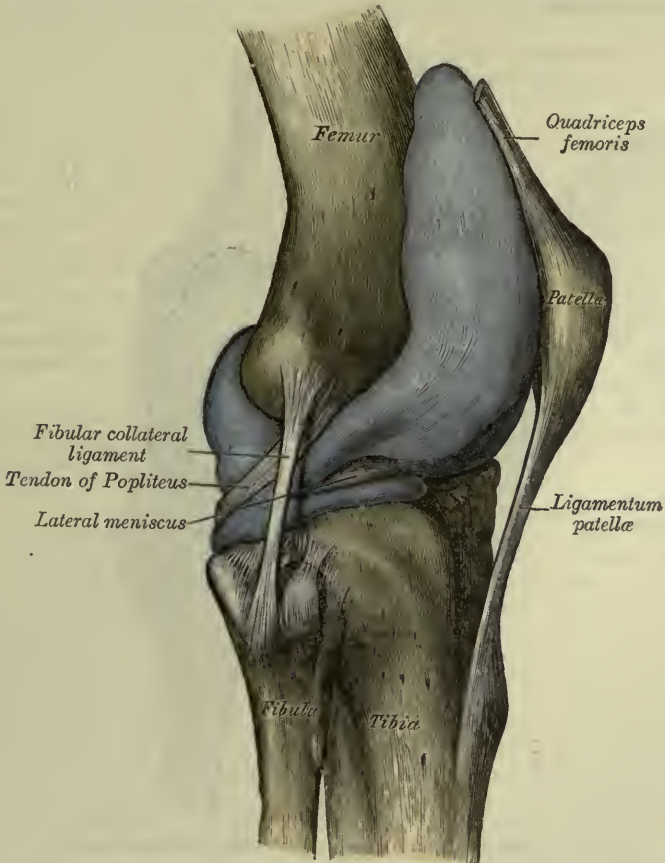


FIG. 351.—Capsule of right knee-joint (distended). Lateral aspect.

medial head of the Gastrocnemius and the tendon of the Semimembranosus and often communicates with the joint; (2) one superficial to the tibial collateral ligament, between it and the tendons of the Sartorius, Gracilis, and Semitendinosus; (3) one deep to the tibial collateral ligament, between it and the tendon of the Semimembranosus (this is sometimes only an expansion from the next bursa); (4) one between the tendon of the Semimembranosus and the head of the tibia; (5) occasionally there is a bursa between the tendons of the Semimembranosus and Semitendinosus.

Structures Around the Joint.—In front, and at the sides, is the Quadriceps femoris; laterally the tendons of the Biceps femoris and Popliteus and the common peroneal nerve; medially, the Sartorius, Gracilis, Semitendinosus, and Semimembranosus; behind, the popliteal vessels and the tibial nerve, Popliteus, Plantaris, and medial and lateral heads of the Gastrocnemius, some lymph glands, and fat.

The **arteries** supplying the joint are the highest genicular (anastomotica magna), a branch

of the femoral, the genicular branches of the popliteal, the recurrent branches of the anterior tibial, and the descending branch from the lateral femoral circumflex of the profunda femoris.

The **nerves** are derived from the obturator, femoral, tibial, and common peroneal.

Movements.—The movements which take place at the knee-joint are flexion and extension, and, in certain positions of the joint, internal and external rotation. The movements of flexion and extension at this joint differ from those in a typical hinge-joint, such as the elbow, in that (a) the axis around which motion takes place is not a fixed one, but shifts forward during extension and backward during flexion; (b) the commencement of flexion and the end of extension are accompanied by rotatory movements associated with the fixation of the limb in a position of great stability. The movement from full flexion to full extension may therefore be described in three phases:

1. In the fully flexed condition the posterior parts of the femoral condyles rest on the corresponding portions of the meniscotibial surfaces, and in this position a slight amount of simple rolling movement is allowed.

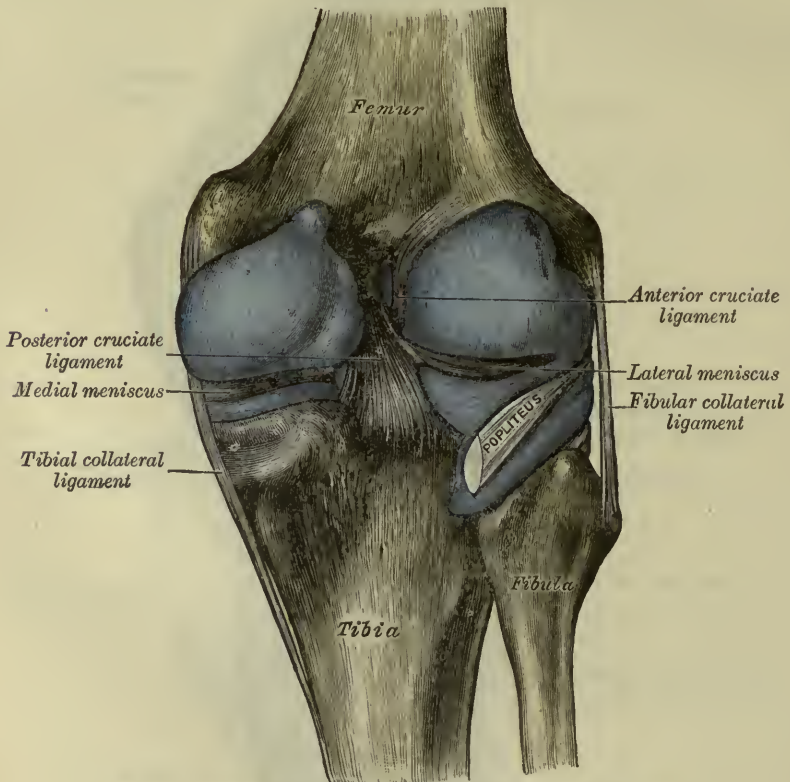


FIG. 352.—Capsule of right knee-joint (distended). Posterior aspect.

2. During the passage of the limb from the flexed to the extended position a gliding movement is superposed on the rolling, so that the axis, which at the commencement is represented by a line through the inner and outer condyles of the femur, gradually shifts forward. In this part of the movement, the posterior two-thirds of the tibial articular surfaces of the two femoral condyles are involved, and as these have similar curvatures and are parallel to one another, they move forward equally.

3. The lateral condyle of the femur is brought almost to rest by the tightening of the anterior cruciate ligament; it moves, however, slightly forward and medialward, pushing before it the anterior part of the lateral meniscus. The tibial surface on the medial condyle is prolonged farther forward than that on the lateral, and this prolongation is directed lateralward. When, therefore, the movement forward of the condyles is checked by the anterior cruciate ligament, continued muscular action causes the medial condyle, dragging with it the meniscus, to travel backward and medialward, thus producing an internal rotation of the thigh on the leg. When the position of full extension is reached the lateral part of the groove on the lateral condyle is pressed against the anterior part of the corresponding meniscus, while the medial part of the

groove rests on the articular margin in front of the lateral process of the tibial intercondyloid eminence. Into the groove on the medial condyle is fitted the anterior part of the medial meniscus, while the anterior cruciate ligament and the articular margin in front of the medial process of the tibial intercondyloid eminence are received into the forepart of the intercondyloid fossa of the femur. This third phase by which all these parts are brought into accurate apposition is known as the "screwing home," or locking movement of the joint.

The complete movement of flexion is the converse of that described above, and is therefore preceded by an external rotation of the femur which unlocks the extended joint.

The axes around which the movements of flexion and extension take place are not precisely at right angles to either bone; in flexion, the femur and tibia are in the same plane, but in extension the one bone forms an angle, opening lateralward with the other.

In addition to the rotatory movements associated with the completion of extension and the initiation of flexion, rotation inward or outward can be effected when the joint is partially flexed; these movements take place mainly between the tibia and the menisci, and are freest when the leg is bent at right angles with the thigh.

Movements of Patella.—The articular surface of the patella is indistinctly divided into seven facets—upper, middle, and lower horizontal pairs, and a medial perpendicular facet (Fig. 353). When the knee is forcibly flexed, the medial perpendicular facet is in contact with the semilunar surface on the lateral part of the medial condyle; this semilunar surface is a prolongation backward of the medial part of the patellar surface. As the leg is carried from the flexed to the extended position, first the highest pair, then the middle pair, and lastly the lowest pair of horizontal facets is successively brought into contact with the patellar surface of the femur. In the extended position, when the Quadriceps femoris is relaxed, the patella lies loosely on the front of the lower end of the femur.

During flexion, the ligamentum patellæ is put upon the stretch, and in extreme flexion the posterior cruciate ligament, the oblique popliteal, and collateral ligaments, and, to a slight extent, the anterior cruciate ligament, are relaxed. Flexion is checked during life by the contact of the leg with the thigh. When the knee-joint is fully extended the oblique popliteal and collateral ligaments, the anterior cruciate ligament, and the posterior cruciate ligament, are rendered tense; in the act of extending the knee, the ligamentum patellæ is tightened by the Quadriceps femoris, but in full extension with the heel supported it is relaxed. Rotation inward is checked by the anterior cruciate ligament; rotation outward tends to uncross and relax the cruciate ligaments, but is checked by the tibial collateral ligament. The main function of the cruciate ligament is to act as a direct bond between the tibia and femur and to prevent the former bone from being carried too far backward or forward. They also assist the collateral ligaments in resisting any bending of the joint to either side. The menisci are intended, as it seems, to adapt the surfaces of the tibia to the shape of the femoral condyles to a certain extent, so as to fill up the intervals which would otherwise be left in the varying positions of the joint, and to obviate the jars which would be so frequently transmitted up the limb in jumping or by falls on the feet; also to permit of the two varieties of motion, flexion and extension, and rotation, as explained above. The patella is a great defence to the front of the knee-joint, and distributes upon a large and tolerably even surface, during kneeling, the pressure which would otherwise fall upon the prominent ridges of the condyles; it also affords leverage to the Quadriceps femoris.

When standing erect in the attitude of "attention," the weight of the body falls in front of a line carried across the centers of the knee-joints, and therefore tends to produce overextension of the articulations; this, however, is prevented by the tension of the anterior cruciate, oblique popliteal, and collateral ligaments.

Extension of the leg on the thigh is performed by the Quadriceps femoris; *flexion* by the Biceps femoris, Semitendinosus, and Semimembranosus, assisted by the Gracilis, Sartorius, Gastrocnemius, Popliteus, and Plantaris. *Rotation outward* is effected by the Biceps femoris, and *rotation inward* by the Popliteus, Semitendinosus, and, to a slight extent, the Semimembranosus, the Sartorius, and the Gracilis. The Popliteus comes into action especially at the commencement of the movement of flexion of the knee; by its contraction the leg is rotated inward, or, if the tibia be fixed, the thigh is rotated outward, and the knee-joint is unlocked.



FIG. 353.—Posterior surface of the right patella, showing diagrammatically the areas of contact with the femur in different positions of the knee.

III. Articulations between the Tibia and Fibula.

The articulations between the tibia and fibula are effected by ligaments which connect the extremities and bodies of the bones. The ligaments may consequently

be subdivided into three sets: (1) those of the Tibiofibular articulation; (2) the interosseous membrane; (3) those of the Tibiofibular syndesmosis.

Tibiofibular Articulation (*articulatio tibiofibularis; superior tibiofibular articulation*).—This articulation is an arthrodial joint between the lateral condyle of the tibia and the head of the fibula. The contiguous surfaces of the bones present flat, oval facets covered with cartilage and connected together by an articular capsule and by anterior and posterior ligaments.

The Articular Capsule (*capsula articularis; capsular ligament*).—The articular capsule surrounds the articulation, being attached around the margins of the articular facets on the tibia and fibula; it is much thicker in front than behind.

The Anterior Ligament (*anterior superior ligament*).—The anterior ligament of the head of the fibula (Fig. 347) consists of two or three broad and flat bands, which pass obliquely upward from the front of the head of the fibula to the front of the lateral condyle of the tibia.

The Posterior Ligament (*posterior superior ligament*).—The posterior ligament of the head of the fibula (Fig. 348) is a single thick and broad band, which passes obliquely upward from the back of the head of the fibula to the back of the lateral condyle of the tibia. It is covered by the tendon of the Popliteus.

Synovial Membrane.—A synovial membrane lines the capsule; it is continuous with that of the knee-joint in occasional cases when the two joints communicate.

Interosseous Membrane (*membrana interossea cruris; middle tibiofibular ligament*).—An interosseous membrane extends between the interosseous crests of the tibia and fibula, and separates the muscles on the front from those on the back of the leg. It consists of a thin, aponeurotic lamina composed of oblique fibers, which for the most part run downward and lateralward; some few fibers, however, pass in the opposite direction. It is broader above than below. Its upper margin does not quite reach the tibiofibular joint, but presents a free concave border, above which is a large, oval aperture for the passage of the anterior tibial vessels to the front of the leg. In its lower part is an opening for the passage of the anterior peroneal vessels. It is continuous below with the interosseous ligament of the tibiofibular syndesmosis, and presents numerous perforations for the passage of small vessels. It is in relation, in *front*, with the Tibialis anterior, Extensor digitorum longus, Extensor hallucis proprius, Peronæus tertius, and the anterior tibial vessels and deep peroneal nerve; *behind*, with the Tibialis posterior and Flexor hallucis longus.

Tibiofibular Syndesmosis (*syndesmosis tibiofibularis; inferior tibiofibular articulation*).—This syndesmosis is formed by the rough, convex surface of the medial side of the lower end of the fibula, and a rough concave surface on the lateral side of the tibia. Below, to the extent of about 4 mm. these surfaces are smooth, and covered with cartilage, which is continuous with that of the ankle-joint. The ligaments are: anterior, posterior, inferior transverse, and interosseous.

The Anterior Ligament (*ligamentum malleoli lateralis anterioris; anterior inferior ligament*).—The anterior ligament of the lateral malleolus (Fig. 355) is a flat, triangular band of fibers, broader below than above, which extends obliquely downward and lateralward between the adjacent margins of the tibia and fibula, on the front aspect of the syndesmosis. It is in relation, in *front*, with the Peronæus tertius, the aponeurosis of the leg, and the integument; *behind*, with the interosseous ligament; and lies in contact with the cartilage covering the talus.

The Posterior Ligament (*ligamentum malleoli lateralis posterioris; posterior inferior ligament*).—The posterior ligament of the lateral malleolus (Fig. 355), smaller than the preceding, is disposed in a similar manner on the posterior surface of the syndesmosis.

The Inferior Transverse Ligament.—The inferior transverse ligament lies in front of the posterior ligament, and is a strong, thick band, of yellowish fibers which passes transversely across the back of the joint, from the lateral malleolus to the posterior border of the articular surface of the tibia, almost as far as its malleolar process. This ligament projects below the margin of the bones, and forms part of the articulating surface for the talus.

The Interosseous Ligament.—The interosseous ligament consists of numerous short, strong, fibrous bands, which pass between the contiguous rough surfaces of the tibia and fibula, and constitute the chief bond of union between the bones. It is continuous, above, with the interosseous membrane (Fig. 356).

Synovial Membrane.—The synovial membrane associated with the small arthroal part of this joint is continuous with that of the ankle-joint.

IV. Talocrural Articulation or Ankle-joint (Articulatio Talocruralis; Tibiotarsal Articulation).

The ankle-joint is a ginglymus, or hinge-joint. The structures entering into its formation are the lower end of the tibia and its malleolus, the malleolus of the

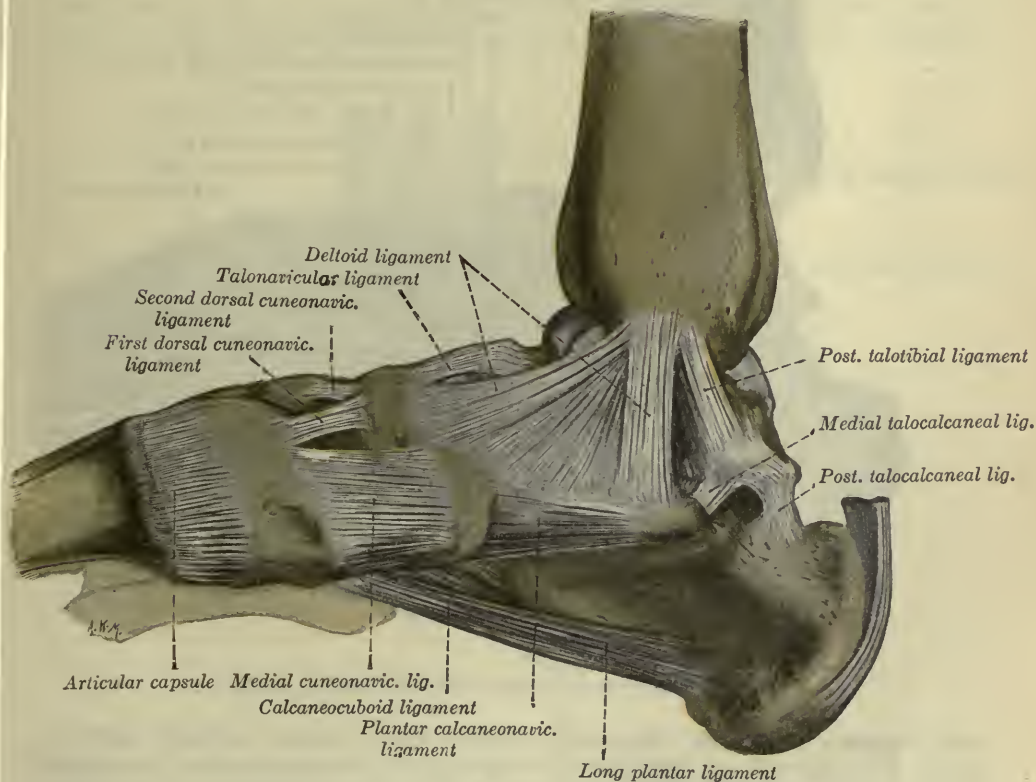


FIG. 354.—Ligaments of the medial aspect of the foot. (Quain.)

fibula, and the transverse ligament, which together form a mortise for the reception of the upper convex surface of the talus and its medial and lateral facets. The bones are connected by the following ligaments:

- | | |
|------------------------|----------------------------|
| The Articular Capsule. | The Anterior Talofibular. |
| The Deltoid. | The Posterior Talofibular. |
| The Calcaneofibular. | |

The Articular Capsule (*capsula articularis; capsular ligament*).—The articular capsule surrounds the joints, and is attached, *above*, to the borders of the articular surfaces of the tibia and malleoli; and *below*, to the talus around its upper articular surface. The anterior part of the capsule (*anterior ligament*) is a broad, thin, membranous layer, attached, *above*, to the anterior margin of the lower end of the tibia; *below*, to the talus, in front of its superior articular surface. It is in relation, in *front*, with the Extensor tendons of the toes, the tendons of the Tibialis anterior and Peronæus tertius, and the anterior tibial vessels and deep peroneal nerve. The posterior part of the capsule (*posterior ligament*) is very thin, and consists principally of transverse fibers. It is attached, *above*, to the margin of the articular surface of the tibia, blending with the transverse ligament; *below*, to the talus behind its superior articular facet. Laterally, it is somewhat thickened, and is attached to the hollow on the medial surface of the lateral malleolus.

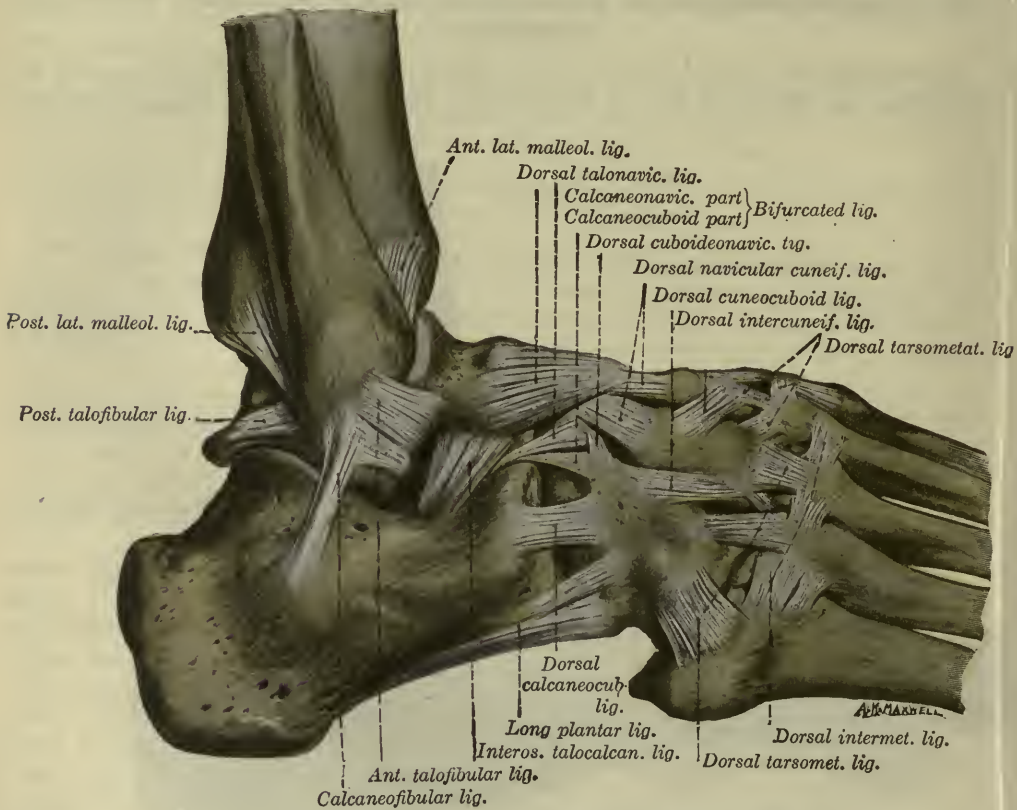


FIG. 355.—The ligaments of the foot from the lateral aspect. (Quain.)

The Deltoid Ligament (*ligamentum deltoideum; internal lateral ligament*) (Fig. 331).—The deltoid ligament is a strong, flat, triangular band, attached, *above*, to the apex and anterior and posterior borders of the medial malleolus. It consists of two sets of fibers, superficial and deep. Of the superficial fibers the most anterior (*tibionavicular*) pass forward to be inserted into the tuberosity of the navicular bone, and immediately behind this they blend with the medial margin of the plantar calcaneonavicular ligament; the middle (*calcaneotibial*) descend almost perpendicularly to be inserted into the whole length of the sustentaculum tali of the calcaneus; the posterior fibers (*posterior talotibial*) pass backward and lateralward to be attached to the inner side of the talus, and to the prominent

tubercle on its posterior surface, medial to the groove for the tendon of the Flexor hallucis longus. The deep fibers (*anterior talotibial*) are attached, *above*, to the tip of the medial malleolus, and, *below*, to the medial surface of the talus. The deltoid ligament is covered by the tendons of the Tibialis posterior and Flexor digitorum longus.

The anterior and posterior talofibular and the calcaneofibular ligaments were formerly described as the three fasciculi of the *external lateral ligament* of the ankle-joint.

The Anterior Talofibular Ligament (*ligamentum talofibulare anterius*) (Fig. 355).—The anterior talofibular ligament, the shortest of the three, passes from the anterior margin of the fibular malleolus, forward and medially, to the talus, in front of its lateral articular facet.

The Posterior Talofibular Ligament (*ligamentum talofibulare posterius*) (Fig. 355).—The posterior talofibular ligament, the strongest and most deeply seated, runs almost horizontally from the depression at the medial and back part of the fibular malleolus to a prominent tubercle on the posterior surface of the talus immediately lateral to the groove for the tendon of the Flexor hallucis longus.

The Calcaneofibular Ligament (*ligamentum calcaneofibulare*) (Fig. 355).—The calcaneofibular ligament, the longest of the three, is a narrow, rounded cord, running from the apex of the fibular malleolus downward and slightly backward to a tubercle on the lateral surface of the calcaneus. It is covered by the tendons of the Peronæi longus and brevis.

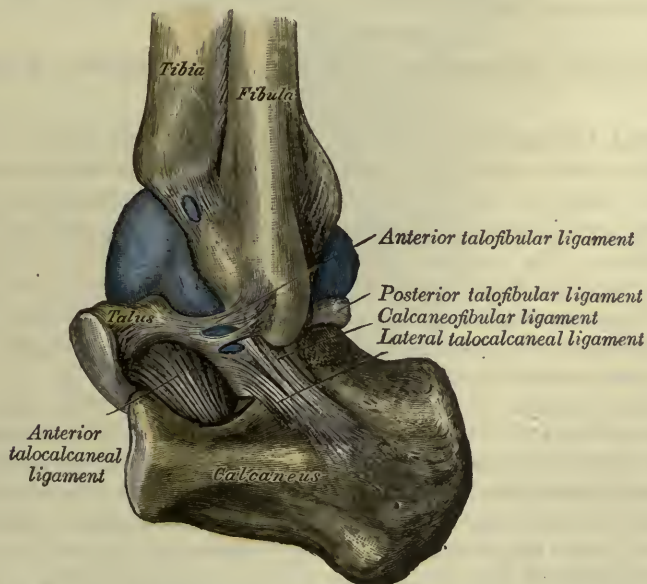

FIG. 356.—Capsule of left talocrura articulation (distended). Lateral aspect.

Synovial Membrane (Fig. 356).—The synovial membrane invests the deep surfaces of the ligaments, and sends a small process upward between the lower ends of the tibia and fibula.

Relations.—The tendons, vessels, and nerves in connection with the joint are, in *front*, from the medial side, the Tibialis anterior, Extensor hallucis proprius, anterior tibial vessels, deep peroneal nerve, Extensor digitorum longus, and Peronæus tertius; *behind*, from the medial side, the Tibialis posterior, Flexor digitorum longus, posterior tibial vessels, tibial nerve, Flexor hallucis longus; and, in the groove behind the fibular malleolus, the tendons of the Peronæi longus and brevis.

The **arteries** supplying the joint are derived from the malleolar branches of the anterior tibial and the peroneal.

The **nerves** are derived from the deep peroneal and tibial.

Movements.—When the body is in the erect position, the foot is at right angles to the leg. The movements of the joint are those of dorsiflexion and extension; dorsiflexion consists in the

approximation of the dorsum of the foot to the front of the leg, while in extension the heel is drawn up and the toes pointed downward. The range of movement varies in different individuals from about 50° to 90°. The transverse axis about which movement takes place is slightly oblique. The malleoli tightly embrace the talus in all positions of the joint, so that any slight degree of side-to-side movement which may exist is simply due to stretching of the ligaments of the talofibular syndesmosis, and slight bending of the body of the fibula. The superior articular surface of the talus is broader in front than behind. In dorsiflexion, therefore, greater space is required between the two malleoli. This is obtained by a slight outward rotatory movement of the lower end of the fibula and a stretching of the ligaments of the syndesmosis; this lateral movement is facilitated by a slight gliding at the tibiofibular articulation, and possibly also by the bending of the body of the fibula. Of the ligaments, the deltoid is of very great power—so much so, that it usually resists a force which fractures the process of bone to which it is attached. Its middle portion, together with the calcaneofibular ligament, binds the bones of the leg firmly to the foot, and resists displacement in every direction. Its anterior and posterior fibers limit extension and flexion of the foot respectively, and the anterior fibers also limit abduction. The posterior talofibular ligament assists the calcaneofibular in resisting the displacement of the foot backward, and deepens the cavity for the reception of the talus. The anterior talofibular is a security against the displacement of the foot forward, and limits extension of the joint.

The movements of inversion and eversion of the foot, together with the minute changes in form by which it is applied to the ground or takes hold of an object in climbing, etc., are mainly effected in the tarsal joints; the joint which enjoys the greatest amount of motion being that between the talus and calcaneus behind and the navicular and cuboid in front. This is often called the **transverse tarsal joint**, and it can, with the subordinate joints of the tarsus, replace the ankle-joint in a great measure when the latter has become ankylosed.

Extension of the foot upon the tibia and fibula is produced by the Gastrocnemius, Soleus, Plantaris, Tibialis posterior, Peronæi longus and brevis, Flexor digitorum longus, and Flexor hallucis longus; *dorsiflexion*, by the Tibialis anterior, Peronæus tertius, Extensor digitorum longus, and Extensor hallucis proprius.¹

V. Intertarsal Articulations (Articulationes Intertarsæ; Articulations of the Tarsus).

Talocalcaneal Articulation (*articulatio talocalcanea; articulation of the calcaneus and astragalus; calcaneo-astragaloid articulation*).—The articulations between the calcaneus and talus are two in number—anterior and posterior. Of these, the anterior forms part of the talocalcaneonavicular joint, and will be described with that articulation. The posterior or talocalcaneal articulation is formed between the posterior calcaneal facet on the inferior surface of the talus, and the posterior facet on the superior surface of the calcaneus. It is an arthrodial joint, and the two bones are connected by an articular capsule and by anterior, posterior, lateral, medial, and interosseous talocalcaneal ligaments.

The Articular Capsule (*capsula articularis*).—The articular capsule envelops the joint, and consists for the most part of short fibers, which are split up into distinct slips; between these there is only a weak fibrous investment.

The Anterior Talocalcaneal Ligament (*ligamentum talocalcaneum anterius; anterior calcaneo-astragaloid ligament*) (Figs. 356, 359).—The anterior talocalcaneal ligament extends from the front and lateral surface of the neck of the talus to the superior surface of the calcaneus. It forms the posterior boundary of the talocalcaneonavicular joint, and is sometimes described as the **anterior interosseous ligament**.

The Posterior Talocalcaneal Ligament (*ligamentum talocalcaneum posterius; posterior calcaneo-astragaloid ligament*) (Fig. 354).—The posterior talocalcaneal ligament connects the lateral tubercle of the talus with the upper and medial part of the calcaneus; it is a short band, and its fibers radiate from their narrow attachment to the talus.

The Lateral Talocalcaneal Ligament (*ligamentum talocalcaneum laterale; external calcaneo-astragaloid ligament*) (Figs. 356, 359).—The lateral talocalcaneal ligament

¹ The student must bear in mind that the Extensor digitorum longus and Extensor hallucis proprius are *extensors* of the toes, but *flexors* of the ankle; and that the Flexor digitorum longus and Flexor hallucis longus are *flexors* of the toes, but *extensors* of the ankle.

is a short, strong fasciculus, passing from the lateral surface of the talus, immediately beneath its fibular facet to the lateral surface of the calcaneus. It is placed in front of, but on a deeper plane than, the calcaneofibular ligament, with the fibers of which it is parallel.

The Medial Talocalcaneal Ligament (*ligamentum talocalcaneum mediale*; *internal calcaneo-astragaloid ligament*).—The medial talocalcaneal ligament connects the medial tubercle of the back of the talus with the back of the sustentaculum tali. Its fibers blend with those of the plantar calcaneonavicular ligament (Fig. 354).

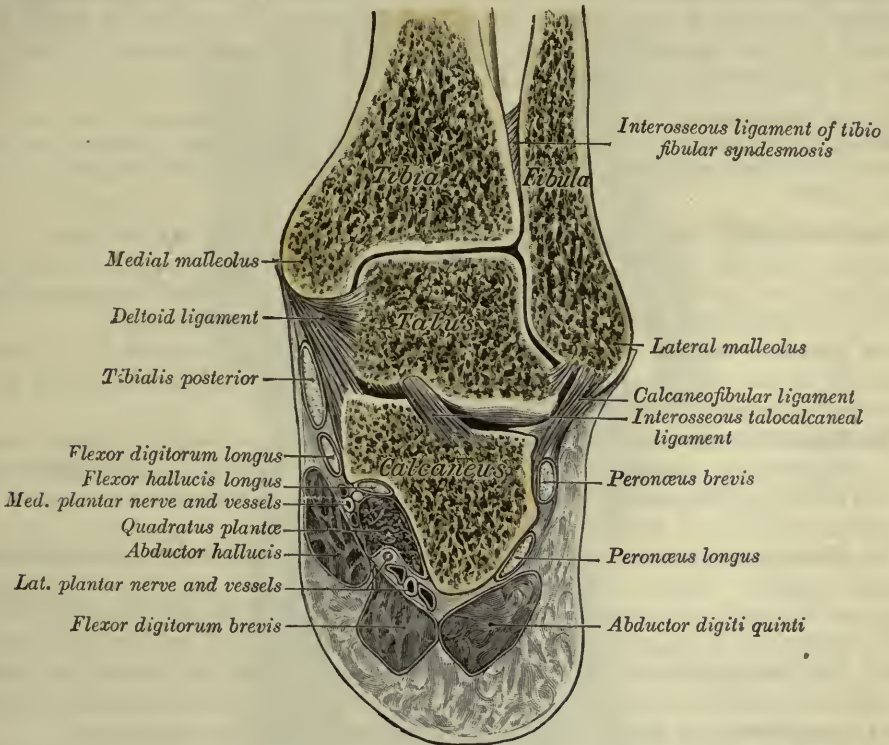


FIG. 357.—Coronal section through right talocrural and talocalcaneal joints.

The Interosseous Talocalcaneal Ligament (*ligamentum talocalcaneum interosseum*) (Figs. 357, 359).—The interosseous talocalcaneal ligament forms the chief bond of union between the bones. It is, in fact, a portion of the united capsules of the talocalcaneonavicular and the talocalcaneal joints, and consists of two partially united layers of fibers, one belonging to the former and the other to the latter joint. It is attached, *above*, to the groove between the articular facets of the under surface of the talus; *below*, to a corresponding depression on the upper surface of the calcaneus. It is very thick and strong, being at least 2.5 cm. in breadth from side to side, and serves to bind the calcaneus and talus firmly together.

Synovial Membrane (Fig. 360).—The synovial membrane lines the capsule of the joint, and is distinct from the other synovial membranes of the tarsus.

Movements.—The movements permitted between the talus and calcaneus are limited to gliding of the one bone on the other backward and forward and from side to side.

Talocalcaneonavicular Articulation (*articulatio talocalcaneonavicularis*).—This articulation is an arthrodial joint: the rounded head of the talus being received into the concavity formed by the posterior surface of the navicular, the anterior articular surface of the calcaneus, and the upper surface of the plantar calcaneo-

navicular ligament. There are two ligaments in this joint: the articular capsule and the dorsal talonavicular.

The Articular Capsule (*capsula articularis*).—The articular capsule is imperfectly developed except posteriorly, where it is considerably thickened and forms, with a part of the capsule of the talocalcaneal joint, the strong interosseous ligament which fills in the canal formed by the opposing grooves on the calcaneus and talus, as above mentioned.

The Dorsal Talonavicular Ligament (*ligamentum talonaviculare dorsale; superior astragalonavicular ligament*) (Fig. 354).—This ligament is a broad, thin band, which connects the neck of the talus to the dorsal surface of the navicular bone; it is covered by the Extensor tendons. The plantar calcaneonavicular supplies the place of a plantar ligament for this joint.

Synovial Membrane.—The synovial membrane lines all parts of the capsule of the joint.

Movements.—This articulation permits of a considerable range of gliding movements, and some rotation; its feeble construction allows occasionally of dislocation of the other bones of the tarsus from the talus.

Calcaneocuboid Articulation (*articulatio calcaneocuboidea; articulation of the calcaneus with the cuboid*).—The ligaments connecting the calcaneus with the cuboid are five in number, viz., the articular capsule, the dorsal calcaneocuboid, part of the bifurcated, the long plantar, and the plantar calcaneocuboid.

The Articular Capsule (*capsula articularis*).—The articular capsule is an imperfectly developed investment, containing certain strengthened bands, which form the other ligaments of the joint.

The Dorsal Calcaneocuboid Ligament (*ligamentum calcaneocuboideum dorsale; superior calcaneocuboid ligament*) (Fig. 355).—The dorsal calcaneocuboid ligament is a thin but broad fasciculus, which passes between the contiguous surfaces of the calcaneus and cuboid, on the dorsal surface of the joint.

The Bifurcated Ligament (*ligamentum bifurcatum; internal calcaneocuboid; interosseous ligament*) (Fig. 355, 359).—The bifurcated ligament is a strong band, attached behind to the deep hollow on the upper surface of the calcaneus and dividing in front in a Y-shaped manner into a calcaneocuboid and a calcaneonavicular part. The **calcaneocuboid part** is fixed to the medial side of the cuboid and forms one of the principal bonds between the first and second rows of the tarsal bones. The **calcaneonavicular part** is attached to the lateral side of the navicular.

The Long Plantar Ligament (*ligamentum plantare longum; long calcaneocuboid ligament; superficial long plantar ligament*) (Fig. 358).—The long plantar ligament is the longest of all the ligaments of the tarsus: it is attached *behind* to the plantar surface of the calcaneus in front of the tuberosity, and in *front* to the tuberosity on the plantar surface of the cuboid bone, the more superficial fibers being continued forward to the bases of the second, third, and fourth metatarsal bones. This ligament converts the groove on the plantar surface of the cuboid into a canal for the tendon of the Peronæus longus.

The Plantar Calcaneocuboid Ligament (*ligamentum calcaneocuboideum plantare; short calcaneocuboid ligament; short plantar ligament*) (Fig. 358).—The plantar calcaneocuboid ligament lies nearer to the bones than the preceding, from which it is separated by a little areolar tissue. It is a short but wide band of great strength, and extends from the tubercle and the depression in front of it, on the forepart of the plantar surface of the calcaneus, to the plantar surface of the cuboid behind the peroneal groove.

Synovial Membrane.—The synovial membrane lines the inner surface of the capsule and is distinct from that of the other tarsal articulations (Fig. 360).

Movements.—The movements permitted between the calcaneus and cuboid are limited to slight gliding movements of the bones upon each other.

The *transverse tarsal joint* is formed by the articulation of the calcaneus with the cuboid, and

the articulation of the talus with the navicular. The movement which takes place in this joint is more extensive than that in the other tarsal joints, and consists of a sort of rotation by means of which the foot may be slightly flexed or extended, the sole being at the same time carried medially (inverted) or laterally (everted).

The Ligaments Connecting the Calcaneus and Navicular.—Though the calcaneus and navicular do not directly articulate, they are connected by two ligaments: the calcaneonavicular part of the bifurcated, and the plantar calcaneonavicular.

The calcaneonavicular part of the bifurcated ligament is described on page 354.

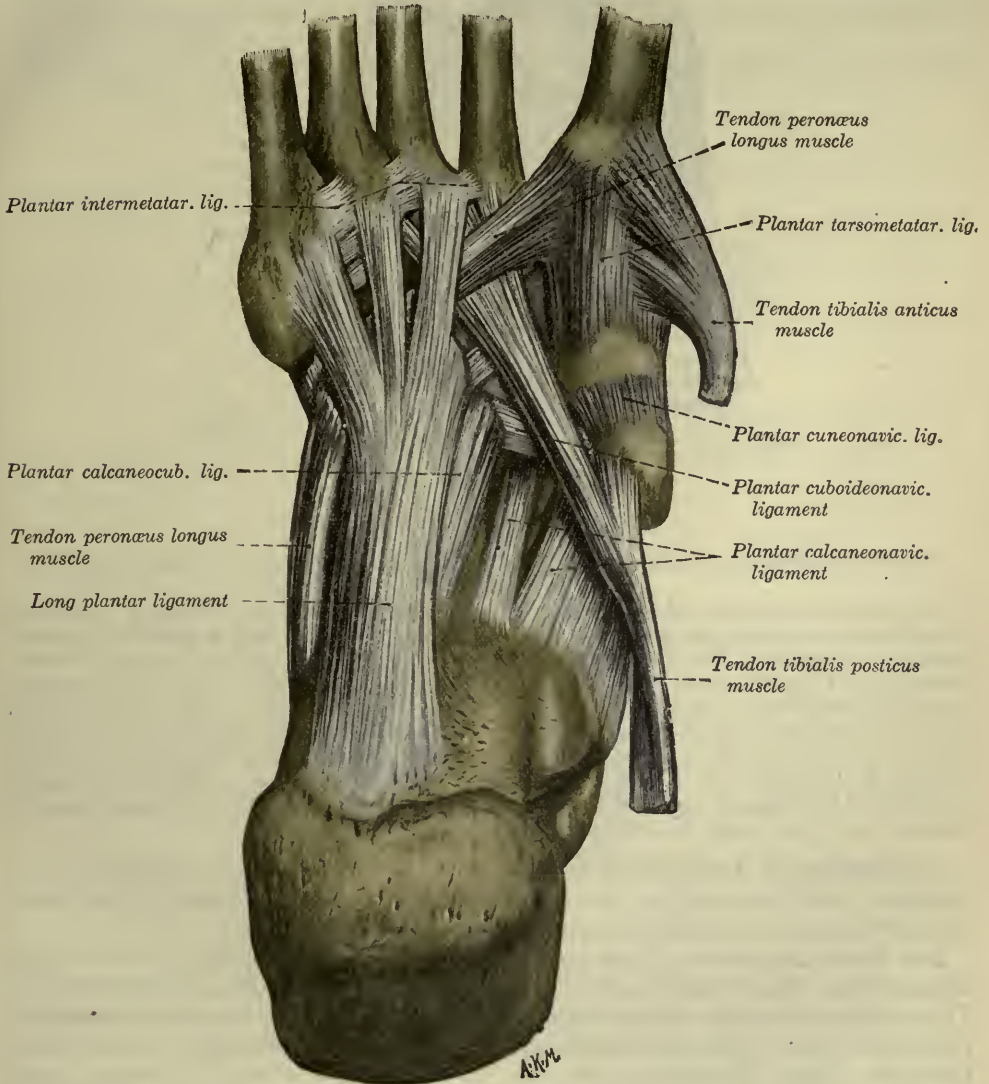


FIG. 358.—Ligaments of the sole of the foot, with the tendons of the Peronæus longus, Tibialis posterior and Tibialis anterior muscles. (Quain.)

The Plantar Calcaneonavicular Ligament (*ligamentum calcaneonaviculare plantare; inferior or internal calcaneonavicular ligament; calcaneonavicular ligament*) (Figs. 354, 358).—The plantar calcaneonavicular ligament is a broad and thick band of fibers, which connects the anterior margin of the sustentaculum tali of the calcaneus to the plantar surface of the navicular. This ligament not only serves to connect the calcaneus and navicular, but supports the head of the talus, forming

part of the articular cavity in which it is received. The **dorsal surface** of the ligament presents a fibrocartilaginous facet, lined by the synovial membrane, and upon this a portion of the head of the talus rests. Its **plantar surface** is supported by the tendon of the Tibialis posterior; its **medial border** is blended with the forepart of the deltoid ligament of the ankle-joint.

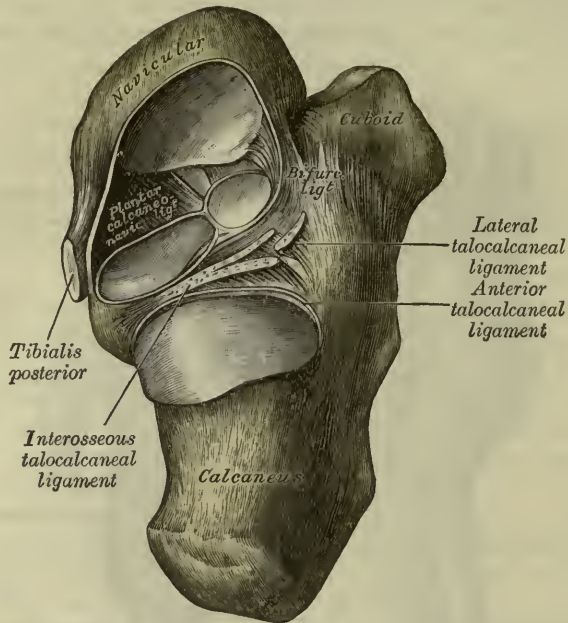


FIG. 359.—Talocalcaneal and talocalcaneonavicular articulations exposed from above by removing the talus.

The plantar calcaneonavicular ligament, by supporting the head of the talus, is principally concerned in maintaining the arch of the foot. When it yields, the head of the talus is pressed downward, medialward, and forward by the weight of the body, and the foot becomes flattened, expanded, and turned lateralward, and exhibits the condition known as *flat-foot*. This ligament contains a considerable amount of elastic fibers, so as to give elasticity to the arch and spring to the foot; hence it is sometimes called the "spring" ligament. It is supported, on its plantar surface, by the tendon of the Tibialis posterior, which spreads out at its insertion into a number of fasciculi, to be attached to most of the tarsal and metatarsal bones. This prevents undue stretching of the ligament, and is a protection against the occurrence of flat-foot; hence muscular weakness is, in most cases, the primary cause of the deformity.

Cuneonavicular Articulation (*articulatio cuneonavicularis*; articulation of the navicular with the cuneiform bones).—The navicular is connected to the three cuneiform bones by dorsal and plantar ligaments.

The Dorsal Ligaments (*ligamenta navicularicuneiformia dorsalia*).—The dorsal ligaments are three small bundles, one attached to each of the cuneiform bones. The bundle connecting the navicular with the first cuneiform is continuous around the medial side of the articulation with the plantar ligament which unites these two bones (Figs. 354, 355).

The Plantar Ligaments (*ligamenta navicularicuneiformia plantaria*).—The plantar ligaments have a similar arrangement to the dorsal, and are strengthened by slips from the tendon of the Tibialis posterior (Fig. 358).

Synovial Membrane.—The synovial membrane of these joints is part of the great tarsal synovial membrane (Fig. 360).

Movements.—Mere gliding movements are permitted between the navicular and cuneiform bones.

Cuboideonavicular Articulation.—The navicular bone is connected with the cuboid by dorsal, plantar, and interosseous ligaments.

The Dorsal Ligament (*ligamentum cuboideonaviculare dorsale*).—The dorsal ligament extends obliquely forward and lateralward from the navicular to the cuboid bone (Fig. 355).

The Plantar Ligament (*ligamentum cuboideonaviculare plantare*).—The plantar ligament passes nearly transversely between these two bones (Fig. 358).

The Interosseous Ligament.—The interosseous ligament consists of strong transverse fibers, and connects the rough non-articular portions of the adjacent surfaces of the two bones Fig. 360).

Synovial Membrane.—The synovial membrane of this joint is part of the great tarsal synovial membrane (Fig. 360).

Movements.—The movements permitted between the navicular and cuboid bones are limited to a slight gliding upon each other.

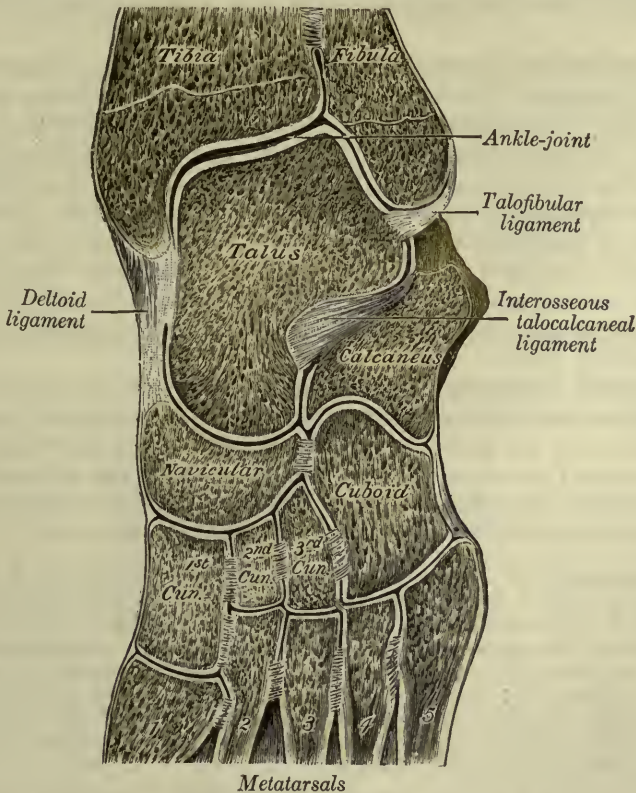


FIG. 360.—Oblique section of left intertarsal and tarsometatarsal articulations, showing the synovial cavities.

Intercuneiform and Cuneocuboid Articulations.—The three cuneiform bones and the cuboid are connected together by dorsal, plantar, and interosseous ligaments.

The Dorsal Ligaments (*ligamenta intercuneiformia dorsalia*).—The dorsal ligaments consist of three transverse bands: one connects the first with the second cuneiform, another the second with the third cuneiform, and another the third cuneiform with the cuboid.

The Plantar Ligaments (*ligamenta intercuneiformia plantaria*).—The plantar ligaments have a similar arrangement to the dorsal, and are strengthened by slips from the tendon of the Tibialis posterior.

The Interosseous Ligaments (*ligamenta intercuneiformia interossea*).—The interosseous ligaments consist of strong transverse fibers which pass between the rough non-articular portions of the adjacent surfaces of the bones (Fig. 360).

Synovial Membrane.—The synovial membrane of these joints is part of the great tarsal synovial membrane (Fig. 360).

Movements.—The movements permitted between these bones are limited to a slight gliding upon each other.

VI. Tarsometatarsal Articulations (*Articulationes Tarsometatarsæ*).

These are arthrodial joints. The bones entering into their formation are the first, second, and third cuneiforms, and the cuboid, which articulate with the bases of the metatarsal bones. The first metatarsal bone articulates with the first cuneiform; the second is deeply wedged in between the first and third cuneiforms articulating by its base with the second cuneiform; the third articulates with the third cuneiform; the fourth, with the cuboid and third cuneiform; and the fifth, with the cuboid. The bones are connected by dorsal, plantar, and interosseous ligaments.

The Dorsal Ligaments (*ligamenta tarsometatarsæ dorsalia*).—The dorsal ligaments are strong, flat bands. The first metatarsal is joined to the first cuneiform by a broad, thin band; the second has three, one from each cuneiform bone; the third has one from the third cuneiform; the fourth has one from the third cuneiform and one from the cuboid; and the fifth, one from the cuboid (Figs. 354, 355).

The Plantar Ligaments (*ligamenta tarsometatarsæ plantaria*).—The plantar ligaments consist of longitudinal and oblique bands, disposed with less regularity than the dorsal ligaments. Those for the first and second metatarsals are the strongest; the second and third metatarsals are joined by oblique bands to the first cuneiform; the fourth and fifth metatarsals are connected by a few fibers to the cuboid (Fig. 358).

The Interosseous Ligaments (*ligamenta cuneometatarsæ interossia*).—The interosseous ligaments are three in number. The first is the strongest, and passes from the lateral surface of the first cuneiform to the adjacent angle of the second metatarsal. The second connects the third cuneiform with the adjacent angle of the second metatarsal. The third connects the lateral angle of the third cuneiform with the adjacent side of the base of the third metatarsal.

Synovial Membrane (Fig. 360).—The synovial membrane between the first cuneiform and the first metatarsal forms a distinct sac. The synovial membrane between the second and third cuneiforms behind, and the second and third metatarsal bones in front, is part of the great tarsal synovial membrane. Two prolongations are sent forward from it, one between the adjacent sides of the second and third, and another between those of the third and fourth metatarsal bones. The synovial membrane between the cuboid and the fourth and fifth metatarsal bones forms a distinct sac. From it a prolongation is sent forward between the fourth and fifth metatarsal bones.

Movements.—The movements permitted between the tarsal and metatarsal bones are limited to slight gliding of the bones upon each other.

Nerve Supply.—The intertarsal and tarsometatarsal joints are supplied by the deep peroneal nerve.

VII. Intermetatarsal Articulations (*Articulationes Intermetatarsæ*).

The base of the first metatarsal is not connected with that of the second by any ligaments; in this respect the great toe resembles the thumb.

The bases of the other four metatarsals are connected by the dorsal, plantar, and interosseous ligaments.

The Dorsal Ligaments (*ligamenta basium [oss. metatars.] dorsalia*) pass transversely between the dorsal surfaces of the bases of the adjacent metatarsal bones.

The Plantar Ligaments (*ligamenta basium [oss. metatars.] plantaria*).—The plantar ligaments have a similar arrangement to the dorsal.

The Interosseous Ligaments (*ligamenta basium [oss. metatars.] interossea*).—The interosseous ligaments consist of strong transverse fibers which connect the rough non-articular portions of the adjacent surfaces.

Synovial Membranes (Fig. 360).—The synovial membranes between the second and third, and the third and fourth metatarsal bones are part of the great tarsal synovial membrane; that between the fourth and fifth is a prolongation of the synovial membrane of the cuboideometatarsal joint.

Movements.—The movement permitted between the tarsal ends of the metatarsal bones is limited to a slight gliding of the articular surfaces upon one another.

The heads of all the metatarsal bones are connected together by the transverse metatarsal ligament.

The Transverse Metatarsal Ligament.—The transverse metatarsal ligament is a narrow band which runs across and connects together the heads of all the metatarsal bones; it is blended anteriorly with the plantar (glenoid) ligaments of the metatarsophalangeal articulations. Its plantar surface is concave where the Flexor tendons run below it; above it the tendons of the Interossei pass to their insertions. It differs from the transverse metacarpal ligament in that it connects the metatarsal to the others.

The Synovial Membranes in the Tarsal and Tarsometatarsal Joints. (Fig. 360).—The synovial membranes found in the articulations of the tarsus and metatarsus are six in number: one for the talocalcaneal articulation; a second for the talocalcaneonavicular articulation; a third for the calcaneocuboid articulation; and a fourth for the cuneonavicular, intercuneiform, and cuneocuboid articulations, the articulations of the second and third cuneiforms with the bases of the second and third metatarsal bones, and the adjacent surfaces of the bases of the second, third, and fourth metatarsal bones; a fifth for the first cuneiform with the metatarsal bone of the great toe; and a sixth for the articulation of the cuboid with the fourth and fifth metatarsal bones. A small synovial cavity is sometimes found between the contiguous surfaces of the navicular and cuboid bones.

VIII. Metatarsophalangeal Articulations (*Articulationes Metatarsophalangeæ*).

The metatarsophalangeal articulations are of the condyloid kind, formed by the reception of the rounded heads of the metatarsal bones in shallow cavities on the ends of the first phalanges.

The ligaments are the plantar and two collateral.

The Plantar Ligaments (*ligamenta accessoria plantaria; glenoid ligaments of Cruveilhier*).—The plantar ligaments are thick, dense, fibrous structures. They are placed on the plantar surfaces of the joints in the intervals between the collateral ligaments, to which they are connected; they are loosely united to the metatarsal bones, but very firmly to the bases of the first phalanges. Their plantar surfaces are intimately blended with the transverse metatarsal ligament, and grooved for the passage of the Flexor tendons, the sheaths surrounding which are connected to the sides of the grooves. Their deep surfaces form part of the articular facets for the heads of the metatarsal bones, and are lined by synovial membrane.

The Collateral Ligaments (*ligamenta collateralia; lateral ligaments*).—The collateral ligaments are strong, rounded cords, placed one on either side of each joint, and attached, by one end, to the posterior tubercle on the side of the head of the metatarsal bone, and, by the other, to the contiguous extremity of the phalanx.

The place of dorsal ligaments is supplied by the Extensor tendons on the dorsal surfaces of the joints.

Movements.—The movements permitted in the metatarsophalangeal articulations are flexion, extension, abduction, and adduction.

IX. Articulations of the Digits (*Articulationes Digitorum Pedis; Articulationes of the Phalanges*).

The interphalangeal articulations are ginglymoid joints, and each has a plantar and two collateral ligaments.

The arrangement of these ligaments is similar to that in the metatarsophalangeal articulations; the Extensor tendons supply the places of dorsal ligaments.

Movements.—The only movements permitted in the joints of the digits are flexion and extension; these movements are more extensive between the first and second phalanges than between the second and third. The amount of flexion is very considerable, but extension is limited by the plantar and collateral ligaments.

Arches of the Foot.

In order to allow it to support the weight of the body in the erect posture with the least expenditure of material, the foot is constructed of a series of arches formed by the tarsal and metatarsal bones, and strengthened by the ligaments and tendons of the foot.

The main arches are the **antero-posterior arches**, which may, for descriptive purposes, be regarded as divisible into two types—a medial and a lateral. The **medial arch** (see Fig. 290, page 276) is made up by the calcaneus, the talus, the navicular, the three cuneiforms, and the first, second, and third metatarsals. Its summit is at the superior articular surface of the talus, and its two extremities or piers, on which it rests in standing, are the tuberosity on the plantar surface of the calcaneus posteriorly and the heads of the first, second, and third metatarsal bones anteriorly. The chief characteristic of this arch is its elasticity, due to its height and to the number of small joints between its component parts. Its weakest part, *i. e.*, the part most liable to yield from overpressure, is the joint between the talus and navicular, but this portion is braced by the plantar calcaneonavicular ligament, which is elastic and is thus able to quickly restore the arch to its pristine condition when the disturbing force is removed. The ligament is strengthened medially by blending with the deltoid ligament of the ankle-joint, and is supported inferiorly by the tendon of the Tibialis posterior, which is spread out in a fan-shaped insertion and prevents undue tension of the ligament or such an amount of stretching as would permanently elongate it. The arch is further supported by the plantar aponeurosis, by the small muscles in the sole of the foot, by the tendons of the Tibialis anterior and posterior and Peronæus longus, and by the ligaments of all the articulations involved. The **lateral arch** (see Fig. 291, page 277) is composed of the calcaneus, the cuboid, and the fourth and fifth metatarsals. Its summit is at the talocalcaneal articulation, and its chief joint is the calcaneocuboid, which possesses a special mechanism for locking, and allows only a limited movement. The most marked features of this arch are its solidity and its slight elevation; two strong ligaments, the long plantar and the plantar calcaneocuboid, together with the Extensor tendons and the short muscles of the little toe, preserve its integrity.

While these medial and lateral arches may be readily demonstrated as the component antero-posterior arches of the foot, yet the **fundamental longitudinal arch** is contributed to by both, and consists of the calcaneus, cuboid, third cuneiform, and third metatarsal: all the other bones of the foot may be removed without destroying this arch.

In addition to the longitudinal arches the foot presents a series of **transverse arches**. At the posterior part of the metatarsus and the anterior part of the tarsus the arches are complete, but in the middle of the tarsus they present more the characters of half-domes the concavities of which are directed downward and medialward, so that when the medial borders of the feet are placed in apposition a complete tarsal dome is formed. The transverse arches are strengthened by the interosseous, plantar, and dorsal ligaments, by the short muscles of the first and fifth toes (especially the transverse head of the Adductor hallucis), and by the Peronæus longus, whose tendon stretches across between the piers of the arches.

BIBLIOGRAPHY.

R. FICK: Handbuch der Anatomie und Mechanik der Gelenke (Bardeleben's Handbuch der Anatomie).

MYOLOGY.¹

THE Muscles are connected with the bones, cartilages, ligaments, and skin, either directly, or through the intervention of fibrous structures called tendons or aponeuroses. Where a muscle is attached to bone or cartilage, the fibers end in blunt extremities upon the periosteum or perichondrium, and do not come into direct relation with the osseous or cartilaginous tissue. Where muscles are connected with its skin, they lie as a flattened layer beneath it, and are connected with its areolar tissue by larger or smaller bundles of fibers, as in the muscles of the face.

The muscles vary extremely in their form. In the limbs, they are of considerable length, especially the more superficial ones; they surround the bones, and constitute an important protection to the various joints. In the trunk, they are broad, flattened, and expanded, and assist in forming the walls of the trunk cavities. Hence the reason of the terms, **long, broad, short**, etc., used in the description of a muscle.

There is considerable variation in the arrangement of the fibers of certain muscles with reference to the tendons to which they are attached. In some muscles the fibers are parallel and run directly from their origin to their insertion; these are quadrilateral muscles, such as the Thyreohyoideus. A modification of these is found in the fusiform muscles, in which the fibers are not quite parallel, but slightly curved, so that the muscle tapers at either end; in their actions, however, they resemble the quadrilateral muscles. Secondly, in other muscles the fibers are convergent; arising by a broad origin, they converge to a narrow or pointed insertion. This arrangement of fibers is found in the triangular muscles—*e. g.*, the Temporalis. In some muscles, which otherwise would belong to the quadrilateral or triangular type, the origin and insertion are not in the same plane, but the plane of the line of origin intersects that of the line of insertion; such is the case in the Pectineus. Thirdly, in some muscles (*e. g.*, the Peronei) the fibers are oblique and converge, like the plumes of a quill pen, to one side of a tendon which runs the entire length of the muscle; such muscles are termed **unipennate**. A modification of this condition is found where oblique fibers converge to both sides of a central tendon; these are called **bipennate**, and an example is afforded in the Rectus femoris. Finally, there are muscles in which the fibers are arranged in curved bundles in one or more planes, as in the Sphincters. The arrangement of the fibers is of considerable importance in respect to the relative strength and range of movement of the muscle. Those muscles where the fibers are long and few in number have great range, but diminished strength; where, on the other hand, the fibers are short and more numerous, there is great power, but lessened range.

The names applied to the various muscles have been derived: (1) from their situation, as the Tibialis, Radialis, Ulnaris, Peronæus; (2) from their direction, as the Rectus abdominis, Obliqui capitis, Transversus abdominis; (3) from their uses, as Flexors, Extensors, Abductors, etc.; (4) from their shape, as the Deltoideus,

¹ The muscles and fasciæ are described conjointly, in order that the student may consider the arrangement of the latter in his dissection of the former. It is rare for the student of anatomy in this country to have the opportunity of dissecting the fasciæ separately; and it is for this reason, as well as from the close connection that exists between the muscles and their investing sheaths, that they are considered together. Some general observations are first made on the anatomy of the muscles and fasciæ, the special descriptions being given in connection with the different regions.

Rhomboideus; (5) from the number of their divisions, as the Biceps and Triceps; (6) from their points of attachment, as the Sternocleidomastoideus, Sternohyoideus, Sternothyreoides.

In the description of a muscle, the term **origin** is meant to imply its more fixed or central attachment; and the term **insertion** the movable point on which the force of the muscle is applied; but the origin is absolutely fixed in only a small number of muscles, such as those of the face which are attached by one extremity to immovable bones, and by the other to the movable integument; in the greater number, the muscle can be made to act from either extremity.

In the dissection of the muscles, attention should be directed to the exact *origin*, *insertion*, and *actions* of each, and to its more important *relations* with surrounding parts. While accurate knowledge of the points of attachment of the muscles is of great importance in the determination of their actions, it is not to be regarded as conclusive. The action of the muscle deduced from its attachments, or even by pulling on it in the dead subject, is not necessarily its action in the living. By pulling, for example, on the Brachioradialis in the cadaver the hand may be slightly supinated when in the prone position and slightly pronated when in the supine position, but there is no evidence that these actions are performed by the muscle during life. It is impossible for an individual to throw into action any one muscle; in other words, movements, not muscles, are represented in the central nervous system. To carry out a movement a definite combination of muscles is called into play, and the individual has no power either to leave out a muscle from this combination or to add one to it. One (or more) muscle of the combination is the chief moving force; when this muscle passes over more than one joint other muscles (**synergic muscles**) come into play to inhibit the movements not required; a third set of muscles (**fixation muscles**) fix the limb—*i. e.*, in the case of the limb-movements—and also prevent disturbances of the equilibrium of the body generally. As an example, the movement of the closing of the fist may be considered: (1) the prime movers are the Flexores digitorum, Flexor pollicis longus, and the small muscles of the thumb; (2) the synergic muscles are the Extensores carpi, which prevent flexion of the wrist; while (3) the fixation muscles are the Biceps and Triceps brachii, which steady the elbow and shoulder. A further point which must be borne in mind in considering the actions of muscles is that in certain positions a movement can be effected by gravity, and in such a case the muscles acting are the antagonists of those which might be supposed to be in action. Thus in flexing the trunk when no resistance is interposed the Sacrospinales contract to regulate the action of gravity, and the Recti abdominis are relaxed.¹

By a consideration of the action of the muscles, the surgeon is able to explain the causes of displacement in various forms of fracture, and the causes which produce distortion in various deformities, and, consequently, to adopt appropriate treatment in each case. The relations, also, of some of the muscles, especially those in immediate apposition with the larger bloodvessels, and the surface markings they produce, should be remembered, as they form useful guides in the application of ligatures to those vessels.

MECHANICS OF MUSCLE.²

In studying the mechanical action of muscles the individual muscle cannot always be treated as a single unit, since different parts of the same muscle may have entirely different actions, as with the Pectoralis major, the Deltoid, and the Trapezius where the nerve impulses control and stimulate different portions of the

¹ Consult in this connection the Croonian Lectures (1903) on "Muscular Movements and Their Representation in the Central Nervous System," by Charles E. Beevor, M.D.

² R. Fick. Bd. ii, in Bardeleben's Handbuch der Anatomie des Menschen.

muscle in succession or at different times. Most muscles are, however, in a mechanical sense units. But in either case the muscle fibers constitute the elementary motor elements.

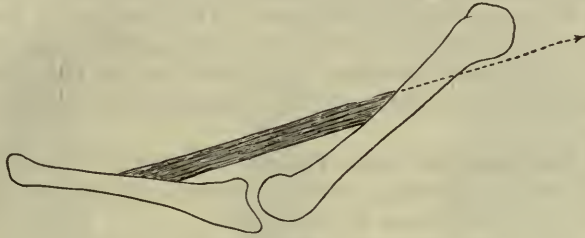


FIG. 361

The Direction of the Muscle Pull.—In those muscles where the fibers always run in a straight line from origin to insertion in all positions of the joint, a straight line joining the middle of the surface of origin with the middle of the insertion surface

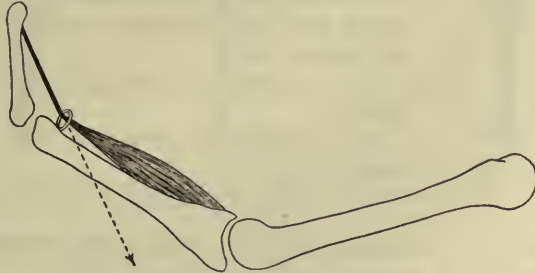

FIG. 362

will give the direction of the pull (Fig. 361). If, however, the muscle or its tendon is bent out of a straight line by a bony process or ligament so that it runs over a pulley-like arrangement, the direction of the muscle pull is naturally bent out of



FIG. 363

line. The direction of the pull in such cases is from the middle point of insertion to the middle point of the pulley where the muscle or tendon is bent. Muscles or tendons of muscles which pass over more than one joint and pass through more than

one pulley may be resolved, so far as the direction of the pull is concerned, into two or more units or single-joint muscles (Fig. 362). The tendons of the Flexor profundus digitorum, for example, pass through several pulleys formed by fibrous sheaths. The direction of the pull is different for each joint and varies for each joint according to the position of the bones. The direction is determined in each case, however, by a straight line between the centers of the pulleys on either side of the joint (Fig. 363). The direction of the pull in any of the segments would not be altered by any change in the position or origin of the muscle belly above the proximal pulley.

The Action of the Muscle Pull on the Tendon.—Where the muscle fibers are parallel or nearly parallel to the direction of the tendon the entire strength of the muscle contraction acts in the direction of the tendon.

In pinnate muscles, however, only a portion of the strength of contraction is efficient in the direction of the tendon, since a portion of the pull would tend to draw the tendon to one side, this is mostly annulled by pressure of surrounding parts. In bipinnate muscles this lateral pull is counterbalanced. If, for example, the muscle

fibers are inserted into the tendon at an angle of 60 degrees (Fig. 364), it is easy to determine by the parallelogram of forces that the strength of the pull along the direction of the tendon is equal to one-half the muscle pull.

T = tendon, m = strength and direction of muscle pull.

t = component acting in the direction of the tendon.

ϕ = angle of insertion of muscle fibers into tendon.

$$\cos \phi = \frac{t}{m} \quad \cos \angle 60^\circ = 0.50000$$

$$0.5 = \frac{t}{m} \quad t = \frac{1}{2} m$$

$$\text{If } \angle \phi = 72^\circ 30' \quad \cos = \frac{1}{3}$$

$$\angle \phi = 41^\circ 20' \quad \cos = \frac{3}{4}$$

$$\angle \phi = 90^\circ \quad \cos = 0$$

$$\angle \phi = 0^\circ \quad \cos = 1$$

The more acute the angle ϕ , that is the smaller the angle, the greater the component acting in the direction of the tendon pull. At $41^\circ 20'$ three-fourths of the pull would be exerted in the direction of the tendon and at 0° the entire strength.

On the other hand, the greater the angle the smaller the tendon component; at $72^\circ 30'$ one-third the muscle strength would act in the direction of the tendon and at 90° the tendon component would be *nil*.

The Strength of Muscles.—The strength of a muscle depends upon the number of fibers in what is known as the physiological cross-section, that is, a section which passes through practically all of the fibers. In a muscle with parallel or nearly parallel fibers which have the same direction as the tendon this corresponds to the anatomical cross-section, but in unipinnate and bipinnate muscles the physiological cross-section may be nearly at right angles to the anatomical cross-section as shown in Fig. 365. Since Huber has shown that muscle fibers in a single fasciculus of a given muscle vary greatly in length, in some fasciculi from 9 mm. to 30.4 mm., it is unlikely that the physiological cross-section will pass through all the fibers. Estimates have been made of the strength of muscles and it is probable that coarse-fibered muscles are somewhat stronger per square centimeter of physiological

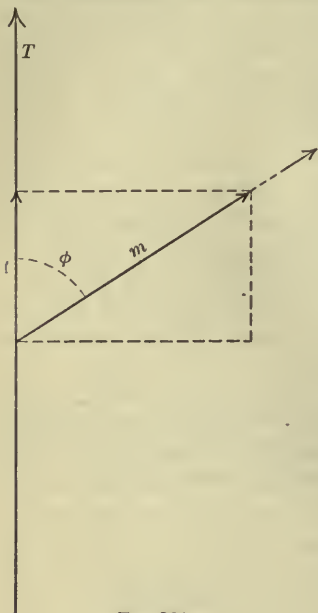


FIG. 364

cross-section than are the fine-fibered muscles. Fick estimates the average strength as about 10 kg. per square cm. This is known as the **absolute muscle strength**. The total strength of a muscle would be equal to the number of square centimeters in its physiological cross-section \times 10 kg.

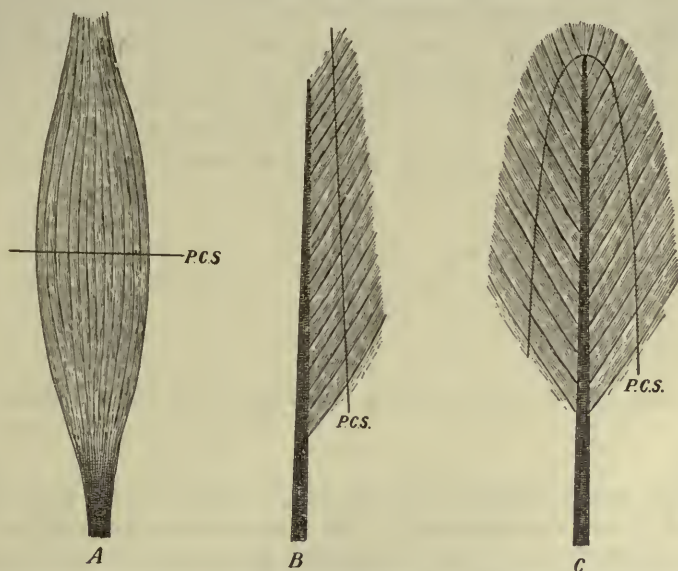


FIG. 365.—A, fusiform; B, unipinnate; C, bipinnate; P.C.S., physiological cross-section.

The Work Accomplished by Muscles.—For practical uses this should be expressed in *kilogrammeters*. In order to reckon the amount of work which a muscle can perform under the most favorable conditions it is necessary to know (1) its **physiological cross-section** (2) the **maximum shortening**, and (3) the **position of the joint** when the latter is obtained.

Work = lifted weight \times height through which the weight is lifted; or

Work = tension \times distance; tension = physiological cross-section \times absolute muscle strength.

If a muscle has a physiological cross-section of 5 sq. cm. its tension strength = 5×10 or 50 kg. If it shortens 5 cm. the work = $50 \times .05 = 2.5$ kilogrammeters. If one determines then the physiological cross-section and multiplies the absolute muscle strength, 10 kg. by this, the amount of tension is easily obtained. Then one must determine only the amount of shortening of the muscle for any particular position of the joint in order to determine the amount of work the muscle can do, since work = tension \times distance.

The tension of a muscle is, however, not constant during the course of contraction but is continually decreasing during contraction. It is at a maximum at the beginning and gradually decreases.

This can be illustrated by the work diagram Fig. 366.

$A M D$ (ordinate) = tension.

$A V X$ (abscissa) = shortening.

$A D$ = tension of muscle in extended or antagonistic position.

$A V$ = amount of actual shortening.

$A M$ = tension in midposition = absolute muscle strength.

$D V$ = shows how the tension sinks from maximum (in the extended position of the muscle) where it is about double that in the midposition (M) to nothing on complete contraction.

$\triangle A D V$ = work diagram, in reality the hypotenuse is not straight but has a concave curve. The \triangle has the same area as the rectangle $A M M' V$.
 $A M$ = the average tension.

Work = $A M \times A V$ kilogrammeters if the size of the ordinate as expressed in kilograms and the abscissa in meters.

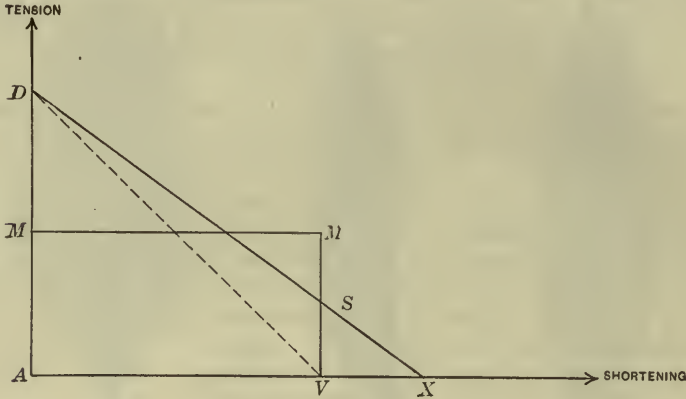


FIG. 366

Although the muscle works with a changing tension, yet the accomplishment is the same as if it were contracting with the tension of the midposition.

In reality the amount of work is somewhat greater since even in extreme contraction the muscle still retains a certain amount of tension so that the maximum amount of work is more nearly like $A D X$. We know that a muscle may have an extreme actual shortening of about 80 per cent. of its length when the tendon of insertion is cut.

The trapezoid $A D S V$ represents more nearly the amount of work, but since there are only approximate values and $A D S V$ is not much larger than $A M M' V$, we may use the latter.

Only the tension and amount of shortening are needed to determine the amount of work of the muscle. Neither the *lever arm* nor the *fiber angle* in pinnate muscles need be considered.

The diagram Fig. 367 shows that the *lever arm* is of no importance for determining the amount of work the muscle performs.

$J B$ and $J B^1$ = two bones jointed at J . $C D$ and $E F$ = the direction of the pull of two muscles of equal cross-section, each having a muscle tension of 1000 gms.

The centers of the attachments are such that perpendiculars $J c$ and $J e$ to $C D$ and $E F$ are equal to 40 and 23 mm. respectively, $J c = 40$ mm. and $J e = 23$ mm. The static moments are equal to 1000×40 and 1000×23 , therefore the first muscle can hold a much larger load (L) on the bone $J B^1$ at H^1 (100 mm. from J) than the second muscle whose load can be designated as L^1 .

Equilibrium exists for the first muscle if

$$L \times 100 = 1000 \times 40 \text{ or } L = \frac{1000 \times 40}{100} = 400 \text{ gms.}$$

For the second muscle $L^1 \times 100 = 1000 \times 23$.

$$L^1 = \frac{1000 \times 23}{100} = 230 \text{ gms.}$$

If we suppose $J B$ to be fixed and $J B^1$ to move in the plane of the paper about J and the muscle $C D$ to shorten 5 mm. $C d = C D - 5$ mm. and with the tension of 1000 gms., $J B^1$ will take the position $J B^2$ and the load (L) will be lifted from H^1 to H^2 .

If the second muscle likewise shortens 5 mm. then $E f = E F - 5$ mm., and with the tension of 1000 gms. the bone $J B^1$ will take the position $J B^3$ and the weight or load (L^1) will be lifted from H^1 to H^3 . The question now is to prove that the work done is the same in both cases, namely, 5×1000 grammillimeters. If so, $400 \times H^1 H^2 = 230 \times H^1 H^3 = 5000$ grammillimeters.

Since the two radii $C d$ and $C d'$ are very long as compared with the arc $d d'$ we may consider this short arc as a line \perp to $C D$ at d' , likewise the arc $f f'$ may be considered as a straight line \perp to $E F$. In the same manner we can consider the short arcs $F f$, $D d$, $H^1 H^2$ and $H^1 H^3$ \perp to the line $J B^1$. The sides $D d'$ and $F f'$ of the $\triangle D d d'$ and $F f f'$ are each 5 mm.

The lever arm $D J = 60$ mm. and $J F = 30$ mm.

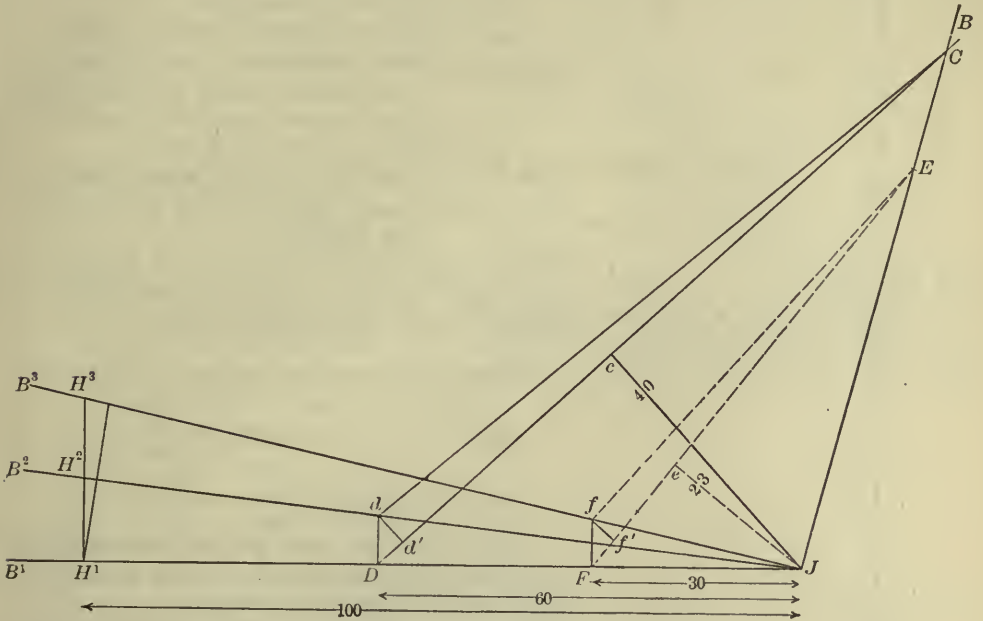


FIG. 367

The $\triangle D d d'$ is similar to the $\triangle D c J$

$$\text{hence } D d : 5 :: 60 : 40 \quad D d = \frac{300}{40}$$

$$\text{also } H^1 H^2 : D d :: 100 : 60$$

$$H^1 H^2 : \frac{300}{40} :: 100 : 60 \quad H^1 H^2 = \frac{300}{24}$$

The $\triangle F f f'$ is similar to $F e J$

$$\text{hence } F f : 5 :: 30 : 23 \quad F f = \frac{150}{23}$$

$$\text{also } H^1 H^3 : F f :: 100 : 30$$

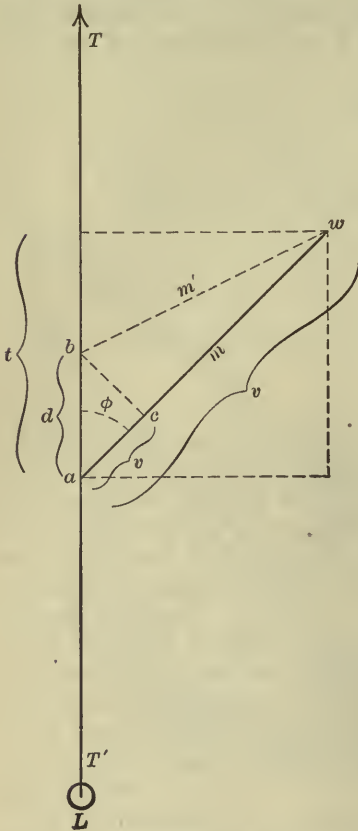
$$H^1 H^3 : \frac{150}{23} :: 100 : 30 \quad H^1 H^3 = \frac{1500}{69}$$

$$\therefore 400 \times \frac{300}{24} = 230 \times \frac{1500}{69} = 5000$$

Thus we see that the work of the two muscles depends on the size of the contraction and on the tension and not on the lever arm in very small contractions or in

the summation of such contractions and therefore for large contractions. In the first muscle a large load is moved through a short distance and in the second muscle a lighter load is moved through a greater distance.

The amount of work accomplished by pinnate muscles is not dependent upon the angle of insertion of the muscle fibers into the tendon, as will be seen by the following diagram Fig. 368.



- T' T = direction of the tendon pull.
- $w a$ = direction of muscle fiber before contraction.
- m' = direction of muscle fiber after contraction.
- v = amount of contraction.
- m = tension of the muscle.
- ϕ = angle of insertion of muscle fiber.
- t = tendon component = $m \times \cos \phi$ = the weight carried by the tendon to balance the muscle tension.
- d = distance tendon is drawn up.

- (1) $m \times v$ = work done by the muscle fiber.
- (2) $t \times d$ = work done by the movement of the tendon.

If we consider the distance v as being very short then the line $b c$ can be dealt with as though it were perpendicular to $a c$.

$$\text{then } v = d \times \cos \phi \text{ or } d = \frac{v}{\cos \phi}$$

$$\text{since } t = m \times \cos \phi \text{ or } m = \frac{t}{\cos \phi}$$

$$m \times v = \frac{t}{\cos \phi} \times d \times \cos \phi = t \times d$$

If this is true for very minute contractions it is likewise true for a series of such contraction and hence for larger contractions.

If we assume that $\phi = 60^\circ$, $m = 10$ kg. and $v = 5$ mm., the work done by the contracting muscle fiber = $m v$ or 10×5 kilogrammillimeters.

$$\cos 60^\circ = \frac{1}{2}; \text{ hence } t = \frac{1}{2} m; \text{ and } d = \frac{v}{\frac{1}{2}} = 2 v; \frac{1}{2} m = 5 \text{ kg.}; \text{ and } 2 v = 10 \text{ mm.}$$

hence $t d = 50$ kilogrammillimeters or the work done by the movement of the tendon in lifting the load of 5 kg. a distance of 10 mm., and is exactly the same as that done by the muscle fiber. The load on the tendon is but one-half the tension of the muscle, but the distance through which the load is lifted is twice that of the amount of shortening of the muscle.

$$\text{If } \phi = 41^\circ 20' \text{ then } \cos \phi = \frac{3}{4} \\ \text{hence } t = \frac{3}{4} m \text{ and } d = \frac{4}{3} v \text{ and } t d = m v$$

In pinnate muscles, then, we have the rather unexpected condition in which the same amount of movement of the tendon can be accomplished with less contraction of the muscle than in muscles where the fibers have the same direction as the tendon.

The Action of Muscles on Joints.—If we consider now the action of a single muscle extending over a single joint in which one bone is fixed and the other movable, we

will find that muscle pull can be resolved into two components, a turning component and a friction or pressure component as shown in Fig. 369.

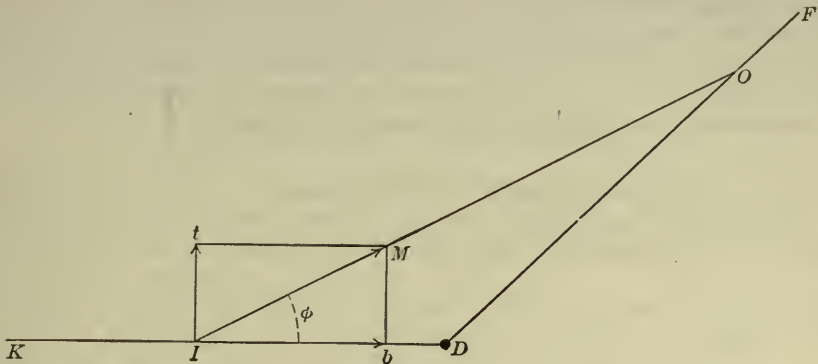


FIG. 369

DF = the fixed bone from which the muscle takes its origin.

DK = the movable bone.

OI = a line from the middle of origin to the middle of insertion.

IM = size and direction of the muscle pull.

If the parallelogram is constructed with It and $Mb \perp$ to DK , then It = the turning component and Ib = the component which acts against the joint.

The size of the two components depends upon the insertion angle ϕ . The smaller this angle the smaller the turning component, and the nearer this angle ϕ is to 90° the larger the turning component.

$$It = IM \times \sin \phi$$

$$Ib = IM \times \cos \phi$$

If $\phi = 90^\circ$ $\cos \phi = 0$, $\sin \phi = 1$
 hence $Ib = 0$ and $It = Im$

If $\phi = 0^\circ$ $\cos \phi = 1$, $\sin \phi = 0$
 hence $Ib = 1$ and $It = 0$

With movements of the bone DK the angle of insertion is continually changing, and hence the two components are changing in value.

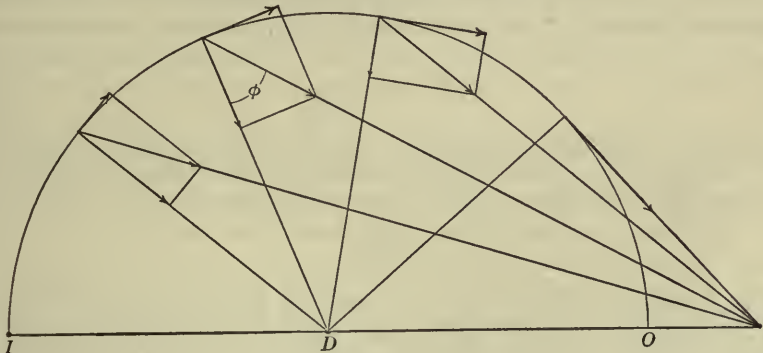


FIG. 370

If, for example, the distance from origin O to the joint D is greater than from D to I , as in the Brachialis or Biceps muscles, the turning component increases until the insertion angle $\phi = 90^\circ$, which is the optimum angle for muscle action, while the pressure component gradually decreases. If the movement continues beyond

this point the turning component gradually decreases and the pressure component changes into a component which tends to draw the two bones apart and which gradually increases as shown in Fig. 370.

When the bone DK is in such a position that the insertion angle $\phi = 41^\circ 20'$ the pressure component $= \frac{3}{4} I m$ and the turning component $\frac{1}{4} I m$, at 60° the two components are equal, at 90° the pressure component $= 0$ and the turning component $= I M$ and at $131^\circ 21'$ the pressure component has been converted into a pulling component $= \frac{1}{4} I M$ and the turning component $= \frac{3}{4} I M$.

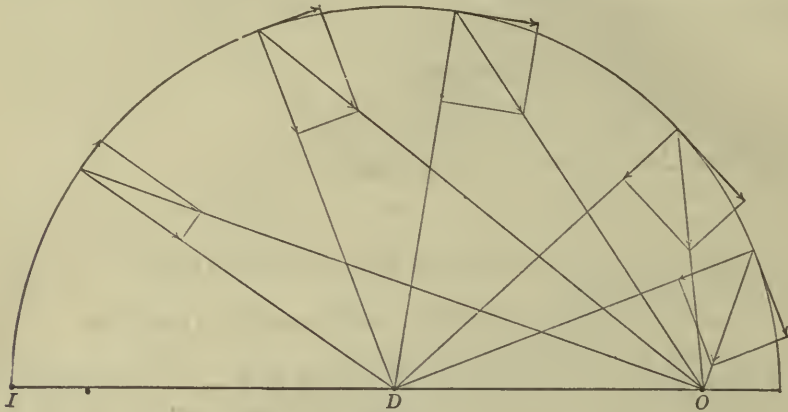


FIG. 371

If, for example, the distance from the origin O to the joint D is less than the distance from the insertion I to the joint D , as in the Brachioradialis muscle, the insertion angle increases with the flexion but never reaches 90° . The turning component gradually increases to a certain point and then slowly decreases as shown in Fig. 371, while the pressure component gradually decreases and then slowly increases. It always remains large and its action is always in the direction of the joint.

Levers.—The majority of the muscles of the body act on bones as the power on levers. Levers of the III class are the most common, as the action of the Biceps, and the Brachialis muscles on the forearm bones. Levers of the I Class are found in movements of the head where the occipito-atlantal joint acts as the fulcrum and the muscles on the back of the neck as the power. Another common example is

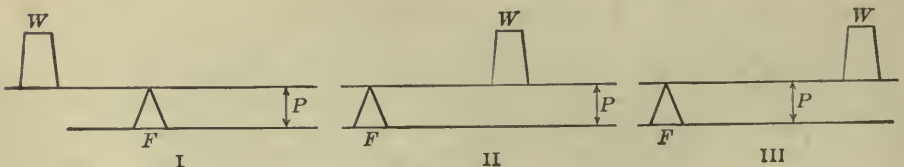


FIG. 372

the foot when one raises the body by contracting the Gastrocnemius and Soleus. Here the ankle-joint acts as the fulcrum and the pressure of the toes on the ground as the weight. This is frequently, though wrongly, considered a lever of the II Class. If one were to stand on one's head with the legs up and with a weight on the plantar surface of the toes, it is easy to see that we would have a lever of the I Class if the weight were raised by contraction of the Gastrocnemius muscle. The confusion has arisen by not considering the fact that the fulcrum and the power in all three classes of levers must have a common basis of action, as shown in Fig. 372.

If the fulcrum rests on the earth the power must either directly or indirectly push from the earth or be attached to the earth either by gravity or otherwise if it pulls toward the earth. If the power were attached to the weight no lever action could be obtained.

There are no levers of the II Class represented in the body.

DEVELOPMENT OF THE MUSCLES.

Both the cross-striated and smooth muscles, with the exception of a few that are of ectodermal origin, arise from the mesoderm. The intrinsic muscles of the trunk are derived from the myotomes while the muscles of the head and limbs differentiate directly from the mesoderm.

The Myotomic Muscles.—The intrinsic muscles of the trunk which are derived directly from the myotomes are conveniently treated in two groups, the deep muscles of the back and the thoraco-abdominal muscles.

The deep muscles of the back extend from the sacral to the occipital region and vary much in length and size. They act chiefly on the vertebral column. The shorter muscles, such as the Interspinales, Intertransversarii, the deeper layers of the Multifidus, the Rotatores, Levatores costarum, Obliquus capitis inferior, Obliquus capitis superior and Rectus capitis posterior minor which extend between adjoining vertebræ, retain the primitive segmentation of the myotomes. Other muscles, such as the Splenius capitis, Splenius cervicis, Sacrospinalis, Semispinalis, Multifidus, Iliocostalis, Longissimus, Spinales, Semispinales, and Rectus capitis posterior major, which extend over several vertebræ, are formed by the fusion of successive myotomes and the splitting into longitudinal columns.

The fascia lumbo-dorsalis develops between the true myotomic muscles and the more superficial ones which migrate over the back such as the Trapezius, Rhomboideus, and Latissimus.

The anterior vertebral muscles, the Longus colli, Longus capitis, Rectus capitis anterior and Rectus capitis lateralis are derived from the ventral part of the cervical myotomes as are probably also the Scaleri.

The thoraco-abdominal muscles arise through the ventral extension of the thoracic myotomes into the body wall. This process takes place coincident with the ventral extension of the ribs. In the thoracic region the primitive myotomic segments still persist as the intercostal muscles, but over the abdomen these ventral myotomic processes fuse into a sheet which splits in various ways to form the Rectus, the Obliquus externus and internus, and the Transversalis. Such muscles as the Pectoralis major and minor and the Serratus anterior do not belong to the above group.

The Ventrolateral Muscles of the Neck.—The intrinsic muscles of the tongue, the Infrahyoid muscles and the diaphragm are derived from a more or less continuous pre-muscle mass which extends on each side from the tongue into the lateral region of the upper half of the neck and into it early extend the hypoglossal and branches of the upper cervical nerves. The two halves which form the Infrahyoid muscles and the diaphragm are at first widely separated from each other by the heart. As the latter descends into the thorax the diaphragmatic portion of each lateral mass is carried with its nerve down into the thorax and the laterally placed Infrahyoid muscles move toward the midventral line of the neck.

Muscles of the Shoulder Girdle and Arm.—The Trapezius and Sternocleidomastoideus arise from a common pre-muscle mass in the occipital region just caudal to the last branchial arch; as the mass increases in size it spreads downward to the shoulder girdle to which it later becomes attached. It also spreads backward and downward to the spinous processes, gaining attachment at a still later period.

The Levator scapulæ, Serratus anterior and the Rhomboids arise from pre-muscle tissue in the lower cervical region and undergo extensive migration.

The Latissimus dorsi and Teres major are associated in their origin from the pre-muscle sheath of the arm as are also the two Pectoral muscles when the arm bud lies in the lower cervical region.

The intrinsic muscles of the arm develop *in situ* from the mesoderm of the arm bud and probably do not receive cells or buds from the myotomes. The nerves enter the arm bud when it still lies in the cervical region and as the arm shifts caudally over the thorax the lower cervical nerves which unite to form the brachial plexus, acquire a caudal direction.

The Muscles of the Leg.—The muscles of the leg like those of the arm develop *in situ* from the mesoderm of the leg bud, the myotomes apparently taking no part in their formation.

The Muscles of the Head.—The muscles of the orbit arise from the mesoderm over the dorsal and caudal sides of the optic stalk.

The muscles of mastication arise from the mesoderm of the mandibular arch. The mandibular division of the trigeminal nerve enters this pre-muscle mass before it splits into the Temporal, Masseter and Pterygoideus.

The facial muscles (muscles of expression) arise from the mesoderm of the hyoid arch. The facial nerve enters this mass before it begins to split, and as the muscle mass spreads out over the face and head and neck it splits more or less incompletely into the various muscles.

The early differentiation of the muscular system apparently goes on independently of the nervous system and only later does it appear that muscles are dependent on the functional stimuli of the nerves for their continued existence and growth. Although the nervous system does not influence muscle differentiation, the nerves, owing to their early attachments to the muscle rudiments, are in a general way indicators of the position of origin of many of the muscles and likewise in many instances the nerves indicate the paths along which the developing muscles have migrated during development. The muscle of the diaphragm, for example, has its origin in the region of the fourth and fifth cervical segments. The phrenic nerve enters the muscle mass while the latter is in this region and is drawn out as the diaphragm migrates through the thorax. The Trapezius and Sternocleidomastoideus arise in the lateral occipital region as a common muscle mass, into which at a very early period the nervus accessorius extends and as the muscle mass migrates and extends caudally the nerve is carried with it. The Pectoralis major and minor arise in the cervical region, receive their nerves while in this position and as the muscle mass migrates and extends caudally over the thorax the nerves are carried along. The Latissimus dorsi and Serratus anterior are excellent examples of migrating muscles whose nerve supply indicates their origin in the cervical region. The Rectus abdominis and the other abdominal muscles migrate or shift from a lateral to a ventrolateral or abdominal position, carrying with them the nerves.

The facial nerve, which early enters the common facial muscle mass of the second branchial or hyoid arch, is dragged about with the muscle as it spreads over the head and face and neck, and as the muscle splits into the various muscles of expression, the nerve is correspondingly split. The mandibular division of the trigeminal nerve enters at an early time the muscle mass in the mandibular arch and as this mass splits and migrates apart to form the muscles of mastication the nerve splits into its various branches.

The nerve supply then serves as a key to the common origin of certain groups of muscles. The muscles supplied by the oculomotor nerve arise from a single mass in the eye region; the lingual muscles arise from a common mass supplied by the hypoglossal nerve.

Striped or Voluntary Muscle.—Striped or voluntary muscle is composed of bundles of fibers each enclosed in a delicate web called the **perimysium** in contradistinction to the sheath of areolar tissue which invests the entire muscle, the **epimysium**. The bundles are termed **fasciculi**; they are prismatic in shape, of different sizes in different muscles, and are for the most part placed parallel to one another, though they have a tendency to converge toward their tendinous attachments. Each fasciculus is made up of a strand of **fibers**, which also run parallel with each other, and are separated from one another by a delicate connective tissue derived from the perimysium and termed **endomysium**. This does not form the sheath of the fibers, but serves to support the bloodvessels and nerves ramifying between them.

A **muscular fiber** may be said to consist of a soft contractile substance, enclosed in a tubular sheath named by Bowman the **sarcolemma**. The fibers are cylindrical or prismatic in shape (Fig. 373), and are of no great length, not exceeding, as a rule, 40 mm. Huber¹ has recently found that the muscle fibers in the adductor muscle of the thigh of the rabbit vary greatly in length even in the same fasciculus. In a fasciculus 40 mm. in length the fibers varied from 30.4 mm. to 9 mm. in length. Their breadth varies in man from 0.01 to 0.1 mm. As a rule, the fibers do not

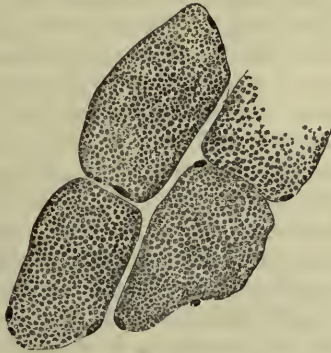

Fig. 373.—Transverse section of human striped muscle fibers. $\times 255$.

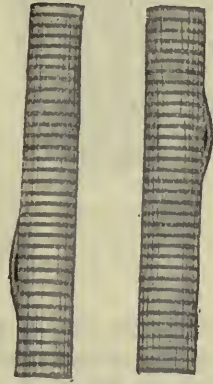


Fig. 374.—Striped muscle fibers from tongue of cat. $\times 250$.

divide or anastomose; but occasionally, especially in the tongue and facial muscles, they may be seen to divide into several branches. In the substance of the muscle, the fibers end by tapering extremities which are joined to the ends of other fibers by the sarcolemma. At the tendinous end of the muscle the sarcolemma appears to blend with a small bundle of fibers, into which the tendon becomes subdivided, while the muscular substance ends abruptly and can be readily made to retract from the point of junction. The areolar tissue between the fibers appears to be prolonged more or less into the tendon, so as to form a kind of sheath around the tendon bundles for a longer or shorter distance. When muscular fibers are attached to skin or mucous membranes, their fibers become continuous with those of the areolar tissue.

The **sarcolemma**, or tubular sheath of the fiber, is a transparent, elastic, and apparently homogeneous membrane of considerable toughness, so that it sometimes remains entire when the included substance is ruptured. On the internal surface of the sarcolemma in mammalia, and also in the substance of the fiber in frogs, elongated nuclei are seen, and in connection with these is a little granular protoplasm.

Upon examination of a voluntary muscular fiber by transmitted light, it is

¹Anat. Rec., 1916, 11.

found to be marked by alternate light and dark bands or striæ, which pass transversely across the fiber (Fig. 374). When examined by polarized light the dark bands are found to be doubly refracting (anisotropic), while the clear stripes are singly refracting (isotropic). The dark and light bands are of nearly equal breadth, and alternate with great regularity; they vary in breadth from about

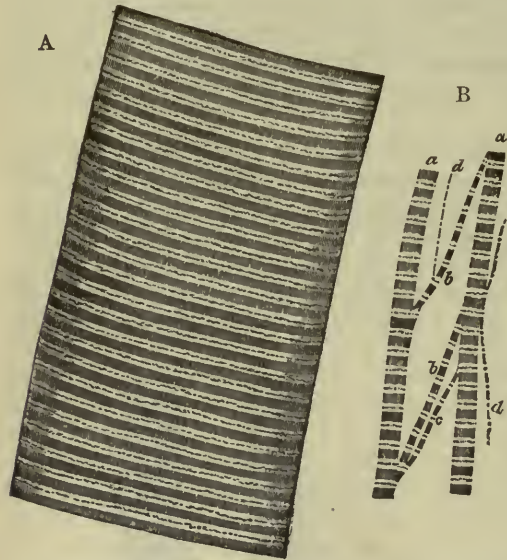


FIG. 375.—A. Portion of a medium-sized human muscular fiber. Magnified nearly 800 diameters. B. Separated bundles of fibrils, equally magnified. *a, a*, Larger, and *b, b*, smaller collections. *c*, Still smaller. *d, d*, The smallest which could be detached.

1 to 2μ . If the surface be carefully focussed, rows of granules will be detected at the points of junction of the dark and light bands, and very fine longitudinal lines may be seen running through the dark bands and joining these granules together. By treating the specimen with certain reagents (*e. g.*, chloride of gold) fine lines may be seen running transversely between the granules and uniting them together. This appearance is believed to be due to a reticulum or network of interstitial substance lying between the contractile portions of the muscle. The longitudinal striation gives the fiber the appearance of being made up of a bundle of fibrils which have been termed **sarcostyles** or **muscle columns**, and if the fiber be hardened in alcohol, it can be broken up longitudinally and the sarcostyles separated from each other (Fig. 375.) The reticulum, with its longitudinal and transverse meshes, is called **sarcoplasm**.

In a transverse section, the muscular fiber is seen to be divided into a number of areas, called the **areas of Cohnheim**, more or less polyhedral in shape and consisting of the transversely divided sarcostyles, surrounded by transparent sarcoplasm (Fig. 373).

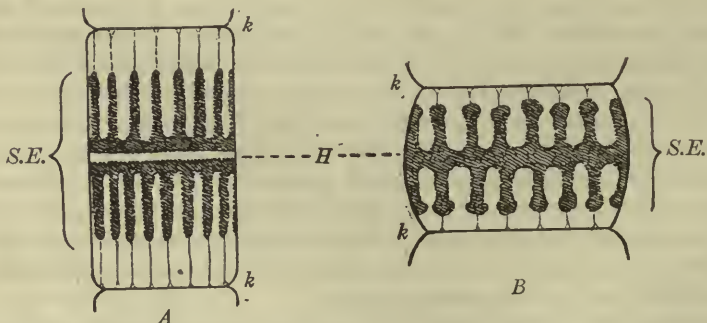


FIG. 376.—Diagram of a sarcomere. (After Schäfer.) A. In moderately extended condition. B. In a contracted condition. *k, k*, Membranes of Krause. *H*, Line or plane of Hensen. *S.E.*, Poriferous sarcoous element.

Upon closer examination, and by somewhat altering the focus, the appearances become more complicated, and are susceptible of various interpretations. The transverse striation, which in Fig. 374 appears as a mere alternation of dark and light bands, is resolved into the appearance seen in Fig. 375, which shows a series of broad dark bands, separated by light bands, each of which is divided into two

by a dark dotted line. This line is termed **Dobie's line** or **Krause's membrane** (Fig. 376, *k*), because it was believed by Krause to be an actual membrane, continuous with the sarcolemma, and dividing the light band into two compartments. In addition to the membrane of Krause, fine clear lines may be made out, with a sufficiently high power, crossing the center of the dark band; these are known as the **lines of Hensen** (Fig. 376, *H*).

Schäfer has worked out the minute anatomy of muscular fiber, particularly in the wing muscles of insects, which are peculiarly adapted for this purpose on account of the large amount of interstitial sarcoplasm which separates the sarcostyles. In the following description that given by Schäfer will be closely followed.

A sarcostyle may be said to be made up of successive portions, each of which is termed a **sarcomere**. The sarcomere is situated between two membranes of Krause and consists of (1) a central dark part, which forms a portion of the dark band of the whole fiber, and is named a **sarcous element**. This sarcous element really consists of two parts, superimposed one on the top of the other, and when the fiber is stretched these two parts become separated from each other at the line of Hensen (Fig. 376, *A*). (2) On either side of this central dark portion is a clear layer, most visible when the fiber is extended; this is situated between the dark center and the membrane of Krause, and when the sarcomeres are joined together to form the sarcostyle, constitutes the light band of the striated muscular fiber.

When the sarcostyle is extended, the clear intervals are well-marked and plainly to be seen; when, on the other hand, the sarcostyle is contracted, that is to say, when the muscle is in a state of contraction, these clear portions are very small or they may have disappeared altogether (Fig. 376, *B*). When the sarcostyle is stretched to its full extent, not only is the clear portion well-marked, but the dark portion—the sarcous element—is separated into its two constituents along the line of Hensen. The sarcous element does not lie free in the sarcomere, for when the sarcostyle is stretched, so as to render the clear portion visible, very fine lines, which are probably septa, may be seen running through it from the sarcous element to the membrane of Krause.

Schäfer explains these phenomena in the following way: He considers that each sarcous element is made up of a number of longitudinal channels, which open into the clear part toward the membrane of Krause but are closed at the line of Hensen. When the muscular fiber is contracted the *clear* part of the muscular substance is driven into these channels or tubes, and is therefore hidden from sight, but at the same time it swells up the sarcous element and widens and shortens the sarcomere. When, on the other hand, the fiber is extended, this clear substance is driven out of the tubes and collects between the sarcous element and the membrane of Krause, and gives the appearance of the light part between these two structures; by this means it elongates and narrows the sarcomere.

If this view be true, it is a matter of great interest, and, as Schäfer has shown, harmonizes the contraction of muscle with the ameboid action of protoplasm. In an ameboid cell, there is a framework of spongioplasm, which stains with hematoxylin and similar reagents, enclosing in its meshes a clear substance, hyaloplasm, which will not stain with these reagents. Under stimulation the hyaloplasm passes into the pores of the spongioplasm; without stimulation it tends to pass out as in the formation of pseudopodia. In muscle there is the same thing, viz., a framework of spongioplasm staining with hematoxylin—the substance of the sarcous element—and this encloses a clear hyaloplasm, the clear substance of the sarcomere, which resists staining with this reagent. During contraction of the muscle—*i. e.*, stimulation—this clear substance passes into the pores of the spongioplasm; while during extension of the muscle—*i. e.*, when there is no stimulation—it tends to pass out of the spongioplasm.

In this way the contraction is brought about: under stimulation the proto-

plasmic material (the clear substance of the sarcomere) recedes into the sarcous element, causing the sarcomere to widen out and shorten. The contraction of the muscle is merely the sum total of this widening out and shortening of these bodies.

Vessels and Nerves of Striped Muscle.—The capillaries of striped muscle are very abundant, and form a sort of rectangular network, the branches of which run longitudinally in the endomysium between the muscular fibers, and are joined at short intervals by transverse anastomosing branches. In the red muscles of the rabbit dilatations occur on the transverse branches of the capillary network. The larger vascular channels, arteries and veins, are found only in the perimysium, between the muscular fasciculi. **Nerves** are profusely distributed to striped muscle. Their mode of termination is described on page 730. The existence of **lymphatic vessels** in striped muscle has not been ascertained, though they have been found in tendons and in the sheaths of the muscles.

Ossification of muscular tissue as a result of repeated strain or injury is not infrequent. It is oftenest found about the tendon of the Adductor longus and Vastus medialis in horsemen, or in the Pectoralis major and Deltoideus of soldiers. It may take the form of exostoses firmly fixed to the bone—*e. g.*, "rider's bone" on the femur—or of layers or spicules of bone lying in the muscles or their fasciæ and tendons. Busse states that these bony deposits are preceded by a hemorrhagic myositis due to injury, the effused blood organizing and being finally converted into bone. In the rarer disease, progressive myositis ossificans, there is an unexplained tendency for practically any of the voluntary muscles to become converted into solid and brittle bony masses which are completely rigid.

TENDONS, APONEUROSES, AND FASCIÆ.

Tendons are white, glistening, fibrous cords, varying in length and thickness, sometimes round, sometimes flattened, and devoid of elasticity. They consist almost entirely of white fibrous tissue, the fibrils of which have an undulating course parallel with each other and are firmly united together. When boiled in water tendon is almost completely converted into gelatin, the white fibers being composed of the albuminoid collagen, which is often regarded as the anhydride of gelatin. They are very sparingly supplied with bloodvessels, the smaller tendons presenting in their interior no trace of them. Nerves supplying tendons have special modifications of their terminal fibers, named **organs of Golgi**.

Aponeuroses are flattened or ribbon-shaped tendons, of a pearly white color, iridescent, glistening, and similar in structure to the tendons. They are only sparingly supplied with bloodvessels.

The tendons and aponeuroses are connected, on the one hand, with the muscles, and, on the other hand, with the movable structures, as the bones, cartilages ligaments, and fibrous membranes (for instance, the sclera). Where the muscular fibers are in a direct line with those of the tendon or aponeurosis, the two are directly continuous. But where the muscular fibers join the tendon or aponeurosis at an oblique angle, they end, according to Kölliker, in rounded extremities which are received into corresponding depressions on the surface of the latter, the connective tissue between the muscular fibers being continuous with that of the tendon. The latter mode of attachment occurs in all the penniform and bipenniform muscles, and in those muscles the tendons of which commence in a membranous form, as the Gastrocnemius and Soleus.

The **fasciæ** are fibroareolar or aponeurotic laminæ, of variable thickness and strength, found in all regions of the body, investing the softer and more delicate organs. During the process of development many of the cells of the mesoderm are differentiated into bones, muscles, vessels, etc.; the cells of the mesoderm which are not so utilized form an investment for these structures and are differentiated into the true skin and the fasciæ of the body. They have been subdivided, from the situations in which they occur, into superficial and deep.

The **superficial fascia** is found immediately beneath the integument over almost the entire surface of the body. It connects the skin with the deep fascia, and consists of fibroareolar tissue, containing in its meshes pellicles of fat in varying quantity. Fibro-areolar tissue is composed of **white fibers** and **yellow elastic fibers** intercrossing in all directions, and united together by a homogeneous cement or ground substance, the **matrix**.

The cells of areolar tissue are of four principal kinds: (1) Flattened **lamellar cells**, which may be either branched or unbranched. The branched lamellar cells are composed of clear cytoplasm, and contain oval nuclei; the processes of these cells may unite so as to form an open network, as in the cornea. The unbranched cells are joined edge to edge like the cells of an epithelium; the "tendon cells," presently to be described, are examples of this variety. (2) **Clasmatocytes**, large irregular cells characterized by the presence of granules or vacuoles in their protoplasm,

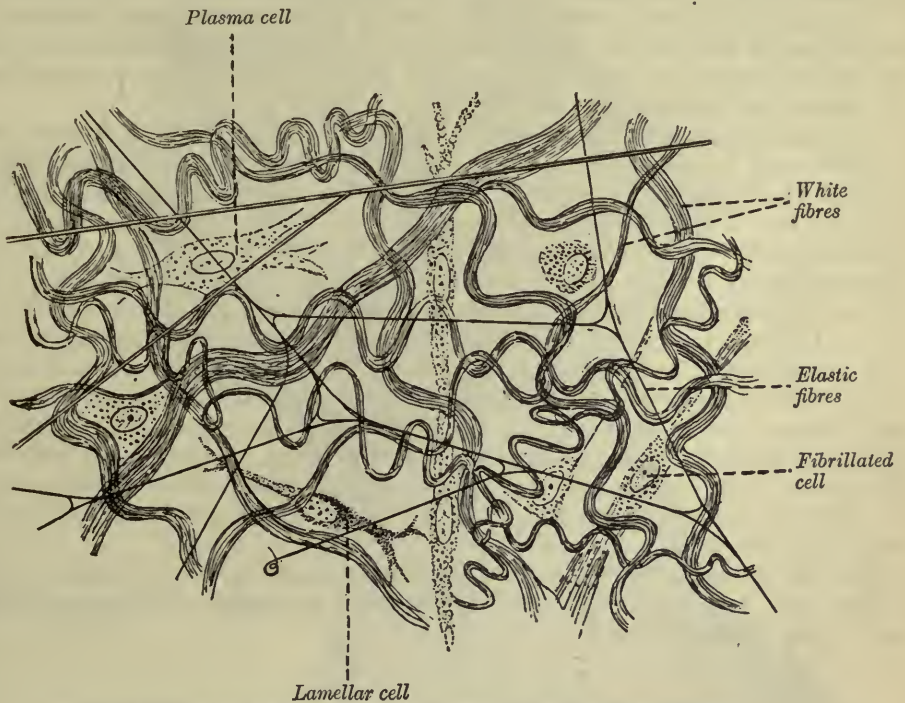


FIG. 377.—Subcutaneous tissue from a young rabbit. Highly magnified. (Schäfer.)

and containing oval nuclei. (3) **Granule cells** (*Mastzellen*), which are ovoid or spheroidal in shape. They are formed of a soft protoplasm, containing granules which are basophil in character. (4) **Plasma cells** of Waldeyer, usually spheroidal and distinguished by containing a vacuolated protoplasm. The vacuoles are filled with fluid, and the protoplasm between the spaces is clear, with occasionally a few scattered basophil granules.

In addition to these four typical forms of connective-tissue corpuscles, areolar tissue may be seen to possess **wandering cells**, *i. e.*, leucocytes which have emigrated from the neighboring vessels; in some instances, as in the choroid coat of the eye cells filled with granules of pigment (**pigment cells**) are found.

The cells lie in spaces in the ground substance between the bundles of fibers, and these spaces may be brought into view by treating the tissue with nitrate of silver and exposing it to the light. This will color the ground substance and leave the cell-spaces unstained.

Fat is entirely absent in the subcutaneous tissue of the eyelids, of the penis and scrotum, and of the labia minora. It varies in thickness in different parts of the body; in the groin it is so thick that it may be subdivided into several laminae. Beneath the fatty layer there is generally another layer of superficial fascia, comparatively devoid of adipose tissue, in which the trunks of the subcutaneous vessels and nerves are found, as the superficial epigastric vessels in the abdominal region, the superficial veins in the forearm, the saphenous veins in the leg and thigh, and the superficial lymph glands. Certain cutaneous muscles also are situated in the superficial fascia, as the *Platysma* in the neck, and the *Orbicularis oculi* around the eyelids. This fascia is most distinct at the lower part of the abdomen, perineum, and extremities; it is very thin in those regions where muscular fibers are inserted into the integument, as on the side of the neck, the face, and around the margin of the anus. It is very dense in the scalp, in the palms of the hands, and soles of the feet, forming a fibro-fatty layer, which binds the integument firmly to the underlying structures.

The superficial fascia connects the skin to the subjacent parts, facilitates the movement of the skin, serves as a soft nidus for the passage of vessels and nerves to the integument, and retains the warmth of the body, since the fat contained in its areolae is a bad conductor of heat.

The **deep fascia** is a dense, inelastic, fibrous membrane, forming sheaths for the muscles, and in some cases affording them broad surfaces for attachment. It consists of shining tendinous fibers, placed parallel with one another, and connected together by other fibers disposed in a rectilinear manner. It forms a strong investment which not only binds down collectively the muscles in each region, but gives a separate sheath to each, as well as to the vessels and nerves. The fasciæ are thick in unprotected situations, as on the lateral side of a limb, and thinner on the medial side. The deep fasciæ assist the muscles in their actions, by the degree of tension and pressure they make upon their surfaces; the degree of tension and pressure is regulated by the associated muscles, as, for instance, by the *Tensor fasciæ latæ* and *Glutæus maximus* in the thigh, by the *Biceps* in the upper and lower extremities, and *Palmaris longus* in the hand. In the limbs, the fasciæ not only invest the entire limb, but give off septa which separate the various muscles, and are attached to the periosteum: these prolongations of fasciæ are usually spoken of as intermuscular septa.

The Fasciæ and Muscles may be arranged, according to the general division of the body, into those of the **head and neck**; of the **trunk**; of the **upper extremity**; and of the **lower extremity**.

THE FASCIÆ AND MUSCLES OF THE HEAD.

I. THE MUSCLE OF THE SCALP.

Epicranius.

The Skin of the Scalp.—This is thicker than in any other part of the body. It is intimately adherent to the superficial fascia, which attaches it firmly to the underlying aponeurosis and muscle. Movements of the muscle move the skin. The hair follicles are very closely set together, and extend throughout the whole thickness of the skin. It also contains a number of sebaceous glands.

The **superficial fascia** in the cranial region is a firm, dense, fibro-fatty layer, intimately adherent to the integument, and to the Epicranius and its tendinous aponeurosis; it is continuous, behind, with the superficial fascia at the back of the neck; and, laterally, is continued over the temporal fascia. It contains between its layers the superficial vessels and nerves and much granular fat.

The **Epicranius** (*Occipitofrontalis*) (Fig. 378) is a broad, musculofibrous layer,

which covers the whole of one side of the vertex of the skull, from the occipital bone to the eyebrow. It consists of two parts, the Occipitalis and the Frontalis, connected by an intervening tendinous aponeurosis, the *galea aponeurotica*.

The **Occipitalis**, thin and quadrilateral in form, *arises* by tendinous fibers from the lateral two-thirds of the superior nuchal line of the occipital bone, and from the mastoid part of the temporal. It ends in the *galea aponeurotica*.

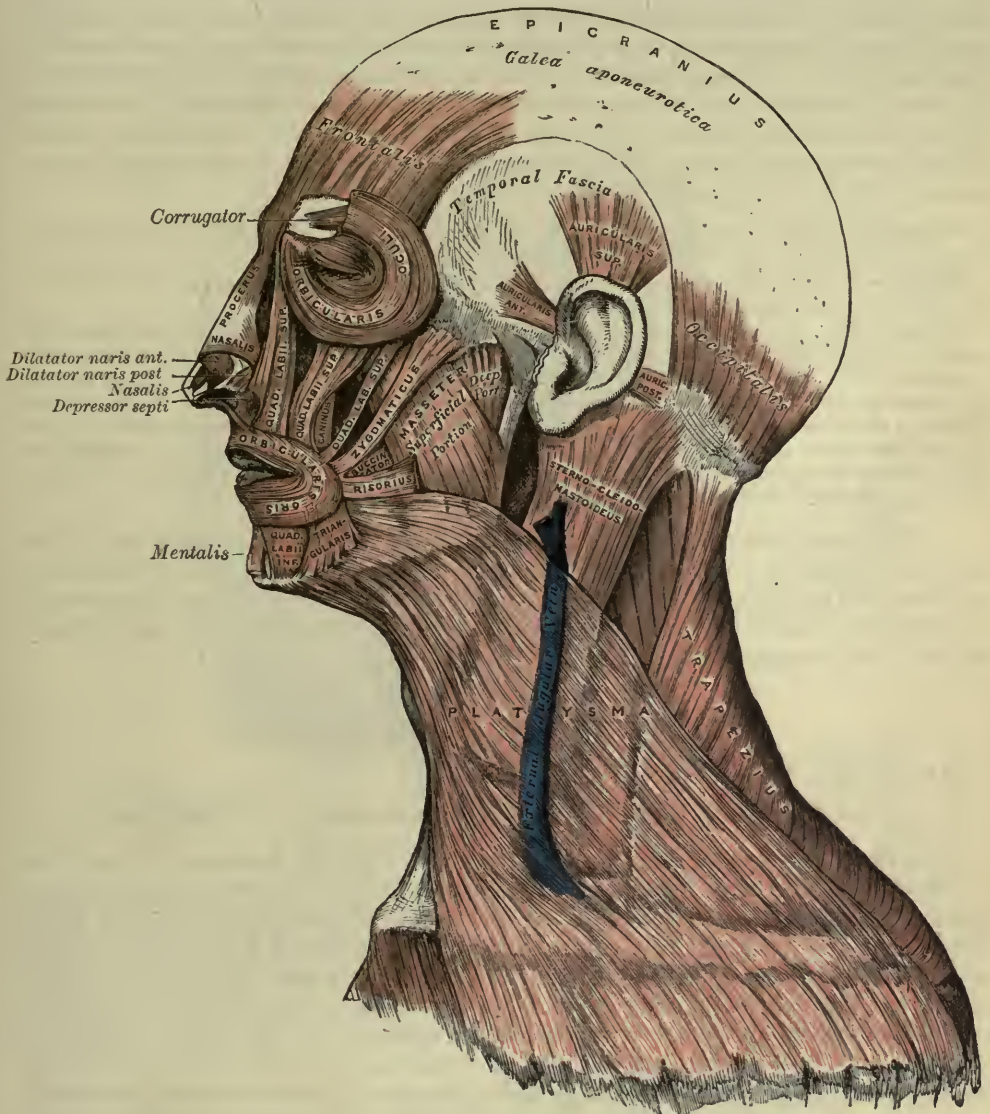


FIG. 378.—Muscles of the head, face, and neck.

The **Frontalis** is thin, of a quadrilateral form, and intimately adherent to the superficial fascia. It is broader than the Occipitalis and its fibers are longer and paler in color. It has no bony attachments. Its medial fibers are continuous with those of the Procerus; its immediate fibers blend with the Corrugator and Orbicularis oculi; and its lateral fibers are also blended with the latter muscle over the zygomatic process of the frontal bone. From these attachments the fibers are directed upward, and join the *galea aponeurotica* below the coronal suture.

The medial margins of the Frontales are joined together for some distance above the root of the nose; but between the Occipitales there is a considerable, though variable, interval, occupied by the galea aponeurotica.

The **galea aponeurotica** (*epicranial aponeurosis*) covers the upper part of the cranium; behind, it is attached, in the interval between its union with the Occipitales, to the external occipital protuberance and highest nuchal lines of the occipital bone; in front, it forms a short and narrow prolongation between its union with the Frontales. On either side it gives origin to the Auriculares anterior and superior; in this situation it loses its aponeurotic character, and is continued over the temporal fascia to the zygomatic arch as a layer of laminated areolar tissue. It is closely connected to the integument by the firm, dense, fibro-fatty layer which forms the superficial fascia of the scalp: it is attached to the pericranium by loose cellular tissue, which allows the aponeurosis, carrying with it the integument to move through a considerable distance.

Variations.—Both Frontalis and Occipitalis vary considerably in size and in extent of attachment; either may be absent; fusion of Frontalis to skin has been noted.

Nerves.—The Frontalis is supplied by the temporal branches of the facial nerve, and the Occipitalis by the posterior auricular branch of the same nerve.

Actions.—The Frontales raise the eyebrows and the skin over the root of the nose, and at the same time draw the scalp forward, throwing the integument of the forehead into transverse wrinkles. The Occipitales draw the scalp backward. By bringing alternately into action the Frontales and Occipitales the entire scalp may be moved forward and backward. In the ordinary action of the muscles, the eyebrows are elevated, and at the same time the aponeurosis is fixed by the Occipitales, thus giving to the face the expression of surprise; if the action be exaggerated, the eyebrows are still further raised, and the skin of the forehead thrown into transverse wrinkles, as in the expression of fright or horror.

A thin muscular slip, the **Transversus nuchæ**, is present in a considerable proportion (25 per cent.) of cases; it *arises* from the external occipital protuberance or from the superior nuchal line, either superficial or deep to the Trapezius; it is frequently *inserted* with the Auricularis posterior, but may join the posterior edge of the Sternocleidomastoideus.

II. THE MUSCLES OF THE EYELIDS.

The muscles of the eyelids are:

Levator palpebræ superioris. Orbicularis oculi. Corrugator.

The Levator palpebræ superioris is described with the Anatomy of the Eye.

The **Orbicularis oculi** (*Orbicularis palpebrarum*) (Fig. 379) *arises* from the nasal part of the frontal bone, from the frontal process of the maxilla in front of the lacrimal groove, and from the anterior surface and borders of a short fibrous band, the **medial palpebral ligament**. From this origin, the fibers are directed lateralward, forming a broad and thin layer, which occupies the eyelids or palpebræ, surrounds the circumference of the orbit, and spreads over the temple, and downward on the cheek. The **palpebral portion** of the muscle is thin and pale; it *arises* from the bifurcation of the medial palpebral ligament, forms a series of concentric curves, and is *inserted* into the lateral palpebral raphé. The **orbital portion** is thicker and of a reddish color; its fibers form a complete ellipse without interruption at the lateral palpebral commissure; the upper fibers of this portion blend with the Frontalis and Corrugator. The **lacrimal part** (*Tensor tarsi*) is a small, thin muscle, about 6 mm. in breadth and 12 mm. in length, situated behind the medial palpebral ligament and lacrimal sac (Fig. 379). It *arises* from the posterior crest and adjacent part of the orbital surface of the lacrimal bone, and passing behind the lacrimal sac, divides into two slips, upper and lower, which are *inserted* into the superior and inferior tarsi medial to the puncta lacrimalia; occasionally it is very indistinct.

The **medial palpebral ligament** (*tendo oculi*), about 4 mm. in length and 2 mm. in breadth, is attached to the frontal process of the maxilla in front of the lacrimal groove. Crossing the lacrimal sac, it divides into two parts, upper and lower, each attached to the medial end of the corresponding tarsus. As the ligament crosses the lacrimal sac, a strong aponeurotic lamina is given off from its posterior surface; this expands over the sac, and is attached to the posterior lacrimal crest.

The **lateral palpebral raphé** is a much weaker structure than the medial palpebral ligament. It is attached to the margin of the frontosphenoidal process of the zygomatic bone, and passes medialward to the lateral commissure of the eyelids, where it divides into two slips, which are attached to the margins of the respective tarsi.

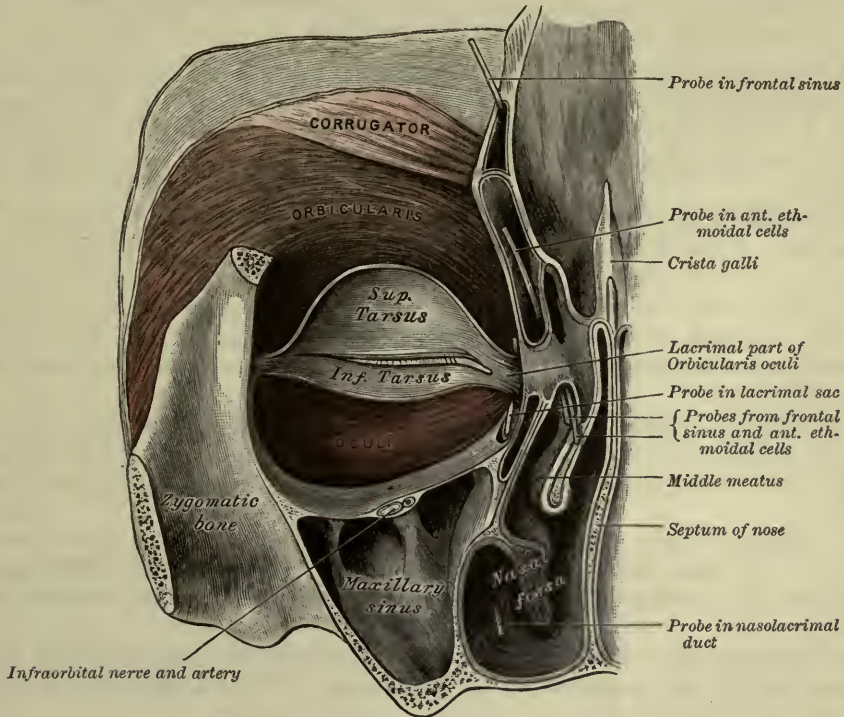


FIG. 379.—Left orbicularis oculi, seen from behind.

The **Corrugator**¹ (*Corrugator superciliï*) is a small, narrow, pyramidal muscle, placed at the medial end of the eyebrow, beneath the Frontalis and Orbicularis oculi. It *arises* from the medial end of the superciliary arch; and its fibers pass upward and lateralward, between the palpebral and orbital portions of the Orbicularis oculi, and are *inserted* into the deep surface of the skin, above the middle of the orbital arch.

Nerves.—The Orbicularis oculi and Corrugator are supplied by the facial nerve.

Actions.—The Orbicularis oculi is the sphincter muscle of the eyelids. The palpebral portion acts involuntarily, closing the lids gently, as in sleep or in blinking; the orbital portion is subject to the will. When the entire muscle is brought into action, the skin of the forehead, temple, and cheek is drawn toward the medial angle of the orbit, and the eyelids are firmly closed, as in photophobia. The skin thus drawn upon is thrown into folds, especially radiating from the lateral angle of the eyelids; these folds become permanent in old age, and form the so-called "crows' feet." The Levator palpebræ superioris is the direct antagonist of this muscle; it raises the upper eyelid and exposes the front of the bulb of the eye. Each time the eyelids are closed through the action of the Orbicularis, the medial palpebral ligament is tightened, the wall of the lacrimal sac is thus drawn lateralward and forward, so that a vacuum is made in it and the

¹ The corrugator is not recognized as a separate muscle in the Basle Nomenclature.

tears are sucked along the lacrimal canals into it. The lacrimal part of the Orbicularis oculi draws the eyelids and the ends of the lacrimal canals medialward and compresses them against the surface of the globe of the eye, thus placing them in the most favorable situation for receiving the tears; it also compresses the lacrimal sac. The Corrugator draws the eyebrow downward and medialward, producing the vertical wrinkles of the forehead. It is the "frowning" muscle, and may be regarded as the principal muscle in the expression of suffering.

III. THE MUSCLES OF THE NOSE (Fig. 378).

The muscles of the nose comprise:

Procerus.	Depressor septi.
Nasalis.	Dilatator naris posterior.
Dilatator naris anterior.	

The **Procerus** (*Pyramidalis nasi*) is a small pyramidal slip arising by tendinous fibers from the fascia covering the lower part of the nasal bone and upper part of the lateral nasal cartilage; it is inserted into the skin over the lower part of the forehead between the two eyebrows, its fibers decussating with those of the Frontalis.

The **Nasalis** (*Compressor naris*) consists of two parts, transverse and alar. The transverse part arises from the maxilla, above and lateral to the incisive fossa; its fibers proceed upward and medialward, expanding into a thin aponeurosis which is continuous on the bridge of the nose with that of the muscle of the opposite side, and with the aponeurosis of the Procerus. The alar part is attached by one end to the greater alar cartilage, and by the other to the integument at the point of the nose.

The **Depressor septi** (*Depressor alæ nasi*) arises from the incisive fossa of the maxilla; its fibers ascend to be inserted into the septum and back part of the ala of the nose. It lies between the mucous membrane and muscular structure of the lip.

The **Dilatator naris posterior** is placed partly beneath the Quadratus labii superioris. It arises from the margin of the nasal notch of the maxilla, and from the lesser alar cartilages, and is inserted into the skin near the margin of the nostril.

The **Dilatator naris anterior** is a delicate fasciculus, passing from the greater alar cartilage to the integument near the margin of the nostril; it is situated in front of the preceding.

Variations.—These muscles vary in size and strength or may be absent.

Nerves.—All the muscles of this group are supplied by the facial nerve.

Actions.—The Procerus draws down the medial angle of the eyebrows and produces transverse wrinkles over the bridge of the nose. The two Dilatatores enlarge the aperture of the nares. Their action in ordinary breathing is to resist the tendency of the nostrils to close from atmospheric pressure, but in difficult breathing, as well as in some emotions, such as anger, they contract strongly. The Depressor septi is a direct antagonist of the other muscles of the nose, drawing the ala of the nose downward, and thereby constricting the aperture of the nares. The Nasalis depresses the cartilaginous part of the nose and draws the ala toward the septum.

IV. THE MUSCLES OF THE MOUTH.

The muscles of the mouth are:

Quadratus labii superioris.	Quadratus labii inferioris.
Caninus.	Triangularis.
Zygomaticus.	Buccinator.
Mentalis.	Orbicularis oris.
	Risorius.

The **Quadratus labii superioris** is a broad sheet, the origin of which extends from the side of the nose to the zygomatic bone. Its medial fibers form the **angular head**, which *arises* by a pointed extremity from the upper part of the frontal process of the maxilla and passing obliquely downward and lateralward divides into two slips. One of these is *inserted* into the greater alar cartilage and skin of the nose; the other is prolonged into the lateral part of the upper lip, blending with the infraorbital head and with the Orbicularis oris. The intermediate portion or **infraorbital head** *arises* from the lower margin of the orbit immediately above the infraorbital foramen, some of its fibers being attached to the maxilla, others to the zygomatic bone. Its fibers converge, to be *inserted* into the muscular substance of the upper lip between the angular head and the Caninus. The lateral fibers, forming the **zygomatic head**, *arise* from the malar surface of the zygomatic bone immediately behind the zygomaticomaxillary suture and pass downward and medialward to the upper lip.

The **Caninus** (*Levator anguli oris*) *arises* from the canine fossa, immediately below the infraorbital foramen; its fibers are *inserted* into the angle of the mouth, intermingling with those of the Zygomaticus, Triangularis, and Orbicularis oris.

The **Zygomaticus** (*Zygomaticus major*) *arises* from the zygomatic bone, in front of the zygomaticotemporal suture, and descending obliquely with a medial inclination, is *inserted* into the angle of the mouth, where it blends with the fibers of the Caninus, Orbicularis oris, and Triangularis.

Nerves.—This group of muscles is supplied by the facial nerve.

Actions.—The Quadratus labii superioris is the proper elevator of the upper lip, carrying it at the same time a little forward. Its angular head acts as a dilator of the nares; the infraorbital and zygomatic heads assist in forming the nasolabial furrow, which passes from the side of the nose to the upper lip and gives to the face an expression of sadness. When the whole muscle is in action it gives to the countenance an expression of contempt and disdain. The Quadratus labii superioris raises the angle of the mouth and assists the Caninus in producing the nasolabial furrow. The Zygomaticus draws the angle of the mouth backward and upward, as in laughing.

The **Mentalis** (*Levator menti*) is a small conical fasciculus, situated at the side of the frenulum of the lower lip. It *arises* from the incisive fossa of the mandible, and descends to be *inserted* into the integument of the chin.

The **Quadratus labii inferioris** (*Depressor labii inferioris*; *Quadratus menti*) is a small quadrilateral muscle. It *arises* from the oblique line of the mandible, between the symphysis and the mental foramen, and passes upward and medialward, to be *inserted* into the integument of the lower lip, its fibers blending with the Orbicularis oris, and with those of its fellow of the opposite side. At its origin it is continuous with the fibers of the Platysma. Much yellow fat is intermingled with the fibers of this muscle.

The **Triangularis** (*Depressor anguli oris*) *arises* from the oblique line of the mandible, whence its fibers converge, to be *inserted*, by a narrow fasciculus, into the angle of the mouth. At its origin it is continuous with the Platysma, and at its insertion with the Orbicularis oris and Risorius; some of its fibers are directly continuous with those of the Caninus, and others are occasionally found crossing from the muscle of one side to that of the other; these latter fibers constitute the **Transversus menti**.

Nerves.—This group of muscles is supplied by the facial nerve.

Actions.—The Mentalis raises and protrudes the lower lip, and at the same time wrinkles the skin of the chin, expressing doubt or disdain. The Quadratus labii inferioris draws the lower lip directly downward and a little lateralward, as in the expression of irony. The Triangularis depresses the angle of the mouth, being the antagonist of the Caninus and Zygomaticus; acting with the Caninus, it will draw the angle of the mouth medialward. The Platysma which retracts and depresses the angle of the mouth belongs with this group.

The **Buccinator** (Fig. 380) is a thin quadrilateral muscle, occupying the interval between the maxilla and the mandible at the side of the face. It *arises* from the outer surfaces of the alveolar processes of the maxilla and mandible, corresponding to the three molar teeth; and behind, from the anterior border of the pterygomandibular raphé which separates it from the Constrictor pharyngis superior. The fibers converge toward the angle of the mouth, where the central fibers intersect each other, those from below being continuous with the upper segment of the Orbicularis oris, and those from above with the lower segment; the upper and lower fibers are continued forward into the corresponding lip without decussation.

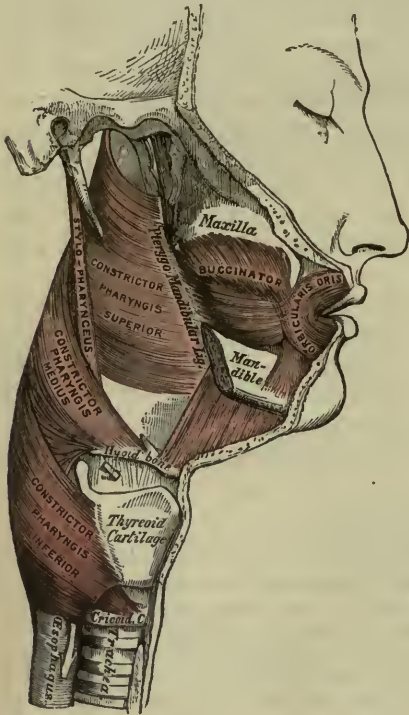


Fig. 380.—Muscles of the pharynx and cheek.

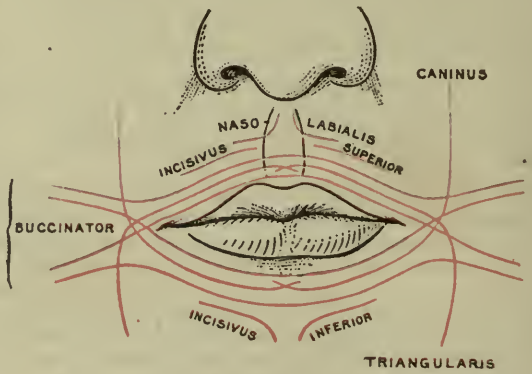


Fig. 381.—Scheme showing arrangement of fibers of Orbicularis oris.

Relations.—The Buccinator is covered by the buccopharyngeal fascia, and is in relation by its *superficial surface*, behind, with a large mass of fat, which separates it from the ramus of the mandible, the Masseter, and a small portion of the Temporalis; this fat has been named the *suctorial pad*, because it is supposed to assist in the act of sucking. The parotid duct pierces the Buccinator opposite the second molar tooth of the maxilla. The *deep surface* is in relation with the buccal glands and mucous membrane of the mouth.

The **pterygomandibular raphé** (*pterygomandibular ligament*) is a tendinous band of the buccopharyngeal fascia, attached by one extremity to the hamulus of the medial pterygoid plate, and by the other to the posterior end of the mylohyoid line of the mandible. Its *medial surface* is covered by the mucous membrane of the mouth. Its *lateral surface* is separated from the ramus of the mandible by a quantity of adipose tissue. Its *posterior border* gives attachment to the Constrictor pharyngis superior; its *anterior border*, to part of the Buccinator (Fig. 380).

The **Orbicularis oris** (Fig. 381) is not a simple sphincter muscle like the Orbicularis oculi; it consists of numerous strata of muscular fibers surrounding the orifice of the mouth but having different direction. It consists partly of fibers derived from the other facial muscles which are inserted into the lips, and partly of fibers proper to the lips. Of the former, a considerable number are derived from the Buccinator and form the deeper stratum of the Orbicularis. Some of the Buccinator fibers—namely, those near the middle of the muscle—decussate at the angle of the mouth, those arising from the maxilla passing to the lower lip, and those from the mandible to the upper lip. The uppermost and lowermost fibers of the Buccinator pass across the lips from side to side without decussation. Superficial to this stratum is a second, formed on either side by the Caninus and

Triangularis, which cross each other at the angle of the mouth; those from the Caninus passing to the lower lip, and those from the Triangularis to the upper lip, along which they run, to be inserted into the skin near the median line. In addition to these there are fibers from the Quadratus labii superioris, the Zygomaticus, and the Quadratus labii inferioris; these intermingle with the transverse fibers above described, and have principally an oblique direction. The proper fibers of the lips are oblique, and pass from the under surface of the skin to the mucous membrane, through the thickness of the lip. Finally there are fibers by which the muscle is connected with the maxillæ and the septum of the nose above and with the mandible below. In the upper lip these consist of two bands, lateral and medial, on either side of the middle line; the **lateral band** (*m. incisivus labii superioris*) arises from the alveolar border of the maxilla, opposite the lateral incisor tooth, and arching lateralward is continuous with the other muscles at the angle of the mouth; the **medial band** (*m. nasolabialis*) connects the upper lip to the back of the septum of the nose. The interval between the two medial bands corresponds with the depression, called the **philtrum**, seen on the lip beneath the septum of the nose. The additional fibers for the lower lip constitute a slip (*m. incisivus labii inferioris*) on either side of the middle line; this arises from the mandible, lateral to the Mentalis, and intermingles with the other muscles at the angle of the mouth.

The **Risorius** arises in the fascia over the Masseter and, passing horizontally forward, superficial to the Platysma, is inserted into the skin at the angle of the mouth (Fig. 378). It is a narrow bundle of fibers, broadest at its origin, but varies much in its size and form.

Variations.—The zygomatic head of the Quadratus labii superioris and Risorius are frequently absent and more rarely the Zygomaticus. The Zygomaticus and Risorius may be doubled or the latter greatly enlarged or blended with the Platysma.

Nerves.—The muscles in this group are all supplied by the facial nerve.

Actions.—The Orbicularis oris in its ordinary action effects the direct closure of the lips; by its deep fibers, assisted by the oblique ones, it closely applies the lips to the alveolar arch. The superficial part, consisting principally of the decussating fibers, brings the lips together and also protrudes them forward. The Buccinators compress the cheeks, so that, during the process of mastication, the food is kept under the immediate pressure of the teeth. When the cheeks have been previously distended with air, the Buccinator muscles expel it from between the lips, as in blowing a trumpet; hence the name (*buccina*, a trumpet). The Risorius retracts the angle of the mouth, and produces an unpleasant grinning expression.

For more extensive consideration of the facial muscles, see Charles Darwin, *Expression of the Emotions in Man and Animals*.

IV. THE MUSCLES OF MASTICATION.

The chief muscles of mastication are:

Masseter.
Temporalis.

Pterygoideus externus.
Pterygoideus internus.

Parotidomasseteric Fascia (*masseteric fascia*).—Covering the Masseter, and firmly connected with it, is a strong layer of fascia derived from the deep cervical fascia. Above, this fascia is attached to the lower border of the zygomatic arch, and behind, it invests the parotid gland.

The **Masseter** (Fig. 378) is a thick, somewhat quadrilateral muscle, consisting of two portions, superficial and deep. The **superficial portion**, the larger, arises by a thick, tendinous aponeurosis from the zygomatic process of the maxilla, and from the anterior two-thirds of the lower border of the zygomatic arch: its fibers pass downward and backward, to be inserted into the angle and lower half of the lateral surface of the ramus of the mandible. The **deep portion** is much smaller,

and more muscular in texture; it *arises* from the posterior third of the lower border and from the whole of the medial surface of the zygomatic arch; its fibers pass downward and forward, to be *inserted* into the upper half of the ramus and the lateral surface of the coronoid process of the mandible. The deep portion of the muscle is partly concealed, in front, by the superficial portion; behind, it is covered by the parotid gland. The fibers of the two portions are continuous at their insertion.

Temporal Fascia.—The temporal fascia covers the Temporalis muscle. It is a strong, fibrous investment, covered, laterally, by the Auricularis anterior and superior, by the galea aponeurotica, and by part of the Orbicularis oculi. The superficial temporal vessels and the auriculotemporal nerve cross it from below upward. *Above*, it is a single layer, attached to the entire extent of the superior temporal line; but *below*, where it is fixed to the zygomatic arch, it consists of two layers, one of which is inserted into the lateral, and the other into the medial border of the arch. A small quantity of fat, the orbital branch of the superficial temporal artery, and a filament from the zygomatic branch of the maxillary nerve, are contained between these two layers. It affords attachment by its deep surface to the superficial fibers of the Temporalis.

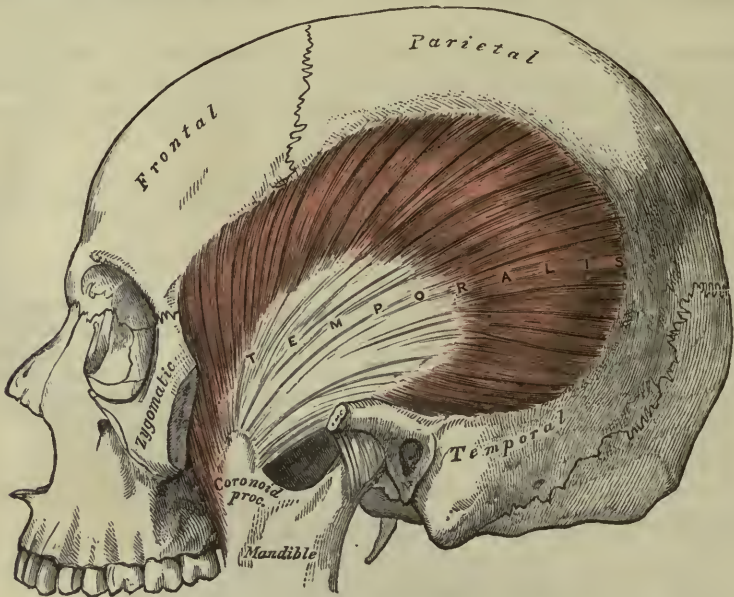


FIG. 382.—The Temporalis; the zygomatic arch and Masseter have been removed.

The **Temporalis** (*Temporal muscle*) (Fig. 382) is a broad, radiating muscle, situated at the side of the head. It *arises* from the whole of the temporal fossa (except that portion of it which is formed by the zygomatic bone) and from the deep surface of the temporal fascia. Its fibers converge as they descend, and end in a tendon, which passes deep to the zygomatic arch and is inserted into the medial surface, apex, and anterior border of the coronoid process, and the anterior border of the ramus of the mandible nearly as far forward as the last molar tooth.

The **Pterygoideus externus** (*External pterygoid muscle*) (Fig. 383) is a short, thick muscle, somewhat conical in form, which extends almost horizontally between the infratemporal fossa and the condyle of the mandible. It *arises* by two heads; an **upper** from the lower part of the lateral surface of the great wing of the sphenoid and from the infratemporal crest; a **lower** from the lateral surface of the lateral pterygoid plate. Its fibers pass horizontally backward and lateralward, to be

inserted into a depression in front of the neck of the condyle of the mandible, and into the front margin of the articular disk of the temporomandibular articulation.

The **Pterygoideus internus** (*Internal pterygoid muscle*) (Fig. 383) is a thick, quadrilateral muscle. It arises from the medial surface of the lateral pterygoid plate and the grooved surface of the pyramidal process of the palatine bone; it has a second slip of origin from the lateral surfaces of the pyramidal process of the palatine and tuberosity of the maxilla. Its fibers pass downward, lateralward, and backward, and are inserted, by a strong tendinous lamina, into the lower and back part of the medial surface of the ramus and angle of the mandible, as high as the mandibular foramen.

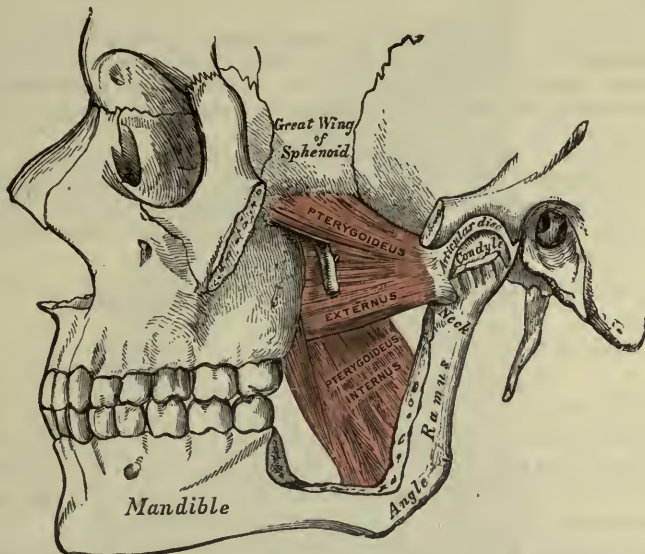


FIG. 383.—The Pterygoidei; the zygomatic arch and a portion of the ramus of the mandible have been removed.

Nerves.—The muscles of mastication are supplied by the mandibular nerve.

Actions.—The Temporalis, Masseter, and Pterygoideus internus raise the mandible against the maxillæ with great force. The Pterygoideus externus assists in opening the mouth, but its main action is to draw forward the condyle and articular disk so that the mandible is protruded and the inferior incisors projected in front of the upper; in this action it is assisted by the Pterygoideus internus. The mandible is retracted by the posterior fibers of the Temporalis. If the Pterygoidei internus and externus of one side act, the corresponding side of the mandible is drawn forward while the opposite condyle remains comparatively fixed, and side-to-side movements, such as occur during the trituration of food, take place.

THE FASCIÆ AND MUSCLES OF THE ANTERO-LATERAL REGION OF THE NECK.

The antero-lateral muscles of the neck may be arranged into the following groups:

- | | |
|--------------------------|-----------------------------|
| I. Superficial Cervical. | III. Supra- and Infrahyoid. |
| II. Lateral Cervical. | IV. Anterior Vertebral. |
| V. Lateral Vertebral. | |

I. THE SUPERFICIAL CERVICAL MUSCLE.

Platysma.

The **Superficial Fascia** of the neck is a thin lamina investing the Platysma, and is hardly demonstrable as a separate membrane.

The **Platysma** (Fig. 378) is a broad sheet *arising* from the fascia covering the upper parts of the Pectoralis major and Deltoideus; its fibers cross the clavicle, and proceed obliquely upward and medialward along the side of the neck. The anterior fibers interlace, below and behind the symphysis menti, with the fibers of the muscle of the opposite side; the posterior fibers cross the mandible, some being inserted into the bone below the oblique line, others into the skin and subcutaneous tissue of the lower part of the face, many of these fibers blending with the muscles about the angle and lower part of the mouth. Sometimes fibers can be traced to the Zygomaticus, or to the margin of the Orbicularis oculi. Beneath the Platysma, the external jugular vein descends from the angle of the mandible to the clavicle.

Variations occur in the extension over the face and over the clavicle and shoulder; it may be absent or interdigitate with the muscle of the opposite side in front of the neck; attachment to clavicle, mastoid process or occipital bone occurs. A more or less independent fasciculus, the *Occipitalis minor*, may extend from the fascia over the Trapezius to fascia over the insertion of the Sternocleidomastoideus.

Nerve.—The Platysma is supplied by the cervical branch of the facial nerve.

Actions.—When the entire Platysma is in action it produces a slight wrinkling of the surface of the skin of the neck in an oblique direction. Its anterior portion, the thickest part of the muscle, depresses the lower jaw; it also serves to draw down the lower lip and angle of the mouth in the expression of melancholy.

II. THE LATERAL CERVICAL MUSCLES.

The lateral muscles are:

Trapezius and Sternocleidomastoideus.

The Trapezius is described on page 432.

The Fascia Colli (*deep cervical fascia*) (Fig. 384).—The fascia colli lies under cover of the Platysma, and invests the neck; it also forms sheaths for the carotid vessels, and for the structures situated in front of the vertebral column.

The investing portion of the fascia is attached behind to the ligamentum nuchæ and to the spinous process of the seventh cervical vertebra. It forms a thin investment to the Trapezius, and at the anterior border of this muscle is continued forward as a rather loose areolar layer, covering the posterior triangle of the neck, to the posterior border of the Sternocleidomastoideus, where it begins to assume the appearance of a fascial membrane. Along the hinder edge of the Sternocleidomastoideus it divides to enclose the muscle, and at the anterior margin again forms a single lamella, which covers the anterior triangle of the neck, and reaches forward to the middle line, where it is continuous with the corresponding part from the opposite side of the neck. In the middle line of the neck it is attached to the symphysis menti and the body of the hyoid bone.

Above, the fascia is attached to the superior nuchal line of the occipital, to the mastoid process of the temporal, and to the whole length of the inferior border of the body of the mandible. Opposite the angle of the mandible the fascia is very strong, and binds the anterior edge of the Sternocleidomastoideus firmly to that bone. Between the mandible and the mastoid process it ensheathes the parotid gland—the layer which covers the gland extends upward under the name of the **parotideomasseteric fascia** and is fixed to the zygomatic arch. From the part which passes under the parotid gland a strong band extends upward to the styloid process, forming the **stylomandibular ligament**. Two other bands may be defined: the **sphenomandibular** (page 297) and the **pterygospinous ligaments**. The **pterygospinous ligament** stretches from the upper part of the posterior border of the lateral pterygoid plate to the spinous process of the sphenoid. It occasionally ossifies, and in such cases, between its upper border and the base of the skull, a foramen is formed which transmits the branches of the mandibular nerve to the muscles of mastication.

Below, the fascia is attached to the acromion, the clavicle, and the manubrium sterni. Some little distance above the last it splits into two layers, superficial and deep. The former is attached to the anterior border of the manubrium, the latter to its posterior border and to the interclavicular ligament. Between these two layers is a slit-like interval, the **suprasternal space** (*space of Burns*); it contains a small quantity of areolar tissue, the lower portions of the anterior jugular veins and their transverse connecting branch, the sternal heads of the Sternocleidomastoidei, and sometimes a lymph gland.

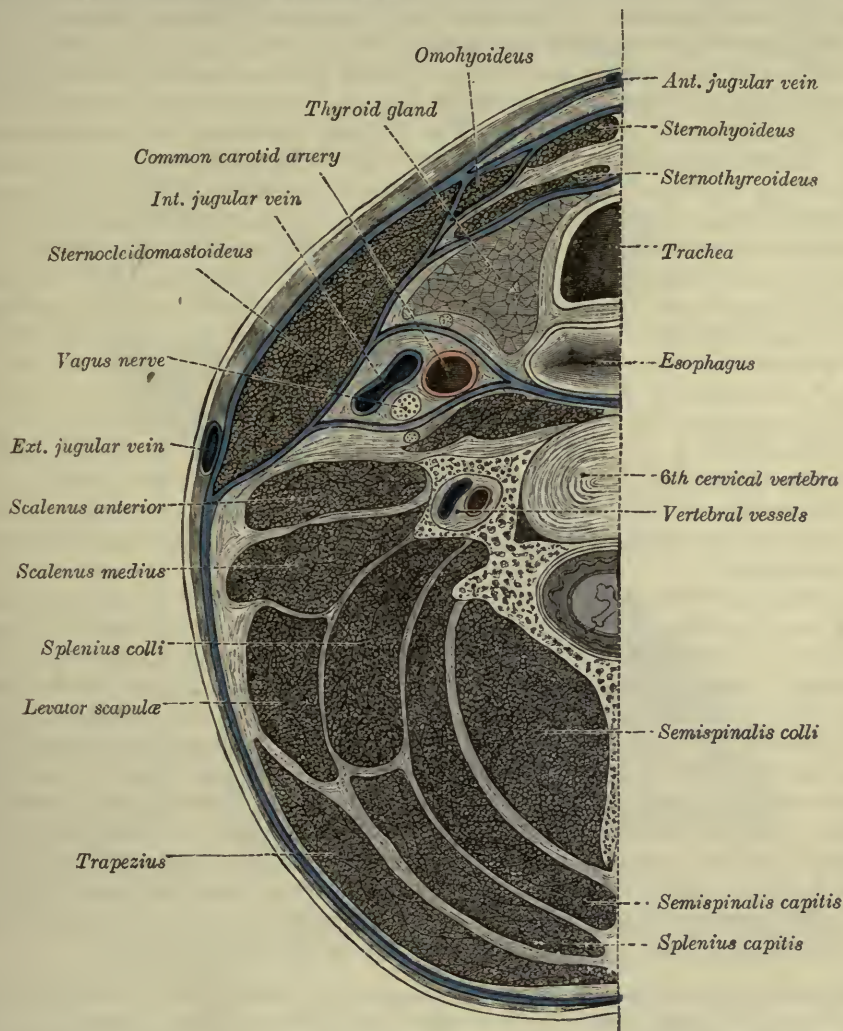


FIG. 384.—Section of the neck at about the level of the sixth cervical vertebra. Showing the arrangement of the fascia coli.

The fascia which lines the deep surface of the Sternocleidomastoideus gives off the following processes: (1) A process envelops the tendon at the Omohyoideus, and binds it down to the sternum and first costal cartilage. (2) A strong sheath, the **carotid sheath**, encloses the carotid artery, internal jugular vein, and vagus nerve. (3) The **prevertebral fascia** extends medialward behind the carotid vessels, where it assists in forming their sheath, and passes in front of the prevertebral muscles. It forms the posterior limit of a fibrous compartment, which contains the larynx and trachea, the thyroid gland, and the pharynx and esophagus. The

prevertebral fascia is fixed above to the base of the skull, and below is continued into the thorax in front of the Longus colli muscles. Parallel to the carotid sheath and along its medial aspect the prevertebral fascia gives off a thin lamina, the **buccopharyngeal fascia**, which closely invests the Constrictor muscles of the pharynx, and is continued forward from the Constrictor pharyngis superior on to the Buccinator. It is attached to the prevertebral layer by loose connective tissue only, and thus an easily distended space, the **retropharyngeal space**, is found between them. This space is limited above by the base of the skull, while below it extends behind the esophagus into the posterior mediastinal cavity of the thorax. The prevertebral fascia is prolonged downward and lateralward behind the carotid vessels and in front of the Scaleni, and forms a sheath for the brachial nerves and subclavian vessels in the posterior triangle of the neck; it is continued under the clavicle as the axillary sheath and is attached to the deep surface of the coracoclavicular fascia. Immediately above and behind the clavicle an areolar space exists between the investing layer and the sheath of the subclavian vessels, and in this space are found the lower part of the external jugular vein, the descending clavicular nerves, the transverse scapular and transverse cervical vessels, and the inferior belly of the Omohyoideus muscle. This space is limited below by the fusion of the coracoclavicular fascia with the anterior wall of the axillary sheath. (4) The **pretrachial fascia** extends medially in front of the carotid vessels, and assists in forming the carotid sheath. It is continued behind the depressor muscles of the hyoid bone, and, after enveloping the thyroid gland, is prolonged in front of the trachea to meet the corresponding layer of the opposite side. Above, it is fixed to the hyoid bone, while below it is carried downward in front of the trachea and large vessels at the root of the neck, and ultimately blends with the fibrous pericardium. This layer is fused on either side with the prevertebral fascia, and with it completes the compartment containing the larynx and trachea, the thyroid gland, and the pharynx and esophagus.¹

The **Sternocleidomastoideus** (*Sternomastoid muscle*) (Fig. 385) passes obliquely across the side of the neck. It is thick and narrow at its central part, but broader and thinner at either end. It *arises* from the sternum and clavicle by two heads. The **medial** or **sternal head** is a rounded fasciculus, tendinous in front, fleshy behind, which *arises* from the upper part of the anterior surface of the manubrium sterni, and is directed upward, lateralward, and backward. The **lateral** or **clavicular head**, composed of fleshy and aponeurotic fibers, *arises* from the superior border and anterior surface of the medial third of the clavicle; it is directed almost vertically upward. The two heads are separated from one another at their origins by a triangular interval, but gradually blend, below the middle of the neck, into a thick, rounded muscle which is *inserted*, by a strong tendon, into the lateral surface of the mastoid process, from its apex to its superior border, and by a thin aponeurosis into the lateral half of the superior nuchal line of the occipital bone.

Variations.—The Sternocleidomastoideus varies much in the extent of its origin from the clavicle: in some cases the clavicular head may be as narrow as the sternal; in others it may be as much as 7.5 cm. in breadth. When the clavicular origin is broad, it is occasionally subdivided into several slips, separated by narrow intervals. More rarely, the adjoining margins of the Sternocleidomastoideus and Trapezius have been found in contact. The *Supraclavicularis muscle* arises from the manubrium behind the Sternocleidomastoideus and passes behind the Sternocleidomastoideus to the upper surface of the clavicle.

Triangles of the Neck.—This muscle divides the quadrilateral area of the side of the neck into two triangles, an anterior and a posterior. The boundaries of the **anterior triangle** are, in *front*, the median line of the neck; *above*, the lower border of the body of the mandible, and an imaginary line drawn from the angle of the mandible to the Sternocleidomastoideus; *behind*, the anterior border of the Sternocleidomastoideus. The apex of the triangle is at the upper

¹ F. G. Parsons (Journal of Anatomy and Physiology, vol. xlv) regards the carotid sheath and the fascial planes in the neck as structures which are artificially produced by dissection.

border of the sternum. The boundaries of the **posterior triangle** are, in *front*, the posterior border of the Sternocleidomastoideus; *below*, the middle third of the clavicle; *behind*, the anterior margin of the Trapezius. The apex corresponds with the meeting of the Sternocleidomastoideus and Trapezius on the occipital bone. The anatomy of these triangles will be more fully described with that of the vessels of the neck (p. 562).

Nerves.—The Sternocleidomastoideus is supplied by the accessory nerve and branches from the anterior divisions of the second and third cervical nerves.

Actions.—When only one Sternocleidomastoideus acts, it draws the head toward the shoulder of the same side, assisted by the Splenius and the Obliquus capitis inferior of the opposite side. At the same time it rotates the head so as to carry the face toward the opposite side. Acting together from their sternoclavicular attachments the muscles will flex the cervical part of the vertebral column. If the head be fixed, the two muscles assist in elevating the thorax in forced inspiration.

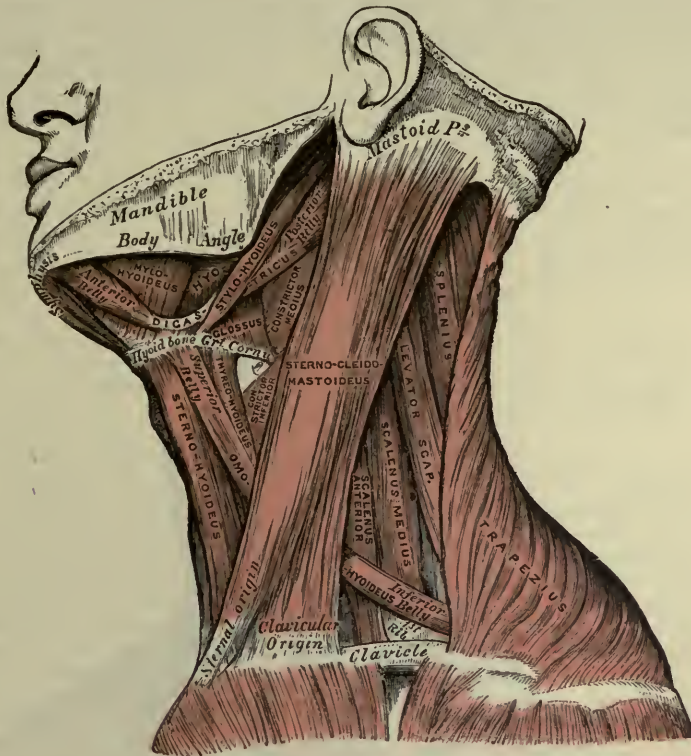


FIG. 335.—Muscles of the neck. Lateral view.

III. THE SUPRA- AND INFRAHYOID MUSCLES (Figs. 385, 386).

The suprahyoid muscles are:

Digastricus.
Stylohyoideus.

Mylohyoideus.
Geniohyoideus.

The **Digastricus** (*Digastric muscle*) consists of two fleshy bellies united by an intermediate rounded tendon. It lies below the body of the mandible, and extends, in a curved form, from the mastoid process to the symphysis menti. The **posterior belly**, longer than the anterior, *arises* from the mastoid notch of the temporal bone and passes downward and forward. The **anterior belly** *arises* from a depression on the inner side of the lower border of the mandible, close to the symphysis, and passes downward and backward. The two bellies end in an intermediate tendon which perforates the Stylohyoideus muscle, and is held in connection with the side of the body and the greater cornu of the hyoid bone by a fibrous loop, which is

sometimes lined by a mucous sheath. A broad aponeurotic layer is given off from the tendon of the Digastricus on either side, to be attached to the body and greater cornu of the hyoid bone; this is termed the **suprahyoid aponeurosis**.

Variations are numerous. The posterior belly may arise partly or entirely from the styloid process, or be connected by a slip to the middle or inferior constrictor; the anterior belly may be double or extra slips from this belly may pass to the jaw or Mylohyoideus or decussate with a similar slip on opposite side; anterior belly may be absent and posterior belly inserted into the middle of the jaw or hyoid bone. The tendon may pass in front, more rarely behind the Stylohyoideus. The *Mentohyoideus muscle* passes from the body of hyoid bone to chin.

The Digastricus divides the anterior triangle of the neck into three smaller triangles (1) the **submaxillary triangle**, bounded above by the lower border of the body of the mandible, and a line drawn from its angle to the Sternocleidomastoideus, below by the posterior belly of the Digastricus and the Stylohyoideus, in front by the anterior belly of the Digastricus; (2) the **carotid triangle**, bounded above by the posterior belly of the Digastricus and Stylohyoideus, behind by the Sternocleidomastoideus, below by the Omohyoideus; (3) the **suprahyoid or submental triangle**, bounded laterally by the anterior belly of the Digastricus, medially by the middle line of the neck from the hyoid bone to the symphysis menti, and inferiorly by the body of the hyoid bone.

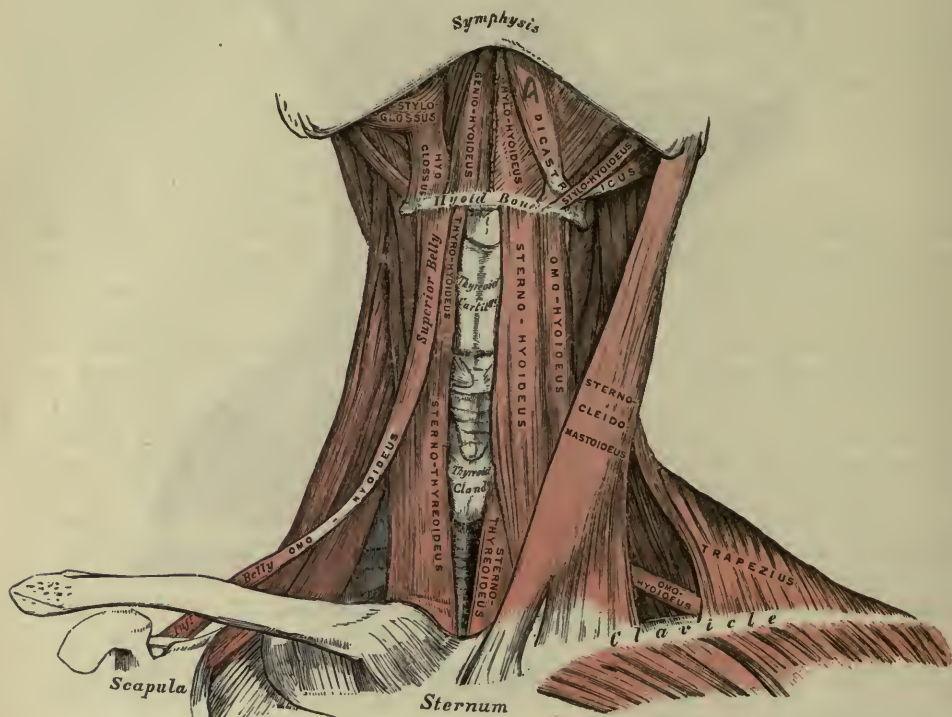


FIG. 386.—Muscles of the neck. Anterior view.

The **Stylohyoideus** (*Stylohyoid muscle*) is a slender muscle, lying in front of, and above, the posterior belly of the Digastricus. It *arises* from the back and lateral surface of the styloid process, near the base; and, passing downward and forward, is *inserted* into the body of the hyoid bone, at its junction with the greater cornu, and just above the Omohyoideus. It is perforated, near its insertion, by the tendon of the Digastricus.

Variations.—It may be absent or doubled, lie beneath the carotid artery, or be inserted into the Omohyoideus, Thyrohyoideus, or Mylohyoideus.

The **Stylohyoid Ligament** (*ligamentum stylohyoideus*).—In connection with the Stylohyoideus muscle a ligamentous band, the **stylohyoid ligament**, may be

described. It is a fibrous cord, which is attached to the tip of the styloid process of the temporal and the lesser cornu of the hyoid bone. It frequently contains a little cartilage in its center, is often partially ossified, and in many animals forms a distinct bone, the **epihyal**.

The **Mylohyoideus** (*Mylohyoid muscle*), flat and triangular, is situated immediately above the anterior belly of the Digastricus, and forms, with its fellow of the opposite side, a muscular floor for the cavity of the mouth. It *arises* from the whole length of the mylohyoid line of the mandible, extending from the symphysis in front to the last molar tooth behind. The posterior fibers pass medialward and slightly downward, to be *inserted* into the body of the hyoid bone. The middle and anterior fibers are *inserted* into a median fibrous raphé extending from the symphysis menti to the hyoid bone, where they join at an angle with the fibers of the opposite muscle. This median raphé is sometimes wanting; the fibers of the two muscles are then continuous.

Variations.—It may be united to or replaced by the anterior belly of the Digastricus; accessory slips to other hyoid muscles are frequent.

The **Geniohyoideus** (*Geniohyoid muscle*) is a narrow muscle, situated above the medial border of the Mylohyoideus. It *arises* from the inferior mental spine on the back of the symphysis menti, and runs backward and slightly downward, to be *inserted* into the anterior surface of the body of the hyoid bone; it lies in contact with its fellow of the opposite side.

Variations.—It may be blended with the one on opposite side or double; slips to greater cornu of hyoid bone and Genioglossus occur.

Nerves.—The Mylohyoideus and anterior belly of the Digastricus are supplied by the mylohyoid branch of the inferior alveolar; the Stylohyoideus and posterior belly of the Digastricus, by the facial; the Geniohyoideus, by the hypoglossal.

Actions.—These muscles perform two very important actions. During the act of deglutition they raise the hyoid bone, and with it the base of the tongue; when the hyoid bone is fixed by its depressors and those of the larynx, they depress the mandible. During the first act of deglutition, when the mass of food is being driven from the mouth into the pharynx, the hyoid bone and with it the tongue, is carried upward and forward by the anterior bellies of the Digastrici, the Mylohyoidei, and Geniohyoidei. In the second act, when the mass is passing through the pharynx, the direct elevation of the hyoid bone takes place by the combined action of all the muscles; and after the food has passed, the hyoid bone is carried upward and backward by the posterior bellies of the Digastrici and the Stylohyoidei, which assist in preventing the return of the food into the mouth.

The infrahyoid muscles are:

Sternohyoideus.

Sternothyreoideus.

Thyreohyoideus.

Omo-hyoideus.

The **Sternohyoideus** (*Sternohyoid muscle*) is a thin, narrow muscle, which *arises* from the posterior surface of the medial end of the clavicle, the posterior sternoclavicular ligament, and the upper and posterior part of the manubrium sterni. Passing upward and medialward, it is *inserted*, by short, tendinous fibers, into the lower border of the body of the hyoid bone. Below, this muscle is separated from its fellow by a considerable interval; but the two muscles come into contact with one another in the middle of their course, and from this upward, lie side by side. It sometimes presents, immediately above its origin, a transverse tendinous inscription.

Variations.—Doubling; accessory slips (Cleidohyoideus); absence.

The **Sternothyreoideus** (*Sternothyroid muscle*) is shorter and wider than the preceding muscle, beneath which it is situated. It *arises* from the posterior surface of the manubrium sterni, below the origin of the Sternohyoideus, and from the edge of the cartilage of the first rib, and sometimes that of the second rib, it is *inserted*

into the oblique line on the lamina of the thyroid cartilage. This muscle is in close contact with its fellow at the lower part of the neck, but diverges somewhat as it ascends; it is occasionally traversed by a transverse or oblique tendinous inscription.

Variations.—Doubling; absence; accessory slips to Thyreohyoideus, Inferior constrictor, or carotid sheath.

The **Thyreohyoideus** (*Thyrohyoid muscle*) is a small, quadrilateral muscle appearing like an upward continuation of the Sternothyreideus. It *arises* from the oblique line on the lamina of the thyroid cartilage, and is *inserted* into the lower border of the greater cornu of the hyoid bone.

The **Omohyoideus** (*Omohyoid muscle*) consists of two fleshy bellies united by a central tendon. It *arises* from the upper border of the scapula, and occasionally from the superior transverse ligament which crosses the scapular notch, its extent of attachment to the scapula varying from a few millimetres to 2.5 cm. From this origin, the inferior belly forms a flat, narrow fasciculus, which inclines forward and slightly upward across the lower part of the neck, being bound down to the clavicle by a fibrous expansion; it then passes behind the Sternocleidomastoideus, becomes tendinous and changes its direction, forming an obtuse angle. It ends in the superior belly, which passes almost vertically upward, close to the lateral border of the Sternohyoideus, to be inserted into the lower border of the body of the hyoid bone, lateral to the insertion of the Sternohyoideus. The central tendon of this muscle varies much in length and form, and is held in position by a process of the deep cervical fascia, which sheaths it, and is prolonged down to be attached to the clavicle and first rib; it is by this means that the angular form of the muscle is maintained.

Variations.—Doubling; absence; origin from clavicle; absence or doubling of either belly.

The inferior belly of the Omohyoideus divides the posterior triangle of the neck into an upper or **occipital triangle** and a lower or **subclavian triangle**, while its superior belly divides the anterior triangle into an upper or **carotid triangle** and a lower or **muscular triangle**.

Nerves.—The Infrahyoid muscles are supplied by branches from the first three cervical nerves. From the first two nerves the branch joins the hypoglossal trunk, runs with it some distance, and sends off a branch to the Thyreohyoideus; it then leaves the hypoglossal to form the descendens hypoglossi and unites with the communicantes cerviculis from the second and third cervical nerves to form the ansa hypoglossi from which nerves pass to the other Infrahyoid muscles.

Actions.—These muscles depress the larynx and hyoid bone, after they have been drawn up with the pharynx in the act of deglutition. The Omohyoidei not only depress the hyoid bone, but carry it backward and to one or the other side. They are concerned especially in prolonged inspiratory efforts; for by rendering the lower part of the cervical fascia tense they lessen the inward suction of the soft parts, which would otherwise compress the great vessels and the apices of the lungs. The Thyreohyoideus may act as an elevator of the thyroid cartilage, when the hyoid bone ascends, drawing the thyroid cartilage up behind the hyoid bone. The Sternothyreideus acts as a depressor of the thyroid cartilage.

IV. THE ANTERIOR VERTEBRAL MUSCLES (Fig. 387).

The anterior vertebral muscles are:

Longus colli.

Longus capitis.

Rectus capitis anterior.

Rectus capitis lateralis.

The **Longus colli** is situated on the anterior surface of the vertebral column, between the atlas and the third thoracic vertebra. It is broad in the middle, narrow and pointed at either end, and consists of three portions, a superior oblique, an inferior oblique, and a vertical. The **superior oblique portion** *arises* from the anterior tubercles of the transverse processes of the third, fourth, and fifth cervical vertebræ; and, ascending obliquely with a medial inclination, is *inserted* by a narrow

tendon into the tubercle on the anterior arch of the atlas. The **inferior oblique portion**, the smallest part of the muscle, *arises* from the front of the bodies of the first two or three thoracic vertebræ; and, ascending obliquely in a lateral direction, is *inserted* into the anterior tubercles of the transverse processes of the fifth and sixth cervical vertebræ. The **vertical portion** *arises*, below, from the front of the bodies of the upper three thoracic and lower three cervical vertebræ, and is *inserted* into the front of the bodies of the second, third, and fourth cervical vertebræ.

The **Longus capitis** (*Rectus capitis anticus major*), broad and thick above, narrow below, *arises* by four tendinous slips, from the anterior tubercles of the transverse processes of the third, fourth, fifth, and sixth cervical vertebræ, and ascends, converging toward its fellow of the opposite side, to be *inserted* into the inferior surface of the basilar part of the occipital bone.

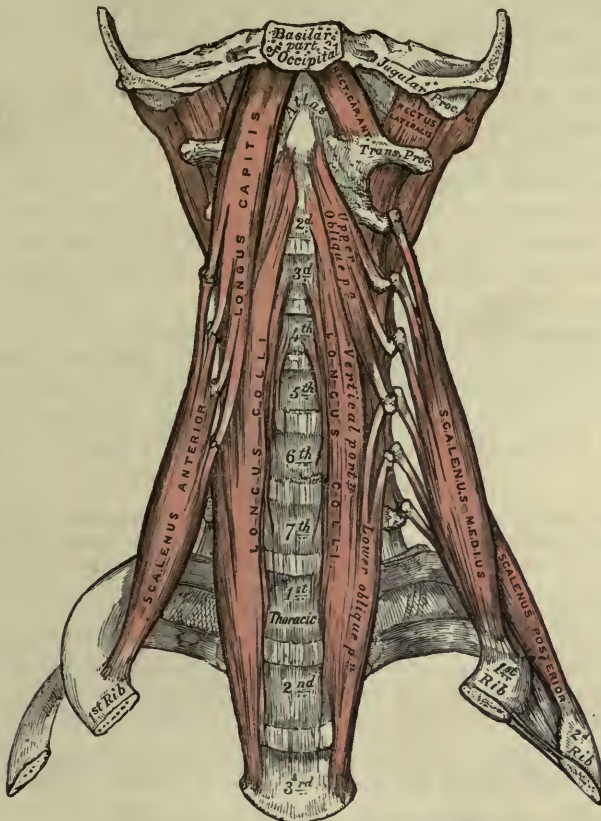

FIG. 387.—The anterior vertebral muscles.

The **Rectus capitis anterior** (*Rectus capitis anticus minor*) is a short, flat muscle, situated immediately behind the upper part of the Longus capitis. It *arises* from the anterior surface of the lateral mass of the atlas, and from the root of its transverse process, and passing obliquely upward and medialward, is *inserted* into the inferior surface of the basilar part of the occipital bone immediately in front of the foramen magnum.

The **Rectus capitis lateralis**, a short, flat muscle, *arises* from the upper surface of the transverse process of the atlas, and is *inserted* into the under surface of the jugular process of the occipital bone.

Nerves.—The Rectus capitis anterior and the Rectus capitis lateralis are supplied from the loop between the first and second cervical nerves; the Longus capitis, by branches from the

first, second, and third cervical; the Longus colli, by branches from the second to the seventh cervical nerves.

Actions.—The Longus capitis and Rectus capitis anterior are the direct antagonists of the muscles at the back of the neck, serving to restore the head to its natural position after it has been drawn backward. These muscles also flex the head, and from their obliquity, rotate it, so as to turn the face to one or the other side. The Rectus lateralis, acting on one side, bends the head laterally. The Longus colli flexes and slightly rotates the cervical portion of the vertebral column.

V. THE LATERAL VERTEBRAL MUSCLES (Fig. 387).

The lateral vertebral muscles are:

Scalenus anterior.

Scalenus posterior.

Scalenus medius.

The **Scalenus anterior** (*Scalenus anticus*) lies deeply at the side of the neck, behind the Sternocleidomastoideus. It *arises* from the anterior tubercles of the transverse processes of the third, fourth, fifth, and sixth cervical vertebræ, and descending, almost vertically, is *inserted* by a narrow, flat tendon into the scalene tubercle on the inner border of the first rib, and into the ridge on the upper surface of the rib in front of the subclavian groove.

The **Scalenus medius**, the largest and longest of the three Scaleni, *arises* from the posterior tubercles of the transverse processes of the lower six cervical vertebræ, and descending along the side of the vertebral column, is *inserted* by a broad attachment into the upper surface of the first rib, between the tubercle and the subclavian groove.

The **Scalenus posterior** (*Scalenus posticus*), the smallest and most deeply seated of the three Scaleni, *arises*, by two or three separate tendons, from the posterior tubercles of the transverse processes of the lower two or three cervical vertebræ, and is *inserted* by a thin tendon into the outer surface of the second rib, behind the attachment of the Serratus anterior. It is occasionally blended with the Scalenus medius.

Variations.—The Scaleni muscles vary considerably in their attachments and in the arrangement of their fibers. A slip from the Scalenus anticus may pass behind the subclavian artery. The Scalenus posticus may be absent or extend to the third rib. The *Scalenus pleuralis muscle* extends from the transverse process of the seventh cervical vertebra to the fascia supporting the dome of the pleura and inner border of first rib.

Nerves.—The Scaleni are supplied by branches from the second to the seventh cervical nerves.

Actions.—When the Scaleni act from above, they elevate the first and second ribs, and are, therefore, inspiratory muscles. Acting from below, they bend the vertebral column to one or other side; if the muscles of both sides act, the vertebral column is slightly flexed.

THE FASCIÆ AND MUSCLES OF THE TRUNK.

The muscles of the trunk may be arranged in six groups:

- | | |
|------------------------------|------------------------------|
| I. Deep Muscles of the Back. | IV. Muscles of the Abdomen. |
| II. Suboccipital Muscles. | V. Muscles of the Pelvis. |
| III. Muscles of the Thorax. | VI. Muscles of the Perineum. |

I. THE DEEP MUSCLES OF THE BACK (Fig. 388).

The deep or intrinsic muscles of the back consist of a complex group of muscles extending from the pelvis to the skull. They are:

- | | |
|--------------------|---------------------|
| Splenius capitis. | Multifidus. |
| Splenius cervicis. | Rotatores. |
| Sacrospinalis. | Interspinales. |
| Semispinalis. | Intertransversarii. |

The Lumbodorsal Fascia (*fascia lumbodorsalis*; *lumbar aponeurosis and vertebral fascia*).—The lumbodorsal fascia is a deep investing membrane which covers the deep muscles of the back of the trunk. *Above*, it passes in front of the Serratus posterior superior and is continuous with a similar investing layer on the back of the neck—the **nuchal fascia**.

In the thoracic region the lumbodorsal fascia is a thin fibrous lamina which serves to bind down the Extensor muscles of the vertebral column and to separate them from the muscles connecting the vertebral column to the upper extremity. It contains both longitudinal and transverse fibers, and is attached, **medially**, to the spinous processes of the thoracic vertebræ; **laterally** to the angles of the ribs.

In the lumbar region the fascia (*lumbar aponeurosis*) is in two layers, anterior and posterior (Figs. 388, 409). The posterior layer is attached to the spinous processes of the lumbar and sacral vertebræ and to the supraspinal ligament; the anterior layer is attached, **medially**, to the tips of the transverse processes of the lumbar vertebræ and to the intertransverse ligaments, *below*, to the iliolumbar ligament, and *above*, to the lumbocostal ligament. The two layers unite at the lateral margin of the Sacrospinalis, to form the tendon of origin of the Transversus abdominis. The aponeurosis of origin of the Serratus posterior inferior and the Latissimus dorsi are intimately blended with the lumbodorsal fascia.

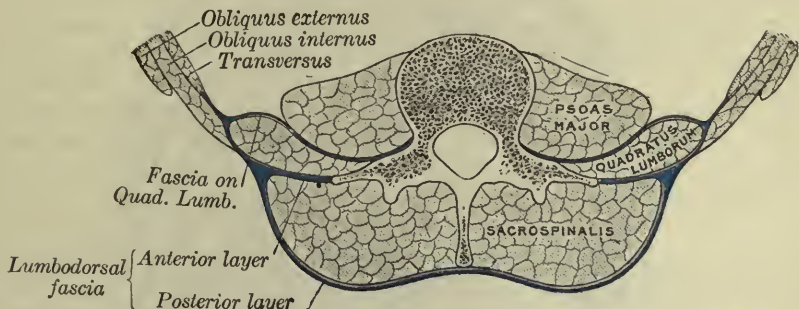


FIG. 388.—Diagram of a transverse section of the posterior abdominal wall, to show the disposition of the lumbodorsal fascia.

The **Splenius capitis** (Fig. 409) *arises* from the lower half of the ligamentum nuchæ, from the spinous process of the seventh cervical vertebra, and from the spinous processes of the upper three or four thoracic vertebræ. The fibers of the muscle are directed upward and lateralward and are *inserted*, under cover of the Sternocleidomastoideus, into the mastoid process of the temporal bone, and into the rough surface on the occipital bone just below the lateral third of the superior nuchal line.

The **Splenius cervicis** (*Splenius colli*) (Fig. 409) *arises* by a narrow tendinous band from the spinous processes of the third to the sixth thoracic vertebræ; it is *inserted*, by tendinous fasciculi, into the posterior tubercles of the transverse processes of the upper two or three cervical vertebræ.

Variations.—The origin is frequently moved up or down one or two vertebræ. Accessory slips are occasionally found.

Nerves.—The Splenii are supplied by the lateral branches of the posterior divisions of the middle and lower cervical nerves.

Actions.—The Splenii of the two sides, acting together, draw the head directly backward, assisting the Trapezius and Semispinalis capitis; acting separately, they draw the head to one side, and slightly rotate it, turning the face to the same side. They also assist in supporting the head in the erect position.

The **Sacrospinalis** (*Erector spinæ*) (Fig. 389), and its prolongations in the thoracic and cervical regions, lie in the groove on the side of the vertebral column.

They are covered in the lumbar and thoracic regions by the lumbodorsal fascia, and in the cervical region by the nuchal fascia. This large muscular and tendinous

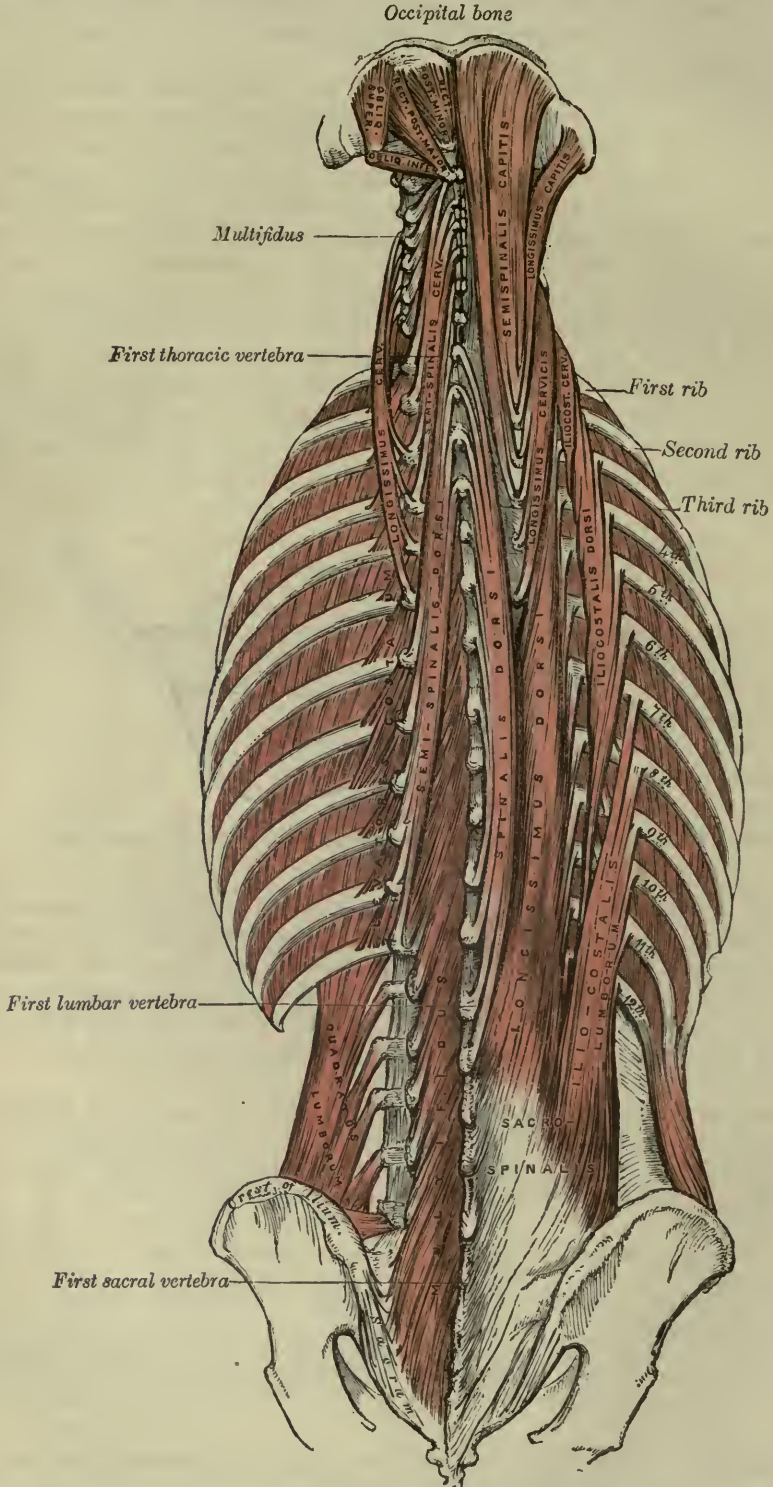


FIG. 389.—Deep muscles of the back.

mass varies in size and structure at different parts of the vertebral column. In the sacral region it is narrow and pointed, and at its origin chiefly tendinous in structure. In the lumbar region it is larger, and forms a thick fleshy mass which, on being followed upward, is subdivided into three columns; these gradually diminish in size as they ascend to be inserted into the vertebræ and ribs.

The *Sacrospinalis* arises from the anterior surface of a broad and thick tendon, which is attached to the medial crest of the sacrum, to the spinous processes of the lumbar and the eleventh and twelfth thoracic vertebræ, and the supraspinal ligament, to the back part of the inner lip of the iliac crests and to the lateral crests of the sacrum, where it blends with the sacrotuberous and posterior sacroiliac ligaments. Some of its fibers are continuous with the fibers of origin of the *Glutæus maximus*. The muscular fibers form a large fleshy mass which splits, in the upper lumbar region into three columns, viz., a lateral, the **Iliocostalis**, an intermediate, the **Longissimus**, and a medial, the **Spinalis**. Each of these consists from below upward, of three parts, as follows:

<i>Lateral Column.</i>	<i>Intermediate Column.</i>	<i>Medial Column.</i>
Iliocostalis.	Longissimus.	Spinalis.
(a) I. lumborum.	(a) L. dorsi.	(a) S. dorsi.
(b) I. dorsi.	(b) L. cervicis.	(b) S. cervicis.
(c) I. cervicis.	(c) L. capitis.	(c) S. capitis.

The **Iliocostalis lumborum** (*Iliocostalis muscle*; *Sacrolumbalis muscle*) is inserted, by six or seven flattened tendons, into the inferior borders of the angles of the lower six or seven ribs.

The **Iliocostalis dorsi** (*Musculus accessorius*) arises by flattened tendons from the upper borders of the angles of the lower six ribs medial to the tendons of insertion of the *Iliocostalis lumborum*; these become muscular, and are inserted into the upper borders of the angles of the upper six ribs and into the back of the transverse process of the seventh cervical vertebra.

The **Iliocostalis cervicis** (*Cervicalis ascendens*) arises from the angles of the third, fourth, fifth, and sixth ribs, and is inserted into the posterior tubercles of the transverse processes of the fourth, fifth, and sixth cervical vertebræ.

The **Longissimus dorsi** is the intermediate and largest of the continuations of the *Sacrospinalis*. In the lumbar region, where it is as yet blended with the *Iliocostalis lumborum*; some of its fibers are attached to the whole length of the posterior surfaces of the transverse processes and the accessory processes of the lumbar vertebræ, and to the anterior layer of the lumbodorsal fascia. In the thoracic region it is inserted, by rounded tendons, into the tips of the transverse processes of all the thoracic vertebræ, and by fleshy processes into the lower nine or ten ribs between their tubercles and angles.

The **Longissimus cervicis** (*Transversalis cervicis*), situated medial to the *Longissimus dorsi*, arises by long thin tendons from the summits of the transverse processes of the upper four or five thoracic vertebræ, and is inserted by similar tendons into the posterior tubercles of the transverse processes of the cervical vertebræ from the second to the sixth inclusive.

The **Longissimus capitis** (*Trachelomastoid muscle*) lies medial to the *Longissimus cervicis*, between it and the *Semispinalis capitis*. It arises by tendons from the transverse processes of the upper four or five thoracic vertebræ, and the articular processes of the lower three or four cervical vertebræ, and is inserted into the posterior margin of the mastoid process, beneath the *Splenius capitis* and *Sternocleidomastoideus*. It is almost always crossed by a tendinous intersection near its insertion.

The **Spinalis dorsi**, the medial continuation of the *Sacrospinalis*, is scarcely separable as a distinct muscle. It is situated at the medial side of the *Longissimus*

dorsi, and is intimately blended with it; it *arises* by three or four tendons from the spinous processes of the first two lumbar and the last two thoracic vertebræ: these, uniting, form a small muscle which is *inserted* by separate tendons into the spinous processes of the upper thoracic vertebræ, the number varying from four to eight. It is intimately united with the Semispinalis dorsi, situated beneath it.

The **Spinalis cervicis** (*Spinalis colli*) is an inconstant muscle, which *arises* from the lower part of the ligamentum nuchæ, the spinous process of the seventh cervical, and sometimes from the spinous processes of the first and second thoracic vertebræ, and is *inserted* into the spinous process of the axis, and occasionally into the spinous processes of the two vertebræ below it.

The **Spinalis capitis** (*Biventer cervicis*) is usually inseparably connected with the Semispinalis capitis (see below).

The **Semispinalis dorsi** consists of thin, narrow, fleshy fasciculi, interposed between tendons of considerable length. It *arises* by a series of small tendons from the transverse processes of the sixth to the tenth thoracic vertebræ, and is *inserted*, by tendons, into the spinous processes of the upper four thoracic and lower two cervical vertebræ.

The **Semispinalis cervicis** (*Semispinalis colli*), thicker than the preceding, *arises* by a series of tendinous and fleshy fibers from the transverse processes of the upper five or six thoracic vertebræ, and is inserted into the cervical spinous processes, from the axis to the fifth inclusive. The fasciculus connected with the axis is the largest, and is chiefly muscular in structure.

The **Semispinalis capitis** (*Complexus*) is situated at the upper and back part of the neck, beneath the Splenius, and medial to the Longissimus cervicis and capitis. It *arises* by a series of tendons from the tips of the transverse processes of the upper six or seven thoracic and the seventh cervical vertebræ, and from the articular processes of the three cervical above this. The tendons, uniting, form a broad muscle, which passes upward, and is *inserted* between the superior and inferior nuchal lines of the occipital bone. The medial part, usually more or less distinct from the remainder of the muscle, is frequently termed the **Spinalis capitis**; it is also named the **Biventer cervicis** since it is traversed by an imperfect tendinous inscription.

The **Multifidus** (*Multifidus spinæ*) consists of a number of fleshy and tendinous fasciculi, which fill up the groove on either side of the spinous processes of the vertebræ, from the sacrum to the axis. In the sacral region, these fasciculi *arise* from the back of the sacrum, as low as the fourth sacral foramen, from the aponeurosis of origin of the Sacrospinalis, from the medial surface of the posterior superior iliac spine, and from the posterior sacroiliac ligaments; in the lumbar region, from all the mamillary processes; in the thoracic region, from all the transverse processes; and in the cervical region, from the articular processes of the lower four vertebræ. Each fasciculus, passing obliquely upward and medialward, is *inserted* into the whole length of the spinous process of one of the vertebræ above. These fasciculi vary in length: the most superficial, the longest, pass from one vertebra to the third or fourth above; those next in order run from one vertebra to the second or third above; while the deepest connect two contiguous vertebræ.

The **Rotatores** (*Rotatores spinæ*) lie beneath the Multifidus and are found only in the thoracic region; they are eleven in number on either side. Each muscle is small and somewhat quadrilateral in form; it *arises* from the upper and back part of the transverse process, and is *inserted* into the lower border and lateral surface of the lamina of the vertebra above, the fibers extending as far as the root of the spinous process. The first is found between the first and second thoracic vertebræ; the last, between the eleventh and twelfth. Sometimes the number of these muscles is diminished by the absence of one or more from the upper or lower end.

The **Interspinales** are short muscular fasciculi, placed in pairs between the

spinous processes of the contiguous vertebræ, one on either side of the interspinal ligament. In the *cervical region* they are most distinct, and consist of six pairs, the first being situated between the axis and third vertebra, and the last between the seventh cervical and the first thoracic. They are small narrow bundles, attached, above and below, to the apices of the spinous processes. In the *thoracic region*, they are found between the first and second vertebræ, and sometimes between the second and third, and between the eleventh and twelfth. In the *lumbar region* there are four pairs in the intervals between the five lumbar vertebræ. There is also occasionally one between the last thoracic and first lumbar, and one between the fifth lumbar and the sacrum.

The **Extensor coccygis** is a slender muscular fasciculus, which is not always present; it extends over the lower part of the posterior surface of the sacrum and coccyx. It *arises* by tendinous fibers from the last segment of the sacrum, or first piece of the coccyx, and passes downward to be *inserted* into the lower part of the coccyx. It is a rudiment of the Extensor muscle of the caudal vertebræ of the lower animals.

The **Intertransversarii** (*Intertransversales*) are small muscles placed between the transverse processes of the vertebræ. In the *cervical region* they are best developed, consisting of rounded muscular and tendinous fasciculi, and are placed in pairs, passing between the anterior and the posterior tubercles respectively of the transverse processes of two contiguous vertebræ, and separated from one another by an anterior primary division of the cervical nerve, which lies in the groove between them. The muscles connecting the anterior tubercles are termed the **Intertransversarii anteriores**; those between the posterior tubercles, the **Intertransversarii posteriores**; both sets are supplied by the anterior divisions of the spinal nerves (Lickley¹). There are seven pairs of these muscles, the first pair being between the atlas and axis, and the last pair between the seventh cervical and first thoracic vertebræ. In the *thoracic region* they are present between the transverse processes of the lower three thoracic vertebræ, and between the transverse processes of the last thoracic and the first lumbar. In the *lumbar region* they are arranged in pairs, on either side of the vertebral column, one set occupying the entire interspace between the transverse processes of the lumbar vertebræ, the **Intertransversarii laterales**; the other set, **Intertransversarii mediales**, passing from the accessory process of one vertebra to the mammillary of the vertebra below. The **Intertransversarii laterales** are supplied by the anterior divisions, and the **Intertransversarii mediales** by the posterior divisions of the spinal nerves (Lichley, *op. cit.*).

II. THE SUBOCCIPITAL MUSCLES (Fig. 389).

The suboccipital group comprises:

Rectus capitis posterior major.
Rectus capitis posterior minor.

Obliquus capitis inferior.
Obliquus capitis superior.

The **Rectus capitis posterior major** (*Rectus capitis posticus major*) *arises* by a pointed tendon from the spinous process of the axis, and, becoming broader as it ascends, is *inserted* into the lateral part of the inferior nuchal line of the occipital bone and the surface of the bone immediately below the line. As the muscles of the two sides pass upward and lateralward, they leave between them a triangular space, in which the *Recti capitis posteriores minores* are seen.

The **Rectus capitis posterior minor** (*Rectus capitis posticus minor*) *arises* by a narrow pointed tendon from the tubercle on the posterior arch of the atlas, and, widening as it ascends, is *inserted* into the medial part of the inferior nuchal line of the occipital bone and the surface between it and the foramen magnum.

¹ Journal of Anatomy and Physiology, 1904, vol. xxxix.

The **Obliquus capitis inferior** (*Obliquus inferior*), the larger of the two Oblique muscles, *arises* from the apex of the spinous process of the axis, and passes lateralward and slightly upward, to be *inserted* into the lower and back part of the transverse process of the atlas.

The **Obliquus capitis superior** (*Obliquus superior*), narrow below, wide and expanded above, *arises* by tendinous fibers from the upper surface of the transverse process of the atlas, joining with the insertion of the preceding. It passes upward and medialward, and is *inserted* into the occipital bone, between the superior and inferior nuchal lines, lateral to the Semispinalis capitis.

The Suboccipital Triangle.—Between the Obliqui and the Rectus capitis posterior major is the **suboccipital triangle**. It is bounded, *above* and *medially*, by the Rectus capitis posterior major; *above* and *laterally*, by the Obliquus capitis superior; *below* and *laterally*, by the Obliquus capitis inferior. It is covered by a layer of dense fibro-fatty tissue, situated beneath the Semispinalis capitis. The floor is formed by the posterior occipito-atlantal membrane, and the posterior arch of the atlas. In the deep groove on the upper surface of the posterior arch of the atlas are the vertebral artery and the first cervical or suboccipital nerve.

Nerves.—The deep muscles of the back and the suboccipital muscles are supplied by the posterior primary divisions of the spinal nerves.

Actions.—The Sacrospinalis and its upward continuations and the Spinales serve to maintain the vertebral column in the erect posture; they also serve to bend the trunk backward when it is required to counterbalance the influence of any weight at the front of the body—as, for instance, when a heavy weight is suspended from the neck, or when there is any great abdominal distension, as in pregnancy or dropsy; the peculiar gait under such circumstances depends upon the vertebral column being drawn backward, by the counterbalancing action of the Sacrospinales. The muscles which form the continuation of the Sacrospinales on to the head and neck steady those parts and fix them in the upright position. If the Iliocostalis lumborum and Longissimus dorsi of one side act, they serve to draw down the chest and vertebral column to the corresponding side. The Iliocostales cervicis, taking their fixed points from the cervical vertebræ, elevate those ribs to which they are attached; taking their fixed points from the ribs, both muscles help to extend the neck; while one muscle bends the neck to its own side. When both Longissimi cervicis act from below, they bend the neck backward. When both Longissimi capitis act from below, they bend the head backward; while, if only one muscle acts, the face is turned to the side on which the muscle is acting, and then the head is bent to the shoulder. The two Recti draw the head backward. The Rectus capitis posterior major, owing to its obliquity, rotates the skull, with the atlas, around the odontoid process, turning the face to the same side. The Multifidus acts successively upon the different parts of the column; thus, the sacrum furnishes a fixed point from which the fasciculi of this muscle acts upon the lumbar region; which in turn becomes the fixed point for the fasciculi moving the thoracic region, and so on throughout the entire length of the column. The Multifidus also serves to rotate the column, so that the front of the trunk is turned to the side opposite to that from which the muscle acts, this muscle being assisted in its action by the Obliquus externus abdominis. The Obliquus capitis superior draws the head backward and to its own side. The Obliquus inferior rotates the atlas, and with it the skull, around the odontoid process, turning the face to the same side. When the Semispinales of the two sides act together, they help to extend the vertebral column; when the muscles of only one side act, they rotate the thoracic and cervical parts of the column, turning the body to the opposite side. The Semispinales capitis draw the head directly backward; if one muscle acts, it draws the head to one side, and rotates it so that the face is turned to the opposite side. The Interspinales by approximating the spinous processes help to extend the column. The Intertransversarii approximate the transverse processes, and help to bend the column to one side. The Rotatores assist the Multifidus to rotate the vertebral column, so that the front of the trunk is turned to the side opposite to that from which the muscles act.

III. THE MUSCLES OF THE THORAX.

The muscles belonging to this group are the

Intercostales externi.
Intercostales interni.
Subcostales.
Transversus thoracis.

Levatores costarum.
Serratus posterior superior.
Serratus posterior inferior.
Diaphragm.

Intercostal Fasciæ.—In each intercostal space thin but firm layers of fascia cover the outer surface of the Intercostalis externus and the inner surface of the

Intercostalis internus; and a third, more delicate layer, is interposed between the two planes of muscular fibers. They are best marked in those situations where the muscular fibers are deficient, as between the Intercostales externi and sternum in front, and between the Intercostales interni and vertebral column behind.

The **Intercostales** (*Intercostal muscles*) (Fig. 411) are two thin planes of muscular and tendinous fibers occupying each of the intercostal spaces. They are named **external** and **internal** from their surface relations—the external being superficial to the internal.

The **Intercostales externi** (*External intercostals*) are *eleven* in number on either side. They extend from the tubercles of the ribs behind, to the cartilages of the ribs in front, where they end in thin membranes, the **anterior intercostal membranes**, which are continued forward to the sternum. Each *arises* from the lower border of a rib, and is *inserted* into the upper border of the rib below. In the two lower spaces they extend to the ends of the cartilages, and in the upper two or three spaces they do not quite reach the ends of the ribs. They are thicker than the Intercostales interni, and their fibers are directed obliquely downward and lateralward on the back of the thorax, and downward, forward, and medialward on the front.

Variations.—Continuation with the Obliquus externus or Serratus anterior: A *Supracostalis muscle*, from the anterior end of the first rib down to the second, third or fourth ribs occasionally occurs.

The **Intercostales interni** (*Internal intercostals*) are also *eleven* in number on either side. They commence anteriorly at the sternum, in the interspaces between the cartilages of the true ribs, and at the anterior extremities of the cartilages of the false ribs, and extend backward as far as the angles of the ribs, whence they are continued to the vertebral column by thin aponeuroses, the **posterior intercostal membranes**. Each *arises* from the ridge on the inner surface of a rib, as well as from the corresponding costal cartilage, and is *inserted* into the upper border of the rib below. Their fibers are also directed obliquely, but pass in a direction opposite to those of the Intercostales externi.

The **Subcostales** (*Infracostales*) consist of muscular and aponeurotic fasciculi, which are usually well-developed only in the lower part of the thorax; each *arises* from the inner surface of one rib near its angle, and is *inserted* into the inner surface of the second or third rib below. Their fibers run in the same direction as those of the Intercostales interni.

The **Transversus thoracis** (*Triangularis sterni*) is a thin plane of muscular and tendinous fibers, situated upon the inner surface of the front wall of the chest (Fig. 390). It *arises* on either side from the lower third of the posterior surface of the body of the sternum, from the posterior surface of the xiphoid process, and from the sternal ends of the costal cartilages of the lower three or four true ribs. Its fibers diverge upward and lateralward, to be *inserted* by slips into the lower borders and inner surfaces of the costal cartilages of the second, third, fourth, fifth, and sixth ribs. The lowest fibers of this muscle are horizontal in their direction, and are continuous with those of the Transversus abdominis; the intermediate fibers are oblique, while the highest are almost vertical. This muscle varies in its attachments, not only in different subjects, but on opposite sides of the same subject.

The **Levatores costarum** (Fig. 389), *twelve* in number on either side, are small tendinous and fleshy bundles, which *arise* from the ends of the transverse processes of the seventh cervical and upper eleven thoracic vertebræ; they pass obliquely downward and lateralward, like the fibers of the Intercostales externi, and each is *inserted* into the outer surface of the rib immediately below the vertebra from which it takes origin, between the tubercle and the angle (**Levatores costarum breves**). Each of the four lower muscles divides into two fasciculi, one

The **Obliquus capitis inferior** (*Obliquus inferior*), the larger of the two Oblique muscles, *arises* from the apex of the spinous process of the axis, and passes lateralward and slightly upward, to be *inserted* into the lower and back part of the transverse process of the atlas.

The **Obliquus capitis superior** (*Obliquus superior*), narrow below, wide and expanded above, *arises* by tendinous fibers from the upper surface of the transverse process of the atlas, joining with the insertion of the preceding. It passes upward and medialward, and is *inserted* into the occipital bone, between the superior and inferior nuchal lines, lateral to the Semispinalis capitis.

The Suboccipital Triangle.—Between the Obliqui and the Rectus capitis posterior major is the **suboccipital triangle**. It is bounded, *above* and *medially*, by the Rectus capitis posterior major; *above* and *laterally*, by the Obliquus capitis superior; *below* and *laterally*, by the Obliquus capitis inferior. It is covered by a layer of dense fibro-fatty tissue, situated beneath the Semispinalis capitis. The floor is formed by the posterior occipito-atlantal membrane, and the posterior arch of the atlas. In the deep groove on the upper surface of the posterior arch of the atlas are the vertebral artery and the first cervical or suboccipital nerve.

Nerves.—The deep muscles of the back and the suboccipital muscles are supplied by the posterior primary divisions of the spinal nerves.

Actions.—The Sacrospinalis and its upward continuations and the Spinales serve to maintain the vertebral column in the erect posture; they also serve to bend the trunk backward when it is required to counterbalance the influence of any weight at the front of the body—as, for instance, when a heavy weight is suspended from the neck, or when there is any great abdominal distension, as in pregnancy or dropsy; the peculiar gait under such circumstances depends upon the vertebral column being drawn backward, by the counterbalancing action of the Sacrospinales. The muscles which form the continuation of the Sacrospinales on to the head and neck steady those parts and fix them in the upright position. If the Iliocostalis lumborum and Longissimus dorsi of one side act, they serve to draw down the chest and vertebral column to the corresponding side. The Iliocostales cervicis, taking their fixed points from the cervical vertebræ, elevate those ribs to which they are attached; taking their fixed points from the ribs, both muscles help to extend the neck; while one muscle bends the neck to its own side. When both Longissimi cervicis act from below, they bend the neck backward. When both Longissimi capitis act from below, they bend the head backward; while, if only one muscle acts, the face is turned to the side on which the muscle is acting, and then the head is bent to the shoulder. The two Recti draw the head backward. The Rectus capitis posterior major, owing to its obliquity, rotates the skull, with the atlas, around the odontoid process, turning the face to the same side. The Multifidus acts successively upon the different parts of the column; thus, the sacrum furnishes a fixed point from which the fasciculi of this muscle acts upon the lumbar region; which in turn becomes the fixed point for the fasciculi moving the thoracic region, and so on throughout the entire length of the column. The Multifidus also serves to rotate the column, so that the front of the trunk is turned to the side opposite to that from which the muscle acts, this muscle being assisted in its action by the Obliquus externus abdominis. The Obliquus capitis superior draws the head backward and to its own side. The Obliquus inferior rotates the atlas, and with it the skull, around the odontoid process, turning the face to the same side. When the Semispinales of the two sides act together, they help to extend the vertebral column; when the muscles of only one side act, they rotate the thoracic and cervical parts of the column, turning the body to the opposite side. The Semispinales capitis draw the head directly backward; if one muscle acts, it draws the head to one side, and rotates it so that the face is turned to the opposite side. The Interspinales by approximating the spinous processes help to extend the column. The Interspinales approximate the transverse processes, and help to bend the column to one side. The Rotatores assist the Multifidus to rotate the vertebral column, so that the front of the trunk is turned to the side opposite to that from which the muscles act.

III. THE MUSCLES OF THE THORAX.

The muscles belonging to this group are the

Intercostales externi.	Levatores costarum.
Intercostales interni.	Serratus posterior superior.
Subcostales.	Serratus posterior inferior.
Transversus thoracis.	Diaphragm.

Intercostal Fasciæ.—In each intercostal space thin but firm layers of fascia cover the outer surface of the Intercostalis externus and the inner surface of the

Intercostalis internus; and a third, more delicate layer, is interposed between the two planes of muscular fibers. They are best marked in those situations where the muscular fibers are deficient, as between the Intercostales externi and sternum in front, and between the Intercostales interni and vertebral column behind.

The **Intercostales** (*Intercostal muscles*) (Fig. 411) are two thin planes of muscular and tendinous fibers occupying each of the intercostal spaces. They are named **external** and **internal** from their surface relations—the external being superficial to the internal.

The **Intercostales externi** (*External intercostals*) are *eleven* in number on either side. They extend from the tubercles of the ribs behind, to the cartilages of the ribs in front, where they end in thin membranes, the **anterior intercostal membranes**, which are continued forward to the sternum. Each *arises* from the lower border of a rib, and is *inserted* into the upper border of the rib below. In the two lower spaces they extend to the ends of the cartilages, and in the upper two or three spaces they do not quite reach the ends of the ribs. They are thicker than the Intercostales interni, and their fibers are directed obliquely downward and lateralward on the back of the thorax, and downward, forward, and medialward on the front.

Variations.—Continuation with the Obliquus externus or Serratus anterior: A *Supracostalis muscle*, from the anterior end of the first rib down to the second, third or fourth ribs occasionally occurs.

The **Intercostales interni** (*Internal intercostals*) are also *eleven* in number on either side. They commence anteriorly at the sternum, in the interspaces between the cartilages of the true ribs, and at the anterior extremities of the cartilages of the false ribs, and extend backward as far as the angles of the ribs, whence they are continued to the vertebral column by thin aponeuroses, the **posterior intercostal membranes**. Each *arises* from the ridge on the inner surface of a rib, as well as from the corresponding costal cartilage, and is *inserted* into the upper border of the rib below. Their fibers are also directed obliquely, but pass in a direction opposite to those of the Intercostales externi.

The **Subcostales** (*Infracostales*) consist of muscular and aponeurotic fasciculi, which are usually well-developed only in the lower part of the thorax; each *arises* from the inner surface of one rib near its angle, and is *inserted* into the inner surface of the second or third rib below. Their fibers run in the same direction as those of the Intercostales interni.

The **Transversus thoracis** (*Triangularis sterni*) is a thin plane of muscular and tendinous fibers, situated upon the inner surface of the front wall of the chest (Fig. 390). It *arises* on either side from the lower third of the posterior surface of the body of the sternum, from the posterior surface of the xiphoid process, and from the sternal ends of the costal cartilages of the lower three or four true ribs. Its fibers diverge upward and lateralward, to be *inserted* by slips into the lower borders and inner surfaces of the costal cartilages of the second, third, fourth, fifth, and sixth ribs. The lowest fibers of this muscle are horizontal in their direction, and are continuous with those of the Transversus abdominis; the intermediate fibers are oblique, while the highest are almost vertical. This muscle varies in its attachments, not only in different subjects, but on opposite sides of the same subject.

The **Levatores costarum** (Fig. 389), *twelve* in number on either side, are small tendinous and fleshy bundles, which *arise* from the ends of the transverse processes of the seventh cervical and upper eleven thoracic vertebræ; they pass obliquely downward and lateralward, like the fibers of the Intercostales externi, and each is *inserted* into the outer surface of the rib immediately below the vertebra from which it takes origin, between the tubercle and the angle (**Levatores costarum breves**). Each of the four lower muscles divides into two fasciculi, one

of which is inserted as above described; the other passes down to the second rib below its origin (*Levatores costarum longi*).

The **Serratus posterior superior** (*Serratus posticus superior*) is a thin, quadrilateral muscle, situated at the upper and back part of the thorax. It *arises* by a thin and broad aponeurosis from the lower part of the ligamentum nuchae, from the spinous processes of the seventh cervical and upper two or three thoracic vertebræ and from the supraspinal ligament. Inclining downward and lateralward it becomes muscular, and is *inserted*, by four fleshy digitations, into the upper borders of the second, third, fourth, and fifth ribs, a little beyond their angles.

Variations.—Increase or decrease in size and number of slips or entire absence.

The **Serratus posterior inferior** (*Serratus posticus inferior*) (Fig. 409) is situated at the junction of the thoracic and lumbar regions: it is of an irregularly quadrilateral form, broader than the preceding, and separated from it by a wide interval. It *arises* by a thin aponeurosis from the spinous processes of the lower two thoracic and upper two or three lumbar vertebræ, and from the supraspinal ligament. Passing obliquely upward and lateralward, it becomes fleshy, and divides into four flat digitations, which are *inserted* into the inferior borders of the lower four ribs, a little beyond their angles. The thin aponeurosis of origin is intimately blended with the lumbodorsal fascia, and aponeurosis of the Latissimus dorsi.

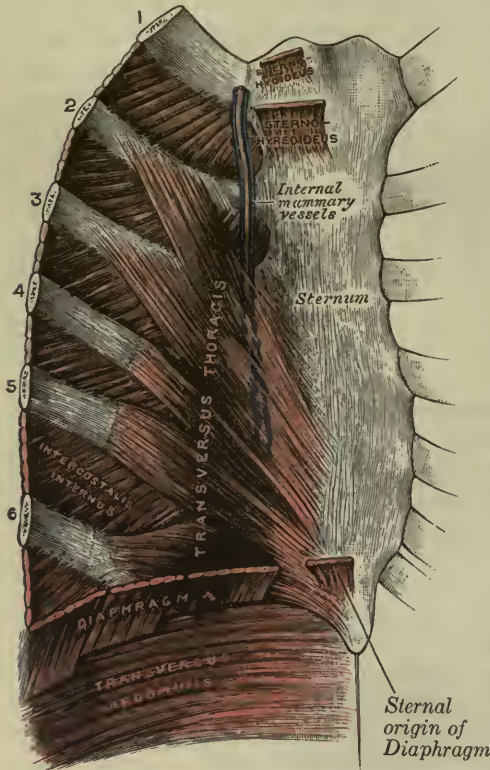


FIG. 390.—Posterior surface of sternum and costal cartilages, showing Transversus thoracis.

Variations.—Increase or decrease in size and number of slips or entire absence.

Nerves.—The muscles of this group are supplied by the intercostal nerves.

The **Diaphragm** (Fig. 391) is a dome-shaped musculofibrous septum which separates the thoracic from the abdominal cavity, its convex upper surface forming the floor of the former, and its concave under surface the roof of the latter. Its peripheral part consists of muscular fibers which take origin from the circumference of the thoracic outlet and converge to be *inserted* into a central tendon.

The muscular fibers may be grouped according to their origins into three parts—sternal, costal, and lumbar. The **sternal part** *arises* by two fleshy slips from the back of the xiphoid process; the **costal part** from the inner surfaces of the cartilages and adjacent portions of the lower six ribs on either side, interdigitating with the Transversus abdominis; and the **lumbar part** from aponeurotic arches, named the lumbocostal arches, and from the lumbar vertebræ by two pillars or **crura**. There are two lumbocostal arches, a medial and a lateral, on either side.

The **Medial Lumbocostal Arch** (*arcus lumbocostalis medialis* [Halleri]; *internal arcuate ligament*) is a tendinous arch in the fascia covering the upper part of the Psoas major; medially, it is continuous with the lateral tendinous margin of the corresponding crus, and is attached to the side of the body of the first or second

lumbar vertebra; laterally, it is fixed to the front of the transverse process of the first and, sometimes also, to that of the second lumbar vertebra.

The **Lateral Lumbocostal Arch** (*arcus lumbocostalis lateralis* [Halleri]; *external arcuate ligament*) arches across the upper part of the *Quadratus lumborum*, and is attached, medially, to the front of the transverse process of the first lumbar vertebra, and, laterally, to the tip and lower margin of the twelfth rib.

The Crura.—At their origins the crura are tendinous in structure, and blend with the anterior longitudinal ligament of the vertebral column. The **right crus**, larger and longer than the left, *arises* from the anterior surfaces of the bodies and intervertebral fibrocartilages of the upper three lumbar vertebrae, while the **left crus** *arises* from the corresponding parts of the upper two only. The medial tendinous margins of the crura pass forward and medialward, and meet in the middle line to form an arch across the front of the aorta; this arch is often poorly defined.

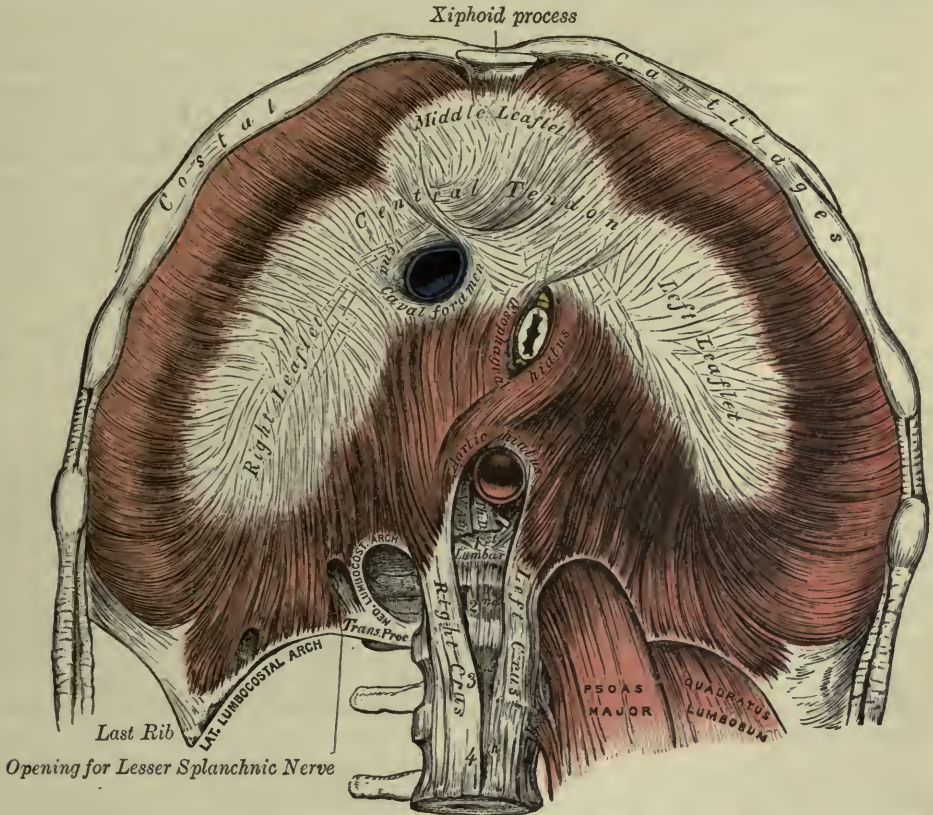


FIG. 391.—The diaphragm. Under surface.

From this series of origins the fibers of the diaphragm converge to be inserted into the central tendon. The fibers arising from the xiphoid process are very short, and occasionally aponeurotic; those from the medial and lateral lumbocostal arches, and more especially those from the ribs and their cartilages, are longer, and describe marked curves as they ascend and converge to their insertion. The fibers of the crura diverge as they ascend, the most lateral being directed upward and lateralward to the central tendon. The medial fibers of the right crus ascend on the left side of the esophageal hiatus, and occasionally a fasciculus of the left crus crosses the aorta and runs obliquely through the fibers of the right crus toward the vena caval foramen (Low¹).

¹ Journal of Anatomy and Physiology, vol. xlii.

The Central Tendon.—The central tendon of the diaphragm is a thin but strong aponeurosis situated near the center of the vault formed by the muscle, but somewhat closer to the front than to the back of the thorax, so that the posterior muscular fibers are the longer. It is situated immediately below the pericardium, with which it is partially blended. It is shaped somewhat like a trefoil leaf, consisting of three divisions or leaflets separated from one another by slight indentations. The right leaflet is the largest, the middle, directed toward the xiphoid process, the next in size, and the left the smallest. In structure the tendon is composed of several planes of fibers, which intersect one another at various angles and unite into straight or curved bundles—an arrangement which gives it additional strength.

Openings in the Diaphragm.—The diaphragm is pierced by a series of apertures to permit of the passage of structures between the thorax and abdomen. Three large openings—the **aortic**, the **esophageal**, and the **vena caval**—and a series of smaller ones are described.

The **aortic hiatus** is the lowest and most posterior of the large apertures; it lies at the level of the twelfth thoracic vertebra. Strictly speaking, it is not an aperture in the diaphragm but an osseoaponeurotic opening between it and the vertebral column, and therefore behind the diaphragm; occasionally some tendinous fibers prolonged across the bodies of the vertebræ from the medial parts of the lower ends of the crura pass behind the aorta, and thus convert the hiatus into a fibrous ring. The hiatus is situated slightly to the left of the middle line, and is bounded in front by the crura, and behind by the body of the first lumbar vertebra. Through it pass the aorta, the azygos vein, and the thoracic duct; occasionally the azygos vein is transmitted through the right crus.

The **esophageal hiatus** is situated in the muscular part of the diaphragm at the level of the tenth thoracic vertebra, and is elliptical in shape. It is placed above, in front, and a little to the left of the aortic hiatus, and transmits the esophagus, the vagus nerves, and some small esophageal arteries.

The **vena caval foramen** is the highest of the three, and is situated about the level of the fibrocartilage between the eighth and ninth thoracic vertebræ. It is quadrilateral in form, and is placed at the junction of the right and middle leaflets of the central tendon, so that its margins are tendinous. It transmits the inferior vena cava, the wall of which is adherent to the margins of the opening, and some branches of the right phrenic nerve.

Of the **lesser apertures**, two in the right crus transmit the greater and lesser right splanchnic nerves; three in the left crus give passage to the greater and lesser left splanchnic nerves and the hemiazygos vein. The gangliated trunks of the sympathetic usually enter the abdominal cavity behind the diaphragm, under the medial lumbocostal arches.

On either side two small intervals exist at which the muscular fibers of the diaphragm are deficient and are replaced by areolar tissue. One between the sternal and costal parts transmits the superior epigastric branch of the internal mammary artery and some lymphatics from the abdominal wall and convex surface of the liver. The other, between the fibers springing from the medial and lateral lumbocostal arches, is less constant; when this interval exists, the upper and back part of the kidney is separated from the pleura by areolar tissue only.

Variations.—The sternal portion of the muscle is sometimes wanting and more rarely defects occur in the lateral part of the central tendon or adjoining muscle fibers.

Nerves.—The diaphragm is supplied by the phrenic and lower intercostal nerves.

Actions.—The diaphragm is the principal muscle of inspiration, and presents the form of a dome concave toward the abdomen. The central part of the dome is tendinous, and the pericardium is attached to its upper surface; the circumference is muscular. During inspiration the lowest ribs are fixed, and from these and the crura the muscular fibers contract and draw downward and forward the central tendon with the attached pericardium. In this movement the curvature of the diaphragm is scarcely altered, the dome moving downward nearly parallel

to its original position and pushing before it the abdominal viscera. The descent of the abdominal viscera is permitted by the elasticity of the abdominal wall, but the limit of this is soon reached. The central tendon applied to the abdominal viscera then becomes a fixed point for the action of the diaphragm, the effect of which is to elevate the lower ribs and through them to push forward the body of the sternum and the upper ribs. The right cupola of the diaphragm, lying on the liver, has a greater resistance to overcome than the left, which lies over the stomach, but to compensate for this the right crus and the fibers of the right side generally are stronger than those of the left.

In all expulsive acts the diaphragm is called into action to give additional power to each expulsive effort. Thus, before sneezing, coughing, laughing, crying, or vomiting, and previous to the expulsion of urine or feces, or of the fetus from the uterus, a deep inspiration takes place. The height of the diaphragm is constantly varying during respiration; it also varies with the degree of distension of the stomach and intestines and with the size of the liver. After a forced expiration the right cupola is on a level in front with the fourth costal cartilage, at the side with the fifth, sixth, and seventh ribs, and behind with the eighth rib; the left cupola is a little lower than the right. Halls Dally¹ states that the absolute range of movement between deep inspiration and deep expiration averages in the male and female 30 mm. on the right side and 28 mm. on the left; in quiet respiration the average movement is 12.5 mm. on the right side and 12 mm. on the left.

Skiagraphy shows that the height of the diaphragm in the thorax varies considerably with the position of the body. It stands highest when the body is horizontal and the patient on his back, and in this position it performs the largest respiratory excursions with normal breathing. When the body is erect the dome of the diaphragm falls, and its respiratory movements become smaller. The dome falls still lower when the sitting posture is assumed, and in this position its respiratory excursions are smallest. These facts may, perhaps, explain why it is that patients suffering from severe dyspnoea are most comfortable and least short of breath when they sit up. When the body is horizontal and the patient on his side, the two halves of the diaphragm do not behave alike. The uppermost half sinks to a level lower even than when the patient sits, and moves little with respiration; the lower half rises higher in the thorax than it does when the patient is supine, and its respiratory excursions are much increased. In unilateral disease of the pleura or lungs analogous interference with the position or movement of the diaphragm can generally be observed skiagraphically.

It appears that the position of the diaphragm in the thorax depends upon three main factors, viz.: (1) the elastic retraction of the lung tissue, tending to pull it upward; (2) the pressure exerted on its under surface by the viscera; this naturally tends to be a negative pressure, or downward suction, when the patient sits or stands, and positive, or an upward pressure, when he lies; (3) the intra-abdominal tension due to the abdominal muscles. These are in a state of contraction in the standing position and not in the sitting; hence the diaphragm, when the patient stands, is pushed up higher than when he sits.

The Intercostales interni and externi have probably no action in moving the ribs. They contract simultaneously and form strong elastic supports which prevent the intercostal spaces being pushed out or drawn in during respiration. The anterior portions of the Intercostales interni probably have an additional function in keeping the sternocostal and interchondral joint surfaces in apposition, the posterior parts of the Intercostales externi performing a similar function for the costovertebral articulations. The Levatores costarum being inserted near the fulcra of the ribs can have little action on the ribs; they act as rotators and lateral flexors of the vertebral column. The Transversus thoracis draws down the costal cartilages, and is therefore a muscle of expiration.

The Serrati are respiratory muscles. The Serratus posterior superior elevates the ribs and is therefore an inspiratory muscle. The Serratus posterior inferior draws the lower ribs downward and backward, and thus elongates the thorax; it also fixes the lower ribs, thus assisting the inspiratory action of the diaphragm and resisting the tendency it has to draw the lower ribs upward and forward. It must therefore be regarded as a muscle of inspiration.

Mechanism of Respiration.—The respiratory movements must be examined during (a) quiet respiration, and (b) deep respiration.

Quiet Respiration.—The first and second pairs of ribs are fixed by the resistance of the cervical structures; the last pair, and through it the eleventh, by the Quadratus lumborum. The other ribs are elevated, so that the first two intercostal spaces are diminished while the others are increased in width. It has already been shown (p. 304) that elevation of the third, fourth, fifth, and sixth ribs leads to an increase in the antero-posterior and transverse diameters of the thorax; the vertical diameter is increased by the descent of the diaphragmatic dome so that the lungs are expanded in all directions except backward and upward. Elevation of the eighth, ninth, and tenth ribs is accompanied by a lateral and backward movement, leading to an increase in the transverse diameter of the upper part of the abdomen; the elasticity of the anterior abdominal

¹ Journal of Anatomy and Physiology, 1908, vol. xliii.

ones being attached close to the cartilages of the corresponding ribs, the lowest to the apex of the cartilage of the last rib, the intermediate ones to the ribs at some distance from their cartilages. The five superior serrations increase in size from above downward, and are received between corresponding processes of the Serratus anterior; the three lower ones diminish in size from above downward and receive between them corresponding processes from the Latissimus dorsi. From these attachments the fleshy fibers proceed in various directions. Those from the lowest ribs pass nearly vertically downward, and are inserted into the anterior half of the outer lip of the iliac crest; the middle and upper fibers, directed downward and forward, end in an aponeurosis, opposite a line drawn from the prominence of the ninth costal cartilage to the anterior superior iliac spine.

The **aponeurosis of the Obliquus externus abdominis** is a thin but strong membranous structure, the fibers of which are directed downward and medialward. It is joined with that of the opposite muscle along the middle line, and covers the whole of the front of the abdomen; *above*, it is covered by and gives origin to the lower fibers of the Pectoralis major; *below*, its fibers are closely aggregated together, and extend obliquely across from the anterior superior iliac spine to the pubic tubercle and the pectineal line. In the middle line, it interlaces with the aponeurosis of the opposite muscle, forming the **linea alba**, which extends from the xiphoid process to the symphysis pubis.

That portion of the aponeurosis which extends between the anterior superior iliac spine and the pubic tubercle is a thick band, folded inward, and continuous below with the fascia lata; it is called the **inguinal ligament**. The portion which is reflected from the inguinal ligament at the pubic tubercle is attached to the pectineal line and is called the **lacunar ligament**. From the point of attachment of the latter to the pectineal line, a few fibers pass upward and medialward, behind the medial crus of the subcutaneous inguinal ring, to the linea alba; they diverge as they ascend, and form a thin triangular fibrous band which is called the **reflected inguinal ligament**.

In the aponeurosis of the Obliquus externus, immediately above the crest of the pubis, is a triangular opening, the **subcutaneous inguinal ring**, formed by a separation of the fibers of the aponeurosis in this situation.

The following structures require further description, viz., the **subcutaneous inguinal ring**, the **intercrural fibers and fascia**, and the **inguinal, lacunar, and reflected inguinal ligaments**.

The Subcutaneous Inguinal Ring (*annulus inguinalis subcutaneus; external abdominal ring*) (Fig. 393).—The subcutaneous inguinal ring is an interval in the aponeurosis of the Obliquus externus, just above and lateral to the crest of the pubis. The aperture is oblique in direction, somewhat triangular in form, and corresponds with the course of the fibers of the aponeurosis. It usually measures from base to apex about 2.5 cm., and transversely about 1.25 cm. It is bounded *below* by the crest of the pubis; on either *side* by the margins of the opening in the aponeurosis, which are called the **crura of the ring**; and *above*, by a series of curved **intercrural fibers**. The **inferior crus** (*external pillar*) is the stronger and is formed by that portion of the inguinal ligament which is inserted into the pubic tubercle; it is curved so as to form a kind of groove, upon which, in the male, the spermatic cord rests. The **superior crus** (*internal pillar*) is a broad, thin, flat band, attached to the front of the symphysis pubis and interlacing with its fellow of the opposite side.

The subcutaneous inguinal ring gives passage to the spermatic cord and ilioinguinal nerve in the male, and to the round ligament of the uterus and the ilioinguinal nerve in the female; it is much larger in men than in women, on account of the large size of the spermatic cord.

The Intercrural Fibers (*fibrae intercrurales; intercolumnar fibers*).—The intercrural fibers are a series of curved tendinous fibers, which arch across the lower part of

the aponeurosis of the Obliquus externus, describing curves with the convexities downward. They have received their name from stretching across between the two crura of the subcutaneous inguinal ring, and they are much thicker and stronger at the inferior crus, where they are connected to the inguinal ligament, than superiorly, where they are inserted into the linea alba. The intercrural fibers increase the strength of the lower part of the aponeurosis, and prevent the divergence of the crura from one another; they are more strongly developed in the male than in the female.

As they pass across the subcutaneous inguinal ring, they are connected together by delicate fibrous tissue, forming a fascia, called the **intercrural fascia**. This inter-

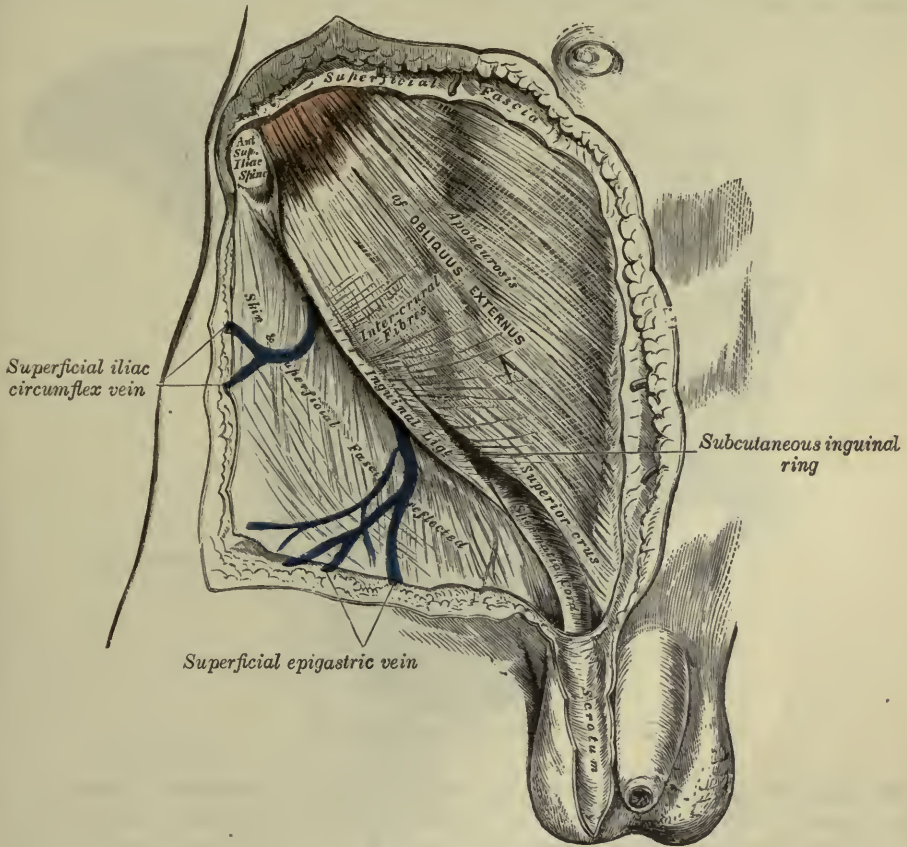


FIG. 393.—The subcutaneous inguinal ring.

crural fascia is continued down as a tubular prolongation around the spermatic cord and testis, and encloses them in a sheath; hence it is also called the **external spermatic fascia**. The subcutaneous inguinal ring is seen as a distinct aperture only after the intercrural fascia has been removed.

The Inguinal Ligament (*ligamentum inguinale* [Poupart]; *Poupart's ligament*) (Fig. 394).—The inguinal ligament is the lower border of the aponeurosis of the Obliquus externus, and extends from the anterior superior iliac spine to the pubic tubercle. From this latter point it is reflected backward and lateralward to be attached to the pectineal line for about 1.25 cm., forming the lacunar ligament. Its general direction is convex downward toward the thigh, where it is continuous with the fascia lata. Its lateral half is rounded, and oblique in direction; its

medial half gradually widens at its attachment to the pubis, is more horizontal in direction, and lies beneath the spermatic cord.

The Lacunar Ligament (*ligamentum lacunare* [Gimbernati]; *Gimbernat's ligament*) (Fig. 394).—The lacunar ligament is that part of the aponeurosis of the Obliquus externus which is reflected backward and lateralward, and is attached to the pectineal line. It is about 1.25 cm. long, larger in the male than in the female, almost horizontal in direction in the erect posture, and of a triangular form with the base directed lateralward. Its base is concave, thin, and sharp, and forms the medial boundary of the femoral ring. Its apex corresponds to the pubic tubercle. Its posterior margin is attached to the pectineal line, and is continuous with the pectineal fascia. Its anterior margin is attached to the inguinal ligament. Its surfaces are directed upward and downward.

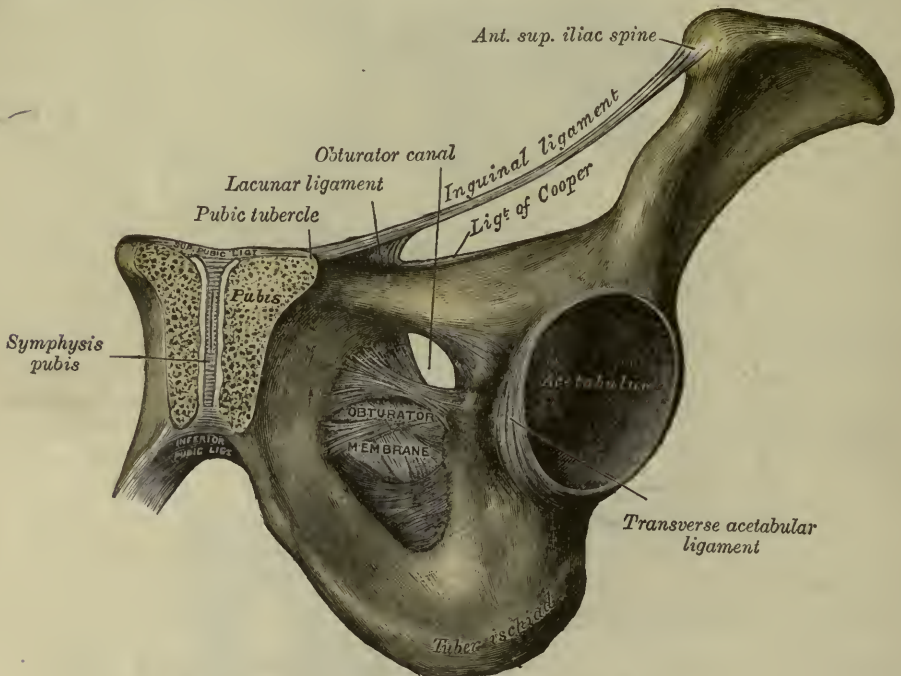


FIG. 394.—The inguinal and lacunar ligaments.

The Reflected Inguinal Ligament (*ligamentum inguinale reflexum* [Collesi]; *triangular fascia*).—The reflected inguinal ligament is a layer of tendinous fibers of a triangular shape, formed by an expansion from the lacunar ligament and the inferior crus of the subcutaneous inguinal ring. It passes medialward behind the spermatic cord, and expands into a somewhat fan-shaped band, lying behind the superior crus of the subcutaneous inguinal ring, and in front of the inguinal aponeurotic falx, and interlaces with the ligament of the other side of the linea alba (Fig. 396).

Ligament of Cooper.—This is a strong fibrous band, which was first described by Sir Astley Cooper. It extends lateralward from the base of the lacunar ligament (Fig. 394) along the pectineal line, to which it is attached. It is strengthened by the pectineal fascia, and by a lateral expansion from the lower attachment of the linea alba (*adimniculum lineæ albæ*).

Variations.—The Obliquus externus may show decrease or doubling of its attachments to the ribs; addition slips from lumbar aponeurosis; doubling between lower ribs and ilium or inguinal ligament. Rarely tendinous inscriptions occur.

The **Obliquus internus abdominis** (*Internal or ascending oblique muscle*) (Fig. 395), thinner and smaller than the Obliquus externus, beneath which it lies, is of

an irregularly quadrilateral form, and situated at the lateral and anterior parts of the abdomen. It arises, by fleshy fibers, from the lateral half of the grooved upper surface of the inguinal ligament, from the anterior two-thirds of the middle lip of the iliac crest, and from the posterior lamella of the lumbodorsal fascia. From this origin the fibers diverge; those from the inguinal ligament, few in number and paler in color than the rest, arch downward and medialward across the spermatic cord in the male and the round ligament of the uterus in the female, and, becoming tendinous, are inserted, conjointly with those of the Transversus, into the crest of the pubis and medial part of the pectineal line behind the lacunar ligament, forming what is known as the **inguinal aponeurotic falx**. Those from the

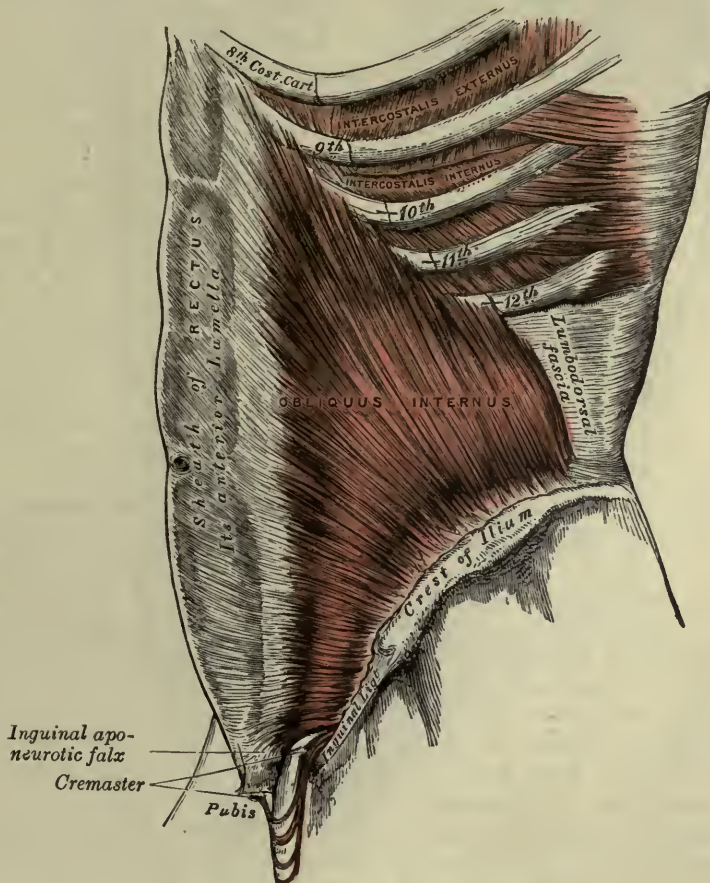


FIG. 395.—The Obliquus internus abdominis.

anterior third of the iliac origin are horizontal in their direction, and, becoming tendinous along the lower fourth of the linea semilunaris, pass in front of the Rectus abdominis to be inserted into the linea alba. Those arising from the middle third of the iliac origin run obliquely upward and medialward, and end in an aponeurosis; this divides at the lateral border of the Rectus into two lamellæ, which are continued forward, one in front of and the other behind this muscle, to the linea alba: the posterior lamella has an attachment to the cartilages of the seventh, eighth, and ninth ribs. The most posterior fibers pass almost vertically upward, to be inserted into the inferior borders of the cartilages of the three lower ribs, being continuous with the Intercostales interni.

Variations.—Occasionally, tendinous inscriptions occur from the tips of the tenth or eleventh cartilages or even from the ninth; an additional slip to the ninth cartilage is sometimes found; separation between iliac and inguinal parts may occur.

The **Cremaster** (Fig. 396) is a thin muscular layer, composed of a number of fasciculi which *arise* from the middle of the inguinal ligament where its fibers

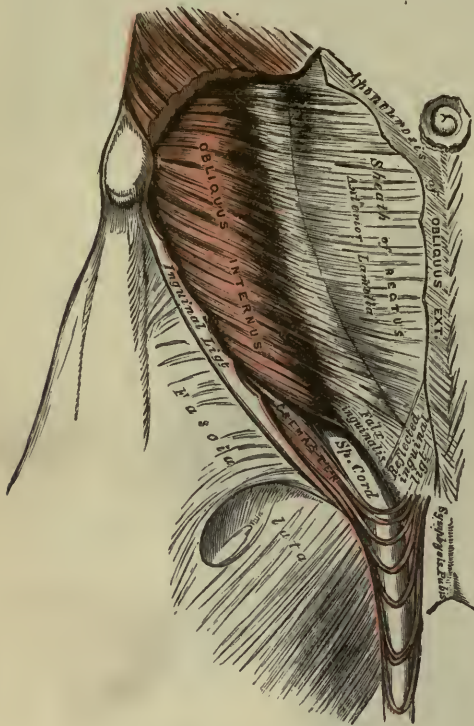


FIG. 396.—The Cremaster.

are continuous with those of the Obliquus internus and also occasionally with the Transversus. It passes along the lateral side of the spermatic cord, descends with it through the subcutaneous inguinal ring upon the front and sides of the cord, and forms a series of loops which differ in thickness and length in different subjects. At the upper part of the cord the loops are short, but they become in succession longer and longer, the longest reaching down as low as the testis, where a few are inserted into the tunica vaginalis. These loops are united together by areolar tissue, and form a thin covering over the cord and testis, the **cremasteric fascia**. The fibers ascend along the medial side of the cord, and are inserted by a small pointed tendon into the tubercle and crest of the pubis and into the front of the sheath of the Rectus abdominis.

The **Transversus abdominis** (*Transversalis muscle*) (Fig. 397), so called from the direction of its fibers, is the most internal of the flat muscles of the abdomen, being placed im-

mediately beneath the Obliquus internus. It *arises*, by fleshy fibers, from the lateral third of the inguinal ligament, from the anterior three-fourths of the inner lip of the iliac crest, from the inner surfaces of the cartilages of the lower six ribs, interdigitating with the diaphragm, and from the lumbodorsal fascia. The muscle ends in front in a broad aponeurosis, the lower fibers of which curve downward and medialward, and are *inserted*, together with those of the Obliquus internus, into the crest of the pubis and pectineal line, forming the inguinal aponeurotic falx. Throughout the rest of its extent the aponeurosis passes horizontally to the middle line, and is inserted into the linea alba; its upper three-fourths lie behind the Rectus and blend with the posterior lamella of the aponeurosis of the Obliquus internus; its lower fourth is in front of the Rectus.

Variations.—It may be more or less fused with the Obliquus internus or absent. The spermatic cord may pierce its lower border. Slender muscle slips from the ileopectineal line to transversalis fascia, the aponeurosis of the Transversus abdominis, or the outer end of the linea semicircularis and other slender slips are occasionally found.

The **inguinal aponeurotic falx** (*falx aponeurotica inguinalis*; *conjoined tendon of Internal oblique and Transversalis muscle*) of the Obliquus internus and Transversus is mainly formed by the lower part of the tendon of the Transversus, and is inserted into the crest of the pubis and pectineal line immediately behind the subcutaneous inguinal ring, serving to protect what would otherwise be a

weak point in the abdominal wall. Lateral to the falx is a ligamentous band connected with the lower margin of the Transversus and extending down in front of the inferior epigastric artery to the superior ramus of the pubis; it is termed the **interfoveolar ligament of Hesselbach** (Fig. 398) and sometimes contains a few muscular fibers.

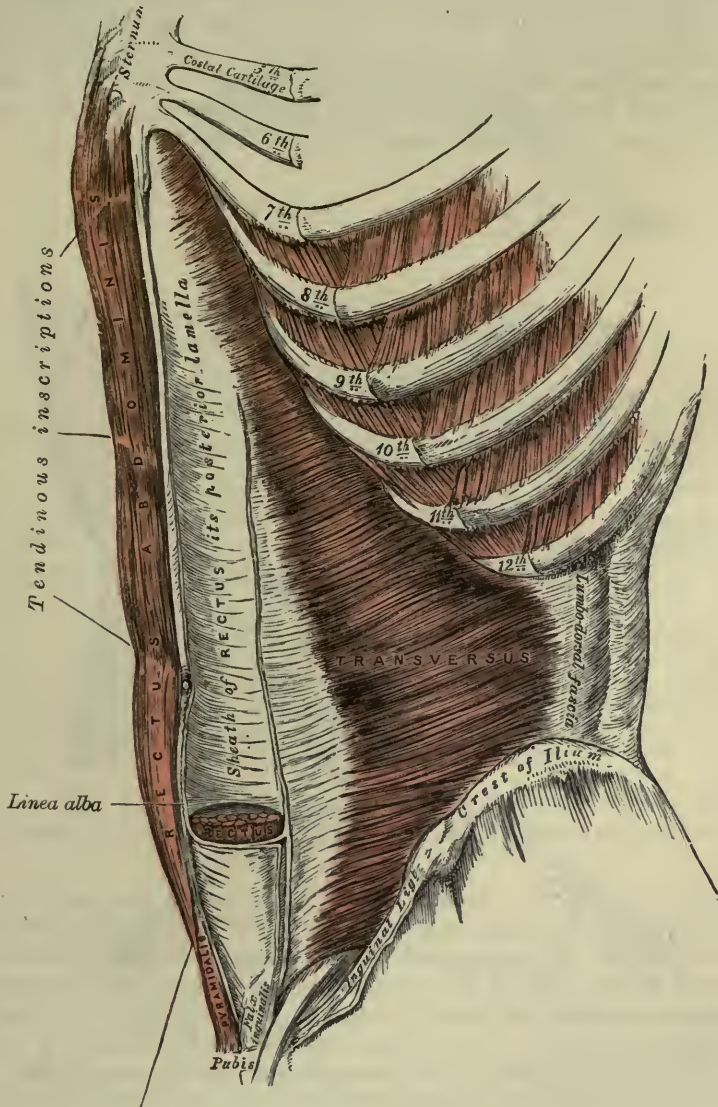


FIG. 397.—The Transversus abdominis, Rectus abdominis, and Pyramidalis.

The **Rectus abdominis** (Fig. 397) is a long flat muscle, which extends along the whole length of the front of the abdomen, and is separated from its fellow of the opposite side by the linea alba. It is much broader, but thinner, above than below, and *arises* by two tendons; the lateral or larger is attached to the crest of the pubis, the medial interlaces with its fellow of the opposite side, and is connected with the ligaments covering the front of the symphysis pubis. The muscle is *inserted* by three portions of unequal size into the cartilages of the fifth, sixth, and seventh ribs. The upper portion, attached principally to the cartilage of the

fifth rib, usually has some fibers of insertion into the anterior extremity of the rib itself. Some fibers are occasionally connected with the costoxiphoid ligaments, and the side of the xiphoid process.

The Rectus is crossed by fibrous bands, three in number, which are named the **tendinous inscriptions**; one is usually situated opposite the umbilicus, one at the extremity of the xiphoid process, and the third about midway between the xiphoid process and the umbilicus. These inscriptions pass transversely or obliquely across the muscle in a zigzag course; they rarely extend completely through its substance and may pass only halfway across it; they are intimately adherent in front to the sheath of the muscle. Sometimes one or two additional inscriptions, generally incomplete, are present below the umbilicus.

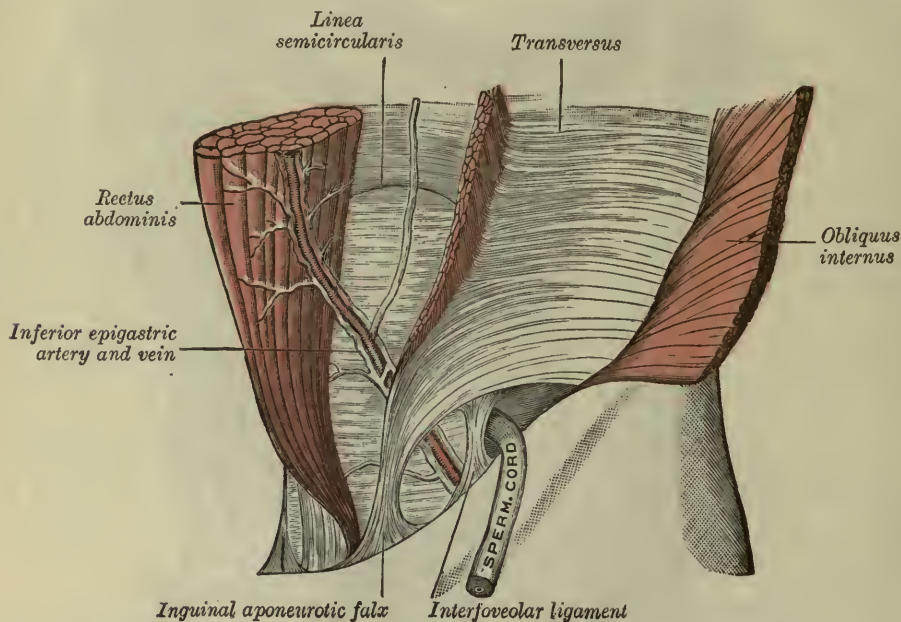


FIG. 398.—The interfoveolar ligament, seen from in front. (Modified from Braune.)

The Rectus is enclosed in a sheath (Fig. 399) formed by the aponeuroses of the Obliqui and Transversus, which are arranged in the following manner. At the lateral margin of the Rectus, the aponeurosis of the Obliquus internus divides into two lamellæ, one of which passes in front of the Rectus, blending with the aponeurosis of the Obliquus externus, the other, behind it, blending with the aponeurosis of the Transversus, and these, joining again at the medial border of the Rectus, are inserted into the linea alba. This arrangement of the aponeurosis exists from the costal margin to midway between the umbilicus and symphysis pubis, where the posterior wall of the sheath ends in a thin curved margin, the **linea semicircularis**, the concavity of which is directed downward: below this level the aponeuroses of all three muscles pass in front of the Rectus. The Rectus, in the situation where its sheath is deficient below, is separated from the peritoneum by the transversalis fascia (Fig. 400). Since the tendons of the Obliquus internus and Transversus only reach as high as the costal margin, it follows that above this level the sheath of the Rectus is deficient behind, the muscle resting directly on the cartilages of the ribs, and being covered merely by the tendon of the Obliquus externus.

The **Pyramidalis** (Fig. 397) is a small triangular muscle, placed at the lower part of the abdomen, in front of the Rectus, and contained in the sheath of that

muscle. It arises by tendinous fibers from the front of the pubis and the anterior pubic ligament; the fleshy portion of the muscle passes upward, diminishing in size as it ascends, and ends by a pointed extremity which is inserted into the linea alba, midway between the umbilicus and pubis. This muscle may be wanting on one or both sides; the lower end of the Rectus then becomes proportionately increased in size. Occasionally it is double on one side, and the muscles of the two sides are sometimes of unequal size. It may extend higher than the level stated.

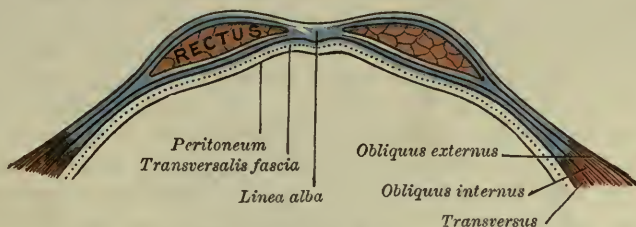


FIG. 399.—Diagram of sheath of Rectus.

Besides the Rectus and Pyramidalis, the sheath of the Rectus contains the superior and inferior epigastric arteries, and the lower intercostal nerves.

Variations.—The Rectus may insert as high as the fourth or third rib or may fail to reach the fifth. Fibers may spring from the lower part of the linea alba.

Nerves.—The abdominal muscles are supplied by the lower intercostal nerves. The Obliquus internus and Transversus also receive filaments from the anterior branch of the iliohypogastric and sometimes from the ilioinguinal. The Cremaster is supplied by the external spermatic branch of the genitofemoral and the Pyramidalis usually by the twelfth thoracic.

The Linea Alba.—The linea alba is a tendinous raphé in the middle line of the abdomen, stretching between the xiphoid process and the symphysis pubis. It is placed between the medial borders of the Recti, and is formed by the blending of the aponeuroses of the Obliqui and Transversi. It is narrow below, corresponding to the linear interval existing between the Recti; but broader above, where these muscles diverge from one another. At its lower end the linea alba has a double attachment—its superficial fibers passing in front of the medial heads of the Recti to the symphysis pubis, while its deeper fibers form a triangular lamella, attached behind the Recti to the posterior lip of the crest of the pubis, and named the *adminiculum lineæ albæ*. It presents apertures for the passage of vessels and nerves; the umbilicus, which in the fetus exists as an aperture and transmits the umbilical vessels, is closed in the adult.

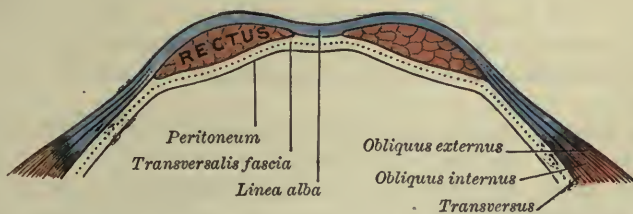


FIG. 400.—Diagram of a transverse section through the anterior abdominal wall, below the linea semicircularis

The Lineæ Semilunares.—The lineæ semilunares are two curved tendinous lines placed one on either side of the linea alba. Each corresponds with the lateral border of the Rectus, extends from the cartilage of the ninth rib to the pubic tubercle, and is formed by the aponeurosis of the Obliquus internus at its line of division to enclose the Rectus, reinforced in front by that of the Obliquus externus, and behind by that of the Transversus.

Actions.—When the pelvis and thorax are fixed, the abdominal muscles compress the abdominal viscera by constricting the cavity of the abdomen, in which action they are materially assisted by the descent of the diaphragm. By these means assistance is given in expelling the feces from the rectum, the urine from the bladder, the fetus from the uterus, and the contents of the stomach in vomiting.

If the pelvis and vertebral column be fixed, these muscles compress the lower part of the thorax, materially assisting expiration. If the pelvis alone be fixed, the thorax is bent directly forward, when the muscles of both sides act; when the muscles of only one side contract, the trunk is bent toward that side and rotated toward the opposite side.

If the thorax be fixed, the muscles, acting together, draw the pelvis upward, as in climbing; or, acting singly, they draw the pelvis upward, and bend the vertebral column to one side or the other. The Recti, acting from below, depress the thorax, and consequently flex the vertebral column; when acting from above, they flex the pelvis upon the vertebral column. The Pyramidales are tensors of the linea alba.

The Transversalis Fascia.—The transversalis fascia is a thin aponeurotic membrane which lies between the inner surface of the Transversus and the extraperitoneal fat. It forms part of the general layer of fascia lining the abdominal parietes, and is directly continuous with the iliac and pelvic fasciæ. In the inguinal region, the transversalis fascia is thick and dense in structure and is joined by fibers from the aponeurosis of the Transversus, but it becomes thin as it ascends to the diaphragm, and blends with the fascia covering the under surface of this muscle. *Behind*, it is lost in the fat which covers the posterior surfaces of the kidneys. *Below*, it has the following attachments: *posteriorly*, to the whole length of the iliac crest, between the attachments of the Transversus and Iliacus; between the anterior superior iliac spine and the femoral vessels it is connected to the posterior margin of the inguinal ligament, and is there continuous with the iliac fascia. Medial to the femoral vessels it is thin and attached to the pubis and pectineal line, behind the inguinal aponeurotic falx, with which it is united; it descends in front of the femoral vessels to form the anterior wall of the femoral sheath. Beneath the inguinal ligament it is strengthened by a band of fibrous tissue, which is only loosely connected to the ligament, and is specialized as the **deep crural arch**. The spermatic cord in the male and the round ligament of the uterus in the female pass through the transversalis fascia at a spot called the **abdominal inguinal ring**. This opening is not visible externally, since the transversalis fascia is prolonged on these structures as the infundibuliform fascia.

The Abdominal Inguinal Ring (*annulus inguinalis abdominis; internal or deep abdominal ring*).—The abdominal inguinal ring is situated in the transversalis fascia, midway between the anterior superior iliac spine and the symphysis pubis, and about 1.25 cm. above the inguinal ligament (Fig. 401). It is of an oval form, the long axis of the oval being vertical; it varies in size in different subjects, and is much larger in the male than in the female. It is bounded, *above* and *laterally*, by the arched lower margin of the Transversus; *below* and *medially*, by the inferior epigastric vessels. It transmits the spermatic cord in the male and the round ligament of the uterus in the female. From its circumference a thin funnel-shaped membrane, the **infundibuliform fascia**, is continued around the cord and testis, enclosing them in a distinct covering.

The Inguinal Canal (*canalis inguinalis; spermatic canal*).—The inguinal canal contains the spermatic cord and the ilioinguinal nerve in the male, and the round ligament of the uterus and the ilioinguinal nerve in the female. It is an oblique canal about 4 cm. long, slanting downward and medialward, and placed parallel with and a little above the inguinal ligament; it extends from the abdominal inguinal ring to the subcutaneous inguinal ring. It is bounded, *in front*, by the integument and superficial fascia, by the aponeurosis of the Obliquus externus throughout its whole length, and by the Obliquus internus in its lateral third; *behind*, by the reflected inguinal ligament, the inguinal aponeurotic falx, the transversalis fascia, the extraperitoneal connective tissue and the peritoneum; *above*, by the arched fibers of Obliquus internus and Transversus abdominis; *below*, by the union of the transversalis fascia with the inguinal ligament, and at its medial end by the lacunar ligament.

Extraperitoneal Connective Tissue.—Between the inner surface of the general layer of the fascia which lines the interior of the abdominal and pelvic cavities, and the peritoneum, there is a considerable amount of connective tissue, termed the **extraperitoneal** or **subperitoneal connective tissue**.

The **parietal portion** lines the cavity in varying quantities in different situations. It is especially abundant on the posterior wall of the abdomen, and particularly around the kidneys, where it contains much fat. On the anterior wall of the abdomen, except in the pubic region, and on the lateral wall above the iliac crest, it is scanty, and here the transversalis fascia is more closely connected with the peritoneum. There is a considerable amount of extraperitoneal connective tissue in the pelvis.

The **visceral portion** follows the course of the branches of the abdominal aorta between the layers of the mesenterics and other folds of peritoneum which connect the various viscera to the abdominal wall. The two portions are directly continuous with each other.

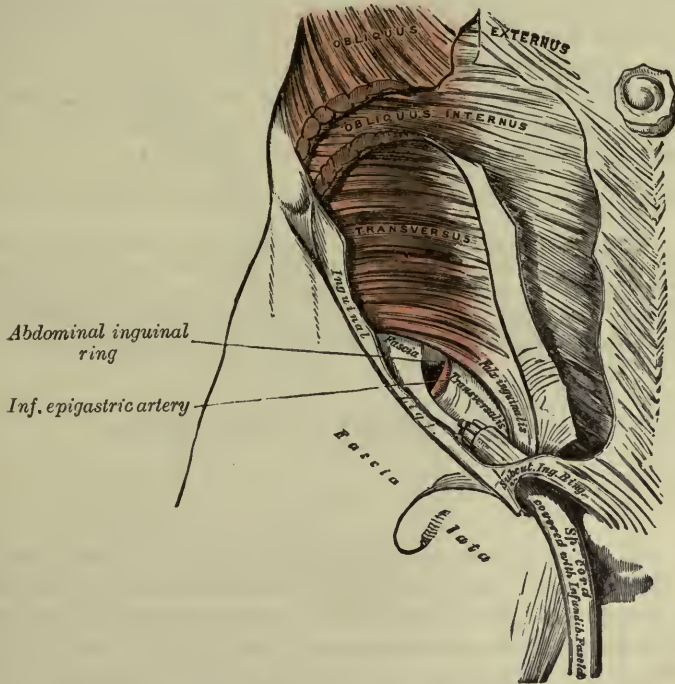


FIG. 401.—The abdominal inguinal ring.

The Deep Crural Arch.—Curving over the external iliac vessels, at the spot where they become femoral, on the abdominal side of the inguinal ligaments and loosely connected with it, is a thickened band of fibers called the deep crural arch. It is apparently a thickening of the transversalis fascia joined laterally to the center of the lower margin of the inguinal ligament, and arching across the front of the femoral sheath to be inserted by a broad attachment into the pubic tubercle and pectineal line, behind the inguinal aponeurotic falx. In some subjects this structure is not very prominently marked, and not infrequently it is altogether wanting.

2. The Posterior Muscles of the Abdomen.

Psoas major.
Psoas minor.

Iliacus.
Quadratus lumborum.

The Psoas major, the Psoas minor, and the Iliacus, with the fasciæ covering them, will be described with the muscles of the lower extremity (see page 466).

The Fascia Covering the Quadratus Lumborum.—This is a thin layer attached, *medially*, to the bases of the transverse processes of the lumbar vertebræ; *below*,

to the iliolumbar ligament; *above*, to the apex and lower border of the last rib. The upper margin of this fascia, which extends from the transverse process of the first lumbar vertebra to the apex and lower border of the last rib, constitutes the lateral lumbocostal arch (page 405). Laterally, it blends with the lumbodorsal fascia, the anterior layer of which intervenes between the *Quadratus lumborum* and the *Sacrospinalis*.

The *Quadratus lumborum* (Fig. 389, page 398) is irregularly quadrilateral in shape, and broader below than above. It *arises* by aponeurotic fibers from the iliolumbar ligament and the adjacent portion of the iliac crest for about 5 cm., and is *inserted* into the lower border of the last rib for about half its length, and by four small tendons into the apices of the transverse processes of the upper four lumbar vertebræ. Occasionally a second portion of this muscle is found in front of the preceding. It *arises* from the upper borders of the transverse processes of the lower three or four lumbar vertebræ, and is *inserted* into the lower margin of the last rib. In front of the *Quadratus lumborum* are the colon, the kidney, the *Psoas major* and *minor*, and the diaphragm; between the fascia and the muscle are the twelfth thoracic, ilioinguinal, and iliohypogastric nerves.

Variations.—The number of attachments to the vertebræ and the extent of its attachment to the last rib vary.

Nerve Supply.—The twelfth thoracic and first and second lumbar nerves supply this muscle.

Actions.—The *Quadratus lumborum* draws down the last rib, and acts as a muscle of inspiration by helping to fix the origin of the diaphragm. If the thorax and vertebral column are fixed, it may act upon the pelvis, raising it toward its own side when only one muscle is put in action; and when both muscles act together, either from below or above, they flex the trunk.

V. THE MUSCLES AND FASCIAE OF THE PELVIS.

Obturator internus.
Piriformis.

Levator ani.
Coccygeus.

The muscles within the pelvis may be divided into two groups: (1) the *Obturator internus* and the *Piriformis*, which are muscles of the lower extremity, and will be described with these (pages 476 and 477); (2) the *Levator ani* and the *Coccygeus*, which together form the **pelvic diaphragm** and are associated with the pelvic viscera. The classification of the two groups under a common heading is convenient in connection with the fasciæ investing the muscles. These fasciæ are closely related to one another and to the deep fascia of the perineum, and in addition have special connections with the fibrous coverings of the pelvic viscera; it is customary therefore to describe them together under the term **pelvic fascia**.

Pelvic Fascia.—The fascia of the pelvis may be resolved into: (a) the fascial sheaths of the *Obturator internus*, *Piriformis*, and *pelvic diaphragm*; (b) the fascia associated with the pelvic viscera.

The **fascia of the *Obturator internus*** covers the pelvic surface of, and is attached around the margin of the origin of, the muscle. *Above*, it is loosely connected to the back part of the arcuate line, and here it is continuous with the iliac fascia. In front of this, as it follows the line of origin of the *Obturator internus*, it gradually separates from the iliac fascia and the continuity between the two is retained only through the periosteum. It arches beneath the obturator vessels and nerve, completing the obturator canal, and at the front of the pelvis is attached to the back of the superior ramus of the pubis. *Below*, the obturator fascia is attached to the falciform process of the sacrotuberous ligament and to the pubic arch, where it becomes continuous with the superior fascia of the urogenital diaphragm. *Behind*, it is prolonged into the gluteal region.

The internal pudendal vessels and pudendal nerve cross the pelvic surface of

the Obturator internus and are enclosed in a special canal—Alcock's canal—formed by the obturator fascia.

The fascia of the Piriformis is very thin and is attached to the front of the sacrum and the sides of the greater sciatic foramen; it is prolonged on the muscle into the gluteal region. At its sacral attachment around the margins of the anterior sacral foramina it comes into intimate association with and ensheathes the nerves emerging from these foramina. Hence the sacral nerves are frequently described as lying behind the fascia. The internal iliac vessels and their branches, on the other hand, lie in the subperitoneal tissue in front of the fascia, and the branches to the gluteal region emerge in special sheaths of this tissue, above and below the Piriformis muscle.

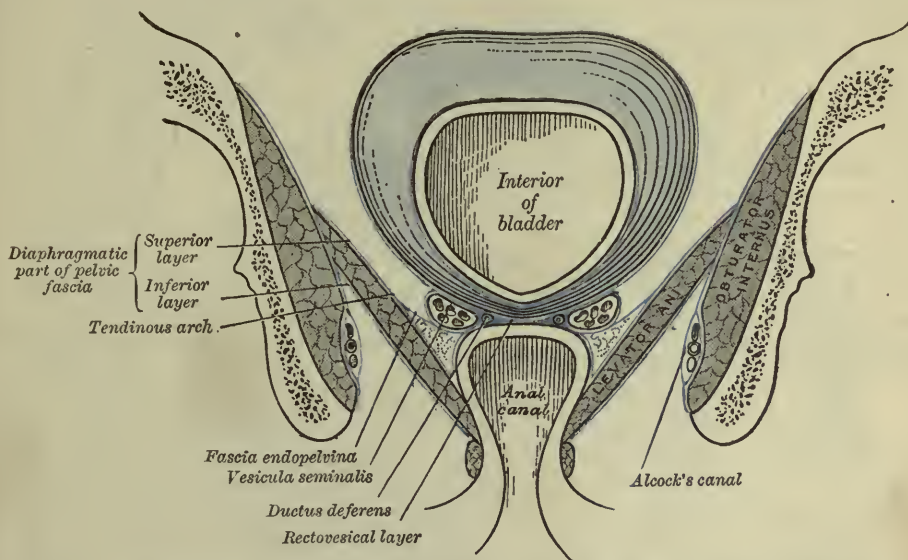


FIG. 402.—Coronal section of pelvis, showing arrangement of fasciae. Viewed from behind. (Diagrammatic.)

The diaphragmatic part of the pelvic fascia (Fig. 402) covers both surfaces of the Levatores ani. The inferior layer is known as the anal fascia; it is attached above to the obturator fascia along the line of origin of the Levator ani, while below it is continuous with the superior fascia of the urogenital diaphragm, and with the fascia on the Sphincter ani internus. The layer covering the upper surface of the pelvic diaphragm follows, above, the line of origin of the Levator ani and is therefore somewhat variable. In front it is attached to the back of the symphysis pubis about 2 cm. above its lower border. It can then be traced laterally across the back of the superior ramus of the pubis for a distance of about 1.25 cm., when it reaches the obturator fascia. It is attached to this fascia along a line which pursues a somewhat irregular course to the spine of the ischium. The irregularity of this line is due to the fact that the origin of the Levator ani, which in lower forms is from the pelvic brim, is in man lower down, on the obturator fascia. Tendinous fibers of origin of the muscle are therefore often found extending up toward, and in some cases reaching, the pelvic brim, and on these the fascia is carried.

It will be evident that the fascia covering that part of the Obturator internus which lies above the origin of the Levator ani is a composite fascia and includes the following: (a) the obturator fascia; (b) the fascia of the Levator ani; (c) degenerated fibers of origin of the Levator ani.

The lower margin of the fascia covering the upper surface of the pelvic diaphragm is attached along the line of insertion of the Levator ani.

At the level of a line extending from the lower part of the symphysis pubis to the spine of the ischium is a thickened whitish band in this upper layer of the diaphragmatic part of the pelvic fascia. It is termed the **tendinous arch or white line of the pelvic fascia**, and marks the line of attachment of the special fascia (*pars endopelvina fasciæ pelvis*) which is associated with the pelvic viscera.

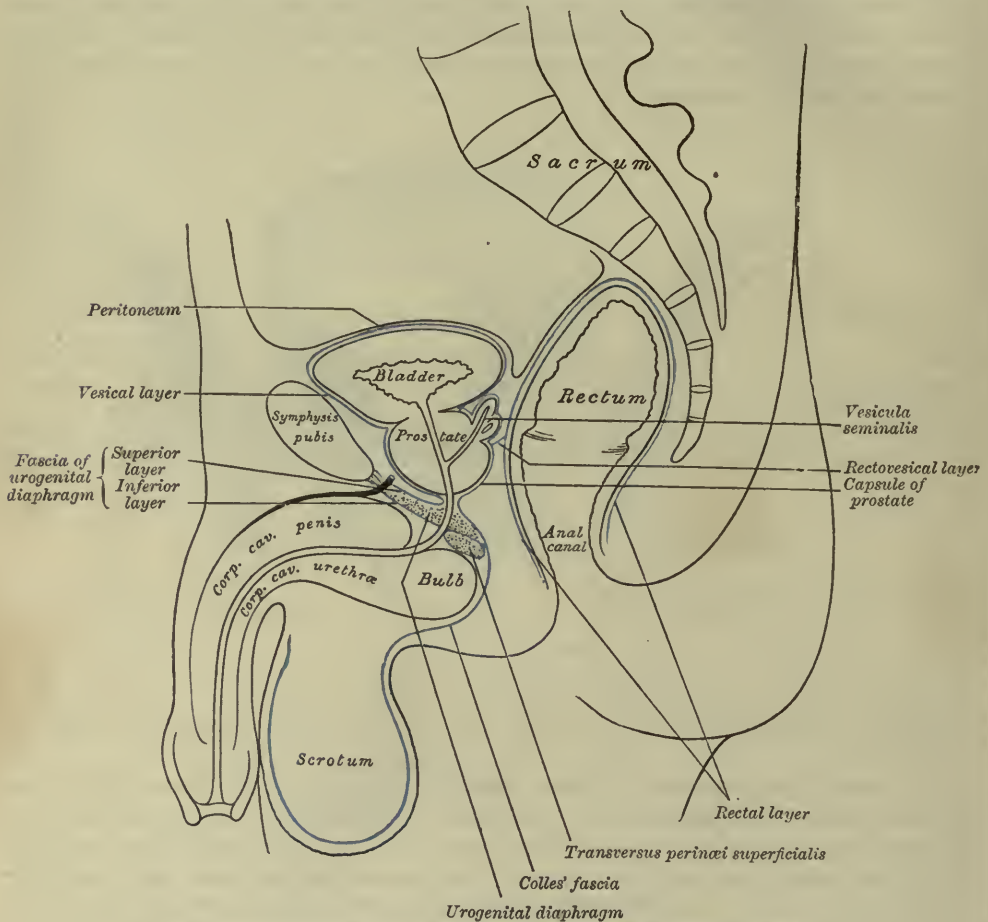


FIG. 403.—Median sagittal section of pelvis, showing arrangement of fasciæ.

The **endopelvic part of the pelvic fascia** is continued over the various pelvic viscera (Fig. 403) to form for them fibrous coverings which will be described later (see section on Splanchnology). It is attached to the diaphragmatic part of the pelvic fascia along the tendinous arch, and has been subdivided in accordance with the viscera to which it is related. Thus its anterior part, known as the **vesical layer**, forms the anterior and lateral ligaments of the bladder. Its middle part crosses the floor of the pelvis between the rectum and vesiculæ seminales as the **rectovesical layer**; in the female this is perforated by the vagina. Its posterior portion passes to the side of the rectum; it forms a loose sheath for the rectum, but is firmly attached around the anal canal; this portion is known as the **rectal layer**.

The **Levator ani** (Fig. 404) is a broad, thin muscle, situated on the side of the pelvis. It is attached to the inner surface of the side of the lesser pelvis, and unites

with its fellow of the opposite side to form the greater part of the floor of the pelvic cavity. It supports the viscera in this cavity, and surrounds the various structures which pass through it. It *arises*, in front, from the posterior surface of the superior ramus of the pubis lateral to the symphysis; behind, from the inner surface of the spine of the ischium; and between these two points, from the obturator fascia. Posteriorly, this fascial origin corresponds, more or less closely, with the tendinous arch of the pelvic fascia, but in front, the muscle arises from the fascia at a varying distance above the arch, in some cases reaching nearly as high as the canal

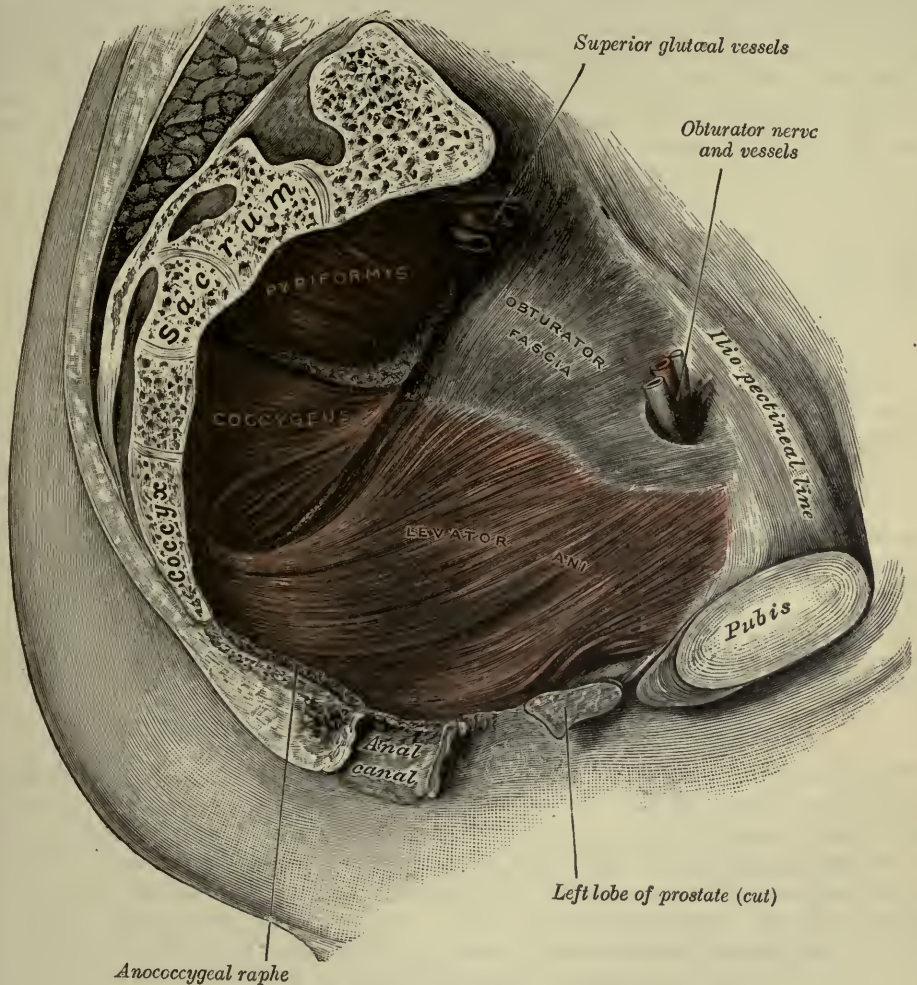


FIG. 404.—Left Levator ani from within.

for the obturator vessels and nerve. The fibers pass downward and backward to the middle line of the floor of the pelvis; the most posterior are inserted into the side of the last two segments of the coccyx; those placed more anteriorly unite with the muscle of the opposite side, in a median fibrous raphé (*anococcygeal raphé*), which extends between the coccyx and the margin of the anus. The middle fibers are inserted into the side of the rectum, blending with the fibers of the Sphincter muscles; lastly, the anterior fibers descend upon the side of the prostate to unite beneath it with the muscle of the opposite side, joining with the fibers of the Sphincter ani externus and Transversus perinæi, at the central tendinous point of the perineum.

The anterior portion is occasionally separated from the rest of the muscle by connective tissue. From this circumstance, as well as from its peculiar relation with the prostate, which it supports as in a sling, it has been described as a distinct muscle, under the name of *Levator prostatae*. In the female the anterior fibers of the Levator ani descend upon the side of the vagina.

The Levator ani may be divided into iliococcygeal and pubococcygeal parts.

The *Iliococcygeus* arises from the ischial spine and from the posterior part of the tendinous arch of the pelvic fascia, and is attached to the coccyx and anococcygeal raphé; it is usually thin, and may fail entirely, or be largely replaced by fibrous tissue. An accessory slip at its posterior part is sometimes named the *Iliosacralis*. The *Pubococcygeus* arises from the back of the pubis and from the anterior part of the obturator fascia, and "is directed backward almost horizontally along the side of the anal canal toward the coccyx and sacrum, to which it finds attachment. Between the termination of the vertebral column and the anus, the two Pubococcygei muscles come together and form a thick, fibromuscular layer lying on the raphé formed by the Iliococcygei" (Peter Thompson). The greater part of this muscle is *inserted* into the coccyx and into the last one or two pieces of the sacrum. This insertion into the vertebral column is, however, not admitted by all observers. The fibers which form a sling for the rectum are named the *Puborectalis* or *Sphincter recti*. They arise from the lower part of the symphysis pubis, and from the superior fascia of the urogenital diaphragm. They meet with the corresponding fibers of the opposite side around the lower part of the rectum, and form for it a strong sling.

Nerve Supply.—The Levator ani is supplied by a branch from the fourth sacral nerve and by a branch which is sometimes derived from the perineal, sometimes from the inferior hemorrhoidal division of the pudendal nerve.

The **Coccygeus** (Fig. 404) is situated behind the preceding. It is a triangular plane of muscular and tendinous fibers, *arising* by its apex from the spine of the ischium and sacrospinous ligament, and *inserted* by its base into the margin of the coccyx and into the side of the lowest piece of the sacrum. It assists the Levator ani and Piriformis in closing in the back part of the outlet of the pelvis.

Nerve Supply.—The Coccygeus is supplied by a branch from the fourth and fifth sacral nerves.

Actions.—The Levatores ani constrict the lower end of the rectum and vagina. They elevate and invert the lower end of the rectum after it has been protruded and everted during the expulsion of the feces. They are also muscles of forced expiration. The Coccygei pull forward and support the coccyx, after it has been pressed backward during defecation or parturition. The Levatores ani and Coccygei together form a muscular diaphragm which supports the pelvic viscera.

VI. THE MUSCLES AND FASCIÆ OF THE PERINEUM.

The perineum corresponds to the outlet of the pelvis. Its deep boundaries are—in *front*, the pubic arch and the arcuate ligament of the pubis; *behind*, the tip of the coccyx; and on either side the inferior rami of the pubis and ischium, and the sacrotuberous ligament. The space is somewhat lozenge-shaped and is limited on the surface of the body by the scrotum in front, by the buttocks behind, and laterally by the medial side of the thigh. A line drawn transversely across in front of the ischial tuberosities divides the space into two portions. The posterior contains the termination of the anal canal and is known as the **anal region**; the anterior, which contains the external urogenital organs, is termed the **urogenital region**.

The muscles of the perineum may therefore be divided into two groups:

1. Those of the anal region.
2. Those of the urogenital region: A, In the male; B, In the female.

1. The Muscles of the Anal Region.

Corrugator cutis ani. Sphincter ani externus. Sphincter ani internus.

The Superficial Fascia.—The superficial fascia is very thick, areolar in texture, and contains much fat in its meshes. On either side a pad of fatty tissue extends

deeply between the Levator ani and Obturator internus into a space known as the ischiorectal fossa.

The Deep Fascia.—The deep fascia forms the lining of the ischiorectal fossa; it comprises the anal fascia, and the portion of obturator fascia below the origin of Levator ani.

Ischiorectal Fossa (*fossa ischiorectalis*) (Fig. 405).—The fossa is somewhat prismatic in shape, with its base directed to the surface of the perineum, and its apex at the line of meeting of the obturator and anal fasciæ. It is bounded *medially* by the Sphincter ani externus and the anal fascia; *laterally*, by the tuberosity of the ischium and the obturator fascia; *anteriorly*, by the fascia of Colles covering the Transversus perinæi superficialis, and by the inferior fascia of the urogenital diaphragm; *posteriorly*, by the Glutæus maximus and the sacrotuberous ligament. Crossing the space transversely are the inferior hemorrhoidal vessels and nerves;

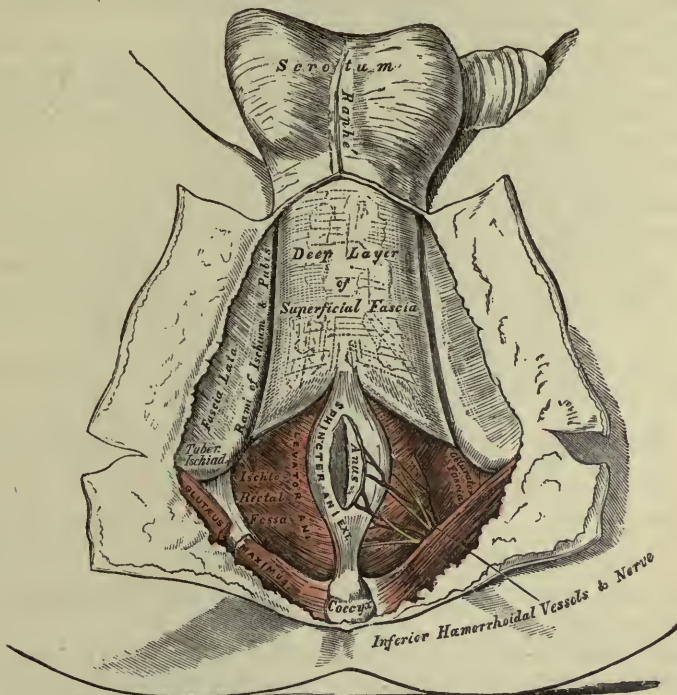


FIG. 405.—The perineum. The integument and superficial layer of superficial fascia reflected.

at the back part are the perineal and perforating cutaneous branches of the pudendal plexus; while from the forepart the posterior scrotal (or labial) vessels and nerves emerge. The internal pudendal vessels and pudendal nerve lie in Alcock's canal on the lateral wall. The fossa is filled with fatty tissue across which numerous fibrous bands extend from side to side.

The Corrugator Cutis Ani.—Around the anus is a thin stratum of involuntary muscular fiber, which radiates from the orifice. *Medially* the fibers fade off into the submucous tissue, while *laterally* they blend with the true skin. By its contraction it raises the skin into ridges around the margin of the anus.

The **Sphincter ani externus** (*External sphincter ani*) (Fig 405) is a flat plane of muscular fibers, elliptical in shape and intimately adherent to the integument surrounding the margin of the anus. It measures about 8 to 10 cm. in length, from its anterior to its posterior extremity, and is about 2.5 cm. broad opposite the anus. It consists of two strata, superficial and deep. The *superficial*, constituting

the main portion of the muscle, arises from a narrow tendinous band, the **anococcygeal raphé**, which stretches from the tip of the coccyx to the posterior margin of the anus; it forms two flattened planes of muscular tissue, which encircle the anus and meet in front to be inserted into the central tendinous point of the perineum, joining with the *Transversus perinæi superficialis*, the *Levator ani*, and the *Bulbocavernosus*. The *deeper portion* forms a complete sphincter to the anal canal. Its fibers surround the canal, closely applied to the *Sphincter ani internus*, and in front blend with the other muscles at the central point of the perineum. In a considerable proportion of cases the fibers decussate in front of the anus, and are continuous with the *Transversi perinæi superficiales*. Posteriorly, they are not attached to the coccyx, but are continuous with those of the opposite side behind the anal canal. The upper edge of the muscle is ill-defined, since fibers are given off from it to join the *Levator ani*.

Nerve Supply.—A branch from the fourth sacral and twigs from the inferior hemorrhoidal branch of the pudendal supply the muscle.

Actions.—The action of this muscle is peculiar. (1) It is, like other muscles, always in a state of tonic contraction, and having no antagonistic muscle it keeps the anal canal and orifice closed. (2) It can be put into a condition of greater contraction under the influence of the will, so as more firmly to occlude the anal aperture, in expiratory efforts unconnected with defecation. (3) Taking its fixed point at the coccyx, it helps to fix the central point of the perineum, so that the *Bulbocavernosus* may act from this fixed point.

The **Sphincter ani internus** (*Internal sphincter ani*) is a muscular ring which surrounds about 2.5 cm. of the anal canal; its inferior border is in contact with, but quite separate from, the *Sphincter ani externus*. It is about 5 mm. thick, and is formed by an aggregation of the involuntary circular fibers of the intestine. Its lower border is about 6 mm. from the orifice of the anus.

Actions.—Its action is entirely involuntary. It helps the *Sphincter ani externus* to occlude the anal aperture and aids in the expulsion of the feces.

2. A. The Muscles of the Urogenital Region in the Male (Fig. 406).

<i>Transversus perinæi superficialis.</i>	<i>Ischiocavernosus.</i>
<i>Bulbocavernosus.</i>	<i>Transversus perinæi profundus.</i>
<i>Sphincter urethræ membranaceæ.</i>	

Superficial Fascia.—The superficial fascia of this region consists of two layers, superficial and deep.

The **superficial layer** is thick, loose, areolar in texture, and contains in its meshes much adipose tissue, the amount of which varies in different subjects. In *front*, it is continuous with the dartos tunic of the scrotum; *behind*, with the subcutaneous areolar tissue surrounding the anus; and, on *either side*, with the same fascia on the inner sides of the thighs. In the *middle line*, it is adherent to the skin on the raphé and to the deep layer of the superficial fascia.

The **deep layer of superficial fascia** (*fascia of Colles*) (Fig. 405) is thin, aponeurotic in structure, and of considerable strength, serving to bind down the muscles of the root of the penis. It is continuous, in *front*, with the dartos tunic, the deep fascia of the penis, the fascia of the spermatic cord, and Scarpa's fascia upon the anterior wall of the abdomen; on *either side* it is firmly attached to the margins of the rami of the pubis and ischium, lateral to the crus penis and as far back as the tuberosity of the ischium; *posteriorly*, it curves around the *Transversi perinæi superficiales* to join the lower margin of the inferior fascia of the urogenital diaphragm. In the *middle line*, it is connected with the superficial fascia and with the median septum of the *Bulbocavernosus*. This fascia not only covers the muscles in this region, but at its back part sends upward a vertical septum from its deep surface, which separates the posterior portion of the subjacent space into two.

The Central Tendinous Point of the Perineum.—This is a fibrous point in the middle line of the perineum, between the urethra and anus, and about 1.25 cm. in front of the latter. At this point six muscles converge and are attached: viz., the Sphincter ani externus, the Bulbocavernosus, the two Transversi perinæi superficiales, and the anterior fibers of the Levatores ani.

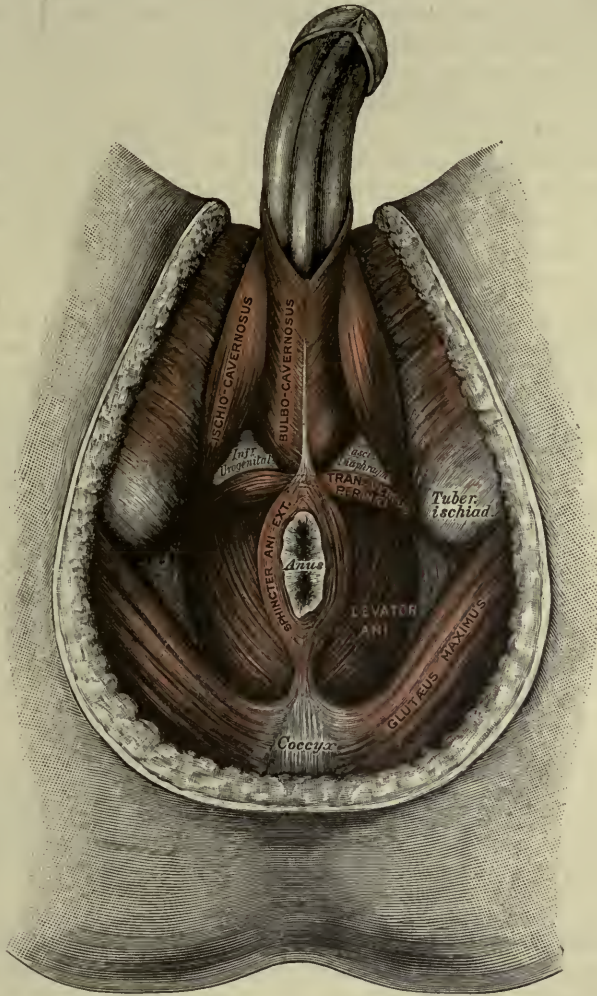


FIG. 406.—Muscles of male perineum.

The **Transversus perinæi superficialis** (*Transversus perinæi*; *Superficial transverse perineal muscle*) is a narrow muscular slip, which passes more or less transversely across the perineal space in front of the anus. It arises by tendinous fibers from the inner and forepart of the tuberosity of the ischium, and, running medialward, is inserted into the central tendinous point of the perineum, joining in this situation with the muscle of the opposite side, with the Sphincter ani externus behind, and with the Bulbocavernosus in front. In some cases, the fibers of the deeper layer of the Sphincter ani externus decussate in front of the anus and are continued into this muscle. Occasionally it gives off fibers, which join with the Bulbocavernosus of the same side.

Variations are numerous. It may be absent or double, or insert into Bulbocavernosus or External sphincter.

Actions.—The simultaneous contraction of the two muscles serves to fix the central tendinous point of the perineum.

The **Bulbocavernosus** (*Ejaculator urinæ; Accelerator urinæ*) is placed in the middle line of the perineum, in front of the anus. It consists of two symmetrical parts, united along the median line by a tendinous raphé. It *arises* from the central tendinous point of the perineum and from the median raphé in front. Its fibers diverge like the barbs of a quill-pen; the most posterior form a thin layer, which is lost on the inferior fascia of the urogenital diaphragm; the middle fibers encircle the bulb and adjacent parts, of the corpus cavernosum urethræ, and join with the fibers of the opposite side, on the upper part of the corpus cavernosum urethræ, in a strong aponeurosis; the anterior fibers, spread out over the side of the corpus cavernosum penis, to be inserted partly into that body, anterior to the Ischiocavernosus, occasionally extending to the pubis, and partly ending in a tendinous expansion which covers the dorsal vessels of the penis. The latter fibers are best seen by dividing the muscle longitudinally, and reflecting it from the surface of the corpus cavernosum urethræ.

Actions.—This muscle serves to empty the canal of the urethra, after the bladder has expelled its contents; during the greater part of the act of micturition its fibers are relaxed, and it only comes into action at the end of the process. The middle fibers are supposed by Krause to assist in the erection of the corpus cavernosum urethræ, by compressing the erectile tissue of the bulb. The anterior fibers, according to Tyrrel, also contribute to the erection of the penis by compressing the deep dorsal vein of the penis as they are inserted into, and continuous with, the fascia of the penis.

The **Ischiocavernosus** (*Erector penis*) covers the crus penis. It is an elongated muscle, broader in the middle than at either end, and situated on the lateral boundary of the perineum. It *arises* by tendinous and fleshy fibers from the inner surface of the tuberosity of the ischium, behind the crus penis; and from the rami of the pubis and ischium on either side of the crus. From these points fleshy fibers succeed, and end in an aponeurosis which is *inserted* into the sides and under surface of the crus penis.

Action.—The Ischiocavernosus compresses the crus penis, and retards the return of the blood through the veins, and thus serves to maintain the organ erect.

Between the muscles just examined a triangular space exists, bounded medially by the Bulbocavernosus, laterally by the Ischiocavernosus, and behind by the Transversus perinæi superficialis; the floor is formed by the inferior fascia of the urogenital diaphragm. Running from behind forward in the space are the posterior scrotal vessels and nerves, and the perineal branch of the posterior femoral cutaneous nerve; the transverse perineal artery courses along its posterior boundary on the Transversus perinæi superficialis.

The Deep Fascia.—The deep fascia of the urogenital region forms an investment for the Transversus perinæi profundus and the Sphincter urethræ membranaceæ, but within it lie also the deep vessels and nerves of this part, the whole forming a transverse septum which is known as the **urogenital diaphragm**. From its shape it is usually termed the **triangular ligament**, and is stretched almost horizontally across the pubic arch, so as to close in the front part of the outlet of the pelvis. It consists of two dense membranous laminæ (Fig. 407), which are united along their posterior borders, but are separated in front by intervening structures. The superficial of these two layers, the **inferior fascia of the urogenital diaphragm**, is triangular in shape, and about 4 cm. in depth. Its apex is directed forward, and is separated from the arcuate pubic ligament by an oval opening for the transmission of the deep dorsal vein of the penis. Its lateral margins are attached on either side to the inferior rami of the pubis and ischium, above the crus penis. Its base is directed toward the rectum, and connected to the central tendinous point of the perineum. It is continuous with the deep layer of the superficial fascia behind the Transversus perinæi superficialis, and with the inferior layer of the diaphragmatic

part of the pelvic fascia. It is perforated, about 2.5 cm. below the symphysis pubis, by the urethra, the aperture for which is circular and about 6 mm. in diameter by the arteries to the bulb and the ducts of the bulbourethral glands close to the urethral orifice; by the deep arteries of the penis, one on either side close to the pubic arch and about halfway along the attached margin of the fascia; by the dorsal arteries and nerves of the penis near the apex of the fascia. Its base is also perforated by the perineal vessels and nerves, while between its apex and the arcuate pubic ligament the deep dorsal vein of the penis passes upward into the pelvis.

If the inferior fascia of the urogenital diaphragm be detached on either side, the following structures will be seen between it and the superior fascia: the deep dorsal vein of the penis; the membranous portion of the urethra; the *Transversus perinæi profundus* and *Sphincter urethræ membranaceæ* muscles; the bulbourethral glands and their ducts; the pudendal vessels and dorsal nerves of the penis; the arteries and nerves of the urethral bulb, and a plexus of veins.

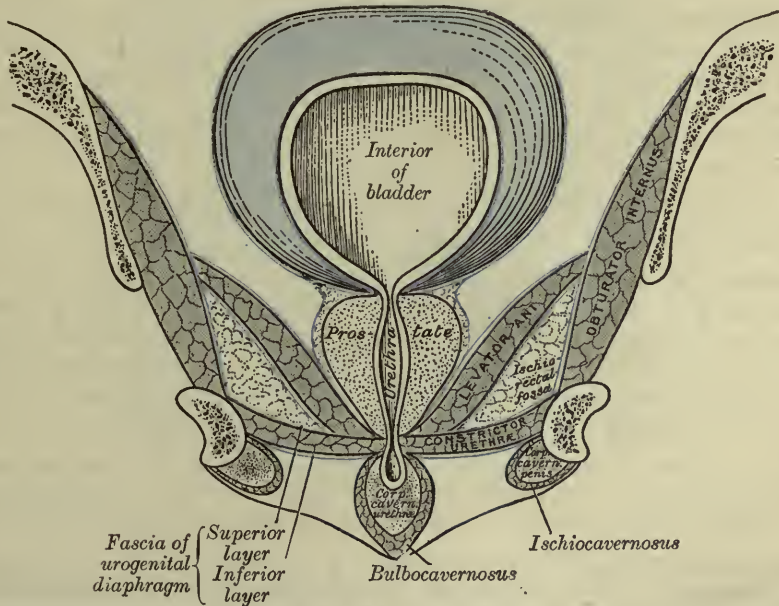


FIG. 407.—Coronal section of anterior part of pelvis, through the pubic arch. Seen from in front. (Diagrammatic.)

The superior fascia of the urogenital diaphragm is continuous with the obturator fascia and stretches across the pubic arch. If the obturator fascia be traced medially after leaving the Obturator internus muscle, it will be found attached by some of its deeper or anterior fibers to the inner margin of the pubic arch, while its superficial or posterior fibers pass over this attachment to become continuous with the superior fascia of the urogenital diaphragm. Behind, this layer of the fascia is continuous with the inferior fascia and with the fascia of Colles; in front it is continuous with the fascial sheath of the prostate, and is fused with the inferior fascia to form the transverse ligament of the pelvis.

The *Transversus perinæi profundus* arises from the inferior rami of the ischium and runs to the median line, where it interlaces in a tendinous raphé with its fellow of the opposite side. It lies in the same plane as the *Sphincter urethræ membranaceæ*; formerly the two muscles were described together as the *Constrictor urethræ*.

The *Sphincter urethræ membranaceæ* surrounds the whole length of the membranous portion of the urethra, and is enclosed in the fasciæ of the urogenital diaphragm. Its external fibers arise from the junction of the inferior rami of the pubis

and ischium to the extent of 1.25 to 2 cm., and from the neighboring fasciæ. They arch across the front of the urethra and bulbourethral glands, pass around the urethra, and behind it unite with the muscle of the opposite side, by means of a tendinous raphé. Its *innermost* fibers form a continuous circular investment for the membranous urethra.

Nerve Supply.—The perineal branch of the pudendal nerve supplies this group of muscles.

Actions.—The muscles of both sides act together as a sphincter, compressing the membranous portion of the urethra. During the transmission of fluids they, like the Bulbocavernosus, are relaxed, and only come into action at the end of the process to eject the last drops of the fluid.

2. B. The Muscles of the Urogenital Region in the Female (Fig. 408).

Transversus perinæi superficialis.

Ischiocavernosus.

Bulbocavernosus.

Transversus perinæi profundus.

Sphincter urethræ membranacea.

The **Transversus perinæi superficialis** (*Transversus perinæi*; *Superficial transverse perineal muscle*) in the female is a narrow muscular slip, which *arises* by a small tendon from the inner and forepart of the tuberosity of the ischium, and is inserted into the central tendinous point of the perineum, joining in this situation with the muscle of the opposite side, the Sphincter ani externus behind, and the Bulbocavernosus in front.

Action.—The simultaneous contraction of the two muscles serves to fix the central tendinous point of the perineum.

The **Bulbocavernosus** (*Sphincter vaginæ*) surrounds the orifice of the vagina. It covers the lateral parts of the vestibular bulbs, and is attached posteriorly to the central tendinous point of the perineum, where it blends with the Sphincter ani externus. Its fibers pass forward on either side of the vagina to be inserted into the corpora cavernosa clitoridis, a fasciculus crossing over the body of the organ so as to compress the deep dorsal vein.

Actions.—The Bulbocavernosus diminishes the orifice of the vagina. The anterior fibers contribute to the erection of the clitoris, as they are inserted into and are continuous with the fascia of the clitoris, compressing the deep dorsal vein during the contraction of the muscle.

The **Ischiocavernosus** (*Erector clitoridis*) is smaller than the corresponding muscle in the male. It covers the unattached surface of the crus clitoridis. It is an elongated muscle, broader at the middle than at either end, and situated on the side of the lateral boundary of the perineum. It *arises* by tendinous and fleshy fibers from the inner surface of the tuberosity of the ischium, behind the crus clitoridis; from the surface of the crus; and from the adjacent portion of the ramus of the ischium. From these points fleshy fibers succeed, and end in an aponeurosis, which is inserted into the sides and under surface of the crus clitoridis.

Actions.—The Ischiocavernosus compresses the crus clitoridis and retards the return of blood through the veins, and thus serves to maintain the organ erect.

The **fascia of the urogenital diaphragm** in the female is not so strong as in the male. It is attached to the pubic arch, its apex being connected with the arcuate pubic ligament. It is divided in the middle line by the aperture of the vagina, with the external coat of which it becomes blended, and in front of this is perforated by the urethra. Its posterior border is continuous, as in the male, with the deep layer of the superficial fascia around the Transversus perinæi superficialis.

Like the corresponding fascia in the male, it consists of two layers, between which are to be found the following structures: the deep dorsal vein of the clitoris, a portion of the urethra and the Constrictor urethra muscle, the larger vestibular

glands and their ducts; the internal pudendal vessels and the dorsal nerves of the clitoris; the arteries and nerves of the bulbi vestibuli, and a plexus of veins.

The **Transversus perinæi profundus** arises from the inferior rami of the ischium and runs across to the side of the vagina. The Sphincter urethræ membranaceæ (*Constrictor urethræ*), like the corresponding muscle on the male, consists of external

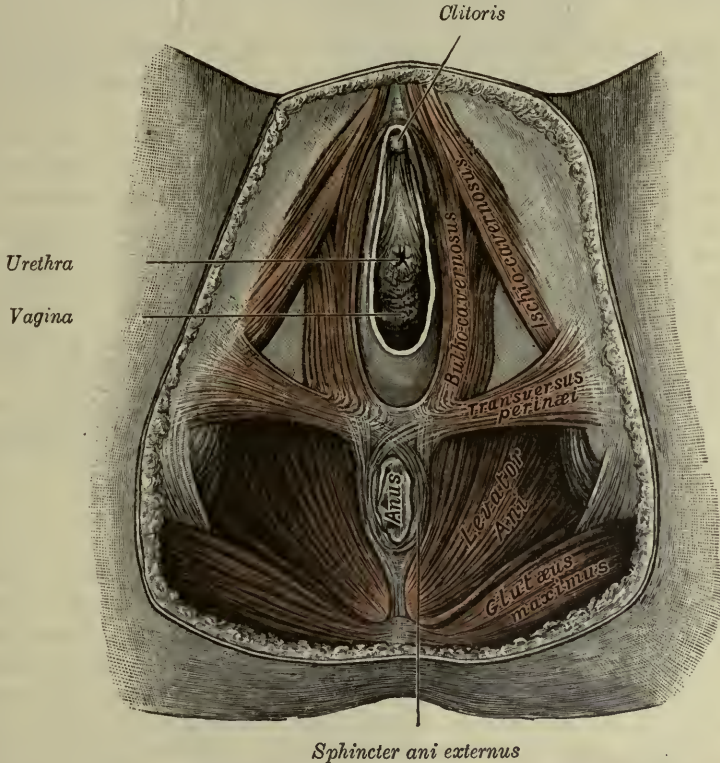


FIG. 403.—Muscles of the female perineum. (Modified from a drawing by Peter Thompson.)

and internal fibers. The *external* fibers arise on either side from the margin of the inferior ramus of the pubis. They are directed across the pubic arch in front of the urethra, and pass around it to blend with the muscular fibers of the opposite side, between the urethra and vagina. The *innermost* fibers encircle the lower end of the urethra.

Nerve Supply.—The muscles of this group are supplied by the perineal branch of the pudendal.

THE MUSCLES AND FASCIAE OF THE UPPER EXTREMITY.

The muscles of the upper extremity are divisible into groups, corresponding with the different regions of the limb.

- I. Muscles Connecting the Upper Extremity to the Vertebral Column.
- II. Muscles Connecting the Upper Extremity to the Anterior and Lateral Thoracic Walls.
- III. Muscles of the Shoulder.
- IV. Muscles of the Arm.
- V. Muscles of the Forearm.
- VI. Muscles of the Hand.

I. THE MUSCLES CONNECTING THE UPPER EXTREMITY TO THE VERTEBRAL COLUMN.

The muscles of this group are:

Trapezius.	Rhomboideus major.
Latissimus dorsi.	Rhomboideus minor.
Levator scapulæ.	

Superficial Fascia.—The superficial fascia of the back forms a layer of considerable thickness and strength, and contains a quantity of granular fat. It is continuous with the general superficial fascia.

Deep Fascia.—The deep fascia is a dense fibrous layer, attached above to the superior nuchal line of the occipital bone; in the middle line it is attached to the ligamentum nuchæ and supraspinal ligament, and to the spinous processes of all the vertebræ below the seventh cervical; laterally, in the neck it is continuous with the deep cervical fascia; over the shoulder it is attached to the spine of the scapula and to the acromion, and is continued downward over the Deltoideus to the arm; on the thorax it is continuous with the deep fascia of the axilla and chest, and on the abdomen with that covering the abdominal muscles; below, it is attached to the crest of the ilium.

The **Trapezius** (Fig. 409) is a flat, triangular muscle, covering the upper and back part of the neck and shoulders. It *arises* from the external occipital protuberance and the medial third of the superior nuchal line of the occipital bone, from the ligamentum nuchæ, the spinous process of the seventh cervical, and the spinous processes of all the thoracic vertebræ, and from the corresponding portion of the supraspinal ligament. From this origin, the superior fibers proceed downward and lateralward, the inferior upward and lateralward, and the middle horizontally; the superior fibers are inserted into the posterior border of the lateral third of the clavicle; the middle fibers into the medial margin of the acromion, and into the superior lip of the posterior border of the spine of the scapula; the inferior fibers converge near the scapula, and end in an aponeurosis, which glides over the smooth triangular surface on the medial end of the spine, to be inserted into a tubercle at the apex of this smooth triangular surface. At its occipital origin, the Trapezius is connected to the bone by a thin fibrous lamina, firmly adherent to the skin. At the middle it is connected to the spinous processes by a broad semi-elliptical aponeurosis, which reaches from the sixth cervical to the third thoracic vertebræ, and forms, with that of the opposite muscle, a tendinous ellipse. The rest of the muscle arises by numerous short tendinous fibers. The two Trapezius muscles together resemble a trapezium, or diamond-shaped quadrangle: two angles corresponding to the shoulders; a third to the occipital protuberance; and the fourth to the spinous process of the twelfth thoracic vertebra.

Variations.—The attachments to the dorsal vertebræ are often reduced and the lower ones are often wanting; the occipital attachment is often wanting; separation between cervical and dorsal portions is frequent. Extensive deficiencies and complete absence occur.

The clavicular *insertion* of this muscle varies in extent; it sometimes reaches as far as the middle of the clavicle, and occasionally may blend with the posterior edge of the Sternocleidomastoideus, or overlap it.

The **Latissimus dorsi** (Fig. 409) is a triangular, flat muscle, which covers the lumbar region and the lower half of the thoracic region, and is gradually contracted into a narrow fasciculus at its insertion into the humerus. It *arises* by tendinous fibers from the spinous processes of the lower six thoracic vertebræ and from the posterior layer of the lumbodorsal fascia (see page 397), by which it is attached to the spines of the lumbar and sacral vertebræ, to the supraspinal ligament, and to the posterior part of the crest of the ilium. It also *arises* by

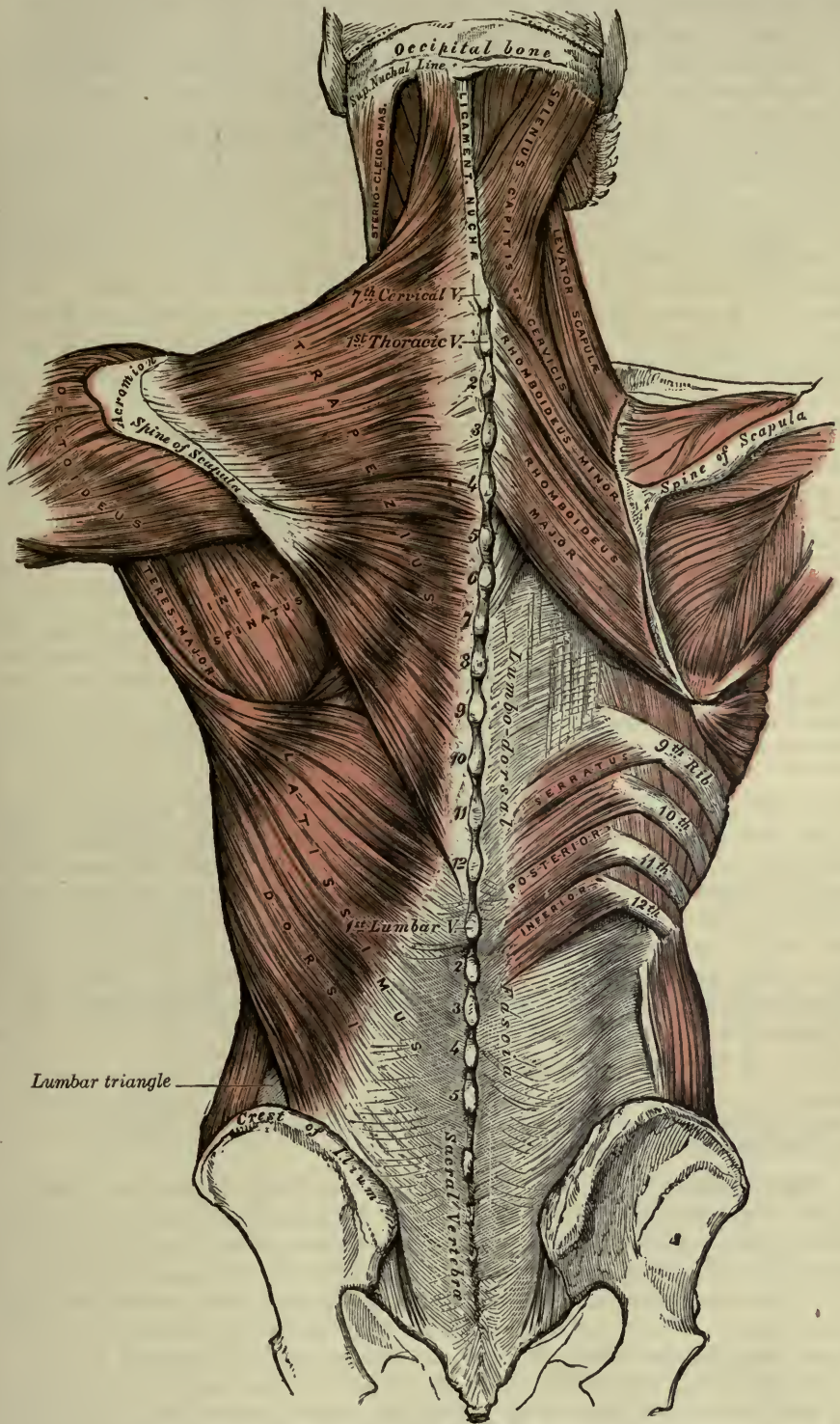


FIG 409.—Muscles connecting the upper extremity to the vertebral column.

muscular fibers from the external lip of the crest of the ilium lateral to the margin of the Sacrospinalis, and from the three or four lower ribs by fleshy digitations, which are interposed between similar processes of the *Obliquus abdominis externus* (Fig. 392, page 409). From this extensive origin the fibers pass in different directions, the upper ones horizontally, the middle obliquely upward, and the lower vertically upward, so as to converge and form a thick fasciculus, which crosses the inferior angle of the scapula, and usually receives a few fibers from it. The muscle curves around the lower border of the *Teres major*, and is twisted upon itself, so that the superior fibers become at first posterior and then inferior, and the vertical fibers at first anterior and then superior. It ends in a quadrilateral tendon, about 7 cm. long, which passes in front of the tendon of the *Teres major*, and is inserted into the bottom of the intertubercular groove of the humerus; its insertion extends higher on the humerus than that of the tendon of the *Pectoralis major*. The lower border of its tendon is united with that of the *Teres major*, the surfaces of the two being separated near their insertions by a bursa; another bursa is sometimes interposed between the muscle and the inferior angle of the scapula. The tendon of the muscle gives off an expansion to the deep fascia of the arm.

Variations.—The number of dorsal vertebræ to which it is attached vary from four to seven or eight; the number of costal attachments varies; muscle fibers may or may not reach the crest of the ilium.

A muscular slip, the **axillary arch**, varying from 7 to 10 cm. in length, and from 5 to 15 mm. in breadth, occasionally springs from the upper edge of the *Latissimus dorsi* about the middle of the posterior fold of the axilla, and crosses the axilla in front of the axillary vessels and nerves, to join the under surface of the tendon of the *Pectoralis major*, the *Coracobrachialis*, or the fascia over the *Biceps brachii*. This axillary arch crosses the axillary artery, just above the spot usually selected for the application of a ligature, and may mislead the surgeon during the operation. It is present in about 7 per cent. of subjects and may be easily recognized by the transverse direction of its fibers.

A fibrous slip usually passes from the lower border of the tendon of the *Latissimus dorsi*, near its insertion, to the long head of the *Triceps brachii*. This is occasionally muscular, and is the representative of the *Dorsoepitrochlearis brachii* of apes.

The lateral margin of the *Latissimus dorsi* is separated below from the *Obliquus externus abdominis* by a small triangular interval, the **lumbar triangle of Petit**, the base of which is formed by the iliac crest, and its floor by the *Obliquus internus abdominis*. Another triangle is situated behind the scapula. It is bounded above by the *Trapezius*, below by the *Latissimus dorsi*, and laterally by the vertebral border of the scapula; the floor is partly formed by the *Rhomboideus major*. If the scapula be drawn forward by folding the arms across the chest, and the trunk bent forward, parts of the sixth and seventh ribs and the interspace between them become subcutaneous and available for auscultation. The space is therefore known as the **triangle of auscultation**.

Nerves.—The *Trapezius* is supplied by the accessory nerve, and by branches from the third and fourth cervical nerves; the *Latissimus dorsi* by the sixth, seventh, and eighth cervical nerves through the thoracodorsal (long subscapular) nerve.

The ***Rhomboideus major*** (Fig. 409) *arises* by tendinous fibers from the spinous processes of the second, third, fourth, and fifth thoracic vertebræ and the supra-spinal ligament, and is *inserted* into a narrow tendinous arch, attached above to the lower part of the triangular surface at the root of the spine of the scapula; below to the inferior angle, the arch being connected to the vertebral border by a thin membrane. When the arch extends, as it occasionally does, only a short distance, the muscular fibers are inserted directly into the scapula.

The ***Rhomboideus minor*** (Fig. 409) *arises* from the lower part of the ligamentum nuchæ and from the spinous processes of the seventh cervical and first thoracic vertebræ. It is *inserted* into the base of the triangular smooth surface at the root of the spine of the scapula, and is usually separated from the *Rhomboideus major*

by a slight interval, but the adjacent margins of the two muscles are occasionally united.

Variations.—The vertebral and scapular attachments of the two muscles vary in extent. A small slip from the scapula to the occipital bone close to the minor occasionally occurs, the *Rhomboideus occipitalis muscle*.

The **Levator scapulæ** (*Levator anguli scapulæ*) (Fig. 469) is situated at the back and side of the neck. It *arises* by tendinous slips from the transverse processes of the atlas and axis and from the posterior tubercles of the transverse processes of the third and fourth cervical vertebræ. It is *inserted* into the vertebral border of the scapula, between the medial angle and the triangular smooth surface at the root of the spine.

Variations.—The number of vertebral attachments varies; a slip may extend to the occipital or mastoid, to the Trapezius, Scalene or Serratus anterior, or to the first or second rib. The muscle may be subdivided into several distinct parts from origin to insertion. *Levator claviculæ* from the transverse processes of one or two upper cervical vertebræ to the outer end of the clavicle corresponds to a muscle of lower animals. More or less union with the Serratus anterior.

Nerves.—The Rhomboidei are supplied by the dorsal scapular nerve from the fifth cervical; the Levator scapulæ by the third and fourth cervical nerves, and frequently by a branch from the dorsal scapular.

Actions.—The movements effected by the preceding muscles are numerous, as may be conceived from their extensive attachments. When the whole Trapezius is in action it retracts the scapula and braces back the shoulder; if the head be fixed, the upper part of the muscle will elevate the point of the shoulder, as in supporting weights; when the lower fibers contract they assist in depressing the scapula. The middle and lower fibers of the muscle rotate the scapula, causing elevation of the acromion. If the shoulders be fixed, the Trapezii, acting together, will draw the head directly backward; or if only one act, the head is drawn to the corresponding side.

When the Latissimus dorsi acts upon the humerus, it depresses and draws it backward, and at the same time rotates it inward. It is the muscle which is principally employed in giving a downward blow, as in felling a tree or in sabre practice. If the arm be fixed, the muscle may act in various ways upon the trunk; thus, it may raise the lower ribs and assist in forcible inspiration; or, if both arms be fixed, the two muscles may assist the abdominal muscles and Pectorales in suspending and drawing the trunk forward, as in climbing.

If the head be fixed, the Levator scapulæ raises the medial angle of the scapula; if the shoulder be fixed, the muscle inclines the neck to the corresponding side and rotates it in the same direction. The Rhomboidei carry the inferior angle backward and upward, thus producing a slight rotation of the scapula upon the side of the chest, the Rhomboideus major acting especially on the inferior angle of the scapula, through the tendinous arch by which it is inserted. The Rhomboidei, acting together with the middle and inferior fibers of the Trapezius, will retract the scapula.

II. THE MUSCLES CONNECTING THE UPPER EXTREMITY TO THE ANTERIOR AND LATERAL THORACIC WALLS.

The muscles of the anterior and lateral thoracic regions are:

Pectoralis major.
Pectoralis minor.

Subclavius.
Serratus anterior.

Superficial Fascia.—The superficial fascia of the anterior thoracic region is continuous with that of the neck and upper extremity above, and of the abdomen below. It encloses the mamma and gives off numerous septa which pass into the gland, supporting its various lobes. From the fascia over the front of the mamma, fibrous processes pass forward to the integument and papilla; these were called by Sir A. Cooper the *ligamenta suspensoria*.

Pectoral Fascia.—The pectoral fascia is a thin lamina, covering the surface of the Pectoralis major, and sending numerous prolongations between its fasciculi: it is attached, in the middle line, to the front of the sternum; above, to the clavicle; laterally and below it is continuous with the fascia of the shoulder, axilla, and thorax. It is very thin over the upper part of the Pectoralis major, but thicker

in the interval between it and the *Latissimus dorsi*, where it closes in the axillary space and forms the **axillary fascia**; it divides at the lateral margin of the *Latis-simus dorsi* into two layers, one of which passes in front of, and the other behind it; these proceed as far as the spinous processes of the thoracic vertebræ, to which they are attached. As the fascia leaves the lower edge of the *Pectoralis major* to cross the floor of the axilla it sends a layer upward under cover of the muscle; this lamina splits to envelop the *Pectoralis minor*, at the upper edge of which it is continuous with the coracoclavicular fascia. The hollow of the armpit, seen when the arm is abducted, is produced mainly by the traction of this fascia on the axillary floor, and hence the lamina is sometimes named the **suspensory ligament of the axilla**. At the lower part of the thoracic region the deep fascia is well-developed, and is continuous with the fibrous sheaths of the *Recti abdominis*.

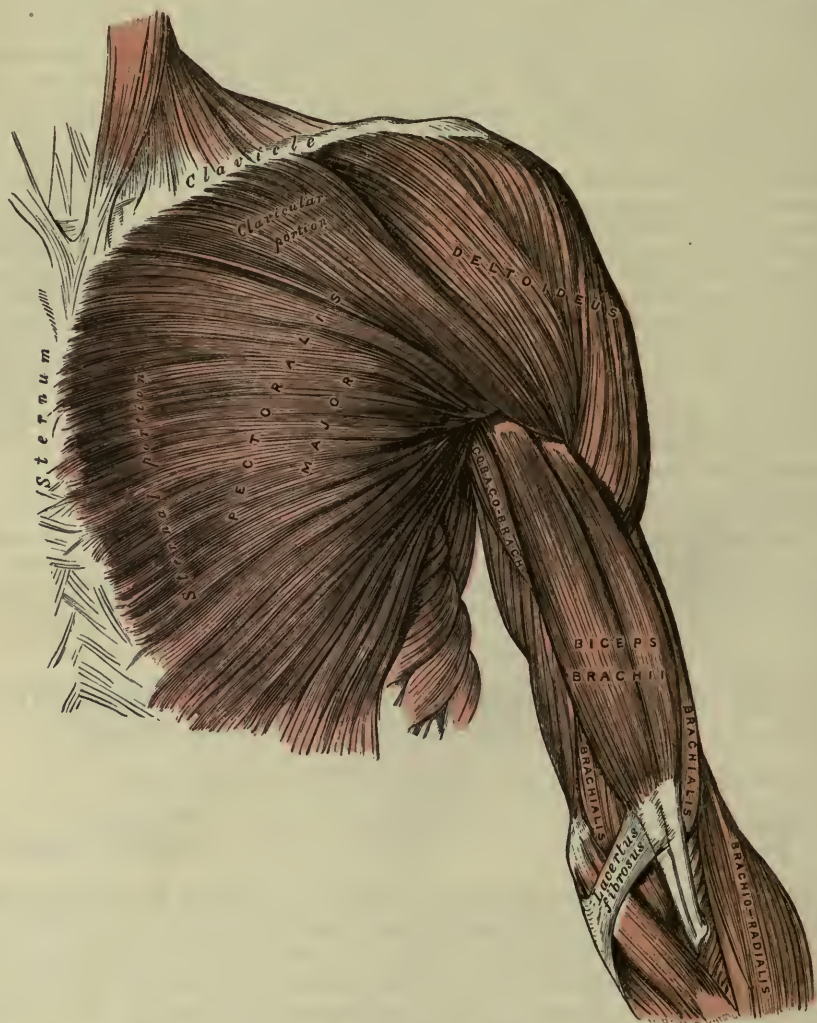

FIG. 410.—Superficial muscles of the chest and front of the arm.

The **Pectoralis major** (Fig. 410) is a thick, fan-shaped muscle, situated at the upper and forepart of the chest. It *arises* from the anterior surface of the sternal half of the clavicle; from half the breadth of the anterior surface of the sternum, as low down as the attachment of the cartilage of the sixth or seventh rib; from the

cartilages of all the true ribs, with the exception, frequently, of the first or seventh, or both, and from the aponeurosis of the *Obliquus externus abdominis*. From this extensive origin the fibers converge toward their insertion; those arising from the clavicle pass obliquely downward and lateralward, and are usually separated from the rest by a slight interval; those from the lower part of the sternum, and the cartilages of the lower true ribs, run upward and lateralward; while the middle fibers pass horizontally. They all end in a flat tendon, about 5 cm. broad, which is *inserted* into the crest of the greater tubercle of the humerus. This tendon consists of two laminae, placed one in front of the other, and usually blended together below. The anterior lamina, the thicker, receives the clavicular and the uppermost sternal fibers; they are inserted in the same order as that in which they arise: that is to say, the most lateral of the clavicular fibers are inserted at the upper part of the anterior lamina; the uppermost sternal fibers pass down to the lower part of the lamina which extends as low as the tendon of the *Deltoides* and joins with it. The posterior lamina of the tendon receives the attachment of the greater part of the sternal portion and the deep fibers, *i. e.*, those from the costal cartilages. These deep fibers, and particularly those from the lower costal cartilages, ascend the higher, turning backward successively behind the superficial and upper ones, so that the tendon appears to be twisted. The posterior lamina reaches higher on the humerus than the anterior one, and from it an expansion is given off which covers the intertubercular groove and blends with the capsule of the shoulder-joint. From the deepest fibers of this lamina at its insertion an expansion is given off which lines the intertubercular groove, while from the lower border of the tendon a third expansion passes downward to the fascia of the arm.

Variations.—The more frequent variations are greater or less extent of attachment to the ribs and sternum, varying size of the abdominal part or its absence, greater or less extent of separation of sternocostal and clavicular parts, fusion of clavicular part with deltoid, decussation in front of the sternum. Deficiency or absence of the sternocostal part is not uncommon. Absence of the clavicular part is less frequent. Rarely the whole muscle is wanting.

Costocoracoideus is a muscular band occasionally found arising from the ribs or aponeurosis of the External oblique between the *Pectoralis major* and *Latissimus dorsi* and inserted into the coracoid process.

Chondro-epitrochlearis is a muscular slip occasionally found arising from the costal cartilages or from the aponeurosis of the External oblique below the *Pectoralis major* or from the *Pectoralis major* itself. The insertion is variable on the inner side of the arm to fascia, intermuscular septum or internal condyle.

Sternalis, in front of the sternal end of the *Pectoralis major* parallel to the margin of the sternum. It is supplied by the anterior thoracic nerves and is probably a misplaced part of the pectoralis.

Coracoclavicular Fascia (*fascia coracoclavicularis*; *costocoracoid membrane*; *claviopectoral fascia*).—The coracoclavicular fascia is a strong fascia situated under cover of the clavicular portion of the *Pectoralis major*. It occupies the interval between the *Pectoralis minor* and *Subclavius*, and protects the axillary vessels and nerves. Traced upward, it splits to enclose the *Subclavius*, and its two layers are attached to the clavicle, one in front of and the other behind the muscle; the latter layer fuses with the deep cervical fascia and with the sheath of the axillary vessels. Medially, it blends with the fascia covering the first two intercostal spaces, and is attached also to the first rib medial to the origin of the *Subclavius*. Laterally, it is very thick and dense, and is attached to the coracoid process. The portion extending from the first rib to the coracoid process is often whiter and denser than the rest, and is sometimes called the **costocoracoid ligament**. Below this it is thin, and at the upper border of the *Pectoralis minor* it splits into two layers to invest the muscle; from the lower border of the *Pectoralis minor* it is continued downward to join the axillary fascia, and lateralward to join the fascia over the short head of the *Biceps brachii*. The coracoclavicular fascia is pierced by the cephalic vein, thoracoacromial artery and vein, and external anterior thoracic nerve.

The **Pectoralis minor** (Fig. 411) is a thin, triangular muscle, situated at the upper part of the thorax, beneath the Pectoralis major. It *arises* from the upper margins and outer surfaces of the third, fourth, and fifth ribs, near their cartilage and from the aponeuroses covering the Intercostalis; the fibers pass upward and lateralward and converge to form a flat tendon, which is inserted into the medial border and upper surface of the coracoid process of the scapula.

Variations.—Origin from second, third and fourth or fifth ribs. The tendon of insertion may extend over the coracoid process to the greater tubercle. May be split into several parts. Absence rare.

Pectoralis minimus, first rib-cartilage to coracoid process. Rare.

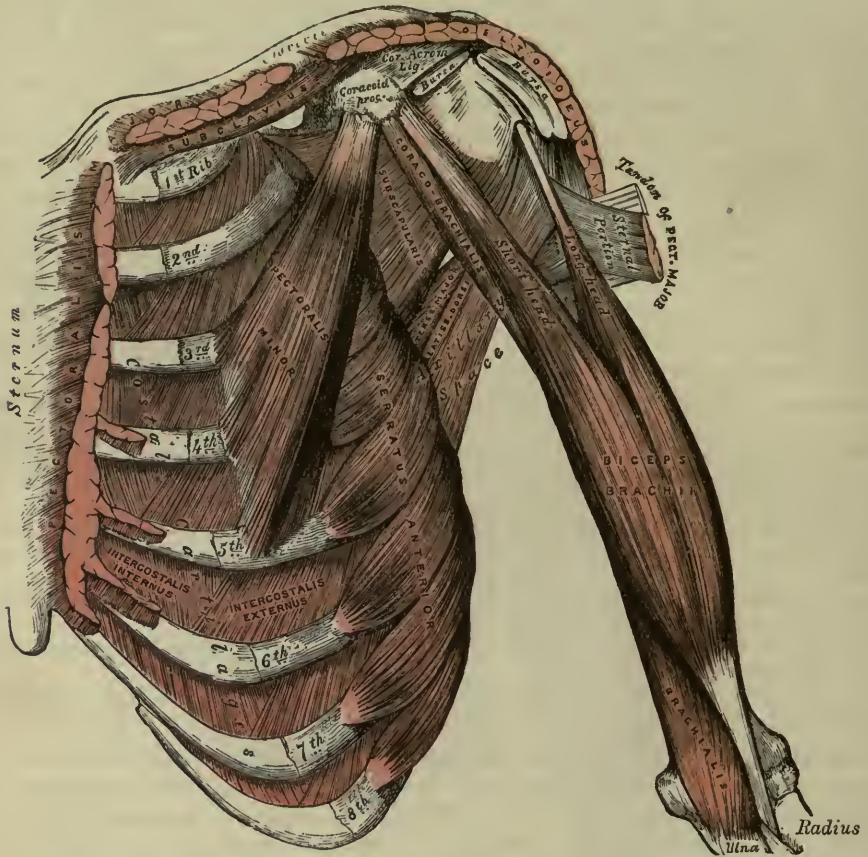


FIG. 411.—Deep muscles of the chest and front of the arm, with the boundaries of the axilla.

The **Subclavius** (Fig. 411) is a small triangular muscle, placed between the clavicle and the first rib. It *arises* by a short, thick tendon from the first rib and its cartilage at their junction, in front of the costoclavicular ligament; the fleshy fibers proceed obliquely upward and lateralward, to be *inserted* into the groove on the under surface of the clavicle between the costoclavicular and conoid ligaments.

Variations.—Insertion into coracoid process instead of clavicle or into both clavicle and coracoid process. *Sternoscapular* fasciculus to the upper border of scapula. *Sternoclavicularis* from manubrium to clavicle between Pectoralis major and coracoclavicular fascia.

The **Serratus anterior** (*Serratus magnus*) (Fig. 411) is a thin muscular sheet, situated between the ribs and the scapula at the upper and lateral part of

the chest. It *arises* by fleshy digitations from the outer surfaces and superior borders of the upper eight or nine ribs, and from the aponeuroses covering the intervening Intercostales. Each digitation (except the first) arises from the corresponding rib; the first springs from the first and second ribs; and from the fascia covering the first intercostal space. From this extensive attachment the fibers pass backward, closely applied to the chest-wall, and reach the vertebral border of the scapula, and are inserted into its ventral surface in the following manner. The first digitation is inserted into a triangular area on the ventral surface of the medial angle. The next two digitations spread out to form a thin, triangular sheet, the base of which is directed backward and is inserted into nearly the whole length of the ventral surface of the vertebral border. The lower five or six digitations converge to form a fan-shaped mass, the apex of which is inserted, by muscular and tendinous fibers, into a triangular impression on the ventral surface of the inferior angle. The lower four slips interdigitate at their origins with the upper five slips of the *Obliquus externus abdominis*.

Variations.—Attachment to tenth rib. Absence of attachments to first rib, to one or more of the lower ribs. Division into three parts; absence or defect of middle part. Union with *Levator scapulæ*, *External intercostals* or *External oblique*.

Nerves.—The *Pectoralis major* is supplied by the medial and lateral anterior thoracic nerves; through these nerves the muscle receives filaments from all the spinal nerves entering into the formation of the brachial plexus; the *Pectoralis minor* receives its fibers from the eighth cervical and first thoracic nerves through the medial anterior thoracic nerve. The *Subclavius* is supplied by a filament from the fifth and sixth cervical nerves; the *Serratus anterior* is supplied by the long thoracic, which is derived from the fifth, sixth, and seventh cervical nerves.

Actions.—If the arm has been raised by the *Deltoides*, the *Pectoralis major* will, conjointly with the *Latissimus dorsi* and *Teres major*, depress it to the side of the chest. If acting alone, it adducts and draws forward the arm, bringing it across the front of the chest, and at the same time rotates it inward. The *Pectoralis minor* depresses the point of the shoulder, drawing the scapula downward and medialward toward the thorax, and throwing the inferior angle backward. The *Subclavius* depresses the shoulder, carrying it downward and forward. When the arms are fixed, all three of these muscles act upon the ribs; drawing them upward and expanding the chest, and thus becoming very important agents in forced inspiration. The *Serratus anterior*, as a whole, carries the scapula forward, and at the same time raises the vertebral border of the bone. It is therefore concerned in the action of pushing. Its lower and stronger fibers move forward the lower angle and assist the *Trapezius* in rotating the bone at the sternoclavicular joint, and thus assist this muscle in raising the acromion and supporting weights upon the shoulder. It is also an assistant to the *Deltoides* in raising the arm, inasmuch as during the action of this latter muscle it fixes the scapula and so steadies the glenoid cavity on which the head of the humerus rotates. After the *Deltoides* has raised the arm to a right angle with the trunk, the *Serratus anterior* and the *Trapezius*, by rotating the scapula, raise the arm into an almost vertical position. It is possible that when the shoulders are fixed the lower fibers of the *Serratus anterior* may assist in raising and everting the ribs; but it is not the important inspiratory muscle it was formerly believed to be.

III. THE MUSCLES AND FASCIÆ OF THE SHOULDER.

In this group are included:

<i>Deltoides</i> .	<i>Infraspinatus</i> .
<i>Subscapularis</i> .	<i>Teres minor</i> .
<i>Supraspinatus</i> .	<i>Teres major</i> .

Deep Fascia.—The deep fascia covering the *Deltoides* invests the muscle, and sends numerous septa between its fasciculi. In front it is continuous with the fascia covering the *Pectoralis major*; behind, where it is thick and strong, with that covering the *Infraspinatus*; above, it is attached to the clavicle, the acromion, and the spine of the scapula; below, it is continuous with the deep fascia of the arm.

The *Deltoides* (*Deltoid muscle*) (Fig. 410) is a large, thick, triangular muscle, which covers the shoulder-joint in front, behind, and laterally. It *arises* from the anterior

border and upper surface of the lateral third of the clavicle; from the lateral margin and upper surface of the acromion, and from the lower lip of the posterior border of the spine of the scapula, as far back as the triangular surface at its medial end. From this extensive origin the fibers converge toward their insertion, the middle passing vertically, the anterior obliquely backward and lateralward, the posterior obliquely forward and lateralward; they unite in a thick tendon, which is inserted into the deltoid prominence on the middle of the lateral side of the body of the humerus. At its *insertion* the muscle gives off an expansion to the deep fascia of the arm. This muscle is remarkably coarse in texture, and the arrangement of its fibers is somewhat peculiar; the central portion of the muscle—that is to say, the part arising from the acromion—consists of oblique fibers; these arise in a bipenniform manner from the sides of the tendinous intersections, generally four in number, which are attached above to the acromion and pass downward parallel to one another in the substance of the muscle. The oblique fibers thus formed are inserted into similar tendinous intersections, generally three in number, which pass upward from the insertion of the muscle and alternate with the descending septa. The portions of the muscle arising from the clavicle and spine of the scapula are not arranged in this manner, but are inserted into the margins of the inferior tendon.

Variations.—Large variations uncommon. More or less splitting common. Continuation into the Trapezius; fusion with the Pectoralis major; additional slips from the vertebral border of the scapula, infraspinous fascia and axillary border of scapula not uncommon. Insertion varies in extent or rarely is prolonged to origin of Brachioradialis.

Nerves.—The Deltoides is supplied by the fifth and sixth cervical through the axillary nerve.

Actions.—The Deltoides raises the arm from the side, so as to bring it at right angles with the trunk. Its anterior fibers, assisted by the Pectoralis major, draw the arm forward; and its posterior fibers, aided by the Teres major and Latissimus dorsi, draw it backward.

Subscapular Fascia (*fascia subscapularis*).—The subscapular fascia is a thin membrane attached to the entire circumference of the subscapular fossa, and affording attachment by its deep surface to some of the fibers of the Subscapularis.

The **Subscapularis** (Fig. 411) is a large triangular muscle which fills the subscapular fossa, and *arises* from its medial two-thirds and from the lower two-thirds of the groove on the axillary border of the bone. Some fibers *arise* from tendinous laminae which intersect the muscle and are attached to ridges on the bone; others from an aponeurosis, which separates the muscle from the Teres major and the long head of the Triceps brachii. The fibers pass lateralward, and, gradually converging, end in a tendon which is *inserted* into the lesser tubercle of the humerus and the front of the capsule of the shoulder-joint. The tendon of the muscle is separated from the neck of the scapula by a large bursa, which communicates with the cavity of the shoulder-joint through an aperture in the capsule.

Nerves.—The Subscapularis is supplied by the fifth and sixth cervical nerves through the upper and lower subscapular nerves.

Actions.—The Subscapularis rotates the head of the humerus inward; when the arm is raised, it draws the humerus forward and downward. It is a powerful defence to the front of the shoulder-joint, preventing displacement of the head of the humerus.

Supraspinatous Fascia (*fascia supraspinata*).—The supraspinatous fascia completes the osseofibrous case in which the Supraspinatus muscle is contained; it affords attachment, by its deep surface, to some of the fibers of the muscle. It is thick medially, but thinner laterally under the coracoacromial ligament.

The **Supraspinatus** (Fig. 412) occupies the whole of the supraspinatous fossa, *arising* from its medial two-thirds, and from the strong supraspinatous fascia. The muscular fibers converge to a tendon, which crosses the upper part of the

shoulder-joint, and is *inserted* into the highest of the three impressions on the greater tubercle of the humerus; the tendon is intimately adherent to the capsule of the shoulder-joint.

Infraspinatus Fascia (*fascia infraspinata*).—The infraspinatus fascia is a dense fibrous membrane, covering the Infraspinatus muscle and fixed to the circumference of the infraspinatus fossa; it affords attachment, by its deep surface, to some fibers of that muscle. It is intimately attached to the deltoid fascia along the overlapping border of the Deltoides.

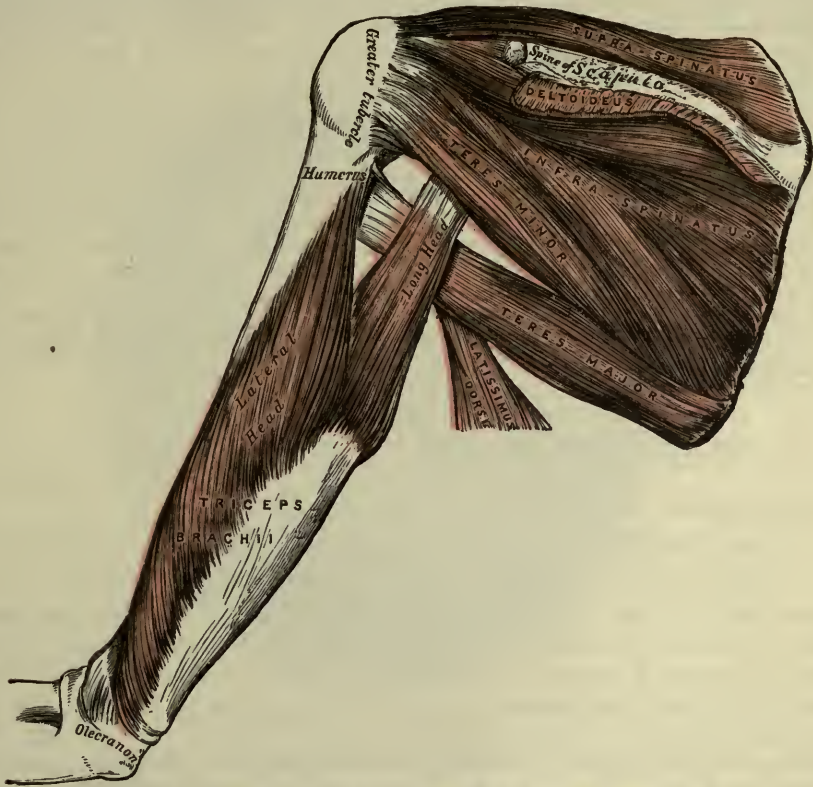

FIG. 412.—Muscles on the dorsum of the scapula, and the Triceps brachii.

The **Infraspinatus** (Fig. 412) is a thick triangular muscle, which occupies the chief part of the infraspinatus fossa; it *arises* by fleshy fibers from its medial two-thirds, and by tendinous fibers from the ridges on its surface; it also arises from the infraspinatus fascia which covers it, and separates it from the Teretes major and minor. The fibers converge to a tendon, which glides over the lateral border of the spine of the scapula, and, passing across the posterior part of the capsule of the shoulder-joint, is *inserted* into the middle impression on the greater tubercle of the humerus. The tendon of this muscle is sometimes separated from the capsule of the shoulder-joint by a bursa, which may communicate with the joint cavity.

The **Teres minor** (Fig. 412) is a narrow, elongated muscle, which *arises* from the dorsal surface of the axillary border of the scapula for the upper two-thirds of its extent, and from two aponeurotic laminae, one of which separates it from the Infraspinatus, the other from the Teres major. Its fibers run obliquely upward and lateralward; the upper ones end in a tendon which is *inserted* into the lowest of the three impressions on the greater tubercle of the humerus; the lowest fibers are *inserted* directly into the humerus immediately below this impression. The

tendon of this muscle passes across, and is united with, the posterior part of the capsule of the shoulder-joint.

Variations.—It is sometimes inseparable from the Infraspinatus.

The **Teres major** (Fig. 412) is a thick but somewhat flattened muscle, which *arises* from the oval area on the dorsal surface of the inferior angle of the scapula, and from the fibrous septa interposed between the muscle and the Teres minor and Infraspinatus; the fibers are directed upward and lateralward, and end in a flat tendon, about 5 cm. long, which is *inserted* into the crest of the lesser tubercle of the humerus. The tendon, at its insertion, lies behind that of the Latissimus dorsi, from which it is separated by a bursa, the two tendons being, however, united along their lower borders for a short distance.

Nerves.—The Supraspinatus and Infraspinatus are supplied by the fifth and sixth cervical nerves through the suprascapular nerve; the Teres minor, by the fifth cervical, through the axillary; and the Teres major, by the fifth and sixth cervical, through the lowest subscapular.

Actions.—The Supraspinatus assists the Deltoideus in raising the arm from the side of the trunk and fixes the head of the humerus in the glenoid cavity. The Infraspinatus and Teres minor rotate the head of the humerus outward; they also assist in carrying the arm backward. One of the most important uses of these three muscles is to protect the shoulder-joint, the Supraspinatus supporting it above, and the Infraspinatus and Teres minor behind. The Teres major assists the Latissimus dorsi in drawing the previously raised humerus downward and backward, and in rotating it inward; when the arm is fixed it may assist the Pectorales and the Latissimus dorsi in drawing the trunk forward.

IV. THE MUSCLES AND FASCIÆ OF THE ARM.

The muscles of the arm are:

Coracobrachialis.

Biceps brachii.

Brachialis.

Triceps brachii.

Brachial Fascia (*fascia brachii; deep fascia of the arm*).—The brachial fascia is continuous with that covering the Deltoideus and the Pectoralis major, by means of which it is attached, above, to the clavicle, acromion, and spine of the scapula; it forms a thin, loose, membranous sheath for the muscles of the arm, and sends septa between them; it is composed of fibers disposed in a circular or spiral direction, and connected together by vertical and oblique fibers. It differs in thickness at different parts, being thin over the Biceps brachii, but thicker where it covers the Triceps brachii, and over the epicondyles of the humerus: it is strengthened by fibrous aponeuroses, derived from the Pectoralis major and Latissimus dorsi medially, and from the Deltoideus laterally. On either side it gives off a strong intermuscular septum, which is attached to the corresponding supracondylar ridge and epicondyle of the humerus. The **lateral intermuscular septum** extends from the lower part of the crest of the greater tubercle, along the lateral supracondylar ridge, to the lateral epicondyle; it is blended with the tendon of the Deltoideus, gives attachment to the Triceps brachii behind, to the Brachialis, Brachioradialis, and Extensor carpi radialis longus in front, and is perforated by the radial nerve and profunda branch of the brachial artery. The **medial intermuscular septum**, thicker than the preceding, extends from the lower part of the crest of the lesser tubercle of the humerus below the Teres major, along the medial supracondylar ridge to the medial epicondyle; it is blended with the tendon of the Coracobrachialis, and affords attachment to the Triceps brachii behind and the Brachialis in front. It is perforated by the ulnar nerve, the superior ulnar collateral artery, and the posterior branch of the inferior ulnar collateral artery. At the elbow, the deep fascia is attached to the epicondyles of the humerus and the olecranon of the ulna, and is continuous with the deep fascia of the forearm.

Just below the middle of the arm, on its medial side, is an oval opening in the deep fascia, which transmits the basilic vein and some lymphatic vessels.

The **Coracobrachialis** (Fig. 411), the smallest of the three muscles in this region, is situated at the upper and medial part of the arm. It *arises* from the apex of the coracoid process, in common with the short head of the Biceps brachii, and from the intermuscular septum between the two muscles; it is *inserted* by means of a flat tendon into an impression at the middle of the medial surface and border of the body of the humerus between the origins of the Triceps brachii and Brachialis. It is perforated by the musculocutaneous nerve.

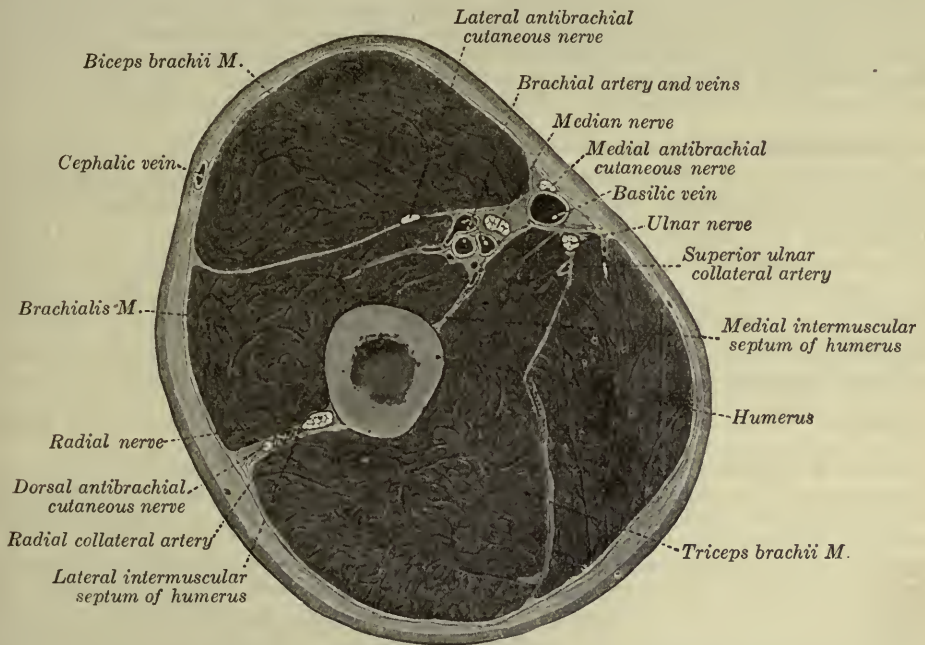


FIG. 413.—Cross-section through the middle of upper arm. (Eycleshymer and Schoemaker.¹)

Variations.—A bony head may reach the medial epicondyle; a short head more rarely found may insert into the lesser tubercle.

The **Biceps brachii** (*Biceps*; *Biceps flexor cubiti*) (Fig. 411) is a long fusiform muscle, placed on the front of the arm, and *arising* by two heads, from which circumstance it has received its name. The **short head** *arises* by a thick flattened tendon from the apex of the coracoid process, in common with the Coracobrachialis. The **long head** *arises* from the supraglenoid tuberosity at the upper margin of the glenoid cavity, and is continuous with the glenoidal labrum. This tendon, enclosed in a special sheath of the synovial membrane of the shoulder-joint, arches over the head of the humerus; it emerges from the capsule through an opening close to the humeral attachment of the ligament, and descends in the intertubercular groove; it is retained in the groove by the transverse humeral ligament and by a fibrous prolongation from the tendon of the Pectoralis major. Each tendon is succeeded by an elongated muscular belly, and the two bellies, although closely applied to each other, can readily be separated until within about 7.5 cm. of the elbow-joint. Here they end in a flattened tendon, which is inserted into the rough posterior portion of the tuberosity of the radius, a bursa being interposed between the tendon and the front part of the tuberosity. As the tendon of the muscle approaches the radius it is twisted upon itself, so that its anterior surface becomes

¹ A Cross-section Anatomy, New York, 1911.

lateral and is applied to the tuberosity of the radius at its insertion. Opposite the bend of the elbow the tendon gives off, from its medial side, a broad aponeurosis, the *lacertus fibrosus* (*bicipital fascia*) which passes obliquely downward and medialward across the brachial artery, and is continuous with the deep fascia covering the origins of the Flexor muscles of the forearm (Fig. 410).

Variations.—A third head (10 per cent.) to the Biceps brachii is occasionally found, arising at the upper and medial part of the Brachialis, with the fibers of which it is continuous, and inserted into the lacertus fibrosus and medial side of the tendon of the muscle. In most cases this additional slip lies behind the brachial artery in its course down the arm. In some instances the third head consists of two slips, which pass down, one in front of and the other behind the artery, concealing the vessel in the lower half of the arm. More rarely a fourth head occurs arising from the outer side of the humerus, from the intertubercular groove, or from the greater tubercle. Other heads are occasionally found. Slips sometimes pass from the inner border of the muscle over the brachial artery to the medial intermuscular septum, or the medial epicondyle; more rarely to the Pronator teres or Brachialis. The long head may be absent or arise from the intertubercular groove.

The **Brachialis** (*Brachialis anticus*) (Fig. 411) covers the front of the elbow-joint and the lower half of the humerus. It *arises* from the lower half of the front of the humerus, commencing above at the insertion of the Deltoideus, which it embraces by two angular processes. Its origin extends below to within 2.5 cm. of the margin of the articular surface. It also arises from the intermuscular septa, but more extensively from the medial than the lateral; it is separated from the lateral below by the Brachioradialis and Extensor carpi radialis longus. Its fibers converge to a thick tendon, which is *inserted* into the tuberosity of the ulna and the rough depression on the anterior surface of the coronoid process.

Variations.—Occasionally doubled; additional slips to the Supinator, Pronator teres, Biceps, lacertus fibrosus, or radius are more rarely found.

Nerves.—The Coracobrachialis, Biceps brachii and Brachialis are supplied by the musculocutaneous nerve; the Brachialis usually receives an additional filament from the radial. The Coracobrachialis receives its supply primarily from the seventh cervical, the Biceps brachii and Brachialis from the fifth and sixth cervical nerves.

Actions.—The Coracobrachialis draws the humerus forward and medialward, and at the same time assists in retaining the head of the bone in contact with the glenoid cavity. The Biceps brachii is a flexor of the elbow and, to a less extent, of the shoulder; it is also a powerful supinator, and serves to render tense the deep fascia of the forearm by means of the lacertus fibrosus given off from its tendon. The Brachialis is a flexor of the forearm, and forms an important defence to the elbow-joint. When the forearm is fixed, the Biceps brachii and Brachialis flex the arm upon the forearm, as in efforts of climbing.

The **Triceps brachii** (*Triceps*; *Triceps extensor cubiti*) (Fig. 412) is situated on the back of the arm, extending the entire length of the dorsal surface of the humerus. It is of large size, and arises by three heads (long, lateral, and medial), hence its name.

The **long head** *arises* by a flattened tendon from the infraglenoid tuberosity of the scapula, being blended at its upper part with the capsule of the shoulder-joint; the muscular fibers pass downward between the two other heads of the muscle, and join with them in the tendon of insertion.

The **lateral head** *arises* from the posterior surface of the body of the humerus, between the insertion of the Teres minor and the upper part of the groove for the radial nerve, and from the lateral border of the humerus and the lateral intermuscular septum; the fibers from this origin converge toward the tendon of insertion.

The **medial head** *arises* from the posterior surface of the body of the humerus, below the groove for the radial nerve; it is narrow and pointed above, and extends from the insertion of the Teres major to within 2.5 cm. of the trochlea: it also arises from the medial border of the humerus and from the back of the whole length of the medial intermuscular septum. Some of the fibers are directed downward to the olecranon, while others converge to the tendon of insertion.

The **tendon of the Triceps brachii** begins about the middle of the muscle: it con-

sists of two aponeurotic laminae, one of which is subcutaneous and covers the back of the lower half of the muscle; the other is more deeply seated in the substance of the muscle. After receiving the attachment of the muscular fibers, the two lamellae join together above the elbow, and are inserted, for the most part, into the posterior portion of the upper surface of the olecranon; a band of fibers is, however, continued downward, on the lateral side, over the Anconæus, to blend with the deep fascia of the forearm.

The long head of the Triceps brachii descends between the Teres minor and Teres major, dividing the triangular space between these two muscles and the humerus into two smaller spaces, one triangular, the other quadrangular (Fig. 412). The triangular space contains the scapular circumflex vessels; it is bounded by the Teres minor above, the Teres major below, and the scapular head of the Triceps laterally. The quadrangular space transmits the posterior humeral circumflex vessels and the axillary nerve; it is bounded by the Teres minor and capsule of the shoulder-joint above, the Teres major below, the long head of the Triceps brachii medially, and the humerus laterally.

Variations.—A fourth head from the inner part of the humerus; a slip between Triceps and Latissimus dorsi corresponding to the *Dorso-epitrochlearis*.

The **Subanconæus** is the name given to a few fibers which spring from the deep surface of the lower part of the Triceps brachii, and are inserted into the posterior ligament and synovial membrane of the elbow-joint.

Nerves.—The Triceps brachii is supplied by the seventh and eighth cervical nerves through the radial nerve.

Actions.—The Triceps brachii is the great extensor muscle of the forearm, and is the direct antagonist of the Biceps brachii and Brachialis. When the arm is extended, the long head of the muscle may assist the Teres major and Latissimus dorsi in drawing the humerus backward and in adducting it to the thorax. The long head supports the under part of the shoulder-joint. The Subanconæus draws up the synovial membrane of the elbow-joint during extension of the forearm.

V. THE MUSCLES AND FASCIAE OF THE FOREARM.

Antibrachial Fascia (*fascia antibrachii; deep fascia of the forearm*).—The antibrachial fascia continuous above with the brachial fascia, is a dense, membranous investment, which forms a general sheath for the muscles in this region; it is attached, *behind*, to the olecranon and dorsal border of the ulna, and gives off from its deep surface numerous intermuscular septa, which enclose each muscle separately. Over the Flexor tendons as they approach the wrist it is especially thickened, and forms the volar carpal ligament. This is continuous with the transverse carpal ligament, and forms a sheath for the tendon of the Palmaris longus which passes over the transverse carpal ligament to be inserted into the palmar aponeurosis. *Behind*, near the wrist-joint, it is thickened by the addition of many transverse fibers, and forms the dorsal carpal ligament. It is much thicker on the dorsal than on the volar surface, and at the lower than at the upper part of the forearm, and is strengthened above by tendinous fibers derived from the Biceps brachii in front, and from the Triceps brachii behind. It gives origin to muscular fibers, especially at the upper part of the medial and lateral sides of the forearm, and forms the boundaries of a series of cone-shaped cavities, in which the muscles are contained. Besides the vertical septa separating the individual muscles, transverse septa are given off both on the volar and dorsal surfaces of the forearm, separating the deep from the superficial layers of muscles. Apertures exist in the fascia for the passage of vessels and nerves; one of these apertures of large size, situated at the front of the elbow, serves for the passage of a communicating branch between the superficial and deep veins.

The antibrachial or forearm muscles may be divided into a **volar** and a **dorsal** group.

1. The Volar Antibrachial Muscles.

These muscles are divided for convenience of description into two groups, superficial and deep.

The Superficial Group (Fig. 414).

Pronator teres.

Palmaris longus.

Flexor carpi radialis.

Flexor carpi ulnaris.

Flexor digitorum sublimis.

The muscles of this group take origin from the medial epicondyle of the humerus by a common tendon; they receive additional fibers from the deep fascia of the forearm near the elbow, and from the septa which pass from this fascia between the individual muscles.

The **Pronator teres** has two heads of origin—humeral and ulnar. The **humeral head**, the larger and more superficial, *arises* immediately above the medial epicondyle, and from the tendon common to the origin of the other muscles; also from the intermuscular septum between it and the Flexor carpi radialis and from the antibrachial fascia. The **ulnar head** is a thin fasciculus, which *arises* from the medial side of the coronoid process of the ulna, and joins the preceding at an acute angle. The median nerve enters the forearm between the two heads of the muscle, and is separated from the ulnar artery by the ulnar head. The muscle passes obliquely across the forearm, and ends in a flat tendon, which is inserted into a rough impression at the middle of the lateral surface of the body of the radius. The lateral border of the muscle forms the medial boundary of a triangular hollow situated in front of the elbow-joint and containing the brachial artery, median nerve, and tendon of the Biceps brachii.

Variations.—Absence of ulnar head; additional slips from the medial intermuscular septum, from the Biceps and from the Brachialis anticus occasionally occur.

The **Flexor carpi radialis** lies on the medial side of the preceding muscle. It *arises* from the medial epicondyle by the common tendon; from the fascia of the forearm; and from the intermuscular septa between it and the Pronator teres laterally, the Palmaris longus medially, and the Flexor digitorum sublimis beneath. Slender and aponeurotic in structure at its commencement, it increases in size, and ends in a tendon which forms rather more than the lower half of its length. This tendon passes through a canal in the lateral part of the transverse carpal ligament and runs through a groove on the greater multangular bone; the groove is converted into a canal by fibrous tissue, and lined by a mucous sheath. The tendon is inserted into the base of the second metacarpal bone, and sends a slip to the base of the third metacarpal bone. The radial artery, in the lower part of the forearm, lies between the tendon of this muscle and the Brachioradialis.

Variations.—Slips from the tendon of the Biceps, the lacertus fibrosus, the coronoid, and the radius have been found. Its insertion often varies and may be mostly into the annular ligament, the trapezium, or the fourth metacarpal as well as the second or third. The muscle may be absent.

The **Palmaris longus** is a slender, fusiform muscle, lying on the medial side of the preceding. It *arises* from the medial epicondyle of the humerus by the common tendon, from the intermuscular septa between it and the adjacent muscles, and from the antibrachial fascia. It ends in a slender, flattened tendon, which passes over the upper part of the transverse carpal ligament, and is *inserted* into the central part of the transverse carpal ligament and lower part of the palmar aponeurosis, frequently sending a tendinous slip to the short muscles of the thumb.

Variations.—One of the most variable muscles in the body. This muscle is often absent about (10 per cent.), and is subject to many variations; it may be tendinous above and muscular below; or it may be muscular in the center with a tendon above and below; or it may present two muscular bundles with a central tendon; or finally it may consist solely of a tendinous band. The muscle may be double. Slips of origin from the coronoid process or from the radius have been seen.

Partial or complete insertion into the fascia of the forearm, into the tendon of the Flexor carpi ulnaris and pisiform bone, into the navicular, and into the muscles of the little finger have been observed.

The **Flexor carpi ulnaris** lies along the ulnar side of the forearm. It *arises* by two heads, humeral and ulnar, connected by a tendinous arch, beneath which the ulnar nerve and posterior ulnar recurrent artery pass. The humeral head *arises* from the



FIG. 414.—Front of the left forearm. Superficial muscles.

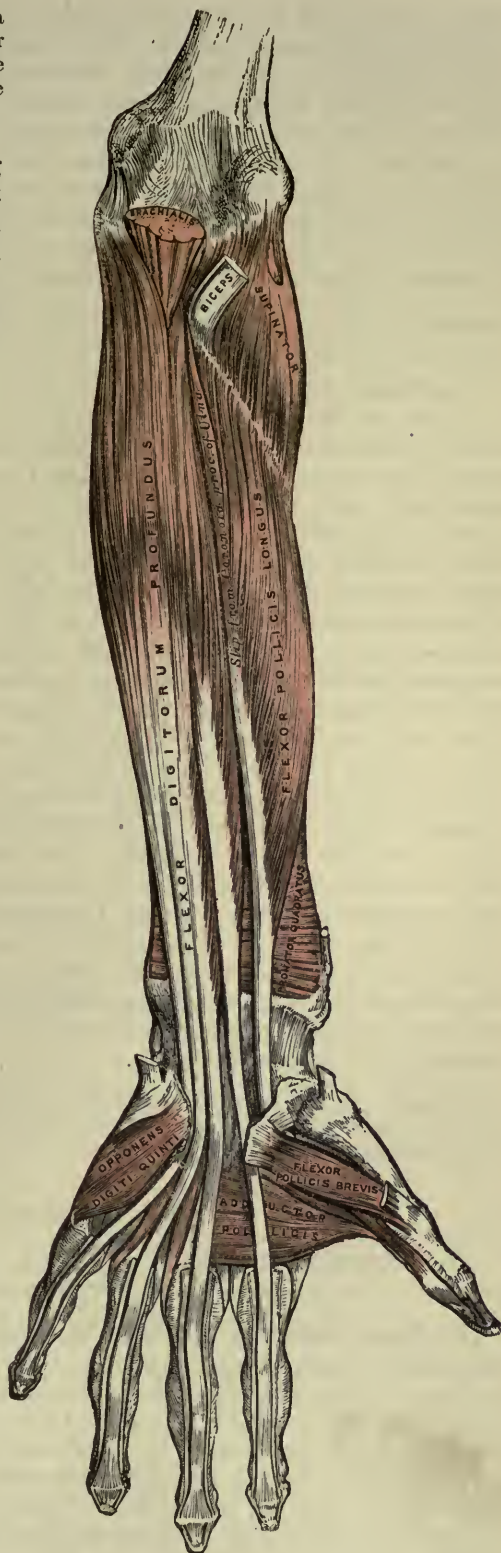


FIG. 415.—Front of the left forearm. Deep muscles.

medial epicondyle of the humerus by the common tendon; the **ulnar head** *arises* from the medial margin of the olecranon and from the upper two-thirds of the dorsal border of the ulna by an aponeurosis, common to it and the Extensor carpi ulnaris and Flexor digitorum profundus; and from the intermuscular septum between it and the Flexor digitorum sublimis. The fibers end in a tendon, which occupies the anterior part of the lower half of the muscle and is *inserted* into the pisiform bone, and is prolonged from this to the hamate and fifth metacarpal bones by the pisohamate and pisometacarpal ligaments; it is also attached by a few fibers to the transverse carpal ligament. The ulnar vessels and nerve lie on the lateral side of the tendon of this muscle, in the lower two-thirds of the forearm.

Variations.—Slips of origin from the coronoid. The *Epitrochleo-anconæus*, a small muscle often present runs from the back of the inner condyle to the olecranon, over the ulnar nerve.

The **Flexor digitorum sublimis** is placed beneath the previous muscle; it is the largest of the muscles of the superficial group, and arises by three heads—humeral, ulnar, and radial. The **humeral head** *arises* from the medial epicondyle of the humerus by the common tendon, from the ulnar collateral ligament of the elbow-joint, and from the intermuscular septa between it and the preceding muscles. The **ulnar head** *arises* from the medial side of the coronoid process, above the ulnar origin of the Pronator teres (see Fig. 213, page 216). The **radial head** *arises* from the oblique line of the radius, extending from the radial tuberosity to the insertion of the Pronator teres. The muscle speedily separates into two planes of muscular fibers, superficial and deep: the superficial plane divides into two parts which end in tendons for the middle and ring fingers; the deep plane gives off a muscular slip to join the portion of the superficial plane which is associated with the tendon of the ring finger, and then divides into two parts, which end in tendons for the index and little fingers. As the four tendons thus formed pass beneath the transverse carpal ligament into the palm of the hand, they are arranged in pairs, the superficial pair going to the middle and ring fingers, the deep pair to the index and little fingers. The tendons diverge from one another in the palm and form dorsal relations to the superficial volar arch and digital branches of the median and ulnar nerves. Opposite the bases of the first phalanges each tendon divides into two slips to allow of the passage of the corresponding tendon of the Flexor digitorum profundus; the two slips then reunite and form a grooved channel for the reception of the accompanying tendon of the Flexor digitorum profundus. Finally the tendon divides and is inserted into the sides of the second phalanx about its middle.

Variations.—Absence of radial head, of little finger portion; accessory slips from ulnar tuberosity to the index and middle finger portions; from the inner head to the Flexor profundus; from the ulnar or annular ligament to the little finger.

The Deep Group (Fig. 415).

Flexor digitorum profundus.

Flexor pollicis longus.

Pronator quadratus.

The **Flexor digitorum profundus** is situated on the ulnar side of the forearm, immediately beneath the superficial Flexors. It *arises* from the upper three-fourths of the volar and medial surfaces of the body of the ulna, embracing the insertion of the Brachialis above, and extending below to within a short distance of the Pronator quadratus. It also arises from a depression on the medial side of the coronoid process; by an aponeurosis from the upper three-fourths of the dorsal border of the ulna, in common with the Flexor and Extensor carpi ulnaris; and from the ulnar half of the interosseous membrane. The muscle ends in four tendons which run under the transverse carpal ligament dorsal to the tendons of the Flexor

digitorum sublimis. Opposite the first phalanges the tendons pass through the openings in the tendons of the *Flexor digitorum sublimis*, and are finally *inserted* into the bases of the last phalanges. The portion of the muscle for the index finger is usually distinct throughout, but the tendons for the middle, ring, and little fingers are connected together by areolar tissue and tendinous slips, as far as the palm of the hand.

Fibrous Sheaths of the Flexor Tendons.—After leaving the palm, the tendons of the *Flexores digitorum sublimis* and *profundus* lie in osseo-aponeurotic canals (Fig. 427), formed behind by the phalanges and in front by strong fibrous bands, which arch across the tendons, and are attached on either side to the margins of the phalanges. Opposite the middle of the proximal and second phalanges the bands (digital vaginal ligaments) are very strong, and the fibers are transverse; but opposite the joints they are much thinner, and consist of *annular* and *cruciate* ligamentous fibers. Each canal contains a mucous sheath, which is reflected on the contained tendons.

Within each canal the tendons of the *Flexores digitorum sublimis* and *profundus* are connected to each other, and to the phalanges, by slender, tendinous bands, called *vincula tendina* (Fig. 416). There are two sets of these; (*a*) the *vincula brevia*, which are two in number in each finger, and consist of triangular bands of fibers, one connecting the tendon of the *Flexor digitorum sublimis* to the front of the first interphalangeal joint and head of the first phalanx, and the other the tendon of the *Flexor digitorum profundus* to the front of the second interphalangeal joint and head of the second phalanx; (*b*) the *vincula longa*, which connect the under surfaces of the tendons of the *Flexor digitorum profundus* to those of the subjacent *Flexor sublimis* after the tendons of the former have passed through the latter.

Variations.—The index finger portion may arise partly from the upper part of the radius. Slips from the inner head of the *Flexor sublimis*, medial epicondyle, or the coronoid are found. Connection with the *Flexor pollicis longus*.

Four small muscles, the *Lumbricales*, are connected with the tendons of the *Flexor profundus* in the palm. They will be described with the muscles of the hand (page 464).

The ***Flexor pollicis longus*** is situated on the radial side of the forearm, lying in the same plane as the preceding. It *arises* from the grooved volar surface of the body of the radius, extending from immediately below the tuberosity and oblique line to within a short distance of the *Pronator quadratus*. It *arises* also from the adjacent part of the interosseous membrane, and generally by a fleshy slip from the medial border of the coronoid process, or from the medial epicondyle of the humerus. The fibers end in a flattened tendon, which passes beneath the transverse carpal ligament, is then lodged between the lateral head of the *Flexor pollicis brevis* and the oblique part of the *Adductor pollicis*, and, entering an osseo-aponeurotic canal similar to those for the *Flexor* tendons of the fingers, is *inserted* into the base of the distal phalanx of the thumb. The volar interosseous nerve and vessels pass downward on the front of the interosseous membrane between the *Flexor pollicis longus* and *Flexor digitorum profundus*.

Variations.—Slips may connect with *Flexor sublimis*, or *Profundus*, or *Pronator teres*. An additional tendon to the index finger is sometimes found.

The ***Pronator quadratus*** is a small, flat, quadrilateral muscle, extending across the front of the lower parts of the radius and ulna. It *arises* from the pronator ridge on the lower part of the volar surface of the body of the ulna; from the medial part of the volar surface of the lower fourth of the ulna; and from a strong aponeurosis which covers the medial third of the muscle. The fibers pass lateralward

and slightly downward, to be inserted into the lower fourth of the lateral border and the volar surface of the body of the radius. The deeper fibers of the muscle are inserted into the triangular area above the ulnar notch of the radius—an attachment comparable with the origin of the Supinator from the triangular area below the radial notch of the ulna.

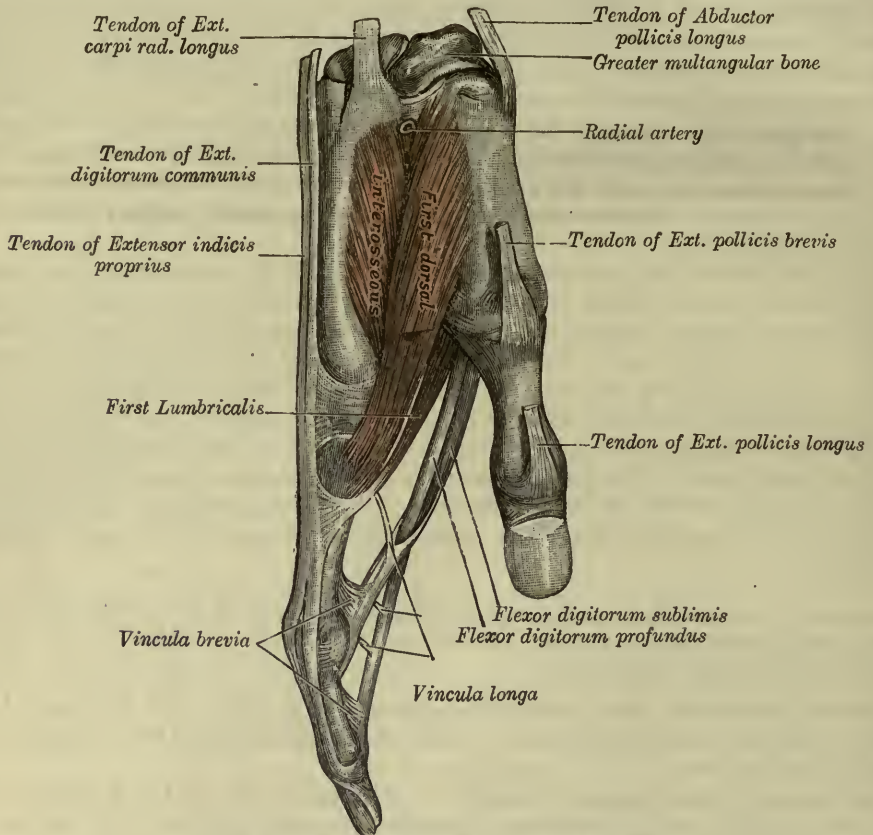


FIG. 416.—Tendons of forefinger and vincula tendina

Variations.—Rarely absent; split into two or three layers; increased attachment upward or downward.

Nerves.—All the muscles of the superficial layer are supplied by the median nerve, excepting the Flexor carpi ulnaris, which is supplied by the ulnar. The Pronator teres, the Flexor carpi radialis, and the Palmaris longus derive their supply primarily from the sixth cervical nerve; the Flexor digitorum sublimis from the seventh and eighth cervical and first thoracic nerves, and the Flexor carpi ulnaris from the eighth cervical and first thoracic. Of the deep layer, the Flexor digitorum profundus is supplied by the eighth cervical and first thoracic through the ulnar, and the volar interosseous branch of the median. The Flexor pollicis longus and Pronator quadratus are supplied by the eighth cervical and first thoracic through the volar interosseous branch of the median.

Actions.—These muscles act upon the forearm, the wrist, and hand. The Pronator teres rotates the radius upon the ulna, rendering the hand prone; when the radius is fixed, it assists in flexing the forearm. The Flexor carpi radialis is a flexor and abductor of the wrist; it also assists in pronating the hand, and in bending the elbow. The Flexor carpi ulnaris is a flexor and adductor of the wrist; it also assists in bending the elbow. The Palmaris longus is a flexor of the wrist-joint; it also assists in flexing the elbow. The Flexor digitorum sublimis flexes first the middle and then the proximal phalanges; it also assists in flexing the wrist and elbow. The Flexor digitorum profundus is one of the flexors of the phalanges. After the Flexor sublimis has bent the second phalanx, the Flexor profundus flexes the terminal one; but it cannot do so until after the contraction of the superficial muscle. It also assists in flexing the wrist. The

Flexor pollicis longus is a flexor of the phalanges of the thumb; when the thumb is fixed, it assists in flexing the wrist. The Pronator quadratus rotates the radius upon the ulna, rendering the hand prone.

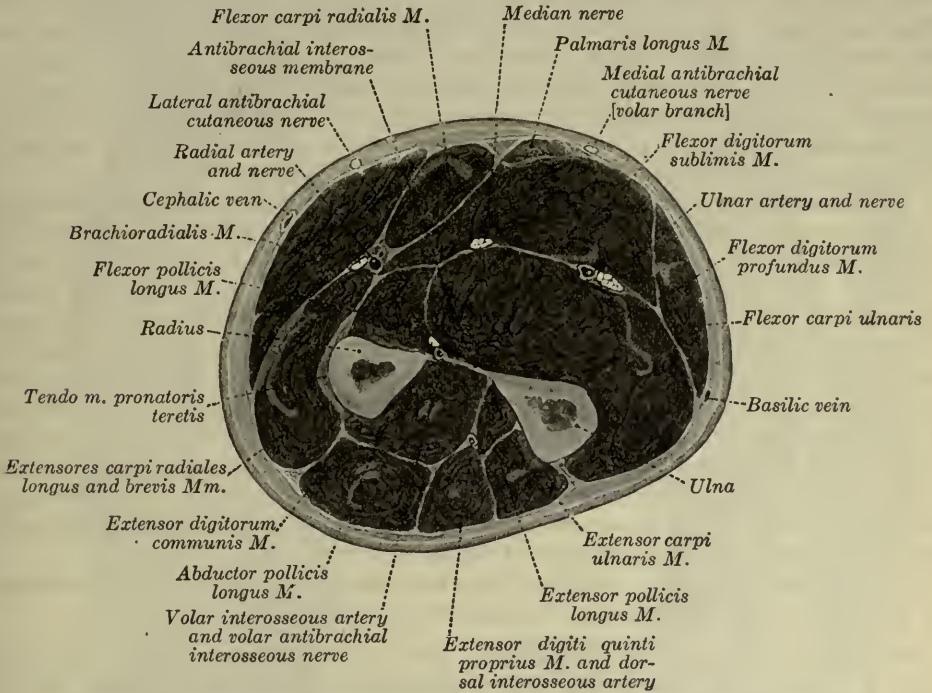


FIG. 417.—Cross-section through the middle of the forearm. (Eycleshymer and Schoemaker.)

2. The Dorsal Antibrachial Muscles.

These muscles are divided for convenience of description into two groups, superficial and deep.

The Superficial Group (Fig. 418).

- | | |
|---------------------------------|----------------------------------|
| Brachioradialis. | Extensor digitorum communis. |
| Extensor carpi radialis longus. | Extensor digiti quinti proprius. |
| Extensor carpi radialis brevis. | Extensor carpi ulnaris. |
| Anconæus. | |

The **Brachioradialis** (*Supinator longus*) is the most superficial muscle on the radial side of the forearm. It arises from the upper two-thirds of the lateral supracondylar ridge of the humerus, and from the lateral intermuscular septum, being limited above by the groove for the radial nerve. Interposed between it and the Brachialis are the radial nerve and the anastomosis between the anterior branch of the profunda artery and the radial recurrent. The fibers end above the middle of the forearm in a flat tendon, which is inserted into the lateral side of the base of the styloid process of the radius. The tendon is crossed near its insertion by the tendons of the Abductor pollicis longus and Extensor pollicis brevis; on its ulnar side is the radial artery.

Variations.—Fusion with the Brachialis; tendon of insertion may be divided into two or three slips; insertion partial or complete into the middle of the radius, fasciculi to the tendon of the Biceps, the tuberosity or oblique line of the radius; slips to the Extensor carpi radialis longus or Abductor pollicis longus; absence; rarely doubled.

The **Extensor carpi radialis longus** (*Extensor carpi radialis longior*) is placed partly beneath the Brachioradialis. It *arises* from the lower third of the lateral supracondylar ridge of the humerus, from the lateral intermuscular septum, and by a few fibers from the common tendon of origin of the Extensor muscles of the forearm. The fibers end at the upper third of the forearm in a flat tendon, which runs along the lateral border of the radius, beneath the Abductor pollicis longus and Extensor pollicis brevis; it then passes beneath the dorsal carpal ligament, where it lies in a groove on the back of the radius common to it and the Extensor carpi radialis brevis, immediately behind the styloid process. It is *inserted* into the dorsal surface of the base of the second metacarpal bone, on its radial side.

The **Extensor carpi radialis brevis** (*Extensor carpi radialis brevior*) is shorter and thicker than the preceding muscle, beneath which it is placed. It *arises* from the lateral epicondyle of the humerus, by a tendon common to it and the three following muscles; from the radial collateral ligament of the elbow-joint; from a strong aponeurosis which covers its surface; and from the intermuscular septa between it and the adjacent muscles. The fibers end about the middle of the forearm in a flat tendon, which is closely connected with that of the preceding muscle, and accompanies it to the wrist; it passes beneath the Abductor pollicis longus and Extensor pollicis brevis, then beneath the dorsal carpal ligament, and is *inserted* into the dorsal surface of the base of the third metacarpal bone on its radial side. Under the dorsal carpal ligament the tendon lies on the back of the radius in a shallow groove, to the ulnar side of that which lodges the tendon of the Extensor carpi radialis, longus, and separated from it by a faint ridge.

The tendons of the two preceding muscles pass through the same compartment of the dorsal carpal ligament in a single mucous sheath.

Variations.—Either muscle may split into two or three tendons of insertion to the second and third or even the fourth metacarpal. The two muscles may unite into a single belly with two tendons. Cross slips between the two muscles may occur. The *Extensor carpi radialis intermedius* rarely arises as a distinct muscle from the humerus, but is not uncommon as an accessory slip from one or both muscles to the second or third or both metacarpals. The *Extensor carpi radialis accessorius* is occasionally found arising from the humerus with or below the Extensor carpi radialis longus and inserted into the first metacarpal, the Abductor pollicis brevis, the First dorsal interosseous, or elsewhere.

The **Extensor digitorum communis** *arises* from the lateral epicondyle of the humerus, by the common tendon; from the intermuscular septa between it and the adjacent muscles, and from the antibrachial fascia. It divides below into four tendons, which pass, together with that of the Extensor indicis proprius, through a separate compartment of the dorsal carpal ligament, within a mucous sheath. The tendons then diverge on the back of the hand, and are *inserted* into the second and third phalanges of the fingers in the following manner. Opposite the metacarpophalangeal articulation each tendon is bound by fasciculi to the collateral ligaments and serves as the dorsal ligament of this joint; after having crossed the joint, it spreads out into a broad aponeurosis, which covers the dorsal surface of the first phalanx and is reinforced, in this situation, by the tendons of the Interossei and Lumbricalis. Opposite the first interphalangeal joint this aponeurosis divides into three slips; an intermediate and two collateral: the former is inserted into the base of the second phalanx; and the two collateral, which are continued onward along the sides of the second phalanx, unite by their contiguous margins, and are *inserted* into the dorsal surface of the last phalanx. As the tendons cross the interphalangeal joints, they furnish them with dorsal ligaments. The tendon to the index finger is accompanied by the Extensor indicis proprius, which lies on its ulnar side. On the back of the hand, the tendons to the middle, ring, and little fingers are connected by two obliquely placed bands, one from the third tendon passing downward and lateralward to the second tendon, and the other

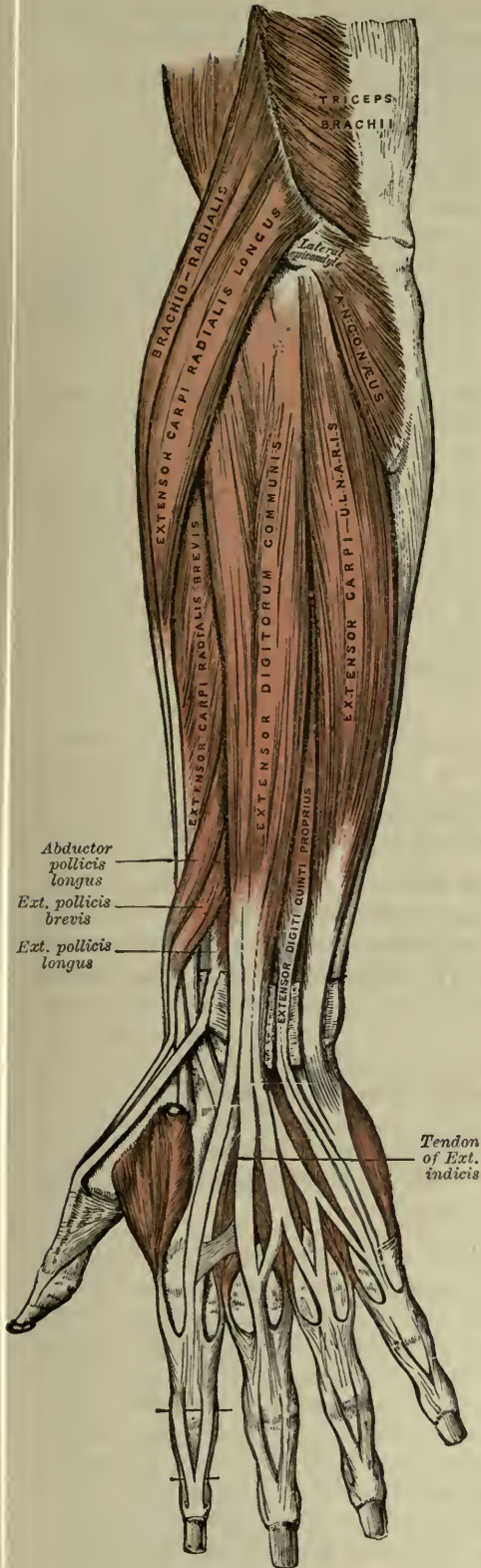


FIG. 418.—Posterior surface of the forearm. Superficial muscles.

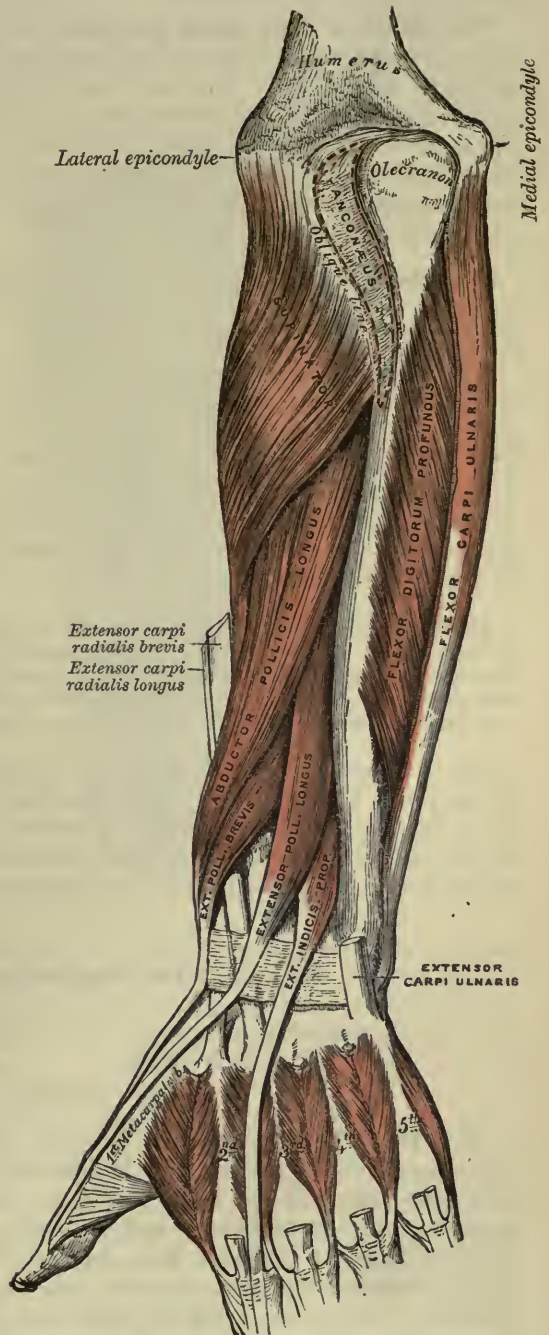


FIG. 419.—Posterior surface of the forearm. Deep muscles.

passing from the same tendon downward and medialward to the fourth. Occasionally the first tendon is connected to the second by a thin transverse band.

Variations.—An increase or decrease in the number of tendons is common; an additional slip to the thumb is sometimes present.

The **Extensor digiti quinti proprius** (*Extensor minimi digiti*) is a slender muscle placed on the medial side of the Extensor digitorum communis, with which it is generally connected. It *arises* from the common Extensor tendon by a thin tendinous slip, from the intermuscular septa between it and the adjacent muscles. Its tendon runs through a compartment of the dorsal carpal ligament behind the distal radio-ulnar joint, then divides into two as it crosses the hand, and finally joins the expansion of the Extensor digitorum communis tendon on the dorsum of the first phalanx of the little finger.

Variations.—An additional fibrous slip from the lateral epicondyle; the tendon of insertion may not divide or may send a slip to the ring finger. Absence of muscle rare; fusion of the belly with the Extensor digitorum communis not uncommon.

The **Extensor carpi ulnaris** lies on the ulnar side of the forearm. It *arises* from the lateral epicondyle of the humerus, by the common tendon; by an aponeurosis from the dorsal border of the ulna in common with the Flexor carpi ulnaris and the Flexor digitorum profundus; and from the deep fascia of the forearm. It ends in a tendon, which runs in a groove between the head and the styloid process of the ulna, passing through a separate compartment of the dorsal carpal ligament, and is *inserted* into the prominent tubercle on the ulnar side of the base of the fifth metacarpal bone.

Variations.—Doubling; reduction to tendinous band; insertion partially into fourth metacarpal. In many cases (52 per cent.) a slip is continued from the insertion of the tendon anteriorly over the Opponens digiti quinti, to the fascia covering that muscle, the metacarpal bone, the capsule of the metacarpophalangeal articulation, or the first phalanx of the little finger. This slip may be replaced by a muscular fasciculus arising from or near the pisiform.

The **Anconæus** is a small triangular muscle which is placed on the back of the elbow-joint, and appears to be a continuation of the Triceps brachii. It *arises* by a separate tendon from the back part of the lateral epicondyle of the humerus; its fibers diverge and are *inserted* into the side of the olecranon, and upper fourth of the dorsal surface of the body of the ulna.

The Deep Group (Fig. 419).

Supinator.	Extensor pollicis brevis.
Abductor pollicis longus.	Extensor pollicis longus.
Extensor indicis proprius.	

The **Supinator** (*Supinator brevis*) (Fig. 420) is a broad muscle, curved around the upper third of the radius. It consists of two planes of fibers, between which the deep branch of the radial nerve lies. The two planes *arise* in common—the superficial one by tendinous and the deeper by muscular fibers—from the lateral epicondyle of the humerus; from the radial collateral ligament of the elbow-joint, and the annular ligament; from the ridge on the ulna, which runs obliquely downward from the dorsal end of the radial notch; from the triangular depression below the notch; and from a tendinous expansion which covers the surface of the muscle. The superficial fibers surround the upper part of the radius, and are inserted into the lateral edge of the radial tuberosity and the oblique line of the radius, as low down as the insertion of the Pronator teres. The upper fibers of the deeper plane

form a sling-like fasciculus, which encircles the neck of the radius above the tuberosity and is attached to the back part of its medial surface; the greater part of this portion of the muscle is inserted into the dorsal and lateral surfaces of the body of the radius, midway between the oblique line and the head of the bone.

The **Abductor pollicis longus** (*Extensor oss. metacarpi pollicis*) lies immediately below the Supinator and is sometimes united with it. It arises from the lateral part of the dorsal surface of the body of the ulna below the insertion of the Anconæus, from the interosseous membrane, and from the middle third of the dorsal surface of the body of the radius. Passing obliquely downward and lateralward, it ends in a tendon, which runs through a groove on the lateral side of the lower end of the radius, accompanied by the tendon of the Extensor pollicis brevis, and is inserted into the radial side of the base of the first metacarpal bone. It occasionally gives off two slips near its insertion: one to the greater multangular bone and the other to blend with the origin of the Abductor pollicis brevis.

Variations.—More or less doubling of muscle and tendon with insertion of the extra tendon into the first metacarpal, the greater multangular, or into the Abductor pollicis brevis or Opponens pollicis.

The **Extensor pollicis brevis** (*Extensor primi internodii pollicis*) lies on the medial side of, and is closely connected with, the Abductor pollicis longus. It arises from the dorsal surface of the body of the radius below that muscle, and from the interosseous membrane. Its direction is similar to that of the Abductor pollicis longus, its tendon passing through the same groove on the lateral side of the lower end of the radius, to be inserted into the base of the first phalanx of the thumb.

Variations.—Absence; fusion of tendon with that of the Extensor pollicis longus.

The **Extensor pollicis longus** (*Extensor secundi internodii pollicis*) is much larger than the preceding muscle, the origin of which it partly covers. It arises from the lateral part of the middle third of the dorsal surface of the body of the ulna below the origin of the Abductor pollicis longus, and from the interosseous membrane. It ends in a tendon, which passes through a separate compartment in the dorsal carpal ligament, lying in a narrow, oblique groove on the back of the lower end of the radius. It then crosses obliquely the tendons of the Extensores carpi radialis longus and brevis, and is separated from the Extensor brevis pollicis by a triangular interval, in which the radial artery is found; and is finally inserted into the base of the last phalanx of the thumb. The radial artery is crossed by the

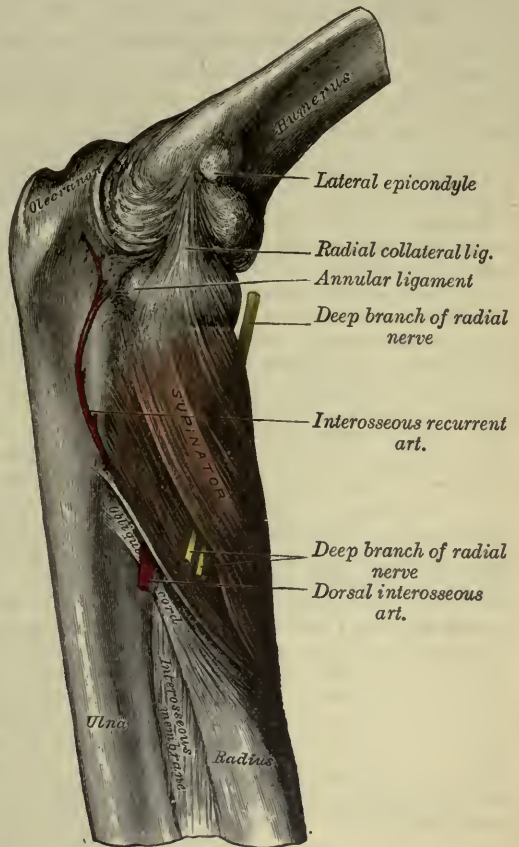


FIG. 420.—The Supinator.

tendons of the Abductor pollicis longus and of the Extensores pollicis longus and brevis.

The **Extensor indicis proprius** (*Extensor indicis*) is a narrow, elongated muscle, placed medial to, and parallel with, the preceding. It arises, from the dorsal surface of the body of the ulna below the origin of the Extensor pollicis longus, and from the interosseous membrane. Its tendon passes under the dorsal carpal ligament in the same compartment as that which transmits the tendons of the Extensor digitorum communis, and opposite the head of the second metacarpal bone, joins the ulnar side of the tendon of the Extensor digitorum communis which belongs to the index finger.

Variations.—Doubling; the ulnar part may pass beneath the dorsal carpal ligament with the Extensor digitorum communis; a slip from the tendon may pass to the index finger.

Nerves.—The Brachioradialis is supplied by the fifth and sixth, the Extensores carpi radialis longus and brevis by the sixth and seventh, and the Anconæus by the seventh and eighth cervical nerves, through the radial nerve; the remaining muscles are innervated through the deep radial nerve, the Supinator being supplied by the sixth, and all the other muscles by the seventh cervical.

Actions.—The muscles of the lateral and dorsal aspects of the forearm, which comprise all the Extensor muscles and the Supinator, act upon the forearm, wrist, and hand; they are the direct antagonists of the Pronator and Flexor muscles. The Anconæus assists the Triceps in extending the forearm. The Brachioradialis is a flexor of the elbow-joint, but only acts as such when the movement of flexion has been initiated by the Biceps brachii and Brachialis. The action of the Supinator is suggested by its name; it assists the Biceps in bringing the hand into the supine position. The Extensor carpi-radialis longus extends the wrist and abducts the hand. It may also assist in bending the elbow-joint; at all events it serves to fix or steady this articulation. The Extensor carpi-radialis brevis extends the wrist, and may also act slightly as an abductor of the hand. The Extensor carpi ulnaris extends the wrist, but when acting alone inclines the hand toward the ulnar side; by its continued action it extends the elbow-joint. The Extensor digitorum communis extends the phalanges, then the wrist, and finally the elbow. It acts principally on the proximal phalanges, the middle and terminal phalanges being extended mainly by the Interossei and Lumbricales. It tends to separate the fingers as it extends them. The Extensor digiti quinti proprius extends the little finger, and by its continued action assists in extending the wrist. It is owing to this muscle that the little finger can be extended or pointed while the others are flexed. The chief action of the Abductor pollicis longus is to carry the thumb laterally from the palm of the hand. By its continued action it helps to extend and abduct the wrist. The Extensor pollicis brevis extends the proximal phalanx, and the Extensor pollicis longus the terminal phalanx of the thumb; by their continued action they help to extend and abduct the wrist. The Extensor indicis proprius extends the index finger, and by its continued action assists in extending the wrist.

VI. THE MUSCLES AND FASCIÆ OF THE HAND.

The muscles of the hand are subdivided into three groups: (1) those of the thumb, which occupy the radial side and produce the **thenar eminence**; (2) those of the little finger, which occupy the ulnar side and give rise to the **hypothenar eminence**; (3) those in the middle of the palm and between the metacarpal bones.

Volar Carpal Ligament (*ligamentum carpi volare*).—The volar carpal ligament is the thickened band of antibrachial fascia which extends from the radius to the ulna over the Flexor tendons as they enter the wrist.

Transverse Carpal Ligament (*ligamentum carpi transversum*; *anterior annular ligament*) (Figs. 421, 422).—The transverse carpal ligament is a strong, fibrous band, which arches over the carpus, converting the deep groove on the front of the carpal bones into a tunnel, through which the Flexor tendons of the digits and the median nerve pass. It is attached, medially, to the pisiform and the hamulus of the hamate bone; laterally, to the tuberosity of the navicular, and to the medial part of the volar surface and the ridge of the greater multangular. It is continuous, above, with the volar carpal ligament; and below, with the palmar aponeurosis. It is crossed by the ulnar vessels and nerve, and the cutaneous branches of the median and ulnar nerves. At its lateral end is the tendon of the

Flexor carpi radialis, which lies in the groove on the greater multangular between the attachments of the ligament to the bone. On its volar surface the tendons of the Palmaris longus and Flexor carpi ulnaris are partly inserted; below, it gives origin to the short muscles of the thumb and little finger

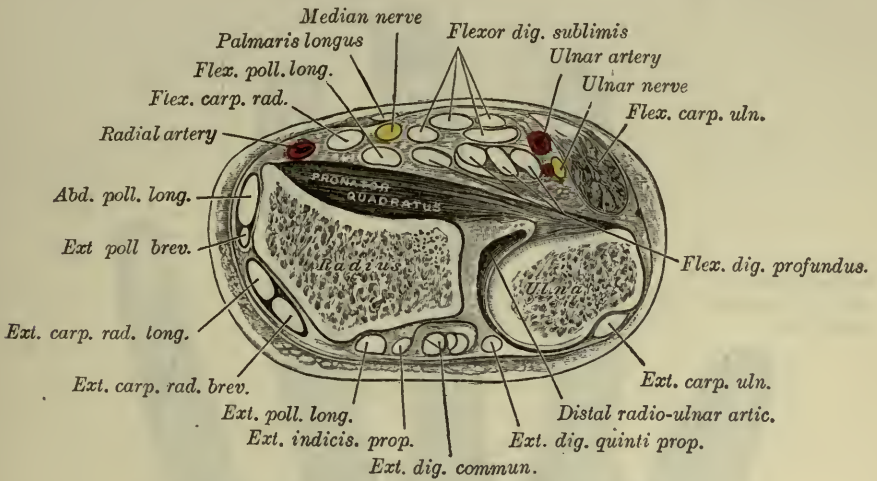


FIG. 421.—Transverse section across distal ends of radius and ulna.

The Mucous Sheaths of the Tendons on the Front of the Wrist.—Two sheaths envelop the tendons as they pass beneath the transverse carpal ligament, one for the Flexores digitorum sublimis and profundus, the other for the Flexor pollicis longus (Fig. 423). They extend into the forearm for about 2.5 cm. above the transverse carpal ligament, and occasionally communicate with each other under

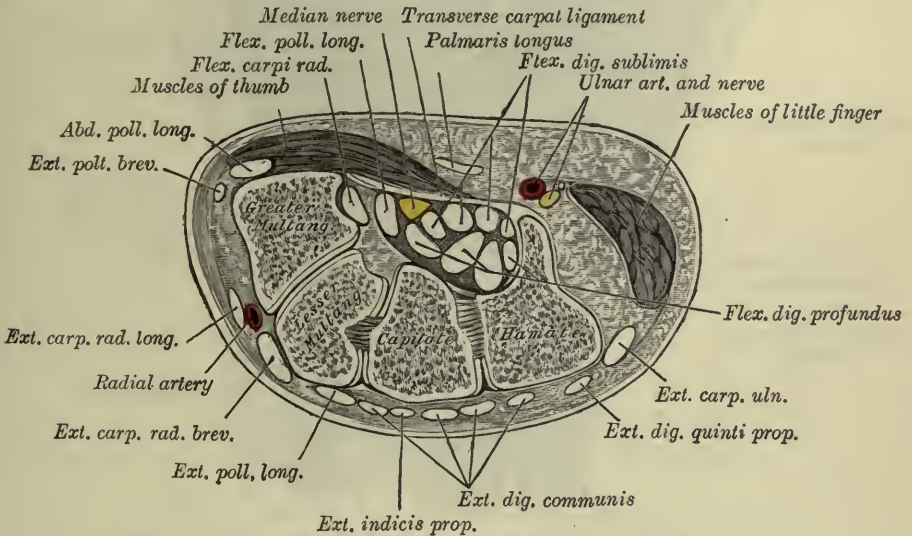


FIG. 422.—Transverse section across the wrist and digits.

the ligament. The sheath which surrounds the Flexores digitorum extends downward about half-way along the metacarpal bones, where it ends in blind diverticula around the tendons to the index, middle, and ring fingers. It is prolonged on the tendons to the little finger and usually communicates with the mucous

sheath of these tendons. The sheath of the tendon of the Flexor pollicis longus is continued along the thumb as far as the insertion of the tendon. The mucous sheaths enveloping the terminal parts of the tendons of the Flexores digitorum have been described on page 449.

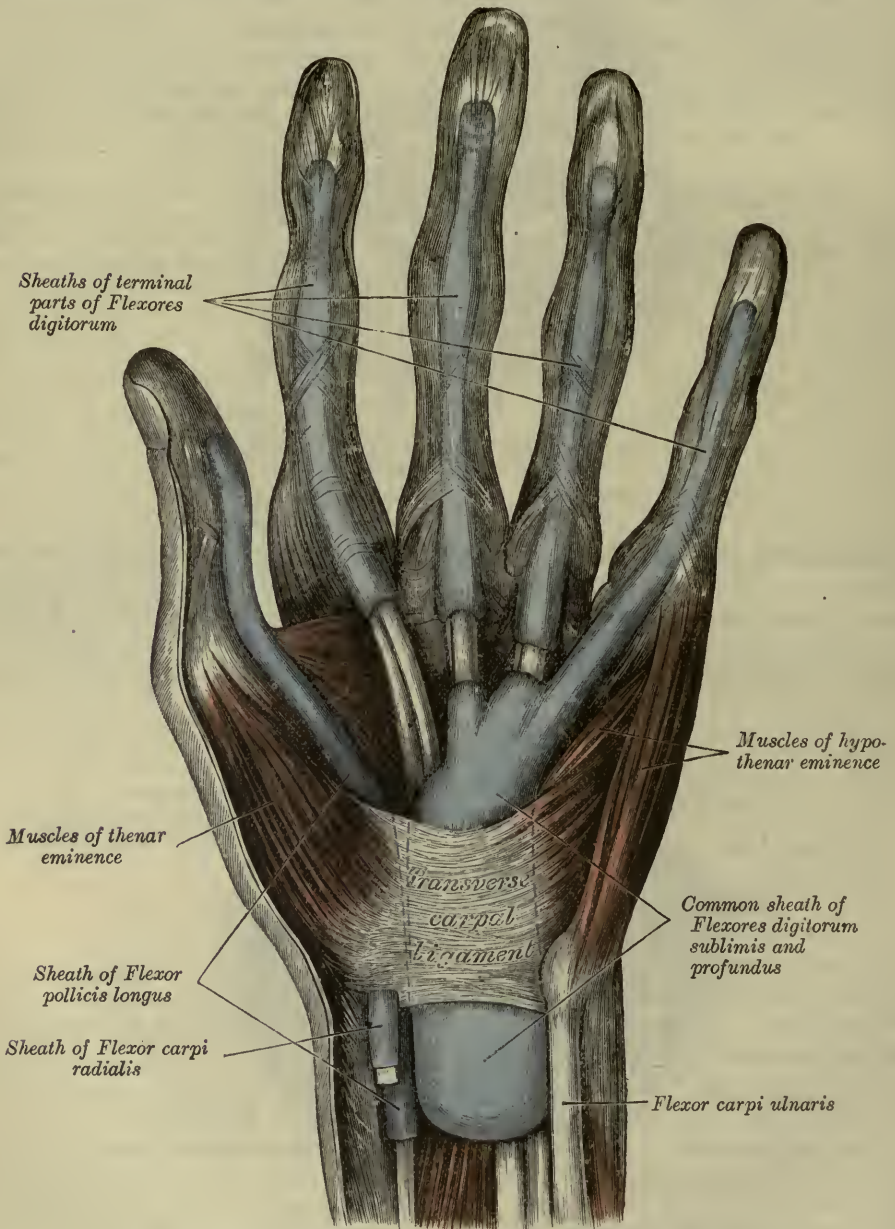


FIG. 423.—The mucous sheaths of the tendons on the front of the wrist and digits.

Dorsal Carpal Ligament (*ligamentum carpi dorsale*; *posterior annular ligament*) (Figs. 421, 422).—The dorsal carpal ligament is a strong, fibrous band, extending obliquely downward and medialward across the back of the wrist, and consisting of part of the deep fascia of the back of the forearm, strengthened by the addition of some transverse fibers. It is attached, *medially*, to the styloid process of the ulna

and to the triangular and pisiform bones; *laterally*, to the lateral margin of the radius; and, in its passage across the wrist, to the ridges on the dorsal surface of the radius.

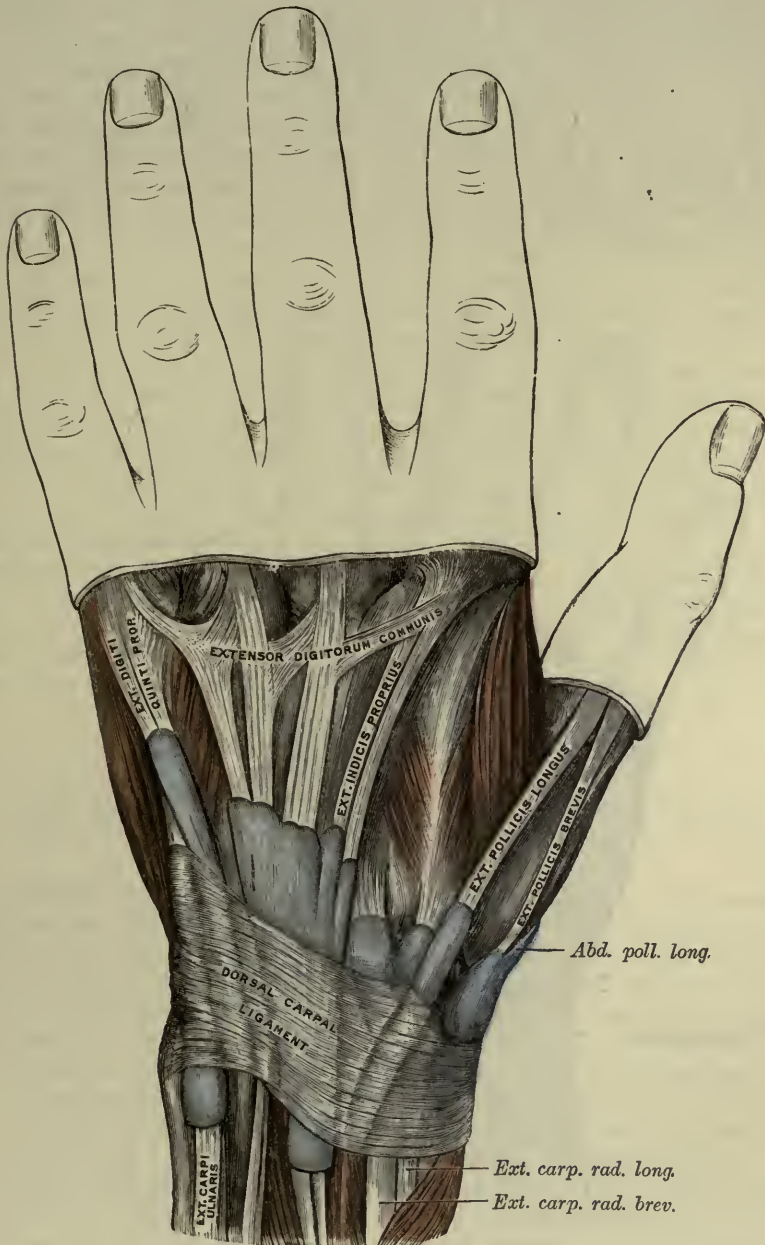


FIG. 424.—The mucous sheaths of the tendons on the back of the wrist.

The Mucous Sheaths of the Tendons on the Back of the Wrist.—Between the dorsal carpal ligament and the bones six compartments are formed for the passage of tendons, each compartment having a separate mucous sheath. One is found in each of the following positions (Fig. 424): (1) on the lateral side of the styloid process, for the tendons of the Abductor pollicis longus and Extensor pollicis brevis; (2) behind the styloid process, for the tendons of the Extensores carpi radialis

longus and brevis; (3) about the middle of the dorsal surface of the radius, for the tendon of the Extensor pollicis longus; (4) to the medial side of the latter, for the tendons of the Extensor digitorum communis and Extensor indicis proprius; (5) opposite the interval between the radius and ulna, for the Extensor digiti quinti proprius; (6) between the head and styloid process of the ulna, for the tendon of the Extensor carpi ulnaris. The sheaths lining these compartments extend from above the dorsal carpal ligament; those for the tendons of Abductor pollicis longus, Extensor brevis pollicis, Extensores carpi radialis, and Extensor carpi ulnaris stop immediately proximal to the bases of the metacarpal bones, while the sheaths for Extensor communis digitorum, Extensor indicis proprius, and Extensor digiti quinti proprius are prolonged to the junction of the proximal and intermediate thirds of the metacarpus.

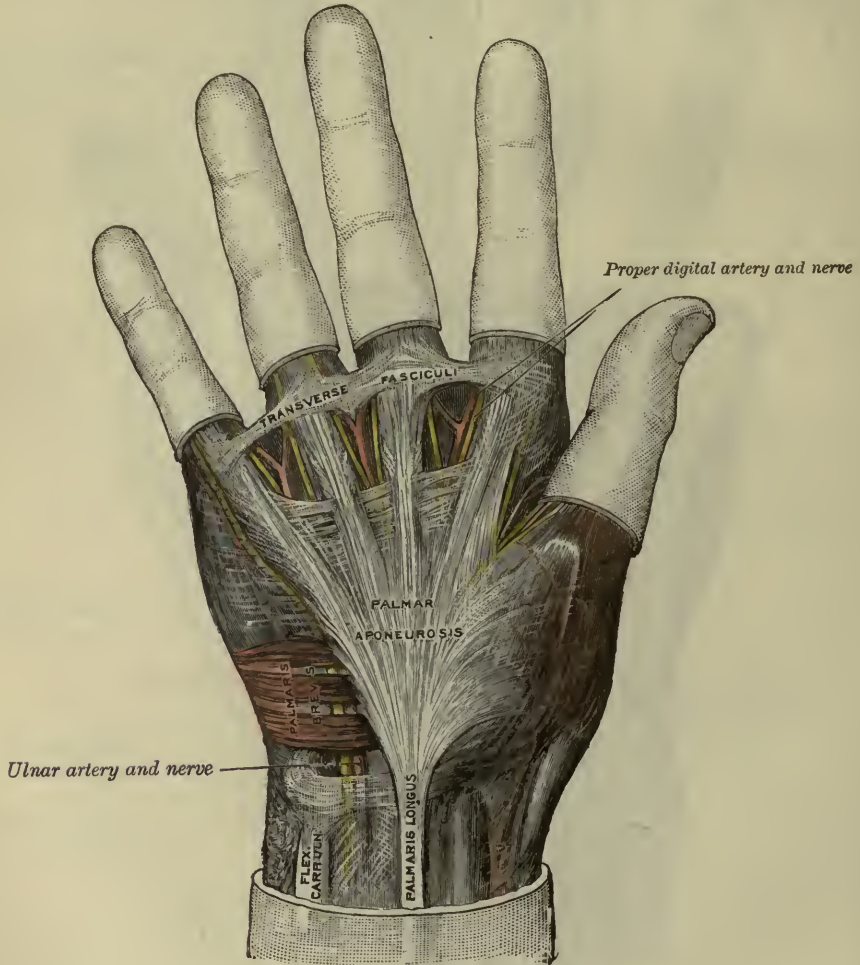


FIG. 425.—The palmar aponeurosis.

Palmar Aponeurosis (*aponeurosis palmaris*; *palmar fascia*) (Fig. 425).—The palmar aponeurosis invests the muscles of the palm, and consists of central, lateral, and medial portions.

The **central portion** occupies the middle of the palm, is triangular in shape, and of great strength and thickness. Its apex is continuous with the lower margin of the transverse carpal ligament, and receives the expanded tendon of the Pal-

maris longus. Its base divides below into four slips, one for each finger. Each slip gives off superficial fibers to the skin of the palm and finger, those to the palm joining the skin at the furrow corresponding to the metacarpophalangeal articulations, and those to the fingers passing into the skin at the transverse fold at the bases of the fingers. The deeper part of each slip subdivides into two processes, which are inserted into the fibrous sheaths of the Flexor tendons. From the sides of these processes offsets are attached to the transverse metacarpal ligament. By this arrangement short channels are formed on the front of the heads of the metacarpal bones; through these the Flexor tendons pass. The intervals between the four slips transmit the digital vessels and nerves, and the tendons of the Lumbricales. At the points of division into the slips mentioned, numerous strong, transverse fasciculi bind the separate processes together. The central part of the palmar aponeurosis is intimately bound to the integument by dense fibroareolar tissue forming the superficial palmar fascia, and gives origin by its medial margin to the Palmaris brevis. It covers the superficial volar arch, the tendons of the Flexor muscles, and the branches of the median and ulnar nerves; and on either side it gives off a septum, which is continuous with the interosseous aponeurosis, and separates the intermediate from the collateral groups of muscles.

The lateral and medial portions of the palmar aponeurosis are thin, fibrous layers, which cover, on the radial side, the muscles of the ball of the thumb, and, on the ulnar side, the muscles of the little finger; they are continuous with the central portion and with the fascia on the dorsum of the hand.

The Superficial Transverse Ligament of the Fingers is a thin band of transverse fasciculi (Fig. 425); it stretches across the roots of the four fingers, and is closely attached to the skin of the clefts, and medially to the fifth metacarpal bone, forming a sort of rudimentary web. Beneath it the digital vessels and nerves pass to their destinations.

1. The Lateral Volar Muscles (Figs. 426, 427).

Abductor pollicis brevis.	Flexor pollicis brevis.
Opponens pollicis.	Adductor pollicis (obliquus).
	Adductor pollicis (transversus).

The **Abductor pollicis brevis** (*Abductor pollicis*) is a thin, flat muscle, placed immediately beneath the integument. It *arises* from the transverse carpal ligament, the tuberosity of the navicular, and the ridge of the greater multangular, frequently by two distinct slips. Running lateralward and downward, it is *inserted* by a thin, flat tendon into the radial side of the base of the first phalanx of the thumb and the capsule of the metacarpophalangeal articulation.

The **Opponens pollicis** is a small, triangular muscle, placed beneath the preceding. It *arises* from the ridge on the greater multangular and from the transverse carpal ligament, passes downward and lateralward, and is *inserted* into the whole length of the metacarpal bone of the thumb on its radial side.

The **Flexor pollicis brevis** consists of two portions, lateral and medial. The lateral and more superficial portion *arises* from the lower border of the transverse carpal ligament and the lower part of the ridge on the greater multangular bone; it passes along the radial side of the tendon of the Flexor pollicis longus, and, becoming tendinous, is *inserted* into the radial side of the base of the first phalanx of the thumb; in its tendon of insertion there is a sesamoid bone. The medial and deeper portion of the muscle is very small, and *arises* from the ulnar side of the first metacarpal bone between the Adductor pollicis (obliquus) and the lateral head of the first Interosseous dorsalis, and is *inserted* into the ulnar side of the base of the first phalanx with the Adductor pollicis (obliquus). The medial part of the Flexor brevis pollicis is sometimes described as the **first Interosseous volaris**.

The **Adductor pollicis (obliquus)** (*Adductor obliquus pollicis*) arises by several slips from the capitatum bone, the bases of the second and third metacarpals, the intercarpal ligaments, and the sheath of the tendon of the Flexor carpi radialis. From this origin the greater number of fibers pass obliquely downward and converge to a tendon, which, uniting with the tendons of the medial portion of the Flexor pollicis brevis and the transverse part of the Adductor, is *inserted* into the ulnar side of the base of the first phalanx of the thumb, a sesamoid bone being present in the tendon. A considerable fasciculus, however, passes more obliquely beneath the tendon of the Flexor pollicis longus to join the lateral portion of the Flexor brevis and the Abductor pollicis brevis.

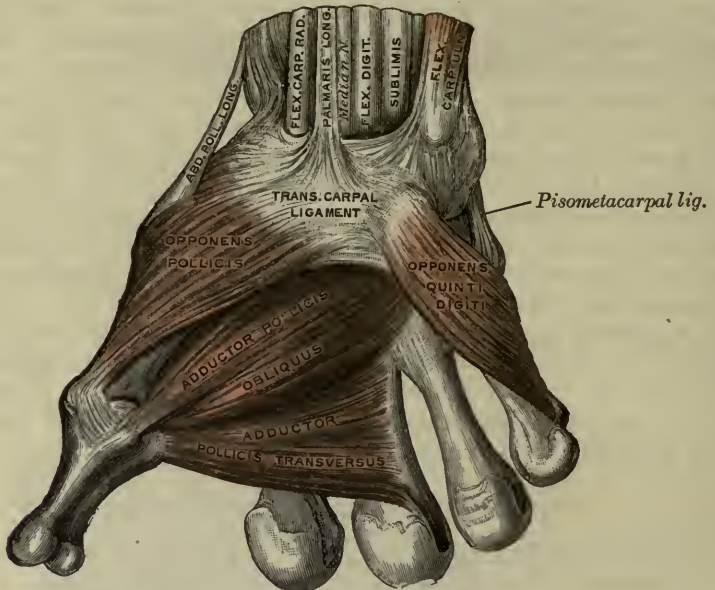


FIG. 426.—The muscles of the thumb.

The **Adductor pollicis (transversus)** (*Adductor transversus pollicis*) (Fig. 426) is the most deeply seated of this group of muscles. It is of a triangular form arising by a broad base from the lower two-thirds of the volar surface of the third metacarpal bone; the fibers converge, to be *inserted* with the medial part of the Flexor pollicis brevis and the Adductor pollicis (obliquus) into the ulnar side of the base of the first phalanx of the thumb.

Variations.—The Abductor pollicis brevis is often divided into an outer and an inner part; accessory slips from the tendon of the Abductor pollicis longus or Palmaris longus, more rarely from the Extensor carpi radialis longus, from the styloid process or Opponens pollicis or from the skin over the thenar eminence. The deep head of the Flexor pollicis brevis may be absent or enlarged. The two adductors vary in their relative extent and in the closeness of their connection. The Adductor obliquus may receive a slip from the transverse metacarpal ligament.

Nerves.—The Abductor brevis, Opponens, and lateral head of the Flexor pollicis brevis are supplied by the sixth and seventh cervical nerves through the median nerve; the medial head of the Flexor brevis, and the Adductor, by the eighth cervical through the ulnar nerve.

Actions.—The Abductor pollicis brevis draws the thumb forward in a plane at right angles to that of the palm of the hand. The Adductor pollicis is the opponent of this muscle, and approximates the thumb to the palm. The Opponens pollicis flexes the metacarpal bone, *i. e.*, draws it medialward over the palm; the Flexor pollicis brevis flexes and adducts the proximal phalanx.

2. The Medial Volar Muscles (Figs. 426, 427).

Palmaris brevis.
Abductor digiti quinti.

Flexor digiti quinti brevis.
Opponens digiti quinti.

The **Palmaris brevis** is a thin, quadrilateral muscle, placed beneath the integument of the ulnar side of the hand. It *arises* by tendinous fasciculi from the transverse carpal ligament and palmar aponeurosis; the fleshy fibers are inserted into the skin on the ulnar border of the palm of the hand.

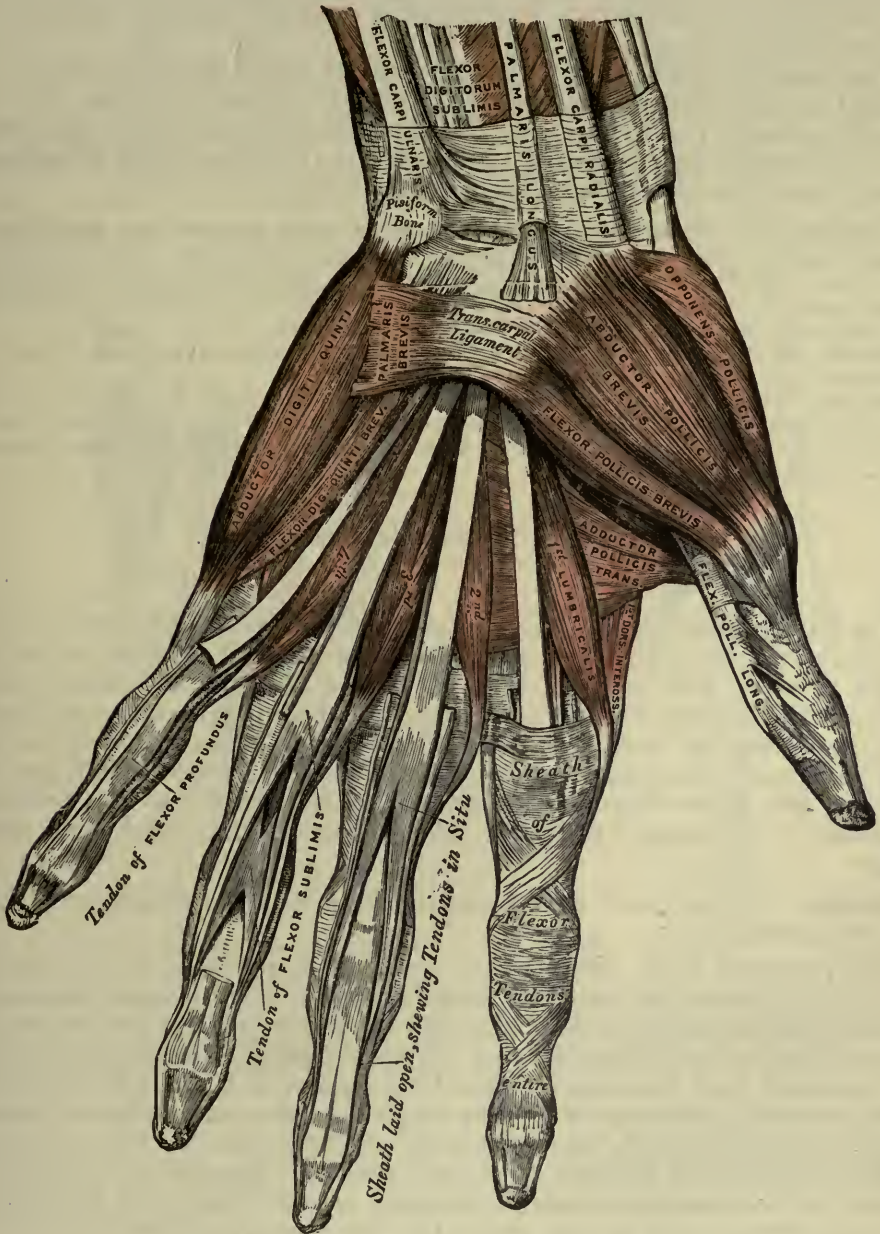

FIG. 427.—The muscles of the left hand. Palmar surface.

The **Abductor digiti quinti** (*Abductor minimi digiti*) is situated on the ulnar border of the palm of the hand. It *arises* from the pisiform bone and from the tendon of the Flexor carpi ulnaris, and ends in a flat tendon, which divides into two slips; one is *inserted* into the ulnar side of the base of the first phalanx of the little finger; the other into the ulnar border of the aponeurosis of the Extensor digiti quinti proprius.

The **Flexor digiti quinti brevis** (*Flexor brevis minimi digiti*) lies on the same plane as the preceding muscle, on its radial side. It *arises* from the convex surface of the hamulus of the hamate bone, and the volar surface of the transverse carpal ligament, and is *inserted* into the ulnar side of the base of the first phalanx of the little finger. It is separated from the Abductor, at its origin, by the deep branches of the ulnar artery and nerve. This muscle is sometimes wanting; the Abductor is then, usually, of large size.

The **Opponens digiti quinti** (*Opponens minimi digiti*) (Fig. 426) is of a triangular form, and placed immediately beneath the preceding muscles. It *arises* from the convexity of the hamulus of the hamate bone, and contiguous portion of the transverse carpal ligament; it is inserted into the whole length of the metacarpal bone of the little finger, along its ulnar margin.

Variations.—The Palmaris brevis varies greatly in size. The Abductor digiti quinti may be divided into two or three slips or united with the Flexor digiti quinti brevis. Accessory head from the tendon of the Flexor carpi ulnaris, the transverse carpal ligament, the fascia of the forearm or the tendon of the Palmaris longus. A portion of the muscle may insert into the metacarpal, or separate slips the *Pisimetarpus*, *Pisiuncinatus* or the *Pisiannularis* muscle may exist.

Nerves.—All the muscles of this group are supplied by the eighth cervical nerve through the ulnar nerve.

Actions.—The Abductor and Flexor digiti quinti brevis abduct the little finger from the ring finger and assist in flexing the proximal phalanx. The Opponens digiti quinti draws forward the fifth metacarpal bone, so as to deepen the hollow of the palm. The Palmaris brevis corrugates the skin on the ulnar side of the palm.

3. The Intermediate Muscles.

Lumbricales.

Interossei.

The **Lumbricales** (Fig. 427) are four small fleshy fasciculi, associated with the tendons of the Flexor digitorum profundus. The first and second *arise* from the radial sides and volar surfaces of the tendons of the index and middle fingers respectively; the third, from the contiguous sides of the tendons of the middle and ring fingers; and the fourth, from the contiguous sides of the tendons of the ring and little fingers. Each passes to the radial side of the corresponding finger, and opposite the metacarpophalangeal articulation is *inserted* into the tendinous expansion of the Extensor digitorum communis covering the dorsal aspect of the finger.

Variations.—The Lumbricales vary in number from two to five or six and there is considerable variation in insertions.

The **Interossei** (Figs. 428, 429) are so named from occupying the intervals between the metacarpal bones, and are divided into two sets, a dorsal and a volar.

The **Interossei dorsales** (*Dorsal interossei*) are *four* in number, and occupy the intervals between the metacarpal bones. They are bipenniform muscles, each *arising* by two heads from the adjacent sides of the metacarpal bones, but more extensively from the metacarpal bone of the finger into which the muscle is inserted. They are inserted into the bases of the first phalanges and into the aponeuroses of the tendons of the Extensor digitorum communis. Between the double origin of each of these muscles is a narrow triangular interval; through the first of these the radial artery passes; through each of the other three a perforating branch from the deep volar arch is transmitted.

The **first** or **Abductor indicis** is larger than the others. It is flat, triangular in form, and *arises* by two heads, separated by a fibrous arch for the passage of the radial artery from the dorsum to the palm of the hand. The lateral head *arises* from the proximal half of the ulnar border of the first metacarpal bone; the medial head, from almost the entire length of the radial border of the second metacarpal bone; the tendon is inserted into the radial side of the index finger. The **second**

and **third** are inserted into the middle finger, the former into its radial, the latter into its ulnar side. The **fourth** is inserted into the ulnar side of the ring finger.

The **Interossei volares** (*Palmar interossei*), three in number, are smaller than the **Interossei dorsales**, and placed upon the volar surfaces of the metacarpal bones, rather than between them. Each *arises* from the entire length of the metacarpal bone of one finger, and is *inserted* into the side of the base of the first phalanx and aponeurotic expansion of the **Extensor communis** tendon to the same finger.

The **first** *arises* from the ulnar side of the second metacarpal bone, and is *inserted* into the same side of the first phalanx of the index finger. The **second** *arises* from the radial side of the fourth metacarpal bone, and is *inserted* into the same side of the ring finger. The **third** *arises* from the radial side of the fifth metacarpal bone, and is *inserted* into the same side of the little finger. From this account it may be seen that each finger is provided with two **Interossei**, with the exception of the little finger, in which the **Abductor** takes the place of one of the pair.

As already mentioned (p. 461), the medial head of the **Flexor pollicis brevis** is sometimes described as the **Interosseus volaris primus**.

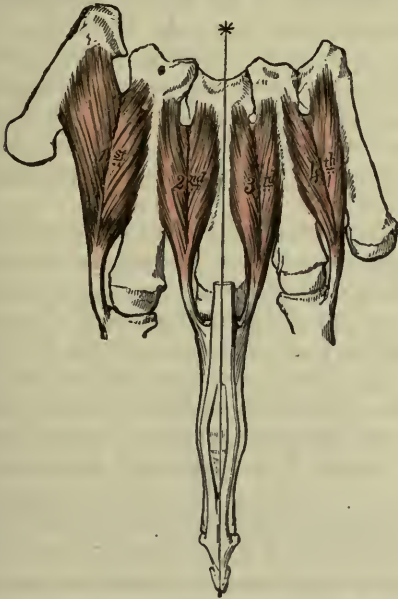


FIG. 428.—The **Interossei dorsales** of left hand.

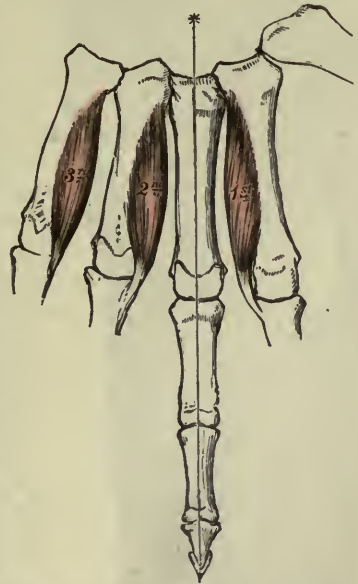


FIG. 429.—The **Interossei volares** of left hand.

Nerves.—The two lateral **Lumbricales** are supplied by the sixth and seventh cervical nerves, through the third and fourth digital branches of the median nerve; the two medial **Lumbricales** and all the **Interossei** are supplied by the eighth cervical nerve, through the deep palmar branch of the ulnar nerve. The third **Lumbricalis** frequently receives a twig from the median.

Actions.—The **Interossei volares** adduct the fingers to an imaginary line drawn longitudinally through the center of the middle finger; and the **Interossei dorsales** abduct the fingers from that line. In addition to this the **Interossei**, in conjunction with the **Lumbricales**, flex the first phalanges at the metacarpophalangeal joints, and extend the second and third phalanges in consequence of their insertions into the expansions of the **Extensor** tendons. The **Extensor digitorum communis** is believed to act almost entirely on the first phalanges.

THE MUSCLES AND FASCIÆ OF THE LOWER EXTREMITY.

The muscles of the lower extremity are subdivided into groups corresponding with the different regions of the limb.

I. Muscles of the Iliac Region.

II. Muscles of the Thigh.

III. Muscles of the Leg.

IV. Muscles of the Foot.

I. THE MUSCLES AND FASCIAE OF THE ILIAC REGION (Fig. 430).

Psoas major. Psoas minor. Iliacus.

The Fascia Covering the Psoas and Iliacus is thin above, and becomes gradually thicker below as it approaches the inguinal ligament.

The portion covering the Psoas is thickened above to form the medial lumbocostal arch, which stretches from the transverse process of the first lumbar vertebra to the body of the second. *Medially*, it is attached by a series of arched processes to the intervertebral fibrocartilages, and prominent margins of the bodies of the vertebræ, and to the upper part of the sacrum; the intervals left, opposite the constricted portions of the bodies, transmit the lumbar arteries and veins and filaments of the sympathetic trunk. *Laterally*, above the crest of the ilium, it is continuous with the fascia covering the front of the Quadratus lumborum (see page 419), while below the crest of the ilium it is continuous with the fascia covering the Iliacus.

The portions investing the Iliacus (*fascia iliaca; iliac fascia*) is connected, *laterally* to the whole length of the inner lip of the iliac crest; and *medially*, to the linea terminalis of the lesser pelvis, where it is continuous with the periosteum. At the iliopectineal eminence it receives the tendon of insertion of the Psoas minor, when that muscle exists. Lateral to the femoral vessels it is intimately connected to the posterior margin of the inguinal ligament, and is continuous with the transversalis fascia. Immediately lateral to the femoral vessels the iliac fascia is prolonged backward and medialward from the inguinal ligament as a band, the *iliopectineal fascia*, which is attached to the iliopectineal eminence. This fascia divides the space between the inguinal ligament and the hip bone into two lacunæ or compartments, the medial of which transmits the femoral vessels, the lateral the Psoas major and Iliacus and the femoral nerve. Medial to the vessels the iliac fascia is attached to the pectineal line behind the inguinal aponeurotic falx, where it is again continuous with the transversalis fascia. On the thigh the fasciæ of the Iliacus and Psoas form a single sheet termed the *iliopectineal fascia*. Where the external iliac vessels pass into the thigh, the fascia descends behind them, forming the posterior wall of the femoral sheath. The portion of the iliopectineal fascia which passes behind

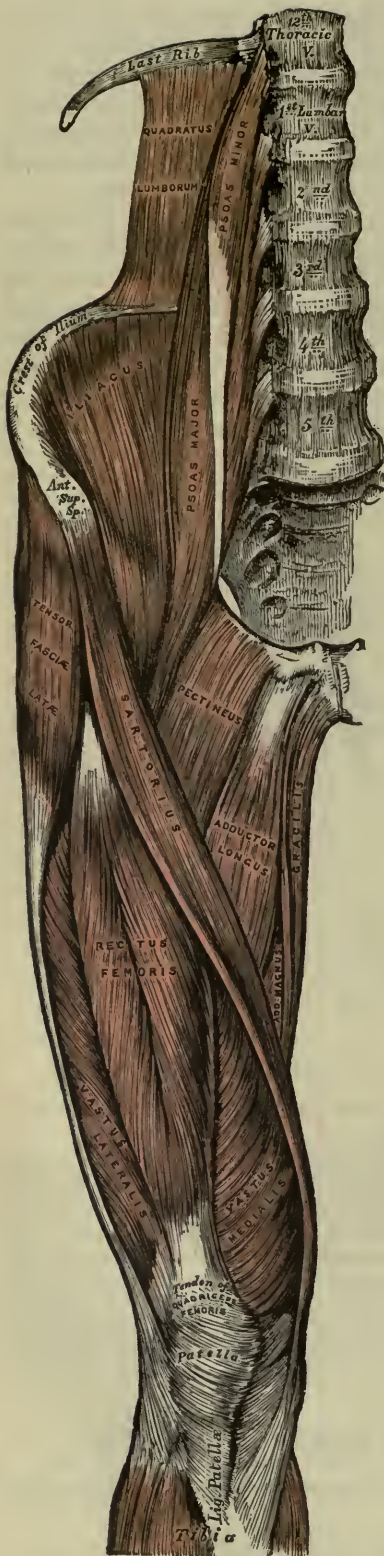

FIG. 430—Muscles of the iliac and anterior femoral regions.

the femoral vessels is also attached to the pectineal line beyond the limits of the attachment of the inguinal aponeurotic falx; at this part it is continuous with the pectineal fascia. The external iliac vessels lie in front of the iliac fascia, but all the branches of the lumbar plexus are behind it; it is separated from the peritoneum by a quantity of loose areolar tissue.

The **Psoas major** (*Psoas magnus*) (Fig. 430) is a long fusiform muscle placed on the side of the lumbar region of the vertebral column and brim of the lesser pelvis. It *arises* (1) from the anterior surfaces of the bases and lower borders of the transverse processes of all the lumbar vertebræ; (2) from the sides of the bodies and the corresponding intervertebral fibrocartilages of the last thoracic and all the lumbar vertebræ by five slips, each of which is attached to the adjacent upper and lower margins of two vertebræ, and to the intervertebral fibrocartilage; (3) from a series of tendinous arches which extend across the constricted parts of the bodies of the lumbar vertebræ between the previous slips; the lumbar arteries and veins, and filaments from the sympathetic trunk pass beneath these tendinous arches. The muscle proceeds downward across the brim of the lesser pelvis, and diminishing gradually in size, passes beneath the inguinal ligament and in front of the capsule of the hip-joint and ends in a tendon; the tendon receives nearly the whole of the fibers of the Iliacus and is *inserted* into the lesser trochanter of the femur. A large bursa which may communicate with the cavity of the hip-joint, separates the tendon from the pubis and the capsule of the joint.

The **Psoas minor** (*Psoas parvus*) is a long slender muscle, placed in front of the Psoas major. It *arises* from the sides of the bodies of the twelfth thoracic and first lumbar vertebræ and from the fibrocartilage between them. It ends in a long flat tendon which is *inserted* into the pectineal line and iliopectineal eminence, and, by its lateral border, into the iliac fascia. This muscle is often absent.

The **Iliacus** is a flat, triangular muscle, which fills the iliac fossa. It *arises* from the upper two-thirds of this fossa, and from the inner lip of the iliac crest; behind, from the anterior sacroiliac and the iliolumbar ligaments, and base of the sacrum; in front, it reaches as far as the anterior superior and anterior inferior iliac spines, and the notch between them. The fibers converge to be inserted into the lateral side of the tendon of the Psoas major, some of them being prolonged on to the body of the femur for about 2.5 cm. below and in front of the lesser trochanter.¹

Variations.—The *Iliacus minor* or *Iliocapsularis*, a small detached part of the Iliacus is frequently present. It arises from the anterior inferior spine of the ilium and is inserted into the lower part of the intertrochanteric line of the femur or into the iliofemoral ligament.

Nerves.—The Psoas major is supplied by branches of the second and third lumbar nerve; the Psoas minor by a branch of the first lumbar nerve; and the Iliacus by branches of the second and third lumbar nerves through the femoral nerve.

Actions.—The Psoas major, acting from above, flexes the thigh upon the pelvis, being assisted by the Iliacus; acting from below, with the femur fixed, it bends the lumbar portion of the vertebral column forward and to its own side, and then, in conjunction with the Iliacus, tilts the pelvis forward. When the muscles of both sides are acting from below, they serve to maintain the erect posture by supporting the vertebral column and pelvis upon the femora, or in continued bend the trunk and pelvis forward, as in raising the trunk from the recumbent posture.

The Psoas minor is a tensor of the iliac fascia.

II. THE MUSCLES AND FASCIÆ OF THE THIGH.

1. The Anterior Femoral Muscles (Fig. 430).

Sartorius.	Quadriceps femoris.	{ Rectus femoris. Vastus lateralis. Vastus medialis. Vastus intermedius.
	Articularis genu.	

¹ The Psoas major and iliacus are sometimes regarded as a single muscle named the *Iliopsoas*.

Superficial Fascia.—The superficial fascia forms a continuous layer over the whole of the thigh; it consists of areolar tissue containing in its meshes much fat, and may be separated into two or more layers, between which are found the superficial vessels and nerves. It varies in thickness in different parts of the limb; in the groin it is thick, and the two layers are separated from one another by the superficial inguinal lymph glands, the great saphenous vein, and several smaller vessels. The superficial layer is continuous above with the superficial fascia of the abdomen. The deep layer of the superficial fascia is a very thin, fibrous stratum, best marked on the medial side of the great saphenous vein and below the inguinal ligament. It is placed beneath the subcutaneous vessels and nerves and upon the surface of the fascia lata. It is intimately adherent to the fascia lata a little below the inguinal ligament. It covers the *fossa ovalis* (*saphenous opening*), being closely united to its circumference, and is connected to the sheath of the femoral vessels. The portion of fascia covering this fossa is perforated by the great saphenous vein and by numerous blood and lymphatic vessels, hence it has been termed the *fascia cribrosa*, the openings for these vessels having been likened to the holes in a sieve. A large subcutaneous bursa is found in the superficial fascia over the patella.

Deep Fascia.—The deep fascia of the thigh is named, from its great extent, the *fascia lata*; it constitutes an investment for the whole of this region of the limb, but varies in thickness in different parts. Thus, it is thicker in the upper and lateral part of the thigh, where it receives a fibrous expansion from the *Glutæus maximus*, and where the *Tensor fasciæ latæ* is inserted between its layers; it is very thin behind and at the upper and medial part, where it covers the *Adductor* muscles, and again becomes stronger around the knee, receiving fibrous expansions from the tendon of the *Biceps femoris* laterally, from the *Sartorius* medially, and from the *Quadriceps femoris* in front. The *fascia lata* is attached, above and behind, to the back of the sacrum and coccyx; laterally, to the iliac crest; in front, to the inguinal ligament, and to the superior ramus of the pubis; and medially, to the inferior ramus of the pubis, to the inferior ramus and tuberosity of the ischium, and to the lower border of the sacrotuberous ligament. From its attachment to the iliac crest it passes down over the *Glutæus medius* to the upper border of the *Glutæus maximus*, where it splits into two layers, one passing superficial to and the other beneath this muscle; at the lower border of the muscle the two layers reunite. Laterally, the *fascia lata* receives the greater part of the tendon of insertion of the *Glutæus maximus*, and becomes proportionately thickened. The portion of the *fascia lata* attached to the front part of the iliac crest, and corresponding to the origin of the *Tensor fasciæ latæ*, extends down the lateral side of the thigh as two layers, one superficial to and the other beneath this muscle; at the lower end of the muscle these two layers unite and form a strong band, having first received the insertion of the muscle. This band is continued downward, under the name of the *iliotibial band* (*tractus iliotibialis*) and is attached to the lateral condyle of the tibia. The part of the *iliotibial band* which lies beneath the *Tensor fasciæ latæ* is prolonged upward to join the lateral part of the capsule of the hip-joint. Below, the *fasciæ lata* is attached to all the prominent points around the knee-joint, viz., the condyles of the femur and tibia, and the head of the fibula. On either side of the patella it is strengthened by transverse fibers from the lower parts of the *Vasti*, which are attached to and support this bone. Of these the lateral are the stronger, and are continuous with the *iliotibial band*. The deep surface of the *fascia lata* gives off two strong intermuscular septa, which are attached to the whole length of the *linea aspera* and its prolongations above and below; the lateral and stronger one, which extends from the insertion of the *Glutæus maximus* to the lateral condyle, separates the *Vastus lateralis* in front from the short head of the *Biceps femoris* behind, and gives partial origin to these muscles; the medial and thinner one separates the *Vastus medialis* from the *Adduc-*

tores and Pectineus. Besides these there are numerous smaller septa, separating the individual muscles, and enclosing each in a distinct sheath.

The Fossa Ovalis (*saphenous opening*) (Fig. 431).—At the upper and medial part of the thigh, a little below the medial end of the inguinal ligament, is a large oval-shaped aperture in the fascia lata; it transmits the great saphenous vein, and other, smaller vessels, and is termed the **fossa ovalis**. The fascia cribrosa, which is pierced by the structures passing through the opening, closes the aperture and must be removed to expose it. The fascia lata in this part of the thigh is described as consisting of a superficial and a deep portion.

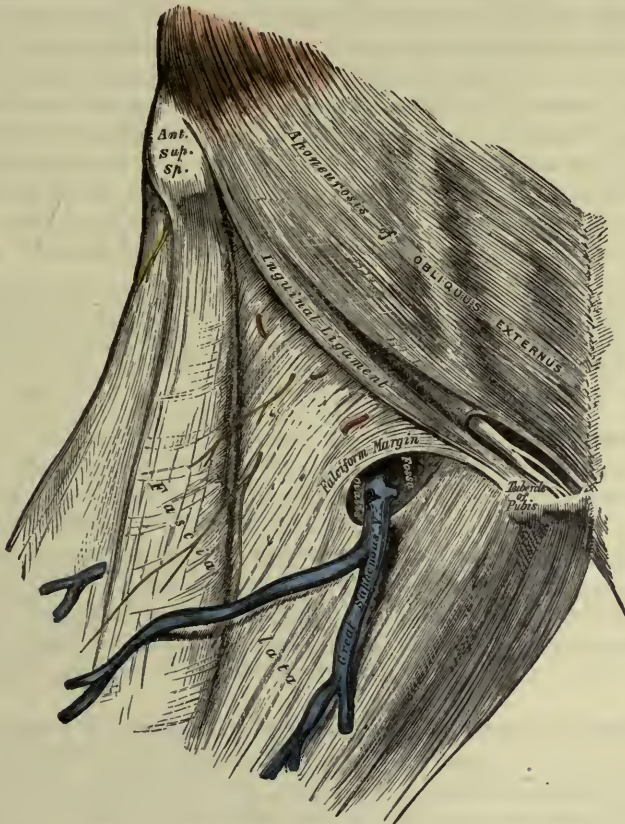


FIG. 431.—The fossa ovalis.

The **superficial portion** of the fascia lata is the part on the lateral side of the fossa ovalis. It is attached, *laterally*, to the crest and anterior superior spine of the ilium, to the whole length of the inguinal ligament, and to the pectineal line in conjunction with the lacunar ligament. From the tubercle of the pubis it is reflected downward and lateralward, as an arched margin, the **falciform margin**, forming the lateral boundary of the fossa ovalis; this margin overlies and is adherent to the anterior layer of the sheath of the femoral vessels: to its edge is attached the fascia cribrosa. The upward and medial prolongation of the falciform margin is named the **superior cornu**; its downward and medial prolongation, the **inferior cornu**. The latter is well-defined, and is continuous behind the great saphenous vein with the pectineal fascia.

The **deep portion** is situated on the medial side of the fossa ovalis, and at the lower margin of the fossa is continuous with the superficial portion; traced upward,

it covers the Pectineus, Adductor longus, and Gracilis, and, passing behind the sheath of the femoral vessels, to which it is closely united, is continuous with the iliopectineal fascia, and is attached to the pectineal line.

From this description it may be observed that the superficial portion of the fascia lata lies in front of the femoral vessels, and the deep portion behind them, so that an apparent aperture exists between the two, through which the great saphenous passes to join the femoral vein.

The **Sartorius**, the longest muscle in the body, is narrow and ribbon-like; it arises by tendinous fibers from the anterior superior iliac spine and the upper half of the notch below it. It passes obliquely across the upper and anterior part of the thigh, from the lateral to the medial side of the limb, then descends vertically, as far as the medial side of the knee, passing behind the medial condyle of the femur to end in a tendon. This curves obliquely forward and expands into a broad aponeurosis, which is inserted, in front of the Gracilis and Semitendinosus, into the upper part of the medial surface of the body of the tibia, nearly as far forward as the anterior crest. The upper part of the aponeurosis is curved backward over the upper edge of the tendon of the Gracilis so as to be inserted behind it. An offset, from its upper margin, blends with the capsule of the knee-joint, and another from its lower border, with the fascia on the medial side of the leg.

Variations.—Slips of origin from the outer end of the inguinal ligament, the notch of the ilium, the ilio-pectineal line or the pubis occur. The muscle may be split into two parts, and one part may be inserted into the fascia lata, the femur, the ligament of the patella or the tendon of the Semitendinosus. The tendon of insertion may end in the fascia lata, the capsule of the knee-joint, or the fascia of the leg. The muscle may be absent.

The **Quadriceps femoris** (*Quadriceps extensor*) includes the four remaining muscles on the front of the thigh. It is the great extensor muscle of the leg, forming a large fleshy mass which covers the front and sides of the femur. It is subdivided into separate portions, which have received distinctive names. One occupying the middle of the thigh, and connected above with the ilium, is called from its straight course the **Rectus femoris**. The other three lie in immediate connection with the body of the femur, which they cover from the trochanters to the condyles. The portion on the lateral side of the femur is termed the **Vastus lateralis**; that covering the medial side, the **Vastus medialis**; and that in front, the **Vastus intermedius**.

The **Rectus femoris** is situated in the middle of the front of the thigh; it is fusiform in shape, and its superficial fibers are arranged in a bipenniform manner, the deep fibers running straight down to the deep aponeurosis. It arises by two tendons: one, the anterior or straight, from the anterior inferior iliac spine; the other, the posterior or reflected, from a groove above the brim of the acetabulum. The two unite at an acute angle, and spread into an aponeurosis which is prolonged downward on the anterior surface of the muscle, and from this the muscular fibers arise. The muscle ends in a broad and thick aponeurosis which occupies the lower two-thirds of its posterior surface, and, gradually becoming narrowed into a flat-tendon, is inserted into the base of the patella.

The **Vastus lateralis** (*Vastus externus*) is the largest part of the Quadriceps femoris. It arises by a broad aponeurosis, which is attached to the upper part of the intertrochanteric line, to the anterior and inferior borders of the greater trochanter, to the lateral lip of the gluteal tuberosity, and to the upper half of the lateral lip of the linea aspera; this aponeurosis covers the upper three-fourths of the muscle, and from its deep surface many fibers take origin. A few additional fibers arise from the tendon of the Gluteus maximus, and from the lateral intermuscular septum between the Vastus lateralis and short head of the Biceps femoris. The fibers form a large fleshy mass, which is attached to a strong aponeurosis, placed on the deep surface of the lower part of the muscle: this aponeurosis becomes

contracted and thickened into a flat tendon inserted into the lateral border of the patella, blending with the Quadriceps femoris tendon, and giving an expansion to the capsule of the knee-joint.

The *Vastus medialis* and *Vastus intermedius* appear to be inseparably united, but when the *Rectus femoris* has been reflected a narrow interval will be observed extending upward from the medial border of the patella between the two muscles, and the separation may be continued as far as the lower part of the intertrochanteric line, where, however, the two muscles are frequently continuous.

The *Vastus medialis* (*Vastus internus*) arises from the lower half of the intertrochanteric line, the medial lip of the linea aspera, the upper part of the medial supracondylar line, the tendons of the *Adductor longus* and the *Adductor magnus* and the medial intermuscular septum. Its fibers are directed downward and forward, and are chiefly attached to an aponeurosis which lies on the deep surface of the muscle and is inserted into the medial border of the patella and the *Quadriceps femoris* tendon, an expansion being sent to the capsule of the knee-joint.

The *Vastus intermedius* (*Crureus*) arises from the front and lateral surfaces of the body of the femur in its upper two-thirds and from the lower part of the lateral intermuscular septum. Its fibers end in a superficial aponeurosis, which forms the deep part of the *Quadriceps femoris* tendon.

The tendons of the different portions of the *Quadriceps* unite at the lower part of the thigh, so as to form a single strong tendon, which is inserted into the base of the patella, some few fibers passing over it to blend with the *ligamentum patellæ*. More properly, the patella may be regarded as a sesamoid bone, developed in the tendon of the *Quadriceps*; and the *ligamentum patellæ*, which is continued from the apex of the patella to the tuberosity of the tibia, as the proper tendon of insertion of the muscle, the medial and lateral patellar retinacula (see p. 338) being expansions from its borders. A bursa, which usually communicates with the cavity of the knee-joint, is situated between the femur and the portion of the *Quadriceps* tendon above the patella; another is interposed between the tendon and the upper part of the front of the tibia; and a third, the *prepatellar bursa*, is placed over the patella itself.

The *Articularis genu* (*Subcrureus*) is a small muscle, usually distinct from the *Vastus intermedius*, but occasionally blended with it; it arises from the anterior surface of the lower part of the body of the femur, and is inserted into the upper part of the synovial membrane of the knee-joint. It sometimes consists of several separate muscular bundles.

Nerves.—The muscles of this region are supplied by the second, third, and fourth lumbar nerves, through the femoral nerve.

Actions.—The *Sartorius* flexes the leg upon the thigh, and, continuing to act, flexes the thigh upon the pelvis; it next abducts and rotates the thigh outward. When the knee is bent, the *Sartorius* assists the *Semitendinosus*, *Semimembranosus*, and *Popliteus* in rotating the tibia inward. Taking its fixed point from the leg, it flexes the pelvis upon the thigh, and, if one muscle acts, assists in rotating the pelvis. The *Quadriceps femoris* extends the leg upon the thigh. The *Rectus femoris* assists the *Psoas major* and *Iliacus* in supporting the pelvis and trunk upon the femur. It also assists in flexing the thigh on the pelvis, or if the thigh be fixed it will flex the pelvis. The *Vastus medialis* draws the patella medialward as well as upward.

2. The Medial Femoral Muscles.

Gracilis.

Adductor longus.

Adductor magnus.

Pectineus.

Adductor brevis.

The *Gracilis* (Fig. 430) is the most superficial muscle on the medial side of the thigh. It is thin and flattened, broad above, narrow and tapering below. It arises by a thin aponeurosis from the anterior margins of the lower half of the symphysis pubis and the upper half of the pubic arch. The fibers run vertically downward, and end in a rounded tendon, which passes behind the medial condyle of the femur, curves around the medial condyle of the tibia, where it becomes flat-

tened, and is *inserted* into the upper part of the medial surface of the body of the tibia, below the condyle. A few of the fibers of the lower part of the tendon are prolonged into the deep fascia of the leg. At its insertion the tendon is situated immediately above that of the Semitendinosus, and its upper edge is overlapped by the tendon of the Sartorius, with which it is in part blended. It is separated from the tibial collateral ligament of the knee-joint, by a bursa common to it and the tendon of the Semitendinosus.

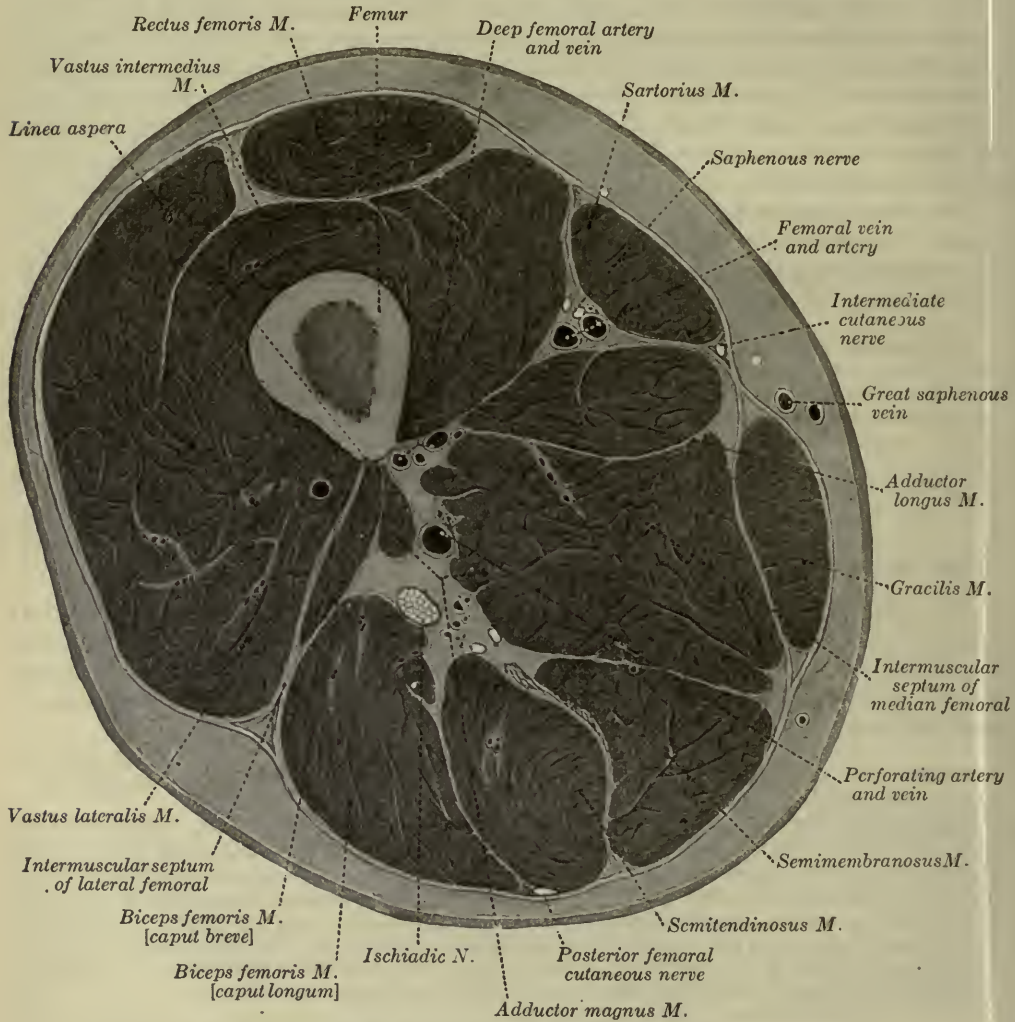


FIG. 432.—Cross-section through the middle of the thigh. (Eycleshymer and Schoemaker.)

The **Pectineus** (Fig. 430) is a flat, quadrangular muscle, situated at the anterior part of the upper and medial aspect of the thigh. It *arises* from the pectineal line, and to a slight extent from the surface of bone in front of it, between the iliopectineal eminence and tubercle of the pubis, and from the fascia covering the anterior surface of the muscle; the fibers pass downward, backward, and lateralward, to be inserted into a rough line leading from the lesser trochanter to the linea aspera.

The **Adductor longus** (Fig. 433), the most superficial of the three Adductores, is a triangular muscle, lying in the same plane as the Pectineus. It *arises* by a flat, narrow tendon, from the front of the pubis, at the angle of junction of the crest

with the symphysis; and soon expands into a broad fleshy belly. This passes downward, backward, and lateralward, and is *inserted*, by an aponeurosis, into the *linea aspera*, between the *Vastus medialis* and the *Adductor magnus*, with both of which it is usually blended.

The **Adductor brevis** (Fig. 433) is situated immediately behind the two preceding muscles. It is somewhat triangular in form, and *arises* by a narrow origin from the outer surfaces of the superior and inferior rami of the pubis, between the *Gracilis* and *Obturator externus*. Its fibers, passing backward, lateralward, and downward, are *inserted*, by an aponeurosis, into the line leading from the lesser trochanter to the *linea aspera* and into the upper part of the *linea aspera*, immediately behind the *Pectineus* and upper part of the *Adductor longus*.

The **Adductor magnus** (Fig. 433) is a large triangular muscle, situated on the medial side of the thigh. It *arises* from a small part of the inferior ramus of the pubis, from the inferior ramus of the ischium, and from the outer margin of the inferior part of the tuberosity of the ischium. Those fibers which arise from the ramus of the pubis are short, horizontal in direction, and are inserted into the rough line leading from the greater trochanter to the *linea aspera*, medial to the *Glutæus maximus*; those from the ramus of the ischium are directed downward and lateralward with different degrees of obliquity, to be *inserted*, by means of a broad aponeurosis, into the *linea aspera* and the upper part of its medial prolongation below. The medial portion of the muscle, composed principally of the fibers arising from the tuberosity of the ischium, forms a thick fleshy mass consisting of coarse bundles which descend almost vertically, and end about the lower third of the thigh in a rounded tendon which is inserted into the adductor tubercle on the medial condyle of the femur, and is connected by a fibrous expansion to the line leading upward from the tubercle to the *linea aspera*. At the *insertion* of the muscle, there is a series of osseoaponeurotic openings, formed by tendinous arches attached to the bone. The upper four openings are small, and give passage to the perforating branches of the profunda femoris artery. The lowest is of large size, and transmits the femoral vessels to the popliteal fossa.

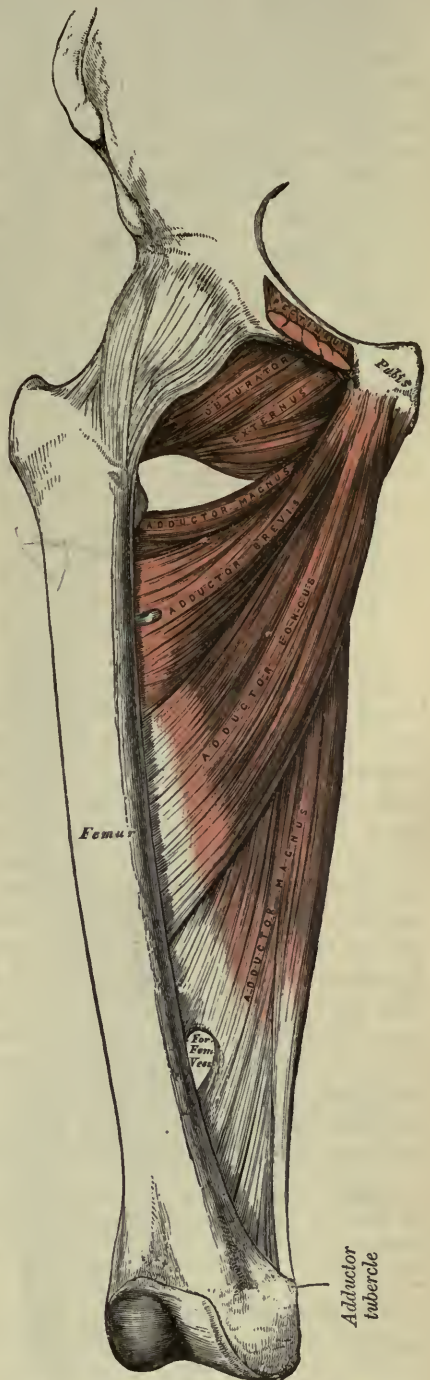


FIG. 433.—Deep muscles of the medial femoral region.

Variations.—The *Pectineus* is sometimes divided into an outer part supplied by the femoral nerve and an inner part supplied by the obturator nerve. The muscle may be attached to or inserted into the capsule of the hip-joint. The *Adductor longus* may be double, may extend to the knee, or be more or less united with the *Pectineus*. The *Adductor brevis* may be divided into two or three parts, or it may be united to the *Adductor magnus*. The *Adductor magnus* may be more or less segmented, the anterior and superior portion is often described as a separate muscle, the *Adductor minimus*. The muscle may be fused with the *Quadratus femoris*.

Nerves.—The three *Adductores* and the *Gracilis* are supplied by the third and fourth lumbar nerves through the obturator nerve; the *Adductor magnus* receiving an additional branch from the sacral plexus through the sciatic. The *Pectineus* is supplied by the second, third, and fourth lumbar nerves through the femoral nerve, and by the third lumbar through the accessory obturator when this latter exists. Occasionally it receives a branch from the obturator nerve.¹

Actions.—The *Pectineus* and three *Adductores* adduct the thigh powerfully; they are especially used in horse exercise, the sides of the saddle being grasped between the knees by the contraction of these muscles. In consequence of the obliquity of their insertions into the *linea aspera*, they rotate the thigh outward, assisting the external Rotators, and when the limb has been abducted, they draw it medialward, carrying the thigh across that of the opposite side. The *Pectineus* and *Adductores brevis* and *longus* assist the *Psoas major* and *Iliacus* in flexing the thigh upon the pelvis. In progression, all these muscles assist in drawing forward the lower limb. The *Gracilis* assists the *Sartorius* in flexing the leg and rotating it inward; it is also an adductor of the thigh. If the lower extremities be fixed, these muscles, taking their fixed points below, may act upon the pelvis, serving to maintain the body in an erect posture; or, if their action be continued, flex the pelvis forward upon the femur.

3. The Muscles of the Gluteal Region (Fig. 434).

Glutæus maximus.	Obturator internus.
Glutæus medius.	Gemellus superior.
Glutæus minimus.	Gemellus inferior.
Tensor fasciæ latæ.	Quadratus femoris.
Piriformis.	Obturator externus.

The **Glutæus maximus**, the most superficial muscle in the gluteal region, is a broad and thick fleshy mass of a quadrilateral shape, and forms the prominence of the nates. Its large size is one of the most characteristic features of the muscular system in man, connected as it is with the power he has of maintaining the trunk in the erect posture. The muscle is remarkably coarse in structure, being made up of fasciculi lying parallel with one another and collected together into large bundles separated by fibrous septa. It *arises* from the posterior gluteal line of the ilium, and the rough portion of bone including the crest, immediately above and behind it; from the posterior surface of the lower part of the sacrum and the side of the coccyx; from the aponeurosis of the *Sacrospinalis*, the sacrotuberous ligament, and the fascia (gluteal aponeurosis) covering the *Glutæus medius*. The fibers are directed obliquely downward and lateralward; those forming the upper and larger portion of the muscle, together with the superficial fibers of the lower portion, end in a thick tendinous lamina, which passes across the greater trochanter, and is *inserted* into the iliotibial band of the fascia lata; the deeper fibers of the lower portion of the muscle are inserted into the gluteal tuberosity between the *Vastus lateralis* and *Adductor magnus*.

Bursæ.—Three *bursæ* are usually found in relation with the deep surface of this muscle. One of these, of large size, and generally multilocular, separates it from the greater trochanter; a second, often wanting, is situated on the tuberosity of the ischium; a third is found between the tendon of the muscle and that of the *Vastus lateralis*.

The **Glutæus medius** is a broad, thick, radiating muscle, situated on the outer surface of the pelvis. Its posterior third is covered by the *Glutæus maximus*, its

¹ The *Pectineus* may consist of two incompletely separated strata; the lateral or dorsal stratum, which is constant, is supplied by a branch from the femoral nerve, or in the absence of this branch by the accessory obturator nerve; the medial or ventral stratum, when present, is supplied by the obturator nerve.—A. M. Paterson. *Journal of Anatomy and Physiology*, xxvi, 43.

anterior two-thirds by the gluteal aponeurosis, which separates it from the superficial fascia and integument. It *arises* from the outer surface of the ilium between the iliac crest and posterior gluteal line above, and the anterior gluteal line below; it also *arises* from the gluteal aponeurosis covering its outer surface. The fibers converge to a strong flattened tendon, which is *inserted* into the oblique ridge which runs downward and forward on the lateral surface of the greater trochanter. A bursa separates the tendon from the surface of the trochanter over which it glides.

Variations.—The posterior border may be more or less closely united to the Piriformis, or some of the fibers end on its tendon.

The **Glutæus minimus**, the smallest of the three Glutæi, is placed immediately beneath the preceding. It is fan-shaped, *arising* from the outer surface of the ilium, between the anterior and inferior gluteal lines, and behind, from the margin of the greater sciatic notch. The fibers converge to the deep surface of a radiated aponeurosis, and this ends in a tendon which is inserted into an impression on the anterior border of the greater trochanter, and gives an expansion to the capsule of the hip-joint. A bursa is interposed between the tendon and the greater trochanter. Between the Glutæus medius and Glutæus minimus are the deep branches of the superior gluteal vessels and the superior gluteal nerve. The deep surface of the Glutæus minimus is in relation with the reflected tendon of the Rectus femoris and the capsule of the hip-joint.

Variations.—The muscle may be divided into an anterior and a posterior part, or it may send slips to the Piriformis, the Gemellus superior or the outer part of the origin of the Vastus lateralis.

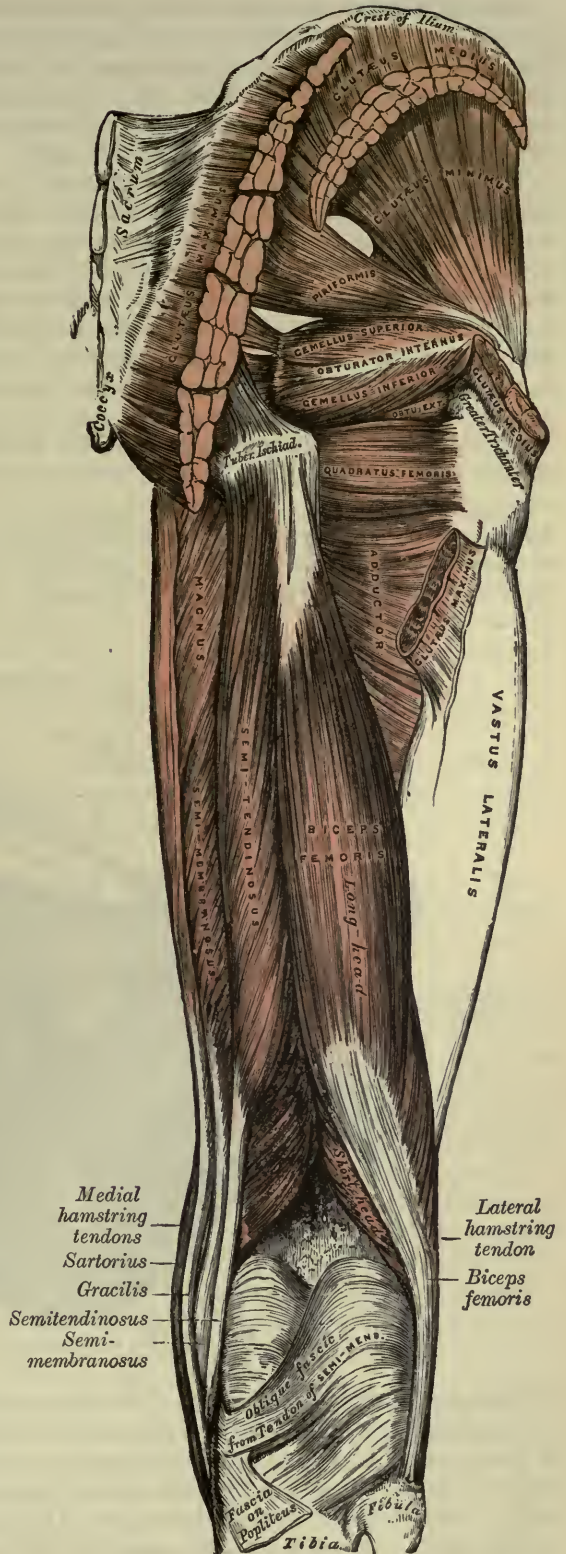


FIG. 434.—Muscles of the gluteal and posterior femoral regions.

The **Tensor fasciæ latæ** (*Tensor fascia femoris*) arises from the anterior part of the outer lip of the iliac crest; from the outer surface of the anterior superior iliac spine, and part of the outer border of the notch below it, between the *Glutæus medius* and *Sartorius*; and from the deep surface of the fascia lata. It is inserted between the two layers of the iliotibial band of the fascia lata about the junction of the middle and upper thirds of the thigh.

The **Piriformis** is a flat muscle, pyramidal in shape, lying almost parallel with the posterior margin of the *Glutæus medius*. It is situated partly within the pelvis against its posterior wall, and partly at the back of the hip-joint. It arises from the front of the sacrum by three fleshy digitations, attached to the portions of bone between the first, second, third, and fourth anterior sacral foramina, and to the grooves leading from the foramina: a few fibers also arise from the margin of the greater sciatic foramen, and from the anterior surface of the sacrotuberous ligament. The muscle passes out of the pelvis through the greater sciatic foramen, the upper part of which it fills, and is inserted by a rounded tendon into the upper border of the greater trochanter behind, but often partly blended with, the common tendon of the *Obturator internus* and *Gemelli*.

Variations.—It is frequently pierced by the common peroneal nerve and thus divided more or less into two parts. It may be united with the *Glutæus medius*, or send fibers to the *Glutæus minimus* or receive fibers from the *Gemellus superior*. It may have only one or two sacral attachments or be inserted into the capsule of the hip-joint. It may be absent.

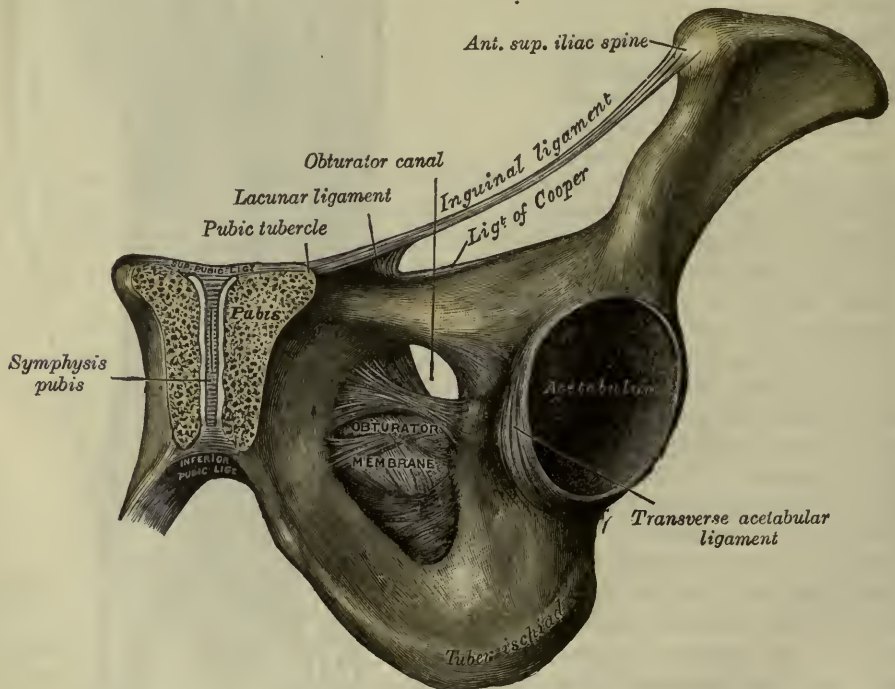


FIG. 435.—The obturator membrane.

Obturator Membrane (Fig. 435).—The obturator membrane is a thin fibrous sheet, which almost completely closes the obturator foramen. Its fibers are arranged in interlacing bundles mainly transverse in direction; the uppermost bundle is attached to the obturator tubercles and completes the obturator canal for the passage of the obturator vessels and nerve. The membrane is attached to the sharp margin of the obturator foramen except at its lower lateral angle, where it is fixed

to the pelvic surface of the inferior ramus of the ischium, *i. e.*, within the margin. Both obturator muscles are connected with this membrane.

The **Obturator internus** is situated partly within the lesser pelvis, and partly at the back of the hip-joint. It *arises* from the inner surface of the antero-lateral wall of the pelvis, where it surrounds the greater part of the obturator foramen, being attached to the inferior rami of the pubis and ischium, and at the side to the inner surface of the hip bone below and behind the pelvic brim, reaching from the upper part of the greater sciatic foramen above and behind to the obturator foramen below and in front. It also arises from the pelvic surface of the obturator membrane except in the posterior part, from the tendinous arch which completes the canal for the passage of the obturator vessels and nerve, and to a slight extent from the obturator fascia, which covers the muscle. The fibers converge rapidly toward the lesser sciatic foramen, and end in four or five tendinous bands, which are found on the deep surface of the muscle; these bands are reflected at a right angle over the grooved surface of the ischium between its spine and tuberosity. This bony surface is covered by smooth cartilage, which is separated from the tendon by a bursa, and presents one or more ridges corresponding with the furrows between the tendinous bands. These bands leave the pelvis through the lesser sciatic foramen and unite into a single flattened tendon, which passes horizontally across the capsule of the hip-joint, and, after receiving the attachments of the Gemelli, is *inserted* into the forepart of the medial surface of the greater trochanter above the trochanteric fossa. A bursa, narrow and elongated in form, is usually found between the tendon and the capsule of the hip-joint; it occasionally communicates with the bursa between the tendon and the ischium.

The **Gemelli** are two small muscular fasciculi, accessories to the tendon of the Obturator internus which is received into a groove between them.

The **Gemellus superior**, the smaller of the two, *arises* from the outer surface of the spine of the ischium, blends with the upper part of the tendon of the Obturator internus, and is *inserted* with it into the medial surface of the greater trochanter. It is sometimes wanting.

The **Gemellus inferior** *arises* from the upper part of the tuberosity of the ischium, immediately below the groove for the Obturator internus tendon. It blends with the lower part of the tendon of the Obturator internus, and is *inserted* with it into the medial surface of the greater trochanter. Rarely absent.

The **Quadratus femoris** is a flat, quadrilateral muscle, between the Gemellus inferior and the upper margin of the Adductor magnus; it is separated from the latter by the terminal branches of the medial femoral circumflex vessels. It *arises* from the upper part of the external border of the tuberosity of the ischium, and is *inserted* into the upper part of the linea quadrata—that is, the line which extends vertically downward from the intertrochanteric crest. A bursa is often found between the front of this muscle and the lesser trochanter. Sometimes absent.

The **Obturator externus** (Fig. 436) is a flat, triangular muscle, which covers the outer surface of the anterior wall of the pelvis. It *arises* from the margin of bone immediately around the medial side of the obturator foramen, *viz.*, from the rami of the pubis, and the inferior ramus of the ischium; it also arises from the medial two-thirds of the outer surface of the obturator membrane, and from the tendinous arch which completes the canal for the passage of the obturator vessels and nerves. The fibers springing from the pubic arch extend on to the inner surface of the bone, where they obtain a narrow origin between the margin of the foramen and the attachment of the obturator membrane. The fibers converge and pass backward, lateralward, and upward, and end in a tendon which runs across the back of the neck of the femur and lower part of the capsule of the hip-joint and is *inserted* into the trochanteric fossa of the femur. The obturator vessels lie between the muscle and the obturator membrane; the anterior branch of the

obturator nerve reaches the thigh by passing in front of the muscle, and the posterior branch by piercing it.

Nerves.—The *Glutæus maximus* is supplied by the fifth lumbar and first and second sacra nerves through the inferior gluteal nerve; the *Glutæi medius* and *minimus* and the *Tensor fasciæ latæ* by the fourth and fifth lumbar and first sacral nerves through the superior gluteal; the *Piriformis* is supplied by the first and second sacral nerves; the *Gemellus inferior* and *Quadratus femoris* by the last lumbar and first sacral nerves; the *Gemellus superior* and *Obturator internus* by the first, second, and third sacral nerves, and the *Obturator externus* by the third and fourth lumbar nerves through the obturator.

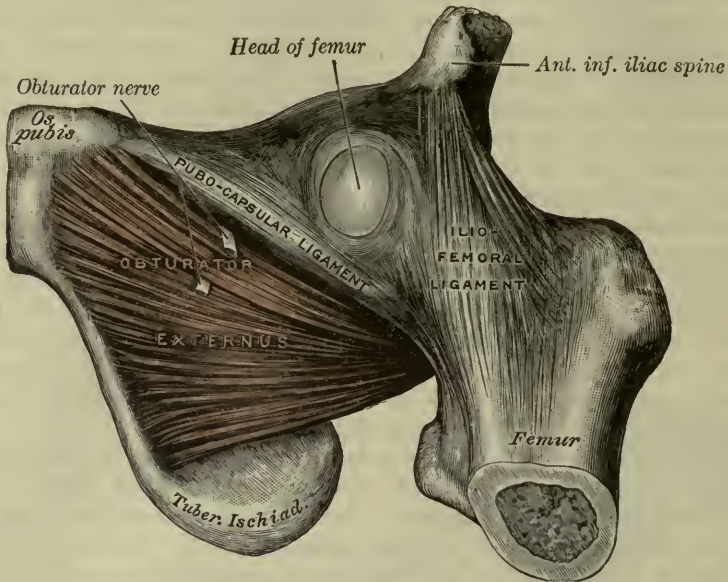


FIG. 436.—The *Obturator externus*.

Actions.—When the *Glutæus maximus* takes its fixed point from the pelvis, it extends the femur and brings the bent thigh into a line with the body. Taking its fixed point from below, it acts upon the pelvis, supporting it and the trunk upon the head of the femur; this is especially obvious in standing on one leg. Its most powerful action is to cause the body to regain the erect position after stooping, by drawing the pelvis backward, being assisted in this action by the *Biceps femoris*, *Semitendinosus*, and *Semimembranosus*. The *Glutæus maximus* is a tensor of the fascia lata, and by its connection with the iliotibial band steadies the femur on the articular surfaces of the tibia during standing, when the *Extensor muscles* are relaxed. The lower part of the muscle also acts as an adductor and external rotator of the limb. The *Glutæi medius* and *minimus* abduct the thigh, when the limb is extended, and are principally called into action in supporting the body on one limb, in conjunction with the *Tensor fasciæ latæ*. Their anterior fibers, by drawing the greater trochanter forward, rotate the thigh inward, in which action they are also assisted by the *Tensor fasciæ latæ*. The *Tensor fasciæ latæ* is a tensor of the fascia lata; continuing its action, the oblique direction of its fibers enables it to abduct the thigh and to rotate it inward. In the erect posture, acting from below, it will serve to steady the pelvis upon the head of the femur; and by means of the iliotibial band it steadies the condyles of the femur on the articular surfaces of the tibia, and assists the *Glutæus maximus* in supporting the knee in the extended position. The remaining muscles are powerful external rotators of the thigh. In the sitting posture, when the thigh is flexed upon the pelvis, their action as rotators ceases, and they become abductors, with the exception of the *Obturator externus*, which still rotates the femur outward.

4. The Posterior Femoral Muscles (Hamstring Muscles) (Fig. 434).

Biceps femoris.

Semitendinosus.

Semimembranosus.

The *Biceps femoris* (*Biceps*) is situated on the posterior and lateral aspect of the thigh. It has two heads of origin; one, the *long head*, *arises* from the lower and inner

impression on the back part of the tuberosity of the ischium, by a tendon common to it and the Semitendinosus, and from the lower part of the sacrotuberous ligament; the other, the **short head**, *arises* from the lateral lip of the linea aspera, between the Adductor magnus and Vastus lateralis, extending up almost as high as the insertion of the Glutæus maximus; from the lateral prolongation of the linea aspera to within 5 cm. of the lateral condyle; and from the lateral intermuscular septum. The fibers of the long head form a fusiform belly, which passes obliquely downward and lateralward across the sciatic nerve to end in an aponeurosis which covers the posterior surface of the muscle, and receives the fibers of the short head; this aponeurosis becomes gradually contracted into a tendon, which is *inserted* into the lateral side of the head of the fibula, and by a small slip into the lateral condyle of the tibia. At its insertion the tendon divides into two portions, which embrace the fibular collateral ligament of the knee-joint. From the posterior border of the tendon a thin expansion is given off to the fascia of the leg. The tendon of insertion of this muscle forms the lateral hamstring; the common peroneal nerve descends along its medial border.

Variations.—The short head may be absent; additional heads may arise from the ischial tuberosity, the linea aspera, the medial supracondylar ridge of the femur or from various other parts. A slip may pass to the Gastrocnemius.

The **Semitendinosus**, remarkable for the great length of its tendon of insertion, is situated at the posterior and medial aspect of the thigh. It *arises* from the lower and medial impression on the tuberosity of the ischium, by a tendon common to it and the long head of the Biceps femoris; it also arises from an aponeurosis which connects the adjacent surfaces of the two muscles to the extent of about 7.5 cm. from their origin. The muscle is fusiform and ends a little below the middle of the thigh in a long round tendon which lies along the medial side of the popliteal fossa; it then curves around the medial condyle of the tibia and passes over the tibial collateral ligament of the knee-joint, from which it is separated by a bursa, and is *inserted* into the upper part of the medial surface of the body of the tibia, nearly as far forward as its anterior crest. At its insertion it gives off from its lower border a prolongation to the deep fascia of the leg and lies behind the tendon of the Sartorius, and below that of the Gracilis, to which it is united. A tendinous intersection is usually observed about the middle of the muscle.

The **Semimembranosus**, so called from its membranous tendon of origin, is situated at the back and medial side of the thigh. It *arises* by a thick tendon from the upper and outer impression on the tuberosity of the ischium, above and lateral to the Biceps femoris and Semitendinosus. The tendon of origin expands into an aponeurosis, which covers the upper part of the anterior surface of the muscle; from this aponeurosis muscular fibers arise, and converge to another aponeurosis which covers the lower part of the posterior surface of the muscle and contracts into the tendon of insertion. It is inserted mainly into the horizontal groove on the posterior medial aspect of the medial condyle of the tibia. The tendon of insertion gives off certain fibrous expansions: one, of considerable size, passes upward and lateralward to be *inserted* into the back part of the lateral condyle of the femur, forming part of the oblique popliteal ligament of the knee-joint; a second is continued downward to the fascia which covers the Popliteus muscle; while a few fibers join the tibial collateral ligament of the joint and the fascia of the leg. The muscle overlaps the upper part of the popliteal vessels.

Variations.—It may be reduced or absent, or double, arising mainly from the sacrotuberous ligament and giving a slip to the femur or Adductor magnus.

The tendons of insertion of the two preceding muscles form the medial hamstrings.

Nerves.—The muscles of this region are supplied by the fourth and fifth lumbar and the first, second, and third sacral nerves; the nerve to the short head of the Biceps femoris is derived from the common peroneal, the other muscles are supplied through the tibial nerve.

Actions.—The hamstring muscles flex the leg upon the thigh. When the knee is semiflexed, the Biceps femoris in consequence of its oblique direction rotates the leg slightly outward; and the Semitendinosus, and to a slight extent the Semimembranosus, rotate the leg inward, assisting the Popliteus. Taking their fixed point from below, these muscles serve to support the pelvis upon the head of the femur, and to draw the trunk directly backward, as in raising it from the stooping position or in feats of strength, when the body is thrown backward in the form of an arch. As already indicated on page 285, complete flexion of the hip cannot be effected unless the knee-joint is also flexed, on account of the shortness of the hamstring muscles.

III. THE MUSCLES AND FASCIÆ OF THE LEG.

The muscles of the leg may be divided into three groups: anterior, posterior, and lateral.

1. The Anterior Crural Muscles (Fig. 437).

Tibialis anterior.

Extensor hallucis longus.

Extensor digitorum longus.

Peronæus tertius.

Deep Fascia (*fascia cruris*).—The deep fascia of the leg forms a complete investment to the muscles, and is fused with the periosteum over the subcutaneous surfaces of the bones. It is continuous *above* with the fascia lata, and is attached around the knee to the patella, the ligamentum patellæ, the tuberosity and condyles of the tibia, and the head of the fibula. *Behind*, it forms the popliteal fascia, covering in the popliteal fossa; here it is strengthened by transverse fibers, and perforated by the small saphenous vein. It receives an expansion from the tendon of the Biceps femoris laterally, and from the tendons of the Sartorius, Gracilis, Semitendinosus, and Semimembranosus medially; in *front*, it blends with the periosteum covering the subcutaneous surface of the tibia, and with that covering the head and malleolus of the fibula; below, it is continuous with the transverse crural and laciniated ligaments. It is thick and dense in the upper and anterior part of the leg, and gives attachment, by its deep surface, to the Tibialis anterior and Extensor digitorum longus; but thinner behind, where it covers the Gastrocnemius and Soleus. It gives off from its deep surface, on the lateral side of the leg, two strong intermuscular septa, the **anterior** and **posterior peroneal septa**, which enclose the Peronæi longus and brevis, and separate them from the muscles of the anterior and posterior crural regions, and several more slender processes which enclose the individual muscles in each region. A broad transverse intermuscular septum, called the **deep transverse fascia of the leg**, intervenes between the superficial and deep posterior crural muscles.

The **Tibialis anterior** (*Tibialis anticus*) is situated on the lateral side of the tibia; it is thick and fleshy above, tendinous below. It *arises* from the lateral condyle and upper half or two-thirds of the lateral surface of the body of the tibia; from the adjoining part of the interosseous membrane; from the deep surface of the fascia; and from the intermuscular septum between it and the Extensor digitorum longus. The fibers run vertically downward, and end in a tendon, which is apparent on the anterior surface of the muscle at the lower third of the leg. After passing through the most medial compartments of the transverse and cruciate crural ligaments, it is *inserted* into the medial and under surface of the first cuneiform bone, and the base of the first metatarsal bone. This muscle overlaps the anterior tibial vessels and deep peroneal nerve in the upper part of the leg.

Variations.—A deep portion of the muscle is rarely inserted into the talus, or a tendinous slip may pass to the head of the first metatarsal bone or the base of the first phalanx of the great toe. The *Tibiofascialis anterior*, a small muscle from the lower part of the tibia to the transverse or cruciate crural ligaments or deep fascia.

The **Extensor hallucis longus** (*Extensor proprius hallucis*) is a thin muscle, situated between the Tibialis anterior and the Extensor digitorum longus. It *arises* from the anterior surface of the fibula for about the middle two-fourths of its extent, medial to the origin of the Extensor digitorum longus; it also *arises* from the interosseous membrane to a similar extent. The anterior tibial vessels and deep peroneal nerve lie between it and the Tibialis anterior. The fibers pass downward, and end in a tendon, which occupies the anterior border of the muscle, passes through a distinct compartment in the cruciate crural ligament, crosses from the lateral to the medial side of the anterior tibial vessels near the bend of the ankle, and is *inserted* into the base of the distal phalanx of the great toe. Opposite the metatarsophalangeal articulation, the tendon gives off a thin prolongation on either side, to cover the surface of the joint. An expansion from the medial side of the tendon is usually inserted into the base of the proximal phalanx.

Variations.—Occasionally united at its origin with the Extensor digitorum longus. *Extensor ossis metatarsi hallucis*, a small muscle, sometimes found as a slip from the Extensor hallucis longus, or from the Tibialis anterior, or from the Extensor digitorum longus, or as a distinct muscle; it traverses the same compartment of the transverse ligament with the Extensor hallucis longus.

The **Extensor digitorum longus** is a penniform muscle, situated at the lateral part of the front of the leg. It *arises* from the lateral condyle of the tibia; from the upper three-fourths of the anterior surface of the body of the fibula; from the upper part of the interosseous membrane; from the deep surface of the fascia; and from the intermuscular septa between it and the Tibialis anterior on the medial, and the Peronæi on the lateral side. Between it and the Tibialis anterior are the upper portions of the anterior tibial vessels and deep peroneal nerve. The tendon passes under the transverse and cruciate crural ligaments in company with the Peronæus tertius, and divides into four slips, which run forward on the dorsum of the foot, and are *inserted* into the second and third phalanges of the four lesser toes. The tendons to the second, third, and fourth toes are each joined, opposite the metatarsophalangeal articulation, on the lateral side by a tendon of the Extensor digitorum brevis. The tendons are inserted in the following manner: each receives a fibrous expansion from the Interossei and Lumbricalis, and then spreads out into a broad aponeurosis, which covers the dorsal surface of the

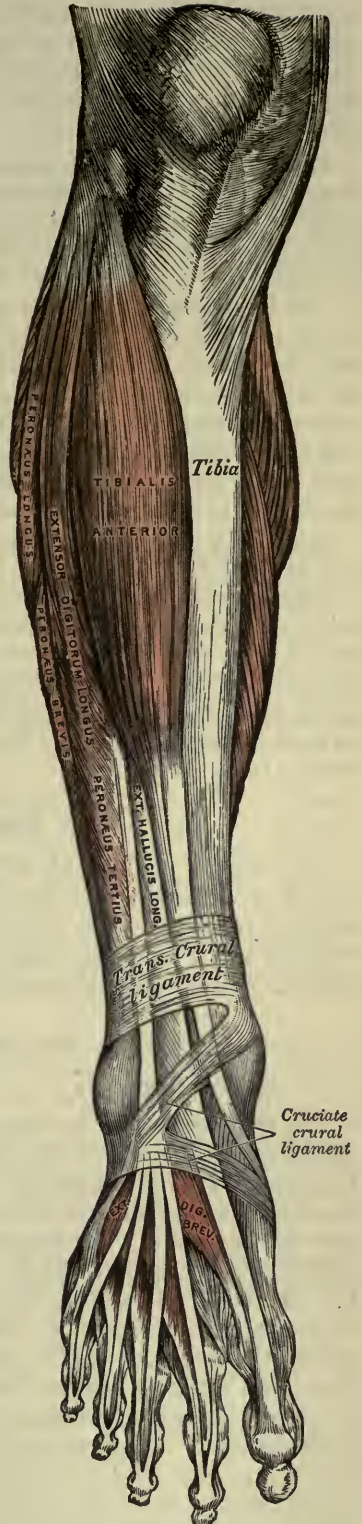

FIG. 437.—Muscles of the front of the leg.

first phalanx: this aponeurosis, at the articulation of the first with the second phalanx, divides into three slips—an intermediate, which is inserted into the base of the second phalanx; and two collateral slips, which, after uniting on the dorsal surface of the second phalanx, are continued onward, to be inserted into the base of the third phalanx.

Variations.—This muscle varies considerably in the modes of origin and the arrangement of its various tendons. The tendons to the second and fifth toes may be found doubled, or extra slips are given off from one or more tendons to their corresponding metatarsal bones, or to the short extensor, or to one of the interosseous muscles. A slip to the great toe from the innermost tendon has been found.

The **Peronæus tertius** is a part of the Extensor digitorum longus, and might be described as its fifth tendon. The fibers belonging to this tendon *arise* from the lower third or more of the anterior surface of the fibula; from the lower part of the interosseous membrane; and from an intermuscular septum between it and the Peronæus brevis. The tendon, after passing under the transverse and cruciate crural ligaments in the same canal as the Extensor digitorum longus, is *inserted* into the dorsal surface of the base of the metatarsal bone of the little toe. This muscle is sometimes wanting.

Nerves.—These muscles are supplied by the fourth and fifth lumbar and first sacral nerves through the deep peroneal nerve.

Actions.—The Tibialis anterior and Peronæus tertius are the direct flexors of the foot at the ankle-joint; the former muscle, when acting in conjunction with the Tibialis posterior, raises the medial border of the foot, *i. e.*, inverts the foot; and the latter, acting with the Peronæi brevis and longus, raises the lateral border of the foot, *i. e.*, everts the foot. The Extensor digitorum longus and Extensor hallucis longus extend the phalanges of the toes, and, continuing their action, flex the foot upon the leg. Taking their fixed points from below, in the erect posture, all these muscles serve to fix the bones of the leg in the perpendicular position, and give increased strength to the ankle-joint.

2. The Posterior Crural Muscles.

The muscles of the back of the leg are subdivided into two groups—superficial and deep. Those of the superficial group constitute a powerful muscular mass, forming the calf of the leg. Their large size is one of the most characteristic features of the muscular apparatus in man, and bears a direct relation to his erect attitude and his mode of progression.

The Superficial Group (Fig. 438).

Gastrocnemius.

Soleus.

Plantaris.

The **Gastrocnemius** is the most superficial muscle, and forms the greater part of the calf. It *arises* by two heads, which are connected to the condyles of the femur by strong, flat tendons. The **medial and larger head** takes its origin from a depression at the upper and back part of the medial condyle and from the adjacent part of the femur. The **lateral head** *arises* from an impression on the side of the lateral condyle and from the posterior surface of the femur immediately above the lateral part of the condyle. Both heads, also, *arise* from the subjacent part of the capsule of the knee. Each tendon spreads out into an aponeurosis, which covers the posterior surface of that portion of the muscle to which it belongs. From the anterior surfaces of these tendinous expansions, muscular fibers are given off; those of the medial head being thicker and extending lower than those of the lateral. The fibers unite at an angle in the middle line of the muscle in a tendinous raphé, which expands into a broad aponeurosis on the anterior surface of the muscle, and into this the remaining fibers are inserted. The aponeurosis, gradually contracting, unites with the tendon of the Soleus, and forms with it the tendo calcaneus.

Variations.—Absence of the outer head or of the entire muscle. Extra slips from the popliteal surface of the femur.

The **Soleus** is a broad flat muscle situated immediately in front of the Gastrocnemius. It *arises* by tendinous fibers from the back of the head of the fibula, and from the upper third of the posterior surface of the body of the bone; from the popliteal line, and the middle third of the medial border of the tibia; some fibers also arise from a tendinous arch placed between the tibial and fibular origins of the muscle, in front of which the popliteal vessels and tibial nerve run. The fibers end in an aponeurosis which covers the posterior surface of the muscle, and, gradually becoming thicker and narrower, joins with the tendon of the Gastrocnemius, and forms with it the tendo calcaneus.

Variations.—Accessory head to its lower and inner part usually ending in the tendocalcaneus, or the calcaneus, or the lacinate ligament.

The Gastrocnemius and Soleus together form a muscular mass which is occasionally described as the **Triceps suræ**; its tendon of insertion is the tendo calcaneus.

Tendo Calcaneus (*tendo Achillis*).—The tendo calcaneus, the common tendon of the Gastrocnemius and Soleus, is the thickest and strongest in the body. It is about 15 cm. long, and begins near the middle of the leg, but receives fleshy fibers on its anterior surface, almost to its lower end. Gradually becoming contracted below, it is inserted into the middle part of the posterior surface of the calcaneus, a bursa being interposed between the tendon and the upper part of this surface. The tendon spreads out somewhat at its lower end, so that its narrowest part is about 4 cm. above its insertion. It is covered by the fascia and the integument, and is separated from the deep muscles and vessels by a considerable interval filled up with areolar and adipose tissue. Along its lateral side, but superficial to it, is the small saphenous vein.

The **Plantaris** is placed between the Gastrocnemius and Soleus. It *arises* from the lower part of the lateral prolongation of the linea aspera, and from the oblique popliteal ligament of the knee-joint. It forms a small fusiform belly, from 7 to 10 cm. long, ending in a long slender tendon which crosses obliquely between the two muscles of the calf, and runs along the medial border of the tendo calcaneus, to be *inserted* with it into the posterior part of the calcaneus. This muscle is sometimes double, and at other times wanting. Occasionally, its tendon is lost in the lacinate ligament, or in the fascia of the leg.

Nerves.—The Gastrocnemius and Soleus are supplied by the first and second sacral nerves, and the Plantaris by the fourth and fifth lumbar and first sacral nerves, through the tibial nerve.

Actions.—The muscles of the calf are the chief extensors of the foot at the ankle-joint. They possess considerable power, and are constantly called into use in standing, walking, dancing, and leaping; hence the large size they usually present. In walking, these muscles raise the heel from the ground; the body being thus supported on the raised foot, the opposite limb can be carried forward. In standing, the Soleus, taking its fixed point from below, steadies the leg upon the foot and prevents the body from falling forward. The Gastrocnemius, acting from below, serves to flex the femur upon the tibia, assisted by the Popliteus. The Plantaris is the rudiment of a large muscle which in some of the lower animals is continued over the calcaneus to be inserted into the plantar aponeurosis. In man it is an accessory to the Gastrocnemius, extending the ankle if the foot be free, or bending the knee if the foot be fixed.

The Deep Group (Fig. 439).

Popliteus.

Flexor hallucis longus.

Flexor digitorum longus.

Tibialis posterior.

Deep Transverse Fascia.—The deep transverse fascia of the leg is a transversely placed, intermuscular septum, between the superficial and deep muscles of the back of the leg. At the sides it is connected to the margins of the tibia and

fibula. *Above*, where it covers the Popliteus, it is thick and dense, and receives an expansion from the tendon of the Semimembranosus; it is thinner in the middle

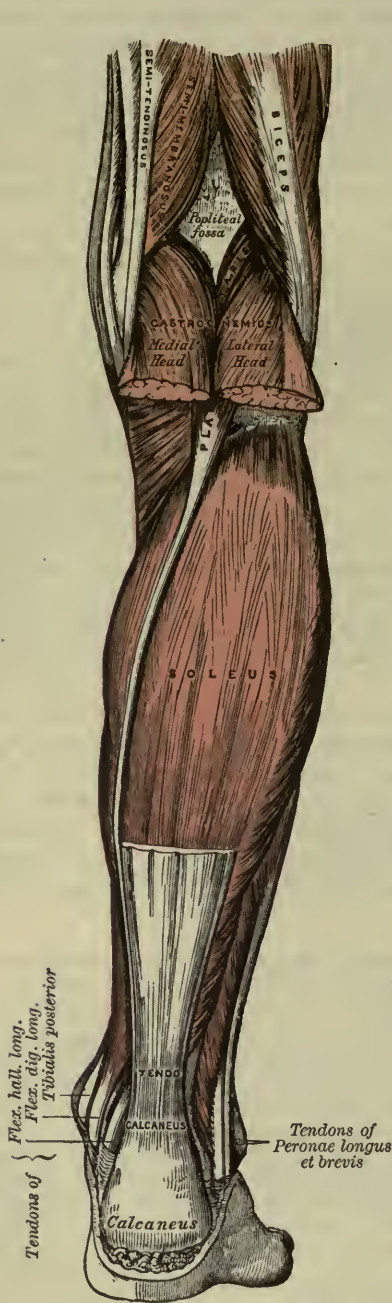


FIG. 438.—Muscles of the back of the leg. Superficial layer.

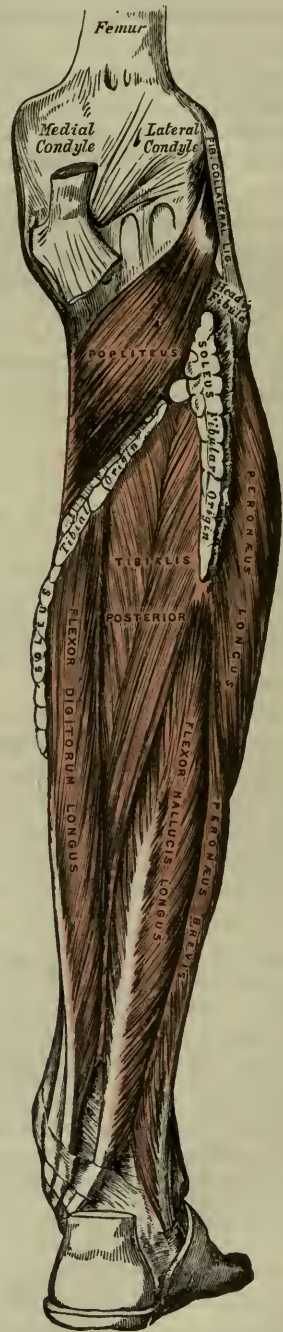


FIG. 439.—Muscles of the back of the leg. Deep layer.

of the leg; but *below*, where it covers the tendons passing behind the malleoli, it is thickened and continuous with the lacinate ligament.

The **Popliteus** is a thin, flat, triangular muscle, which forms the lower part of

the floor of the popliteal fossa. It *arises* by a strong tendon about 2.5 cm. long, from a depression at the anterior part of the groove on the lateral condyle of the femur, and to a small extent from the oblique popliteal ligament of the knee-joint; and is *inserted* into the medial two-thirds of the triangular surface above the popliteal line on the posterior surface of the body of the tibia, and into the tendinous expansion covering the surface of the muscle.

Variations.—Additional head from the sesamoid bone in the outer head of the Gastrocnemius. *Popliteus minor*, rare, origin from femur on the inner side of the Plantaris, insertion into the posterior ligament of the knee-joint. *Peroneotibialis*, 14 per cent., origin inner side of the head of the fibula, insertion into the upper end of the oblique line of the tibia, it lies beneath the Popliteus.

The **Flexor hallucis longus** is situated on the fibular side of the leg. It *arises* from the inferior two-thirds of the posterior surface of the body of the fibula, with the exception of 2.5 cm. at its lowest part; from the lower part of the interosseous membrane; from an intermuscular septum between it and the Peronæi, laterally, and from the fascia covering the Tibialis posterior, medially. The fibers pass obliquely downward and backward, and end in a tendon which occupies nearly the whole length of the posterior surface of the muscle. This tendon lies in a groove which crosses the posterior surface of the lower end of the tibia, the posterior surface of the talus, and the under surface of the sustentaculum tali of the calcaneus; in the sole of the foot it runs forward between the two heads of the Flexor hallucis brevis, and is *inserted* into the base of the last phalanx of the great toe. The grooves on the talus and calcaneus, which contain the tendon of the muscle, are converted by tendinous fibers into distinct canals, lined by a mucous sheath. As the tendon passes forward in the sole of the foot, it is situated above, and crosses from the lateral to the medial side of the tendon of the Flexor digitorum longus, to which it is connected by a fibrous slip.

Variations.—Usually a slip runs to the Flexor digitorum and frequently an additional slip runs from the Flexor digitorum to the Flexor hallucis. *Peroneocalcaneus internus*, rare, origin below or outside the Flexor hallucis from the back of the fibula, passes over the sustentaculum tali with the Flexor hallucis and is inserted into the calcaneum.

The **Flexor digitorum longus** is situated on the tibial side of the leg. At its origin it is thin and pointed; but it gradually increases in size as it descends. It *arises* from the posterior surface of the body of the tibia, from immediately below the popliteal line to within 7 or 8 cm. of its lower extremity, medial to the tibial origin of the Tibialis posterior; it also *arises* from the fascia covering the Tibialis posterior. The fibers end in a tendon, which runs nearly the whole length of the posterior surface of the muscle. This tendon passes behind the medial malleolus, in a groove, common to it and the Tibialis posterior, but separated from the latter by a fibrous septum, each tendon being contained in a special compartment lined by a separate mucous sheath. It passes obliquely forward and lateralward, superficial to the deltoid ligament of the ankle-joint, into the sole of the foot (Fig. 444), where it crosses below the tendon of the Flexor hallucis longus, and receives from it a strong tendinous slip. It then expands and is joined by the Quadratus plantæ, and finally divides into four tendons, which are *inserted* into the bases of the last phalanges of the second, third, fourth, and fifth toes, each tendon passing through an opening in the corresponding tendon of the Flexor digitorum brevis opposite the base of the first phalanx.

Variations.—*Flexor accessorius longus digitorum*, not infrequent, origin from fibula, or tibia, or the deep fascia and ending in a tendon which, after passing beneath the lacinate ligament, joins the tendon of the long flexor or the Quadratus plantæ.

The **Tibialis posterior** (*Tibialis posticus*) lies between the two preceding muscles, and is the most deeply seated of the muscles on the back of the leg. It begins above by two pointed processes, separated by an angular interval through which

the anterior tibial vessels pass forward to the front of the leg. It *arises* from the whole of the posterior surface of the interosseous membrane, excepting its lowest part; from the lateral portion of the posterior surface of the body of the tibia, between the commencement of the popliteal line above and the junction of the middle and lower thirds of the body below; and from the upper two-thirds of the medial surface of the fibula; some fibers also arise from the deep transverse fascia, and from the intermuscular septa separating it from the adjacent muscles. In the lower fourth of the leg its tendon passes in front of that of the Flexor digitorum longus and lies with it in a groove behind the medial malleolus, but enclosed in a separate sheath; it next passes under the laciniated and over the deltoid ligament into the foot, and then beneath the plantar calcaneonavicular ligament. The tendon contains a sesamoid fibrocartilage, as it runs under the plantar calcaneonavicular ligament. It is *inserted* into the tuberosity of the navicular bone, and gives off fibrous expansions, one of which passes backward to the sustentaculum tali of the calcaneus, others forward and lateralward to the three cuneiforms, the cuboid, and the bases of the second, third, and fourth metatarsal bones.

Nerves.—The Popliteus is supplied by the fourth and fifth lumbar and first sacral nerves, the Flexor digitorum longus and Tibialis posterior by the fifth lumbar and first sacral, and the Flexor hallucis longus by the fifth lumbar and the first and second sacral nerves, through the tibial nerve.

Actions.—The Popliteus assists in flexing the leg upon the thigh; when the leg is flexed, it will rotate the tibia inward. It is especially called into action at the beginning of the act of bending the knee, inasmuch as it produces the slight inward rotation of the tibia which is essential in the early stage of this movement. The Tibialis posterior is a direct extensor of the foot at the ankle-joint; acting in conjunction with the Tibialis anterior, it turns the sole of the foot upward and medialward, *i. e.*, inverts the foot, antagonizing the Peronæi, which turn it upward and lateralward (evert it). In the sole of the foot the tendon of the Tibialis posterior lies directly below the plantar calcaneonavicular ligament, and is therefore an important factor in maintaining the arch of the foot. The Flexor digitorum longus and Flexor hallucis longus are the direct flexors of the phalanges, and, continuing their action, extend the foot upon the leg; they assist the Gastrocnemius and Soleus in extending the foot, as in the act of walking, or in standing on tiptoe. In consequence of the oblique direction of its tendons the Flexor digitorum longus would draw the toes medialward, were it not for the Quadratus plantæ, which is inserted into the lateral side of the tendon, and draws it to the middle line of the foot. Taking their fixed point from the foot, these muscles serve to maintain the upright posture by steadying the tibia and fibula perpendicularly upon the talus.

3. The Lateral Crural Muscles (Fig. 439).

Peronæus longus.

Peronæus brevis.

The **Peronæus longus** is situated at the upper part of the lateral side of the leg, and is the more superficial of the two muscles. It *arises* from the head and upper two-thirds of the lateral surface of the body of the fibula, from the deep surface of the fascia, and from the intermuscular septa between it and the muscles on the front and back of the leg; occasionally also by a few fibers from the lateral condyle of the tibia. Between its attachments to the head and to the body of the fibula there is a gap through which the common peroneal nerve passes to the front of the leg. It ends in a long tendon, which runs behind the lateral malleolus, in a groove common to it and the tendon of the Peronæus brevis, behind which it lies; the groove is converted into a canal by the superior peroneal retinaculum, and the tendons in it are contained in a common mucous sheath. The tendon then extends obliquely forward across the lateral side of the calcaneus, below the trochlear process, and the tendon of the Peronæus brevis, and under cover of the inferior peroneal retinaculum. It crosses the lateral side of the cuboid, and then runs on the under surface of that bone in a groove which is converted into a canal by the long plantar ligament; the tendon then crosses the sole of the foot obliquely, and is inserted into the lateral side of the base of the first metatarsal bone and the lateral

side of the first cuneiform. Occasionally it sends a slip to the base of the second metatarsal bone. The tendon changes its direction at two points: first, behind the lateral malleolus; secondly, on the cuboid bone; in both of these situations the tendon is thickened, and, in the latter, a sesamoid fibrocartilage (sometimes a bone), is usually developed in its substance.

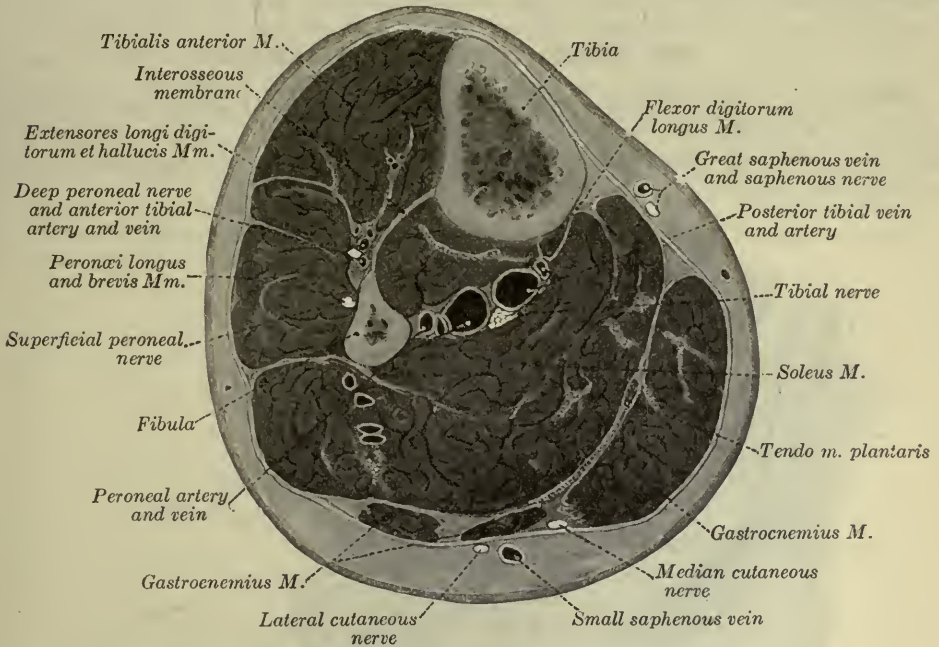


FIG. 440.—Cross-section through middle of leg. (Eycleshymer and Schoemaker.)

The **Peronæus brevis** lies under cover of the Peronæus longus, and is a shorter and smaller muscle. It *arises* from the lower two-thirds of the lateral surface of the body of the fibula; medial to the Peronæus longus; and from the intermuscular septa separating it from the adjacent muscles on the front and back of the leg. The fibers pass vertically downward, and end in a tendon which runs behind the lateral malleolus along with but in front of that of the preceding muscle, the two tendons being enclosed in the same compartment, and lubricated by a common mucous sheath. It then runs forward on the lateral side of the calcaneus, above the trochlear process and the tendon of the Peronæus longus, and is *inserted* into the tuberosity at the base of the fifth metatarsal bone, on its lateral side.

On the lateral surface of the calcaneus the tendons of the Peronæi longus and brevis occupy separate osseoaponeurotic canals formed by the calcaneus and the perineal retinacula; each tendon is enveloped by a forward prolongation of the common mucous sheath.

Variations.—Fusion of the two peronæi is rare. A slip from the Peronæus longus to the base of the third, fourth or fifth metatarsal bone, or to the Adductor hallucis is occasionally seen.

Peronæus accessorius, origin from the fibula between the longus and brevis, joins the tendon of the longus in the sole of the foot.

Peronæus quinti digiti, rare, origin lower fourth of the fibula under the brevis, insertion into the Extensor aponeurosis of the little toe. More common as a slip of the tendon of the Peronæus brevis.

Peronæus quartus, 13 per cent. (Gruber), origin back of fibula between the brevis and the Flexor hallucis, insertion into the peroneal spine of the calcaneum, (*peroneocalcaneus externum*), or less frequently into the tuberosity of the cuboid (*peroneocuboideus*).

Nerves.—The Peronæi longus and brevis are supplied by the fourth and fifth lumbar and first sacral nerves through the superficial peroneal nerve.

Actions.—The Peronæi longus and brevis extend the foot upon the leg, in conjunction with the Tibialis posterior, antagonizing the Tibialis anterior and Peronæus tertius, which are flexors of the foot. The Peronæus longus also everts the sole of the foot, and from the oblique direction of the tendon across the sole of the foot is an important agent in the maintenance of the transverse arch. Taking their fixed points below, the Peronæi serve to steady the leg upon the foot. This is especially the case in standing upon one leg, when the tendency of the superincumbent weight is to throw the leg medialward; the Peronæus longus overcomes this tendency by drawing on the lateral side of the leg.

THE FASCIA AROUND THE ANKLE.

Fibrous bands, or thickened portions of the fascia, bind down the tendons in front of and behind the ankle in their passage to the foot. They comprise three ligaments, viz., the transverse crural, the cruciate crural and the laciniate; and the superior and inferior peroneal retinacula.

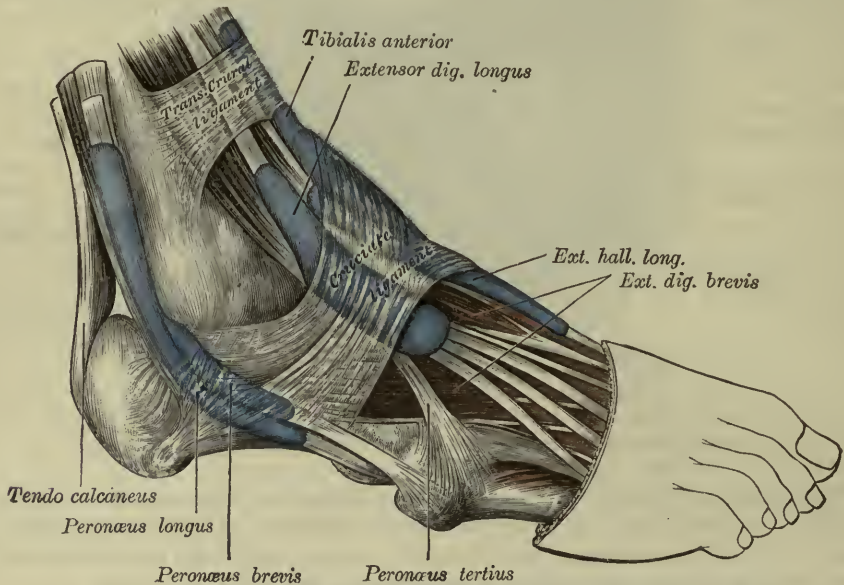


FIG. 441.—The mucous sheaths of the tendons around the ankle. Lateral aspect.

Transverse Crural Ligament (*ligamentum transversum cruris*; upper part of anterior annular ligament) (Fig. 441).—The transverse crural ligament binds down the tendons of Extensor digitorum longus, Extensor hallucis longus, Peronæus tertius, and Tibialis anterior as they descend on the front of the tibia and fibula; under it are found also the anterior tibial vessels and deep peroneal nerve. It is attached laterally to the lower end of the fibula, and medially to the tibia; above it is continuous with the fascia of the leg.

Cruciate Crural Ligament (*ligamentum cruciatum cruris*; lower part of anterior annular ligament) (Figs. 441, 442).—The cruciate crural ligament is a Y-shaped band placed in front of the ankle-joint, the stem of the Y being attached laterally to the upper surface of the calcaneus, in front of the depression for the interosseous talocalcanean ligament; it is directed medialward as a double layer, one lamina passing in front of, and the other behind, the tendons of the Peronæus tertius and Extensor digitorum longus. At the medial border of the latter tendon these two layers join together, forming a compartment in which the tendons are enclosed. From the medial extremity of this sheath the two limbs of the Y diverge: one is directed upward and medialward, to be attached to the tibial malleolus, passing over the Extensor hallucis longus and the vessels and nerves, but enclosing

the Tibialis anterior by a splitting of its fibers. The other limb extends downward and medialward, to be attached to the border of the plantar aponeurosis, and passes over the tendons of the Extensor hallucis longus and Tibialis anterior and also the vessels and nerves.

Lacinate Ligament (*ligamentum laciniatum; internal annular ligament*).—The lacinate ligament is a strong fibrous band, extending from the tibial malleolus above to the margin of the calcaneus below, converting a series of bony grooves in this situation into canals for the passage of the tendons of the Flexor muscles and the posterior tibial vessels and tibial nerve into the sole of the foot. It is continuous by its upper border with the deep fascia of the leg, and by its lower border with the plantar aponeurosis and the fibers of origin of the Abductor hallucis muscle. Enumerated from the medial side, the four canals which it forms transmit the tendon of the Tibialis posterior; the tendon of the Flexor digitorum longus; the posterior tibial vessels and tibial nerve, which run through a broad space beneath the ligament; and lastly, in a canal formed partly by the talus, the tendon of the Flexor hallucis longus.

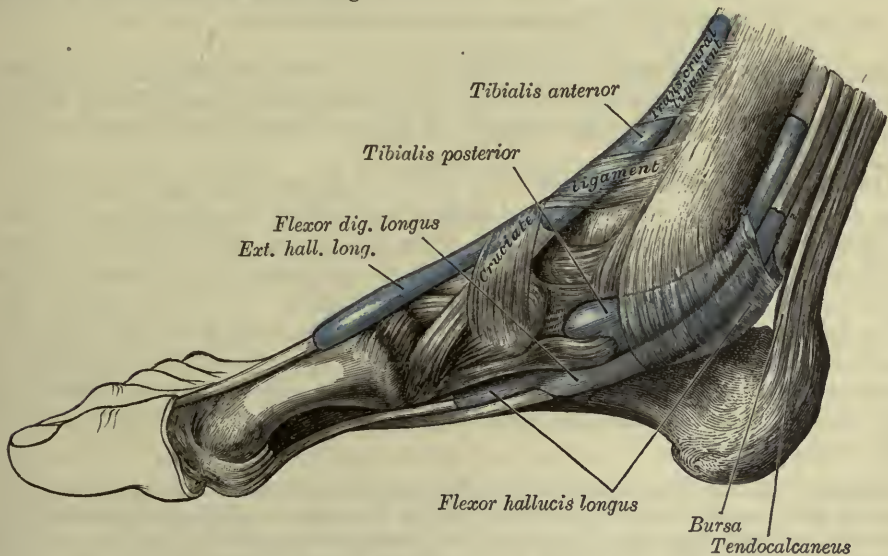


FIG. 442.—The mucous sheaths of the tendons around the ankle. Medial aspect.

Peroneal Retinacula.—The peroneal retinacula are fibrous bands which bind down the tendons of the Peronæi longus and brevis as they run across the lateral side of the ankle. The fibers of the **superior retinaculum** (*external annular ligament*) are attached *above* to the lateral malleolus and *below* to the lateral surface of the calcaneus. The fibers of the **inferior retinaculum** are continuous in *front* with those of the cruciate crural ligament; *behind* they are attached to the lateral surface of the calcaneus; some of the fibers are fixed to the peroneal trochlea, forming a septum between the tendons of the Peronæi longus and brevis.

The Mucous Sheaths of the Tendons Around the Ankle.—All the tendons crossing the ankle-joint are enclosed for part of their length in mucous sheaths which have an almost uniform length of about 8 cm. each. On the *front* of the ankle (Fig. 441) the sheath for the Tibialis anterior extends from the upper margin of the transverse crural ligament to the interval between the diverging limbs of the cruciate ligament; those for the Extensor digitorum longus and Extensor hallucis longus reach upward to just above the level of the tips of the malleoli, the former being the higher. The sheath of the Extensor hallucis longus is prolonged on to the base of the first metatarsal bone, while that of the Extensor digitorum longus reaches

only to the level of the base of the fifth metatarsal. On the *medial side* of the ankle (Fig. 442) the sheath for the Tibialis posterior extends highest up—to about 4 cm. above the tip of the malleolus—while below it stops just short of the tuberosity of the navicular. The sheath for Flexor hallucis longus reaches up to the level of the tip of the malleolus, while that for the Flexor digitorum longus is slightly higher; the former is continued to the base of the first metatarsal, but the latter stops opposite the first cuneiform bone.

On the *lateral side* of the ankle (Fig. 441) a sheath which is single for the greater part of its extent encloses the Peronæi longus and brevis. It extends upward for about 4 cm. above the tip of the malleolus and downward and forward for about the same distance.

IV. THE MUSCLES AND FASCIAE OF THE FOOT.

1. The Dorsal Muscle of the Foot.

Extensor digitorum brevis.

The *fascia* on the dorsum of the foot is a thin membranous layer, continuous above with the transverse and cruciate crural ligaments; on either side it blends with the plantar aponeurosis; anteriorly it forms a sheath for the tendons on the dorsum of the foot.

The **Extensor digitorum brevis** (Fig. 441) is a broad, thin muscle, which *arises* from the forepart of the upper and lateral surfaces of the calcaneus, in front of the groove for the Peronæus brevis; from the lateral talocalcanean ligament; and from the common limb of the cruciate crural ligament. It passes obliquely across the dorsum of the foot, and ends in four tendons. The most medial, which is the largest, is *inserted* into the dorsal surface of the base of the first phalanx of the great toe, crossing the dorsalis pedis artery; it is frequently described as a separate muscle—the **Extensor hallucis brevis**. The other three are *inserted* into the lateral sides of the tendons of the Extensor digitorum longus of the second, third, and fourth toes.

Variations.—Accessory slips of origin from the talus and navicular, or from the external cuneiform and third metatarsal bones to the second slip of the muscle, and one from the cuboid to the third slip have been observed. The tendons vary in number and position; they may be reduced to two, or one of them may be doubled, or an additional slip may pass to the little toe. A supernumerary slip ending on one of the metatarsophalangeal articulations, or joining a dorsal interosseous muscle is not uncommon. Deep slips between this muscle and the Dorsal interossei occur.

Nerves.—It is supplied by the deep peroneal nerve.

Actions.—The Extensor digitorum brevis extends the phalanges of the four toes into which it is inserted, but in the great toe acts only on the first phalanx. The obliquity of its direction counteracts the oblique movement given to the toes by the long Extensor, so that when both muscles act, the toes are evenly extended.

2. The Plantar Muscles of the Foot.

Plantar Aponeurosis (*aponeurosis plantaris; plantar fascia*).—The plantar aponeurosis is of great strength, and consists of pearly white glistening fibers, disposed, for the most part, longitudinally: it is divided into central, lateral, and medial portions.

The **central portion**, the thickest, is narrow behind and *attached* to the medial process of the tuberosity of the calcaneus, posterior to the origin of the Flexor digitorum brevis; and becoming broader and thinner in front, divides near the heads of the metatarsal bones into five processes, one for each of the toes. Each of these processes divides opposite the metatarsophalangeal articulation into two strata, superficial and deep. The superficial stratum is *inserted* into the skin of

the transverse sulcus which separates the toes from the sole. The deeper stratum divides into two slips which embrace the side of the Flexor tendons of the toes, and blend with the sheaths of the tendons, and with the transverse metatarsal ligament, thus forming a series of arches through which the tendons of the short and long Flexors pass to the toes. The intervals left between the five processes allow the digital vessels and nerves and the tendons of the Lumbricales to become superficial. At the point of division of the aponeurosis, numerous transverse fasciculi are superadded; these serve to increase the strength of the aponeurosis at this part by binding the processes together, and connecting them with the integument. The central portion of the plantar aponeurosis is continuous with the lateral and medial portions and sends upward into the foot, at the lines of junction, two strong vertical intermuscular septa, broader in front than behind, which separate the intermediate from the lateral and medial plantar groups of muscles; from these again are derived thinner transverse septa which separate the various layers of muscles in this region. The upper surface of this aponeurosis gives origin behind to the Flexor digitorum brevis.

The lateral and medial portions of the plantar aponeurosis are thinner than the central piece, and cover the sides of the sole of the foot.

The **lateral portion** covers the under surface of the Abductor digiti quinti; it is thin in front and thick behind, where it forms a strong band between the lateral process of the tuberosity of the calcaneus and the base of the fifth metatarsal bone; it is continuous medially with the central portion of the plantar aponeurosis, and laterally with the dorsal fascia.

The **medial portion** is thin, and covers the under surface of the Abductor hallucis; it is *attached* behind to the lacinate ligament, and is continuous around the side of the foot with the dorsal fascia, and laterally with the central portion of the plantar aponeurosis.

The muscles in the plantar region of the foot may be divided into three groups, in a similar manner to those in the hand. Those of the medial plantar region are connected with the great toe, and correspond with those of the thumb; those of the lateral plantar region are connected with the little toe, and correspond with those of the little finger; and those of the intermediate plantar region are connected with the tendons intervening between the two former groups. But in order to facilitate the description of these muscles, it is more convenient to divide them into four layers, in the order in which they are successively exposed.

The First Layer (Fig. 443).

Abductor hallucis.

Flexor digitorum brevis.

Abductor digiti quinti.

The **Abductor hallucis** lies along the medial border of the foot and covers the origins of the plantar vessels and nerves. It *arises* from the medial process of the tuberosity of the calcaneus, from the lacinate ligament, from the plantar aponeurosis, and from the intermuscular septum between it and the Flexor digitorum brevis. The fibers end in a tendon, which is *inserted*, together with the medial tendon of the Flexor hallucis brevis, into the tibial side of the base of the first phalanx of the great toe.

Variations.—Slip to the base of the first phalanx of the second toe.

The **Flexor digitorum brevis** lies in the middle of the sole of the foot, immediately above the central part of the plantar aponeurosis, with which it is firmly united. Its deep surface is separated from the lateral plantar vessels and nerves

by a thin layer of fascia. It *arises* by a narrow tendon, from the medial process of the tuberosity of the calcaneus, from the central part of the plantar aponeurosis, and from the intermuscular septa between it and the adjacent muscles. It passes forward, and divides into four tendons, one for each of the four lesser toes. Opposite the bases of the first phalanges, each tendon divides into two slips, to allow of the passage of the corresponding tendon of the Flexor digitorum longus; the two portions of the tendon then unite and form a grooved channel for the reception of the accompanying long Flexor tendon. Finally, it divides a second time, and is *inserted* into the sides of the second phalanx about its middle. The mode of division of the tendons of the Flexor digitorum brevis, and of their insertion into the phalanges, is analogous to that of the tendons of the Flexor digitorum sublimis in the hand.

Variations.—Slip to the little toe frequently wanting, 23 per cent.; or it may be replaced by a small fusiform muscle arising from the long flexor tendon or from the Quadratus plantæ.

Fibrous Sheaths of the Flexor Tendons.—The terminal portions of the tendons of the long and short Flexor muscles are contained in osseoaponeurotic canals similar in their arrangement to those in the fingers. These canals are formed above by the phalanges and below by fibrous bands, which arch across the tendons, and are attached on either side to the margins of the phalanges. Opposite the bodies of the proximal and second phalanges the fibrous bands are strong, and the fibers are transverse; but opposite the joints they are much thinner, and the fibers are directed obliquely. Each canal contains a mucous sheath, which is reflected on the contained tendons.

The **Abductor digiti quinti** (*Abductor minimi digiti*) lies along the lateral border of the foot, and is in relation by its medial margin with the lateral plantar vessels and nerves. It *arises*, by a broad origin, from the lateral process of the tuberosity of the calcaneus, from the under surface of the calcaneus between the two processes of the tuberosity, from the forepart of the medial process, from the plantar aponeurosis, and from the intermuscular septum between it and the Flexor digitorum brevis. Its tendon, after gliding over a smooth facet on the

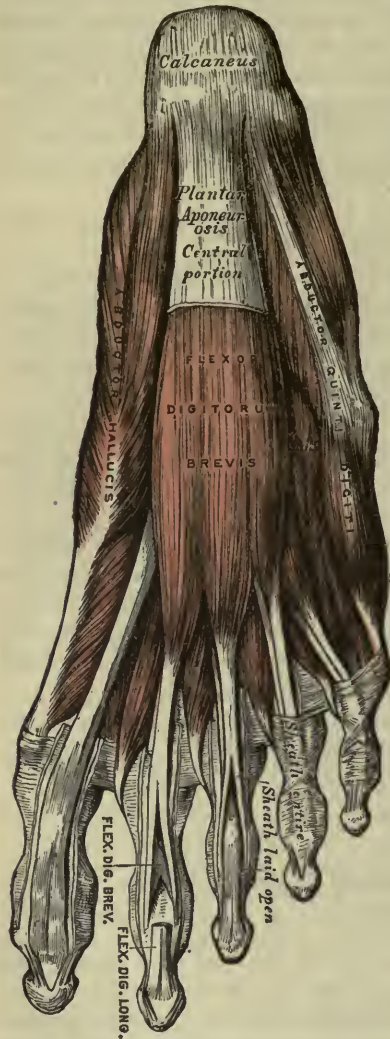

FIG. 443.—Muscles of the sole of the foot. First layer.

under surface of the base of the fifth metatarsal bone, is *inserted*, with the Flexor digiti quinti brevis, into the fibular side of the base of the first phalanx of the fifth toe.

Variations.—Slips of origin from the tuberosity at the base of the fifth metatarsal. *Abductor ossis metatarsi quinti*, origin external tubercle of the calcaneus, insertion into tuberosity of the fifth metatarsal bone in common with or beneath the outer margin of the plantar fascia.

The Second Layer (Fig. 444).

Quadratus plantæ.

Lumbricales.

The **Quadratus plantæ** (*Flexor accessorius*) is separated from the muscles of the first layer by the lateral plantar vessels and nerve. It *arises* by two heads, which are separated from each other by the long plantar ligament: the **medial or larger head** is muscular, and is attached to the medial concave surface of the calcaneus, below the groove which lodges the tendon of the Flexor hallucis longus; the **lateral head**, flat and tendinous, *arises* from the lateral border of the inferior surface of the calcaneus, in front of the lateral process of its tuberosity, and from the long plantar ligament. The two portions join at an acute angle, and end in a flattened band which is *inserted* into the lateral margin and upper and under surfaces of the tendon of the Flexor digitorum longus, forming a kind of groove, in which the tendon is lodged. It usually sends slips to those tendons of the Flexor digitorum longus which pass to the second, third, and fourth toes.

Variations.—Lateral head often wanting; entire muscle absent. Variation in the number of digital tendons to which fibers can be traced. Most frequent offsets are sent to the second, third and fourth toes; in many cases to the fifth as well; occasionally to two toes only.

The **Lumbricales** are four small muscles, accessory to the tendons of the Flexor digitorum longus and numbered from the medial side of the foot; they *arise* from these tendons, as far back as their angles of division, each springing from two tendons, except the first. The muscles end in tendons, which pass forward on the medial sides of the four lesser toes, and are *inserted* into the expansions of the tendons of the Extensor digitorum longus on the dorsal surfaces of the first phalanges.

Variations.—Absence of one or more; doubling of the third or fourth. Insertion partly or wholly into the first phalanges.

The Third Layer (Fig. 445).

Flexor hallucis brevis.

Adductor hallucis.

Flexor digiti quinti brevis.

The **Flexor hallucis brevis** *arises*, by a pointed tendinous process, from the medial part of the under surface of the cuboid bone, from the contiguous portion of the third cuneiform, and from the prolongation of the tendon of the Tibialis posterior which is attached to that bone. It divides in front into two portions, which are inserted into the medial and lateral sides of the base of the first phalanx of the great toe, a sesamoid bone being present in each tendon at its insertion. The **medial portion** is blended with the Abductor hallucis previous to its insertion; the **lateral portion** with the Adductor hallucis; the tendon of the Flexor hallucis longus lies in a groove between them; the lateral portion is sometimes described as the **first Interosseous plantaris**.

Variations.—Origin subject to considerable variation; it often receives fibers from the calcaneus or long plantar ligament. Attachment to the cuboid sometimes wanting. Slip to first phalanx of the second toe.

The **Adductor hallucis** (*Adductor obliquus hallucis*) *arises* by two heads—oblique and transverse. The **oblique head** is a large, thick, fleshy mass, crossing the foot obliquely and occupying the hollow space under the first, second, third, and fourth metatarsal bones. It *arises* from the bases of the second, third, and fourth metatarsal bones, and from the sheath of the tendon of the Peronæus longus, and is *inserted*, together with the lateral portion of the Flexor hallucis brevis, into the lateral side of the base of the first phalanx of the great toe. The **transverse head** (*Transversus pedis*) is a narrow, flat fasciculus which *arises* from the plantar meta-

tarsophalangeal ligaments of the third, fourth, and fifth toes (sometimes only from the third and fourth), and from the transverse ligament of the metatarsus. It is *inserted* into the lateral side of the base of the first phalanx of the great toe, its fibers blending with the tendon of insertion of the oblique head.

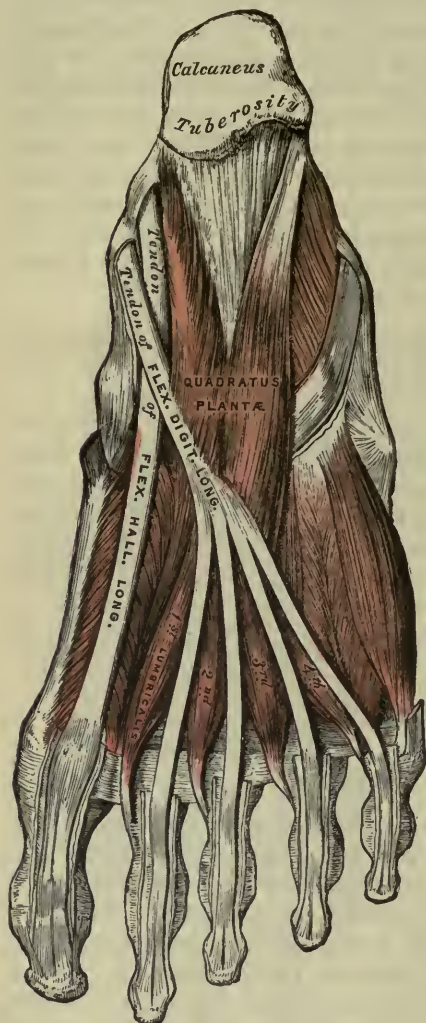


FIG. 444.—Muscles of the sole of the foot.
Second layer.

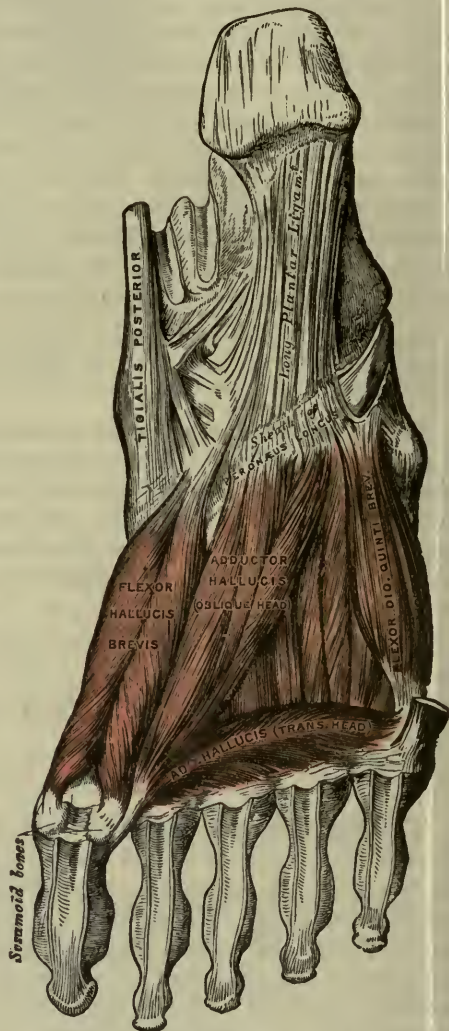

FIG. 445.—Muscles of the sole of the foot.
Third layer.

Variations.—Slips to the base of the first phalanx of the second toe. *Opponens hallucis*, occasional slips from the adductor to the metatarsal bone of the great toe.

The Abductor, Flexor brevis, and Adductor of the great toe, like the similar muscles of the thumb, give off, at their insertions, fibrous expansions to blend with the tendons of the Extensor digitorum longus.

The **Flexor digiti quinti brevis** (*Flexor brevis minimi digiti*) lies under the metatarsal bone of the little toe, and resembles one of the Interossei. It *arises* from the base of the fifth metatarsal bone, and from the sheath of the Peronæus longus; its tendon is *inserted* into the lateral side of the base of the first phalanx of the fifth toe. Occasionally a few of the deeper fibers are inserted into the lateral part of the distal half of the fifth metatarsal bone; these are described by some as a distinct muscle, the **Opponens digiti quinti**.

The Fourth Layer.

Interossei.

The **Interossei** in the foot are similar to those in the hand, with this exception, that they are grouped around the middle line of the *second* digit, instead of that of the *third*. They are seven in number, and consist of two groups, dorsal and plantar.

The **Interossei dorsales** (*Dorsal interossei*) (Fig. 446), *four* in number, are situated between the metatarsal bones. They are bipenniform muscles, each *arising* by two heads from the adjacent sides of the metatarsal bones between which it is placed; their tendons are *inserted* into the bases of the first phalanges, and into the aponeurosis of the tendons of the Extensor digitorum longus. In the angular interval left between the heads of each of the three lateral muscles, one of the perforating arteries passes to the dorsum of the foot; through the space between the heads of the first muscle the deep plantar branch of the dorsalis pedis artery enters the sole of the foot. The first is *inserted* into the medial side of the second toe; the other three are *inserted* into the lateral sides of the second, third, and fourth toes.

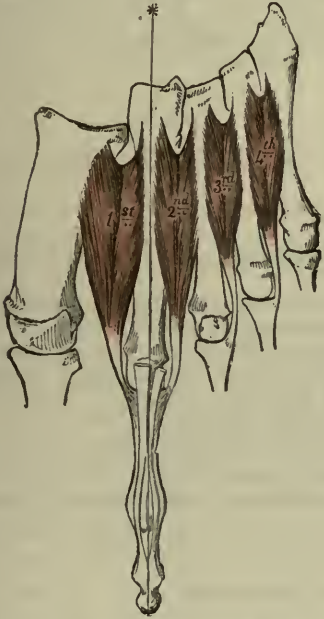


FIG. 446.—The Interossei dorsales. Left foot.

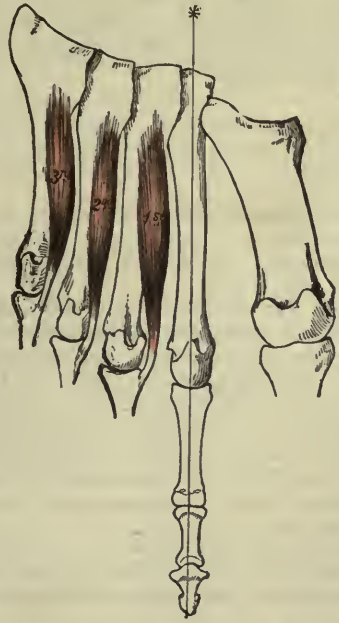


FIG. 447.—The Interossei plantares. Left foot.

The **Interossei plantares** (*Plantar interossei*) (Fig. 447), *three* in number, lie beneath rather than between the metatarsal bones, and each is connected with but one metatarsal bone. They *arise* from the bases and medial sides of the bodies of the third, fourth, and fifth metatarsal bones, and are *inserted* into the medial sides of the bases of the first phalanges of the same toes, and into the aponeuroses of the tendons of the Extensor digitorum longus.

Nerves.—The Flexor digitorum brevis, the Flexor hallucis brevis, the Abductor hallucis, and the first Lumbricalis are supplied by the medial plantar nerve; all the other muscles in the sole of the foot by the lateral plantar. The first Interosseous dorsalis frequently receives an extra filament from the medial branch of the deep peroneal nerve on the dorsum of the foot, and the second Interosseous dorsalis a twig from the lateral branch of the same nerve.

Actions.—All the muscles of the foot act upon the toes, and may be grouped as abductors, adductors, flexors, or extensors. The *abductors* are the Interossei dorsales, the Abductor hallucis,

and the Abductor digiti quinti. The Interossei dorsales are abductors from an imaginary line passing through the axis of the second toe, so that the first muscle draws the second toe medialward, toward the great toe, the second muscle draws the same toe lateralward, and the third and fourth draw the third and fourth toes in the same direction. Like the Interossei in the hand, each assists in flexing the first phalanx and extending the second and third phalanges. The Abductor hallucis abducts the great toe from the second, and also flexes its proximal phalanx. In the same way the action of the Abductor digiti quinti is twofold, as an abductor of this toe from the fourth, and also as a flexor of its proximal phalanx. The *adductors* are the Interossei plantares and the Adductor hallucis. The Interossei plantares adduct the third, fourth, and fifth toes toward the imaginary line passing through the second toe, and by means of their insertions into the aponeuroses of the Extensor tendons they assist in flexing the proximal phalanges and extending the middle and terminal phalanges. The oblique head of the Adductor hallucis is chiefly concerned in adducting the great toe toward the second one, but also assists in flexing this toe; the transverse head approximates all the toes and thus increases the curve of the transverse arch of the metatarsus. The *flexors* are the Flexor digitorum brevis, the Quadratus plantæ, the Flexor hallucis brevis, the Flexor digiti quinti brevis, and the Lumbricales. The Flexor digitorum brevis flexes the second phalanges upon the first, and, continuing its action, flexes the first phalanges also, and brings the toes together. The Quadratus plantæ assists the Flexor digitorum longus and converts the oblique pull of the tendons of that muscle into a direct backward pull upon the toes. The Flexor digiti quinti brevis flexes the little toe and draws its metatarsal bone downward and medialward. The Lumbricales, like the corresponding muscles in the hand, assist in flexing the proximal phalanges, and by their insertions into the tendons of the Extensor digitorum longus aid that muscle in straightening the middle and terminal phalanges. The Extensor digitorum brevis extends the first phalanx of the great toe and assists the long Extensor in extending the next three toes, and at the same time gives to the toes a lateral direction when they are extended.

BIBLIOGRAPHY.

BARDEEN, C. R.: Development and Variation, etc., of the Inferior Extremity, etc., Am. Jour. Anat., 1907, vi.

BARDEEN and LEWIS: Development of the Back, Body Wall and Limbs in Man, Am. Jour. Anat., 1901, i.

EISLER, P.: Die Muskeln des Stammes, v. Bardeleben's Handbuch der Anatomie des Menschen, Bd. ii, Abt. ii, Teil 1.

FICK, R.: Anatomie und Mechanik der Gelenke unter Berücksichtigung der bewegenden Muskeln, v. Bardeleben's Handbuch der Anatomie des Menschen, Bd. ii, Abt. i, Teil 2 and 3.

FROESE and FRÄNKEL: Die Muskeln des Menschlichen Beines; Die Muskeln des Menschlichen Armes, Handbuch der Anatomie des Menschen, von Bardeleben, Bd. ii, Abt. ii, Teil 2, A and B.

HENLE, J.: Handbuch der Systematischen Anatomie des Menschen, 1871-79.

KOCH, J. C.: The Laws of Bone Architecture, Am. Jour. Anat., 1917, xxi.

LE DOUBLE: Traité des Variations du Systeme Musculaire de L'Homme, 1897.

LEWIS, W. H.: Development of the Arm in Man, Am. Jour. Anat., 1901, i.

LEWIS, W. H.: Development of the Muscular System, Keibel and Mall, Manual of Human Embryology.

POIRIER, P., et CHARPY, A.: Traité d'Anatomie, 1899-1901.

TESTUT, L.: Traité d'Anatomie Humaine, 1893-94.

WOLFF, J.: Das Gesetz der Transformation der Knochen, Berlin, 1892.

ANGIOLOGY.

THE vascular system is divided for descriptive purposes into (a) the **blood vascular system**, which comprises the heart and bloodvessels for the circulation of the blood; and (b) the **lymph vascular system**, consisting of lymph glands and lymphatic vessels, through which a colorless fluid, the **lymph**, circulates. It must be noted, however, that the two systems communicate with each other and are intimately associated developmentally.

The heart is the central organ of the blood vascular system, and consists of a hollow muscle; by its contraction the blood is pumped to all parts of the body through a complicated series of tubes, termed **arteries**. The arteries undergo enormous ramification in their course throughout the body, and end in minute vessels, called **arterioles**, which in their turn open into a close-meshed network of microscopic vessels, termed **capillaries**. After the blood has passed through the capillaries it is collected into a series of larger vessels, called **veins**, by which it is returned to the heart. The passage of the blood through the heart and bloodvessels constitutes what is termed the **circulation of the blood**, of which the following is an outline.

The human heart is divided by septa into right and left halves, and each half is further divided into two cavities, an upper termed the **atrium** and a lower the **ventricle**. The heart therefore consists of four chambers, two, the right atrium and right ventricle, forming the right half, and two, the left atrium and left ventricle the left half. The right half of the heart contains venous or impure blood; the left, arterial or pure blood. The atria are receiving chambers, and the ventricles distributing ones. From the cavity of the left ventricle the pure blood is carried into a large artery, the **aorta**, through the numerous branches of which it is distributed to all parts of the body, with the exception of the lungs. In its passage through the capillaries of the body the blood gives up to the tissues the materials necessary for their growth and nourishment, and at the same time receives from the tissues the waste products resulting from their metabolism. In doing so it is changed from arterial into venous blood, which is collected by the veins and through them returned to the right atrium of the heart. From this cavity the impure blood passes into the right ventricle, and is thence conveyed through the **pulmonary arteries** to the lungs. In the capillaries of the lungs it again becomes arterialized, and is then carried to the left atrium by the **pulmonary veins**. From the left atrium it passes into the left ventricle, from which the cycle once more begins.

The course of the blood from the left ventricle through the body generally to the right side of the heart constitutes the greater or **systemic circulation**, while its passage from the right ventricle through the lungs to the left side of the heart is termed the lesser or **pulmonary circulation**.

It is necessary, however, to state that the blood which circulates through the spleen, pancreas, stomach, small intestine, and the greater part of the large intestine is not returned directly from these organs to the heart, but is conveyed by the **portal vein** to the liver. In the liver this vein divides, like an artery, and ultimately ends in capillary-like vessels (*sinusoids*), from which the rootlets of a series of veins, called the **hepatic veins**, arise; these carry the blood into the inferior vena cava,

whence it is conveyed to the right atrium. From this it will be seen that the blood contained in the portal vein passes through two sets of vessels: (1) the capillaries in the spleen, pancreas, stomach, etc., and (2) the sinusoids in the liver. The blood in the portal vein carries certain of the products of digestion: the carbohydrates, which are mostly taken up by the liver cells and stored as glycogen, and the protein products which remain in solution and are carried into the general circulation to the various tissues and organs of the body.

Speaking generally, the arteries may be said to contain pure and the veins impure blood. This is true of the systemic, but not of the pulmonary vessels, since it has been seen that the impure blood is conveyed from the heart to the lungs by the pulmonary arteries, and the pure blood returned from the lungs to the heart by the pulmonary veins. Arteries, therefore, must be defined as vessels which convey blood *from* the heart, and veins as vessels which return blood *to* the heart.

Structure of Arteries (Fig. 448).—The arteries are composed of three coats: an internal or endothelial coat (*tunica intima* of Kölliker); a middle or muscular coat (*tunica media*); and an external or connective-tissue coat (*tunica adventitia*). The two inner coats together are very easily separated from the external, as by the ordinary operation of tying a ligature around an artery. If a fine string be tied forcibly upon an artery and then taken off, the external coat will be found undivided, but the two inner coats are divided in the track of the ligature and can easily be further dissected from the outer coat.

The **inner coat** (*tunica intima*) can be separated from the middle by a little maceration, or it may be stripped off in small pieces; but, on account of its friability, it cannot be separated as a complete membrane. It is a fine, transparent, colorless structure which is highly elastic, and, after death, is commonly corrugated into longitudinal wrinkles. The inner coat consists of: (1) A layer of pavement endothelium, the cells of which are polygonal, oval, or fusiform, and have very distinct round or oval nuclei. This endothelium is brought into view most distinctly by staining with nitrate of silver. (2) A subendothelial layer, consisting of delicate connective tissue with branched cells lying in the interspaces of the tissue; in arteries of less than 2 mm. in diameter the subendothelial layer consists of a single stratum of stellate cells, and the connective tissue is only largely developed in vessels of a considerable size. (3) An elastic or fenestrated layer, which consists of a membrane containing a net-work of elastic fibers, having principally a longitudinal direction, and in which, under the microscope, small elongated apertures or perforations may be seen, giving it a fenestrated appearance. It was therefore called by Henle the **fenestrated membrane**. This membrane forms the chief thickness of the inner coat, and can be separated into several layers, some of which present the appearance of a net-work of longitudinal elastic fibers, and others a more membranous character, marked by pale lines having a longitudinal direction. In minute arteries

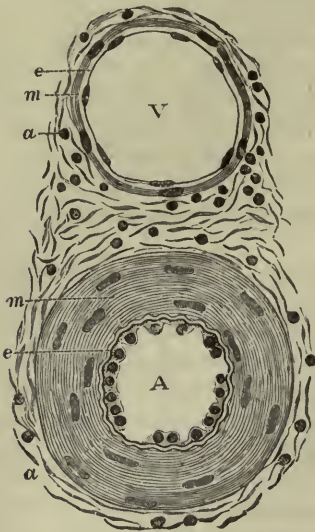


FIG. 448.—Transverse section through a small artery and vein of the mucous membrane of the epiglottis of a child. $\times 350$. (Klein and Noble Smith.) A. Artery, showing the nucleated endothelium, *e*, which lines it; the vessel being contracted, the endothelial cells appear very thick. Underneath the endothelium is the wavy elastic lamina. The chief part of the wall of the vessel is occupied by the circular muscle coat *m*; the rod-shaped nuclei of the muscle cells are well seen. Outside this is *a*, part of the adventitia. This is composed of bundles of connective tissue fibers, shown in section, with the nuclei of the connective tissue corpuscles. The adventitia gradually merges into the surrounding connective tissue. V. Vein showing a thin endothelial membrane, *e*, raised accidentally from the intima, which on account of its delicacy is seen as a mere line on the media *m*. This latter is composed of a few circular unstriped muscle cells *a*. The adventitia, similar in structure to that of an artery.

the fenestrated membrane is a very thin layer; but in the larger arteries, and especially in the aorta, it has a very considerable thickness.

The **middle coat** (*tunica media*) is distinguished from the inner by its color and by the transverse arrangement of its fibers. In the smaller arteries it consists principally of plain muscle fibers in fine bundles, arranged in lamellæ and disposed circularly around the vessel. These lamellæ vary in number according to the size of the vessel; the smallest arteries having only a single layer (Fig. 449), and those slightly larger three or four layers. It is to this coat that the thickness of the wall of the artery is mainly due (Fig. 448A, *m*). In the larger arteries, as the

iliac, femoral, and carotid, elastic fibers unite to form lamellæ which alternate with the layers of muscular fibers; these lamellæ are united to one another by elastic fibers which pass between the muscular bundles, and are connected with the fenestrated membrane of the inner coat (Fig. 450). In the largest arteries, as the aorta and innominate, the amount of elastic tissue is very considerable; in these vessels a few bundles of white connective tissue also have been found in the middle coat. The muscle fiber cells are about 50μ in length and contain well-marked, rod-shaped nuclei, which are often slightly curved.

The **external coat** (*tunica adventitia*) consists mainly of fine and closely felted bundles of white connective tissue, but also contains elastic fibers in all but the smallest arteries. The elastic tissue is much more abundant next the tunica media, and it is sometimes described as forming here, between the adventitia and media, a special layer, the **tunica elastica externa** of Henle. This layer is most marked in arteries of medium size. In the largest vessels the external coat is relatively thin; but in small arteries it is of greater proportionate thickness. In the smaller arteries it consists of a single layer of white connective tissue and elastic fibers; while in the smallest arteries, just above the capillaries, the elastic fibers are wanting, and the connective tissue of which the coat is composed becomes more nearly homogeneous the nearer it approaches the capillaries, and is gradually reduced to a thin membranous envelope, which finally disappears.

Some arteries have extremely thin walls in proportion to their size; this is especially the case in those situated in the cavity of the cranium and vertebral canal, the difference depending on the thinness of the external and middle coats.

The arteries, in their distribution throughout the body, are included in thin fibro-areolar investments, which form their **sheaths**. The vessel is loosely connected with its sheath by delicate areolar tissue; and the sheath usually encloses the accompanying veins, and sometimes a nerve. Some arteries, as those in the cranium, are not included in sheaths.

All the larger arteries, like the other organs of the body, are supplied with bloodvessels. These nutrient vessels, called the **vasa vasorum**, arise from a branch of the artery, or from a neighboring vessel, at some considerable distance from the point at which they are distributed; they ramify in the loose areolar tissue connecting the artery with its sheath, and are distributed to the external coat, but do not, in man, penetrate the other coats; in some of the larger mammals a few vessels have been traced into the middle coat. Minute veins return the blood from these vessels; they empty themselves into the vein or veins accompanying the artery. Lymphatic vessels are also present in the outer coat.

Arteries are also supplied with nerves, which are derived from the sympathetic, but may pass through the cerebrospinal nerves. They form intricate plexuses upon the surfaces of the larger trunks, and run along the smaller arteries as single filaments, or bundles of filaments which twist around the vessel and unite with each other in a plexiform manner. The branches derived from these plexuses penetrate the external coat and are distributed principally to the muscular tissue of the middle coat, and thus regulate, by causing the contraction and relaxation of this tissue the amount of blood sent to any part.

The Capillaries.—The smaller arterial branches (excepting those of the cavernous structure of the sexual organs, of the splenic pulp, and of the placenta) terminate in net-works of vessels which pervade nearly every tissue of the body. These vessels, from their minute size, are termed capillaries. They are interposed between the smallest branches of the arteries and the commencing veins, constituting a net-work, the branches of which maintain the same diameter throughout; the meshes of the net-work are more uniform in shape and size than those formed by the anastomoses of the small arteries and veins.

The **diameters** of the capillaries vary in the different tissues of the body, the usual size being about 8μ . The smallest are those of the brain and the mucous membrane of the intestines; and the largest those of the skin and the marrow of bone, where they are stated to be as large as 20μ in diameter. The **form** of the capillary net varies in the different tissues, the meshes being generally rounded or elongated.

The **rounded form of mesh** is most common, and prevails where there is a dense network, as in the lungs, in most glands and mucous membranes, and in the cutis; the meshes are not of an absolutely circular outline, but more or less angular, sometimes nearly quadrangular, or polygonal, or more often irregular.



FIG. 449.—Small artery and vein, pia mater of sheep. $\times 250$. Surface view above the interrupted line; longitudinal section below. Artery in red; vein in blue.

Elongated meshes are observed in the muscles and nerves, the meshes resembling parallelograms in form, the long axis of the mesh running parallel with the long axis of the nerve or muscle. Sometimes the capillaries have a *looped arrangement*; a single vessel projecting from the common net-work and returning after forming one or more loops, as in the papillæ of the tongue and skin.

The number of the capillaries and the size of the meshes determine the degree of vascularity of a part. The closest network and the smallest interspaces are found in the lungs and in the choroid coat of the eye. In these situations the interspaces are smaller than the capillary vessels themselves. In the intertubular plexus of the kidney, in the conjunctiva, and in the cutis, the interspaces are from three to four times as large as the capillaries which form them; and in the brain from eight to ten times as large as the capillaries in their long diameters, and from four to six times as large in their transverse diameters. In the adventitia of arteries the width of the meshes is ten times that of the capillary vessels. As a general rule, the more active the function of the organ, the closer is its capillary net and the larger its supply of blood; the meshes of the network are very narrow in all growing parts, in the glands, and in the mucous membranes, wider in bones and ligaments which are comparatively inactive; bloodvessels are nearly altogether absent in tendons, in which very little organic change occurs after their formation. In the liver the capillaries take a more or less radial course toward the intralobular vein, and their walls are incomplete, so that the blood comes into direct contact with the liver cells. These vessels in the liver are not true capillaries but "sinusoids;" they are developed by the growth of columns of liver cells into the blood spaces of the embryonic organ.

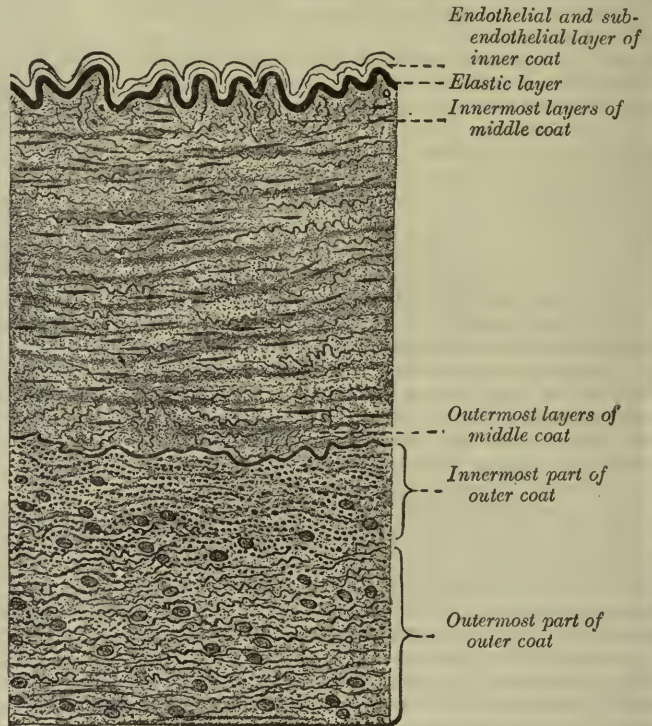


FIG. 450.—Section of a medium-sized artery. (After Grünstein.)

Structure.—The wall of a capillary consists of a fine transparent endothelial layer, composed of cells joined edge to edge by an interstitial cement substance, and continuous with the endothelial cells which line the arteries and veins. When stained with nitrate of silver the edges which bound the epithelial cells are brought into view (Fig. 451). These cells are of large size and of an irregular polygonal or lanceolate shape, each containing an oval nucleus which may be displayed by carmine or hematoxylin. Between their edges, at various points of their meeting, roundish dark spots are sometimes seen, which have been described as stomata, though they are closed by intercellular substance. They have been believed to be the situations through which the colorless corpuscles of the blood, when migrating from the bloodvessels, emerge; but this view, though probable, is not universally accepted.

Kolossow describes these cells as having a rather more complex structure. He states that

each consists of two parts: of hyaline ground plates, and of a protoplasmic granular part, in which is imbedded the nucleus, on the outside of the ground plates. The hyaline internal coat of the capillaries does not form a complete membrane, but consists of "plates" which are inelastic, and though in contact with each other are not continuous; when therefore the capillaries are subjected to intravascular pressure, the plates become separated from each other; the protoplasmic portions of the cells, on the other hand, are united together. In some organs, *e. g.*, the glomeruli of the kidneys, intercellular cement cannot be demonstrated in the capillary wall and the cells are believed to form a syncytium.

In many situations a delicate sheath or envelope of branched nucleated connective tissue cells is found around the simple capillary tube, particularly in the larger ones; and in other places, especially in the glands, the capillaries are invested with retiform connective tissue.

Sinusoids.—In certain organs, *viz.*, the heart, the liver, the suprarenal and parathyroid glands, the glomus caroticum and glomus coccygeum, the smallest bloodvessels present various differences from true capillaries. They are wider, with an irregular lumen, and have no connective tissue covering, their endothelial cells being in direct contact with the cells of the organ. Moreover, they are either arterial or venous and not intermediate as are the true capillaries. These vessels have been called *sinusoids* by Minot. They are formed by columns of cells or trabeculae pushing their way into a large bloodvessel or blood space and carrying its endothelium before them; at the same time the wall of the vessel or space grows out between the cell columns.

Structure of Veins.—The veins, like the arteries, are composed of three coats: internal, middle, and external; and these coats are, with the necessary modifications, analogous to the coats of the arteries; the internal being the endothelial, the middle the muscular, and the external the connective tissue or areolar (Fig. 452). The main difference between the veins and the arteries is in the comparative weakness of the middle coat in the former.

In the smallest veins the three coats are hardly to be distinguished (Fig. 449). The endothelium is supported on a membrane separable into two layers, the outer of which is the thicker, and consists of a delicate, nucleated membrane (*adventitia*), while the inner is composed of a network of longitudinal elastic fibers (*media*). In the veins next above these in size (0.4 mm. in diameter), according to Kölliker, a connective tissue layer containing numerous muscle fibers circularly disposed can be traced, forming the middle coat, while the elastic and connective tissue elements of the outer coat become more distinctly perceptible. In the middle-sized veins the typical structure of these vessels becomes clear. The endothelium is of the same character as in the arteries, but its cells are more oval and less fusiform. It is supported by a connective tissue layer, consisting of a delicate net-work of branched cells, and external to this is a layer of elastic fibers disposed in the form of a net-work in place of the definite fenestrated membrane seen in the arteries. This constitutes the **internal coat**. The **middle coat** is composed of a thick layer of connective tissue with elastic fibers, intermixed, in some veins, with a transverse layer of muscular tissue. The white fibrous element is in considerable excess, and the elastic fibers are in much smaller proportion in the veins than in the arteries. The **outer coat** consists, as in the arteries, of areolar tissue, with longitudinal elastic fibers. In the largest veins the outer coat is from two to five times thicker than the middle coat, and contains a large number of longitudinal muscular fibers. These are most distinct in the inferior vena cava, especially at the termination of this vein in the heart, in the trunks of the hepatic veins, in all the large trunks of the portal vein, and in the external iliac, renal, and azygos veins. In the renal and portal veins they extend through the whole thickness of the outer coat, but in the other veins mentioned a layer of connective and elastic tissue is found external to the muscular fibers. All the large veins which open into the heart are covered for a short distance with a layer of striped muscular tissue continued on to them from the heart. Muscular tissue is wanting: (1) in the veins of the maternal part of the placenta; (2) in the venous sinuses of the dura mater and the veins of the pia mater of the brain and medulla spinalis; (3) in the veins of the retina; (4) in the veins of the cancellous tissue of bones; (5) in the venous spaces of the corpora cavernosa. The veins of the above-mentioned parts consist of an internal endothelial lining supported on one or more layers of areolar tissue.

Most veins are provided with valves which serve to prevent the reflux of the blood. Each valve is formed by a reduplication of the inner coat, strengthened by connective tissue and elastic

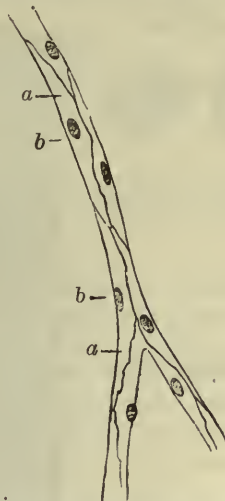


FIG. 451.—Capillaries from the mesentery of a guinea-pig, after treatment with solution of nitrate of silver. *a.* Cells. *b.* Their nuclei.

fibers, and is covered on both surfaces with endothelium, the arrangement of which differs on the two surfaces. On the surface of the valve next the wall of the vein the cells are arranged transversely; while on the other surface, over which the current of blood flows, the cells are arranged longitudinally in the direction of the current. Most commonly two such valves are found placed opposite one another, more especially in the smaller veins or in the larger trunks at the point where they are joined by smaller branches; occasionally there are three and sometimes only one. The valves are semilunar. They are attached by their convex edges to the wall of the vein; the concave margins are free, directed in the course of the venous current, and lie in close apposition with the wall of the vein as long as the current of blood takes its natural course; if, however, any regurgitation takes place, the valves become distended, their opposed edges are brought into contact, and the current is interrupted. The wall of the vein on the cardiac side of the point of attachment of each valve is expanded into a pouch or sinus, which gives to the vessel, when injected or distended with blood, a knotted appearance. The valves are very numerous in the veins of the extremities, especially of the lower extremities, these vessels

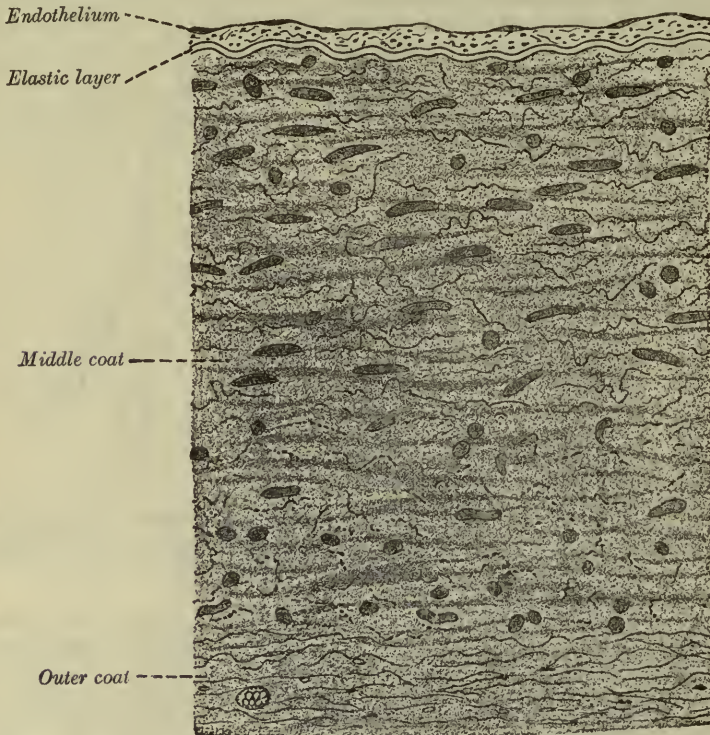


FIG. 452.—Section of a medium-sized vein.

having to conduct the blood against the force of gravity. They are absent in the very small veins, *i. e.*, those less than 2 mm. in diameter, also in the venæ cavae, hepatic, renal, uterine, and ovarian veins. A few valves are found in each spermatic vein, and one also at its point of junction with the renal vein or inferior vena cava respectively. The cerebral and spinal veins, the veins of the cancellated tissue of bone, the pulmonary veins, and the umbilical vein and its branches, are also destitute of valves. A few valves are occasionally found in the azygos and intercostal veins. Rudimentary valves are found in the tributaries of the portal venous system.

The veins, like the arteries, are supplied with nutrient vessels, *vasa vasorum*. Nerves also are distributed to them in the same manner as to the arteries, but in much less abundance.

THE BLOOD.

The blood is an opaque, rather viscid fluid, of a bright red or scarlet color when it flows from the arteries, of a dark red or purple color when it flows from the veins. It is salt to the taste, and has a peculiar faint odor and an alkaline reaction. Its specific gravity is about 1.06, and its temperature is generally about 37° C., though varying slightly in different parts of the body.

General Composition of the Blood.—Blood consists of a faintly yellow fluid, the plasma or liquor sanguinis, in which are suspended numerous minute particles, the blood corpuscles, the majority of which are colored and give to the blood its red tint. If a drop of blood be placed in a thin layer on a glass slide and examined under the microscope, a number of these corpuscles will be seen floating in the plasma.

The **Blood Corpuscles** are of three kinds: (1) colored corpuscles or erythrocytes; (2) colorless corpuscles or leucocytes; (3) blood platelets.

1. **Colored or red corpuscles** (*erythrocytes*), when examined under the microscope, are seen to be circular disks, biconcave in profile. The disk has no nucleus, but, in consequence of its biconcave shape, presents, according to the alterations of focus under an ordinary high power, a central part, sometimes bright, sometimes

dark, which has the appearance of a nucleus (Fig. 453, *a*). It is to the aggregation of the red corpuscles that the blood owes its red hue, although when examined by transmitted light their color appears to be only a faint reddish yellow. The corpuscles vary slightly in size even in the same drop of blood, but the average diameter is about 7.5μ ,¹ and the thickness about 2μ . Besides these there are found certain smaller corpuscles of about one-half of the size just indicated; these are termed **microcytes**, and are very scarce in normal blood; in diseased conditions (*e. g.*, anemia), however, they are more numerous. The number of red corpuscles in the blood is enormous; between 4,000,000 and 5,000,000 are contained in a cubic millimetre. Power states that the red corpuscles of an adult would present an aggregate surface of about 3000 square yards.

If the web of a living frog's foot be spread out and examined under the microscope the blood is seen to flow in a continuous stream through the vessels, and the corpuscles show no tendency to adhere to each other or to the wall of the vessel. Doubtless the same is the case in the human body; but when human blood is drawn and examined on a slide without reagents the corpuscles tend to collect into heaps like rouleaux of coins (Fig. 453, *b*). It has been suggested that this phenomenon may be explained by alteration in surface tension. During life the red corpuscles may be seen to change their shape under pressure so as to adapt themselves, to some extent, to the size of the vessel. They are, however, highly elastic, and speedily recover their shape when the pressure is removed. They are readily influenced by the medium in which they are placed. In water they swell up, lose their shape, and become globular (*endosmosis*) (Fig. 453, *c*). Subsequently the hemoglobin is dissolved out, and the envelope can barely be distinguished as a faint circular outline. Solutions of salt or sugar, denser than the plasma, give them a stellate or crenated appearance (*exosmosis*) (Fig. 453, *d*), but the usual shape may be restored by diluting the solution to the same tonicity as the plasma. The crenated outline may be produced as the first effect of the passage of an electric shock: subsequently, if sufficiently strong, the shock ruptures the envelope. A solution of salt, isotonic with the plasma, merely separates the blood corpuscles mechanically, without changing their shape. Two views are held with regard to

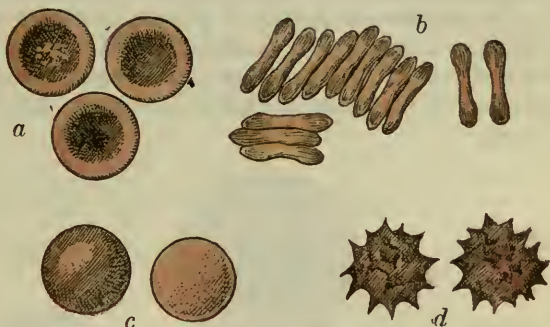


FIG. 453.—Human red blood corpuscles. Highly magnified. *a*. Seen from the surface. *b*. Seen in profile and forming rouleaux. *c*. Rendered spherical by water. *d*. Rendered crenate by salt solution.

¹ A micromillimetre (μ) is 1/1000 of a millimetre or 1/25000 of an inch.

the structure of the erythrocytes. The older view, that of Rollett, supposes that the corpuscle consists of a sponge work or stroma permeated by a solution of hemoglobin. Schäfer, on the other hand, believes that the hemoglobin solution is contained within an envelope or membrane, and the facts stated above with regard to the osmotic behavior of the erythrocyte support this belief. The envelope consists mainly of lecithin, cholesterin, and nucleoprotein.

The **colorless corpuscles** or **leucocytes** are of various sizes, some no larger, others smaller, than the red corpuscles. In human blood, however, the majority are rather larger than the red corpuscles, and measure about 10μ in diameter. On the average from 7000 to 12,000 leucocytes are found in each cubic millimetre of blood.

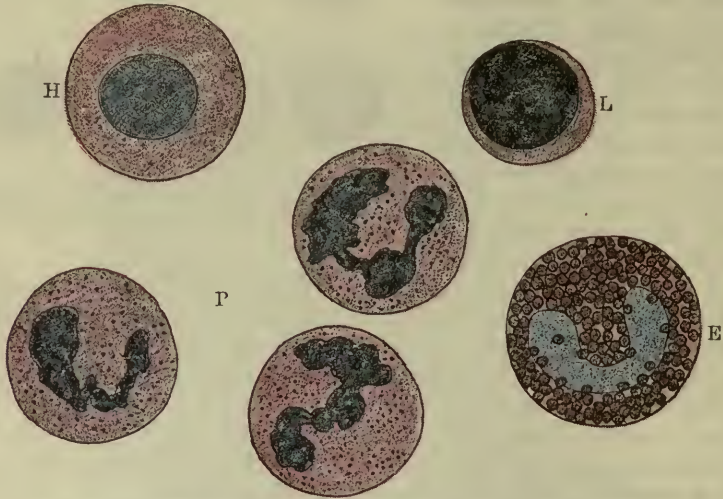


FIG. 454.—Varieties of leucocytes found in human blood. Highly magnified.

They consist of minute masses of nucleated protoplasm, and exhibit several varieties, which are differentiated from each other chiefly by the occurrence or non-occurrence of granules in their protoplasm, and by the staining reactions of these granules when present (Fig. 454). (1) The most numerous (60 per cent.) and important are irregular in shape, possessed of the power of ameboid movement, and are characterized by nuclei which often consist of two or three parts (multi-partite) connected together by fine threads of chromatin. The protoplasm is clear, and contains a number of very fine granules, which stain with acid dyes, such as eosin, or with neutral dyes, and are therefore called **oxyphil** or **neutrophil** (Fig. 454, *P*). These cells are termed the **polymorphonuclear leucocytes**. (2) A second variety comprises from 1 to 4 per cent. of the leucocytes; they are larger than the previous kind, and are made up of coarsely granular protoplasm, the granules being highly refractile and grouped around single nuclei of horse-shoe shape (Fig. 454, *E*). The granules stain deeply with eosin, and the cells are therefore often termed **eosinophil corpuscles**. (3) The third variety is called the **hyaline cell** or **macrocyte** (Fig. 454, *H*). This is usually about the same size as the eosinophil cell, and, when at rest, is spherical in shape and contains a single round or oval nucleus. The protoplasm is free from granules, but is not quite transparent, having the appearance of ground glass. (4) The fourth kind of colorless corpuscle is designated the **lymphocyte** (Fig. 454, *L*), because it is identical with the cell derived from the lymph glands or other lymphoid tissue. It is the smallest of the leucocytes, and consists chiefly of a spheroidal nucleus with a very little surrounding protoplasm of a homogeneous nature; it is regarded as the immature form of the

hyaline cell. The third and fourth varieties together constitute from 20 to 30 per cent. of the colorless corpuscles, but of these two varieties the lymphocytes are by far the more numerous. Leucocytes having in their protoplasm granules which stain with basic dyes (basophil) have been described as occurring in human blood, but they are rarely found except in disease.

The colorless corpuscles are very various in shape in living blood (Fig. 455), because many of them have the power of constantly changing their form by protruding finger-shaped or filamentous processes of their substance, by which they move and take up granules from the surrounding medium. In locomotion the corpuscle pushes out a process of its substance—a **pseudopodium**, as it is called

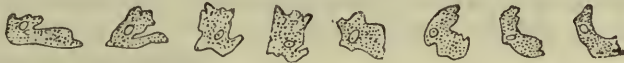

FIG. 455.—Human colorless blood corpuscle, showing its successive changes of outline within ten minutes when kept moist on a warm stage. (Schofield.)

—and then shifts the rest of the body into it. In the same way when any granule or particle comes in its way the corpuscle wraps a pseudopodium around it, and then withdraws the pseudopodium with the contained particle into its own substance. By means of these amoeboid properties the cells have the power of wandering or emigrating from the bloodvessels by penetrating their walls and thus finding their way into the extravascular spaces. A chemical investigation of the protoplasm of the leucocytes shows the presence of nucleoprotein and of a globulin. The occurrence of small amounts of fat, lecithin, and glycogen may also be demonstrated.

The **blood platelets** (Fig. 456) are discoid or irregularly shaped, colorless, refractile bodies, much smaller than the red corpuscles. Each contains a central chromatin mass resembling a nucleus. Blood platelets possess the power of amoeboid movement. When blood is shed they rapidly disintegrate and form granular masses, setting free **prothrombin** and the substance called by Howell **thromboplastin**. It is doubtful whether they exist normally in circulating blood.

DEVELOPMENT OF THE VASCULAR SYSTEM.

Bloodvessels first make their appearance in several scattered *vascular areas* which are developed simultaneously between the entoderm and the mesoderm of the yolk-sac, *i. e.*, outside the body of the embryo. Here a new type of cell, the **angioblast** or **vasoformative cell**, is differentiated from the mesoderm. These cells as they divide form small, dense syncytial masses which soon join with similar masses by means of fine processes to form **plexuses**. These plexuses increase both by division and growth of its cells and by the addition of new angioblasts which differentiate from the mesoderm. Within these solid plexuses and also within the isolated masses of angioblasts vacuoles appear through liquefaction of the central part of the syncytium into plasma. The lumen of the bloodvessels thus formed is probably intracellular. The flattened cells at the periphery form the endothelium. The nucleated red blood corpuscles develop either from small masses of the original angioblast left attached to the inner wall of the lumen or directly from the flat endothelial cells. In either case the syncytial mass thus

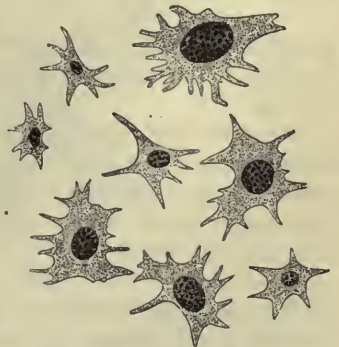


FIG. 456.—Blood platelets. Highly magnified. (After Kopsch.)

formed projects from and is attached to the wall of the vessel. Such a mass is known as a blood island and hemoglobin gradually accumulates within it. Later the cells on the surface round up, giving the mass a mulberry-like appearance. Then the red blood cells break loose and are carried away in the plasma. Such free blood cells continue to divide. The term **blood island** was originally used for the syncytial masses of angioblasts found in the area vasculosa, but it is probably best to limit the term to the masses within the lumen from which the red blood cells arise as Sabin¹ has done. Blood islands have been seen in the area vasculosa in the omphalomesenteric vein and arteries, and in the dorsal aorta.

The differentiation of angioblasts from the mesoderm occurs not only in the area vasculosa but within the embryo and probably most of the larger bloodvessels are developed *in situ* in this manner. This process of the differentiation of angioblasts from the mesoderm probably ceases in different regions of the embryo at different periods and after its cessation new vessels are formed by sprouts from vessels already laid down in the form of capillary plexuses.

The first rudiment of the **heart** appears as a pair of tubular vessels which are developed in the splanchnopleure of the pericardial area (Fig. 457). These are named the **primitive aortæ**, and a direct continuity is soon established between them and the vessels of the yolk-sac. Each receives anteriorly a vein—the **vitelline vein**—from the yolk-sac, and is prolonged backward on the lateral aspect of the notochord under the name of the

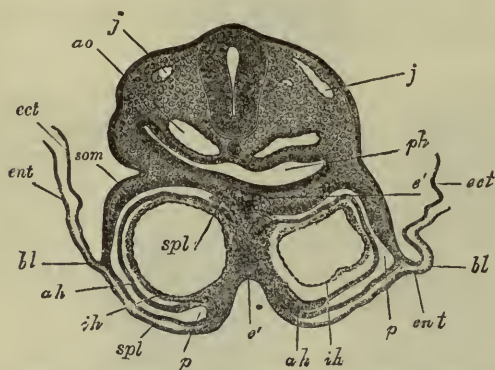


FIG. 457.—Transverse section through the region of the heart in a rabbit embryo of nine days. $\times 80$. (Kölliker.) *j, j.* Jugular veins. *ao.* Aorta. *ph.* Pharynx. *som.* Somatopleure. *bl.* Proamnion. *ect.* Ectoderm. *ent.* Entoderm. *p.* Pericardium. *spl.* Splanchnopleure. *ah.* Outer wall of heart. *ih.* Endothelial lining of heart. *e'.* Septum between heart tubes.

dorsal aorta. The dorsal aortæ give branches to the yolk-sac, and are continued backward through the body-stalk as the umbilical arteries to the villi of the chorion.

Eternod² describes the circulation in an embryo which he estimated to be about thirteen days old (Fig. 458). The rudiment of the heart is situated immediately below the fore-gut and consists of a short stem. It gives off two vessels, the primitive aortæ, which run backward, one on either side of the notochord, and then pass into the body-stalk along which they are carried to the chorion. From the chorionic villi the blood is returned by a pair of umbilical veins which unite in the body-stalk to form a single vessel and subsequently encircle the mouth of the yolk-sac and open into the heart. At the junction of the yolk-sac and body-stalk each vein is joined by a branch from the vascular plexus of the yolk-sac. From his observations it seems that, in the human embryo, the chorionic circulation is established before that on the yolk-sac.

By the forward growth and flexure of the head the pericardial area and the anterior portions of the primitive aortæ are folded backward on the ventral aspect of the fore-gut, and the original relation of the somatopleure and splanchnopleure layers of the pericardial area is reversed. Each primitive aorta now consists of a ventral and a dorsal part connected anteriorly by an arch (Fig. 459); these three parts are named respectively the anterior ventral aorta, the dorsal aorta, and the first cephalic arch. The vitelline veins which enter the embryo through the

¹ Anatomical Record, 1917, vol. xiii, p. 199.

² Anat. Anzeiger, 1899, vol. xv.

anterior wall of the umbilical orifice are now continuous with the posterior ends of the anterior ventral aorta. With the formation of the tail-fold the posterior parts of the primitive aortæ are carried forward in a ventral direction to form the posterior ventral aortæ and primary caudal arches.¹ In the pericardial region the two primitive aortæ grow together, and fuse to form a single tubular heart (Fig. 460), the posterior end of which receives the two vitelline veins, while from its anterior end the two anterior ventral aortæ emerge.² The first cephalic arches pass through the mandibular arches, and behind them five additional pairs subsequently develop, so that altogether six pairs of aortic arches are formed; the fifth arches are very transitory vessels connecting the ventral aortæ with the dorsal ends of the sixth arches. By the rhythmical contraction of the tubular heart the blood is forced through the aortæ and bloodvessels of the vascular area, from which it is returned to the heart by the vitelline veins. This constitutes the **vitelline circulation** (Fig. 459), and by means of it nutriment is absorbed from the yolk (vitellus.)

The vitelline veins at first open separately into the posterior end of the tubular heart, but after a time their terminal portions fuse to form a single vessel. The vitelline veins ultimately drain the blood from the digestive tube, and are modified to form the portal vein. This is caused by the growth of the liver, which interrupts their direct continuity with the heart; and the blood returned by them circulates through the liver before reaching the heart.

With the atrophy of the yolk-sac the vitelline circulation diminishes and ultimately ceases, while an increasing amount of blood is carried through the umbilical arteries to the villi of the chorion. Subsequently, as the non-placental chorionic villi atrophy, their vessels disappear; and then the umbilical arteries convey the whole of their contents to the placenta, whence it is returned to the heart by the umbilical veins. In this manner the placental circulation is established, and by means of it nutritive materials are absorbed from, and waste products given up to the maternal blood.

The umbilical veins, like the vitelline, undergo interruption in the developing liver, and the blood returned by them passes through this organ before reaching the heart. Ultimately the right umbilical vein shrivels up and disappears.

During the occurrence of these changes great alterations take place in the primitive heart and bloodvessels.

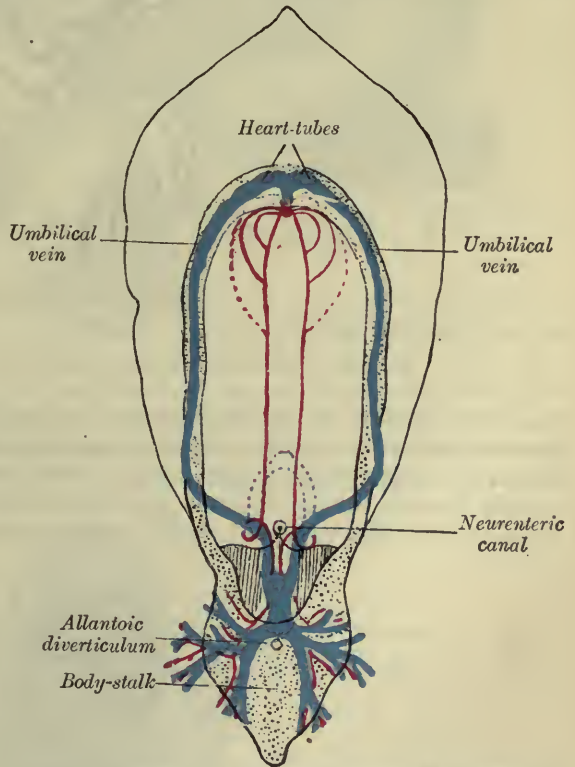


FIG. 458.—Diagram of the vascular channels in a human embryo of the second week. (After Eternod.) The red lines are the dorsal aortæ continued into the umbilical arteries. The red dotted lines are the ventral aortæ, and the blue dotted lines the vitelline veins.

¹ Young and Robinson, *Journal of Anatomy and Physiology*, vol. xxxii.

² In most fishes and in the amphibia the heart originates as a single median tube.

Further Development of the Heart.—Between the endothelial lining and the outer wall of the heart there exists for a time an intricate trabecular network of mesodermal tissue from which, at a later stage, the *musculi papillares*, *chordæ tendineæ*, and *trabeculæ carneæ* are developed. The simple tubular heart, already

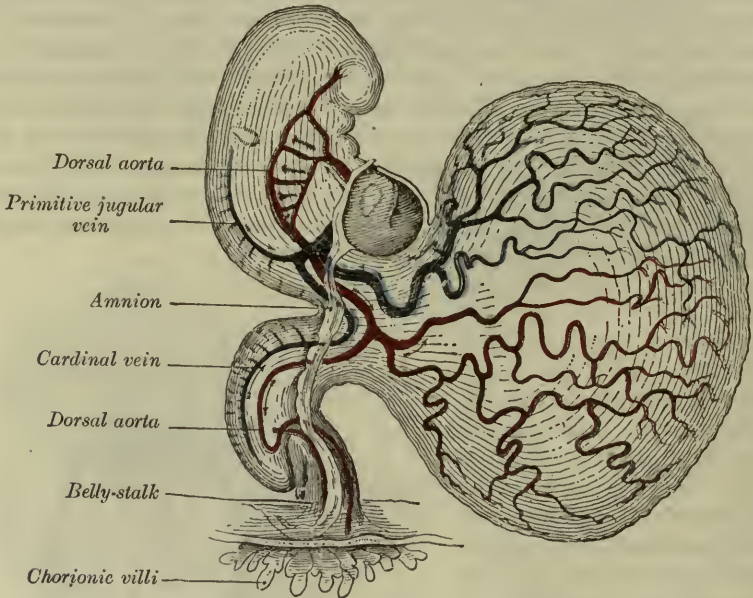


FIG. 459.—Human embryo of about fourteen days, with yolk-sac. (After His.)

described, becomes elongated and bent on itself so as to form an S-shaped loop, the anterior part bending to the right and the posterior part to the left (Fig. 460). The intermediate portion arches transversely from left to right, and then turns sharply forward into the anterior part of the loop. Slight constrictions make their appearance in the tube and divide it from behind forward into five parts, viz.:

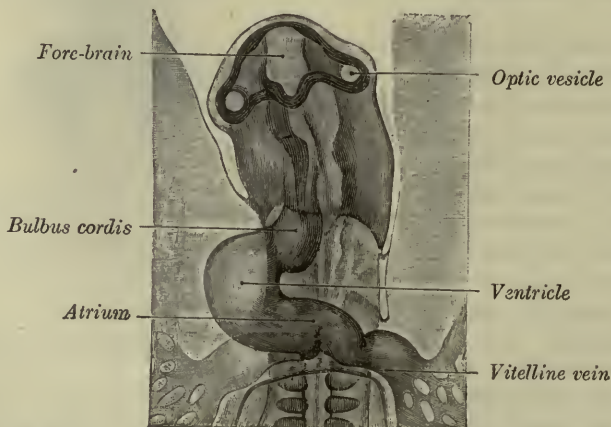


FIG. 460.—Head of chick embryo of about thirty-eight hours' incubation, viewed from the ventral surface. $\times 26$ (Duval.)

(1) the *sinus venosus*; (2) the *primitive atrium*; (3) the *primitive ventricle*; (4) the *bulbus cordis*, and (5) the *truncus arteriosus* (Figs. 461, 462). The constriction between the atrium and ventricle constitutes the *atrial canal*, and indicates the site of the future *atrioventricular valves*.

The *sinus venosus* is at first situated in the septum transversum (a layer of mesoderm in which the liver and the central tendon of the diaphragm are developed) behind the primitive atrium, and is formed by the union of the vitelline veins. The veins or ducts of Cuvier from the body of the embryo and the umbilical veins from the placenta subsequently open into it (Fig. 463). The sinus is at first placed transversely, and opens by a median aperture into the primitive atrium.

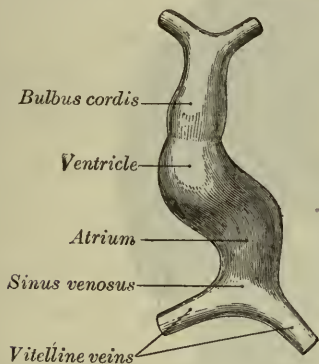


FIG. 461.—Diagram to illustrate the simple tubular condition of the heart. (Drawn from Ecker-Ziegler model.)



FIG. 462.—Heart of human embryo of about fourteen days. (From model by His.)

Soon, however, it assumes an oblique position, and becomes crescentic in form; its right half or horn increases more rapidly than the left, and the opening into the atrium now communicates with the right portion of the atrial cavity. The right horn and transverse portion of the sinus ultimately become incorporated with and form a part of the adult right atrium, the line of union between it and the auricula being indicated in the interior of the atrium by a vertical crest, the *crista terminalis* of His. The left horn, which ultimately receives only the left duct of Cuvier,

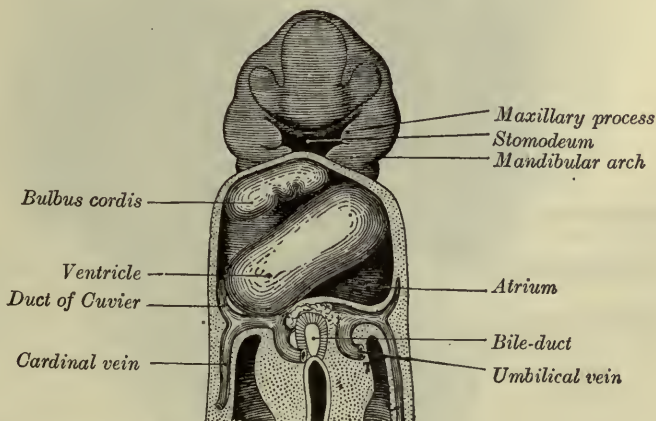


FIG. 463.—Heart of human embryo of about fifteen days. (Reconstruction by His.)

persists as the coronary sinus (Fig. 464). The vitelline and umbilical veins are soon replaced by a single vessel, the *inferior vena cava*, and the three veins (inferior vena cava and right and left Cuvierian ducts) open into the dorsal aspect of the atrium by a common slit-like aperture (Fig. 465). The upper part of this aperture represents the opening of the permanent superior vena cava, the lower that of the inferior vena cava, and the intermediate part the orifice of the coronary sinus. The slit-

like aperture lies obliquely, and is guarded by two halves, the **right and left venous valves**; above the opening these unite with each other and are continuous with a

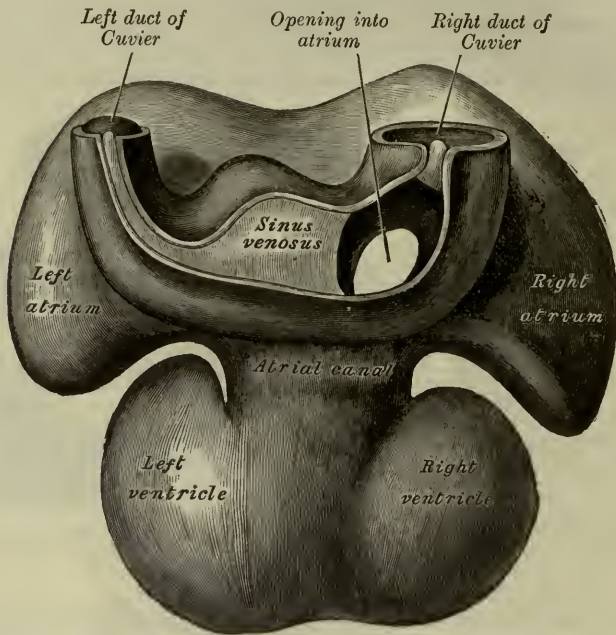


FIG. 464.—Dorsal surface of heart of human embryo of thirty-five days. (From model by His.)

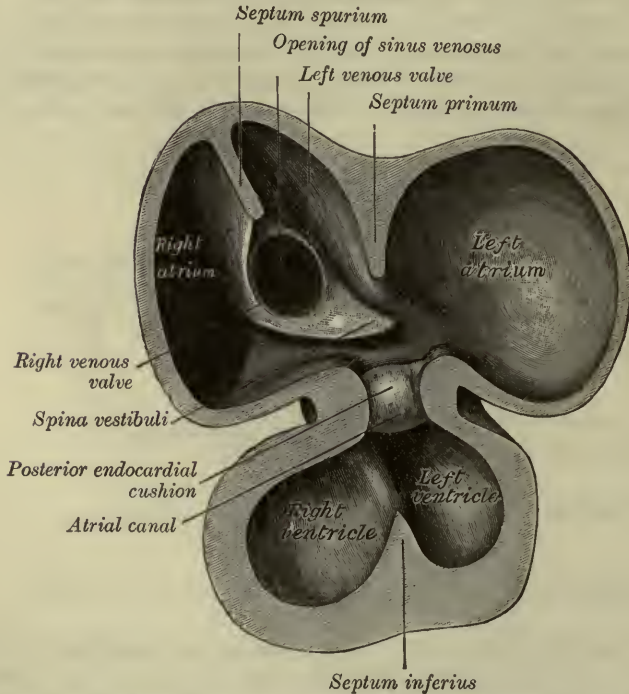


FIG. 465.—Interior of dorsal half of heart from a human embryo of about thirty days. (From model by His.)

fold named the **septum spurium**; below the opening they fuse to form a triangular thickening—the **spina vestibuli**. The right venous valve is retained; a small

septum, the *sinus septum*, grows from the posterior wall of the sinus venosus to fuse with the valve and divide it into two parts—an upper, the valve of the inferior vena cava, and a lower, the valve of the coronary sinus (Fig. 468). The extreme upper portion of the right venous valve, together with the *septum spurium*, form

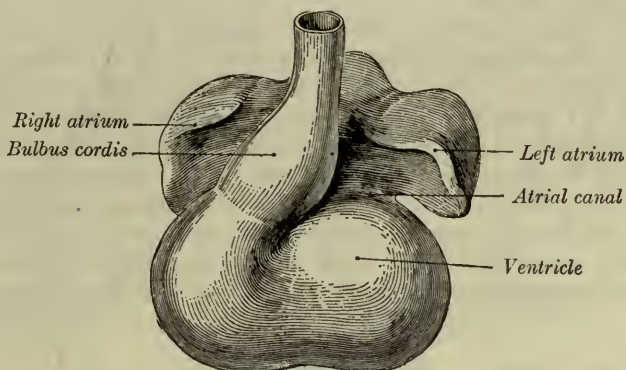


FIG. 466.—Heart showing expansion of the atria. (Drawn from Ecker-Zeigler model.)

the *crista terminalis* already mentioned. The upper and middle thirds of the left venous valve disappear; the lower third is continued into the *spina vestibuli*, and later fuses with the *septum secundum* of the atria and takes part in the formation of the *limbus fossæ ovalis*.

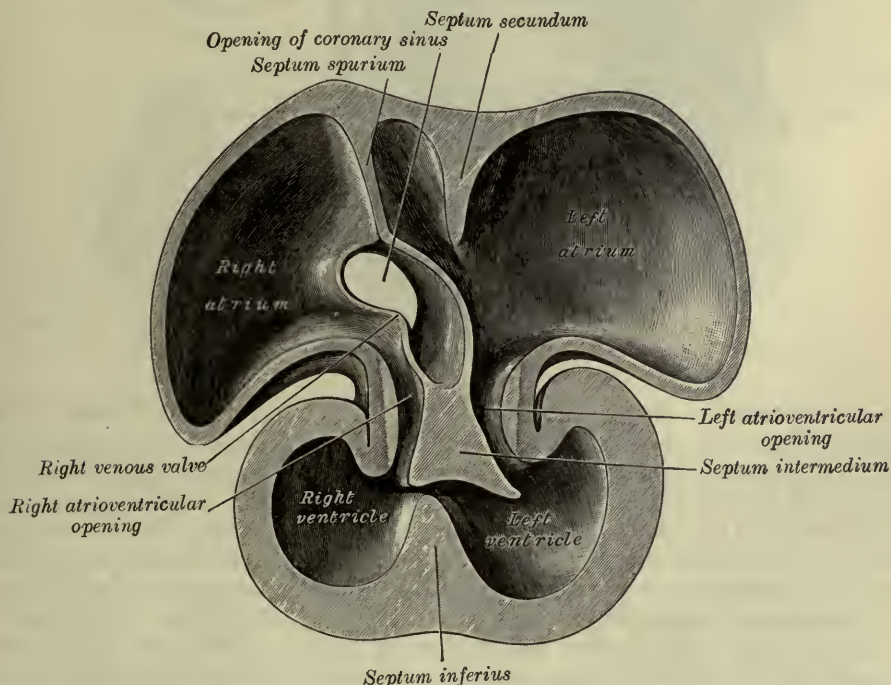


FIG. 467.—Interior of dorsal half of heart of human embryo of about thirty-five days. (From model by His.)

The atrial canal is at first a short straight tube connecting the atrial with the ventricular portion of the heart, but its growth is relatively slow, and it becomes overlapped by the atria and ventricles so that its position on the surface of the heart is indicated only by an annular constriction (Fig. 466). Its lumen is reduced to a

transverse slit, and two thickenings appear, one on its dorsal and another on its ventral wall. These thickenings, or **endocardial cushions** (Fig. 465) as they are termed, project into the canal, and, meeting in the middle line, unite to form the **septum intermedium** which divides the canal into two channels, the future right and left atrioventricular orifices.

The **primitive atrium** grows rapidly and partially encircles the bulbus cordis; the groove against which the bulbus cordis lies is the first indication of a division into right and left atria. The cavity of the primitive atrium becomes subdivided into right and left chambers by a septum, the **septum primum** (Fig. 465), which grows downward into the cavity. For a time the atria communicate with each other by an opening, the **ostium primum of Born**, below the free margin of the septum. This opening is closed by the union of the septum primum with the septum intermedium, and the communication between the atria is reestablished through an opening which is developed in the upper part of the septum primum; this opening is known as the **foramen ovale** (*ostium secundum of Born*) and persists until birth.

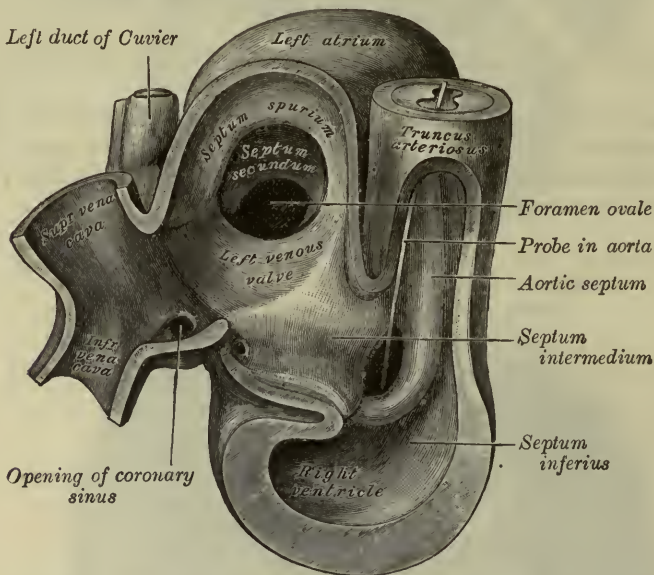


FIG. 468.—Same heart as in Fig. 467, opened on right side. (From model by His.)

A second septum, the **septum secundum** (Figs. 467, 468), semilunar in shape, grows downward from the upper wall of the atrium immediately to the right of the primary septum and foramen ovale. Shortly after birth it fuses with the primary septum, and by this means the foramen ovale is closed, but sometimes the fusion is incomplete and the upper part of the foramen remains patent. The *limbus fossæ ovalis* denotes the free margin of the septum secundum. Issuing from each lung is a pair of pulmonary veins; each pair unites to form a single vessel, and these in turn join in a common trunk which opens into the left atrium. Subsequently the common trunk and the two vessels forming it expand and form the vestibule or greater part of the atrium, the expansion reaching as far as the openings of the four vessels, so that in the adult all four veins open separately into the left atrium.

The **primitive ventricle** becomes divided by a septum, the **septum inferius** or **ventricular septum** (Figs. 465, 466, 467), which grows upward from the lower part of the ventricle, its position being indicated on the surface of the heart by a furrow. Its dorsal part increases more rapidly than its ventral portion, and fuses with the dorsal part of the septum intermedium. For a time an interventricular foramen

exists above its ventral portion (Fig. 468), but this foramen is ultimately closed by the fusion of the aortic septum with the ventricular septum.

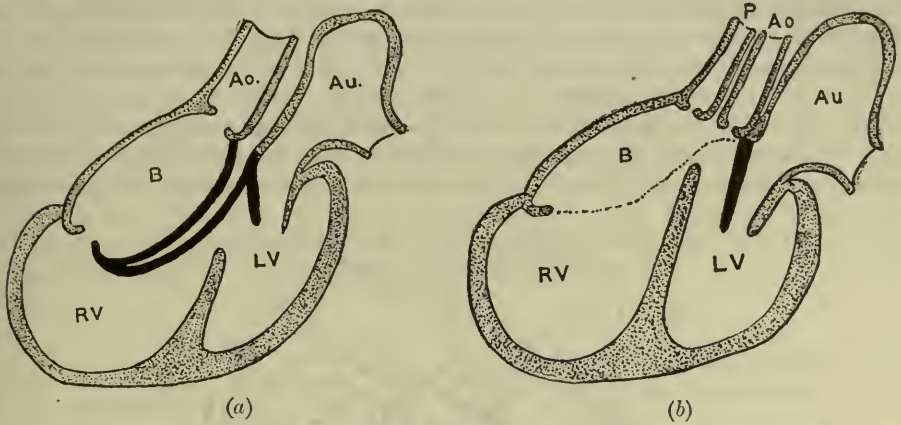


FIG. 469.—Diagrams to illustrate the transformation of the bulbus cordis. (Keith.) Ao. Truncus arteriosus. Au. Atrium. B. Bulbus cordis. RV. Right ventricle. LV. Left ventricle. P. Pulmonary artery.

When the heart assumes its S-shaped form the **bulbus cordis** lies ventral to and in front of the primitive ventricle. The adjacent walls of the bulbus cordis and ventricle approximate, fuse, and finally disappear, and the bulbus cordis now

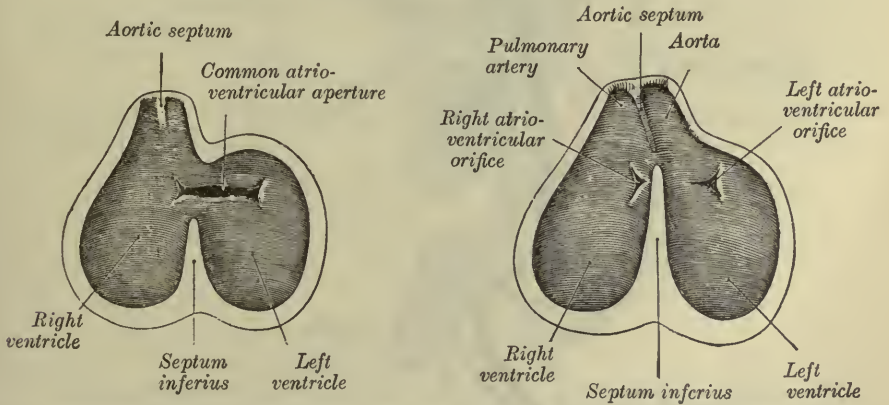


FIG. 470.—Diagrams to show the development of the septum of the aortic bulb and of the ventricles. (Born.)

communicates freely with the right ventricle, while the junction of the bulbus with the truncus arteriosus is brought directly ventral to and applied to the atrial canal. By the upgrowth of the ventricular septum the bulbus cordis is in great measure

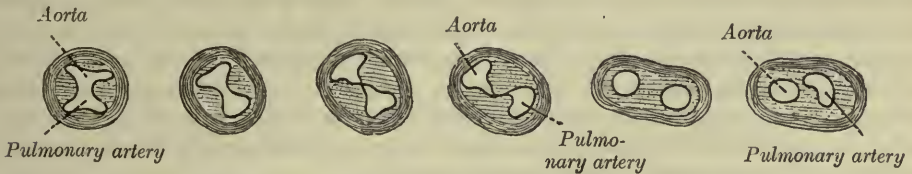


FIG. 471.—Transverse sections through the aortic bulb to show the growth of the aortic septum. The lowest section is on the left, the highest on the right of the figure. (After His.)

separated from the left ventricle, but remains an integral part of the right ventricle, of which it forms the infundibulum (Fig. 469).

The *truncus arteriosus* and *bulbus cordis* are divided by the *aortic septum* (Fig. 470). This makes its appearance in three portions. (1) Two distal ridge-like thickenings project into the lumen of the tube; these increase in size, and ultimately meet and fuse to form a septum, which takes a spiral course toward the proximal end of the *truncus arteriosus*. It divides the distal part of the *truncus* into two vessels, the *aorta* and *pulmonary artery*, which lie side by side above, but near the heart the *pulmonary artery* is in front of the *aorta*. (2) Four endocardial cushions appear in the proximal part of the *truncus arteriosus* in the region of the future *semilunar valves*; the manner in which these are related to the *aortic septum* is described below. (3) Two endocardial thickenings—*anterior* and *posterior*—

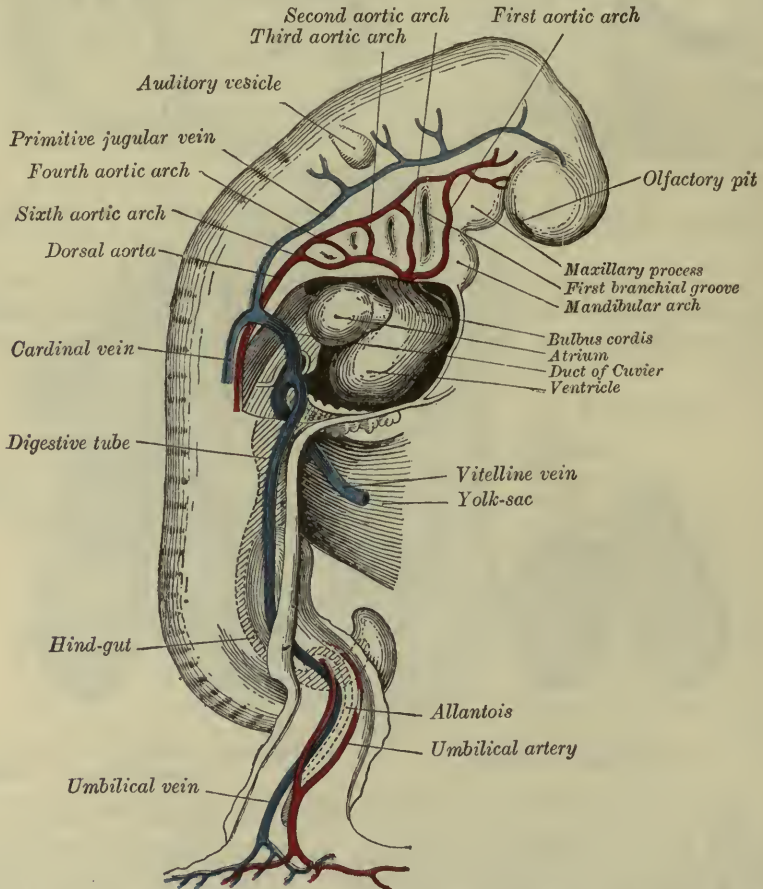


FIG. 472.—Profile view of a human embryo estimated at twenty or twenty-one days old. (After His.)

develop in the *bulbus cordis* and unite to form a short septum; this joins above with the *aortic septum* and below with the *ventricular septum*. The septum grows down into the *ventricle* as an *oblique partition*, which ultimately blends with the *ventricular septum* in such a way as to bring the *bulbus cordis* into communication with the *pulmonary artery*, and through the latter with the *sixth pair of aortic arches*; while the *left ventricle* is brought into continuity with the *aorta*, which communicates with the remaining *aortic arches*.

The Valves of the Heart.—The *atrioventricular valves* are developed in relation to the *atrial canal*. By the upward expansion of the bases of the *ventricles* the canal becomes invaginated into the *ventricular cavities*. The invaginated margin forms the rudiments of the *lateral cusps* of the *atrioventricular valves*; the *mesial* or

septal cusps of the valves are developed as downward prolongations of the septum intermedium (Fig. 467). The aortic and pulmonary semilunar valves are formed from four endocardial thickenings—an anterior, a posterior, and two lateral—which appear at the proximal end of the truncus arteriosus. As the aortic septum grows downward it divides each of the lateral thickenings into two, thus giving rise to six thickenings—the rudiments of the semilunar valves—three at the aortic and three at the pulmonary orifice (Fig. 471).

Further Development of the Arteries.—Recent observations show that practically none of the main vessels of the adult arise as such in the embryo. In the site of each vessel a capillary network forms, and by the enlargement of definite paths in this the larger arteries and veins are developed. The branches of the main arteries are not always simple modifications of the vessels of the capillary network, but may arise as new outgrowths from the enlarged stem.

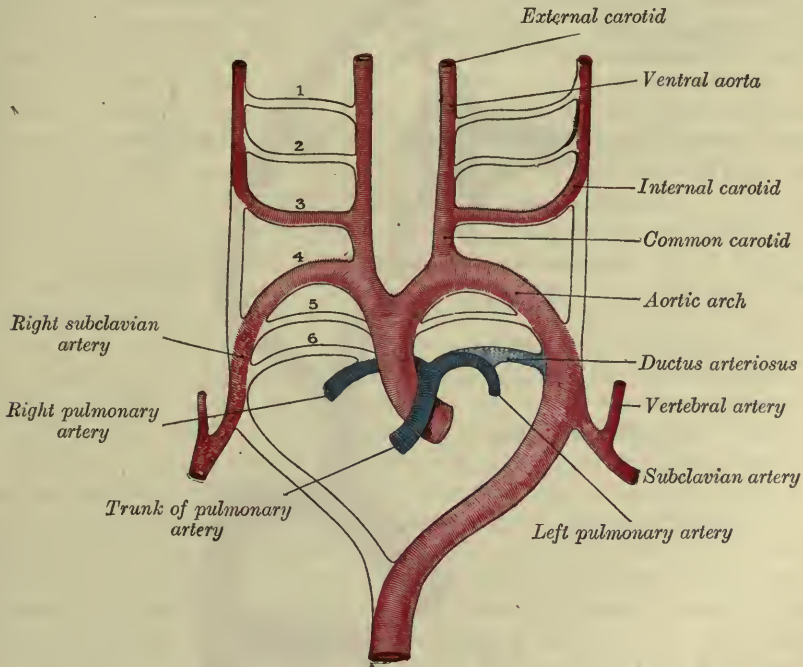


FIG. 473.—Scheme of the aortic arches and their destination. (Modified from Kollmann.)

It has been seen (page 506) that each primitive aorta consists of a ventral and a dorsal part which are continuous through the first aortic arch. The dorsal aortæ at first run backward separately on either side of the notochord, but about the third week they fuse from about the level of the fourth thoracic to that of the fourth lumbar segment to form a single trunk, the descending aorta. The first aortic arches run through the mandibular arches, and behind them five additional pairs are developed within the visceral arches; so that, in all, six pairs of aortic arches are formed (Figs. 472, 473). The first and second arches pass between the ventral and dorsal aortæ, while the others arise at first by a common trunk from the truncus arteriosus, but end separately in the dorsal aortæ. As the neck elongates, the ventral aortæ are drawn out, and the third and fourth arches arise directly from these vessels.

In fishes these arches persist and give off branches to the gills, in which the blood is oxygenated. In mammals some of them remain as permanent structures, while others disappear or become obliterated (Fig. 473).

The Anterior Ventral Aortæ.—These persist on both sides. The right forms (*a*) the innominate artery, (*b*) the right common and external carotid arteries. The left gives rise to (*a*) the short portion of the aortic arch, which reaches from the origin of the innominate artery to that of the left common carotid artery; (*b*) the left common and external carotid arteries.

The Aortic Arches.—The first and second arches disappear early, but the dorsal end of the second gives origin to the stapedia artery (Fig. 474), a vessel which atrophies in man but persists in some mammals. It passes through the ring of the stapes and divides into supraorbital, infraorbital, and mandibular branches which follow the three divisions of the trigeminal nerve. The infraorbital and man-

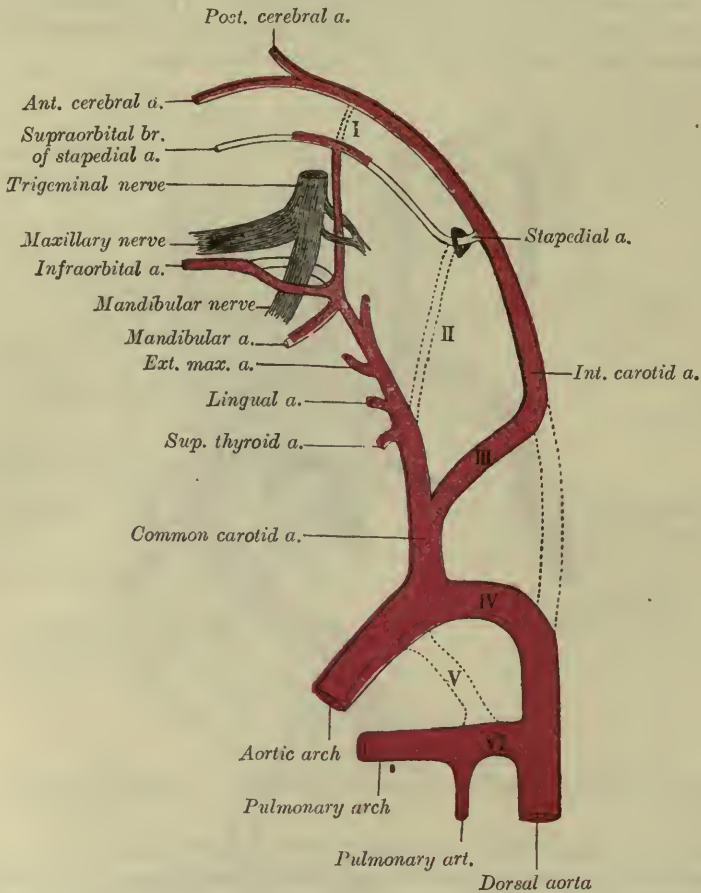


FIG. 474.—Diagram showing the origins of the main branches of the carotid arteries. (Founded on Tandler.)

dibular arise from a common stem, the terminal part of which anastomoses with the external carotid. On the obliteration of the stapedia artery this anastomosis enlarges and forms the internal maxillary artery, and the branches of the stapedia artery are now branches of this vessel. The common stem of the infraorbital and mandibular branches passes between the two roots of the auriculotemporal nerve and becomes the middle meningeal artery; the original supraorbital branch of the stapedia is represented by the orbital twigs of the middle meningeal. The third aortic arch constitutes the commencement of the internal carotid artery, and is therefore named the carotid arch. The fourth right arch forms the right subclavian as far as the origin of its internal mammary branch; while the fourth left arch constitutes the arch of the aorta between the origin of the left carotid artery

and the termination of the ductus arteriosus. The fifth arch disappears on both sides. The sixth right arch disappears; the sixth left arch gives off the pulmonary arteries and forms the ductus arteriosus; this duct remains pervious during the whole of fetal life, but is obliterated a few days after birth. His showed that in the early embryo the right and left arches each gives a branch to the lungs, but that later both pulmonary arteries take origin from the left arch.

The Dorsal Aortæ.—In front of the third aortic arches the dorsal aortæ persist and form the continuations of the internal carotid arteries; these arteries pass to the brain and each divides into an anterior and a posterior branch, the former giving off the ophthalmic and the anterior and middle cerebral arteries, while the latter turns back and joins the cerebral part of the vertebral artery. Behind the third arch the right dorsal aorta disappears as far as the point where the two dorsal aortæ fuse to form the descending aorta. The part of the left dorsal aorta between the third and fourth arches disappears, while the remainder persists to form the descending part of the arch of the aorta. A constriction, the **aortic isthmus**, is sometimes seen in the aorta between the origin of the left subclavian and the attachment of the ductus arteriosus.

Sometimes the right subclavian artery arises from the aortic arch distal to the origin of the left subclavian and passes upward and to the right behind the trachea and esophagus. This condition may be explained by the persistence of the right dorsal aorta and the obliteration of the fourth right arch.

In birds the fourth right arch forms the arch of the aorta; in reptiles the fourth arch on both sides persists and gives rise to the double aortic arch in these animals.

The heart originally lies on the ventral aspect of the pharynx, immediately behind the stomodeum. With the elongation of the neck and the development of the lungs it recedes within the thorax, and, as a consequence, the anterior ventral aortæ are drawn out and the original position of the fourth and fifth arches is greatly modified. Thus, on the right side the fourth recedes to the root of the neck, while on the left side it is withdrawn within the thorax. The recurrent nerves originally pass to the larynx under the sixth pair of arches, and are therefore pulled backward with the descent of these structures, so that in the adult the left nerve hooks around the ligamentum arteriosum; owing to the disappearance of the fifth and the sixth right arches the right nerve hooks around that immediately above them, *i. e.*, the commencement of the subclavian artery. Segmental arteries arise from the primitive dorsal aortæ and course between successive segments. The seventh segmental artery is of special interest, since it forms the lower end of the vertebral artery and, when the forelimb bud appears, sends a branch to it (the subclavian artery). From the seventh segmental arteries the entire left subclavian and the greater part of the right subclavian are formed. The second pair of segmental arteries accompany the hypoglossal nerves to the brain and are named the hypoglossal arteries. Each sends forward a branch which forms the cerebral part of the vertebral artery and anastomoses with the posterior branch of the internal carotid. The two vertebrales unite on the ventral surface of the hind-brain to form the basilar artery. Later the hypoglossal artery atrophies and the vertebral is connected with the first segmental artery. The cervical part of the vertebral is developed from a longitudinal anastomosis between the first seven segmental arteries, so that the seventh of these ultimately becomes the source of the artery. As a result of the growth of the upper limb the subclavian artery increases greatly in size and the vertebral then appears to spring from it.

Recent observations show that several segmental arteries contribute branches to the upper limb-bud and form in it a free capillary anastomosis. Of these branches, only one, *viz.*, that derived from the seventh segmental artery, persists to form the subclavian artery. The subclavian artery is prolonged into the limb under the names of the axillary and brachial arteries, and these together constitute the

arterial stem for the upper arm, the direct continuation of this stem in the forearm is the volar interosseous artery. A branch which accompanies the median nerve soon increases in size and forms the main vessel (median artery) of the forearm, while the volar interosseous diminishes. Later the radial and ulnar arteries are developed as branches of the brachial part of the stem and coincidentally with their enlargement the median artery recedes; occasionally it persists as a vessel of some considerable size and then accompanies the median nerve into the palm of the hand.

The primary arterial stem for the lower limb is formed by the inferior gluteal (sciatic) artery, which accompanies the sciatic nerve along the posterior aspect of the thigh to the back of the knee, whence it is continued as the peroneal artery. This arrangement exists in reptiles and amphibians. The femoral artery arises later as a branch of the common iliac, and, passing down the front and medial side of the thigh to the bend of the knee, joins the inferior gluteal artery. The femoral quickly enlarges, and, coincidentally with this, the part of the inferior gluteal immediately above the knee undergoes atrophy. The anterior and posterior tibial arteries are branches of the main arterial stem.

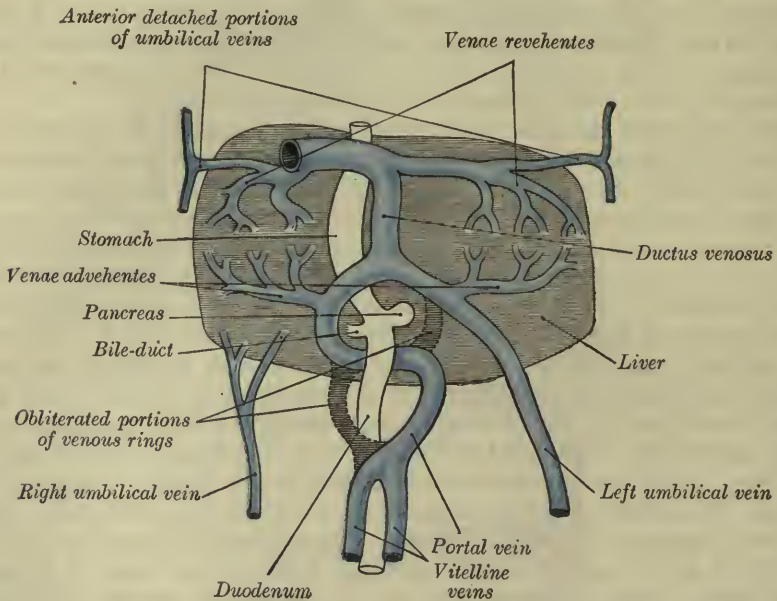


FIG. 475.—The liver and the veins in connection with it, of a human embryo, twenty-four or twenty-five days old, as seen from the ventral surface. (After His.)

Further Development of the Veins.—The formation of the great veins of the embryo may be best considered by dividing them into two groups, **visceral** and **parietal**.

The Visceral Veins.—The visceral veins are the two **vitelline** or **omphalomesenteric veins** bringing the blood from the yolk-sac, and the two **umbilical veins** returning the blood from the placenta; these four veins open close together into the sinus venosus.

The **Vitelline Veins** run upward at first in front, and subsequently on either side of the intestinal canal. They unite on the ventral aspect of the canal, and beyond this are connected to one another by two anastomotic branches, one on the dorsal, and the other on the ventral aspect of the duodenal portion of the intestine, which is thus encircled by two venous rings (Fig. 475); into the middle or dorsal anastomosis the superior mesenteric vein opens. The portions of the veins above the upper ring become interrupted by the developing liver and broken up by it into

a plexus of small capillary-like vessels termed **sinusoids** (Minot). The branches conveying the blood to this plexus are named the **venæ advehentes**, and become the branches of the portal vein; while the vessels draining the plexus into the sinus venosus are termed the **venæ revehentes**, and form the future hepatic veins (Figs. 475, 476). Ultimately the left vena revehens no longer communicates directly with the sinus venosus, but opens into the right vena revehens. The persistent part of the upper venous ring, above the opening of the superior mesenteric vein, forms the trunk of the portal vein.

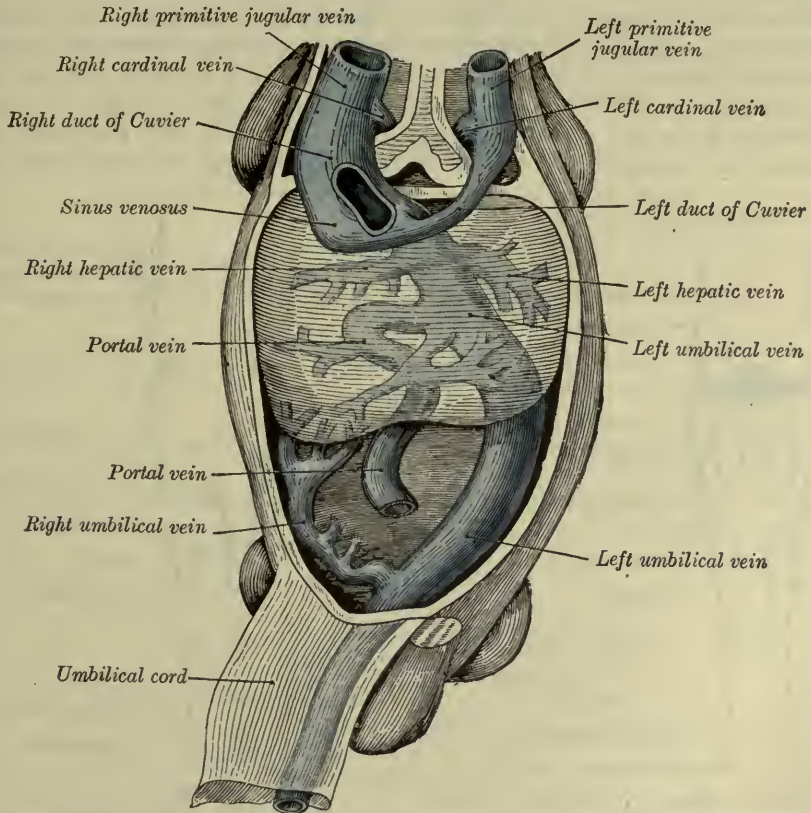


FIG. 476.—Human embryo with heart and anterior body-wall removed to show the sinus venosus and its tributaries. (After His.)

The two **Umbilical Veins** fuse early to form a single trunk in the body-stalk, but remain separate within the embryo and pass forward to the sinus venosus in the side walls of the body. Like the vitelline veins, their direct connection with the sinus venosus becomes interrupted by the developing liver, and thus at this stage the whole of the blood from the yolk-sac and placenta passes through the substance of the liver before it reaches the heart. The right umbilical and right vitelline veins shrivel and disappear; the left umbilical, on the other hand, becomes enlarged and opens into the upper venous ring of the vitelline veins; with the atrophy of the yolk-sac the left vitelline vein also undergoes atrophy and disappears. Finally a direct branch is established between this ring and the right hepatic vein; this branch is named the **ductus venosus**, and, enlarging rapidly, it forms a wide channel through which most of the blood, returned from the placenta, is carried direct to the heart without passing through the liver. A small proportion of the blood from the placenta is, however, conveyed from the left umbilical vein to the liver through the left vena advehens. The left umbilical

vein and the ductus venosus undergo atrophy and obliteration after birth, and form respectively the ligamentum teres and ligamentum venosum of the liver.

The Parietal Veins.—The first indication of a parietal system consists in the appearance of two short transverse veins, the **ducts of Cuvier**, which open, one on either side, into the sinus venosus. Each of these ducts receives an ascending and descending vein. The ascending veins return the blood from the parietes of the trunk and from the Wolffian bodies, and are called **cardinal veins**. The descending veins return the blood from the head, and are called **primitive jugular veins** (Fig. 477). The blood from the lower limbs is collected by the right and left iliac and hypogastric veins, which, in the earlier stages of development, open into the corresponding right and left cardinal veins; later, a transverse branch (the left common iliac vein) is developed between the lower parts of the two cardinal veins (Fig. 479), and through this the blood is carried into the right cardinal vein. The portion of the left cardinal vein below the left renal vein atrophies and disappears up to the point of entrance of the left spermatic vein; the portion above

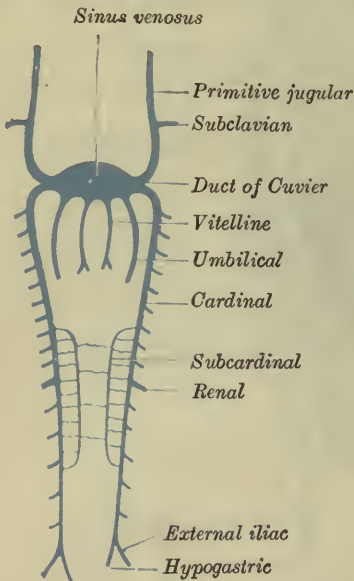


FIG. 477.—Scheme of arrangement of parietal veins.

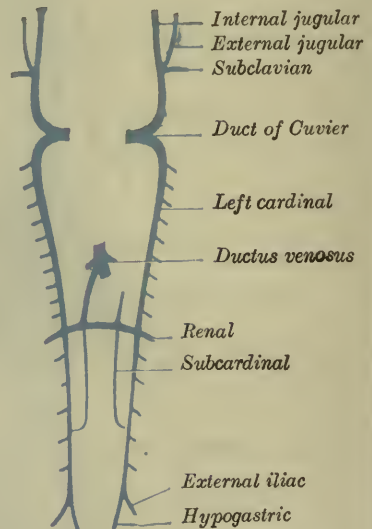


FIG. 478.—Scheme showing early stages of development of the inferior vena cava.

the left renal vein persists as the hemiazygos and accessory hemiazygos veins and the lower portion of the highest left intercostal vein. The right cardinal vein which now receives the blood from both lower extremities, forms a large venous trunk along the posterior abdominal wall; up to the level of the renal veins it forms the lower part of the inferior vena cava. Above the level of the renal veins the right cardinal vein persists as the azygos vein and receives the right intercostal veins, while the hemiazygos veins are brought into communication with it by the development of transverse branches in front of the vertebral column (Figs. 479, 480)

Inferior Vena Cava.—The development of the inferior vena cava is associated with the formation of two veins, the **subcardinal veins** (Figs. 477, 478). These lie parallel to, and on the ventral aspect of, the cardinal veins, and originate as longitudinal anastomosing channels which link up the tributaries from the mesentery to the cardinal veins; they communicate with the cardinal veins above and below, and also by a series of transverse branches. The two subcardinals are for a time connected with each other in front of the aorta by cross branches, but these disappear and are replaced by a single transverse channel at the level where the

renal veins join the cardinals, and at the same level a cross communication is established on either side between the cardinal and subcardinal (Fig. 478). The portion of the right subcardinal behind this cross communication disappears, while

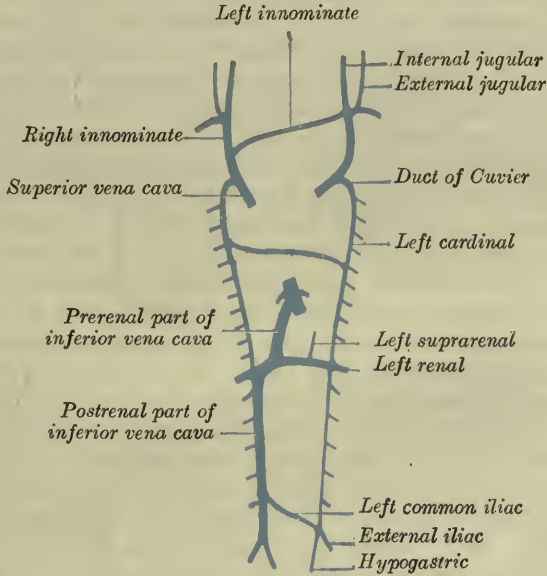


FIG. 479.—Diagram showing development of main cross branches between jugulars and between cardinals.

that in front, *i. e.*, the prerenal part, forms a connection with the ductus venosus at the point of opening of the hepatic veins, and, rapidly enlarging, receives the

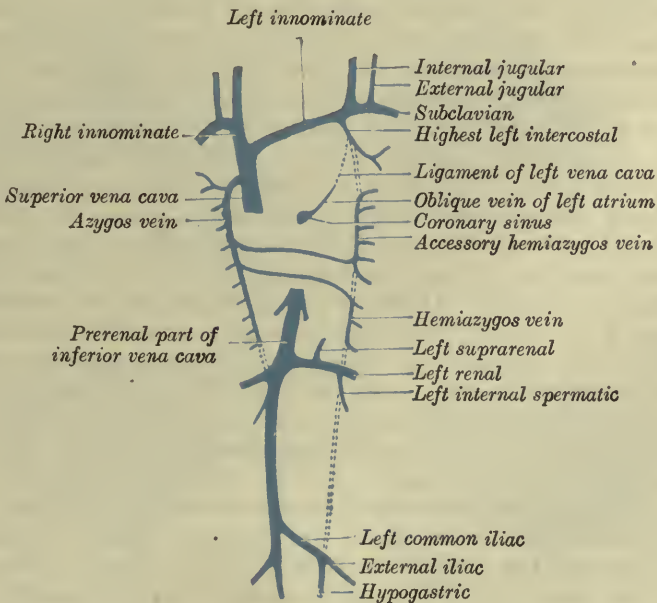


FIG. 480.—Diagram showing completion of development of the parietal veins.

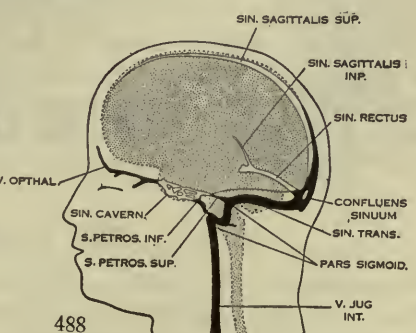
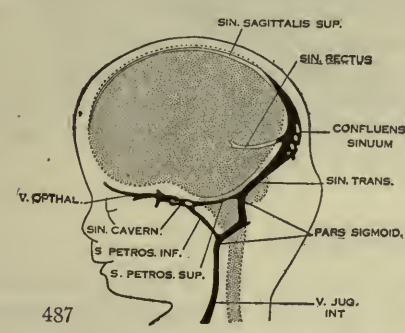
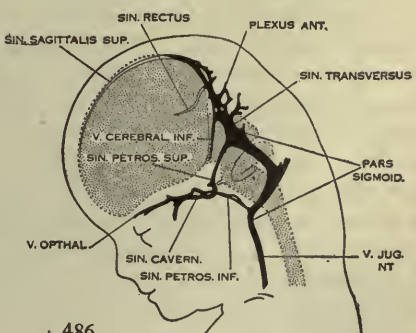
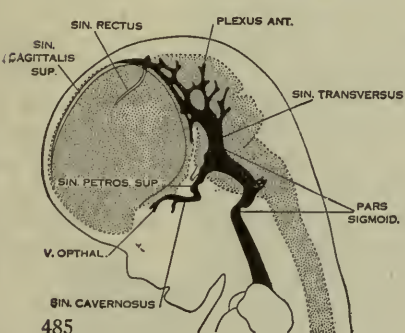
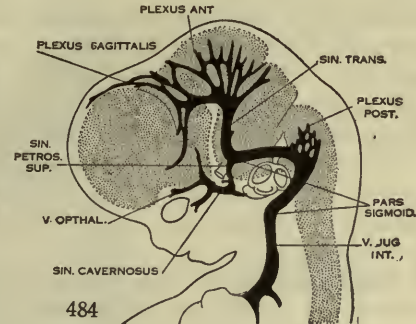
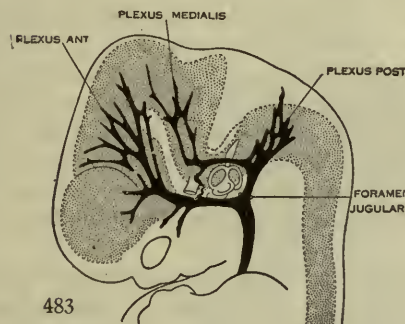
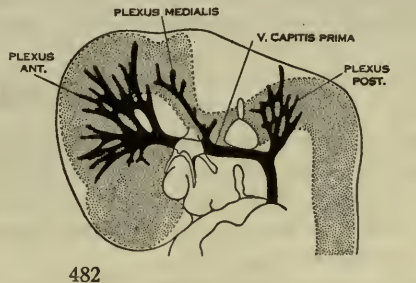
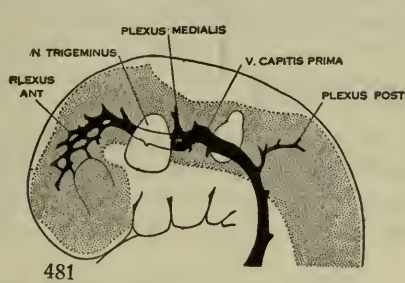
blood from the postrenal part of the right cardinal through the cross communication referred to. In this manner a single trunk, the **inferior vena cava** (Fig. 480), is formed, and consists of the proximal part of the ductus venosus, the prerenal part

of the right subcardinal vein, the postrenal part of the right cardinal vein, and the cross branch which joins these two veins. The left subcardinal disappears, except the part immediately in front of the renal vein, which is retained as the left supra-renal vein. The spermatic (or ovarian) vein opens into the postrenal part of the corresponding cardinal vein. This portion of the right cardinal, as already explained, forms the lower part of the inferior vena cava, so that the right spermatic opens directly into that vessel. The postrenal segment of the left cardinal disappears, with the exception of the portion between the spermatic and renal vein, which is retained as the terminal part of the left spermatic vein.

In consequence of the atrophy of the Wolffian bodies the cardinal veins diminish in size; the primitive jugular veins, on the other hand, become enlarged, owing to the rapid development of the head and brain. They are further augmented by receiving the veins (*subclavian*) from the upper extremities, and so come to form the chief veins of the Cuvierian ducts; these ducts gradually assume an almost vertical position in consequence of the descent of the heart into the thorax. The right and left Cuvierian ducts are originally of the same diameter, and are frequently termed the **right and left superior venæ cavæ**. By the development of a transverse branch, the **left innominate vein** between the two primitive jugular veins, the blood is carried across from the left to the right primitive jugular (Figs. 479, 480). The portion of the right primitive jugular vein between the left innominate and the azygos vein forms the upper part of the superior vena cava of the adult; the lower part of this vessel, *i. e.*, below the entrance of the azygos vein, is formed by the right Cuvierian duct. Below the origin of the transverse branch the left primitive jugular vein and left Cuvierian duct atrophy, the former constituting the upper part of the highest left intercostal vein, while the latter is represented by the ligament of the left vena cava, **vestigial fold of Marshall**, and the oblique vein of the left atrium, **oblique vein of Marshall** (Fig. 480). Both right and left superior venæ cavæ are present in some animals, and are occasionally found in the adult human being. The oblique vein of the left atrium passes downward across the back of the left atrium to open into the coronary sinus, which, as already indicated, represents the persistent left horn of the sinus venosus.

Venous Sinuses of the Dura Mater.¹—The primary arrangement for drainage of the capillaries of the head (Figs. 481, 488) consists of a primary head vein which starts in the region of the midbrain and runs caudalward along the side of the brain tube to terminate at the duct of Cuvier. The primary head vein drains three plexuses of capillaries: the anterior dural plexus, the middle dural plexus and the posterior dural plexus. The growth of the cartilaginous capsule of the ear and the growth and alteration in form of the brain bring about changes in this primary arrangement (Figs. 483–488). Owing to the growth of the otic capsule and middle ear the course of the primary head vein becomes unfavorable and a segment of it becomes obliterated. To make the necessary adjustment an anastomosis is established above the otic capsule (Fig. 483) and the middle plexus drains into the posterior plexus. Then the anterior plexus fuses with the middle plexus (Fig. 484) and drains through it and the newly established channel, dorsal to the otic capsule. All that remains of the primary head vein is the cardinal portion or internal jugular and the part in the region of the trigeminal nerve which may be called the cavernous sinus. Into it drain the orbital veins. The drainage from the cavernous sinus is now upward through the original trunk of the middle plexus, which is now the superior petrosal sinus, into the newly established dorsal channel. This dorsal channel is the transverse sinus (Figs. 485–488). The inferior petrosal sinus appears later (Fig. 486). From the anterior plexus a sagittal plexus extends forward from which develops the superior sagittal sinus (Figs. 484–488). The straight sinus is

formed in the ventral part of the sagittal plexus. As the hemispheres extend backward these sinuses elongate by incorporating the more caudal loops of the plexus. The anterior part of the sinus is completed first.



Figs. 481 to 488.—Profile drawings of the dural veins showing principal stages in their development in human embryos from 4 mm. to birth. It is of particular interest to notice their adaptation to the growth and changes in the form of the central nervous system. Fig. 481, 4 mm.; Fig. 482, 14 mm.; Fig. 483, 18 mm.; Fig. 484, 21 mm.; Fig. 485, 35 mm.; Fig. 486, 50 mm. crown-rump length; Fig. 487, 80 mm. crown-rump length; Fig. 488, adult. (After Streeter.)

The external jugular vein at first drains the region behind the ear (posterior auricular) and enters the primitive jugular as a lateral tributary. A group of veins from the face and lingual region converge to form a common vein, the *linguo-facial*,¹ which also terminates in the primitive jugular. Later, cross communications develop between the external jugular and the *linguo-facial*, with the result that the posterior group of facial veins is transferred to the external jugular.

THE THORACIC CAVITY.

The heart and lungs are situated in the thorax, the walls of which afford them protection. The heart lies between the two lungs, and is enclosed within a fibrous bag, the *pericardium*, while each lung is invested by a serous membrane, the *pleura*. The skeleton of the thorax, and the shape and boundaries of the cavity, have already been described (page 117).

The Cavity of the Thorax.—The capacity of the cavity of the thorax does not correspond with its apparent size externally, because (1) the space enclosed by the lower ribs is occupied by some of the abdominal viscera; and (2) the cavity extends above the anterior parts of the first ribs into the neck. The size of the thoracic cavity is constantly varying during life with the movements of the ribs and diaphragm, and with the degree of distention of the abdominal viscera. From the collapsed state of the lungs as seen when the thorax is opened in the dead body, it would appear as if the viscera only partly filled the cavity, but during life there is no vacant space, that which is seen after death being filled up by the expanded lungs.

The Upper Opening of the Thorax.—The parts which pass through the upper opening of the thorax are, from before backward, in or near the middle line, the *Sternohyoideus* and *Sternothyreoideus* muscles, the remains of the thymus, the inferior thyroid veins, the trachea, esophagus, thoracic duct, and the *Longus colli* muscles; at the sides, the innominate artery, the left common carotid, left subclavian and internal mammary arteries and the costocervical trunks, the innominate veins, the vagus, cardiac, phrenic, and sympathetic nerves, the greater parts of the anterior divisions of the first thoracic nerves, and the recurrent nerve of the left side. The apex of each lung, covered by the *pleura*, also projects through this aperture, a little above the level of the sternal end of the first rib.

The Lower Opening of the Thorax.—The lower opening of the thorax is wider transversely than from before backward. It slopes obliquely downward and backward, so that the thoracic cavity is much deeper behind than in front. The diaphragm (see page 404) closes the opening and forms the floor of the thorax. The floor is flatter at the center than at the sides, and higher on the right side than on the left; in the dead body the right side reaches the level of the upper border of the fifth costal cartilage, while the left extends only to the corresponding part of the sixth costal cartilage. From the highest point on each side the floor slopes suddenly downward to the costal and vertebral attachments of the diaphragm; this slope is more marked behind than in front, so that only a narrow space is left between the diaphragm and the posterior wall of the thorax.

THE PERICARDIUM.

The *pericardium* (Fig. 489) is a conical fibro-serous sac, in which the heart and the roots of the great vessels are contained. It is placed behind the sternum and the cartilages of the third, fourth, fifth, sixth, and seventh ribs of the left side, in the mediastinal cavity.

In **front**, it is separated from the anterior wall of the thorax, in the greater part of its extent, by the lungs and pleuræ; but a small area, somewhat variable in size, and usually corresponding with the left half of the lower portion of the body of the sternum and the medial ends of the cartilages of the fourth and fifth ribs of the left side, comes into direct relationship with the chest wall. The lower extremity of the thymus, in the child, is in contact with the front of the upper part of the pericardium. **Behind**, it rests upon the bronchi, the esophagus, the descending thoracic aorta, and the posterior part of the mediastinal surface of each lung. **Laterally**, it is covered by the pleuræ, and is in relation with the mediastinal surfaces of the lungs; the phrenic nerve, with its accompanying vessels, descends between the pericardium and pleura on either side.

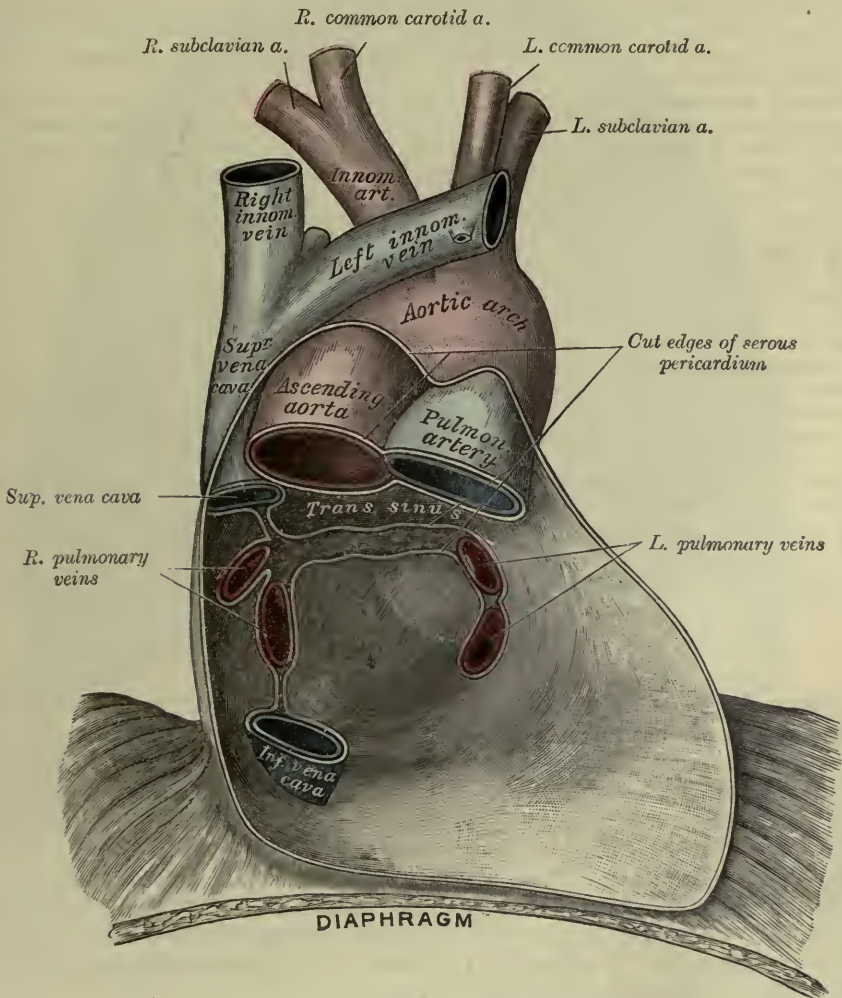


FIG. 489.—Posterior wall of the pericardial sac, showing the lines of reflection of the serous pericardium on the great vessels.

Structure of the Pericardium.—Although the pericardium is usually described as a single sac, an examination of its structure shows that it consists essentially of two sacs intimately connected with one another, but totally different in structure. The outer sac, known as the **fibrous pericardium**, consists of fibrous tissue. The inner sac, or **serous pericardium**, is a delicate membrane which lies within the fibrous sac and lines its walls; it is composed of a single layer of

flattened cells resting on loose connective tissue. The heart invaginates the wall of the serous sac from above and behind, and practically obliterates its cavity, the space being merely a potential one.

The **fibrous pericardium** forms a flask-shaped bag, the neck of which is closed by its fusion with the external coats of the great vessels, while its base is attached to the central tendon and to the muscular fibers of the left side of the diaphragm. In some of the lower mammals the base is either completely separated from the diaphragm or joined to it by some loose areolar tissue; in man much of its diaphragmatic attachment consists of loose fibrous tissue which can be readily broken down, but over a small area the central tendon of the diaphragm and the pericardium are completely fused. *Above*, the fibrous pericardium not only blends with the external coats of the great vessels, but is continuous with the pretracheal layer of the deep cervical fascia. By means of these upper and lower connections it is securely anchored within the thoracic cavity. It is also attached to the posterior surface of the sternum by the **superior** and **inferior sternopericardiac ligaments**; the upper passing to the manubrium, and the lower to the xiphoid process.

The vessels receiving fibrous prolongations from this membrane are: the aorta, the superior vena cava, the right and left pulmonary arteries, and the four pulmonary veins. The inferior vena cava enters the pericardium through the central tendon of the diaphragm, and receives no covering from the fibrous layer.

The **serous pericardium** is, as already stated, a closed sac which lines the fibrous pericardium and is invaginated by the heart; it therefore consists of a **visceral** and a **parietal portion**. The visceral portion, or **epicardium**, covers the heart and the great vessels, and from the latter is continuous with the parietal layer which lines the fibrous pericardium. The portion which covers the vessels is arranged in the form of two tubes. The aorta and pulmonary artery are enclosed in one tube, the **arterial mesocardium**. The superior and inferior venæ cavæ and the four pulmonary veins are enclosed in a second tube, the **venous mesocardium**, the attachment of which to the parietal layer presents the shape of an inverted U. The *cul-de-sac* enclosed between the limbs of the U lies behind the left atrium and is known as the **oblique sinus**, while the passage between the venous and arterial mesocardia—*i. e.*, between the aorta and pulmonary artery in front and the atria behind—is termed the **transverse sinus**.

The **Ligament of the Left Vena Cava**.—Between the left pulmonary artery and subjacent pulmonary vein is a triangular fold of the serous pericardium; it is known as the **ligament of the left vena cava** (*vestigial fold of Marshall*). It is formed by the duplicature of the serous layer over the remnant of the lower part of the left superior vena cava (*duct of Cuvier*), which becomes obliterated during fetal life, and remains as a fibrous band stretching from the highest left intercostal vein to the left atrium, where it is continuous with a small vein, the **vein of the left atrium** (*oblique vein of Marshall*), which opens into the coronary sinus.

The **arteries** of the pericardium are derived from the internal mammary and its musculophrenic branch, and from the descending thoracic aorta.

The **nerves** of the pericardium are derived from the vagus and phrenic nerves, and the sympathetic trunks.

THE HEART (COR).

The **heart** is a hollow muscular organ of a somewhat conical form; it lies between the lungs in the middle mediastinum and is enclosed in the pericardium (Fig. 490). It is placed obliquely in the chest behind the body of the sternum and adjoining parts of the rib cartilages, and projects farther into the left than into the right half of the thoracic cavity, so that about one-third of it is situated on the right and two-thirds on the left of the median plane.

Size.—The heart, in the adult, measures about 12 cm. in length, 8 to 9 cm. in breadth at the broadest part, and 6 cm. in thickness. Its weight, in the male, varies from 280 to 340 grams; in the female, from 230 to 280 grams. The heart continues to increase in weight and size up to an advanced period of life; this increase is more marked in men than in women.

Component Parts.—As has already been stated (page 497), the heart is subdivided by septa into right and left halves, and a constriction subdivides each half of the organ into two cavities, the upper cavity being called the **atrium**, the lower the **ventricle**. The heart therefore consists of four chambers, *viz.*, right and left atria, and right and left ventricles.

The division of the heart into four cavities is indicated on its surface by grooves. The atria are separated from the ventricles by the **coronary sulcus** (*auriculo-*

ventricular groove); this contains the trunks of the nutrient vessels of the heart, and is deficient in front, where it is crossed by the root of the pulmonary artery. The *interatrial groove*, separating the two atria, is scarcely marked on the posterior surface, while anteriorly it is hidden by the pulmonary artery and aorta. The ventricles are separated by two grooves, one of which, the *anterior longitudinal sulcus*, is situated on the sternocostal surface of the heart, close to its left margin, the other *posterior longitudinal sulcus*, on the diaphragmatic surface near the right margin; these grooves extend from the base of the ventricular portion to a notch, the *incisura apicis cordis*, on the acute margin of the heart just to the right of the apex.

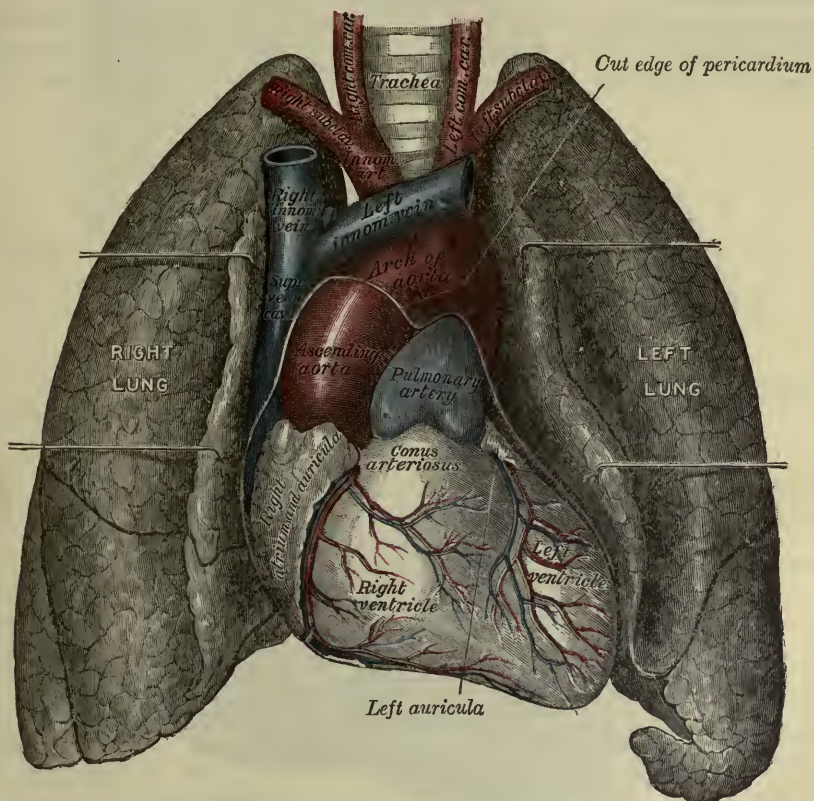


FIG. 490.—Front view of heart and lungs.

The *base (basis cordis)* (Fig. 491), directed upward, backward, and to the right, is separated from the fifth, sixth, seventh, and eighth thoracic vertebræ by the esophagus, aorta, and thoracic duct. It is formed mainly by the left atrium, and, to a small extent, by the back part of the right atrium. Somewhat quadrilateral in form, it is in relation above with the bifurcation of the pulmonary artery, and is bounded below by the posterior part of the coronary sulcus, containing the coronary sinus. On the right it is limited by the sulcus terminalis of the right atrium, and on the left by the ligament of the left vena cava and the oblique vein of the left atrium. The four pulmonary veins, two on either side, open into the left atrium, while the superior vena cava opens into the upper, and the anterior vena cava into the lower, part of the right atrium.

The *Apex (apex cordis)*.—The apex is directed downward, forward, and to the left, and is overlapped by the left lung and pleura: it lies behind the fifth left intercostal space, 8 to 9 cm. from the mid-sternal line, or about 4 cm. below and 2 mm. to the medial side of the left mammary papilla.

The **sternocostal surface** (Fig. 492) is directed forward, upward, and to the left. Its lower part is convex, formed chiefly by the right ventricle, and traversed near its left margin by the anterior longitudinal sulcus. Its upper part is separated from the lower by the coronary sulcus, and is formed by the atria; it presents a deep concavity (Fig. 494), occupied by the ascending aorta and the pulmonary artery.

The **diaphragmatic surface** (Fig. 491), directed downward and slightly backward, is formed by the ventricles, and rests upon the central tendon and a small part of the left muscular portion of the diaphragm. It is separated from the base by the posterior part of the coronary sulcus, and is traversed obliquely by the posterior longitudinal sulcus.

The **right margin** of the heart is long, and is formed by the right atrium above and the right ventricle below. The atrial portion is rounded and almost vertical; it is situated behind the third, fourth, and fifth right costal cartilages about

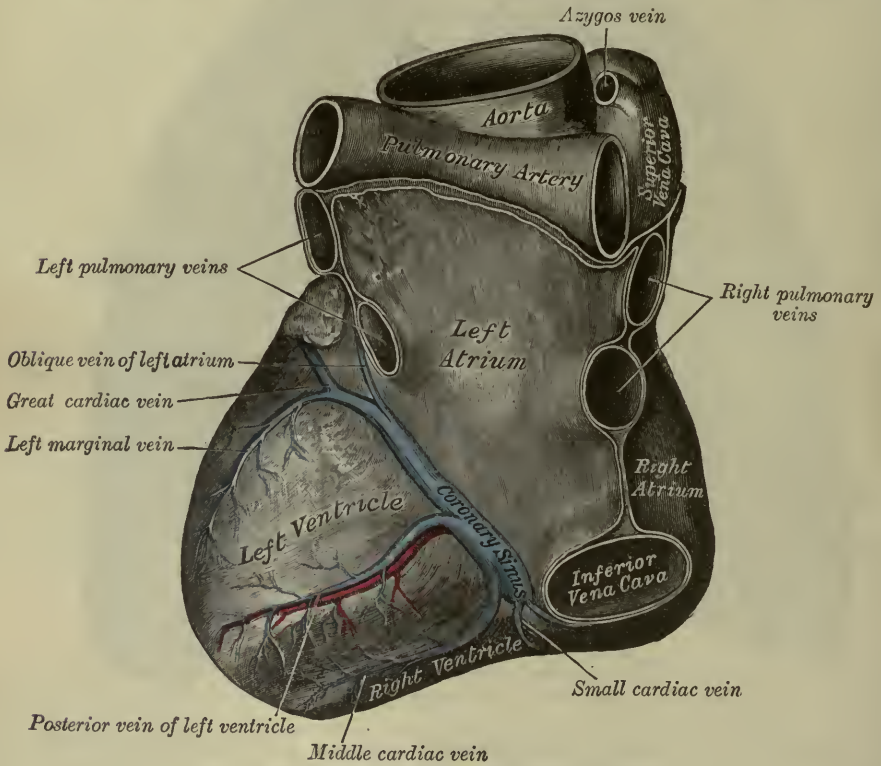


FIG. 491.—Base and diaphragmatic surface of heart.

1.25 cm. from the margin of the sternum. The ventricular portion, thin and sharp, is named the **acute margin**; it is nearly horizontal, and extends from the sternal end of the sixth right costal cartilage to the apex of the heart.

The **left or obtuse margin** is shorter, full, and rounded: it is formed mainly by the left ventricle, but to a slight extent, above, by the left atrium. It extends from a point in the second left intercostal space, about 2.5 mm. from the sternal margin, obliquely downward, with a convexity to the left, to the apex of the heart.

Right Atrium (*atrium dextrum*; *right auricle*).—The right atrium is larger than the left, but its walls are somewhat thinner, measuring about 2 mm.; its cavity is capable of containing about 57 c.c. It consists of two parts: a principal cavity, or **sinus venarum**, situated posteriorly, and an anterior, smaller portion, the **auricula**.

Sinus Venarum (*sinus venosus*).—The sinus venarum is the large quadrangular cavity placed between the two venæ cavæ. Its walls, which are extremely thin,

are connected below with the right ventricle, and medially with the left atrium, but are free in the rest of their extent.

Auricula (*auricula dextra; right auricular appendix*).—The auricula is a small conical muscular pouch, the margins of which present a dentated edge. It projects from the upper and front part of the sinus forward and toward the left side, overlapping the root of the aorta.

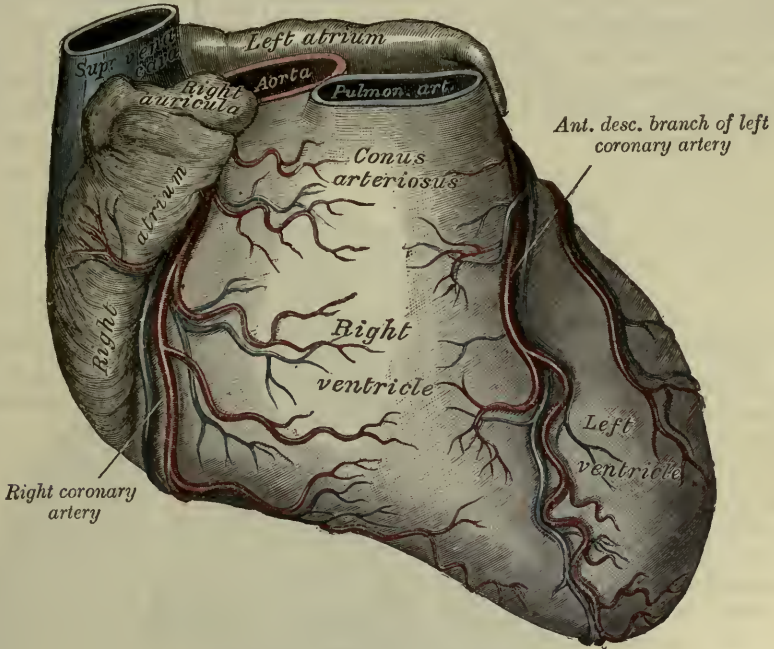


FIG. 492.—Sternocostal surface of heart.

The separation of the auricula from the sinus venarum is indicated externally by a groove, the **terminal sulcus**, which extends from the front of the superior vena cava to the front of the inferior vena cava, and represents the line of union of the sinus venosus of the embryo with the primitive atrium. On the inner wall of the atrium the separation is marked by a vertical, smooth, muscular ridge, the **terminal crest**. Behind the crest the internal surface of the atrium is smooth, while in front of it the muscular fibers of the wall are raised into parallel ridges resembling the teeth of a comb, and hence named the **musculi pectinati**.

Its interior (Fig. 493) presents the following parts for examination:

- | | | | | | |
|----------|---|--------------------------------|--------|---|----------------------------------|
| Openings | { | Superior vena cava. | Valves | { | Valve of the inferior vena cava. |
| | | Inferior vena cava. | | | Valve of the coronary sinus. |
| | | Coronary sinus. | | | |
| | | Foramina venarum
minimarum. | | | |
| | | Atrioventricular. | | | |
| | | | | | Fossa ovalis. |
| | | | | | Limbus fossæ ovalis. |
| | | | | | Intervenous tubercle. |
| | | | | | Musculi pectinati. |
| | | | | | Crista terminalis. |

The **superior vena cava** returns the blood from the upper half of the body, and opens into the upper and back part of the atrium, the direction of its orifice being downward and forward. Its opening has no valve.

The **inferior vena cava**, larger than the superior, returns the blood from the lower half of the body, and opens into the lowest part of the atrium, near the atrial septum, its orifice being directed upward and backward, and guarded by a rudimentary valve, the **valve of the inferior vena cava** (*Eustachian valve*). The blood entering the atrium through the superior vena cava is directed downward and forward, *i. e.*, toward the atrioventricular orifice, while that entering through the inferior vena cava is directed upward and backward, toward the atrial septum. This is the normal direction of the two currents in fetal life.

The **coronary sinus** opens into the atrium, between the orifice of the inferior vena cava and the atrioventricular opening. It returns blood from the substance of the heart and is protected by a semicircular valve, the **valve of the coronary sinus** (*valve of Thebesius*).

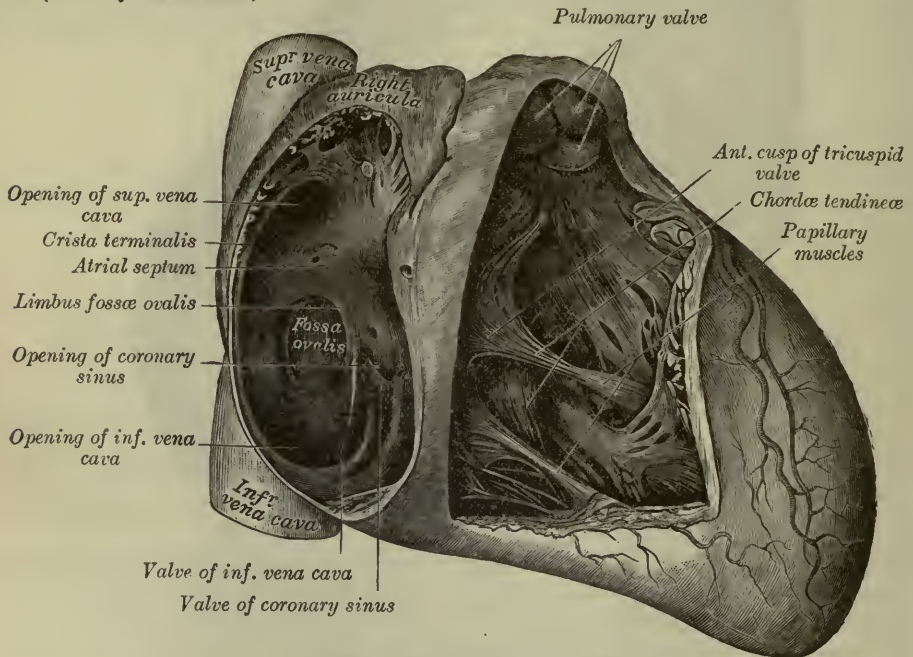


FIG. 493.—Interior of right side of heart.

The **foramina venarum minimarum** (*foramina Thebesii*) are the orifices of minute veins (*venæ cordis minimæ*), which return blood directly from the muscular substance of the heart.

The **atrioventricular opening** (*tricuspid orifice*) is the large oval aperture of communication between the atrium and the ventricle; it will be described with the right ventricle.

The **valve of the inferior vena cava** (*valvula venæ cavæ inferioris* [*Eustachii*]; *Eustachian valve*) is situated in front of the orifice of the inferior vena cava. It is semilunar in form, its convex margin being attached to the anterior margin of the orifice; its concave margin, which is free, ends in two cornua, of which the left is continuous with the anterior edge of the limbus fossæ ovalis while the right is lost on the wall of the atrium. The valve is formed by a duplicature of the lining membrane of the atrium, containing a few muscular fibers. *In the fetus* this valve is of large size, and serves to direct the blood from the inferior vena cava, through the foramen ovale, into the left atrium. *In the adult* it occasionally persists, and may assist in preventing the reflux of blood into the inferior vena cava; more commonly it is small, and may present a cribriform or filamentous appearance; sometimes it is altogether wanting.

The **valve of the coronary sinus** (*valvula sinus coronarii* [*Thebesii*]; *Thebesian valve*) is a semicircular fold of the lining membrane of the atrium, at the orifice of the coronary sinus. It prevents the regurgitation of blood into the sinus during the contraction of the atrium. This valve may be double or it may be cribriform.

The **fossa ovalis** is an oval depression on the septal wall of the atrium, and corresponds to the situation of the foramen ovale in the fetus. It is situated at the lower part of the septum, above and to the left of the orifice of the inferior vena cava.

The **limbus fossæ ovalis** (*annulus ovalis*) is the prominent oval margin of the fossa ovalis. It is most distinct above and at the sides of the fossa; below, it is deficient. A small slit-like valvular opening is occasionally found, at the upper margin of the fossa, leading upward beneath the limbus, into the left atrium; it is the remains of the fetal aperture between the two atria.

The **intervenous tubercle** (*tuberculum intervenosum*; *tubercle of Lower*) is a small projection on the posterior wall of the atrium, above the fossa ovalis. It is distinct in the hearts of quadrupeds, but in man is scarcely visible. It was supposed by Lower to direct the blood from the superior vena cava toward the atrioventricular opening.

Right Ventricle (*ventriculus dexter*).—The right ventricle is triangular in form, and extends from the right atrium to near the apex of the heart. Its antero-superior surface is rounded and convex, and forms the larger part of the sternocostal surface of the heart. Its under surface is flattened, rests upon the diaphragm, and forms a small part of the diaphragmatic surface of the heart. Its posterior wall is formed by the ventricular septum, which bulges into the right ventricle, so that a transverse section of the cavity presents a semilunar outline. Its upper and left angle forms a conical pouch, the **conus arteriosus**, from which the pulmonary artery arises. A tendinous band, which may be named the **tendon of the conus arteriosus**, extends upward from the right atrioventricular fibrous ring and connects the posterior surface of the conus arteriosus to the aorta. The wall of the right ventricle is thinner than that of the left, the proportion between them being as 1 to 3; it is thickest at the base, and gradually becomes thinner toward the apex. The cavity equals in size that of the left ventricle, and is capable of containing about 85 c.c.

Its interior (Fig. 493) presents the following parts for examination:

Openings	{ Right atrioventricular. Pulmonary artery.	Valves	{ Tricuspid. Pulmonary.
Trabeculæ carneæ.		Chordæ tendineæ.	

The **right atrioventricular orifice** is the large oval aperture of communication between the right atrium and ventricle. Situated at the base of the ventricle, it measures about 4 cm. in diameter and is surrounded by a fibrous ring, covered by the lining membrane of the heart; it is considerably larger than the corresponding aperture on the left side, being sufficient to admit the ends of four fingers. It is guarded by the tricuspid valve.

The **opening of the pulmonary artery** is circular in form, and situated at the summit of the conus arteriosus, close to the ventricular septum. It is placed above and to the left of the atrioventricular opening, and is guarded by the pulmonary semilunar valves.

The **tricuspid valve** (*valvula tricuspidalis*) (Figs. 493, 495) consists of three somewhat triangular cusps or segments. The largest cusp is interposed between the atrioventricular orifice and the conus arteriosus and is termed the **anterior** or **infundibular cusp**. A second, the **posterior** or **marginal cusp**, is in relation to the right margin of the ventricle, and a third, the **medial** or **septal cusp**, to the ventricular septum. They are formed by duplicatures of the lining membrane of the heart, strengthened

by intervening layers of fibrous tissue: their central parts are thick and strong, their marginal portions thin and translucent, and in the angles between the latter small intermediate segments are sometimes seen. Their bases are attached to a fibrous ring surrounding the atrioventricular orifice and are also joined to each other so as to form a continuous annular membrane, while their apices project into the ventricular cavity. Their atrial surfaces, directed toward the blood current from the atrium, are smooth; their ventricular surfaces, directed toward the wall of the ventricle, are rough and irregular, and, together with the apices and margins of the cusps, give attachment to a number of delicate tendinous cords, the *chordæ tendineæ*.

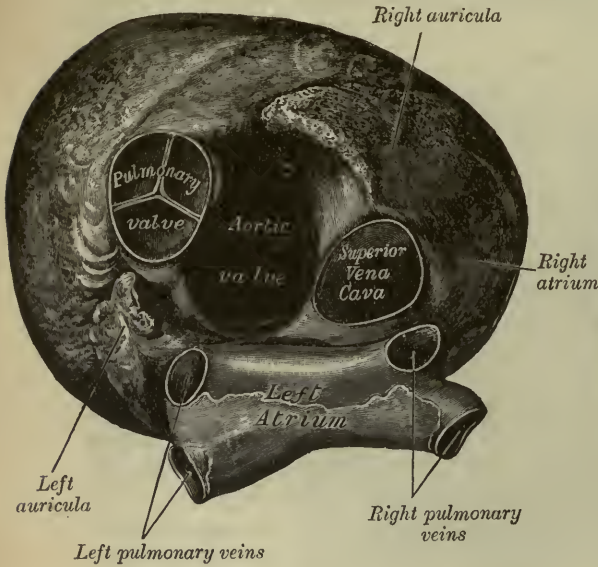


FIG. 494.—Heart seen from above.

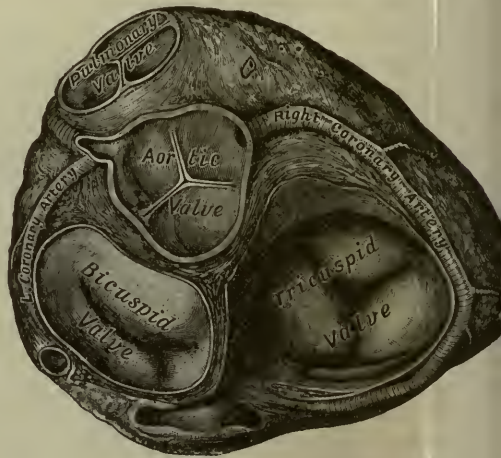


FIG. 495.—Base of ventricles exposed by removal of the atria.

The *trabeculæ carneæ* (*columnæ carneæ*) are rounded or irregular muscular columns which project from the whole of the inner surface of the ventricle, with the exception of the *conus arteriosus*. They are of three kinds: some are attached along their entire length on one side and merely form prominent ridges, others are fixed at their extremities but free in the middle, while a third set (*musculi papillares*) are continuous by their bases with the wall of the ventricle, while their apices give origin to the *chordæ tendineæ* which pass to be attached to the segments of the tricuspid valve. There are two papillary muscles, anterior and posterior: of these, the anterior is the larger, and its *chordæ tendineæ* are connected with the anterior and posterior cusps of the valve: the posterior papillary muscle sometimes consists of two or three parts; its *chordæ tendineæ* are connected with the posterior and medial cusps. In addition to these, some *chordæ tendineæ* spring directly from the ventricular septum, or from small papillary eminences on it, and pass to the anterior and medial cusps. A muscular band, well-marked in sheep and some other animals, frequently extends from the base of the anterior papillary muscle to the ventricular septum. From its attachments it may assist in preventing overdistension of the ventricle, and so has been named the *moderator band*.

The *pulmonary semilunar valves* (Fig. 494) are three in number, two in front and one behind, formed by duplicatures of the lining membrane, strengthened by fibrous tissue. They are attached, by their convex margins, to the wall of the artery, at its junction with the ventricle, their free borders being directed upward into the lumen of the vessel. The free and attached margins of each are strength-

ened by tendinous fibers, and the former presents, at its middle, a thickened nodule (*corpus Arantii*). From this nodule tendinous fibers radiate through the segment to its attached margin, but are absent from two narrow crescentic portions, the *lunulæ*, placed one on either side of the nodule immediately adjoining the free margin. Between the semilunar valves and the wall of the pulmonary artery are three *pouches or sinuses* (*sinuses of Valsalva*).

Left Atrium (*atrium sinistum; left auricle*).—The left atrium is rather smaller than the right, but its walls are thicker, measuring about 3 mm.; it consists, like the right, of two parts, a **principal cavity** and an **auricula**.

The **principal cavity** is cuboidal in form, and concealed, in front, by the pulmonary artery and aorta; in front and to the right it is separated from the right atrium by the atrial septum; opening into it on either side are the two pulmonary veins.

Auricula (*auricula sinistra; left auricular appendix*).—The auricula is somewhat constricted at its junction with the principal cavity; it is longer, narrower, and more curved than that of the right side, and its margins are more deeply indented. It is directed forward and toward the right and overlaps the root of the pulmonary artery.

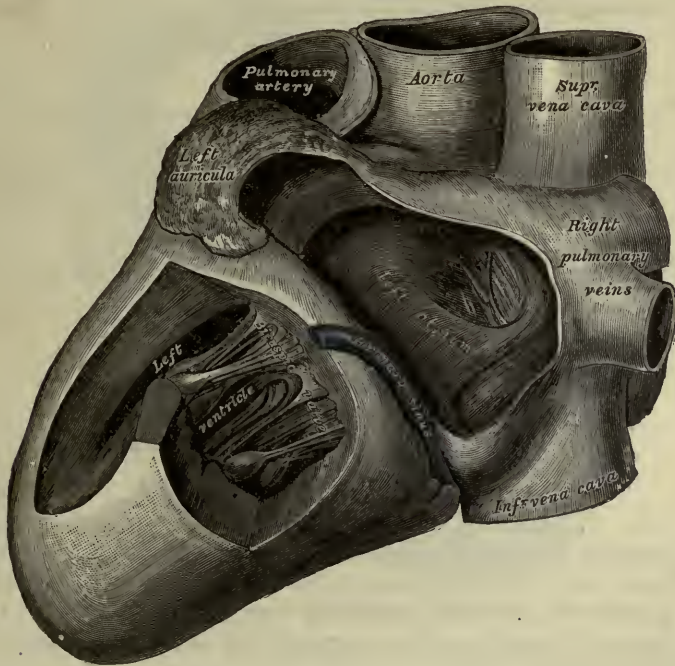

FIG. 496.—Interior of left side of heart.

The interior of the left atrium (Fig. 496) presents the following parts for examination:

- Openings of the four pulmonary veins.
- Left atrioventricular opening.
- Musculi pectinati.

The **pulmonary veins**, four in number, open into the upper part of the posterior surface of the left atrium—two on either side of its middle line: they are not provided with valves. The two left veins frequently end by a common opening.

The **left atrioventricular opening** is the aperture between the left atrium and ventricle, and is rather smaller than the corresponding opening on the right side.

The **musculi pectinati**, fewer and smaller than in the right auricula, are confined to the inner surface of the auricula.

On the atrial septum may be seen a lunated impression, bounded below by a crescentic ridge, the concavity of which is turned upward. The depression is just above the fossa ovalis of the right atrium.

Left Ventricle (*ventriculus sinister*).—The left ventricle is longer and more conical in shape than the right, and on transverse section its concavity presents an oval or nearly circular outline. It forms a small part of the sternocostal surface and a considerable part of the diaphragmatic surface of the heart; it also forms the apex of the heart. Its walls are about three times as thick as those of the right ventricle.

Its interior (Fig. 496) presents the following parts for examination:

Openings	{ Left atrioventricular.	Valves	{ Bicuspid or Mitral.
	{ Aortic.		{ Aortic.
Trabeculæ carneæ.		Chordæ tendineæ.	

The **left atrioventricular opening** (*mitral orifice*) is placed below and to the left of the aortic orifice. It is a little smaller than the corresponding aperture of the opposite side, admitting only two fingers. It is surrounded by a dense fibrous ring, covered by the lining membrane of the heart, and is guarded by the bicuspid or mitral valve.

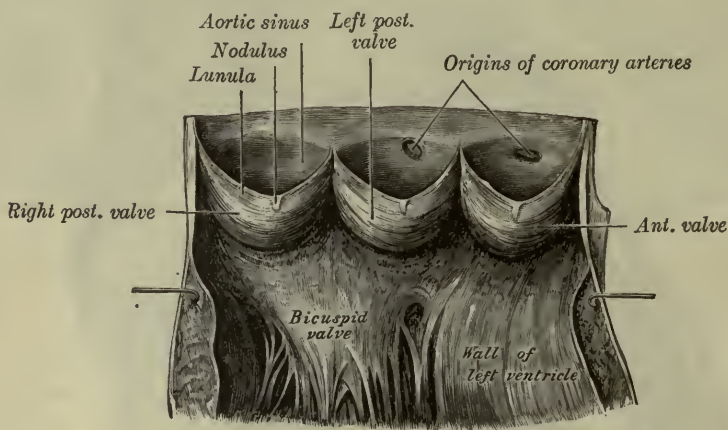


FIG. 497.—Aorta laid open to show the semilunar valves.

The **aortic opening** is a circular aperture, in front and to the right of the atrioventricular, from which it is separated by the anterior cusp of the bicuspid valve. Its orifice is guarded by the **aortic semilunar valves**. The portion of the ventricle immediately below the aortic orifice is termed the **aortic vestibule**, and possesses fibrous instead of muscular walls.

The **bicuspid** or **mitral valve** (*valvula bicuspidalis* [*metralis*]) (Figs. 495, 496) is attached to the circumference of the left atrioventricular orifice in the same way that the tricuspid valve is on the opposite side. It consists of two triangular cusps, formed by duplicatures of the lining membrane, strengthened by fibrous tissue, and containing a few muscular fibers. The cusps are of unequal size, and are larger, thicker, and stronger than those of the tricuspid valve. The larger cusp is placed in front and to the right between the atrioventricular and aortic orifices, and is known as the **anterior** or **aortic cusp**; the smaller or **posterior cusp** is placed behind and to the left of the opening. Two smaller cusps are usually found at the angles of junction of the larger. The cusps of the bicuspid valve are furnished with chordæ tendineæ, which are attached in a manner similar to those on the right side; they are, however, thicker, stronger, and less numerous.

The **aortic semilunar valves** (Figs. 494, 497) are three in number, and surround the orifice of the aorta; two are anterior (right and left) and one posterior. They are similar in structure, and in their mode of attachment, to the pulmonary semilunar valves, but are larger, thicker, and stronger; the lunulæ are more distinct, and the noduli or corpora Arantii thicker and more prominent. Opposite the valves the aorta presents slight dilatations, the **aortic sinuses** (*sinuses of Valsalva*), which are larger than those at the origin of the pulmonary artery.

The **trabeculæ carneæ** are of three kinds, like those upon the right side, but they are more numerous, and present a dense interlacement, especially at the apex, and upon the posterior wall of the ventricle. The **musculi papillares** are two in number, one being connected to the anterior, the other to the posterior wall; they are of large size, and end in rounded extremities from which the chordæ tendineæ arise. The chordæ tendineæ from each papillary muscle are connected to both cusps of the bicuspid valve.

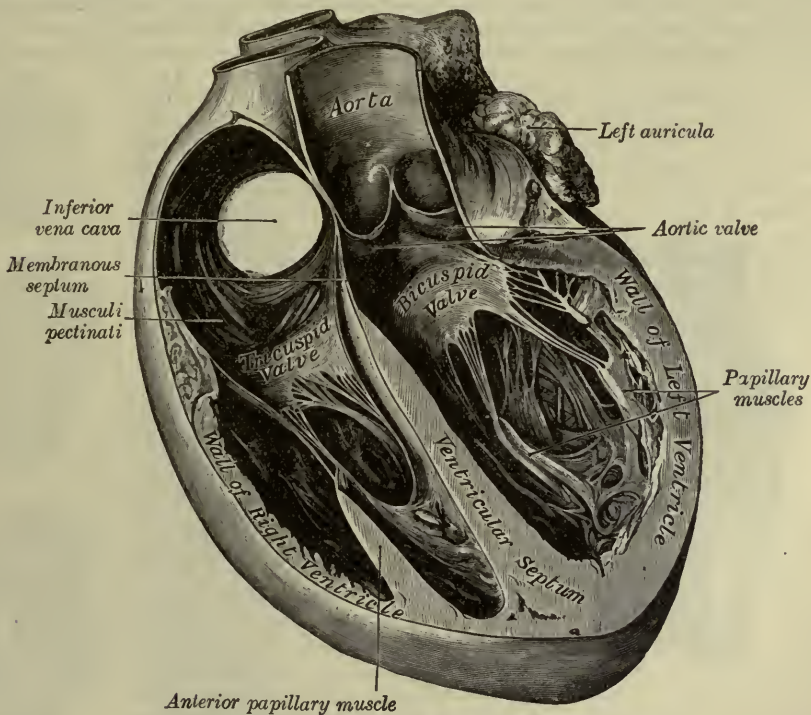


FIG. 498.—Section of the heart showing the ventricular septum.

Ventricular Septum (*septum ventriculorum*; *interventricular septum*) (Fig. 498).—The ventricular septum is directed obliquely backward and to the right, and is curved with the convexity toward the right ventricle: its margins correspond with the anterior and posterior longitudinal sulci. The greater portion of it is thick and muscular and constitutes the **muscular ventricular septum**, but its upper and posterior part, which separates the aortic vestibule from the lower part of the right atrium and upper part of the right ventricle, is thin and fibrous, and is termed the **membranous ventricular septum**. An abnormal communication may exist between the ventricles at this part owing to defective development of the membranous septum.

Structure.—The heart consists of muscular fibers, and of fibrous rings which serve for their attachment. It is covered by the visceral layer of the serous pericardium (**epicardium**), and lined by the **endocardium**. Between these two membranes is the muscular wall or **myocardium**.

The **endocardium** is a thin, smooth membrane which lines and gives the glistening appear-

ance to the inner surface of the heart; it assists in forming the valves by its reduplications, and is continuous with the lining membrane of the large bloodvessels. It consists of connective tissue and elastic fibers, and is attached to the muscular structure by loose elastic tissue which contains bloodvessels and nerves; its free surface is covered by endothelial cells.

The **fibrous rings** surround the atrioventricular and arterial orifices, and are stronger upon the left than on the right side of the heart. The atrioventricular rings serve for the attachment of the muscular fibers of the atria and ventricles, and for the attachment of the bicuspid and tricuspid valves. The left atrioventricular ring is closely connected, by its right margin, with the aortic arterial ring; between these and the right atrioventricular ring is a triangular mass of fibrous tissue, the **trigonum fibrosum**, which represents the *os cordis* seen in the heart of some of the larger animals, as the ox and elephant. Lastly, there is the tendinous band, already referred to, the posterior surface of the conus arteriosus.

The fibrous rings surrounding the arterial orifices serve for the attachment of the great vessels and semilunar valves. Each ring receives, by its ventricular margin, the attachment of some of the muscular fibers of the ventricles; its opposite margin presents three deep semicircular notches, to which the middle coat of the artery is firmly fixed. The attachment of the artery to its fibrous ring is strengthened by the external coat and serous membrane externally, and by the endocardium internally. From the margins of the semicircular notches the fibrous structure of the ring is continued into the segments of the valves. The middle coat of the artery in this situation is thin, and the vessel is dilated to form the sinuses of the aorta and pulmonary artery.



FIG. 499.—Anastomosing muscular fibers of the heart seen in a longitudinal section. On the right the limits of the separate cells with their nuclei are exhibited somewhat diagrammatically.

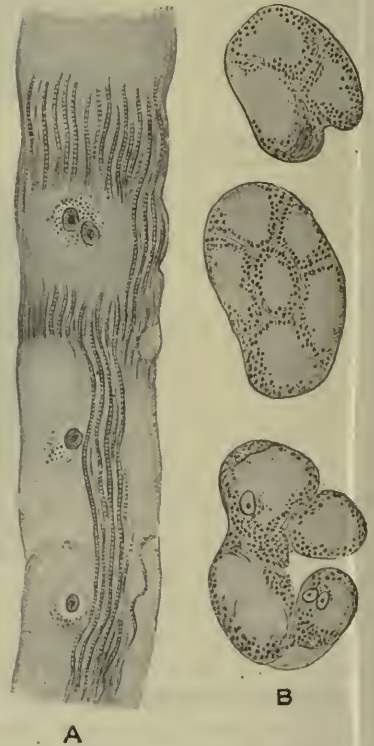


FIG. 500.—Purkinje's fibers from the sheep's heart. A. In longitudinal section. B. In transverse section.

Cardiac Muscular Tissue.—The fibers of the heart differ very remarkably from those of other striped muscles. They are smaller by one-third, and their transverse striae are by no means so well-marked. They show faint longitudinal striation. The fibers are made up of distinct quadrangular cells, joined end to end so as to form a syncytium (Fig. 499). Each cell contains a clear oval nucleus, situated near its center. The extremities of the cells have a tendency to branch or divide, the subdivisions uniting with offsets from other cells, and thus producing an anastomosis of the fibers. The connective tissue between the bundles of fibers is much less than in ordinary striped muscle, and no sarcolemma has been proved to exist.

Purkinje Fibers (Fig. 500).—Between the endocardium and the ordinary cardiac muscle are found, imbedded in a small amount of connective tissue, peculiar fibers known as Purkinje fibers. They are found in certain mammals and in birds, and can be best seen in the sheep's heart, where

they form a considerable portion of the moderator band and also appear as gelatinous-looking strands on the inner walls of the atria and ventricles. They also occur in the human heart associated with the terminal distributions of the bundle of His. The fibers are very much larger in size than the cardiac cells and differ from them in several ways. In longitudinal section they are quadrilateral in shape, being about twice as long as they are broad. The central portion of each fiber contains one or more nuclei and is made up of granular protoplasm, with no indication of striations, while the peripheral portion is clear and has distinct transverse striations. The fibers are intimately connected with each other, possess no definite sarcolemma, and do not branch.

The **muscular structure of the heart** consists of bands of fibers, which present an exceedingly intricate interlacement. They comprise (a) the fibers of the atria, (b) the fibers of the ventricles, and (c) the atrioventricular bundle of His.

The **fibers of the atria** are arranged in two layers—a superficial, common to both cavities, and a deep, proper to each. The **superficial fibers** are most distinct on the front of the atria, across the bases of which they run in a transverse direction, forming a thin and incomplete layer. Some of these fibers run into the atrial septum. The **deep fibers** consist of looped and annular fibers. The *looped fibers* pass upward over each atrium, being attached by their two extremities to the corresponding atrioventricular ring, in front and behind. The *annular fibers* surround the auriculæ, and form annular bands around the terminations of the veins and around the fossa ovalis.

The **fibers of the ventricles** are arranged in a complex manner, and various accounts have been given of their course and connections; the following description is based on the work of McCallum.¹ They consist of superficial and deep layers, all of which, with the exception of two, are inserted into the papillary muscles of the ventricles. The **superficial layers** consist of the following: (a) Fibers which spring from the tendon of the conus arteriosus and sweep downward and toward the left across the anterior longitudinal sulcus and around the apex of the heart, where they pass upward and inward to terminate in the papillary muscles of the left ventricle; those arising from the upper half of the tendon of the conus arteriosus pass to the anterior papillary muscle, those from the lower half to the posterior papillary muscle and the papillary muscles of the septum. (b) Fibers which arise from the right atrioventricular ring and run diagonally across the diaphragmatic surface of the right ventricle and around its right border on to its costosternal surface, where they dip beneath the fibers just described, and, crossing the anterior longitudinal sulcus, wind around the apex of the heart and end in the posterior papillary muscle of the left ventricle. (c) Fibers which spring from the left atrioventricular ring, and, crossing the posterior longitudinal sulcus, pass successively into the right ventricle and end in its papillary muscles. The **deep layers** are three in number; they arise in the papillary muscles of one ventricle and, curving in an S-shaped manner, turn in at the longitudinal sulcus and end in the papillary muscles of the other ventricle. The layer which is most superficial in the right ventricle lies next the lumen of the left, and *vice versa*. Those of the first layer almost encircle the right ventricle and, crossing in the septum to the left, unite with the superficial fibers from the right atrioventricular ring to form the posterior papillary muscle. Those of the second layer have a less extensive course in the wall of the right ventricle, and a correspondingly greater course in the left, where they join with the superficial fibers from the anterior half of the tendon of the conus arteriosus to form the papillary muscles of the septum. Those of the third layer pass almost entirely around the left ventricle and unite with the superficial fibers from the lower half of the tendon of the conus arteriosus to form the anterior papillary muscle. Besides the layers just described there are two bands which do not end in papillary muscles. One springs from the right atrioventricular ring and crosses in the atrioventricular septum; it then encircles the deep layers of the left ventricle and ends in the left atrioventricular ring. The second band is apparently confined to the left ventricle; it is attached to the left atrioventricular ring, and encircles the portion of the ventricle adjacent to the aortic orifice.

The **atrioventricular bundle of His** (Fig. 501), is the only direct muscular connection known to exist between the atria and the ventricles. Its cells differ from ordinary cardiac muscle cells in being more spindle-shaped. They are, moreover, more loosely arranged and have a richer vascular supply than the rest of the heart muscle. It arises in connection with two small collections of spindle-shaped cells, the sinoatrial and atrioventricular nodes. The **sinoatrial node** is situated on the anterior border of the opening of the superior vena cava; from its strands of fusiform fibers run under the endocardium of the wall of the atrium to the atrioventricular node. The **atrioventricular node** lies near the orifice of the coronary sinus in the annular and septal fibers of the right atrium; from it the atrioventricular bundle passes forward in the lower part of the membranous septum, and divides into right and left fasciculi. These run down in the right and left ventricles, one on either side of the ventricular septum, covered by endocardium. In the lower parts of the ventricles they break up into numerous strands which end in the papillary muscles and in the ventricular muscle generally. The greater portion of the atrioventricular bundle consists of narrow, somewhat fusiform fibers, but its terminal strands are composed of Purkinje fibers.

¹ Johns Hopkins Hospital Reports, vo

Dr. A. Morison¹ has shown that in the sheep and pig the atrioventricular bundle "is a great avenue for the transmission of nerves from the auricular to the ventricular heart; large and numerous nerve trunks entering the bundle and coursing with it." From these, branches pass off and form plexuses around groups of Purkinje cells, and from these plexuses fine fibrils go to innervate individual cells.

Clinical and experimental evidence go to prove that this bundle conveys the impulse to systolic contraction from the atrial septum to the ventricles.

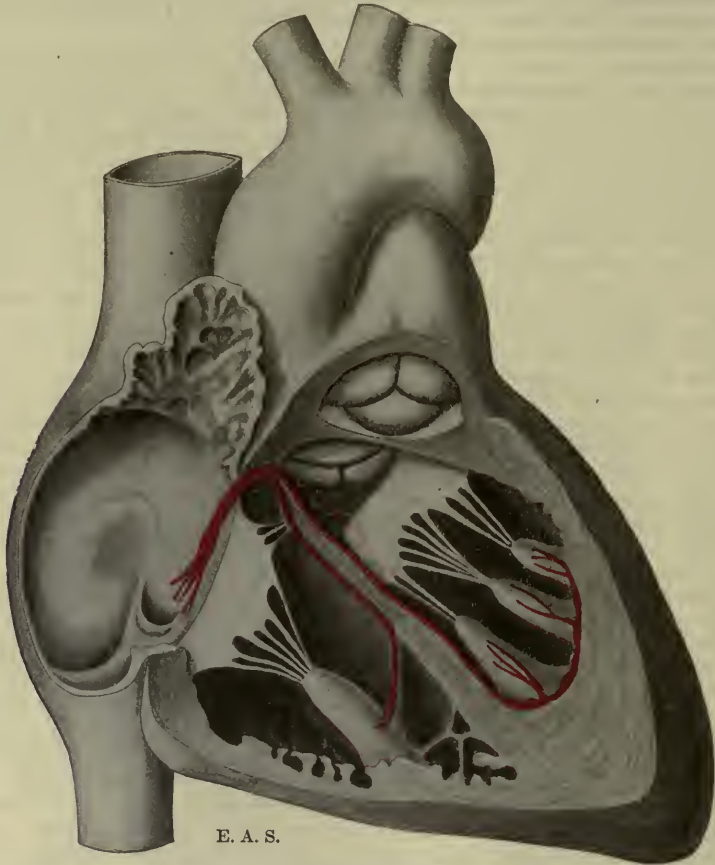


FIG. 501.—Schematic representation of the atrioventricular bundle of His. The bundle, represented in red originates near the orifice of the coronary sinus, undergoes slight enlargement to form a node, passes forward to the ventricular septum, and divides into two limbs. The ultimate distribution cannot be completely shown in this diagram.

Vessels and Nerves.—The **arteries** supplying the heart are the right and left coronary from the aorta; the **veins** end in the right atrium.

The **lymphatics** end in the thoracic and right lymphatic ducts.

The **nerves** are derived from the cardiac plexus, which are formed partly from the vagi, and partly from the sympathetic trunks. They are freely distributed both on the surface and in the substance of the heart, the separate nerve filaments being furnished with small ganglia.

The Cardiac Cycle and the Actions of the Valves.—By the contractions of the heart the blood is pumped through the arteries to all parts of the body. These contractions occur regularly and at the rate of about seventy per minute. Each wave of contraction or *period of activity* is followed by a *period of rest*, the two periods constituting what is known as a **cardiac cycle**.

Each cardiac cycle consists of three phases, which succeed each other as follows: (1) a short simultaneous contraction of both atria, termed the **atrial systole**, fol-

¹ Journal of Anatomy and Physiology, vol. xlvi.

lowed, after a slight pause, by (2) a simultaneous, but more prolonged, contraction of both ventricles, named the **ventricular systole**, and (3) a **period of rest**, during which the whole heart is relaxed. The atrial contraction commences around the venous openings, and sweeping over the atria forces their contents through the atrio-ventricular openings into the ventricles, regurgitation into the veins being prevented by the contraction of their muscular coats. When the ventricles contract, the tricuspid and bicuspid valves are closed, and prevent the passage of the blood back into the atria; the muscoli papillares at the same time are shortened, and, pulling on the chordæ tendineæ, prevent the inversion of the valves into the atria. As soon as the pressure in the ventricles exceeds that in the pulmonary artery and aorta, the valves guarding the orifices of these vessels are opened and the blood is driven from the right ventricle into the pulmonary artery and from the left into the aorta. The moment the systole of the ventricles ceases, the pressure of the blood in the pulmonary artery and aorta closes the pulmonary and aortic semilunar valves to prevent regurgitation of blood into the ventricles, the valves remaining shut until reopened by the next ventricular systole. During the period of rest the tension of the tricuspid and bicuspid valves is relaxed, and blood is flowing from the veins into the atria, being aspirated by negative intrathoracic pressure, and slightly also from the atria into the ventricles. The average duration of a cardiac cycle is about $\frac{8}{10}$ of a second, made up as follows:

Atrial systole, $\frac{1}{10}$.	Atrial diastole, $\frac{7}{10}$.
Ventricular systole, $\frac{3}{10}$.	Ventricular diastole, $\frac{5}{10}$.
Total systole, $\frac{4}{10}$.	Complete diastole, $\frac{4}{10}$.

The rhythmical action of the heart is *muscular* in origin—that is to say, the heart muscle itself possesses the inherent property of contraction apart from any nervous stimulation. The more embryonic the muscle the better is it able to initiate and propagate the contraction wave; this explains why the normal systole of the heart starts at the entrance of the veins, for there the muscle is most embryonic in nature. At the atrioventricular junction there is a slight pause in the wave of muscular contraction. To obviate this so far as possible a peculiar band of marked embryonic type passes across the junction and so carries on the contraction wave to the ventricles. This band, composed of special fibers, is the atrioventricular bundle of His (p. 537). The nerves, although not concerned in originating the contractions of the heart muscle, play an important role in regulating their force and frequency in order to subserve the physiological needs of the organism.

PECULIARITIES IN THE VASCULAR SYSTEM OF THE FETUS.

The chief peculiarities of the fetal heart are the direct communication between the atria through the foramen ovale, and the large size of the valve of the inferior vena cava. Among other peculiarities the following may be noted. (1) In early fetal life the heart lies immediately below the mandibular arch and is relatively large in size. As development proceeds it is gradually drawn within the thorax, but at first it lies in the middle line; toward the end of pregnancy it gradually becomes oblique in direction. (2) For a time the atrial portion exceeds the ventricular in size, and the walls of the ventricles are of equal thickness: toward the end of fetal life the ventricular portion becomes the larger and the wall of the left ventricle exceeds that of the right in thickness. (3) Its size is large as compared with that of the rest of the body, the proportion at the second month being 1 to 50, and at birth, 1 to 120, while in the adult the average is about 1 to 160.

The **foramen ovale**, situated at the lower part of the atrial septum, forms a free communication between the atria until the end of fetal life. A septum (*septum secundum*) grows down from the upper wall of the atrium to the right of the primary

septum in which the foramen ovale is situated; shortly after birth it fuses with the primary septum and the foramen ovale is obliterated.

The **valve of the inferior vena cava** serves to direct the blood from that vessel through the foramen ovale into the left atrium.

The peculiarities in the arterial system of the fetus are the communication between the pulmonary artery and the aorta by means of the ductus arteriosus, and the continuation of the hypogastric arteries as the umbilical arteries to the placenta.

The **ductus arteriosus** is a short tube, about 1.25 cm. in length at birth, and of the diameter of a goose-quill. In the early condition it forms the continuation of the pulmonary artery, and opens into the aorta, just beyond the origin of the left subclavian artery; and so conducts the greater amount of the blood from the right ventricle into the aorta. When the branches of the pulmonary artery have become larger relatively to the ductus arteriosus, the latter is chiefly connected to the left pulmonary artery.

The **hypogastric arteries** run along the sides of the bladder and thence upward on the back of the anterior abdominal wall to the umbilicus; here they pass out of the abdomen and are continued as the **umbilical arteries** in the umbilical cord to the placenta. They convey the fetal blood to the placenta.

The peculiarities in the venous system of the fetus are the communications established between the placenta and the liver and portal vein, through the umbilical vein; and between the umbilical vein and the inferior vena cava through the ductus venosus.

Fetal Circulation (Fig. 502).—The fetal blood is returned from the placenta to the fetus by the umbilical vein. This vein enters the abdomen at the umbilicus, and passes upward along the free margin of the falciform ligament of the liver to the under surface of that organ, where it gives off two or three branches, one of large size to the left lobe, and others to the lobus quadratus and lobus caudatus. At the **porta hepatis** (*transverse fissure of the liver*) it divides into two branches: of these, the larger is joined by the portal vein, and enters the right lobe; the smaller is continued upward, under the name of the **ductus venosus**, and joins the inferior vena cava. The blood, therefore, which traverses the umbilical vein, passes to the inferior vena cava in three different ways. A considerable quantity circulates through the liver with the portal venous blood, before entering the inferior vena cava by the hepatic veins; some enters the liver directly, and is carried to the inferior cava by the hepatic veins; the remainder passes directly into the inferior vena cava through the ductus venosus.

In the inferior vena cava, the blood carried by the ductus venosus and hepatic veins becomes mixed with that returning from the lower extremities and abdominal wall. It enters the right atrium, and, guided by the valve of the inferior vena cava, passes through the foramen ovale into the left atrium, where it mixes with a small quantity of blood returned from the lungs by the pulmonary veins. From the left atrium it passes into the left ventricle; and from the left ventricle into the aorta, by means of which it is distributed almost entirely to the head and upper extremities, a small quantity being probably carried into the descending aorta. From the head and upper extremities the blood is returned by the superior vena cava to the right atrium, where it mixes with a small portion of the blood from the inferior vena cava. From the right atrium it descends into the right ventricle, and thence passes into the pulmonary artery. The lungs of the fetus being inactive, only a small quantity of the blood of the pulmonary artery is distributed to them by the right and left pulmonary arteries, and returned by the pulmonary veins to the left atrium: the greater part passes through the ductus arteriosus into the aorta, where it mixes with a small quantity of the blood transmitted by the left ventricle into the aorta. Through this vessel it descends, and is in part distributed

to the lower extremities and the viscera of the abdomen and pelvis, but the greater amount is conveyed by the umbilical arteries to the placenta.

From the preceding account of the circulation of the blood in the fetus the following facts will be evident: (1) The placenta serves the purposes of nutrition

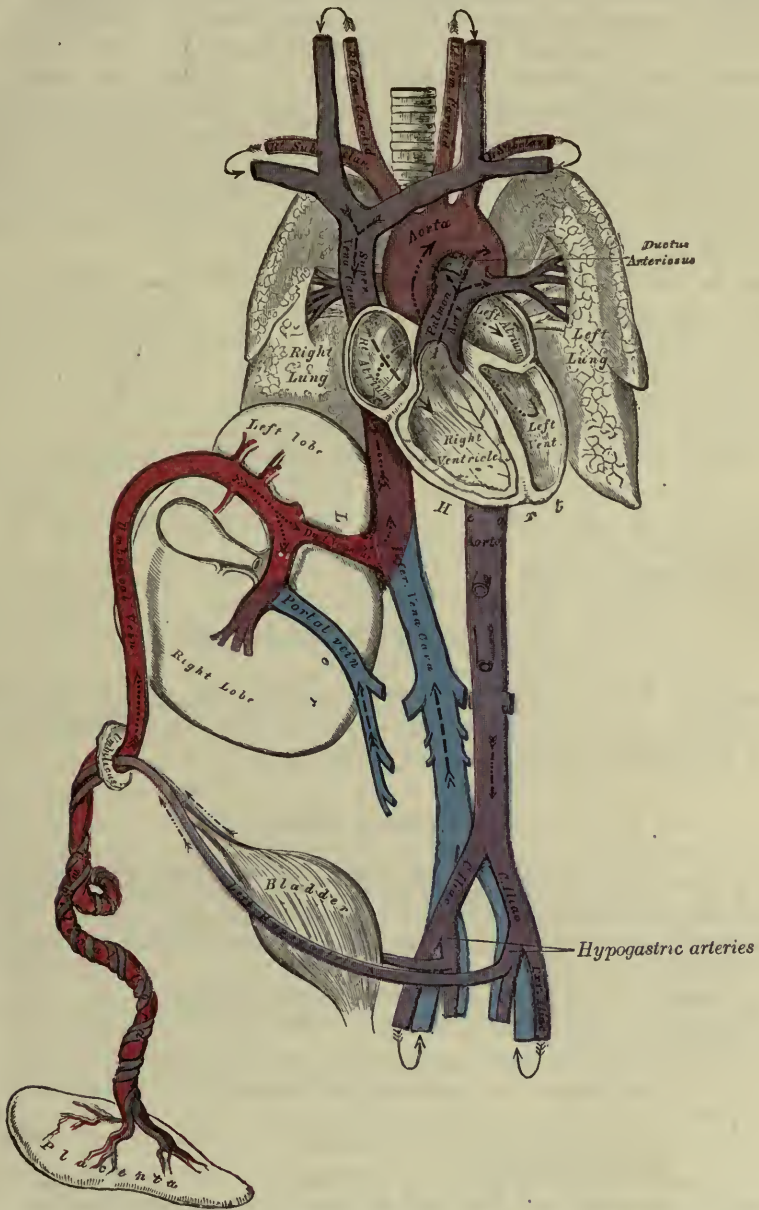


FIG. 502.—Plan of the fetal circulation. In this plan the figured arrows represent the kind of blood, as well as the direction which it takes in the vessels. Thus—arterial blood is figured >----->; venous blood, >- - - ->; mixed (arterial and venous) blood, >- - - - ->.

and excretion, receiving the impure blood from the fetus, and returning it purified and charged with additional nutritive material. (2) Nearly the whole of the blood of the umbilical vein traverses the liver before entering the inferior vena cava; hence the large size of the liver, especially at an early period of fetal life. (3) The right atrium is the point of meeting of a double current, the blood in the inferior

vena cava being guided by the valve of this vessel into the left atrium, while that in the superior vena cava descends into the right ventricle. At an early period of fetal life it is highly probable that the two streams are quite distinct; for the inferior vena cava opens almost directly into the left atrium, and the valve of the inferior vena cava would exclude the current from the right ventricle. At a later period, as the separation between the two atria becomes more distinct, it seems probable that some mixture of the two streams must take place. (4) The pure blood carried from the placenta to the fetus by the umbilical vein, mixed with the blood from the portal vein and inferior vena cava, passes almost directly to the arch of the aorta, and is distributed by the branches of that vessel to the head and upper extremities. (5) The blood contained in the descending aorta, chiefly derived from that which has already circulated through the head and limbs, together with a small quantity from the left ventricle, is distributed to the abdomen and lower extremities.

Changes in the Vascular System at Birth.—At birth, when respiration is established, an increased amount of blood from the pulmonary artery passes through the lungs, and the placental circulation is cut off. The foramen ovale is closed by about the tenth day after birth: the valvular fold above mentioned adheres to the margin of the foramen for the greater part of its circumference, but a slit-like opening is left between the two atria above, and this sometimes persists.

The **ductus arteriosus** begins to contract immediately after respiration is established, and is completely closed from the fourth to the tenth day; it ultimately degenerates into an impervious cord, the **ligamentum arteriosum**, which connects the left pulmonary artery to the arch of the aorta.

Of the **hypogastric arteries**, the parts extending from the sides of the bladder to the umbilicus become obliterated between the second and fifth days after birth, and project as fibrous cords, the **lateral umbilical ligaments**, toward the abdominal cavity, carrying on them folds of peritoneum.

The **umbilical vein** and **ductus venosus** are completely obliterated between the second and fifth days after birth; the former becomes the **ligamentum teres**, the latter the **ligamentum venosum**, of the liver.

BIBLIOGRAPHY.

- BREMER, J. L.: The Earliest Bloodvessels in Man, *Am. Jour. Anat.*, 1914, xvi.
 EVANS, H. M.: On the Development of the Aorta, Cardinal and Umbilical Veins and Other Bloodvessels of the Vertebrate Embryos from Capillaries, *Anat. Rec.*, 1909, iii.
 EVANS, H. M.: The Development of the Vascular System, Keibel and Mall, *Manual of Human Embryology*.
 HIS, W.: *Anatomie Menschlichen Embryonen*, Leipzig, 1880–85.
 MACCALLUM, J. B.: On the Muscular Architecture and Growth of the Ventricles of the Heart, *Johns Hop. Hosp. Rep.*, 1900, ix.
 MALL, F. P.: A Study of the Structural Unit of the Liver, *Am. Jour. Anat.*, 1906, v.
 MALL, F. P.: On the Muscular Architecture of the Ventricles of the Human Heart, *Am. Jour. Anat.*, 1911, xi.
 MALL, F. P.: The Development of the Internal Mammary and Deep Epigastric Arteries in Man, *Johns Hop. Hosp. Bulletin*, 1898.
 STOCKARD, C. R.: A Study of Wandering Mesenchymal Cells on the Living Yolk Sac and Their Developmental Products: Chromatophores, Vascular Endothelium and Blood Cells, *Am. Jour. Anat.*, 1915, xviii.
 STREETER, G. L.: The Development of the Venous Sinuses of the Dura Mater in the Human Embryo, *Am. Jour. Anat.*, 1915, xviii.
 THOMA, R.: *Text-book of General Pathology and Pathological Anatomy*, Translated by Bruce, London, 1896.

THE ARTERIES.

THE distribution of the systematic arteries is like a highly ramified tree, the common trunk of which, formed by the aorta, commences at the left ventricle, while the smallest ramifications extend to the peripheral parts of the body and the contained organs. Arteries are found in all parts of the body, except in the hairs, nails, epidermis, cartilages, and cornea; the larger trunks usually occupy the most protected situations, running, in the limbs, along the flexor surface, where they are less exposed to injury.

There is considerable variation in the mode of division of the arteries: occasionally a short trunk subdivides into several branches at the same point, as may be observed in the celiac artery and the thyrocervical trunk: the vessel may give off several branches in succession, and still continue as the main trunk, as is seen in the arteries of the limbs; or the division may be dichotomous, as, for instance, when the aorta divides into the two common iliacs.

A branch of an artery is smaller than the trunk from which it arises; but if an artery divides into two branches, the combined sectional area of the two vessels is, in nearly every instance, somewhat greater than that of the trunk; and the combined sectional area of all the arterial branches greatly exceeds that of the aorta; so that the arteries collectively may be regarded as a cone, the apex of which corresponds to the aorta, and the base to the capillary system.

The arteries, in their distribution, communicate with one another, forming what are called **anastomoses**, and these communications are very free between the large as well as between the smaller branches. The anastomosis between trunks of equal size is found where great activity of the circulation is requisite, as in the brain; here the two vertebral arteries unite to form the basilar, and the two anterior cerebral arteries are connected by a short communicating trunk; it is also found in the abdomen, where the intestinal arteries have very ample anastomoses between their larger branches. In the limbs the anastomoses are most numerous and of largest size around the joints, the branches of an artery above uniting with branches from the vessels below. These anastomoses are of considerable interest to the surgeon, as it is by their enlargement that a **collateral circulation** is established after the application of a ligature to an artery. The smaller branches of arteries anastomose more frequently than the larger; and between the smallest twigs these anastomoses become so numerous as to constitute a close network that pervades nearly every tissue of the body.

Throughout the body generally the larger arterial branches pursue a fairly straight course, but in certain situations they are tortuous. Thus the external maxillary artery in its course over the face, and the arteries of the lips, are extremely tortuous to accommodate themselves to the movements of the parts. The uterine arteries are also tortuous, to accommodate themselves to the increase of size which the uterus undergoes during pregnancy.

The Pulmonary Artery (**A. Pulmonalis**) (Figs. 503, 504).

The **pulmonary artery** conveys the venous blood from the right ventricle of the heart to the lungs. It is a short, wide vessel, about 5 cm. in length and 3 cm. in

diameter, arising from the conus arteriosus of the right ventricle. It extends obliquely upward and backward, passing at first in front and then to the left

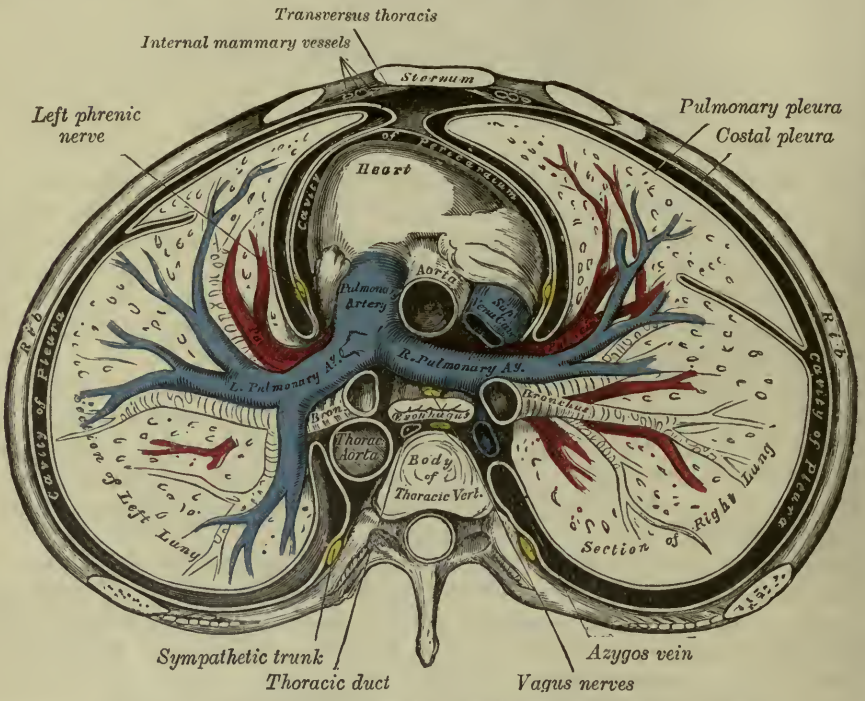


FIG. 503.—Transverse section of thorax, showing relations of pulmonary artery.

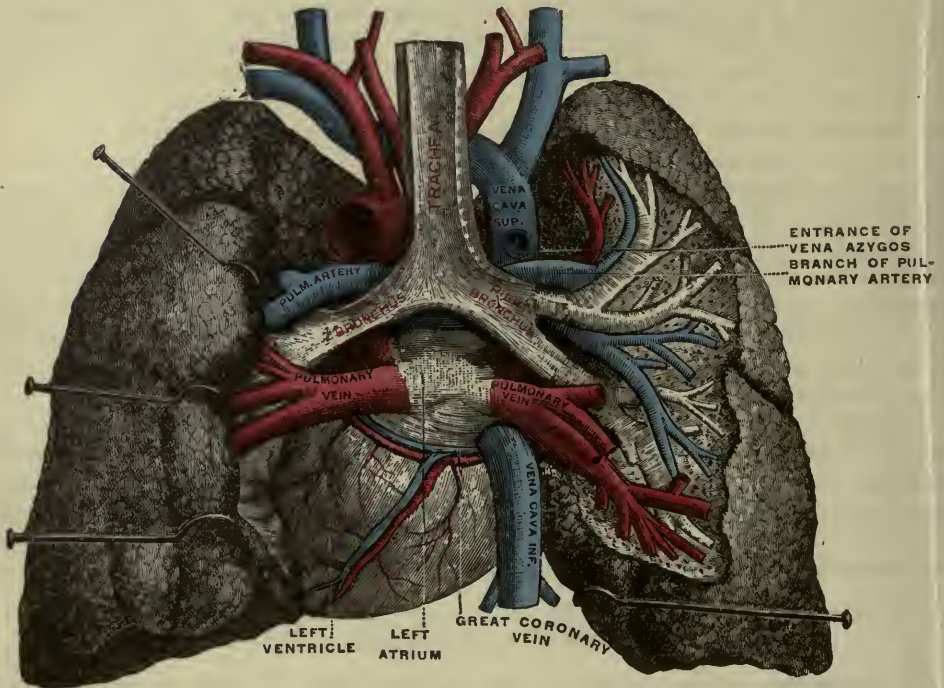


FIG. 504.—Pulmonary vessels, seen in a dorsal view of the heart and lungs. The lungs have been pulled away from the median line, and a part of the right lung has been cut away to display the air-ducts and bloodvessels.

of the ascending aorta, as far as the under surface of the aortic arch, where it divides, about the level of the fibrocartilage between the fifth and sixth thoracic vertebræ, into right and left branches of nearly equal size.

Relations.—The whole of this vessel is contained within the pericardium. It is enclosed with the ascending aorta in a single tube of the visceral layer of the serous pericardium, which is continued upward upon them from the base of the heart. The fibrous layer of the pericardium is gradually lost upon the external coats of the two branches of the artery. In *front*, the pulmonary artery is separated from the anterior end of the second left intercostal space by the pleura and left lung, in addition to the pericardium; it rests at first upon the ascending aorta, and higher up lies in front of the left atrium on a plane posterior to the ascending aorta. On *either side* of its origin is the auricula of the corresponding atrium and a coronary artery, the left coronary artery passing, in the first part of its course, behind the vessel. The superficial part of the cardiac plexus lies above its bifurcation, between it and the arch of the aorta.

The **right branch of the pulmonary artery** (*ramus dexter a. pulmonalis*), longer and larger than the left, runs horizontally to the right, behind the ascending aorta and superior vena cava and in front of the right bronchus, to the root of the right lung, where it divides into two branches. The lower and larger of these goes to the middle and lower lobes of the lung; the upper and smaller is distributed to the upper lobe.

The **left branch of the pulmonary artery** (*ramus sinister a. pulmonalis*), shorter and somewhat smaller than the right, passes horizontally in front of the descending aorta and left bronchus to the root of the left lung, where it divides into two branches, one for each lobe of the lung.

Above, it is connected to the concavity of the aortic arch by the ligamentum arteriosum, on the left of which is the left recurrent nerve, and on the right the superficial part of the cardiac plexus. *Below*, it is joined to the upper left pulmonary vein by the ligament of the left vena cava.

The terminal branches of the pulmonary arteries will be described with the anatomy of the lungs.

THE AORTA.

The **aorta** is the main trunk of a series of vessels which convey the oxygenated blood to the tissues of the body for their nutrition. It commences at the upper part of the left ventricle, where it is about 3 cm. in diameter, and after ascending for a short distance, arches backward and to the left side, over the root of the left lung; it then descends within the thorax on the left side of the vertebral column, passes into the abdominal cavity through the aortic hiatus in the diaphragm, and ends, considerably diminished in size (about 1.75 cm. in diameter), opposite the lower border of the fourth lumbar vertebra, by dividing into the right and left common iliac arteries. Hence it is described in several portions, viz., the **ascending aorta**, the **arch of the aorta**, and the **descending aorta**, which last is again divided into the **thoracic and abdominal aortæ**.

THE ASCENDING AORTA (AORTA ASCENDENS) (Fig. 505).

The **ascending aorta** is about 5 cm. in length. It commences at the upper part of the base of the left ventricle, on a level with the lower border of the third costal cartilage behind the left half of the sternum; it passes obliquely upward, forward, and to the right, in the direction of the heart's axis, as high as the upper border of the second right costal cartilage, describing a slight curve in its course, and being situated, about 6 cm. behind the posterior surface of the sternum. At its origin it presents, opposite the segments of the aortic valve, three small dilatations called the **aortic sinuses**. At the union of the ascending aorta with the aortic arch the caliber of the vessel is increased, owing to a bulging of its right wall. This dilatation is termed the **bulb of the aorta**, and on transverse section presents a some-

what oval figure. The ascending aorta is contained within the pericardium, and is enclosed in a tube of the serous pericardium, common to it and the pulmonary artery.

Relations.—The ascending aorta is covered at its commencement by the trunk of the pulmonary artery and the right auricula, and, higher up, is separated from the sternum by the pericardium, the right pleura, the anterior margin of the right lung, some loose areolar tissue, and the remains of the thymus; *posteriorly*, it rests upon the left atrium and right pulmonary artery. On the *right side*, it is in relation with the superior vena cava and right atrium, the former lying partly behind it; on the *left side*, with the pulmonary artery.

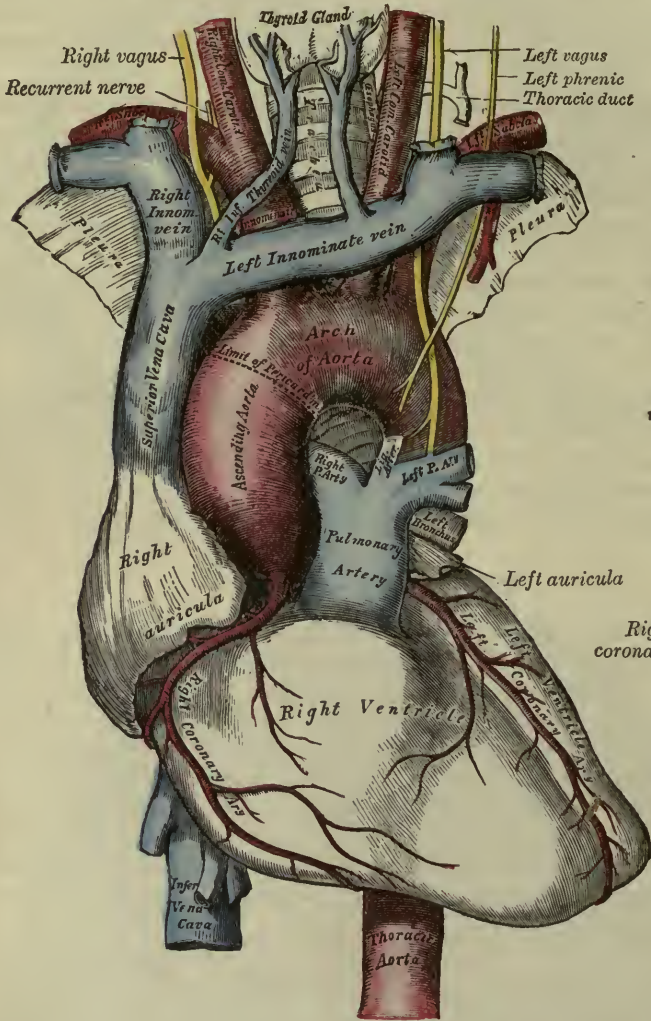


FIG. 505.—The arch of the aorta, and its branches.

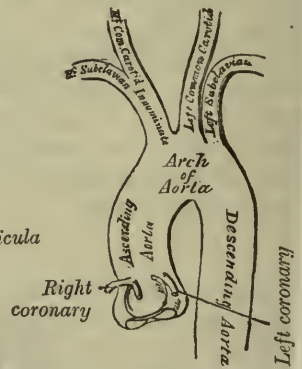


FIG. 506.—Plan of the branches.

Branches.—The only branches of the ascending aorta are the two coronary arteries which supply the heart; they arise near the commencement of the aorta immediately above the attached margins of the semilunar valves.

The Coronary Arteries.—The **Right Coronary Artery** (*a. coronaria [cordis] dextra*) arises from the right anterior aortic sinus. It passes at first between the conus arteriosus and the right auricula and then runs in the right portion of the coronary sulcus, coursing at first from the left to right and then on the diaphragmatic surface of the heart from right to left as far as the posterior longitudinal sulcus, down

which it is continued to the apex of the heart as the **posterior descending branch**. It gives off a large **marginal branch** which follows the acute margin of the heart and supplies branches to both surfaces of the right ventricle. It also gives twigs to the right atrium and to the part of the left ventricle which adjoins the posterior longitudinal sulcus.

The **Left Coronary Artery** (*a. coronaria [cordis] sinistra*), larger than the right, arises from the left anterior aortic sinus and divides into an anterior descending and a circumflex branch. The **anterior descending branch** passes at first behind the pulmonary artery and then comes forward between that vessel and the left auricula to reach the anterior longitudinal sulcus, along which it descends to the incisura apicis cordis; it gives branches to both ventricles. The **circumflex branch** follows the left part of the coronary sulcus, running first to the left and then to the right, reaching nearly as far as the posterior longitudinal sulcus; it gives branches to the left atrium and ventricle. There is a free anastomosis between the minute branches of the two coronary arteries in the substance of the heart.

Peculiarities.—These vessels occasionally arise by a common trunk, or their number may be increased to three, the additional branch being of small size. More rarely, there are two additional branches.

THE ARCH OF THE AORTA (ARCUS AORTÆ; TRANSVERSE AORTA) (Fig. 505).

The **arch of the aorta** begins at the level of the upper border of the second sterno-costal articulation of the right side, and runs at first upward, backward, and to the left in front of the trachea; it is then directed backward on the left side of the trachea and finally passes downward on the left side of the body of the fourth thoracic vertebra, at the lower border of which it becomes continuous with the descending aorta. It thus forms two curvatures: one with its convexity upward, the other with its convexity forward and to the left. Its upper border is usually about 2.5 cm. below the superior border to the manubrium sterni.

Relations.—The arch of the aorta is covered *anteriorly* by the pleura and anterior margins of the lungs, and by the remains of the thymus. As the vessel runs backward its *left* side is in contact with the left lung and pleura. Passing downward on the left side of this part of the arch are four nerves; in order from before backward these are, the left phrenic, the lower of the superior cardiac branches of the left vagus, the superior cardiac branch of the left sympathetic, and the trunk of the left vagus. As the last nerve crosses the arch it gives off its recurrent branch, which hooks around below the vessel and then passes upward on its right side. The highest left inter-costal vein runs obliquely upward and forward on the left side of the arch, between the phrenic and vagus nerves. On the *right* are the deep part of the cardiac plexus, the left recurrent nerve, the esophagus, and the thoracic duct; the trachea lies behind and to the right of the vessel. *Above* are the innominate, left common carotid, and left subclavian arteries, which arise from the convexity of the arch and are crossed close to their origins by the left innominate vein. *Below* are the bifurcation of the pulmonary artery, the left bronchus, the ligamentum arteriosum, the superficial part of the cardiac plexus, and the left recurrent nerve. As already stated, the ligamentum arteriosum connects the commencement of the left pulmonary artery to the aortic arch.

Between the origin of the left subclavian artery and the attachment of the ductus arteriosus the lumen of the fetal aorta is considerably narrowed, forming what is termed the **aortic isthmus**, while immediately beyond the ductus arteriosus the vessel presents a fusiform dilation which His has named the **aortic spindle**—the point of junction of the two parts being marked in the concavity of the arch by an indentation or angle. These conditions persist, to some extent, in the adult, where His found that the average diameter of the spindle exceeded that of the isthmus by 3 mm.

Distinct from this diffuse and moderate stenosis at the isthmus is the condition known as *coarctation of the aorta*, or marked stenosis often amounting to complete obliteration of its lumen, seen in adults and occurring at or near, oftenest a little below, the insertion of the ligamentum

arteriosum into the aorta. According to Bonnet¹ this coarctation is never found in the fetus or at birth, and is due to an abnormal extension of the peculiar tissue of the ductus into the aortic wall, which gives rise to a simultaneous stenosis of both vessels as it contracts after birth—the ductus is usually obliterated in these cases. An extensive collateral circulation is set up, by the costocervicals, internal mammaries, and the descending branches of the transverse cervical above the stenosis, and below it by the first four aortic intercostals, the pericardiacophrenics, and the superior and inferior epigastrics.

Peculiarities.—The height to which the aorta rises in the thorax is usually about 2.5 cm. below the upper border of the sternum; but it may ascend nearly to the top of the bone. Occasionally it is found 4 cm., more rarely from 5 to 8 cm. below this point. Sometimes the aorta arches over the root of the right lung (right aortic arch) instead of over that of the left, and passes down on the right side of the vertebral column, a condition which is found in birds. In such cases all the thoracic and abdominal viscera are transposed. Less frequently the aorta, after arching over the root of the right lung, is directed to its usual position on the left side of the vertebral column; this peculiarity is not accompanied by transposition of the viscera. The aorta occasionally divides, as in some quadrupeds, into an ascending and a descending trunk, the former of which is directed vertically upward, and subdivides into three branches, to supply the head and upper extremities. Sometimes the aorta subdivides near its origin into two branches, which soon reunite. In one of these cases the esophagus and trachea were found to pass through the interval between the two branches; this is the normal condition of the vessel in the reptilia.

Branches (Figs. 505, 506).—The branches given off from the arch of the aorta are three in number: the **innominate**, the **left common carotid**, and the **left subclavian**.

Peculiarities.—*Position of the Branches.*—The branches, instead of arising from the highest part of the arch, may spring from the commencement of the arch or upper part of the ascending aorta; or the distance between them at their origins may be increased or diminished, the most frequent change in this respect being the approximation of the left carotid toward the innominate artery.

The number of the primary branches may be reduced to one, or more commonly two; the left carotid arising from the innominate artery; or (more rarely) the carotid and subclavian arteries of the left side arising from a left innominate artery. But the number may be increased to four, from the right carotid and subclavian arteries arising directly from the aorta, the innominate being absent. In most of these latter cases the right subclavian has been found to arise from the left end of the arch; in other cases it is the second or third branch given off, instead of the first. Another common form in which there are four primary branches is that in which the left vertebral artery arises from the arch of the aorta between the left carotid and subclavian arteries. Lastly, the number of trunks from the arch may be increased to five or six; in these instances, the external and internal carotids arise separately from the arch, the common carotid being absent on one or both sides. In some few cases six branches have been found, and this condition is associated with the origin of both vertebral arteries from the arch.

Number Usual, Arrangement Different.—When the aorta arches over to the right side, the three branches have an arrangement the reverse of what is usual; the innominate artery is a left one, and the right carotid and subclavian arise separately. In other cases, where the aorta takes its usual course, the two carotids may be joined in a common trunk, and the subclavians arise separately from the arch, the right subclavian generally arising from the left end of the arch.

In some instances other arteries spring from the arch of the aorta. Of these the most common are the bronchial, one or both, and the thyroidea ima; but the internal mammary and the inferior thyroid have been seen to arise from this vessel.

The Innominate Artery (A. Anonyma; Brachiocephalic Artery) (Fig. 505).

The **innominate artery** is the largest branch of the arch of the aorta, and is from 4 to 5 cm. in length. It *arises*, on a level with the upper border of the second right costal cartilage, from the commencement of the arch of the aorta, on a plane anterior to the origin of the left carotid; it ascends obliquely upward, backward, and to the right to the level of the upper border of the right sternoclavicular articulation, where it divides into the right common carotid and right subclavian arteries.

Relations.—*Anteriorly*, it is separated from the manubrium sterni by the Sternohyoideus and Sternothyroideus, the remains of the thymus, the left innominate and right inferior thyroid veins which cross its root, and sometimes the superior cardiac branches of the right vagus. *Posterior*

¹ Rev. de Méd., Paris, 1903.

to it is the trachea, which it crosses obliquely. On the *right side* are the right innominate vein, the superior vena cava, the right phrenic nerve, and the pleura; and on the *left side*, the remains of the thymus, the origin of the left common carotid artery, the inferior thyroid veins, and the trachea.

Branches.—The innominate artery usually gives off no branches; but occasionally a small branch, the *thyreoidea ima*, arises from it. Sometimes it gives off a thymic or bronchial branch.

The *thyreoidea ima* (*a. thyreoidea ima*) ascends in front of the trachea to the lower part of the thyroid gland, which it supplies. It varies greatly in size, and appears to compensate for deficiency or absence of one of the other thyroid vessels. It occasionally arises from the aorta, the right common carotid, the subclavian or the internal mammary.

Point of Division.—The innominate artery sometimes divides above the level of the sternoclavicular joint, less frequently below it.

Position.—When the aortic arch is on the right side, the innominate is directed to the left side of the neck.

Collateral Circulation.—Allan Burns demonstrated, on the dead subject, the possibility of the establishment of the collateral circulation after ligature of the innominate artery, by tying and dividing that artery. He then found that "Even coarse injection, impelled into the aorta, passed freely by the anastomosing branches into the arteries of the right arm, filling them and all the vessels of the head completely."¹ The branches by which this circulation would be carried on are very numerous; thus, all the communications across the middle line between the branches of the carotid arteries of opposite sides would be available for the supply of blood to the right side of the head and neck; while the anastomosis between the costocervical of the subclavian and the first aortic intercostal (see *infra* on the collateral circulation after obliteration of the thoracic aorta) would bring the blood, by a free and direct course, into the right subclavian. The numerous connections, also, between the intercostal arteries and the branches of the axillary and internal mammary arteries would, doubtless, assist in the supply of blood to the right arm, while the inferior epigastric from the external iliac would, by means of its anastomosis with the internal mammary, compensate for any deficiency in the vascularity of the wall of the chest.

THE ARTERIES OF THE HEAD AND NECK.

The principal arteries of supply to the head and neck are the two **common carotids**; they ascend in the neck and each divides into two branches, viz., (1) the **external carotid**, supplying the exterior of the head, the face, and the greater part of the neck; (2) the **internal carotid**, supplying to a great extent the parts within the cranial and orbital cavities.

THE COMMON CAROTID ARTERY (A. CAROTIS COMMUNIS).

The **common carotid arteries** differ in length and in their mode of origin. The *right* begins at the bifurcation of the innominate artery behind the sternoclavicular joint and is confined to the neck. The *left* springs from the highest part of the arch of the aorta to the left of, and on a plane posterior to the innominate artery, and therefore consists of a thoracic and a cervical portion.

The **thoracic portion of the left common carotid artery** ascends from the arch of the aorta through the superior mediastinum to the level of the left sternoclavicular joint, where it is continuous with the cervical portion.

Relations.—*In front*, it is separated from the manubrium sterni by the Sternohyoideus and Sternothyroideus, the anterior portions of the left pleura and lung, the left innominate vein, and the remains of the thymus; *behind*, it lies on the trachea, esophagus, left recurrent nerve, and thoracic duct. To its *right side* below is the innominate artery, and above, the trachea, the inferior thyroid veins, and the remains of the thymus; to its *left side* are the left vagus and phrenic nerves, left pleura, and lung. The left subclavian artery is posterior and slightly lateral to it.

¹ Surgical Anatomy of the Head and Neck, p. 62.

The cervical portions of the common carotids resemble each other so closely that one description will apply to both (Fig. 507). Each vessel passes obliquely upward, from behind the sternoclavicular articulation, to the level of the upper border of the thyroid cartilage, where it divides into the external and internal carotid arteries.

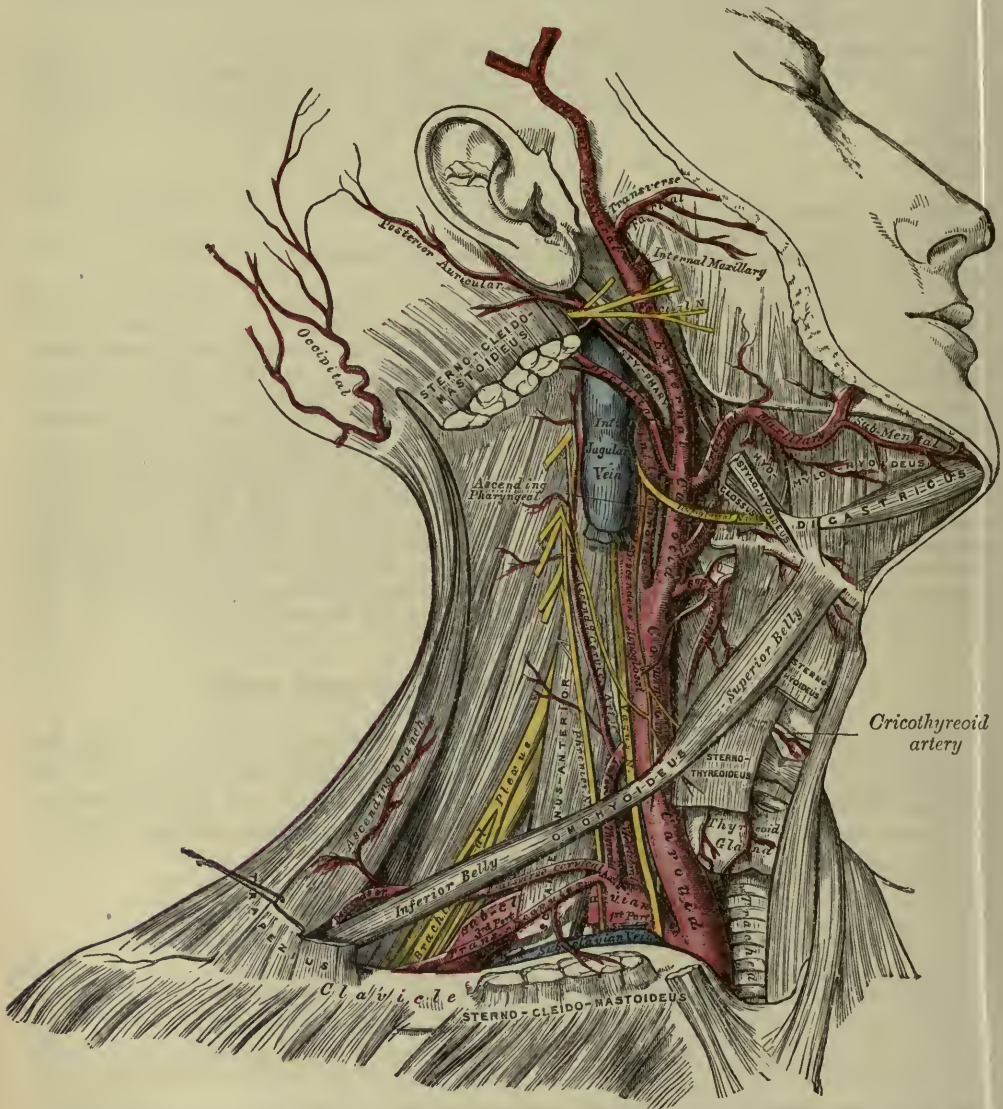


FIG. 507.—Superficial dissection of the right side of the neck, showing the carotid and subclavian arteries.

At the lower part of the neck the two common carotid arteries are separated from each other by a very narrow interval which contains the trachea; but at the upper part, the thyroid gland, the larynx and pharynx project forward between the two vessels. The common carotid artery is contained in a sheath, which is derived from the deep cervical fascia and encloses also the internal jugular vein and vagus nerve, the vein lying lateral to the artery, and the nerve between the artery and vein, on a plane posterior to both. On opening the sheath, each of these three structures is seen to have a separate fibrous investment.

Relations.—At the lower part of the neck the common carotid artery is very deeply seated, being covered by the integument, superficial fascia, Platysma, and deep cervical fascia, the Sternocleidomastoideus, Sternohyoideus, Sternothyroideus, and Omohyoideus; in the upper part of its course it is more superficial, being covered merely by the integument, the superficial fascia, Platysma, deep cervical fascia, and medial margin of the Sternocleidomastoideus. When the latter muscle is drawn backward, the artery is seen to be contained in a triangular space, the **carotid triangle**, bounded behind by the Sternocleidomastoideus, above by the Stylohyoideus and posterior belly of the Digastricus, and below by the superior belly of the Omohyoideus. This part of the artery is crossed obliquely, from its medial to its lateral side, by the sternocleidomastoid branch of the superior thyroid artery; it is also crossed by the superior and middle thyroid veins which end in the internal jugular; descending in front of its sheath is the descending branch of the hypoglossal nerve, this filament being joined by one or two branches from the cervical nerves, which cross the vessel obliquely. Sometimes the descending branch of the hypoglossal nerve is contained within the sheath. The superior thyroid vein crosses the artery near its termination, and the middle thyroid vein a little below the level of the cricoid cartilage; the anterior jugular vein crosses the artery just above the clavicle, but is separated from it by the Sternohyoideus and Sternothyroideus. *Behind*, the artery is separated from the transverse processes of the cervical vertebrae by the Longus colli and Longus capitis, the sympathetic trunk being interposed between it and the muscles. The inferior thyroid artery crosses behind the lower part of the vessel. *Medially*, it is in relation with the esophagus, trachea, and thyroid gland (which overlaps it), the inferior thyroid artery and recurrent nerve being interposed; higher up, with the larynx and pharynx. *Lateral* to the artery are the internal jugular vein and vagus nerve.

At the lower part of the neck, the right recurrent nerve crosses obliquely behind the artery; the right internal jugular vein diverges from the artery, but the left approaches and often overlaps the lower part of the artery.

Behind the angle of bifurcation of the common carotid artery is a reddish-brown oval body, known as the **glomus caroticum** (*carotid body*). It is similar in structure to the **glomus coccygeum** (*coccygeal body*) which is situated on the middle sacral artery.

Peculiarities as to Origin.—The *right common carotid* may arise above the level of the upper border of the sternoclavicular articulation; this variation occurs in about 12 per cent. of cases. In other cases the artery may arise as a separate branch from the arch of the aorta, or in conjunction with the left carotid. The *left common carotid* varies in its origin more than the right. In the majority of abnormal cases it arises with the innominate artery; if that artery is absent, the two carotids arise usually by a single trunk. It is rarely joined with the left subclavian, except in cases of transposition of the aortic arch.

Peculiarities as to Point of Division.—In the majority of abnormal cases this occurs higher than usual, the artery dividing opposite or even above the hyoid bone; more rarely, it occurs below, opposite the middle of the larynx, or the lower border of the cricoid cartilage; one case is related by Morgagni, where the artery was only 4 cm. in length and divided at the root of the neck. Very rarely, the common carotid ascends in the neck without any subdivision, either the external or the internal carotid being wanting; and in a few cases the common carotid has been found to be absent, the external and internal carotids arising directly from the arch of the aorta. This peculiarity existed on both sides in some instances, on one side in others.

Occasional Branches.—The common carotid usually gives off no branch previous to its bifurcation, but it occasionally gives origin to the superior thyroid or its laryngeal branch, the ascending pharyngeal, the inferior thyroid, or, more rarely, the vertebral artery.

Collateral Circulation.—After ligation of the common carotid, the collateral circulation can be perfectly established, by the free communication which exists between the carotid arteries of opposite sides, both without and within the cranium, and by enlargement of the branches of the subclavian artery on the side corresponding to that on which the vessel has been tied. The chief communications outside the skull take place between the superior and inferior thyroid arteries, and the profunda cervicis and ramus descendens of the occipital; the vertebral takes the place of the internal carotid within the cranium.

The External Carotid Artery (A. Carotis Externa) (Fig. 507).

The external carotid artery begins opposite the upper border of the thyroid cartilage, and, taking a slightly curved course, passes upward and forward, and then inclines backward to the space behind the neck of the mandible, where it divides into the superficial temporal and internal maxillary arteries. It rapidly diminishes in size in its course up the neck, owing to the number and large size of the branches given off from it. In the child, it is somewhat smaller than the internal carotid; but in the adult, the two vessels are of nearly equal size. At its

origin, this artery is more superficial, and placed nearer the middle line than the internal carotid, and is contained within the carotid triangle.

Relations.—The external carotid artery is covered by the skin, superficial fascia, Platysma, deep fascia, and anterior margin of the Sternocleidomastoideus; it is crossed by the hypoglossal nerve, by the lingual, ranine, common facial, and superior thyroid veins; and by the Digastricus and Stylohyoideus; higher up it passes deeply into the substance of the parotid gland, where it lies deep to the facial nerve and the junction of the temporal and internal maxillary veins. *Medial* to it are the hyoid bone, the wall of the pharynx, the superior laryngeal nerve, and a portion of the parotid gland. *Lateral* to it, in the lower part of its course, is the internal carotid artery. *Posterior* to it, near its origin, is the superior laryngeal nerve; and higher up, it is separated from the internal carotid by the Styloglossus and Stylopharyngeus, the glossopharyngeal nerve, the pharyngeal branch of the vagus, and part of the parotid gland.

Branches.—The branches of the external carotid artery may be divided into four sets.

<i>Anterior.</i>	<i>Posterior.</i>	<i>Ascending.</i>	<i>Terminal.</i>
Superior Thyroid.	Occipital.	Ascending	Superficial Temporal.
Lingual.	Posterior Auricular.	Pharyngeal.	Internal Maxillary.
External Maxillary.			

1. The **superior thyroid artery** (*a. thyreoidea superior*) (Fig. 507) arises from the external carotid artery just below the level of the greater cornu of the hyoid bone and ends in the thyroid gland.

Relations.—From its origin under the anterior border of the Sternocleidomastoideus it runs upward and forward for a short distance in the carotid triangle, where it is covered by the skin, Platysma, and fascia; it then arches downward beneath the Omohyoideus, Sternohyoideus, and Sternothyreoideus. To its medial side are the Constrictor pharyngis inferior and the external branch of the superior laryngeal nerve.

Branches.—It distributes twigs to the adjacent muscles, and numerous branches to the thyroid gland, anastomosing with its fellow of the opposite side, and with the inferior thyroid arteries. The branches to the gland are generally two in number; one, the larger, supplies principally the anterior surface; on the isthmus of the gland it anastomoses with the corresponding artery of the opposite side: a second branch descends on the posterior surface of the gland and anastomoses with the inferior thyroid artery.

Besides the arteries distributed to the muscles and to the thyroid gland, the branches of the superior thyroid are:

Hyoid.	Superior Laryngeal.
Sternocleidomastoid.	Cricothyroid.

The **Hyoid Branch** (*ramus hyoideus; infrahyoid branch*) is small and runs along the lower border of the hyoid bone beneath the Thyreohyoideus and anastomoses with the vessel of the opposite side.

The **Sternocleidomastoid Branch** (*ramus sternocleidomastoideus; sternomastoid branch*) runs downward and lateralward across the sheath of the common carotid artery, and supplies the Sternocleidomastoideus and neighboring muscles and integument; it frequently arises as a separate branch from the external carotid.

The **Superior Laryngeal Artery** (*a. laryngea superior*), larger than either of the preceding, accompanies the internal laryngeal branch of the superior laryngeal nerve, beneath the Thyreohyoideus; it pierces the hyothyroid membrane, and supplies the muscles, mucous membrane, and glands of the larynx, anastomosing with the branch from the opposite side.

The **Cricothyroid Branch** (*ramus cricothyreoideus*) is small and runs transversely across the cricothyroid membrane, communicating with the artery of the opposite side.

2. The **lingual artery** (*a. lingualis*) (Fig. 513) *arises* from the external carotid between the superior thyroid and external maxillary; it first runs obliquely upward and medialward to the greater cornu of the hyoid bone; it then curves downward and forward, forming a loop which is crossed by the hypoglossal nerve, and passing beneath the Digastricus and Stylohyoideus it runs horizontally forward, beneath the Hyoglossus, and finally, ascending almost perpendicularly to the tongue, turns forward on its lower surface as far as the tip, under the name of the **profunda linguæ**.

Relations.—Its first, or oblique, portion is superficial, and is contained within the carotid triangle; it rests upon the Constrictor pharyngis medius, and is covered by the Platysma and the fascia of the neck. Its second, or curved, portion also lies upon the Constrictor pharyngis medius, being covered at first by the tendon of the Digastricus and by the Stylohyoideus, and afterward by the Hyoglossus. Its third, or horizontal, portion lies between the Hyoglossus and Genioglossus. The fourth, or terminal part, under the name of the **profunda linguæ** (*ranine artery*) runs along the under surface of the tongue to its tip; here it is superficial, being covered only by the mucous membrane; above it is the Longitudinalis inferior, and on the medial side the Genioglossus. The hypoglossal nerve crosses the first part of the lingual artery, but is separated from the second part by the Hyoglossus.

Branches.—The branches of the lingual artery are:

Hyoid.	Sublingual.
Dorsales linguæ.	Profunda linguæ.

The **Hyoid Branch** (*ramus hyoideus; suprahyoid branch*) runs along the upper border of the hyoid bone, supplying the muscles attached to it and anastomosing with its fellow of the opposite side.

The **Arteriæ Dorsales Linguæ** (*rami dorsales linguæ*) consist usually of two or three small branches which *arise* beneath the Hyoglossus; they ascend to the back part of the dorsum of the tongue, and supply the mucous membrane in this situation, the glossopalatine arch, the tonsil, soft palate, and epiglottis; anastomosing with the vessels of the opposite side.

The **Sublingual Artery** (*a. sublingualis*) *arises* at the anterior margin of the Hyoglossus, and runs forward between the Genioglossus and Mylohyoideus to the sublingual gland. It supplies the gland and gives branches to the Mylohyoideus and neighboring muscles, and to the mucous membrane of the mouth and gums. One branch runs behind the alveolar process of the mandible in the substance of the gum to anastomose with a similar artery from the other side; another pierces the Mylohyoideus and anastomoses with the submental branch of the external maxillary artery.

The **Arteria Profunda Linguæ** (*ranine artery; deep lingual artery*) is the terminal portion of the lingual artery; it pursues a tortuous course and runs along the under surface of the tongue, below the Longitudinalis inferior, and above the mucous membrane; it lies on the lateral side of the Genioglossus, accompanied by the lingual nerve. At the tip of the tongue, it is said to anastomose with the artery of the opposite side, but this is denied by Hyrtl. In the mouth, these vessels are placed one on either side of the frenulum linguæ.

3. The **external maxillary artery** (*a. maxillaris externa; facial artery*) (Fig. 508), *arises* in the carotid triangle a little above the lingual artery and, sheltered by the ramus of the mandible, passes obliquely up beneath the Digastricus and Stylohyoideus, over which it arches to enter a groove on the posterior surface of the submaxillary gland. It then curves upward over the body of the mandible at the antero-inferior angle of the Masseter; passes forward and upward across the cheek to the angle of the mouth, then ascends along the side of the nose, and ends at the medial commissure of the eye, under the name of the **angular artery**. This vessel, both in the neck and on the face, is remarkably tortuous: in the former

situation, to accommodate itself to the movements of the pharynx in deglutition; and in the latter, to the movements of the mandible, lips, and cheeks.

Relations.—*In the neck*, its origin is superficial, being covered by the integument, Platysma, and fascia; it then passes beneath the Digastricus and Stylohyoideus muscles and part of the submaxillary gland, and frequently beneath the hypoglossal nerve. It lies upon the Constrictores pharyngis medius and superior, the latter of which separates it, at the summit of its arch, from the lower and back part of the tonsil. *On the face*, where it passes over the body of the mandible, it is comparatively superficial, lying immediately beneath the Platysma. In its course over the face, it is covered by the integument, the fat of the cheek, and, near the angle of the mouth, by the Platysma, Risorius, and Zygomaticus. It rests on the Buccinator and Caninus, and passes either over or under the infraorbital head of the Quadratus labii superioris. The anterior facial vein lies lateral to the artery, and takes a more direct course across the face, where it is separated from the artery by a considerable interval. In the neck it lies superficial to the artery. The branches of the facial nerve cross the artery from behind forward.

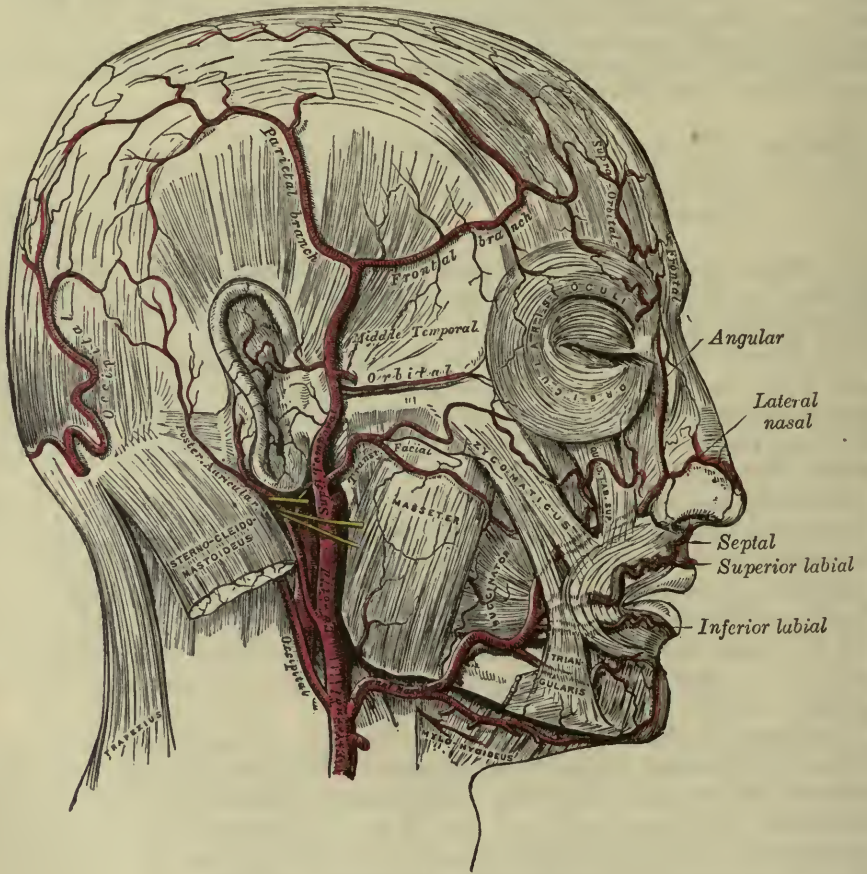


FIG. 508.—The arteries of the face and scalp.¹

Branches.—The branches of the artery may be divided into two sets: those given off in the neck (*cervical*), and those on the face (*facial*).

- Cervical Branches.*
 Ascending Palatine.
 Tonsillar.
 Glandular.
 Submental.
 Muscular.

- Facial Branches.*
 Inferior Labial.
 Superior Labial.
 Lateral Nasal.
 Angular.
 Muscular.

¹ The muscular tissue of the lips must be supposed to have been cut away, in order to show the course of the labial arteries.

The **Ascending Palatine Artery** (*a. palatina ascendens*) (Fig. 513) arises close to the origin of the external maxillary artery and passes up between the Styloglossus and Stylopharyngeus to the side of the pharynx, along which it is continued between the Constrictor pharyngis superior and the Pterygoideus internus to near the base of the skull. It divides near the Levator veli palatini into two branches: one follows the course of this muscle, and, winding over the upper border of the Constrictor pharyngis superior, supplies the soft palate and the palatine glands, anastomosing with its fellow of the opposite side and with the descending palatine branch of the internal maxillary artery; the other pierces the Constrictor pharyngis superior and supplies the palatine tonsil and auditory tube, anastomosing with the tonsillar and ascending pharyngeal arteries.

The **Tonsillar Branch** (*ramus tonsillaris*) (Fig. 513) ascends between the Pterygoideus internus and Styloglossus, and then along the side of the pharynx, perforating the Constrictor pharyngis superior, to ramify in the substance of the palatine tonsil and root of the tongue.

The **Glandular Branches** (*rami glandulares; submaxillary branches*) consist of three or four large vessels, which supply the submaxillary gland, some being prolonged to the neighboring muscles, lymph glands, and integument.

The **Submental Artery** (*a. submentalis*) the largest of the cervical branches, is given off from the facial artery just as that vessel quits the submaxillary gland: it runs forward upon the Mylohyoideus, just below the body of the mandible, and beneath the Digastricus. It supplies the surrounding muscles, and anastomoses with the sublingual artery and with the mylohyoid branch of the inferior alveolar; at the symphysis menti it turns upward over the border of the mandible and divides into a superficial and a deep branch. The superficial branch passes between the integument and Quadratus labii inferioris, and anastomoses with the inferior labial artery; the deep branch runs between the muscle and the bone, supplies the lip, and anastomoses with the inferior labial and mental arteries.

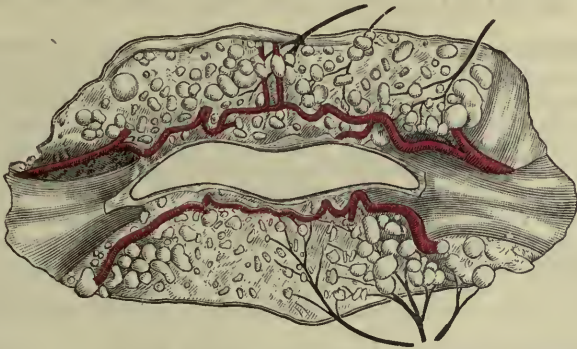

FIG. 509.—The labial coronary arteries, the glands of the lips, and the nerves of the right side seen from the posterior surface after removal of the mucous membrane. (Poirier and Charpy.)

The **Inferior Labial Artery** (*a. labialis inferior; inferior coronary artery*) arises near the angle of the mouth; it passes upward and forward beneath the Triangularis and, penetrating the Orbicularis oris, runs in a tortuous course along the edge of the lower lip between this muscle and the mucous membrane. It supplies the labial glands, the mucous membrane, and the muscles of the lower lip; and anastomoses with the artery of the opposite side, and with the mental branch of the inferior alveolar artery.

The **Superior Labial Artery** (*a. labialis superior; superior coronary artery*) is larger and more tortuous than the inferior. It follows a similar course along the edge of the upper lip, lying between the mucous membrane and the Orbicularis oris, and anastomoses with the artery of the opposite side. It supplies the upper lip,

and gives off in its course two or three vessels which ascend to the nose; a **septal branch** ramifies on the nasal septum as far as the point of the nose, and an **alar branch** supplies the ala of the nose.

The **Lateral Nasal branch** is derived from the external maxillary as that vessel ascends along the side of the nose. It supplies the ala and dorsum of the nose, anastomosing with its fellow, with the septal and alar branches, with the dorsal nasal branch of the ophthalmic, and with the infraorbital branch of the internal maxillary.

The **Angular Artery** (*a. angularis*) is the terminal part of the external maxillary; it ascends to the medial angle of the orbit, imbedded in the fibers of the angular head of the *Quadratus labii superioris*, and accompanied by the angular vein. On the cheek it distributes branches which anastomose with the infraorbital; after supplying the lacrimal sac and *Orbicularis oculi*, it ends by anastomosing with the dorsal nasal branch of the ophthalmic artery.

The **Muscular Branches** in the neck are distributed to the *Pterygoideus internus* and *Stylohyoideus*, and on the face to the *Masseter* and *Buccinator*. The anastomoses of the external maxillary artery are very numerous, not only with the vessel of the opposite side, but, *in the neck*, with the sublingual branch of the lingual, with the ascending pharyngeal, and by its ascending palatine and tonsillar branches with the palatine branch of the internal maxillary; *on the face*, with the mental branch of the inferior alveolar as it emerges from the mental foramen, with the transverse facial branch of the superficial temporal, with the infraorbital branch of the internal maxillary, and with the dorsal nasal branch of the ophthalmic.

Peculiarities.—The external maxillary artery not infrequently arises in common with the lingual. It varies in its size and in the extent to which it supplies the face; it occasionally ends as the submental, and not infrequently extends only as high as the angle of the mouth or nose. The deficiency is then compensated for by enlargement of one of the neighboring arteries.

4. The **occipital artery** (*a. occipitalis*) (Fig. 508) *arises* from the posterior part of the external carotid, opposite the external maxillary, near the lower margin of the posterior belly of the *Digastricus*, and ends in the posterior part of the scalp.

Course and Relations.—At its origin, it is covered by the posterior belly of the *Digastricus* and the *Stylohyoideus*, and the hypoglossal nerve winds around it from behind forward; higher up, it crosses the internal carotid artery, the internal jugular vein, and the vagus and accessory nerves. It next ascends to the interval between the transverse process of the atlas and the mastoid process of the temporal bone, and passes horizontally backward, grooving the surface of the latter bone, being covered by the *Sternocleidomastoideus*, *Splenius capitis*, *Longissimus capitis*, and *Digastricus*, and resting upon the *Rectus capitis lateralis*, the *Obliquus superior*, and *Semispinalis capitis*. It then changes its course and runs vertically upward, pierces the fascia connecting the cranial attachment of the *Trapezius* with the *Sternocleidomastoideus*, and ascends in a tortuous course in the superficial fascia of the scalp, where it divides into numerous branches, which reach as high as the vertex of the skull and anastomose with the posterior auricular and superficial temporal arteries. Its terminal portion is accompanied by the greater occipital nerve.

Branches.—The branches of the occipital artery are:

Muscular.	Sternocleidomastoid.	Auricular.
	Meningeal.	Descending.

The **Muscular Branches** (*rami musculares*) supply the *Digastricus*, *Stylohyoideus*, *Splenius*, and *Longissimus capitis*.

The **Sternocleidomastoid Artery** (*a. sternocleidomastoidea; sternomastoid artery*) generally *arises* from the occipital close to its commencement, but sometimes springs directly from the external carotid. It passes downward and backward over the hypoglossal nerve, and enters the substance of the muscle, in company with the accessory nerve.

The **Auricular Branch** (*ramus auricularis*) supplies the back of the concha and frequently gives off a branch, which enters the skull through the mastoid foramen

and supplies the dura mater, the diploë, and the mastoid cells; this latter branch sometimes arises from the occipital artery, and is then known as the **mastoid branch**.

The **Meningeal Branch** (*ramus meningeus; dural branch*) ascends with the internal jugular vein, and enters the skull through the jugular foramen and condyloid canal, to supply the dura mater in the posterior fossa.

The **Descending Branch** (*ramus descendens; arteria princeps cervicis*) (Fig. 513), the largest branch of the occipital, descends on the back of the neck, and divides into a superficial and deep portion. The superficial portion runs beneath the Splenius, giving off branches which pierce that muscle to supply the Trapezius and anastomose with the ascending branch of the transverse cervical: the deep portion runs down between the Semispinales capitis and colli, and anastomoses with the vertebral and with the *a. profunda cervicalis*, a branch of the costocervical trunk. The anastomosis between these vessels assists in establishing the collateral circulation after ligation of the common carotid or subclavian artery.

The terminal branches of the occipital artery are distributed to the back of the head: they are very tortuous, and lie between the integument and Occipitalis, anastomosing with the artery of the opposite side and with the posterior auricular and temporal arteries, and supplying the Occipitalis, the integument, and pericranium. One of the terminal branches may give off a meningeal twig which passes through the parietal foramen.

5. The **posterior auricular artery** (*a. auricularis posterior*) (Fig. 508) is small and *arises* from the external carotid, above the Digastricus and Stylohyoideus, opposite the apex of the styloid process. It ascends, under cover of the parotid gland, on the styloid process of the temporal bone, to the groove between the cartilage of the ear and the mastoid process, immediately above which it divides into its auricular and occipital branches.

Branches.—Besides several small branches to the Digastricus, Stylohyoideus, and Sternocleidomastoideus, and to the parotid gland, this vessel gives off three branches:

Stylomastoid.

Auricular.

Occipital.

The **Stylomastoid Artery** (*a. stylomastoidea*) enters the stylomastoid foramen and supplies the tympanic cavity, the tympanic antrum and mastoid cells, and the semicircular canals. In the young subject a branch from this vessel forms, with the anterior tympanic artery from the internal maxillary, a vascular circle, which surrounds the tympanic membrane, and from which delicate vessels ramify on that membrane. It anastomoses with the superficial petrosal branch of the middle meningeal artery by a twig which enters the hiatus canalis facialis.

The **Auricular Branch** (*ramus auricularis*) ascends behind the ear, beneath the Auricularis posterior, and is distributed to the back of the auricula, upon which it ramifies minutely, some branches curving around the margin of the cartilage, others perforating it, to supply the anterior surface. It anastomoses with the parietal and anterior auricular branches of the superficial temporal.

The **Occipital Branch** (*ramus occipitalis*) passes backward, over the Sternocleidomastoideus, to the scalp above and behind the ear. It supplies the Occipitalis and the scalp in this situation and anastomoses with the occipital artery.

6. The **ascending pharyngeal artery** (*a. pharyngea ascendens*) (Fig. 513), the smallest branch of the external carotid, is a long, slender vessel, deeply seated in the neck, beneath the other branches of the external carotid and under the Stylopharyngeus. It *arises* from the back part of the external carotid, near the commencement of that vessel, and ascends vertically between the internal carotid and the side of the pharynx, to the under surface of the base of the skull, lying on the Longus capitis.

Branches.—Its branches are:

Pharyngeal.	Prevertebral.
Palatine.	Inferior Tympanic.
Posterior Meningeal.	

The **Pharyngeal Branches** (*rami pharyngei*) are three or four in number. Two of these descend to supply the *Constrictores pharyngis medius* and *inferior* and the *Stylopharyngeus*, ramifying in their substance and in the mucous membrane lining them.

The **Palatine Branch** varies in size, and may take the place of the ascending palatine branch of the facial artery, when that vessel is small. It passes inward upon the *Constrictor pharyngis superior*, sends ramifications to the soft palate and tonsil, and supplies a branch to the auditory tube.

The **Prevertebral Branches** are numerous small vessels, which supply the *Longi capitis* and *colli*, the sympathetic trunk, the hypoglossal and vagus nerves, and the lymph glands; they anastomose with the ascending cervical artery.

The **Inferior Tympanic Artery** (*a. tympanica inferior*) is a small branch which passes through a minute foramen in the petrous portion of the temporal bone, in company with the tympanic branch of the glossopharyngeal nerve, to supply the medial wall of the tympanic cavity and anastomose with the other tympanic arteries.

The **Meningeal Branches** are several small vessels, which supply the dura mater. One, the **posterior meningeal**, enters the cranium through the jugular foramen; a second passes through the foramen lacerum; and occasionally a third through the canal for the hypoglossal nerve.

7. The **superficial temporal artery** (*a. temporalis superficialis*) (Fig. 508), the smaller of the two terminal branches of the external carotid, appears, from its direction, to be the continuation of that vessel. It begins in the substance of the parotid gland, behind the neck of the mandible, and crosses over the posterior root of the zygomatic process of the temporal bone; about 5 cm. above this process it divides into two branches, a frontal and a parietal.

Relations.—As it crosses the zygomatic process, it is covered by the *Auricularis anterior* muscle, and by a dense fascia; it is crossed by the temporal and zygomatic branches of the facial nerve and one or two veins, and is accompanied by the auriculotemporal nerve, which lies immediately behind it.

Branches.—Besides some twigs to the parotid gland, to the temporomandibular joint, and to the *Masseter* muscle, its branches are:

Transverse Facial.	Anterior Auricular.
Middle Temporal.	Frontal.
Parietal.	

The **Transverse Facial Artery** (*a. transversa faciei*) is given off from the superficial temporal before that vessel quits the parotid gland; running forward through the substance of the gland, it passes transversely across the side of the face, between the parotid duct and the lower border of the zygomatic arch, and divides into numerous branches, which supply the parotid gland and duct, the *Masseter*, and the integument, and anastomose with the external maxillary, masseteric, buccinator, and infraorbital arteries. This vessel rests on the *Masseter*, and is accompanied by one or two branches of the facial nerve.

The **Middle Temporal Artery** (*a. temporalis media*) arises immediately above the zygomatic arch, and, perforating the temporal fascia, gives branches to the *Temporalis*, anastomosing with the deep temporal branches of the internal maxillary. It occasionally gives off a **zygomatooörbital branch**, which runs along the upper border of the zygomatic arch, between the two layers of the temporal fascia, to the lateral angle of the orbit. This branch, which may arise directly from the

superficial temporal artery, supplies the Orbicularis oculi, and anastomoses with the lacrimal and palpebral branches of the ophthalmic artery.

The **Anterior Auricular Branches** (*rami auriculares anteriores*) are distributed to the anterior portion of the auricula, the lobule, and part of the external meatus, anastomosing with the posterior auricular.

The **Frontal Branch** (*ramus frontalis; anterior temporal*) runs tortuously upward and forward to the forehead, supplying the muscles, integument, and pericranium in this region, and anastomosing with the supraorbital and frontal arteries.

The **Parietal Branch** (*ramus parietalis; posterior temporal*) larger than the frontal, curves upward and backward on the side of the head, lying superficial to the temporal fascia, and anastomosing with its fellow of the opposite side, and with the posterior auricular and occipital arteries.

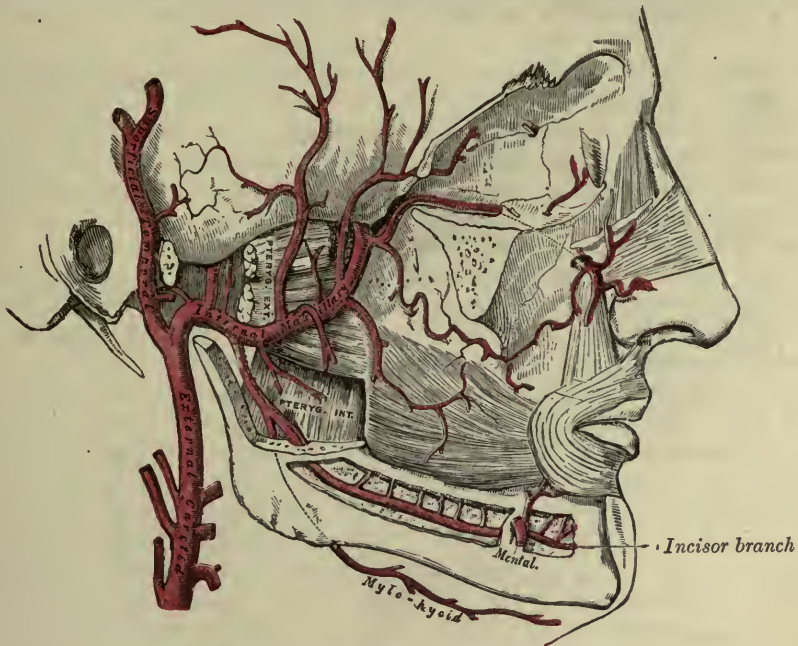


FIG. 510.—Plan of branches of internal maxillary artery.

8. The **internal maxillary artery** (*a. maxillaris interna*) (Fig. 510), the larger of the two terminal branches of the external carotid, *arises* behind the neck of the mandible, and is at first imbedded in the substance of the parotid gland; it passes forward between the ramus of the mandible and the sphenomandibular ligament, and then runs, either superficial or deep to the Pterygoideus externus, to the pterygopalatine fossa. It supplies the deep structures of the face, and may be divided into **mandibular**, **pterygoid**, and **pterygopalatine portions**.

The **first or mandibular portion** passes horizontally forward, between the ramus of the mandible and the sphenomandibular ligament, where it lies parallel to and a little below the auriculotemporal nerve; it crosses the inferior alveolar nerve, and runs along the lower border of the Pterygoideus externus.

The **second or pterygoid portion** runs obliquely forward and upward under cover of the ramus of the mandible and insertion of the Temporalis, on the superficial (very frequently on the deep) surface of the Pterygoideus externus; it then passes between the two heads of origin of this muscle and enters the fossa.

The **third or pterygopalatine portion** lies in the pterygopalatine fossa in relation with the sphenopalatine ganglion.

The branches of this vessel may be divided into three groups (Fig. 511), corresponding with its three divisions.

Branches of the First or Mandibular Portions.—

Anterior Tympanic.
Deep Auricular.

Middle Meningeal.
Accessory Meningeal

Inferior Alveolar.

The **Anterior Tympanic Artery** (*a. tympanica anterior*; *tympanic artery*) passes upward behind the temporomandibular articulation, enters the tympanic cavity through the petrotympanic fissure, and ramifies upon the tympanic membrane, forming a vascular circle around the membrane with the stylomastoid branch of the posterior auricular, and anastomosing with the artery of the pterygoid canal and with the caroticotympanic branch from the internal carotid.

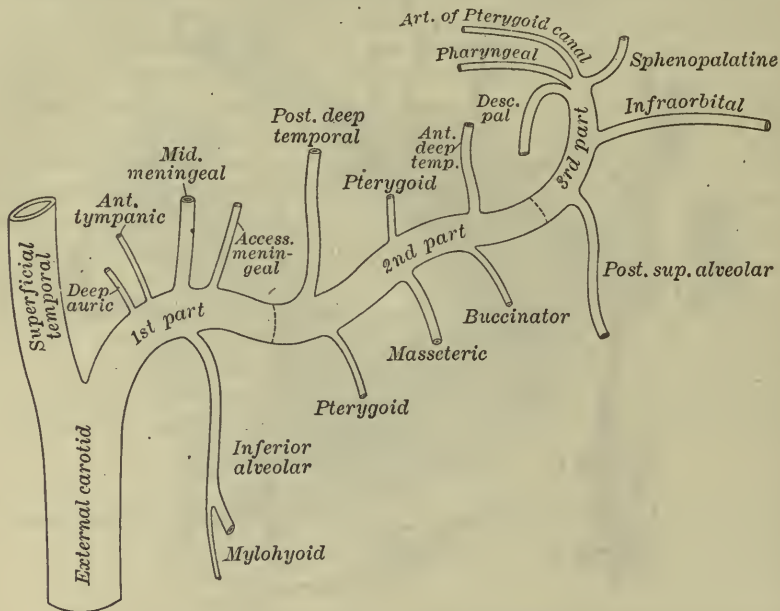


Fig. 511.—Plan of branches of internal maxillary artery.

The **Deep Auricular Artery** (*a. auricularis profunda*) often arises in common with the preceding. It ascends in the substance of the parotid gland, behind the temporomandibular articulation, pierces the cartilaginous or bony wall of the external acoustic meatus, and supplies its cuticular lining and the outer surface of the tympanic membrane. It gives a branch to the temporomandibular joint.

The **Middle Meningeal Artery** (*a. meningea media*; *medidural artery*) is the largest of the arteries which supply the dura mater. It ascends between the sphenomandibular ligament and the Pterygoideus externus, and between the two roots of the auriculotemporal nerve to the foramen spinosum of the sphenoid bone, through which it enters the cranium; it then runs forward in a groove on the great wing of the sphenoid bone, and divides into two branches, anterior and posterior. The **anterior branch**, the larger, crosses the great wing of the sphenoid, reaches the groove, or canal, in the sphenoidal angle of the parietal bone, and then divides into branches which spread out between the dura mater and internal surface of the cranium, some passing upward as far as the vertex, and others backward to the occipital region. The **posterior branch** curves backward on the squama of the temporal bone, and, reaching the parietal some distance in front of its mastoid angle, divides into branches which supply the posterior part of the dura mater and

cranium. The branches of the middle meningeal artery are distributed partly to the dura mater, but chiefly to the bones; they anastomose with the arteries of the opposite side, and with the anterior and posterior meningeal.

The middle meningeal on entering the cranium gives off the following branches: (1) Numerous small vessels supply the semilunar ganglion and the dura mater in this situation. (2) A **superficial petrosal** branch enters the hiatus of the facial canal, supplies the facial nerve, and anastomoses with the stylomastoid branch of the posterior auricular artery. (3) A **superior tympanic artery** runs in the canal for the Tensor tympani, and supplies this muscle and the lining membrane of the canal. (4) **Orbital branches** pass through the superior orbital fissure or through separate canals in the great wing of the sphenoid, to anastomose with the lacrimal or other branches of the ophthalmic artery. (5) **Temporal branches** pass through foramina in the great wing of the sphenoid, and anastomose in the temporal fossa with the deep temporal arteries.

The **Accessory Meningeal Branch** (*ramus meningeus accessorius; small meningeal or parvidural branch*) is sometimes derived from the preceding. It enters the skull through the foramen ovale, and supplies the semilunar ganglion and dura mater.

The **Inferior Alveolar Artery** (*a. alveolaris inferior; inferior dental artery*) descends with the inferior alveolar nerve to the mandibular foramen on the medial surface of the ramus of the mandible. It runs along the mandibular canal in the substance of the bone, accompanied by the nerve, and opposite the first premolar tooth divides into two branches, incisor and mental. The **incisor branch** is continued forward beneath the incisor teeth as far as the middle line, where it anastomoses with the artery of the opposite side; the **mental branch** escapes with the nerve at the mental foramen, supplies the chin, and anastomoses with the submental and inferior labial arteries. Near its origin the inferior alveolar artery gives off a **lingual branch** which descends with the lingual nerve and supplies the mucous membrane of the mouth. As the inferior alveolar artery enters the foramen, it gives off a **mylohyoid branch** which runs in the mylohyoid groove, and ramifies on the under surface of the Mylohyoideus. The inferior alveolar artery and its incisor branch during their course through the substance of the bone give off a few twigs which are lost in the cancellous tissue, and a series of branches which correspond in number to the roots of the teeth: these enter the minute apertures at the extremities of the roots, and supply the pulp of the teeth.

Branches of the Second or Pterygoid Portion.—

Deep Temporal.
Pterygoid.

Masseteric.
Buccinator.

The **Deep Temporal Branches**, two in number, **anterior** and **posterior**, ascend between the Temporalis and the pericranium; they supply the muscle, and anastomose with the middle temporal artery; the anterior communicates with the lacrimal artery by means of small branches which perforate the zygomatic bone and great wing of the sphenoid.

The **Pterygoid Branches** (*rami pterygoidei*), irregular in their number and origin, supply the Pterygoidei.

The **Masseteric Artery** (*a. masseterica*) is small and passes lateralward through the mandibular notch to the deep surface of the Masseter. It supplies the muscle, and anastomoses with the masseteric branches of the external maxillary and with the transverse facial artery.

The **Buccinator Artery** (*a. buccinatoria; buccal artery*) is small and runs obliquely forward, between the Pterygoideus internus and the insertion of the Temporalis, to the outer surface of the Buccinator, to which it is distributed, anastomosing with branches of the external maxillary and with the infraorbital.

Branches of the Third or Pterygopalatine Portion.—

Posterior Superior Alveolar.
Infraorbital.
Descending Palatine.

Artery of the Pterygoid Canal.
Pharyngeal.
Sphenopalatine.

The **Posterior Superior Alveolar Artery** (*a. alveolaris superior posterior; alveolar or posterior dental artery*) is given off from the internal maxillary, frequently in conjunction with the infraorbital just as the trunk of the vessel is passing into the pterygopalatine fossa. Descending upon the tuberosity of the maxilla, it divides into numerous branches, some of which enter the alveolar canals, to supply the molar and premolar teeth and the lining of the maxillary sinus, while others are continued forward on the alveolar process to supply the gums.

The **Infraorbital Artery** (*a. infraorbitalis*) appears, from its direction, to be the continuation of the trunk of the internal maxillary, but often *arises* in conjunction with the posterior superior alveolar. It runs along the infraorbital groove and canal with the infraorbital nerve, and emerges on the face through the infraorbital foramen, beneath the infraorbital head of the *Quadratus labii superioris*. While in the canal, it gives off (*a*) **orbital branches** which assist in supplying the *Rectus inferior* and *Obliquus inferior* and the lacrimal sac, and (*b*) **anterior superior alveolar branches** which descend through the anterior alveolar canals to supply the upper incisor and canine teeth and the mucous membrane of the maxillary sinus. On the face, some branches pass upward to the medial angle of the orbit and the lacrimal sac, anastomosing with the angular branch of the external maxillary artery; others run toward the nose, anastomosing with the dorsal nasal branch of the ophthalmic; and others descend between the *Quadratus labii superioris* and the *Caninus*, and anastomose with the external maxillary, transverse facial, and buccinator arteries. The four remaining branches *arise* from that portion of the internal maxillary which is contained in the pterygopalatine fossa.

The **Descending Palatine Artery** (*a. palatina descendens*) descends through the pterygopalatine canal with the anterior palatine branch of the sphenopalatine ganglion, and, emerging from the greater palatine foramen, runs forward in a groove on the medial side of the alveolar border of the hard palate to the incisive canal; the terminal branch of the artery passes upward through this canal to anastomose with the sphenopalatine artery. Branches are distributed to the gums, the palatine glands, and the mucous membrane of the roof of the mouth; while in the pterygopalatine canal it gives off twigs which descend in the lesser palatine canals to supply the soft palate and palatine tonsil, anastomosing with the ascending palatine artery.

The **Artery of the Pterygoid Canal** (*a. canalis pterygoidei; Vidian artery*) passes backward along the pterygoid canal with the corresponding nerve. It is distributed to the upper part of the pharynx and to the auditory tube, sending into the tympanic cavity a small branch which anastomoses with the other tympanic arteries.

The **Pharyngeal Branch** is very small; it runs backward through the pharyngeal canal with the pharyngeal nerve, and is distributed to the upper part of the pharynx and to the auditory tube.

The **Sphenopalatine Artery** (*a. sphenopalatina; nasopalatine artery*) passes through the sphenopalatine foramen into the cavity of the nose, at the back part of the superior meatus. Here it gives off its **posterior lateral nasal branches** which spread forward over the conchæ and meatuses, anastomose with the ethmoidal arteries and the nasal branches of the descending palatine, and assist in supplying the frontal, maxillary, ethmoidal, and sphenoidal sinuses. Crossing the under surface of the sphenoid the sphenopalatine artery ends on the nasal septum as the **posterior septal branches**; these anastomose with the ethmoidal arteries and the septal branch of the superior labial; one branch descends in a groove on the vomer to the incisive canal and anastomoses with the descending palatine artery.

THE TRIANGLES OF THE NECK (Fig. 512).

The side of the neck presents a somewhat quadrilateral outline, limited, *above*, by the lower border of the body of the mandible, and an imaginary line extending

from the angle of the mandible to the mastoid process; *below*, by the upper border of the clavicle; in *front*, by the middle line of the neck; *behind*, by the anterior margin of the Trapezius. This space is subdivided into two large triangles by the Sternocleidomastoideus, which passes obliquely across the neck, from the sternum and clavicle below, to the mastoid process and occipital bone above. The triangular space in front of this muscle is called the **anterior triangle**; and that behind it, the **posterior triangle**.

Anterior Triangle.—The anterior triangle is bounded, in *front*, by the middle line of the neck; *behind*, by the anterior margin of the Sternocleidomastoideus; its *base*, directed upward, is formed by the lower border of the body of the mandible, and a line extending from the angle of the mandible to the mastoid process; its apex is below, at the sternum. This space is subdivided into four smaller triangles by the Digastricus above, and the superior belly of the Omohyoideus below. These smaller triangles are named the **inferior carotid**, the **superior carotid**, the **submaxillary**, and the **suprahyoid**.

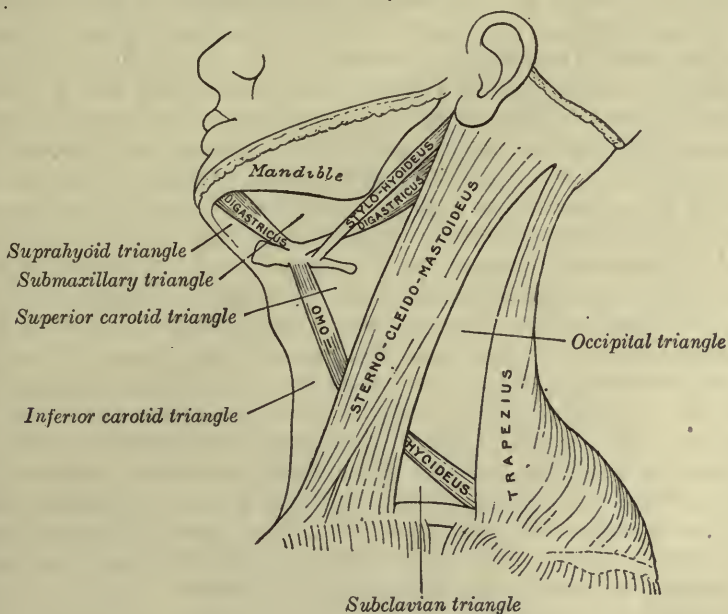


FIG. 512.—The triangles of the neck.

The **Inferior Carotid**, or **Muscular Triangle**, is bounded, in *front*, by the median line of the neck from the hyoid bone to the sternum; *behind*, by the anterior margin of the Sternocleidomastoideus; above, by the superior belly of the Omohyoideus. It is covered by the integument, superficial fascia, Platysma, and deep fascia, ramifying in which are some of the branches of the supraclavicular nerves. Beneath these superficial structures are the Sternohyoideus and Sternothyroideus, which, together with the anterior margin of the Sternocleidomastoideus, conceal the lower part of the common carotid artery.¹ This vessel is enclosed within its sheath, together with the internal jugular vein and vagus nerve; the vein lies lateral to the artery on the right side of the neck, but overlaps it below on the left side; the nerve lies between the artery and vein, on a plane posterior to both.

¹ Therefore the common carotid artery and internal jugular vein are not, strictly speaking, contained in this triangle, since they are covered by the Sternocleidomastoideus; that is to say, they lie under that muscle, which forms the posterior border of the triangle. But as they lie very close to the structures which are really contained in the triangle, and whose position it is essential to remember in operating on this part of the artery, it is expedient to study the relations of all these parts together.

In front of the sheath are a few descending filaments from the ansa hypoglossi; behind the sheath are the inferior thyroid artery, the recurrent nerve, and the sympathetic trunk; and on its medial side, the esophagus, the trachea, the thyroid gland, and the lower part of the larynx. By cutting into the upper part of this space, and slightly displacing the Sternocleidomastoideus, the common carotid artery may be tied below the Omohyoideus.

The **Superior Carotid**, or **Carotid Triangle**, is bounded, *behind* by the Sternocleidomastoideus; *below*, by the superior belly of the Omohyoideus; and *above*, by the Stylohyoideus and the posterior belly of the Digastricus. It is covered by the integument, superficial fascia, Platysma and deep fascia; ramifying in which are branches of the facial and cutaneous cervical nerves. Its floor is formed by parts of the Thyrohyoideus, Hyoglossus, and the Constrictores pharyngis medius and inferior. This space when dissected is seen to contain the upper part of the common carotid artery, which bifurcates opposite the upper border of the thyroid cartilage into the external and internal carotid. These vessels are somewhat concealed from view by the anterior margin of the Sternocleidomastoideus, which overlaps them. The external and internal carotids lie side by side, the external being the more anterior of the two. The following branches of the external carotid are also met with in this space: the superior thyroid, running forward and downward; the lingual, directly forward; the external maxillary, forward and upward; the occipital, backward; and the ascending pharyngeal, directly upward on the medial side of the internal carotid. The veins met with are: the internal jugular, which lies on the lateral side of the common and internal carotid arteries; and veins corresponding to the above-mentioned branches of the external carotid—viz., the superior thyroid, the lingual, common facial, ascending pharyngeal, and sometimes the occipital—all of which end in the internal jugular. The nerves in this space are the following. In front of the sheath of the common carotid is the ramus descendens hypoglossi. The hypoglossal nerve crosses both the internal and external carotids above, curving around the origin of the occipital artery. Within the sheath, between the artery and vein, and behind both, is the vagus nerve; behind the sheath, the sympathetic trunk. On the lateral side of the vessels, the accessory nerve runs for a short distance before it pierces the Sternocleidomastoideus; and on the medial side of the external carotid, just below the hyoid bone, may be seen the internal branch of the superior laryngeal nerve; and, still more inferiorly, the external branch of the same nerve. The upper portion of the larynx and lower portion of the pharynx are also found in the front part of this space.

The **Submaxillary** or **Digastric Triangle** corresponds to the region of the neck immediately beneath the body of the mandible. It is bounded, *above*, by the lower border of the body of the mandible, and a line drawn from its angle to the mastoid process; *below*, by the posterior belly of the Digastricus and the Stylohyoideus; *in front*, by the anterior belly of the Digastricus. It is covered by the integument, superficial fascia, Platysma, and deep fascia, ramifying in which are branches of the facial nerve and ascending filaments of the cutaneous cervical nerve. Its *floor* is formed by the Mylohyoideus, Hyoglossus, and Constrictor pharyngis superior. It is divided into an anterior and a posterior part by the stylomandibular ligament. The anterior part contains the submaxillary gland, superficial to which is the anterior facial vein, while imbedded in the gland is the external maxillary artery and its glandular branches; beneath the gland, on the surface of the Mylohyoideus, are the submental artery and the mylohyoid artery and nerve. The posterior part of this triangle contains the external carotid artery, ascending deeply in the substance of the parotid gland; this vessel lies here in front of, and superficial to, the internal carotid, being crossed by the facial nerve, and gives off in its course the posterior auricular, superficial temporal, and internal maxillary branches: more deeply are the internal carotid, the internal jugular vein, and the

vagus nerve, separated from the external carotid by the Styloglossus and Stylopharyngeus, and the glossopharyngeal nerve.¹

The **Suprahyoid Triangle** is limited *behind* by the anterior belly of the Digastricus, in *front* by the middle line of the neck between the mandible and the hyoid bone; *below*, by the body of the hyoid bone; its *floor* is formed by the Mylohyoideus. It contains one or two lymph glands and some small veins; the latter unite to form the anterior jugular vein.

Posterior Triangle.—The posterior triangle is bounded, in *front*, by the Sternocleidomastoideus; *behind*, by the anterior margin of the Trapezius; its *base* is formed by the middle third of the clavicle; its *apex*, by the occipital bone. The space is crossed, about 2.5 cm. above the clavicle, by the inferior belly of the Omohyoideus, which divides it into two triangles, an **upper or occipital**, and a **lower or subclavian**.

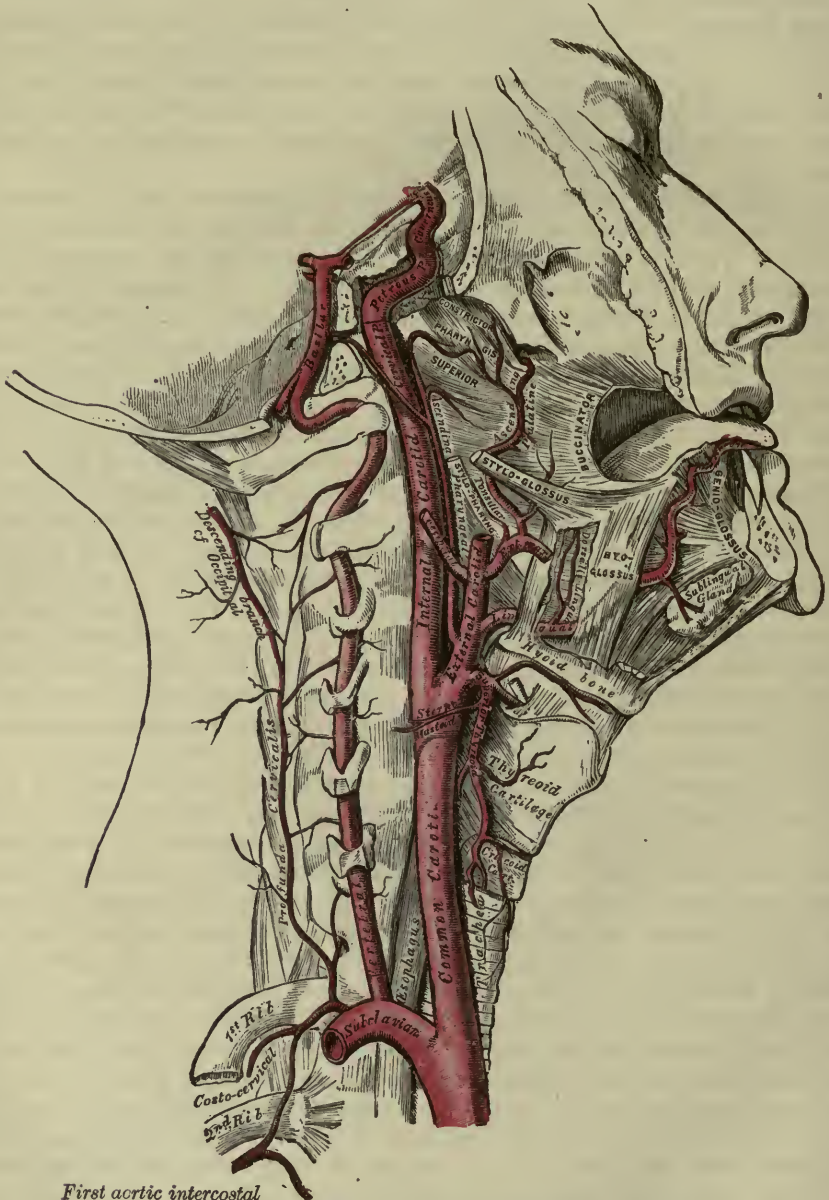
The **Occipital Triangle**, the larger division of the posterior triangle, is bounded, in *front*, by the Sternocleidomastoideus; *behind*, by the Trapezius; *below*, by the Omohyoideus. Its *floor* is formed from above downward by the Splenius capitis, Levator scapulæ, and the Scaleni medius and posterior. It is covered by the skin, the superficial and deep fasciæ, and by the Platysma below. The accessory nerve is directed obliquely across the space from the Sternocleidomastoideus, which it pierces, to the under surface of the Trapezius; below, the supraclavicular nerves and the transverse cervical vessels and the upper part of the brachial plexus cross the space. A chain of lymph glands is also found running along the posterior border of the Sternocleidomastoideus, from the mastoid process to the root of the neck.

The **Subclavian Triangle**, the smaller division of the posterior triangle, is bounded, *above*, by the inferior belly of the Omohyoideus; *below*, by the clavicle; its *base* is formed by the posterior border of the Sternocleidomastoideus. Its *floor* is formed by the first rib with the first digitation of the Serratus anterior. The size of the subclavian triangle varies with the extent of attachment of the clavicular portions of the Sternocleidomastoideus and Trapezius, and also with the height at which the Omohyoideus crosses the neck. Its height also varies according to the position of the arm, being diminished by raising the limb, on account of the ascent of the clavicle, and increased by drawing the arm downward, when that bone is depressed. This space is covered by the integument, the superficial and deep fasciæ and the Platysma, and crossed by the supraclavicular nerves. Just above the level of the clavicle, the third portion of the subclavian artery curves lateralward and downward from the lateral margin of the Scalenus anterior, across the first rib, to the axilla, and this is the situation most commonly chosen for ligaturing the vessel. Sometimes this vessel rises as high as 4 cm. above the clavicle; occasionally, it passes in front of the Scalenus anterior, or pierces the fibers of that muscle. The subclavian vein lies behind the clavicle, and is not usually seen in this space; but in some cases it rises as high as the artery, and has even been seen to pass with that vessel behind the Scalenus anterior. The brachial plexus of nerves lies above the artery, and in close contact with it. Passing transversely behind the clavicle are the transverse scapular vessels; and traversing its upper angle in the same direction, the transverse cervical artery and vein. The external jugular vein runs vertically downward behind the posterior border of the Sternocleidomastoideus, to terminate in the subclavian vein; it receives the transverse cervical and transverse scapular veins, which form a plexus in front of the artery, and occasionally a small vein which crosses the clavicle from the cephalic. The small nerve to the Subclavius also crosses this triangle about its middle, and some lymph glands are usually found in the space.

¹ The remark made about the inferior carotid triangle applies also to this one. The structures enumerated as contained in its posterior part lie, strictly speaking, beneath the muscles which form the posterior boundary of the triangle; but as it is very important to bear in mind their close relation to the parotid gland, all these parts are spoken of together.

The Internal Carotid Artery (A. Carotis Interna) (Fig. 513).

The internal carotid artery supplies the anterior part of the brain, the eye and its appendages, and sends branches to the forehead and nose. Its size, in the adult, is equal to that of the external carotid, though, in the child, it is larger than that



First aortic intercostal

FIG. 513.—The internal carotid and vertebral arteries. Right side.

vessel. It is remarkable for the number of curvatures that it presents in different parts of its course. It occasionally has one or two flexures near the base of the skull, while in its passage through the carotid canal and along the side of the body of the sphenoid bone it describes a double curvature and resembles the italic letter S.

Course and Relations.—In considering the course and relations of this vessel it may be divided into four portions: **cervical**, **petrous**, **cavernous**, and **cerebral**.

Cervical Portion.—This portion of the internal carotid begins at the bifurcation of the common carotid, opposite the upper border of the thyroid cartilage, and runs perpendicularly upward, in front of the transverse processes of the upper three cervical vertebræ, to the carotid canal in the petrous portion of the temporal bone. It is comparatively superficial at its commencement, where it is contained in the carotid triangle, and lies behind and lateral to the external carotid, overlapped by the Sternocleidomastoideus, and covered by the deep fascia, Platysma, and integument: it then passes beneath the parotid gland, being crossed by the hypoglossal nerve, the Digastricus and Stylohyoideus, and the occipital and posterior auricular arteries. Higher up, it is separated from the external carotid by the Styloglossus and Stylopharyngeus, the tip of the styloid process and the stylohyoid ligament, the glossopharyngeal nerve and the pharyngeal branch of the vagus. It is in relation, *behind*, with the Longus capitis, the superior cervical ganglion of the sympathetic trunk, and the superior laryngeal nerve; *laterally*, with the internal jugular vein and vagus nerve, the nerve lying on a plane posterior to the artery; *medially*, with the pharynx, superior laryngeal nerve, and ascending pharyngeal artery. At the base of the skull the glossopharyngeal, vagus, accessory, and hypoglossal nerves lie between the artery and the internal jugular vein.

Petrous Portion.—When the internal carotid artery enters the canal in the petrous portion of the temporal bone, it first ascends a short distance, then curves forward and medialward, and again ascends as it leaves the canal to enter the cavity of the skull between the lingula and petrosal process of the sphenoid. The artery lies at first in front of the cochlea and tympanic cavity; from the latter cavity it is separated by a thin, bony lamella, which is cribriform in the young subject, and often partly absorbed in old age. Farther forward it is separated from the semilunar ganglion by a thin plate of bone, which forms the floor of the fossa for the ganglion and the roof of the horizontal portion of the canal. Frequently this bony plate is more or less deficient, and then the ganglion is separated from the artery by fibrous membrane. The artery is separated from the bony wall of the carotid canal by a prolongation of dura mater, and is surrounded by a number of small veins and by filaments of the carotid plexus, derived from the ascending branch of the superior cervical ganglion of the sympathetic trunk.

Cavernous Portion.—In this part of its course, the artery is situated between the layers of the dura mater forming the cavernous sinus, but covered by the lining membrane of the sinus. It at first ascends toward the posterior clinoid process, then passes forward by the side of the body of the sphenoid bone, and again curves upward on the medial side of the anterior clinoid process, and perforates the dura mater forming the roof of the sinus. This portion of the artery is surrounded by filaments of the sympathetic nerve, and on its lateral side is the abducent nerve.

Cerebral Portion.—Having perforated the dura mater on the medial side of the anterior clinoid process, the internal carotid passes between the optic and oculomotor nerves to the anterior perforated substance at the medial extremity of the lateral cerebral fissure, where it gives off its terminal or cerebral branches.

Peculiarities.—The length of the internal carotid varies according to the length of the neck, and also according to the point of bifurcation of the common carotid. It arises sometimes from the arch of the aorta; in such rare instances, this vessel has been found to be placed nearer the middle line of the neck than the external carotid, as far upward as the larynx, when the latter vessel crossed the internal carotid. The course of the artery, instead of being straight, may be very tortuous. A few instances are recorded in which this vessel was altogether absent; in one of these the common carotid passed up the neck, and gave off the usual branches of the external carotid; the cranial portion of the internal carotid was replaced by two branches of the internal maxillary, which entered the skull through the foramen rotundum and foramen ovale, and joined to form a single vessel.

Branches.—The cervical portion of the internal carotid gives off no branches. Those from the other portions are:

<i>From the Petrous Portion</i>	{ Caroticotympanic. Artery of the Pterygoid Canal.
<i>From the Cavernous Portion</i>	{ Cavernous. Hypophyseal. Semilunar. Anterior Meningeal. Ophthalmic.
<i>From the Cerebral Portion</i>	{ Anterior Cerebral. Middle Cerebral. Posterior Communicating. Choroidal.

1. The **caroticotympanic branch** (*ramus caroticotympanicus; tympanic branch*) is small; it enters the tympanic cavity through a minute foramen in the carotid canal, and anastomoses with the anterior tympanic branch of the internal maxillary, and with the stylomastoid artery.

2. The **artery of the pterygoid canal** (*a. canalis pterygoidei [Vidii]; Vidian artery*) is a small, inconstant branch which passes into the pterygoid canal and anastomoses with a branch of the internal maxillary artery.

3. The **cavernous branches** are numerous small vessels which supply the hypophysis, the semilunar ganglion, and the walls of the cavernous and inferior petrosal sinuses. Some of them anastomose with branches of the middle meningeal.

4. The **hypophyseal branches** are one or two minute vessels supplying the hypophysis.

5. The **semilunar branches** are small vessels to the semilunar ganglion.

6. The **anterior meningeal branch** (*a. meningea anterior*) is a small branch which passes over the small wing of the sphenoid to supply the dura mater of the anterior cranial fossa; it anastomoses with the meningeal branch from the posterior ethmoidal artery.

7. The **ophthalmic artery** (*a. ophthalmica*) (Fig. 514) *arises* from the internal carotid, just as that vessel is emerging from the cavernous sinus, on the medial side of the anterior clinoid process, and enters the orbital cavity through the optic foramen, below and lateral to the optic nerve. It then passes over the nerve to reach the medial wall of the orbit, and thence horizontally forward, beneath the lower border of the Obliquus superior, and divides it into two terminal branches, the **frontal** and **dorsal nasal**. As the artery crosses the optic nerve it is accompanied by the nasociliary nerve, and is separated from the frontal nerve by the Rectus superior and Levator palpebræ superioris.

Branches.—The branches of the ophthalmic artery may be divided into an **orbital group**, distributed to the orbit and surrounding parts; and an **ocular group**, to the muscles and bulb of the eye.

<i>Orbital Group.</i>	<i>Ocular Group.</i>
Lacrimal.	Central Artery of the Retina.
Supraorbital.	Short Posterior Ciliary.
Posterior Ethmoidal.	Long Posterior Ciliary.
Anterior Ethmoidal.	Anterior Ciliary.
Medial Palpebral.	Muscular.
Frontal.	
Dorsal Nasal.	

The **Lacrimal Artery** (*a. lacrimalis*) arises close to the optic foramen, and is one of the largest branches derived from the ophthalmic: not infrequently it is given off before the artery enters the orbit. It accompanies the lacrimal nerve along the upper border of the Rectus lateralis, and supplies the lacrimal gland. Its terminal branches, escaping from the gland, are distributed to the eyelids and conjunctiva: of those supplying the eyelids, two are of considerable size and are named the **lateral palpebral arteries**; they run medialward in the upper and lower lids respectively and anastomose with the medial palpebral arteries, forming an arterial circle in this situation. The lacrimal artery give off one or two **zygomatic branches**, one of which passes through the zygomatico-temporal foramen, to reach the temporal fossa, and anastomoses with the deep temporal arteries; another appears on the cheek through the zygomatico-facial foramen, and anastomoses with the transverse facial. A **recurrent branch** passes backward through the lateral part of the superior orbital fissure to the dura mater, and anastomoses with a branch of the middle meningeal artery. The lacrimal artery is sometimes derived from one of the anterior branches of the middle meningeal artery.

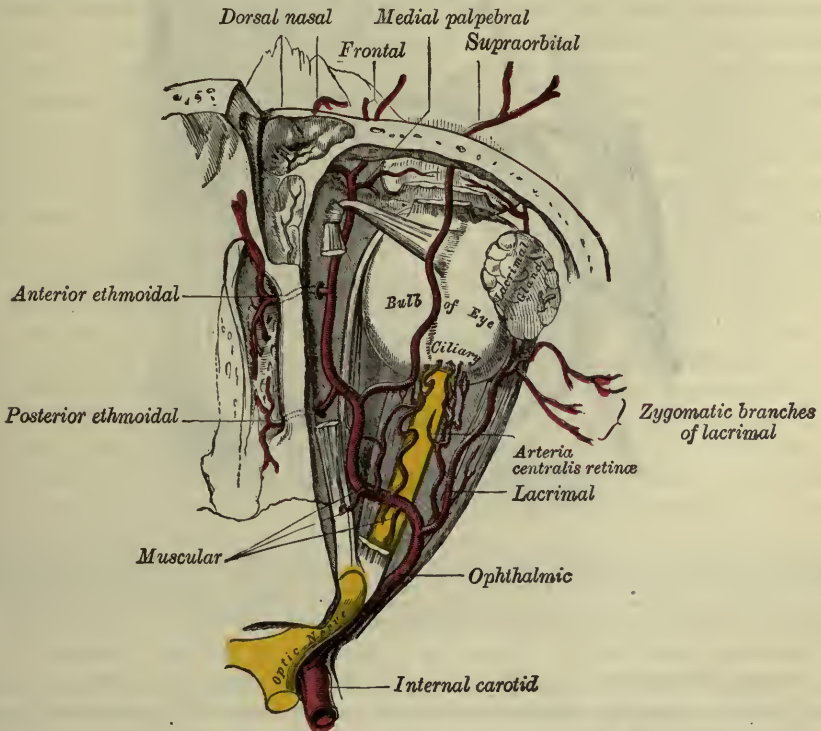


FIG. 514.—The ophthalmic artery and its branches.

The **Supraorbital Artery** (*a. supraorbitalis*) springs from the ophthalmic as that vessel is crossing over the optic nerve. It passes upward on the medial borders of the Rectus superior and Levator palpebræ, and meeting the supraorbital nerve accompanies it between the periosteum and Levator palpebræ to the supraorbital foramen; passing through this it divides into a superficial and a deep branch, which supply the integument, the muscles, and the pericranium of the forehead, anastomosing with the frontal, the frontal branch of the superficial temporal, and the artery of the opposite side. This artery in the orbit supplies the Rectus superior and the Levator palpebræ, and sends a branch across the pulley of the Obliquus superior, to supply the parts at the medial palpebral commissure. At the supra-orbital foramen it frequently transmits a branch to the diploë.

The **Ethmoidal Arteries** are two in number: **posterior** and **anterior**. The **posterior ethmoidal artery**, the smaller, passes through the posterior ethmoidal canal, supplies the posterior ethmoidal cells, and, entering the cranium, gives off a meningeal branch to the dura mater, and nasal branches which descend into the nasal cavity through apertures in the cribriform plate, anastomosing with branches of the sphenopalatine. The **anterior ethmoidal artery** accompanies the nasociliary nerve through the anterior ethmoidal canal, supplies the anterior and middle ethmoidal cells and frontal sinus, and, entering the cranium, gives off a meningeal branch to the dura mater, and nasal branches; these latter descend into the nasal cavity through the slit by the side of the crista galli, and, running along the groove on the inner surface of the nasal bone, supply branches to the lateral wall and septum of the nose, and a terminal branch which appears on the dorsum of the nose between the nasal bone and the lateral cartilage.

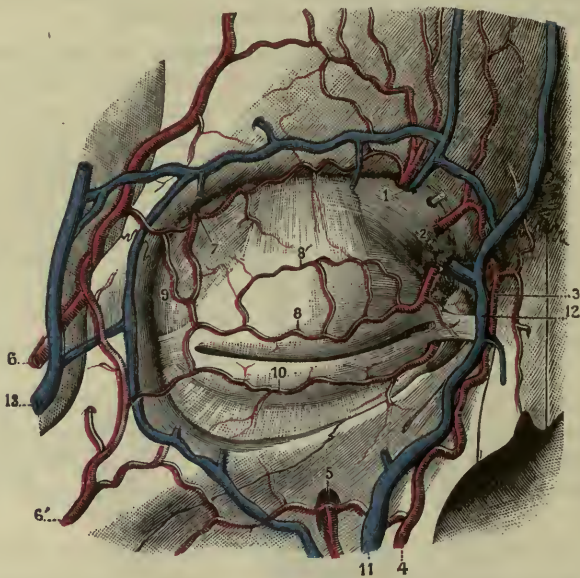


FIG. 515.—Bloodvessels of the eyelids, front view. 1, supraorbital artery and vein; 2, nasal artery; 3, angular artery, the terminal branch of 4, the facial artery; 5, suborbital artery; 6, anterior branch of the superficial temporal artery; 6', malar branch of the transverse artery of the face; 7, lacrimal artery; 8, superior palpebral artery with 8', its external arch; 9, anastomoses of the superior palpebral with the superficial temporal and lacrimal; 10, inferior palpebral artery; 11, facial vein; 12, angular vein; 13, branch of the superficial temporal vein. (Testut.)

The **Medial Palpebral Arteries** (*aa. palpebrales mediales; internal palpebral arteries*), two in number, **superior** and **inferior**, arise from the ophthalmic, opposite the pulley of the *Obliquus superior*; they leave the orbit to encircle the eyelids near their free margins, forming a superior and an inferior arch, which lie between the *Orbicularis oculi* and the tarsi. The **superior palpebral** anastomoses, at the lateral angle of the orbit, with the zygomaticoörbital branch of the temporal artery and with the upper of the two lateral palpebral branches from the lacrimal artery; the **inferior palpebral** anastomoses, at the lateral angle of the orbit, with the lower of the two lateral palpebral branches from the lacrimal and with the transverse facial artery, and, at the medial part of the lid, with a branch from the angular artery. From this last anastomoses a branch passes to the nasolacrimal duct, ramifying in its mucous membrane, as far as the inferior meatus of the nasal cavity.

The **Frontal Artery** (*a. frontalis*), one of the terminal branches of the ophthalmic, leaves the orbit at its medial angle with the supratrochlear nerve, and, ascending

on the forehead, supplies the integument, muscles, and pericranium, anastomosing with the supraorbital artery, and with the artery of the opposite side.

The **Dorsal Nasal Artery** (*a. dorsalis nasi; nasal artery*), the other terminal branch of the ophthalmic, emerges from the orbit above the medial palpebral ligament, and, after giving a twig to the upper part of the lacrimal sac, divides into two branches, one of which crosses the root of the nose, and anastomoses with the angular artery, the other runs along the dorsum of the nose, supplies its outer surface; and anastomoses with the artery of the opposite side, and with the lateral nasal branch of the external maxillary.

The **Central Artery of the Retina** (*a. centralis retinae*) is the first and one of the smallest branches of the ophthalmic artery. It runs for a short distance within the dural sheath of the optic nerve, but about 1.25 cm. behind the eyeball it pierces the nerve obliquely, and runs forward in the center of its substance to the retina. Its mode of distribution will be described with the anatomy of the eye.

The **Ciliary Arteries** (*aa. ciliares*) are divisible into three groups, the long and short, posterior, and the anterior. The **short posterior ciliary arteries** from six to twelve in number, arise from the ophthalmic, or its branches; they pass forward around the optic nerve to the posterior part of the eyeball, pierce the sclera around the entrance of the nerve, and supply the choroid and ciliary processes. The **long posterior ciliary arteries**, two in number, pierce the posterior part of the sclera at some little distance from the optic nerve, and run forward, along either side of the eyeball, between the sclera and choroid, to the ciliary muscle, where they divide into two branches; these form an arterial circle, the **circulus arteriosus major**, around the circumference of the iris, from which numerous converging branches run, in the substance of the iris, to its pupillary margin, where they form a second arterial circle, the **circulus arteriosus minor**. The **anterior ciliary arteries** are derived from the muscular branches; they run to the front of the eyeball in company with the tendons of the Recti, form a vascular zone beneath the conjunctiva, and then pierce the sclera a short distance from the cornea and end in the circulus arteriosus major.

The **Muscular Branches**, (*rami musculares*), two in number, **superior and inferior**, frequently spring from a common trunk. The **superior**, often wanting, supplies the Levator palpebrae superioris, Rectus superior, and Obliquus superior. The **inferior**, more constantly present, passes forward between the optic nerve and Rectus inferior, and is distributed to the Recti lateralis, medialis, and inferior, and the Obliquus inferior. This vessel gives off most of the anterior ciliary arteries. Additional muscular branches are given off from the lacrimal and supraorbital arteries, or from the trunk of the ophthalmic.

8. The **anterior cerebral artery** (*a. cerebri anterior*) (Figs. 516, 517, 518) arises from the internal carotid, at the medial extremity of the lateral cerebral fissure. It passes forward and medialward across the anterior perforated substance, above the optic nerve, to the commencement of the longitudinal fissure. Here it comes into close relationship with the opposite artery, to which it is connected by a short trunk, the **anterior communicating artery**. From this point the two vessels run side by side in the longitudinal fissure, curve around the genu of the corpus callosum, and turning backward continue along the upper surface of the corpus callosum to its posterior part, where they end by anastomosing with the posterior cerebral arteries.

Branches.—In its course the anterior cerebral artery gives off the following branches:

Antero-medial Ganglionic.	Anterior.	Posterior.
Inferior.	Middle.	

The **Antero-medial Ganglionic Branches** are a group of small arteries which arise at the commencement of the anterior cerebral artery; they pierce the anterior

perforated substance and lamina terminalis, and supply the rostrum of the corpus callosum, the septum pellucidum, and the head of the caudate nucleus. The **inferior branches**, two or three in number, are distributed to the orbital surface of the frontal lobe, where they supply the olfactory lobe, gyrus rectus, and internal orbital gyrus. The **anterior branches** supply a part of the superior frontal gyrus, and send twigs over the edge of the hemisphere to the superior and middle frontal gyri and upper part of the anterior central gyrus. The **middle branches** supply the corpus callosum, the cingulate gyrus, the medial surface of the superior frontal gyrus, and the upper part of the anterior central gyrus. The **posterior branches** supply the precuneus and adjacent lateral surface of the hemisphere.

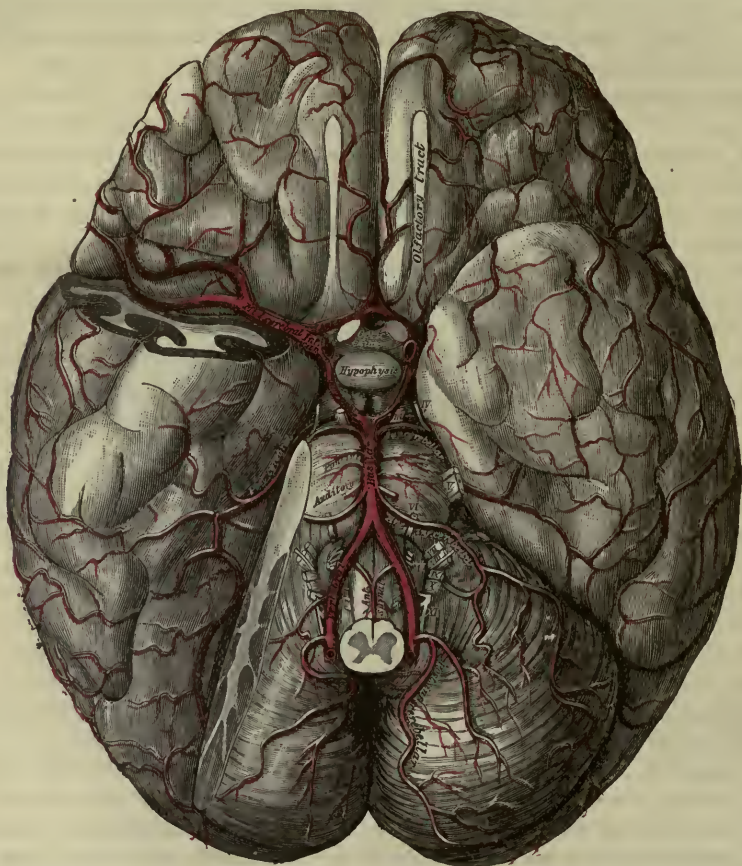


FIG. 516.—The arteries of the base of the brain. The temporal pole of the cerebrum and a portion of the cerebellar hemisphere have been removed on the right side.

The **Anterior Communicating Artery** (*a. communicans anterior*) connects the two anterior cerebral arteries across the commencement of the longitudinal fissure. Sometimes this vessel is wanting, the two arteries joining together to form a single trunk, which afterward divides; or it may be wholly, or partially, divided into two. Its length averages about 4 mm., but varies greatly. It gives off some of the antero-medial ganglionic vessels, but these are principally derived from the anterior cerebral.

9. The **middle cerebral artery** (*a. cerebri media*) (Figs. 516, 517), the largest branch of the internal carotid, runs at first lateralward in the lateral cerebral or Sylvian fissure and then backward and upward on the surface of the insula, where

it divides into a number of branches which are distributed to the lateral surface of the cerebral hemisphere.

Branches.—The branches of this vessel are the:

Antero-lateral Ganglionic.
Inferior Lateral Frontal.
Ascending Frontal.

Ascending Parietal.
Parietotemporal.
Temporal.

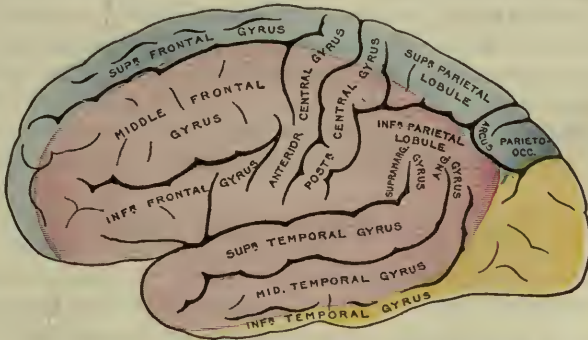


FIG. 517.—Outer surface of cerebral hemisphere, showing areas supplied by cerebral arteries.

The **Antero-lateral Ganglionic Branches**, a group of small arteries which *arise* at the commencement of the middle cerebral artery, are arranged in two sets: one, the **internal striate**, passes upward through the inner segments of the lentiform nucleus, and supplies it, the caudate nucleus, and the internal capsule; the other, the **external striate**, ascends through the outer segment of the lentiform nucleus, and supplies the caudate nucleus and the thalamus. One artery of this group is of larger size than the rest, and is of special importance, as being the artery in the brain most frequently ruptured; it has been termed by Charcot the **artery of cerebral hemorrhage**. It ascends between the lentiform nucleus and the external capsule, and ends in the caudate nucleus. The **inferior lateral frontal** supplies

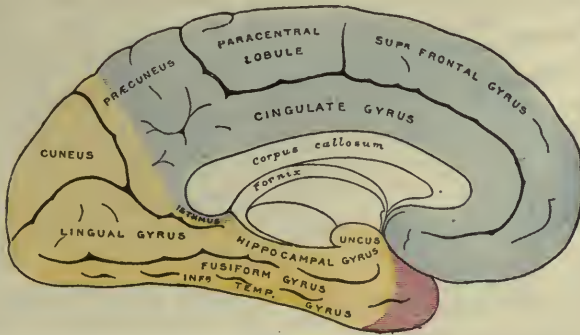


FIG. 518.—Medial surface of cerebral hemisphere, showing areas supplied by cerebral arteries.

the inferior frontal gyrus (*Broca's convolution*) and the lateral part of the orbital surface of the frontal lobe. The **ascending frontal** supplies the anterior central gyrus. The **ascending parietal** is distributed to the posterior central gyrus and the lower part of the superior parietal lobule. The **parietotemporal** supplies the supra-marginal and angular gyri, and the posterior parts of the superior and middle temporal gyri. The **temporal branches**, two or three in number, are distributed to the lateral surface of the temporal lobe.

10. The **posterior communicating artery** (*a. communicans posterior*) (Fig. 516) runs backward from the internal carotid, and anastomoses with the posterior

cerebral, a branch of the basilar. It varies in size, being sometimes small, and occasionally so large that the posterior cerebral may be considered as arising from the internal carotid rather than from the basilar. It is frequently larger on one side than on the other. From its posterior half are given off a number of small branches, the **postero-medial ganglionic branches**, which, with similar vessels from the posterior cerebral, pierce the posterior perforated substance and supply the medial surface of the thalami and the walls of the third ventricle.

11. The **anterior choroidal** (*a. chorioidea; choroid artery*) is a small but constant branch, which *arises* from the internal carotid, near the posterior communicating artery. Passing backward and lateralward between the temporal lobe and the cerebral peduncle, it enters the inferior horn of the lateral ventricle through the choroidal fissure and ends in the choroid plexus. It is distributed to the hippocampus, fimbria, tela chorioidea of the third ventricle, and choroid plexus.

THE ARTERIES OF THE BRAIN.

Since the mode of distribution of the vessels of the brain has an important bearing upon a considerable number of the pathological lesions which may occur in this part of the nervous system, it is important to consider a little more in detail the manner in which the vessels are distributed.

The cerebral arteries are derived from the internal carotid and vertebral, which at the base of the brain form a remarkable anastomosis known as the **arterial circle of Willis**. It is formed in front by the anterior cerebral arteries, branches of the internal carotid, which are connected together by the anterior communicating; behind by the two posterior cerebral arteries, branches of the basilar, which are connected on either side with the internal carotid by the posterior communicating (Figs. 516, 519). The parts of the brain included within this arterial circle are the lamina terminalis, the optic chiasma, the infundibulum, the tuber cinereum, the corpora mammillaria, and the posterior perforated substance.

The three trunks which together supply each cerebral hemisphere arise from the arterial circle of Willis. From its anterior part proceed the two anterior cerebrals, from its antero-lateral parts the middle cerebrals, and from its posterior part the posterior cerebrals. Each of these principal arteries gives origin to two different

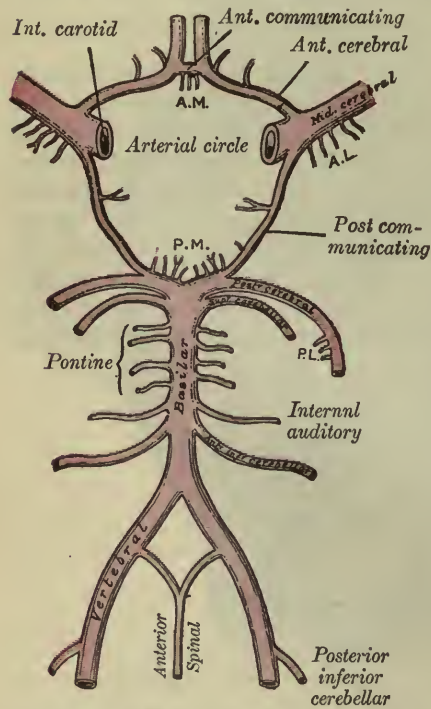


FIG. 519.—Diagram of the arterial circulation at the base of the brain. *A.L.* Antero-lateral. *A.M.* Antero-medial. *P.L.* Postero-lateral. *P.M.* Postero-medial ganglionic branches.

systems of secondary vessels. One of these is named the **ganglionic system**, and the vessels belonging to it supply the thalami and corpora striata; the other is the **cortical system**, and its vessels ramify in the pia mater and supply the cortex and subjacent brain substance. These two systems do not communicate at any point of their peripheral distribution, but are entirely independent of each other, and there is between the parts supplied by the two systems a borderland of diminished nutritive activity, where, it is said, softening is especially liable to occur in the brains of old people.

The Ganglionic System.—All the vessels of this system are given off from the arterial circle of Willis, or from the vessels close to it. They form six principal groups: (I) the **antero-medial group**, derived from the anterior cerebrals and anterior communicating; (II) the **postero-medial group**, from the posterior cerebrals and posterior communicating; (III and IV) the right and left **antero-lateral groups**, from the middle cerebrals; and (V and VI) the right and left **postero-lateral groups**, from the posterior cerebrals, after they have wound around the cerebral peduncles. The vessels of this system are larger than those of the cortical system, and are what Cohnheim designated **terminal arteries**—that is to say, vessels which from their origin to their termination neither supply nor receive any anastomotic branch, so that, through any one of the vessels only a limited area of the thalamus or corpus striatum can be injected, and the injection cannot be driven beyond the area of the part supplied by the particular vessel which is the subject of the experiment.

The Cortical Arterial System.—The vessels forming this system are the terminal branches of the anterior, middle, and posterior cerebral arteries. They divide and ramify in the substance of the pia mater, and give off branches which penetrate the brain cortex, perpendicularly. These branches are divisible into two classes, long and short. The **long**, or **medullary arteries**, pass through the gray substance and penetrate the subjacent white substance to the depth of 3 or 4 cm., without intercommunicating otherwise than by very fine capillaries, and thus constitute so many independent small systems. The **short vessels** are confined to the cortex, where they form with the long vessels a compact net-work in the middle zone of the gray substance, the outer and inner zones being sparingly supplied with blood. The vessels of the cortical arterial system are not so strictly "terminal" as those of the ganglionic system, but they approach this type very closely, so that injection of one area from the vessel of another area, though possible, is frequently very difficult, and is only effected through vessels of small caliber. As a result of this, obstruction of one of the main branches, or its divisions, may have the effect of producing softening in a limited area of the cortex.

THE ARTERIES OF THE UPPER EXTREMITY.

The artery which supplies the upper extremity continues as a single trunk from its commencement down to the elbow; but different portions of it have received different names, according to the regions through which they pass. That part of the vessel which extends from its origin to the outer border of the first rib is termed the **subclavian**; beyond this point to the lower border of the axilla it is named the **axillary**; and from the lower margin of the axillary space to the bend of the elbow it is termed **brachial**; here the trunk ends by dividing into two branches the **radial** and **ulnar**.

THE SUBCLAVIAN ARTERY (A. SUBCLAVIA) (Fig. 520).

On the right side the **subclavian artery** *arises* from the innominate artery behind the right sternoclavicular articulation; on the left side it springs from the arch of the aorta. The two vessels, therefore, in the first part of their course, differ in length, direction, and relation with neighboring structures.

In order to facilitate the description, each subclavian artery is divided into three parts. The first portion extends from the origin of the vessel to the medial border of the *Scalenus anterior*; the second lies behind this muscle; and the third extends from the lateral margin of the muscle to the outer border of the first rib, where it becomes the axillary artery. The first portions of the two vessels require separate descriptions; the second and third parts of the two arteries are practically alike.

First Part of the Right Subclavian Artery (Figs. 505, 520).—The first part of the right subclavian artery *arises* from the innominate artery, behind the upper part of the right sternoclavicular articulation, and passes upward and lateralward to the medial margin of the Scalenus anterior. It ascends a little above the clavicle, the extent to which it does so varying in different cases.

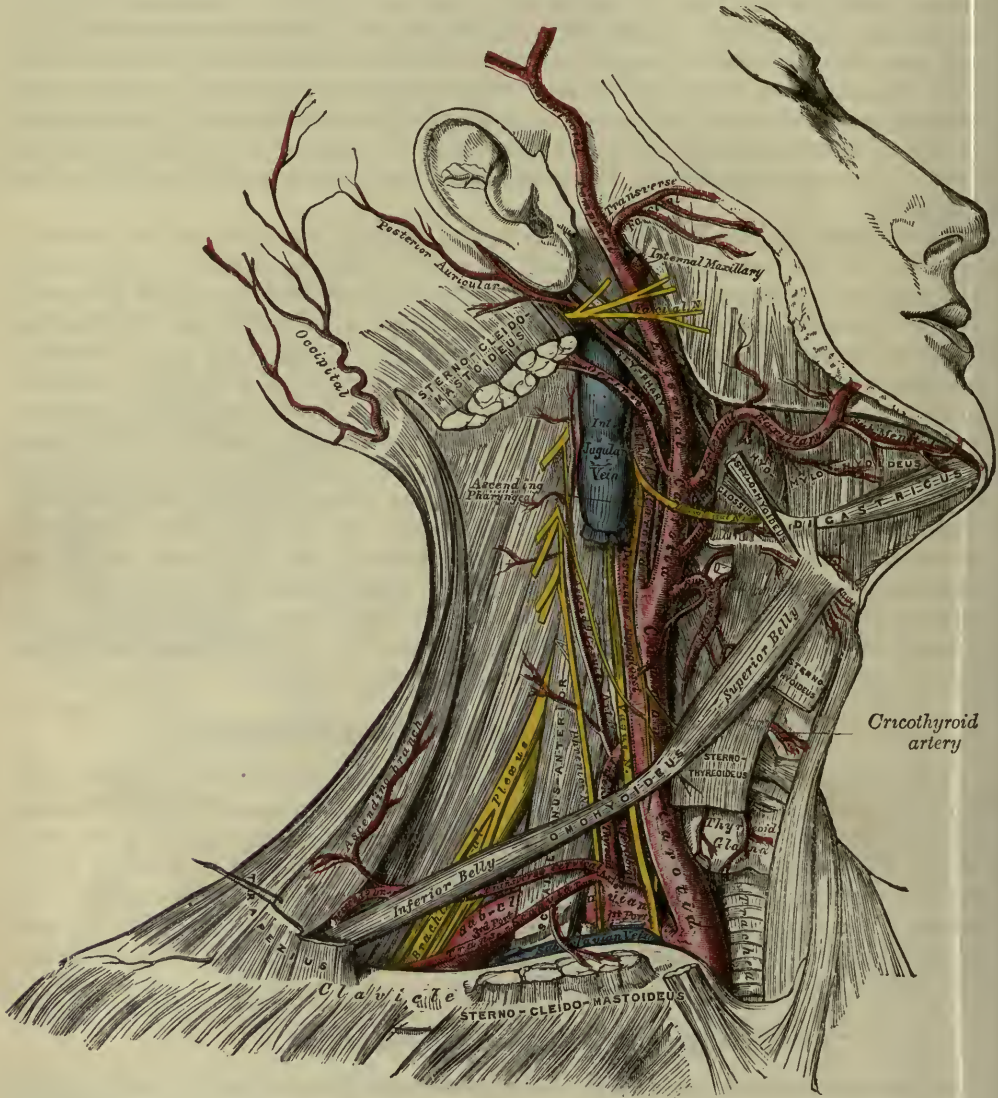


FIG. 520.—Superficial dissection of the right side of the neck, showing the carotid and subclavian arteries.

Relations.—It is covered, *in front*, by the integument, superficial fascia, Platysma, deep fascia, the clavicular origin of the Sternocleidomastoideus, the Sternohyoideus, and Sternothyroideus, and another layer of the deep fascia. It is crossed by the internal jugular and vertebral veins, by the vagus nerve and the cardiac branches of the vagus and sympathetic, and by the subclavian loop of the sympathetic trunk which forms a ring around the vessel. The anterior jugular vein is directed lateralward in front of the artery, but is separated from it by the Sternohyoideus and Sternothyroideus. *Below and behind* the artery is the pleura, which separates it from the apex of the lung; *behind* is the sympathetic trunk, the Longus colli and the first thoracic vertebra. The right recurrent nerve winds around the lower and back part of the vessel.

First Part of the Left Subclavian Artery (Fig. 505).—The first part of the left subclavian artery *arises* from the arch of the aorta, behind the left common carotid, and at the level of the fourth thoracic vertebra; it ascends in the superior mediastinal cavity to the root of the neck and then arches lateralward to the medial border of the Scalenus anterior.

Relations.—It is in relation, *in front*, with the vagus, cardiac, and phrenic nerves, which lie parallel with it, the left common carotid artery, left internal jugular and vertebral veins, and the commencement of the left innominate vein, and is covered by the Sternothyroideus, Sternohyoideus, and Sternocleidomastoideus; *behind*, it is in relation with the esophagus, thoracic duct, left recurrent nerve, inferior cervical ganglion of the sympathetic trunk, and Longus colli; higher up, however, the esophagus and thoracic duct lie to its right side; the latter ultimately arching over the vessel to join the angle of union between the subclavian and internal jugular veins. *Medial* to it are the esophagus, trachea, thoracic duct, and left recurrent nerve; *lateral* to it, the left pleura and lung.

Second and Third Parts of the Subclavian Artery (Fig. 520).—The second portion of the subclavian artery lies behind the Scalenus anterior; it is very short, and forms the highest part of the arch described by the vessel.

Relations.—It is covered, *in front*, by the skin, superficial fascia, Platysma, deep cervical fascia, Sternocleidomastoideus, and Scalenus anterior. On the right side of the neck the phrenic nerve is separated from the second part of the artery by the Scalenus anterior, while on the left side it crosses the first part of the artery close to the medial edge of the muscle. *Behind* the vessel are the pleura and the Scalenus medius; *above*, the brachial plexus of nerves; *below*, the pleura. The subclavian vein lies below and in front of the artery, separated from it by the Scalenus anterior.

The third portion of the subclavian artery runs downward and lateralward from the lateral margin of the Scalenus anterior to the outer border of the first rib, where it becomes the axillary artery. This is the most superficial portion of the vessel, and is contained in the subclavian triangle (see page 565).

Relations.—It is covered, *in front*, by the skin, the superficial fascia, the Platysma, the supraclavicular nerves, and the deep cervical fascia. The external jugular vein crosses its medial part and receives the transverse scapular, transverse cervical, and anterior jugular veins, which frequently form a plexus in front of the artery. Behind the veins, the nerve to the Subclavius descends in front of the artery. The terminal part of the artery lies behind the clavicle and the Subclavius and is crossed by the transverse scapular vessels. The subclavian vein is in front of and at a slightly lower level than the artery. *Behind*, it lies on the lowest trunk of the brachial plexus, which intervenes between it and the Scalenus medius. *Above* and to its *lateral* side are the upper trunks of the brachial plexus and the Omohyoideus. *Below*, it rests on the upper surface of the first rib.

Peculiarities.—The subclavian arteries vary in their origin, their course, and the height to which they rise in the neck.

The origin of the right subclavian from the innominate takes place, in some cases, above the sternoclavicular articulation, and occasionally, but less frequently, below that joint. The artery may arise as a separate trunk from the arch of the aorta, and in such cases it may be either the first, second, third, or even the last branch derived from that vessel; in the majority, however, it is the first or last, rarely the second or third. When it is the first branch, it occupies the ordinary position of the innominate artery; when the second or third, it gains its usual position by passing behind the right carotid; and when the last branch, it arises from the left extremity of the arch, and passes obliquely toward the right side, usually behind the trachea, esophagus, and right carotid, sometimes between the esophagus and trachea, to the upper border of the first rib, whence it follows its ordinary course. In very rare instances, this vessel arises from the thoracic aorta, as low down as the fourth thoracic vertebra. Occasionally, it perforates the Scalenus anterior; more rarely it passes in front of that muscle. Sometimes the subclavian vein passes with the artery behind the Scalenus anterior. The artery may ascend as high as 4 cm. above the clavicle, or any intermediate point between this and the upper border of the bone, the right subclavian usually ascending higher than the left.

The left subclavian is occasionally joined at its origin with the left carotid.

The left subclavian artery is more deeply placed than the right in the first part of its course, and, as a rule, does not reach quite as high a level in the neck. The posterior border of the Sternocleidomastoideus corresponds pretty closely to the lateral border of the Scalenus anterior, so that the third portion of the artery, the part most accessible for operation, lies immediately lateral to the posterior border of the Sternocleidomastoideus.

Collateral Circulation.—After ligation of the third part of the subclavian artery, the collateral circulation is established mainly by three sets of vessels, thus described in a dissection:

1. A posterior set, consisting of the transverse scapular and the descending ramus of the transverse cervical branches of the subclavian, anastomosing with the subscapular from the axillary.

2. A medial set, produced by the connection of the internal mammary on the one hand, with the highest intercostal and lateral thoracic arteries, and the branches from the subscapular on the other.

3. A middle or axillary set, consisting of a number of small vessels derived from branches of the subclavian, above, and, passing through the axilla, terminating either in the main trunk, or some of the branches of the axillary below. This last set presented most conspicuously the peculiar character of newly formed or, rather, dilated arteries, being excessively tortuous, and forming a complete plexus.

The chief agent in the restoration of the axillary artery below the tumor was the subscapular artery, which communicated most freely with the internal mammary, transverse scapular and descending ramus of the transverse cervical branches of the subclavian, from all of which it received so great an influx of blood as to dilate it to three times its natural size.¹

When a ligation is applied to the first part of the subclavian artery, the collateral circulation is carried on by: (1) the anastomosis between the superior and inferior thyroids; (2) the anastomosis of the two vertebrals; (3) the anastomosis of the internal mammary with the inferior epigastric and the aortic intercostals; (4) the costocervical anastomosing with the aortic intercostals; (5) the profunda cervicis anastomosing with the descending branch of the occipital; (6) the scapular branches of the thyrocervical trunk anastomosing with the branches of the axillary, and (7) the thoracic branches of the axillary anastomosing with the aortic intercostals.

Branches.—The branches of the subclavian artery are:

Vertebral.

Internal mammary.

Thyrocervical.

Costocervical.

On the left side all four branches generally *arise* from the first portion of the vessel; but on the right side (Fig. 520) the costocervical trunk usually springs from the second portion of the vessel. On both sides of the neck, the first three branches arise close together at the medial border of the Scalenus anterior; in the majority of cases, a free interval of from 1.25 to 2.5 cm. exists between the commencement of the artery and the origin of the nearest branch.

1. The **vertebral artery** (*a. vertebralis*) (Fig. 514), is the first branch of the subclavian, and *arises* from the upper and back part of the first portion of the vessel. It is surrounded by a plexus of nerve fibers derived from the inferior cervical ganglion of the sympathetic trunk, and ascends through the foramina in the transverse processes of the upper six cervical vertebræ; it then winds behind the superior articular process of the atlas and, entering the skull through the foramen magnum, unites, at the lower border of the pons, with the vessel of the opposite side to form the basilar artery.

Relations.—The vertebral artery may be divided into four parts: The **first part** runs upward and backward between the Longus colli and the Scalenus anterior. In front of it are the internal jugular and vertebral veins, and it is crossed by the inferior thyroid artery; the left vertebral is crossed by the thoracic duct also. Behind it are the transverse process of the seventh cervical vertebra, the sympathetic trunk and its inferior cervical ganglion. The **second part** runs upward through the foramina in the transverse processes of the upper six cervical vertebræ, and is surrounded by branches from the inferior cervical sympathetic ganglion and by a plexus of veins which unite to form the vertebral vein at the lower part of the neck. It is situated in front of the trunks of the cervical nerves, and pursues an almost vertical course as far as the transverse process of the atlas, above which it runs upward and lateralward to the foramen in the transverse process of the atlas. The **third part** issues from the latter foramen on the medial side of the Rectus capitis lateralis, and curves backward behind the superior articular process of the atlas, the anterior ramus of the first cervical nerve being on its medial side; it then lies in the groove on the upper surface of the posterior arch of the atlas, and enters the vertebral canal by passing beneath the posterior atlantooccipital membrane. This part of the artery is covered by the Semispinalis capitis and is contained in the **suboccipital triangle**—a triangular space

¹ Guy's Hospital Reports, vol. i, 1836. Case of axillary aneurism, in which Aston Key had tied the subclavian artery on the lateral edge of the Scalenus anterior, twelve years previously.

² The vertebral artery sometimes enters the foramen in the transverse process of the fifth vertebra, and has been seen entering that of the seventh vertebra.

bounded by the Rectus capitis posterior major, the Obliquus superior, and the Obliquus inferior. The first cervical or suboccipital nerve lies between the artery and the posterior arch of the atlas. The **fourth part** pierces the dura mater and inclines medialward to the front of the medulla oblongata; it is placed between the hypoglossal nerve and the anterior root of the first cervical nerve and beneath the first digitation of the ligamentum denticulatum. At the lower border of the pons it unites with the vessel of the opposite side to form the basilar artery.

Branches.—The branches of the vertebral artery may be divided into two sets: those given off in the neck, and those within the cranium.

Cervical Branches.

Spinal.
Muscular.

Cranial Branches.

Meningeal.
Posterior Spinal.
Anterior Spinal.
Posterior Inferior Cerebellar.
Medullary.

Spinal Branches (*rami spinales*) enter the vertebral canal through the intervertebral foramina, and each divides into two branches. Of these, one passes along the roots of the nerves to supply the medulla spinalis and its membranes, anastomosing with the other arteries of the medulla spinalis; the other divides into an ascending and a descending branch, which unite with similar branches from the arteries above and below, so that two lateral anastomotic chains are formed on the posterior surfaces of the bodies of the vertebræ, near the attachment of the pedicles. From these anastomotic chains branches are supplied to the periosteum and the bodies of the vertebræ, and others form communications with similar branches from the opposite side; from these communications small twigs arise which join similar branches above and below, to form a central anastomotic chain on the posterior surface of the bodies of the vertebræ.

Muscular Branches are given off to the deep muscles of the neck, where the vertebral artery curves around the articular process of the atlas. They anastomose with the occipital, and with the ascending and deep cervical arteries.

The **Meningeal Branch** (*ramus meningeus; posterior meningeal branch*) springs from the vertebral opposite the foramen magnum, ramifies between the bone and dura mater in the cerebellar fossa, and supplies the falx cerebelli. It is frequently represented by one or two small branches.

The **Posterior Spinal Artery** (*a. spinalis posterior; dorsal spinal artery*) arises from the vertebral, at the side of the medulla oblongata; passing backward, it descends on this structure, lying in front of the posterior roots of the spinal nerves, and is reinforced by a succession of small branches, which enter the vertebral canal through the intervertebral foramina; by means of these it is continued to the lower part of the medulla spinalis, and to the cauda equina. Branches from the posterior spinal arteries form a free anastomosis around the posterior roots of the spinal nerves, and communicate, by means of very tortuous transverse branches, with the vessels of the opposite side. Close to its origin each gives off an ascending branch, which ends at the side of the fourth ventricle.

The **Anterior Spinal Artery** (*a. spinalis anterior; ventral spinal artery*) is a small branch, which *arises* near the termination of the vertebral, and, descending in front of the medulla oblongata, unites with its fellow of the opposite side at the level of the foramen magnum. One of these vessels is usually larger than the other, but occasionally they are about equal in size. The single trunk, thus formed, descends on the front of the medulla spinalis, and is reinforced by a succession of small branches which enter the vertebral canal through the intervertebral foramina; these branches are derived from the vertebral and the ascending cervical of the inferior thyroid in the neck; from the intercostals in the thorax; and from the lumbar, iliolumbar, and lateral sacral arteries in the abdomen and pelvis. They unite, by means of ascending and descending branches, to form a single

anterior median artery, which extend as far as the lower part of the medulla spinalis, and is continued as a slender twig on the filum terminale. This vessel is placed in the pia mater along the anterior median fissure; it supplies that membrane, and the substance of the medulla spinalis, and sends off branches at its lower part to be distributed to the cauda equina.

The **Posterior Inferior Cerebellar Artery** (*a. cerebelli inferior posterior*) (Fig. 516), the largest branch of the vertebral, winds backward around the upper part of the medulla oblongata, passing between the origins of the vagus and accessory nerves, over the inferior peduncle to the under surface of the cerebellum, where it divides into two branches. The **medial branch** is continued backward to the notch between the two hemispheres of the cerebellum; while the **lateral** supplies the under surface of the cerebellum, as far as its lateral border, where it anastomoses with the anterior inferior cerebellar and the superior cerebellar branches of the basilar artery. Branches from this artery supply the choroid plexus of the fourth ventricle.

The **Medullary Arteries** (*bulbar arteries*) are several minute vessels which spring from the vertebral and its branches and are distributed to the medulla oblongata.

The **Basilar Artery** (*a. basilaris*) (Fig. 516), so named from its position at the base of the skull, is a single trunk formed by the junction of the two vertebral arteries: it extends from the lower to the upper border of the pons, lying in its median groove, under cover of the arachnoid. It ends by dividing into the two posterior cerebral arteries.

Its branches, on either side, are the following:

Pontine.	Anterior Inferior Cerebellar.
Internal Auditory.	Superior Cerebellar.
	Posterior Cerebral.

The **pontine branches** (*rami ad pontem; transverse branches*) are a number of small vessels which come off at right angles from either side of the basilar artery and supply the pons and adjacent parts of the brain.

The **internal auditory artery** (*a. auditiva interna; auditory artery*), a long slender branch, *arises* from near the middle of the artery; it accompanies the acoustic nerve through the internal acoustic meatus, and is distributed to the internal ear.

The **anterior inferior cerebellar artery** (*a. cerebelli inferior anterior*) passes backward to be distributed to the anterior part of the under surface of the cerebellum, anastomosing with the posterior inferior cerebellar branch of the vertebral.

The **superior cerebellar artery** (*a. cerebelli superior*) *arises* near the termination of the basilar. It passes lateralward, immediately below the oculomotor nerve, which separates it from the posterior cerebral artery, winds around the cerebral peduncle, close to the trochlear nerve, and, arriving at the upper surface of the cerebellum, divides into branches which ramify in the pia mater and anastomose with those of the inferior cerebellar arteries. Several branches are given to the pineal body, the anterior medullary velum, and the tela chorioidea of the third ventricle.

The **posterior cerebral artery** (*a. cerebri posterior*) (Figs. 516, 517, 518) is larger than the preceding, from which it is separated near its origin by the oculomotor nerve. Passing lateralward, parallel to the superior cerebellar artery, and receiving the posterior communicating from the internal carotid, it winds around the cerebral peduncle, and reaches the tentorial surface of the occipital lobe of the cerebrum, where it breaks up into branches for the supply of the temporal and occipital lobes.

The branches of the posterior cerebral artery are divided into two sets, **ganglionic** and **cortical**:

Ganglionic	{	Posterior-medial.			
		Posterior Choroidal.		Cortical	{
		Postero-lateral.			Anterior Temporal.
					Posterior Temporal.
					Calcarine.
					Parietooccipital.

Ganglionic.—The **postero-medial ganglionic branches** (Fig. 519) are a group of small arteries which *arise* at the commencement of the posterior cerebral artery; these, with similar branches from the posterior communicating, pierce the posterior perforated substance, and supply the medial surfaces of the thalami and the walls of the third ventricle. The **posterior choroidal branches** run forward beneath the splenium of the corpus callosum, and supply the tela chorioidea of the third ventricle and the choroid plexus. The **postero-lateral ganglionic branches** are small arteries which *arise* from the posterior cerebral artery after it has turned around the cerebral peduncle; they supply a considerable portion of the thalamus.

Cortical.—The cortical branches are: the **anterior temporal**, distributed to the uncus and the anterior part of the fusiform gyrus; the **posterior temporal**, to the fusiform and the inferior temporal gyri; the **calcarine**, to the cuneus and gyrus linguallis and the back part of the convex surface of the occipital lobe; and the **parietooccipital**, to the cuneus and the precuneus.

2. The **thyrocervical trunk** (*truncus thyrocervicalis; thyroid axis*) (Fig. 520) is a short thick trunk, which *arises* from the front of the first portion of the subclavian artery, close to the medial border of the Scalenus anterior, and divides almost immediately into three branches, the **inferior thyroid**, **transverse scapular**, and **transverse cervical**.

The **Inferior Thyroid Artery** (*a. thyreoidea inferior*) passes upward, in front of the vertebral artery and Longus colli; then turns medialward behind the carotid sheath and its contents, and also behind the sympathetic trunk, the middle cervical ganglion resting upon the vessel. Reaching the lower border of the thyroid gland it divides into two branches, which supply the postero-inferior parts of the gland, and anastomose with the superior thyroid, and with the corresponding artery of the opposite side. The recurrent nerve passes upward generally behind, but occasionally in front, of the artery.

The **branches** of the inferior thyroid are:

Inferior Laryngeal.
Tracheal.

Esophageal.
Ascending Cervical.

Muscular.

The **inferior laryngeal artery** (*a. laryngea inferior*) ascends upon the trachea to the back part of the larynx under cover of the Constrictor pharyngis inferior, in company with the recurrent nerve, and supplies the muscles and mucous membrane of this part, anastomosing with the branch from the opposite side, and with the superior laryngeal branch of the superior thyroid artery.

The **tracheal branches** (*rami tracheales*) are distributed upon the trachea, and anastomose below with the bronchial arteries.

The **esophageal branches** (*rami œsophagei*) supply the esophagus, and anastomose with the esophageal branches of the aorta.

The **ascending cervical artery** (*a. cervicalis ascendens*) is a small branch which *arises* from the inferior thyroid as that vessel is passing behind the carotid sheath; it runs up on the anterior tubercles of the transverse processes of the cervical vertebræ in the interval between the Scalenus anterior and Longus capitis. To the muscles of the neck it gives twigs which anastomose with branches of the vertebral, and it sends one or two spinal branches into the vertebral canal through the intervertebral foramina to be distributed to the medulla spinalis and its membranes, and to the bodies of the vertebræ, in the same manner as the spinal branches from the vertebral. It anastomoses with the ascending pharyngeal and occipital arteries.

The **muscular branches** supply the depressors of the hyoid bone, and the Longus colli, Scalenus anterior, and Constrictor pharyngis inferior.

The **Transverse Scapular Artery** (*a. transversa scapulæ*; *suprascapular artery*) passes at first downward and lateralward across the

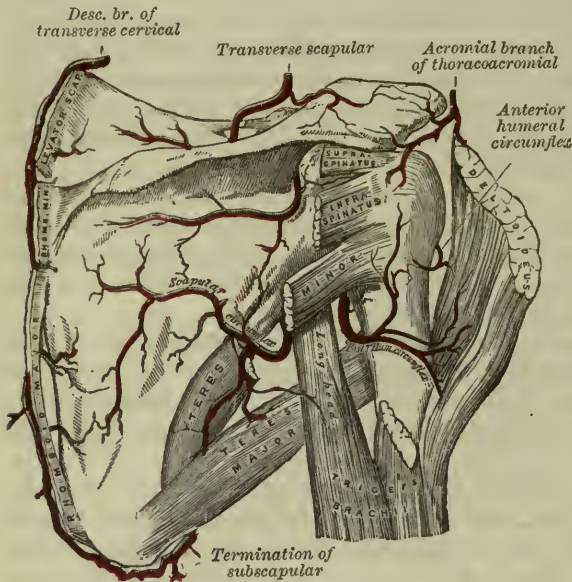


FIG. 521.—The scapular and circumflex arteries.

reach the infraspinatus fossa, where it anastomoses with the scapular circumflex and the descending branch of the transverse cervical. Besides distributing branches to the Sternocleidomastoideus, Subclavius, and neighboring muscles, it gives off a **suprasternal branch**, which crosses over the sternal end of the clavicle to the skin of the upper part of the chest; and an **acromial branch**, which pierces the Trapezius and supplies the skin over the acromion, anastomosing with the thoracoacromial artery. As the artery passes over the superior transverse ligament of the scapula, it sends a branch into the subscapular fossa, where it ramifies beneath the Subscapularis, and anastomoses with the subscapular artery and with the descending branch of the transverse cervical. It also sends articular branches to the acromioclavicular and shoulder-joints, and a nutrient artery to the clavicle.

The **Transverse Cervical Artery** (*a. transversa colli*; *transversalis colli artery*) lies at a higher level than the transverse scapular; it passes transversely above the inferior belly of the Omohyoideus to the anterior margin of the Trapezius, beneath which it divides into an **ascending** and a **descending branch**. It crosses in front of the phrenic nerve and the Scaleni, and in front of or between the divisions of the brachial plexus, and is covered by the Platysma and Sternocleidomastoideus, and crossed by the Omohyoideus and Trapezius.

The **ascending branch** (*ramus ascendens*; *superficial cervical artery*) ascends beneath the anterior margin of the Trapezius, distributing branches to it, and to the neighboring muscles and lymph glands in the neck, and anastomosing with the superficial branch of the descending ramus of the occipital artery.

The **descending branch** (*ramus descendens*; *posterior scapular artery*) (Fig. 521) passes beneath the Levator scapulæ to the medial angle of the scapula, and then descends under the Rhomboidei along the vertebral border of that bone as far as the inferior angle. It supplies the Rhomboidei, Latissimus dorsi and Trapezius, and anastomoses with the transverse scapular and subscapular arteries, and with the posterior branches of some of the intercostal arteries.

Scalenus anterior and phrenic nerve, being covered by the Sternocleidomastoideus; it then crosses the subclavian artery and the brachial plexus, and runs behind and parallel with the clavicle and Subclavius, and beneath the inferior belly of the Omohyoideus, to the superior border of the scapula; it passes over the superior transverse ligament of the scapula which separates it from the suprascapular nerve, and enters the suprascapular fossa (Fig. 521). In this situation it lies close to the bone, and ramifies between it and the Supraspinatus, to which it supplies branches. It then descends behind the neck of the scapula, through the great scapular notch and under cover of the inferior transverse ligament, to

Peculiarities.—The ascending branch of the transverse cervical frequently arises directly from the thyrocervical trunk; and the descending branch from the third, more rarely from the second, part of the subclavian.

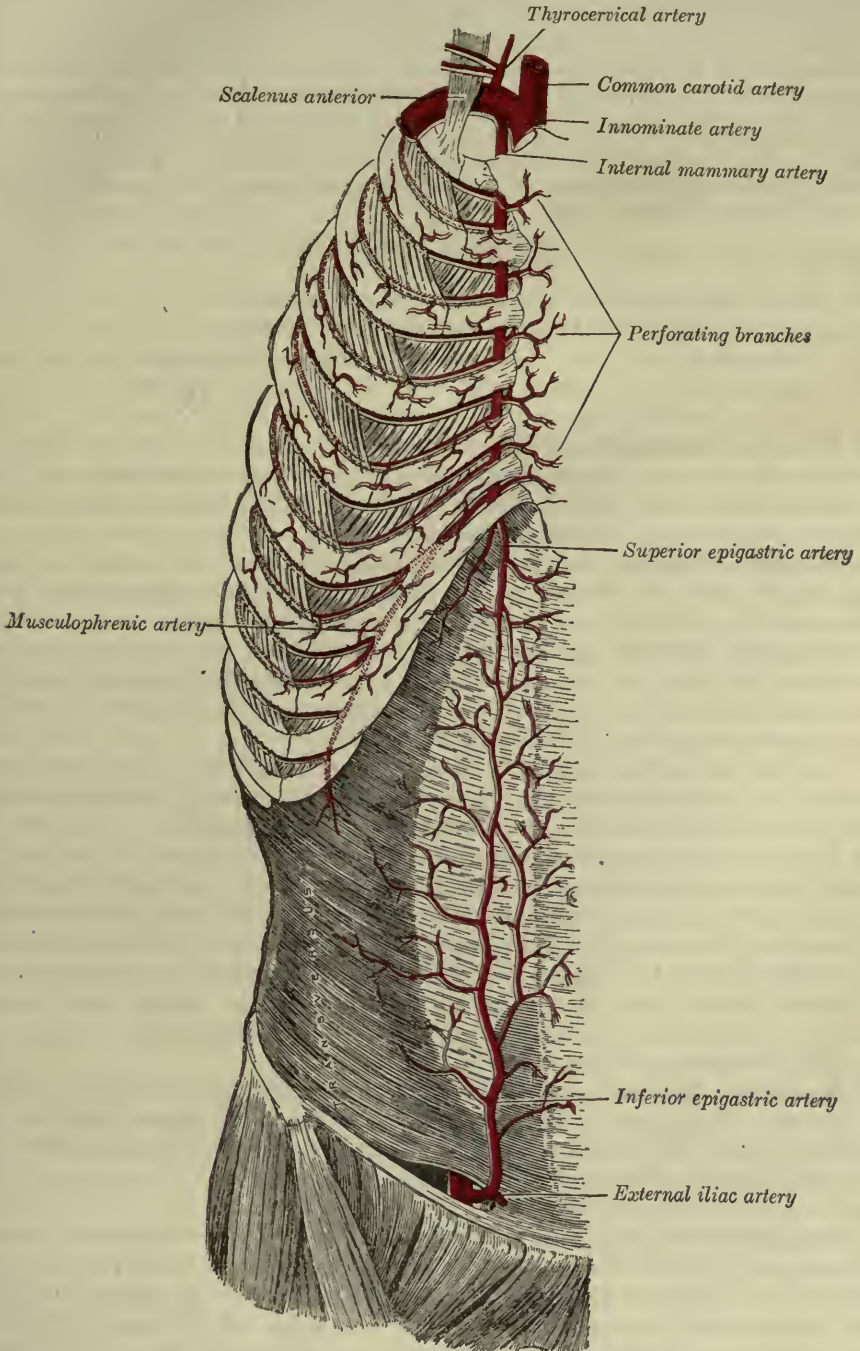


FIG. 522.—The internal mammary artery and its branches.

3. The **internal mammary artery** (*a. mammaria interna*) (Fig. 522) arises from the under surface of the first portion of the subclavian, opposite the thyrocervical trunk. It descends behind the cartilages of the upper six ribs at a distance

of about 1.25 cm. from the margin of the sternum, and at the level of the sixth intercostal space divides into the **musculophrenic** and **superior epigastric arteries**.

Relations.—It is directed at first downward, forward, and medialward behind the sternal end of the clavicle, the subclavian and internal jugular veins, and the first costal cartilage, and passes forward close to the lateral side of the innominate vein. As it enters the thorax the phrenic nerve crosses from its lateral to its medial side. Below the first costal cartilage it descends almost vertically to its point of bifurcation. It is covered in front by the cartilages of the upper six ribs and the intervening Intercostales interni and anterior intercostal membranes, and is crossed by the terminal portions of the upper six intercostal nerves. It rests on the pleura, as far as the third costal cartilage; below this level, upon the Transversus thoracis. It is accompanied by a pair of veins; these unite above to form a single vessel, which runs medial to the artery and ends in the corresponding innominate vein.

Branches.—The branches of the internal mammary are:

Pericardiophrenic.	Intercostal.
Anterior Mediastinal.	Perforating.
Pericardial.	Musculophrenic.
Sternal.	Superior Epigastric.

The **Pericardiophrenic Artery** (*a. pericardiophrenica*; *a. comes nervi phrenici*) is a long slender branch, which accompanies the phrenic nerve, between the pleura and pericardium, to the diaphragm, to which it is distributed; it anastomoses with the musculophrenic and inferior phrenic arteries.

The **Anterior Mediastinal Arteries** (*aa. mediastinales anteriores*; *mediastinal arteries*) are small vessels, distributed to the areolar tissue and lymph glands in the anterior mediastinal cavity, and to the remains of the thymus.

The **Pericardial Branches** supply the upper part of the anterior surface of the pericardium; the lower part receives branches from the musculophrenic artery.

The **Sternal Branches** (*rami sternales*) are distributed to the Transversus thoracis, and to the posterior surface of the sternum.

The anterior mediastinal, pericardial, and sternal branches, together with some twigs from the pericardiophrenic, anastomose with branches from the intercostal and bronchial arteries, and form a **subpleural mediastinal plexus**.

The **Intercostal Branches** (*rami intercostales*; *anterior intercostal arteries*) supply the upper five or six intercostal spaces. Two in number in each space, these small vessels pass lateralward, one lying near the lower margin of the rib above, and the other near the upper margin of the rib below, and anastomose with the intercostal arteries from the aorta. They are at first situated between the pleura and the Intercostales interni, and then between the Intercostales interni and externi. They supply the Intercostales and, by branches which perforate the Intercostales externi, the Pectorales and the mamma.

The **Perforating Branches** (*rami perforantes*) correspond to the five or six intercostal spaces. They pass forward through the intercostal spaces, and, curving lateralward, supply the Pectoralis major and the integument. Those which correspond to the second, third, and fourth spaces give branches to the mamma, and during lactation are of large size.

The **Musculophrenic Artery** (*a. musculophrenica*) is directed obliquely downward and lateralward, behind the cartilages of the false ribs; it perforates the diaphragm at the eighth or ninth costal cartilage, and ends, considerably reduced in size, opposite the last intercostal space. It gives off intercostal branches to the seventh, eighth, and ninth intercostal spaces; these diminish in size as the spaces decrease in length, and are distributed in a manner precisely similar to the intercostals from the internal mammary. The musculophrenic also gives branches to the lower part of the pericardium, and others which run backward to the diaphragm, and downward to the abdominal muscles.

The **Superior Epigastric Artery** (*a. epigastrica superior*) continues in the original direction of the internal mammary; it descends through the interval between the costal and sternal attachments of the diaphragm, and enters the sheath of the Rectus abdominis, at first lying behind the muscle, and then perforating and supplying it, and anastomosing with the inferior epigastric artery from the external iliac. Branches perforate the anterior wall of the sheath of the Rectus, and supply the muscles of the abdomen and the integument, and a small branch passes in front of the xiphoid process and anastomoses with the artery of the opposite side. It also gives some twigs to the diaphragm, while from the artery of the right side small branches extend into the falciform ligament of the liver and anastomose with the hepatic artery.

4. The **costocervical trunk** (*truncus costocervicalis; superior intercostal artery*) (Fig. 513) arises from the upper and back part of the subclavian artery, behind the Scalenus anterior on the right side, and medial to that muscle on the left side. Passing backward, it gives off the **profunda cervicalis**, and, continuing as the **highest intercostal artery**, descends behind the pleura in front of the necks of the first and second ribs, and anastomoses with the first aortic intercostal. As it crosses the neck of the first rib it lies medial to the anterior division of the first thoracic nerve, and lateral to the first thoracic ganglion of the sympathetic trunk.

In the first intercostal space, it gives off a branch which is distributed in a manner similar to the distribution of the aortic intercostals. The branch for the second intercostal space usually joins with one from the highest aortic intercostal artery. This branch is not constant, but is more commonly found on the right side; when absent, its place is supplied by an intercostal branch from the aorta. Each intercostal gives off a posterior branch which goes to the posterior vertebral muscles, and sends a small spinal branch through the corresponding intervertebral foramen to the medulla spinalis and its membranes.

The **Profunda Cervicalis** (*a. cervicalis profunda; deep cervical branch*) arises, in most cases, from the costocervical trunk, and is analogous to the posterior branch of an aortic intercostal artery: occasionally it is a separate branch from the subclavian artery. Passing backward, above the eighth cervical nerve and between the transverse process of the seventh cervical vertebra and the neck of the first rib, it runs up the back of the neck, between the Semispinales capitis and colli, as high as the axis vertebra, supplying these and adjacent muscles, and anastomosing with the deep division of the descending branch of the occipital, and with branches of the vertebral. It gives off a spinal twig which enters the canal through the intervertebral foramen between the seventh cervical and first thoracic vertebræ.

THE AXILLA.

The axilla is a pyramidal space, situated between the upper lateral part of the chest and the medial side of the arm.

Boundaries.—The *apex*, which is directed upward toward the root of the neck, corresponds to the interval between the outer border of the first rib, the superior border of the scapula, and the posterior surface of the clavicle, and through it the axillary vessels and nerves pass. The *base*, directed downward, is broad at the chest but narrow and pointed at the arm; it is formed by the integument and a thick layer of fascia, the **axillary fascia**, extending between the lower border of the Pectoralis major in front, and the lower border of the Latissimus dorsi behind. The *anterior wall* is formed by the Pectorales major and minor, the former covering the whole of this wall, the latter only its central part. The space between the upper border of the Pectoralis minor and the clavicle is occupied by the coracoclavicular fascia. The *posterior wall*, which extends somewhat lower than the anterior, is formed by the Subscapularis above, the Teres major and Latissimus dorsi below.

On the *medial side* are the first four ribs with their corresponding Intercostales, and part of the Serratus anterior. On the *lateral side*, where the anterior and posterior walls converge, the space is narrow, and bounded by the humerus, the Coracobrachialis, and the Biceps brachii.

Contents.—It contains the axillary vessels, and the brachial plexus of nerves, with their branches, some branches of the intercostal nerves, and a large number of lymph glands, together with a quantity of fat and loose areolar tissue. The axillary artery and vein, with the brachial plexus of nerves, extend obliquely along the lateral boundary of the axilla, from its apex to its base, and are placed much nearer to the anterior than to the posterior wall, the vein lying to the thoracic side of the artery and partially concealing it. At the forepart of the axilla, in contact with the Pectorales, are the thoracic branches of the axillary artery, and along the lower margin of the Pectoralis minor the lateral thoracic artery extends to the side of the chest. At the back part, in contact with the lower margin of the Subscapularis, are the subscapular vessels and nerves; winding around the lateral border of this muscle are the scapular circumflex vessels; and, close to the neck of the humerus, the posterior humeral circumflex vessels and the axillary nerve curve backward to the shoulder. Along the medial or thoracic side no vessel of any importance exists, the upper part of the space being crossed merely by a few small branches from the highest thoracic artery. There are some important nerves, however, in this situation, viz., the long thoracic nerve, descending on the surface of the Serratus anterior, to which it is distributed; and the intercostobrachial nerve, perforating the upper and anterior part of this wall, and passing across the axilla to the medial side of the arm.

The position and arrangement of the lymph glands are described on pages 699 and 700.

The Axillary Artery (A. Axillaris) (Fig. 523).

The **axillary artery**, the continuation of the subclavian, commences at the outer border of the first rib, and ends at the lower border of the tendon of the Teres major, where it takes the name of brachial. Its direction varies with the position of the limb; thus the vessel is nearly straight when the arm is directed at right angles with the trunk, concave upward when the arm is elevated above this, and convex upward and lateralward when the arm lies by the side. At its origin the artery is very deeply situated, but near its termination is superficial, being covered only by the skin and fascia. To facilitate the description of the vessel it is divided into three portions; the first part lies above, the second behind, and the third below the Pectoralis minor.

Relations.—The **first portion** of the axillary artery is covered *anteriorly* by the clavicular portion of the Pectoralis major and the coracoclavicular fascia, and is crossed by the lateral anterior thoracic nerve, and the thoracoacromial and cephalic veins; *posterior* to it are the first intercostal space, the corresponding Intercostalis externus, the first and second digitations of the Serratus anterior, and the long thoracic and medial anterior thoracic nerves, and the medial cord of the brachial plexus; on its *lateral side* is the brachial plexus, from which it is separated by a little areolar tissue; on its *medial*, or thoracic side, is the axillary vein which overlaps the artery. It is enclosed, together with the axillary vein and the brachial plexus, in a fibrous sheath—the **axillary sheath**—continuous above with the deep cervical fascia.

The **second portion** of the axillary artery is covered, *anteriorly*, by the Pectorales major and minor; posterior to it are the posterior cord of the brachial plexus, and some areolar tissue which intervenes between it and the Subscapularis; on the *medial side* is the axillary vein, separated from the artery by the medial cord of the brachial plexus and the medial anterior thoracic nerve; on the *lateral side* is the lateral cord of the brachial plexus. The brachial plexus thus surrounds the artery on three sides, and separates it from direct contact with the vein and adjacent muscles.

The **third portion** of the axillary artery extends from the lower border of the Pectoralis minor to the lower border of the tendon of the Teres major. *In front*, it is covered by the lower part of the Pectoralis major above, but only by the integument and fascia below; *behind*, it is in relation with the lower part of the Subscapularis, and the tendons of the Latissimus dorsi and Teres

major; on its *lateral side* is the Coracobrachialis, and on its *medial* or thoracic side, the axillary vein. The nerves of the brachial plexus bear the following relations to this part of the artery: on the *lateral side* are the lateral head and the trunk of the median, and the musculocutaneous for a short distance; on the *medial side* the ulnar (between the vein and artery) and medial brachial cutaneous (to the medial side of the vein); *in front* are the medial head of the median and the medial antibrachial cutaneous, and *behind*, the radial and axillary, the latter only as far as the lower border of the Subscapularis.

Collateral Circulation after Ligature of the Axillary Artery.—If the artery be tied above the origin of the thoracoacromial, the collateral circulation will be carried on by the same branches as after the ligature of the third part of the subclavian; if at a lower point, between the thoracoacromial and the subscapular, the latter vessel, by its free anastomosis with the transverse scapular and transverse cervical branches of the subclavian, will become the chief agent in carrying on the circulation; the lateral thoracic, if it be below the ligature, will materially contribute by its anastomoses with the intercostal and internal mammary arteries. If the point included in the ligature is below the origin of the subscapular artery, it will most probably also be below the origins of the two humeral circumflex arteries. The chief agents in restoring the circulation will then be the subscapular and the two humeral circumflex arteries anastomosing with the a. profunda brachii.

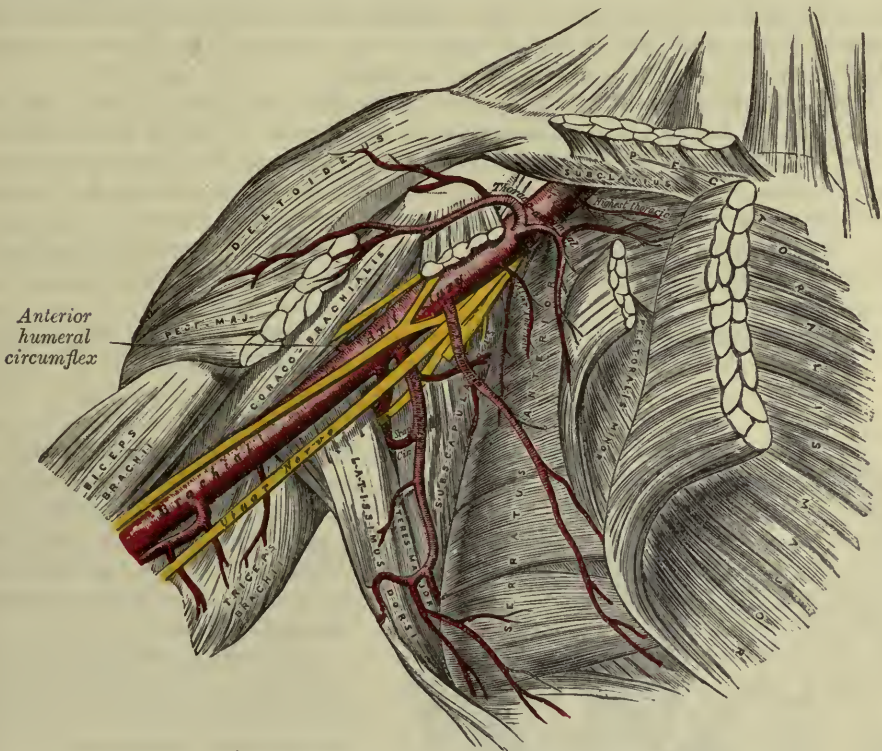


FIG. 523.—The axillary artery and its branches.

Branches.—The branches of the axillary are:

From first part, Highest Thoracic.	From second part	{ Thoracoacromial.
		{ Lateral Thoracic.
From third part		{ Subscapular.
		{ Posterior Humeral Circumflex.
		{ Anterior Humeral Circumflex.

1. The **highest thoracic artery** (*a. thoracalis suprema; superior thoracic artery*) is a small vessel, which may arise from the thoracoacromial: Running forward and medialward along the upper border of the Pectoralis minor, it passes between it and the Pectoralis major to the side of the chest. It supplies branches to these

muscles, and to the parietes of the thorax, and anastomoses with the internal mammary and intercostal arteries.

2. The **thoracoacromial artery** (*a. thoracoacromialis*; *acromiothoracic artery*; *thoracic axis*) is a short trunk, which *arises* from the forepart of the axillary artery, its origin being generally overlapped by the upper edge of the Pectoralis minor. Projecting forward to the upper border of this muscle, it pierces the coracoclavicular fascia and divides into four branches—pectoral, acromial, clavicular, and deltoid. The **pectoral branch** descends between the two Pectorales, and is distributed to them and to the mamma, anastomosing with the intercostal branches of the internal mammary and with the lateral thoracic. The **acromial branch** runs lateralward over the coracoid process and under the Deltoideus, to which it gives branches; it then pierces that muscle and ends on the acromion in an arterial network formed by branches from the transverse scapular, thoracoacromial, and posterior humeral circumflex arteries. The **clavicular branch** runs upward and medialward to the sternoclavicular joint, supplying this articulation, and the Subclavius. The **deltoid (humeral) branch**, often arising with the acromial, crosses over the Pectoralis minor and passes in the same groove as the cephalic vein, between the Pectoralis major and Deltoideus, and gives branches to both muscles.

3. The **lateral thoracic artery** (*a. thoracalis lateralis*; *long thoracic artery*; *external mammary artery*) follows the lower border of the Pectoralis minor to the side of the chest, supplying the Serratus anterior and the Pectoralis, and sending branches across the axilla to the axillary glands and Subscapularis; it anastomoses with the internal mammary, subscapular, and intercostal arteries, and with the pectoral branch of the thoracoacromial. In the female it supplies an **external mammary branch** which turns round the free edge of the Pectoralis major and supplies the mamma.

4. The **subscapular artery** (*a. subscapularis*) the largest branch of the axillary artery, *arises* at the lower border of the Subscapularis, which it follows to the inferior angle of the scapula, where it anastomoses with the lateral thoracic and intercostal arteries and with the descending branch of the transverse cervical, and ends in the neighboring muscles. About 4 cm. from its origin it gives off a branch, the **scapular circumflex artery**.

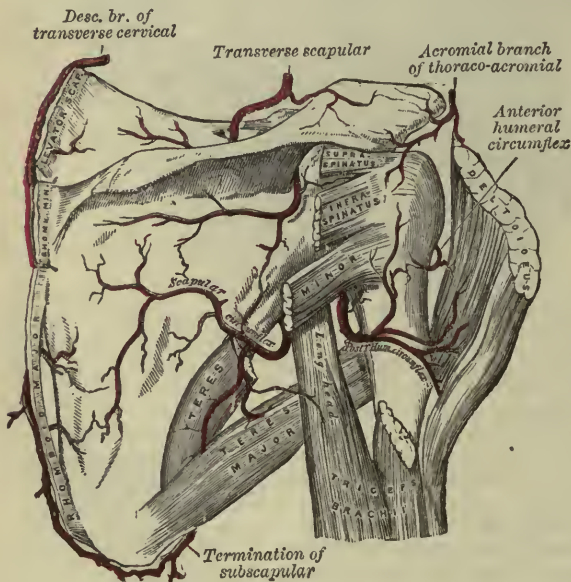


FIG. 524.—The scapular and circumflex arteries.

The **Scapular Circumflex Artery** (*a. circumflexa scapulæ*; *dorsalis scapulæ artery*) is generally larger than the continuation of the subscapular. It curves around the axillary border of the scapula, traversing the space between the Subscapularis above, the Teres major below, and the long head of the Triceps laterally (Fig. 524); it enters the infraspinatous fossa under cover of the Teres minor, and anastomoses with the transverse scapular

artery and the descending branch of the transverse cervical. In its course it gives off two branches: one (*infrascapular*) enters the subscapular fossa beneath the Subscapularis, which it supplies, anastomosing with the transverse scapular

artery and the descending branch of the transverse cervical; the other is continued along the axillary border of the scapula, between the Teres major and minor, and at the dorsal surface of the inferior angle anastomoses with the descending branch of the transverse cervical. In addition to these, small branches are distributed to the back part of the Deltoideus and the long head of the Triceps brachii, anastomosing with an ascending branch of the a. profunda brachii.

5. The **posterior humeral circumflex artery** (*a. circumflexa humeri posterior; posterior circumflex artery*) (Fig. 524) arises from the axillary artery at the lower border of the Subscapularis, and runs backward with the axillary nerve through the quadrangular space bounded by the Subscapularis and Teres minor above, the Teres major below, the long head of the Triceps brachii medially, and the surgical neck of the humerus laterally. It winds around the neck of the humerus and is distributed to the Deltoideus and shoulder-joint, anastomosing with the anterior humeral circumflex and profunda brachii.

6. The **anterior humeral circumflex artery** (*a. circumflexa humeri anterior; anterior circumflex artery*) (Fig. 524), considerably smaller than the posterior, arises nearly opposite it, from the lateral side of the axillary artery. It runs horizontally, beneath the Coracobrachialis and short head of the Biceps brachii, in front of the neck of the humerus. On reaching the intertubercular sulcus, it gives off a branch which ascends in the sulcus to supply the head of the humerus and the shoulder-joint. The trunk of the vessel is then continued onward beneath the long head of the Biceps brachii and the Deltoideus, and anastomoses with the posterior humeral circumflex artery.

Peculiarities.—The branches of the axillary artery vary considerably in different subjects. Occasionally the subscapular, humeral circumflex, and profunda arteries arise from a common trunk, and when this occurs the branches of the brachial plexus surround this trunk instead of the main vessel. Sometimes the axillary artery divides into the radial and ulnar arteries, and occasionally it gives origin to the volar interosseous artery of the forearm.

The Brachial Artery (A. Brachialis) (Fig. 525).

The **brachial artery** commences at the lower margin of the tendon of the Teres major, and, passing down the arm, ends about 1 cm. below the bend of the elbow, where it divides into the **radial** and **ulnar arteries**. At first the brachial artery lies medial to the humerus; but as it runs down the arm it gradually gets in front of the bone, and at the bend of the elbow it lies midway between its two epicondyles.

Relations.—The artery is superficial throughout its entire extent, being covered, *in front*, by the integument and the superficial and deep fasciæ; the lacertus fibrosus (*bicipital fascia*) lies in front of it opposite the elbow and separates it from the vena mediana cubiti; the median nerve crosses from its lateral to its medial side opposite the insertion of the Coracobrachialis. *Behind*, it is separated from the long head of the Triceps brachii by the radial nerve and a. profunda brachii. It then lies upon the medial head of the Triceps brachii, next upon the insertion of the Coracobrachialis, and lastly on the Brachialis. *Laterally*, it is in relation above with the median nerve and the Coracobrachialis, below with the Biceps brachii, the two muscles overlapping the artery to a considerable extent. *Medially*, its upper half is in relation with the medial antibrachial cutaneous and ulnar nerves, its lower half with the median nerve. The basilic vein lies on its medial side, but is separated from it in the lower part of the arm by the deep fascia. The artery is accompanied by two venæ comitantes, which lie in close contact with it, and are connected together at intervals by short transverse branches.

The **Anticubital Fossa.**—At the bend of the elbow the brachial artery sinks deeply into a triangular interval, the **anticubital fossa**. The base of the triangle is directed upward, and is represented by a line connecting the two epicondyles of the humerus; the sides are formed by the medial edge of the Brachioradialis and the lateral margin of the Pronator teres; the floor is formed by the Brachialis and Supinator. This space contains the brachial artery, with its accompanying veins; the radial and ulnar arteries; the median and radial nerves; and the tendon of the Biceps brachii. The brachial artery occupies the middle of the space, and

divides opposite the neck of the radius into the radial and ulnar arteries; it is covered, *in front*, by the integument, the superficial fascia, and the vena mediana cubiti, the last being separated from the artery by the lacertus fibrosus. *Behind* it is the Brachialis which separates it from the elbow-joint. The median nerve lies

close to the medial side of the artery, above, but is separated from it below by the ulnar head of the Pronator teres. The tendon of the Biceps brachii lies to the lateral side of the artery; the radial nerve is situated upon the Supinator, and concealed by the Brachioradialis.

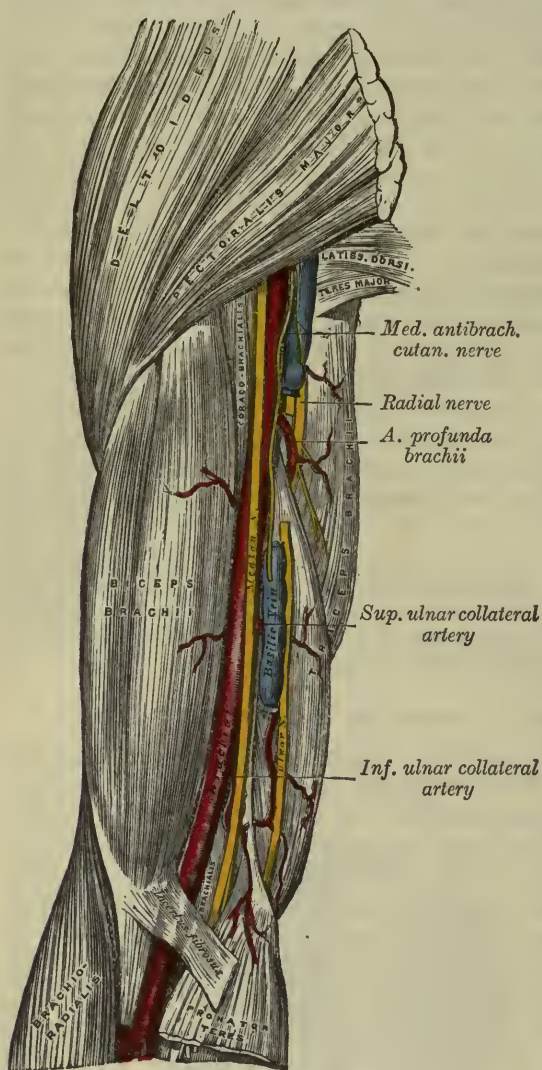


FIG. 525.—The brachial artery.

Varieties in Muscular Relations.—The brachial artery is occasionally concealed, in some part of its course, by muscular or tendinous slips derived from the Coracobrachialis, Biceps brachii, Brachialis, or Pronator teres.

Collateral Circulation.—After the application of a ligature to the brachial artery in the upper third of the arm, the circulation is carried on by branches from the humeral circumflex and subscapular arteries anastomosing with ascending branches from the profunda brachii. If the artery be tied *below* the origin of the profunda brachii and superior ulnar collateral, the circulation is maintained by the branches of these two arteries anastomosing with the inferior ulnar collateral, the radial and ulnar recurrenents, and the dorsal interosseous.

Branches.—The branches of the brachial artery are:

Profunda Brachii.
Nutrient.

Superior Ulnar Collateral.
Inferior Ulnar Collateral.

Muscular.

Peculiarities of the Brachial Artery as Regards its Course.—The brachial artery, accompanied by the median nerve, may leave the medial border of the Biceps brachii, and descend toward the medial epicondyle of the humerus; in such cases it usually passes behind the *supracondylar process* of the humerus, from which a fibrous arch is in most cases thrown over the artery; it then runs beneath or through the substance of the Pronator teres, to the bend of the elbow. This variation bears considerable analogy with the normal condition of the artery in some of the carnivora; it has been referred to in the description of the humerus (p. 212).

As Regards its Division.—Occasionally, the artery is divided for a short distance at its upper part into two trunks, which are united below. Frequently the artery divides at a higher level than usual, and the vessels concerned in this high division are three, viz., radial, ulnar, and interosseous. Most frequently the radial is given off high up, the other limb of the bifurcation consisting of the ulnar and interosseous; in some instances the ulnar arises above the ordinary level, and the radial and interosseous form the other limb of the division; occasionally the interosseous arises high up.

Sometimes, long slender vessels, *vasa aberrantia*, connect the brachial or the axillary artery with one of the arteries of the forearm, or branches from them. These vessels usually join the radial.

1. The **arteria profunda brachii** (*superior profunda artery*) is a large vessel which arises from the medial and back part of the brachial, just below the lower border of the *Teres major*. It follows closely the radial nerve, running at first backward between the medial and lateral heads of the *Triceps brachii*, then along the groove for the radial nerve, where it is covered by the lateral head of the *Triceps brachii*, to the lateral side of the arm; there it pierces the lateral intermuscular septum, and, descending between the *Brachioradialis* and the *Brachialis* to the front of the lateral epicondyle of the humerus, ends by anastomosing with the radial recurrent artery. It gives branches to the *Deltoideus* and to the muscles between which it lies; it supplies an occasional **nutrient artery** which enters the humerus behind the deltoid tuberosity. A branch ascends between the long and lateral heads of the *Triceps brachii* to anastomose with the posterior humeral circumflex artery; a **middle collateral branch** descends in the middle head of the *Triceps brachii* and assists in forming the anastomosis above the olecranon; and, lastly, a **radial collateral branch** runs down behind the lateral intermuscular septum to the back of the lateral epicondyle of the humerus, where it anastomoses with the interosseous recurrent and the inferior ulnar collateral arteries.

2. The **nutrient artery** (*a. nutricia humeri*) of the body of the humerus arises about the middle of the arm and enters the nutrient canal near the insertion of the *Coracobrachialis*.

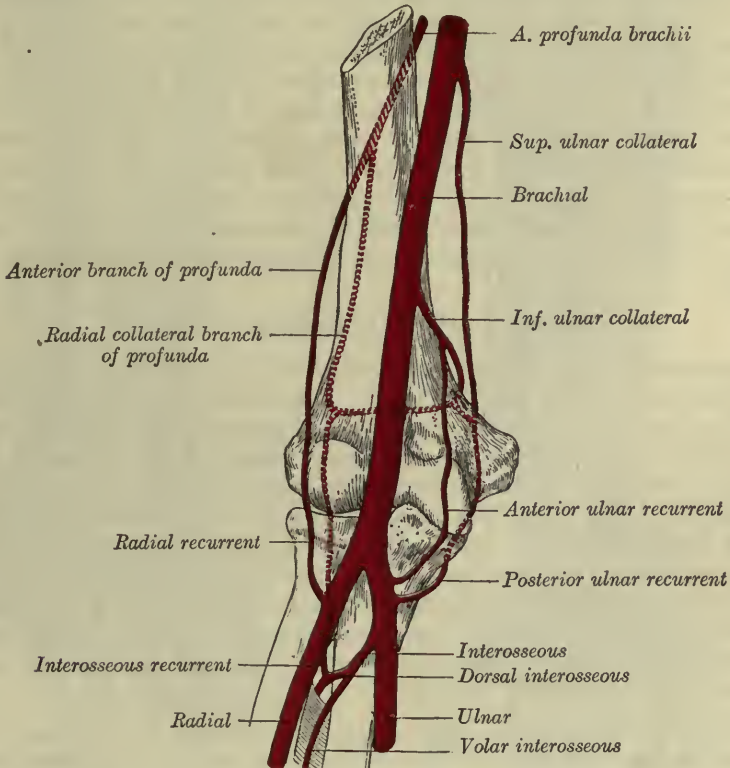


FIG. 526.—Diagram of the anastomosis around the elbow-joint.

3. The **superior ulnar collateral artery** (*a. collateralis ulnaris superior; inferior profunda artery*), of small size, arises from the brachial a little below the middle of the arm; it frequently springs from the upper part of the *a. profunda brachii*. It pierces the medial intermuscular septum, and descends on the surface of the medial head of the *Triceps brachii* to the space between the medial epicondyle and

olecranon, accompanied by the ulnar nerve, and ends under the Flexor carpi ulnaris by anastomosing with the posterior ulnar recurrent, and inferior ulnar collateral. It sometimes sends a branch in front of the medial epicondyle, to anastomose with the anterior ulnar recurrent.

4. The **inferior ulnar collateral artery** (*a. collateralis ulnaris inferior; anastomotica magna artery*) arises about 5 cm. above the elbow. It passes medialward upon the Brachialis, and piercing the medial intermuscular septum, winds around the back of the humerus between the Triceps brachii and the bone, forming, by its junction with the profunda brachii, an arch above the olecranon fossa. As the vessel lies on the Brachialis, it gives off branches which ascend to join the superior ulnar collateral: others descend in front of the medial epicondyle, to anastomose with the anterior ulnar recurrent. Behind the medial epicondyle a branch anastomoses with the superior ulnar collateral and posterior ulnar recurrent arteries.

5. The **muscular branches** (*rami musculares*) three or four in number, are distributed to the Coracobrachialis, Biceps brachii, and Brachialis.

The Anastomosis Around the Elbow-joint (Fig. 526).—The vessels engaged in this anastomosis may be conveniently divided into those situated *in front* of and those *behind* the medial and lateral epicondyles of the humerus. The branches anastomosing *in front* of the medial epicondyle are: the anterior branch of the inferior ulnar collateral, the anterior ulnar recurrent, and the anterior branch of the superior ulnar collateral. Those *behind* the medial epicondyle are: the inferior ulnar collateral, the posterior ulnar recurrent, and the posterior branch of the superior ulnar collateral. The branches anastomosing *in front* of the lateral epicondyle are: the radial recurrent and the terminal part of the profunda brachii. Those *behind* the lateral epicondyle (perhaps more properly described as being situated between the lateral epicondyle and the olecranon) are: the inferior ulnar collateral, the interosseous recurrent, and the radial collateral branch of the profunda brachii. There is also an arch of anastomosis above the olecranon, formed by the interosseous recurrent joining with the inferior ulnar collateral and posterior ulnar recurrent (Fig. 529).

The Radial Artery (A. Radialis) (Fig. 527).

The **radial artery** appears, from its direction, to be the continuation of the brachial, but it is smaller in caliber than the ulnar. It commences at the bifurcation of the brachial, just below the bend of the elbow, and passes along the radial side of the forearm to the wrist. It then winds backward, around the lateral side of the carpus, beneath the tendons of the Abductor pollicis longus and Extensores pollicis longus and brevis to the upper end of the space between the metacarpal bones of the thumb and index finger. Finally it passes forward between the two heads of the first Interosseous dorsalis, into the palm of the hand, where it crosses the metacarpal bones and at the ulnar side of the hand unites with the deep volar branch of the ulnar artery to form the deep volar arch. The radial artery therefore consists of three portions, one in the forearm, a second at the back of the wrist, and a third in the hand.

Relations.—(a) *In the forearm* the artery extends from the neck of the radius to the forepart of the styloid process, being placed to the medial side of the body of the bone above, and in front of it below. Its upper part is overlapped by the fleshy belly of the Brachioradialis; the rest of the artery is superficial, being covered by the integument and the superficial and deep fasciæ. In its course downward, it lies upon the tendon of the Biceps brachii, the Supinator, the Pronator teres, the radial origin of the Flexor digitorum sublimis, the Flexor pollicis longus, the Pronator quadratus, and the lower end of the radius. In the upper third of its course it lies between the Brachioradialis and the Pronator teres; in the lower two-thirds, between the tendons of the Brachioradialis and Flexor carpi radialis. The superficial branch of the radial nerve is close to the lateral side of the artery in the middle third of its course; and some filaments of the lateral antibrachial cutaneous nerve run along the lower part of the artery as it winds around the wrist. The vessel is accompanied by a pair of venæ comitantes throughout its whole course.

(b) At the wrist the artery reaches the back of the carpus by passing between the radial collateral ligament of the wrist and the tendons of the Abductor pollicis longus and Extensor pollicis brevis.

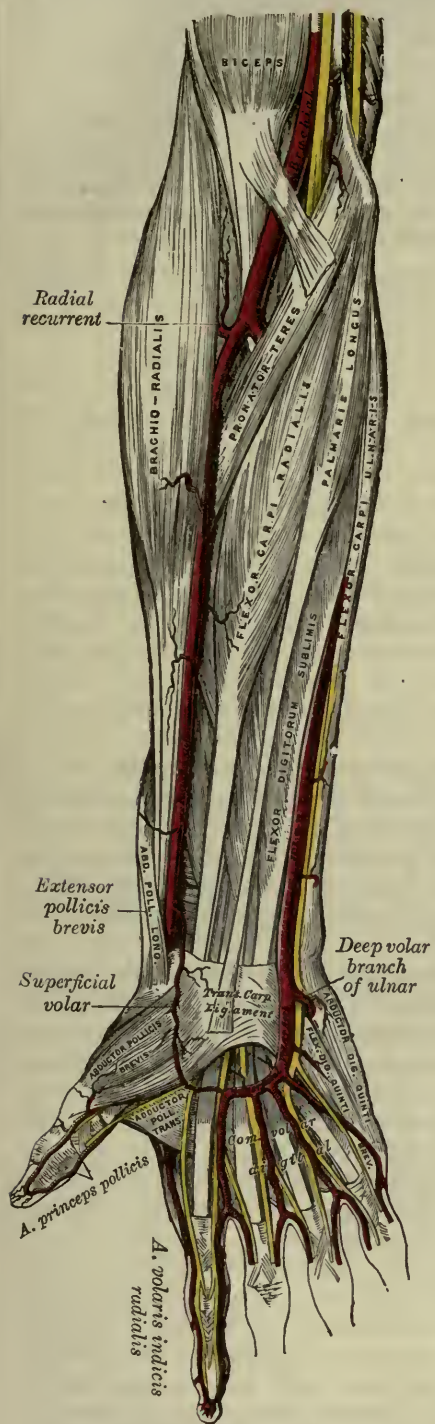


FIG. 527.—The radial and ulnar arteries.

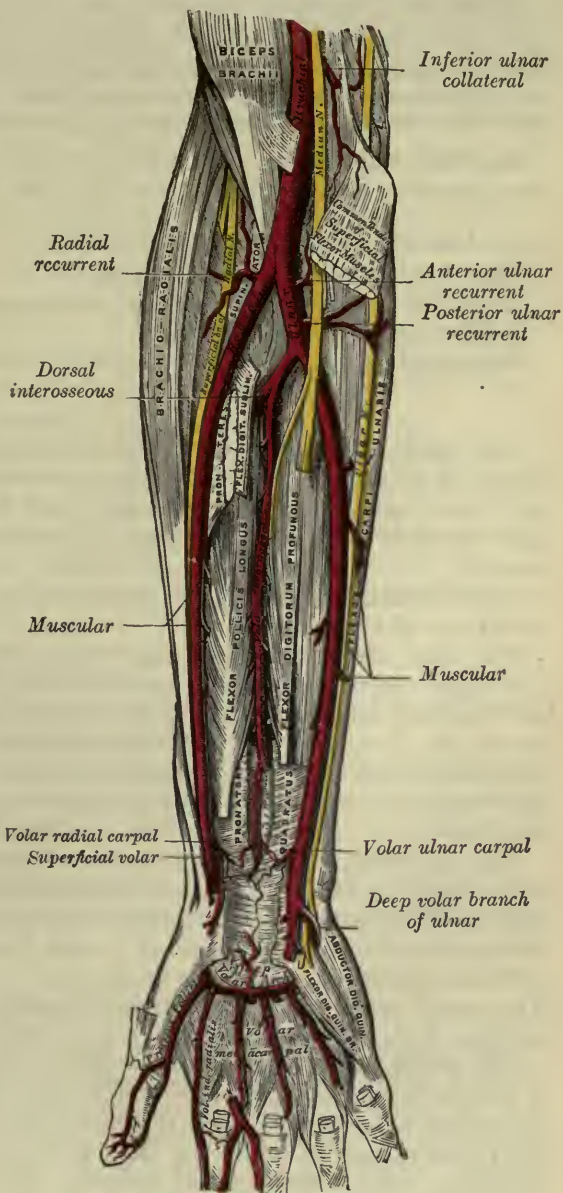


FIG. 528.—Ulnar and radial arteries. Deep view.

It then descends on the navicular and greater multangular bones, and before disappearing between the heads of the first Interosseus dorsalis is crossed by the tendon of the Extensor pollicis

longus. In the interval between the two Extensores pollicis it is crossed by the digital rami of the superficial branch of the radial nerve which go to the thumb and index finger.

(c) *In the hand*, it passes from the upper end of the first interosseous space, between the heads of the first Interosseus dorsalis, transversely across the palm between the Adductor pollicis obliquus and Adductor pollicis transversus, but sometimes piercing the latter muscle, to the base of the metacarpal bone of the little finger, where it anastomoses with the deep volar branch from the ulnar artery, completing the **deep volar arch** (Fig. 528).

Peculiarities.—The origin of the radial artery is, in nearly one case in eight, higher than usual; more often it arises from the axillary or upper part of the brachial than from the lower part of the latter vessel. In the forearm it deviates less frequently from its normal position than the ulnar. It has been found lying on the deep fascia instead of beneath it. It has also been observed on the surface of the Brachioradialis, instead of under its medial border; and in turning around the wrist, it has been seen lying on, instead of beneath, the Extensor tendons of the thumb.

Branches.—The branches of the radial artery may be divided into three groups, corresponding with the three regions in which the vessel is situated.

<i>In the Forearm.</i>	<i>At the Wrist.</i>	<i>In the Hand.</i>
Radial Recurrent.	Dorsal Carpal.	Princeps Pollicis.
Muscular.	First Dorsal Metacarpal.	Volaris Indicis Radialis.
Volar Carpal.		Volar Metacarpal.
Superficial Volar.		Perforating.
		Recurrent.

The **radial recurrent artery** (*a. recurrens radialis*) arises immediately below the elbow. It ascends between the branches of the radial nerve, lying on the Supinator and then between the Brachioradialis and Brachialis, supplying these muscles and the elbow-joint, and anastomosing with the terminal part of the profunda brachii.

The **muscular branches** (*rami musculares*) are distributed to the muscles on the radial side of the forearm.

The **volar carpal branch** (*ramus carpeus volaris; anterior radial carpal artery*) is a small vessel which arises near the lower border of the Pronator quadratus, and, running across the front of the carpus, anastomoses with the volar carpal branch of the ulnar artery. This anastomosis is joined by a branch from the volar interosseous above, and by recurrent branches from the deep volar arch below, thus forming a **volar carpal net-work** which supplies the articulations of the wrist and carpus.

The **superficial volar branch** (*ramus volaris superficialis; superficialis volar artery*) arises from the radial artery, just where this vessel is about to wind around the lateral side of the wrist. Running forward, it passes through, occasionally over, the muscles of the ball of the thumb, which it supplies, and sometimes anastomoses with the terminal portion of the ulnar artery, completing the **superficial volar arch**. This vessel varies considerably in size: usually it is very small, and ends in the muscles of the thumb; sometimes it is as large as the continuation of the radial

The **dorsal carpal branch** (*ramus carpeus dorsalis; posterior radial carpal artery*) is a small vessel which arises beneath the Extensor tendons of the thumb; crossing the carpus transversely toward the medial border of the hand, it anastomoses with the dorsal carpal branch of the ulnar and with the volar and dorsal interosseous arteries to form a **dorsal carpal network**. From this network are given off three slender **dorsal metacarpal arteries**, which run downward on the second, third, and fourth Interossei dorsales and bifurcate into the dorsal digital branches for the supply of the adjacent sides of the middle, ring, and little fingers respectively, communicating with the proper volar digital branches of the superficial volar arch. Near their origins they anastomose with the deep volar arch by the **superior perforating arteries**, and near their points of bifurcation with the common volar digital vessels of the superficial volar arch by the **inferior perforating arteries**.

The **first dorsal metacarpal** *arises* just before the radial artery passes between the two heads of the first Interosseous dorsalis and divides almost immediately into two branches which supply the adjacent sides of the thumb and index finger; the radial side of the thumb receives a branch directly from the radial artery.

The **arteria princeps pollicis** *arises* from the radial just as it turns medialward to the deep part of the hand; it descends between the first Interosseous dorsalis and Adductor pollicis obliquus, along the ulnar side of the metacarpal bone of the thumb to the base of the first phalanx, where it lies beneath the tendon of the Flexor pollicis longus and divides into two branches. These make their appearance between the medial and lateral insertions of the Adductor pollicis obliquus, and run along the sides of the thumb, forming on the volar surface of the last phalanx an arch, from which branches are distributed to the integument and subcutaneous tissue of the thumb.

The **arteria volaris indicis radialis** (*radialis indicis artery*) *arises* close to the preceding, descends between the first Interosseous dorsalis and Adductor pollicis transversus, and runs along the radial side of the index finger to its extremity, where it anastomoses with the proper digital artery, supplying the ulnar side of the finger. At the lower border of the Adductor pollicis transversus this vessel anastomoses with the princeps pollicis, and gives a communicating branch to the superficial volar arch. The a. princeps pollicis and a. volaris indicis radialis may spring from a common trunk termed the **first volar metacarpal artery**.

The **deep volar arch** (*arcus volaris profundus; deep palmar arch*) (Fig. 528) is formed by the anastomosis of the terminal part of the radial artery with the deep volar branch of the ulnar. It lies upon the carpal extremities of the metacarpal bones and on the Interossei, being covered by the Adductor pollicis obliquus, the Flexor tendons of the fingers, and the Lumbricales. Alongside of it, but running in the opposite direction—that is to say, toward the radial side of the hand—is the deep branch of the ulnar nerve.

The **volar metacarpal arteries** (*aa. metacarpeæ volares; palmar interosseous arteries*), three or four in number, arise from the convexity of the deep volar arch; they run distally upon the Interossei, and anastomose at the clefts of the fingers with the common digital branches of the superficial volar arch.

The **perforating branches** (*rami perforantes*), three in number, pass backward from the deep volar arch, through the second, third, and fourth interosseous spaces and between the heads of the corresponding Interossei dorsalis, to anastomose with the dorsal metacarpal arteries.

The **recurrent branches** *arise* from the concavity of the deep volar arch. They ascend in front of the wrist, supply the intercarpal articulations, and end in the volar carpal network.

The Ulnar Artery (A. Ulnaris) (Fig. 528).

The **ulnar artery**, the larger of the two terminal branches of the brachial, begins a little below the bend of the elbow, and, passing obliquely downward, reaches the ulnar side of the forearm at a point about midway between the elbow and the wrist. It then runs along the ulnar border to the wrist, crosses the transverse carpal ligament on the radial side of the pisiform bone, and immediately beyond this bone divides into two branches, which enter into the formation of the superficial and deep volar arches.

Relations.—(a) *In the forearm.*—In its *upper half*, it is deeply seated, being covered by the Pronator teres, Flexor carpi radialis, Palmaris longus, and Flexor digitorum sublimis; it lies upon the Brachialis and Flexor digitorum profundus. The median nerve is in relation with the medial side of the artery for about 2.5 cm. and then crosses the vessel, being separated from it by the ulnar head of the Pronator teres. In the *lower half* of the forearm it lies upon the Flexor digitorum profundus, being covered by the integument and the superficial and deep fasciæ,

and placed between the Flexor carpi ulnaris and Flexor digitorum sublimis. It is accompanied by two venæ comitantes, and is overlapped in its middle third by the Flexor carpi ulnaris; the ulnar nerve lies on the medial side of the lower two-thirds of the artery, and the palmar cutaneous branch of the nerve descends on the lower part of the vessel to the palm of the hand.

(b) *At the wrist* (Fig. 527) the ulnar artery is covered by the integument and the volar carpal ligament, and lies upon the transverse carpal ligament. On its medial side is the pisiform bone, and, somewhat behind the artery, the ulnar nerve.

Peculiarities.—The ulnar artery varies in its origin in the proportion of about one in thirteen cases; it may arise about 5 to 7 cm. below the elbow, but more frequently higher, the brachial being more often the source of origin than the axillary. Variations in the position of this vessel are more common than in the radial. When its origin is normal, the course of the vessel is rarely changed. When it arises high up, it is almost invariably superficial to the Flexor muscles in the forearm, lying commonly beneath the fascia, more rarely between the fascia and integument. In a few cases, its position was subcutaneous in the upper part of the forearm, and subaponeurotic in the lower part.

Branches.—The branches of the ulnar artery may be arranged in the following groups:

<i>In the Forearm</i>	{	Anterior Recurrent.	<i>At the Wrist</i>	{	Volar Carpal.
		Posterior Recurrent.			Dorsal Carpal.
		Common Interosseous.	<i>In the Hand</i>	{	Deep Volar.
		Muscular.			Superficial Volar Arch.

The **anterior ulnar recurrent artery** (*a. recurrentes ulnaris anterior*) arises immediately below the elbow-joint, runs upward between the Brachialis and Pronator teres, supplies twigs to those muscles, and, in front of the medial epicondyle, anastomoses with the superior and inferior ulnar collateral arteries.

The **posterior ulnar recurrent artery** (*a. recurrentes ulnaris posterior*) is much larger, and arises somewhat lower than the preceding. It passes backward and medialward on the Flexor digitorum profundus, behind the Flexor digitorum sublimis, and ascends behind the medial epicondyle of the humerus. In the interval between this process and the olecranon, it lies beneath the Flexor carpi ulnaris, and ascending between the heads of that muscle, in relation with the ulnar nerve, it supplies the neighboring muscles and the elbow-joint, and anastomoses with the superior and inferior ulnar collateral and the interosseous recurrent arteries (Fig. 529).

The **common interosseous artery** (*a. interossea communis*) (Fig. 528), about 1 cm. in length, arises immediately below the tuberosity of the radius, and, passing backward to the upper border of the interosseous membrane, divides into two branches, the **volar and dorsal interosseous arteries**.

The **Volar Interosseous Artery** (*a. interossea volaris; anterior interosseous artery*) (Fig. 528), passes down the forearm on the volar surface of the interosseous membrane. It is accompanied by the volar interosseous branch of the median nerve, and overlapped by the contiguous margins of the Flexor digitorum profundus and Flexor pollicis longus, giving off in this situation **muscular branches**, and the **nutrient arteries** of the radius and ulna. At the upper border of the Pronator quadratus it pierces the interosseous membrane and reaches the back of the forearm, where it anastomoses with the dorsal interosseous artery (Fig. 529). It then descends, in company with the terminal portion of the dorsal interosseous nerve, to the back of the wrist to join the dorsal carpal net-work. The volar interosseous artery gives off a slender branch, the **arteria mediana**, which accompanies the median nerve, and gives offsets to its substance; this artery is sometimes much enlarged, and runs with the nerve into the palm of the hand. Before it pierces the interosseous membrane the volar interosseous sends a branch downward behind the Pronator quadratus to join the volar carpal network.

The **Dorsal Interosseous Artery** (*a. interossea dorsalis; posterior interosseous artery*) (Fig. 529) passes backward between the oblique cord and the upper border of the interosseous membrane. It appears between the contiguous borders of the Supinator

and the Abductor pollicis longus, and runs down the back of the forearm between the superficial and deep layers of muscles, to both of which it distributes branches. Where it lies upon the Abductor pollicis longus and the Extensor pollicis brevis,

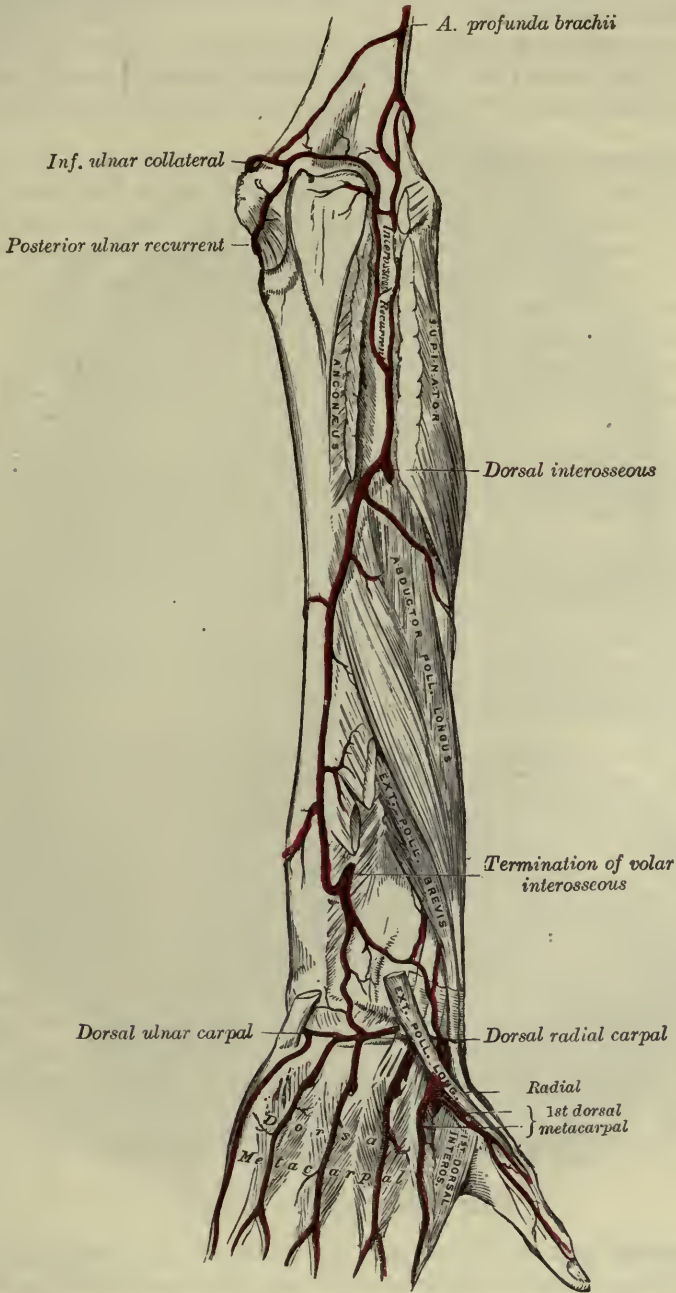


FIG. 529.—Arteries of the back of the forearm and hand.

it is accompanied by the dorsal interosseous nerve. At the lower part of the forearm it anastomoses with the termination of the volar interosseous artery, and with the dorsal carpal network. It gives off, near its origin, the **interosseous recurrent artery**, which ascends to the interval between the lateral epicondyle and olecranon,

on or through the fibers of the Supinator, but beneath the Anconæus, and anastomoses with the radial collateral branch of the profunda brachii, the posterior ulnar recurrent and the inferior ulnar collateral.

The **muscular branches** (*rami musculares*) are distributed to the muscles along the ulnar side of the forearm.

The **volar carpal branch** (*ramus carpeus volares; anterior ulnar carpal artery*) is a small vessel which crosses the front of the carpus beneath the tendons of the Flexor digitorum profundus, and anastomoses with the corresponding branch of the radial artery.

The **dorsal carpal branch** (*ramus carpeus dorsalis; posterior ulnar carpal artery*) arises immediately above the pisiform bone, and winds backward beneath the tendon of the Flexor carpi ulnaris; it passes across the dorsal surface of the carpus beneath the Extensor tendons, to anastomose with a corresponding branch of the radial artery. Immediately after its origin, it gives off a small branch, which runs along the ulnar side of the fifth metacarpal bone, and supplies the ulnar side of the dorsal surface of the little finger.

The **deep volar branch** (*ramus volaris profundus; profunda branch*) (Fig. 528) passes between the Abductor digiti quinti and Flexor digiti quinti brevis and through the origin of the Opponens digiti quinti; it anastomoses with the radial artery, and completes the deep volar arch.

The **superficial volar arch** (*arcus volaris superficialis; superficial palmar arch*) (Fig. 527) is formed by the ulnar artery, and is usually completed by a branch from the a. volaris indicis radialis, but sometimes by the superficial volar or by a branch from the a. princeps pollicis of the radial artery. The arch passes across the palm, describing a curve, with its convexity downward.

Relations.—The superficial volar arch is covered by the skin, the Palmaris brevis, and the palmar aponeurosis. It lies upon the transverse carpal ligament, the Flexor digiti quinti brevis and Opponens digiti quinti, the tendons of the Flexor digitorum sublimis, the Lumbricales, and the divisions of the median and ulnar nerves.

Three **Common Volar Digital Arteries** (*aa. digitales volares communes; palmar digital arteries*) (Fig. 527) arise from the convexity of the arch and proceed downward on the second, third, and fourth Lumbricales. Each receives the corresponding volar metacarpal artery and then divides into a pair of **proper volar digital arteries** (*aa. digitales volares propriæ; collateral digital arteries*) which run along the contiguous sides of the index, middle, ring, and little fingers, behind the corresponding digital nerves; they anastomose freely in the subcutaneous tissue of the finger tips and by smaller branches near the interphalangeal joints. Each gives off a couple of dorsal branches which anastomose with the dorsal digital arteries, and supply the soft parts on the back of the second and third phalanges, including the matrix of the finger-nail. The proper volar digital artery for medial side of the little finger springs from the ulnar artery under cover of the Palmaris brevis.

THE ARTERIES OF THE TRUNK.

THE DESCENDING AORTA.

The **descending aorta** is divided into two portions, the **thoracic** and **abdominal**, in correspondence with the two great cavities of the trunk in which it is situated.

The Thoracic Aorta (Aorta Thoracalis) (Fig. 530).

The **thoracic aorta** is contained in the posterior mediastinal cavity. It begins at the lower border of the fourth thoracic vertebra where it is continuous with the aortic arch, and ends in front of the lower border of the twelfth at the aortic

hiatus in the diaphragm. At its commencement, it is situated on the left of the vertebral column; it approaches the median line as it descends; and, at its termination, lies directly in front of the column. The vessel describes a curve which is concave forward, and as the branches given off from it are small, its diminution in size is inconsiderable.

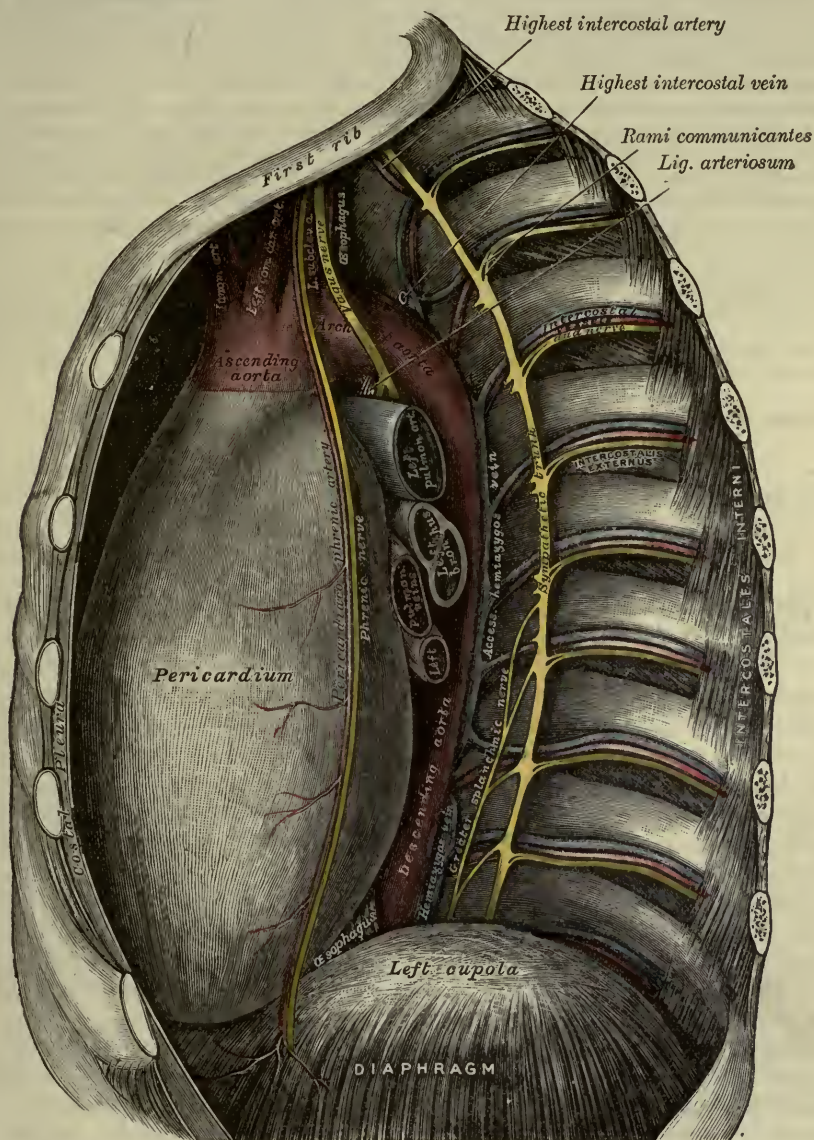


FIG. 530.—The thoracic aorta, viewed from the left side.

Relations.—It is in relation, *anteriorly*, from above downward, with the root of the left lung, the pericardium, the esophagus, and the diaphragm; *posteriorly*, with the vertebral column and the hemiazygos veins; on the *right side*, with the azygos vein and thoracic duct; on the *left side*, with the left pleura and lung. The esophagus, with its accompanying plexus of nerves, lies on the right side of the aorta above; but at the lower part of the thorax it is placed in front of the aorta, and, close to the diaphragm, is situated on its left side.

Peculiarities.—The aorta is occasionally found to be obliterated at the junction of the arch with the thoracic aorta, just below the ductus arteriosus. Whether this is the result of disease, or of congenital malformation, is immaterial to our present purpose; it affords an interesting opportunity of observing the resources of the collateral circulation. The course of the anastomosis-

ing vessels, by which the blood is brought from the upper to the lower part of the artery, will be found well described in an account of two cases in the *Pathological Transactions*, vols. viii and x. In the former, Sydney Jones thus sums up the detailed description of the anastomosing vessels: The principal communications by which the circulation was carried on were: (1) The internal mammary, anastomosing with the intercostal arteries, with the inferior phrenic of the abdominal aorta by means of the musculophrenic and pericardiacophrenic, and largely with the inferior epigastric. (2) The costocervical trunk, anastomosing anteriorly by means of a large branch with the first aortic intercostal, and posteriorly with the posterior branch of the same artery. (3) The inferior thyroid, by means of a branch about the size of an ordinary radial, forming a communication with the first aortic intercostal. (4) The transverse cervical, by means of very large communications with the posterior branches of the intercostals. (5) The branches (of the subclavian and axillary) going to the side of the chest were large, and anastomosed freely with the lateral branches of the intercostals. In the second case Wood describes the anastomoses in a somewhat similar manner, adding the remark that "the blood which was brought into the aorta through the anastomosis of the intercostal arteries appeared to be expended principally in supplying the abdomen and pelvis; while the supply to the lower extremities had passed through the internal mammary and epigastrics."

In a few cases an apparently double descending thoracic aorta has been found, the two vessels lying side by side, and eventually fusing to form a single tube in the lower part of the thorax or in the abdomen. One of them is the aorta, the other represents a dissecting aortic aneurism which has become canalized; opening above and below into the true aorta, and at first sight presenting the appearances of a proper bloodvessel.

Branches of the Thoracic Aorta.—

<i>Visceral</i>	{	Pericardial. Bronchial. Esophageal. Mediastinal.	<i>Parietal</i>	{	Intercostal. Subcostal. Superior Phrenic.
-----------------	---	---	-----------------	---	---

The **pericardial branches** (*rami pericardiaci*) consist of a few small vessels which are distributed to the posterior surface of the pericardium.

The **bronchial arteries** (*aa. bronchiales*) vary in number, size, and origin. There is as a rule only one **right bronchial artery**, which *arises* from the first aortic intercostal, or from the upper left bronchial artery. The **left bronchial arteries** are usually two in number, and *arise* from the thoracic aorta. The upper left bronchial arises opposite the fifth thoracic vertebra, the lower just below the level of the left bronchus. Each vessel runs on the back part of its bronchus, dividing and subdividing along the bronchial tubes, supplying them, the areolar tissue of the lungs, the bronchial lymph glands, and the esophagus.

The **esophageal arteries** (*aa. œsophageæ*) four or five in number, *arise* from the front of the aorta, and pass obliquely downward to the esophagus, forming a chain of anastomoses along that tube, anastomosing with the esophageal branches of the inferior thyroid arteries above, and with ascending branches from the left inferior phrenic and left gastric arteries below.

The **mediastinal branches** (*rami mediastinales*) are numerous small vessels which supply the lymph glands and loose areolar tissue in the posterior mediastinum.

Intercostal Arteries (*aa. intercostales*).—There are usually nine pairs of aortic intercostal arteries. They *arise* from the back of the aorta, and are redistributed to the lower nine intercostal spaces, the first two spaces being supplied by the highest intercostal artery, a branch of the costocervical trunk of the subclavian. The **right aortic intercostals** are longer than the left, on account of the position of the aorta on the left side of the vertebral column; they pass across the bodies of the vertebræ behind the esophagus, thoracic duct, and vena azygos, and are covered by the right lung and pleura. The **left aortic intercostals** run backward on the sides of the vertebræ and are covered by the left lung and pleura; the upper two vessels are crossed by the highest left intercostal vein, the lower vessels by the hemiazygos veins. The further course of the intercostal arteries is practically the same on both sides. Opposite the heads of the ribs the sympathetic trunk

passes downward in front of them, and the splanchnic nerves also descend in front by the lower arteries. Each artery then divides into an **anterior** and a **posterior ramus**.

The **Anterior Ramus** crosses the corresponding intercostal space obliquely toward the angle of the upper rib, and thence is continued forward in the costal groove. It is placed at first between the pleura and the posterior intercostal membrane, then it pierces this membrane, and lies between it and the Intercostalis externus as far as the angle of the rib; from this onward it runs between the Intercostales externus and internus, and anastomoses in front with the intercostal branch of the internal mammary or musculophrenic. Each artery is accompanied by a vein and a nerve, the former being above and the latter below the artery, except in the upper spaces, where the nerve is at first above the artery. The first aortic intercostal artery anastomoses with the intercostal branch of the costocervical trunk, and may form the chief supply of the second intercostal space. The lower two intercostal arteries are continued anteriorly from the intercostal spaces into the abdominal wall, and anastomose with the subcostal, superior epigastric, and lumbar arteries.

Branches.—The anterior rami give off the following branches:

Collateral Intercostal.

Lateral Cutaneous.

Muscular.

Mammary.

The **collateral intercostal branch** comes off from the intercostal artery near the angle of the rib, and descends to the upper border of the rib below, along which it courses to anastomose with the intercostal branch of the internal mammary.

Muscular branches are given to the Intercostales and Pectorales and to the Serratus anterior; they anastomose with the highest and lateral thoracic branches of the axillary artery.

The **lateral cutaneous branches** accompany the lateral cutaneous branches of the thoracic nerves.

Mammary branches are given off by the vessels in the third, fourth, and fifth spaces. They supply the mamma, and increase considerably in size during the period of lactation.

The **Posterior Ramus** runs backward through a space which is bounded above and below by the necks of the ribs, medially by the body of a vertebra, and laterally by an anterior costotransverse ligament. It gives off a **spinal branch** which enters the vertebral canal through the intervertebral foramen and is distributed to the medulla spinalis and its membranes and the vertebræ. It then courses over the transverse process with the posterior division of the thoracic nerve, supplies branches to the muscles of the back and cutaneous branches which accompany the corresponding cutaneous branches of the posterior division of the nerve.

The **subcostal arteries**, so named because they lie below the last ribs, constitute the lowest pair of branches derived from the thoracic aorta, and are in series with the intercostal arteries. Each passes along the lower border of the twelfth rib behind the kidney and in front of the Quadratus lumborum muscle; and is accompanied by the twelfth thoracic nerve. It then pierces the posterior aponeurosis of the Transversus abdominis, and, passing forward between this muscle and the Obliquus internus, anastomoses with the superior epigastric, lower intercostal, and lumbar arteries. Each subcostal artery gives off a posterior branch which has a similar distribution to the posterior ramus of an intercostal artery.

The **superior phrenic branches** are small and *arise* from the lower part of the thoracic aorta; they are distributed to the posterior part of the upper surface of the diaphragm, and anastomose with the musculophrenic and pericardiacophrenic arteries.

A small **aberrant artery** is sometimes found *arising* from the right side of the thoracic aorta near the origin of the right bronchial. It passes upward and to the right

behind the trachea and the esophagus, and may anastomose with the highest right intercostal artery. It represents the remains of the right dorsal aorta, and in a small proportion of cases is enlarged to form the first part of the right subclavian artery.

The Abdominal Aorta (Aorta Abdominalis) (Fig. 531).

The abdominal aorta begins at the aortic hiatus of the diaphragm, in front of the lower border of the body of the last thoracic vertebra, and, descending in

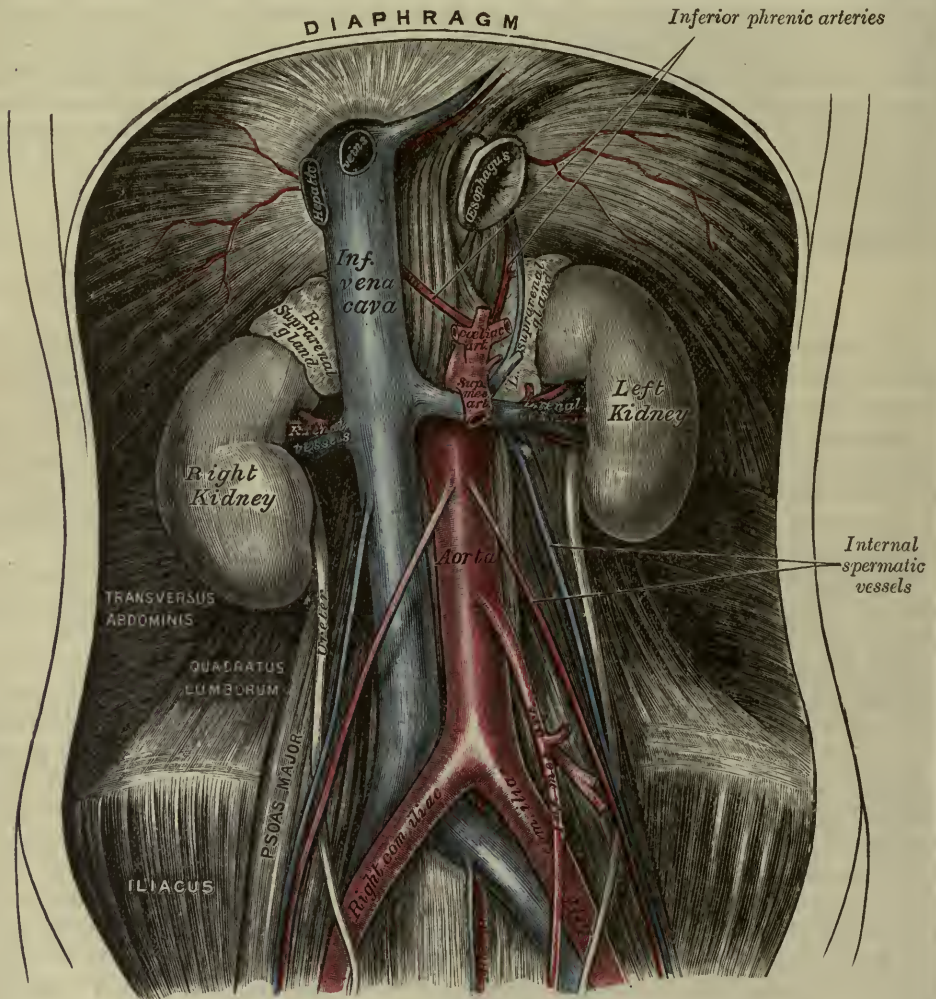


FIG. 531.—The abdominal aorta and its branches.

front of the vertebral column, ends on the body of the fourth lumbar vertebra, commonly a little to the left of the middle line,¹ by dividing into the two common iliac arteries. It diminishes rapidly in size, in consequence of the many large branches which it gives off. As it lies upon the bodies of the vertebræ, the curve which it describes is convex forward, the summit of the convexity corresponding to the third lumbar vertebra.

¹ Lord Lister, having accurately examined 30 bodies in order to ascertain the exact point of termination of this vessel, found it "either absolutely, or almost absolutely, mesial in 15, while in 13 it deviated more or less to the left, and in 2 was slightly to the right." *System of Surgery*, edited by T. Holmes, 2d ed., v, 652.

Relations.—The abdominal aorta is covered, *anteriorly*, by the lesser omentum and stomach, behind which are the branches of the celiac artery and the celiac plexus; below these, by the lienal vein, the pancreas, the left renal vein, the inferior part of the duodenum, the mesentery, and aortic plexus. *Posteriorly*, it is separated from the lumbar vertebræ and intervertebral fibrocartilages by the anterior longitudinal ligament and left lumbar veins. On the *right side* it is in relation above with the azygos vein, cisterna chyli, thoracic duct, and the right crus of the diaphragm—the last separating it from the upper part of the inferior vena cava, and from the right celiac ganglion; the inferior vena cava is in contact with the aorta below. On the *left side* are the left crus of the diaphragm, the left celiac ganglion, the ascending part of the duodenum, and some coils of the small intestine.

Collateral Circulation.—The collateral circulation would be carried on by the anastomoses between the internal mammary and the inferior epigastric; by the free communication between the superior and inferior mesenterics, if the ligature were placed between these vessels; or by the anastomosis between the inferior mesenteric and the internal pudendal, when (as is more common) the point of ligature is below the origin of the inferior mesenteric; and possibly by the anastomoses of the lumbar arteries with the branches of the hypogastric.

Branches.—The branches of the abdominal aorta may be divided into three sets: visceral, parietal, and terminal.

Visceral Branches.

Celiac.
Superior Mesenteric.
Inferior Mesenteric.
Middle Suprarenals.
Renals.
Internal Spermatics.
Ovarian (in the female).

Parietal Branches.

Inferior Phrenics.
Lumbar.
Middle Sacral.

Terminal Branches.

Common Iliacs.

Of the visceral branches, the celiac artery and the superior and inferior mesenteric arteries are unpaired, while the suprarenals, renals, internal spermatics, and ovarian are paired. Of the parietal branches the inferior phrenics and lumbar are paired; the middle sacral is unpaired. The terminal branches are paired.

The **celiac artery** (*a. cœliaca; celiac axis*) (Figs. 532, 533) is a short thick trunk, about 1.25 cm. in length, which *arises* from the front of the aorta, just below the aortic hiatus of the diaphragm, and, passing nearly horizontally forward, divides into three large branches, the **left gastric**, the **hepatic**, and the **splenic**; it occasionally gives off one of the inferior phrenic arteries.

Relations.—The celiac artery is covered by the lesser omentum. On the *right side* it is in relation with the right celiac ganglion and the caudate process of the liver; on the *left side*, with the left celiac ganglion and the cardiac end of the stomach. *Below*, it is in relation to the upper border of the pancreas, and the lienal vein.

1. The **Left Gastric Artery** (*a. gastrica sinistra; gastric or coronary artery*), the smallest of the three branches of the celiac artery, passes upward and to the left, posterior to the omental bursa, to the cardiac orifice of the stomach. Here it distributes branches to the esophagus, which anastomose with the aortic esophageal arteries; others supply the cardiac part of the stomach, anastomosing with branches of the lienal artery. It then runs from left to right, along the lesser curvature of the stomach to the pylorus, between the layers of the lesser omentum; it gives branches to both surfaces of the stomach and anastomoses with the right gastric artery.

2. The **Hepatic Artery** (*a. hepatica*) in the adult is intermediate in size between the left gastric and lienal; in the fetus, it is the largest of the three branches of the celiac artery. It is first directed forward and to the right, to the upper margin of the superior part of the duodenum, forming the lower boundary of the epiploic foramen (*foramen of Winslow*). It then crosses the portal vein anteriorly and ascends between the layers of the lesser omentum, and in front of the epiploic foramen, to the porta hepatis, where it divides into two branches, right and left, which supply the corresponding lobes of the liver, accompanying the ramifications of the

portal vein and hepatic ducts. The hepatic artery, in its course along the right border of the lesser omentum, is in relation with the common bile-duct and portal vein, the duct lying to the right of the artery, and the vein behind.

Its branches are:

Right Gastric.

Gastroduodenal } Right Gastroepiploic.
 Superior Pancreaticoduodenal.

Cystic.

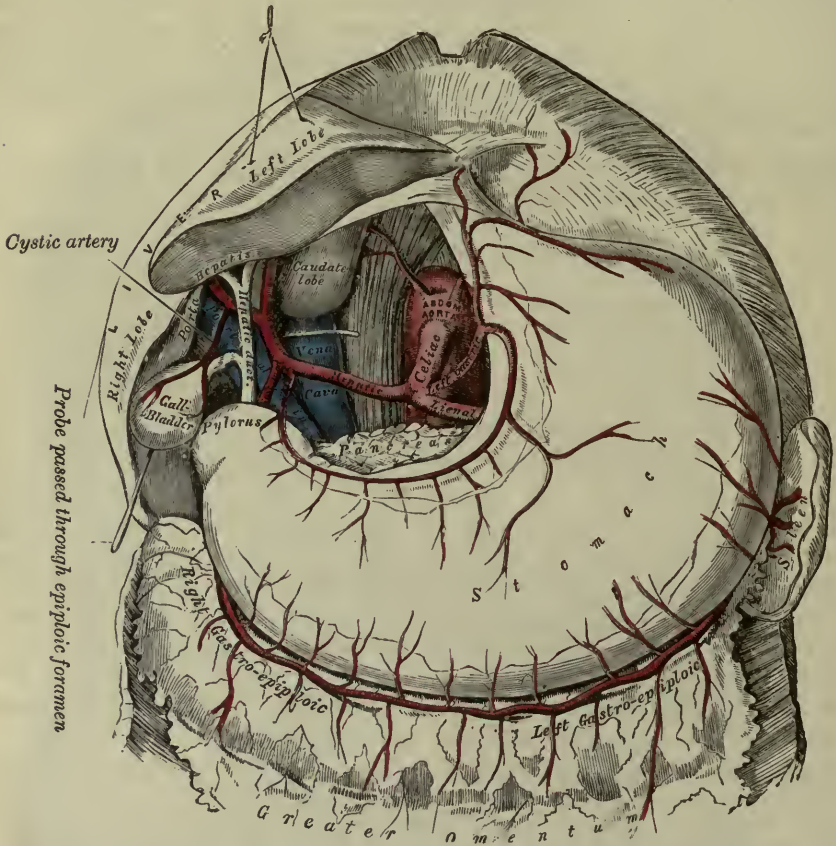


FIG. 532.—The celiac artery and its branches; the liver has been raised, and the lesser omentum and anterior layer of the greater omentum removed.

The **right gastric artery** (*a. gastrica dextra*; *pyloric artery*) arises from the hepatic, above the pylorus, descends to the pyloric end of the stomach, and passes from right to left along its lesser curvature, supplying it with branches, and anastomosing with the left gastric artery.

The **gastroduodenal artery** (*a. gastroduodenalis*) (Fig. 533) is a short but large branch, which descends, near the pylorus, between the superior part of the duodenum and the neck of the pancreas, and divides at the lower border of the duodenum into two branches, the **right gastroepiploic** and the **superior pancreaticoduodenal**. Previous to its division it gives off two or three small branches to the pyloric end of the stomach and to the pancreas.

The **right gastroepiploic artery** (*a. gastroepiploica dextra*) runs from right to left along the greater curvature of the stomach, between the layers of the greater omentum, anastomosing with the left gastroepiploic branch of the lienal artery. Except at the pylorus, where it is in contact with the stomach, it lies about a finger's

breadth from the greater curvature. This vessel gives off numerous branches, some of which ascend to supply both surfaces of the stomach, while others descend to supply the greater omentum and anastomose with branches of the middle colic.

The **superior pancreaticoduodenal artery** (*a. pancreaticoduodenalis superior*) descends between the contiguous margins of the duodenum and pancreas. It supplies both these organs, and anastomoses with the inferior pancreaticoduodenal branch of the superior mesenteric artery, and with the pancreatic branches of the lienal artery.

Branches to greater omentum

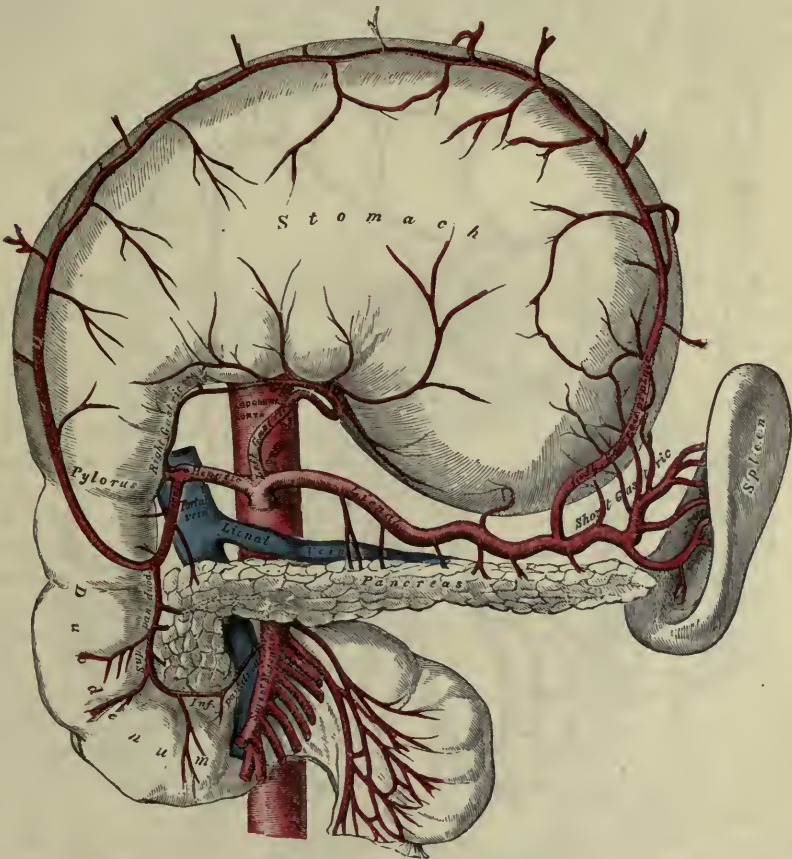


FIG. 533.—The celiac artery and its branches; the stomach has been raised and the peritoneum removed.

The **cystic artery** (*a. cystica*) (Fig. 532), usually a branch of the right hepatic, passes downward and forward along the neck of the gall-bladder, and divides into two branches, one of which ramifies on the free surface, the other on the attached surface of the gall-bladder.

3. The **Lienal or Splenic Artery** (*a. lienalis*), the largest branch of the celiac artery, is remarkable for the tortuosity of its course. It passes horizontally to the left side, behind the stomach and the omental bursa of the peritoneum, and along the upper border of the pancreas, accompanied by the lienal vein, which lies below it; it crosses in front of the upper part of the left kidney, and, on arriving near the spleen, divides into branches, some of which enter the hilus of that organ between the two layers of the phrenicolienal ligament to be distributed to the tissues of the spleen; some are given to the pancreas, while others pass to the greater curvature of the stomach between the layers of the gastrolieual ligament. Its branches are:

Pancreatic.

Short Gastric.

Left Gastroepiploic.

The **pancreatic branches** (*rami pancreatici*) are numerous small vessels derived from the lienal as it runs behind the upper border of the pancreas, supplying its body and tail. One of these, larger than the rest, is sometimes given off near the tail of the pancreas; it runs from left to right near the posterior surface of the gland, following the course of the pancreatic duct, and is called the **arteria pancreatica magna**. These vessels anastomose with the pancreatic branches of the pancreatico-duodenal and superior mesenteric arteries.

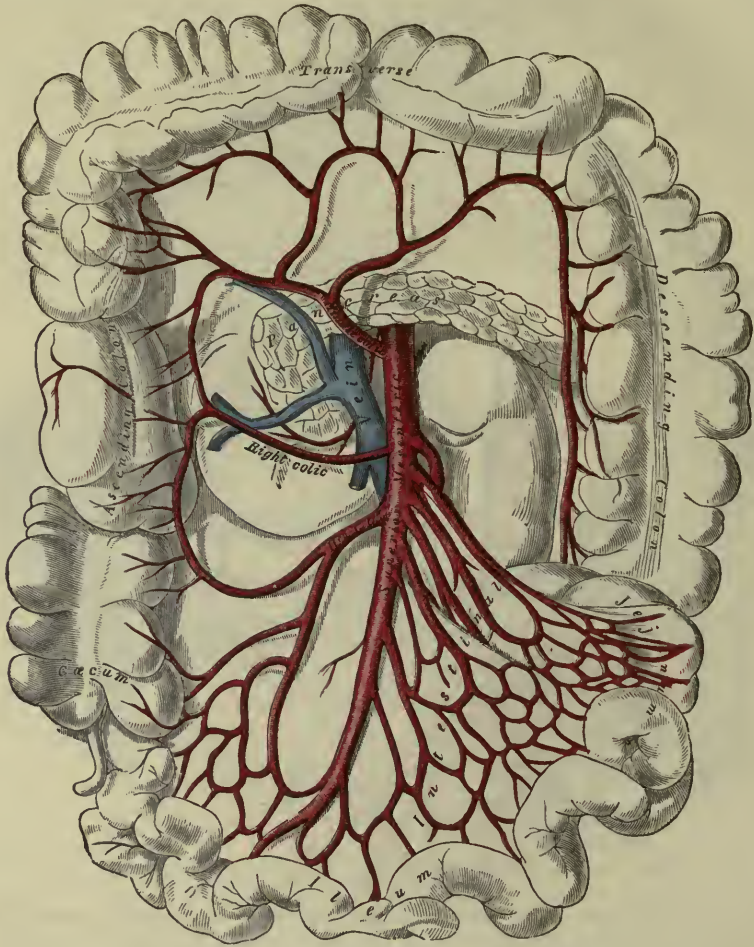


FIG. 534.—The superior mesenteric artery and its branches.

The **short gastric arteries** (*aa. gastricae breves; vasa brevia*) consist of from five to seven small branches, which arise from the end of the lienal artery, and from its terminal divisions. They pass from left to right, between the layers of the gastro-lienal ligament, and are distributed to the greater curvature of the stomach, anastomosing with branches of the left gastric and left gastroepiploic arteries.

The **left gastroepiploic artery** (*a. gastroepiploica sinistra*) the largest branch of the lienal, runs from left to right about a finger's breadth or more from the greater curvature of the stomach, between the layers of the greater omentum, and anastomoses with the right gastroepiploic. In its course it distributes several ascending branches to both surfaces of the stomach; others descend to supply the greater omentum and anastomose with branches of the middle colic.

The **superior mesenteric artery** (*a. mesenterica superior*) (Fig. 534) is a large

vessel which supplies the whole length of the small intestine, except the superior part of the duodenum; it also supplies the cecum and the ascending part of the colon and about one-half of the transverse part of the colon. It arises from the front of the aorta, about 1.25 cm. below the celiac artery, and is crossed at its origin by the lienal vein and the neck of the pancreas. It passes downward and forward, anterior to the processus uncinatus of the head of the pancreas and inferior part of the duodenum, and descends between the layers of the mesentery to the right iliac fossa, where, considerably diminished in size, it anastomoses with one of its own branches, viz., the ileocolic. In its course it crosses in front of the inferior vena cava, the right ureter and Psoas major, and forms an arch, the convexity of which is directed forward and downward to the left side, the concavity backward and upward to the right. It is accompanied by the superior mesenteric vein, which lies to its right side, and it is surrounded by the superior mesenteric plexus of nerves.

Branches.—Its branches are:

Inferior Pancreaticoduodenal.
Intestinal.

Ileocolic.
Right Colic.

Middle Colic.

The **Inferior Pancreaticoduodenal Artery** (*a. pancreaticoduodenalis inferior*) is given off from the superior mesenteric or from its first intestinal branch, opposite the upper border of the inferior part of the duodenum. It courses to the right between the head of the pancreas and duodenum, and then ascends to anastomose with the superior pancreaticoduodenal artery. It distributes branches to the head of the pancreas and to the descending and inferior parts of the duodenum.

The **Intestinal Arteries** (*aa. intestinales; vasa intestini tenuis*) arise from the convex side of the superior mesenteric artery. They are usually from twelve to fifteen in number, and are distributed to the jejunum and ileum. They run nearly parallel with one another between the layers of the mesentery, each vessel dividing into two branches, which unite with adjacent branches, forming a series of arches, the convexities of which are directed toward the intestine (Fig. 535). From this first set of arches branches arise, which unite with similar branches from above and below and thus a second series of arches is formed; from the lower branches of the artery, a third, a fourth, or even a fifth series of arches may be formed, diminishing in size the nearer they approach the intestine. In the short, upper part of the mesentery only one set of arches exists, but as the depth of the mesentery increases, second, third, fourth, or even fifth groups are developed. From the terminal arches numerous small straight vessels arise which encircle the intestine, upon which they are distributed, ramifying between its coats. From the intestinal arteries small branches are given off to the lymph glands and other structures between the layers of the mesentery.

The **Ileocolic Artery** (*a. ileocolica*) is the lowest branch arising from the concavity of the superior mesenteric artery. It passes downward and to the right behind the peritoneum toward the right iliac fossa, where it divides into a superior and an inferior branch; the inferior anastomoses with the end of the superior mesenteric artery, the superior with the right colic artery.

The inferior branch of the ileocolic runs toward the upper border of the ileocolic junction and supplies the following branches (Fig. 536):

(a) **colic**, which pass upward on the ascending colon; (b) **anterior** and **posterior cecal**, which are distributed to the front and back of the cecum; (c) an **appendicular artery**, which descends behind the termination of the ileum and enters the mesenteriole of the vermiform process; it runs near the free margin of this mesenteriole and ends in branches which supply the vermiform process; and (d) **ileal**, which run upward and to the left on the lower part of the ileum, and anastomose with the termination of the superior mesenteric.

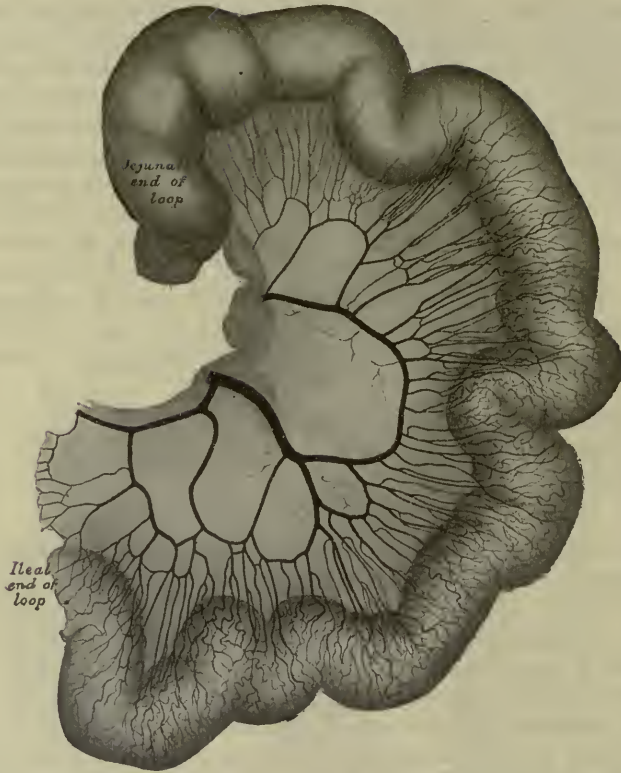


FIG. 535.—Loop of small intestine showing distribution of intestinal arteries. (From a preparation by Mr. Hamilton Drummond.) The vessels were injected while the gut was *in situ*; the gut was then removed, and an x-ray photograph taken.

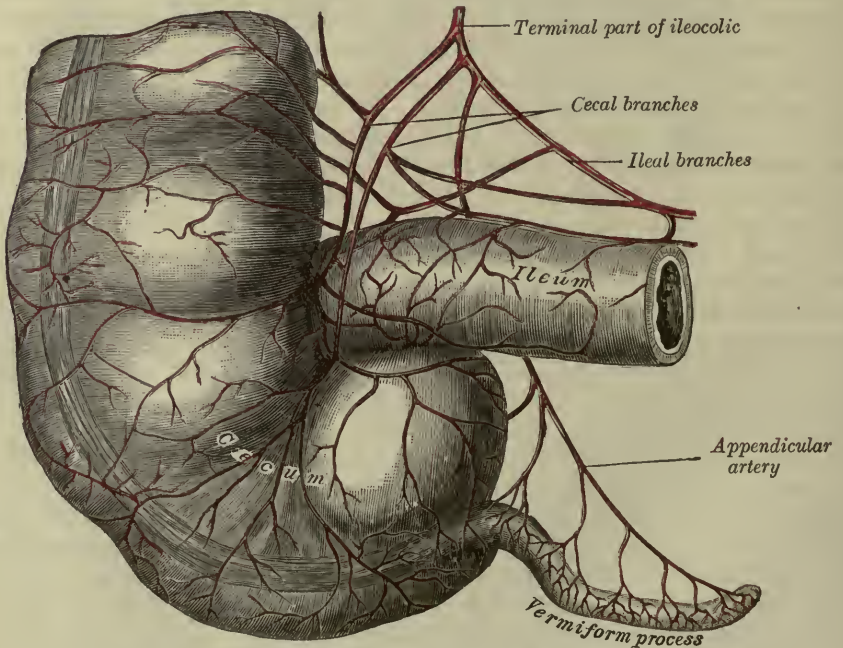


FIG. 536.—Arteries of cecum and vermiform process.

The **Right Colic Artery** (*a. colica dextra*) arises from about the middle of the concavity of the superior mesenteric artery, or from a stem common to it and the ileocolic. It passes to the right behind the peritoneum, and in front of the right internal spermatic or ovarian vessels, the right ureter and the Psoas major, toward the middle of the ascending colon; sometimes the vessel lies at a higher level, and crosses the descending part of the duodenum and the lower end of the right kidney. At the colon it divides into a descending branch, which anastomoses with the ileocolic, and an ascending branch, which anastomoses with the middle colic. These branches form arches, from the convexity of which vessels are distributed to the ascending colon.

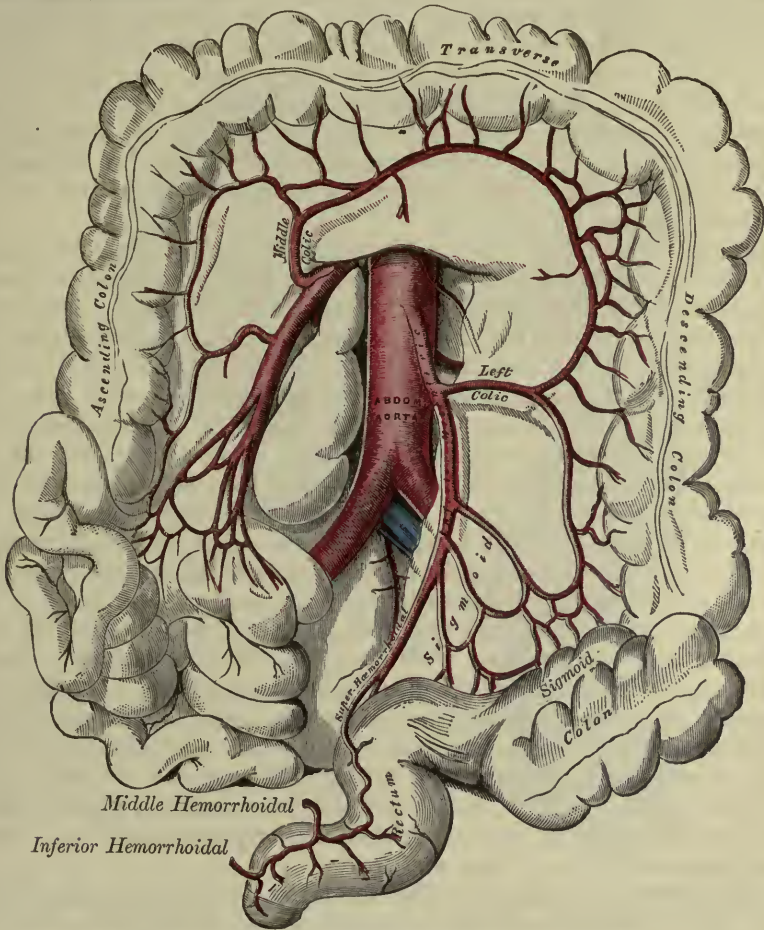


FIG. 537.—The inferior mesenteric artery and its branches.

The **Middle Colic Artery** (*a. colica media*) arises from the superior mesenteric just below the pancreas and, passing downward and forward between the layers of the transverse mesocolon, divides into two branches, right and left; the former anastomoses with the right colic; the latter with the left colic, a branch of the inferior mesenteric. The arches thus formed are placed about two fingers' breadth from the transverse colon, to which they distribute branches.

The **inferior mesenteric artery** (*a. mesenterica inferior*) (Fig. 537) supplies the left half of the transverse part of the colon, the whole of the descending and iliac parts of the colon, the sigmoid colon, and the greater part of the rectum. It is smaller than the superior mesenteric, and arises from the aorta, about 3 or 4 cm.

above its division into the common iliacs and close to the lower border of the inferior part of the duodenum. It passes downward posterior to the peritoneum, lying at first anterior to and then on the left side of the aorta. It crosses the left common iliac artery and is continued into the lesser pelvis under the name of the **superior hemorrhoidal artery**, which descends between the two layers of the sigmoid mesocolon and ends on the upper part of the rectum.

Branches.—Its branches are:

Left Colic.

Sigmoid.

Superior Hemorrhoidal.

The **Left Colic Artery** (*a. colica sinistra*) runs to the left behind the peritoneum and in front of the Psoas major, and after a short, but variable, course divides into an ascending and a descending branch; the stem of the artery or its branches cross the left ureter and left internal spermatic vessels. The ascending branch crosses in front of the left kidney and ends, between the two layers of the transverse mesocolon, by anastomosing with the middle colic artery; the descending branch anastomoses with the highest sigmoid artery. From the arches formed by these anastomoses branches are distributed to the descending colon and the left part of the transverse colon.

The **Sigmoid Arteries** (*aa. sigmoideæ*) (Fig. 53S), two or three in number, run obliquely downward and to the left behind the peritoneum and in front of the Psoas major, ureter, and internal spermatic vessels. Their branches supply the lower part of the descending colon, the iliac colon, and the sigmoid or pelvic colon; anastomosing above with the left colic, and below with the superior hemorrhoidal artery.

The **Superior Hemorrhoidal Artery** (*a. hæmorrhoidalis superior*) (Fig. 53S), the continuation of the inferior mesenteric, descends into the pelvis between the layers of the mesentery of the sigmoid colon, crossing, in its course, the left common iliac vessels. It divides, opposite the third sacral vertebra, into two branches, which descend one on either side of the rectum, and about 10 or 12 cm. from the anus break up into several small branches. These pierce the muscular coat of the bowel and run downward, as straight vessels, placed at regular intervals from each other in the wall of the gut between its muscular and mucous coats, to the level of the Sphincter ani internus; here they form a series of loops around the lower end of the rectum, and communicate with the middle hemorrhoidal branches of the hypogastric, and with the inferior hemorrhoidal branches of the internal pudendal.

The **middle suprarenal arteries** (*aa. suprarenales media; middle capsular arteries; suprarenal arteries*) are two small vessels which arise, one from either side of the aorta, opposite the superior mesenteric artery. They pass lateralward and slightly upward, over the crura of the diaphragm, to the suprarenal glands, where they anastomose with suprarenal branches of the inferior phrenic and renal arteries. In the fetus these arteries are of large size.

The **renal arteries** (*aa. renales*) (Fig. 531), are two large trunks, which arise from the side of the aorta, immediately below the superior mesenteric artery. Each is directed across the crus of the diaphragm, so as to form nearly a right angle with the aorta. The right is longer than the left, on account of the position of the aorta; it passes behind the inferior vena cava, the right renal vein, the head of the pancreas, and the descending part of the duodenum. The left is somewhat higher than the right; it lies behind the left renal vein, the body of the pancreas and the lienal vein, and is crossed by the inferior mesenteric vein. Before reaching the hilus of the kidney, each artery divides into four or five branches; the greater number of these lie between the renal vein and ureter, the vein being in front, the ureter behind, but one or more branches are usually situated behind the ureter. Each vessel gives off some small **inferior suprarenal branches** to the suprarenal gland, the ureter, and the surrounding cellular tissue and muscles. One or two accessory renal arteries are frequently found, more especially on the left side

they usually arise from the aorta, and may come off above or below the main artery, the former being the more common position. Instead of entering the kidney at the hilus, they usually pierce the upper or lower part of the gland.

The **internal spermatic arteries** (*aa. spermaticæ internæ; spermatic arteries*) (Fig. 531) are distributed to the testes. They are two slender vessels of considerable length, and *arise* from the front of the aorta a little below the renal arteries. Each passes obliquely downward and lateralward behind the peritoneum, resting on the Psoas major, the right spermatic lying in front of the inferior vena cava and behind the middle colic and ileocolic arteries and the terminal part of the ileum, the left behind the left colic and sigmoid arteries and the iliac colon. Each crosses obliquely over the ureter and the lower part of the external iliac artery

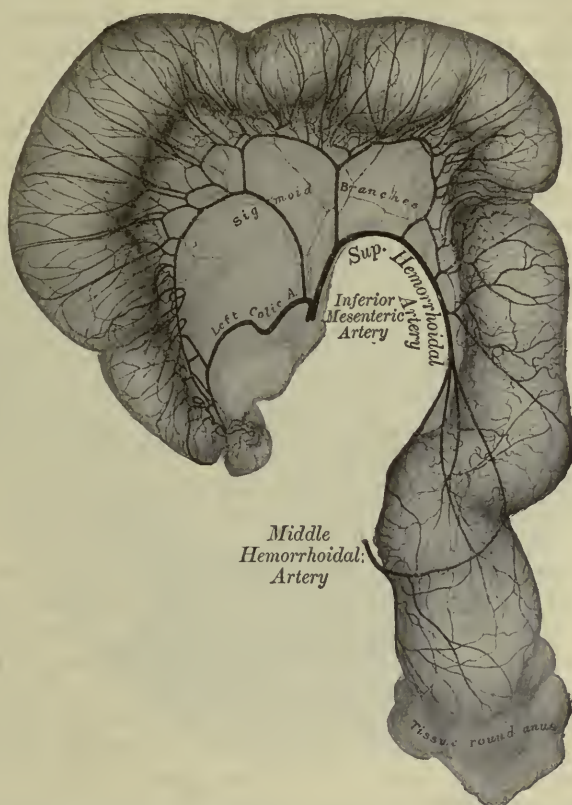


FIG. 538.—Sigmoid colon and rectum, showing distribution of branches of inferior mesenteric artery and their anastomoses. (From a preparation by Mr. Hamilton Drummond.) Prepared in same manner as Fig. 535.

to reach the abdominal inguinal ring, through which it passes, and accompanies the other constituents of the spermatic cord along the inguinal canal to the scrotum, where it becomes tortuous, and divides into several branches. Two or three of these accompany the ductus deferens, and supply the epididymis, anastomosing with the artery of the ductus deferens; others pierce the back part of the tunica albuginea, and supply the substance of the testis. The internal spermatic artery supplies one or two small branches to the ureter, and in the inguinal canal gives one or two twigs to the Cremaster.

The **ovarian arteries** (*aa. ovaricæ*) are the corresponding arteries in the female to the internal spermatic in the male. They supply the ovaries, are shorter than the internal spermatics, and do not pass out of the abdominal cavity. The origin and course of the first part of each artery are the same as those of the internal

spermatic, but on arriving at the upper opening of the lesser pelvis the ovarian artery passes inward, between the two layers of the ovario pelvic ligament and of the broad ligament of the uterus, to be distributed to the ovary. Small branches are given to the ureter and the uterine tube, and one passes on to the side of the uterus, and unites with the uterine artery. Other offsets are continued on the round ligament of the uterus, through the inguinal canal, to the integument of the labium majus and groin.

At an early period of fetal life, when the testes or ovaries lie by the side of the vertebral column, below the kidneys, the internal spermatic or ovarian arteries are short; but with the descent of these organs into the scrotum or lesser pelvis, the arteries are gradually lengthened.

The **inferior phrenic arteries** (*aa. phrenicæ inferiores*) (Fig. 531) are two small vessels, which supply the diaphragm but present much variety in their origin. They may *arise* separately from the front of the aorta, immediately above the celiac artery, or by a common trunk, which may spring either from the aorta or from the celiac artery. Sometimes one is derived from the aorta, and the other from one of the renal arteries; they rarely arise as separate vessels from the aorta. They diverge from one another across the crura of the diaphragm, and then run obliquely upward and lateralward upon its under surface. The left phrenic passes behind the esophagus, and runs forward on the left side of the esophageal hiatus. The right phrenic passes behind the inferior vena cava, and along the right side of the foramen which transmits that vein. Near the back part of the central tendon each vessel divides into a medial and a lateral branch. The **medial branch** curves forward, and anastomoses with its fellow of the opposite side, and with the musculophrenic and pericardiophrenic arteries. The **lateral branch** passes toward the side of the thorax, and anastomoses with the lower intercostal arteries, and with the musculophrenic. The lateral branch of the right phrenic gives off a few vessels to the inferior vena cava; and the left one, some branches to the esophagus. Each vessel gives off **superior suprarenal branches** to the suprarenal gland of its own side. The spleen and the liver also receive a few twigs from the left and right vessels respectively.

The **lumbar arteries** (*aa. lumbales*) are in series with the intercostals. They are usually four in number on either side, and *arise* from the back of the aorta, opposite the bodies of the upper four lumbar vertebræ. A fifth pair, small in size, is occasionally present: they *arise* from the middle sacral artery. They run lateralward and backward on the bodies of the lumbar vertebræ, behind the sympathetic trunk, to the intervals between the adjacent transverse processes, and are then continued into the abdominal wall. The arteries of the right side pass behind the inferior vena cava, and the upper two on each side run behind the corresponding crus of the diaphragm. The arteries of both sides pass beneath the tendinous arches which give origin to the Psoas major, and are then continued behind this muscle and the lumbar plexus. They now cross the Quadratus lumborum, the upper three arteries running behind, the last usually in front of the muscle. At the lateral border of the Quadratus lumborum they pierce the posterior aponeurosis of the Transversus abdominis and are carried forward between this muscle and the Obliquus internus. They anastomose with the lower intercostal, the subcostal, the iliolumbar, the deep iliac circumflex, and the inferior epigastric arteries.

Branches.—In the interval between the adjacent transverse processes each lumbar artery gives off a **posterior ramus** which is continued backward between the transverse processes and is distributed to the muscles and skin of the back; it furnishes a **spinal branch** which enters the vertebral canal and is distributed in a manner similar to the spinal branches of the posterior rami of the intercostal arteries (page 601). **Muscular branches** are supplied from each lumbar artery and from its posterior ramus to the neighboring muscles.

The **middle sacral artery** (*a. sacralis media*) (Fig. 531) is a small vessel, which arises from the back of the aorta, a little above its bifurcation. It descends in the middle line in front of the fourth and fifth lumbar vertebræ, the sacrum and coccyx, and ends in the glomus coccygeum (*coccygeal gland*). From it, minute branches are said to pass to the posterior surface of the rectum. On the last lumbar vertebra it anastomoses with the lumbar branch of the iliolumbar artery; in front of the sacrum it anastomoses with the lateral sacral arteries, and sends offsets into the anterior sacral foramina. It is crossed by the left common iliac vein, and is accompanied by a pair of venæ comitantes; these unite to form a single vessel, which opens into the left common iliac vein.

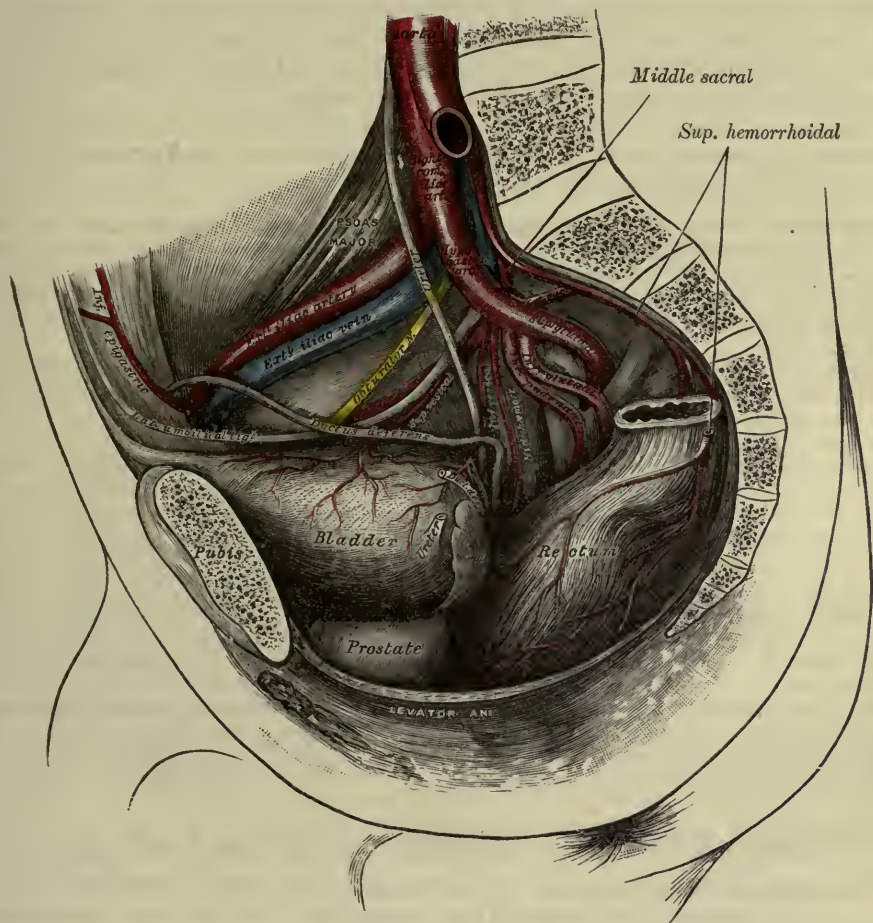


FIG. 539.—The arteries of the pelvis.

THE COMMON ILIAC ARTERIES (AA. ILIACÆ COMMUNES) (Figs. 531, 539).

The abdominal aorta divides, on the left side of the body of the fourth lumbar vertebra, into the two **common iliac arteries**. Each is about 5 cm. in length. They diverge from the termination of the aorta, pass downward and lateralward, and divide, opposite the intervertebral fibrocartilage between the last lumbar vertebra and the sacrum, into two branches, the **external iliac** and **hypogastric arteries**; the former supplies the lower extremity; the latter, the viscera and parietes of the pelvis.

The **right common iliac artery** (Fig. 539) is somewhat longer than the left, and passes more obliquely across the body of the last lumbar vertebra. *In front of* it are the peritoneum, the small intestines, branches of the sympathetic nerves, and, at its point of division, the ureter. *Behind*, it is separated from the bodies of the fourth and fifth lumbar vertebræ, and the intervening fibrocartilage, by the terminations of the two common iliac veins and the commencement of the inferior vena cava. *Laterally*, it is in relation, above, with the inferior vena cava and the right common iliac vein; and, below, with the Psoas major. *Medial* to it, above, is the left common iliac vein.

The **left common iliac artery** is in relation, *in front*, with the peritoneum, the small intestines, branches of the sympathetic nerves, and the superior hemorrhoidal artery; and is crossed at its point of bifurcation by the ureter. It rests on the bodies of the fourth and fifth lumbar vertebræ, and the intervening fibrocartilage. The left common iliac vein lies partly *medial* to, and partly behind the artery; *laterally*, the artery is in relation with the Psoas major.

Branches.—The common iliac arteries give off small branches to the peritoneum, Psoas major, ureters, and the surrounding areolar tissue, and occasionally give origin to the iliolumbar, or accessory renal arteries.

Peculiarities.—The *point of origin* varies according to the bifurcation of the aorta. In three-fourths of a large number of cases, the aorta bifurcated either upon the fourth lumbar vertebra, or upon the fibrocartilage between it and the fifth; the bifurcation being, in one case out of nine, below, and in one out of eleven, above this point. In about 80 per cent. of the cases the aorta bifurcated within 1.25 cm. above or below the level of the crest of the ilium; more frequently below than above.

The *point of division* is subject to great variety. In two-thirds of a large number of cases it was between the last lumbar vertebra and the upper border of the sacrum; being above that point in one case out of eight, and below it in one case out of six. The left common iliac artery divides lower down more frequently than the right.

The *relative lengths*, also, of the two common iliac arteries vary. The right common iliac was the longer in sixty-three cases; the left in fifty-two; while they were equal in fifty-three. The length of the arteries varied, in five-sevenths of the cases examined, from 3.5 to 7.5 cm.; in about half of the remaining cases the artery was longer, and in the other half, shorter; the minimum length being less than 1.25 cm., the maximum, 11 cm. In rare instances, the right common iliac has been found wanting, the external iliac and hypogastric arising directly from the aorta.

Collateral Circulation.—The principal agents in carrying on the collateral circulation after the application of a ligature to the common iliac are: the anastomoses of the hemorrhoidal branches of the hypogastric with the superior hemorrhoidal from the inferior mesenteric; of the uterine, ovarian, and vesical arteries of the opposite sides; of the lateral sacral with the middle sacral artery; of the inferior epigastric with the internal mammary, inferior intercostal, and lumbar arteries; of the deep iliac circumflex with the lumbar arteries; of the iliolumbar with the last lumbar artery; of the obturator artery, by the means of its pubic branch, with the vessel of the opposite side and with the inferior epigastric.

The Hypogastric Artery (A. Hypogastrica; Internal Iliac Artery) (Fig. 539).

The **hypogastric artery** supplies the walls and viscera of the pelvis, the buttock, the generative organs, and the medial side of the thigh. It is a short, thick vessel, smaller than the external iliac, and about 4 cm. in length. It *arises* at the bifurcation of the common iliac, opposite the lumbosacral articulation, and, passing downward to the upper margin of the greater sciatic foramen, divides into two large trunks, an **anterior** and a **posterior**.

Relations.—It is in relation *in front* with the ureter; *behind*, with the internal iliac vein, the lumbosacral trunk, and the Piriformis muscle; *laterally*, near its origin, with the external iliac vein, which lies between it and the Psoas major muscle; lower down, with the obturator nerve.

In the fetus, the hypogastric artery is twice as large as the external iliac, and is the direct continuation of the common iliac. It ascends along the side of the bladder, and runs upward on the back of the anterior wall of the abdomen to the umbilicus, converging toward its fellow of the opposite side. Having passed through

the umbilical opening, the two arteries, now termed **umbilical**, enter the umbilical cord, where they are coiled around the umbilical vein, and ultimately ramify in the placenta.

At birth, when the placental circulation ceases, the pelvic portion only of the artery remains patent and constitutes the hypogastric and the first part of the superior vesical artery of the adult; the remainder of the vessel is converted into a solid fibrous cord, the **lateral umbilical ligament** (*obliterated hypogastric artery*) which extends from the pelvis to the umbilicus.

Peculiarities as Regards Length.—In two-thirds of a large number of cases, the length of the hypogastric varied between 2.25 and 3.4 cm.; in the remaining third it was more frequently longer than shorter, the maximum length being about 7 cm. the minimum about 1 cm.

The lengths of the common iliac and hypogastric arteries bear an inverse proportion to each other, the hypogastric artery being long when the common iliac is short, and *vice versa*.

As Regards its Place of Division.—The place of division of the hypogastric varies between the upper margin of the sacrum and the upper border of the greater sciatic foramen.

The right and left hypogastric arteries in a series of cases often differed in length, but neither seemed constantly to exceed the other.

Collateral Circulation.—The circulation after ligature of the hypogastric artery is carried on by the anastomoses of the uterine and ovarian arteries; of the vesical arteries of the two sides; of the hemorrhoidal branches of the hypogastric with those from the inferior mesenteric; of the obturator artery, by means of its pubic branch, with the vessel of the opposite side, and with the inferior epigastric and medial femoral circumflex; of the circumflex and perforating branches of the profunda femoris with the inferior gluteal; of the superior gluteal with the posterior branches of the lateral sacral arteries; of the iliolumbar with the last lumbar; of the lateral sacral with the middle sacral; and of the iliac circumflex with the iliolumbar and superior gluteal.¹

Branches.—The branches of the hypogastric artery are:

From the Anterior Trunk.

Superior Vesical.
Middle Vesical.
Inferior Vesical.
Middle Hemorrhoidal.
Obturator.
Internal Pudendal.
Inferior Gluteal.
Uterine }
Vaginal } *In the Female.*

From the Posterior Trunk.

Iliolumbar.
Lateral Sacral.
Superior Gluteal.

The **superior vesical artery** (*a. vesicalis superior*) supplies numerous branches to the upper part of the bladder. From one of these a slender vessel, the **artery to the ductus deferens**, takes origin and accompanies the duct in its course to the testis, where it anastomoses with the internal spermatic artery. Other branches supply the ureter. The first part of the superior vesical artery represents the terminal section of the pervious portion of the fetal hypogastric artery.

The **middle vesical artery** (*a. vesicalis medialis*), usually a branch of the superior, is distributed to the fundus of the bladder and the vesiculæ seminales.

The **inferior vesical artery** (*a. vesicalis inferior*) frequently arises in common with the middle hemorrhoidal, and is distributed to the fundus of the bladder, the prostate, and the vesiculæ seminales. The branches to the prostate communicate with the corresponding vessels of the opposite side.

The **middle hemorrhoidal artery** (*a. hæmorrhoidalis media*) usually arises with the preceding vessel. It is distributed to the rectum, anastomosing with the inferior vesical and with the superior and inferior hemorrhoidal arteries. It gives offshoots to the vesiculæ seminales and prostate.

The **uterine artery** (*a. uterina*) (Fig. 540) springs from the anterior division of

¹ For a description of a case in which Owen made a dissection ten years after ligature of the hypogastric artery, see *Med.-Chir. Trans.*, vol. xvi.

the hypogastric and runs medialward on the Levator ani and toward the cervix uteri; about 2 cm. from the cervix it crosses above and in front of the ureter, to which it supplies a small branch. Reaching the side of the uterus it ascends in a tortuous manner between the two layers of the broad ligament to the junction of the uterine tube and uterus. It then runs lateralward toward the hilus of the ovary, and ends by joining with the ovarian artery. It supplies branches to the cervix uteri and others which descend on the vagina; the latter anastomose with branches of the vaginal arteries and form with them two median longitudinal vessels—the **azygos arteries of the vagina**—one of which runs down in front of and the other behind the vagina. It supplies numerous branches to the body of the uterus, and from its terminal portion twigs are distributed to the uterine tube and the round ligament of the uterus.

The **vaginal artery** (*a. vaginalis*) usually corresponds to the inferior vesical in the male; it descends upon the vagina, supplying its mucous membrane, and sends branches to the bulb of the vestibule, the fundus of the bladder, and the contiguous part of the rectum. It assists in forming the azygos arteries of the vagina, and is frequently represented by two or three branches.

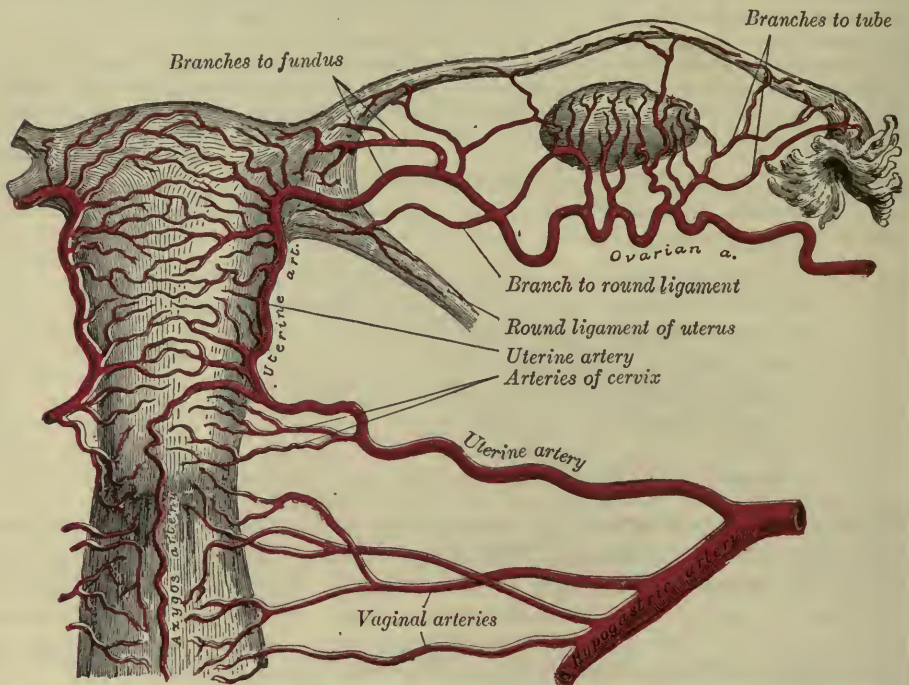


FIG. 540.—The arteries of the internal organs of generation of the female, seen from behind. (After Hyrtl.)

The **obturator artery** (*a. obturatoria*) passes forward and downward on the lateral wall of the pelvis, to the upper part of the obturator foramen, and, escaping from the pelvic cavity through the obturator canal, it divides into an **anterior** and a **posterior branch**. In the pelvic cavity this vessel is in relation, laterally, with the obturator fascia; medially, with the ureter, ductus deferens, and peritoneum; while a little below it is the obturator nerve.

Branches.—*Inside the pelvis* the obturator artery gives off **iliac branches** to the iliac fossa, which supply the bone and the Iliacus, and anastomose with the ilio-lumbar artery; a **vesical branch**, which runs backward to supply the bladder; and a **pubic branch**, which is given off from the vessel just before it leaves the pelvic cavity. The pubic branch ascends upon the back of the pubis, communicating

with the corresponding vessel of the opposite side, and with the inferior epigastric artery.

Outside the pelvis, the obturator artery divides at the upper margin of the obturator foramen, into an anterior and a posterior branch which encircle the foramen under cover of the Obturator externus.

The **anterior branch** runs forward on the outer surface of the obturator membrane and then curves downward along the anterior margin of the foramen. It distributes branches to the Obturator externus, Pectineus, Adductores, and Gracilis, and anastomoses with the posterior branch and with the medial femoral circumflex artery.

The **posterior branch** follows the posterior margin of the foramen and turns forward on the inferior ramus of the ischium, where it anastomoses with the anterior branch. It gives twigs to the muscles attached to the ischial tuberosity and anastomoses with the inferior gluteal. It also supplies an articular branch which enters the hip-joint through the acetabular notch, ramifies in the fat at the bottom of the acetabulum and sends a twig along the ligamentum teres to the head of the femur.

Peculiarities.—The obturator artery sometimes arises from the main stem or from the posterior trunk of the hypogastric, or it may spring from the superior gluteal artery; occasionally it arises from the external iliac. In about two out of every seven cases it springs from the inferior epigastric and descends almost vertically to the upper part of the obturator foramen. The artery in this course usually lies in contact with the external iliac vein, and on the lateral side of the femoral ring (Fig. 541A); in such cases it would not be endangered in the operation for strangulated femoral hernia. Occasionally, however, it curves along the free margin of the lacunar ligament (Fig. 541B), and if in such circumstances a femoral hernia occurred, the vessel would almost completely encircle the neck of the hernial sac, and would be in great danger of being wounded if an operation were performed for strangulation.

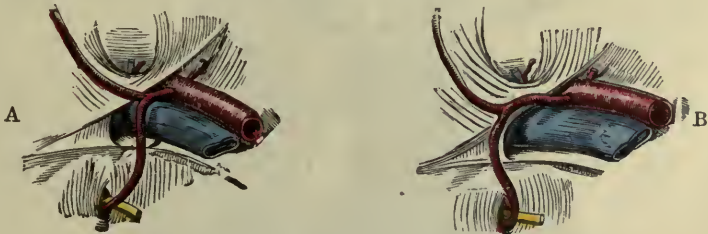


FIG. 541.—Variations in origin and course of obturator artery.

The **internal pudendal artery** (*a. pudenda interna; internal pudic artery*) is the smaller of the two terminal branches of the anterior trunk of the hypogastric, and supplies the external organs of generation. Though the course of the artery is the same in the two sexes, the vessel is smaller in the female than in the male, and the distribution of its branches somewhat different. The description of its arrangement in the male will first be given, and subsequently the differences which it presents in the female will be mentioned.

The **internal pudendal artery in the male** passes downward and outward to the lower border of the greater sciatic foramen, and emerges from the pelvis between the Piriformis and Coccygeus; it then crosses the ischial spine, and enters the perineum through the lesser sciatic foramen. The artery now crosses the Obturator internus, along the lateral wall of the ischiorectal fossa, being situated about 4 cm. above the lower margin of the ischial tuberosity. It gradually approaches the margin of the inferior ramus of the ischium and passes forward between the two layers of the fascia of the urogenital diaphragm; it then runs forward along the medial margin of the inferior ramus of the pubis, and about 1.25 cm. behind the pubic arcuate ligament it pierces the inferior fascia of the urogenital diaphragm and divides into the dorsal and deep arteries of the penis.

Relations.—Within the pelvis, it lies in front of the Piriformis muscle, the sacral plexus of nerves, and the inferior gluteal artery. As it crosses the ischial spine, it is covered by the Glutæus maximus and overlapped by the sacrotuberous ligament. Here the pudendal nerve lies to the medial side and the nerve to the Obturator internus to the lateral side of the vessel. In the perineum it lies on the lateral wall of the ischioanal fossa, in a canal (*Alcock's canal*) formed by the splitting of the obturator fascia. It is accompanied by a pair of venæ comitantes and the pudendal nerve.

Peculiarities.—The internal pudendal artery is sometimes smaller than usual, or fails to give off one or two of its usual branches; in such cases the deficiency is supplied by branches derived from an additional vessel, the **accessory pudendal**, which generally arises from the internal pudendal artery before its exit from the greater sciatic foramen. It passes forward along the lower part of the bladder and across the side of the prostate to the root of the penis, where it perforates the urogenital diaphragm, and gives off the branches usually derived from the internal pudendal artery. The deficiency most frequently met with is that in which the internal pudendal ends as the artery of the urethral bulb, the dorsal and deep arteries of the penis being derived from the accessory pudendal. The internal pudendal artery may also end as the perineal, the artery of the urethral bulb being derived, with the other two branches, from the accessory vessel. Occasionally the accessory pudendal artery is derived from one of the other branches of the hypogastric artery, most frequently the inferior vesical or the obturator.

Branches.—The branches of the internal pudendal artery (Figs. 542, 543) are:

Muscular.	Artery of the Urethral Bulb.
Inferior Hemorrhoidal.	Urethral.
Perineal.	Deep Artery of the Penis.
	Dorsal Artery of the Penis.

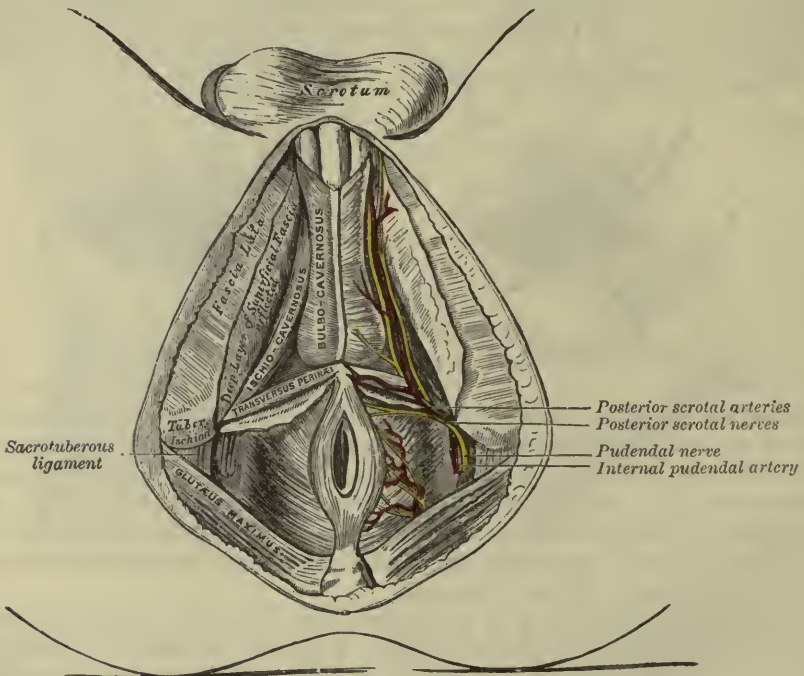


FIG. 542.—The superficial branches of the internal pudendal artery.

The **Muscular Branches** consist of two sets: one given off in the pelvis; the other, as the vessel crosses the ischial spine. The former consists of several small offsets which supply the Levator ani, the Obturator internus, the Piriformis, and the Coccygeus. The branches given off outside the pelvis are distributed to the adjacent parts of the Glutæus maximus and external rotator muscles. They anastomose with branches of the inferior gluteal artery.

The **Inferior Hemorrhoidal Artery** (*a. hæmorrhoidalis inferior*) arises from the internal pudendal as it passes above the ischial tuberosity. Piercing the wall of Alcock's canal it divides into two or three branches which cross the ischio-rectal fossa, and are distributed to the muscles and integument of the anal region, and send offshoots around the lower edge of the Glutæus maximus to the skin of the buttock. They anastomose with the corresponding vessels of the opposite side, with the superior and middle hemorrhoidal, and with the perineal artery.

The **Perineal Artery** (*a. perinei*; *superficial perineal artery*) arises from the internal pudendal, in front of the preceding branches, and turns upward, crossing either over or under the Transversus perinæi superficialis, and runs forward, parallel to the pubic arch, in the interspace between the Bulbocavernosus and Ischiocavernosus, both of which it supplies, and finally divides into several **posterior scrotal branches** which are distributed to the skin and dartos tunic of the scrotum. As it crosses the Transversus perinæi superficialis it gives off the **transverse perineal artery** which runs transversely on the cutaneous surface of the muscle, and anastomoses with the corresponding vessel of the opposite side and with the perineal and inferior hemorrhoidal arteries. It supplies the Transversus perinæi superficialis and the structures between the anus and the urethral bulb.

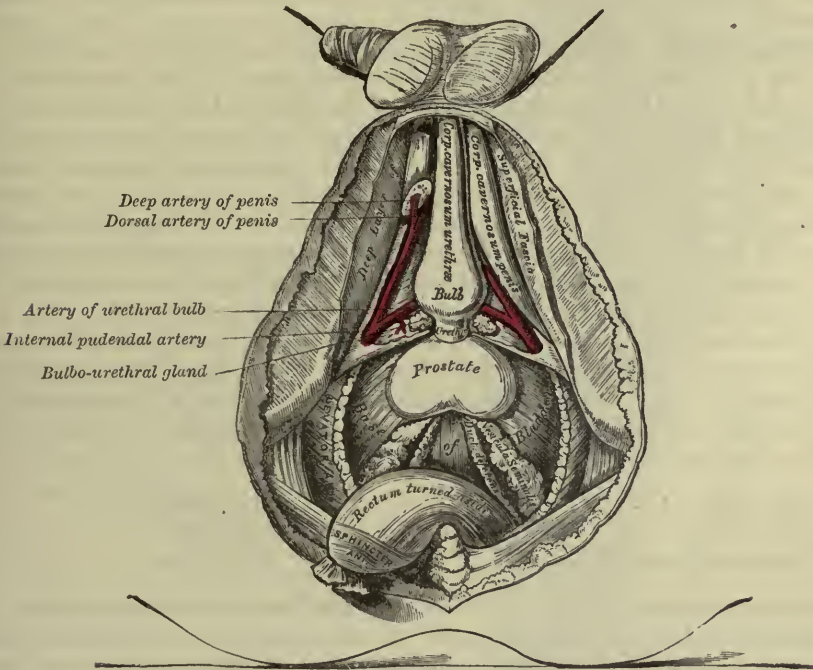


FIG. 543.—The deeper branches of the internal pudendal artery.

The **Artery of the Urethral Bulb** (*a. bulbi urethrae*) is a short vessel of large caliber which arises from the internal pudendal between the two layers of fascia of the urogenital diaphragm; it passes medialward, pierces the inferior fascia of the urogenital diaphragm, and gives off branches which ramify in the bulb of the urethra and in the posterior part of the corpus cavernosum urethrae. It gives off a small branch to the bulbo-urethral gland.

The **Urethral Artery** (*a. urethralis*) arises a short distance in front of the artery of the urethral bulb. It runs forward and medialward, pierces the inferior fascia of the urogenital diaphragm and enters the corpus cavernosum urethrae, in which it is continued forward to the glans penis.

The **Deep Artery of the Penis** (*a. profunda penis; artery to the corpus cavernosum*), one of the terminal branches of the internal pudendal, *arises* from that vessel while it is situated between the two fasciæ of the urogenital diaphragm; it pierces the inferior fascia, and, entering the crus penis obliquely, runs forward in the center of the corpus cavernosum penis, to which its branches are distributed.

The **Dorsal Artery of the Penis** (*a. dorsalis penis*) ascends between the crus penis and the pubic symphysis, and, piercing the inferior fascia of the urogenital diaphragm, passes between the two layers of the suspensory ligament of the penis, and runs forward on the dorsum of the penis to the glans, where it divides into two branches, which supply the glans and prepuce. On the penis, it lies between the dorsal nerve and deep dorsal vein, the former being on its lateral side. It supplies the integument and fibrous sheath of the corpus cavernosum penis, sending branches through the sheath to anastomose with the preceding vessel.

The **internal pudendal artery in the female** is smaller than in the male. Its origin and course are similar, and there is considerable analogy in the distribution of its branches. The perineal artery supplies the labia pudendi; the artery of the bulb supplies the bulbus vestibuli and the erectile tissue of the vagina; the deep artery of the clitoris supplies the corpus cavernosum clitoridis; and the dorsal artery of the clitoris supplies the dorsum of that organ, and ends in the glans and prepuce of the clitoris.

The **inferior gluteal artery** (*a. glutæa inferior; sciatic artery*) (Fig. 544), the larger of the two terminal branches of the anterior trunk of the hypogastric, is distributed chiefly to the buttock and back of the thigh. It passes down on the sacral plexus of nerves and the Piriformis, behind the internal pudendal artery, to the lower part of the greater sciatic foramen, through which it escapes from the pelvis between the Piriformis and Coccygeus. It then descends in the interval between the greater trochanter of the femur and tuberosity of the ischium, accompanied by the sciatic and posterior femoral cutaneous nerves, and covered by the Glutæus maximus, and is continued down the back of the thigh, supplying the skin, and anastomosing with branches of the perforating arteries.

Inside the pelvis it distributes branches to the Piriformis, Coccygeus, and Levator ani; some branches which supply the fat around the rectum, and occasionally take the place of the middle hemorrhoidal artery; and vesical branches to the fundus of the bladder, vesiculæ seminales, and prostate. *Outside the pelvis* it gives off the following branches:

Muscular.	Anastomotic.
Coccygeal.	Articular.
Comitans Nervi Ischiadici.	Cutaneous.

The **Muscular Branches** supply the Glutæus maximus, anastomosing with the superior gluteal artery in the substance of the muscle; the external rotators, anastomosing with the internal pudendal artery; and the muscles attached to the tuberosity of the ischium, anastomosing with the posterior branch of the obturator and the medial femoral circumflex arteries.

The **Coccygeal Branches** run medialward, pierce the sacrotuberous ligament, and supply the Glutæus maximus, the integument, and other structures on the back of the coccyx.

The **Arteria Comitans Nervi Ischiadici** is a long, slender vessel, which accompanies the sciatic nerve for a short distance; it then penetrates it, and runs in its substance to the lower part of the thigh.

The **Anastomotic** is directed downward across the external rotators, and assists in forming the so-called **crucial anastomosis** by joining with the first perforating and medial and lateral femoral circumflex arteries.

The **Articular Branch**, generally derived from the anastomotic, is distributed to the capsule of the hip-joint.

The **Cutaneous Branches** are distributed to the skin of the buttock and back of the thigh.

The **iliolumbar artery** (*a. iliolumbalis*) a branch of the posterior trunk of the hypogastric, turns upward behind the obturator nerve and the external iliac vessels, to the medial border of the Psoas major, behind which it divides into a lumbar and an iliac branch.

The **Lumbar Branch** (*ramus lumbalis*) supplies the Psoas major and Quadratus lumborum, anastomoses with the last lumbar artery, and sends a small **spinal branch** through the intervertebral foramen between the last lumbar vertebra and the sacrum, into the vertebral canal, to supply the cauda equina.

The **Iliac Branch** (*ramus iliacus*) descends to supply the Iliacus; some offsets, running between the muscle and the bone, anastomose with the iliac branches of the obturator; one of these enters an oblique canal to supply the bone, while others run along the crest of the ilium, distributing branches to the gluteal and abdominal muscles, and anastomosing in their course with the superior gluteal, iliac circumflex, and lateral femoral circumflex arteries.

The **lateral sacral arteries** (*aa. sacrales laterales*) (Fig. 539) arise from the posterior division of the hypogastric; there are usually two, a **superior** and an **inferior**.

The **superior**, of large size, passes medialward, and, after anastomosing with branches from the middle sacral, enters the first or second anterior sacral foramen, supplies branches to the contents of the sacral canal, and, escaping by the corresponding posterior sacral foramen, is distributed to the skin and muscles on the dorsum of the sacrum, anastomosing with the superior gluteal.

The **inferior** runs obliquely across the front of the Piriformis and the sacral nerves to the medial side of the anterior sacral foramina, descends on the front of the sacrum, and anastomoses over the coccyx with the middle sacral and opposite lateral sacral artery. In its course it gives off branches, which enter the anterior sacral foramina; these, after supplying the contents of the sacral canal, escapes by the posterior sacral foramina, and are distributed to the muscles and skin on the dorsal surface of the sacrum, anastomosing with the gluteal arteries.

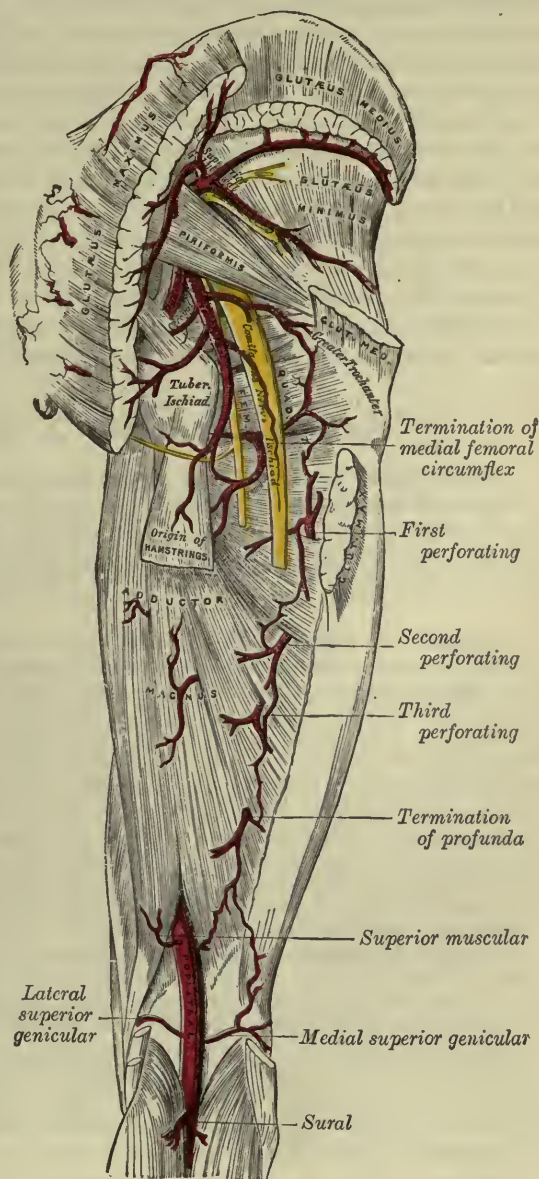


FIG. 544.—The arteries of the gluteal and posterior femoral regions.

The **superior gluteal artery** (*a. glutæa superior; gluteal artery*) (Fig. 544) is the largest branch of the hypogastric, and appears to be the continuation of the posterior division of that vessel. It is a short artery which runs backward between the lumbosacral trunk and the first sacral nerve, and, passing out of the pelvis above the upper border of the Piriformis, immediately divides into a **superficial** and a **deep branch**. Within the pelvis it gives off a few branches to the Iliacus, Piriformis, and Obturator internus, and just previous to quitting that cavity, a nutrient artery which enters the ilium.

The **superficial branch** enters the deep surface of the Glutæus maximus, and divides into numerous branches, some of which supply the muscle and anastomose with the inferior gluteal, while others perforate its tendinous origin, and supply the integument covering the posterior surface of the sacrum, anastomosing with the posterior branches of the lateral sacral arteries.

The **deep branch** lies under the Glutæus medius and almost immediately subdivides into two. Of these, the **superior division**, continuing the original course of the vessel, passes along the upper border of the Glutæus minimus to the anterior superior spine of the ilium, anastomosing with the deep iliac circumflex artery and the ascending branch of the lateral femoral circumflex artery. The **inferior division** crosses the Glutæus minimus obliquely to the greater trochanter, distributing branches to the Glutæi and anastomoses with the lateral femoral circumflex artery. Some branches pierce the Glutæus minimus and supply the hip-joint.

The External Iliac Artery (*A. Iliaca Externa*) (Fig. 539).

The **external iliac artery** is larger than the hypogastric, and passes obliquely downward and lateralward along the medial border of the Psoas major, from the bifurcation of the common iliac to a point beneath the inguinal ligament, midway between the anterior superior spine of the ilium and the symphysis pubis, where it enters the thigh and becomes the femoral artery.

Relations.—*In front and medially*, the artery is in relation with the peritoneum, subperitoneal areolar tissue, the termination of the ileum and frequently the vermiform process on the right side, and the sigmoid colon on the left, and a thin layer of fascia, derived from the iliac fascia, which surrounds the artery and vein. At its origin it is crossed by the ovarian vessels in the female, and occasionally by the ureter. The internal spermatic vessels lie for some distance upon it near its termination, and it is crossed in this situation by the external spermatic branch of the genitofemoral nerve and the deep iliac circumflex vein; the ductus deferens in the male, and the round ligament of the uterus in the female, curve down across its medial side. *Behind*, it is in relation with the medial border of the Psoas major, from which it is separated by the iliac fascia. At the upper part of its course, the external iliac vein lies partly behind it, but lower down lies entirely to its medial side. *Laterally*, it rests against the Psoas major, from which it is separated by the iliac fascia. Numerous lymphatic vessels and lymph glands lie on the front and on the medial side of the vessel.

Collateral Circulation.—The principal anastomoses in carrying on the collateral circulation, after the application of a ligature to the external iliac, are: the iliolumbar with the iliac circumflex; the superior gluteal with the lateral femoral circumflex; the obturator with the medial femoral circumflex; the inferior gluteal with the first perforating and circumflex branches of the profunda artery; and the internal pudendal with the external pudendal. When the obturator arises from the inferior epigastric, it is supplied with blood by branches, from either the hypogastric, the lateral sacral, or the internal pudendal. The inferior epigastric receives its supply from the internal mammary and lower intercostal arteries, and from the hypogastric by the anastomoses of its branches with the obturator.¹

Branches.—Besides several small branches to the Psoas major and the neighboring lymph glands, the external iliac gives off two branches of considerable size:

Inferior Epigastric.

Deep Iliac Circumflex.

¹ Sir Astley Cooper describes in Guy's Hospital Reports, vol. i, the dissection of a limb eighteen years after successful ligature of the external iliac artery.

The **inferior epigastric artery** (*a. epigastrica inferior; deep epigastric artery*) (Fig. 547) arises from the external iliac, immediately above the inguinal ligament. It curves forward in the subperitoneal tissue, and then ascends obliquely along the medial margin of the abdominal inguinal ring; continuing its course upward, it pierces the transversalis fascia, and, passing in front of the linea semicircularis, ascends between the Rectus abdominis and the posterior lamella of its sheath. It finally divides into numerous branches, which anastomose, above the umbilicus, with the superior epigastric branch of the internal mammary and with the lower intercostal arteries (Fig. 522). As the inferior epigastric artery passes obliquely upward from its origin it lies along the lower and medial margins of the abdominal inguinal ring, and behind the commencement of the spermatic cord. The ductus deferens, as it leaves the spermatic cord in the male, and the round ligament of the uterus in the female, winds around the lateral and posterior aspects of the artery.

Branches.—The branches of the vessel are: the **external spermatic artery** (*cremasteric artery*), which accompanies the spermatic cord, and supplies the Cremaster and other coverings of the cord, anastomosing with the internal spermatic artery (in the female it is very small and accompanies the round ligament); a **pubic branch** which runs along the inguinal ligament, and then descends along the medial margin of the femoral ring to the back of the pubis, and there anastomoses with the pubic branch of the obturator artery; **muscular branches**, some of which are distributed to the abdominal muscles and peritoneum, anastomosing with the iliac circumflex and lumbar arteries; branches which perforate the tendon of the Obliquus externus, and supply the integument, anastomosing with branches of the superficial epigastric.

Peculiarities.—The origin of the inferior epigastric may take place from any part of the external iliac between the inguinal ligament and a point 6 cm. above it; or it may arise below this ligament, from the femoral. It frequently springs from the external iliac, by a common trunk with the obturator. Sometimes it arises from the obturator, the latter vessel being furnished by the hypogastric, or it may be formed of two branches, one derived from the external iliac, the other from the hypogastric.

The **deep iliac circumflex artery** (*a. circumflexa ilium profunda*) arises from the lateral aspect of the external iliac nearly opposite the inferior epigastric artery. It ascends obliquely lateralward behind the inguinal ligament, contained in a fibrous sheath formed by the junction of the transversalis fascia and iliac fascia, to the anterior superior iliac spine, where it anastomoses with the ascending branch of the lateral femoral circumflex artery. It then pierces the transversalis fascia and passes along the inner lip of the crest of the ilium to about its middle, where it perforates the Transversus, and runs backward between that muscle and the Obliquus internus, to anastomose with the iliolumbar and superior gluteal arteries. Opposite the anterior superior spine of the ilium it gives off a large branch, which ascends between the Obliquus internus and Transversus muscles, supplying them, and anastomosing with the lumbar and inferior epigastric arteries.

THE ARTERIES OF THE LOWER EXTREMITY.

The artery which supplies the greater part of the lower extremity is the direct continuation of the external iliac. It runs as a single trunk from the inguinal ligament to the lower border of the Popliteus, where it divides into two branches, the **anterior** and **posterior tibial**. The upper part of the main trunk is named the **femoral**, the lower part the **popliteal**.

THE FEMORAL ARTERY (A. FEMORALIS) (Figs. 549, 550).

The **femoral artery** begins immediately behind the inguinal ligament, midway between the anterior superior spine of the ilium and the symphysis pubis, and

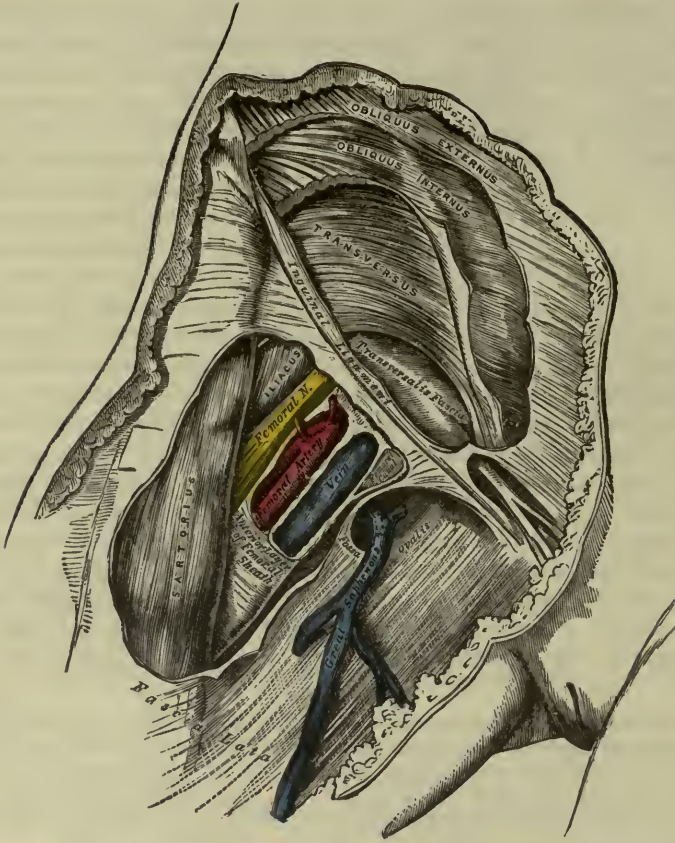


FIG. 545.—Femoral sheath laid open to show its three compartments.

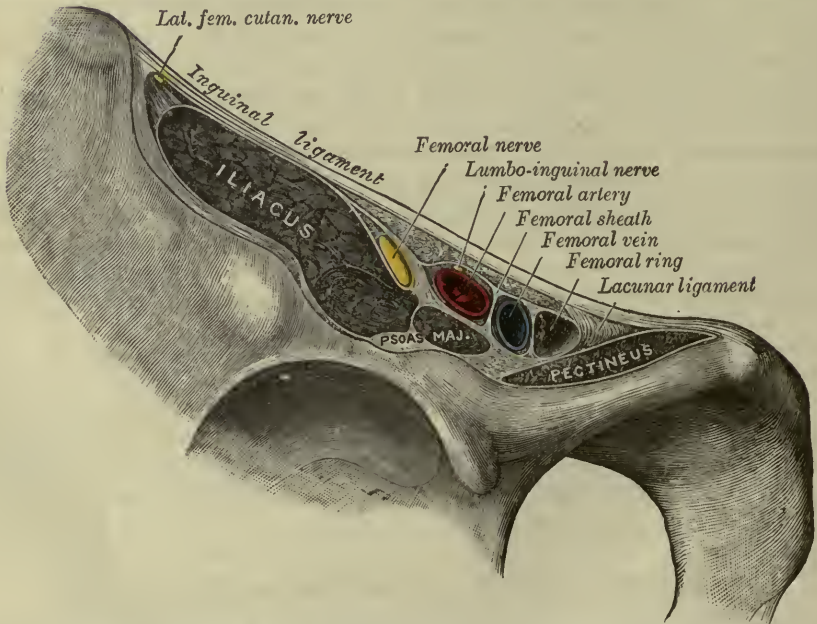


FIG. 546.—Structures passing behind the inguinal ligament.

passes down the front and medial side of the thigh. It ends at the junction of the middle with the lower third of the thigh, where it passes through an opening in the Adductor magnus to become the popliteal artery. The vessel, at the upper part of the thigh, lies in front of the hip-joint; in the lower part of its course it lies to the medial side of the body of the femur, and between these two parts, where it crosses the angle between the head and body, the vessel is some distance from the bone. The first 4 cm. of the vessel is enclosed, together with the femoral vein, in a fibrous sheath—the **femoral sheath**. In the upper third of the thigh the femoral artery is contained in the **femoral triangle** (*Scarpa's triangle*), and in the middle third of the thigh, in the **adductor canal** (*Hunter's canal*).

The **femoral sheath** (*crural sheath*) (Figs. 545, 546) is formed by a prolongation downward, behind the inguinal ligament, of the fasciæ which line the abdomen, the transversalis fascia being continued down in front of the femoral vessels and the iliac fascia behind them. The sheath assumes the form of a short funnel, the wide end of which is directed upward, while the lower, narrow end fuses with the

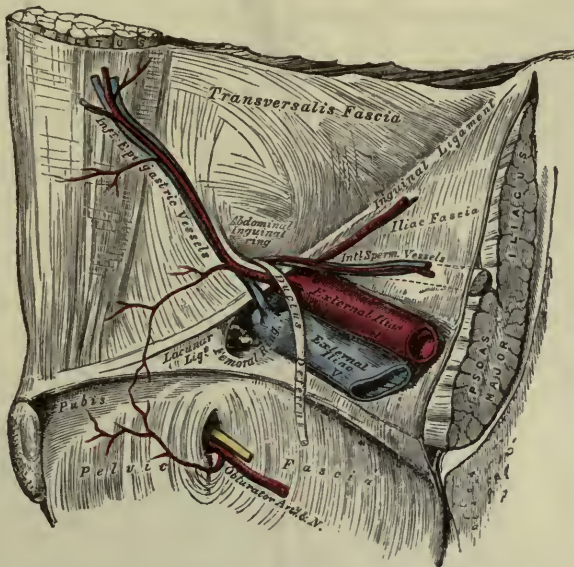


FIG. 547.—The relations of the femoral and abdominal inguinal rings, seen from within the abdomen. Right side.

fascial investment of the vessels, about 4 cm. below the inguinal ligament. It is strengthened in front by a band termed the **deep crural arch** (page 419). The lateral wall of the sheath is vertical and is perforated by the lumboinguinal nerve; the medial wall is directed obliquely downward and lateralward, and is pierced by the great saphenous vein and by some lymphatic vessels. The sheath is divided by two vertical partitions which stretch between its anterior and posterior walls. The lateral compartment contains the femoral artery, and the intermediate the femoral vein, while the medial and smallest compartment is named the **femoral canal**, and contains some lymphatic vessels and a lymph gland imbedded in a small amount of areolar tissue. The femoral canal is conical and measures about 1.25 cm. in length. Its base, directed upward and named the **femoral ring**, is oval in form, its long diameter being directed transversely and measuring about 1.25 cm. The femoral ring (Figs. 546, 547) is bounded in *front* by the inguinal ligament, *behind* by the Pectineus covered by the pectineal fascia, *medially* by the crescentic base of the lacunar ligament, and *laterally* by the fibrous septum on the medial side of the femoral vein. The spermatic cord in the male and the round ligament

of the uterus in the female lie immediately above the anterior margin of the ring, while the inferior epigastric vessels are close to its upper and lateral angle. The femoral ring is closed by a somewhat condensed portion of the extraperitoneal fatty tissue, named the **septum femorale** (*crural septum*), the abdominal surface of which supports a small lymph gland and is covered by the parietal layer of the peritoneum. The septum femorale is pierced by numerous lymphatic vessels passing from the deep inguinal to the external iliac lymph glands, and the parietal peritoneum immediately above it presents a slight depression named the **femoral fossa**.

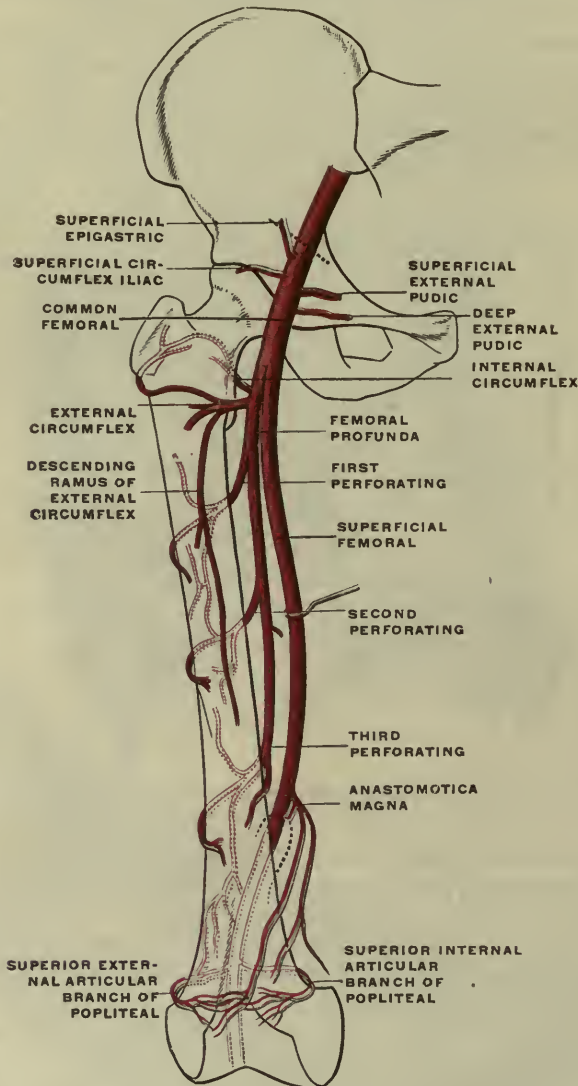


FIG. 548.—Scheme of the femoral artery. (Poirier and Charpy.)

The **femoral triangle** (*trigonum femorale*; *Scarpa's triangle*) (Fig. 549) corresponds to the depression seen immediately below the fold of the groin. Its apex is directed downward, and the sides are formed laterally by the medial margin of the Sartorius, medially by the medial margin of the Adductor longus, and above by the inguinal ligament. The floor of the space is formed from its lateral to its medial side by the Iliacus, Psoas major, Pectineus, in some cases a small part of

the Adductor brevis, and the Adductor longus; and it is divided into two nearly equal parts by the femoral vessels, which extend from near the middle of its base to its apex: the artery giving off in this situation its superficial and profunda branches, the vein receiving the deep femoral and great saphenous tributaries. On the lateral side of the femoral artery is the femoral nerve dividing into its branches. Besides the vessels and nerves, this space contains some fat and lymphatics.

The **adductor canal** (*canalis adductorius*; *Hunter's canal*) is an aponeurotic tunnel in the middle third of the thigh, extending from the apex of the femoral triangle to the opening in the Adductor magnus. It is bounded, in front and laterally, by the Vastus medialis; behind by the Adductores longus and magnus; and is covered in by a strong aponeurosis which extends from the Vastus medialis, across the femoral vessels to the Adductores longus and magnus; lying on the aponeurosis is the Sartorius muscle. The canal contains the femoral artery and vein, the saphenous nerve, and the nerve to the Vastus medialis.

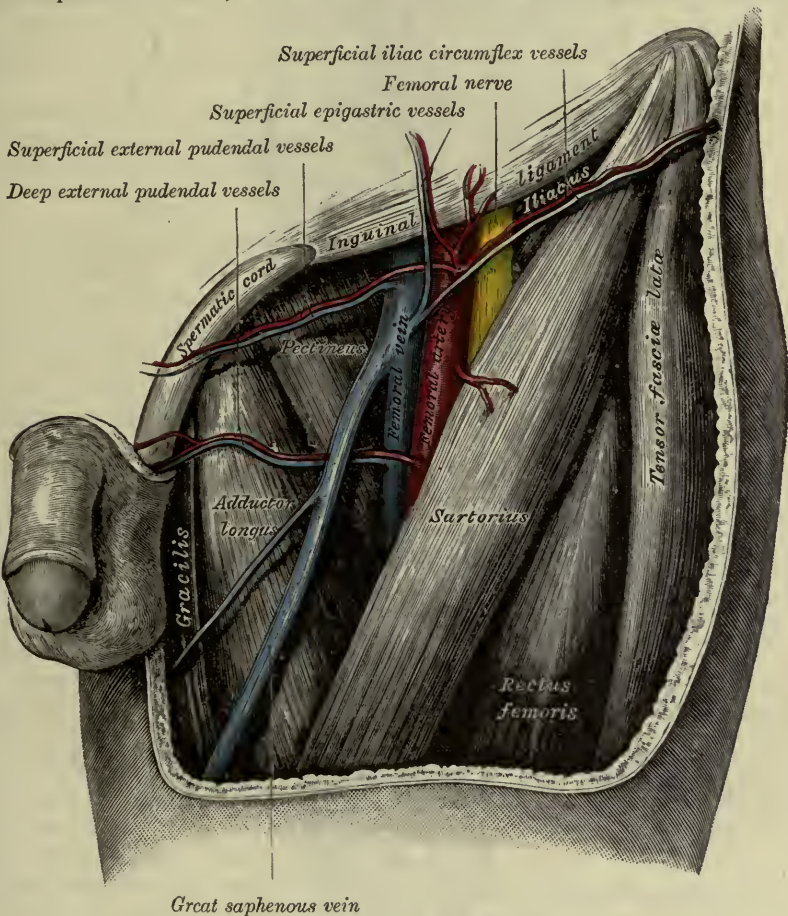


FIG. 549.—The left femoral triangle.

Relations of the Femoral Artery.—In the *femoral triangle* (Fig. 549) the artery is superficial. In front of it are the skin and superficial fascia, the superficial subinguinal lymph glands, the superficial iliac circumflex vein, the superficial layer of the fascia lata and the anterior part of the femoral sheath. The lumboinguinal nerve courses for a short distance within the lateral compartment of the femoral sheath, and lies at first in front and then lateral to the artery. Near the apex of the femoral triangle the medial branch of the anterior femoral cutaneous nerve crosses the artery from its lateral to its medial side.

Behind the artery are the posterior part of the femoral sheath, the pectineal fascia, the medial part of the tendon of the Psoas major, the Pectineus and the Adductor longus. The artery is separated from the capsule of the hip-joint by the tendon of the Psoas major, from the Pectineus by the femoral vein and profunda vessels, and from the Adductor longus by the femoral vein. The nerve to the Pectineus passes medialward behind the artery. On the lateral side of the artery, but separated from it by some fibers of the Psoas major, is the femoral nerve. The femoral vein is on the medial side of the upper part of the artery, but is behind the vessel in the lower part of the femoral triangle.

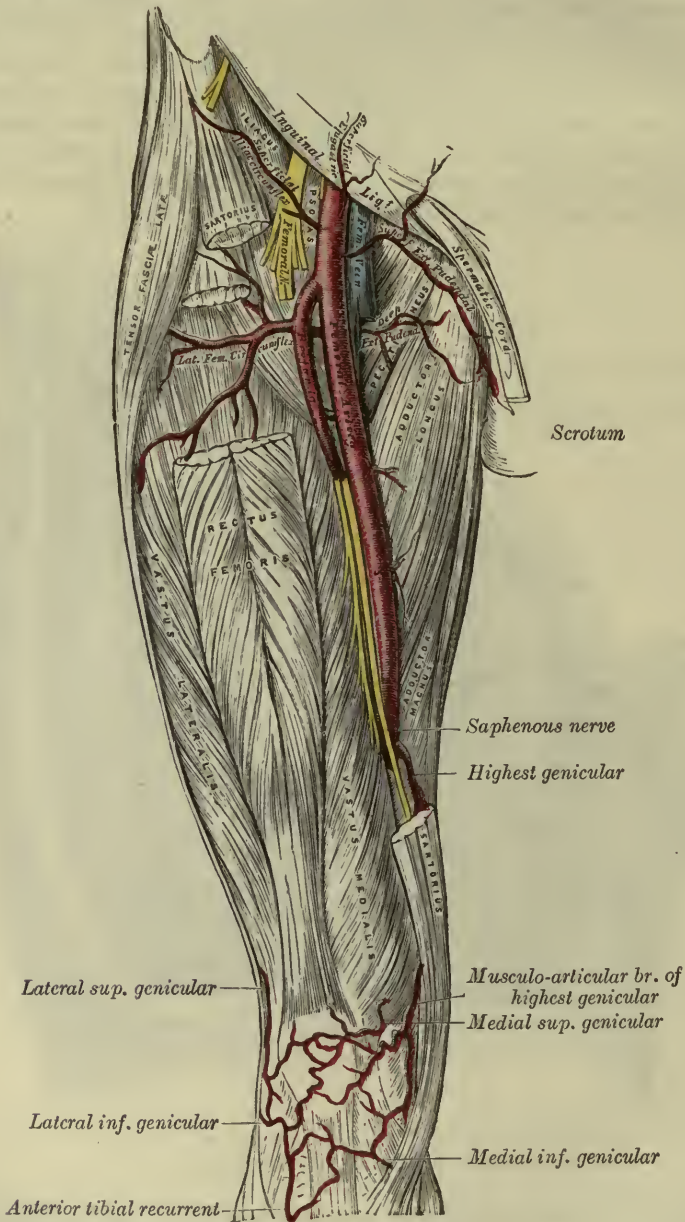


FIG. 550.—The femoral artery.

In the *adductor canal* (Fig. 550) the femoral artery is more deeply situated, being covered by the integument, the superficial and deep fasciæ, the Sartorius and the fibrous roof of the canal; the saphenous nerve crosses from its lateral to its medial side. Behind the artery are the Adduc-

tores longus and magnus; in front and lateral to it is the Vastus medialis. The femoral vein lies posterior to the upper part, and lateral to the lower part of the artery.

Peculiarities.—Several cases are recorded in which the femoral artery divided into two trunks below the origin of the profunda, and became reunited near the opening in the Adductor magnus, so as to form a single popliteal artery. One occurred in a patient who was operated upon for popliteal aneurism. A few cases have been recorded in which the femoral artery was absent, its place being supplied by the inferior gluteal artery which accompanied the sciatic nerve to the popliteal fossa. The external iliac in these cases was small, and terminated in the profunda. The femoral vein is occasionally placed along the medial side of the artery throughout the entire extent of the femoral triangle; or it may be split so that a large vein is placed on either side of the artery for a greater or lesser distance.

Collateral Circulation.—After ligation of the femoral artery, the main channels for carrying on the circulation are the anastomoses between—(1) the superior and inferior gluteal branches of the hypogastric with the medial and lateral femoral circumflex and first perforating branches of the profunda femoris; (2) the obturator branch of the hypogastric with the medial femoral circumflex of the profunda; (3) the internal pudendal of the hypogastric with the superficial and deep external pudendal of the femoral; (4) the deep iliac circumflex of the external iliac with the lateral femoral circumflex of the profunda and the superficial iliac circumflex of the femoral, and (5) the inferior gluteal of the hypogastric with the perforating branches of the profunda.

Branches.—The branches of the femoral artery are:

Superficial Epigastric.	Deep External Pudendal.
Superficial Iliac Circumflex.	Muscular.
Superficial External Pudendal.	Profunda Femoris.
	Highest Genicular.

The **superficial epigastric artery** (*a. epigastrica superficialis*) arises from the front of the femoral artery about 1 cm. below the inguinal ligament, and, passing through the femoral sheath and the fascia cribrosa, turns upward in front of the inguinal ligament, and ascends between the two layers of the superficial fascia of the abdominal wall nearly as far as the umbilicus. It distributes branches to the superficial subinguinal lymph glands, the superficial fascia, and the integument; it anastomoses with branches of the inferior epigastric, and with its fellow of the opposite side.

The **superficial iliac circumflex artery** (*a. circumflexa ilium superficialis*), the smallest of the cutaneous branches, arises close to the preceding, and, piercing the fascia lata, runs lateralward, parallel with the inguinal ligament, as far as the crest of the ilium; it divides into branches which supply the integument of the groin, the superficial fascia, and the superficial subinguinal lymph glands, anastomosing with the deep iliac circumflex, the superior gluteal and lateral femoral circumflex arteries.

The **superficial external pudendal artery** (*a. pudenda externa superficialis; superficial external pudic artery*) arises from the medial side of the femoral artery, close to the preceding vessels, and, after piercing the femoral sheath and fascia cribrosa, courses medialward, across the spermatic cord (or round ligament in the female), to be distributed to the integument on the lower part of the abdomen, the penis and scrotum in the male, and the labium majus in the female, anastomosing with branches of the internal pudendal.

The **deep external pudendal artery** (*a. pudenda externa profunda; deep external pudic artery*), more deeply seated than the preceding, passes medialward across the Pectineus and the Adductor longus muscles; it is covered by the fascia lata, which it pierces at the medial side of the thigh, and is distributed, in the male, to the integument of the scrotum and perineum, in the female to the labium majus; its branches anastomose with the scrotal (or labial) branches of the perineal artery.

Muscular branches (*rami musculares*) are supplied by the femoral artery to the Sartorius, Vastus medialis, and Adductores.

The **profunda femoris artery** (*a. profunda femoris; deep femoral artery*) (Fig. 550) is a large vessel arising from the lateral and back part of the femoral artery,

from 2 to 5 cm. below the inguinal ligament. At first it lies lateral to the femoral artery; it then runs behind it and the femoral vein to the medial side of the femur, and, passing downward behind the Adductor longus, ends at the lower third of the thigh in a small branch, which pierces the Adductor magnus, and is distributed on the back of the thigh to the hamstring muscles. The terminal part of the profunda is sometimes named the **fourth perforating artery**.

Relations.—*Behind it*, from above downward, are the Iliacus, Pectineus, Adductor brevis, and Adductor magnus. *In front* it is separated from the femoral artery by the femoral and profunda veins above and by the Adductor longus below. *Laterally*, the origin of the Vastus medialis intervenes between it and the femur.

Peculiarities.—This vessel sometimes arises from the medial side, and, more rarely, from the back of the femoral artery; but a more important peculiarity, from a surgical point of view, is that relating to the height at which the vessel arises. In three-fourths of a large number of cases it arose from 2.25 to 5 cm. below the inguinal ligament; in a few cases the distance was less than 2.25 cm.; more rarely, opposite the ligament; and in one case above the inguinal ligament, from the external iliac. Occasionally the distance between the origin of the vessel and the inguinal ligament exceeds 5 cm.

Branches.—The profunda gives off the following branches:

Lateral Femoral Circumflex.	Perforating.
Medial Femoral Circumflex.	Muscular.

The **Lateral Femoral Circumflex Artery** (*a. circumflexa femoris lateralis; external circumflex artery*) arises from the lateral side of the profunda, passes horizontally between the divisions of the femoral nerve, and behind the Sartorius and Rectus femoris, and divides into ascending, transverse, and descending branches.

The **ascending branch** passes upward, beneath the Tensor fasciæ latæ, to the lateral aspect of the hip, and anastomoses with the terminal branches of the superior gluteal and deep iliac circumflex arteries.

The **descending branch** runs downward, behind the Rectus femoris, upon the Vastus lateralis, to which it gives offsets; one long branch descends in the muscle as far as the knee, and anastomoses with the superior lateral genicular branch of the popliteal artery. It is accompanied by the branch of the femoral nerve to the Vastus lateralis.

The **transverse branch**, the smallest, passes lateralward over the Vastus intermedius, pierces the Vastus lateralis, and winds around the femur, just below the greater trochanter, anastomosing on the back of the thigh with the medial femoral circumflex, inferior gluteal, and first perforating arteries.

The **Medial Femoral Circumflex Artery** (*a. circumflexa femoris medialis; internal circumflex artery*) arises from the medial and posterior aspect of the profunda, and winds around the medial side of the femur, passing first between the Pectineus and Psoas major, and then between the Obturator externus and the Adductor brevis. At the upper border of the Adductor brevis it gives off two branches: one is distributed to the Adductores, the Gracilis, and Obturator externus, and anastomoses with the obturator artery; the other descends beneath the Adductor brevis, to supply it and the Adductor magnus; the continuation of the vessel passes backward and divides into superficial, deep, and acetabular branches. The **superficial branch** appears between the Quadratus femoris and upper border of the Adductor magnus, and anastomoses with the inferior gluteal, lateral femoral circumflex, and first perforating arteries (*crucial anastomosis*). The **deep branch** runs obliquely upward upon the tendon of the Obturator externus and in front of the Quadratus femoris toward the trochanteric fossa, where it anastomoses with twigs from the gluteal arteries. The **acetabular branch** arises opposite the acetabular notch and enters the hip-joint beneath the transverse ligament in company with an articular branch from the obturator artery; it supplies the fat in the bottom of the acetabulum, and is continued along the round ligament to the head of the femur.

The **Perforating Arteries** (Fig. 544), usually three in number, are so named because they perforate the tendon of the Adductor magnus to reach the back of the thigh: They pass backward close to the linea aspera of the femur under cover of small tendinous arches in the muscle. The first is given off above the Adductor brevis, the second in front of that muscle, and the third immediately below it.

The **first perforating artery** (*a. perforans prima*) passes backward between the Pectineus and Adductor brevis (sometimes it perforates the latter); it then pierces the Adductor magnus close to the linea aspera. It gives branches to the Adductores brevis and magnus, Biceps femoris, and Glutæus maximus, and anastomoses with the inferior gluteal, medial and lateral femoral circumflex and second perforating arteries.

The **second perforating artery** (*a. perforans secunda*), larger than the first, pierces the tendons of the Adductores brevis and magnus, and divides into ascending and descending branches, which supply the posterior femoral muscles, anastomosing with the first and third perforating. The second artery frequently *arises* in common with the first. The **nutrient artery** of the femur is usually given off from the second perforating artery; when two nutrient arteries exist, they usually spring from the first and third perforating vessels.

The **third perforating artery** (*a. perforans tertia*) is given off below the Adductor brevis; it pierces the Adductor magnus, and divides into branches which supply the posterior femoral muscles; anastomosing above with the higher perforating arteries, and below with the terminal branches of the profunda and the muscular branches of the popliteal. The nutrient artery of the femur may arise from this branch. The termination of the profunda artery, already described, is sometimes termed the **fourth perforating artery**.

Numerous **muscular branches** *arise* from the profunda; some of these end in the Adductores, others pierce the Adductor magnus, give branches to the hamstrings, and anastomose with the medial femoral circumflex artery and with the superior muscular branches of the popliteal.

The **highest genicular artery** (*a. genu suprema; anastomotica magna artery*) (Fig. 550) *arises* from the femoral just before it passes through the opening in the tendon of the Adductor magnus, and immediately divides into a saphenous and a musculo-articular branch.

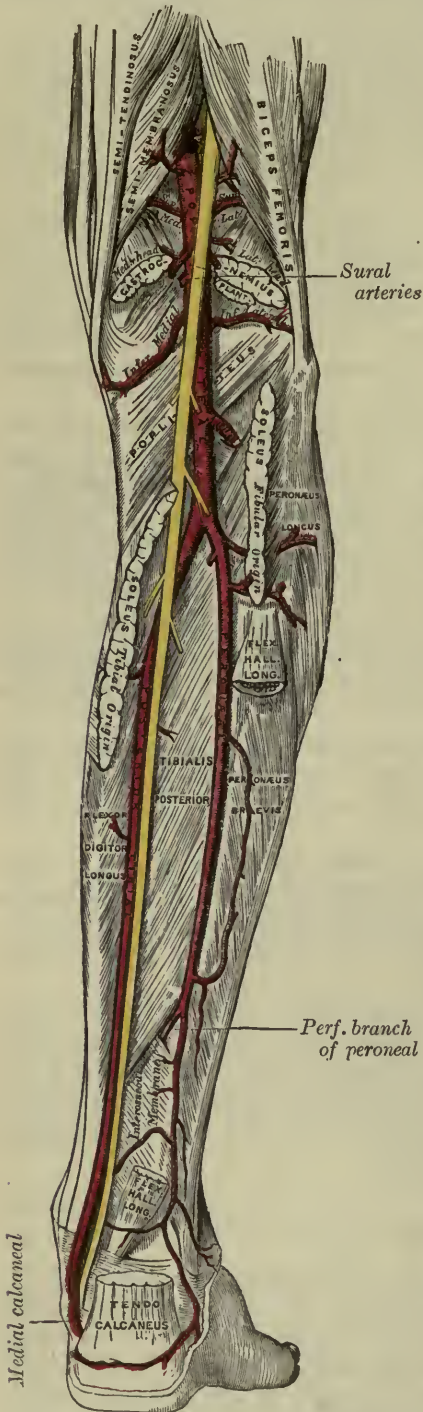
The **saphenous branch** pierces the aponeurotic covering of the adductor canal, and accompanies the saphenous nerve to the medial side of the knee. It passes between the Sartorius and Gracilis, and, piercing the fascia lata, is distributed to the integument of the upper and medial part of the leg, anastomosing with the medial inferior genicular artery.

The **musculo-articular branch** descends in the substance of the Vastus medialis, and in front of the tendon of the Adductor magnus, to the medial side of the knee, where it anastomoses with the medial superior genicular artery and anterior recurrent tibial artery. A branch from this vessel crosses above the patellar surface of the femur, forming an anastomotic arch with the lateral superior genicular artery, and supplying branches to the knee-joint.

THE POPLITEAL FOSSA (Fig. 551).

Boundaries.—The **popliteal fossa** or **space** is a lozenge-shaped space, at the back of the knee-joint. Laterally it is bounded by the Biceps femoris above, and by the Plantaris and the lateral head of the Gastrocnemius below; medially it is limited by the Semitendinosus and Semimembranosus above, and by the medial head of the Gastrocnemius below. The floor is formed by the popliteal surface of the femur, the oblique popliteal ligament of the knee-joint, the upper end of the tibia, and the fascia covering the Popliteus; the fossa is covered in by the fascia lata.

Contents.—The popliteal fossa contains the popliteal vessels, the tibial and the common peroneal nerves, the termination of the small saphenous vein, the lower part of the posterior femoral cutaneous nerve, the articular branch from the obturator nerve, a few small lymph glands, and a considerable quantity of fat. The tibial nerve descends through the middle of the fossa, lying under the deep fascia and crossing the vessels posteriorly from the lateral to the medial side. The common peroneal nerve descends on the lateral side of the upper part of the fossa, close to the tendon of the Biceps femoris. On the floor of the fossa are the popliteal vessels, the vein being superficial to the artery and united to it by dense areolar tissue; the vein is a thick-walled vessel, and lies at first lateral to the artery, and then crosses it posteriorly to gain its medial side below; sometimes it is double, the artery lying between the two veins, which are usually connected by short transverse branches. The articular branch from the obturator nerve descends upon the artery to the knee-joint. The popliteal lymph glands, six or seven in number, are imbedded in the fat; one lies beneath the popliteal fascia near the termination of the external saphenous vein, another between the popliteal artery and the back of the knee-joint, while the others are placed at the sides of the popliteal vessel. Arising from the artery, and passing off from it at right angles, are its genicular branches.



The Popliteal Artery (A. Poplitea) (Fig. 551).

The **popliteal artery** is the continuation of the femoral, and courses through the popliteal fossa. It extends from the opening in the Adductor magnus, at the junction of the middle and lower thirds of the thigh, downward and lateralward to the intercondyloid fossa of the femur, and then vertically downward to the lower border of the Popliteus, where it divides into **anterior** and **posterior tibial arteries**.

Relations.—In *front* of the artery from above downward are the popliteal surface of the femur (which is separated from the vessel by some fat), the back of the knee-joint, and the fascia covering the Popliteus. *Behind*, it is overlapped by the Semimembranosus above, and is covered by the Gastrocnemius and Plantaris below. In the middle part of its course the artery is separated from the integument and fasciæ by a quantity of fat, and is

FIG. 551.—The popliteal, posterior tibial, and peroneal arteries.

crossed from the lateral to the medial side by the tibial nerve and the popliteal vein, the vein being between the nerve and the artery and closely adherent to the latter. On its *lateral* side, above, are the Biceps femoris, the tibial nerve, the popliteal vein, and the lateral condyle of the femur; below, the Plantaris and the lateral head of the Gastrocnemius. On its *medial* side, above, are the Semimembranosus and the medial condyle of the femur; below, the tibial nerve, the popliteal vein, and the medial head of the Gastrocnemius. The relations of the popliteal lymph glands to the artery are described above.

Peculiarities in Point of Division.—Occasionally the popliteal artery divides into its terminal branches opposite the knee-joint. The anterior tibial under these circumstances usually passes in front of the Popliteus.

Unusual Branches.—The artery sometimes divides into the anterior tibial and peroneal, the posterior tibial being wanting, or very small. Occasionally it divides into three branches, the anterior and posterior tibial, and peroneal.

Branches.—The branches of the popliteal artery are:

Muscular	{ Superior	Lateral Superior Genicular.
	{ Sural.	Middle Genicular.
Cutaneous.		Medial Inferior Genicular.
Medial Superior Genicular		Lateral Inferior Genicular.

The **superior muscular branches**, two or three in number, *arise* from the upper part of the artery, and are distributed to the lower parts of the Adductor magnus and hamstring muscles, anastomosing with the terminal part of the profunda femoris.

The **sural arteries** (*aa. surales; inferior muscular arteries*) are two large branches, which are distributed to the Gastrocnemius, Soleus, and Plantaris. They *arise* from the popliteal artery opposite the knee-joint.

The **cutaneous branches** *arise* either from the popliteal artery or from some of its branches; they descend between the two heads of the Gastrocnemius, and, piercing the deep fascia, are distributed to the skin of the back of the leg. One branch usually accompanies the small saphenous vein.

The **superior genicular arteries** (*aa. genu superiores; superior articular arteries*) (Figs. 550, 551), two in number, *arise* one on either side of the popliteal, and wind around the femur immediately above its condyles to the front of the knee-joint. The **medial superior genicular** runs in front of the Semimembranosus and Semitendinosus, above the medial head of the Gastrocnemius, and passes beneath the tendon of the Adductor magnus. It divides into two branches, one of which supplies the Vastus medialis, anastomosing with the highest genicular and medial inferior genicular arteries; the other ramifies close to the surface of the femur, supplying it and the knee-joint, and anastomosing with the lateral superior genicular artery. The medial superior genicular artery is frequently of small size, a condition, which is associated with an increase in the size of the highest genicular. The **lateral superior genicular** passes above the lateral condyle of the femur, beneath the tendon of the Biceps femoris, and divides into a superficial and a deep branch; the superficial branch supplies the Vastus lateralis, and anastomoses with the descending branch of the lateral femoral circumflex and the lateral inferior genicular arteries; the deep branch supplies the lower part of the femur and knee-joint, and forms an anastomotic arch across the front of the bone with the highest genicular and the medial inferior genicular arteries.

The **middle genicular artery** (*a. genu media; azygos articular artery*) is a small branch, *arising* opposite the back of the knee-joint. It pierces the oblique popliteal ligament, and supplies the ligaments and synovial membrane in the interior of the articulation.

The **inferior genicular arteries** (*aa. genu inferiores; inferior articular arteries*) (Figs. 550, 551), two in number, *arise* from the popliteal beneath the Gastrocnemius. The **medial inferior genicular** first descends along the upper margin of the Popliteus, to which it gives branches; it then passes below the medial condyle of the tibia, beneath

the tibial collateral ligament, at the anterior border of which it ascends to the front and medial side of the joint, to supply the upper end of the tibia and the articulation of the knee, anastomosing with the lateral inferior and medial superior genicular arteries. The **lateral inferior genicular** runs lateralward above the head of the fibula to the front of the knee-joint, passing in its course beneath the lateral head of the Gastrocnemius, the fibular collateral ligament, and the tendon of the Biceps femoris. It ends by dividing into branches, which anastomose with the medial inferior and lateral superior genicular arteries, and with the anterior recurrent tibial artery.

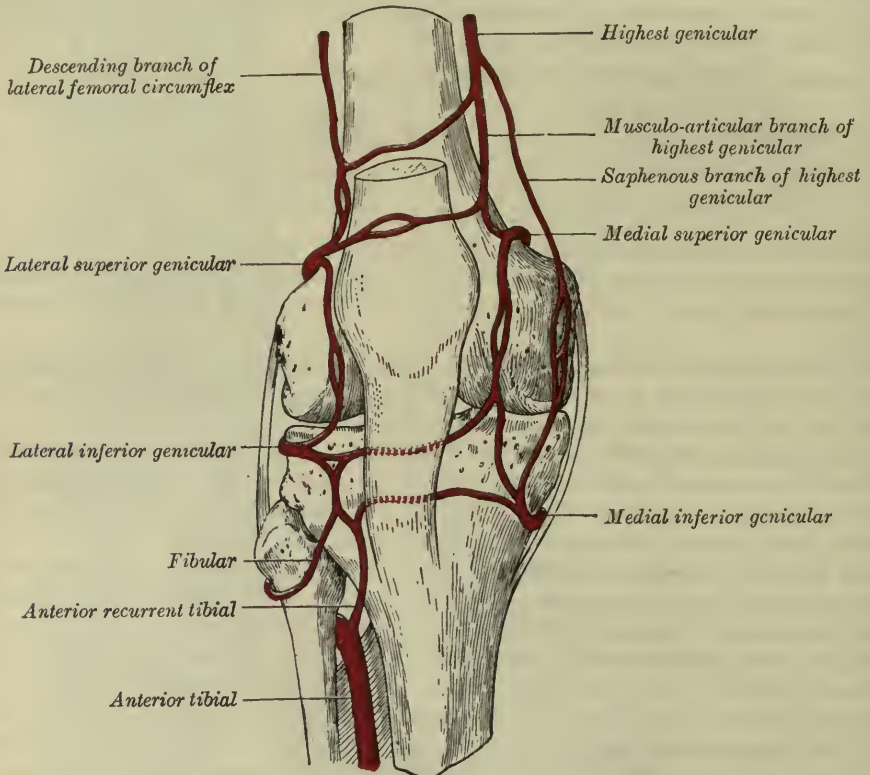


FIG. 552.—Circumpatellar anastomosis.

The Anastomosis Around the Knee-joint (Fig. 552).—Around and above the patella, and on the contiguous ends of the femur and tibia, is an intricate net-work of vessels forming a superficial and a deep plexus. The **superficial plexus** is situated between the fascia and skin around about the patella, and forms three well-defined arches: one, above the upper border of the patella, in the loose connective tissue over the Quadriceps femoris; the other two, below the level of the patella, are situated in the fat behind the ligamentum patellæ. The **deep plexus**, which forms a close net-work of vessels, lies on the lower end of the femur and upper end of the tibia around their articular surfaces, and sends numerous offsets into the interior of the joint. The arteries which form this plexus are the two medial and the two lateral genicular branches of the popliteal, the highest genicular, the descending branch of the lateral femoral circumflex, and the anterior recurrent tibial.

The Anterior Tibial Artery (A. Tibialis Anterior) (Fig. 553).

The **anterior tibial artery** commences at the bifurcation of the popliteal, at the lower border of the Popliteus, passes forward between the two heads of the Tibialis

posterior, and through the aperture above the upper border of the interosseous membrane, to the deep part of the front of the leg: it here lies close to the medial side of the neck of the fibula. It then descends on the anterior surface of the interosseous membrane, gradually approaching the tibia; at the lower part of the leg it lies on this bone, and then on the front of the ankle-joint, where it is more superficial, and becomes the *dorsalis pedis*.

Relations.—In the upper two-thirds of its extent, the anterior tibial artery rests upon the interosseous membrane; in the lower third, upon the front of the tibia, and the anterior ligament of the ankle-joint. In the upper third of its course, it lies between the *Tibialis anterior* and *Extensor digitorum longus*; in the middle third between the *Tibialis anterior* and *Extensor hallucis longus*. At the ankle it is crossed from the lateral to the medial side by the tendon of the *Extensor hallucis longus*, and lies between it and the first tendon of the *Extensor digitorum longus*. It is covered in the upper two-thirds of its course, by the muscles which lie on either side of it, and by the deep fascia; in the lower third, by the integument and fascia, and the transverse and cruciate crural ligaments.

The anterior tibial artery is accompanied by a pair of *venæ comitantes* which lie one on either side of the artery; the deep peroneal nerve, coursing around the lateral side of the neck of the fibula, comes into relation with the lateral side of the artery shortly after it has reached the front of the leg; about the middle of the leg the nerve is in front of the artery; at the lower part it is generally again on the lateral side.

Peculiarities in Size.—This vessel may be diminished in size, may be deficient to a greater or less extent, or may be entirely wanting, its place being supplied by perforating branches from the posterior tibial, or by the perforating branch of the peroneal artery.

Course.—The artery occasionally deviates toward the fibular side of the leg, regaining its usual position at the front of the ankle. In rare instances the vessel has been found to approach the surface in the middle of the leg, being covered merely by the integument and fascia below that point.

Branches.—The branches of the anterior tibial artery are:

Posterior Tibial Recurrent.	Muscular.
Fibular.	Anterior Medial Malleolar.
Anterior Tibial Recurrent.	Anterior Lateral Malleolar.

The **posterior tibial recurrent artery** (*a. recurrens tibialis posterior*) an inconstant branch, is given off from the anterior tibial before that vessel passes through the interosseous space. It ascends in front of the *Popliteus*, which it supplies, and anastomoses with the inferior genicular branches of the popliteal artery, giving an offset to the tibiofibular joint.

The **fibular artery** is sometimes derived from the anterior tibial, sometimes from the posterior tibial. It passes lateralward, around the neck of the fibula, through the *Soleus*, which it supplies, and ends in the substance of the *Peroneus longus*.

The **anterior tibial recurrent artery** (*a. recurrens tibialis anterior*) arises from the anterior tibial, as soon as that vessel has passed through the interosseous space; it ascends in the *Tibialis anterior*, ramifies on the front and sides of the knee-joint, and assists in the formation of the patellar plexus by anastomosing with the genicular branches of the popliteal, and with the highest genicular artery.

The **muscular branches** (*rami musculares*) are numerous; they are distributed to the muscles which lie on either side of the vessel, some piercing the deep fascia to supply the integument, others passing through the interosseous membrane, and anastomosing with branches of the posterior tibial and peroneal arteries.

The **anterior medial malleolar artery** (*a. malleolaris anterior medialis; internal malleolar artery*) arises about 5 cm. above the ankle-joint, and passes behind the tendons of the *Extensor hallucis longus* and *Tibialis anterior*, to the medial side of the ankle, upon which it ramifies, anastomosing with branches of the posterior tibial and medial plantar arteries and with the medial calcaneal from the posterior tibial.

The **anterior lateral malleolar artery** (*a. malleolaris anterior lateralis; external malleolar artery*) passes beneath the tendons of the *Extensor digitorum*

longus and Peronæus tertius and supplies the lateral side of the ankle, anastomosing with the perforating branch of the peroneal artery, and with ascending twigs from the lateral tarsal artery.

The arteries around the ankle-joint anastomose freely with one another and form net-works below the corresponding malleoli. The **medial malleolar net-work** is formed by the anterior medial malleolar branch of the anterior tibial, the medial tarsal branches of the dorsalis pedis, the posterior medial malleolar and medial calcaneal branches of the posterior tibial and branches from the medial plantar artery. The **lateral malleolar net-work** is formed by the anterior lateral malleolar branch of the anterior tibial, the lateral tarsal branch of the dorsalis pedis, the perforating and the lateral calcaneal branches of the peroneal, and twigs from the lateral plantar artery.

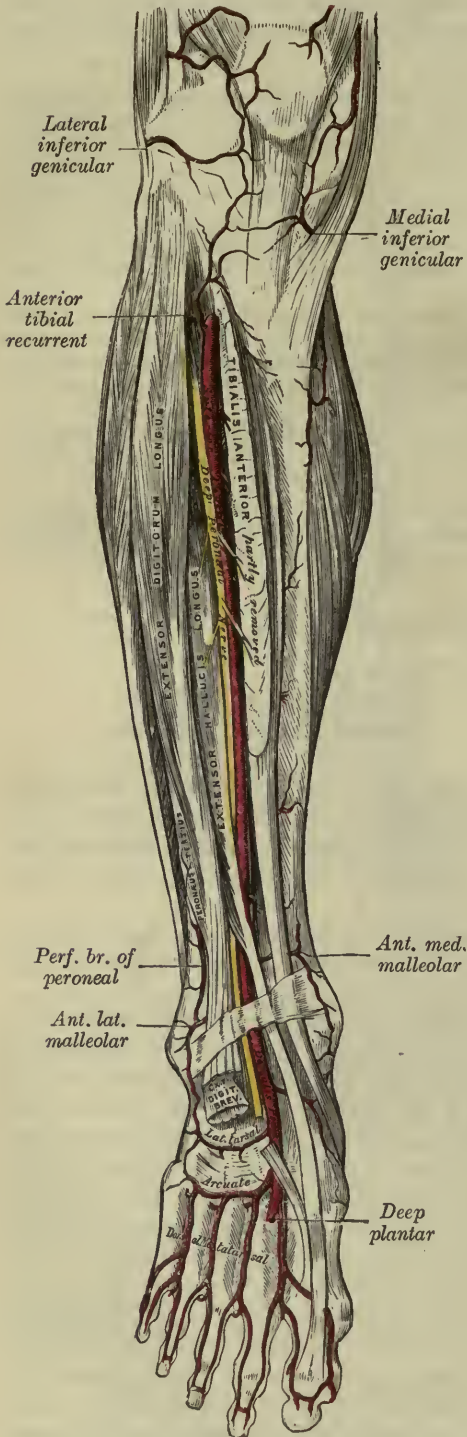


FIG. 553.—Anterior tibial and dorsalis pedis arteries.

The Arteria Dorsalis Pedis (Dorsalis Pedis Artery) (Fig. 553).

The *arteria dorsalis pedis*, the continuation of the anterior tibial, passes forward from the ankle-joint along the tibial side of the dorsum of the foot to the proximal part of the first intermetatarsal space, where it divides into two branches, the **first dorsal metatarsal** and the **deep plantar**.

Relations.—This vessel, in its course forward, rests upon the front of the articular capsule of the ankle-joint, the talus, navicular, and second cuneiform bones, and the ligaments connecting them, being covered by the integument, fascia and cruciate ligament, and crossed near its termination by the first tendon of the Extensor digitorum brevis. On its *tibial side* is the tendon of the Extensor hallucis longus; on its *fibular side*, the first tendon of the Extensor digitorum longus, and the termination of the deep peroneal nerve. It is accompanied by two veins.

Peculiarities in Size.—The dorsal artery of the foot may be larger than usual, to compensate for a deficient plantar artery; or its terminal branches to the toes may be absent, the toes then being supplied by the medial plantar; or its place may be taken altogether by a large perforating branch of the peroneal artery.

Position.—This artery frequently curves lateralward, lying lateral to the line between the middle of the ankle and the back part of the first interosseous space.

Branches.—The branches of the arteria dorsalis pedis are:

Lateral Tarsal.	Arcuate.
Medial Tarsal.	First Dorsal Metatarsal.
	Deep Plantar.

The **lateral tarsal artery** (*a. tarsea lateralis; tarsal artery*) arises from the dorsalis pedis, as that vessel crosses the navicular bone; it passes in an arched direction lateralward, lying upon the tarsal bones, and covered by the Extensor digitorum brevis; it supplies this muscle and the articulations of the tarsus, and anastomoses with branches of the arcuate, anterior lateral malleolar and lateral plantar arteries, and with the perforating branch of the peroneal artery.

The **medial tarsal arteries** (*aa. tarseæ mediales*) are two or three small branches which ramify on the medial border of the foot and join the medial malleolar net-work.

The **arcuate artery** (*a. arcuata; metatarsal artery*) arises a little anterior to the lateral tarsal artery; it passes lateralward, over the bases of the metatarsal bones, beneath the tendons of the Extensor digitorum brevis, its direction being influenced by its point of origin; and it anastomoses with the lateral tarsal and lateral plantar arteries. This vessel gives off the **second, third, and fourth dorsal metatarsal arteries**, which run forward upon the corresponding Interossei dorsales; in the clefts between the toes, each divides into two dorsal digital branches for the adjoining toes. At the proximal parts of the interosseous spaces these vessels receive the posterior perforating branches from the plantar arch, and at the distal parts of the spaces they are joined by the anterior perforating branches, from the plantar metatarsal arteries. The fourth dorsal metatarsal artery gives off a branch which supplies the lateral side of the fifth toe.

The **first dorsal metatarsal artery** (*a. dorsalis hallucis*) runs forward on the first Interosseous dorsalis, and at the cleft between the first and second toes divides into two branches, one of which passes beneath the tendon of the Extensor hallucis longus, and is distributed to the medial border of the great toe; the other bifurcates to supply the adjoining sides of the great and second toes.

The **deep plantar artery** (*ramus plantaris profundus; communicating artery*) descends into the sole of the foot, between the two heads of the first Interosseous dorsalis, and unites with the termination of the lateral plantar artery, to complete the plantar arch. It sends a branch along the medial side of the great toe, and is continued forward along the first interosseous space as the **first plantar metatarsal artery**, which bifurcates for the supply of the adjacent sides of the great and second toes.

The Posterior Tibial Artery (A. Tibialis Posterior) (Fig. 551).

The **posterior tibial artery** begins at the lower border of the Popliteus, opposite the interval between the tibia and fibula; it extends obliquely downward, and, as it descends, it approaches the tibial side of the leg, lying behind the tibia, and in the lower part of its course is situated midway between the medial malleolus and the medial process of the calcaneal tuberosity. Here it divides beneath the origin of the Adductor hallucis into the **medial and lateral plantar arteries**.

Relations.—The posterior tibial artery lies successively upon the Tibialis posterior, the Flexor digitorum longus, the tibia, and the back of the ankle-joint. It is covered by the deep transverse fascia of the leg, which separates it above from the Gastrocnemius and Soleus; at its termination it is covered by the Abductor hallucis. In the lower third of the leg, where it is more superficial, it is covered only by the integument and fascia, and runs parallel with the medial border of the tendo calcaneus. It is accompanied by two veins, and by the tibial nerve, which lies at first to the medial side of the artery, but soon crosses it posteriorly, and is in the greater part of its course on its lateral side.

Behind the medial malleolus, the tendons, bloodvessels, and nerve are arranged, under cover of the lacinate ligament, in the following order from the medial to the lateral side: (1) the

tendons of the Tibialis posterior and Flexor digitorum longus, lying in the same groove, behind the malleolus, the former being the more medial. Next is the posterior tibial artery, with a vein on either side of it; and lateral to the vessels is the tibial nerve; about 1.25 cm. nearer the heel is the tendon of the Flexor hallucis longus.

Peculiarities in Size.—The posterior tibial is not infrequently smaller than usual, or absent, its place being supplied by a large peroneal artery, which either joins the small posterior tibial artery, or continues alone to the sole of the foot.

Branches.—The branches of the posterior tibial artery are:

Peroneal.	Posterior Medial Malleolar.
Nutrient.	Communicating.
Muscular.	Medial Calcaneal.

The **peroneal artery** (*a. peronæa*) is deeply seated on the back of the fibular side of the leg. It arises from the posterior tibial, about 2.5 cm. below the lower border of the Popliteus, passes obliquely toward the fibula, and then descends along the medial side of that bone, contained in a fibrous canal between the Tibialis posterior and the Flexor hallucis longus, or in the substance of the latter muscle. It then runs behind the tibiofibular syndesmosis and divides into lateral calcaneal branches which ramify on the lateral and posterior surfaces of the calcaneus.

It is covered, in the *upper* part of its course, by the Soleus and deep transverse fascia of the leg; *below*, by the Flexor hallucis longus.

Peculiarities in Origin.—The peroneal artery may arise 7 or 8 cm. below the Popliteus, or from the posterior tibial high up, or even from the popliteal.

Its size is more frequently increased than diminished; and then it either reinforces the posterior tibial by its junction with it, or altogether takes the place of the posterior tibial in the lower part of the leg and foot, the latter vessel only existing as a short muscular branch. In those rare cases where the peroneal artery is smaller than usual, a branch from the posterior tibial supplies its place; and a branch from the anterior tibial compensates for the diminished anterior peroneal artery. In one case the peroneal artery was entirely wanting.

Branches.—The branches of the peroneal are:

Muscular.	Perforating.
Nutrient.	Communicating.
Lateral Calcaneal.	

Muscular Branches.—The peroneal artery, in its course, gives off branches to the Soleus, Tibialis posterior, Flexor hallucis longus, and Peronei.

The **Nutrient Artery** (*a. nutricia fibulæ*) supplies the fibula, and is directed downward.

The **Perforating Branch** (*ramus perforans; anterior peroneal artery*) pierces the interosseous membrane, about 5 cm. above the lateral malleolus, to reach the front of the leg, where it anastomoses with the anterior lateral malleolar; it then passes down in front of the tibiofibular syndesmosis, gives branches to the tarsus, and anastomoses with the lateral tarsal. The perforating branch is sometimes enlarged, and takes the place of the dorsalis pedis artery.

The **Communicating Branch** (*ramus communicans*) is given off from the peroneal about 2.5 cm. from its lower end, and joins the communicating branch of the posterior tibial.

The **Lateral Calcaneal** (*ramus calcaneus lateralis; external calcaneal*) are the terminal branches of the peroneal artery; they pass to the lateral side of the heel, and communicate with the lateral malleolar and, on the back of the heel, with the medial calcaneal arteries.

The **nutrient artery** (*a. nutricia tibiæ*) of the tibia arises from the posterior tibial, near its origin, and after supplying a few muscular branches enters the nutrient canal of the bone, which it traverses obliquely from above downward. This is the largest nutrient artery of bone in the body.

The **muscular branches** of the posterior tibial are distributed to the Soleus and deep muscles along the back of the leg.

The **posterior medial malleolar artery** (*a. malleolaris posterior medialis; internal malleolar artery*) is a small branch which winds around the tibial malleolus and ends in the medial malleolar net-work.

The **communicating branch** (*ramus communicans*) runs transversely across the back of the tibia, about 5 cm. above its lower end, beneath the Flexor hallucis longus, and joins the communicating branch of the peroneal.

The **medial calcaneal** (*rami calcanei mediales; internal calcaneal*) are several large arteries which arise from the posterior tibial just before its division; they pierce the lacinate ligament and are distributed to the fat and integument behind the tendo calcaneus and about the heel, and to the muscles on the tibial side of the sole, anastomosing with the peroneal and medial malleolar and, on the back of the heel, with the lateral calcaneal arteries.

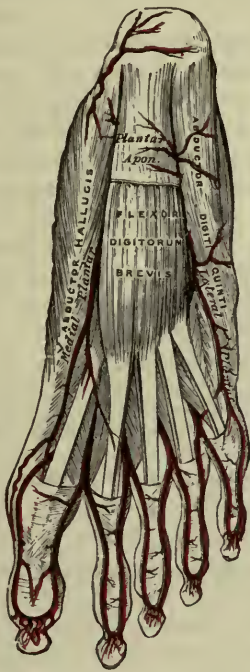


FIG. 554.—The plantar arteries. Superficial view.

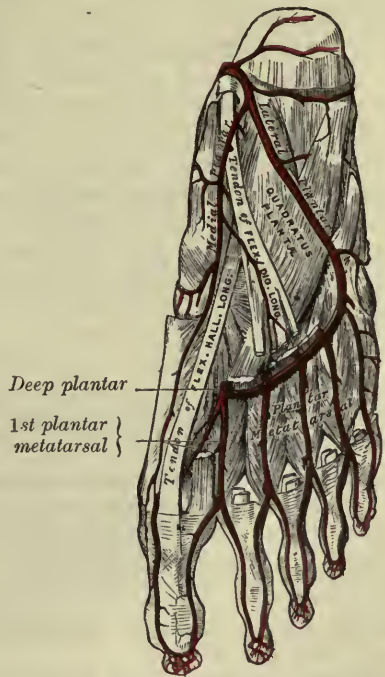


FIG. 555.—The plantar arteries. Deep view.

The **medial plantar artery** (*a. plantaris medialis; internal plantar artery*) (Figs. 554 and 555), much smaller than the lateral, passes forward along the medial side of the foot. It is at first situated above the Abductor hallucis, and then between it and the Flexor digitorum brevis, both of which it supplies. At the base of the first metatarsal bone, where it is much diminished in size, it passes along the medial border of the first toe, anastomosing with the first dorsal metatarsal artery. Small superficial digital branches accompany the digital branches of the medial plantar nerve and join the plantar metatarsal arteries of the first three spaces.

The **lateral plantar artery** (*a. plantaris lateralis; external plantar artery*), much larger than the medial, passes obliquely lateralward and forward to the base of the fifth metatarsal bone. It then turns medialward to the interval between the bases of the first and second metatarsal bones, where it unites with the deep plantar branch of the dorsalis pedis artery, thus completing the **plantar arch**. As this artery passes lateralward, it is first placed between the calcaneus and Abductor hallucis,

and then between the Flexor digitorum brevis and Quadratus plantæ; as it runs forward to the base of the little toe it lies more superficially between the Flexor digitorum brevis and Abductor digiti quinti, covered by the plantar aponeurosis and integument. The remaining portion of the vessel is deeply situated; it extends from the base of the fifth metatarsal bone to the proximal part of the first interosseous space, and forms the plantar arch; it is convex forward, lies below the bases of the second, third, and fourth metatarsal bones and the corresponding Interossei, and upon the oblique part of the Adductor hallucis.

Branches.—The plantar arch, besides distributing numerous branches to the muscles, integument, and fasciæ in the sole, gives off the following branches:

Perforating.

Plantar Metatarsal.

The **Perforating Branches** (*rami perforantes*) are *three* in number; they ascend through the proximal parts of the second, third, and fourth interosseous spaces, between the heads of the Interossei dorsales, and anastomose with the dorsal metatarsal arteries.

The **Plantar Metatarsal Arteries** (*aa. metatarsæ plantares; digital branches*) are *four* in number, and run forward between the metatarsal bones and in contact with the Interossei. Each divides into a pair of plantar digital arteries which supply the adjacent sides of the toes. Near their points of division each sends upward an **anterior perforating branch** to join the corresponding dorsal metatarsal artery. The **first plantar metatarsal artery** (*arteria princeps hallucis*) springs from the junction between the lateral plantar and deep plantar arteries and sends a digital branch to the medial side of the first toe. The digital branch for the lateral side of the fifth toe arise from the lateral plantar artery near the base of the fifth metatarsal bone.

BIBLIOGRAPHY.

- BEAN, R. B.: A Composite Study of the Subclavian Artery in Man, *Am. Jour. Anat.*, 1905, iv.
 BREMER, J. L.: On the Origin of the Renal Artery in Mammals and its Anomalies, *Am. Jour. Anat.*, 1915, xviii.
 BROMAN, IVAR: Ueber die Entwicklung "Wanderung," und Variation der Bauchaaortenzweige bei den Wirbeltieren, *Ergebnisse der Anat. u. Entwickl.*, 1906, xvi.
 EATON, P. B.: The Celiac Axis, *Anat. Rec.*, 1917, xiii.
 HENLE, J.: *Anatomie des Menschen*.
 HITZROT, J. M.: A Composite Study of the Axillary Artery in Man, *Johns Hop. Hosp. Bull.*, 1901, xii.
 LIPSHUTZ, B. B.: Studies on the Blood Vascular Tree. I. A Composite Study of the Femoral Artery, *Anat. Rec.*, 1916, x.
 POIRIER et CHARPY: *Traité d'Anatomie Humaine*.
 Quain's *Anatomy*.

THE VEINS.

THE Veins convey the blood from the capillaries of the different parts of the body to the heart. They consist of two distinct sets of vessels, the **pulmonary** and **systemic**.

The **Pulmonary Veins**, unlike other veins, contain arterial blood, which they return from the lungs to the left atrium of the heart.

The **Systemic Veins** return the venous blood from the body generally to the right atrium of the heart.

The **Portal Vein**, an appendage to the systemic venous system, is confined to the abdominal cavity, and returns the venous blood from the spleen and the viscera of digestion to the liver. This vessel ramifies in the substance of the liver and there breaks up into a minute network of capillary-like vessels, from which the blood is conveyed by the hepatic veins to the inferior vena cava.

The veins commence by minute plexuses which receive the blood from the capillaries. The branches arising from these plexuses unite together into trunks, and these, in their passage toward the heart, constantly increase in size as they receive tributaries, or join other veins. The veins are larger and altogether more numerous than the arteries; hence, the entire capacity of the venous system is much greater than that of the arterial; the capacity of the pulmonary veins, however, only slightly exceeds that of the pulmonary arteries. The veins are cylindrical like the arteries; their walls, however, are thin and they collapse when the vessels are empty, and the uniformity of their surfaces is interrupted at intervals by slight constrictions, which indicate the existence of valves in their interior. They communicate very freely with one another, especially in certain regions of the body; and these communications exist between the larger trunks as well as between the smaller branches. Thus, between the venous sinuses of the cranium, and between the veins of the neck, where obstruction would be attended with imminent danger to the cerebral venous system, large and frequent anastomoses are found. The same free communication exists between the veins throughout the whole extent of the vertebral canal, and between the veins composing the various venous plexuses in the abdomen and pelvis, *e. g.*, the spermatic, uterine, vesical, and pudendal.

The systemic venous channels are subdivided into three sets, *viz.*, **superficial** and **deep veins**, and **venous sinuses**.

The **Superficial Veins** (*cutaneous veins*) are found between the layers of the superficial fascia immediately beneath the skin; they return the blood from these structures, and communicate with the deep veins by perforating the deep fascia.

The **Deep Veins** accompany the arteries, and are usually enclosed in the same sheaths with those vessels. With the smaller arteries—as the radial, ulnar, brachial, tibial, peroneal—they exist generally in pairs, one lying on each side of the vessel, and are called **venæ comitantes**. The larger arteries—such as the axillary, subclavian, popliteal, and femoral—have usually only one accompanying vein. In certain organs of the body, however, the deep veins do not accompany the arteries; for instance, the veins in the skull and vertebral canal, the hepatic veins in the liver, and the larger veins returning blood from the bones.

Venous Sinuses are found only in the interior of the skull, and consist of canals formed by a separation of the two layers of the dura mater; their outer coat consists of fibrous tissue, their inner of an endothelial layer continuous with the lining membrane of the veins.

THE PULMONARY VEINS (VENÆ PULMONALES).

The **pulmonary veins** return the arterialized blood from the lungs to the left atrium of the heart. They are four in number, two from each lung, and are destitute of valves. They commence in a capillary net-work upon the walls of the air sacs, where they are continuous with the capillary ramifications of the pulmonary artery, and, joining together, form one vessel for each lobule. These vessels uniting successively, form a single trunk for each lobe, three for the right, and two for the left lung. The vein from the middle lobe of the right lung generally unites with that from the upper lobe, so that ultimately two trunks from each lung are formed; they perforate the fibrous layer of the pericardium and open separately into the upper and back part of the left atrium. Occasionally the three veins on the right side remain separate. Not infrequently the two left pulmonary veins end by a common opening.

At the root of the lung, the superior pulmonary vein lies in front of and a little below the pulmonary artery; the inferior is situated at the lowest part of the hilus of the lung and on a plane posterior to the upper vein. Behind the pulmonary artery is the bronchus.

Within the pericardium, their anterior surfaces are invested by the serous layer of this membrane.

The right pulmonary veins pass behind the right atrium and superior vena cava; the left in front of the descending thoracic aorta.

THE SYSTEMIC VEINS.

The **systemic veins** may be arranged into three groups: (1) The veins of the heart. (2) The veins of the upper extremities, head, neck, and thorax, which end in the superior vena cava. (3) The veins of the lower extremities, abdomen, and pelvis, which end in the inferior vena cava.

THE VEINS OF THE HEART (VV. Cordis) (Fig. 556).

Coronary Sinus (*sinus coronarius*).—Most of the veins of the heart open into the coronary sinus. This is a wide venous channel about 2.25 cm. in length situated in the posterior part of the coronary sulcus, and covered by muscular fibers from the left atrium. It ends in the right atrium between the opening of the inferior vena cava and the atrioventricular aperture, its orifice being guarded by a semilunar valve, the **valve of the coronary sinus** (*valve of Thebesius*).

Tributaries.—Its tributaries are the great, small, and middle cardiac veins, the posterior vein of the left ventricle, and the oblique vein of the left atrium, all of which, except the last, are provided with valves at their orifices.

1. The **Great Cardiac Vein** (*v. cordis magna; left coronary vein*) begins at the apex of the heart and ascends along the anterior longitudinal sulcus to the base of the ventricles. It then curves to the left in the coronary sulcus, and reaching the back of the heart, opens into the left extremity of the coronary sinus. It receives tributaries from the left atrium and from both ventricles: one, the **left marginal vein**, is of considerable size, and ascends along the left margin of the heart.

2. The **Small Cardiac Vein** (*v. cordis parva; right coronary vein*) runs in the coronary sulcus between the right atrium and ventricle, and opens into the right extremity of the coronary sinus. It receives blood from the back of the right atrium and ventricle; the **right marginal vein** ascends along the right margin of the heart and joins it in the coronary sulcus, or opens directly into the right atrium.

3. The **Middle Cardiac Vein** (*v. cordis media*) commences at the apex of the heart, ascends in the posterior longitudinal sulcus, and ends in the coronary sinus near its right extremity.

4. The **Posterior Vein of the Left Ventricle** (*v. posterior ventriculi sinistri*) runs on the diaphragmatic surface of the left ventricle to the coronary sinus, but may end in the great cardiac vein.

5. The **Oblique Vein of the Left Atrium** (*v. obliqua atrii sinistri* [Marshalli]; *oblique vein of Marshall*) is a small vessel which descends obliquely on the back of the left atrium and ends in the coronary sinus near its left extremity; it is continuous above with the **ligament of the left vena cava** (*lig. venæ cavæ sinistræ*; *vestigial fold of Marshall*), and the two structures form the remnant of the left Cuvierian duct.

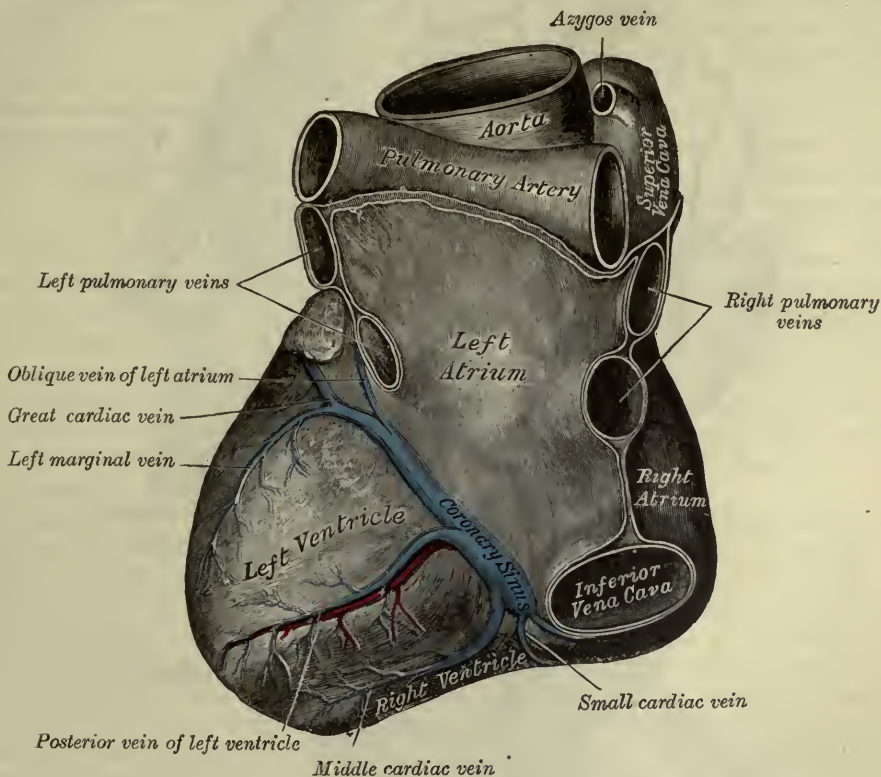


FIG. 556.—Base and diaphragmatic surface of heart.

The following cardiac veins do not end in the coronary sinus: (1) the **anterior cardiac veins**, comprising three or four small vessels which collect blood from the front of the right ventricle and open into the right atrium; the right marginal vein frequently opens into the right atrium, and is therefore sometimes regarded as belonging to this group; (2) the **smallest cardiac veins** (*veins of Thebesius*), consisting of a number of minute veins which arise in the muscular wall of the heart; the majority open into the atria, but a few end in the ventricles.

THE VEINS OF THE HEAD AND NECK.

The veins of the head and neck may be subdivided into three groups: (1) The **veins of the exterior of the head and face**. (2) The **veins of the neck**. (3) The **diploic veins**, the **veins of the brain**, and the **venous sinuses of the dura mater**.

The Veins of the Exterior of the Head and Face (Fig. 557).

The veins of the exterior of the head and face are:

- | | |
|------------------|----------------------|
| Frontal. | Superficial Temporal |
| Supraorbital. | Internal Maxillary. |
| Angular. | Posterior Facial. |
| Anterior Facial. | Posterior Auricular. |
| | Occipital. |

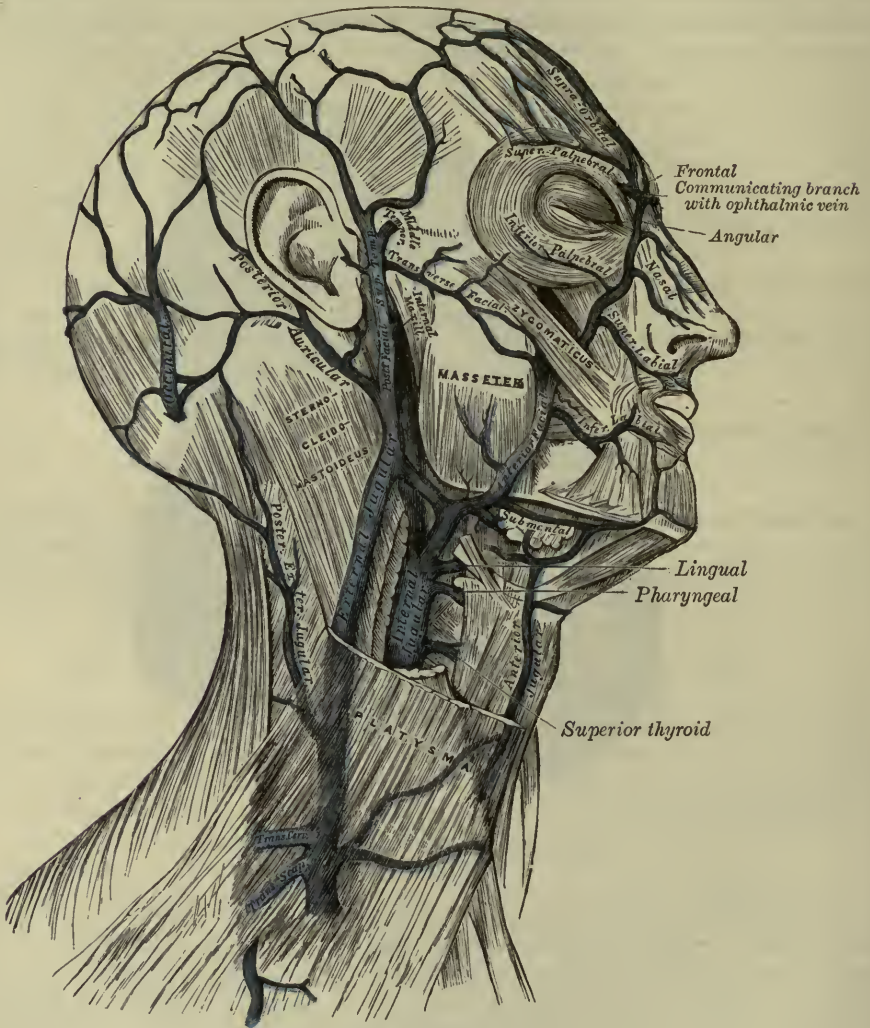


FIG. 557.—Veins of the head and neck.

The **frontal vein** (*v. frontalis*) begins on the forehead in a venous plexus which communicates with the frontal branches of the superficial temporal vein. The veins converge to form a single trunk, which runs downward near the middle line of the forehead parallel with the vein of the opposite side. The two veins are joined, at the root of the nose, by a transverse branch, called the **nasal arch**, which receives some small veins from the dorsum of the nose. At the root of the nose the veins diverge, and, each at the medial angle of the orbit, joins the **supraorbital vein**, to

form the **angular vein**. Occasionally the frontal veins join to form a single trunk, which bifurcates at the root of the nose into the two angular veins.

The **supraorbital vein** (*v. supraorbitalis*) begins on the forehead where it communicates with the frontal branch of the superficial temporal vein. It runs downward superficial to the Frontalis muscle, and joins the frontal vein at the medial angle of the orbit to form the **angular vein**. Previous to its junction with the frontal vein, it sends through the supraorbital notch into the orbit a branch which communicates with the ophthalmic vein; as this vessel passes through the notch, it receives the frontal diploic vein through a foramen at the bottom of the notch.

The **angular vein** (*v. angularis*) formed by the junction of the frontal and supraorbital veins, runs obliquely downward, on the side of the root of the nose, to the level of the lower margin of the orbit, where it becomes the anterior facial vein. It receives the veins of the ala nasi, and communicates with the superior ophthalmic vein through the nasofrontal vein, thus establishing an important anastomosis between the anterior facial vein and the cavernous sinus.

The **anterior facial vein** (*v. facialis anterior; facial vein*) commences at the side of the root of the nose, and is a direct continuation of the angular vein. It lies behind the external maxillary (facial) artery and follows a less tortuous course. It runs obliquely downward and backward, beneath the Zygomaticus and zygomatic head of the Quadratus labii superioris, descends along the anterior border and then on the superficial surface of the Masseter, crosses over the body of the mandible, and passes obliquely backward, beneath the Platysma and cervical fascia, superficial to the submaxillary gland, the Digastricus and Stylohyoideus. It unites with the posterior facial vein to form the **common facial vein**, which crosses the external carotid artery and enters the internal jugular vein at a variable point below the hyoid bone. From near its termination a communicating branch often runs down the anterior border of the Sternocleidomastoideus to join the lower part of the anterior jugular vein. The facial vein has no valves, and its walls are not so flaccid as most superficial veins.

Tributaries.—The anterior facial vein receives a branch of considerable size, the **deep facial vein**, from the pterygoid venous plexus. It is also joined by the superior and inferior palpebral, the superior and inferior labial, the buccinator and the masseteric veins. Below the mandible it receives the submental, palatine, and submaxillary veins, and, generally, the vena comitans of the hypoglossal nerve.

The **superficial temporal vein** (*v. temporalis superficialis*) begins on the side and vertex of the skull in a plexus which communicates with the frontal and supraorbital veins, with the corresponding vein of the opposite side, and with the posterior auricular and occipital veins. From this network frontal and parietal branches arise, and unite above the zygomatic arch to form the trunk of the vein, which is joined in this situation by the **middle temporal vein**, from the substance of the Temporalis. It then crosses the posterior root of the zygomatic arch, enters the substance of the parotid gland, and unites with the internal maxillary vein to form the **posterior facial vein**.

Tributaries.—The superficial temporal vein receives in its course some parotid veins, articular veins from the temporomandibular joint, anterior auricular veins from the auricula, and the **transverse facial** from the side of the face. The middle temporal vein receives the **orbital vein**, which is formed by some lateral palpebral branches, and passes backward between the layers of the temporal fascia to join the superficial temporal vein.

The **pterygoid plexus** (*plexus pterygoideus*) is of considerable size, and is situated between the Temporalis and Pterygoideus externus, and partly between the two Pterygoidei. It receives tributaries corresponding with the branches of the internal maxillary artery. Thus it receives the sphenopalatine, the middle meningeal, the deep temporal, the pterygoid, masseteric, buccinator, alveolar, and some palatine

veins, and a branch which communicates with the ophthalmic vein through the inferior orbital fissure. This plexus communicates freely with the anterior facial vein; it also communicates with the cavernous sinus, by branches through the foramen Vesalii, foramen ovale, and foramen lacerum.

The **internal maxillary vein** (*v. maxillaris interna*) is a short trunk which accompanies the first part of the internal maxillary artery. It is formed by a confluence of the veins of the pterygoid plexus, and passes backward between the sphenomandibular ligament and the neck of the mandible, and unites with the temporal vein to form the posterior facial vein.

The **posterior facial vein** (*v. facialis posterior; temporomaxillary vein*), formed by the union of the superficial temporal and internal maxillary veins, descends in the substance of the parotid gland, superficial to the external carotid artery but beneath the facial nerve, between the ramus of the mandible and the Sternocleidomastoideus muscle. It divides into two branches, an **anterior**, which passes forward and unites with the anterior facial vein to form the common facial vein and a **posterior**, which is joined by the posterior auricular vein and becomes the external jugular vein.

The **posterior auricular vein** (*v. auricularis posterior*) begins upon the side of the head, in a plexus which communicates with the tributaries of the occipital, and superficial temporal veins. It descends behind the auricula, and joins the posterior division of the posterior facial vein to form the external jugular. It receives the stylomastoid vein, and some tributaries from the cranial surface of the auricula.

The **occipital vein** (*v. occipitalis*) begins in a plexus at the back part of the vertex of the skull. From the plexus emerges a single vessel, which pierces the cranial attachment of the Trapezius and, dipping into the suboccipital triangle, joins the deep cervical and vertebral veins. Occasionally it follows the course of the occipital artery and ends in the internal jugular; in other instances, it joins the posterior auricular and through it opens into the external jugular. The parietal emissary vein connects it with the superior sagittal sinus; and as it passes across the mastoid portion of the temporal bone, it receives the mastoid emissary vein which connects it with the transverse sinus. The occipital diploic vein sometimes joins it.

The Veins of the Neck (Fig. 558).

The veins of the neck, which return the blood from the head and face, are:

External Jugular.	Anterior Jugular.
Posterior External Jugular.	Internal Jugular.
	Vertebral.

The **external jugular vein** (*v. jugularis externa*) receives the greater part of the blood from the exterior of the cranium and the deep parts of the face, being formed by the junction of the posterior division of the posterior facial with the posterior auricular vein. It commences in the substance of the parotid gland, on a level with the angle of the mandible, and runs perpendicularly down the neck, in the direction of a line drawn from the angle of the mandible to the middle of the clavicle at the posterior border of the Sternocleidomastoideus. In its course it crosses the Sternocleidomastoideus obliquely, and in the subclavian triangle perforates the deep fascia, and ends in the subclavian vein, lateral to or in front of the Scalenus anterior. It is separated from the Sternocleidomastoideus by the investing layer of the deep cervical fascia, and is covered by the Platysma, the superficial fascia, and the integument; it crosses the cutaneous cervical nerve, and its upper half runs parallel with the great auricular nerve. The external jugular vein varies in size, bearing an inverse proportion to the other veins of the neck, it is occasionally

double. It is provided with two pairs of valves, the lower pair being placed at its entrance into the subclavian vein, the upper in most cases about 4 cm. above the clavicle. The portion of vein between the two sets of valves is often dilated, and is termed the *sinus*. These valves do not prevent the regurgitation of the blood, or the passage of injection from below upward.

Tributaries.—This vein receives the occipital occasionally, the posterior external jugular, and, near its termination, the transverse cervical, transverse scapular, and anterior jugular veins; in the substance of the parotid, a large branch of communication from the internal jugular joins it.

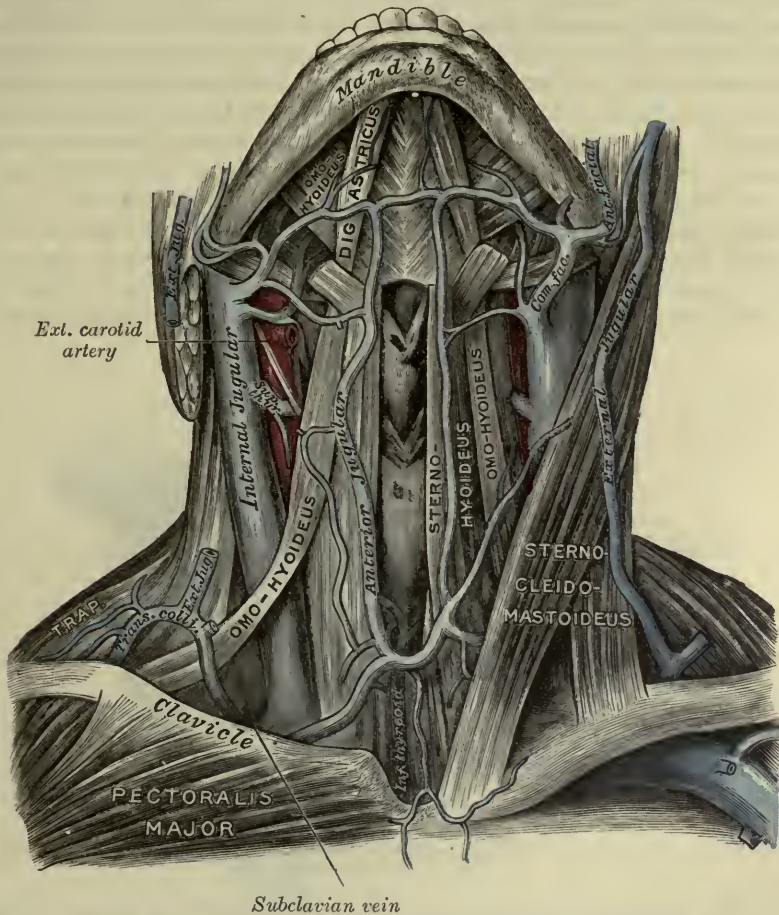


FIG. 558.—The veins of the neck, viewed from in front. (Spalteholz.)

The **posterior external jugular vein** (*v. jugularis posterior*) begins in the occipital region and returns the blood from the skin and superficial muscles in the upper and back part of the neck, lying between the Splenius and Trapezius. It runs down the back part of the neck, and opens into the external jugular vein just below the middle of its course.

The **anterior jugular vein** (*v. jugularis anterior*) begins near the hyoid bone by the confluence of several superficial veins from the submaxillary region. It descends between the median line and the anterior border of the Sternocleidomastoideus, and, at the lower part of the neck, passes beneath that muscle to open into the termination of the external jugular, or, in some instances, into the subclavian vein (Figs. 557, 558). It varies considerably in size, bearing usually an inverse propor-

tion to the external jugular; most frequently there are two anterior jugulars, a right and left; but sometimes only one. Its tributaries are some laryngeal veins, and occasionally a small thyroid vein. Just above the sternum the two anterior jugular veins communicate by a transverse trunk, the **venous jugular arch**, which receive tributaries from the inferior thyroid veins; each also communicates with the internal jugular. There are no valves in this vein.

The **internal jugular vein** (*v. jugularis interna*) collects the blood from the brain, from the superficial parts of the face, and from the neck. It is directly continuous with the transverse sinus, and begins in the posterior compartment of the jugular foramen, at the base of the skull. At its origin it is somewhat dilated, and this dilatation is called the **superior bulb**. It runs down the side of the neck in a vertical direction, lying at first lateral to the internal carotid artery, and then lateral to the common carotid, and at the root of the neck unites with the subclavian vein to form the innominate vein; a little above its termination is a second dilatation, the **inferior bulb**. Above, it lies upon the Rectus capitis lateralis, behind the internal carotid artery and the nerves passing through the jugular foramen; lower down, the vein and artery lie upon the same plane, the glossopharyngeal and hypoglossal nerves passing forward between them; the vagus descends between and behind the vein and the artery in the same sheath, and the accessory runs obliquely backward, superficial or deep to the vein. At the root of the neck the right internal jugular vein is placed at a little distance from the common carotid artery, and

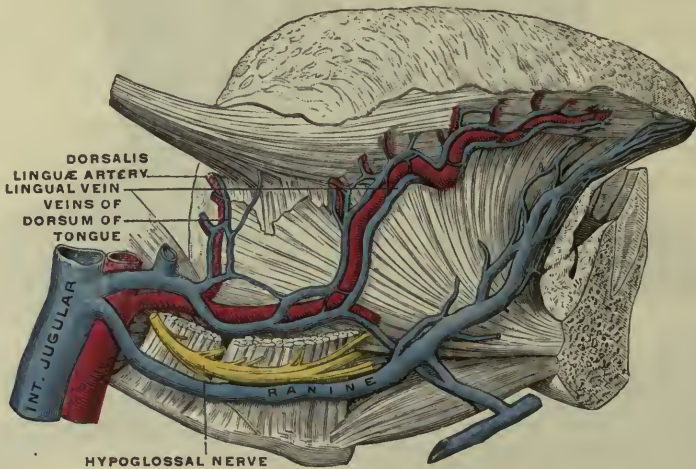


Fig. 559.—Veins of the tongue. The hypoglossal nerve has been displaced downward in this preparation. (Testut after Hirschfeld.)

crosses the first part of the subclavian artery, while the left internal jugular vein usually overlaps the common carotid artery. The left vein is generally smaller than the right, and each contains a pair of valves, which are placed about 2.5 cm. above the termination of the vessel.

Tributaries.—This vein receives in its course the inferior petrosal sinus, the common facial, lingual, pharyngeal, superior and middle thyroid veins, and sometimes the occipital. The thoracic duct on the left side and the right lymphatic duct on the right side open into the angle of union of the internal jugular and subclavian veins.

The **Inferior Petrosal Sinus** (*sinus petrosus inferior*) leaves the skull through the anterior part of the jugular foramen, and joins the superior bulb of the internal jugular vein.

The **Lingual Veins** (*vv. linguales*) begin on the dorsum, sides, and under surface of the tongue, and, passing backward along the course of the lingual artery, end in the internal jugular vein. The vena comitans of the hypoglossal nerve (**ranine**

vein), a branch of considerable size, begins below the tip of the tongue, and may join the lingual; generally, however, it passes backward on the Hyoglossus, and joins the common facial.

The **Pharyngeal Veins** (*vv. pharyngeæ*) begin in the **pharyngeal plexus** on the outer surface of the pharynx, and, after receiving some posterior meningeal veins and the vein of the pterygoid canal, end in the internal jugular. They occasionally open into the facial, lingual, or superior thyroid vein.

The **Superior Thyroid Vein** (*v. thyroidea superioris*) (Fig. 560) begins in the substance and on the surface of the thyroid gland, by tributaries corresponding with the branches of the superior thyroid artery, and ends in the upper part of the internal jugular vein. It receives the superior laryngeal and cricothyroid veins.

The **Middle Thyroid Vein** (Figs. 561, 562) collects the blood from the lower part of the thyroid gland, and after being joined by some veins from the larynx and trachea, ends in the lower part of the internal jugular vein.

The **common facial** and **occipital veins** have been described.

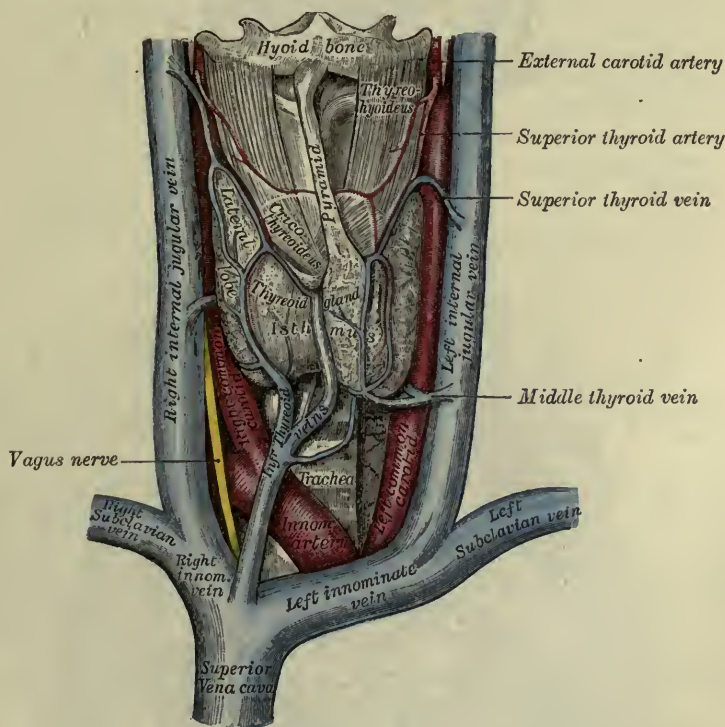


FIG. 560.—The veins of the thyroid gland.

The **vertebral vein** (*v. vertebralis*) is formed in the suboccipital triangle, from numerous small tributaries which spring from the internal vertebral venous plexuses and issue from the vertebral canal above the posterior arch of the atlas. They unite with small veins from the deep muscles at the upper part of the back of the neck, and form a vessel which enters the foramen in the transverse process of the atlas, and descends, forming a dense plexus around the vertebral artery, in the canal formed by the foramina transversaria of the cervical vertebræ. This plexus ends in a single trunk, which emerges from the foramen transversarium of the sixth cervical vertebra, and opens at the root of the neck into the back part of the innominate vein near its origin, its mouth being guarded by a pair of valves. On the right side, it crosses the first part of the subclavian artery.

Tributaries.—The vertebral vein communicates with the transverse sinus by a vein which passes through the condyloid canal, when that canal exists. It

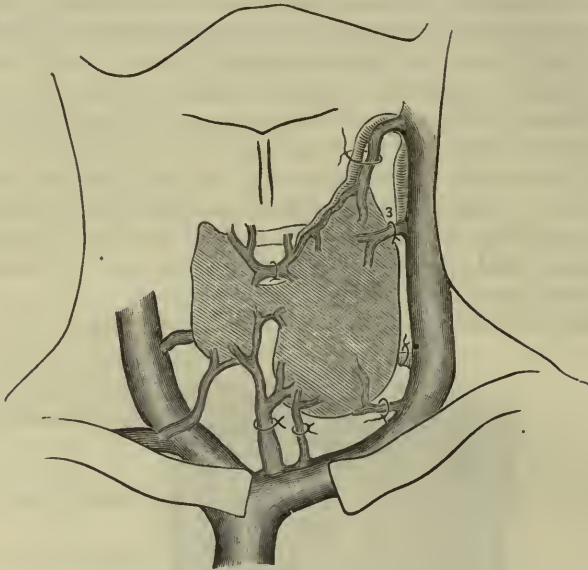


FIG. 561.—Diagram showing common arrangement of thyroid veins. (Kocher.)

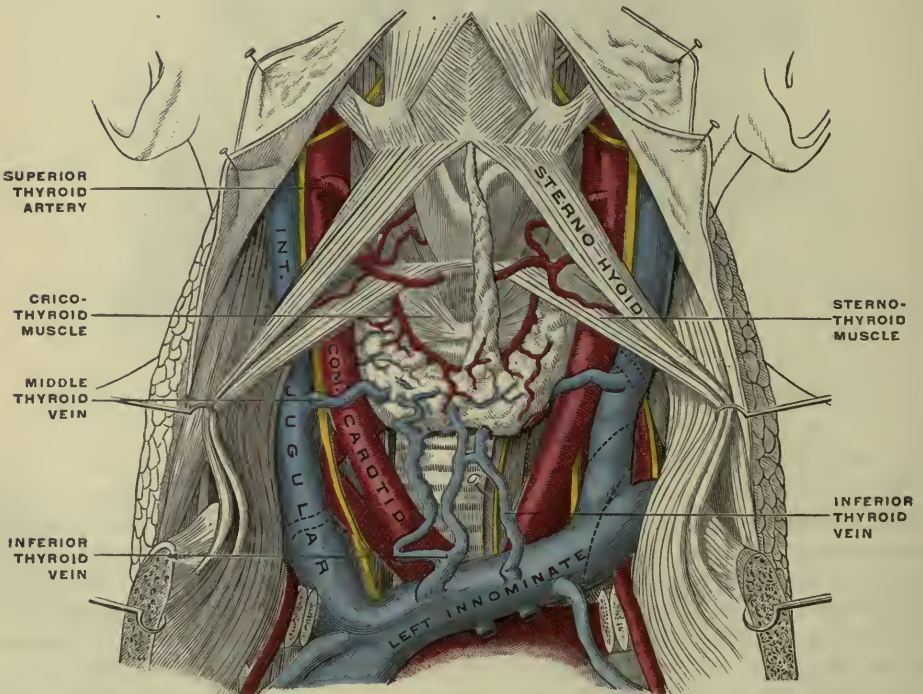


FIG. 562.—The fascia and middle thyroid veins. The veins here designated the inferior thyroid are called by Kocher the thyroidea ima. (Poirier and Charpy.)

receives branches from the occipital vein and from the prevertebral muscles, from the internal and external vertebral venous plexuses, from the anterior vertebral

and the deep cervical veins; close to its termination it is sometimes joined by the first intercostal vein.

The **Anterior Vertebral Vein** commences in a plexus around the transverse processes of the upper cervical vertebræ, descends in company with the ascending cervical artery between the *Scalenus anterior* and *Longus capitis* muscles, and opens into the terminal part of the vertebral vein.

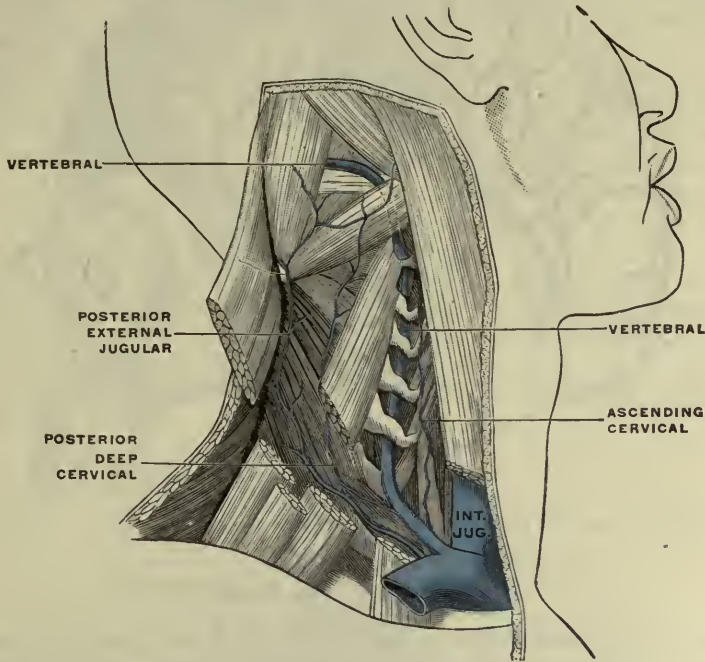


FIG. 563.—The vertebral vein. (Poirier and Charpy.)

The **Deep Cervical Vein** (*v. cervicalis profunda*; *posterior vertebral* or *posterior deep cervical vein*) accompanies its artery between the *Semispinales capitis* and *colli*. It begins in the suboccipital region by communicating branches from the occipital vein and by small veins from the deep muscles at the back of the neck. It receives tributaries from the plexuses around the spinous processes of the cervical vertebræ, and terminates in the lower part of the vertebral vein.

The Diploic Veins (*Venæ Diploicæ*) (Fig. 564).

The **diploic veins** occupy channels in the diploë of the cranial bones. They are large and exhibit at irregular intervals pouch-like dilatations; their walls are thin, and formed of endothelium resting upon a layer of elastic tissue.

So long as the cranial bones are separable from one another, these veins are confined to the particular bones; but when the sutures are obliterated, they unite with each other, and increase in size. They communicate with the meningeal veins and the sinuses of the dura mater, and with the veins of the pericranium. They consist of (1) the **frontal**, which opens into the supraorbital vein and the superior sagittal sinus; (2) the **anterior temporal**, which is confined chiefly to the frontal bone, and opens into the sphenoparietal sinus and into one of the deep temporal veins, through an aperture in the great wing of the sphenoid; (3) the **posterior temporal**, which is situated in the parietal bone, and ends in the transverse sinus, through an aperture at the mastoid angle of the parietal bone or through the

mastoid foramen; and (4) the **occipital**, the largest of the four, which is confined to the occipital bone, and opens either externally into the occipital vein, or internally into the transverse sinus or into the confluence of the sinuses (*torcular Herophili*).

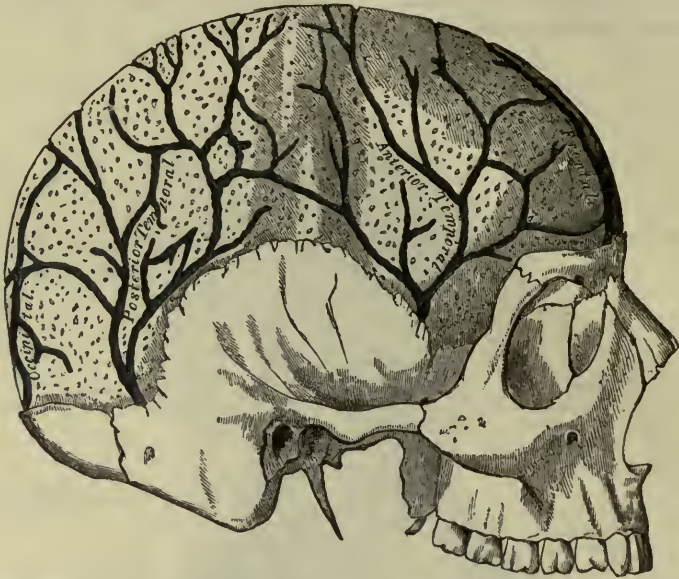


FIG. 564.—Veins of the diploë as displayed by the removal of the outer table of the skull.

The Veins of the Brain.

The veins of the brain possess no valves, and their walls, owing to the absence of muscular tissue, are extremely thin. They pierce the arachnoid membrane and the inner or meningeal layer of the dura mater, and open into the cranial venous sinuses. They may be divided into two sets, **cerebral** and **cerebellar**.

The **cerebral veins** (*vv. cerebri*) are divisible into external and internal groups according as they drain the outer surfaces or the inner parts of the hemispheres.

The **external veins** are the superior, inferior, and middle cerebral.

The **Superior Cerebral Veins** (*vv. cerebri superiores*), eight to twelve in number, drain the superior, lateral, and medial surfaces of the hemispheres, and are mainly lodged in the sulci between the gyri, but some run across the gyri. They open into the superior sagittal sinus; the anterior veins run nearly at right angles to the sinus; the posterior and larger veins are directed obliquely forward and open into the sinus in a direction more or less opposed to the current of the blood contained within it.

The **Middle Cerebral Vein** (*v. cerebri media; superficial Sylvian vein*) begins on the lateral surface of the hemisphere, and, running along the lateral cerebral fissure, ends in the cavernous or the sphenoparietal sinus. It is connected (*a*) with the superior sagittal sinus by the **great anastomotic vein of Trolard**, which opens into one of the superior cerebral veins; (*b*) with the transverse sinus by the **posterior anastomotic vein of Labbé**, which courses over the temporal lobe.

The **Inferior Cerebral Veins** (*vv. cerebri inferiores*), of small size, drain the under surfaces of the hemispheres. Those on the orbital surface of the frontal lobe join the superior cerebral veins, and through these open into the superior sagittal sinus; those of the temporal lobe anastomose with the middle cerebral and basal veins, and join the cavernous, sphenoparietal, and superior petrosal sinuses.

The **basal vein** is formed at the anterior perforated substance by the union of (a) a small **anterior cerebral vein** which accompanies the anterior cerebral artery, (b) the **deep middle cerebral vein** (*deep Sylvian vein*), which receives tributaries from the insula and neighboring gyri, and runs in the lower part of the lateral cerebral fissure, and (c) the **inferior striate veins**, which leave the corpus striatum through the anterior perforated substance. The basal vein passes backward around the cerebral peduncle, and ends in the internal cerebral vein (*vein of Galen*); it receives tributaries from the interpeduncular fossa, the inferior horn of the lateral ventricle, the hippocampal gyrus, and the mid-brain.

The **Internal Cerebral Veins** (*vv. cerebri internæ; veins of Galen; deep cerebral veins*) drain the deep parts of the hemisphere and are two in number; each is formed near the interventricular foramen by the union of the **terminal** and **choroid veins**. They run backward parallel with one another, between the layers of the tela chorioidea of the third ventricle, and beneath the splenium of the corpus callosum, where they unite to form a short trunk, the **great cerebral vein**; just before their union each receives the corresponding basal vein.

The **terminal vein** (*v. terminalis; vena corporis striati*) commences in the groove between the corpus striatum and thalamus, receives numerous veins from both of these parts, and unites behind the crus fornicis with the choroid vein, to form one of the internal cerebral veins. The **choroid vein** runs along the whole length of the choroid plexus, and receives veins from the hippocampus, the fornix, and the corpus callosum.

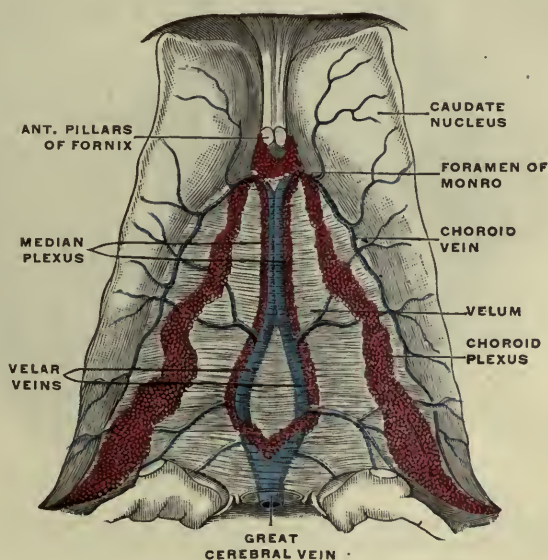


Fig. 565.—Velum interpositum. (Poirier and Charpy.)

The **Great Cerebral Vein** (*v. cerebri magna [Galen]; great vein of Galen*) (Fig. 565), formed by the union of the two internal cerebral veins, is a short median trunk which curves backward and upward around the splenium of the corpus callosum and ends in the anterior extremity of the straight sinus.

The **cerebellar veins** are placed on the surface of the cerebellum, and are disposed in two sets, superior and inferior. The **superior cerebellar veins** (*vv. cerebelli superiores*) pass partly forward and medialward, across the superior vermis, to end in the straight sinus and the internal cerebral veins, partly lateralward to the transverse and superior petrosal sinuses. The **inferior cerebellar veins** (*vv. cerebelli inferiores*) of large size, end in the transverse, superior petrosal, and occipital sinuses.

The Sinuses of the Dura Mater (*Sinus Duræ Matris*). Ophthalmic Veins and Emissary Veins.

The sinuses of the dura mater are venous channels which drain the blood from the brain; they are devoid of valves, and are situated between the two layers of the dura mater and lined by endothelium continuous with that which lines the veins. They may be divided into two groups: (1) a **postero-superior**, at the upper and back part of the skull, and (2) an **antero-inferior**, at the base of the skull.

The postero-superior group comprises the

Superior Sagittal.
Inferior Sagittal.

Straight.
Two Transverse.

Occipital.

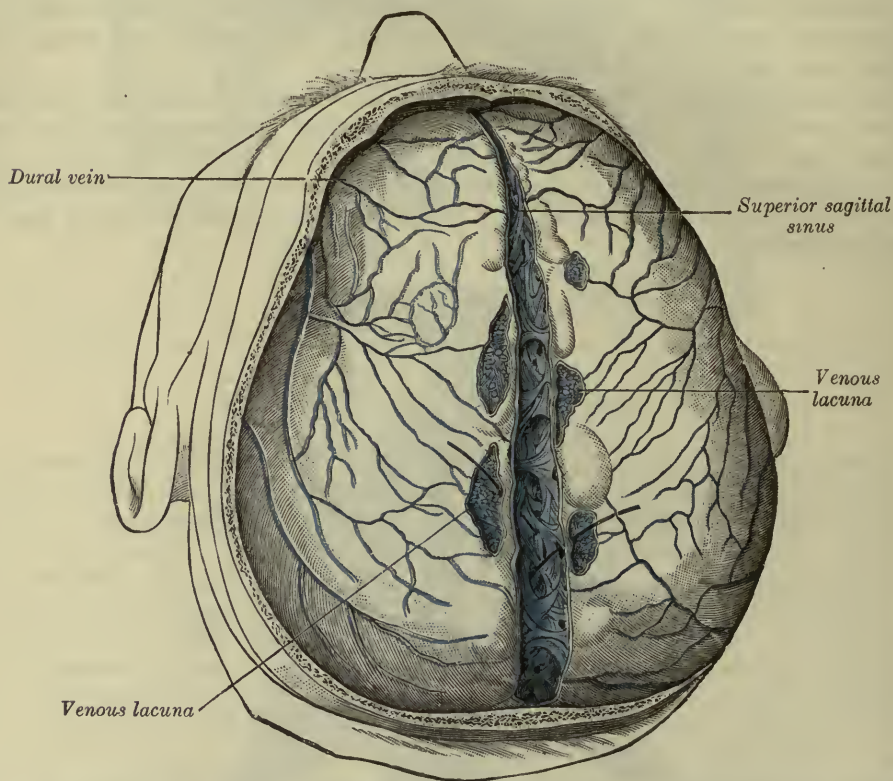


FIG. 566.—Superior sagittal sinus laid open after removal of the skull cap. The chordæ Willisii are clearly seen. The venous lacunæ are also well shown; from two of them probes are passed into the superior sagittal sinus. (Poirier and Charpy.)

The **superior sagittal sinus** (*sinus sagittalis superior*; *superior longitudinal sinus*) (Figs. 566, 567) occupies the attached or convex margin of the falx cerebri. Commencing at the foramen cecum, through which it receives a vein from the nasal cavity, it runs from before backward, grooving the inner surface of the frontal, the adjacent margins of the two parietals, and the superior division of the cruciate eminence of the occipital; near the internal occipital protuberance it deviates to one or other side (usually the right), and is continued as the corresponding transverse sinus. It is triangular in section, narrow in front, and gradually increases in size as it passes backward. Its inner surface presents the openings of the superior cerebral veins, which run, for the most part, obliquely forward, and open chiefly at the back part of the sinus, their orifices being concealed by fibrous folds; numerous

fibrous bands (*chordæ Willisii*) extend transversely across the inferior angle of the sinus; and, lastly, small openings communicate with irregularly shaped venous spaces (*venous lacunæ*) in the dura mater near the sinus. There are usually three lacunæ on either side of the sinus: a small frontal, a large parietal, and an occipital, intermediate in size between the other two (Sargent¹). Most of the cerebral veins from the outer surface of the hemisphere open into these lacunæ, and numerous **arachnoid granulations** (*Pacchionian bodies*) project into them from below. The superior sagittal sinus receives the superior cerebral veins, veins from the diploë and dura mater, and, near the posterior extremity of the sagittal suture, veins from the pericranium, which pass through the parietal foramina.

The numerous communications exist between this sinus and the veins of the nose, scalp, and diploë.

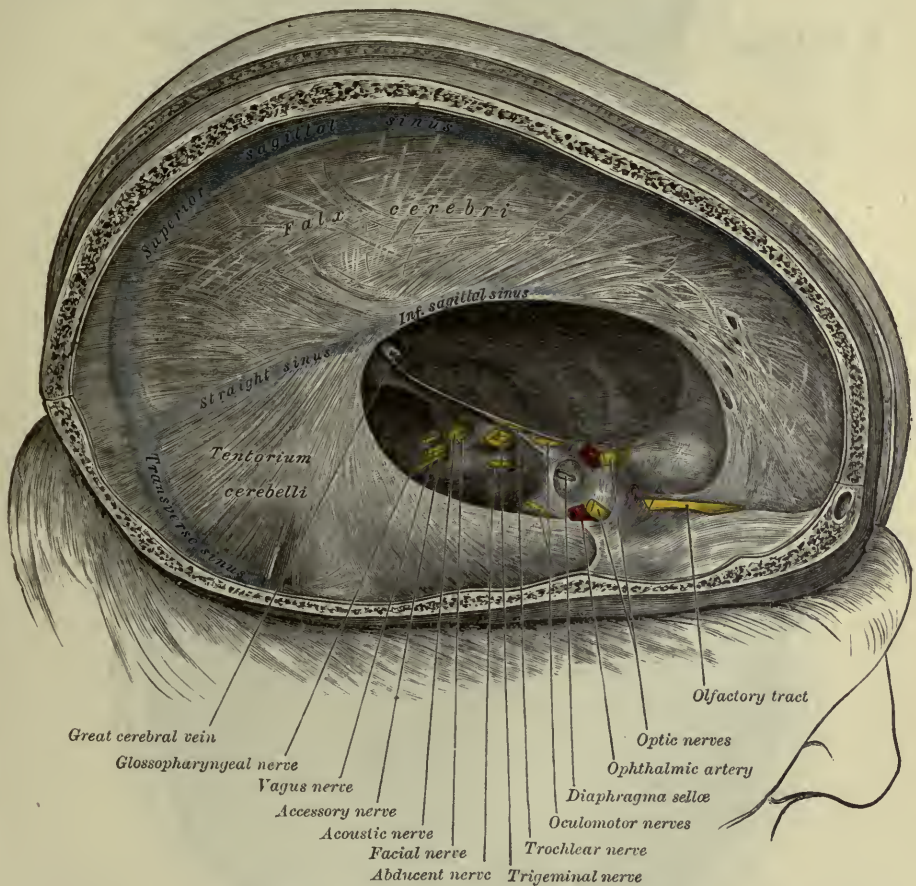


FIG. 567.—Dura mater and its processes exposed by removing part of the right half of the skull, and the brain.

The **inferior sagittal sinus** (*sinus sagittalis inferior; inferior longitudinal sinus*) (Fig. 567) is contained in the posterior half or two-thirds of the free margin of the falx cerebri. It is of a cylindrical form, increases in size as it passes backward, and ends in the straight sinus. It receives several veins from the falx cerebri, and occasionally a few from the medial surfaces of the hemispheres.

The **straight sinus** (*sinus rectus; tentorial sinus*) (Figs. 567, 569) is situated at the line of junction of the falx cerebri with the tentorium cerebelli. It is triangular

¹ Journal of Anatomy and Physiology, vol. xlv.

in section, increases in size as it proceeds backward, and runs downward and backward from the end of the inferior sagittal sinus to the transverse sinus of the oppo-

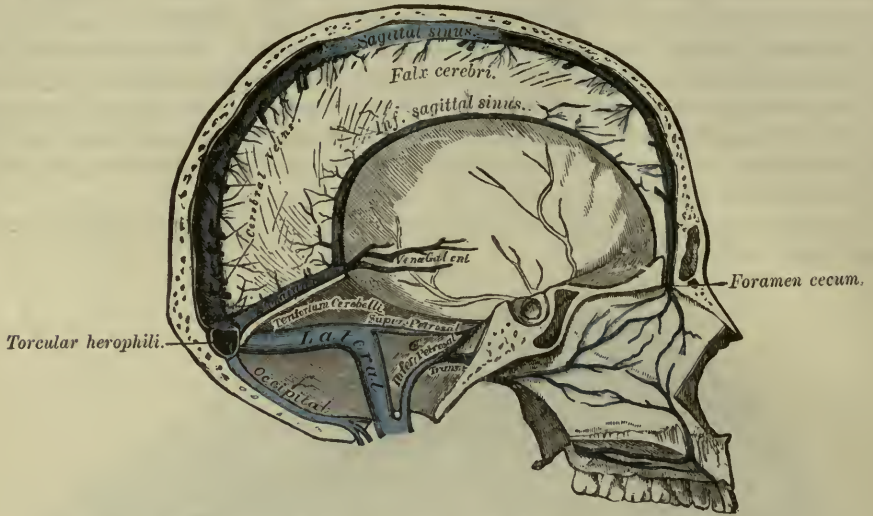

FIG. 568.—Sagittal section of the skull, showing the sinuses of the dura.

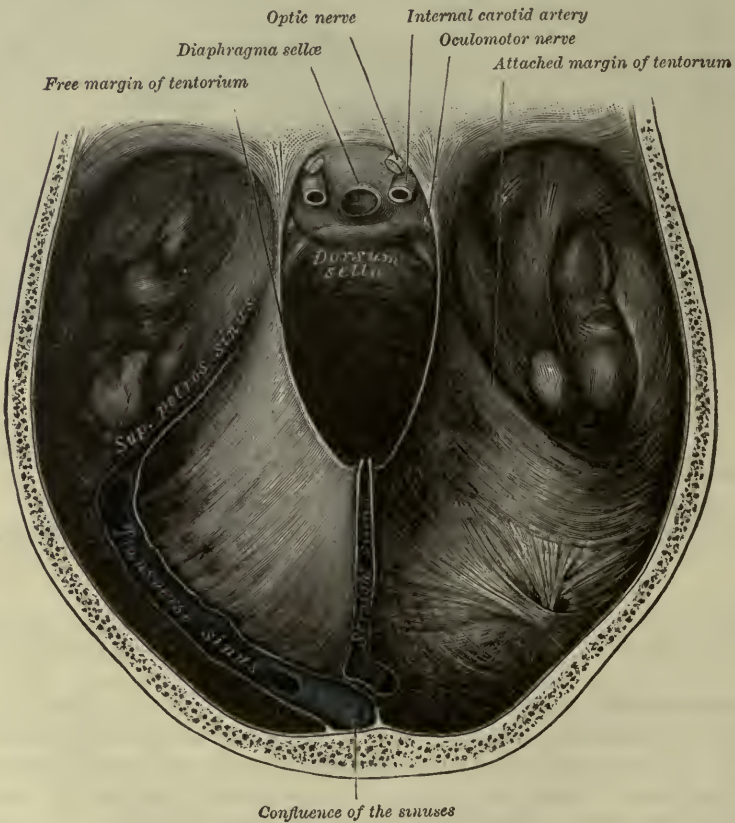


FIG. 569.—Tentorium cerebelli from above.

site side to that into which the superior sagittal sinus is prolonged. Its terminal part communicates by a cross branch with the confluence of the sinuses. Besides

the inferior sagittal sinus, it receives the great cerebral vein (*great vein of Galen*) and the superior cerebellar veins. A few transverse bands cross its interior.

The **transverse sinuses** (*sinus transversus; lateral sinuses*) (Figs. 569, 570) are of large size and begin at the internal occipital protuberance; one, generally the right, being the direct continuation of the superior sagittal sinus, the other of the straight sinus. Each transverse sinus passes lateralward and forward, describing a slight curve with its convexity upward, to the base of the petrous portion of the temporal bone, and lies, in this part of its course, in the attached margin of the tentorium cerebelli; it then leaves the tentorium and curves downward and

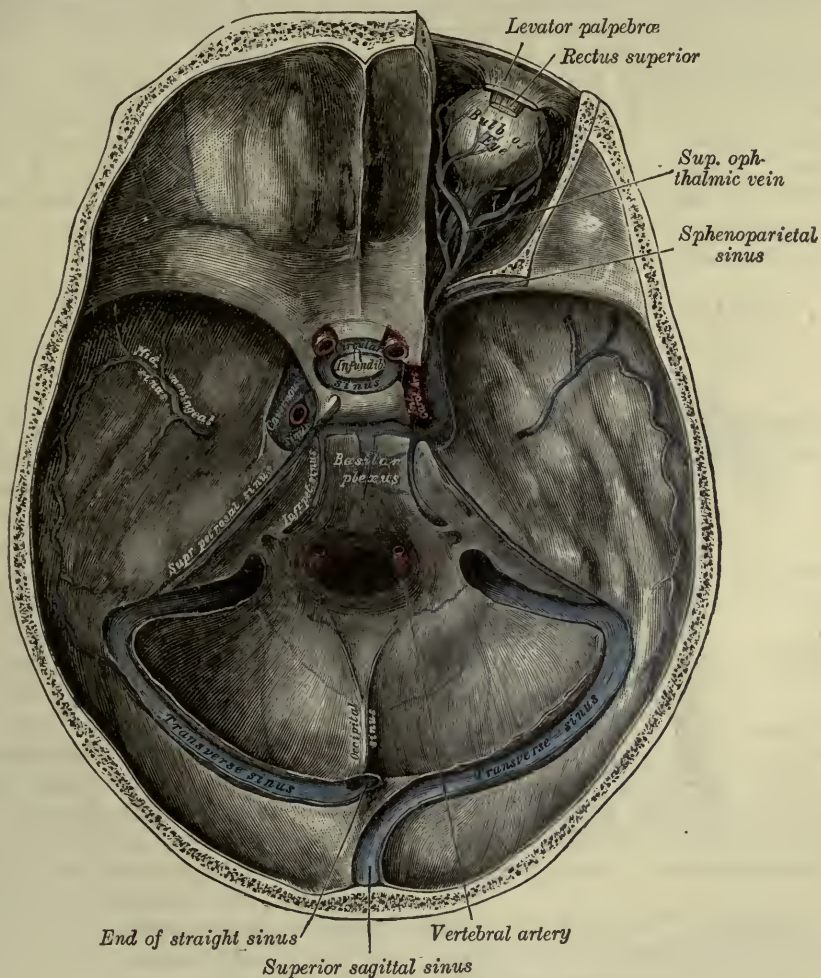


FIG. 570.—The sinuses at the base of the skull.

medialward to reach the jugular foramen, where it ends in the internal jugular vein. In its course it rests upon the squama of the occipital, the mastoid angle of the parietal, the mastoid part of the temporal, and, just before its termination, the jugular process of the occipital; the portion which occupies the groove on the mastoid part of the temporal is sometimes termed the **sigmoid sinus**. The transverse sinuses are frequently of unequal size, that formed by the superior sagittal sinus being the larger; they increase in size as they proceed from behind forward. On transverse section the horizontal portion exhibits a prismatic, the curved portion a semicylindrical form. They receive the blood from the superior petrosal

sinuses at the base of the petrous portion of the temporal bone; they communicate with the veins of the pericranium by means of the mastoid and condyloid emissary veins; and they receive some of the inferior cerebral and inferior cerebellar veins, and some veins from the diploë. The **petrosquamous sinus**, when present, runs backward along the junction of the squama and petrous portion of the temporal, and opens into the transverse sinus.

The **occipital sinus** (*sinus occipitalis*) (Fig. 570) is the smallest of the cranial sinuses. It is situated in the attached margin of the falx cerebelli, and is generally single, but occasionally there are two. It commences around the margin of the foramen magnum by several small venous channels, one of which joins the terminal part of the transverse sinus; it communicates with the posterior internal vertebral venous plexuses and ends in the confluence of the sinuses.

The **Confluence of the Sinuses** (*confluens sinuum; torcular Herophili*) is the term applied to the dilated extremity of the superior sagittal sinus. It is of irregular form, and is lodged on one side (generally the right) of the internal occipital protuberance. From it the transverse sinus of the same side is derived. It receives also the blood from the occipital sinus, and is connected across the middle line with the commencement of the transverse sinus of the opposite side.

The antero-inferior group of sinuses comprises the

Two Cavernous.

Two Intercavernous

Two Superior Petrosal.

Two Inferior Petrosal.

Basilar Plexus.

The **cavernous sinuses** (*sinus cavernosus*) (Figs. 570, 571) are so named because they present a reticulated structure, due to their being traversed by numerous interlacing filaments. They are of irregular form, larger behind than in front, and are placed one on either side of the body of the sphenoid bone, extending from the superior orbital fissure to the apex of the petrous portion of the temporal bone. Each opens behind into the petrosal sinuses. On the medial wall of each sinus is the internal carotid artery, accompanied by filaments of the carotid plexus; near the artery is the abducent nerve; on the lateral wall are the oculomotor and trochlear nerves, and the ophthalmic and maxillary divisions of

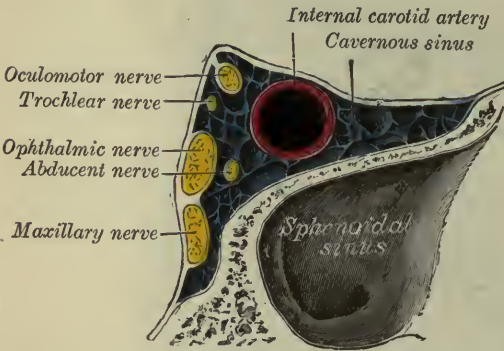


FIG. 571.—Oblique section through the cavernous sinus.

the trigeminal nerve (Fig. 571). These structures are separated from the blood flowing along the sinus by the lining membrane of the sinus. The cavernous sinus receives the superior ophthalmic vein through the superior orbital fissure, some of the cerebral veins, and also the small **sphenoparietal sinus**, which courses along the under surface of the small wing of the sphenoid. It communicates with the transverse sinus by means of the superior petrosal sinus; with the internal jugular vein through the inferior petrosal sinus and a plexus of veins on the internal carotid artery; with the pterygoid venous plexus through the foramen Vesalii, foramen ovale, and foramen lacerum, and with the angular vein through the ophthalmic vein. The two sinuses also communicate with each other by means of the anterior and posterior intercavernous sinuses.

The **ophthalmic veins** (Fig. 572), two in number, superior and inferior, are devoid of valves.

The **Superior Ophthalmic Vein** (*v. ophthalmica superior*) begins at the inner angle of the orbit in a vein named the **nasofrontal** which communicates anteriorly with the angular vein; it pursues the same course as the ophthalmic artery, and receives tributaries corresponding to the branches of that vessel. Forming a short single trunk, it passes between the two heads of the Rectus lateralis and through the medial part of the superior orbital fissure, and ends in the cavernous sinus.

The **Inferior Ophthalmic Vein** (*v. ophthalmica inferior*) begins in a venous network at the forepart of the floor and medial wall of the orbit; it receives some veins from the Rectus inferior, Obliquus inferior, lacrimal sac and eyelids, runs backward in the lower part of the orbit and divides into two branches. One of these passes through the inferior orbital fissure and joins the pterygoid venous plexus, while the other enters the cranium through the superior orbital fissure and ends in the cavernous sinus, either by a separate opening, or more frequently in common with the superior ophthalmic vein.

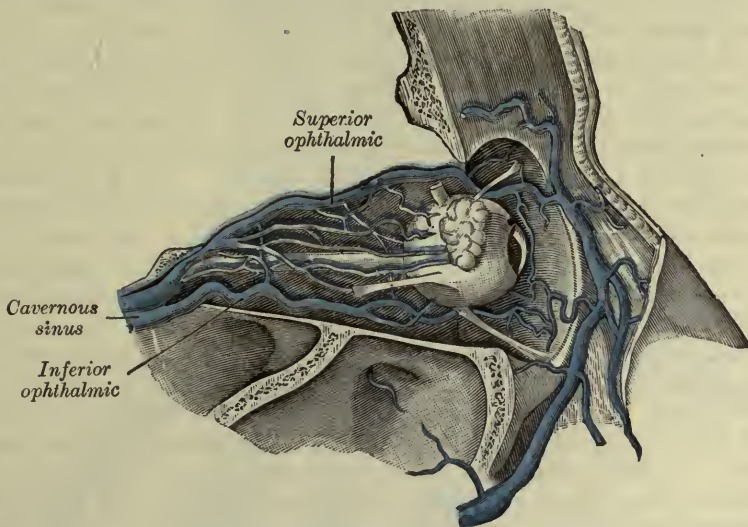


FIG. 572.—Veins of orbit. (Poirier and Charpy.)

The **intercavernous sinuses** (*sini intercavernosi*) (Fig. 570) are two in number, an anterior and a posterior, and connect the two cavernous sinuses across the middle line. The **anterior** passes in front of the hypophysis cerebri, the **posterior** behind it, and they form with the cavernous sinuses a venous circle (**circular sinus**) around the hypophysis. The anterior one is usually the larger of the two, and one or other is occasionally absent.

The **superior petrosal sinus** (*sinus petrosus superior*) (Fig. 570) small and narrow, connects the cavernous with the transverse sinus. It runs lateralward and backward, from the posterior end of the cavernous sinus, over the trigeminal nerve, and lies in the attached margin of the tentorium cerebelli and in the superior petrosal sulcus of the temporal bone; it joins the transverse sinus where the latter curves downward on the inner surface of the mastoid part of the temporal. It receives some cerebellar and inferior cerebral veins, and veins from the tympanic cavity.

The **inferior petrosal sinus** (*sinus petrosus inferior*) (Fig. 570) is situated in the inferior petrosal sulcus formed by the junction of the petrous part of the temporal with the basilar part of the occipital. It begins in the postero-inferior part of the cavernous sinus, and, passing through the anterior part of the jugular foramen, ends in the superior bulb of the internal jugular vein. The inferior petrosal sinus

receives the internal auditory veins and also veins from the medulla oblongata, pons, and under surface of the cerebellum.

The exact relation of the parts to one another in the jugular foramen is as follows: the inferior petrosal sinus lies medially and anteriorly with the meningeal branch of the ascending pharyngeal artery, and is directed obliquely downward and backward; the transverse sinus is situated at the lateral and back part of the foramen with a meningeal branch of the occipital artery, and between the two sinuses are the glossopharyngeal, vagus, and accessory nerves. These three sets of structures are divided from each other by two processes of fibrous tissue. The junction of the inferior petrosal sinus with the internal jugular vein takes place on the lateral aspect of the nerves.

The **basilar plexus** (*plexus basilaris; transverse or basilar sinus*) (Fig. 571) consists of several interlacing venous channels between the layers of the dura mater over the basilar part of the occipital bone, and serves to connect the two inferior petrosal sinuses. It communicates with the anterior vertebral venous plexus.

Emissary Veins (*emissaria*).—The emissary veins pass through apertures in the cranial wall and establish communication between the sinuses inside the skull and the veins external to it. Some are always present, others only occasionally so. The principal emissary veins are the following: (1) A mastoid emissary vein, usually present, runs through the mastoid foramen and unites the transverse sinus with the posterior auricular or with the occipital vein. (2) A parietal emissary vein passes through the parietal foramen and connects the superior sagittal sinus with the veins of the scalp. (3) A net-work of minute veins (*rete canalis hypoglossi*) traverses the hypoglossal canal and joins the transverse sinus with the vertebral vein and deep veins of the neck. (4) An inconstant condyloid emissary vein passes through the condyloid canal and connects the transverse sinus with the deep veins of the neck. (5) A net-work of veins (*rete foraminis ovalis*) unites the cavernous sinus with the pterygoid plexus through the foramen ovale. (6) Two or three small veins run through the foramen lacerum and connect the cavernous sinus with the pterygoid plexus. (7) The emissary vein of the foramen of Vesalius connects the same parts. (8) An internal carotid plexus of veins traverses the carotid canal and unites the cavernous sinus with the internal jugular vein. (9) A vein is transmitted through the foramen cecum and connects the superior sagittal sinus with the veins of the nasal cavity.

THE VEINS OF THE UPPER EXTREMITY AND THORAX.

The veins of the upper extremity are divided into two sets, **superficial** and **deep**; the two sets anastomose frequently with each other. The superficial veins are placed immediately beneath the integument between the two layers of superficial fascia. The deep veins accompany the arteries, and constitute the *venæ comitantes* of those vessels. Both sets are provided with valves, which are more numerous in the deep than in the superficial veins.

The Superficial Veins of the Upper Extremity.

The **superficial veins** of the upper extremity are the **digital**, **metacarpal**, **cephalic**, **basilic**, **median**.

Digital Veins.—The **dorsal digital veins** pass along the sides of the fingers and are joined to one another by oblique communicating branches. Those from the adjacent sides of the fingers unite to form three **dorsal metacarpal veins** (Fig. 573), which end in a dorsal venous net-work opposite the middle of the metacarpus. The radial part of the net-work is joined by the dorsal digital vein from the radial side of the index finger and by the dorsal digital veins of the thumb, and is prolonged upward as the cephalic vein. The ulnar part of the net-work receives

the dorsal digital vein of the ulnar side of the little finger and is continued upward as the basilic vein. A communicating branch frequently connects the dorsal venous network with the cephalic vein about the middle of the forearm.

The **volar digital veins** on each finger are connected to the dorsal digital veins by oblique **intercapitular veins**. They drain into a venous plexus which is situated over the thenar and hypothenar eminences and across the front of the wrist.

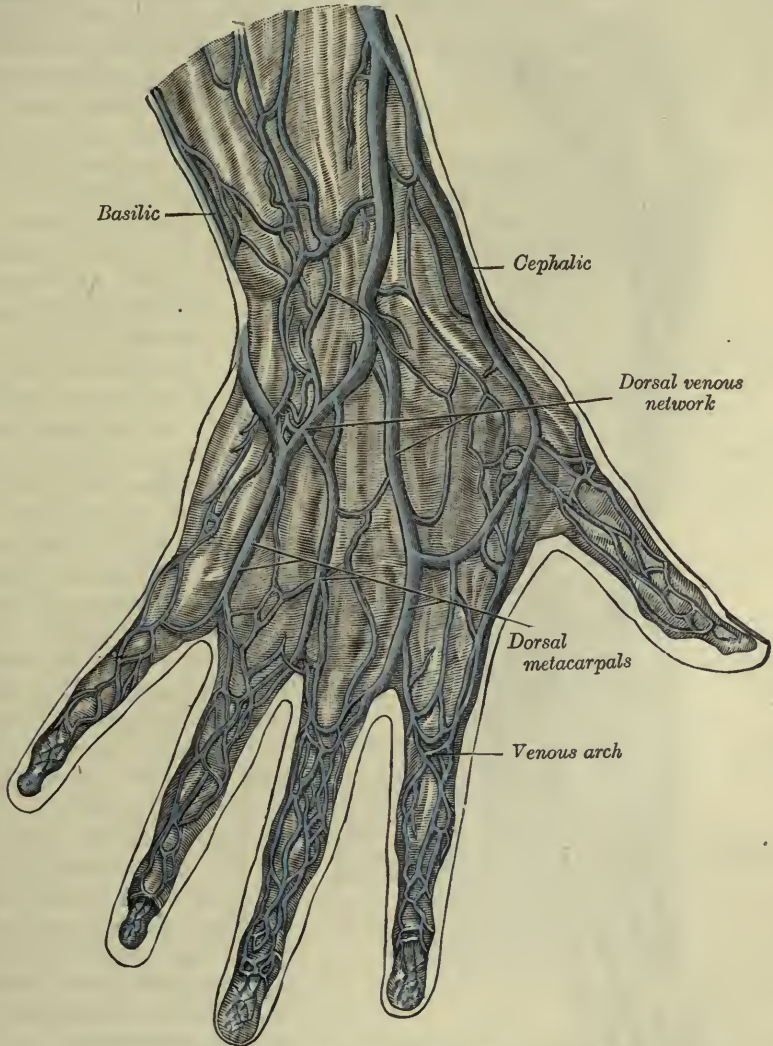


FIG. 573.—The veins on the dorsum of the hand. (Bourguery.)

The **cephalic vein** (Fig. 574) begins in the radial part of the dorsal venous network and winds upward around the radial border of the forearm, receiving tributaries from both surfaces. Below the front of the elbow it gives off the **vena mediana cubiti** (*median basilic vein*), which receives a communicating branch from the deep veins of the forearm and passes across to join the basilic vein. The cephalic vein then ascends in front of the elbow in the groove between the Brachioradialis and the Biceps brachii. It crosses superficial to the musculocutaneous nerve and ascends in the groove along the lateral border of the Biceps brachii. In the upper third of the arm it passes between the Pectoralis major and Deltoideus, where it is accom-

panied by the deltoid branch of the thoracoacromial artery. It pierces the coraco-clavicular fascia and, crossing the axillary artery, ends in the axillary vein just below the clavicle. Sometimes it communicates with the external jugular vein by a branch which ascends in front of the clavicle.

The **accessory cephalic vein** (*v. cephalica accessoria*) arises either from a small tributary plexus on the back of the forearm or from the ulnar side of the dorsal venous network; it joins the cephalic below the elbow. In some cases the accessory cephalic springs from the cephalic above the wrist and joins it again higher up. A large oblique branch frequently connects the basilic and cephalic veins on the back of the forearm.

The **basilic vein** (*v. basilica*) (Fig. 574) begins in the ulnar part of the dorsal venous network. It runs up the posterior surface of the ulnar side of the forearm and inclines forward to the anterior surface below the elbow, where it is joined by the *vena mediana cubiti*. It ascends obliquely in the groove between the *Biceps brachii* and *Pronator teres* and crosses the brachial artery, from which it is separated by the *lacertus fibrosus*; filaments of the medial antibrachial cutaneous nerve pass both in front of and behind this portion of the vein. It then runs upward along the medial border of the *Biceps brachii*, perforates the deep fascia a little below the middle of the arm, and, ascending on the medial side of the brachial artery to the lower border of the *Teres major*, is continued onward as the axillary vein.

The **median antibrachial vein** (*v. mediana antibrachii*) drains the venous plexus on the volar surface of the hand. It ascends on the ulnar side of the front of the forearm and ends in the basilic vein or in the *vena mediana cubiti*; in a small proportion of cases it divides into two branches, one of which joins the basilic, the other the cephalic, below the elbow.

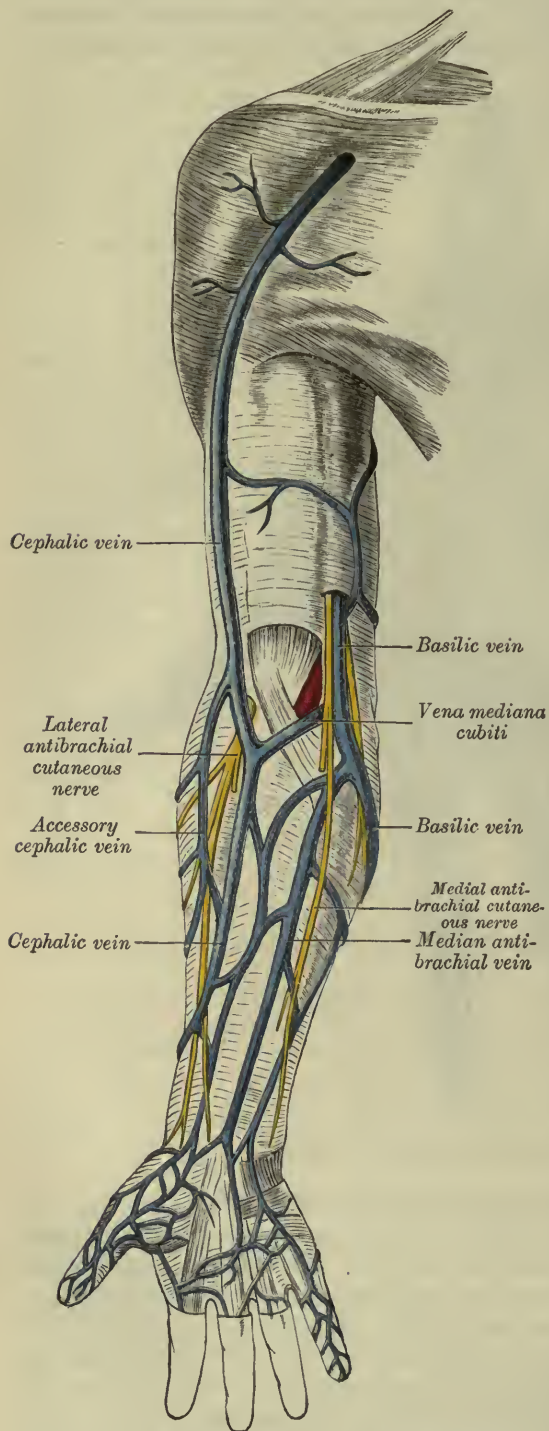


FIG. 574.—The superficial veins of the upper extremity.

The Deep Veins of the Upper Extremity.

The deep veins follow the course of the arteries, forming their *venæ comitantes*. They are generally arranged in pairs, and are situated one on either side of the corresponding artery, and connected at intervals by short transverse branches.

Deep Veins of the Hand.—The superficial and deep volar arterial arches are each accompanied by a pair of *venæ comitantes* which constitute respectively the superficial and deep volar venous arches, and receive the veins corresponding to the branches of the arterial arches; thus the common volar digital veins, formed by the union of the proper volar digital veins, open into the superficial, and the volar metacarpal veins into the deep volar venous arches. The dorsal metacarpal veins receive perforating branches from the volar metacarpal veins and end in the radial veins and in the superficial veins on the dorsum of the wrist.

The deep veins of the forearm are the *venæ comitantes* of the radial and ulnar veins and constitute respectively the upward continuations of the deep and superficial volar venous arches; they unite in front of the elbow to form the brachial veins. The radial veins are smaller than the ulnar and receive the dorsal metacarpal veins. The ulnar veins receive tributaries from the deep volar venous arches and communicate with the superficial veins at the wrist; near the elbow they receive the volar and dorsal interosseous veins and send a large communicating branch (*profunda vein*) to the *vena mediana cubiti*.

The brachial veins (*vv. brachiales*) are placed one on either side of the brachial artery, receiving tributaries corresponding with the branches given off from that vessel; near the lower margin of the *Subscapularis*, they join the axillary vein; the medial one frequently joins the basilic vein.

These deep veins have numerous anastomoses, not only with each other, but also with the superficial veins.

The axillary vein (*v. axillaris*) begins at the lower border of the *Teres major*, as the continuation of the basilic vein, increases in size as it ascends, and ends at the outer border of the first rib as the subclavian vein. Near the lower border of the *Subscapularis* it receives the brachial veins and, close to its termination, the cephalic vein; its other tributaries correspond with the branches of the axillary artery. It lies on the medial side of the artery, which it partly overlaps; between the two vessels are the medial cord of the brachial plexus, the median, the ulnar,

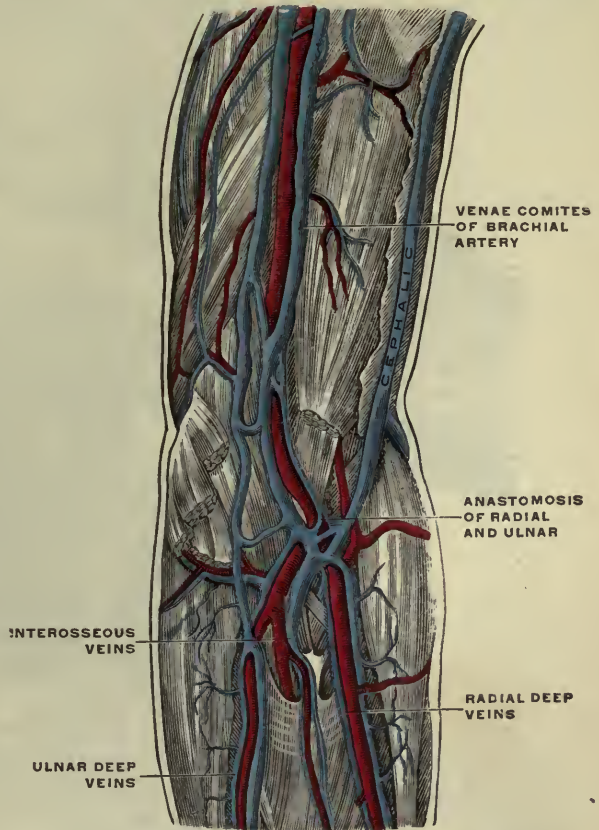


FIG. 575.—The deep veins of the upper extremity. (Bourguery.)

and the medial anterior thoracic nerves. It is provided with a pair of valves opposite the lower border of the Subscapularis; valves are also found at the ends of the cephalic and subscapular veins.

The **subclavian vein** (*v. subclavia*), the continuation of the axillary, extends from the outer border of the first rib to the sternal end of the clavicle, where it unites with the internal jugular to form the innominate vein. It is in relation, in *front*, with the clavicle and Subclavius; *behind* and *above*, with the subclavian artery, from which it is separated medially by the Scalenus anterior and the phrenic nerve. *Below*, it rests in a depression on the first rib and upon the pleura. It is usually provided with a pair of valves, which are situated about 2.5 cm. from its termination.

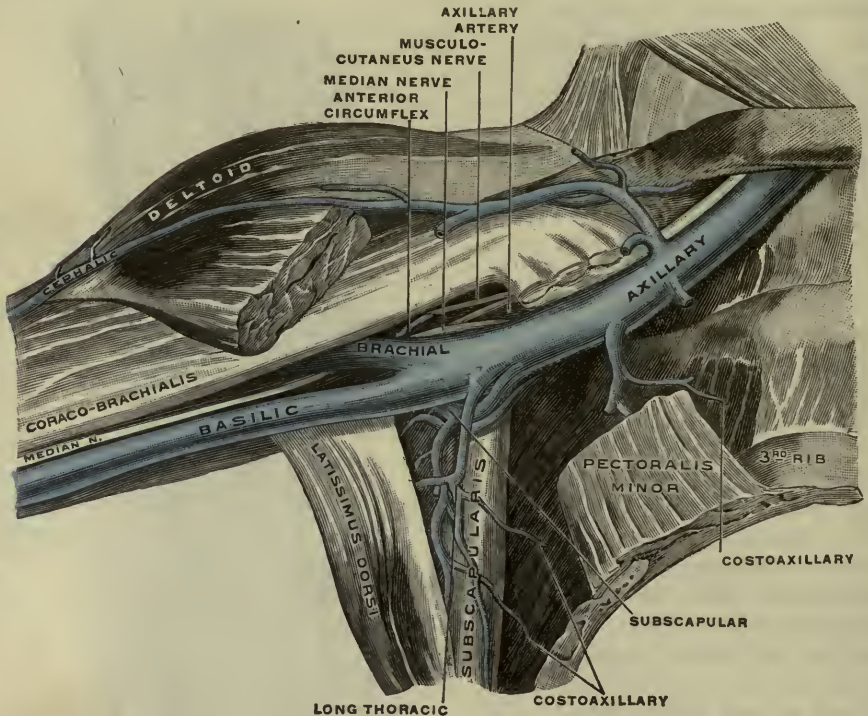


FIG. 576.—The veins of the right axilla, viewed from in front. (Spatteholz.)

The subclavian vein occasionally rises in the neck to a level with the third part of the subclavian artery, and occasionally passes with this vessel behind the Scalenus anterior.

Tributaries.—This vein receives the external jugular vein, sometimes the anterior jugular vein, and occasionally a small branch, which ascends in front of the clavicle, from the cephalic. At its angle of junction with the internal jugular, the left subclavian vein receives the thoracic duct, and the right subclavian vein the right lymphatic duct.

The Veins of the Thorax (Fig. 577)

The **innominate veins** (*vv. anonymæ; brachiocephalic veins*) are two large trunks, placed one on either side of the root of the neck, and formed by the union of the internal jugular and subclavian veins of the corresponding side; they are devoid of valves.

The **Right Innominate Vein** (*v. anonyma dextra*) is a short vessel, about 2.5 cm. in length, which begins behind the sternal end of the clavicle, and, passing almost vertically downward, joins with the left innominate vein just below the cartilage

of the first rib, close to the right border of the sternum, to form the superior vena cava. It lies in front and to the right of the innominate artery; on its right side

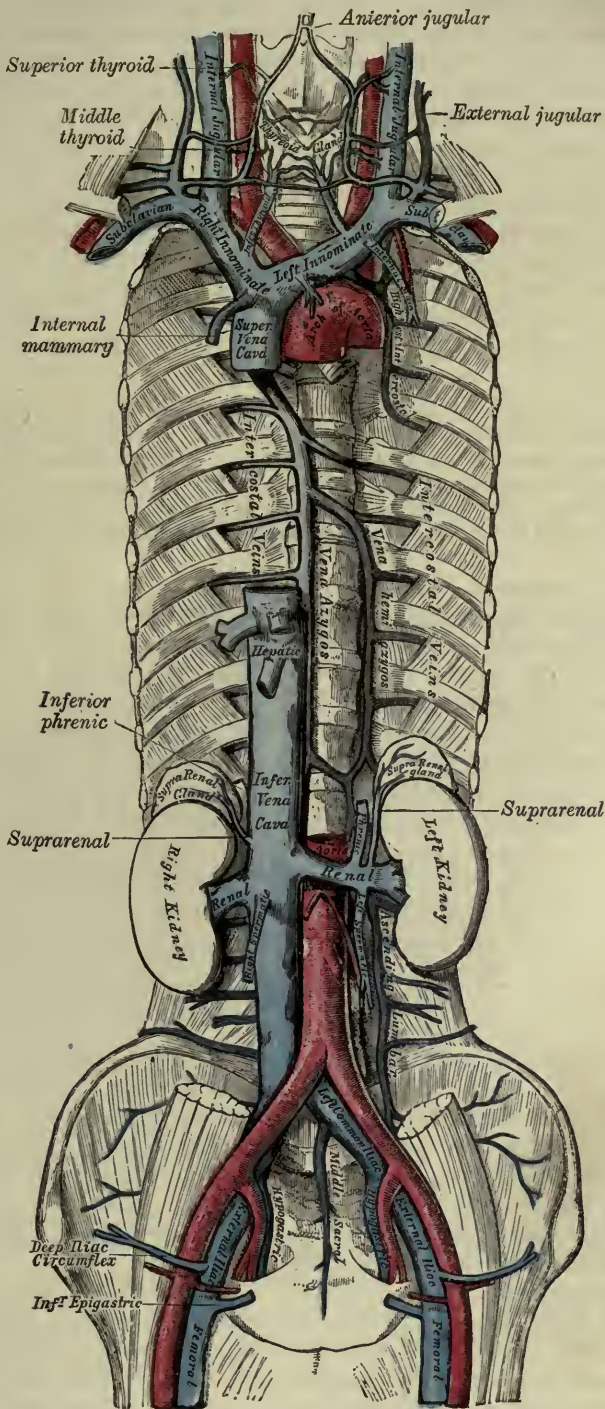


FIG. 577.—The venæ cavæ and azygos veins, with their tributaries.

are the phrenic nerve and the pleura, which are interposed between it and the apex of the lung. This vein, at its commencement, receives the right vertebral vein; and,

lower down, the right internal mammary and right inferior thyroid veins, and sometimes the vein from the first intercostal space.

The **Left Innominate Vein** (*v. anonyma sinistra*), about 6 cm. in length, *begins* behind the sternal end of the clavicle and runs obliquely downward and to the right behind the upper half of the manubrium sterni to the sternal end of the first right costal cartilage, where it unites with the right innominate vein to form the **superior vena cava**. It is separated from the manubrium sterni by the Sternohyoideus and Sternothyreoides, the thymus or its remains, and some loose areolar tissue. Behind it are the three large arteries, innominate, left common carotid, and left subclavian, arising from the aortic arch, together with the vagus and phrenic nerves. The left innominate vein may occupy a higher level, crossing the jugular notch and lying directly in front of the trachea.

Tributaries.—Its tributaries are the left vertebral, left internal mammary, left inferior thyroid, and the left highest intercostal veins, and occasionally some thymic and pericardiac veins.

Peculiarities.—Sometimes the innominate veins open separately into the right atrium; in such cases the right vein takes the ordinary course of the superior vena cava; the left vein—*left superior vena cava*, as it is then termed—which may communicate by a small branch with the right one, passes in front of the root of the left lung, and, turning to the back of the heart, ends in the right atrium. This occasional condition in the adult is due to the persistence of the early fetal condition, and is the normal state of things in birds and some mammalia.

The **internal mammary veins** (*vv. mammariæ internæ*) are *venæ comitantes* to the lower half of the internal mammary artery, and receive tributaries corresponding to the branches of the artery. They then unite to form a single trunk, which runs up on the medial side of the artery and ends in the corresponding innominate vein. The **superior phrenic vein**, *i. e.*, the vein accompanying the pericardiophrenic artery, usually opens into the internal mammary vein.

The **inferior thyroid veins** (*vv. thyreoidæ inferiores*) two, frequently three or four, in number, *arise* in the venous plexus on the thyroid gland, communicating with the middle and superior thyroid veins. They form a plexus in front of the trachea, behind the Sternothyreoides. From this plexus, a left vein descends and joins the left innominate trunk, and a right vein passes obliquely downward and to the right across the innominate artery to open into the right innominate vein, just at its junction with the superior vena cava; sometimes the right and left veins open by a common trunk in the latter situation. These veins receive esophageal tracheal, and inferior laryngeal veins, and are provided with valves at their terminations in the innominate veins.

The **highest intercostal vein** (*v. intercostalis suprema; superior intercostal veins*) (right and left) drain the blood from the upper three or four intercostal spaces. The **right vein** (*v. intercostalis suprema dextra*) passes downward and opens into the vena azygos; the **left vein** (*v. intercostalis suprema sinistra*) runs across the arch of the aorta and the origins of the left subclavian and left common carotid arteries and opens into the left innominate vein. It usually receives the left bronchial vein, and sometimes the left superior phrenic vein, and communicates below with the accessory hemiazygos vein.

The **superior vena cava** (*v. cava superior*) drains the blood from the upper half of the body. It measures about 7 cm. in length, and is formed by the junction of the two innominate veins. It *begins* immediately below the cartilage of the right first rib close to the sternum, and, descending vertically behind the first and second intercostal spaces, ends in the upper part of the right atrium opposite the upper border of the third right costal cartilage: the lower half of the vessel is within the pericardium. In its course it describes a slight curve, the convexity of which is to the right side.

Relations.—*In front* are the anterior margins of the right lung and pleura with the pericardium intervening below; these separate it from the first and second intercostal spaces and from the second and third right costal cartilages; *behind* it are the root of the right lung and the right vagus nerve. On its *right side* are the phrenic nerve and right pleura; on its *left side*, the commencement of the innominate artery and the ascending aorta, the latter overlapping it. Just before it pierces the pericardium, it receives the azygos vein and several small veins from the pericardium and other contents of the mediastinal cavity. The portion contained within the pericardium is covered, in front and laterally, by the serous layer of the membrane. The superior vena cava has no valves.

The **azygos vein** (*v. azygos; vena azygos major*) begins opposite the first or second lumbar vertebra, by a branch, the **ascending lumbar vein** (page 678); sometimes by a branch from the right renal vein, or from the inferior vena cava. It enters the thorax through the aortic hiatus in the diaphragm, and passes along the right side of the vertebral column to the fourth thoracic vertebra, where it arches forward over the root of the right lung, and ends in the superior vena cava, just before that vessel pierces the pericardium. In the aortic hiatus, it lies with the thoracic duct on the right side of the aorta; in the thorax it lies upon the intercostal arteries, on the right side of the aorta and thoracic duct, and is partly covered by pleura.

Tributaries.—It receives the right subcostal and intercostal veins, the upper three or four of these latter opening by a common stem, the highest superior intercostal vein. It receives the hemiazygos veins, several esophageal, mediastinal, and pericardial veins, and, near its termination, the right bronchial vein. A few imperfect valves are found in the azygos vein; but its tributaries are provided with complete valves.

The intercostal veins on the left side, below the upper three intercostal spaces, usually form two trunks, named the **hemiazygos** and **accessory hemiazygos veins**.

The **Hemiazygos Vein** (*v. hemiazygos; vena azygos minor inferior*) begins in the left ascending lumbar or renal vein. It enters the thorax, through the left crus of the diaphragm, and, ascending on the left side of the vertebral column, as high as the ninth thoracic vertebra, passes across the column, behind the aorta, esophagus, and thoracic duct, to end in the azygos vein. It receives the lower four or five intercostal veins and the subcostal vein of the left side, and some esophageal and mediastinal veins.

The **Accessory Hemiazygos Vein** (*v. hemiazygos accessoria; vena azygos minor superior*) descends on the left side of the vertebral column, and varies inversely in size with the highest left intercostal vein. It receives veins from the three or four intercostal spaces between the highest left intercostal vein and highest tributary of the hemiazygos; the left bronchial vein sometimes opens into it. It either crosses the body of the eighth thoracic vertebra to join the azygos vein or ends in the hemiazygos. When this vein is small, or altogether wanting, the left highest intercostal vein may extend as low as the fifth or sixth intercostal space.

In obstruction of the superior vena cava, the azygos and hemiazygos veins are one of the principal means by which the venous circulation is carried on, connecting as they do the superior and inferior venæ cavæ, and communicating with the common iliac veins; by the ascending lumbar veins and with many of the tributaries of the inferior vena cava.

The **Bronchial Veins** (*vv. bronchiales*) return the blood from the larger bronchi, and from the structures at the roots of the lungs; that of the right side opens into the azygos vein, near its termination; that of the left side, into the highest left intercostal or the accessory hemiazygos vein. A considerable quantity of the blood which is carried to the lungs through the bronchial arteries is returned to the left side of the heart through the pulmonary veins.

The Veins of the Vertebral Column (Figs. 578, 579).

The veins which drain the blood from the vertebral column, the neighboring muscles, and the meninges of the medulla spinalis form intricate plexuses extending

along the entire length of the column; these plexuses may be divided into two groups, external and internal, according to their positions inside or outside the vertebral canal. The plexuses of the two groups anastomose freely with each other and end in the intervertebral veins.

The **external vertebral venous plexuses** (*plexus venosi vertebrales externi; extra-spinal veins*) best marked in the cervical region, consist of anterior and posterior plexuses which anastomose freely with each other. The **anterior external plexuses** lie in front of the bodies of the vertebræ, communicate with the basivertebral and intervertebral veins, and receive tributaries from the vertebral bodies. The **posterior external plexuses** are placed partly on the posterior surfaces of the vertebral arches and their processes, and partly between the deep dorsal muscles. They are best developed in the cervical region, and there anastomose with the vertebral, occipital, and deep cervical veins.

The **internal vertebral venous plexuses** (*plexus venosi vertebrales interni; intra-spinal veins*) lie within the vertebral canal between the dura mater and the vertebræ, and receive tributaries from the bones and from the medulla spinalis. They

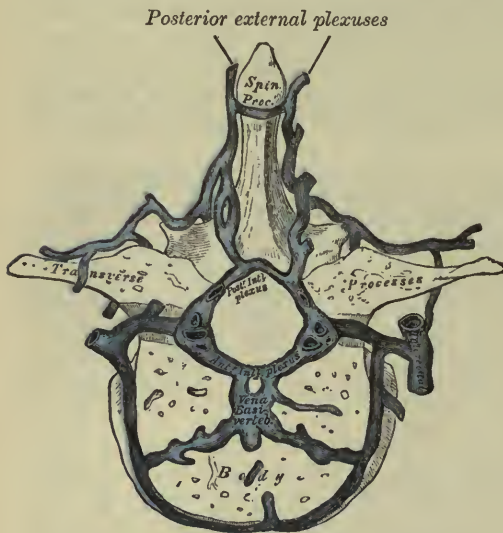


FIG. 578.—Transverse section of a thoracic vertebra, showing the vertebral venous plexuses.

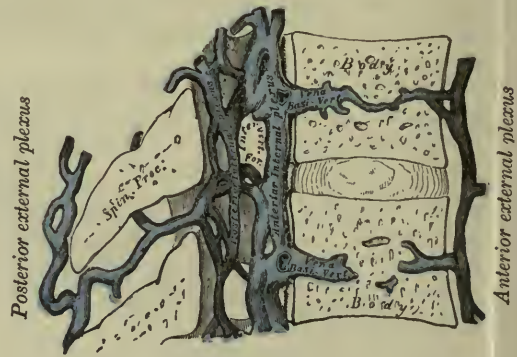

FIG. 579.—Median sagittal section of two thoracic vertebrae, showing the vertebral venous plexuses.

form a closer net-work than the external plexuses, and, running mainly in a vertical direction, form four longitudinal veins, two in front and two behind; they therefore may be divided into anterior and posterior groups. The **anterior internal plexuses** consist of large veins which lie on the posterior surfaces of the vertebral bodies and intervertebral fibrocartilages on either side of the posterior longitudinal ligament; under cover of this ligament they are connected by transverse branches into which the basivertebral veins open. The **posterior internal plexuses** are placed, one on either side of the middle line in front of the vertebral arches and ligamenta flava, and anastomose by veins passing through those ligaments with the posterior external plexuses. The anterior and posterior plexuses communicate freely with one another by a series of **venous rings** (*retia venosa vertebrarum*), one opposite each vertebra. Around the foramen magnum they form an intricate net-work which opens into the vertebral veins and is connected above with the occipital sinus, the basilar plexus, the condyloid emissary vein, and the rete canalis hypoglossi.

The **basivertebral veins** (*vv. basivertebrales*) emerge from the foramina on the posterior surfaces of the vertebral bodies. They are contained in large, tortuous

channels in the substance of the bones, similar in every respect to those found in the diploë of the cranial bones. They communicate through small openings on the front and sides of the bodies of the vertebræ with the anterior external vertebral plexuses, and converge behind to the principal canal, which is sometimes double toward its posterior part, and open by valved orifices into the transverse branches which unite the anterior internal vertebral plexuses. They become greatly enlarged in advanced age.

The **intervertebral veins** (*vv. intervertebrales*) accompany the spinal nerves through the intervertebral foramina; they receive the veins from the medulla spinalis, drain the internal and external vertebral plexuses and end in the vertebral, intercostal, lumbar, and lateral sacral veins, their orifices being provided with valves.

The **veins of the medulla spinalis** (*vv. spinales; veins of the spinal cord*) are situated in the pia mater and form a minute, tortuous, venous plexus. They emerge chiefly from the median fissures of the medulla spinalis and are largest in the lumbar region. In this plexus there are (1) two median longitudinal veins, one in front of the anterior fissure, and the other behind the posterior sulcus of the cord, and (2) four lateral longitudinal veins which run behind the nerve roots. They end in the intervertebral veins. Near the base of the skull they unite, and form two or three small trunks, which communicate with the vertebral veins, and then end in the inferior cerebellar veins, or in the inferior petrosal sinuses.

THE VEINS OF THE LOWER EXTREMITY, ABDOMEN, AND PELVIS.

The veins of the lower extremity are subdivided, like those of the upper, into two sets, **superficial** and **deep**; the superficial veins are placed beneath the integument between the two layers of superficial fascia; the deep veins accompany the arteries. Both sets of veins are provided with valves, which are more numerous in the deep than in the superficial set. Valves are also more numerous in the veins of the lower than in those of the upper limb.

The Superficial Veins of the Lower Extremity.

The **superficial veins** of the lower extremity are the **great and small saphenous veins** and their tributaries.

On the **dorsum of the foot** the **dorsal digital veins** receive, in the clefts between the toes, the **intercapitular veins** from the plantar cutaneous venous arch and join to form short **common digital veins** which unite across the distal ends of the metatarsal bones in a **dorsal venous arch**. Proximal to this arch is an irregular venous network which receives tributaries from the deep veins and is joined at the sides of the foot by a **medial** and a **lateral marginal vein**, formed mainly by the union of branches from the superficial parts of the sole of the foot.

On the **sole of the foot** the superficial veins form a **plantar cutaneous venous arch** which extends across the roots of the toes and opens at the sides of the foot into the medial and lateral marginal veins. Proximal to this arch is a **plantar cutaneous venous net-work** which is especially dense in the fat beneath the heel; this net-work communicates with the cutaneous venous arch and with the deep veins, but is chiefly drained into the medial and lateral marginal veins.

The **great saphenous vein** (*v. saphena magna; internal or long saphenous vein*) (Fig. 581), the longest vein in the body, *begins* in the medial marginal vein of the dorsum of the foot and ends in the femoral vein about 3 cm. below the inguinal ligament. It ascends in front of the tibial malleolus and along the medial side of the leg in relation with the saphenous nerve. It runs upward behind the medial

condyles of the tibia and femur and along the medial side of the thigh and, passing through the fossa ovalis, ends in the femoral vein.

Tributaries.—At the ankle it receives branches from the sole of the foot through the medial marginal vein; in the leg it anastomoses freely with the small saphenous vein, communicates with the anterior and posterior tibial veins and receives many cutaneous veins; in the thigh it communicates with the femoral vein and receives numerous tributaries; those from the medial and posterior parts of the thigh frequently unite to form a large **accessory saphenous vein** which joins the main vein at a variable level. Near the fossa ovalis (Fig. 580) it is joined by the superficial epigastric, superficial iliac circumflex, and superficial external pudendal veins. A vein, named the **thoracoepigastric**, runs along the lateral aspect of the trunk between the superficial epigastric vein below and the lateral thoracic vein above and establishes an important communication between the femoral and axillary veins.

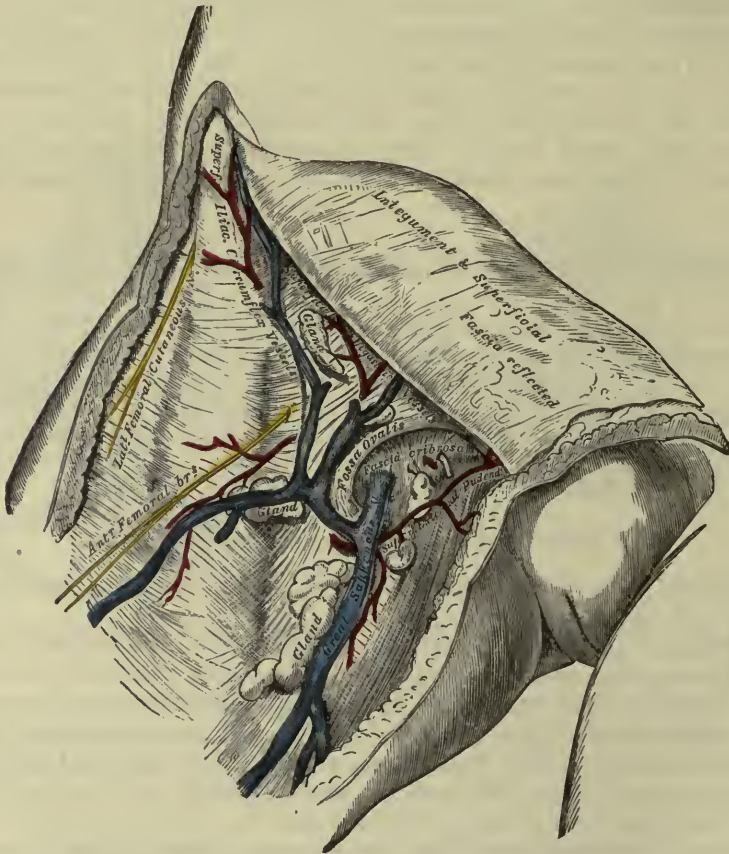


FIG. 580.—The great saphenous vein and its tributaries at the fossa ovalis.

The valves in the great saphenous vein vary from ten to twenty in number; they are more numerous in the leg than in the thigh.

The **small saphenous vein** (*v. saphena parva*; *external or short saphenous vein*) (Fig. 582) begins behind the lateral malleolus as a continuation of the lateral marginal vein; it first ascends along the lateral margin of the tendocalcaneus, and then crosses it to reach the middle of the back of the leg. Running directly upward, it perforates the deep fascia in the lower part of the popliteal fossa, and ends in the popliteal vein, between the heads of the Gastrocnemius. It commu-

nicates with the deep veins on the dorsum of the foot, and receives numerous large tributaries from the back of the leg. Before it pierces the deep fascia, it gives off a branch which runs upward and forward to join the great saphenous vein. The small saphenous vein possesses from nine to twelve valves, one of which is always found near its termination in the popliteal vein. In the lower third of the leg the small saphenous vein is in close relation with the sural nerve, in the upper two-thirds with the medial sural cutaneous nerve.

The Deep Veins of the Lower Extremity.

The deep veins of the lower extremity accompany the arteries and their branches; they possess numerous valves.

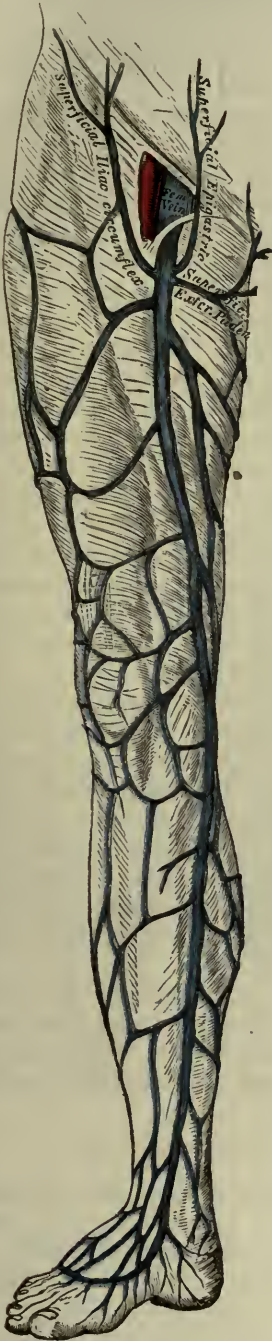

FIG. 581.—The great saphenous vein and its tributaries.

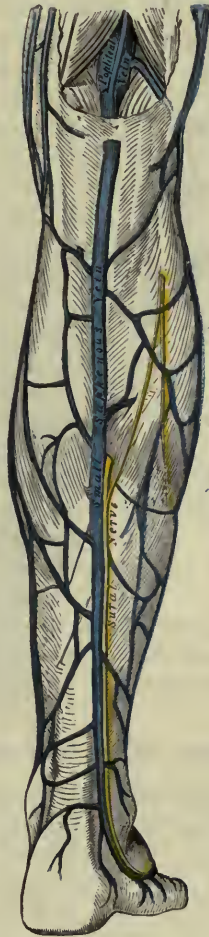

FIG. 582.—The small saphenous vein.

The plantar digital veins (*vv. digitales plantares*) arise from plexuses on the plantar surfaces of the digits, and, after sending intercavernous veins to join the

dorsal digital veins, unite to form four **metatarsal veins**; these run backward in the metatarsal spaces, communicate, by means of perforating veins, with the veins on the dorsum of the foot, and unite to form the **deep plantar venous arch** which lies alongside the plantar arterial arch. From the deep plantar venous arch the **medial and lateral plantar veins** run backward close to the corresponding arteries and, after communicating with the great and small saphenous veins, unite behind the medial malleolus to form the posterior tibial veins.

The **posterior tibial veins** (*vv. tibiales posteriores*) accompany the posterior tibial artery, and are joined by the **peroneal veins**.

The **anterior tibial veins** (*vv. tibiales anteriores*) are the upward continuation of the venæ comitantes of the dorsalis pedis artery. They leave the front of the leg by passing between the tibia and fibula, over the interosseous membrane, and unite with the posterior tibial, to form the **popliteal vein**.

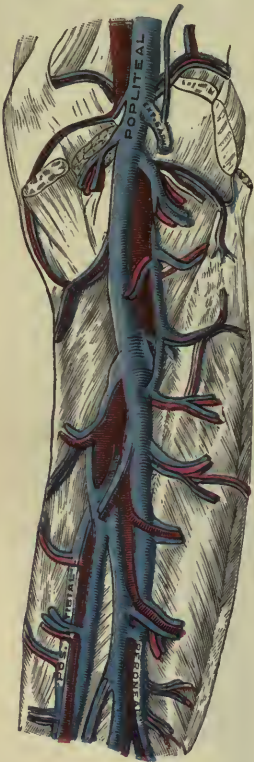

FIG. 583.—The popliteal vein.

The **Popliteal Vein** (*v. poplitea*) (Fig. 583) is formed by the junction of the anterior and posterior tibial veins at the lower border of the Popliteus; it ascends through the popliteal fossa to the aperture in the Adductor magnus, where it becomes the femoral vein. In the lower part of its course it is placed medial to the artery; between the heads of the Gastrocnemius it is superficial to that vessel; but above the knee-joint, it is close to its lateral side. It receives tributaries corresponding to the branches of the popliteal artery, and it also receives the small saphenous vein. The valves in the popliteal vein are usually four in number.

The **femoral vein** (*v. femoralis*) accompanies the femoral artery through the upper two-thirds of the thigh. In the lower part of its course it lies lateral to the artery; higher up, it is behind it; and at the inguinal ligament, it lies on its medial side, and on the same plane. It receives numerous muscular tributaries, and about 4 cm. below the inguinal ligament is joined by the *v. profunda femoris*; near its termination it is joined by the great saphenous vein. The valves in the femoral vein are three in number.

The **Deep Femoral Vein** (*v. profunda femoris*) receives tributaries corresponding to the perforating branches of the profunda artery, and through these establishes communications with the popliteal vein below and the inferior gluteal vein above. It also receives the medial and lateral femoral circumflex veins.

The Veins of the Abdomen and Pelvis (Figs. 585, 586, 587).

The **external iliac vein** (*v. iliaca externa*), the upward continuation of the femoral vein, begins behind the inguinal ligament, and, passing upward along the brim of the lesser pelvis, ends opposite the sacroiliac articulation, by uniting with the hypogastric vein to form the common iliac vein. On the right side, it lies at first medial to the artery: but, as it passes upward, gradually inclines behind it. On the left side, it lies altogether on the medial side of the artery. It frequently contains one, sometimes two, valves.

Tributaries.—The external iliac vein receives the inferior epigastric, deep iliac circumflex, and pubic veins.

The **Inferior Epigastric Vein** (*v. epigastrica inferior; deep epigastric vein*) is formed

by the union of the venæ comitantes of the inferior epigastric artery, which communicate above with the superior epigastric vein; it joins the external iliac about 1.25 cm. above the inguinal ligament.

The **Deep Iliac Circumflex Vein** (*v. circumflexa ilium profunda*) is formed by the union of the venæ comitantes of the deep iliac circumflex artery, and joins the external iliac vein about 2 cm. above the inguinal ligament.

The **Pubic Vein** communicates with the obturator vein in the obturator foramen, and ascends on the back of the pubis to the external iliac vein.

The **hypogastric vein** (*v. hypogastrica; internal iliac vein*) begins near the upper part of the greater sciatic foramen, passes upward behind and slightly medial to the hypogastric artery and, at the brim of the pelvis, joins with the external iliac to form the common iliac vein.

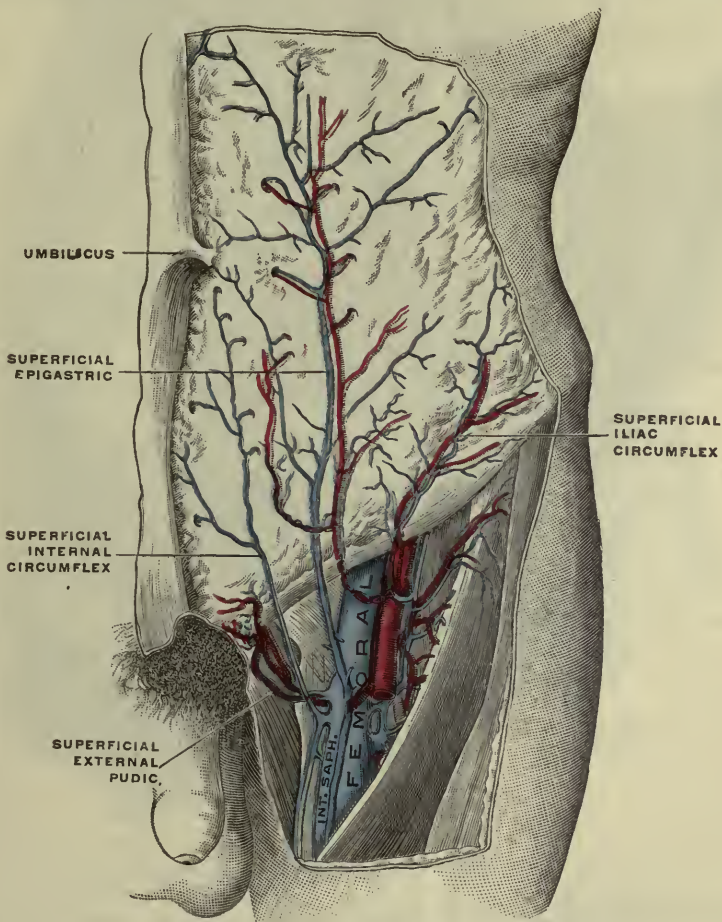


FIG. 534.—The femoral vein and its tributaries. (Poirier and Charpy.)

Tributaries.—With the exception of the fetal umbilical vein which passes upward and backward from the umbilicus to the liver, and the iliolumbar vein which usually joins the common iliac vein, the tributaries of the hypogastric vein correspond with the branches of the hypogastric artery. It receives (a) the **gluteal, internal pudendal, and obturator veins**, which have their origins outside the pelvis; (b) the **lateral sacral veins**, which lie in front of the sacrum; and (c) the **middle hemorrhoidal, vesical, uterine, and vaginal veins**, which originate in venous plexuses connected with the pelvic viscera.

1. The **Superior Gluteal Veins** (*vv. glutaæ superiores; gluteal veins*) are venæ comitantes of the superior gluteal artery; they receive tributaries from the buttock corresponding with the branches of the artery, and enter the pelvis through the greater sciatic foramen, above the Piriformis, and frequently unite before ending in the hypogastric vein.

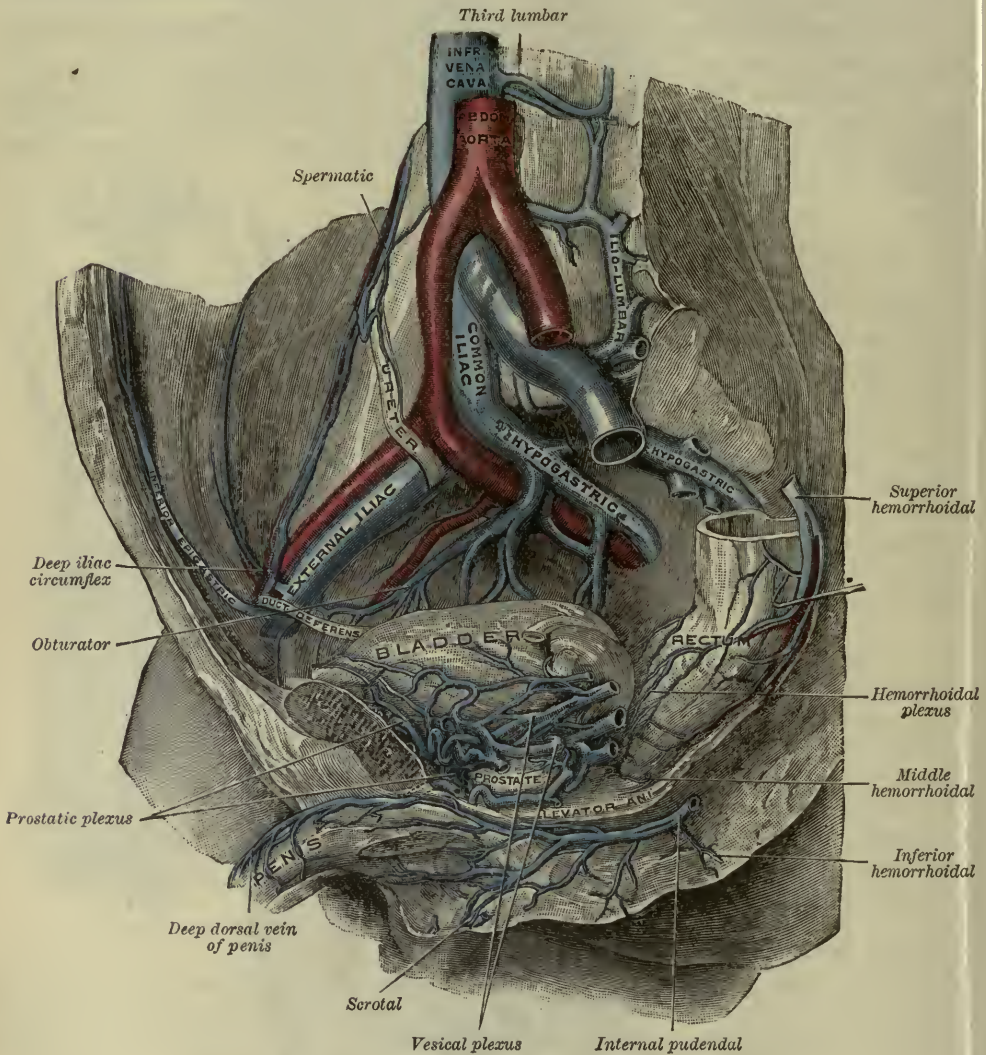


FIG. 585.—The veins of the right half of the male pelvis. (Spalteholz).

2. The **Inferior Gluteal Veins** (*vv. glutaæ inferiores; sciatic veins*), or venæ comitantes of the inferior gluteal artery, *begin* on the upper part of the back of the thigh, where they anastomose with the medial femoral circumflex and first perforating veins. They enter the pelvis through the lower part of the greater sciatic foramen and join to form a single stem which opens into the lower part of the hypogastric vein.

3. The **Internal Pudendal Veins** (*internal pudic veins*) are the venæ comitantes of the internal pudendal artery. They *begin* in the deep veins of the penis which issue from the corpus cavernosum penis, accompany the internal pudendal artery, and unite to form a single vessel, which ends in the hypogastric vein. They receive the veins from the urethral bulb, and the perineal and inferior hemorrhoidal veins.

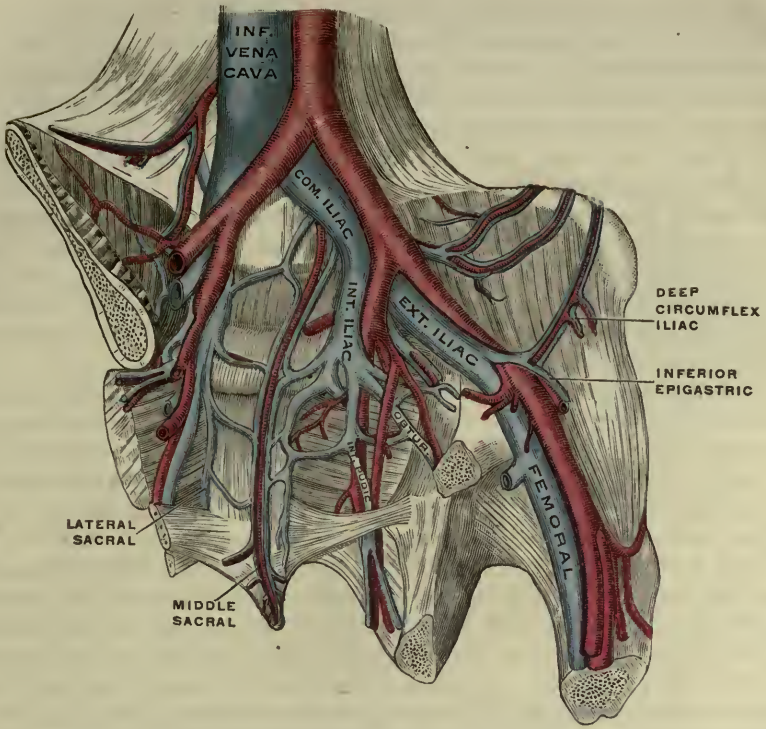


FIG. 586.—The iliac veins. (Poirier and Charpy.)

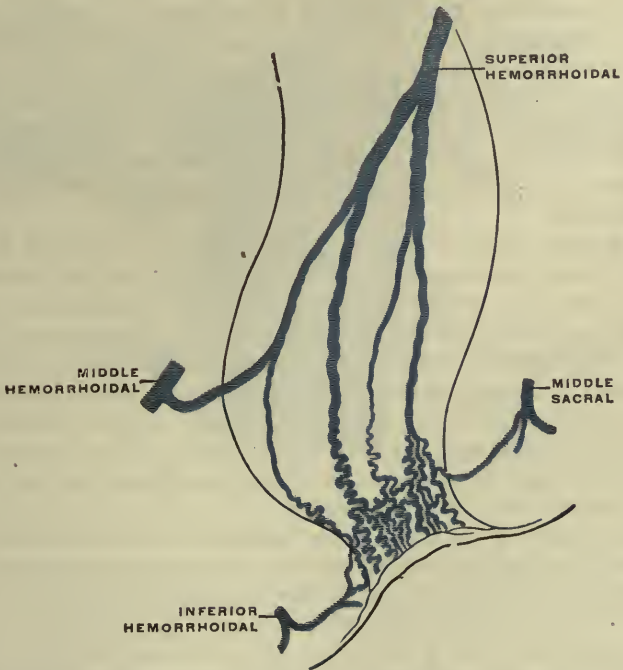

FIG. 587.—Scheme of the anastomosis of the veins of the rectum. (Poirier and Charpy.)

The deep dorsal vein of the penis communicates with the internal pudendal veins, but ends mainly in the pudendal plexus.

4. The **Obturator Vein** (*v. obturatoria*) begins in the upper portion of the adductor region of the thigh and enters the pelvis through the upper part of the obturator foramen. It runs backward and upward on the lateral wall of the pelvis below the obturator artery, and then passes between the ureter and the hypogastric artery, to end in the hypogastric vein.

5. The **Lateral Sacral Veins** (*vv. sacrales laterales*) accompany the lateral sacral arteries on the anterior surface of the sacrum and end in the hypogastric vein.

6. The **Middle Hemorrhoidal Vein** (*v. hæmorrhoidalis media*) takes origin in the hemorrhoidal plexus and receives tributaries from the bladder, prostate, and seminal vesicle; it runs lateralward on the pelvic surface of the Levator ani to end in the hypogastric vein.

The **hemorrhoidal plexus** (*plexus hæmorrhoidalis*) surrounds the rectum, and communicates in front with the vesical plexus in the male, and the uterovaginal plexus in the female. It consists of two parts, an **internal** in the submucosa, and an **external** outside the muscular coat. The internal plexus presents a series of dilated pouches which are arranged in a circle around the tube, immediately above the anal orifice, and are connected by transverse branches.

The lower part of the external plexus is drained by the inferior hemorrhoidal veins into the internal pudendal vein; the middle part by the middle hemorrhoidal vein which joins the hypogastric vein; and the upper part by the superior hemorrhoidal vein which forms the commencement of the inferior mesenteric vein, a tributary of the portal vein. A free communication between the portal and systemic venous systems is established through the hemorrhoidal plexus.

The veins of the hemorrhoidal plexus are contained in very loose, connective tissue, so that they get less support from surrounding structures than most other veins, and are less capable of resisting increased blood-pressure.

The **pudendal plexus** (*plexus pudendalis; vesicoprostatic plexus*) lies behind the arcuate pubic ligament and the lower part of the symphysis pubis, and in front of the bladder and prostate. Its chief tributary is the deep dorsal vein of the penis, but it also receives branches from the front of the bladder and prostate. It communicates with the vesical plexus and with the internal pudendal vein and drains into the vesical and hypogastric veins. The **prostatic veins** form a well-marked **prostatic plexus** which lies partly in the fascial sheath of the prostate and partly between the sheath and the prostatic capsule. It communicates with the pudendal and vesical plexuses.

The **vesical plexus** (*plexus vesicalis*) envelops the lower part of the bladder and the base of the prostate and communicates with the pudendal and prostatic plexuses. It is drained, by means of several vesical veins, into the hypogastric veins.

The **Dorsal Veins of the Penis** (*vv. dorsales penis*) are two in number, a superficial and a deep. The **superficial vein** drains the prepuce and skin of the penis, and, running backward in the subcutaneous tissue, inclines to the right or left, and opens into the corresponding superficial external pudendal vein, a tributary of the great saphenous vein. The **deep vein** lies beneath the deep fascia of the penis; it receives the blood from the glans penis and corpora cavernosa penis and courses backward in the middle line between the dorsal arteries; near the root of the penis it passes between the two parts of the suspensory ligament and then through an aperture between the arcuate pubic ligament and the transverse ligament of the pelvis, and divides into two branches, which enter the pudendal plexus. The deep vein also communicates below the symphysis pubis with the internal pudendal vein.

The **uterine plexuses** lie along the sides and superior angles of the uterus between the two layers of the broad ligament, and communicate with the ovarian and vaginal plexuses. They are drained by a pair of uterine veins on either side: these

arise from the lower part of the plexuses, opposite the external orifice of the uterus, and open into the corresponding hypogastric vein.

The **vaginal plexuses** are placed at the sides of the vagina; they communicate with the uterine, vesical, and hemorrhoidal plexuses, and are drained by the vaginal veins, one on either side, into the hypogastric veins.

The **common iliac veins** (*vv. iliaca communes*) are formed by the union of the external iliac and hypogastric veins, in front of the sacroiliac articulation; passing obliquely upward toward the right side, they end upon the fifth lumbar vertebra, by uniting with each other at an acute angle to form the inferior vena cava. The **right common iliac** is shorter than the left, nearly vertical in its direction, and ascends behind and then lateral to its corresponding artery. The **left common iliac**, longer than the right and more oblique in its course, is at first situated on the medial side of the corresponding artery, and then behind the right common iliac. Each common iliac receives the iliolumbar, and sometimes the lateral sacral veins. The left receives, in addition, the middle sacral vein. No valves are found in these veins.

The **Middle Sacral Veins** (*vv. sacrales mediales*) accompany the corresponding artery along the front of the sacrum, and join to form a single vein, which ends in the left common iliac vein; sometimes in the angle of junction of the two iliac veins.

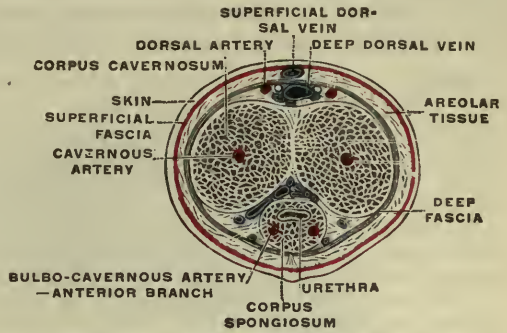


FIG. 588.—The penis in transverse section, showing the bloodvessels. (Testut.)

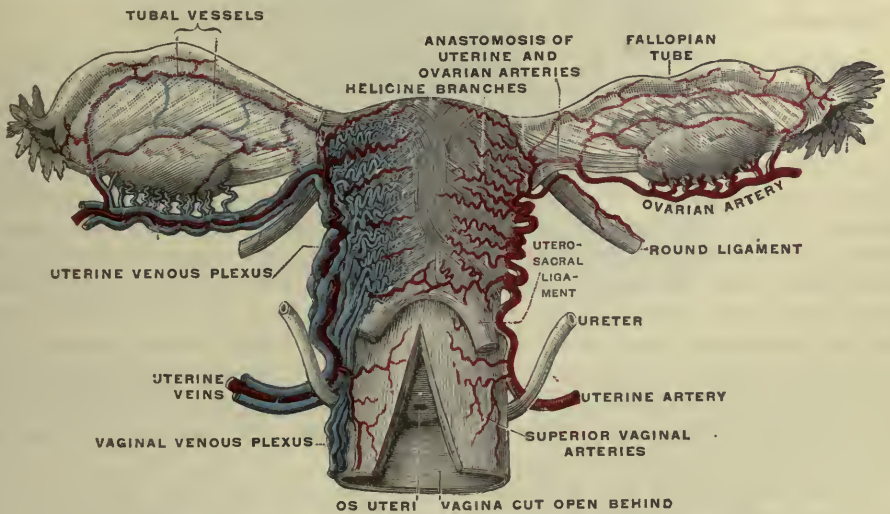


FIG. 589.—Vessels of the uterus and its appendages, rear view. (Testut.)

Peculiarities.—The left common iliac vein, instead of joining with the right in its usual position, occasionally ascends on the left side of the aorta as high as the kidney, where, after receiving the left renal vein, it crosses over the aorta, and then joins with the right vein to form the vena cava. In these cases, the two common iliacs are connected by a small communicating branch at the spot where they are usually united.

The **inferior vena cava** (*v. cava inferior*) (Fig. 577), returns to the heart the blood from the parts below the diaphragm. It is formed by the junction of the two common iliac veins, on the right side of the fifth lumbar vertebra. It ascends along

the front of the vertebral column, on the right side of the aorta, and, having reached the liver, is continued in a groove on its posterior surface. It then perforates the diaphragm between the median and right portions of its central tendon; it subsequently inclines forward and medialward for about 2.5 cm., and, piercing the fibrous pericardium, passes behind the serous pericardium to open into the lower and back part of the right atrium. In front of its atrial orifice is a semilunar valve, termed the **valve of the inferior vena cava**: this is rudimentary in the adult, but is of large size and exercises an important function in the fetus (see page 540).

Relations.—The *abdominal portion* of the inferior vena cava is in relation *in front*, from below upward, with the right common iliac artery, the mesentery, the right internal spermatic artery, the inferior part of the duodenum, the pancreas, the common bile duct, the portal vein, and the posterior surface of the liver; the last partly overlaps and occasionally completely surrounds it; *behind*, with the vertebral column, the right Psoas major, the right crus of the diaphragm, the right inferior phrenic, suprarenal, renal and lumbar arteries, right sympathetic trunk and right celiac ganglion, and the medial part of the right suprarenal gland; on the *right side*, with the right kidney and ureter; on the *left side*, with the aorta, right crus of the diaphragm, and the caudate lobe of the liver.

The *thoracic portion* is only about 2.5 cm. in length, and is situated partly inside and partly outside the pericardial sac. The *extrapericardial part* is separated from the right pleura and lung by a fibrous band, named the **right phrenicopericardiac ligament**. This ligament, often feebly marked, is attached below to the margin of the vena-caval opening in the diaphragm, and above to the pericardium in front of and behind the root of the right lung. The *intrapericardiac part* is very short, and is covered antero-laterally by the serous layer of the pericardium.

Peculiarities.—*In Position.*—This vessel is sometimes placed on the left side of the aorta, as high as the left renal vein, and, after receiving this vein, crosses over to its usual position on the right side; or it may be placed altogether on the left side of the aorta, and in such a case the abdominal and thoracic viscera, together with the great vessels, are all transposed.

Point of Termination.—Occasionally the inferior vena cava joins the azygos vein, which is then of large size. In such cases, the superior vena cava receives the whole of the blood from the body before transmitting it to the right atrium, except the blood from the hepatic veins, which passes directly into the right atrium.

Tributaries.—The inferior vena cava receives the following veins:

Lumbar.	Renal.	Inferior Phrenic.
Right Spermatic or Ovarian.	Suprarenal.	Hepatic.

The **Lumbar Veins** (*vv. lumbales*) four in number on each side, collect the blood by dorsal tributaries from the muscles and integument of the loins, and by abdominal tributaries from the walls of the abdomen, where they communicate with the epigastric veins. At the vertebral column, they receive veins from the vertebral plexuses, and then pass forward, around the sides of the bodies of the vertebræ, beneath the Psoas major, and end in the back part of the inferior cava. The left lumbar veins are longer than the right, and pass behind the aorta. The lumbar veins are connected together by a longitudinal vein which passes in front of the transverse processes of the lumbar vertebræ, and is called the **ascending lumbar**; it forms the most frequent origin of the corresponding azygos or hemiazygos vein, and serves to connect the common iliac, iliolumbar, and azygos or hemiazygos veins of its own side of the body.

The **Spermatic Veins** (*vv. spermaticæ*) (Fig. 590) emerge from the back of the testis, and receive tributaries from the epididymis; they unite and form a convoluted plexus, called the **pampiniform plexus**, which constitutes the greater mass of the spermatic cord; the vessels composing this plexus are very numerous, and ascend along the cord, in front of the ductus deferens. Below the subcutaneous inguinal ring they unite to form three or four veins, which pass along the inguinal canal, and, entering the abdomen through the abdominal inguinal ring, coalesce to form two veins, which ascend on the Psoas major, behind the peritoneum, lying one on either side of the internal spermatic artery. These unite to form a single vein, which opens on the right side into the inferior vena cava, at an acute angle; on the left side into the left renal vein, at a right angle. The spermatic veins

are provided with valves.¹ The left spermatic vein passes behind the iliac colon, and is thus exposed to pressure from the contents of that part of the bowel.

The **Ovarian Veins** (*vv. ovaricæ*) correspond with the spermatic in the male; they form a plexus in the broad ligament near the ovary and uterine tube, and communicate with the uterine plexus. They end in the same way as the spermatic veins in the male. Valves are occasionally found in these veins. Like the uterine veins, they become much enlarged during pregnancy.

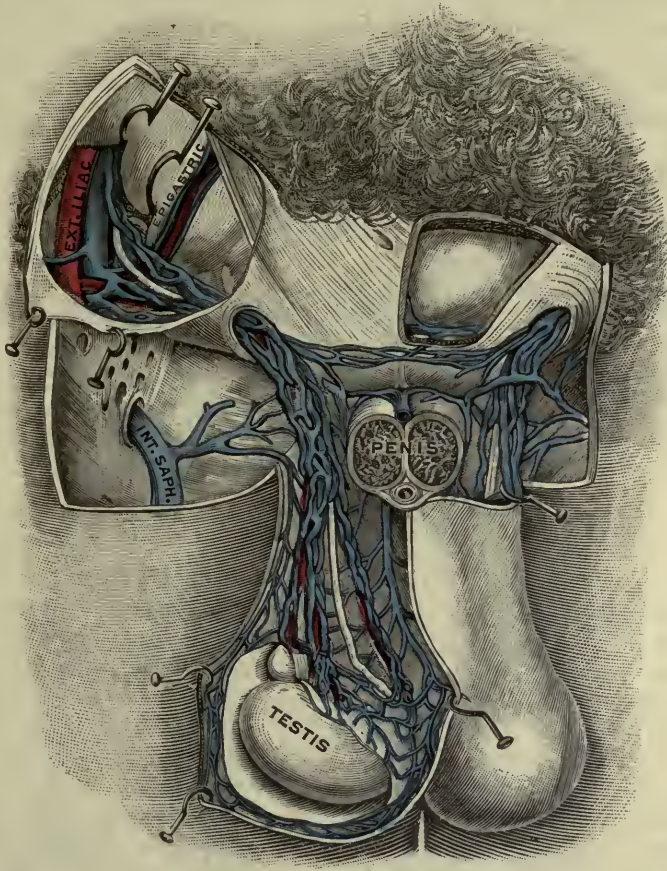


FIG. 590.—Spermatic veins. (Testut.)

The **Renal Veins** (*vv. renales*) are of large size, and placed in front of the renal arteries. The left is longer than the right, and passes in front of the aorta, just below the origin of the superior mesenteric artery. It receives the left spermatic and left inferior phrenic veins, and, generally, the left suprarenal vein. It opens into the inferior vena cava at a slightly higher level than the right.

The **Suprarenal Veins** (*vv. suprarenales*) are two in number: the right ends in the inferior vena cava; the left, in the left renal or left inferior phrenic vein.

The **Inferior Phrenic Veins** (*vv. phrenicæ inferiores*) follow the course of the inferior phrenic arteries; the right ends in the inferior vena cava; the left is often represented by two branches, one of which ends in the left renal or suprarenal vein, while the other passes in front of the esophageal hiatus in the diaphragm and opens into the inferior vena cava.

¹ Rivington has pointed out that valves are usually found at the orifices of both the right and left spermatic veins. When no valves exist at the opening of the left spermatic vein into the left renal vein, valves are generally present in the left renal vein within 6 mm from the orifice of the spermatic vein.—*Journal of Anatomy and Physiology*, vii, 163.

The **Hepatic Veins** (*vv. hepaticæ*) commence in the substance of the liver, in the terminations of the portal vein and hepatic artery, and are arranged in two groups, upper and lower. The **upper group** usually consists of three large veins, which converge toward the posterior surface of the liver, and open into the inferior vena cava, while that vessel is situated in the groove on the back part of the liver. The veins of the **lower group** vary in number, and are of small size; they come from the right and caudate lobes. The hepatic veins run singly, and are in direct contact with the hepatic tissue. They are destitute of valves.

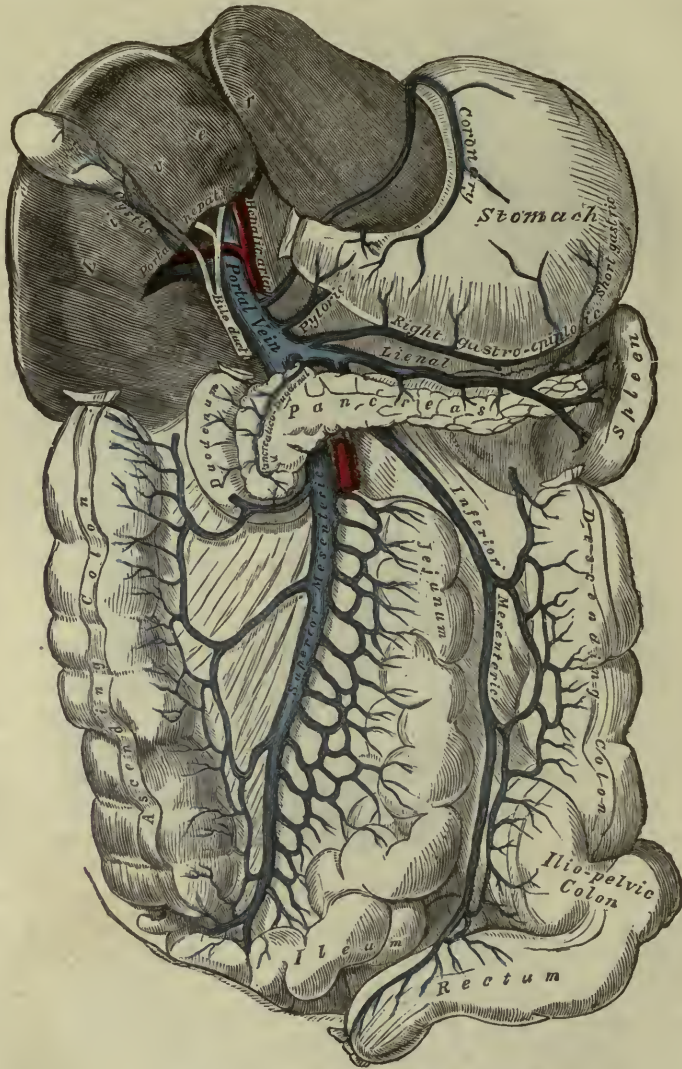


FIG. 591.—The portal vein and its tributaries.

THE PORTAL SYSTEM OF VEINS (Fig. 591).

The **portal system** includes all the veins which drain the blood from the abdominal part of the digestive tube (with the exception of the lower part of the rectum) and from the spleen, pancreas, and gall-bladder. From these viscera the blood is conveyed to the liver by the **portal vein**. In the liver this vein ramifies like an artery and ends in capillary-like vessels termed **sinusoids**, from which the blood is

conveyed to the inferior vena cava by the hepatic veins. From this it will be seen that the blood of the portal system passes through two sets of minute vessels, viz., (a) the capillaries of the digestive tube, spleen, pancreas, and gall-bladder; and (b) the sinusoids of the liver. In the adult the portal vein and its tributaries are destitute of valves; in the fetus and for a short time after birth valves can be demonstrated in the tributaries of the portal vein; as a rule they soon atrophy and disappear, but in some subjects they persist in a degenerate form.

The **portal vein** (*vena portæ*) is about 8 cm. in length, and is formed at the level of the second lumbar vertebra by the junction of the superior mesenteric and lienal veins, the union of these veins taking place in front of the inferior vena cava and behind the neck of the pancreas. It passes upward behind the superior part of the duodenum and then ascends in the right border of the lesser omentum to the right extremity of the porta hepatis, where it divides into a right and a left branch, which accompany the corresponding branches of the hepatic artery into the substance of the liver. In the lesser omentum it is placed behind and between the common bile duct and the hepatic artery, the former lying to the right of the latter. It is surrounded by the hepatic plexus of nerves, and is accompanied by numerous lymphatic vessels and some lymph glands. The **right branch** of the portal vein enters the right lobe of the liver, but before doing so generally receives the cystic vein. The **left branch**, longer but of smaller caliber than the right, crosses the left sagittal fossa, gives branches to the caudate lobe, and then enters the left lobe of the liver. As it crosses the left sagittal fossa it is joined in front by a fibrous cord, the **ligamentum teres** (*obliterated umbilical vein*), and is united to the inferior vena cava by a second fibrous cord, the **ligamentum venosum** (*obliterated ductus venosus*).

Tributaries.—The tributaries of the portal vein are:

Lienal.	Pyloric.
Superior Mesenteric.	Cystic.
Coronary.	Parumbilical.

The **Lienal Vein** (*v. lienalis; splenic vein*) commences by five or six large branches which return the blood from the spleen. These unite to form a single vessel, which passes from left to right, grooving the upper and back part of the pancreas, below the lineal artery, and ends behind the neck of the pancreas by uniting at a right angle with the superior mesenteric to form the portal vein. The lienal vein is of large size, but is not tortuous like the artery.

Tributaries.—The lineal vein receives the short gastric veins, the left gastroepiploic vein, the pancreatic veins, and the inferior mesenteric veins.

The **short gastric veins** (*vv. gastricæ breves*), four or five in number, drain the fundus and left part of the greater curvature of the stomach, and pass between the two layers of the gastrolial ligament to end in the lienal vein or in one of its large tributaries.

The **left gastroepiploic vein** (*v. gastroepiploica sinistra*) receives branches from the antero-superior and postero-inferior surfaces of the stomach and from the greater omentum; it runs from right to left along the greater curvature of the stomach and ends in the commencement of the lienal vein.

The **pancreatic veins** (*vv. pancreaticæ*) consist of several small vessels which drain the body and tail of the pancreas, and open into the trunk of the lienal vein.

The **inferior mesenteric vein** (*v. mesenterica inferior*) returns blood from the rectum and the sigmoid, and descending parts of the colon. It begins in the rectum as the **superior hemorrhoidal vein**, which has its origin in the hemorrhoidal plexus, and through this plexus communicates with the middle and inferior hemorrhoidal veins. The superior hemorrhoidal vein leaves the lesser pelvis and crosses the left common iliac vessels with the superior-hemorrhoidal artery, and is continued upward as the inferior mesenteric vein. This vein lies to the left of its artery, and ascends behind the peritoneum and in front of the left Psoas major;

it then passes behind the body of the pancreas and opens into the lienal vein; sometimes it ends in the angle of union of the lienal and superior mesenteric veins.

Tributaries.—The inferior mesenteric vein receives the **sigmoid veins** from the sigmoid colon and iliac colon, and the **left colic vein** from the descending colon and left colic flexure.

The **Superior Mesenteric Vein** (*v. mesenterica superior*) returns the blood from the small intestine, from the cecum, and from the ascending and transverse portions of the colon. It begins in the right iliac fossa by the union of the veins which drain the terminal part of the ileum, the cecum, and vermiform process, and ascends between the two layers of the mesentery on the right side of the superior mesenteric artery. In its upward course it passes in front of the right ureter, the inferior vena cava, the inferior part of the duodenum, and the lower portion of the head of the pancreas. Behind the neck of the pancreas it unites with the lienal vein to form the portal vein.

Tributaries.—Besides the tributaries which correspond with the branches of the superior mesenteric artery, viz., the **intestinal, ileocolic, right colic, and middle colic veins**, the superior mesenteric vein is joined by the right gastroepiploic and pancreaticoduodenal veins.

The **right gastroepiploic vein** (*v. gastroepiploica dextra*) receives branches from the greater omentum and from the lower parts of the antero-superior and postero-inferior surfaces of the stomach; it runs from left to right along the greater curvature of the stomach between the two layers of the greater omentum.

The **pancreaticoduodenal veins** (*vv. pancreaticoduodenales*) accompany their corresponding arteries; the lower of the two frequently joins the right gastroepiploic vein.

The **Coronary Vein** (*v. coronaria ventriculi; gastric vein*) derives tributaries from both surfaces of the stomach; it runs from right to left along the lesser curvature of the stomach, between the two layers of the lesser omentum, to the esophageal opening of the stomach, where it receives some esophageal veins. It then turns backward and passes from left to right behind the ommental bursa and ends in the portal vein.

The **Pyloric Vein** is of small size, and runs from left to right along the pyloric portion of the lesser curvature of the stomach, between the two layers of the lesser omentum, to end in the portal vein.

The **Cystic Vein** (*v. cystica*) drains the blood from the gall-bladder, and, accompanying the cystic duct, usually ends in the right branch of the portal vein.

Parumbilical Veins (*vv. parumbilicales*).—In the course of the ligamentum teres of the liver and of the middle umbilical ligament, small veins (*parumbilical*) are found which establish an anastomosis between the veins of the anterior abdominal wall and the portal, hypogastric, and iliac veins. The best marked of these small veins is one which commences at the umbilicus and runs backward and upward in, or on the surface of, the ligamentum teres between the layers of the falciform ligament to end in the left portal vein.

Collateral venous circulation to relieve portal obstruction in the liver may be effected by communications between (a) the gastric veins and the esophageal veins which often project as a varicose bunch into the stomach, emptying themselves into the hemiazygos vein; (b) the veins of the colon and duodenum and the left renal vein; (c) the accessory portal system of Sappey, branches of which pass in the round and falciform ligaments (particularly the latter) to unite with the epigastric and internal mammary veins, and through the diaphragmatic veins with the azygos; a single large vein, shown to be a parumbilical vein, may pass from the hilus of the liver by the round ligament to the umbilicus, producing there a bunch of prominent varicose veins known as the *caput medusæ*; (d) the veins of Retzius, which connect the intestinal veins with the inferior vena cava and its retroperitoneal branches; (e) the inferior mesenteric veins, and the hemorrhoidal veins that open into the hypogastriacs; (f) very rarely the ductus venosus remains patent, affording a direct connection between the portal vein and the inferior vena cava.

THE LYMPHATIC SYSTEM.

THE lymphatic system consists (1) of complex capillary networks which collect the lymph in the various organs and tissues; (2) of an elaborate system of collecting vessels which conduct the lymph from the capillaries to the large veins of the neck at the junction of the internal jugular and subclavian veins, where the lymph is poured into the blood stream; and (3) lymph glands or nodes which are interspaced in the pathways of the collecting vessels filtering the lymph as it passes through them and contributing lymphocytes to it. The lymphatic capillaries and collecting vessels are lined throughout by a continuous layer of endothelial cells, forming thus a closed system. The lymphatic vessels of the small intestine receive the special designation of lacteals or chyliferous vessels; they differ in no respect from the lymphatic vessels generally excepting that during the process of digestion they contain a milk-white fluid, the chyle.

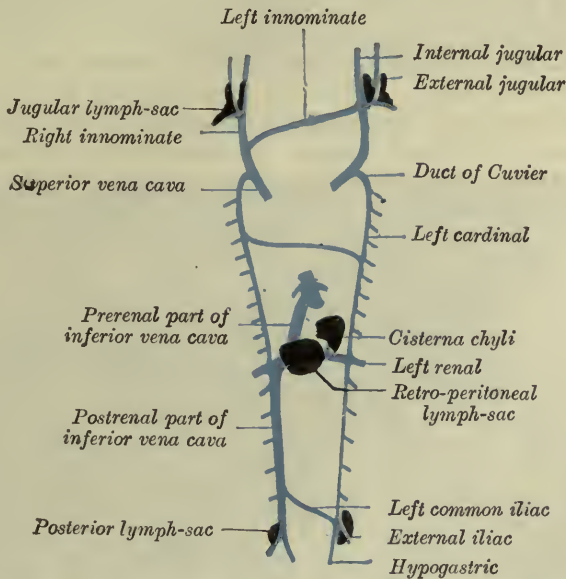


FIG. 592.—Scheme showing relative positions of primary lymph sacs based on the description given by Florence Sabin.

The Development of the Lymphatic Vessels.—The lymphatic system begins as a series of sacs¹ at the points of junction of certain of the embryonic veins. These lymph-sacs are developed by the confluence of numerous venous capillaries, which at first lose their connections with the venous system, but subsequently, on the formation of the sacs, regain them. The lymphatic system is therefore developmentally an offshoot of the venous system, and the lining walls of its vessels are always endothelial.

In the human embryo the lymph sacs from which the lymphatic vessels are

¹ Sabin, *Am. Jour. Anat.*, 1909, vol. ix; *Johns Hopkins Hospital Reports*, 1913.

derived are six in number; two paired, the jugular and the posterior lymph-sacs; and two unpaired, the retroperitoneal and the cisterna chyli. In lower mammals an additional pair, subclavian, is present, but in the human embryo these are merely extensions of the jugular sacs.

The position of the sacs is as follows: (1) jugular sac, the first to appear, at the junction of the subclavian vein with the primitive jugular; (2) posterior sac, at the junction of the iliac vein with the cardinal; (3) retroperitoneal, in the root of the mesentery near the suprarenal glands; (4) cisterna chyli, opposite the third and fourth lumbar vertebræ (Fig. 592). From the lymph-sacs the lymphatic vessels bud out along fixed lines corresponding more or less closely to the course of the embryonic bloodvessels. Both in the body-wall and in the wall of the intestine, the deeper plexuses are the first to be developed; by continued growth of these the vessels in the superficial layers are gradually formed. The thoracic duct is probably formed from anastomosing outgrowths from the jugular sac and cisterna chyli. At its connection with the cisterna chyli it is at first double, but the two vessels soon join.

All the lymph-sacs except the cisterna chyli are, at a later stage, divided up by slender connective tissue bridges and transformed into groups of lymph glands. The lower portion of the cisterna chyli is similarly converted, but its upper portion remains as the adult cisterna.

Lymphatic Capillaries.—The complex capillary plexuses which consist of a single layer of thin flat endothelial cells lie in the connective-tissue spaces in the various regions of the body to which they are distributed and are bathed by the intercellular tissue fluids. Two views are at present held as to the mode in which the lymph is formed: one being by the physical processes of filtration, diffusion, and osmosis, and the other, that in addition to these physical processes the endothelial cells have an active secretory function. The colorless liquid lymph has about the same composition as the blood plasma. It contains many lymphocytes and frequently red blood corpuscles. Granules and bacteria are also taken up by the lymph from the connective-tissue spaces, partly by the action of lymphocytes which pass into the lymph between the endothelial cells and partly by the direct passage of the granules through the endothelial cells.

The lymphatic capillary plexuses vary greatly in form; the anastomoses are usually numerous; blind ends or cul-de-sacs are especially common in the intestinal villi, the dermal papillæ and the filiform papillæ of the tongue. The plexuses are often in two layers: a superficial and a deep, the superficial being of smaller caliber than the deep. The caliber, however, varies greatly in a given plexus from a few micromillimeters to one millimeter. The capillaries are without valves.

Distribution.—*The Skin.*—Lymphatic capillaries are abundant in the dermis where they form superficial and deep plexuses, the former sending blind ends into the dermal papillæ. The plexuses are especially rich over the palmar surface of the hands and fingers and over the plantar surface of the feet and toes. The epidermis is without capillaries. The conjunctiva has an especially rich plexus.

The *subcutaneous tissue* is without capillaries.

The tendons of *striated muscle* and *muscle sheaths* are richly supplied. In muscle, however, their existence is still disputed.

The *periosteum of bone* is richly supplied and they have been described in the Haversian canals. They are absent in cartilage and probably in bone marrow.

The *joint capsules* are richly supplied with lymphatic capillaries, they do not, however, open into the joint cavities.

Beneath the mesothelium lining of the *pleural, peritoneal* and *pericardial cavities* are rich plexuses; they do not open into these cavities.

The *alimentary canal* is supplied with rich plexuses beneath the epithelium, often as a superficial plexus in the mucosa and a deeper submucosal plexus. Cul-de-sacs

extend into the filiform papillæ of the tongue and the villi of the small intestine. Those portions of the alimentary canal covered by peritoneum, have in addition a subserous lymphatic capillary plexus beneath the mesothelium.




FIG. 593.—Lymph capillaries of the human conjunctiva: *a*, conjunctiva corneæ; *b*, conjunctiva scleroticæ. $\times 40$ dia. (Teichmann.)

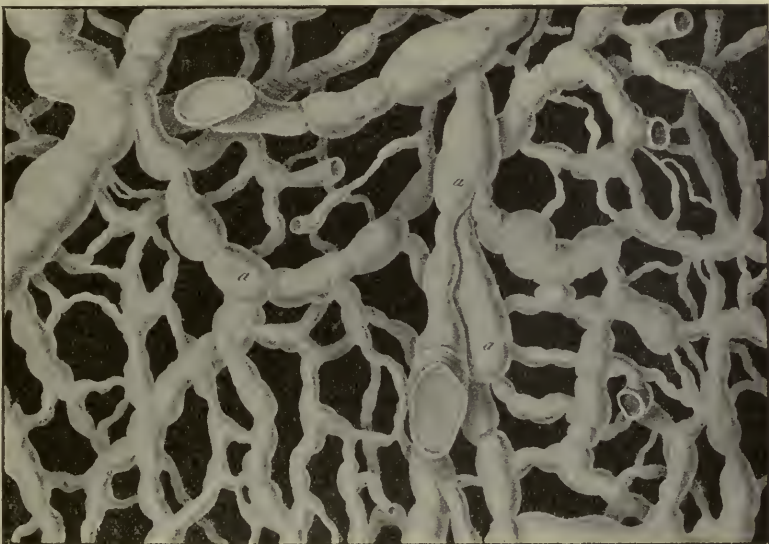


FIG. 594.—Lymph capillaries from the human scrotum, showing also transition from capillaries to the collecting vessels *a, a*. $\times 20$ dia. (Teichmann.)

The *salivary glands* are supplied with lymphatic capillaries.

The *liver* has a rich subserous plexus in the capsule and also extensive plexuses which accompany the hepatic artery and portal vein. The lymphatic capillaries have not been followed into the liver lobules. The lymph from the liver forms a

large part of that which flows through the thoracic duct. The *gall-bladder* and *bile ducts* have rich subepithelial plexuses and the former a subserous plexus.

The *spleen* has a rich subserous set and a capsular set of lymphatic capillaries. Their presence in the parenchyma is uncertain.

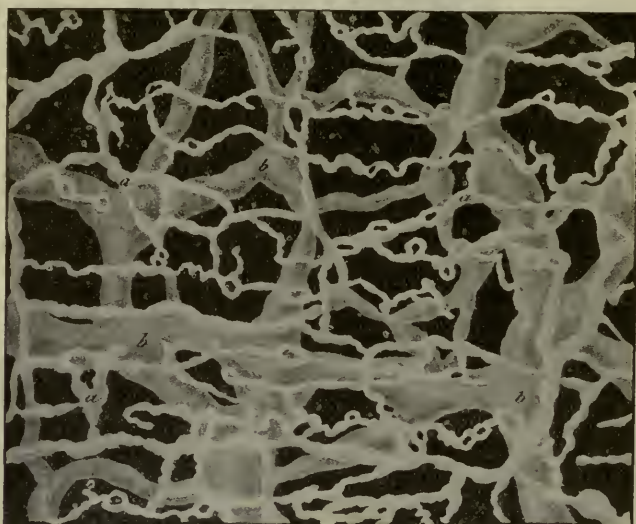


FIG. 595.—Lymph capillaries of the cutis from the inner border of the sole of the human foot. *a, a*, outer layer; *b, b*, inner layer. $\times 30$ dia. (Teichmann.)

The *nasal cavity* has extensive capillary plexuses in the mucosa and submucosa.

The *trachea* and *bronchi* have plexuses in the mucosa and submucosa but the smaller bronchi have only a single layer. The capillaries do not extend to the air-cells. The plexuses around the smaller bronchi connect with the rich subserous plexus of the lungs in places where the veins reach the surface.

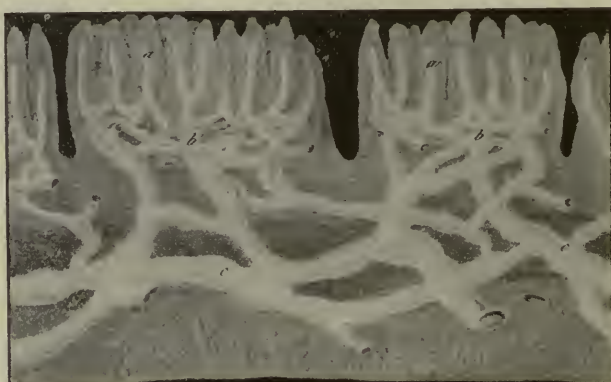


FIG. 596.—Vertical section through human tongue; *a, a*, blind lymph capillaries in the filiform papillæ with the underlying lymphatic plexus. $\times 45$. (Teichmann.)

Lymphatics have been described in the *thyroid gland* and in the *thymus*.

The *adrenal* has a superficial plexus divided into two layers, one in the loose tissue about the gland and the other beneath the capsule. Capillaries have also been described within the parenchyma.

The *kidney* is supplied with a coarse subserous plexus and a deeper plexus of finer capillaries in the capsule. Lymphatics have been described within the substance of the kidney surrounding the tubules.

The *urinary bladder* has a rich plexus of lymphatic capillaries just beneath the epithelial lining, also a subserous set which anastomoses with the former through the muscle layer. The submucous plexus is continuous with the submucous plexus of the urethra.

The *prostate* has a rich lymphatic plexus surrounding the gland and a wide-meshed subcapsular plexus.

The *testis* has a rich superficial plexus beneath the tunica albuginea. The presence of deep lymphatics is disputed.

The *uterus* is provided with a subserous plexus, the deeper lymphatics are uncertain. Subepithelial plexuses are found in the vagina.

The *ovary* has a rich superficial plexus and a deep interstitial plexus.

The *heart* has a rich subserous plexus beneath the epicardium. Lymphatic capillaries have also been described beneath the endocardium and throughout the muscle.

Lymphatic capillaries are probably absent in the central nervous system, the meninges, the eyeball (except the conjunctiva), the orbit, the internal ear, within striated muscle, the liver lobule, the spleen pulp and kidney parenchyma. They are entirely absent in cartilage. In many places further investigation is needed.

Lymphatic Vessels.—The lymphatic vessels are exceedingly delicate, and their coats are so transparent that the fluid they contain is readily seen through them. They are interrupted at intervals by constrictions, which give them a knotted or beaded appearance; these constrictions correspond to the situations of valves in their interior. Lymphatic vessels have been found in nearly every texture and organ of the body which contains bloodvessels. Such non-vascular structures as cartilage, the nails, cuticle, and hair have none, but with these exceptions it is probable that eventually all parts will be found to be permeated by these vessels.

Structure of Lymphatic Vessels.—The larger lymphatic vessels are each composed of three coats. The *internal* coat is thin, transparent, slightly elastic, and consists of a layer of elongated endothelial cells with wavy margins by which the contiguous cells are dovetailed into one another; the cells are supported on an elastic membrane. The *middle* coat is composed of smooth muscular and fine elastic fibers, disposed in a transverse direction. The *external* coat consists of connective tissue, intermixed with smooth muscular fibers longitudinally or obliquely disposed; it forms a protective covering to the other coats, and serves to connect the vessel with the neighboring structures. In the smaller vessels there are no muscular or elastic fibers, and the wall consists only of a connective-tissue coat, lined by endothelium. The thoracic duct has a more complex structure than the other lymphatic vessels; it presents a distinct subendothelial layer of branched corpuscles, similar to that found in the arteries; in the middle coat there is, in addition to the muscular and elastic fibers, a layer of connective tissue with its fibers arranged longitudinally. The lymphatic vessels are supplied by nutrient vessels, which are distributed to their outer and middle coats; and here also have been traced many non-medullated nerves in the form of a fine plexus of fibrils.

The valves of the lymphatic vessels are formed of thin layers of fibrous tissue covered on both surfaces by endothelium which presents the same arrangement as on the valves of veins (p. 501). In form the valves are semilunar; they are attached by their convex edges to the wall of the vessel, the concave edges being free and directed along the course of the contained current. Usually two such valves, of equal size, are found opposite one another; but occasionally exceptions occur, especially at or near the anastomoses of lymphatic vessels. Thus, one valve may be of small size and the other increased in proportion.

In the lymphatic vessels the valves are placed at much shorter intervals than in the veins. They are most numerous near the lymph glands, and are found more frequently in the lymphatic vessels of the neck and upper extremity than in those of the lower extremity. The wall of the lymphatic vessel immediately above the point of attachment of each segment of a valve is expanded into a pouch or sinus which gives to these vessels, when distended, the knotted or beaded appearance already referred to. Valves are wanting in the vessels composing the plexiform net-work in which the lymphatic vessels usually originate on the surface of the body.

Lymph Glands (*lymphoglandula*).—The lymph glands are small oval or bean-shaped bodies, situated in the course of lymphatic and lacteal vessels so that the lymph and chyle pass through them on their way to the blood. Each generally presents on one side a slight depression—the **hilus**—through which the bloodvessels enter and leave the interior. The efferent lymphatic vessel also emerges from the gland at this spot, while the afferent vessels enter the organ at different parts of the periphery. On section (Fig. 597) a lymph gland displays two different structures: an external, of lighter color—the **cortical**; and an internal, darker—the **medullary**. The cortical structure does not form a complete investment, but is deficient at the hilus, where the medullary portion reaches the surface of the gland; so that the efferent vessel is derived directly from the medullary structures, while the afferent vessels empty themselves into the cortical substance.

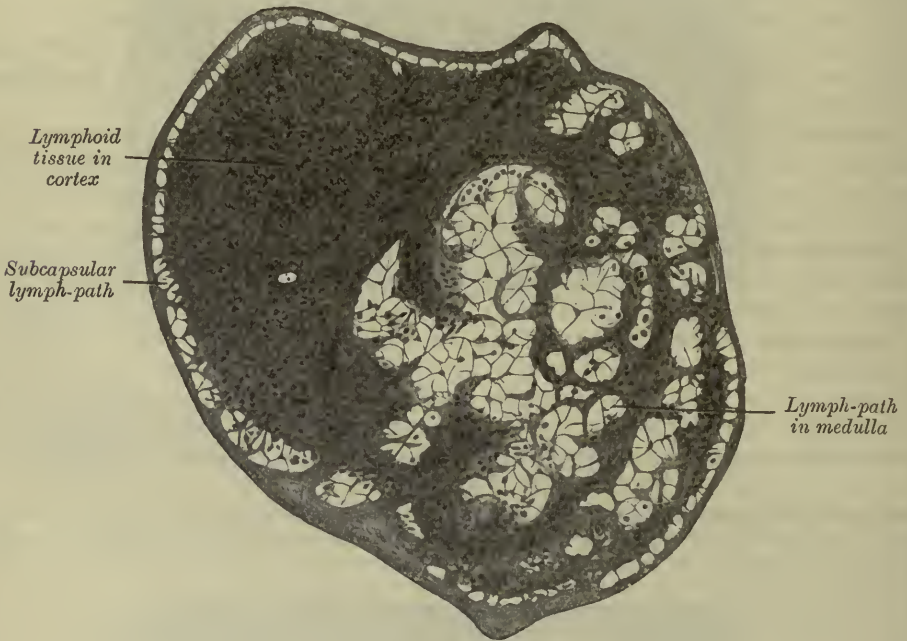


FIG. 597.—Section of small lymph gland of rabbit. $\times 100$.

Structure of Lymph Glands.—A lymph gland consists of (1) a fibrous envelope, or **capsule**, from which a frame-work of processes (*trabeculae*) proceeds inward, imperfectly dividing the gland into open spaces freely communicating with each other; (2) a quantity of lymphoid tissue occupying these spaces without completely filling them; (3) a free supply of bloodvessels, which are supported in the trabeculae; and (4) the **afferent** and **efferent vessels** communicating through the lymph paths in the substance of the gland. The nerves passing into the hilus are few in number and are chiefly distributed to the bloodvessels supplying the gland.

The **capsule** is composed of connective tissue with some plain muscle fibers, and from its internal surface are given off a number of membranous processes or trabeculae, consisting, in man, of connective tissue, with a small admixture of plain muscle fibers; but in many of the lower animals composed almost entirely of involuntary muscle. They pass inward, radiating toward the center of the gland, for a certain distance—that is to say, for about one-third or one-fourth of the space between the circumference and the center of the gland. In some animals they are sufficiently well-marked to divide the peripheral or cortical portion of the gland into a number of compartments (so-called follicles), but in man this arrangement is not obvious. The larger trabeculae springing from the capsule break up into finer bands, and these interlace to form a mesh-work in the central or medullary portion of the gland. In these spaces formed by the interlacing trabeculae is contained the proper gland substance or lymphoid tissue. The gland pulp does not, however, completely fill the spaces, but leaves, between its outer margin and the enclosing trabeculae, a channel or space of uniform width throughout. This is termed the **lymph path**

or **lymph sinus** (Fig. 597). Running across it are a number of finer trabeculae of retiform connective tissue, the fibers of which are, for the most part, covered by ramifying cells.

On account of the peculiar arrangement of the frame-work of the organ, the gland pulp in the cortical portion is disposed in the form of nodules, and in the medullary part in the form of rounded cords. It consists of ordinary lymphoid tissue (Fig. 598), being made up of a delicate net-work of retiform tissue, which is continuous with that in the lymph paths, but marked off from it by a closer reticulation; it is probable, moreover, that the reticular tissue of the gland pulp and the lymph paths is continuous with that of the trabeculae, and ultimately with that of the capsule of the gland. In its meshes, in the nodules and cords of lymphoid tissue, are closely packed lymph corpuscles. The gland pulp is traversed by a dense plexus of capillary bloodvessels. The nodules or follicles in the cortical portion of the gland frequently show, in their centers, areas where karyokinetic figures indicate a division of the lymph corpuscles. These areas are termed **germ centers**. The cells composing them have more abundant protoplasm than the peripheral cells.

The **afferent vessels**, as stated above, enter at all parts of the periphery of the gland, and after branching and forming a dense plexus in the substance of the capsule, open into the lymph sinuses of the cortical part. In doing this they lose all their coats except their endothelial lining, which is continuous with a layer of similar cells lining the lymph paths. In like manner the **efferent vessel** commences from the lymph sinuses of the medullary portion. The stream of lymph carried to the gland by the afferent vessels thus passes through the plexus in the capsule to the lymph

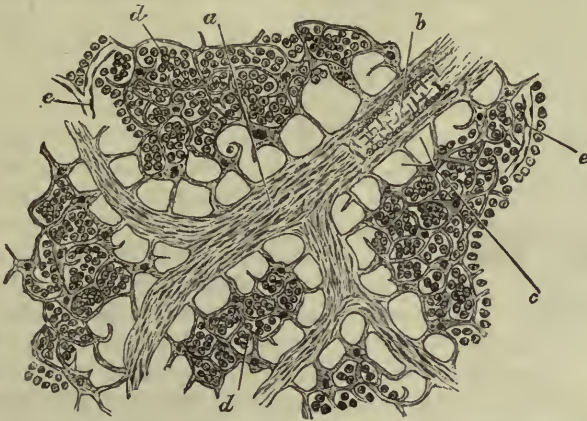


FIG. 598.—Lymph gland tissue. Highly magnified. *a*, Trabeculae. *b*, Small artery in substance of same. *c*, Lymph paths. *d*, Lymph corpuscles. *e*, Capillary plexus.

paths of the cortical portion, where it is exposed to the action of the gland pulp; flowing through these it enters the paths or sinuses of the medullary portion, and finally emerges from the hilus by means of the efferent vessel. The stream of lymph in its passage through the lymph sinuses is much retarded by the presence of the reticulum, hence morphological elements, either normal or morbid, are easily arrested and deposited in the sinuses. Many lymph corpuscles pass with the efferent lymph stream to join the general blood stream. The arteries of the gland enter at the hilus, and either go at once to the gland pulp, to break up into a capillary plexus, or else run along the trabeculae, partly to supply them and partly running across the lymph paths, to assist in forming the capillary plexus of the gland pulp. This plexus traverses the lymphoid tissue, but does not enter into the lymph sinuses. From it the veins commence and emerge from the organ at the same place as that at which the arteries enter.

The lymphatic vessels are arranged into a **superficial** and a **deep set**. On the surface of the body the **superficial** lymphatic vessels are placed immediately beneath the integument, accompanying the superficial veins; they join the deep lymphatic vessels in certain situations by perforating the deep fascia. In the interior of the body they lie in the submucous areolar tissue, throughout the whole length of the digestive, respiratory, and genito-urinary tracts; and in the subserous tissue of the thoracic and abdominal walls. Plexiform networks of minute lymphatic vessels are found interspersed among the proper elements and bloodvessels of the several tissues; the vessels composing the net-work, as well as the meshes

between them, are much larger than those of the capillary plexus. From these net-works small vessels emerge, which pass, either to a neighboring gland, or to join some larger lymphatic trunk. The **deep** lymphatic vessels, fewer in number, but larger than the superficial, accompany the deep bloodvessels. Their mode of origin is probably similar to that of the superficial vessels. The lymphatic vessels of any part or organ exceed the veins in number, but in size they are much smaller. Their anastomoses also, especially those of the large trunks, are more frequent, and are effected by vessels equal in diameter to those which they connect, the continuous trunks retaining the same diameter.

Hemolymph nodes or **glands** and **hemal nodes** which are so abundant in some mammals are probably not present in man.

Lymph.—Lymph, found only in the closed lymphatic vessels, is a transparent, colorless, or slightly yellow, watery fluid of specific gravity about 1.015; it closely resembles the blood plasma, but is more dilute. When it is examined under the microscope, leucocytes of the lymphocyte class are found floating in the transparent fluid; they are always increased in number after the passage of the lymph through lymphoid tissue, as in lymph glands. Lymph should be distinguished from "tissue fluid"¹ which is found outside the lymphatic vessels in the tissue spaces.

THE THORACIC DUCT.

The **thoracic duct** (*ductus thoracicus*) (Fig. 599) conveys the greater part of the lymph and chyle into the blood. It is the common trunk of all the lymphatic vessels of the body, excepting those on the right side of the head, neck, and thorax, and right upper extremity, the right lung, right side of the heart, and the convex surface of the liver. In the adult it varies in length from 38 to 45 cm. and extends from the second lumbar vertebra to the root of the neck. It begins in the abdomen by a triangular dilatation, the **cisterna chyli**, which is situated on the front of the body of the second lumbar vertebra, to the right side of and behind the aorta, by the side of the right crus of the diaphragm. It enters the thorax through the aortic hiatus of the diaphragm, and ascends through the posterior mediastinal cavity between the aorta and azygos vein. Behind it in this region are the vertebral column, the right intercostal arteries, and the hemiazygos veins as they cross to open into the azygos vein; in front of it are the diaphragm, esophagus, and pericardium, the last being separated from it by a recess of the right pleural cavity. Opposite the fifth thoracic vertebra, it inclines toward the left side, enters the superior mediastinal cavity, and ascends behind the aortic arch and the thoracic part of the left subclavian artery and between the left side of the esophagus and the left pleura, to the upper orifice of the thorax. Passing into the neck it forms an arch which rises about 3 or 4 cm. above the clavicle and crosses anterior to the subclavian artery, the vertebral artery and vein, and the thyrocervical trunk or its branches. It also passes in front of the phrenic nerve and the medial border of the Scalenus anterior, but is separated from these two structures by the pre-vertebral fascia. In front of it are the left common carotid artery, vagus nerve, and internal jugular vein; it ends by opening into the angle of junction of the left subclavian vein with the left internal jugular vein. The thoracic duct, at its commencement, is about equal in diameter to a goose-quill, but it diminishes considerably in caliber in the middle of the thorax, and is again dilated just before its termination. It is generally flexuous, and constricted at intervals so as to present a varicose appearance. Not infrequently it divides in the middle of its course into two vessels of unequal size which soon reunite, or into several branches which form

¹ Sabin, Harvey Lecture, Series ix, New York, 1915-16.

a plexiform interlacement. It occasionally divides at its upper part into two branches, right and left; the left ending in the usual manner, while the right opens into the right subclavian vein, in connection with the right lymphatic duct. The thoracic duct has several valves; at its termination it is provided with a pair, the free borders of which are turned toward the vein, so as to prevent the passage of venous blood into the duct.

The **cisterna chyli** (*receptaculum chyli*) (Fig. 600) receives the two lumbar lymphatic trunks, right and left, and the intestinal lymphatic trunk. The **lumbar trunks** are formed by the union of the efferent vessels from the lateral aortic lymph glands. They receive the lymph from the lower limbs, from the walls and viscera of the pelvis, from the kidneys and suprarenal glands and the deep lymphatics of the greater part of the abdominal wall. The **intestinal trunk** receives the lymph from the stomach and intestine, from the pancreas and spleen, and from the lower and front part of the liver.

Tributaries.—Opening into the commencement of the thoracic duct, on either side, is a descending trunk from the posterior intercostal lymph glands of the lower six or seven intercostal spaces. In the thorax the duct is joined, on either side, by a trunk which drains the upper lumbar lymph glands and pierces the crus of the diaphragm. It also receives the efferents from the posterior mediastinal lymph glands and from the posterior intercostal lymph glands of the upper six left spaces. In the neck it is joined by the **left jugular** and **left subclavian trunks**, and sometimes by the **left broncho-mediastinal trunk**; the last-named, however, usually opens independently into the junction of the left subclavian and internal jugular veins.

The **right lymphatic duct** (*ductus lymphaticus dexter*) (Fig. 601), about 1.25 cm. in length, courses along the medial border of the *Scalenus anterior* at the root of the neck and ends in the right subclavian vein, at its angle of junction with the right internal jugular vein. Its orifice is guarded by two semilunar valves, which prevent the passage of venous blood into the duct.

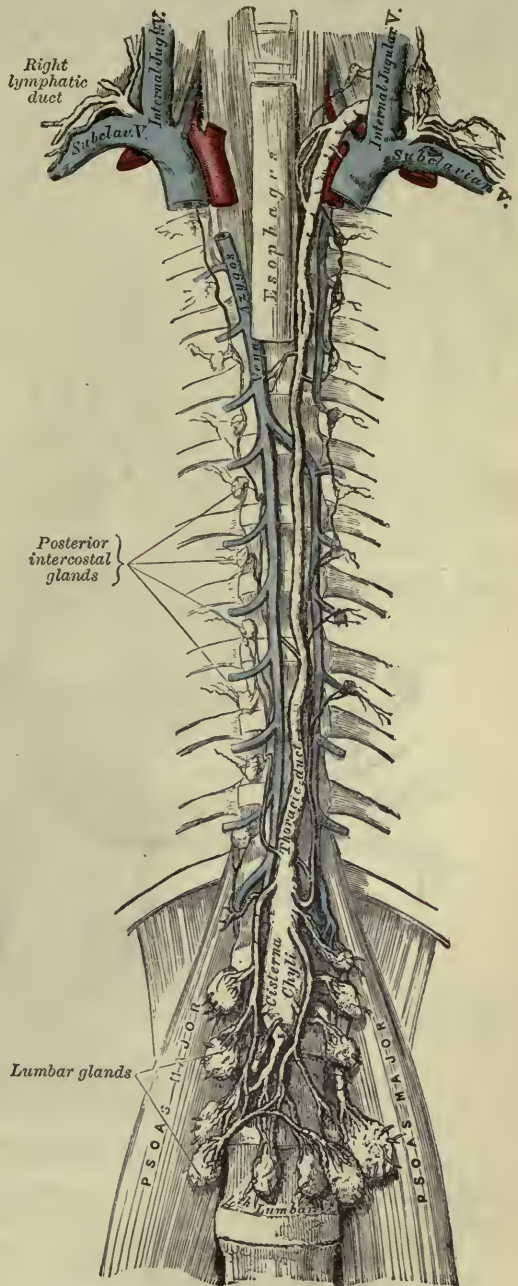


FIG. 599.—The thoracic and right lymphatic ducts.

Tributaries.—The right lymphatic duct receives the lymph from the right side of the head and neck through the **right jugular trunk**; from the right upper extremity through the **right subclavian trunk**; from the right side of the thorax, right lung,

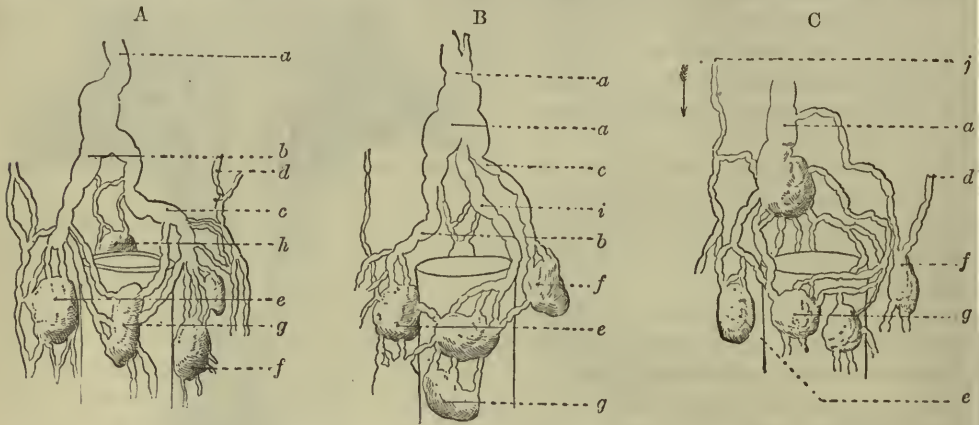


FIG. 600.—Modes of origin of thoracic duct. (Poirier and Charpy.) *a*, Thoracic duct. *a'*, Cisterna chyli. *b, c*, Efferent trunks from lateral aortic glands. *d*, An efferent vessel which pierces the left crus of the diaphragm. *e, f*, Lateral aortic glands. *h*, Retroaortic glands. *i*, Intestinal trunk. *j*, Descending branch from intercostal lymphatics.

right side of the heart, and part of the convex surface of the liver, through the **right bronchomediastinal trunk**. These three collecting trunks frequently open separately in the angle of union of the two veins.

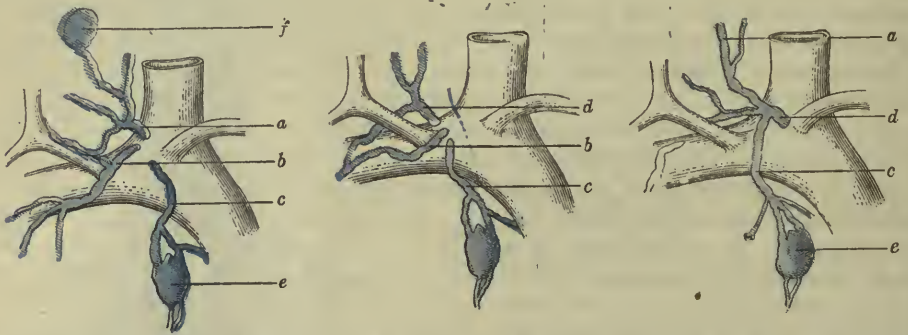


FIG. 601.—Terminal collecting trunks of right side. *a*, Jugular trunk. *b*, Subclavian trunk. *c*, Bronchomediastinal trunk. *d*, Right lymphatic trunk. *e*, Gland of internal mammary chain. *f*, Gland of deep cervical chain. (Poirier and Charpy.)

THE LYMPHATICS OF THE HEAD, FACE, AND NECK.

The Lymph Glands of the Head (Fig. 602).

The lymph glands of the head are arranged in the following groups:

Occipital.	Facial.
Posterior Auricular.	Deep Facial.
Anterior Auricular.	Lingual.
Parotid.	Retropharyngeal.

The **occipital glands** (*lymphoglandulae occipitales*), one to three in number, are placed on the back of the head close to the margin of the Trapezius and resting on the insertion of the Semispinalis capitis. Their afferent vessels drain the occipital region of the scalp, while their efferents pass to the superior deep cervical glands.

The **posterior auricular glands** (*lymphoglandulae auriculares*; *mastoid glands*), usually two in number, are situated on the mastoid insertion of the Sternocleidomastoideus, beneath the Auricularis posterior. Their afferent vessels drain the posterior part of the temporoparietal region, the upper part of the cranial surface of the auricula or pinna, and the back of the external acoustic meatus; their efferents pass to the superior deep cervical glands.

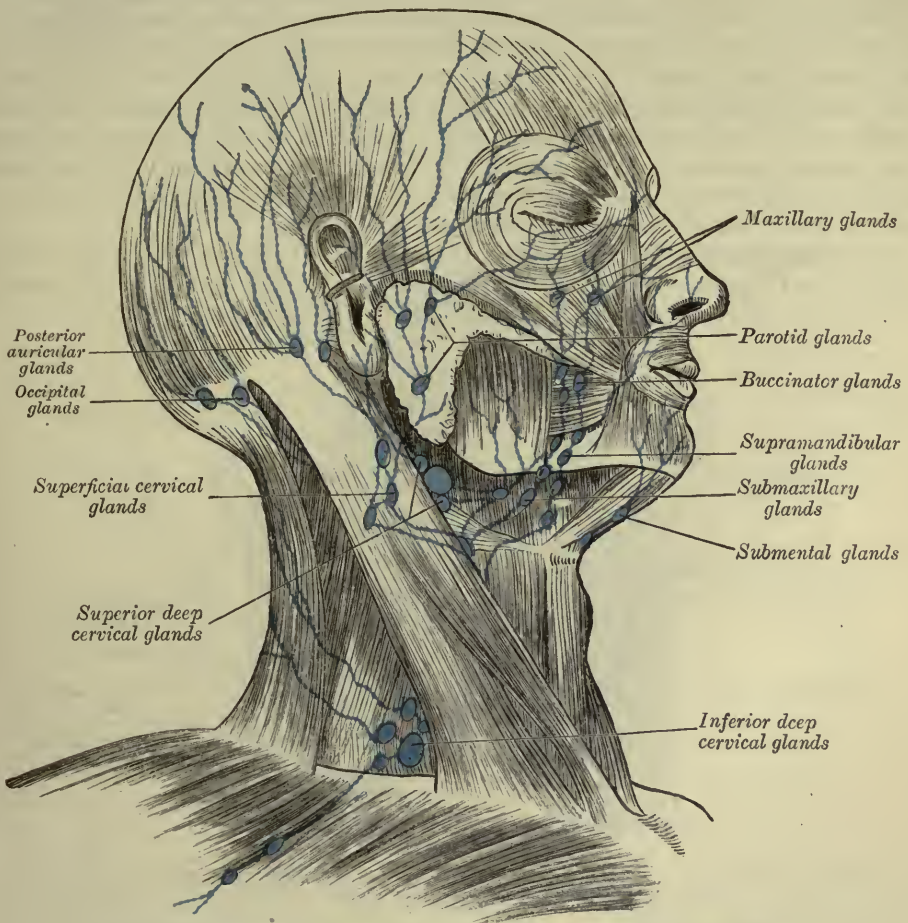


FIG. 602.—Superficial lymph glands and lymphatic vessels of head and neck.

The **anterior auricular glands** (*lymphoglandulae auriculares anteriores*; *superficial parotid or preauricular glands*), from one to three in number, lie immediately in front of the tragus. Their afferents drain the lateral surface of the auricula and the skin of the adjacent part of the temporal region; their efferents pass to the superior deep cervical glands.

The **parotid glands** (*lymphoglandulae parotideae*), form two groups in relation with the parotid salivary gland, viz., a group imbedded in the substance of the gland, and a group of subparotid glands lying on the lateral wall of the pharynx. Occasionally small glands are found in the subcutaneous tissue over the parotid gland. Their afferent vessels drain the root of the nose, the eyelids, the frontotemporal region, the external acoustic meatus and the tympanic cavity, possibly also the posterior parts of the palate and the floor of the nasal cavity. The efferents of these glands pass to the superior deep cervical glands. The afferents of the sub-

parotid glands drain the nasal part of the pharynx and the posterior parts of the nasal cavities; their efferents pass to the superior deep cervical glands.

The **facial glands** comprise three groups: (a) **infraorbital** or **maxillary**, scattered over the infraorbital region from the groove between the nose and cheek to the zygomatic arch; (b) **buccinator**, one or more placed on the Buccinator opposite the angle of the mouth; (c) **supramandibular**, on the outer surface of the mandible, in front of the Masseter and in contact with the external maxillary artery and anterior facial vein. Their efferent vessels drain the eyelids, the conjunctiva, and the skin and mucous membrane of the nose and cheek; their efferents pass to the submaxillary glands.

The **deep facial glands** (*lymphoglandulæ faciales profunda; internal maxillary glands*) are placed beneath the ramus of the mandible, on the outer surface of the Pterygoideus externus, in relation to the internal maxillary artery. Their afferent vessels drain the temporal and infratemporal fossæ and the nasal part of the pharynx their efferents pass to the superior deep cervical glands.

The **lingual glands** (*lymphoglandulæ linguales*) are two or three small nodules lying on the Hyoglossus and under the Genioglossus. They form merely glandular substations in the course of the lymphatic vessels of the tongue.

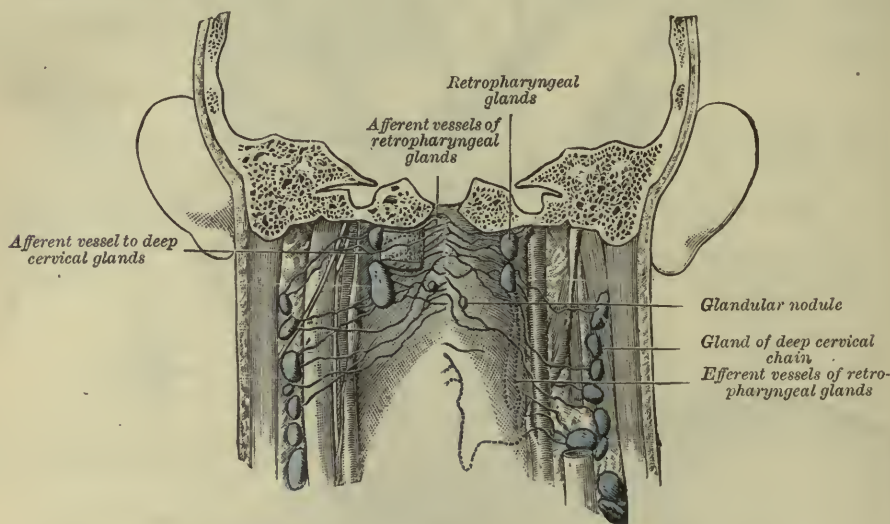


FIG. 603.—Lymphatics of pharynx. (Poirier and Charpy.)

The **retropharyngeal glands** (Fig. 603), from one to three in number, lie in the buccopharyngeal fascia, behind the upper part of the pharynx and in front of the arch of the atlas, being separated, however, from the latter by the Longus capitis. Their afferents drain the nasal cavities, the nasal part of the pharynx, and the auditory tubes; their efferents pass to the superior deep cervical glands.

The **lymphatic vessels of the scalp** are divisible into (a) those of the frontal region, which terminate in the anterior auricular and parotid glands; (b) those of the temporoparietal region, which end in the parotid and posterior auricular glands; and (c) those of the occipital region, which terminate partly in the occipital glands and partly in a trunk which runs down along the posterior border of the Sternocleidomastoideus to end in the inferior deep cervical glands.

The **lymphatic vessels of the auricula and external acoustic meatus** are also divisible into three groups: (a) an anterior, from the lateral surface of the auricula and anterior wall of the meatus to the anterior auricular glands; (b) a posterior, from the margin of the auricula, the upper part of its cranial surface, the internal surface

and posterior wall of the meatus to the posterior auricular and superior deep cervical glands; (c) an inferior, from the floor of the meatus and from the lobule of the auricula to the superficial and superior deep cervical glands.

The **lymphatic vessels of the face** (Fig. 604) are more numerous than those of the scalp. Those from the eyelids and conjunctiva terminate partly in the submaxillary but mainly in the parotid glands. The vessels from the posterior part of the cheek also pass to the parotid glands, while those from the anterior portion of the cheek, the side of the nose, the upper lip, and the lateral portions of the lower lip end in the submaxillary glands. The deeper vessels from the temporal and infratemporal fossæ pass to the deep facial and superior deep cervical glands. The deeper vessels of the cheek and lips end, like the superficial, in the submaxillary glands. Both superficial and deep vessels of the central part of the lower lip run to the submental glands.

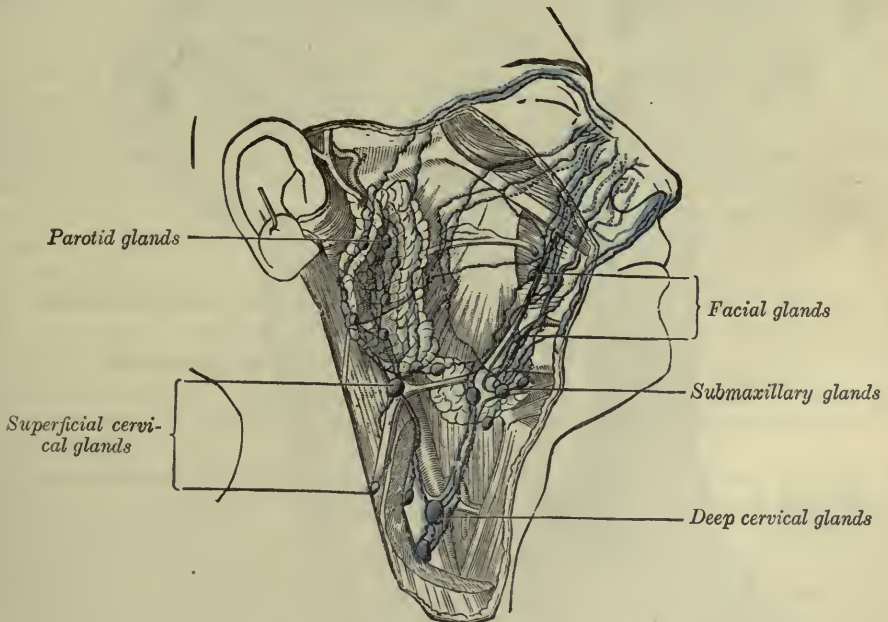


FIG. 604.—The lymphatics of the face. (After Küttner.)

Lymphatic Vessels of the Nasal Cavities.—Those from the anterior parts of the nasal cavities communicate with the vessels of the integument of the nose and end in the submaxillary glands; those from the posterior two-thirds of the nasal cavities and from the accessory air sinuses pass partly to the retropharyngeal and partly to the superior deep cervical glands.

Lymphatic Vessels of the Mouth.—The vessels of the gums pass to the submaxillary glands; those of the hard palate are continuous in front with those of the upper gum, but pass backward to pierce the Constrictor pharyngis superior and end in the superior deep cervical and subparotid glands; those of the soft palate pass backward and lateralward and end partly in the retropharyngeal and subparotid, and partly in the superior deep cervical glands. The vessels of the anterior part of the floor of the mouth pass either directly to the inferior glands of the superior deep cervical group, or indirectly through the submental glands; from the rest of the floor of the mouth the vessels pass to the submaxillary and superior deep cervical glands.

The **lymphatic vessels of the palatine tonsil**, usually three to five in number, pierce the buccopharyngeal fascia and constrictor pharyngis superior and pass

between the Stylohyoideus and internal jugular vein to the uppermost of the superior deep cervical glands. They end in a gland which lies at the side of the posterior belly of the Digastricus, on the internal jugular vein; occasionally one or two additional vessels run to small glands on the lateral side of the vein under cover of the Sternocleidomastoideus.

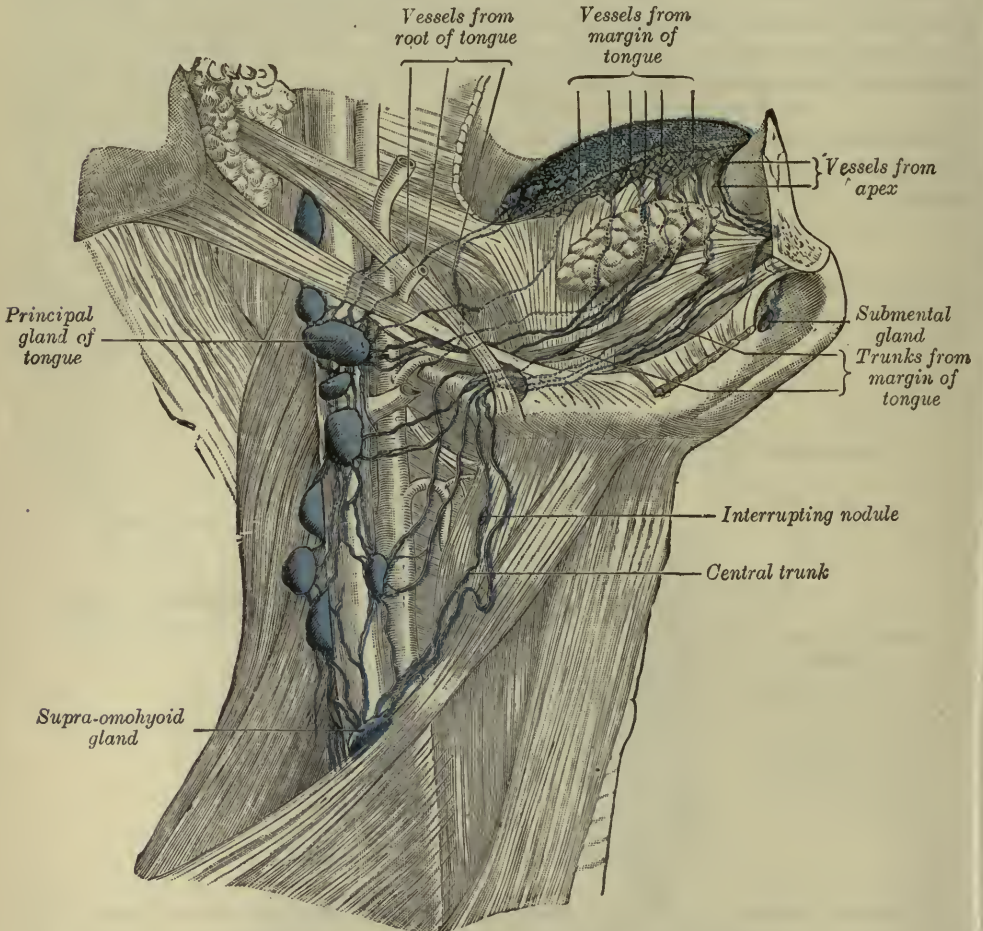


FIG. 605.—Lymphatics of the tongue. (Poirier and Charpy.)

The lymphatic vessels of the tongue (Fig. 605) are drained chiefly into the deep cervical glands lying between the posterior belly of the Digastricus and the superior belly of the Omohyoideus; one gland situated at the bifurcation of the common carotid artery is so intimately associated with these vessels that it is known as the **principal gland of the tongue**. The lymphatic vessels of the tongue may be divided into four groups: (1) apical, from the tip of the tongue to the suprahyoid glands and principal gland of the tongue; (2) lateral, from the margin of the tongue—some of these pierce the Mylohyoideus to end in the submaxillary glands, others pass down on the Hyoglossus to the superior deep cervical glands; (3) basal, from the region of the vallate papillæ to the superior deep cervical glands; and (4) median, a few of which perforate the Mylohyoideus to reach the submaxillary glands, while the majority turn around the posterior border of the muscle to enter the superior deep cervical glands.

The Lymph Glands of the Neck.

The lymph glands of the neck include the following groups:

Submaxillary.	Superficial Cervical.
Submental.	Anterior Cervical.
	Deep Cervical.

The **submaxillary glands** (*lymphoglandulae submaxillares*) (Fig. 604), three to six in number, are placed beneath the body of the mandible in the submaxillary triangle, and rest on the superficial surface of the submaxillary salivary gland. One gland, the **middle gland of Stahr**, which lies on the external maxillary artery as it turns over the mandible, is the most constant of the series; small lymph glands are sometimes found on the deep surface of the submaxillary salivary glands. The afferents of the submaxillary glands drain the medial palpebral commissure, the cheek, the side of the nose, the upper lip, the lateral part of the lower lip, the gums, and the anterior part of the margin of the tongue; efferent vessels from the facial and submental glands also enter the submaxillary glands. Their efferent vessels pass to the superior deep cervical glands.

The **submental** or **suprahyoid glands** are situated between the anterior bellies of the Digastrici. Their afferents drain the central portions of the lower lip and floor of the mouth and the apex of the tongue; their efferents pass partly to the submaxillary glands and partly to a gland of the deep cervical group situated on the internal jugular vein at the level of the cricoid cartilage.

The **superficial cervical glands** (*lymphoglandulae cervicales superficiales*) lie in close relationship with the external jugular vein as it emerges from the parotid gland, and, therefore, superficial to the Sternocleidomastoideus. Their afferents drain the lower parts of the auricula and parotid region, while their efferents pass around the anterior margin of the Sternocleidomastoideus to join the superior deep cervical glands.

The **anterior cervical glands** form an irregular and inconstant group on the front of the larynx and trachea. They may be divided into (a) a **superficial set**, placed on the anterior jugular vein; (b) a **deeper set**, which is further subdivided into prelaryngeal, on the middle cricothyroid ligament, and pretracheal, on the front of the trachea. This deeper set drains the lower part of the larynx, the thyroid gland, and the upper part of the trachea; its efferents pass to the lowest of the superior deep cervical glands.

The **deep cervical glands** (*lymphoglandulae cervicales profundae*) (Figs. 602, 605) are numerous and of large size: they form a chain along the carotid sheath, lying by the side of the pharynx, esophagus, and trachea, and extending from the base of the skull to the root of the neck. They are usually described in two groups: (1) the **superior deep cervical glands** lying under the Sternocleidomastoideus in close relation with the accessory nerve and the internal jugular vein, some of the glands lying in front of and others behind the vessel; (2) the **inferior deep cervical glands** extending beyond the posterior margin of the Sternocleidomastoideus into the supraclavicular triangle, where they are closely related to the brachial plexus and subclavian vein. A few minute **paratracheal glands** are situated alongside the recurrent nerves on the lateral aspects of the trachea and esophagus. The superior deep cervical glands drain the occipital portion of the scalp, the auricula, the back of the neck, a considerable part of the tongue, the larynx, thyroid gland, trachea, nasal part of the pharynx, nasal cavities, palate, and esophagus. They receive also the efferent vessels from all the other glands of the head and neck, except those from the inferior deep cervical glands. The inferior deep cervical glands drain the back of the scalp and neck, the superficial pectoral region, part of the arm (see page 701), and, occasionally, part of the superior surface of the

liver. In addition, they receive vessels from the superior deep cervical glands. The efferents of the superior deep cervical glands pass partly to the inferior deep cervical glands and partly to a trunk which unites with the efferent vessel of the inferior deep cervical glands and forms the **jugular trunk**. On the right side, this trunk ends in the junction of the internal jugular and subclavian veins; on the left side it joins the thoracic duct.

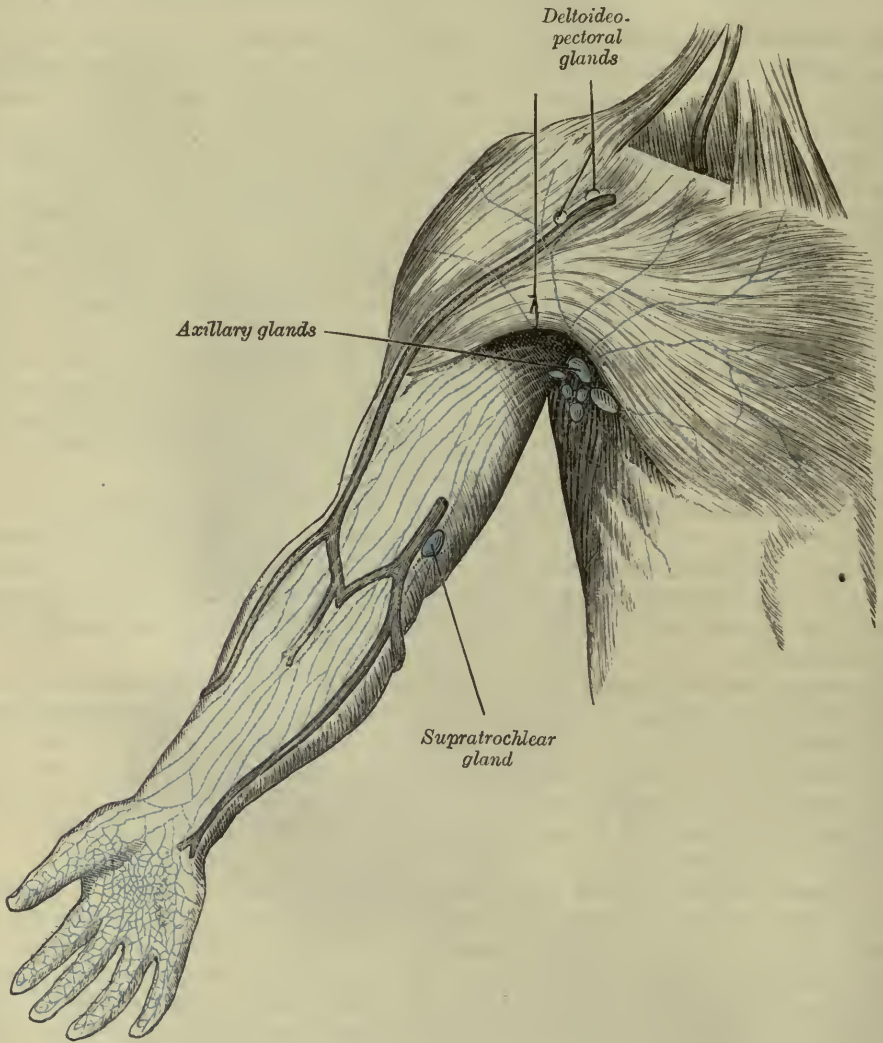


FIG. 606.—The superficial lymph glands and lymphatic vessels of the upper extremity.

The **lymphatic vessels of the skin and muscles of the neck** pass to the deep cervical glands. From the upper part of the *pharynx* the lymphatic vessels pass to the retropharyngeal, from the lower part to the deep cervical glands. From the *larynx* two sets of vessels arise, an upper and a lower. The vessels of the upper set pierce the hyothyroid membrane and join the superior deep cervical glands. Of the lower set, some pierce the conus elasticus and join the pretracheal and pre-laryngeal glands; others run between the cricoid and first tracheal ring and enter the inferior deep cervical glands. The lymphatic vessels of the *thyroid gland* consist of two sets, an upper, which accompanies the superior thyroid artery and enters the superior deep cervical glands, and a lower, which runs partly to the pretracheal

glands and partly to the small paratracheal glands which accompany the recurrent nerves. These latter glands receive also the lymphatic vessels from the cervical portion of the trachea.

THE LYMPHATICS OF THE UPPER EXTREMITY.

The Lymph Glands of the Upper Extremity (Fig. 606).

The lymph glands of the upper extremity are divided into two sets, **superficial** and **deep**.

The **superficial lymph glands** are few and of small size. One or two **supra-trochlear glands** are placed above the medial epicondyle of the humerus, medial to the basilic vein. Their afferents drain the middle, ring, and little fingers, the medial portion of the hand, and the superficial area over the ulnar side of the forearm; these vessels are, however, in free communication with the other lymphatic vessels of the forearm. Their efferents accompany the basilic vein and join the deeper vessels. One or two **deltoideopectoral glands** are found beside the cephalic vein, between the Pectoralis major and Deltoideus, immediately below the clavicle. They are situated in the course of the external collecting trunks of the arm.

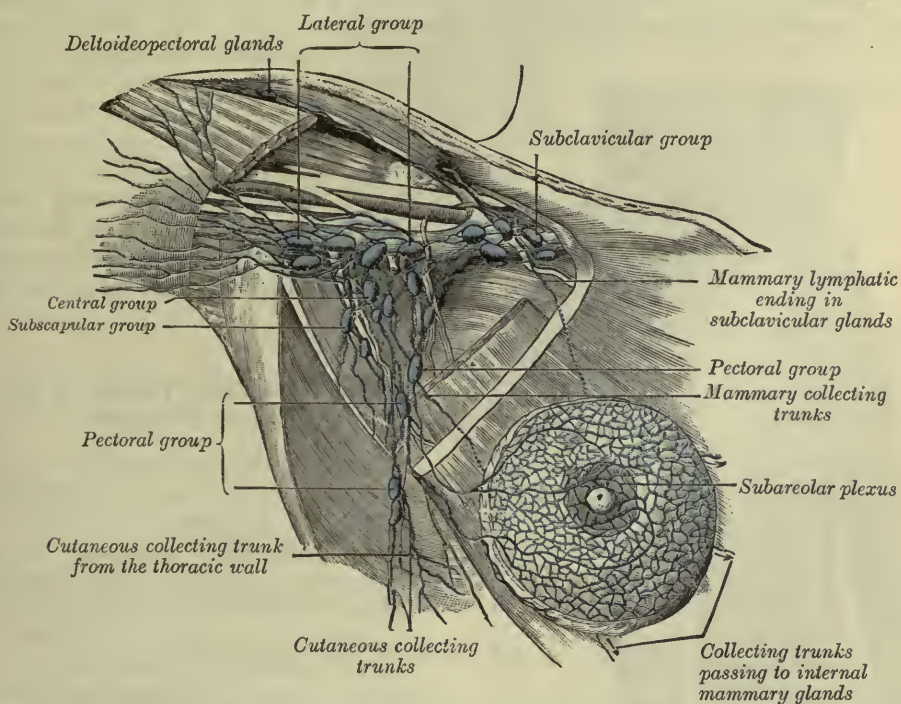


FIG. 607.—Lymphatics of the mamma, and the axillary glands (semidiagrammatic). (Poirier and Charpy.)

The **deep lymph glands** are chiefly grouped in the axilla, although a few may be found in the forearm, in the course of the radial, ulnar, and interosseous vessels, and in the arm along the medial side of the brachial artery.

The **Axillary Glands** (*lymphoglandulae axillares*) (Fig. 607) are of large size, vary from twenty to thirty in number, and may be arranged in the following groups:

1. A **lateral group** of from four to six glands lies in relation to the medial and posterior aspects of the axillary vein; the afferents of these glands drain the whole arm with the exception of that portion whose vessels accompany the cephalic

vein. The efferent vessels pass partly to the central and subclavicular groups of axillary glands and partly to the inferior deep cervical glands.

2. An **anterior or pectoral group** consists of four or five glands along the lower border of the Pectoralis minor, in relation with the lateral thoracic artery. Their afferents drain the skin and muscles of the anterior and lateral thoracic walls, and the central and lateral parts of the mamma; their efferents pass partly to the central and partly to the subclavicular groups of axillary glands.

3. A **posterior or subscapular group** of six or seven glands is placed along the lower margin of the posterior wall of the axilla in the course of the subscapular artery. The afferents of this group drain the skin and muscles of the lower part of the back of the neck and of the posterior thoracic wall; their efferents pass to the central group of axillary glands.

4. A **central or intermediate group** of three or four large glands is imbedded in the adipose tissue near the base of the axilla. Its afferents are the efferent vessels of all the preceding groups of axillary glands; its efferents pass to the subclavicular group.

5. A **medial or subclavicular group** of six to twelve glands is situated partly posterior to the upper portion of the Pectoralis minor and partly above the upper border of this muscle. Its only direct territorial afferents are those which accompany the cephalic vein and one which drains the upper peripheral part of the mamma, but it receives the efferents of all the other axillary glands. The efferent vessels

of the subclavicular group unite to form the **subclavian trunk**, which opens either directly into the junction of the internal jugular and subclavian veins or into the jugular lymphatic trunk; on the left side it may end in the thoracic duct. A few efferents from the subclavicular glands usually pass to the inferior deep cervical glands.

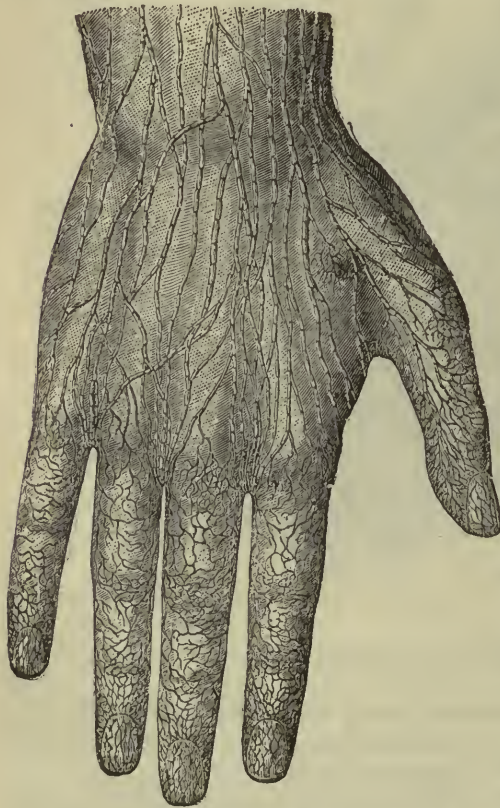


FIG. 608.—Lymphatic vessels of the dorsal surface of the hand. (Sappey.)

The Lymphatic Vessels of the Upper Extremity.

The lymphatic vessels of the upper extremity are divided into two sets, superficial and deep.

The **superficial lymphatic vessels** commence (Fig. 608) in the lymphatic plexus which everywhere pervades the skin; the meshes of the plexus are much finer in the palm and on the flexor aspect of the digits than elsewhere. The digital plexuses are drained by a pair of vessels which run on the sides of each digit, and incline backward to reach the dorsum of the hand. From the dense plexus of the palm, vessels pass in different directions, viz., upward toward the wrist, downward to join the digital vessels, medialward to join the vessels on the ulnar border of the hand, and lateralward to those on the thumb. Several vessels from the central part of the plexus unite to

form a trunk, which passes around the metacarpal bone of the index finger to join the vessels on the back of that digit and on the back of the thumb. Running upward in front of and behind the wrist, the lymphatic vessels are collected into radial, median, and ulnar groups, which accompany respectively the cephalic, median, and basilic veins in the forearm. A few of the ulnar lymphatics end in the supratrochlear glands, but the majority pass directly to the lateral group of axillary glands. Some of the radial vessels are collected into a trunk which ascends with the cephalic vein to the deltoideopectoral glands; the efferents from this group pass either to the subclavicular axillary glands or to the inferior cervical glands.

The **deep lymphatic vessels** accompany the deep bloodvessels. In the forearm, they consist of four sets, corresponding with the radial, ulnar, volar, and dorsal interosseous arteries; they communicate at intervals with the superficial lymphatics, and some of them end in the glands which are occasionally found beside the arteries. In their course upward, a few end in the glands which lie upon the brachial artery; but most of them pass to the lateral group of axillary glands.

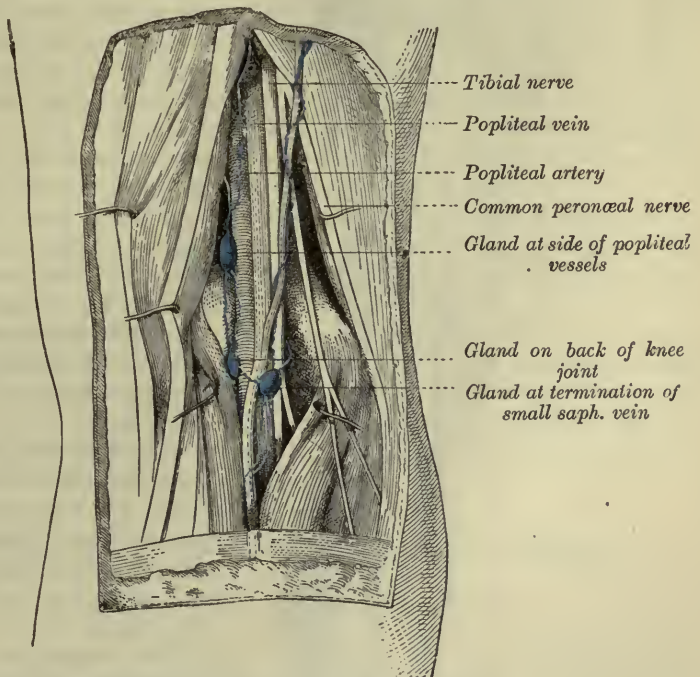


FIG. 609.—Lymph glands of popliteal fossa. (Poirier and Charpy.)

THE LYMPHATICS OF THE LOWER EXTREMITY.

The Lymph Glands of the Lower Extremity.

The lymph glands of the lower extremity consist of the **anterior tibial gland** and the **popliteal** and **inguinal glands**.

The **anterior tibial gland** (*lymphoglandula tibialis anterior*) is small and inconstant. It lies on the interosseous membrane in relation to the upper part of the anterior tibial vessels, and constitutes a substation in the course of the anterior tibial lymphatic trunks.

The **popliteal glands** (*lymphoglandulae popliteae*) (Fig. 609), small in size and some six or seven in number, are imbedded in the fat contained in the popliteal

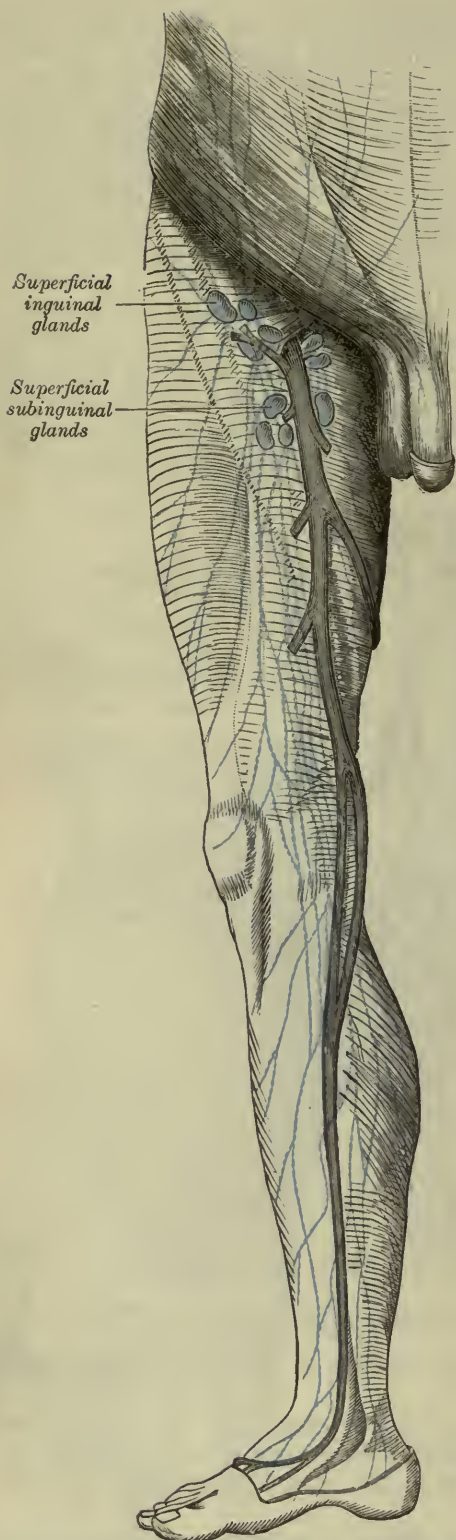


FIG. 610.—The superficial lymph glands and lymphatic vessels of the lower extremity.

fossa. One lies immediately beneath the popliteal fascia, near the terminal part of the small saphenous vein, and drains the region from which this vein derives its tributaries. Another is placed between the popliteal artery and the posterior surface of the knee-joint; it receives the lymphatic vessels from the knee-joint together with those which accompany the genicular arteries. The others lie at the sides of the popliteal vessels, and receive as efferents the trunks which accompany the anterior and posterior tibial vessels. The efferents of the popliteal glands pass almost entirely alongside the femoral vessels to the deep inguinal glands, but a few may accompany the great saphenous vein, and end in the glands of the superficial subinguinal group.

The **inguinal glands** (*lymphoglandulæ inguinales*) (Fig. 610), from twelve to twenty in number, are situated at the upper part of the femoral triangle. They may be divided into two groups by a horizontal line at the level of the termination of the great saphenous vein; those lying above this line are termed the **superficial inguinal glands**, and those below it the **subinguinal glands**, the latter group consisting of a *superficial* and a *deep* set.

The **Superficial Inguinal Glands** form a chain immediately below the inguinal ligament. They receive as afferents lymphatic vessels from the integument of the penis, scrotum, perineum, buttock, and abdominal wall below the level of the umbilicus.

The **Superficial Subinguinal Glands** (*lymphoglandulæ subinguinales superficiales*) are placed on either side of the upper part of the great saphenous vein; their efferents consist chiefly of the superficial lymphatic vessels of the lower extremity; but they also receive some of the vessels which drain the integument of the penis, scrotum, perineum, and buttock.

The **Deep Subinguinal Glands** (*lymphoglandulæ subinguinales profundæ*) vary from one to three in number, and are placed under the fascia lata, on the medial side of the femoral vein. When

three are present, the lowest is situated just below the junction of the great saphenous and femoral veins, the middle in the femoral canal, and the highest in the lateral part of the femoral ring. The middle one is the most inconstant of the three, but the highest, the **gland of Cloquet or Rosenmüller**, is also frequently absent. They receive as afferents the deep lymphatic trunks which accompany the femoral vessels, the lymphatics from the glans penis vel clitoridis, and also some of the efferents from the superficial subinguinal glands.

The Lymphatic Vessels of the Lower Extremity.

The lymphatic vessels of the lower extremity consist of two sets, superficial and deep, and in their distribution correspond closely with the veins.

The **superficial lymphatic vessels** lie in the superficial fascia, and are divisible into two groups: a medial, which follows the course of the great saphenous vein, and a lateral, which accompanies the small saphenous vein. The vessels of the **medial group** (Fig. 610) are larger and more numerous than those of the lateral group, and commence on the tibial side and dorsum of the foot; they ascend both in front of and behind the medial malleolus, run up the leg with the great saphenous vein, pass with it behind the medial condyle of the femur, and accompany it to the groin, where they end in the subinguinal group of superficial glands. The vessels of the **lateral group** arise from the fibular side of the foot; some ascend in front of the leg, and, just below the knee, cross the tibia to join the lymphatics on the medial side of the thigh; others pass behind the lateral malleolus, and, accompanying the small saphenous vein, enter the popliteal glands.

The **deep lymphatic vessels** are few in number, and accompany the deep bloodvessels. In the leg, they consist of three sets, the anterior tibial, posterior tibial, and peroneal, which accompany the corresponding bloodvessels, two or three with each artery; they enter the popliteal lymph glands.

The deep lymphatic vessels of the gluteal and ischial regions follow the course of the corresponding bloodvessels. Those accompanying the superior gluteal vessels end in a gland which lies on the intrapelvic portion of the superior gluteal artery near the upper border of the greater sciatic foramen. Those following the inferior gluteal vessels traverse one or two small glands which lie below the Piriformis muscle, and end in the hypogastric glands.

THE LYMPHATICS OF THE ABDOMEN AND PELVIS.

The Lymph Glands of the Abdomen and Pelvis.

The lymph glands of the abdomen and pelvis may be divided, from their situations, into (*a*) **parietal**, lying behind the peritoneum and in close association with the larger bloodvessels; and (*b*) **visceral**, which are found in relation to the visceral arteries.

The **parietal glands** (Figs. 611, 612) include the following groups:

External Iliac.	Iliac Circumflex.	Lumbar	{ Lateral Aortic. Preaortic. Retroaortic.
Common Iliac.	Hypogastric.		
Epigastric.	Sacral.		

The **External Iliac Glands**, from eight to ten in number, lie along the external iliac vessels. They are arranged in three groups, one on the lateral, another on the medial, and a third on the anterior aspect of the vessels; the third group is, however, sometimes absent. Their principal afferents are derived from the inguinal and subinguinal glands, the deep lymphatics of the abdominal wall below the umbilicus and of the adductor region of the thigh, and the lymphatics from the glans

penis vel clitoridis, the membranous urethra, the prostate, the fundus of the bladder, the cervix uteri, and upper part of the vagina.

The **Common Iliac Glands**, four to six in number, are grouped behind and on the sides of the common iliac artery, one or two being placed below the bifurcation of the aorta, in front of the fifth lumbar vertebra. They drain chiefly the hypogastric and external iliac glands, and their efferents pass to the lateral aortic glands.

The **Epigastric Glands** (*lymphoglandulæ epigastricæ*), three or four in number, are placed alongside the lower portion of the inferior epigastric vessels.

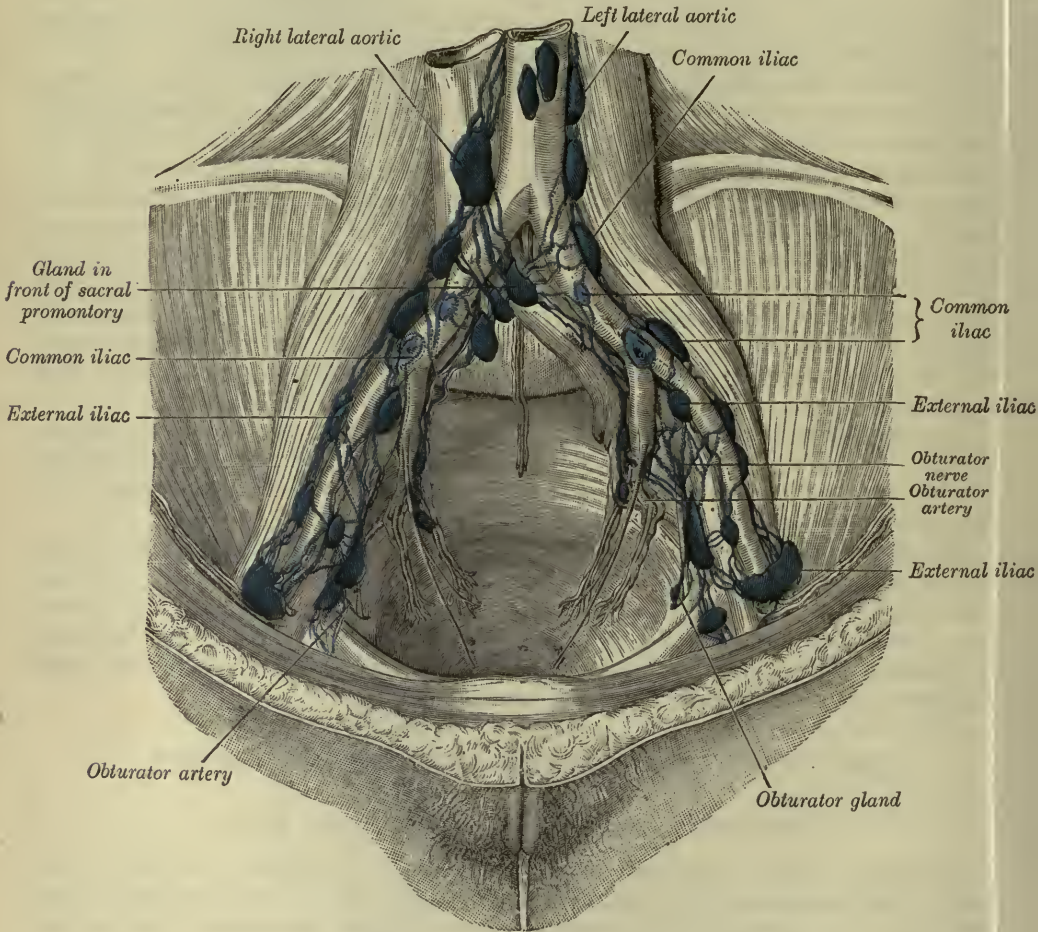


FIG. 611.—The parietal lymph glands of the pelvis. (Cunéo and Marcille.)

The **Iliac Circumflex Glands**, two to four in number, are situated along the course of the deep iliac circumflex vessels; they are sometimes absent.

The **Hypogastric Glands** (*lymphoglandulæ hypogastricæ*; *internal iliac gland*) (Fig. 612) surround the hypogastric vessels, and receive the lymphatics corresponding to the distribution of the branches of the hypogastric artery, *i. e.*, they receive lymphatics from all the pelvic viscera, from the deeper parts of the perineum, including the membranous and cavernous portions of the urethra, and from the buttock and back of the thigh. An **obturator gland** is sometimes seen in the upper part of the obturator foramen.

The **Sacral Glands** are placed in the concavity of the sacrum, in relation to the

middle and lateral sacral arteries; they receive lymphatics from the rectum and posterior wall of the pelvis.

The efferents of the hypogastric group end in the common iliac glands.

The **Lumbar Glands** (*lymphoglandulae lumbales*) are very numerous, and consist of right and left lateral aortic, preaortic, and retroaortic groups.

The **right lateral aortic glands** are situated partly in front of the inferior vena cava, near the termination of the renal vein, and partly behind it on the origin of the Psoas major, and on the right crus of the diaphragm. The **left lateral aortic glands** form a chain on the left side of the abdominal aorta in front of the origin of the Psoas major and left crus of the diaphragm. The glands on either side receive (a) the efferents of the common iliac glands, (b) the lymphatics from the testis in the male and from the ovary, uterine tube, and body of the uterus in the

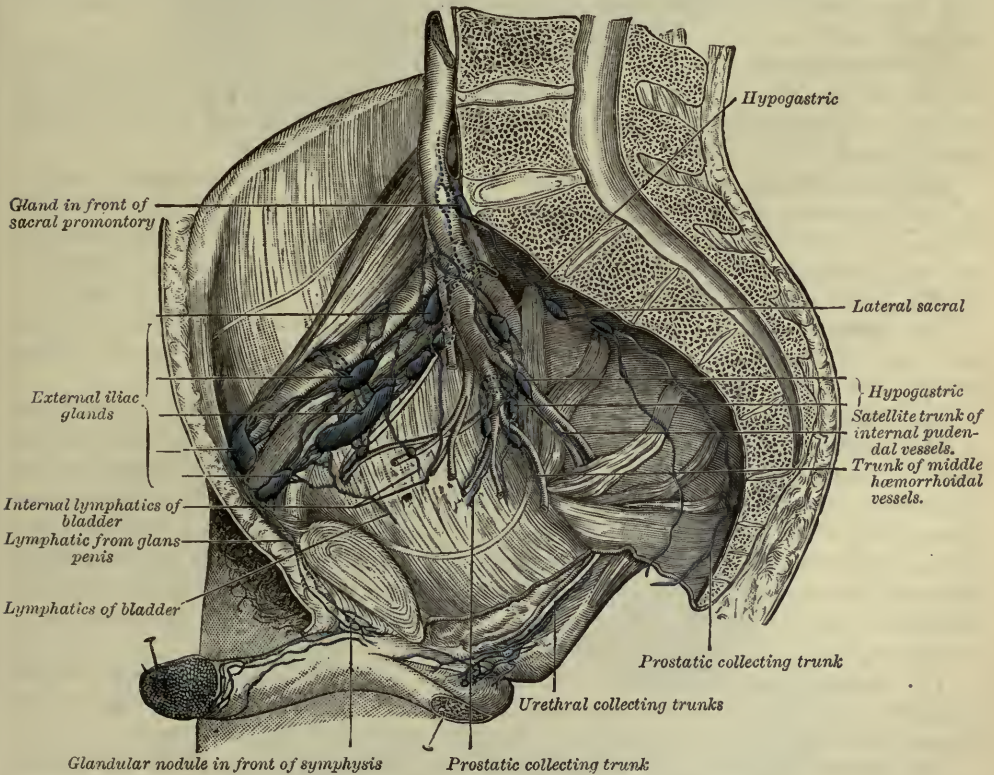


FIG. 612.—Iliopelvic glands (lateral view). (Cunéo and Marcille.)

female; (c) the lymphatics from the kidney and suprarenal gland; and (d) the lymphatics draining the lateral abdominal muscles and accompanying the lumbar veins. Most of the efferent vessels of the lateral aortic glands converge to form the **right and left lumbar trunks** which join the cisterna chyli, but some enter the pre- and retroaortic glands, and others pierce the crura of the diaphragm to join the lower end of the thoracic duct. The **preaortic glands** lie in front of the aorta, and may be divided into **celiac**, **superior mesenteric**, and **inferior mesenteric** groups, arranged around the origins of the corresponding arteries. They receive a few vessels from the lateral aortic glands, but their principal afferents are derived from the viscera supplied by the three arteries with which they are associated. Some of their efferents pass to the retroaortic glands, but the majority unite to form the **intestinal trunk**, which enters the cisterna chyli. The **retroaortic glands** are placed

below the cisterna chyli, on the bodies of the third and fourth lumbar vertebræ. They receive lymphatic trunks from the lateral and preaortic glands, while their efferents end in the cisterna chyli.

The Lymphatic Vessels of the Abdomen and Pelvis.

The lymphatic vessels of the walls of the abdomen and pelvis may be divided into two sets, superficial and deep.

The **superficial vessels** follow the course of the superficial bloodvessels and converge to the superficial inguinal glands; those derived from the integument of the front of the abdomen below the umbilicus follow the course of the superficial epigastric vessels, and those from the sides of the lumbar part of the abdominal wall pass along the crest of the ilium, with the superficial iliac circumflex vessels. The superficial lymphatic vessels of the gluteal region turn horizontally around the buttock, and join the superficial inguinal and subinguinal glands.

The **deep vessels** run alongside the principal bloodvessels. Those of the parietes of the pelvis, which accompany the superior and inferior gluteal, and obturator vessels, follow the course of the hypogastric artery, and ultimately join the lateral aortic glands.

Lymphatic Vessels of the Perineum and External Genitals.—The lymphatic vessels of the perineum, of the integument of the penis, and of the scrotum (or vulva), follow the course of the external pudendal vessels, and end in the superficial inguinal and subinguinal glands. Those of the glans penis vel clitoridis terminate partly in the deep subinguinal glands and partly in the external iliac glands.

The **visceral glands** are associated with the branches of the celiac, superior and inferior mesenteric arteries. Those related to the branches of the celiac artery form three sets, gastric, hepatic, and pancreaticolienal.

The **Gastric Glands** (Figs. 613, 614) consist of two sets, **superior** and **inferior**.

The **Superior Gastric Glands** (*lymphoglandulæ gastricæ superiores*) accompany the left gastric artery and are divisible into three groups, viz.: (a) **upper**, on the stem of the artery; (b) **lower**, accompanying the descending branches of the artery along the cardiac half of the lesser curvature of the stomach, between the two layers of the lesser omentum; and (c) **paracardial** outlying members of the gastric glands, disposed in a manner comparable to a chain of beads around the neck of the stomach (Jamieson and Dobson¹). They receive their afferents from the stomach; their efferents pass to the celiac group of preaortic glands.

The **Inferior Gastric Glands** (*lymphoglandulæ gastricæ inferiores*; *right gastroepiploic gland*), four to seven in number, lie between the two layers of the greater omentum along the pyloric half of the greater curvature of the stomach.

The **Hepatic Glands** (*lymphoglandulæ hepaticæ*) (Fig. 613), consist of the following groups: (a) **hepatic**, on the stem of the hepatic artery, and extending upward along the common bile duct, between the two layers of the lesser omentum, as far as the porta hepatis; the **cystic gland**, a member of this group, is placed near the neck of the gall-bladder; (b) **subpyloric**, four or five in number, in close relation to the bifurcation of the gastroduodenal artery, in the angle between the superior and descending parts of the duodenum; an outlying member of this group is sometimes found above the duodenum on the right gastric (pyloric) artery. The glands of the hepatic chain receive afferents from the stomach, duodenum, liver, gall-bladder, and pancreas; their efferents join the celiac group of preaortic glands.

The **Pancreaticolienal Glands** (*lymphoglandulæ pancreaticolienales*; *splenic glands*) (Fig. 614) accompany the lienal (splenic) artery, and are situated in relation to the posterior surface and upper border of the pancreas; one or two members

¹ Lancet, April 20 and 27, 1907.

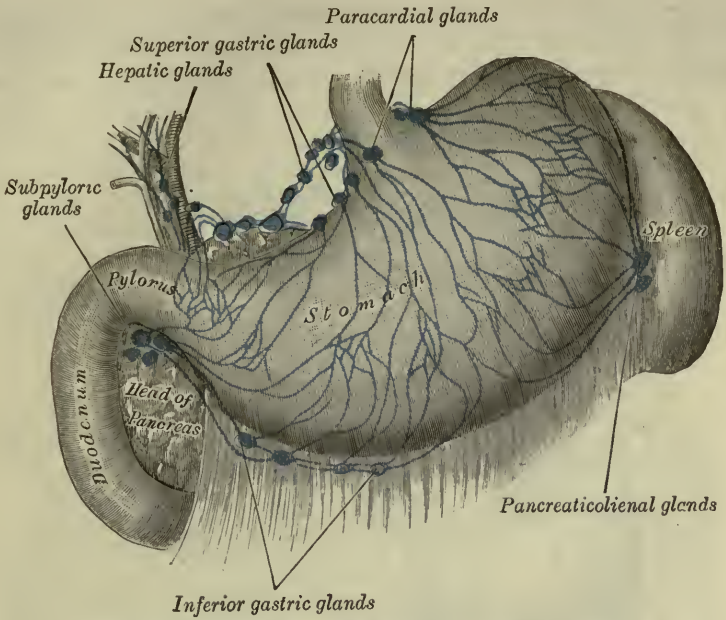


FIG. 613.—Lymphatics of stomach, etc. (Jamieson and Dobson.)

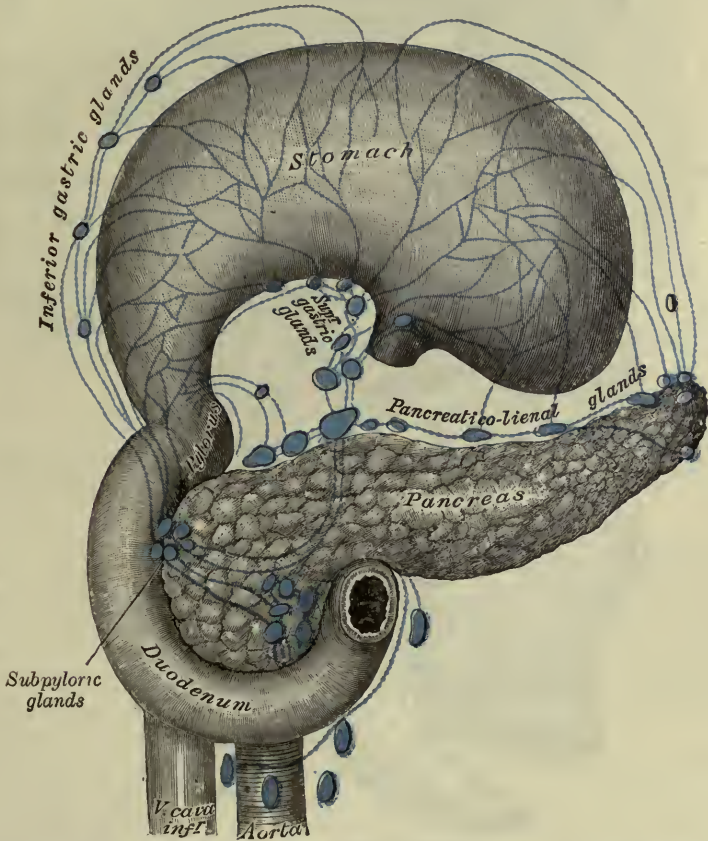


FIG. 614.—Lymphatics of stomach, etc. The stomach has been turned upward. (Jamieson and Dobson.)

of this group are found in the gastrolial ligament (Jamieson and Dobson, *op. cit.*). Their afferents are derived from the stomach, spleen, and pancreas, their efferents join the celiac group of preaortic glands.

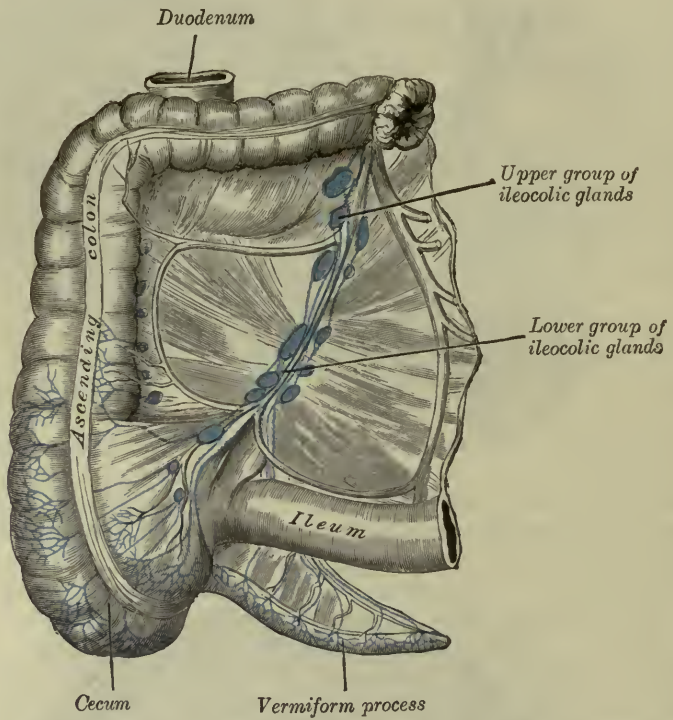


FIG. 615.—The lymphatics of cecum and vermiform process from the front. (Jamieson and Dobson.)

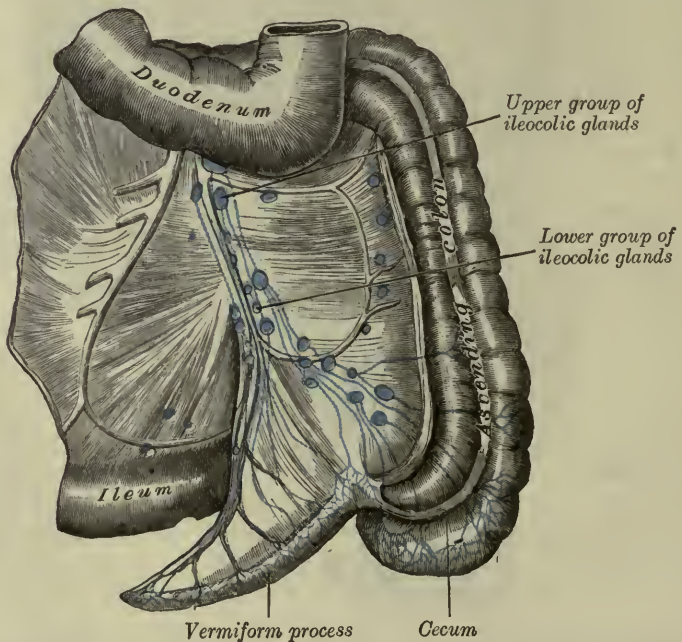


FIG. 616.—The lymphatics of cecum and vermiform process from behind. (Jamieson and Dobson.)

The **superior mesenteric glands** may be divided into three principal groups: **mesenteric**, **ileocolic**, and **mesocolic**.

The **Mesenteric Glands** (*lymphoglandulæ mesentericæ*) lie between the layers of the mesentery. They vary from one hundred to one hundred and fifty in number, and may be grouped into three sets, viz.: one lying close to the wall of the small intestine, among the terminal twigs of the superior mesenteric artery; a second, in relation to the loops and primary branches of the vessels; and a third along the trunk of the artery.

The **Ileocolic glands** (Figs. 615, 616), from ten to twenty in number, form a chain around the ileocolic artery, but show a tendency to subdivision into two groups, one near the duodenum and another on the lower part of the trunk of the artery.

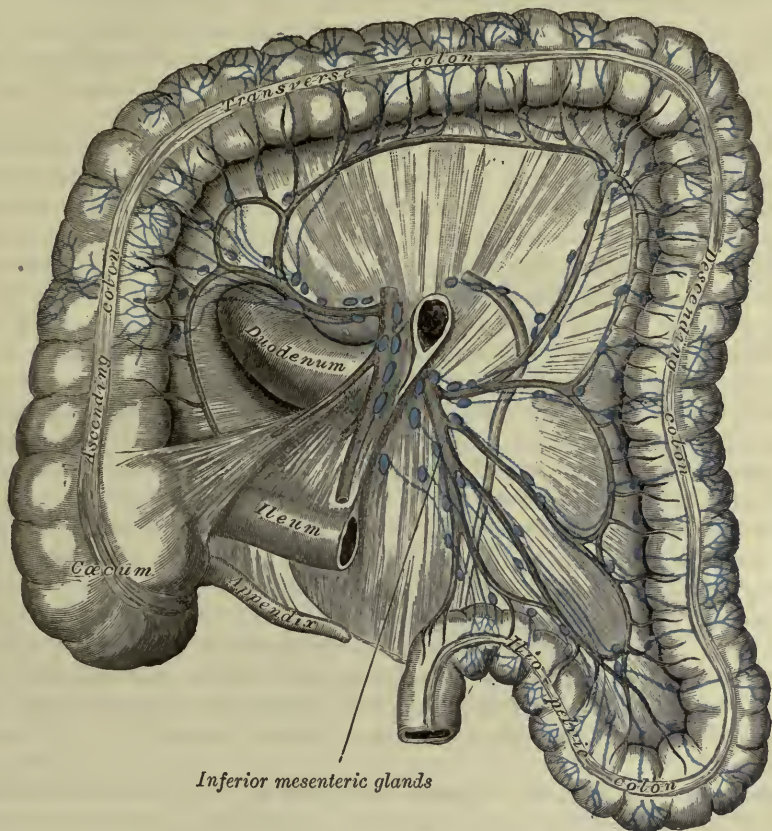


FIG. 617.—Lymphatics of colon. (Jamieson and Dobson.)

Where the vessel divides into its terminal branches the chain is broken up into several groups, viz.: (a) **ileal**, in relation to the ileal branch of the artery; (b) **anterior ileocolic**, usually of three glands, in the ileocolic fold, near the wall of the cecum; (c) **posterior ileocolic**, mostly placed in the angle between the ileum and the colon, but partly lying behind the cecum at its junction with the ascending colon; (d) a single gland, between the layers of the mesenteriole of the vermiform process; (e) **right colic**, along the medial side of the ascending colon.

The **Mesocolic Glands** (*lymphoglandulæ mesocolicæ*) are numerous, and lie between the layers of the transverse mesocolon, in close relation to the transverse colon; they are best developed in the neighborhood of the right and left colic flexures. One or two small glands are occasionally seen along the trunk of the right colic artery and others are found in relation to the trunk and branches of the middle colic artery.

The superior mesenteric glands receive afferents from the jejunum, ileum, cecum, vermiform process, and the ascending and transverse parts of the colon; their efferents pass to the preaortic glands.

The **inferior mesenteric glands** (Fig. 617) consist of: (a) small glands on the branches of the left colic and sigmoid arteries; (b) a group in the sigmoid mesocolon, around the superior hemorrhoidal artery; and (c) a **pararectal** group in contact with the muscular coat of the rectum. They drain the descending iliac and sigmoid parts of the colon and the upper part of the rectum; their efferents pass to the preaortic glands.

The Lymphatic Vessels of the Abdominal and Pelvic Viscera.

The lymphatic vessels of the abdominal and pelvic viscera consist of (1) those of the subdiaphragmatic portion of the digestive tube and its associated glands, the liver and pancreas; (2) those of the spleen and suprarenal glands; (3) those of the urinary organs; (4) those of the reproductive organs.

1. The **lymphatic vessels of the subdiaphragmatic portion of the digestive tube** are situated partly in the mucous membrane and partly in the seromuscular coats, but as the former system drains into the latter, the two may be considered as one.

The **Lymphatic Vessels of the Stomach** (Figs. 613, 614) are continuous at the cardiac orifice with those of the esophagus, and at the pylorus with those of the duodenum. They mainly follow the bloodvessels, and may be arranged in four sets. Those of the first set accompany the branches of the left gastric artery, receiving tributaries from a large area on either surface of the stomach, and terminate in the superior gastric glands. Those of the second set drain the fundus and body of the stomach on the left of a line drawn vertically from the esophagus; they accompany, more or less closely, the short gastric and left gastroepiploic arteries, and end in the pancreaticocolic glands. The vessels of the third set drain the right portion of the greater curvature as far as the pyloric portion, and end in the inferior gastric glands, the efferents of which pass to the subpyloric group. Those of the fourth set drain the pyloric portion and pass to the hepatic and subpyloric glands, and to the superior gastric glands.

The **Lymphatic Vessels of the Duodenum** consist of an anterior and a posterior set, which open into a series of small **pancreaticoduodenal glands** on the anterior and posterior aspects of the groove between the head of the pancreas and the duodenum. The efferents of these glands run in two directions, upward to the hepatic glands and downward to the preaortic glands around the origin of the superior mesenteric artery.

The **Lymphatic Vessels of the Jejunum and Ileum** are termed lacteals, from the milk-white fluid they contain during intestinal digestion. They run between the layers of the mesentery and enter the mesenteric glands, the efferents of which end in the preaortic glands.

The **Lymphatic Vessels of the Vermiform Process and Cecum** (Figs. 615, 616) are numerous, since in the wall of this process there is a large amount of adenoid tissue. From the body and tail of the vermiform process eight to fifteen vessels ascend between the layers of the mesenteriole, one or two being interrupted in the gland which lies between the layers of this peritoneal fold. They unite to form three or four vessels, which end partly in the lower and partly in the upper glands of the ileocolic chain. The vessels from the root of the vermiform process and from the cecum consist of an anterior and a posterior group. The anterior vessels pass in front of the cecum, and end in the anterior ileocolic glands and in the upper and lower glands of the ileocolic chain; the posterior vessels ascend over the back of the cecum and terminate in the posterior ileocolic glands and in the lower glands of the ileocolic chain.

Lymphatic Vessels of the Colon (Fig. 617).—The lymphatic vessels of the ascending and transverse parts of the colon finally end in the mesenteric glands, after traversing the right colic and mesocolic glands. Those of the descending and iliac sigmoid parts of the colon are interrupted by the small glands on the branches of the left colic and sigmoid arteries, and ultimately end in the preaortic glands around the origin of the inferior mesenteric artery.

Lymphatic Vessels of the Anus, Anal Canal, and Rectum.—The lymphatics from the anus pass forward and end with those of the integument of the perineum and scrotum in the superficial inguinal glands; those from the anal canal accompany the middle and inferior hemorrhoidal arteries, and end in the hypogastric glands; while the vessels from the rectum traverse the pararectal glands and pass to those in the sigmoid mesocolon; the efferents of the latter terminate in the preaortic glands around the origin of the inferior mesenteric artery.

The **Lymphatic Vessels of the Liver** are divisible into two sets, superficial and deep. The former arise in the subperitoneal areolar tissue over the entire surface of the organ, and may be grouped into (a) those on the convex surface, (b) those on the inferior surface.

(a) On the **convex surface**: The vessels from the back part of this surface reach their terminal glands by three different routes; the vessels of the middle set, five or six in number, pass through the vena-caval foramen in the diaphragm and end in one or two glands which are situated around the terminal part of the inferior vena cava; a few vessels from the left side pass backward toward the esophageal hiatus, and terminate in the paracardial group of superior gastric glands; the vessels from the right side, one or two in number, run on the abdominal surface of the diaphragm, and, after crossing its right crus, end in the preaortic glands which surround the origin of the celiac artery. From the portions of the right and left lobes adjacent to the falciform ligament, the lymphatic vessels converge to form two trunks, one of which accompanies the inferior vena cava through the diaphragm, and ends in the glands around the terminal part of this vessel; the other runs downward and forward, and, turning around the anterior sharp margin of the liver, accompanies the upper part of the ligamentum teres, and ends in the upper hepatic glands. From the anterior surface a few additional vessels turn around the anterior sharp margin to reach the upper hepatic glands.

(b) On the **inferior surface**: The vessels from this surface mostly converge to the porta hepatis, and accompany the deep lymphatics, emerging from the porta to the hepatic glands; one or two from the posterior parts of the right and caudate lobes accompany the inferior vena cava through the diaphragm, and end in the glands around the terminal part of this vein.

The deep lymphatics converge to ascending and descending trunks. The ascending trunks accompany the hepatic veins and pass through the diaphragm to end in the glands around the terminal part of the inferior vena cava. The descending trunks emerge from the porta hepatis, and end in the hepatic glands.

The **Lymphatic Vessels of the Gall-bladder** pass to the hepatic glands in the porta hepatis; those of the common bile duct to the hepatic glands alongside the duct and to the upper pancreaticoduodenal glands.

The **Lymphatic Vessels of the Pancreas** follow the course of its bloodvessels. Most of them enter the pancreaticocolic glands, but some end in the pancreaticoduodenal glands, and others in the preaortic glands near the origin of the superior mesenteric artery.

2. The lymphatic vessels of the spleen and suprarenal glands.

The **Lymphatic Vessels of the Spleen**, both superficial and deep, pass to the pancreaticocolic glands.

The **Lymphatic Vessels of the Suprarenal Glands** usually accompany the suprarenal veins, and end in the lateral aortic glands; occasionally some of them

pierce the crura of the diaphragm and end in the glands of the posterior mediastinum.

3. The lymphatic vessels of the urinary organs.

The **Lymphatic Vessels of the Kidney** form three plexuses: one in the substance of the kidney, a second beneath its fibrous capsule, and a third in the perinephric fat; the second and third communicate freely with each other. The vessels from the plexus in the kidney substance converge to form four or five trunks which issue at the hilum. Here they are joined by vessels from the plexus under the capsule, and, following the course of the renal vein, end in the lateral aortic glands. The perinephric plexus is drained directly into the upper lateral aortic glands.

The **Lymphatic Vessels of the Ureter** run in different directions. Those from its upper portion end partly in the efferent vessels of the kidney and partly in the lateral aortic glands; those from the portion immediately above the brim of the lesser pelvis are drained into the common iliac glands; while the vessels from the intrapelvic portion of the tube either join the efferents from the bladder, or end in the hypogastric glands.

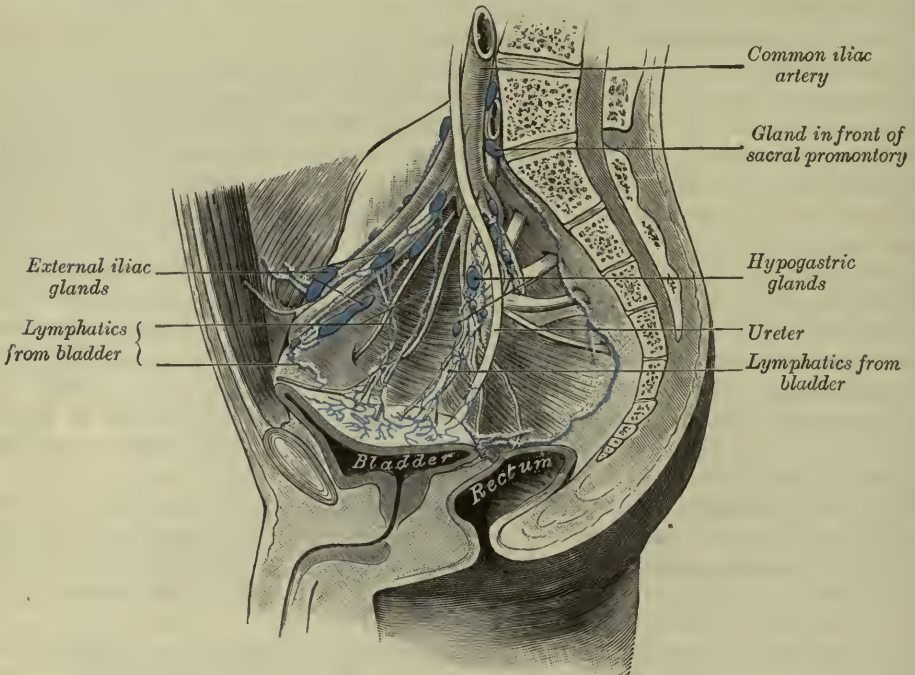


FIG. 618.—Lymphatics of the bladder. (Cunéo and Marcille.)

The **Lymphatic Vessels of the Bladder** (Fig. 618) originate in two plexuses, an intra- and an extramuscular, it being generally admitted that the mucous membrane is devoid of lymphatics.¹ The efferent vessels are arranged in two groups, one from the anterior and another from the posterior surface of the bladder. The vessels from the *anterior* surface pass to the external iliac glands, but in their course minute glands are situated. These minute glands are arranged in two groups, an **anterior vesical**, in front of the bladder, and a **lateral vesical**, in relation to the lateral umbilical ligament. The vessels from the *posterior* surface pass to the hypogastric, external, and common iliac glands; those draining the upper part of this surface traverse the lateral vesical glands.

¹ Some authorities maintain that a plexus of lymphatic vessels does exist in the mucous membrane of the bladder (consult *Médecine opératoire des Voies urinaires*, par J. Albarran, Paris, 1909).

The **Lymphatic Vessels of the Prostate** (Fig. 619) terminate chiefly in the hypogastric and sacral glands, but one trunk from the posterior surface ends in the external iliac glands, and another from the anterior surface joins the vessels which drain the membranous part of the urethra.

Lymphatic Vessels of the Urethra.—The lymphatics of the cavernous portion of the urethra accompany those of the glans penis, and terminate with them in the deep subinguinal and external iliac glands. Those of the *membranous and prostatic* portions, and those of the whole urethra in the female, pass to the hypogastric glands.

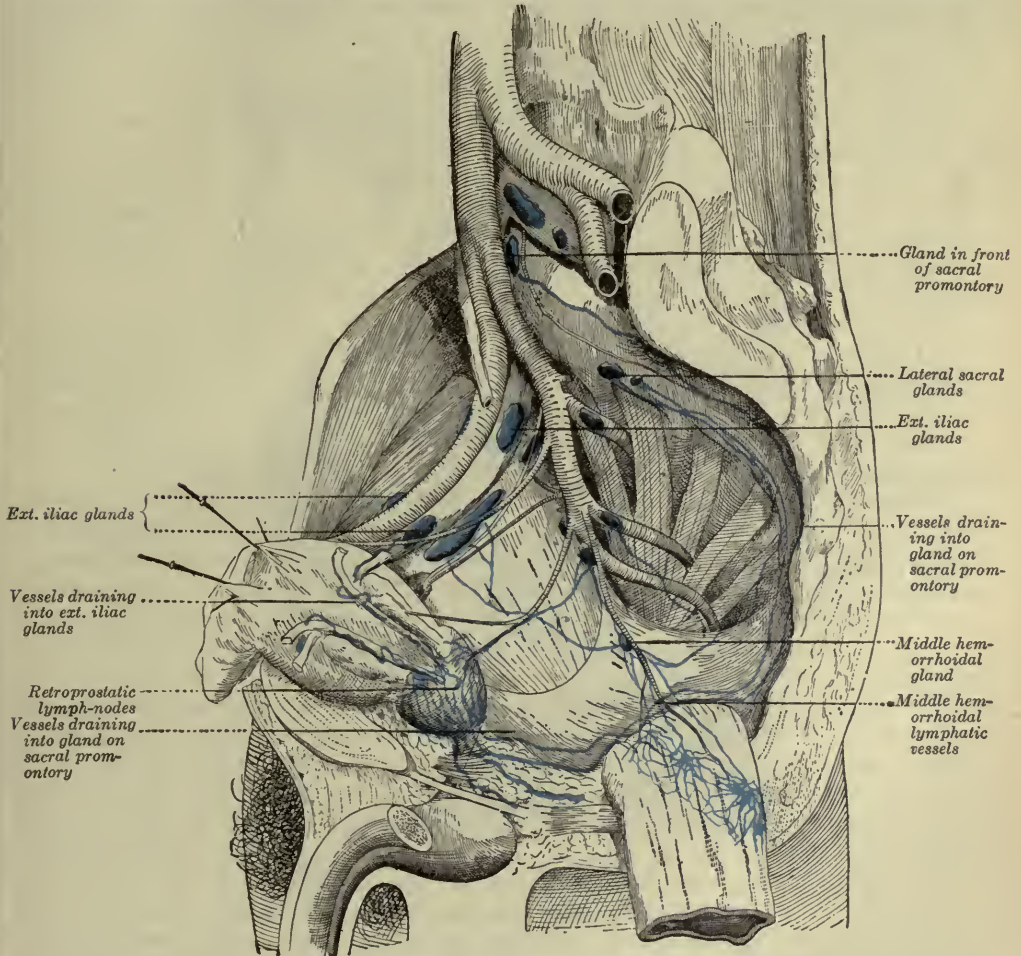


FIG. 619.—Lymphatics of the prostate. (Cunéo and Marcille.)

(4) The lymphatic vessels of the reproductive organs.

The **Lymphatic Vessels of the Testes** consist of two sets, superficial and deep, the former commencing on the surface of the tunica vaginalis, the latter in the epididymis and body of the testis. They form from four to eight collecting trunks which ascend with the spermatic veins in the spermatic cord and along the front of the Psoas major to the level where the spermatic vessels cross the ureter and end in the lateral and preaortic groups of lumbar glands.¹

The **Lymphatic Vessels of the Ductus Deferens** pass to the external iliac glands; those of the *vesiculæ seminales* partly to the hypogastric and partly to the external glands.

¹ "The Lymphatics of the Testicle," by Jamieson and Dobson, *Lancet*, February 19, 1900.

The **Lymphatic Vessels of the Ovary** are similar to those of the testis, and ascend with the ovarian artery to the lateral and preaortic glands.

The **Lymphatic Vessels of the Uterine Tube** pass partly with those of the ovary and partly with those of the uterus.

The **Lymphatic Vessels of the Uterus** (Fig. 620) consist of two sets, superficial and deep, the former being placed beneath the peritoneum, the latter in the substance of the organ. The lymphatics of the cervix uteri run in three directions: transversely to the external iliac glands, postero-laterally to the hypogastric glands, and posteriorly to the common iliac glands. The majority of the vessels of the body

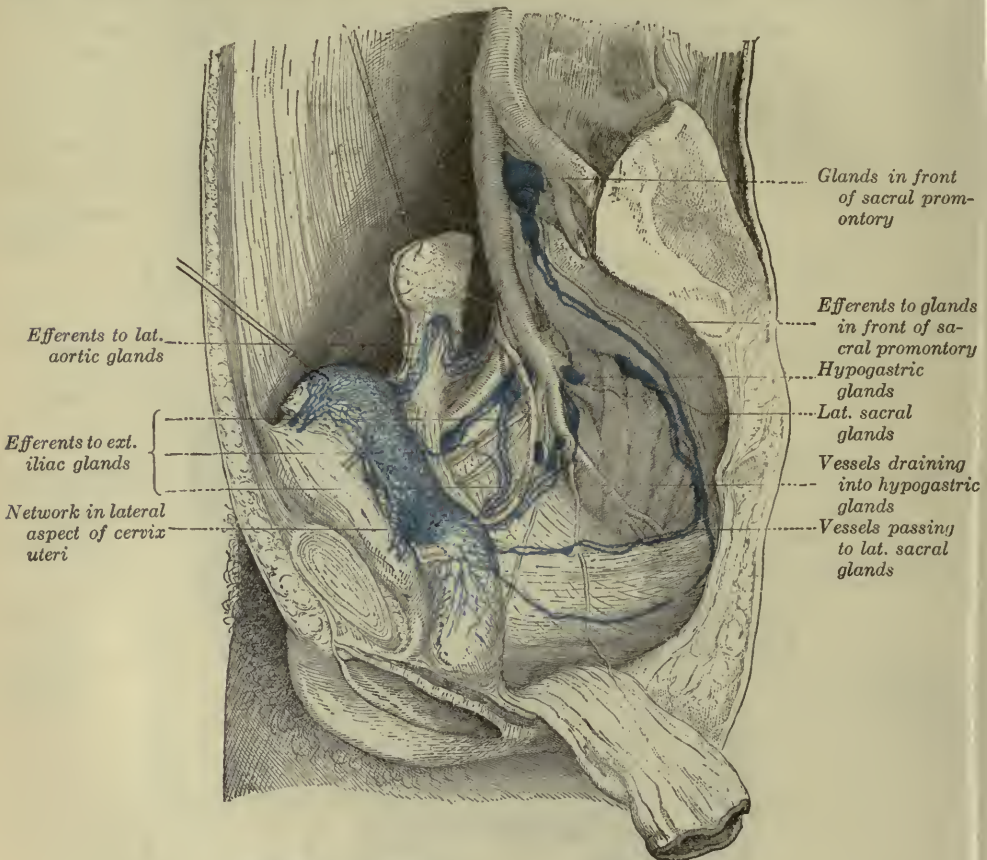


FIG. 620.—Lymphatics of the uterus. (Cunéo and Mareille.)

and fundus of the uterus pass lateralward in the broad ligaments, and are continued up with the ovarian vessels to the lateral and preaortic glands; a few, however, run to the external iliac glands, and one or two to the superficial inguinal glands. In the unimpregnated uterus the lymphatic vessels are very small, but during gestation they are greatly enlarged.

The **Lymphatic Vessels of the Vagina** are carried in three directions: those of the upper part of the vagina to the external iliac glands, those of the middle part to the hypogastric glands, and those of the lower part to the common iliac glands. On the course of the vessels from the middle and lower parts small glands are situated. Some lymphatic vessels from the lower part of the vagina join those of the vulva and pass to the superficial inguinal glands. The lymphatics of the vagina anastomose with those of the cervix uteri, vulva, and rectum, but not with those of the bladder.

THE LYMPHATICS OF THE THORAX.

The lymph glands of the thorax may be divided into parietal and visceral—the former being situated in the thoracic wall, the latter in relation to the viscera.

The parietal lymph glands include the sternal, intercostal, and diaphragmatic glands.

1. The **Sternal Glands** (*lymphoglandulæ sternales; internal mammary glands*) are placed at the anterior ends of the intercostal spaces, by the side of the internal mammary artery. They derive afferents from the mamma, from the deeper structures of the anterior abdominal wall above the level of the umbilicus, from the upper surface of the liver through a small group of glands which lie behind the xiphoid process, and from the deeper parts of the anterior portion of the thoracic wall. Their efferents usually unite to form a single trunk on either side; this may open directly into the junction of the internal jugular and subclavian veins, or that of the right side may join the right subclavian trunk, and that of the left the thoracic duct.

2. The **Intercostal Glands** (*lymphoglandulæ intercostales*) occupy the posterior parts of the intercostal spaces, in relation to the intercostal vessels. They receive the deep lymphatics from the postero-lateral aspect of the chest; some of these vessels are interrupted by small lateral intercostal glands. The efferents of the glands in the lower four or five spaces unite to form a trunk, which descends and opens either into the cisterna chyli or into the commencement of the thoracic duct. The efferents of the glands in the upper spaces of the left side end in the thoracic duct; those of the corresponding right spaces, in the right lymphatic duct.

3. The **Diaphragmatic Glands** lie on the thoracic aspect of the diaphragm, and consist of three sets, anterior, middle, and posterior.

The anterior set comprises (a) two or three small glands behind the base of the xiphoid process, which receive afferents from the convex surface of the liver, and (b) one or two glands on either side near the junction of the seventh rib with its cartilage, which receive lymphatic vessels from the front part of the diaphragm. The efferent vessels of the anterior set pass to the sternal glands.

The middle set consists of two or three glands on either side close to where the phrenic nerves enter the diaphragm. On the right side some of the glands of this group lie within the fibrous sac of the pericardium, on the front of the termination of the inferior vena cava. The afferents of this set are derived from the middle part of the diaphragm, those on the right side also receiving afferents from the convex surface of the liver. Their efferents pass to the posterior mediastinal glands.

The posterior set consists of a few glands situated on the back of the crura of the diaphragm, and connected on the one hand with the lumbar glands and on the other with the posterior mediastinal glands.

The superficial lymphatic vessels of the thoracic wall ramify beneath the skin and converge to the axillary glands. Those over the Trapezius and Latissimus dorsi run forward and unite to form about ten or twelve trunks which end in the subscapular group. Those over the pectoral region, including the vessels from the skin covering the peripheral part of the mamma, run backward, and those over the Serratus anterior upward, to the pectoral group. Others near the lateral margin of the sternum pass inward between the rib cartilages and end in the sternal glands, while the vessels of opposite sides anastomose across the front of the sternum. A few vessels from the upper part of the pectoral region ascend over the clavicle to the supraclavicular group of cervical glands.

The Lymphatic Vessels of the Mamma originate in a plexus in the interlobular spaces and on the walls of the galactoporous ducts. Those from the central part of the gland pass to an intricate plexus situated beneath the areola, a plexus which receives also the lymphatics from the skin over the central part of the gland and

those from the areola and nipple. Its efferents are collected into two trunks which pass to the pectoral group of axillary glands. The vessels which drain the medial part of the mamma pierce the thoracic wall and end in the sternal glands, while a vessel has occasionally been seen to emerge from the upper part of the mamma and, piercing the Pectoralis major, terminate in the subclavicular glands (Fig. 607).

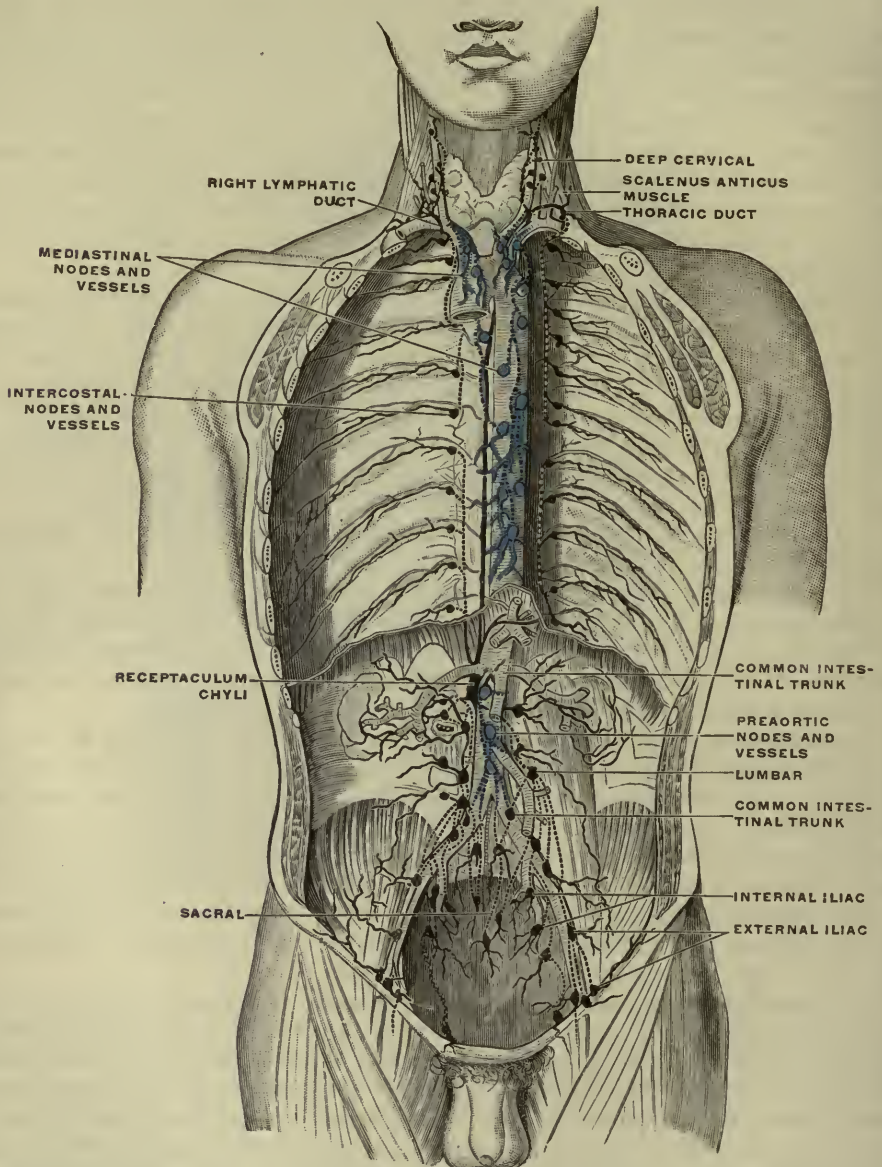


FIG. 621.—Deep lymph nodes and vessels of the thorax and abdomen (diagrammatic). Afferent vessels are represented by continuous lines, and efferent and internodular vessels by dotted lines. (Cunningham.)

The deep lymphatic vessels of the thoracic wall (Fig. 621) consist of:

1. The lymphatics of the muscles which lie on the ribs: most of these end in the axillary glands, but some from the Pectoralis major pass to the sternal glands.
2. The intercostal vessels which drain the Intercostales and parietal pleura. Those draining the Intercostales externi run backward and, after receiving the vessels

which accompany the posterior branches of the intercostal arteries, end in the intercostal glands. Those of the *Intercostales interni* and parietal pleura consist of a single trunk in each space. These trunks run forward in the subpleural tissue and the upper six open separately into the sternal glands or into the vessels which unite them; those of the lower spaces unite to form a single trunk which terminates in the lowest of the sternal glands. 3. The **lymphatic vessels of the diaphragm**, which form two plexuses, one on its thoracic and another on its abdominal surface. These plexuses anastomose freely with each other, and are best marked on the parts covered respectively by the pleuræ and peritoneum. That on the thoracic surface communicates with the lymphatics of the costal and mediastinal parts of the pleura, and its efferents consist of three groups: (a) anterior, passing to the gland which lie near the junction of the seventh rib with its cartilage; (b) middle, to the glands on the esophagus and to those around the termination of the inferior vena cava; and (c) posterior, to the glands which surround the aorta at the point where this vessel leaves the thoracic cavity.

The plexus on the abdominal surface is composed of fine vessels, and anastomoses with the lymphatics of the liver and, at the periphery of the diaphragm, with those of the subperitoneal tissue. The efferents from the right half of this plexus terminate partly in a group of glands on the trunk of the corresponding inferior phrenic artery, while others end in the right lateral aortic glands. Those from the left half of the plexus pass to the pre- and lateral aortic glands and to the glands on the terminal portion of the esophagus.

The **visceral lymph glands** consist of three groups, viz.: **anterior mediastinal**, **posterior mediastinal**, and **tracheobronchial**.

The **Anterior Mediastinal Glands** (*lymphoglandulæ mediastinales anteriores*) are placed in the anterior part of the superior mediastinal cavity, in front of the aortic arch and in relation to the innominate veins and the large arterial trunks which arise from the aortic arch. They receive afferents from the thymus and pericardium, and from the sternal glands; their efferents unite with those of the tracheobronchial glands, to form the right and left bronchomediastinal trunks.

The **Posterior Mediastinal Glands** (*lymphoglandulæ mediastinales posteriores*) lie behind the pericardium in relation to the esophagus and descending thoracic aorta. Their afferents are derived from the esophagus, the posterior part of the pericardium, the diaphragm, and the convex surface of the liver. Their efferents mostly end in the thoracic duct, but some join the tracheobronchial glands.

The **Tracheobronchial Glands** (Fig. 622) form four main groups: (a) **tracheal**, on either side of the trachea; (b) **bronchial**, in the angles between the lower part of the trachea and bronchi and in the angle between the two bronchi; (c) **bronchopulmonary**, in the hilus of each lung; and (d) **pulmonary**, in the lung substance, on the larger branches of the bronchi. The afferents of the tracheobronchial glands drain the lungs and bronchi, the thoracic part of the trachea and the heart; some of the efferents of the posterior mediastinal glands also end in this group. Their efferent vessels ascend upon the trachea and unite with efferents of the internal mammary and anterior mediastinal glands to form the **right and left bronchomediastinal trunks**. The right bronchomediastinal trunk may join the right lymphatic duct, and the left the thoracic duct, but more frequently they open independently of these ducts into the junction of the internal jugular and subclavian veins of their own side.

In all town dwellers there are continually being swept into these glands from the bronchi and alveoli large quantities of the dust and black carbonaceous pigment that are so freely inhaled in cities. At first the glands are moderately enlarged, firm, inky black, and gritty on section; later they enlarge still further, often becoming fibrous from the irritation set up by the minute foreign bodies with which they are crammed, and may break down into a soft slimy mass or may calcify.

The lymphatic vessels of the thoracic viscera comprise those of the heart and pericardium, lungs and pleura, thymus, and esophagus.

The Lymphatic Vessels of the Heart consist of two plexuses: (a) deep, immediately under the endocardium; and (b) superficial, subjacent to the visceral pericardium. The deep plexus opens into the superficial, the efferents of which form right and left collecting trunks. The left trunks, two or three in number, ascend in the anterior longitudinal sulcus, receiving, in their course, vessels from both ventricles. On reaching the coronary sulcus they are joined by a large trunk from the diaphragmatic surface of the heart, and then unite to form a single vessel which ascends between the pulmonary artery and the left atrium and ends in one of the tracheobronchial

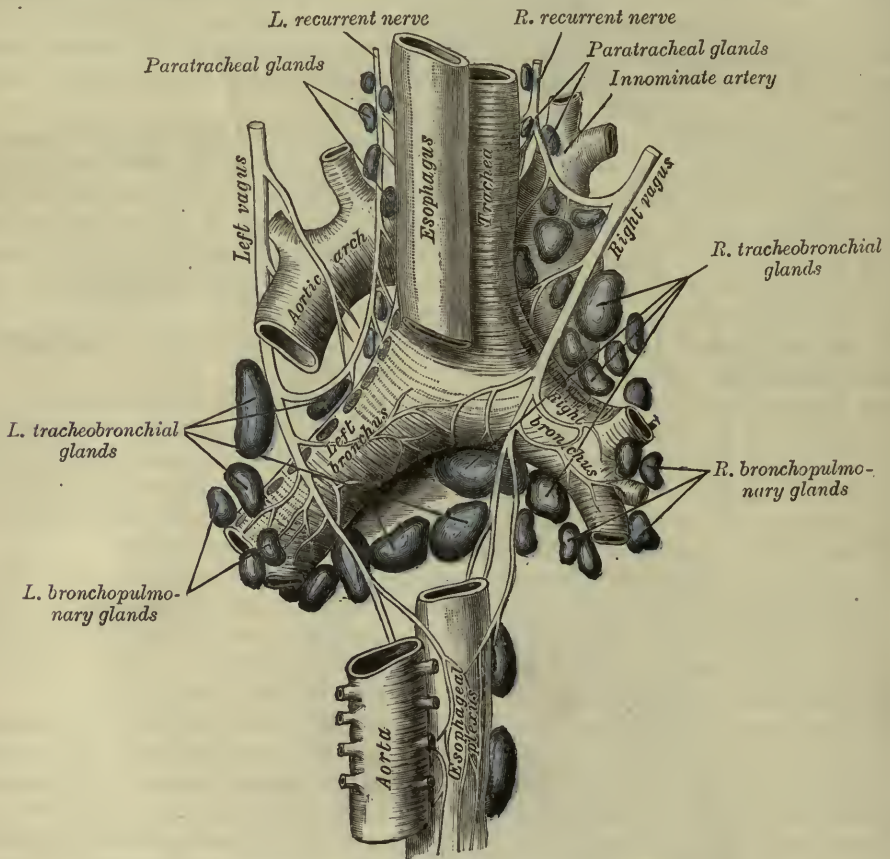


FIG. 622.—The tracheobronchial lymph glands. (From a figure designed by M. Hallé.)

glands. The right trunk receives its afferents from the right atrium and from the right border and diaphragmatic surface of the right ventricle. It ascends in the posterior longitudinal sulcus and then runs forward in the coronary sulcus, and passes up behind the pulmonary artery, to end in one of the tracheobronchial glands.

The Lymphatic Vessels of the Lungs originate in two plexuses, a superficial and a deep. The superficial plexus is placed beneath the pulmonary pleura. The deep accompanies the branches of the pulmonary vessels and the ramifications of the bronchi. In the case of the larger bronchi the deep plexus consists of two networks—one, submucous, beneath the mucous membrane, and another, peribronchial, outside the walls of the bronchi. In the smaller bronchi there is but a single plexus, which extends as far as the bronchioles, but fails to reach the alveoli, in the walls

of which there are no traces of lymphatic vessels. The superficial efferents turn around the borders of the lungs and the margins of their fissures, and converge to end in some glands situated at the hilus; the deep efferents are conducted to the hilus along the pulmonary vessels and bronchi, and end in the tracheobronchial glands. Little or no anastomosis occurs between the superficial and deep lymphatics of the lungs, except in the region of the hilus.

The **Lymphatic Vessels of the Pleura** consist of two sets—one in the visceral and another in the parietal part of the membrane. Those of the visceral pleura drain into the superficial efferents of the lung, while the lymphatics of the parietal pleura have three modes of ending, viz.: (a) those of the costal portion join the lymphatics of the Intercostales interni and so reach the sternal glands; (b) those of the diaphragmatic part are drained by the efferents of the diaphragm; while (c) those of the mediastinal portion terminate in the posterior mediastinal glands.

The **Lymphatic Vessels of the Thymus** end in the anterior mediastinal, tracheo-bronchial, and sternal glands.

The **Lymphatic Vessels of the Esophagus** form a plexus around that tube, and the collecting vessels from the plexus drain into the posterior mediastinal glands.

BIBLIOGRAPHY.

BARTELS, P.: Das Lymphgefäßsystem, Bardeleben's Handbuch der Anatomie des Menschen, 1909.

CLARK, E. R.: Observations on Living, Growing Lymphatics in the Tail of the Frog Larva, Anat. Rec., 1909, iii.

HUNTINGTON, G.: The Genetic Principles of the Development of the Systemic Lymphatic Vessels in the Mammalian Embryo, Anat. Rec., 1910, iv.

HUNTINGTON and McCLURE: The Anatomy and Development of the Jugular Lymph Sacs in the Domestic Cat, Am. Jour. Anat., 1910, x.

SAPPY: Description et Iconographie des Vaisseaux Lymphatiques, Paris, 1885.

SABIN, F. R.: The Development of the Lymphatic System, Keibel and Mall, Manual of Human Embryology, 1912.

TEICHMAN: Das Saugadermsystem, Leipzig, 1861.

NEUROLOGY.

THE **Nervous System** is the most complicated and highly organized of the various systems which make up the human body. It is the mechanism concerned with the correlation and integration of various bodily processes and the reactions and adjustments of the organism to its environment. In addition the cerebral cortex is concerned with conscious life. It may be divided into two parts, **central** and **peripheral**.

The **central nervous system** consists of the **encephalon** or **brain**, contained within the cranium, and the **medulla spinalis** or **spinal cord**, lodged in the vertebral canal; the two portions are continuous with one another at the level of the upper border of the atlas vertebra.

The **peripheral nervous system** consists of a series of nerves by which the central nervous system is connected with the various tissues of the body. For descriptive purposes these nerves may be arranged in two groups, **cerebrospinal** and **sympathetic**, the arrangement, however, being an arbitrary one, since the two groups are intimately connected and closely intermingled. Both the cerebrospinal and sympathetic nerves have nuclei of origin (the somatic efferent and sympathetic efferent) as well as nuclei of termination (somatic afferent and sympathetic afferent) in the central nervous system. The cerebrospinal nerves are forty-three in number on either side—twelve **cranial**, attached to the brain, and thirty-one **spinal**, to the medulla spinalis. They are associated with the functions of the special and general senses and with the voluntary movements of the body. The sympathetic nerves transmit the impulses which regulate the movements of the viscera, determine the caliber of the bloodvessels, and control the phenomena of secretion. In relation with them are two rows of **central ganglia**, situated one on either side of the middle line in front of the vertebral column; these ganglia are intimately connected with the medulla spinalis and the spinal nerves, and are also joined to each other by vertical strands of nerve fibers so as to constitute a pair of knotted cords, the **sympathetic trunks**, which reach from the base of the skull to the coccyx. The sympathetic nerves issuing from the ganglia form three great prevertebral plexuses which supply the thoracic, abdominal, and pelvic viscera; in relation to the walls of these viscera intricate nerve plexuses and numerous **peripheral ganglia** are found.

STRUCTURE OF THE NERVOUS SYSTEM.

The nervous tissues are composed of **nerve cells** and their various processes, together with a supporting tissue called **neuroglia**, which, however, is found only in the brain and medulla spinalis. Certain long processes of the nerve cells are of special importance, and it is convenient to consider them apart from the cells; they are known as **nerve fibers**.

To the naked eye a difference is obvious between certain portions of the brain and medulla spinalis, viz., the **gray substance** and the **white substance**. The gray substance is largely composed of nerve cells, while the white substance contains only their long processes, the nerve fibers. It is in the former that nervous impressions are received, stored, and transformed into efferent impulses, and by the latter

that they are conducted. Hence the gray substance forms the essential constituent of all the ganglionic centers, both those in the isolated ganglia and those aggregated in the brain and medulla spinalis; while the white substance forms the bulk of the commissural portions of the nerve centers and the peripheral nerves.

Neuroglia.—Neuroglia, the peculiar ground substance in which are imbedded the true nervous constituents of the brain and medulla spinalis, consists of cells and fibers. Some of the cells are stellate in shape, with ill-defined cell body, and their fine processes become neuroglia fibers, which extend radially and unbranched (Fig. 623, *B*) among the nerve cells and fibers which they aid in supporting. Other cells give off fibers which branch repeatedly (Fig. 623, *A*). Some of the fibers start from the epithelial cells lining the ventricles of the brain and central canal of the medulla spinalis, and pass through the nervous tissue, branching repeatedly to end in slight enlargements on the pia mater. Thus, neuroglia is evidently a connective tissue in function but is not so in development; it is ectodermal in origin, whereas all connective tissues are mesodermal.

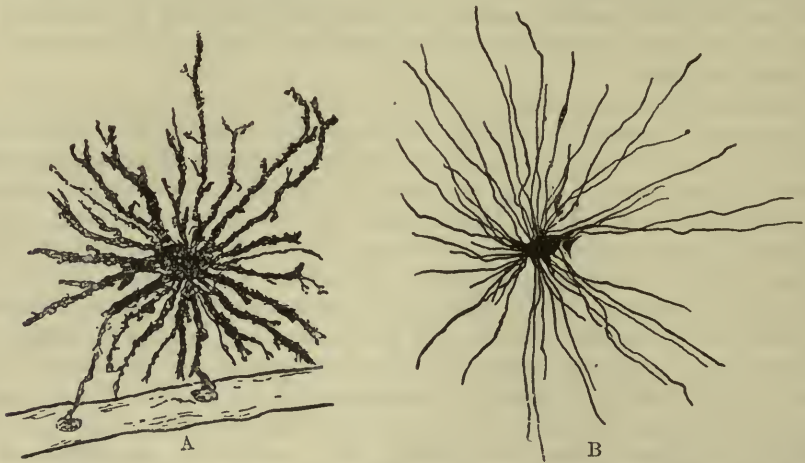


FIG. 623.—Neuroglia cells of brain shown by Golgi's method. *A.* Cell with branched processes. *B.* Spider cell with unbranched processes. (After Andriezen.)

Nerve Cells (Fig. 624).—Nerve cells are largely aggregated in the gray substance of the brain and medulla spinalis, but smaller collections of these cells also form the swellings, called ganglia, seen on many nerves. These latter are found chiefly upon the spinal and cranial nerve roots and in connection with the sympathetic nerves.

The nerve cells vary in shape and size, and have one or more processes. They may be divided for purposes of description into three groups, according to the number of processes which they possess: (1) **Unipolar cells**, which are found in the spinal ganglia; the single process, after a short course, divides in a T-shaped manner (Fig. 624, *E*). (2) **Bipolar cells**, also found in the spinal ganglia (Fig. 625), when the cells are in an embryonic condition. They are best demonstrated in the spinal ganglia of fish. Sometimes the processes come off from opposite poles of the cell, and the cell then assumes a spindle shape; in other cells both processes emerge at the same point. In some cases where two fibers are apparently connected with a cell, one of the fibers is really derived from an adjoining nerve cell and is passing to end in a ramification around the ganglion cell, or, again, it may be coiled spirally around the nerve process which is issuing from the cell. (3) **Multipolar cells**, which are pyramidal or stellate in shape, and characterized by their large size and by the numerous processes which issue from them. The

processes are of two kinds: one of them is termed the **axis-cylinder process** or **axon** because it becomes the axis-cylinder of a nerve fiber (Figs. 626, 627, 628). The others are termed the **protoplasmic processes** or **dendrons**; they begin to divide and

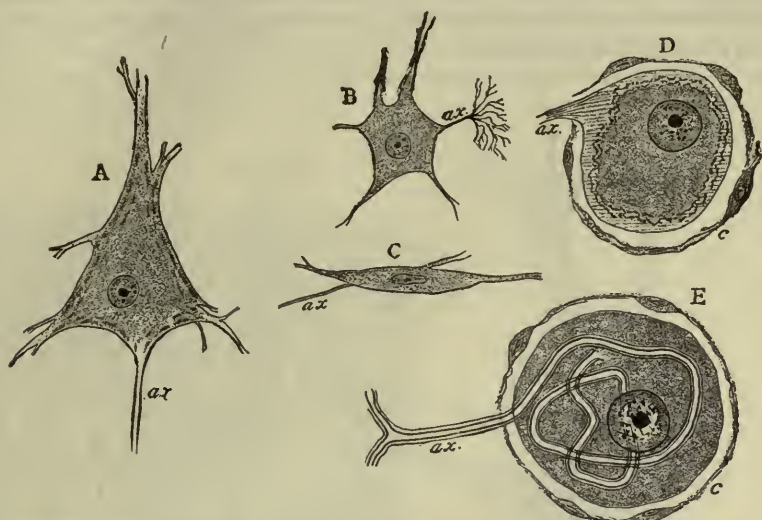


FIG. 624.—Various forms of nerve cells. A. Pyramidal cell. B. Small multipolar cell, in which the axon quickly divides into numerous branches. C. Small fusiform cell. D and E. Ganglion cells (E shows T-shaped division of axon). ax. Axon. c. Capsule.

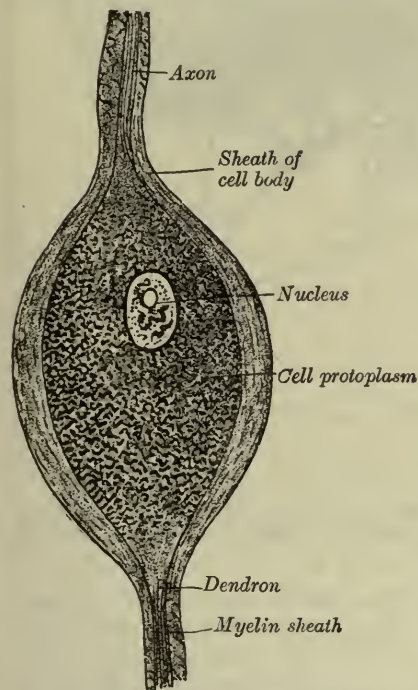


FIG. 625.—Bipolar nerve cell from the spinal ganglion of the pike. (After Kölliker.)

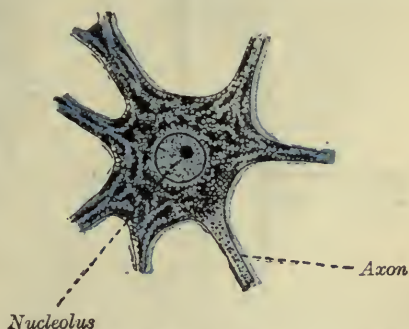


FIG. 626.—Motor nerve cell from ventral horn of medulla spinalis of rabbit. The angular and spindle-shaped Nissl bodies are well shown. (After Nissl.)

subdivide soon after they emerge from the cell, and finally end in minute twigs and become lost among the other elements of the nervous tissue.

The body of the nerve cell, known as the **cyton**, consists of a finely fibrillated protoplasmic material, of a reddish or yellowish-brown color, which occasionally presents patches of a deeper tint, caused by the aggregation of pigment granules at one side of the nucleus, as in the substantia nigra and

locus cæruleus of the brain. The protoplasm also contains peculiar angular granules, which stain deeply with basic dyes, such as methylene blue; these are known as **Nissl's granules** (Fig. 626). They extend into the dendritic processes but not into the axis-cylinder; the small clear area at the point of exit of the axon in

some cell types is termed the **cone of origin**. These granules disappear (*chromatolysis*) during fatigue or after prolonged stimulation of the nerve fibers connected with the cells. They are supposed to represent a store of nervous energy, and in various mental diseases are deficient or absent. The nucleus is, as a rule, a large, well-defined, spherical body, often presenting an intranuclear network, and containing a well-marked nucleolus.

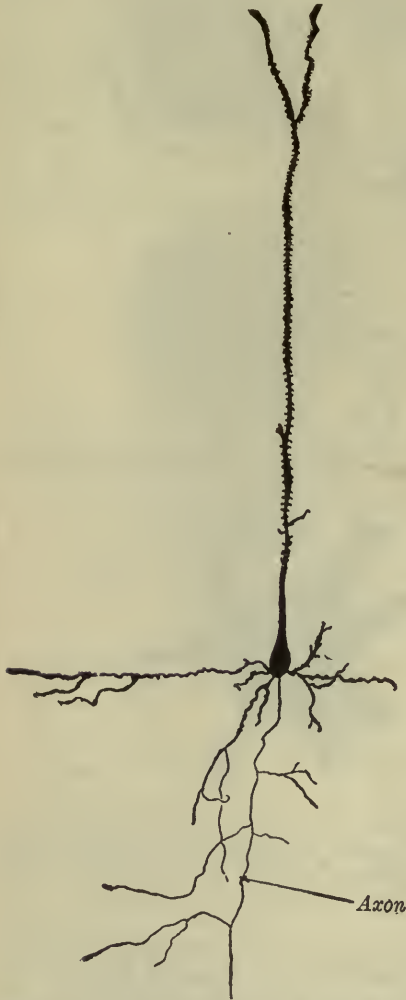


FIG. 627.—Pyramidal cell from the cerebral cortex of a mouse. (After Ramón y Cajal.)

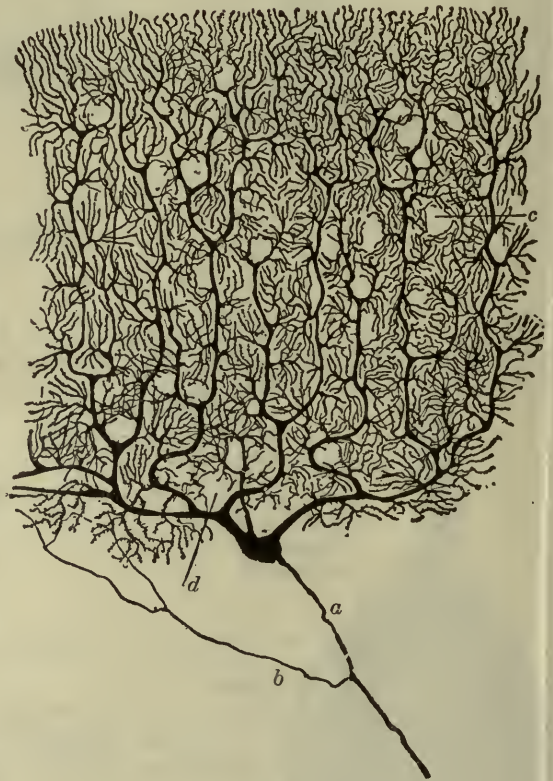

FIG. 628.—Cell of Purkinje from the cerebellum. Golgi method. (Cajal.) *a*, Axon. *b*, Collateral. *c* and *d*, Dendrons.

In addition to the protoplasmic network described above, each nerve cell may be shown to have delicate neurofibrils running through its substance (Fig. 629); these fibrils are continuous with the fibrils of the axon, and are believed to convey nerve impulses. Golgi has also described an extracellular network, which is probably a supporting structure.

Nerve Fibers.—Nerve fibers are found universally in the peripheral nerves and in the white substance of the brain and medulla spinalis. They are of two kinds—viz., **medullated** or **white fibers**, and **non-medullated** or **gray fibers**.

The **medullated fibers** form the white part of the brain and medulla spinalis, and also the greater part of every cranial and spinal nerve, and give to these structures

their opaque, white aspect. When perfectly fresh they appear to be homogeneous; but soon after removal from the body each fiber presents, when examined by transmitted light, a double outline or contour, as if consisting of two parts (Fig. 630). The central portion is named the **axis-cylinder**; around this is a sheath of fatty material, staining black with osmic acid, named the **white substance of Schwann** or **medullary sheath**, which gives to the fiber its double contour, and the whole is enclosed in a delicate membrane, the **neurolemma**, **primitive sheath**, or **nucleated sheath of Schwann** (Fig. 633)

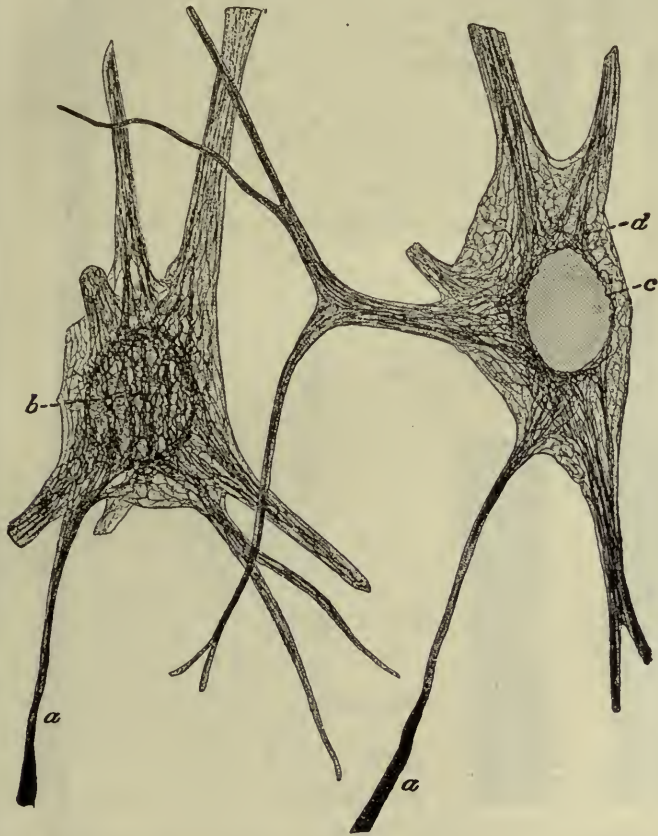


FIG. 629.—Nerve cells of kitten, showing neurofibrils. (Cajal.) a. Axon. b. Cyton. c. Nucleus. d. Neurofibrils.

The **axis-cylinder** is the essential part of the nerve fiber, and is always present; the medullary sheath and the neurolemma are occasionally absent, especially at the origin and termination of the nerve fiber. The axis-cylinder undergoes no interruption from its origin in the nerve center to its peripheral termination, and must be regarded as a direct prolongation of a nerve cell. It constitutes about one-half or one-third of the nerve fiber, being greater in proportion in the fibers of the central organs than in those of the nerves. It is quite transparent, and is therefore indistinguishable in a perfectly fresh and natural state of the nerve. It is made up of exceedingly fine fibrils, which stain darkly with gold chloride (Fig. 632), and at its termination may be seen to break up into these fibrillæ. The fibrillæ have been termed the **primitive fibrillæ of Schultze**. The axis-cylinder is said by some to be enveloped in a special reticular sheath, which separates it from the medullary sheath, and is composed of a substance called **neurokeratin**. The more common opinion is that this network or reticulum is contained in the white

matter of Schwann, and by some it is believed to be produced by the action of the reagents employed to show it.

The medullary sheath, or white matter of Schwann (Fig. 631), is regarded as being a fatty matter in a fluid state, which insulates and protects the essential part of the nerve—the axis-cylinder. It varies in thickness, in some forming a layer of extreme

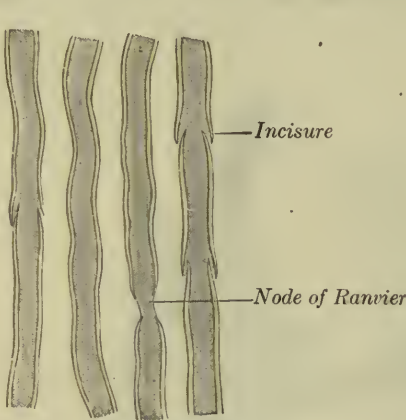


FIG. 630.—Medullated nerve fibers. $\times 350$.

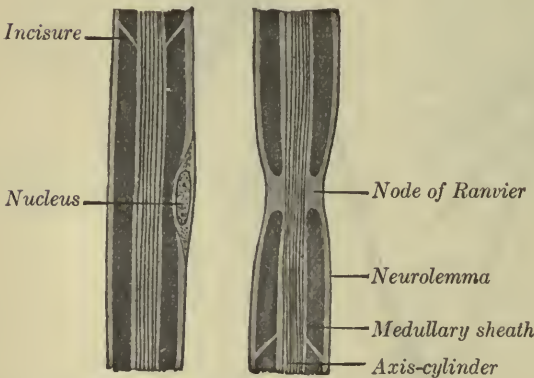


FIG. 631.—Diagram of longitudinal sections of medullated nerve fibers. Osmic acid.

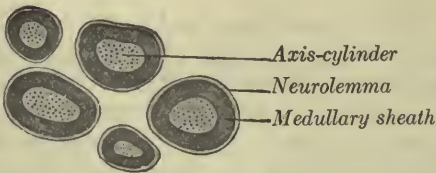


FIG. 632.—Transverse sections of medullated nerve fibers. Osmic acid.

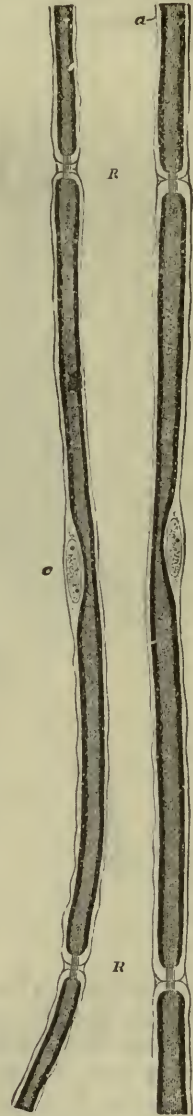


FIG. 633.—Diagram of medullated nerve fibers stained with osmic acid. $\times 425$. (Schäfer.) R. Nodes of Ranvier. a. Neurolemma. c. Nucleus.

thinness, so as to be scarcely distinguishable, in others forming about one-half the nerve fiber. The variation in diameter of the nerve fibers (from 2 to 16 μ) depends mainly upon the amount of the white substance, though the axis cylinder also varies within certain limits. The medullary sheath undergoes interruptions in its continuity at regular intervals, giving to the fiber the appearance of constriction

at these points: these are known as the **nodes of Ranvier** (Figs. 631 and 633). The portion of nerve fiber between two nodes is called an **internodal segment**. The neurolemma or primitive sheath is not interrupted at the nodes, but passes over them as a continuous membrane. If the fiber be treated with silver nitrate the reagent penetrates the neurolemma at the nodes, and on exposure to light reduction takes place, giving rise to the appearance of black crosses, **Ranvier's crosses**, on the axis-cylinder. There may also be seen transverse lines beyond the nodes termed **Frommann's lines** (Fig. 634); the significance of these is not understood. In addition to these interruptions oblique clefts may be seen in the medullary sheath, subdividing it into irregular portions, which are termed **medullary segments**, or **segments of Lantermann** (Fig. 631); there is reason to believe that these clefts are artificially produced in the preparation of the specimens. Medullated nerve fibers, when examined in the fresh condition, frequently present a beaded or varicose appearance: this is due to manipulation and pressure causing the oily matter to collect into drops, and in consequence of the extreme delicacy of the primitive sheath, even slight pressure will cause the transudation of the fatty matter, which collects as drops of oil outside the membrane.

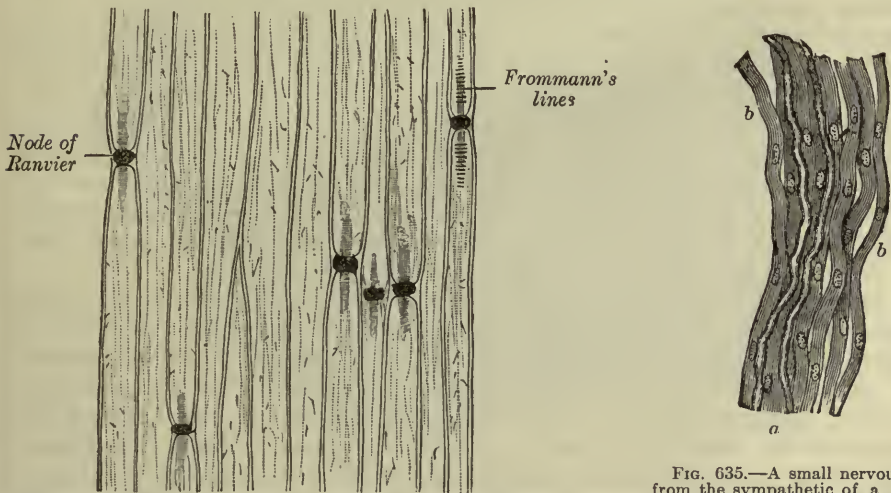


FIG. 634.—Medullated nerve fibers stained with silver nitrate.

FIG. 635.—A small nervous branch from the sympathetic of a mammal. a. Two medullated nerve fibers among a number of gray nerve fibers, b.

The **neurolemma** or **primitive sheath** presents the appearance of a delicate, structureless membrane. Here and there beneath it, and situated in depressions in the white matter of Schwann, are nuclei surrounded by a small amount of protoplasm. The nuclei are oval and somewhat flattened, and bear a definite relation to the nodes of Ranvier, one nucleus generally lying in the center of each internode. The primitive sheath is not present in all medullated nerve fibers, being absent in those fibers which are found in the brain and medulla spinalis.

Wallerian Degeneration.—When nerve fibers are cut across, the central ends of the fibers degenerate as far as the first node of Ranvier; but the peripheral ends degenerate simultaneously throughout their whole length. The axons break up into fragments and become surrounded by drops of fatty substance which are formed from the breaking down of the medullary sheath. The nuclei of the primitive sheath proliferate, and finally absorption of the axons and fatty substance occurs. If the cut ends of the nerve be sutured together regeneration of the nerve fibers takes place by the downgrowth of axons from the central end of the nerve. At one time it was believed that the regeneration was peripheral in origin, but this has been disproved, the proliferated nuclei in the peripheral portions taking part merely in the formation of the so-called scaffolding along which the new axons pass.

Non-medullated Fibers.—Most of the fibers of the sympathetic system, and some of the cerebrospinal, consist of the **gray or gelatinous nerve fibers** (*fibers of Remak*) (Fig. 635). Each of these consists of an axis-cylinder to which nuclei are applied at intervals. These nuclei are believed to be in connection with a delicate sheath corresponding with the neurolemma of the medullated nerve fiber. In external appearance the non-medullated nerve fibers are semitransparent and gray or yellowish gray. The individual fibers vary in size, generally averaging about half the size of the medullated fibers.

Structure of the Peripheral Nerves and Ganglia.—The cerebrospinal nerves consist of numerous nerve fibers collected together and enclosed in membranous sheaths (Fig. 636). A small bundle of fibers, enclosed in a tubular sheath, is called a **funiculus**; if the nerve is of small size, it may consist only of a single funiculus; but if large, the funiculi are collected together into larger bundles or **fasciculi**, which are bound together in a common membranous investment. In structure the common membranous investment, or sheath of the whole nerve (**epineurium**), as well as the septa given off from it to separate the fasciculi, consist of connective tissue, composed of white and yellow elastic fibers, the latter existing in great abundance. The tubular sheath of the funiculi (**perineurium**) is a fine, smooth, transparent membrane, which may be easily separated, in the form of a tube, from the fibers it encloses; in structure it is made up of connective tissue, which has a distinctly lamellar arrangement. The nerve fibers are held together and supported within the funiculus by delicate connective tissue, called the **endoneurium**. It is continuous with septa which pass inward from the innermost layer of the perineurium, and shows a ground substance in which are imbedded fine bundles of fibrous connective tissue running for the most part longitudinally. It serves to support capillary vessels, arranged so as to form a net-work with elongated meshes. The cerebrospinal nerves consist almost exclusively of medullated nerve fibers, only a very small proportion of non-medullated being present.

The bloodvessels supplying a nerve end in a minute capillary plexus, the vessels composing which pierce the perineurium, and run, for the most part, parallel with the fibers; they are connected together by short, transverse vessels, forming narrow, oblong meshes, similar to the capillary system of muscle. Fine non-medullated nerve fibers, **vasomotor fibers**, accompany these capillary vessels, and break up into elementary fibrils, which form a network around the vessels. Horsley has demonstrated certain medullated fibers running in the epineurium and terminating in small **spheroidal tactile corpuscles** or **end bulbs of Krause**. These nerve fibers, which Marshall believes to be sensory, and which he has termed **nervi nervorum**, are considered by him to have an important bearing upon certain neuralgic pains.

The nerve fibers, so far as is at present known, do not coalesce, but pursue an uninterrupted course from the center to the periphery. In separating a nerve, however, into its component funiculi, it may be seen that these do not pursue a perfectly insulated course, but occasionally join at a very acute angle with other funiculi proceeding in the same direction; from this, branches are given off, to joint again in like manner with other funiculi. It must be distinctly understood, however, that in these communications the individual nerve fibers do not coalesce, but merely pass into the sheath of the adjacent nerve, become intermixed with its nerve fibers, and again pass on to intermingle with the nerve fibers in some adjoining funiculus.

Nerves, in their course, subdivide into branches, and these frequently communicate with branches of a neighboring nerve. The communications which thus take place form what is called a **plexus**. Sometimes a plexus is formed by the primary branches of the trunks of the nerves—as the cervical, brachial, lumbar, and sacral plexuses—and occasionally by the terminal funiculi, as in the plexuses formed at the periphery of the body. In the formation of a plexus, the component nerves

divide, then join, and again subdivide in such a complex manner that the individual funiculi become interlaced most intricately; so that each branch leaving a plexus may contain filaments from all the primary nervous trunks which form the plexus. In the formation also of smaller plexuses at the periphery of the body there is a free interchange of the funiculi and primitive fibers. In each case, however, the individual fibers remain separate and distinct.

It is probable that through this interchange of fibers, every branch passing off from a plexus has a more extensive connection with the spinal cord than if it had proceeded to its distribution without forming connections with other nerves. Consequently the parts supplied by these nerves have more extended relations with the nervous centers; by this means, also, groups of muscles may be associated for combined action.

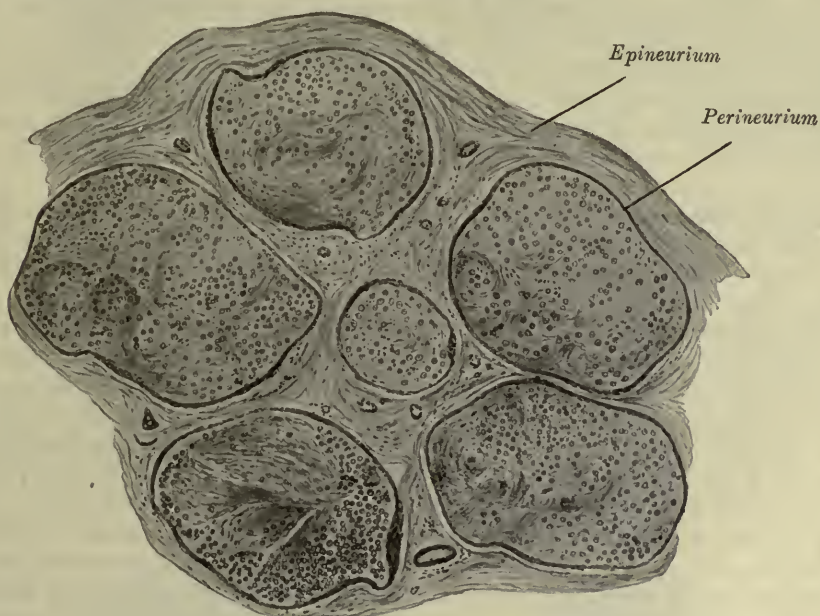


FIG. 636.—Transverse section of human tibial nerve.

The **sympathetic nerves** are constructed in the same manner as the cerebrospinal nerves, but consist mainly of non-medullated fibers, collected in funiculi and enclosed in sheaths of connective tissue. There is, however, in these nerves a certain admixture of medullated fibers. The number of the latter varies in different nerves, and may be estimated by the color of the nerve. Those branches of the sympathetic, which present a well-marked gray color, are composed chiefly of non-medullated nerve fibers, intermixed with a few medullated fibers; while those of a white color contain many of the latter fibers, and few of the former.

The cerebrospinal and sympathetic nerve fibers convey various impressions. The **sensory nerves**, called also **centripetal** or **afferent nerves**, transmit to the nervous centers impressions made upon the peripheral extremities of the nerves, and in this way the mind, through the medium of the brain, becomes conscious of external objects. The **centrifugal** or **efferent nerves** transmit impressions from the nervous centers to the parts to which the nerves are distributed, these impressions either exciting muscular contraction or influencing the processes of nutrition, growth, and secretion.

Origins and Terminations of Nerves.—By the expression “the terminations of nerve fibers” is signified their connections with the nerve centers and with the parts

they supply. The former are sometimes called their **origins** or **central terminations**; the latter their **peripheral terminations**.

Origins of Nerves.—The origin in some cases is single—that is to say, the whole nerve emerges from the nervous center by a single root; in other instances the nerve arises by two or more roots which come off from different parts of the nerve center, sometimes widely apart from each other, and it often happens, when a nerve arises in this way by two roots, that the functions of these two roots are different; as, for example, in the spinal nerves, each of which arises by two roots, the anterior of which is motor, and the posterior sensory. The point where the nerve root or roots emerge from the surface of the nervous center is named the **superficial** or **apparent origin**, but the fibers of the nerve can be traced for a certain distance into the substance of the nervous center to some portion of the gray matter, which constitutes the **deep** or **real origin** of the nerve. The centrifugal or efferent nerve fibers originate in the nerve cells of the gray substance, the axis-cylinder processes of these cells being prolonged to form the fibers. In the case of the centripetal or afferent nerves the fibers grow inward either from nerve cells in the organs of special sense, *e. g.*, the retina, or from nerve cells in the ganglia. Having entered the nerve center they branch and send their ultimate twigs among the cells, without, however, uniting with them.

Peripheral Terminations of Nerves.—Nerve fibers terminate peripherally in various ways, and these may be conveniently studied in the sensory and motor nerves respectively. The terminations of the sensory nerves are dealt with in the section on Sense Organs.

Motor nerves can be traced into either unstriped or striped muscular fibers. In the *unstriped* or *involuntary muscles* the nerves are derived from the sympathetic, and are composed mainly of non-medullated fibers. Near their terminations they divide into numerous branches, which communicate and form intimate plexuses. At the junction of the branches small triangular nuclear bodies (ganglion cells) are situated. From these plexuses minute branches are given off which divide and break up into the ultimate fibrillæ of which the nerves are composed. These fibrillæ course between the involuntary muscle cells, and, according to Elischer, terminate on the surfaces of the cells, opposite the nuclei, in minute swellings.

In the *striped* or *voluntary muscle* the nerves supplying the muscular fibers are derived from the cerebrospinal nerves, and are composed mainly of medullated fibers. The nerve, after entering the sheath of the muscle, breaks up into fibers or bundles of fibers, which form plexuses, and gradually divide until, as a rule, a single nerve fiber enters a single muscular fiber. Sometimes, however, if the muscular fiber be long, more than one nerve fiber enters it. Within the muscular fiber the nerve terminates in a special expansion, called by Kühne, who first accurately described it, a **motor end-plate** (Fig. 637). The nerve fiber, on approaching the muscular fiber, suddenly loses its medullary sheath, the neurolemma becomes continuous with the sarcolemma of the muscle, and only the axis-cylinder enters the muscular fiber. There it at once spreads out, ramifying like the roots of a tree, immediately beneath the sarcolemma, and becomes imbedded in a layer of granular matter, containing a number of clear, oblong nuclei, the whole constituting an end-plate from which the contractile wave of the muscular fiber is said to start.

Ganglia are small aggregations of nerve cells. They are found on the posterior roots of the spinal nerves; on the sensory roots of the trigeminal, facial, glossopharyngeal, and vagus nerves, and on the acoustic nerves. They are also found in connection with the sympathetic nerves. On section they are seen to consist of a reddish-gray substance, traversed by numerous white nerve fibers; they vary considerably in form and size; the largest are found in the cavity of the abdomen; the smallest, not visible to the naked eye, exist in considerable numbers upon the nerves distributed to the different viscera. Each ganglion is invested by a smooth

and firm, closely adhering, membranous envelope, consisting of dense areolar tissue; this sheath is continuous with the perineurium of the nerves, and sends numerous processes into the interior to support the bloodvessels supplying the substance of the ganglion.

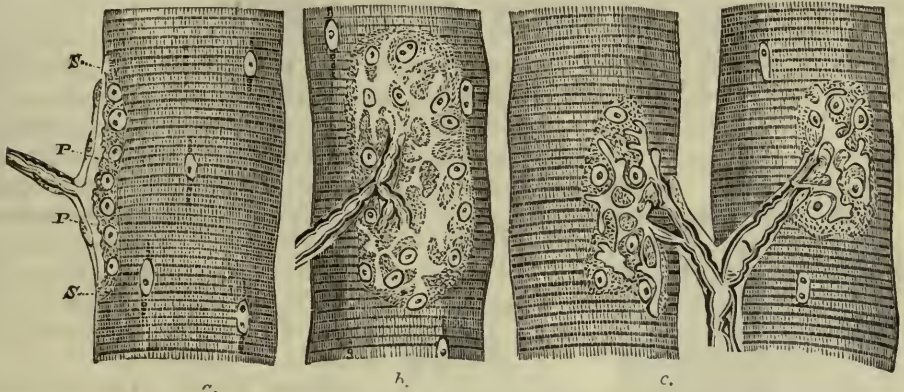


FIG. 637.—Muscular fibers of *Lacerta viridis* with the terminations of nerves. *a.* Seen in profile. *P, P.* The nerve end-plates. *S, S.* The base of the plate, consisting of a granular mass with nuclei. *b.* The same as seen in looking at a perfectly fresh fiber, the nervous ends being probably still excitable. (The forms of the variously divided plate can hardly be represented in a woodcut by sufficiently delicate and pale contours to reproduce correctly what is seen in nature.) *c.* The same as seen two hours after death from poisoning by curare.

In structure all ganglia are essentially similar, consisting of the same structural elements—viz., nerve cells and nerve fibers. Each nerve cell has a nucleated sheath which is continuous with the neurolemma of the nerve fiber with which the cell is connected. The nerve cells in the ganglia of the spinal nerves (Fig. 638) are pyriform in shape, and have each a single process. A short distance from the cell and while still within the ganglion this process divides in a T-shaped manner, one limb of the cross-bar turning into the medulla spinalis, the other limb passing out-

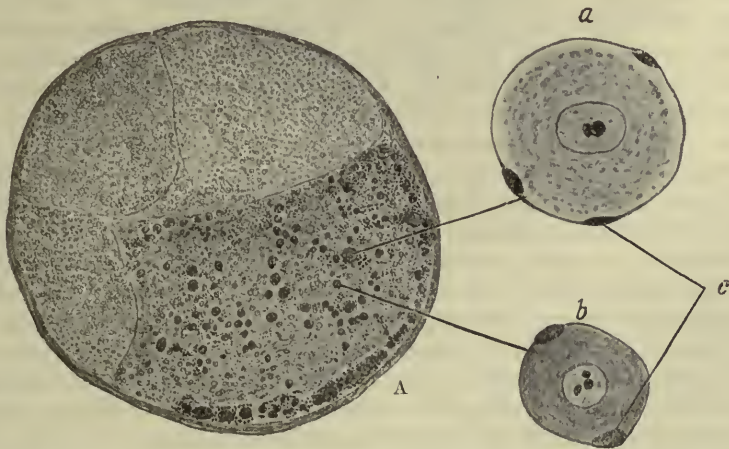


FIG. 638.—Transverse section of spinal ganglion of rabbit. *A.* Ganglion. $\times 30$. *a.* Large clear nerve cell. *b.* Small deeply staining nerve cell. *c.* Nuclei of capsule. $\times 250$. The lines in the center point to the corresponding cells in the ganglion.

ward to the periphery. In the sympathetic ganglia (Fig. 639) the nerve cells are multipolar and each has one axis-cylinder process and several dendrons; the axon emerges from the ganglion as a non-medullated nerve fiber. Similar cells are found in the ganglia connected with the trigeminal nerve, and these ganglia are therefore

regarded as the cranial portions of the sympathetic system. The sympathetic nervous system includes those portions of the nervous mechanism in which a medullated nerve fiber from the central system passes to a ganglion, sympathetic or peripheral, from which fibers, usually non-medullated, are distributed to such structures, *e. g.*, bloodvessels, as are not under voluntary control. The spinal and sympathetic ganglia differ somewhat in the size and disposition of the cells and in the number of nerve fibers entering and leaving them. In the spinal ganglia (Fig. 638) the nerve cells are much larger and for the most part collected in groups near the periphery, while the fibers, which are mostly medullated, traverse the central

portion of the ganglion; whereas in the sympathetic ganglia (Fig. 639) the cells are smaller and distributed in irregular groups throughout the whole ganglion; the fibers also are irregularly scattered; some of the entering ones are medullated, while many of those leaving the ganglion are non-medullated.

Neuron Theory.—The nerve cell and its processes collectively constitute what is termed a **neuron**, and Waldeyer formulated the theory that the nervous system is built up of numerous neurons, "anatomically and genetically independent of one another." According to this theory (*neuron theory*) the processes of one neuron only come into contact, and are never in direct continuity, with those of other neurons.

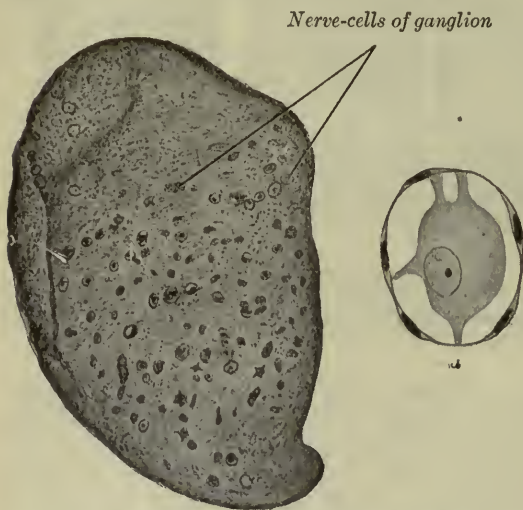


Fig. 639.—Transverse section of sympathetic ganglion of cat. A. Ganglion. $\times 50$. a. A nerve cell. $\times 250$.

while impulses are transmitted from one nerve cell to another through these points of contact, the synapses. The **synapse** or **synaptic membrane** seems to allow nervous impulses to pass in one direction only, namely, from the terminals of the axis-cylinder to the dendrons. This theory is based on the following facts, *viz.*: (1) embryonic nerve cells or neuroblasts are entirely distinct from one another; (2) when nervous tissues are stained by the Golgi method no continuity is seen even between neighboring neurons; and (3) when degenerative changes occur in nervous tissue, either as the result of disease or experiment, they never spread from one neuron to another, but are limited to the individual neurons, or groups of neurons, primarily affected. It must, however, be added that within the past few years the validity of the neuron theory has been called in question by certain eminent histologists, who maintain that by the employment of more delicate histological methods, minute fibrils can be followed from one nerve cell into another. Their existence, however, in the living is open to question. Mott and Marinesco made careful examinations of living cells, using even the ultramicroscope and agree that neither Nissl bodies nor neurofibrils are present in the living state.

For the present we may look upon the neurons as the units or structural elements of the nervous system. All the neurons are present at birth which are present in the adult, their division ceases before birth; they are not all functionally active at birth, but gradually assume functional activity. There is no indication of any regeneration after the destruction of the cell-body of any individual neuron.

Fasciculi, tracts or fiber systems are groups of axons having homologous origin and homologous distribution (as regards their collaterals, subdivisions and terminals) and are often named in accordance with their origin and termination, the

name of the nucleus or the location of the cell body from which the axon or fiber arises preceding that of the nucleus or location of its termination. A given topographical area seldom represents a pure tract, as in most cases fibers of different systems are mixed.

DEVELOPMENT OF THE NERVOUS SYSTEM.

The entire nervous system is of ectodermal origin, and its first rudiment is seen in the neural groove which extends along the dorsal aspect of the embryo (Fig. 17). By the elevation and ultimate fusion of the neural folds, the groove is converted into the neural tube (Fig. 19). The anterior end of the neural tube becomes expanded to form the three primary brain-vesicles; the cavity of the tube is subsequently modified to form the ventricular cavities of the brain, and the central canal of the medulla spinalis; from the wall the nervous elements and the neuroglia of the brain and medulla spinalis are developed.

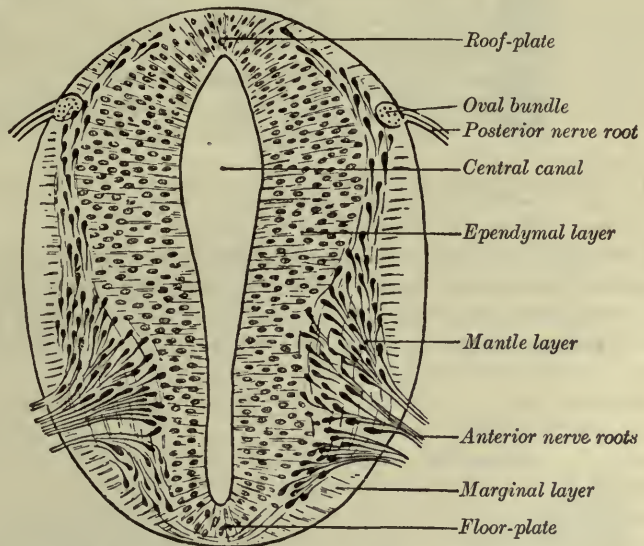


FIG. 640.—Section of medulla spinalis of a four weeks' embryo. (His.)

The Medulla Spinalis.—At first the wall of the neural tube is composed of a single layer of columnar ectodermal cells. Soon the side-walls become thickened, while the dorsal and ventral parts remain thin, and are named the **roof-** and **floor-plates** (Figs. 640, 642, 643). A transverse section of the tube at this stage presents an oval outline, while its lumen has the appearance of a slit. The cells which constitute the wall of the tube proliferate rapidly, lose their cell-boundaries and form a syncytium. This syncytium consists at first of dense protoplasm with closely packed nuclei, but later it opens out and forms a looser meshwork with the cellular strands arranged in a radiating manner from the central canal. Three layers may now be defined—an internal or ependymal, an intermediate or mantle, and an external or marginal. The **ependymal layer** is ultimately converted into the ependyma of the central canal; the processes of its cells pass outward toward the periphery of the medulla spinalis. The **marginal layer** is devoid of nuclei, and later forms the supporting framework for the white funiculi of the medulla spinalis. The **mantle layer** represents the whole of the future gray columns of the medulla spinalis; in it the cells are differentiated into two sets, viz., (*a*) **spongioblasts** or **young neuroglia cells**, and (*b*) **germinal cells**, which are the parents of the **neuroblasts**

or young nerve cells (Fig. 641). The spongioblasts are at first connected to one another by filaments of the syncytium: in these, fibrils are developed, so that as the neuroglial cells become defined they exhibit their characteristic mature appearance with multiple processes proceeding from each cell. The germinal cells are large,

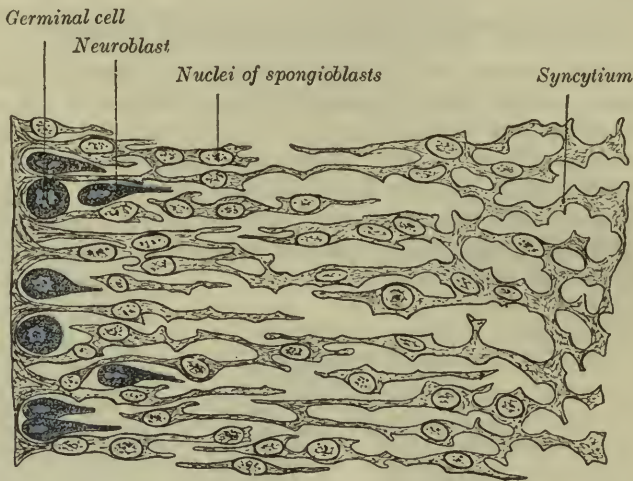
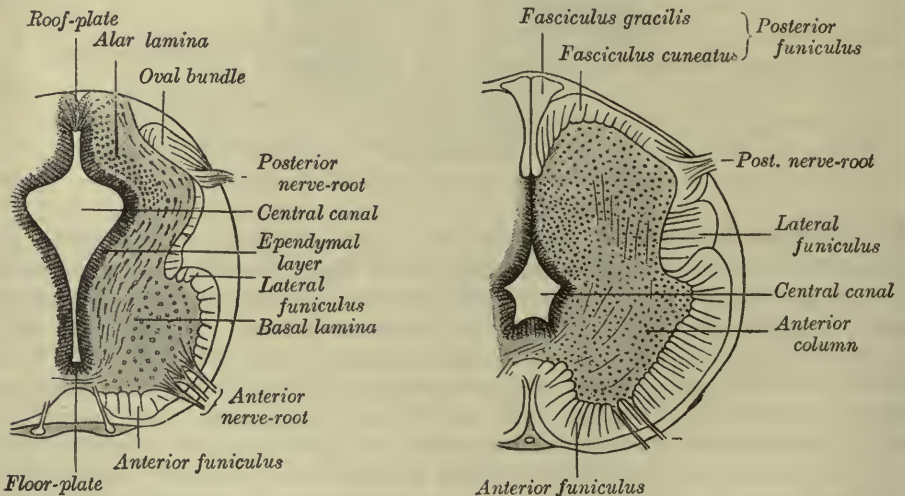


FIG. 641.—Transverse section of the medulla spinalis of a human embryo at the beginning of the fourth week. The left edge of the figure corresponds to the lining of the central canal. (His.)

round or oval, and first make their appearance between the ependymal cells on the sides of the central canal. They increase rapidly in number, so that by the fourth week they form an almost continuous layer on each side of the tube. No germinal cells are found in the roof- or floor-plates; the roof-plate retains, in certain



FIGS. 642, 643.—Transverse sections through the medullæ spiniales of human embryos. (His.) Fig. 642, aged about four and a half weeks. Fig. 643, aged about three months.

regions of the brain, its epithelial character; elsewhere, its cells become spongioblasts. By subdivision the germinal cells give rise to the neuroblasts or young nerve cells, which migrate outward from the sides of the central canal into the mantle layer and neural crest, and at the same time become pear-shaped; the

tapering part of the cell undergoes still further elongation, and forms the axis-cylinder of the cell.

The lateral walls of the medulla spinalis continue to increase in thickness, and the canal widens out near its dorsal extremity, and assumes a somewhat lozenge-shaped appearance. The widest part of the canal serves to subdivide the lateral wall of the neural tube into a **dorsal** or **alar**, and a **ventral** or **basal lamina** (Figs. 642, 643), a subdivision which extends forward into the brain. At a later stage the ventral part of the canal widens out, while the dorsal part is first reduced to a mere slit and then becomes obliterated by the approximation and fusion of its walls; the ventral part of the canal persists and forms the central canal of the adult medulla spinalis. The caudal end of the canal exhibits a conical expansion which is known as the **terminal ventricle**.

The ventral part of the mantle layer becomes thickened, and on cross-section appears as a triangular patch between the marginal and ependymal layers. This thickening is the rudiment of the anterior column of gray substance, and contains many neuroblasts, the axis-cylinders of which pass out through the marginal layer and form the anterior roots of the spinal nerves (Figs. 640, 642, 643). The thickening of the mantle layer gradually extends in a dorsal direction, and forms the posterior column of gray substance. The axons of many of the neuroblasts in the alar lamina run forward, and cross in the floor-plate to the opposite side of the medulla spinalis; these form the rudiment of the anterior white commissure.

About the end of the fourth week nerve fibers begin to appear in the marginal layer. The first to develop are the short intersegmental fibers from the neuroblasts in the mantle zone, and the fibers of the dorsal nerve roots which grow into the medulla spinalis from the cells of the spinal ganglia. By the sixth week these dorsal root fibers form a well-defined **oval bundle** in the peripheral part of the alar lamina; this bundle gradually increases in size, and spreading toward the middle line forms the rudiment of the posterior funiculus. The long intersegmental fibers begin to appear about the third month and the cerebrospinal fibers about the fifth month. All nerve fibers are at first destitute of medullary sheaths. Different groups of fibers receive their sheaths at different times—the dorsal and ventral nerve roots about the fifth month, the cerebrospinal fibers after the ninth month.

By the growth of the anterior columns of gray substance, and by the increase in size of the anterior funiculi, a furrow is formed between the lateral halves of the cord anteriorly; this gradually deepens to form the anterior median fissure. The mode of formation of the posterior septum is somewhat uncertain. Many believe that it is produced by the growing together of the walls of the posterior part of the central canal and by the development from its ependymal cells of a septum of fibrillated tissue which separates the future funiculi graciles.

Up to the third month of fetal life the medulla spinalis occupies the entire length of the vertebral canal, and the spinal nerves pass outward at right angles to the medulla spinalis. From this time onward, the vertebral column grows more rapidly than the medulla spinalis, and the latter, being fixed above through its continuity with the brain, gradually assumes a higher position within the canal. By the sixth month its lower end reaches only as far as the upper end of the sacrum; at birth it is on a level with the third lumbar vertebra, and in the adult with the lower border of the first or upper border of the second lumbar vertebra. A delicate filament, the **filum terminale**, extends from its lower end as far as the coccyx.

The Spinal Nerves.—Each spinal nerve is attached to the medulla spinalis by an anterior or ventral and a posterior or dorsal root.

The fibers of the anterior roots are formed by the axons of the neuroblasts which lie in the ventral part of the mantle layer; these axons grow out through the overlying marginal layer and become grouped to form the anterior nerve root (Fig. 641).

The fibers of the posterior roots are developed from the cells of the spinal ganglia. Before the neural groove is closed to form the neural tube a ridge of ectodermal cells, the **ganglion ridge** or **neural crest** (Fig. 644), appears along the prominent margin of each neural fold. When the folds meet in the middle line the two ganglion ridges fuse and form a wedge-shaped area along the line of closure of the tube. The cells of this area proliferate rapidly opposite the primitive segments and then migrate in a lateral and ventral direction to the sides of the neural tube, where they ultimately form a series of oval-shaped masses, the future spinal ganglia. These ganglia are arranged symmetrically on the two sides of the neural tube and, except in the region of the tail, are equal in number to the primitive segments. The cells of the ganglia, like the cells of the mantle layer, are of two kinds, viz., **spongioblasts** and **neuroblasts**. The spongioblasts develop into the neuroglial cells of the ganglia. The neuroblasts are at first round or oval in shape, but soon assume the form of spindles the extremities of which gradually elongate into central and

peripheral processes. The central processes grow medialward and, becoming connected with the neural tube, constitute the fibers of the posterior nerve roots, while the peripheral processes grow lateralward to mingle with the fibers of the anterior root in the spinal nerve. As development proceeds the original bipolar form of the cells changes; the two processes become approximated until they ultimately arise from a single stem in a T-shaped manner. Only in the ganglia of the acoustic nerve is the bipolar form retained. More recent observers hold, however, that the T-form is derived from the branching of a single process which grows out from the cell.

The anterior or ventral and the posterior or dorsal nerve roots join immediately beyond the spinal ganglion to form the **spinal nerve**, which then divides into anterior, posterior, and visceral divisions. The anterior and posterior divisions proceed directly to their areas of distribution without further association with ganglion cells (Fig. 645). The visceral divisions are distributed to the thoracic, abdominal, and pelvic viscera, to reach which they pass through the sympathetic trunk, and many of the fibers form arborizations around the ganglion cells of this trunk. Visceral branches are not given off from all the spinal nerves; they form two groups, viz., (a) **thoracico-lumbar**, from the first or second thoracic, to the second or third lumbar nerves; and (b) **pelvic**, from the second and third, or third and fourth sacral nerves.

The Brain.—The brain is developed from the anterior end of the neural tube, which at an early period becomes expanded into three vesicles, the primary cerebral vesicles (Fig. 18). These are marked off from each other by intervening constrictions, and are named the **fore-brain** or **prosencephalon**, the **mid-brain** or **mesencephalon**, and the **hind-brain** or **rhombencephalon**—the last being continuous with the medulla spinalis. As the result of unequal growth of these different parts three flexures are formed and the embryonic brain becomes bent on itself in a somewhat zigzag fashion; the two earliest flexures are concave ventrally and are associated with corresponding flexures of the whole head. The first flexure

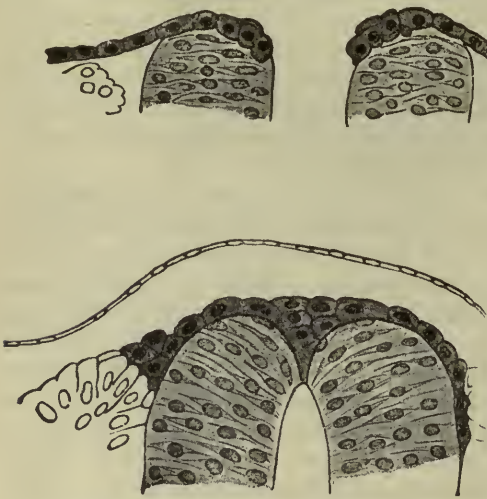


FIG. 644.—Two stages in the development of the neural crest in the human embryo. (Lenhossék.)

appears in the region of the mid-brain, and is named the **ventral cephalic flexure** (Fig. 650). By means of it the fore-brain is bent in a ventral direction around the anterior end of the notochord and fore-gut, with the result that the floor of the fore-brain comes to lie almost parallel with that of the hind-brain. This flexure causes the mid-brain to become, for a time, the most prominent part of the brain, since its dorsal surface corresponds with the convexity of the curve.

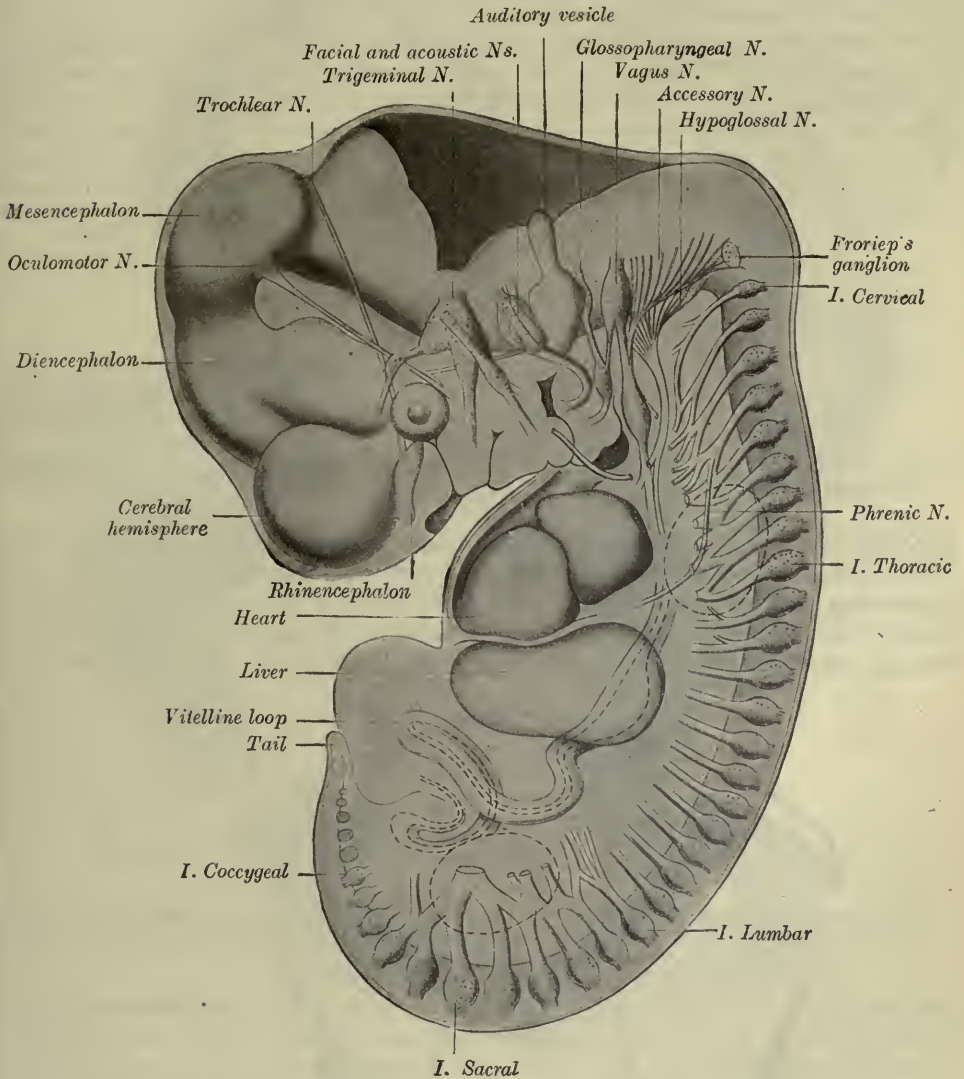


Fig. 645.—Reconstruction of periphera nerves of a human embryo of 10.2 mm. (After His.) The abducent nerve is not labelled, but is seen passing forward to the eye under the mandibular and maxillary nerves.

The second bend appears at the junction of the hind-brain and medulla spinalis. This is termed the **cervical flexure** (Fig. 652), and increases from the third to the end of the fifth week, when the hind-brain forms nearly a right angle with the medulla spinalis; after the fifth week erection of the head takes place and the cervical flexure diminishes and disappears. The third bend is named the **pontine flexure** (Fig. 652), because it is found in the region of the future pons Varoli. It differs from the other two in that (a) its convexity is forward, and (b) it does not affect

the head. The lateral walls of the brain-tube, like those of the medulla spinalis, are divided by internal furrows into alar or dorsal and basal or ventral laminae (Fig. 646).

The Hind-brain or Rhombencephalon.—The cavity of the hind-brain becomes the fourth ventricle. At the time when the ventral cephalic flexure makes its

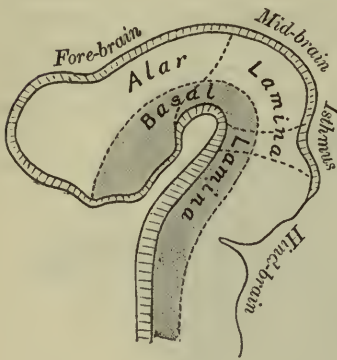

FIG. 646.—Diagram to illustrate the alar and basal laminae of brain vesicles. (His.)

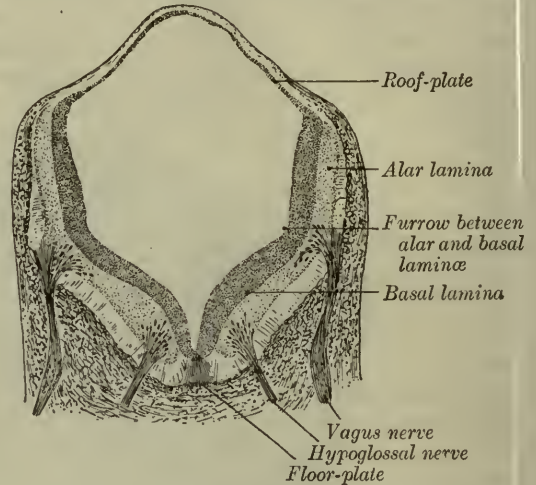


FIG. 647.—Transverse section of medulla oblongata of human embryo. $\times 32$. (Kollmann.)

appearance, the length of the hind-brain exceeds the combined lengths of the other two vesicles. Immediately behind the mid-brain it exhibits a marked constriction, the *isthmus rhombencephali* (Fig. 650, *Isthmus*), which is best seen when the brain is viewed from the dorsal aspect. From the isthmus the anterior medullary velum and the superior peduncle of the cerebellum are formed. It is customary to

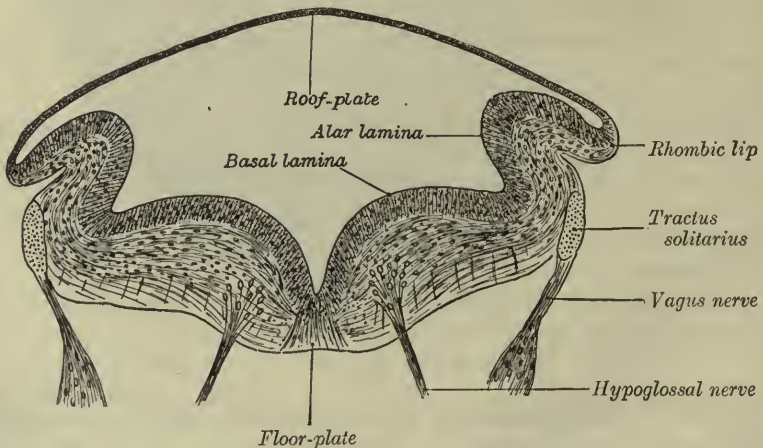


FIG. 648.—Transverse section of medulla oblongata of human embryo. (After His.)

divide the rest of the hind-brain into two parts, viz., an upper, called the **metencephalon**, and a lower, the **myelencephalon**. The cerebellum is developed by a thickening of the roof, and the pons by a thickening in the floor and lateral walls of the metencephalon. The floor and lateral walls of the myelencephalon are thickened to form the medulla oblongata; its roof remains thin, and, retaining to

a great extent its epithelial nature, is expanded in a lateral direction. Later, by the growth and backward extension of the cerebellum, the roof is folded inward toward the cavity of the fourth ventricle; it assists in completing the dorsal wall of this cavity, and is also invaginated to form the ependymal covering of its choroid plexuses. Above it is continuous with the posterior medullary velum; below, with the obex and ligulæ.

The development of the **medulla oblongata** resembles that of the medulla spinalis, but at the same time exhibits one or two interesting modifications. On transverse section the myelencephalon at an early stage is seen to consist of two lateral walls, connected across the middle line by floor- and roof-plates (Figs. 647 and 648). Each lateral wall consists of an alar and a basal lamina, separated by an internal furrow, the remains of which are represented in the adult brain by the sulcus limitans on the rhomboid fossa. The contained cavity is more or less triangular

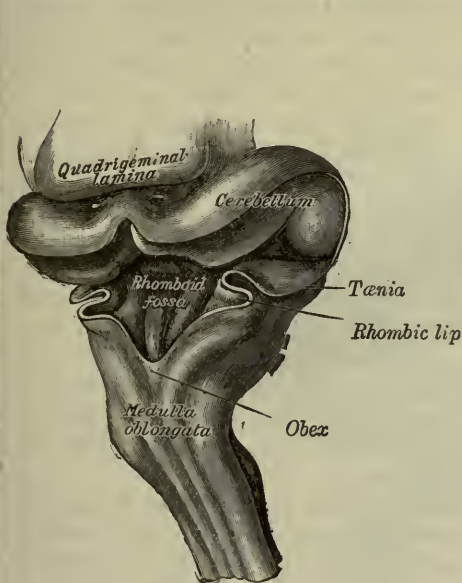


FIG. 649.—Hind-brain of a human embryo of three months—viewed from behind and partly from left side. (From model by His.)

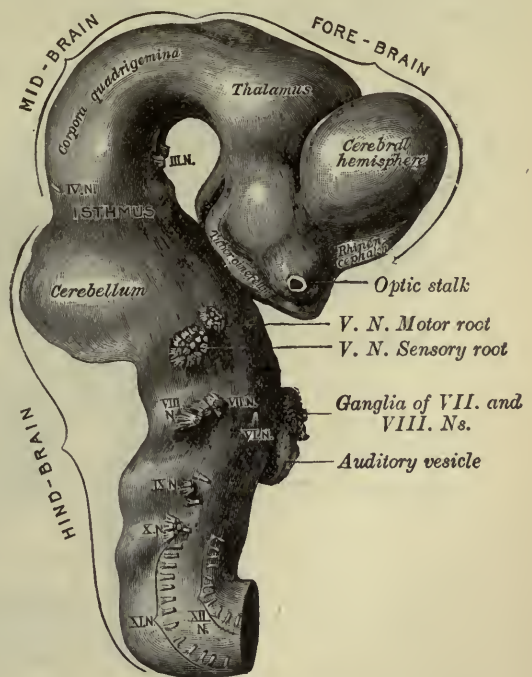


FIG. 650.—Exterior of brain of human embryo of four and a half weeks. (From model by His.)

in outline, the base being formed by the roof-plate, which is thin and greatly expanded transversely. Pear-shaped neuroblasts are developed in the alar and basal laminae, and their narrow stalks are elongated to form the axis-cylinders of the nerve fibers. Opposite the furrow or boundary between the alar and basal laminae a bundle of nerve fibers attaches itself to the outer surface of the alar lamina. This is named the **tractus solitarius** (Fig. 648), and is formed by the sensory fibers of the glossopharyngeal and vagus nerves. It is the homologue of the **oval bundle** seen in the medulla spinalis, and, like it, is developed by an ingrowth of fibers from the ganglia of the neural crest. At first it is applied to the outer surface of the alar lamina, but it soon becomes buried, owing to the growth over it of the neighboring parts. By the fifth week the dorsal part of the alar lamina bends in a lateral direction along its entire length, to form what is termed the **rhombic lip** (Figs. 648, 649). Within a few days this lip becomes applied to, and unites

with, the outer surface of the main part of the alar lamina, and so covers in the tractus solitarius and also the spinal root of the trigeminal nerve; the nodulus and flocculus of the cerebellum are developed from the rhombic lip.

Neuroblasts accumulate in the mantle layer; those in the basal lamina correspond with the cells in the anterior gray column of the medulla spinalis, and, like them, give origin to motor nerve fibers; in the medulla oblongata they are, however, arranged in groups or nuclei, instead of forming a continuous column. From the alar lamina and its rhombic lip, neuroblasts migrate into the basal lamina, and become aggregated to form the olivary nuclei, while many send their axis-cylinders through the floor-plate to the opposite side, and thus constitute the rudiment of the raphé of the medulla oblongata. By means of this thickening of the ventral portion, the motor nuclei are buried deeply in the interior, and, in the adult, are found close to the rhomboid fossa. This is still further accentuated: (a) by the development of the pyramids, which are formed about the fourth month by the downward growth of the motor fibers from the cerebral cortex; and (b) by the fibers which pass to and from the cerebellum. On the rhomboid fossa a series of six temporary furrows appears; these are termed the **rhombic grooves**. They bear a definite relationship to certain of the cranial nerves; thus, from before backward the first and second grooves overlie the nucleus of the trigeminal; the third, the nucleus of the facial; the fourth, that of the abducent; the fifth, that of the glosso-pharyngeal; and the sixth, that of the vagus.

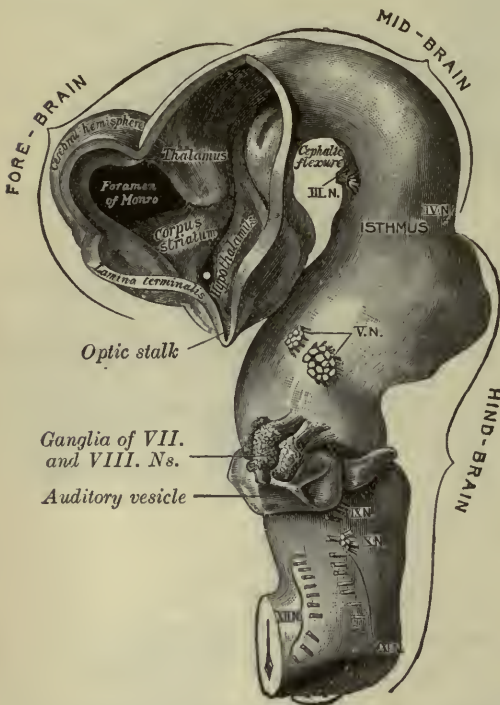


FIG. 651.—Brain of human embryo of four and a half weeks, showing interior of fore-brain. (From model by His.)

The **pons** is developed from the ventro-lateral wall of the metencephalon by a process similar to that which has been described for the medulla oblongata. The **cerebellum** is developed in the roof of the anterior part of the hind-brain (Figs. 649 to 654). The alar laminae of this region become thickened to form two lateral plates which soon fuse in the middle line and produce a thick lamina which roofs in the upper part of the cavity of the hind-brain vesicle; this constitutes the rudiment of the cerebellum, the outer surface of which is originally smooth and convex. The fissures of the cerebellum appear first in the vermis and floccular region, and traces of them are found during the third month; the fissures on the cerebellar hemispheres do not appear until the fifth month. The primitive fissures are not developed in the order of their relative size in the adult—thus the horizontal sulcus in the fifth month is merely a shallow groove. The best marked of the early fissures are: (a) the **fissura prima** between the developing culmen and declive, and (b) the **fissura secunda** between the future pyramid and uvula. The flocculus and nodule are developed from the rhombic lip, and are therefore recognizable as separate portions before any of the other cerebellar lobules. The groove produced by the bending over of the rhombic lip is here known as the

floccular fissure; when the two lateral walls fuse, the right and left floccular fissures join in the middle line and their central part becomes the **post-nodular fissure**.

On the ventricular surface of the cerebellar lamina a transverse furrow, the **incisura fastigii**, appears, and deepens to form the tent-like recess of the roof of the fourth ventricle. The rudiment of the cerebellum at first projects in a dorsal direction; but, by the backward growth of the cerebrum, it is folded downward and somewhat flattened, and the thin roof-plate of the fourth ventricle, originally continuous with the posterior border of the cerebellum, is projected inward toward the cavity of the ventricle.

The Mid-brain or Mesencephalon.—The mid-brain (Figs. 650 to 654) exists for a time as a thin-walled cavity of some size, and is separated from the isthmus rhombencephali behind, and from the fore-brain in front, by slight constrictions. Its cavity becomes relatively reduced in diameter, and forms the cerebral aqueduct of the adult brain. Its basal laminæ increase in thickness to form the cerebral peduncles, which are at first of small size, but rapidly enlarge after the fourth month.

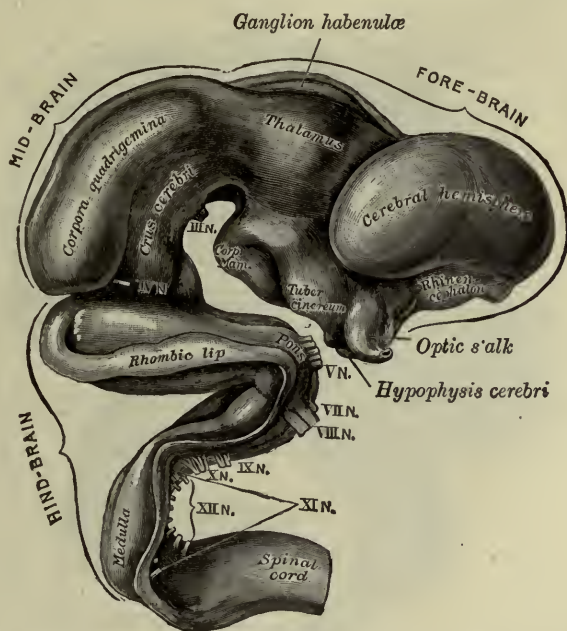


FIG. 652.—Exterior of brain of human embryo of five weeks. (From model by His.)

The neuroblasts of these laminæ are grouped in relation to the sides and floor of the cerebral aqueduct, and constitute the nuclei of the oculomotor and trochlear nerves, and of the mesencephalic root of the trigeminal nerve. By a similar thickening process its alar laminæ are developed into the quadrigeminal lamina. The dorsal part of the wall for a time undergoes expansion, and presents an internal median furrow and a corresponding external ridge; these, however, disappear, and the latter is replaced by a groove. Subsequently two oblique furrows extend medialward and backward, and the thickened lamina is thus subdivided into the superior and inferior colliculi.

The Fore-brain or Prosencephalon.—A transverse section of the early fore-brain shows the same parts as are displayed in similar sections of the medulla spinalis and medulla oblongata, viz., a pair of thick lateral walls connected by thin floor- and roof-plates. Moreover, each lateral wall exhibits a division into a dorsal or alar and a ventral or basal lamina separated internally by a furrow termed the **sulcus**

of Monro. This sulcus ends anteriorly at the medial end of the optic stalk, and in the adult brain is retained as a slight groove extending backward from the interventricular foramen to the cerebral aqueduct.

At a very early period—in some animals before the closure of the cranial part of the neural tube—two lateral diverticula, the **optic vesicles**, appear, one on either side of the fore-brain; for a time they communicate with the cavity of the fore-brain by relatively wide openings. The peripheral parts of the vesicles expand, while the proximal parts are reduced to tubular stalks, the **optic stalks**. The optic vesicle gives rise to the retina and the epithelium on the back of the ciliary body and iris; the optic stalk is invaded by nerve fibers to form the optic nerve. The fore-brain then grows forward, and from the alar laminae of this front portion the cerebral hemispheres originate as diverticula which rapidly expand to form two large pouches, one on either side. The cavities of these diverticula are the rudiments of the lateral ventricles; they communicate with the median part of the fore-brain cavity by relatively wide openings, which ultimately form the interventricular

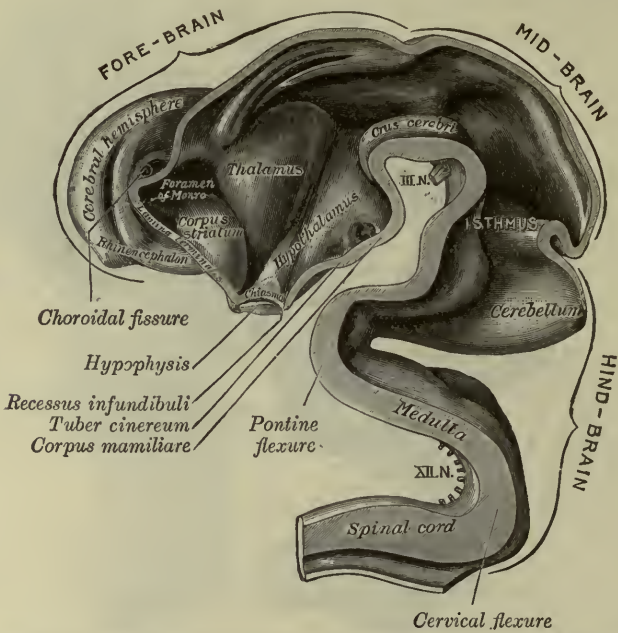


FIG. 653.—Interior of brain of human embryo of five weeks. (From model by His.)

foramen. The median portion of the wall of the fore-brain vesicle consists of a thin lamina, the **lamina terminalis** (Figs. 654, 657), which stretches from the interventricular foramen to the recess at the base of the optic stalk. The anterior part of the fore-brain, including the rudiments of the cerebral hemispheres, is named the **telencephalon**, and its posterior portion is termed the **diencephalon**; both of these contribute to the formation of the third ventricle.

The Diencephalon.—From the alar lamina of the diencephalon, the thalamus, métalthalamus, and epithalamus are developed. The **thalamus** (Figs. 650 to 654) arises as a thickening which involves the anterior two-thirds of the alar lamina. The two thalami are visible, for a time, on the surface of the brain, but are subsequently hidden by the cerebral hemispheres which grow backward over them. The thalami extend medialward and gradually narrow the cavity between them into a slit-like aperture which forms the greater part of the third ventricle; their medial surfaces ultimately adhere, in part, to each other, and the **intermediate**

mass of the ventricle is developed across the area of contact. The **metathalamus** comprises the geniculate bodies which originate as slight outward bulgings of the alar lamina. In the adult the lateral geniculate body appears as an eminence on the lateral part of the posterior end of the thalamus, while the medial is situated on the lateral aspect of the mid-brain. The **epithalamus** includes the pineal body, the posterior commissure, and the trigonum habenulæ. The pineal body arises as an upward evagination of roof-plate immediately in front of the mid-brain; this evagination becomes solid with the exception of its proximal part, which persists as the recessus pinealis. In lizards the pineal evagination is elongated into a stalk, and its peripheral extremity is expanded into a vesicle, in which a rudimentary lens and retina are formed; the stalk becomes solid and nerve fibers make their appearance in it, so that in these animals the pineal body forms a rudimentary eye. The posterior commissure is formed by the ingrowth of fibers into the depression behind and below the pineal evagination, and the trigonum habenulæ is developed in front of the pineal recess.

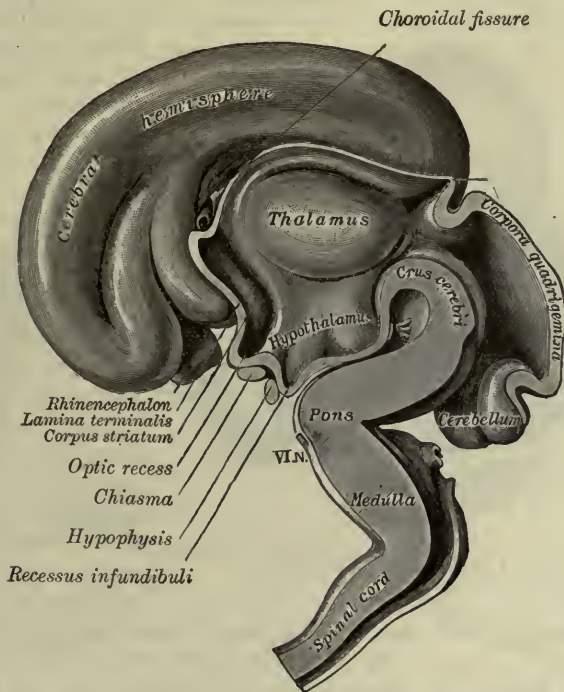


FIG. 654.—Median sagittal section of brain of human embryo of three months. (From model by His.)

From the basal laminae of the diencephalon the **pars mamillaris hypothalami** is developed; this comprises the corpora mamillaria and the posterior part of the tuber cinereum. The corpora mamillaria arise as a single thickening, which becomes divided into two by a median furrow during the third month.

The roof-plate of the diencephalon, in front of the pineal body, remains thin and epithelial in character, and is subsequently invaginated by the choroid plexuses of the third ventricle.

The Telencephalon.—This consists of a median portion and two lateral diverticula. The median portion forms the anterior part of the cavity of the third ventricle, and is closed below and in front by the lamina terminalis. The lateral diverticula consist of outward pouchings of the alar laminae; the cavities represent the lateral ventricles, and their walls become thickened to form the nervous

matter of the cerebral hemispheres. The roof-plate of the telencephalon remains thin, and is continuous in front with the lamina terminalis and behind with the roof-plate of the diencephalon. In the basal laminae and floor-plate the **pars optica hypothalami** is developed; this comprises the anterior part of the tuber cinereum, the infundibulum and posterior lobe of the hypophysis, and the optic chiasma. The anterior part of the tuber cinereum is derived from the posterior part of the floor of the telencephalon; the infundibulum and posterior lobe of the hypophysis arise as a downward diverticulum from the floor. The most dependent part of the diverticulum becomes solid and forms the posterior lobe of the hypophysis; the anterior lobe of the hypophysis is developed from a diverticulum of the ectodermal lining of the stomodeum. The optic chiasma is formed by the meeting and partial decussation of the optic nerves, which subsequently grow backward as the optic tracts and end in the diencephalon.

The **cerebral hemispheres** arise as diverticula of the alar laminae of the telencephalon (Figs. 650 to 654); they increase rapidly in size and ultimately overlap the structures developed from the mid- and hind-brains. This great expansion

of the hemispheres is a characteristic feature of the brains of mammals, and attains its maximum development in the brain of man. Elliott-Smith divides each cerebral hemisphere into three fundamental parts, viz., the **rhinencephalon**, the **corpus striatum**, and the **neopallium**.

The **rhinencephalon** (Fig. 655) represents the oldest part of the telencephalon, and forms almost the whole of the hemisphere in fishes, amphibians, and reptiles. In man it is feebly developed in comparison with the rest of the hemisphere, and comprises the following parts, viz., the olfactory lobe (con-

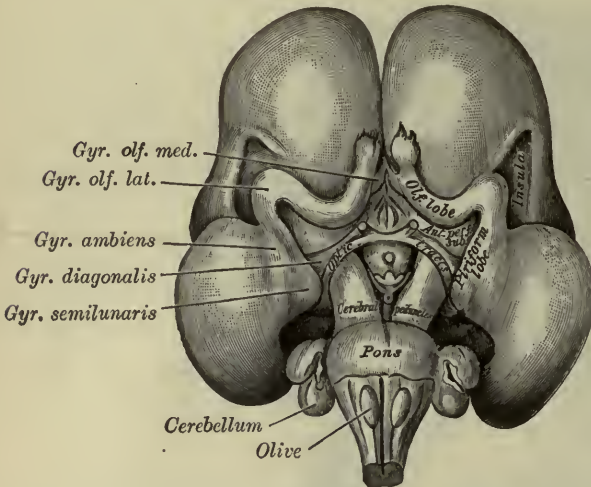


FIG. 655.—Inferior surface of brain of embryo at beginning of fourth month. (From Kollmann.)

sisting of the olfactory tract and bulb and the trigonum olfactorium), the anterior perforated substance, the septum pellucidum, the subcallosal, supracallosal, and dentate gyri, the fornix, the hippocampus, and the uncus. The rhinencephalon appears as a longitudinal elevation, with a corresponding internal furrow, on the under surface of the hemisphere close to the lamina terminalis; it is separated from the lateral surface of the hemisphere by a furrow, the **external rhinal fissure**, and is continuous behind with that part of the hemisphere, which will ultimately form the anterior end of the temporal lobe. The elevation becomes divided by a groove into an anterior and a posterior part. The anterior grows forward as a hollow stalk the lumen of which is continuous with the anterior part of the ventricular cavity. During the third month the stalk becomes solid and forms the rudiment of the olfactory bulb and tract; a strand of gelatinous tissue in the interior of the bulb indicates the position of the original cavity. From the posterior part the anterior perforated substance and the pyriform lobe are developed; at the beginning of the fourth month the latter forms a curved elevation continuous behind with the medial surface of the temporal lobe, and consisting, from before backward, of the gyrus olfactorius lateralis, gyrus ambiens, and gyrus semilunaris, parts which

in the adult brain are represented by the lateral root of the olfactory tract and the uncus. The position and connections of the remaining portions of the rhinencephalon are described with the anatomy of the brain.

The **corpus striatum** (Figs. 651 and 653) appears in the fourth week as a triangular thickening of the floor of the telencephalon between the optic recess and the interventricular foramen, and continuous behind with the thalamic part of the diencephalon. It increases in size, and by the second month is seen as a swelling in the floor of the future lateral ventricle; this swelling reaches as far as the posterior end of the primitive hemisphere, and when this part of the hemisphere grows backward and downward to form the temporal lobe, the posterior part of the corpus striatum is carried into the roof of the inferior horn of the ventricle, where it is seen as the tail of the caudate nucleus in the adult brain. During the fourth and fifth months the corpus striatum becomes incompletely subdivided by the fibers of the internal capsule into two masses, an inner, the **caudate nucleus**, and an outer, the **lentiform nucleus**. In front, the corpus striatum is continuous with the anterior perforated substance; laterally it is confluent for a time with that portion of the wall of the vesicle which is developed into the insula, but this continuity is subsequently interrupted by the fibers of the external capsule.

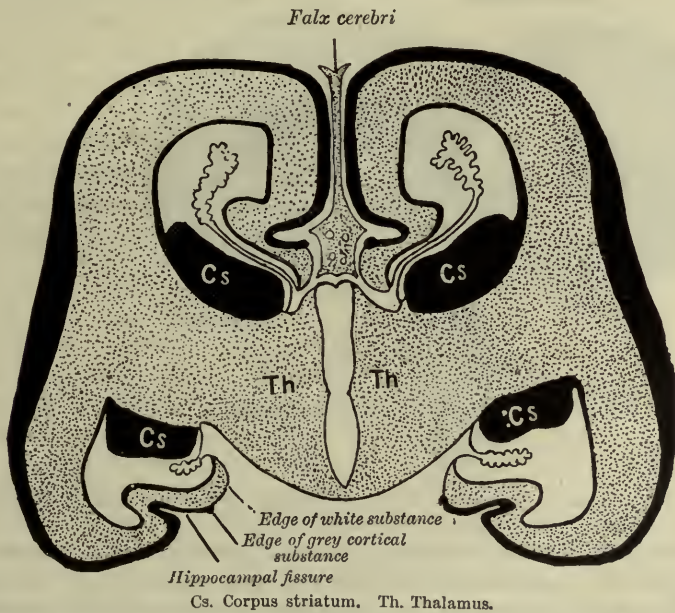


FIG. 656.—Diagrammatic coronal section of brain to show relations of neopallium. (After His.) Cs. Corpus striatum. Th. Thalamus.

The **neopallium** (Fig. 656) forms the remaining, and by far the greater, part of the cerebral hemisphere. It consists, at an early stage, of a relatively large, more or less hemispherical cavity—the primitive **lateral ventricle**—enclosed by a thin wall from which the cortex of the hemisphere is developed. The vesicle expands in all directions, but more especially upward and backward, so that by the third month the hemispheres cover the diencephalon, by the sixth they overlap the mid-brain, and by the eighth the hind-brain.

The median lamina uniting the two hemispheres does not share in their expansion, and thus the hemispheres are separated by a deep cleft, the forerunner of the longitudinal fissure, and this cleft is occupied by a septum of mesodermal tissue which constitutes the primitive **falx cerebri**. Coincidentally with the expansion of the vesicle, its cavity is drawn out into three prolongations which represent

the horns of the future lateral ventricle; the hinder end of the vesicle is carried downward and forward and forms the inferior horn; the posterior horn is produced somewhat later, in association with the backward growth of the occipital lobe of the hemisphere. The roof-plate of the primitive fore-brain remains thin and of an epithelial character; it is invaginated into the lateral ventricle along the medial wall of the hemisphere. This invagination constitutes the choroidal fissure, and extends from the interventricular foramen to the posterior end of the vesicle. Mesodermal tissue, continuous with that of the primitive falx cerebri, and carrying bloodvessels with it, spreads between the two layers of the invaginated fold and forms the rudiment of the tela choroidea; the margins of the tela become highly vascular and form the choroid plexuses which for some months almost completely fill the ventricular cavities; the tela at the same time invaginates the epithelial roof of the diencephalon to form the choroid plexuses of the third ventricle. By the downward and forward growth of the posterior end of the vesicle to form the temporal lobe the choroidal fissure finally reaches from the interventricular foramen to the extremity of the inferior horn of the ventricle.

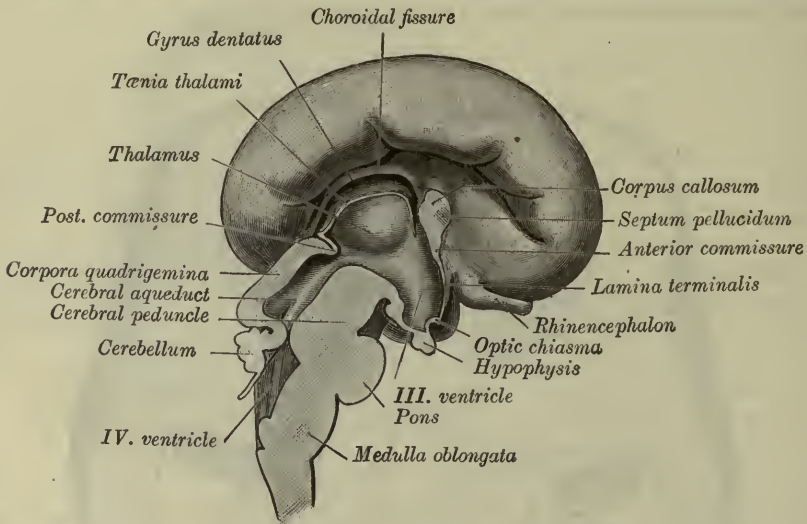


FIG. 657.—Median sagittal section of brain of human embryo of four months. (Marchand.)

Parallel with but above and in front of the choroidal fissure the medial wall of the cerebral vesicle becomes folded outward and gives rise to the **hippocampal fissure** on the medial surface and to a corresponding elevation, the **hippocampus**, within the ventricular cavity. The gray or ganglionic covering of the wall of the vesicle ends at the inferior margin of the fissure is a thickened edge; beneath this the marginal or reticular layer (future white substance) is exposed and its lower thinned edge is continuous with the epithelial invagination covering the choroid plexus (Fig. 656). As a result of the later downward and forward growth of the temporal lobe the hippocampal fissure and the parts associated with it extend from the interventricular foramen to the end of the inferior horn of the ventricle. The thickened edge of gray substance becomes the gyrus dentatus, the fasciola cinerea and the supra- and subcallosal gyri, while the free edge of the white substance forms the fimbria hippocampi and the body and crus of the fornix. The corpus callosum is developed within the arch of the hippocampal fissure, and the upper part of the fissure forms, in the adult brain, the callosal fissure on the medial surface of the hemisphere.

The Commissures (Fig. 657).—The development of the posterior commissure has already been referred to (page 743). The great commissures of the hemi-

spheres, viz., the **corpus callosum**, the **fornix**, and **anterior commissures**, arise from the lamina terminalis. About the fourth month a small thickening appears in this lamina, immediately in front of the interventricular foramen. The lower part of this thickening is soon constricted off, and fibers appear in it to form the anterior commissure. The upper part continues to grow with the hemispheres, and is invaded by two sets of fibers. Transverse fibers, extending between the hemispheres, pass into its dorsal part, which is now differentiated as the corpus callosum (in rare cases the corpus callosum is not developed). Into the ventral part longitudinal fibers from the hippocampus pass to the lamina terminalis, and through that structure to the corpora mamillaria; these fibers constitute the fornix. A small portion, lying antero-inferiorly between the corpus callosum and fornix, is not invaded by the commissural fibers; it remains thin, and later a cavity, the cavity of the **septum pellucidum**, forms in its interior.

Fissures and Sulci.—The outer surface of the cerebral hemisphere is at first smooth, but later it exhibits a number of elevations or convolutions, separated from each other by fissures and sulci, most of which make their appearance during the sixth or seventh months of fetal life. The term *fissure* is applied to such grooves as involve the entire thickness of the cerebral wall, and thus produce corresponding eminences in the ventricular cavity, while the *sulci* affect only the superficial part of the wall, and therefore leave no impressions in the ventricle. The fissures comprise the **choroidal** and **hippocampal** already described, and two others, viz., the **calcarine** and **collateral**, which produce the swellings known respectively as the **calcar avis** and the **collateral eminence** in the ventricular cavity. Of the sulci the following may be referred to, viz., the **central sulcus** (*fissure of Rolando*), which is developed in two parts; the **intraparietal sulcus** in four parts; and the **cingulate sulcus** in two or three parts. The **lateral cerebral** or **Sylvian fissure** differs from all the other fissures in its mode of development. It appears about the third month as a depression, the **Sylvian fossa**, on the lateral surface of the hemisphere (Fig. 658); this fossa corresponds with the position of the corpus striatum, and its floor is moulded to form the insula. The intimate connection which exists between the cortex of the insula and the subjacent corpus striatum prevents this part of the hemisphere wall from expanding at the same rate as the portions which surround it. The neighboring parts of the hemisphere therefore gradually grow over and cover in the insula, and constitute the temporal, parietal, frontal, and orbital opercula of the adult brain. The frontal and orbital opercula are the last to form, but by the end of the first year after birth the insula is completely submerged by the approximation of the opercula. The fissures separating the opposed margins of the opercula constitute the composite lateral cerebral fissure.

If a section across the wall of the hemisphere about the sixth week be examined microscopically it will be found to consist of a thin marginal or reticular layer, a thick ependymal layer, and a thin intervening mantle layer. Neuroblasts from the ependymal and mantle layers migrate into the deep part of the marginal layer and form the cells of the cerebral cortex. The nerve fibers which form the underlying white substance of the hemispheres consist at first of outgrowths from the cells of

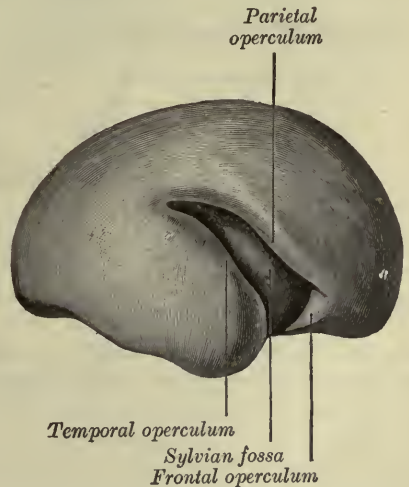


FIG. 658.—Outer surface of cerebral hemisphere of human embryo of about five months.

the corpora striata and thalami; later the fibers from the cells of the cortex are added. Medullation of these fibers begins about the time of birth and continues until puberty. A summary of the parts derived from the brain vesicles is given in the following table:

Hind-brain or Rhombencephalon	{ 1. Myelencephalon 2. Metencephalon 3. Isthmus rhombencephali	{ Medulla oblongata Lower part of fourth ventricle.
		{ Pons Cerebellum Intermediate part of fourth ventricle.
		{ Anterior medullary velum Brachia conjunctiva cerebelli. Upper part of fourth ventricle.
Mid-brain or Mesencephalon		{ Cerebral peduncles Lamina quadrigemina Cerebral aqueduct.
Fore-brain or Prosencephalon	{ 1. Diencephalon 2. Telencephalon	{ Thalamus Metathalamus Epithalamus Pars mamillaris hypothalami Posterior part of third ventricle.
		{ Anterior part of third ventricle Pars optica hypothalami Cerebral hemispheres Lateral ventricles Interventricular foramen.

The Cranial Nerves.—With the exception of the olfactory, optic, and acoustic nerves, which will be especially considered, the cranial nerves are developed in a similar manner to the spinal nerves (see page 735). The sensory or afferent nerves are derived from the cells of the ganglion rudiments of the neural crest. The central processes of these cells grow into the brain and form the roots of the nerves, while the peripheral processes extend outward and constitute their fibers of distribution (Fig. 645). It has been seen, in considering the development of the medulla oblongata (page 739), that the *tractus solitarius* (Fig. 660), derived from the fibers which grow inward from the ganglion rudiments of the glossopharyngeal and vagus nerves; is the homologue of the **oval bundle** in the cord which had

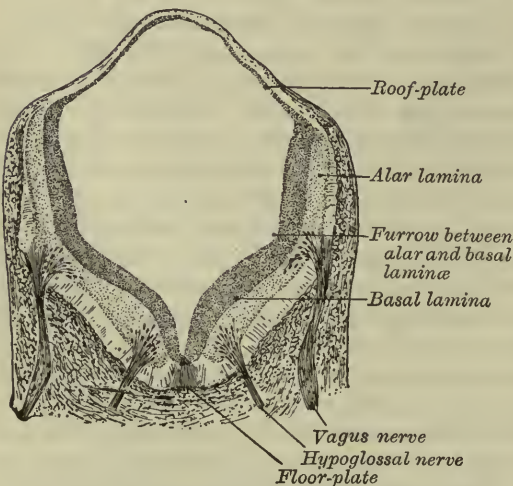


FIG. 659.—Transverse section of medulla oblongata of human embryo. X 32. (Kollmann)

its origin in the posterior nerve roots. The motor or efferent nerves arise as outgrowths of the neuroblasts situated in the basal laminae of the mid- and hind-brain. While, however, the spinal motor nerve roots arise in one series from the basal lamina, the cranial motor nerves are grouped into two sets, according as they spring from the medial or lateral parts of the basal lamina. To the former set belong the oculomotor, trochlear, abducent, and hypoglossal nerves; to the latter, the accessory and the motor fibers of the trigeminal, facial, glossopharyngeal, vagus nerves (Figs. 659, 660).

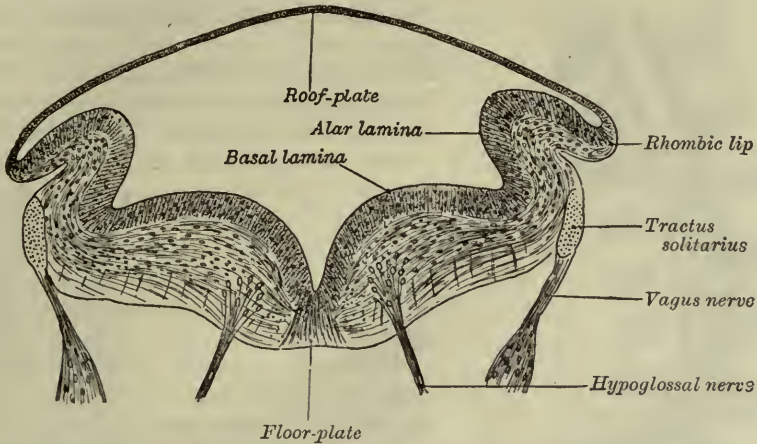


FIG. 660.—Transverse section of medulla oblongata of human embryo. (After His.)

THE MEDULLA SPINALIS OR SPINAL CORD.

The *medulla spinalis* or *spinal cord* forms the elongated, nearly cylindrical, part of the central nervous system which occupies the upper two-thirds of the vertebral canal. Its average length in the male is about 45 cm., in the female from 42 to 43 cm., while its weight amounts to about 30 gms. It extends from the level of the upper border of the atlas to that of the lower border of the first, or upper border of the second, lumbar vertebra. Above, it is continuous with the brain; below, it ends in a conical extremity, the *conus medullaris*, from the apex of which a delicate filament, the *filum terminale*, descends as far as the first segment of the coccyx (Fig. 661).

The position of the *medulla spinalis* varies with the movements of the vertebral column, its lower extremity being drawn slightly upward when the column is flexed. It also varies at different periods of life; up to the third month of fetal life the *medulla spinalis* is as long as the vertebral canal, but from this stage onward the vertebral column elongates more rapidly than the *medulla spinalis*, so that by the end of the fifth month the *medulla spinalis* terminates at the base of the sacrum, and at birth about the third lumbar vertebra.

The *medulla spinalis* does not fill the part of the vertebral canal in which it lies; it is enshathed by three protective membranes, separated from each other by two concentric spaces. The three membranes are named from without inward, the *dura mater*, the *arachnoid*, and the *pia mater*. The *dura mater* is a strong, fibrous membrane which forms a wide, tubular sheath; this sheath extends below the termination of the *medulla spinalis* and ends in a pointed cul-de-sac at the level of the lower border of the second sacral vertebra. The *dura mater* is separated from the wall of the vertebral canal by the *epidural cavity*, which contains a quantity of loose areolar tissue and a plexus of veins; between the *dura mater* and the subjacent *arachnoid* is a capillary interval, the *subdural cavity*, which contains a small quantity of fluid, probably of the nature of lymph. The *arachnoid* is a thin, transparent

sheath, separated from the pia mater by a comparatively wide interval, the **subarachnoid cavity**, which is filled with cerebrospinal fluid. The **pia mater** closely invests the medulla spinalis and sends delicate septa into its substance; a narrow band, the **ligamentum denticulatum**, extends along each of its lateral surfaces and is attached by a series of pointed processes to the inner surface of the dura mater.

Thirty-one pairs of spinal nerves spring from the medulla spinalis, each nerve having an anterior or ventral, and a posterior or dorsal root, the latter being distinguished by the presence of an oval swelling, the **spinal ganglion**, which contains numerous nerve cells. Each root consists of several bundles of nerve fibers, and at its attachment extends for some distance along the side of the medulla spinalis. The pairs of spinal nerves are grouped as follows: cervical 8, thoracic 12, lumbar 5, sacral 5, coccygeal 1, and, for convenience of description, the medulla spinalis is divided into cervical, thoracic, lumbar and sacral regions, corresponding with the attachments of the different groups of nerves.

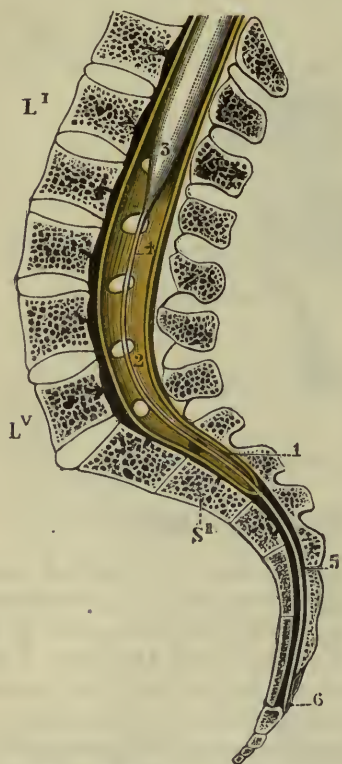


FIG. 661.—Sagittal section of vertebral canal to show the lower end of the medulla spinalis and the filum terminale. *L₁*, *L₅*, First and fifth lumbar vertebræ. *S₁*, Second sacral vertebra. 1. Dura mater. 2. Lower part of tube of dura mater. 3. Lower extremity of medulla spinalis. 4. Intradural, and 5. Extradural portions of filum terminale. 6. Attachment of filum terminale to first segment of coccyx. (Testut.)

Although no trace of transverse segmentation is visible on the surface of the medulla spinalis, it is convenient to regard it as being built up of a series of superimposed **spinal segments** or **neuromeres**, each of which has a length equivalent to the extent of attachment of a pair of spinal nerves. Since the extent of attachment of the successive pairs of nerves varies in different parts, it follows that the spinal segments are of varying lengths; thus, in the cervical region they average about 13 mm., in the mid-thoracic region about 26 mm., while in the lumbar and sacral regions they diminish rapidly from about 15 mm. at the level of the first pair of lumbar nerves to about 4 mm. opposite the attachments of the lower sacral nerves.

As a consequence of the relative inequality in the rates of growth of the medulla spinalis and vertebral column, the nerve roots, which in the early embryo passed transversely outward to reach their respective intervertebral foramina, become more and more oblique in direction from above downward, so that the lumbar and sacral nerves descend almost vertically to reach their points of exit. From the appearance these nerves present at their attachment to the medulla spinalis and from their great length they are collectively termed the **cauda equina** (Fig. 662).

The **filum terminale** is a delicate filament, about 20 cm. in length, prolonged downward from the apex of the conus medullaris. It consists of two parts, an upper and a lower. The upper part, or **filum terminale internum**, measures about 15 cm. in length and reaches as far as the lower border of the second sacral vertebra. It is contained within the tubular sheath of dura mater, and is surrounded by the nerves forming the cauda equina, from which it can be readily recognized by its bluish-white color. The lower part, or **filum terminale externum**, is closely invested

by, and is adherent to, the dura mater; it extends downward from the apex of the tubular sheath and is attached to the back of the first segment of the coccyx. The filum terminale consists mainly of fibrous tissue, continuous above with that of the pia mater. Adhering to its outer surface, however, are a few strands of nerve fibers which probably represent rudimentary second and third coccygeal nerves; further, the central canal of the medulla spinalis extends downward into it for 5 or 6 cm.

Enlargements.—The medulla spinalis is not quite cylindrical, being slightly flattened from before backward; it also

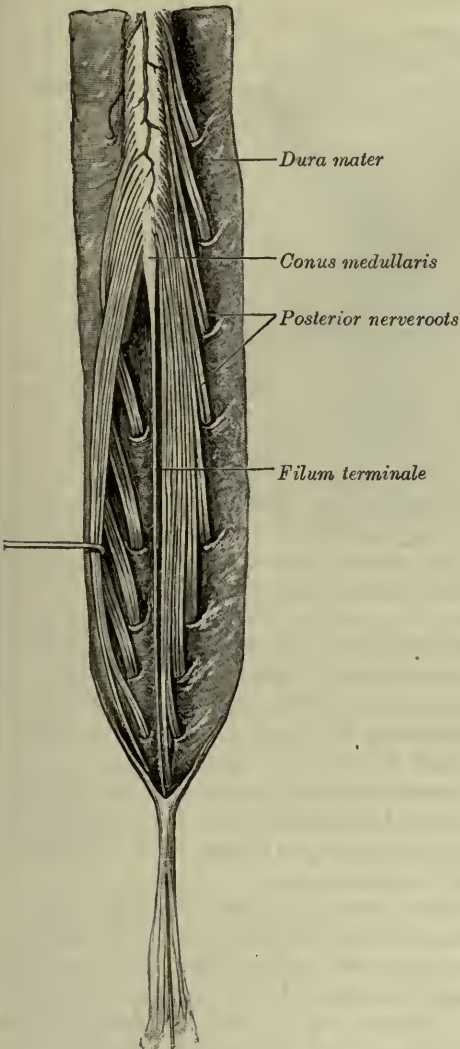


FIG. 662.—Cauda equina and filum terminale seen from behind. The dura mater has been opened and spread out, and the arachnoid has been removed.

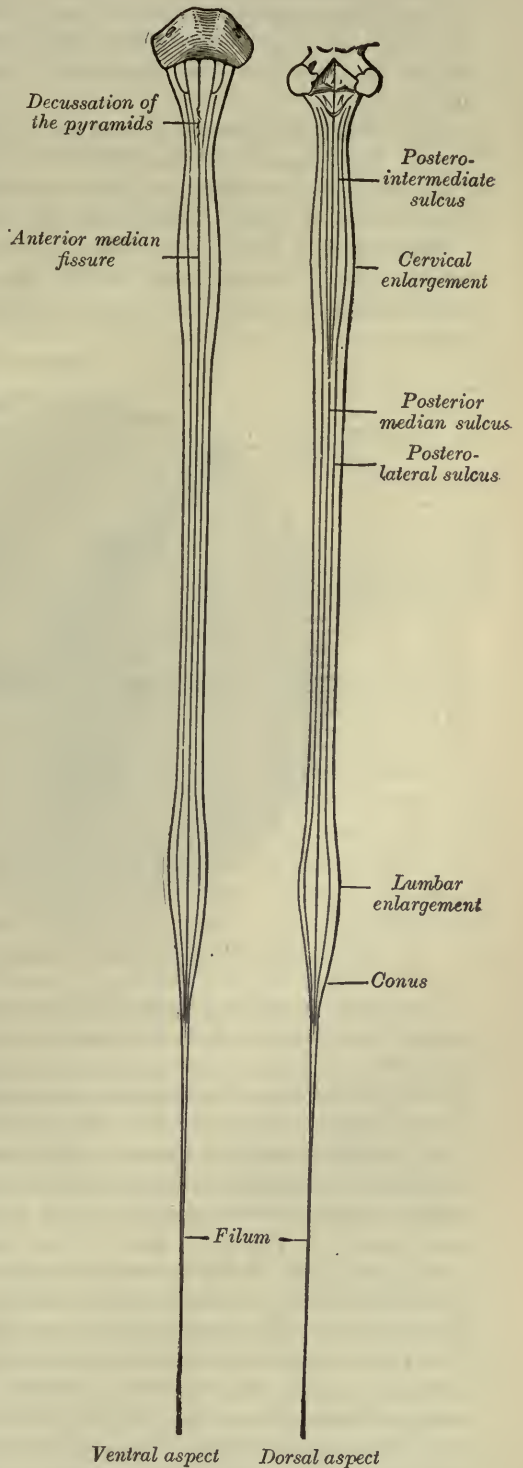


FIG. 663.—Diagrams of the medulla spinalis.

presents two swellings or enlargements, an upper or cervical, and a lower or lumbar (Fig. 663).

The **cervical enlargement** is the more pronounced, and corresponds with the attachments of the large nerves which supply the upper limbs. It extends from about the third cervical to the second thoracic vertebra, its maximum circumference (about 38 mm.) being on a level with the attachment of the sixth pair of cervical nerves.

The **lumbar enlargement** gives attachment to the nerves which supply the lower limbs. It commences about the level of the ninth thoracic vertebra, and reaches its maximum circumference, of about 33 mm., opposite the last thoracic vertebra, below which it tapers rapidly into the conus medullaris.

Fissures and Sulci (Fig. 664).—An anterior median fissure and a posterior median sulcus incompletely divide the medulla spinalis into two symmetrical parts, which are joined across the middle line by a commissural band of nervous matter.

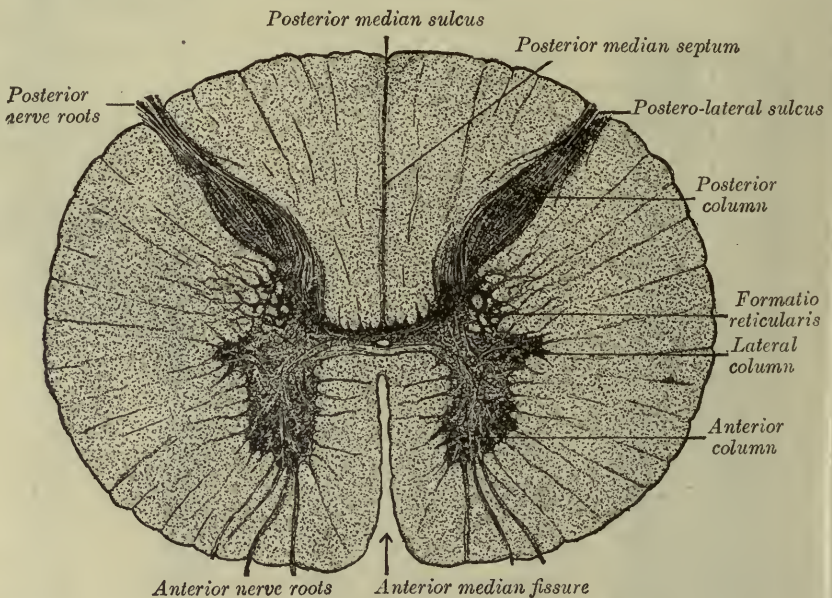


FIG. 664.—Transverse section of the medulla spinalis in the mid-thoracic region.

The **Anterior Median Fissure** (*fissura mediana anterior*) has an average depth of about 3 mm., but this is increased in the lower part of the medulla spinalis. It contains a double fold of pia mater, and its floor is formed by a transverse band of white substance, the **anterior white commissure**, which is perforated by blood-vessels on their way to or from the central part of the medulla spinalis.

The **Posterior Median Sulcus** (*sulcus medianus posterior*) is very shallow; from it a septum of neuroglia reaches rather more than half-way into the substance of the medulla spinalis; this septum varies in depth from 4 to 6 mm., but diminishes considerably in the lower part of the medulla spinalis.

On either side of the posterior median sulcus, and at a short distance from it, the posterior nerve roots are attached along a vertical furrow named the **postero-lateral sulcus**. The portion of the medulla spinalis which lies between this and the posterior median sulcus is named the **posterior funiculus**. In the cervical and upper thoracic regions this funiculus presents a longitudinal furrow, the **postero-intermediate sulcus**; this marks the position of a septum which extends into the posterior funiculus and subdivides it into two fasciculi—a medial, named the **fasciculus gracilis** (*tract of Goll*); and a lateral, the **fasciculus cuneatus** (*tract of Burdach*).

(Fig. 672). The portion of the medulla spinalis which lies in front of the postero-lateral sulcus is termed the **antero-lateral region**. The anterior nerve roots, unlike the posterior, are not attached in linear series, and their position of exit is not marked by a sulcus. They arise by separate bundles which spring from the anterior column of gray substance and, passing forward through the white substance, emerge over an area of some slight width. The most lateral of these bundles is generally taken as a dividing line which separates the antero-lateral region into two parts, viz., an **anterior funiculus**, between the anterior median fissure and the most lateral of the anterior nerve roots; and a **lateral funiculus**, between the exit of these roots and the postero-lateral sulcus. In the upper part of the cervical region a series of nerve roots passes outward through the lateral funiculus of the medulla spinalis; these unite to form the spinal portion of the accessory nerve, which runs upward and enters the cranial cavity through the foramen magnum.

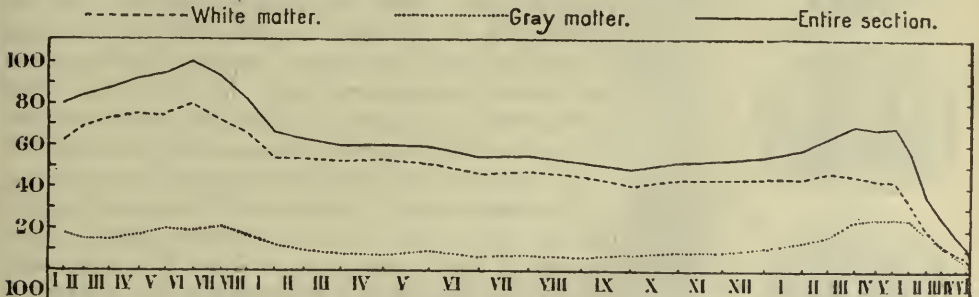


FIG. 665.—Curves showing the sectional area at different levels of the cord. The ordinates show the area in sq. mm. (Donaldson and Davis.)

The Internal Structure of the Medulla Spinalis.—On examining a transverse section of the medulla spinalis (Fig. 664) it is seen to consist of gray and white nervous substance, the former being enclosed within the latter.

Gray Substance (*substantia grisea centralis*).—The gray substance consists of two symmetrical portions, one in each half of the medulla spinalis: these are joined across the middle line by a transverse commissure of gray substance, through which runs a minute canal, the **central canal**, just visible to the naked eye. In a transverse section each half of the gray substance is shaped like a comma or crescent, the concavity of which is directed laterally; and these, together with the intervening gray commissure, present the appearance of the letter H. An imaginary coronal plane through the central canal serves to divide each crescent into an **anterior or ventral**, and a **posterior or dorsal column**.

The **Anterior Column** (*columna anterior; anterior cornu*), directed forward, is broad and of a rounded or quadrangular shape. Its posterior part is termed the **base**, and its anterior part the **head**, but these are not differentiated from each other by any well-defined constriction. It is separated from the surface of the medulla spinalis by a layer of white substance which is traversed by the bundles of the anterior nerve roots. In the thoracic region, the postero-lateral part of the anterior column projects lateralward as a triangular field, which is named the **lateral column** (*columna lateralis; lateral cornu*).

The **Posterior Column** (*columna posterior; posterior cornu*) is long and slender, and is directed backward and lateralward: it reaches almost as far as the postero-lateral sulcus, from which it is separated by a thin layer of white substance, the **tract of Lissauer**. It consists of a **base**, directly continuous with the base of the anterior horn, and a **neck** or slightly constricted portion, which is succeeded by an oval or fusiform area, termed the **head**, of which the **apex** approaches the postero-lateral sulcus. The apex is capped by a V-shaped or crescentic mass of translucent, gelatinous neuroglia, termed the **substantia gelatinosa of Rolando**, which

contains both neuroglia cells, and small nerve cells. Between the anterior and posterior columns the gray substance extends as a series of processes into the lateral funiculus, to form a net-work called the **formatio reticularis**.

The quantity of gray substance, as well as the form which it presents on transverse section, varies markedly at different levels. In the thoracic region it is small, not only in amount but relatively to the surrounding white substance. In the cervical and lumbar enlargements it is greatly increased: in the latter, and especially in the conus medullaris, its proportion to the white substance is greatest (Fig. 665). In the cervical region its posterior column is comparatively narrow, while its anterior is broad and expanded; in the thoracic region, both columns are attenuated, and the lateral column is evident; in the lumbar enlargement, both are expanded; while in the conus medullaris the gray substance assumes the form of two oval masses, one in each half of the cord, connected together by a broad gray commissure.

The **Central Canal** (*canalis centralis*) runs throughout the entire length of the medulla spinalis. The portion of gray substance in front of the canal is named the **anterior gray commissure**; that behind it, the **posterior gray commissure**. The former is thin, and is in contact anteriorly with the anterior white commissure: it contains a couple of longitudinal veins, one on either side of the middle line. The posterior gray commissure reaches from the central canal to the posterior median septum, and is thinnest in the thoracic region, and thickest in the conus medullaris. The central canal is continued upward through the lower part of the medulla oblongata, and opens into the fourth ventricle of the brain; below, it reaches for a short distance into the filum terminale. In the lower part of the conus medullaris it exhibits a fusiform dilatation, the **terminal ventricle**; this has a vertical measurement of from 8 to 10 mm., is triangular on cross-section with its base directed forward, and tends to undergo obliteration after the age of forty years.

Throughout the cervical and thoracic regions the central canal is situated in the anterior third of the medulla spinalis; in the lumbar enlargement it is near the middle, and in the conus medullaris it approaches the posterior surface. It is filled with cerebrospinal fluid, and lined by ciliated, columnar epithelium, outside of which is an encircling band of gelatinous substance, the **substantia gelatinosa centralis**. This gelatinous substance consists mainly of neuroglia, but contains a few nerve cells and fibers; it is traversed by processes from the deep ends of the columnar ciliated cells which line the central canal (Fig. 667).

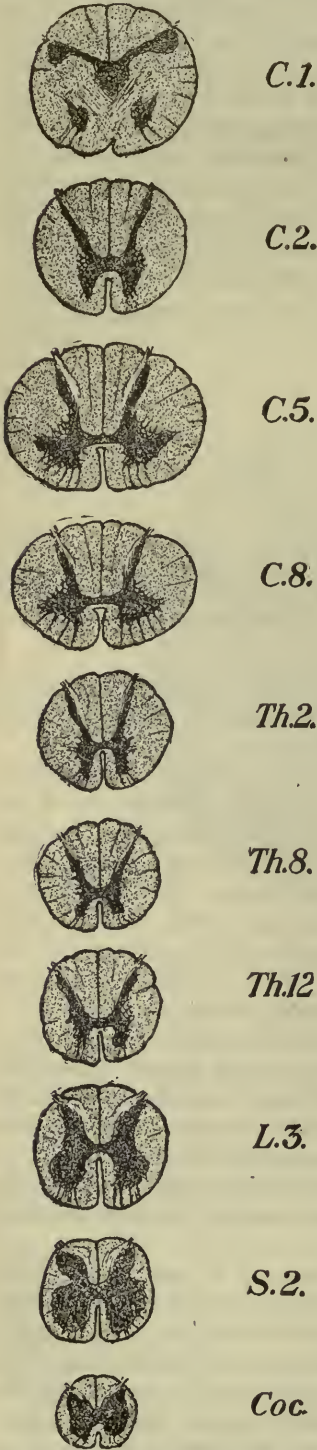


FIG. 666.—Transverse sections of the medulla spinalis at different levels.

Structure of the Gray Substance.—The gray substance consists of numerous nerve cells and nerve fibers held together by neuroglia. Throughout the greater part of the gray substance the neuroglia presents the appearance of a sponge-like network, but around the central canal and on the apices of the posterior columns it consists of the gelatinous substance already referred to. The nerve cells are multipolar, and vary greatly in size and shape. They consist of (1) motor cells of large size, which are situated in the anterior horn, and are especially numerous in the cervical and lumbar enlargements; the axons of most of these cells pass out to form the anterior nerve roots, but before leaving the white substance they frequently give off collaterals, which reënter and ramify in the gray substance.¹ (2) Cells of small or medium size, whose axons pass into the white matter, where some pursue an ascending, and others a descending course, but most of them divide in a T-shape manner into descending and ascending processes. They give off collaterals which enter and ramify in the gray substance, and the terminations of the axons behave in a similar manner. The lengths of these axons vary greatly: some are short and pass only between adjoining spinal segments, while others are longer and connect more

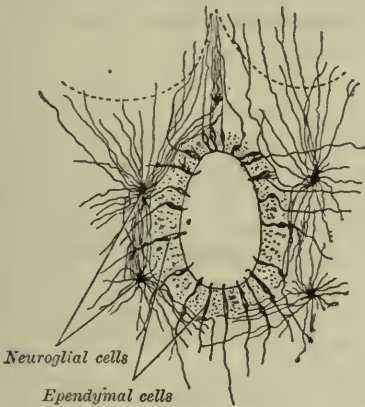


FIG. 667.—Section of central canal of medulla spinalis, showing ependymal and neuroglial cells. (v. Lenhossek.)




FIG. 668.—Cells of medulla spinalis. Diagram showing in longitudinal section the intersegmental neurons of the medulla spinalis. The gray and white parts correspond respectively to the gray and white substance of the medulla spinalis. (Poirier.)

distant segments. These cells and their processes constitute a series of **association** or **intersegmental neurons** (Fig. 668), which link together the different parts of the medulla spinalis. The axons of most of these cells are confined to that side of the medulla spinalis in which the nerve cells are situated, but some cross to the opposite side through the anterior commissure, and are termed **crossed commissural fibers**. Some of these latter end directly in the gray substance, while others enter the white substance, and ascend or descend in it for varying distances, before finally terminating in the gray substance. (3) Cells of the type II of Golgi, limited for the

¹ Lenhossek and Cajal found that in the chick embryo the axons of a few of these nerve cells passed backward through the posterior column, and emerged as the *motor fibers of the posterior nerve roots*. These fibers are said to control the peristaltic movements of the intestine. Their presence, in man, has not yet been determined.

most part to the posterior column, are found also in the substantia gelatinosa of Rolando; their axons are short and entirely confined to the gray substance, in which

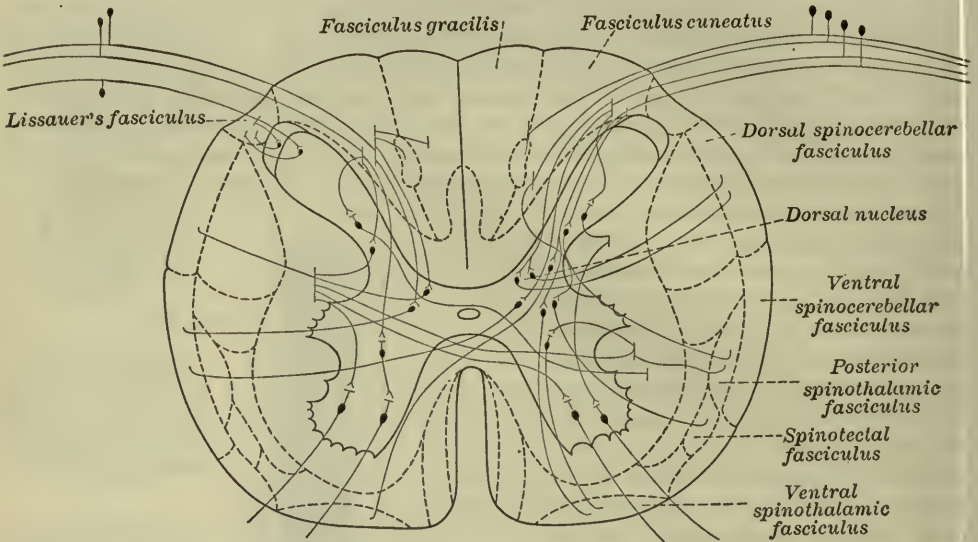


FIG. 669.—Diagram showing a few of the connections of afferent (sensory) fibers of the posterior root with the efferent fibers from the ventral column and with the various long ascending fasciculi.

they break up into numerous fine filaments. Most of the nerve cells are arranged in longitudinal columns, and appear as groups on transverse section (Figs. 669, 670, 671).

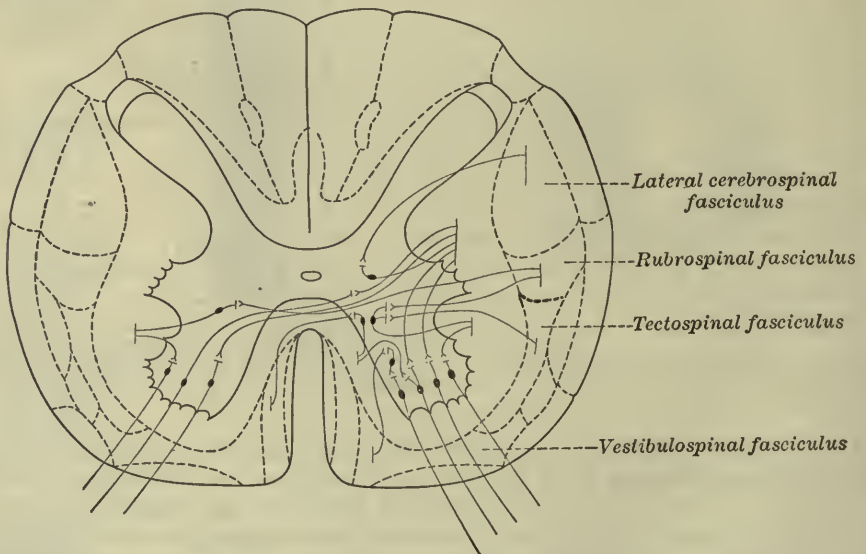


FIG. 670.—Diagram showing possible connection of long descending fibers from higher centers with the motor cells of the ventral column through association fibers.

Nerve Cells in the Anterior Column.—The nerve cells in the anterior column are arranged in columns of varying length. The longest occupies the medial part of the anterior column, and is named the **antero-medial column**: it is well marked in C4, C5, again from C8 to L4, it disappears in L5 and S1 but is well marked in

S2, S3 and S4 (Bruce).¹ Behind it is a **dorso-medial column** of small cells, which is not represented in L5, S1, S2 nor below S4. Its axons probably pass into the dorsal rami of the spinal nerves to supply the dorsal musculature of the spinal column. In the cervical and lumbar enlargements, where the anterior column is expanded in a lateral direction, the following additional columns are present, viz.: (a) **antero-lateral**, which consists of two groups, one in C4, C5, C6 the other in C6, C7, C8 in the cervical enlargement and of a group from L2 to S2 in the lumbo-sacral enlargement; (b) **postero-lateral**, in the lower five cervical, lower four lumbar, and upper three sacral segments; (c) **post-postero-lateral**, in the last cervical, first thoracic, and upper three sacral segments; and (d) a **central**, in the lower four lumbar and upper two sacral segments. These cell groups are evidently related to the nerve roots of the brachial and sacral plexuses and supply fibers to the muscles of the arm and leg. Throughout the base of the anterior column are scattered solitary cells, the axons of some of which form crossed commissural fibers, while others constitute the motor fibers of the posterior nerve roots. (See footnote, page 755.)

Nerve Cells in the Lateral Column.
—These form a column which is best marked where the lateral gray column is differentiated, viz., in the thoracic region;² but it can be traced throughout the entire length of the medulla spinalis in the form of groups of small cells which are situated in the anterior part of the formatio reticularis. In the upper part of the cervical region and lower part of the medulla oblongata as well as in the third and fourth sacral segments this column is again differentiated. In the medulla it is known as the **lateral nucleus**. The cells of this column are fusiform or star-shaped, and of a medium size: the axons of some of them pass into

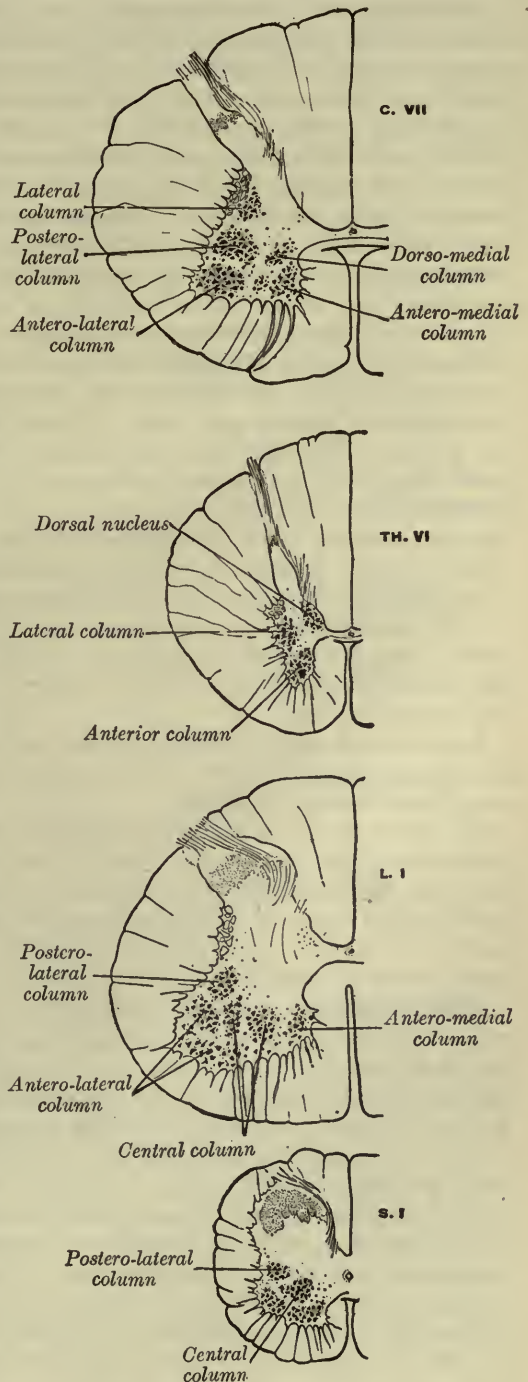


FIG. 671.—Transverse sections of the medulla spinalis at different levels to show the arrangement of the principal cell columns.

¹ Topographical Atlas of the Spinal Cord, 1901.

² According to Bruce and Pirie (B. M. J., November 17, 1906) this column extends from the middle of the eighth cervical segment to the lower part of the second lumbar or the upper part of the third lumbar segment.

the anterior nerve roots, by which they are carried to the sympathetic nerves; they constitute the white rami and are sympathetic or visceral efferent fibers; they are also known as **preganglionic fibers of the sympathetic system**; the axons of others pass into the anterior and lateral funiculi, where they become longitudinal.

Nerve Cells in the Posterior Column.—1. The **dorsal nucleus** (*nucleus dorsalis; column of Clarke*) occupies the medial part of the base of the posterior column, and appears on the transverse section as a well-defined oval area. It begins below at the level of the second or third lumbar nerve, and reaches its maximum size opposite the twelfth thoracic nerve. Above the level of the ninth thoracic nerve its size diminishes, and the column ends opposite the last cervical or first thoracic nerve. It is represented, however, in the other regions by scattered cells, which become aggregated to form a **cervical nucleus** opposite the third cervical nerve, and a **sacral nucleus** in the middle and lower part of the sacral region. Its cells are of medium size, and of an oval or pyriform shape; their axons pass into the peripheral part of the lateral funiculus of the same side, and there ascend, probably in **dorsal spinocerebellar** (*direct cerebellar*) **fasciculus**. 2. The nerve cells in the **substantia gelatinosa of Rolando** are arranged in three zones: a posterior or marginal, of large angular or fusiform cells; an intermediate, of small fusiform cells; and an anterior, of star-shaped cells. The axons of these cells pass into the lateral and posterior funiculi; and there assume a vertical course. In the anterior zone some Golgi cells are found whose short axons ramify in the gray substance. 3. **Solitary cells** of varying form and size are scattered throughout the posterior column. Some of these are grouped to form the **posterior basal column** in the base of the posterior column, lateral to the dorsal nucleus; the posterior basal column is well-marked in the gorilla (Waldeyer), but is ill-defined in man. The axons of its cells pass partly to the posterior and lateral funiculi of the same side, and partly through the anterior white commissure to the lateral funiculus of the opposite side. Golgi cells, type II, located in this region send axons to the lateral and ventral columns.

A few star-shaped or fusiform nerve cells of varying size are found in the **substantia gelatinosa centralis**. Their axons pass into the lateral funiculus of the same, or of the opposite side.

The nerve fibers in the gray substance form a dense interlacement of minute fibrils among the nerve cells. This interlacement is formed partly of axons which pass from the cells in the gray substance to enter the white funiculi or nerve roots; partly of the axons of Golgi's cells which ramify only in the gray substance; and partly of collaterals from the nerve fibers in the white funiculi which, as already stated, enter the gray substance and ramify within it.

White Substance (*substantia alba*).—The white substance of the medulla spinalis consists of medullated nerve fibers imbedded in a spongelike net-work of neuroglia, and is arranged in three funiculi: anterior, lateral, and posterior. The anterior funiculus lies between the anterior median fissure and the most lateral of the anterior nerve roots: the lateral funiculus between these nerve roots and the postero-lateral sulcus; and the posterior funiculus between the postero-lateral and the posterior median sulci (Fig. 672). The fibers vary greatly in thickness, the smallest being found in the fasciculus gracilis, the **tract of Lissauer**, and inner part of the lateral funiculus; while the largest are situated in the anterior funiculus, and in the peripheral part of the lateral funiculus. Some of the nerve fibers assume a more or less transverse direction, as for example those which cross from side to side in the anterior white commissure, but the majority pursue a longitudinal course and are divisible into (1) those connecting the medulla spinalis with the brain and conveying impulses to or from the latter, and (2) those which are confined to the medulla spinalis and link together its different segments, *i. e.*, intersegmental or association fibers.

Nerve Fasciculi.—The longitudinal fibers are grouped into more or less definite bundles or fasciculi. These are not recognizable from each other in the normal state, and their existence has been determined by the following methods: (1) A. Waller discovered that if a bundle of nerve fibers be cut, the portions of the fibers which are separated from their cells rapidly degenerate and become atrophied, while the cells and the parts of the fibers connected with them undergo little alteration.¹ This is known as **Wallerian degeneration**. Similarly, if a group of nerve cells be destroyed, the fibers arising from them undergo degeneration. Thus, if the motor cells of the cerebral cortex be destroyed, or if the fibers arising from these cells be severed, a **descending degeneration** from the seat of injury takes place in the fibers. In the same manner, if a spinal ganglion be destroyed, or the fibers which pass from it into the medulla spinalis be cut, an **ascending degeneration** will extend along these fibers. (2) Pathological changes, especially in man, have given important information by causing ascending and descending degeneration.

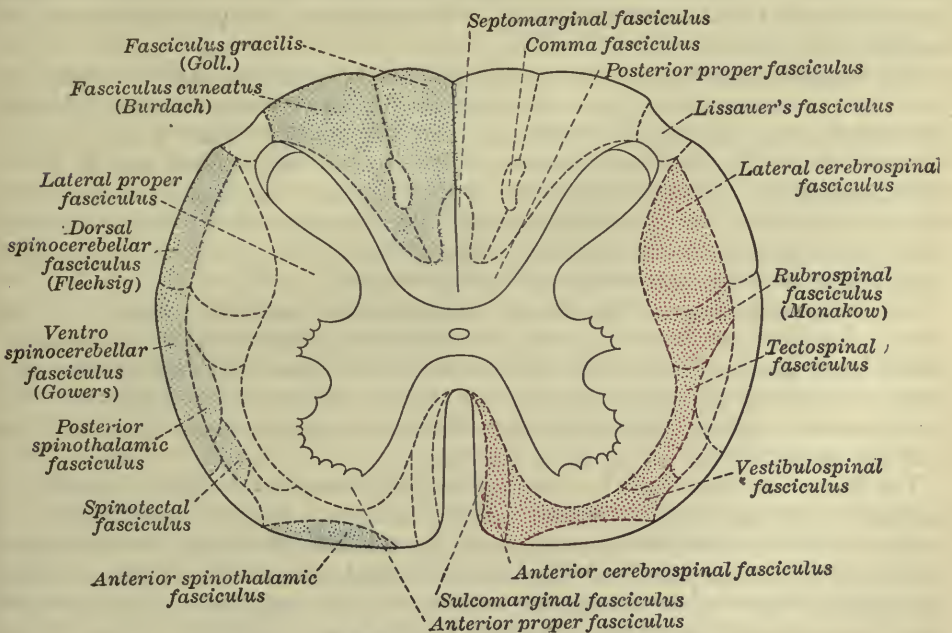


FIG. 672.—Diagram of the principal fasciculi of the spinal cord.

tions. (3) By tracing the development of the nervous system, it has been observed that at first the nerve fibers are merely naked axis-cylinders, and that they do not all acquire their medullary sheaths at the same time; hence the fibers can be grouped into different bundles according to the dates at which they receive their medullary sheaths. (4) Various methods of staining nervous tissue are of great value in tracing the course and mode of termination of the axis-cylinder processes.

Fasciculi in the Anterior Funiculus.—*Descending Fasciculi.*—The **anterior cerebrospinal** (*fasciculus cerebrospinalis anterior*; *direct pyramidal tract*), which is usually small, but varies inversely in size with the lateral cerebrospinal fasciculus. It lies close to the anterior median fissure, and is present only in the upper part of the medulla spinalis; gradually diminishing in size as it descends, it ends about the middle of the thoracic region. It consists of descending fibers which arise

¹ Somewhat later a change, termed *chromatolysis*, takes place in the nerve cells, and consists of a breaking down and an ultimate disappearance of the Nissl bodies. Further, the body of the cell is swollen, the nucleus displaced toward the periphery, and the part of the axon still attached to the altered cell is diminished in size and somewhat atrophied. Under favorable conditions the cell is capable of reassuming its normal appearance, and its axon may grow again.

from cells in the motor area of the cerebral hemisphere of the same side, and which, as they run downward in the medulla spinalis, cross in succession through the anterior white commissure to the opposite side, where they end, either directly or indirectly, by arborizing around the motor cells in the anterior column. A few of its fibers are said to pass to the lateral column of the same side and to the gray matter at the base of the posterior column. They conduct voluntary motor impulses from the precentral gyrus to the motor centers of the cord.

The **vestibulospinal fasciculus**, situated chiefly in the marginal part of the funiculus and mainly derived from the cells of Deiters' nucleus, of the same and the opposite side, *i. e.*, the chief terminal nucleus of the vestibular nerve. Fibers are also contributed to this fasciculus from scattered cells of the articular formation of the medulla oblongata, the pons and the mid-brain (tegmentum). The other terminal nuclei of the vestibular nerve also contribute fibers. In the brain stem these fibers form part of the median longitudinal bundle. The fasciculus can be traced to the sacral region. Its terminals and collaterals end either directly or indirectly among the motor cells of the anterior column. This fasciculus is probably concerned with equilibratory reflexes.

The **tectospinal fasciculus**, situated partly in the anterior and partly in the lateral funiculus, is mainly derived from the opposite superior colliculus of the mid-brain. The fibers from the superior colliculus cross the median raphé in the fountain decussation of Meynert and descend as the ventral longitudinal bundle in the reticular formation of the brain-stem. Its collaterals and terminals end either directly or indirectly among the motor cells of the anterior column of the same side. Since the superior colliculus is an important visual reflex center, the tectospinal fasciculus is probably concerned with visual reflexes.

Ascending Fasciculi.—The **ventral spinothalamic fasciculus**, situated in the marginal part of the funiculus and intermingled more or less with the vestibulospinal fasciculus, is derived from cells in the posterior column or intermediate gray matter of the opposite side. Their axons cross in the anterior commissure. This is a somewhat doubtful fasciculus and its fibers are supposed to end in the thalamus and to conduct certain of the touch impulses.

The remaining fibers of the anterior funiculus constitute what is termed the **anterior proper fasciculus** (*fasciculus anterior proprius; anterior basis bundle*). It consists of (*a*) longitudinal intersegmental fibers which arise from cells in the gray substance, more especially from those of the medial group of the anterior column, and, after a longer or shorter course, reënter the gray substance; (*b*) fibers which cross in the anterior white commissure from the gray substance of the opposite side.

Fasciculi in the Lateral Funiculus.—1. *Descending Fasciculi.*—(*a*) The **lateral cerebrospinal fasciculus** (*fasciculus cerebrospinalis lateralis; crossed pyramidal tract*) extends throughout the entire length of the medulla spinalis, and on transverse section appears as an oval area in front of the posterior column and medial to the cerebellospinal. Its fibers arise from cells in the motor area of the cerebral hemisphere of the opposite side. They pass downward in company with those of the anterior cerebrospinal fasciculus through the same side of the brain as that from which they originate, but they cross to the opposite side in the medulla oblongata and descend in the lateral funiculus of the medulla spinalis.

It is probable¹ that the fibers of the anterior and lateral cerebrospinal fasciculi are not related in this direct manner with the cells of the anterior column, but terminate by arborizing around the cells at the base of the posterior column and the cells of Clarke's column, which in turn link them to the motor cells in the anterior column, usually of several segments of the cord. In consequence of these interposed

¹ Schäfer, Proc. Physiolog. Soc., 1899.

neurons the fibers of the cerebrospinal fasciculi correspond not to individual muscles, but to associated groups of muscles.

The anterior and lateral cerebrospinal fasciculi constitute the motor fasciculi of the medulla spinalis and have their origins in the motor cells of the cerebral cortex. They descend through the internal capsule of the cerebrum, traverse the cerebral peduncles and pons and enter the pyramid of the medulla oblongata. In the lower part of the latter about two-thirds of them cross the middle line and run downward in the lateral funiculus as the lateral cerebrospinal fasciculus, while the remaining fibers do not cross the middle line, but are continued into the same side of the medulla spinalis, where they form the anterior cerebrospinal fasciculus. The fibers of the latter, however, cross the middle line in the anterior white commissure, and thus all the motor fibers from one side of the brain ultimately reach the opposite side of the medulla spinalis. The proportion of fibers which cross in the medulla oblongata is not a constant one, and thus the anterior and lateral cerebrospinal fasciculi vary inversely in size. Sometimes the former is absent, and in such cases it may be presumed that the decussation of the motor fibers in the medulla oblongata has been complete. The fibers of these two fasciculi do not acquire their medullary sheaths until after birth. In some animals the motor fibers are situated in the posterior funiculus.

(b) The **rubrospinal fasciculus** (Monakow) (*prepyramidal tract*), lies on the ventral aspect of the lateral cerebrospinal fasciculus and on transverse section appears as a somewhat triangular area. Its fibers descend from the mid-brain, where they have their origin in the red nucleus of the tegmentum of the opposite side. Its terminals and collaterals end either directly or indirectly in relation with the motor cells of the anterior column. The rubrospinal fasciculus is supposed to be concerned with cerebellar reflexes since fibers which pass from the cerebellum through the superior peduncle send many collaterals and terminals to the red nucleus.

(c) The **olivospinal fasciculus** (Helweg) arises in the vicinity of the inferior olivary nucleus in the medulla oblongata, and is seen only in the cervical region of the medulla spinalis, where it forms a small triangular area at the periphery, close to the most lateral of the anterior nerve roots. Its exact origin and its mode of ending have not yet been definitely made out.

2. *Ascending Fasciculi*.—(a) The **dorsal spinocerebellar fasciculus** (*fasciculus cerebellospinalis*; *direct cerebellar tract of Flechsig*) is situated at the periphery of the posterior part of the lateral funiculus, and on transverse section appears as a flattened band reaching as far forward as a line drawn transversely through the central canal. Medially, it is in contact with the lateral cerebrospinal fasciculus, behind, with the fasciculus of Lissauer. It begins about the level of the second or third lumbar nerve, and increasing in size as it ascends, passes to the vermis of the cerebellum through the inferior peduncle. Its fibers are generally regarded as being formed by the axons of the cells of the dorsal nucleus (*Clarke's column*); they receive their medullary sheaths about the sixth or seventh month of fetal life. Its fibers are supposed to conduct impulses of unconscious muscle sense.

The **superficial antero-lateral fasciculus** (*tract of Gowers*) consists of four fasciculi, the ventral spinocerebellar, the lateral spinothalamic, the spinotectal and the ventral spinothalamic.

(b) The **ventral spinocerebellar fasciculus** (*Gowers*) skirts the periphery of the lateral funiculus in front of the dorsal spinocerebellar fasciculus. In transverse section it is shaped somewhat like a comma, the expanded end of which lies in front of the dorsal spinocerebellar fasciculus while the tail reaches forward into the anterior funiculus. Its fibers come from the same but mostly from the opposite side of the medulla spinalis and cross both in the anterior white commissure and in the gray commissure; they are probably derived from the cells of the dorsal nucleus and from other cells of the posterior column and the intermediate portion

of the gray matter. The ventral spinocerebellar fasciculus begins about the level of the third pair of lumbar nerves, and can be followed into the medulla oblongata and pons almost to the level of the inferior colliculus where it crosses over the superior peduncle and then passes backward along its medial border to reach the vermis of the cerebellum. In the pons it lies along the lateral edge of the lateral lemniscus. Some of its fibers join the dorsal spinocerebellar fasciculus at the level of the inferior peduncle and pass with them into the cerebellum. Other fibers are said to continue upward in the dorso-lateral part of the tegmentum of the mid-brain probably as far as the thalamus.

(c) The **lateral spinothalamic fasciculus** is supposed to come from cells in the dorsal column and the intermediate gray matter whose axons cross in the anterior commissure to the opposite lateral funiculus where they pass upward on the medial side of the ventral spinocerebellar fasciculus; on reaching the medulla oblongata they continue in the formatio reticularis near the median fillet and probably terminate in the ventro-lateral region of the thalamus. It is supposed to conduct impulses of pain and temperature. The lateral and ventral spinothalamic fasciculi are sometimes termed the **secondary sensory fasciculus** or **spinal lemniscus**.

(d) The **spinotectal fasciculus** is supposed to arise in the dorsal column and terminate in the (inferior ?) and superior colliculi. It is situated ventral to the lateral spinothalamic fasciculus, but its fibers are more or less intermingled with it. It is also known as the **spino-quadrigeminal system of Mott**. In the brain-stem the fibers run lateral from the inferior olive, ventro-lateral from the superior olive, then ventro-medial from the spinal tract of the trigeminal; the fibers come to lie in the medial portion of the lateral lemniscus.

(e) The **fasciculus of Lissauer** is a small strand situated in relation to the tip of the posterior column close to the entrance of the posterior nerve roots. It consists of fine fibers which do not receive their medullary sheaths until toward the close of fetal life. It is usually regarded as being formed by some of the fibers of the posterior nerve roots, which ascend for a short distance in the tract and then enter the posterior column, but since its fibers are myelinated later than those of the posterior nerve roots, and do not undergo degeneration in locomotor ataxia, they are probably intersegmental in character.

In addition the fasciculus or tract of Lissauer contains great numbers of fine non-medullated fibers derived mostly from the dorsal roots but partly endogenous in origin. These fibers are intimately related to the substantia gelatinosa which is probably the terminal nucleus. The non-medullated fibers ascend or descend for short distances not exceeding one or two segments, but most of them enter the substantia gelatinosa at or near the level of their origin. Ransom¹ suggests that these non-medullated fibers and the substantia gelatinosa are concerned with the reflexes associated with pain impulses.

(f) The **lateral proper fasciculus** (*fasciculus lateralis proprius; lateral basis bundle*) constitutes the remainder of the lateral column, and is continuous in front with the anterior proper fasciculus. It consists chiefly of intersegmental fibers which arise from cells in the gray substance, and, after a longer or shorter course, reënter the gray substance and ramify in it. Some of its fibers are, however, continued upward into the brain under the name of the **medial longitudinal fasciculus**.

Fasciculi in the Posterior Funiculus.—This funiculus comprises two main fasciculi, viz., the **fasciculus gracilis**, and the **fasciculus cuneatus**. These are separated from each other in the cervical and upper thoracic regions by the postero-intermediate septum, and consist mainly of ascending fibers derived from the posterior nerve roots.

The **fasciculus gracilis** (*tract of Goll*) is wedge-shaped on transverse section, and lies next the posterior median septum, its base being at the surface of the medulla

¹ Ransom, Am. Jour. Anat., 1914; Brain, 1915.

spinalis, and its apex directed toward the posterior gray commissure. It increases in size from below upward, and consists of long thin fibers which are derived from the posterior nerve roots, and ascend as far as the medulla oblongata, where they end in the nucleus gracilis.

The *fasciculus cuneatus* (*tract of Burdach*) is triangular on transverse section, and lies between the *fasciculus gracilis* and the posterior column, its base corresponding with the surface of the medulla spinalis. Its fibers, larger than those of

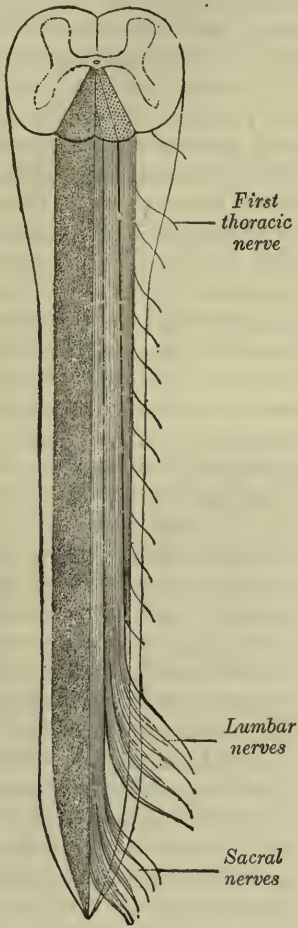


FIG. 673.—Formation of the fasciculus gracilis. Medulla spinalis viewed from behind. To the left, the fasciculus gracilis is shaded. To the right, the drawing shows that the fasciculus gracilis is formed by the long fibers of the posterior roots, and that in this tract the sacral nerves lie next the median plane, the lumbar to their lateral side, and the thoracic still more laterally. (Poirier.)

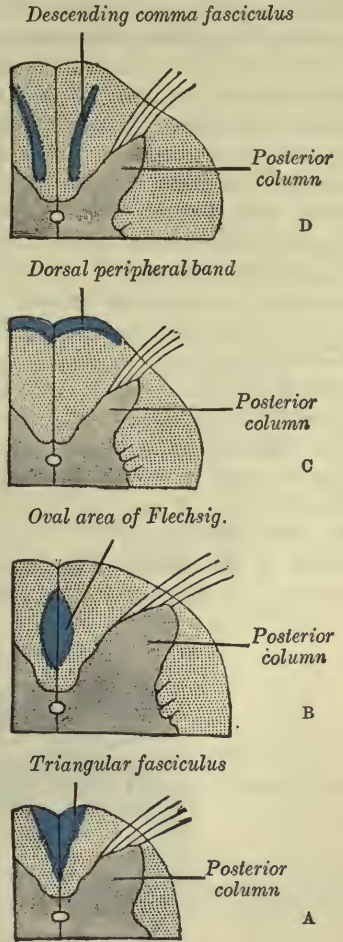


FIG. 674.—Descending fibers in the posterior funiculi, shown at different levels. A. In the conus medullaris. B. In the lumbar region. C. In the lower thoracic region. D. In the upper thoracic region. (After Testut.)

the fasciculus gracilis, are mostly derived from the same source, viz., the posterior nerve roots. Some ascend for only a short distance in the tract, and, entering the gray matter, come into close relationship with the cells of the dorsal nucleus; while others can be traced as far as the medulla oblongata, where they end in the gracile and cuneate nuclei.

The fasciculus gracilis and fasciculus cuneatus conduct (1) impulses of conscious muscle sense, neurons of the second order from the nucleus gracilis and nucleus cuneatus, pass in the median lemniscus to the thalamus and neurons of the third

order from the thalamus to the cerebral cortex; (2) impulses of unconscious muscle sense, *via* neurons of the second order from the nucleus gracilis and nucleus cuneatus pass in the internal and external arcuate fibers of the medulla oblongata to the inferior peduncle and through it to the cerebellum; (3) impulses of tactile discrimination, *via* neurons of the second order from the nucleus cuneatus and nucleus gracilis pass in the median lemniscus to the thalamus, neurons of the third order pass from the thalamus to the cortex.

The **Posterior Proper Fasciculus** (*posterior ground bundle; posterior basis bundle*) arises from cells in the posterior column; their axons bifurcate into ascending and descending branches which occupy the ventral part of the funiculus close to the gray column. They are intersegmental and run for varying distances sending off collaterals and terminals to the gray matter.

Some descending fibers occupy different parts at different levels. In the cervical and upper thoracic regions they appear as a **comma-shaped fasciculus** in the lateral part of the fasciculus cuneatus, the blunt end of the comma being directed toward the posterior gray commissure; in the lower thoracic region they form a **dorsal peripheral band** on the posterior surface of the funiculus; in the lumbar region, they are situated by the side of the posterior median septum, and appear on section as a semi-elliptical bundle, which, together with the corresponding bundle of the opposite side, forms the **oval area of Flechsig**; while in the conus medullaris they assume the form of a **triangular strand** in the postero-medial part of the fasciculus gracilis. These descending fibers are mainly intersegmental in character and derived from cells in the posterior column, but some consist of the descending branches of the posterior nerve roots. The comma-shaped fasciculus was supposed to belong to the second category, but against this view is the fact that it does not undergo descending degeneration when the posterior nerve roots are destroyed.

Roots of the Spinal Nerves.—As already stated, each spinal nerve possesses two roots, an **anterior** and a **posterior**, which are attached to the surface of the medulla spinalis opposite the corresponding column of gray substance (Fig. 675); their fibers become medullated about the fifth month of fetal life.

The **Anterior Nerve Root** (*radix anterior*) consists of efferent fibers, which are the axons of the nerve cells in the ventral part of the anterior and lateral columns. A short distance from their origins, these axons are invested by medullary sheaths and, passing forward, emerge in two or three irregular rows over an area which measures about 3 mm. in width.

The **Posterior Root** (*radix posterior*) comprises some six or eight fasciculi, attached in linear series along the postero-lateral sulcus.

It consists of afferent fibers which arise from the nerve cells in a spinal ganglion. Each ganglion cell gives off a single fiber which divides in a T-shaped manner into two processes, medial and lateral. The lateral processes extend to the sensory end-organs of the skin, muscles, tendons, joints, etc. (*somatic receptors*), and to the sensory end-organs of the viscera (*visceral*

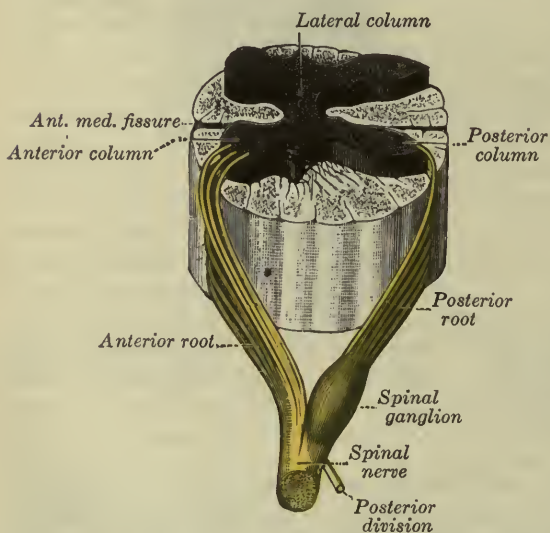


FIG. 675.—A spinal nerve with its anterior and posterior roots.

arise from the nerve cells in a spinal ganglion. Each ganglion cell gives off a single fiber which divides in a T-shaped manner into two processes, medial and lateral. The lateral processes extend to the sensory end-organs of the skin, muscles, tendons, joints, etc. (*somatic receptors*), and to the sensory end-organs of the viscera (*visceral*

receptors). The medial processes of the ganglion cells grow into the medulla spinalis as the posterior roots of the spinal nerves.

The posterior nerve root enters the medulla spinalis in three chief bundles, medial, intermediate, and lateral. The **medial** strand passes directly into the fasciculus cuneatus: it consists of coarse fibers, which acquire their medullary sheaths about the fifth month of intrauterine life; the **intermediate** strand consists of coarse fibers, which enter the gelatinous substance of Rolando; the **lateral** is composed of fine fibers, which assume a longitudinal direction in the tract of Lissauer, and do not acquire their medullary sheaths until after birth. In addition to these medullated fibers there are great numbers of non-medullated fibers which enter with the lateral bundle. They are more numerous than the myelinated fibers. They arise from the small cells of the spinal ganglia by T-shaped axons similar to the myelinated. They are distributed with the peripheral nerves chiefly to the skin, only a few are found in the nerves to the muscles.¹

Having entered the medulla spinalis, all the fibers of the posterior nerve roots divide into ascending and descending branches, and these in their turn give off collaterals which enter the gray substance (Fig. 676). The descending fibers are short, and soon enter the gray substance. The ascending fibers are grouped into long, short, and intermediate: the long fibers ascend in the fasciculus cuneatus and fasciculus gracilis as far as the medulla oblongata, where they end by arborizing around the cells of the cuneate and gracile nuclei; the short fibers run upward for a distance of only 5 or 6 mm. and enter the gray substance; while the intermediate fibers, after a somewhat longer course, have a similar destination. All fibers entering the gray substance end by arborizing around its nerve cells or the dendrites of cells, those of intermediate length being especially associated with the cells of the dorsal nucleus.

The long fibers of the posterior nerve roots pursue an oblique course upward, being situated at first in the lateral part of the fasciculus cuneatus: higher up, they occupy the middle of this fasciculus, having been displaced by the accession of other entering fibers; while still higher, they ascend in the fasciculus gracilis. The upper cervical fibers do not reach this fasciculus, but are entirely confined to the fasciculus cuneatus. The localization of these fibers is very precise: the sacral nerves lie in the medial part of the fasciculus gracilis and near its periphery, the lumbar nerves lateral to them, the thoracic nerves still more laterally; while the cervical nerves are confined to the fasciculus cuneatus (Fig. 673).

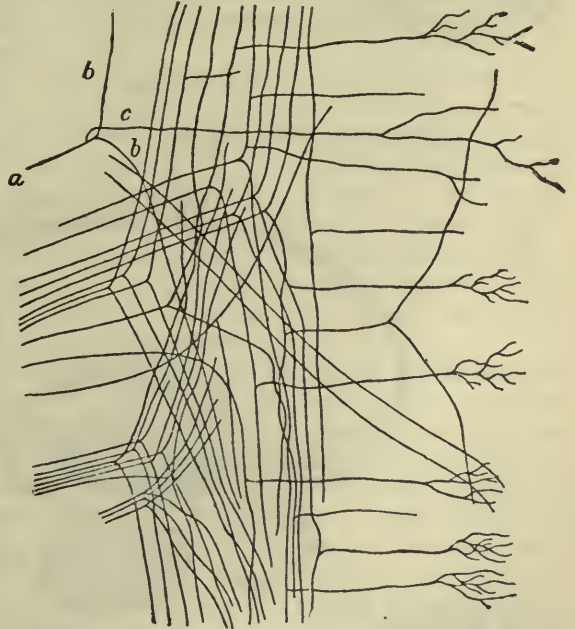


FIG. 676.—Posterior roots entering medulla spinalis and dividing into ascending and descending branches. (Van Gehuchten.) a. Stem fiber. b, b. Ascending and descending limbs of bifurcation. c. Collateral arising from stem fiber.

¹ Ransom, Brain, 1915, 38.

THE ENCEPHALON OR BRAIN.

General Considerations and Divisions.—The brain, is contained within the cranium, and constitutes the upper, greatly expanded part of the central nervous system. In its early embryonic condition it consists of three hollow vesicles, termed the **hind-brain** or **rhombencephalon**, the **mid-brain** or **mesencephalon**, and the **fore-brain** or **prosencephalon**; and the parts derived from each of these can be recognized in the adult (Fig. 677). Thus in the process of development the wall of the hind-brain undergoes modification to form the medulla oblongata, the pons, and cerebellum, while its cavity is expanded to form the fourth ventricle. The mid-brain forms only a small part of the adult brain; its cavity becomes the **cerebral aqueduct** (*aqueduct of*

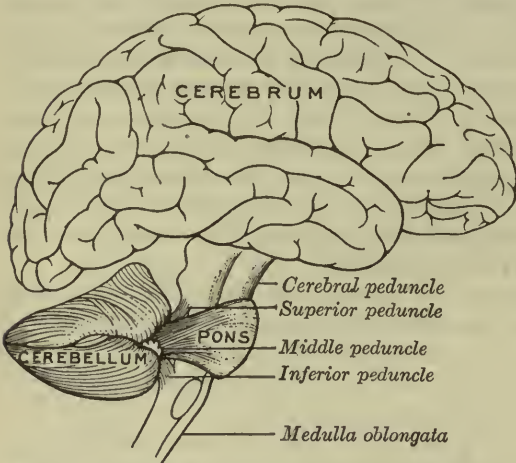


Fig. 677.—Scheme showing the connections of the several parts of the brain. (After Schwalbe.)

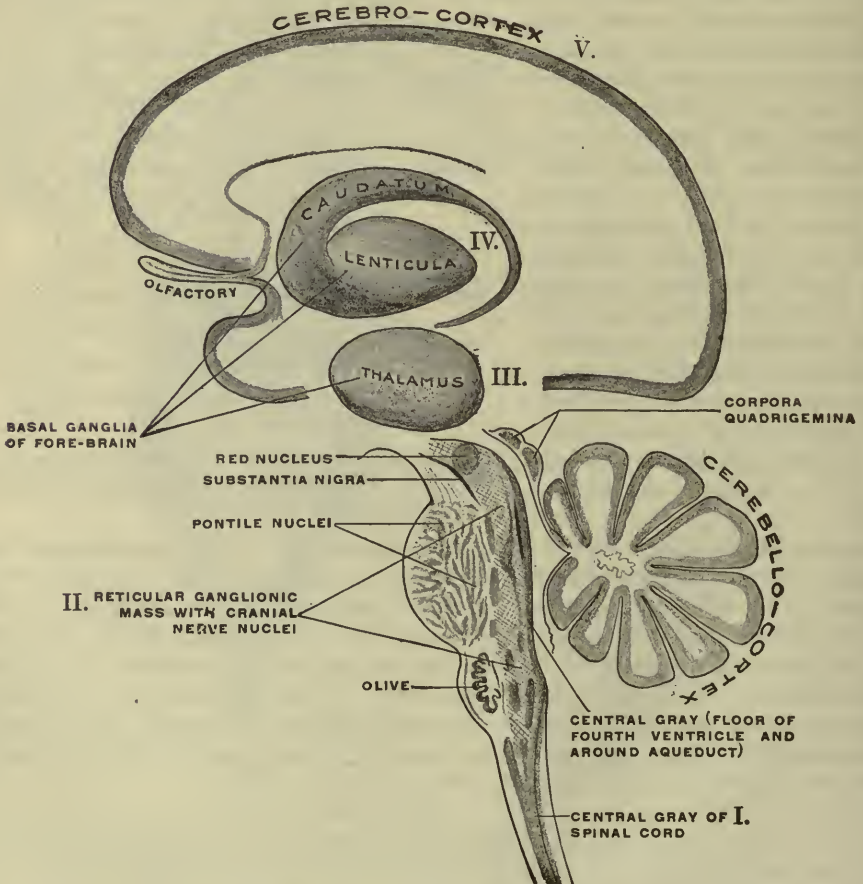


Fig. 678.—Schematic representation of the chief ganglionic categories (I to V). (Spitzka.)

Sylvius), which serves as a tubular communication between the third and fourth ventricles; while its walls are thickened to form the corpora quadrigemina and cerebral peduncles. The fore-brain undergoes great modification: its anterior part or **telencephalon** expands laterally in the form of two hollow vesicles, the cavities of which become the lateral ventricles, while the surrounding walls form the cerebral hemispheres and their commissures; the cavity of the posterior part or **diencephalon** forms the greater part of the third ventricle, and from its walls are developed most of the structures which bound that cavity.

THE HIND-BRAIN OR RHOMBENCEPHALON.

The **hind-brain** or **rhombencephalon** occupies the posterior fossa of the cranial cavity and lies below a fold of dura mater, the **tentorium cerebelli**. It consists of (a) the **myelencephalon**, comprising the medulla oblongata and the lower part of the fourth ventricle; (b) the **metencephalon**, consisting of the pons, cerebellum, and the intermediate part of the fourth ventricle; and (c) the **isthmus rhombencephali**, a constricted portion immediately adjoining the mid-brain and including the superior peduncles of the cerebellum, the anterior medullary velum, and the upper part of the fourth ventricle.

The Medulla Oblongata (*spinal bulb*).—The medulla oblongata extends from the lower margin of the pons to a plane passing transversely below the pyramidal decussation and above the first pair of cervical nerves; this plane corresponds with the upper border of the atlas behind, and the middle of the odontoid process of the axis in front; at this level the medulla oblongata is continuous with the medulla spinalis. Its anterior surface is separated from the basilar part of the occipital bone and the upper part of the odontoid process by the membranes of the brain and the occipitoaxial ligaments. Its posterior surface is received into the fossa between the hemispheres of the cerebellum, and the upper portion of it forms the lower part of the floor of the fourth ventricle.

The medulla oblongata is pyramidal in shape, its broad extremity being directed upward toward the pons, while its narrow, lower end is continuous with the medulla spinalis. It measures about 3 cm. in length, about 2 cm. in breadth at its widest part, and about 1.25 cm. in thickness. The central canal of the medulla spinalis is prolonged into its lower half, and then opens into the cavity of the fourth ventricle; the medulla oblongata may therefore be divided into a lower *closed part* containing the central canal, and an upper *open part* corresponding with the lower portion of the fourth ventricle.

The **Anterior Median Fissure** (*fissura mediana anterior; ventral or ventromedian fissure*) contains a fold of pia mater, and extends along the entire length of the medulla oblongata: it ends at the lower border of the pons in a small triangular expansion, termed the **foramen cecum**. Its lower part is interrupted by bundles of fibers which cross obliquely from one side to the other, and constitute the **pyramidal decussation**. Some fibers, termed the **anterior external arcuate fibers**, emerge from the fissure above this decussation and curve lateralward and upward over the surface of the medulla oblongata to join the inferior peduncle.

The **Posterior Median Fissure** (*fissura mediana posterior; dorsal or dorsomedian fissure*) is a narrow groove; and exists only in the closed part of the medulla oblongata; it becomes gradually shallower from below upward, and finally ends about the middle of the medulla oblongata, where the central canal expands into the cavity of the fourth ventricle.

These two fissures divide the closed part of the medulla oblongata into symmetrical halves, each presenting elongated eminences which, on surface view, are continuous with the funiculi of the medulla spinalis. In the open part the halves are separated by the anterior median fissure, and by a median raphe which

extends from the bottom of the fissure to the floor of the fourth ventricle. Further, certain of the cranial nerves pass through the substance of the medulla oblongata, and are attached to its surface in series with the roots of the spinal nerves; thus, the fibers of the hypoglossal nerve represent the upward continuation of the anterior nerve roots, and emerge in linear series from a furrow termed the **antero-lateral sulcus**. Similarly, the accessory, vagus, and glossopharyngeal nerves correspond with the posterior nerve roots, and are attached to the bottom of a sulcus named the **postero-lateral sulcus**. Advantage is taken of this arrangement to subdivide each half of the medulla oblongata into three districts, **anterior**, **middle**, and **posterior**. Although these three districts appear to be directly continuous with the corresponding funiculi of the medulla spinalis, they do not necessarily contain the same fibers, since some of the fasciculi of the medulla spinalis end in the medulla oblongata, while others alter their course in passing through it.

The **anterior district** (Fig. 679) is named the **pyramid** (*pyramis medullæ oblongatæ*) and lies between the anterior median fissure and the antero-lateral sulcus. Its upper end is slightly constricted, and between it and the pons the fibers of the abducent nerve emerge; a little below the pons it becomes enlarged and prominent, and finally tapers into the anterior funiculus of the medulla spinalis, with which, at first sight, it appears to be directly continuous.

The two pyramids contain the motor fibers which pass from the brain to the medulla oblongata and medulla spinalis, corticobulbar and corticospinal fibers. When these pyramidal fibers are traced down-

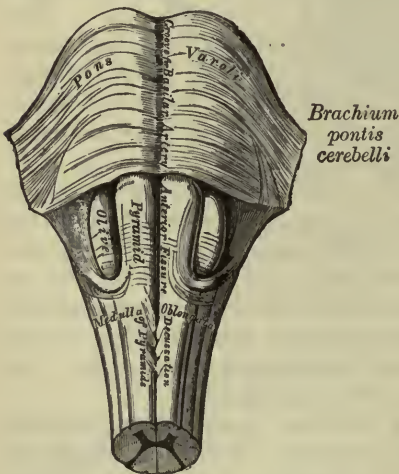


FIG. 679.—Medulla oblongata and pons. Anterior surface.

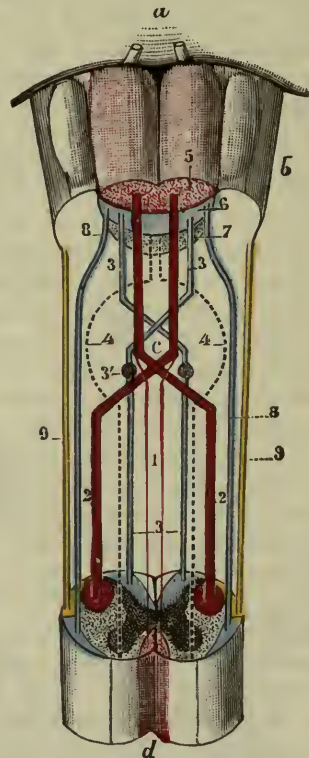


FIG. 680.—Decussation of pyramids. Scheme showing passage of various fasciculi from medulla spinalis to medulla oblongata. *a*, Pons. *b*, Medulla oblongata. *c*, Decussation of the pyramids. *d*, Section of cervical part of medulla spinalis. 1, Anterior cerebrospinal fasciculus (in red). 2, Lateral cerebrospinal fasciculus (in blue). 3, Sensory tract (fasciculi gracilis et cuneatus) (in blue). 3', Gracile and cuneate nuclei. 4, Antero-lateral proper fasciculus (in dotted line). 5, Pyramid. 6, Lemniscus. 7, Medial longitudinal fasciculus. 8, Ventral spinocerebellar fasciculus (in blue). 9, Dorsal spinocerebellar fasciculus (in yellow). (Testut.)

ward it is found that some two-thirds or more of them leave the pyramids in successive bundles, and decussate in the anterior median fissure, forming what is termed the **pyramidal decussation**. Having crossed the middle line, they pass down in the posterior part of the lateral funiculus as the lateral cerebrospinal fascic-

ulus. The remaining fibers—*i. e.*, those which occupy the lateral part of the pyramid—do not cross the middle line, but are carried downward as the anterior cerebrospinal fasciculus (Fig. 680) into the anterior funiculus of the same side.

The greater part of the anterior proper fasciculus of the medulla spinalis is continued upward through the medulla oblongata under the name of the **medial longitudinal fasciculus**.

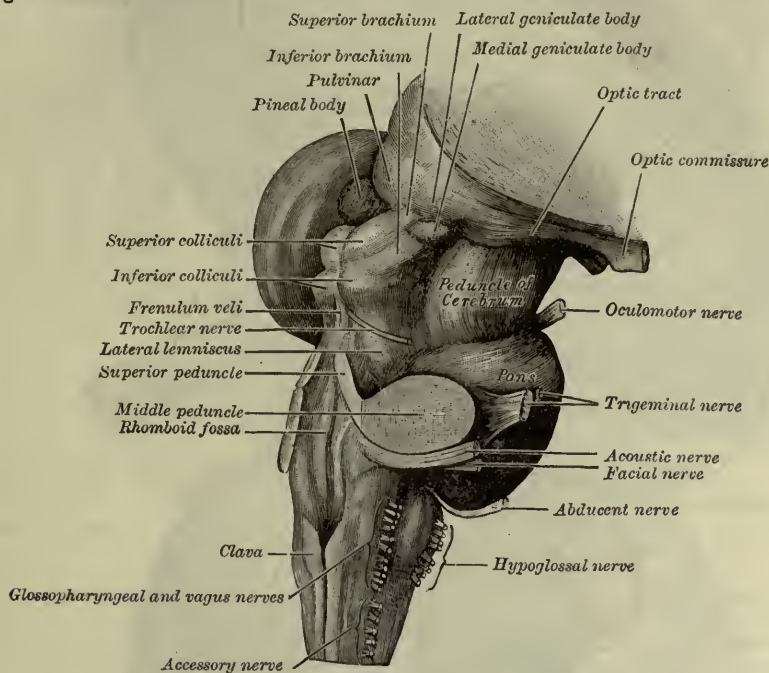


FIG. 681.—Hind- and mid-brains; postero-lateral view.

The **lateral district** (Fig. 681) is limited in front by the antero-lateral sulcus and the roots of the hypoglossal nerve, and behind by the postero-lateral sulcus and the roots of the accessory, vagus, and glossopharyngeal nerves. Its upper part consists of a prominent oval mass which is named the **olive**, while its lower part is of the same width as the lateral funiculus of the medulla spinalis, and appears on the surface to be a direct continuation of it. As a matter of fact, only a portion of the lateral funiculus is continued upward into this district, for the lateral cerebrospinal fasciculus passes into the pyramid of the opposite side, and the dorsal spinocerebellar fasciculus is carried into the inferior peduncle in the posterior district. The ventral spinocerebellar fasciculus is continued upward on the lateral surface of the medulla oblongata in the same relative position it occupies in the spinal cord until it passes under cover of the external arcuate fibers. It passes beneath these fibers just dorsal to the olive and ventral to the roots of the vagus and glossopharyngeal nerves; it continues upward through the pons along the dorso-lateral edge of the lateral lemniscus. The remainder of the lateral funiculus consists chiefly of the lateral proper fasciculus. Most of these fibers dip beneath the olive and disappear from the surface; but a small strand remains superficial to the olive. In a depression at the upper end of this strand is the acoustic nerve.

The **olive** (*oliva; olivary body*) is situated lateral to the pyramid, from which it is separated by the antero-lateral sulcus, and the fibers of the hypoglossal nerve. Behind, it is separated from the postero-lateral sulcus by the ventral spinocerebellar fasciculus. In the depression between the upper end of the olive and the pons lies the acoustic nerve. It measures about 1.25 cm. in length, and between its upper

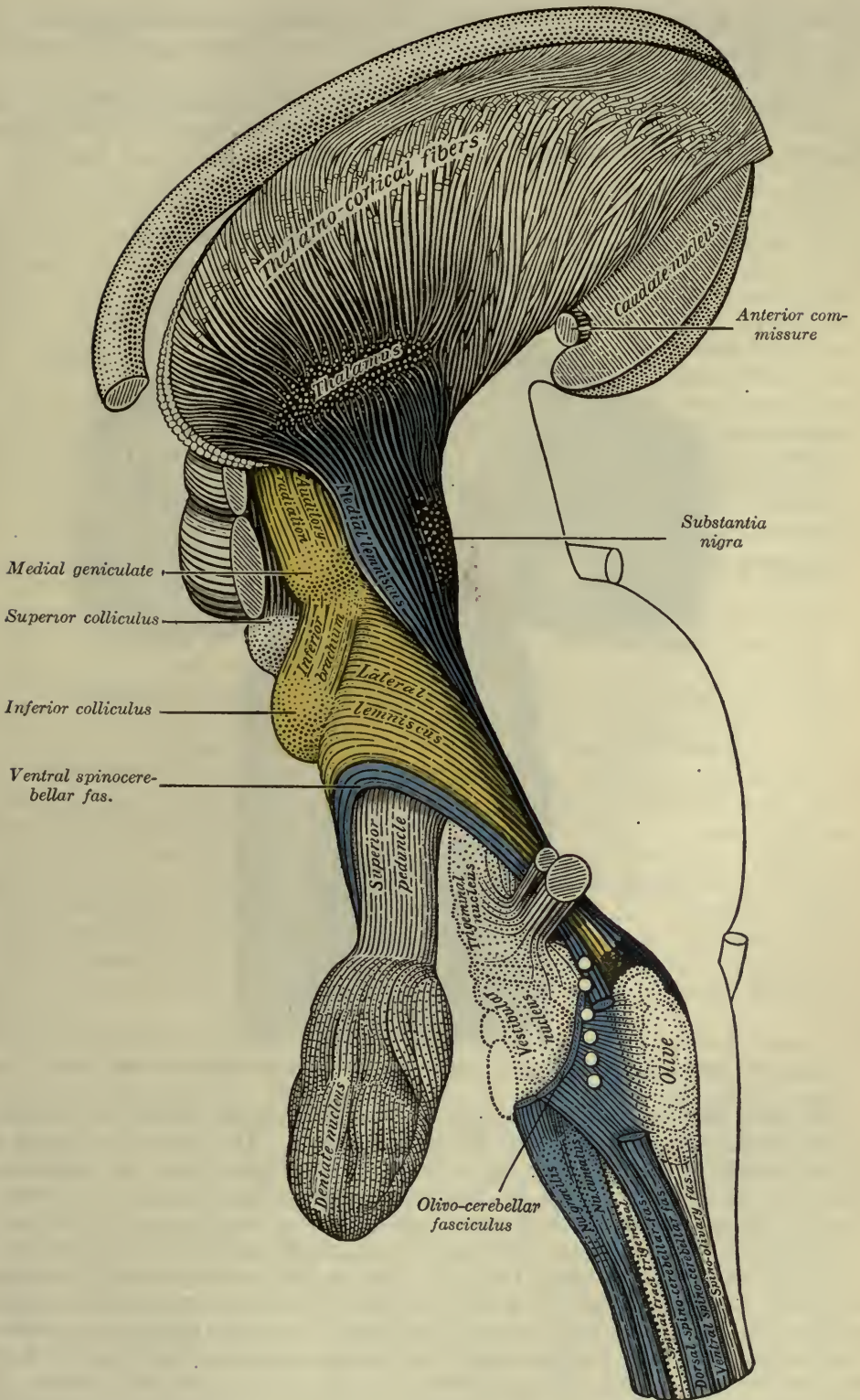


FIG. 685.—Deep dissection of brain-stem. Lateral view.

end and the pons there is a slight depression to which the roots of the facial nerve are attached. The external arcuate fibers wind across the lower part of the pyramid and olive and enter the inferior peduncle.

The posterior district (Fig. 686) lies behind the postero-lateral sulcus and the roots of the accessory, vagus, and the glossopharyngeal nerves, and, like the lateral district, is divisible into a lower and an upper portion.

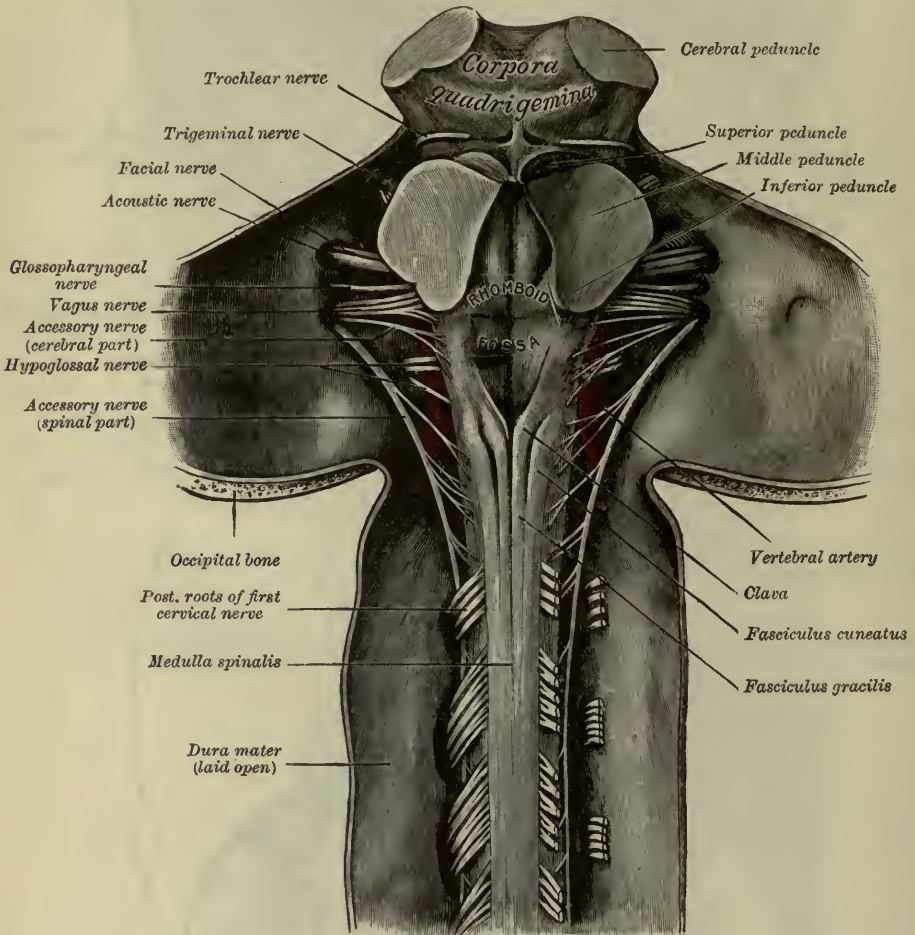


FIG. 686.—Upper part of medulla spinalis and hind- and mid-brains; posterior aspect, exposed *in situ*.

The lower part is limited behind by the posterior median fissure, and consists of the **fasciculus gracilis** and the **fasciculus cuneatus**. The fasciculus gracilis is placed parallel to and along the side of the posterior median fissure, and separated from the fasciculus cuneatus by the postero-intermediate sulcus and septum. The gracile and cuneate fasciculi are at first vertical in direction; but at the lower part of the rhomboid fossa they diverge from the middle line in a V-shaped manner, and each presents an elongated swelling. That on the fasciculus gracilis is named the **clava**, and is produced by a subjacent nucleus of gray matter, the **nucleus gracilis**; that on the fasciculus cuneatus is termed the **cuneate tubercle**, and is likewise caused by a gray nucleus, named the **nucleus cuneatus**. The fibers of these fasciculi terminate by arborizing around the cells in their respective nuclei. A third elevation, produced by the substantia gelatinosa of Rolando, is present in the lower part of the posterior district of the medulla oblongata. It lies on the

lateral aspect of the fasciculus cuneatus, and is separated from the surface of the medulla oblongata by a band of nerve fibers which form the spinal tract (spinal root) of the trigeminal nerve. Narrow below, this elevation gradually expands above, and ends, about 1.25 cm. below the pons, in a tubercle, the **tubercle of Rolando** (*tuber cinereum*).

The upper part of the posterior district of the medulla oblongata is occupied by the **inferior peduncle**, a thick rope-like strand situated between the lower part of the fourth ventricle and the roots of the glossopharyngeal and vagus nerves. The inferior peduncles connect the medulla spinalis and medulla oblongata with the cerebellum, and are sometimes named the **restiform bodies**. As they pass upward, they diverge from each other, and assist in forming the lower part of the lateral boundaries of the fourth ventricle; higher up, they are directed backward, each passing to the corresponding cerebellar hemisphere. Near their entrance, into the cerebellum they are crossed by several strands of fibers, which run to the median sulcus of the rhomboid fossa, and are named the **striæ medullares**. The inferior peduncle appears to be the upward continuation of the fasciculus gracilis and fasciculus cuneatus; this, however, is not so, as the fibers of these fasciculi end in the gracile and cuneate nuclei. The constitution of the inferior peduncle will be subsequently discussed.

Caudal to the striæ medullares the inferior peduncle is partly covered by the corpus pontobulbare (Essick¹), a thin mass of cells and fibers extending from the pons between the origin of the VII and VIII cranial nerves.

Internal Structure of the Medulla Oblongata.—Although the external form of the medulla oblongata bears a certain resemblance to that of the upper part of the medulla spinalis, its internal structure differs widely from that of the latter, and this for the following principal reasons: (1) certain fasciculi which extend from the medulla spinalis to the brain, and *vice versa*, undergo a rearrangement in their passage through the medulla oblongata; (2) others which exist in the medulla spinalis end in the medulla oblongata; (3) new fasciculi originate in the gray substance of the medulla oblongata and pass to different parts of the brain; (4) the gray substance, which in the medulla spinalis forms a continuous H-shaped column, becomes greatly modified and subdivided in the medulla oblongata, where also new masses of gray substance are added; (5) on account of the opening out of the central canal of the medulla spinalis, certain parts of the gray substance, which in the medulla spinalis were more or less centrally-situated, are displayed in the rhomboid fossa; (6) the medulla oblongata is intimately associated with many of the cranial nerves, some arising from, and others ending in, nuclei within its substance.

The Cerebrospinal Fasciculi.—The downward course of these fasciculi from the pyramids of the medulla oblongata and their partial decussation have already been described (page 761). In crossing to reach the lateral funiculus of the opposite side, the fibers of the lateral cerebrospinal fasciculi extend backward through the anterior columns, and separate the head of each of these columns from its base (Figs. 687, 688). The base retains its position in relation to the ventral aspect of the central canal, and, when the latter opens into the fourth ventricle, appears in the rhomboid fossa close to the middle line, where it forms the nuclei of the hypoglossal and abducent nerves; while above the level of the ventricle it exists as the nuclei of the trochlear and oculomotor nerves in relation to the floor of the cerebral aqueduct. The head of the column is pushed lateralward and forms the **nucleus ambiguus**, which gives origin from below upward to the cranial part of the accessory and the motor fibers of the vagus and glossopharyngeal, and still higher to the motor fibers of the facial and trigeminal nerves.

¹ Essick, Am. Jour. Anat., 1907.

The fasciculus gracilis and fasciculus cuneatus constitute the posterior sensory fasciculi of the medulla spinalis; they are prolonged upward into the lower part

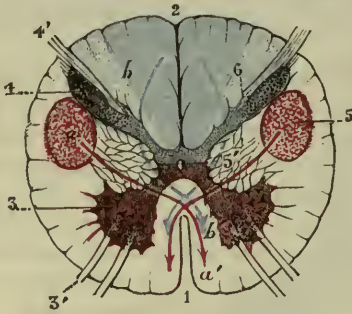


FIG. 687.—Section of the medulla oblongata through the lower part of the decussation of the pyramids. (Testut.) 1. Anterior median fissure. 2. Posterior median sulcus. 3. Anterior column (in red), with 3', anterior root. 4. Posterior column (in blue), with 4', posterior roots. 5. Lateral cerebrospinal fasciculus. 6. Posterior funiculus. The red arrow, *a, a'*, indicates the course the lateral cerebrospinal fasciculus takes at the level of the decussation of the pyramids; the blue arrow, *b, b'*, indicates the course which the sensory fibers take.

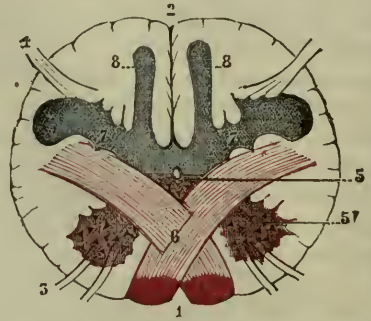


FIG. 688.—Section of the medulla oblongata at the level of the decussation of the pyramids. (Testut.) 1. Anterior median fissure. 2. Posterior median sulcus. 3. Motor roots. 4. Sensory roots. 5. Base of the anterior column, from which the head (5') has been detached by the lateral cerebrospinal fasciculus. 6. Decussation of the lateral cerebrospinal fasciculus. 7. Posterior columns (in blue). 8. Gracile nucleus.

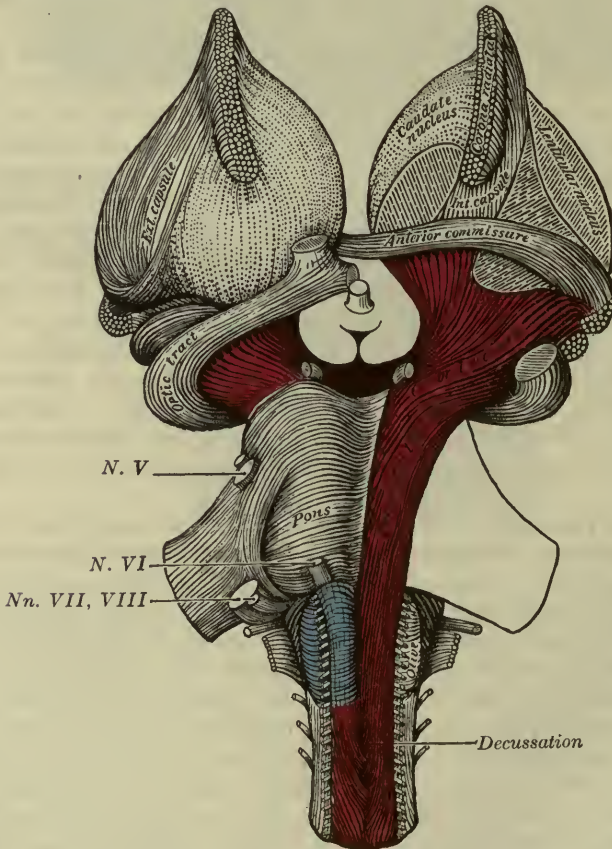


FIG. 689.—Superficial dissection of brain-stem. Ventral view.

of the medulla oblongata, where they end respectively in the nucleus gracilis and nucleus cuneatus. These two nuclei are continuous with the central gray substance

of the medulla spinalis, and may be regarded as dorsal projections of this, each being covered superficially by the fibers of the corresponding fasciculus. On transverse section (Fig. 694) the nucleus gracilis appears as a single, more or less quadrangular mass, while the nucleus cuneatus consists of two parts: a larger, somewhat triangular, **medial nucleus**, composed of small or medium-sized cells, and a smaller **lateral nucleus** containing large cells.

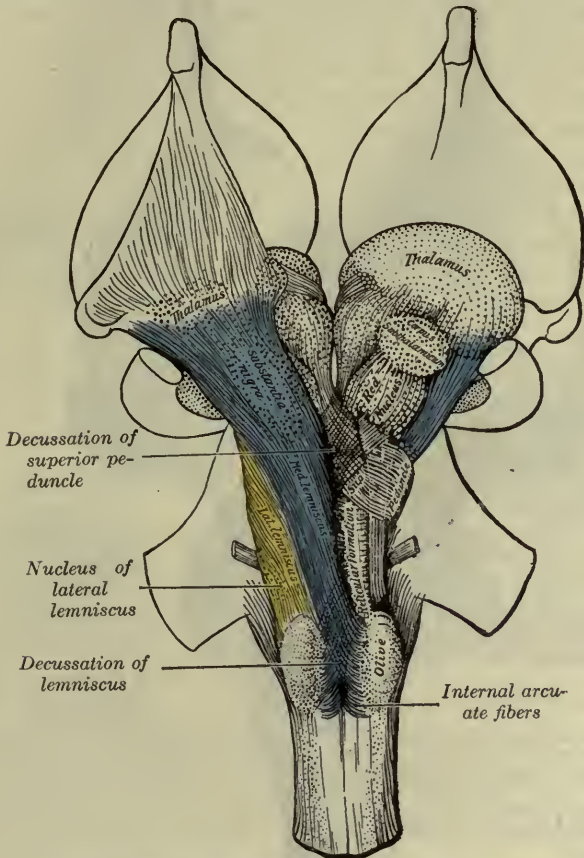


FIG. 690.—Deep dissection of brain-stem. Ventral view.

The fibers of the fasciculus gracilis and fasciculus cuneatus end by arborizing around the cells of these nuclei (Fig. 692). From the cells of the nuclei new fibers arise; some of these are continued as the posterior external arcuate fibers into the inferior peduncle, and through it to the cerebellum, but most of them pass forward through the neck of the posterior column, thus cutting off its head from its base (Fig. 693). Curving forward, they decussate in the middle line with the corresponding fibers of the opposite side, and run upward immediately behind the cerebrospinal fibers, as a flattened band, named the **lemniscus** or **fillet**. The decussation of these sensory fibers is situated above that of the motor fibers, and is named the **decussation of the lemniscus** or **sensory decussation**. The **lemniscus** is joined by the spinothalamic fasciculus (page 762), the fibers of which are derived from the cells of the gray substance of the opposite side of the medulla spinalis.

The base of the posterior column at first lies on the dorsal aspect of the central canal, but when the latter opens into the fourth ventricle, it appears in the lateral part of the rhomboid fossa. It forms the terminal nuclei of the sensory fibers of

the vagus and glossopharyngeal nerves, and is associated with the vestibular part of the acoustic nerve and the sensory root of the facial nerve. Still higher, it forms a mass of pigmented cells—the *locus cæruleus*—in which some of the sensory fibers of the trigeminal nerve appear to end. The head of the posterior column forms a long nucleus, in which the fibers of the spinal tract of the trigeminal nerve largely end.

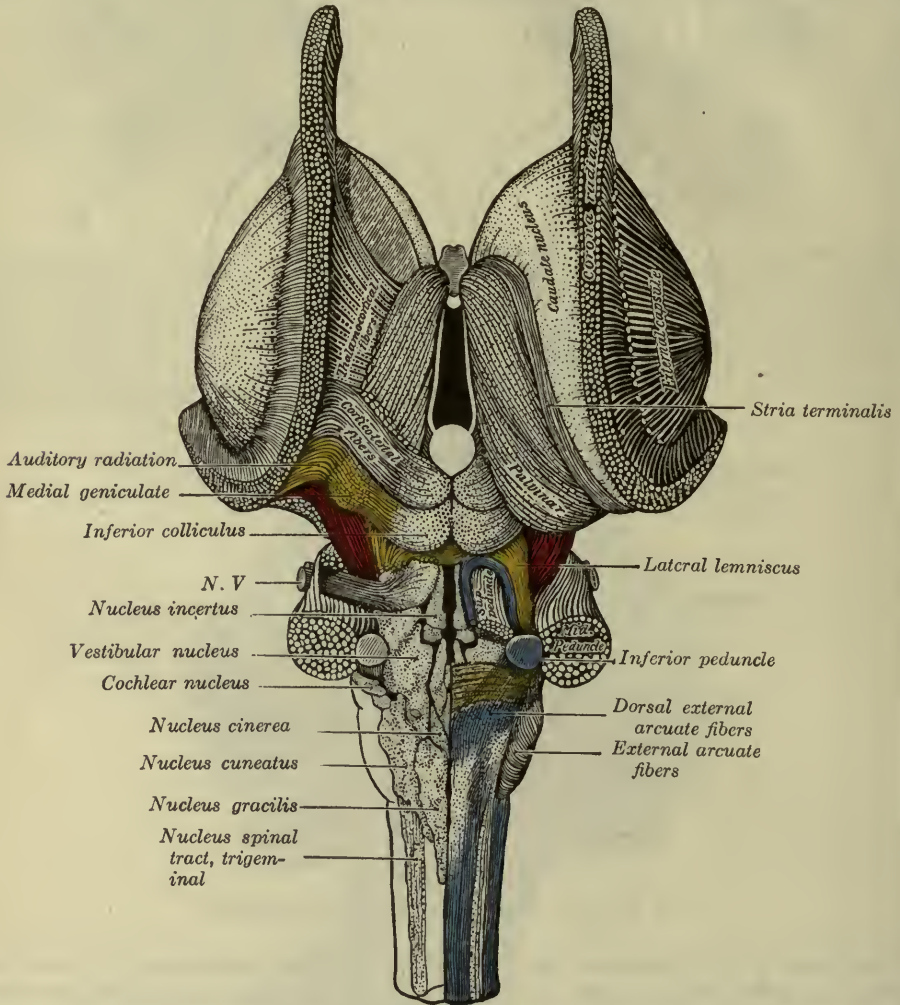


FIG. 691.—Dissection of brain-stem. Dorsal view. The nuclear masses of the medulla are taken from model by Weed, Carnegie Publication, No. 19.

The **dorsal spinocerebellar fasciculus** (*fasciculus cerebellospinalis*; *direct cerebellar tract*) leaves the lateral district of the medulla oblongata; most of its fibers are carried backward into the inferior peduncle of the same side, and through it are conveyed to the cerebellum; but some run upward with the fibers of the lemniscus, and, reaching the inferior colliculus, undergo decussation, and are carried to the cerebellum through the superior peduncle.

The **proper fasciculi** (*basis bundles*) of the anterior and lateral funiculi largely consist of intersegmental fibers, which link together the different segments of the medulla spinalis; they assist in the production of the *formatio reticularis* of the medulla oblongata, and many of them are accumulated into a fasciculus which runs up close to the median raphé between the lemniscus and the rhomboid fossa;

this strand is named the **medial longitudinal fasciculus**, and will be again referred to.

Gray Substance of the Medulla Oblongata (Figs. 694, 695).—In addition to the gracile and cuneate nuclei, there are several other nuclei to be considered. Some of these are traceable from the gray substance of the medulla spinalis, while others are unrepresented in it.

1. The **hypoglossal nucleus** is derived from the base of the anterior column; in the lower closed part of the medulla oblongata it is situated on the ventro-lateral aspect of the central canal; but in the upper part it approaches the rhomboid fossa, where it lies close to the middle line, under an eminence named the **trigonum hypoglossi** (Fig. 709). Numerous fibers connect the two nuclei, both nuclei send long dendrons across the midline to the opposite nucleus; commissure fibers also connect them. The nucleus measures about 2 cm. in length, and con-

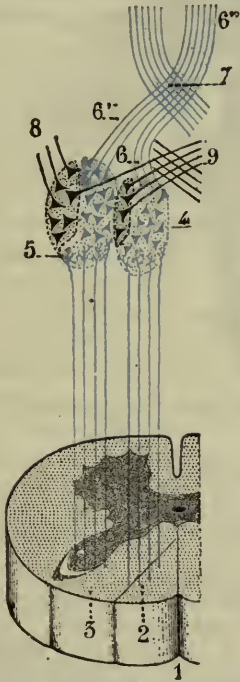


FIG. 692.—Superior terminations of the posterior fasciculi of the medulla spinalis. 1. Posterior median sulcus. 2. Fasciculus gracilis. 3. Fasciculus cuneatus. 4. Gracile nucleus. 5. Cuneate nucleus. 6, 6', 6''. Sensory fibers forming the lemniscus. 7. Sensory decussation. 8. Cerebellar fibers uncrossed (in black). 9. Cerebellar fibers crossed (in black). (Testut.)

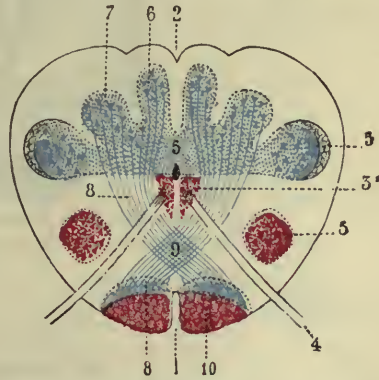


FIG. 693.—Transverse section passing through the sensory decussation. (Schematic.) 1. Anterior median fissure. 2. Posterior median sulcus. 3, 3'. Head and base of anterior column (in red). 4. Hypoglossal nerve. 5. Bases of posterior columns. 6. Gracile nucleus. 7. Cuneate nucleus. 8, 8. Lemniscus. 9. Sensory decussation. 10. Cerebrospinal fasciculus. (Testut.)

sists of large multipolar nerve cells, similar to those in the anterior column of the spinal cord, whose axons constitute the roots of the hypoglossal nerve. These nerve roots leave the ventral side of the nucleus, pass forward between the white reticular formation and the gray reticular formation, some between the inferior olivary nucleus and the medial accessory olivary nucleus, and emerge from the antero-lateral sulcus.

2. The **nucleus ambiguus** (Figs. 696, 697), the somatic motor nucleus of the glosso-pharyngeal, vagus and cranial portion of the accessory nerves, is the continuation into the medulla oblongata of the dorso-lateral cell group of the anterior column of the spinal cord. Its large multipolar cells are like those in the anterior column of the cord; they form a slender column in the deep part of the formatio reticularis grisea about midway between the dorsal accessory olive and the nucleus of the spinal tract of the trigeminal. It extends from the level of the decussation of the median fillet to the upper end of the medulla oblongata. Its fibers first pass backward toward the floor of the fourth ventricle and then curve rather abruptly lateralward and ventrally to join the fibers from the dorsal nucleus.

3. The dorsal nucleus (Figs. 696, 698), nucleus ala cinerea, often called the sensory nucleus or the terminal nucleus of the sensory fibers of the glossopharyngeal

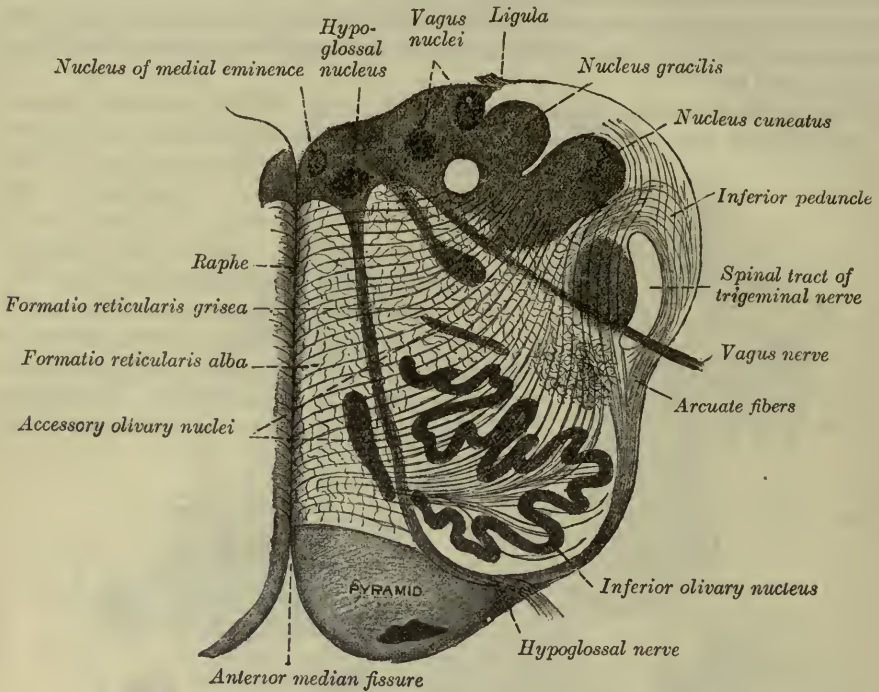


FIG. 694.—Section of the medulla oblongata at about the middle of the olive. (Schwalbe.)

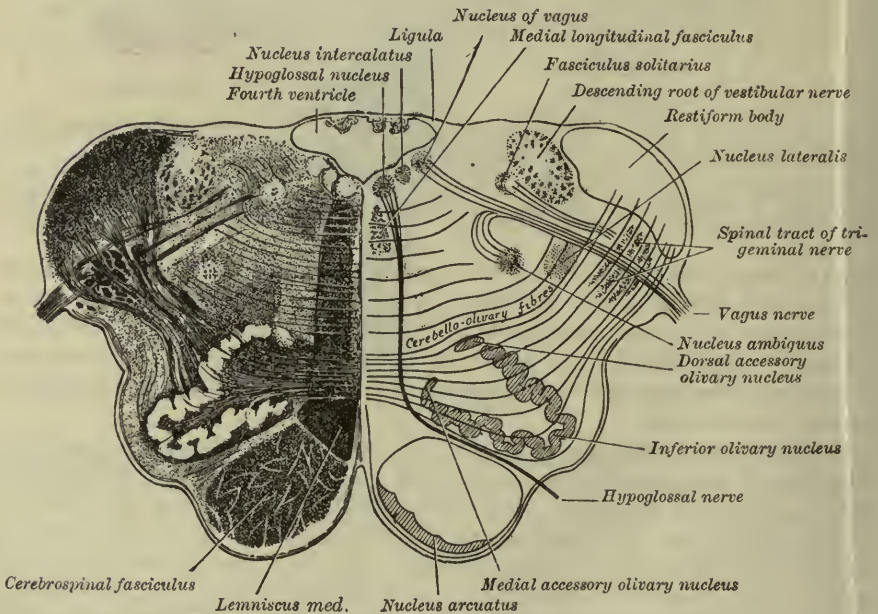


FIG. 695.—Transverse section of medulla oblongata below the middle of the olive.

and vagus nerves, is probably a mixed nucleus and contains not only the terminations of the sympathetic afferent or sensory fibers and the cells connected with them but contains also cells which give rise to sympathetic efferent or preganglionic fibers.

These preganglionic fibers terminate in sympathetic ganglia from which the impulses are carried by other neurons. The cells of the dorsal nucleus are spindle-shaped, like those of the posterior column of the spinal cord, and the nucleus is usually considered as representing the base of the posterior column. It measures about 2 cm. in length, and in the lower, closed part of the medulla oblongata is situated behind the hypoglossal nucleus; whereas in the upper, open part it lies lateral to that nucleus, and corresponds to an eminence, named the *ala cinerea* (*trigonum vagi*), in the rhomboid fossa.

4. The nuclei of the cochlear and vestibular nerves are described on page 788.

5. The olivary nuclei (Fig. 694) are three in number on either side of the middle line, viz., the inferior olivary nucleus, and the medial and dorsal accessory olivary nuclei; they consist of small, round, yellowish cells and numerous fine nerve fibers. (a) The inferior olivary nucleus is the largest, and is situated within the olive. It consists of a gray folded lamina arranged in the form of an incomplete capsule, opening medially by an aperture called the *hilum*; emerging from the hilum are numerous fibers which collectively constitute the *peduncle of the olive*. The axons, *olivocerebellar fibers*, which leave the olivary nucleus pass out through the hilum and decussate with those from the opposite olive in the raphé, then as internal arcuate fibers they pass partly through and partly around the opposite olive and enter the inferior peduncle to be distributed to the cerebellar hemisphere of the opposite side from which they arise. The fibers are smaller than the internal arcuate fibers connected with the median lemniscus. Fibers passing in the opposite direction from the cerebellum to the olivary nucleus are often described but their existence is doubtful. Much uncertainty also exists in regard to the connections

of the olive and the spinal cord. Important connections between the cerebrum and the olive of the same side exist but the exact pathway is unknown. Many collaterals from the reticular formation and from the pyramids enter the inferior olivary nucleus. Removal of one cerebellar hemisphere is followed by atrophy of the opposite olivary nucleus. (b) The *medial accessory olivary nucleus* lies between the inferior olivary nucleus and the pyramid, and forms a curved lamina, the concavity of which is directed laterally. The fibers of the hypoglossal nerve, as they

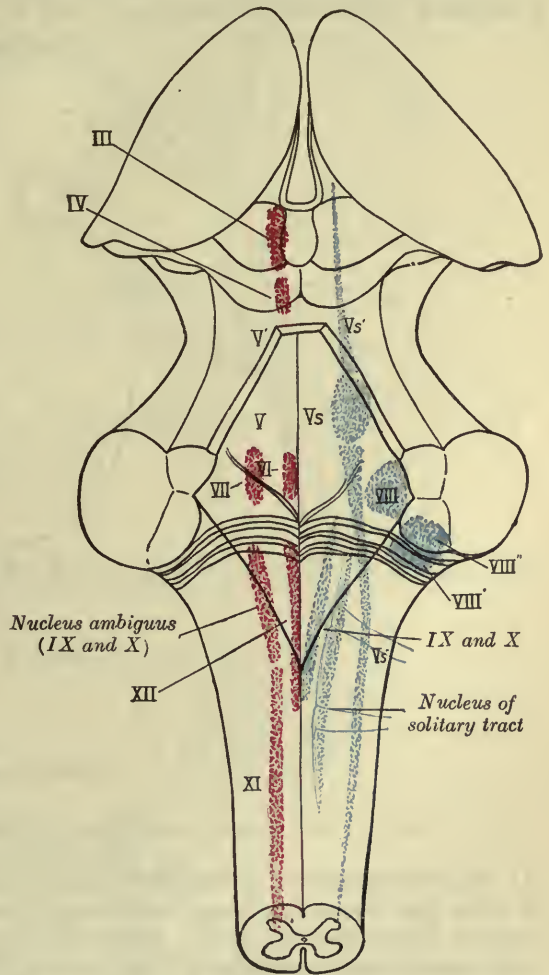


FIG. 696.—The cranial nerve nuclei schematically represented; dorsal view. Motor nuclei in red; sensory in blue. (The olfactory and optic centers are not represented.)

traverse the medulla, pass between the medial accessory and the inferior olivary nuclei. (c) The **dorsal accessory olivary nucleus** is the smallest, and appears on transverse section as a curved lamina behind the inferior olivary nucleus.

6. The **nucleus arcuatus** is described below with the anterior external arcuate fibers.

Inferior Peduncle (*restiform body*).—The position of the inferior peduncles has already been described (page 775). Each comprises:

- (1) Fibers from the **dorsal spinocerebellar fasciculus**, which ascends from the lateral funiculus of the medulla spinalis.
- (2) The **olivocerebellar fibers** from the opposite olivary nucleus.
- (3) **Internal arcuate fibers** from the gracile and cuneate nuclei of the opposite side; these fibers form the deeper and larger part of the inferior peduncle.

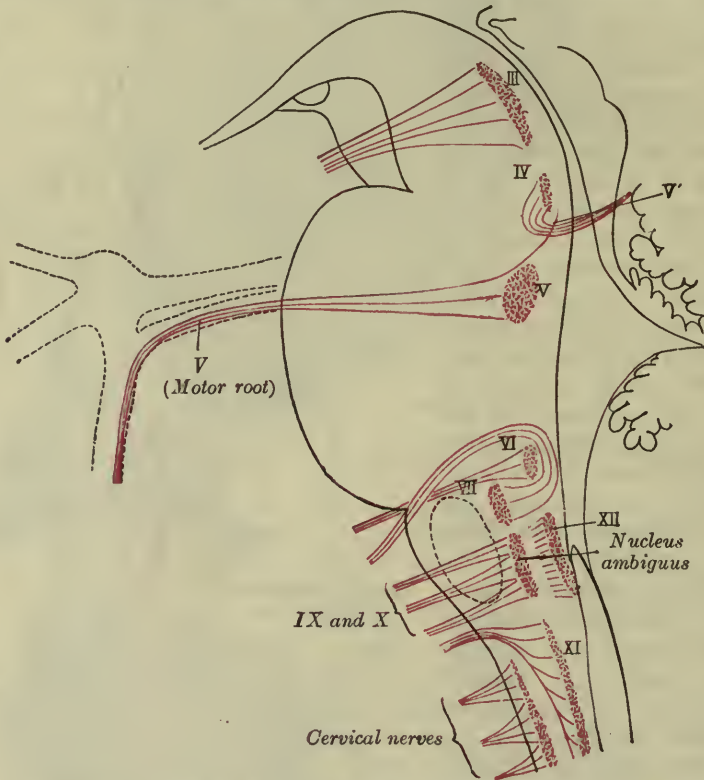


FIG. 697.—Nuclei of origin of cranial motor nerves schematically represented; lateral view.

(4) The **anterior external arcuate fibers** vary as to their prominence in different cases: in some they form an almost continuous layer covering the pyramid and olive, while in others they are barely visible on the surface. They arise from the cells of the gracile and cuneate nuclei, and passing forward through the formatio reticularis, decussate in the middle line. Most of them reach the surface by way of the anterior median fissure, and arch backward over the pyramid. Reinforced by others which emerge between the pyramid and olive, they pass backward over the olive and lateral district of the medulla oblongata, and enter the inferior peduncle. They thus connect the cerebellum with the gracile and cuneate nuclei of the opposite side. As the fibers arch across the pyramid, they enclose a small nucleus which lies in front of and medial to the pyramid. This is named the **nucleus arcuatus**, and is serially continuous above with the nuclei pontis in the pons; it contains small fusiform cells, around which some of the arcuate fibers end, and from which others arise.

(5) The **posterior external arcuate fibers** also take origin in the gracile and cuneate nuclei; they pass to the inferior peduncle of the same side. It is uncertain whether

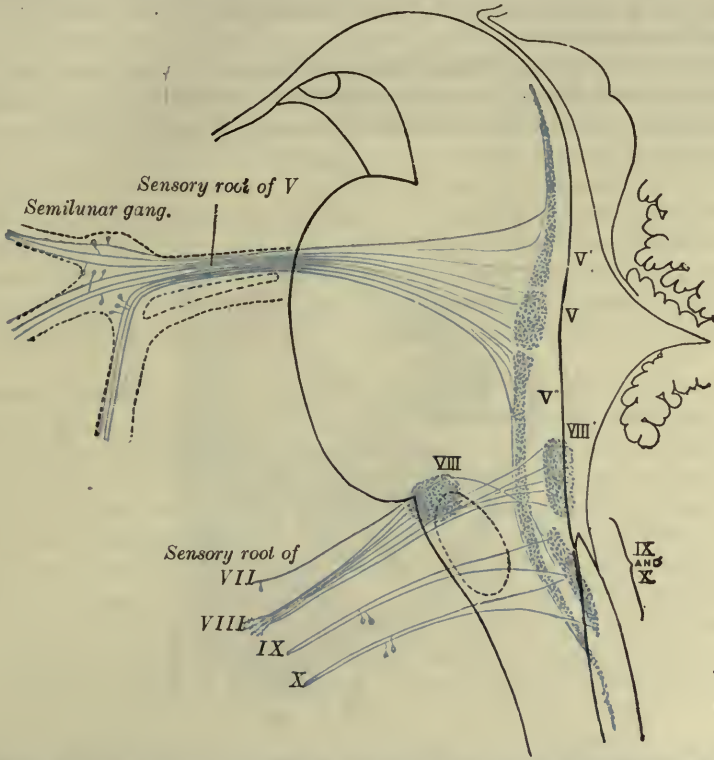


FIG. 698.—Primary terminal nuclei of the afferent (sensory) cranial nerves schematically represented; lateral view. The olfactory and optic centers are not represented.

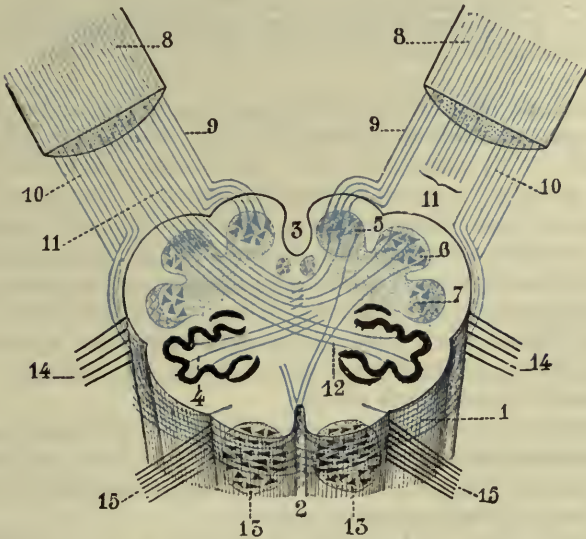


FIG. 699.—Diagram showing the course of the arcuate fibers. (Testut.) 1. Medulla oblongata anterior surface. 2. Anterior median fissure. 3. Fourth ventricle. 4. Inferior olivary nucleus, with the accessory olivary nuclei. 5. Gracile nucleus. 6. Cuneate nucleus. 7. Trigeminal. 8. Inferior peduncles, seen from in front. 9. Posterior external arcuate fibers. 10. Anterior external arcuate fibers. 11. Internal arcuate fibers. 12. Peduncle of inferior olivary nucleus. 13. Nucleus arcuatus. 14. Vagus. 15. Hypoglossal.

fibers are continued directly from the gracile and cuneate fasciculi into the inferior peduncle.

(6) Fibers from the **terminal sensory nuclei** of the cranial nerves, especially the vestibular. Some of the fibers of the vestibular nerve are thought to continue directly into the cerebellum.

(7) Fibers from the **ventral spinocerebellar fasciculus**.

(8) The existence of fibers from the **cerebellum** (cerebellobulbar, cerebelloölivary, and cerebellospinal) to the medulla and spinal cord is very uncertain.

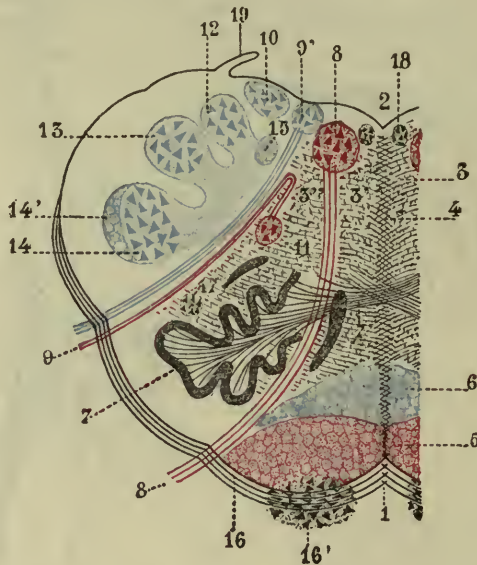


FIG. 700.—The formatio reticularis of the medulla oblongata, shown by a transverse section passing through the middle of the olive. (Testut.) 1. Anterior median fissure. 2. Fourth ventricle. 3. Formatio reticularis, with 3', its internal part (reticularis alba), and 3'', its external part (reticularis grisea). 4. Raphé. 5. Pyramid. 6. Lemniscus. 7. Inferior olivary nucleus with the two accessory olivary nuclei. 8. Hypoglossal nerve, with 8', its nucleus of origin. 9. Vagus nerve, with 9', its nucleus of termination. 10. Lateral dorsal acoustic nucleus. 11. Nucleus ambiguus (nucleus of origin of motor fibers of glossopharyngeal, vagus, and cerebral portion of spinal accessory). 12. Gracile nucleus. 13. Cuneate nucleus. 14. Head of posterior column, with 14', the lower sensory root of trigeminal nerve. 15. Fasciculus solitarius. 16. Anterior external arcuate fibers, with 16', the nucleus arcuatus. 17. Nucleus lateralis. 18. Nucleus of fasciculus teres. 19. Ligula.

Formatio Reticularis (Fig. 700).—This term is applied to the coarse reticulum which occupies the anterior and lateral districts of the medulla oblongata. It is situated behind the pyramid and olive, extending laterally as far as the inferior peduncles, and dorsally to within a short distance of the rhomboid fossa. The reticulum is caused by the intersection of bundles of fibers running at right angles to each other, some being longitudinal, others more or less transverse in direction. The formatio reticularis presents a different appearance in the anterior district from what it does in the lateral; in the former, there is an almost entire absence of nerve cells, and hence this part is known as the **reticularis alba**; whereas in the lateral district nerve cells are numerous, and as a consequence it presents a gray appearance, and is termed the **reticularis grisea**.

In the substance of the formatio reticularis are two small nuclei of gray matter: one, the **inferior central nucleus** (*nucleus of Roller*), near the dorsal aspect of the hilus of the inferior olivary nucleus; the other, the **nucleus lateralis**, between the olive and the spinal tract of the trigeminal nerve.

In the reticularis alba the longitudinal fibers form two well-defined fasciculi, viz.: (1) the **lemniscus**, which lies close to the raphé, immediately behind the fibers of the pyramid; and (2) the **medial longitudinal fasciculus**, which is continued upward from the anterior and lateral proper fasciculi of the medulla spinalis, and,

in the upper part of the medulla oblongata, lies between the lemniscus and the gray substance of the rhomboid fossa. The longitudinal fibers in the reticularis grisea are derived from the lateral funiculus of the medulla spinalis after the lateral cerebrospinal fasciculus has passed over to the opposite side, and the dorsal spino-cerebellar fasciculus has entered the inferior peduncle. They form indeterminate fibers, with the exception of a bundle named the **fasciculus solitarius**, which is made up of descending fibers of the vagus and glossopharyngeal nerves. The transverse fibers of the formatio reticularis are the arcuate fibers already described (page 782).

The Pons (*pons Varoli*).—The pons or forepart of the hind-brain is situated in front of the cerebellum. From its superior surface the cerebral peduncles emerge, one on either side of the middle line. Curving around each peduncle, close to the upper surface of the pons, a thin white band, the **tænia pontis**, is frequently seen; it enters the cerebellum between the middle and superior peduncles. Behind and below, the pons is continuous with the medulla oblongata, but is separated from it in front by a furrow in which the abducent, facial, and acoustic nerves appear.

Its **ventral or anterior surface** (*pars basilaris pontis*) is very prominent, markedly convex from side to side, less so from above downward. It consists of transverse fibers arched like a bridge across the middle line, and gathered on either side into a compact mass which forms the **middle peduncle**. It rests upon the clivus of the sphenoidal bone, and is limited above and below by well-defined borders. In the middle line is the **sulcus basilaris** for the lodgement of the basilar artery; this sulcus is bounded on either side by an eminence caused by the descent of the cerebrospinal fibers through the substance of the pons. Outside these eminences, near the upper border of the pons, the trigeminal nerves make their exit, each consisting of a smaller, medial, motor root, and a larger, lateral, sensory root; vertical lines drawn immediately beyond the trigeminal nerves, may be taken as the boundaries between the ventral surface of the pons and the middle cerebellar peduncle.

Its **dorsal or posterior surface** (*pars dorsalis pontis*), triangular in shape, is hidden by the cerebellum, and is bounded laterally by the superior peduncle; it forms the upper part of the rhomboid fossa, with which it will be described.

Structure (Fig. 701).—Transverse sections of the pons show it to be composed of two parts which differ in appearance and structure: thus, the basilar or ventral portion consists for the most part of fibers arranged in transverse and longitudinal bundles, together with a small amount of gray substance; while the dorsal tegmental portion is a continuation of the reticular formation of the medulla oblongata, and most of its constituents are continued into the tegmenta of the cerebral peduncles.

The **basilar part** of the pons consists of—(a) superficial and deep transverse fibers, (b) longitudinal fasciculi, and (c) some small nuclei of gray substance, termed the **nuclei pontis** which give rise to the transverse fibers.

The **superficial transverse fibers** (*fibræ pontis superficiales*) constitute a rather thick layer on the ventral surface of the pons, and are collected into a large rounded bundle on either side of the middle line. This bundle, with the addition of some transverse fibers from the deeper part of the pons, forms the greater part of the **brachium pontis**.

The **deep transverse fibers** (*fibræ pontis profundæ*) partly intersect and partly lie on the dorsal aspect of the cerebrospinal fibers. They course to the lateral border of the pons, and form part of the middle peduncle; the further connections of this brachium will be discussed with the anatomy of the cerebellum.

The **longitudinal fasciculi** (*fasciculi longitudinales*) are derived from the cerebral peduncles, and enter the upper surface of the pons. They stream downward on either side of the middle line in larger or smaller bundles, separated from each other by the deep transverse fibers; these longitudinal bundles cause a forward

projection of the superficial transverse fibers, and thus give rise to the eminences on the anterior surface. Some of these fibers end in, or give off collateral to, the nuclei pontis. An important pathway is thus formed between the cerebral cortex and the cerebellum, the first neuron having its cell body in the cortex and sending its axon through the internal capsule and cerebral peduncle to form synapses either by terminals or collaterals with cell bodies situated in the nuclei pontis. Axons from these cells form the transverse fibers which pass through the middle peduncle into the cerebellum. Others after decussating, terminate either directly or indirectly in the motor nuclei of the trigeminal, abducent, facial, and hypoglossal nerves; but most of them are carried through the pons, and at its lower surface are collected into the pyramids of the medulla. The fibers which end in the motor nuclei of the cranial nerves are derived from the cells of the cerebral cortex, and bear the same relation to the motor cells of the cranial nerves that the cerebro-

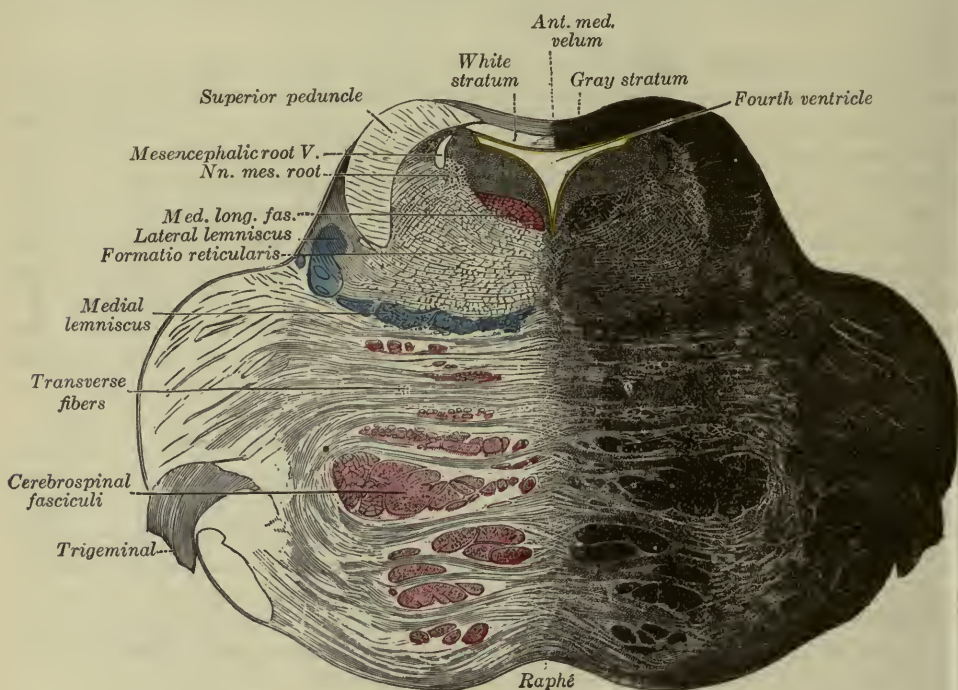


Fig. 701.—Coronal section of the pons, at its upper part.

spinal fibers bear to the motor cells in the anterior column of the medulla spinalis. Probably none of the collaterals or terminals of the cerebrospinal and cerebrolular fibers end directly in the motor nuclei of the spinal and cranial nerves, one or more association neurons are probably interpolated in the pathway.

The **nuclei pontis** are serially continuous with the arcuate nuclei in the medulla, and consist of small groups of multipolar nerve cells which are scattered between the bundles of transverse fibers.

The **dorsal or tegmental part** of the pons is chiefly composed of an upward continuation of the reticular formation and gray substance of the medulla oblongata. It consists of transverse and longitudinal fibers and also contains important gray nuclei, and is subdivided by a median raphé, which, however, does not extend into the basilar part, being obliterated by the transverse fibers. The transverse fibers in the lower part of the pons are collected into a distinct strand, named the

trapezoid body. This consists of fibers which arise from the cells of the cochlear nucleus, and will be referred to in connection with the cochlear division of the acoustic nerve. In the substance of the trapezoid body is a collection of nerve cells, which constitutes the **trapezoid nucleus**. The longitudinal fibers, which are continuous with those of the medulla oblongata, are mostly collected into two fasciculi on either side. One of these lies between the trapezoid body and the reticular formation, and forms the upward prolongation of the lemniscus; the second is situated near the floor of the fourth ventricle, and is the **medial longitudinal fasciculus**. Other longitudinal fibers, more diffusely distributed, arise from the cells of the gray substance of the pons.

The rest of the dorsal part of the pons is a continuation upward of the formatio reticularis of the medulla oblongata, and, like it, presents the appearance of a network, in the meshes of which are numerous nerve cells. Besides these scattered nerve cells, there are some larger masses of gray substance, viz., the superior olivary nucleus and the nuclei of the trigeminal, abducent, facial, and acoustic nerves (Fig. 696).

1. The **superior olivary nucleus** (*nucleus olivaris superior*) is a small mass of gray substance situated on the dorsal surface of the lateral part of the trapezoid body. Rudimentary in man, but well developed in certain animals, it exhibits the same structure as the inferior olivary nucleus, and is situated immediately above it. Some of the fibers of the trapezoid body end by arborizing around the cells of this nucleus, while others arise from these cells.

2. The **nuclei of the trigeminal nerve** (*nuclei n. trigemini*) in the pons are two in number: a motor and a sensory. The **motor nucleus** is situated in the upper part of the pons, close to its posterior surface and along the line of the lateral margin of the fourth ventricle. It is serially homologous with the nucleus ambiguus and the dorso-lateral cell group of the anterior column of the spinal cord. The axis-cylinder processes of its cells form the motor root of the trigeminal nerve. The **mesencephalic root** arises from the gray substance of the floor of the cerebral aqueduct, joins the motor root and probably conveys fibers of muscle sense from the temporal, masseter and pterygoid muscles. It is not altogether clear whether the mesencephalic root is motor or sensory. The **sensory nucleus** is lateral to the motor one, and beneath the superior peduncle. Some of the sensory fibers of the trigeminal nerve end in this nucleus; but the greater number descend, under the name of the spinal tract of the trigeminal nerve, to end in the substantia gelatinosa of Rolando. The roots, motor and sensory, of the trigeminal nerve pass through the substance of the pons and emerge near the upper margin of its anterior surface.

3. The **nucleus of the abducent nerve** (*nucleus n. abducentis*) is a circular mass of gray substance situated close to the floor of the fourth ventricle, above the striæ medullares and subjacent to the medial eminence: it lies a little lateral to the ascending part of the facial nerve. The fibers of the abducent nerve pass forward through the entire thickness of the pons on the medial side of the superior olivary nucleus, and between the lateral fasciculi of the cerebrospinal fibers, and emerge in the furrow between the lower border of the pons and the pyramid of the medulla oblongata.

4. The **nucleus of the facial nerve** (*nucleus n. facialis*) is situated deeply in the reticular formation of the pons, on the dorsal aspect of the superior olivary nucleus, and the roots of the nerve derived from it pursue a remarkably tortuous course in the substance of the pons. At first they pass backward and medialward until they reach the rhomboid fossa, close to the median sulcus, where they are collected into a round bundle; this passes upward and forward, producing an elevation, the **colliculus facialis**, in the rhomboid fossa, and then takes a sharp bend, and arches lateralward through the substance of the pons to emerge at its lower border in the interval between the olive and the inferior peduncle of the medulla oblongata.

5. The nucleus of the cochlear nerve consists of: (a) the lateral cochlear nucleus, corresponding to the tuberculum acusticum on the dorso-lateral surface of the inferior peduncle; and (b) the ventral or accessory cochlear nucleus, placed between the two divisions of the nerve, on the ventral aspect of the inferior peduncle.

The nuclei of the vestibular nerve. (a) The medial (dorsal or chief vestibular nucleus), corresponding to the lower part of the area acustica in the rhomboid fossa; the caudal end of this nucleus is sometimes termed the descending or spinal vestibular nucleus. (b) The lateral or nucleus of Deiters, consisting of large cells and situated in the lateral angle of the rhomboid fossa; the dorso-lateral part of this nucleus is sometimes termed the nucleus of Bechterew.

The fibers of the vestibular nerve enter the medulla oblongata on the medial side of those of the cochlear, and pass between the inferior peduncle and the spinal tract of the trigeminal. They then divide into ascending and descending fibers. The latter end by arborizing around the cells of the medial nucleus, which is situated in the area acustica of the rhomboid fossa. The ascending fibers either end in the same manner or in the lateral nucleus, which is situated lateral to the area acustica and farther from the ventricular floor. Some of the axons of the cells of the lateral nucleus, and possibly also of the medial nucleus, are continued upward through the inferior peduncle to the roof nuclei of the opposite side of the cerebellum, to which also other fibers of the vestibular root are prolonged without interruption in the nuclei of the medulla oblongata. A second set of fibers from the medial and lateral nuclei end partly in the tegmentum, while the remainder ascend in the medial longitudinal fasciculus to arborize around the cells of the nuclei of the oculomotor nerve.

The Cerebellum.—The cerebellum constitutes the largest part of the hind-brain. It lies behind the pons and medulla oblongata; between its central portion and these structures is the cavity of the fourth ventricle. It rests on the inferior occipital fossæ, while above it is the tentorium cerebelli; a fold of dura mater which separates it from the tentorial surface of the cerebrum. It is somewhat oval in form, but constricted medially and flattened from above downward, its greatest diameter being from side to side. Its surface is not convoluted like that of the cerebrum, but is traversed by numerous curved furrows or sulci, which vary in depth at different parts, and separate the laminae of which it is composed. Its average weight in the male is about 150 gms. In the adult the proportion between the cerebellum and cerebrum is about 1 to 8, in the infant about 1 to 20.

Lobes of the Cerebellum.—The cerebellum consists of three parts, a median and two lateral, which are continuous with each other, and are substantially the same in structure. The median portion is constricted, and is called the **vermis**, from its annulated appearance which it owes to the transverse ridges and furrows upon it; the lateral expanded portions are named the **hemispheres**. On the upper surface of the cerebellum the vermis is elevated above the level of the hemispheres, but on the under surface it is sunk almost out of sight in the bottom of a deep depression between them; this depression is called the **vallecula cerebelli**, and lodges the posterior part of the medulla oblongata. The part of the vermis on the upper surface of the cerebellum is named the **superior vermis**; that on the lower surface, the **inferior vermis**. The hemispheres are separated below and behind by a deep notch, the **posterior cerebellar notch**, and in front by a broader shallower notch, the **anterior cerebellar notch**. The anterior notch lies close to the pons and upper part of the medulla, and its superior edge encircles the inferior colliculi and the superior cerebellar peduncle. The posterior notch contains the upper part of the falx cerebelli, a fold of dura mater.

The cerebellum is characterized by a laminated or foliated appearance; it is marked by deep, somewhat curved fissures, which extend for a considerable dis-

tance into its substance, and divide it into a series of layers or leaves. The largest and deepest fissure is named the **horizontal sulcus**. It commences in front of the pons, and passes horizontally around the free margin of the hemisphere to the middle line behind, and divides the cerebellum into an upper and a lower portion. Several secondary but deep fissures separate the cerebellum into lobes, and these are further subdivided by shallower sulci, which separate the individual folia or laminæ from each other. Sections across the laminæ show that the folia, though differing in appearance from the convolutions of the cerebrum, are analogous to them, inasmuch as they consist of central white substance covered by gray substance.

The cerebellum is connected to the cerebrum, pons, and medulla oblongata; to the cerebrum by the superior peduncle, to the pons by the middle peduncle, and to the medulla oblongata by the inferior peduncles.

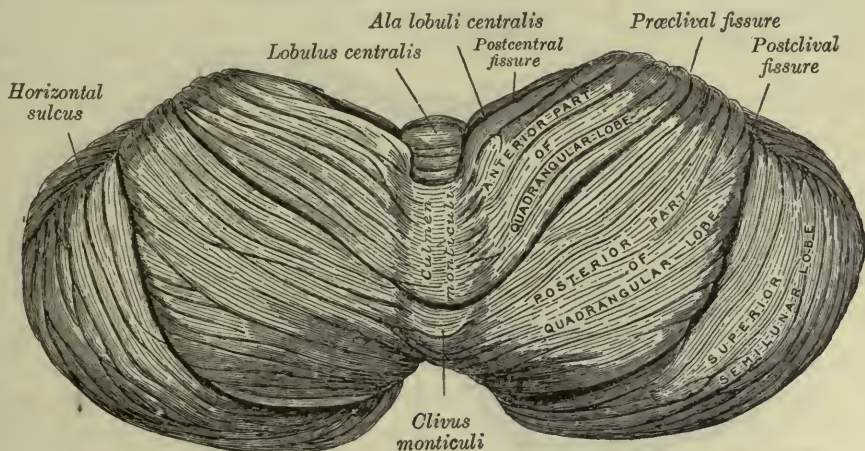


Fig. 702.—Upper surface of the cerebellum. (Schäfer.)

The **upper surface of the cerebellum** (Fig. 702) is elevated in the middle and sloped toward the circumference, the hemispheres being connected together by the superior vermis, which assumes the form of a raised median ridge, most prominent in front, but not sharply defined from the hemispheres. The superior vermis is subdivided from before backward into the lingula, the lobulus centralis, the monticulus and the folium vermis, and each of these, with the exception of the lingula, is continuous with the corresponding parts of the hemispheres—the lobulus centralis with the alæ, the monticulus with the quadrangular lobules, and the folium vermis with the superior semilunar lobules.

The **lingula** (*lingula cerebelli*) is a small tongue-shaped process, consisting of four or five folia; it lies in front of the lobulus centralis, and is concealed by it. Anteriorly, it rests on the dorsal surface of the anterior medullary velum, and its white substance is continuous with that of the velum.

The **Lobulus Centralis and Alæ**.—The **lobulus centralis** is a small square lobule, situated in the anterior cerebellar notch. It overlaps the lingula, from which it is separated by the **precentral fissure**; laterally, it extends along the upper and anterior part of each hemisphere, where it forms a wing-like prolongation, the **ala lobuli centralis**.

The **Monticulus and Quadrangular Lobules**.—The **monticulus** is the largest part of the superior vermis. Anteriorly, it overlaps the lobulus centralis, from which it is separated by the **postcentral fissure**; laterally, it is continuous with the **quadrangular lobule** in the hemispheres. It is divided by the **preclival fissure** into an

anterior, raised part, the **culmen** or **summit**, and a posterior sloped part, the **clivus**; the quadrangular lobule is similarly divided. The culmen and the anterior parts of the quadrangular lobules form the **lobus culminis**; the clivus and the posterior parts, the **lobus clivi**.

The Folium Vermis and Superior Semilunar Lobule.—The **folium vermis** (*folium cacuminis*; *cacuminal lobe*) is a short, narrow, concealed band at the posterior extremity of the vermis, consisting apparently of a single folium, but in reality marked on its upper and under surfaces by secondary fissures. Laterally, it expands in either hemisphere into a considerable lobule, the **superior semilunar lobule** (*lobulus semilunaris superior*; *postero-superior lobules*), which occupies the posterior third of the upper surface of the hemisphere, and is bounded below by the **horizontal sulcus**. The superior semilunar lobules and the folium vermis form the **lobus semilunaris**.

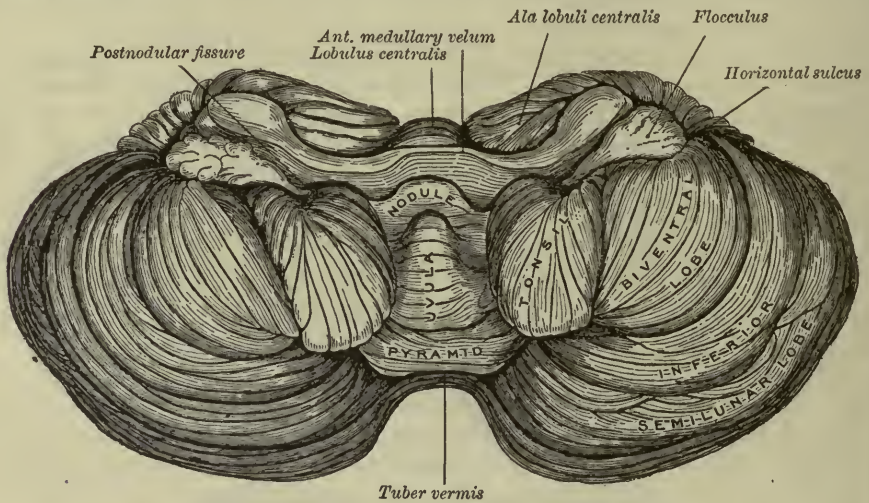


FIG. 703.—Under surface of the cerebellum. (Schäfer.)

The **under surface of the cerebellum** (Fig. 703) presents, in the middle line, the **inferior vermis**, buried in the vallecule, and separated from the hemisphere on either side by a deep groove, the **sulcus vallecule**. Here, as on the upper surface, there are deep fissures, dividing it into separate segments or lobules; but the arrangement is more complicated, and the relation of the segments of the vermis to those of the hemispheres is less clearly marked. The inferior vermis is subdivided from before backward, into (1) the **nodule**, (2) the **uvula**, (3) the **pyramid**, and (4) the **tuber vermis**; the corresponding parts on the hemispheres are (1) the **flocculus**, (2) the **tonsilla cerebelli**, (3) the **biventral lobule**, and (4) the **inferior semilunar lobule**. The three main fissures are (1) the **postnodular fissure**, which runs transversely across the vermis, between the nodule and the uvula. In the hemispheres this fissure passes in front of the tonsil, crosses between the flocculus in front and the biventral lobule behind, and joins the anterior end of the horizontal sulcus. (2) The **prepyramidal fissure** crosses the vermis between the uvula in front and the pyramid behind, then curves forward between the tonsil and the biventral lobule, to join the postnodular fissure. (3) The **postpyramidal fissure** passes across the vermis between the pyramid and the tuber vermis, and, in the hemispheres, courses behind the tonsil and biventral lobules, and then along the lateral border of the biventral lobule to the postnodular sulcus; in the hemisphere it forms the anterior boundary of the inferior semilunar lobule.

The Nodule and Flocculus.—The **nodule** (*nodulus vermis*; *nodular lobe*), or anterior end of the inferior vermis, abuts against the roof of the fourth ventricle, and can

only be distinctly seen after the cerebellum has been separated from the medulla oblongata and pons. On either side of the nodule is a thin layer of white substance, named the **posterior medullary velum**. It is semilunar in form, its convex border being continuous with the white substance of the cerebellum; it extends on either side as far as the flocculus. The **flocculus** is a prominent, irregular lobule, situated in front of the biventral lobule, between it and the middle cerebellar peduncle. It is subdivided into a few small laminae, and is connected to the inferior medullary velum by its central white core. The flocculi, together with the posterior medullary velum and nodule, constitute the **lobus noduli**.

The Uvula and Tonsilla.—The **uvula** (*uvula vermis; uvular lobe*) forms a considerable portion of the inferior vermis; it is separated on either side from the tonsil by the **sulcus vallecule**, at the bottom of which it is connected to the tonsil by a ridge of gray matter, indented on its surface by shallow furrows, and hence called the **furrowed band**. The **tonsilla** (*tonsilla cerebelli; amygdaline nucleus*) is a rounded mass, situated in the hemispheres. Each lies in a deep fossa, termed the **bird's nest** (*nidus avis*), between the uvula and the biventral lobule. The uvula and tonsillae form the **lobus uvulae**.

The **Pyramid and Biventral lobules** constitute the **lobus pyramidis**. The **pyramid** is a conical projection, forming the largest prominence of the inferior vermis. It is separated from the hemispheres by the **sulcus vallecule**, across which it is connected to the biventral lobule by an indistinct gray band, analogous to the furrowed band already described. The **biventral lobule** is triangular in shape; its apex points backward, and is joined by the gray band to the pyramid. The lateral border is separated from the inferior semilunar lobule by the postpyramidal fissure. The base is directed forward, and is on a line with the anterior border of the tonsil, and is separated from the flocculus by the postnodular fissure.

The **Tuber Vermis** (*tuber valvulae*) and the **Inferior Semilunar Lobule** (*lobulus semilunaris inferior; postero-superior lobule*) collectively form the **lobus tuberus** (*tuberae lobe*). The **tuber vermis**, the most posterior division of the inferior vermis, is of small size, and laterally spreads out into the large inferior semilunar lobules, which comprise at least two-thirds of the inferior surface of the hemisphere.

Internal Structure of the Cerebellum.—The cerebellum consists of white and gray substance.

White Substance.—If a sagittal section (Fig. 704) be made through either hemisphere, the interior will be found to consist of a central stem of white substance, in the middle of which is a gray mass, the **dentate nucleus**. From the surface of this central white stem a series of plates is prolonged; these are covered with gray substance and form the laminae. In consequence of the main branches from the central stem dividing and subdividing, a characteristic appearance, named the **arbor vitae**, is presented. If the sagittal section be made through the middle of the vermis, it will be found that the central stem divides into a vertical and a horizontal branch. The **vertical** branch passes upward to the culmen monticuli, where it subdivides freely, one of its ramifications passing forward and upward to the central lobule. The **horizontal** branch passes backward to the folium vermis, greatly diminished in size in consequence of having given off large secondary branches; one, from its upper surface, ascends to the clivus monticuli; the others descend, and enter the lobes in the inferior vermis, viz., the tuber vermis, the pyramid, the uvula, and the nodule.

The white substance of the cerebellum includes two sets of nerve fibers: (1) **projection fibers**, (2) **fibrae propriae**.

Projection Fibers.—The cerebellum is connected to the other parts of the brain by three large bundles of projection fibers, viz., to the cerebrum by the superior peduncle, to the pons by the middle peduncle, and to the medulla oblongata by the inferior peduncles (Fig. 705).

The superior cerebellar peduncles (*brachia conjunctiva*), two in number, emerge from the upper and medial part of the white substance of the hemispheres and are placed under cover of the upper part of the cerebellum. They are joined to each other across the middle line by the anterior medullary velum, and can be followed

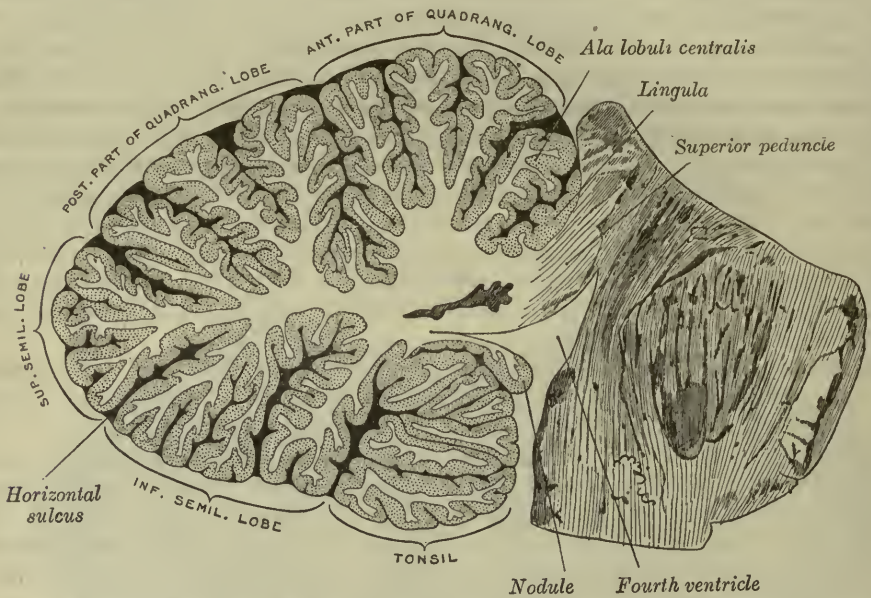


FIG. 704.—Sagittal section of the cerebellum, near the junction of the vermis with the hemisphere. (Schäfer.)

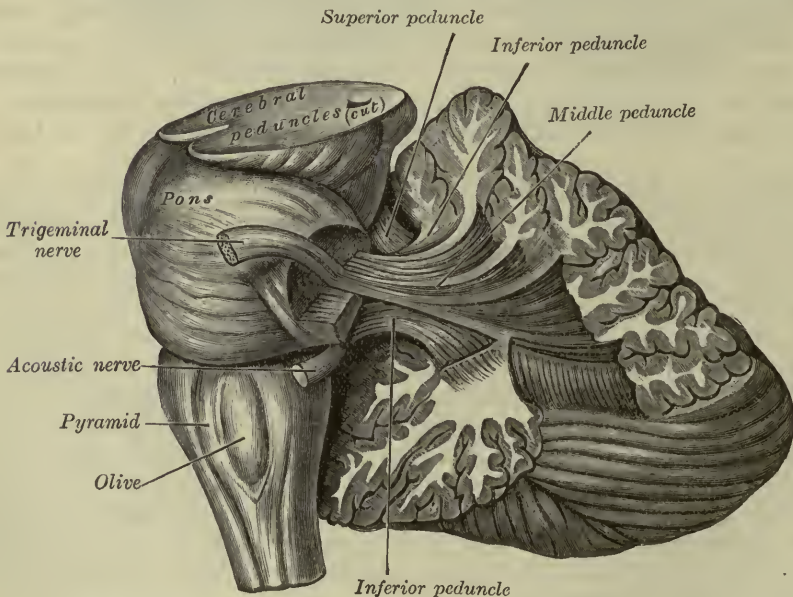


FIG. 705.—Dissection showing the projection fibers of the cerebellum. (After E. B. Jamieson.)

upward as far as the inferior colliculi, under which they disappear. Below, they form the upper lateral boundaries of the fourth ventricle, but as they ascend they converge on the dorsal aspect of the ventricle and thus assist in roofing it in.

The fibers of the superior peduncle are mainly derived from the cells of the

dentate nucleus of the cerebellum and emerge from the hilus of this nucleus; a few arise from the cells of the smaller gray nuclei in the cerebellar white substance, and others from the cells of the cerebellar cortex. They are continued upward beneath the corpora quadrigemina, and the fibers of the two peduncles undergo a complete decussation ventral to the Sylvian aqueduct. Having crossed the middle line they divide into ascending and descending groups of fibers, the former ending in the red nucleus, the thalamus, and the nucleus of the oculomotor nerve, while the descending fibers can be traced as far as the dorsal part of the pons; Cajal believes them to be continued into the anterior funiculus of the medulla spinalis.

As already stated (page 762), the majority of the fibers of the **ventral spinocerebellar fasciculus** of the medulla spinalis pass to the cerebellum, which they reach by way of the superior peduncle.

The **middle cerebellar peduncles** (*brachia pontis*) (Fig. 705) are composed entirely of centripetal fibers, which arise from the cells of the nuclei pontis of the opposite side and end in the cerebellar cortex; the fibers are arranged in three fasciculi, superior, inferior, and deep. The **superior fasciculus**, the most superficial, is derived from the upper transverse fibers of the pons; it is directed backward and lateralward superficial to the other two fasciculi, and is distributed mainly to the lobules on the inferior surface of the cerebellar hemisphere and to the parts of the superior surface adjoining the posterior and lateral margins. The **inferior fasciculus** is formed by the lowest transverse fibers of the pons; it passes under cover of the superior fasciculus and is continued downward and backward more or less parallel with it, to be distributed to the folia on the under surface close to the vermis.

The **deep fasciculus** comprises most of the deep transverse fibers of the pons. It is at first covered by the superior and inferior fasciculi, but crosses obliquely and appears on the medial side of the superior, from which it receives a bundle; its fibers spread out and pass to the upper anterior cerebellar folia. The fibers of this fasciculus cover those of the restiform body.¹

The **inferior cerebellar peduncles** (*restiform bodies*) pass at first upward and lateralward, forming part of the lateral walls of the fourth ventricle, and then bend abruptly backward to enter the cerebellum between the superior and middle peduncles. Each contains the following fasciculi: (1) the dorsal spinocerebellar fasciculus of the medulla spinalis, which ends mainly in the superior vermis; (2) fibers from the gracile and cuneate nuclei of the same and of the opposite sides; (3) fibers from the opposite olivary nuclei; (4) crossed and uncrossed fibers from the reticular formation of the medulla oblongata; (5) vestibular fibers, derived partly from the vestibular division of the acoustic nerve and partly from the nuclei in which this division ends—these fibers occupy the medial segment of the inferior peduncle and divide into ascending and descending groups of fibers, the ascending fibers partly end in the roof nucleus of the opposite side of the cerebellum; (6) cerebellobulbar fibers which come from the opposite roof nucleus and probably from the dentate nucleus, and are said to end in the nucleus of Deiters and in the formatio reticularis of the medulla oblongata; (7) some fibers from the ventral spinocerebellar fasciculus are said to join the dorsal spinocerebellar fasciculus.

The **anterior medullary velum** (*velum medullare anterius; valve of Vieussens; superior medullary velum*) is a thin, transparent lamina of white substance, which stretches between the superior peduncle; on the dorsal surface of its lower half the folia and lingula are prolonged. It forms, together with the superior peduncle, the roof of the upper part of the fourth ventricle; it is narrow above, where it passes beneath the inferior colliculi, and broader below, where it is continuous with the white substance of the superior vermis. A slightly elevated ridge, the **frænulum**

¹ See article by E. B. Jamieson, *Journal of Anatomy and Physiology*, vol. xliv.

veli, descends upon its upper part from between the inferior colliculi, and on either side of this the trochlear nerve emerges.

The **posterior medullary velum** (*velum medullare posterius; inferior medullary velum*) is a thin layer of white substance, prolonged from the white center of the cerebellum, above and on either side of the nodule; it forms a part of the roof of the fourth ventricle. Somewhat semilunar in shape, its convex edge is continuous with the white substance of the cerebellum, while its thin concave margin is apparently free; in reality, however, it is continuous with the epithelium of the ventricle, which is prolonged downward from the posterior medullary velum to the ligulæ.

The two medullary vela are in contact with each other along their line of emergence from the white substance of the cerebellum; and this line of contact forms the summit of the roof of the fourth ventricle, which, in a vertical section through the cavity, appears as a pointed angle.

The **Fibræ Propriæ** of the cerebellum are of two kinds: (1) **commissural fibers**, which cross the middle line at the anterior and posterior parts of the vermis and connect the opposite halves of the cerebellum; (2) **arcuate or association fibers**, which connect adjacent laminae with each other.

Gray Substance.—The gray substance of the cerebellum is found in two situations: (1) on the surface, forming the cortex; (2) as independent masses in the anterior.

(1) The **gray substance of the cortex** presents a characteristic foliated appearance, due to the series of laminae which are given off from the central white substance; these in their turn give off secondary laminae, which are covered by gray substance. Externally, the cortex is covered by pia mater; internally is the medullary center, consisting mainly of nerve fibers.

Microscopic Appearance of the Cortex (Fig. 706).—The cortex consists of two layers, viz., an external gray molecular layer, and an internal rust-colored nuclear layer; between these is an incomplete stratum of cells which are characteristic of the cerebellum, viz., the **cells of Purkinje**.

The **external gray or molecular layer** consists of fibers and cells. The nerve fibers are delicate fibrillæ, and are derived from the following sources: (a) the dendrites and axon collaterals of Purkinje's cells; (b) fibers from cells in the nuclear layer; (c) fibers from the central white substance of the cerebellum; (d) fibers derived from cells in the molecular layer itself. In addition to these are other fibers, which have a vertical direction, and are the processes of large neuroglia cells, situated in the nuclear layer. They pass outward to the periphery of the gray matter, where they expand into little conical enlargements which form a sort of limiting membrane beneath the pia mater, analogous to the *membrana limitans interna* in the retina, formed by the sustentacular fibers of Müller.

The **cells of the molecular layer** are small, and are arranged in two strata, an outer and an inner. They all possess branched axons; those of the inner layer are termed **basket cells**; they run for some distance parallel with the surface of the folium—giving off collaterals which pass in a vertical direction toward the bodies of Purkinje's cells, around which they become enlarged, and form basket-like net-works.

The **cells of Purkinje** form a single stratum of large, flask-shaped cells at the junction of the molecular and nuclear layers, their bases resting against the latter; in fishes and reptiles they are arranged in several layers. The cells are flattened in a direction transverse to the long axis of the folium, and thus appear broad in sections carried across the folium, and fusiform in sections parallel to the long axis of the folium. From the neck of the flask one or more dendrites arise and pass into the molecular layer, where they subdivide and form an extremely rich arborescence, the various subdivisions of the dendrites being covered by lateral spine-like processes. This arborescence is not circular, but, like the cell, is flattened at right angles to the long axis of the folium; in other words, it does not resemble

a round bush, but has been aptly compared by Obersteiner to the branches of a fruit tree trained against a trellis or a wall. Hence, in sections carried across the folium the arborescence is broad and expanded; whereas in those which are parallel to the long axis of the folium, the arborescence, like the cell itself, is seen in profile, and is limited to a narrow area.

From the bottom of the flask-shaped cell the axon arises; this passes through the nuclear layer, and, becoming medullated, is continued as a nerve fiber in the subjacent white substance. As this axon traverses the granular layer it gives off fine collaterals, some of which run back into the molecular layer.

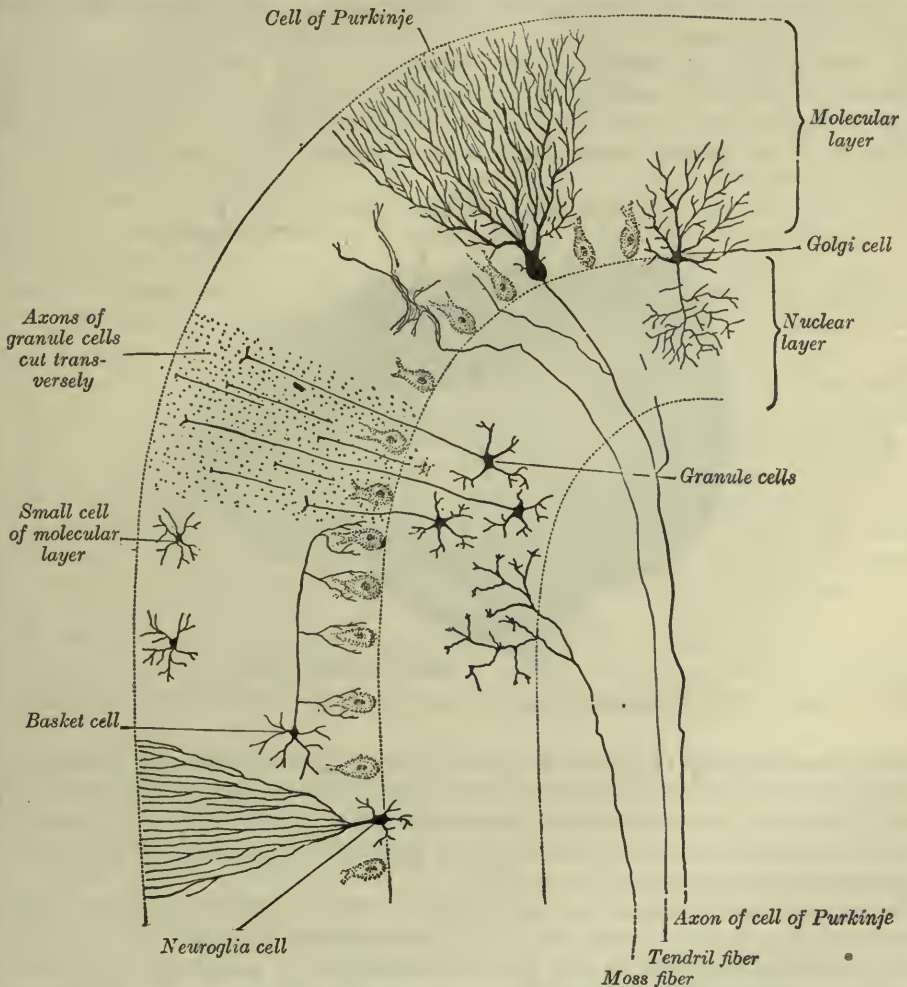


FIG. 706.—Transverse section of a cerebellar folium. (Diagrammatic, after Cajal and Kölliker.)

The **internal rust-colored or nuclear layer** (Fig. 706) is characterized by containing numerous small nerve cells of a reddish-brown color, together with many nerve fibrils. Most of the cells are nearly spherical and provided with short dendrites which spread out in a spider-like manner in the nuclear layer. Their axons pass outward into the molecular layer, and, bifurcating at right angles, run for some distance parallel with the surface. In the outer part of the nuclear layer are some larger cells, of the type II of Golgi. Their axons undergo frequent division as soon as they leave the nerve cells, and pass into the nuclear layer; while their dendrites ramify chiefly in the molecular layer.

Finally, in the gray substance of the cerebellar cortex there are fibers which come from the white center and penetrate the cortex. The cell-origin of these fibers is unknown, though it is believed that it is probably in the gray substance of the medulla spinalis. Some of these fibers end in the nuclear layer by dividing into numerous branches, on which are to be seen peculiar moss-like appendages; hence they have been termed by Ramón y Cajal the **moss fibers**; they form an arborescence around the cells of the nuclear layer and are said to come from fibers in the inferior peduncle. Other fibers, the **clinging** or **tendrill fibers**, derived from the medullary center can be traced into the molecular layer, where their branches cling around the dendrites of Purkinje's cells. They are said to come from fibers of the middle peduncle.

(2) The **independent centers of gray substance** in the cerebellum are four in number on either side: one is of large size, and is known as the **nucleus dentatus**; the other three, much smaller, are situated near the middle of the cerebellum, and are known as the **nucleus emboliformis**, **nucleus globosus**, and **nucleus fastigii**.

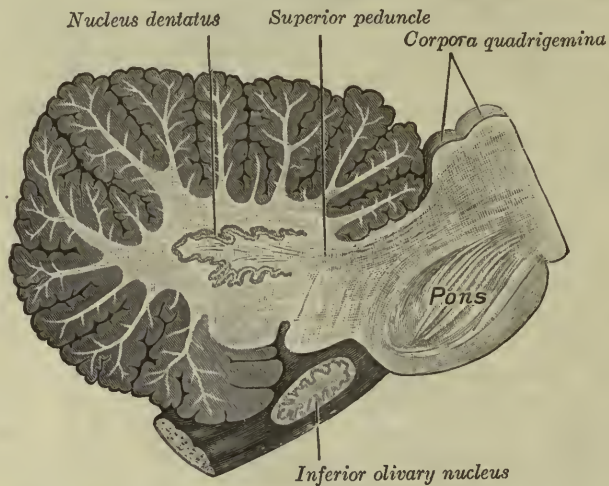


FIG. 707.—Sagittal section through right cerebellar hemisphere. The right olive has also been cut sagittally.

The **nucleus dentatus** (Fig. 707) is situated a little to the medial side of the center of the stem of the white substance of the hemisphere. It consists of an irregularly folded lamina, of a grayish-yellow color, containing white fibers, and presenting on its antero-medial aspect an opening, the **hilus**, from which most of the fibers of the superior peduncle emerge (page 792).

The **nucleus emboliformis** lies immediately to the medial side of the nucleus dentatus, and partly covering its hilus. The **nucleus globosus** is an elongated mass, directed antero-posteriorly, and placed medial to preceding. The **nucleus fastigii** is somewhat larger than the other two, and is situated close to the middle line at the anterior end of the superior vermis, and immediately over the roof of the fourth ventricle, from which it is separated by a thin layer of white substance.

The cerebellum is concerned with the coördination of movements necessary in equilibration, locomotion and prehension. In it terminate pathways conducting impulses of muscle sense, tendon sense, joint sense and equilibratory disturbances. With the exception of the ventral spinocerebellar fasciculus these impulses enter through the inferior peduncle. The reflex arc is completed by fibers in the superior peduncle which pass to the red nucleus and the thalamus and thence by additional neurons (rubrospinal tract) to the motor centers. The exact functions of its different parts are still quite uncertain, owing to the contradictory nature of the evidence furnished by (1) ablation experiments upon animals, and (2) clinical observations in man of the effects produced by abscesses or tumors affecting different portions of the organ.

The Fourth Ventricle (*ventriculus quartus*).—The fourth ventricle, or cavity of the hind-brain, is situated in front of the cerebellum and behind the pons and upper half of the medulla oblongata. Developmentally considered, the fourth ventricle consists of three parts: a **superior** belonging to the isthmus rhombencephali, an **intermediate**, to the metencephalon, and an **inferior**, to the myelencephalon. It is lined by ciliated epithelium, and is continuous below with the central canal of the medulla oblongata;¹ above, it communicates, by means of a passage termed the cerebral aqueduct, with the cavity of the third ventricle. It presents four **angles**, and possesses a **roof** or dorsal wall, a **floor** or ventral wall, and **lateral boundaries**.

Angles.—The **superior angle** is on a level with the upper border of the pons, and is continuous with the lower end of the cerebral aqueduct. The **inferior angle** is on a level with the lower end of the olive, and opens into the central canal of the medulla oblongata. Each **lateral angle** corresponds with the point of meeting of the brachia and inferior peduncle. A little below the lateral angles, on a level with the striæ medullares, the ventricular cavity is prolonged outward in the form of two narrow **lateral recesses**, one on either side; these are situated between the inferior peduncles and the flocculi, and reach as far as the attachments of the glossopharyngeal and vagus nerves.

Lateral Boundaries.—The lower part of each lateral boundary is constituted by the clava, the fasciculus cuneatus, and the inferior peduncle; the upper part by the middle and the superior peduncle.

Roof or Dorsal Wall (Fig. 708).—The upper portion of the roof is formed by the superior peduncle and the anterior medullary velum; the lower portion, by the posterior medullary velum, the epithelial lining of the ventricle covered by the tela chorioidea inferior, the tæniæ of the fourth ventricle, and the obex.

The **superior peduncle** (page 792), on emerging from the central white substance of the cerebellum, pass upward and forward, forming at first the lateral boundaries of the upper part of the cavity; on approaching the inferior colliculi, they converge, and their medial portions overlap the cavity and form part of its roof.

The **anterior medullary velum** (page 793) fills in the angular interval between the superior peduncle, and is continuous behind with the central white substance of the cerebellum; it is covered on its dorsal surface by the lingula of the superior vermis.

The **posterior medullary velum** (page 794) is continued downward and forward from the central white substance of the cerebellum in front of the nodule and tonsils, and ends inferiorly in a thin, concave, somewhat ragged margin. Below this margin the roof is devoid of nervous matter except in the immediate vicinity of the lower lateral boundaries of the ventricle, where two narrow white bands, the **tæniæ of the fourth ventricle** (*ligulæ*), appear; these bands meet over the inferior angle of the ventricle in a thin triangular lamina, the **obex**. The non-nervous part of the roof is formed by the **epithelial lining of the ventricle**, which is prolonged downward as a thin membrane, from the deep surface of the posterior medullary velum to the corresponding surface of the obex and tæniæ, and thence on to the floor of the ventricular cavity; it is covered and strengthened by a portion of the pia mater, which is named the **tela chorioidea of the fourth ventricle**.

The **tæniæ of the fourth ventricle** (*tænia ventriculi quarti*; *ligula*) are two narrow bands of white matter, one on either side, which complete the lower part of the roof of the cavity. Each consists of a vertical and a horizontal part. The vertical part is continuous below the obex with the clava, to which it is adherent by its lateral

¹ J. T. Wilson (*Journal of Anatomy and Physiology*, vol. xl) has pointed out that the central canal of the medulla oblongata, immediately below its entrance into the fourth ventricle, retains the cleft-like form presented by the fetal medulla spinalis, and that it is marked by dorso- and ventro-lateral sulci.

border. The horizontal portion extends transversely across the inferior peduncle, below the striæ medullares, and roofs in the lower and posterior part of the lateral recess; it is attached by its lower margin to the inferior peduncle, and partly encloses the choroid plexus, which, however, projects beyond it like a cluster of grapes; and hence this part of the tænia has been termed the **cornucopia** (Bochdalek). The **obex** is a thin, triangular, gray lamina, which roofs in the lower angle of the ventricle and is attached by its lateral margins to the clavae. The **tela chorioidea of the fourth ventricle** is the name applied to the triangular fold of pia mater which is carried upward between the cerebellum and the medulla oblongata. It consists of two layers, which are continuous with each other in front, and are more or less adherent throughout. The posterior layer covers the antero-inferior surface of the cerebellum, while the anterior is applied to the structures which form the lower part of the roof of the ventricle, and is continuous inferiorly with the pia mater on the inferior peduncles and closed part of the medulla.

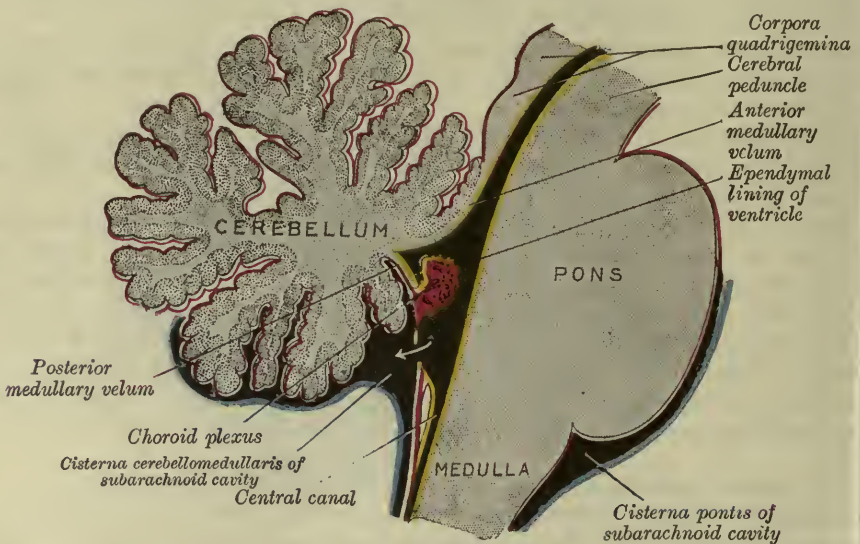


FIG. 708.—Scheme of roof of fourth ventricle. The arrow is in the foramen of Majendie.

Choroid Plexuses.—These consist of two highly vascular inflexions of the tela chorioidea, which invaginate the lower part of the roof of the ventricle and are everywhere covered by the epithelial lining of the cavity. Each consists of a vertical and a horizontal portion: the former lies close to the middle line, and the latter passes into the lateral recess and projects beyond its apex. The vertical parts of the plexuses are distinct from each other, but the horizontal portions are joined in the middle line; and hence the entire structure presents the form of the letter T, the vertical limb of which, however, is double.

Openings in the Roof.—In the roof of the fourth ventricle there are three openings, a medial and two lateral: the **medial aperture** (*foramen Majendii*), is situated immediately above the inferior angle of the ventricle; the **lateral apertures**, (*foramina of Luschka*) are found at the extremities of the lateral recesses. By means of these three openings the ventricle communicates with the subarachnoid cavity, and the cerebrospinal fluid can circulate from the one to the other.

Rhomboid Fossa (*fossa rhomboidea*; “*floor*” of the fourth ventricle) (Fig. 709).—The anterior part of the fourth ventricle is named, from its shape, the **rhomboid fossa**, and its anterior wall, formed by the back of the pons and medulla oblongata, constitutes the floor of the fourth ventricle. It is covered by a thin layer of gray

substance continuous with that of the medulla spinalis; superficial to this is a thin lamina of neuroglia which constitutes the ependyma of the ventricle and supports a layer of ciliated epithelium. The fossa consists of three parts, superior, intermediate, and inferior. The **superior part** is triangular in shape and limited laterally by the superior cerebellar peduncle; its apex, directed upward, is continuous with the cerebral aqueduct; its base is represented by an imaginary line at the level of the upper ends of the superior foveæ. The **intermediate part** extends from this level to that of the horizontal portions of the tæniæ of the ventricle; it is narrow above where it is limited laterally by the middle peduncle, but widens below and is prolonged into the lateral recesses of the ventricle. The **inferior part** is triangular, and its downwardly directed apex, named the **calamus scriptorius**, is continuous with the central canal of the closed part of the medulla oblongata.

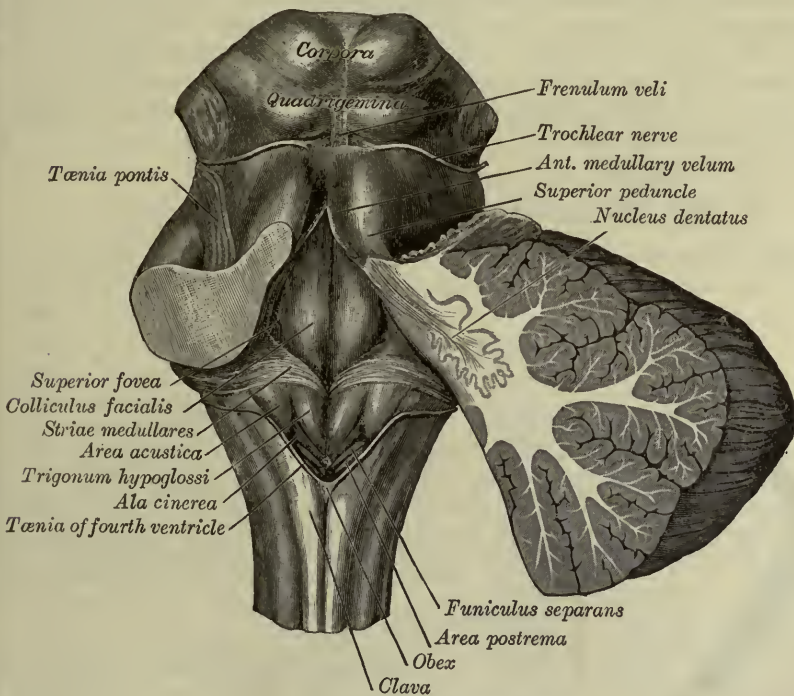


FIG. 709.—Rhomboid fossa.

The rhomboid fossa is divided into symmetrical halves by a **median sulcus** which reaches from the upper to the lower angles of the fossa and is deeper below than above. On either side of this sulcus is an elevation, the **medial eminence**, bounded laterally by a sulcus, the **sulcus limitans**. In the superior part of the fossa the medial eminence has a width equal to that of the corresponding half of the fossa, but opposite the superior fovea it forms an elongated swelling, the **colliculus facialis**, which overlies the nucleus of the abducent nerve, and is, in part at least, produced by the ascending portion of the root of the facial nerve. In the inferior part of the fossa the medial eminence assumes the form of a triangular area, the **trigonum hypoglossi**. When examined under water with a lens this trigone is seen to consist of a medial and a lateral area separated by a series of oblique furrows; the medial area corresponds with the upper part of the nucleus of the hypoglossal nerve, the lateral with a small nucleus, the **nucleus intercalatus**.

The **sulcus limitans** forms the lateral boundary of the medial eminence. In the superior part of the rhomboid fossa it corresponds with the lateral limit of the

fossa and presents a bluish-gray area, the *locus cæruleus*, which owes its color to an underlying patch of deeply pigmented nerve cells, termed the *substantia ferruginea*. At the level of the colliculus facialis the sulcus limitans widens into a flattened depression, the *superior fovea*, and in the inferior part of the fossa appears as a distinct dimple, the *inferior fovea*. Lateral to the foveæ is a rounded elevation named the *area acustica*, which extends into the lateral recess and there forms a feebly marked swelling, the *tuberculum acusticum*. Winding around the inferior peduncle and crossing the area acustica and the medial eminence are a number of white strands, the *striæ medullares*, which form a portion of the cochlear division of the acoustic nerve and disappear into the median sulcus. Below the inferior fovea, and between the trigonum hypoglossi and the lower part of the area acustica is a triangular dark field, the *ala cinerea*, which corresponds to the sensory nucleus of the vagus and glossopharyngeal nerves. The lower end of the ala cinerea is crossed by a narrow translucent ridge, the *funiculus separans*, and between this funiculus and the clava, is a small tongue-shaped area, the *area postrema*. On section it is seen that the funiculus separans is formed by a strip of thickened ependyma, and the area postrema by loose, highly vascular, neuroglial tissue containing nerve cells of moderate size.

THE MID-BRAIN OR MESENCEPHALON.

The mid-brain or mesencephalon (Fig. 681) is the short, constricted portion which connects the pons and cerebellum with the thalamencephalon and cerebral hemispheres. It is directed upward and forward, and consists of (1) a ventrolateral portion, composed of a pair of cylindrical bodies, named the *cerebral peduncles*; (2) a dorsal portion, consisting of four rounded eminences, named the *corpora quadrigemina*; and (3) an intervening passage or tunnel, the *cerebral aqueduct*, which represents the original cavity of the mid-brain and connects the third with the fourth ventricle (Fig. 710).

The *cerebral peduncles* (*pedunculus cerebri*; *crus cerebri*) are two cylindrical masses situated at the base of the brain, and largely hidden by the temporal lobes of the cerebrum, which must be drawn aside or removed in order to expose them. They emerge from the upper surface of the pons, one on either side of the middle line, and, diverging as they pass upward and forward, disappear into the substance of the cerebral hemispheres. The depressed area between the crura is termed the *interpeduncular fossa*, and consists of a layer of grayish substance, the *posterior perforated substance*, which is pierced by small apertures for the transmission of bloodvessels; its lower part lies on the ventral aspect of the medial portions of the tegmenta, and contains a nucleus named the *interpeduncular ganglion* (page 802); its upper part assists in forming the floor of the third ventricle. The ventral sur-

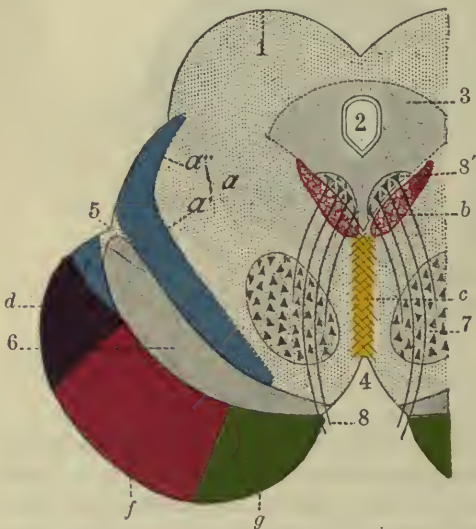


FIG. 710.—Coronal section through mid-brain. (Schematic.) (Testut.) 1. Corpora quadrigemina. 2. Cerebral aqueduct. 3. Central gray stratum. 4. Interpeduncular space. 5. Sulcus lateralis. 6. Substantia nigra. 7. Red nucleus of tegmentum. 8. Oculomotor nerve, with *S'*, its nucleus of origin. *a*. Lemniscus (in blue) with *a'* the medial lemniscus and *a''* the lateral lemniscus. *b*. Medial longitudinal fasciculus. *c*. Raphé. *d*. Temporopontine fibers. *e*. Portion of medial lemniscus, which runs to the lentiform nucleus and insula. *f*. Cerebrospinal fibers. *g*. Frontopontine fibers.

perforated substance, which is pierced by small apertures for the transmission of bloodvessels; its lower part lies on the ventral aspect of the medial portions of the tegmenta, and contains a nucleus named the *interpeduncular ganglion* (page 802); its upper part assists in forming the floor of the third ventricle. The ventral sur-

face of each peduncle is crossed from the medial to the lateral side by the superior cerebellar and posterior cerebral arteries; its lateral surface is in relation to the gyrus hippocampi of the cerebral hemisphere and is crossed from behind forward by the trochlear nerve. Close to the point of disappearance of the peduncle into the cerebral hemisphere, the optic tract winds forward around its ventro-lateral

med
12-15 ant
inf of anterior horn

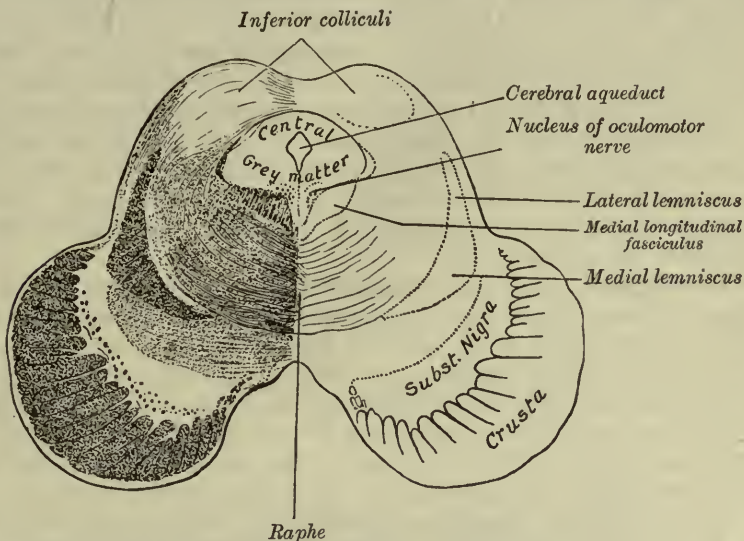


FIG. 711.—Transverse section of mid-brain at level of inferior colliculi.

surface. The medial surface of the peduncle forms the lateral boundary of the interpeduncular fossa, and is marked by a longitudinal furrow, the **oculomotor sulcus**, from which the roots of the oculomotor nerve emerge. On the lateral surface of each peduncle there is a second longitudinal furrow, termed the **lateral sulcus**; the fibers of the lateral lemniscus come to the surface in this sulcus, and pass backward and upward, to disappear under the inferior colliculus.

Cerebral crus
1 - Sup mesent.
2 - Sup med
3 - inf med
4 - inf med

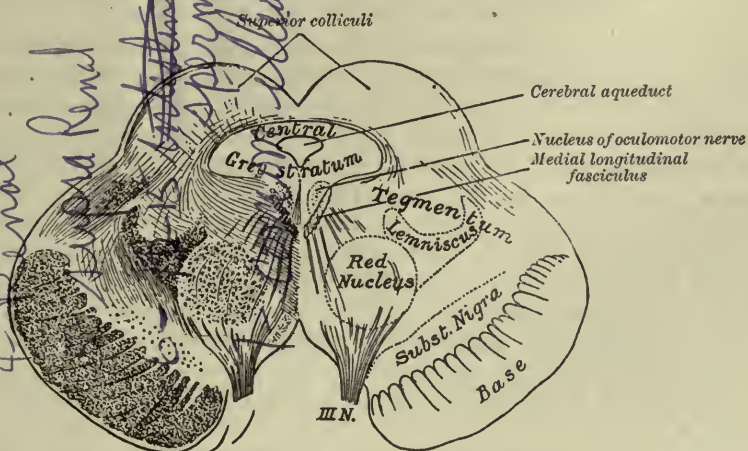


FIG. 712.—Transverse section of mid-brain at level of superior colliculi.

Structure of the Cerebral Peduncles (Figs. 711, 712).—On transverse section, each peduncle is seen to consist of a dorsal and a ventral part, separated by a deeply pigmented lamina of gray substance, termed the **substantia nigra**. The dorsal part

is named the **tegmentum**; the ventral, the **base** or **crusta**; the two bases are separated from each other, but the tegmenta are joined in the median plane by a forward prolongation of the raphé of the pons. Laterally, the tegmenta are free; dorsally, they blend with the corpora quadrigemina.

The **base** (*basis pedunculi*; *crusta* or *pes*) is semilunar on transverse section, and consists almost entirely of longitudinal bundles of efferent fibers, which arise from the cells of the cerebral cortex and are grouped into three principal sets, viz., cerebrosplinal, frontopontine, and temporo-pontine (Fig. 710). The **cerebrosplinal fibers**, derived from the cells of the motor area of the cerebral cortex, occupy the middle three-fifths of the base; they are continued partly to the nuclei of the motor cranial nerves, but mainly into the pyramids of the medulla oblongata. The **frontopontine fibers** are situated in the medial fifth of the base; they arise from the cells of the frontal lobe and end in the nuclei of the pons. The **temporo-pontine fibers** are lateral to the cerebrosplinal fibers; they originate in the temporal lobe and end in the nuclei pontis.¹

The **substantia nigra** (*intercalatum*) is a layer of gray substance containing numerous deeply pigmented, multipolar nerve cells. It is semilunar on transverse section, its concavity being directed toward the tegmentum; from its convexity, prolongations extend between the fibers of the base of the peduncle. Thicker medially than laterally, it reaches from the oculomotor sulcus to the lateral sulcus, and extends from the upper surface of the pons to the subthalamie region; its medial part is traversed by the fibers of the oculomotor nerve as these stream forward to reach the oculomotor sulcus. The connections of the cells of the substantia nigra have not been definitely established. It receives collaterals from the medial lemniscus and the pyramidal bundles. Bechterew is of the opinion that the fibers from the motor area of the cerebral cortex form synapses with cells whose axons pass to the motor nucleus of the trigeminal nerve and serve for the coördination of the muscles of mastication.

The **tegmentum** is continuous below with the reticular formation of the pons, and, like it, consists of longitudinal and transverse fibers, together with a considerable amount of gray substance. The principal gray masses of the tegmentum are the red nucleus and the interpeduncular ganglion; of its fibers the chief longitudinal tracts are the superior peduncle, the medial longitudinal fasciculus, and the lemniscus.

GRAY SUBSTANCE.—The **red nucleus** is situated in the anterior part of the tegmentum, and is continued upward into the posterior part of the subthalamie region. In sections at the level of the superior colliculus it appears as a circular mass which is traversed by the fibers of the oculomotor nerve. It receives many terminals and collaterals from the superior cerebellar peduncle also collaterals from the ventral longitudinal bundle, from Gudden's bundle and the median lemniscus. The axons of its larger cells cross the middle line and are continued downward into the lateral funiculus of the medulla spinalis as the rubrospinal tract (page 761); those of its smaller cells end mainly in the thalamus. The rubrospinal tract forms an important part of the pathway from the cerebellum to the lower motor centers.

The **interpeduncular ganglion** is a median collection of nerve cells situated in the ventral part of the tegmentum. The fibers of the fasciculus retroflexus of Meynert, which have their origin in the cells of the ganglion habenulæ (page 812), end in it.

Besides the two nuclei mentioned, there are small collections of cells which form the dorsal and ventral nuclei and the central nucleus or nucleus of the raphé.

¹ A band of fibers, the *tractus peduncularis transversus*, is sometimes seen emerging from in front of the superior colliculus; it passes around the ventral aspect of the peduncle about midway between the pons and the optic tract, and dips into the oculomotor sulcus. This band is a constant structure in many mammals, but is only present in about 30 per cent. of human brains. Since it undergoes atrophy after enucleation of the eyeballs, it may be considered as forming a path for visual sensations.

WHITE SUBSTANCE.—(1) The origin and course of the *superior peduncle* have already been described (page 792).

(2) The **medial (posterior) longitudinal fasciculus** is continuous below with the proper fasciculi of the anterior and lateral funiculi of the medulla spinalis. In the medulla oblongata and pons it runs close to the middle line, near the floor of the fourth ventricle; in the mid-brain it is situated on the ventral aspect of the cerebral aqueduct, below the nuclei of the oculomotor and trochlear nerves. Its connections are imperfectly known, but it consists largely of ascending and descending intersegmental or association fibers, which connect the nuclei of the hind-brain and mid-brain to each other. Many of the fibers arise in **Deiters's nucleus (lateral vestibular nucleus)** and divide into ascending and descending branches which send terminals and collaterals to the motor nuclei of the cranial and spinal nerves. Its spinal portion is located in the anterior funiculus and is known as the **vestibulospinal fasciculus**. Other fibers pass to the median longitudinal bundle from cells in the reticular formation of the medulla, pons and mid-brain and also from certain large cells in the terminal nucleus of the trigeminal nerve. According to Edinger it extends to the so-called nucleus of the posterior longitudinal bundle in the hypothalamic region, but this is uncertain and the fibers above the nucleus of the oculomotor are smaller in diameter than the rest of the bundle. According to Held fibers from the posterior commissure can be traced into the posterior longitudinal bundle, and according to the same author many of the descending fibers arise in the superior colliculus, and, after decussating in the middle line, end in the motor nuclei of the pons and medulla oblongata. These fibers from the superior colliculus probably pass into the ventral longitudinal bundle. Fibers are said to pass through the medial longitudinal fasciculus from the nucleus of the abducent nerve into the oculomotor nerve of the opposite side, and through this nerve to the Rectus medialis oculi. Fraser, however, denies the existence of such fibers. Again, fibers are said to be prolonged through this fasciculus from the nucleus of the oculomotor nerve into the facial nerve, and are distributed to the Orbicularis oculi, the Corrugator, and the Frontalis.¹

The **ventral longitudinal bundle** consists for the most part of the **tectospinal fasciculus**, and arises from the superior colliculus, the fibers arch ventrally around the central gray matter and cross the midline in the fountain-decussation of Meynert. They then descend in the tegmentum, part of them passing through the red nucleus ventral to the medial longitudinal bundle. In the medulla oblongata and spinal cord its fibers are more or less intermingled with the medial longitudinal bundle and the rubrospinal tract. It descends in the adjoining region of the ventral and lateral funiculi. Collaterals and terminals are given off to the red nucleus and probably other nuclei of the brain stem and to the anterior column of the spinal cord. It is probably concerned in optic reflexes.

(3) The **medial lemniscus** or **medial fillet** (Fig. 713).—The fibers of the medial lemniscus take origin in the gracile and cuneate nuclei of the medulla oblongata, and as internal arcuate fibers they cross to the opposite side in the sensory decussation (page 777). They then pass in the interolivary stratum upward through the medulla oblongata, in which they are situated behind the cerebrospinal fibers and between the olives. In the pons and lower part of the mid-brain it occupies the ventral part of the reticular formation and tegmentum close to the raphé, while above it gradually shifts to the dorso-lateral part of the tegmentum in the angle between the red nucleus and the substantia nigra. In the pons it assumes a flattened ribbon-like appearance, and is placed dorsal to the trapezium. As the lemniscus ascends, it receives additional fibers from the terminal sensory nuclei of the cranial

¹ A. Bruce and J. H. Harvey Pirrie, "On the Origin of the Facial Nerve," Review of Neurology and Psychiatry, December, 1908, No. 12, vol. vi, produce weighty evidence against the view that the facial nerve derives fibers from the nucleus of the oculomotor nerve.

nerves of the opposite side. Many of the fibers which arise from the terminal sensory nuclei of the cranial nerves pass upward in the formatio reticularis as a separate bundle, known as the **central tract of the cranial nerves**, to the thalamus.

Many fibers either terminate in or send off collaterals to the gray matter of the medulla, the pons, and the mid-brain. Large numbers of fibers pass to or from the substantia nigra. Many collaterals enter the red nucleus and other fibers are said to run to the superior colliculus. The great bulk of the fibers, however, enter the ventro-lateral portion of the thalamus, give off collaterals to the posterior semi-lunar nucleus and then terminate in the principal sensory nucleus of the thalamus.

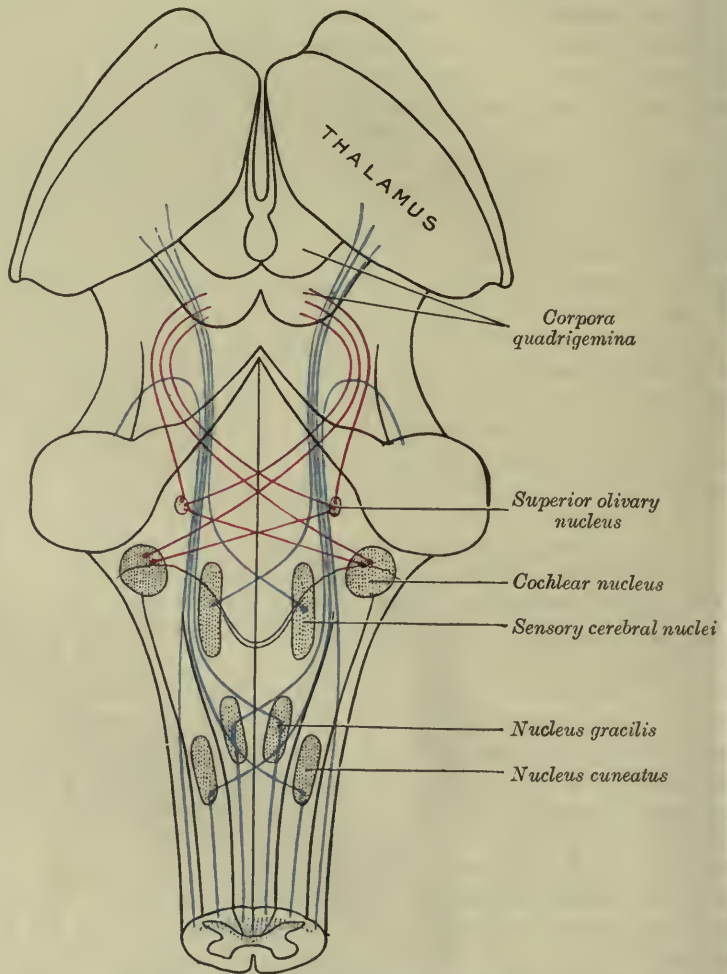


FIG. 713.—Scheme showing the course of the fibers of the lemniscus; medial lemniscus in blue, lateral in red.

In the cerebral peduncle, a few of its fibers pass upward in the lateral part of the base of the peduncle, on the dorsal aspect of the temporopontine fibers, and reach the lentiform nucleus and the insula. The greater part of the medial lemniscus, on the other hand, is prolonged through the tegmentum, and most of its fibers end in the thalamus; probably some are continued directly through the occipital part of the internal capsule to the cerebral cortex. From the cells of the thalamus a relay of fibers is prolonged to the cerebral cortex.

The medial lemniscus may be considered as the upward continuation of the posterior funiculus of the spinal cord and to convey conscious impulses of muscle sense and tactile discrimination.

The **central or thalamic tract of the cranial nerves** is closely associated with the medial lemniscus. The fibers of the spinothalamic fasciculi are continued from the spinal cord into this tract which passes upward in the reticular formation and the tegmentum to the thalamus along the dorsal side of the median lemniscus. It receives fibers from the opposite terminal sensory nuclei of the vagus, glossopharyngeal, facial, trigeminal and probably the vestibular nerves. Many of the secondary sensory fibers of the trigeminal cross the raphé from its terminal nucleus and pass upward to the thalamus by a more or less separate but closely associated pathway known as the **central tract of the trigeminal nerve** which also lies on the dorsal aspect of the lemniscus. These two tracts give off collaterals to the posterior semilunar nucleus of the thalamus and terminate in the anterior semilunar nucleus of the ventro-lateral region of the thalamus sending collaterals into the zona incerta.

The fibers of the **rubrospinal tract** (*bundle of Monakow*) arise in the red nucleus, cross the midline in the decussation of Forel and pass downward in the formatio reticularis of the brain-stem into the lateral funiculus of the spinal cord ventral to the crossed pyramidal tract.

The **lateral lemniscus** (*lemniscus lateralis*) comes to the surface of the mid-brain along its lateral sulcus, and disappears under the inferior colliculus. It consists of fibers from the terminal nuclei of the cochlear division of the acoustic nerve, together with others from the superior olivary and trapezoid nuclei. Most of these fibers are crossed, but some are uncrossed. Many of them pass to the inferior colliculus of the same or opposite side, but others are prolonged to the thalamus, and thence through the occipital part of the internal capsule to the middle and superior temporal gyri.

The **corpora quadrigemina** (Fig. 720) are four rounded eminences which form the dorsal part of the mid-brain. They are situated above and in front of the anterior medullary velum and superior peduncle, and below and behind the third ventricle and posterior commissure. They are covered by the splenium of the corpus callosum, and are partly overlapped on either side by the medial angle, or **pulvinar**, of the posterior end of the thalamus; on the lateral aspect, under cover of the pulvinar, is an oval eminence, named the **medial geniculate body**. The corpora quadrigemina are arranged in pairs (**superior and inferior colliculi**), and are separated from one another by a crucial sulcus. The longitudinal part of this sulcus expands superiorly to form a slight depression which supports the **pineal body**, a cone-like structure which projects backward from the thalamencephalon and partly obscures the superior colliculi. From the inferior end of the longitudinal sulcus, a white band, termed the **frenulum veli**, is prolonged downward to the anterior medullary velum; on either side of this band the trochlear nerve emerges, and passes forward on the lateral aspect of the cerebral peduncle to reach the base of the brain. The **superior colliculi** are larger and darker in color than the inferior, and are oval in shape. The **inferior colliculi** are hemispherical, and somewhat more prominent than the superior. The superior colliculi are associated with the sense of sight, the inferior with that of hearing.

From the lateral aspect of each colliculus a white band, termed the **brachium**, is prolonged upward and forward. The **superior brachium** extends lateralward from the superior colliculus, and, passing between the pulvinar and medial geniculate

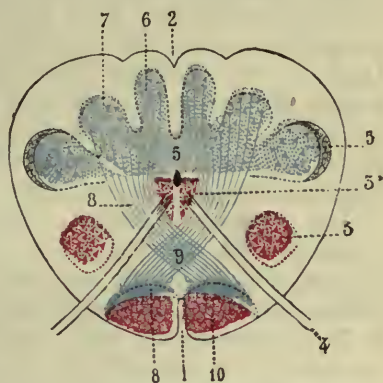


FIG. 714.—Transverse section passing through the sensory decussation. Schematic. (Testut.) 1. Anterior median fissure. 2. Posterior median sulcus. 3, 3'. Head and base of anterior column (in red). 4. Hypoglossal nerve. 5. Bases of posterior column. 6. Gracile nucleus. 7. Cuneate nucleus. 8, 8. Lemniscus. 9. Sensory decussation. 10. Cerebrospinal fasciculus.

late body, is partly continued into an eminence called the **lateral geniculate body**, and partly into the optic tract. The **inferior brachium** passes forward and upward from the inferior colliculus and disappears under cover of the **medial geniculate body**.

In close relationship with the corpora quadrigemina are the superior peduncles, which emerge from the upper and medial parts of the cerebellar hemispheres. They run upward and forward, and, passing under the inferior colliculi, enter the tegmenta as already described (page 792).

Structure of the Corpora Quadrigemina.—The **inferior colliculus** (*colliculus inferior; inferior quadrigeminal body; postgemina*) consists of a compact nucleus of gray substance containing large and small multipolar nerve cells, and more or less completely surrounded by white fibers derived from the lateral lemniscus. Most of these fibers end in the gray nucleus of the same side, but some cross the middle line and end in that of the opposite side. From the cells of the gray nucleus, fibers are prolonged through the inferior brachium into the tegmentum of the cerebral peduncle, and are carried to the thalamus and the cortex of the temporal lobe; other fibers cross the middle line and end in the opposite colliculus.

The **superior colliculus** (*colliculus superior; superior quadrigeminal body; pregemina*) is covered by a thin stratum (**stratum zonale**) of white fibers, the majority of which are derived from the optic tract. Beneath this is the **stratum cinereum**, a cap-like layer of gray substance, thicker in the center than at the circumference, and consisting of numerous small multipolar nerve cells, imbedded in a fine network of nerve fibers. Still deeper is the **stratum opticum**, containing large multipolar nerve cells, separated by numerous fine nerve fibers. Finally, there is the **stratum lemnisci**, consisting of fibers derived partly from the lemniscus and partly from the cells of the stratum opticum; interspersed among these fibers are many large multipolar nerve cells. The two last-named strata are sometimes termed the **gray-white layers**, from the fact that they consist of both gray and white substance. Of the afferent fibers which reach the superior colliculus, some are derived from the lemniscus, but the majority have their origins in the retina and are conveyed to it through the superior brachium; all of them end by arborizing around the cells of the gray substance. Of the efferent fibers, some cross the middle line to the opposite colliculus; many ascend through the superior brachium, and finally reach the cortex of the occipital lobe of the cerebrum; while others, after undergoing decussation (**fountain decussation of Meynert**) form the tectospinal fasciculus which descends through the formatio reticularis of the mid-brain, pons, and medulla oblongata into the medulla spinalis, where it is found partly in the anterior funiculus and partly intermingled with the fibers of the rubrospinal tract.

The corpora quadrigemina are larger in the lower animals than in man. In fishes, reptiles, and birds they are hollow, and only two in number (corpora bigemina); they represent the superior colliculi of mammals, and are frequently termed the optic lobes, because of their intimate connection with the optic tracts.

The **cerebral aqueduct** (*aqueductus cerebri; aqueduct of Sylvius*) is a narrow canal, about 15 mm. long, situated between the corpora quadrigemina and tegmenta, and connecting the third with the fourth ventricle. Its shape, as seen in transverse section, varies at different levels, being T-shaped, triangular above, and oval in the middle; the central part is slightly dilated, and was named by Retzius the **ventricle of the mid-brain**. It is lined by ciliated columnar epithelium, and is surrounded by a layer of gray substance named the **central gray stratum**: this is continuous below with the gray substance in the rhomboid fossa, and above with that of the third ventricle. Dorsally, it is partly separated from the gray substance of the quadrigeminal bodies by the fibers of the lemniscus; ventral to it are the medial longitudinal fasciculus, and the formatio reticularis of the tegmentum. Scattered throughout the central gray stratum are numerous nerve

cells of various sizes, interlaced, by a net-work of fine fibers. Besides these scattered cells it contains three groups which constitute the nuclei of the oculomotor and trochlear nerves, and the nucleus of the mesencephalic root of the trigeminal nerve. The **nucleus of the trigeminal nerve** extends along the entire length of the aqueduct, and occupies the lateral part of the gray stratum, while the nuclei of the oculomotor and trochlear nerves are situated in its ventral part. The **nucleus of the oculomotor nerve** is about 10 cm. long, and lies under the superior colliculus, beyond which, however, it extends for a short distance into the gray substance of the third ventricle. The **nucleus of the trochlear nerve** is small and nearly circular, and is on a level with a plane carried transversely through the upper part of the inferior colliculus.

THE FORE-BRAIN OR PROSENCEPHALON.

The fore-brain or prosencephalon consists of: (1) the **diencephalon**, corresponding in a large measure to the third ventricle and the structures which bound it; and (2) the **telencephalon**, comprising the largest part of the brain, viz., the cerebral hemispheres; these hemispheres are intimately connected with each other across the middle line, and each contains a large cavity, named the lateral ventricle. The lateral ventricles communicate through the interventricular foramen with the third ventricle, but are separated from each other by a medial septum, the **septum pellucidum**; this contains a slit-like cavity, which does not communicate with the ventricles.

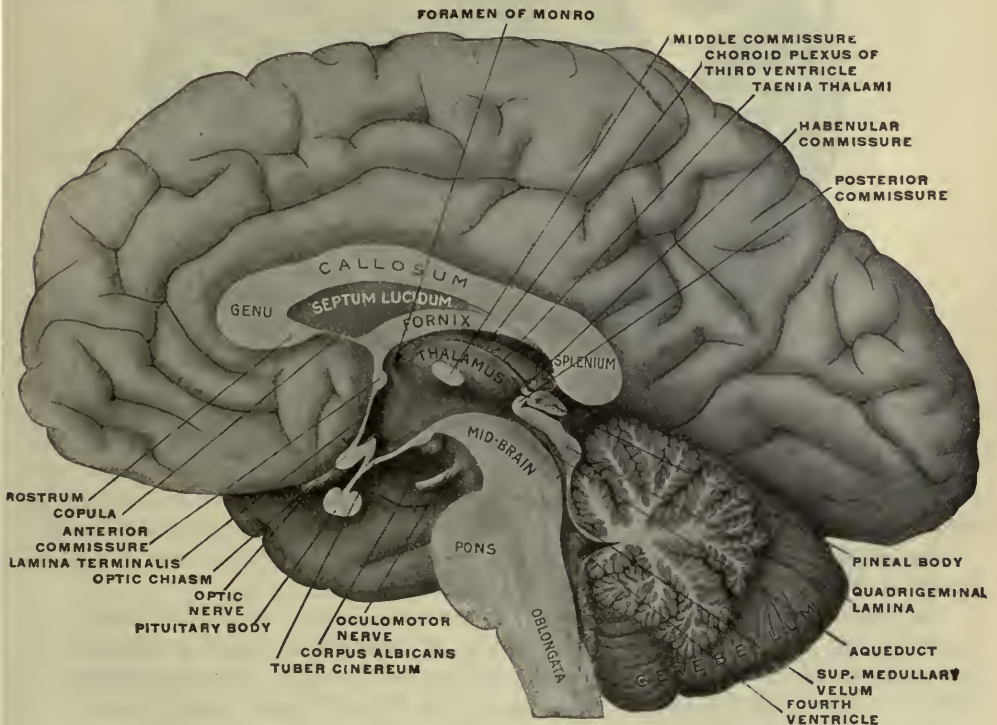


Fig. 715.—Mesal aspect of a brain sectioned in the median sagittal plane.

The Diencephalon.—The diencephalon is connected above and in front with the cerebral hemispheres; behind with the mid-brain. Its upper surface is concealed by the corpus callosum, and is covered by a fold of pia mater, named the tela chorioidea of the third ventricle; inferiorly it reaches to the base of the brain.

The diencephalon comprises: (1) the **thalamencephalon**; (2) the **pars mamillaris**

hypothalami; and (3) the posterior part of the third ventricle. For descriptive purposes, however, it is more convenient to consider the whole of the third ventricle and its boundaries together; this necessitates the inclusion, under this heading, of the pars optica hypothalami and the corresponding part of the third ventricle—structures which properly belong to the telencephalon.

The Thalamencephalon.—The thalamencephalon comprises: (1) the **thalamus**; (2) the **metathalamus** or **corpora geniculata**; and (3) the **epithalamus**, consisting of the trigonum habenulæ, the pineal body, and the posterior commissure.

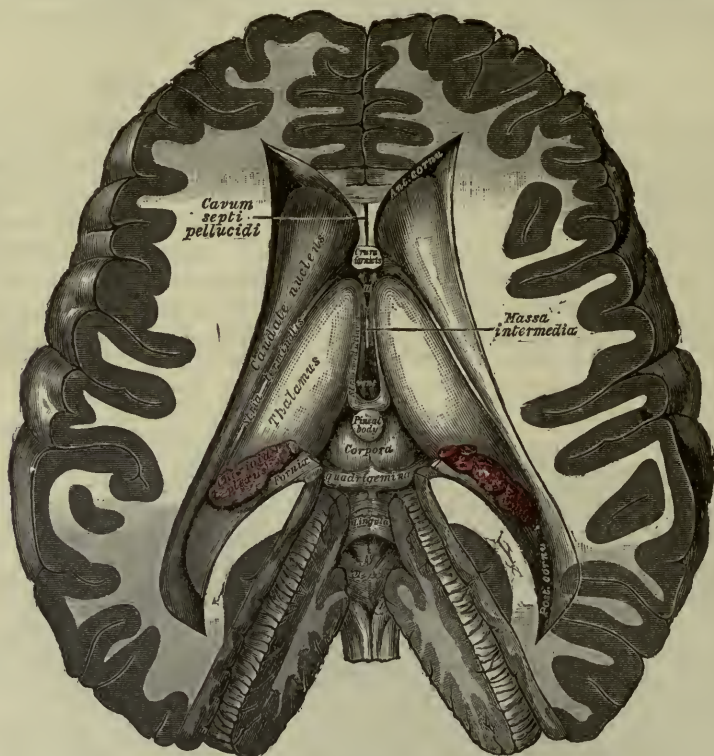

FIG. 716.—Dissection showing the ventricles of the brain.

The **Thalami** (*optic thalamus*) (Figs. 716, 717) are two large ovoid masses, situated one on either side of the third ventricle and reaching for some distance behind that cavity. Each measures about 4 cm. in length, and presents two extremities, an anterior and a posterior, and four surfaces, superior, inferior, medial, and lateral.

The **anterior extremity** is narrow; it lies close to the middle line and forms the posterior boundary of the interventricular foramen.

The **posterior extremity** is expanded, directed backward and lateralward, and overlaps the superior colliculus. Medially it presents an angular prominence, the **pulvinar**, which is continued laterally into an oval swelling, the **lateral geniculate body**, while beneath the pulvinar, but separated from it by the superior brachium, is a second oval swelling, the **medial geniculate body**.

The **superior surface** is free, slightly convex, and covered by a layer of white substance, termed the **stratum zonale**. It is separated laterally from the caudate nucleus by a white band, the **stria terminalis**, and by the terminal vein. It is divided into a medial and a lateral portion by an oblique shallow furrow which runs from behind forward and medialward and corresponds with the lateral margin of the fornix; the lateral part forms a portion of the floor of the lateral ventricle, and is

covered by the epithelial lining of this cavity; the medial part is covered by the tela chorioidea of the third ventricle, and is destitute of an epithelial covering. In front, the superior is separated from the medial surface by a salient margin, the *tænia thalami*, along which the epithelial lining of the third ventricle is reflected on to the under surface of the tela chorioidea. Behind, it is limited medially by a groove, the *sulcus habenulæ*, which intervenes between it and a small triangular area, termed the *trigonum habenulæ*.

The **inferior surface** rests upon and is continuous with the upward prolongation of the tegmentum (**subthalamie tegmental region**), in front of which it is related to the **substantia innominata** of Meynert.

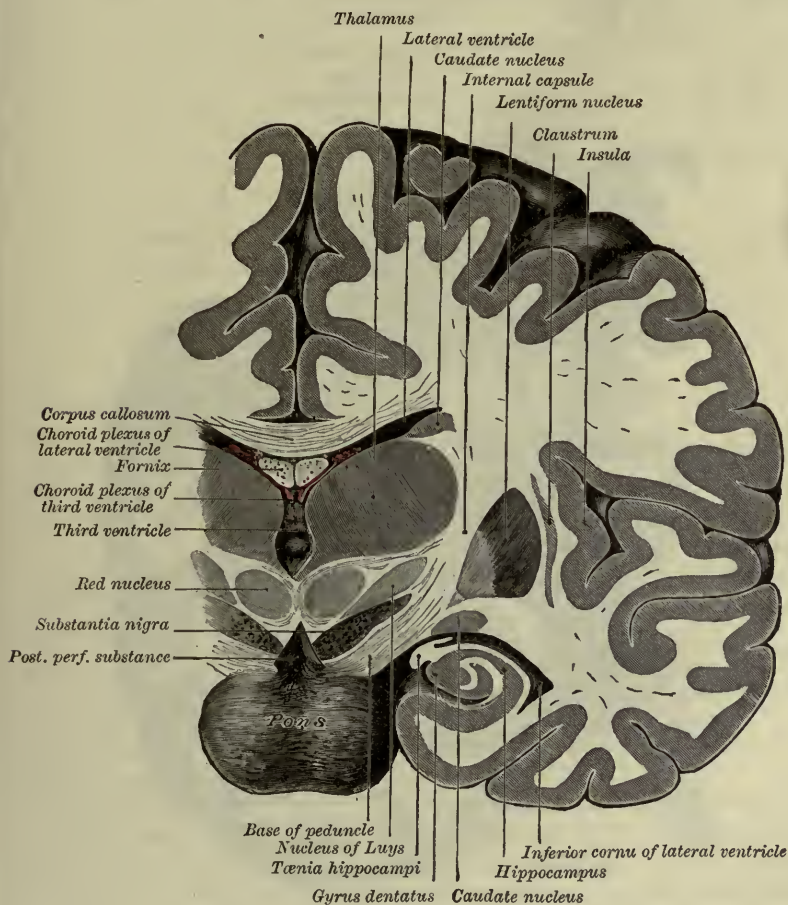


Fig. 717.—Coronal section of brain immediately in front of pons.

The **medial surface** constitutes the upper part of the lateral wall of the third ventricle, and is connected to the corresponding surface of the opposite thalamus by a flattened gray band, the **massa intermedia** (*middle or gray commissure*). This mass averages about 1 cm. in its antero-posterior diameter: it sometimes consists of two parts and occasionally is absent. It contains nerve cells and nerve fibers; a few of the latter may cross the middle line, but most of them pass toward the middle line and then curve lateralward on the same side.

The **lateral surface** is in contact with a thick band of white substance which forms the occipital part of the internal capsule and separates the thalamus from the lentiform nucleus of the corpus striatum.

Structure.—The thalamus consists chiefly of gray substance, but its upper surface is covered by a layer of white substance, named the **stratum zonale**, and its lateral surface by a similar layer termed the **lateral medullary lamina**. Its gray substance is incompletely subdivided into three parts—**anterior**, **medial**, and **lateral**—by a white layer, the **medial medullary lamina**. The anterior part comprises the anterior tubercle, the medial part lies next the lateral wall of the third ventricle while the lateral and largest part is interposed between the medullary laminae and includes the pulvinar. The lateral part is traversed by numerous fibers which radiate from the thalamus into the internal capsule, and pass through the latter to the cerebral cortex. These three parts are built up of numerous nuclei, the connections of many of which are imperfectly known.

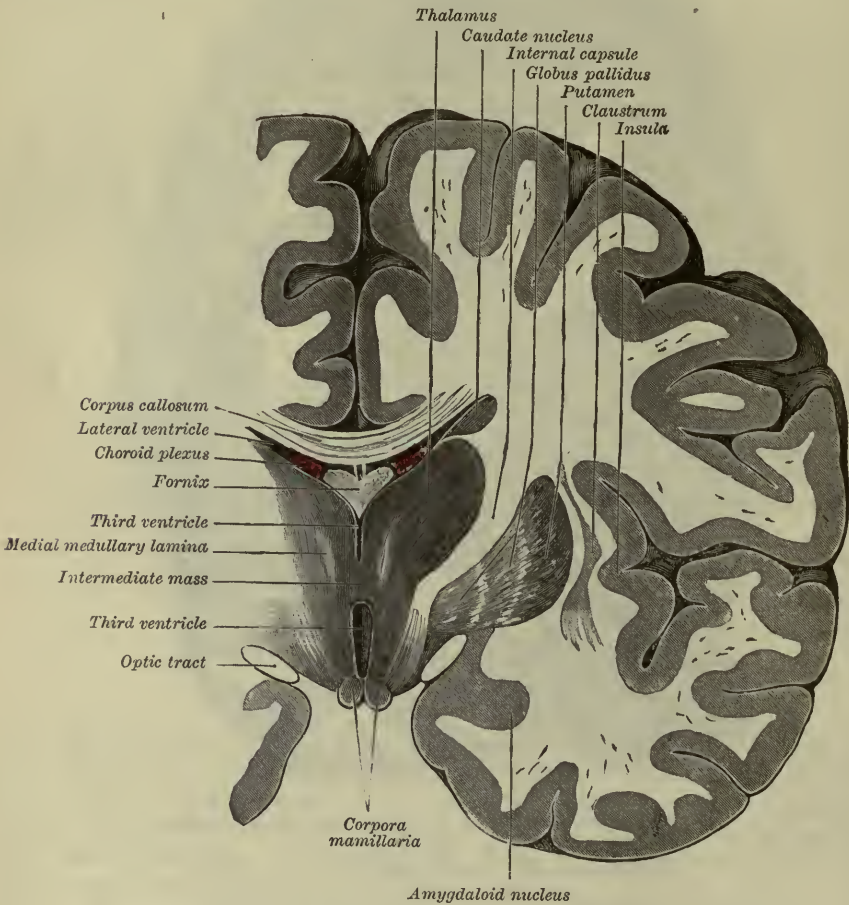


FIG. 718.—Coronal section of brain through intermediate mass of third ventricle.

Connections.—The thalamus may be regarded as a large ganglionic mass in which the ascending tracts of the tegmentum and a considerable proportion of the fibers of the optic tract end, and from the cells of which numerous fibers (thalamocortical) take origin, and radiate to almost every part of the cerebral cortex. The lemniscus, together with the other longitudinal strands of the tegmentum, enters its ventral part: the **thalamomammillary fasciculus** (*bundle of Vicq d'Azyr*), from the corpus mammillare, enters in its anterior tubercle, while many of the fibers of the optic tract terminate in its posterior end. The thalamus also receives numerous fibers (corticothalamic) from the cells of the cerebral cortex. The fibers that arise from

the cells of the thalamus form four principal groups or stalks: (a) those of the **anterior stalk** pass through the frontal part of the internal capsule to the frontal lobe; (b) the fibers of the **posterior stalk** (*optic radiations*) arise in the pulvinar and are conveyed through the occipital part of the internal capsule to the occipital lobe; (c) the fibers of the **inferior stalk** leave the under and medial surfaces of the thalamus, and pass beneath the lentiform nucleus to the temporal lobe and insula; (d) those of the **parietal stalk** pass from the lateral nucleus of the thalamus to the parietal lobe. Fibers also extend from the thalamus into the corpus striatum—those destined for the caudate nucleus leave the lateral surface, and those for the lentiform nucleus, the inferior surface of the thalamus.

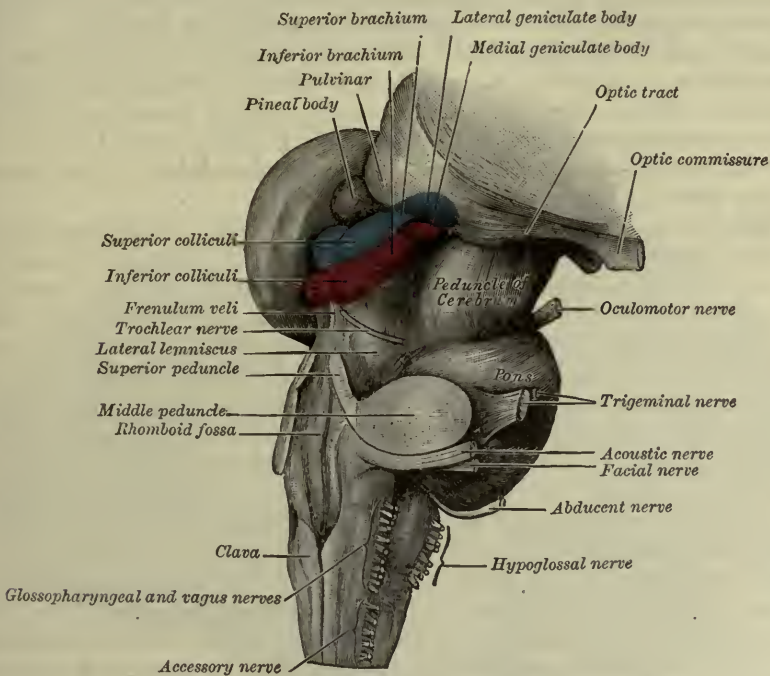


FIG. 719.—Hind- and mid-brains; postero-lateral view.

The **Metathalamus** (Fig. 719) comprises the **geniculate bodies**, which are two in number—a **medial** and a **lateral**—on each side.

The **medial geniculate body** (*corpus geniculatum mediale; internal geniculate body; postgeniculatum*) lies under cover of the pulvinar of the thalamus and on the lateral aspect of the corpora quadrigemina. Oval in shape, with its long axis directed forward and lateralward, it is lighter in color and smaller in size than the lateral. The inferior brachium from the inferior colliculus disappears under cover of it while from its lateral extremity a strand of fibers passes to join the optic tract. Entering it are many acoustic fibers from the lateral lemniscus. The medial geniculate bodies are connected with one another by the commissure of Gudden, which passes through the posterior part of the optic chiasma.

The **lateral geniculate body** (*corpus geniculatum laterale; external geniculate body; pregeniculatum*) is an oval elevation on the lateral part of the posterior end of the thalamus, and is connected with the superior colliculus by the superior brachium. It is of a dark color, and presents a laminated arrangement consisting of alternate layers of gray and white substance. It receives numerous fibers from the optic tract, while other fibers of this tract pass over or through it into the pulvinar. Its cells are large and pigmented; their axons pass to the visual area in the occipital part of the cerebral cortex.

The superior colliculus, the pulvinar, and the lateral geniculate body receive many fibers from the optic tracts, and are therefore intimately connected with sight, constituting what are termed the **lower visual centers**. Extirpation of the eyes in a newly born animal entails an arrest of the development of these centers, but has no effect on the medial geniculate bodies or on the inferior colliculi. Moreover, the latter are well-developed in the mole, an animal in which the superior colliculi are rudimentary.

The **Epithalamus** comprises the **trigonum habenulæ**, the **pineal body**, and the **posterior commissure**.

The **trigonum habenulæ** is a small depressed triangular area situated in front of the superior colliculus and on the lateral aspect of the posterior part of the *tænia thalami*. It contains a group of nerve cells termed the **ganglion habenulæ**. Fibers enter it from the stalk of the pineal body, and others, forming what is termed the **habenular commissure**, pass across the middle line to the corresponding ganglion of the opposite side. Most of its fibers are, however, directed downward and form a bundle, the **fasciculus retroflexus** of Meynert, which passes medial to the red nucleus, and, after decussating with the corresponding fasciculus of the opposite side, ends in the interpeduncular ganglion.

The **pineal body** (*corpus pineale; epiphysis*) is a small, conical, reddish-gray body which lies in the depression between the superior colliculi. It is placed beneath the splenium of the corpus callosum, but is separated from this by the *tela chorioidea* of the third ventricle, the lower layer of which envelops it. It measures about 8 mm. in length, and its base, directed forward, is attached by a stalk or peduncle of white substance. The **stalk** of the pineal body divides anteriorly into two laminae, a dorsal and a ventral, separated from one another by the pineal recess of the third ventricle. The ventral lamina is continuous with the posterior commissure; the dorsal lamina is continuous with the habenular commissure and divides into two strands the medullary striæ, which run forward, one on either side, along the junction of the medial and upper surfaces of the thalamus to blend in front with the columns of the fornix.

The **posterior commissure** is a rounded band of white fibers crossing the middle line on the dorsal aspect of the upper end of the cerebral aqueduct. Its fibers acquire their medullary sheaths early, but their connections have not been definitely determined. Most of them have their origin in a nucleus, the **nucleus of the posterior commissure** (*nucleus of Darkschewitsch*), which lies in the central gray substance of the upper end of the cerebral aqueduct, in front of the nucleus of the oculomotor nerve. Some are probably derived from the posterior part of the thalamus and from the superior colliculus, while others are believed to be continued downward into the medial longitudinal fasciculus.

The **Hypothalamus** (Fig. 720) includes the **subthalamie tegmental region** and the structures forming the greater part of the floor of the third ventricle, viz., the **corpora mammillaria**, **tuber cinereum**, **infundibulum**, **hypophysis**, and **optic chiasma**.

The **subthalamie tegmental region** consists of the upward continuation of the tegmentum; it lies on the ventro-lateral aspect of the thalamus and separates it from the fibers of the internal capsule. The red nucleus and the *substantia nigra* are prolonged into its lower part; in front it is continuous with the *substantia innominata* of Meynert, medially with the gray substance of the floor of the third ventricle.

It consists from above downward of three strata: (1) **stratum dorsale**, directly applied to the under surface of the thalamus and consisting of fine longitudinal fibers; (2) **zona incerta**, a continuation forward of the *formatio reticularis* of the tegmentum; and (3) the **corpus subthalamieum** (*nucleus of Luys*), a brownish mass presenting a lenticular shape on transverse section, and situated on the dorsal aspect of the fibers of the base of the cerebral peduncle; it is encapsuled by a lamina

of nerve fibers and contains numerous medium-sized nerve cells, the connections of which are as yet not fully determined.

The **corpora mammillaria** (*corpus albicantia*) are two round white masses, each about the size of a small pea, placed side by side below the gray substance of the floor of the third ventricle in front of the posterior perforated substance. They consist of white substance externally and of gray substance internally, the cells of the latter forming two nuclei, a **medial** of smaller and a **lateral** of larger cells. The white substance is mainly formed by the fibers of the columns of the fornix, which descend to the base of the brain and end partly in the corpora mammillaria. From the cells of the gray substance of each mammillary body two fasciculi arise: one, the **thalamomammillary fasciculus** (*bundle of Vicq d' Azyr*), passes upward into the anterior nucleus of the thalamus; the other is directed downward into the tegmentum. Afferent fibers are believed to reach the corpus mammillare from the medial lemniscus and from the tegmentum.

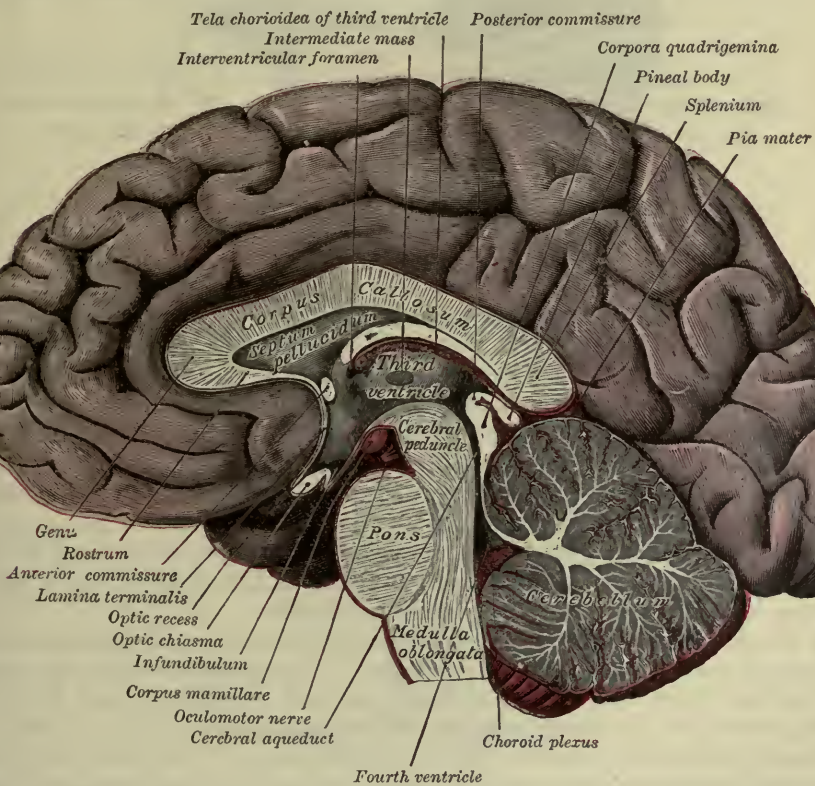


FIG. 720.—Median sagittal section of brain. The relations of the pia mater are indicated by the red color.

The **tuber cinereum** is a hollow eminence of gray substance situated between the corpora mammillaria behind, and the optic chiasma in front. Laterally it is continuous with the anterior perforated substances and anteriorly with a thin lamina, the **lamina terminalis**. From the under surface of the tuber cinereum a hollow conical process, the **infundibulum**, projects downward and forward and is attached to the posterior lobe of the hypophysis.

In the lateral part of the tuber cinereum is a nucleus of nerve cells, the **basal optic nucleus of Meynert**, while close to the cavity of the third ventricle are three additional nuclei. Between the tuber cinereum and the corpora mammillaria a small elevation, with a corresponding depression in the third ventricle, is sometimes seen. Retzius has named it the **eminentia saccularis**, and regards it as a representative of the **sacculus vasculosus** found in this situation in some of the lower vertebrates.

The **hypophysis** (*pituitary body*) (Fig. 721) is a reddish-gray, somewhat oval mass, measuring about 12.5 mm. in its transverse, and about 8 mm. in its antero-posterior diameter. It is attached to the end of the infundibulum, and is situated in the fossa hypophyseos of the sphenoidal bone, where it is retained by a circular fold of dura mater, the **diaphragma sellae**; this fold almost completely roofs in the fossa, leaving only a small central aperture through which the infundibulum passes.

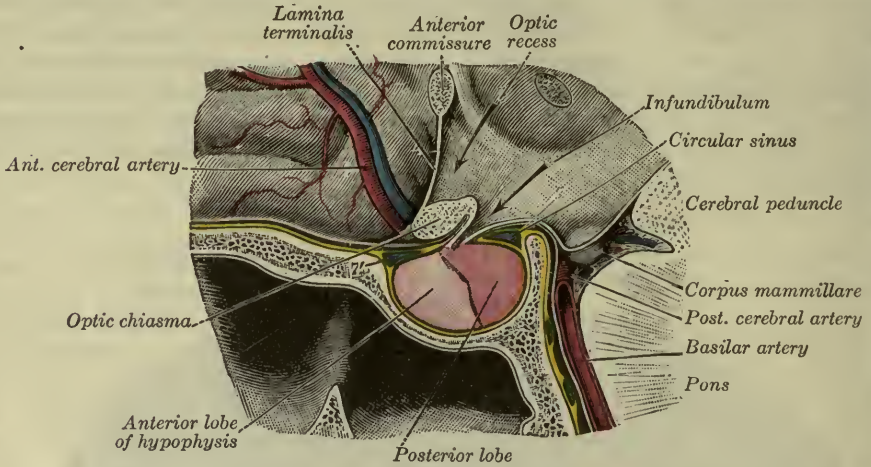


FIG. 721.—The hypophysis cerebri, in position. Shown in sagittal section.

Optic Chiasma (*chiasma opticum*; *optic commissure*).—The optic chiasma is a flattened, somewhat quadrilateral band of fibers, situated at the junction of the floor and anterior wall of the third ventricle. Most of its fibers have their origins in the retina, and reach the chiasma through the optic nerves, which are continuous with its antero-lateral angles. In the chiasma, they undergo a partial decussation (Fig. 722); the fibers from the nasal half of the retina decussate and enter the optic tract of the opposite side, while the fibers from the temporal half of the retina do not undergo decussation, but pass back into the optic tract of the same side. Occupying the posterior part of the commissure, however, is a strand of fibers, the **commissure of Gudden**, which is not derived from the optic nerves; it forms a connecting link between the medial geniculate bodies.

Optic Tracts.—The optic tracts are continued backward and lateralward from the postero-lateral angles of the optic chiasma. Each passes between the anterior perforated substance and the tuber cinereum, and, winding around the ventro-lateral aspect of the cerebral peduncle, divides into a medial and a lateral root. The former comprises the fibers of Gudden's commissure. The lateral root consists mainly of afferent fibers which arise in the retina and undergo partial decussation in the optic chiasma, as described; but it also contains a few fine efferent fibers which have their origins in the brain and their terminations in the retina. When traced backward, the afferent fibers of the lateral root are found to end in the lateral geniculate body and pulvinar of the thalamus, and in the superior colliculus; and these three structures constitute the **lower visual centers**. Fibers arise from the nerve cells in these centers and pass through the occipital part of the internal capsule, under the name of the **optic radiations**, to the cortex of the occipital lobe of the cerebrum, where the **higher** or **cortical visual center** is situated. Some of the fibers of the optic radiations take an opposite course, arising from the cells of the occipital cortex and passing to the lower visual centers. Some fibers are detached from the optic tract, and pass through the cerebral peduncle to the nucleus of the oculomotor nerve. These may be regarded as the afferent branches for the

Sphincter pupillæ and Ciliaris muscles. Other fibers have been described as reaching the cerebellum through the superior peduncle; while others, again, are lost in the pons.

The Third Ventricle (*ventriculus tertius*) (Figs. 716, 720).—The third ventricle is a median cleft between the two thalami. Behind, it communicates with the fourth ventricle through the cerebral aqueduct, and in front with the lateral ventricles through the interventricular foramen. Somewhat triangular in shape, with the apex directed backward, it has a **roof**, a **floor**, an **anterior** and a **posterior boundary** and a pair of **lateral walls**.

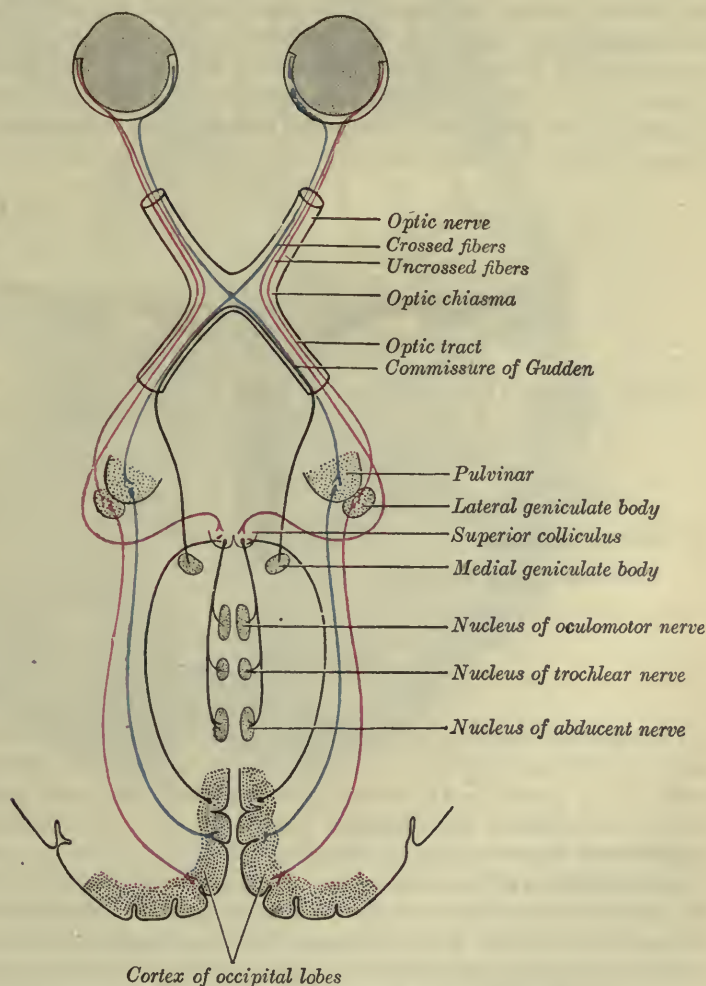


FIG. 722.—Scheme showing central connections of the optic nerves and optic tracts.

The **roof** (Fig. 723) is formed by a layer of epithelium, which stretches between the upper edges of the lateral walls of the cavity and is continuous with the epithelial lining of the ventricle. It is covered by and adherent to a fold of pia mater, named the tela chorioidea of the third ventricle, from the under surface of which a pair of vascular fringed processes, the **choroid plexuses of the third ventricle**, project downward, one on either side of the middle line, and invaginate the epithelial roof into the ventricular cavity.

The **floor** slopes downward and forward and is formed mainly by the structures which constitute the hypothalamus: from before backward these are: the optic

chiasma, the tuber cinereum and infundibulum, and the corpora mammillaria. Behind the last, the floor is formed by the interpeduncular fossa and the tegmenta of the cerebral peduncles. The ventricle is prolonged downward as a funnel-shaped recess, the **recessus infundibuli**, into the infundibulum, and to the apex of the latter the hypophysis is attached.

The **anterior boundary** is constituted below by the **lamina terminalis**, a thin layer of gray substance stretching from the upper surface of the optic chiasma to the rostrum of the corpus callosum; above by the columns of the fornix and the anterior commissure. At the junction of the floor and anterior wall, immediately above the optic chiasma, the ventricle presents a small angular recess or diverticulum, the **optic recess**. Between the columns of the fornix, and above the anterior commissure, is a second recess termed the **vulva**. At the junction of the roof and anterior wall of the ventricle, and situated between the thalami behind and the columns of the fornix in front, is the **interventricular foramen** (*foramen of Monro*) through which the third communicates with the lateral ventricles.

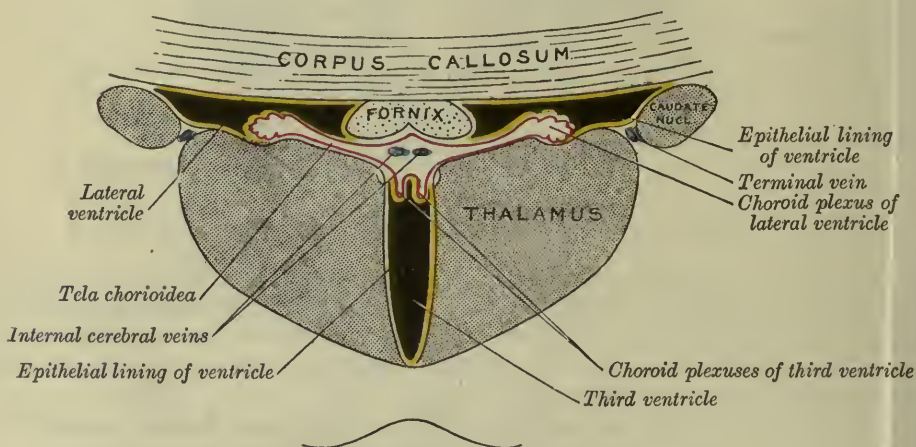


FIG. 723.—Coronal section of lateral and third ventricles. (Diagrammatic.)

The **posterior boundary** is constituted by the pineal body, the posterior commissure and the cerebral aqueduct. A small recess, the **recessus pinealis**, projects into the stalk of the pineal body, while in front of and above the pineal body is a second recess, the **recessus suprapinealis**, consisting of a diverticulum of the epithelium which forms the ventricular roof.

Each **lateral wall** consists of an upper portion formed by the medial surface of the anterior two-thirds of the thalamus, and a lower consisting of an upward continuation of the gray substance of the ventricular floor. These two parts correspond to the alar and basal laminae respectively of the lateral wall of the fore-brain vesicle and are separated from each other by a furrow, the **sulcus of Monro**, which extends from the interventricular foramen to the cerebral aqueduct (pages 741 and 742). The lateral wall is limited above by the *tænia thalami*. The columns of the fornix curve downward in front of the interventricular foramen, and then run in the lateral walls of the ventricle, where, at first, they form distinct prominences, but subsequently are lost to sight. The lateral walls are joined to each other across the cavity of the ventricle by a band of gray matter, the **massa intermedia** (page 809).

Interpeduncular Fossa (Fig. 724).—This is a somewhat lozenge-shaped area of the base of the brain, limited in front by the optic chiasma, behind by the antero-superior surface of the pons, antero-laterally by the converging optic tracts,

and postero-laterally by the diverging cerebral peduncles. The structures contained in it have already been described; from behind forward, they are the posterior perforated substance, corpora mamillaria, tuber cinereum, infundibulum, and hypophysis.

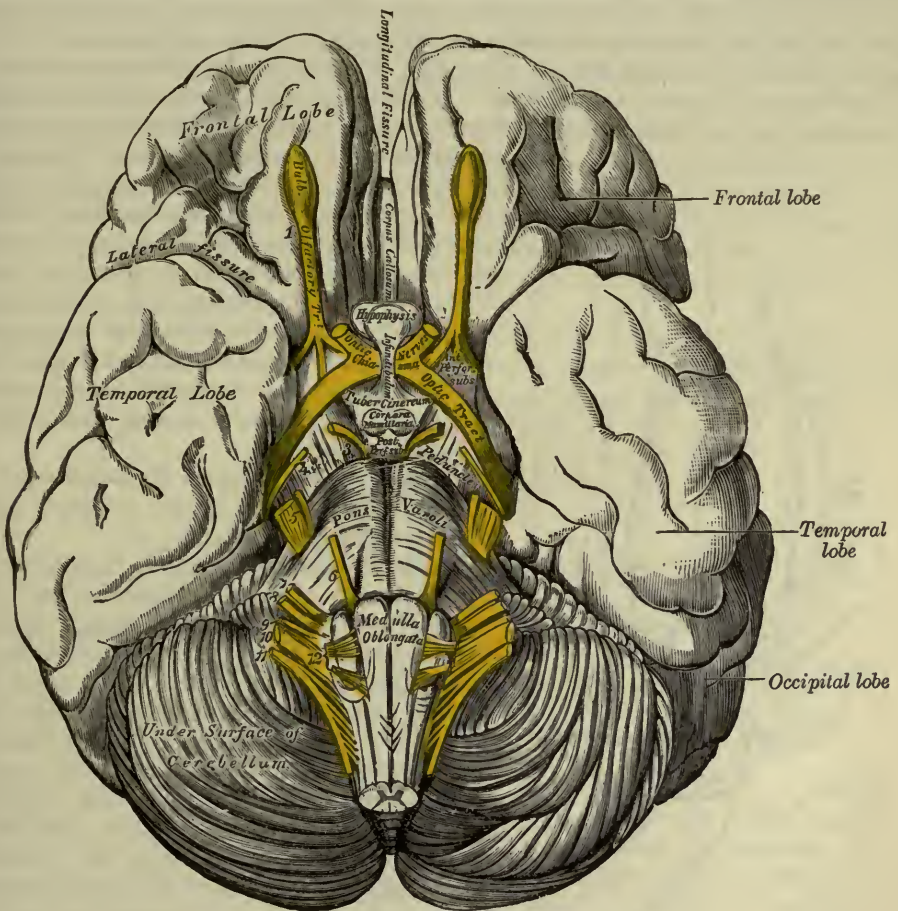


FIG. 724.—Base of brain.

The Telencephalon.—The telencephalon includes: (1) the cerebral hemispheres with their cavities, the lateral ventricles; and (2) the *pars optica hypothalami* and the anterior portion of the third ventricle (already described under the diencephalon). As previously stated (see page 744), each cerebral hemisphere may be divided into three fundamental parts, viz., the rhinencephalon, the corpus striatum, and the neopallium. The rhinencephalon, associated with the sense of smell, is the oldest part of the telencephalon, and forms almost the whole of the hemisphere in some of the lower animals, *e. g.*, fishes, amphibians, and reptiles. In man it is rudimentary, whereas the neopallium undergoes great development and forms the chief part of the hemisphere.

The Cerebral Hemispheres.—The cerebral hemispheres constitute the largest part of the brain, and, when viewed together from above, assume the form of an ovoid mass broader behind than in front, the greatest transverse diameter corresponding with a line connecting the two parietal eminences. The hemispheres are separated medially by a deep cleft, named the **longitudinal cerebral fissure**, and each possesses a central cavity, the lateral ventricle.

The **Longitudinal Cerebral Fissure** (*fissura cerebri longitudinalis*; *great longitudinal fissure*) contains a sickle-shaped process of dura mater, the **falx cerebri**. It front and behind, the fissure extends from the upper to the under surfaces of the hemispheres and completely separates them, but its middle portion separates them for only about one-half of their vertical extent; for at this part they are connected across the middle line by a great central white commissure, the **corpus callosum**.

In a median sagittal section (Fig. 720) the cut corpus callosum presents the appearance of a broad, arched band. Its thick posterior end, termed the **splenium**, overlaps the mid-brain, but is separated from it by the tela chorioidea of the third ventricle and the pineal body. Its anterior curved end, termed the **genu**, gradually tapers into a thinner portion, the **rostrum**, which is continued downward and backward in front of the anterior commissure to join the lamina terminalis. Arching backward from immediately behind the anterior commissure to the under surface of the splenium is a second white band named the **fornix**: between this and the corpus callosum are the laminae and cavity of the septum pellucidum.

Surfaces of the Cerebral Hemispheres.—Each hemisphere presents three surfaces: **lateral**, **medial**, and **inferior**.

The **lateral surface** is convex in adaptation to the concavity of the corresponding half of the vault of the cranium. The **medial surface** is flat and vertical, and is separated from that of the opposite hemisphere by the great longitudinal fissure and the falx cerebri. The **inferior surface** is of an irregular form, and may be divided into three areas: anterior, middle, and posterior. The anterior area, formed by the orbital surface of the frontal lobe, is concave, and rests on the roof of the orbit and nose; the middle area is convex, and consists of the under surface of the temporal lobe: it is adapted to the corresponding half of the middle cranial fossa. The posterior area is concave, directed medialward as well as downward, and is named the **tentorial surface**, since it rests upon the tentorium cerebelli, which intervenes between it and the upper surface of the cerebellum.

These three surfaces are separated from each other by the following **borders**: (a) **supero-medial**, between the lateral and medial surfaces; (b) **infero-lateral**, between the lateral and inferior surfaces; the anterior part of this border separating the lateral from the orbital surface, is known as the **superciliary border**; (c) **medial occipital**, separating the medial and tentorial surfaces; and (d) **medial orbital**, separating the orbital from the medial surface. The anterior end of the hemisphere is named the **frontal pole**; the posterior, the **occipital pole**; and the anterior end of the temporal lobe, the **temporal pole**. About 5 cm. in front of the occipital pole on the infero-lateral border is an indentation or notch, named the **preoccipital notch**.

The surfaces of the hemispheres are moulded into a number of irregular emi-

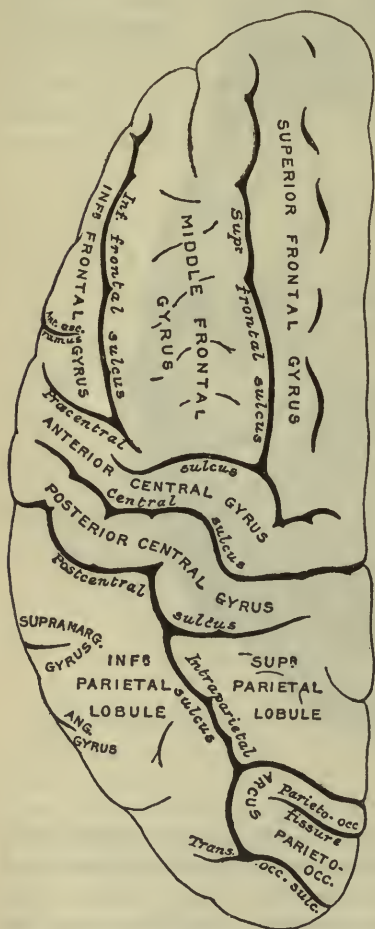


FIG. 725.—Lateral surface of left cerebral hemisphere, viewed from above.

nences, named **gyri** or **convolutions**, and separated by furrows termed **fissures** and **sulci**. The furrows are of two kinds, *complete* and *incomplete*. The former appear early in fetal life, are few in number, and are produced by infoldings of the entire thickness of the brain wall, and give rise to corresponding elevations in the interior of the ventricle. They comprise the hippocampal fissure, and parts of the calcarine and collateral fissures. The incomplete furrows are very numerous, and only indent the subjacent white substance, without producing any corresponding elevations in the ventricular cavity.

The gyri and their intervening fissures and the sulci are fairly constant in their arrangement; at the same time they vary within certain limits, not only in different individuals, but on the two hemispheres of the same brain. The convoluted condition of the surface permits of a great increase of the gray matter without the sacrifice of much additional space. The number and extent of the gyri, as well as the depth of the intervening furrows, appear to bear a direct relation to the intellectual powers of the individual.

Certain of the fissures and sulci are utilized for the purpose of dividing the hemisphere into lobes, and are therefore termed **interlobular**; included under this category are the lateral cerebral, parietoöccipital, calcarine, and collateral fissures, the central and cingulate sulci, and the sulcus circularis.

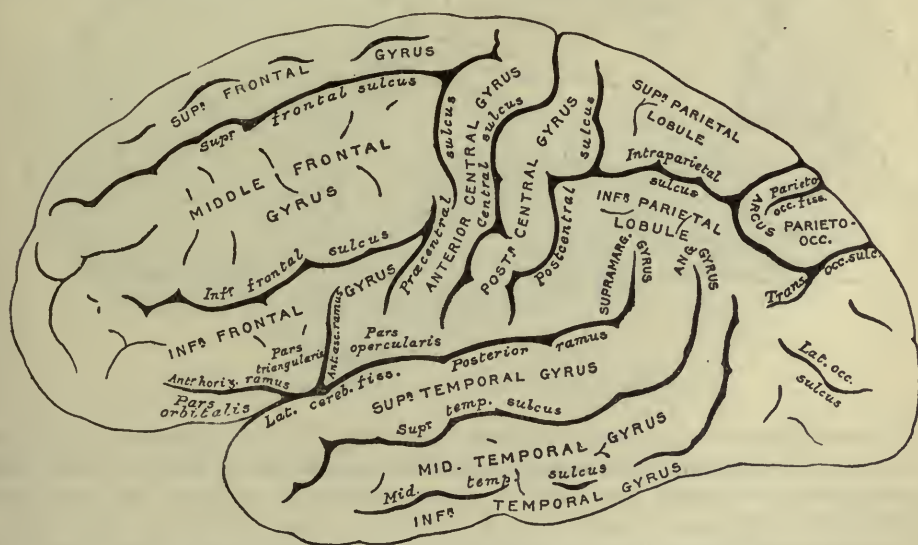


FIG. 726.—Lateral surface of left cerebral hemisphere, viewed from the side.

The **Lateral Cerebral Fissure** (*fissura cerebri lateralis* [Sylvii]; *fissure of Sylvius*) (Fig. 726) is a well-marked cleft on the inferior and lateral surfaces of the hemisphere, and consists of a short stem which divides into three rami. The **stem** is situated on the base of the brain, and commences in a depression at the lateral angle of the anterior perforated substance. From this point it extends between the anterior part of the temporal lobe and the orbital surface of the frontal lobe, and reaches the lateral surface of the hemisphere. Here it divides into three rami: an anterior horizontal, an anterior ascending, and a posterior. The **anterior horizontal ramus** passes forward for about 2.5 cm. into the inferior frontal gyrus, while the **anterior ascending ramus** extends upward into the same convolution for about an equal distance. The **posterior ramus** is the longest; it runs backward and slightly upward for about 7 cm., and ends by an upward inflexion in the parietal lobe.

The **Central Sulcus** (*sulcus centralis* [Rolandi]; *fissure of Rolando*; *central fissure*)

(Figs. 725, 726) is situated about the middle of the lateral surface of the hemisphere, and begins in or near the longitudinal cerebral fissure, a little behind its mid-point. It runs sinuously downward and forward, and ends a little above the posterior ramus of the lateral fissure, and about 2.5 cm. behind the anterior ascending ramus of the same fissure. It described two chief curves: a **superior genu** with its concavity directed forward, and an **inferior genu** with its concavity directed backward. The central sulcus forms an angle opening forward of about 70° with the median plane.

The Parietoöccipital Fissure (*fissura parietoöccipitalis*).—Only a small part of this fissure is seen on the lateral surface of the hemisphere, its chief part being on the medial surface.

The **lateral part** of the parietoöccipital fissure (Fig. 726) is situated about 5 cm. in front of the occipital pole of the hemisphere, and measures about 1.25 cm. in length.

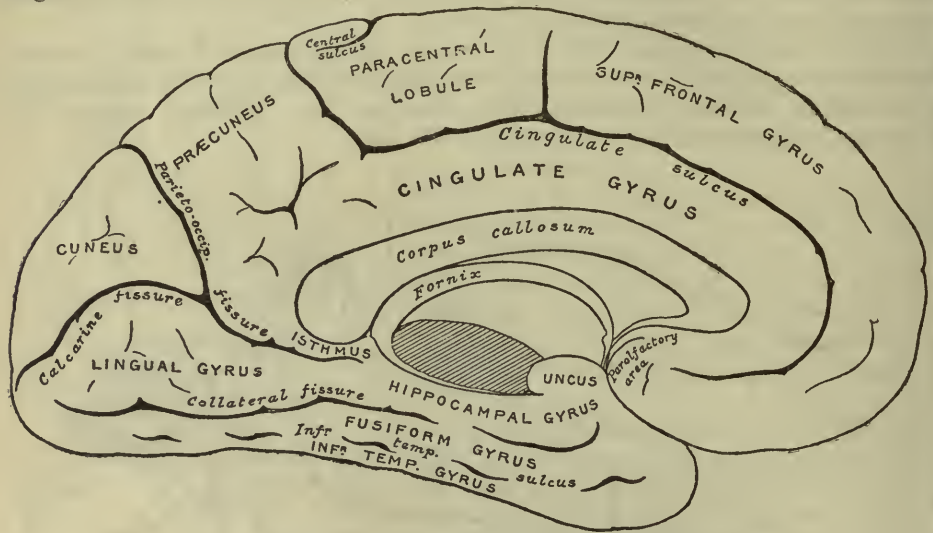


FIG. 727.—Medial surface of left cerebral hemisphere.

The **medial part** of the parietoöccipital fissure (Fig. 727) runs downward and forward as a deep cleft on the medial surface of the hemisphere, and joins the calcarine fissure below and behind the posterior end of the corpus callosum. In most cases it contains a submerged gyrus.

The **Calcarine Fissure** (*fissura calcarina*) (Fig. 727) is on the medial surface of the hemisphere. It begins near the occipital pole in two converging rami, and runs forward to a point a little below the splenium of the corpus callosum, where it is joined at an acute angle by the medial part of the parietoöccipital fissure. The anterior part of this fissure gives rise to the prominence of the **calcar avis** in the posterior cornu of the lateral ventricle.

The **Cingulate Sulcus** (*sulcus cinguli; callosomarginal fissure*) (Fig. 727) is on the medial surface of the hemisphere; it begins below the anterior end of the corpus callosum and runs upward and forward nearly parallel to the rostrum of this body and, curving in front of the genu, is continued backward above the corpus callosum, and finally ascends to the supero-medial border of the hemisphere a short distance behind the upper end of the central sulcus. It separates the superior frontal from the cingulate gyrus.

The **Collateral Fissure** (*fissura collateralis*) (Fig. 727) is on the tentorial surface of the hemisphere and extends from near the occipital pole to within a short distance of the temporal pole. Behind, it lies below and lateral to the calcarine fissure,

from which it is separated by the lingual gyrus; in front, it is situated between the hippocampal gyrus and the anterior part of the fusiform gyrus.

The **Sulcus Circularis** (*circuminsular fissure*) (Fig. 731) is on the lower and lateral surfaces of the hemisphere: it surrounds the insula and separates it from the frontal, parietal, and temporal lobes.

Lobes of the Hemispheres.—By means of these fissures and sulci, assisted by certain arbitrary lines, each hemisphere is divided into the following lobes: the **frontal**, the **parietal**, the **temporal**, the **occipital**, the **limbic**, and the **insula**.

Frontal Lobe (*lobus frontalis*).—On the lateral surface of the hemisphere this lobe extends from the frontal pole to the central sulcus, the latter separating it from the parietal lobe. Below, it is limited by the posterior ramus of the lateral fissure, which intervenes between it and the central lobe. On the medial surface, it is separated from the cingulate gyrus by the cingulate sulcus; and on the inferior surface, it is bounded behind by the stem of the lateral fissure.

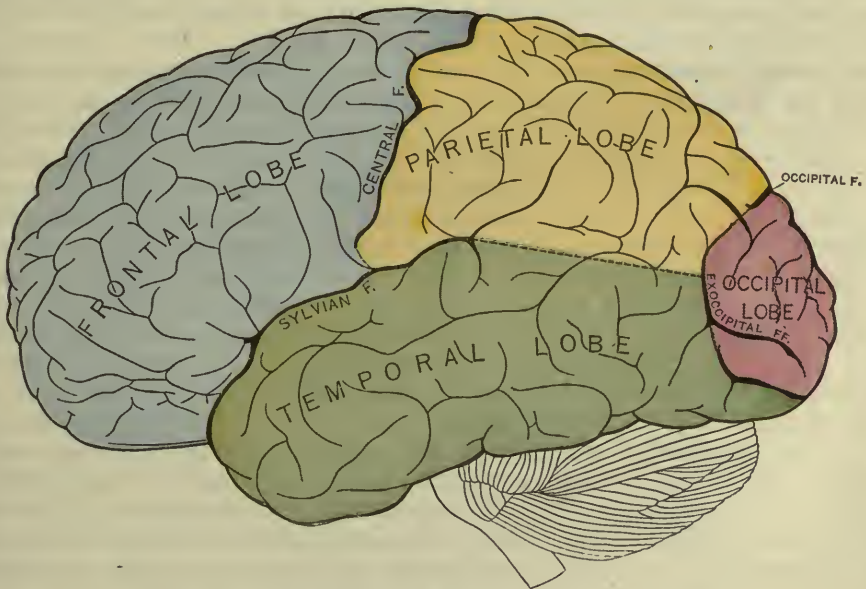


FIG. 728.—Principal fissures and lobes of the cerebrum viewed laterally.

The lateral surface of the frontal lobe (Fig. 726) is traversed by three sulci which divide it into four gyri: the sulci are named the precentral, and the superior and inferior frontal; the gyri are the anterior central, and the superior, middle, and inferior frontal. The **precentral sulcus** runs parallel to the central sulcus, and is usually divided into an upper and a lower part; between it and the central sulcus is the **anterior central gyrus**. From the precentral sulcus, the **superior** and **inferior frontal sulci** run forward and downward, and divide the remainder of the lateral surface of the lobe into three parallel gyri, named, respectively the **superior**, **middle**, and **inferior frontal gyri**.

The **anterior central gyrus** (*gyrus centralis anterior; ascending frontal convolution; precentral gyre*) is bounded in front by the precentral sulcus, behind by the central sulcus; it extends from the supero-medial border of the hemisphere to the posterior ramus of the lateral fissure.

The **superior frontal gyrus** (*gyrus frontalis superior; superfrontal gyre*) is situated above the superior frontal sulcus and is continued on to the medial surface of the hemisphere. The portion on the lateral surface of the hemisphere is usually more or less completely subdivided into an upper and a lower part by an antero-

posterior sulcus, the **paramedial sulcus**, which, however, is frequently interrupted by bridging gyri.

The **middle frontal gyrus** (*gyrus frontalis medius; medifrontal gyre*), between the superior and inferior frontal sulci, is continuous with the anterior orbital gyrus on the inferior surface of the hemisphere; it is frequently subdivided into two by a horizontal sulcus, the **medial frontal sulcus** of Eberstaller, which ends anteriorly in a wide bifurcation.

The **inferior frontal gyrus** (*gyrus frontalis inferior; subfrontal gyre*) lies below the inferior frontal sulcus, and extends forward from the lower part of the precentral sulcus; it is continuous with the lateral and posterior orbital gyri on the under surface of the lobe. It is subdivided by the anterior horizontal and ascending rami of the lateral fissure into three parts, viz., (1) the **orbital part**, below the anterior horizontal ramus of the fissure; (2) the **triangular part** (*cap of Broca*), between the ascending and horizontal rami; and (3) the **basilar part**, behind the anterior ascending ramus. The left inferior frontal gyrus is, as a rule, more highly developed than the right, and is named the **gyrus of Broca**, from the fact that Broca described it as the center for articulate speech.

The **inferior or orbital surface** of the frontal lobe is concave, and rests on the orbital plate of the frontal bone (Fig. 729). It is divided into four orbital gyri by a well-marked H-shaped **orbital sulcus**. These are named, from their position, the **medial, anterior, lateral, and posterior orbital gyri**. The medial orbital gyrus presents a well-marked antero-posterior sulcus, the **olfactory sulcus**, for the olfactory tract; the portion medial to this is named the **straight gyrus**, and is continuous with the superior frontal gyrus on the medial surface.

The **medial surface** of the frontal lobe is occupied by the medial part of the superior frontal gyrus (*marginal gyrus*) (Fig. 727). It lies between the ingulate sulcus and the supero-medial margin of the hemisphere. The posterior part of this gyrus is sometimes marked off by a vertical sulcus, and is distinguished as the **paracentral lobule**, because it is continuous with the anterior and posterior central gyri.

Parietal Lobe (*lobus parietalis*).—The parietal lobe is separated from the frontal lobe by the central sulcus, but its boundaries below and behind are not so definite.

Posteriorly, it is limited by the parietooccipital fissure, and by a line carried across the hemisphere from the end of this fissure toward the preoccipital notch. Below, it is separated from the temporal lobe by the posterior ramus of the lateral fissure, and by a line carried backward from it to meet the line passing downward to the preoccipital notch.

The **lateral surface** of the parietal lobe (Fig. 726) is cleft by a well-marked furrow, the **intraparietal sulcus** of Turner, which consists of an oblique and a horizontal portion. The oblique part is named the **postcentral sulcus**, and commences below, about midway between the lower end of the central sulcus and the upturned end of the lateral fissure. It runs upward and backward, parallel to the central sulcus, and is sometimes divided into an *upper* and a *lower* ramus. It forms the hinder limit of the posterior central gyrus.

From about the middle of the postcentral sulcus, or from the upper end of its inferior ramus, the **horizontal portion** of the intraparietal sulcus is carried backward and slightly upward on the parietal lobe, and is prolonged, under the name of the

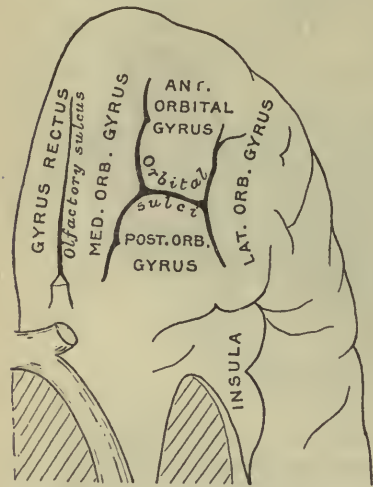


Fig. 729.—Orbital surface of left frontal lobe.

occipital ramus, on to the occipital lobe, where it divides into two parts, which form nearly a right angle with the main stem and constitute the **transverse occipital sulcus**. The part of the parietal lobe above the horizontal portion of the intraparietal sulcus is named the **superior parietal lobule**; the part below, the **inferior parietal lobule**.

The **posterior central gyrus** (*gyrus centralis posterior*; *ascending parietal convolution*; *postcentral gyre*) extends from the longitudinal fissure above to the posterior ramus of the lateral fissure below. It lies parallel with the anterior central gyrus, with which it is connected below, and also, sometimes, above, the central sulcus.

The **superior parietal lobule** (*lobulus parietalis superior*) is bounded in front by the upper part of the postcentral sulcus, but is usually connected with the posterior central gyrus above the end of the sulcus; behind it is the lateral part of the parietooccipital fissure, around the end of which it is joined to the occipital lobe by a curved gyrus, the **arcus parietooccipitalis**; below, it is separated from the inferior parietal lobule by the horizontal portion of the intraparietal sulcus.

The **inferior parietal lobule** (*lobulus parietalis inferior*; *subparietal district or lobule*) lies below the horizontal portion of the intraparietal sulcus, and behind the lower part of the postcentral sulcus. It is divided from before backward into two gyri. One, the **supramarginal**, arches over the upturned end of the lateral fissure; it is continuous in front with the postcentral gyrus, and behind with the superior temporal gyrus. The second, the **angular**, arches over the posterior end of the superior temporal sulcus, behind which it is continuous with the middle temporal gyrus.

The **medial surface** of the parietal lobe (Fig. 727) is bounded behind by the medial part of the parietooccipital fissure; in front, by the posterior end of the cingulate sulcus; and below, it is separated from the cingulate gyrus by the **subparietal sulcus**. It is of small size, and consists of a square-shaped convolution, which is termed the **precuneus** or **quadrate lobe**.

Occipital Lobe (*lobus occipitalis*).—The occipital lobe is small and pyramidal in shape; it presents three surfaces: **lateral**, **medial**, and **tentorial**.

The **lateral surface** is limited in front by the lateral part of the parietooccipital fissure, and by a line carried from the end of this fissure to the preoccipital notch; it is traversed by the transverse occipital and the lateral occipital sulci. The **transverse occipital sulcus** is continuous with the posterior end of the occipital ramus of the intraparietal sulcus, and runs across the upper part of the lobe, a short distance behind the parietooccipital fissure. The **lateral occipital sulcus** extends from behind forward, and divides the lateral surface of the occipital lobe into a **superior** and an **inferior gyrus**, which are continuous in front with the parietal and temporal lobes.¹

The **medial surface** of the occipital lobe is bounded in front by the medial part of the parietooccipital fissure, and is traversed by the calcarine fissure, which subdivides it into the cuneus and the lingual gyrus. The cuneus is a wedge-shaped area between the calcarine fissure and the medial part of the parietooccipital fissure. The **lingual gyrus** lies between the calcarine fissure and the posterior part of the collateral fissure; behind, it reaches the occipital pole; in front, it is continued on to the tentorial surface of the temporal lobe, and joins the hippocampal gyrus.

The **tentorial surface** of the occipital lobe is limited in front by an imaginary transverse line through the preoccipital notch, and consists of the posterior part of the **fusiform gyrus** (*occipitotemporal convolution*) and the lower part of the lingual gyrus, which are separated from each other by the posterior segment of the collateral fissure.

Temporal Lobe (*lobus temporalis*).—The temporal lobe presents **superior**, **lateral**, and **inferior surfaces**.

¹ Elliot Smith has named the lateral occipital sulcus the *sulcus lunatus*; he regards it as the representative, in the human brain, of the "Affenspalte" of the brain of the ape.

The **superior surface** forms the lower limit of the lateral fissure and overlaps the insula. On opening out the lateral fissure, three or four gyri will be seen springing from the depth of the hinder end of the fissure, and running obliquely forward and outward on the posterior part of the upper surface of the superior temporal gyrus; these are named the **transverse temporal gyri** (Heschl) (Fig. 730).

The **lateral surface** (Fig. 726) is bounded above by the posterior ramus of the lateral fissure, and by the imaginary line continued backward from it; below, it is limited by the infero-lateral border of the hemisphere. It is divided into superior, middle, and inferior gyri by the superior and middle temporal sulci. The **superior temporal sulcus** runs from before backward across the temporal lobe, some little distance below, but parallel with, the posterior ramus of the lateral fissure; and hence it is often termed the **parallel sulcus**. The **middle temporal sulcus** takes the same direction as the superior, but is situated at a lower level, and is usually subdivided into two or more parts. The **superior temporal gyrus** lies between

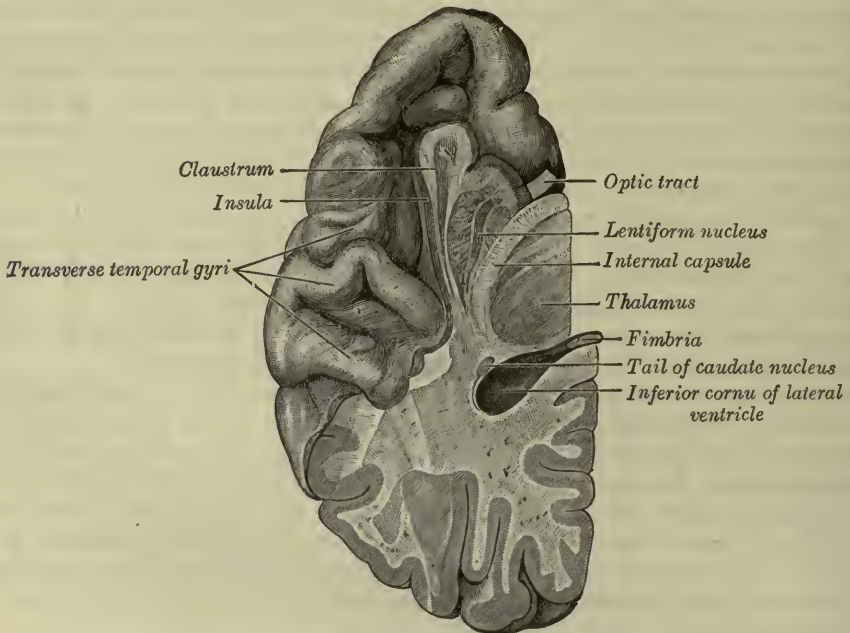


FIG. 730.—Section of brain showing upper surface of temporal lobe.

the posterior ramus of the lateral fissure and the superior temporal sulcus, and is continuous behind with the supramarginal and angular gyri. The **middle temporal gyrus** is placed between the superior and middle temporal sulci, and is joined posteriorly with the angular gyrus. The **inferior temporal gyrus** is placed below the middle temporal sulcus, and is connected behind with the inferior occipital gyrus; it also extends around the infero-lateral border on to the inferior surface of the temporal lobe, where it is limited by the inferior sulcus.

The **inferior surface** is concave, and is continuous posteriorly with the tentorial surface of the occipital lobe. It is traversed by the **inferior temporal sulcus**, which extends from near the occipital pole behind, to within a short distance of the temporal pole in front, but is frequently subdivided by bridging gyri. Lateral to this fissure is the narrow tentorial part of the inferior temporal gyrus, and medial to it the **fusiform gyrus**, which extends from the occipital to the temporal pole; this gyrus is limited medially by the collateral fissure, which separates it from the lingual gyrus behind and from the hippocampal gyrus in front.

The **Insula** (*island of Reil; central lobe*) (Fig. 731) lies deeply in the lateral or Sylvian fissure, and can only be seen when the lips of that fissure are widely separated, since it is overlapped and hidden by the gyri which bound the fissure. These gyri are termed the **opercula of the insula**; they are separated from each other by the three rami of the lateral fissure, and are named the orbital, frontal, frontoparietal, and temporal opercula. The **orbital operculum** lies below the anterior horizontal ramus of the fissure, the **frontal** between this and the anterior ascending ramus, the **parietal** between the anterior ascending ramus and the upturned end of the posterior ramus, and the **temporal** below the posterior ramus. The frontal operculum is of small size in those cases where the anterior horizontal and ascending rami of the lateral fissure arise from a common stem. The insula is surrounded by a deep **circular sulcus** which separates it from the frontal, parietal, and temporal lobes. When the opercula have been removed, the insula is seen as a triangular eminence, the apex of which is directed toward the anterior perforated substance. It is divided into a larger anterior and a smaller posterior part by a deep sulcus, which runs backward and upward from the apex of the insula. The anterior part is subdivided by shallow sulci into three or four **short gyri**, while the posterior part is formed by one **long gyrus**, which is often bifurcated at its upper end. The cortical gray substance of the insula is continuous with that of the different opercula, while its deep surface corresponds with the lentiform nucleus of the corpus striatum.

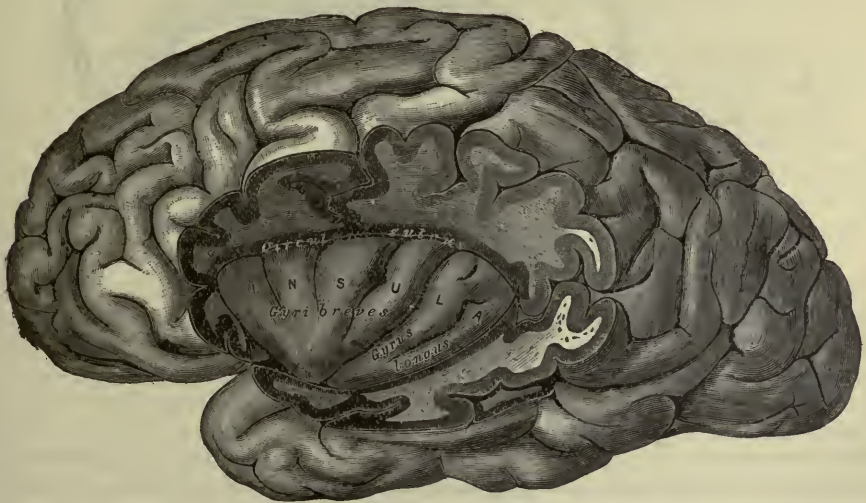

Fig. 731.—The insula of the left side, exposed by removing the opercula.

Limbic Lobe (Fig. 727).—The term limbic lobe was introduced by Broca, and under it he included the cingulate and hippocampal gyri, which together arch around the corpus callosum and the hippocampal fissure. These he separated on the morphological ground that they are well-developed in animals possessing a keen sense of smell (osmatic animals), such as the dog and fox. They were thus regarded as a part of the rhinencephalon, but it is now recognized that they belong to the neopallium; the cingulate gyrus is therefore sometimes described as a part of the frontal lobe, and the hippocampal as a part of the temporal lobe.

The **cingulate gyrus** (*gyrus cinguli; callosal convolution*) is an arch-shaped convolution, lying in close relation to the superficial surface of the corpus callosum, from which it is separated by a slit-like fissure, the **callosal fissure**. It commences below the rostrum of the corpus callosum, curves around in front of the genu, extends along the upper surface of the body, and finally turns downward behind the splenium, where it is connected by a narrow **isthmus** with the hippocampal

gyrus. It is separated from the medial part of the superior frontal gyrus by the cingulate sulcus, and from the precuneus by the subparietal sulcus.

The **hippocampal gyrus** (*gyrus hippocampi*) is bounded above by the hippocampal fissure, and below by the anterior part of the collateral fissure. Behind, it is continuous superiorly, through the isthmus, with the cingulate gyrus and inferiorly with the lingual gyrus. Running in the substance of the cingulate and hippocampal gyri, and connecting them together, is a tract of arched fibers, named the **cingulum** (page 843). The anterior extremity of the hippocampal gyrus is recurved in the form of a hook (**uncus**), which is separated from the apex of the temporal lobe by a slight fissure, the **incisura temporalis**. Although superficially continuous with the hippocampal gyrus, the uncus forms morphologically a part of the rhinencephalon.

The **Hippocampal Fissure** (*fissura hippocampi; dentate fissure*) begins immediately behind the splenium of the corpus callosum, and runs forward between the hippocampal and dentate gyri to end in the uncus. It is a complete fissure (page 819), and gives rise to the prominence of the hippocampus in the inferior cornu of the lateral ventricle.

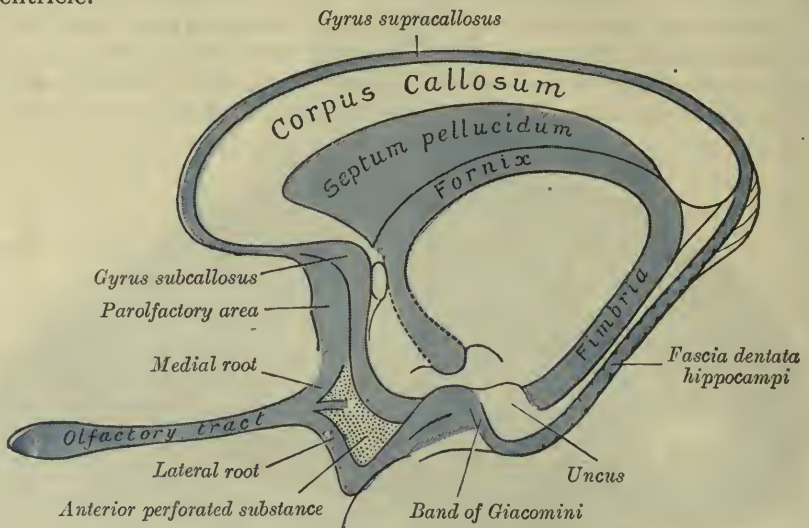


FIG. 732.—Scheme of rhinencephalon.

Rhinencephalon (Fig. 732).—The rhinencephalon comprises the olfactory lobe, the uncus, the subcallosal and supracallosal gyri, the fascia dentata hippocampi, the septum pellucidum, the fornix, and the hippocampus.

1. The **Olfactory Lobe** (*lobus olfactorius*) is situated under the inferior or orbital surface of the frontal lobe. In many vertebrates it constitutes a well-marked portion of the hemisphere and contains an extension of the lateral ventricle; but in man and some other mammals it is rudimentary. It consists of the olfactory bulb and tract, the olfactory trigone, the parolfactory area of Broca, and the anterior perforated substance.

(a) The **olfactory bulb** (*bulbus olfactorius*) is an oval, reddish-gray mass which rests on the cribriform plate of the ethmoid and forms the anterior expanded extremity of the olfactory tract. Its under surface receives the olfactory nerves, which pass upward through the cribriform plate from the olfactory region of the nasal cavity. Its minute structure is described on page 848.

(b) The **olfactory tract** (*tractus olfactorius*) is a narrow white band, triangular on coronal section, the apex being directed upward. It lies in the olfactory sulcus on the inferior surface of the frontal lobe, and divides posteriorly into two striæ, a medial and a lateral. The **lateral stria** is directed across the lateral part of the

anterior perforated substance and then bends abruptly medialward toward the uncus of the hippocampal gyrus. The **medial stria** turns medialward behind the parolfactory area and ends in the subcallosal gyrus; in some cases a small **intermediate stria** is seen running backward to the anterior perforated substance.

(c) The **olfactory trigone** (*trigonum olfactorium*) is a small triangular area in front of the anterior perforated substance. Its apex, directed forward, occupies the posterior part of the olfactory sulcus, and is brought into view by throwing back the olfactory tract.

(d) The **parolfactory area of Broca** (*area parolfactoria*) is a small triangular field on the medial surface of the hemisphere in front of the subcallosal gyrus, from which it is separated by the posterior parolfactory sulcus; it is continuous below with the olfactory trigone, and above and in front with the cingulate gyrus; it is limited anteriorly by the anterior parolfactory sulcus.

(e) The **anterior perforated substance** (*substantia perforata anterior*) is an irregularly quadrilateral area in front of the optic tract and behind the olfactory trigone, from which it is separated by the **fissure prima**; medially and in front it is continuous with the subcallosal gyrus; laterally it is bounded by the lateral stria of the olfactory tract and is continued into the uncus. Its gray substance is confluent above with that of the corpus striatum, and is perforated anteriorly by numerous small bloodvessels.

2. The **Uncus** has already been described (page 826) as the recurved, hook-like portion of the hippocampal gyrus.

3. The **Subcallosal, Supracallosal, and Dentate Gyri** form a rudimentary arch-shaped lamina of gray substance extending over the corpus callosum and above the hippocampal gyrus from the anterior perforated substance to the uncus.

(a) The **subcallosal gyrus** (*gyrus subcallosus*; *peduncle of the corpus callosum*) is a narrow lamina on the medial surface of the hemisphere in front of the lamina terminalis, behind the parolfactory area, and below the rostrum of the corpus callosum. It is continuous around the genu of the corpus callosum with the supracallosal gyrus.

(b) The **supracallosal gyrus** (*indusium griseum*; *gyrus epicallosus*) consists of a thin layer of gray substance in contact with the upper surface of the corpus callosum and continuous laterally with the gray substance of the cingulate gyrus. It contains two longitudinally directed strands of fibers termed respectively the **medial and lateral longitudinal striæ**. The supracallosal gyrus is prolonged around the splenium of the corpus callosum as a delicate lamina, the **fasciola cinerea**, which is continuous below with the fascia dentata hippocampi.

(c) The **fascia dentata hippocampi** (*gyrus dentatus*) is a narrow band extending downward and forward above the hippocampal gyrus but separated from it by the hippocampal fissure; its free margin is notched and overlapped by the fimbria—the **fimbriodentate fissure** intervening. Anteriorly it is continued into the notch of the uncus, where it forms a sharp bend and is then prolonged as a delicate band, the **band of Giacomini**, over the uncus, on the lateral surface of which it is lost.

The remaining parts of the rhinencephalon, viz., the septum pellucidum, fornix, and hippocampus, will be described in connection with the lateral ventricle.

Interior of the Cerebral Hemispheres.—If the upper part of either hemisphere be removed, at a level about 1.25 cm. above the corpus callosum, the central white substance will be exposed as an oval-shaped area, the **centrum ovale minus**, surrounded by a narrow convoluted margin of gray substance, and studded with numerous minute red dots (**puncta vasculosa**), produced by the escape of blood from divided bloodvessels. If the remaining portions of the hemispheres be slightly drawn apart a broad band of white substance, the **corpus callosum**, will be observed, connecting them at the bottom of the longitudinal fissure; the margins of the hemispheres which overlap the corpus callosum are called the **labia cerebri**. Each labrium is

part of the cingulate gyrus already described; and the slit-like interval between it and the upper surface of the corpus callosum is termed the **callosal fissure** (Fig. 727). If the hemispheres be sliced off to a level with the upper surface of the corpus callosum, the white substance of that structure will be seen connecting the two hemispheres. The large expanse of medullary matter now exposed, surrounded by the convoluted margin of gray substance, is called the **centrum ovale majus**.

The **Corpus Callosum** (Fig. 733) is the great transverse commissure which unites the cerebral hemispheres and roofs in the lateral ventricles. A good conception of its position and size is obtained by examining a median sagittal section of the brain (Fig. 720), when it is seen to form an arched structure about 10 cm. long. Its anterior end is about 4 cm. from the frontal pole, and its posterior end about 6 cm. from the occipital pole of the hemisphere.

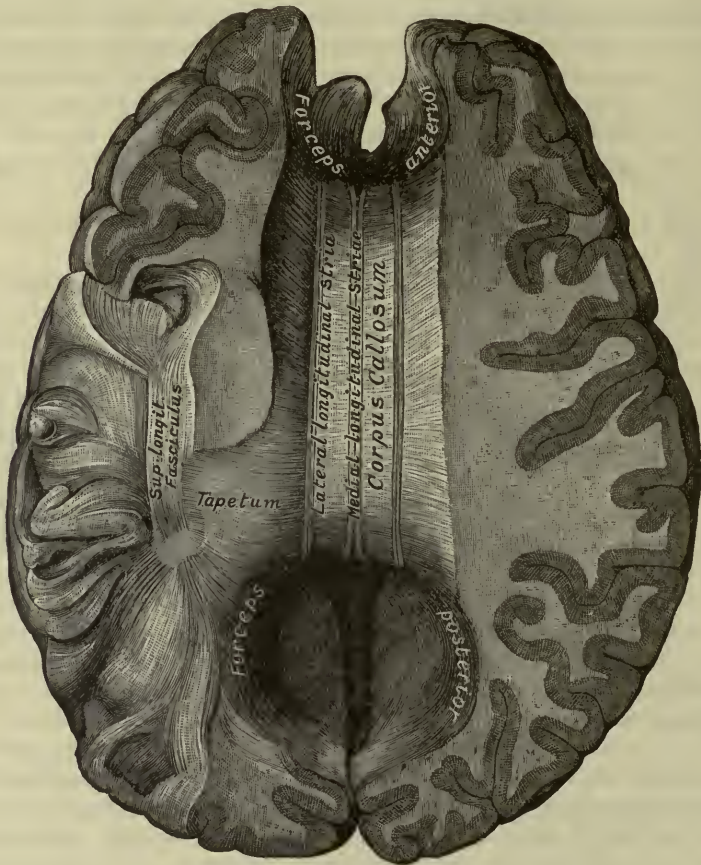


FIG. 733.—Corpus callosum from above.

The **anterior end** is named the **genu**, and is bent downward and backward in front of the septum pellucidum; diminishing rapidly in thickness, it is prolonged backward under the name of the **rostrum**, which is connected below with the lamina terminalis. The anterior cerebral arteries are in contact with the under surface of the rostrum; they then arch over the front of the genu, and are carried backward above the body of the corpus callosum.

The **posterior end** is termed the **splenium** and constitutes the thickest part of the corpus callosum. It overlaps the tela chorioidea of the third ventricle and the mid-brain, and ends in a thick, convex, free border. A sagittal section of

the splenium shows that the posterior end of the corpus callosum is acutely bent forward, the upper and lower parts being applied to each other.

The **superior surface** is convex from before backward, and is about 2.5 cm. wide. Its medial part forms the bottom of the longitudinal fissure, and is in contact posteriorly with the lower border of the falx cerebri. Laterally it is overlapped by the cingulate gyrus, but is separated from it by the slit-like callosal fissure. It is traversed by numerous transverse ridges and furrows, and is covered by a thin layer of gray matter, the **supracallosal gyrus**, which exhibits on either side of the middle line the medial and lateral longitudinal striæ, already described (page 827).

The **inferior surface** is concave, and forms on either side of the middle line the roof of the lateral ventricle. Medially, this surface is attached in front to the septum pellucidum; behind this it is fused with the upper surface of the body of the fornix, while the splenium is in contact with the tela chorioidea.

On either side, the fibers of the corpus callosum radiate in the white substance and pass to the various parts of the cerebral cortex; those curving forward from the genu into the frontal lobe constitute the **forceps anterior**, and those curving backward into the occipital lobe, the **forceps posterior**. Between these two parts is the main body of the fibers which constitute the **tapetum** and extend laterally on either side into the temporal lobe, and cover in the central part of the lateral ventricle.

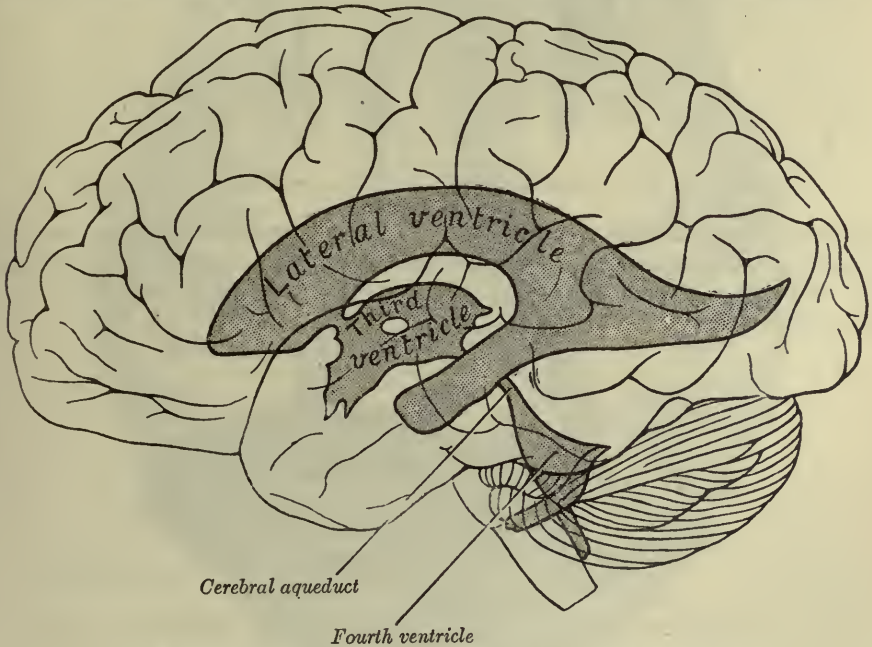


FIG. 734.—Scheme showing relations of the ventricles to the surface of the brain.

The Lateral Ventricles (*ventriculus lateralis*) (Fig. 734).—The two lateral ventricles are irregular cavities situated in the lower and medial parts of the cerebral hemispheres, one on either side of the middle line. They are separated from each other by a median vertical partition, the **septum pellucidum**, but communicate with the third ventricle and indirectly with each other through the **interventricular foramen**. They are lined by a thin, diaphanous membrane, the **ependyma**, covered by ciliated epithelium, and contain cerebrospinal fluid, which, even in health, may be secreted in considerable amount. Each lateral ventricle consists of a **central part** or **body**, and three prolongations from it, termed **cornua** (Figs. 735, 736).

The **central part** (*pars centralis ventriculi lateralis; cella*) (Fig. 737) of the lateral ventricle extends from the interventricular foramen to the splenium of the corpus

callosum. It is an irregularly curved cavity, triangular on transverse section, with a roof, a floor, and a medial wall. The roof is formed by the under surface of the corpus callosum; the floor by the following parts, enumerated in their order of position, from before backward: the caudate nucleus of the corpus striatum, the

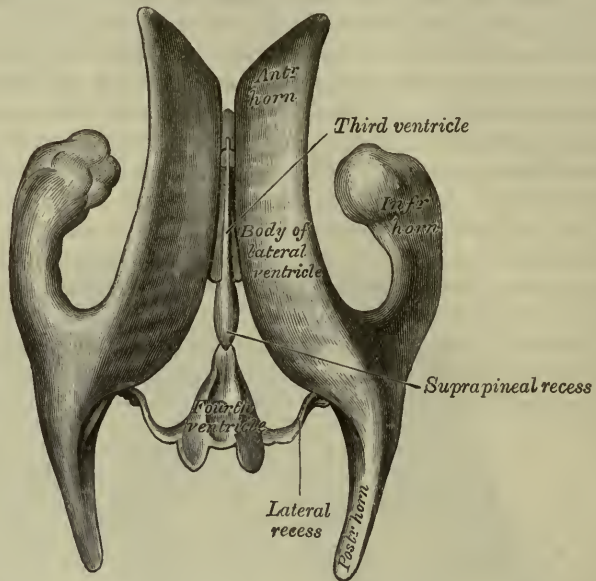


FIG. 735.—Drawing of a cast of the ventricular cavities, viewed from above. (Retzius.)

stria terminalis and the terminal vein, the lateral portion of the upper surface of the thalamus, the choroid plexus, and the lateral part of the fornix; the medial wall is the posterior part of the septum pellucidum, which separates it from the opposite ventricle.

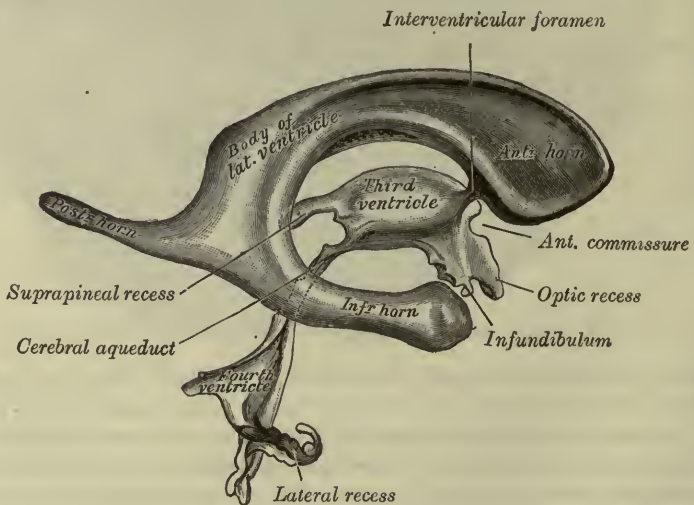


FIG. 736.—Drawing of a cast of the ventricular cavities, viewed from the side. (Retzius.)

The **anterior cornu** (*cornu anterius*; *anterior horn*; *precornu*) (Fig. 736) passes forward and lateralward, with a slight inclination downward, from the interventricular foramen into the frontal lobe, curving around the anterior end of the caudate nucleus. Its floor is formed by the upper surface of the reflected portion of the

corpus callosum, the **rostrum**. It is bounded medially by the anterior portion of the septum pellucidum, and laterally by the head of the caudate nucleus. Its apex reaches the posterior surface of the genu of the corpus callosum.

The **posterior cornu** (*cornu posterius; postcornu*) (Figs. 737, 738) passes into the occipital lobe, its direction being backward and lateralward, and then medialward. Its roof is formed by the fibers of the corpus callosum passing to the temporal and occipital lobes. On its medial wall is a longitudinal eminence, the **calcar avis** (*hippocampus minor*), which is an involution of the ventricular wall produced by the calcarine fissure. Above this the forceps posterior of the corpus callosum, sweeping around to enter the occipital lobe, causes another projection, termed the **bulb of the posterior cornu**. The calcar avis and bulb of the posterior cornu are extremely variable in their degree of development; in some cases they are ill-defined, in others prominent.

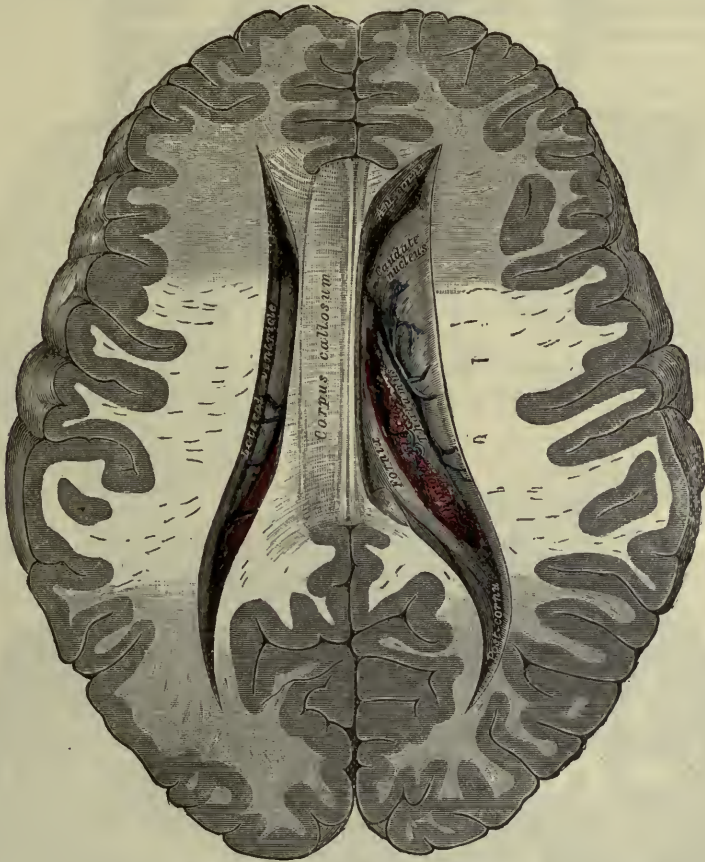

Fig. 737.—Central part and anterior and posterior cornua of lateral ventricles exposed from above.

The **inferior cornu** (*cornu inferior; descending horn; middle horn; medicornu*) (Fig. 739), the largest of the three, traverses the temporal lobe of the brain, forming in its course a curve around the posterior end of the thalamus. It passes at first backward, lateralward, and downward, and then curves forward to within 2.5 cm. of the apex of the temporal lobe, its direction being fairly well indicated on the surface of the brain by that of the superior temporal sulcus. Its roof is formed chiefly by the inferior surface of the tapetum of the corpus callosum, but the tail of the caudate nucleus and the stria terminalis also extend forward in the roof of the inferior cornu to its extremity; the tail of the caudate nucleus joins the

putamen. Its floor presents the following parts: the hippocampus, the fimbria hippocampi, the collateral eminence, and the choroid plexus. When the

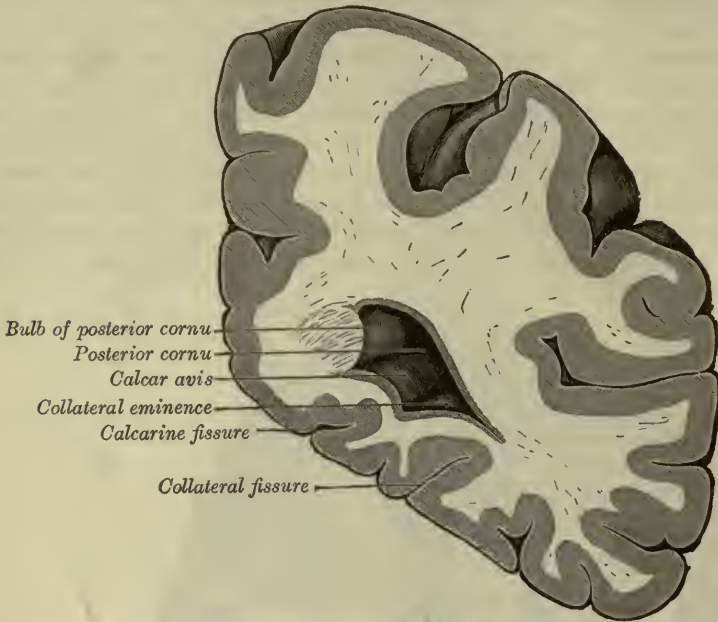


FIG. 738.—Coronal section through posterior cornua of lateral ventricle

choroid plexus is removed, a cleft-like opening is left along the medial wall of the inferior cornu; this cleft constitutes the lower part of the choroidal fissure.

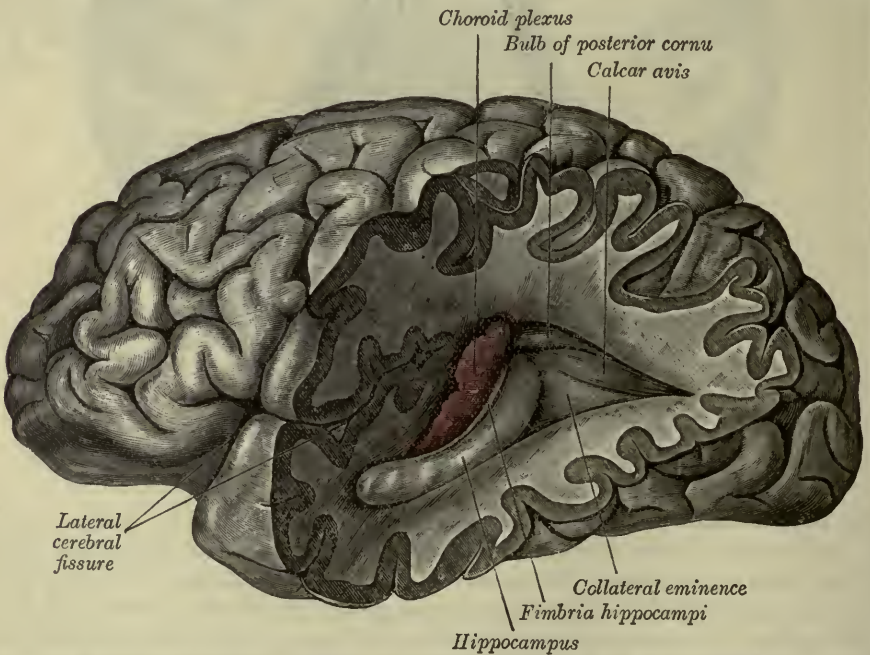


FIG. 739.—Posterior and inferior cornua of left lateral ventricle exposed from the side.

The hippocampus (*hippocampus major*) (Figs. 739, 740) is a curved eminence, about 5 cm. long, which extends throughout the entire length of the floor of the

inferior cornu. Its lower end is enlarged, and presents two or three rounded elevations or digitations which give it a paw-like appearance, and hence it is named the **pes hippocampi**. If a transverse section be made through the hippocampus, it will be seen that this eminence is produced by the folding of the wall of the hemisphere to form the hippocampal fissure. The main mass of the hippocampus consists of gray substance, but on its ventricular surface is a thin white layer, the **alveus**, which is continuous with the fimbria hippocampi.

The **collateral eminence** (*eminencia collateralis*) (Fig. 740) is an elongated swelling lying lateral to and parallel with the hippocampus. It corresponds with the middle part of the collateral fissure, and its size depends on the depth and direction of this fissure. It is continuous behind with a flattened triangular area, the **trigonum collaterale**, situated between the posterior and inferior cornua.

The fimbria hippocampi is a continuation of the crus of the fornix, and will be discussed with that body; a description of the choroid plexus will be found on page 840.

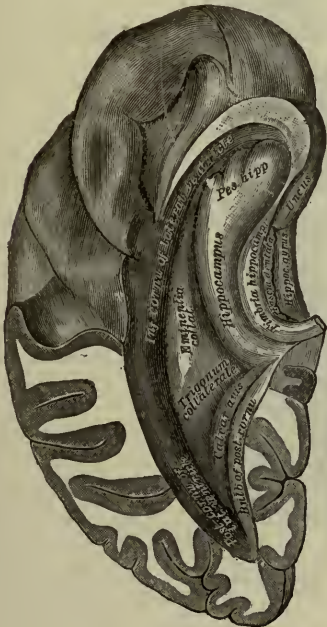

FIG. 740.—Inferior and posterior cornua, viewed from above.

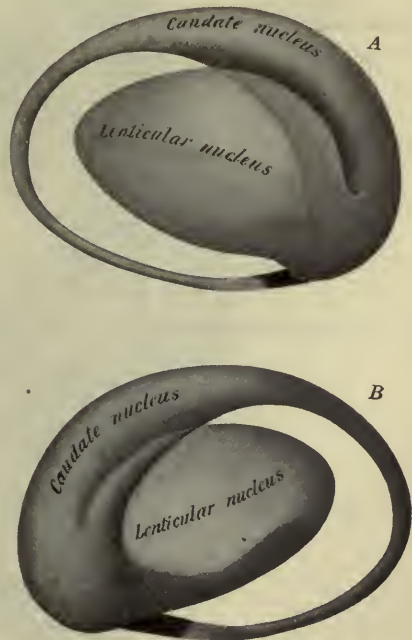


FIG. 741.—Two views of a model of the striatum: A, lateral aspect; B, mesal aspect.

The **corpus striatum** has received its name from the striped appearance which a section of its anterior part presents, in consequence of diverging white fibers being mixed with the gray substance which forms its chief mass. A part of the corpus striatum is imbedded in the white substance of the hemisphere, and is therefore external to the ventricle; it is termed the **extraventricular portion**, or the **lentiform nucleus**; the remainder, however, projects into the ventricle, and is named the **intraventricular portion**, or the **caudate nucleus** (Fig. 737).

The **caudate nucleus** (*nucleus caudatus; caudatum*) (Figs. 741, 742) is a pear-shaped, highly arched gray mass; its broad extremity, or **head**, is directed forward into the anterior cornu of the lateral ventricle, and is continuous with the anterior perforated substance and with the anterior end of the lentiform nucleus; its narrow end, or **tail**, is directed backward on the lateral side of the thalamus, from which it is

separated by the stria terminalis and the terminal vein. It is then continued downward into the roof of the inferior cornu, and ends in the putamen near the apex of the temporal lobe. It is covered by the lining of the ventricle, and crossed by some veins of considerable size. It is separated from the lentiform nucleus, in the greater part of its extent, by a thick lamina of white substance, called the **internal capsule**, but the two portions of the corpus striatum are united in front (Figs. 743, 744).

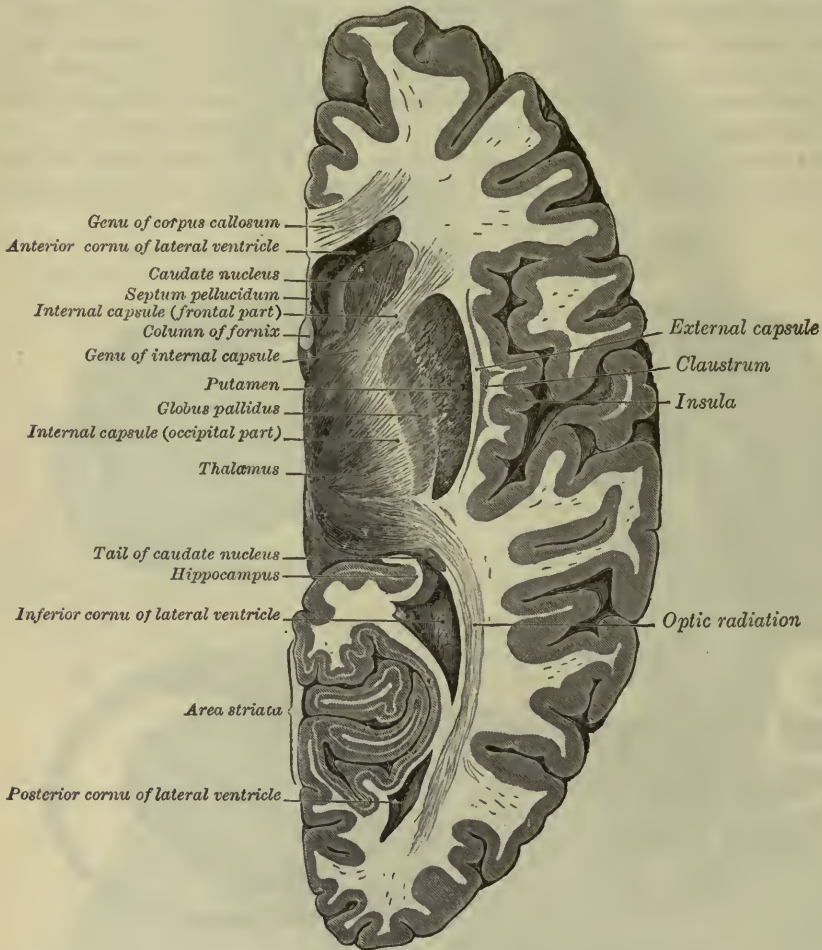


FIG. 742.—Horizontal section of right cerebral hemisphere.

The **lentiform nucleus** (*nucleus lentiformis*; *lenticular nucleus*; *lenticula*) (Fig. 741) is lateral to the caudate nucleus and thalamus, and is seen only in sections of the hemisphere. When divided horizontally, it exhibits, to some extent, the appearance of a biconvex lens (Fig. 742), while a coronal section of its central part presents a somewhat triangular outline. It is shorter than the caudate nucleus and does not extend as far forward. It is bounded laterally by a lamina of white substance called the **external capsule**, and lateral to this is a thin layer of gray substance termed the **claustrum**. Its anterior end is continuous with the lower part of the head of the caudate nucleus and with the anterior perforated substance.

In a coronal section through the middle of the lentiform nucleus, two **medullary laminae** are seen dividing it into three parts. The lateral and largest part is of a reddish color, and is known as the **putamen**, while the medial and intermediate are of

a yellowish tint, and together constitute the **globus pallidus**; all three are marked by fine radiating white fibers, which are most distinct in the putamen (Fig. 744).

The gray substance of the corpus striatum is traversed by nerve fibers, some of which originate in it. The cells are multipolar, both large and small; those of the lentiform nucleus contain yellow pigment. The caudate and lentiform nuclei are not only directly continuous with each other anteriorly, but are connected to each other by numerous fibers. The corpus striatum is also connected: (1) to the cerebral cortex, by what are termed the **corticostriate fibers**; (2) to the thalamus, by fibers which pass through the internal capsule, and by a strand named the **ansa lentiformis**; (3) to the cerebral peduncle, by fibers which leave the lower aspect of the caudate and lentiform nuclei.

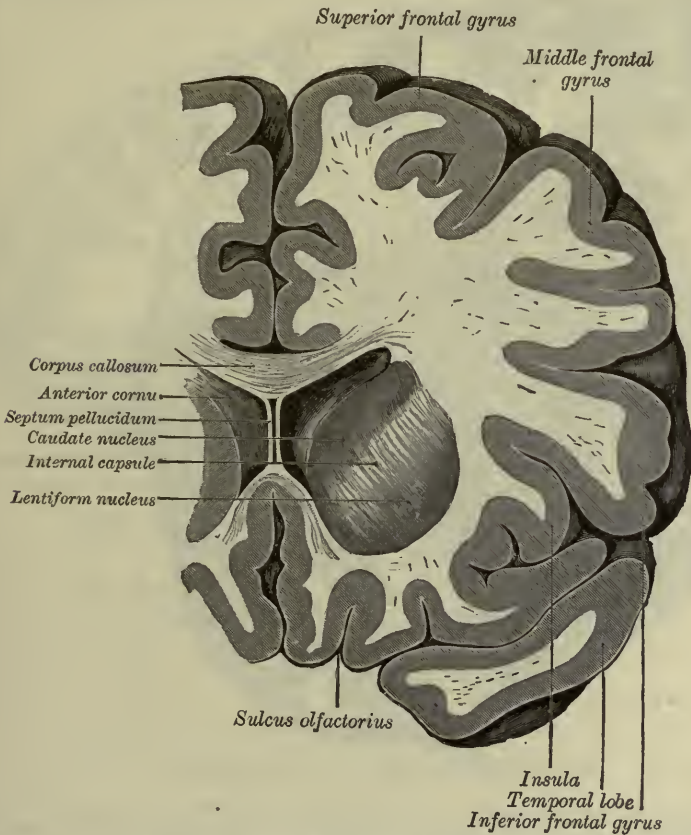


FIG. 743.—Coronal section through anterior cornua of lateral ventricles.

The **claustrum** (Figs. 742, 744) is a thin layer of gray substance, situated on the lateral surface of the external capsule. Its transverse section is triangular, with the apex directed upward. Its medial surface, contiguous to the external capsule, is smooth, but its lateral surface presents ridges and furrows corresponding with the gyri and sulci of the insula, with which it is in close relationship. The claustrum is regarded as a detached portion of the gray substance of the insula, from which it is separated by a layer of white fibers, the **capsula extrema** (*band of Baillarger*). Its cells are small and spindle-shaped, and contain yellow pigment; they are similar to those of the deepest layer of the cortex.

The **nucleus amygdalæ** (*amygdala*) (Fig. 741), is an ovoid gray mass, situated at the lower end of the roof of the inferior cornu. It is merely a localized thickening of the

gray cortex, continuous with that of the uncus; in front it is continuous with the putamen, behind with the stria terminalis and the tail of the caudate nucleus.

The **internal capsule** (*capsula interna*) (Figs. 745, 746) is a flattened band of white fibers, between the lentiform nucleus on the lateral side and the caudate nucleus and thalamus on the medial side. In horizontal section (Figs. 742) it is seen to be somewhat abruptly curved, with its convexity inward; the prominence of the curve is called the **genu**, and projects between the caudate nucleus and the thalamus. The portion in front of the genu is termed the **frontal part**, and separates the lentiform from the caudate nucleus; the portion behind the genu is the **occipital part**, and separates the lentiform nucleus from the thalamus.

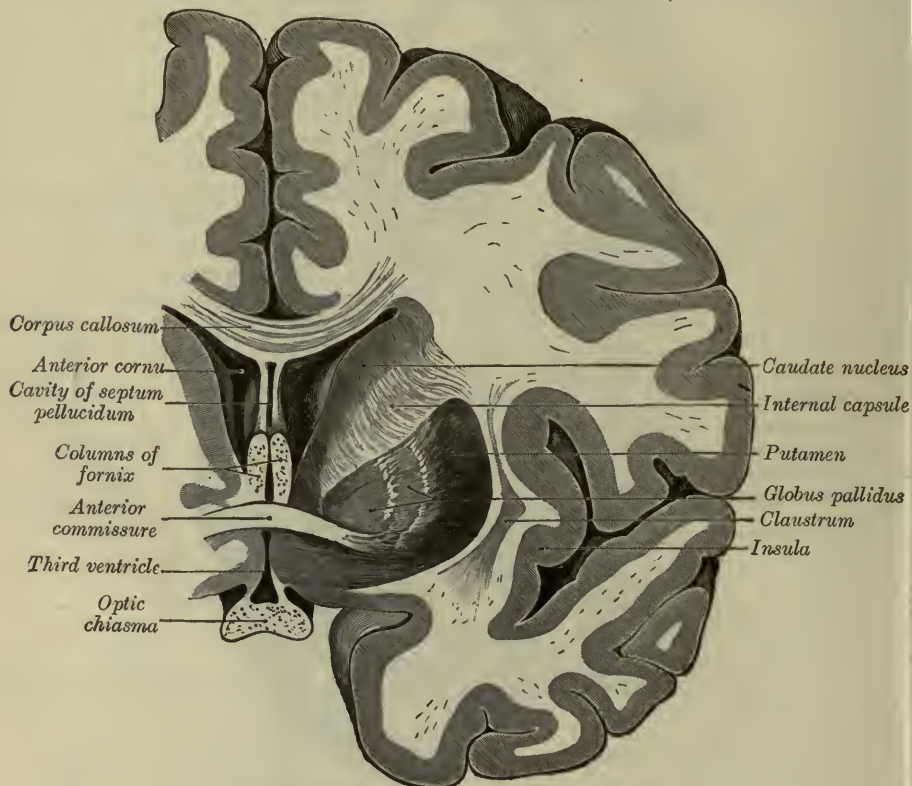


FIG. 744.—Coronal section of brain through anterior commissure.

The *frontal part* of the internal capsule contains: (1) fibers running from the thalamus to the frontal lobe; (2) fibers connecting the lentiform and caudate nuclei; (3) fibers connecting the cortex with the corpus striatum; and (4) fibers passing from the frontal lobe through the medial fifth of the base of the cerebral peduncle to the nuclei pontis. The fibers in the region of the genu are named the **geniculate fibers**; they originate in the motor part of the cerebral cortex, and, after passing downward through the base of the cerebral peduncle with the cerebrospinal fibers, undergo decussation and end in the motor nuclei of the cranial nerves of the opposite side. The anterior two-thirds of the occipital part of the internal capsule contains the **cerebrospinal fibers**, which arise in the motor area of the cerebral cortex and, passing downward through the middle three-fifths of the base of the cerebral peduncle, are continued into the pyramids of the medulla oblongata. The posterior third of the occipital part contains: (1) sensory fibers, largely derived from the thalamus, though some may be continued upward from

the medial lemniscus; (2) the fibers of optic radiation, from the lower visual centers to the cortex of the occipital lobe; (3) acoustic fibers, from the lateral lemniscus to the temporal lobe; and (4) fibers which pass from the occipital and temporal lobes to the nuclei pontis.

The fibers of the internal capsule radiate widely as they pass to and from the various parts of the cerebral cortex, forming the **corona radiata** (Fig. 745) and intermingling with the fibers of the corpus callosum.

The **external capsule** (*capsula externa*) (Fig. 742) is a lamina of white substance, situated lateral to the lentiform nucleus, between it and the claustrum, and continuous with the internal capsule below and behind the lentiform nucleus. It probably contains fibers derived from the thalamus, the anterior commissure, and the subthalamic region.

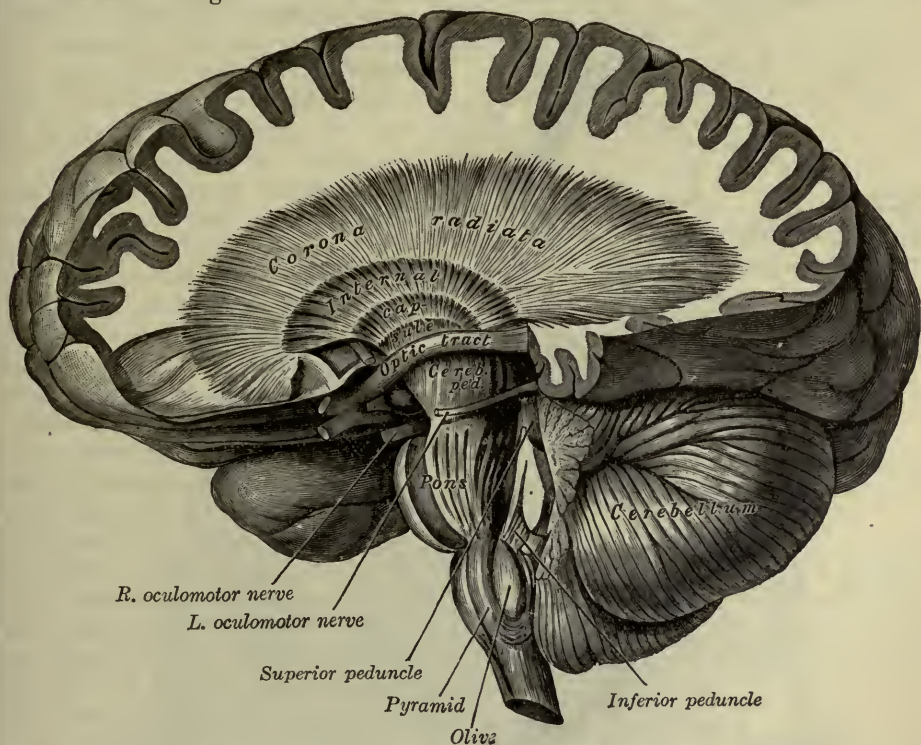


FIG. 745.—Dissection showing the course of the cerebrospinal fibers. (E. B. Jamieson.)

The **substantia innominata of Meynert** is a stratum consisting partly of gray and partly of white substance, which lies below the anterior part of the thalamus and lentiform nucleus. It consists of three layers, superior, middle, and inferior. The *superior* layer is named the **ansa lentiformis**, and its fibers, derived from the medullary lamina of the lentiform nucleus, pass medially to end in the thalamus and subthalamic region, while others are said to end in the tegmentum and red nucleus. The *middle* layer consists of nerve cells and nerve fibers; fibers enter it from the parietal lobe through the external capsule, while others are said to connect it with the medial longitudinal fasciculus. The *inferior* layer forms the main part of the inferior stalk of the thalamus, and connects this body with the temporal lobe and the insula.

The **stria terminalis** (*tænia semicircularis*) is a narrow band of white substance situated in the depression between the caudate nucleus and the thalamus. Anteriorly, its fibers are partly continued into the column of the fornix; some, however, pass over the anterior commissure to the gray substance between the caudate

nucleus and septum pellucidum, while others are said to enter the caudate nucleus. Posteriorly, it is continued into the roof of the inferior cornu of the lateral ventricle, at the extremity of which it enters the nucleus amygdalæ. Superficial to it is a large vein, the **terminal vein** (*vein of the corpus striatum*), which receives numerous tributaries from the corpus striatum and thalamus; it runs forward to the interventricular foramen and there joins with the vein of the choroid plexus to form

the corresponding internal cerebral vein. On the surface of the terminal vein is a narrow white band, named the **lamina affixa**.

The **Fornix** (Figs. 720, 747, 748) is a longitudinal, arch-shaped lamella of white substance, situated below the corpus callosum, and continuous with it behind, but separated from it in front by the septum pellucidum. It may be described as consisting of two symmetrical bands, one for either hemisphere. The two portions are not united to each other in front and behind, but their central parts are joined together in the middle line. The anterior parts are called the **columns** of the fornix; the intermediate united portions, the **body**; and the posterior parts, the **crura**.

The **body** (*corpus fornicis*) of the fornix is triangular, narrow in front, and broad behind. The medial part of its upper surface is connected to the septum pellucidum in front and to the corpus callosum behind. The lateral portion of this surface forms part of the floor of the lateral ventricle, and is covered by the ventricular epithelium. Its lateral edge overlaps the choroid plexus, and is continuous with the epithelial covering of this structure. The under surface rests upon the tela choroidea of the third ventricle, which separates it from the epithelial roof of that cavity, and from the medial portions of the upper surfaces of the thalami. Below, the lateral portions of the body of the fornix are joined

by a thin triangular lamina, named the **psalterium** (*lyra*). This lamina contains some transverse fibers which connect the two hippocampi across the middle line and constitute the **hippocampal commissure**. Between the psalterium and the corpus callosum a horizontal cleft, the so-called **ventricle of the fornix** (*ventricle of Verga*), is sometimes found.

The **columns** (*columna fornicis*; *anterior pillars*; *fornicolumns*) of the fornix arch downward in front of the interventricular foramen and behind the anterior commis-

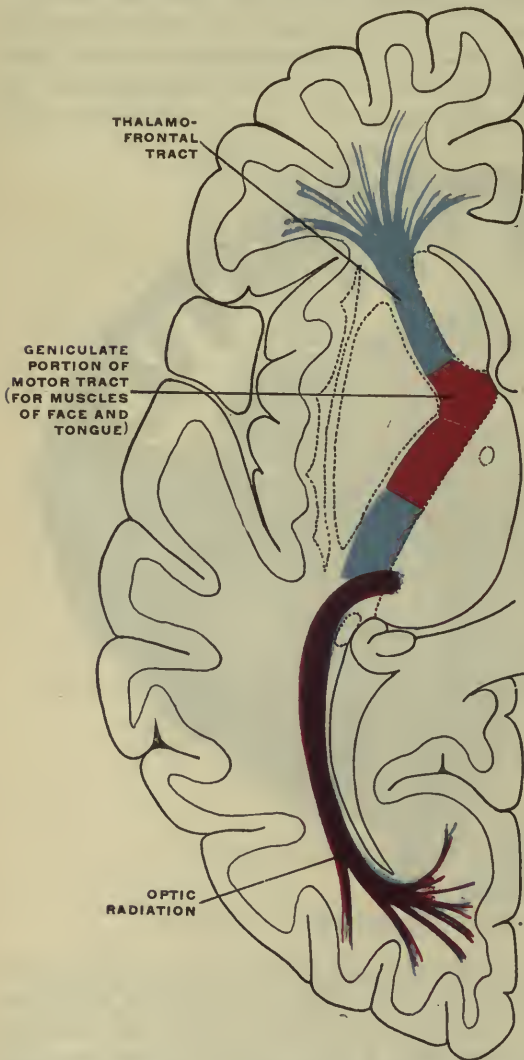


FIG. 746.—Diagram of the tracts in the internal capsule. Motor tract red. The sensory tract (blue) is not direct, but formed of neurons receiving impulses from below in the thalamus and transmitting them to the cortex. The optic radiation (occipitohthalmic) is shown in violet.

sure, and each descends through the gray substance in the lateral wall of the third ventricle to the base of the brain, where it ends in the corpus mammillare. From the cells of the corpus mammillare the thalamomammillary fasciculus (*bundle of Vicq*

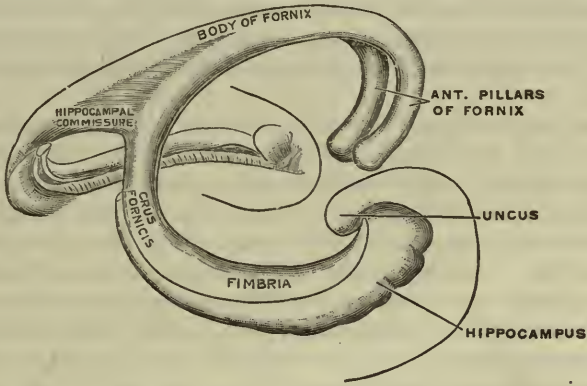


FIG. 747.—Diagram of the fornix. (Spitzka.)

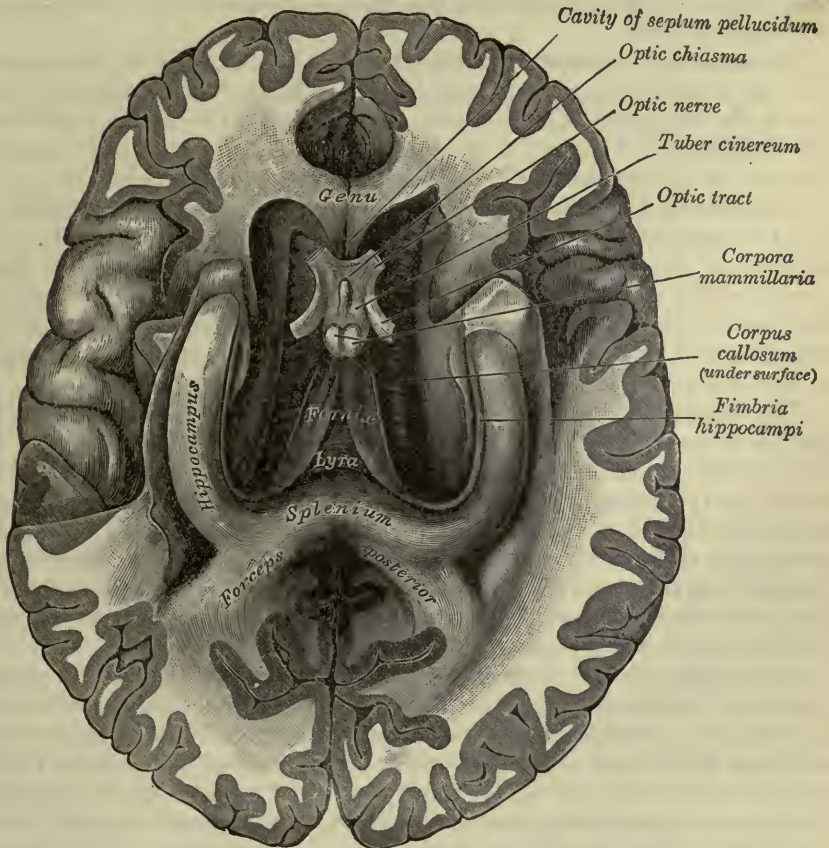


FIG. 748.—The fornix and corpus callosum from below. (From a specimen in the Department of Human Anatomy of the University of Oxford.)

d' Azyr) takes origin and is prolonged into the anterior nucleus of the thalamus. The column of the fornix and the thalamomammillary fasciculus together form a loop resembling the figure 8, but the continuity of the loop is broken in the corpus

mammillare. The column of the fornix is joined by the stria medullaris of the pineal body and by the superficial fibers of the stria terminalis, and is said to receive also fibers from the septum pellucidum. Zuckerkandl describes an **olfactory fasciculus** which becomes detached from the main portion of the column of the fornix, and passes downward in front of the anterior commissure to the base of the brain, where it divides into two bundles, one joining the medial stria of the olfactory tract; the other joins the subcallosal gyrus, and through it reaches the hippocampal gyrus.

The **crura** (*crus fornicis; posterior pillars*) of the fornix are prolonged backward from the body. They are flattened bands, and at their commencement are intimately connected with the under surface of the corpus callosum. Diverging from one another, each curves around the posterior end of the thalamus, and passes downward and forward into the inferior cornu of the lateral ventricle (Fig. 750). Here it lies along the concavity of the hippocampus, on the surface of which some of its fibers are spread out to form the **alveus**, while the remainder are continued as a narrow white band, the **fimbria hippocampi**, which is prolonged into the uncus of the hippocampal gyrus. The inner edge of the fimbria overlaps the **fascia dentata hippocampi** (*dentate gyrus*) (page 827), from which it is separated by the **fimbriodentate fissure**; from its lateral margin, which is thin and ragged, the ventricular epithelium is reflected over the choroid plexus as the latter projects into the chorioideal fissure.

Interventricular Foramen (*foramen of Monro*).—Between the columns of the fornix and the anterior ends of the thalami, an oval aperture is present on either side: this is the interventricular foramen, and through it the lateral ventricles communicate with the third ventricle. Behind the epithelial lining of the foramen the choroid plexuses of the lateral ventricles are joined across the middle line.

The **Anterior Commissure** (*precommissure*) is a bundle of white fibers, connecting the two cerebral hemispheres across the middle line, and placed in front of the columns of the fornix. On sagittal section it is oval in shape, its long diameter being vertical and measuring about 5 mm. Its fibers can be traced lateralward and backward on either side beneath the corpus striatum into the substance of the temporal lobe. It serves in this way to connect the two temporal lobes, but it also contains decussating fibers from the olfactory tracts.

The **Septum Pellucidum** (*septum lucidum*) (Fig. 720) is a thin, vertically placed partition consisting of two laminae, separated in the greater part of their extent by a narrow chink or interval, the **cavity of the septum pellucidum**. It is attached, above, to the under surface of the corpus callosum; below, to the anterior part of the fornix behind, and the reflected portion of the corpus callosum in front. It is triangular in form, broad in front and narrow behind; its inferior angle corresponds with the upper part of the anterior commissure. The lateral surface of each lamina is directed toward the body and anterior cornu of the lateral ventricle, and is covered by the ependyma of that cavity.

The **cavity of the septum pellucidum** (*cavum septi pellucidi; pseudocele; fifth ventricle*) is generally regarded as part of the longitudinal cerebral fissure, which has become shut off by the union of the hemispheres in the formation of the corpus callosum above and the fornix below. Each half of the septum therefore forms part of the medial wall of the hemisphere, and consists of a medial layer of gray substance, derived from that of the cortex, and a lateral layer of white substance continuous with that of the cerebral hemispheres. This cavity is not developed from the cavity of the cerebral vesicles, and never communicates with the ventricles of the brain.

The **Choroid Plexus of the Lateral Ventricle** (*plexus chorioideus ventriculus lateralis; paraplexus*) (Fig. 750) is a highly vascular, fringe-like process of pia mater, which projects into the ventricular cavity. The plexus, however, is everywhere

covered by a layer of epithelium continuous with the epithelial lining of the ventricle. It extends from the interventricular foramen, where it is joined with the plexus of the opposite ventricle, to the end of the inferior cornu. The part in relation to the body of the ventricle forms the vascular fringed margin of a triangular process of pia mater, named the **tela chorioidea of the third ventricle**, and projects from under cover of the lateral edge of the fornix. It lies upon the upper surface of the thalamus, from which the epithelium is reflected over the plexus on to the edge of the fornix (Fig. 723). The portion in relation to the inferior cornu lies in the concavity of the hippocampus and overlaps the fimbria hippocampi: from the lateral edge of the fimbria the epithelium is reflected over the plexus on to the roof of the cornu (Fig. 749). It consists of minute and highly vascular villous processes, each with an afferent and an efferent vessel. The *arteries* of the plexus are: (a) the anterior choroidal, a branch of the internal carotid, which enters the plexus at the end of the inferior cornu; and (b) the posterior choroidal, one or two small branches of the posterior cerebral, which pass forward under the splenium. The *veins* of the choroid plexus unite to form a tortuous vein, which courses from behind forward to the interventricular foramen and there joins with the terminal vein to form the corresponding internal cerebral vein.

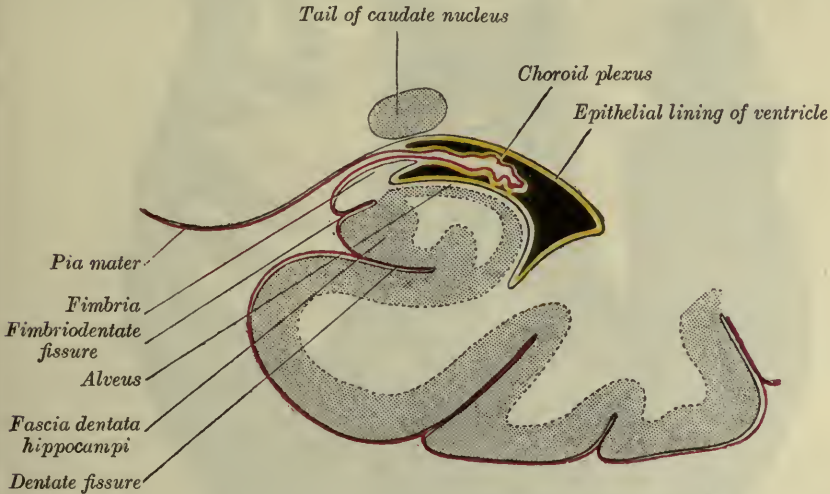


FIG. 749.—Coronal section of inferior horn of lateral ventricle. (Diagrammatic.)

When the choroid plexus is pulled away, the continuity between its epithelial covering and the epithelial lining of the ventricle is severed, and a cleft-like space is produced. This is named the **choroidal fissure**; like the plexus, it extends from the interventricular foramen to the end of the inferior cornu. The upper part of the fissure, *i. e.*, the part nearest the interventricular foramen is situated between the lateral edge of the fornix and the upper surface of the thalamus; farther back at the beginning of the inferior cornu it is between the commencement of the fimbria hippocampi and the posterior end of the thalamus, while in the inferior cornu it lies between the fimbria in the floor and the stria terminalis in the roof of the cornu.

The **tela chorioidea of the third ventricle** (*tela chorioidea ventriculi tertii; velum interpositum*) (Fig. 750) is a double fold of pia mater, triangular in shape, which lies beneath the fornix. The lateral portions of its lower surface rest upon the thalami, while its medial portion is in contact with the epithelial roof of the third ventricle. Its apex is situated at the interventricular foramen; its base corresponds with the splenium of the corpus callosum, and occupies the interval between that structure above and the corpora quadrigemina and pineal body below. This

interval, together with the lower portions of the choroidal fissures, is sometimes spoken of as the **transverse fissure of the brain**. At its base the two layers of the velum separate from each other, and are continuous with the pia mater investing the brain in this region. Its lateral margins are modified to form the highly vascular choroid plexuses of the lateral ventricles. It is supplied by the anterior and posterior choroidal arteries already described. The veins of the tela chorioidea are named the **internal cerebral veins** (*venæ Galeni*); they are two in number, and run backward between its layers, each being formed at the interventricular foramen by the union of the terminal vein with the choroidal vein. The internal cerebral veins unite posteriorly in a single trunk, the **great cerebral vein** (*vena magna Galeni*), which passes backward beneath the splenium and ends in the straight sinus.

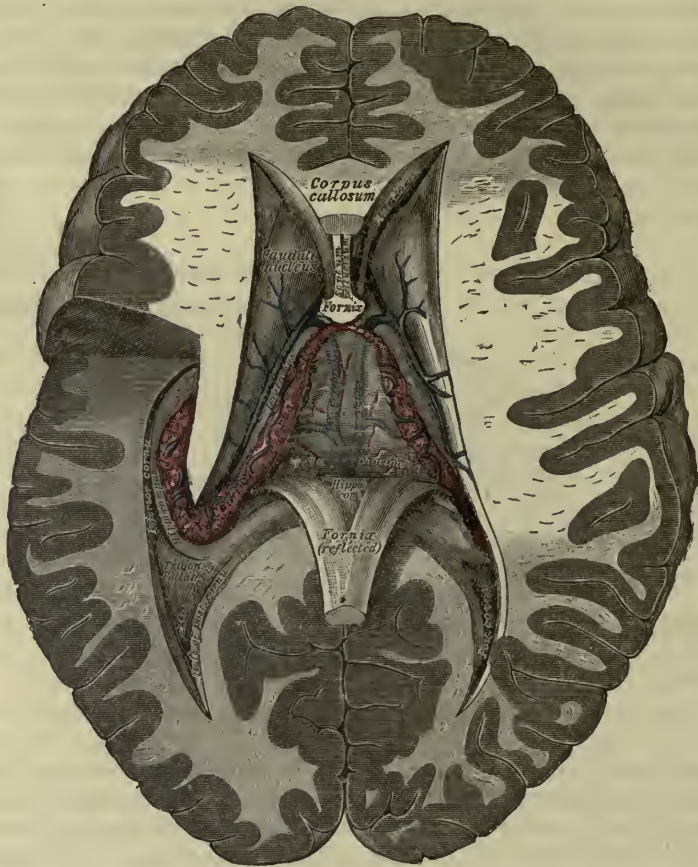

FIG. 750.—Tela chorioidea of the third ventricle, and the choroid plexus of the left lateral ventricle, exposed from above.

Structure of the Cerebral Hemispheres.—The cerebral hemispheres are composed of gray and white substance: the former covers their surface, and is termed the **cortex**; the latter occupies the interior of the hemispheres.

The **white substance** consists of medullated fibers, varying in size, and arranged in bundles separated by neuroglia. They may be divided, according to their course and connections, into three distinct systems. (1) **Projection fibers** connect the hemisphere with the lower parts of the brain and with the medulla spinalis. (2) **Transverse or commissural fibers** unite the two hemispheres. (3) **Association fibers** connect different structures in the same hemisphere; these are, in many

instances, collateral branches of the projection fibers, but others are the axons of independent cells.

1. The **projection fibers** consist of efferent and afferent fibers uniting the cortex with the lower parts of the brain and with the medulla spinalis. The principal efferent strands are: (1) the *motor tract*, occupying the genu and anterior two-thirds of the occipital part of the internal capsule, and consisting of (a) the geniculate fibers, which decussate and end in the motor nuclei of the cranial nerves of the opposite side; and (b) the cerebrospinal fibers, which are prolonged through the pyramid of the medulla oblongata into the medulla spinalis: (2) the *corticopontine fibers*, ending in the nuclei pontis. The chief afferent fibers are: (1) those of the lemniscus which are not interrupted in the thalamus; (2) those of the superior cerebellar peduncle which are not interrupted in the red nucleus and thalamus; (3) numerous fibers arising within the thalamus, and passing through its stalks to the different parts of the cortex (page 810); (4) optic and acoustic fibers, the former passing to the occipital, the latter to the temporal lobe.

2. The **transverse or commissural fibers** connect the two hemispheres. They include: (a) the *transverse fibers* of the corpus callosum, (b) the anterior commissure, (c) the posterior commissure, and (d) the lyra or hippocampal commissure; they have already been described.

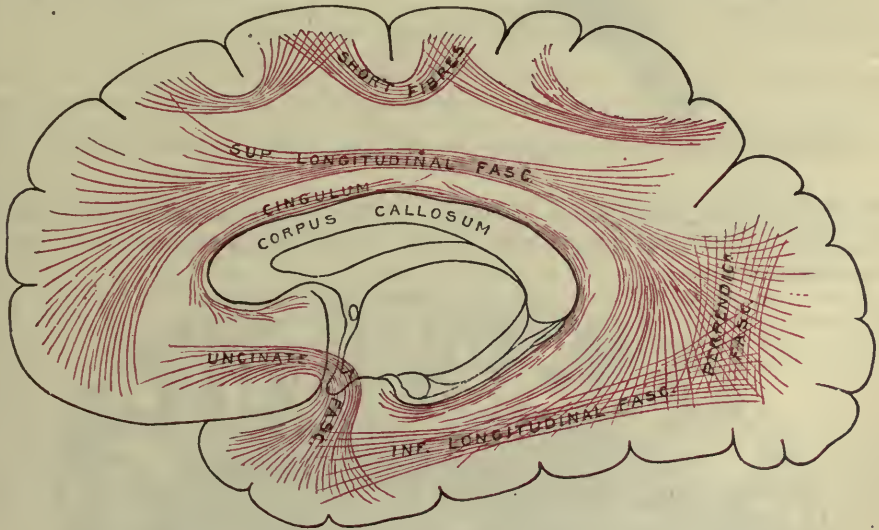


FIG. 751.—Diagram showing principal systems of association fibers in the cerebrum.

3. The **association fibers** (Fig. 751) unite different parts of the same hemisphere, and are of two kinds: (1) those connecting adjacent gyri, **short association fibers**; (2) those passing between more distant parts, **long association fibers**.

The *short association fibers* lie immediately beneath the gray substance of the cortex of the hemispheres, and connect together adjacent gyri.

The *long association fibers* include the following: (a) the uncinat fasciculus; (b) the cingulum; (c) the superior longitudinal fasciculus; (d) the inferior longitudinal fasciculus; (e) the perpendicular fasciculus; (f) the occipitofrontal fasciculus; and (g) the fornix.

(a) The *uncinate fasciculus* passes across the bottom of the lateral fissure, and unites the gyri of the frontal lobe with the anterior end of the temporal lobe.

(b) The *cingulum* is a band of white matter contained within the cingulate gyrus. Beginning in front at the anterior perforated substance, it passes forward and upward parallel with the rostrum, winds around the genu, runs backward above the corpus callosum, turns around the splenium, and ends in the hippocampal gyrus.

(c) The *superior longitudinal fasciculus* passes backward from the frontal lobe above the lentiform nucleus and insula; some of its fibers end in the occipital lobe, and others curve downward and forward into the temporal lobe.

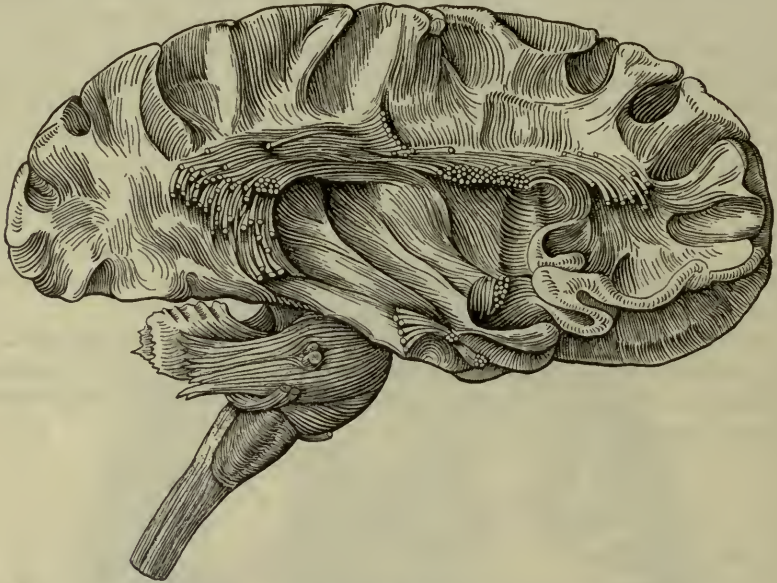

FIG. 752.—Dissection of cortex and brain-stem showing association fibers and island of Reil after removal of its superficial gray substance.

(d) The *inferior longitudinal fasciculus* connects the temporal and occipital lobes, running along the lateral walls of the inferior and posterior cornua of the lateral ventricle.

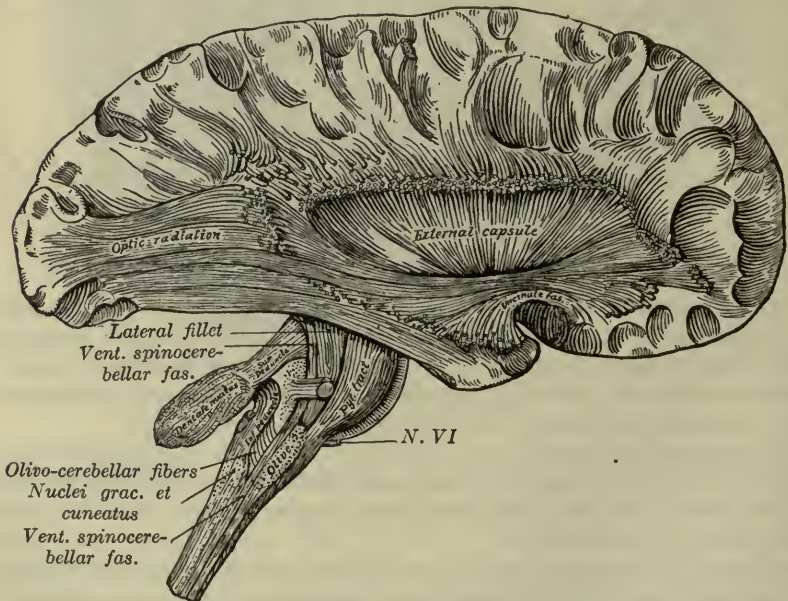


FIG. 753.—Deep dissection of cortex and brain-stem.

(e) The *perpendicular fasciculus* runs vertically through the front part of the occipital lobe, and connects the inferior parietal lobule with the fusiform gyrus.

(f) The *occipitofrontal fasciculus* passes backward from the frontal lobe, along the lateral border of the caudate nucleus, and on the mesial aspect of the corona

radiata; its fibers radiate in a fan-like manner and pass into the occipital and temporal lobes lateral to the posterior and inferior cornua. Déjerine regards the fibers of the tapetum as being derived from this fasciculus, and not from the corpus callosum.

(g) The *fornix* connects the hippocampal gyrus with the corpus mammillare and, by means of the thalamomammillary fasciculus, with the thalamus (see page 839). Through the fibers of the hippocampal commissure it probably also unites the opposite hippocampal gyri.

The gray substance of the hemisphere is divided into: (1) that of the cerebral cortex, and (2) that of the caudate nucleus, the lentiform nucleus, the claustrum, and the nucleus amygdalæ.

Structure of the Cerebral Cortex (Fig. 754).—The cerebral cortex differs in thickness and structure in different parts of the hemisphere. It is thinner in the occipital region than in the anterior and posterior central gyri, and it is also much thinner at the bottom of the sulci than on the top of the gyri. Again, the minute structure of the anterior central differs from that of the posterior central gyrus, and areas possessing a specialized type of cortex can be mapped out in the occipital lobe.

On examining a section of the cortex with a lens, it is seen to consist of alternating white and gray layers thus disposed from the surface inward: (1) a thin layer of white substance; (2) a layer of gray substance; (3) a second white layer (*outer band of Baillarger* or *band of Gennari*); (4) a second gray layer; (5) a third white layer (*inner band of Baillarger*); (6) a third gray layer, which rests on the medullary substance of the gyrus.

The cortex is made up of nerve cells of varying size and shape, and of nerve fibers which are either medullated or naked axis-cylinders, imbedded in a matrix of neuroglia.

Nerve Cells.—According to Cajal, the nerve cells are arranged in four layers, named from the surface inward as follows: (1) the molecular layer, (2) the layer of small pyramidal cells, (3) the layer of large pyramidal cells, (4) the layer of polymorphous cells.

The Molecular Layer.—In this layer the cells are polygonal, triangular, or fusiform in shape. Each polygonal cell gives off some four or five dendrites, while its axon may arise directly from the cell or from one of its dendrites. Each triangular cell gives off two or three dendrites, from one of which the axon arises. The fusiform cells are placed with their long axes parallel to the surface and are mostly bipolar, each pole being prolonged into a dendrite, which runs horizontally for some distance and furnishes ascending branches. Their axons, two or three in number, arise from the dendrites, and, like them, take a horizontal course, giving off numerous ascending collaterals. The distribution of the axons and dendrites of all three sets of cells is limited to the molecular layer.

The Layer of Small and the Layer of Large Pyramidal Cells.—The cells in these two layers may be studied together, since, with the exception of the difference in size and the more superficial position of the smaller cells, they resemble each other. The average length of the small cells is from 10 to 15 μ ; that of the large cells from 20 to 30 μ . The body of each cell is pyramidal in shape, its base being directed to the deeper parts and its apex toward the surface. It contains granular pigment, and stains deeply with ordinary reagents. The nucleus is of large size, and round or oval in shape. The base of the cell gives off the axis cylinder, and this runs into the central white substance, giving off collaterals in its course, and is distributed as a projection, commissural, or association fiber. The apical and basal parts of the cell give off dendrites; the apical dendrite is directed toward the surface, and ends in the molecular layer by dividing into numerous branches, all of which may be seen, when prepared by the silver or methylene-blue method, to be studded with projecting bristle-like processes. The largest pyramidal cells are found in the upper part of the anterior central gyrus and in the paracentral lobule; they are often arranged in groups or nests of from three to five, and are named the *giant cells of Betz*. In the former situation they may exceed 50 μ in length and 40 μ in breadth, while in the paracentral lobule they may attain a length of 65 μ .

Layer of Polymorphous Cells.—The cells in this layer, as their name implies, are very irregular in contour; they may be fusiform, oval, triangular, or star-shaped. Their dendrites are directed outward, but do not reach so far as the molecular layer; their axons pass into the subjacent white matter.

There are two other kinds of cells in the cerebral cortex. They are: (a) the *cells of Golgi*, the axons of which divide immediately after their origins into a large number of branches, which are directed toward the surface of the cortex; (b) the *cells of Martinotti*, which are chiefly found in the polymorphous layer; their dendrites are short, and may have an ascending or descending course, while their axons pass out into the molecular layer and form an extensive horizontal arborization.

Nerve Fibers.—These fill up a large part of the intervals between the cells, and may be medullated or non-medullated—the latter comprising the axons of the smallest pyramidal cells and the cells of Golgi. In their direction the fibers may be either tangential or radial. The *tangential fibers* run parallel to the surface of the hemisphere, intersecting the radial fibers at a right angle. They constitute several strata, of which the following are the more important: (1) a stratum of white fibers covering the superficial aspect of the molecular layer (*plexus of Exner*); (2) the band of Bechterew, in the outer part of the layer of small pyramidal cells; (3) the band of Gennari

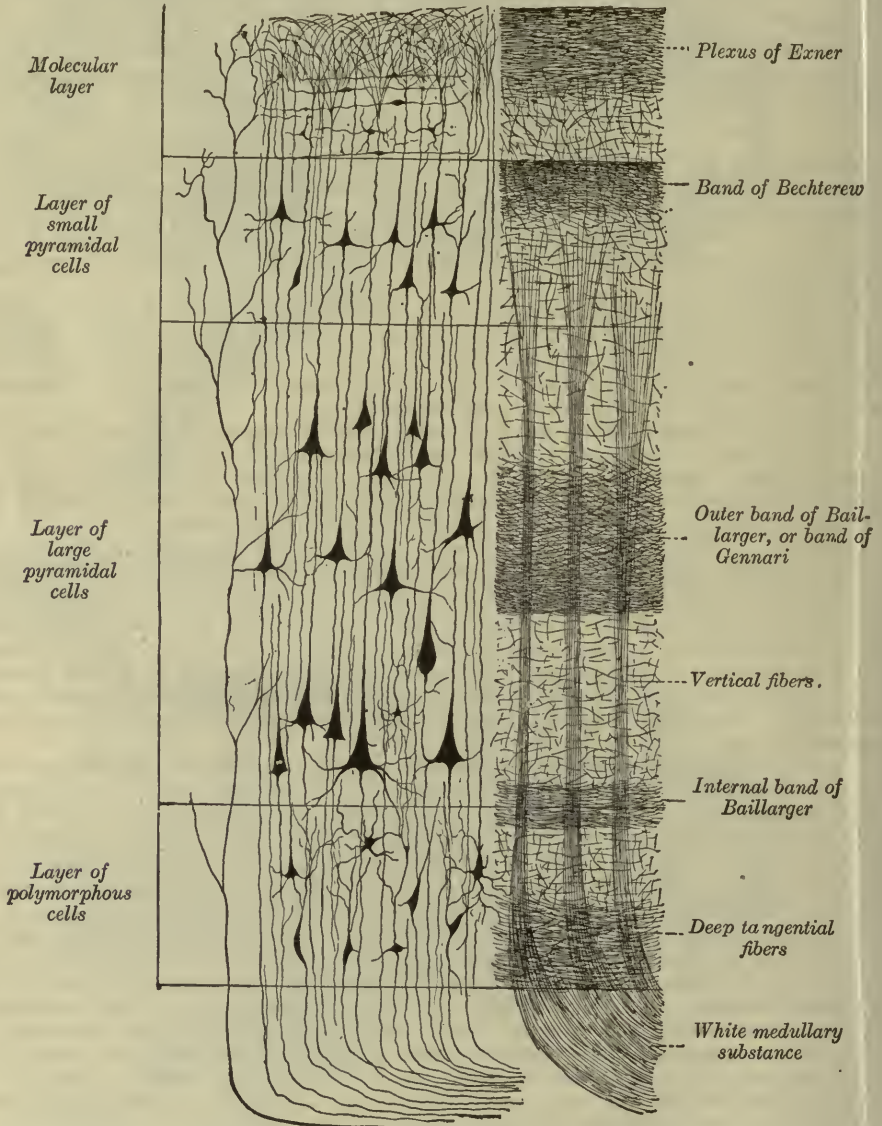


FIG. 754.—Cerebral cortex. (Poirier.) To the left, the groups of cells; to the right, the systems of fibers. Quite to the left of the figure a sensory nerve fiber is shown.

or external band of Baillarger, running through the layer of large pyramidal cells; (4) the internal band of Baillarger, between the layer of large pyramidal cells and the polymorphous layer; (5) the deep tangential fibers, in the lower part of the polymorphous layer. The tangential fibers consist of (a) the collaterals of the pyramidal and polymorphous cells and of the cells of Martinotti; (b) the branching axons of Golgi's cells; (c) the collaterals and terminal arborizations of the projection, commissural, or association fibers. *The radial fibers.*—Some of these, viz., the axons of the pyramidal and polymorphous cells, descend into the central white-matter, while others,

the terminations of the projection, commissural, or association fibers, ascend to end in the cortex. The axons of the cells of Martinotti are also ascending fibers.

Special Types of Cerebral Cortex.—It has been already pointed out that the minute structure of the cortex differs in different regions of the hemisphere; and A. W. Campbell¹ has endeavored to prove, as the result of an exhaustive examination of a series of human and anthropoid brains, "that there exists a direct correlation between physiological function and histological structure." The principal regions where the "typical" structure is departed from will now be referred to.

1. In the calcarine fissure and the gyri bounding it, the internal band of Baillarger is absent, while the band of Gennari is of considerable thickness, and forms a characteristic feature of this region of the cortex. If a section be examined microscopically, an additional layer of cells is seen to be interpolated between the molecular layer and the layer of small pyramidal cells. This extra layer consists of two or three strata of fusiform cells, the long axes of which are at right angles to the surface; each cell gives off two dendrites, external and internal, from the latter of which the axon arises and passes into the white central substance. In the layer of small pyramidal cells, fusiform cells, identical with the above, are seen, as well as ovoid or star-like cells with ascending axons (*cells of Martinotti*). This is the *visual area* of the cortex, and it has been shown by J. S. Bolton² that in old-standing cases of optic atrophy the thickness of Gennari's band is reduced by nearly 50 per cent.

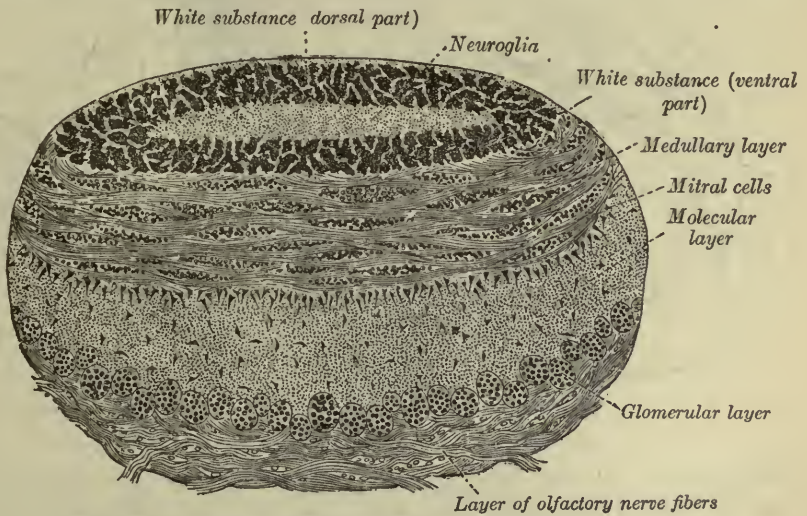


FIG. 755.—Coronal section of olfactory bulb. (Schwalbe.)

A. W. Campbell says: "Histologically, two distinct types of cortex can be made out in the occipital lobe. The first of these coats the walls and bounding convolutions of the calcarine fissure, and is distinguished by the well-known line of Gennari or Vicq d'Azyr; the second area forms an investing zone a centimetre or more broad around the first, and is characterized by a remarkable wealth of fibers, as well as by curious pyriform cells of large size richly stocked with chromophilic elements—cells which seem to have escaped the observation of Ramón y Cajal, Bolton, and others who have worked at this region. As to the functions of these two regions there is abundant evidence, anatomical, embryological, and pathological, to show that the first or calcarine area is that to which visual sensations primarily pass, and we are gradually obtaining proof to the effect that the second investing area is constituted for the interpretation and further elaboration of these sensations. These areas therefore deserve the names *visuo-sensory* and *visuo-psychic*."

2. The anterior central gyrus is characterized by the presence of the giant cells of Betz and by "a wealth of nerve fibers immeasurably superior to that of any other part" (Campbell), and in these respects differs from the posterior central gyrus. These two gyri, together with the paracentral lobule, were long regarded as constituting the "motor areas" of the hemisphere; but Sherrington and Grunbaum have shown³ that in the chimpanzee the motor area never extends on to the free face of the posterior central gyrus, but occupies the entire length of the anterior central gyrus, and in most cases the greater part or the whole of its width. It extends into the depth of the central sulcus, occupying the anterior wall, and in some places the floor, and in some extending even into the deeper part of the posterior wall of the sulcus.

¹ Histological Studies on the Localization of Cerebral Function, Cambridge University Press.

² Philosophical Transactions of Royal Society, Series B, cxciiii, 165.

³ Transactions of the Pathological Society of London, vol. liii.

3. In the hippocampus the molecular layer is very thick and contains a large number of Golgi cells. It has been divided into three strata: (a) *s. convolutum* or *s. granulosum*, containing many tangential fibers; (b) *s. lacunosum*, presenting numerous vascular spaces; (c) *s. radiatum*, exhibiting a rich plexus of fibrils. The two layers of pyramidal cells are condensed into one, and the cells are mostly of large size. The axons of the cells in the polymorphous layer may run in an ascending, a descending, or a horizontal direction. Between the polymorphous layer and the ventricular ependyma is the white substance of the alveus.

4. In the fascia dentata hippocampi or dentate gyrus the molecular layer contains some pyramidal cells, while the layer of pyramidal cells is almost entirely represented by small ovoid cells.

5. *The Olfactory Bulb.*—In many of the lower animals this contains a cavity which communicates through the olfactory tract with the lateral ventricle. In man the original cavity is filled up by neuroglia and its wall becomes thickened, but much more so on its ventral than on its dorsal aspect. Its dorsal part contains a small amount of gray and white substance, but it is scanty and ill-defined. A section through the ventral part (Fig. 755) shows it to consist of the following layers from without inward:

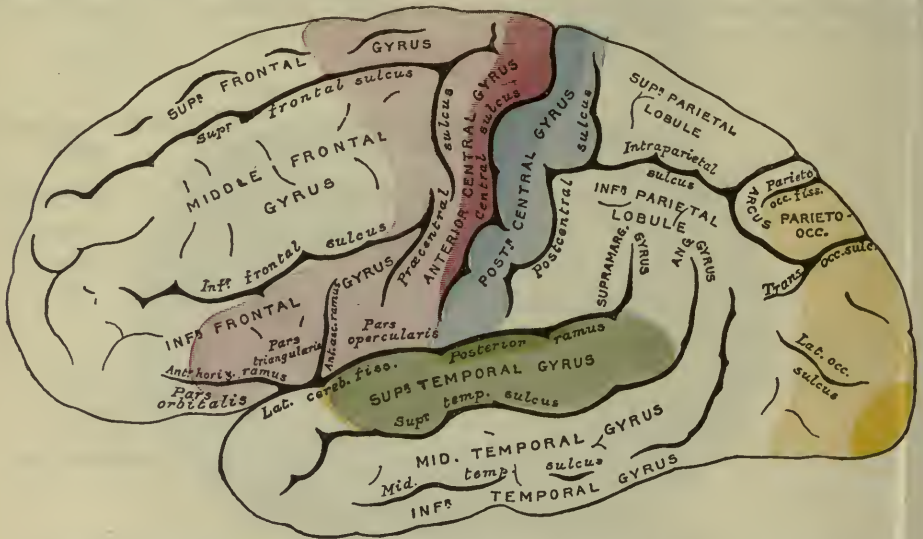


FIG. 756.—Areas of localization on lateral surface of hemisphere. Motor area in red. Area of general sensations in blue. Auditory area in green. Visual area in yellow. The psychic portions are in lighter tints.

1. A layer of olfactory nerve fibers, which are the non-medullated axons prolonged from the olfactory cells of the nasal cavity, and reach the bulb by passing through the cribriform plate of the ethmoid bone. At first they cover the bulb, and then penetrate it to end by forming synapses with the dendrites of the mitral cells, presently to be described.

2. *Glomerular Layer.*—This contains numerous spheroidal reticulated enlargements, termed **glomeruli**, produced by the branching and arborization of the processes of the olfactory nerve fibres with the descending dendrites of the mitral cells.

3. *Molecular Layer.*—This is formed of a matrix of neuroglia, imbedded in which are the *mitral cells*. These cells are pyramidal in shape, and the basal part of each gives off a thick dendrite which descends into the glomerular layer, where it arborizes as indicated above, and others which interlace with similar dendrites of neighboring mitral cells. The axons pass through the next layer into the white matter of the bulb, and after becoming bent on themselves at a right angle, are continued into the olfactory tract.

4. *Nerve Fiber Layer.*—This lies next the central core of neuroglia, and its fibers consist of the axons or afferent processes of the mitral cells passing to the brain; some efferent fibers are, however, also present, and end in the molecular layer, but nothing is known as to their exact origin.

Weight of the Encephalon.—The average weight of the brain, in the adult male, is about 1380 gms.; that of the female, about 1250 gms. In the male, the maximum weight out of 278 cases was 1840 gms. and the minimum weight 964 gms. The maximum weight of the adult female brain, out of 191 cases, was 1585 gms. and the minimum weight 879 gms. The brain increases rapidly during the first four years of life, and reaches its maximum weight by about the twentieth year. As age advances, the brain decreases slowly in weight; in old age the decrease takes place more rapidly, to the extent of about 28 gms.

The human brain is heavier than that of any of the lower animals, except the elephant and whale. The brain of the former weighs from 3.5 to 5.4 kilogram., and that of a whale, in a specimen 19 metres long, weighed rather more than 6.7 kilogram.

Cerebral Localization.—Physiological and pathological research have now gone far to prove that a considerable part of the surface of the brain may be mapped out into a series of more or less definite areas, each of which is intimately connected with some well-defined function.

The chief areas are indicated in Figs. 756 and 757.

Motor Areas.—The motor area occupies the anterior central and frontal gyri and the paracentral lobule. The centers for the lower limb are located on the uppermost part of the anterior central gyrus and its continuation on to the paracentral lobule; those for the trunk are on the upper portion, and those for the upper limb on the middle portion of the anterior central gyrus. The facial centers are situated on the lower part of the anterior central gyrus, those for the tongue, larynx, muscles of mastication, and pharynx on the frontal operculum, while those for the head and neck occupy the posterior end of the middle frontal gyrus.

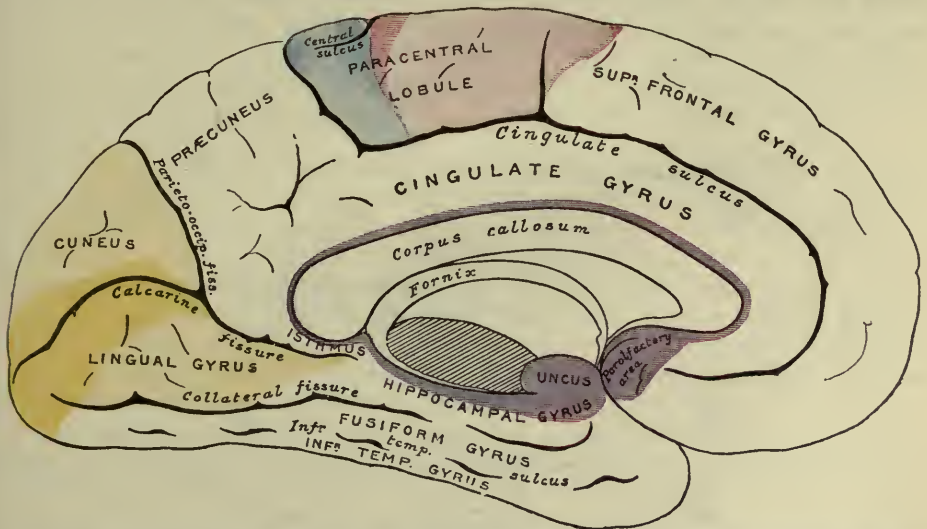


FIG. 757.—Areas of localization on medial surface of hemisphere. Motor area in red. Area of general sensations in blue. Visual area in yellow. Olfactory area in purple. The psychic portions are in lighter tints.

Sensory Areas.—Tactile and temperature senses are located on the posterior central gyrus, while the sense of form and solidity is on the superior parietal lobule and precuneus. With regard to the special senses, the area for the sense of taste is probably related to the uncus and hippocampal gyrus. The auditory area occupies the middle third of the superior temporal gyrus and the adjacent gyri in the lateral fissure; the visual area, the calcarine fissure and cuneus; the olfactory area, the rhinencephalon. As special centers of much importance may be noted: the emissive center for speech on the left inferior frontal and anterior central gyri (Broca); the auditory receptive center on the transverse and superior temporal gyri, and the visual receptive center on the lingual gyrus and cuneus.

COMPOSITION AND CENTRAL CONNECTIONS OF THE SPINAL NERVES.

The typical spinal nerve consists of at least four types of fibers, the somatic sensory, sympathetic afferent or sensory, somatic motor and sympathetic efferent or preganglionic. The somatic sensory fibers, afferent fibers, arise from cells in the spinal ganglia and are found in all the spinal nerves, except occasionally the first cervical, and conduct impulses of pain, touch and temperature from the surface of the body through the posterior roots to the spinal cord and impulses of muscle sense, tendon sense and joint sense from the deeper structures. The sympathetic afferent fibers, conduct sensory impulses from the viscera through the rami communicantes and posterior roots to the spinal cord. They are probably limited to the white rami connected with the spinal nerves in two groups, viz., the first thoracic to the second

lumbar and the second sacral to the fourth sacral nerves. The somatic motor fibers, efferent fibers, arise from cells in the anterior column of the spinal cord and pass out through the anterior roots to the voluntary muscles. The sympathetic efferent fibers, probably arise from cells in the lateral column or the base of the anterior column and emerge through the anterior roots and white rami communicantes. These are preganglionic fibers which end in various sympathetic ganglia from which postganglionic fibers conduct the motor impulses to the smooth muscles of the viscera and vessels and secretory impulses to the glands. These fibers are also limited to two regions, the first thoracic to the second lumbar and the second sacral to the fourth sacral nerves.

The afferent fibers which pass into the spinal cord establish various types of connections, some within the cord itself for spinal reflexes, others for reflexes connected with higher centers in the brain, while still others conduct impulses of conscious sensation by a series of neurons to the cerebral cortex.

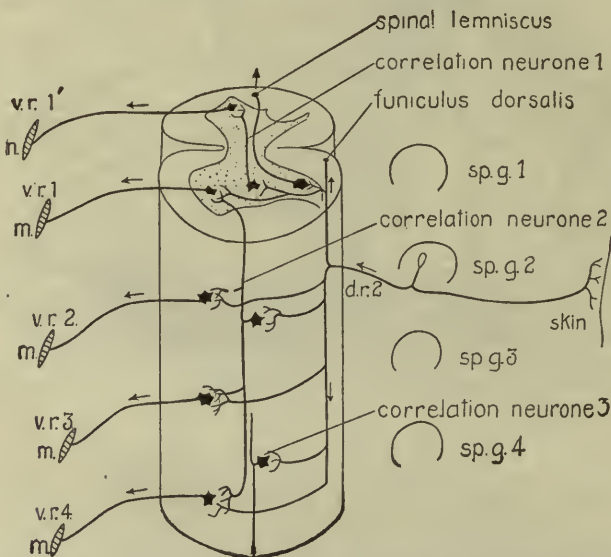


FIG. 758.—Diagram of the spinal cord reflex apparatus. Some of the connections of a single afferent neuron from the skin (*d.r.2*) are indicated: *d.r.2*, dorsal root from second spinal ganglion; *m*, muscles; *sp.g.1* to *sp.g.4*, spinal ganglia; *v.r.1'* to *v.r.4*, ventral roots. (After Herrick.)

The Intrinsic Spinal Reflex Paths.—The collaterals and terminals of the ascending and descending branches of the posterior root fibers which leave the fasciculus cuneatus to enter the gray matter of the spinal cord end in various ways. Many end in the dorsal column, some near its apex, others in the substance of Rolando, others in the intermediate region between the dorsal and ventral columns, others traverse the whole thickness of the gray matter to reach the ventral column, others end in the dorsal nucleus, and others pass through the gray commissure to the dorsal column of the opposite side. All of these collaterals and terminals end in connection with cells or dendrites of cells in the gray columns. The axons of these cells have various destinations, some pass out into the lateral and ventral funiculi and turn upward to reach the brain. Those concerned with the intrinsic spinal reflexes come into relation either directly or indirectly with motor cells in the anterior column. It is very unlikely that either the terminals or collaterals of the dorsal root fibers effect simple direct connections with the motor cells of the ventral column, there is at least one if not several intercalated neurons in the path. These intercalated or correlation neurons may have short axons that do not pass out of the gray matter or the axons may pass out into the proper fasciculi and extend for varying distances

up and down or in both directions giving off collaterals and finally terminating in the gray matter of the same or the opposite side. The shortest fibers of the proper fasciculi lie close to the gray matter, the longest ones are nearer the periphery of the proper fasciculi and are more or less intermingled with the long ascending and descending fasciculi which occupy the more marginal regions of the spinal cord.

Each sensory neuron, with its ascending and descending branches, giving off as it does many collaterals into the gray matter, each one of which may form a synapse with one or several correlation neurons, is thus brought into relation with many correlation neurons and each one of these in turn, with its ascending and descending branches and their numerous collaterals, is brought into relation, either directly or through the intercalation of additional correlation neurons, with great numbers of motor cells in the anterior column. The great complexity of these so-called simple reflex mechanisms, in the least complex portion of the nervous system the spinal cord, renders them extremely difficult of exact analysis.

The association or correlation neurons are concerned not only with the reflex mechanisms of the spinal cord but play an equally important role in the transmission of impulses from the higher centers in the brain to the motor neurons of the spinal cord.

The complex mechanisms just described are probably concerned not so much in the contraction of individual muscles as in the complicated action of groups of muscles concerned in the enormous number of movements, which the limbs and trunk exhibit in the course of our daily life.

Sensory Pathways from the Spinal Cord to the Brain.—The posterior root fibers conducting the impulses of **conscious muscle sense**, tendon sense and joint sense, those impulses which have to do with the coördination and adjustment of muscular movements, ascend in the fasciculus gracilis and fasciculus cuneatus to the nucleus gracilis and nucleus cuneatus in the medulla oblongata (Fig. 759).

In the nucleus gracilis and nucleus cuneatus synaptic relations are found with neurons whose cell bodies are located in these nuclei and whose axons pass by way of the internal arcuate fibers, cross in the raphé to the opposite side in the region between the olives and turn abruptly upward to form the medial lemniscus or medial fillet. The medial fillet passes upward in the ventral part of the formatio reticularis through the medulla oblongata, pons and mid-brain to the principal sensory nucleus of the ventro-lateral region of the thalamus. Here the terminals form synapses with neurons of the third order whose axons pass through the internal capsule and corona radiata to the somatic sensory area of the cortex in the post-central gyrus.

Fibers conducting the impulses of **unconscious muscle sense** pass to the cerebellum partly by way of the fasciculus gracilis and fasciculus cuneatus to the nucleus gracilis and nucleus cuneatus, thence neurons of the second order convey the impulses either via the dorsal external arcuate fibers directly into the inferior peduncle of the cerebellum or via the ventral external arcuate fibers which are continued from the internal arcuate fibers through the ventral part of the raphé and after crossing the midline emerge on the surface of the medulla in the ventral sulcus between the pyramids or in the groove between the pyramid and the olive. They pass over the lateral surface of the medulla and olive to reach the inferior peduncle through which they pass to the cerebellum.

Other fibers conducting impulses of unconscious muscle sense pass upward in the dorsal spinocerebellar fasciculus, which arises from cells in the nucleus dorsalis. The posterior root fibers conducting these impulses pass into the fasciculus cuneatus and the collaterals from them to the nucleus dorsalis are said to come almost exclusively from the middle area of the fasciculus cuneatus. They form by their multiple division baskets about the individual cells of the nucleus dorsalis, each fiber coming in relation with the bodies and dendrites of several cells. The axons of the second order pass into the dorsal spinocerebellar fasciculus of the same side

and ascend along the lateral surface of the spinal cord and medulla oblongata until they arrive at the level of the olive, they then curve backward beneath the external arcuate fibers into the inferior peduncle and pass into the cerebellum. Here they give off collaterals to the dentate nucleus and finally terminate in the cortex of the dorsal and superior portion of the vermis, partly on the same side, but to a great

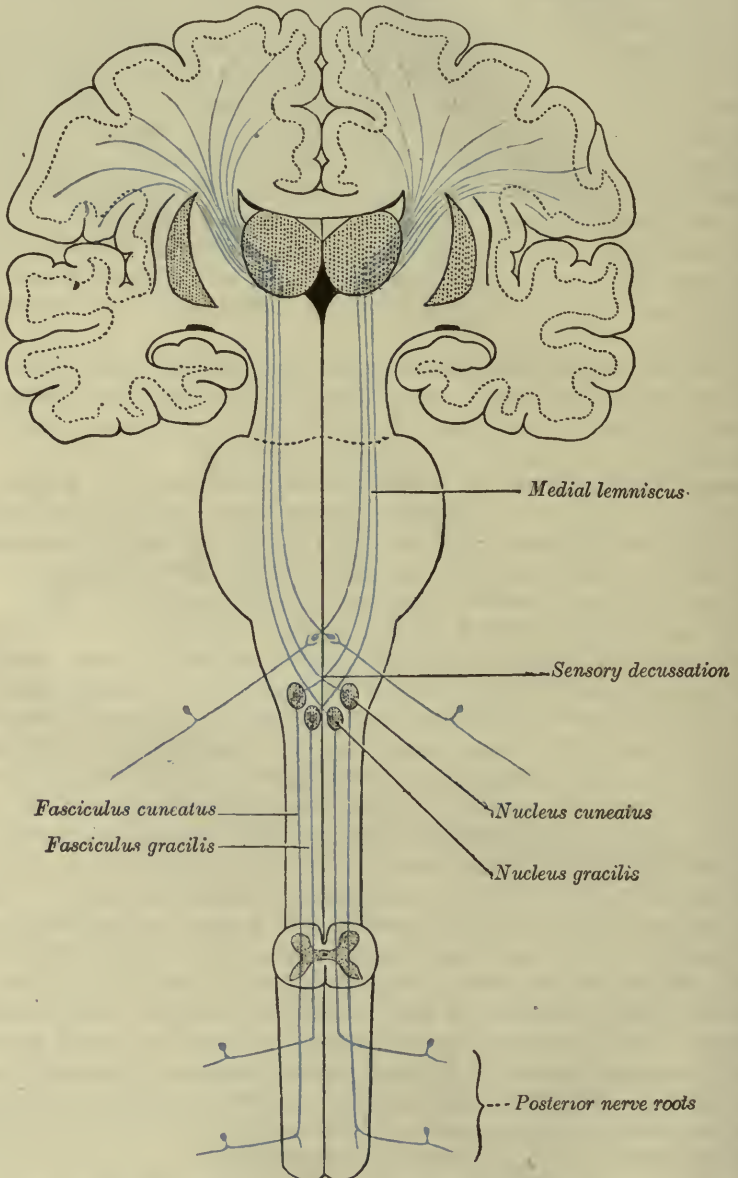


FIG. 759.—The sensory tract. (Modified from Poirier.)

extent by way of a large commissure to the opposite side. The fibers lose their myelin sheaths as they enter the gray substance and terminate by end ramifications among the nerve cells and their processes. Some of the fibers are said to end in the nucleus dentatus and the roof nuclei of the cerebellum (the nucleus globosus, nucleus emboliformis and nucleus fastigius) and others pass through them to terminate in the inferior vermis. A few fibers of the dorsal spinocerebellar fasciculus

are said not to enter the inferior peduncle but to pass with the ventral spinocerebellar fasciculus. The cerebellar reflex arc is supposed to be completed by the fibers of the superior peduncle which pass from the cerebellum to the red nucleus of the mid-brain where some of their terminals and collaterals form synapses with neurons whose axons descend to the spinal cord in the rubrospinal fasciculus. The terminal and collaterals of this fasciculus end either directly or indirectly about the motor cells in the anterior column.

The ventral spinocerebellar fasciculus, since most of its fibers pass to the cerebellum, is also supposed to be concerned in the conduction of unconscious muscle sense. The location of its cells of origin is uncertain. They are probably in or near the dorsal nucleus of the same and the opposite side; various other locations are given, the dorsal column, the intermediate zone of the gray matter and the central portion of the anterior column. The neurons of the first order whose central fibers enter the fasciculus cuneatus from the dorsal roots send collaterals and terminals to form synapses with these cells. The fibers which come from the opposite gray columns cross some in the white and some in the gray commissure and pass with fibers from the same side through the lateral funiculus to the marginal region ventral to the dorsal spinocerebellar fasciculus. The fasciculus begins about the level of the third lumbar nerve and continues upward on the lateral surface of the spinal cord and medulla oblongata until it passes under cover of the external arcuate fibers. It passes just dorsal to the olive and above this joins the lateral edge of the lateral lemniscus along which it runs, ventral to the roots of the trigeminal nerve, almost to the level of the superior colliculus, it then crosses over the superior peduncle, turns abruptly backward along its medial border, enters the cerebellum with it and ends in the vermis of the same and the opposite side. Some of its fibers are said to join the dorsal spinocerebellar fasciculus in the medulla oblongata and enter the cerebellum through the inferior peduncle. A number of fibers are said to continue upward in the dorsolateral part of the tegmentum as far as the superior colliculus and a few pass to the thalamus. They probably form part of the sensory or higher reflex path.

The posterior root fibers conducting impulses of **pain** and **temperature** probably terminate in the posterior column or the intermediate region of the gray matter soon after they enter the spinal cord. The neurons of the second order are supposed to pass through the anterior commissure to the superficial antero-lateral fasciculus (tract of Gowers) and pass upward in that portion of it known as the lateral spinothalamic fasciculus. This fasciculus lies along the medial side of the ventral spinocerebellar fasciculus. It is stated by some authors that the pain fibers pass upward in the antero-lateral ground bundles. In some of the lower mammals this pathway carries the pain fibers upward by a series of neurons some of which cross to the opposite side, so that in part there is a double path. In man, however, the lateral spinothalamic fasciculus is probably the most important pathway. On reaching the medulla these fibers continue upward through the formatio reticularis in the neighborhood of the median fillet to the thalamus, probably its ventro-lateral region. Whether higher neurons convey the pain impulses to the cortex through the internal capsule is uncertain. The pathway is probably more complex and Head is of the opinion that our sensations of pain are essentially thalamic. The pain and temperature pathways in the lateral spinothalamic fasciculus are not so closely intermingled but that one can be destroyed without injury to the other.

Ransom suggests that the non-medullated fibers of the posterior roots, which turn into Lissauer's tract and ascend or descend for short distances not exceeding one or two segments and finally end in the substantia gelatinosa, are in part at least pain fibers and that the fasciculus of Lissauer and the substantia gelatinosa represent part of the mechanism for reflexes associated with pain conduction and reception while the fibers to the higher centers pass up in the spinothalamic tract.

The fibers of **tactile discrimination**, according to Head and Thompson, pass up in the fasciculus cuneatus and fasciculus gracilis of the same side and follow the path of the muscle-sense fibers. The axons of the second order arising in the nucleus cuneatus and gracilis cross with the internal arcuate fibers and ascend to the thalamus with the medial lemniscus, thence by neurons of higher order the impulses are carried to the somatic sensory area of the cortex through the internal capsule. The other **touch fibers**, shortly after entering the spinal cord, terminate in the dorsal column or intermediate gray matter. Neurons of the second order send their axons through the anterior commissure to pass upward in the antero-lateral funiculus probably in the **ventral spinothalamic fasciculus**. In the medulla they join or pass upward in the neighborhood of the medial lemniscus to the thalamus and thence by neurons of higher order to the somatic sensory area of the cortex.

The remaining ascending fasciculi form a part of the complex known as the **superficial antero-lateral fasciculus** (*tract of Gowers*). The **spinotectal fasciculus**, as its name indicates, is supposed to have its origin in the gray matter of the cord and terminations in the superior and inferior (?) colliculi of the mid-brain serving for reflexes between the cord and the visceral and auditory centers of the mid-brain.

The **spino-olivary fasciculus** (*olivospinal; bulbospinal, Helweg's bundle*) is likewise of unknown constitution and function; there is uncertainty even in regard to the direction of its fibers.

Sympathetic afferent fibers (*visceral afferent; viscero-sensory; splanchnic afferent*) enter the spinal cord by the posterior roots of the thoracic and first two or three lumbar nerves and the second to the fourth sacral nerves. The fibers pass to these nerves from the peripheral sympathetic system through the white rami communicantes. Some of the cell bodies of these afferent fibers are located in the spinal ganglia and others are in the sympathetic ganglia. Some of the afferent sympathetic fibers end about the cell bodies of somatic sensory neurons and visceral impulses are thus transmitted to these neurons which conduct them as well as their own special impulses to the spinal cord. Other sympathetic afferent neurons whose cell bodies are located in the spinal ganglia send collaterals to neighboring cells of somatic sensory neurons and thus have a double path of transmission to the spinal cord. Such an arrangement provides a mechanism for some of the referred pains.

These sympathetic afferent fibers presumably divide on entering the spinal cord into ascending and descending branches. Their distribution and termination within the spinal cord are unknown. Some of them probably eventually come into relation with the sympathetic efferent fibers whose cell bodies are located in the lateral column. Our knowledge concerning both the termination and origin of these fibers is very unsatisfactory.

The **sympathetic efferent fibers** (*splanchnic motor; viscero-motor; preganglionic fibers*) are supposed to arise from cells in the intermediate zone between the dorsal and ventral gray columns and in the intermedio-lateral column at the margin of the lateral column. These preganglionic sympathetic fibers are not distributed throughout the entire series of spinal nerves but are confined to two groups, the thoraco-lumbar from the first thoracic to the second or third lumbar nerves and the sacral group from the second to the fourth sacral nerves. They pass out with the anterior root fibers and through the rami communicantes to end in sympathetic ganglia. The impulses are distributed from cells in these ganglia through post-ganglionic fibers to the smooth muscles and glands. The thoraco-lumbar outflow and the sacral outflow form two distinct functional groups which are considered more fully under the sympathetic system.

COMPOSITION AND CENTRAL CONNECTIONS OF THE CRANIAL NERVES.

The cranial nerves are more varied in their composition than the spinal nerves. Some, for example, contain somatic motor fibers only, others contain the various types of fibers found in the spinal nerves, namely, somatic motor, sympathetic efferent, somatic sensory and sympathetic sensory. In addition there are included the nerves of the special senses, namely, the nerves of smell, sight, hearing, equilibration and taste.

The **Hypoglossal Nerve** (*XII cranial*) consists of somatic motor fibers only and supplies the muscles of the tongue. Its axons arise from cells in the hypoglossal nucleus and pass forward between the white reticular formation and the gray reticular formation to emerge from the antero-lateral sulcus of the medulla. The hypoglossal nuclei of the two sides are connected by many commissural fibers and also by dendrites of motor cells which extend across the midline to the opposite nucleus. The hypoglossal nucleus receives either directly or indirectly numerous collaterals and terminals from the opposite pyramidal tract (cortico-bulbar or cerebro-bulbar fibers) which convey voluntary motor impulses from the cerebral cortex. Many reflex collaterals enter the nucleus from the secondary sensory paths of the trigeminal and vagus and probably also from the nervus intermedius and the glossopharyngeal. Collaterals from the posterior longitudinal bundle and the ventral longitudinal bundle are said to pass to the nucleus.

The **Accessory Nerve** (*XI cranial*) contains somatic motor fibers. The **spinal part** arises from lateral cell groups in the anterior column near its dorso-lateral margin in the upper five or six segments of the cord, its roots pass through the lateral funiculus to the lateral surface of the cord. It supplies the Trapezius and Sternocleidomastoideus. The **cranial part** arises from the nucleus ambiguus, the continuation in the medulla oblongata of the lateral cell groups of the anterior column of the spinal cord from which the spinal part has origin. The upper part of the nucleus ambiguus gives motor fibers to the vagus and glossopharyngeal nerves. The cranial part sends its fibers through the vagus to the laryngeal nerves to supply the muscles of the larynx. The root fibers of the cranial part of the accessory nerve pass anterior to the spinal tract of the trigeminal while those of the vagus pass through or dorsal to the trigeminal root, and emerge in the line of the postero-lateral sulcus. The nucleus of origin of the spinal part undoubtedly receives either directly or indirectly terminals and collaterals controlling voluntary movements from the pyramidal tracts. It is probable that terminals and collaterals reach the nucleus either directly or indirectly from the rubrospinal and the vestibulospinal tracts. It is also connected indirectly with the spinal somatic sensory nerves by association fibers of the proper fasciculi. The cranial part receives indirectly or directly terminals and collaterals from the opposite pyramidal tract and form the terminal sensory nuclei of the cranial nerves. A few fibers of the cranial part are said to arise in the dorsal nucleus of the vagus and are thus sympathetic efferent. They are said to join the vagus nerve.

The **Vagus Nerve** (*X cranial*) contains somatic sensory, sympathetic afferent, somatic motor, sympathetic efferent and (taste fibers?). The afferent fibers (somatic sensory, sympathetic, and taste) have their cells of origin in the jugular ganglion and in the nodosal ganglion (ganglion of the trunk) and on entering the medulla divide into ascending and descending branches as do the sensory fibers of the posterior roots of the spinal nerves after they enter the spinal cord.

(1) The **somatic sensory fibers** are few in number, convey impulses from a limited area of the skin on the back of the ear and posterior part of the external auditory meatus, and probably join the spinal tract of the trigeminal nerve to terminate in its nucleus. Connections are probably established through the central path of the trigeminal with the thalamus and somatic sensory area of the cortex for the

conscious recognition of impulses. The descending fibers in the spinal tract of the trigeminal terminating in the nucleus of the tract probably establish relations through connecting neurons with motor nuclei in the anterior column of the spinal cord and with motor nuclei of the medulla.

(2) The **sympathetic afferent fibers** are usually described as terminating in the dorsal nucleus of the vagus and glossopharyngeal. Some authors, however, believe they join the tractus solitarius and terminate in its nucleus. These afferent fibers convey impulses from the heart, the pancreas, and probably from the stomach, esophagus and respiratory tract. Their terminals in the dorsal nucleus come into relation with neurons whose axons probably descend into the spinal cord, conveying impulses to the motor nuclei supplying fibers to the muscles of respiration, *i. e.*, the phrenic nerve and the nerves to the intercostal and levatores costarum muscles. Other axons probably convey vasomotor impulses to certain sympathetic efferent neurons throughout the spinal cord. The dorsal nucleus (nucleus of the ala cinerea) and the posterior continuation of it into the commissural nucleus of the ala cinerea constitute probably the so-called respiratory and vaso-motor center of the medulla. The shorter reflex neurons of the dorsal nucleus probably effect connections either directly or indirectly with motor cells of the vagus itself and other cranial nerves.

(3) **Taste fibers** conducting impulses from the epiglottis and larynx are supposed to pass in the vagus and to join the tractus solitarius, finally terminating in the nucleus of the tractus solitarius. It is not certain that this nucleus represents the primary terminal center for taste and some authors maintain that the taste fibers terminate in the dorsal nucleus. The secondary ascending pathways from the primary gustatory nucleus to the cortex as well as the location of the cortical center for taste are unknown. A gustatory center has been described near the anterior end of the temporal lobe. The nucleus of the tractus solitarius is connected with motor centers of the pons, medulla and spinal cord for the reactions of mastication and swallowing.

(4) **Somatic motor fibers** to the cross striated muscles of the pharynx and larynx arise in the nucleus ambiguus. This nucleus undoubtedly receives either directly or indirectly collaterals or terminals from the opposite pyramidal tract controlling the voluntary movements of the pharynx and larynx. The reflex pathways conveying impulses from the terminal sensory nuclei are unknown, but probably form part of the intricate maze of fibers constituting the reticular formation.

(5) **Sympathetic efferent fibers** arise from cells in the dorsal nucleus (nucleus of the ala cinerea). These are preganglionic fibers of the sympathetic system and all terminate in sympathetic ganglia from which postganglionic fibers are distributed to various organs, *i. e.*, motor fibers to the esophagus, stomach, small intestine, gall-bladder, and to the lungs; inhibitory fibers to the heart; secretory fibers to the stomach and pancreas. The dorsal nucleus not only receives terminals of sympathetic afferent fibers for reflexes but undoubtedly receives terminals and collaterals from many other sources, but the exact pathways are at present unknown.

The **Glossopharyngeal Nerve** (*IX cranial*) is similar to the vagus nerve as regards its central connections and is usually described with it. It contains somatic sensory, sympathetic afferent, taste, somatic motor and sympathetic efferent fibers. The afferent sensory fibers arise from cells in the superior ganglion and in the petrosal ganglion. The same uncertainty exists concerning the nuclei of termination and nuclei of origin of the various components as for the vagus.

(1) The **somatic sensory fibers** are few in number. Some are distributed with the auricular branch of the vagus to the external ear; others probably pass to the pharynx and fauces. They are supposed to join the spinal tract of the trigeminal and terminate in its nucleus. The connections are similar to those of the somatic sensory fibers of the vagus.

(2) **Sympathetic afferent fibers** from the pharynx and middle ear are supposed to terminate in the dorsal nucleus. Connections are probably established with motor nuclei concerned in chewing and swallowing; very little is known, however, about the connections with other parts of the brain.

(3) **Taste fibers** from the tongue probably terminate in the nucleus of the tractus solitarius. These fibers together with similar fibers from the facial (*nervus intermedius*) and the vagus are supposed to form the tractus solitarius and terminate in its nucleus. The central connections have been considered under the vagus.

(4) **Somatic motor fibers** to the Stylopharyngeus muscle arise in the upper end of the nucleus ambiguus. The existence of these fibers in the roots of the glossopharyngeal is uncertain, as there are other paths by which such fibers might reach the glossopharyngeal from the vagus. The sources of impulses passing to the nucleus ambiguus are considered under the vagus.

(5) **Sympathetic efferent fibers** (*motor and secretory fibers*) arise from the nucleus dorsalis. Some authors believe that the secretory fibers to the parotid gland arise from a distinct nucleus, the inferior salivatory nucleus, situated near the dorsal nucleus. The preganglionic fibers from this nucleus terminate in the otic ganglion; the postganglionic fibers from the otic ganglion pass to the parotid gland.

The **Acoustic Nerve** (*VIII cranial*) consists of two distinct nerves the **cochlear nerve**, the nerve of hearing, and the **vestibular nerve**, the nerve of equilibration.

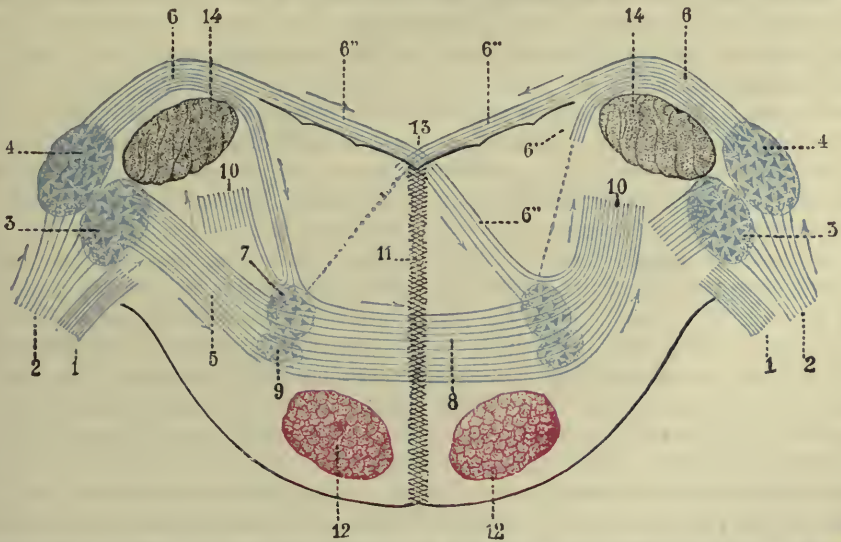


FIG. 760.—Terminal nuclei of the cochlear nerve, with their upper connections. (Schematic.) The vestibular nerve with its terminal nuclei and their efferent fibers have been suppressed. On the other hand, in order not to obscure the trapezoid body, the efferent fibers of the terminal nuclei on the right side have been resected in a considerable portion of their extent. The trapezoid body, therefore, shows only one-half of its fibers, viz., those which come from the left. 1. Vestibular nerve, divided at its entrance into the medulla oblongata. 2. Cochlear nerve. 3. Accessory nucleus of acoustic nerve. 4. Tuberculum acusticum. 5. Efferent fibers of accessory nucleus. 6. Efferent fibers of tuberculum acusticum, forming the *striae medullares*, with 6', their direct bundle going to the superior olivary nucleus of the same side; 6'', their decussating bundles going to the superior olivary nucleus of the opposite side. 7. Superior olivary nucleus. 8. Trapezoid body. 9. Trapezoid nucleus. 10. Central acoustic tract (lateral lemniscus). 11. Raphé. 12. Cerebrospinal fasciculus. 13. Fourth ventricle. 14. Inferior peduncle. (Testut.)

The **Cochlear Nerve** arises from bipolar cells in the spiral ganglion of the cochlea; the peripheral fibers end in the organ of Corti, the central fibers bifurcate as they enter the **cochlear nucleus**; the short ascending branches end in the ventral portion of the nucleus, the longer descending branches terminate in the dorsal portion of the nucleus. From the dorsal portion of the cochlear nucleus axons arise which pass across the dorsal aspect of the inferior peduncle and the floor of the fourth ventricle, the *striae medullares*, to the median sulcus. Here they dip into the substance of the pons, cross the median plane, and join the lateral lemniscus. Some

of the fibers terminate in the superior olivary nucleus. The fibers of the *striæ medullares* are not always visible on the floor of the rhomboid fossa. From the ventral portion of the cochlear nucleus axons pass into the trapezoid body, here some of them end in the superior olivary nucleus of the same side, others cross the midline and end in the superior olivary nucleus of the opposite side or pass by these nuclei, giving off collaterals to them, and join the lateral lemniscus. Other fibers either terminate in or give off collaterals to the nucleus of the trapezoid body of the same or the opposite side. Other fibers from the ventral portion of the cochlear nucleus pass dorsal to the inferior peduncle and then dip into the substance of the pons to join the trapezoid body or the superior olivary nucleus of the same side. From the superior olivary nucleus of the same and opposite sides axons join the lateral lemniscus. Collaterals and probably terminals also pass from the lateral lemniscus to other nuclei in its path and receive in turn axons from these nuclei. They are the accessory nucleus, the medial preolivary nucleus, the lateral preolivary or semilunar nucleus and the nucleus of the lateral lemniscus.

The **trapezoid body** consists of horizontal fibers in the ventral part of the *formatio reticularis* of the lower part of the pons behind its deep transverse fibers and the pyramid bundles. The axons come from the dorsal and ventral portions of the cochlear nucleus. After crossing the *raphé*, where they decussate with those from the opposite side, they turn upward to form the lateral lemniscus. Fibers from the *striæ medullares* contribute to the trapezoid body, in addition it sends terminals or collaterals to and receives axons from the superior olivary nucleus, the nucleus of the trapezoid body, the lateral preolivary or semilunar nucleus and the mesial preolivary nucleus.

The **cochlear nucleus**, the terminal nucleus for the nerve of hearing, is usually described as consisting of a larger dorsal nucleus on the dorsal and lateral aspect of the inferior peduncle forming a prominent projection, the **acoustic tubercle**, and a ventral or accessory cochlear nucleus more ventral to the inferior peduncle. The two nuclei are continuous and are merely portions of one large nucleus. The axons from cells of the spiral ganglion of the cochlear nerve on reaching the nucleus divide into ascending and descending branches which enter the ventral and dorsal nuclei respectively. Axons from the large fusiform cells of the dorsal nucleus pass partly by way of the *striæ medullares* to the trapezoid body and lateral lemniscus and the nuclei associated with the former, and partly transversely beneath the inferior peduncle and spinal tract of the trigeminal to the trapezoid body. Axons from the ventral cochlear nucleus pass partly by the *striæ medullares* but for the most part horizontally to the trapezoid body.

The **superior olivary nucleus** is a small mass of gray matter situated on the dorsal surface of the lateral part of the trapezoid body. Some of its axons pass backward to the abducent nucleus, this bundle is known as the **peduncle of the superior olivary nucleus**. Other fibers from the nucleus join the posterior longitudinal bundle and terminate in the nuclei of the trochlear and oculomotor nerves. The majority of its axons, after giving off collaterals to the nucleus itself join the lateral lemniscus of the same side, other axons pass in the trapezoid body toward the ventral portion of the cochlear nucleus.

The **nucleus of the trapezoid body** lies between the root fibers of the abducent nerve and the superior olivary nucleus. Its cells lie among the fibers of the trapezoid body. In it terminate fibers and collaterals of the trapezoid body which come from the cochlear nucleus of the opposite and probably the same side and from the opposite trapezoid nucleus. They terminate in the nucleus of the trapezoid body in diffuse arborizations and peculiar end plaques or acoustic calyces of yellowish color which fuse with the cell bodies. Its cells are round and of medium size; their axons pass into the trapezoid body, cross the median line and probably join the lateral fillet.

The **lateral preolivary** or **semilunar nucleus** lies ventral to the superior olivary nucleus. In it end terminals and collaterals of the trapezoid body and probably fibers of the opposite cochlear nucleus. Its axons mingle with the trapezoid body and join the lateral fillet.

The **mesial preolivary nucleus** is in contact with the ventral side of the nucleus of the trapezoid body. It receives many collaterals from the trapezoid body. Its cells are smaller than those of the trapezoid nucleus, their axons join the lateral fillet.

The **lateral lemniscus** (*lateral fillet*), the continuation upward of the central path of hearing, consists of fibers which come from the cochlear nuclei of the same and the opposite side by way of the trapezoid body and from the preolivary nuclei. It lies in the ventral or ventro-lateral part of the reticular formation of the pons, at first ventral then lateral to the median fillet. Above the pons these ascending fibers come to the surface at the side of the reticular formation in the trigonum lemnisci and are covered by a layer of ependyma. This part of the lateral lemniscus is known as the **fillet of Reil**. On reaching the level of the inferior colliculus the dorsal fibers which overlie the superior peduncle decussate in the velum medullare anterius with similar fibers of the opposite side. Numerous small masses of cells are scattered along the path of the lateral lemniscus above the superior olivary nucleus and constitute **lower and upper nuclei of the lateral lemniscus**. They are supplied with many collaterals and possibly terminals from the fibers of the lemniscus. The axons of the lower nucleus of the lateral lemniscus, which arise from the larger stellate or spindle-shaped cells, with long, smooth, much branched dendrites, are said by some authors to join the lateral lemniscus, but according to Cajal they pass medially toward the raphé; their termination is unknown. The cells of the upper nucleus of the lateral lemniscus are more scattered. The same uncertainty exists in regard to their termination.

The fibers of the lateral lemniscus end by terminals or collaterals in the inferior colliculus and the medial geniculate body. A few of the fibers are said to pass by the inferior colliculus to terminate in the middle portion of the stratum griseum of the superior colliculus, and are probably concerned with reflex movements of the eyes depending on acoustic stimuli.

The **inferior colliculi** (*lower or posterior quadrigeminal bodies*) are important auditory reflex centers. Each consists of a compact nucleus of gray matter covered by a superficial white layer and separated from the central gray matter about the aqueduct by a thin, deep, white layer. Many of the axons which appear in the superficial white layer ascend through the inferior brachium to the medial geniculate body. Others mainly from large cells in the dorso-mesial part of the nucleus pass through the deep white layer into the tegmentum of the same and the opposite side and descend. Their termination is unknown, but they probably constitute an auditory reflex path to the lower motor centers, perhaps descending into the spinal cord with the tectospinal fasciculus. Other axons are said to descend in the lateral lemniscus to the various nuclei in the auditory path (Held) and probably to motor nuclei of the medulla and spinal cord.

The **medial geniculate body** receives terminals and collaterals from the lateral lemniscus (the central auditory path) and also large numbers of axons from the inferior colliculus of the same side and a few from the opposite side. It is thus a station in the central auditory path. A large proportion of its axons pass forward beneath the optic tract to join the corona radiata and then sweep backward and lateralward as the auditory radiation to terminate in the cortex of the superior temporal gyrus. V. Monakow holds that Golgi cells type II are interpolated between the terminations of the incoming fibers to the medial geniculate body and the cells located there which give rise to the fibers of the auditory radiation. The medial geniculate bodies are united by the long, slender **commissure of Gudden**. These

fibers join the optic tract as it passes over the edge of the medial geniculate and passes through the posterior part of the optic chiasma. It is probably a commissure connected with the auditory system.

The **Vestibular Nerve** (*vestibular root, VIII cranial*) arise from the bipolar cells in the vestibular ganglion (Scarpa's ganglion). The peripheral fibers end in the semicircular canals, the saccule and the utricle, the end-organs concerned with mechanism for the maintenance of bodily equilibrium. The central fibers enter the medulla oblongata and pass between the inferior peduncle and the spinal tract of the trigeminal. They bifurcate into ascending and descending branches as do the dorsal root fibers of all the spinal nerves and all afferent cranial nerves. The descending branches terminate in the dorsal (medial) vestibular nucleus, the principal nucleus of the vestibular nerve. This nucleus is prolonged downward into a descending portion in which end terminals and collaterals of the descending branch. The ascending branches pass to Deiters's nucleus, to Bechterew's nucleus

and through the inferior peduncle of the cerebellum to the nucleus tecti of the opposite side.

The **dorsal vestibular nucleus** (*medial or principal nucleus*) is a large mass of small cells in the floor of the fourth ventricle under the area acustica, located partly in the medulla and partly in the pons. The *striae medullares* cross the upper part of it. It is separated from the median plane by the nucleus intercalatus. Its axons pass into the posterior longitudinal bundle of the same and the opposite side and ascend to terminate in the nucleus abducens of the same side and in the trochlear nucleus and the oculo-motor nucleus of the opposite side, and to the motor nuclei of the trigeminal on both sides. The descending portion, the nucleus of the descend-

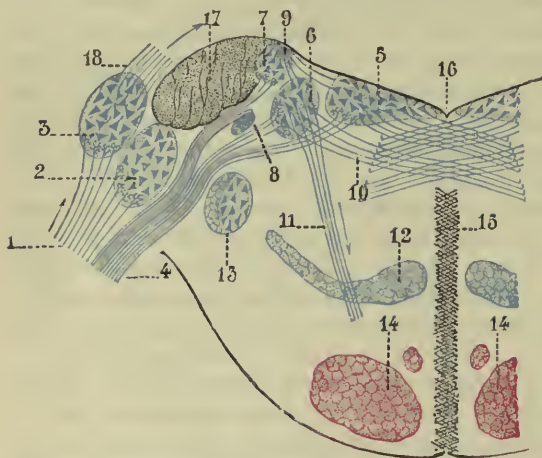


FIG. 761.—Terminal nuclei of the vestibular nerve, with their upper connections. (Schematic.) 1. Cochlear nerve, with its two nuclei. 2. Accessory nucleus. 3. Tuberculum acusticum. 4. Vestibular nerve. 5. Internal nucleus. 6. Nucleus of Deiters. 7. Nucleus of Bechterew. 8. Inferior or descending root of acoustic. 9. Ascending cerebellar fibers. 10. Fibers going to raphé. 11. Fibers taking an oblique course. 12. Lemniscus. 13. Inferior sensory root of trigeminal. 14. Cerebrospinal fasciculus. 15. Raphé. 16. Fourth ventricle. 17. Inferior peduncle. 18. Origin of *striae medullares*. (Testut.)

ing tract extends downward as far as the upper end of the nucleus gracilis, and the decussation of the medial lemniscus. It is sometimes called the **inferior vestibular nucleus**. Many of its axons cross the midline and probably ascend with the medial lemniscus to the ventro-lateral region of the thalamus.

The **lateral vestibular nucleus** (*Deiters's nucleus*) is the continuation upward and lateralward of the principal nucleus, and in it terminate many of the ascending branches of the vestibular nerve. It consists of very large multipolar cells whose axons form an important part of the posterior longitudinal bundle of the same and the opposite side. The axons bifurcate as they enter the posterior longitudinal bundle, the ascending branches send terminals and collaterals to the motor nuclei of the abducens, trochlear and oculomotor nerves, and are concerned in coördinating the movements of the eyes with alterations in the position of the head; the descending branches pass down in the posterior longitudinal bundle into the anterior funiculus of the spinal cord as the vestibulospinal fasciculus (anterior marginal bundle) and are distributed to motor nuclei of the anterior column by terminals and collaterals. Other fibers are said to pass directly to the vestibulospinal fasciculus without passing into the posterior longitudinal bundle. The fibers which pass into the

vestibulospinal fasciculus are intimately concerned with equilibratory reflexes. Other axons from Deiters's nucleus are supposed to cross and ascend in the opposite medial lemniscus to the ventro-lateral nuclei of the thalamus; still other fibers pass into the cerebellum with the inferior peduncle and are distributed to the cortex of the vermis and the roof nuclei of the cerebellum; according to Cajal they merely pass through the nucleus fastigii on their way to the cortex of the vermis and the hemisphere.

The **superior vestibular nucleus** (*Bechterew's nucleus*) is the dorso-lateral part of the vestibular nucleus and receives collaterals and terminals from the ascending branches of the vestibular nerve. Its axons terminate in much the same manner as do those from the lateral nucleus.

The **Facial Nerve** (*VII cranial*) consists of somatic sensory, sympathetic afferent, taste, somatic motor and sympathetic efferent fibers. The afferent or sensory fibers arise from cells in the geniculate ganglion. This portion of the nerve is often described as the *nervus intermedius*.

(1) The **somatic sensory fibers** are few in number and convey sensory impulses from the middle ear region. Their existence has not been fully confirmed. Their central termination is likewise uncertain, it is possible that they join the spinal tract of the trigeminal as do the somatic sensory fibers of the vagus and glosso-pharyngeal.

(2) The **sympathetic afferent fibers** are likewise few in number and of unknown termination.

(3) **Taste fibers** convey impulses from the anterior two-thirds of the tongue via the chorda tympani. They are supposed to join the tractus solitarius and terminate in its nucleus. The central connections of this nucleus have already been considered.

(4) **Somatic motor fibers**, supplying the muscles derived from the hyoid arch, arise from the large multipolar cells of the nucleus of the facial nerve. This nucleus is serially homologous with the nucleus ambiguus and lateral part of the anterior column of the spinal cord. Voluntary impulses from the cerebral cortex are conveyed by terminals and collaterals of the pyramidal tract of the opposite side, indirectly, that is with the interpolation of a connecting neuron, to the facial nucleus. This nucleus undoubtedly receives many reflex fibers from various sources, *i. e.*, from the superior colliculus via the ventral longitudinal bundle (*tectospinal fasciculus*) for optic reflexes; from the inferior colliculus via the auditory reflex path; and indirectly from the terminal sensory nuclei of the brain-stem. Through the posterior longitudinal bundle it is intimately connected with other motor nuclei of the brain-stem.

(5) **Sympathetic efferent fibers** (*preganglionic fibers*) arise according to some authors from the small cells of the facial nucleus, or according to others from a special nucleus of cells scattered in the reticular formation, dorso-medial to the facial nucleus. This is sometimes called the **superior salivatory nucleus**. These preganglionic fibers are distributed partly via the chorda tympani and lingual nerves to the submaxillary ganglion, thence by postganglionic (vasodilator) fibers to the submaxillary and sublingual glands. Some of the preganglionic fibers pass to the sphenopalatine ganglion via the great superficial petrosal nerve.

The **Abducens Nerve** (*VI cranial*) contains somatic motor fibers only which supply the lateral rectus muscle of the eye. The fibers arise from the nucleus of the abducens nerve and pass ventrally through the formatio reticularis of the pons to emerge in the transverse groove between the caudal edge of the pons and the pyramid. The nucleus is serially homologous with the nuclei of the trochlear and oculomotor above and with the hypoglossal and medial part of the anterior column of the spinal cord below. It is situated close to the floor of the fourth ventricle, just above the level of the *striae medullares*. Voluntary impulses from the cerebral

cortex are conducted by the pyramidal tract fibers (**corticopontine fibers**). These fibers probably terminate in relation with association neurons which control the coördinated action of all the eye muscles. This association and coördination mechanism is interposed between the terminals and collaterals of the voluntary fibers and the neurons within the nuclei of origin of the motor fibers to the eye muscles. The fibers of the posterior longitudinal bundle are supposed to play an important role in the coördination of the movements of the eyeball. Whether it is concerned only with coördinations between the vestibular apparatus and the eye or with more extensive coördinations is unknown. Many fibers of the posterior longitudinal bundle have their origin in the terminal nuclei of the vestibular nerve and from the posterior longitudinal bundle many collaterals and terminals are given off to the abducent nucleus as well as to the trochlear and oculomotor nuclei. The abducens nucleus probably receives collaterals and terminals from the ventral longitudinal bundle (tectospinal fasciculus); fibers which have their origin in the superior colliculus, the primary visual center, and are concerned with visual reflexes. Others probably come from the reflex auditory center in the inferior colliculus and from other sensory nuclei of the brain-stem.

The **Trigeminal Nerve** (*V cranial*) contains somatic motor and somatic sensory fibers. The motor fibers arise in the motor nucleus of the trigeminal and pass ventro-laterally through the pons to supply the muscles of mastication. The sensory fibers arise from the unipolar cells of the semilunar ganglion; the peripheral branches of the T-shaped fibers are distributed to the face and anterior two-thirds of the head; the central fibers pass into the pons with the motor root and bifurcate into ascending and descending branches which terminate in the sensory nuclei of the trigeminal.

The **motor nucleus** of the trigeminal is situated in the upper part of the pons beneath the lateral angle of the fourth ventricle. It is serially homologous with the facial nucleus and the nucleus ambiguus (motor nucleus of the vagus and glossopharyngeal) which belong to the motor nuclei of the lateral somatic group. The axons arise from large pigmented multipolar cells. The motor nucleus receives reflex collaterals and terminals, (1) from the terminal nucleus of the trigeminal of the same and a few from the opposite side, via the central sensory tract (trigemino-thalamic tract); (2) from the mesencephalic root of the trigeminal; (3) from the posterior longitudinal bundle; (4) and probably from fibers in the *formatio reticularis*. It also receives collaterals and terminals from the opposite pyramidal tract (corticopontine fibers) for voluntary movements. There is probably a connecting or association neuron interposed between these fibers and the motor neurons.

The **terminal sensory nucleus** consists of an enlarged upper end, the **main sensory nucleus**, and a long more slender descending portion which passes down through the pons and medulla to become continuous with the dorsal part of the posterior column of the gray matter especially the *substantia gelatinosa* of the spinal cord. This descending portion consists mainly of *substantia gelatinosa* and is called the **nucleus of the spinal tract of the trigeminal nerve**.

The **main sensory nucleus** lies lateral to the motor nucleus beneath the superior peduncle. It receives the short ascending branches of the sensory root. The descending branches which form the **tractus spinalis**, pass down through the pons and medulla on the lateral side of the **nucleus of the tractus spinalis**, in which they end by collaterals and terminals, into the spinal cord on the level of the second cervical segment. It decreases rapidly in size as it descends. At first it is located between the emergent part of the facial nerve and the vestibular nerve, then between the nucleus of the facial nerve and the inferior peduncle. Lower down in the upper part of the medulla it lies beneath the inferior peduncle and is broken up into bundles by the olivocerebellar fibers and the roots of the ninth and tenth cranial nerves. Finally it comes to the surface of the medulla under the tubercle of

Rolando and continues in this position lateral to the fasciculus cuneatus as far as the upper part of the cervical region where it disappears.

The cells of the sensory nucleus are of large and medium size and send their axons into the *formatio reticularis* where they form a distinct bundle, the **central path of the trigeminal** (*trigeminothalamic tract*), which passes upward through the *formatio reticularis* and tegmentum to the ventro-lateral part of the thalamus. Most of the fibers cross to the trigeminothalamic tract of the opposite side. This tract lies dorsal to the medial fillet; approaches close to it in the tegmentum and terminates in a distinct part of the thalamus. From the thalamus impulses are conveyed to the somatic sensory area of the cortex by axons of cells in the thalamus through the internal capsule and corona radiata. Many collaterals are given off in the medulla and pass from the trigeminothalamic tract to the motor nuclei, especially to the nucleus ambiguus, the facial nucleus and the motor nucleus of the trigeminal.

The somatic sensory fibers of the vagus, the glossopharyngeal and the facial nerves probably end in the nucleus of the descending tract of the trigeminal and their cortical impulses are probably carried up in the central sensory path of the trigeminal.

The **mesencephalic root** (*descending root of the trigeminal*) arises from unipolar cells arranged in scattered groups in a column at the lateral edge of the central gray matter surrounding the upper end of the fourth ventricle and the cerebral aqueduct. They have usually been considered as motor fibers that join the motor root, but Johnston claims that they join the sensory root of the trigeminal, that they develop in the alar, not in the basal lamina, and that the pear-shaped unipolar cells are sensory in type.

The **Trochlear Nerve** (*IV cranial*) contains somatic motor fibers only. It supplies the superior oblique muscle of the eye. Its nucleus of origin, **trochlear nucleus**, is a small, oval mass situated in the ventral part of the central gray matter of the cerebral aqueduct at the level of the upper part of the inferior colliculus. The axons from the nucleus pass downward in the tegmentum toward the pons, but turn abruptly dorsalward before reaching it, and pass into the superior medullary velum, in which they cross horizontally, to decussate with the nerve of the opposite side, and emerges from the surface of the velum, immediately behind the inferior colliculus. The cells of the trochlear nucleus are large, irregular and yellowish in color. The nuclei of the two sides are separated by the raphé through which dendrites extend from one nucleus to the other. They receive many collaterals and terminals from the posterior longitudinal bundle which lies on the ventral side of the nucleus.

There are no branches from the fibers of the pyramidal tracts to these nuclei; the volitional pathway must be an indirect one, as is the case with other motor nuclei.

The **Oculomotor Nerve** (*III cranial*) contains somatic motor fibers to the Obliquus inferior, Rectus inferior, Rectus superior, Levator palpebræ superioris and Rectus medialis muscles and sympathetic efferent fibers (preganglionic fibers) to the ciliary ganglion. The postganglionic fibers connected with these supply the ciliary muscle and the sphincter of the iris. The axons arise from the nucleus of the oculomotor nerve and pass in bundles through the posterior longitudinal bundle, the tegmentum, the red nucleus and the medial margin of the substantia nigra in a series of curves and finally emerge from the oculomotor sulcus on the medial side of the cerebral peduncle.

The **oculomotor nucleus** lies in the gray substance of the floor of the cerebral aqueduct subjacent to the superior colliculus and extends in front of the aqueduct a short distance into the floor of the third ventricle. The inferior end is continuous with the trochlear nucleus. It is from 6 to 10 mm. in length. It is intimately

related to the posterior longitudinal bundle which lies against its ventro-lateral aspect and many of its cells lie among the fibers of the posterior longitudinal bundle. The nucleus of the oculomotor nerve contains several distinct groups of cells which differ in size and appearance from each other and are supposed to send their axons each to a separate muscle. Much uncertainty still exists as to which group supplies which muscle. There are seven of these groups or nuclei on either side of the midline and one medial nucleus. The cells of the anterior nuclei are smaller and are supposed to give off the sympathetic efferent axons. The majority of fibers arise from the nucleus of the same side some, however, cross from the opposite side and are supposed to supply the Rectus medialis muscle. Since oculomotor and abducens nuclei are intimately connected by the posterior longitudinal bundle this decussation of fibers to the Medial rectus may facilitate the conjugate movements of the eyes in which the Medial and Lateral recti are especially involved.

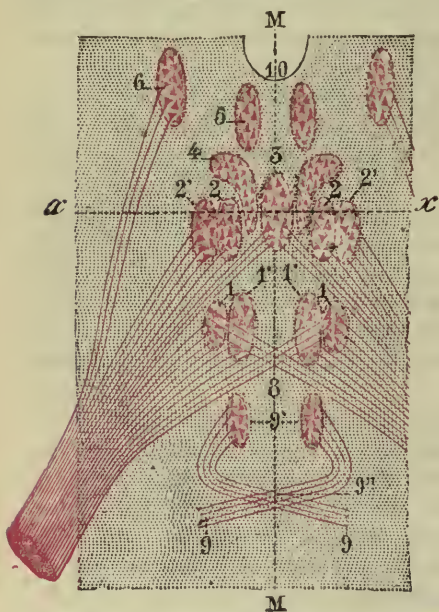


FIG. 762.—Figure showing the different groups of cells, which constitute, according to Perlia, the nucleus of origin of the oculomotor nerve. 1. Posterior dorsal nucleus. 1'. Posterior ventral nucleus. 2. Anterior dorsal nucleus. 2'. Anterior ventral nucleus. 3. Central nucleus. 4. Nucleus of Edinger and Westphal. 5. Antero-internal nucleus. 6. Antero-external nucleus. 8. Crossed fibers. 9. Trochlear nerve, with 9', its nucleus of origin, and 9'', its decussation. 10. Third ventricle. M, M. Median line. (Testut.)

Many collaterals and terminals are given off to the oculomotor nucleus from the posterior longitudinal bundle and thus connect it with the vestibular nucleus, the trochlear and abducens nuclei and probably with other cranial nuclei. Fibers from the visual reflex center in the superior colliculus pass to the nucleus. It is also connected with the cortex of the occipital lobe of the cerebrum by fibers which pass through the optic radiation. The pathway for voluntary motor impulses is probably similar to that for the abducent nerve.

The **Optic Nerve or Nerve of Sight (II cranial)** consists chiefly of coarse fibers which arise from the ganglionic layer of the retina. They constitute the third neuron in the series composing the visual path and are supposed to convey only visual impressions. A number of fine fibers also pass in the optic nerve from the retina to the primary centers and are supposed to be concerned in the pupillary reflexes. There are in addition a few fibers which pass from the brain to the retina; they are supposed to control chemical changes in the retina

and the movements of the pigment cells and cones. Each optic nerve has, according to Salzer, about 500,000 fibers.

In the optic chiasma the nerves from the medial half of each retina cross to enter the opposite optic tract, while the nerves from the lateral half of each retina pass into the optic tract of the same side. The crossed fibers tend to occupy the medial side of each optic nerve, but in the chiasma and in the optic tract they are more intermingled. The optic tract is attached to the tuber cinereum and lamina terminalis and also to the cerebral peduncle as it crosses obliquely over its under surface. These are not functional connections. A small band of fibers from the medial geniculate body joins the optic tract as the latter passes over it and crosses to the opposite tract and medial geniculate body in the posterior part of the chiasma. This is the commissure of Gudden and is probably connected with the auditory system.

Most of the fibers of the optic tract terminate in the lateral geniculate body, some pass through the superior brachium to the superior colliculus, and others

either pass over or through the lateral geniculate body to the pulvina of the thalamus. These end-stations are often called the **primary visual centers**.

The **lateral geniculate body** consists of medium-sized pigmented nerve cells arranged in several layers by the penetrating fibers of the optic tract. Their axons pass upward beneath the longer fibers of the optic tract, the tænia semicircularis, the caudate nucleus and the posterior horn of the lateral ventricle where they join the optic radiation of Gratiolet. They pass backward and medially to terminate in the visuo-sensory cortex in the immediate neighborhood of the calcarine fissure

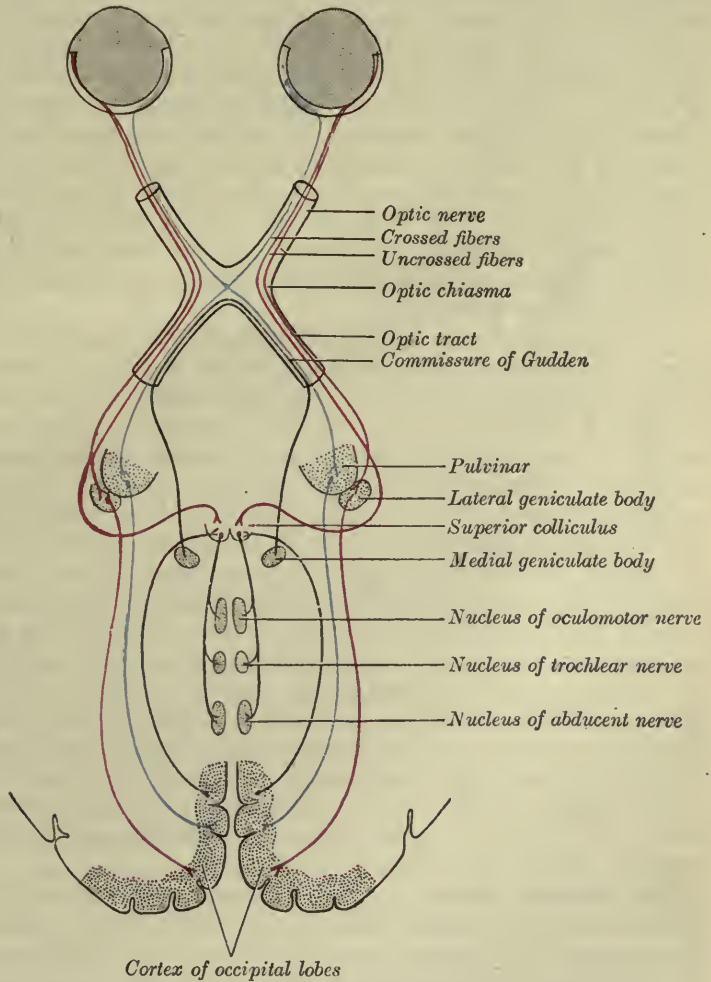


FIG. 763.—Scheme showing central connections of the optic nerves and optic tracts.

of the occipital lobe. This center is connected with the one in the opposite side by commissural fibers which course in the optic radiation and the splenium of the corpus callosum. Association fibers connect it with other regions of the cortex of the same side.

The region of the pulvina in which optic tract fibers terminate resembles in structure the lateral geniculate body. Its axons also have a similar course though in a somewhat more dorsal plane.

The **superior colliculus** receives fibers from the optic tract through the superior brachium. Some enter by the superficial white layer (**stratum zonale**), others appear to dip down into the gray cap (**stratum cinereum**) while others probably

decussate across the midline to the opposite colliculus. Other fibers from the superior brachium pass into the **stratum opticum** (upper gray-white layer). Some of these turn upward into the gray cap while others terminate among the cells of this layer. Since the superior colliculi appear to be the central organs concerned in the control of eye-muscle movements and eye-muscle reflexes we should expect to find them receiving fibers from other sensory paths. Many fibers pass to the superior colliculus from the medial fillet as the latter passes through the tegmentum bringing the superior colliculus into relation with the sensory fibers of the spinal cord. Fibers from the central sensory path of the trigeminal probably pass with these. Part of the ventral spinocerebellar tract (Gowers) is said to pass up through the reticular formation of the pons and mid-brain toward the superior colliculus and the thalamus. The superior colliculus is intimately connected with the central auditory path (the **lateral lemniscus**), as part of its fibers pass the inferior colliculus and terminate in the superior colliculus. They are probably concerned with reflex movements of the eyes depending on auditory stimuli. The superior colliculus is said to receive fibers from the stria medullaris thalamis of the opposite side which pass through the commissura habenulæ and turn back to the roof of the mid-brain, especially to the superior colliculus. By this path both the primary and cortical olfactory centers are brought into relation with the eye-muscle reflex apparatus.

The fibers which pass to the nuclei of the eye muscles arise from large cells in the stratum opticum and stratum lemnisci and pass around the ventral aspect of the central gray matter where most of them cross the midline in the fountain decussation of Meynert, and then turn downward to form the ventral longitudinal bundle. This bundle runs down partly through the red nucleus, in the formatio reticularis, ventral to the posterior longitudinal bundle of the mid-brain, pons and medulla oblongata into the ventral funiculus of the spinal cord where it is known as the **tectospinal fasciculus**. Some of the fibers are said to pass down with the rubrospinal tract in the lateral funiculus. Some fibers do not decussate but pass down in the ventral longitudinal bundle of the same side on which they arise unless possibly they come from the opposite colliculus over the aqueduct. From the ventral longitudinal bundle collaterals are given off to the nuclei of the eye muscles, the oculomotor, the trochlear and the abducens. Many collaterals pass to the red nucleus, and are probably concerned with the reflexes of the rubrospinal tract. The fibers of the tectospinal tract end by collaterals and terminals either directly or indirectly among the motor cells in the anterior column of the spinal cord.

The superior colliculus receives fibers from the visual sensory area of the occipital cortex; they pass in the optic radiation. Probably no fibers pass from the superior colliculus to the visual sensory cortex.

The **Olfactory Nerves** (*I cranial*) or **nerves of smell** arise from spindle-shaped bipolar cells in the surface epithelium of the olfactory region of the nasal cavity. The non-medullated axons pass upward in groups through numerous foramina in the cribriform plate to the olfactory bulb; here several fibers, each ending in a tuft of terminal filaments, come into relation with the brush-like end of a single dendrite from a mitral cell. This interlacing gives rise to the olfactory glomeruli of the bulb. The termination of several or many olfactory fibers in a single glomerulus where they form synapses with the dendrites of one or two mitral cells provides for the summation of stimuli in the mitral cells and accounts in part at least for the detection by the olfactory organs of very dilute solutions. Lateral arborizations of the dendrites of the mitral cells and the connection of neighboring glomeruli by the axons of small cells of the glomeruli and the return of impulses of the mitral cells by collaterals either directly or through the interpolation of granule cells to the dendrites of the mitral cells reinforce the discharge of the mitral cells along their axons. The axons turn abruptly backward in the deep fiber layer of the bulb to

form the olfactory tract. The olfactory tract is continued into the olfactory trigone, just in front of the anterior perforated substance. The axons of the mitral cells on reaching the olfactory trigone separate into three bundles, the **lateral olfactory stria**, the **medial olfactory stria** and the less marked **intermedial olfactory stria**.

The **lateral olfactory striæ** curve lateralward, a few of the fibers end in the olfactory trigone and the antero-lateral portion of the anterior perforated substance. Most of the fibers, however, pass into the uncus, the anterior end of the hippocampal gyrus, and there end in the complicated cortex of the hippocampal gyri. The lateral striæ more or less disappear as they cross the antero-lateral region of the anterior perforated substance.

The greater mass of the fibers of the olfactory tract pass into the lateral stria. Numerous collaterals are given into the plexiform layer of the subfrontal cortex, over which the striæ pass on their way to the uncus, where they intermingle with the apical dendrons of the medium-sized and small pyramidal cells of the pyramidal layer of this subfrontal or frontal olfactory cortex. The axons give rise to projection fibers which take an antero-posterior direction to the subthalamic region sending collaterals and terminal branches to the stria medullaris and others toward the thalamus. Some of the fibers extend farther back and are believed to reach the pons and medulla oblongata.

Most of the fibers of the lateral olfactory stria pass to the hippocampal region of the cortex, especially to the gyrus hippocampi, which may be regarded as the main ending place of the secondary olfactory path derived from axons of the mitral cells.

The fibers of the **medial olfactory striæ** terminate for the most part in the parolfactory area (*Broca's area*), a few end in the subcallosal gyrus and a few in the anterior perforated substance and the adjoining part of the septum pellucidum. Some of the fibers pass into the anterior commissure (**pars olfactoria**) to the olfactory tract of the opposite side where they end partly within the granular layer and partly in the neighborhood of the glomeruli of the olfactory bulb, thus connecting the bulbs of the two sides.

The **intermediate olfactory striæ** are as a rule scarcely visible, the fibers terminate in the anterior perforated substance, a few are said to continue to the uncus.

The trigonum olfactorium, anterior perforated substance and the adjoining part of the septum pellucidum are important primary olfactory centers, especially for olfactory reflexes; in these centers terminate many axons from the mitral cells of the olfactory bulb. In addition the gray substance of the olfactory tract and the gyrus subcallosus receive terminals of the mitral cells.

The pathways from these centers to lower centers in the brain-stem and spinal cord are only partially known. The most direct path, the **tractus olfactomesencephalicus** (*basal olfactory bundle of Wallenburg*), is supposed to arise from cells in the gray substance of the olfactory tract, the olfactory trigone, the anterior perforated substance and the adjoining part of the septum pellucidum. The fibers are said to pass direct to the tuber cinereum, to the corpus mammillare, to the brain-stem and the spinal cord. The fibers which enter the mammillary body probably come into relation with cells whose axons give rise to the **fasciculus mammillo-tegmentalis** (*mammillo-tegmental bundle of Gudden*) which is supposed to end in the gray substance of the tegmentum and of the aqueduct; some of its fibers are said to join the posterior longitudinal bundle and others to extend as far as the reticular formation of the pons.

Some of the fibers of the medial olfactory stria came into relation with cells in the parolfactory area of Broca and in the anterior perforated substance, whose axons course in the medullary stria of the thalamus. As the axons pass through the lower part of the septum pellucidum they are joined by other fibers whose cells

receive impulses from the mitral cells. These fibers of the medullary stria end for the most part in the habenular nucleus of the same side, some, however, cross in the habenular commissure (dorsal part of the posterior commissure) to the habenular nucleus of the opposite side. A few fibers of the medullary stria are said to pass by the habenular nucleus to the roof of the mid-brain, especially the superior colliculus, while a few others come into relation with the posterior longitudinal bundle and association tracts of the mesencephalon.

The ganglion of the habenulæ located in the trigonum habenulæ just in front of the superior colliculus contains a mesial nucleus with small cells and a lateral nucleus with larger cells. The axons of these cells are grouped together in a bundle, the **fasciculus retroflexus of Meynert**, which passes ventrally medial to the red nucleus and terminates in a small medial ganglion in the substantia perforata posterior, immediately in front of the pons, called the **interpeduncular ganglion**.

The **interpeduncular ganglion** has rather large nerve cells whose axons curve backward and downward as the **tegmental bundle of Gudden**, to end partly in the dorsal tegmental nucleus and surrounding gray substance where they come into relation with association neurons and the dorsal longitudinal bundle of Schütz.

The majority of the axons that arise from the mitral cells of the olfactory bulb and course in the olfactory tract course in the lateral olfactory stria to the uncus and hippocampal gyrus, and terminate in the cortex. Other fibers probably pass to the uncus and hippocampal gyrus from the primary olfactory centers in the trigonum and anterior perforated substance. The gyrus hippocampus is continued through the isthmus into the gyrus cinguli which passes over the corpus callosum to the area parolfactoria. The cortical portions of these gyri are connected together by a thick association bundle, the **cingulum**, that lies buried in the depth of the gyrus cinguli extending forward to the parolfactory area and backward into the hippocampal region. The axons from the gyrus cinguli pass into the cingulum, many of them bifurcate, the anterior branches together with the axons which run in that direction are traceable as far forward as the anterior part of the septum pellucidum and the anterior end of the corpus striatum, where some of them are incorporated with projection fibers passing toward the internal capsule. The branches and axons which pass backward terminate partly in the hippocampus, the dentate gyrus and hippocampal gyrus. Shorter association fibers connect various sections of the gyrus fornicatus (cingulate gyrus, isthmus, and hippocampal gyrus) and these with other regions of the cortex. These gyri constitute the cortical center for smell.

The **dentate gyrus** which may be considered as a modified part of the hippocampus is partially separated from the gyrus hippocampus by the hippocampal fissure and from the fimbria by the fimbrio-dentate sulcus; it is intimately connected with the hippocampal gyrus and the hippocampus. When followed backward the dentate gyrus separates from the fimbria at the splenium, loses its incisions and knobs, and as the fasciola cinerea passes over the splenium onto the dorsal surface of the corpus callosum and spreads out into a thin layer of gray substance known as the **indusium**, which can be traced forward around the genu of the corpus callosum into the gyrus subcallosus. The white matter of the indusium known as the **medial longitudinal striæ** (*nerves of Lancisi*) and the **lateral longitudinal striæ**, are related to the indusium somewhat as the cingulum is to the gyrus cinguli. Axons from the indusium pass into the longitudinal striæ, some running forward and others backward while some after entering the medial longitudinal stria, pierce the corpus callosum to join the fornix. Some of the fibers which pass forward extend around the front of the corpus callosum and the anterior commissure, then curve downward, according to Cajal, to enter the corpus striatum where they join the olfactory projection-path. Other fibers are said to arise in the parolfactory area, the **gyrus subcallosus** and the **anterior perforated substance** (*diagonal band of*

Broca) and course backward in the longitudinal striæ to the dentate gyrus and the hippocampal region. The indusium is usually considered as a rudimentary part of the rhinencephalon.

The **olfactory projection fibers** which arise from the pyramid cells of the uncus and hippocampus and from the polymorphic cells of the dentate gyrus form a dense stratum on the ventricular surface, especially on the hippocampus, called the **alveus**. These fibers pass over into the fimbria and are continued into the **fornix**. About one-fourth of all the fibers of the fimbria are large projection fibers, the other three-fourths consist of fine commissural fibers which pass from the hippocampus of one side through the fimbria and **hippocampal commissure** (*ventral psalterium or lyre*), to the fimbria and hippocampus of the opposite side where they penetrate the pyramidal layer and terminate in the stratum radiatum. The fibers which course in the fornix pass forward and downward into the corpora mammillare where numerous collaterals are given off and a few terminate. Most of the fibers in the fornix, however, pass through the corpora, cross the middle line and turn downward in the reticular formation in which they are said to be traceable as far as the pons and possibly farther. As the fornix passes beneath the corpus callosum it receives fibers from the longitudinal striæ of the indusium and from the cingulum; these are the perforating fibers of the fornix which pass through the corpus callosum and course in the fornix toward the mammillary body. As the fornix passes the anterior end of the thalamus a few fibers are given off to the stria medullaris of the thalamus and turn back in the stria to the habenular ganglion of the same and the opposite side, having probably the same relation that the reflex fibers have which arise from the primary centers and course in the stria medullaris of the thalamus. Aside from the fibers of the fornix which pass through the mammillary body to decussate and descend (as the mammillo-mesencephalic fasciculus), many fibers are said to pass into the **bundle of Vicq d'Azyr**, and one bundle of fibers is said to pass from the fornix to the tuber cinereum.

The mammillary bodies receive collaterals and terminals then from the cortical centers via the fornix and probably other collaterals and terminals are received directly from the primary centers through the tractus olfactomesencephalicus. According to Cajal fibers also reach the mammillary body through the peduncle of the corpus mammillare from the arcuate fibers of the tegmentum and from the main fillet. The fornix probably brings the cortical centers into relation with the reflex path that runs from the primary centers to the mammillary body and the tuber cinereum.

The **bundle of Vicq d'Azyr** (*mammillo-thalamic fasciculus*) arises from cells in both the medial and lateral nuclei of the mammillary body and by fibers that are directly continued from the fornix. There axons divide within the gray matter; the coarser branches pass into the anterior nucleus of the thalamus as the bundle of Vicq d'Azyr, the finer branches pass downward as the mammillo-tegmental bundle of Gudden. The bundle of Vicq d'Azyr spreads out fan-like as it terminates in the anterior or dorsal nucleus of the thalamus. A few of the fibers pass through the dorsal nucleus to the angular nucleus of the thalamus. The axons from these nuclei are supposed to form part of the thalamocortical system.

The mammillo-tegmental bundle has already been considered under the olfactory reflex paths.

The **amygdaloid nucleus** and the **tænia semicircularis** (*stria terminalis*) probably belong to the central olfactory apparatus. The tænia semicircularis extends from the region of the anterior perforated substance to the nucleus amygdalæ. Its anterior connections are not clearly understood. Fibers are said to arise from cells in the anterior perforated substance; some of the fibers pass in front of the anterior commissure, others join the fornix for a short distance as they pass behind the anterior commissure. The two strands ultimately join to form the tænia and pass

backward in the groove between the caudate nucleus and the thalamus to the amygdaloid nucleus. Other fibers are said to pass in the opposite direction from the amygdaloid nucleus to the thalamus.

PATHWAYS FROM THE BRAIN TO THE SPINAL CORD.

The descending fasciculi which convey impulses from the higher centers to the spinal cord and located in the lateral and ventral funiculi.

The **Motor Tract** (Fig. 764), conveying voluntary impulses, arises from the pyramid cells situated in the motor area of the cortex, the anterior central and the posterior portions of the frontal gyri and the paracentral lobule. The fibers are at first somewhat widely diffused, but as they descend through the corona radiata they gradually approach each other, and pass between the lentiform nucleus and thalamus, in the genu and anterior two-thirds of the occipital part of the internal capsule; those in the genu are named the **geniculate fibers**, while the remainder constitute the **cerebrospinal fibers**; proceeding downward they enter the middle three-fifths of the base of the cerebral peduncle. The geniculate fibers cross the middle line, and end by arborizing around the cells of the motor nuclei of the cranial nerves. The cerebrospinal fibers are continued downward into the pyramids of the medulla oblongata, and the transit of the fibers from the medulla oblongata is effected by two paths. The fibers nearest to the anterior median fissure cross the middle line, forming the **decussation of the pyramids**, and descend in the opposite side of the medulla spinalis, as the **lateral cerebrospinal fasciculus** (*crossed pyramidal tract*). Throughout the length of the medulla spinalis fibers from this column pass into the gray substance, to terminate either directly or indirectly around the motor cells of the anterior column. The more laterally placed portion of the tract does not decussate in the medulla oblongata, but descends as the **anterior cerebrospinal fasciculus** (*direct pyramidal tract*); these fibers, however, end in the anterior gray column of the opposite side of the medulla spinalis by passing across in the anterior white commissure. There is considerable variation in the extent to which decussation takes place in the medulla oblongata; about two-thirds or three-fourths of the fibers usually decussate in the medulla oblongata and the remainder in the medulla spinalis.

The axons of the motor cells in the anterior column pass out as the fibers of the anterior roots of the spinal nerves, along which the impulses are conducted to the muscles of the trunk and limbs.

From this it will be seen that all the fibers of the motor tract pass to the nuclei of the motor nerves on the opposite side of the brain or medulla spinalis, a fact which explains why a lesion involving the motor area of one side causes paralysis of the muscles of the opposite side of the body. Further, it will be seen that there is a break in the continuity of the motor chain; in the case of the cranial nerves this break occurs in the nuclei of these nerves; and in the case of the spinal nerves, in the anterior gray column of the medulla spinalis. For clinical purposes it is convenient to emphasize this break and divide the motor tract into two portions: (1) a series of **upper motor neurons** which comprises the motor cells in the cortex and their descending fibers down to the nuclei of the motor nerves; (2) a series of **lower motor neurons** which includes the cells of the nuclei of the motor cerebral nerves or the cells of the anterior columns of the medulla spinalis and their axis-cylinder processes to the periphery.

The **rubrospinal fasciculus** arises from the large cells of the red nucleus. The fibers cross the raphe of the mid-brain in the decussation of Forel and descend in the formatio reticularis of the pons and medulla dorsal to the medial lemniscus and as they pass into the spinal cord come to lie in a position ventral to the crossed pyramidal tracts in the lateral funiculus. The rubrospinal fibers end either directly or

indirectly by terminals and collaterals about the motor cells in the anterior column on the side opposite from their origin in the red nucleus. A few are said to pass down on the same side. Since the red nucleus is intimately related to the cerebellum by terminals and collaterals of the superior peduncle which arises in the dentate nucleus of the cerebellum, the rubrospinal fasciculus is supposed to be concerned

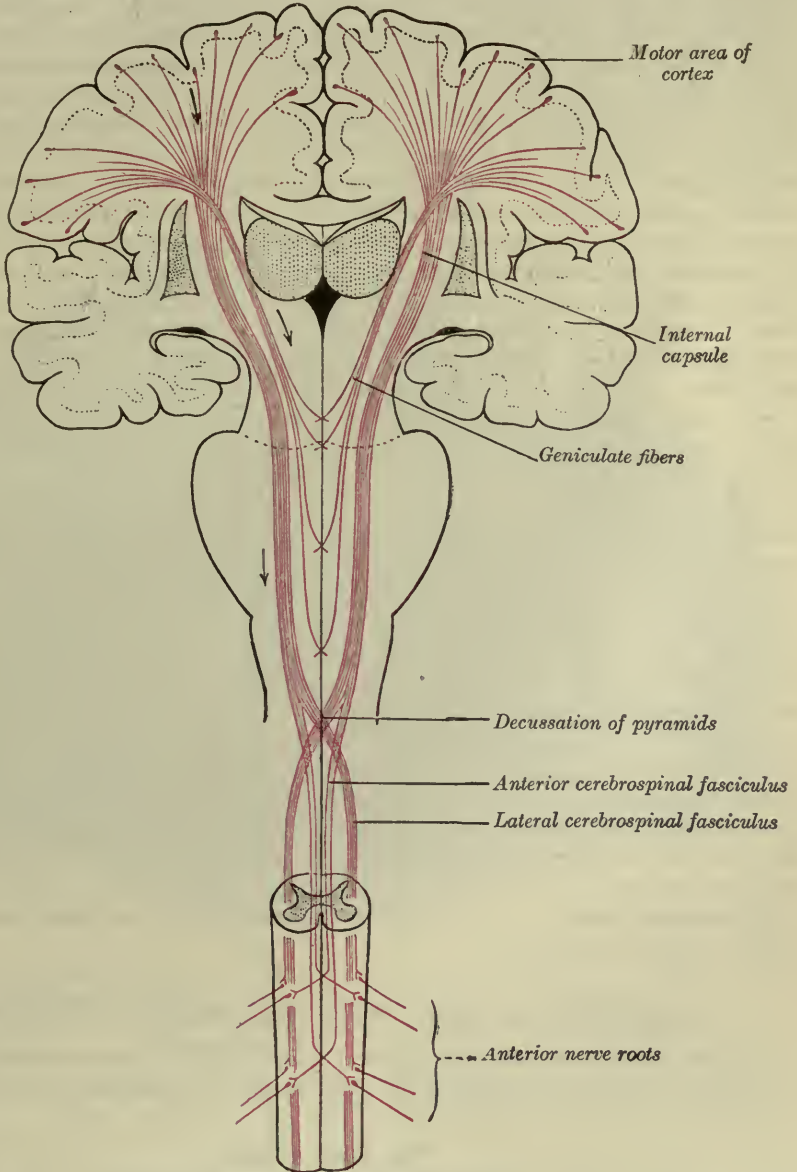


FIG. 764.—The motor tract. (Modified from Poirier.)

with cerebellar reflexes, complex motor coördinations necessary in locomotion and equilibrium. The afferent paths concerned in these reflexes have already been partly considered, namely, the dorsal and ventral spinocerebellar fasciculi, and probably some of the fibers of the posterior funiculi which reach the cerebellum by the inferior peduncle.

The **tectospinal fasciculus** arises from the superior colliculus of the roof (tectum)

of the mid-brain. The axons come from large cells in the stratum opticum and stratum lemnisci and sweep ventrally around the central gray matter of the aqueduct, cross the raphé in the fountain decussation of Meynert and turn downward in the tegmentum in the ventral longitudinal bundle. Some of the fibers do not cross in the raphé but pass down on the same side; it is uncertain whether they come from the superior colliculus of the same side or arch over the aqueduct from the colliculus of the opposite side. The tectospinal fasciculus which comprises the major part of the ventral longitudinal bundle passes down through the tegmentum and reticular formation of the pons and medulla oblongata ventral to the medial longitudinal bundle. In the medulla the two bundles are more or less intermingled and the tectospinal portion is continued into the antero-lateral funiculus of the spinal cord ventral to the rubrospinal fasciculus with which some of its fibers are intermingled. Some of the fibers of the tectospinal fasciculus pass through the red nucleus giving off collaterals to it, others are given off to the motor nuclei of the cranial nerves and in the spinal cord they terminate either directly or indirectly by terminals and collaterals among the nuclei of the anterior column. Since the superior colliculus is an important optic reflex center, this tract is probably concerned in optic reflexes; and possibly also with auditory reflexes since some of the fibers of the central auditory path, the lateral lemniscus, terminate in the superior colliculus.

The **vestibulospinal fasciculus** (*part of the anterior marginal fasciculus* or *Loewenthal's tract*) situated chiefly in the marginal part of the anterior funiculus is mainly derived from the cells of the terminal nuclei of the vestibular nerve, probably Deiters's and Bechterew's, and some of its fibers are supposed to come from the nucleus fastigius (roof nucleus of the cerebellum). The latter nucleus is intimately connected with Dieters's and Bechterew's nuclei. The vestibulospinal fasciculus is concerned with equilibratory reflexes. Its terminals and collaterals end about the motor cells in the anterior column. It extends to the sacral region of the cord. Its fibers are intermingled with the ascending spinothalamic fasciculus, with the anterior proper fasciculus and laterally with the tectospinal fasciculus. Its fibers are supposed to be both crossed and uncrossed. In the brain-stem it is associated with the dorsal longitudinal bundle.

The **pontospinal fasciculus** (*Bechterew*) arises from the cells in the reticular formation of the pons from the same and the opposite side and is associated in the brain-stem with the ventral longitudinal bundle. In the cord it is intermingled with the fibers of the vestibulospinal fasciculus in the anterior funiculus. Not much is known about this tract.

There are probably other descending fasciculi such as the thalamospinal but not much is known about them.

MENINGES OF THE BRAIN AND MEDULLA SPINALIS.

The brain and medulla spinalis are enclosed within three membranes. These are named from without inward: the **dura mater**, the **arachnoid**, and the **pia mater**.

The Dura Mater.

The **dura mater** is a thick and dense inelastic membrane. The portion which encloses the brain differs in several essential particulars from that which surrounds the medulla spinalis, and therefore it is necessary to describe them separately; but at the same time it must be distinctly understood that the two form one complete membrane, and are continuous with each other at the foramen magnum.

The **Cranial Dura Mater** (*dura mater encephali*; *dura of the brain*) lines the interior of the skull, and serves the twofold purpose of an internal periosteum

to the bones, and a membrane for the protection of the brain. It is composed of two layers, an inner or meningeal and an outer or endosteal, closely connected together, except in certain situations, where, as already described (page 654), they separate to form sinuses for the passage of venous blood. Its outer surface is rough and fibrillated, and adheres closely to the inner surfaces of the bones, the adhesions being most marked opposite the sutures and at the base of the skull its inner surface is smooth and lined by a layer of endothelium. It sends inward four processes which divide the cavity of the skull into a series of freely communicating compartments, for the lodgement and protection of the different parts of the brain; and it is prolonged to the outer surface of the skull, through the various foramina which exist at the base, and thus becomes continuous with the pericranium; its fibrous layer forms sheaths for the nerves which pass through these apertures. Around the margin of the foramen magnum it is closely adherent to the bone, and is continuous with the spinal dura mater.

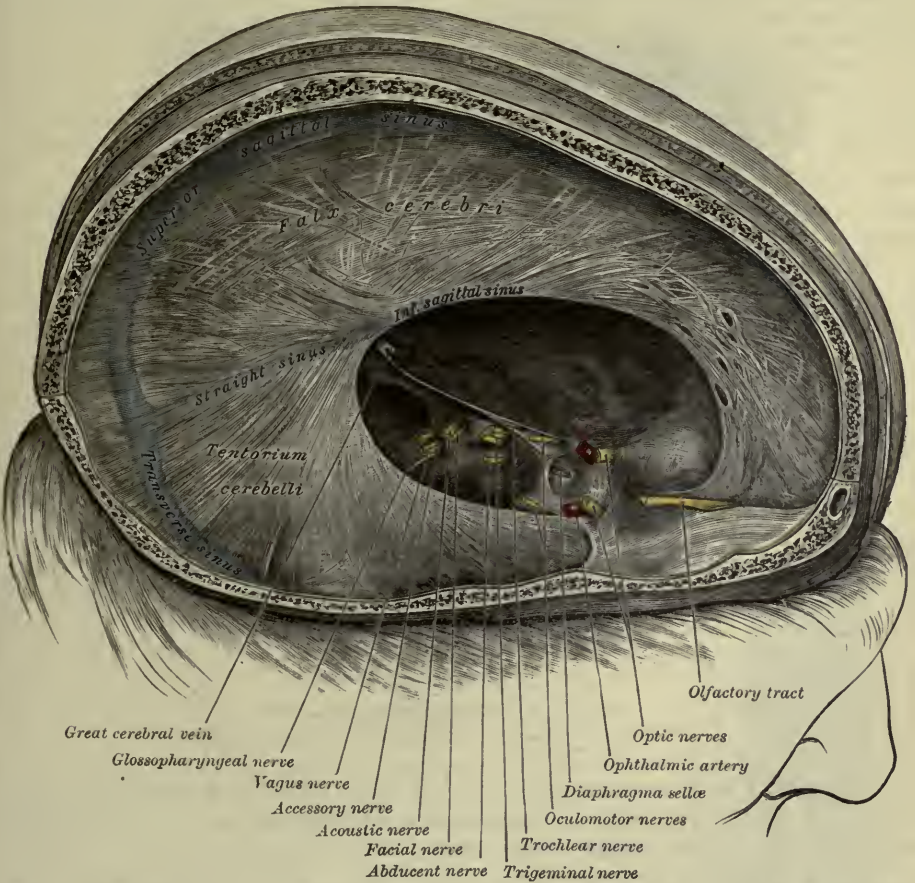


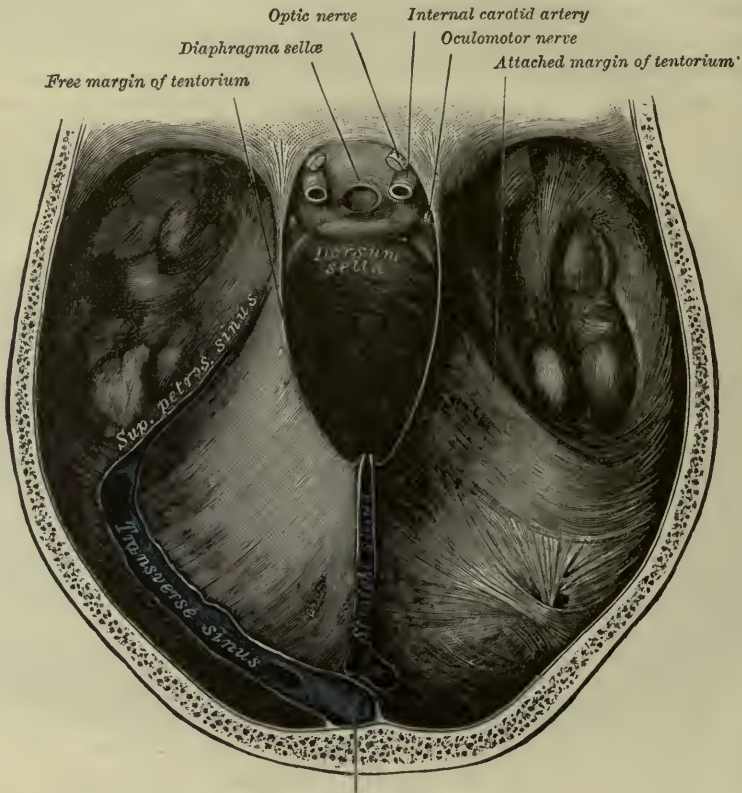
FIG. 765.—Dura mater and its processes exposed by removing part of the right half of the skull and the brain.

Processes.—The processes of the cranial dura mater, which projects into the cavity of the skull, are formed by reduplications of the inner or meningeal layer of the membrane, and are four in number: the **falx cerebri**, the **tentorium cerebelli**, the **falx cerebelli**, and the **diaphragma sellæ**.

The **falx cerebri** (Fig. 765), so named from its sickle-like form, is a strong, arched process which descends vertically in the longitudinal fissure between the cerebral hemispheres. It is narrow in front, where it is attached to the crista galli of the ethmoid; and broad behind, where it is connected with the upper surface of the

tentorium cerebelli. Its upper margin is convex, and attached to the inner surface of the skull in the middle line, as far back as the internal occipital protuberance; it contains the superior sagittal sinus. Its lower margin is free and concave, and contains the inferior sagittal sinus.

The **tentorium cerebelli** (Fig. 766) is an arched lamina, elevated in the middle, and inclining downward toward the circumference. It covers the superior surface of the cerebellum, and supports the occipital lobes of the brain. Its anterior border is free and concave, and bounds a large oval opening, the *incisura tentorii*, for the transmission of the cerebral peduncles. It is attached, behind, by its convex border, to the transverse ridges upon the inner surface of the occipital bone, and there encloses the transverse sinuses; in front, to the superior angle of the petrous part



End of superior sagittal sinus
FIG. 766.—Tentorium cerebelli seen from above.

of the temporal bone on either side, enclosing the superior petrosal sinuses. At the apex of the petrous part of the temporal bone the free and attached borders meet, and, crossing one another, are continued forward to be fixed to the anterior and posterior clinoid processes respectively. To the middle line of its upper surface the posterior border of the falx cerebri is attached, the straight sinus being placed at their line of junction.

The **falx cerebelli** is a small triangular process of dura mater, received into the posterior cerebellar notch. Its base is attached, above, to the under and back part of the tentorium; its posterior margin, to the lower division of the vertical crest on the inner surface of the occipital bone. As it descends, it sometimes divides into two smaller folds, which are lost on the sides of the foramen magnum.

The **diaphragma sellæ** is a small circular horizontal fold, which roofs in the sella turcica and almost completely covers the hypophysis; a small central opening transmits the infundibulum.

Structure.—The cranial dura mater consists of white fibrous tissue and elastic fibers arranged in flattened laminae which are imperfectly separated by lacunar spaces and bloodvessels into two layers, **endosteal** and **meningeal**. The **endosteal layer** is the internal periosteum for the cranial bones, and contains the bloodvessels for their supply. At the margin of the foramen magnum it is continuous with the periosteum lining the vertebral canal. The **meningeal or supporting layer** is lined on its inner surface by a layer of nucleated flattened mesothelium, similar to that found on serous membranes.

The **arteries** of the dura mater are very numerous. Those in the anterior fossa are the anterior meningeal branches of the anterior and posterior ethmoidal and internal carotid, and a branch from the middle meningeal. Those in the middle fossa are the middle and accessory meningeal of the internal maxillary; a branch from the ascending pharyngeal, which enters the skull through the foramen lacerum; branches from the internal carotid, and a recurrent branch from the lacrimal. Those in the posterior fossa are meningeal branches from the occipital, one entering the skull through the jugular foramen, and another through the mastoid foramen; the posterior meningeal from the vertebral; occasional meningeal branches from the ascending pharyngeal, entering the skull through the jugular foramen and hypoglossal canal; and a branch from the middle meningeal.

The **veins** returning the blood from the cranial dura mater anastomose with the diploic veins and end in the various sinuses. Many of the meningeal veins do not open directly into the sinuses, but indirectly through a series of ampullae, termed **venous lacunae**. These are found on either side of the superior sagittal sinus, especially near its middle portion, and are often invaginated by arachnoid granulations; they also exist near the transverse and straight sinuses. They communicate with the underlying cerebral veins, and also with the diploic and emissary veins.

The **nerves** of the cranial dura mater are filaments from the semilunar ganglion, from the ophthalmic, maxillary, mandibular, vagus, and hypoglossal nerves, and from the sympathetic.

The **Spinal Dura Mater** (*dura mater spinalis; spinal dura*) (Fig. 767) forms a loose sheath around the medulla spinalis, and represents only the inner or meningeal layer of the cranial dura mater; the outer or endosteal layer ceases at the foramen magnum, its place being taken by the periosteum lining the vertebral canal. The spinal dura mater is separated from the arachnoid by a potential cavity, the **subdural cavity**; the two membranes are, in fact, in contact with each other, except where they are separated by a minute quantity of fluid, which serves to moisten the apposed surfaces. It is separated from the wall of the vertebral canal by a space, the **epidural space**, which contains a quantity of loose areolar tissue and a plexus of veins; the situation of these veins between the dura mater and the periosteum of the vertebræ corresponds therefore to that of the cranial sinuses between the meningeal and endosteal layers of the cranial dura mater. The spinal dura mater is attached to the circumference of the foramen magnum, and to the second and third cervical vertebræ; it is also connected to the posterior longitudinal ligament, especially near the lower end of the vertebral canal, by fibrous slips. The subdural cavity ends at the lower border of the second sacral vertebra; below this level the dura mater closely invests the filum terminale and descends to the back of the coccyx, where it blends with the periosteum. The sheath of dura mater is much larger than is necessary for the accommodation of its contents, and its size is greater in the cervical and lumbar regions than in the thoracic. On each side may be seen the double openings which transmit the two roots of the corresponding spinal nerve, the dura mater being continued in the form of tubular prolongations on them as they pass through the intervertebral foramina. These prolongations are short in the upper part of the vertebral column, but gradually become longer below, forming a number of tubes of fibrous membrane, which enclose the lower spinal nerves and are contained in the vertebral canal.

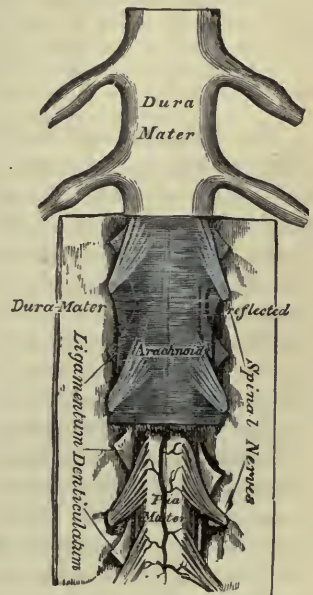


FIG. 767.—The medulla spinalis and its membranes.

Structure.—The spinal dura mater resembles in structure the meningeal or supporting layer of the cranial dura mater, consisting of white fibrous and elastic tissue arranged in bands or lamellæ which, for the most part, are parallel with one another and have a longitudinal arrangement. Its internal surface is smooth and covered by a layer of mesothelium. It is sparingly supplied with bloodvessels, and a few nerves have been traced into it.

The Arachnoid.

The arachnoid is a delicate membrane enveloping the brain and medulla spinalis and lying between the pia mater internally and the dura mater externally; it is separated from the pia mater by the subarachnoid cavity, which is filled with cerebrospinal fluid.

The **Cranial Part** (*arachnoidea encephali*) of the arachnoid invests the brain loosely, and does not dip into the sulci between the gyri, nor into the fissures, with the exception of the longitudinal. On the upper surface of the brain the arachnoid is thin and transparent; at the base it is thicker, and slightly opaque toward the central part, where it extends across between the two temporal lobes in front of the pons, so as to leave a considerable interval between it and the brain.

The **Spinal Part** (*arachnoidea spinalis*) of the arachnoid is a thin, delicate, tubular membrane loosely investing the medulla spinalis. *Above*, it is continuous with the cranial arachnoid; *below*, it widens out and invests the cauda equina and the nerves proceeding from it. It is separated from the dura mater by the **subdural space**, but here and there this space is traversed by isolated connective-tissue trabeculæ, which are most numerous on the posterior surface of the medulla spinalis.

The arachnoid surrounds the cranial and spinal nerves, and encloses them in loose sheaths as far as their points of exit from the skull and vertebral canal.

Structure.—The arachnoid consists of bundles of white fibrous and elastic tissue intimately blended together. Its outer surface is covered with a layer of low cuboidal mesothelium. The inner surface and the trabeculæ are likewise covered by a somewhat low type of cuboidal mesothelium which in places are flattened to a pavement type. Vessels of considerable size, but few in number, and, according to Bochdalek, a rich plexus of nerves derived from the motor root of the trigeminal, the facial, and the accessory nerves, are found in the arachnoid.

The **Subarachnoid Cavity** (*cavum subarachnoideale*; *subarachnoid space*) is the interval between the arachnoid and pia mater. It is occupied by a spongy tissue consisting of trabeculæ of delicate connective tissue, and intercommunicating channels in which the subarachnoid fluid is contained. This cavity is small on the surface of the hemispheres of the brain; on the summit of each gyrus the pia mater and the arachnoid are in close contact; but in the sulci between the gyri, triangular spaces are left, in which the subarachnoid trabecular tissue is found, for the pia mater dips into the sulci, whereas the arachnoid bridges across them from gyrus to gyrus. At certain parts of the base of the brain, the arachnoid is separated from the pia mater by wide intervals, which communicate freely with each other and are named **subarachnoid cisternæ**; in these the subarachnoid tissue is less abundant.

Subarachnoid Cisternæ (*cisternæ subarachnoidales*) (Fig. 768).—The **cisterna cerebellomedullaris** (*cisterna magna*) is triangular on sagittal section, and results from the arachnoid bridging over the interval between the medulla oblongata and the under surfaces of the hemispheres of the cerebellum; it is continuous with the subarachnoid cavity of the medulla spinalis at the level of the foramen magnum. The **cisterna pontis** is a considerable space on the ventral aspect of the pons. It contains the basilar artery, and is continuous behind with the subarachnoid cavity of the medulla spinalis, and with the cisterna cerebellomedullaris; and in front of the pons with the cisterna interpeduncularis. The **cisterna interpeduncularis** (*cisterna basalis*) is a wide cavity where the arachnoid extends across between the two temporal lobes. It encloses the cerebral peduncles and the structures contained in the interpeduncular fossa, and contains the arterial circle of Willis.

In front, the cisterna interpeduncularis extends forward across the optic chiasma, forming the **cisterna chiasmatis**, and on to the upper surface of the corpus callosum, for the arachnoid stretches across from one cerebral hemisphere to the other immediately beneath the free border of the falx cerebri, and thus leaves a space in which the anterior cerebral arteries are contained. The **cisterna fossæ cerebri lateralis** is formed in front of either temporal lobe by the arachnoid bridging across the lateral fissure. This cavity contains the middle cerebral artery. The **cisterna venæ magnæ cerebri** occupies the interval between the splenium of the corpus callosum and the superior surface of the cerebellum; it extends between the layers of the tela chorioidea of the third ventricle and contains the great cerebral vein.

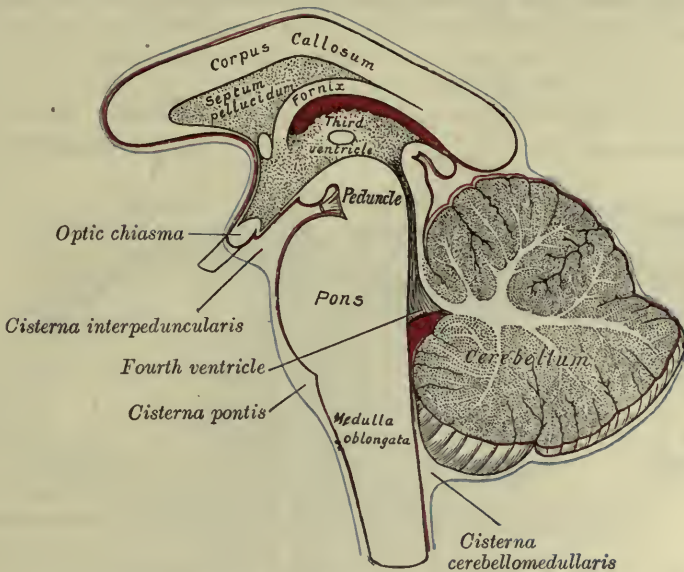


FIG. 768.—Diagram showing the positions of the three principal subarachnoid cisternæ.

The subarachnoid cavity communicates with the general ventricular cavity of the brain by three openings; one, the **foramen of Majendie**, is in the middle line at the inferior part of the roof of the fourth ventricle; the other two are at the extremities of the lateral recesses of that ventricle, behind the upper roots of the glossopharyngeal nerves and are known as the **foramina of Luschka**. It is still somewhat uncertain whether these foramina are actual openings or merely modified areas of the inferior velum which permit the passage of the cerebrospinal fluid from the ventricle into the subarachnoid spaces as through a permeable membrane.

The spinal part of the subarachnoid cavity is a very wide interval, and is the largest at the lower part of the vertebral canal, where the arachnoid encloses the nerves which form the cauda equina. Above, it is continuous with the cranial subarachnoid cavity; below, it ends at the level of the lower border of the second sacral vertebra. It is partially divided by a longitudinal septum, the **subarachnoid septum**, which connects the arachnoid with the pia mater opposite the posterior median sulcus of the medulla spinalis, and forms a partition, incomplete and cribriform above, but more perfect in the thoracic region. The spinal subarachnoid cavity is further subdivided by the **ligamentum denticulatum**, which will be described with the pia mater.

The cerebrospinal fluid is a clear limpid fluid, having a saltish taste, and a slightly alkaline reaction. According to Lassaigne, it consists of 98.5 parts of water, the remaining 1.5 per cent. being solid matters, animal and saline. It varies in quantity, being most abundant in old persons, and is quickly secreted.

The **Arachnoid Villi** (*granulationes arachnoideales*; *glandulæ Pacchioni*; *Pacchionian bodies*) (Fig. 769) are small, fleshy-looking elevations, usually collected into clusters of variable size, which are present upon the outer surface of the dura mater, in the vicinity of the superior sagittal sinus, and in some other situations. Upon laying open the sagittal sinus and the venous lacunæ on either side of it villi will be found protruding into its interior. They are not seen in infancy, and very rarely until the third year. They are usually found after the seventh year; and from this period they increase in number and size as age advances. They are not glandular in structure, but are enlarged normal villi of the arachnoid. As they grow they push the thinned dura mater before them, and cause absorption of the bone from pressure, and so produce the pits or depressions on the inner wall of the calvarium.

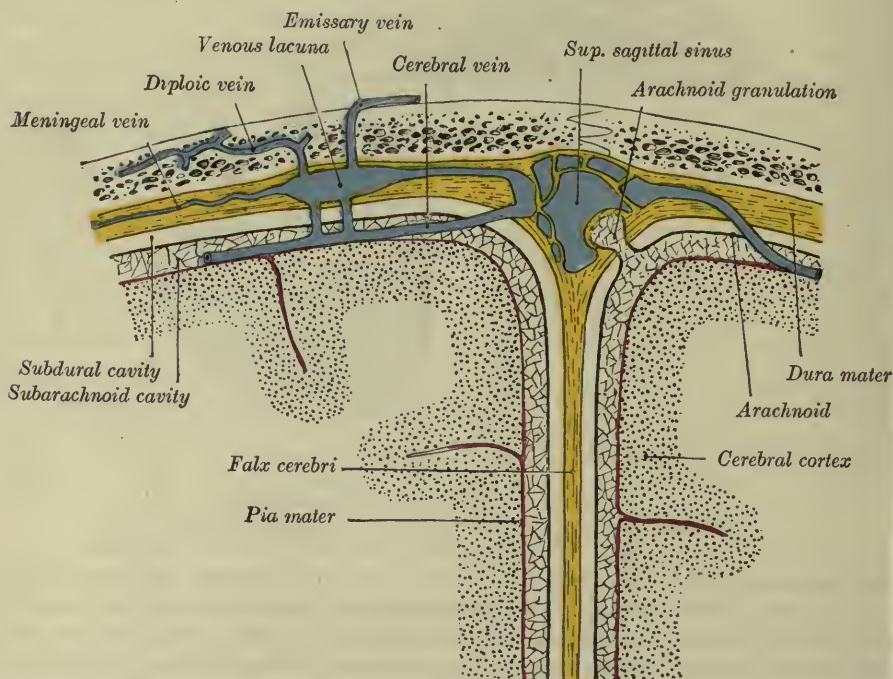


FIG. 769.—Diagrammatic representation of a section across the top of the skull, showing the membranes of the brain, etc. (Modified from Testut.)

Structure.—An arachnoidal villus represents an invasion of the dura by the arachnoid membrane, the latter penetrates the dura in such a manner that the arachnoid mesothelial cells come to lie directly beneath the vascular endothelium of the great dural sinuses. It consists of the following parts: (1) In the interior is a core of subarachnoid tissue, continuous with the mesh-work of the general subarachnoid tissue through a narrow pedicle, by which the villus is attached to the arachnoid. (2) Around this tissue is a layer of arachnoid membrane, limiting and enclosing the subarachnoid tissue. (3) Outside this is the thinned wall of the lacuna, which is separated from the arachnoid by a potential space which corresponds to and is continuous with the subdural cavity. (4) And finally, if the villus projects into the sagittal sinus, it will be covered by the greatly thinned wall of the sinus which may consist merely of endothelium. It will be seen, therefore, that fluid injected into the subarachnoid cavity will find its way into these villi, and it has been found experimentally that it passes from the villi into the venous sinuses into which they project.

The Pia Mater.

The **pia mater** is a vascular membrane, consisting of a minute plexus of blood-vessels, held together by an extremely fine areolar tissue and covered by a reflexion of the mesothelial cells from the arachnoid trabeculæ. It is an incomplete mem-

brane, absent probably at the foramen of Majendie and the two foramina of Luschka and perforated in a peculiar manner by all the bloodvessels as they enter or leave the nervous system. In the perivascular spaces, the pia apparently enters as a mesothelial lining of the outer surface of the space; a variable distance from the exterior these cells become unrecognizable and are apparently lacking, replaced by neuroglia elements. The inner walls of these perivascular spaces seem likewise covered for a certain distance by the mesothelial cells, reflected with the vessels from the arachnoid covering of these vascular channels as they traverse the sub-arachnoid spaces.

The **Cranial Pia Mater** (*pia mater encephali*; *pia of the brain*) invests the entire surface of the brain, dips between the cerebral gyri and cerebellar laminae, and is invaginated to form the tela chorioidea of the third ventricle, and the choroid plexuses of the lateral and third ventricles (pages 840 and 841); as it passes over the roof of the fourth ventricle, it forms the tela chorioidea and the choroid plexuses of this ventricle. On the cerebellum the membrane is more delicate; the vessels from its deep surface are shorter, and its relations to the cortex are not so intimate.

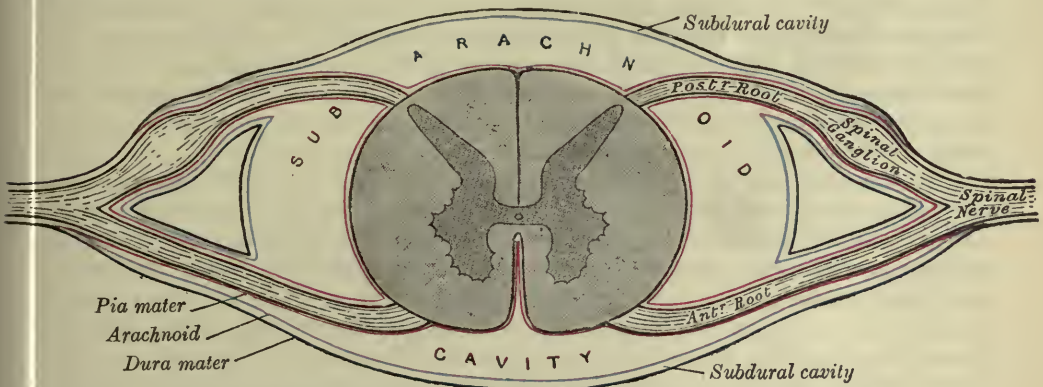


FIG. 770.—Diagrammatic transverse section of the medulla spinalis and its membranes.

The **Spinal Pia Mater** (*pia mater spinalis*; *pia of the cord*) (Figs. 767, 770) is thicker, firmer, and less vascular than the cranial pia mater: this is due to the fact that it consists of two layers, the outer or additional one being composed of bundles of connective-tissue fibers, arranged for the most part longitudinally. Between the layers are cleft-like spaces which communicate with the subarachnoid cavity, and a number of bloodvessels which are enclosed in perivascular lymphatic sheaths. The spinal pia mater covers the entire surface of the medulla spinalis, and is very intimately adherent to it; in front it sends a process backward into the anterior fissure. A longitudinal fibrous band, called the **linea splendens**, extends along the middle line of the anterior surface; and a somewhat similar band, the **ligamentum denticulatum**, is situated on either side. Below the conus medullaris, the pia mater is continued as a long, slender filament (**filum terminale**), which descends through the center of the mass of nerves forming the cauda equina. It blends with the dura mater at the level of the lower border of the second sacral vertebra, and extends downward as far as the base of the coccyx, where it fuses with the periosteum. It assists in maintaining the medulla spinalis in its position during the movements of the trunk, and is, from this circumstance, called the **central ligament** of the medulla spinalis.

The pia mater forms sheaths for the cranial and spinal nerves; these sheaths are closely connected with the nerves, and blend with their common membranous investments.

The *ligamentum denticulatum* (*dentate ligament*) (Fig. 767) is a narrow fibrous band situated on either side of the medulla spinalis throughout its entire length, and separating the anterior from the posterior nerve roots. Its medial border is continuous with the pia mater at the side of the medulla spinalis. Its lateral border presents a series of triangular tooth-like processes, the points of which are fixed at intervals to the dura mater. These processes are twenty-one in number, on either side, the first being attached to the dura mater, opposite the margin of the foramen magnum, between the vertebral artery and the hypoglossal nerve; and the last near the lower end of the medulla spinalis.

THE CEREBROSPINAL FLUID.¹

The cerebrospinal fluid, for the most part elaborated by the choroid plexuses, is poured into the cerebral ventricles which are lined by smooth ependyma. That portion of the fluid formed in the lateral ventricles escapes by the foramen of Monro into the third ventricle and thence by the aqueduct into the fourth ventricle. Likewise an ascending current of fluid apparently occurs in the central canal of the spinal cord; this, representing a possible product of the ependyma, may be added to the intraventricular supply. From the fourth ventricle the fluid is poured into the subarachnoid spaces through the medial foramen of Majendie and the two lateral foramina of Luschka. There is no evidence that functional communications between the cerebral ventricles and the subarachnoid spaces exist in any region except from the fourth ventricle.

In addition to the elaboration of the cerebrospinal fluid by the choroid plexuses, there seems fairly well established a second source of the fluid from the nervous system itself. The bloodvessels that enter and leave the brain are surrounded by perivascular channels. It seems most likely that the outer wall of these channels is lined by a continuation inward of the pial mesothelium while the inner wall is probably derived from the mesothelial covering of the vessels, which are thus protected throughout the subarachnoid spaces. These mesothelial cells continue inward only a short distance, neuroglia cells probably replacing on the outer surface the mesothelial elements. Through these perivascular channels there is probably a small amount of fluid flowing from nerve-cell to subarachnoid space. The chemical differences between the subarachnoid fluid (product of choroid plexuses and perivascular system) and the ventricular fluid (product of choroid plexuses alone) indicate that the products of nerve-metabolism are poured into the subarachnoid space.

The absorption of the cerebrospinal fluid is a dual process, being chiefly a rapid drainage through the arachnoid villi into the great dural sinuses, and, in small part, a slow escape into the true lymphatic vessels, by way of an abundant but indirect perineural course.

In general the arachnoid channels are equipped as fluid retainers with unquestionable powers of diffusion or absorption in regard to certain elements in the normal cerebrospinal fluid, deriving in this way a cellular nutrition.

The subdural space (between arachnoid and dura) is usually considered to be a part of the cerebrospinal channels. It is a very small space, the two limiting surfaces being separated by merely a capillary layer of fluid. Whether this fluid is exactly similar to the cerebrospinal fluid is very difficult to ascertain. Likewise our knowledge of the connections between the subdural and subarachnoid spaces is hardly definite. In some ways the subdural space may be likened to a serous cavity. The inner surface of the dura is covered by flattened polygonal mesothelial cells but the outer surface of the arachnoid is covered by somewhat cuboidal mesothelium. The fluid of the subdural space has probably a local origin from the cells lining it.

¹ Weed, L. H., *Anat. Record*, 1917, 12.

THE CRANIAL NERVES (NERVI CEREBRALES; CEREBRAL NERVES).

There are twelve pairs of cranial nerves; they are attached to the brain and are transmitted through foramina in the base of the cranium. The different pairs are named from before backward as follows:

- | | |
|------------------|------------------------|
| 1st. Olfactory. | 7th. Facial. |
| 2d. Optic. | 8th. Acoustic. |
| 3d. Oculomotor. | 9th. Glossopharyngeal. |
| 4th. Trochlear. | 10th. Vagus. |
| 5th. Trigeminal. | 11th. Accessory. |
| 6th. Abducent. | 12th. Hypoglossal. |

The area of attachment of a cranial nerve to the surface of the brain is termed its **superficial** or **apparent origin**. The fibers of the nerve can be traced into the substance of the brain to a special *nucleus* of gray substance. The motor or efferent cranial nerves arise within the brain from groups of nerve cells which constitute their **nuclei of origin**. The sensory or afferent cranial nerves arise from groups of nerve cells outside the brain; these nerve cells may be grouped to form ganglia on the trunks of the nerves or may be situated in peripheral sensory organs such as the nose and eye. The central processes of these cells run into the brain, and there end by arborizing around nerve cells, which are grouped to form **nuclei of termination**. The nuclei of origin of the motor nerves and the nuclei of termination of the sensory nerves are brought into relationship with the cerebral cortex, the former through the geniculate fibers of the internal capsule, the latter through the lemniscus. The geniculate fibers arise from the cells of the motor area of the cortex, and, after crossing the middle line, end by arborizing around the cells of the nuclei of origin of the motor cranial nerves. On the other hand, fibers arise from the cells of the nuclei of termination of the sensory nerves, and after crossing to the opposite side, join the lemniscus, and thus connect these nuclei, directly or indirectly, with the cerebral cortex.

THE OLFACTORY NERVES (NN. OLFACTORII; FIRST NERVE) (Fig. 771).

The olfactory nerves or nerves of smell are distributed to the mucous membrane of the olfactory region of the nasal cavity: this region comprises the superior nasal

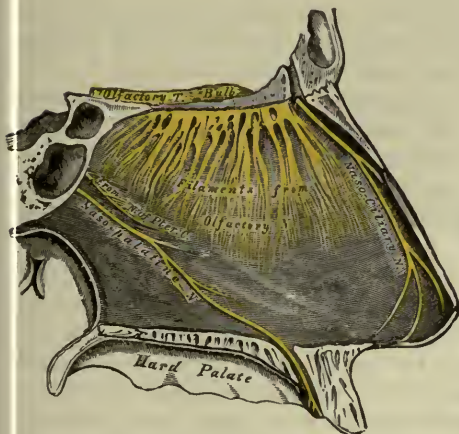

FIG. 771.—Nerves of septum of nose. Right side.

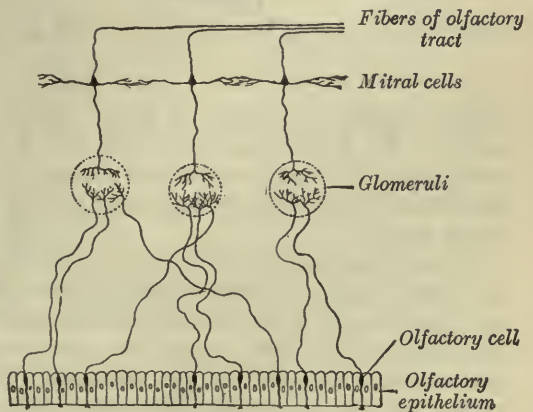


FIG. 772.—Plan of olfactory neurons.

concha, and the corresponding part of the nasal septum. The nerves originate from the central or deep processes of the olfactory cells of the nasal mucous mem-

brane. They form a plexiform net-work in the mucous membrane, and are then collected into about twenty branches, which pierce the cribriform plate of the ethmoid bone in two groups, a **lateral** and a **medial group**, and end in the glomeruli of the olfactory bulb (Fig. 772). Each branch receives tubular sheaths from the dura mater and pia mater, the former being lost in the periosteum of the nose, the latter in the neurolemma of the nerve.

The olfactory nerves are non-medullated, and consist of axis-cylinders surrounded by nucleated sheaths, in which, however, there are fewer nuclei than are found in the sheaths of ordinary non-medullated nerve fibers.

The olfactory center in the cortex is generally associated with the rhinencephalon (page 826).

The olfactory nerves are developed from the cells of the ectoderm which lines the olfactory pits; these cells undergo proliferation and give rise to what are termed the **olfactory cells** of the nose. The axons of the olfactory cells grow into the overlying olfactory bulb and form the olfactory nerves.

THE OPTIC NERVE (N. OPTICUS; SECOND NERVE) (Fig. 773).

The **optic nerve**, or **nerve of sight**, consists mainly of fibers derived from the ganglionic cells of the retina. These axons terminate in arborizations around the cells in the lateral geniculate body, pulvinar, and superior colliculus which constitute the lower or primary visual centers. From the cells of the lateral geniculate body and the pulvinar fibers pass to the cortical visual center, situated in the cuneus and in the neighborhood of the calcarine fissure. A few fibers of the optic nerve, of small caliber, pass from the primary centers to the retina and are supposed to govern chemical changes in the retina and also the movements of some of its elements (pigment cells and cones). There are also a few fine fibers, afferent fibers, extending from the retina to the brain, that are supposed to be concerned in pupillary reflexes.

The optic nerve is peculiar in that its fibers and ganglion cells are probably third in the series of neurons from the receptors to the brain. Consequently the optic nerve corresponds rather to a tract of fibers within the brain than to the other cranial nerves. Its fibers pass backward and medialward through the orbit and optic foramen to the optic commissure where they partially decussate. The mixed fibers from the two nerves are continued in the optic tracts, the **primary visual centers of the brain**.

The orbital portion of the optic nerve is from 20 mm. to 30 mm. in length and has a slightly sinuous course to allow for movements of the eyeball. It is invested by an outer sheath of dura mater and an inner sheath from the arachnoid which are attached to the sclera around the area where the nerve fibers pierce the choroid and sclera of the bulb. A little behind the bulb of the eye the central artery of the retina with its accompanying vein perforates the optic nerve, and runs within it to the retina. As the nerve enters the optic foramen its dural sheath becomes continuous with that lining the orbit and the optic foramen. In the optic foramen the ophthalmic artery lies below and to its outer side. The intercranial portion of the optic nerve is about 10 mm. in length.

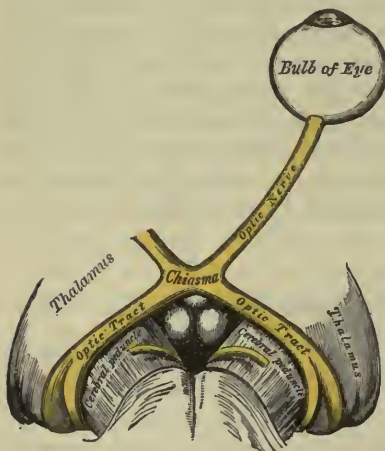


FIG. 773.—The left optic nerve and the optic tracts.

The **Optic Chiasma** (*chiasma opticum*), somewhat quadrilateral in form, rests upon the tuberculum sellæ and on the anterior part of the diaphragma sellæ. It is in relation, *above*, with the lamina terminalis; *behind*, with the tuber cinereum; on *either side*, with the anterior perforated substance. Within the chiasma, the optic nerves undergo a partial decussation. The fibers forming the medial part of each tract and posterior part of the chiasma have no connection with the optic nerves. They simply cross in the chiasma, and connect the medial geniculate bodies of the two sides; they form the **commissure of Gudden**. The remaining and principal part of the chiasma consists of two sets of fibers, crossed and uncrossed. The **crossed fibers** which are the more numerous, occupy the central part of the chiasma, and pass from the optic nerve of one side to the optic tract of the other, decussating in the chiasma with similar fibers of the opposite optic nerve. The **uncrossed fibers** occupy the lateral part of the chiasma, and pass from the nerve of one side into the tract of the same side.¹

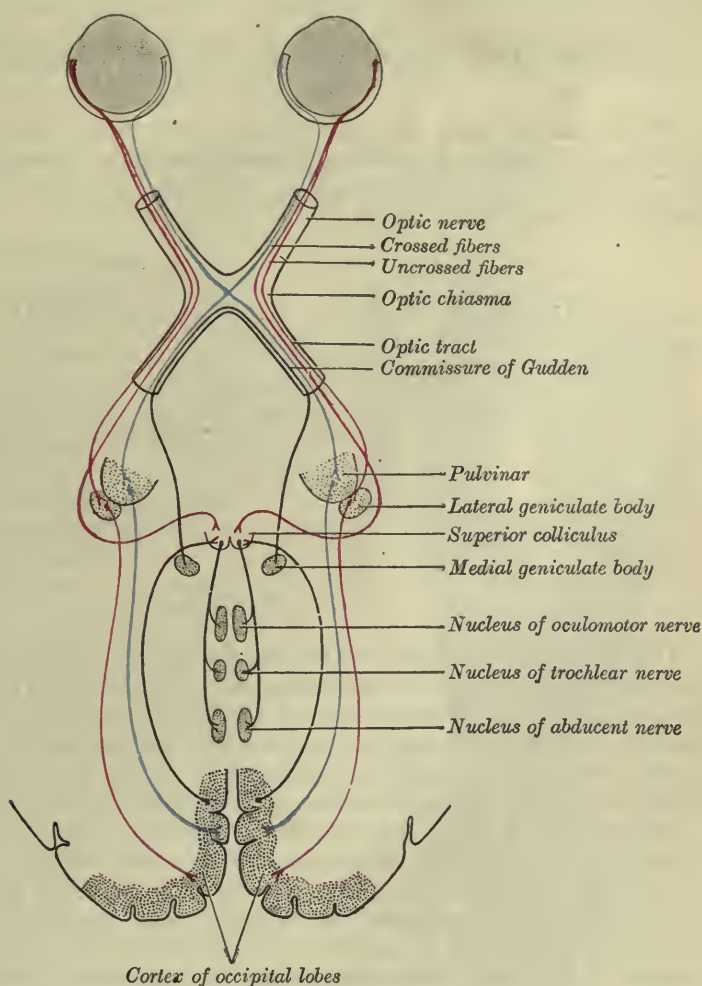


FIG. 774.—Scheme showing central connections of the optic nerves and optic tracts.

The crossed fibers of the optic nerve tend to occupy the medial side of the nerve and the uncrossed fibers the lateral side. In the optic tract, however, the fibers are much more intermingled.

¹ A specimen of congenital absence of the optic chiasma is to be found in the Museum of the Westminster Hospital. See also Henle, *Nerventehre*, p 393, ed. 2.

The **Optic Tract** (Fig. 774), passes backward and outward from the optic chiasma over the tuber cinereum and anterior perforated space to the cerebral peduncle and winds obliquely across its under surface. Its fibers terminate in the lateral geniculate body, the pulvinar and the superior colliculus. It is adherent to the tuber cinereum and the cerebral peduncle as it passes over them. In the region of the lateral geniculate body it splits into two bands. The medial and smaller one is a part of the commissure of Gudden and ends in the medial geniculate body.

From its mode of development, and from its structure, the optic nerve must be regarded as a prolongation of the brain substance, rather than as an ordinary cerebrospinal nerve. As it passes from the brain it receives sheaths from the three cerebral membranes, a perineural sheath from the pia mater, an intermediate sheath from the arachnoid, and an outer sheath from the dura mater, which is also connected with the periosteum as it passes through the optic foramen. These sheaths are separated from each other by cavities which communicate with the subdural and subarachnoid cavities respectively. The innermost or perineural sheath sends a process around the arteria centralis retinae into the interior of the nerve, and enters intimately into its structure.

THE OCULOMOTOR NERVE (N. OCULOMOTORIUS; THIRD NERVE)

(Figs. 775, 776, 777).

The **oculomotor nerve** supplies somatic motor fibers to all the ocular muscles, except the Obliquus superior and Rectus lateralis; it also supplies through its connections with the ciliary ganglion, sympathetic motor fibers to the Sphincter pupillae and the Ciliaris muscles.

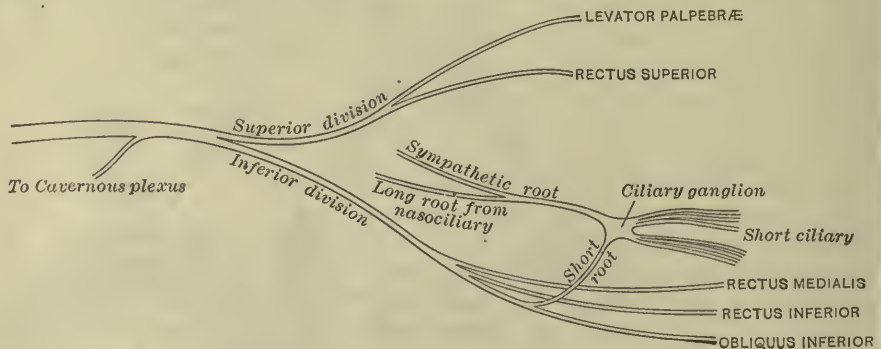


FIG. 775.—Plan of oculomotor nerve.

The fibers of the oculomotor nerve arise from a nucleus which lies in the gray substance of the floor of the cerebral aqueduct and extends in front of the aqueduct for a short distance into the floor of the third ventricle. From this nucleus the fibers pass forward through the tegmentum, the red nucleus, and the medial part of the substantia nigra, forming a series of curves with a lateral convexity, and emerge from the oculomotor sulcus on the medial side of the cerebral peduncle.

The nucleus of the oculomotor nerve does not consist of a continuous column of cells, but is broken up into a number of smaller nuclei, which are arranged in two groups, anterior and posterior. Those of the posterior group are six in number, five of which are symmetrical on the two sides of the middle line, while the sixth is centrally placed and is common to the nerves of both sides. The anterior group consists of two nuclei, an antero-medial and an antero-lateral (Fig. 762).

The nucleus of the oculomotor nerve, considered from a physiological standpoint, can be subdivided into several smaller groups of cells, each group controlling a particular muscle.

On emerging from the brain, the nerve is invested with a sheath of pia mater, and enclosed in a prolongation from the arachnoid. It passes between the superior cerebellar and posterior cerebral arteries, and then pierces the dura mater in front

of and lateral to the posterior clinoid process, passing between the free and attached borders of the tentorium cerebelli. It runs along the lateral wall of the cavernous sinus, above the other orbital nerves, receiving in its course one or two filaments from the cavernous plexus of the sympathetic, and a communicating branch from the ophthalmic division of the trigeminal. It then divides into two branches, which enter the orbit through the superior orbital fissure, between the two heads of the Rectus lateralis. Here the nerve is placed below the trochlear nerve and the frontal and lacrimal branches of the ophthalmic nerve, while the nasociliary nerve is placed between its two rami.

The **superior ramus**, the smaller, passes medialward over the optic nerve, and supplies the Rectus superior and Levator palpebræ superioris. The **inferior ramus**, the larger, divides into three branches. One passes beneath the optic nerve to the Rectus medialis; another, to the Rectus inferior; the third and longest runs forward between the Recti inferior and lateralis to the Obliquus inferior. From the last a short thick branch is given off to the lower part of the ciliary ganglion, and forms its **short root**. All these branches enter the muscles on their ocular surfaces, with the exception of the nerve to the Obliquus inferior, which enters the muscle at its posterior border.

THE TROCHLEAR NERVE (N. TROCHLEARIS; FOURTH NERVE) (Fig. 776).

The **trochlear nerve**, the smallest of the cranial nerves, supplies the Obliquus superior oculi.

It *arises* from a nucleus situated in the floor of the cerebral aqueduct, opposite the upper part of the inferior colliculus. From its origin it runs downward through the tegmentum, and then turns backward into the upper part of the anterior medullary velum. Here it decussates with its fellow of the opposite side and emerges from the surface of the velum at the side of the frenulum veli, immediately behind the inferior colliculus.

The nerve is directed across the superior cerebellar peduncle, and then winds forward around the cerebral peduncle, immediately above the pons, pierces the dura mater in the free border of the tentorium cerebelli, just behind, and lateral to, the posterior clinoid process, and passes forward in the lateral wall of the cavernous sinus, between the oculomotor nerve and the ophthalmic division of the trigeminal. It crosses the oculomotor nerve, and enters the orbit through the superior orbital fissure. It now becomes the highest of all the nerves, and lies medial to the frontal nerve. In the orbit it passes medialward, above the origin of the Levator palpebræ superioris, and finally enters the orbital surface of the Obliquus superior.

In the lateral wall of the cavernous sinus the trochlear nerve forms communications with the ophthalmic division of the trigeminal and with the cavernous plexus

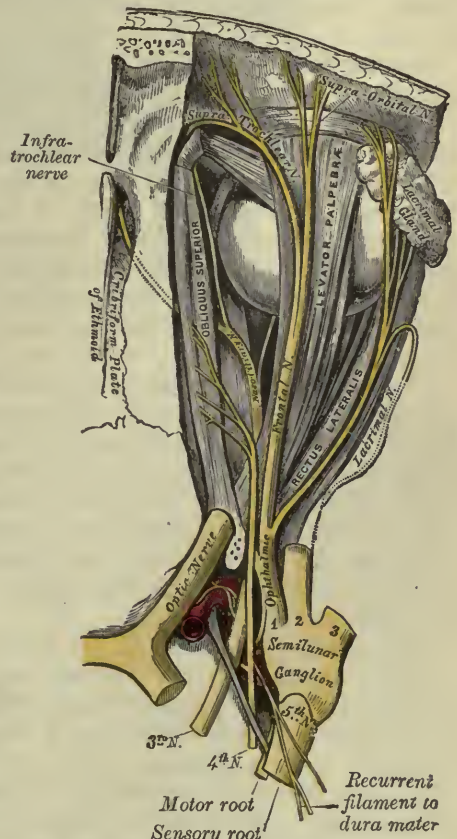


FIG. 776.—Nerves of the orbit. Seen from above.

of the sympathetic. In the superior orbital fissure it occasionally gives off a branch to the lacrimal nerve. It gives off a recurrent branch which passes backward between the layers of the tentorium cerebelli and divides into two or three filaments which may be traced as far as the wall of the transverse sinus.

THE TRIGEMINAL NERVE (N. TRIGEMINUS; FIFTH OR TRIFACIAL NERVE).

The **trigeminal nerve** is the largest cranial nerve and is the great sensory nerve of the head and face, and the motor nerve of the muscles of mastication.

It emerges from the side of the pons, near its upper border, by a small *motor* and a large *sensory root*—the former being situated in front of and medial to the latter.

Motor Root.—The fibers of the motor root *arise* from two nuclei, a superior and an inferior. The **superior nucleus** consists of a strand of cells occupying the whole length of the lateral portion of the gray substance of the cerebral aqueduct. The **inferior** or **chief nucleus** is situated in the upper part of the pons, close to its dorsal surface, and along the line of the lateral margin of the rhomboid fossa. The fibers from the superior nucleus constitute the **mesencephalic root**: they descend through the mid-brain, and, entering the pons, join with the fibers from the lower nucleus, and the motor root, thus formed, passes forward through the pons to its point of emergence. It is uncertain whether the mesencephalic root is motor or sensory.

Sensory Root.—The fibers of the sensory root *arise* from the cells of the semilunar ganglion which lies in a cavity of the dura mater near the apex of the petrous part of the temporal bone. They pass backward below the superior petrosal sinus and tentorium cerebelli, and, entering the pons, divide into upper and lower roots. The upper root ends partly in a nucleus which is situated in the pons lateral to the lower motor nucleus, and partly in the locus cæruleus; the lower root descends through the pons and medulla oblongata, and ends in the upper part of the substantia gelatinosa of Rolando. This lower root is sometimes named the **spinal root** of the nerve. Medullation of the fibers of the sensory root begins about the fifth month of fetal life, but the whole of its fibers are not medullated until the third month after birth.

The **Semilunar Ganglion** (*ganglion semilunare* [Gasseri]; *Gasserian ganglion*) occupies a cavity (*cavum Meckelii*) in the dura mater covering the trigeminal impression near the apex of the petrous part of the temporal bone. It is somewhat crescentic in shape, with its convexity directed forward: medially, it is in relation with the internal carotid artery and the posterior part of the cavernous sinus. The motor root runs in front of and medial to the sensory root, and passes beneath the ganglion; it leaves the skull through the foramen ovale, and, immediately below this foramen, joins the mandibular nerve. The greater superficial petrosal nerve lies also underneath the ganglion.

The ganglion receives, on its medial side, filaments from the carotid plexus of the sympathetic. It give off minute branches to the tentorium cerebelli, and to the dura mater in the middle fossa of the cranium. From its convex border, which is directed forward and lateralward, three large nerves proceed, viz., the **ophthalmic**, **maxillary**, and **mandibular**. The ophthalmic and maxillary consist exclusively of sensory fibers; the mandibular is joined outside the cranium by the motor root.

Associated with the three divisions of the trigeminal nerve are four small ganglia. The **ciliary ganglion** is connected with the ophthalmic nerve; the **sphenopalatine ganglion** with the maxillary nerve; and the **otic** and **submaxillary ganglia** with the mandibular nerve. All four receive sensory filaments from the trigeminal, and

motor and sympathetic filaments from various sources; these filaments are called the roots of the ganglia.

The **Ophthalmic Nerve** (*n. ophthalmicus*) (Figs. 776, 777), or first division of the trigeminal, is a sensory nerve. It supplies branches to the cornea, ciliary body, and iris; to the lacrimal gland and conjunctiva; to the part of the mucous membrane of the nasal cavity; and to the skin of the eyelids, eyebrow, forehead, and nose. It is the smallest of the three divisions of the trigeminal, and arises from the upper part of the semilunar ganglion as a short, flattened band, about 2.5 cm. long, which passes forward along the lateral wall of the cavernous sinus, below the oculomotor and trochlear nerves; just before entering the orbit, through the superior orbital fissure, it divides into three branches, **lacrimal**, **frontal**, and **nasociliary**.

The ophthalmic nerve is joined by filaments from the cavernous plexus of the sympathetic, and communicates with the oculomotor, trochlear, and abducent nerves; it gives off a recurrent filament which passes between the layers of the tentorium.

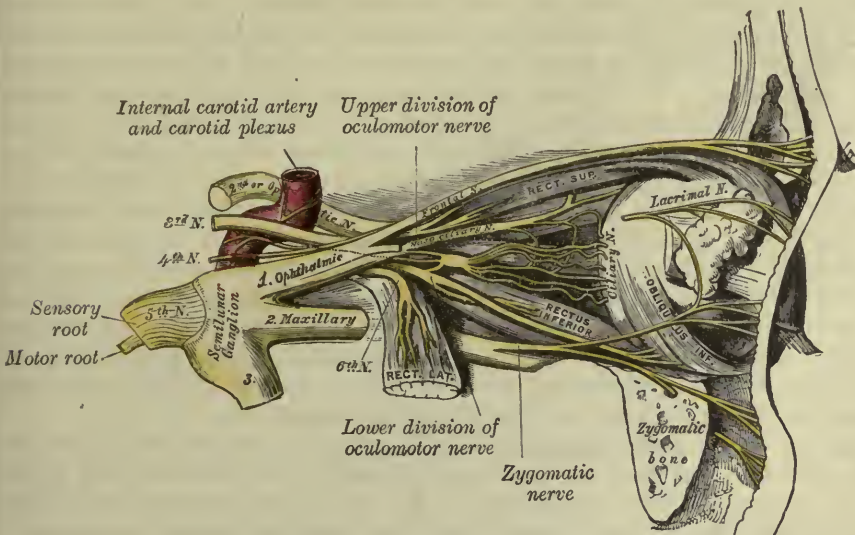


FIG. 777.—Nerves of the orbit, and the ciliary ganglion. Side view.

The **Lacrimal Nerve** (*n. lacrimalis*) is the smallest of the three branches of the ophthalmic. It sometimes receives a filament from the trochlear nerve, but this is possibly derived from the branch which goes from the ophthalmic to the trochlear nerve. It passes forward in a separate tube of dura mater, and enters the orbit through the narrowest part of the superior orbital fissure. In the orbit it runs along the upper border of the Rectus lateralis, with the lacrimal artery, and communicates with the zygomatic branch of the maxillary nerve. It enters the lacrimal gland and gives off several filaments, which supply the gland and the conjunctiva. Finally it pierces the orbital septum, and ends in the skin of the upper eyelid, joining with filaments of the facial nerve. The lacrimal nerve is occasionally absent, and its place is then taken by the zygomaticotemporal branch of the maxillary. Sometimes the latter branch is absent, and a continuation of the lacrimal is substituted for it.

The **Frontal Nerve** (*n. frontalis*) is the largest branch of the ophthalmic, and may be regarded, both from its size and direction, as the continuation of the nerve. It enters the orbit through the superior orbital fissure, and runs forward between the Levator palpebrae superioris and the periosteum. Midway between the apex and base of the orbit it divides into two branches, **supratrochlear** and **supraorbital**.

The **supratrochlear nerve** (*n. supratrochlearis*), the smaller of the two, passes above the pulley of the Obliquus superior, and gives off a descending filament, to join the infratrochlear branch of the nasociliary nerve. It then escapes from the orbit between the pulley of the Obliquus superior and the supraorbital foramen, curves up on to the forehead close to the bone, ascends beneath the Corrugator and Frontalis, and dividing into branches which pierce these muscles, it supplies the skin of the lower part of the forehead close to the middle line and sends filaments to the conjunctiva and skin of the upper eyelid.

The **supraorbital nerve** (*n. supraorbitalis*) passes through the supraorbital foramen, and gives off, in this situation, palpebral filaments to the upper eyelid. It then ascends upon the forehead, and ends in two branches, a medial and a lateral, which supply the integument of the scalp, reaching nearly as far back as the lambdoidal suture; they are at first situated beneath the Frontalis, the medial branch perforating the muscle, the lateral branch the galea aponeurotica. Both branches supply small twigs to the pericranium.

The **Nasociliary Nerve** (*n. nasociliaris; nasal nerve*) is intermediate in size between the frontal and lacrimal, and is more deeply placed. It enters the orbit between the two heads of the Rectus lateralis, and between the superior and inferior rami of the oculomotor nerve. It passes across the optic nerve and runs obliquely beneath the Rectus superior and Obliquus superior, to the medial wall of the orbital cavity. Here it passes through the anterior ethmoidal foramen, and, entering the cavity of the cranium, traverses a shallow groove on the lateral margin of the front part of the cribriform plate of the ethmoid bone, and runs down, through a slit at the side of the crista galli, into the nasal cavity. It supplies **internal nasal branches** to the mucous membrane of the front part of the septum and lateral wall of the nasal cavity. Finally, it emerges, as the **external nasal branch**, between the lower border of the nasal bone and the lateral nasal cartilage, and, passing down beneath the Nasalis muscle, supplies the skin of the ala and apex of the nose.

The nasociliary nerve gives off the following branches, viz.: the **long root of the ciliary ganglion**, the **long ciliary**, and the **ethmoidal nerves**.

The **long root of the ciliary ganglion** (*radix longa ganglii ciliaris*) usually arises from the nasociliary between the two heads of the Rectus lateralis. It passes forward on the lateral side of the optic nerve, and enters the postero-superior angle of the ciliary ganglion; it is sometimes joined by a filament from the cavernous plexus of the sympathetic, or from the superior ramus of the trochlear nerve.

The **long ciliary nerves** (*nn. ciliares longi*), two or three in number, are given off from the nasociliary, as it crosses the optic nerve. They accompany the short ciliary nerves from the ciliary ganglion, pierce the posterior part of the sclera, and running forward between it and the choroid, are distributed to the iris and cornea. The long ciliary nerves are supposed to contain sympathetic fibers from the superior cervical ganglion to the Dilator pupillæ muscle.

The **infratrochlear nerve** (*n. infratrochlearis*) is given off from the nasociliary just before it enters the anterior ethmoidal foramen. It runs forward along the upper border of the Rectus medialis, and is joined, near the pulley of the Obliquus superior, by a filament from the supratrochlear nerve. It then passes to the medial angle of the eye, and supplies the skin of the eyelids and side of the nose, the conjunctiva, lacrimal sac, and caruncula lacrimalis.

The **ethmoidal branches** (*nn. ethmoidales*) supply the ethmoidal cells; the posterior branch leaves the orbital cavity through the posterior ethmoidal foramen and gives some filaments to the sphenoidal sinus.

The **Ciliary Ganglion** (*ophthalmic or lenticular ganglion*) (Figs. 775, 777).—The ciliary ganglion is a small, sympathetic ganglion, of a reddish-gray color, and about the size of a pin's head; it is situated at the back part of the orbit, in some loose fat between the optic nerve and the Rectus lateralis muscle, lying generally on the lateral side of the ophthalmic artery.

Its **roots** are three in number, and enter its posterior border. One, the long or sensory root, is derived from the nasociliary nerve, and joins its postero-superior angle. The second, the short or motor root, is a thick nerve (occasionally divided into two parts) derived from the branch of the oculomotor nerve to the Obliquus inferior, and connected with the postero-inferior angle of the ganglion. The motor root is supposed to contain sympathetic efferent fibers (preganglionic fibers) from the nucleus of the third nerve in the mid-brain to the ciliary ganglion where they form synapses with neurons whose fibers (postganglionic) pass to the Ciliary muscle and to Sphincter muscle of the pupil. The third, the sympathetic root, is a slender filament from the cavernous plexus of the sympathetic; it is frequently blended with the long root. According to Tiedemann, the ciliary ganglion receives a twig of communication from the sphenopalatine ganglion.

Its **branches** are the **short ciliary nerves**. These are delicate filaments, from six to ten in number, which *arise* from the forepart of the ganglion in two bundles connected with its superior and inferior angles; the lower bundle is the larger. They run forward with the ciliary arteries in a wavy course, one set above and the other below the optic nerve, and are accompanied by the long ciliary nerves from the nasociliary. They pierce the sclera at the back part of the bulb of the eye, pass forward in delicate grooves on the inner surface of the sclera, and are distributed to the Ciliaris muscle, iris, and cornea. Tiedemann has described a small branch as penetrating the optic nerve with the arteria centralis retinae.

The **Maxillary Nerve** (*n. maxillaris; superior maxillary nerve*) (Fig. 778), or **second division** of the trigeminal, is a sensory nerve. It is intermediate, both in position and size, between the ophthalmic and mandibular. It begins at the middle of the semilunar ganglion as a flattened plexiform band, and, passing horizontally forward, it leaves the skull through the foramen rotundum, where it becomes more cylindrical in form, and firmer in texture. It then crosses the pterygopalatine fossa, inclines lateralward on the back of the maxilla, and enters the orbit through the inferior orbital fissure; it traverses the infraorbital groove and canal in the floor of the orbit, and appears upon the face at the infraorbital foramen.¹ At its termination, the nerve lies beneath the Quadratus labii superioris, and divides into a leash of branches which spread out upon the side of the nose, the lower eyelid, and the upper lip, joining with filaments of the facial nerve.

Branches.—Its branches may be divided into four groups, according as they are given off in the **cranium**, in the **pterygopalatine fossa**, in the **infraorbital canal**, or on the **face**.

In the Cranium	Middle meningeal.
In the Pterygopalatine Fossa	{ Zygomatic.
	{ Sphenopalatine.
	{ Posterior superior alveolar.
In the Infraorbital Canal	{ Anterior superior alveolar.
	{ Middle superior alveolar.
	{ Inferior palpebral.
On the Face	{ External nasal.
	{ Superior labial.

The **Middle Meningeal Nerve** (*n. meningeus medius; meningeal or dural branch*) is given off from the maxillary nerve directly after its origin from the semilunar ganglion; it accompanies the middle meningeal artery and supplies the dura mater.

The **Zygomatic Nerve** (*n. zygomaticus; temporomalar nerve; orbital nerve*) arises in the pterygopalatine fossa, enters the orbit by the inferior orbital fissure, and divides at the back of that cavity into two branches, **zygomaticotemporal** and **zygomaticofacial**.

¹ After it enters the infraorbital canal, the nerve is frequently called the *infraorbital*.

The **zygomaticotemporal branch** (*ramus zygomaticotemporalis; temporal branch*) runs along the lateral wall of the orbit in a groove in the zygomatic bone, receives a branch of communication from the lacrimal, and, passing through a foramen in the zygomatic bone, enters the temporal fossa. It ascends between the bone, and substance of the Temporalis muscle, pierces the temporal fascia about 2.5 cm. above the zygomatic arch, and is distributed to the skin of the side of the forehead, and communicates with the facial nerve and with the auriculotemporal branch of the mandibular nerve. As it pierces the temporal fascia, it gives off a slender twig, which runs between the two layers of the fascia to the lateral angle of the orbit.

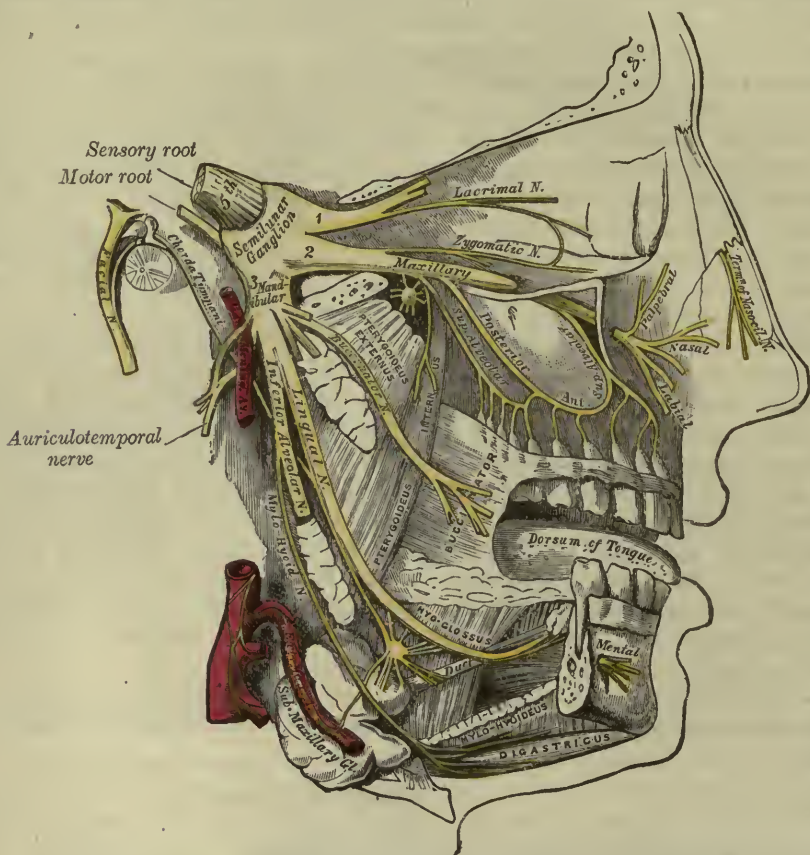


FIG. 778.—Distribution of the maxillary and mandibular nerves, and the submaxillary ganglion.

The **zygomaticofacial branch** (*ramus zygomaticofacialis; malar branch*) passes along the infero-lateral angle of the orbit, emerges upon the face through a foramen in the zygomatic bone, and, perforating the Orbicularis oculi, supplies the skin on the prominence of the cheek. It joins with the facial nerve and with the inferior palpebral branches of the maxillary.

The **Sphenopalatine Branches** (*nn. sphenopalatini*), two in number, descend to the sphenopalatine ganglion.

The **Posterior Superior Alveolar Branches** (*rami alveolares superiores posteriores; posterior superior dental branches*) arise from the trunk of the nerve just before it enters the infraorbital groove; they are generally two in number, but sometimes arise by a single trunk. They descend on the tuberosity of the maxilla and give off several twigs to the gums and neighboring parts of the mucous membrane of the cheek. They then enter the posterior alveolar canals on the infratemporal surface

of the maxilla, and, passing from behind forward in the substance of the bone, communicate with the middle superior alveolar nerve, and give off branches to the lining membrane of the maxillary sinus and three twigs to each molar tooth; these twigs enter the foramina at the apices of the roots of the teeth.

The **Middle Superior Alveolar Branch** (*ramus alveolaris superior medius; middle superior dental branch*), is given off from the nerve in the posterior part of the infra-orbital canal, and runs downward and forward in a canal in the lateral wall of the maxillary sinus to supply the two premolar teeth. It forms a superior dental plexus with the anterior and posterior superior alveolar branches.

The **Anterior Superior Alveolar Branch** (*ramus alveolaris superior anteriores; anterior superior dental branch*), of considerable size, is given off from the nerve just before its exit from the infraorbital foramen; it descends in a canal in the anterior wall of the maxillary sinus, and divides into branches which supply the incisor and canine teeth. It communicates with the middle superior alveolar branch, and gives off a **nasal branch**, which passes through a minute canal in the lateral wall of the inferior meatus, and supplies the mucous membrane of the anterior part of the inferior meatus and the floor of the nasal cavity, communicating with the nasal branches from the sphenopalatine ganglion.

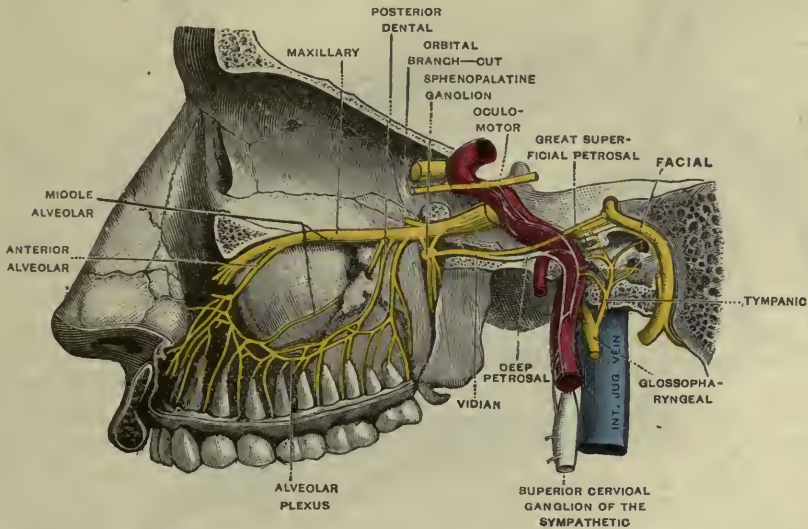


FIG. 779.—Alveolar branches of superior maxillary nerve and sphenopalatine ganglion. (Testut.)

The **Inferior Palpebral Branches** (*rami palpebrales inferiores; palpebral branches*) ascend behind the Orbicularis oculi. They supply the skin and conjunctiva of the lower eyelid, joining at the lateral angle of the orbit with the facial and zygomaticofacial nerves.

The **External Nasal Branches** (*rami nasales externi*) supply the skin of the side of the nose and of the septum mobile nasi, and join with the terminal twigs of the nasociliary nerve.

The **Superior Labial Branches** (*rami labiales superiores; labial branches*), the largest and most numerous, descend behind the Quadratus labii superioris, and are distributed to the skin of the upper lip, the mucous membrane of the mouth, and labial glands. They are joined, immediately beneath the orbit, by filaments from the facial nerve, forming with them the **infraorbital plexus**.

Sphenopalatine Ganglion (*ganglion of Meckel*) (Fig. 780).—The sphenopalatine ganglion, the largest of the sympathetic ganglia associated with the branches of the trigeminal nerve, is deeply placed in the pterygopalatine fossa, close to the sphen-

palatine foramen. It is triangular or heart-shaped, of a reddish-gray color, and is situated just below the maxillary nerve as it crosses the fossa. It receives a sensory, a motor, and a sympathetic root.

Its **sensory root** is derived from two sphenopalatine branches of the maxillary nerve; their fibers, for the most part, pass directly into the palatine nerves; a few, however, enter the ganglion, constituting its sensory root. Its **motor root** is probably derived from the nervus intermedius through the greater superficial petrosal nerve and is supposed to consist in part of sympathetic efferent (preganglionic) fibers from the medulla. In the sphenopalatine ganglion they form synapses with neurons whose postganglionic axons, vasodilator and secretory fibers, are distributed with the deep branches of the trigeminal to the mucous membrane of the nose, soft palate, tonsils, uvula, roof of the mouth, upper lip and gums, and to the upper part of the pharynx. Its **sympathetic root** is derived from the carotid plexus through the deep petrosal nerve. These two nerves join to form the nerve of the pterygoid canal before their entrance into the ganglion.

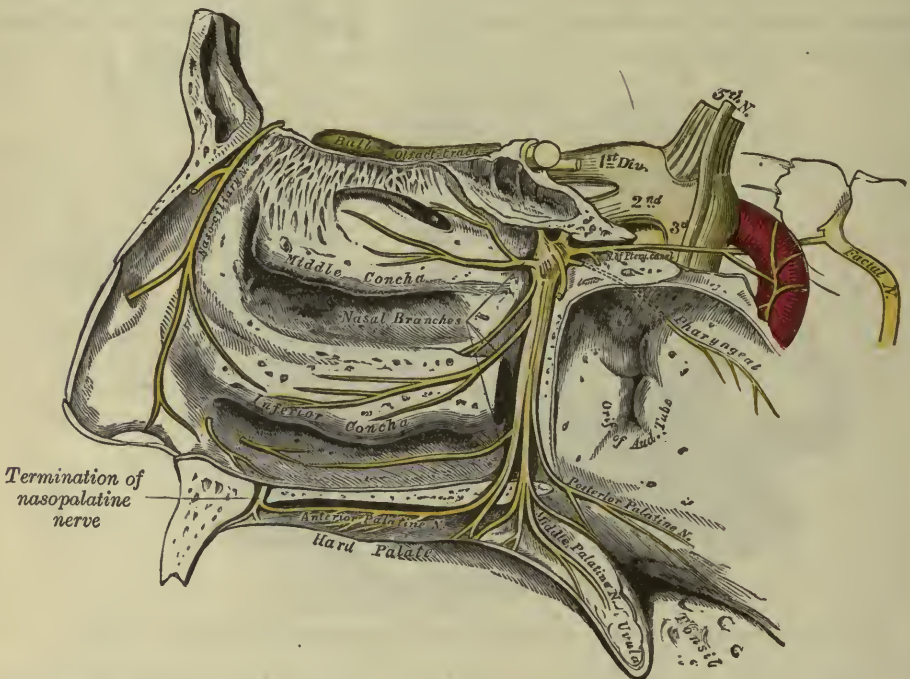

FIG. 780.—The sphenopalatine ganglion and its branches.

The **greater superficial petrosal nerve** (*n. petrosus superficialis major*; *large superficial petrosal nerve*) is given off from the genicular ganglion of the facial nerve; it passes through the hiatus of the facial canal, enters the cranial cavity, and runs forward beneath the dura mater in a groove on the anterior surface of the petrous portion of the temporal bone. It then enters the cartilaginous substance which fills the foramen lacerum, and joining with the deep petrosal branch forms the nerve of the pterygoid canal.

The **deep petrosal nerve** (*n. petrosus profundus*; *large deep petrosal nerve*) is given off from the carotid plexus, and runs through the carotid canal lateral to the internal carotid artery. It then enters the cartilaginous substance which fills the foramen lacerum, and joins with the greater superficial petrosal nerve to form the nerve of the pterygoid canal.

The **nerve of the pterygoid canal** (*n. canalis pterygoidei* [Vidii]; *Vidian nerve*),

formed by the junction of the two preceding nerves in the cartilaginous substance which fills the foramen lacerum, passes forward, through the pterygoid canal, with the corresponding artery, and is joined by a small ascending **sphenoidal branch** from the otic ganglion. Finally, it enters the pterygopalatine fossa, and joins the posterior angle of the sphenopalatine ganglion.

Branches of Distribution.—These are divisible into four groups, viz., **orbital, palatine, posterior superior nasal, and pharyngeal.**

The **orbital branches** (*rami orbitales; ascending branches*) are two or three delicate filaments, which enter the orbit by the inferior orbital fissure, and supply the periosteum. According to Luschka, some filaments pass through foramina in the fronto-ethmoidal suture to supply the mucous membrane of the posterior ethmoidal and sphenoidal sinuses.

The **palatine nerves** (*nn. palatini; descending branches*) are distributed to the roof of the mouth, soft palate, tonsil, and lining membrane of the nasal cavity. Most of their fibers are derived from the sphenopalatine branches of the maxillary nerve. They are three in number: **anterior, middle, and posterior.**

The **anterior palatine nerve** (*n. palatinus anterior*) descends through the pterygopalatine canal, emerges upon the hard palate through the greater palatine foramen, and passes forward in a groove in the hard palate, nearly as far as the incisor teeth. It supplies the gums, the mucous membrane and glands of the hard palate, and communicates in front with the terminal filaments of the nasopalatine nerve. While in the pterygopalatine canal, it gives off **posterior inferior nasal branches**, which enter the nasal cavity through openings in the palatine bone, and ramify over the inferior nasal concha and middle and inferior meatuses; at its exit from the canal, a palatine branch is distributed to both surfaces of the soft palate.

The **middle palatine nerve** (*n. palatinus medius*) emerges through one of the minor palatine canals and distributes branches to the uvula, tonsil, and soft palate. It is occasionally wanting.

The **posterior palatine nerve** (*n. palatinus posterior*) descends through the pterygopalatine canal, and emerges by a separate opening behind the greater palatine foramen; it supplies the soft palate, tonsil, and uvula. The middle and posterior palatine join with the tonsillar branches of the glossopharyngeal to form a plexus (**circulus tonsillaris**) around the tonsil.

The **posterior superior nasal branches** (*rami nasales posteriores superiores*) are distributed to the septum and lateral wall of the nasal fossa. They enter the posterior part of the nasal cavity by the sphenopalatine foramen and supply the mucous membrane covering the superior and middle nasal conchæ, the lining of the posterior ethmoidal cells, and the posterior part of the septum. One branch, longer and larger than the others, is named the **nasopalatine nerve**. It enters the nasal cavity through the sphenopalatine foramen, passes across the roof of the nasal cavity below the orifice of the sphenoidal sinus to reach the septum, and then runs obliquely downward and forward between the periosteum and mucous membrane of the lower part of the septum. It descends to the roof of the mouth through the incisive canal and communicates with the corresponding nerve of the opposite side and with the anterior palatine nerve. It furnishes a few filaments to the mucous membrane of the nasal septum.

The **pharyngeal nerve** (*pterygopalatine nerve*) is a small branch arising from the posterior part of the ganglion. It passes through the pharyngeal canal with the pharyngeal branch of the internal maxillary artery, and is distributed to the mucous membrane of the nasal part of the pharynx, behind the auditory tube.

The **mandibular nerve** (*n. mandibularis; inferior maxillary nerve*) (Figs. 778, 781) supplies the teeth and gums of the mandible, the skin of the temporal region, the auricula, the lower lip, the lower part of the face, and the muscles of mastication; it also supplies the mucous membrane of the anterior two-thirds of the tongue.

It is the largest of the three divisions of the fifth, and is made up of two roots: a large, **sensory root** proceeding from the inferior angle of the semilunar ganglion, and a small **motor root** (the motor part of the trigeminal), which passes beneath the ganglion, and unites with the sensory root, just after its exit through the foramen ovale. Immediately beneath the base of the skull, the nerve gives off from its medial side a recurrent branch (nervus spinosus) and the nerve to the Pterygoideus internus, and then divides into two trunks, an anterior and a posterior.

The **Nervus Spinosus** (*recurrent or meningeal branch*) enters the skull through the foramen spinosum with the middle meningeal artery. It divides into two branches, anterior and posterior, which accompany the main divisions of the artery and supply the dura mater; the posterior branch also supplies the mucous lining of the mastoid cells; the anterior communicates with the meningeal branch of the maxillary nerve.

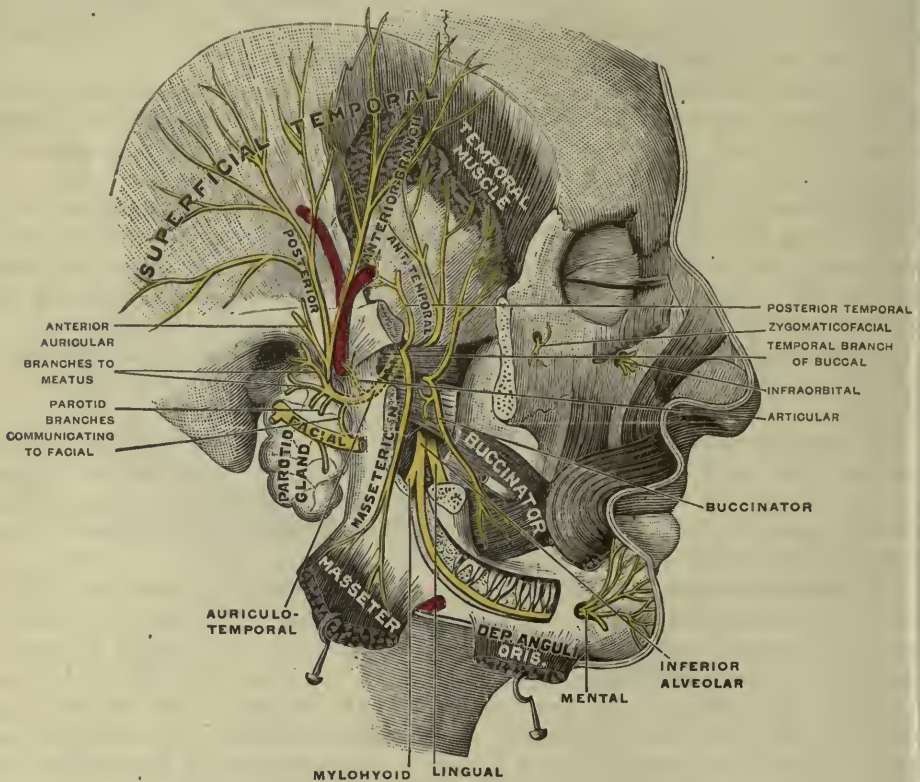


FIG. 781.—Mandibular division of the trifacial nerve. (Testut.)

The Internal Pterygoid Nerve (*n. pterygoideus internus*).—The nerve to the Pterygoideus internus is a slender branch, which enters the deep surface of the muscle; it gives off one or two filaments to the otic ganglion.

The anterior and smaller division of the mandibular nerve receives nearly the whole of the fibers of the motor root of the nerve, and supplies the muscles of mastication and the skin and mucous membrane of the cheek. Its branches are the masseteric, deep temporal, buccinator, and external pterygoid.

The **Masseteric Nerve** (*n. massetericus*) passes lateralward, above the Pterygoideus externus, in front of the temporomandibular articulation, and behind the tendon of the Temporalis; it crosses the mandibular notch with the masseteric artery, to the deep surface of the Masseter, in which it ramifies nearly as far as its anterior border. It gives a filament to the temporomandibular joint.

The **Deep Temporal Nerves** (*nn. temporales profundæ*) are two in number, anterior and posterior. They pass above the upper border of the Pterygoideus externus and enter the deep surface of the Temporalis. The **posterior branch**, of small size, is placed at the back of the temporal fossa, and sometimes arises in common with the masseteric nerve. The **anterior branch** is frequently given off from the buccinator nerve, and then turns upward over the upper head of the Pterygoideus externus. Frequently a third or intermediate branch is present.

The **Buccinator Nerve** (*n. buccinatorius; long buccal nerve*) passes forward between the two heads of the Pterygoideus externus, and downward beneath or through the lower part of the Temporalis; it emerges from under the anterior border of the Masseter, ramifies on the surface of the Buccinator, and unites with the buccal branches of the facial nerve. It supplies a branch to the Pterygoideus externus during its passage through that muscle, and may give off the anterior deep temporal nerve. The buccinator nerve supplies the skin over the Buccinator, and the mucous membrane lining its inner surface.

External Pterygoid Nerve (*n. pterygoideus externus*).—The nerve to the Pterygoideus externus frequently *arises* in conjunction with the buccinator nerve, but it may be given off separately from the anterior division of the mandibular nerve. It enters the deep surface of the muscle.

The posterior and larger division of the mandibular nerve is for the most part sensory, but receives a few filaments from the motor root. It divides into **auriculotemporal, lingual, and inferior alveolar nerves**.

The **Auriculotemporal Nerve** (*n. auriculotemporalis*) generally *arises* by two roots, between which the middle meningeal artery ascends. It runs backward beneath the Pterygoideus externus to the medial side of the neck of the mandible. It then turns upward with the superficial temporal artery, between the auricula and condyle of the mandible, under cover of the parotid gland; escaping from beneath the gland, it ascends over the zygomatic arch, and divides into superficial temporal branches.

The **branches of communication** of the auriculotemporal nerve are with the facial nerve and with the otic ganglion. The branches to the facial, usually two in number, pass forward from behind the neck of the mandible and join the facial nerve at the posterior border of the Masseter. The filaments to the otic ganglion are derived from the roots of the auriculotemporal nerve close to their origin.

Its **branches of distribution** are:

Anterior auricular.	Articular.
Branches to the external acoustic meatus.	Parotid.
Superficial temporal.	

The **anterior auricular branches** (*nn. auriculares anteriores*) are usually two in number; they supply the front of the upper part of the auricula, being distributed principally to the skin covering the front of the helix and tragus.

The **branches to the external acoustic meatus** (*n. meatus auditorii externi*), two in number, enter the meatus between its bony and cartilaginous portions and supply the skin lining it; the upper one sends a filament to the tympanic membrane.

The **articular branches** consist of one or two twigs which enter the posterior part of the temporomandibular joint.

The **parotid branches** (*rami parotidei*) supply the parotid gland.

The **superficial temporal branches** (*rami temporales superficiales*) accompany the superficial temporal artery to the vertex of the skull; they supply the skin of the temporal region and communicate with the facial and zygomaticotemporal nerves.

The **Lingual Nerve** (*n. lingualis*) supplies the mucous membrane of the anterior two-thirds of the tongue. It lies at first beneath the Pterygoideus externus, medial to and in front of the inferior alveolar nerve, and is occasionally joined to this

nerve by a branch which may cross the internal maxillary artery. The chorda tympani also joins it at an acute angle in this situation. The nerve then passes between the Pterygoideus internus and the ramus of the mandible, and crosses obliquely to the side of the tongue over the Constrictor pharyngis superior and Styloglossus, and then between the Hyoglossus and deep part of the submaxillary gland; it finally runs across the duct of the submaxillary gland, and along the tongue to its tip, lying immediately beneath the mucous membrane.

Its **branches of communication** are with the facial (through the chorda tympani), the inferior alveolar and hypoglossal nerves, and the submaxillary ganglion. The branches to the submaxillary ganglion are two or three in number; those connected with the hypoglossal nerve form a plexus at the anterior margin of the Hyoglossus.

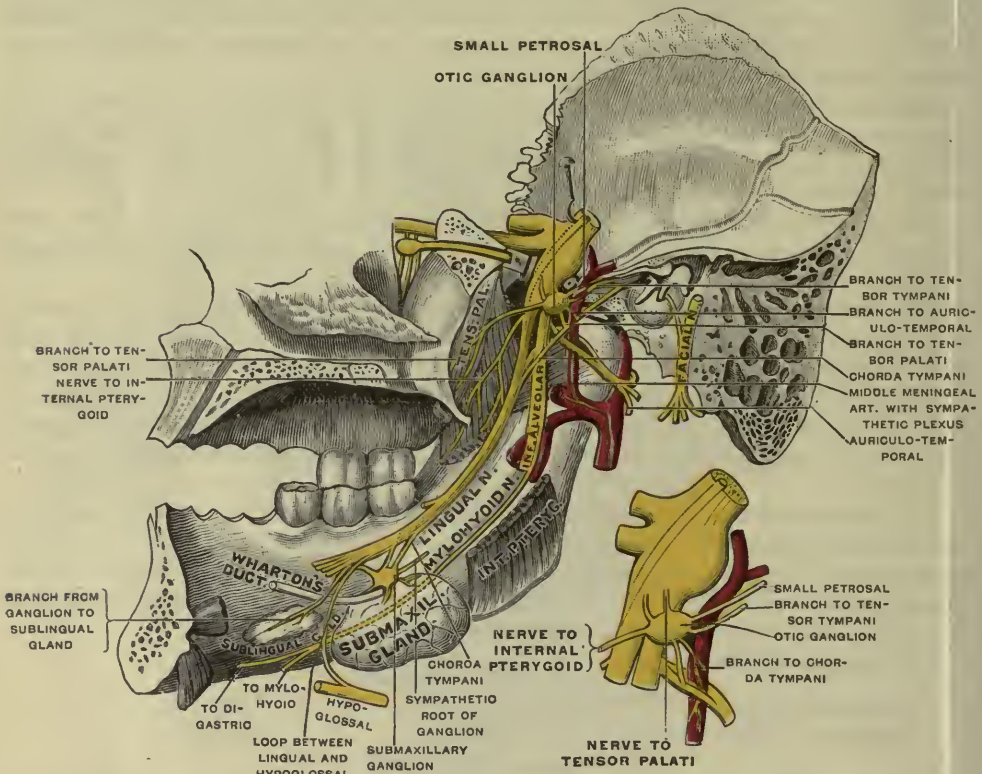


FIG. 782.—Mandibular division of trifacial nerve, seen from the middle line. The small figure is an enlarged view of the otic ganglion. (Testut.)

Its **branches of distribution** supply the sublingual gland, the mucous membrane of the mouth, the gums, and the mucous membrane of the anterior two-thirds of the tongue; the terminal filaments communicate, at the tip of the tongue, with the hypoglossal nerve.

The **Inferior Alveolar Nerve** (*n. alveolaris inferior*; *inferior dental nerve*) (Fig. 782) is the largest branch of the mandibular nerve. It descends with the inferior alveolar artery, at first beneath the Pterygoideus externus, and then between the sphenomandibular ligament and the ramus of the mandible to the mandibular foramen. It then passes forward in the mandibular canal, beneath the teeth, as far as the mental foramen, where it divides into two terminal branches, incisive and mental.

The branches of the inferior alveolar nerve are the **mylohyoid**, **dental**, **incisive**, and **mental**.

The **mylohyoid nerve** (*n. mylohyoideus*) is derived from the inferior alveolar just

before it enters the mandibular foramen. It descends in a groove on the deep surface of the ramus of the mandible, and reaching the under surface of the Mylohyoideus supplies this muscle and the anterior belly of the Digastricus.

The **dental branches** supply the molar and premolar teeth. They correspond in number to the roots of those teeth; each nerve entering the orifice at the point of the root, and supplying the pulp of the tooth; above the alveolar nerve they form an **inferior dental plexus**.

The **incisive branch** is continued onward within the bone, and supplies the canine and incisor teeth.

The **mental nerve** (*n. mentalis*) emerges at the mental foramen, and divides beneath the Triangularis muscle into three branches; one descends to the skin of the chin, and two ascend to the skin and mucous membrane of the lower lip; these branches communicate freely with the facial nerve.

Two small ganglia, the **otic** and the **submaxillary**, are connected with the mandibular nerve.

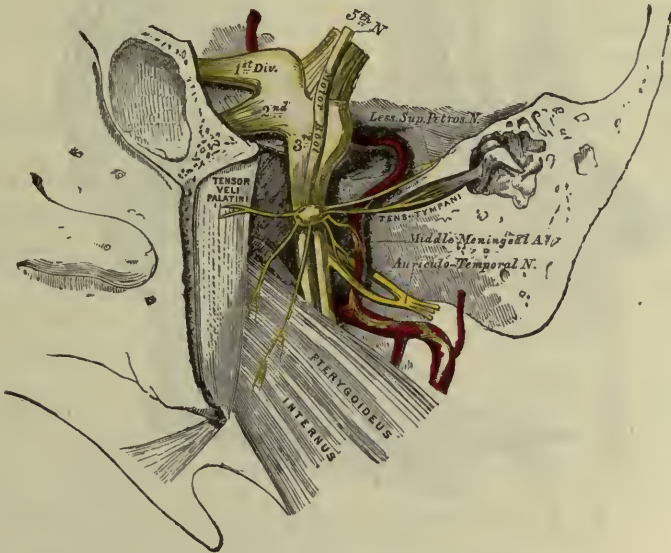


FIG. 783.—The otic ganglion and its branches.

Otic Ganglion (*ganglion oticum*) (Fig. 783).—The otic ganglion is a small, oval-shaped, flattened ganglion of a reddish-gray color, situated immediately below the foramen ovale; it lies on the medial surface of the mandibular nerve, and surrounds the origin of the nerve to the Pterygoideus internus. It is in relation, *laterally*, with the trunk of the mandibular nerve at the point where the motor and sensory roots join; *medially*, with the cartilaginous part of the auditory tube, and the origin of the Tensor veli palatini; *posteriorly*, with the middle meningeal artery.

Branches of Communication.—It is connected by two or three short filaments with the nerve to the Pterygoideus internus, from which it may obtain a motor, and possibly a sensory root. It communicates with the glossopharyngeal and facial nerves, through the lesser superficial petrosal nerve continued from the tympanic plexus, and through this nerve it probably receives a root from the glossopharyngeal and a motor root from the facial; its sympathetic root consists of a filament from the plexus surrounding the middle meningeal artery. The fibers from the glossopharyngeal which pass to the otic ganglion in the small superficial petrosal are supposed to be sympathetic efferent (preganglionic) fibers from the

dorsal nucleus or inferior salivatory nucleus of the medulla. Fibers (postganglionic) from the otic ganglion with which these form synapses are supposed to pass with the auriculotemporal nerve to the parotid gland. A slender filament (sphenoidal) ascends from it to the nerve of the Pterygoid canal, and a small branch connects it with the chorda tympani.

Its **branches of distribution** are: a filament to the Tensor tympani, and one to the Tensor veli palatini. The former passes backward, lateral to the auditory tube; the latter arises from the ganglion, near the origin of the nerve to the Pterygoideus internus, and is directed forward. The fibers of these nerves are, however, mainly derived from the nerve to the Pterygoideus internus.

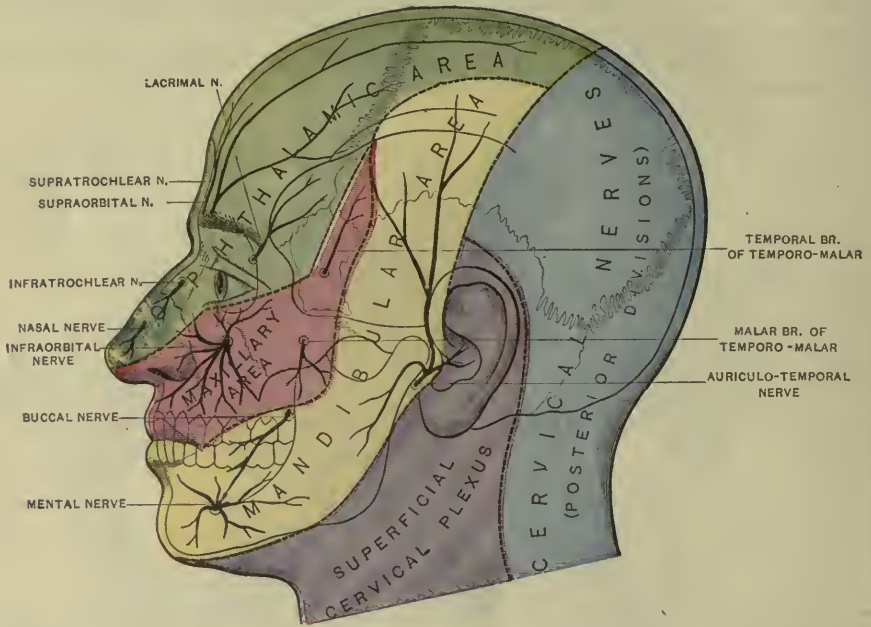


FIG. 784.—Sensory areas of the head, showing the general distribution of the three divisions of the fifth nerve. (Modified from Testut.)

Submaxillary Ganglion (*ganglion submaxillare*) (Fig. 778).—The submaxillary ganglion is of small size and is fusiform in shape. It is situated above the deep portion of the submaxillary gland, on the hyoglossus, near the posterior border of the Mylohyoideus, and is connected by filaments with the lower border of the lingual nerve. It is suspended from the lingual nerve by two filaments which join the anterior and posterior parts of the ganglion. Through the posterior of these it receives a branch from the chorda tympani nerve which runs in the sheath of the lingual; these are sympathetic efferent (preganglionic) fibers from the facial nucleus or the superior salivatory nucleus of the medulla oblongata that terminate in the submaxillary ganglion. The postganglionic fibers pass to the submaxillary gland, it communicates with the sympathetic by filaments from the sympathetic plexus around the external maxillary artery.

Its **branches of distribution** are five or six in number; they *arise* from the lower part of the ganglion, and supply the mucous membrane of the mouth and the duct of the submaxillary gland, some being lost in the submaxillary gland. The branch of communication from the lingual to the forepart of the ganglion is by some regarded as a branch of distribution, through which filaments pass from the ganglion to the lingual nerve, and by it are conveyed to the sublingual gland and the tongue.

Trigeminal Nerve Reflexes.—Pains referred to various branches of the trigeminal nerve are of very frequent occurrence, and should always lead to a careful examination in order to discover a local cause. As a general rule the diffusion of pain over the various branches of the nerve is at first confined to one only of the main divisions, and the search for the causative lesion should always commence with a thorough examination of all those parts which are supplied by that division; although in severe cases pain may radiate over the branches of the other main divisions. The commonest example of this condition is the neuralgia which is so often associated with dental caries—here, although the tooth itself may not appear to be painful, the most distressing referred pains may be experienced, and these are at once relieved by treatment directed to the affected tooth.

Many other examples of trigeminal reflexes could be quoted, but it will be sufficient to mention the more common ones. Dealing with the ophthalmic nerve, severe supraorbital pain is commonly associated with acute glaucoma or with disease of the frontal or ethmoidal air cells. Malignant growths or empyema of the maxillary antrum, or unhealthy conditions about the inferior conchæ or the septum of the nose, are often found giving rise to "second division" neuralgia, and should be always looked for in the absence of dental disease in the maxilla.

It is on the mandibular nerve, however, that some of the most striking reflexes are seen. It is quite common to meet with patients who complain of pain in the ear, in whom there is no sign of aural disease, and the cause is usually to be found in a carious tooth in the mandible. Moreover, with an ulcer or cancer of the tongue, often the first pain to be experienced is one which radiates to the ear and temporal fossa, over the distribution of the auriculotemporal nerve.

THE ABDUCENT NERVE (N. ABDUCENS; SIXTH NERVE) (Fig. 777).

The abducent nerve supplies the Rectus lateralis oculi.

Its fibers arise from a small nucleus situated in the upper part of the rhomboid fossa, close to the middle line and beneath the colliculus facialis. They pass downward and forward through the pons, and emerge in the furrow between the lower border of the pons and the upper end of the pyramid of the medulla oblongata.

From the nucleus of the sixth nerve, fibers are said to pass through the medial longitudinal fasciculus to the oculomotor nerve of the opposite side, along which they are carried to the Rectus medialis. The Rectus lateralis of one eye and the Rectus medialis of the other may therefore be said to receive their nerves from the same nucleus (Fig. 785).

The nerve pierces the dura mater on the dorsum sellæ of the sphenoid, runs through a notch in the bone below the posterior clinoid process, and passes forward through the cavernous sinus, on the lateral side of the internal carotid artery. It enters the orbit through the superior orbital fissure, above the ophthalmic vein, from which it is separated by a lamina of dura mater. It then passes between the two heads of the Rectus lateralis, and enters the ocular surface of that muscle. The abducent nerve is joined by several filaments from the carotid and cavernous plexuses, and by one from the ophthalmic nerve. The oculomotor, trochlear, ophthalmic, and abducent nerves bear certain relations to each

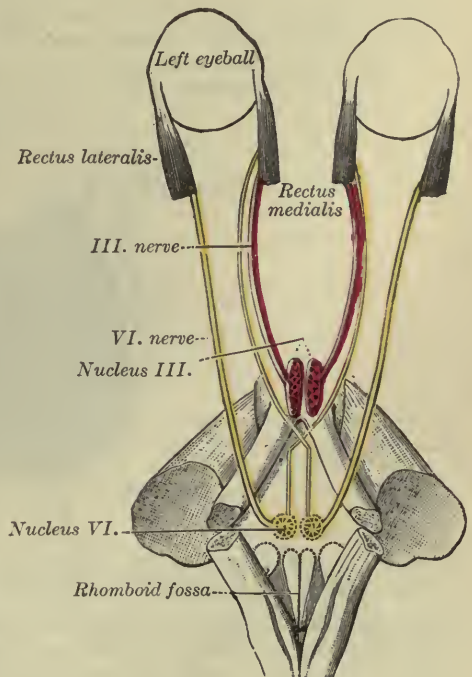


FIG. 785.—Figure showing the mode of innervation of the Recti medialis and lateralis of the eye (after Duval and Laborde).

other in the cavernous sinus, at the superior orbital fissure, and in the cavity of the orbit, as follows:

In the **cavernous sinus** (Fig. 786), the oculomotor, trochlear, and ophthalmic nerves are placed in the lateral wall of the sinus, in the order given, from above downward. The abducent nerve lies at the lateral side of the internal carotid artery. As these nerves pass forward to the superior orbital fissure, the oculomotor and ophthalmic divide into branches, and the abducent nerve approaches the others; so that their relative positions are considerably changed.

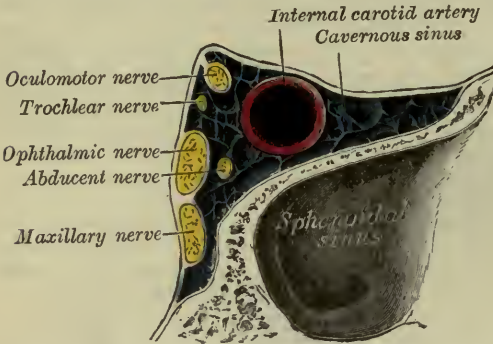


FIG. 786.—Oblique section through the right cavernous sinus.

In the **superior orbital fissure** (Fig. 787), the trochlear nerve and the frontal and lacrimal divisions of the ophthalmic lie in this order from the medial to the lateral side upon the same plane; they enter the cavity of the orbit above the muscles. The remaining nerves enter the orbit between the two heads of the Rectus lateralis. The superior division of

the oculomotor is the highest of these; beneath this lies the nasociliary branch of the ophthalmic; then the inferior division of the oculomotor; and the abducent lowest of all.

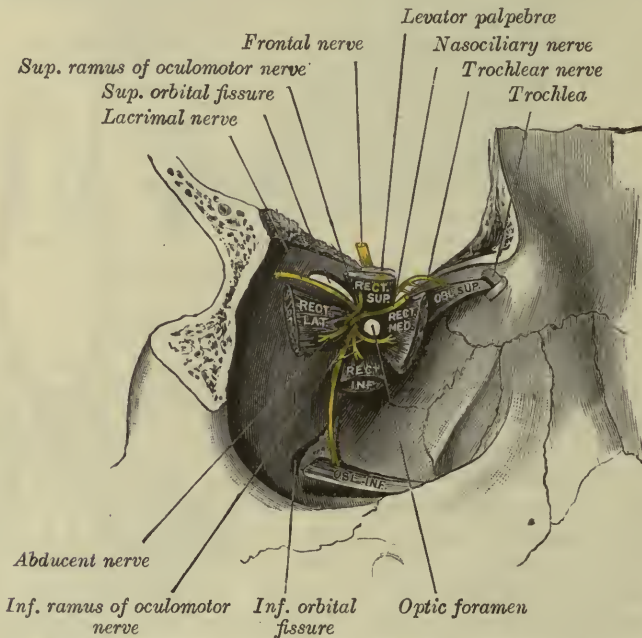


FIG. 787.—Dissection showing origins of right ocular muscles, and nerves entering by the superior orbital fissure.

In the **orbit**, the trochlear, frontal, and lacrimal nerves lie immediately beneath the periosteum, the trochlear nerve resting on the Obliquus superior, the frontal on the Levator palpebrae superioris, and the lacrimal on the Rectus lateralis. The superior division of the oculomotor nerve lies immediately beneath the Rectus

superior, while the nasociliary nerve crosses the optic nerve to reach the medial wall of the orbit. Beneath these is the optic nerve, surrounded in front by the ciliary nerves, and having the ciliary ganglion on its lateral side, between it and the Rectus lateralis. Below the optic nerve are the inferior division of the oculomotor, and the abducent, the latter lying on the medial surface of the Rectus lateralis.

THE FACIAL NERVE (N. FACIALIS; SEVENTH NERVE) (Figs. 788, 790).

The **facial nerve** consists of a motor and a sensory part, the latter being frequently described under the name of the **nervus intermedius** (*pars intermedii* of *Wrisberg*) (Fig. 788). The two parts emerge at the lower border of the pons in the recess between the olive and the inferior peduncle, the motor part being the more medial, immediately to the lateral side of the sensory part is the acoustic nerve.

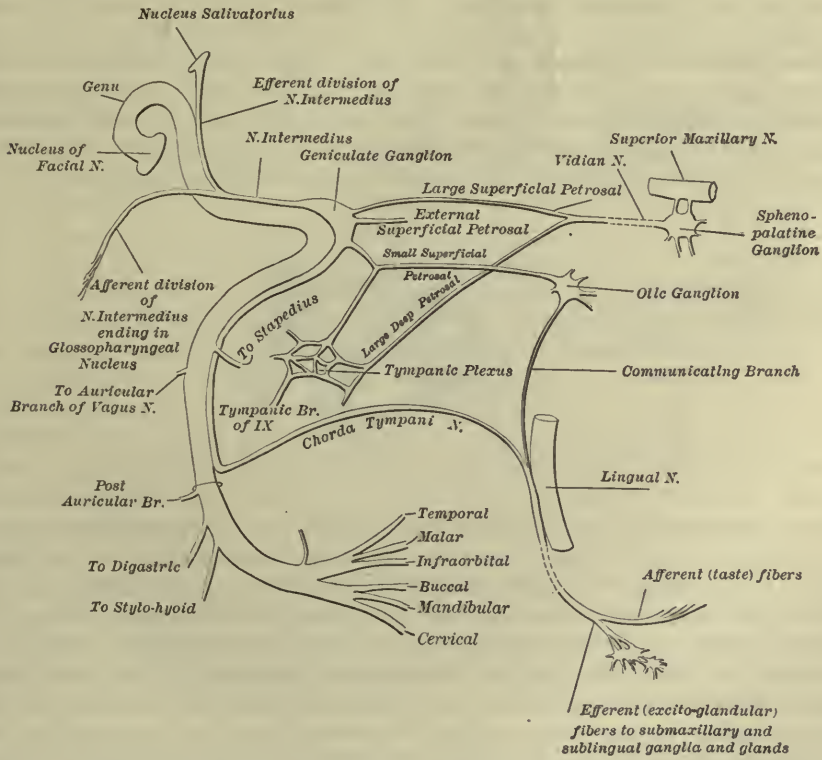


Fig. 788.—Plan of the facial and intermediate nerves and their communication with other nerves.

The motor part supplies somatic motor fibers to the muscles of the face, scalp, and auricle, the Buccinator and Platysma, the Stapedius, the Stylohyoideus, and posterior belly of the Digastricus; it also contains some sympathetic motor fibers which constitute the vasodilator nerves of the submaxillary and sublingual glands, and are conveyed through the chorda tympani nerve. These are preganglionic fibers of the sympathetic system and terminate in the submaxillary ganglion and small ganglia in the hilus of the submaxillary gland. From these ganglia postganglionic fibers are conveyed to these glands. The sensory part contains the fibers of taste for the anterior two-thirds of the tongue and a few somatic

sensory fibers from the middle ear region. A few splanchnic sensory fibers are also present.

The **motor root** *arises* from a nucleus which lies deeply in the reticular formation of the lower part of the pons. This nucleus is situated above the nucleus ambiguus, behind the superior olivary nucleus, and medial to the spinal tract of the trigeminal nerve. From this origin the fibers pursue a curved course in the substance of the pons. They first pass backward and medialward toward the rhomboid fossa, and, reaching the posterior end of the nucleus of the abducent nerve, run upward close to the middle line beneath the colliculus fasciculus. At the anterior end of the nucleus of the abducent nerve they make a second bend, and run downward and forward through the pons to their point of emergence between the olive and the inferior peduncle.

The **sensory root** *arises* from the genicular ganglion, which is situated on the geniculum of the facial nerve in the facial canal, behind the hiatus of the canal. The cells of this ganglion are unipolar, and the single process divides in a T-shaped manner into central and peripheral branches. The central branches leave the trunk of the facial nerve in the internal acoustic meatus, and form the sensory root; the peripheral branches are continued into the chorda tympani and greater superficial petrosal nerves. Entering the brain at the lower border of the pons between the motor root and the acoustic nerve, the fibers of the sensory root pass into the substance of the medulla oblongata and end in the upper part of the terminal nucleus of the glossopharyngeal nerve and in the fasciculus solitarius.

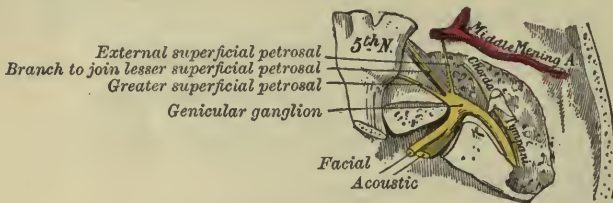


Fig. 789.—The course and connections of the facial nerve in the temporal bone.

From their superficial attachments to the brain, the two roots of the facial nerve pass lateralward and forward with the acoustic nerve to the internal acoustic meatus. In the meatus the motor root lies in a groove on the upper and anterior surface of the acoustic nerve, the sensory root being placed between them.

At the bottom of the meatus, the facial nerve enters the facial canal, which it traverses to its termination at the stylomastoid foramen. It is at first directed lateralward between the cochlea and vestibule toward the medial wall of the tympanic cavity; it then bends suddenly backward and arches downward behind the tympanic cavity to the stylomastoid foramen. The point where it changes its direction is named the **geniculum**; it presents a reddish gangliform swelling, the **genicular ganglion** (*ganglion geniculi*; *geniculate ganglion*; *nucleus of the sensory root of the nerve*) (Fig. 789). On emerging from the stylomastoid foramen, the facial nerve runs forward in the substance of the parotid gland, crosses the external carotid artery, and divides behind the ramus of the mandible into branches, from which numerous offsets are distributed over the side of the head, face, and upper part of the neck, supplying the superficial muscles in these regions. The branches and their offsets unite to form the **parotid plexus**.

Branches of Communication.—The branches of communication of the facial nerve may be arranged as follows:

In the internal acoustic meatus	With the acoustic nerve.
At the genicular ganglion	{ With the sphenopalatine ganglion by the greater superficial petrosal nerve.
	{ With the otic ganglion by a branch which joins the lesser superficial petrosal nerve.
	{ With the sympathetic on the middle meningeal artery.
In the facial canal	With the auricular branch of the vagus.
At its exit from the stylomastoid foramen	{ With the glossopharyngeal.
	{ With the vagus.
	{ With the great auricular.
	{ With the auriculotemporal.
Behind the ear	With the lesser occipital.
On the face	With the trigeminal.
In the neck	With the cutaneous cervical.

In the internal acoustic meatus some minute filaments pass from the facial to the acoustic nerve.

The **greater superficial petrosal nerve** (*large superficial petrosal nerve*) arises from the genicular ganglion, and consists chiefly of sensory branches which are distributed to the mucous membrane of the soft palate; but it probably contains a few motor fibers which form the motor root of the sphenopalatine ganglion. It passes forward through the hiatus of the facial canal, and runs in a sulcus on the anterior surface of the petrous portion of the temporal bone beneath the semilunar ganglion, to the foramen lacerum. It receives a twig from the tympanic plexus, and in the foramen is joined by the deep petrosal, from the sympathetic plexus on the internal carotid artery, to form the nerve of the pterygoid canal which passes forward through the pterygoid canal and ends in the sphenopalatine ganglion. The genicular ganglion is connected with the otic ganglion by a branch which joins the lesser superficial petrosal nerve, and also with the sympathetic filaments accompanying the middle meningeal artery. According to Arnold, a twig passes back from the ganglion to the acoustic nerve. Just before the facial nerve emerges from the stylomastoid foramen, it generally receives a twig from the auricular branch of the vagus.

After its exit from the stylomastoid foramen, the facial nerve sends a twig to the glossopharyngeal, and communicates with the auricular branch of the vagus, with the great auricular nerve of the cervical plexus, with the auriculotemporal nerve in the parotid gland, and with the lesser occipital behind the ear; on the face with the terminal branches of the trigeminal, and in the neck with the cutaneous cervical nerve.

Branches of Distribution.—The branches of distribution (Fig. 788) of the facial nerve may be thus arranged:

With the facial canal	{ Nerve to the Stapedius muscle.
	{ Chorda tympani.
At its exit from the stylomastoid foramen	{ Posterior auricular.
	{ Digastric.
	{ Stylohyoid.
On the face	{ Temporal.
	{ Zygomatic.
	{ Buccal.
	{ Mandibular.
	{ Cervical.

the majority of its fibers are afferent, and are continued onward through the muscular substance of the tongue to the mucous membrane covering its anterior two-thirds; they constitute the nerve of taste for this portion of the tongue. Before uniting with the lingual nerve the chorda tympani is joined by a small branch from the otic ganglion.

The **Posterior Auricular Nerve** (*n. auricularis posterior*) arises close to the stylo-mastoid foramen, and runs upward in front of the mastoid process; here it is joined by a filament from the auricular branch of the vagus, and communicates with the posterior branch of the great auricular, and with the lesser occipital. As it ascends between the external acoustic meatus and mastoid process it divides into auricular and occipital branches. The **auricular branch** supplies the Auricularis posterior and the intrinsic muscles on the cranial surface of the auricula. The **occipital branch**, the larger, passes backward along the superior nuchal line of the occipital bone, and supplies the Occipitalis.

The **Digastric Branch** (*ramus digastricus*) arises close to the stylo-mastoid foramen, and divides into several filaments, which supply the posterior belly of the Digastricus; one of these filaments joins the glossopharyngeal nerve.

The **Stylohyoid Branch** (*ramus stylohyoideus*) frequently arises in conjunction with the digastric branch; it is long and slender, and enters the Stylohyoideus about its middle.

The **Temporal Branches** (*rami temporales*) cross the zygomatic arch to the temporal region, supplying the Auriculares anterior and superior, and joining with the zygomaticotemporal branch of the maxillary, and with the auriculotemporal branch of the mandibular. The more anterior branches supply the Frontalis, the Orbicularis oculi, and the Corrugator, and join the supraorbital and lacrimal branches of the ophthalmic.

The **Zygomatic Branches** (*rami zygomatici; malar branches*) run across the zygomatic bone to the lateral angle of the orbit, where they supply the Orbicularis oculi, and join with filaments from the lacrimal nerve and the zygomaticofacial branch of the maxillary nerve.

The **Buccal Branches** (*rami buccales; infraorbital branches*), of larger size than the rest, pass horizontally forward to be distributed below the orbit and around the mouth. The **superficial branches** run beneath the skin and above the superficial muscles of the face, which they supply: some are distributed to the Procerus, joining at the medial angle of the orbit with the infratrochlear and nasociliary branches of the ophthalmic. The **deep branches** pass beneath the Zygomaticus and the Quadratus labii superioris, supplying them and forming an **infraorbital plexus** with the infraorbital branch of the maxillary nerve. These branches also supply the small muscles of the nose. The lower deep branches supply the Buccinator and Orbicularis oris, and join with filaments of the buccinator branch of the mandibular nerve.

The **Mandibular Branch** (*ramus marginalis mandibularæ*) passes forward beneath the Platysma and Triangularis, supplying the muscles of the lower lip and chin, and communicating with the mental branch of the inferior alveolar nerve.

The **Cervical Branch** (*ramus colli*) runs forward beneath the Platysma, and forms a series of arches across the side of the neck over the suprahyoid region. One branch descends to join the cervical cutaneous nerve from the cervical plexus; others supply the Platysma.

THE ACOUSTIC NERVE (EIGHTH NERVE).

The **acoustic nerve** consists of two distinct sets of fibers which differ in their peripheral endings, central connections, functions, and time of medullation. It is soft in texture and devoid of neurilemma.

Cochlear Nerve.—The cochlear nerve or root, the **nerve of hearing**, arises from bipolar cells in the spiral ganglion of the cochlea, situated near the inner edge of the osseous spiral lamina. The peripheral fibers pass to the organ of Corti. The central ones pass down the modiolus and then through the foramina of the tractus spiralis foraminosus or through the foramen centrale into the lateral or outer end of the internal auditory meatus. The nerve passes along the internal auditory meatus with the vestibular nerve and across the subarachnoid space, just above the flocculus, almost directly medialward toward the inferior peduncle to terminate in the cochlear nucleus.

The cochlear nerve is placed lateral to the vestibular root. Its fibers end in two nuclei: one, the **accessory nucleus**, lies immediately in front of the inferior peduncle; the other, the **tuberculum acusticum**, somewhat lateral to it.

The **striæ medullares** (*striæ acusticæ*) are the axons of the cells of the tuberculum acusticum. They pass over the inferior peduncle, and across the rhomboid fossa to the median sulcus. Here they dip into the substance of the pons, to end around the cells of the superior olivary nuclei of both sides. There are, however, other fibers, and these are both direct and crossed, which pass into the lateral lemniscus. The cells of the accessory nucleus give origin to fibers which run transversely in the pons and constitute the trapezium. Of the trapezoid fibers some end around the cells of the superior olivary nucleus or of the trapezoid nucleus of the same or opposite side, while others, crossed or uncrossed, pass directly into the lateral lemniscus.

If the further connections of the cochlear nerve of one side, say the left, be considered, it is found that they lie lateral to the main sensory tract, the lemniscus, and are therefore termed the **lateral lemniscus**. The fibers comprising the left lateral lemniscus *arise* in the superior olivary and trapezoid nuclei of the same or opposite side, while others are the uninterrupted fibers already alluded to, and these are either crossed or uncrossed, the former being the axons of the cells of the right accessory nucleus or of the cells of the right tuberculum acusticum, while the latter are derived from the cells of the left nuclei. In the upper part of the lateral lemniscus there is a collection of nerve cells, the **nucleus of the lateral lemniscus**, around the cells of which some of the fibers arborize and from the cells of which axons originate to continue upward the tract of the lateral lemniscus. The ultimate ending of the left lateral lemniscus is partly in the opposite medial geniculate body, and partly in the inferior colliculi. From the cells of these bodies new fibers arise and ascend in the occipital part of the internal capsule to reach the posterior three-fifths of the left superior temporal gyrus and the transverse temporal gyri.

Vestibular Nerve.—The vestibular nerve or root, the **nerve of equilibration**, arises from bipolar cells in the vestibular ganglion, **ganglion of Scarpa**, which is situated in the upper part of the outer end of the internal auditory meatus. The peripheral fibers divide into three branches: the superior branch passes through the foramina in the area vestibularis superior and ends in the utricle and in the ampullæ of the superior and lateral semicircular ducts; the fibers of the inferior branch traverse the foramina in the area vestibularis inferior and end in the saccule; the posterior branch runs through the foramen singulare and supplies the ampulla of the posterior semicircular duct.

THE GLOSSOPHARYNGEAL NERVE (N. GLOSSOPHARYNGEUS; NINTH NERVE) (Figs. 791, 792, 793).

The **glossopharyngeal nerve** contains both motor and sensory fibers, and is distributed, as its name implies, to the tongue and pharynx. It is the nerve of ordinary sensation to the mucous membrane of the pharynx, fauces, and palatine tonsil, and the nerve of taste to the posterior part of the tongue. It is attached by three or

four filaments to the upper part of the medulla oblongata, in the groove between the olive and the inferior peduncle.

The **sensory fibers** arise from the cells of the superior and petrous ganglia, which are situated on the trunk of the nerve, and will be presently described. When traced into the medulla, some of the sensory fibers, probably sympathetic afferent, end by arborizing around the cells of the upper part of a nucleus which lies beneath the ala cinerea in the lower part of the rhomboid fossa. Many of the fibers, probably the **taste fibers**, contribute to form a strand, named the **fasciculus solitarius**, which descends in the medulla oblongata. Associated with this strand are numerous nerve cells, and around these the fibers of the fasciculus end. The **somatic sensory fibers**, few in number, are said to join the spinal tract of the trigeminal nerve.

The **somatic motor fibers** spring from the cells of the

nucleus ambiguus, which lies some distance from the surface of the rhomboid fossa in the lateral part of the medulla and is continuous below with the anterior gray column of the medulla spinalis. From this nucleus the fibers are first directed backward, and then they bend forward and lateralward to join the fibers of the sensory root. The nucleus ambiguus gives origin to the motor branches of the glossopharyngeal and vagus nerves, and to the cranial part of the accessory nerve.

The **sympathetic efferent fibers** from the nucleus beneath the ala cinerea, the dorsal nucleus, are probably both preganglionic motor fibers and preganglionic secretory fibers of the sympathetic system. The secretory fibers pass to the otic ganglion and from it secondary neurons are distributed to the parotid gland. Some authors describe these fibers as arising from a distinct nucleus the inferior salivatory nucleus, which lies near the dorsal nucleus.

From the medulla oblongata, the glossopharyngeal nerve passes lateralward across the flocculus, and leaves the skull through the central part of the jugular foramen, in a separate sheath of the dura mater, lateral to and in front of the vagus and accessory nerves (Fig. 792). In its passage through the jugular foramen, it grooves the lower border of the petrous part of the temporal bone; and, at its exit from the skull, passes forward between the internal jugular vein and internal carotid artery; it descends in front of the latter vessel, and beneath the styloid process and the muscles connected with it, to the lower border of the Stylopharyngeus. It then curves forward, forming an arch on the side of the neck and lying upon the Stylopharyngeus and Constrictor pharyngis medius. Thence it passes under cover of the Hyoglossus, and is finally distributed to the palatine tonsil, the mucous membrane of the fauces and base of the tongue, and the mucous glands of the mouth.

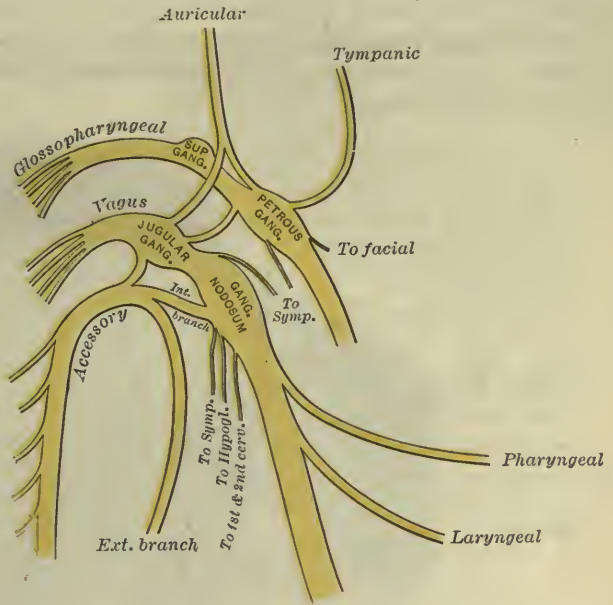


FIG. 791.—Plan of upper portions of glossopharyngeal, vagus, and accessory nerves.

In passing through the jugular foramen, the nerve presents two ganglia, the superior and the petrous (Fig. 791).

The **Superior Ganglion** (*ganglion superius; jugular ganglion*) is situated in the upper part of the groove in which the nerve is lodged during its passage through the jugular foramen. It is very small, and is usually regarded as a detached portion of the petrous ganglion.

The **Petrous Ganglion** (*ganglion petrosum; inferior ganglion*) is larger than the superior and is situated in a depression in the lower border of the petrous portion of the temporal bone.

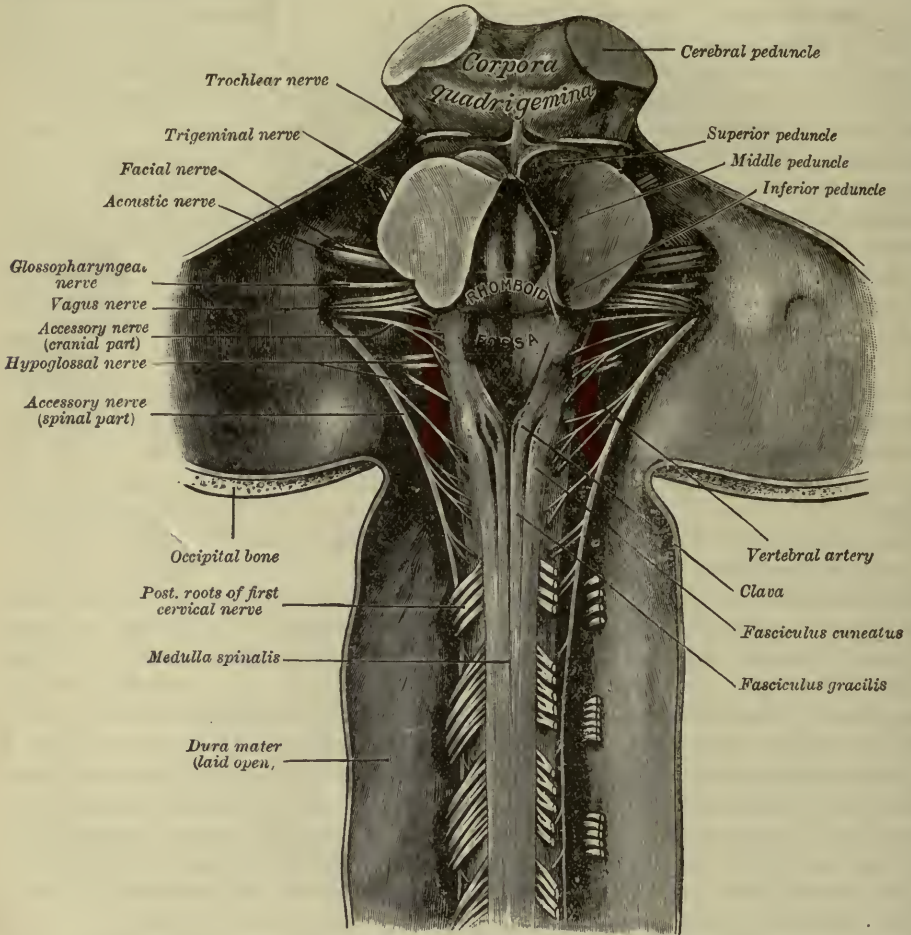


FIG. 792.—Upper part of medulla spinalis and hind- and mid-brains; posterior aspect, exposed *in situ*.

Branches of Communication.—The glossopharyngeal nerve communicates with the vagus, sympathetic, and facial.

The branches to the vagus are two filaments which arise from the petrous ganglion, one passing to the auricular branch, and the other to the jugular ganglion, of the vagus. The petrous ganglion is connected by a filament with the superior cervical ganglion of the sympathetic. The branch of communication with the facial perforates the posterior belly of the Digastricus. It arises from the trunk of the glossopharyngeal below the petrous ganglion, and joins the facial just after the exit of that nerve from the stylomastoid foramen.

Branches of Distribution.—The branches of distribution of the glossopharyngeal are: the tympanic, carotid, pharyngeal, muscular, tonsillar, and lingual.

The **Tympanic Nerve** (*n. tympanicus*; *nerve of Jacobson*) arises from the petrous ganglion, and ascends to the tympanic cavity through a small canal on the under surface of the petrous portion of the temporal bone on the ridge which separates the carotid canal from the jugular fossa. In the tympanic cavity it divides into branches which form the **tympanic plexus** and are contained in grooves upon the surface of the promontory. This plexus gives off: (1) the lesser superficial petrosal nerve; (2) a branch to join the greater superficial petrosal nerve; and (3) branches to the tympanic cavity, all of which will be described in connection with the anatomy of the middle ear.

The **Carotid Branches** (*n. caroticotympanicus superior* and *n. caroticotympanicus inferior*) descend along the trunk of the internal carotid artery as far as its origin, communicating with the pharyngeal branch of the vagus, and with branches of the sympathetic.

The **Pharyngeal Branches** (*rami pharyngei*) are three or four filaments which unite, opposite the Constrictor pharyngis medius, with the pharyngeal branches of the vagus and sympathetic, to form the **pharyngeal plexus**; branches from this plexus perforate the muscular coat of the pharynx and supply its muscles and mucous membrane.

The **Muscular Branch** (*ramus stylopharyngeus*) is distributed to the Stylopharyngeus.

The **Tonsillar Branches** (*rami tonsillares*) supply the palatine tonsil, forming around it a plexus from which filaments are distributed to the soft palate and fauces, where they communicate with the palatine nerves.

The **Lingual Branches** (*rami linguales*) are two in number; one supplies the papillæ vallatæ and the mucous membrane covering the base of the tongue; the other supplies the mucous membrane and follicular glands of the posterior part of the tongue, and communicates with the lingual nerve.

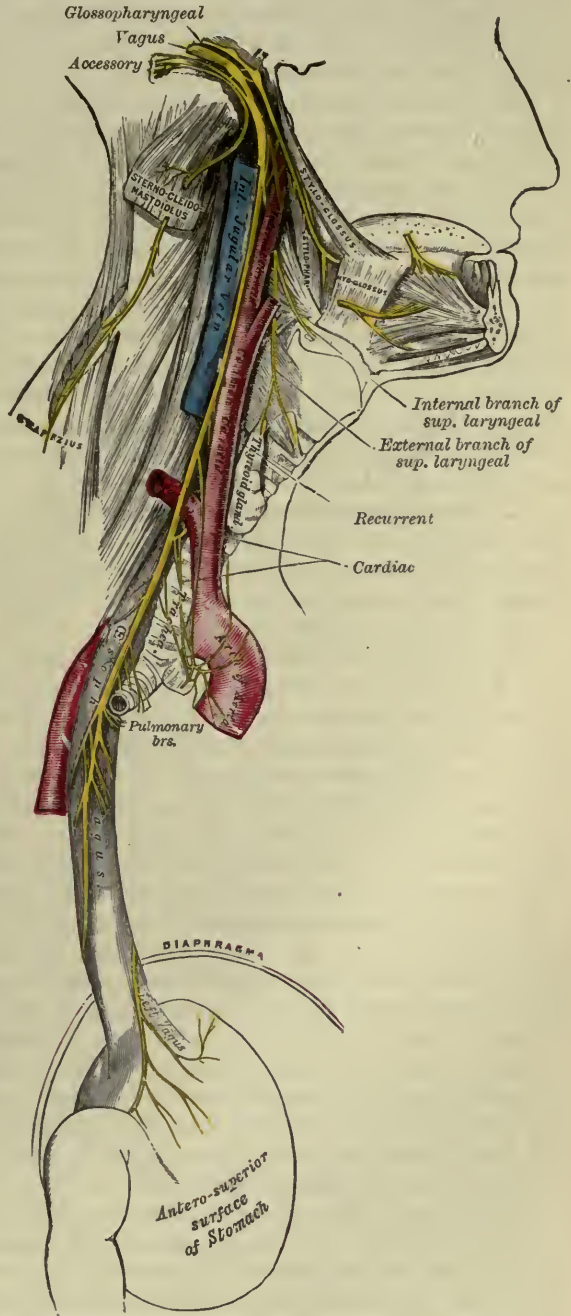


FIG. 793.—Course and distribution of the glossopharyngeal, vagus, and accessory nerves.

THE VAGUS NERVE (N. VAGUS; TENTH NERVE; PNEUMOGASTRIC NERVE) (Figs. 791, 792, 793).

The **vagus nerve** is composed of both motor and sensory fibers, and has a more extensive course and distribution than any of the other cranial nerves, since it passes through the neck and thorax to the abdomen.

The vagus is attached by eight or ten filaments to the medulla oblongata in the groove between the olive and the inferior peduncle, below the glossopharyngeal. The **sensory fibers** arise from the cells of the jugular ganglion and ganglion nodosum of the nerve, and, when traced into the medulla oblongata mostly end by arborizing around the cells of the inferior part of a nucleus which lies beneath the ala cinerea in the lower part of the rhomboid fossa. These are the sympathetic afferent fibers. Some of the sensory fibers of the glossopharyngeal nerve have been seen to end in the upper part of this nucleus. A few of the sensory fibers of the vagus, probably **taste fibers**, descend in the fasciculus solitarius and end around its cells. The **somatic sensory fibers**, few in number, from the posterior part of the external auditory meatus and the back of the ear, probably join the spinal tract of the trigeminal as it descends in the medulla. The **somatic motor fibers** arise from the cells of the nucleus ambiguus, already referred to in connection with the motor root of the glossopharyngeal nerve.

The **sympathetic efferent fibers**, distributed probably as preganglionic fibers to the thoracic and abdominal viscera, *i. e.*, as motor fibers to the bronchial tree, inhibitory fibers to the heart, motor fibers to the esophagus, stomach, small intestine and gall passages, and as secretory fibers to the stomach and pancreas, arise from the dorsal nucleus of the vagus.

The filaments of the nerve unite, and form a flat cord, which passes beneath the flocculus to the jugular foramen, through which it leaves the cranium. In emerging through this opening, the vagus is accompanied by and contained in the same sheath of dura mater with the accessory nerve, a septum separating them from the glossopharyngeal which lies in front (Fig. 792). In this situation the vagus presents a well-marked ganglionic enlargement, which is called the **jugular ganglion** (*ganglion of the root*); to it the accessory nerve is connected by one or two filaments. After its exit from the jugular foramen the vagus is joined by the cranial portion of the accessory nerve, and enlarges into a second gangliform swelling, called the **ganglion nodosum** (*ganglion of the trunk*); through this the fibers of the cranial portion of the accessory pass without interruption, being principally distributed to the pharyngeal and superior laryngeal branches of the vagus, but some of its fibers descend in the trunk of the vagus, to be distributed with the recurrent nerve and probably also with the cardiac nerves.

The vagus nerve passes vertically down the neck within the carotid sheath, lying between the internal jugular vein and internal carotid artery as far as the upper border of the thyroid cartilage, and then between the same vein and the common carotid artery to the root of the neck. The further course of the nerve differs on the two sides of the body.

On the *right side*, the nerve passes across the subclavian artery between it and the right innominate vein, and descends by the side of the trachea to the back of the root of the lung, where it spreads out in the **posterior pulmonary plexus**. From the lower part of this plexus two cords descend on the esophagus, and divide to form, with branches from the opposite nerve, the **esophageal plexus**. Below, these branches are collected into a single cord, which runs along the back of the esophagus enters the abdomen, and is distributed to the postero-inferior surface of the stomach, joining the left side of the celiac plexus, and sending filaments to the lienal plexus.

On the *left side*, the vagus enters the thorax between the left carotid and subclavian arteries, behind the left innominate vein. It crosses the left side of the

arch of the aorta, and descends behind the root of the left lung, forming there the **posterior pulmonary plexus**. From this it runs along the anterior surface of the esophagus, where it unites with the nerve of the right side in the **esophageal plexus**, and is continued to the stomach, distributing branches over its antero-superior surface; some of these extend over the fundus, and others along the lesser curvature. Filaments from these branches enter the lesser omentum, and join the hepatic plexus.

The **Jugular Ganglion** (*ganglion jugulare; ganglion of the root*) is of a grayish color, spherical in form, about 4 mm. in diameter.

Branches of Communication.—This ganglion is connected by several delicate filaments to the cranial portion of the accessory nerve; it also communicates by a twig with the petrous ganglion of the glossopharyngeal, with the facial nerve by means of its auricular branch, and with the sympathetic by means of an ascending filament from the superior cervical ganglion.

The **Ganglion Nodosum** (*ganglion of the trunk; inferior ganglion*) is cylindrical in form, of a reddish color, and 2.5 cm. in length. Passing through it is the cranial portion of the accessory nerve, which blends with the vagus below the ganglion.

Branches of Communication.—This ganglion is connected with the hypoglossal, the superior cervical ganglion of the sympathetic, and the loop between the first and second cervical nerves.

Branches of Distribution.—The branches of distribution of the vagus are:

In the Jugular Fossa	{ Meningeal. Auricular. Pharyngeal.
In the Neck	{ Superior laryngeal. Recurrent. Superior cardiac. Inferior cardiac.
In the Thorax	{ Anterior bronchial. Posterior bronchial. Esophageal.
In the Abdomen	{ Gastric. Celiac. Hepatic.

The **Meningeal Branch** (*ramus meningeus; dural branch*) is a recurrent filament given off from the jugular ganglion; it is distributed to the dura mater in the posterior fossa of the base of the skull.

The **Auricular Branch** (*ramus auricularis; nerve of Arnold*) arises from the jugular ganglion, and is joined soon after its origin by a filament from the petrous ganglion of the glossopharyngeal; it passes behind the internal jugular vein, and enters the mastoid canaliculus on the lateral wall of the jugular fossa. Traversing the substance of the temporal bone, it crosses the facial canal about 4 mm. above the stylo-mastoid foramen, and here it gives off an ascending branch which joins the facial nerve. The nerve reaches the surface by passing through the tympanomastoid fissure between the mastoid process and the tympanic part of the temporal bone, and divides into two branches: one joins the posterior auricular nerve, the other is distributed to the skin of the back of the auricula and to the posterior part of the external acoustic meatus.

The **Pharyngeal Branch** (*ramus pharyngeus*), the principal motor nerve of the pharynx, arises from the upper part of the ganglion nodosum, and consists principally of filaments from the cranial portion of the accessory nerve. It passes across the internal carotid artery to the upper border of the Constrictor pharyngis

medius, where it divides into numerous filaments, which join with branches from the glossopharyngeal, sympathetic, and external laryngeal to form the **pharyngeal plexus**. From the plexus, branches are distributed to the muscles and mucous membrane of the pharynx and the muscles of the soft palate, except the Tensor veli palatini. A minute filament descends and joins the hypoglossal nerve as it winds around the occipital artery.

The **Superior Laryngeal Nerve** (*n. laryngeus superior*) larger than the preceding, *arises* from the middle of the ganglion nodosum and in its course receives a branch from the superior cervical ganglion of the sympathetic. It descends, by the side of the pharynx, behind the internal carotid artery, and divides into two branches, **external** and **internal**.

The **external branch** (*ramus externus*), the smaller, descends on the larynx, beneath the Sternothyreoideus, to supply the Cricothyreoideus. It gives branches to the pharyngeal plexus and the Constrictor pharyngis inferior, and communicates with the superior cardiac nerve, behind the common carotid artery.

The **internal branch** (*ramus internus*) descends to the hyothyroid membrane, pierces it in company with the superior laryngeal artery, and is distributed to the mucous membrane of the larynx. Of these branches some are distributed to the epiglottis, the base of the tongue, and the epiglottic glands; others pass backward, in the aryepiglottic fold, to supply the mucous membrane surrounding the entrance of the larynx, and that lining the cavity of the larynx as low down as the vocal folds. A filament descends beneath the mucous membrane on the inner surface of the thyroid cartilage and joins the recurrent nerve.

The **Recurrent Nerve** (*n. recurrens; inferior or recurrent laryngeal nerve*) *arises*, on the *right side*, in front of the subclavian artery; winds from before backward around that vessel, and ascends obliquely to the side of the trachea behind the common carotid artery, and either in front of or behind the inferior thyroid artery. On the *left side*, it *arises* on the left of the arch of the aorta, and winds below the aorta at the point where the ligamentum arteriosum is attached, and then ascends to the side of the trachea. The nerve on either side ascends in the groove between the trachea and esophagus, passes under the lower border of the Constrictor pharyngis inferior, and enters the larynx behind the articulation of the inferior cornu of the thyroid cartilage with the cricoid; it is distributed to all the muscles of the larynx, excepting the Cricothyreoideus. It communicates with the internal branch of the superior laryngeal nerve, and gives off a few filaments to the mucous membrane of the lower part of the larynx.

As the recurrent nerve hooks around the subclavian artery or aorta, it gives off several cardiac filaments to the deep part of the cardiac plexus. As it ascends in the neck it gives off branches, more numerous on the left than on the right side, to the mucous membrane and muscular coat of the esophagus; branches to the mucous membrane and muscular fibers of the trachea; and some pharyngeal filaments to the Constrictor pharyngis inferior.

The **Superior Cardiac Branches** (*rami cardiaci superiores; cervical cardiac branches*), two or three in number, *arise* from the vagus, at the upper and lower parts of the neck.

The **upper branches** are small, and communicate with the cardiac branches of the sympathetic. They can be traced to the deep part of the cardiac plexus.

The **lower branch** *arises* at the root of the neck, just above the first rib. That from the right vagus passes in front or by the side of the innominate artery, and proceeds to the deep part of the cardiac plexus; that from the left runs down across the left side of the arch of the aorta, and joins the superficial part of the cardiac plexus.

The **Inferior Cardiac Branches** (*rami cardiaci inferiores; thoracic cardiac branches*), on the right side, *arise* from the trunk of the vagus as it lies by the side of the

trachea, and from its recurrent nerve; on the left side from the recurrent nerve only; passing inward, they end in the deep part of the cardiac plexus.

The **Anterior Bronchial Branches** (*rami bronchiales anteriores; anterior or ventral pulmonary branches*), two or three in number, and of small size, are distributed on the anterior surface of the root of the lung. They join with filaments from the sympathetic, and form the **anterior pulmonary plexus**.

The **Posterior Bronchial Branches** (*rami bronchiales posteriores; posterior or dorsal pulmonary branches*), more numerous and larger than the anterior, are distributed on the posterior surface of the root of the lung; they are joined by filaments from the third and fourth (sometimes also from the first and second) thoracic ganglia of the sympathetic trunk, and form the **posterior pulmonary plexus**. Branches from this plexus accompany the ramifications of the bronchi through the substance of the lung.

The **Esophageal Branches** (*rami œsophagei*) are given off both above and below the bronchial branches; the lower are numerous and larger than the upper. They form, together with the branches from the opposite nerve, the **esophageal plexus**. From this plexus filaments are distributed to the back of the pericardium.

The **Gastric Branches** (*rami gastrici*) are distributed to the stomach. The right vagus forms the **posterior gastric plexus** on the postero-inferior surface of the stomach and the left the **anterior gastric plexus** on the antero-superior surface.

The **Celiac Branches** (*rami cœliaci*) are mainly derived from the right vagus: they join the celiac plexus and through it supply branches to the pancreas, spleen, kidneys, suprarenal bodies, and intestine.

The **Hepatic Branches** (*rami hepatici*) arise from the left vagus: they join the hepatic plexus and through it are conveyed to the liver.

THE ACCESSORY NERVE (N. ACCESSORIUS; ELEVENTH NERVE; SPINAL ACCESSORY NERVE) (Figs. 792, 793, 794).

The **accessory nerve** consists of two parts: a **cranial** and a **spinal**.

The **Cranial Part** (*ramus internus; accessory portion*) is the smaller of the two. Its fibers arise from the cells of the **nucleus ambiguus** and emerge as four or five delicate rootlets from the side of the medulla oblongata, below the roots of the vagus. It runs lateralward to the jugular foramen, where it interchanges fibers with the spinal portion or becomes united to it for a short distance; here it is also connected by one or two filaments with the jugular ganglion of the vagus. It then passes through the jugular foramen, separates from the spinal portion and is continued over the surface of the ganglion nodosum of the vagus, to the surface of which it is adherent, and is distributed principally to the pharyngeal and superior laryngeal branches of the vagus. Through the pharyngeal branch it probably supplies the *Musculus uvulæ* and *Levator veli palatini*. Some few filaments from it are continued into the trunk of the vagus below the ganglion, to be distributed with the recurrent nerve and probably also with the cardiac nerves.

The **Spinal Part** (*ramus externus; spinal portion*) is firm in texture, and its fibers arise from the motor cells in the lateral part of the anterior column of the gray substance of the medulla spinalis as low as the fifth cervical nerve. Passing through the lateral funiculus of the medulla spinalis, they emerge on its surface and unite to form a single trunk, which ascends between the *ligamentum denticulatum* and the posterior roots of the spinal nerves, enters the skull through the foramen magnum, and is then directed to the jugular foramen, through which it passes, lying in the same sheath of *dura mater* as the vagus, but separated from it by a fold of the arachnoid. In the jugular foramen, it receives one or two filaments from the cranial part of the nerve, or else joins it for a short distance and then separates from

it again. As its exit from the jugular foramen, it runs backward in front of the internal jugular vein in 66.6 per cent. of cases, and behind in it 33.3 per cent. (Tandler). The nerve then descends obliquely behind the Digastricus and Stylohyoideus to the upper part of the Sternocleidomastoideus; it pierces this muscle, and courses obliquely across the posterior triangle of the neck, to end in the deep surface of the Trapezius. As it traverses the Sternocleidomastoideus it gives several filaments to the muscle, and joins with branches from the second cervical nerve. In the posterior triangle it unites with the second and third cervical nerves, while beneath the Trapezius it forms a plexus with the third and fourth cervical nerves, and from this plexus fibers are distributed to the muscle.

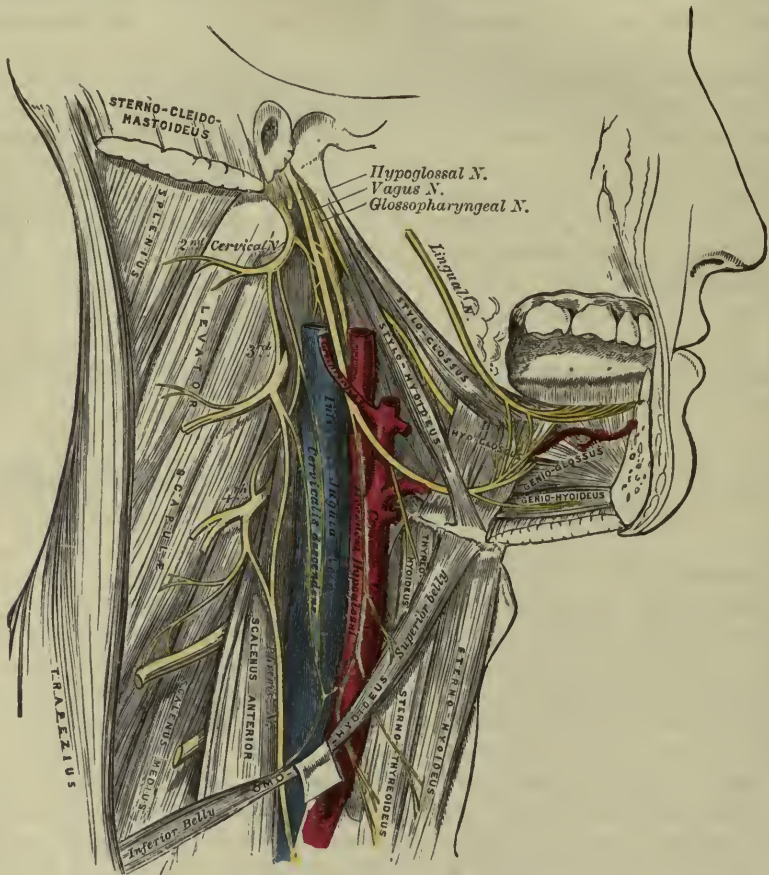


FIG. 794.—Hypoglossal nerve, cervical plexus, and their branches.

THE HYPOGLOSSAL NERVE (N. HYPOGLOSSUS; TWELFTH NERVE) (Figs. 794, 795).

The hypoglossal nerve is the motor nerve of the tongue.

Its fibers arise from the cells of the hypoglossal nucleus, which is an upward prolongation of the base of the anterior column of gray substance of the medulla spinalis. This nucleus is about 2 cm. in length, and its upper part corresponds with the *trigonum hypoglossi*, or lower portion of the medial eminence of the rhomboid fossa (page 779). The lower part of the nucleus extends downward into the closed part of the medulla oblongata, and there lies in relation to the ventro-lateral

aspect of the central canal. The fibers run forward through the medulla oblongata, and emerge in the antero-lateral sulcus between the pyramid and the olive.

The rootlets of this nerve are collected into two bundles, which perforate the dura mater separately, opposite the hypoglossal canal in the occipital bone, and unite together after their passage through it; in some cases the canal is divided into two by a small bony spicule. The nerve descends almost vertically to a point corresponding with the angle of the mandible. It is at first deeply seated beneath the internal carotid artery and internal jugular vein, and intimately connected with the vagus nerve; it then passes forward between the vein and artery, and lower

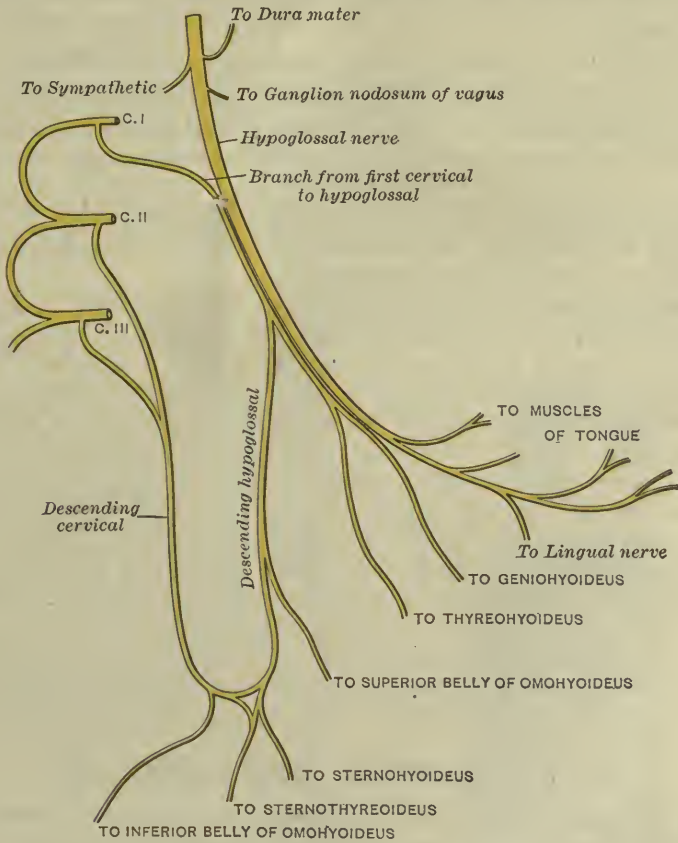


FIG. 795.—Plan of hypoglossal nerve.

down in the neck becomes superficial below the Digastricus. The nerve then loops around the occipital artery, and crosses the external carotid and lingual arteries below the tendon of the Digastricus. It passes beneath the tendon of the Digastricus, the Stylohyoideus, and the Mylohyoideus, lying between the last-named muscle and the Hyoglossus, and communicates at the anterior border of the Hyoglossus with the lingual nerve; it is then continued forward in the fibers of the Genioglossus as far as the tip of the tongue, distributing branches to its muscular substance.

Branches of Communication.—Its branches of communication are, with the
 Vagus. First and second cervical nerves.
 Sympathetic. Lingual.

The communications with the vagus take place close to the skull, numerous filaments passing between the hypoglossal and the ganglion nodosum of the vagus

through the mass of connective tissue which unites the two nerves. As the nerve winds around the occipital artery it gives off a filament to the pharyngeal plexus.

The communication with the sympathetic takes place opposite the atlas by branches derived from the superior cervical ganglion, and in the same situation the nerve is joined by a filament derived from the loop connecting the first and second cervical nerves.

The communications with the lingual take place near the anterior border of the Hyoglossus by numerous filaments which ascend upon the muscle.

Branches of Distribution.—The branches of distribution of the hypoglossal nerve are:

Meningeal.	Thyrohyoid.
Descending.	Muscular.

Of these branches, the meningeal, descending, thyrohyoid, and the muscular twig to the Geniohyoideus, are probably derived mainly from the branch which passes from the loop between the first and second cervical to join the hypoglossal (Fig. 795).

Meningeal Branches (*dural branches*).—As the hypoglossal nerve passes through the hypoglossal canal it gives off, according to Luschka, several filaments to the dura mater in the posterior fossa of the skull.

The **Descending Ramus** (*ramus descendens; descendens hypoglossi*), long and slender, quits the hypoglossal where it turns around the occipital artery and descends in front of or in the sheath of the carotid vessels; it gives a branch to the superior belly of the Omohyoideus, and then joins the communicantes cervicales from the second and third cervical nerves; just below the middle of the neck, to form a loop, the **ansa hypoglossi**. From the convexity of this loop branches pass to supply the Sternohyoideus, the Sternothyreideus, and the inferior belly of the Omohyoideus. According to Arnold, another filament descends in front of the vessels into the thorax, and joins the cardiac and phrenic nerves.

The **Thyrohyoid Branch** (*ramus thyrohyoideus*) arises from the hypoglossal near the posterior border of the hyoglossus; it runs obliquely across the greater cornu of the hyoid bone, and supplies the Thyreohyoideus muscle.

The **Muscular Branches** are distributed to the Styloglossus, Hyoglossus, Geniohyoideus, and Genioglossus. At the under surface of the tongue numerous slender branches pass upward into the substance of the organ to supply its intrinsic muscles.

THE SPINAL NERVES (NERVI SPINALES).

The **spinal nerves** spring from the medulla spinalis, and are transmitted through the intervertebral foramina. They number thirty-one pairs, which are grouped as follows: Cervical, 8; Thoracic, 12; Lumbar, 5; Sacral, 5; Coccygeal, 1.

The **first cervical nerve** emerges from the vertebral canal between the occipital bone and the atlas, and is therefore called the **suboccipital nerve**; the eighth issues between the seventh cervical and first thoracic vertebræ.

Nerve Roots.—Each nerve is attached to the medulla spinalis by two roots, an **anterior** or **ventral**, and a **posterior** or **dorsal**, the latter being characterized by the presence of a ganglion, the **spinal ganglion**.

The **Anterior Root** (*radix anterior; ventral root*) emerges from the anterior surface of the medulla spinalis as a number of rootlets or filaments (*fila radicularia*), which coalesce to form two bundles near the intervertebral foramen.

The **Posterior Root** (*radix posterior; dorsal root*) is larger than the anterior owing to the greater size and number of its rootlets; these are attached along the posterolateral furrow of the medulla spinalis and unite to form two bundles which join the spinal ganglion. The posterior root of the first cervical nerve is exceptional in that it is smaller than the anterior; it is occasionally wanting.

The **Spinal Ganglia** (*ganglion spinale*) are collections of nerve cells on the posterior roots of the spinal nerves. Each ganglion is oval in shape, reddish in color, and its size bears a proportion to that of the nerve root on which it is situated; it is bifid medially where it is joined by the two bundles of the posterior nerve root. The ganglia are usually placed in the intervertebral foramina, immediately outside the points where the nerve roots perforate the dura mater, but there are exceptions to this rule; thus the ganglia of the first and second cervical nerves lie on the vertebral arches of the atlas and axis respectively, those of the sacral nerves are inside the vertebral canal, while that on the posterior root of the coccygeal nerve is placed within the sheath of dura mater.

Structure (Fig. 638).—The ganglia consist chiefly of unipolar nerve cells, and from these the fibers of the posterior root take origin—the single process of each cell dividing after a short course into a central fiber which enters the medulla spinalis and a peripheral fiber which runs into the spinal nerve. Two other forms of cells are, however, present, viz.: (a) the cells of Dogiel, whose axons ramify close to the cell (type II, of Golgi), and are distributed entirely within the ganglion; and (b) multipolar cells similar to those found in the sympathetic ganglia.

The ganglia of the first cervical nerve may be absent, while small *aberrant ganglia* consisting of groups of nerve cells are sometimes found on the posterior roots between the spinal ganglia and the medulla spinalis.

Each nerve root receives a covering from the pia mater, and is loosely invested by the arachnoid, the latter being prolonged as far as the points where the roots pierce the dura mater. The two roots pierce the dura mater separately, each receiving a sheath from this membrane; where the roots join to form the spinal nerve this sheath is continuous with the epineurium of the nerve.

Size and Direction.—The roots of the upper four *cervical* nerves are small, those of the lower four are large. The posterior roots of the cervical nerves bear a proportion to the anterior of three to one, which is greater than in the other regions; their individual filaments are also larger than those of the anterior roots. The posterior root of the first cervical is an exception to this rule, being smaller than the anterior root; in eight per cent. of cases it is wanting. The roots of the first and second cervical nerves are short, and run nearly horizontally to their points of exit from the vertebral canal. From the second to the eighth cervical they are directed obliquely downward, the obliquity and length of the roots successively increasing; the distance, however, between the level of attachment of any of these roots to the medulla spinalis and the points of exit of the corresponding nerves never exceeds the depth of one vertebra.

The roots of the *thoracic* nerves, with the exception of the first, are of small size, and the posterior only slightly exceed the anterior in thickness. They increase successively in length, from above downward, and in the lower part of the thoracic

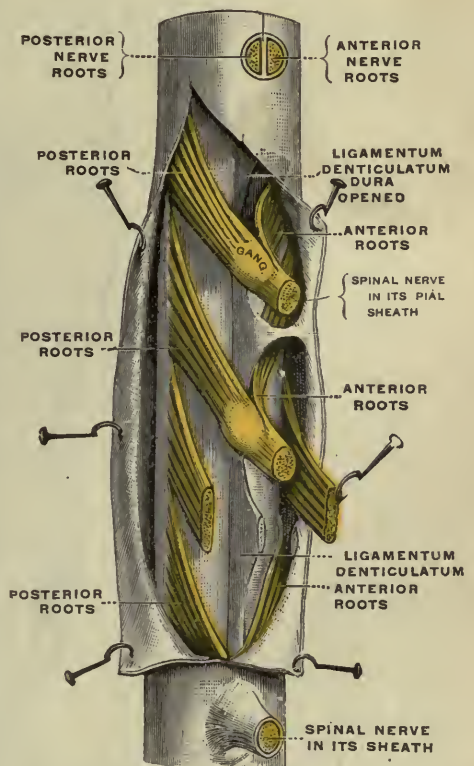


FIG. 796.—A portion of the spinal cord, showing its right lateral surface. The dura is opened and arranged to show the nerve roots. (Testut.)

region descend in contact with the medulla spinalis for a distance equal to the height of at least two vertebræ before they emerge from the vertebral canal.

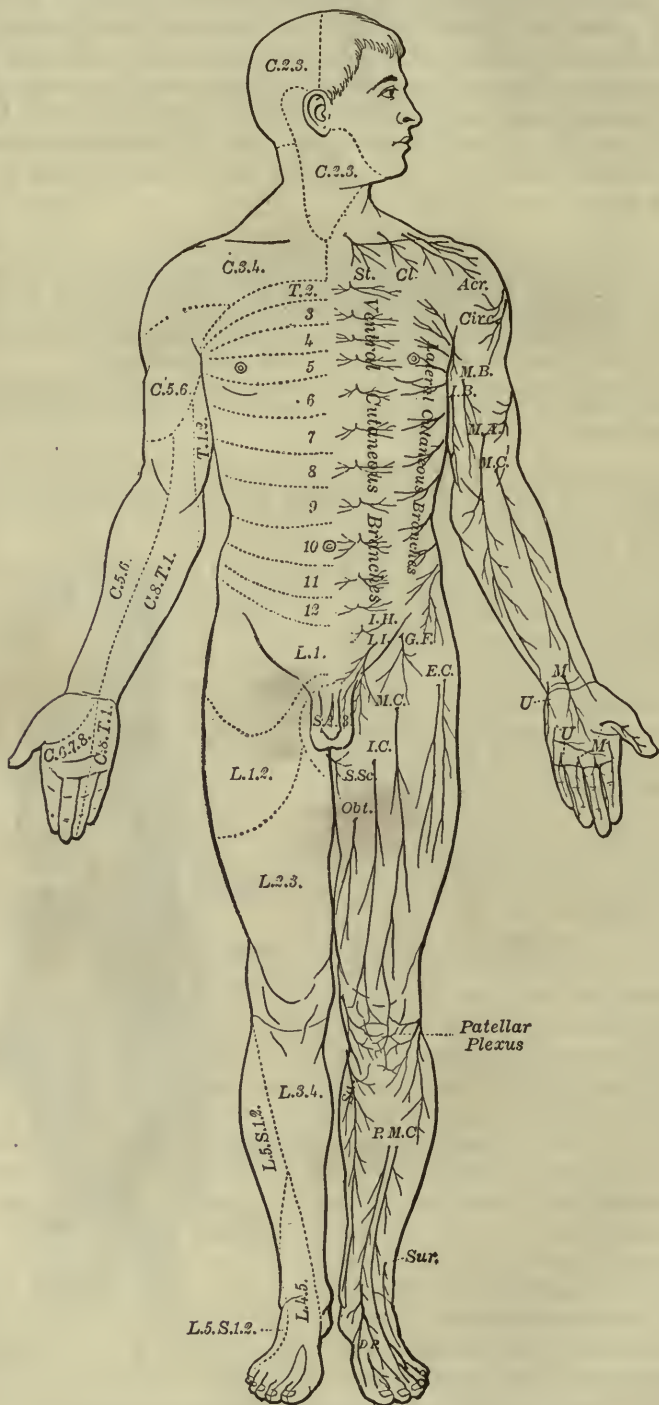


FIG. 797.—Distribution of cutaneous nerves. Ventral aspect.

The roots of the lower lumbar and upper sacral nerves are the largest, and their individual filaments the most numerous of all the spinal nerves, while the roots of the coccygeal nerve are the smallest.

The roots of the lumbar, sacral, and coccygeal nerves run vertically downward to their respective exits, and as the medulla spinalis ends near the lower border

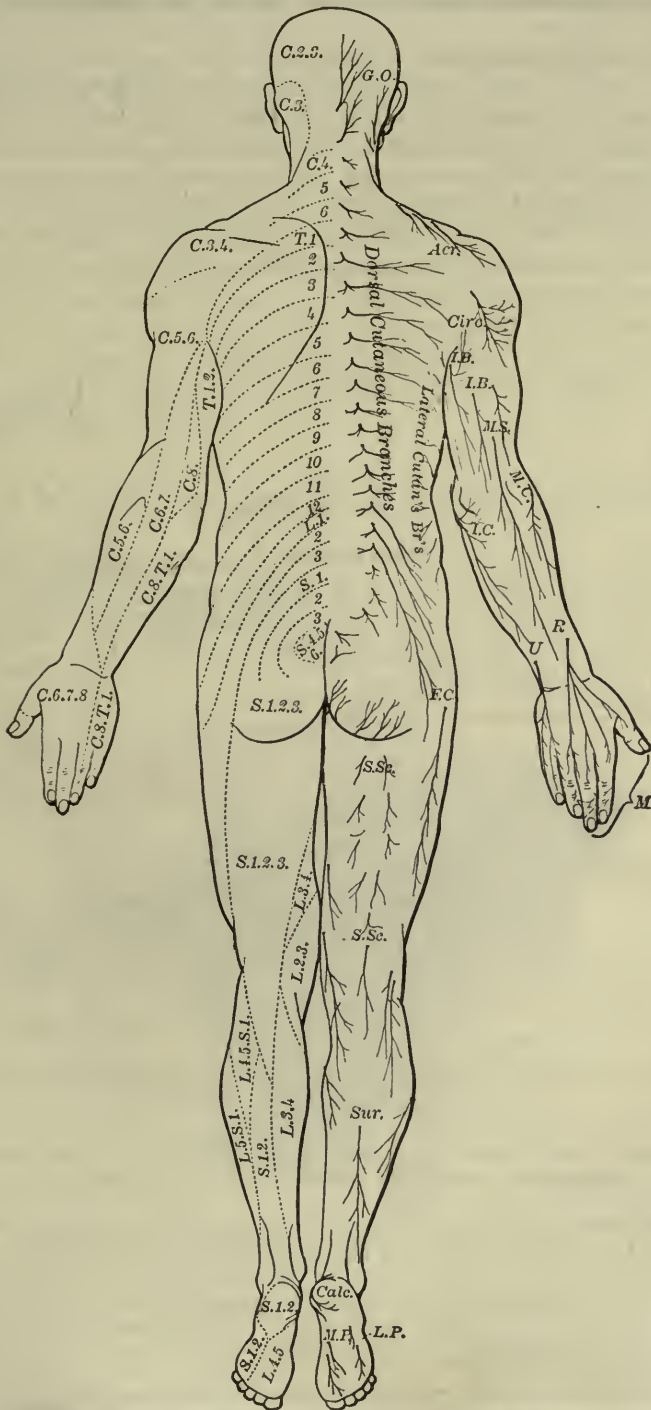


FIG. 798.—Distribution of cutaneous nerves. Dorsal aspect.

of the first lumbar vertebra it follows that the length of the successive roots must rapidly increase. As already mentioned (page 750), the term **cauda equina** is applied to this collection of nerve roots.

From the description given it will be seen that the largest nerve roots, and consequently the largest spinal nerves, are attached to the cervical and lumbar swellings of the medulla spinalis; these nerves are distributed to the upper and lower limbs.

Connections with Sympathetic.—Immediately beyond the spinal ganglion, the anterior and posterior nerve roots unite to form the **spinal nerve** which emerges through the intervertebral foramen. Each spinal nerve receives a branch (**gray ramus communicans**) from the adjacent ganglion of the sympathetic trunk, while the thoracic, and the first and second lumbar nerves each contribute a branch (**white ramus communicans**) to the adjoining sympathetic ganglion. The second, third, and fourth sacral nerves also supply white rami; these, however, are not connected with the ganglia of the sympathetic trunk, but run directly into the pelvic plexuses of the sympathetic.

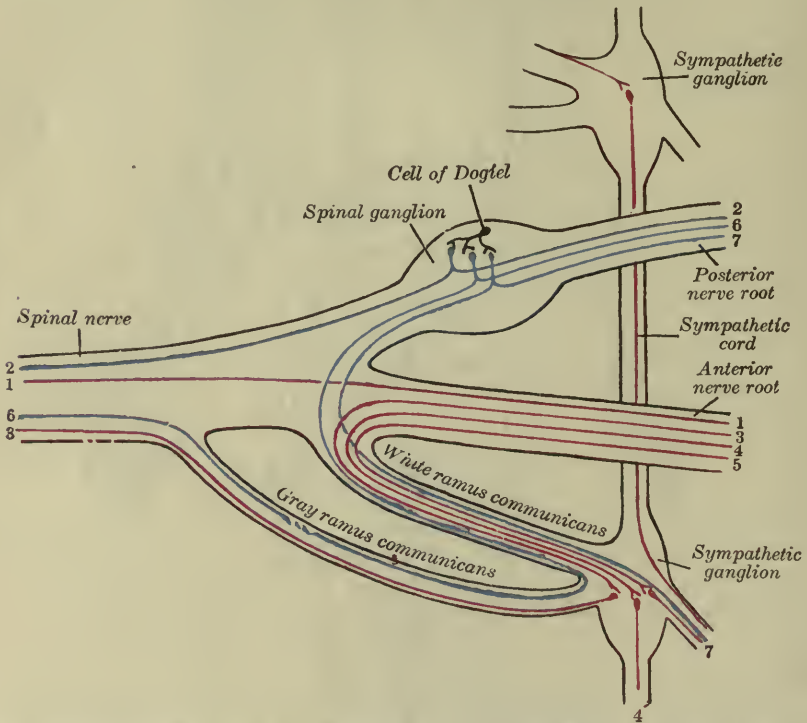


FIG. 799.—Scheme showing structure of a typical spinal nerve. 1. Somatic efferent. 2. Somatic afferent. 3, 4, 5. Sympathetic efferent. 6, 7. Sympathetic afferent.

Structure.—Each typical spinal nerve contains fibers belonging to two systems, viz., the **somatic**, and the **sympathetic** or **splanchnic**, as well as fibers connecting these systems with each other (Fig. 799).

1. The **somatic fibers** are efferent and afferent. The *efferent fibers* originate in the cells of the anterior column of the medulla spinalis, and run outward through the anterior nerve roots to the spinal nerve. They convey impulses to the voluntary muscles, and are continuous from their origin to their peripheral distribution. The *afferent fibers* convey impressions inward from the skin, etc., and originate in the unipolar nerve cells of the spinal ganglia. The single processes of these cells divide into peripheral and central fibers, and the latter enter the medulla spinalis through the posterior nerve roots.

2. The **sympathetic fibers** are also efferent and afferent. The *efferent fibers*, preganglionic fibers, originate in the lateral column of the medulla spinalis, and are conveyed through the anterior nerve root and the white ramus communicans to the corresponding ganglion of the sympathetic trunk; here they may end by forming synapses around its cells, or may run through the ganglion to end in another of the ganglia of the sympathetic trunk, or in a more distally placed ganglion

in one of the sympathetic plexuses. In all cases they end by forming synapses around other nerve cells. From the cells of the ganglia of the sympathetic trunk other fibers, postganglionic fibers, take origin; some of these run through the gray rami communicantes to join the spinal nerves, along which they are carried to the bloodvessels of the trunk and limbs, while others pass to the viscera, either directly or after interruption in one of the distal ganglia. The afferent fibers are derived partly from the unipolar cells and partly from the multipolar cells of the spinal ganglia. Their peripheral processes are carried through the white rami communicantes, and after passing through one or more sympathetic ganglia (but always without interruption in them) finally end in the tissues of the viscera. The central processes of the unipolar cells enter the medulla spinalis through the posterior nerve root and form synapses around either somatic or sympathetic efferent neurons, thus completing reflex arcs. The dendrites of the multipolar nerve cells form synapses around the cells of type II (cells of Dogiel) in the spinal ganglia, and by this path the original impulse is transferred from the sympathetic to the somatic system, through which it is conveyed to the sensorium.

Divisions.—After emerging from the intervertebral foramen, each spinal nerve gives off a small **meningeal branch** which reënters the vertebral canal through the intervertebral foramen and supplies the vertebræ and their ligaments, and the bloodvessels of the medulla spinalis and its membranes. The spinal nerve then splits into a **posterior or dorsal**, and an **anterior or ventral division**, each receiving fibres from both nerve roots.

POSTERIOR DIVISIONS OF THE SPINAL NERVES (RAMI POSTERIORES).

The **posterior divisions** are as a rule smaller than the anterior. They are directed backward, and, with the exceptions of those of the first cervical, the fourth and fifth sacral, and the coccygeal, divide into medial and lateral branches for the supply of the muscles and skin (Figs. 800, 801, 802) of the posterior part of the trunk.

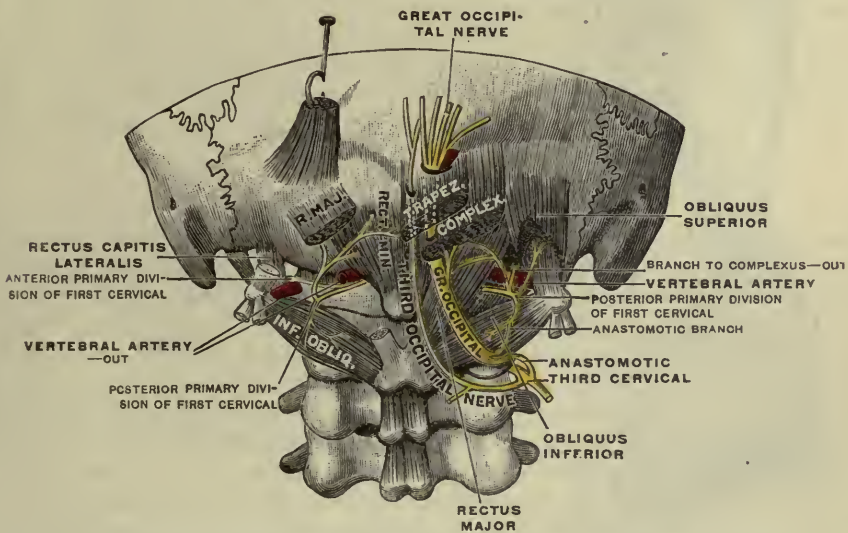


Fig. 800.—Posterior primary divisions of the upper three cervical nerves. (Testut.)

The Cervical Nerves (Nn. Cervicales).

The **posterior division of the first cervical or suboccipital nerve** is larger than the anterior division, and emerges above the posterior arch of the atlas and beneath the vertebral artery. It enters the suboccipital triangle and supplies the muscles which bound this triangle, viz., the Rectus capitis posterior major, and the Obliqui superior and inferior; it gives branches also to the Rectus capitis posterior minor

and the Semispinalis capitis. A filament from the branch to the Obliquus inferior joins the posterior division of the second cervical nerve.

The nerve occasionally gives off a cutaneous branch which accompanies the occipital artery to the scalp, and communicates with the greater and lesser occipital nerves.

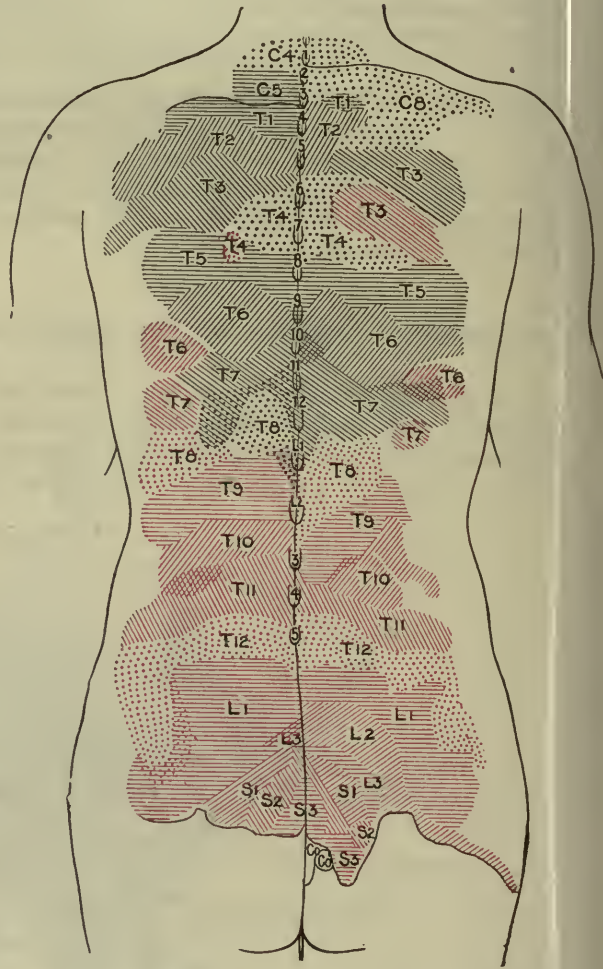
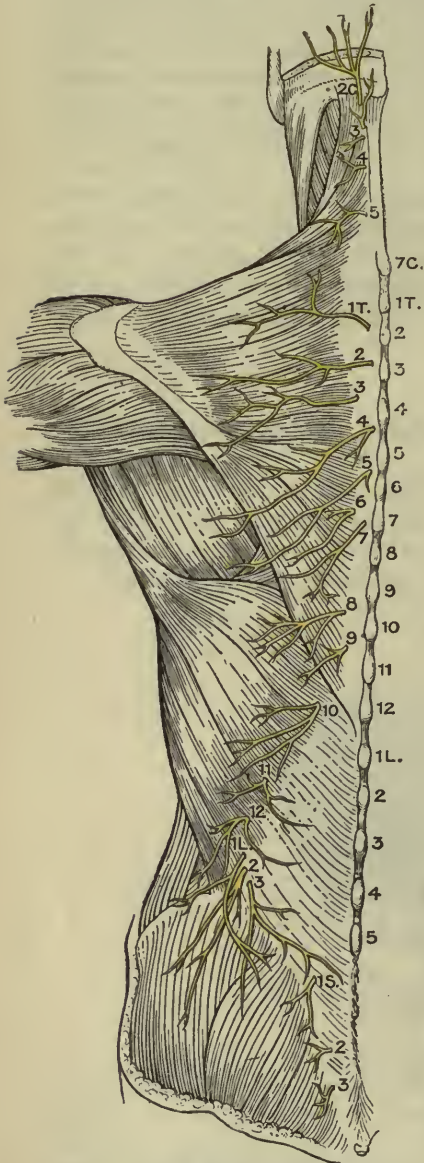


FIG. 801.—Diagram of the distribution of the cutaneous branches of the posterior divisions of the spinal nerves.

FIG. 802.—Areas of distribution of the cutaneous branches of the posterior divisions of the spinal nerves. The areas of the medial branches are in black, those of the lateral in red. (H. M. Johnston.)

The posterior division of the second cervical nerve is much larger than the anterior division, and is the greatest of all the cervical posterior divisions. It emerges between the posterior arch of the atlas and the lamina of the axis, below the Obliquus inferior. It supplies a twig to this muscle, receives a communicating filament from the posterior division of the first cervical, and then divides into a large medial and a small lateral branch.

The **medial branch** (*ramus medialis; internal branch*), called from its size and distribution the **greater occipital nerve** (*n. occipitalis major; great occipital nerve*), ascends obliquely between the Obliquus inferior and the Semispinalis capitis, and pierces the latter muscle and the Trapezius near their attachments to the occipital bone (Fig. 801). It is then joined by a filament from the medial branch of the posterior division of the third cervical, and, ascending on the back of the head with the occipital artery, divides into branches which communicate with the lesser occipital nerve and supply the skin of the scalp as far forward as the vertex of the skull. It gives off muscular branches to the Semispinalis capitis, and occasionally a twig to the back of the auricula. The **lateral branch** (*ramus lateralis; external branch*) supplies filaments to the Splenius, Longus capitis, and Semispinalis capitis, and is often joined by the corresponding branch of the third cervical.

The **posterior division of the third cervical** is intermediate in size between those of the second and fourth. Its **medial branch** runs between the Semispinalis capitis and cervicis, and, piercing the Splenius and Trapezius, ends in the skin. While under the Trapezius it gives off a branch called the **third occipital nerve**, which pierces the Trapezius and ends in the skin of the lower part of the back of the head (Fig. 801). It lies medial to the greater occipital and communicates with it. The **lateral branch** often joins that of the second cervical.

The posterior division of the suboccipital, and the medial branches of the posterior division of the second and third cervical nerves are sometimes joined by communicating loops to form the *posterior cervical plexus* (Cruveilhier).

The **posterior divisions of the lower five cervical nerves** divide into medial and lateral branches. The **medial branches** of the fourth and fifth run between the Semispinales cervicis and capitis, and, having reached the spinous processes, pierce the Splenius and Trapezius to end in the skin (Fig. 801). Sometimes the branch of the fifth fails to reach the skin. Those of the lower three nerves are small, and end in the Semispinales cervicis and capitis, Multifidus, and Interspinales. The **lateral branches** of the lower five nerves supply the Iliocostalis cervicis, Longissimus cervicis, and Longissimus capitis.

The Thoracic Nerves (Nn. Thoracales).

The **medial branches** (*ramus medialis; internal branch*) of the **posterior divisions of the upper six thoracic nerves** run between the Semispinalis dorsi and Multifidus, which they supply; they then pierce the Rhomboidei and Trapezius, and reach the skin by the sides of the spinous processes (Fig. 801). The medial branches of the **lower six** are distributed chiefly to the Multifidus and Longissimus dorsi, occasionally they give off filaments to the skin near the middle line.

The **lateral branches** (*ramus lateralis; external branch*) increase in size from above downward. They run through or beneath the Longissimus dorsi to the interval between it and the Iliocostales, and supply these muscles; the lower five or six also give off cutaneous branches which pierce the Serratus posterior inferior and Latissimus dorsi in a line with the angles of the ribs (Fig. 801). The lateral branches of a variable number of the upper thoracic nerves also give filaments to the skin. The lateral branch of the twelfth thoracic, after sending a filament medialward along the iliac crest, passes downward to the skin of the buttock.

The medial cutaneous branches of the posterior divisions of the thoracic nerves descend for some distance close to the spinous processes before reaching the skin, while the lateral branches travel downward for a considerable distance—it may be as much as the breadth of four ribs—before they become superficial; the branch from the twelfth thoracic, for instance, reaches the skin only a little way above the iliac crest.¹

The Lumbar Nerves (Nn. Lumbales).

The **medial branches** of the posterior divisions of the lumbar nerves run close to the articular processes of the vertebræ and end in the Multifidus.

The **lateral branches** supply the Sacrospinalis. The upper three give off cutaneous nerves which pierce the aponeurosis of the Latissimus dorsi at the lateral border of the Sacrospinalis and descend across the posterior part of the iliac crest to the skin of the buttock (Fig. 801), some of their twigs running as far as the level of the greater trochanter.

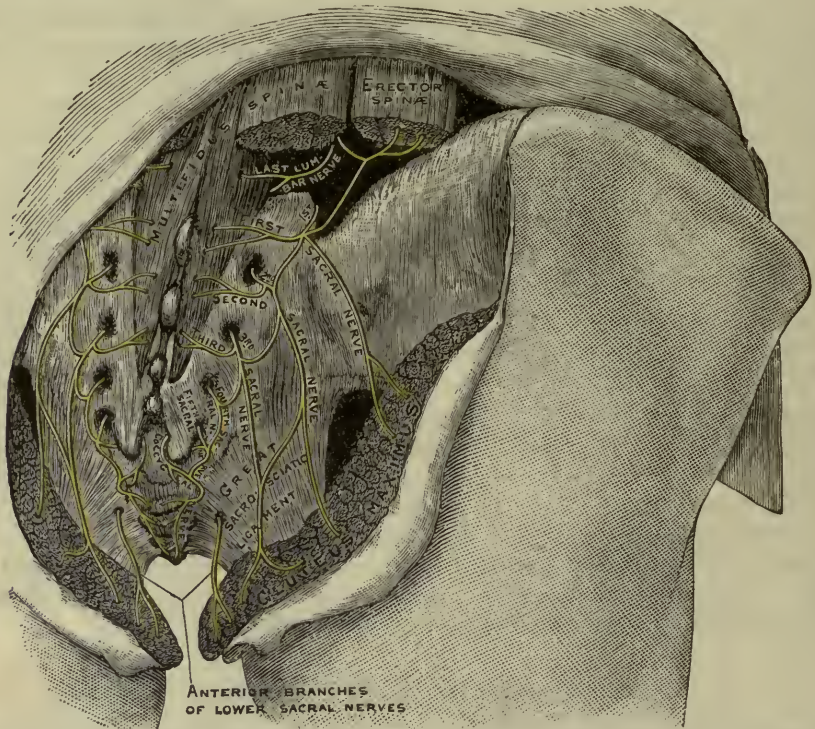


FIG. 803.—The posterior divisions of the sacral nerves.

The Sacral Nerves (Nn. Sacrales).

The **posterior divisions of the sacral nerves** (*rami posteriores*) (Fig. 803) are small, and diminish in size from above downward; they emerge, except the last, through the posterior sacral foramina. The *upper three* are covered at their points of exit by the Multifidus, and divide into medial and lateral branches.

The **medial branches** are small, and end in the Multifidus.

The **lateral branches** join with one another and with the lateral branches of the posterior divisions of the last lumbar and fourth sacral to form loops on the dorsal surface of the sacrum. From these loops branches run to the dorsal surface of the sacrotuberous ligament and form a second series of loops under the Glutæus maximus. From this second series cutaneous branches, two or three in number, pierce the Glutæus maximus along a line drawn from the posterior superior iliac spine to the tip of the coccyx; they supply the skin over the posterior part of the buttock.

The posterior divisions of the *lower two* sacral nerves are small and lie below the Multifidus. They do not divide into medial and lateral branches, but unite with each other and with the posterior division of the coccygeal nerve to form loops on the back of the sacrum; filaments from these loops supply the skin over the coccyx.

The Coccygeal Nerve (N. Coccygeus).

The posterior division of the coccygeal nerve (*ramus posterior*) does not divide into a medial and a lateral branch, but receives, as already stated, a communicating branch from the last sacral; it is distributed to the skin over the back of the coccyx.

ANTERIOR DIVISIONS OF THE SPINAL NERVES (RAMI ANTERIORES).

The anterior divisions of the spinal nerves supply the antero-lateral parts of the trunk, and the limbs; they are for the most part larger than the posterior divisions. In the thoracic region they run independently of one another, but in the cervical, lumbar, and sacral regions they unite near their origins to form plexuses.

The Cervical Nerves (Nn. Cervicales).

The anterior divisions of the cervical nerves (*rami anteriores*), with the exception of the first, pass outward between the Intertransversarii anterior and posterior, lying on the grooved upper surfaces of the transverse processes of the vertebræ. The anterior division of the first or suboccipital nerve issues from the vertebral canal above the posterior arch of the atlas and runs forward around the lateral aspect of its superior articular process, medial to the vertebral artery. In most cases it descends medial to and in front of the Rectus capitis lateralis, but occasionally it pierces the muscle.

The anterior divisions of the upper four cervical nerves unite to form the cervical plexus, and each receives a gray ramus communicans from the superior cervical ganglion of the sympathetic trunk. Those of the lower four cervical, together with the greater part of the first thoracic, form the brachial plexus. They each receive a gray ramus communicans, those for the fifth and sixth being derived from the middle, and those for the seventh and eighth from the lowest, cervical ganglion of the sympathetic trunk.

The Cervical Plexus (*plexus cervicalis*) (Fig. 804).—The cervical plexus is formed by the anterior divisions of the upper four cervical nerves; each nerve, except the first, divides into an upper and a lower branch, and the branches unite to form three loops. The plexus is situated opposite the upper four cervical vertebræ, in front of the Levator scapulæ and Scalenus medius, and covered by the Sternocleidomastoideus.

Its branches are divided into two groups, superficial and deep, and are here given in tabular form; the figures following the names indicate the nerves from which the different branches take origin:

<i>Superficial</i>	. . .	{	Smaller occipital	2, C.				
			Great auricular	2, 3, C.				
			Cutaneous cervical	2, 3, C.				
			Supraclavicular	3, 4, C.				
<i>Deep</i>	.	{	Internal	{	Communicating	{	With hypoglossal	1, 2, C.
						" vagus	1, 2, C.	
						" sympathetic	1, 2, 3, 4, C.	
				Muscular	Rectus capitis lateralis	1, C.		
			Rectus capitis anterior		1, 2, C.			
			Longus capitis		1, 2, 3, C.			
			Communicantes cervicales		2, 3, C.			
				Phrenic	3, 4, 5, C.			
			External		{	Communicating with accessory	2, 3, 4, C.	
						Sternocleidomastoideus	2, C.	
	Muscular	Trapezius	3, 4, C.					
		Levator scapulæ	3, 4, C.					
		Scalenus medius	3, 4, C.					

Superficial Branches of the Cervical Plexus (Fig. 805).—The **Smaller Occipital Nerve** (*n. occipitalis minor*; *small occipital nerve*) arises from the second cervical nerve, sometimes also from the third; it curves around and ascends along the posterior border of the Sternocleidomastoideus. Near the cranium it perforates the deep fascia, and is continued upward along the side of the head behind the auricula, supplying the skin and communicating with the greater occipital, the great auricular, and the posterior auricular branch of the facial. The smaller occipital varies in size, and is sometimes duplicated.

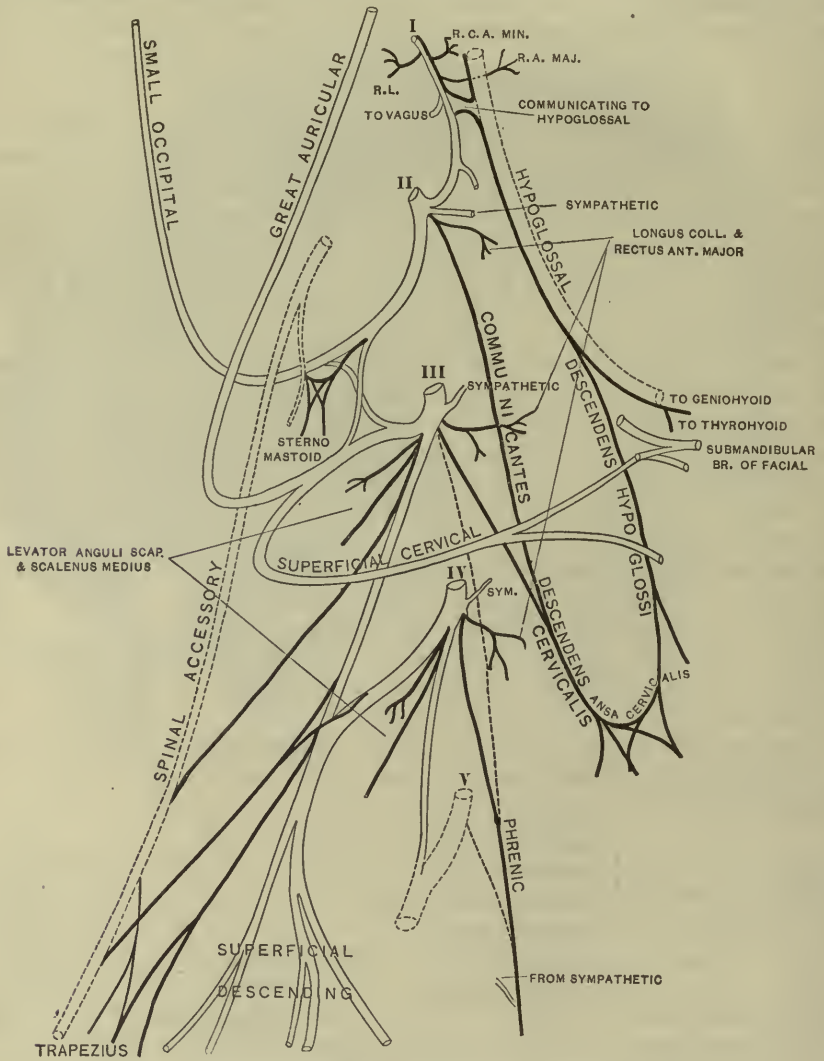


FIG. 804.—Plan of the cervical plexus. (Gerrish.)

It gives off an **auricular branch**, which supplies the skin of the upper and back part of the auricula; communicating with the mastoid branch of the great auricular. This branch is occasionally derived from the greater occipital nerve.

The **Great Auricular Nerve** (*n. auricularis magnus*) is the largest of the ascending branches. It arises from the second and third cervical nerves, winds around the posterior border of the Sternocleidomastoideus, and, after perforating the deep

and form a plexus with the cervical branch of the facial nerve beneath the Platysma; others pierce that muscle, and are distributed to the skin of the upper and front part of the neck.

The **descending branches** (*rami inferiores*) pierce the Platysma, and are distributed to the skin of the side and front of the neck, as low as the sternum.

The **Supraclavicular Nerves** (*nn. supraclaviculares; descending branches*) arise from the third and fourth cervical nerves; they emerge beneath the posterior border of the Sternocleidomastoideus, and descend in the posterior triangle of the neck beneath the Platysma and deep cervical fascia. Near the clavicle they perforate the fascia and Platysma to become cutaneous, and are arranged, according to their position, into three groups—**anterior, middle and posterior**.

The **anterior supraclavicular nerves** (*nn. supraclaviculares anteriores; suprasternal nerves*) cross obliquely over the external jugular vein and the clavicular and sternal heads of the Sternocleidomastoideus, and supply the skin as far as the middle line. They furnish one or two filaments to the sternoclavicular joint.

The **middle supraclavicular nerves** (*nn. supraclaviculares medii; supraclavicular nerves*) cross the clavicle, and supply the skin over the Pectoralis major and Deltoides, communicating with the cutaneous branches of the upper intercostal nerves.

The **posterior supraclavicular nerves** (*nn. supraclaviculares posteriores; supra-acromial nerves*) pass obliquely across the outer surface of the Trapezius and the acromion, and supply the skin of the upper and posterior parts of the shoulder.

Deep Branches of the Cervical Plexus. INTERNAL SERIES.—The **Communicating Branches** consist of several filaments, which pass from the loop between the first and second cervical nerves to the vagus, hypoglossal, and sympathetic. The branch to the hypoglossal ultimately leaves that nerve as a series of branches, viz., the descending ramus, the nerve to the Thyreo-hyoideus and the nerve, to the Genio-hyoideus (see page 916). A communicating branch also passes from the fourth to the fifth cervical, while each of the first four cervical nerves receives a gray ramus communicans from the superior cervical ganglion of the sympathetic.

Muscular Branches supply the Longus capitis, Rectus capitis anterior, and Rectus capitis lateralis.

The **Communicantes Cervicales** (*communicantes hypoglossi*) (Fig. 804) consist usually of two filaments, one derived from the second, and the other from the third cervical. These filaments join to form the **descendens cervicalis**, which passes downward on the lateral side of the internal jugular vein, crosses in front of the vein a little below the middle of the neck, and forms a loop (**ansa hypoglossi**) with the descending ramus of the hypoglossal in front of the sheath of the carotid vessels (see page 916). Occasionally, the loop is formed within the sheath.

The **Phrenic Nerve** (*n. phrenicus; internal respiratory nerve of Bell*) contains motor and sensory fibers in the proportion of about two to one. It arises chiefly from the fourth cervical nerve, but receives a branch from the third and another from the fifth; the fibers from the fifth occasionally come through the nerve to the Subclavius. It descends to the root of the neck, running obliquely across the front of the Scalenus anterior, and beneath the Sternocleidomastoideus, the inferior belly of the Omohyoideus, and the transverse cervical and transverse scapular vessels. It next passes in front of the first part of the subclavian artery, between it and the subclavian vein, and, as it enters the thorax, crosses the internal mammary artery near its origin. Within the thorax, it descends nearly vertically in front of the root of the lung, and then between the pericardium and the mediastinal pleura, to the diaphragm, where it divides into branches, which pierce that muscle, and are distributed to its under surface. In the thorax it is accompanied by the pericardiophrenic branch of the internal mammary artery.

The two phrenic nerves differ in their length, and also in their relations at the upper part of the thorax.

The **right nerve** is situated more deeply, and is shorter and more vertical in direction than the left; it lies lateral to the right innominate vein and superior vena cava.

The **left nerve** is rather longer than the right, from the inclination of the heart to the left side, and from the diaphragm being lower on this than on the right side. At the root of the neck it is crossed by the thoracic duct; in the superior mediastinal cavity it lies between the left common carotid and left subclavian arteries, and crosses superficial to the vagus on the left side of the arch of the aorta.

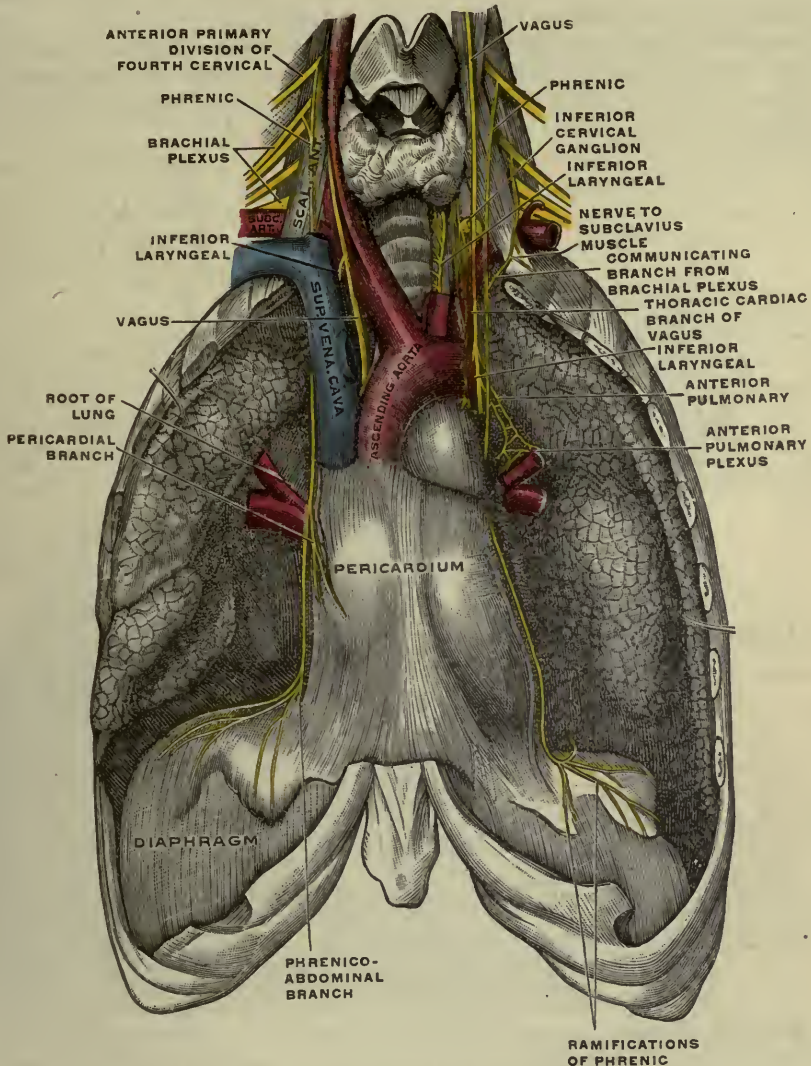


FIG. 806.—The phrenic nerve and its relations with the vagus nerve.

Each nerve supplies filaments to the pericardium and pleura, and at the root of the neck is joined by a filament from the sympathetic, and, occasionally, by one from the ansa hypoglossi. Branches have been described as passing to the peritoneum.

From the *right nerve*, one or two filaments pass to join in a small **phrenic ganglion** with phrenic branches of the celiac plexus; and branches from this ganglion are

distributed to the falciform and coronary ligaments of the liver, the suprarenal gland, inferior vena cava, and right atrium. From the *left nerve*, filaments pass to join the phrenic branches of the celiac plexus, but without any ganglionic enlargement; and a twig is distributed to the left suprarenal gland.

Deep Branches of the Cervical Plexus. EXTERNAL SERIES.—**Communicating Branches.**—The external series of deep branches of the cervical plexus communicates with the accessory nerve, in the substance of the Sternocleidomastoideus, in the posterior triangle, and beneath the Trapezius.

Muscular Branches are distributed to the Sternocleidomastoideus, Trapezius, Levator scapulæ, and Scalenus medius.

The branch for the Sternocleidomastoideus is derived from the second cervical; the Trapezius and Levator scapulæ receive branches from the third and fourth. The Scalenus medius receives twigs either from the third or fourth, or occasionally from both.

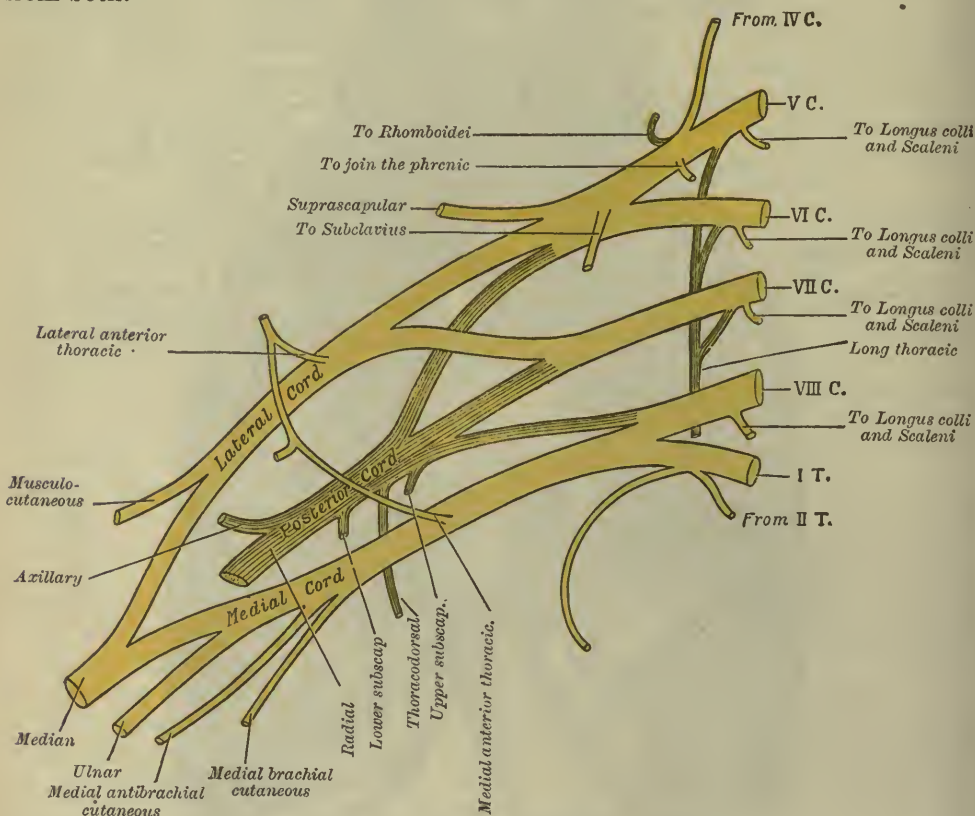


FIG. 807.—Plan of brachial plexus.

The Brachial Plexus (*plexus brachialis*) (Fig. 807).—The brachial plexus is formed by the union of the anterior divisions of the lower four cervical nerves and the greater part of the anterior division of the first thoracic nerve; the fourth cervical usually gives a branch to the fifth cervical, and the first thoracic frequently receives one from the second thoracic. The plexus extends from the lower part of the side of the neck to the axilla. The nerves which form it are nearly equal in size, but their mode of communication is subject to some variation. The following is, however, the most constant arrangement. The fifth and sixth cervical unite soon after their exit from the intervertebral foramina to form a trunk. The eighth cervical and first thoracic also unite to form one trunk, while the seventh cervical

runs out alone. Three trunks—upper, middle, and lower—are thus formed, and, as they pass beneath the clavicle, each splits into an anterior and a posterior division.¹ The anterior divisions of the upper and middle trunks unite to form a cord, which is situated on the lateral side of the second part of the axillary artery, and is called the lateral cord or fasciculus of the plexus. The anterior division of the lower trunk passes down on the medial side of the axillary artery, and forms the medial cord or fasciculus of the brachial plexus. The posterior divisions of all three trunks unite to form the posterior cord or fasciculus of the plexus, which is situated behind the second portion of the axillary artery.

Relations.—*In the neck*, the brachial plexus lies in the posterior triangle, being covered by the skin, Platysma, and deep fascia; it is crossed by the supraclavicular nerves, the inferior belly of the Omohyoideus, the external jugular vein, and the transverse cervical artery. It emerges between the Scalenus anterior and medius; its upper part lies above the third part of the subclavian artery, while the trunk formed by the union of the eighth cervical and first thoracic is placed behind the artery; the plexus next passes behind the clavicle, the Subclavius, and the transverse scapular vessels, and lies upon the first digitation of the Serratus anterior, and the Subscapularis. *In the axilla* it is placed lateral to the first portion of the axillary artery; it surrounds the second part of the artery, one cord lying medial to it, one lateral to it, and one behind it; at the lower part of the axilla it gives off its terminal branches to the upper limb.

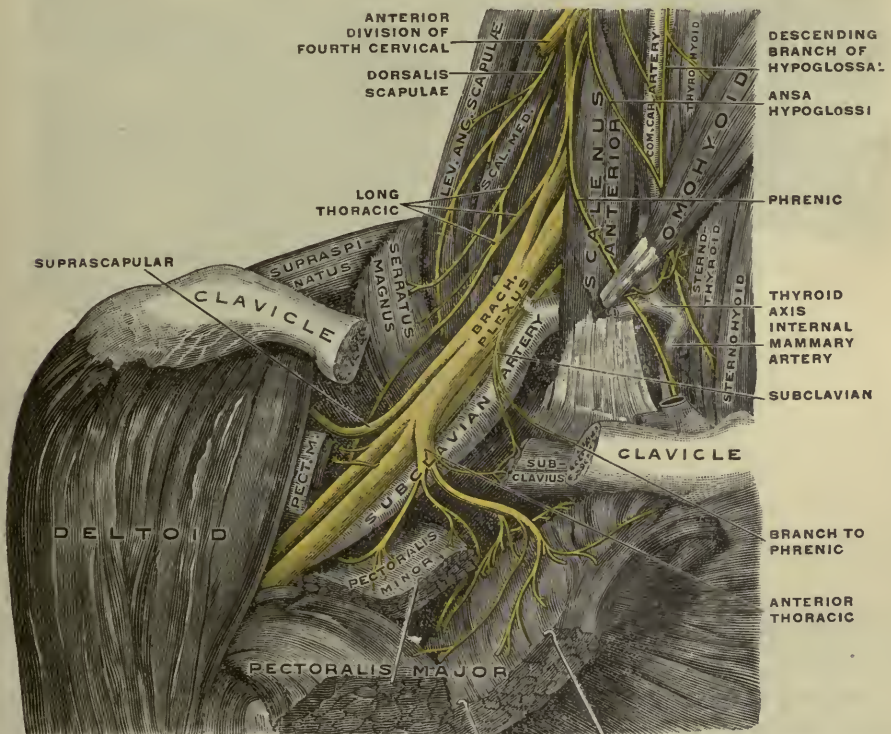


FIG. 808.—The right brachial plexus with its short branches, viewed from in front. The Sternomastoid and Trapezius muscles have been completely, the Omohyoideus and Subclavius have been partially, removed; a piece has been sawed out of the clavicle; the Pectoralis muscles have been incised and reflected. (Spalteholz.)

Branches of Communication.—Close to their exit from the intervertebral foramina the fifth and sixth cervical nerves each receive a gray ramus communicans from the middle cervical ganglion of the sympathetic trunk, and the seventh and eighth cervical similar twigs from the inferior ganglion. The first thoracic nerve receives a gray ramus from, and contributes a white ramus to, the first thoracic ganglion.

¹ The posterior division of the lower trunk is very much smaller than the others, and is frequently derived entirely from the eighth cervical nerve.

On the Scalenus anterior the phrenic nerve is joined by a branch from the fifth cervical.

Branches of Distribution.—The branches of distribution of the brachial plexus may be arranged into two groups, viz., those given off above and those below the clavicle.

SUPRACLAVICULAR BRANCHES.

Dorsal scapular	5 C.
Suprascapular	5, 6 C.
Nerve to Subclavius	5, 6 C.
Long thoracic	5, 6, 7 C.
To Longus colli and Scaleni	5, 6, 7, 8 C.

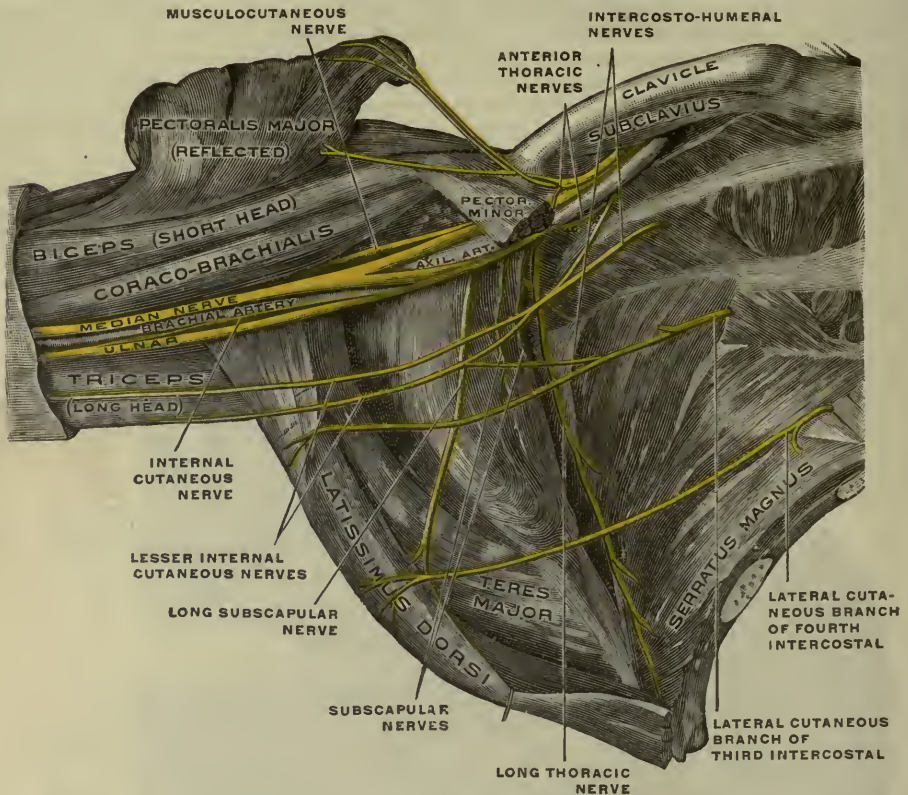


FIG. 809.—The right brachial plexus (infraclavicular portion) in the axillary fossa; viewed from below and in front. The Pectoralis major and minor muscles have been in large part removed; their attachments have been reflected. (Spalteholz.)

The **Dorsal Scapular Nerve** (*n. dorsalis scapulæ*; *nerve to the Rhomboidei*; *posterior scapular nerve*) arises from the fifth cervical, pierces the Scalenus medius, passes beneath the Levator scapulæ, to which it occasionally gives a twig, and ends in the Rhomboidei.

The **Suprascapular** (*n. suprascapularis*) (Fig. 818) arises from the trunk formed by the union of the fifth and sixth cervical nerves. It runs lateralward beneath the Trapezius and the Omohyoideus, and enters the suprascapular fossa through the suprascapular notch, below, the superior transverse scapular ligament; it then passes beneath the Suprascapularis, and curves around the lateral border of the spine of the scapula to the infraspinatus fossa. In the suprascapular fossa it gives off two branches to the Suprascapularis muscle, and an articular filament to the shoulder-joint; and in the infraspinatus fossa it gives off two branches

to the Infraspinatus muscle, besides some filaments to the shoulder-joint and scapula.

The **Nerve to the Subclavius** (*n. subclavius*) is a small filament, which *arises* from the point of junction of the fifth and sixth cervical nerves; it descends to the muscle in front of the third part of the subclavian artery and the lower trunk of the plexus, and is usually connected by a filament with the phrenic nerve.

The **Long Thoracic Nerve** (*n. thoracalis longus; external respiratory nerve of Bell; posterior thoracic nerve*) (Fig. 816) supplies the Serratus anterior. It usually *arises* by three roots from the fifth, sixth, and seventh cervical nerves; but the root from the seventh nerve may be absent. The roots from the fifth and sixth nerves pierce the Scalenus medius, while that from the seventh passes in front of the muscle. The nerve descends behind the brachial plexus and the axillary vessels, resting on the outer surface of the Serratus anterior. It extends along the side of the thorax to the lower border of that muscle, supplying filaments to each of its digitations.

The branches for the Longus colli and Scaleni arise from the lower four cervical nerves at their exit from the intervertebral foramina.

INFRACLAVICULAR BRANCHES.

The infraclavicular branches are derived from the three cords of the brachial plexus, but the fasciculi of the nerves may be traced through the plexus to the spinal nerves from which they originate. They are as follows:

Lateral cord	{	Musculocutaneous	5, 6, 7 C.
		Lateral anterior thoracic	5, 6, 7 C.
		Lateral head of median	6, 7 C.
Medial cord	{	Medial anterior thoracic	} 8 C, 1 T.
		Medial antibrachial cutaneous	
		Medial brachial cutaneous	
		Ulnar	
		Medial head of median	
Posterior cord	{	Upper subscapular	5, 6 C.
		Lower subscapular	5, 6 C.
		Thoracodorsal	5, 6, 7 C.
		Axillary	5, 6 C.
		Radial	6, 7, 8 C, 1 T.

The **Anterior Thoracic Nerves** (*nn. thoracales anteriores*) (Fig. 816) supply the Pectorales major and minor.

The **lateral anterior thoracic** (*fasciculus lateralis*) the larger of the two, *arises* from the lateral cord of the brachial plexus, and through it from the fifth, sixth, and seventh cervical nerves. It passes across the axillary artery and vein, pierces the coracoclavicular fascia, and is distributed to the deep surface of the Pectoralis major. It sends a filament to join the medial anterior thoracic and form with it a loop in front of the first part of the axillary artery.

The **medial anterior thoracic** (*fasciculus medialis*) *arises* from the medial cord of the plexus and through it from the eighth cervical and first thoracic. It passes behind the first part of the axillary artery, curves forward between the axillary artery and vein, and unites in front of the artery with a filament from the lateral nerve. It then enters the deep surface of the Pectoralis minor, where it divides into a number of branches, which supply the muscle. Two or three branches pierce the muscle and end in the Pectoralis major.

The **Subscapular Nerves** (*nn. subscapulares*), two in number, spring from the posterior cord of the plexus and through it from the fifth and sixth cervical nerves.

The **upper subscapular** (*short subscapular*), the smaller enters the upper part of the Subscapularis, and is frequently represented by two branches.

The **lower subscapular** supplies the lower part of the Subscapularis, and ends in the Teres major; the latter muscle is sometimes supplied by a separate branch.

The **Thoracodorsal Nerve** (*n. thoracodorsalis*; *middle or long subscapular nerve*), a branch of the posterior cord of the plexus, derives its fibers from the fifth, sixth, and seventh cervical nerves; it follows the course of the subscapular artery, along the posterior wall of the axilla to the Latissimus dorsi, in which it may be traced as far as the lower border of the muscle.

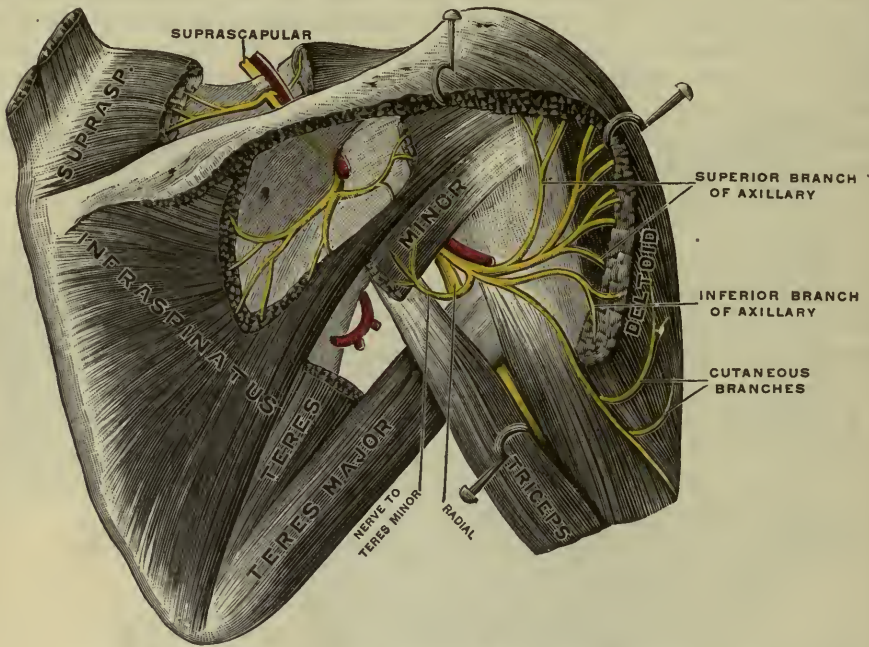


FIG. 810.—Suprascapular and axillary nerves of right side, seen from behind. (Testut.)

The **Axillary Nerve** (*n. axillaris*; *circumflex nerve*) (Fig. 818) arises from the posterior cord of the brachial plexus, and its fibers are derived from the fifth and sixth cervical nerves. It lies at first behind the axillary artery, and in front of the Subscapularis, and passes downward to the lower border of that muscle. It then winds backward, in company with the posterior humeral circumflex artery, through a quadrilateral space bounded above by the Subscapularis, below by the Teres major, medially by the long head of the Triceps brachii, and laterally by the surgical neck of the humerus, and divides into an anterior and a posterior branch.

The **anterior branch** (*upper branch*) winds around the surgical neck of the humerus, beneath the Deltoides, with the posterior humeral circumflex vessels, as far as the anterior border of that muscle, supplying it, and giving off a few small cutaneous branches, which pierce the muscle and ramify in the skin covering its lower part.

The **posterior branch** (*lower branch*) supplies the Teres minor and the posterior part of the Deltoides; upon the branch to the Teres minor an oval enlargement (pseudoganglion) usually exists. The posterior branch then pierces the deep fascia and is continued as the **lateral brachial cutaneous nerve**, which sweeps around the posterior border of the Deltoides and supplies the skin over the lower two-thirds of the posterior part of this muscle, as well as that covering the long head of the Triceps brachii (Figs 811, 813).

The trunk of the axillary nerve gives off an articular filament which enters the shoulder-joint below the Subscapularis.

The **Musculocutaneous Nerve** (*n. musculocutaneus*) (Fig. 816) arises from the lateral cord of the brachial plexus, opposite the lower border of the Pectoralis

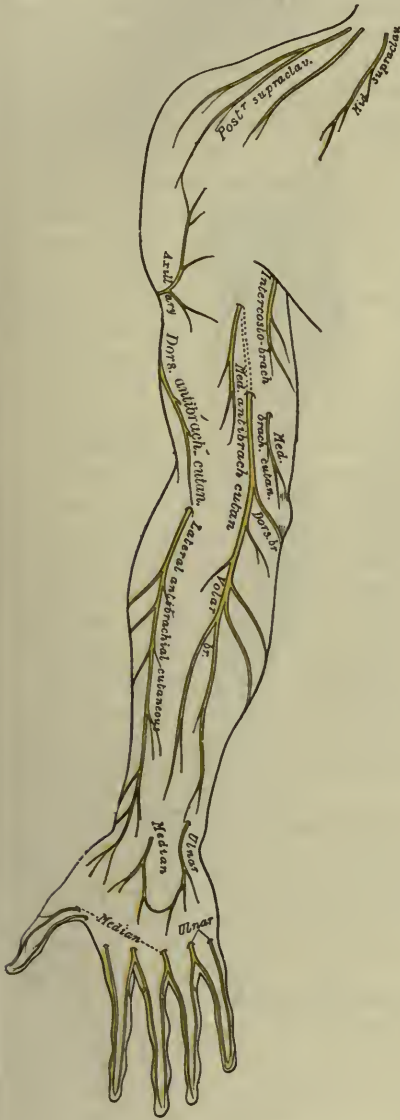


Fig. 811.—Cutaneous nerves of right upper extremity. Anterior view.

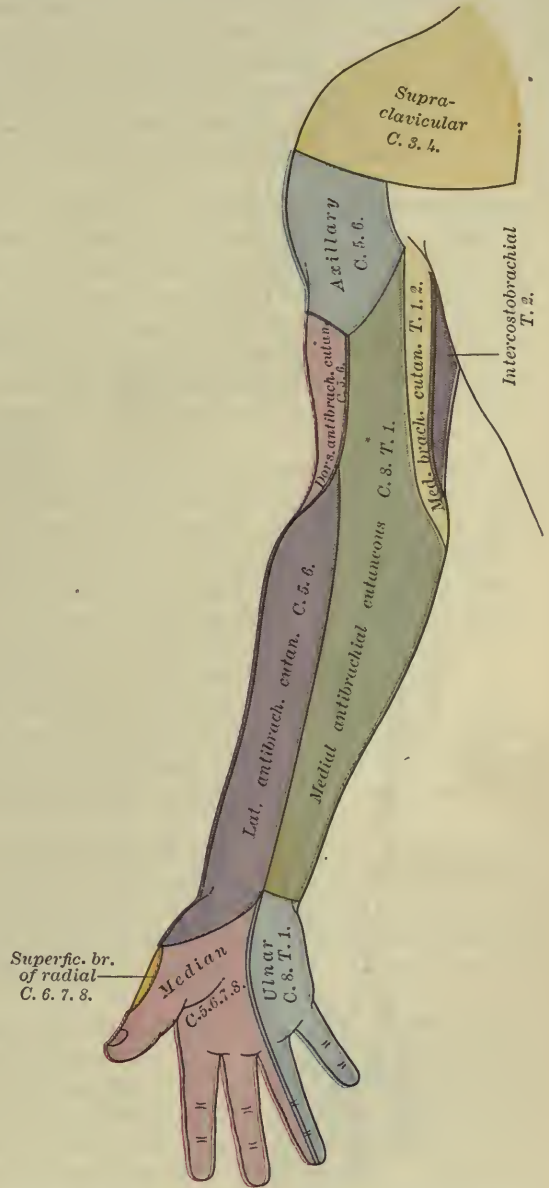


Fig. 812.—Diagram of segmental distribution of the cutaneous nerves of the right upper extremity. Anterior view.

minor, its fibers being derived from the fifth, sixth, and seventh cervical nerves. It pierces the Coracobrachialis muscle and passes obliquely between the Biceps brachii and the Brachialis, to the lateral side of the arm; a little above the elbow it pierces the deep fascia lateral to the tendon of the Biceps brachii and is continued into the forearm as the lateral antibrachial cutaneous nerve. In its course through

the arm it supplies the Coracobrachialis, Biceps brachii, and the greater part of the Brachialis. The branch to the Coracobrachialis is given off from the nerve close to its origin, and in some instances as a separate filament from the lateral cord of the plexus; it is derived from the seventh cervical nerve. The branches to the Biceps brachii and Brachialis are given off after the musculocutaneous has pierced

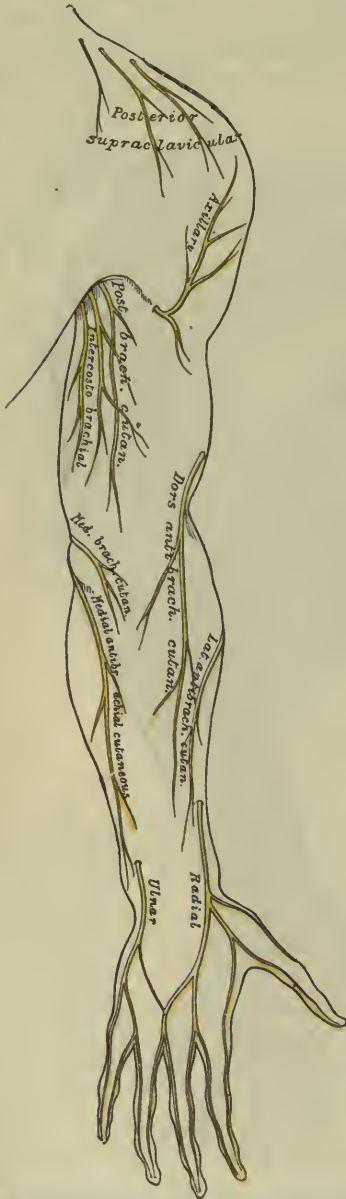


FIG. 813.—Cutaneous nerves of right upper extremity. Posterior view.

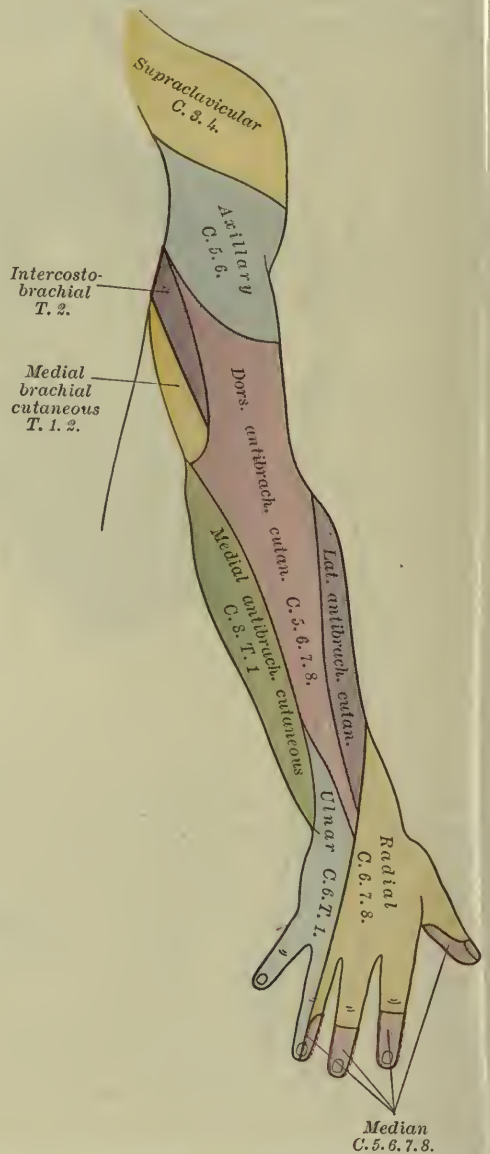


FIG. 814.—Diagram of segmental distribution of the cutaneous nerves of the right upper extremity. Posterior view.

the Coracobrachialis; that supplying the Brachialis gives a filament to the elbow-joint. The nerve also sends a small branch to the bone, which enters the nutrient foramen with the accompanying artery.

The lateral antibrachial cutaneous nerve (*n. cutaneus antibrachii cutaneus lateralis*; branch of musculocutaneous nerve) passes behind the cephalic vein, and divides, opposite the elbow-joint, into a volar and a dorsal branch (Figs. 811, 813).

The **volar branch** (*ramus volaris; anterior branch*) descends along the radial border of the forearm to the wrist, and supplies the skin over the lateral half of its volar surface. At the wrist-joint it is placed in front of the radial artery, and some filaments, piercing the deep fascia, accompany that vessel to the dorsal surface of the carpus. The nerve then passes downward to the ball of the thumb, where it ends in cutaneous filaments. It communicates with the superficial branch of the radial nerve, and with the palmar cutaneous branch of the median nerve.

The **dorsal branch** (*ramus dorsalis; posterior branch*) descends, along the dorsal surface of the radial side of the forearm to the wrist. It supplies the skin of the lower two-thirds of the dorso-lateral surface of the forearm, communicating with the superficial branch of the radial nerve and the dorsal antibrachial cutaneous branch of the radial.

The musculocutaneous nerve presents frequent irregularities. It may adhere for some distance to the median and then pass outward, beneath the Biceps brachii, instead of through the Coracobrachialis. Some of the fibers of the median may run for some distance in the musculocutaneous and then leave it to join their proper trunk; less frequently the reverse is the case, and the median sends a branch to join the musculocutaneous. The nerve may pass under the Coracobrachialis or through the Biceps brachii. Occasionally it gives a filament to the Pronator teres, and it supplies the dorsal surface of the thumb when the superficial branch of the radial nerve is absent.

The **Medial Antibrachial Cutaneous Nerve** (*n. cutaneus antibrachii medialis; internal cutaneous nerve*) (Fig. 816) arises from the medial cord of the brachial plexus. It derives its fibers from the eighth cervical and first thoracic nerves, and at its commencement is placed medial to the axillary artery. It gives off, near the axilla, a filament, which pierces the fascia and supplies the integument covering the Biceps brachii, nearly as far as the elbow. The nerve then runs down the ulnar side of the arm medial to the brachial artery, pierces the deep fascia with the basilic vein, about the middle of the arm, and divides into a volar and an ulnar branch.

The **volar branch** (*ramus volaris; anterior branch*), the larger, passes usually in front of, but occasionally behind, the vena mediana cubiti (*median basilic vein*). It then descends on the front of the ulnar side of the forearm, distributing filaments to the skin as far as the wrist, and communicating with the palmar cutaneous branch of the ulnar nerve (Fig. 811).

The **ulnar branch** (*ramus ulnaris; posterior branch*) passes obliquely downward on the medial side of the basilic vein, in front of the medial epicondyle of the humerus, to the back of the forearm, and descends on its ulnar side as far as the wrist, distributing filaments to the skin. It communicates with the medial brachial cutaneous, the dorsal antibrachial cutaneous branch of the radial, and the dorsal branch of the ulnar (Fig. 813).

The **Medial Brachial Cutaneous Nerve** (*n. cutaneus brachii medialis; lesser internal cutaneous nerve; nerve of Wrisberg*) is distributed to the skin on the ulnar side of the arm (Figs. 811, 813). It is the smallest branch of the brachial plexus, and arising from the medial cord receives its fibers from the eighth cervical and first thoracic nerves. It passes through the axilla, at first lying behind, and then medial to the axillary vein, and communicates with the intercostobrachial nerve. It descends along the medial side of the brachial artery to the middle of the arm, where it pierces the deep fascia, and is distributed to the skin of the back of the lower third of the arm, extending as far as the elbow, where some filaments are lost in the skin in front of the medial epicondyle, and others over the olecranon. It communicates with the ulnar branch of the medial antibrachial cutaneous nerve.

In some cases the medial brachial cutaneous and intercostobrachial are connected by two or three filaments, which form a plexus in the axilla. In other cases the intercostobrachial is of large size, and takes the place of the medial brachial cutaneous, receiving merely a filament of communication from the brachial plexus, which represents the latter nerve; in a few cases, this filament is wanting.

The **Median Nerve** (*n. medianus*) (Fig. 816) extends along the middle of the arm and forearm to the hand. It *arises* by two roots, one from the lateral and one from the medial cord of the brachial plexus; these embrace the lower part of the axillary artery, uniting either in front of or lateral to that vessel. Its fibers are derived from the sixth, seventh, and eighth cervical and first thoracic nerves. As it descends through the arm, it lies at first lateral to the brachial artery; about the level of the insertion of the Coracobrachialis it crosses the artery, usually in front of, but occasionally behind it, and lies on its medial side at the bend of the elbow, where it is situated behind the lacertus fibrosus (*bicipital fascia*), and is separated from the elbow-joint by the Brachialis. **In the forearm** it passes between the two heads of the Pronator teres and crosses the ulnar artery, but is separated from this vessel by the deep head of the Pronator teres. It descends beneath the Flexor digitorum sublimis, lying on the Flexor digitorum profundus, to within 5 cm. of the transverse carpal ligament; here it becomes more superficial, and is situated between the tendons of the Flexor digitorum sublimis and Flexor carpi radialis. In this situation it lies behind, and rather to the radial side of, the tendon of the Palmaris longus, and is covered by the skin and fascia. It then passes behind the transverse carpal ligament into the palm of the hand. In its course through the forearm it is accompanied by the median artery, a branch of the volar interosseous artery.

Branches.—With the exception of the nerve to the Pronator teres, which sometimes arises above the elbow-joint, the median nerve gives off no branches in the arm. As it passes in front of the elbow, it supplies one or two twigs to the joint.

In the forearm its branches are: **muscular**, **volar interosseous**, and **palmar**.

The **muscular branches** (*rami musculares*) are derived from the nerve near the elbow and supply all the superficial muscles on the front of the forearm, except the Flexor carpi ulnaris.

The **volar interosseous nerve** (*n. interosseus [antibrachii] volaris; anterior interosseous nerve*) supplies the deep muscles on the front of the forearm, except the ulnar half of the Flexor digitorum profundus. It accompanies the volar interosseous artery along the front of the interosseous membrane, in the interval between the Flexor pollicis longus and Flexor digitorum profundus, supplying the whole of the former and the radial half of the latter, and ending below in the Pronator quadratus and wrist-joint.

The **palmar branch** (*ramus cutaneus palmaris n. mediani*) of the median nerve *arises* at the lower part of the forearm. It pierces the volar carpal ligament, and divides into a lateral and a medial branch; the lateral branch supplies the skin over the ball of the thumb, and communicates with the volar branch of the lateral antibrachial cutaneous nerve; the medial branch supplies the skin of the palm and communicates with the palmar cutaneous branch of the ulnar.

In the palm of the hand the median nerve is covered by the skin and the palmar aponeurosis, and rests on the tendons of the Flexor muscles. Immediately after emerging from under the transverse carpal ligament the nerve becomes enlarged and flattened and splits into a smaller, lateral, and a larger, medial portion. The **lateral portion** supplies a short, stout branch to certain of the muscles of the ball of the thumb, viz., the Abductor brevis, the Opponens, and the superficial head of the Flexor brevis, and then divides into three **proper volar digital nerves**; two of these supply the sides of the thumb, while the third gives a twig to the first Lumbricalis and is distributed to the radial side of the index finger. The **medial portion** of the nerve divides into two **common volar digital nerves**. The first of these gives a twig to the second Lumbricalis and runs toward the cleft between the index and middle fingers, where it divides into two proper digital nerves for the adjoining sides of these digits; the second runs toward the cleft between the middle and ring fingers, and splits into two proper digital nerves for the adjoining sides of these digits;

it communicates with a branch from the ulnar nerve and sometimes sends a twig to the third Lumbricalis.

Each proper digital nerve, opposite the base of the first phalanx, gives off a dorsal branch which joins the dorsal digital nerve from the superficial branch of the radial nerve, and supplies the integument on the dorsal aspect of the last phalanx. At the end of the digit, the proper digital nerve divides into two branches, one of which supplies the pulp of the finger, the other ramifies around and beneath the nail. The proper digital nerves, as they run along the fingers, are placed superficial to the corresponding arteries.

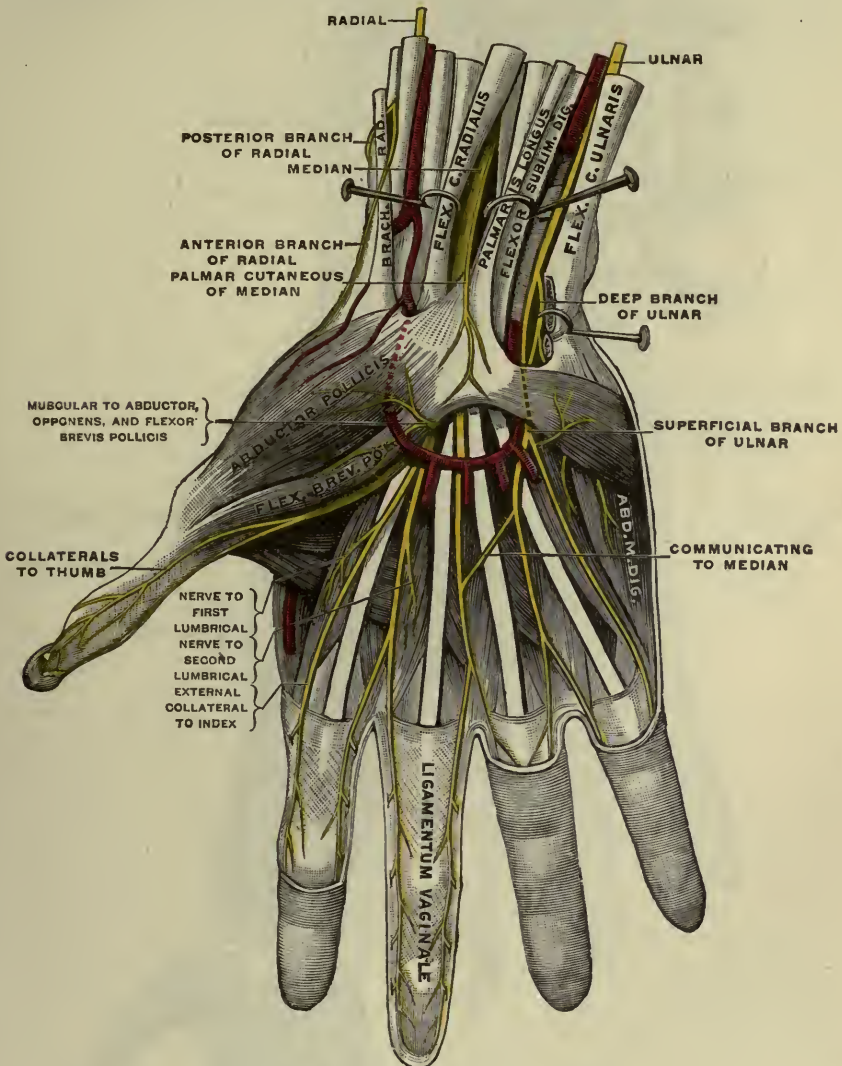


FIG. 815.—Superficial palmar nerves. (Testut.)

The **Ulnar Nerve** (*n. ulnaris*) (Fig. 816) is placed along the medial side of the limb, and is distributed to the muscles and skin of the forearm and hand. It arises from the medial cord of the brachial plexus, and derives its fibers from the eighth cervical and first thoracic nerves. It is smaller than the median, and lies at first behind it, but diverges from it in its course down the arm. At its origin it lies

medial to the axillary artery, and bears the same relation to the brachial artery as far as the middle of the arm. Here it pierces the medial intermuscular septum,

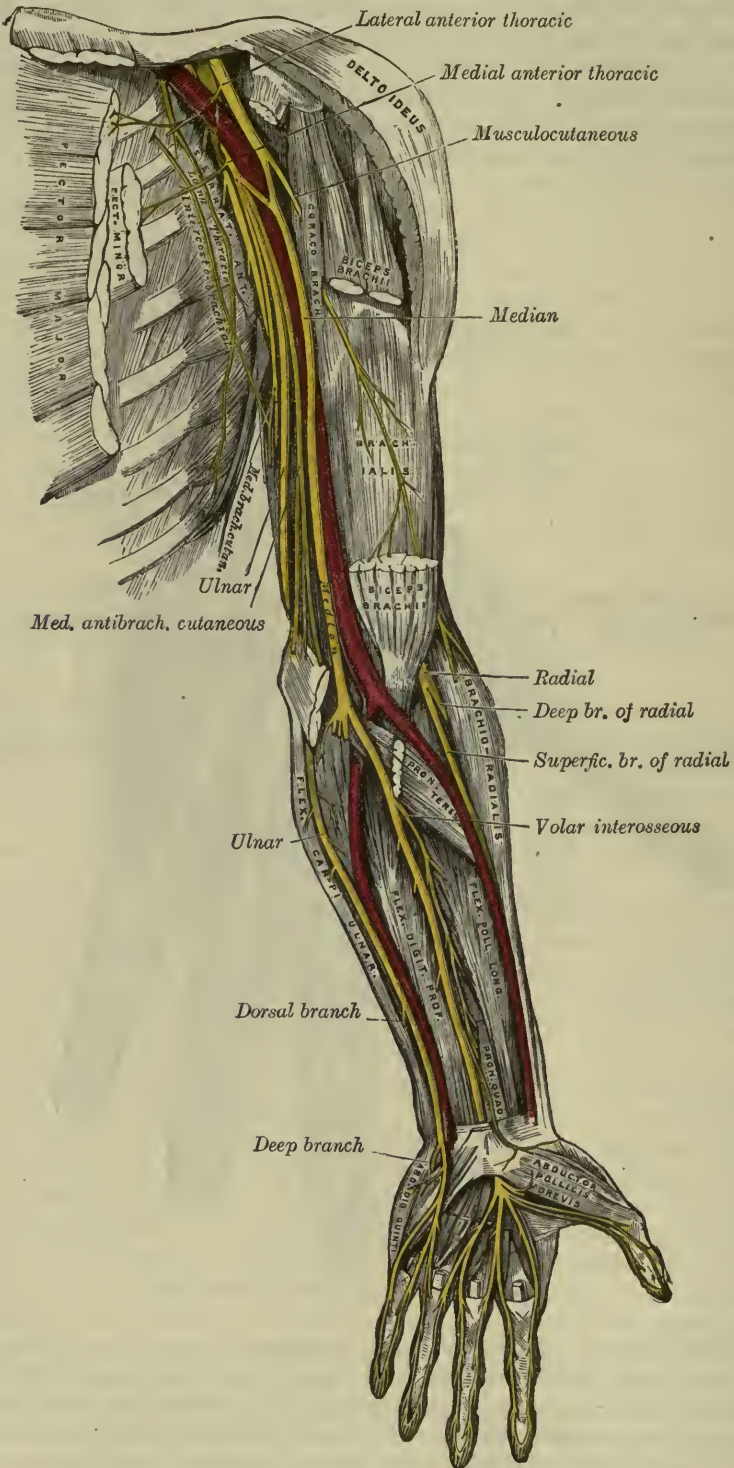


FIG. 816.—Nerves of the left upper extremity.

runs obliquely across the medial head of the Triceps brachii, and descends to the groove between the medial epicondyle and the olecranon, accompanied by the superior ulnar collateral artery. At the elbow, it rests upon the back of the medial epicondyle, and enters the forearm between the two heads of the Flexor carpi ulnaris. In the forearm, it descends along the ulnar side, lying upon the Flexor digitorum profundus; its upper half is covered by the Flexor carpi ulnaris, its lower

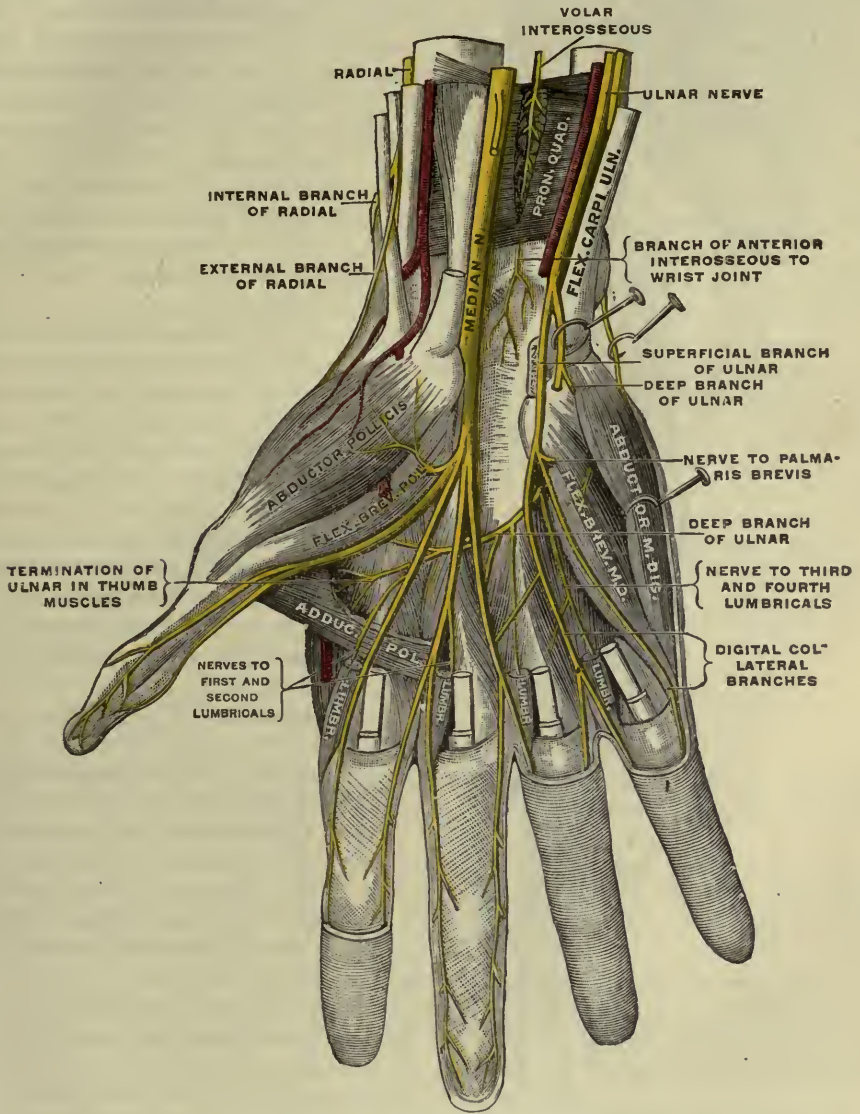


FIG. 817.—Deep palmar nerves. (Testut.)

half lies on the lateral side of the muscle, covered by the integument and fascia. In the upper third of the forearm, it is separated from the ulnar artery by a considerable interval, but in the rest of its extent lies close to the medial side of the artery. About 5 cm. above the wrist it ends by dividing into a dorsal and a volar branch.

The branches of the ulnar nerve are: articular to the elbow-joint, muscular, palmar cutaneous, dorsal, and volar.

The **articular branches** to the elbow-joint are several small filaments which arise from the nerve as it lies in the groove between the medial epicondyle and olecranon.

The **muscular branches** (*rami musculares*) two in number, arise near the elbow: one supplies the Flexor carpi ulnaris; the other, the ulnar half of the Flexor digitorum profundus.

The **palmar cutaneous branch** (*ramus cutaneus palmaris*) arises about the middle of the forearm, and descends on the ulnar artery, giving off some filaments to the vessel. It perforates the volar carpal ligament and ends in the skin of the palm, communicating with the palmar branch of the median nerve.

The **dorsal branch** (*ramus dorsalis manus*) arises about 5 cm. above the wrist; it passes backward beneath the Flexor carpi ulnaris, perforates the deep fascia, and, running along the ulnar side of the back of the wrist and hand, divides into two dorsal digital branches; one supplies the ulnar side of the little finger; the other, the adjacent sides of the little and ring fingers. It also sends a twig to join that given by the superficial branch of the radial nerve for the adjoining sides of the middle and ring fingers, and assists in supplying them. A branch is distributed to the metacarpal region of the hand, communicating with a twig of the superficial branch of the radial nerve (Fig. 813).

On the little finger the dorsal digital branches extend only as far as the base of the terminal phalanx, and on the ring finger as far as the base of the second phalanx; the more distal

parts of these digits are supplied by dorsal branches derived from the proper volar digital branches of the ulnar nerve.

The **volar branch** (*ramus volaris manus*) crosses the transverse carpal ligament on the lateral side of the pisiform bone, medial to and a little behind the ulnar artery. It ends by dividing into a superficial and a deep branch.

The **superficial branch** (*ramus superficialis [n. ulnaris]*) supplies the Palmaris brevis, and the skin on the ulnar side of the hand, and divides into a proper volar

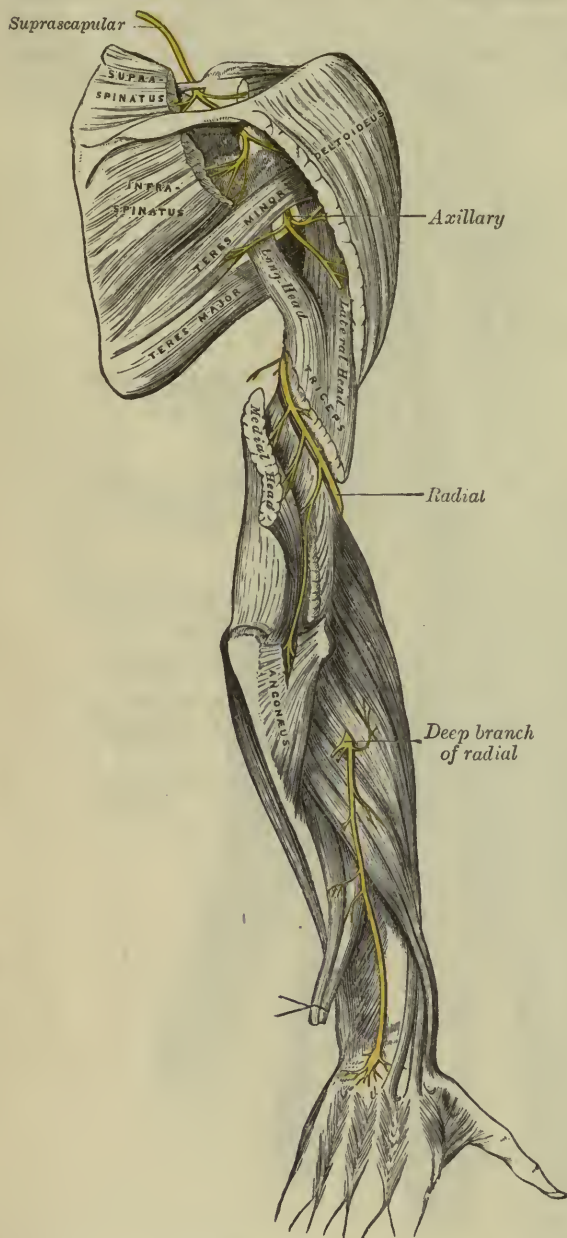


FIG. 818.—The suprascapular, axillary, and radial nerves.

digital branch for the ulnar side of the little finger, and a common volar digital branch which gives a communicating twig to the median nerve and divides into two proper digital nerves for the adjoining sides of the little and ring fingers (Fig. 811). The proper digital branches are distributed to the fingers in the same manner as those of the median.

The **deep branch** (*ramus profundus*) accompanied by the deep branch of the ulnar artery, passes between the Abductor digiti quinti and Flexor digiti quinti brevis; it then perforates the Opponens digiti quinti and follows the course of the deep volar arch beneath the Flexor tendons. At its origin it supplies the three short muscles of the little finger. As it crosses the deep part of the hand, it supplies all the Interossei and the third and fourth Lumbricales; it ends by supplying the Adductores pollicis and the medial head of the Flexor pollicis brevis. It also sends articular filaments to the wrist-joint.

It has been pointed out that the ulnar part of the Flexor digitorum profundus is supplied by the ulnar nerve; the third and fourth Lumbricales, which are connected with the tendons of this part of the muscle, are supplied by the same nerve. In like manner the lateral part of the Flexor digitorum profundus and the first and second Lumbricales are supplied by the median nerve; the third Lumbricalis frequently receives an additional twig from the median nerve.

The **Radial Nerve** (*n. radialis; musculospiral nerve*) (Fig. 818), the largest branch of the brachial plexus, is the continuation of the posterior cord of the plexus. Its fibres are derived from the fifth, sixth, seventh, and eighth cervical and first thoracic nerves. It descends behind the first part of the axillary artery and the upper part of the brachial artery, and in front of the tendons of the Latissimus dorsi and Teres major. It then winds around from the medial to the lateral side of the humerus in a groove with the a. profunda brachii, between the medial and lateral heads of the Triceps brachii. It pierces the lateral intermuscular septum, and passes between the Brachialis and Brachioradialis to the front of the lateral epicondyle, where it divides into a superficial and a deep branch.

The **branches** of the musculospiral nerve are:

Muscular.	Superficial.
Cutaneous.	Deep.

The **muscular branches** (*rami musculares*) supply the Triceps brachii, Anconæus, Brachioradialis, Extensor carpi radialis longus, and Brachialis, and are grouped as medial, posterior, and lateral.

The medial muscular branches supply the medial and long heads of the Triceps brachii. That to the medial head is a long, slender filament, which lies close to the ulnar nerve as far as the lower third of the arm, and is therefore frequently spoken of as the **ulnar collateral nerve**.

The posterior muscular branch, of large size, *arises* from the nerve in the groove between the Triceps brachii and the humerus. It divides into filaments, which supply the medial and lateral heads of the Triceps brachii and the Anconæus muscles. The branch for the latter muscle is a long, slender filament, which descends in the substance of the medial head of the Triceps brachii.

The lateral muscular branches supply the Brachioradialis, Extensor carpi radialis longus, and the lateral part of the Brachialis.

The **cutaneous branches** are two in number, the posterior brachial cutaneous and the dorsal antibrachial cutaneous.

The **posterior brachial cutaneous nerve** (*n. cutaneus brachii posterior; internal cutaneous branch of musculospiral*) *arises* in the axilla, with the medial muscular branch. It is of small size, and passes through the axilla to the medial side of the area supplying the skin on its dorsal surface nearly as far as the olecranon. In its course it crosses behind, and communicates with, the intercostobrachial.

The **dorsal antibrachial cutaneous nerve** (*n. cutaneus antibrachii dorsalis; external cutaneous branch of musculospiral*) perforates the lateral head of the Triceps brachii at its attachment to the humerus. The **upper** and smaller branch of the nerve passes to the front of the elbow, lying close to the cephalic vein, and supplies the skin of the lower half of the arm (Fig. 811). The **lower** branch pierces the deep fascia below the insertion of the Deltoides, and descends along the lateral side of the arm and elbow, and then along the back of the forearm to the wrist, supplying the skin in its course, and joining, near its termination, with the dorsal branch of the lateral antibrachial cutaneous nerve (Fig. 813).

The **Superficial Branch of the Radial Nerve** (*ramus superficialis radial nerve*) passes along the front of the radial side of the forearm to the commencement of its lower third. It lies at first slightly lateral to the radial artery, concealed beneath the Brachioradialis. In the middle third of the forearm, it lies behind the same muscle, close to the lateral side of the artery. It quits the artery about 7 cm. above the wrist, passes beneath the tendon of the Brachioradialis, and, piercing the deep fascia, divides into two branches (Fig. 813).

The lateral branch, the smaller, supplies the skin of the radial side and ball of the thumb, joining with the volar branch of the lateral antibrachial cutaneous nerve.

The medial branch communicates, above the wrist, with the dorsal branch of the lateral antibrachial cutaneous, and, on the back of the hand, with the dorsal branch of the ulnar nerve. It then divides into four digital nerves, which are distributed as follows: the first supplies the ulnar side of the thumb; the second, the radial side of the index finger; the third, the adjoining sides of the index and middle fingers; the fourth communicates with a filament from the dorsal branch of the ulnar nerve, and supplies the adjacent sides of the middle and ring fingers.¹

The **Deep Branch of the Radial Nerve** (*n. interosseus dorsalis; dorsal or posterior interosseous nerve*) winds to the back of the forearm around the lateral side of the radius between the two planes of fibers of the Supinator, and is prolonged downward between the superficial and deep layers of muscles, to the middle of the forearm. Considerably diminished in size, it descends, as the **dorsal interosseous nerve**, on the interosseous membrane, in front of the Extensor pollicis longus, to the back of the carpus, where it presents a gangliform enlargement from which filaments are distributed to the ligaments and articulations of the carpus. It supplies all the muscles on the radial side and dorsal surface of the forearm, excepting the Anconæus, Brachioradialis, and Extensor carpi radialis longus.

The Thoracic Nerves (Nn. Thoracales).

The **anterior divisions of the thoracic nerves** (*rami anteriores; ventral divisions*) are twelve in number on either side. Eleven of them are situated between the ribs, and are therefore termed **intercostal**; the twelfth lies below the last rib. Each nerve is connected with the adjoining ganglion of the sympathetic trunk by a gray and a white ramus communicans. The intercostal nerves are distributed chiefly to the parietes of the thorax and abdomen, and differ from the anterior divisions of the other spinal nerves, in that each pursues an independent course, *i. e.*, there is no plexus formation. The first two nerves supply fibers to the upper limb in addition to their thoracic branches; the next four are limited in their distribution to the parietes of the thorax; the lower five supply the parietes of the thorax and abdomen. The twelfth thoracic is distributed to the abdominal wall and the skin of the buttock.

¹ According to Hutchison, the digital nerve to the thumb reaches only as high as the root of the nail; the one to the forefinger as high as the middle of the second phalanx; and the one to the middle and ring fingers not higher than the first phalangeal joint.—London Hosp. Gaz., iii, 319.

The First Thoracic Nerve.—The anterior division of the first thoracic nerve divides into two branches: one, the larger, leaves the thorax in front of the neck of the first rib, and enters the brachial plexus; the other and smaller branch, the **first intercostal nerve**, runs along the first intercostal space, and ends on the front of the chest as the first anterior cutaneous branch of the thorax. Occasionally this anterior cutaneous branch is wanting. The first intercostal nerve as a rule gives off no lateral cutaneous branch; but sometimes it sends a small branch to communicate with the intercostobrachial. From the second thoracic nerve it frequently receives a connecting twig, which ascends over the neck of the second rib.

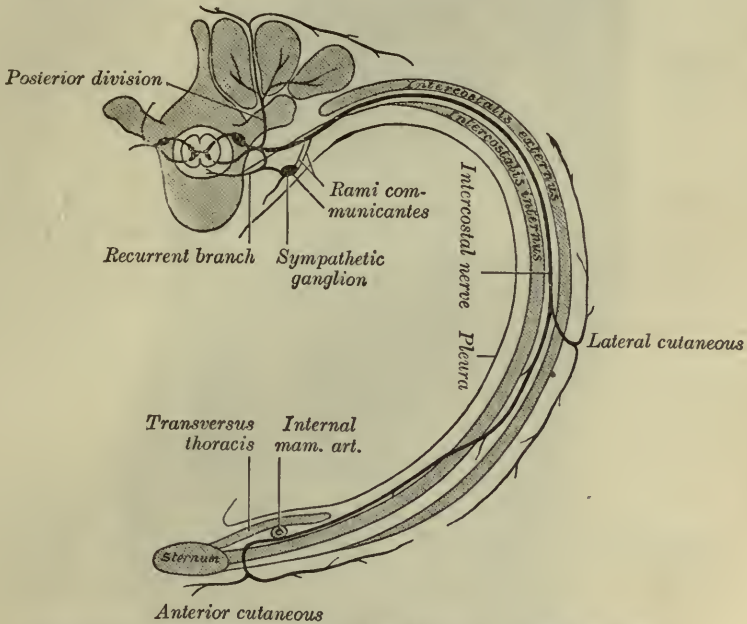


FIG. 819.—Diagram of the course and branches of a typical intercostal nerve.

The Upper Thoracic Nerves (*nn. intercostales*).—The anterior divisions of the second, third, fourth, fifth, and sixth thoracic nerves, and the small branch from the first thoracic, are confined to the parietes of the thorax, and are named **thoracic intercostal nerves**. They pass forward (Fig. 819) in the intercostal spaces below the intercostal vessels. At the back of the chest they lie between the pleura and the posterior intercostal membranes, but soon pierce the latter and run between the two planes of Intercostales muscles as far as the middle of the rib. They then enter the substance of the Intercostales interni, and, running amidst their fibers as far as the costal cartilages, they gain the inner surfaces of the muscles and lie between them and the pleura. Near the sternum, they cross in front of the internal mammary artery and Transversus thoracis muscle, pierce the Intercostales interni, the anterior intercostal membranes, and Pectoralis major, and supply the integument of the front of the thorax and over the mamma, forming the anterior cutaneous branches of the thorax; the branch from the second nerve unites with the anterior supraclavicular nerves of the cervical plexus.

Branches.—Numerous slender muscular filaments supply the Intercostales, the Subcostales, the Levatores costarum, the Serratus posterior superior, and the Transversus thoracis. At the front of the thorax some of these branches cross the costal cartilages from one intercostal space to another.

Lateral cutaneous branches (*rami cutanei laterales*) are derived from the intercostal nerves, about midway between the vertebræ and sternum; they pierce the Inter-

costales externi and Serratus anterior, and divide into anterior and posterior branches. The **anterior branches** run forward to the side and the forepart of the chest, supplying the skin and the mamma; those of the fifth and sixth nerves

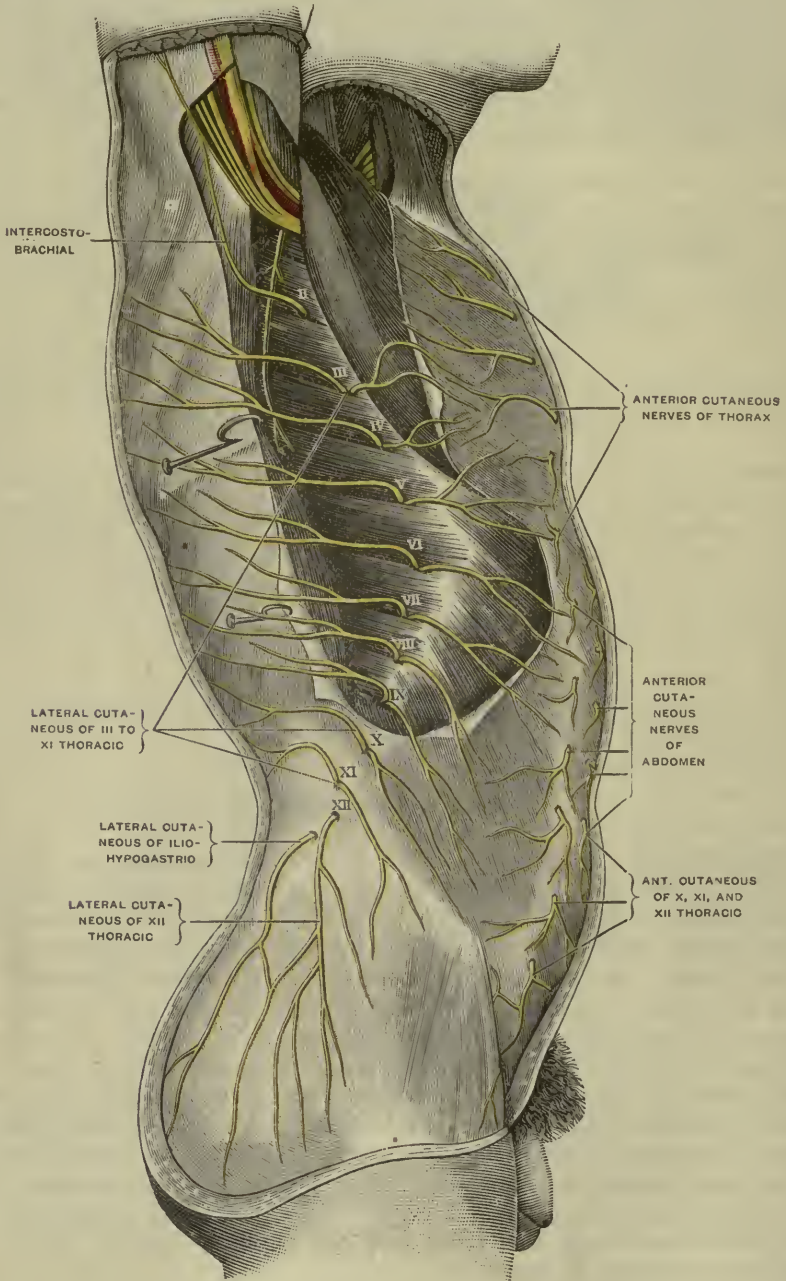


FIG. 820.—Cutaneous distribution of thoracic nerves. (Testut.)

supply the upper digitations of the Obliquus externus abdominis. The **posterior branches** run backward, and supply the skin over the scapula and Latissimus dorsi.

The lateral cutaneous branch of the second intercostal nerve does not divide, like the others, into an anterior and a posterior branch; it is named the **intercosto-**

brachial nerve (Fig. 816). It pierces the Intercostalis externus and the Serratus anterior, crosses the axilla to the medial side of the arm, and joins with a filament from the medial brachial cutaneous nerve. It then pierces the fascia, and supplies the skin of the upper half of the medial and posterior part of the arm, communicat-

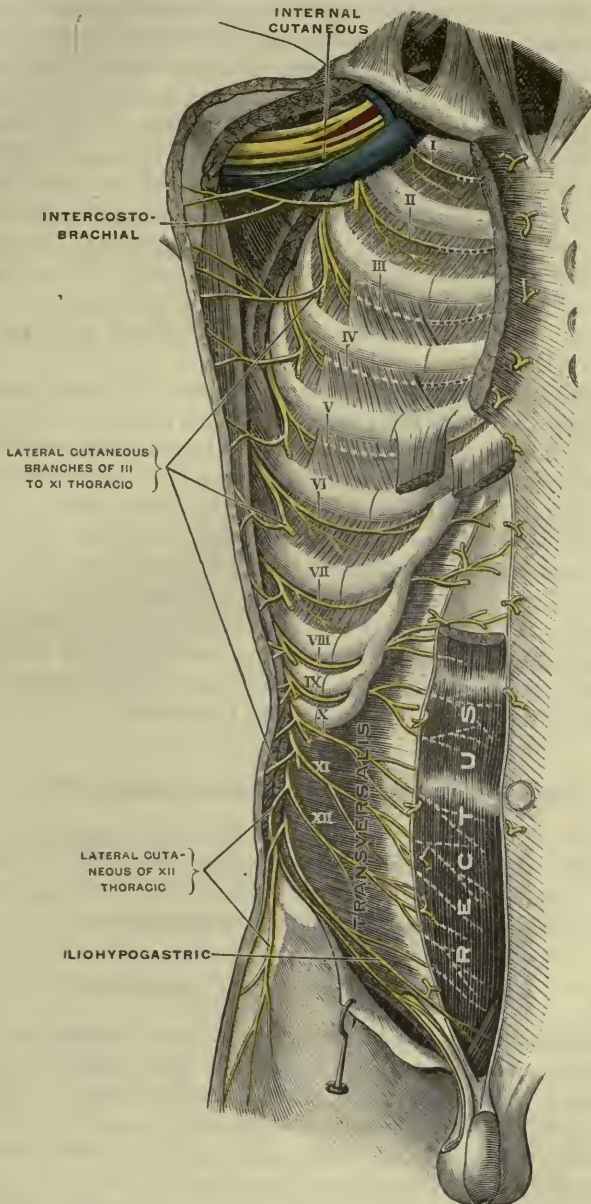


FIG. 821.—Intercostal nerves, the superficial muscles having been removed. (Testut).

ing with the posterior brachial cutaneous branch of the radial nerve. The size of the intercostobrachial nerve is in inverse proportion to that of the medial brachial cutaneous nerve. A second intercostobrachial nerve is frequently given off from the lateral cutaneous branch of the third intercostal; it supplies filaments to the axilla and medial side of the arm.

The Lower Thoracic Nerves.—The anterior divisions of the seventh, eighth, ninth, tenth, and eleventh thoracic nerves are continued anteriorly from the intercostal spaces into the abdominal wall; hence they are named **thoracoabdominal intercostal nerves**. They have the same arrangement as the upper ones as far as the anterior ends of the intercostal spaces, where they pass behind the costal cartilages, and between the Obliquus internus and Transversus abdominis, to the sheath of the Rectus abdominis, which they perforate. They supply the Rectus abdominis and end as the **anterior cutaneous branches** of the abdomen; they supply the skin of the front of the abdomen. The lower intercostal nerves supply the Intercostales and abdominal muscles; the last three send branches to the Serratus posterior inferior. About the middle of their course they give off **lateral cutaneous branches**. These pierce the Intercostales externi and the Obliquus externus abdominis, in the same line as the lateral cutaneous branches of the upper thoracic nerves, and divide into anterior and posterior branches, which are distributed to the skin of the abdomen and back; the anterior branches supply the digitations of the Obliquus externus abdominis, and extend downward and forward nearly as far as the margin of the Rectus abdominis; the posterior branches pass backward to supply the skin over the Latissimus dorsi.

The anterior division of the **twelfth thoracic nerve** is larger than the others; it runs along the lower border of the twelfth rib, often gives a communicating branch to the first lumbar nerve, and passes under the lateral lumbocostal arch. It then runs in front of the Quadratus lumborum, perforates the Transversus, and passes forward between it and the Obliquus internus to be distributed in the same manner as the lower intercostal nerves. It communicates with the iliohypogastric nerve of the lumbar plexus, and gives a branch to the Pyramidalis. The **lateral cutaneous branch** of the last thoracic nerve is large, and does not divide into an anterior and a posterior branch. It perforates the Obliqui internus and externus, descends over the iliac crest in front of the lateral cutaneous branch of the iliohypogastric (Fig. 819), and is distributed to the skin of the front part of the gluteal region, some of its filaments extending as low as the greater trochanter.

The Lumbosacral Plexus (Plexus Lumbosacralis).

The anterior divisions of the lumbar, sacral, and coccygeal nerves form the lumbosacral plexus, the first lumbar nerve being frequently joined by a branch from the twelfth thoracic. For descriptive purposes this plexus is usually divided into three parts—the **lumbar, sacral, and pudendal plexuses**.

The Lumbar Nerves (Nn. Lumbales).

The **anterior divisions of the lumbar nerves** (*rami anteriores*) increase in size from above downward. They are joined, near their origins, by *gray rami communicantes* from the lumbar ganglia of the sympathetic trunk. These rami consist of long, slender branches which accompany the lumbar arteries around the sides of the vertebral bodies, beneath the Psoas major. Their arrangement is somewhat irregular: one ganglion may give rami to two lumbar nerves, or one lumbar nerve may receive rami from two ganglia. The first and second, and sometimes the third and fourth lumbar nerves are each connected with the lumbar part of the sympathetic trunk by a *white ramus communicans*.

The nerves pass obliquely outward behind the Psoas major, or between its fasciculi, distributing filaments to it and the Quadratus lumborum. The first three and the greater part of the fourth are connected together in this situation by anastomotic loops, and form the **lumbar plexus**. The smaller part of the fourth joins with the fifth to form the **lumbosacral trunk**, which assists in the formation

of the sacral plexus. The fourth nerve is named the *nervus furcalis*, from the fact that it is subdivided between the two plexuses.¹

The Lumbar Plexus² (*plexus lumbalis*) (Figs. 822, 823, 824).—The lumbar plexus is formed by the loops of communication between the anterior divisions of the first three and the greater part of the fourth lumbar nerves; the first lumbar often receives a branch from the last thoracic nerve. It is situated in the posterior part of the Psoas major, in front of the transverse processes of the lumbar vertebræ.

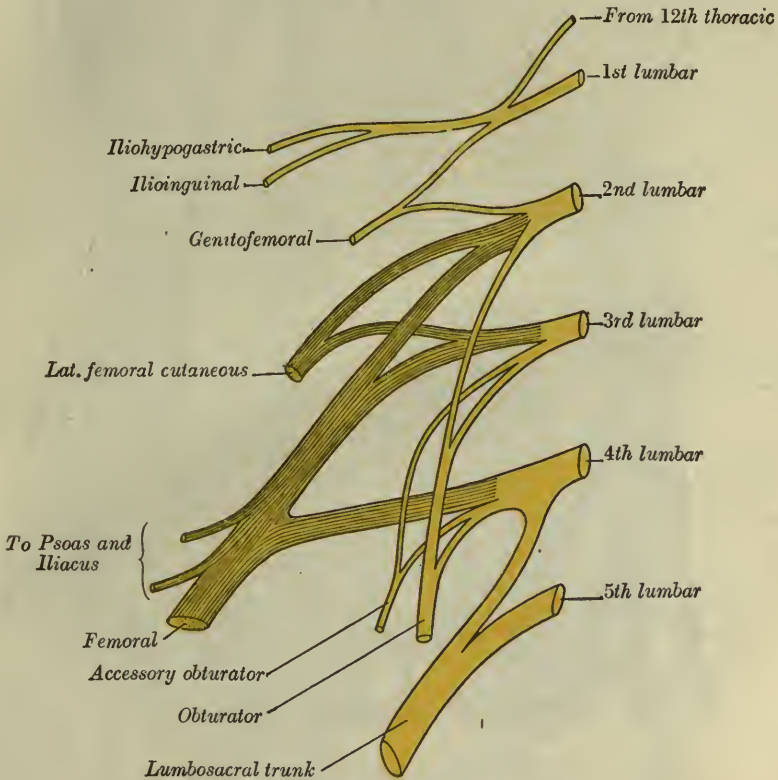


FIG. 822.—Plan of lumbar plexus.

The mode in which the plexus is arranged varies in different subjects. It differs from the brachial plexus in not forming an intricate interlacement, but the several nerves of distribution *arise* from one or more of the spinal nerves, in the following manner: the first lumbar nerve, frequently supplemented by a twig from the last thoracic, splits into an upper and lower branch; the upper and larger branch divides into the iliohypogastric and ilioinguinal nerves; the lower and smaller branch unites with a branch of the second lumbar to form the genitofemoral nerve. The remainder of the second nerve, and the third and fourth nerves, divide into ventral and dorsal divisions. The ventral division of the second unites with the ventral divisions of the third and fourth nerves to form the obturator nerve. The dorsal divisions of the second and third nerves divide into two branches, a smaller branch from each uniting to form the lateral femoral cutaneous nerve, and a larger branch from each joining with the dorsal division of the fourth nerve to form the femoral

¹ In most cases the fourth lumbar is the *nervus furcalis*; but this arrangement is frequently departed from. The third is occasionally the lowest nerve which enters the lumbar plexus, giving at the same time some fibers to the sacral plexus, and thus forming the *nervus furcalis*; or both the third and fourth may be furcal nerves. When this occurs, the plexus is termed *high* or *prefixed*. More frequently the fifth nerve is divided between the lumbar and sacral plexuses, and constitutes the *nervus furcalis*; and when this takes place, the plexus is distinguished as a *low* or *postfixed* plexus. These variations necessarily produce corresponding modifications in the sacral plexus.

² Bardeen, Amer. Jour. Anat., 1907, vol. vi:

nerve. The accessory obturator, when it exists, is formed by the union of two small branches given off from the third and fourth nerves.

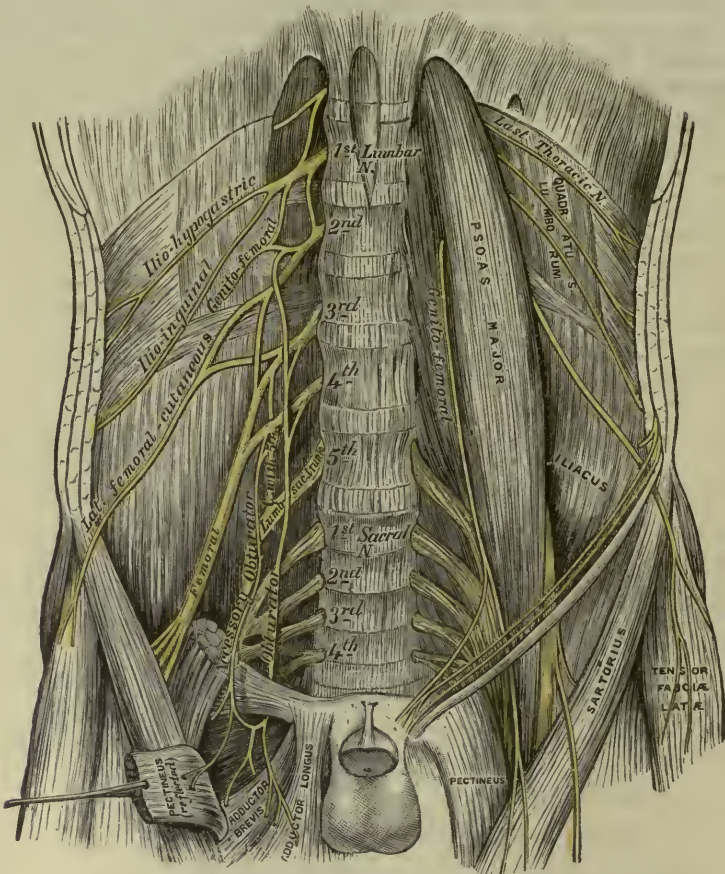


FIG. 823.—The lumbar plexus and its branches.

The branches of the lumbar plexus may therefore be arranged as follows:

Iliohypogastric	1 L.
Ilioinguinal	1 L.
Genitofemoral	1, 2 L.

Dorsal divisions.

Lateral femoral cutaneous	2, 3 L.
Femoral	2, 3, 4 L.

Ventral divisions.

Obturator	2, 3, 4 L.
Accessory obturator	3, 4 L.

The **Iliohypogastric Nerve** (*n. iliohypogastricus*) arises from the first lumbar nerve. It emerges from the upper part of the lateral border of the Psoas major, and crosses obliquely in front of the Quadratus lumborum to the iliac crest. It then perforates the posterior part of the Transversus abdominis, near the crest of the ilium, and

divides between that muscle and the Obliquus internus abdominis into a lateral and an anterior cutaneous branch.

The lateral cutaneous branch (*ramus cutaneus lateralis; iliac branch*) pierces the Obliqui internus and externus immediately above the iliac crest, and is distributed to the skin of the gluteal region, behind the lateral cutaneous branch of the last thoracic nerve (Fig. 830); the size of this branch bears an inverse proportion to that of the lateral cutaneous branch of the last thoracic nerve.

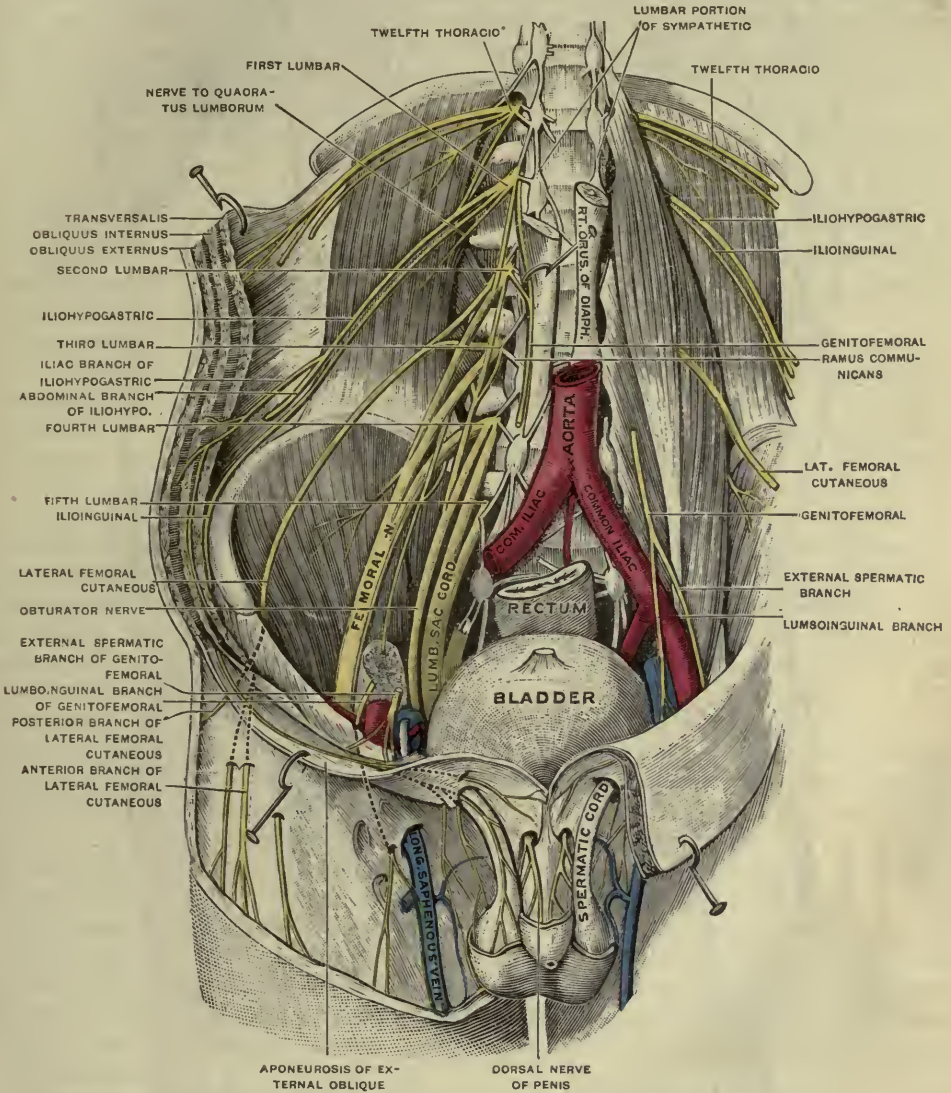


Fig. 824.—Deep and superficial dissection of the lumbar plexus. (Testut.)

The anterior cutaneous branch (*ramus cutaneus anterior; hypogastric branch*) (Fig. 825) continues onward between the Obliquus internus and Transversus. It then pierces the Obliquus internus, becomes cutaneous by perforating the aponeurosis of the Obliquus externus about 2.5 cm. above the subcutaneous inguinal ring, and is distributed to the skin of the hypogastric region.

The iliohypogastric nerve communicates with the last thoracic and ilioinguinal nerves.

The Ilioinguinal Nerve (*n. ilioinguinalis*), smaller than the preceding, arises with it from the first lumbar nerve. It emerges from the lateral border of the Psoas

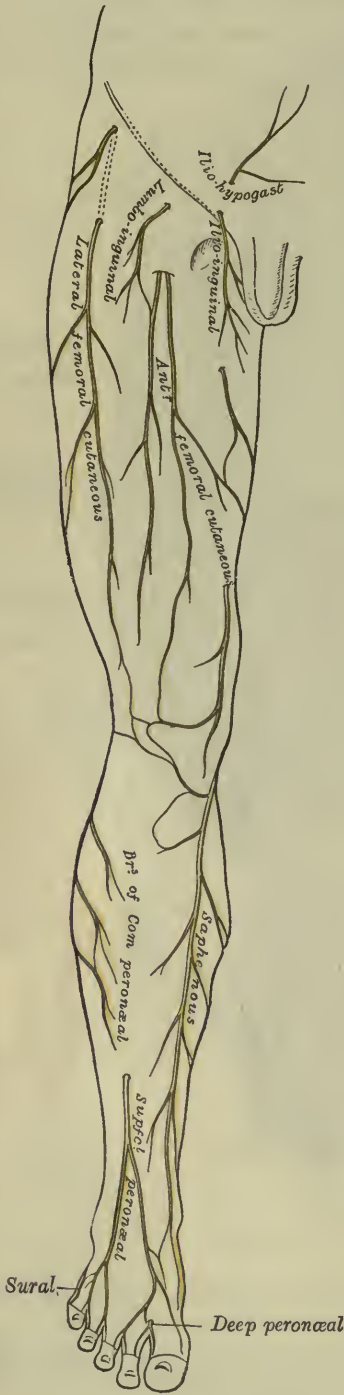


FIG. 825.—Cutaneous nerves of right lower extremity. Front view.

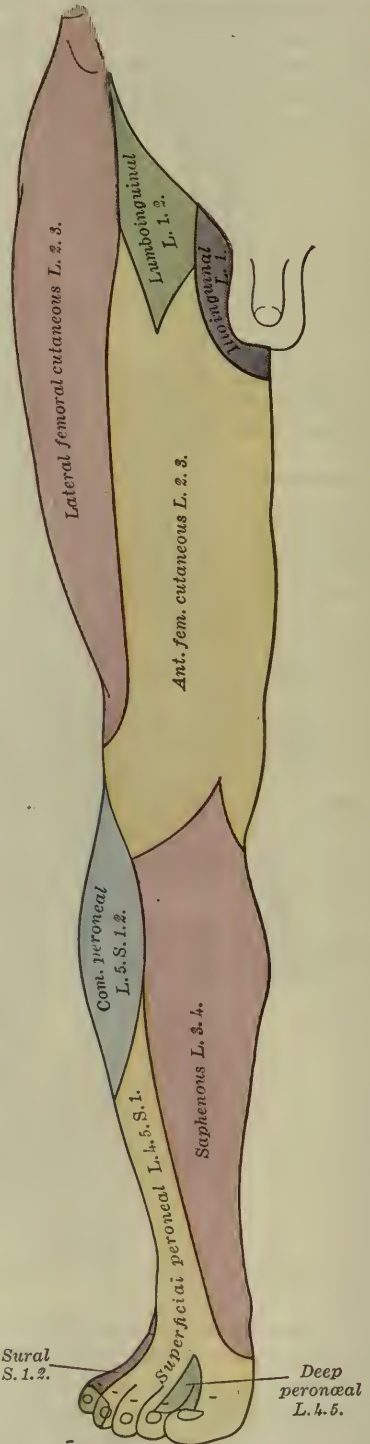


FIG. 826.—Diagram of segmental distribution of the cutaneous nerves of the right lower extremity. Front view.

major just below the iliohypogastric, and, passing obliquely across the Quadratus lumborum and Iliacus, perforates the Transversus abdominis, near the anterior part of the iliac crest, and communicates with the iliohypogastric nerve between the Transversus and the Obliquus internus. The nerve then pierces the Obliquus internus, distributing filaments to it, and, accompanying the spermatic cord through the subcutaneous inguinal ring, is distributed to the skin of the upper and medial part of the thigh, to the skin over the root of the penis and upper part of the scrotum in the male, and to the skin covering the mons pubis and labium majus in the female. The size of this nerve is in inverse proportion to that of the iliohypogastric. Occasionally it is very small, and ends by joining the iliohypogastric; in such cases, a branch from the iliohypogastric takes the place of the ilioinguinal, or the latter nerve may be altogether absent.

The **Genitofemoral Nerve** (*n. genitofemoralis; genitocrural nerve*) arises from the first and second lumbar nerves. It passes obliquely through the substance of the Psoas major, and emerges from its medial border, close to the vertebral column, opposite the fibrocartilage between the third and fourth lumbar vertebræ; it then descends on the surface of the Psoas major, under cover of the peritoneum, and divides into the external spermatic and lumboinguinal nerves. Occasionally these two nerves emerge separately through the substance of the Psoas.

The **external spermatic nerve** (*n. spermaticus externus; genital branch of genitofemoral*) passes outward on the Psoas major, and pierces the fascia transversalis, or passes through the abdominal inguinal ring; it then descends behind the spermatic cord to the scrotum, supplies the Cremaster, and gives a few filaments to the skin of the scrotum. In the female, it accompanies the round ligament of the uterus, and is lost upon it.

The **lumboinguinal nerve** (*n. lumboinguinalis; femoral or crural branch of genitofemoral*) descends on the external iliac artery, sending a few filaments around it, and, passing beneath the inguinal ligament, enters the sheath of the femoral vessels, lying superficial and lateral to the femoral artery. It pierces the anterior layer of the sheath of the vessels and the fascia lata, and supplies the skin of the anterior surface of the upper part of the thigh (Fig. 825). On the front of the thigh it communicates with the anterior cutaneous branches of the femoral nerve. A few filaments from the lumboinguinal nerve may be traced to the femoral artery.

The **Lateral Femoral Cutaneous Nerve** (*n. cutaneus femoralis lateralis; external cutaneous nerve*) arises from the dorsal divisions of the second and third lumbar nerves. It emerges from the lateral border of the Psoas major about its middle, and crosses the Iliacus obliquely, toward the anterior superior iliac spine. It then passes under the inguinal ligament and over the Sartorius muscle into the thigh, where it divides into two branches, an **anterior** and a **posterior** (Fig. 825).

The **anterior branch** becomes superficial about 10 cm. below the inguinal ligament, and divides into branches which are distributed to the skin of the anterior and lateral parts of the thigh, as far as the knee. The terminal filaments of this nerve frequently communicate with the anterior cutaneous branches of the femoral nerve, and with the infrapatellar branch of the saphenous nerve, forming with them the **patellar plexus**.

The **posterior branch** pierces the fascia lata, and subdivides into filaments which pass backward across the lateral and posterior surfaces of the thigh, supplying the skin from the level of the greater trochanter to the middle of the thigh.

The **Obturator Nerve** (*n. obturatorius*) arises from the ventral divisions of the second, third, and fourth lumbar nerves; the branch from the third is the largest, while that from the second is often very small. It descends through the fibers of the Psoas major, and emerges from its medial border near the brim of the pelvis; it then passes behind the common iliac vessels, and on the lateral side of the hypogastric vessels and ureter, which separate it from the ureter, and runs along the

lateral wall of the lesser pelvis, above and in front of the obturator vessels, to the upper part of the obturator foramen. Here it enters the thigh, and divides

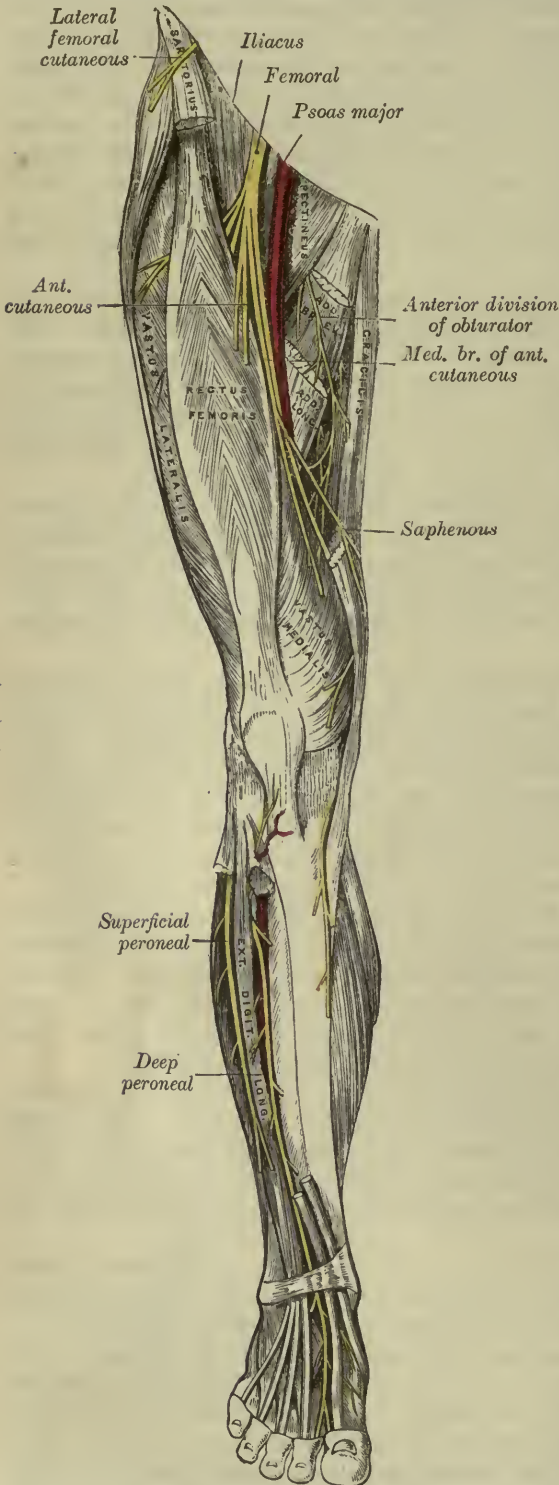


FIG. 827.—Nerves of the right lower extremity. Front view.

into an anterior and a posterior branch, which are separated at first by some of the fibers of the Obturator externus, and lower down by the Adductor brevis.

The **anterior branch** (*ramus anterior*) (Fig. 827) leaves the pelvis in front of the Obturator externus and descends in front of the Adductor brevis, and behind the Pectineus and Adductor longus; at the lower border of the latter muscle it communicates with the anterior cutaneous and saphenous branches of the femoral nerve, forming a kind of plexus. It then descends upon the femoral artery, to which it is finally distributed. Near the obturator foramen the nerve gives off an articular branch to the hip-joint. Behind the Pectineus, it distributes branches to the Adductor longus and Gracilis, and usually to the Adductor brevis, and in rare cases to the Pectineus; it receives a communicating branch from the accessory obturator nerve when that nerve is present.

Occasionally the communicating branch to the anterior cutaneous and saphenous branches of the femoral is continued down, as a cutaneous branch, to the thigh and leg. When this is so, it emerges from beneath the lower border of the Adductor longus, descends along the posterior margin of the Sartorius to the medial side of the knee, where it pierces the deep fascia, communicates with the saphenous nerve, and is distributed to the skin of the tibial side of the leg as low down as its middle.

The **posterior branch** (*ramus posterior*) pierces the anterior part of the Obturator externus, and supplies this muscle; it then passes behind the Adductor brevis on the front of the Adductor

magnus, where it divides into numerous muscular branches which are distributed to the Adductor magnus and the Adductor brevis when the latter does not receive a branch from the anterior division of the nerve. It usually gives off an articular filament to the knee-joint.

The articular branch for the knee-joint is sometimes absent; it either perforates the lower part of the Adductor magnus, or passes through the opening which transmits the femoral artery, and enters the popliteal fossa; it then descends upon the popliteal artery, as far as the back part of the knee-joint, where it perforates the oblique popliteal ligament, and is distributed to the synovial membrane. It gives filaments to the popliteal artery.

The Accessory Obturator Nerve (*n. obturatorius accessorius*) (Fig. 823) is present in about 29 per cent. of cases. It is of small size, and arises from the ventral divisions of the third and fourth lumbar nerves. It descends along the medial border of the Psoas major, crosses the superior ramus of the pubis, and passes under the Pectineus, where it divides into numerous branches. One of these supplies the Pectineus, penetrating its deep surface, another is distributed to the hip-joint; while a third communicates with the anterior branch of the obturator nerve. Occasionally the accessory obturator nerve is very small and is lost in the capsule of the hip-joint. When it is absent, the hip-joint receives two branches from the obturator nerve.

The Femoral Nerve (*n. femoralis; anterior crural nerve*) (Fig. 827), the largest branch of the lumbar plexus, arises from the dorsal divisions of the second, third, and fourth lumbar nerves. It descends through the fibers of the Psoas major, emerging from the muscle at the lower part of its lateral border, and passes down between it and the Iliacus, behind the iliac fascia; it then runs beneath the inguinal ligament, into the thigh, and splits into an anterior and a posterior division. Under the inguinal ligament, it is separated from the femoral artery by a portion of the Psoas major.

Within the abdomen the femoral nerve gives off small branches to the Iliacus, and a branch which is distributed upon the upper part of the femoral artery; the latter branch may arise in the thigh.

In the thigh the anterior division of the femoral nerve gives off anterior cutaneous and muscular branches. The anterior cutaneous branches comprise the intermediate and medial cutaneous nerves (Fig. 825).

The intermediate cutaneous nerve (*ramus cutaneus anterior; middle cutaneous nerve*) pierces the fascia lata (and generally the Sartorius) about 7.5 cm. below the inguinal ligament, and divides into two branches which descend in immediate proximity along the forepart of the thigh, to supply the skin as low as the front of the knee. Here they communicate with the medial cutaneous nerve and the infrapatellar branch of the saphenous, to form the patellar plexus. In the upper part of the thigh the lateral branch of the intermediate cutaneous communicates with the lumboinguinal branch of the genitofemoral nerve.

The medial cutaneous nerve (*ramus cutaneus anterior; internal cutaneous nerve*) passes obliquely across the upper part of the sheath of the femoral artery, and divides in front, or at the medial side of that vessel, into two branches, an anterior and a posterior. The anterior branch runs downward on the Sartorius, perforates the fascia lata at the lower third of the thigh, and divides into two branches: one supplies the integument as low down as the medial side of the knee; the other crosses to the lateral side of the patella, communicating in its course with the infrapatellar branch of the saphenous nerve. The posterior branch descends along the medial border of the Sartorius muscle to the knee, where it pierces the fascia lata, communicates with the saphenous nerve, and gives off several cutaneous branches. It then passes down to supply the integument of the medial side of the leg. Beneath the fascia lata, at the lower border of the Adductor longus, it joins to form a plexi-

form net-work (**subsartorial plexus**) with branches of the saphenous and obturator nerves. When the communicating branch from the obturator nerve is large and continued to the integument of the leg, the posterior branch of the medial cutaneous is small, and terminates in the plexus, occasionally giving off a few cutaneous filaments. The medial cutaneous nerve, before dividing, gives off a few filaments, which pierce the fascia lata, to supply the integument of the medial side of the thigh, accompanying the long saphenous vein. One of these filaments passes through the saphenous opening; a second becomes subcutaneous about the middle of the thigh; a third pierces the fascia at its lower third.

MUSCULAR BRANCHES (*rami musculares*).—The nerve to the **Pectineus** arises immediately below the inguinal ligament, and passes behind the femoral sheath to enter the anterior surface of the muscle; it is often duplicated. The nerve to the **Sartorius** arises in common with the intermediate cutaneous.

The posterior division of the femoral nerve gives off the saphenous nerve, and muscular and articular branches.

The **Saphenous Nerve** (*n. saphenus; long or internal saphenous nerve*) (Fig. 827) is the largest cutaneous branch of the femoral nerve. It approaches the femoral artery where this vessel passes beneath the Sartorius, and lies in front of it, behind the aponeurotic covering of the adductor canal, as far as the opening in the lower part of the Adductor magnus. Here it quits the artery, and emerges from behind the lower edge of the aponeurotic covering of the canal; it descends vertically along the medial side of the knee behind the Sartorius, pierces the fascia lata, between the tendons of the Sartorius and Gracilis, and becomes subcutaneous. The nerve then passes along the tibial side of the leg, accompanied by the great saphenous vein, descends behind the medial border of the tibia, and, at the lower third of the leg, divides into two branches: one continues its course along the margin of the tibia, and ends at the ankle; the other passes in front of the ankle, and is distributed to the skin on the medial side of the foot, as far as the ball of the great toe, communicating with the medial branch of the superficial peroneal nerve.

BRANCHES.—The saphenous nerve, about the middle of the thigh, gives off a branch which joins the subsartorial plexus.

At the medial side of the knee it gives off a large **infrapatellar branch**, which pierces the Sartorius and fascia lata, and is distributed to the skin in front of the patella. This nerve communicates above the knee with the anterior cutaneous branches of the femoral nerve; below the knee, with other branches of the saphenous; and, on the lateral side of the joint, with branches of the lateral femoral cutaneous nerve, forming a plexiform net-work, the **plexus patellæ**. The infrapatellar branch is occasionally small, and ends by joining the anterior cutaneous branches of the femoral, which supply its place in front of the knee.

Below the knee, the branches of the saphenous nerve are distributed to the skin of the front and medial side of the leg, communicating with the cutaneous branches of the femoral, or with filaments from the obturator nerve.

The **muscular branches** supply the four parts of the Quadriceps femoris. The branch to the Rectus femoris enters the upper part of the deep surface of the muscle, and supplies a filament to the hip-joint. The branch to the Vastus lateralis, of large size, accompanies the descending branch of the lateral femoral circumflex artery to the lower part of the muscle. It gives off an articular filament to the knee-joint. The branch to the Vastus medialis descends lateral to the femoral vessels in company with the saphenous nerve. It enters the muscle about its middle, and gives off a filament, which can usually be traced downward, on the surface of the muscle, to the knee-joint. The branches to the Vastus intermedius, two or three in number, enter the anterior surface of the muscle about the middle of the thigh; a filament from one of these descends through the muscle to the Articularis genu and the knee-joint. The **articular branch to the hip-joint** is derived from the nerve to the Rectus femoris.

The articular branches to the knee-joint are three in number. One, a long slender filament, is derived from the nerve to the Vastus lateralis; it penetrates the capsule of the joint on its anterior aspect. Another, derived from the nerve to the Vastus medialis, can usually be traced downward on the surface of this muscle to near the joint; it then penetrates the muscular fibers, and accompanies the articular branch of the highest genicular artery, pierces the medial side of the articular capsule, and supplies the synovial membrane. The third branch is derived from the nerve to the Vastus intermedius.

The Sacral and Coccygeal Nerves (Nn. Sacrales et Coccygeus).

The anterior divisions of the sacral and coccygeal nerves (*rami anteriores*) form the sacral and pudendal plexuses. The anterior divisions of the upper four sacral nerves enter the pelvis through the anterior sacral foramina, that of the fifth between the sacrum and coccyx, while that of the coccygeal nerve curves forward below the rudimentary transverse process of the first piece of the coccyx. The first and second sacral nerves are large; the third, fourth, and fifth diminish progressively from above downward. Each receives a gray ramus communicans from the corresponding ganglion of the sympathetic trunk, while from the third and frequently from the second and the fourth sacral nerves, a white ramus communicans is given to the pelvic plexuses of the sympathetic.

The Sacral Plexus (*plexus sacralis*) (Fig. 828).—The sacral plexus is formed by the lumbosacral trunk, the anterior division of the first, and portions of the anterior divisions of the second and third sacral nerves.

The lumbosacral trunk comprises the whole of the anterior division of the fifth and a part of that of the fourth lumbar nerve; it appears at the medial margin of the Psoas major and runs downward over the pelvic brim to join the first sacral nerve. The anterior division of the third sacral nerve divides into an upper and a lower branch, the former entering the sacral and the latter the pudendal plexus.

The nerves forming the sacral plexus converge toward the lower part of the greater sciatic foramen, and unite to form a flattened band, from the anterior and posterior surfaces of which several branches arise. The band itself is continued as the sciatic nerve, which splits on the back of the thigh into the tibial and common peroneal nerves; these two nerves sometimes arise separately from the plexus, and in all cases their independence can be shown by dissection.

Relations.—The sacral plexus lies on the back of the pelvis between the Piriformis and the pelvic fascia (Fig. 829); in front of it are the hypogastric vessels, the ureter and the sigmoid colon. The superior gluteal vessels run between the lumbosacral trunk and the first sacral nerve, and the inferior gluteal vessels between the second and third sacral nerves.

All the nerves entering the plexus, with the exception of the third sacral, split into ventral and dorsal divisions, and the nerves arising from these are as follows:

	Ventral divisions.	Dorsal divisions.
Nerve to Quadratus femoris and Gemellus inferior	} 4, 5 L, 1 S.	
Nerve to Obturator internus and Gemellus superior		} 5 L, 1, 2 S.
Nerve to Piriformis		
Superior gluteal		4, 5 L, 1 S.
Inferior gluteal		5 L, 1, 2 S.
Posterior femoral cutaneous	2, 3 S	1, 2 S.
Sciatic	{ Tibial 4, 5 L, 1, 2, 3 S.	4, 5 L, 1, 2 S.

The Nerve to the Quadratus Femoris and Gemellus Inferior arises from the ventral divisions of the fourth and fifth lumbar and first sacral nerves: it leaves the pelvis

through the greater sciatic foramen, below the Piriformis, and runs down in front of the sciatic nerve, the Gemelli, and the tendon of the Obturator internus, and enters the anterior surfaces of the muscles; it gives an articular branch to the hip-joint.

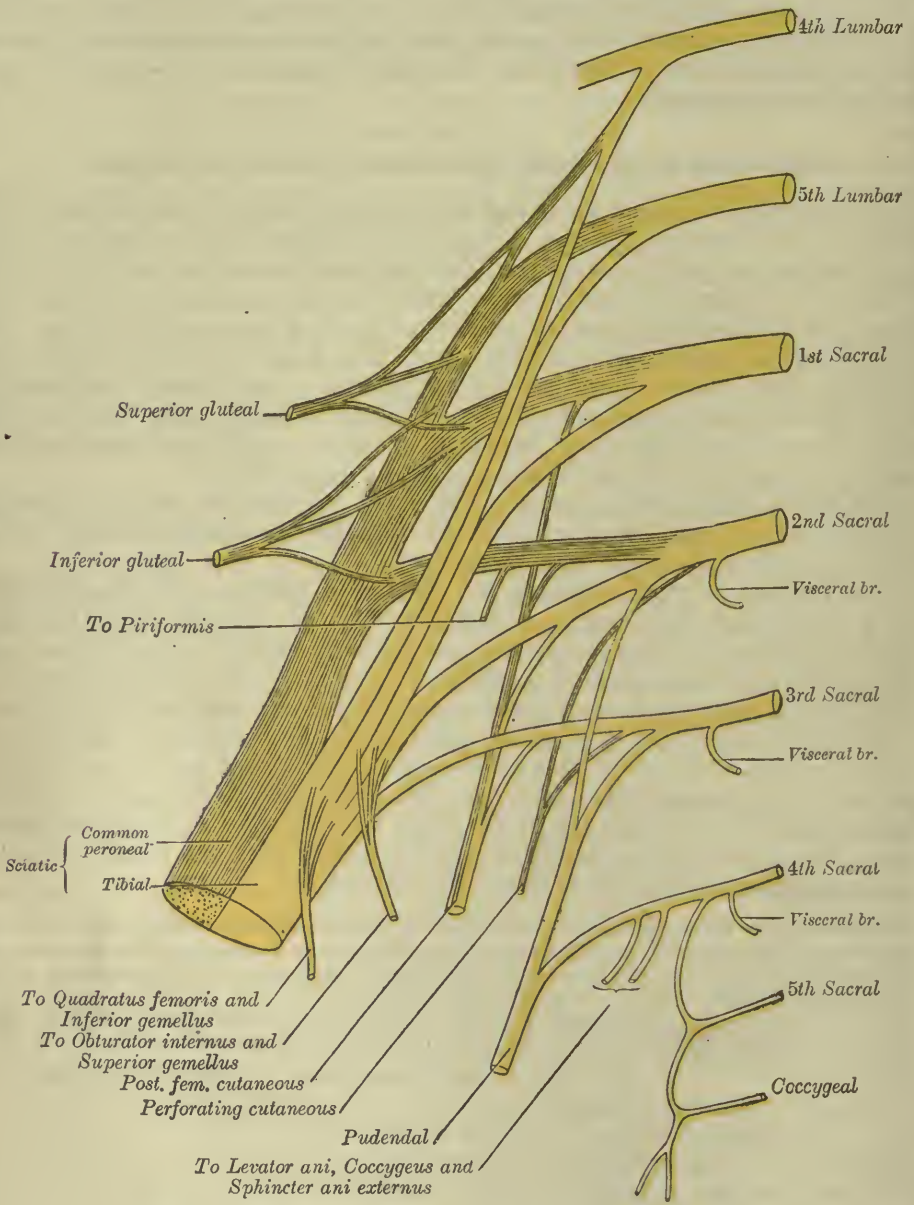


FIG. 828.—Plan of sacral and pudendal plexuses.

The Nerve to the Obturator Internus and Gemellus Superior arises from the ventral divisions of the fifth lumbar and first and second sacral nerves. It leaves the pelvis through the greater sciatic foramen below the Piriformis, and gives off the branch to the Gemellus superior, which enters the upper part of the posterior surface of the muscle. It then crosses the ischial spine, reënters the pelvis through the lesser sciatic foramen, and pierces the pelvic surface of the Obturator internus.

The Nerve to the Piriformis arises from the dorsal division of the second sacral nerve, or the dorsal divisions of the first and second sacral nerves, and enters the anterior surface of the muscle; this nerve may be double.

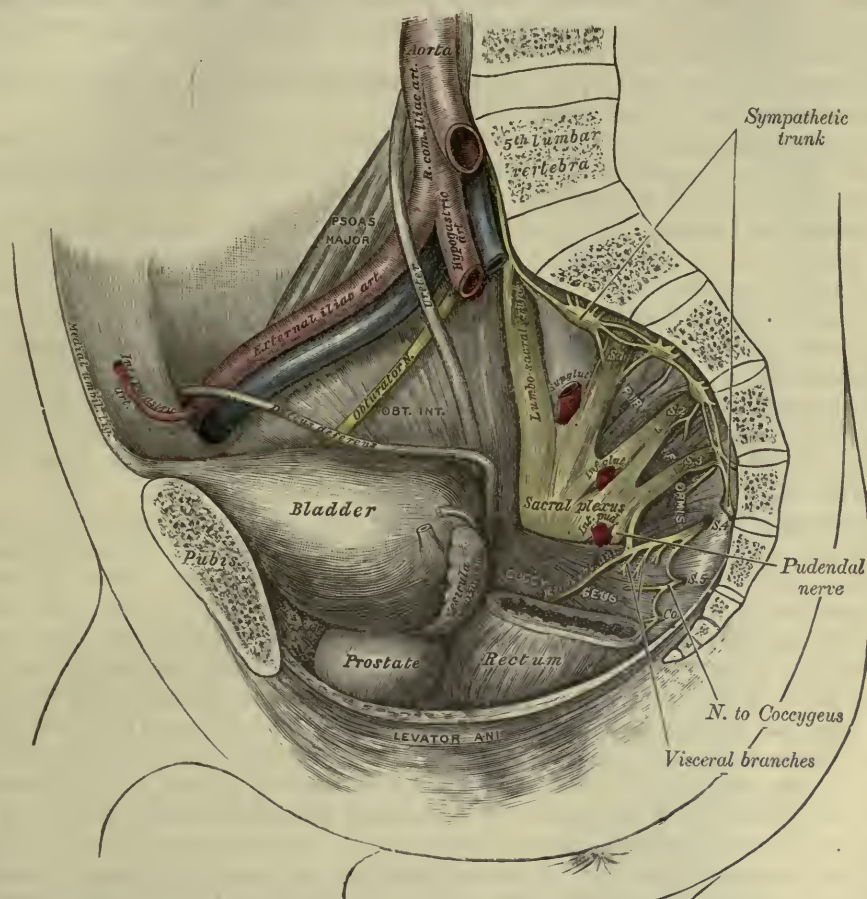


FIG. 829.—Dissection of side wall of pelvis showing sacral and pudendal plexuses. (Testut.)

The **Superior Gluteal Nerve** (*n. glutæus superior*) arises from the dorsal divisions of the fourth and fifth lumbar and first sacral nerves: it leaves the pelvis through the greater sciatic foramen above the Piriformis, accompanied by the superior gluteal vessels, and divides into a superior and an inferior branch. The **superior branch** accompanies the upper branch of the deep division of the superior gluteal artery and ends in the Glutæus minimus. The **inferior branch** runs with the lower branch of the deep division of the superior gluteal artery across the Glutæus minimus; it gives filaments to the Glutæi medius and minimus, and ends in the Tensor fasciæ latæ.

The **Inferior Gluteal Nerve** (*n. glutæus inferior*) arises from the dorsal divisions of the fifth lumbar and first and second sacral nerves: it leaves the pelvis through the greater sciatic foramen, below the Piriformis, and divides into branches which enter the deep surface of the Glutæus maximus.

The **Posterior Femoral Cutaneous Nerve** (*n. cutaneus femoralis posterior; small sciatic nerve*) is distributed to the skin of the perineum and posterior surface of the thigh and leg. It arises partly from the dorsal divisions of the first and second, and from the ventral divisions of the second and third sacral nerves, and issues from

the pelvis through the greater sciatic foramen below the Piriformis. It then descends beneath the Glutæus maximus with the inferior gluteal artery, and runs down the back of the thigh beneath the fascia lata, and over the long head of the Biceps femoris to the back of the knee; here it pierces the deep fascia and accompanies the small saphenous vein to about the middle of the back of the leg, its terminal twigs communicating with the sural nerve.

Its branches are all cutaneous, and are distributed to the gluteal region, the perineum, and the back of the thigh and leg.

The **gluteal branches** (*nn. clunium inferiores*), three or four in number, turn upward around the lower border of the Glutæus maximus, and supply the skin covering the lower and lateral part of that muscle.

The **perineal branches** (*rami perineales*) are distributed to the skin at the upper and medial side of the thigh. One long perineal branch, **inferior pudendal** (*long scrotal nerve*), curves forward below and in front of the ischial tuberosity, pierces the fascia lata, and runs forward beneath the superficial fascia of the perineum to the skin of the scrotum in the male, and of the labium majus in the female. It communicates with the inferior hemorrhoidal and posterior scrotal nerves.

The **branches to the back of the thigh and leg** consist of numerous filaments derived from both sides of the nerve, and distributed to the skin covering the back and medial side of the thigh, the popliteal fossa, and the upper part of the back of the leg (Fig. 830).

The **Sciatic** (*n. ischiadicus; great sciatic nerve*) (Fig. 832) supplies nearly the whole of the skin of the leg, the muscles of the back of the thigh, and those of the leg and foot. It is the largest nerve in the body, measuring 2 cm. in breadth, and is the continuation of the flattened band of the sacral plexus. It passes out of the pelvis through the greater sciatic foramen, below the Piriformis muscle. It descends between the greater trochanter of the femur and the tuberosity of the ischium, and along the back of the thigh to about its lower third, where it divides into two large branches, the tibial and common peroneal nerves. This division may take place at any point between the sacral plexus and the lower third of the thigh. When it occurs at the plexus, the common peroneal nerve usually pierces the Piriformis.

In the upper part of its course the nerve rests upon the posterior surface of the ischium, the nerve to the Quadratus femoris, the Obturator internus and Gemelli, and the Quadratus femoris; it is accompanied by the posterior femoral cutaneous nerve and the inferior gluteal artery, and is covered by the Glutæus maximus. Lower down, it lies upon the Adductor magnus, and is crossed obliquely by the long head of the Biceps femoris.

The nerve gives off articular and muscular branches.

The **articular branches** (*rami articulares*) arise from the upper part of the nerve and supply the hip-joint, perforating the posterior part of its capsule; they are sometimes derived from the sacral plexus.

The **muscular branches** (*rami musculares*) are distributed to the Biceps femoris, Semitendinosus, Semimembranosus, and Adductor magnus. The nerve to the short head of the Biceps femoris comes from the common peroneal part of the sciatic, while the other muscular branches arise from the tibial portion, as may be seen in those cases where there is a high division of the sciatic nerve.

The **Tibial Nerve** (*n. tibialis; internal popliteal nerve*) (Fig. 832) the larger of the two terminal branches of the sciatic, arises from the anterior branches of the fourth and fifth lumbar and first, second, and third sacral nerves. It descends along the back of the thigh and through the middle of the popliteal fossa, to the lower part of the Popliteus muscle, where it passes with the popliteal artery beneath the arch of the Soleus. It then runs along the back of the leg with the posterior tibial vessels to the interval between the medial malleolus and the heel, where it divides beneath the lacinate ligament into the medial and lateral plantar nerves.

In the thigh it is overlapped by the hamstring muscles above, and then becomes more superficial, and lies lateral to, and some distance from, the popliteal vessels;

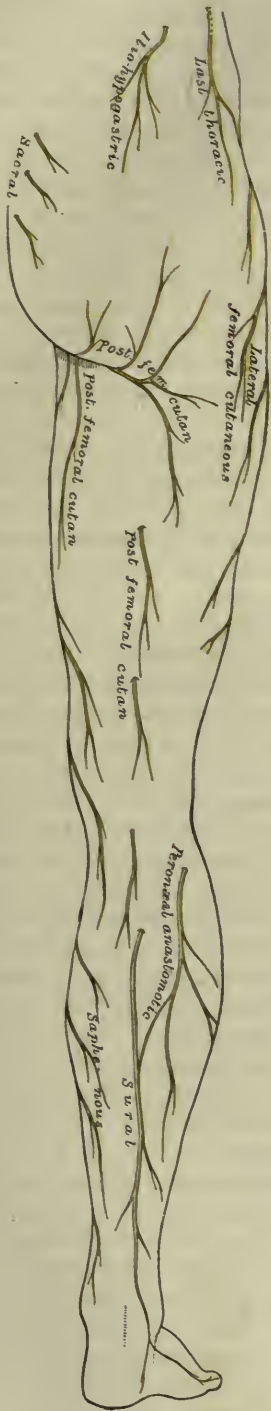


FIG. 830.—Cutaneous nerves of right lower extremity. Posterior view.

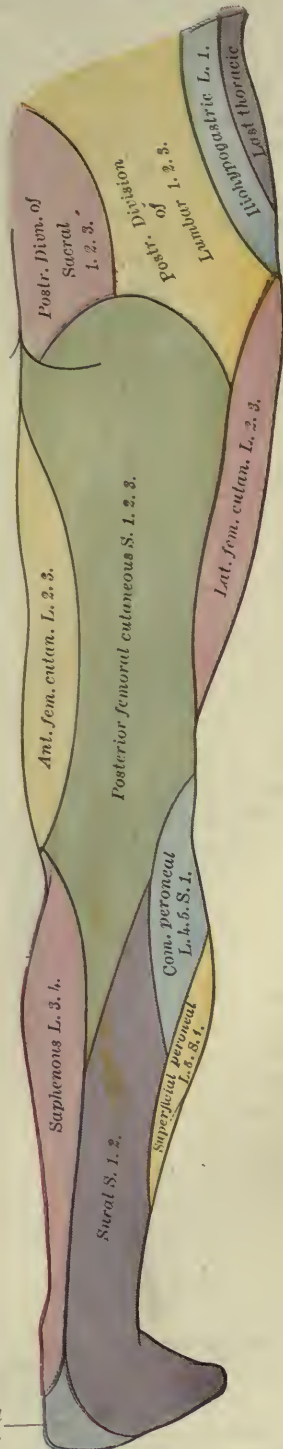


FIG. 831.—Diagram of the segmental distribution of the cutaneous nerves of the right lower extremity. Posterior view.

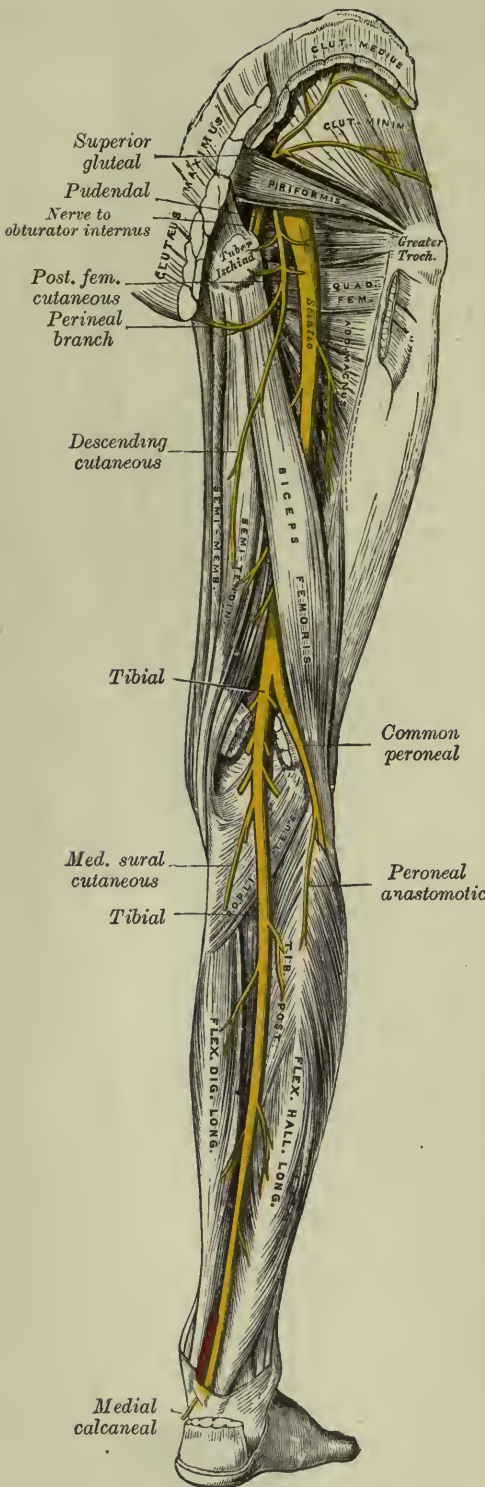


FIG. 832.—Nerves of the right lower extremity Posterior view.

opposite the knee-joint, it is in close relation with these vessels, and crosses to the medial side of the artery. In the leg it is covered in the upper part of its course by the muscles of the calf; lower down by the skin, the superficial and deep fasciæ. It is placed on the deep muscles, and lies at first to the medial side of the posterior tibial artery, but soon crosses that vessel and descends on its lateral side as far as the ankle. In the lower third of the leg it runs parallel with the medial margin of the tendo calcaneus.

The branches of this nerve are: articular, muscular, medial sural cutaneous, medial calcaneal, medial and lateral plantar.

Articular branches (*rami articulares*), usually three in number, supply the knee-joint; two of these accompany the superior and inferior medial genicular arteries; and a third, the middle genicular artery. Just above the bifurcation of the nerve an articular branch is given off to the ankle-joint.

Muscular branches (*rami musculares*), four or five in number, arise from the nerve as it lies between the two heads of the Gastrocnemius muscle; they supply that muscle, and the Plantaris, Soleus, and Popliteus. The branch for the Popliteus turns around the lower border and is distributed to the deep surface of the muscle. Lower down, muscular branches arise separately or by a common trunk and supply the Soleus, Tibialis posterior, Flexor digitorum longus, and Flexor hallucis longus; the branch to the last muscle accompanies the peroneal artery; that to the Soleus enters the deep surface of the muscle.

The medial sural cutaneous nerve (*n. cutaneus suræ medialis; n. communicans tibialis*) descends between the two heads of the Gastrocnemius, and, about the middle of the back of the leg, pierces the deep fascia, and unites with the anastomotic ramus of the common peroneal to form the sural nerve (Fig. 830).

¹ N. B.—In this diagram the medial sural cutaneous and peroneal anastomotic are not in their normal position. They have been displaced by the removal of the superficial muscles.

The **sural nerve** (*n. suralis*; *short saphenous nerve*), formed by the junction of the medial sural cutaneous with the peroneal anastomotic branch, passes downward near the lateral margin of the tendo calcaneus, lying close to the small saphenous vein, to the interval between the lateral malleolus and the calcaneus. It runs forward below the lateral malleolus, and is continued as the **lateral dorsal cutaneous nerve** along the lateral side of the foot and little toe, communicating on the dorsum of the foot with the intermediate dorsal cutaneous nerve, a branch of the superficial peroneal. In the leg, its branches communicate with those of the posterior femoral cutaneous.

The **medial calcaneal branches** (*rami calcanei mediales*; *internal calcaneal branches*) perforate the lacinate ligament, and supply the skin of the heel and medial side of the sole of the foot.

The **medial plantar nerve** (*n. plantaris medialis*; *internal plantar nerve*) (Fig. 833), the larger of the two terminal divisions of the tibial nerve, accompanies the medial plantar artery. From its origin under the lacinate ligament it passes under cover of the Abductor hallucis, and, appearing between this muscle and the Flexor digitorum brevis, gives off a proper digital plantar nerve and finally divides opposite the bases of the metatarsal bones into three common digital plantar nerves.

BRANCHES.—The branches of the medial plantar nerve are: (1) **cutaneous**, (2) **muscular**, (3) **articular**, (4) a **proper digital nerve** to the medial side of the great toe, and (5) three **common digital nerves**.

The **cutaneous branches** pierce the plantar aponeurosis between the Abductor hallucis and the Flexor digitorum brevis and are distributed to the skin of the sole of the foot.

The **muscular branches** supply the Abductor hallucis, the Flexor digitorum brevis, the Flexor hallucis brevis, and the first Lumbricalis; those for the Abductor hallucis and Flexor digitorum brevis arise from the trunk of the nerve near its origin and enter the deep surfaces of the muscles; the branch of the Flexor hallucis brevis springs from the proper digital nerve to the medial side of the great toe, and that for the first Lumbricalis from the first common digital nerve.

The **articular branches** supply the articulations of the tarsus and metatarsus.

The **proper digital nerve of the great toe** (*nn. digitales plantares proprii*; *plantar digital branches*) supplies the Flexor hallucis brevis and the skin on the medial side of the great toe.

The **three common digital nerves** (*nn. digitales plantares communes*) pass between the divisions of the plantar aponeurosis, and each splits into two proper digital nerves—those of the first common digital nerve supply the adjacent sides of the great and second toes; those of the second, the adjacent sides of the second and third toes; and those of the third, the adjacent sides of the third and fourth toes. The third common digital nerve receives a communicating branch from the lateral plantar nerve; the first gives a twig to the first Lumbricalis. Each proper digital nerve gives off cutaneous and articular filaments; and opposite the last phalanx sends upward a dorsal branch, which supplies the structures around the nail, the continuation of the nerve being distributed to the ball of the toe. It will be observed that these digital nerves are similar in their distribution to those of the median nerve in the hand.

The **Lateral Plantar Nerve** (*n. plantaris lateralis*; *external plantar nerve*) (Fig. 833) supplies the skin of the fifth toe and lateral half of the fourth, as well as most of the deep muscles, its distribution being similar to that of the ulnar nerve in the hand. It passes obliquely forward with the lateral plantar artery to the lateral side of the foot, lying between the Flexor digitorum brevis and Quadratus plantæ; and, in the interval between the former muscle and the Abductor digiti quinti, divides into a superficial and a deep branch. Before its division, it supplies the Quadratus plantæ and Abductor digiti quinti.

The superficial branch (*ramus superficialis*) splits into a proper and a common digital nerve; the proper digital nerve supplies the lateral side of the little toe, the Flexor digiti quinti brevis, and the two Interossei of the fourth intermetatarsal space; the common digital nerve communicates with the third common digital branch of the medial plantar nerve and divides into two proper digital nerves which supply the adjoining sides of the fourth and fifth toes.

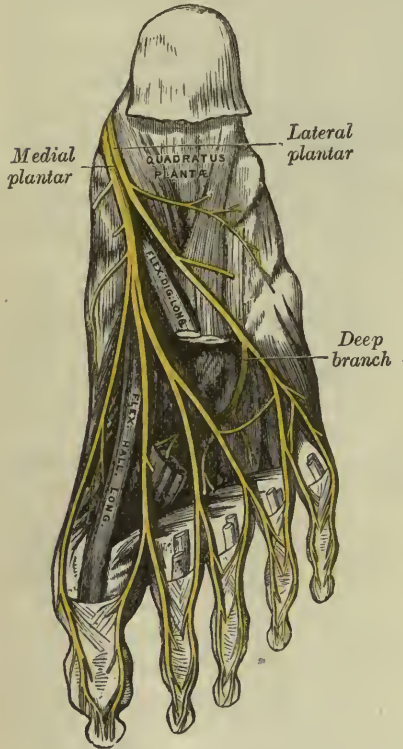


FIG. 833.—The plantar nerves.

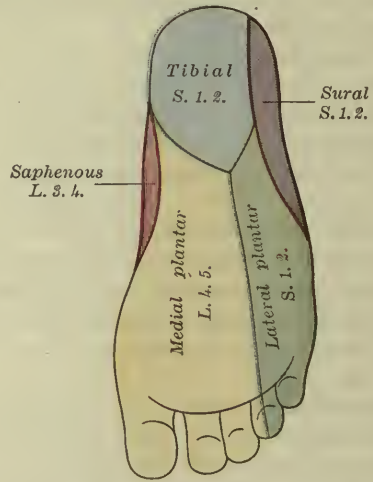


FIG. 834.—Diagram of the segmental distribution of the cutaneous nerves of the sole of the foot.

The deep branch (*ramus profundus; muscular branch*) accompanies the lateral plantar artery on the deep surface of the tendons of the Flexor muscles and the Adductor hallucis, and supplies all the Interossei (except those in the fourth metatarsal space), the second, third, and fourth Lumbricales, and the Adductor hallucis.

The **Common Peroneal Nerve** (*n. peronæus communis; external popliteal nerve; peroneal nerve*) (Fig. 832), about one-half the size of the tibial, is derived from the dorsal branches of the fourth and fifth lumbar and the first and second sacral nerves. It descends obliquely along the lateral side of the popliteal fossa to the head of the fibula, close to the medial margin of the Biceps femoris muscle. It lies between the tendon of the Biceps femoris and lateral head of the Gastrocnemius muscle, winds around the neck of the fibula, between the Peronæus longus and the bone, and divides beneath the muscle into the superficial and deep peroneal nerves. Previous to its division it gives off articular and lateral sural cutaneous nerves.

The **articular branches** (*rami articulares*) are three in number; two of these accompany the superior and inferior lateral genicular arteries to the knee; the upper one occasionally *arises* from the trunk of the sciatic nerve. The third (*recurrent*) articular nerve is given off at the point of division of the common peroneal nerve; it ascends with the anterior recurrent tibial artery through the Tibialis anterior to the front of the knee.

The **lateral sural cutaneous nerve** (*n. cutaneus suræ lateralis; lateral cutaneous branch*) supplies the skin on the posterior and lateral surfaces of the leg; one branch, the **peroneal anastomotic** (*n. communicans fibularis*), *arises* near the head of the fibula, crosses the lateral head of the Gastrocnemius to the middle of the

leg, and joins with the medial sural cutaneous to form the sural nerve. The peroneal anastomotic is occasionally continued down as a separate branch as far as the heel.

The **Deep Peroneal Nerve** (*n. peronæus profundus; anterior tibial nerve*) (Fig. 827) begins at the bifurcation of the common peroneal nerve, between the fibula and upper part of the Peronæus longus, passes obliquely forward beneath the Extensor digitorum longus to the front of the interosseous membrane, and comes into relation with the anterior tibial artery above the middle of the leg; it then descends with the artery to the front of the ankle-joint, where it divides into a lateral and a medial terminal branch. It lies at first on the lateral side of the anterior tibial artery, then in front of it, and again on its lateral side at the ankle-joint.

In the leg, the deep peroneal nerve supplies muscular branches to the Tibialis anterior, Extensor digitorum longus, Peronæus tertius, and Extensor hallucis proprius, and an articular branch to the ankle-joint.

The **lateral terminal branch** (*external or tarsal branch*) passes across the tarsus, beneath the Extensor digitorum brevis, and, having become enlarged like the dorsal interosseous nerve at the wrist, supplies the Extensor digitorum brevis. From the enlargement three minute **interosseous branches** are given off, which supply the tarsal joints and the metatarsophalangeal joints of the second, third, and fourth toes. The first of these sends a filament to the second Interosseus dorsalis muscle.

The **medial terminal branch** (*internal branch*) accompanies the dorsalis pedis artery along the dorsum of the foot, and, at the first interosseous space, divides into two **dorsal digital nerves** (*nn. digitales dorsales hallucis lateralis et digiti secundi medialis*) which supply

the adjacent sides of the great and second toes, communicating with the medial dorsal cutaneous branch of the superficial peroneal nerve. Before it divides it gives off to the first space an **interosseous branch** which supplies the metatarso-

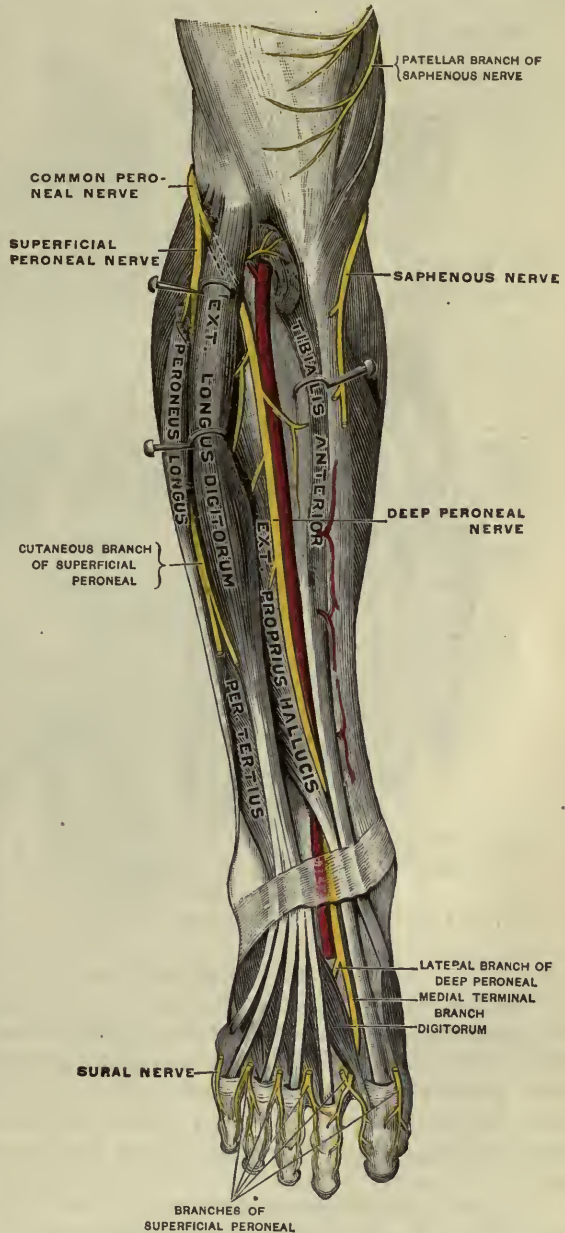


FIG. 835.—Deep nerves of the front of the leg. (Testut.)

phalangeal joint of the great toe and sends a filament to the first Interosseous dorsalis muscle.

The **Superficial Peroneal Nerve** (*n. peronæus superficialis; musculocutaneous nerve*) (Figs. 827, 835) supplies the Peronei longus and brevis and the skin over the greater part of the dorsum of the foot. It passes forward between the Peronæi and the Extensor digitorum longus, pierces the deep fascia at the lower third of the leg, and

divides into a medial and an intermediate dorsal cutaneous nerve. In its course between the muscles, the nerve gives off muscular branches to the Peronæi longus and brevis, and cutaneous filaments to the integument of the lower part of the leg.

The **medial dorsal cutaneous nerve** (*n. cutaneus dorsalis medialis; internal dorsal cutaneous branch*) passes in front of the ankle-joint, and divides into two dorsal digital branches, one of which supplies the medial side of the great toe, the other, the adjacent side of the second and third toes. It also supplies the integument of the medial side of the foot and ankle, and communicates with the saphenous nerve, and with the deep peroneal nerve (Fig. 825).

The **intermediate dorsal cutaneous nerve** (*n. cutaneus dorsalis intermedius; external dorsal cutaneous branch*), the smaller, passes along the lateral part of the dorsum of the foot, and divides into dorsal digital branches, which supply the contiguous sides of the third and fourth, and of the fourth and fifth toes. It also supplies the skin of the lateral

side of the foot and ankle, and communicates with the sural nerve (Fig. 825). The branches of the superficial peroneal nerve supply the skin of the dorsal surfaces of all the toes excepting the lateral side of the little toe, and the adjoining sides of the great and second toes, the former being supplied by the lateral dorsal cutaneous nerve from the sural nerve, and the latter by the medial branch of the deep peroneal nerve. Frequently some of the lateral branches of the superficial peroneal are absent, and their places are then taken by branches of the sural nerve.

The Pudendal Plexus (*plexus pudendus*) (Fig. 828).—The pudendal plexus is not sharply marked off from the sacral plexus, and as a consequence some of the branches which spring from it may arise in conjunction with those of the sacral plexus. It lies on the posterior wall of the pelvis, and is usually formed by branches from the anterior divisions of the second and third sacral nerves, the whole of the anterior divisions of the fourth and fifth sacral nerves, and the coccygeal nerve.

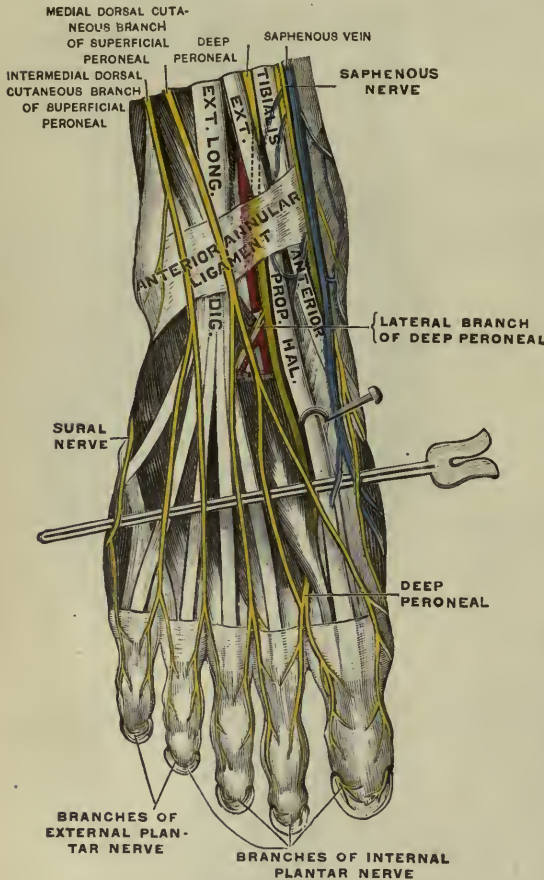


FIG. 836.—Nerves of the dorsum of the foot. (Testut.)

It gives off the following branches:

Perforating cutaneous	2, 3 S.
Pudendal	2, 3, 4 S.
Visceral	3, 4 S.
Muscular	4 S.
Anococcygeal	4, 5 S. and Cocc.

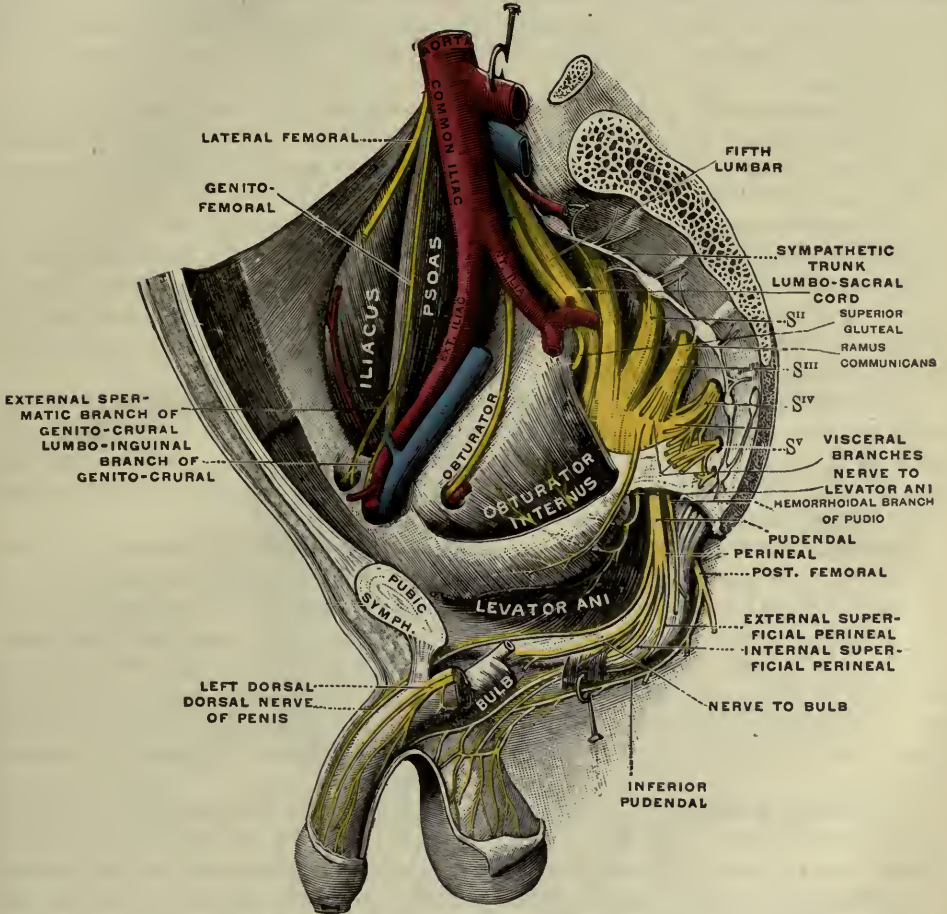


FIG. 837.—Sacral plexus of the right side. (Testut).

The **Perforating Cutaneous Nerve** (*n. clunium inferior medialis*) usually arises from the posterior surface of the second and third sacral nerves. It pierces the lower part of the sacrotuberous ligament, and winding around the inferior border of the Glutæus maximus supplies the skin covering the medial and lower parts of that muscle.

The perforating cutaneous nerve may arise from the pudendal or it may be absent; in the latter case its place may be taken by a branch from the posterior femoral cutaneous nerve or by a branch from the third and fourth, or fourth and fifth, sacral nerves.

The **Pudendal Nerve** (*n. pudendus; internal pudic nerve*) derives its fibers from the ventral branches of the second, third, and fourth sacral nerves. It passes between the Piriformis and Coccygeus muscles and leaves the pelvis through the lower part of the greater sciatic foramen. It then crosses the spine of the ischium, and reënters the pelvis through the lesser sciatic foramen. It accompanies the internal pudendal vessels upward and forward along the lateral wall of the ischiorectal

fossa, being contained in a sheath of the obturator fascia termed **Alcock's canal**, and divides into two terminal branches, viz., the **perineal nerve**, and the **dorsal nerve of the penis or clitoris**. Before its division it gives off the **inferior hemorrhoidal nerve**.

The **inferior hemorrhoidal nerve** (*n. hæmorrhoidalis inferior*) occasionally arises directly from the sacral plexus; it crosses the ischioanal fossa, with the inferior hemorrhoidal vessels, toward the anal canal and the lower end of the rectum, and is distributed to the Sphincter ani externus and to the integument around the anus. Branches of this nerve communicate with the perineal branch of the posterior femoral cutaneous and with the posterior scrotal nerves at the forepart of the perineum.

The **perineal nerve** (*n. perinei*), the inferior and larger of the two terminal branches of the pudendal, is situated below the internal pudendal artery. It accompanies the perineal artery and divides into **posterior scrotal** (or **labial**) and **muscular branches**.

The **posterior scrotal** (or **labial**) branches (*nn. scrotales* (or *labiales*) *posteriores*; *superficial peroneal nerves*) are two in number, medial and lateral. They pierce the fascia of the urogenital diaphragm, and run forward along the lateral part of the urethral triangle in company with the posterior scrotal branches of the perineal artery; they are distributed to the skin of the scrotum and communicate with the perineal branch of the posterior femoral cutaneous nerve. These nerves supply the labium majus in the female.

The **muscular branches** are distributed to the Transversus perinæi superficialis, Bulbocavernosus, Ischiocavernosus, and Constrictor urethræ. A branch, the **nerve to the bulb**, given off from the nerve to the Bulbocavernosus, pierces this muscle, and supplies the corpus cavernosum urethræ, ending in the mucous membrane of the urethra.

The **dorsal nerve of the penis** (*n. dorsalis penis*) is the deepest division of the pudendal nerve; it accompanies the internal pudendal artery along the ramus of the ischium; it then runs forward along the margin of the inferior ramus of the pubis, between the superior and inferior layers of the fascia of the urogenital diaphragm. Piercing the inferior layer it gives a branch to the corpus cavernosum penis, and passes forward, in company with the dorsal artery of the penis, between the layers of the suspensory ligament, on to the dorsum of the penis, and ends on the glans penis. In the female this nerve is very small, and supplies the **clitoris** (*n. dorsalis clitoridis*).

The **Visceral Branches** arise from the third and fourth, and sometimes from the second, sacral nerves, and are distributed to the bladder and rectum and, in the female, to the vagina; they communicate with the pelvic plexuses of the sympathetic.

The **Muscular Branches** are derived from the fourth sacral, and supply the Levator ani, Coccygeus, and Sphincter ani externus. The branches to the Levator ani and Coccygeus enter their pelvic surfaces; that to the Sphincter ani externus (perineal branch) reaches the ischioanal fossa by piercing the Coccygeus or by passing between it and the Levator ani. Cutaneous filaments from this branch supply the skin between the anus and the coccyx.

Anococcygeal Nerves (*nn. anococcygei*).—The fifth sacral nerve receives a communicating filament from the fourth, and unites with the coccygeal nerve to form the **coccygeal plexus**. From this plexus the anococcygeal nerves take origin; they consist of a few fine filaments which pierce the sacrotuberous ligament to supply the skin in the region of the coccyx.

THE SYMPATHETIC NERVOUS SYSTEM.

The **sympathetic nervous system** (Fig. 838) innervates all the smooth muscles and the various glands of the body, and the striated muscle of the heart. The efferent sympathetic fibers which leave the central nervous system in connection with

certain of the cranial and spinal nerves all end in sympathetic ganglia and are known as preganglionic fibers. From these ganglia postganglionic fibers arise and

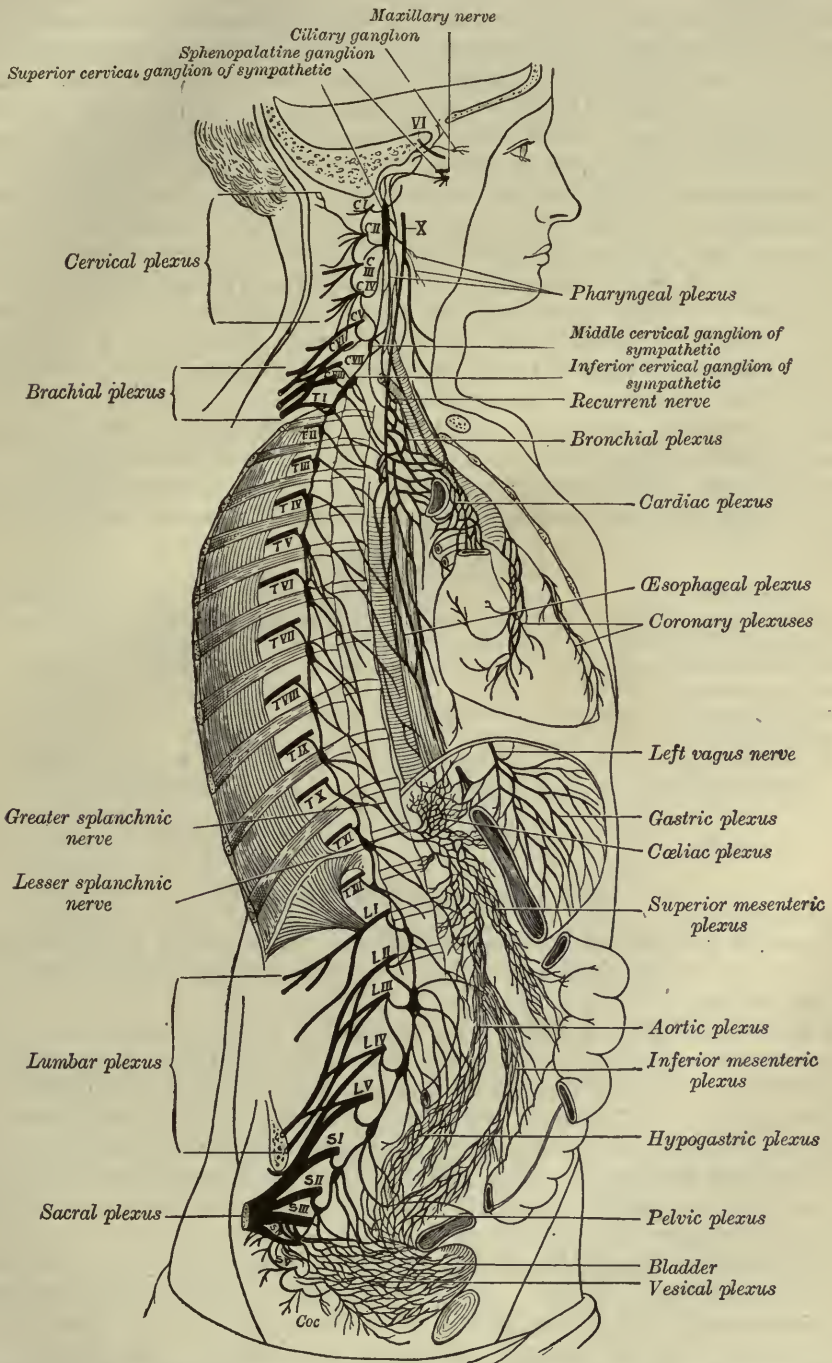


FIG 838.—The right sympathetic chain and its connections with the thoracic, abdominal, and pelvic plexuses. (After Schwalbe.)

conduct impulses to the different organs. In addition, afferent or sensory fibers connect many of these structures with the central nervous system.

The peripheral portion of the sympathetic nervous system is characterized by the presence of numerous ganglia and complicated plexuses. These ganglia are connected with the central nervous system by three groups of sympathetic efferent or preganglionic fibers, *i. e.*, the **cranial**, the **thoracolumbar**, and the **sacral**. These outflows of sympathetic fibers are separated by intervals where no connections exist. The cranial and sacral sympathetics are often grouped together owing to the resemblance between the reactions produced by stimulating them and by the effects of certain drugs. Acetyl-choline, for example, when injected intravenously in very small doses, produces the same effect as the stimulation of the cranial or sacral sympathetics, while the introduction of adrenalin produces the same effect as the stimulation of the thoracolumbar sympathetics. Much of our present knowledge of the sympathetic nervous system has been acquired through the application of various drugs, especially nicotine which paralyzes the connections or synapses between the preganglionic and postganglionic fibers of the sympathetic nerves. When it is injected into the general circulation all such synapses are paralyzed; when it is applied locally on a ganglion only the synapses occurring in that particular ganglion are paralyzed.

Langley,¹ who has contributed greatly to our knowledge, adopted a terminology somewhat different from that used here and still different from that used by the pharmacologists. This has led to considerable confusion, as shown by the arrangement of the terms in the following columns. Gaskell has used the term involuntary nervous system.²

Gray.	Langley.	Meyer and Gottlieb. ³
Sympathetic nervous system.	Autonomic nervous system.	Vegetative nervous system.
Cranio-sacral sympathetics.	Parasympathetics.	Autonomic.
Oculomotor sympathetics.	Tectal autonomies.	Cranial autonomies.
Facial sympathetics.	} Bulbar autonomies.	
Glossopharyngeal sympathetics.		
Vagal sympathetics.		
Sacral sympathetics.	Sacral autonomies.	Sacral autonomies.
Thoracolumbar sympathetics.	Sympathetic.	Sympathetic.
	Thoracic autonomic.	
Enteric.	Enteric.	Enteric.

THE CRANIAL SYMPATHETICS.

The **cranial sympathetics** include sympathetic efferent fibers in the oculomotor, facial, glossopharyngeal and vagus nerves, as well as sympathetic afferent in the last three nerves.

The **Sympathetic Efferent Fibers of the Oculomotor Nerve** probably arise from cells in the anterior part of the oculomotor nucleus which is located in the tegmentum of the mid-brain. These preganglionic fibers run with the third nerve into the orbit and pass to the ciliary ganglion where they terminate by forming synapses with sympathetic motor neurons whose axons, postganglionic fibers, proceed as the short ciliary nerves to the eyeball. Here they supply motor fibers to the Ciliaris muscle and the Sphincter pupillæ muscle. So far as known there are no sympathetic afferent fibers connected with the nerve.

The **Sympathetic Efferent Fibers of the Facial Nerve** are supposed to arise from the small cells of the facial nucleus. According to some authors the fibers to the salivary glands arise from a special nucleus, the superior salivatory nucleus, consisting of cells scattered in the reticular formation, dorso-medial to the facial nucleus. These preganglionic fibers are distributed partly through the chorda tympani and

¹ Schäfer. Textbook of Physiology, 1900.

² Gaskell, W. H., The Involuntary Nervous System, London, 1916.

³ Die Experimentelle Pharmakologie, 1910.

lingual nerves to the submaxillary ganglion where they terminate about the cell bodies of neurons whose axons as postganglionic fibers conduct secretory and vaso-

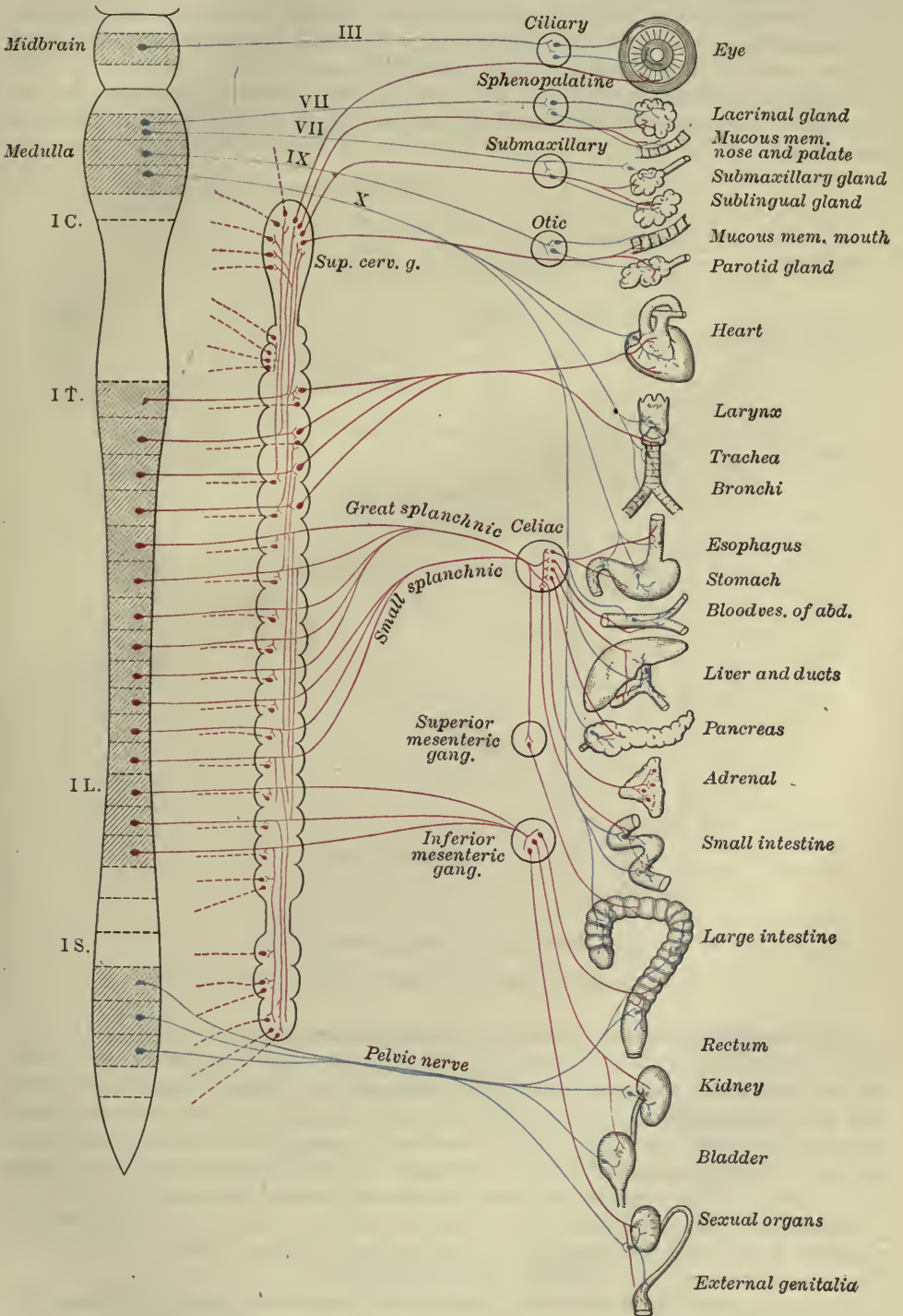


FIG. 839.—Diagram of efferent sympathetic nervous system. Blue, cranial and sacral outflow. Red, thoraco-humeral outflow. -----, Postganglionic fibers to spinal and cranial nerves to supply vasomotors to head, trunk and limbs, motor fibers to smooth muscles of skin and fibers to sweat glands. (Modified after Meyer and Gottlieb.)

dilator impulses to the submaxillary and sublingual glands. Other preganglionic fibers of the facial nerve pass via the great superficial petrosal nerve to the sphenopalatine ganglion where they form synapses with neurons whose postganglionic fibers are distributed with the superior maxillary nerve as vasodilator and secretory fibers to the mucous membrane of the nose, soft palate, tonsils, uvula, roof of the mouth, upper lips and gums, parotid and orbital glands.

There are supposed to be a few sympathetic afferent fibers connected with the facial nerve, whose cell bodies lie in the geniculate ganglion, but very little is known about them.

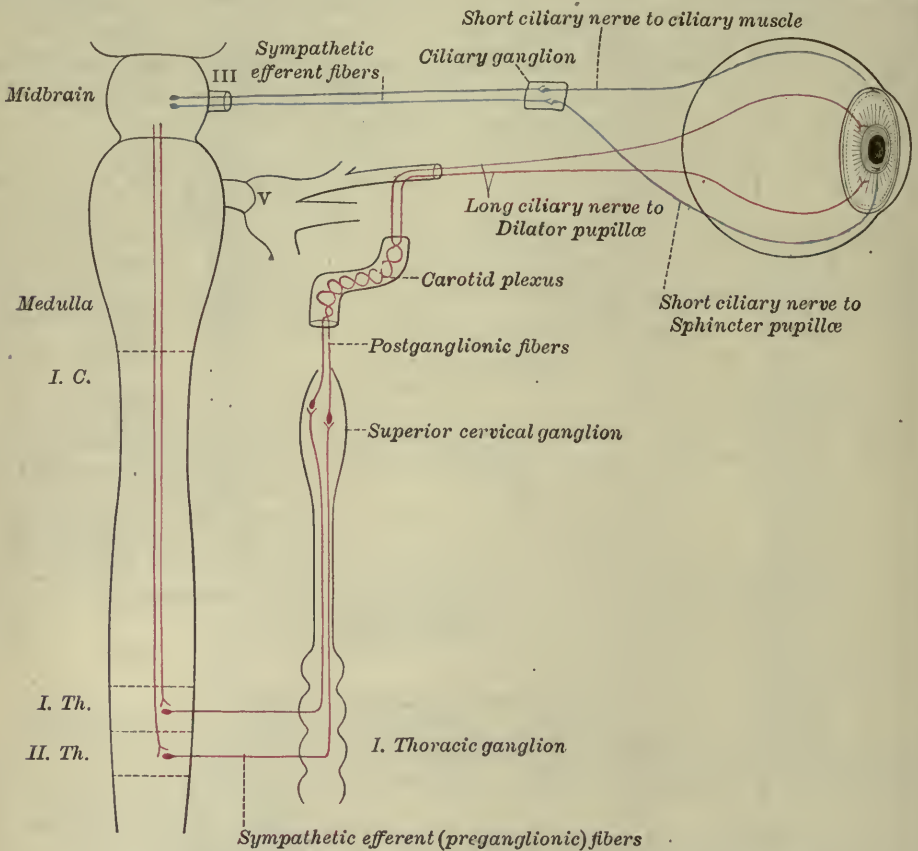


FIG. 840.—Sympathetic connections of the ciliary and superior cervical ganglia.

The **Sympathetic Afferent Fibers of the Glossopharyngeal Nerve** are supposed to arise either in the dorsal nucleus (nucleus ala cinerea) or in a distinct nucleus, the inferior salivatory nucleus, situated near the dorsal nucleus. These preganglionic fibers pass into the tympanic branch of the glossopharyngeal and then with the small superficial petrosal nerve to the otic ganglion. Postganglionic fibers, vasodilator and secretory fibers, are distributed to the parotid gland, to the mucous membrane and its glands on the tongue, the floor of the mouth, and the lower gums.

Sympathetic Afferent Fibers, whose cells of origin lie in the superior or inferior ganglion of the trunk, are supposed to terminate in the dorsal nucleus. Very little is known of the peripheral distribution of these fibers.

The **Sympathetic Efferent Fibers of the Vagus Nerve** are supposed to arise in the dorsal nucleus (nucleus ala cinerea). These preganglionic fibers are all supposed to end in sympathetic ganglia situated in or near the organs supplied by the vagus sym-

pathetics. The inhibitory fibers to the heart probably terminate in the small ganglia of the heart wall especially the atrium, from which inhibitory postganglionic fibers are distributed to the musculature. The preganglionic motor fibers to the esophagus, the stomach, the small intestine, and the greater part of the large intestine are supposed to terminate in the plexuses of Auerbach, from which postganglionic fibers are distributed to the smooth muscles of these organs. Other fibers pass to the smooth muscles of the bronchial tree and to the gall-bladder and its ducts. In addition the vagus is believed to contain secretory fibers to the stomach and pancreas. It probably contains many other efferent fibers than those enumerated above.

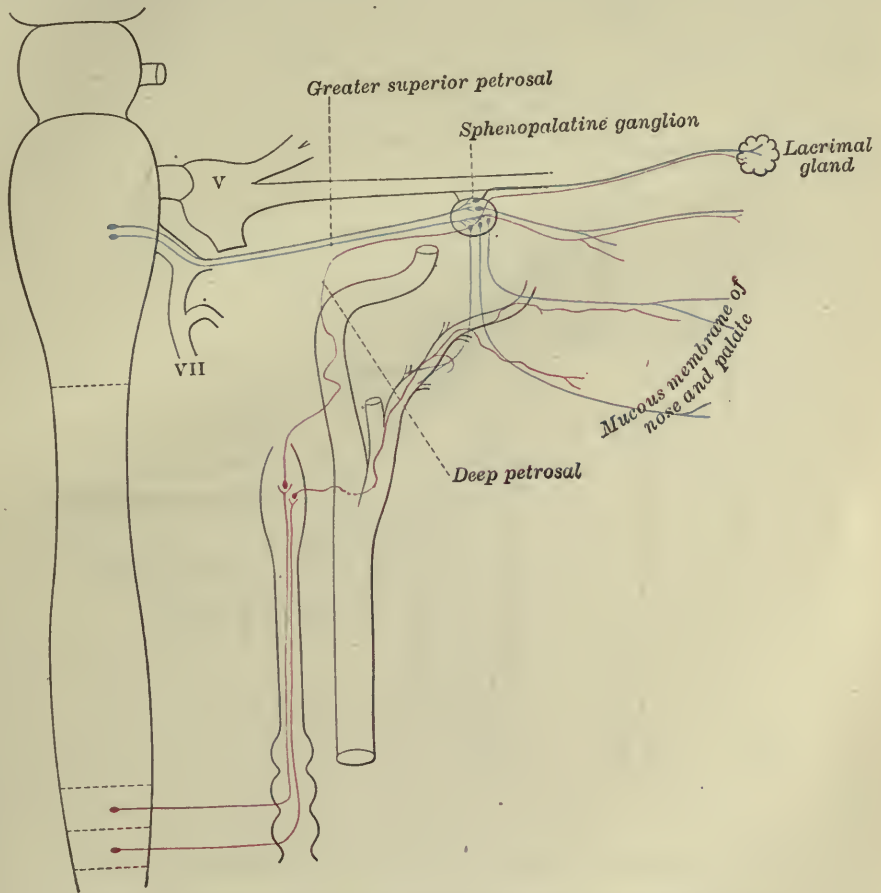


FIG. 841.—Sympathetic connections of the sphenopalatine and superior cervical ganglia.

Sympathetic Afferent Fibers of the Vagus, whose cells of origin lie in the jugular ganglion or the ganglion nodosum, probably terminate in the dorsal nucleus of the medulla oblongata or according to some authors in the nucleus of the tractus solitarius. Peripherally the fibers are supposed to be distributed to the various organs supplied by the sympathetic efferent fibers.

THE SACRAL SYMPATHETICS.

The **Sacral Sympathetic Efferent Fibers** leave the spinal cord with the anterior roots of the second, third and fourth sacral nerves. These small medullated preganglionic fibers are collected together in the pelvis into the nervus erigentes or pelvic nerve

which proceeds to the hypogastric or pelvic plexuses from which postganglionic fibers are distributed to the pelvic viscera. Motor fibers pass to the smooth muscle of the descending colon, rectum, anus and bladder. Vasodilators are distributed to these organs and to the external genitalia, while inhibitory fibers probably pass to the smooth muscles of the external genitalia. **Afferent sympathetic fibers** conduct impulses from the pelvic viscera to the second, third and fourth sacral nerves. Their cells of origin lie in the spinal ganglia.

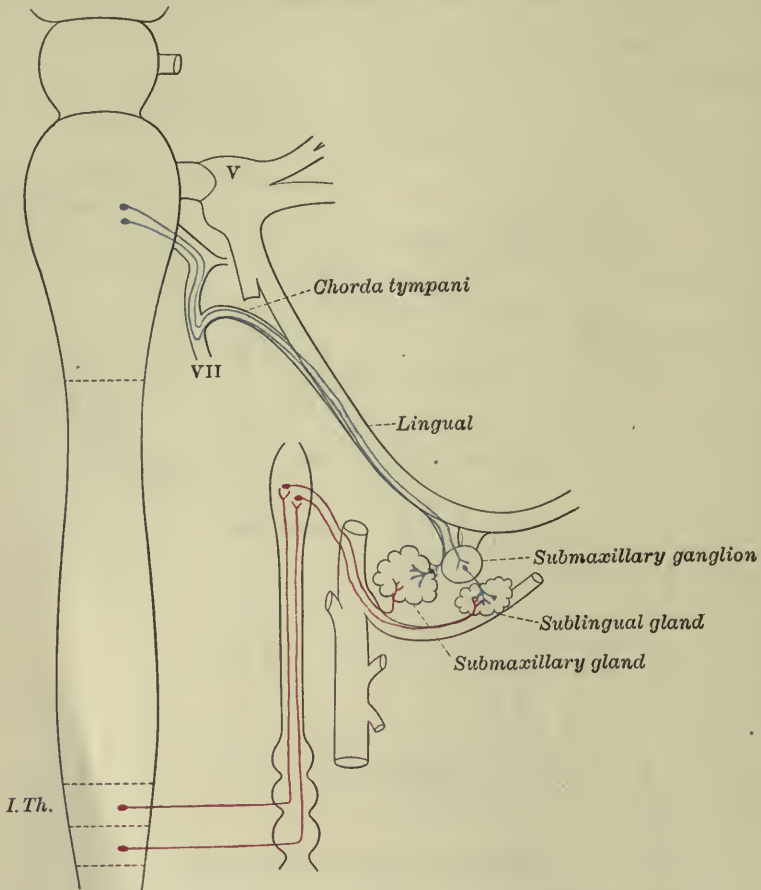


FIG. 842.—Sympathetic connections of the submaxillary and superior cervical ganglia.

THE THORACOLUMBAR SYMPATHETICS.

The **thoracolumbar sympathetic fibers** arise from the dorso-lateral region of the anterior column of the gray matter of the spinal cord and pass with the anterior roots of all the thoracic and the upper two or three lumbar spinal nerves. These preganglionic fibers enter the white rami communicantes and proceed to the sympathetic trunk where many of them end in its ganglia, others pass to the pre-vertebral plexuses and terminate in its collateral ganglia. The postganglionic fibers have a wide distribution. The **vasoconstrictor fibers** to the bloodvessels of the skin of the trunk and limbs, for example, leave the spinal cord as preganglionic fibers in all the thoracic and the upper two or three lumbar spinal nerves and terminate in the ganglia of the sympathetic trunk, either in the ganglion directly connected with its ramus or in neighboring ganglia. Postganglionic fibers arise

in these ganglia, pass through gray rami communicantes to all the spinal nerves, and are distributed with their cutaneous branches, ultimately leaving these branches to join the small arteries. The postganglionic fibers do not necessarily return to the same spinal nerves which contain the corresponding preganglionic fibers. The vasoconstrictor fibers to the head come from the upper thoracic nerves, the preganglionic fibers end in the superior cervical ganglion. The postganglionic fibers pass through the internal carotid nerve and branch from it to join the sensory branches of the various cranial nerves, especially the trigeminal nerve; other fibers to the deep structures and the salivary glands probably accompany the arteries.

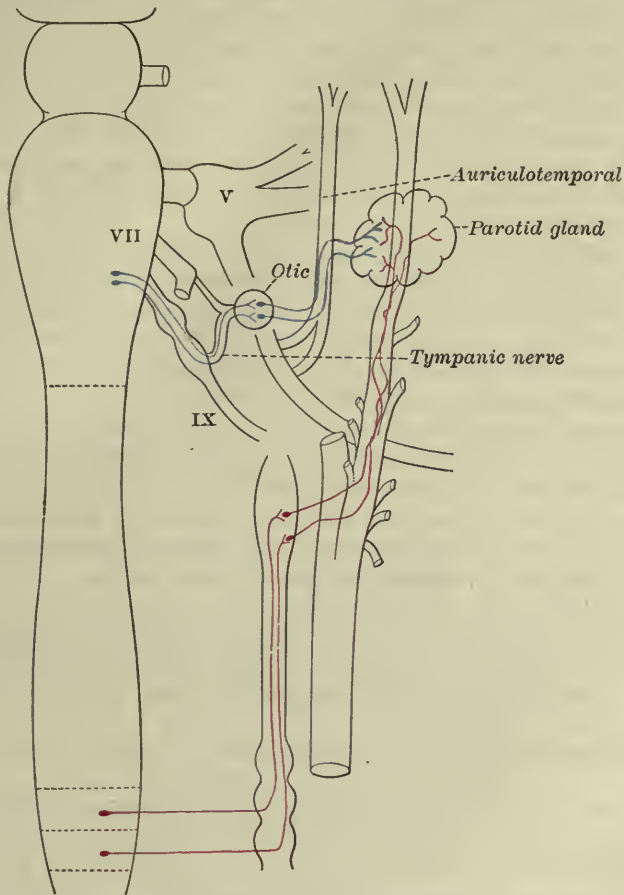


FIG. 843.—Sympathetic connections of the otic and superior cervical ganglia.

The postganglionic vasoconstrictor fibers to the bloodvessels of the abdominal viscera arise in the prevertebral or collateral ganglia in which terminate many preganglionic fibers. Vasoconstrictor fibers to the pelvic viscera arise from the inferior mesenteric ganglia.

The pilomotor fibers to the hairs and the motor fibers to the sweat glands apparently have a distribution similar to that of the vasoconstrictors of the skin.

A vasoconstrictor center has been located by the physiologists in the neighborhood of the facial nucleus. Axons from its cells are supposed to descend in the spinal cord to terminate about cell bodies of the preganglionic fibers located in the dorso-lateral portion of the anterior column of the thoracic and upper lumbar region.

The motor supply to the dilator pupillæ muscle of the eye comes from pregan-

gliconic sympathetic fibers which leave the spinal cord with the anterior roots of the upper thoracic nerves. These fibers pass to the sympathetic trunk through the white rami communicantes and terminate in the superior cervical ganglion. Post-ganglionic fibers from the superior cervical ganglion pass through the internal carotid nerve and the ophthalmic division of the trigeminal nerve to the orbit where the long ciliary nerves conduct the impulses to the eyeball and the dilator pupillæ muscle. The cell bodies of these preganglionic fibers are connected with fibers which descend from the mid-brain.

Other postganglionic fibers from the superior cervical ganglion are distributed as secretory fibers to the salivary glands, the lacrimal glands and to the small glands of the mucous membrane of the nose, mouth and pharynx.

The thoracic sympathetics supply accelerator nerves to the heart. They are supposed to emerge from the spinal cord in the anterior roots of the upper four or five thoracic nerves and pass with the white rami to the first thoracic ganglion, here some terminate, others pass in the ansa subclavia to the inferior cervical ganglion. The postganglionic fibers pass from these ganglia partly through the ansa subclavia to the heart, on their way they intermingle with sympathetic fibers from the vagus to form the cardiac plexus.

Inhibitory fibers to the smooth musculature of the stomach, the small intestine and most of the large intestine are supposed to emerge in the anterior roots of the lower thoracic and upper lumbar nerves. These fibers pass through the white rami and sympathetic trunk and are conveyed by the splanchnic nerves to the pre-vertebral plexus where they terminate in the collateral ganglia. From the celiac and superior mesenteric ganglia postganglionic fibers (inhibitory) are distributed to the stomach, the small intestine and most of the large intestine. Inhibitory fibers to the descending colon, the rectum and Internal sphincter ani are probably post-ganglionic fibers from the inferior mesenteric ganglion.

The thoracolumbar sympathetics are characterized by the presence of numerous ganglia which may be divided into two groups, **central** and **collateral**.

The **central ganglia** are arranged in two vertical rows, one on either side of the middle line, situated partly in front and partly at the sides of the vertebral column. Each ganglion is joined by intervening nervous cords to adjacent ganglia so that two chains, the **sympathetic trunks**, are formed. The **collateral ganglia** are found in connection with three great **prevertebral plexuses**, placed within the thorax, abdomen, and pelvis respectively.

The **sympathetic trunks** (*truncus sympathicus; gangliated cord*) extend from the base of the skull to the coccyx. The cephalic end of each is continued upward through the carotid canal into the skull, and forms a plexus on the internal carotid artery; the caudal ends of the trunks converge and end in a single ganglion, the **ganglion impar**, placed in front of the coccyx. The ganglia of each trunk are distinguished as **cervical**, **thoracic**, **lumbar**, and **sacral** and, except in the neck, they closely correspond in number to the vertebræ. They are arranged thus:

Cervical portion	3 ganglia
Thoracic "	12 "
Lumbar "	4 "
Sacral "	4 or 5 "

In the neck the ganglia lie in front of the transverse processes of the vertebræ; in the thoracic region in front of the heads of the ribs; in the lumbar region on the sides of the vertebral bodies; and in the sacral region in front of the sacrum.

Connections with the Spinal Nerves.—Communications are established between the sympathetic and spinal nerves through what are known as the **gray** and **white rami communicantes** (Fig. 799); the gray rami convey sympathetic fibers into the spinal nerves and the white rami transmit spinal fibers into the sympathetic.

Each spinal nerve receives a gray ramus communicans from the sympathetic trunk, but white rami are not supplied by all the spinal nerves. White rami are derived from the first thoracic to the first lumbar nerves inclusive, while the visceral branches which run from the second, third, and fourth sacral nerves directly to the pelvic plexuses of the sympathetic belong to this category. The fibers which reach the sympathetic through the white rami communicantes are medullated; those which spring from the cells of the sympathetic ganglia are almost entirely non-medullated. The sympathetic nerves consist of efferent and afferent fibers, the origin and course of which are described on page 920).

The **three great gangliated plexuses** (*collateral ganglia*) are situated in front of the vertebral column in the thoracic, abdominal, and pelvic regions, and are named, respectively, the **cardiac**, the **solar** or **epigastric**, and the **hypogastric plexuses**. They consist of collections of nerves and ganglia; the nerves being derived from the sympathetic trunks and from the cerebrospinal nerves. They distribute branches to the viscera.

Development.—The ganglion cells of the sympathetic system are derived from the cells of the neural crests. As these crests move forward along the sides of the neural tube and become segmented off to form the spinal ganglia, certain cells detach themselves from the ventral margins of the crests and migrate toward the sides of the aorta, where some of them are grouped to form the ganglia of the sympathetic trunks, while others undergo a further migration and form the ganglia of the prevertebral and visceral plexuses. The ciliary, sphenopalatine, otic, and submaxillary ganglia which are found on the branches of the trigeminal nerve are formed by groups of cells which have migrated from the part of the neural crest which gives rise to the semilunar ganglion. Some of the cells of the ciliary ganglion are said to migrate from the neural tube along the oculomotor nerve.

THE CEPHALIC PORTION OF THE SYMPATHETIC SYSTEM (PARS CEPHALICA S. SYMPATHICI).

The **cephalic portion** of the sympathetic system begins as the **internal carotid nerve**, which appears to be a direct prolongation of the superior cervical ganglion. It is soft in texture, and of a reddish color. It ascends by the side of the internal carotid artery, and, entering the carotid canal in the temporal bone, divides into two branches, which lie one on the lateral and the other on the medial side of that vessel.

The **lateral branch**, the larger of the two, distributes filaments to the internal carotid artery, and forms the **internal carotid plexus**.

The **medial branch** also distributes filaments to the internal carotid artery, and, continuing onward, forms the **cavernous plexus**.

The **internal carotid plexus** (*plexus caroticus internus; carotid plexus*) is situated on the lateral side of the internal carotid artery, and in the plexus there occasionally exists a small gangliform swelling, the **carotid ganglion**, on the under surface of the artery. The internal carotid plexus communicates with the semilunar ganglion, the abducent nerve, and the sphenopalatine ganglion; it distributes filaments to the wall of the carotid artery, and also communicates with the tympanic branch of the glossopharyngeal nerve.

The communicating branches with the abducent nerve consist of one or two filaments which join that nerve as it lies upon the lateral side of the internal carotid artery. The communication with the sphenopalatine ganglion is effected by a branch, the **deep petrosal**, given off from the plexus on the lateral side of the artery; this branch passes through the cartilage filling up the foramen lacerum, and joins the greater superficial petrosal to form the nerve of the pterygoid canal (*Vidian nerve*), which passes through the pterygoid canal to the sphenopalatine ganglion.

The communication with the tympanic branch of the glossopharyngeal nerve is effected by the **caroticotympanic**, which may consist of two or three delicate filaments.

The **cavernous plexus** (*plexus cavernosus*) is situated below and medial to that part of the internal carotid artery which is placed by the side of the sella turcica in the cavernous sinus, and is formed chiefly by the medial division of the internal carotid nerve. It communicates with the oculomotor, the trochlear, the ophthalmic and the abducent nerves, and with the ciliary ganglion, and distributes filaments to the wall of the internal carotid artery. The branch of communication with the oculomotor nerve joins that nerve at its point of division; the branch to the trochlear nerve joins it as it lies on the lateral wall of the cavernous sinus; other filaments are connected with the under surface of the ophthalmic nerve; and a second filament joins the abducent nerve.

The **filaments of connection** with the ciliary ganglion *arise* from the anterior part of the cavernous plexus and enter the orbit through the superior orbital fissure; they may join the nasociliary branch of the ophthalmic nerve, or be continued forward as a separate branch.

The **terminal filaments** from the internal carotid and cavernous plexuses are prolonged as plexuses around the anterior and middle cerebral arteries and the ophthalmic artery; along the former vessels, they may be traced to the pia mater; along the latter, into the orbit, where they accompany each of the branches of the vessel. The filaments prolonged on to the anterior communicating artery connect the sympathetic nerves of the right and left sides.

THE CERVICAL PORTION OF THE SYMPATHETIC SYSTEM (PARS CERVICALIS S. SYMPATHICI).

The **cervical portion** of the sympathetic trunk consists of three ganglia, distinguished, according to their positions, as the **superior, middle, and inferior ganglia**, connected by intervening cords. This portion receives no white rami communicantes from the cervical spinal nerves; its spinal fibers are derived from the white rami of the upper thoracic nerves, and enter the corresponding thoracic ganglia of the sympathetic trunk, through which they ascend into the neck.

The **superior cervical ganglion** (*ganglion cervicale superius*), the largest of the three, is placed opposite the second and third cervical vertebræ. It is of a reddish-gray color, and usually fusiform in shape; sometimes broad and flattened, and occasionally constricted at intervals; it is believed to be formed by the coalescence of four ganglia, corresponding to the upper four cervical nerves. It is in relation, *in front*, with the sheath of the internal carotid artery and internal jugular vein; *behind*, with the Longus capitis muscle.

Its branches may be divided into **inferior, lateral, medial, and anterior**.

The **Inferior Branch** communicates with the middle cervical ganglion.

The **Lateral Branches** (*external branches*) consist of gray rami communicantes to the upper four cervical nerves and to certain of the cranial nerves. Sometimes the branch to the fourth cervical nerve may come from the trunk connecting the upper and middle cervical ganglia. The branches to the cranial nerves consist of delicate filaments, which run to the ganglion nodosum of the vagus, and to the hypoglossal nerve. A filament, the **jugular nerve**, passes upward to the base of the skull, and divides to join the petrous ganglion of the glossopharyngeal, and the jugular ganglion of the vagus.

The **Medial Branches** (*internal branches*) are peripheral, and are the **laryngopharyngeal branches** and the **superior cardiac nerve**.

The **laryngopharyngeal branches** (*rami laryngopharyngei*) pass to the side of the

pharynx, where they join with branches from the glossopharyngeal, vagus, and external laryngeal nerves to form the **pharyngeal plexus**.

The **superior cardiac nerve** (*n. cardiacus superior*) arises by two or more branches from the superior cervical ganglion, and occasionally receives a filament from the trunk between the first and second cervical ganglia. It runs down the neck behind the common carotid artery, and in front of the Longus colli muscle; and crosses in front of the inferior thyroid artery, and recurrent nerve. The course of the nerves on the two sides then differ. The **right nerve**, at the root of the neck, passes either in front of or behind the subclavian artery, and along the innominate artery to the back of the arch of the aorta, where it joins the deep part of the cardiac plexus. It is connected with other branches of the sympathetic; about the middle of the neck it receives filaments from the external laryngeal nerve; lower down, one or two twigs from the vagus; and as it enters the thorax it is joined by a filament from the recurrent nerve. Filaments from the nerve communicate with the thyroid branches from the middle cervical ganglion. The **left nerve**, in the thorax, runs in front of the left common carotid artery and across the left side of the arch of the aorta, to the superficial part of the cardiac plexus.

The **Anterior Branches** (*nn. carotici externi*) ramify upon the common carotid artery and upon the external carotid artery

and its branches, forming around each a delicate plexus, on the nerves composing which small ganglia are occasionally found. The plexuses accompanying some of these arteries have important communications with other nerves. That surrounding the external maxillary artery communicates with the submaxillary ganglion by a filament; and that accompanying the middle meningeal artery sends an offset to the otic ganglion, and a second, the **external petrosal nerve**, to the genicular ganglion of the facial nerve.

The **middle cervical ganglion** (*ganglion cervicale medium*) is the smallest of the three cervical ganglia, and is occasionally wanting. It is placed opposite the sixth cervical vertebra, usually in front of, or close to, the inferior thyroid artery. It is probably formed by the coalescence of two ganglia corresponding to the fifth and sixth cervical nerves.

It sends gray rami communicantes to the fifth and sixth cervical nerves, and gives off the middle cardiac nerve.

The **Middle Cardiac Nerve** (*n. cardiacus medius*; *great cardiac nerve*), the largest

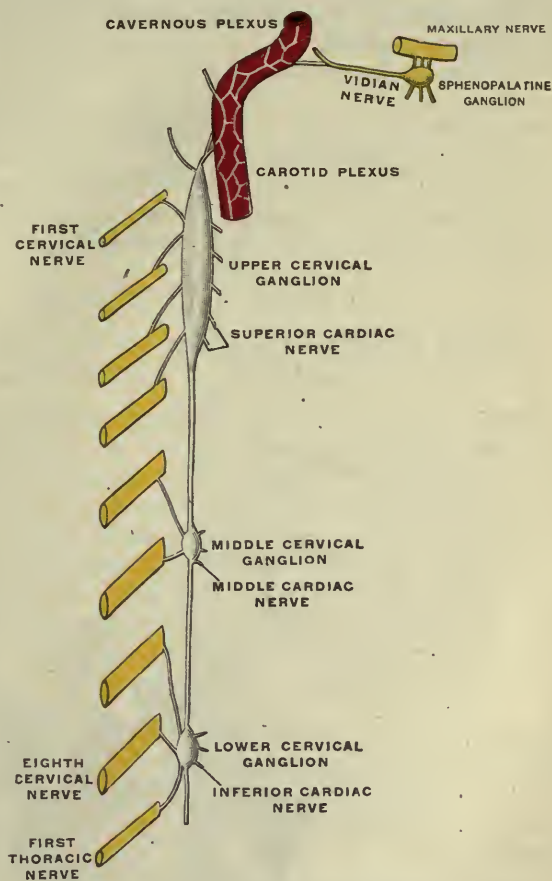


FIG. 844.—Diagram of the cervical sympathetic. (Testut.)

of the three cardiac nerves, *arises* from the middle cervical ganglion, or from the trunk between the middle and inferior ganglia. On the right side it descends behind the common carotid artery, and at the root of the neck runs either in front of or behind the subclavian artery; it then descends on the trachea, receives a few filaments from the recurrent nerve, and joins the right half of the deep part of the cardiac plexus. In the neck, it communicates with the superior cardiac and recurrent nerves. On the left side, the middle cardiac nerve enters the chest between the left carotid and subclavian arteries, and joins the left half of the deep part of the cardiac plexus.

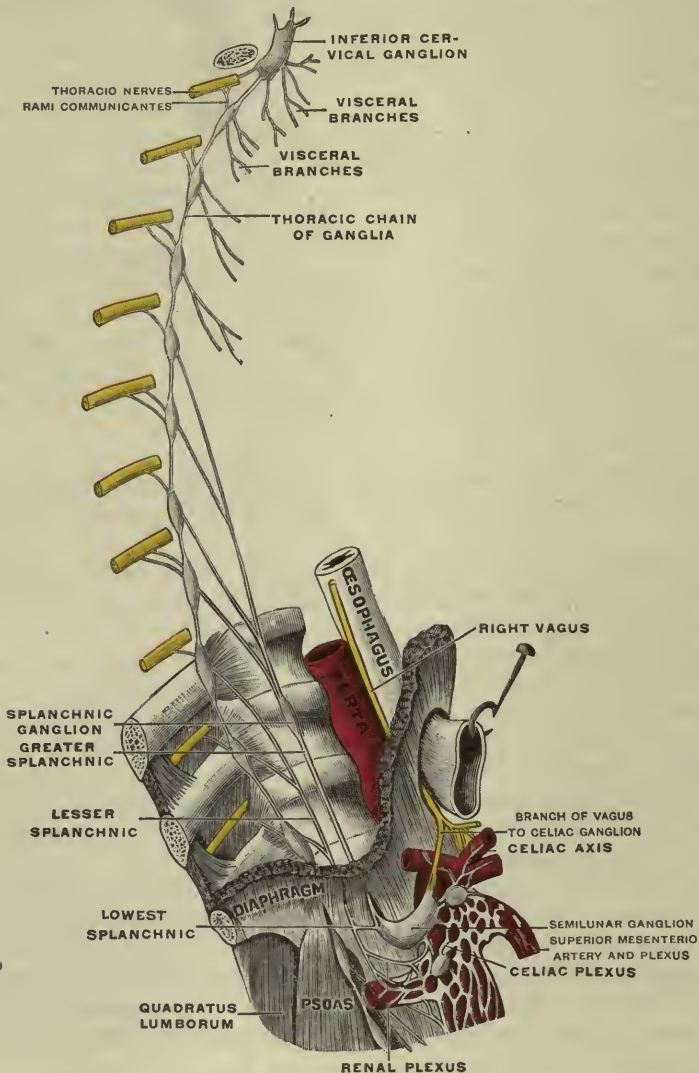


FIG. 845.—Plan of right sympathetic cord and splanchnic nerves. (Testut.)

The **inferior cervical ganglion** (*ganglion cervicale inferius*) is situated between the base of the transverse process of the last cervical vertebra and the neck of the first rib, on the medial side of the costocervical artery. Its form is irregular; it is larger in size than the preceding, and is frequently fused with the first thoracic ganglion. It is probably formed by the coalescence of two ganglia which correspond to the seventh and eighth cervical nerves. It is connected to the middle

cervical ganglion by two or more cords, one of which forms a loop around the subclavian artery and supplies offsets to it. This loop is named the *ansa subclavia* (*Vieussenii*).

The ganglion sends gray rami communicantes to the seventh and eighth cervical nerves.

It gives off the inferior cardiac nerve, and offsets to bloodvessels.

The **inferior cardiac nerve** (*n. cardiacus inferior*) arises from either the inferior cervical or the first thoracic ganglion. It descends behind the subclavian artery and along the front of the trachea, to join the deep part of the cardiac plexus. It communicates freely behind the subclavian artery with the recurrent nerve and the middle cardiac nerve.

The **offsets to bloodvessels** form plexuses on the subclavian artery and its branches. The plexus on the vertebral artery is continued on to the basilar, posterior cerebral, and cerebellar arteries. The plexus on the inferior thyroid artery accompanies the artery to the thyroid gland, and communicates with the recurrent and external laryngeal nerves, with the superior cardiac nerve, and with the plexus on the common carotid artery.

THE THORACIC PORTION OF THE SYMPATHETIC SYSTEM (PARS THORACALIS S. SMYPATHICI) (Fig. 846).

The thoracic portion of the sympathetic trunk consists of a series of ganglia, which usually correspond in number to that of the vertebræ; but, on account of the occasional coalescence of two ganglia, their number is uncertain. The thoracic ganglia rest against the heads of the ribs, and are covered by the costal pleura; the last two, however, are more anterior than the rest, and are placed on the sides of the bodies of the eleventh and twelfth thoracic vertebræ. The ganglia are small in size, and of a grayish color. The first, larger than the others, is of an elongated form, and frequently blended with the inferior cervical ganglion. They are connected together by the intervening portions of the trunk.

Two rami communicantes, a white and a gray, connect each ganglion with its corresponding spinal nerve.

The *branches from the upper five ganglia* are very small; they supply filaments to the thoracic aorta and its branches. Twigs from the second, third, and fourth ganglia enter the posterior pulmonary plexus.

The *branches from the lower seven ganglia* are large, and white in color; they distribute filaments to the aorta, and unite to form the greater, the lesser, and the lowest splanchnic nerves.

The **greater splanchnic nerve** (*n. splanchnicus major; great splanchnic nerve*) is white in color, firm in texture, and of a considerable size; it is formed by branches from the fifth to the ninth or tenth thoracic ganglia, but the fibers in the higher roots may be traced upward in the sympathetic trunk as far as the first or second thoracic ganglion. It descends obliquely on the bodies of the vertebræ, perforates the crus of the diaphragm, and ends in the celiac ganglion. A ganglion (**ganglion splanchnicum**) exists on this nerve opposite the eleventh or twelfth thoracic vertebra.

The **lesser splanchnic nerve** (*n. splanchnicus minor*) is formed by filaments from the ninth and tenth, and sometimes the eleventh thoracic ganglia, and from the cord between them. It pierces the diaphragm with the preceding nerve, and joins the aorticorenal ganglion.

The **lowest splanchnic nerve** (*n. splanchnicus imus; least splanchnic nerve*) arises from the last thoracic ganglion, and, piercing the diaphragm, ends in the renal plexus.

A striking analogy exists between the splanchnic and the cardiac nerves. The cardiac nerves are three in number; they *arise* from all three cervical ganglia,

and are distributed to a large and important organ in the thoracic cavity. The splanchnic nerves, also three in number, are connected probably with all the thoracic ganglia, and are distributed to important organs in the abdominal cavity.

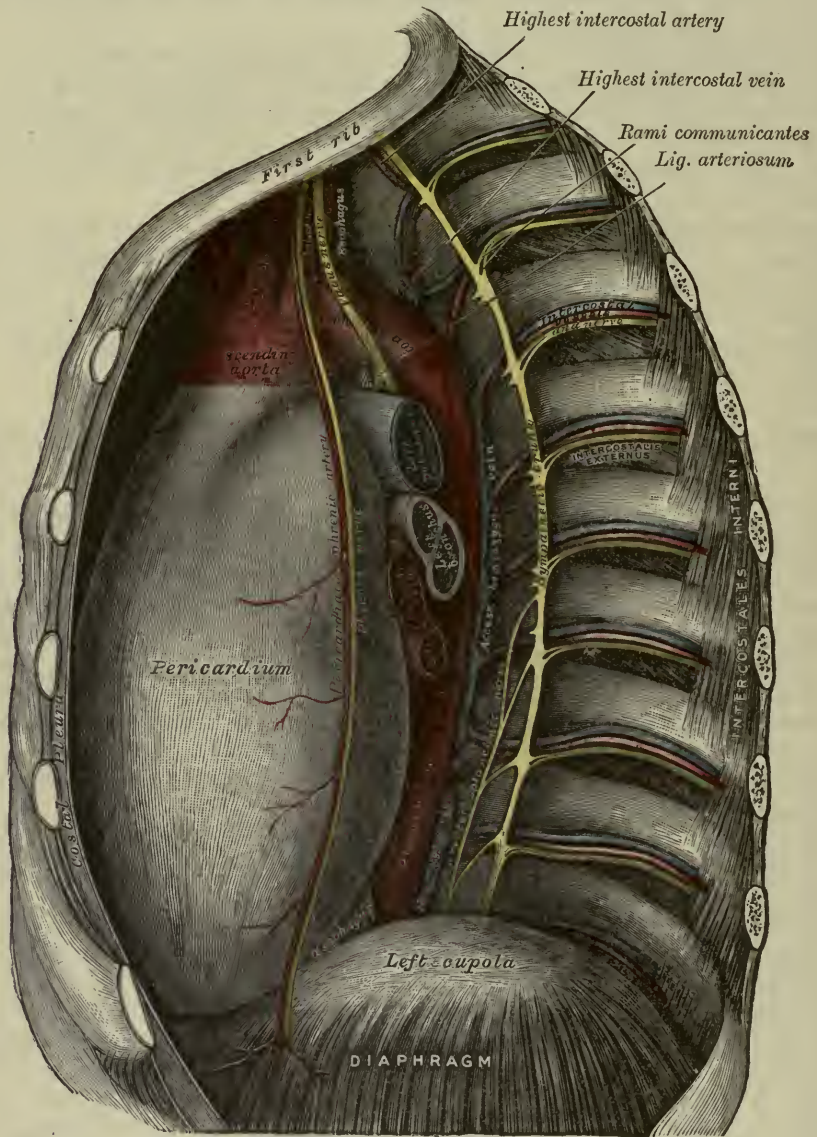


FIG. 846.—Thoracic portion of the sympathetic trunk.

THE ABDOMINAL PORTION OF THE SYMPATHETIC SYSTEM (PARS ABDOMINALIS S. SYMPATHICI; LUMBAR PORTION OF GANGLIATED CORD) (Fig. 847).

The abdominal portion of the sympathetic trunk is situated in front of the vertebral column, along the medial margin of the Psoas major. It consists usually of four lumbar ganglia, connected together by interganglionic cords. It is continuous above with the thoracic portion beneath the medial lumbocostal arch, and below with the pelvic portion behind the common iliac artery. The ganglia are of small size, and placed much nearer the median line than are the thoracic ganglia.

Gray rami communicantes pass from all the ganglia to the lumbar spinal nerves. The first and second, and sometimes the third, lumbar nerves send white rami

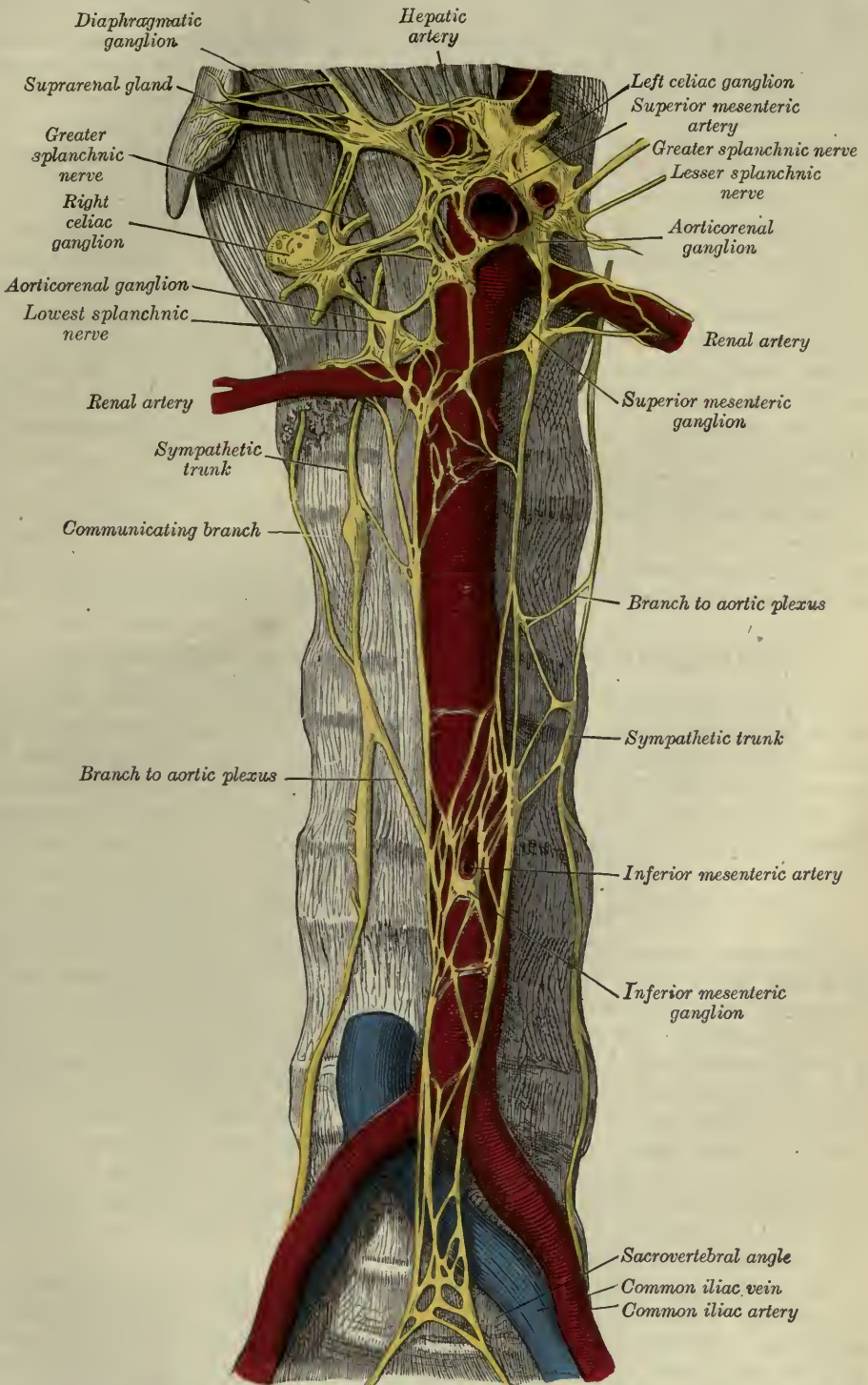


FIG. 847.—Abdominal portion of the sympathetic trunk, with the celiac and hypogastric plexuses. (Henle.)

communicantes to the corresponding ganglia. The rami communicantes are of considerable length, and accompany the lumbar arteries around the sides of the bodies of the vertebræ, passing beneath the fibrous arches from which some of the fibers of the Psoas major arise.

Of the **branches of distribution**, some pass in front of the aorta, and join the aortic plexus; others descend in front of the common iliac arteries, and assist in forming the hypogastric plexus.

THE PELVIC PORTION OF THE SYMPATHETIC SYSTEM (PARS PELVINA S. SYMPATHICI).

The pelvic portion of each sympathetic trunk is situated in front of the sacrum, medial to the anterior sacral foramina. It consists of four or five small sacral ganglia, connected together by interganglionic cords, and continuous above with the abdominal portion. Below, the two pelvic sympathetic trunks converge, and end on the front of the coccyx in a small ganglion, the **ganglion impar**.

Gray rami communicantes pass from the ganglia to the sacral and coccygeal nerves. No white rami communicantes are given to this part of the gangliated cord, but the visceral branches which arise from the third and fourth, and sometimes from the second, sacral, and run directly to the pelvic plexuses, are regarded as white rami communicantes.

The **branches of distribution** communicate on the front of the sacrum with the corresponding branches from the opposite side; some, from the first two ganglia, pass to join the pelvic plexus, and others form a plexus, which accompanies the middle sacral artery and sends filaments to the **glomus coccygeum** (*coccygeal body*).

THE GREAT PLEXUSES OF THE SYMPATHETIC SYSTEM.

The great plexuses of the sympathetic are aggregations of nerves and ganglia, situated in the thoracic, abdominal, and pelvic cavities, and named the **cardiac**, **celiac**, and **hypogastric plexuses**. They consist not only of sympathetic fibers derived from the ganglia, but of fibers from the medulla spinalis, which are conveyed through the white rami communicantes. From the plexuses branches are given to the thoracic, abdominal, and pelvic viscera.

The Cardiac Plexus (Plexus Cardiacus) (Fig. 838).

The **cardiac plexus** is situated at the base of the heart, and is divided into a **superficial part**, which lies in the concavity of the aortic arch, and a **deep part**, between the aortic arch and the trachea. The two parts are, however, closely connected.

The **superficial part of the cardiac plexus** lies beneath the arch of the aorta, in front of the right pulmonary artery. It is formed by the superior cardiac branch of the left sympathetic and the lower superior cervical cardiac branch of the left vagus. A small ganglion, the **cardiac ganglion of Wrisberg**, is occasionally found connected with these nerves at their point of junction. This ganglion, when present, is situated immediately beneath the arch of the aorta, on the right side of the ligamentum arteriosum. The superficial part of the cardiac plexus gives branches (*a*) to the deep part of the plexus; (*b*) to the anterior coronary plexus; and (*c*) to the left anterior pulmonary plexus.

The **deep part of the cardiac plexus** is situated in front of the bifurcation of the trachea, above the point of division of the pulmonary artery, and behind the aortic arch. It is formed by the cardiac nerves derived from the cervical ganglia of the sympathetic, and the cardiac branches of the vagus and recurrent nerves. The only cardiac nerves which do not enter into the formation of the deep part

of the cardiac plexus are the superior cardiac nerve of the left sympathetic, and the lower of the two superior cervical cardiac branches from the left vagus, which pass to the superficial part of the plexus.

The branches from the **right half** of the deep part of the cardiac plexus pass, some in front of, and others behind, the right pulmonary artery; the former, the more numerous, transmit a few filaments to the anterior pulmonary plexus, and are then continued onward to form part of the anterior coronary plexus; those behind the pulmonary artery distribute a few filaments to the right atrium, and are then continued onward to form part of the posterior coronary plexus.

The **left half** of the deep part of the plexus is connected with the superficial part of the cardiac plexus, and gives filaments to the left atrium, and to the anterior pulmonary plexus, and is then continued to form the greater part of the posterior coronary plexus.

The **Posterior Coronary Plexus** (*plexus coronarius posterior; left coronary plexus*) is larger than the anterior, and accompanies the left coronary artery; it is chiefly formed by filaments prolonged from the left half of the deep part of the cardiac plexus, and by a few from the right half. It gives branches to the left atrium and ventricle.

The **Anterior Coronary Plexus** (*plexus coronarius anterior; right coronary plexus*) is formed partly from the superficial and partly from the deep parts of the cardiac plexus. It accompanies the right coronary artery, and gives branches to the right atrium and ventricle.

The Celiac Plexus (Plexus Cœliacus; Solar Plexus) (Figs. 838, 848).

The **celiac plexus**, the largest of the three sympathetic plexuses, is situated at the level of the upper part of the first lumbar vertebra and is composed of two large ganglia, the **celiac ganglia**, and a dense net-work of nerve fibers uniting them together. It surrounds the celiac artery and the root of the superior mesenteric artery. It lies behind the stomach and the omental bursa, in front of the crura of the diaphragm and the commencement of the abdominal aorta, and between the suprarenal glands. The plexus and the ganglia receive the greater and lesser splanchnic nerves of both sides and some filaments from the right vagus, and give off numerous secondary plexuses along the neighboring arteries.

The **Celiac Ganglia** (*ganglia cœliaca; semilunar ganglia*) are two large irregularly-shaped masses having the appearance of lymph glands and placed one on either side of the middle line in front of the crura of the diaphragm close to the suprarenal glands, that on the right side being placed behind the inferior vena cava. The upper part of each ganglion is joined by the greater splanchnic nerve, while the lower part, which is segmented off and named the **aorticorenal ganglion**, receives the lesser splanchnic nerve and gives off the greater part of the renal plexus.

The secondary plexuses springing from or connected with the celiac plexus are the

Phrenic.	Renal.
Hepatic.	Spermatic.
Lienal.	Superior mesenteric.
Superior gastric.	Abdominal aortic.
Suprarenal.	Inferior mesenteric.

The **phrenic plexus** (*plexus phrenicus*) accompanies the inferior phrenic artery to the diaphragm, some filaments passing to the suprarenal gland. It *arises* from the upper part of the celiac ganglion, and is larger on the right than on the left side. It receives one or two branches from the phrenic nerve. At the point of junction of the right phrenic plexus with the phrenic nerve is a small ganglion

(ganglion phrenicum). This plexus distributes branches to the inferior vena cava, and to the suprarenal and hepatic plexuses.

The **hepatic plexus** (*plexus hepaticus*), the largest offset from the celiac plexus, receives filaments from the left vagus and right phrenic nerves. It accompanies the hepatic artery, ramifying upon its branches, and upon those of the portal vein in the substance of the liver. Branches from this plexus accompany all the divisions of the hepatic artery. A considerable plexus accompanies the gastroduodenal artery and is continued as the **inferior gastric plexus** on the right gastroepiploic artery along the greater curvature of the stomach, where it unites with offshoots from the lienal plexus.

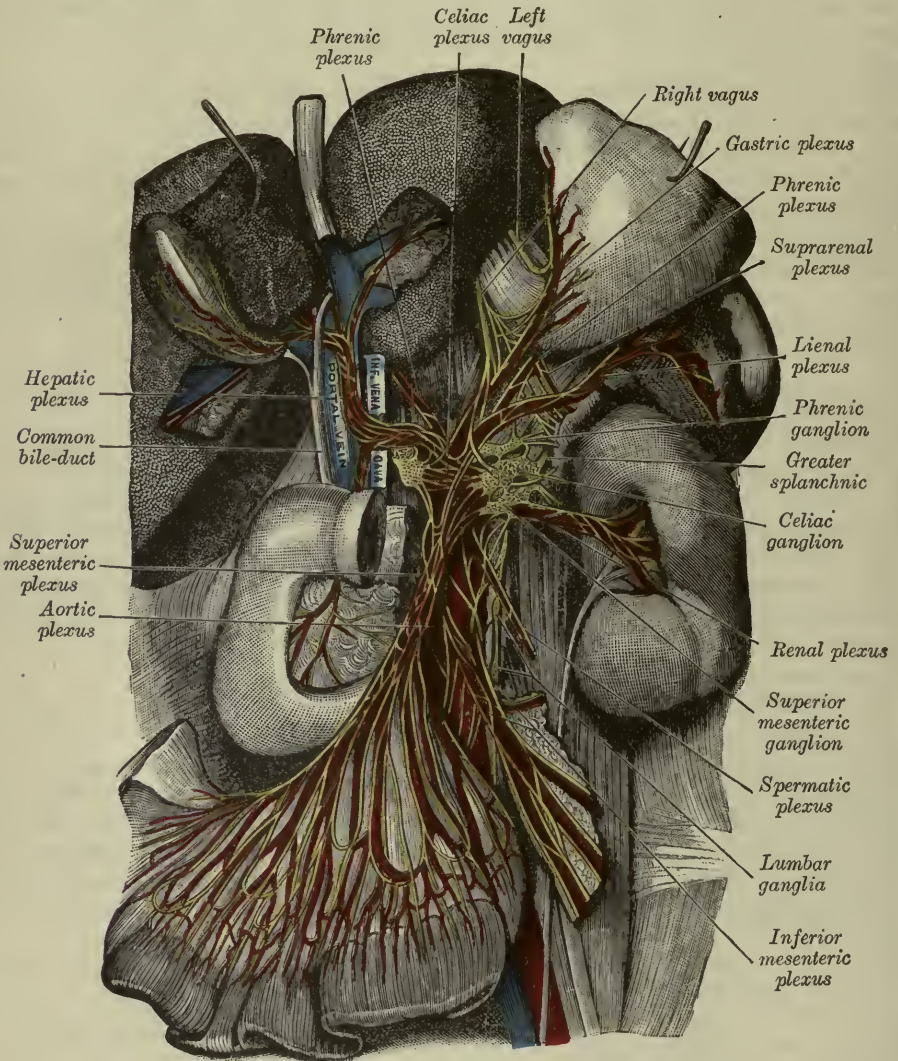


FIG. 848.—The celiac ganglia with the sympathetic plexuses of the abdominal viscera radiating from the ganglia. (Toldt.)

The **lienal plexus** (*plexus lienalis*; *splenic plexus*) is formed by branches from the celiac plexus, the left celiac ganglion, and from the right vagus nerve. It accompanies the lienal artery to the spleen, giving off, in its course, subsidiary plexuses along the various branches of the artery.

The **superior gastric plexus** (*plexus gastricus superior*; *gastric or coronary plexus*) accompanies the left gastric artery along the lesser curvature of the stomach, and joins with branches from the left vagus.

The **suprarenal plexus** (*plexus suprarenalis*) is formed by branches from the celiac plexus, from the celiac ganglion, and from the phrenic and greater splanchnic nerves, a ganglion being formed at the point of junction with the latter nerve. The plexus supplies the suprarenal gland, being distributed chiefly to its medullary portion; its branches are remarkable for their large size in comparison with that of the organ they supply.

The **renal plexus** (*plexus renalis*) is formed by filaments from the celiac plexus, the aorticorenal ganglion, and the aortic plexus. It is joined also by the smallest splanchnic nerve. The nerves from these sources, fifteen or twenty in number, have a few ganglia developed upon them. They accompany the branches of the renal artery into the kidney; some filaments are distributed to the spermatic plexus and, on the right side, to the inferior vena cava.

The **spermatic plexus** (*plexus spermaticus*) is derived from the renal plexus, receiving branches from the aortic plexus. It accompanies the internal spermatic artery to the testis. In the female, the **ovarian plexus** (*plexus arteriæ ovaricæ*) arises from the renal plexus, and is distributed to the ovary, and fundus of the uterus.

The **superior mesenteric plexus** (*plexus mesentericus superior*) is a continuation of the lower part of the celiac plexus, receiving a branch from the junction of the right vagus nerve with the plexus. It surrounds the superior mesenteric artery, accompanies it into the mesentery, and divides into a number of secondary plexuses, which are distributed to all the parts supplied by the artery, viz., pancreatic branches to the pancreas; intestinal branches to the small intestine; and ileocolic, right colic, and middle colic branches, which supply the corresponding parts of the great intestine. The nerves composing this plexus are white in color and firm in texture; in the upper part of the plexus close to the origin of the superior mesenteric artery is a ganglion (*ganglion mesentericum superius*).

The **abdominal aortic plexus** (*plexus aorticus abdominalis*; *aortic plexus*) is formed by branches derived, on either side, from the celiac plexus and ganglia, and receives filaments from some of the lumbar ganglia. It is situated upon the sides and front of the aorta, between the origins of the superior and inferior mesenteric arteries. From this plexus arise part of the spermatic, the inferior mesenteric, and the hypogastric plexuses; it also distributes filaments to the inferior vena cava.

The **inferior mesenteric plexus** (*plexus mesentericus inferior*) is derived chiefly from the aortic plexus. It surrounds the inferior mesenteric artery, and divides into a number of secondary plexuses, which are distributed to all the parts supplied by the artery, viz., the **left colic** and **sigmoid plexuses**, which supply the descending and sigmoid parts of the colon; and the **superior hemorrhoidal plexus**, which supplies the rectum and joins in the pelvis with branches from the pelvic plexuses.

The Hypogastric Plexus (*Plexus Hypogastricus*) (Fig. 838).

The **hypogastric plexus** is situated in front of the last lumbar vertebra and the promontory of the sacrum, between the two common iliac arteries, and is formed by the union of numerous filaments, which descend on either side from the aortic plexus, and from the lumbar ganglia; it divides, below, into two lateral portions which are named the **pelvic plexuses**.

The Pelvic Plexuses (Fig. 838).—The pelvic plexuses supply the viscera of the pelvic cavity, and are situated at the sides of the rectum in the male, and at the sides of the rectum and vagina in the female. They are formed on either side by a continuation of the hypogastric plexus, by the sacral sympathetic efferent fibers

from the second, third, and fourth sacral nerves, and by a few filaments from the first two sacral ganglia. At the points of junction of these nerves small ganglia are found. From these plexuses numerous branches are distributed to the viscera of the pelvis. They accompany the branches of the hypogastric artery.

The **Middle Hemorrhoidal Plexus** (*plexus hæmorrhoidalis medius*) arises from the upper part of the pelvic plexus. It supplies the rectum, and joins with branches of the superior hemorrhoidal plexus.

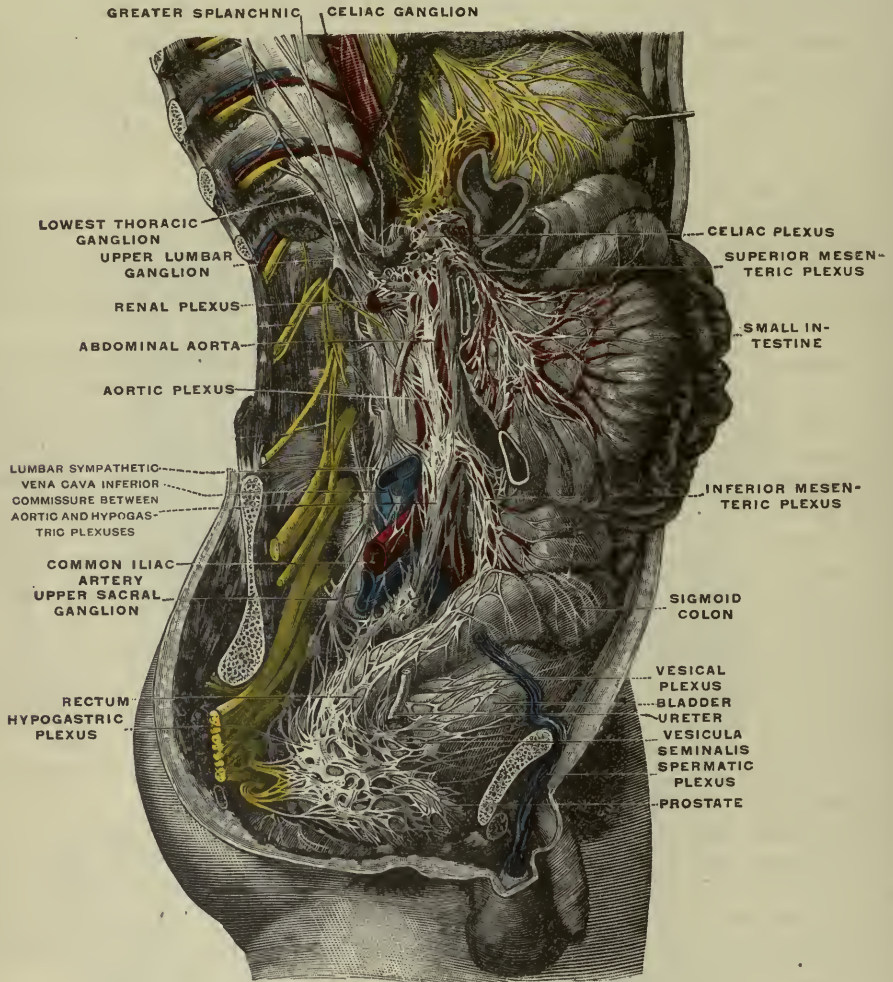


FIG. 849.—Lower half of right sympathetic cord. (Testut after Hirschfeld.)

The **Vesical Plexus** (*plexus vesicalis*) arises from the forepart of the pelvic plexus. The nerves composing it are numerous, and contain a large proportion of spinal nerve fibers. They accompany the vesical arteries, and are distributed to the sides and fundus of the bladder. Numerous filaments also pass to the vesiculæ seminales and ductus deferentes; those accompanying the ductus deferens join, on the spermatic cord, with branches from the spermatic plexus.

The **Prostatic Plexus** (*plexus prostaticus*) is continued from the lower part of the pelvic plexus. The nerves composing it are of large size. They are distributed to the prostate vesiculæ seminales and the corpora cavernosa of the penis and urethra. The nerves supplying the corpora cavernosa consist of two sets, the

lesser and greater cavernous nerves, which arise from the forepart of the prostatic plexus, and, after joining with branches from the pudendal nerve, pass forward beneath the pubic arch.

The **lesser cavernous nerves** (*nn. cavernosi penis minores; small cavernous nerves*) perforate the fibrous covering of the penis, near its root.

The **greater cavernous nerve** (*n. cavernosus penis major; large cavernous plexus*) passes forward along the dorsum of the penis, joins with the dorsal nerve of the penis, and is distributed to the corpora cavernosa.

The **Vaginal Plexus** arises from the lower part of the pelvic plexus. It is distributed to the walls of the vagina, to the erectile tissue of the vestibule, and to the clitoris. The nerves composing this plexus contain, like the vesical, a large proportion of spinal nerve fibers.

The **Uterine Plexus** accompanies the uterine artery to the side of the uterus, between the layers of the broad ligament; it communicates with the ovarian plexus.

BIBLIOGRAPHY.

- BARKER, L. F.: The Nervous System and its Constituent Neurons, 1901.
HERRICK, C. J.: An Introduction to Neurology, 1915.
HUBER, G. C.: Lectures on the Sympathetic Nervous System, Jour. Comp. Neur., 1897, vii, 73-145.
RAMÓN Y CAJAL, S.: Histologie du Système Nerveux, Paris, 1909.
SHERRINGTON, C. S.: The Integrative Action of the Nervous System, 1906.
STREETER, G. L.: The Development of the Nervous System, Keibel and Mall, Manual of Human Embryology, 1912.

THE ORGANS OF THE SENSES AND THE COMMON INTEGUMENT.

THE organs of the senses may be divided into (a) those of the special senses of taste, smell, sight, and hearing, and (b) those associated with the general sensations of heat, cold, pain, pressure, etc.

THE PERIPHERAL ORGANS OF THE SPECIAL SENSES.

THE ORGAN OF TASTE (ORGANON GUSTUS).

The peripheral gustatory or taste organs consist of certain modified epithelial cells arranged in flask-shaped groups termed **gustatory calyculi** (*taste-buds*), which are found on the tongue and adjacent parts. They occupy nests in the stratified epithelium, and are present in large numbers on the sides of the papillæ vallatæ (Fig. 850), and to a less extent on their opposed walls. They are also found on the

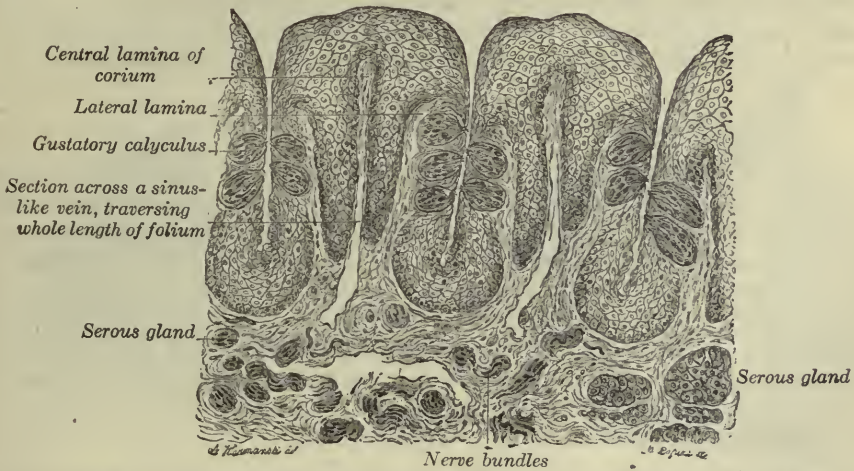

FIG. 850.—Vertical section of papilla foliata of the rabbit, crossing the folia. (Ranvier.)

fungiform papillæ over the back part and sides of the tongue, and in the general epithelial covering of the same areas. They are very plentiful over the fimbriæ linguæ, and are also present on the under surface of the soft palate, and on the posterior surface of the epiglottis.

Structure.—Each taste bud is flask-like in shape (Fig. 851), its broad base resting on the corium, and its neck opening by an orifice, the **gustatory pore**, between the cells of the epithelium. The bud is formed by two kinds of cells: supporting cells and gustatory cells. The **supporting cells** are mostly arranged like the staves of a cask, and form an outer envelope for the bud. Some, however, are found in the interior of the bud between the gustatory cells. The **gustatory cells** occupy the central portion of the bud; they are spindle-shaped, and each possesses a large spherical

nucleus near the middle of the cell. The peripheral end of the cell terminates at the gustatory pore in a fine hair-like filament, the **gustatory hair**. The central process passes toward the deep extremity of the bud, and there ends in single or bifurcated varicosities. The nerve fibrils after losing their medullary sheaths enter the taste bud, and end in fine extremities between the gustatory cells; other nerve fibrils ramify between the supporting cells and terminate in fine extremities; these, however, are believed to be nerves of ordinary sensation and not gustatory.

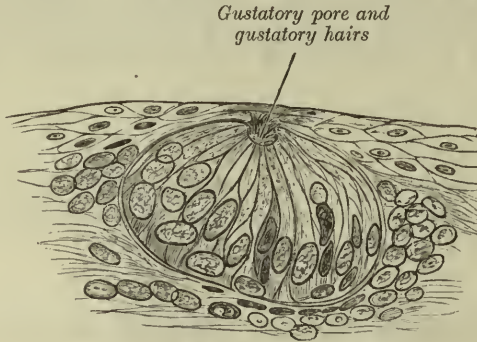


FIG. 851.—Taste-bud, highly magnified.

Nerves of Taste.—The chorda tympani nerve, derived from the sensory root of the facial, is the nerve of taste for the anterior two-thirds of the tongue; the nerve for the posterior third is the glossopharyngeal.

THE ORGAN OF SMELL (*ORGANON OLFACTORIUS*; THE NOSE).

The peripheral olfactory organ or organ of smell consists of two parts: an outer, the **external nose**, which projects from the center of the face; and an internal, the **nasal cavity**, which is divided by a septum into right and left nasal chambers.

The External Nose (*Nasus Externus*; Outer Nose).

The **external nose** is pyramidal in form, and its upper angle or **root** is connected directly with the forehead; its free angle is termed the **apex**. Its **base** is perforated by two elliptical orifices, the **nares**, separated from each other by an antero-posterior septum, the **columna**. The margins of the nares are provided with a number of stiff hairs, or **vibrissæ**, which arrest the passage of foreign substances carried with the current of air intended for respiration. The lateral surfaces of the nose form, by their union in the middle line, the **dorsum nasi**, the direction of which varies considerably in different individuals; the upper part of the dorsum is supported by the nasal bones, and is named the **bridge**. The lateral surface ends below in a rounded eminence, the **ala nasi**.

Structure.—The frame-work of the external nose is composed of bones and cartilages; it is covered by the integument, and lined by mucous membrane.

The **bony frame-work** occupies the upper part of the organ; it consists of the nasal bones, and the frontal processes of the maxillæ.

The **cartilaginous frame-work** (*cartilaginee nasi*) consists of five large pieces, viz., the **cartilage of the septum**, the **two lateral** and the **two greater alar cartilages**, and several smaller pieces, the **lesser alar cartilages** (Figs. 852, 853, 854). The various cartilages are connected to each other and to the bones by a tough fibrous membrane.

The **cartilage of the septum** (*cartilago septi nasi*) is somewhat quadrilateral in form, thicker at its margins than at its center, and completes the separation between the nasal cavities in front. Its anterior margin, thickest above, is connected with the nasal bones, and is continuous with the anterior margins of the lateral cartilages; below, it is connected to the medial crura of the greater alar cartilages by fibrous tissue. Its posterior margin is connected with the perpendicular plate of the ethmoid; its inferior margin with the vomer and the palatine processes of the maxillæ.

It may be prolonged backward (especially in children) as a narrow process, the **sphenoidal process**, for some distance between the vomer and perpendicular plate of the ethmoid. The septal cartilage does not reach as far as the lowest part of the nasal septum. This is formed by the medial crura of the greater alar cartilages and by the skin; it is freely movable, and hence is termed the **septum mobile nasi**.

The **lateral cartilage** (*cartilago nasi lateralis*; *upper lateral cartilage*) is situated below the inferior margin of the nasal bone, and is flattened, and triangular in shape. Its anterior margin is thicker than the posterior, and is continuous above with the cartilage of the septum, but separated from it below by a narrow fissure; its superior margin is attached to the nasal bone and the frontal process of the maxilla; its inferior margin is connected by fibrous tissue with the greater alar cartilage.

The **greater alar cartilage** (*cartilago alaris major*; *lower lateral cartilage*) is a thin, flexible plate, situated immediately below the preceding, and bent upon itself in such a manner as to form the medial and lateral walls of the naris of its own side. The portion which forms the **medial wall** (*crus mediale*) is loosely connected with the corresponding portion of the opposite cartilage, the two forming, together with the thickened integument and subjacent tissue, the **septum mobile nasi**. The part which forms the **lateral wall** (*crus laterale*) is curved to correspond with the ala of the nose; it is oval and flattened, narrow behind, where it is connected with the frontal process of the maxilla by a tough fibrous membrane, in which are found three or four small cartilaginous plates, the **lesser alar cartilages** (*cartilagine alares minores*; *sesamoid cartilages*). Above, it is connected by fibrous tissue to the lateral cartilage and front part of the cartilage of the septum; below, it falls short of the margin of the naris, the ala being completed by fatty and fibrous tissue covered by skin. In front, the greater alar cartilages are separated by a notch which corresponds with the apex of the nose.

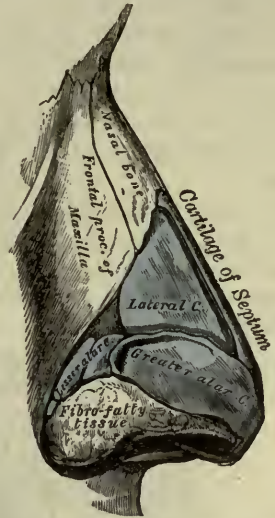

FIG. 852.—Cartilages of the nose. Side view.

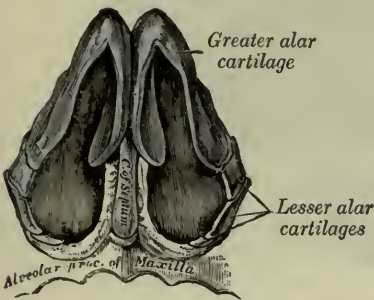


FIG. 853.—Cartilages of the nose, seen from below.

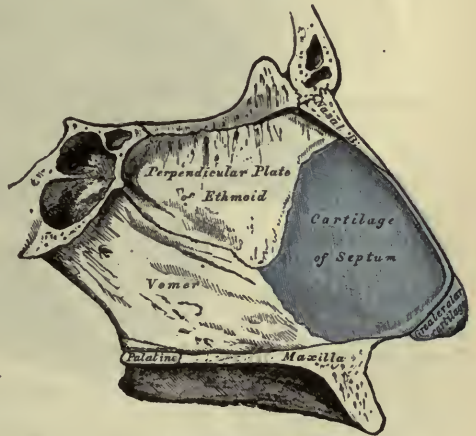


FIG. 854.—Bones and cartilages of septum of nose. Right side.

The **muscles** acting on the external nose have been described in the section on Myology.

The **integument** of the dorsum and sides of the nose is thin, and loosely connected with the subjacent parts; but over the tip and alæ it is thicker and more firmly adherent, and is furnished with a large number of sebaceous follicles, the orifices of which are usually very distinct.

The **arteries** of the external nose are the alar and septal branches of the external maxillary, which supply the alæ and septum; the dorsum and sides being supplied from the dorsal nasal branch of the ophthalmic and the infraorbital branch of the internal maxillary. The **veins** end in the anterior facial and ophthalmic veins.

The **nerves** for the muscles of the nose are derived from the facial, while the skin receives branches from the infratrochlear and nasociliary branches of the ophthalmic, and from the infra-orbital of the maxillary.

The Nasal Cavity (*Cavum Nasi*; *Nasal Fossa*).

The nasal chambers are situated one on either side of the median plane. They open in front through the nares, and communicate behind through the choanæ with the nasal part of the pharynx. The **nares** are somewhat pear-shaped apertures, each measuring about 2.5 cm. antero-posteriorly and 1.25 cm. transversely at its widest part. The **choanæ** are two oval openings each measuring 2.5 cm. in the vertical, and 1.25 cm. in the transverse direction in a well-developed adult skull.

For the description of the bony boundaries of the nasal cavities, see pages 194 and 195.

Inside the aperture of the nostril is a slight dilatation, the **vestibule**, bounded laterally by the ala and lateral crus of the greater alar cartilage, and medially by the medial crus of the same cartilage. It is lined by skin containing hairs and sebaceous glands, and extends as a small recess toward the apex of the nose. Each nasal cavity, above and behind the vestibule, is divided into two parts: an **olfactory region**, consisting of the superior nasal concha and the opposed part of the septum, and a **respiratory region**, which comprises the rest of the cavity.

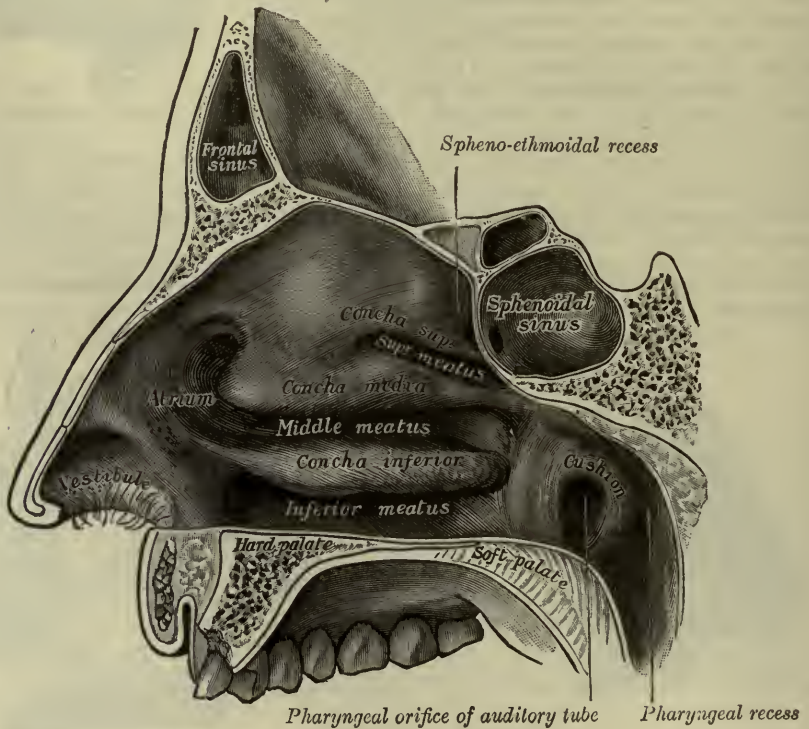


FIG. 855.—Lateral wall of nasal cavity.

Lateral Wall (Figs. 855, 856).—On the lateral wall are the **superior, middle, and inferior nasal conchæ**, and below and lateral to each concha is the corresponding nasal passage or meatus. Above the superior concha is a narrow recess, the **sphenoethmoidal recess**, into which the sphenoidal sinus opens. The **superior meatus** is a short oblique passage extending about half-way along the upper border of the middle concha; the posterior ethmoidal cells open into the front part of this meatus. The **middle meatus** is below and lateral to the middle concha, and is continued anteriorly into a shallow depression, situated above the vestibule and named the **atrium** of the middle meatus. On raising or removing the middle concha

the lateral wall of this meatus is fully displayed. On it is a rounded elevation, the **bullae ethmoidalis**, and below and in front of this is a curved cleft, the **hiatus semilunaris**.

The **bullae ethmoidalis** is caused by the bulging of the middle ethmoidal cells which open on or immediately above it, and the size of the bulla varies with that of its contained cells.

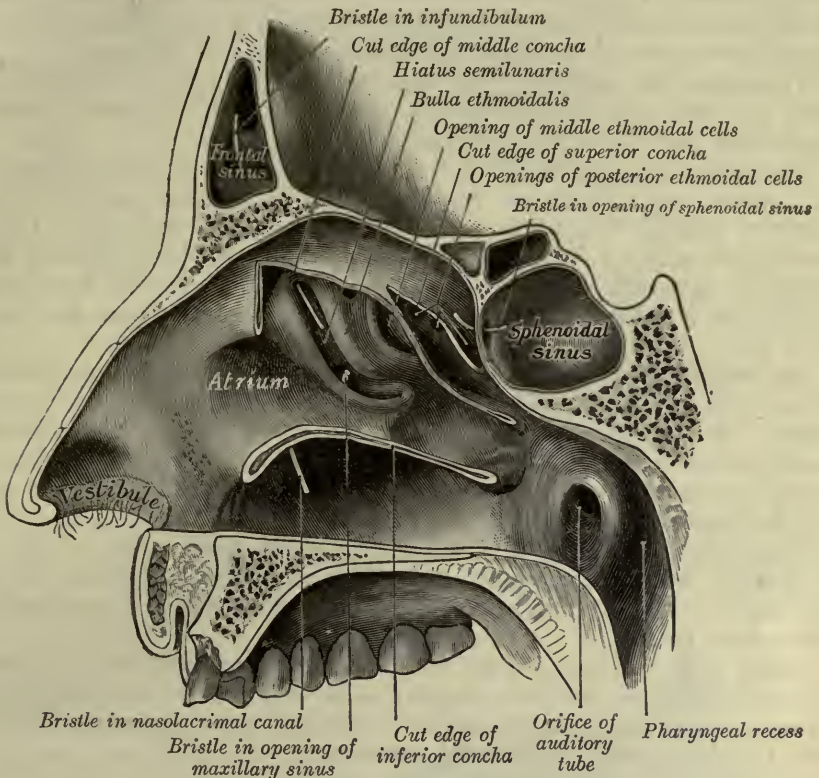


FIG. 856.—Lateral wall of nasal cavity; the three nasal conchæ have been removed.

The **hiatus semilunaris** is bounded inferiorly by the sharp concave margin of the uncinatè process of the ethmoid bone, and leads into a curved channel, the **infundibulum**, bounded above by the **bullae ethmoidalis** and below by the lateral surface of the uncinatè process of the ethmoid. The anterior ethmoidal cells open into the front part of the infundibulum, and this in slightly over 50 per cent. of subjects is directly continuous with the frontonasal duct or passage leading from the frontal air sinus; but when the anterior end of the uncinatè process fuses with the front part of the bulla, this continuity is interrupted and the frontonasal duct then opens directly into the anterior end of the middle meatus.

Below the **bullae ethmoidalis**, and partly hidden by the inferior end of the uncinatè process, is the **ostium maxillare**, or opening from the maxillary sinus; in a frontal section this opening is seen to be placed near the roof of the sinus. An accessory opening from the sinus is frequently present below the posterior end of the middle nasal concha. The **inferior meatus** is below and lateral to the inferior nasal concha; the nasolacrimal duct opens into this meatus under cover of the anterior part of the inferior concha.

Medial Wall (Fig. 854).—The medial wall or septum is frequently more or less deflected from the median plane, thus lessening the size of one nasal cavity

and increasing that of the other; ridges or spurs of bone growing into one or other cavity from the septum are also sometimes present. Immediately over the incisive canal at the lower edge of the cartilage of the septum a depression, the **nasopalatine recess**, is seen. In the septum close to this recess a minute orifice may be discerned; it leads backward into a blind pouch, the rudimentary **vomeronasal organ of Jacobson**, which is supported by a strip of cartilage, the **vomeronasal cartilage**. This organ is well-developed in many of the lower animals, where it apparently plays a part in the sense of smell, since it is supplied by twigs of the olfactory nerve and lined by epithelium similar to that in the olfactory region of the nose.

The **roof** of the nasal cavity is narrow from side to side, except at its posterior part, and may be divided, from behind forward, into sphenoidal, ethmoidal, and frontonasal parts, after the bones which form it.

The **floor** is concave from side to side and almost horizontal antero-posteriorly; its anterior three-fourths are formed by the palatine process of the maxilla, its posterior fourth by the horizontal process of the palatine bone. In its antero-medial part, directly over the incisive foramen, a small depression, the **nasopalatine recess**, is sometimes seen; it points downward and forward and occupies the position of a canal which connected the nasal with the buccal cavity in early fetal life.

The Mucous Membrane (*membrana mucosa nasi*).—The nasal mucous membrane lines the nasal cavities, and is intimately adherent to the periosteum or perichondrium. It is continuous with the skin through the nares, and with the mucous membrane of the nasal part of the pharynx through the choanæ. From the nasal cavity its continuity with the conjunctiva may be traced, through the nasolacrimal and lacrimal ducts; and with the frontal, ethmoidal, sphenoidal, and maxillary sinuses, through the several openings in the meatuses. The mucous membrane is thickest, and most vascular, over the nasal conchæ. It is also thick over the septum; but it is very thin in the meatuses on the floor of the nasal cavities, and in the various sinuses.

Owing to the thickness of the greater part of this membrane, the nasal cavities are much narrower, and the middle and inferior nasal conchæ appear larger and more prominent than in the skeleton; also the various apertures communicating with the meatuses are considerably narrowed.

Structure of the Mucous Membrane (Fig. 857).—The epithelium covering the mucous membrane differs in its character according to the functions of the part of the nose in which it is found. In the **respiratory region** it is columnar and ciliated. Interspersed among the columnar cells are goblet or mucin cells, while between their bases are found smaller pyramidal cells. Beneath the epithelium and its basement membrane is a fibrous layer infiltrated with lymph corpuscles, so as to form in many parts a diffuse adenoid tissue, and under this a nearly continuous layer of small and larger glands, some mucous and some serous, the ducts of which open upon the surface. In the **olfactory region** the mucous membrane is yellowish in color and the epithelial cells are columnar and non-ciliated; they are of two kinds, supporting cells and olfactory cells. The **supporting cells** contain oval nuclei, which are situated in the deeper parts of the cells and constitute the zone of oval nuclei; the superficial part of each cell is columnar, and contains granules of yellow pigment, while its deep part is prolonged as a delicate process which ramifies and communicates with similar processes from neighboring cells, so as to form a net-work in the mucous membrane. Lying between the deep processes of the supporting cells are a number of bipolar nerve cells, the **olfactory cells**, each consisting of a small amount of granular protoplasm with a large spherical nucleus, and possessing two processes—a superficial one which runs between the columnar epithelial cells, and projects on the surface of the mucous membrane as a fine, hair-like process, the **olfactory hair**; the other or deep process runs inward, is frequently beaded, and is continued as the axon of an olfactory nerve fiber. Beneath the epithelium, and extending through the thickness of the mucous membrane, is a layer of tubular, often branched, glands, the **glands of Bowman**, identical in structure with serous glands. The epithelial cells of the nose, fauces and respiratory passages play an important role in the maintenance of an equable temperature, by the moisture with which they keep the surface always slightly lubricated.

Vessels and Nerves.—The **arteries** of the nasal cavities are the anterior and posterior ethmoidal branches of the ophthalmic, which supply the ethmoidal cells, frontal sinuses, and roof

of the nose; the sphenopalatine branch of the internal maxillary, which supplies the mucous membrane covering the conchæ, the meatuses and septum; the septal branch of the superior labial of the external maxillary; the infraorbital and alveolar branches of the internal maxillary, which supply the lining membrane of the maxillary sinus; and the pharyngeal branch of the same artery, distributed to the sphenoidal sinus. The ramifications of these vessels form a close plexiform net-work, beneath and in the substance of the mucous membrane.

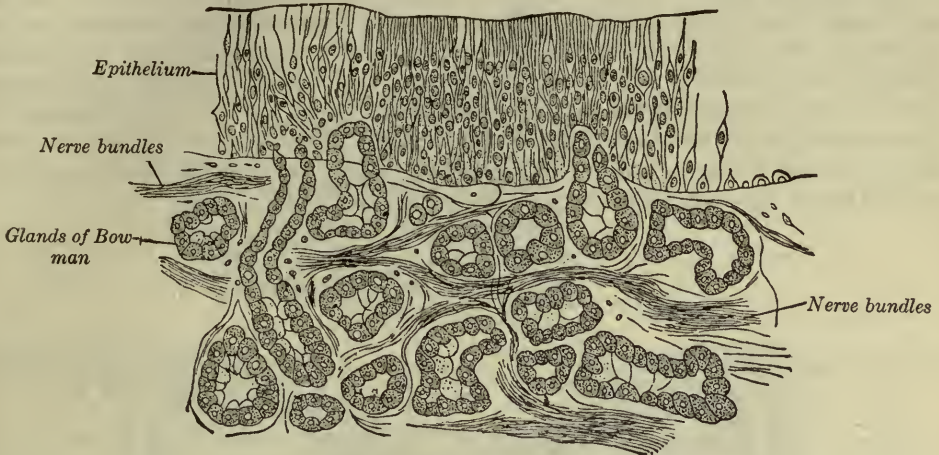

FIG. 857.—Section of the olfactory mucous membrane. (Cadiat.)

The **veins** form a close cavernous plexus beneath the mucous membrane. This plexus is especially well-marked over the lower part of the septum and over the middle and inferior conchæ. Some of the veins open into the sphenopalatine vein; others join the anterior facial vein; some accompany the ethmoidal arteries, and end in the ophthalmic veins; and, lastly, a few communicate with the veins on the orbital surface of the frontal lobe of the brain, through the foramina in the cribriform plate of the ethmoid bone; when the foramen cecum is patent it transmits a vein to the superior sagittal sinus.

The **lymphatics** have already been described (p. 695).

The **nerves** of ordinary sensation are: the nasociliary branch of the ophthalmic, filaments from the anterior alveolar branch of the maxillary, the nerve of the pterygoid canal, the nasopalatine, the anterior palatine, and nasal branches of the sphenopalatine ganglion.

The nasociliary branch of the ophthalmic distributes filaments to the forepart of the septum and lateral wall of the nasal cavity. Filaments from the anterior alveolar nerve supply the inferior meatus and inferior concha. The nerve of the pterygoid canal supplies the upper and back part of the septum, and superior concha; and the upper nasal branches from the sphenopalatine ganglion have a similar distribution. The nasopalatine nerve supplies the middle of the septum. The anterior palatine nerve supplies the lower nasal branches to the middle and inferior conchæ.

The **olfactory**, the special nerve of the sense of smell, is distributed to the olfactory region. Its fibers arise from the bipolar olfactory cells and are destitute of medullary sheaths. They unite in fasciculi which form a plexus beneath the mucous membrane and then ascend in grooves or canals in the ethmoid bone; they pass into the skull through the foramina in the cribriform plate of the ethmoid and enter the under surface of the olfactory bulb, in which they ramify and form synapses with the dendrites of the mitral cells (Fig. 772).

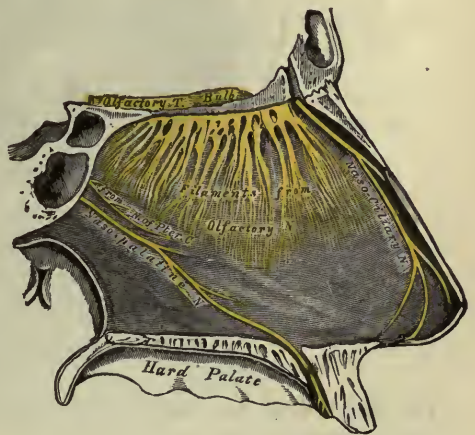


FIG. 858.—Nerves of septum of nose. Right side

The Accessory Sinuses of the Nose (Sinus Paranasales) (Figs. 855, 856, 859).

The accessory sinuses or air cells of the nose are the **frontal, ethmoidal, sphenoidal, and maxillary**; they vary in size and form in different individuals, and are lined by ciliated mucous membrane directly continuous with that of the nasal cavities.

The **Frontal Sinuses** (*sinus frontales*), situated behind the superciliary arches, are rarely symmetrical, and the septum between them frequently deviates to one or other side of the middle line. Their average measurements are as follows: height, 3 cm.; breadth, 2.5 cm.; depth from before backward, 2.5 cm. Each opens into the anterior part of the corresponding middle meatus of the nose through the frontonasal duct which traverses the anterior part of the labyrinth of the ethmoid. Absent at birth, they are generally fairly well developed between the seventh and eighth years, but only reach their full size after puberty.

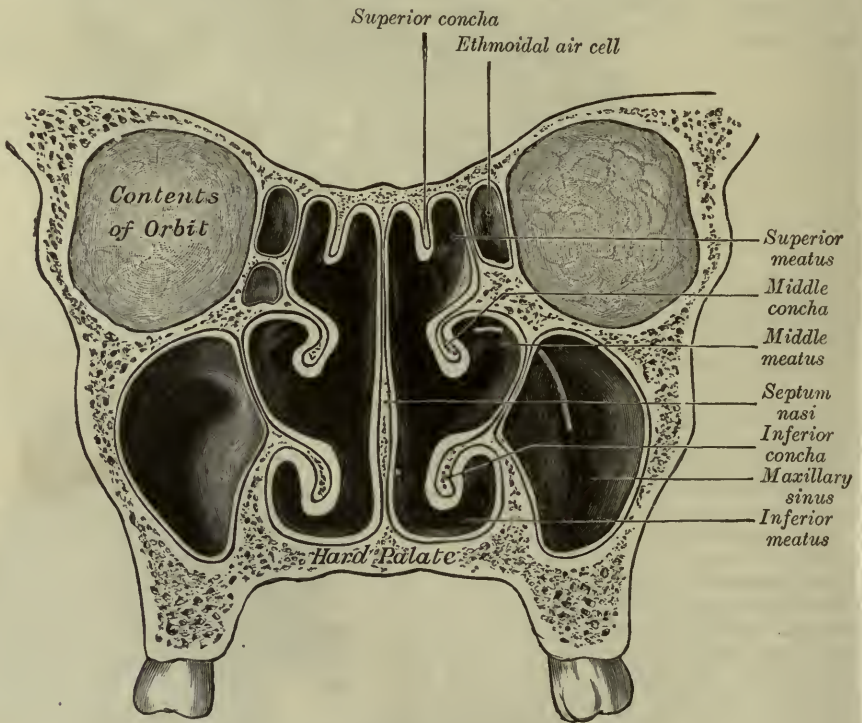


FIG. 859.—Coronal section of nasal cavities.

The **Ethmoidal Air Cells** (*cellulae ethmoidales*) consist of numerous thin-walled cavities situated in the ethmoidal labyrinth and completed by the frontal, maxilla, lacrimal, sphenoidal, and palatine. They lie between the upper parts of the nasal cavities and the orbits, and are separated from these cavities by thin bony laminae. On either side they are arranged in three groups, **anterior, middle, and posterior**. The anterior and middle groups open into the middle meatus of the nose, the former by way of the infundibulum, the latter on or above the bulla ethmoidalis. The posterior cells open into the superior meatus under cover of the superior nasal concha; sometimes one or more opens into the sphenoidal sinus. The ethmoidal cells begin to develop during fetal life.

The **Sphenoidal Sinuses** (*sinus sphenoidales*) contained within the body of the sphenoid vary in size and shape; owing to the lateral displacement of the inter-

vening septum they are rarely symmetrical. The following are their average measurements: vertical height, 2.2 cm.; transverse breadth, 2 cm.; antero-posterior depth, 2.2 cm. When exceptionally large they may extend into the roots of the

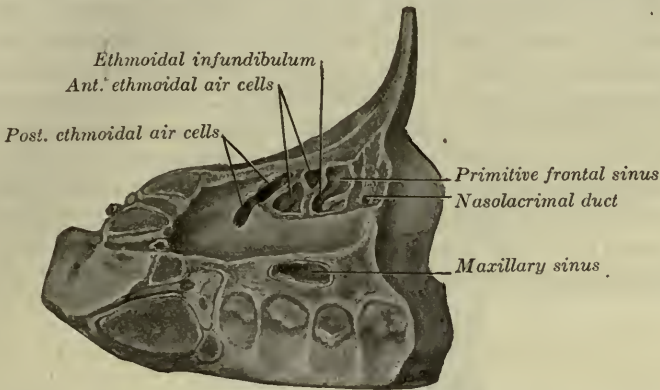


FIG. 860.¹—Specimen from a child eight days old. By sagittal sections removing the lateral portion of frontal bone, lamina papyracea of ethmoid, and lateral portion of maxilla—the sinus maxillaris, cellulae ethmoidales, anterior and posterior, infundibulum ethmoidale, and the primitive sinus frontalis are brought into view. (Davis.)

pterygoid processes or great wings, and may invade the basilar part of the occipital bone. Each sinus communicates with the sphenothmoidal recess by means of an aperture in the upper part of its anterior wall. They are present as minute cavities at birth, but their main development takes place after puberty.

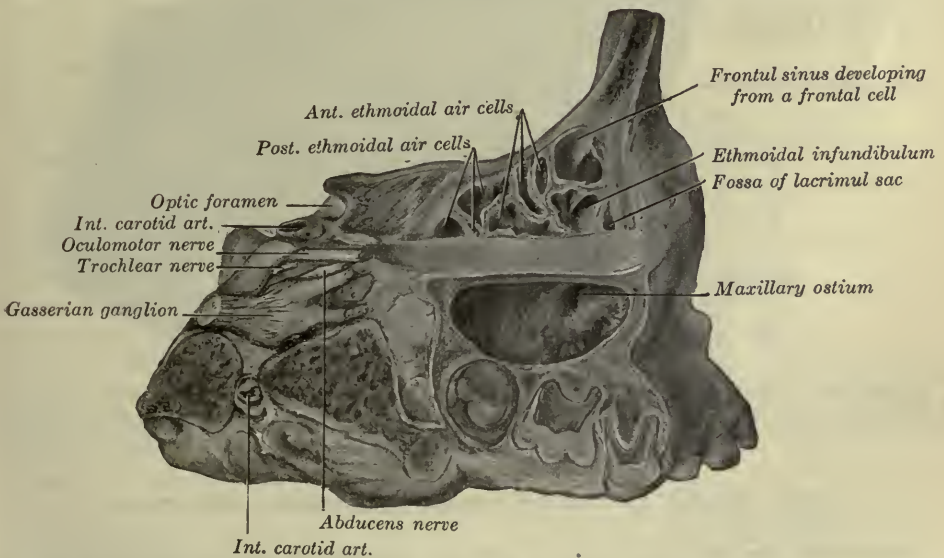


FIG. 861.—Specimen from a child one year, four months, and seven days old. Lateral view of frontal, ethmoidal, and maxillary sinus areas. (Davis.)

The **Maxillary Sinus** (*sinus maxillaris*; *antrum of Highmore*), the largest of the accessory sinuses of the nose, is a pyramidal cavity in the body of the maxilla. Its base is formed by the lateral wall of the nasal cavity, and its apex extends into the zygomatic process. Its roof or orbital wall is frequently ridged by the infra-

¹ Davis, W. B. *Nasal Accessory Sinuses in Man*, 1914.

orbital canal, while its floor is formed by the alveolar process and is usually $\frac{1}{2}$ to 10 mm. below the level of the floor of the nose; projecting into the floor are several conical elevations corresponding with the roots of the first and second molar teeth, and in some cases the floor is perforated by one or more of these roots. The size of the sinus varies in different skulls, and even on the two sides of the same skull. The adult capacity varies from 9.5 c.c. to 20 c.c., average about 14.75 c.c. The following measurements are those of an average-sized sinus: vertical height opposite the first molar tooth, 3.75 cm.; transverse breadth, 2.5 cm.; antero-posterior depth, 3 cm. In the antero-superior part of its base is an opening through which it communicates with the lower part of the hiatus semilunaris; a second orifice is frequently seen in, or immediately behind, the hiatus. The maxillary sinus appears as a shallow groove on the medial surface of the bone about the fourth month of fetal life, but does not reach its full size until after the second dentition.¹ At birth it measures about 7 mm. in the dorso-ventral direction and at twenty months about 20 mm.²

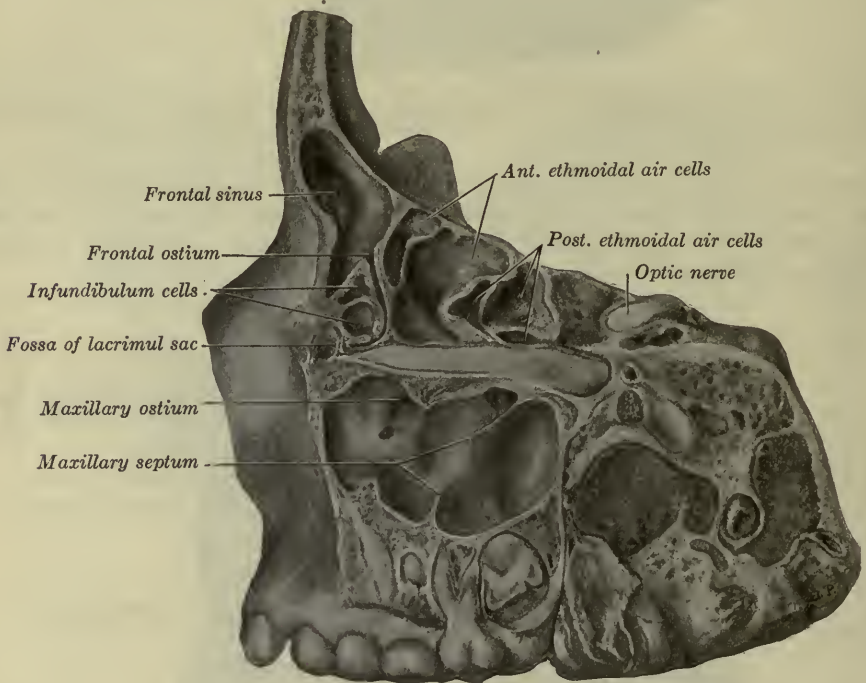


FIG. 862.—Specimen from a child eight years, eight months, and one day old. Lateral view of frontal, ethmoidal and maxillary sinus areas, the lateral portion of each having been removed by sagittal cuts. Note that the sinus frontalis developed directly from the infundibulum ethmoidale. Note also the incomplete septa in the sinus maxillaris. (Davis.)

THE ORGAN OF SIGHT (*ORGANON VISUS*; THE EYE).

The bulb of the eye (*bulbus oculi*; *eyeball*), or organ of sight, is contained in the cavity of the orbit, where it is protected from injury and moved by the ocular muscles. Associated with it are certain accessory structures, viz., the muscles, fasciæ, eyebrows, eyelids, conjunctiva, and lacrimal apparatus.

The bulb of the eye is imbedded in the fat of the orbit, but is separated from it by a thin membranous sac, the *fascia bulbi* (page 1024). It is composed of segments of two spheres of different sizes. The anterior segment is one of a small sphere;

¹ The various measurements of the accessory sinuses of the nose are based on those given by Aldren Turner in his *Accessory Sinuses of the Nose*.

² Schaeffer, J. P., *Am. Jour. Anat.*, 1910, x.

it is transparent, and forms about one-sixth of the bulb. It is more prominent than the posterior segment, which is one of a larger sphere, and is opaque, and forms about five-sixths of the bulb. The term **anterior pole** is applied to the central point of the anterior curvature of the bulb, and that of **posterior pole** to the central point of its posterior curvature; a line joining the two poles forms the **optic axis**. The axes of the two bulbs are nearly parallel, and therefore do not correspond to the

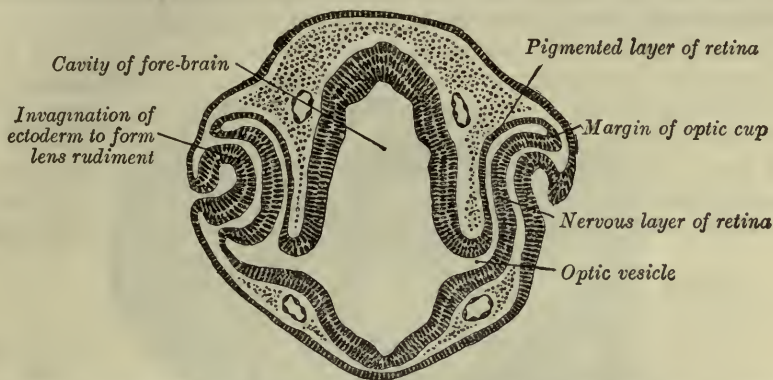


FIG. 863.—Transverse section of head of chick embryo of forty-eight hours' incubation. (Duval.)

axes of the orbits, which are directed forward and lateralward. The optic nerves follow the direction of the axes of the orbits, and are therefore not parallel; each enters its eyeball 3 mm. to the nasal side and a little below the level of the posterior pole. The bulb measures rather more in its transverse and antero-posterior diameters than in its vertical diameter, the former amounting to about 24 mm., the latter to about 23.5 mm.; in the female all three diameters are rather less than in the male; its antero-posterior diameter at birth is about 17.5 mm., and at puberty from 20 to 21 mm.

Development.—The eyes begin to develop as a pair of diverticula from the lateral aspects of the fore-brain. These diverticula make their appearance before the closure of the anterior end of the neural tube; after the closure of the tube they are known as the **optic vesicles**. They project toward the sides of the head, and the peripheral part of each expands to form a hollow bulb, while the proximal part remains narrow and constitutes the **optic stalk** (Figs. 863, 864). The ectoderm overlying the bulb becomes thickened, invaginated, and finally severed from the ectodermal covering of the head as a vesicle of cells, the **lens vesicle**, which constitutes the rudiment of the crystalline lens. The outer wall of the bulb becomes thickened and invaginated, and the bulb is thus converted into a cup, the **optic cup**, consisting of two strata of cells (Fig. 864). These two strata are continuous with each other at the cup margin, which ultimately overlaps the front of the lens and reaches as far forward as the future aperture of the pupil. The invagination is not

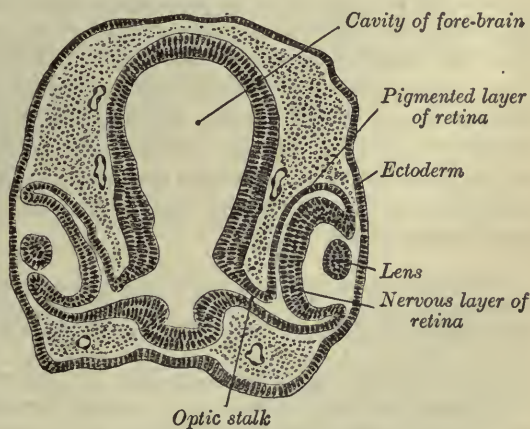


FIG. 864.—Transverse section of head of chick embryo of fifty-two hours' incubation. (Duval.)

limited to the outer wall of the bulb, but involves also its postero-inferior surface

and extends in the form of a groove for some distance along the optic stalk, so that, for a time, a gap or fissure, the **choroidal fissure**, exists in the lower part of the cup (Fig. 865). Through the groove and fissure the mesoderm extends into the optic stalk and cup, and in this mesoderm a bloodvessel is developed; during the seventh week the groove and fissure are closed and the vessel forms the central artery of the retina. Sometimes the choroidal fissure persists, and when this occurs the choroid and iris in the region of the fissure remain undeveloped, giving rise to the condition known as *coloboma* of the choroid or iris.

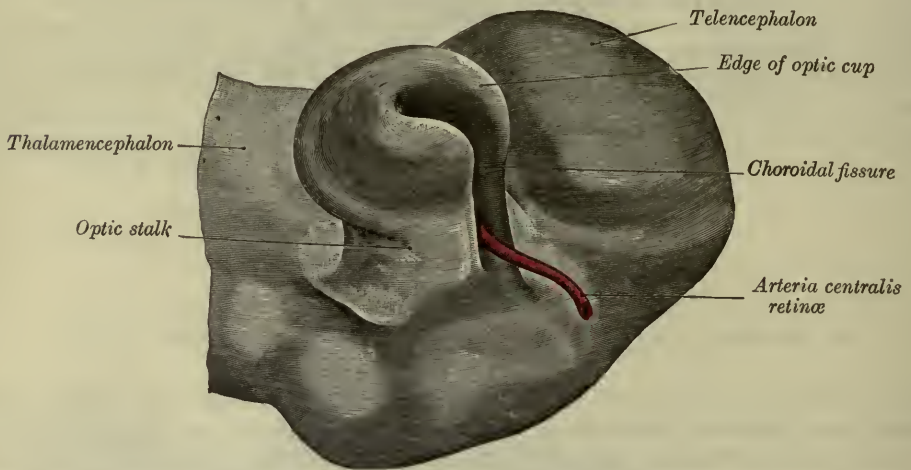


FIG. 865.—Optic cup and choroidal fissure seen from below, from a human embryo of about four weeks. (Kollmann.)

The **retina** is developed from the optic cup. The outer stratum of the cup persists as a single layer of cells which assume a columnar shape, acquire pigment, and form the pigmented layer of the retina; the pigment first appears in the cells near the edge of the cup. The cells of the inner stratum proliferate and form a layer of considerable thickness from which the nervous elements and the sustentacular fibers of the retina, together with a portion of the vitreous body, are developed. In that portion of the cup which overlaps the lens the inner stratum is not differentiated into nervous elements, but forms a layer of columnar cells which is applied to the pigmented layer, and these two strata form the **pars ciliaris** and **pars iridica retinae**.

The cells of the inner or retinal layer of the optic cup become differentiated into spongioblasts and germinal cells, and the latter by their subdivisions give rise to neuroblasts. From the spongioblasts the sustentacular fibers of Müller, the outer and inner limiting membranes, together with the groundwork of the molecular layers of the retina are formed. The neuroblasts become arranged to form the ganglionic and nuclear layers. The layer of rods and cones is first developed in the central part of the optic cup, and from there gradually extends toward the cup margin. All the layers of the retina are completed by the eighth month of fetal life.

The optic stalk is converted into the **optic nerve** by the obliteration of its cavity and the growth of nerve fibers into it. Most of these fibers are centripetal, and grow backward into the optic stalk from the nerve cells of the retina, but a few extend in the opposite direction and are derived from nerve cells in the brain. The fibers of the optic nerve receive their medullary sheaths about the tenth week after birth. The **optic chiasma** is formed by the meeting and partial decussation of the fibers of the two optic nerves. Behind the chiasma the fibers grow backward as the optic tracts to the thalami and mid-brain.

The **crystalline lens** is developed from the lens vesicle, which recedes within the

margin of the cup, and becomes separated from the overlying ectoderm by mesoderm. The cells forming the posterior wall of the vesicle lengthen and are converted into the lens fibers, which grow forward and fill up the cavity of the vesicle (Fig. 866). The cells forming the anterior wall retain their cellular character, and form the epithelium on the anterior surface of the adult lens. By the second month the lens is invested by a vascular mesodermal capsule, the **capsula vasculosa lentis**; the bloodvessels supplying the posterior part of this capsule are derived from the hyaloid artery; those for the anterior part from the anterior ciliary arteries; the portion of the capsule which covers the front of the lens is named the **pupillary membrane**. By the sixth month all the vessels of the capsule are atrophied except the hyaloid artery, which disappears during the ninth month; the position of this artery is indicated in the adult by the hyaloid canal, which reaches from the optic disk to the posterior surface of the lens. With the loss of its bloodvessels the capsula vasculosa lentis disappears, but sometimes the pupillary membrane persists at birth, giving rise to the condition termed *congenital atresia of the pupil*.

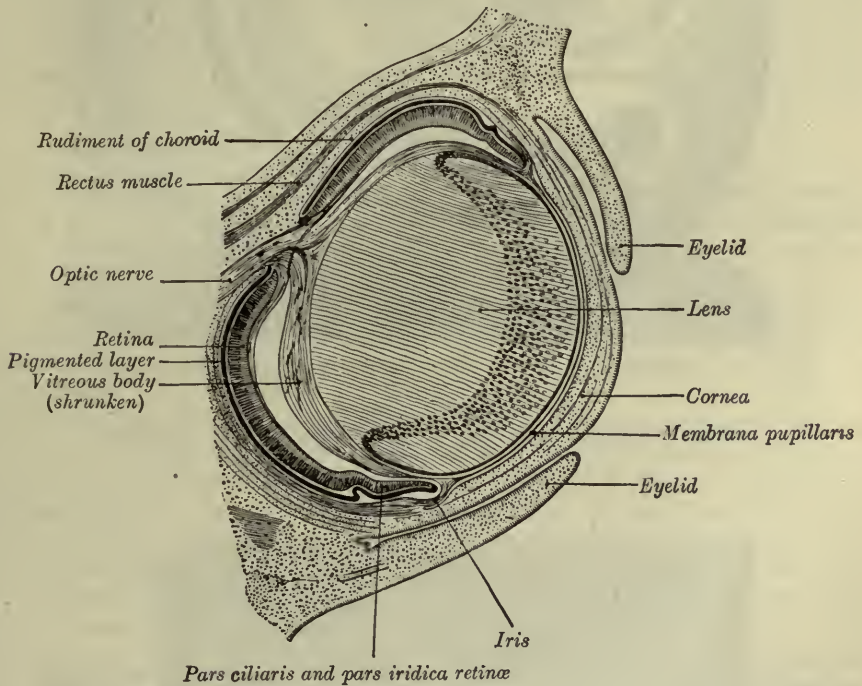


FIG. 866.—Horizontal section through the eye of an eighteen days' embryo rabbit. $\times 30$. (Kölliker.)

The **vitreous body** is developed between the lens and the optic cup. The lens rudiment and the optic vesicle are at first in contact with each other, but after the closure of the lens vesicle and the formation of the optic cup the former withdraws itself from the retinal layer of the cup; the two, however, remain connected by a network of delicate protoplasmic processes. This network, derived partly from the cells of the lens and partly from those of the retinal layer of the cup, constitutes the primitive vitreous body (Figs. 867, 868). At first these protoplasmic processes spring from the whole of the retinal layer of the cup, but later are limited to the ciliary region, where by a process of condensation they appear to form the zonula ciliaris. The mesoderm which enters the cup through the choroidal fissure and around the equator of the lens becomes intimately united with this reticular tissue, and contributes to form the vitreous body, which is therefore derived partly from the ectoderm and partly from the mesoderm.

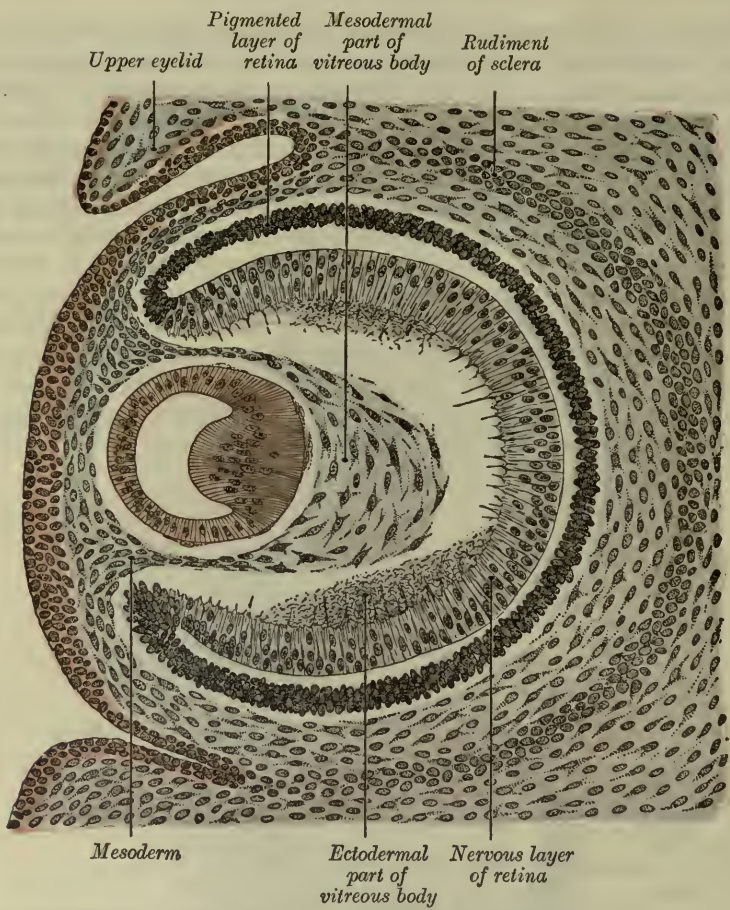


FIG. 867.—Sagittal section of eye of human embryo of six weeks. (Kollmann.)

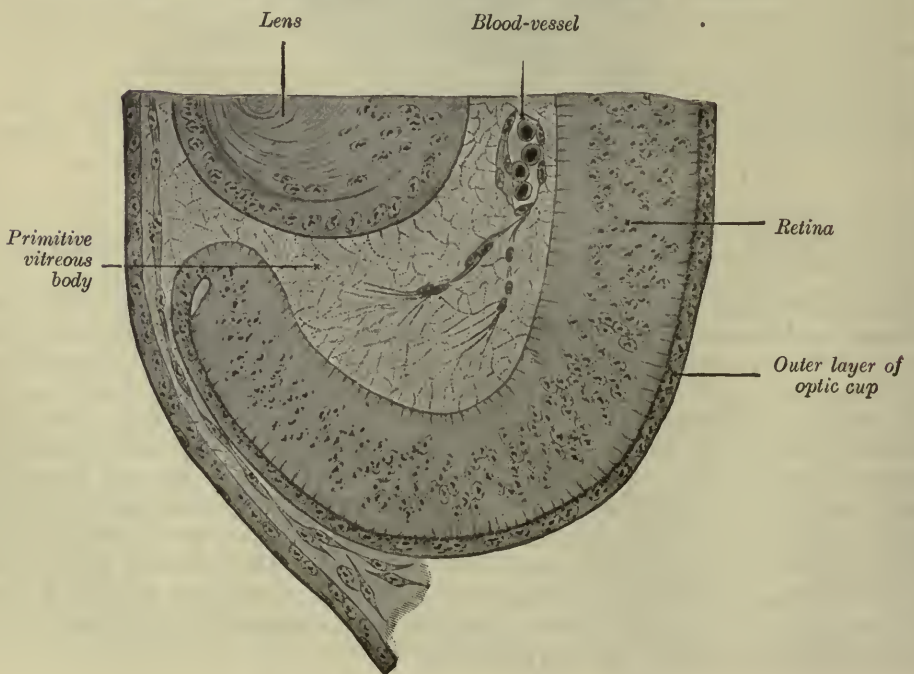


FIG. 868.—Section of developing eye of trout. (Szily.)

The anterior chamber of the eye appears as a cleft in the mesoderm separating the lens from the overlying ectoderm. The layer of mesoderm in front of the cleft forms the substantia propria of the cornea, that behind the cleft the stroma of the iris and the pupillary membrane. The fibers of the ciliary muscle are derived from the mesoderm, but those of the Sphincter and Dilatator pupillæ are of ectodermal origin, being developed from the cells of the pupillary part of the optic cup.

The sclera and choroid are derived from the mesoderm surrounding the optic cup.

The eyelids are formed as small cutaneous folds (Figs. 866, 867), which about the middle of the third month come together and unite in front of the cornea. They remain united until about the end of the sixth month.

The lacrimal sac and nasolacrimal duct result from a thickening of the ectoderm in the groove, *nasoöptic furrow*, between the lateral nasal and maxillary processes. This thickening forms a solid cord of cells which sinks into the mesoderm; during the third month the central cells of the cord break down, and a lumen, the nasolacrimal duct, is established. The lacrimal ducts arise as buds from the upper part of the cord of cells and secondarily establish openings (*puncta lacrimalia*) on the margins of the lids. The epithelium of the cornea and conjunctiva, and that which lines the ducts and alveoli of the lacrimal gland, are of ectodermal origin, as are also the eyelashes and the lining cells of the glands which open on the lid-margins.

The Tunics of the Eye (Fig. 869).

From without inward the three tunics are: (1) A fibrous tunic, consisting of the sclera behind and the cornea in front; (2) a vascular pigmented tunic, comprising, from behind forward, the choroid, ciliary body, and iris; and (3) a nervous tunic, the retina.

The Fibrous Tunic (*tunica fibrosa oculi*).—The sclera and cornea (Fig. 869) form the fibrous tunic of the bulb of the eye; the sclera is opaque, and constitutes the posterior five-sixths of the tunic; the cornea is transparent, and forms the anterior sixth.

The Sclera.—The sclera has received its name from its extreme density and hardness; it is a firm, unyielding membrane, serving to maintain the form of the bulb. It is much thicker behind than in front; the thickness of its posterior part is 1 mm. Its external surface is of white color, and is in contact with the inner surface of the fascia of the bulb; it is quite smooth, except at the points where the Recti and Obliqui are inserted into it; its anterior part is covered by the conjunctival membrane. Its inner surface is brown in color and marked by grooves, in which the ciliary nerves and vessels are lodged; it is separated from the outer surface of the choroid by an extensive lymph space (*spatium perichorioideale*) which is traversed by an exceedingly fine cellular tissue, the *lamina suprachorioidea*. Behind it is pierced by the optic nerve, and is continuous through the fibrous sheath of this nerve with the dura mater. Where the optic nerve passes through the sclera, the latter forms a thin cribriform lamina, the *lamina cribrosa scleræ*; the minute orifices in this lamina serve for the transmission of the nervous filaments, and the fibrous septa dividing them from one another are continuous with the membranous processes which separate the bundles of nerve fibers. One of these openings, larger than the rest, occupies the center of the lamina; it transmits the central artery and vein of the retina. Around the entrance of the optic nerve are numerous small apertures for the transmission of the ciliary vessels and nerves, and about midway between this entrance and the sclerocorneal junction are four or five large apertures for the transmission of veins (*venæ vorticosæ*). In front, the sclera is directly continuous with the cornea, the line of union being termed the *sclerocorneal junction*. In the inner part of the sclera close to this junction is a circular canal, the *sinus venosus scleræ* (*canal of Schlemm*). In a meridional section of this

region this sinus presents the appearance of a cleft, the outer wall of which consists of the firm tissue of the sclera, while its inner wall is formed by a triangular mass of trabecular tissue (Fig. 870); the apex of the mass is directed forward and is continuous with the posterior elastic lamina of the cornea. The sinus is lined by endothelium and communicates externally with the anterior ciliary veins.

The aqueous humor drains into the scleral sinuses by passage through the "pectinate villi" which are analogous in structure and function to the arachnoid villi of the cerebral meninges.¹

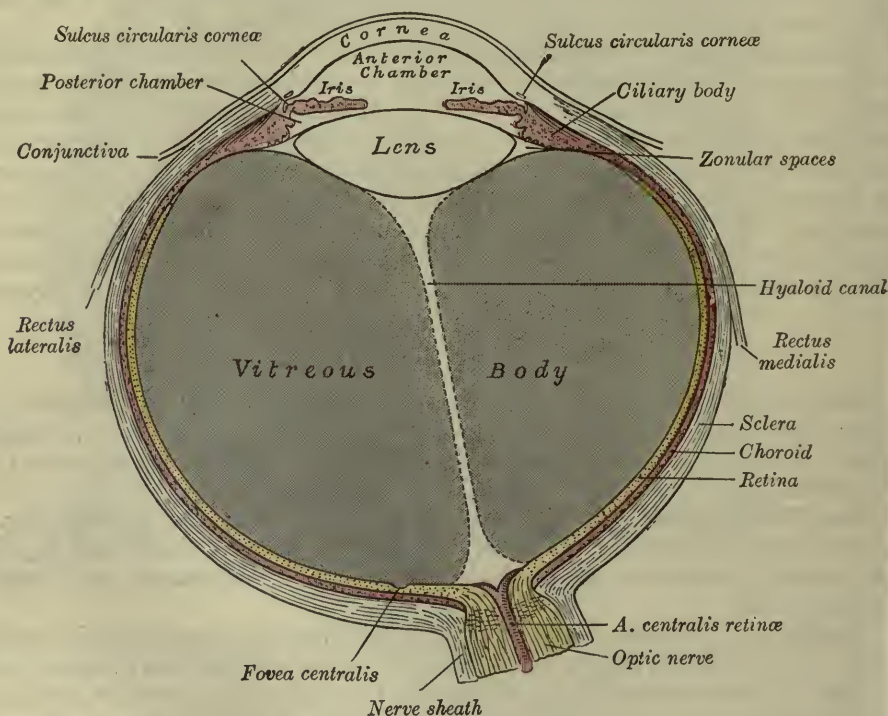


FIG. 869.—Horizontal section of the eyeball.

Structure.—The sclera is formed of white fibrous tissue intermixed with fine elastic fibers; flattened connective-tissue corpuscles, some of which are pigmented, are contained in cell spaces between the fibers. The fibers are aggregated into bundles, which are arranged chiefly in a longitudinal direction. Its vessels are not numerous, the capillaries being of small size, uniting at long and wide intervals. Its nerves are derived from the ciliary nerves, but their exact mode of ending is not known.

The Cornea.—The cornea is the projecting transparent part of the external tunic, and forms the anterior sixth of the surface of the bulb. It is almost circular in outline, occasionally a little broader in the transverse than in the vertical direction. It is convex anteriorly and projects like a dome in front of the sclera. Its degree of curvature varies in different individuals, and in the same individual at different periods of life, being more pronounced in youth than in advanced life. The cornea is dense and of uniform thickness throughout; its posterior surface is perfectly circular in outline, and exceeds the anterior surface slightly in diameter. Immediately in front of the sclero-corneal junction the cornea bulges inward as a thickened rim, and behind this there is a distinct furrow between the attachment of the iris and the sclero-corneal junction. This furrow has been named by Arthur Thomson²

¹ Wegefarth, Jour. Med. Research, September, 1914.

² Atlas of the Eye, Clarendon Press, Oxford, 1912.

the *sulcus circularis corneæ*; it is bounded externally by the trabecular tissue already described as forming the inner wall of the sinus venosus scleræ. Between this tissue and the anterior surface of the attached margin of the iris is an angular recess, named the *iridial angle* or *filtration angle* of the eye (Fig. 870). Immediately outside the filtration angle is a projecting rim of scleral tissue which appears in a meridional section as a small triangular area, termed the *scleral spur*. Its base is continuous with the inner surface of the sclera immediately to the outer side of the filtration angle and its apex is directed forward and inward. To the anterior sloping margin of this spur are attached the bundles of trabecular tissue just referred to; from its posterior margin the meridional fibers of the Ciliaris muscle arise.

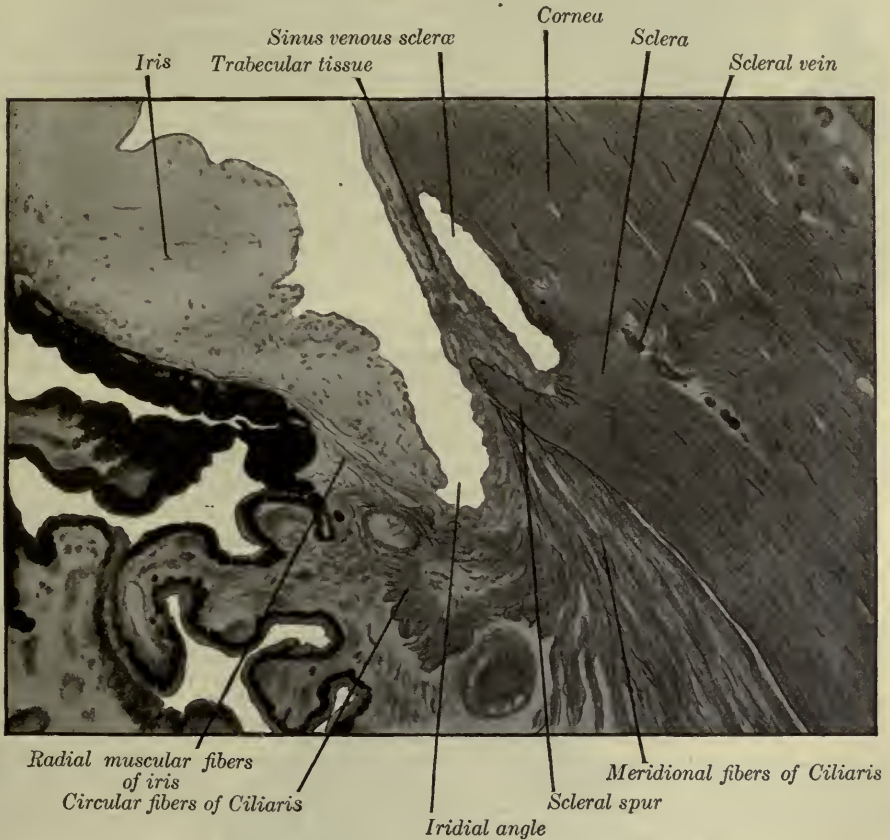


FIG. 870.—Enlarged general view of the iridial angle. (Arthur Thomson.)

Structure (Fig. 871).—The cornea consists from before backward of four layers, viz.: (1) the *corneal epithelium*, continuous with that of the conjunctiva; (2) the *substantia propria*; (3) the *posterior elastic lamina*; and (4) the *endothelium* of the anterior chamber.

The *corneal epithelium* (*epithelium corneæ*; *anterior layer*) covers the front of the cornea and consists of several layers of cells. The cells of the deepest layer are columnar; then follow two or three layers of polyhedral cells, the majority of which are prickle cells similar to those found in the stratum mucosum of the cuticle. Lastly, there are three or four layers of squamous cells, with flattened nuclei.

The *substantia propria* is fibrous, tough, unyielding, and perfectly transparent. It is composed of about sixty flattened lamellæ, superimposed one on another. These lamellæ are made up of bundles of modified connective tissue, the fibers of which are directly continuous with those of the sclera. The fibers of each lamella are for the most part parallel with one another, but at right angles to those of adjacent lamellæ. Fibers, however, frequently pass from one lamella to the next.

The lamellæ are connected with each other by an interstitial cement substance, in which are spaces, the **corneal spaces**. These are stellate in shape and communicate with one another by numerous offsets. Each contains a cell, the **corneal corpuscle**, resembling in form the space in which it is lodged, but not entirely filling it.




FIG. 871.—Vertical section of human cornea from near the margin. (Waldeyer.) Magnified. 1. Epithelium. 2. Anterior elastic lamina. 3. substantia propria. 4. Posterior elastic lamina. 5. Endothelium of the anterior chamber. a. Oblique fibers in the anterior layer of the substantia propria. b. Lamellæ the fibers of which are cut across, producing a dotted appearance. c. Corneal corpuscles appearing fusiform in section. d. Lamellæ the fibers of which are cut longitudinally. e. Transition to the sclera, with more distinct fibrillation, and surmounted by a thicker epithelium. f. Small bloodvessels cut across near the margin of the cornea.

The layer immediately beneath the corneal epithelium presents certain characteristics which have led some anatomists to regard it as a distinct membrane, and it has been named the **anterior elastic lamina** (*lamina elastica anterior*; *anterior limiting layer*; *Bowman's membrane*). It differs, however, from the posterior elastic lamina, in presenting evidence of fibrillar structure, and in not having the same tendency to curl inward, or to undergo fracture, when detached from the other layers of the cornea. It consists of extremely closely interwoven fibrils, similar to those found in the substantia propria, but contains no corneal corpuscles. It may be regarded as a condensed part of the substantia propria.

The **posterior elastic lamina** (*lamina elastica posterior*; *membrane of Descemet*; *membrane of Demours*) covers the posterior surface of the substantia propria, and is an elastic, transparent homogeneous membrane, of extreme thinness, which is not rendered opaque by either water, alcohol, or acids. When stripped from the substantia propria it curls up, or rolls upon itself with the attached surface innermost.

At the margin of the cornea the posterior elastic lamina breaks up into fibers which form the trabecular tissue already described; the spaces between the trabeculæ are termed the

spaces of the angle of the iris (*spaces of Fontana*); they communicate with the sinus venosus sclerae and with the anterior chamber at the filtration angle. Some of the fibers of this trabecular tissue are continued into the substance of the iris, forming the **pectinate ligament of the iris**; while others are connected with the forepart of the sclera and choroid.

The **endothelium of the anterior chamber** (*endothelium camerae anterioris; posterior layer; corneal endothelium*) covers the posterior surface of the elastic lamina, is reflected on to the front of the iris, and also lines the spaces of the angle of the iris; it consists of a single stratum of polygonal, flattened, nucleated cells.

Vessels and Nerves.—The cornea is a non-vascular structure; the capillary vessels ending in loops at its circumference are derived from the anterior ciliary arteries. Lymphatic vessels have not yet been demonstrated in it, but are represented by the channels in which the bundles of nerves run; these channels are lined by an endothelium. The **nerves** are numerous and are derived from the ciliary nerves. Around the periphery of the cornea they form an *annular plexus*, from which fibers enter the substantia propria. They lose their medullary sheaths and ramify throughout its substance in a delicate net-work, and their terminal filaments form a firm and closer plexus on the surface of the cornea proper, beneath the epithelium. This is termed the *subepithelial plexus*, and from it fibrils are given off which ramify between the epithelial cells, forming an *intraepithelial plexus*.

The Vascular Tunic (*tunica vasculosa oculi*) (Figs. 872, 873, 874).—The vascular tunic of the eye is formed from behind forward by the choroid, the ciliary body, and the iris.

The choroid invests the posterior five-sixths of the bulb, and extends as far forward as the ora serrata of the retina. The ciliary body connects the choroid to the circumference of the iris. The iris is a circular diaphragm behind the cornea, and presents near its center a rounded aperture, the pupil.

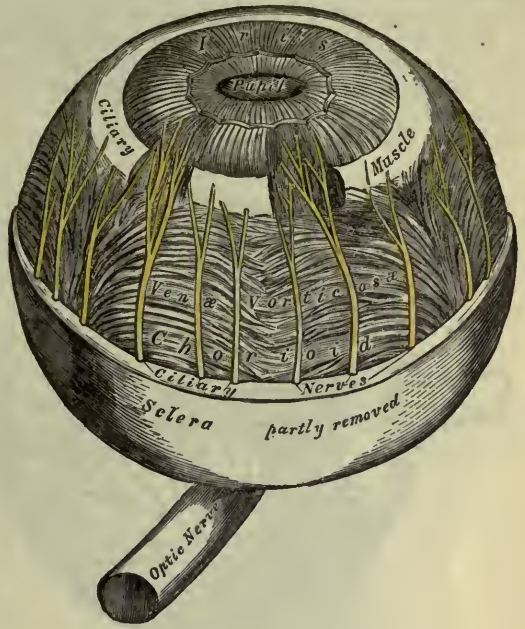


FIG. 872.—The choroid and iris. (Enlarged.)

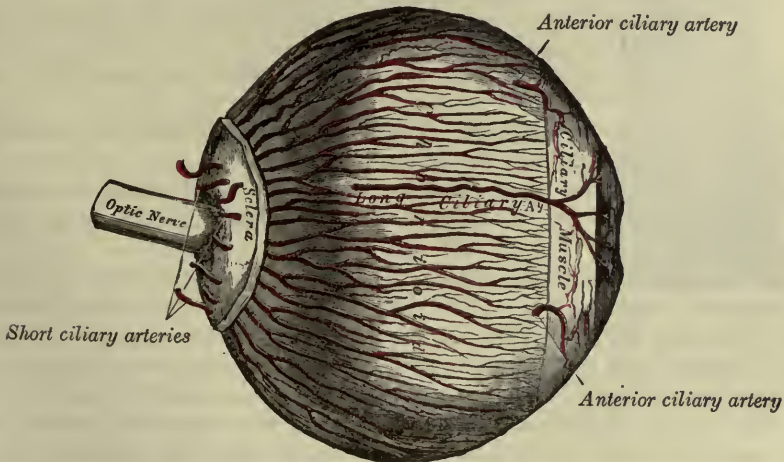


FIG. 873.—The arteries of the choroid and iris. The greater part of the sclera has been removed. (Enlarged.)

The Choroid (*chorioides*).—The choroid is a thin, highly vascular membrane, of a dark brown or chocolate color, investing the posterior five-sixths of the globe;

it is pierced behind by the optic nerve, and in this situation is firmly adherent to the sclera. It is thicker behind than in front. Its outer surface is loosely connected by the lamina suprachorioidea with the sclera; its inner surface is attached to the pigmented layer of the retina.

Structure.—The choroid consists mainly of a dense capillary plexus, and of small arteries and veins carrying blood to and returning it from this plexus. On its external surface is a thin membrane, the **lamina suprachorioidea**, composed of delicate non-vascular lamellæ—each lamella consisting of a net-work of fine elastic fibers among which are branched pigment cells. The spaces between the lamellæ are lined by endothelium, and open freely into the perichoroidal lymph space, which, in its turn, communicates with the periscleral space by the perforations in the sclera through which the vessels and nerves are transmitted.

Internal to this lamina is the **choroid proper**, consisting of two layers: an outer, composed of small arteries and veins, with pigment cells interspersed between them; and an inner, consisting of a capillary plexus. The **outer layer** (*lamina vasculosa*) consists, in part, of the larger branches of the short ciliary arteries which run forward between the veins, before they bend inward to end in the capillaries, but is formed principally of veins, named, from their arrangement, the **venæ vorticosæ**.

They converge to four or five equidistant trunks, which pierce the sclera about midway between the sclero-corneal junction and the entrance of the optic nerve. Interspersed between the vessels are dark star-shaped pigment cells, the processes of which, communicating with those of neighboring cells, form a delicate net-work or stroma, which toward the inner surface of the choroid loses its pigmentary character. The **inner layer** (*lamina choriocapillaris*) consists of an exceedingly fine capillary plexus, formed by the short ciliary vessels; the net-work is closer and finer in the posterior than in the anterior part of the choroid. About 1.25 cm. behind the cornea its meshes become larger, and are continuous with those of the ciliary processes. These two laminae are connected by a **stratum intermedium** consisting of fine elastic fibers. On the inner surface of the lamina choriocapillaris is a very thin, structureless, or faintly

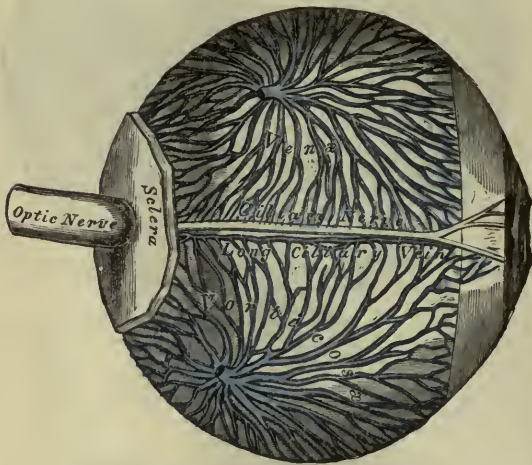


FIG. 874.—The veins of the choroid. (Enlarged.)

fibrous membrane, called the **lamina basalis**; it is closely connected with the stroma of the choroid, and separates it from the pigmentary layer of the retina.

One of the functions of the choroid is to provide nutrition for the retina, and to convey vessels and nerves to the ciliary body and iris.

Tapetum.—This name is applied to the outer and posterior part of the choroid, which in many animals presents an iridescent appearance.

The Ciliary Body (*corpus ciliare*).—The ciliary body comprises the **orbiculus ciliaris**, the **ciliary processes**, and the **Ciliaris muscle**.

The **orbiculus ciliaris** is a zone of about 4 mm. in width, directly continuous with the anterior part of the choroid; it presents numerous ridges arranged in a radial manner (Fig. 875).

The **ciliary processes** (*processus ciliares*) are formed by the inward folding of the various layers of the choroid, *i. e.*, the choroid proper and the lamina basalis, and are received between corresponding foldings of the suspensory ligament of the lens. They are arranged in a circle, and form a sort of frill behind the iris, around the margin of the lens (Fig. 875). They vary from sixty to eighty in number, lie side by side, and may be divided into large and small; the former are about 2.5 mm. in length, and the latter, consisting of about one-third of the entire number, are situated in spaces between them, but without regular arrangement. They are attached by their periphery to three or four of the ridges of the orbiculus ciliaris, and are continuous with the layers of the choroid: their opposite extremities are free and rounded, and are directed toward the posterior chamber of the eyeball and

circumference of the lens. In front, they are continuous with the periphery of the iris. Their posterior surfaces are connected with the suspensory ligament of the lens.

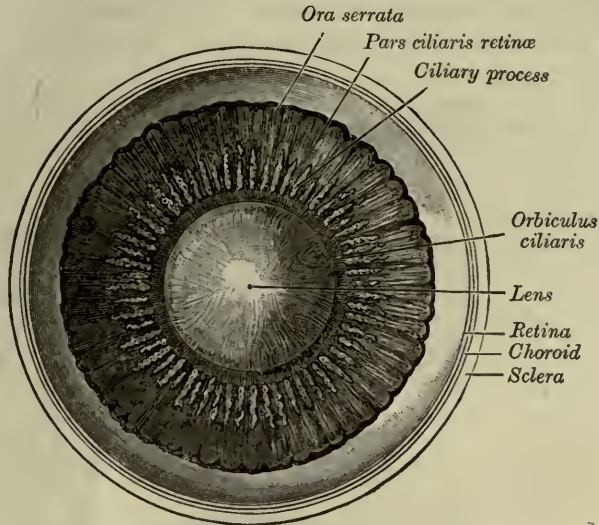


FIG. 875.—Interior of anterior half of bulb of eye.

Structure.—The ciliary processes (Figs. 876, 877) are similar in structure to the choroid, but the vessels are larger, and have chiefly a longitudinal direction. Their posterior surfaces are covered by a bilaminar layer of black pigment cells, which is continued forward from the retina, and is named the *pars ciliaris retinae*. In the stroma of the ciliary processes there are also stellate pigment cells, but these are not so numerous as in the choroid itself.

According to Henderson the aqueous humor is a secretion formed by the active intervention of the epithelial cells lining the apices of the ciliary processes.¹

The *Ciliaris muscle* (*m. ciliaris*; *Bowman's muscle*) consists of unstriped fibers: it forms a grayish, semitransparent, circular band, about 3 mm. broad, on the outer surface of the forepart of the choroid. It is thickest in front, and consists of two sets of fibers, **meridional** and **circular**. The meridional fibers, much the more numerous, arise from the posterior margin of the scleral spur (page 1007); they run backward, and are attached to the ciliary processes and orbiculus ciliaris. One bundle, according to Waldeyer, is inserted into the sclera. The circular fibers are internal to the meridional ones, and in a meridional section appear as a triangular zone behind the filtration angle and close to the circumference of the iris. They are well-developed in hypermetropic, but are rudimentary or absent in myopic eyes. The Ciliaris muscle is the chief agent in accommodation, *i. e.*, in adjusting the eye to the vision of near objects. When it contracts it draws forward the ciliary processes, relaxes the suspensory ligament of the lens, and thus allows the lens to become more convex.



FIG. 876.—Vessels of the choroid, ciliary processes, and iris of a child. (Arnold.) Magnified 10 times. *a*, Capillary network of the posterior part of the choroid, ending at *b*, the ora serrata. *c*, Arteries of the corona ciliaris, supplying the ciliary processes, *d*, and passing into the iris *e*. *f*, The capillary network close to the pupillary margin of the iris.

¹ Henderson, T., *Glaucoma*, London, 1910.

The Iris.—The iris has received its name from its various colors in different individuals. It is a thin, circular, contractile disk, suspended in the aqueous humor between the cornea and lens, and perforated a little to the nasal side of its center by a circular aperture, the **pupil**. By its periphery it is continuous with the ciliary body, and is also connected with the posterior elastic lamina of the

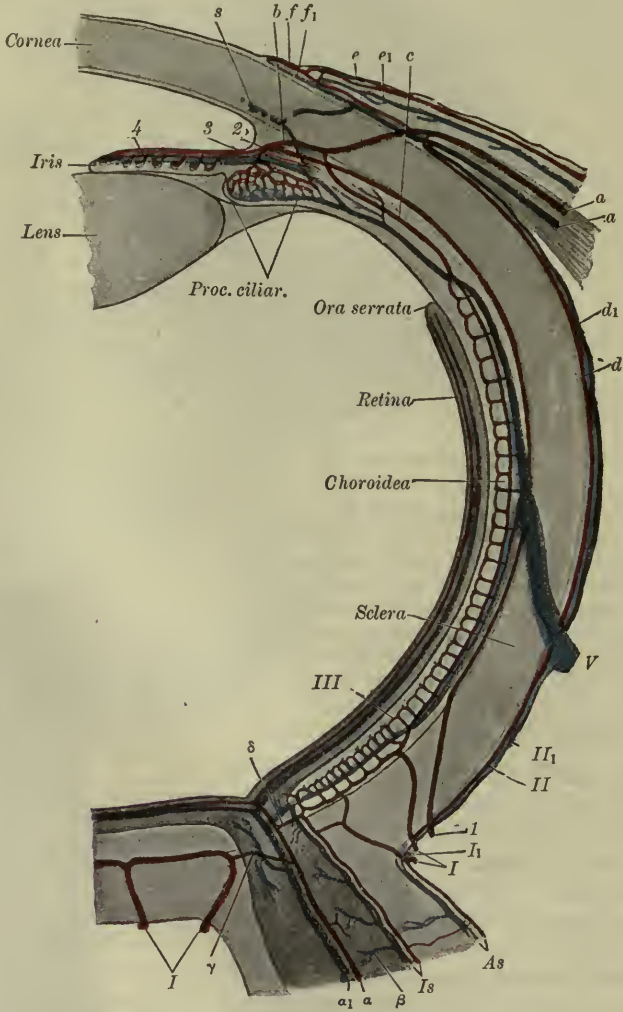


FIG. 877.—Diagram of the bloodvessels of the eye, as seen in a horizontal section. (Leber, after Stöhr.)
 Course of vasa centralia retinae: a. Arteria. a¹. Vena centralis retinae. b. Anastomosis with vessels of outer coats.
 c. Anastomosis with branches of short posterior ciliary arteries. d. Anastomosis with chorioideal vessels.
 Course of vasa ciliar. postic. brev.: I. Arteriae, and I₁. Venae ciliar. postic. brev. II. Episcleral artery. II₁. Episcleral vein. III. Capillaries of lamina chorioicapillaris.
 Course of vasa ciliar. postic. long.: 1. a. ciliar. post. longa. 2. Circulus iridis major cut across. 3. Branches to ciliary body. 4. Branches to iris.
 Course of vasa ciliar. ant.: a. Arteria. a₁. Vena ciliar. ant. b. Junction with the circulus iridis major. c. Junction with lamina chorioicapill. d. Arterial, and d₁. Venous episcleral branches. e. Arterial, and e₁. Venous branches to conjunctiva sclerae. f. Arterial, and f₁. Venous branches to corneal border. V. Vena vorticiosa. S. Transverse section of sinus venosus sclerae.

cornea by means of the pectinate ligament; its surfaces are flattened, and look forward and backward, the anterior toward the cornea, the posterior toward the ciliary processes and lens. The iris divides the space between the lens and the cornea into an anterior and a posterior chamber. The **anterior chamber** of the eye is bounded in front by the posterior surface of the cornea; behind by the front of the iris and the central part of the lens. The **posterior chamber** is a narrow chink

behind the peripheral part of the iris, and in front of the suspensory ligament of the lens and the ciliary processes. In the adult the two chambers communicate through the pupil, but in the fetus up to the seventh month they are separated by the *membrana pupillaris*.

Structure.—The iris is composed of the following structures:

1. In front is a layer of flattened endothelial cells placed on a delicate hyaline basement membrane. This layer is continuous with the endothelium covering the posterior elastic lamina of the cornea, and in individuals with dark-colored irides the cells contain pigment granules.

2. The **stroma** (*stroma iridis*) of the iris consists of fibers and cells. The former are made up of delicate bundles of fibrous tissue; a few fibers at the circumference of the iris have a circular direction; but the majority radiate toward the pupil, forming by their interlacement, delicate meshes, in which the vessels and nerves are contained. Interspersed between the bundles of connective tissue are numerous branched cells with fine processes. In dark eyes many of them contain pigment granules, but in blue eyes and the eyes of albinos they are unpigmented.

3. The **muscular fibers** are involuntary, and consist of circular and radiating fibers. The **circular fibers** form the Sphincter pupillæ; they are arranged in a narrow band about 1 mm. in width which surrounds the margin of the pupil toward the posterior surface of the iris; those near the free margin are closely aggregated; those near the periphery of the band are somewhat separated and form incomplete circles. The **radiating fibers** form the Dilator pupillæ; they converge from the circumference toward the center, and blend with the circular fibers near the margin of the pupil.

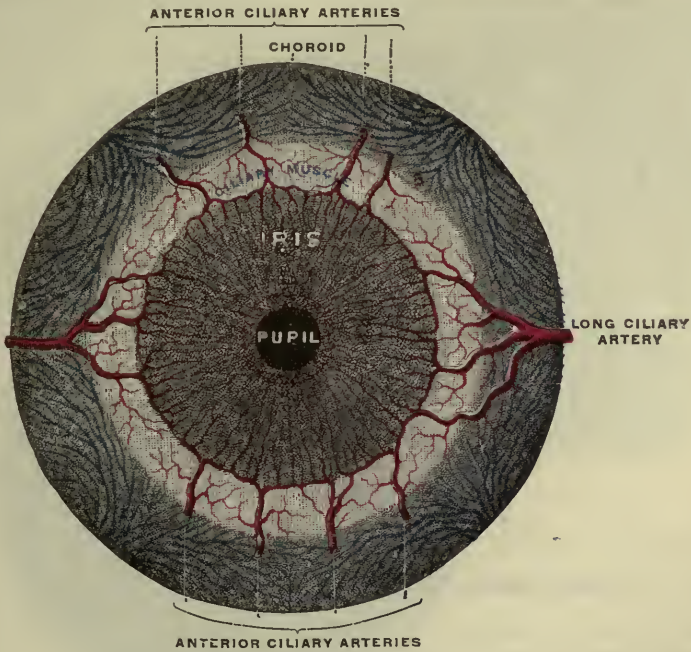


FIG. 878.—Iris, front view.

4. The posterior surface of the iris is of a deep purple tint, being covered by two layers of pigmented columnar epithelium, continuous at the periphery of the iris with the pars ciliaris retinae. This pigmented epithelium is named the **pars iridica retinae**, or, from the resemblance of its color to that of a ripe grape, the **uvea**.

The color of the iris is produced by the reflection of light from dark pigment cells underlying a translucent tissue, and is therefore determined by the amount of the pigment and its distribution throughout the texture of the iris. The number and the situation of the pigment cells differ in different irides. In the albino pigment is absent; in the various shades of blue eyes the pigment cells are confined to the posterior surface of the iris, whereas in gray, brown, and black eyes pigment is found also in the cells of the stroma and in those of the endothelium on the front of the iris.

The iris may be absent, either in part or altogether as a congenital condition, and in some instances the pupillary membrane may remain persistent, though it is rarely complete. Again, the iris may be the seat of a malformation, termed *coloboma*, which consists in a deficiency or

left, clearly due in a great number of cases to an arrest in development. In these cases the cleft is found at the lower aspect, extending directly downward from the pupil, and the gap frequently extends through the choroid to the porus opticus. In some rarer cases the gap is found in other parts of the iris, and is not then associated with any deficiency of the choroid.

Vessels and Nerves.—The arteries of the iris are derived from the long and anterior ciliary arteries, and from the vessels of the ciliary processes (see p. 571). Each of the two long ciliary arteries, having reached the attached margin of the iris, divides into an upper and lower branch; these anastomose with corresponding branches from the opposite side and thus encircle the iris; into this vascular circle (*circulus arteriosus major*) the anterior ciliary arteries pour their blood, and from it vessels converge to the free margin of the iris, and there communicate and form a second circle (*circulus arteriosus minor*) (Figs. 877 and 878).

The nerves of the choroid and iris are the long and short ciliary; the former being branches of the nasociliary nerve, the latter of the ciliary ganglion. They pierce the sclera around the entrance of the optic nerve, run forward in the perichoroidal space, and supply the bloodvessels of the choroid. After reaching the iris they form a plexus around its attached margin; from this are derived non-medullated fibers which end in the Sphincter and Dilatator pupillæ; their exact mode of termination has not been ascertained. Other fibers from the plexus end in a network on the anterior surface of the iris. The fibers derived through the motor root of the ciliary ganglion from the oculomotor nerve, supply the Sphincter, while those derived from the sympathetic supply the Dilatator.

Membrana Pupillaris.—In the fetus, the pupil is closed by a delicate vascular membrane, the *membrana pupillaris*, which divides the space in which the iris is suspended into two distinct chambers. The vessels of this membrane are partly derived from those of the margin of the iris and partly from those of the capsule of the lens; they have a looped arrangement, and converge toward each other without anastomosing. About the sixth month the membrane begins to disappear by absorption from the center toward the circumference, and at birth only a few fragments are present; in exceptional cases it persists.

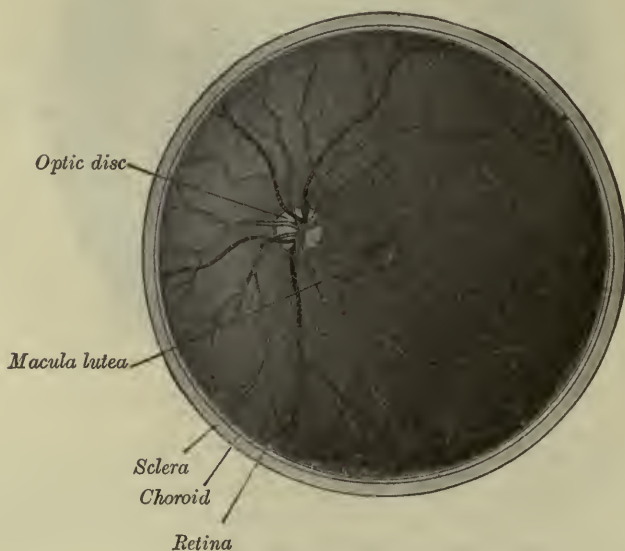


FIG. 879.—Interior of posterior half of bulb of left eye. The veins are darker in appearance than the arteries.

The Retina (*tunica interna*).—The retina is a delicate nervous membrane, upon which the images of external objects are received. Its outer surface is in contact with the choroid; its inner with the hyaloid membrane of the vitreous body. Behind, it is continuous with the optic nerve; it gradually diminishes in thickness from behind forward, and extends nearly as far as the ciliary body, where it appears to end in a jagged margin, the *ora serrata*. Here the nervous tissues of the retina end, but a thin prolongation of the membrane extends forward over the back of

the ciliary processes and iris, forming the *pars ciliaris retinae* and *pars iridica retinae* already referred to. This forward prolongation consists of the pigmentary layer of the retina together with a stratum of columnar epithelium. The retina is soft, semitransparent, and of a purple tint in the fresh state, owing to the presence of a coloring material named *rhodopsin* or *visual purple*; but it soon becomes clouded, opaque, and bleached when exposed to sunlight. Exactly in the center of the posterior part of the retina, corresponding to the axis of the eye, and at a point in which the sense of vision is most perfect, is an oval yellowish area, the *macula lutea*; in the macula is a central depression, the *fovea centralis* (Fig. 879). At the fovea centralis the retina is exceedingly thin, and the dark color of the choroid is distinctly seen through it. About 3 mm. to the nasal side of the macula lutea is the entrance of the optic nerve (*optic disk*), the circumference of which is slightly raised to form an eminence (*colliculus nervi optici*) (Fig. 880); the *arteria centralis retinae* pierces the center of the disk. This is the only part of the surface of the retina which is insensitive to light, and it is termed the *blind spot*.

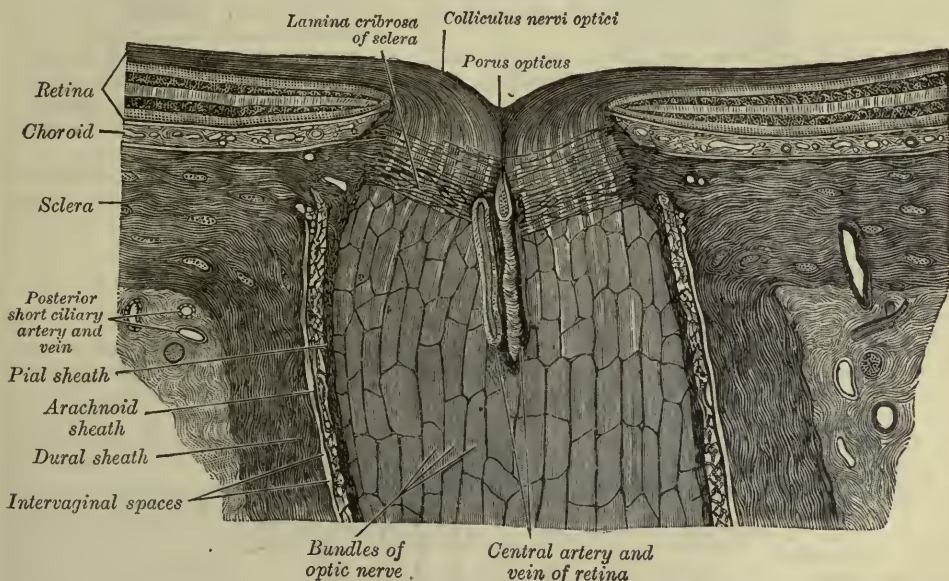


FIG. 880.—The terminal portion of the optic nerve and its entrance into the eyeball, in horizontal section. (Toldt.)

Structure (Figs. 881, 882).—The retina consists of an outer pigmented layer and an inner nervous stratum or retina proper.

The **pigmented layer** consists of a single stratum of cells. When viewed from the outer surface these cells are smooth and hexagonal in shape; when seen in section each cell consists of an outer non-pigmented part containing a large oval nucleus and an inner pigmented portion which extends as a series of straight thread-like processes between the rods, this being especially the case when the eye is exposed to light. In the eyes of albinos the cells of this layer are destitute of pigment.

Retina Proper.—The nervous structures of the retina proper are supported by a series of non-nervous or sustentacular fibers, and, when examined microscopically by means of sections made perpendicularly to the surface of the retina, are found to consist of seven layers, named from within outward as follows:

1. Stratum opticum.
2. Ganglionic layer.
3. Inner plexiform layer.
4. Inner nuclear layer, or layer of inner granules.
5. Outer plexiform layer.
6. Outer nuclear layer, or layer of outer granules.
7. Layer of rods and cones.

1. The **stratum opticum** or **layer of nerve fibers** is formed by the expansion of the fibers of the optic nerve; it is thickest near the porus opticus, gradually diminishing toward the ora serrata.

As the nerve fibers pass through the lamina cribrosa sclerae they lose their medullary sheaths and are continued onward through the choroid and retina as simple axis-cylinders. When they reach the internal surface of the retina they radiate from their point of entrance over this surface grouped in bundles, and in many places arranged in plexuses. Most of the fibers are centripetal, and are the direct continuations of the axis-cylinder processes of the cells of the ganglionic layer, but a few of them are centrifugal and ramify in the inner plexiform and inner nuclear layers, where they end in enlarged extremities.

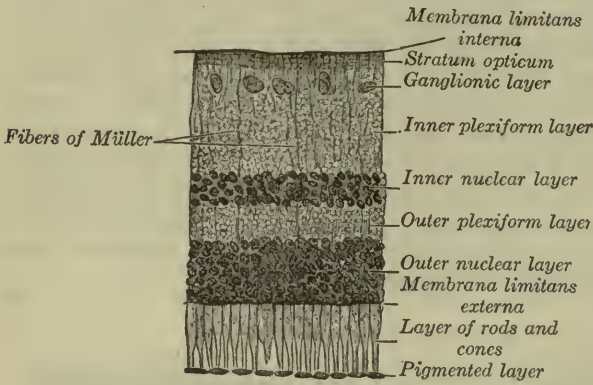


FIG. 881.—Section of retina. (Magnified.)

2. The **ganglionic layer** consists of a single layer of large ganglion cells, except in the macula lutea, where there are several strata. The cells are somewhat flask-shaped; the rounded internal surface of each resting on the stratum opticum, and sending off an axon which is prolonged into it. From the opposite end numerous dendrites extend into the inner plexiform layer, where they branch and form flattened arborizations at different levels. The ganglion cells vary much in

size, and the dendrites of the smaller ones as a rule arborize in the inner plexiform layer as soon as they enter it; while those of the larger cells ramify close to the inner nuclear layer.

3. The **inner plexiform layer** is made up of a dense reticulum of minute fibrils formed by the interlacement of the dendrites of the ganglion cells with those of the cells of the inner nuclear layer; within this reticulum a few branched spongioblasts are sometimes imbedded.

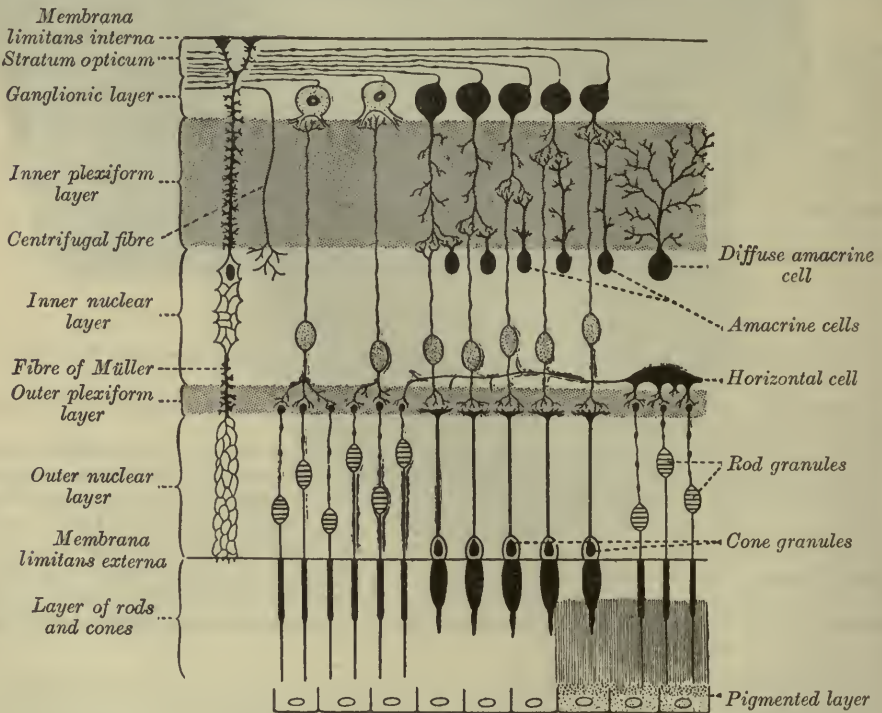


FIG. 882.—Plan of retinal neurons. (After Cajal.)

4. The **inner nuclear layer** or **layer of inner granules** is made up of a number of closely packed cells, of which there are three varieties, viz.: bipolar cells, horizontal cells, and amacrine cells.

The **bipolar cells**, by far the most numerous, are round or oval in shape, and each is prolonged into an inner and an outer process. They are divisible into rod bipolars and cone bipolars. The

inner processes of the **rod bipolars** run through the inner plexiform layer and arborize around the bodies of the cells of the ganglionic layer; their outer processes end in the outer plexiform layer in tufts of fibrils around the button-like ends of the inner processes of the rod granules. The inner processes of the **cone bipolars** ramify in the inner plexiform layer in contact with the dendrites of the ganglionic cells.

The **horizontal cells** lie in the outer part of the inner nuclear layer and possess somewhat flattened cell bodies. Their dendrites divide into numerous branches in the outer plexiform layer, while their axons run horizontally for some distance and finally ramify in the same layer.

The **amacrine cells** are placed in the inner part of the inner nuclear layer, and are so named because they have not yet been shown to possess axis-cylinder processes. Their dendrites undergo extensive ramification in the inner plexiform layer.

5. The **outer plexiform layer** is much thinner than the inner; but, like it, consists of a dense net-work of minute fibrils derived from the processes of the horizontal cells of the preceding layer, and the outer processes of the rod and cone bipolar granules, which ramify in it, forming arborizations around the enlarged ends of the rod fibers and with the branched foot plates of the cone fibers.

6. The **outer nuclear layer** or **layer of outer granules**, like the inner nuclear layer, contains several strata of oval nuclear bodies; they are of two kinds, viz.: rod and cone granules, so named on account of their being respectively connected with the rods and cones of the next layer. The **rod granules** are much the more numerous, and are placed at different levels throughout the layer. Their nuclei present a peculiar cross-striated appearance, and prolonged from either extremity of each cell is a fine process; the outer process is continuous with a single rod of the layer of rods and cones; the inner ends in the outer plexiform layer in an enlarged extremity, and is imbedded in the tuft into which the outer processes of the rod bipolar cells break up. In its course it presents numerous varicosities. The **cone granules**, fewer in number than the rod granules, are placed close to the *membrana limitans externa*, through which they are continuous with the cones of the layer of rods and cones. They do not present any cross-striation; but contain a pyriform nucleus, which almost completely fills the cell. From the inner extremity of the granule a thick process passes into the outer plexiform layer, and there expands into a pyramidal enlargement or foot plate, from which are given off numerous fine fibrils, that come in contact with the outer processes of the cone bipolars.

7. **The Layer of Rods and Cones** (*Jacob's membrane*).—The elements composing this layer are of two kinds, **rods** and **cones**, the former being much more numerous than the latter except in the *macula lutea*. The **rods** are cylindrical, of nearly uniform thickness, and are arranged perpendicularly to the surface. Each rod consists of two segments, an outer and inner, of about equal lengths. The segments differ from each other as regards refraction and in their behavior toward coloring reagents; the inner segment is stained by carmine, iodine, etc.; the outer segment is not stained by these reagents, but is colored yellowish brown by osmic acid. The outer segment is marked by transverse striæ, and tends to break up into a number of thin disks superimposed on one another; it also exhibits faint longitudinal markings. The deeper part of the inner segment is indistinctly granular; its more superficial part presents a longitudinal striation, being composed of fine, bright, highly refracting fibrils. The visual purple or rhodopsin is found only in the outer segments.

The **cones** are conical or flask-shaped, their broad ends resting upon the *membrana limitans externa*, the narrow-pointed extremity being turned to the choroid. Like the rods, each is made up of two segments, outer and inner; the outer segment is a short conical process, which, like the outer segment of the rod, exhibits transverse striæ. The inner segment resembles the inner segment of the rods in structure, presenting a superficial striated and deep granular part, but differs from it in size and shape, being bulged out laterally and flask-shaped. The chemical and optical characters of the two portions are identical with those of the rods.

Supporting Frame-work of the Retina.—The nervous layers of the retina are connected together by a supporting frame-work, formed by the **sustentacular fibers of Müller**; these fibers pass through all the nervous layers, except that of the rods and cones. Each begins on the inner surface of the retina by an expanded, often forked base, which sometimes contains a spheroidal body staining deeply with hematoxylin, the edges of the bases of adjoining fibers being united to form the *membrana limitans interna*. As the fibers pass through the nerve fiber and ganglionic layers they give off a few lateral branches; in the inner nuclear layer they give off numerous lateral processes for the support of the bipolar cells, while in the outer nuclear layer they form a network around the rod- and cone-fibrils, and unite to form the *membrana limitans externa* at the bases of the rods and cones. At the level of the inner nuclear layer each sustentacular fiber contains a clear oval nucleus.

Macula Lutea and Fovea Centralis.—In the *macula lutea* the nerve fibers are wanting as a continuous layer, the ganglionic layer consists of several strata of cells, there are no rods, but only cones, which are longer and narrower than in other parts, and in the outer nuclear layer there are only cone-granules, the processes of which are very long and arranged in curved lines. In the *fovea centralis* the only parts present are (1) the cones; (2) the outer nuclear layer, the

cone-fibers of which are almost horizontal in direction; (3) an exceedingly thin inner plexiform layer. The pigmented layer is thicker and its pigment more pronounced than elsewhere. The color of the macula seems to imbue all the layers except that of the rods and cones; it is of a rich yellow, deepest toward the center of the macula, and does not appear to be due to pigment cells, but simply to a staining of the constituent parts.

At the *ora serrata* the nervous layers of the retina end abruptly, and the retina is continued onward as a single layer of columnar cells covered by the pigmented layer. This double layer is known as the *pars ciliaris retinæ*, and can be traced forward from the ciliary processes on to the back of the iris, where it is termed the *pars iridica retinæ* or *uvea*.

The *arteria centralis retinæ* (Fig. 879) and its accompanying vein pierce the optic nerve, and enter the bulb of the eye through the *porus opticus*. The artery immediately bifurcates into an upper and a lower branch, and each of these again divides into a medial or nasal and a lateral or temporal branch, which at first run between the hyaloid membrane and the nervous layer; but they soon enter the latter, and pass forward, dividing dichotomously. From these branches a minute capillary plexus is given off, which does not extend beyond the inner nuclear layer. The macula receives two small branches (superior and inferior macular arteries) from the temporal branches and small twigs directly from the central artery; these do not, however, reach as far as the *fovea centralis*, which has no bloodvessels. The branches of the *arteria centralis retinæ* do not anastomose with each other—in other words they are terminal arteries. In the fetus, a small vessel, the *arteria hyaloidea*, passes forward as a continuation of the *arteria centralis retinæ* through the vitreous humor to the posterior surface of the capsule of the lens.

The Refracting Media.

The refracting media are three, viz.:

Aqueous humor.

Vitreous body.

Crystalline lens.

The Aqueous Humor (*humor aqueus*).—The aqueous humor fills the anterior and posterior chambers of the eyeball. It is small in quantity, has an alkaline reaction, and consists mainly of water, less than one-fiftieth of its weight being solid matter, chiefly chloride of sodium.

The Vitreous Body (*corpus vitreum*).—The vitreous body forms about four-fifths of the bulb of the eye. It fills the concavity of the retina, and is hollowed in front, forming a deep concavity, the *hyaloid fossa*, for the reception of the lens. It is transparent, of the consistence of thin jelly, and is composed of an albuminous fluid enclosed in a delicate transparent membrane, the *hyaloid membrane*. It has been supposed, by Hannover, that from its surface numerous thin lamellæ are prolonged inward in a radiating manner, forming spaces in which the fluid is contained. In the adult, these lamellæ cannot be detected even after careful microscopic examination in the fresh state, but in preparations hardened in weak chromic acid it is possible to make out a distinct lamellation at the periphery of the body. In the center of the vitreous body, running from the entrance of the optic nerve to the posterior surface of the lens, is a canal, the *hyaloid canal*, filled with lymph and lined by a prolongation of the hyaloid membrane. This canal, in the embryonic vitreous body, conveyed the *arteria hyaloidea* from the central artery of the retina to the back of the lens. The fluid from the vitreous body is nearly pure water; it contains, however, some salts, and a little albumin.

The *hyaloid membrane* envelops the vitreous body. The portion in front of the *ora serrata* is thickened by the accession of radial fibers and is termed the *zonula ciliaris* (*zonule of Zinn*). Here it presents a series of radially arranged furrows, in which the ciliary processes are accommodated and to which they adhere, as is shown by the fact that when they are removed some of their pigment remains attached to the zonula. The *zonula ciliaris* splits into two layers, one of which is thin and lines the *hyaloid fossa*; the other is named the *suspensory ligament of the lens*: it is thicker, and passes over the ciliary body to be attached to the capsule of the lens a short distance in front of its equator. Scattered and delicate fibers are also attached to the region of the equator itself. This ligament retains the lens in position, and is relaxed by the contraction of the meridional fibers of the *Ciliaris* muscle, so that the lens is allowed to become more convex. Behind

the suspensory ligament there is a sacculated canal, the *spatia zonularis* (*canal of Petit*), which encircles the equator of the lens; it can be easily inflated through a fine blowpipe inserted under the suspensory ligament.

No bloodvessels penetrate the vitreous body, so that its nutrition must be carried on by vessels of the retina and ciliary processes, situated upon its exterior.

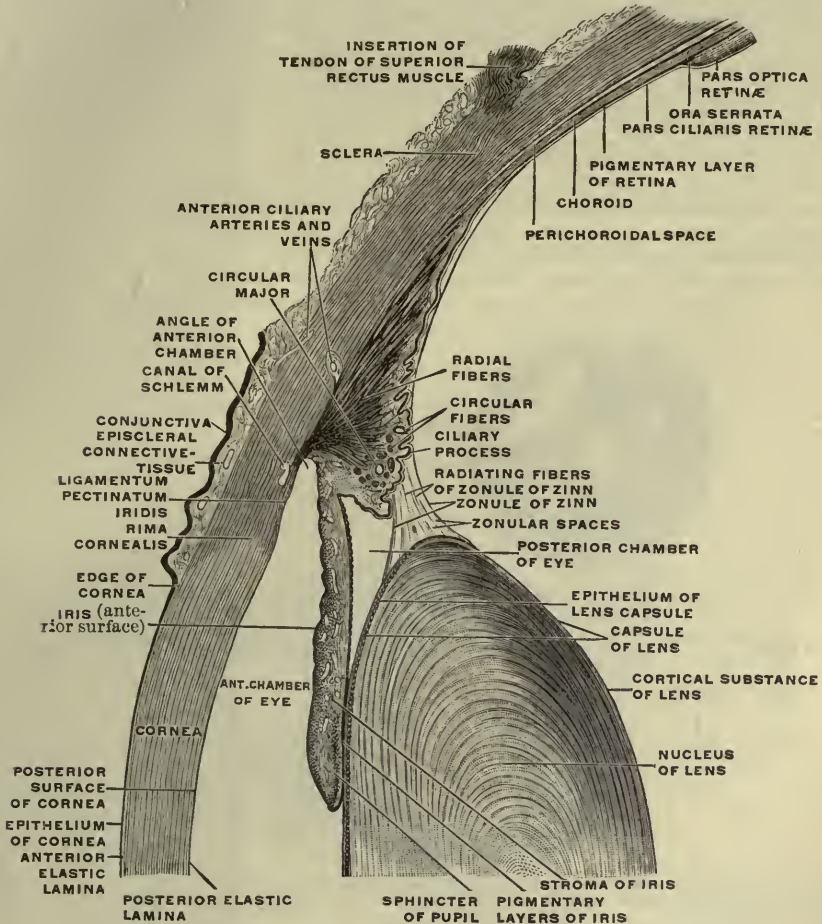


FIG. 883.—The upper half of a sagittal section through the front of the eyeball.

The Crystalline Lens (*lens crystallina*).—The crystalline lens, enclosed in its capsule, is situated immediately behind the iris, in front of the vitreous body, and encircled by the ciliary processes, which slightly overlap its margin.

The **capsule of the lens (*capsula lentis*)** is a transparent, structureless membrane which closely surrounds the lens, and is thicker in front than behind. It is brittle but highly elastic, and when ruptured the edges roll up with the outer surface innermost. It rests, behind, in the hyaloid fossa in the forepart of the vitreous body; in front, it is in contact with the free border of the iris, but recedes from it at the circumference, thus forming the posterior chamber of the eye; it is retained in its position chiefly by the suspensory ligament of the lens, already described.

The **lens** is a transparent, biconvex body, the convexity of its anterior being less than that of its posterior surface. The central points of these surfaces are termed respectively the **anterior** and **posterior poles**; a line connecting the poles constitutes the **axis** of the lens, while the marginal circumference is termed the **equator**.

Structure.—The lens is made up of soft cortical substance and a firm, central part, the **nucleus** (Fig. 884). Faint lines (*radii lentis*) radiate from the poles to the equator. In the adult there may be six or more of these lines, but in the fetus they are only three in number and diverge from each other at angles of 120° (Fig. 885); on the anterior surface one line ascends vertically and the other two diverge downward; on the posterior surface one ray descends vertically and the other two diverge upward. They correspond with the free edges of an equal number of septa composed of an amorphous substance, which dip into the substance of the lens. When the lens has been hardened it is seen to consist of a series of concentrically arranged laminae, each of which is interrupted at the septa referred to. Each lamina is built up of a number of hexagonal, ribbon-like lens fibers, the edges of which are more or less serrated—the serrations fitting between those of neighboring fibers, while the ends of the fibers come into apposition at the septa. The fibers run in a curved manner from the septa on the anterior surface to those on the posterior surface. No fibers pass from pole to pole; they are arranged in such a way that those which begin near the pole on one surface

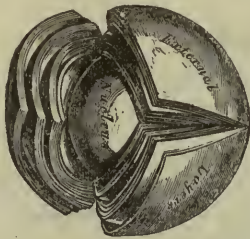


FIG. 884.—The crystalline lens, hardened and divided. (Enlarged.)




FIG. 885.—Diagram to show the direction and arrangement of the radiating lines on the front and back of the fetal lens. A. From the front. B. From the back.

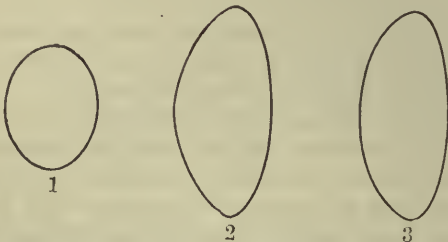


FIG. 886.—Profile views of the lens at different periods of life. 1. In the fetus. 2. In adult life. 3. In old age.

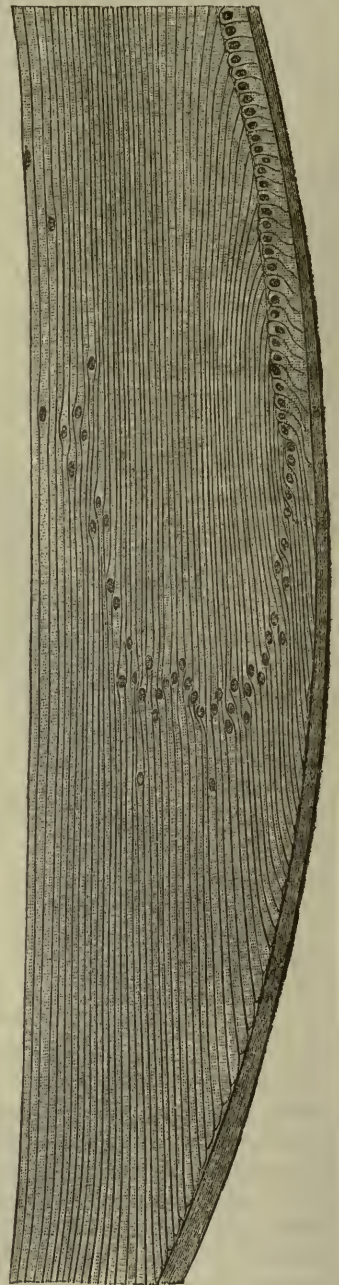


FIG. 887.—Section through the margin of the lens, showing the transition of the epithelium into the lens fibers. (Babuchin.)

of the lens end near the peripheral extremity of the plane on the other, and *vice versa*. The fibers of the outer layers of the lens are nucleated, and together form a nuclear layer, most distinct toward the equator. The anterior surface of the lens is covered by a layer of transparent, columnar, nucleated epithelium. At the equator the cells become elongated, and their gradual transition into lens fibers can be traced (Fig. 887).

In the fetus, the lens is nearly spherical, and has a slightly reddish tint; it is soft and breaks down readily on the slightest pressure. A small branch from the arteria centralis retinae runs forward, as already mentioned, through the vitreous body to the posterior part of the capsule of the lens, where its branches radiate and form a plexiform network, which covers the posterior surface of the capsule, and they are continuous around the margin of the capsule with the vessels of the pupillary membrane, and with those of the iris. In the adult, the lens is colorless, transparent, firm in texture, and devoid of vessels. In old age it becomes flattened on both surfaces, slightly opaque, of an amber tint, and increased in density (Fig. 886).

Vessels and Nerves.—The arteries of the bulb of the eye are the long, short, and anterior ciliary arteries, and the arteria centralis retinae. They have already been described (see p. 571).

The ciliary veins are seen on the outer surface of the choroid, and are named, from their arrangement, the *venae vorticosae*; they converge to four or five equidistant trunks which pierce the sclera midway between the sclero-corneal junction and the porus opticus. Another set of veins accompanies the anterior ciliary arteries. All of these veins open into the ophthalmic veins.

The ciliary nerves are derived from the nasociliary nerve and from the ciliary ganglion.

The Accessory Organs of the Eye (*Organa Oculi Accessoria*).

The accessory organs of the eye include the ocular muscles, the fasciæ, the eyebrows, the eyelids, the conjunctiva, and the lacrimal apparatus.

The Ocular Muscles (*musculi oculi*).—The ocular muscles are the:

Levator palpebræ superioris.	Rectus medialis.
Rectus superior.	Rectus lateralis.
Rectus inferior.	Obliquus superior.
	Obliquus inferior.

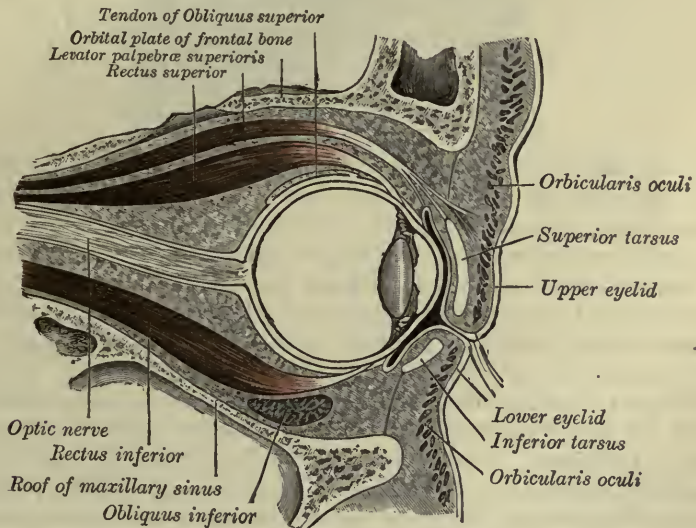


FIG. 888.—Sagittal section of right orbital cavity.

The *Levator palpebræ superioris* (Fig. 888) is thin, flat, and triangular in shape. It arises from the under surface of the small wing of the sphenoid, above and in front of the optic foramen, from which it is separated by the origin of the *Rectus superior*. At its origin, it is narrow and tendinous, but soon becomes broad and fleshy, and ends anteriorly in a wide aponeurosis which splits into three lamellæ. The superficial lamella blends with the upper part of the orbital septum, and is prolonged forward above the superior tarsus to the palpebral part of the *Orbicularis oculi*, and to the deep surface of the skin of the upper eyelid. The middle lamella, largely made up of non-striped muscular fibers, is inserted into the upper margin of the superior tarsus, while the deepest lamella blends with an expansion from the sheath of the *Rectus superior* and with it is attached to the superior fornix of the conjunctiva.

Whitnall¹ has pointed out that the upper part of the sheath of the Levator palpebræ becomes thickened in front and forms, above the anterior part of the muscle, a transverse ligamentous band which is attached to the sides of the orbital cavity. On the medial side it is mainly fixed to the pulley of the Obliquus superior, but some fibers are attached to the bone behind the pulley and a slip passes forward and bridges over the supraorbital notch; on the lateral side it is fixed to the capsule of the lacrimal gland and to the frontal bone. In front of the transverse ligamentous band the sheath is continued over the aponeurosis of the Levator palpebræ, as a thin connective-tissue layer which is fixed to the upper orbital margin immediately behind the attachment of the orbital septum. When the Levator palpebræ contracts, the lateral and medial parts of the ligamentous band are stretched and check the action of the muscle; the retraction of the upper eyelid is checked also by the orbital septum coming into contact with the transverse part of the ligamentous band.

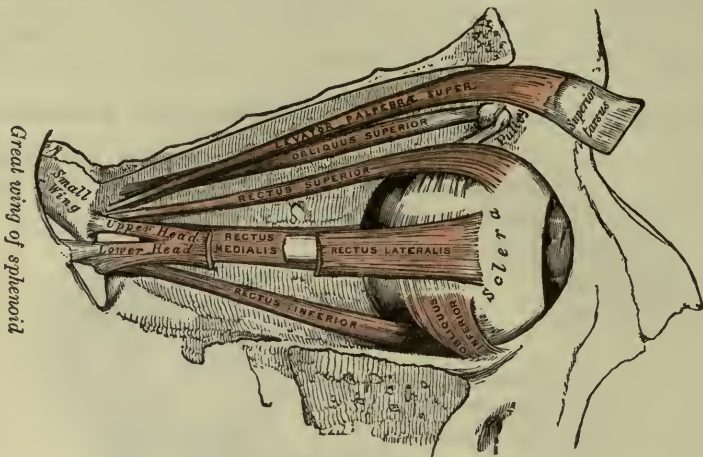


FIG. 889.—Muscles of the right orbit.

The four **Recti** (Fig. 889) arise from a fibrous ring (*annulus tendineus communis*) which surrounds the upper, medial, and lower margins of the optic foramen and encircles the optic nerve (Fig. 890). The ring is completed by a tendinous bridge prolonged over the lower and medial part of the superior orbital fissure and attached to a tubercle on the margin of the great wing of the sphenoid, bounding the fissure. Two specialized parts of this fibrous ring may be made out: a lower, the **ligament or tendon of Zinn**, which gives origin to the Rectus inferior, part of the Rectus internus, and the lower head of origin of the Rectus lateralis; and an upper, which gives origin to the Rectus superior, the rest of the Rectus medialis, and the upper head of the Rectus lateralis. This upper band is sometimes termed the **superior tendon of Lockwood**. Each muscle passes forward in the position implied by its name, to be inserted by a tendinous expansion into the sclera, about 6 mm. from the margin of the cornea. Between the two heads of the Rectus lateralis is a narrow interval, through which pass the two divisions of the oculomotor nerve, the nasociliary nerve, the abducent nerve, and the ophthalmic vein. Although these muscles present a common origin and are inserted in a similar manner into the sclera, there are certain differences to be observed in them as regards their length and breadth. The Rectus medialis is the broadest, the Rectus lateralis the longest, and the Rectus superior the thinnest and narrowest.

The **Obliquus oculi superior** (*superior oblique*) is a fusiform muscle, placed at the upper and medial side of the orbit. It arises immediately above the margin of the optic foramen, above and medial to the origin of the Rectus superior, and, passing forward, ends in a rounded tendon, which plays in a fibrocartilaginous ring or pulley attached to the trochlear fovea of the frontal bone. The contiguous surfaces of the tendon and ring are lined by a delicate mucous sheath, and enclosed in a thin

¹ Journal of Anatomy and Physiology, vol. xlv.

fibrous investment. The tendon is reflected backward, lateralward, and downward beneath the Rectus superior to the lateral part of the bulb of the eye, and is inserted into the sclera, behind the equator of the eyeball, the insertion of the muscle lying between the Rectus superior and Rectus lateralis.

The *Obliquus oculi inferior* (*inferior oblique*) is a thin, narrow muscle, placed near the anterior margin of the floor of the orbit. It arises from the orbital surface of the maxilla, lateral to the lacrimal groove. Passing lateralward, backward, and upward, at first between the Rectus inferior and the floor of the orbit, and then between the bulb of the eye and the Rectus lateralis, it is inserted into the lateral part of the sclera between the Rectus superior and Rectus lateralis, near to, but somewhat behind the insertion of the Obliquus superior.

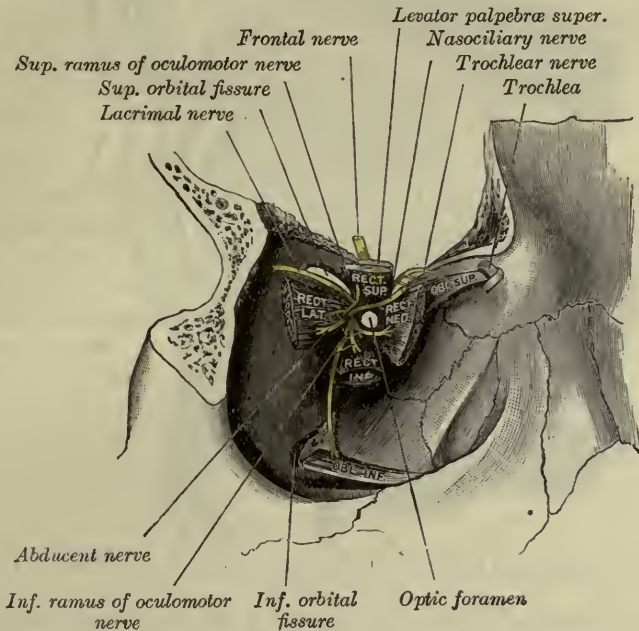


FIG. 890.—Dissection showing origins of right ocular muscles, and nerves entering by the superior orbital fissure.

Nerves.—The Levator palpebrae superioris, Obliquus inferior, and the Recti superior, inferior, and medialis are supplied by the oculomotor nerve; the Obliquus superior, by the trochlear nerve; the Rectus lateralis, by the abducent nerve.

Actions.—The Levator palpebrae raises the upper eyelid, and is the direct antagonist of the Orbicularis oculi. The four Recti are attached to the bulb of the eye in such a manner that, acting singly, they will turn its corneal surface either upward, downward, medialward, or lateralward, as expressed by their names. The movement produced by the Rectus superior or Rectus inferior is not quite a simple one, for inasmuch as each passes obliquely lateralward and forward to the bulb of the eye, the elevation or depression of the cornea is accompanied by a certain deviation medialward, with a slight amount of rotation. These latter movements are corrected by the Obliqui, the Obliquus inferior correcting the medial deviation caused by the Rectus superior and the Obliquus superior that caused by the Rectus inferior. The contraction of the Rectus lateralis or Rectus medialis, on the other hand, produces a purely horizontal movement. If any two neighboring Recti of one eye act together they carry the globe of the eye in the diagonal of these directions, viz., upward and medialward, upward and lateralward, downward and medialward, or downward and lateralward. Sometimes the corresponding Recti of the two eyes act in unison, and at other times the opposite Recti act together. Thus, in turning the eyes to the right, the Rectus lateralis of the right eye will act in unison with the Rectus medialis of the left eye; but if both eyes are directed to an object in the middle line at a short distance, the two Recti mediales will act in unison. The movement of circumduction, as in looking around a room, is performed by the successive actions of the four Recti. The Obliqui rotate the eyeball on its antero-posterior axis, the superior directing the cornea downward and lateralward, and the

inferior directing it upward and lateralward; these movements are required for the correct viewing of an object when the head is moved laterally, as from shoulder to shoulder, in order that the picture may fall in all respects on the same part of the retina of either eye.

A layer of non-stripped muscle, the **Orbitalis muscle** of H. Müller, may be seen bridging across the inferior orbital fissure.

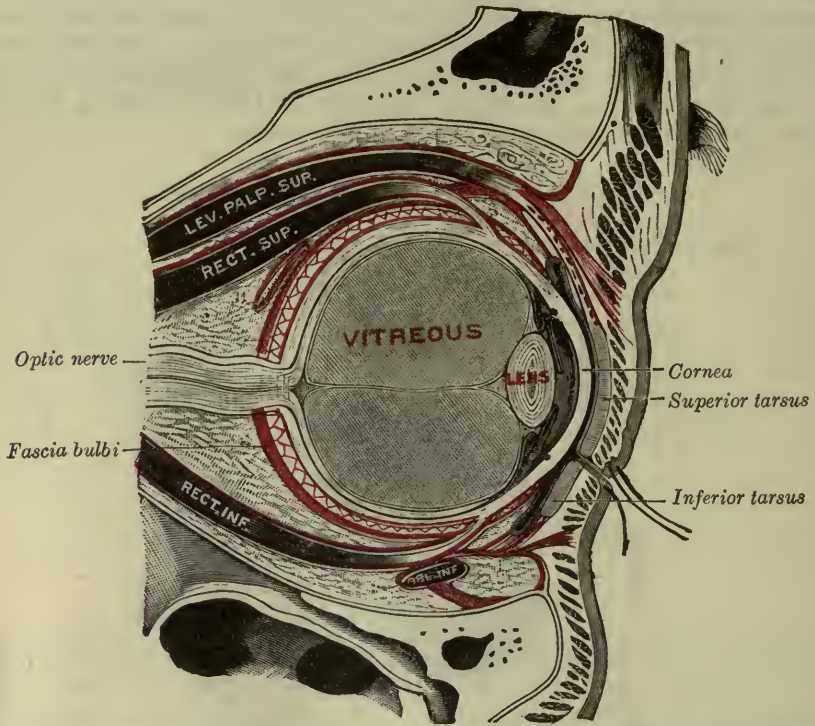


FIG. 891.—The right eye in sagittal section, showing the fascia bulbi (semidiagrammatic). (Testut.)

The **Fascia Bulb** (*capsule of Ténon*) (Fig. 891) is a thin membrane which envelops the bulb of the eye from the optic nerve to the ciliary region, separating it from the orbital fat and forming a socket in which it plays. Its inner surface is smooth, and is separated from the outer surface of the sclera by the **periscleral lymph space**. This lymph space is continuous with the subdural and subarachnoid cavities, and is traversed by delicate bands of connective tissue which extend between the fascia and the sclera. The fascia is perforated behind by the ciliary vessels and nerves, and fuses with the sheath of the optic nerve and with the sclera around the entrance of the optic nerve. In front it blends with the ocular conjunctiva, and with it is attached to the ciliary region of the eyeball. It is perforated by the tendons of the ocular muscles, and is reflected backward on each as a tubular sheath. The sheath of the Obliquus superior is carried as far as the fibrous pulley of that muscle; that on the Obliquus inferior reaches as far as the floor of the orbit, to which it gives off a slip. The sheaths on the Recti are gradually lost in the perimysium, but they give off important expansions. The expansion from the Rectus superior blends with the tendon of the Levator palpebræ; that of the Rectus inferior is attached to the inferior tarsus. The expansions from the sheaths of the Recti lateralis and medialis are strong, especially that from the latter muscle, and are attached to the lacrimal and zygomatic bones respectively. As they probably check the actions of these two Recti they have been named the **medial** and **lateral check ligaments**. Lockwood has described a thickening of the lower part

of the *facia bulbi*, which he has named the **suspensory ligament of the eye**. It is slung like a hammock below the eyeball, being expanded in the center, and narrow at its extremities which are attached to the zygomatic and lacrimal bones respectively.¹

The **Orbital Fascia** forms the periosteum of the orbit. It is loosely connected to the bones and can be readily separated from them. Behind, it is united with the *dura mater* by processes which pass through the optic foramen and superior orbital fissure, and with the sheath of the optic nerve. In front, it is connected with the periosteum at the margin of the orbit, and sends off a process which assists in forming the orbital septum. From it two processes are given off; one to enclose the lacrimal gland, the other to hold the pulley of the *Obliquus superior* in position.

The **Eyebrows** (*supercilia*) are two arched eminences of integument, which surmount the upper circumference of the orbits, and support numerous short, thick hairs, directed obliquely on the surface. The eyebrows consist of thickened integument, connected beneath with the *Orbicularis oculi*, *Corrugator*, and *Frontalis* muscles.

The **Eyelids** (*palpebræ*) are two thin, movable folds, placed in front of the eye, protecting it from injury by their closure. The upper eyelid is the larger, and the more movable of the two, and is furnished with an elevator muscle, the *Levator palpebræ superioris*. When the eyelids are open, an elliptical space, the **palpebral fissure** (*rima palpebrarum*), is left between their margins, the angles of which correspond to the junctions of the upper and lower eyelids, and are called the **palpebral commissures** or **canthi**.

The **lateral palpebral commissure** (*commissura palpebrarum lateralis; external canthus*) is more acute than the medial, and the eyelids here lie in close contact with the bulb of the eye: but the **medial palpebral commissure** (*commissura palpebrarum medialis; internal canthus*) is prolonged for a short distance toward the nose, and the two eyelids are separated by a triangular space, the **lacus lacrimalis** (Fig. 892). At the basal angles of the lacus lacrimalis, on the margin of each eyelid, is a small conical elevation, the **lacrimal papilla**, the apex of which is pierced by a small orifice, the **punctum lacrimale**, the commencement of the lacrimal duct.

The **eyelashes** (*cilia*) are attached to the free edges of the eyelids; they are short, thick, curved hairs, arranged in a double or triple row: those of the upper eyelid, more numerous and longer than those of the lower, curve upward; those of the lower eyelid curve downward, so that they do not interlace in closing the lids. Near the attachment of the eyelashes are the openings of a number of glands, the **ciliary glands**, arranged in several rows close to the free margin of the lid; they are regarded as enlarged and modified sudoriferous glands.

Structure of the Eyelids.—The eyelids are composed of the following structures taken in their order from without inward: integument, areolar tissue, fibers of the *Orbicularis oculi*, tarsus, orbital septum, tarsal glands and conjunctiva. The upper eyelid has, in addition, the aponeurosis of the *Levator palpebræ superioris* (Fig. 893).

The **integument** is extremely thin, and continuous at the margins of the eyelids with the conjunctiva.

The **subcutaneous areolar tissue** is very lax and delicate, and seldom contains any fat.

The **palpebral fibers of the Orbicularis oculi** are thin, pale in color, and possess an involuntary action.

The **tarsi** (*tarsal plates*) (Fig. 894) are two thin, elongated plates of dense connective tissue, about 2.5 cm. in length; one is placed in each eyelid, and contributes to its form and support. The **superior tarsus** (*tarsus superior; superior tarsal plate*), the larger, is of a semilunar form, about 10 mm. in breadth at the center, and gradually narrowing toward its extremities. To the anterior surface of this plate the aponeurosis of the *Levator palpebræ superioris* is attached. The **inferior tarsus** (*tarsus inferior; inferior tarsal plate*), the smaller, is thin, elliptical in form, and

¹ C. B. Lockwood, *Journal of Anatomy and Physiology*, vol. xx.

has a vertical diameter of about 5 mm. The free or ciliary margins of these plates are thick and straight. The attached or orbital margins are connected to the circumference of the orbit by the orbital septum. The lateral angles are attached to the zygomatic bone by the lateral palpebral raphé. The medial angles of the two plates end at the lacus lacrimalis, and are attached to the frontal process of the maxilla by the medial palpebral ligament (page 381).

The **orbital septum** (*septum orbitale*; *palpebral ligament*) is a membranous sheet, attached to the edge of the orbit, where it is continuous with the periosteum. In the upper eyelid it blends

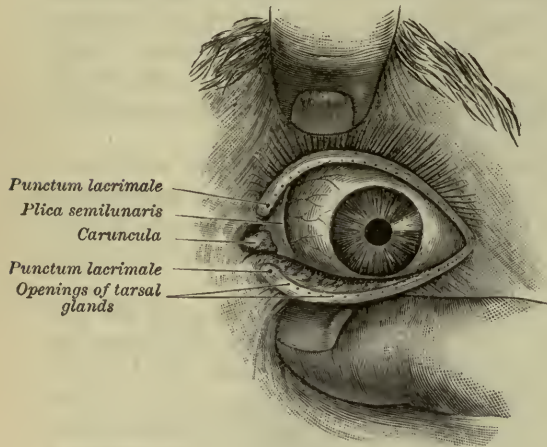


FIG. 892.—Front of left eye with eyelids separated to show medial canthus.

by its peripheral circumference with the tendon of the Levator palpebræ superioris and the superior tarsus, in the lower eyelid with the inferior tarsus. Medially it is thin, and, becoming separated from the medial palpebral ligament, is fixed to the lacrimal bone immediately behind the lacrimal sac. The septum is perforated by the vessels and nerves which pass from the orbital cavity to the face and scalp. The eyelids are richly supplied with blood.

The Tarsal Glands (*glandulæ tarsales* [*Meibomi*]; *Meibomian glands*) (Fig. 895).—The tarsal glands are situated upon the inner surfaces of the eyelids, between the tarsi and conjunctiva, and may be distinctly seen through the latter on everting the eyelids, presenting an appearance like parallel strings of pearls. There are about thirty in the upper eyelid, and somewhat fewer in the lower. They are imbedded in grooves in the inner surfaces of the tarsi, and correspond in length with the breadth of these plates; they are, consequently, longer in the upper than in the lower eyelid. Their ducts open on the free margins of the lids by minute foramina.

Structure.—The tarsal glands are modified sebaceous glands, each consisting of a single straight tube or follicle, with numerous small lateral diverticula. The tubes are supported by a basement membrane, and are lined at their mouths by stratified epithelium; the deeper parts of the tubes and the lateral offshoots are lined by a layer of polyhedral cells.

The **conjunctiva** is the mucous membrane of the eye. It lines the inner surfaces of the eyelids or palpebræ, and is reflected over the forepart of the sclera and cornea.

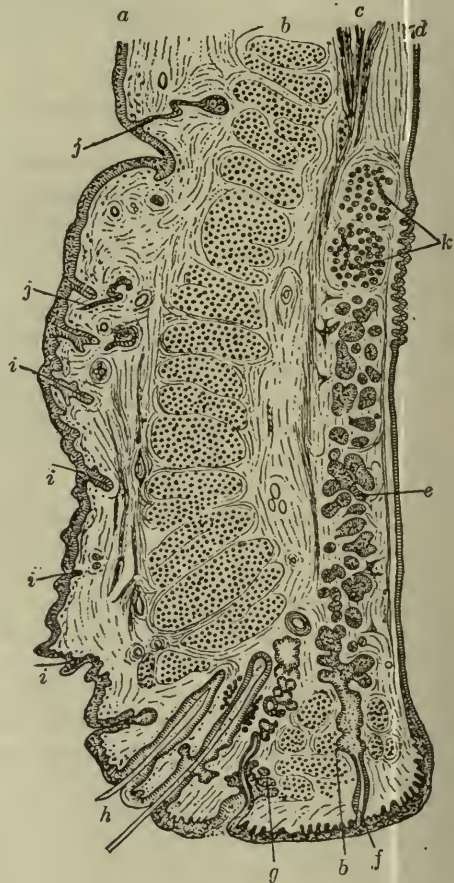


FIG. 893.—Sagittal section through the upper eyelid. (After Waldeyer.) *a.* Skin. *b.* Orbicularis oculi. *b'* Marginal fasciculus of Orbicularis (ciliary bundle). *c.* Levator palpebræ. *d.* Conjunctiva. *e.* Tarsus. *f.* Tarsal gland. *g.* Sebaceous gland. *h.* Eyelashes. *i.* Small hairs of skin. *j.* Sweat glands. *k.* Posterior tarsal glands.

The **Palpebral Portion** (*tunica conjunctiva palpebrarum*) is thick, opaque, highly vascular, and covered with numerous papillæ, its deeper part presenting a considerable amount of lymphoid tissue. At the margins of the lids it becomes continuous with the lining membrane of the ducts of the tarsal glands, and, through the lacrimal ducts, with the lining membrane of the lacrimal sac and nasolacrimal

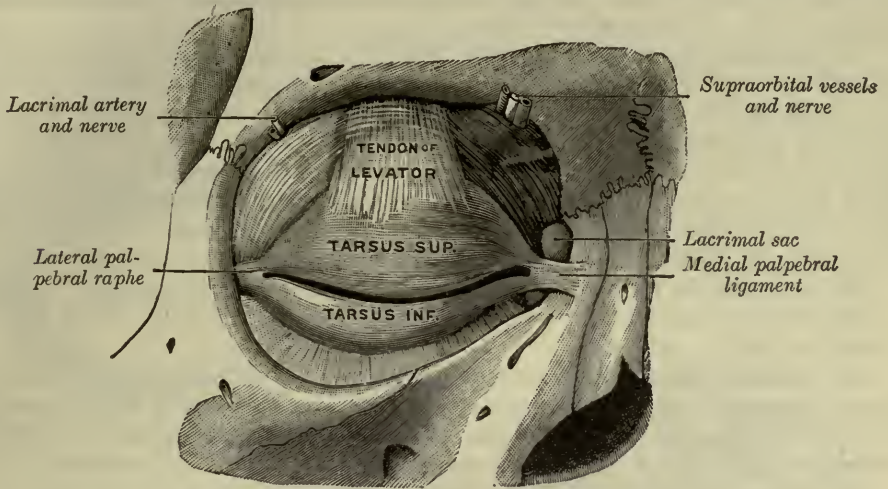


FIG. 894.—The tarsi and their ligaments. Right eye; front view.

duct. At the lateral angle of the upper eyelid the ducts of the lacrimal gland open on its free surface; and at the medial angle it forms a semilunar fold, the **plica semilunaris**. The line of reflection of the conjunctiva from the upper eyelid on to the bulb of the eye is named the **superior fornix**, and that from the lower lid the **inferior fornix**.

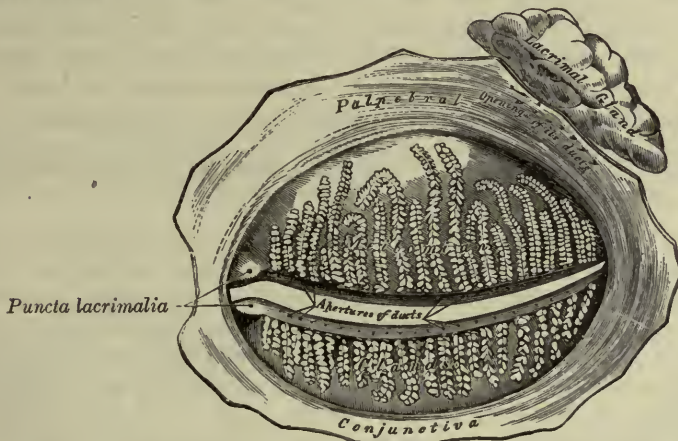


FIG. 895.—The tarsal glands, etc., seen from the inner surface of the eyelids.

The **Bulbar Portion** (*tunica conjunctiva bulbi*).—Upon the *sclera* the conjunctiva is loosely connected to the bulb of the eye; it is thin, transparent, destitute of papillæ, and only slightly vascular. Upon the *cornea*, the conjunctiva consists only of epithelium, constituting the epithelium of the cornea, already described (see page 1007). *Lymphatics* arise in the conjunctiva in a delicate zone around the cornea, and run to the ocular conjunctiva.

In and near the fornices, but more plentiful in the upper than in the lower eyelid, a number of convoluted tubular glands open on the surface of the conjunctiva. Other glands, analogous to lymphoid follicles, and called by Henle **trachoma glands**, are found in the conjunctiva, and, according to Strohmeier, are chiefly situated near the medial palpebral commissure. They were first described by Brush, in his description of Peyer's patches of the small intestine, as "identical structures existing in the under eyelid of the ox."

The **caruncula lacrimalis** is a small, reddish, conical-shaped body, situated at the medial palpebral commissure, and filling up the **lacus lacrimalis**. It consists of a small island of skin containing sebaceous and sudoriferous glands, and is the source of the whitish secretion which constantly collects in this region. A few slender hairs are attached to its surface. Lateral to the caruncula is a slight semi-lunar fold of conjunctiva, the concavity of which is directed toward the cornea; it is called the **plica semilunaris**. Müller found smooth muscular fibers in this fold; in some of the domesticated animals it contains a thin plate of cartilage.

The nerves in the conjunctiva are numerous and form rich plexuses. According to Krause they terminate in a peculiar form of tactile corpuscle, which he terms "terminal bulb."

The **Lacrimal Apparatus** (*apparatus lacrimalis*) (Fig. 896) consists of (a) the **lacrimal gland**, which secretes the tears, and its excretory ducts, which convey the fluid to the surface of the eye; (b) the **lacrimal ducts**, the **lacrimal sac**, and the **nasolacrimal duct**, by which the fluid is conveyed into the cavity of the nose.

The **Lacrimal Gland** (*glandula lacrimalis*).—The lacrimal gland is lodged in the lacrimal fossa, on the medial side of the zygomatic process of the frontal bone. It is of an oval form, about the size and shape of an almond, and consists of two portions, described as the superior and inferior lacrimal glands. The **superior lacrimal gland** is connected to the periosteum of the orbit by a few fibrous bands, and rests upon the tendons of the Recti superioris and lateralis, which separate it from the bulb of the eye. The **inferior lacrimal gland** is separated from the superior by a fibrous septum, and projects into the back part of the upper eyelid, where its deep surface is related to the conjunctiva. The ducts of the glands, from six to twelve in number, run obliquely beneath the conjunctiva for a short distance, and open along the upper and lateral half of the superior conjunctival fornix.

Structures of the Lacrimal Gland (Fig. 897).—In structure and general appearance the lacrimal resembles the serous salivary glands (p. 1136). In the recent state the cells are so crowded with granules that their limits can hardly be defined. They contain oval nuclei, and the cell protoplasm is finely fibrillated.

The **Lacrimal Ducts** (*ductus lacrimalis; lacrimal canals*).—The lacrimal ducts, one in each eyelid, commence at minute orifices, termed **puncta lacrimalia**, on the summits of the **papillæ lacrimales**, seen on the margins of the lids at the lateral extremity of the lacus lacrimalis. The **superior duct**, the smaller and shorter of the two, at first ascends, and then bends at an acute angle, and passes medialward and downward to the lacrimal sac. The **inferior duct** at first descends, and then runs almost horizontally to the lacrimal sac. At the angles they are dilated into **ampullæ**; their walls are dense in structure and their mucous lining is covered by stratified squamous epithelium, placed on a basement membrane. Outside the latter is a layer of striped muscle, continuous with the lacrimal part of the Orbicularis oculi; at the base of each lacrimal papilla the muscular fibers are circularly arranged and form a kind of sphincter.

The **Lacrimal Sac** (*saccus lacrimalis*).—The lacrimal sac is the upper dilated end of the nasolacrimal duct, and is lodged in a deep groove formed by the lacrimal bone and frontal process of the maxilla. It is oval in form and measures from 12 to 15 mm. in length; its upper end is closed and rounded; its lower is continued into the nasolacrimal duct. Its superficial surface is covered by a fibrous expansion derived

from the medial palpebral ligament, and its deep surface is crossed by the lacrimal part of the Orbicularis oculi (page 380), which is attached to the crest on the lacrimal bone.

Structure.—The lacrimal sac consists of a fibrous elastic coat, lined internally by mucous membrane: the latter is continuous, through the lacrimal ducts, with the conjunctiva, and through the nasolacrimal duct with the mucous membrane of the nasal cavity.

The **Nasolacrimal Duct** (*ductus nasolacrimalis; nasal duct*).—The nasolacrimal duct is a membranous canal, about 18 mm. in length, which extends from the lower part of the lacrimal sac to the inferior meatus of the nose, where it ends by a somewhat expanded orifice, provided with an imperfect valve, the **plica lacrimalis** (*Hasneri*), formed by a fold of the mucous membrane. It is contained in an osseous canal, formed by

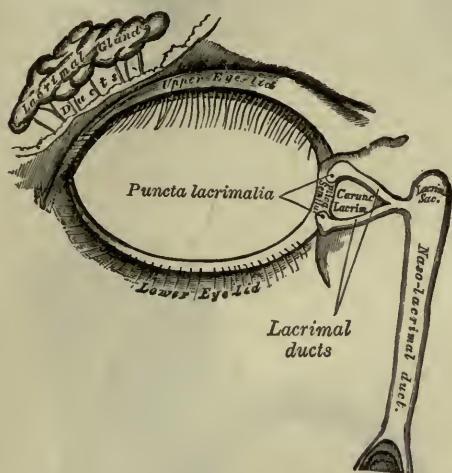


FIG. 896.—The lacrimal apparatus. Right side.

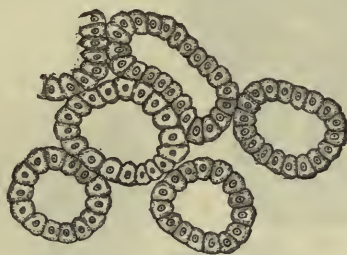


FIG. 897.—Alveoli of lacrimal gland.

the maxilla, the lacrimal bone, and the inferior nasal concha; it is narrower in the middle than at either end, and is directed downward, backward, and a little lateralward. The mucous lining of the lacrimal sac and nasolacrimal duct is covered with columnar epithelium, which in places is ciliated.

THE ORGAN OF HEARING (ORGANON AUDITUS; THE EAR).

The ear, or organ of hearing, is divisible into three parts: the external ear, the middle ear or tympanic cavity, and the internal ear or labyrinth.

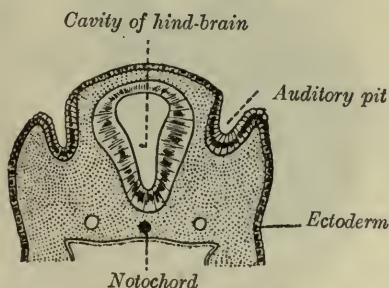


FIG. 898.—Section through the head of a human embryo, about twelve days old, in the region of the hind-brain. (Kollmann.)

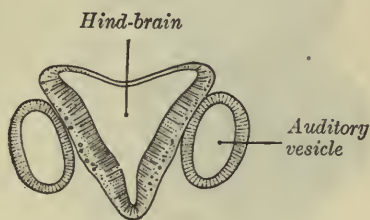


FIG. 899.—Section through hind-brain and auditory vesicles of an embryo more advanced than that of Fig. 898. (After His.)

The Development of the Ear.—The first rudiment of the internal ear appears shortly after that of the eye, in the form of a patch of thickened ectoderm, the **auditory plate**, over the region of the hind-brain. The auditory plate becomes depressed and converted into the **auditory pit** (Fig. 898). The mouth of the pit is

then closed, and thus a shut sac, the **auditory vesicle**, is formed (Fig. 899); from it the epithelial lining of the membranous labyrinth is derived. The vesicle becomes pear-shaped, and the neck of the flask is obliterated (Fig. 900). From the vesicle

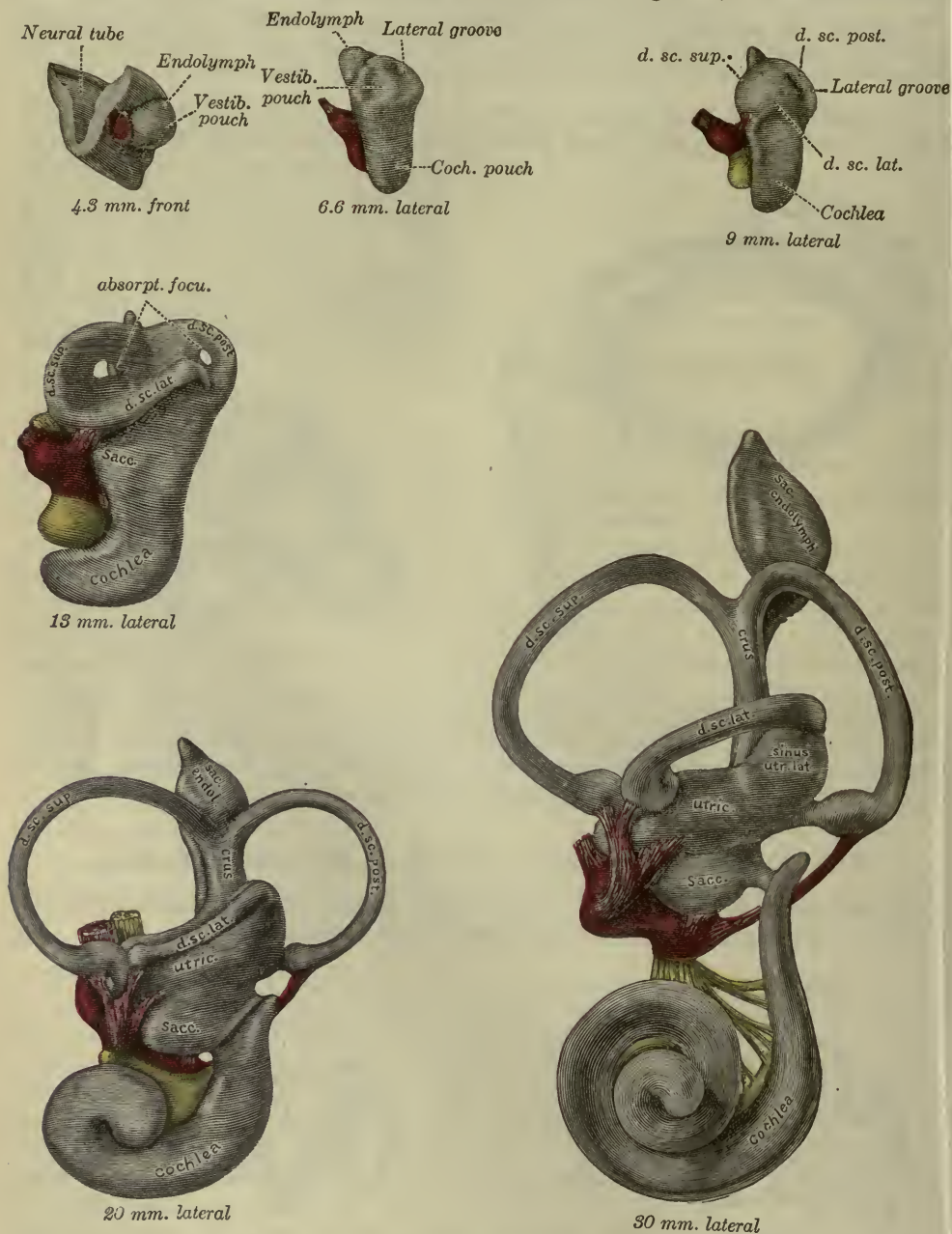


FIG. 900.—Lateral views of membranous labyrinth and acoustic complex. $\times 25$ dia. (Streeter.) *absorpt. focu.*, area of wall where absorption is complete; *amp.*, ampulla membranacea; *crus*, crus commune; *d. sc. lat.*, ductus semicircularis lateralis; *d. sc. post.*, ductus semicircularis posterior; *d. sc. sup.*, ductus semicircularis superior; *coch. or cochlea*, ductus cochlearis; *duct. endolymph.*, ductus endolymphaticus; *d. reuniens*, ductus reuniens Henseni; *endol. or endolymphs*, appendix endolymphaticus; *rec. utr.*, recessus utriculi; *sacc.*, sacculus; *sac. endol.*, saccus endolymphaticus; *sinus utr. lat.*, sinus utriculi lateralis; *utric.*, utriculus; *vestib. p.*, vestibular pouch.

certain diverticula are given off which form the various parts of the membranous labyrinth. One from the middle part forms the ductus and saccus endolymphaticus, another from the anterior end gradually elongates, and, forming a tube coiled on

itself, becomes the cochlear duct, the vestibular extremity of which is subsequently constricted to form the canalis reuniens. Three others appear as disk-like evaginations on the surface of the vesicle; the central parts of the walls of the disks coalesce and disappear, while the peripheral portions persist to form the semi-

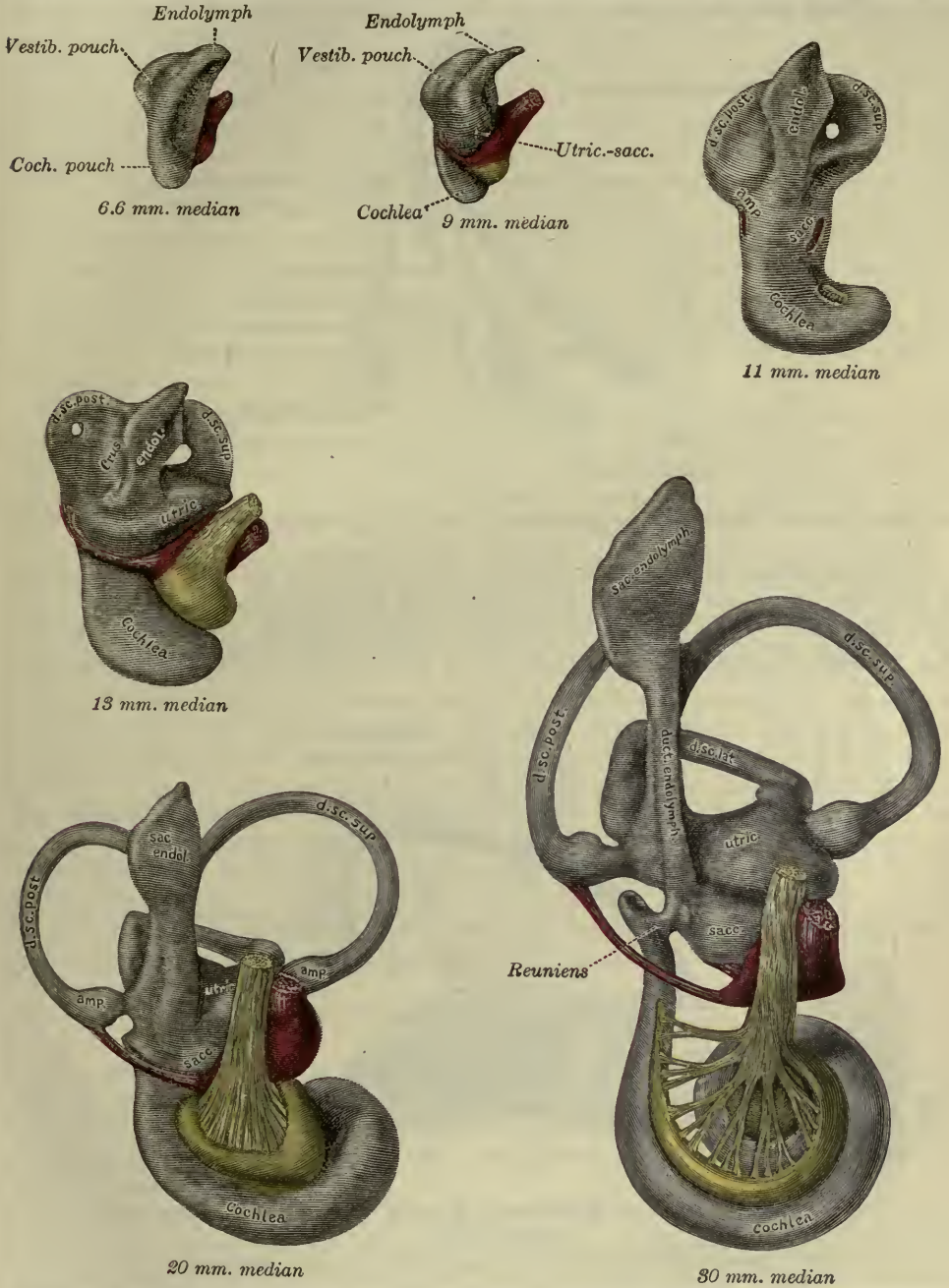


FIG. 901.—Median views of membranous labyrinth and acoustic complex in human embryos. X 25 dia. (Streeter.)

circular ducts; of these the superior is the first and the lateral the last to be completed (Fig. 902). The central part of the vesicle represents the membranous vestibule, and is subdivided by a constriction into a smaller ventral part, the saccule, and a larger dorsal and posterior part, the utricle. This subdivision is

effected by a fold which extends deeply into the proximal part of the ductus endolymphaticus, with the result that the utricle and saccule ultimately communicate with each other by means of a Y-shaped canal. The saccule opens into the cochlear duct, through the canalis reuniens, and the semicircular ducts communicate with the utricle.

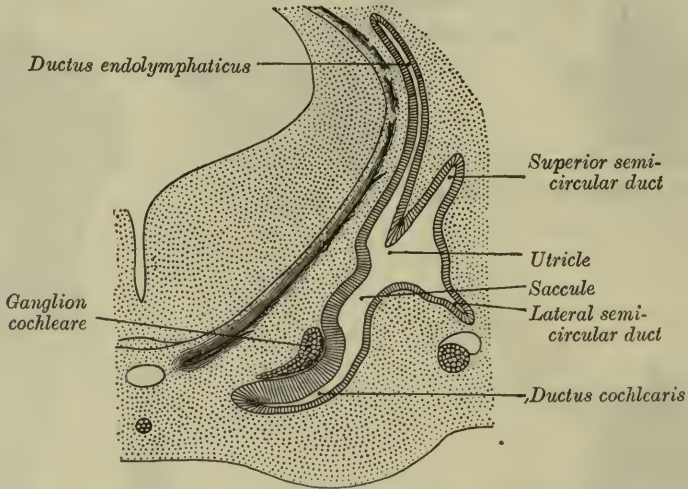


FIG. 902.—Transverse section through head of fetal sheep, in the region of the labyrinth. $\times 30$. (After Boettcher.)

The mesodermal tissue surrounding the various parts of the epithelial labyrinth is converted into a cartilaginous ear-capsule, and this is finally ossified to form the bony labyrinth. Between the cartilaginous capsule and the epithelial structures is a stratum of mesodermal tissue which is differentiated into three layers, viz.,

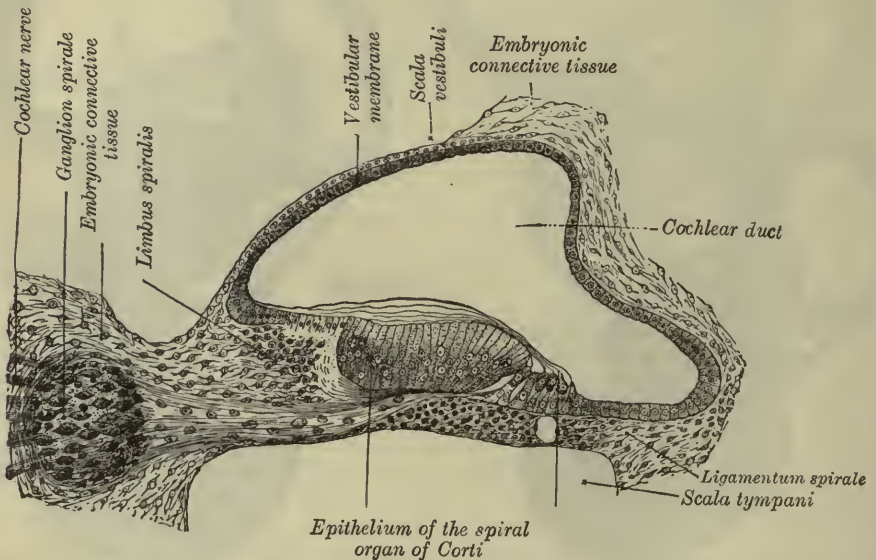


FIG. 903.—Transverse section of the cochlear duct of a fetal cat. (After Boettcher and Ayres.)

an outer, forming the periosteal lining of the bony labyrinth; an inner, in direct contact with the epithelial structures; and an intermediate, consisting of gelatinous tissue: by the absorption of this latter tissue the perilymphatic spaces are developed. The modiolus and osseous spiral lamina of the cochlea are not preformed in cartilage but are ossified directly from connective tissue.

The **middle ear** and **auditory tube** are developed from the first pharyngeal pouch. The entodermal lining of the dorsal end of this pouch is in contact with the ectoderm of the corresponding pharyngeal groove; by the extension of the mesoderm between these two layers the tympanic membrane is formed. During the sixth or seventh month the tympanic antrum appears as an upward and backward expansion of the tympanic cavity. With regard to the exact mode of development of the ossicles of the middle ear there is some difference of opinion. The view generally held is that the **malleus** is developed from the proximal end of the mandibular (Meckel's) cartilage (Fig. 43), the **incus** in the proximal end of the mandibular arch, and that the **stapes** is formed from the proximal end of the hyoid arch. The malleus, with the exception of its anterior process is ossified from a single center which appears near the neck of the bone; the anterior process is ossified separately in membrane and joins the main part of the bone about the sixth month of fetal life. The incus is ossified from one center which appears in the upper part of its long crus and ultimately extends into its lenticular process. The stapes first appears as a ring (*annulus stapedius*) encircling a small vessel, the stapedia artery, which subsequently undergoes atrophy; it is ossified from a single center which appears in its base.

The **external acoustic meatus** is developed from the first branchial groove. The lower part of this groove extends inward as a funnel-shaped tube (primary meatus) from which the cartilaginous portion and a small part of the roof of the osseous portion of the meatus are developed. From the lower part of the funnel-shaped tube an epithelial lamina extends downward and inward along the inferior wall of the primitive tympanic cavity; by the splitting of this lamina the inner part of the meatus (secondary meatus) is produced, while the inner portion of the lamina forms the cutaneous stratum of the tympanic membrane. The **auricula** or **pinna** is developed by the gradual differentiation of tubercles which appear around the margin of the first branchial groove. The rudiment of the **acoustic nerve** appears about the end of the third week as a group of ganglion cells closely applied to the cephalic edge of the auditory vesicle. Whether these cells are derived from the ectoderm adjoining the auditory vesicle, or have migrated from the wall of the neural tube, is as yet uncertain. The ganglion gradually splits into two parts, the **vestibular ganglion** and the **spiral ganglion**. The peripheral branches of the vestibular ganglion pass in two divisions, the pars superior giving rami to the superior ampulla of the superior semicircular duct, to the lateral ampulla and to the utricle; and the pars inferior giving rami to the sacculle and the posterior ampulla. The proximal fibers of the vestibular ganglion form the vestibular nerve; the proximal fibers of the spiral ganglion form the cochlear nerve.

The External Ear.

The **external ear** consists of the expanded portion named the **auricula** or **pinna**, and the **external acoustic meatus**. The former projects from the side of the head and serves to collect the vibrations of the air by which sound is produced; the latter leads inward from the bottom of the auricula and conducts the vibrations to the tympanic cavity.

The **Auricula** or **Pinna** (Fig. 904) is of an ovoid form, with its larger end directed upward. Its lateral surface is irregularly concave, directed slightly forward, and presents numerous eminences and depressions to which names have been assigned. The prominent rim of the auricula is called the **helix**; where the helix turns downward behind, a small tubercle, the **auricular tubercle of Darwin**, is frequently seen; this tubercle is very evident about the sixth month of fetal life when the whole auricula has a close resemblance to that of some of the adult monkeys. Another curved prominence, parallel with and in front of the helix, is called the **antihelix**;

this divides above into two crura, between which is a triangular depression, the *fossa triangularis*. The narrow-curved depression between the helix and the antihelix is called the *scapha*; the antihelix describes a curve around a deep, capacious cavity, the *concha*, which is partially divided into two parts by the *crus* or commencement of the helix; the upper part is termed the *cymba conchæ*, the lower part the *cavum conchæ*. In front of the concha, and projecting backward over the meatus, is a small pointed eminence, the *tragus*, so called from its being generally covered on its under surface with a tuft of hair, resembling a goat's beard. Opposite the tragus, and separated from it by the *intertragic notch*, is a small tubercle, the *antitragus*. Below this is the *lobule*, composed of tough areolar and adipose tissues, and wanting the firmness and elasticity of the rest of the auricula.

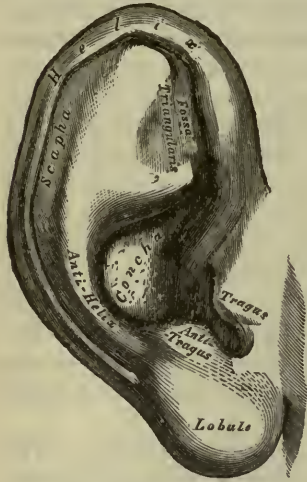


FIG. 904.—The auricula. Lateral surface.

The cranial surface of the auricula presents elevations which correspond to the depressions on its lateral surface and after which they are named, *e. g.*, *eminentia conchæ*, *eminentia triangularis*, etc.

Structure.—The auricula is composed of a thin plate of yellow fibrocartilage, covered with integument, and connected to the surrounding parts by ligaments and muscles; and to the commencement of the external acoustic meatus by fibrous tissue.

The *skin* is thin, closely adherent to the cartilage, and covered with fine hairs furnished with sebaceous glands, which are most numerous in the concha and scaphoid fossa. On the tragus and antitragus the hairs are strong and numerous. The skin of the auricula is continuous with that lining the external acoustic meatus.

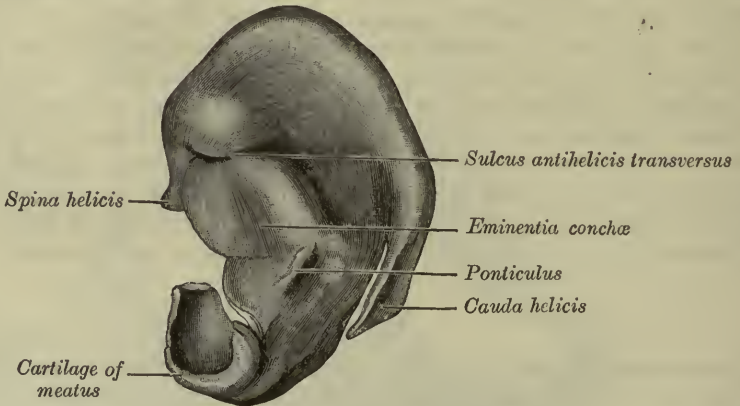


FIG. 905.—Cranial surface of cartilage of right auricula.

The **cartilage of the auricula** (*cartilago auriculæ*; *cartilage of the pinna*) (Figs. 905, 906) consists of a single piece; it gives form to this part of the ear, and upon its surface are found the eminences and depressions above described. It is absent from the lobule; it is deficient, also, between the tragus and beginning of the helix, the gap being filled up by dense fibrous tissue. At the front part of the auricula, where the helix bends upward, is a small projection of cartilage, called the *spina heliciis*, while in the lower part of the helix the cartilage is prolonged downward as a tail-like process, the *cauda heliciis*; this is separated from the antihelix by a fissure, the *fissura antitragoheliciis*. The cranial aspect of the cartilage exhibits a transverse furrow, the *sulcus antiheliciis transversus*, which corresponds with the inferior crus of the antihelix and separates the *eminentia conchæ* from the *eminentia triangularis*. The *eminentia conchæ* is crossed by a vertical ridge (*ponticulus*), which gives attachment to the *Auricularis posterior*

muscle. In the cartilage of the auricula are two fissures, one behind the crus helcis and another in the tragus.

The **ligaments of the auricula** (*ligamenti auricularia* [Valsalva]; *ligaments of the pinna*) consist of two sets: (1) **extrinsic**, connecting it to the side of the head; (2) **intrinsic**, connecting various parts of its cartilage together.

The **extrinsic ligaments** are two in number, anterior and posterior. The *anterior ligament* extends from the tragus and spina helcis to the root of the zygomatic process of the temporal bone. The *posterior ligament* passes from the posterior surface of the concha to the outer surface of the mastoid process.

The chief **intrinsic ligaments** are: (a) a strong fibrous band, stretching from the tragus to the commencement of the helix, completing the meatus in front, and partly encircling the boundary of the concha; and (b) a band between the antihelix and the cauda helcis. Other less important bands are found on the cranial surface of the pinna.

The **muscles of the auricula** (Fig. 906) consist of two sets: (1) the **extrinsic**, which connect it with the skull and scalp and move the auricula as a whole; and (2) the **intrinsic**, which extend from one part of the auricle to another.

The **extrinsic muscles** are the Auriculares anterior, superior, and posterior.

The *Auricularis anterior* (*Attrahens aurem*), the smallest of the three, is thin, fan-shaped, and its fibers are pale and indistinct. It *arises* from the lateral edge of the galea aponeurotica, and its fibers converge to be inserted into a projection on the front of the helix.

The *Auricularis superior* (*Attolens aurem*), the largest of the three, is thin and fan-shaped. Its fibers *arise* from the galea aponeurotica, and converge to be inserted by a thin, flattened tendon into the upper part of the cranial surface of the auricula.

The *Auricularis posterior* (*Retrahens aurem*) consists of two or three fleshy fasciculi, which *arise* from the mastoid portion of the temporal bone by short aponeurotic fibers. They are inserted into the lower part of the cranial surface of the concha.

Actions.—In man, these muscles possess very little action: the Auricularis anterior draws the auricula forward and upward; the Auricularis superior slightly raises it; and the Auricularis posterior draws it backward.

The **intrinsic muscles** are the:

Helicis major.	Antitragicus.
Helicis minor.	Transversus auriculæ.
Tragicus.	Obliquus auriculæ.

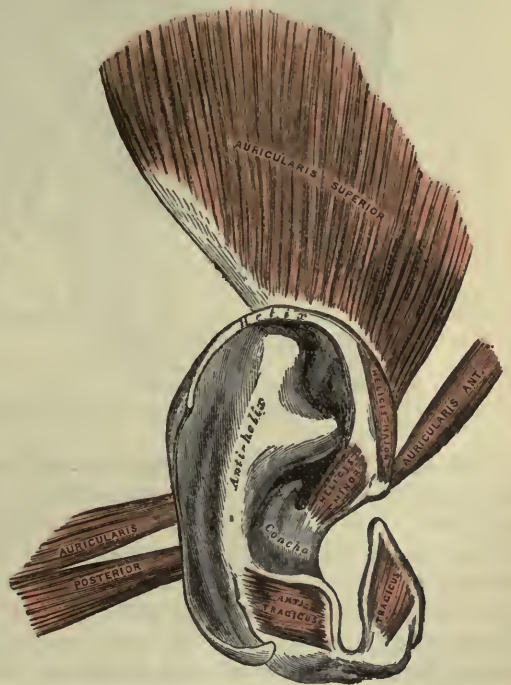

FIG. 906.—The muscles of the auricula.

The *Helicis major* is a narrow vertical band situated upon the anterior margin of the helix. It *arises* below, from the spina helcis, and is inserted into the anterior border of the helix, just where it is about to curve backward.

The *Helicis minor* is an oblique fasciculus, covering the crus helcis.

The *Tragicus* is a short, flattened vertical band on the lateral surface of the tragus.

The *Antitragicus* *arises* from the outer part of the antitragus, and is inserted into the cauda helcis and antihelix.

The *Transversus auriculæ* is placed on the cranial surface of the pinna. It consists of scattered fibers, partly tendinous and partly muscular, extending from the eminentia conchæ to the prominence corresponding with the scapha.

The *Obliquus auriculæ*, also on the cranial surface, consists of a few fibers extending from the upper and back part of the concha to the convexity immediately above it.

Nerves.—The Auriculares anterior and superior and the intrinsic muscles on the lateral surface are supplied by the temporal branch of the facial nerve, the Auricularis posterior and the intrinsic muscles on the cranial surface by the posterior auricular branch of the same nerve.

The **arteries of the auricula** are the posterior auricular from the external carotid, the anterior auricular from the superficial temporal, and a branch from the occipital artery.

The **veins** accompany the corresponding arteries.

The **sensory nerves** are: the great auricular, from the cervical plexus; the auricular branch of the vagus; the auriculotemporal branch of the mandibular nerve; and the lesser occipital from the cervical plexus.

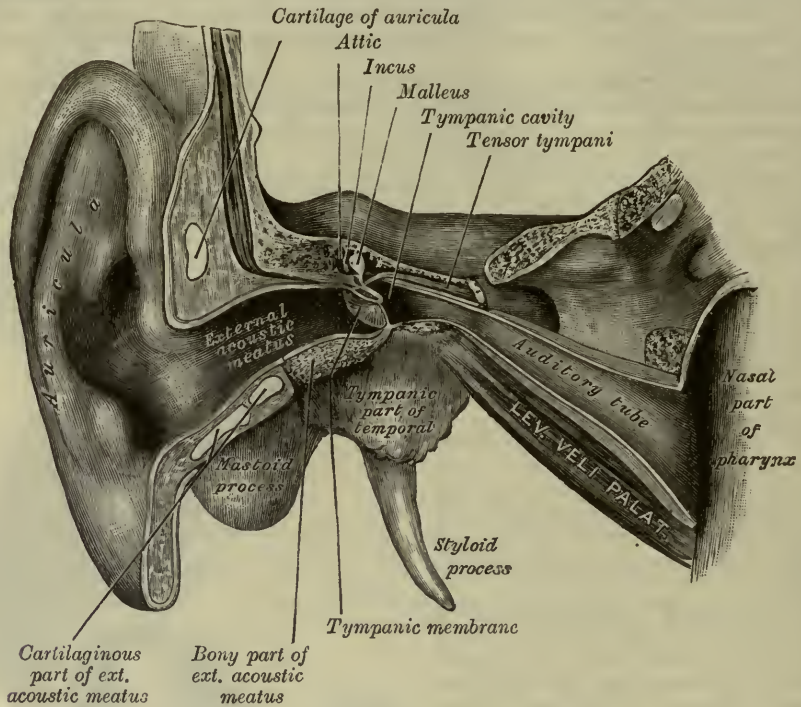


FIG. 907.—External and middle ear, opened from the front. Right side.

The **External Acoustic Meatus** (*meatus acusticus externus*; *external auditory canal or meatus*) extends from the bottom of the concha to the tympanic membrane (Figs. 907, 908). It is about 4 cm. in length if measured from the tragus; from the bottom of the concha its length is about 2.5 cm. It forms an S-shaped curve, and is directed at first inward, forward, and slightly upward (*pars externa*); it then passes inward and backward (*pars media*), and lastly is carried inward, forward, and slightly downward (*pars interna*). It is an oval cylindrical canal, the greatest diameter being directed downward and backward at the external orifice, but nearly horizontally at the inner end. It presents two constrictions, one near the inner end of the cartilaginous portion, and another, the **isthmus**, in the osseous portion, about 2 cm. from the bottom of the concha. The tympanic membrane, which closes the inner end of the meatus, is obliquely directed; in consequence of this the floor and anterior wall of the meatus are longer than the roof and posterior wall.

The external acoustic meatus is formed partly by cartilage and membrane, and partly by bone, and is lined by skin.

The **cartilaginous portion** (*meatus acusticus externus cartilagineus*) is about 8 mm. in length; it is continuous with the cartilage of the auricula, and firmly attached to the circumference of the auditory process of the temporal bone. The cartilage is deficient at the upper and back part of the meatus, its place being supplied by fibrous membrane; two or three deep fissures are present in the anterior part of the cartilage.

The **osseous portion** (*meatus acusticus externus osseus*) is about 16 mm. in length, and is narrower than the cartilaginous portion. It is directed inward and a little

forward, forming in its course a slight curve the convexity of which is upward and backward. Its inner end is smaller than the outer, and sloped, the anterior wall projecting beyond the posterior for about 4 mm.; it is marked, except at its upper part, by a narrow groove, the **tympanic sulcus**, in which the circumference of the tympanic membrane is attached. Its outer end is dilated and rough in the greater part of its circumference, for the attachment of the cartilage of the auricula. The front and lower parts of the osseous portion are formed by a curved plate of bone, the tympanic part of the temporal, which, in the fetus, exists as a separate ring (**annulus tympanicus**), incomplete at its upper part (page 146).

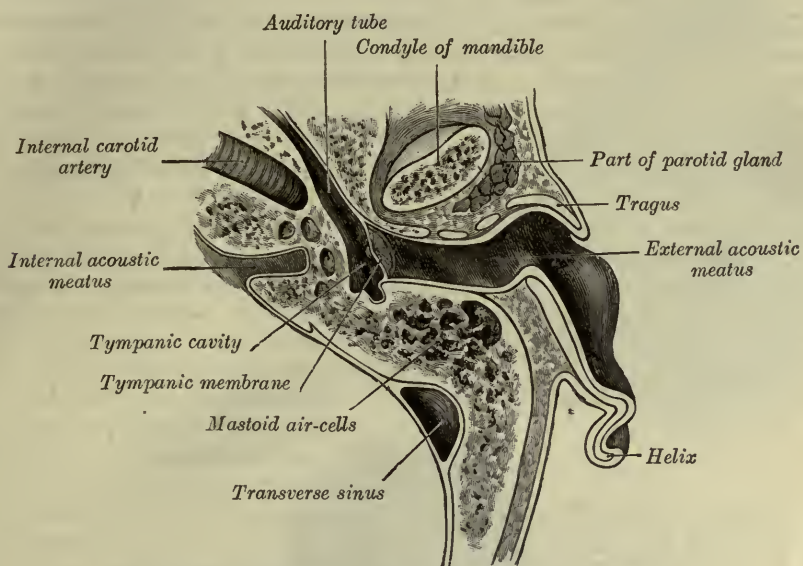


FIG. 90S.—Horizontal section through left ear; upper half of section.

The **skin** lining the meatus is very thin; adheres closely to the cartilaginous and osseous portions of the tube, and covers the outer surface of the tympanic membrane. After maceration, the thin pouch of epidermis, when withdrawn, preserves the form of the meatus. In the thick subcutaneous tissue of the cartilaginous part of the meatus are numerous ceruminous glands, which secrete the ear-wax; their structure resembles that of the sudoriferous glands.

Relations of the Meatus.—In front of the osseous part is the condyle of the mandible, which however, is frequently separated from the cartilaginous part by a portion of the parotid gland. The movements of the jaw influence to some extent the lumen of this latter portion. Behind the osseous part are the mastoid air cells, separated from the meatus by a thin layer of bone.

The **arteries** supplying the meatus are branches from the posterior auricular, internal maxillary, and temporal.

The **nerves** are chiefly derived from the auriculotemporal branch of the mandibular nerve and the auricular branch of the vagus.

The Middle Ear or Tympanic Cavity (*Cavum Tympani*; *Drum*; *Tympanum*).

The **middle ear** or **tympanic cavity** is an irregular, laterally compressed space within the temporal bone. It is filled with air, which is conveyed to it from the nasal part of the pharynx through the auditory tube. It contains a chain of movable bones, which connect its lateral to its medial wall, and serve to convey the vibrations communicated to the tympanic membrane across the cavity to the internal ear.

The tympanic cavity consists of two parts: the **tympanic cavity proper**, opposite the tympanic membrane, and the **attic** or **epitympanic recess**, above the level of the membrane; the latter contains the upper half of the malleus and the greater part of the incus. Including the attic, the vertical and antero-posterior diameters of the cavity are each about 15 mm. The transverse diameter measures about 6 mm. above and 4 mm. below; opposite the center of the tympanic membrane it is only about 2 mm. The tympanic cavity is bounded laterally by the tympanic membrane; medially, by the lateral wall of the internal ear; it communicates, behind, with the tympanic antrum and through it with the mastoid air cells, and in front with the auditory tube (Fig. 907).

The **Tegmental Wall** or **Roof** (*paries tegmentalis*) is formed by a thin plate of bone, the **tegmen tympani**, which separates the cranial and tympanic cavities. It is situated on the anterior surface of the petrous portion of the temporal bone close to its angle of junction with the squama temporalis; it is prolonged backward so as to roof in the tympanic antrum, and forward to cover in the semicanal for the Tensor tympani muscle. Its lateral edge corresponds with the remains of the petrosquamous suture.

The **Jugular Wall** or **Floor** (*paries jugularis*) is narrow, and consists of a thin plate of bone (**fundus tympani**) which separates the tympanic cavity from the jugular fossa. It presents, near the labyrinthine wall, a small aperture for the passage of the tympanic branch of the glossopharyngeal nerve.

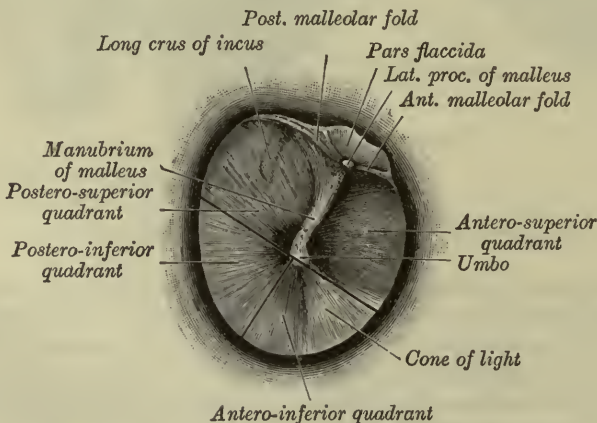


FIG. 909.—Right tympanic membrane as seen through a speculum.

The **Membranous** or **Lateral Wall** (*paries membranacea; outer wall*) is formed mainly by the tympanic membrane, partly by the ring of bone into which this membrane is inserted. This ring of bone is incomplete at its upper part, forming a notch (**notch of Rivinus**), close to which are three small apertures: the **iter chordæ posterius**, the **petrotympanic fissure**, and the **iter chordæ anterioris**.

The **iter chordæ posterius** (*apertura tympanica canaliculi chordæ*) is situated in the angle of junction between the mastoid and membranous wall of the tympanic cavity immediately behind the tympanic membrane and on a level with the upper end of the manubrium of the malleus; it leads into a minute canal, which descends in front of the canal for the facial nerve, and ends in that canal near the stylo-mastoid foramen. Through it the chorda tympani nerve enters the tympanic cavity.

The **petrotympanic fissure** (*fissura petrotympanica; Glaserian fissure*) opens just above and in front of the ring of bone into which the tympanic membrane is inserted; in this situation it is a mere slit about 2 mm. in length. It lodges the anterior process and anterior ligament of the malleus, and gives passage to the anterior tympanic branch of the internal maxillary artery.

The *iter chordæ anterioris* (*canal of Huguier*) is placed at the medial end of the petrotympanic fissure; through it the chorda tympani nerve leaves the tympanic cavity.

The **Tympanic Membrane** (*membrana tympani*) (Figs. 909, 910) separates the tympanic cavity from the bottom of the external acoustic meatus. It is a thin, semitransparent membrane, nearly oval in form, somewhat broader above than below, and directed very obliquely downward and inward so as to form an angle of about fifty-five degrees with the floor of the meatus. Its longest diameter is downward and forward, and measures from 9 to 10 mm.; its shortest diameter measures from 8 to 9 mm. The greater part of its circumference is thickened, and forms a **fibrocartilaginous ring** which is fixed in the **tympanic sulcus** at the inner end of the meatus. This sulcus is deficient superiorly at the notch of Rivinus, and from the ends of this notch two bands, the **anterior** and **posterior malleolar folds**, are prolonged to the lateral process of the malleus. The small, somewhat triangular part of the membrane situated above these folds is lax and thin, and is named the **pars flaccida**; in it a small orifice is sometimes seen. The manubrium of the malleus is firmly attached to the medial surface of the membrane as far as its center, which it draws toward the tympanic cavity; the lateral surface of the membrane is thus concave, and the most depressed part of this concavity is named the **umbo**.

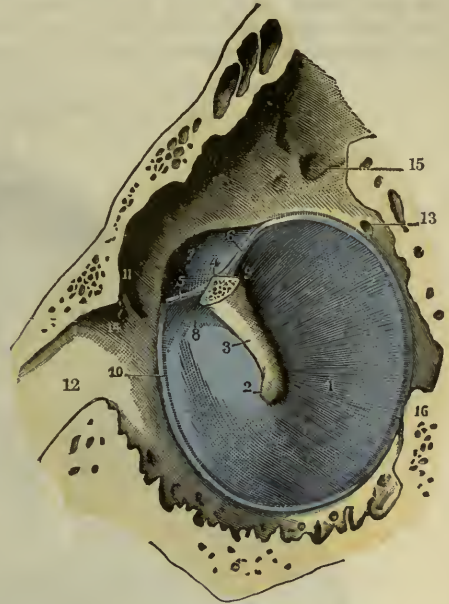


FIG. 910.—The tympanic membrane viewed from within. (Testut.) The malleus has been resected immediately beyond its lateral process, in order to show the tympanomalleolar folds and the membrana flaccida. 1. Tympanic membrane. 2. Umbo. 3. Handle of the malleus. 4. Lateral process. 5. Anterior tympanomalleolar fold. 6. Posterior tympanomalleolar fold. 7. Pars flaccida. 8. Anterior pouch of Tröltsch. 9. Posterior pouch of Tröltsch. 10. Fibrocartilaginous ring. 11. Petrotympanic fissure. 12. Auditory tube. 13. *Iter chordæ posterioris*. 14. *Iter chordæ anterioris*. 15. Fossa incudis for short crus of the incus. 16. Prominentia styloidea.

Structure.—The tympanic membrane is composed of three strata: a **lateral** (*cutaneous*), an **intermediate** (*fibrous*), and a **medial** (*mucous*).

The **cutaneous stratum** is derived from the integument lining the meatus. The **fibrous stratum** consists of two layers: a radiate stratum,

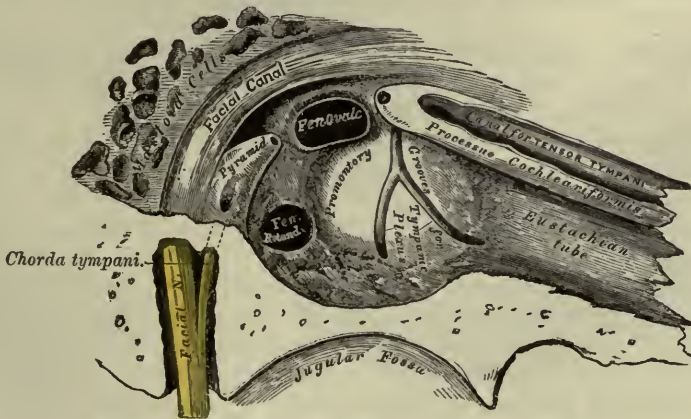


FIG. 911.—View of the inner wall of the tympanum (enlarged.)

the fibers of which diverge from the manubrium of the malleus, and a circular stratum, the fibers of which are plentiful around the circumference but sparse and scattered near the center

of the membrane. Branched or dendritic fibers, as pointed out by Grüber, are also present, especially in the posterior half of the membrane.

Vessels and Nerves.—The arteries of the tympanic membrane are derived from the deep auricular branch of the internal maxillary, which ramifies beneath the cutaneous stratum; and from the stylomastoid branch of the posterior auricular, and tympanic branch of the internal maxillary, which are distributed on the mucous surface. The superficial veins open into the external jugular; those on the deep surface drain partly into the transverse sinus and veins of the dura mater, and partly into a plexus on the auditory tube. The membrane receives its chief nerve supply from the auriculotemporal branch of the mandibular; the auricular branch of the vagus, and the tympanic branch of the glossopharyngeal also supply it.¹

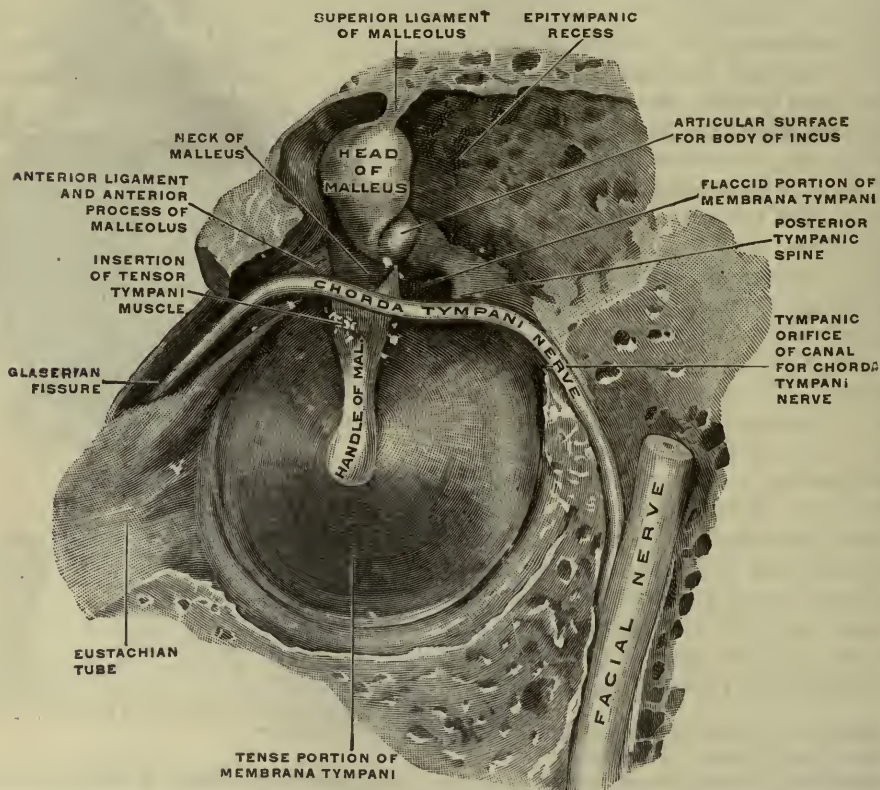


FIG. 912.—The right membrana tympani with the hammer and the chorda tympani, viewed from within, from behind, and from above. (Spalteholz.)

The **Labyrinthine or Medial Wall** (*paries labyrinthica; inner wall*) (Fig. 913) is vertical in direction, and presents for examination the **fenestræ vestibuli and cochleæ**, the **promontory**, and the **prominence of the facial canal**.

The **fenestra vestibuli** (*fenestra ovalis*) is a reniform opening leading from the tympanic cavity into the vestibule of the internal ear; its long diameter is horizontal, and its convex border is upward. In the recent state it is occupied by the base of the stapes, the circumference of which is fixed by the annular ligament to the margin of the foramen.

The **fenestra cochleæ** (*fenestra rotunda*) is situated below and a little behind the fenestra vestibuli, from which it is separated by a rounded elevation, the **promontory**. It is placed at the bottom of a funnel-shaped depression and, in the macerated bone, leads into the cochlea of the internal ear; in the fresh state it is closed by a membrane, the **secondary tympanic membrane**, which is concave toward the tympanic cavity, convex toward the cochlea. This membrane consists of three layers: an

¹ Wilson, J. G.. American Journal of Anatomy, 1911, xi.

external, or mucous, derived from the mucous lining of the tympanic cavity; an internal, from the lining membrane of the cochlea; and an intermediate, or fibrous layer.

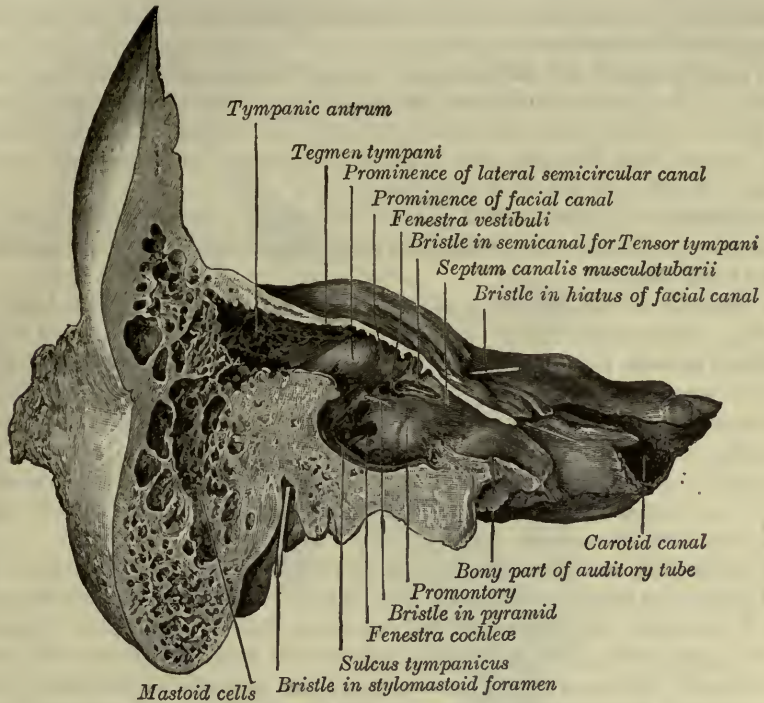


FIG. 913.—Coronal section of right temporal bone.

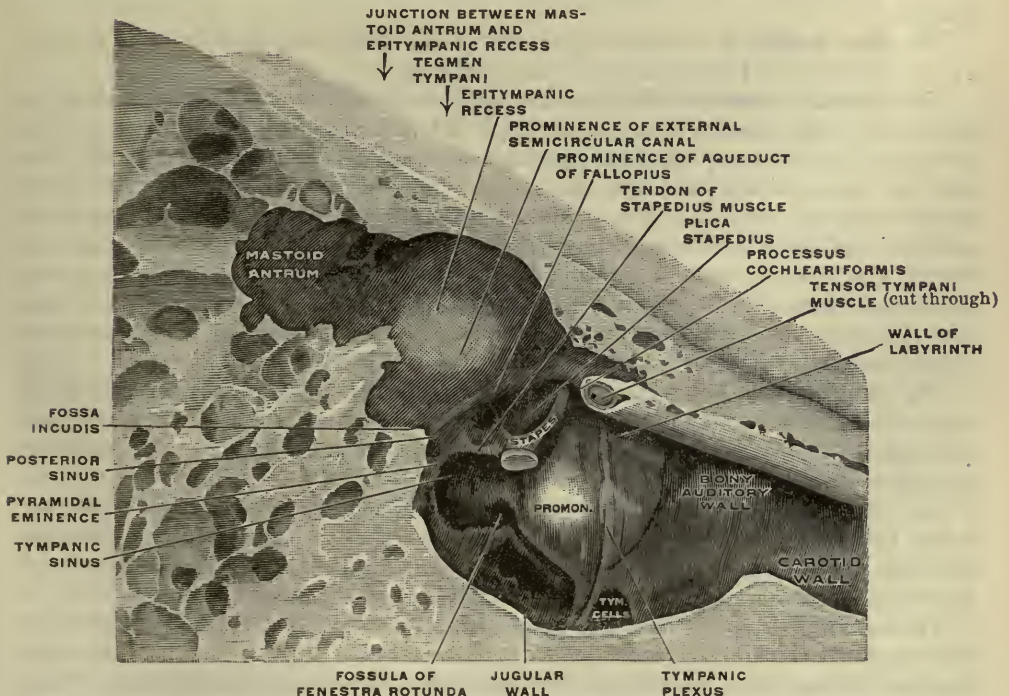


FIG. 914.—The medial wall and part of the posterior and anterior walls of the right tympanic cavity, lateral view. (Spalteholz.)

The **promontory** (*promontorium*) is a rounded hollow prominence, formed by the projection outward of the first turn of the cochlea; it is placed between the fenestræ, and is furrowed on its surface by small grooves, for the lodgement of branches of the tympanic plexus. A minute spicule of bone frequently connects the promontory to the pyramidal eminence.

The **prominence of the facial canal** (*prominentia canalis facialis; prominence of aqueduct of Fallopius*) indicates the position of the bony canal in which the facial nerve is contained; this canal traverses the labyrinthic wall of the tympanic cavity above the fenestra vestibuli, and behind that opening curves nearly vertically downward along the mastoid wall.

The **mastoid or posterior wall** (*paries mastoidea*) is wider above than below, and presents for examination the **entrance to the tympanic antrum**, the **pyramidal eminence**, and the **fossa incudis**.

The **entrance to the antrum** is a large irregular aperture, which leads backward from the epitympanic recess into a considerable air space, named the **tympanic or mastoid antrum** (see page 142). The antrum communicates behind and below with the **mastoid air cells**, which vary considerably in number, size, and form; the antrum and mastoid air cells are lined by mucous membrane, continuous with that lining the tympanic cavity. On the medial wall of the entrance to the antrum is a rounded eminence, situated above and behind the prominence of the facial canal; it corresponds with the position of the ampullated ends of the superior and lateral semicircular canals.

The **pyramidal eminence** (*eminentia pyramidalis; pyramid*) is situated immediately behind the fenestra vestibuli, and in front of the vertical portion of the facial canal; it is hollow, and contains the Stapedius muscle; its summit projects forward toward the fenestra vestibuli, and is pierced by a small aperture which transmits the tendon of the muscle. The cavity in the pyramidal eminence is prolonged downward and backward in front of the facial canal, and communicates with it by a minute aperture which transmits a twig from the facial nerve to the Stapedius muscle.

The **fossa incudis** is a small depression in the lower and back part of the epitympanic recess; it lodges the short crus of the incus.

The **Carotid or Anterior Wall** (*paries carotica*) is wider above than below; it corresponds with the carotid canal, from which it is separated by a thin plate of bone perforated by the tympanic branch of the internal carotid artery, and by the deep petrosal nerve which connects the sympathetic plexus on the internal carotid artery with the tympanic plexus on the promontory. At the upper part of the anterior wall are the orifice of the semicanal for the Tensor tympani muscle and the tympanic orifice of the auditory tube, separated from each other by a thin horizontal plate of bone, the **septum canalis musculotubarii**. These canals run from the tympanic cavity forward and downward to the retiring angle between the squama and the petrous portion of the temporal bone.

The **semicanal for the Tensor tympani** (*semicanalis m. tensoris tympani*) is the superior and the smaller of the two; it is cylindrical and lies beneath the tegmen tympani. It extends on to the labyrinthic wall of the tympanic cavity and ends immediately above the fenestra vestibuli.

The **septum canalis musculotubarii** (*processus cochleariformis*) passes backward below this semicanal, forming its lateral wall and floor; it expands above the anterior end of the fenestra vestibuli and terminates there by curving laterally so as to form a pulley over which the tendon of the muscle passes.

The **auditory tube** (*tuba auditiva; Eustachian tube*) is the channel through which the tympanic cavity communicates with the nasal part of the pharynx. Its length is about 36 mm., and its direction is downward, forward, and medialward, forming an angle of about 45 degrees with the sagittal plane and one of from 30 to 40 degrees

with the horizontal plane. It is formed partly of bone, partly of cartilage and fibrous tissue (Figs. 819, 915).

The **osseous portion** (*pars osseo tubæ auditivæ*) is about 12 mm. in length. It begins in the carotid wall of the tympanic cavity, below the septum canalis musculotubarii, and, gradually narrowing, ends at the angle of junction of the squama and the petrous portion of the temporal bone, its extremity presenting a jagged margin which serves for the attachment of the cartilaginous portion.

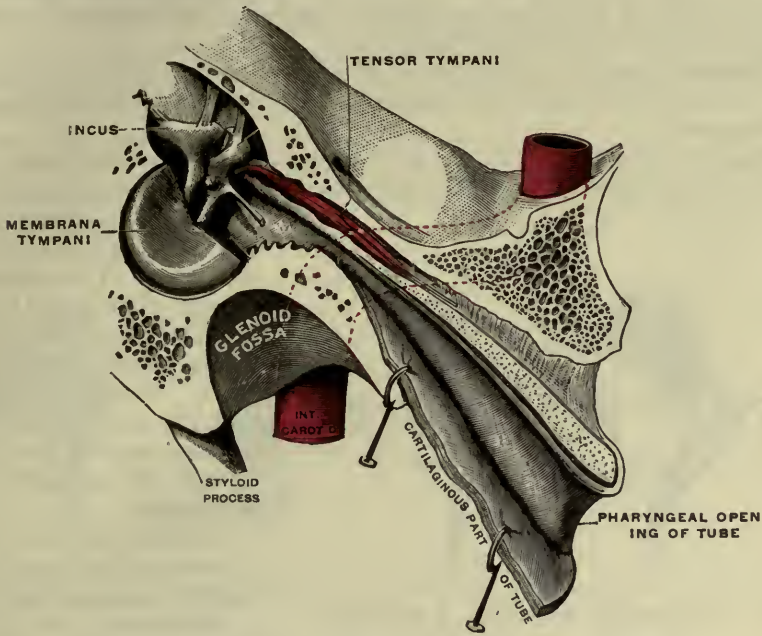


FIG. 915.—Auditory tube, laid open by a cut in its long axis. (Testut.)

The **cartilaginous portion** (*pars cartilaginea tubæ auditivæ*), about 24 mm. in length, is formed of a triangular plate of elastic fibrocartilage, the apex of which is attached to the margin of the medial end of the osseous portion of the tube, while its base lies directly under the mucous membrane of the nasal part of the pharynx, where it forms an elevation, the **torus tubarius** or **cushion**, behind the pharyngeal orifice of the tube. The upper edge of the cartilage is curled upon itself, being bent laterally so as to present on transverse section the appearance of a hook; a groove or furrow is thus produced, which is open below and laterally, and this part of the canal is completed by fibrous membrane. The cartilage lies in a groove between the petrous part of the temporal and the great wing of the sphenoid; this groove ends opposite the middle of the medial pterygoid plate. The cartilaginous and bony portions of the tube are not in the same plane, the former inclining downward a little more than the latter. The diameter of the tube is not uniform throughout, being greatest at the pharyngeal orifice, least at the junction of the bony and cartilaginous portions, and again increased toward the tympanic cavity; the narrowest part of the tube is termed the **isthmus**. The position and relations of the pharyngeal orifice are described with the nasal part of the pharynx. The mucous membrane of the tube is continuous in front with that of the nasal part of the pharynx, and behind with that of the tympanic cavity; it is covered with ciliated epithelium and is thin in the osseous portion, while in the cartilaginous portion it contains many mucous glands and near the pharyngeal orifice a considerable amount of adenoid tissue, which has been named by Gerlach the **tube tonsil**. The tube is opened during deglu-

tion by the Salpingopharyngeus and Dilator tubæ. The latter arises from the hook of the cartilage and from the membranous part of the tube, and blends below with the Tensor veli palatini.

The Auditory Ossicles (Ossicula Auditus).

The tympanic cavity contains a chain of three movable ossicles, the **malleus**, **incus**, and **stapes**. The first is attached to the tympanic membrane, the last to the circumference of the fenestra vestibuli, the incus being placed between and connected to both by delicate articulations.

The **Malleus** (Fig. 916), so named from its fancied resemblance to a hammer, consists of a **head**, **neck**, and three processes, viz., the **manubrium**, the **anterior** and **lateral processes**.

The **head** (*capitulum mallei*) is the large upper extremity of the bone; it is oval in shape, and articulates posteriorly with the incus, being free in the rest of its extent. The facet for articulation with the incus is constricted near the middle, and consists of an upper larger and lower smaller part, which form nearly a right angle with each other. Opposite the constriction the lower margin of the facet projects in the form of a process, the **cog-tooth** or **spur of the malleus**.

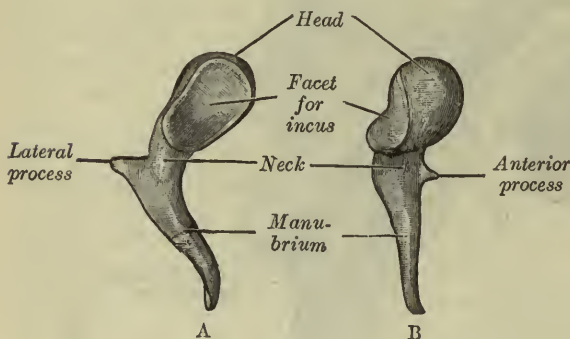


FIG. 916.—Left malleus. A. From behind. B. From within.

The **manubrium mallei** (*handle*) is connected by its lateral margin with the tympanic membrane. It is directed downward, medialward, and backward; it decreases in size toward its free end, which is curved slightly forward, and flattened transversely. On its medial side, near its upper end, is a slight projection, into which the tendon of the Tensor tympani is inserted.

The **anterior process** (*processus anterior* [*Folii*]; *processus gracilis*) is a delicate spicule, which springs from the eminence below the neck and is directed forward to the petrotympanic fissure, to which it is connected by ligamentous fibers. In the fetus this is the longest process of the malleus, and is in direct continuity with the cartilage of Meckel.

The **lateral process** (*processus lateralis*; *processus brevis*) is a slight conical projection, which springs from the root of the manubrium; it is directed laterally, and is attached to the upper part of the tympanic membrane and, by means of the anterior and posterior malleolar folds, to the extremities of the notch of Rivinus.

The **Incus** (Fig. 917) has received its name from its supposed resemblance to an anvil, but it is more like a premolar tooth, with two roots, which differ in length, and are widely separated from each other. It consists of a **body** and **two crura**.

The **body** (*corpus incudis*) is somewhat cubical but compressed transversely. On its anterior surface is a deeply concavo-convex facet, which articulates with the head of the malleus.

The two crura diverge from one another nearly at right angles.

The **short crus** (*crus breve*; *short process*), somewhat conical in shape, projects

almost horizontally backward, and is attached to the **fossa incudis**, in the lower and back part of the epitympanic recess.

The **long crus** (*crus longum*; *long process*) descends nearly vertically behind and parallel to the manubrium of the malleus, and, bending medialward, ends in a rounded projection, the **lenticular process**, which is tipped with cartilage, and articulates with the head of the stapes.

The **Stapes** (Fig. 918), so called from its resemblance to a stirrup, consists of a **head**, **neck**, **two crura**, and a **base**.

The **head** (*capitulum stapedis*) presents a depression, which is covered by cartilage, and articulates with the lenticular process of the incus.

The **neck**, the constricted part of the bone succeeding the head, gives insertion to the tendon of the Stapedius muscle.

The **two crura** (*crus anterior* and *crus posterior*) diverge from the neck and are connected at their ends by a flattened oval plate, the **base** (*basis stapedis*), which forms the foot-plate of the stirrup and is fixed to the margin of the fenestra vestibuli by a ring of ligamentous fibers. Of the two crura the anterior is shorter and less curved than the posterior.

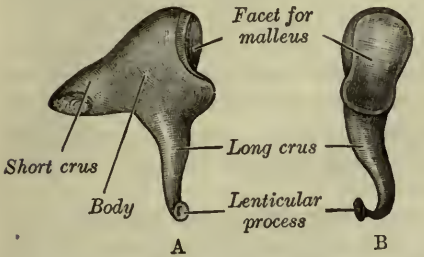


FIG. 917.—Left incus. A. From within. B. From the front.

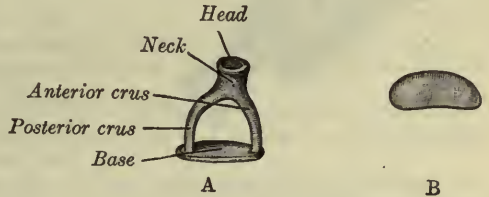


FIG. 918.—A. Left stapes. B. Base of stapes, medial surface.

Articulations of the Auditory Ossicles (*articulationes ossiculorum auditus*).—

The incudomalleolar joint is a saddle-shaped diarthrosis; it is surrounded by an articular capsule, and the joint cavity is incompletely divided into two by a wedge-shaped articular disk or meniscus. The incudostapedial joint is an enarthrosis, surrounded by an articular capsule; some observers have described an articular disk or meniscus in this joint; others regard the joint as a syndesmosis.

Ligaments of the Ossicles (*ligamenta ossiculorum auditus*).—The ossicles are connected with the walls of the tympanic cavity by ligaments: three for the malleus, and one each for the incus and stapes.

The **anterior ligament of the malleus** (*lig. mallei anterior*) is attached by one end to the neck of the malleus, just above the anterior process, and by the other to the anterior wall of the tympanic cavity, close to the petrotympanic fissure, some of its fibers being prolonged through the fissure to reach the spina angularis of the sphenoid.

The **superior ligament of the malleus** (*lig. mallei superior*) is a delicate, round bundle which descends from the roof of the epitympanic recess to the head of the malleus.

The **lateral ligament of the malleus** (*lig. mallei laterale*; *external ligament of the malleus*) is a triangular band passing from the posterior part of the notch of Rivinus to the head of the malleus. Helmholtz described the anterior ligament and the posterior part of the lateral ligament as forming together the **axis ligament** around which the malleus rotates.

The **posterior ligament of the incus** (*lig. incudis posterior*) is a short, thick band connecting the end of the short crus of the incus to the fossa incudis.

A superior ligament of the incus (*lig. incudis superius*) has been described, but it is little more than a fold of mucous membrane.

The vestibular surface and the circumference of the base of the stapes are covered with hyaline cartilage; that encircling the base is attached to the margin of the fenestra vestibuli by a fibrous ring, the **annular ligament of the base of the stapes** (*lig. annulare baseos stapedis*).

The **Muscles of the Tympanic Cavity** (*musculi ossiculorum auditus*) are the Tensor tympani and Stapedius.

The **Tensor tympani**, the larger, is contained in the bony canal above the osseous portion of the auditory tube, from which it is separated by the septum canalis musculotubarii. It arises from the cartilaginous portion of the auditory tube and the adjoining part of the great wing of the sphenoid, as well as from the osseous canal in which it is contained. Passing backward through the canal, it ends in a slender tendon which enters the tympanic cavity, makes a sharp bend around the extremity of the septum, and is inserted into the manubrium of the malleus, near its root. It is supplied by a branch of the mandibular nerve through the otic ganglion.

The **Stapedius** arises from the wall of a conical cavity, hollowed out of the interior of the pyramidal eminence; its tendon emerges from

the orifice at the apex of the eminence, and, passing forward, is inserted into the posterior surface of the neck of the stapes. It is supplied by a branch of the facial nerve.

Actions.—The Tensor tympani draws the tympanic membrane medialward, and thus increases its tension. The Stapedius pulls the head of the stapes backward and thus causes the base of the bone to rotate on a vertical axis drawn through its own center; the back part of the base is pressed inward toward the vestibule, while the forepart is withdrawn from it. By the action of the muscle the tension of the fluid within the internal ear is probably increased.

The **Mucous Membrane of the Tympanic Cavity** is continuous with that of the pharynx, through the auditory tube. It invests the auditory ossicles, and the muscles and nerves contained in the tympanic cavity; forms the medial layer of the tympanic membrane, and the lateral layer of the secondary tympanic membrane, and is reflected into the tympanic antrum and mastoid cells, which it lines throughout. It forms several vascular folds, which extend from the walls of the tympanic cavity of the ossicles; of these, one descends from the roof of the cavity to the head of the malleus and upper margin of the body of the incus, a second invests the Stapedius muscle: other folds invest the chorda tympani nerve and the Tensor tympani muscle. These folds separate off pouch-like cavities, and give the interior of the tympanum a somewhat honey-combed appearance. One of these pouches, the **pouch of Prussak**, is well-marked and lies between the neck of the malleus and the membrana flaccida. Two other recesses may be mentioned: they are formed by the mucous membrane which envelops the chorda tympani nerve and are situated, one in front of, and the other behind the manubrium of the malleus; they are named the **anterior** and **posterior recesses of Troeltsch**. In the tympanic cavity this membrane is pale, thin, slightly vascular, and covered for the most part with columnar ciliated epithelium, but over the pyramidal eminence, ossicles, and tympanic membrane it possesses a flattened non-ciliated epithelium. In the tympanic antrum and mastoid cells its epithelium is also non-ciliated. In the osseous portion of the auditory tube the membrane is thin; but in the cartilaginous portion it is very thick, highly vascular, and provided with numerous mucous glands; the epithelium which lines the tube is columnar and ciliated.

Vessels and Nerves.—The **arteries** are six in number. Two of them are larger than the others, viz., the tympanic branch of the internal maxillary, which supplies the tympanic membrane;

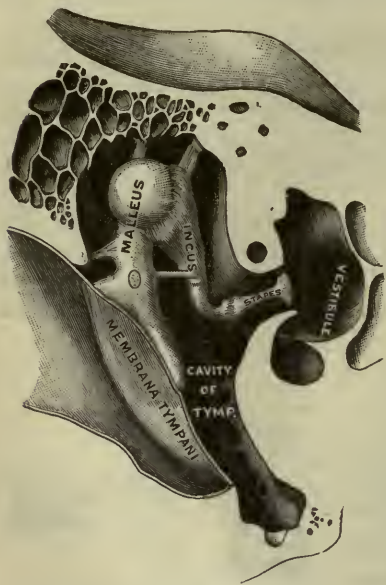

FIG. 919.—Chain of ossicles and their ligaments, seen from the front in a vertical, transverse section of the tympanum. (Testut.)

and the stylomastoid branch of the posterior auricular, which supplies the back part of the tympanic cavity and mastoid cells. The smaller arteries are—the petrosal branch of the middle meningeal, which enters through the hiatus of the facial canal; a branch from the ascending pharyngeal, and another from the artery of the pterygoid canal, which accompany the auditory tube; and the tympanic branch from the internal carotid, given off in the carotid canal and perforating the thin anterior wall of the tympanic cavity. The **veins** terminate in the pterygoid plexus and the superior petrosal sinus. The **nerves** constitute the tympanic plexus, which ramifies upon the surface of the promontory. The plexus is formed by (1) the tympanic branch of the glossopharyngeal; (2) the caroticotympanic nerves; (3) the smaller superficial petrosal nerve; and (4) a branch which joins the greater superficial petrosal.

The **tympanic branch of the glossopharyngeal** (*Jacobson's nerve*) enters the tympanic cavity by an aperture in its floor close to the labyrinthine wall, and divides into branches which ramify on the promontory and enter into the formation of the tympanic plexus. The **superior and inferior caroticotympanic nerves** from the carotid plexus of the sympathetic pass through the wall of the carotid canal, and join the branches of the tympanic branch of the glossopharyngeal. The branch to the greater superficial petrosal passes through an opening on the labyrinthine wall, in front of the fenestra vestibuli. The **smaller superficial petrosal nerve**, from the otic ganglion, passes backward through a foramen in the middle fossa of the base of the skull (sometimes through the foramen ovale), and enters the anterior surface of the petrous part of the temporal bone through a small aperture, situated lateral to the hiatus of the facial canal; it courses downward through the bone, past the genicular ganglion of the facial nerve, receiving a connecting filament from it, and enters the tympanic cavity, where it communicates with the tympanic branch of the glossopharyngeal, and assists in forming the tympanic plexus.

The **branches of distribution** of the tympanic plexus are supplied to the mucous membrane of the tympanic cavity; a branch passes to the fenestra vestibuli, another to the fenestra cochleæ, and a third to the auditory tube. The smaller superficial petrosal may be looked upon as the continuation of the tympanic branch of the glossopharyngeal through the plexus to the otic ganglion.

In addition to the tympanic plexus there are the nerves supplying the muscles. The Tensor tympani is supplied by a branch from the mandibular through the otic ganglion, and the Stapedius by a branch from the facial.

The **chorda tympani nerve** crosses the tympanic cavity. It is given off from the sensory part of the facial, about 6 mm. before the nerve emerges from the stylomastoid foramen. It runs from below upward and forward in a canal, and enters the tympanic cavity through the iter chordæ posterius, and becomes invested with mucous membrane. It traverses the tympanic cavity, crossing medial to the tympanic membrane and over the upper part of the manubrium of the malleus to the carotid wall, where it emerges through the iter chordæ anterior (*canal of Huguet*).

The Internal Ear or Labyrinth (*Auris Interna*).

The **internal ear** is the essential part of the organ of hearing, receiving the ultimate distribution of the auditory nerve. It is called the **labyrinth**, from the complexity of its shape, and consists of two parts: the **osseous labyrinth**, a series of cavities within the petrous part of the temporal bone, and the **membranous labyrinth**, a series of communicating membranous sacs and ducts, contained within the bony cavities.

The **Osseous Labyrinth** (*labyrinthus osseus*) (Figs. 920, 921).—The osseous labyrinth consists of three parts: the **vestibule**, **semicircular canals**, and **cochlea**. These are cavities hollowed out of the substance of the bone, and lined by periosteum; they contain a clear fluid, the **perilymph**, in which the membranous labyrinth is situated.

The **Vestibule** (*vestibulum*).—The vestibule is the central part of the osseous labyrinth, and is situated medial to the tympanic cavity, behind the cochlea, and in front of the semicircular canals. It is somewhat ovoid in shape, but flattened transversely; it measures about 5 mm. from before backward, the same from above downward, and about 3 mm. across. In its *lateral* or *tympanic wall* is the **fenestra vestibuli**, closed, in the fresh state, by the base of the stapes and annular ligament. On its *medial wall*, at the forepart, is a small circular depression, the **recessus sphaericus**, which is perforated, at its anterior and inferior part, by several minute holes (**macula cribrosa media**) for the passage of filaments of the acoustic nerve to the saccule; and behind this depression is an oblique ridge, the **crista vestibuli**,

the anterior end of which is named the **pyramid of the vestibule**. This ridge bifurcates below to enclose a small depression, the **fossa cochlearis**, which is perforated by a number of holes for the passage of filaments of the acoustic nerve which supply the vestibular end of the ductus cochlearis. As the hinder part of the medial wall is the orifice of the **aquæductus vestibuli**, which extends to the posterior surface of

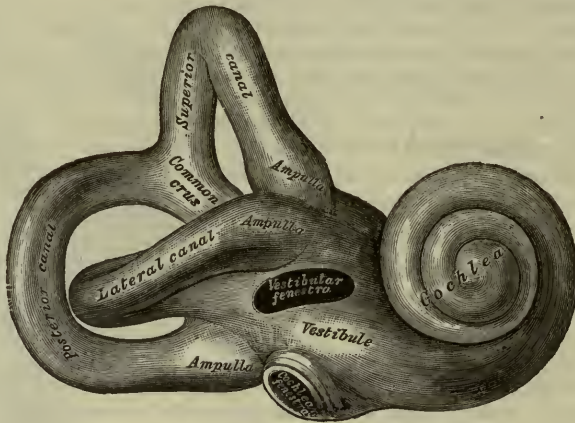


FIG. 920.—Right osseous labyrinth. Lateral view.

the petrous portion of the temporal bone. It transmits a small vein, and contains a tubular prolongation of the membranous labyrinth, the **ductus endolymphaticus**, which ends in a cul-de-sac between the layers of the dura mater within the cranial cavity. On the *upper wall* or roof is a transversely oval depression, the **recessus ellipticus**, separated from the recessus sphericus by the crista vestibuli already mentioned. The pyramid and adjoining part of the recessus ellipticus are perforated

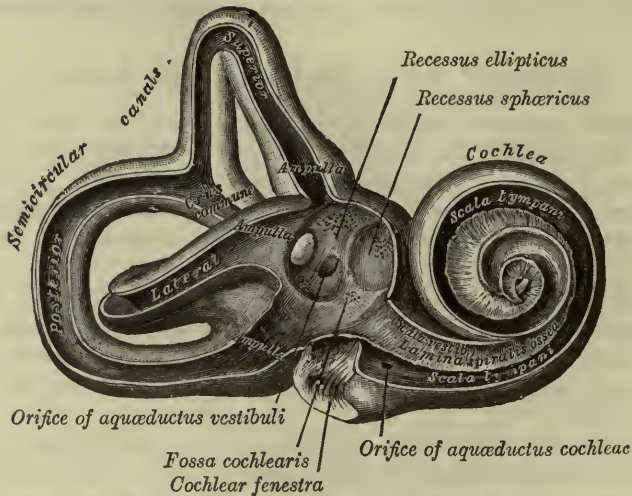


FIG. 921.—Interior of right osseous labyrinth.

by a number of holes (**macula cribrosa superior**). The apertures in the pyramid transmit the nerves to the utricle; those in the recessus ellipticus the nerves to the ampullæ of the superior and lateral semicircular ducts. *Behind* are the five orifices of the semicircular canals. In *front* is an elliptical opening, which communicates with the scala vestibuli of the cochlea.

The Bony Semicircular Canals (*canales semicirculares ossei*).—The bony semicircular canals are three in number, **superior**, **posterior**, and **lateral**, and are situated above and behind the vestibule. They are unequal in length, compressed from side to side, and each describes the greater part of a circle. Each measures about 0.8 mm. in diameter, and presents a dilatation at one end, called the **ampulla**, which measures more than twice the diameter of the tube. They open into the vestibule by five orifices, one of the apertures being common to two of the canals.

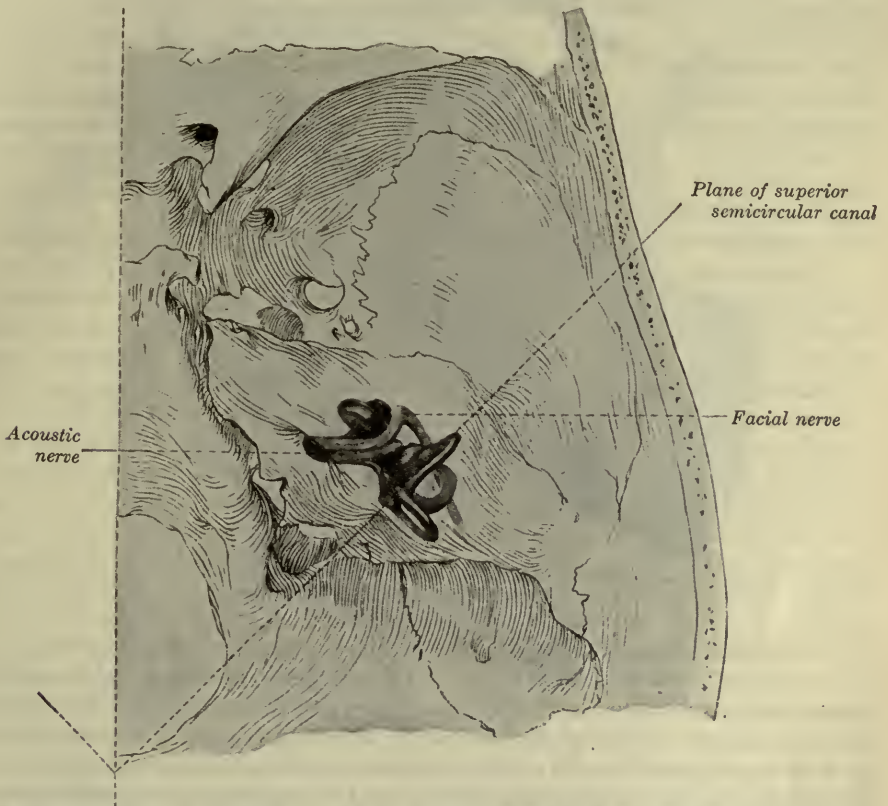


FIG. 922.—Position of the right bony labyrinth of the ear in the skull, viewed from above. The temporal bone is considered transparent and the labyrinth drawn in from a corrosion preparation. (Spalteholz.)

The **superior semicircular canal** (*canalis semicircularis superior*), 15 to 20 mm. in length, is vertical in direction, and is placed transversely to the long axis of the petrous portion of the temporal bone, on the anterior surface of which its arch forms a round projection. It describes about two-thirds of a circle. Its lateral extremity is ampullated, and opens into the upper part of the vestibule; the opposite end joins with the upper part of the posterior canal to form the **crus commune**, which opens into the upper and medial part of the vestibule.

The **posterior semicircular canal** (*canalis semicircularis posterior*), also vertical, is directed backward, nearly parallel to the posterior surface of the petrous bone; it is the longest of the three, measuring from 18 to 22 mm.; its lower or ampullated end opens into the lower and back part of the vestibule, its upper into the crus commune already mentioned.

The **lateral or horizontal canal** (*canalis semicircularis lateralis; external semicircular canal*) is the shortest of the three. It measures from 12 to 15 mm., and its arch is directed horizontally backward and lateralward; thus each semicircular canal stands at right angles to the other two. Its ampullated end corresponds to the

upper and lateral angle of the vestibule, just above the fenestra vestibuli, where it opens close to the ampullated end of the superior canal; its opposite end opens at the upper and back part of the vestibule. The lateral canal of one ear is very nearly in the same plane as that of the other; while the superior canal of one ear is nearly parallel to the posterior canal of the other.

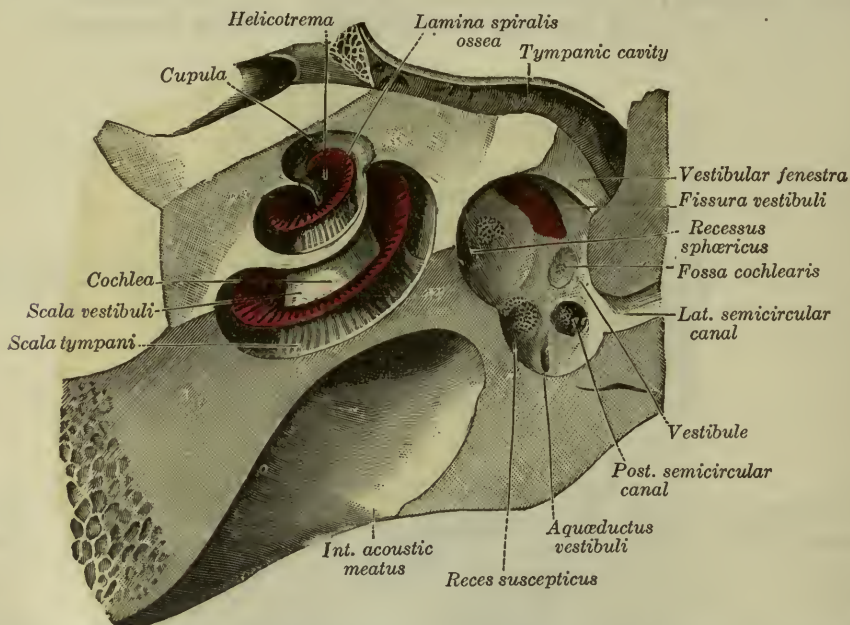


FIG. 923.—The cochlea and vestibule, viewed from above. All the hard parts which form the roof of the internal ear have been removed with the saw.

The **Cochlea** (Figs. 922, 923).—The cochlea bears some resemblance to a common snail-shell; it forms the anterior part of the labyrinth, is conical in form, and placed almost horizontally in front of the vestibule; its **apex** (*cupula*) is directed forward and lateralward, with a slight inclination downward, toward the upper and front part of the labyrinthine wall of the tympanic cavity; its **base** corresponds with the bottom of the internal acoustic meatus, and is perforated by numerous apertures for the passage of the cochlear division of the acoustic nerve. It measures about 5 mm. from base to apex, and its breadth across the base is about 9 mm. It consists of a conical shaped central axis, the **modiolus**; of a canal, the inner wall of which is formed by the central axis, wound spirally around it for two turns and three-quarters, from the base to the apex; and of a delicate lamina, the **osseous spiral lamina**, which projects from the modiolus, and, following the windings of the canal, partially subdivides it into two. In the recent state a membrane, the **basilar membrane**, stretches from the free border of this lamina to the outer wall of the bony cochlea and completely separates the canal into two passages, which, however, communicate with each other at the apex of the modiolus by a small opening named the **helicotrema**.

The **modiolus** is the conical central axis or pillar of the cochlea. Its base is broad, and appears at the bottom of the internal acoustic meatus, where it corresponds with the *area cochleæ*; it is perforated by numerous orifices, which transmit filaments of the cochlear division of the acoustic nerve; the nerves for the first turn and a half pass through the foramina of the *tractus spiralis foraminosus*; those for the apical turn, through the *foramen centrale*. The canals of the *tractus spiralis foraminosus* pass up through the modiolus and successively bend outward

to reach the attached margin of the lamina spiralis ossea. Here they become enlarged, and by their apposition form the **spiral canal of the modiolum**, which follows the course of the attached margin of the osseous spiral lamina and lodges the **spiral ganglion** (*ganglion of Corti*). The foramen centrale is continued into a canal which runs up the middle of the modiolum to its apex. The modiolum diminishes rapidly in size in the second and succeeding coil.

The bony canal of the cochlea takes two turns and three-quarters around the modiolum. It is about 30 mm. in length, and diminishes gradually in diameter from the base to the summit, where it terminates in the **cupula**, which forms the apex of the cochlea. The beginning of this canal is about 3 mm. in diameter; it diverges from the modiolum toward the tympanic cavity and vestibule, and presents three openings. One, the **fenestra cochleæ**, communicates with the tympanic cavity—in the fresh state this aperture is closed by the **secondary tympanic membrane**; another, of an elliptical form, opens into the vestibule. The third is the aperture of the aquæductus cochleæ, leading to a minute funnel-shaped canal, which opens on the inferior surface of the petrous part of the temporal bone and transmits a small vein, and also forms a communication between the subarachnoid cavity and the scala tympani.

The **osseous spiral lamina** (*lamina spiralis ossea*) is a bony shelf or ledge which projects from the modiolum into the interior of the canal, and, like the canal, takes two- and three-quarter turns around the modiolum. It reaches about half-way toward the outer wall of the tube, and partially divides its cavity into two passages or scalæ, of which the upper is named the **scala vestibuli**, while the lower is termed the **scala tympani**. Near the summit of the cochlea the lamina ends in a hook-shaped process, the **hamulus laminae spiralis**; this assists in forming the boundary of a small opening, the **helicotrema**, through which the two scalæ communicate with each other. From the spiral canal of the modiolum numerous canals pass outward through the osseous spiral lamina as far as its free edge. In the lower part of the first turn a second bony lamina, the **secondary spiral lamina**, projects inward from the outer wall of the bony tube; it does not, however, reach the primary osseous spiral lamina, so that if viewed from the vestibule a narrow fissure, the **vestibule fissure**, is seen between them.

The *osseous labyrinth* is lined by an exceedingly thin fibro-serous membrane; its attached surface is rough and fibrous, and closely adherent to the bone; its free surface is smooth and pale, covered with a layer of epithelium, and secretes a thin, limpid fluid, the **perilymph**. A delicate tubular process of this membrane is prolonged along the aqueduct of the cochlea to the inner surface of the *dura mater*.

The Membranous Labyrinth (*labyrinthus membranaceus*) (Figs. 924, 925, 926).—The membranous labyrinth is lodged within the bony cavities just described, and has the same general form as these; it is, however, considerably smaller, and is partly separated from the bony walls by a quantity of fluid, the **perilymph**. In certain places it is fixed to the walls of the cavity. The membranous labyrinth contains fluid, the **endolymph**, and on its walls the ramifications of the acoustic nerve are distributed.

Within the osseous vestibule the membranous labyrinth does not quite preserve the form of the bony cavity, but consists of two membranous sacs, the **utricle**, and the **sacculæ**.

The Utricle (*utriculus*).—The utricle, the larger of the two, is of an oblong form, compressed transversely, and occupies the upper and back part of the vestibule, lying in contact with the recessus ellipticus and the part below it. That portion which is lodged in the recess forms a sort of pouch or cul-de-sac, the floor and anterior wall of which are thickened, and form the **macula acustica utriculi**, which receives the utricular filaments of the acoustic nerve. The cavity of the utricle communi-

cates behind with the semicircular ducts by five orifices. From its anterior wall is given off the *ductus utriculosaccularis*, which opens into the *ductus endolymphaticus*.

The Sacculæ (*sacculus*).—The sacculæ is the smaller of the two vestibular sacs; it is globular in form, and lies in the *recessus sphaericus* near the opening of the *scala vestibuli* of the cochlea. Its anterior part exhibits an oval thickening, the *macula acustica sacculi*, to which are distributed the saccular filaments of the acoustic nerve. Its cavity does not directly communicate with that of the utricle. From the posterior wall a canal, the *ductus endolymphaticus*, is given off; this duct is joined by the *ductus utriculosaccularis*, and then passes along the *aquæductus vestibuli* and ends in a blind pouch (*sacculus endolymphaticus*) on the posterior surface of the petrous portion of the temporal bone, where it is in contact with the *dura mater*. From the lower part of the sacculæ a short tube, the *canalis reuniens of Hensen*, passes downward and opens into the *ductus cochlearis* near its vestibular extremity (Fig. 924).

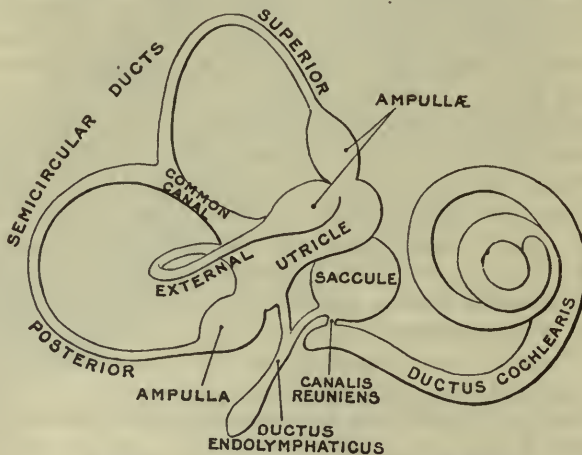


FIG. 924.—The membranous labyrinth. (Enlarged.)

The Semicircular Ducts (*ductus semicirculares; membranous semicircular canals*), (Figs. 925, 926).—The semicircular ducts are about one-fourth of the diameter of the osseous canals, but in number, shape, and general form they are precisely similar, and each presents at one end an ampullæ. They open by five orifices into the utricle, one opening being common to the medial end of the superior and the upper end of the posterior duct. In the ampullæ the wall is thickened, and projects into the cavity as a fiddle-shaped, transversely placed elevation, the *septum transversum*, in which the nerves end.

The utricle, saccule, and semicircular ducts are held in position by numerous fibrous bands which stretch across the space between them and the bony walls.

Structure (Fig. 927).—The walls of the utricle, saccule, and semicircular ducts consist of three layers. The *outer layer* is a loose and flocculent structure, apparently composed of ordinary fibrous tissue containing bloodvessels and some pigment-cells. The *middle layer*, thicker and more transparent, forms a homogeneous *membrana propria*, and presents on its internal surface, especially in the semicircular ducts, numerous papilliform projections, which, on the addition of acetic acid, exhibit an appearance of longitudinal fibrillation. The *inner layer* is formed of polygonal nucleated epithelial cells. In the maculæ of the utricle and saccule, and in the transverse septa of the ampullæ of the semicircular ducts, the middle coat is thickened and the epithelium is columnar, and consists of **supporting cells** and **hair cells**. The former are fusiform, and their deep ends are attached to the *membrana propria*, while their free extremities are united to form a thin cuticle. The hair cells are flask-shaped, and their deep, rounded ends do not reach the *membrana propria*, but lie between the supporting cells. The deep part of each contains a large nucleus, while its more superficial part is granular and pigmented. The free end is surmounted by a long, tapering, hair-like filament, which projects into the cavity. The

filaments of the acoustic nerve enter these parts, and having pierced the outer and middle layers, they lose their medullary sheaths, and their axis-cylinders ramify between the hair cells.

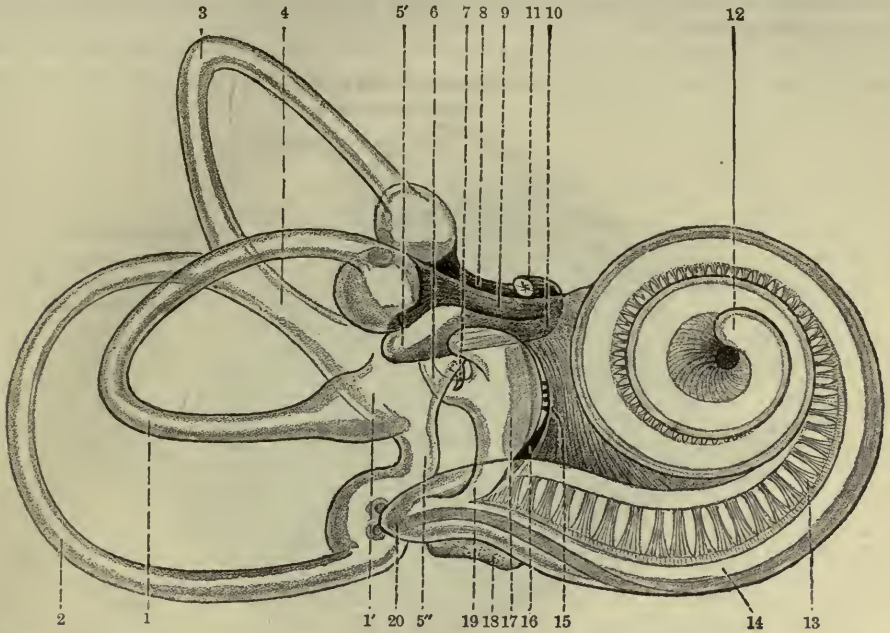


FIG. 925.—Right human membranous labyrinth, removed from its bony enclosure and viewed from the antero-lateral aspect. (G. Retzius.)

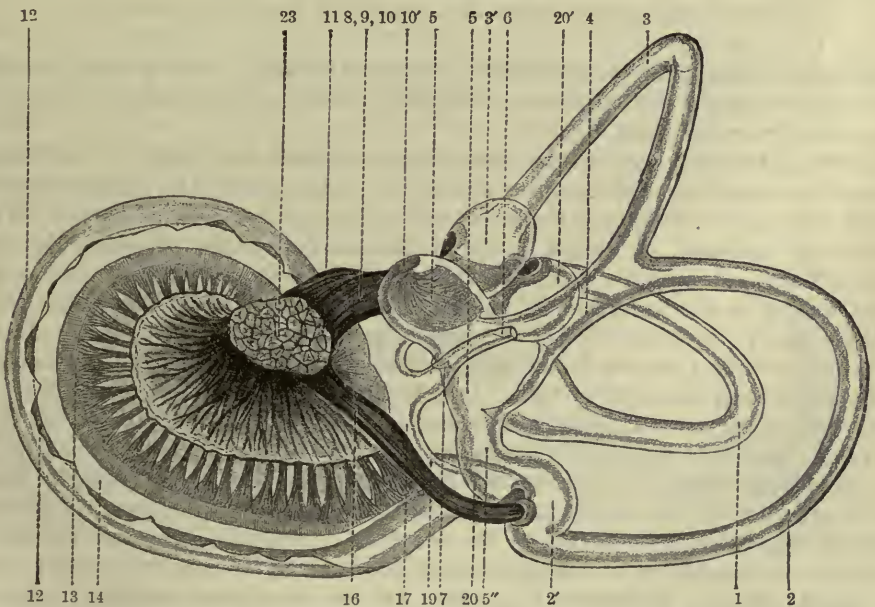


FIG. 926.—The same from the postero-medial aspect. 1. Lateral semicircular canal; 1', its ampulla; 2. Posterior canal; 2', its ampulla. 3. Superior canal; 3', its ampulla. 4. Conjoined limb of superior and posterior canals (*sinus utriculi superior*). 5. Utricle. 5'. Recessus utriculi. 5''. Sinus utriculi posterior. 6. Ductus endolymphaticus. 7. Canalis utriculosaccularis. 8. Nerve to ampulla of superior canal. 9. Nerve to ampulla of lateral canal. 10. Nerve to recessus utriculi (in Fig. 925, the three branches appear conjoined). 10'. Ending of nerve in recessus utriculi. 11. Facial nerve. 12. Lagena cochlea. 13. Nerve of cochlea within spiral lamina. 14. Basilar membrane. 15. Nerve fibers to macula of saccule. 16. Nerve to ampulla of posterior canal. 17. Saccule. 18. Secondary membrane of tympanum. 19. Canalis reuniens. 20. Vestibular end of ductus cochlearis. 23. Section of the facial and acoustic nerves within internal acoustic meatus (the separation between them is not apparent in the section). (G. Retzius.)

Two small rounded bodies termed **otoconia**, each consisting of a mass of minute crystalline grains of carbonate of lime, held together in a mesh of gelatinous tissue, are suspended in the endolymph in contact with the free ends of the hairs projecting from the maculae. According to Bowman, a calcareous material is also sparingly scattered in the cells lining the ampullae of the semicircular ducts.

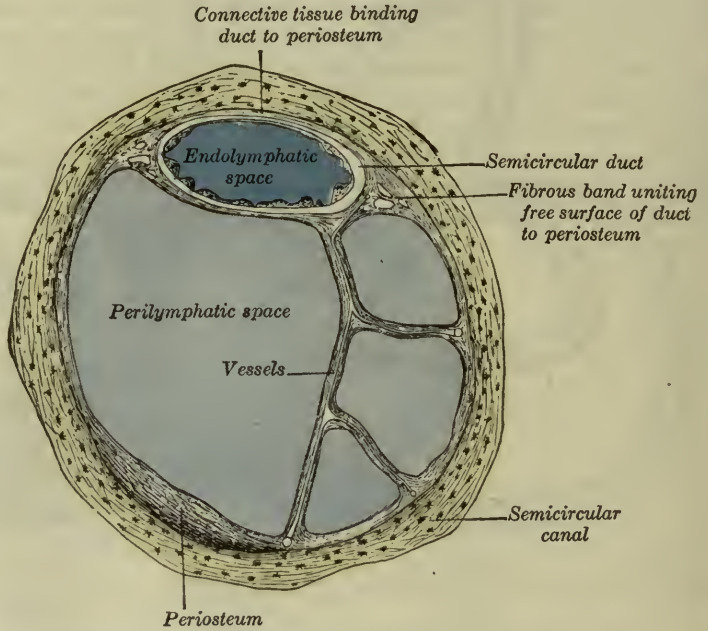


FIG. 927.—Transverse section of a human semicircular canal and duct (after Rüdinger).

The Ductus Cochlearis (*membranous cochlea; scala media*).—The ductus cochlearis consists of a spirally arranged tube enclosed in the bony canal of the cochlea and lying along its outer wall.

As already stated, the osseous spiral lamina extends only part of the distance between the modiolus and the outer wall of the cochlea, while the **basilar membrane** stretches from its free edge to the outer wall of the cochlea, and completes the roof of the scala tympani. A second and more delicate membrane, the **vestibular membrane** (*Reissneri*) extends from the thickened periosteum covering the osseous spiral lamina to the outer wall of the cochlea, where it is attached at some little distance above the outer edge of the basilar membrane. A canal is thus shut off between the scala tympani below and the scala vestibuli above; this is the **ductus cochlearis** or **scala media** (Fig. 928). It is triangular on transverse section, its roof being formed by the vestibular membrane, its outer wall by the periosteum lining the bony canal, and its floor by the membrana basilaris and the outer part of the lamina spiralis ossea. Its extremities are closed; the upper is termed the **lagena** and is attached to the cupula at the upper part of the helicotrema; the lower is lodged in the recessus cochlearis of the vestibule. Near the lower end the ductus cochlearis is brought into continuity with the sacculle by a narrow, short canal, the **canalis reuniens of Hensen** (Fig. 924). On the membrana basilaris is situated the spiral organ of Corti. The vestibular membrane is thin and homogeneous, and is covered on its upper and under surfaces by a layer of epithelium. The periosteum, forming the outer wall of the ductus cochlearis, is greatly thickened and altered in character, and is called the **spiral ligament**. It projects inward below as a triangular prominence, the **basilar crest**, which gives attachment to the outer edge of the basilar membrane; immediately above the crest is a concavity, the

sulcus spiralis externus. The upper portion of the spiral ligament contains numerous capillary loops and small bloodvessels, and is termed the **stria vascularis**.

The osseous spiral lamina consists of two plates of bone, and between these are the canals for the transmission of the filaments of the acoustic nerve. On the upper plate of that part of the lamina which is outside the vestibular membrane, the periosteum is thickened to form the **limbus laminae spiralis** (Fig. 929), this ends externally

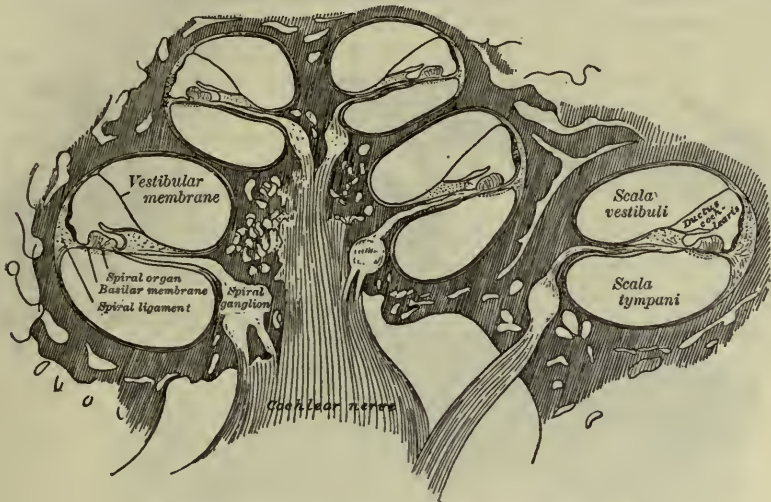

FIG. 928.—Diagrammatic longitudinal section of the cochlea.

in a concavity, the **sulcus spiralis internus**, which represents, on section, the form of the letter C; the upper part, formed by the overhanging extremity of the limbus, is named the **vestibular lip**; the lower part, prolonged and tapering, is called the **tympanic lip**, and is perforated by numerous foramina for the passage of the cochlear nerves. The upper surface of the vestibular lip is intersected at right angles by a number of furrows, between which are numerous elevations; these present the appearance of teeth along the free surface and margin of the lip, and have been

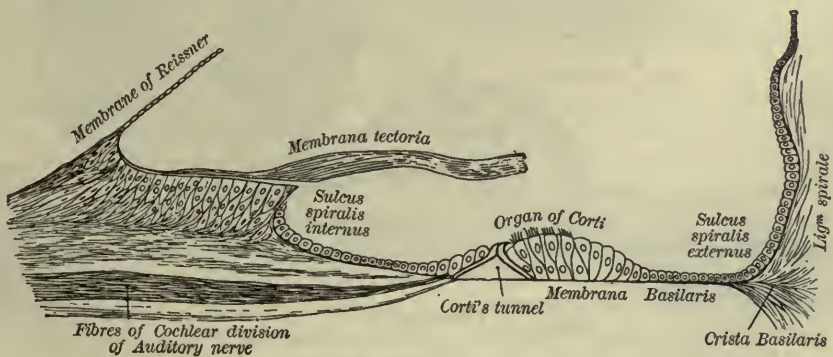


FIG. 929.—Floor of ductus cochlearis.

named by Huschke the **auditory teeth** (Fig. 930). The limbus is covered by a layer of what appears to be squamous epithelium, but the deeper parts of the cells with their contained nuclei occupy the intervals between the elevations and between the auditory teeth. This layer of epithelium is continuous on the one hand with that lining the sulcus spiralis internus, and on the other with that covering the under surface of the vestibular membrane.

Basilar Membrane.—The basilar membrane stretches from the tympanic lip of the osseous spiral lamina to the basilar crest and consists of two parts, an inner and an outer. The inner is thin, and is named the **zona arcuata**: it supports the spiral organ of Corti. The outer is thicker and striated, and is termed the **zona pectinata**. The under surface of the membrane is covered by a layer of vascular connective tissue; one of the vessels in this tissue is somewhat larger than the rest, and is named the **vas spirale**; it lies below Corti's tunnel.

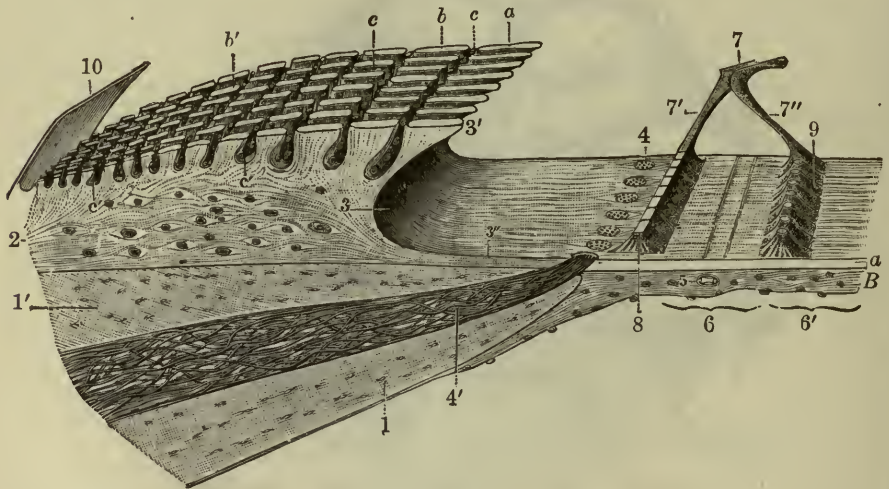


FIG. 930.—Limbus lamina spiralis and membrana basilaris. (Schematic.) 1, 1'. Upper and lower lamella of the lamina spiralis ossea. 2. Limbus lamina spiralis, with *a*, the teeth of the first row; *b*, *b'*, the auditory teeth of the other rows; *c*, *c'*, the interdental grooves and the cells which are lodged in them. 3. Sulcus spiralis internus, with 3', its labium vestibulare, and 3'', its labium tympanicum. 4. Foramina nervosa, giving passage to the nerves from the ganglion spirale or ganglion of Corti. 5. Vas spirale. 6. Zona arcuata, and 6', zona pectinata of the basilar membrane, with *a*, its hyaline layer, *B*, its connective-tissue layer. 7. Arch of spiral organ, with 7', its inner rod, and 7'', its outer rod. 8. Feet of the internal rods, from which the cells are removed. 9. Feet of the external rods. 10. Vestibular membrane, at its origin. (Testut.)

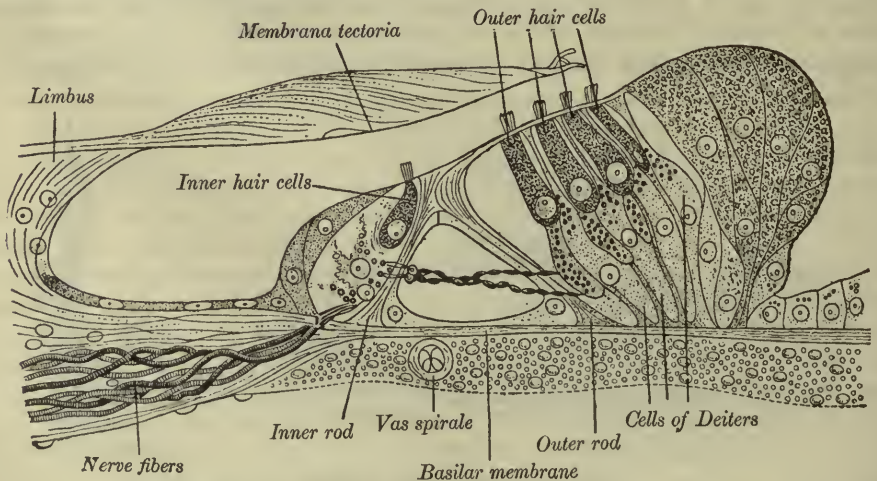


FIG. 931.—Section through the spiral organ of Corti. Magnified. (G. Retzius.)

The **spiral organ of Corti** (*organon spirale* [Corti]; *organ of Corti*) (Figs. 931, 932) is composed of a series of epithelial structures placed upon the inner part of the basilar membrane. The more central of these structures are two rows of rod-like bodies, the **inner and outer rods** or **pillars of Corti**. The bases of the rods are supported on the basilar membrane, those of the inner row at some distance from those of the

outer; the two rows incline toward each other and, coming into contact above, enclose between them and the basilar membrane a triangular tunnel, the **tunnel of Corti**. On the inner side of the inner rods is a single row of hair cells, and on the outer side of the outer rods three or four rows of similar cells, together with certain supporting cells termed the cells of Deiters and Hensen. The free ends of the outer hair cells occupy a series of apertures in a net-like membrane, the **reticular membrane**, and the entire organ is covered by the tectorial membrane.

RODS OF CORTI.—Each of these consists of a base or foot-plate, and elongated part or body, and an upper end or head; the body of each rod is finely striated, but in the head there is an oval non-striated portion which stains deeply with carmine. Occupying the angles between the rods and the basilar membrane are nucleated cells which partly envelop the rods and extend on to the floor of Corti's tunnel; these may be looked upon as the undifferentiated parts of the cells from which the rods have been formed.

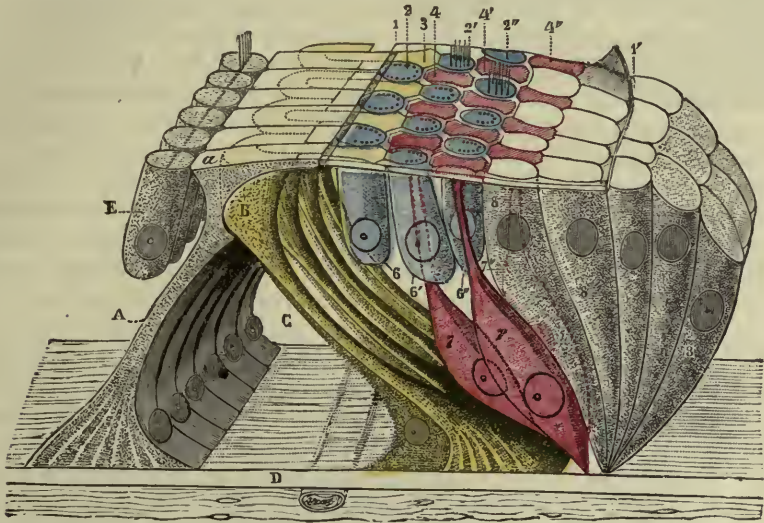


FIG. 932.—The lamina reticularis and subjacent structures. (Schematic.) *A.* Internal rod of Corti, with *a*, its plate. *B.* External rod (in yellow). *C.* Tunnel of Corti. *D.* Membrana basilaris. *E.* Inner hair cells. 1, 1'. Internal and external borders of the membrana reticularis. 2, 2', 2''. The three rows of circular holes (in blue). 3. First row of phalanges (in yellow). 4, 4', 4''. Second, third, and fourth rows of phalanges (in red). 6, 6', 6''. The three rows of outer hair cells (in blue). 7, 7', 7''. Cells of Deiters. 8. Cells of Hensen and Claudius. (Testut.)

The **inner rods** number nearly 6000, and their bases rest on the basilar membrane close to the tympanic lip of the sulcus spiralis internus. The shaft or body of each is sinuously curved and forms an angle of about 60 degrees with the basilar membrane. The head resembles the proximal end of the ulna and presents a deep concavity which accommodates a convexity on the head of the outer rod. The head-plate, or portion overhanging the concavity, overlaps the head-plate of the outer rod.

The **outer rods**, nearly 4000 in number, are longer and more obliquely set than the inner, forming with the basilar membrane an angle of about 40 degrees. Their heads are convex internally; they fit into the concavities on the heads of the inner rods and are continued outward as thin flattened plates, termed **phalangeal processes**, which unite with the phalangeal processes of Deiters' cells to form the reticular membrane.

Hair Cells.—The hair cells are short columnar cells; their free ends are on a level with the heads of Corti's rods, and each is surmounted by about twenty hair-like processes arranged in the form of a crescent with its concavity directed inward. The deep ends of the cells reach about half-way along Corti's rods, and each con-

tains a large nucleus; in contact with the deep ends of the hair cells are the terminal filaments of the cochlear division of the acoustic nerve. The *inner* hair cells are arranged in a single row on the medial side of the inner rods, and their diameters being greater than those of the rods it follows that each hair cell is supported by more than one rod. The free ends of the inner hair cells are encircled by a cuticular membrane which is fixed to the heads of the inner rods. Adjoining the inner hair cells are one or two rows of columnar supporting cells, which, in turn, are continuous with the cubical cells lining the sulcus spiralis internus. The *outer* hair cells number about 12,000, and are nearly twice as long as the inner. In the basal coil of the cochlea they are arranged in three regular rows; in the apical coil, in four, somewhat irregular, rows.

Between the rows of the outer hair cells are rows of supporting cells, called the **cells of Deiters**; their expanded bases are planted on the basilar membrane, while the opposite end of each presents a clubbed extremity or **phalangeal process**. Immediately to the outer side of Deiters' cells are five or six rows of columnar cells, the **supporting cells of Hensen**. Their bases are narrow, while their upper parts are expanded and form a rounded elevation on the floor of the ductus cochlearis. The columnar cells lying outside Hensen's cells are termed the **cells of Claudius**. A space exists between the outer rods of Corti and the adjacent hair cells; this is called the **space of Nuel**.

The **reticular lamina** (Fig. 932) is a delicate frame-work perforated by rounded holes which are occupied by the free ends of the outer hair cells. It extends from the heads of the outer rods of Corti to the external row of the outer hair cells, and is formed by several rows of "minute fiddle-shaped cuticular structures," called **phalanges**, between which are circular apertures containing the free ends of the hair cells. The inner most row of phalanges consists of the phalangeal processes of the outer rods of Corti; the outer rows are formed by the modified free ends of Deiters' cells.

Covering the sulcus spiralis internus and the spiral organ of Corti is the **tectorial membrane**, which is attached to the limbus laminae spiralis close to the inner edge of the vestibular membrane. Its inner part is thin and overlies the auditory teeth of Huschke; its outer part is thick, and along its lower surface, opposite the inner hair cells, is a clear band, named **Hensen's stripe**, due to the intercrossing of its fibers. The lateral margin of the membrane is much thinner. Hardesty¹ considers the tectorial membrane as the vibrating mechanism in the cochlea. It is inconceivably delicate and flexible; far more sensitively flexible in the transverse than in the longitudinal direction and the readiness with which it bends when touched is beyond description. It is ectodermal in origin. It consists of fine colorless fibers embedded in a transparent matrix (the matrix may be a variety of soft keratin), of a soft collagenous, semisolid character with marked adhesiveness. The general transverse direction of the fibers inclines from the radius of the cochlea toward the apex.

The **acoustic nerve** (*n. acusticus*; *auditory nerve* or *nerve of hearing*) divides near the bottom of the internal acoustic meatus into an anterior or cochlear and a posterior or vestibular branch.

The **vestibular nerve** (*n. vestibularis*) supplies the utricle, the saccule, and the ampullæ of the semicircular ducts. On the trunk of the nerve, within the internal acoustic meatus, is a ganglion, the **vestibular ganglion** (*ganglion of Scarpa*); the fibers of the nerve arise from the cells of this ganglion. On the distal side of the ganglion the nerve splits into a superior, an inferior, and a posterior branch.² The filaments of the *superior branch* are transmitted through the foramina in the area vestibularis superior, and end in the macula of the utricle and in the ampullæ of the superior and lateral semicircular ducts; those of the *inferior branch* traverse

¹ American Journal of Anatomy, 1908, viii.

² The nerve sometimes splits on the proximal side of the ganglion, and the latter is then divided into three parts, one on each branch of the nerve.

the foramina in the area vestibularis inferior, and end in the macula of the saccule. The *posterior branch* runs through the foramen singulare at the postero-inferior part of the bottom of the meatus and divides into filaments for the supply of the ampulla of the posterior semicircular duct.

The **cochlear nerve** (*n. cochlearis*) divides into numerous filaments at the base of the modiolus; those for the basal and middle coils pass through the foramina in the

tractus spiralis foraminosus, those for the apical coil through the canalis centralis, and the nerves bend outward to pass between the lamellæ of the osseous spiral lamina. Occupying the spiral canal of the modiolus is the **spiral ganglion of the cochlea** (*ganglion of Corti*) (Fig. 933), consisting of bipolar nerve cells, which constitute the cells of origin of this nerve. Reaching the outer edge of the osseous spiral lamina, the fibers of the nerve pass through the foramina in the tympanic lip; some end by arborizing around the bases of the inner hair cells, while others pass

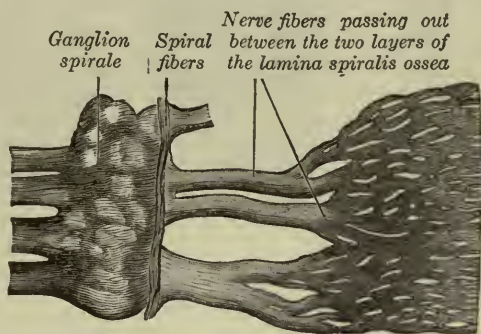


FIG. 933.—Part of the cochlear division of the acoustic nerve, highly magnified. (Henle.)

between Corti's rods and across the tunnel, to end in a similar manner in relation to the outer hair cells. The cochlear nerve gives off a vestibular branch to supply the vestibular end of the ductus cochlearis; the filaments of this branch pass through the foramina in the fossa cochlearis (page 1048).

Vessels.—The **arteries of the labyrinth** are the internal auditory, from the basilar, and the stylomastoid, from the posterior auricular. The internal auditory artery divides at the bottom of the internal acoustic meatus into two branches: cochlear and vestibular. The cochlear branch subdivides into twelve or fourteen twigs, which traverse the canals in the modiolus, and are distributed, in the form of a capillary net-work, in the lamina spiralis and basilar membrane. The vestibular branches are distributed to the utricle, saccule, and semicircular ducts.

The **veins** of the vestibule and semicircular canals accompany the arteries, and, receiving those of the cochlea at the base of the modiolus, unite to form the internal auditory veins which end in the posterior part of the superior petrosal sinus or in the transverse sinus.

PERIPHERAL TERMINATIONS OF NERVES OF GENERAL SENSATIONS.

The peripheral terminations of the nerves associated with general sensations, *i. e.*, the muscular sense and the senses of heat, cold, pain, and pressure, are widely distributed throughout the body. These nerves may end *free* among the tissue elements, or in *special end-organs* where the terminal nerve filaments are enclosed in capsules.

Free nerve-endings occur chiefly in the epidermis and in the epithelium covering certain mucous membranes; they are well seen also in the stratified squamous epithelium of the cornea, and are also found in the root-sheaths and papillæ of the hairs, and around the bodies of the sudoriferous glands. When the nerve fiber approaches its termination, the medullary sheath suddenly disappears, leaving only the axis-cylinder surrounded by the neurolemma. After a time the fiber loses its neurolemma, and consists only of an axis-cylinder, which can be seen, in preparations stained with chloride of gold, to be made up of fine varicose fibrillæ. Finally, the axis-cylinder breaks up into its constituent fibrillæ which often present regular varicosities and anastomose with one another, and end in small knobs or disks between the epithelial cells.

Under this heading may be classed the **tactile disks** described by Merkel as occurring in the epidermis of the pig's snout, where the fibrillæ of the axis-cylinder end in cup-shaped disks in apposition with large epithelial cells.

The **special end-organs** exhibit great variety in size and shape, but have one feature in common, *viz.*, the terminal nerve fibrillæ are enveloped by a capsule. Included in this group are the end-bulbs of Krause, the corpuscles of Grandry, of Pacini, of Golgi and Mazzoni, of Wagner and Meissner, and the neurotendinous and neuromuscular spindles.

The **end-bulbs of Krause** (Fig. 934) are minute cylindrical or oval bodies, consisting of the connective-tissue sheath of a medullated fiber, and containing a soft semifluid core in which the axis-cylinder terminates either in a bulbous extremity or in a coiled-upplexiform mass. End-bulbs are found in the conjunctiva of the eye (where they are spheroidal in shape in man, but cylindrical in most other animals), in the mucous membrane of the lips and tongue, and in the epineurium of nerve trunks. They are also found in the penis and the clitoris, and have received the name of **genital corpuscles**; in these situations they have a mulberry-like appearance, being constricted by connective-tissue septa into from two to six knob-like masses. In the synovial membranes of certain joints, *e. g.*, those of the fingers, rounded or oval end-bulbs occur, and are designated **articular end-bulbs**.

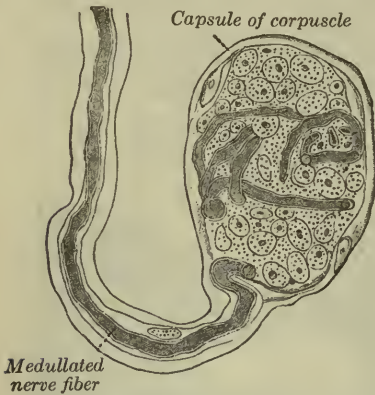


FIG. 934.—End-bulb of Krause. (Klein.)

they also occur in connection with the nerves of the joints, and in some other situations, as in the mesentery and pancreas of the cat and along the tibia of the rabbit. Each of these corpuscles is attached to and encloses the termination of a single nerve fiber. The corpuscle, which is perfectly visible to the naked eye (and which can be most easily demonstrated in the mesentery of a cat), consists of a number of lamellæ or capsules arranged more or less concentrically around a central clear space, in which the nerve fiber is contained. Each lamella is composed of bundles of fine connective-tissue fibers, and is lined on its inner surface by a single layer of flattened epithelioid cells. The central clear space, which is elon-

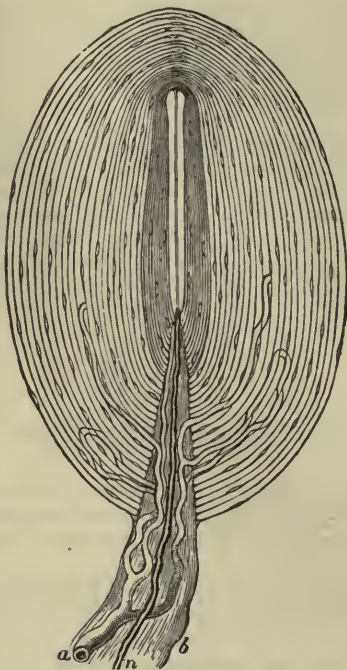

FIG. 935.—Pacinian corpuscle, with its system of capsules and central cavity. *a.* Arterial twig, ending in capillaries, which form loops in some of the intercapsular spaces, and one penetrates to the central capsule. *b.* The fibrous tissue of the stalk. *n.* Nerve tube advancing to the central capsule, there losing its white matter, and stretching along the axis to the opposite end, where it ends by a tuberculated enlargement.

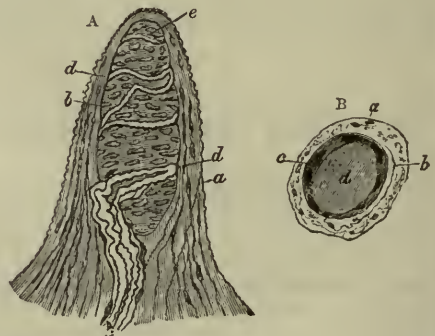


FIG. 936.—Papilla of the hand, treated with acetic acid. Magnified 350 times. *A.* Side view of a papilla of the hand. *a.* Cortical layer. *b.* Tactile corpuscle. *c.* Small nerve of the papilla, with neurolemma. *d.* Its two nervous fibers running with spiral coils around the tactile corpuscle. *e.* Apparent termination of one of these fibers. *B.* A tactile papilla seen from above so as to show its transverse section. *a.* Cortical layer. *b.* Nerve fiber. *c.* Outer layer of the tactile body, with nuclei. *d.* Clear interior substance.

gated or cylindrical in shape, is filled with a transparent core, in the middle of which the axis-cylinder traverses the space to near its distal extremity, where it ends in one or more small knobs. Todd and Bowman have described minute arteries as entering by the sides of the nerves and forming capillary loops in the intercapsular spaces, and even penetrating into the central space.

Herbst has described a nerve-ending somewhat similar to the Pacinian corpuscle, in the mucous membrane of the tongue of the duck, and in some other situations. It differs, however, from the Pacinian corpuscle, in being smaller, in its capsules being more closely approximated, and especially in the fact that the axis-cylinder in the central clear space is coated with a continuous row of nuclei. These bodies are known as the **corpuscles of Herbst**.

The **corpuscles of Golgi and Mazzoni** are found in the subcutaneous tissue of the pulp of the fingers. They differ from Pacinian corpuscles in that their capsules are thinner, their contained cores thicker, and in the latter the axis-cylinders ramify more extensively and end in flat expansions.

The **tactile corpuscles of Wagner and Meissner** (Fig. 936) are oval-shaped bodies. Each is enveloped by a connective-tissue capsule, and imperfect membranous septa derived from this penetrate the interior. The axis-cylinder passes through the capsule, and after making several spiral turns around the body of the corpuscle ends in small globular or pyriform enlargements. These tactile corpuscles occur in the papillæ of the corium of the hand and foot, the front of the forearm, the skin of the lips, the mucous membrane of the tip of the tongue, the palpebral conjunctiva, and the skin of the mammary papilla.

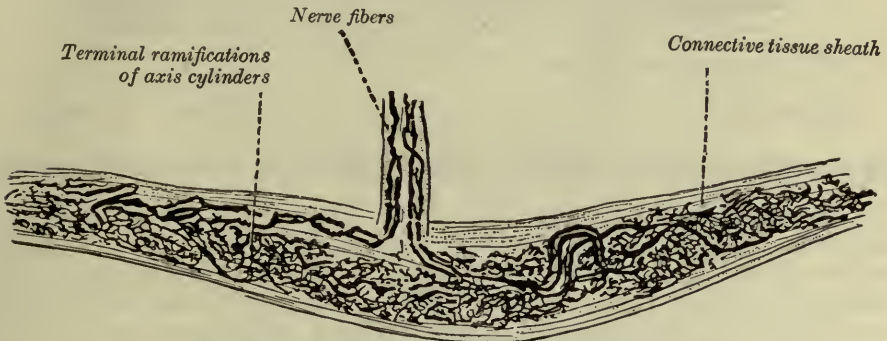


FIG. 937.—Nerve ending of Ruffini. (After A. Ruffini.)

Corpuscles of Ruffini.—Ruffini described a special variety of nerve-ending in the subcutaneous tissue of the human finger (Fig. 937); they are principally situated at the junction of the corium with the subcutaneous tissue. They are oval in shape, and consist of strong connective-tissue sheaths, inside which the nerve fibers divide into numerous branches, which show varicosities and end in small free knobs.

The **neurotendinous spindles (organs of Golgi)** are chiefly found near the junctions of tendons and muscles. Each is enclosed in a capsule which contains a number of enlarged tendon fasciculi (*intrafusal fasciculi*). One or more nerve fibers perforate the side of the capsule and lose their medullary sheaths; the axis-cylinders subdivide and end between the tendon fibers in irregular disks or varicosities (Fig. 938).

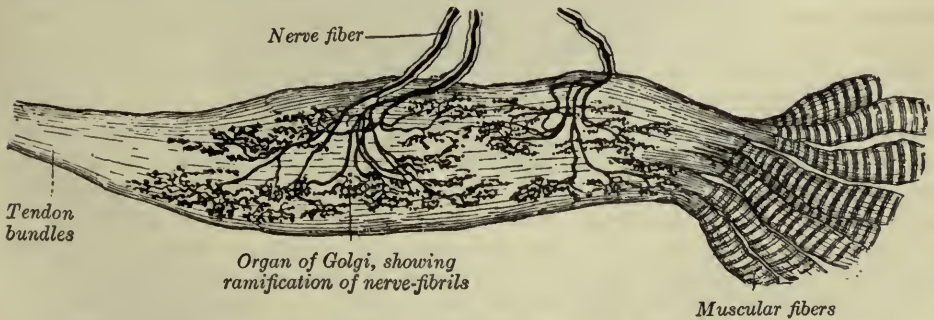


FIG. 938.—Organ of Golgi (neurotendinous spindle) from the human tendo calcaneus. (After Ciaccio.)

The **neuromuscular spindles** are present in the majority of voluntary muscles, and consist of small bundles of peculiar muscular fibers (*intrafusal fibers*), embryonic in type, invested by capsules, within which nerve fibers, experimentally shown to be sensory in origin, terminate. These neuromuscular spindles vary in length from 0.8 mm. to 5 mm., and have a distinctly fusiform appearance. The large medullated nerve fibers passing to the end-organ are from

one to three or four in number; entering the fibrous capsule, they divide several times, and, losing their medullary sheaths, ultimately end in naked axis-cylinders encircling the intrafusal fibers by flattened expansions, or irregular ovoid or rounded disks (Fig. 939). Neuromuscular spindles have not yet been demonstrated in the tongue muscles, and only a few exist in the ocular muscles.

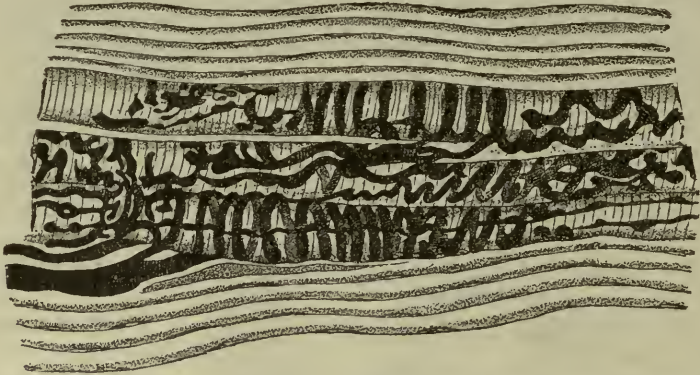


FIG. 939.—Middle third of a terminal plaque in the muscle spindle of an adult cat. (After Ruffini.)

THE COMMON INTEGUMENT (INTEGUMENTUM COMMUNE; SKIN).

The **integument** (Fig. 940) covers the body and protects the deeper tissues from injury, from drying and from invasion by foreign organisms; it contains the peripheral endings of many of the sensory nerves; it plays an important part in the regulation of the body temperature, and has also limited excretory and absorbing powers. It consists principally of a layer of vascular connective tissue, named the **corium** or **cutis vera**, and an external covering of epithelium, termed the **epidermis** or **cuticle**. On the surface of the former layer are sensitive and **vascular papillæ**; within, or beneath it, are certain organs with special functions: namely, the **sudoriferous** and **sebaceous glands**, and the **hair follicles**.

The **epidermis**, **cuticle**, or **scarf skin** is non-vascular, and consists of stratified epithelium (Fig. 941), and is accurately moulded on the papillary layer of the corium. It varies in thickness in different parts. In some situations, as in the palms of the hands and soles of the feet, it is thick, hard, and horny in texture. This may be in a measure due to the fact that these parts are exposed to intermittent pressure, but that this is not the only cause is proved by the fact that the condition exists to a very considerable extent at birth. The more superficial layers of cells, called the **horny layer** (*stratum corneum*), may be separated by maceration from a deeper stratum, which is called the **stratum mucosum**, and which consists of several layers of differently shaped cells. The free surface of the epidermis is marked by a net-work of linear furrows of variable size, dividing the surface into a number of polygonal or lozenge-shaped areas. Some of these furrows are large, as opposite the flexures of the joints, and correspond to the folds in the corium produced by movements. In other situations, as upon the back of the hand, they are exceedingly fine, and intersect one another at various angles. Upon the palmar surfaces of the hands and fingers, and upon the soles of the feet, the epidermal ridges are very distinct, and are disposed in curves; they depend upon the large size and peculiar arrangements of the papillæ upon which the epidermis is placed. The function of these ridges is primarily to increase resistance between contact surfaces for the purpose of preventing slipping whether in walking or prehension. The direction of the ridges is at right angles with the force that tends to produce slipping or to the resultant of such forces when these forces vary in direction.¹ In each individual

¹ Whipple, Inez L., The Ventral Surface of the Mammalian Chiridium, etc., *Zeit. f. Morph. u. Anthropol.*, 1904, vol. vii.

the lines on the tips of the fingers and thumbs form distinct patterns unlike those of any other person. A method of determining the identity of a criminal is based on this fact, impressions ("finger-prints") of these lines being made on paper covered with soot, or on white paper after first covering the fingers with ink. The deep surface of the epidermis is accurately moulded upon the papillary layer of the corium, the papillæ being covered by a basement membrane; so that when the epidermis is removed by maceration, it presents on its under surface a number of pits or depressions corresponding to the papillæ, and ridges corresponding to the intervals between them. Fine tubular prolongations are continued from this layer into the ducts of the sudoriferous and sebaceous glands.

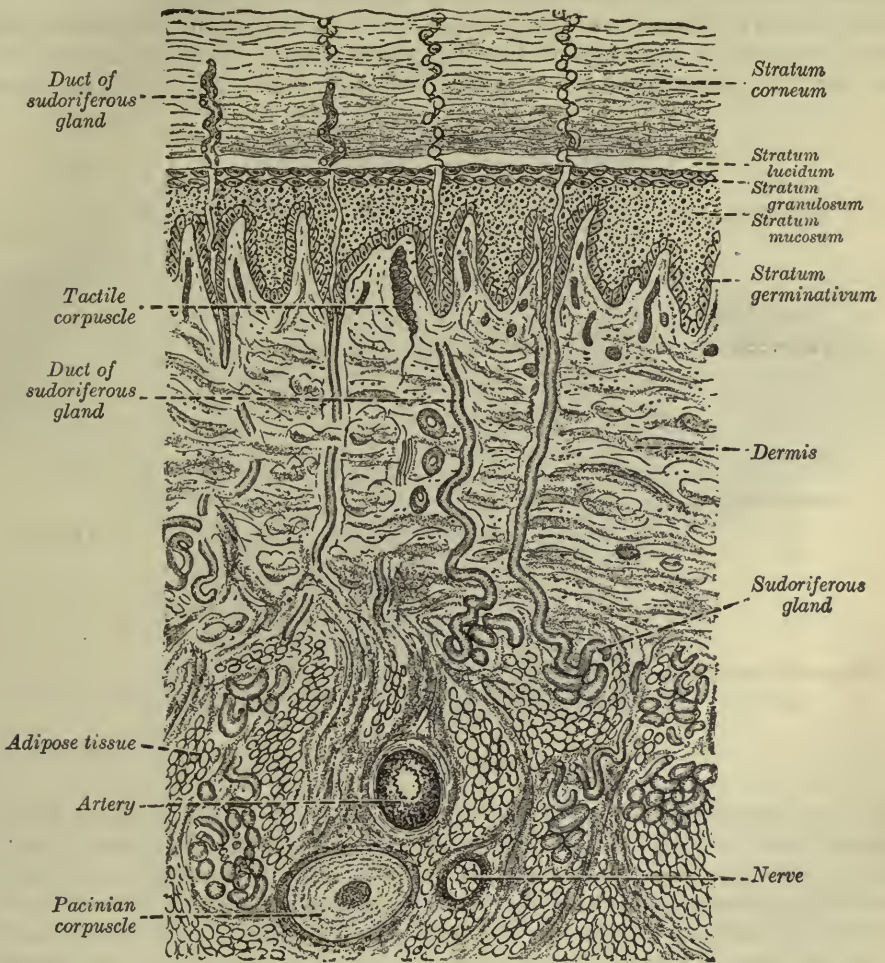


FIG. 940.—A diagrammatic sectional view of the skin (magnified).

The epidermis consists of stratified epithelium which is arranged in four layers from within outward as follows: (a) *stratum mucosum*, (b) *stratum granulosum*, (c) *stratum lucidum*, and (d) *stratum corneum*.

The *stratum mucosum* (*mucous layer*) is composed of several layers of cells; those of the deepest layer are columnar in shape and placed perpendicularly on the surface of the basement membrane, to which they are attached by toothed extremities; this deepest layer is sometimes termed the *stratum germinativum*; the succeeding strata consist of cells of a more rounded or polyhedral form, the contents of

which are soft, opaque, granular, and soluble in acetic acid. These are known as prickle cells because of the bridges by which they are connected to one another. They contain fine fibrils which are continuous across the connecting processes with corresponding fibrils in adjacent cells. Between the bridges are fine intercellular clefts serving for the passage of lymph, and in these lymph corpuscles or pigment granules may be found.

The **stratum granulosum** comprises two or three layers of flattened cells which contain granules of *eleidin*, a substance readily stained by hematoxylin or carmine, and probably an intermediate substance in the formation of keratin. They are supposed to be cells in a transitional stage between the protoplasmic cells of the stratum mucosum and the horny cells of the superficial layers.

The **stratum lucidum** appears in section as a homogeneous or dimly striated membrane, composed of closely packed cells in which traces of flattened nuclei may be found, and in which minute granules of a substance named *keratohyalin* are present.

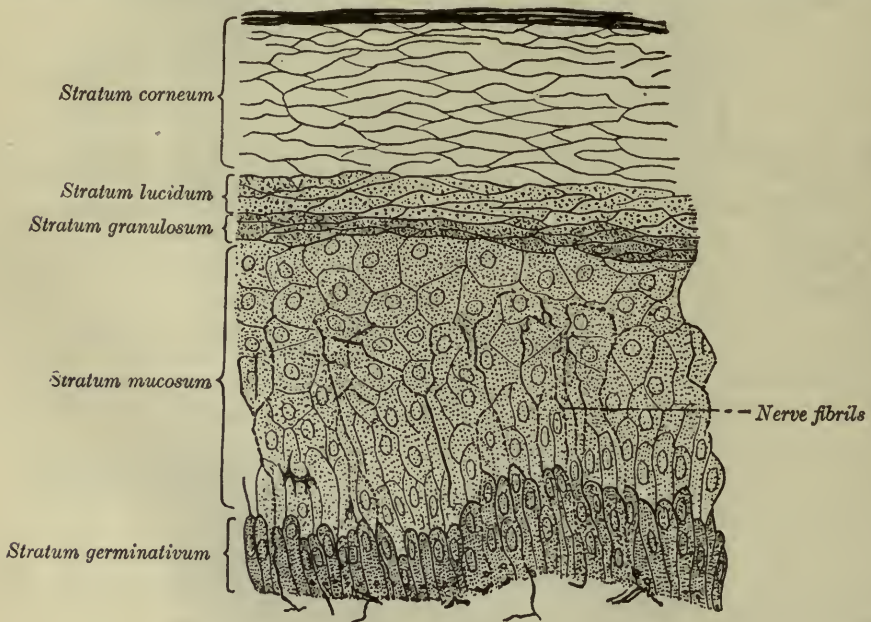


FIG. 941.—Section of epidermis. (Ranvier.)

The **stratum corneum** (*horny layer*) consists of several layers of horny epithelial scales in which no nuclei are discernible, and which are unaffected by acetic acid, the protoplasm having become changed into horny material or **keratin**. According to Ranvier they contain granules of a material which has the characteristics of beeswax.

The black color of the skin in the negro, and the tawny color among some of the white races, is due to the presence of pigment in the cells of the epidermis. This pigment is more especially distinct in the cells of the stratum mucosum, and is similar to that found in the cells of the pigmentary layer of the retina. As the cells approach the surface and desiccate, the color becomes partially lost; the disappearance of the pigment from the superficial layers of the epidermis is, however, difficult to explain.

The pigment (**melanin**) consists of dark brown or black granules of very small size, closely packed together within the cells, but not involving the nucleus.

The main purpose served by the epidermis is that of protection, as the surface is worn away new cells are supplied and thus the true skin, the vessels and nerves which it contains are defended from damage.

The **Corium, Cutis Vera, Dermis, or True Skin** is tough, flexible, and highly elastic. It varies in thickness in different parts of the body. Thus it is very thick in the palms of the hands and soles of the feet; thicker on the posterior aspect of the body than on the front, and on the lateral than on the medial sides of the limbs. In the eyelids, scrotum, and penis it is exceedingly thin and delicate.

It consists of felted connective tissue, with a varying amount of elastic fibers and numerous bloodvessels, lymphatics, and nerves. The connective tissue is arranged in two layers: a deeper or **reticular**, and a superficial or **papillary**. Unstripped muscular fibers are found in the superficial layers of the corium, wherever hairs are present, and in the subcutaneous areolar tissue of the scrotum, penis, labia majora, and nipples. In the nipples the fibers are disposed in bands, closely reticulated and arranged in superimposed laminae.

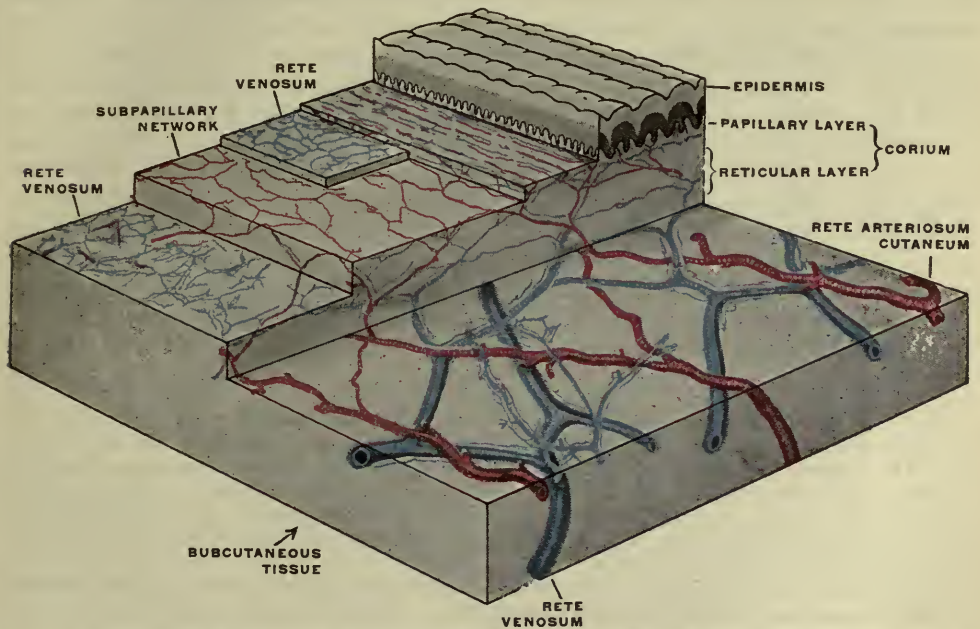


FIG. 942.—The distribution of the bloodvessels in the skin of the sole of the foot. (Spalteholz.)

The **reticular layer** (*stratum reticulare*; *deep layer*) consists of strong interlacing bands, composed chiefly of white fibrous tissue, but containing some fibers of yellow elastic tissue, which vary in number in different parts; and connective-tissue corpuscles, which are often to be found flattened against the white fibrous tissue bundles. Toward the attached surface the fasciculi are large and coarse, and the areolæ left by their interlacement are large, and occupied by adipose tissue and sweat glands. Below the reticular layer is the subcutaneous areolar tissue, which, except in a few situations, contains fat.

The **papillary layer** (*stratum papillare*; *superficial layer*; *corpus papillare of the corium*) consists of numerous small, highly sensitive, and vascular eminences, the **papillæ**, which rise perpendicularly from its surface. The papillæ are minute conical eminences, having rounded or blunted extremities, occasionally divided into two or more parts, and are received into corresponding pits on the under surface of the cuticle. On the general surface of the body, more especially in parts endowed with slight sensibility, they are few in number, and exceedingly minute; but in some situations, as upon the palmar surfaces of the hands and fingers, and upon the plantar surfaces of the feet and toes, they are long, of large size, closely aggregated together, and arranged in parallel curved lines, forming the elevated ridges

seen on the free surface of the epidermis. Each ridge contains two rows of papillæ, between which the ducts of the sudoriferous glands pass outward to open on the summit of the ridge. Each papilla consists of very small and closely interlacing bundles of finely fibrillated tissue, with a few elastic fibers; within this tissue is a capillary loop, and in some papillæ, especially in the palms of the hands and the fingers, there are tactile corpuscles.

Development.—The epidermis and its appendages, consisting of the hairs, nails, sebaceous and sweat glands, are developed from the ectoderm, while the corium or true skin is of mesodermal origin. About the fifth week the epidermis consists of two layers of cells, the deeper one corresponding to the rete mucosum. The subcutaneous fat appears about the fourth month, and the papillæ of the true skin about the sixth. A considerable desquamation of epidermis takes place during fetal life, and this desquamated epidermis, mixed with sebaceous secretion, constitutes the **vernix caseosa**, with which the skin is smeared during the last three months of fetal life. The nails are formed at the third month, and begin to project from the epidermis about the sixth. The hairs appear between the third and fourth months in the form of solid downgrowths of the deeper layer of the epidermis, the growing extremities of which become inverted by papillary projections from the corium. The central cells of the solid downgrowths undergo alteration to form the hair, while the peripheral cells are retained to form the lining cells of the hair-follicle. About the fifth month the fetal hairs (**lanugo**) appear, first on the head and then on the other parts; they drop off after birth, and give place to the permanent hairs. The cellular structures of the sudoriferous and sebaceous glands are formed from the ectoderm, while the connective tissue and bloodvessels are derived from the mesoderm. All the sweat-glands are fully formed at birth; they begin to develop as early as the fourth month.

The **arteries** supplying the skin form a net-work in the subcutaneous tissue, and from this net-work branches are given off to supply the sudoriferous glands, the hair follicles, and the fat. Other branches unite in a plexus immediately beneath the corium; from this plexus, fine capillary vessels pass into the papillæ, forming, in the smaller ones, a single capillary loop, but in the larger, a more or less convoluted vessel. The **lymphatic vessels** of the skin form two net-works, superficial and deep, which communicate with each other and with those of the subcutaneous tissue by oblique branches.

The **nerves** of the skin terminate partly in the epidermis and partly in the corium; their different modes of ending are described on pages 1059 to 1061.

THE APPENDAGES OF THE SKIN.

The appendages of the skin are the **nails**, the **hairs**, and the **sudoriferous and sebaceous glands** with their ducts.

The **Nails** (*ungues*) (Fig. 943) are flattened, elastic structures of a horny texture, placed upon the dorsal surfaces of the terminal phalanges of the fingers and toes. Each nail is convex on its outer surface, concave within, and is implanted by a portion, called the **root**, into a groove in the skin; the exposed portion is called the **body**, and the distal extremity the **free edge**. The nail is firmly adherent to the corium, being accurately moulded upon its surface; the part beneath the body and root of the nail is called the **nail matrix**, because from it the nail is produced. Under the greater part of the body of the nail, the matrix is thick, and raised into a series of longitudinal ridges which are very vascular, and the color is seen through the transparent tissue. Near the root of the nail, the papillæ are smaller, less vascular, and have no regular arrangement, and here the tissue of the nail is not firmly adherent to the connective-tissue stratum but only in contact with it; hence this portion is of a whiter color, and is called the **lunula** on account of its shape.

The cuticle as it passes forward on the dorsal surface of the finger or toe is attached to the surface of the nail a little in advance of its root; at the extremity of

the finger it is connected with the under surface of the nail a little behind its free edge. The cuticle and the horny substance of the nail (both epidermic structures) are thus directly continuous with each other. The superficial, horny part of the nail consists of a greatly thickened stratum lucidum, the stratum corneum forming merely the thin cuticular fold (*eponychium*) which overlaps the lunula; the deeper part consists of the stratum mucosum. The cells in contact with the papillæ of the matrix are columnar in form and arranged perpendicularly to the surface; those which succeed them are of a rounded or polygonal form, the more superficial ones becoming broad, thin, and flattened, and so closely packed as to make the limits of the cells very indistinct. The nails grow in length by the proliferation of the cells of the stratum mucosum at the root of the nail, and in thickness from that part of the stratum mucosum which underlies the lunula.

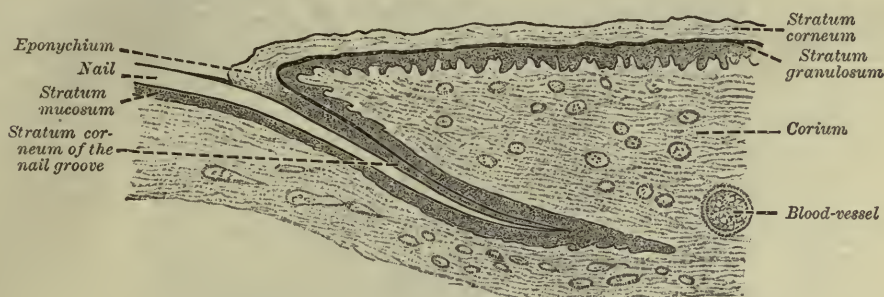


FIG. 943.—Longitudinal section through nail and its nail groove (sulcus).

Hairs (*pili*) are found on nearly every part of the surface of the body, but are absent from the palms of the hands, the soles of the feet, the dorsal surfaces of the terminal phalanges, the glans penis, the inner surface of the prepuce, and the inner surfaces of the labia. They vary much in length, thickness, and color in different parts of the body and in different races of mankind. In some parts, as in the skin of the eyelids, they are so short as not to project beyond the follicles containing them; in others, as upon the scalp, they are of considerable length; again, in other parts, as the eyelashes, the hairs of the pubic region, and the whiskers and beard, they are remarkable for their thickness. Straight hairs are stronger than curly hairs, and present on transverse section a cylindrical or oval outline; curly hairs, on the other hand, are flattened. A hair consists of a **root**, the part implanted in the skin; and a **shaft** or **scapus**, the portion projecting from the surface.

The **root of the hair** (*radix pili*) ends in an enlargement, the **hair bulb**, which is whiter in color and softer in texture than the shaft, and is lodged in a follicular involution of the epidermis called the **hair follicle** (Fig. 944). When the hair is of considerable length the follicle extends into the subcutaneous cellular tissue. The hair follicle commences on the surface of the skin with a funnel-shaped opening, and passes inward in an oblique or curved direction—the latter in curly hairs—to become dilated at its deep extremity, where it corresponds with the hair bulb. Opening into the follicle, near its free extremity, are the ducts of one or more sebaceous glands. At the bottom of each hair follicle is a small conical, vascular eminence or papilla, similar in every respect to those found upon the surface of the skin; it is continuous with the dermic layer of the follicle, and is supplied with nerve fibrils. The hair follicle consists of two coats—an **outer** or **dermic**, and an **inner** or **epidermic**.

The **outer** or **dermic coat** is formed mainly of fibrous tissue; it is continuous with the corium, is highly vascular, and supplied by numerous minute nervous filaments. It consists of three layers (Fig. 945). The most internal is a hyaline basement membrane, which is well-marked in the larger hair follicles, but is not

very distinct in the follicles of minute hairs; it is limited to the deeper part of the follicle. Outside this is a compact layer of fibers and spindle-shaped cells arranged circularly around the follicle; this layer extends from the bottom of the follicle as high as the entrance of the ducts of the sebaceous glands. Externally is a thick layer of connective tissue, arranged in longitudinal bundles, forming a more open texture and corresponding to the reticular part of the corium; in this are contained the bloodvessels and nerves.

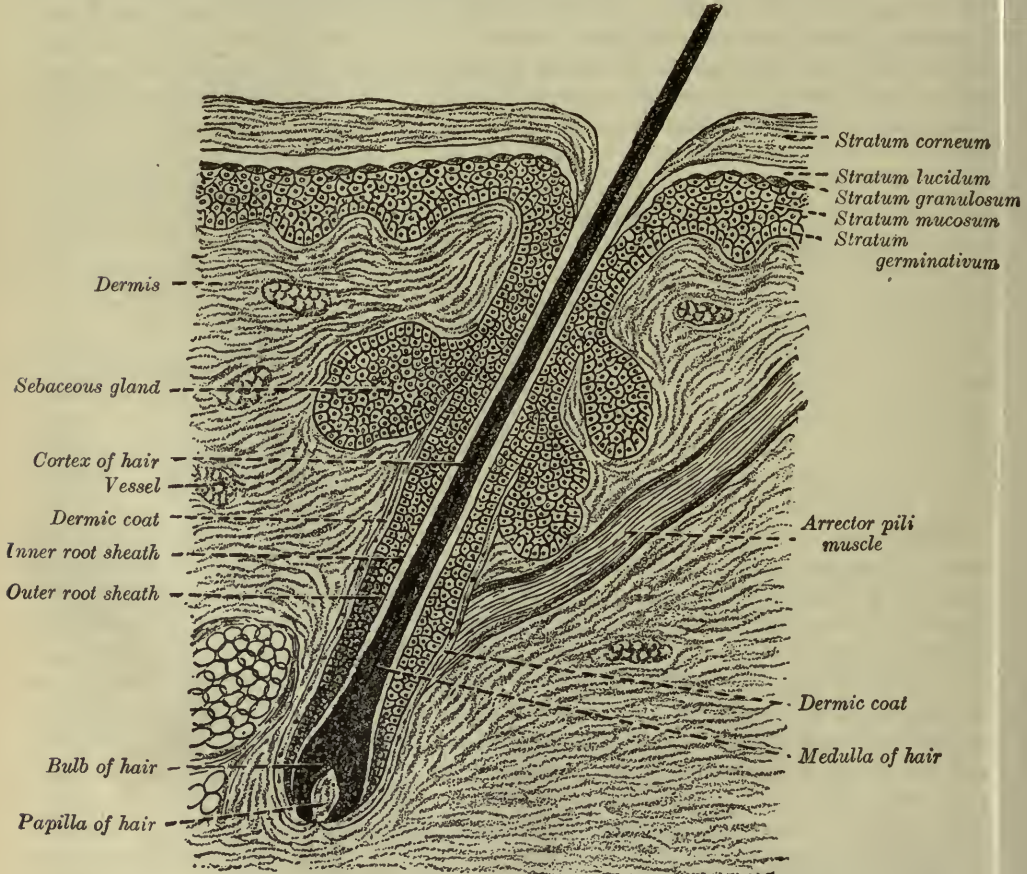


FIG. 944.—Section of skin, showing the epidermis and dermis; a hair in its follicle; the Arrector pili muscle; sebaceous glands.

The **inner** or **epidermic coat** is closely adherent to the root of the hair, and consists of two strata named respectively the **outer** and **inner root sheaths**; the former of these corresponds with the stratum mucosum of the epidermis, and resembles it in the rounded form and soft character of its cells; at the bottom of the hair follicle these cells become continuous with those of the root of the hair. The inner root sheath consists of (1) a delicate cuticle next the hair, composed of a single layer of imbricated scales with atrophied nuclei; (2) one or two layers of horny, flattened, nucleated cells, known as **Huxley's layer**; and (3) a single layer of cubical cells with clear flattened nuclei, called **Henle's layer**.

The hair bulb is moulded over the papilla and composed of polyhedral epithelial cells, which as they pass upward into the root of the hair become elongated and spindle-shaped, except some in the center which remain polyhedral. Some of these latter cells contain pigment granules which give rise to the color of the hair. It occasionally happens that these pigment granules completely fill the cells in

the center of the bulb; this gives rise to the dark tract of pigment often found, of greater or less length, in the axis of the hair.

The **shaft of the hair** (*scapus pili*) consists, from within outward, of three parts, the medulla, the cortex, and the cuticle. The **medulla** is usually wanting in the fine hairs covering the surface of the body, and commonly in those of the head. It is more opaque and deeper colored than the cortex when viewed by transmitted light; but when viewed by reflected light it is white. It is composed of rows of polyhedral cells, containing granules of eleidin and frequently air spaces. The **cortex** constitutes the chief part of the shaft; its cells are elongated and united to form flattened fusiform fibers which contain pigment granules in dark hair, and air in white hair. The **cuticle** consists of a single layer of flat scales which overlap one another from below upward.

Connected with the hair follicles are minute bundles of involuntary muscular fibers, termed the **Arrectores pilorum**. They arise from the superficial layer of the corium, and are inserted into the hair follicle, below the entrance of the duct of the sebaceous gland. They are placed on the side toward which the hair

slopes, and by their action diminish the obliquity of the follicle and elevate the hair (Fig. 944).¹ The sebaceous gland is situated in the angle which the Arrector muscle forms with the superficial portion of the hair follicle, and contraction of the muscle thus tends to squeeze the sebaceous secretion out from the duct of the gland.

The **Sebaceous Glands** (*glandulæ sebaceæ*) are small, sacculated, glandular organs, lodged in the substance of the corium. They are found in most parts of the skin, but are especially abundant in the scalp and face; they are also very numerous around the apertures of the anus, nose, mouth, and external ear, but are wanting in the palms of the hands and soles of the feet. Each gland consists of a single duct, more or less capacious, which emerges from a cluster of oval or flask-shaped alveoli which vary from two to five in number, but in some instances there may be as many as twenty. Each alveolus is composed of a transparent basement membrane, enclosing a number of epithelial cells. The outer or marginal cells are small and polyhedral, and are continuous with the cells lining the duct. The remainder of the alveolus is filled with larger cells, containing fat, except in the center, where the cells have become broken up, leaving a cavity filled with their debris and a mass of fatty matter, which constitutes the **sebum cutaneum**. The ducts open most frequently into the hair follicles, but occasionally upon the general surface, as in the labia minora and the free margin of the lips. On the nose and face

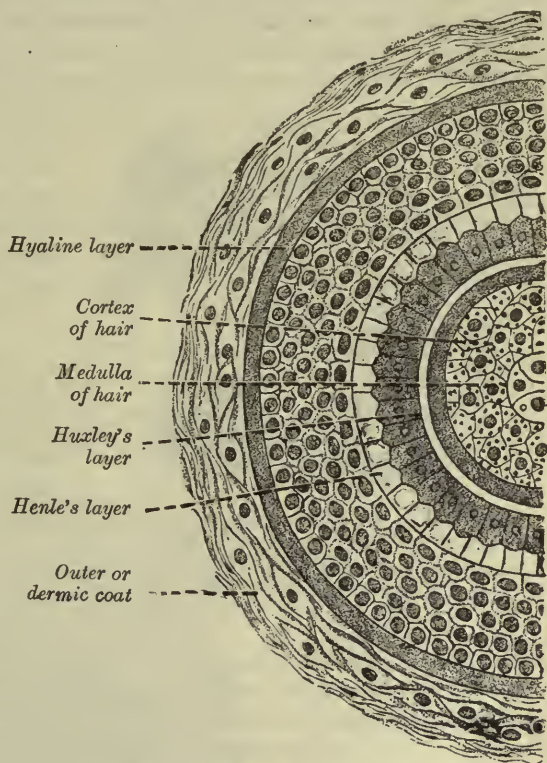


FIG. 945.—Transverse section of hair follicle.

¹ Professor Arthur Thomson, of Oxford, suggests that the contraction of these muscles on follicles which contain weak, flat hairs will tend to produce a permanent curve in the follicle, and this curve will be impressed on the hair which is moulded within it, so that the hair, on emerging through the skin, will be curled. Curved hair follicles are characteristic of the scalp of the Bushman.

the glands are of large size, distinctly lobulated, and often become much enlarged from the accumulation of pent-up secretion. The tarsal glands of the eyelids are elongated sebaceous glands with numerous lateral diverticula.

The **Sudoriferous** or **Sweat Glands** (*glandulæ sudoriferæ*) are found in almost every part of the skin, and are situated in small pits on the under surface of the corium, or, more frequently, in the subcutaneous areolar tissue, surrounded by a quantity of adipose tissue. Each consists of a single tube, the deep part of which is rolled into an oval or spherical ball, named the **body** of the gland, while the super-

ficial part, or **duct**, traverses the corium and cuticle and opens on the surface of the skin by a funnel-shaped aperture. In the superficial layers of the corium the duct is straight, but in the deeper layers it is convoluted or even twisted; where the epidermis is thick, as in the palms of the hands and soles of the feet, the part of the duct which passes through it is spirally coiled. The size of the glands varies. They are especially large in those regions where the amount of perspiration is great, as in the axillæ, where they form a thin, mammillated layer of a reddish color, which corresponds exactly to the situation of the hair in this region; they are large also in the groin. Their number varies. They are very plentiful on the palms

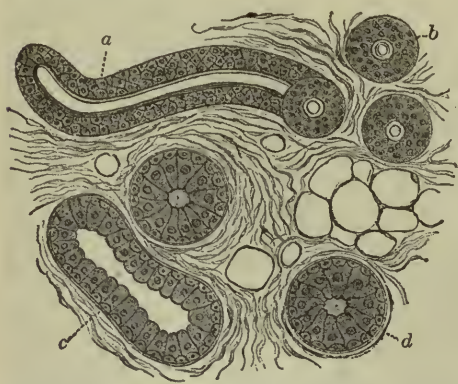


FIG. 946.—Body of a sudoriferous-gland cut in various directions. *a*. Longitudinal section of the proximal part of the coiled tube. *b*. Transverse section of the same. *c*. Longitudinal section of the distal part of the coiled tube. *d*. Transverse section of the same. (Klein and Noble Smith.)

of the hands, and on the soles of the feet, where the orifices of the ducts are exceedingly regular, and open on the curved ridges; they are least numerous in the neck and back. On the palm there are about 370 per square centimeter; on the back of the hand about 200; forehead 175, breast, abdomen and forearm 155, and on the leg and back from 60 to 80 per square centimeter. Krause estimates the total number at about 2,000,000. The average number of sweat glands per square centimeter of skin area in various races as shown by the fingers is as follows:¹

American (white)	558.2
American (negro)	597.2
Filipino	653.6
Moro	684.4
Negrito (adult)	709.2
Hindu	738.2
Negrito (youth)	950.0

They are absent in the deeper portion of the external auditory meatus, the prepuce and the glans penis. The tube, both in the body of the gland and in the duct consists of two layers—an outer, of fine **areolar tissue**, and an inner of **epithelium** (Fig. 946). The outer layer is thin and is continuous with the superficial stratum of the corium. In body of the gland the epithelium consists of a single layer of cubical cells, between the deep ends of which and the basement membrane is a layer of longitudinally or obliquely arranged non-striped muscular fibers. The ducts are destitute of muscular fibers and are composed of a basement membrane lined by two or three layers of polyhedral cells; the lumen of the duct is coated by a thin cuticle. When the cuticle is carefully removed from the surface of the corium, the ducts may be drawn out in the form of short, thread-like processes on its under surface. The ceruminous glands of the external acoustic meatus and the ciliary glands at the margins of the eyelids are modified sudoriferous glands.

¹ Clark and Lhamon, *Anatomical Record*, 1917, xii.

SPLANCHNOLOGY.

UNDER this heading are included the respiratory, digestive, and urogenital organs, and the ductless glands.

THE RESPIRATORY APPARATUS (APPARATUS RESPIRATORIUS; RESPIRATORY SYSTEM).

The respiratory apparatus consists of the larynx, trachea, bronchi, lungs, and pleuræ.

Development.—The rudiment of the respiratory organs appears as a median longitudinal groove in the ventral wall of the pharynx. The groove deepens and its lips fuse to form a septum which grows from below upward and converts the groove into a tube, the laryngo-tracheal tube (Fig. 947), the cephalic

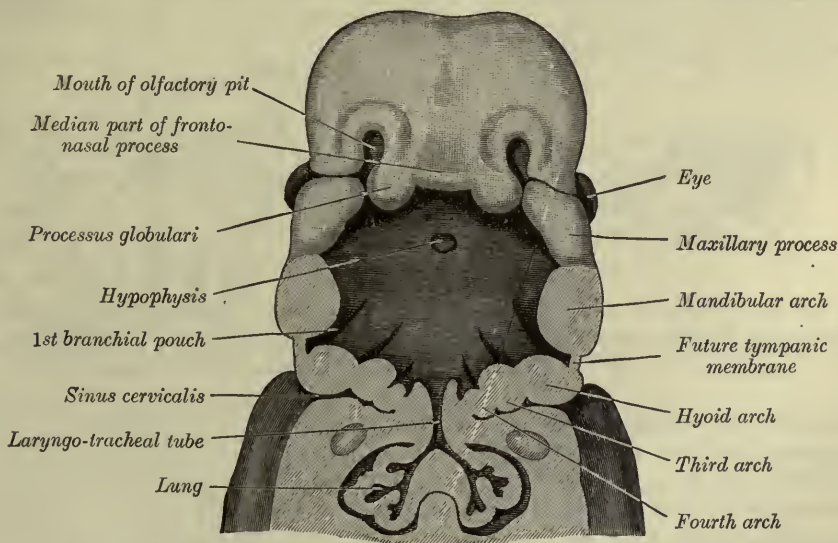


FIG. 947.—The head and neck of a human embryo thirty-two days old, seen from the ventral surface. The floor of the mouth and pharynx have been removed. (His.)

end of which opens into the pharynx by a slit-like aperture formed by the persistent anterior part of the groove. The tube is lined by entoderm from which the epithelial lining of the respiratory tract is developed. The cephalic part of the tube becomes the larynx, and its next succeeding part the trachea, while from its caudal end two lateral outgrowths, the right and left lung buds, arise, and from them the bronchi and lungs are developed. The first rudiment of the larynx consists of two arytenoid swellings, which appear, one on either side of the cephalic end of the laryngo-tracheal groove, and are continuous in front of the groove with a transverse ridge (furcula of His) which lies between the ventral ends of the third branchial arches and from which the epiglottis is subsequently developed (Figs. 980, 981). After the separation of the trachea from the esophagus the arytenoid swellings come

into contact with one another and with the back of the epiglottis, and the entrance to the larynx assumes the form of a T-shaped cleft, the margins of the cleft adhere to one another and the laryngeal entrance is for a time occluded. The mesodermal wall of the tube becomes condensed to form the cartilages of the larynx and trachea. The arytenoid swellings are differentiated into the arytenoid and corniculate cartilages, and the folds joining them to the epiglottis form the aryepiglottic folds in which the cuneiform cartilages are developed as derivatives of the epiglottis. The thyroid cartilage appears as two lateral plates, each chondrified from two centers and united in the mid-ventral line by membrane in which an additional center of chondrification develops. The cricoid cartilage arises from two cartilaginous centers, which soon unite ventrally and gradually extend and ultimately fuse on the dorsal aspect of the tube.

J. Ernest Frazer¹ has made an important investigation on the development of the larynx and the following are his main conclusions:

The opening of the pulmonary diverticulum lies between the two fifth arch masses and behind a "central mass" in the middle line—the proximal end of the diverticulum is compressed between the fifth arch masses. The fifth arch is joined by the fourth to form a "lateral mass" on each side of the opening, and these "lateral masses" grow forward and overlap the central mass and so form a secondary transverse cavity, which is really a part of the cavity of the pharynx. The two parts of the cavity of the larynx are separated in the adult by a line drawn back along the vocal fold and then upward along the border of the arytenoid eminence to the interarytenoid notch. The arytenoid and cricoid are developed in the fifth arch mass. The thyroid is primarily a fourth arch derivative, and if it has a fifth arch element this is a later addition. The epiglottis is derived from the "central mass," and has a third arch element in its oral and upper aspect; the arch value of the "central mass" is doubtful.



FIG. 948.—Lung buds from a human embryo of about four weeks, showing commencing lobulations. (His.)

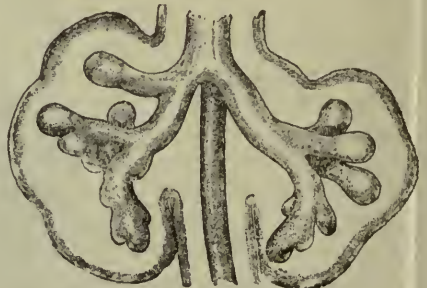


FIG. 949.—Lungs of a human embryo more advanced in development. (His.)

The right and left lung buds grow out behind the ducts of Cuvier, and are at first symmetrical, but their ends soon become lobulated, three lobules appearing on the right, and two on the left; these subdivisions are the early indications of the corresponding lobes of the lungs (Figs. 948, 949). The buds undergo further subdivision and ramification, and ultimately end in minute expanded extremities—the infundibula of the lung. After the sixth month the air-sacs begin to make their appearance on the infundibula in the form of minute pouches. The pulmonary arteries are derived from the sixth aortic arches. During the course of their development the lungs migrate in a caudal direction, so that by the time of birth the bifurcation of the trachea is opposite the fourth thoracic vertebra. As the lungs grow they project into that part of the celom which will ultimately form the pleural cavities, and the superficial layer of the mesoderm enveloping the lung rudiment expands on the growing lung and is converted into the pulmonary pleura.

THE LARYNX.

The **larynx** or **organ of voice** is placed at the upper part of the air passage. It is situated between the trachea and the root of the tongue, at the upper and

¹ Journal of Anatomy and Physiology, vol. xlv.

forepart of the neck, where it presents a considerable projection in the middle line. It forms the lower part of the anterior wall of the pharynx, and is covered behind by the mucous lining of that cavity; on either side of it lie the great vessels of the neck. Its vertical extent corresponds to the fourth, fifth, and sixth cervical vertebræ, but it is placed somewhat higher in the female and also during childhood. Symington found that in infants between six and twelve months of age the tip of the epiglottis was a little above the level of the fibrocartilage between the odontoid process and body of the axis, and that between infancy and adult life the larynx descends for a distance equal to two vertebral bodies and two intervertebral fibrocartilages. According to Sappey the average measurements of the adult larynx are as follows:

	In males.	In females.
Length	44 mm.	36 mm.
Transverse diameter	43 “	41 “
Antero-posterior diameter	36 “	26 “
Circumference	136 “	112 “

Until puberty the larynx of the male differs little in size from that of the female. In the female its increase after puberty is only slight; in the male it undergoes considerable increase; all the cartilages are enlarged and the thyroid cartilage becomes prominent in the middle line of the neck, while the length of the rima glottidis is nearly doubled.

The larynx is broad above, where it presents the form of a triangular box flattened behind and at the sides, and bounded in front by a prominent vertical ridge. Below, it is narrow and cylindrical. It is composed of cartilages, which are connected together by ligaments and moved by numerous muscles. It is lined by mucous membrane continuous above with that of the pharynx and below with that of the trachea.

The **Cartilages of the Larynx** (*cartilagines laryngis*) (Fig. 950) are nine in number, three single and three paired, as follows:

Thyroid.	Two Corniculate.
Cricoid.	Two Cuneiform.
Two Arytenoid.	Epiglottis.

The **Thyroid Cartilage** (*cartilago thyreoidea*) is the largest cartilage of the larynx. It consists of two laminae the anterior borders of which are fused with each other at an acute angle in the middle line of the neck, and form a subcutaneous projection named the **laryngeal prominence** (*pomum Adami*). This prominence is most distinct at its upper part, and is larger in the male than in the female. Immediately above it the laminae are separated by a V-shaped notch, the **superior thyroid notch**. The laminae are irregularly quadrilateral in shape, and their posterior angles are prolonged into processes termed the **superior** and **inferior cornua**.

The **outer surface** of each lamina presents an **oblique line** which runs downward and forward from the superior thyroid tubercle situated near the root of the superior cornu, to the inferior thyroid tubercle on the lower border. This line gives attachment to the Sternothyroideus, Thyreohyoideus, and Constrictor pharyngis inferior.

The **inner surface** is smooth; above and behind, it is slightly concave and covered by mucous membrane. In front, in the angle formed by the junction of the laminae, are attached the stem of the epiglottis, the ventricular and vocal ligaments, the Thyreoarytænoidei, Thyreoepiglottici and Vocales muscles, and the thyroepiglottic ligament.

The **upper border** is concave behind and convex in front; it gives attachment to the corresponding half of the hyothyroid membrane.

The **lower border** is concave behind, and nearly straight in front, the two parts being separated by the inferior thyroid tubercle. A small part of it in and near

the middle line is connected to the cricoid cartilage by the middle cricothyroid ligament.

The **posterior border**, thick and rounded, receives the insertions of the Stylopharyngeus and Pharyngopalatinus. It ends above, in the superior cornu, and below, in the inferior cornu. The **superior cornu** is long and narrow, directed upward, backward, and medialward, and ends in a conical extremity, which gives attachment to the lateral hyothyroid ligament. The **inferior cornu** is short and thick; it is directed downward, with a slight inclination forward and medialward, and presents, on the medial side of its tip, a small oval articular facet for articulation with the side of the cricoid cartilage.

During infancy the laminae of the thyroid cartilage are joined to each other by a narrow, lozenge-shaped strip, named the **intrathyroid cartilage**. This strip extends from the upper to the lower border of the cartilage in the middle line, and is distinguished from the laminae by being more transparent and more flexible.

The **Cricoid Cartilage** (*cartilago cricoidea*) is smaller, but thicker and stronger than the thyroid, and forms the lower and posterior parts of the wall of the larynx. It consists of two parts: a **posterior quadrate lamina**, and a narrow **anterior arch**, one-fourth or one-fifth of the depth of the lamina.

The **lamina** (*lamina cartilaginosa cricoidea; posterior portion*) is deep and broad, and measures from above downward about 2 or 3 cm.; on its posterior surface, in the middle line, is a vertical ridge to the lower part of which are attached the longitudi-

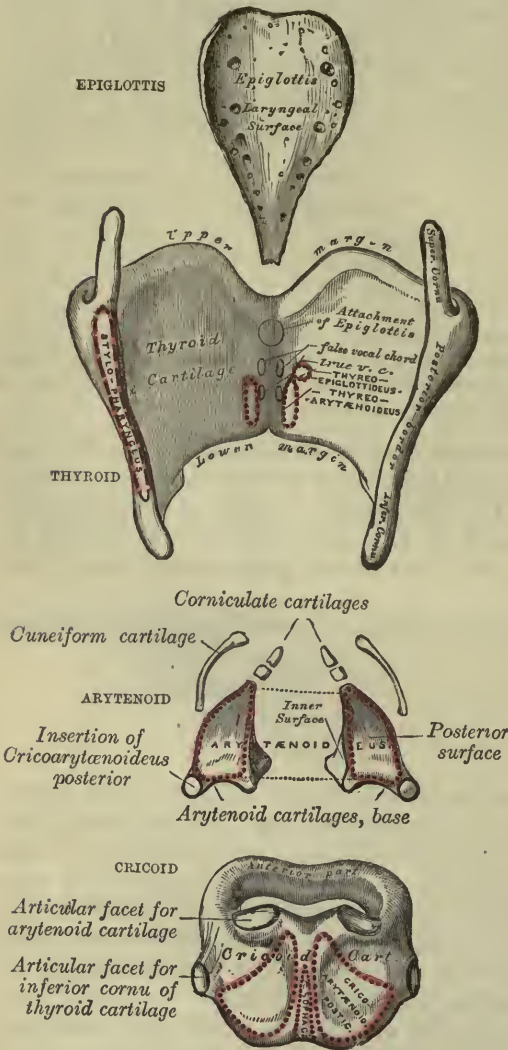


FIG. 950.—The cartilages of the larynx. Posterior view.

nal fibers of the esophagus; and on either side of this a broad depression for the Cricoarytenoid posterior.

The **arch** (*arcus cartilaginosa cricoidea; anterior portion*) is narrow and convex, and measures vertically from 5 to 7 mm.; it affords attachment externally in front and at the sides to the Cricothyreioidi, and behind, to part of the Constrictor pharyngis inferior.

On either side, at the junction of the lamina with the arch, is a small round articular surface, for articulation with the inferior cornu of the thyroid cartilage.

The **lower border** of the cricoid cartilage is horizontal, and connected to the highest ring of the trachea by the cricotracheal ligament.

The **upper border** runs obliquely upward and backward, owing to the great

depth of the lamina. It gives attachment, in front, to the middle cricothyroid ligament; at the side, to the conus elasticus and the Cricoarytænoidei laterales; behind, it presents, in the middle, a shallow notch, and on either side of this is a smooth, oval, convex surface, directed upward and lateralward, for articulation with the base of an arytenoid cartilage.

The **inner surface** of the cricoid cartilage is smooth, and lined by mucous membrane.

The **Arytenoid Cartilages** (*cartilagine arytenoidæ*) are two in number, and situated at the upper border of the lamina of the cricoid cartilage, at the back of the larynx. Each is pyramidal in form, and has three surfaces, a base, and an apex.

The **posterior surface** is a triangular, smooth, concave, and gives attachment to the Arytænoidei obliquus and transversus.

The **antero-lateral surface** is somewhat convex and rough. On it, near the apex of the cartilage, is a rounded elevation (**colliculus**) from which a ridge (**crista arcuata**) curves at first backward and then downward and forward to the vocal process. The lower part of this crest intervenes between two depressions or **foveæ**, an upper, triangular, and a lower oblong in shape; the latter gives attachment to the Vocalis muscle.

The **medial surface** is narrow, smooth, and flattened, covered by mucous membrane, and forms the lateral boundary of the intercartilaginous part of the rima glottidis.

The **base** of each cartilage is broad, and on it is a concave smooth surface, for articulation with the cricoid cartilage. Its lateral angle is short, rounded, and prominent; it projects backward and lateralward, and is termed the **muscular process**; it gives insertion to the Cricoarytænoideus posterior behind, and to the Cricoarytænoideus lateralis in front. Its anterior angle, also prominent, but more pointed, projects horizontally forward; it gives attachment to the vocal ligament, and is called the **vocal process**.

The **apex** of each cartilage is pointed, curved backward and medialward, and surmounted by a small conical, cartilaginous nodule, the **corniculate cartilage**.

The **Corniculate Cartilages** (*cartilagine corniculatæ; cartilages of Santorini*) are two small conical nodules, consisting of yellow elastic cartilage, which articulate with the summits of the arytenoid cartilages and serve to prolong them backward and medialward. They are situated in the posterior parts of the aryepiglottic folds of mucous membrane, and are sometimes fused with the arytenoid cartilages.

The **Cuneiform Cartilages** (*cartilagine cuneiformes; cartilages of Wisberg*) are two small, elongated pieces of yellow elastic cartilage, placed one on either side, in the aryepiglottic fold, where they give rise to small whitish elevations on the surface of the mucous membrane, just in front of the arytenoid cartilages.

The **Epiglottis** (*cartilago epiglottica*) is a thin lamella of fibrocartilage of a yellowish color, shaped like a leaf, and projecting obliquely upward behind the root of the tongue, in front of the entrance to the larynx. The free extremity is broad and rounded; the attached part or stem is long, narrow, and connected by the **thyroepiglottic ligament** to the angle formed by the two laminae of the thyroid cartilage, a short distance below the superior thyroid notch. The lower part of its anterior surface is connected to the upper border of the body of the hyoid bone by an elastic ligamentous band, the **hyoepiglottic ligament**.

The **anterior or lingual surface** is curved forward, and covered on its upper, free part by mucous membrane which is reflected on to the sides and root of the tongue, forming a median and two lateral **glossoepiglottic folds**; the lateral folds are partly attached to the wall of the pharynx. The depressions between the epiglottis and the root of the tongue, on either side of the median fold, are named the **valleculæ**. The lower part of the anterior surface lies behind the hyoid bone, the hyothyroid

membrane, and upper part of the thyroid cartilage, but is separated from these structures by a mass of fatty tissue.

The **posterior or laryngeal surface** is smooth, concave from side to side, concavo-convex from above downward; its lower part projects backward as an elevation, the **tubercle or cushion**. When the mucous membrane is removed, the surface of the cartilage is seen to be indented by a number of small pits, in which mucous glands are lodged. To its sides the aryepiglottic folds are attached.

Structure.—The corniculate and cuneiform cartilages, the epiglottis, and the apices of the arytenoids at first consist of hyaline cartilage, but later elastic fibers are deposited in the matrix, converting them into yellow fibrocartilage, which shows little tendency to calcification. The thyroid, cricoid, and the greater part of the arytenoids consist of hyaline cartilage, and become more or less ossified as age advances. Ossification commences about the twenty-fifth year in the thyroid cartilage, and somewhat later in the cricoid and arytenoids; by the sixty-fifth year these cartilages may be completely converted into bone.

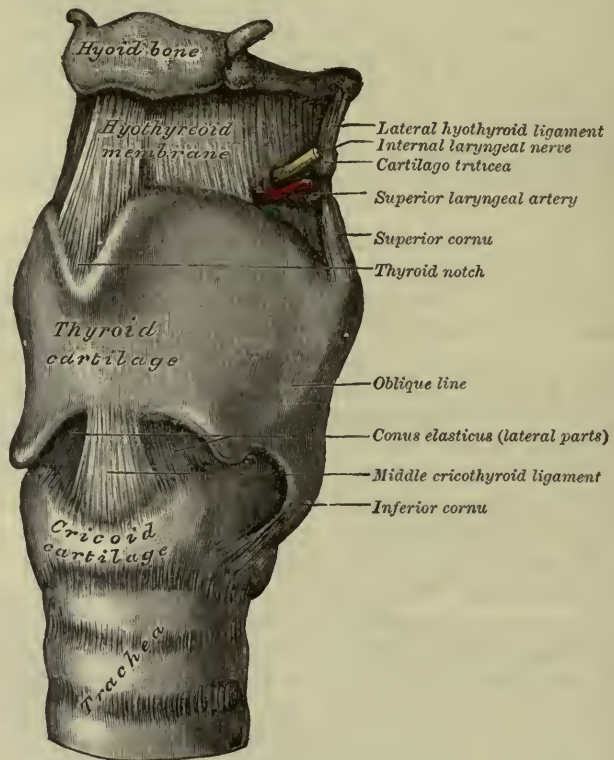


FIG. 951.—The ligaments of the larynx. Antero-lateral view.

Ligaments.—The ligaments of the larynx (Figs. 951, 952) are **extrinsic**, *i. e.*, those connecting the thyroid cartilage and epiglottis with the hyoid bone, and the cricoid cartilage with the trachea; and **intrinsic**, those which connect the several cartilages of the larynx to each other.

Extrinsic Ligaments.—The ligaments connecting the thyroid cartilage with the hyoid bone are the hyothyroid membrane, and a middle and two lateral hyothyroid ligaments.

The **Hyothyroid Membrane** (*membrana hyothyreoidea*; *thyrohyoid membrane*) is a broad, fibro-elastic layer, attached below to the upper border of the thyroid cartilage and to the front of its superior cornu, and above to the upper margin of the posterior surface of the body and greater cornua of the hyoid bone, thus passing behind the posterior surface of the body of the hyoid, and being separated from it

by a mucous bursa, which facilitates the upward movement of the larynx during deglutition. Its middle thicker part is termed the **middle hyothyroid ligament** (*ligamentum hyothyroideum medium*; *middle thyrohyoid ligament*), its lateral thinner portions are pierced by the superior laryngeal vessels and the internal branch of the superior laryngeal nerve. Its anterior surface is in relation with the Thyrohyoideus, Sternohyoideus, and Omohyoideus, and with the body of the hyoid bone.

The **Lateral Hyothyroid Ligament** (*ligamentum hyothyroideum laterale*; *lateral thyrohyoid ligament*) is a round elastic cord, which forms the posterior border of the hyothyroid membrane and passes between the tip of the superior cornu of the thyroid cartilage and the extremity of the greater cornu of the hyoid bone. A small cartilaginous nodule (*cartilago triticea*), sometimes bony, is frequently found in it.

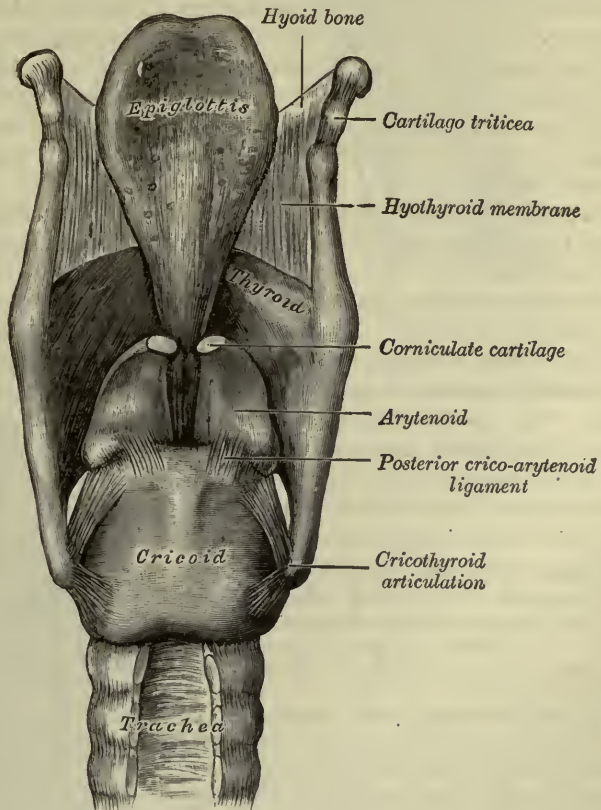


FIG. 952.—Ligaments of the larynx. Posterior view.

The **Epiglottis** is connected with the hyoid bone by an elastic band, the **hyo-epiglottic ligament** (*ligamentum hyoepiglotticum*), which extends from the anterior surface of the epiglottis to the upper border of the body of the hyoid bone. The glossoepiglottic folds of mucous membrane (page 1075) may also be considered as extrinsic ligaments of the epiglottis.

The **Cricotracheal Ligament** (*ligamentum cricotracheale*) connects the cricoid cartilage with the first ring of the trachea. It resembles the fibrous membrane which connects the cartilaginous rings of the trachea to each other.

Intrinsic Ligaments.—Beneath the mucous membrane of the larynx is a broad sheet of fibrous tissue containing many elastic fibers, and termed the **elastic membrane of the larynx**. It is subdivided on either side by the interval between the ven-

tricular and vocal ligaments, the upper portion extends between the arytenoid cartilage and the epiglottis and is often poorly defined; the lower part is a well-marked membrane forming, with its fellow of the opposite side, the conus elasticus which connects the thyroid, cricoid, and arytenoid cartilages to one another. In addition the joints between the individual cartilages are provided with ligaments.

The **Conus Elasticus** (*cricothyroid membrane*) is composed mainly of yellow elastic tissue. It consists of an anterior and two lateral portions. The **anterior part or middle cricothyroid ligament** (*ligamentum cricothyreoideum medium; central part of cricothyroid membrane*) is thick and strong, narrow above and broad below. It connects together the front parts of the contiguous margins of the thyroid and cricoid cartilages. It is overlapped on either side by the Cricothyreoideus, but between these is subcutaneous; it is crossed horizontally by a small anastomotic arterial arch, formed by the junction of the two cricothyroid arteries, branches of which pierce it. The **lateral portions** are thinner and lie close under the mucous membrane of the larynx; they extend from the superior border of the cricoid cartilage to the inferior margin of the vocal ligaments, with which they are continuous. These ligaments may therefore be regarded as the free borders of the lateral portions of the conus elasticus, and extend from the vocal processes of the arytenoid cartilages to the angle of the thyroid cartilage about midway between its upper and lower borders.

An **articular capsule**, strengthened posteriorly by a well-marked fibrous band, encloses the articulation of the inferior cornu of the thyroid with the cricoid cartilage on either side.

Each arytenoid cartilage is connected to the cricoid by a capsule and a posterior cricoarytenoid ligament. The **capsule** (*capsula articularis cricoarytenoidea*) is thin and loose, and is attached to the margins of the articular surfaces. The **posterior cricoarytenoid ligament** (*ligamentum cricoarytenoideum posterius*) extends from the cricoid to the medial and back part of the base of the arytenoid.

The **thyroepiglottic ligament** (*ligamentum thyroepiglotticum*) is a long, slender, elastic cord which connects the stem of the epiglottis with the angle of the thyroid cartilage, immediately beneath the superior thyroid notch, above the attachment of the ventricular ligaments.

Movements.—The articulation between the inferior cornu of the thyroid cartilage and the cricoid cartilage on either side is a diarthrodial one, and permits of rotatory and gliding movements. The rotatory movement is one in which the cricoid cartilage rotates upon the inferior cornua of the thyroid cartilage around an axis passing transversely through both joints. The gliding movement consists in a limited shifting of the cricoid on the thyroid in different directions.

The articulation between the arytenoid cartilages and the cricoid is also a diarthrodial one, and permits of two varieties of movement: one is a rotation of the arytenoid on a vertical axis, whereby the vocal process is moved lateralward or medialward, and the rima glottidis increased or diminished; the other is a gliding movement, and allows the arytenoid cartilages to approach or recede from each other; from the direction and slope of the articular surfaces lateral gliding is accompanied by a forward and downward movement. The two movements of gliding and rotation are associated, the medial gliding being connected with medialward rotation, and the lateral gliding with lateralward rotation. The posterior cricoarytenoid ligaments limit the forward movement of the arytenoid cartilages on the cricoid.

Interior of the Larynx (Figs. 953, 954).—The **cavity of the larynx** (*cavum laryngis*) extends from the laryngeal entrance to the lower border of the cricoid cartilage where it is continuous with that of the trachea. It is divided into two parts by the projection of the vocal folds, between which is a narrow triangular fissure or chink, the **rima glottidis**. The portion of the cavity of the larynx above the vocal folds is called the **vestibule**; it is wide and triangular in shape, its base or anterior wall presenting, however, about its center the backward projection of the tubercle of the epiglottis. It contains the ventricular folds, and between these and the vocal folds are the **ventricles of the larynx**. The portion below the

vocal folds is at first of an elliptical form, but lower down it widens out, assumes a circular form, and is continuous with the tube of the trachea.

The **entrance of the larynx** (Fig. 955) is a triangular opening, wide in front, narrow behind, and sloping obliquely downward and backward. It is bounded, in front, by the epiglottis; behind, by the apices of the arytenoid cartilages, the corniculate cartilages, and the interarytenoid notch; and on either side, by a fold of mucous membrane, enclosing ligamentous and muscular fibers, stretched between the side of the epiglottis and the apex of the arytenoid cartilage; this is the **aryepiglottic fold**, on the posterior part of the margin of which the cuneiform cartilage forms a more or less distinct whitish prominence, the **cuneiform tubercle**.

The **Ventricular Folds** (*plicæ ventriculares*; *superior or false vocal cords*) are two thick folds of mucous membrane, each enclosing a narrow band of fibrous tissue, the **ventricular ligament** which is attached in front to the angle of the thyroid cartilage immediately below the attachment of the epiglottis, and behind to the antero-lateral surface of the arytenoid cartilage, a short distance above the vocal process. The lower border of this ligament, enclosed in mucous membrane, forms a free crescentic margin, which constitutes the upper boundary of the ventricle of the larynx.

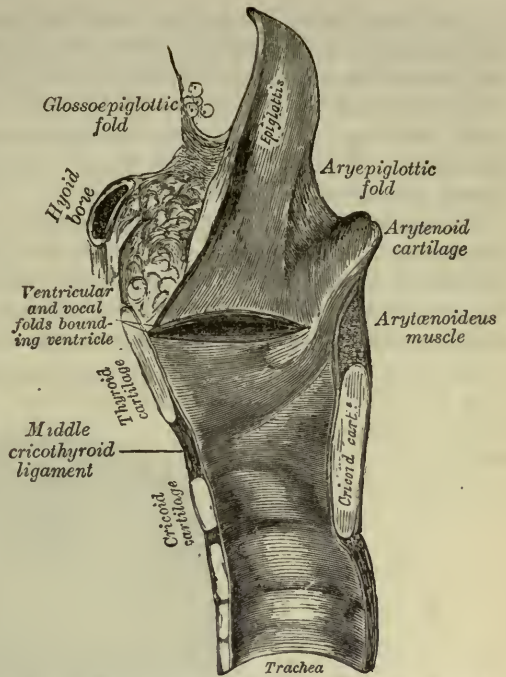


FIG. 953.—Sagittal section of the larynx and upper part of the trachea.

The lower border of this ligament, enclosed in mucous membrane, forms a free crescentic margin, which constitutes the upper boundary of the ventricle of the larynx.

The **Vocal Folds** (*plicæ vocales*; *inferior or true vocal cords*) are concerned in the production of sound, and enclose two strong bands, named the **vocal ligaments** (*ligamenta vocales*; *inferior thyroarytenoid*). Each ligament consists of a band of yellow elastic tissue, attached in front to the angle of the thyroid cartilage, and behind to the vocal process of the arytenoid. Its lower border is continuous with the thin lateral part of the conus elasticus. Its upper border forms the lower boundary of the ventricle of the larynx. Laterally, the Vocalis muscle lies parallel with it. It is covered medially by mucous membrane, which is extremely thin and closely adherent to its surface.

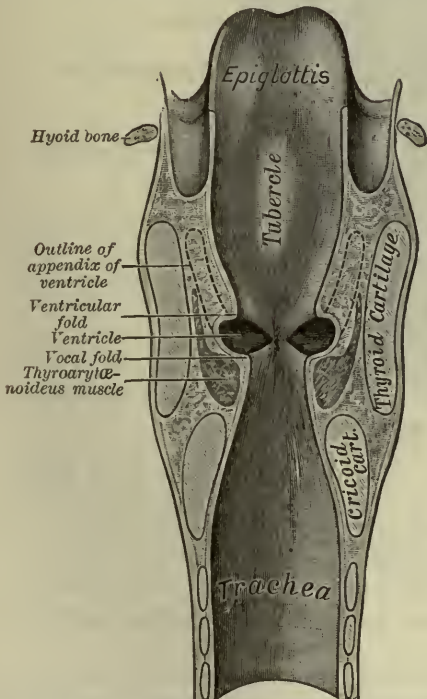


FIG. 954.—Coronal section of larynx and upper part of trachea.

The **Ventricle of the Larynx** (*ventriculus laryngis* [Morgagnii]; *laryngeal sinus*) is a fusiform fossa, situated between the ventricular and vocal folds on either side, and extending nearly their entire length. The fossa is bounded, *above*, by the free crescentic edge of the ventricular fold; *below*, by the straight margin of the vocal fold; *laterally*, by the mucous membrane covering the corresponding Thyreoarytænoideus. The anterior part of the ventricle leads up by a narrow opening into a cecal pouch of mucous membrane of variable size called the **appendix**.

The **appendix of the laryngeal ventricle** (*appendix ventriculi laryngis*; *laryngeal saccule*) is a membranous sac, placed between the ventricular fold and the inner surface of the thyroid cartilage, occasionally extending as far as its upper border or even higher; it is conical in form, and curved slightly backward. On the surface of its mucous membrane are the openings of sixty or seventy mucous glands, which

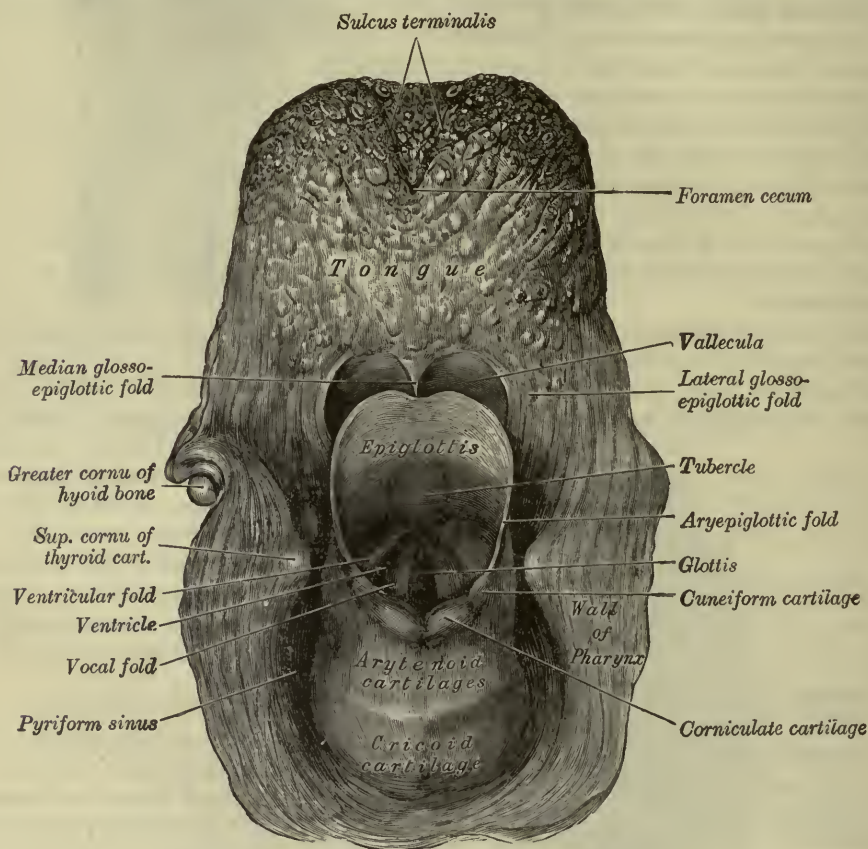


FIG. 955.—The entrance to the larynx, viewed from behind.

are lodged in the submucous areolar tissue. This sac is enclosed in a fibrous capsule, continuous below with the ventricular ligament. Its medial surface is covered by a few delicate muscular fasciculi, which *arise* from the apex of the arytenoid cartilage and become lost in the aryepiglottic fold of mucous membrane; laterally it is separated from the thyroid cartilage by the Thyreoepiglotticus. These muscles compress the sac, and express the secretion it contains upon the vocal folds to lubricate their surfaces.

The **Rima Glottidis** (Fig. 956) is the elongated fissure or chink between the vocal folds in front, and the bases and vocal processes of the arytenoid cartilages behind. It is therefore subdivided into a larger anterior intramembranous part (*glottis vocalis*), which measures about three-fifths of the length of the entire aperture, and a posterior intercartilaginous part (*glottis respiratoria*).

Posteriorly it is limited by the mucous membrane passing between the arytenoid cartilages. The rima glottidis is the narrowest part of the cavity of the larynx, and its level corresponds with the bases of the arytenoid cartilages. Its length, in the male, is about 23 mm.; in the female from 17 to 18 mm. The width and shape of the rima glottidis vary with the movements of the vocal folds and arytenoid cartilages during respiration and phonation. In the condition of rest, *i. e.*, when these structures are uninfluenced by muscular action, as in quiet respiration, the intramembranous part is triangular, with its apex in front and its base behind—the latter being represented by a line, about 8 mm. long, connecting the anterior ends of the vocal processes, while the medial surfaces of the arytenoids are parallel to each other, and hence the intercartilaginous part is rectangular. During extreme adduction of the vocal folds, as in the emission of a high note, the intramembranous part is reduced to a linear slit by the apposition of the vocal folds, while the intercartilaginous part is triangular, its apex corresponding to the anterior ends of the vocal processes of the arytenoids, which are approximated by the medial rotation of the cartilages. Conversely in extreme abduction of the vocal folds, as in forced inspiration, the arytenoids and their

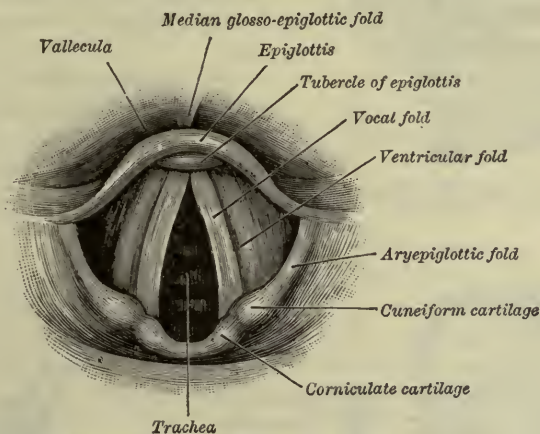


FIG. 956.—Laryngoscopic view of interior of larynx.

vocal processes are rotated lateralward, and the intercartilaginous part is triangular in shape but with its apex directed backward. In this condition the entire glottis is somewhat lozenge-shaped, the sides of the intramembranous part diverging from before backward, those of the intercartilaginous part diverging from behind forward—the widest part of the aperture corresponding with the attachments of the vocal folds to the vocal processes.

Muscles.—The muscles of the larynx are *extrinsic*, passing between the larynx and parts around—these have been described in the section on Myology; and *intrinsic*, confined entirely to the larynx.

The intrinsic muscles are:

Cricothyroideus.	Cricoarytænoideus lateralis.
Cricoarytænoideus posterior.	Arytænoideus.
	Thyroarytænoideus.

The **Cricothyroideus** (*Cricothyroid*) (Fig. 957), triangular in form, *arises* from the front and lateral part of the cricoid cartilage; its fibers diverge, and are arranged in two groups. The lower fibers constitute a **pars obliqua** and slant backward and lateralward to the anterior border of the inferior cornu; the anterior fibers, forming a **pars recta**, run upward, backward, and lateralward to the posterior part of the lower border of the lamina of the thyroid cartilage.

The medial borders of the two muscles are separated by a triangular interval, occupied by the middle cricothyroid ligament.

The **Cricoarytænoideus posterior** (*posterior cricoarytenoid*) (Fig. 958) arises from the broad depression on the corresponding half of the posterior surface of the lamina of the cricoid cartilage; its fibers run upward and lateralward, and converge to be inserted into the back of the muscular process of the arytenoid cartilage. The uppermost fibers are nearly horizontal, the middle oblique, and the lowest almost vertical.

The **Cricoarytænoideus lateralis** (*lateral cricoarytenoid*) (Fig. 959) is smaller than the preceding, and of an oblong form. It arises from the upper border of the arch of the cricoid cartilage, and, passing obliquely upward and backward, is inserted into the front of the muscular process of the arytenoid cartilage.

The **Arytænoideus** (Fig. 958) is a single muscle, filling up the posterior concave surfaces of the arytenoid cartilages. It arises from the posterior surface and lateral border of one arytenoid cartilage, and is inserted into the corre-

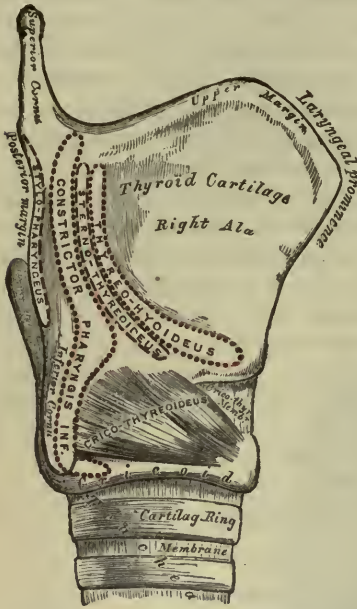

Fig. 957.—Side view of the larynx, showing muscular attachments.

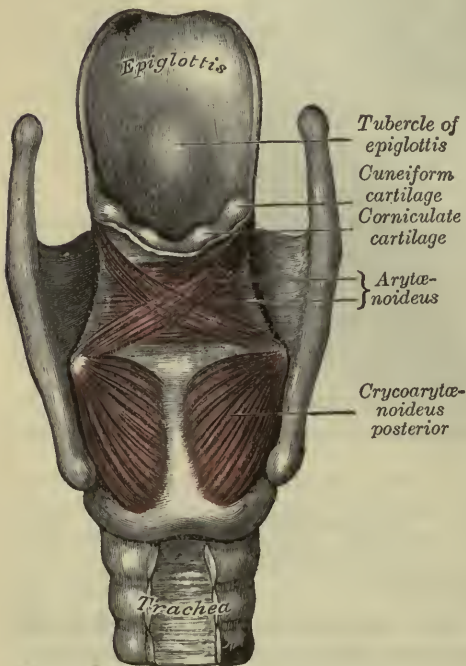


Fig. 958.—Muscles of larynx. Posterior view.

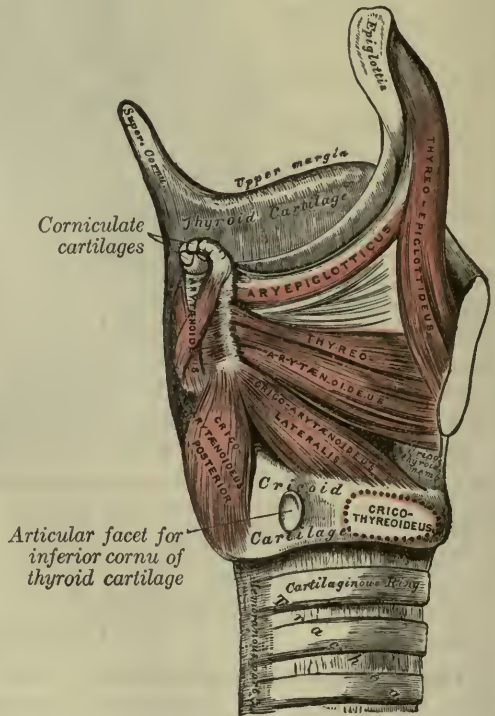


Fig. 959.—Muscles of larynx. Side view. Right lamina of thyroid cartilage removed.

sponding parts of the opposite cartilage. It consists of oblique and transverse parts. The **Arytænoideus obliquus**, the more superficial, forms two fasciculi, which pass

from the base of one cartilage to the apex of the opposite one, and therefore cross each other like the limbs of the letter X; a few fibers are continued around the lateral margin of the cartilage, and are prolonged into the aryepiglottic fold, and are sometimes described as a separate muscle, the **Aryepiglotticus**. The **Arytænoideus transversus** crosses transversely between the two cartilages.

The **Thyreoarütænoideus** (*Thyroarytenoid*) (Figs. 959, 960) is a broad, thin, muscle which lies parallel with and lateral to the vocal fold, and supports the wall of the ventricle and its appendix. It arises in front from the lower half of the angle of the thyroid cartilage, and from the middle cricothyroid ligament. Its fibers pass backward and lateralward, to be inserted into the base and anterior surface of the arytenoid cartilage. The lower and deeper fibers of the muscle can be differentiated as a triangular band which is inserted into the vocal process of the arytenoid cartilage, and into the adjacent portion of its anterior surface; it is termed the **Vocalis**, and lies parallel with the vocal ligament, to which it is adherent.

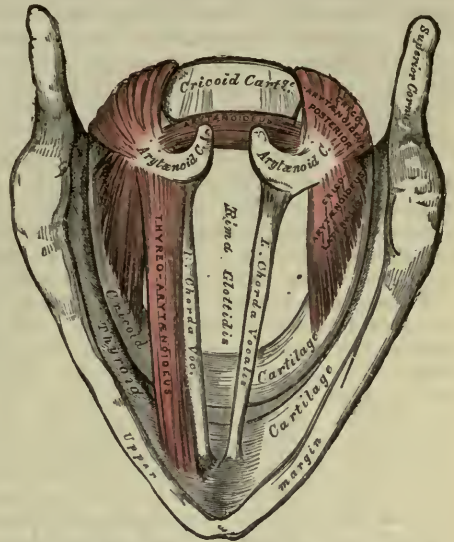


FIG. 960.—Muscles of the larynx, seen from above. (Enlarged.)

A considerable number of the fibers of the **Thyreoarütænoideus** are prolonged into the aryepiglottic fold, where some of them become lost, while others are continued to the margin of the epiglottis. They have received a distinctive name, **Thyreopiglotticus**, and are sometimes described as a separate muscle. A few fibers extend along the wall of the ventricle from the lateral wall of the arytenoid cartilage to the side of the epiglottis and constitute the **Ventricularis** muscle.

Actions.—In considering the actions of the muscles of the larynx, they may be conveniently divided into two groups, viz.: 1. Those which open and close the glottis. 2. Those which regulate the degree of tension of the vocal folds.

The **Cricoarütænoidei posteriores** separate the vocal folds, and, consequently, open the glottis, by rotating the arytenoid cartilages outward around a vertical axis passing through the cricoarytenoid joints; so that their vocal processes and the vocal folds attached to them become widely separated.

The **Cricoarütænoidei laterales** close the glottis by rotating the arytenoid cartilages inward, so as to approximate their vocal processes.

The **Arytænoideus** approximates the arytenoid cartilages, and thus closes the opening of the glottis, especially at its back part.

The **Cricothyroidei** produce tension and elongation of the vocal folds by drawing up the arch of the cricoid cartilage and tilting back the upper border of its lamina; the distance between the vocal processes and the angle of the thyroid is thus increased, and the folds are consequently elongated.

The **Thyreoarütænoidei**, consisting of two parts having different attachments and different directions, are rather complicated as regards their action. Their main use is to draw the arytenoid cartilages forward toward the thyroid, and thus shorten and relax the vocal folds. But, owing to the connection of the deeper portion with the vocal fold, this part, if acting separately, is supposed to modify its elasticity and tension, while the lateral portion rotates the arytenoid cartilage inward, and thus narrows the rima glottidis by bringing the two vocal folds together.

The manner in which the entrance of the larynx is closed during deglutition is referred to on page 1140.

Mucous Membrane.—The mucous membrane of the larynx is continuous above with that lining the mouth and pharynx, and is prolonged through the trachea and bronchi into the lungs. It lines the posterior surface and the upper part of the anterior surface of the epiglottis, to which

it is closely adherent, and forms the aryepiglottic folds which bound the entrance of the larynx. It lines the whole of the cavity of the larynx; forms, by its reduplication, the chief part of the ventricular fold, and, from the ventricle, is continued into the ventricular appendix. It is then reflected over the vocal ligament, where it is thin, and very intimately adherent; covers the inner surface of the conus elasticus and cricoid cartilage; and is ultimately continuous with the lining membrane of the trachea. The anterior surface and the upper half of the posterior surface of the epiglottis, the upper part of the aryepiglottic folds and the vocal folds are covered by stratified squamous epithelium; all the rest of the laryngeal mucous membrane is covered by columnar ciliated cells, but patches of stratified squamous epithelium are found in the mucous membrane above the glottis.

Glands.—The mucous membrane of the larynx is furnished with numerous mucous secreting glands, the orifices of which are found in nearly every part; they are very plentiful upon the epiglottis, being lodged in little pits in its substance; they are also found in large numbers along the margin of the aryepiglottic fold, in front of the arytenoid cartilages, where they are termed the **arytenoid glands**. They exist also in large numbers in the ventricular appendages. None are found on the free edges of the vocal folds.

Vessels and Nerves.—The chief arteries of the larynx are the laryngeal branches derived from the superior and inferior thyroid. The veins accompany the arteries; those accompanying the superior laryngeal artery join the superior thyroid vein which opens into the internal jugular vein; while those accompanying the inferior laryngeal artery join the inferior thyroid vein which opens into the innominate vein. The **lymphatic vessels** consist of two sets, superior and inferior. The former accompany the superior laryngeal artery and pierce the hyothyroid membrane, to end in the glands situated near the bifurcation of the common carotid artery. Of the latter, some pass through the middle cricothyroid ligament and open into a gland lying in front of that ligament or in front of the upper part of the trachea, while others pass to the deep cervical glands and to the glands accompanying the inferior thyroid artery. The **nerves** are derived from the internal and external branches of the superior laryngeal nerve, from the recurrent nerve, and from the sympathetic. The internal laryngeal branch is almost entirely sensory, but some motor filaments are said to be carried by it to the Arytænoideus. It enters the larynx by piercing the posterior part of the hyothyroid membrane above the superior laryngeal vessels, and divides into a branch which is distributed to both surfaces of the epiglottis, a second to the aryepiglottic fold, and a third, the largest, which supplies the mucous membrane over the back of the larynx and communicates with the recurrent nerve. The external laryngeal branch supplies the Cricothyroideus. The recurrent nerve passes upward beneath the lower border of the Constrictor pharyngis inferior immediately behind the cricothyroid joint. It supplies all the muscles of the larynx except the Cricothyroideus, and perhaps a part of the Arytænoideus. The sensory branches of the laryngeal nerves form subepithelial plexuses, from which fibers pass to end between the cells covering the mucous membrane.

Over the posterior surface of the epiglottis, in the aryepiglottic folds, and less regularly in some other parts, taste-buds, similar to those in the tongue, are found.

THE TRACHEA AND BRONCHI (Fig. 961).

The **trachea** or windpipe is a cartilaginous and membranous tube, extending from the lower part of the larynx, on a level with the sixth cervical vertebra, to the upper border of the fifth thoracic vertebra, where it divides into the two bronchi, one for each lung. The trachea is nearly but not quite cylindrical, being flattened posteriorly; it measures about 11 cm. in length; its diameter, from side to side, is from 2 to 2.5 cm., being always greater in the male than in the female. In the child the trachea is smaller, more deeply placed, and more movable than in the adult.

Relations.—The *anterior surface* of the trachea is convex, and covered, in the neck, from above downward, by the isthmus of the thyroid gland, the inferior thyroid veins, the arteria thyroidea ima (when that vessel exists), the Sternothyroideus and Sternohyoideus muscles, the cervical fascia, and, more superficially, by the anastomosing branches between the anterior jugular veins; in the **thorax**, it is covered from before backward by the manubrium sterni, the remains of the thymus, the left innominate vein, the aortic arch, the innominate and left common carotid arteries, and the deep cardiac plexus. Posteriorly it is in contact with the esophagus. *Laterally, in the neck*, it is in relation with the common carotid arteries, the right and left lobes of the thyroid gland, the inferior thyroid arteries, and the recurrent nerves; in the **thorax**, it lies in the superior mediastinum, and is in relation on the right side with the pleura and right vagus, and near the root of the neck with the innominate artery; on its left side are the left recurrent nerve, the aortic arch, and the left common carotid and subclavian arteries.

The **Right Bronchus** (*bronchus dexter*), wider, shorter, and more vertical in direction than the left, is about 2.5 cm. long, and enters the right lung nearly opposite the fifth thoracic vertebra. The azygos vein arches over it from behind; and the right pulmonary artery lies at first below and then in front of it. About 2 cm. from its commencement it gives off a branch to the upper lobe of the right lung. This is termed the **eparterial branch** of the bronchus, because it arises above the right pulmonary artery. The bronchus now passes below the artery, and is known as the **hyparterial branch**; it divides into two branches for the middle and lower lobes.

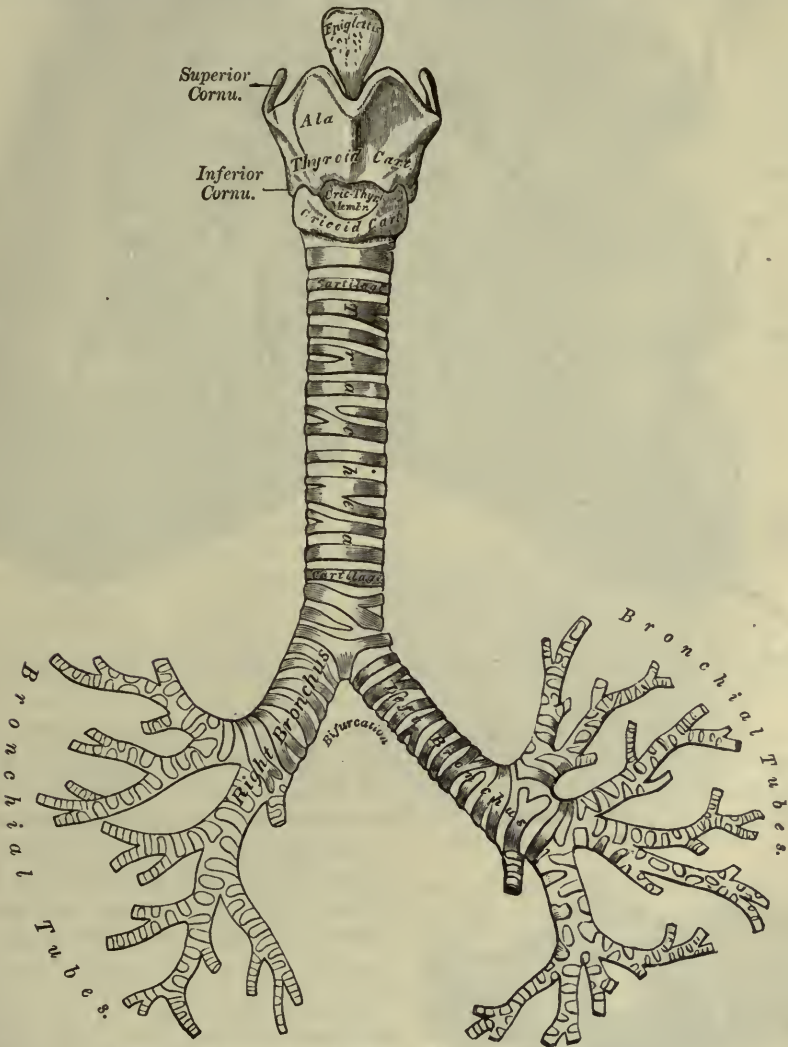


FIG. 961.—Front view of cartilages of larynx, trachea, and bronchi.

The **Left Bronchus** (*bronchus sinister*) is smaller in caliber but longer than the right, being nearly 5 cm. long. It enters the root of the left lung opposite the sixth thoracic vertebra. It passes beneath the aortic arch, crosses in front of the esophagus, the thoracic duct, and the descending aorta, and has the left pulmonary artery lying at first above, and then in front of it. The left bronchus has no eparterial branch, and therefore it has been supposed by some that there is no upper lobe to the left lung, but that the so-called upper lobe corresponds to the middle lobe of the right lung.

The further subdivisions of the bronchi will be considered with the anatomy of the lung.

If a transverse section be made across the trachea a short distance above its point of bifurcation, and a bird's-eye view taken of its interior (Fig. 963), the septum

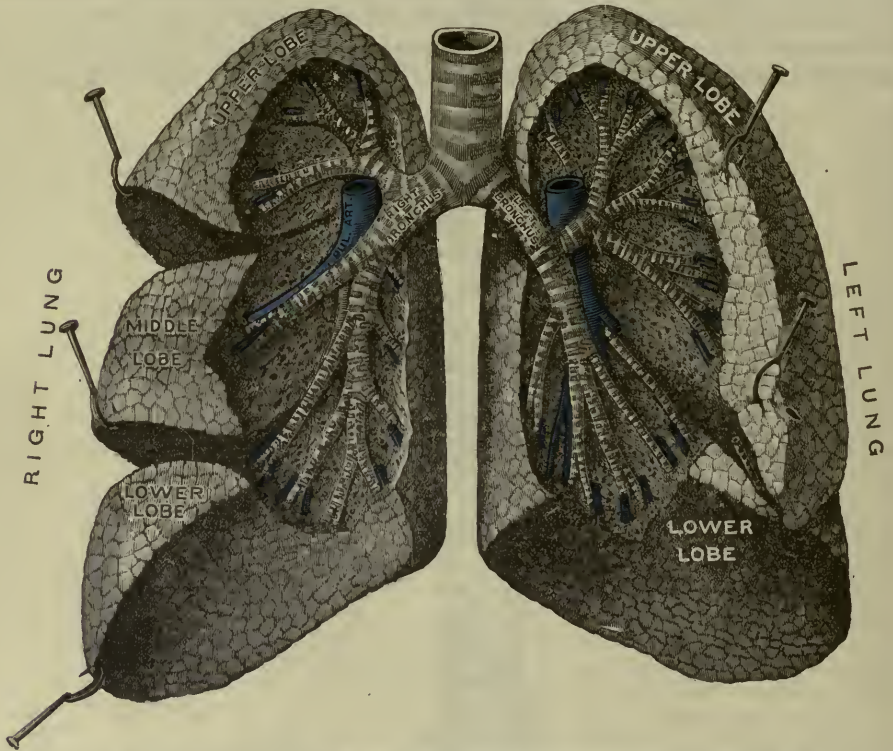


FIG. 962.—Bronchi and bronchioles. The lungs have been widely separated and tissue cut away to expose the air-tubes. (Testut.)

placed at the bottom of the trachea and separating the two bronchi will be seen to occupy the left of the median line, and the right bronchus appears to be a more direct continuation of the trachea than the left, so that any solid body dropping into the trachea would naturally be directed toward the right bronchus. This

tendency is aided by the larger diameter of the right tube as compared with its fellow. This fact serves to explain why a foreign body in the trachea more frequently falls into the right bronchus.¹

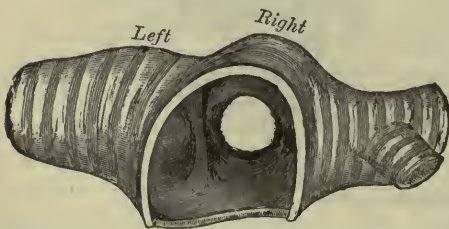


FIG. 963.—Transverse section of the trachea, just above its bifurcation, with a bird's-eye view of the interior.

deficient behind, where the tube is completed by fibrous tissue and unstriped muscular fibers. The cartilages are placed horizontally above each other, separated by narrow intervals. They measure about 4 mm. in depth and 1 mm. in thickness. Their outer surfaces are flattened in a vertical direction, but the internal are convex, the cartilages being thicker in the middle than

¹ Reigel asserts that the entry of a foreign body into the *left* bronchus is by no means so infrequent as is generally supposed. See also *Med.-Chi. Trans.*, lxxi, 121.

at the margins. Two or more of the cartilages often unite, partially or completely, and they are sometimes bifurcated at their extremities. They are highly elastic, but may become calcified in advanced life. In the right bronchus the cartilages vary in number from six to eight; in the left, from nine to twelve. They are shorter and narrower than those of the trachea, but have the same shape and arrangement. The peculiar tracheal cartilages are the first and the last (Fig. 961).

The *first cartilage* is broader than the rest, and often divided at one end; it is connected by the cricotracheal ligament with the lower border of the cricoid cartilage, with which, or with the succeeding cartilage, it is sometimes blended.

The *last cartilage* is thick and broad in the middle, in consequence of its lower border being prolonged into a triangular hook-shaped process, which curves downward and backward between the two bronchi. It ends on each side in an imperfect ring, which encloses the commencement of the bronchus. The cartilage above the last is somewhat broader than the others at its center.

The Fibrous Membrane.—The cartilages are enclosed in an elastic fibrous membrane, which consists of two layers; one, the thicker, passing over the outer surface of the ring, the other over the inner surface: at the upper and lower margins of the cartilages the two layers blend together to form a single membrane, which connects the rings one with another. They are thus invested by the membrane. In the space behind, between the ends of the rings, the membrane forms a single layer.

The **muscular tissue** consists of two layers of non-striated muscle, longitudinal and transverse. The **longitudinal fibers** are external, and consist of a few scattered bundles. The **transverse fibers** (*Trachealis muscle*) are internal, and form a thin layer which extends transversely between the ends of the cartilages.

Mucous Membrane.—The mucous membrane is continuous above with that of the larynx, and below with that of the bronchi. It consists of areolar and lymphoid tissue, and presents a well-marked basement membrane, supporting a stratified epithelium, the surface layer of which is columnar and ciliated, while the deeper layers are composed of oval or rounded cells. Beneath the basement membrane there is a distinct layer of longitudinal elastic fibers with a small amount of intervening areolar tissue. The submucous layer is composed of a loose mesh-work of connective tissue, containing large bloodvessels, nerves, and mucous glands; the ducts of the latter pierce the overlying layers and open on the surface (Fig. 964).

Vessels and Nerves.—The trachea is supplied with blood by the inferior thyroid arteries. The **veins** end in the thyroid venous plexus. The **nerves** are derived from the vagus and the recurrent nerves, and from the sympathetic; they are distributed to the *Trachealis* muscles and between the epithelial cells.

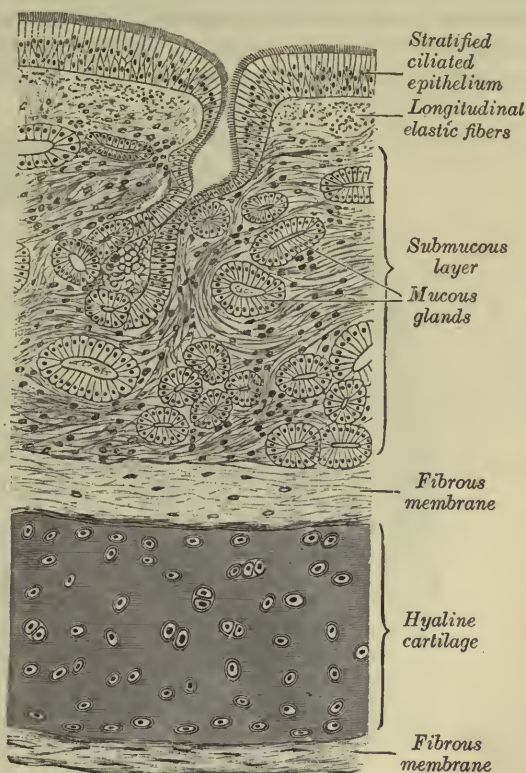


FIG. 964.—Transverse section of trachea.

THE PLEURÆ.

Each lung is invested by an exceedingly delicate serous membrane, the **pleura**, which is arranged in the form of a closed invaginated sac. A portion of the serous membrane covers the surface of the lung and dips into the fissures between its lobes; it is called the **pulmonary pleura**. The rest of the membrane lines the inner surface of the chest wall, covers the diaphragm, and is reflected over the structures occupying the middle of the thorax; this portion is termed the **parietal pleura**. The two layers are continuous with one another around and below the root of the lung;

in health they are in actual contact with one another, but the potential space between them is known as the **pleural cavity**. When the lung collapses or when air or fluid collects between the two layers the cavity becomes apparent. The right and left pleural sacs are entirely separate from one another; between them are all the thoracic viscera except the lungs, and they only touch each other for a short distance in front; opposite the second and third pieces of the sternum the interval between the two sacs is termed the **mediastinum**.

Different portions of the parietal pleura have received special names which indicate their position: thus, that portion which lines the inner surfaces of the ribs and Intercostales is the **costal pleura**; that clothing the convex surface of the diaphragm is the **diaphragmatic pleura**; that which rises into the neck, over the summit of the lung, is the **cupula of the pleura** (*cervical pleura*); and that which is applied to the other thoracic viscera is the **mediastinal pleura**.

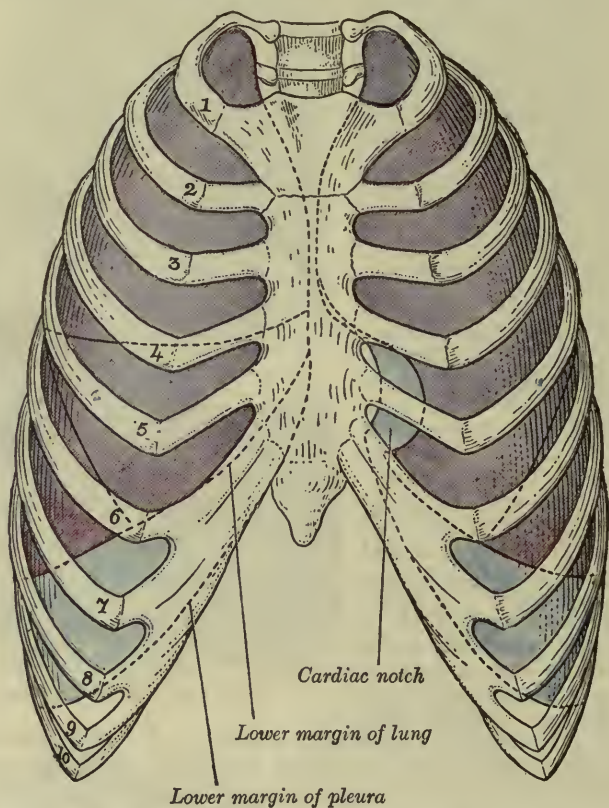


Fig. 965.—Front view of thorax, showing the relations of the pleurae and lungs to the chest wall. Pleura in blue; lungs in purple.

Reflections of the Pleura (Figs. 965, 966).—Commencing at the sternum, the pleura passes lateralward, lines the inner surfaces of the costal cartilages, ribs, and Intercostales, and at the back part of the thorax passes over the sympathetic trunk and its branches, and is reflected upon the sides of the bodies of the vertebræ, where it is separated by a narrow interval, the **posterior mediastinum**, from the opposite pleura. From the vertebral column the pleura passes to the side of the pericardium, which it covers to a slight extent; it then covers the back part of the root of the lung, from the lower border of which a triangular sheet descends vertically toward the diaphragm. This sheet is the **posterior layer of a wide fold**, known as the **pulmonary ligament**. From the back of the lung root, the pleura

may be traced over the costal surface of the lung, the apex and base, and also over the sides of the fissures between the lobes, on to its mediastinal surface and the front part of its root. It is continued from the lower margin of the root as the anterior layer of the pulmonary ligament, and from this it is reflected on to the pericardium (**pericardial pleura**), and from it to the back of the sternum. Above the level of the root of the lung, however, the mediastinal pleura passes uninterruptedly from the vertebral column to the sternum over the structures in the superior mediastinum. *Below*, it covers the upper surface of the diaphragm and extends, in front, as low as the costal cartilage of the seventh rib; at the side of the chest, to the lower border of the tenth rib on the left side and to the upper border of the same rib on the right side; and *behind*, it reaches as low as the twelfth rib, and sometimes even to the transverse process of the first lumbar vertebra. *Above*, its cupula projects through the superior opening of the thorax into the neck, extending from 2.5 to 5 cm. above the sternal end of the first rib; this portion of the sac is strengthened by a dome-like expansion of fascia (**Sibson's fascia**), attached in front to the inner border of the first rib, and behind to the anterior border of the transverse process of the seventh cervical vertebra. This is covered and strengthened by a few spreading muscular fibers derived from the *Scaleni*.

In the front of the chest, where the parietal pleura is reflected backward to the pericardium, the two pleural sacs are in contact for a short distance. At the upper part of the chest, behind the manubrium, they are separated by an angular interval; the line of reflection being represented by a line drawn from the sternoclavicular articulation to the mid-point of the junction of the manubrium with the body of the sternum. From this point the two pleuræ descend in close contact to the level of the fourth costal cartilages, and the line of reflection on the right side is continued downward in nearly a straight line to the xiphoid process, and then turns lateralward, while on the left side the line of reflection diverges lateralward and is continued downward, close to the left border of the sternum, as far as the sixth costal cartilage. The inferior limit of the pleura is on a considerably lower level than the corresponding limit of the lung, but does not extend to the attachment of the diaphragm, so that below the line of reflection of the pleura from the chest wall on to the diaphragm the latter is in direct contact with the rib cartilages and the *Intercostales interni*. Moreover, in ordinary inspiration the thin inferior margin of the lung does not extend as low as the line of the pleural reflection, with the result that the costal and diaphragmatic pleuræ are here in contact, the intervening narrow slit being termed the **phrenicocostal sinus**. A similar condition

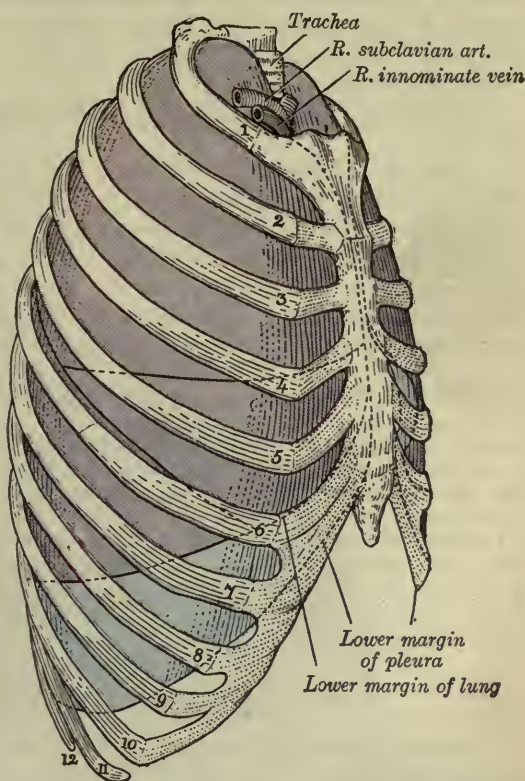


FIG. 966.—Lateral view of thorax, showing the relations of the pleuræ and lungs to the chest wall. Pleura in blue; lungs in purple.

exists behind the sternum and rib cartilages, where the anterior thin margin of the lung falls short of the line of pleural reflection, and where the slit-like cavity between the two layers of pleura forms what is called the **costomediastinal sinus**.

The line along which the right pleura is reflected from the chest-wall to the diaphragm starts in front, immediately below the seventh sternocostal joint, and runs downward and backward behind the seventh costal cartilage so as to cross the tenth rib in the mid-axillary line, from which it is prolonged to the spinous process of the twelfth thoracic vertebra. The reflection of the left pleura follows at first the ascending part of the sixth costal cartilage, and in the rest of its course is slightly lower than that of the right side.

The free surface of the pleura is smooth, polished, and moistened by a serous fluid; its attached surface is intimately adherent to the lung, and to the pulmonary vessels as they emerge from the pericardium; it is also adherent to the upper surface of the diaphragm: throughout the rest of its extent it is easily separable from the adjacent parts.

The right pleural sac is shorter, wider, and reaches higher in the neck than the left.

Pulmonary Ligament (*ligamentum pulmonale; ligamentum latum pulmonis*).—From the above description it will be seen that the root of the lung is covered in front, above, and behind by pleura, and that at its lower border the investing layers come into contact. Here they form a sort of mesenteric fold, the pulmonary ligament, which extends between the lower part of the mediastinal surface of the lung and the pericardium. Just above the diaphragm the ligament ends in a free falciform border. It serves to retain the lower part of the lung in position.

Structure of Pleura.—Like other serous membranes, the pleura is covered by a single layer of flattened, nucleated cells, united at their edges by cement substance. These cells are modified connective-tissue corpuscles, and rest on a basement membrane. Beneath the basement membrane there are net-works of yellow elastic and white fibers, imbedded in ground substance which also contains connective-tissue cells. Bloodvessels, lymphatics, and nerves are distributed in the substance of the pleura.

Vessels and Nerves.—The **arteries of the pleura** are derived from the intercostal, internal mammary, musculophrenic, thymic, pericardiac, and bronchial vessels. The **veins** correspond to the arteries. The **lymphatics** are described on page 719. The **nerves** are derived from the phrenic and sympathetic (Luschka). Kölliker states that nerves accompany the ramifications of the bronchial arteries in the pulmonary pleura.

THE MEDIASTINUM (INTERPLEURAL SPACE).

The **mediastinum** lies between the right and left pleuræ in and near the median sagittal plane of the chest. It extends from the sternum in front to the vertebral column behind, and contains all the thoracic viscera excepting the lungs. It may be divided for purposes of description into two parts: an upper portion, above the upper level of the pericardium, which is named the **superior mediastinum**; and a lower portion, below the upper level of the pericardium. This lower portion is again subdivided into three parts, viz., that in front of the pericardium, the **anterior mediastinum**; that containing the pericardium and its contents, the **middle mediastinum**; and that behind the pericardium, the **posterior mediastinum**.

The **Superior Mediastinum** (Fig. 967) is that portion of the interpleural space which lies between the manubrium sterni in front, and the upper thoracic vertebræ behind. It is bounded below by a slightly oblique plane passing backward from the junction of the manubrium and body of the sternum to the lower part of the body of the fourth thoracic vertebra, and laterally by the pleuræ. It contains the origins of the Sternohyoidei and Sternothyreoidi and the lower ends of the Longi colli; the aortic arch; the innominate artery and the thoracic portions of the left common carotid and the left subclavian arteries; the innominate veins

into its two branches, the right and left pulmonary veins, the phrenic nerves, and some bronchial lymph glands.

The **Posterior Mediastinum** (Figs. 968, 969) is an irregular triangular space running parallel with the vertebral column; it is bounded in front by the pericardium above, and by the posterior surface of the diaphragm below, behind by the vertebral column from the lower border of the fourth to the twelfth thoracic vertebra, and on either side by the mediastinal pleura. It contains the thoracic part of the descending aorta, the azygos and the two hemiazygos veins, the vagus and splanchnic nerves, the esophagus, the thoracic duct, and some lymph glands.

THE LUNGS (PULMONES).

The **lungs** are the essential organs of respiration; they are two in number, placed one on either side within the thorax, and separated from each other by the heart and other contents of the mediastinum (Fig. 970). The substance of the lung is of a light, porous, spongy texture; it floats in water, and crepitates when handled, owing to the presence of air in the alveoli; it is also highly elastic; hence the retracted state of these organs when they are removed from the closed cavity of the thorax. The surface is smooth, shining, and marked out into numerous polyhedral areas, indicating the lobules of the organ: each of these areas is crossed by numerous lighter lines.

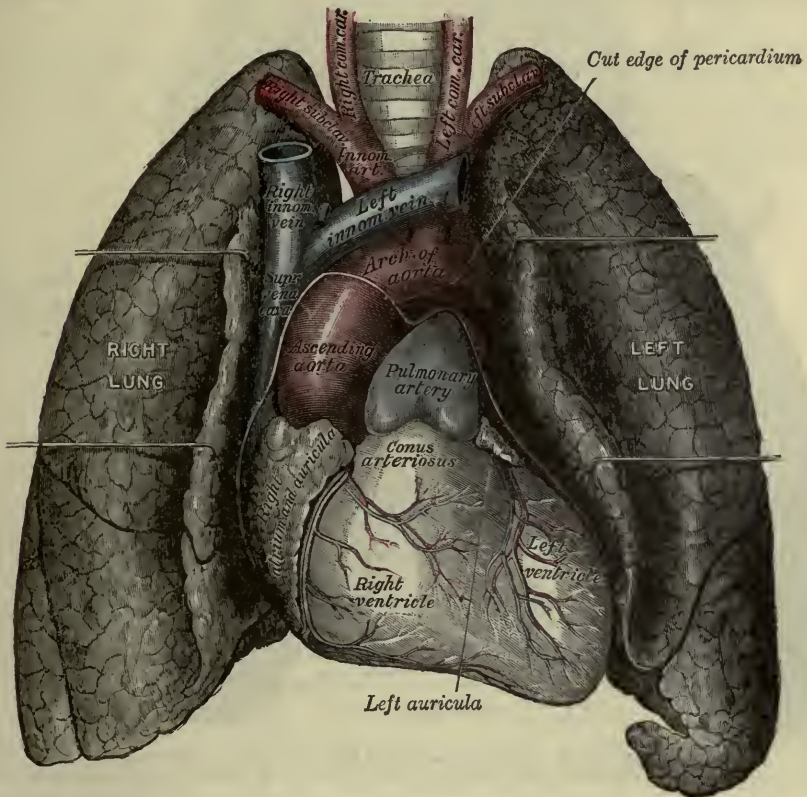


FIG. 970.—Front view of heart and lungs.

At birth the lungs are pinkish white in color; in adult life the color is a dark slaty gray, mottled in patches; and as age advances, this mottling assumes a black color. The coloring matter consists of granules of a carbonaceous substance deposited in the areolar tissue near the surface of the organ. It increases in quan-

tity as age advances, and is more abundant in males than in females. As a rule, the posterior border of the lung is darker than the anterior.

The right lung usually weighs about 625 gm., the left 567 gm., but much variation is met with according to the amount of blood or serous fluid they may contain. The lungs are heavier in the male than in the female, their proportion to the body being, in the former, as 1 to 37, in the latter as 1 to 43.

Each lung is conical in shape, and presents for examination an **apex**, a **base**, **three borders**, and **two surfaces**.

The **apex** (*apex pulmonis*) is rounded, and extends into the root of the neck, reaching from 2.5 to 4 cm. above the level of the sternal end of the first rib. A sulcus produced by the subclavian artery as it curves in front of the pleura runs upward and lateralward immediately below the apex.

The **base** (*basis pulmonis*) is broad, concave, and rests upon the convex surface of the diaphragm, which separates the right lung from the right lobe of the liver, and the left lung from the left lobe of the liver, the stomach, and the spleen. Since the diaphragm extends higher on the right than on the left side, the concavity on the base of the right lung is deeper than that on the left. Laterally and behind, the base is bounded by a thin, sharp margin which projects for some distance into the phrenicocostal sinus of the pleura, between the lower ribs and the costal attachment of the diaphragm. The base of the lung descends during inspiration and ascends during expiration.

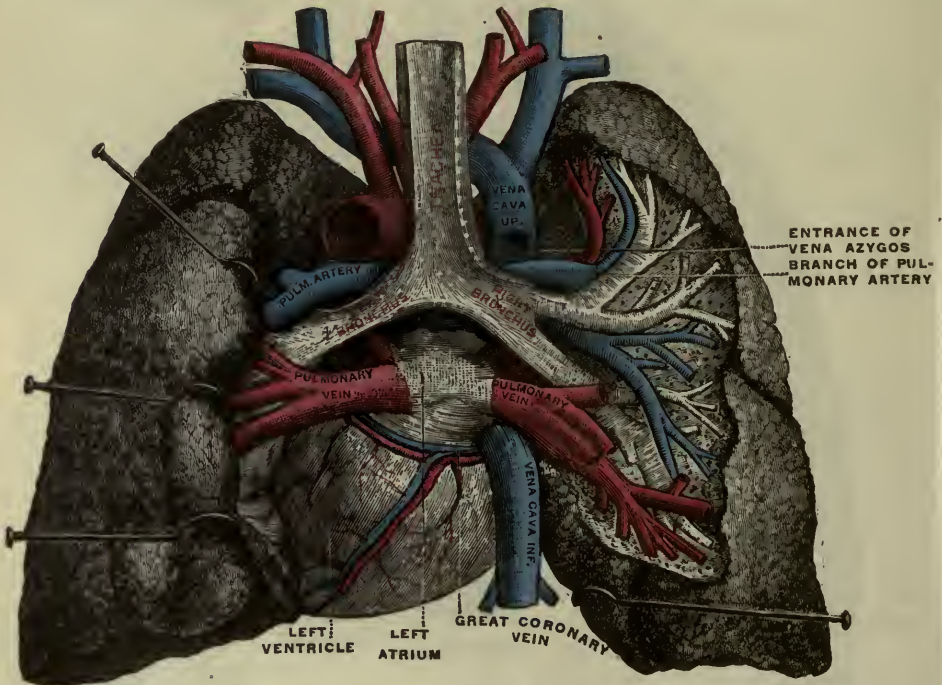


FIG. 971.—Pulmonary vessels, seen in a dorsal view of the heart and lungs. The lungs have been pulled away from the median line, and a part of the right lung has been cut away to display the air-ducts and bloodvessels. (Testut.)

Surfaces.—The **costal surface** (*facies costalis; external or thoracic surface*) is smooth, convex, of considerable extent, and corresponds to the form of the cavity of the chest, being deeper behind than in front. It is in contact with the costal pleura, and presents, in specimens which have been hardened *in situ*, slight grooves corresponding with the overlying ribs.

The **mediastinal surface** (*facies mediastinalis*; *inner surface*) is in contact with the mediastinal pleura. It presents a deep concavity, the **cardiac impression**, which accommodates the pericardium; this is larger and deeper on the left than on the right lung, on account of the heart projecting farther to the left than to the right side of the median plane. Above and behind this concavity is a triangular depression named the **hilum**, where the structures which form the root of the lung enter and leave the viscus. These structures are invested by pleura, which, below the hilum and behind the pericardial impression, forms the pulmonary ligament. On the *right lung* (Fig. 972), immediately above the hilus, is an arched furrow which accommodates the azygos vein; while running upward, and then arching lateralward some little distance below the apex, is a wide groove for the superior vena cava and right innominate vein; behind this, and nearer the apex, is a furrow

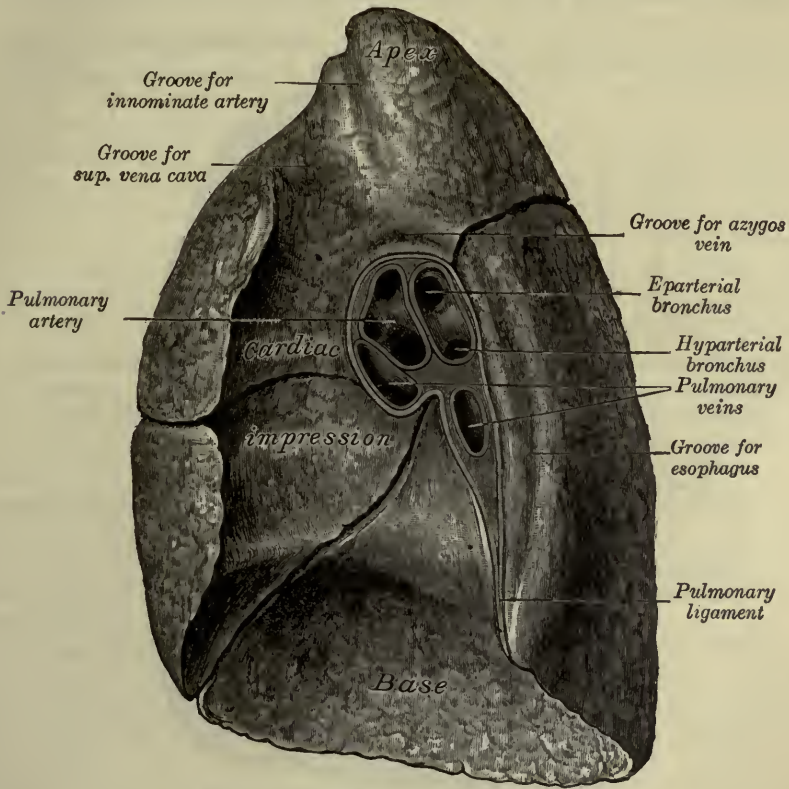


FIG. 972.—Mediastinal surface of right lung.

for the innominate artery. Behind the hilum and the attachment of the pulmonary ligament is a vertical groove for the esophagus; this groove becomes less distinct below, owing to the inclination of the lower part of the esophagus to the left of the middle line. In front and to the right of the lower part of the esophageal groove is a deep concavity for the extrapericardiac portion of the thoracic part of the inferior vena cava. On the *left lung* (Fig. 973), immediately above the hilus, is a well-marked curved furrow produced by the aortic arch, and running upward from this toward the apex is a groove accommodating the left subclavian artery; a slight impression in front of the latter and close to the margin of the lung lodges the left innominate vein. Behind the hilum and pulmonary ligament is a vertical furrow produced by the descending aorta, and in front of this, near the base of the lung, the lower part of the esophagus causes a shallow impression.

Borders.—The **inferior border** (*margo inferior*) is thin and sharp where it separates the base from the costal surface and extends into the phrenicocostal sinus; medially where it divides the base from the mediastinal surface it is blunt and rounded.

The **posterior border** (*margo posterior*) is broad and rounded, and is received into the deep concavity on either side of the vertebral column. It is much longer than the anterior border, and projects, below, into the phrenicocostal sinus.

The **anterior border** (*margo anterior*) is thin and sharp, and overlaps the front of the pericardium. The anterior border of the *right lung* is almost vertical, and projects into the costomediastinal sinus; that of the *left* presents, below, an angular notch, the **cardiac notch**, in which the pericardium is exposed. Opposite this notch the anterior margin of the left lung is situated some little distance lateral to the line of reflection of the corresponding part of the pleura.

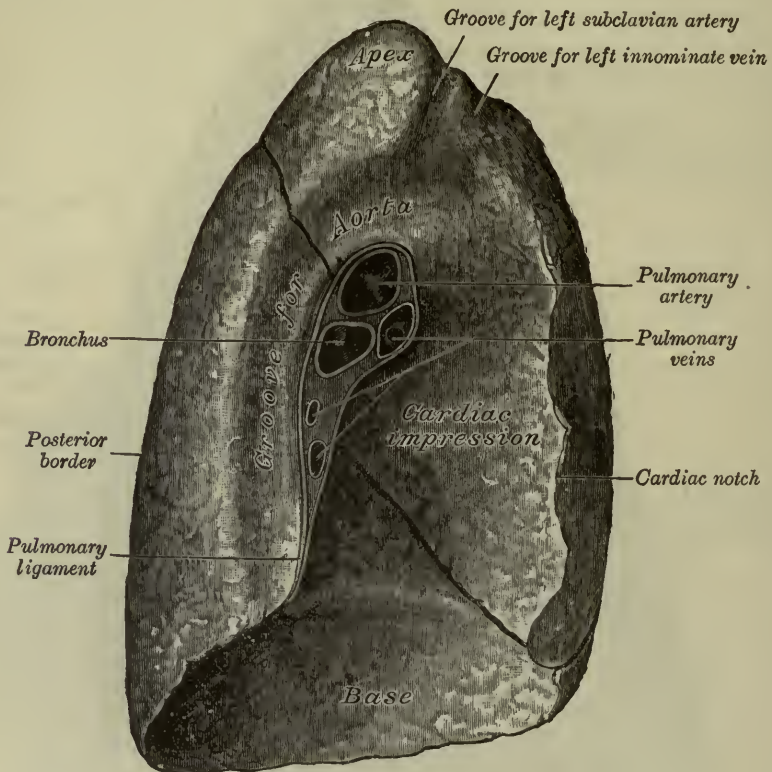


FIG. 973.—Mediastinal surface of left lung.

Fissures and Lobes of the Lungs.—The **left lung** is divided into two lobes, an upper and a lower, by an interlobular fissure, which extends from the costal to the mediastinal surface of the lung both above and below the hilus. As seen on the surface, this fissure begins on the mediastinal surface of the lung at the upper and posterior part of the hilus, and runs backward and upward to the posterior border, which it crosses at a point about 6 cm. below the apex. It then extends downward and forward over the costal surface, and reaches the lower border a little behind its anterior extremity, and its further course can be followed upward and backward across the mediastinal surface as far as the lower part of the hilus. The **superior lobe** lies above and in front of this fissure, and includes the apex, the anterior border, and a considerable part of the costal surface and the greater part of the mediastinal surface of the lung. The **inferior lobe**, the larger

of the two, is situated below and behind the fissure, and comprises almost the whole of the base, a large portion of the costal surface, and the greater part of the posterior border.

The **right lung** is divided into three lobes, superior, middle, and inferior, by two interlobular fissures. One of these separates the inferior from the middle and superior lobes, and corresponds closely with the fissure in the left lung. Its direction is, however, more vertical, and it cuts the lower border about 7.5 cm. behind its anterior extremity. The other fissure separates the superior from the middle lobe. It begins in the previous fissure near the posterior border of the lung, and, running horizontally forward, cuts the anterior border on a level with the sternal end of the fourth costal cartilage; on the mediastinal surface it may be traced backward to the hilus. The **middle lobe**, the smallest lobe of the right lung, is wedge-shaped, and includes the lower part of the anterior border and the anterior part of the base of the lung.

The right lung, although shorter by 2.5 cm. than the left, in consequence of the diaphragm rising higher on the right side to accommodate the liver, is broader, owing to the inclination of the heart to the left side; its total capacity is greater and it weighs more than the left lung.

The Root of the Lung (*radix pulmonis*).—A little above the middle of the mediastinal surface of each lung, and nearer its posterior than its anterior border, is its root, by which the lung is connected to the heart and the trachea. The root is formed by the bronchus, the pulmonary artery, the pulmonary veins, the bronchial arteries and veins, the pulmonary plexuses of nerves, lymphatic vessels, bronchial lymph glands, and areolar tissue, all of which are enclosed by a reflection of the pleura. The root of the right lung lies behind the superior vena cava and part of the right atrium, and below the azygos vein. That of the left lung passes beneath the aortic arch and in front of the descending aorta; the phrenic nerve, the pericardiophrenic artery and vein, and the anterior pulmonary plexus, lie in front of each, and the vagus and posterior pulmonary plexus behind each; below each is the pulmonary ligament.

The chief structures composing the root of each lung are arranged in a similar manner from before backward on both sides, viz., the upper of the two pulmonary veins in front; the pulmonary artery in the middle; and the bronchus, together with the bronchial vessels, behind. From above downward, on the two sides, their arrangement differs, thus:

On the right side their position is—eparterial bronchus, pulmonary artery, hyperarterial bronchus, pulmonary veins, but on the left side their position is—pulmonary artery, bronchus, pulmonary veins. The lower of the two pulmonary veins, is situated below the bronchus, at the apex or lowest part of the hilus (Figs. 972, 973).

Divisions of the Bronchi.—Just as the lungs differ from each other in the number of their lobes, so the bronchi differ in their mode of subdivision.

The **right bronchus** gives off, about 2.5 cm. from the bifurcation of the trachea, a branch for the superior lobe. This branch arises above the level of the pulmonary artery, and is therefore named the **eparterial bronchus**. All the other divisions of the main stem come off below the pulmonary artery, and consequently are termed **hyperarterial bronchi**. The first of these is distributed to the middle lobe, and the main tube then passes downward and backward into the inferior lobe, giving off in its course a series of large ventral and small dorsal branches. The ventral and dorsal branches arise alternately, and are usually eight in number—four of each kind. The branch to the middle lobe is regarded as the first of the ventral series.

The **left bronchus** passes below the level of the pulmonary artery before it divides, and hence all its branches are hyperarterial; it may therefore be looked upon as

equivalent to that portion of the right bronchus which lies on the distal side of its eparterial branch. The first branch of the left bronchus arises about 5 cm. from the bifurcation of the trachea, and is distributed to the superior lobe. The main stem then enters the inferior lobe, where it divides into ventral and dorsal branches similar to those in the right lung. The branch to the superior lobe of the left lung is regarded as the first of the ventral series.

Structure.—The lungs are composed of an external serous coat, a subserous areolar tissue and the pulmonary substance or parenchyma.

The **serous coat** is the pulmonary pleura (page 1090); it is thin, transparent, and invests the entire organ as far as the root.

The **subserous areolar tissue** contains a large proportion of elastic fibers; it invests the entire surface of the lung, and extends inward between the lobules.

The **parenchyma** is composed of secondary lobules which, although closely connected together by an interlobular areolar tissue, are quite distinct from one another, and may be teased asunder without much difficulty in the fetus. The secondary lobules vary in size; those on the surface are large, of pyramidal form, the base turned toward the surface; those in the interior smaller, and of various forms. Each secondary lobule is composed of several primary lobules, the anatomical units of the lung. The primary lobule consists of an alveolar duct, the air spaces connected with it and their bloodvessels, lymphatics and nerves.

The **intrapulmonary bronchi** divide and subdivide throughout the entire organ, the smallest subdivisions constituting the lobular bronchioles. The *larger divisions* consist of: (1) an outer coat of fibrous tissue in which are found at intervals irregular plates of hyaline cartilage, most developed at the points of division; (2) internal to the fibrous coat, a layer of circularly disposed smooth muscle fibers, the bronchial muscle; and (3) most internally, the mucous membrane, lined by columnar ciliated epithelium resting on a basement membrane. The corium of the mucous membrane contains numerous elastic fibers running longitudinally, and a certain amount of lymphoid tissue; it also contains the ducts of mucous glands, the acini of which lie in the fibrous coat. The **lobular bronchioles** differ from the larger tubes in containing no cartilage and in the fact that the ciliated epithelial cells are cubical in shape. The lobular bronchioles are about 0.2 mm. in diameter.

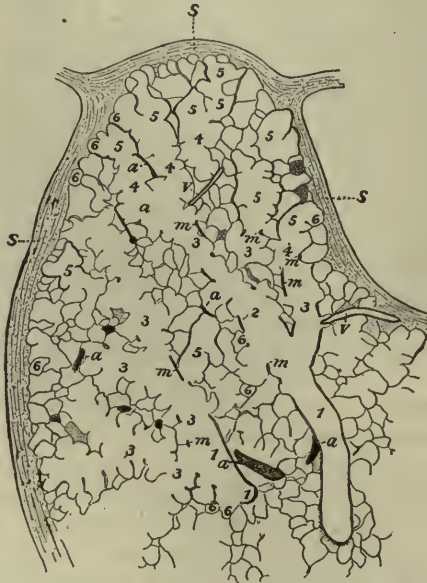

FIG. 974.—Part of a secondary lobule from the depth of a human lung, showing parts of several primary lobules. 1, bronchiole; 2, respiratory bronchiole; 3, alveolar duct; 4, atria; 5, alveolar sac; 6, alveolus or air cell; *m*, smooth muscle; *a*, branch pulmonary artery; *v*, branch pulmonary vein; *s*, septum between secondary lobules. Camera drawing of one 50 μ section. $\times 20$ diameters. (Miller.)

Each *bronchiole* divides into two or more **respiratory bronchioles**, with scattered alveoli, and each of these again divides into several **alveolar ducts**, with a greater number of alveoli connected with them. Each alveolar duct is connected with a variable number of irregularly spherical spaces, which also possess alveoli, the **atria**. With each atrium a variable number (2–5) of **alveolar sacs** are connected which bear on all parts of their circumference **alveoli** or air sacs. (Miller.)

The **alveoli** are lined by a delicate layer of simple squamous epithelium, the cells of which are united at their edges by cement substance. Between the squames are here and there smaller,

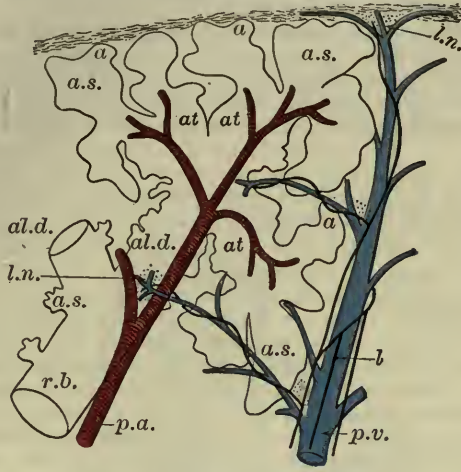

FIG. 975.—Schematic longitudinal section of a primary lobule of the lung (anatomical unit); r. b., respiratory bronchiole, al. d., alveolar duct; at., atria; a. s., alveolar sac; a. alveolus or air cell; p. a., pulmonary artery; p. v., pulmonary vein; l., lymphatic; l. n., lymph node. (Miller.)

polygonal, nucleated cells. Outside the epithelial lining is a little delicate connective tissue containing numerous elastic fibers and a close net-work of blood capillaries, and forming a common wall to adjacent alveoli (Fig. 975).

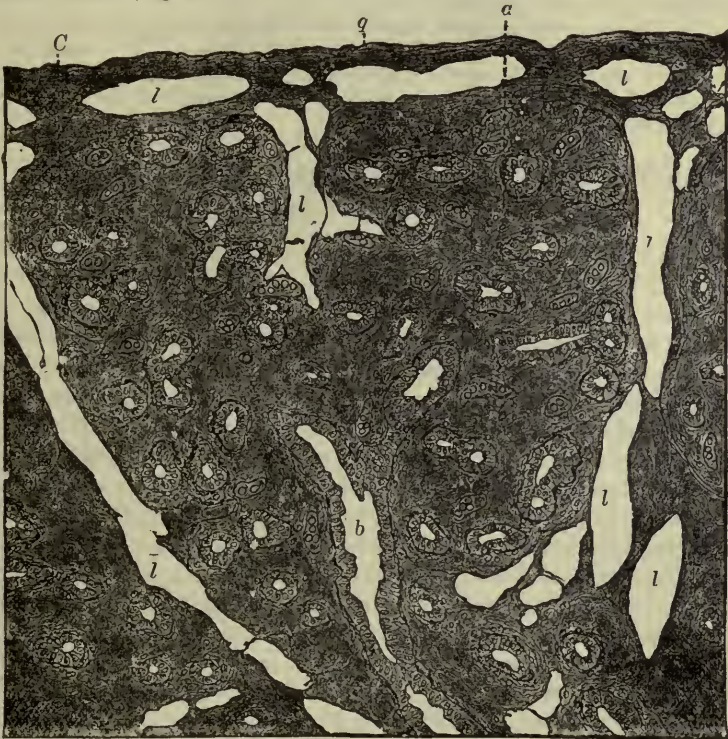


FIG. 976.—Section of lung of pig embryo, 13 cm. long, showing the glandular character of the developing alveoli (J. M. Flint.) $\times 70$. a. Interstitial connective tissue. b. A bronchial tube. c. An Alveolus. l. lymphatic clefts. q. Pleura.

The fetal lung resembles a gland in that the alveoli have a small lumen and are lined by cubical epithelium (Fig. 976). After the first respiration the alveoli become distended, and the epithelium takes on the characters described above.

Vessels and Nerves.—The **pulmonary artery** conveys the venous blood to the lungs; it divides into branches which accompany the bronchial tubes and end in a dense capillary net-work in the walls of the alveoli. In the lung the branches of the pulmonary artery are usually above and in front of a bronchial tube, the vein below.

The **pulmonary capillaries** form plexuses which lie immediately beneath the lining epithelium, in the walls and septa of the alveoli and of the infundibula. In the septa between the alveoli the capillary net-work forms a single layer. The capillaries form a very minute net-work, the meshes of which are smaller than the vessels themselves; their walls are also exceedingly thin. The arteries of neighboring lobules are independent of each other, but the veins freely anastomose.

The **pulmonary veins** commence in the pulmonary capillaries, the radicles coalescing into larger branches which run through the substance of the lung, independently of the pulmonary arteries and bronchi. After freely communicating with other branches they form large vessels, which ultimately come into relation with the arteries and bronchial tubes, and accompany them to the hilus of the organ. Finally they open into the left atrium of the heart, conveying oxygenated blood to be distributed to all parts of the body by the aorta.

The **bronchial arteries** supply blood for the nutrition of the lung; they are derived from the thoracic aorta or from the upper aortic intercostal arteries, and, accompanying the bronchial tubes, are distributed to the bronchial glands and upon the walls of the larger bronchial tubes and pulmonary vessels. Those supplying the bronchial tubes form a capillary plexus in the muscular coat, from which branches are given off to form a second plexus in the mucous coat; this plexus communicates with small venous trunks that empty into the pulmonary veins. Others are distributed in the interlobular areolar tissue, and end partly in the deep, partly in the superficial, bronchial veins. Lastly, some ramify upon the surface of the lung, beneath the pleura, where they form a capillary network.

The **bronchial vein** is formed at the root of the lung, receiving superficial and deep veins corresponding to branches of the bronchial artery. It does not, however, receive all the blood supplied by the artery, as some of it passes into the pulmonary veins. It ends on the right side in the azygos vein, and on the left side in the highest intercostal or in the accessory hemiazygos vein.

The **lymphatics** are described on page 718.

Nerves.—The lungs are supplied from the anterior and posterior pulmonary plexuses, formed chiefly by branches from the sympathetic and vagus. The filaments from these plexuses accompany the bronchial tubes, supplying efferent fibers to the bronchial muscle and afferent fibers to the bronchial mucous membrane and probably to the alveoli of the lung. Small ganglia are found upon these nerves.

THE DIGESTIVE APPARATUS (APPARATUS DIGESTORIUS; ORGANS OF DIGESTION).

The apparatus for the digestion of the food consists of the **digestive tube** and of certain **accessory organs**.

The **Digestive Tube** (*alimentary canal*) is a musculomembranous tube, about 9 metres long, extending from the mouth to the anus, and lined throughout its entire extent by mucous membrane. It has received different names in the various parts of its course: at its commencement is the **mouth**, where provision is made for the mechanical division of the food (*mastication*), and for its admixture with a fluid secreted by the salivary glands (*insalivation*); beyond this are the organs of deglutition, the **pharynx** and the **esophagus**, which convey the food into the **stomach**, in which it is stored for a time and in which also the first stages of the digestive process take place; the stomach is followed by the **small intestine**, which is divided for purposes of description into three parts, the **duodenum**, the **jejunum**, and **ileum**. In the small intestine the process of digestion is completed and the resulting products are absorbed into the blood and lacteal vessels. Finally the small intestine ends in the **large intestine**, which is made up of **cecum**, **colon**, **rectum**, and **anal canal**, the last terminating on the surface of the body at the **anus**.

The accessory organs are the **teeth**, for purposes of mastication; the three pairs of **salivary glands**—the **parotid**, **submaxillary**, and **sublingual**—the secretion from which mixes with the food in the mouth and converts it into a bolus and acts chemically on one of its constituents; the **liver** and **pancreas**, two large glands in the abdomen, the secretions of which, in addition to that of numerous minute glands in the walls of the alimentary canal, assist in the process of digestion.

The Development of the Digestive Tube.—The primitive digestive tube consists of two parts, viz.: (1) the **fore-gut**, within the cephalic flexure, and dorsal to the heart; and (2) the **hind-gut**, within the caudal flexure (Fig. 977). Between these is the wide opening of the yolk-sac, which is gradually narrowed and reduced to a small foramen leading into the vitelline duct. At first the fore-gut and hind-gut end blindly. The anterior end of the fore-gut is separated from the stomodeum by the buccopharyngeal membrane (Fig. 977); the hind-gut ends in the cloaca, which is closed by the cloacal membrane.

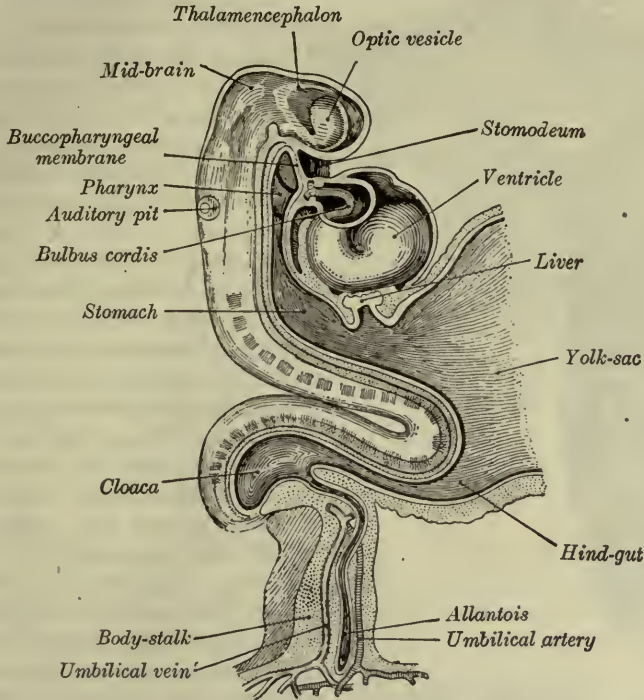


FIG. 977.—Human embryo about fifteen days old. Brain and heart represented from right side. Digestive tube and yolk sac in median section. (After His.)

The Mouth.—The mouth is developed partly from the stomodeum, and partly from the floor of the anterior portion of the fore-gut. By the growth of the head end of the embryo, and the formation of the cephalic flexure, the pericardial area and the buccopharyngeal membrane come to lie on the ventral surface of the embryo. With the further expansion of the brain, and the forward bulging of the pericardium, the buccopharyngeal membrane is depressed between these two prominences. This depression constitutes the **stomodeum** (Fig. 977). It is lined by ectoderm, and is separated from the anterior end of the fore-gut by the buccopharyngeal membrane. This membrane is devoid of mesoderm, being formed by the apposition of the stomodeal ectoderm with the fore-gut entoderm; at the end of the third week it disappears, and thus a communication is established between the mouth and the future pharynx. No trace of the membrane is found in the adult; and the communication just mentioned must not be confused with the permanent isthmus faucium. The lips, teeth, and gums are formed from the walls of the stomodeum, but the tongue is developed in the floor of the pharynx.

The visceral arches extend in a ventral direction between the stomodeum and the pericardium; and with the completion of the mandibular arch and the formation of the maxillary processes, the mouth assumes the appearance of a pentagonal orifice. The orifice is bounded in front by the fronto-nasal process, behind by the

mandibular arch, and laterally by the maxillary processes (Fig. 978). With the inward growth and fusion of the palatine processes (Figs. 50, 51), the stomodeum is divided into an upper nasal, and a lower buccal part. Along the free margins of the processes bounding the mouth cavity a shallow groove appears; this is termed the **primary labial groove**, and from the bottom of it a downgrowth of ectoderm takes place into the underlying mesoderm. The central cells of the ectodermal downgrowth degenerate and a **secondary labial groove** is formed; by the deepening of this, the lips and cheeks are separated from the alveolar processes of the maxillæ and mandible.

The Salivary Glands.—The salivary glands arise as buds from the epithelial lining of the mouth; the parotid appears during the fourth week in the angle between the maxillary process and the mandibular arch; the submaxillary appears in the sixth week, and the sublingual during the ninth week in the hollow between the tongue and the mandibular arch.

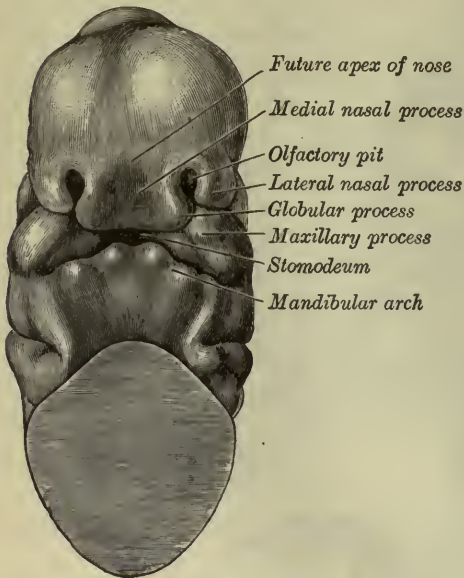


FIG. 978.—Head end of human embryo of about thirty to thirty-one days. (From model by Peters.)

The Tongue (Figs. 979 to 981).—The tongue is developed in the floor of the pharynx, and consists of an anterior or buccal and a posterior or pharyngeal part which are separated in the adult by the V-shaped sulcus terminalis. During the third week there appears, immediately behind the ventral ends of the two halves of the mandibular arch, a rounded swelling named the **tuberculum impar**, which was described by His as undergoing enlargement to form the buccal part of the tongue. More recent researches, however, show that this part of the tongue is mainly, if not entirely, developed from a pair of lateral swellings which rise from and meet in the middle line. The tuberculum impar is said to form the central part of the tongue immediately in front

the inner surface of the mandibular arch and meet in the middle line. The tuberculum impar is said to form the central part of the tongue immediately in front

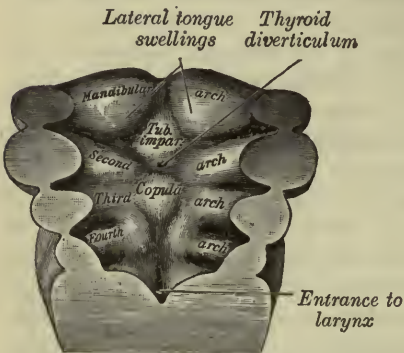


FIG. 979.—Floor of pharynx of human embryo about twenty-six days old. (From model by Peters.)

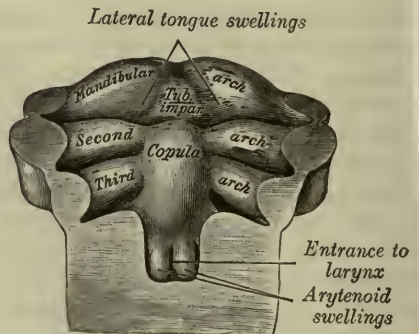


FIG. 980.—Floor of pharynx of human embryo of about the end of the fourth week. (From model by Peters.)

of the foramen cecum, but Hammar insists that it is purely a transitory structure and forms no part of the adult tongue. From the ventral ends of the fourth arch

there arises a second and larger elevation, in the center of which is a median groove or furrow. This elevation was named by His the *furcula*, and is at first separated from the *tuberculum impar* by a depression, but later by a ridge, the *copula*, formed by the forward growth and fusion of the ventral ends of the second and third arches. The posterior or pharyngeal part of the tongue is developed from the *copula*, which extends forward in the form of a V, so as to embrace between its two limbs the buccal part of the tongue. At the apex of the V a pit-like invagination occurs, to form the thyroid gland, and this depression is represented in the adult by the *foramen cecum* of the tongue. In the adult the union of the anterior and posterior parts of the tongue is marked by the V-shaped *sulcus terminalis*, the apex of which is at the *foramen cecum*, while the two limbs run lateralward and forward, parallel to, but a little behind, the *vallate papillæ*.

The Palatine Tonsils.—The palatine tonsils are developed from the dorsal angles of the second branchial pouches.

The entoderm which lines these pouches grows in the form of a number of solid buds into the surrounding mesoderm. These buds become hollowed out by the degeneration and casting off of their central cells, and by this means the tonsillar crypts are formed. Lymphoid cells accumulate around the crypts, and become grouped to form the lymphoid follicles; the latter, however, are not well-defined until after birth.

The Further Development of the Digestive Tube.—The upper part of the fore-gut becomes dilated to form the pharynx (Fig. 977), in relation to which the branchial arches are developed (see page 65); the succeeding part remains tubular, and with the descent of the stomach is elongated to form the esophagus. About the fourth week a fusiform dilatation, the future stomach, makes its appearance, and beyond this the gut opens freely into the yolk-sac (Fig. 982, *A* and *B*). The opening is at first wide, but is gradually narrowed into a tubular stalk, the *yolk-stalk* or *vitelline duct*. Between the stomach and the mouth of the yolk-sac the liver diverticulum appears. From the stomach to the rectum the alimentary canal is attached to the notochord by a band of mesoderm, from which the common mesentery of the gut is subsequently developed. The stomach has an additional attachment, viz., to the ventral abdominal wall as far as the umbilicus by the *septum transversum*. The cephalic portion of the septum takes part in the formation of the diaphragm, while the caudal portion into which the liver grows forms the *ventral mesogastrum* (Fig. 984). The stomach undergoes a further dilatation, and its two curvatures can be recognized (Figs. 983, *B*, and 984), the greater directed toward the vertebral column and the lesser toward the anterior wall of the abdomen, while its two surfaces look to the right and left respectively. Behind the stomach the gut undergoes great elongation, and forms a V-shaped loop which projects downward and forward; from the bend or angle of the loop the vitelline duct passes to the umbilicus (Fig. 984). For a time a considerable part of the loop extends beyond the abdominal cavity into the umbilical cord, but by the end of the third month it is withdrawn within the cavity. With the lengthening of the tube, the mesoderm, which attaches it to the future vertebral column and carries the bloodvessels for the supply of the gut, is thinned and drawn out to form the *posterior common mesentery*. The portion of this mesentery attached to the greater curvature of the stomach is named the *dorsal mesogastrum*, and the part which suspends the

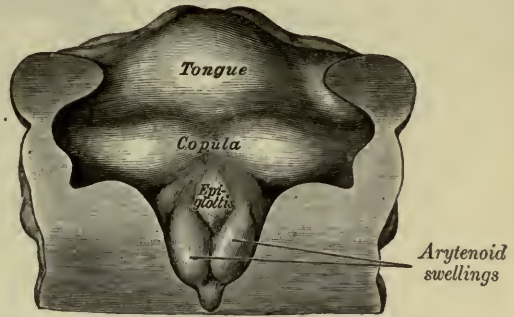


FIG. 981.—Floor of pharynx of human embryo about thirty days old. (From model by Peter.)

colon is termed the **mesocolon** (Fig. 985). About the sixth week a diverticulum of the gut appears just behind the opening of the vitelline duct, and indicates

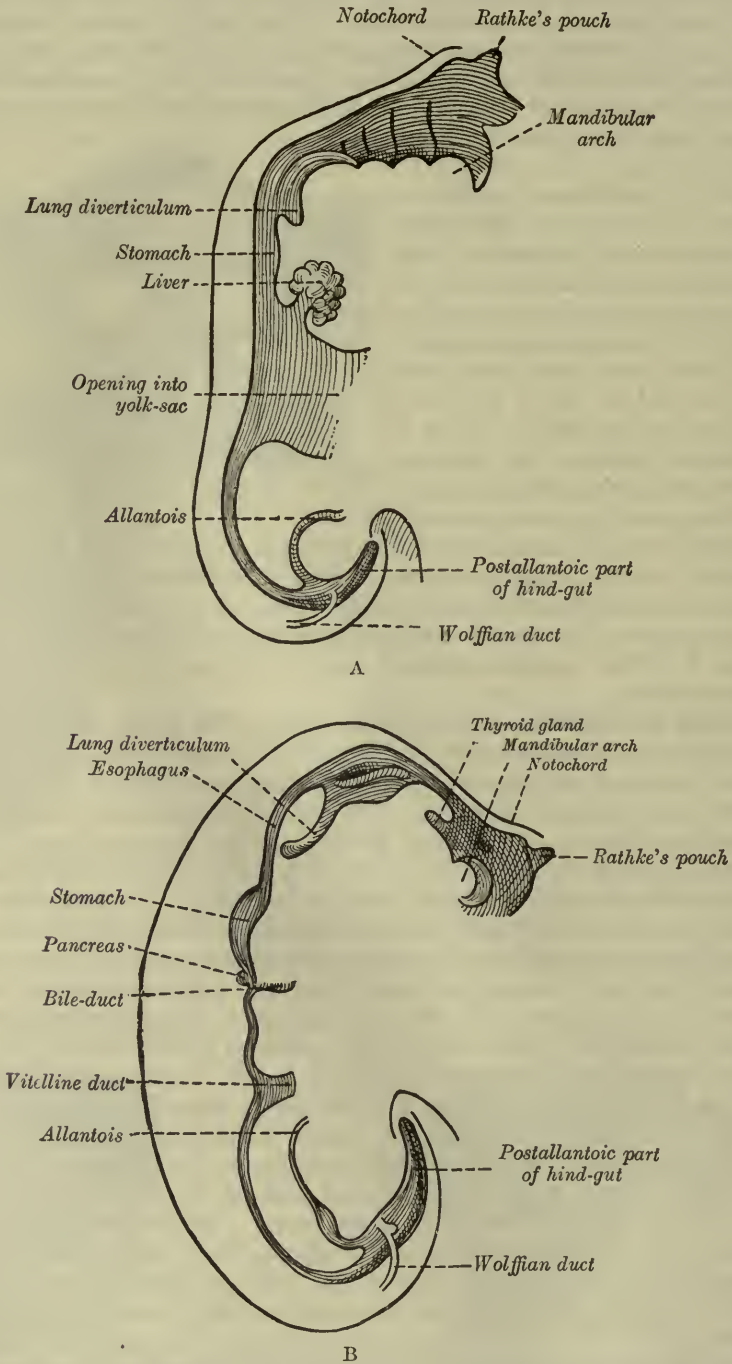


FIG. 982.—Sketches in profile of two stages in the development of the human digestive tube. (His.)
 A X 30. B X 20.

the future cecum and vermiform process. The part of the loop on the distal side of the cecal diverticulum increases in diameter and forms the future ascending

and transverse portions of the large intestine. Until the fifth month the cecal diverticulum has a uniform caliber, but from this time onward its distal part remains rudimentary and forms the vermiform process, while its proximal part expands to form the cecum. Changes also take place in the shape and position of the stomach. Its dorsal part or greater curvature, to which the dorsal meso-

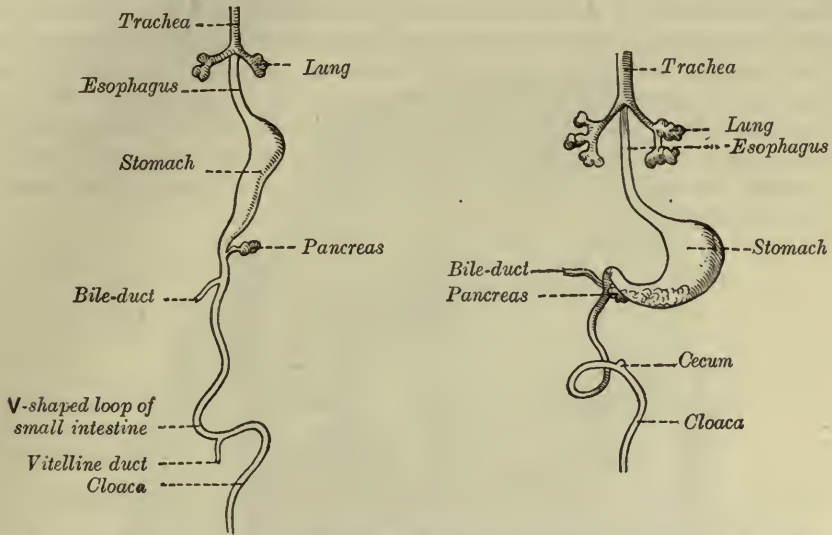


FIG. 983.—Front view of two successive stages in the development of the digestive tube. (His.)

gastrum is attached, grows much more rapidly than its ventral part or lesser curvature to which the ventral mesogastrium is fixed. Further, the greater curvature is carried downward and to the left, so that the right surface of the stomach is now directed backward and the left surface forward (Fig. 986), a change in position

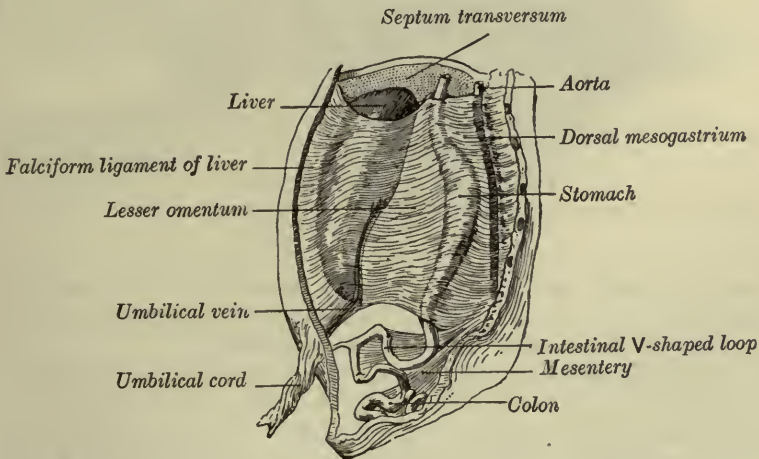


FIG. 984.—The primitive mesentery of a six weeks' human embryo, half schematic. (Kollmann.)

which explains why the left vagus nerve is found on the front, and the right vagus on the back of the stomach. The dorsal mesogastrium being attached to the greater curvature must necessarily follow its movements, and hence it becomes greatly elongated and drawn lateralward and ventralward from the vertebral column, and, as in the case of the stomach, the right surfaces of both the dorsal and ventral

mesogastria are now directed backward, and the left forward. In this way a pouch, the **bursa omentalis**, is formed behind the stomach, and this increases in size as the digestive tube undergoes further development; the entrance to the pouch constitutes the future **foramen epiploicum** or **foramen of Winslow**. The duodenum is developed from that part of the tube which immediately succeeds the stomach; it undergoes little elongation, being more or less fixed in position by the liver and pancreas, which arise as diverticula from it. The duodenum is at first suspended by a mesentery, and projects forward in the form of a loop. The loop and its mesentery are subsequently displaced by the transverse colon, so that the right surface of the duodenal mesentery is directed backward, and, adhering to the parietal peritoneum, is lost. The remainder of the digestive tube becomes greatly elongated, and as a consequence the tube is coiled on itself, and this elongation demands a corresponding increase in the width of the intestinal attachment of the mesentery, which becomes folded.

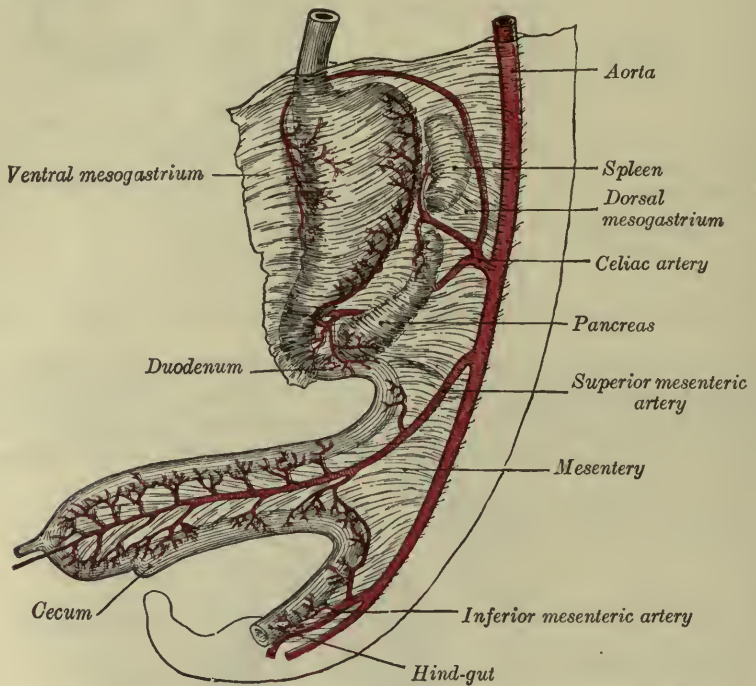


FIG. 985.—Abdominal part of digestive tube and its attachment to the primitive or common mesentery. Human embryo of six weeks. (After Toldt.)

At this stage the small and large intestines are attached to the vertebral column by a common mesentery, the coils of the small intestine falling to the right of the middle line, while the large intestine lies on the left side.¹

The gut is now rotated upon itself, so that the large intestine is carried over in front of the small intestine, and the cecum is placed immediately below the liver; about the sixth month the cecum descends into the right iliac fossa, and the large intestine forms an arch consisting of the ascending, transverse, and descending portions of the colon—the transverse portion crossing in front of the duodenum and lying just below the greater curvature of the stomach; within this arch the coils of the small intestine are disposed (Fig. 988). Sometimes the downward

¹ Sometimes this condition persists throughout life, and it is then found that the duodenum does not cross from the right to the left side of the vertebral column, but lies entirely on the right side of the median plane, where it is continued into the jejunum; the arteries to the small intestine (*aa. intestinales*) also arise from the right instead of the left side of the superior mesenteric artery.

progress of the cecum is arrested, so that in the adult it may be found lying immediately below the liver instead of in the right iliac region.

Further changes take place in the bursa omentalis and in the common mesentery, and give rise to the peritoneal relations seen in the adult. The bursa omentalis, which at first reaches only as far as the greater curvature of the stomach, grows downward to form the greater omentum, and this downward extension lies in front of the transverse colon and the coils of the small intestine (Fig. 989). Above, before the pleuro-peritoneal opening is closed, the bursa omentalis sends up a diverticulum

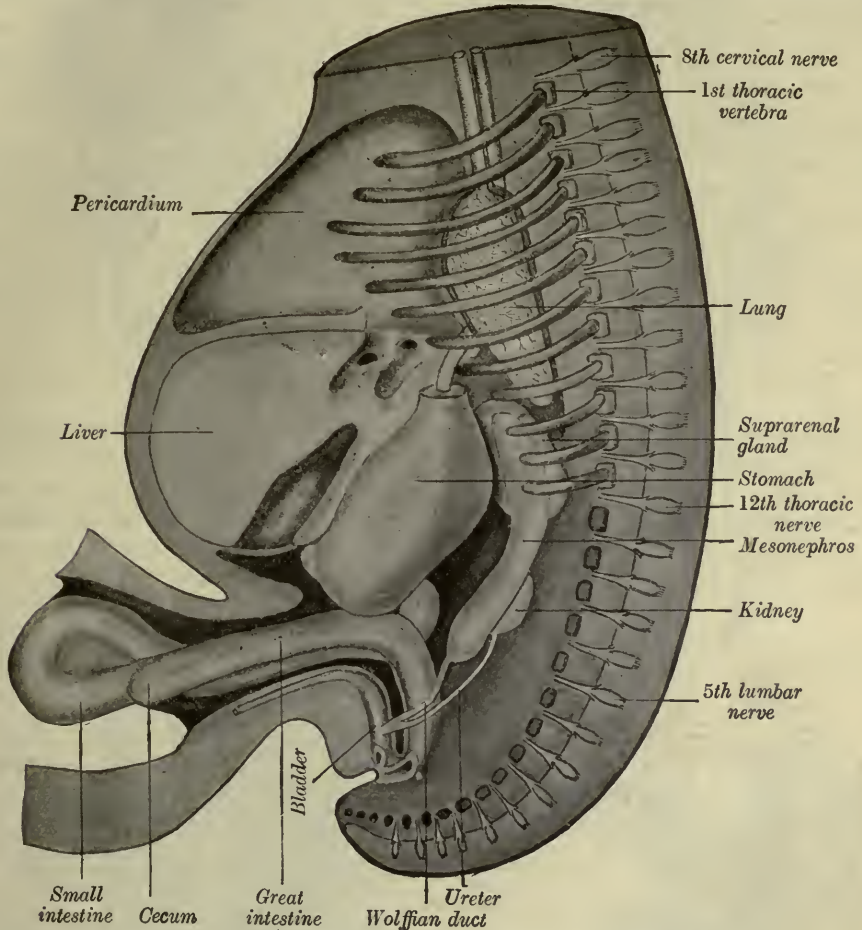


FIG. 986.—Reconstruction of a human embryo of 17 mm. (After Mall.)

on either side of the esophagus; the left diverticulum soon disappears, but the right is constricted off and persists in most adults as a small sac lying within the thorax on the right side of the lower end of the esophagus. The anterior layer of the transverse mesocolon is at first distinct from the posterior layer of the greater omentum, but ultimately the two blend, and hence the greater omentum appears as if attached to the transverse colon (Fig. 990). The mesenteries of the ascending and descending parts of the colon disappear in the majority of cases, while that of the small intestine assumes the oblique attachment characteristic of its adult condition.

The lesser omentum is formed, as indicated above, by a thinning of the mesoderm or **ventral mesogastrium**, which attaches the stomach and duodenum to the anterior abdominal wall. By the subsequent growth of the liver this leaf of mesoderm is divided into two parts, viz., the lesser omentum between the stomach

and liver, and the falciform and coronary ligaments between the liver and the abdominal wall and diaphragm (Fig. 989).

The Rectum and Anal Canal.—The hind-gut is at first prolonged backward into the body-stalk as the tube of the allantois; but, with the growth and flexure of the

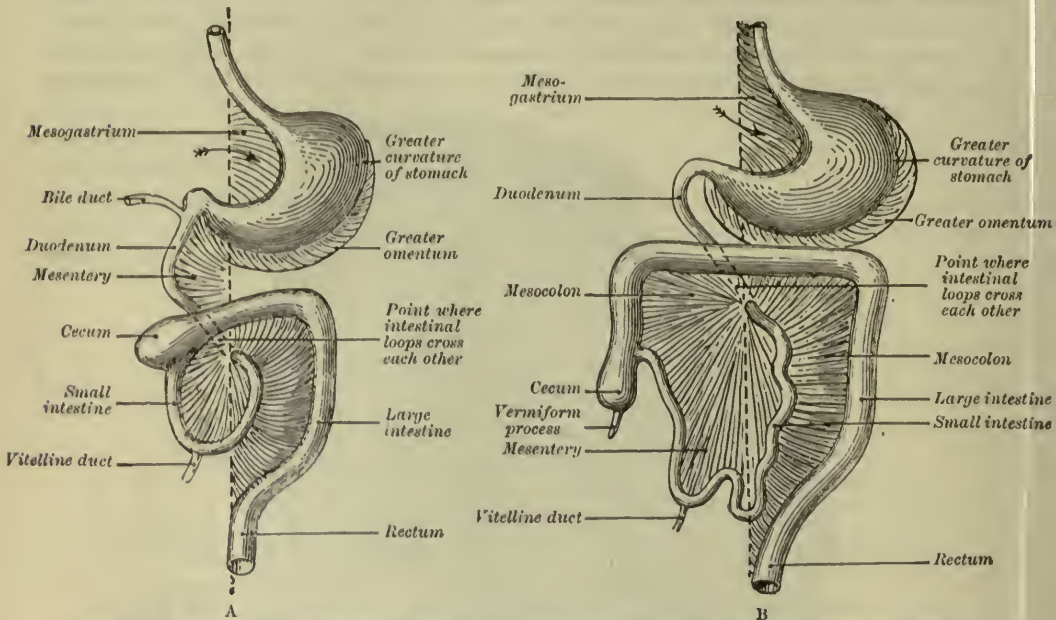


FIG. 987.—Diagrams to illustrate two stages in the development of the digestive tube and its mesentery. The arrow indicates the entrance to the bursa omentalis.

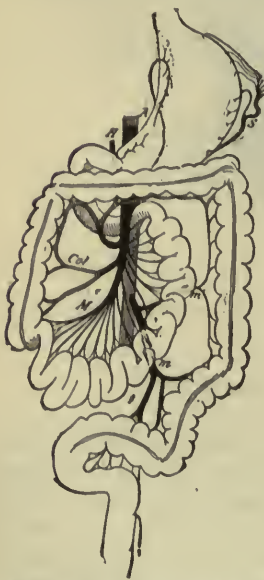

FIG. 988.—Final disposition of the intestines and their vascular relations. (Jonnescq.) A, Aorta. H, Hepatic artery. M, Col, Branches of superior mesenteric artery. m, m', Branches of inferior mesenteric artery. S, Splenic artery.

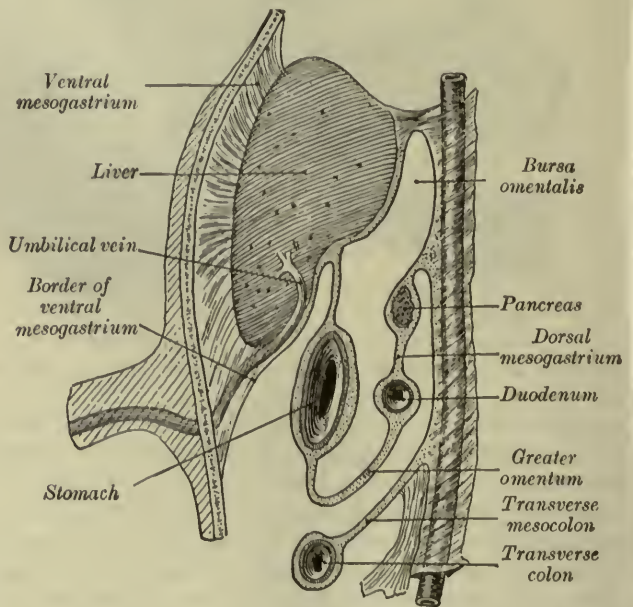


FIG. 989.—Schematic figure of the bursa omentalis, etc. Human embryo of eight weeks. (Kollmann.)

tail-end of the embryo, the body-stalk, with its contained allantoic tube, is carried forward to the ventral aspect of the body, and consequently a bend is formed at the

junction of the hind-gut and allantois. This bend becomes dilated into a pouch, which constitutes the **entodermal cloaca**; into its dorsal part the hind-gut opens, and from its ventral part the allantois passes forward. At a later stage the Wolffian and Müllerian ducts open into its ventral portion. The cloaca is, for a time, shut

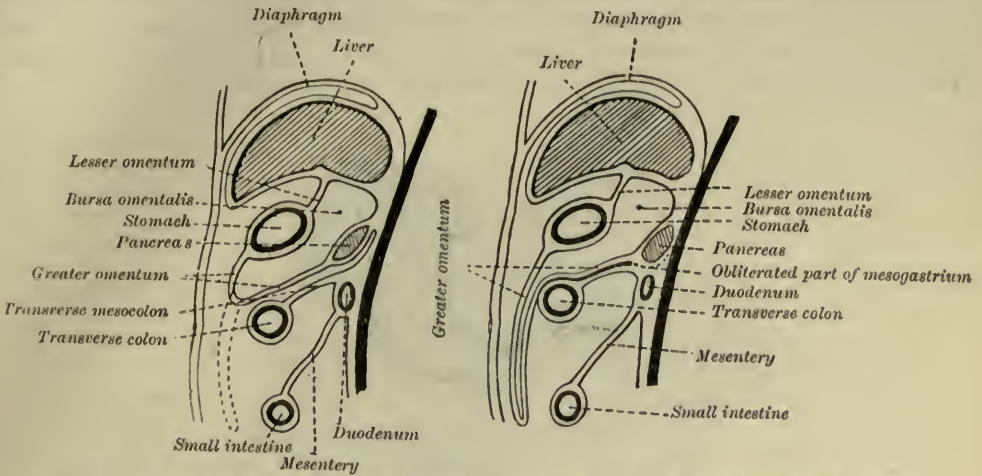


FIG. 990.—Diagrams to illustrate the development of the greater omentum and transverse mesocolon.

off from the anterior by a membrane, the **cloacal membrane**, formed by the apposition of the ectoderm and entoderm, and reaching, at first, as far forward as the future umbilicus. Behind the umbilicus, however, the mesoderm subsequently extends to form the lower part of the abdominal wall and symphysis pubis. By the growth of the surrounding tissues the cloacal membrane comes to lie at the bottom of a depression, which is lined by ectoderm and named the **ectodermal cloaca** (Fig. 991).

The entodermal cloaca is divided into a dorsal and a ventral part by means of a partition, the **urorectal septum** (Fig. 992), which grows downward from the ridge

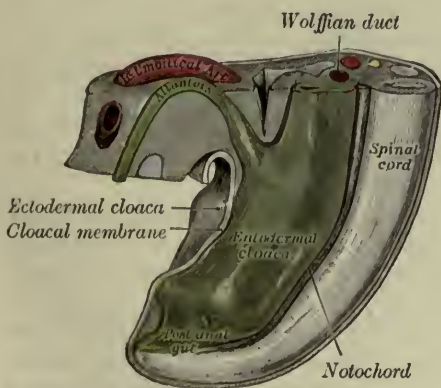


FIG. 991.—Tail end of human embryo from fifteen to eighteen days old. (From model by Kaibel.)

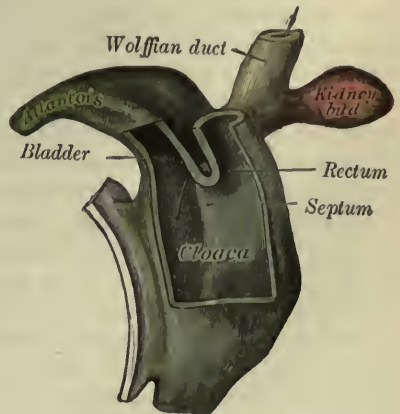


FIG. 992.—Cloaca of human embryo from twenty-five to twenty-seven days old. (From model by Kaibel.)

separating the allantoic from the cloacal opening of the intestine and ultimately fuses with the cloacal membrane and divides it into an anal and a urogenital part. The dorsal part of the cloaca forms the rectum, and the anterior part of the urogenital sinus and bladder. For a time a communication named the **cloacal duct**

exists between the two parts of the cloaca below the urorectal septum; this duct occasionally persists as a passage between the rectum and urethra. The anal canal is formed by an invagination of the ectoderm behind the urorectal septum. This invagination is termed the **proctodeum**, and it meets with the entoderm of the hind-gut and forms with it the **anal membrane**. By the absorption of this membrane the anal canal becomes continuous with the rectum (Fig. 993). A small part of the hind-gut projects backward beyond the anal membrane; it is named the **post-anal gut** (Fig. 991), and usually becomes obliterated and disappears.¹

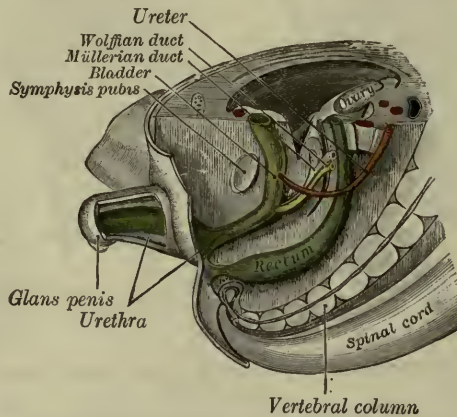


FIG. 993.—Tail end of human embryo, from eight and a half to nine weeks old. (From model by Keibel.)

THE MOUTH (CAVUM ORIS; ORAL OR BUCCAL CAVITY).

The **cavity of the mouth** is placed at the commencement of the digestive tube (Fig. 994); it is a nearly oval-shaped cavity which consists of two parts: an outer, smaller portion, the **vestibule**, and an inner, larger part, the **mouth cavity proper**.

The **Vestibule** (*vestibulum oris*) is a slit-like space, bounded externally by the lips and cheeks; internally by the gums and teeth. It communicates with the surface of the body by the **rima** or **orifice of the mouth**. Above and below, it is limited by the reflection of the mucous membrane from the lips and cheeks to the gum covering the upper and lower alveolar arch respectively. It receives the secretion from the parotid salivary glands, and communicates, when the jaws are closed, with the mouth cavity proper by an aperture on either side behind the wisdom teeth, and by narrow clefts between opposing teeth.

The **Mouth Cavity Proper** (*cavum oris proprium*) (Fig. 1014) is bounded laterally and in front by the alveolar arches with their contained teeth; behind, it communicates with the pharynx by a constricted aperture termed the **isthmus faucium**. It is roofed in by the hard and soft palates, while the greater part of the floor is formed by the tongue, the remainder by the reflection of the mucous membrane from the sides and under surface of the tongue to the gum lining the inner aspect of the mandible. It receives the secretion from the submaxillary and sublingual salivary glands.

Structure.—The **mucous membrane** lining the mouth is continuous with the integument at the free margin of the lips, and with the mucous lining of the pharynx behind; it is of a rose-pink tinge during life, and very thick where it overlies the hard parts bounding the cavity. It is covered by stratified squamous epithelium.

¹ Consult, in this connection, the following article: "A Contribution to the Morphology of the Human Urinogenital Tract," by D. Berry Hart, M.D., F.R.C.P.E., *Journal of Anatomy and Physiology*, April, 1901, vol. xxxv.

The **Lips** (*labia oris*), the two fleshy folds which surround the rima or orifice of the mouth, are formed externally of integument and internally of mucous membrane, between which are found the Orbicularis oris muscle, the labial vessels, some nerves, areolar tissue, and fat, and numerous small labial glands. The inner surface of each lip is connected in the middle line to the corresponding gum by a fold of mucous membrane, the **frenulum**—the upper being the larger.

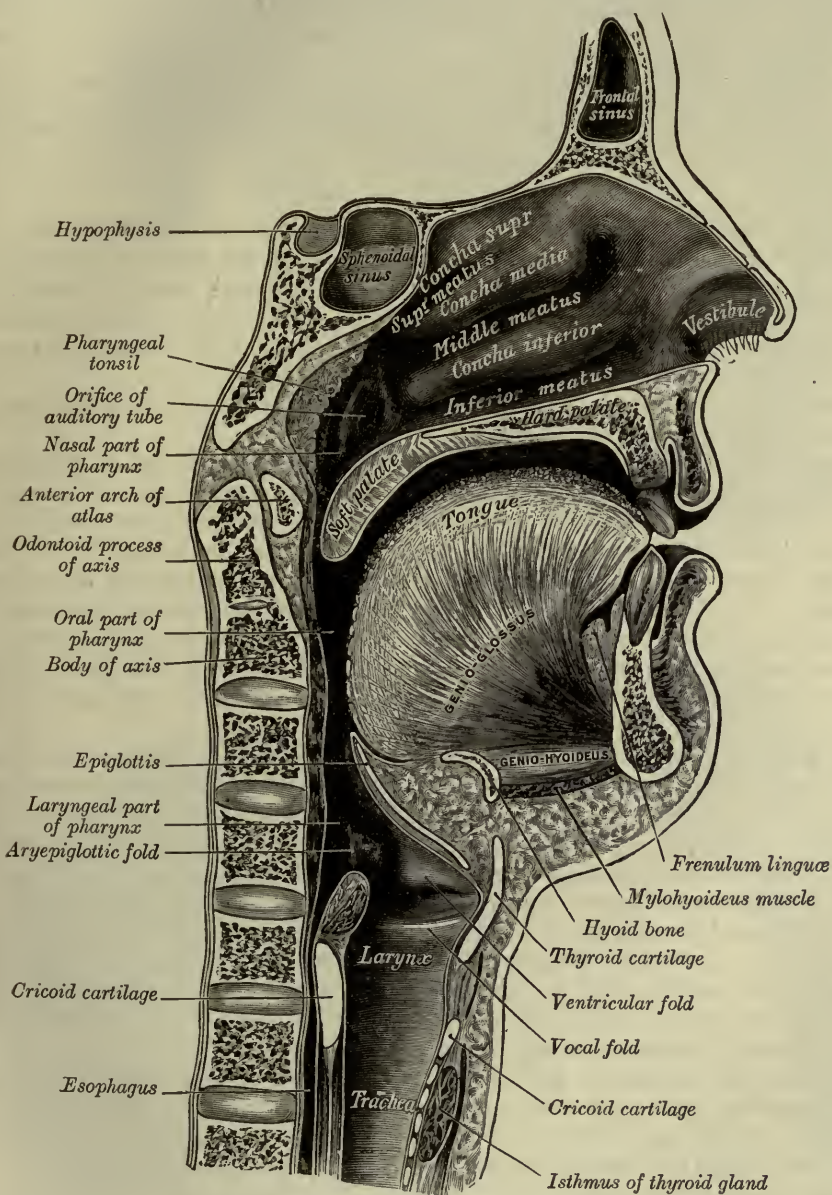


FIG. 994.—Sagittal section of nose, mouth, pharynx, and larynx.

The **Labial Glands** (*glandulæ labiales*) are situated between the mucous membrane and the Orbicularis oris, around the orifice of the mouth. They are circular in form, and about the size of small peas; their ducts open by minute orifices upon the mucous membrane. In structure they resemble the salivary glands.

The **Cheeks** (*buccæ*) form the sides of the face, and are continuous in front with the lips. They are composed externally of integument; internally of mucous membrane; and between the two of a muscular stratum, besides a large quantity of fat, areolar tissue, vessels, nerves, and buccal glands.

Structure.—The **mucous membrane** lining the cheek is reflected above and below upon the gums, and is continuous behind with the lining membrane of the soft palate. Opposite the second molar tooth of the maxilla is a papilla, on the summit of which is the aperture of the parotid duct. The principal muscle of the cheek is the Buccinator; but other muscles enter into its formation, viz., the Zygomaticus, Risorius, and Platysma.

The **buccal glands** are placed between the mucous membrane and Buccinator muscle: they are similar in structure to the labial glands, but smaller. About five, of a larger size than the rest, are placed between the Masseter and Buccinator muscles around the distal extremity of the parotid duct; their ducts open in the mouth opposite the last molar tooth. They are called **molar glands**.

The **Gums** (*gingivæ*) are composed of dense fibrous tissue, closely connected to the periosteum of the alveolar processes, and surrounding the necks of the teeth. They are covered by smooth and vascular mucous membrane, which is remarkable for its limited sensibility. Around the necks of the teeth this membrane presents numerous fine papillæ, and is reflected into the alveoli, where it is continuous with the periosteal membrane lining these cavities.

The **Palate** (*palatum*) forms the roof of the mouth; it consists of two portions, the **hard palate** in front, the **soft palate** behind.

The **Hard Palate** (*palatum durum*) (Fig. 1014) is bounded in front and at the sides by the alveolar arches and gums; behind, it is continuous with the soft palate. It is covered by a dense structure, formed by the periosteum and mucous membrane of the mouth, which are intimately adherent. Along the middle line is a linear raphé, which ends anteriorly in a small papilla corresponding with the incisive canal. On either side and in front of the raphé the mucous membrane is thick, pale in color, and corrugated; behind, it is thin, smooth, and of a deeper color; it is covered with stratified squamous epithelium, and furnished with numerous palatal glands, which lie between the mucous membrane and the surface of the bone.

The **Soft Palate** (*palatum molle*) (Fig. 1014) is a movable fold, suspended from the posterior border of the hard palate, and forming an incomplete septum between the mouth and pharynx. It consists of a fold of mucous membrane enclosing muscular fibers, an aponeurosis, vessels, nerves, adenoid tissue, and mucous glands. When occupying its usual position, *i. e.*, relaxed and pendent, its anterior surface is concave, continuous with the roof of the mouth, and marked by a median raphé. Its posterior surface is convex, and continuous with the mucous membrane covering the floor of the nasal cavities. Its upper border is attached to the posterior margin of the hard palate, and its sides are blended with the pharynx. Its lower border is free. Its lower portion, which hangs like a curtain between the mouth and pharynx is termed the **palatine velum**.

Hanging from the middle of its lower border is a small, conical, pendulous process, the **palatine uvula**; and arching lateralward and downward from the base of the uvula on either side are two curved folds of mucous membrane, containing muscular fibers, called the **arches** or **pillars of the fauces**.

The Teeth (*dentes*) (Figs. 995 to 997).—Man is provided with two sets of teeth, which make their appearance at different periods of life. Those of the first set appear in childhood, and are called the **deciduous** or **milk teeth**. Those of the second set, which also appear at an early period, may continue until old age, and are named **permanent**.

The **deciduous teeth** are twenty in number: four incisors, two canines, and four molars, in each jaw.

The permanent teeth are thirty-two in number: four incisors, two canines, four premolars, and six molars, in each jaw.

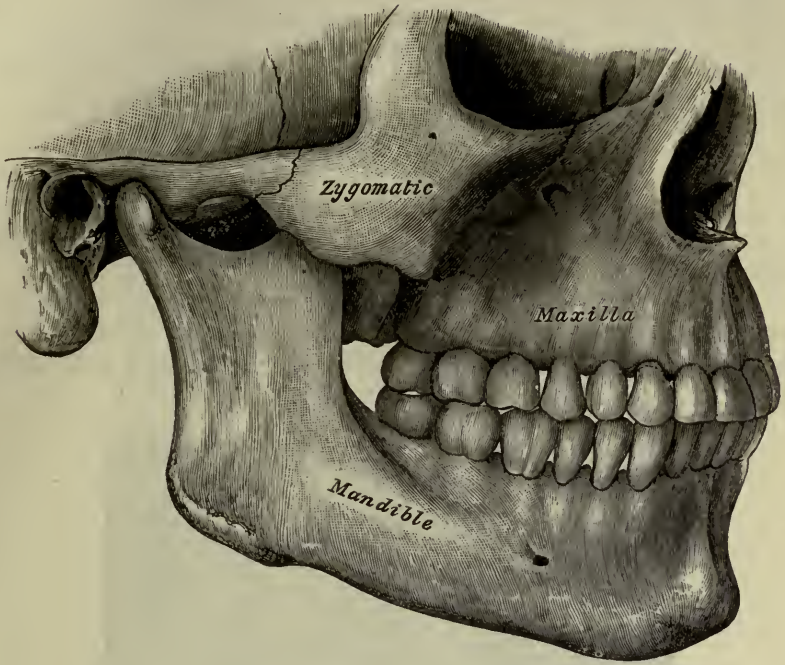


FIG. 995.—Side view of the teeth and jaws.

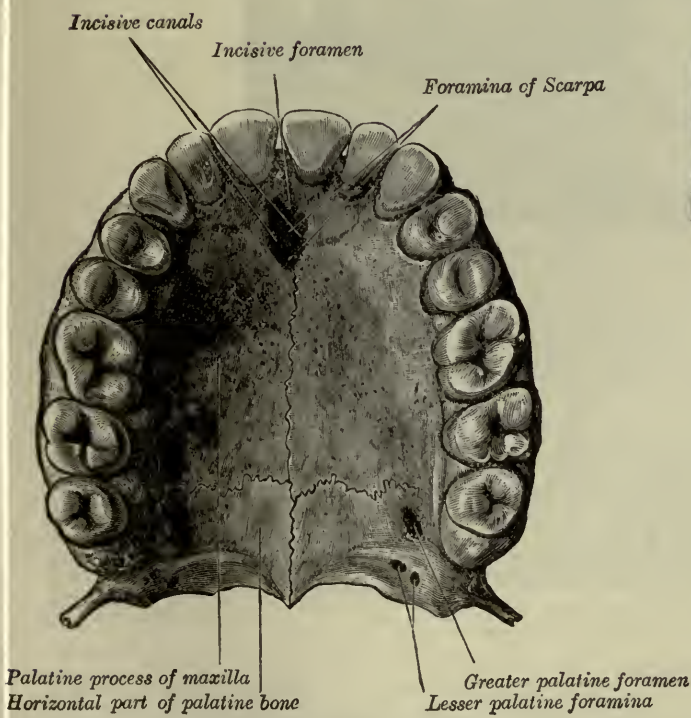


FIG. 996.—Permanent teeth of upper dental arch, seen from below.

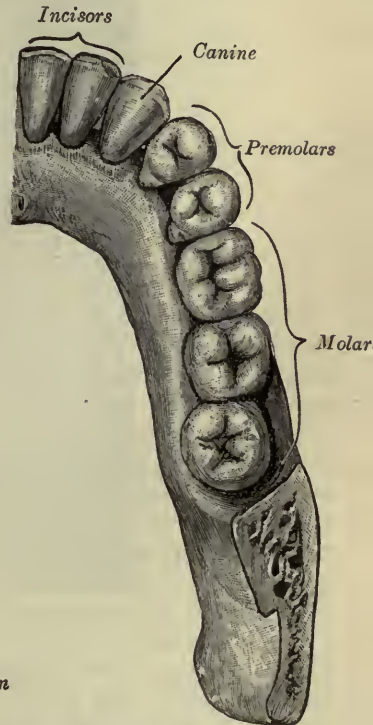


FIG. 997.—Permanent teeth of right half of lower dental arch, seen from above.

The dental formulæ may be represented as follows:

Deciduous Teeth.

	mol.	can.	in.	in.	can.	mol.	
Upper jaw	2	1	2	2	1	2	} Total 20
Lower jaw	2	1	2	2	1	2	

Permanent Teeth.

	mol.	pr. mol.	can.	in.	in.	can.	pr. mcl.	mol.	
Upper jaw	3	2	1	2	2	1	2	3	} Total 32
Lower jaw	3	2	1	2	2	1	2	3	

General Characteristics.—Each tooth consists of three portions: the **crown**, projecting above the gum; the **root**, imbedded in the alveolus; and the **neck**, the constricted portion between the crown and root.

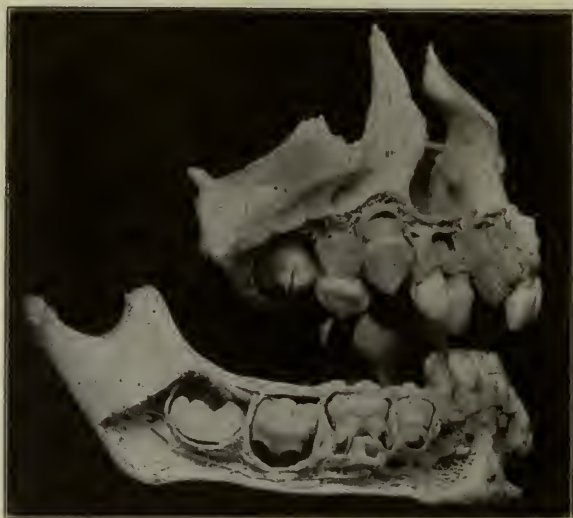

FIG. 998.—Maxillæ at about one year. (Noyes.)

The roots of the teeth are firmly implanted in depressions within the alveoli; these depressions are lined with periosteum which invests the tooth as far as the neck. At the margins of the alveoli, the periosteum is continuous with the fibrous structure of the gums.

In consequence of the curve of the dental arch, terms such as anterior and posterior, as applied to the teeth, are misleading and confusing. Special terms are therefore used to indicate the different surfaces of a tooth: the surface directed toward the lips or cheek is known as the **labial** or **buccal surface**; that directed toward the tongue is described as the **lingual surface**; those surfaces which touch neighboring teeth are termed **surfaces of contact**. In the case of the incisor and canine teeth the surfaces of contact are medial and lateral; in the premolar and molar teeth they are anterior and posterior.

The superior dental arch is larger than the inferior, so that in the normal condition the teeth in the maxillæ slightly overlap those of the mandible both in front and at the sides. Since the upper central incisors are wider than the lower, the other teeth in the upper arch are thrown somewhat distally, and the two sets do

not quite correspond to each other when the mouth is closed: thus the upper canine tooth rests partly on the lower canine and partly on the first premolar, and the cusps of the upper molar teeth lie behind the corresponding cusps of the lower molar teeth. The two series, however, end at nearly the same point behind; this is mainly because the molars in the upper arch are the smaller.

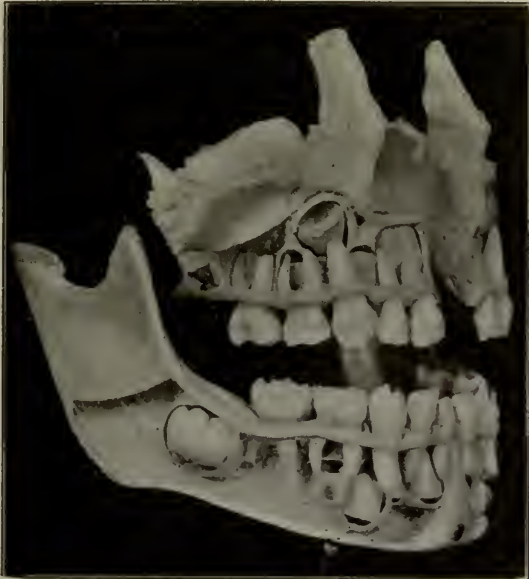

FIG. 999.—The complete temporary dentition (about three years), showing the relation of the developing permanent teeth. (Noyes.)

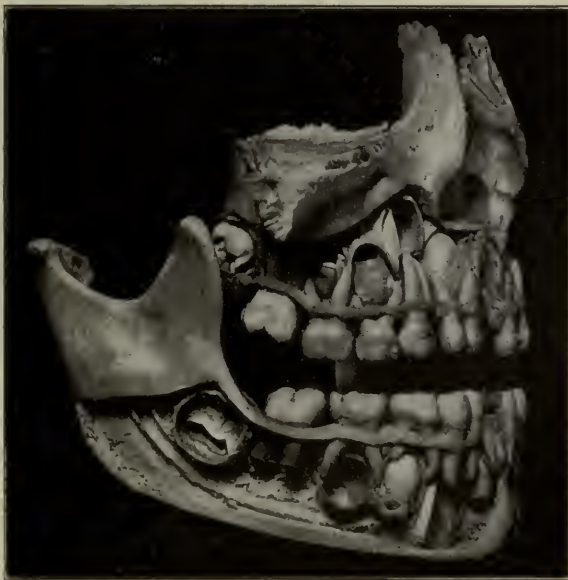

FIG. 1000.—The complete temporary dentition and the first permanent molar. Note the relation of the bicuspid to the temporary molars. (In the seventh year.) (Noyes.)

The Permanent Teeth (*dentes permanentes*) (Figs. 1002, 1003).—The **Incisors** (*dentes incisivi*; *incisive* or *cutting teeth*) are so named from their presenting a sharp cutting edge, adapted for biting the food. They are eight in number, and form the four front teeth in each dental arch.

The **crown** is directed vertically, and is chisel-shaped, being bevelled at the expense of its lingual surface, so as to present a sharp horizontal cutting edge, which, before being subjected to attrition, presents three small prominent points separated by two slight notches. It is convex, smooth, and highly polished on its labial surface; concave on its lingual surface, where, in the teeth of the upper arch, it is frequently marked by an inverted V-shaped eminence, situated near the gum. This is known as the **basal ridge** or **cingulum**. The **neck** is constricted. The **root** is long, single, conical, transversely flattened, thicker in front than behind, and slightly grooved on either side in the longitudinal direction.

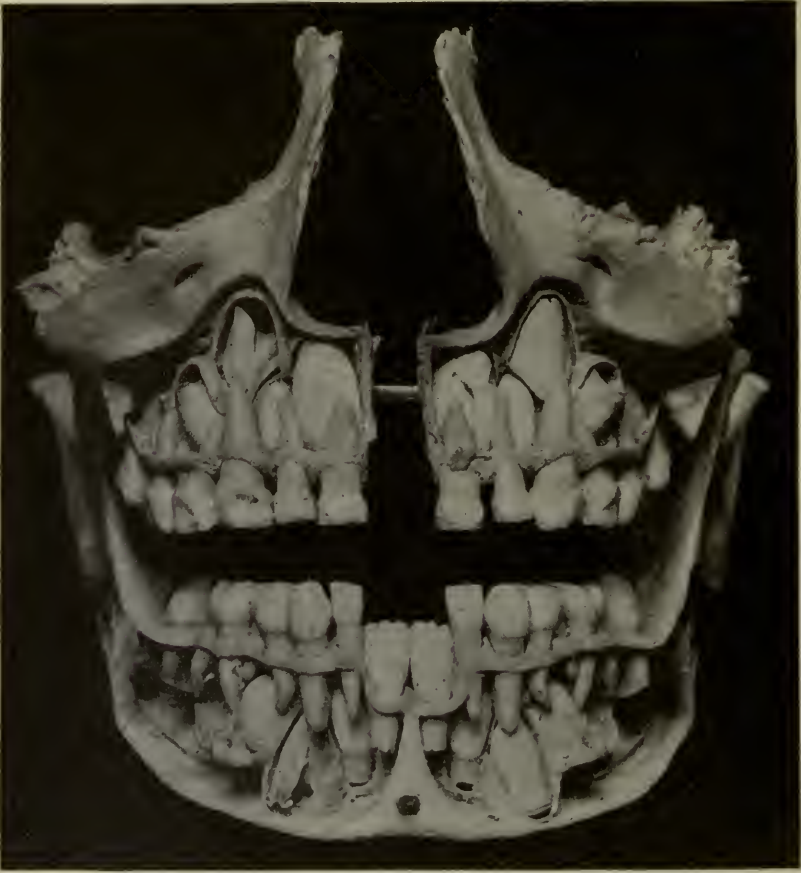

FIG. 1001.—Front view of the skull shown in Fig. 1000. Note the relation of the permanent incisors and cusps to each other and the roots of the temporary teeth. (Noyes.)

The **upper incisors** are larger and stronger than the lower, and are directed obliquely downward and forward. The central ones are larger than the lateral, and their roots are more rounded.

The **lower incisors** are smaller than the upper: the central ones are smaller than the lateral, and are the smallest of all the incisors. They are placed vertically and are somewhat bevelled in front, where they have been worn down by contact with the overlapping edge of the upper teeth. The cingulum is absent.

The **Canine Teeth** (*dentes canini*) are four in number, two in the upper, and two in the lower arch, one being placed laterally to each lateral incisor. They are larger and stronger than the incisors, and their roots sink deeply into the bones, and cause well-marked prominences upon the surface.

The **crown** is large and conical, very convex on its labial surface, a little hollowed and uneven on its lingual surface, and tapering to a blunted point or cusp, which projects beyond the level of the other teeth. The **root** is single, but longer and thicker than that of the incisors, conical in form, compressed laterally, and marked by a slight groove on each side.

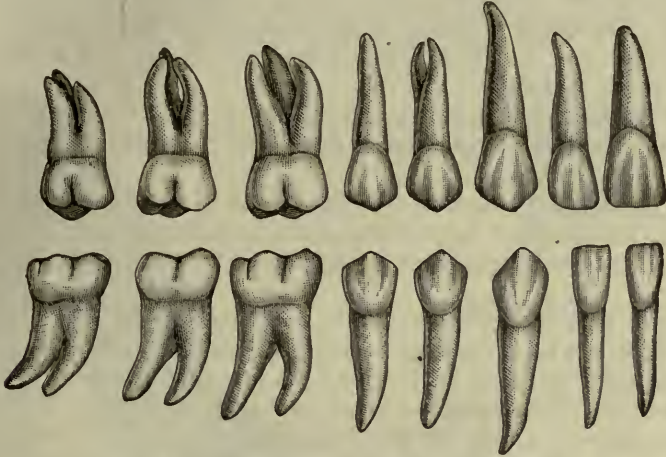


FIG. 1002.—Permanent teeth. Right side. (Burchard.)

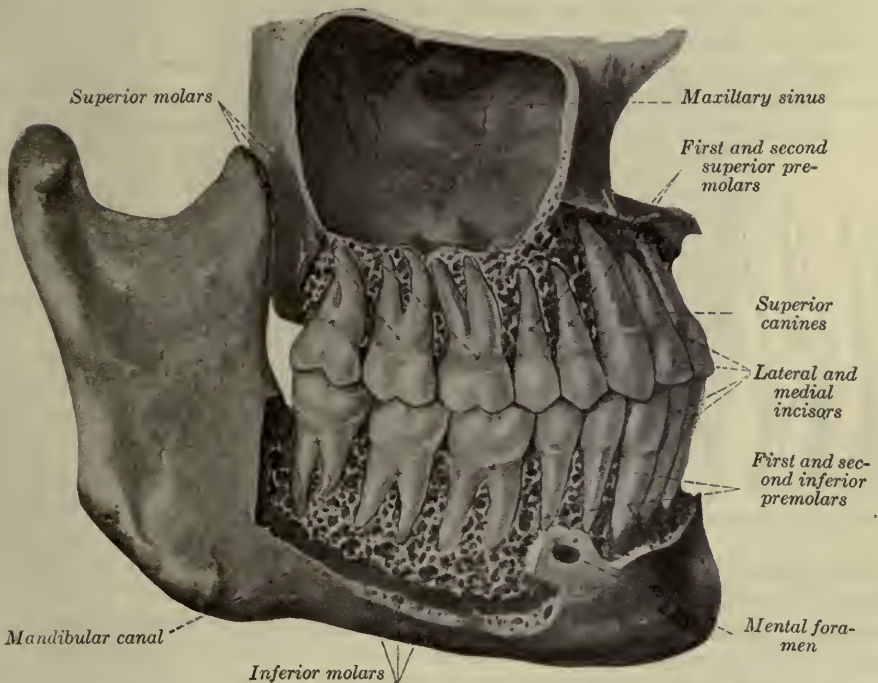


FIG. 1003.—The permanent teeth, viewed from the right. The external layer of bone has been partly removed and the maxillary sinus has been opened. (Spalteholz.)

The **upper canine teeth** (popularly called *eye teeth*) are larger and longer than the lower, and usually present a distinct basal ridge.

The **lower canine teeth** (popularly called *stomach teeth*) are placed nearer the middle line than the upper, so that their summits correspond to the intervals between the upper canines and the lateral incisors.

The **Premolars** or **Bicuspid teeth** (*dentes præmolares*) are eight in number, four in each arch. They are situated lateral to and behind the canine teeth, and are smaller and shorter than they.

The **crown** is compressed antero-posteriorly, and surmounted by two pyramidal eminences or cusps, a labial and a lingual, separated by a groove; hence their name **bicuspid**. Of the two cusps the labial is the larger and more prominent. The **neck** is oval. The **root** is generally single, compressed, and presents in front and behind a deep groove, which indicates a tendency in the root to become double. The apex is generally bifid.

The **upper premolars** are larger, and present a greater tendency to the division of their roots than the lower; this is especially the case in the first upper premolar.

The **Molar Teeth** (*dentes molares*) are the largest of the permanent set, and their broad crowns are adapted for grinding and pounding the food. They are twelve in number; six in each arch, three being placed posterior to each of the second premolars.

The **crown** of each is nearly cubical in form, convex on its buccal and lingual surfaces, flattened on its surfaces of contact; it is surmounted by four or five tubercles, or cusps, separated from each other by a crucial depression; hence the molars are sometimes termed **multicuspids**. The **neck** is distinct, large, and rounded.

Upper Molars.—As a rule the first is the largest, and the third the smallest of the upper molars. The crown of the first has usually four tubercles; that of the second, three or four; that of the third, three. Each upper molar has three roots, and of these two are buccal and nearly parallel to one another; the third is lingual and diverges from the others as it runs upward. The roots of the third molar (*dens serotinus* or *wisdom-tooth*) are more or less fused together.

Lower Molars.—The lower molars are larger than the upper. On the crown of the first there are usually five tubercles; on those of the second and third, four or five. Each lower molar has two roots, an anterior, nearly vertical, and a posterior, directed obliquely backward; both roots are grooved longitudinally, indicating a tendency to division. The two roots of the third molar (*dens serotinus* or *wisdom tooth*) are more or less united.

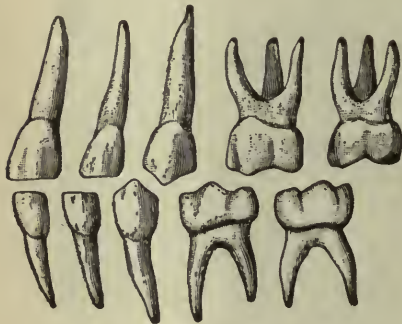

FIG. 1004.—Deciduous teeth. Left side.

The Deciduous Teeth (*dentes decidui; temporary or milk teeth*) (Fig. 1004).—The deciduous are smaller than, but, generally speaking, resemble in form, the teeth which bear the same names in the permanent set. The hinder of the two molars is the largest of all the deciduous teeth, and is succeeded by the second premolar. The first upper molar has only three cusps—two labial, one lingual; the second upper molar has four cusps. The first lower molar has four cusps; the second lower molar has five. The roots of the deciduous molars are smaller and more divergent than those of the permanent molars, but in other respects bear a strong resemblance to them.

Structure of the Teeth.—On making a vertical section of a tooth (Fig. 1005), a cavity will be found in the interior of the crown and the center of each root; it opens by a minute orifice at the extremity of the latter. This is called the **pulp cavity**, and contains the **dental pulp**, a loose connective tissue richly supplied with vessels and nerves, which enter the cavity through the small aperture at the point of each root. Some of the cells of the pulp are arranged as a layer on the wall of the pulp cavity; they are named the **odontoblasts of Waldeyer**, and during the development of the tooth, are columnar in shape, but later on, after the dentin is fully formed, they become flattened and resemble osteoblasts. Each has two fine processes, the outer one

passing into a dental canaliculus, the inner being continuous with the processes of the connective-tissue cells of the pulp matrix.

The solid portion of the tooth consists of (1) the **ivory** or **dentin**, which forms the bulk of the tooth; (2) the **enamel**, which covers the exposed part of the crown; and (3) a thin layer of bone, the **cement** or **crusta petrosa**, which is disposed on the surface of the root.

The **dentin** (*substantia eburnea; ivory*) (Fig. 1007) forms the principal mass of a tooth. It is a modification of osseous tissue, from which it differs, however, in structure. On microscopic examination it is seen to consist of a number of minute wavy and branching tubes, the **dental canaliculi**, imbedded in a dense homogeneous substance, the **matrix**.

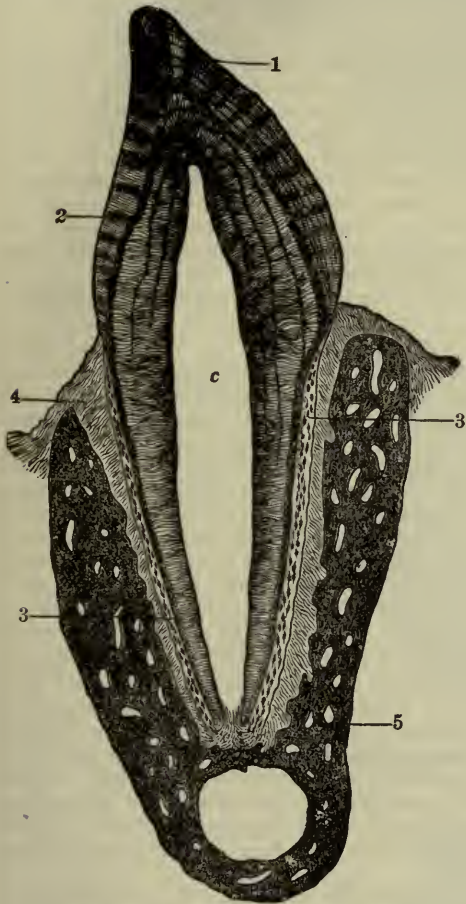

FIG. 1005.—Vertical section of a tooth *in situ*. $\times 15$. *c* is placed in the pulp cavity, opposite the neck of the tooth; the part above it is the crown, that below is the root. 1. Enamel with radial and concentric markings. 2. Dentin with tubules and incremental lines. 3. Cement or crusta petrosa, with bone corpuscles. 4. Dental periosteum. 5. Mandible.

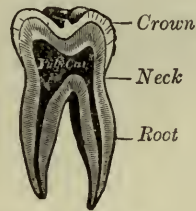


FIG. 1006.—Vertical section of a molar tooth.

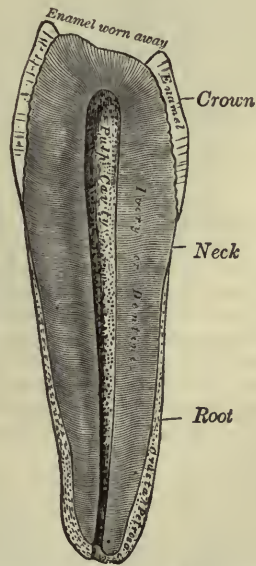


FIG. 1007.—Vertical section of a premolar tooth. (Magnified.)

The **dental canaliculi** (*dental tubules*) (Fig. 1008) are placed parallel with one another, and open at their inner ends into the pulp cavity. In their course to the periphery they present two or three curves, and are twisted on themselves in a spiral direction. These canaliculi vary in direction: thus in a tooth of the mandible they are vertical in the upper portion of the crown, becoming oblique and then horizontal in the neck and upper part of the root, while toward the lower part of the root they are inclined downward. In their course they divide and subdivide dichotomously, and, especially in the root, give off minute branches, which join together in loops in the matrix, or end blindly. Near the periphery of the dentin, the finer ramifications of the canaliculi terminate imperceptibly by free ends. The dental canaliculi have definite walls, consisting of an elastic homogeneous membrane, the **dental sheath of Neumann**, which resists the action of acids; they contain slender cylindrical prolongations of the odontoblasts, first described by Tomes, and named **Tomes' fibers** or **dental fibers**.

The **matrix** (*intertubular dentin*) is translucent, and contains the chief part of the earthy matter of the dentin. In it are a number

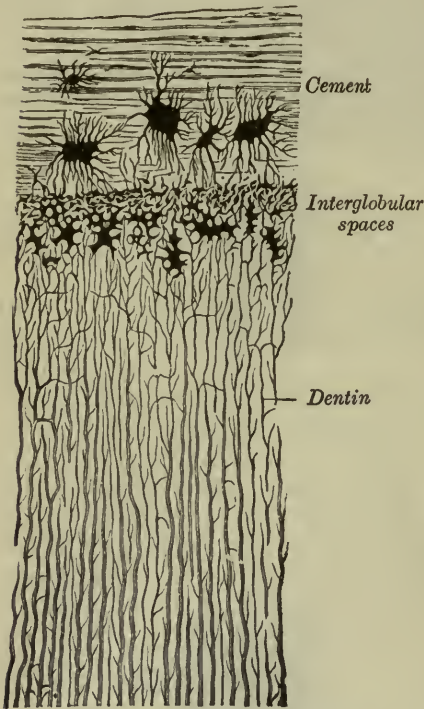


FIG. 1008.—Transverse section of a portion of the root of a canine tooth. $\times 300$.

of fine fibrils, which are continuous with the fibrils of the dental pulp. After the earthy matter has been removed by steeping a tooth in weak acid, the animal basis remaining may be torn into laminae which run parallel with the pulp cavity, across the direction of the tubes. A section of dry dentin often displays a series of somewhat parallel lines—the **incremental lines of Salter**. These lines are composed of imperfectly calcified dentin arranged in layers. In consequence of the imperfection in the calcifying process, little irregular cavities are left, termed **interglobular spaces** (Fig. 1008). Normally a series of these spaces is found toward the outer surface of the dentin, where they form a layer which is sometimes known as the **granular layer**. They have received their name from the fact that they are surrounded by minute nodules or globules of dentin. Other curved lines may be seen parallel to the surface. These are the **lines of Schreger**, and are due to the optical effect of simultaneous curvature of the dentinal fibers.

Chemical Composition.—According to Berzelius and von Bibra, dentin consists of 28 parts of animal and 72 parts of earthy matter. The animal matter is converted by boiling into gelatin. The earthy matter consists of phosphate of lime, carbonate of lime, a trace of fluoride of calcium, phosphate of magnesium, and other salts.

The **enamel** (*substantia adamantina*) is the hardest and most compact part of the tooth, and forms a thin crust over the exposed part of the crown, as far as the commencement of the root. It is thickest on the grinding surface of the crown, until worn away by attrition, and becomes thinner toward the neck. It consists of minute hexagonal rods or columns

termed **enamel fibers** or **enamel prisms** (*prismata adamantina*). They lie parallel with one another, resting by one extremity upon the dentin, which presents a number of minute depressions for their reception; and forming the free surface of the crown by the other extremity. The columns are directed vertically on the summit of the crown, horizontally at the sides; they are about 4μ in diameter, and pursue a more or less wavy course. Each column is a six-sided prism and presents numerous dark transverse shadings; these shadings are probably due to the manner in which the columns are developed in successive stages, producing shallow constrictions, as will be subsequently explained. Another series of lines, having a brown appearance, the **parallel striæ** or **colored lines of Retzius**, is seen on section. According to Ebner, they are produced by air in the interprismatic spaces; others believe that they are the result of true pigmentation.

Numerous minute interstices intervene between the enamel fibers near their dentinal ends, a provision calculated to allow of the permeation of fluids from the dental canaliculi into the substance of the enamel.

Chemical Composition.—According to von Bibra, enamel consists of 96.5 per cent. of earthy matter, and 3.5 per cent. of animal matter. The earthy matter consists of phosphate of lime, with traces of fluoride of calcium, carbonate of lime, phosphate of magnesium, and other salts. According to Tomes, the enamel contains the merest trace of organic matter.

The **crusta petrosa** or **cement** (*substantia ossea*) is disposed as a thin layer on the roots of the teeth, from the termination of the enamel to the apex of each root, where it is usually very thick. In structure and chemical composition it resembles bone. It contains, sparingly, the lacunæ and canaliculi which characterize true bone; the lacunæ placed near the surface receive the canaliculi radiating from the side of the lacunæ toward the periodontal membrane; and those more deeply placed join with the adjacent dental canaliculi. In the thicker portions of the crusta petrosa, the lamellæ and Haversian canals peculiar to bone are also found.

As age advances, the cement increases in thickness, and gives rise to those bony growths or exostoses so common in the teeth of the aged; the pulp cavity also becomes partially filled up by a hard substance, intermediate in structure between dentin and bone (*osteodentin*, Owen; *secondary dentin*, Tomes). It appears to be formed by a slow conversion of the dental pulp, which shrinks, or even disappears.

Development of the Teeth (Figs. 1009 to 1012).—In describing the development of the teeth, the mode of formation of the deciduous teeth must first be considered, and then that of the permanent series.

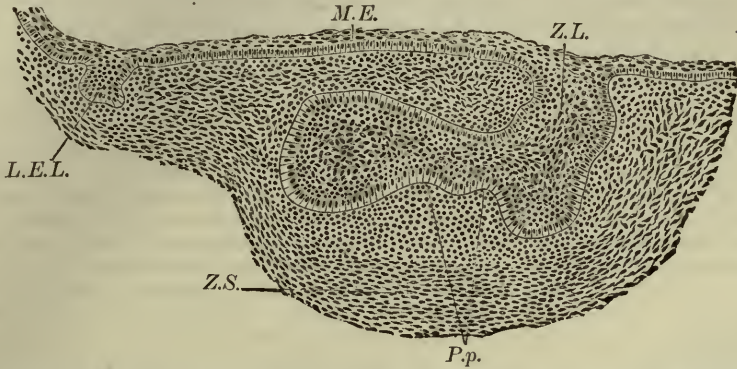


FIG. 1009.—Sagittal section through the first lower deciduous molar of a human embryo 30 mm. long. (Röse.) $\times 100$. *L.E.L.* Labiidental lamina, here separated from the dental lamina. *Z.L.* Placed over the shallow dental furrow, points to the dental lamina, which is spread out below to form the enamel germ. *P.p.* Bicuspidate papilla, capped by the enamel germ. *Z.S.* Condensed tissue forming dental sac. *M.E.* Mouth epithelium

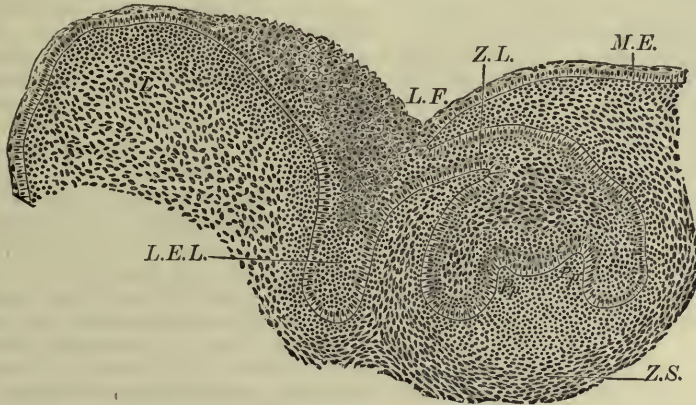


FIG. 1010.—Similar section through the canine tooth of an embryo 40 mm. long. (Röse.) $\times 100$. *L.F.* Labio dental furrow. The other lettering as in Fig. 1009.

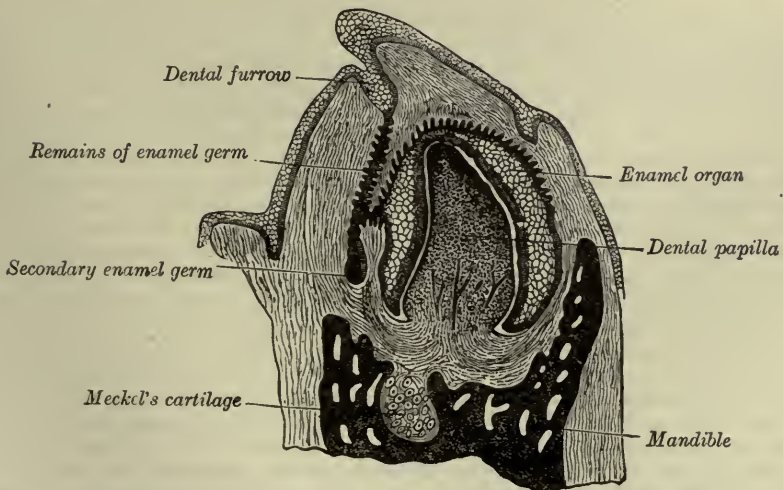


FIG. 1011.—Vertical section of the mandible of an early human fetus. $\times 25$.

Development of the Deciduous Teeth.—The development of the deciduous teeth begins about the sixth week of fetal life as a thickening of the epithelium along the line of the future jaw, the thickening being due to a rapid multiplication of the more deeply situated epithelial cells. As the cells multiply they extend into the subjacent mesoderm, and thus form a ridge or strand of cells imbedded in mesoderm. About the seventh week a longitudinal splitting or cleavage of this strand of cells takes place, and it becomes divided into two strands; the separation begins in front and extends laterally, the process occupying four or five weeks. Of the two strands thus formed, the **labial** forms the **labiodental lamina**; while the other, the **lingual**, is the ridge of cells in connection with which the teeth, both deciduous and permanent, are developed. Hence it is known as the **dental lamina** or **common dental germ**. It forms a flat band of cells, which grows into the substance of the embryonic jaw, at first horizontally inward, and then, as the teeth develop, vertically, *i. e.*, upward in the upper jaw, and downward in the lower jaw. While still maintaining a horizontal direction it has two edges—an **attached edge**, continuous with the epithelium lining the mouth, and a **free edge**, projecting inward, and imbedded in the mesodermal tissue of the embryonic jaw. Along its line of attachment to the buccal epithelium is a shallow groove, the **dental furrow**.

About the ninth week the dental lamina begins to develop enlargements along its free border. These are ten in number in each jaw, and each corresponds to a future deciduous tooth. They consist of masses of epithelial cells; and the cells of the deeper part—that is, the part farthest from the margin of the jaw—**increase rapidly and spread out in all directions**. Each mass thus comes to assume a club shape, connected with the general epithelial lining of the mouth by a narrow neck, embraced by mesoderm. They are now known as **special dental germs**. After a time the lower expanded portion inclines outward, so as to form an angle with the superficial constricted portion, which is sometimes known as the neck of the special dental germ. About the tenth week the mesodermal tissue beneath these special dental germs becomes differentiated into papillæ; these grow upward, and come in contact with the epithelial cells of the special dental germs, which become folded over them like a hood or cap. There is, then, at this stage a papilla (or papillæ) which has already begun to assume somewhat the shape of the crown of the future tooth, and from which the dentin and pulp of the tooth are formed, surmounted by a dome or cap of epithelial cells from which the enamel is derived.

In the meantime, while these changes have been going on, the dental lamina has been extending backward behind the special dental germ corresponding to the second deciduous molar tooth, and at about the seventeenth week it presents an enlargement, the special dental germ; for the first permanent molar, soon followed by the formation

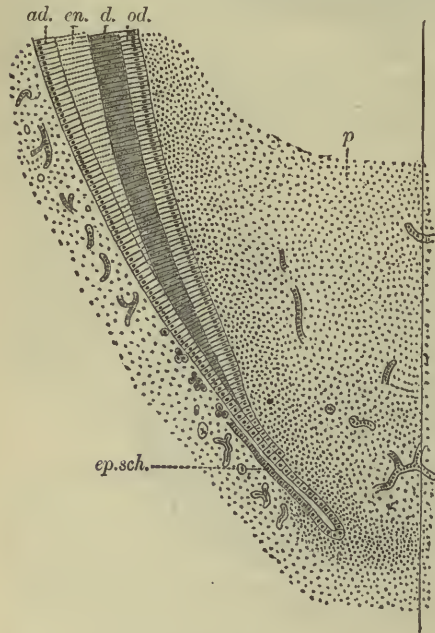


FIG. 1012.—Longitudinal section of the lower part of a growing tooth, showing the extension of the layer of adamantoblasts beyond the crown to mark off the limit of formation of the dentin of the root. (Röse.) *ad.* Adamantoblasts, continuous below with *ep. sch.*, the epithelial sheath of Hertwig. *d.* Dentin. *en.* Enamel. *od.* Odontoblasts. *p.* Pulp.

of a papilla in the mesodermal tissue for the same tooth. This is followed, about the sixth month after birth, by a further extension backward of the dental lamina, with the formation of another enlargement and its corresponding papilla for the second molar. And finally the process is repeated for the third molar, its papilla appearing about the fifth year of life.

After the formation of the special dental germs, the dental lamina undergoes atrophic changes and becomes cribriform, except on the lingual and lateral aspects of each of the special germs of the temporary teeth, where it undergoes a local thickening forming the special dental germ of each of the successional permanent teeth—*i. e.*, the ten anterior ones in each jaw. Here the same process goes on as has been described in connection with those of the deciduous teeth: that is, they recede into the substance of the gum behind the germs of the deciduous teeth. As they recede they become club-shaped, form expansions at their distal extremities, and finally meet papillæ, which have been formed in the mesoderm, just in the same manner as was the case in the deciduous teeth. The apex of each papilla indents the dental germ, which encloses it, and, forming a cap for it, becomes converted into the enamel, while the papilla forms the dentin and pulp of the permanent tooth.

The special dental germs consist at first of rounded or polyhedral epithelial cells; after the

formation of the papillæ, these cells undergo a differentiation into three layers. Those which are in immediate contact with the papilla become elongated, and form a layer of well-marked columnar epithelium coating the papilla. They are the cells which form the enamel fibers, and are therefore termed **enamel cells** or **adamantoblasts**. The cells of the outer layer of the special dental germ, which are in contact with the inner surface of the dental sac, presently to be described, are much shorter, cubical in form, and are named the **external enamel epithelium**. All the intermediate round cells of the dental germ between these two layers undergo a peculiar change. They become stellate in shape and develop processes, which unite to form a net-work into which fluid is secreted; this has the appearance of a jelly, and to it the name of enamel pulp is given. This transformed special dental germ is now known under the name of **enamel organ** (Fig. 1011).

While these changes are going on, a sac is formed around each enamel organ from the surrounding mesodermal tissue. This is known as the **dental sac**, and is a vascular membrane of connective tissue. It grows up from below, and thus encloses the whole tooth germ; as it grows it causes the neck of the enamel organ to atrophy and disappear; so that all communication between the enamel organ and the superficial epithelium is cut off. At this stage there are vascular papillæ surmounted by caps of epithelial cells, the whole being surrounded by by membranous sacs.

Formation of the Enamel.—The enamel is formed exclusively from the enamel cells or adamantoblasts of the special dental germ, either by direct calcification of the columnar cells, which become elongated into the hexagonal rods of the enamel; or, as is more generally believed, as a secretion from the adamantoblasts, within which calcareous matter is subsequently deposited.

The process begins at the apex of each cusp, at the ends of the enamel cells in contact with the dental papilla. Here a fine globular deposit takes place, being apparently shed from the end of the adamantoblasts. It is known by the name of the **enamel droplet**, and resembles keratin in its resistance to the action of mineral acids. This droplet then becomes fibrous and calcifies and forms the first layer of the enamel; a second droplet now appears and calcifies, and so on; successive droplets of keratin-like material are shed from the adamantoblasts and form successive layers of enamel, the adamantoblasts gradually receding as each layer is produced, until at the termination of the process they have almost disappeared. The intermediate cells of the enamel pulp atrophy and disappear, so that the newly formed calcified material and the external enamel epithelium come into apposition. This latter layer, however, soon disappears on the emergence of the tooth beyond the gum. After its disappearance the crown of the tooth is still covered by a distinct membrane, which persists for some time. This is known as the **cuticula dentis**, or **Nasmyth's membrane**, and is believed to be the last-formed layer of enamel derived from the adamantoblasts, which has not become calcified. It forms a horny layer, which may be separated from the subjacent calcified mass by the action of strong acids. It is marked by the hexagonal impressions of the enamel prisms, and, when stained by nitrate of silver, shows the characteristic appearance of epithelium.

Formation of the Dentin.—While these changes are taking place in the epithelium to form the enamel, contemporaneous changes occurring in the differentiated mesoderm of the dental papillæ result in the formation of the dentin. As before stated, the first germs of the dentin are the papillæ, corresponding in number to the teeth, formed from the soft mesodermal tissue which bounds the depressions containing the special enamel germs. The papillæ grow upward into the enamel germs and become covered by them, both being enclosed in a vascular connective tissue, the **dental sac**, in the manner above described. Each papilla then constitutes the formative pulp from which the dentin and permanent pulp are developed; it consists of rounded cells and is very vascular, and soon begins to assume the shape of the future tooth. The next step is the appearance of the **odontoblasts**, which have a relation to the development of the teeth similar to that of the osteoblasts to the formation of bone. They are formed from the cells of the periphery of the papilla—that is to say, from the cells in immediate contact with the adamantoblasts of the special dental germ. These cells become elongated, one end of the elongated cell resting against the epithelium of the special dental germs, the other being tapered and often branched. By the direct transformation of the peripheral ends of these cells, or by a secretion from them, a layer of uncalcified matrix (**prodentin**) is formed which caps the cusp or cusps, if there are more than one, of the papillæ. This matrix becomes fibrillated, and in it islets of calcification make their appearance, and coalescing give rise to a continuous layer of calcified material which covers each cusp and constitutes the first layer of dentin. The odontoblasts, having thus formed the first layer, retire toward the center of the papilla, and, as they do so, produce successive layers of dentin from their peripheral extremities—that is to say, they form the dentinal matrix in which calcification subsequently takes place. As they thus recede from the periphery of the papilla, they leave behind them filamentous processes of cell protoplasm, provided with finer side processes; these are surrounded by calcified material, and thus form the dental canaliculi, and, by their side branches, the anastomosing canaliculi: the processes of protoplasm contained within them constitute the **dentinal fibers** (*Tomes' fibers*). In this way the entire thickness of the dentin is developed, each canaliculus being completed

throughout its whole length by a single odontoblast. The central part of the papilla does not undergo calcification, but persists as the pulp of the tooth. In this process of formation of dentin it has been shown that an uncalcified matrix is first developed, and that in this matrix islets of calcification appear which subsequently blend together to form a cap to each cusp: in like manner successive layers are produced, which ultimately become blended with each other. In certain places this blending is not complete, portions of the matrix remaining uncalcified between the successive layers; this gives rise to little spaces, which are the interglobular spaces alluded to above.

Formation of the Cement.—The root of the tooth begins to be formed shortly before the crown emerges through the gum, but is not completed until some time afterward. It is produced by a downgrowth of the epithelium of the dental germ, which extends almost as far as the situation of the apex of the future root, and determines the form of this portion of the tooth. This fold of epithelium is known as the **epithelial sheath**, and on its papillary surface odontoblasts appear, which in turn form dentin, so that the dentin formation is identical in the crown and root of the tooth. After the dentin of the root has been developed, the vascular tissues of the dental sac begin to break through the epithelial sheath, and spread over the surface of the root as a layer of bone-forming material. In this osteoblasts make their appearance, and the process of ossification goes on in identically the same manner as in the ordinary intramembranous ossification of bone. In this way the cement is formed, and consists of ordinary bone containing canaliculi and lacunæ.

Formation of the Alveoli.—About the fourteenth week of embryonic life the dental lamina becomes enclosed in a trough or groove of mesodermal tissue, which at first is common to all the dental germs, but subsequently becomes divided by bony septa into loculi, each loculus containing the special dental germ of a deciduous tooth and its corresponding permanent tooth. After birth each cavity becomes subdivided, so as to form separate loculi (the future alveoli) for the deciduous tooth and its corresponding permanent tooth. Although at one time the whole of the growing tooth is contained in the cavity of the alveolus, the latter never completely encloses it, since there is always an aperture over the top of the crown filled by soft tissue, by which the dental sac is connected with the surface of the gum, and which in the permanent teeth is called the **gubernaculum dentis**.

Development of the Permanent Teeth.—The permanent teeth as regards their development may be divided into two sets: (1) those which replace the deciduous teeth, and which, like them, are ten in number in each jaw: these are the **successional permanent teeth**; and (2) those which have no deciduous predecessors, but are superadded distal to the temporary dental series. These are three in number on either side in each jaw, and are termed **superadded permanent teeth**. They are the three molars of the permanent set, the molars of the deciduous set being replaced by the premolars of the permanent set. The development of the successional permanent teeth—the ten anterior ones in either jaw—has already been indicated. During their development the permanent teeth, enclosed in their sacs, come to be placed on the lingual side of the deciduous teeth and more distant from the margin of the future gum, and, as already stated, are separated from them by bony partitions. As the crown of the permanent tooth grows, absorption of these bony partitions and of the root of the deciduous tooth takes place, through the agency of **osteoclasts**, which appear at this time, and finally nothing but the crown of the deciduous tooth remains. This is shed or removed, and the permanent tooth takes its place.

The superadded permanent teeth are developed in the manner already described, by extensions backward of the posterior part of the dental lamina in each jaw.

Eruption of the Teeth.—When the calcification of the different tissues of the tooth is sufficiently advanced to enable it to bear the pressure to which it will be afterward subjected, eruption takes place, the tooth making its way through the gum. The gum is absorbed by the pressure of the crown of the tooth against it, which is itself pressed up by the increasing size of the root. At the same time the septa between the dental sacs ossify, and constitute the alveoli; these firmly embrace the necks of the teeth, and afford them a solid basis of support.

The eruption of the deciduous teeth commences about the seventh month after birth, and is completed about the end of the second year, the teeth of the lower jaw preceding those of the upper.

The following, according to C. S. Tomes, are the most usual times of eruption:

Lower central incisors	6 to 9 months.
Upper incisors	8 to 10 months.
Lower lateral incisors and first molars	15 to 21 months.
Canines	16 to 20 months.
Second molars	20 to 24 months.

There are, however, considerable variations in these times; thus, according to Holt:

At the age of 1 year	a child should have	6 teeth.
“ “ 1½ years	“ “	12 “
“ “ 2 “	“ “	16 “
“ “ 2½ “	“ “	20 “

Calcification of the permanent teeth proceeds in the following order in the lower jaw (in the upper jaw it takes place a little later): the first molar, soon after birth; the central and lateral incisors, and the canine, about six months after birth; the premolars, at the second year, or a little later; the second molar, about the end of the second year; the third molar, about the twelfth year.

The eruption of the permanent teeth takes place at the following periods, the teeth of the lower jaw preceding those of the upper by short intervals:

First molars	6th year.
Two central incisors	7th year.
Two lateral incisors	8th year.
First premolars	9th year.
Second premolars	10th year.
Canines	11th to 12th year.
Second molars	12th to 13th year.
Third molars	17th to 25th year.

Toward the sixth year, before the shedding of the deciduous teeth begins, there are twenty-four teeth in each jaw, viz., the ten deciduous teeth and the crowns of all the permanent teeth except the third molars.

The Tongue (*lingua*).—The tongue is the principal organ of the sense of taste, and an important organ of speech; it also assists in the mastication and deglutition of the food. It is situated in the floor of the mouth, within the curve of the body of the mandible.

Its **Root** (*radix linguae; base*) (Fig. 954) is directed backward, and connected with the hyoid bone by the Hyoglossi and Genioglossi muscles and the hyoglossal membrane; with the epiglottis by three folds (*glossoepiglottic*) of mucous membrane; with the soft palate by the glossopalatine arches; and with the pharynx by the *Constrictores pharyngis superiores* and the mucous membrane.

Its **Apex** (*apex linguae; tip*), thin and narrow, is directed forward against the lingual surfaces of the lower incisor teeth.

Its **Inferior Surface** (*facies inferior linguae; under surface*) (Fig. 1013) is connected with the mandible by the Genioglossi; the mucous membrane is reflected from it to the lingual surface of the gum and on to the floor of the mouth, where, in the middle line, it is elevated into a distinct vertical fold, the **frenulum linguae**. On either side lateral to the frenulum is a slight fold of the mucous membrane, the **plica fimbriata**, the free edge of which occasionally exhibits a series of fringe-like processes.

The apex of the tongue, part of the inferior surface, the sides, and dorsum are free.

The **Dorsum of the Tongue** (*dorsum linguae*) (Fig. 1014) is convex and marked by a **median sulcus**, which divides it into symmetrical halves; this sulcus ends behind, about 2.5 cm. from the root of the organ, in a depression, the **foramen cecum**, from which a shallow groove, the **sulcus terminalis**, runs lateralward and forward on either side to the margin of the tongue. The part of the dorsum of the tongue in front of this groove, forming about two-thirds of its surface, looks upward, and is rough and covered with papillae; the posterior third looks backward, and is

smoother, and contains numerous muciparous glands and lymph follicles (**lingual tonsil**). The foramen cecum is the remains of the upper part of the **thyroglossal duct** or diverticulum from which the thyroid gland is developed; the pyramidal lobe of the thyroid gland indicates the position of the lower part of the duct.

The **Papillæ of the Tongue** (Fig. 1014) are projections of the corium. They are thickly distributed over the anterior two-thirds of its dorsum, giving to this surface its characteristic roughness. The varieties of papillæ met with are the **papillæ vallatæ**, **papillæ fungiformes**, **papillæ filiformes**, and **papillæ simplices**.

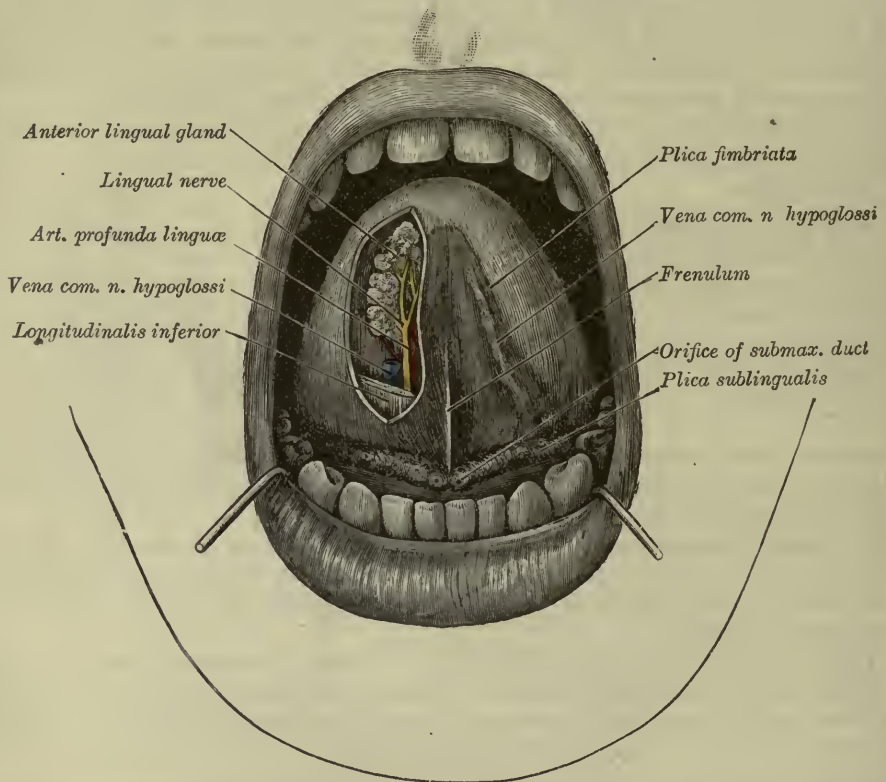


FIG. 1013.—The mouth cavity. The apex of the tongue is turned upward, and on the right side a superficial dissection of its under surface has been made.

The **papillæ vallatæ** (*circumvallate papillæ*) (Fig. 1015) are of large size, and vary from eight to twelve in number. They are situated on the dorsum of the tongue immediately in front of the foramen cecum and sulcus terminalis, forming a row on either side; the two rows run backward and medialward, and meet in the middle line, like the limbs of the letter V inverted. Each papilla consists of a projection of mucous membrane from 1 to 2 mm. wide, attached to the bottom of a circular depression of the mucous membrane; the margin of the depression is elevated to form a wall (*vallum*), and between this and the papilla is a circular sulcus termed the fossa. The papilla is shaped like a truncated cone, the smaller end being directed downward and attached to the tongue, the broader part or base projecting a little above the surface of the tongue and being studded with numerous small secondary papillæ and covered by stratified squamous epithelium.

The **papillæ fungiformes** (*fungiform papillæ*) (Fig. 1017), more numerous than the preceding, are found chiefly at the sides and apex, but are scattered irregularly and sparingly over the dorsum. They are easily recognized, among the other

papillæ, by their large size, rounded eminences, and deep red color. They are narrow at their attachment to the tongue, but broad and rounded at their free extremities, and covered with secondary papillæ.

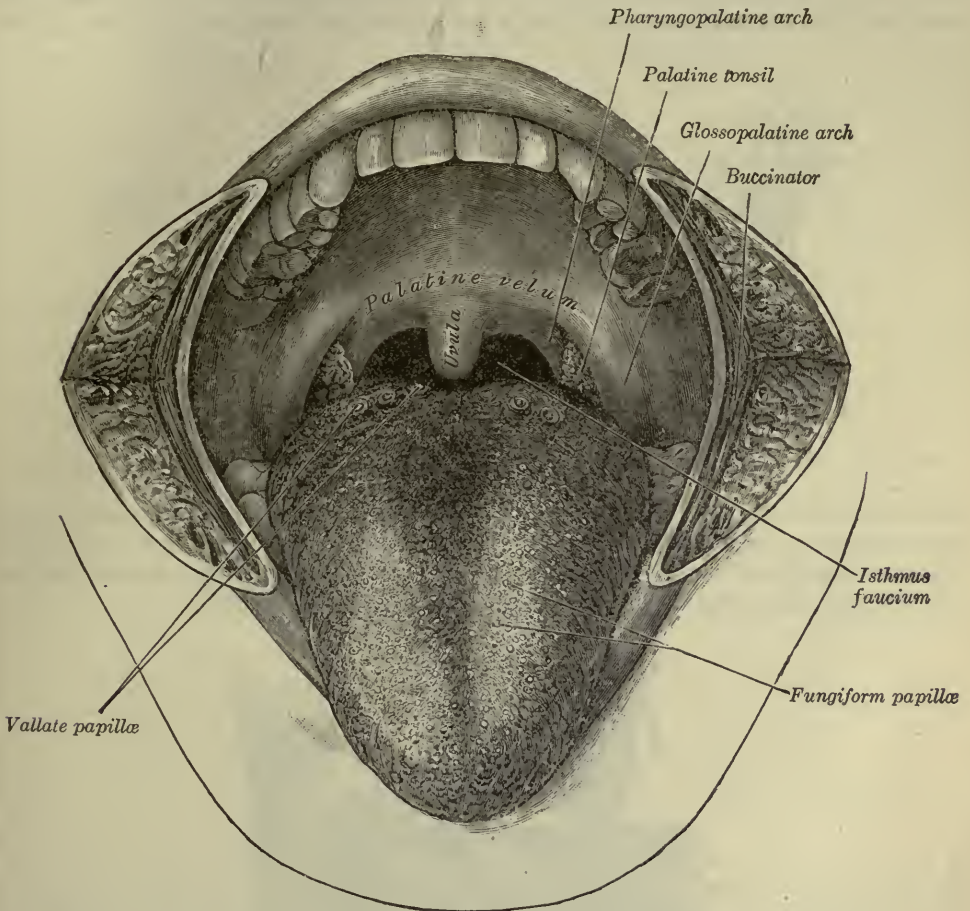


FIG. 1014.—The mouth cavity. The cheeks have been slit transversely and the tongue pulled forward.



FIG. 1015.—Circumvallate papilla in vertical section, showing arrangement of the taste-buds and nerves.

The *papillæ filiformes* (*filiform* or *conical papillæ*) (Fig. 1016) cover the anterior two-thirds of the dorsum. They are very minute, filiform in shape, and arranged

in lines parallel with the two rows of the papillæ vallatæ, excepting at the apex of the organ, where their direction is transverse. Projecting from their apices are numerous filamentous processes, or secondary papillæ; these are of a whitish tint, owing to the thickness and density of the epithelium of which they are composed, which has here undergone a peculiar modification, the cells having be-

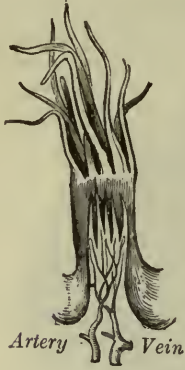

FIG. 1016.—A filiform papilla. Magnified

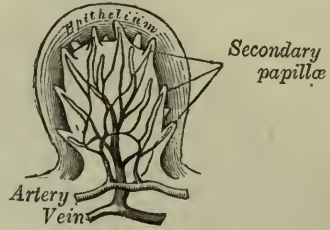


FIG. 1017.—Section of a fungiform papilla. Magnified.

come cornified and elongated into dense, imbricated, brush-like processes. They contain also a number of elastic fibers, which render them firmer and more elastic than the papillæ of mucous membrane generally. The larger and longer papillæ of this group are sometimes termed **papillæ conicæ**.

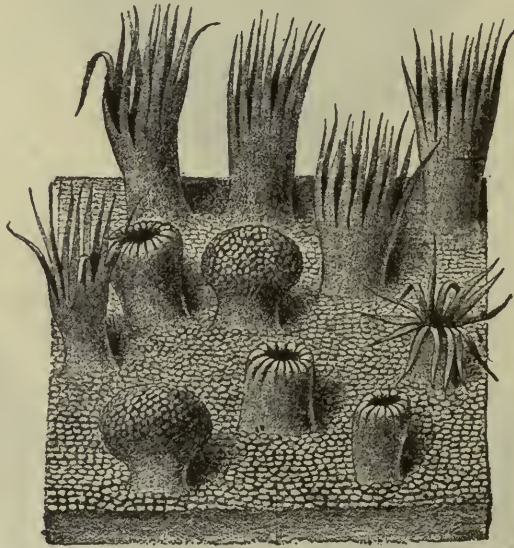


FIG. 1018.—Semidiagrammatic view of a portion of the mucous membrane of the tongue. Two fungiform papillæ are shown. On some of the filiform papillæ the epithelial prolongations stand erect, in one they are spread out, and in three they are folded in.

The **papillæ simplices** are similar to those of the skin, and cover the whole of the mucous membrane of the tongue, as well as the larger papillæ. They consist of closely set microscopic elevations of the corium, each containing a capillary loop, covered by a layer of epithelium.

Muscles of the Tongue.—The tongue is divided into lateral halves by a median fibrous septum which extends throughout its entire length and is fixed below to the

hyoid bone. In either half there are two sets of muscles, extrinsic and intrinsic; the former have their origins outside the tongue, the latter are contained entirely within it.

The extrinsic muscles (Fig. 1019) are:

Genioglossus.
Hyoglossus.

Chondroglossus.
Styloglossus.

Glossopalatinus.¹

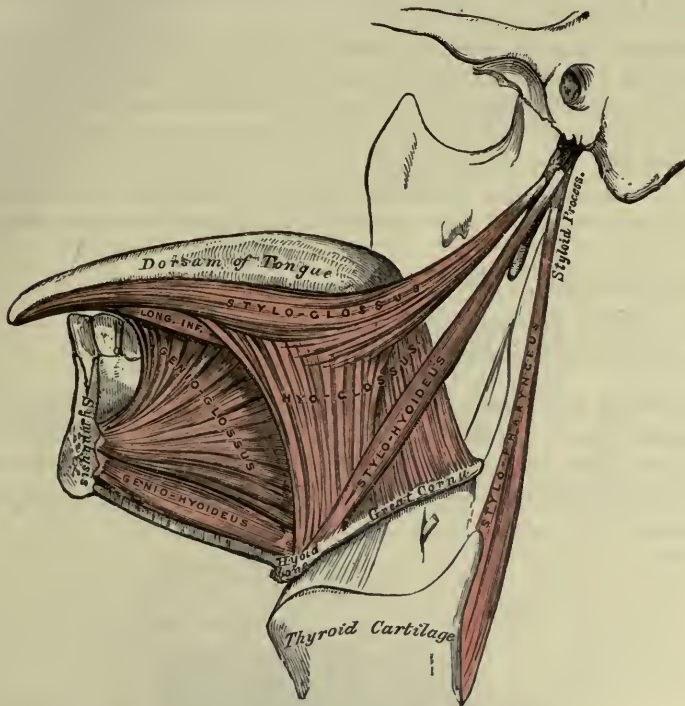


FIG. 1019.—Extrinsic muscles of the tongue. Left side.

The **Genioglossus** (*Geniohyoglossus*) is a flat triangular muscle close to and parallel with the median plane, its apex corresponding with its point of origin from the mandible, its base with its insertion into the tongue and hyoid bone. It *arises* by a short tendon from the superior mental spine on the inner surface of the symphysis menti, immediately above the Geniohyoideus, and from this point spreads out in a fan-like form. The inferior fibers extend downward, to be attached by a thin aponeurosis to the upper part of the body of the hyoid bone, a few passing between the Hyoglossus and Chondroglossus to blend with the Constrictores pharyngis; the middle fibers pass backward, and the superior ones upward and forward, to enter the whole length of the under surface of the tongue, from the root to the apex. The muscles of opposite sides are separated at their insertions by the median fibrous septum of the tongue; in front, they are more or less blended owing to the decussation of fasciculi in the median plane.

The **Hyoglossus**, thin and quadrilateral, *arises* from the side of the body and from the whole length of the greater cornu of the hyoid bone, and passes almost vertically upward to enter the side of the tongue, between the Styloglossus and Longitudinalis inferior. The fibers arising from the body of the hyoid bone overlap those from the greater cornu.

¹ The *Glossopalatinus* (*Palatoglossus*), although one of the muscles of the tongue, is more closely associated with the soft palate both in situation and function; it has consequently been described with the muscles of that structure (p. 1139).

The **Chondroglossus** is sometimes described as a part of the Hyoglossus, but is separated from it by fibers of the Genioglossus, which pass to the side of the pharynx. It is about 2 cm. long, and *arises* from the medial side and base of the lesser cornu and contiguous portion of the body of the hyoid bone, and passes directly upward to blend with the intrinsic muscular fibers of the tongue, between the Hyoglossus and Genioglossus.

A small slip of muscular fibers is occasionally found, arising from the cartilago triticea in the lateral hyothyroid ligament and entering the tongue with the hindermost fibers of the Hyoglossus.

The **Styloglossus**, the shortest and smallest of the three styloid muscles, *arises* from the anterior and lateral surfaces of the styloid process, near its apex, and from the stylomandibular ligament. Passing downward and forward between the internal and external carotid arteries, it divides upon the side of the tongue into two portions: one, longitudinal, enters the side of the tongue near its dorsal surface, blending with the fibers of the Longitudinalis inferior in front of the Hyoglossus; the other, oblique, overlaps the Hyoglossus and decussates with its fibers.

The **intrinsic muscles** (Fig. 1020) are:

Longitudinalis superior.
Longitudinalis inferior.

Transversus.
Verticalis.

The **Longitudinalis linguæ superior** (*Superior lingualis*) is a thin stratum of oblique and longitudinal fibers immediately underlying the mucous membrane on the dorsum of the tongue. It *arises* from the submucous fibrous layer close to the epiglottis and from the median fibrous septum, and runs forward to the edges of the tongue.

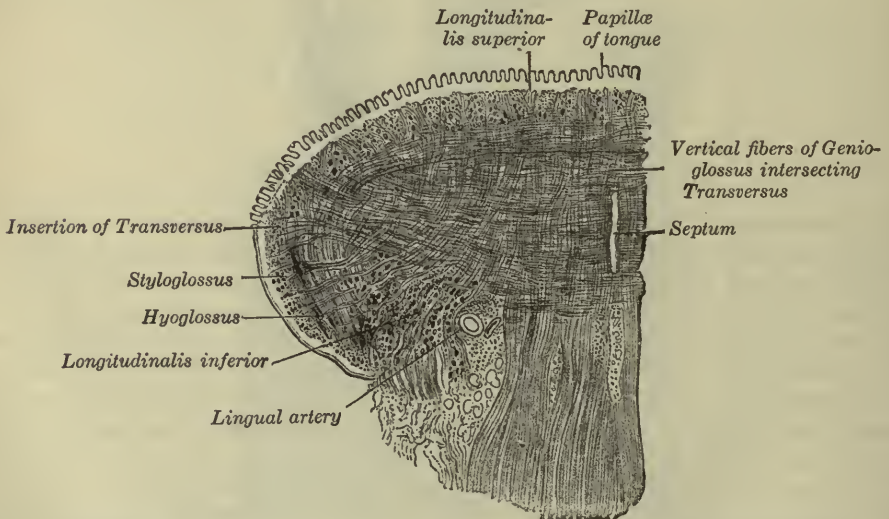


FIG. 1020.—Coronal section of tongue, showing intrinsic muscles. (Altered from Krause.)

The **Longitudinalis linguæ inferior** (*Inferior lingualis*) is a narrow band situated on the under surface of the tongue between the Genioglossus and Hyoglossus. It extends from the root to the apex of the tongue: behind, some of its fibers are connected with the body of the hyoid bone; in front it blends with the fibers of the Styloglossus.

The **Transversus linguæ** (*Transverse lingualis*) consists of fibers which *arise* from the median fibrous septum and pass lateralward to be inserted into the submucous fibrous tissue at the sides of the tongue.

The **Verticalis linguæ** (*Vertical lingualis*) is found only at the borders of the fore-part of the tongue. Its fibers extend from the upper to the under surface of the organ.

The median fibrous septum of the tongue is very complete, so that the anastomosis between the two lingual arteries is not very free.

Nerves.—The muscles of the tongue described above are supplied by the hypoglossal nerve.

Actions.—The movements of the tongue, although numerous and complicated, may be understood by carefully considering the direction of the fibers of its muscles. The Genioglossi, by means of their posterior fibers, draw the root of the tongue forward, and protrude the apex from the mouth. The anterior fibers draw the tongue back into the mouth. The two muscles acting in their entirety draw the tongue downward, so as to make its superior surface concave from side to side, forming a channel along which fluids may pass toward the pharynx, as in sucking. The Hyoglossi depress the tongue, and draw down its sides. The Styloglossi draw the tongue upward and backward. The Glossopalatini draw the root of the tongue upward. The intrinsic muscles are mainly concerned in altering the shape of the tongue, whereby it becomes shortened, narrowed, or curved in different directions; thus, the Longitudinalis superior and inferior tend to shorten the tongue, but the former, in addition, turn the tip and sides upward so as to render the dorsum concave, while the latter pull the tip downward and render the dorsum convex. The Transversus narrows and elongates the tongue, and the Verticalis flattens and broadens it. The complex arrangement of the muscular fibers of the tongue, and the various directions in which they run, give to this organ the power of assuming the forms necessary for the enunciation of the different consonantal sounds; and Macalister states "there is reason to believe that the musculature of the tongue varies in different races owing to the hereditary practice and habitual use of certain motions required for enunciating the several vernacular languages."

Structure of the Tongue.—The tongue is partly invested by mucous membrane and a sub-mucous fibrous layer.

The **mucous membrane** (*tunica mucosa linguæ*) differs in different parts. That covering the under surface of the organ is thin, smooth, and identical in structure with that lining the rest of the oral cavity. The mucous membrane of the dorsum of the tongue behind the foramen cecum and sulcus terminalis is thick and freely movable over the subjacent parts. It contains a large number of lymphoid follicles, which together constitute what is sometimes termed the **lingual tonsil**. Each follicle forms a rounded eminence, the center of which is perforated by a minute orifice leading into a funnel-shaped cavity or recess; around this recess are grouped numerous oval or rounded nodules of lymphoid tissue, each enveloped by a capsule derived from the submucosa, while opening into the bottom of the recesses are also seen the ducts of mucous glands. The mucous membrane on the anterior part of the dorsum of the tongue is thin, intimately adherent to the muscular tissue, and presents numerous minute surface eminences, the **papillæ** of the tongue. It consists of a layer of connective tissue, the **corium** or **mucosa**, covered with epithelium.

The epithelium is of the stratified squamous variety, similar to but much thinner than that of the skin: and each papilla has a separate investment from root to summit. The deepest cells may sometimes be detached as a separate layer, corresponding to the rete mucosum, but they never contain coloring matter.

The **corium** consists of a dense felt-work of fibrous connective tissue, with numerous elastic fibers, firmly connected with the fibrous tissue forming the septa between the muscular bundles of the tongue. It contains the ramifications of the numerous vessels and nerves from which the papillæ are supplied, large plexuses of lymphatic vessels, and the glands of the tongue.

Structure of the Papillæ.—The papillæ apparently resemble in structure those of the cutis, consisting of cone-shaped projections of connective tissue, covered with a thick layer of stratified squamous epithelium, and containing one or more capillary loops among which nerves are distributed in great abundance. If the epithelium be removed, it will be found that they are not simple elevations like the papillæ of the skin, for the surface of each is studded with minute conical processes which form secondary papillæ. In the papillæ vallatæ, the nerves are numerous and of large size; in the papillæ fungiformes they are also numerous, and end in a plexiform net-work, from which brush-like branches proceed; in the papillæ filiformes, their mode of termination is uncertain.

Glands of the Tongue.—The tongue is provided with mucous and serous glands.

The **mucous glands** are similar in structure to the labial and buccal glands. They are found especially at the back part behind the vallate papillæ, but are also present at the apex and marginal parts. In this connection the anterior lingual glands (Blandin or Nuhn) require special notice. They are situated on the under surface of the apex of the tongue (Fig. 1013), one on either side of the frenulum, where they are covered by a fasciculus of muscular fibers derived from the Styloglossus and Longitudinalis inferior. They are from 12 to 25 mm. long, and about 8 mm. broad, and each opens by three or four ducts on the under surface of the apex.

The **serous glands** occur only at the back of the tongue in the neighborhood of the taste-buds,

their ducts opening for the most part into the fossæ of the vallate papillæ. These glands are racemose, the duct of each branching into several minute ducts, which end in alveoli, lined by a single layer of more or less columnar epithelium. Their secretion is of a watery nature, and probably assists in the distribution of the substance to be tasted over the taste area. (Ebner.)

The **septum** consists of a vertical layer of fibrous tissue, extending throughout the entire length of the median plane of the tongue, though not quite reaching the dorsum. It is thicker behind than in front, and occasionally contains a small fibrocartilage, about 6 mm. in length. It is well displayed by making a vertical section across the organ.

The **hyoglossal membrane** is a strong fibrous lamina, which connects the under surface of the root of the tongue to the body of the hyoid bone. This membrane receives, in front, some of the fibers of the Genioglossi.

Taste-buds, the end-organs of the gustatory sense, are scattered over the mucous membrane of the mouth and tongue at irregular intervals. They occur especially in the sides of the vallate papillæ. In the rabbit there is a localized area at the side of the base of the tongue, the **papilla foliata**, in which they are especially abundant (Fig. 1021). They are described under the organs of the senses (page 991).

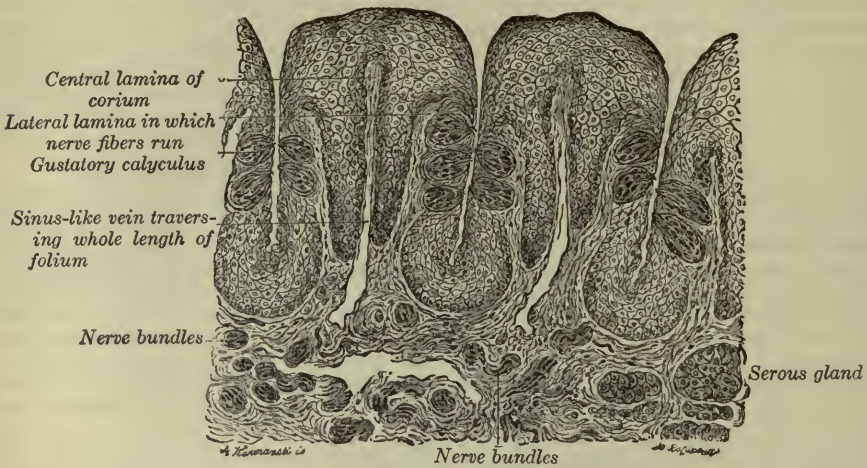


FIG. 1021.—Vertical section of papilla foliata of the rabbit, passing across the folia. (Ranvier.)

Vessels and Nerves.—The main artery of the tongue is the lingual branch of the external carotid, but the external maxillary and ascending pharyngeal also give branches to it. The veins open into the internal jugular.

The lymphatics of the tongue have been described on page 696.

The sensory nerves of the tongue are: (1) the lingual branch of the mandibular, which is distributed to the papillæ at the forepart and sides of the tongue, and forms the nerve of ordinary sensibility for its anterior two-thirds; (2) the chorda tympani branch of the facial, which runs in the sheath of the lingual, and is generally regarded as the nerve of taste for the anterior two-thirds; this nerve is a continuation of the sensory root of the facial (*nervus intermedius*); (3) the lingual branch of the glossopharyngeal, which is distributed to the mucous membrane at the base and sides of the tongue, and to the papillæ vallatæ, and which supplies both gustatory filaments and fibers of general sensation to this region; (4) the superior laryngeal, which sends some fine branches to the root near the epiglottis.

The Salivary Glands (Fig. 1024).—Three large pairs of salivary glands communicate with the mouth, and pour their secretion into its cavity; they are the parotid, submaxillary, and sublingual.

Parotid Gland (*glandula parotis*).—The parotid gland (Figs. 1022, 1023), the largest of the three, varies in weight from 14 to 28 gm. It lies upon the side of the face, immediately below and in front of the external ear. The main portion of the gland is superficial, somewhat flattened and quadrilateral in form, and is placed between the ramus of the mandible in front and the mastoid process and Sternocleidomastoideus behind, overlapping, however, both boundaries. Above, it is broad and reaches nearly to the zygomatic arch; below, it tapers somewhat to about

the level of a line joining the tip of the mastoid process to the angle of the mandible. The remainder of the gland is irregularly wedge-shaped, and extends deeply inward toward the pharyngeal wall.

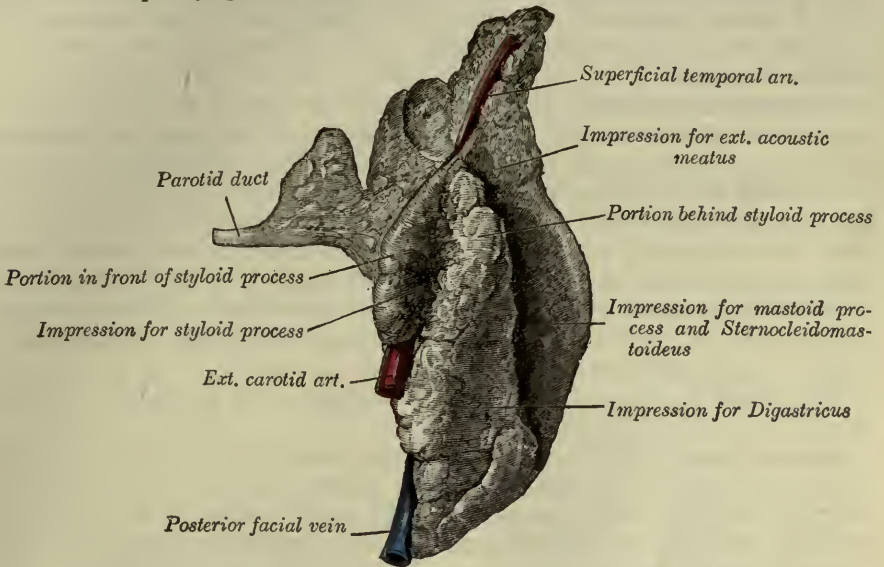


FIG. 1022.—Right parotid gland. Posterior and deep aspects.

The gland is enclosed within a capsule continuous with the deep cervical fascia; the layer covering the superficial surface is dense and closely adherent to the gland; a portion of the fascia, attached to the styloid process and the angle of the mandible, is thickened to form the stylomandibular ligament which intervenes between the parotid and submaxillary glands.

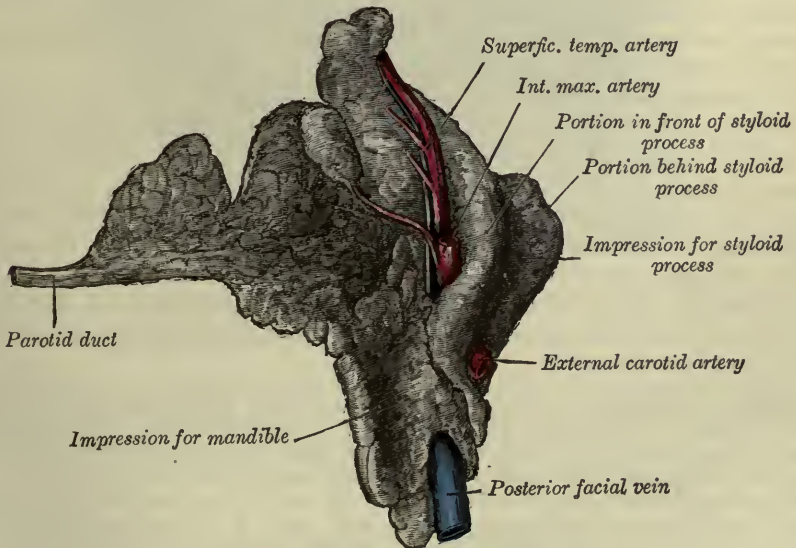


FIG. 1023.—Right parotid gland. Deep and anterior aspects.

The **anterior surface** of the gland is moulded on the posterior border of the ramus of the mandible, clothed by the Pterygoideus internus and Masseter. The inner lip of the groove dips, for a short distance, between the two Pterygoid muscles,

while the outer lip extends for some distance over the superficial surface of the Masseter; a small portion of this lip immediately below the zygomatic arch is usually detached, and is named the **accessory part** (*socia parotidis*) of the gland.

The **posterior surface** is grooved longitudinally and abuts against the external acoustic meatus, the mastoid process, and the anterior border of the Sternocleidomastoideus.

The **superficial surface**, slightly lobulated, is covered by the integument, the superficial fascia containing the facial branches of the great auricular nerve and some small lymph glands, and the fascia which forms the capsule of the gland.

The **deep surface** extends inward by means of two processes, one of which lies on the Digastricus, styloid process, and the styloid group of muscles, and projects under the mastoid process and Sternocleidomastoideus; the other is situated in front of the styloid process, and sometimes passes into the posterior part of the mandibular fossa behind the temporomandibular joint. The deep surface is in contact with the internal and external carotid arteries, the internal jugular vein, and the vagus and glossopharyngeal nerves.

The gland is separated from the pharyngeal wall by some loose connective tissue.

Structures within the Gland.—The *external carotid artery* lies at first on the deep surface, and then in the substance of the gland. The artery gives off its *posterior auricular* branch which emerges from the gland behind; it then divides into its terminal branches, the *internal maxillary* and *superficial temporal*; the former runs forward deep to the neck of the mandible; the latter runs upward across the zygomatic arch and gives off its *transverse facial* branch which emerges from the front of the gland. Superficial to the arteries are the *superficial temporal* and *internal maxillary veins*, uniting to form the *posterior facial vein*; in the lower part of the gland this vein splits into anterior and posterior divisions. The anterior division emerges from the gland and unites with the anterior facial to form the *common facial vein*; the posterior unites in the gland with the posterior auricular to form the *external jugular vein*. On a still more superficial plane is the facial nerve, the branches of which emerge from the borders of the gland. Branches of the *great auricular nerve* pierce the gland to join the facial, while the *auriculotemporal nerve* issues from the upper part of the gland.

The **parotid duct** (*ductus parotideus*; *Stensen's duct*) is about 7 cm. long. It begins by numerous branches from the anterior part of the gland, crosses the Masseter, and at the anterior border of this muscle turns inward nearly at a right angle, passes through the corpus adiposum of the cheek and pierces the Buccinator; it then runs for a short distance obliquely forward between the Buccinator and mucous membrane of the mouth, and opens upon the oral surface of the cheek by a small orifice, opposite the second upper molar tooth. While crossing the Masseter, it receives the duct of the accessory portion; in this position it lies between the branches of the facial nerve; the accessory part of the gland and the transverse facial artery are above it.

Structure.—The parotid duct is dense, its wall being of considerable thickness; its canal is about the size of a crow-quill, but at its orifice on the oral surface of the cheek its lumen is greatly reduced in size. It consists of a thick external fibrous coat which contains contractile fibers, and of an internal or mucous coat lined with short columnar epithelium.

Vessels and Nerves.—The **arteries** supplying the parotid gland are derived from the external carotid, and from the branches given off by that vessel in or near its substance. The **veins** empty themselves into the external jugular, through some of its tributaries. The **lymphatics** end in the superficial and deep cervical lymph glands, passing in their course through two or three glands, placed on the surface and in the substance of the parotid. The **nerves** are derived from the plexus of the sympathetic on the external carotid artery, the facial, the auriculotemporal, and the great auricular nerves. It is probable that the branch from the auriculotemporal nerve is derived from the glossopharyngeal through the otic ganglion. At all events, in some of the lower animals this has been proved experimentally to be the case.

Submaxillary Gland (*glandula submaxillaris*).— The submaxillary gland (Fig. 1024) is irregular in form and about the size of a walnut. A considerable part of it is situated in the submaxillary triangle, reaching forward to the anterior belly of the Digastricus and backward to the stylomandibular ligament, which intervenes between it and the parotid gland. Above, it extends under cover of the body of the mandible; below, it usually overlaps the intermediate tendon of the Digastricus and the insertion of the Stylohyoideus, while from its deep surface a tongue-like *deep process* extends forward above the Mylohyoideus muscle.

Its **superficial surface** consists of an upper and a lower part. The **upper part** is directed outward, and lies partly against the submaxillary depression on the inner surface of the body of the mandible, and partly on the Pterygoideus internus. The **lower part** is directed downward and outward, and is covered by the skin, superficial fascia, Platysma, and deep cervical fascia; it is crossed by the anterior facial vein and by filaments of the facial nerve; in contact with it, near the mandible, are the submaxillary lymph glands.

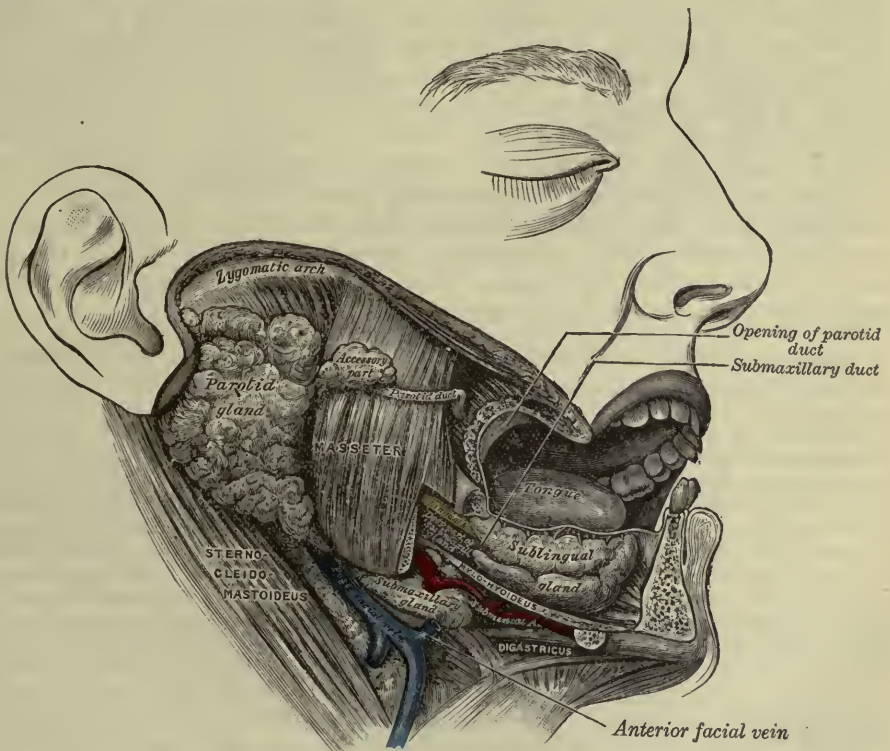


FIG. 1024.—Dissection, showing salivary glands of right side.

The **deep surface** is in relation with the Mylohyoideus, Hyoglossus, Styloglossus, Stylohyoideus, and posterior belly of the Digastricus; in contact with it are the mylohyoid nerve and the mylohyoid and submental vessels.

The external maxillary artery is imbedded in a groove in the posterior border of the gland.

The **deep process** of the gland extends forward between the Mylohyoideus below and externally, and the Hyoglossus and Styloglossus internally; above it is the lingual nerve and submaxillary ganglion; below it the hypoglossal nerve and its accompanying vein.

The **submaxillary duct** (*ductus submaxillaris*; *Wharton's duct*) is about 5 cm. long, and its wall is much thinner than that of the parotid duct. It begins by numerous

branches from the deep surface of the gland, and runs forward between the Mylohyoideus and the Hyoglossus and Genioglossus, then between the sublingual gland and the Genioglossus, and opens by a narrow orifice on the summit of a small papilla, at the side of the frenulum linguæ. On the Hyoglossus it lies between the lingual and hypoglossal nerves, but at the anterior border of the muscle it is crossed laterally by the lingual nerve; the terminal branches of the lingual nerve ascend on its medial side.

Vessels and Nerves.—The arteries supplying the submaxillary gland are branches of the external maxillary and lingual. Its veins follow the course of the arteries. The nerves are derived from the submaxillary ganglion, through which it receives filaments from the chorda tympani of the facial nerve and the lingual branch of the mandibular, sometimes from the mylohyoid branch of the inferior alveolar, and from the sympathetic.

Sublingual Gland (*glandula sublingualis*).—The sublingual gland (Fig. 1024) is the smallest of the three glands. It is situated beneath the mucous membrane of the floor of the mouth, at the side of the frenulum linguæ, in contact with the sublingual depression on the inner surface of the mandible, close to the symphysis. It is narrow, flattened, shaped somewhat like an almond, and weighs nearly 2 gm. It is in relation, *above*, with the mucous membrane; *below*, with the Mylohyoideus; *behind*, with the deep part of the submaxillary gland; *laterally*, with the mandible; and *medially*, with the Genioglossus, from which it is separated by the lingual nerve and the submaxillary duct. Its excretory ducts are from eight to twenty in number. Of the **smaller sublingual ducts** (*ducts of Rivinus*), some join the submaxillary duct; others open separately into the mouth, on the elevated crest of mucous membrane (*plica sublingualis*), caused by the projection of the gland, on either side of the frenulum linguæ. One or more join to form the **larger sublingual duct** (*duct of Bartholin*), which opens into the submaxillary duct.

Vessels and Nerves.—The sublingual gland is supplied with blood from the sublingual and submental arteries. Its nerves are derived from the lingual, the chorda tympani, and the sympathetic.

Structure of the Salivary Glands.—The salivary glands are compound racemose glands, consisting of numerous lobes, which are made up of smaller lobules, connected together by dense areolar tissue, vessels, and ducts. Each lobule consists of the ramifications of a single duct, the branches ending in dilated ends or alveoli on which the capillaries are distributed. The alveoli are enclosed by a basement membrane, which is continuous with the membrana propria of the duct and consists of a net-work of branched and flattened nucleated cells.

The alveoli of the salivary glands are of two kinds, which differ in the appearance of their secreting cells, in their size, and in the nature of their secretion. (1) The mucous variety secretes a viscid fluid, which contains mucin; (2) the serous variety secretes a thinner and more watery fluid. The sublingual gland consists of mucous, the parotid of serous alveoli. The submaxillary contains both mucous and serous alveoli, the latter, however, preponderating.

The cells in the **mucous alveoli** are columnar in shape. In the fresh condition they contain large granules of mucinogen. In hardened preparations a delicate protoplasmic net-work is seen, and the cells are clear and transparent. The nucleus is usually situated near the basement membrane, and is flattened.

In some alveoli are seen peculiar crescentic bodies, lying between the cells and the membrana propria. They are termed the **crescents of Gianuzzi**, or the **demilunes of Heidenhain** (Fig. 1025), and are composed of polyhedral granular cells, which Heidenhain regards as young epithelial cells destined to supply the place of those salivary cells which have undergone disintegration. This view, however, is not accepted by Klein. Fine canaliculi pass between the mucus-secreting cells to reach the demilunes and even penetrate the cells forming these structures.

In the **serous alveoli** the cells almost completely fill the cavity, so that there is hardly any lumen perceptible; they contain secretory granules imbedded in a closely reticulated protoplasm (Fig. 1026). The cells are more cubical than those of the mucous type; the nucleus of each is spherical and placed near the center of the cell, and the granules are smaller.

Both mucous and serous cells vary in appearance according to whether the gland is in a resting condition or has been recently active. In the former case the cells are large and contain many secretory granules; in the latter case they are shrunken and contain few granules, chiefly collected at the inner ends of the cells. The granules are best seen in fresh preparations.

The ducts are lined at their origins by epithelium which differs little from the pavement form. As the ducts enlarge, the epithelial cells change to the columnar type, and the part of the cell next the basement membrane is finely striated.

The lobules of the salivary glands are richly supplied with bloodvessels which form a dense net-work in the interalveolar spaces. Fine plexuses of nerves are also found in the interlobular tissue. The nerve fibrils pierce the basement membrane of the alveoli, and end in branched varicose filaments between the secreting cells. In the hilus of the submaxillary gland there is a collection of nerve cells termed **Langley's ganglion**.

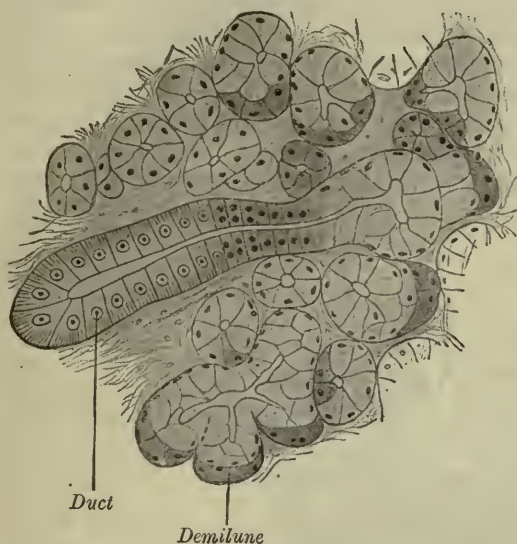

FIG. 1025.—Section of submaxillary gland of kitten. Duct semidiagrammatic. $\times 200$.

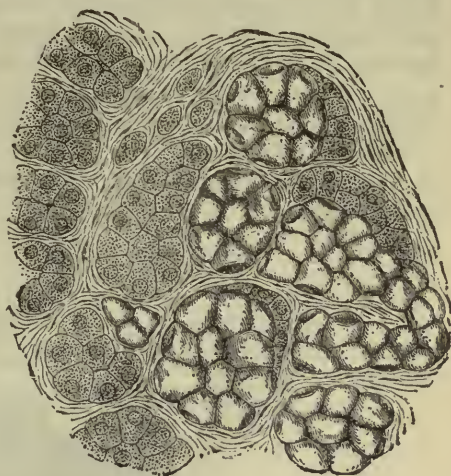


FIG. 1026.—Human submaxillary gland. (R. Heidenhain.) At the right is a group of mucous alveoli, at the left a group of serous alveoli.

Accessory Glands.—Besides the salivary glands proper, numerous other glands are found in the mouth. Many of these glands are found at the posterior part of the dorsum of the tongue behind the vallate papillæ, and also along its margins as far forward as the apex. Others lie around and in the palatine tonsil between its crypts, and large numbers are present in the soft palate, the lips, and cheeks. These glands are of the same structure as the larger salivary glands, and are of the mucous or mixed type.

THE FAUCES.

The aperture by which the mouth communicates with the pharynx is called the **isthmus faucium**. It is bounded, above, by the soft palate; below, by the dorsum of the tongue; and on either side, by the glossopalatine arch.

The **glossopalatine arch** (*arcus glossopalatinus*; *anterior pillar of fauces*) on either side runs downward, lateralward, and forward to the side of the base of the tongue, and is formed by the projection of the Glossopalatinus with its covering mucous membrane.

The **pharyngopalatine arch** (*arcus pharyngopalatinus*; *posterior pillar of fauces*) is larger and projects farther toward the middle line than the anterior; it runs downward, lateralward, and backward to the side of the pharynx, and is formed by the projection of the Pharyngopalatinus, covered by mucous membrane. On either side the two arches are separated below by a triangular interval, in which the palatine tonsil is lodged.

The **Palatine Tonsils** (*tonsillæ palatinæ*; *tonsil*) are two prominent masses situated one on either side between the glossopalatine and pharyngopalatine arches. Each tonsil consists fundamentally of an aggregation of lymphoid tissue underlying the mucous membrane between the palatine arches. The lymphoid mass, however,

does not completely fill the interval between the two arches, so that a small depression, the **supratonsillar fossa**, exists at the upper part of the interval. Further, the tonsil extends for a variable distance under cover of the glossopalatine arch, and is here covered by a reduplication of mucous membrane; the upper part of this fold reaches across the supratonsillar fossa, between the two arches, as a thin fold sometimes termed the **plica semilunaris**; the remainder of the fold is called the **plica triangularis**. Between the plica triangularis and the surface of the tonsil is a space known as the **tonsillar sinus**; in many cases, however, this sinus is obliterated by its walls becoming adherent. From this description it will be apparent that a portion of the tonsil is below the level of the surrounding mucous membrane, *i. e.*, is imbedded, while the remainder projects as the visible tonsil. In the child the tonsils are relatively (and frequently absolutely) larger than in the adult, and about one-third of the tonsil is imbedded. After puberty the imbedded portion diminishes considerably in size and the tonsil assumes a disk-like form, flattened from side to side; the shape and size of the tonsil, however, vary considerably in different individuals.

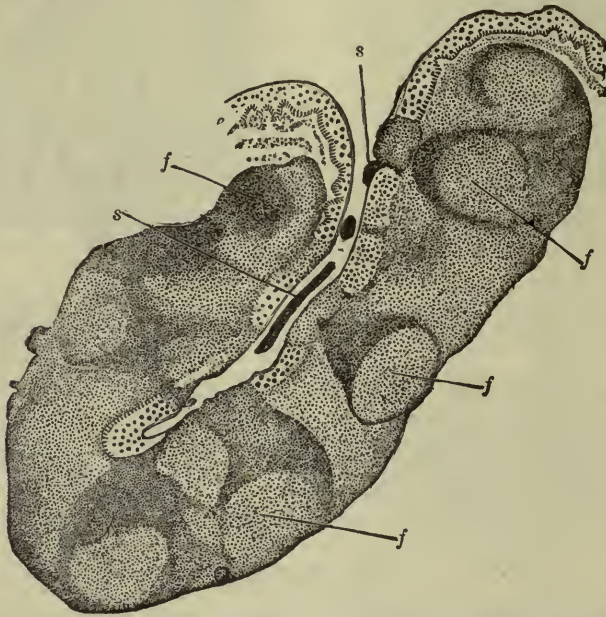


FIG. 1027.—Section through one of the crypts of the tonsil. (Stöhr.) Magnified. *e*. Stratified epithelium of general surface, continued into crypt. *f, f*. Nodules of lymphoid tissue—opposite each nodule numbers of lymph cells are passing into or through the epithelium. *s, s*. Cells which have thus escaped to mix with the saliva as salivary corpuscles.

The **medial surface** of the tonsil is free except anteriorly, where it is covered by the plica triangularis; it presents from twelve to fifteen orifices leading into small crypts or recesses from which numerous follicles branch out into the tonsillar substance.

The **lateral or deep surface** is adherent to a fibrous capsule which is continued into the plica triangularis. It is separated from the inner surface of the Constrictor pharyngis superior usually by some loose connective tissue; this muscle intervenes between the tonsil and the external maxillary artery with its tonsillar and ascending palatine branches. The internal carotid artery lies behind and lateral to the tonsil at a distance of 20 to 25 mm. from it.

The tonsils form part of a circular band of adenoid tissue which guards the opening into the digestive and respiratory tubes. The anterior part of the ring is formed by the submucous adenoid collections (**lingual tonsil**) on the posterior part of the tongue; the lateral portions consist of the palatine tonsils and the ade-

of the epiglottis—a movement produced by the contraction of the Thyreoarytænoidei, the Arytænoidei, and the Arytænoepiglottidei.

After leaving the tongue the bolus passes on to the posterior or laryngeal surface of the epiglottis, and glides along this for a certain distance; then the Glossopalatini, the constrictors of the fauces, contract behind it; the palatine velum is slightly raised by the Levator veli palatini, and made tense by the Tensor veli palatini; and the Pharyngopalatini, by their contraction, pull the pharynx upward over the bolus, and come nearly together, the uvula filling up the slight interval between them. By these means the food is prevented from passing into the nasal part of the pharynx; at the same time, the Pharyngopalatini form an inclined plane, directed obliquely downward and backward along the under surface of which the bolus descends into the lower part of the pharynx. The Salpingopharyngei raise the upper and lateral parts of the pharynx—*i. e.*, those parts which are above the points where the Stylopharyngei are attached to the pharynx.

Mucous Membrane.—The *mucous membrane of the soft palate* is thin, and covered with stratified squamous epithelium on both surfaces, excepting near the pharyngeal ostium of the auditory tube, where it is columnar and ciliated. According to Klein, the mucous membrane on the nasal surface of the soft palate in the fetus is covered throughout by columnar ciliated epithelium, which subsequently becomes squamous; some anatomists state that it is covered with columnar ciliated epithelium, except at its free margin, throughout life. Beneath the mucous membrane on the oral surface of the soft palate is a considerable amount of adenoid tissue. The palatine glands form a continuous layer on its posterior surface and around the uvula:

Vessels and Nerves.—The *arteries* supplying the palate are the descending palatine branch of the internal maxillary, the ascending palatine branch of the external maxillary, and the palatine branch of the ascending pharyngeal. The *veins* end chiefly in the pterygoid and tonsillar plexuses. The *lymphatic vessels* pass to the deep cervical glands. The *sensory nerves* are derived from the palatine and nasopalatine nerves and from the glossopharyngeal.

THE PHARYNX.

The **pharynx** is that part of the digestive tube which is placed behind the nasal cavities, mouth, and larynx. It is a musculomembranous tube, somewhat conical in form, with the base upward, and the apex downward, extending from the under surface of the skull to the level of the cricoid cartilage in front, and that of the sixth cervical vertebra behind.

The cavity of the pharynx is about 12.5 cm. long, and broader in the transverse than in the antero-posterior diameter. Its greatest breadth is immediately below the base of the skull, where it projects on either side, behind the pharyngeal ostium of the auditory tube, as the **pharyngeal recess** (*fossa of Rosenmüller*); its narrowest point is at its termination in the esophagus. It is limited, *above*, by the body of the sphenoid and basilar part of the occipital bone; *below*, it is continuous with the esophagus; *posteriorly*, it is connected by loose areolar tissue with the cervical portion of the vertebral column, and the prevertebral fascia covering the Longus colli and Longus capitis muscles; *anteriorly*, it is incomplete, and is attached in succession to the medial pterygoid plate, pterygomandibular raphé, mandible, tongue, hyoid bone, and thyroid and cricoid cartilages; *laterally*, it is connected to the styloid processes and their muscles, and is in contact with the common and internal carotid arteries, the internal jugular veins, the glossopharyngeal, vagus, and hypoglossal nerves, and the sympathetic trunks, and above with small parts of the Pterygoidei interni. Seven cavities communicate with it, *viz.*, the two nasal cavities, the two tympanic cavities, the mouth, the larynx, and the esophagus. The cavity of the pharynx may be subdivided from above downward into three parts: **nasal, oral, and laryngeal** (Fig. 994).

Nasal Part of the Pharynx (*pars nasalis pharyngis; nasopharynx*) lies behind the soft palate and above the level of the soft palate: it differs from the oral and laryngeal parts of the pharynx in that its cavity always remains patent. In front (Fig. 994) it communicates through the choanæ with the nasal cavities. On its lateral surface the **pharyngeal ostium of the auditory tube**, somewhat triangular in shape, is indented behind by a firm prominence, the **torus** or **cushion**, caused by the elevation of the cartilage of the tube which elevates the mucous membrane.

does not completely fill the interval between the two arches, so that a small depression, the **supratonsillar fossa**, exists at the upper part of the interval. Further, the tonsil extends for a variable distance under cover of the glossopalatine arch, and is here covered by a reduplication of mucous membrane; the upper part of this fold reaches across the supratonsillar fossa, between the two arches, as a thin fold sometimes termed the **plica semilunaris**; the remainder of the fold is called the **plica triangularis**. Between the plica triangularis and the surface of the tonsil is a space known as the **tonsillar sinus**; in many cases, however, this sinus is obliterated by its walls becoming adherent. From this description it will be apparent that a portion of the tonsil is below the level of the surrounding mucous membrane, *i. e.*, is imbedded, while the remainder projects as the visible tonsil. In the child the tonsils are relatively (and frequently absolutely) larger than in the adult, and about one-third of the tonsil is imbedded. After puberty the imbedded portion diminishes considerably in size and the tonsil assumes a disk-like form, flattened from side to side; the shape and size of the tonsil, however, vary considerably in different individuals.

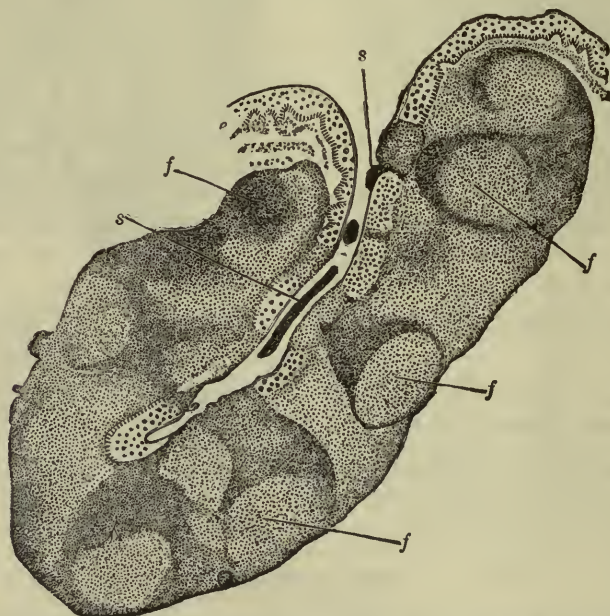


FIG. 1027.—Section through one of the crypts of the tonsil. (Stöhr.) Magnified. *e*. Stratified epithelium of general surface, continued into crypt. *f, f*. Nodules of lymphoid tissue—opposite each nodule numbers of lymph cells are passing into or through the epithelium. *s, s*. Cells which have thus escaped to mix with the saliva as salivary corpuscles.

The **medial surface** of the tonsil is free except anteriorly, where it is covered by the plica triangularis; it presents from twelve to fifteen orifices leading into small crypts or recesses from which numerous follicles branch out into the tonsillar substance.

The **lateral or deep surface** is adherent to a fibrous capsule which is continued into the plica triangularis. It is separated from the inner surface of the Constrictor pharyngis superior usually by some loose connective tissue; this muscle intervenes between the tonsil and the external maxillary artery with its tonsillar and ascending palatine branches. The internal carotid artery lies behind and lateral to the tonsil at a distance of 20 to 25 mm. from it.

The tonsils form part of a circular band of adenoid tissue which guards the fauces opening into the digestive and respiratory tubes. The anterior part of the same entrance is formed by the submucous adenoid collections (**lingual tonsil**) on the pre-cushion part of the tongue; the lateral portions consist of the palatine tonsils and

of the epiglottis—a movement produced by the contraction of the Thyreoarytænoidei, the Arytænoidei, and the Arytænoepiglottidei.

After leaving the tongue the bolus passes on to the posterior or laryngeal surface of the epiglottis, and glides along this for a certain distance; then the Glossopalatini, the constrictors of the fauces, contract behind it; the palatine velum is slightly raised by the Levator veli palatini, and made tense by the Tensor veli palatini; and the Pharyngopalatini, by their contraction, pull the pharynx upward over the bolus, and come nearly together, the uvula filling up the slight interval between them. By these means the food is prevented from passing into the nasal part of the pharynx; at the same time, the Pharyngopalatini form an inclined plane, directed obliquely downward and backward along the under surface of which the bolus descends into the lower part of the pharynx. The Salpingopharyngei raise the upper and lateral parts of the pharynx—*i. e.*, those parts which are above the points where the Stylopharyngei are attached to the pharynx.

Mucous Membrane.—The *mucous membrane of the soft palate* is thin, and covered with stratified squamous epithelium on both surfaces, excepting near the pharyngeal ostium of the auditory tube, where it is columnar and ciliated. According to Klein, the mucous membrane on the nasal surface of the soft palate in the fetus is covered throughout by columnar ciliated epithelium, which subsequently becomes squamous; some anatomists state that it is covered with columnar ciliated epithelium, except at its free margin, throughout life. Beneath the mucous membrane on the oral surface of the soft palate is a considerable amount of adenoid tissue. The palatine glands form a continuous layer on its posterior surface and around the uvula:

Vessels and Nerves.—The *arteries* supplying the palate are the descending palatine branch of the internal maxillary, the ascending palatine branch of the external maxillary, and the palatine branch of the ascending pharyngeal. The *veins* end chiefly in the pterygoid and tonsillar plexuses. The *lymphatic vessels* pass to the deep cervical glands. The *sensory nerves* are derived from the palatine and nasopalatine nerves and from the glossopharyngeal.

THE PHARYNX.

The **pharynx** is that part of the digestive tube which is placed behind the nasal cavities, mouth, and larynx. It is a musculomembranous tube, somewhat conical in form, with the base upward, and the apex downward, extending from the under surface of the skull to the level of the cricoid cartilage in front, and that of the sixth cervical vertebra behind.

The cavity of the pharynx is about 12.5 cm. long, and broader in the transverse than in the antero-posterior diameter. Its greatest breadth is immediately below the base of the skull, where it projects on either side, behind the pharyngeal ostium of the auditory tube, as the **pharyngeal recess** (*fossa of Rosenmüller*); its narrowest point is at its termination in the esophagus. It is limited, *above*, by the body of the sphenoid and basilar part of the occipital bone; *below*, it is continuous with the esophagus; *posteriorly*, it is connected by loose areolar tissue with the cervical portion of the vertebral column, and the prevertebral fascia covering the Longus colli and Longus capitis muscles; *anteriorly*, it is incomplete, and is attached in succession to the medial pterygoid plate, pterygomandibular raphé, mandible, tongue, hyoid bone, and thyroid and cricoid cartilages; *laterally*, it is connected to the styloid processes and their muscles, and is in contact with the common and internal carotid arteries, the internal jugular veins, the glossopharyngeal, vagus, and hypoglossal nerves, and the sympathetic trunks, and above with small parts of the Pterygoidei interni. Seven cavities communicate with it, *viz.*, the two nasal cavities, the two tympanic cavities, the mouth, the larynx, and the esophagus. The cavity of the pharynx may be subdivided from above downward into three parts: nasal, oral, and laryngeal (Fig. 994).

The **Nasal Part of the Pharynx** (*pars nasalis pharyngis; nasopharynx*) lies behind the nose and above the level of the soft palate: it differs from the oral and laryngeal parts of the pharynx in that its cavity always remains patent. In front (Fig. 1029) it communicates through the choanæ with the nasal cavities. On its lateral wall is the **pharyngeal ostium of the auditory tube**, somewhat triangular in shape, and bounded behind by a firm prominence, the **torus** or **cushion**, caused by the medial end of the cartilage of the tube which elevates the mucous membrane.

A vertical fold of mucous membrane, the **salpingopharyngeal fold**, stretches from the lower part of the torus; it contains the Salpingopharyngeus muscle. A second and smaller fold, the **salpingopalatine fold**, stretches from the upper part of the torus to the palate. Behind the ostium of the auditory tube is a deep recess, the **pharyngeal recess** (*fossa of Rosenmüller*). On the posterior wall is a prominence, best marked in childhood, produced by a mass of lymphoid tissue, which is known as the **pharyngeal tonsil**. Above the pharyngeal tonsil, in the middle line, an irregular flask-shaped depression of the mucous membrane sometimes extends up as far as the basilar process of the occipital bone; it is known as the **pharyngeal bursa**.

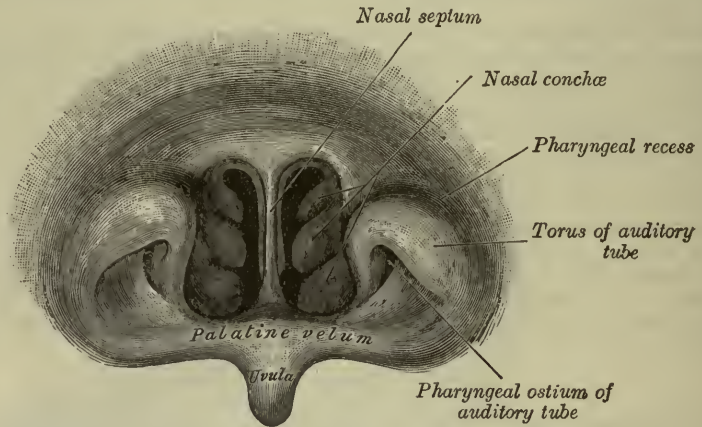


FIG. 1029.—Front of nasal part of pharynx, as seen with the laryngoscope.

The **Oral Part of the Pharynx** (*pars oralis pharyngis*) reaches from the soft palate to the level of the hyoid bone. It opens anteriorly, through the isthmus faucium, into the mouth, while in its lateral wall, between the two palatine arches, is the **palatine tonsil**.

The **Laryngeal Part of the Pharynx** (*pars laryngea pharyngis*) reaches from the hyoid bone to the lower border of the cricoid cartilage, where it is continuous with the esophagus. In front it presents the triangular entrance of the larynx, the base of which is directed forward and is formed by the epiglottis, while its lateral boundaries are constituted by the aryepiglottic folds. On either side of the laryngeal orifice is a recess, termed the **sinus piriformis**, which is bounded medially by the aryepiglottic fold, laterally by the thyroid cartilage and hyothyroid membrane.

Muscles of the Pharynx.—The muscles of the pharynx (Fig. 1030) are:

Constrictor inferior.	Stylopharyngeus.
Constrictor medius.	Salpingopharyngeus.
Constrictor superior.	Pharyngopalatinus. ¹

The **Constrictor pharyngis inferior** (*Inferior constrictor*) (Figs. 1030, 1031), the thickest of the three constrictors, *arises* from the sides of the cricoid and thyroid cartilage. From the cricoid cartilage it arises in the interval between the Cricothyroideus in front, and the articular facet for the inferior cornu of the thyroid cartilage behind. On the thyroid cartilage it arises from the oblique line on the side of the lamina, from the surface behind this nearly as far as the posterior border and from the inferior cornu. From these origins the fibers spread backward and medialward to be *inserted* with the muscle of the opposite side into the fibrous raphé in the posterior median line of the pharynx. The inferior fibers are horizontal and continuous with the circular fibers of the esophagus; the rest ascend, increasing in obliquity, and overlap the Constrictor medius.

¹ The Pharyngopalatinus is described with the muscles of the palate (p. 1139).

orifice of the stomach, opposite the eleventh thoracic vertebra. The general direction of the esophagus is vertical; but it presents two slight curves in its course. At its commencement it is placed in the middle line; but it inclines to the left side as far as the root of the neck, gradually passes to the middle line again at the level of the fifth thoracic vertebra, and finally deviates to the left as it passes forward to the esophageal hiatus in the diaphragm. The esophagus also presents antero-posterior flexures corresponding to the curvatures of the cervical and thoracic portions of the vertebral column. It is the narrowest part of the digestive tube, and is most contracted at its commencement, and at the point where it passes through the diaphragm.

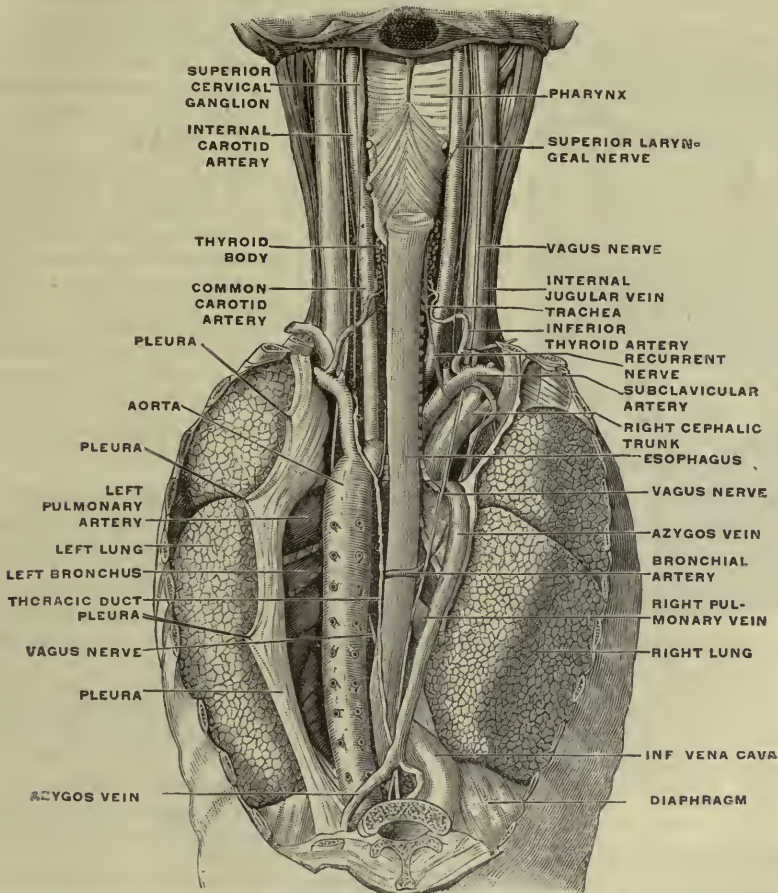


Fig. 1032.—The position and relation of the esophagus in the cervical region and in the posterior mediastinum. Seen from behind. (Poirier and Charpy.)

Relations.—The **cervical portion** of the esophagus is in relation, *in front*, with the trachea; and at the lower part of the neck, where it projects to the left side, with the thyroid gland; *behind*, it rests upon the vertebral column and Longus colli muscles; *on either side* it is in relation with the common carotid artery (especially the left, as it inclines to that side), and parts of the lobes of the thyroid gland; the recurrent nerves ascend between it and the trachea; to its left side is the thoracic duct.

The **thoracic portion** of the esophagus is at first situated in the superior mediastinum between the trachea and the vertebral column, a little to the left of the median line. It then passes behind and to the right of the aortic arch, and descends in the posterior mediastinum along the right side of the descending aorta, then runs in front and a little to the left of the aorta, and enters the abdomen through the diaphragm at the level of the tenth thoracic vertebra. Just before it perforates the diaphragm it presents a distinct dilatation. It is in

relation, *in front*, with the trachea, the left bronchus, the pericardium, and the diaphragm; *behind*, it rests upon the vertebral column, the Longus colli muscles, the right aortic intercostal arteries, the thoracic duct, and the hemiazygos veins; and below, near the diaphragm, upon the front of the aorta. On its *left* side, in the superior mediastinum, are the terminal part of the aortic arch, the left subclavian artery, the thoracic duct, and left pleura, while running upward in the angle between it and the trachea is the left recurrent nerve; below, it is in relation with the descending thoracic aorta. On its *right* side are the right pleura, and the azygos vein which it overlaps. Below the roots of the lungs the vagi descend in close contact with it, the right nerve passing down behind, and the left nerve in front of it; the two nerves uniting to form a plexus around the tube.

In the lower part of the posterior mediastinum the thoracic duct lies to the right side of the esophagus; higher up, it is placed behind it, and, crossing about the level of the fourth thoracic vertebra, is continued upward on its left side.

The **abdominal portion** of the esophagus lies in the esophageal groove on the posterior surface of the left lobe of the liver. It measures about 1.25 cm. in length, and only its front and left aspects are covered by peritoneum. It is somewhat conical with its base applied to the upper orifice of the stomach, and is known as the **antrum cardiacum**.

Structure (Fig. 1033).—The esophagus has four coats: an **external or fibrous**, a **muscular**, a **submucous or areolar**, and an **internal or mucous coat**.

The **muscular coat** (*tunica muscularis*) is composed of two planes of considerable thickness: an external of longitudinal and an internal of circular fibers.

The **longitudinal fibers** are arranged, at the commencement of the tube, in three fasciculi: one in front, which is attached to the vertical ridge on the posterior surface of the lamina of the cricoid cartilage; and one at either side, which is continuous with the muscular fibers of the pharynx: as they descend they blend together, and form a uniform layer, which covers the outer surface of the tube.

Accessory slips of muscular fibers pass between the esophagus and the left pleura, where the latter covers the thoracic aorta, or the root of the left bronchus, or the back of the pericardium.

The **circular fibers** are continuous above with the Constrictor pharyngis inferior; their direction is transverse at the upper and lower parts of the tube, but oblique in the intermediate part.

The muscular fibers in the upper part of the esophagus are of a red color, and consist chiefly of the striped variety; but below they consist for the most part of involuntary fibers.

The **areolar or submucous coat** (*tela submucosa*) connects loosely the mucous and muscular coats. It contains bloodvessels, nerves, and mucous glands.

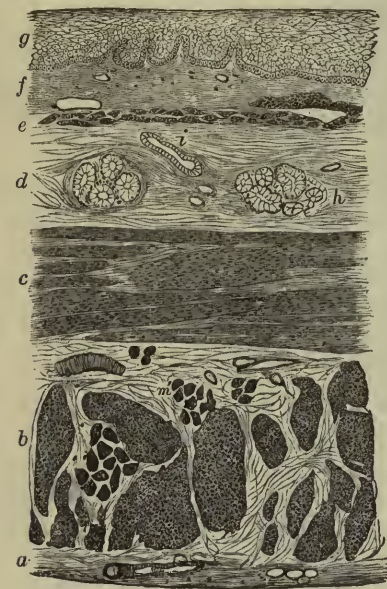


FIG. 1033.—Section of the human esophagus. (From a drawing by V. Horsley.) Moderately magnified. The section is transverse and from near the middle of the gullet. *a*. Fibrous covering. *b*. Divided fibers of longitudinal muscular coat. *c*. Transverse muscular fibers. *d*. Submucous or areolar layer. *e*. Muscularis mucosae. *f*. Mucous membrane, with vessels and part of a lymphoid nodule. *g*. Stratified epithelial lining. *h*. Mucous gland. *i*. Gland duct. *m'*. Striated muscular fibers cut across.

The **mucous coat** (*tunica mucosa*) is thick, of a reddish color above, and pale below. It is disposed in longitudinal folds, which disappear on distension of the tube. Its surface is studded with minute papillae, and it is covered throughout with a thick layer of stratified squamous epithelium. Beneath the mucous membrane, between it and the areolar coat, is a layer of longitudinally arranged non-striped muscular fibers. This is the **muscularis mucosæ**. At the commencement of the esophagus it is absent, or only represented by a few scattered bundles; lower down it forms a considerable stratum.

The **esophageal glands** (*glandulae œsophageæ*) are small compound racemose glands of the mucous type: they are lodged in the submucous tissue, and each opens upon the surface by a long excretory duct.

Vessels and Nerves.—The **arteries** supplying the esophagus are derived from the inferior thyroid branch of the thyrocervical trunk, from the descending thoracic aorta, from the left gastric branch of the celiac artery, and from the left inferior phrenic of the abdominal aorta. They have for the most part a longitudinal direction.

The **nerves** are derived from the vagi and from the sympathetic trunks; they form a plexus, in which are groups of ganglion cells, between the two layers of the muscular coats, and also a second plexus in the submucous tissue.

THE ABDOMEN.

The **abdomen** is the largest cavity in the body. It is of an oval shape, the extremities of the oval being directed upward and downward. The upper extremity is formed by the diaphragm which extends as a dome over the abdomen, so that the cavity extends high into the bony thorax, reaching on the right side, in the mammary line, to the upper border of the fifth rib; on the left side it falls below this level by about 2.5 cm. The lower extremity is formed by the structures which clothe the inner surface of the bony pelvis, principally the Levator ani and Coccygeus on either side. These muscles are sometimes termed the **diaphragm of the pelvis**. The cavity is wider above than below, and measures more in the vertical than in the transverse diameter. In order to facilitate description, it is artificially divided into two parts: an upper and larger part, the **abdomen proper**; and a lower and smaller part, the **pelvis**. These two cavities are not separated from each other, but the limit between them is marked by the superior aperture of the lesser pelvis.

The **abdomen proper** differs from the other great cavities of the body in being bounded for the most part by muscles and fasciæ, so that it can vary in capacity and shape according to the condition of the viscera which it contains; but, in addition to this, the abdomen varies in form and extent with age and sex. In the adult male, with moderate distension of the viscera, it is oval in shape, but at the same time flattened from before backward. In the adult female, with a fully developed pelvis, it is ovoid with the narrower pole upward, and in young children it is also ovoid but with the narrower pole downward.

Boundaries.—It is bounded *in front* and *at the sides* by the abdominal muscles and the Iliacus muscles; *behind* by the vertebral column and the Psoas and Quadratus lumborum muscles; *above* by the diaphragm; *below* by the plane of the superior aperture of the lesser pelvis. The muscles forming the boundaries of the cavity are lined upon their inner surfaces by a layer of fascia.

The abdomen contains the greater part of the digestive tube; some of the accessory organs to digestion, viz., the liver and pancreas; the spleen, the kidneys, and the suprarenal glands. Most of these structures, as well as the wall of the cavity in which they are contained, are more or less covered by an extensive and complicated serous membrane, the **peritoneum**.

The Apertures in the Walls of the Abdomen.—The apertures in the walls of the abdomen, for the transmission of structures to or from it, are, *in front*, the **umbilical** (in the fetus), for the transmission of the umbilical vessels, the allantois, and vitelline duct; *above*, the **vena caval opening**, for the transmission of the inferior vena cava, the **aortic hiatus**, for the passage of the aorta, azygos vein, and thoracic duct, and the **esophageal hiatus**, for the esophagus and vagi. *Below*, there are two apertures on either side: one for the passage of the femoral vessels and lumbo-inguinal nerve, and the other for the transmission of the spermatic cord in the male, and the round ligament of the uterus in the female.

Regions.—For convenience of description of the viscera, as well as of reference to the morbid conditions of the contained parts, the abdomen is artificially divided into nine regions by imaginary planes, two horizontal and two sagittal, passing through the cavity, the edges of the planes being indicated by lines drawn on the surface of the body. Of the horizontal planes the upper or **transpyloric** is indicated by a line encircling the body at the level of a point midway between the jugular notch and the symphysis pubis, the lower by a line carried around the trunk at the level of a point midway between the transpyloric and the symphysis pubis. The latter is practically the **intertubercular plane** of Cunningham, who pointed out¹ that its level corresponds with the prominent and easily defined tubercle on the iliac crest about 5 cm. behind the anterior superior iliac spine. By means of these

¹ Journal of Anatomy and Physiology, vol. xxvii.

imaginary planes the abdomen is divided into three zones, which are named from above downward the subcostal, umbilical, and hypogastric zones. Each of these is

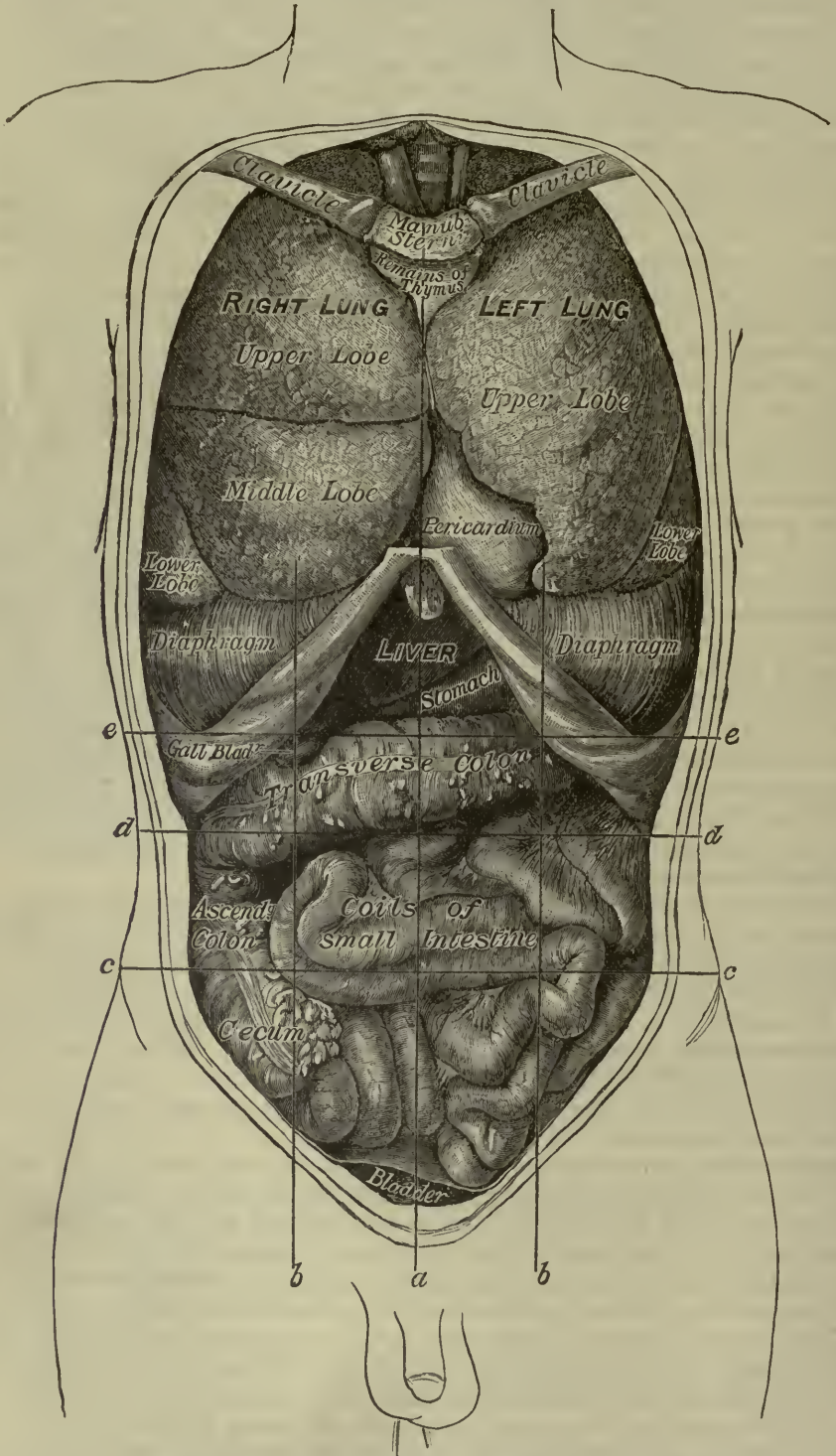


FIG. 1034.—Front view of the thoracic and abdominal viscera. *a*. Median plane. *b b*. Lateral planes. *c c*. Trans-tubercular plane. *d d*. Subcostal plane. *e e*. Transpyloric plane.

further subdivided into three regions by the two sagittal planes, which are indicated on the surface by lines drawn vertically through points half-way between the anterior superior iliac spines and the symphysis pubis.¹

The middle region of the upper zone is called the **epigastric**; and the two lateral regions, the **right** and **left hypochondriac**. The central region of the middle zone is the **umbilical**; and the two lateral regions, the **right** and **left lumbar**. The middle region of the lower zone is the **hypogastric** or **pubic region**; and the lateral regions are the **right** and **left iliac** or **inguinal** (Fig. 1034).

The **pelvis** is that portion of the abdominal cavity which lies below and behind a plane passing through the promontory of the sacrum, lineæ terminales of the hip bones, and the pubic crests. It is bounded behind by the sacrum, coccyx, Piriformes, and the sacrospinous and sacrotuberous ligaments; in front and laterally by the pubes and ischia and Obturatores interni; above it communicates with the abdomen proper; below it is closed by the Levatores ani and Coccygei and the urogenital diaphragm. The pelvis contains the urinary bladder, the sigmoid colon and rectum, a few coils of the small intestine, and some of the generative organs.

When the anterior abdominal wall is removed, the viscera are partly exposed as follows: above and to the right side is the liver, situated chiefly under the shelter of the right ribs and their cartilages, but extending across the middle line and reaching for some distance below the level of the xiphoid process. To the left of the liver is the stomach, from the lower border of which an apron-like fold of peritoneum, the **greater omentum**, descends for a varying distance, and obscures, to a greater or lesser extent, the other viscera. Below it, however, some of the coils of the small intestine can generally be seen, while in the right and left iliac regions respectively the cecum and the iliac colon are partly exposed. The bladder occupies the anterior part of the pelvis, and, if distended, will project above the symphysis pubis; the rectum lies in the concavity of the sacrum, but is usually obscured by the coils of the small intestine. The sigmoid colon lies between the rectum and the bladder.

When the stomach is followed from left to right it is seen to be continuous with the first part of the small intestine, or duodenum, the point of continuity being marked by a thickened ring which indicates the position of the pyloric valve. The duodenum passes toward the under surface of the liver, and then, curving downward, is lost to sight. If, however, the greater omentum be thrown upward over the chest, the inferior part of the duodenum will be observed passing across the vertebral column toward the left side, where it becomes continuous with the coils of the jejunum and ileum. These measure some 6 meters in length, and if followed downward the ileum will be seen to end in the right iliac fossa by opening into the cecum, the commencement of the large intestine. From the cecum the large intestine takes an arched course, passing at first upward on the right side, then across the middle line and downward on the left side, and forming respectively the ascending transverse, and descending parts of the colon. In the pelvis it assumes the form of a loop, the sigmoid colon, and ends in the rectum.

The spleen lies behind the stomach in the left hypochondriac region, and may be in part exposed by pulling the stomach over toward the right side.

The glistening appearance of the deep surface of the abdominal wall and of the surfaces of the exposed viscera is due to the fact that the former is lined, and the latter are more or less completely covered, by a serous membrane, the **peritoneum**.

The Peritoneum (Tunica Serosa).

The peritoneum is the largest serous membrane in the body, and consists, in the male, of a closed sac, a part of which is applied against the abdominal parietes,

¹Journal of Anatomy and Physiology, vols. xxxiii, xxxiv, xxxv.

while the remainder is reflected over the contained viscera. In the female the peritoneum is not a closed sac, since the free ends of the uterine tubes open directly into the peritoneal cavity. The part which lines the parietes is named the **parietal portion** of the peritoneum; that which is reflected over the contained viscera constitutes the **visceral portion** of the peritoneum. The *free surface* of the membrane is smooth, covered by a layer of flattened mesothelium, and lubricated by a small quantity of serous fluid. Hence the viscera can glide freely against the wall of the cavity or upon one another with the least possible amount of friction. The *attached surface* is rough, being connected to the viscera and inner surface of the parietes by means of areolar tissue, termed the **subserous areolar tissue**. The parietal portion is loosely connected with the fascial lining of the abdomen and pelvis, but is more closely adherent to the under surface of the diaphragm, and also in the middle line of the abdomen.

The space between the parietal and visceral layers of the peritoneum is named the **peritoneal cavity**; but under normal conditions this cavity is merely a potential one, since the parietal and visceral layers are in contact. The peritoneal cavity gives off a large diverticulum, the **omental bursa**, which is situated behind the stomach and adjoining structures; the neck of communication between the cavity and the bursa is termed the **epiploic foramen** (*foramen of Winslow*). Formerly the main portion of the cavity was described as the greater, and the omental bursa as the lesser sac.

The peritoneum differs from the other serous membranes of the body in presenting a much more complex arrangement, and one that can be clearly understood only by following the changes which take place in the digestive tube during its development.

To trace the membrane from one viscus to another, and from the viscera to the parietes, it is necessary to follow its continuity in the vertical and horizontal directions, and it will be found simpler to describe the main portion of the cavity and the omental bursa separately.

Vertical Disposition of the Main Peritoneal Cavity (*greater sac*) (Fig. 1035).—It is convenient to trace this from the back of the abdominal wall at the level of the umbilicus. On following the peritoneum upward from this level it is seen to be reflected around a fibrous cord, the **ligamentum teres** (*obliterated umbilical vein*), which reaches from the umbilicus to the under surface of the liver. This reflection forms a somewhat triangular fold, the **falciform ligament of the liver**, attaching the upper and anterior surfaces of the liver to the diaphragm and abdominal wall. With the exception of the line of attachment of this ligament the peritoneum covers the whole of the under surface of the anterior part of the diaphragm, and is continued from it on to the upper surface of the right lobe of the liver as the **superior layer of the coronary ligament**, and on to the upper surface of the left lobe as the **superior layer of the left triangular ligament** of the liver. Covering the upper and anterior surfaces of the liver, it is continued around its sharp margin on to the under surface, where it presents the following relations: (*a*) It covers the under surface of the right lobe and is reflected from the back part of this on to the right suprarenal gland and upper extremity of the right kidney, forming in this situation the **inferior layer of the coronary ligament**; a special fold, the **hepatorenal ligament**, is frequently present between the inferior surface of the liver and the front of the kidney. From the kidney it is carried downward to the duodenum and right colic flexure and medialward in front of the inferior vena cava, where it is continuous with the posterior wall of the omental bursa. Between the two layers of the coronary ligament there is a large triangular surface of the liver devoid of peritoneal covering; this is named the **bare area** of the liver, and is attached to the diaphragm by areolar tissue. Toward the right margin of the liver the two layers of the coronary ligament gradually approach each other, and ultimately

fuse to form a small triangular fold connecting the right lobe of the liver to the diaphragm, and named the **right triangular ligament** of the liver. The apex of the triangular bare area corresponds with the point of meeting of the two layers of the coronary ligament, its base with the fossa for the inferior vena cava. (b) It covers the lower surface of the quadrate lobe, the under and lateral surfaces of the gall-bladder, and the under surface and posterior border of the left lobe; it is then reflected from the upper surface of the left lobe to the diaphragm as the **inferior layer of the left triangular ligament**, and from the porta of the liver and the fossa for the ductus venosus to the lesser curvature of the stomach and the first 2.5 cm. of the duodenum as the anterior layer of the **hepatogastric** and **hepatoduodenal ligaments**, which together constitute the **lesser omentum**. If this layer of the lesser omentum be followed to the right it will be found to turn around the hepatic artery, bile duct, and portal vein, and become continuous with the anterior wall of the

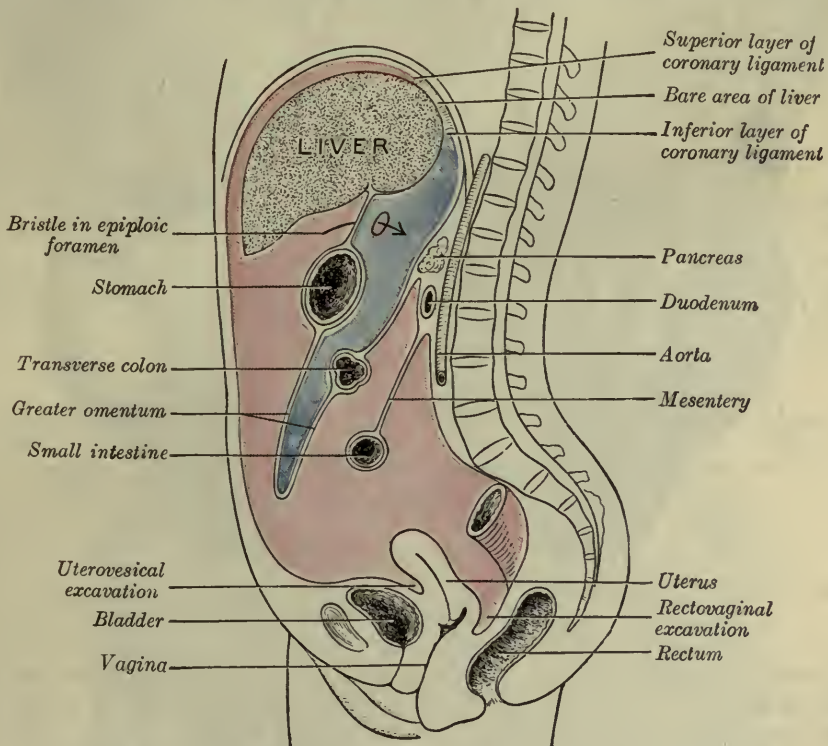


FIG. 1035.—Vertical disposition of the peritoneum. Main cavity, red; omental bursa, blue.

omental bursa, forming a free folded edge of peritoneum. Traced downward, it covers the antero-superior surface of the stomach and the commencement of the duodenum, and is carried down into a large free fold, known as the **gastrocolic ligament** or **greater omentum**. Reaching the free margin of this fold, it is reflected upward to cover the under and posterior surfaces of the transverse colon, and thence to the posterior abdominal wall as the inferior layer of the **transverse mesocolon**. It reaches the abdominal wall at the head and anterior border of the pancreas, is then carried down over the lower part of the head and over the inferior surface of the pancreas on the superior mesenteric vessels, and thence to the small intestine as the anterior layer of the **mesentery**. It encircles the intestine, and subsequently may be traced, as the posterior layer of the mesentery, upward and backward to the abdominal wall. From this it sweeps down over the aorta into the pelvis, where it invests the sigmoid colon, its reduplication forming the **sigmoid mesocolon**.

Leaving first the sides and then the front of the rectum, it is reflected on to the seminal vesicles and fundus of the urinary bladder and, after covering the upper surface of that viscus, is carried along the medial and lateral umbilical ligaments (Fig. 1036) on to the back of the abdominal wall to the level from which a start was made.

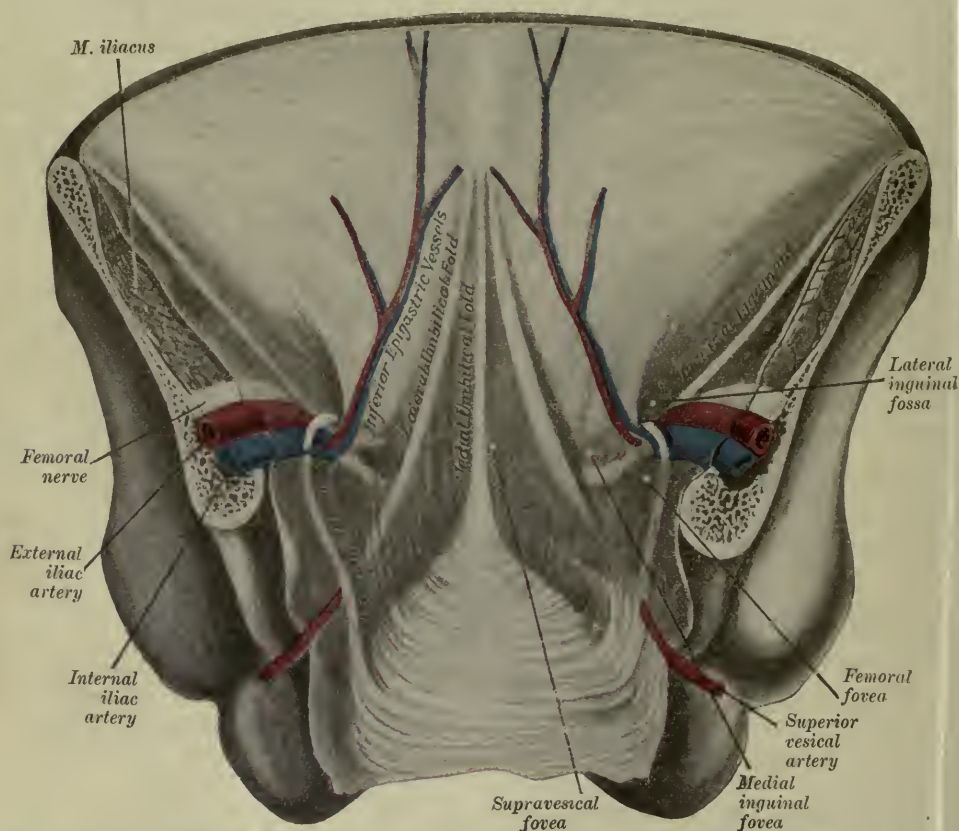


FIG. 1036.—Posterior view of the anterior abdominal wall in its lower half. The peritoneum is in place, and the various cords are shining through. (After Joessel.)

Between the rectum and the bladder it forms, in the male, a pouch, the **rectovesical excavation**, the bottom of which is slightly below the level of the upper ends of the vesiculæ seminales—*i. e.*, about 7.5 cm. from the orifice of the anus. When the bladder is distended, the peritoneum is carried up with the expanded viscus so that a considerable part of the anterior surface of the latter lies directly against the abdominal wall without the intervention of peritoneal membrane (*pre-vesical space of Retzius*). In the female the peritoneum is reflected from the rectum over the posterior vaginal fornix to the cervix and body of the uterus, forming the **rectouterine excavation** (*pouch of Douglas*). It is continued over the intestinal surface and fundus of the uterus on to its vesical surface, which it covers as far as the junction of the body and cervix uteri, and then to the bladder, forming here a second, but shallower, pouch, the **vesicouterine excavation**. It is also reflected from the sides of the uterus to the lateral walls of the pelvis as two expanded folds, the **broad ligaments of the uterus**, in the free margin of each of which is the uterine tube.

Vertical Disposition of the Omental Bursa (*lesser peritoneal sac*) (Fig. 1035).—A start may be made in this case on the posterior abdominal wall at the anterior border of the pancreas. From this region the peritoneum may be followed upward

over the pancreas on to the inferior surface of the diaphragm, and thence on to the caudate lobe and caudate process of the liver to the fossa from the ductus venosus and the porta of the liver. Traced to the right, it is continuous over the inferior vena cava with the posterior wall of the main cavity. From the liver it is carried downward to the lesser curvature of the stomach and the commencement of the duodenum as the posterior layer of the lesser omentum, and is continuous on the right, around the hepatic artery, bile duct, and portal vein, with the anterior layer of this omentum. The posterior layer of the lesser omentum is carried down as a covering for the postero-inferior surfaces of the stomach and commencement of the duodenum, and is continued downward as the deep layer of the **gastrocolic ligament** or **greater omentum**. From the free margin of this fold it is reflected upward on itself to the anterior and superior surfaces of the transverse colon, and thence as the superior layer of the transverse mesocolon to the anterior border of the pancreas, the level from which a start was made. It will be seen that the loop formed by the wall of the omental bursa below the transverse colon follows, and is closely applied to, the deep surface of that formed by the peritoneum of the main cavity, and that the greater omentum or large fold of peritoneum which hangs in front of the small intestine therefore consists of four layers, two anterior and two posterior separated by the potential cavity of the omental bursa.

Horizontal Disposition of the Peritoneum.—Below the transverse colon the arrangement is simple, as it includes only the main cavity; above the level of the transverse colon it is more complicated on account of the existence of the omental bursa. Below the transverse colon it may be considered in the two regions, viz., in the **pelvis** and in the **abdomen proper**.

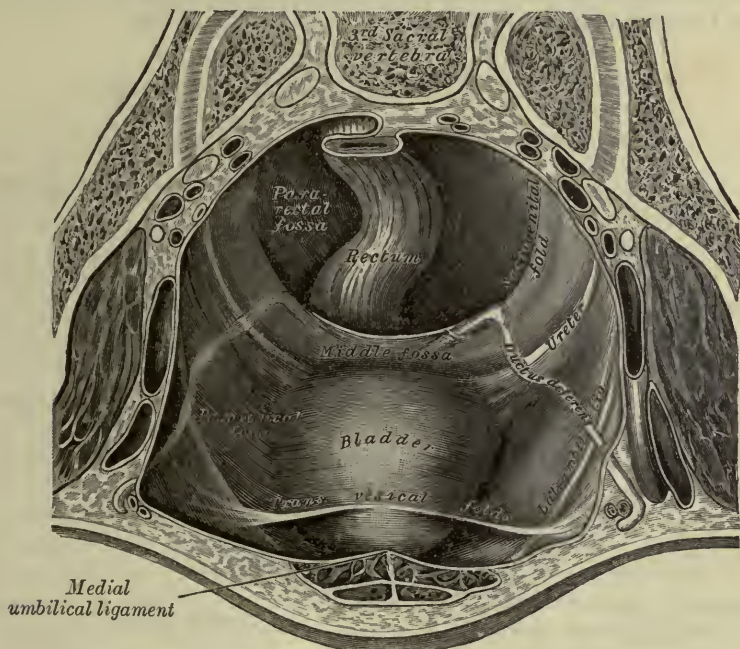


FIG. 1037.—The peritoneum of the male pelvis. (Dixon and Birmingham.)

(1) **In the Pelvis.**—The peritoneum here follows closely the surfaces of the pelvic viscera and the inequalities of the pelvic walls, and presents important differences in the two sexes. (a) **In the male** (Fig. 1037) it encircles the sigmoid colon, from which it is reflected to the posterior wall of the pelvis as a fold, the **sigmoid mesocolon**. It then leaves the sides and, finally, the front of the rectum,

and is continued on to the upper ends of the seminal vesicles and the bladder; on either side of the rectum it forms a fossa, the **pararectal fossa**, which varies in size with the distension of the rectum. In front of the rectum the peritoneum forms the rectovesical excavation, which is limited laterally by peritoneal folds extending from the sides of the bladder to the rectum and sacrum. These folds are known from their position as the **rectovesical** or **sacrogenital folds**. The peritoneum of the anterior pelvic wall covers the superior surface of the bladder, and on either side of this viscus forms a depression, termed the **paravesical fossa**, which is limited laterally by the fold of peritoneum covering the ductus deferens. The size of this fossa is dependent on the state of distension of the bladder; when the bladder is empty, a variable fold of peritoneum, the **plica vesicalis transversa**, divides the fossa into two portions. On the peritoneum between the paravesical and pararectal fossæ the only elevations are those produced by the ureters and the hypogastric vessels. (b) **In the female**, pararectal and paravesical fossæ similar to those in the male are present: the lateral limit of the paravesical fossa is the peritoneum investing the round ligament of the uterus. The rectovesical excavation is, however, divided by the uterus and vagina into a small anterior vesicouterine and a large, deep, posterior rectouterine excavation. The sacrogenital folds form the margins of the latter, and are continued on to the back of the uterus to form a transverse fold, the **torus uterinus**. The broad ligaments extend from the sides of the uterus to the lateral walls of the pelvis; they contain in their free margins the uterine tubes, and in their posterior layers the ovaries. Below, the broad ligaments are continuous with the peritoneum on the lateral walls of the pelvis. On the lateral pelvic wall behind the attachment of the broad ligament, in the angle between the elevations produced by the diverging hypogastric and external iliac vessels is a slight fossa, the **ovarian fossa**, in which the ovary normally lies.

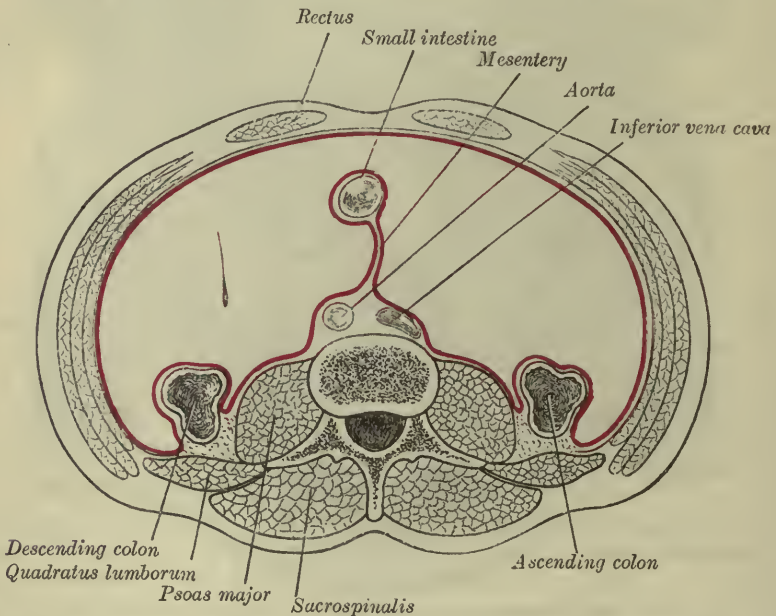


FIG. 1038.—Horizontal disposition of the peritoneum in the lower part of the abdomen.

(2) **In the Lower Abdomen** (Fig. 1038).—Starting from the linea alba, below the level of the transverse colon, and tracing the continuity of the peritoneum in a horizontal direction to the right, the membrane covers the inner surface of the abdominal wall almost as far as the lateral border of the *Quadratus lumborum*;

it encloses the cecum and vermiform process, and is reflected over the sides and front of the ascending colon; it may then be traced over the duodenum, Psoas major, and inferior vena cava toward the middle line, whence it passes along the mesenteric vessels to invest the small intestine, and back again to the large vessels in front of the vertebral column, forming the **mesentery**, between the layers of which are contained the mesenteric bloodvessels, lacteals, and glands. It is then continued over the left Psoas; it covers the sides and front of the descending colon, and, reaching the abdominal wall, is carried on it to the middle line.

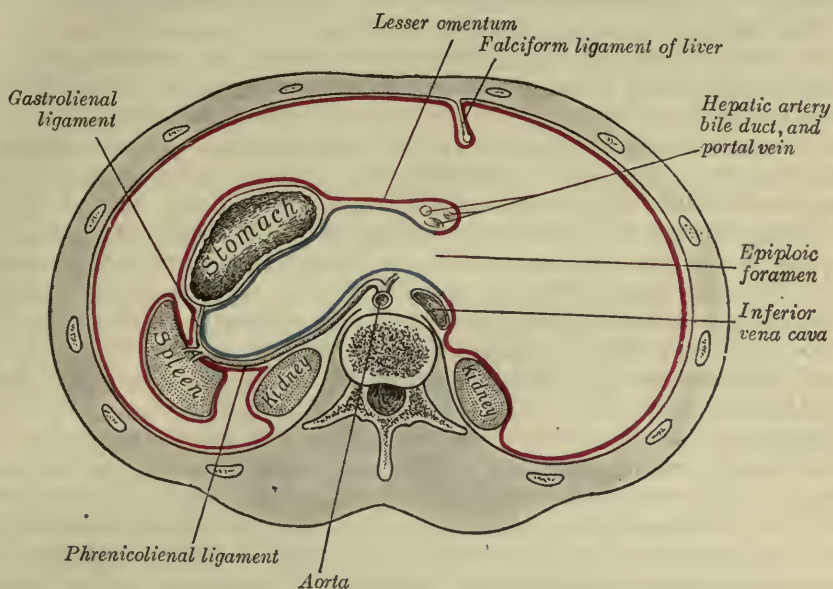


FIG. 1039.—Horizontal disposition of the peritoneum in the upper part of the abdomen.

(3) **In the Upper Abdomen** (Fig. 1039).—Above the transverse colon the omental bursa is superadded to the general sac, and the communication of the two cavities with one another through the epiploic foramen can be demonstrated.

(a) **Main Cavity**.—Commencing on the posterior abdominal wall at the inferior vena cava, the peritoneum may be followed to the right over the front of the suprarenal gland and upper part of the right kidney on to the antero-lateral abdominal wall. From the middle line of the anterior wall a backwardly directed fold encircles the obliterated umbilical vein and forms the falciform ligament of the liver. Continuing to the left, the peritoneum lines the antero-lateral abdominal wall and covers the lateral part of the front of the left kidney, and is reflected to the posterior border of the hilus of the spleen as the posterior layer of the **phrenicocoliatal ligament**. It can then be traced around the surface of the spleen to the front of the hilus, and thence to the cardiac end of the greater curvature of the stomach as the anterior layer of the **gastrosplenic ligament**. It covers the antero-superior surfaces of the stomach and commencement of the duodenum, and extends up from the lesser curvature of the stomach to the liver as the anterior layer of the lesser omentum.

(b) **Omental Bursa** (*bursa omentalis*; *lesser peritoneal sac*).—On the posterior abdominal wall the peritoneum of the general cavity is continuous with that of the omental bursa in front of the inferior vena cava. Starting from here, the bursa may be traced across the aorta and over the medial part of the front of the left kidney and diaphragm to the hilus of the spleen as the anterior layer of the phrenicocoliatal ligament. From the spleen it is reflected to the stomach as

the posterior layer of the gastrosplenic ligament. It covers the postero-inferior surfaces of the stomach and commencement of the duodenum, and extends upward to the liver as the posterior layer of the lesser omentum; the right margin of this layer is continuous around the hepatic artery, bile duct, and portal vein, with the wall of the general cavity.

The **epiploic foramen** (*foramen epiploicum; foramen of Winslow*) is the passage of communication between the general cavity and the omental bursa. It is bounded *in front* by the free border of the lesser omentum, with the common bile duct, hepatic artery, and portal vein between its two layers; *behind* by the peritoneum covering the inferior vena cava; *above* by the peritoneum on the caudate process of the liver, and *below* by the peritoneum covering the commencement of the duodenum and the hepatic artery, the latter passing forward below the foramen before ascending between the two layers of the lesser omentum.

The boundaries of the *omental bursa* will now be evident. It is bounded *in front*, from above downward, by the caudate lobe of the liver, the lesser omentum, the stomach, and the anterior two layers of the greater omentum. *Behind*, it is limited, from below upward, by the two posterior layers of the greater omentum, the transverse colon, and the ascending layer of the transverse mesocolon, the upper surface of the pancreas, the left suprarenal gland, and the upper end of the left kidney. To the right of the esophageal opening of the stomach it is formed by that part of the diaphragm which supports the caudate lobe of the liver. *Laterally*, the bursa extends from the epiploic foramen to the spleen, where it is limited by the phrenicolienal and gastrolienal ligaments.

The omental bursa, therefore, consists of a series of pouches or recesses to which the following terms are applied: (1) the **vestibule**, a narrow channel continued from the epiploic foramen, over the head of the pancreas to the **gastropancreatic fold**; this fold extends from the omental tuberosity of the pancreas to the right side of the fundus of the stomach, and contains the left gastric artery and coronary vein; (2) the **superior omental recess**, between the caudate lobe of the liver and the diaphragm; (3) the **lienal recess**, between the spleen and the stomach; (4) the **inferior omental recess**, which comprises the remainder of the bursa.

In the fetus the bursa reaches as low as the free margin of the greater omentum, but in the adult its vertical extent is usually more limited owing to adhesions between the layers of the omentum. During a considerable part of fetal life the transverse colon is suspended from the posterior abdominal wall by a mesentery of its own, the two posterior layers of the greater omentum passing at this stage in front of the colon. This condition occasionally persists throughout life, but as a rule adhesion occurs between the mesentery of the transverse colon and the posterior layer of the greater omentum, with the result that the colon appears to receive its peritoneal covering by the splitting of the two posterior layers of the latter fold. In the adult the omental bursa intervenes between the stomach and the structures on which that viscus lies, and performs therefore the functions of a serous bursa for the stomach.

Numerous peritoneal folds extend between the various organs or connect them to the parietes; they serve to hold the viscera in position, and, at the same time, enclose the vessels and nerves proceeding to them. They are grouped under the three headings of **ligaments**, **omenta**, and **mesenteries**.

The **ligaments** will be described with their respective organs.

There are two **omenta**, the lesser and the greater.

The **lesser omentum** (*omentum minus; small omentum; gastrohepatic omentum*) is the duplicature which extends to the liver from the lesser curvature of the stomach and the commencement of the duodenum. It is extremely thin, and is continuous with the two layers of peritoneum which cover respectively the antero-superior and postero-inferior surfaces of the stomach and first part of the duodenum. When these two layers reach the lesser curvature of the stomach and the upper border of the

duodenum, they join together and ascend as a double fold to the porta of the liver; to the left of the porta the fold is attached to the bottom of the fossa for the ductus venosus, along which it is carried to the diaphragm, where the two layers separate to embrace the end of the esophagus. At the right border of the omentum the two layers are continuous, and form a free margin which constitutes the anterior boundary of the epiploic foramen. The portion of the lesser omentum extending between the liver and stomach is termed the **hepatogastric ligament**, while that between the liver and duodenum is the **hepatoduodenal ligament**. Between the two layers of the lesser omentum, close to the right free margin, are the hepatic artery, the common bile duct, the portal vein, lymphatics, and the hepatic plexus of nerves—all these structures being enclosed in a **fibrous capsule** (*Glisson's capsule*). Between the layers of the lesser omentum, where they are attached to the stomach, run the right and left gastric vessels.

The **greater omentum** (*omentum majus; great omentum; gastrocolic omentum*) is the largest peritoneal fold. It consists of a double sheet of peritoneum, folded on itself so that it is made up of four layers. The two layers which descend from the stomach and commencement of the duodenum pass in front of the small intestines, sometimes as low down as the pelvis; they then turn upon themselves, and ascend again as far as the transverse colon, where they separate and enclose that part of the intestine. These individual layers may be easily demonstrated in the young subject, but in the adult they are more or less inseparably blended. The left border of the greater omentum is continuous with the gastrosplenic ligament; its right border extends as far as the commencement of the duodenum. The greater omentum is usually thin, presents a cribriform appearance, and always contains some adipose tissue, which in fat people accumulates in considerable quantity. Between its two anterior layers, a short distance from the greater curvature of the stomach, is the anastomosis between the right and left gastroepiploic vessels.

The **mesenteries** are: the **mesentery proper**, the **transverse mesocolon**, and the **sigmoid mesocolon**. In addition to these there are sometimes present an ascending and a descending mesocolon.

The **mesentery proper** (*mesenterium*) is the broad, fan-shaped fold of peritoneum which connects the convolutions of the jejunum and ileum with the posterior wall of the abdomen. Its **root**—the part connected with the structures in front of the vertebral column—is narrow, about 15 cm. long, and is directed obliquely from the duodenojejunal flexure at the left side of the second lumbar vertebra to the right sacroiliac articulation (Fig. 1040). Its **intestinal border** is about 6 metres long; and here the two layers separate to enclose the intestine, and form its peritoneal coat. It is narrow above, but widens rapidly to about 20 cm., and is thrown into numerous plaits or folds. It suspends the small intestine, and contains between its layers the intestinal branches of the superior mesenteric artery, with their accompanying veins and plexuses of nerves, the lacteal vessels, and mesenteric lymph glands.

The **transverse mesocolon** (*mesocolon transversum*) is a broad fold, which connects the transverse colon to the posterior wall of the abdomen. It is continuous with the two posterior layers of the greater omentum, which, after separating to surround the transverse colon, join behind it, and are continued backward to the vertebral column, where they diverge in front of the anterior border of the pancreas. This fold contains between its layers the vessels which supply the transverse colon.

The **sigmoid mesocolon** (*mesocolon sigmoideum*) is the fold of peritoneum which retains the sigmoid colon in connection with the pelvic wall. Its line of attachment forms a V-shaped curve, the apex of the curve being placed about the point of division of the left common iliac artery. The curve begins on the medial side of the left Psoas major, and runs upward and backward to the apex, from which it bends sharply downward, and ends in the median plane at the level of the third sacral vertebra. The sigmoid and superior hemorrhoidal vessels run between the two layers of this fold.

In most cases the peritoneum covers only the front and sides of the ascending and descending parts of the colon. Sometimes, however, these are surrounded by the serous membrane and attached to the posterior abdominal wall by an ascending and a descending mesocolon respectively. A fold of peritoneum, the **phrenicocolic ligament**, is continued from the left colic flexure to the diaphragm opposite the tenth and eleventh ribs; it passes below and serves to support the spleen, and therefore has received the name of **sustentaculum lienis**.

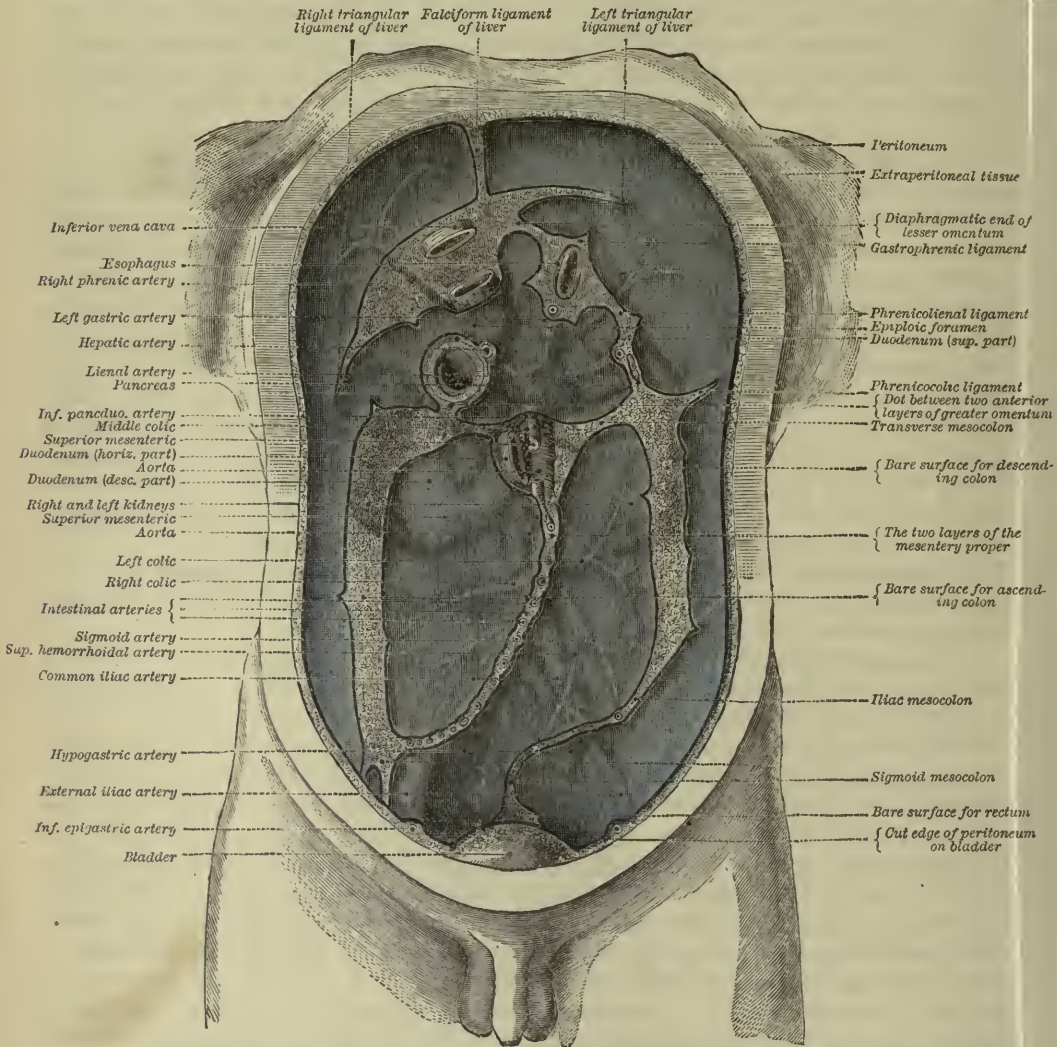


FIG. 1040.—Diagram devised by Delépine to show the lines along which the peritoneum leaves the wall of the abdomen to invest the viscera.

The **appendices epiploicæ** are small pouches of the peritoneum filled with fat and situated along the colon and upper part of the rectum. They are chiefly appended to the transverse and sigmoid parts of the colon.

Peritoneal Recesses or Fossæ (*retroperitoneal fossæ*).—In certain parts of the abdominal cavity there are recesses of peritoneum forming culs-de-sac or pouches, which are of surgical interest in connection with the possibility of the occurrence of “retroperitoneal” herniæ. The largest of these is the omental bursa (already described), but several others, of smaller size, require mention, and may be divided into three groups, viz.: **duodenal**, **cecal**, and **intersigmoid**.

1. Duodenal Fossæ (Figs. 1041, 1042).—Three are fairly constant, viz.: (a) The inferior duodenal fossa, present in from 70 to 75 per cent. of cases, is situated opposite the third lumbar vertebra on the left side of the ascending portion of the duodenum. Its opening is directed upward, and is bounded by a thin sharp

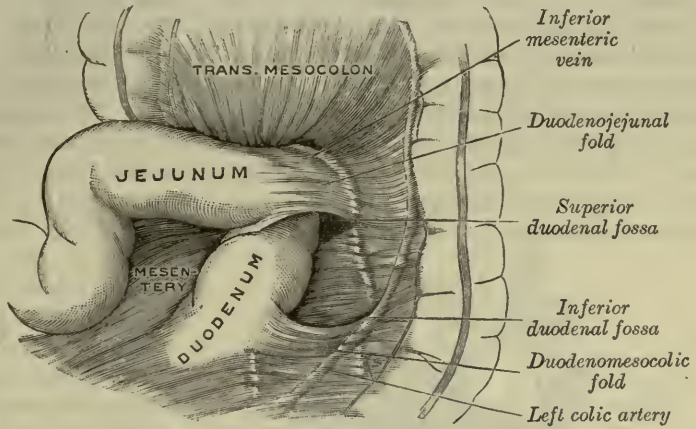


FIG. 1041.—Superior and inferior duodenal fossæ. (Poirier and Charpy.)

fold of peritoneum with a concave margin, called the **duodenumesocolic fold**. The tip of the index finger introduced into the fossa under the fold passes some little distance behind the ascending portion of the duodenum. (b) The **superior duodenal fossa**, present in from 40 to 50 per cent. of cases, often coexists with the inferior one, and its orifice looks downward. It lies on the left of the ascending

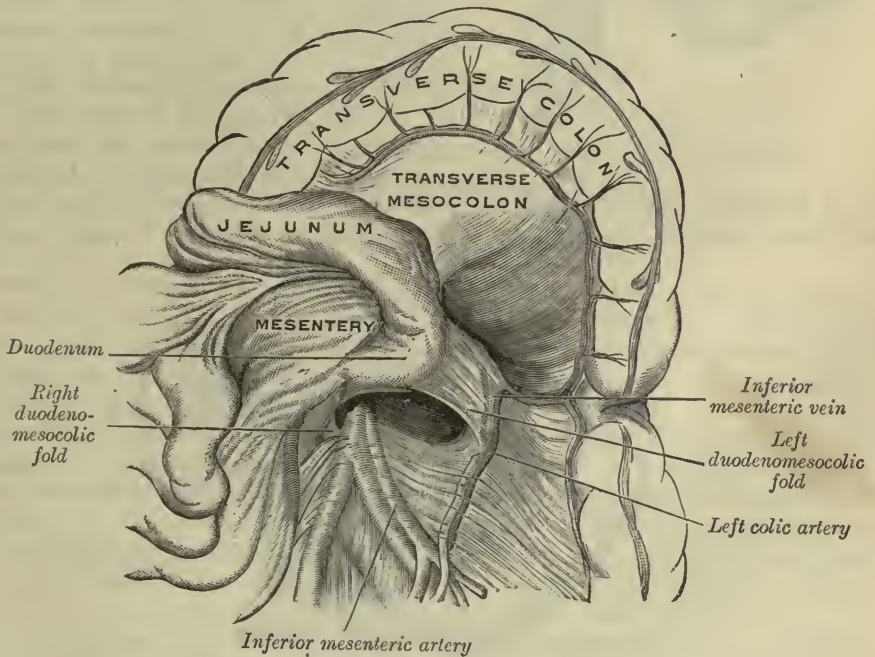


FIG. 1042.—Duodenojejunal fossa. (Poirier and Charpy.)

portion of the duodenum, in front of the second lumbar vertebra, and behind a sickle-shaped fold of peritoneum, the **duodenojejunal fold**, and has a depth of about 2 cm. (c) The **duodenojejunal fossa** exists in from 15 to 20 per cent. of cases, but has never yet been found in conjunction with the other forms of duodenal

fossæ; it can be seen by pulling the jejunum downward and to the right, after the transverse colon has been pulled upward. It is bounded above by the pancreas, to the right by the aorta, and to the left by the kidney; beneath is the left renal vein. It has a depth of from 2 to 3 cm., and its orifice, directed downward and to the right, is nearly circular and will admit the tip of the little finger.

2. **Cecal Fossæ** (*pericecal folds or fossæ*).—There are three principal pouches or recesses in the neighborhood of the cecum (Figs. 1043 to 1045): (a) The **superior ileocecal fossa** is formed by a fold of peritoneum, arching over the branch of the ileocolic artery which supplies the ileocolic junction. The fossa is a narrow chink situated between the mesentery of the small intestine, the ileum, and the small portion of the cecum behind. (b) The **inferior ileocecal fossa** is situated behind the angle of junction of the ileum and cecum. It is formed by the **ileocecal fold** of peritoneum (*bloodless fold of Treves*), the upper border of which is fixed to the ileum,

opposite its mesenteric attachment, while the lower border, passing over the ileocecal junction, joins the mesenteriole of the vermiform process, and sometimes the process itself. Between this fold and the mesenteriole of the vermiform process is the inferior ileocecal fossa. It is bounded above by the posterior surface of the ileum and the mesentery; in front and below by the ileocecal fold, and behind by the upper part of the mesenteriole of the vermiform process. (c) The **cecal fossa** is situated immediately behind the cecum, which has to be raised to bring it into view. It varies much in size and extent. In some cases

it is sufficiently large to admit the index finger, and extends upward behind the ascending colon in the direction of the kidney; in others it is merely a shallow

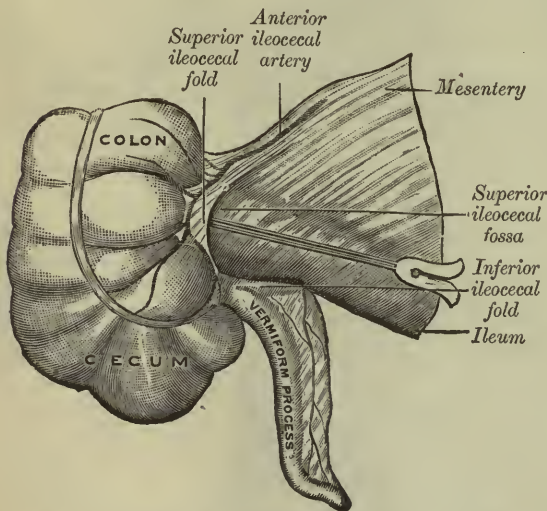


FIG. 1043.—Superior ileocecal fossa. (Poirier and Charpy.)

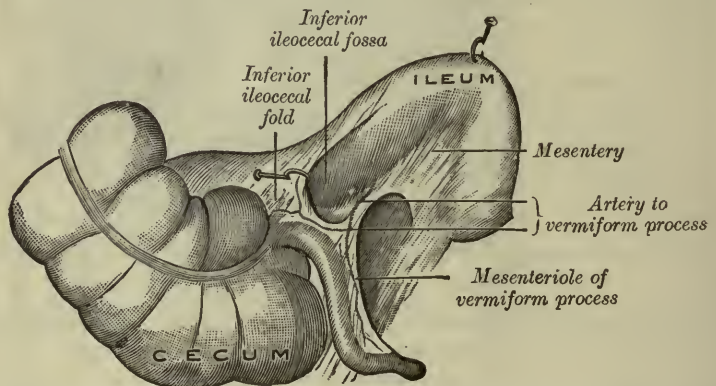


FIG. 1044.—Inferior ileocecal fossa. The cecum and ascending colon have been drawn lateralward and downward, the ileum upward and backward, and the vermiform process downward. (Poirier and Charpy.)

depression. It is bounded on the right by the cecal fold, which is attached by one edge to the abdominal wall from the lower border of the kidney to the iliac

fossa and by the other to the postero-lateral aspect of the colon. In some instances additional fossæ, the **retrocecal fossæ**, are present.

3. The **intersigmoid fossa** (*recessus intersigmoideus*) is constant in the fetus and during infancy, but disappears in a certain percentage of cases as age advances. Upon drawing the sigmoid colon upward, the left surface of the sigmoid mesocolon is exposed, and on it will be seen a funnel-shaped recess of the peritoneum, lying on the external iliac vessels, in the interspace between the Psoas and Iliacus muscles. This is the orifice leading to the intersigmoid fossa, which lies behind the sigmoid mesocolon, and in front of the parietal peritoneum. The fossa varies in size; in some instances it is a mere dimple, whereas in others it will admit the whole of the index finger.¹

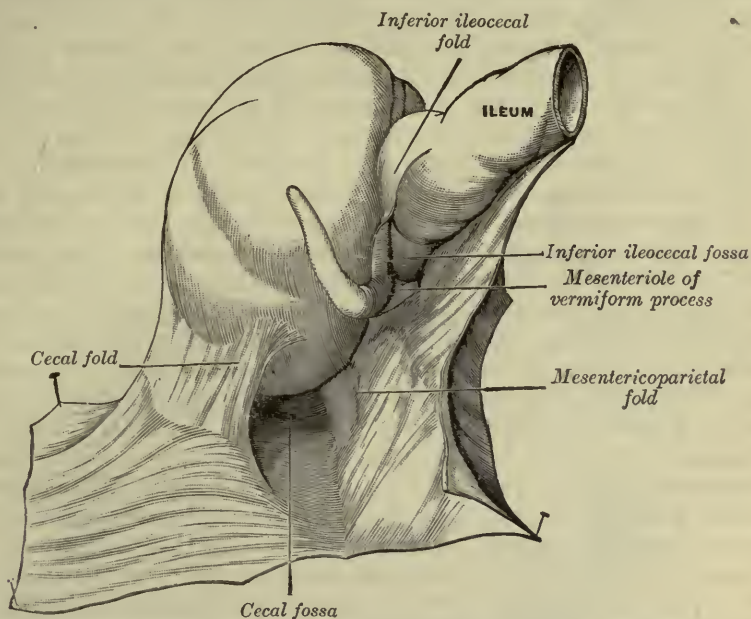


FIG. 1045.—The cecal fossa. The ileum and cecum are drawn backward and upward. (Souligoux.)

The Stomach (Ventriculus; Gaster).

The **stomach** is the most dilated part of the digestive tube, and is situated between the end of the esophagus and the beginning of the small intestine. It lies in the epigastric, umbilical, and left hypochondriac regions of the abdomen, and occupies a recess bounded by the upper abdominal viscera, and completed in front and on the left side by the anterior abdominal wall and the diaphragm.

The **shape and position** of the stomach are so greatly modified by changes within itself and in the surrounding viscera that no one form can be described as typical. The chief modifications are determined by (1) the amount of the stomach contents, (2) the stage which the digestive process has reached, (3) the degree of development of the gastric musculature, and (4) the condition of the adjacent intestines. It is, however, possible by comparing a series of stomachs to determine certain markings more or less common to all (Figs. 1046, 1047, 1048, 1049).

The stomach presents two **openings**, two **borders or curvatures**, and two **surfaces**.

Openings.—The opening by which the esophagus communicates with the stomach is known as the **cardiac orifice**, and is situated on the left of the middle line at the level of the tenth thoracic vertebra. The short abdominal portion of the esophagus (*antrum cardiacum*) is conical in shape and curved sharply to the left,

¹ On the anatomy of these fossæ, see the Arris and Gale Lectures by Moynihan, 1899.

the base of the cone being continuous with the cardiac orifice of the stomach. The right margin of the esophagus is continuous with the lesser curvature of the stomach, while the left margin joins the greater curvature at an acute angle, termed the *incisura cardiaca*.

The **pyloric orifice** communicates with the duodenum, and its position is usually indicated on the surface of the stomach by a circular groove, the **duodenopyloric constriction**. This orifice lies to the right of the middle line at the level of the upper border of the first lumbar vertebra.

Curvatures.—The **lesser curvature** (*curvatura ventriculi minor*), extending between the cardiac and pyloric orifices, forms the right or posterior border of the stomach. It descends as a continuation of the right margin of the esophagus in front of the fibers of the right crus of the diaphragm, and then, turning to the right, it crosses the first lumbar vertebra and ends at the pylorus. Nearer its pyloric than its cardiac end is a well-marked notch, the *incisura angularis*, which varies somewhat in position with the state of distension of the viscus; it serves to separate the stomach into a right and a left portion. The lesser curvature gives attachment to the two layers of the hepatogastric ligament, and between these two layers are the left gastric artery and the right gastric branch of the hepatic artery.

The **greater curvature** (*curvatura ventriculi major*) is directed mainly forward, and is four or five times as long as the lesser curvature. Starting from the cardiac orifice at the *incisura cardiaca*, it forms an arch backward, upward, and to the left; the highest point of the convexity is on a level with the sixth left costal cartilage. From this level it may be followed downward and forward, with a slight convexity to the left as low as the cartilage of the ninth rib; it then turns to the right, to the end of the pylorus. Directly opposite the *incisura angularis* of the lesser curvature the greater curvature presents a dilatation, which is the left extremity of the **pyloric part**; this dilatation is limited on the right by a slight groove, the **sulcus intermedius**, which is about 2.5 cm, from the duodenopyloric constriction. The portion between the *sulcus intermedius* and the duodenopyloric constriction is termed the **pyloric antrum**. At its commencement the greater curvature is covered by peritoneum continuous with that covering the front of the organ. The left part of the curvature gives attachment to the gastrolial ligament, while to its anterior portion are attached the two layers of the greater omentum, separated from each other by the gastroepiploic vessels.

Surfaces.—When the stomach is in the contracted condition, its surfaces are directed upward and downward respectively, but when the viscus is distended they are directed forward, and backward. They may therefore be described as antero-superior and postero-inferior.

Antero-superior Surface.—The left half of this surface is in contact with the diaphragm, which separates it from the base of the left lung, the pericardium, and the seventh, eighth, and ninth ribs, and intercostal spaces of the left side. The right half is in relation with the left and quadrate lobes of the liver and with the anterior abdominal wall. When the stomach is empty, the transverse colon may lie on the front part of this surface. The whole surface is covered by peritoneum.

The **Postero-inferior Surface** is in relation with the diaphragm, the spleen, the left suprarenal gland, the upper part of the front of the left kidney, the anterior surface of the pancreas, the left colic flexure, and the upper layer of the transverse mesocolon. These structures form a shallow bed, the **stomach bed**, on which the viscus rests. The transverse mesocolon separates the stomach from the duodeno-jejunal flexure and small intestine. The postero-inferior surface is covered by peritoneum, except over a small area close to the cardiac orifice; this area is limited by the lines of attachment of the **gastrophrenic ligament**, and lies in apposition with the diaphragm, and frequently with the upper portion of the left suprarenal gland.

Component Parts of the Stomach.—A plane passing through the incisura angularis on the lesser curvature and the left limit of the opposed dilatation on the greater curvature divides the stomach into a left portion or **body** and a right or **pyloric portion**. The left portion of the body is known as the **fundus**, and is marked off from the remainder of the body by a plane passing horizontally through the cardiac orifice. The pyloric portion is divided by a plane through the sulcus intermedius at right angles to the long axis of this portion; the part to the right of this plane is the **pyloric antrum** (Fig. 1046).

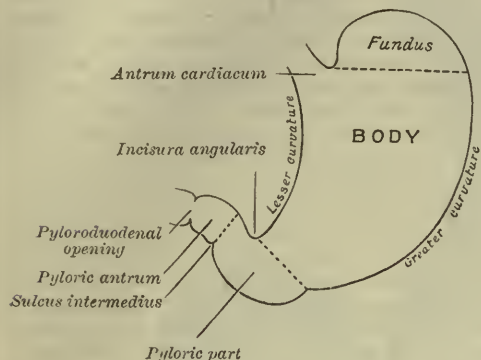


FIG. 1046.—Outline of stomach, showing its anatomical landmarks.

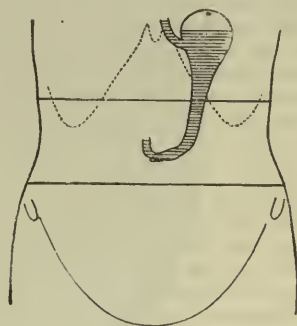


FIG. 1047.—Diagram showing shape and position of empty stomach. Erect posture. (Hertz.)

If the stomach be examined during the process of digestion it will be found divided by a muscular constriction into a large dilated left portion, and a narrow contracted tubular right portion. The constriction is in the body of the stomach, and does not follow any of the anatomical landmarks; indeed, it shifts gradually toward the left as digestion progresses, *i. e.*, more of the body is gradually absorbed into the tubular part (Figs. 1047, 1048, 1049).

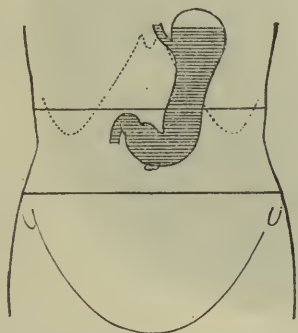


FIG. 1048.—Diagram showing shape and position of moderately filled stomach. Erect posture. (Hertz.)

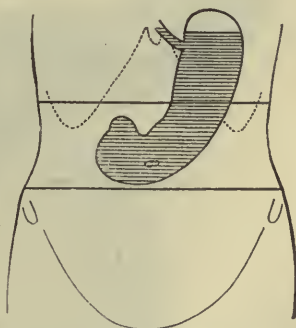


FIG. 1049.—Diagram showing shape and position of distended stomach. Erect posture. (Hertz.)

Position of the Stomach.—The position of the stomach varies with the posture, with the amount of the stomach contents and with the condition of the intestines on which it rests. In the erect posture the empty stomach is somewhat J-shaped; the part above the cardiac orifice is usually distended with gas; the pylorus descends to the level of the second lumbar vertebra and the most dependent part of the stomach is at the level of the umbilicus. Variation in the amount of its contents affects mainly the cardiac portion, the pyloric portion remaining in a more or less contracted condition during the process of digestion. As the stomach fills it tends to expand forward and downward in the direction of least resistance, but when this is interfered with by a distended condition of the colon or intestines the fundus presses upward on the liver and diaphragm and gives rise to the feelings of oppression and palpitation complained of in such cases. His¹ and Cunningham² have shown by hardening the viscera *in situ* that the contracted stomach has a sickle shape, the fundus looking directly backward. The surfaces are directed upward and downward, the upper surface having, however, a gradual downward slope to the right. The greater curvature is in front and at a slightly higher level than the lesser.

¹ Archiv für Anatomie und Physiologie, anat. Abth., 1903.

² Transactions of the Royal Society of Edinburgh, vol. xlv, part i.

The position of the full stomach depends, as already indicated, on the state of the intestines; when these are empty the fundus expands vertically and also forward. The pylorus is displaced toward the right and the whole organ assumes an oblique position, so that its surfaces are directed more forward and backward. The lowest part of the stomach is at the pyloric vestibule, which reaches to the region of the umbilicus. Where the intestines interfere with the downward expansion of the fundus the stomach retains the horizontal position which is characteristic of the contracted viscus.

Examination of the stomach during life by *x*-rays has confirmed these findings, and has demonstrated that, in the erect posture, the full stomach usually presents a hook-like appearance, the long axis of the clinical fundus being directed downward, medialward, and forward toward the umbilicus, while the pyloric portion curves upward to the duodenopyloric junction.

Interior of the Stomach.—When examined after death, the stomach is usually fixed at some temporary stage of the digestive process. A common form is that shown in Fig. 1050. If the viscus be laid open by a section through the plane of its two curvatures, it is seen to consist of two segments: (a) a large globular portion on the left and (b) a narrow tubular part on the right. These correspond to the clinical subdivisions of fundus and pyloric portions already described, and are separated by a constriction which indents the body and greater curvature, but does not involve the lesser curvature. To the left of the cardiac orifice is the *incisura cardiaca*: the projection of this notch into the cavity of the stomach increases as the organ distends, and has been supposed to act as a valve preventing regurgitation into the esophagus. In the pyloric portion are seen: (a) the elevation corresponding to the *incisura angularis*, and (b) the circular projection from the duodenopyloric constriction which forms the pyloric valve; the separation of the pyloric antrum from the rest of the pyloric part is scarcely indicated.

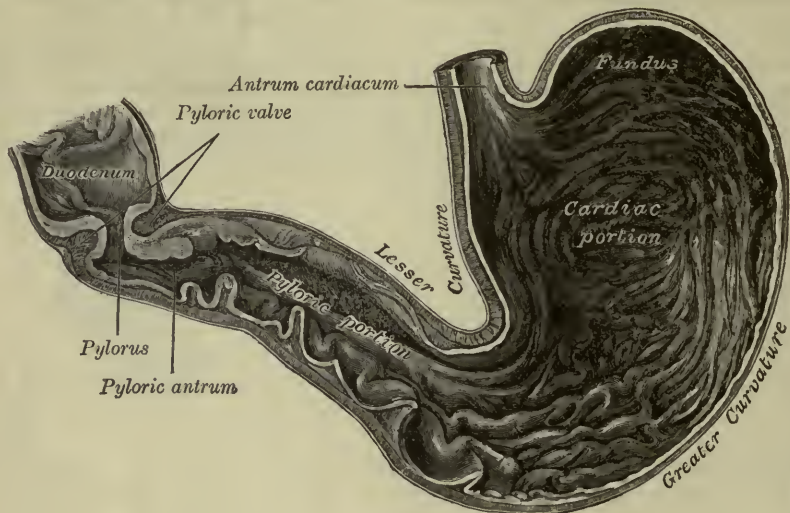


FIG. 1050.—Interior of the stomach.

The **pyloric valve** (*valvula pylori*) is formed by a reduplication of the mucous membrane of the stomach, covering a muscular ring composed of a thickened portion of the circular layer of the muscular coat. Some of the deeper longitudinal fibers turn in and interlace with the circular fibers of the valve.

Structure.—The wall of the stomach consists of four coats: **serous, muscular, areolar, and mucous**, together with vessels and nerves.

The **serous coat** (*tunica serosa*) is derived from the peritoneum, and covers the entire surface of the organ, excepting along the greater and lesser curvatures at the points of attachment of the greater and lesser omenta; here the two layers of peritoneum leave a small triangular space, along which the nutrient vessels and nerves pass. On the posterior surface of the stomach, close to the cardiac orifice, there is also a small area uncovered by peritoneum, where the organ is in contact with the under surface of the diaphragm.

The **muscular coat** (*tunica muscularis*) (Figs. 1051, 1052) is situated immediately beneath the serous covering, with which it is closely connected. It consists of three sets of smooth muscle fibers: longitudinal, circular and oblique.

The **longitudinal fibers** (*stratum longitudinale*) are the most superficial, and are arranged in

two sets. The first set consists of fibers continuous with the longitudinal fibers of the esophagus; they radiate in a stellate manner from the cardiac orifice and are practically all lost before the pyloric portion is reached. The second set commences on the body of the stomach and passes

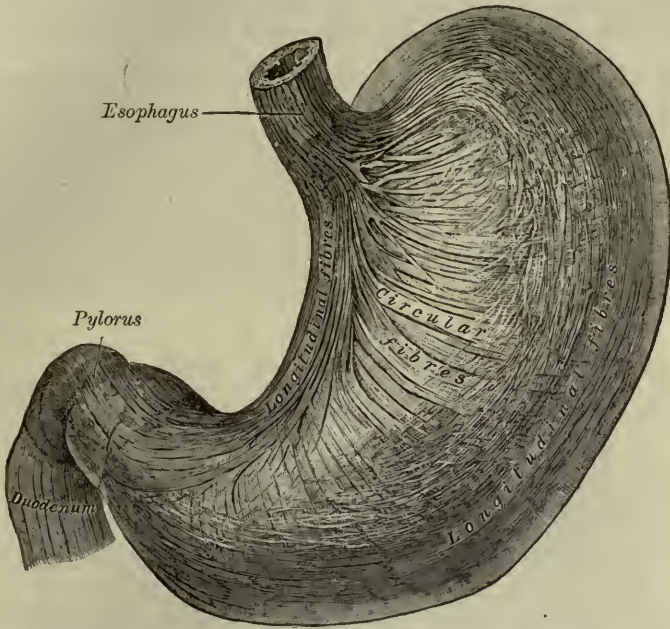


FIG. 1051.—The longitudinal and circular muscular fibers of the stomach, viewed from above and in front. (Spalteholz.)

to the right, its fibers becoming more thickly distributed as they approach the pylorus. Some of the more superficial fibers of this set pass on to the duodenum, but the deeper fibers dip inward and interlace with the circular fibers of the pyloric valve.

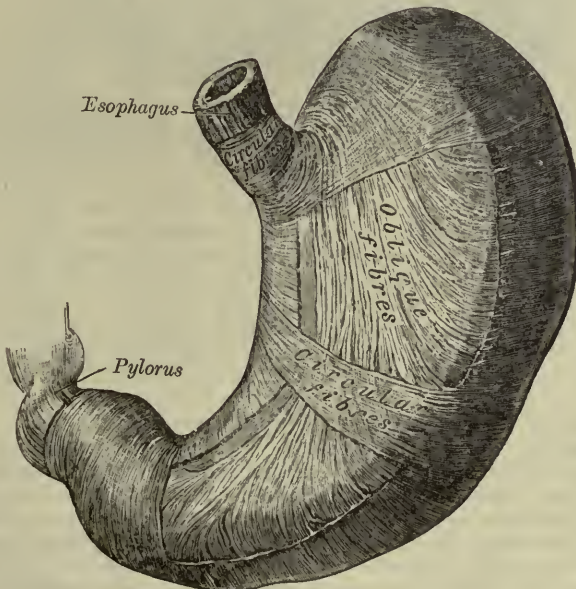


FIG. 1052.—The oblique muscular fibers of the stomach, viewed from above and in front. (Spalteholz.)

The circular fibers (*stratum circulare*) form a uniform layer over the whole extent of the stomach beneath the longitudinal fibers. At the pylorus they are most abundant, and are aggregated into

a circular ring, which projects into the lumen, and forms, with the fold of mucous membrane covering its surface, the **pyloric valve**. They are continuous with the circular fibers of the esophagus, but are sharply marked off from the circular fibers of the duodenum.

The *oblique fibers* (*fibræ obliquæ*) internal to the circular layer, are limited chiefly to the cardiac end of the stomach, where they are disposed as a thick uniform layer, covering both surfaces, some passing obliquely from left to right, others from right to left, around the cardiac end.

The **areolar or submucous coat** (*tela submucosa*) consists of a loose, areolar tissue, connecting the mucous and muscular layers.

The **mucous membrane** (*tunica mucosa*) is thick and its surface is smooth, soft, and velvety. In the fresh state it is of a pinkish tinge at the pyloric end, and of a red or reddish-brown color over the rest of its surface. In infancy it is of a brighter hue, the vascular redness being more marked. It is thin at the cardiac extremity, but thicker toward the pylorus. During the contracted state of the organ it is thrown into numerous plaits or rugæ, which, for the most part, have a longitudinal direction, and are most marked toward the pyloric end of the stomach, and along the greater curvature (Fig. 1050). These folds are entirely obliterated when the organ becomes distended.

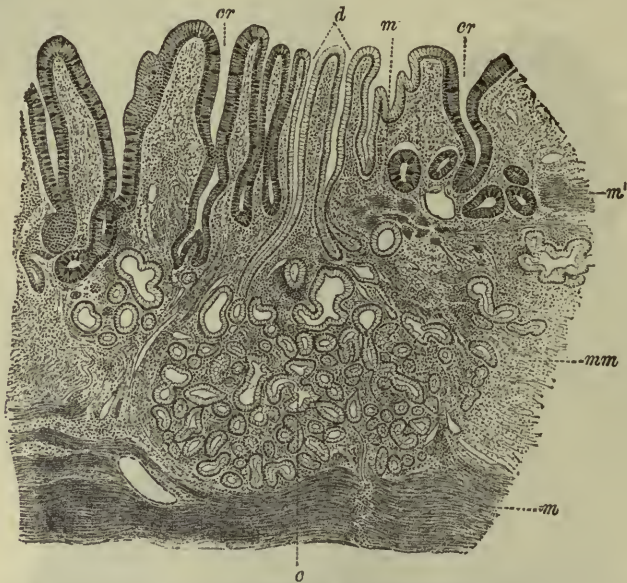

FIG. 1053.—Section of mucous membrane of human stomach, near the cardiac orifice. (v. Ebner, after J. Schaffer.) X 45. *c.* Cardiac glands. *d.* Their ducts. *cr.* Gland similar to the intestinal glands, with goblet cells. *mm.* Mucous membrane. *m.* Muscularis mucosæ. *m'.* Muscular tissue within the mucous membrane.

Structure of the Mucous Membrane.—When examined with a lens, the inner surface of the mucous membrane presents a peculiar honeycomb appearance from being covered with small shallow depressions or alveoli, of a polygonal or hexagonal form, which vary from 0.12 to 0.25 mm. in diameter. These are the ducts of the gastric glands, and at the bottom of each may be seen one or more minute orifices, the openings of the gland tubes. The surface of the mucous membrane is covered by a single layer of columnar epithelium with occasional goblet cells. This epithelium commences very abruptly at the cardiac orifice, where there is a sudden transition from the stratified epithelium of the esophagus. The epithelial lining of the gland ducts is of the same character and is continuous with the general epithelial lining of the stomach (Fig. 1055).

The Gastric Glands.—The gastric glands are of three kinds: (*a*) **pyloric**, (*b*) **cardiac**, and (*c*) **fundus** or **oxyntic glands**. They are tubular in character, and are formed of a delicate basement membrane, consisting of flattened transparent endothelial cells lined by epithelium. The **pyloric glands** (Fig. 1054) are found in the pyloric portion of the stomach. They consist of two or three short closed tubes opening into a common duct or mouth. These tubes are wavy, and are about one-half the length of the duct. The duct is lined by columnar cells, continuous with the epithelium lining the surface of the mucous membrane of the stomach, the tubes by shorter and more cubical cell which are finely granular. The **cardiac glands** (Fig. 1053), few in number, occur close to the cardiac orifice. They are of two kinds: (1) simple tubular glands resembling those of the pyloric end of the stomach, but with short ducts; (2) compound racemose glands resembling the duodenal glands. The **fundus glands** (Fig. 1055) are found in the body and fundus of the stomach; they are simple tubes, two or more of which

open into a single duct. The duct, however, in these glands is shorter than in the pyloric variety, sometimes not amounting to more than one-sixth of the whole length of the gland; it is lined throughout by columnar epithelium. The gland tubes are straight and parallel to each other. At the point where they open into the duct, which is termed the neck, the epithelium alters, and consists of short columnar or polyhedral, granular cells, which almost fill the tube, so that the lumen becomes suddenly constricted and is continued down as a very fine channel. They are known as the **chief** or **central cells** of the glands. Between these cells and the basement membrane, larger oval cells, which stain deeply with eosin, are found; these cells are studded throughout the tube at intervals, giving it a beaded or varicose appearance. These are known as the **parietal** or **oxyntic cells**, and they are connected with the lumen by fine channels which run into their substance. Between the glands the mucous membrane consists of a connective-tissue frame-work, with lymphoid tissue. In places, this latter tissue, especially in early life, is collected into little masses, which to a certain extent resemble the solitary nodules of the intestine, and are termed the **lenticular glands** of the stomach. They are not, however, so distinctly circumscribed as the solitary nodules. Beneath the mucous membrane, and between it and the submucous coat, is a thin stratum of involuntary muscular fiber (*muscularis mucosa*), which in some parts consists only of a single longitudinal layer; in others of two layers, an inner circular and an outer longitudinal.

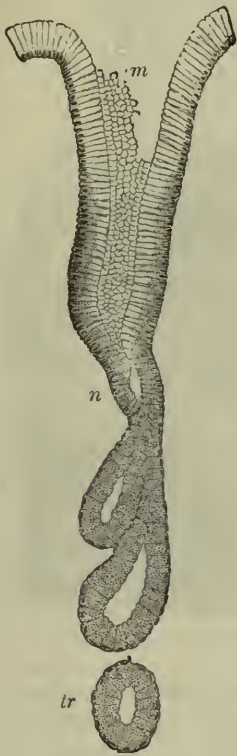


FIG. 1054.—A pyloric gland, from a section of the dog's stomach. (Ebstein.) *m*. Mouth. *n*. Neck. *tr*. A deep portion of a tubule cut transversely.

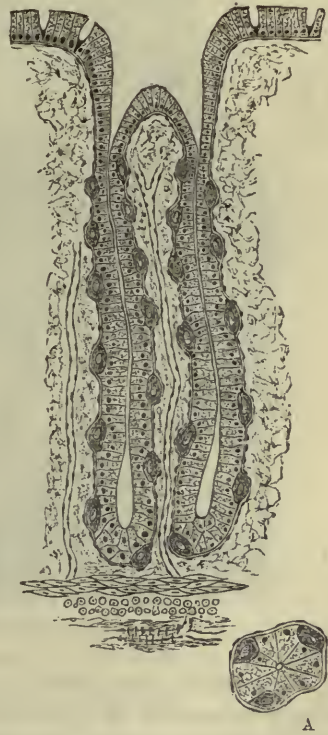

FIG. 1055.—A fundus gland. *A*. Transverse section of gland.

Vessels and Nerves.—The arteries supplying the stomach are: the left gastric, the right gastric and right gastroepiploic branches of the hepatic, and the left gastroepiploic and short gastric branches of the lienal. They supply the muscular coat, ramify in the submucous coat, and are finally distributed to the mucous membrane. The arrangement of the vessels in the mucous membrane is somewhat peculiar. The arteries break up at the base of the gastric tubules into a plexus of fine capillaries which run upward between the tubules, anastomosing with each other, and ending in a plexus of larger capillaries, which surround the mouths of the tubes, and also form hexagonal meshes around the ducts. From these the **veins** arise, and pursue a straight course downward, between the tubules, to the submucous tissue; they end either in the lienal and superior mesenteric veins, or directly in the portal vein. The **lymphatics** are numerous: they consist of a superficial and a deep set, and pass to the lymph glands found along the two curvatures of the organ (page 706). The **nerves** are the terminal branches of the right and left

vagi, the former being distributed upon the back, and the latter upon the front part of the organ. A great number of branches from the celiac plexus of the sympathetic are also distributed to it. Nerve plexuses are found in the submucous coat and between the layers of the muscular coat as in the intestine. From these plexuses fibrils are distributed to the muscular tissue and the mucous membrane.

The Small Intestine (Intestinum Tenue).

The **small intestine** is a convoluted tube, extending from the pylorus to the colic valve, where it ends in the large intestine. It is about 7 metres long,¹ and gradually diminishes in size from its commencement to its termination. It is contained in the central and lower part of the abdominal cavity, and is surrounded above and at the sides by the large intestine; a portion of it extends below the superior aperture of the pelvis and lies in front of the rectum. It is in relation, in front, with the greater omentum and abdominal parietes, and is connected to the vertebral column by a fold of peritoneum, the **mesentery**. The small intestine is divisible into three portions: the **duodenum**, the **jejunum**, and the **ileum**.

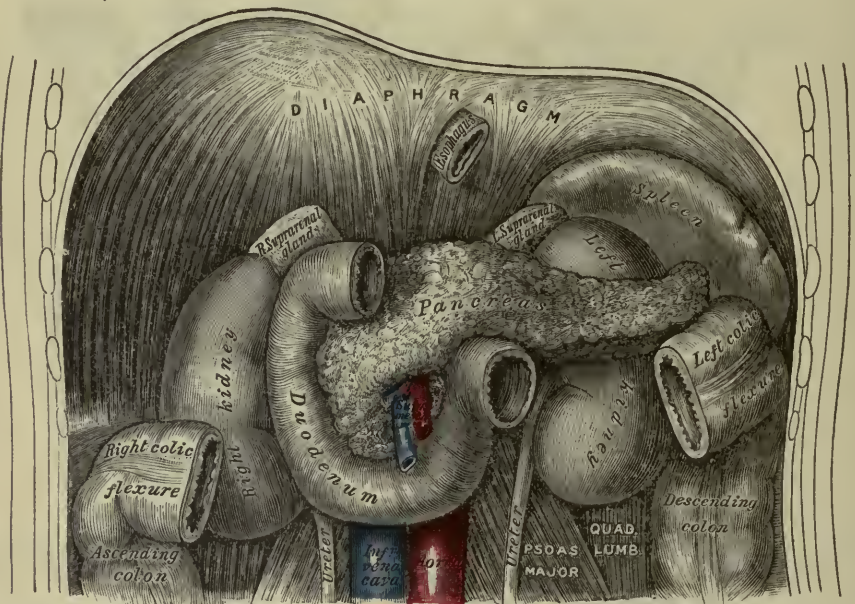


FIG. 1056.—The duodenum and pancreas.

The **Duodenum** (Fig. 1056) has received its name from being about equal in length to the breadth of twelve fingers (25 cm.). It is the shortest, the widest, and the most fixed part of the small intestine, and has no mesentery, being only partially covered by peritoneum. Its course presents a remarkable curve, somewhat of the shape of an imperfect circle, so that its termination is not far removed from its starting-point.

In the adult the course of the duodenum is as follows: commencing at the pylorus it passes backward, upward, and to the right, beneath the quadrate lobe of the liver to the neck of the gall-bladder, varying slightly in direction according to the degree of distension of the stomach: it then takes a sharp curve and descends along the right margin of the head of the pancreas, for a variable distance, generally to the level of the upper border of the body of the fourth lumbar vertebra. It

¹ Treves states that, in one hundred cases, the average length of the small intestine in the adult male was 22 feet 6 inches, and in the adult female 23 feet 4 inches; but that it varies very much, the extremes in the male being 31 feet 10 inches, and 15 feet 6 inches. He states that in the adult the length of the bowel is independent of age, height, and weight.

now takes a second bend, and passes from right to left across the vertebral column, having a slight inclination upward; and on the left side of the vertebral column it ascends for about 2.5 cm., and then ends opposite the second lumbar vertebra in the jejunum. As it unites with the jejunum it turns abruptly forward, forming the **duodenojejunal flexure**. From the above description it will be seen that the duodenum may be divided into four portions: **superior, descending, horizontal, and ascending**.

Relations.—The **superior portion** (*pars superior; first portion*) is about 5 cm. long. Beginning at the pylorus, it ends at the neck of the gall-bladder. It is the most movable of the four portions. It is almost completely covered by peritoneum, but a small part of its posterior surface near the neck of the gall-bladder and the inferior

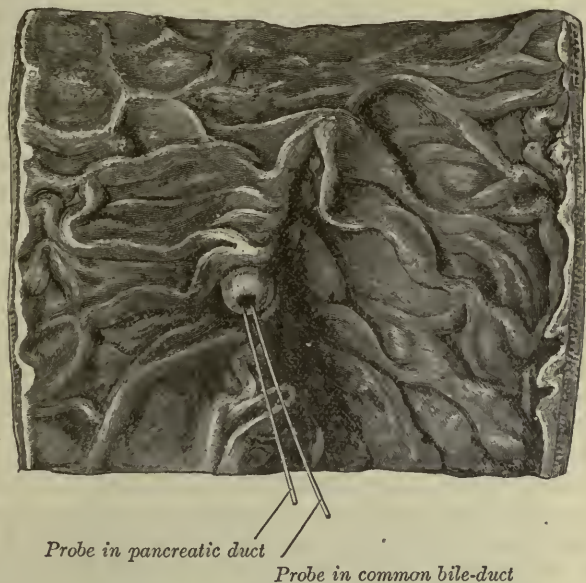

FIG. 1057.—Interior of the descending portion of the duodenum, showing bile papilla.

vena cava is uncovered; the upper border of its first half has the hepatoduodenal ligament attached to it, while to the lower border of the same segment the greater omentum is connected. It is in such close relation with the gall-bladder that it is usually found to be stained by bile after death, especially on its anterior surface. It is in relation above and in front with the quadrate lobe of the liver and the gall-bladder; behind with the gastroduodenal artery, the common bile duct, and the portal vein; and below and behind with the head and neck of the pancreas.

The **descending portion** (*pars descendens; second portion*) is from 7 to 10 cm. long, and extends from the neck of the gall-bladder, on a level with the first lumbar vertebra, along the right side of the vertebral column as low as the upper border of the body of the fourth lumbar vertebra. It is crossed in its middle third by the transverse colon, the posterior surface of which is uncovered by peritoneum and is connected to the duodenum by a small quantity of connective tissue. The supra- and infracolic portions are covered in front by peritoneum, the infracolic part by the right leaf of the mesentery. Posteriorly the descending portion of the duodenum is not covered by peritoneum. The descending portion is in relation, in front, from above downward, with the duodenal impression on the right lobe of the liver, the transverse colon, and the small intestine; behind, it has a variable relation to the front of the right kidney in the neighborhood of the hilum, and is connected to it by loose areolar tissue; the renal vessels, the inferior vena cava, and the Psoas below,

are also behind it. At its medial side is the head of the pancreas, and the common bile duct; to its lateral side is the right colic flexure. The common bile duct and the pancreatic duct together perforate the medial side of this portion of the intestine obliquely (Figs. 1057 and 1100), some 7 to 10 cm. below the pylorus; the accessory pancreatic duct sometimes pierces it about 2 cm. above and slightly in front of these.

The **horizontal portion** (*pars horizontalis*; *third or preaortic or transverse portion*) is from 5 to 7.5 cm. long. It begins at the right side of the upper border of the fourth lumbar vertebra and passes from right to left, with a slight inclination upward, in front of the great vessels and crura of the diaphragm, and ends in the ascending portion in front of the abdominal aorta. It is crossed by the superior mesenteric vessels and the mesentery. Its front surface is covered by peritoneum, except near the middle line, where it is crossed by the superior mesenteric vessels. Its posterior surface is uncovered by peritoneum, except toward its left extremity, where the posterior layer of the mesentery may sometimes be found covering it to a variable extent. This surface rests upon the right crus of the diaphragm, the inferior vena cava, and the aorta. The upper surface is in relation with the head of the pancreas.

The **ascending portion** (*pars ascendens*; *fourth portion*) of the duodenum is about 2.5 cm long. It ascends on the left side of the aorta, as far as the level of the upper border of the second lumbar vertebra, where it turns abruptly forward to become the jejunum, forming the **duodenojejunal flexure**. It lies in front of the left Psoas major and left renal vessels, and is covered in front, and partly at the sides, by peritoneum continuous with the left portion of the mesentery.

The superior part of the duodenum, as stated above, is somewhat movable, but the rest is practically fixed, and is bound down to neighboring viscera and the posterior abdominal wall by the peritoneum. In addition to this, the ascending part of the duodenum and the duodenojejunal flexure are fixed by a structure to which the name of *Musculus suspensorius duodeni* has been given. This structure commences in the connective tissue around the celiac artery and left crus of the diaphragm, and passes downward to be inserted into the superior border of the duodenojejunal curve and a part of the ascending duodenum, and from this it is continued into the mesentery. It possesses, according to Treitz, plain muscular fibers mixed with the fibrous tissue of which it is principally made up. It is of little importance as a muscle, but acts as a suspensory ligament.

Vessels and Nerves.—The **arteries** supplying the duodenum are the right gastric and superior pancreaticoduodenal branches of the hepatic, and the inferior pancreaticoduodenal branch of the superior mesenteric. The **veins** end in the lienal and superior mesenteric. The **nerves** are derived from the celiac plexus.

Jejunum and Ileum.—The remainder of the small intestine from the end of the duodenum is named **jejunum** and **ileum**; the former term being given to the upper two-fifths and the latter to the lower three-fifths. There is no morphological line of distinction between the two, and the division is arbitrary; but at the same time the character of the intestine gradually undergoes a change from the commencement of the jejunum to the end of the ileum, so that a portion of the bowel taken from these two situations would present characteristic and marked differences. These are briefly as follows:

The **Jejunum** (*intestinum jejunum*) is wider, its diameter being about 4 cm., and is thicker, more vascular, and of a deeper color than the ileum, so that a given length weighs more. The circular folds (*valvula conniventes*) of its mucous membrane are large and thickly set, and its villi are larger than in the ileum. The aggregated lymph nodules are almost absent in the upper part of the jejunum, and in the lower part are less frequently found than in the ileum, and are smaller and tend to assume a circular form. By grasping the jejunum between the finger and thumb the circular folds can be felt through the walls of the gut; these being absent in

the lower part of the ileum, it is possible in this way to distinguish the upper from the lower part of the small intestine.

The **Ileum** (*intestinum ileum*) is narrow, its diameter being 3.75 cm., and its coats thinner and less vascular than those of the jejunum. It possesses but few circular folds, and they are small and disappear entirely toward its lower end, but aggregated lymph nodules (Peyer's patches) are larger and more numerous. The jejunum for the most part occupies the umbilical and left iliac regions, while

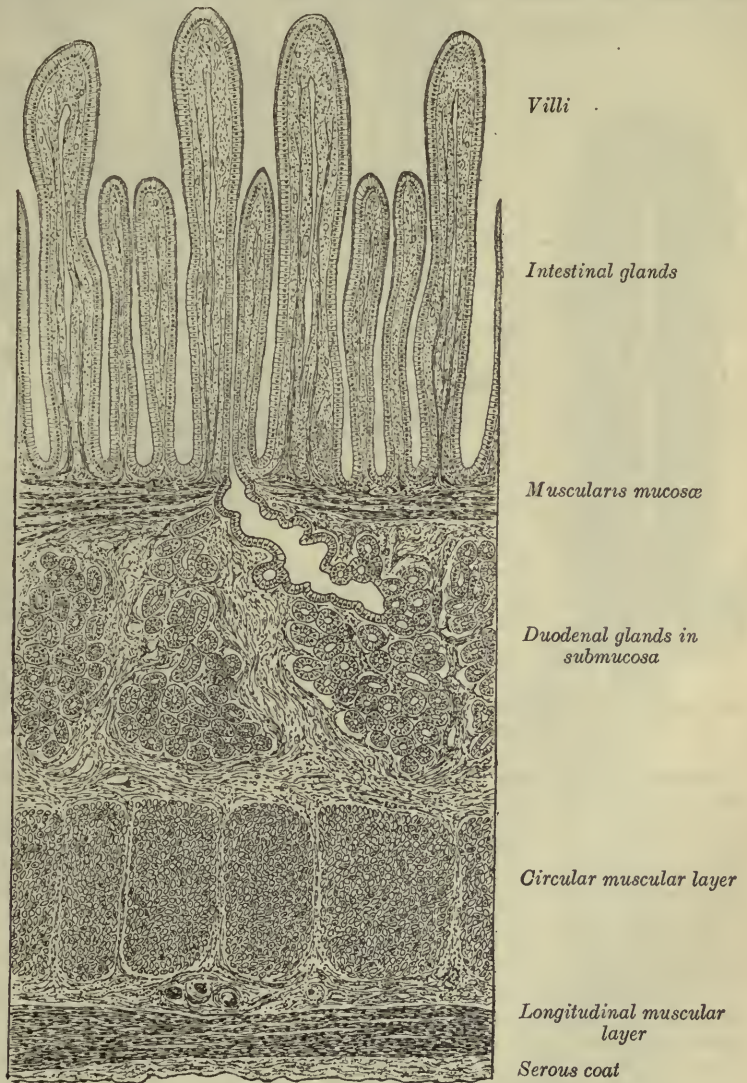


FIG. 1058.—Section of duodenum of cat. (After Schäfer.) $\times 60$.

the ileum occupies chiefly the umbilical, hypogastric, right iliac, and pelvic regions. The terminal part of the ileum usually lies in the pelvis, from which it ascends over the right Psoas and right iliac vessels; it ends in the right iliac fossa by opening into the medial side of the commencement of the large intestine. The jejunum and ileum are attached to the posterior abdominal wall by an extensive fold of peritoneum, the **mesentery**, which allows the freest motion, so that each coil can accommodate itself to changes in form and position. The mesentery is fan-shaped;

its posterior border or root, about 15 cm. long, is attached to the posterior abdominal wall from the left side of the body of the second lumbar vertebra to the right sacroiliac articulation, crossing successively the horizontal part of the duodenum, the aorta, the inferior vena cava, the ureter, and right Psoas muscle (Fig. 1040). Its breadth between its vertebral and intestinal borders averages about 20 cm., and is greater in the middle than at its upper and lower ends. According to Lockwood it tends to increase in breadth as age advances. Between the two layers of which it is composed are contained bloodvessels, nerves, lacteals, and lymph glands, together with a variable amount of fat.

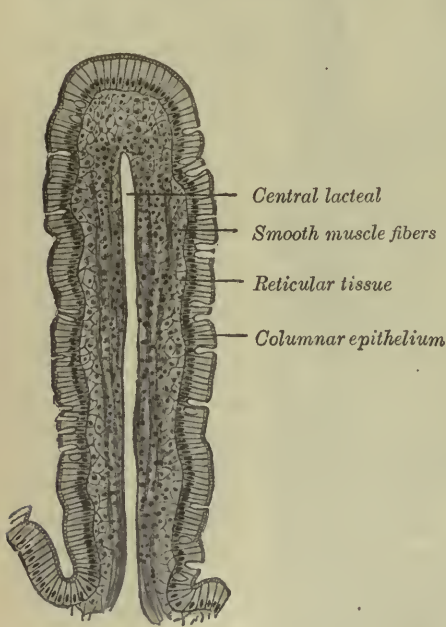


FIG. 1059.—Vertical section of a villus from the dog's small intestine. $\times 80$.

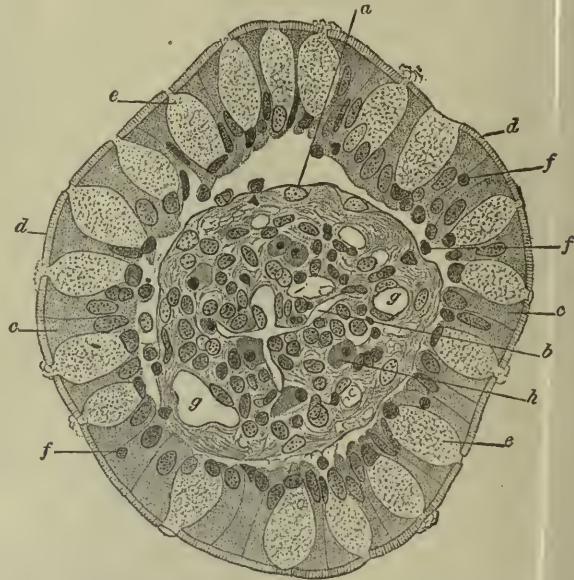


FIG. 1060.—Transverse section of a villus, from the human intestine. (v. Ebner.) $\times 350$. *a*, Basement membrane, here somewhat shrunken away from the epithelium. *b*, Lacteal. *c*, Columnar epithelium. *d*, Its striated border. *e*, Goblet cells. *f*, Leucocytes in epithelium. *f'*, Leucocytes below epithelium. *g*, Bloodvessels. *h*, Muscle cells cut across.

Meckel's Diverticulum (*diverticulum ilei*).—This consists of a pouch which projects from the lower part of the ileum in about 2 per cent. of subjects. Its average position is about 1 meter above the colic valve, and its average length about 5 cm. Its caliber is generally similar to that of the ileum, and its blind extremity may be free or may be connected with the abdominal wall or with some other portion of the intestine by a fibrous band. It represents the remains of the proximal part of the vitelline duct, the duct of communication between the yolk-sac and the primitive digestive tube in early fetal life.

Structure.—The wall of the small intestine (Fig. 1058) is composed of four coats: **serous, muscular, areolar, and mucous.**

The **serous coat** (*tunica serosa*) is derived from the peritoneum. The superior portion of the duodenum is almost completely surrounded by this membrane near its pyloric end, but is only covered in front at the other extremity; the descending portion is covered by it in front, except where it is carried off by the transverse colon; and the inferior portion lies behind the peritoneum which passes over it without being closely incorporated with the other coats of this part of the intestine, and is separated from it in and near the middle line by the superior mesenteric vessels. The rest of the small intestine is surrounded by the peritoneum, excepting along its attached or mesenteric border; here a space is left for the vessels and nerves to pass to the gut.

The **muscular coat** (*tunica muscularis*) consists of two layers of unstriated fibers: an external, longitudinal, and an internal, circular layer. The *longitudinal fibers* are thinly scattered over the surface of the intestine, and are more distinct along its free border. The *circular fibers* form a thick, uniform layer, and are composed of plain muscle cells of considerable length. The muscular coat is thicker at the upper than at the lower part of the small intestine.

The **areolar or submucous coat** (*tela submucosa*) connects together the mucous and muscular layers. It consists of loose, filamentous areolar tissue containing bloodvessels, lymphatics, and nerves. It is the strongest layer of the intestine.

The **mucous membrane** (*tunica mucosa*) is thick and highly vascular at the upper part of the small intestine, but somewhat paler and thinner below. It consists of the following structures:

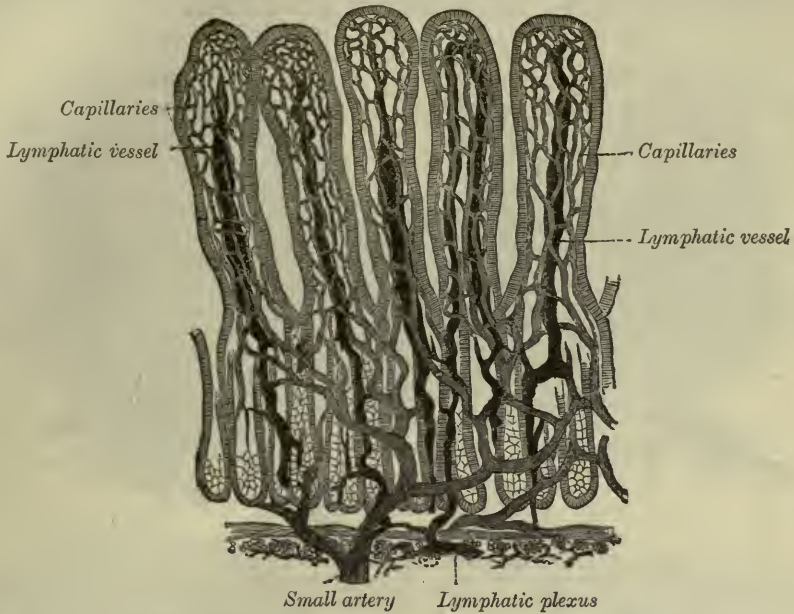


FIG. 1061.—Villi of small intestine, showing bloodvessels and lymphatic vessels. (Cadiat.)

next the areolar or submucous coat is a double layer of unstriated muscular fibers, outer longitudinal and inner circular, the **muscularis mucosæ**; internal to this is a quantity of retiform tissue, enclosing in its meshes lymph corpuscles, and in this the bloodvessels and nerves ramify; lastly, a basement membrane, supporting a single layer of epithelial cells, which throughout the intestine are columnar in character. The cells are granular in appearance, and each possesses a clear oval nucleus. At their superficial or unattached ends they present a distinct layer of highly refracting material, marked by vertical striæ, the **striated border**.

The mucous membrane presents for examination the following structures, contained within it or belonging to it:

- | | |
|--------------------|-------------------------------|
| Circular folds. | Duodenal glands. |
| Villi. | Solitary lymphatic nodules. |
| Intestinal glands. | Aggregated lymphatic nodules. |

The **circular folds** (*plicæ circulares* [Kerkringi]; *valvulae conniventes*; *valves of Kerkring*) are large valvular flaps projecting into the lumen of the bowel. They are composed of reduplications of the mucous membrane, the two layers of the fold being bound together by submucous tissue; unlike the folds in the stomach, they are permanent, and are not obliterated when the intestine is distended. The majority extend transversely around the cylinder of the intestine for about one-half or two-thirds of its circumference, but some form complete circles, and others have a spiral direction; the latter usually extend a little more than once around the bowel, but occasionally two or three times. The larger folds are about 8 mm. in depth at their broadest part; but the greater number are of smaller size. The larger and smaller folds alternate with each other. They are not found at the commencement of the duodenum, but begin to appear about 2.5 or 5 cm. beyond the pylorus. In the lower part of the descending portion, below the point where the bile and pancreatic ducts enter the intestine, they are very large and closely approximated. In the horizontal and ascending portions of the duodenum and upper half of the jejunum they are large and numerous, but

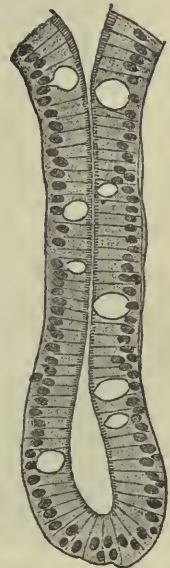


FIG. 1062.—An intestinal gland from the human intestine. (Flemming.)

from this point, down to the middle of the ileum, they diminish considerably in size. In the lower part of the ileum they almost entirely disappear; hence the comparative thinness of this portion of the intestine, as compared with the duodenum and jejunum. The circular folds retard the passage of the food along the intestines, and afford an increased surface for absorption.

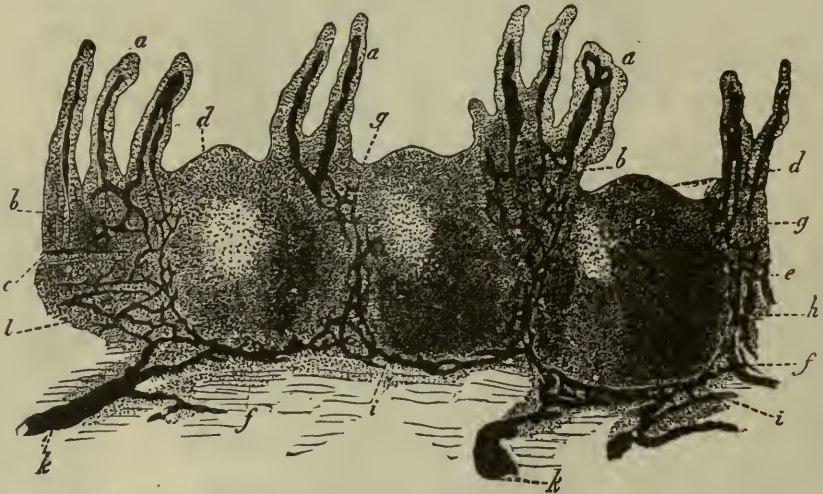


FIG. 1063.—Vertical section of a human aggregated lymphatic nodule, injected through its lymphatic canals. *a*. Villi with their chyle passages. *b*. Intestinal glands. *c*. Muscularis mucosae. *d*. Cupola or apex of solitary nodule. *e*. Mesial zone of nodule. *f*. Base of nodule. *g*. Points of exit of the lacteals from the villi, and entrance into the true mucous membrane. *h*. Retiform arrangement of the lymphatics in the mesial zone. *i*. Course of the latter at the base of the nodule. *k*. Confluence of the lymphatics opening into the vessels of the submucous tissue. *l*. Follicular tissue of the latter.

The **intestinal villi** (*villi intestinales*) are highly vascular processes, projecting from the mucous membrane of the small intestine throughout its whole extent, and giving to its surface a velvety appearance. They are largest and most numerous in the duodenum and jejunum, and become fewer and smaller in the ileum.

Structure of the villi (Figs. 1059, 1060).—The essential parts of a villus are: the lacteal vessel, the bloodvessels, the epithelium, the basement-membrane, and the muscular tissue of the mucosa, all being supported and held together by retiform lymphoid tissue.

The *lacteals* are in some cases double, and in some animals multiple, but usually there is a single vessel. Situated in the axis of the villus, each commences by dilated cecal extremities near to, but not quite at, the summit of the villus. The walls are composed of a single layer of endothelial cells.

The *muscular fibers* are derived from the muscularis mucosae, and are arranged in longitudinal bundles around the lacteal vessel, extending from the base to the summit of the villus, and giving off, laterally, individual muscle cells, which are enclosed by the reticulum, and by it are attached to the basement-membrane and to the lacteal.

The *bloodvessels* (Fig. 1061) form a plexus under the basement membrane, and are enclosed in the reticular tissue.

These structures are surrounded by the *basement membrane*, which is made up of a stratum

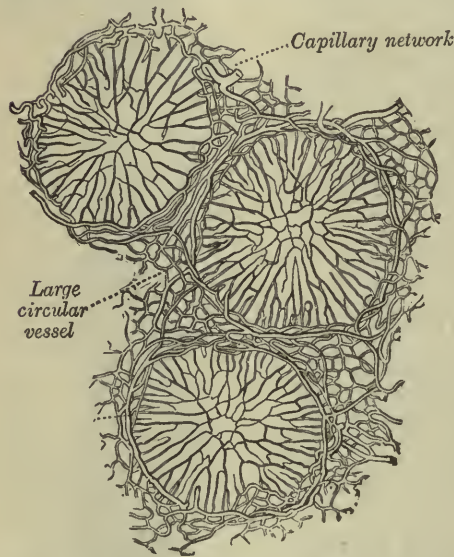


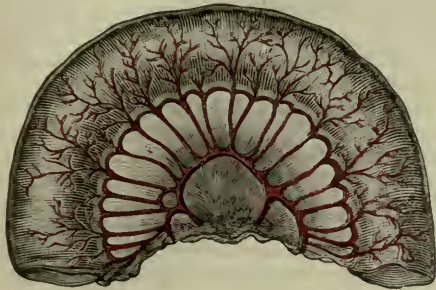FIG. 1064.—Transverse section through the equatorial plane of three aggregated lymphatic nodules from the rabbit.

of endothelial cells, and upon this is placed a layer of *columnar epithelium*, the characteristics of which have been described. The *retiform tissue* forms a net-work (Fig. 1030) in the meshes of which a number of leucocytes are found.

The **intestinal glands** (*glandulae intestinales* [*Lieberkühni*]; *crypts of Lieberkühn*) (Fig. 1062) are

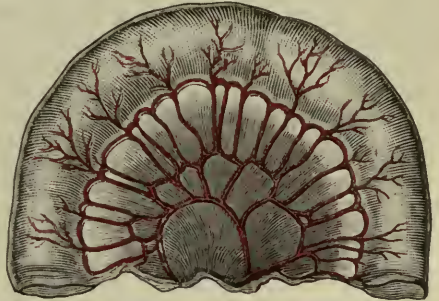
found in considerable numbers over every part of the mucous membrane of the small intestine. They consist of minute tubular depressions of the mucous membrane, arranged perpendicularly to the surface, upon which they open by small circular apertures. They may be seen with the aid

FIG. 1065



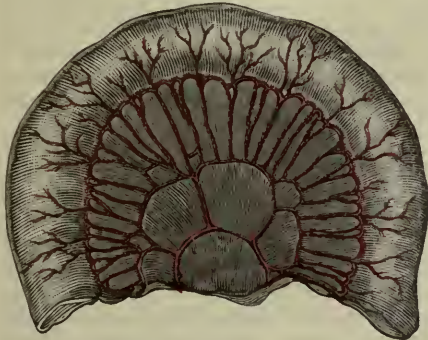Three feet.

FIG. 1066



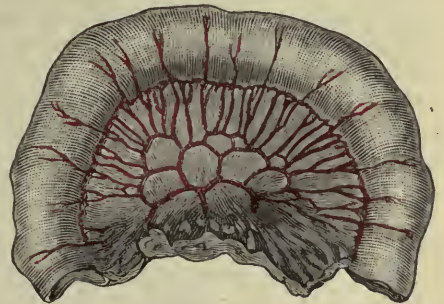
Six feet.

FIG. 1067



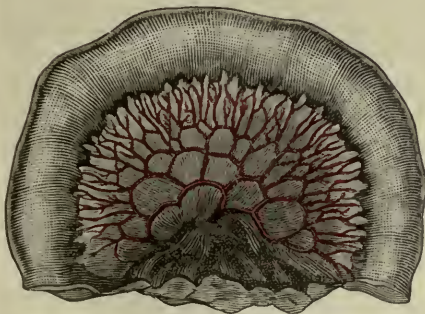
Nine feet.

FIG. 1068



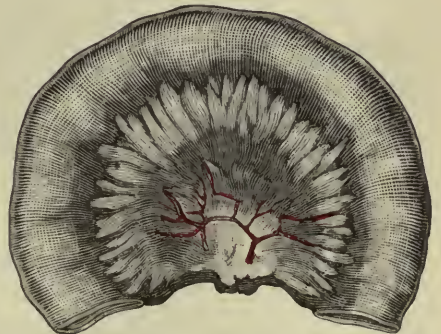Twelve feet.

FIG. 1069



Seventeen feet.

FIG. 1070



Twenty feet.

FIGS. 1065, 1066, 1067, 1068, 1069, 1070.—Diagrams showing the arrangement and variations of the loops of the mesenteric vessels for various segments of the small intestine of average length. Nearest the duodenum the mesenteric loops are primary, the vasa recta are long and regular in distribution, and the translucent spaces (lunettes) are extensive. Toward the ileocolic junction, secondary and tertiary loops are observed, the vessels are smaller and become obscured by numerous fat-tabs. (After Monks.)

of a lens, their orifices appearing as minute dots scattered between the villi. Their walls are thin, consisting of a basement membrane lined by columnar epithelium, and covered on their exterior by capillary vessels.

The **duodenal glands** (*glandulae duodenales* [Brunneri]; *Brunner's glands*) are limited to the duodenum (Fig. 1058), and are found in the submucous areolar tissue. They are largest and most numerous near the pylorus, forming an almost complete layer in the superior portion and upper half of the descending portions of the duodenum. They then begin to diminish in number, and practically disappear at the junction of the duodenum and jejunum. They are small compound acinotubular glands consisting of a number of alveoli lined by short columnar epithelium and opening by a single duct on the inner surface of the intestine.

The **solitary lymphatic nodules** (*noduli lymphatici solitarii*; *solitary glands*) are found scattered throughout the mucous membrane of the small intestine, but are most numerous in the lower part of the ileum. Their free surfaces are covered with rudimentary villi, except at the summits, and each gland is surrounded by the openings of the intestinal glands. Each consists of a dense interlacing retiform tissue closely packed with lymph-corpuscles, and permeated with an abundant capillary network. The interspaces of the retiform tissue are continuous with larger lymph spaces which surround the gland, through which they communicate with the lacteal system. They are situated partly in the submucous tissue, partly in the mucous membrane, where they form slight projections of its epithelial layer (see Fig. 1082).

The **aggregated lymphatic nodules** (*noduli lymphatici aggregati*; *Peyer's patches*; *Peyer's glands*; *agminated follicles*; *tonsillae intestinales*) (Fig. 1063) form circular or oval patches, from twenty to thirty in number, and varying in length from 2 to 10 cm. They are largest and most numerous in the ileum. In the lower part of the jejunum they are small, circular, and few in number. They are occasionally seen in the duodenum. They are placed lengthwise in the intestine, and are situated in the portion of the tube most distant from the attachment of the mesentery. Each patch is formed of a group of solitary lymphatic nodules covered with mucous membrane, but the patches do not, as a rule, possess villi on their free surfaces. They are best marked in the young subject, become indistinct in middle age, and sometimes disappear altogether in advanced life. They are freely supplied with bloodvessels (Fig. 1064), which form an abundant plexus around each follicle and give off fine branches permeating the lymphoid tissue in the interior of the follicle. The lymphatic plexuses are especially abundant around these patches.

Vessels and Nerves.—The jejunum and ileum are supplied by the **superior mesenteric artery**, the intestinal branches of which, having reached the attached border of the bowel, run between

the serous and muscular coats, with frequent in-osculations to the free border, where they also anastomose with other branches running around the opposite surface of the gut. From these vessels numerous branches are given off, which pierce the muscular coat, supplying it and forming an intricate plexus in the submucous tissue. From this plexus minute vessels pass to the glands and villi of the mucous membrane. The **veins** have a similar course and arrangement to the

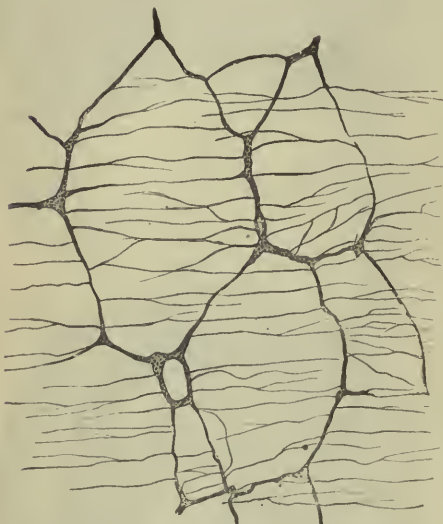


FIG. 1071.—The myenteric plexus from the rabbit.
× 50.

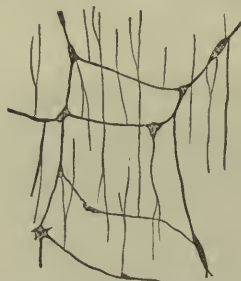


FIG. 1072.—The plexus of the submucosa from the rabbit
× 50.

arteries. The **lymphatics** of the small intestine (lacteals) are arranged in two sets, those of the mucous membrane and those of the muscular coat. The lymphatics of the villi commence in these structures in the manner described above. They form an intricate plexus in the mucous and submucous tissue, being joined by the lymphatics from the lymph spaces at the bases of the solitary nodules, and from this pass to larger vessels at the mesenteric border of the gut. The lymphatics of the muscular coat are situated to a great extent between the two layers of muscular fibers, where they form a close plexus; throughout their course they communicate freely with

the lymphatics from the mucous membrane, and empty themselves in the same manner as these into the origins of the lacteal vessels at the attached border of the gut.

The **nerves** of the small intestines are derived from the plexuses of sympathetic nerves around the superior mesenteric artery. From this source they run to the **myenteric plexus** (*Auerbach's plexus*) (Fig. 1071) of nerves and ganglia situated between the circular and longitudinal muscular fibers from which the nervous branches are distributed to the muscular coats of the intestine. From this a secondary plexus, the **plexus of the submucosa** (*Meissner's plexus*) (Fig. 1072) is derived, and is formed by branches which have perforated the circular muscular fibers. This plexus lies in the submucous coat of the intestine; it also contains ganglia from which nerve fibers pass to the muscularis mucosæ and to the mucous membrane. The nerve bundles of the submucous plexus are finer than those of the myenteric plexus.

The Large Intestine (*Intestinum Crassum*).

The **large intestine** extends from the end of the ileum to the anus. It is about 1.5 meters long, being one-fifth of the whole extent of the intestinal canal. Its caliber is largest at its commencement at the cecum, and gradually diminishes as far as the rectum, where there is a dilatation of considerable size just above the anal canal. It differs from the small intestine in its greater caliber, its more fixed position, its sacculated form, and in possessing certain appendages to its external coat, the **appendices epiploicæ**. Further, its longitudinal muscular fibers do not form a continuous layer around the gut, but are arranged in three **longitudinal bands** or **tæniæ**. The large intestine, in its course, describes an arch which surrounds the convolutions of the small intestine. It commences in the right iliac region, in a dilated part, the **cecum**. It ascends through the right lumbar and hypochondriac regions to the under surface of the liver; it here takes a bend, the **right colic flexure**, to the left and passes transversely across the abdomen on the confines of the epigastric and umbilical regions, to the left hypochondriac region; it then bends again, the **left colic flexure**, and descends through the left lumbar and iliac regions to the pelvis, where it forms a bend called the **sigmoid flexure**; from this it is continued along the posterior wall of the pelvis to the anus. The large intestine is divided into the **cecum, colon, rectum, and anal canal**.

The **Cecum** (*intestinum cæcum*) (Fig. 1073), the commencement of the large intestine, is the large blind pouch situated below the colic valve. Its blind end is directed downward, and its open end upward, communicating directly with the colon, of which this blind pouch appears to be the beginning or head, and hence the old name of **caput cæcum coli** was applied to it. Its size is variously estimated by different authors, but on an average it may be said to be 6.25 cm. in length and 7.5 in breadth. It is situated in the right iliac fossa, above the lateral half of the inguinal ligament: it rests on the Iliacus and Psoas major, and usually lies in contact with the anterior abdominal wall, but the greater omentum and, if the cecum be empty, some coils of small intestine may lie in front of it. As a rule, it is entirely enveloped by peritoneum, but in a certain number of cases (5 per cent., Berry) the peritoneal covering is not complete, so that the upper part of the posterior surface is uncovered and connected to the iliac fascia by connective tissue. The cecum lies quite free in the abdominal cavity and enjoys a considerable amount of movement, so that it may become herniated down the right inguinal canal, and has occasionally been found in an inguinal hernia on the left side. The cecum varies in shape, but, according to Treves, in man it may be classified under one of four types. In early fetal life it is short, conical, and broad at the base, with its apex turned upward and medialward toward the ileocolic junction. It then resembles the cecum of some monkeys, *e. g.*, mangabey monkey. As the fetus grows the cecum increases in length more than in breadth, so that it forms a longer tube than in the primitive form and without the broad base, but with the same inclination of the apex toward the ileocolic junction. This form is seen in other monkeys, *e. g.*, the spider monkey. As development goes on, the lower part of the tube ceases to grow and the upper

part becomes greatly increased, so that at birth there is a narrow tube, the vermiform process, hanging from a conical projection, the cecum. This is the infantile form, and as it persists throughout life in about 2 per cent. of cases, it is regarded by Treves as the *first* of his four types of human ceca. The cecum is conical and the appendix rises from its apex. The three longitudinal bands start from the appendix and are equidistant from each other. In the second type, the conical cecum has become quadrate by the growing out of a saccule on either side of the anterior longitudinal band. These saccules are of equal size, and the appendix arises from between them, instead of from the apex of a cone. This type is found in about 3 per cent. of cases. The *third* type is the normal type of man. Here the two saccules, which in the second type were uniform, have grown at unequal rates: the right with greater rapidity than the left. In consequence of this an apparently new apex has been formed by the growing downward of the right saccule, and the original apex, with the appendix attached, is pushed over to the left

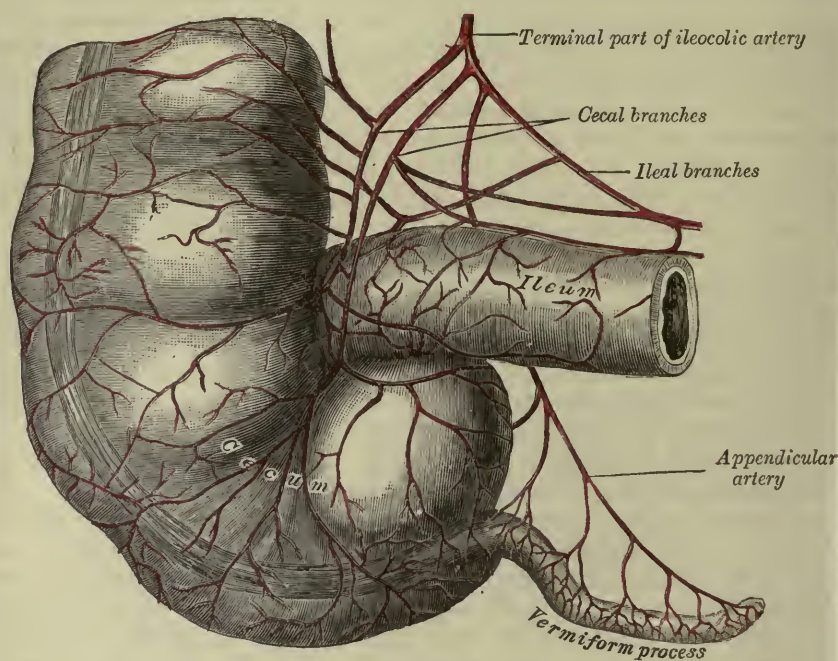


FIG. 1073.—The cecum and vermiform process, with their arteries.

toward the ileocolic junction. The three longitudinal bands still start from the base of the vermiform process, but they are now no longer equidistant from each other, because the right saccule has grown between the anterior and posterolateral bands, pushing them over to the left. This type occurs in about 90 per cent. of cases. The *fourth* type is merely an exaggerated condition of the third; the right saccule is still larger, and at the same time the left saccule has become atrophied, so that the original apex of the cecum, with the vermiform process, is close to the ileocolic junction, and the anterior band courses medialward to the same situation. This type is present in about 4 per cent. of cases.

The **Vermiform Process** or **Appendix** (*processus vermiformis*) (Fig. 1073) is a long, narrow, worm-shaped tube, which starts from what was originally the apex of the cecum, and may pass in one of several directions: upward behind the cecum; to the left behind the ileum and mesentery; or downward into the lesser pelvis. It varies from 2 to 20 cm. in length, its average being about 8.3 cm. It is retained in position by a fold of peritoneum (mesenteriole), derived from the left leaf of

the mesentery. This fold, in the majority of cases, is more or less triangular in shape, and as a rule extends along the entire length of the tube. Between its two layers and close to its free margin lies the appendicular artery (Fig. 1073). The canal of the vermiform process is small, extends throughout the whole length of the tube, and communicates with the cecum by an orifice which is placed below and behind the ileocecal opening. It is sometimes guarded by a semilunar valve formed by a fold of mucous membrane, but this is by no means constant.

Structure.—The coats of the vermiform process are the same as those of the intestine: serous, muscular, submucous, and mucous. The **serous coat** forms a complete investment for the tube, except along the narrow line of attachment of its mesenteriole in its proximal two-thirds. The *longitudinal muscular fibers* do not form three bands as in the greater part of the large intestine, but invest the whole organ, except at one or two points where both the longitudinal and circular fibers are deficient so that the peritoneal and submucous coats are contiguous over small areas.

The *circular muscle fibers* form a much thicker layer than the longitudinal fibers, and are separated from them by a small amount of connective tissue. The **submucous coat** is well marked, and contains a large number of masses of lymphoid tissue which cause the mucous membrane to bulge into the lumen and so render the latter of small size and irregular shape. The **mucous membrane** is lined by columnar epithelium and resembles that of the rest of the large intestine, but the intestinal glands are fewer in number (Fig. 1074).

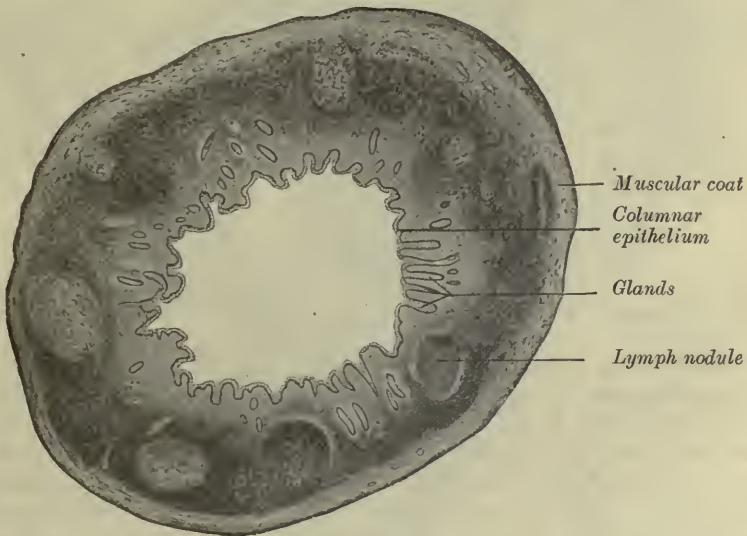


FIG. 1074.—Transverse section of human vermiform process. $\times 20$.

The Colic Valve (*valvula coli; ileocecal valve*) (Fig. 1075).—The lower end of the ileum ends by opening into the medial and back part of the large intestine, at the point of junction of the cecum with the colon. The opening is guarded by a valve, consisting of two segments or lips, which project into the lumen of the large intestine. If the intestine has been inflated and dried, the lips are of a semilunar shape. The upper one, nearly horizontal in direction, is attached by its convex border to the line of junction of the ileum with the colon; the lower lip, which is longer and more concave, is attached to the line of junction of the ileum with the cecum. At the ends of the aperture the two segments of the valve coalesce, and are continued as narrow membranous ridges around the canal for a short distance, forming the **frenula of the valve**. The left or anterior end of the aperture is rounded; the right or posterior is narrow and pointed. In the fresh condition, or in specimens which have been hardened *in situ*, the lips project as thick cushion-like folds into the lumen of the large gut, while the opening between them may present the appearance of a slit or may be somewhat oval in shape.

Each lip of the valve is formed by a reduplication of the mucous membrane and of the circular muscular fibers of the intestine, the longitudinal fibers and peritoneum being continued uninterruptedly from the small to the large intestine.

The surfaces of the valve directed toward the ileum are covered with villi, and present the characteristic structure of the mucous membrane of the small intestine; while those turned toward the large intestine are destitute of villi, and marked with the orifices of the numerous tubular glands peculiar to the mucous membrane of the large intestine. These differences in structure continue as far as the free margins of the valve. It is generally maintained that this valve prevents reflux from the cecum into the ileum, but in all probability it acts as a sphincter around the end of the ileum and prevents the contents of the ileum from passing too quickly into the cecum.

The **Colon** is divided into four parts: the ascending, transverse, descending, and sigmoid.

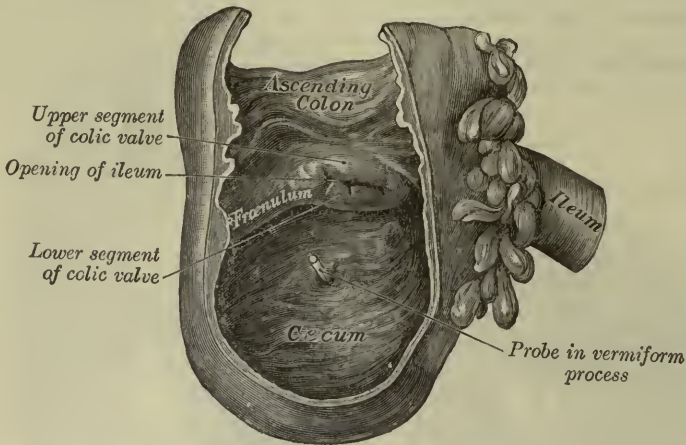


FIG. 1075.—Interior of the cecum and lower end of ascending colon, showing colic valve.

The **Ascending Colon** (*colon ascendens*) is smaller in caliber than the cecum, with which it is continuous. It passes upward, from its commencement at the cecum, opposite the colic valve, to the under surface of the right lobe of the liver, on the right of the gall-bladder, where it is lodged in a shallow depression, the **colic impression**; here it bends abruptly forward and to the left, forming the **right colic (hepatic) flexure** (Fig. 1056). It is retained in contact with the posterior wall of the abdomen by the peritoneum, which covers its anterior surface and sides, its posterior surface being connected by loose areolar tissue with the Iliacus, Quadratus lumborum, aponeurotic origin of Transversus abdominis, and with the front of the lower and lateral part of the right kidney. Sometimes the peritoneum completely invests it, and forms a distinct but narrow mesocolon.¹ It is in relation, in front, with the convolutions of the ileum and the abdominal parietes.

The **Transverse Colon** (*colon transversum*) the longest and most movable part of the colon, passes with a downward convexity from the right hypochondriac region across the abdomen, opposite the confines of the epigastric and umbilical zones, into the left hypochondriac region, where it curves sharply on itself beneath the lower end of the spleen, forming the **left colic (splenic) flexure**. In its course it describes an arch, the concavity of which is directed backward and a little upward; toward its splenic end there is often an abrupt U-shaped curve which may descend

¹ Treves states that, after a careful examination of one hundred subjects, he found that in fifty-two there was neither an ascending nor a descending mesocolon. In twenty-two there was a descending mesocolon, but no trace of a corresponding fold on the other side. In fourteen subjects there was a mesocolon to both the ascending and the descending segments of the bowel; while in the remaining twelve there was an ascending mesocolon, but no corresponding fold on the left side. It follows, therefore, that in performing lumbar colotomy a mesocolon may be expected upon the left side in 36 per cent. of all cases, and on the right in 26 per cent.—The Anatomy of the Intestinal Canal and Peritoneum in Man, 1885, p. 55.

lower than the main curve. It is almost completely invested by peritoneum, and is connected to the inferior border of the pancreas by a large and wide duplicature of that membrane, the **transverse mesocolon**. It is in relation, by its upper surface, with the liver and gall-bladder, the greater curvature of the stomach, and the lower end of the spleen; by its under surface, with the small intestine; by its anterior surface, with the anterior layers of the greater omentum and the abdominal parietes; its posterior surface is in relation from right to left with the descending portion of the duodenum, the head of the pancreas, and some of the convolutions of the jejunum and ileum.

The **left colic** or **splenic flexure** (Fig. 1056) is situated at the junction of the transverse and descending parts of the colon, and is in relation with the lower end of the spleen and the tail of the pancreas; the flexure is so acute that the end of the transverse colon usually lies in contact with the front of the descending colon. It lies at a higher level than, and on a plane posterior to, the right colic flexure, and is attached to the diaphragm, opposite the tenth and eleventh ribs, by a peritoneal fold, named the **phrenicocolic ligament**, which assists in supporting the lower end of the spleen (see page 1158).

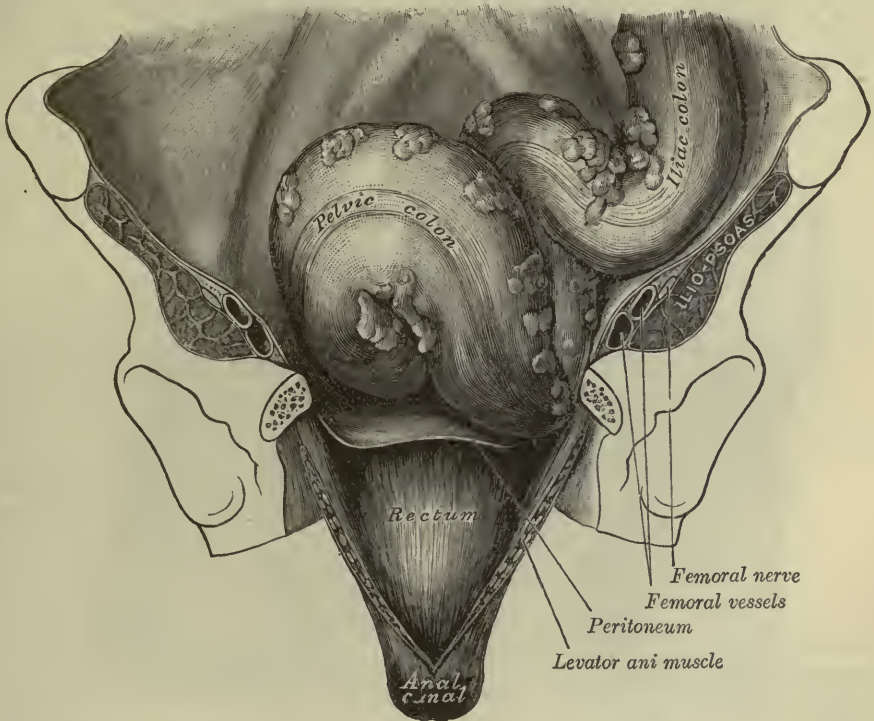


FIG. 1076.—Iliac colon, sigmoid or pelvic colon, and rectum seen from the front, after removal of pubic bones and bladder.

The **Descending Colon**¹ (*colon descendens*) passes downward through the left hypochondriac and lumbar regions along the lateral border of the left kidney. At the lower end of the kidney it turns medialward toward the lateral border of the Psoas, and then descends, in the angle between Psoas and Quadratus lumborum, to the crest of the ilium, where it ends in the iliac colon. The peritoneum covers its anterior surface and sides, while its posterior surface is connected by areolar tissue with the lower and lateral part of the left kidney, the aponeurotic origin of

¹ In the Basle nomenclature the descending colon is the portion between the left colic flexure and the superior aperture of the lesser pelvis; it is, however, convenient to describe its lowest part as the iliac colon.

the *Transversus abdominis*, and the *Quadratus lumborum* (Fig. 1056). It is smaller in caliber and more deeply placed than the ascending colon, and is more frequently covered with peritoneum on its posterior surface than the ascending colon (Treves). In front of it are some coils of small intestine.

The **Iliac Colon** (Fig. 1076) is situated in the left iliac fossa, and is about 12 to 15 cm. long. It begins at the level of the iliac crest, where it is continuous with the descending colon, and ends in the sigmoid colon at the superior aperture of the lesser pelvis. It curves downward and medialward in front of the *Iliacus* and *Psoas*, and, as a rule, is covered by peritoneum on its sides and anterior surface only.

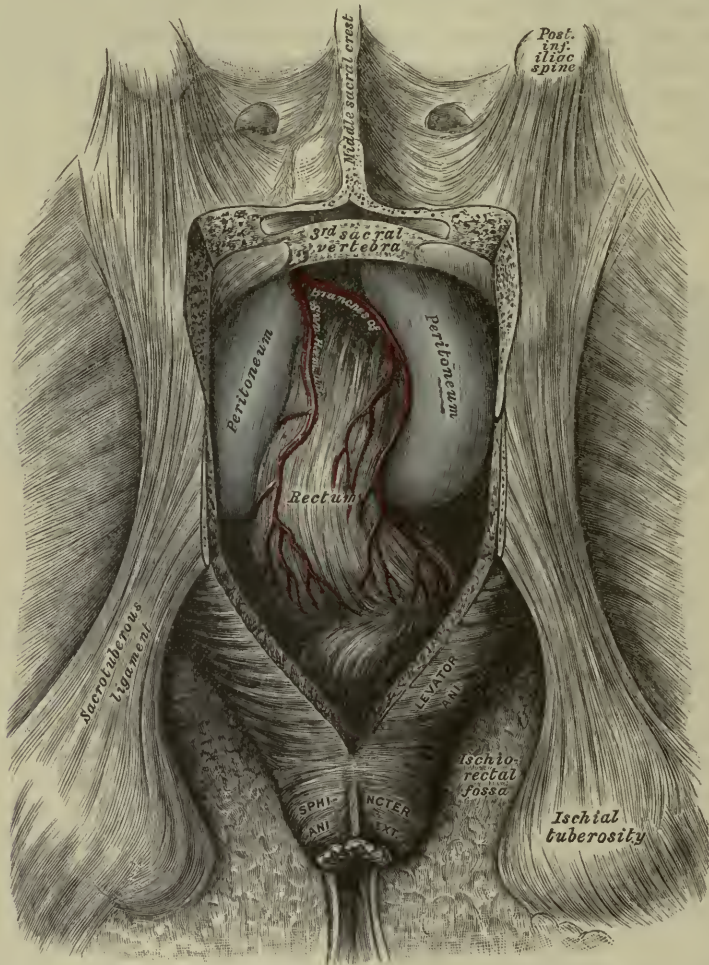


FIG. 1077.—The posterior aspect of the rectum exposed by removing the lower part of the sacrum and the coccyx.

The **Sigmoid Colon** (*colon sigmoideum*; *pelvic colon*; *sigmoid flexure*) (Fig. 1076) forms a loop which averages about 40 cm. in length, and normally lies within the pelvis, but on account of its freedom of movement it is liable to be displaced into the abdominal cavity. It begins at the superior aperture of the lesser pelvis, where it is continuous with the iliac colon, and passes transversely across the front of the sacrum to the right side of the pelvis; it then curves on itself and turns toward the left to reach the middle line at the level of the third piece of the sacrum, where it bends downward and ends in the rectum. It is completely surrounded by peritoneum, which forms a mesentery (**sigmoid mesocolon**), which diminishes in

length from the center toward the ends of the loop, where it disappears, so that the loop is fixed at its junctions with the iliac colon and rectum, but enjoys a considerable range of movement in its central portion. *Behind* the sigmoid colon are the external iliac vessels, the left Piriformis, and left sacral plexus of nerves; in *front*, it is separated from the bladder in the male, and the uterus in the female, by some coils of the small intestine.

The **Rectum** (*intestinum rectum*) (Fig. 1077) is continuous above with the sigmoid colon, while below it ends in the anal canal. From its origin at the level of the third sacral vertebra it passes downward, lying in the sacrococcygeal curve, and extends for about 2.5 cm. in front of, and a little below, the tip of the coccyx, as far as the apex of the prostate. It then bends sharply backward into the anal canal. It therefore presents two antero-posterior curves: an upper, with its convexity backward, and a lower, with its convexity forward. Two lateral curves are also described, one to the right opposite the junction of the third and fourth sacral vertebrae, and the other to the left, opposite the left sacrococcygeal articulation; they are, however, of little importance. The rectum is about 12 cm. long, and at its commencement its caliber is similar to that of the sigmoid colon, but near its termination it is dilated to form the **rectal ampulla**. The rectum has no sacculations comparable to those of the colon, but when the lower part of the rectum is contracted, its mucous membrane is thrown into a number of folds, which are longitudinal in direction and are effaced by the distension of the gut. Besides these there are certain permanent transverse folds, of a semilunar shape, known as **Houston's valves** (Fig. 1078). They are usually three in number; sometimes a fourth is found, and occasionally only two are present. One is situated near the commencement of the rectum, on the right side; a second extends inward from the left side of the tube, opposite the middle of the sacrum; a third, the largest and most constant, projects backward from the forepart of the rectum, opposite the fundus of the urinary bladder. When a fourth is present, it is situated nearly 2.5 cm. above the anus on the left and posterior wall of the tube. These folds are about 12 mm. in width, and contain some of the circular fibers of the gut. In the empty state of the intestine they overlap each other, as Houston remarks, so effectually as to require considerable maneuvering to conduct a bougie or the finger along the canal. Their use seems to be, "to support the weight of fecal matter, and prevent its urging toward the anus, where its presence always excites a sensation demanding its discharge."¹

The peritoneum is related to the upper two-thirds of the rectum, covering at first its front and sides, but lower down its front only; from the latter it is reflected on to the seminal vesicles in the male and the posterior vaginal wall in the female.

The level at which the peritoneum leaves the anterior wall of the rectum to be reflected on to the viscus in front of it is of considerable importance from a surgical

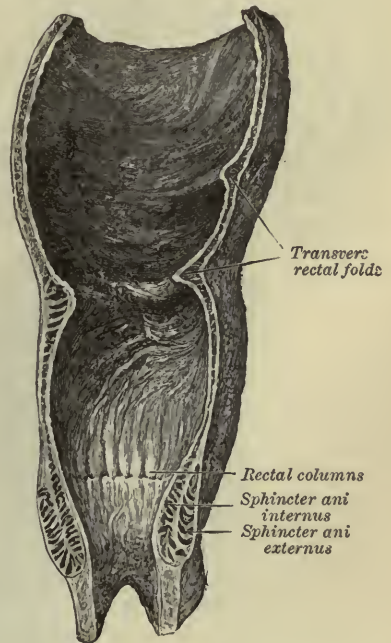


FIG. 1078.—Coronal section of rectum and anal canal.

¹ Paterson ("The Form of the Rectum," *Journal of Anatomy and Physiology*, vol. xliiii) utilizes the third fold for the purpose of dividing the rectum into an upper and a lower portion; he considers the latter "to be just as much a duct as the narrower anal canal below," and maintains that, under normal conditions, it does not contain feces except during the act of defecation.

point of view, in connection with the removal of the lower part of the rectum. It is higher in the male than in the female. In the former the height of the rectovesical excavation is about 7.5 cm., *i. e.*, the height to which an ordinary index finger can reach from the anus. In the female the height of the rectouterine excavation is about 5.5 cm. from the anal orifice. The rectum is surrounded by a dense tube of fascia derived from the fascia endopelvina, but fused behind with the fascia covering the sacrum and coccyx. The facial tube is loosely attached to the rectal wall by areolar tissue in order to allow of distension of the viscus.

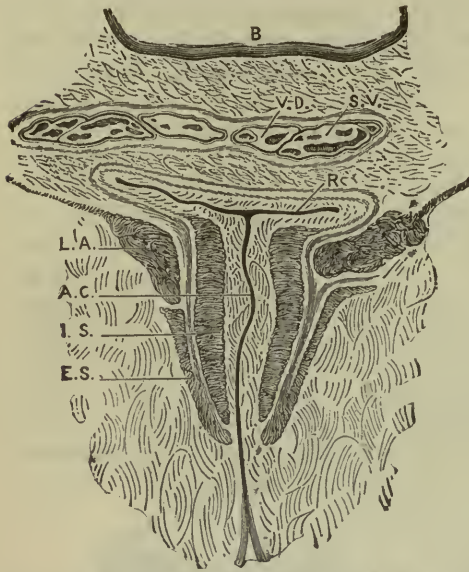


FIG. 1079.—Coronal section through the anal canal. (Symington.) B. Cavity of urinary bladder. V.D. Ductus deferens. S.V. Seminal vesicle. R. Second part of rectum. A.C. Anal canal. L.A. Levator ani. I.S. Sphincter ani internus. E.S. Sphincter ani externus.

Relations of the Rectum.—The upper part of the rectum is in relation, *behind*, with the superior hemorrhoidal vessels, the left Piri-formis, and left sacral plexus of nerves, which separate it from the pelvic surfaces of the sacral vertebræ; in its lower part it lies directly on the sacrum, coccyx, and Levatores ani, a dense fascia alone intervening; *in front*, it is separated above, in the male, from the fundus of the bladder; in the female, from the intestinal surface of the uterus and its appendages, by some convolutions of the small intestine, and frequently by the sigmoid colon; *below*, it is in relation in the male with the triangular portion of the fundus of the bladder, the vesiculæ seminales, and ductus deferentes, and more anteriorly with the posterior surface of the prostate; in the female, with the posterior wall of the vagina.

The **Anal Canal** (*pars analis recti*) (Figs. 1079, 1080, 1081), or terminal portion of the large intestine, begins at the level of the apex of the prostate, is directed downward and backward, and ends at the anus. It forms an angle with the lower part of

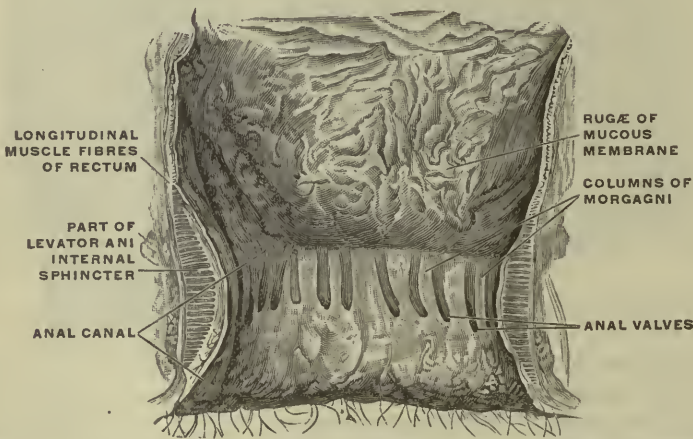


FIG. 1080.—The interior of the anal canal and lower part of the rectum, showing the columns of Morgagni and the anal valves between their lower ends. The columns were more numerous in the specimen than usual. (Cunningham.)

the rectum, and measures from 2.5 to 4 cm. in length. It has no peritoneal covering, but is invested by the Sphincter ani internus, supported by the Levatores ani, and surrounded at its termination by the Sphincter ani externus. In the

empty condition it presents the appearance of an antero-posterior longitudinal slit. Behind it is a mass of muscular and fibrous tissue, the **anococcygeal body** (Symington); in front of it, in the male, but separated by connective tissue from it, are the membranous portion and bulb of the urethra, and the fascia of the urogenital diaphragm; and in the female it is separated from the lower end of the vagina by a mass of muscular and fibrous tissue, named the **perineal body**.

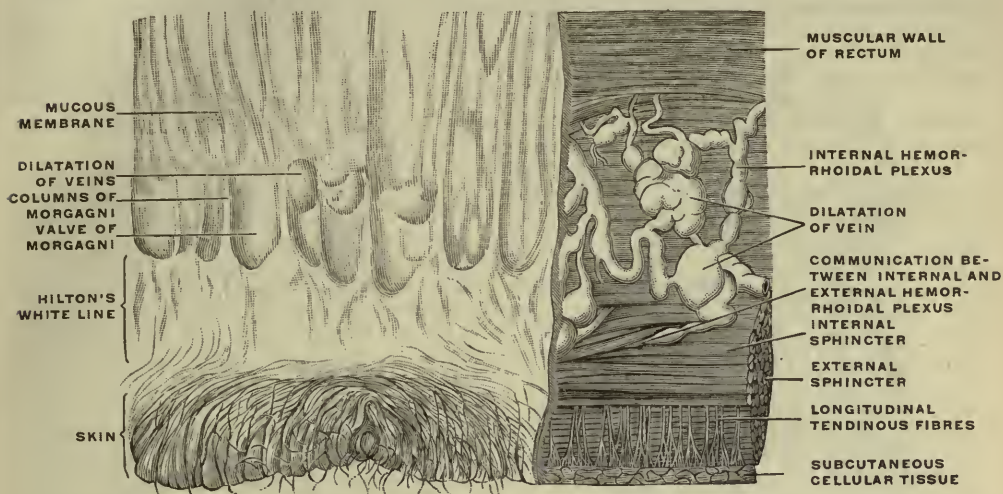


FIG. 1081.—Inner wall of the lower end of the rectum and anus. On the right the mucous membrane has been removed to show the dilatation of the veins and how they pass through the muscular wall to anastomose with the external hemorrhoidal plexus. (Luschka.)

The lumen of the anal canal presents, in its upper half, a number of vertical folds, produced by an infolding of the mucous membrane and some of the muscular tissue. They are known as the **rectal columns** [*Morgagni*] (Fig. 1078), and are

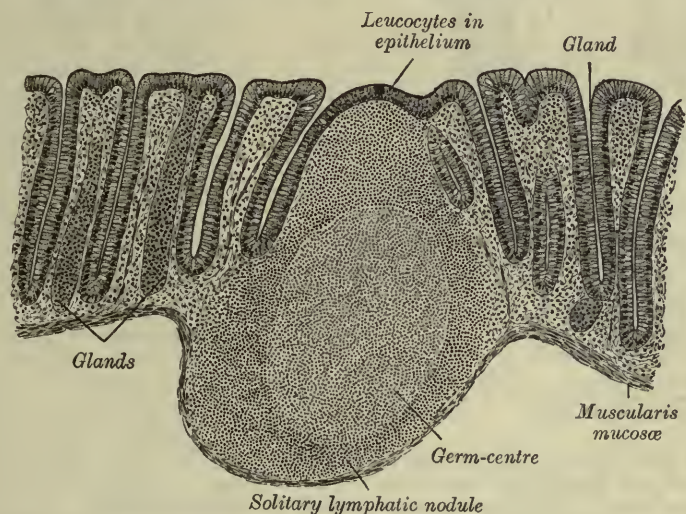


FIG. 1082.—Section of mucous membrane of human rectum. (Sobotta.) $\times 60$.

separated from one another by furrows (**rectal sinuses**), which end below in small valve-like folds, termed **anal valves**, which join together the lower ends of the rectal columns.

Structure of the Colon.—The large intestine has four coats: **serous, muscular, areolar, and mucous.**

The **serous coat** (*tunica serosa*) is derived from the peritoneum, and invests the different portions of the large intestine to a variable extent. The cecum is completely covered by the serous membrane, except in about 5 per cent. of cases where the upper part of the posterior surface is uncovered. The ascending, descending, and iliac parts of the colon are usually covered only in front and at the sides; a variable amount of the posterior surface is uncovered.¹ The transverse colon is almost completely invested, the parts corresponding to the attachment of the greater omentum and transverse mesocolon being alone excepted. The sigmoid colon is entirely surrounded. The rectum is covered above on its anterior surface and sides; below, on its anterior aspect only; the anal canal is entirely devoid of any serous covering. In the

course of the colon the peritoneal coat is thrown into a number of small pouches filled with fat, called **appendices epiploicæ**. They are most numerous on the transverse colon.

The **muscular coat** (*tunica muscularis*) consists of an external longitudinal, and an internal circular, layer of non-striped muscular fibers.

The *longitudinal fibers* do not form a continuous layer over the whole surface of the large intestine. In the cecum and colon they are especially collected into three flat longitudinal bands (*tenari coli*), each of about 12 mm. in width; one, the posterior, is placed along the attached border of the intestine; the anterior, the largest, corresponds along the arch of the colon to the attachment of the greater omentum, but is in front in the ascending, descending, and iliac parts of the colon, and in the sigmoid colon; the third, or lateral band, is found on the medial side of the ascending and descending parts of the colon, and on the under aspect of the transverse colon. These bands are shorter than the other coats of the intestine, and serve to produce the sacculi which are characteristic of the cecum and colon; accordingly, when they are dissected off, the tube can be lengthened, and its sacculated character disappears. In the sigmoid colon the longitudinal fibers become more scattered; and around the rectum they spread out and form a layer, which completely encircles this portion of the gut, but is thicker on the anterior and posterior surfaces, where it forms two bands, than on the lateral surfaces. In addition,

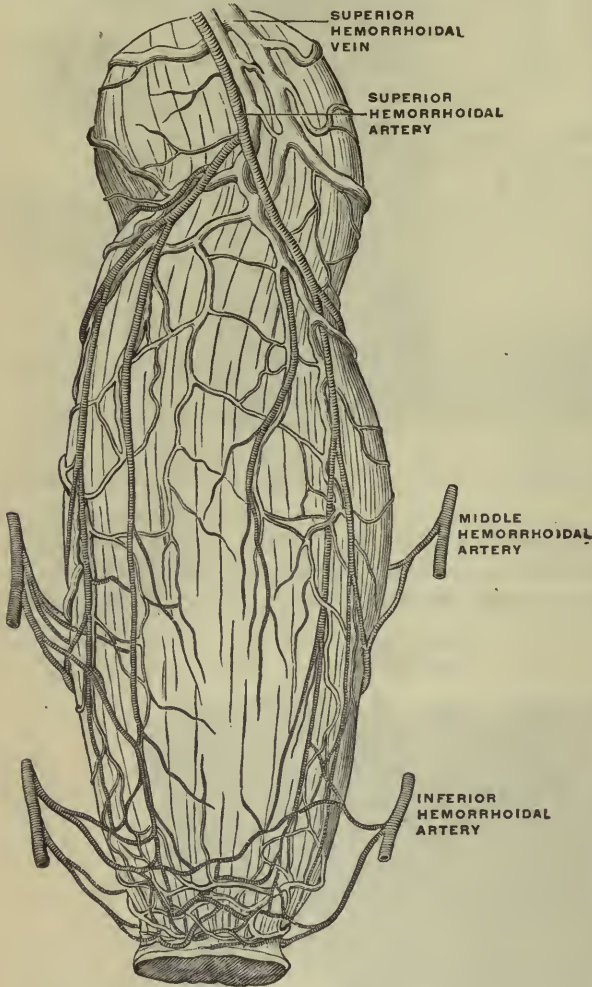

FIG. 1083.—The bloodvessels of the rectum and anus, showing the distribution and anastomosis on the posterior surface near the termination of the gut. (Poirier and Charpy)

two bands of plain muscular tissue arise from the second and third coccygeal vertebræ, and pass downward and forward to blend with the longitudinal muscular fibers on the posterior wall of the anal canal. These are known as the **Rectococcygeal muscles**.

The *circular fibers* form a thin layer over the cecum and colon, being especially accumulated in the intervals between the sacculi; in the rectum they form a thick layer, and in the anal canal they become numerous, and constitute the Sphincter ani internus.

The **areolar coat** (*tela submucosa*; *submucous coat*) connects the muscular and mucous layers closely together.

The **mucous membrane** (*tunica mucosa*) in the cecum and colon, is pale, smooth, destitute of villi, and raised into numerous crescentic folds which correspond to the intervals between

¹ See footnote, p. 1183.

the sacculi. In the rectum it is thicker, of a darker color, more vascular, and connected loosely to the muscular coat, as in the esophagus.

As in the small intestine, the mucous membrane (Fig. 1082) consists of a muscular layer, the muscularis mucosæ; a quantity of retiform tissue in which the vessels ramify; a basement membrane and epithelium which is of the columnar variety, and resembles the epithelium found in the small intestine. The mucous membrane of the large intestine presents for examination glands and solitary lymphatic nodules.

The glands of the great intestine are minute tubular prolongations of the mucous membrane arranged perpendicularly, side by side, over its entire surface; they are longer, more numerous, and placed in much closer apposition than those of the small intestine; and they open by minute rounded orifices upon the surface, giving it a cribriform appearance. Each gland is lined by short columnar epithelium and contains numerous goblet cells.

The **solitary lymphatic nodules** (*noduli lymphatici solitarii*) (Fig. 1082) of the large intestine are most abundant in the cecum and vermiform process, but are irregularly scattered also over the rest of the intestine. They are similar to those of the small intestine.

Vessels and Nerves.—The **arteries** supplying the colon are derived from the colic and sigmoid branches of the mesenteric arteries. They give off large branches, which ramify between and supply the muscular coats, and after dividing into small vessels in the submucous tissue, pass to the mucous membrane. The rectum is supplied by the superior hemorrhoidal branch of the inferior mesenteric, and the anal canal by the middle hemorrhoidal from the hypogastric, and the inferior hemorrhoidal from the internal pudendal artery. The superior hemorrhoidal, the continuation of the inferior mesenteric, divides into two branches, which run down either side of the rectum to within about 12.5 cm. of the anus; they here split up into about six branches which pierce the muscular coat and descend between it and the mucous membrane in a longitudinal direction, parallel with each other as far as the Sphincter ani internus, where they anastomose with the other hemorrhoidal arteries and form a series of loops around the anus. The **veins** of the rectum commence in a plexus of vessels which surrounds the anal canal. In the vessels forming this plexus are smaller saccular dilatations just within the margin of the anus; from the plexus about six vessels of considerable size are given off. These ascend between the muscular and mucous coats for about 12.5 cm., running parallel to each other; they then pierce the muscular coat, and, by their union, form a single trunk, the superior hemorrhoidal vein. This arrangement is termed the **hemorrhoidal plexus**; it communicates with the tributaries of the middle and inferior hemorrhoidal veins, at its commencement, and thus a communication is established between the systemic and portal circulations. The **lymphatics** of the large intestine are described on page 711. The **nerves** are derived from the sympathetic plexuses around the branches of the superior and inferior mesenteric arteries. They are distributed in a similar way to those found in the small intestine.

Congenital Hernia.—There are some varieties of oblique inguinal hernia (Fig. 1084) depending upon congenital defects in the saccus vaginalis, the pouch of peritoneum which precedes the descent of the testis. Normally this pouch is closed before birth, closure commencing at two points, viz., at the abdominal inguinal ring and at the top of the epididymis, and gradually extending until the whole of the intervening portion is converted into a fibrous cord. From failure in the completion of this process, variations in the relation of the hernial protrusion to the testis and tunica vaginalis are produced; these constitute distinct varieties of inguinal hernia, viz., the hernia of the funicular process and the complete congenital variety.

Where the saccus vaginalis remains patent throughout, the cavity of the tunica vaginalis communicates directly with that of the peritoneum. The intestine descends along this pouch into the cavity of the tunica vaginalis which constitutes the sac of the hernia, and the gut lies in contact with the testis. Though this form of hernia is termed *complete congenital*, the term

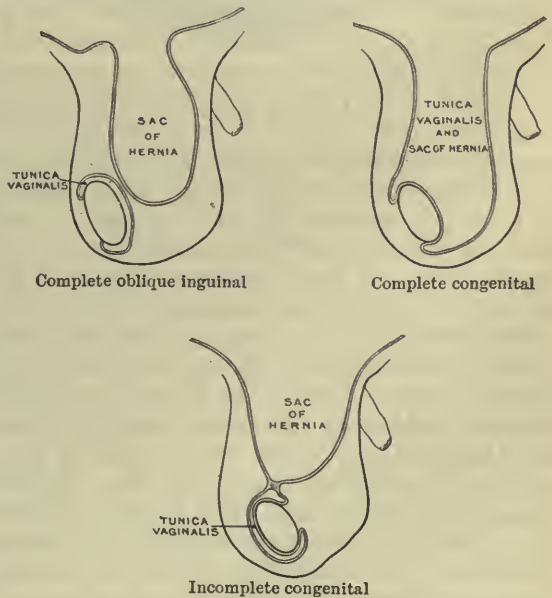


FIG. 1084.—Varieties of oblique inguinal hernia.

does not imply that the hernia existed at birth, but merely that a condition is present which may allow of the descent of the hernia at any moment. As a matter of fact, congenital herniæ frequently do not appear until adult life.

Where the processus vaginalis is occluded at the lower point only, *i. e.*, just above the testis, the intestine descends into the pouch of peritoneum as far as the testis, but is prevented from entering the sac of the tunica vaginalis by the septum which has formed between it and the pouch. This is known as *hernia into the funicular process* or *incomplete congenital hernia*; it differs from the former in that instead of enveloping the testis it lies above it.

The Liver (Hepar).

The **liver**, the largest gland in the body, has both external and internal secretions, which are formed in the hepatic cells. Its external secretion, the **bile**, is collected after passing through the bile capillaries by the bile ducts, which join like the twigs and branches of a tree to form two large ducts that unite to form the hepatic duct. The bile is either carried to the gall-bladder by the cystic duct or poured directly into the duodenum by the common bile duct where it aids in digestion. The internal secretions are concerned with the metabolism of both nitrogenous and carbohydrate materials absorbed from the intestine and carried to the liver by the portal vein. The carbohydrates are stored in the hepatic cells in the form of glycogen which is secreted in the form of sugar directly into the blood stream. Some of the cells lining the blood capillaries of the liver are concerned in the destruction of red blood corpuscles. It is situated in the upper and right parts of the abdominal cavity, occupying almost the whole of the right hypochondrium, the greater part of the epigastrium, and not uncommonly extending into the left hypochondrium as far as the mammillary line. In the male it weighs from 1.4 to 1.6 kilogram., in the female from 1.2 to 1.4 kilogram. It is relatively much larger in the fetus than in the adult, constituting, in the former, about one-eighteenth, and in the latter about one thirty-sixth of the entire body weight. Its greatest transverse measurement is from 20 to 22.5 cm. Vertically, near its lateral or right surface, it measures about 15 to 17.5 cm., while its greatest antero-posterior diameter is on a level with the upper end of the right kidney, and is from 10 to 12.5 cm. Opposite the vertebral column its measurement from before backward is reduced to about 7.5 cm. Its consistence is that of a soft solid; it is friable, easily lacerated and highly vascular; its color is a dark reddish brown, and its specific gravity is 1.05.

To obtain a correct idea of its shape it must be hardened *in situ*, and it will then be seen to present the appearance of a wedge, the base of which is directed to the right and the thin edge toward the left. Symington describes its shape as that "of a right-angled triangular prism with the right angle rounded off."

Surfaces.—The liver possesses three surfaces, *viz.*, **superior**, **inferior** and **posterior**. A sharp, well-defined margin divides the inferior from the superior in front; the other margins are rounded. The superior surface is attached to the diaphragm and anterior abdominal wall by a triangular or falciform fold of peritoneum, the **falciform ligament**, in the free margin of which is a rounded cord, the **ligamentum teres** (*obliterated umbilical vein*). The line of attachment of the falciform ligament divides the liver into two parts, termed the **right** and **left lobes**, the right being much the larger. The inferior and posterior surfaces are divided into four lobes by five fossæ, which are arranged in the form of the letter H. The left limb of the H marks on these surfaces the division of the liver into right and left lobes; it is known as the **left sagittal fossa**, and consists of two parts, *viz.*, the **fossa for the umbilical vein** in front and the **fossa for the ductus venosus** behind. The right limb of the H is formed in front by the **fossa for the gall-bladder**, and behind by the **fossa for the inferior vena cava**; these two fossæ are separated from one another by a band of liver substance, termed the **caudate process**. The bar connecting the two limbs of the H is the **porta** (*transverse fissure*); in front of it is the **quadrate lobe**, behind it the **caudate lobe**.

The **superior surface** (*facies superior*) (Fig. 1085) comprises a part of both lobes, and, as a whole, is convex, and fits under the vault of the diaphragm which in front separates it on the right from the sixth to the tenth ribs and their cartilages, and on the left from the seventh and eighth costal cartilages. Its middle part lies behind the xiphoid process, and, in the angle between the diverging rib cartilage of opposite sides, is in contact with the abdominal wall. Behind this the diaphragm separates the liver from the lower part of the lungs and pleuræ, the heart and pericardium and the right costal arches from the seventh to the eleventh inclusive. It is completely covered by peritoneum except along the line of attachment of the falciform ligament.

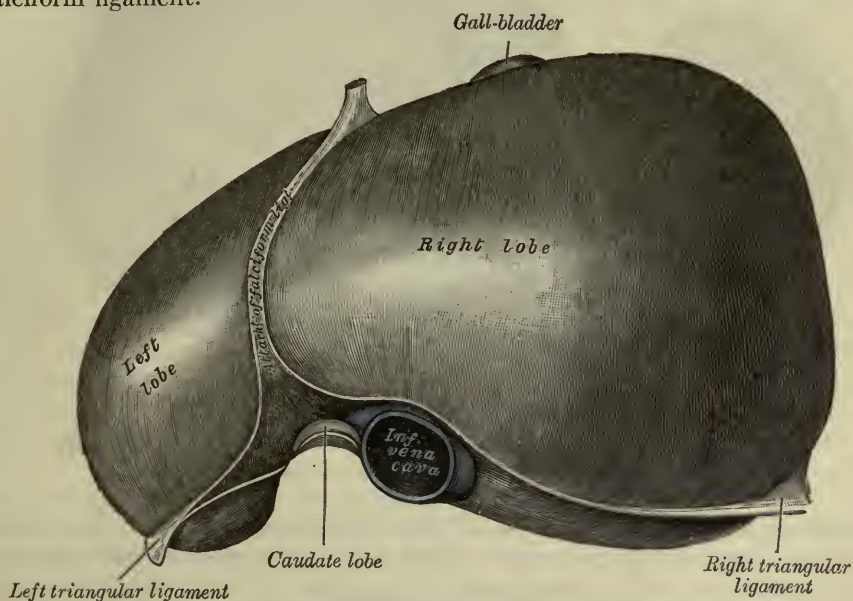


FIG. 1085.—The superior surface of the liver. (From model by His.)

The **inferior surface** (*facies inferior; visceral surface*) (Figs. 1086, 1087), is uneven, concave, directed downward, backward, and to the left, and is in relation with the stomach and duodenum, the right colic flexure, and the right kidney and suprarenal gland. The surface is almost completely invested by peritoneum; the only parts devoid of this covering are where the gall-bladder is attached to the liver, and at the porta hepatis where the two layers of the lesser omentum are separated from each other by the bloodvessels and ducts of the liver. The inferior surface of the left lobe presents behind and to the left the **gastric impression**, moulded over the antero-superior surface of the stomach, and to the right of this a rounded eminence, the **tuber omentale**, which fits into the concavity of the lesser curvature of the stomach and lies in front of the anterior layer of the lesser omentum. The under surface of the right lobe is divided into two unequal portions by the fossa for the gall-bladder; the portion to the left, the smaller of the two, is the **quadrate lobe**, and is in relation with the pyloric end of the stomach, the superior portion of the duodenum, and the transverse colon. The portion of the under surface of the right lobe to the right of the fossa for the gall-bladder presents two impressions, one situated behind the other, and separated by a ridge. The anterior of these two impressions, the **colic impression**, is shallow and is produced by the right colic flexure; the posterior, the **renal impression**, is deeper and is occupied by the upper part of the right kidney and lower part of the right suprarenal gland. Medial to the renal impression is a third and slightly marked impression, lying between it and the neck of the gall-bladder. This is caused by the descending portion of the

duodenum, and is known as the **duodenal impression**. Just in front of the inferior vena cava is a narrow strip of liver tissue, the **caudate process**, which connects the right inferior angle of the caudate lobe to the under surface of the right lobe. It forms the upper boundary of the epiploic foramen of the peritoneum.

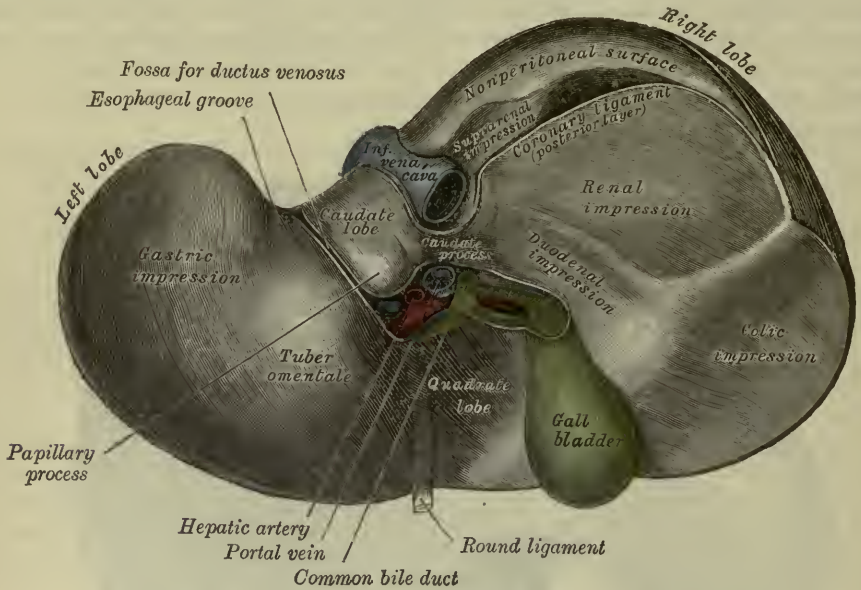


FIG. 1086.—Inferior surface of the liver. (From model by His.)

The **posterior surface** (*facies posterior*) (Fig. 1087) is rounded and broad behind the right lobe, but narrow on the left. Over a large part of its extent it is not

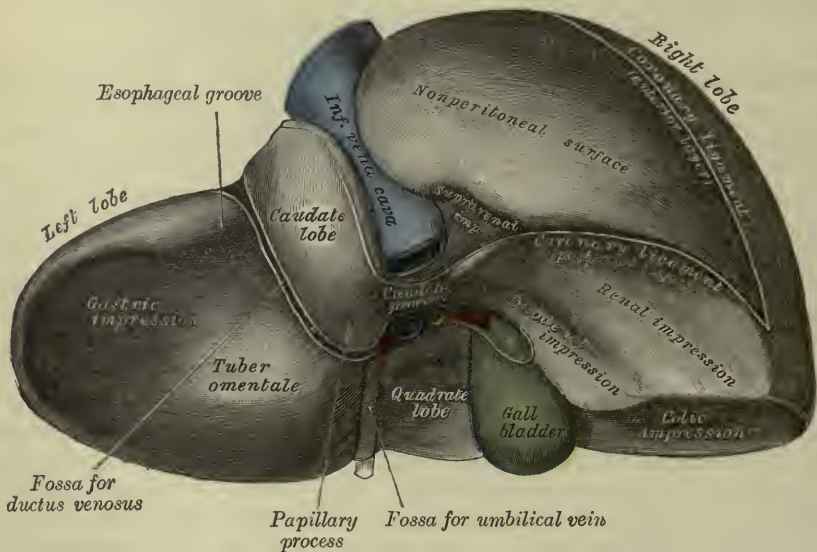


FIG. 1087.—Posterior and inferior surfaces of the liver. (From model by His.)

covered by peritoneum; this uncovered portion is about 7.5 cm. broad at its widest part, and is in direct contact with the diaphragm. It is marked off from the upper surface by the line of reflection of the upper layer of the coronary ligament, and

from the under surface by the line of reflection of the lower layer of the coronary ligament. The central part of the posterior surface presents a deep concavity which is moulded on the vertebral column and crura of the diaphragm. To the right of this the inferior vena cava is lodged in its fossa between the uncovered area and the caudate lobe. Close to the right of this fossa and immediately above the renal impression is a small triangular depressed area, the **suprarenal impression**, the greater part of which is devoid of peritoneum; it lodges the right suprarenal gland. To the left of the inferior vena cava is the **caudate lobe**, which lies between the fossa for the vena cava and the fossa for the ductus venosus. Its lower end projects and forms part of the posterior boundary of the porta; on the right, it is connected with the under surface of the right lobe of the liver by the **caudate process**, and on the left it presents an elevation, the **papillary process**. Its posterior surface rests upon the diaphragm, being separated from it merely by the upper part of the omental bursa. To the left of the fossa for the ductus venosus is a groove in which lies the antrum cardiacum of the esophagus.

The **anterior border** (*margo anterior*) is thin and sharp, and marked opposite the attachment of the falciform ligament by a deep notch, the **umbilical notch**, and opposite the cartilage of the ninth rib by a second notch for the fundus of the gall-bladder. In adult males this border generally corresponds with the lower margin of the thorax in the right mammillary line; but in women and children it usually projects below the ribs.

The **left extremity of the liver** is thin and flattened from above downward.

Fossæ.—The **left sagittal fossa** (*fossa sagittalis sinistra; longitudinal fissure*) is a deep groove, which extends from the notch on the anterior margin of the liver to the upper border of the posterior surface of the organ; it separates the right and left lobes. The porta joins it, at right angles, and divides it into two parts. The anterior part, or **fossa for the umbilical vein**, lodges the umbilical vein in the fetus, and its remains (the ligamentum teres) in the adult; it lies between the quadrate lobe and the left lobe of the liver, and is often partially bridged over by a prolongation of the hepatic substance, the **pons hepatis**. The posterior part, or **fossa for the ductus venosus**, lies between the left lobe and the caudate lobe; it lodges in the fetus, the ductus venosus, and in the adult a slender fibrous cord, the **ligamentum venosum**, the obliterated remains of that vessel.

The **porta** or **transverse fissure** (*porta hepatis*) is a short but deep fissure, about 5 cm. long, extending transversely across the under surface of the left portion of the right lobe, nearer its posterior surface than its anterior border. It joins nearly at right angles with the left sagittal fossa, and separates the quadrate lobe in front from the caudate lobe and process behind. It transmits the portal vein, the hepatic artery and nerves, and the hepatic duct and lymphatics. The hepatic duct lies in front and to the right, the hepatic artery to the left, and the portal vein behind and between the duct and artery.

The **fossa for the gall-bladder** (*fossa vesicæ felleæ*) is a shallow, oblong fossa, placed on the under surface of the right lobe, parallel with the left sagittal fossa. It extends from the anterior free margin of the liver, which is notched by it, to the right extremity of the porta.

The **fossa for the inferior vena cava** (*fossa venæ cavæ*) is a short deep depression, occasionally a complete canal in consequence of the substance of the liver surrounding the vena cava. It extends obliquely upward on the posterior surface between the caudate lobe and the bare area of the liver, and is separated from the porta by the caudate process. On slitting open the inferior vena cava the orifices of the hepatic veins will be seen opening into this vessel at its upper part, after perforating the floor of this fossa.

Lobes.—The **right lobe** (*lobus hepatis dexter*) is much larger than the left; the proportion between them being as six to one. It occupies the right hypo-

chondrium, and is separated from the left lobe on its upper surface by the falciform ligament; on its under and posterior surfaces by the left sagittal fossa; and in front by the umbilical notch. It is of a somewhat quadrilateral form, its under and posterior surfaces being marked by three fossæ: the porta and the fossæ for the gall-bladder and inferior vena cava, which separate its left part into two smaller lobes; the **quadrate** and **caudate lobes**. The impressions on the right lobe have already been described.

The **quadrate lobe** (*lobus quadratus*) is situated on the under surface of the right lobe, bounded in front by the anterior margin of the liver; behind by the porta; on the right, by the fossa for the gall-bladder; and on the left, by the fossa for the umbilical vein. It is oblong in shape, its antero-posterior diameter being greater than its transverse.

The **caudate lobe** (*lobus caudatus*; *Spigelian lobe*) is situated upon the posterior surface of the right lobe of the liver, opposite the tenth and eleventh thoracic vertebræ. It is bounded, below, by the porta; on the right, by the fossa for the inferior vena cava; and, on the left, by the fossa for the ductus venosus. It looks backward, being nearly vertical in position; it is longer from above downward than from side to side, and is somewhat concave in the transverse direction. The **caudate process** is a small elevation of the hepatic substance extending obliquely lateralward, from the lower extremity of the caudate lobe to the under surface of the right lobe. It is situated behind the porta, and separates the fossa for the gall-bladder from the commencement of the fossa for the inferior vena cava.

The **left lobe** (*lobus hepatis sinister*) is smaller and more flattened than the right. It is situated in the epigastric and left hypochondriac regions. Its upper surface is slightly convex and is moulded on to the diaphragm; its under surface presents the gastric impression and omental tuberosity, already referred to page 1189.

Ligaments.—The liver is connected to the under surface of the diaphragm and to the anterior wall of the abdomen by five ligaments; four of these—the **falciform**, the **coronary**, and the two **lateral**—are peritoneal folds; the fifth, the **round ligament**, is a fibrous cord, the obliterated umbilical vein. The liver is also attached to the lesser curvature of the stomach by the hepatogastric and to the duodenum by the hepatoduodenal ligament (see page 1157).

The **falciform ligament** (*ligamentum falciforme hepatis*) is a broad and thin antero-posterior peritoneal fold, falciform in shape, its base being directed downward and backward, its apex upward and backward. It is situated in an antero-posterior plane, but lies obliquely so that one surface faces forward and is in contact with the peritoneum behind the right Rectus and the diaphragm, while the other is directed backward and is in contact with the left lobe of the liver. It is attached by its left margin to the under surface of the diaphragm, and the posterior surface of the sheath of the right Rectus as low down as the umbilicus; by its right margin it extends from the notch on the anterior margin of the liver, as far back as the posterior surface. It is composed of two layers of peritoneum closely united together. Its base or free edge contains between its layers the round ligament and the parumbilical veins.

The **coronary ligament** (*ligamentum coronarium hepatis*) consists of an upper and a lower layer. The *upper layer* is formed by the reflection of the peritoneum from the upper margin of the bare area of the liver to the under surface of the diaphragm, and is continuous with the right layer of the falciform ligament. The *lower layer* is reflected from the lower margin of the bare area on to the right kidney and suprarenal gland, and is termed the **hepatorenal ligament**.

The **triangular ligaments** (*lateral ligaments*) are two in number, right and left. The **right triangular ligament** (*ligamentum triangulare dextrum*) is situated at the right extremity of the bare area, and is a small fold which passes to the diaphragm, being formed by the apposition of the upper and lower layers of the coronary

ligament. The **left triangular ligament** (*ligamentum triangulare sinistrum*) is a fold of some considerable size, which connects the posterior part of the upper surface of the left lobe to the diaphragm; its anterior layer is continuous with the left layer of the falciform ligament.

The **round ligament** (*ligamentum teres hepatis*) is a fibrous cord resulting from the obliteration of the umbilical vein. It ascends from the umbilicus, in the free margin of the falciform ligament, to the umbilical notch of the liver, from which it may be traced in its proper fossa on the inferior surface of the liver to the porta, where it becomes continuous with the *ligamentum venosum*.

Fixation of the Liver.—Several factors contribute to maintain the liver in place. The attachments of the liver to the diaphragm by the coronary and triangular ligaments and the intervening connective tissue of the uncovered area, together with the intimate connection of the inferior vena cava by the connective tissue and hepatic veins would hold up the posterior part of the liver. Some support is derived from the pressure of the abdominal viscera which completely fill the abdomen whose muscular walls are always in a state of tonic contraction. The superior surface of the liver is perfectly fitted to the under surface of the diaphragm so that atmospheric pressure alone would be enough to hold it against the diaphragm. The latter in turn is held up by the negative pressure in the thorax. The lax falciform ligament certainly gives no support though it probably limits lateral displacement.

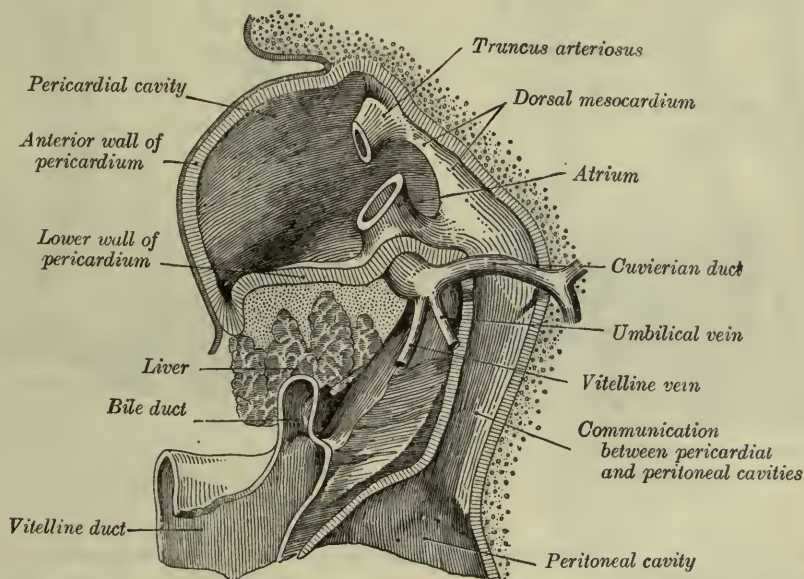
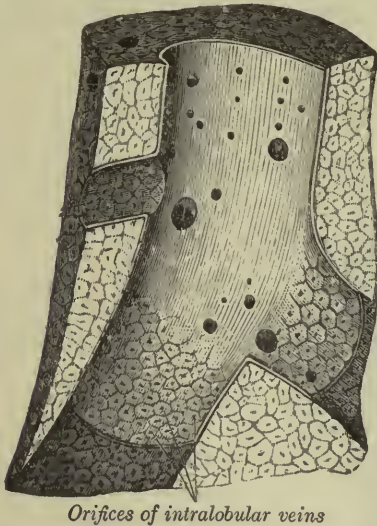


FIG. 1088.—Liver with the septum transversum. Human embryo 3 mm. long. (After model and figure by His.)

Development.—The liver arises in the form of a diverticulum or hollow outgrowth from the ventral surface of that portion of the gut which afterward becomes the descending part of the duodenum (Fig. 1088). This diverticulum is lined by entoderm, and grows upward and forward into the septum transversum, a mass of mesoderm between the vitelline duct and the pericardial cavity, and there gives off two solid buds of cells which represent the right and the left lobes of the liver. The solid buds of cells grow into columns or cylinders, termed the **hepatic cylinders**, which branch and anastomose to form a close meshwork. This network invades the vitelline and umbilical veins, and breaks up these vessels into a series of capillary-like vessels termed **sinusoids** (Minot), which ramify in the meshes of the cellular

network and ultimately form the venous capillaries of the liver. By the continued growth and ramification of the hepatic cylinders the mass of the liver is gradually formed. The original diverticulum from the duodenum forms the common bile-duct, and from this the cystic duct and gall-bladder arise as a solid outgrowth which later acquires a lumen. The opening of the common duct is at first in the ventral wall of the duodenum; later, owing to the rotation of the gut, the opening is carried to the left and then dorsalward to the position it occupies in the adult.

As the liver undergoes enlargement, both it and the ventral mesogastrium of the fore-gut are gradually differentiated from the septum transversum; and from the under surface of the latter the liver projects downward into the abdominal cavity. By the growth of the liver the ventral mesogastrium is divided into two parts, of which the anterior forms the falciform and coronary ligaments, and the posterior the lesser omentum. About the third month the liver almost fills the abdominal cavity, and its left lobe is nearly as large as its right. From this period the relative development of the liver is less active, more especially that of the left lobe, which actually undergoes some degeneration and becomes smaller than the right; but up to the end of fetal life the liver remains relatively larger than in the adult.



Orifices of intralobular veins

FIG. 1089.—Longitudinal section of a hepatic vein. (After Kiernan.)

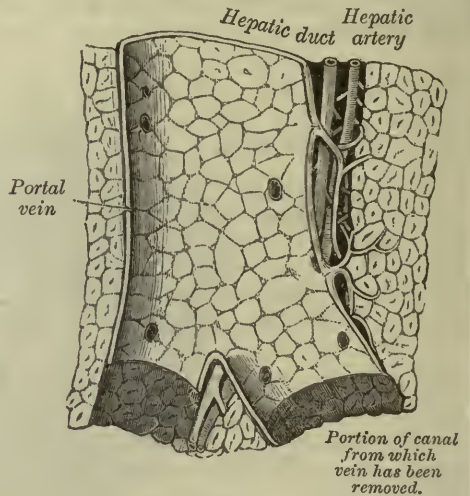


FIG. 1090.—Longitudinal section of a small portal vein and canal. (After Kiernan.)

Vessels and Nerves.—The vessels connected with the liver are: the **hepatic artery**, the **portal vein**, and the **hepatic veins**.

The **hepatic artery** and **portal vein**, accompanied by numerous nerves, ascend to the porta, between the layers of the lesser omentum. The **bile duct** and the lymphatic vessels descend from the porta between the layers of the same omentum. The relative positions of the three structures are as follows: the bile duct lies to the right, the hepatic artery to the left, and the portal vein behind and between the other two. They are enveloped in a loose areolar tissue, the **fibrous capsule of Glisson**, which accompanies the vessels in their course through the portal canals in the interior of the organ (Fig. 1090).

The **hepatic veins** (Fig. 1089) convey the blood from the liver, and are described on page 680. They have very little cellular investment, and what there is binds their parietes closely to the walls of the canals through which they run; so that, on section of the organ, they remain widely open and are solitary, and may be easily distinguished from the branches of the portal vein, which are more or less collapsed, and always accompanied by an artery and duct.

The **lymphatic vessels** of the liver are described on page 711.

The **nerves** of the liver, derived from the left vagus and sympathetic, enter at the porta and accompany the vessels and ducts to the interlobular spaces. Here, according to Korolkow, the

medullated fibers are distributed almost exclusively to the coats of the bloodvessels; while the non-medullated enter the lobules and ramify between the cells and even within them.¹

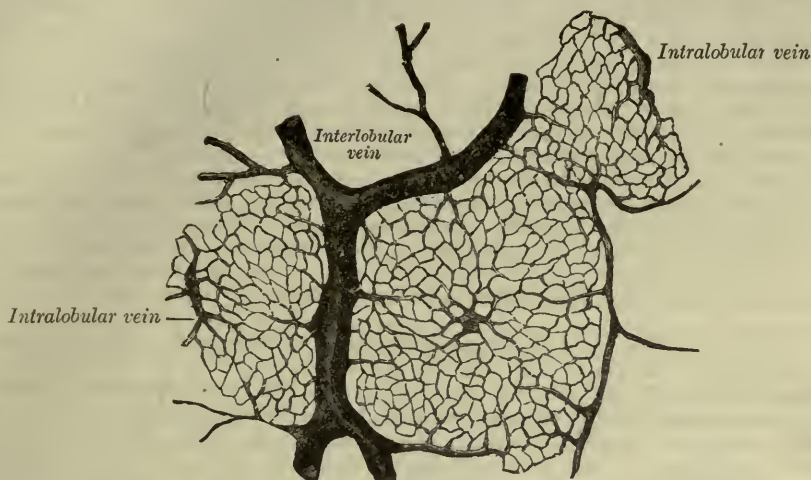

FIG. 1091.—Section of injected liver (dog).

Structure of the Liver.—The substance of the liver is composed of lobules, held together by an extremely fine areolar tissue, in which ramify the portal vein, hepatic ducts, hepatic artery, hepatic veins, lymphatics, and nerves; the whole being invested by a serous and a fibrous coat.

The **serous coat** (*tunica serosa*) is derived from the peritoneum, and invests the greater part of the surface of the organ. It is intimately adherent to the fibrous coat.

The **fibrous coat** (*capsula fibrosa* [Glissoni]; *areolar coat*) lies beneath the serous investment, and covers the entire surface of the organ. It is difficult of demonstration, excepting where the serous coat is deficient. At the porta it is continuous with the fibrous capsule of Glisson, and on the surface of the organ with the areolar tissue separating the lobules.

The **lobules** (*lobuli hepatis*) form the chief mass of the hepatic substance; they may be seen either on the surface of the organ, or by making a section through the gland, as small granular bodies, about the size of a millet-seed, measuring from 1 to 2.5 mm. in diameter. In the human subject their outlines are very irregular; but in some of the lower animals (for example, the pig) they are well-defined, and, when divided transversely, have polygonal outlines. The bases of the lobules are clustered around the smallest radicles (*sublobular*) of the hepatic veins, to which each is connected (Fig. 1089) by means of a small branch which issues from the center of the lobule (*intralobular*). The remaining part of the surface of each lobule is imperfectly isolated from the surrounding lobules by a thin stratum of areolar tissue, in which is contained a plexus of vessels, the **interlobular plexus**, and ducts. In some animals, as the pig, the lobules are completely isolated from one another by the interlobular areolar tissue (Fig. 1092).

If one of the sublobular veins be laid open, the bases of the lobules may be seen through the thin wall of the vein on which they rest, arranged in a form resembling a tessellated pavement,

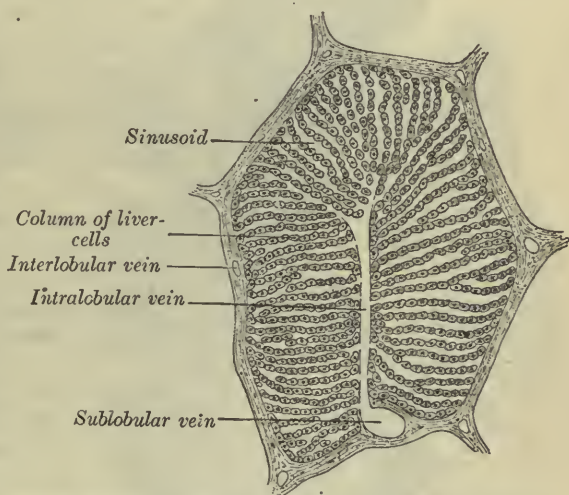


FIG. 1092.—A single lobule of the liver of a pig. X 60.

¹ Berkeley, Anat., Aug., 8, 1893; MacCallum, A. B., Quart. Jour. Micr. Sci., 1887, 27; Allegra, Anat., Aug. 25, 1904.

the center of each polygonal space presenting a minute aperture, the mouth of an intralobular vein (Fig. 1089).

Microscopic Appearance (Fig. 1092).—Each lobule consists of a mass of cells, **hepatic cells**, arranged in irregular radiating columns between which are the blood channels (*sinusoids*). These convey the blood from the circumference to the center of the lobule, and end in the **intralobular vein**, which runs through its center, to open at its base into one of the **sublobular veins**. Between the cells are also the minute bile capillaries. Therefore, in the lobule there are all the essentials of a secreting gland; that is to say: (1) **cells**, by which the secretion is formed; (2) **blood vessels**, in close relation with the cells, containing the blood from which the secretion is derived; (3) **ducts**, by which the secretion, when formed, is carried away.

1. The **hepatic cells** are polyhedral in form. They vary in size from 12 to 25 μ in diameter. They contain one or sometimes two distinct nuclei. The nucleus exhibits an intranuclear network and one or two refractile nucleoli. The cells usually contain granules; some of which are protoplasmic, while others consist of glycogen, fat, or an iron compound. In the lower vertebrates, *e. g.*, frog, the cells are arranged in tubes with the bile duct forming the lumen and bloodvessels externally. According to Delépine, evidences of this arrangement can be found in the human liver.

2. **The Bloodvessels**.—The blood in the capillary plexus around the liver cells is brought to the liver principally by the portal vein, but also to a certain extent by the hepatic artery.

The **hepatic artery**, entering the liver at the porta with the portal vein and hepatic duct, ramifies with these vessels through the portal canals. It gives off **vaginal branches**, which ramify in the fibrous capsule of Glisson, and appear to be destined chiefly for the nutrition of the coats of the vessels and ducts. It also gives off **capsular branches**, which reach the surface of the organ, ending in its fibrous coat in stellate plexuses. Finally, it gives off **interlobular branches**, which form a plexus outside each lobule, to supply the walls of the interlobular veins and the accompanying bile ducts. From this plexus lobular branches enter the lobule and end in the net-work of sinusoids between the cells.

The **portal vein** also enters at the porta, and runs through the portal canals (Fig. 1093), enclosed in Glisson's capsule, dividing in its course into branches, which finally break up into a plexus, the **interlobular plexus**, in the interlobular spaces. These branches receive the vaginal and capsular veins, corresponding to the vaginal and capsular branches of the hepatic artery.

Thus it will be seen that all the blood carried to the liver by the portal vein and hepatic artery finds its way into the interlobular plexus. From this plexus the blood is carried into the lobule by fine branches which converge from the circumference to the

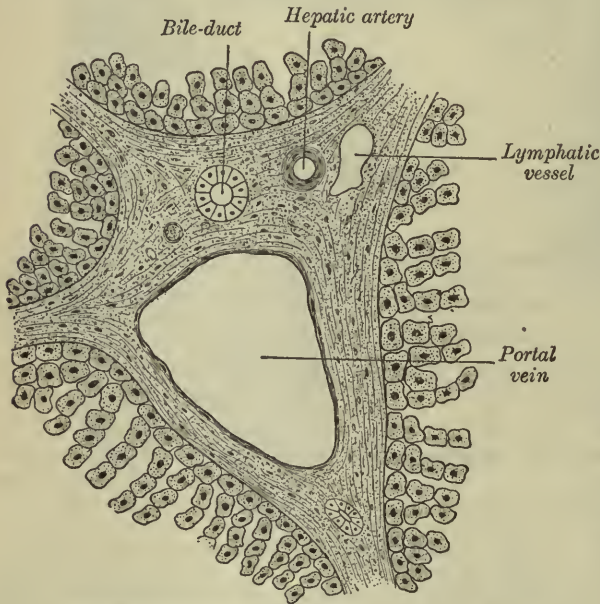


FIG. 1093.—Section across portal canal of pig. $\times 250$.

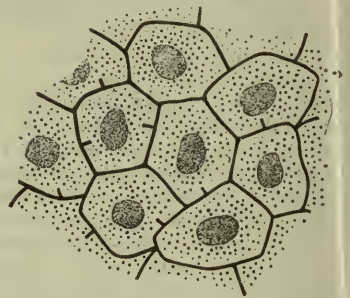


FIG. 1094.—Bile capillaries of rabbit, shown by Golgi's method. $\times 450$.

center of the lobule, and are connected by transverse branches (Fig. 1091). The walls of these small vessels are incomplete so that the blood is brought into direct relationship with the liver cells. The lining endothelium consists of irregularly branched, disconnected cells (*stellate cells of Kupffer*). Moreover, according to Herring and Simpson, minute channels penetrate the liver cells themselves, conveying the constituents of the blood into their substance. It will be seen that the blood capillaries of the liver lobule differ structurally from capillaries elsewhere. Developmentally they are formed by the growth of the columns of liver cells into large blood spaces or sinuses, and hence they have received the name of "sinusoids." Arrived at the center of the lobule,

the sinusoids empty themselves into one vein, of considerable size, which runs down the center of the lobule from apex to base, and is called the **intralobular vein**. At the base of the lobule this vein opens directly into the **sublobular vein**, with which the lobule is connected. The sublobular veins unite to form larger and larger trunks, and end at last in the hepatic veins, these converge to form three large trunks which open into the inferior vena cava while that vessel is situated in its fossa on the posterior surface of the liver.

3. The **bile ducts** commence by little passages in the liver cells which communicate with canaliculi termed **intercellular biliary passages** (*bile capillaries*). These passages are merely little channels or spaces left between the contiguous surfaces of two cells, or in the angle where three or more liver cells meet (Fig. 1094), and they are always separated from the blood capillaries by at least half the width of a liver cell. The channels thus formed radiate to the circumference of the lobule, and open into the interlobular bile ducts which run in Glisson's capsule, accompanying the portal vein and hepatic artery (Fig. 1093). These join with other ducts to form two main trunks, which leave the liver at the transverse fissure, and by their union form the **hepatic duct**.

Structure of the Ducts.—The walls of the biliary ducts consist of a connective-tissue coat, in which are muscle cells, arranged both circularly and longitudinally, and an epithelial layer, consisting of short columnar cells resting on a distinct basement membrane.

Excretory Apparatus of the Liver.—The excretory apparatus of the liver consists of (1) the **hepatic duct**, formed by the junction of the two main ducts, which pass out of the liver at the porta; (2) the **gall-bladder**, which serves as a reservoir for the bile; (3) the **cystic duct**, or the duct of the gall-bladder; and (4) the **common bile duct**, formed by the junction of the hepatic and cystic ducts.

The Hepatic Duct (*ductus hepaticus*).—Two main trunks of nearly equal size issue from the liver at the porta, one from the right, the other from the left lobe; these unite to form the hepatic duct, which passes downward and to the right for about 4 cm., between the layers of the lesser omentum, where it is joined at an acute angle by the cystic duct, and so forms the common bile duct. The hepatic duct is accompanied by the hepatic artery and portal vein.

The Gall-bladder (*vesica fellea*) (Fig. 1095).—The gall-bladder is a conical or pear-shaped musculomembranous sac, lodged in a fossa on the under surface of the right lobe of the liver, and extending from near the right extremity of the porta to the anterior border of the organ. It is from 7 to 10 cm. in length, 2.5 cm. in breadth at its widest part, and holds from 30 to 35 c.c. It is divided into a fundus, body, and neck. The **fundus**, or broad extremity, is directed downward, forward, and to the right, and projects beyond the anterior border of the liver; the **body** and **neck** are directed upward and backward to the left. The upper surface of the gall-bladder is attached to the liver by connective tissue and vessels. The under surface is covered by peritoneum, which is reflected on to it from the surface of the liver. Occasionally the whole of the organ is invested by the serous membrane, and is then connected to the liver by a kind of mesentery.

Relations.—The **body** is in relation, by its upper surface, with the liver; by its under surface, with the commencement of the transverse colon; and farther back usually with the upper end

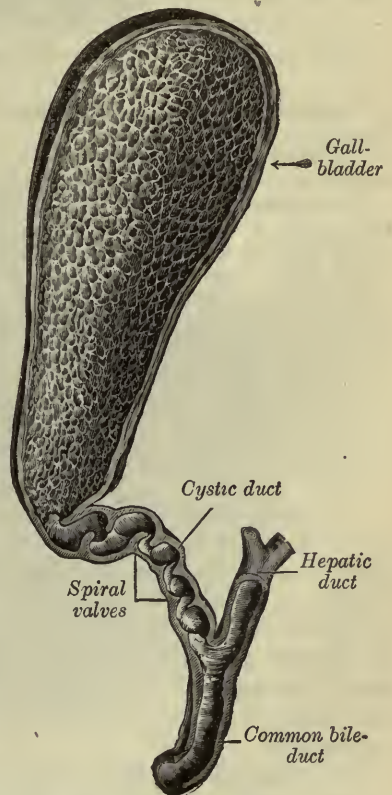


FIG. 1095.—The gall-bladder and bile ducts laid open. (Spalteholz.)

of the descending portion of the duodenum, but sometimes with the superior portion of the duodenum or pyloric end of the stomach. The **fundus** is completely invested by peritoneum; it is in relation, in front, with the abdominal parietes, immediately below the ninth costal cartilage; behind with the transverse colon. The **neck** is narrow, and curves upon itself like the letter S; at its point of connection with the cystic duct it presents a well-marked constriction.

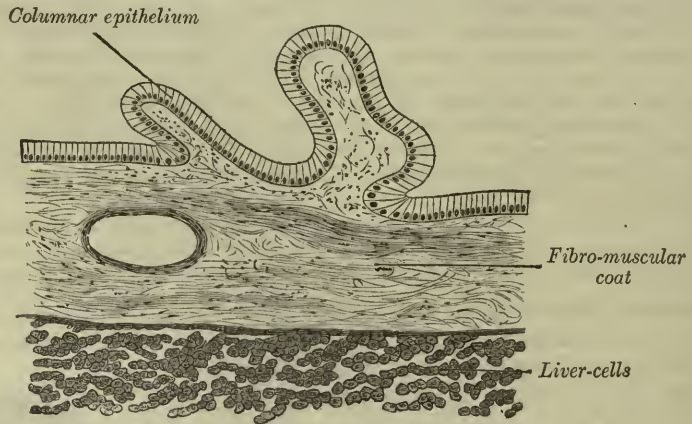


FIG. 1036.—Transverse section of gall-bladder.

Structure (Fig. 1036).—The gall-bladder consists of three coats: **serous**, **fibromuscular**, and **mucous**.

The **external** or **serous coat** (*tunica serosa vesicæ felleæ*) is derived from the peritoneum; it completely invests the fundus, but covers the body and neck only on their under surfaces.

The **fibromuscular coat** (*tunica muscularis vesicæ felleæ*), a thin but strong layer forming the frame-work of the sac, consists of dense fibrous tissue, which interlaces in all directions, and is mixed with plain muscular fibers, disposed chiefly in a longitudinal direction, a few running transversely.

The **internal** or **mucous coat** (*tunica mucosa vesicæ felleæ*) is loosely connected with the fibrous layer. It is generally of a yellowish-brown color, and is elevated into minute rugæ. Opposite the neck of the gall-bladder the mucous membrane projects inward in the form of oblique ridges or folds, forming a sort of spiral valve.

The mucous membrane is continuous through the hepatic duct with the mucous membrane lining the ducts of the liver, and through the common bile duct with the mucous membrane of the duodenum. It is covered with columnar epithelium, and secretes mucin; in some animals it secretes a nucleoprotein instead of mucin.

The **Cystic Duct** (*ductus cysticus*).—The cystic duct about 4 cm. long, runs backward, downward, and to the left from the neck of the gall-bladder, and joins the hepatic duct to form the common bile duct. The mucous membrane lining its interior is thrown into a series of crescentic folds, from five to twelve in number, similar to those found in the neck of the gall-bladder. They project into the duct in regular succession, and are directed obliquely around the tube, presenting much the appearance of a continuous spiral valve. When the duct is distended, the spaces between the folds are dilated, so as to give to its exterior a twisted appearance.

The **Common Bile Duct** (*ductus choledochus*).—The common bile duct is formed by the junction of the cystic and hepatic ducts; it is about 7.5 cm. long, and of the diameter of a goose-quill.

It descends along the right border of the lesser omentum behind the superior portion of the duodenum, in front of the portal vein, and to the right of the hepatic artery; it then runs in a groove near the right border of the posterior surface of the head of the pancreas; here it is situated in front of the inferior vena cava, and is occasionally completely imbedded in the pancreatic substance. At its termination it lies for a short distance along the right side of the terminal part of the pancreatic duct and passes with it obliquely between the mucous and muscular coats. The

two ducts unite and open by a common orifice upon the summit of the duodenal papilla, situated at the medial side of the descending portion of the duodenum, a little below its middle and about 7 to 10 cm. from the pylorus (Fig. 1100). The short tube formed by the union of the two ducts is dilated into an ampulla, the *ampulla of Vater*.

Structure.—The coats of the large biliary ducts are an **external** or **fibrous**, and an **internal** or **mucous**. The **fibrous coat** is composed of strong fibroareolar tissue, with a certain amount of muscular tissue, arranged, for the most part, in a circular manner around the duct. The **mucous coat** is continuous with the lining membrane of the hepatic ducts and gall-bladder, and also with that of the duodenum; and, like the mucous membrane of these structures, its epithelium is of the columnar variety. It is provided with numerous mucous glands, which are lobulated and open by minute orifices scattered irregularly in the larger ducts.

The Pancreas (Figs. 1097, 1098).

The **pancreas** is a compound racemose gland, analogous in its structures to the salivary glands, though softer and less compactly arranged than those organs. Its secretion, the **pancreatic juice**, carried by the pancreatic duct to the duodenum, is an important digestive fluid. In addition the pancreas has an important internal secretion, probably elaborated by the cells of Langerhans, which is taken up by the blood stream and is concerned with sugar metabolism. It is long and irregularly

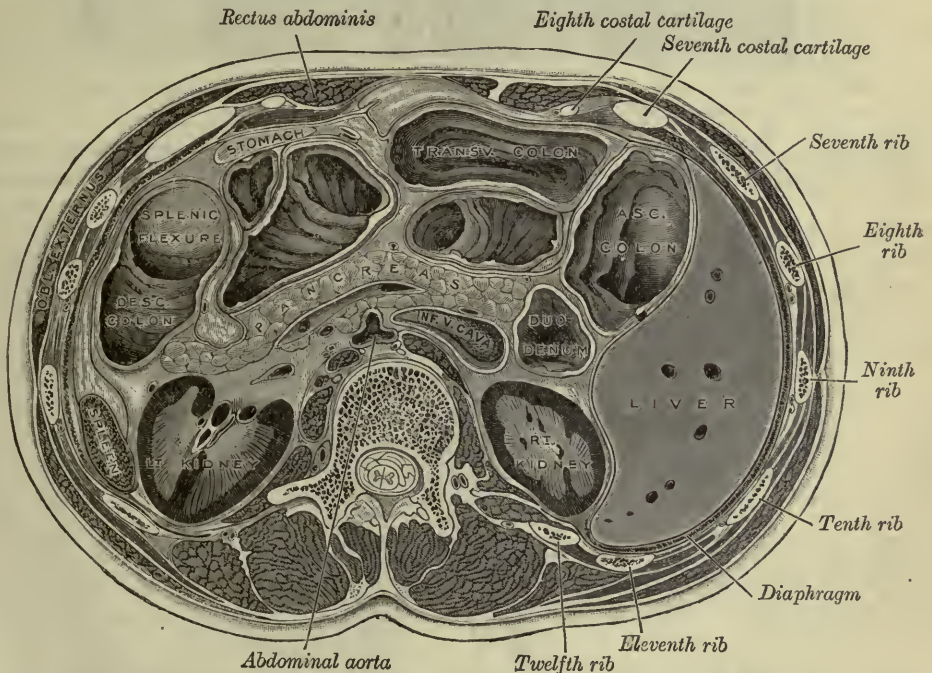


FIG. 1097.—Transverse section through the middle of the first lumbar vertebra, showing the relations of the pancreas. (Braune.)

prismatic in shape; its right extremity, being broad, is called the **head**, and is connected to the main portion of the organ, or **body**, by a slight constriction, the **neck**; while its left extremity gradually tapers to form the **tail**. It is situated transversely across the posterior wall of the abdomen, at the back of the epigastric and left hypochondriac regions. Its length varies from 12.5 to 15 cm., and its weight from 60 to 100 gm.

Relations.—The **Head** (*caput pancreatis*) is flattened from before backward, and is lodged within the curve of the duodenum. Its upper border is overlapped by the

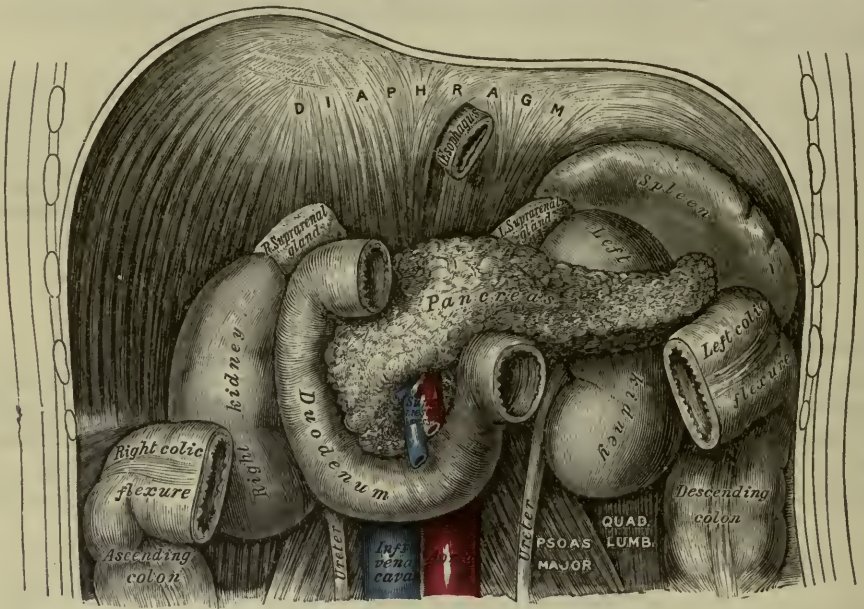


FIG. 1098.—The duodenum and pancreas.

superior part of the duodenum and its lower overlaps the horizontal part; its right and left borders overlap in front, and insinuate themselves behind, the descending

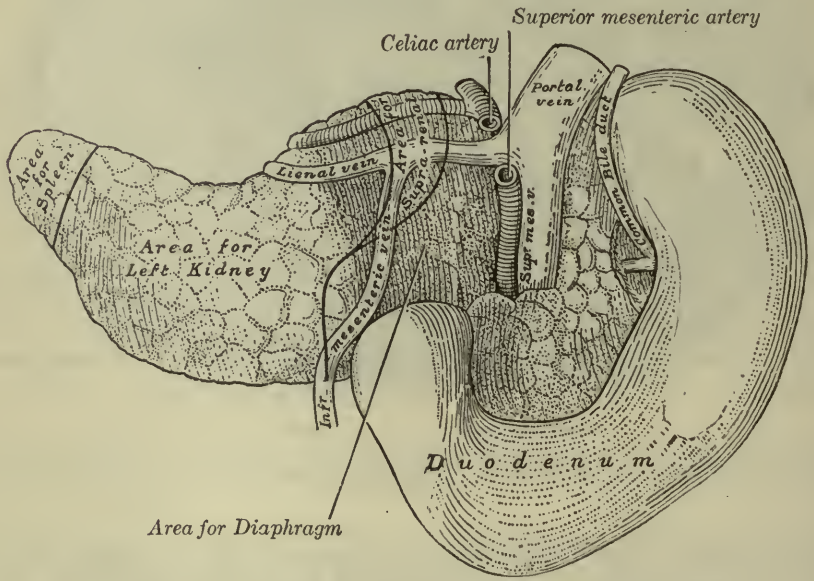


FIG. 1099.—The pancreas and duodenum from behind. (From model by His.)

and ascending parts of the duodenum respectively. The angle of junction of the lower and left lateral borders forms a prolongation, termed the **uncinate process**. In

the groove between the duodenum and the right lateral and lower borders in front are the anastomosing superior and inferior pancreaticoduodenal arteries; the common bile duct descends behind, close to the right border, to its termination in the descending part of the duodenum.

Anterior Surface.—The greater part of the right half of this surface is in contact with the transverse colon, only areolar tissue intervening. From its upper part the **neck** springs, its right limit being marked by a groove for the gastroduodenal artery. The lower part of the right half, below the transverse colon, is covered by peritoneum continuous with the inferior layer of the transverse mesocolon, and is in contact with the coils of the small intestine. The superior mesenteric artery passes down in front of the left half across the uncinatè process; the superior mesenteric vein runs upward on the right side of the artery and, behind the neck, joins with the lienal vein to form the portal vein.

Posterior Surface.—The posterior surface is in relation with the inferior vena cava, the common bile duct, the renal veins, the right crus of the diaphragm, and the aorta.

The **Neck** springs from the right upper portion of the front of the head. It is about 2.5 cm. long, and is directed at first upward and forward, and then upward and to the left to join the body; it is somewhat flattened from above downward and backward. Its antero-superior surface supports the pylorus; its postero-inferior surface is in relation with the commencement of the portal vein; on the right it is grooved by the gastroduodenal artery.

The **Body** (*corpus pancreatis*) is somewhat prismatic in shape, and has three surfaces: **anterior**, **posterior**, and **inferior**.

The **anterior surface** (*facies anterior*) is somewhat concave; and is directed forward and upward: it is covered by the postero-inferior surface of the stomach which rests upon it, the two organs being separated by the omental bursa. Where it joins the neck there is a well-marked prominence, the **tuber omentale**, which abuts against the posterior surface of the lesser omentum.

The **posterior surface** (*facies posterior*) is devoid of peritoneum, and is in contact with the aorta, the lienal vein, the left kidney and its vessels, the left suprarenal gland, the origin of the superior mesenteric artery, and the crura of the diaphragm.

The **inferior surface** (*facies inferior*) is narrow on the right but broader on the left, and is covered by peritoneum; it lies upon the duodenojejunal flexure and on some coils of the jejunum; its left extremity rests on the left colic flexure.

The **superior border** (*margo superior*) is blunt and flat to the right; narrow and sharp to the left, near the tail. It commences on the right in the omental tuberosity, and is in relation with the celiac artery, from which the hepatic artery courses to the right just above the gland, while the lienal artery runs toward the left in a groove along this border.

The **anterior border** (*margo anterior*) separates the anterior from the inferior surface, and along this border the two layers of the transverse mesocolon diverge from one another; one passing upward over the anterior surface, the other backward over the inferior surface.

The **inferior border** (*margo inferior*) separates the posterior from the inferior surface; the superior mesenteric vessels emerge under its right extremity.

The **Tail** (*cauda pancreatis*) is narrow; it extends to the left as far as the lower part of the gastric surface of the spleen, lying in the phrenicocolic ligament, and it is in contact with the left colic flexure.

Birmingham described the body of the pancreas as projecting forward as a prominent ridge into the abdominal cavity and forming part of a shelf on which the stomach lies. "The portion of the pancreas to the left of the middle line has a very considerable antero-posterior thickness; as a result the anterior surface is of considerable extent; it looks strongly upward, and forms a large and important

part of the shelf. As the pancreas extends to the left toward the spleen it crosses the upper part of the kidney, and is so moulded on to it that the top of the kidney forms an extension inward and backward of the upper surface of the pancreas and extends the bed in this direction. On the other hand, the extremity of the pancreas comes in contact with the spleen in such a way that the plane of its upper surface runs with little interruption upward and backward into the concave gastric surface of the spleen, which completes the bed behind and to the left, and, running upward, forms a partial cap for the wide end of the stomach.¹

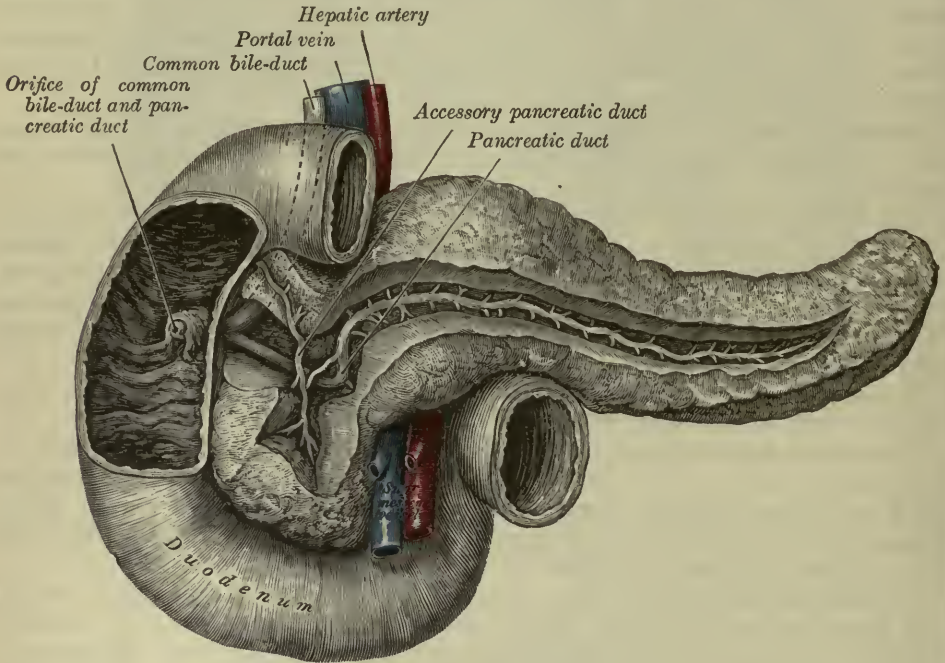


FIG. 1100.—The pancreatic duct.

The **Pancreatic Duct** (*ductus pancreaticus* [*Wirsungi*]; *duct of Wirsung*) extends transversely from left to right through the substance of the pancreas (Fig. 1100). It commences by the junction of the small ducts of the lobules situated in the tail of the pancreas, and, running from left to right through the body, it receives the ducts of the various lobules composing the gland. Considerably augmented in size, it reaches the neck, and turning downward, backward, and to the right, it comes into relation with the common bile duct, which lies to its right side; leaving the head of the gland, it passes very obliquely through the mucous and muscular coats of the duodenum, and ends by an orifice common to it and the common bile duct upon the summit of the duodenal papilla, situated at the medial side of the descending portion of the duodenum, 7.5 to 10 cm. below the pylorus. The pancreatic duct, near the duodenum, is about the size of an ordinary quill. Sometimes the pancreatic duct and the common bile duct open separately into the duodenum. Frequently there is an additional duct, which is given off from the pancreatic duct in the neck of the pancreas and opens into the duodenum about 2.5 cm. above the duodenal papilla. It receives the ducts from the lower part of the head, and is known as the **accessory pancreatic duct** (*duct of Santorini*).

Development (Figs. 1101, 1102).—The pancreas is developed in two parts, a dorsal and a ventral. The former arises as a diverticulum from the dorsal aspect

¹ Journal of Anatomy and Physiology, pt. 1, xxxi, 102.

of the duodenum a short distance above the hepatic diverticulum, and, growing upward and backward into the dorsal mesogastrum, forms a part of the head and uncinete process and the whole of the body and tail of the pancreas. The ventral part appears in the form of a diverticulum from the primitive bile-duct and forms the remainder of the head and uncinete process of the pancreas. The duct of the dorsal part (**accessory pancreatic duct**) therefore opens independently into the duodenum, while that of the ventral part (**pancreatic duct**) opens with the common bile-duct. About the sixth week the two parts of the pancreas meet and fuse

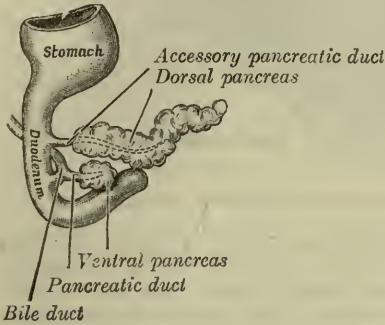


FIG. 1101.—Pancreas of a human embryo of five weeks. (Kollmann.)

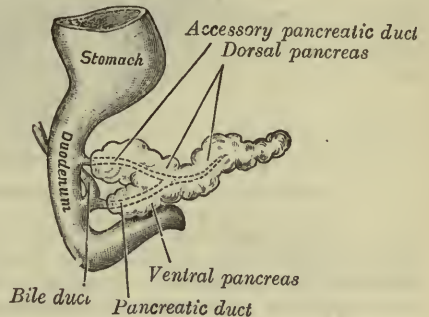


FIG. 1102.—Pancreas of a human embryo at end of sixth week. (Kollmann.)

and a communication is established between their ducts. After this has occurred the terminal part of the accessory duct, *i. e.*, the part between the duodenum and the point of meeting of the two ducts, undergoes little or no enlargement, while the pancreatic duct increases in size and forms the main duct of the gland. The opening of the accessory duct into the duodenum is sometimes obliterated, and even when it remains patent it is probable that the whole of the pancreatic secretion is conveyed through the pancreatic duct.

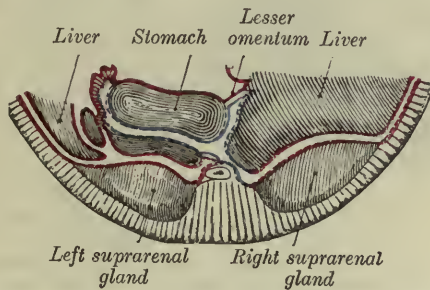


FIG. 1103.—Schematic and enlarged cross-section through the body of a human embryo in the region of the mesogastrum. Beginning of third month. (Toldt.)

At first the pancreas is directed upward and backward between the two layers of the dorsal mesogastrum, which give to it a complete peritoneal investment, and its surfaces look to the right and left. With the change in the position of the stomach the dorsal mesogastrum is drawn downward and to the left, and the right side of the pancreas is directed backward and the left forward (Fig. 1103). The right surface becomes applied to the posterior abdominal wall, and the peritoneum which covered it undergoes absorption (Fig. 1104); and thus, in the adult, the gland appears to lie behind the peritoneal cavity.

Structure (Fig. 1105).—In structure, the pancreas resembles the salivary glands. It differs from them, however, in certain particulars, and is looser and softer in its texture. It is not enclosed in a distinct capsule, but is surrounded by areolar tissue, which dips into its interior,

and connects together the various lobules of which it is composed. Each lobule, like the lobules of the salivary glands, consists of one of the ultimate ramifications of the main duct, ending in a number of cecal pouches or alveoli, which are tubular and somewhat convoluted. The minute ducts connected with the alveoli are narrow and lined with flattened cells. The alveoli are

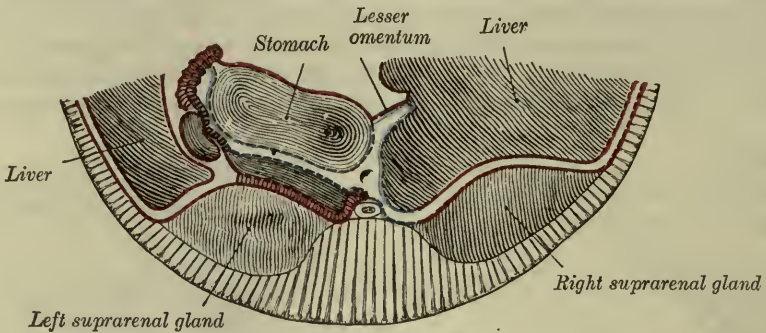


FIG. 1104.—Section through same region as in Fig. 1103, at end of third month. (Toldt.)

almost completely filled with secreting cells, so that scarcely any lumen is visible. In some animals spindle-shaped cells occupy the center of the alveolus and are known as the **centro-acinar cells of Langerhans**. These are prolongations of the terminal ducts. The true secreting cells which line the wall of the alveolus are very characteristic. They are columnar in shape and present two zones: an outer one, clear and finely striated next the basement membrane, and an inner granular one next the lumen. In hardened specimens the outer zone stains deeply with various dyes, whereas the inner zone stains slightly. During activity the granular zone gradually diminishes in size, and when exhausted is only seen as a small area next to the lumen. During the resting stages it gradually increases until it forms nearly three-fourths of the cell. In some of the secreting cells of the pancreas is a spherical mass, staining more easily than the rest of the cell; this is termed the **paranucleus**, and is believed to be an extension from the nucleus. The connective tissue between the alveoli presents in certain parts collections of cells, which are termed **interalveolar cell islets (islands of Langerhans)**. The cells of these stain lightly with hematoxylin or carmine, and are more or less polyhedral in shape, forming a net-work in which ramify many

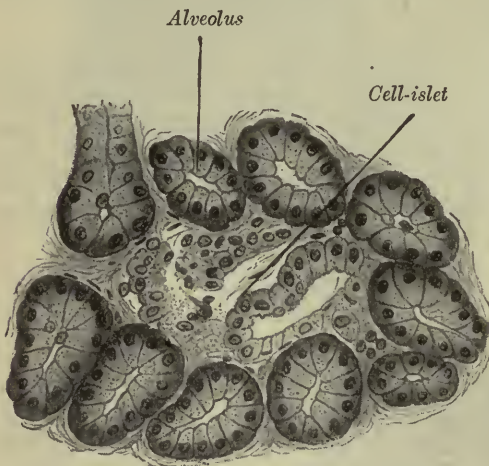


FIG. 1105.—Section of pancreas of dog. $\times 250$.

capillaries. There are two main types of cell in the islets, distinguished as A-cells and B-cells according to the special staining reactions of the granules they contain. The cell islets have been supposed to produce the internal secretion of the pancreas which is necessary for carbohydrate metabolism, but numerous researches have so far failed to elucidate their real function.

The walls of the pancreatic duct are thin, consisting of two coats, an external fibrous and an internal mucous; the latter is smooth, and furnished near its termination with a few scattered follicles.

Vessels and Nerves.—The **arteries** of the pancreas are derived from the lienal, and the pancreaticoduodenal branches of the hepatic and superior mesenteric. Its **veins** open into the lienal and superior mesenteric veins. Its **lymphatics** are described on page 711. Its **nerves** are filaments from the lienal plexus.

THE UROGENITAL APPARATUS (APPARATUS UROGENITALIS; UROGENITAL ORGANS).

The urogenital apparatus consists of (a) the **urinary organs** for the secretion and discharge of the urine, and (b) the **genital organs**, which are concerned with the process of reproduction.

DEVELOPMENT OF THE URINARY AND GENERATIVE ORGANS.

The urinary and generative organs are developed from the intermediate cell-mass which is situated between the primitive segments and the lateral plates of mesoderm. The permanent organs of the adult are preceded by a set of structures which are purely embryonic, and which with the exception of the ducts disappear almost entirely before the end of fetal life. These embryonic structures are on either side; the **pronephros**, the **mesonephros**, the **metanephros**, and the **Wolffian** and **Müllerian ducts**. The pronephros disappears very early; the structural elements of the mesonephros mostly degenerate, but in their place is developed the genital gland in association with which the Wolffian duct remains as the duct of the male genital gland, the Müllerian as that of the female; some of the tubules of the metanephros form part of the permanent kidney.

The Pronephros and Wolffian Duct.—In the outer part of the intermediate cell-mass, immediately under the ectoderm, in the region from the fifth cervical to the third thoracic segments, a series of short evaginations from each segment grows dorsalward and extends caudalward, fusing successively from before backward to form the **pronephric duct**. This continues to grow caudalward until it opens into the ventral part of the cloaca; beyond the pronephros it is termed the **Wolffian duct**.

The original evaginations form a series of transverse tubules each of which communicates by means of a funnel-shaped ciliated opening with the celomic cavity, and in the course of each duct a glomerulus also is developed. A secondary glomerulus is formed ventral to each of these, and the complete group constitutes the **pronephros**. The pronephros undergoes rapid atrophy and disappears.

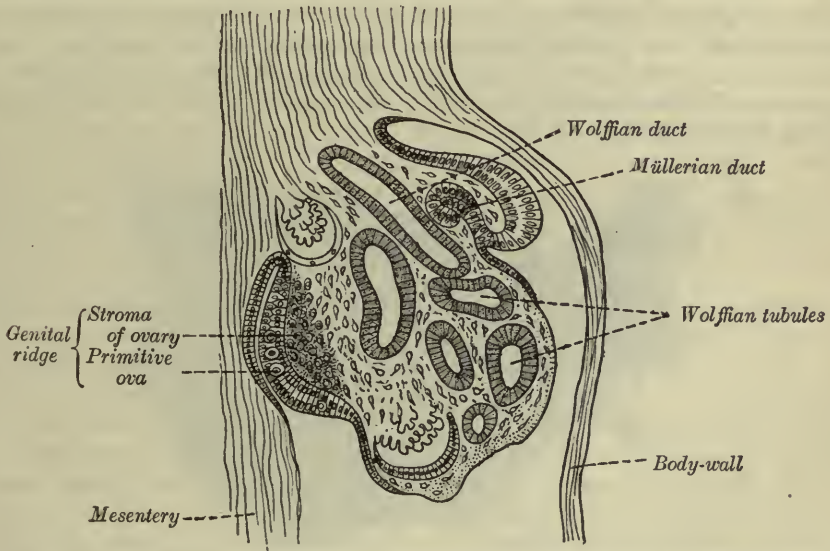


FIG. 1106.—Section of the urogenital fold of a chick embryo of the fourth day. (Waldeyer.)

The Mesonephros, Müllerian Duct, and Genital Gland.—On the medial side of the Wolffian duct, from the sixth cervical to the third lumbar segments, a series of tubules, the **Wolffian tubules** (Fig. 1106), is developed; at a later stage in development they increase in number by outgrowths from the original tubules. These tubules first appear as solid masses of cells, which later become hollowed in the center; one end grows toward and finally opens into the Wolffian duct, the other dilates and is invaginated by a tuft of capillary bloodvessels to form a glomerulus. The tubules collectively constitute the **mesonephros** or **Wolffian body** (Figs. 986,

1107). By the fifth or sixth week this body forms an elongated spindle-shaped structure, termed the **urogenital fold** (Fig. 1106), which projects into the celomic cavity at the side of the dorsal mesentery, reaching from the septum transversum in front to the fifth lumbar segment behind; in this fold the reproductive glands are developed. The Wolffian bodies persist and form the permanent kidneys in fishes and amphibians, but in reptiles, birds, and mammals, they atrophy and for the most part disappear coincidentally with the development of the permanent kidneys. The atrophy begins during the sixth or seventh week and rapidly proceeds, so that by the beginning of the fifth month only the ducts and a few of the tubules remain.

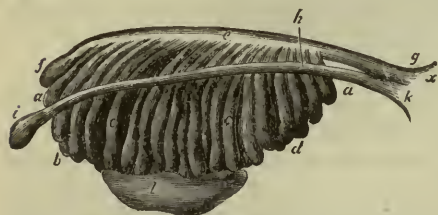

FIG. 1107.—Enlarged view from the front of the left Wolffian body before the establishment of the distinction of sex. (From Farre, after Kobelt.) *a*, *b*, *c*, *d*. Tubular structure of the Wolffian body. *e*. Wolffian duct. *f*. Its upper extremity. *g*. Its termination in *x*, the urogenital sinus. *h*. The duct of Müller. *i*. Its upper, funnel-shaped extremity. *k*. Its lower end, terminating in the urogenital sinus. *l*. The genital gland.

In the male the Wolffian duct persists, and forms the tube of the epididymis, the ductus deferens and the ejaculatory duct, while the seminal vesicle arises during the third month as a lateral diverticulum from its hinder end. A large part of the head end of the mesonephros atrophies and disappears; of the remainder the anterior tubules form the efferent ducts of the testis; while the posterior tubules are represented by the ductuli aberrantes, and by the paradidymis, which is sometimes found in front of the spermatic cord above the head of the epididymis (Fig. 1110, C).

In the female the Wolffian bodies and ducts atrophy. The remains of the Wolffian tubules are represented by the **epoöphoron** or **organ of Rosenmüller**, and the **paroöphoron**, two small collections of rudimentary blind tubules which are situated in the mesosalpinx (Fig. 1108). The lower part of the Wolffian duct disappears, while the upper part persists as the longitudinal duct of the epoöphoron or **duct of Gärtner**¹ (Fig. 1110, B).

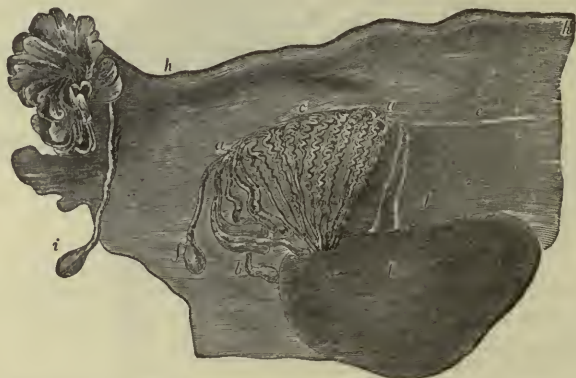

FIG. 1108.—Broad ligament of adult, showing epoöphoron. (From Farre, after Kobelt.) *a*, *a*. Epoöphoron formed from the upper part of the Wolffian body. *b*. Remains of the uppermost tubes sometimes forming appendices. *c*. Middle set of tubes. *d*. Some lower atrophied tubes. *e*. Atrophied remains of the Wolffian duct. *f*. The terminal bulb or hydatid. *h*. The uterine tube, originally the duct of Müller. *i*. Appendix attached to the extremity. *l*. The ovary.

The Müllerian Ducts.—Shortly after the formation of the Wolffian ducts a second pair of ducts is developed; these are named the **Müllerian ducts**. Each arises on the lateral aspect of the corresponding Wolffian duct as a tubular invag-

¹ Berry Hart (*op. cit.*) has described the Wolffian ducts as ending at the site of the future hymen in bulbous enlargements, which he has named the *Wolffian bulbs*; and states that the hymen is formed by these bulbs, "aided by a special involution from below of the cells lining the urogenital sinus." He further believes that "the lower third of the vagina is due to the coalescence of the upper portion of the urogenital sinus and the lower ends of the Wolffian ducts," and that "the epithelial lining of the vagina is derived from the Wolffian bulbs." He also regards the colliculus seminalis of the male urethra as being formed from the lower part of the Wolffian ducts.

ination of the cells lining the celom (Fig. 1106). The orifice of the invagination remains patent, and undergoes enlargement and modification to form the abdominal ostium of the uterine tube. The ducts pass backward lateral to the Wolffian ducts, but toward the posterior end of the embryo they cross to the medial side of these ducts, and thus come to lie side by side between and behind the latter—the four ducts forming what is termed the **genital cord** (Fig. 1109). The Müllerian ducts end in an epithelial elevation, the **Müllerian eminence**, on the ventral part of the cloaca between the orifices of the Wolffian ducts; at a later date they open into the cloaca in this situation.

In the male the Müllerian ducts atrophy, but traces of their anterior ends are represented by the **appendices testis** (*hydatids of Morgagni*), while their terminal fused portions form the utriculus in the floor of the prostatic portion of the urethra (Fig. 1110, *C*).

In the female the Müllerian ducts persist and undergo further development. The portions which lie in the genital core fuse to form the uterus and vagina; the parts in front of this cord remain separate, and each forms the corresponding uterine tube—the abdominal ostium of which is developed from the anterior extremity of the original tubular invagination from the celom (Fig. 1110, *B*). The fusion of the Müllerian ducts begins in the third month, and the septum formed by their fused medial walls disappears from below upward, and thus the cavities of the vagina and uterus are produced. About the fifth month an annular constriction marks the position of the neck of the uterus, and after the sixth month the walls of the uterus begin to thicken. For a time the vagina is represented by a solid rod of epithelial cells. A ring-like outgrowth of this epithelium occurs at the lower end of the uterus and marks the future vaginal fornices; about the fifth or sixth month the lumen of the vagina is produced by the breaking down of the central cells of the epithelium. The hymen represents the remains of the Müllerian eminence.

Genital Glands.—The first appearance of the genital gland is essentially the same in the two sexes, and consists in a thickening of the epithelial layer which lines the peritoneal cavity on the medial side of the urogenital fold (Fig. 1106). The thick plate of epithelium extends deeply, pushing before it the mesoderm and forming a distinct projection. This is termed the **genital ridge** (Fig. 1106), and from it the testis in the male and the ovary in the female are developed. At first the mesonephros and genital ridge are suspended by a common mesentery, but as the embryo grows the genital ridge gradually becomes pinched off from the mesonephros, with which it is at first continuous, though it still remains connected to the remnant of this body by a fold of peritoneum, the **mesorchium** or **mesovarium** (Fig. 1111). About the seventh week the distinction of sex in the genital ridge begins to be perceptible.

The Ovary.—The ovary, thus formed from the genital ridge, is at first a mass of cells derived from the celomic epithelium; later the mass is differentiated into a central part or medulla (Fig. 1112) covered by a surface layer, the **germinal epithelium**. Between the cells of the germinal epithelium a number of larger cells, the **primitive ova**, are found, and these are carried into the subjacent stroma by bud-like ingrowths (**genital cords**) of the germinal epithelium (Fig. 1113). The surface epithelium ultimately forms the permanent epithelial covering of this

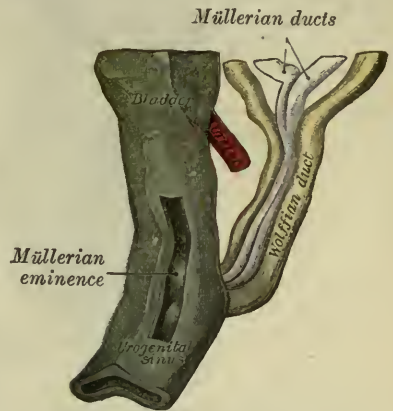
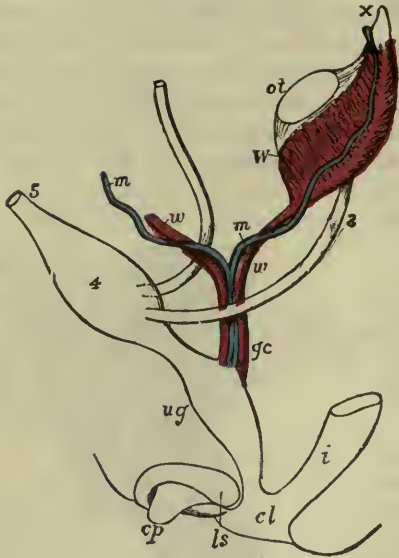
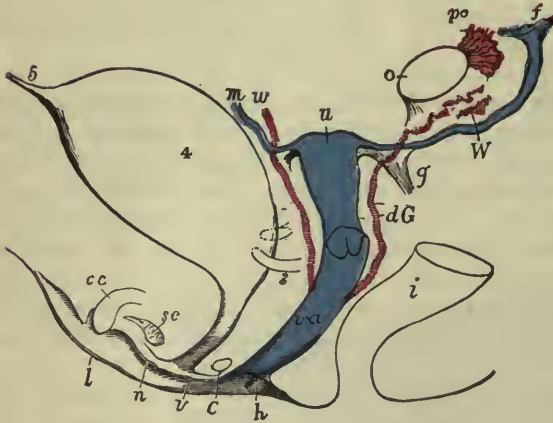


FIG. 1109.—Urogenital sinus of female human embryo of eight and a half to nine weeks old. (From model by Keibel)

A



B



C

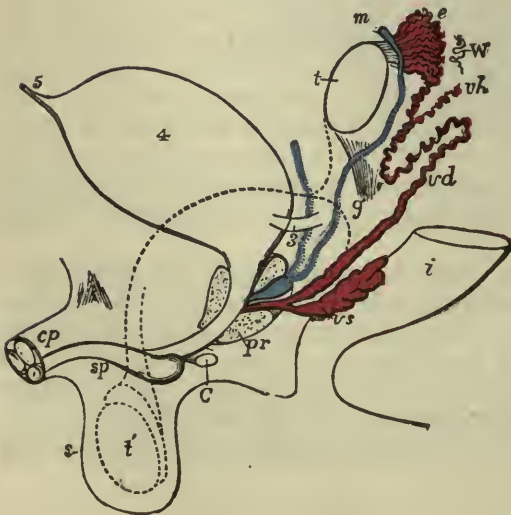

FIG. 1110.—Diagrams to show the development of male and female generative organs from a common type. (Allen Thomson.)

A.—Diagram of the primitive urogenital organs in the embryo previous to sexual distinction. 3. Ureter. 4. Urinary bladder. 5. Urachus. *cl*, Cloaca. *cp*, Elevation which becomes clitoris or penis. *i*, Lower part of the intestine. *ls*, Fold of integument from which the labia majora or scrotum are formed. *m, m*, Right and left Müllerian ducts uniting together and running with the Wolffian ducts in *gc*, the genital cord. *ot*, The genital ridge from which either the ovary or testis is formed. *ug*, Sinus urogenitalis. *W*, Left Wolffian body. *w, w*, Right and left Wolffian ducts.

B.—Diagram of the female type of sexual organs. *C*, Greater vestibular gland, and immediately above it the urethra. *cc*, Corpus cavernosum clitoridis. *dG*, Remains of the left Wolffian duct, such as give rise to the duct of Cärtner, represented by dotted lines; that of the right side is marked *w*. *f*, The abdominal opening of the left uterine tube. *g*, Round ligament, corresponding to gubernaculum. *h*, Situation of the left uterine tube. *b*, Situation of the right uterine tube. *l*, Labium major. *n*, Labium minus. *o*, The left ovary. *po*, Epiphoron. *sc*, Corpus cavernosum urethrae. *u*, Uterus. The uterine tube of the right side is marked *m*. *v*, Vulva. *va*, Vagina. *W*, Scattered remains of Wolffian tubes near it (paroöphoron of Waldeyer).

C.—Diagram of the male type of sexual organs. *C*, Bulbo-urethral gland of one side. *cp*, Corpora cavernosa penis cut short. *e*, Caput epididymis. *g*, The gubernaculum. *i*, Lower part of the intestine. *m*, Müllerian duct, the upper part of which remains as the hydatid of Morgagni; the lower part, represented by a dotted line descending to the prostatic utricle, constitutes the occasionally existing cornu and tube of the uterus masculinus. *pr*, The prostate. *s*, Scrotum, *sp*, Corpus cavernosum urethrae. *t*, Testis in the place of its original formation. *t*, together with the dotted lines above, indicates the direction in which the testis and epididymis descend from the abdomen into the scrotum. *vd*, Ductus deferens. *vh*, Ductus aberrans. *vs*, The vesicula seminalis. *W*, Scattered remains of the Wolffian body, constituting the organ of Giralde's, or the paradidymis of Waldeyer.

organ; it soon loses its connection with the central mass, and a tunica albuginea develops between them. The ova are chiefly derived from the cells of the central mass; these are separated from one another by the growth of connective tissue in an irregular manner; each ovum assumes a covering of connective tissue (follicle) cells, and in this way the rudiments of the ovarian follicles are formed (Fig. 1113). According to Beard the primitive ova are early set apart during the segmentation of the ovum and migrate into the germinal ridge.

Waldeyer taught that the primitive germ cells are derived from the "germinal epithelium," covering the genital ridge. Beard,¹ on the other hand, maintains that in the skate they are not derived from this epithelium, but are probably formed during the later stages of cell cleavage, before there is any trace of an embryo; and a similar view was advanced by Nussbaum as to their origin in amphibia. Beard says: "At the close of segmentation many of the future germ cells lie in the segmentation cavity just beneath the site of the future embryo, and there is no doubt they subsequently wander into it." The germ cells, "after they enter the resting phase, are sharply marked off from the cells of the embryo by entire absence of mitoses among them." They can be further recognized by their irregular form and ameboid processes, and by

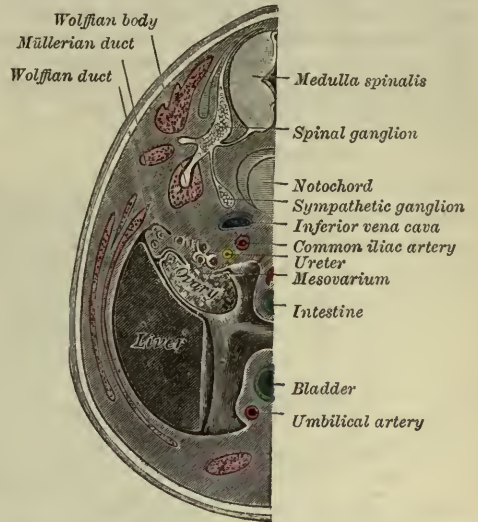


FIG. 1111.—Transverse section of human embryo eight and a half to nine weeks old. (From model by Keibel.)

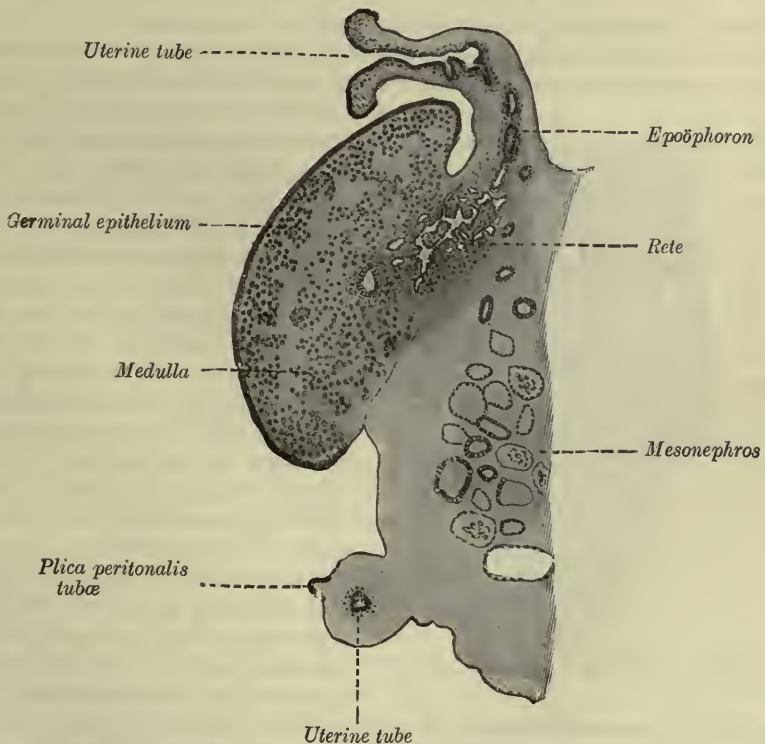


FIG. 1112.—Longitudinal section of ovary of cat embryo of 9.4 cm. long. Schematic. (After Coert.)

¹ Journal of Anatomy and Physiology, vol. xxxviii.

the fact that their cytoplasm has no affinity for ordinary stains, but assumes a brownish tinge when treated by osmic acid. The path along which they travel into the embryo is a very definite one, viz., "from the yolk sac upward between the splanchnopleure and gut in the hinder portion of the embryo." This pathway, named by Beard the **germinal path**, "leads them directly to the position which they ought finally to take up in the 'germinal ridge' or nidus." A considerable number apparently never reach their proper destination, since "vagrant germ cells are found in all sorts of places, but more particularly on the mesentery." Some of these may possibly find their way into the germinal ridge; some probably undergo atrophy, while others may persist and become the seat of dermoid tumors.

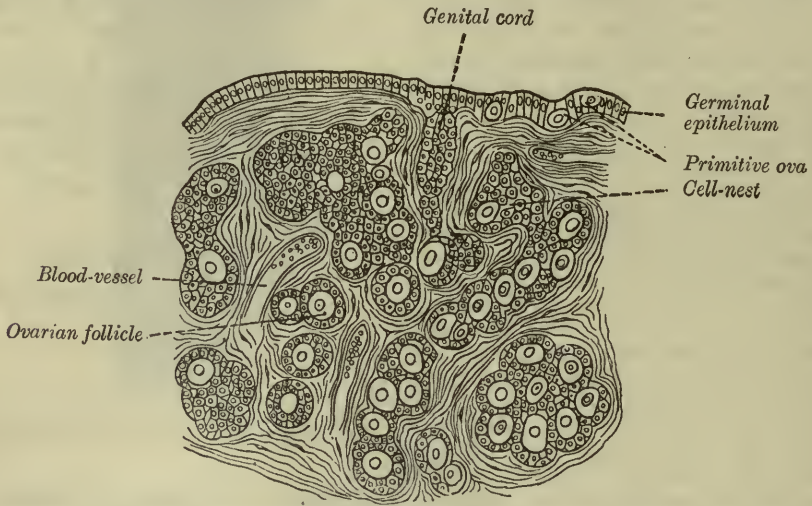


FIG. 1113.—Section of the ovary of a newly born child. (Waldeyer.)

The Testis.—The testis is developed in much the same way as the ovary. Like the ovary, in its earliest stages it consists of a central mass of epithelium covered by a surface epithelium. In the central mass a series of cords appear (Fig. 1114),

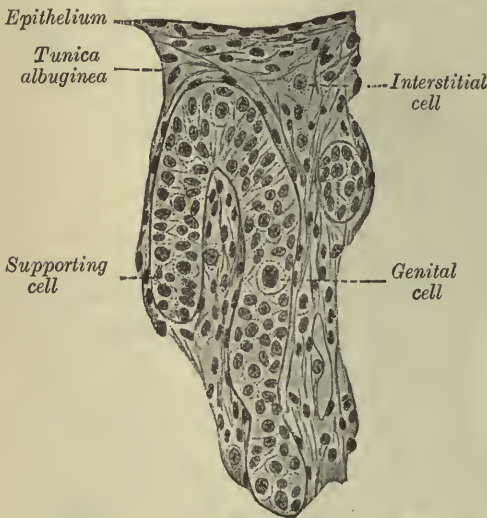


FIG. 1114.—Section of a genital cord of the testis of a human embryo 3.5 cm. long. (Felix and Bühler.)

and the periphery of the mass is converted into the tunica albuginea, thus excluding the surface epithelium from any part in the formation of the tissue of the testis. The cords of the central mass run together toward the future hilus and form a network which ultimately becomes the rete testis. From the cords the seminiferous tubules are developed, and between them connective-tissue septa extend. The seminiferous tubules become connected with outgrowths from the Wolffian body, which, as before mentioned, form the efferent ducts of the testis.

Descent of the Testes.—The testes, at an early period of fetal life, are placed at the back part of the abdominal cavity, behind the peritoneum, and each is attached by a peritoneal fold, the **mesorchium**, to the mesonephros. From the front of the mesonephros a fold of peritoneum termed the **inguinal fold** grows forward to meet and fuse with a peritoneal fold, the **inguinal crest**, which grows backward from the

antero-lateral abdominal wall. The testis thus acquires an indirect connection with the anterior abdominal wall; and at the same time a portion of the peritoneal cavity lateral to these fused folds is marked off as the future saccus vaginalis. In the inguinal crest a peculiar structure, the **gubernaculum testis**, makes its appearance. This is at first a slender band, extending from that part of the skin of the groin which afterward forms the scrotum through the inguinal canal to the body and epididymis of the testis. As development advances, the peritoneum enclosing the gubernaculum forms two folds, one above the testis and the other below it. The one above the testis is the **plica vascularis**, and contains ultimately the internal spermatic vessels; the one below, the **plica gubernatrix**, contains the lower part of the gubernaculum, which has now grown into a thick cord; it ends below at the abdominal inguinal ring in a tube of peritoneum, the **saccus vaginalis**, which protrudes itself down the inguinal canal. By the fifth month the lower part of the gubernaculum has become a thick cord, while the upper part has disappeared. The lower part now consists of a central core of unstriped muscle fiber, and outside this of a firm layer of striped elements, connected, behind the peritoneum, with the abdominal wall. As the scrotum develops, the main portion of the lower end of the gubernaculum is carried, with the skin to which it is attached, to the bottom of this pouch; other bands are carried to the medial side of the thigh and to the perineum. The tube of peritoneum constituting the saccus vaginalis projects itself downward into the inguinal canal, and emerges at the cutaneous inguinal ring, pushing before it a part of the *Obliquus internus* and the aponeurosis of the *Obliquus externus*, which form respectively the *Cremaster* muscle and the intercrural fascia. It forms a gradually elongating pouch, which eventually reaches the bottom of the scrotum, and behind this pouch the testis is drawn by the growth of the body of the fetus, for the gubernaculum does not grow commensurately with the growth of other parts, and therefore the testis, being attached by the gubernaculum to the bottom of the scrotum, is prevented from rising as the body grows, and is drawn first into the inguinal canal and eventually into the scrotum. It seems certain also that the gubernaculum becomes shortened as development proceeds, and this assists in causing the testis to reach the bottom of the scrotum. By the end of the eighth month the testis has reached the scrotum, preceded by the saccus vaginalis, which communicates by its upper extremity with the peritoneal cavity. Just before birth the upper part of the saccus vaginalis usually becomes closed, and this obliteration extends gradually downward to within a short distance of the testis. The process of peritoneum surrounding the testis is now entirely cut off from the general peritoneal cavity and constitutes the **tunica vaginalis**.

Descent of the Ovaries.—In the female there is also a gubernaculum, which effects a considerable change in the position of the ovary, though not so extensive a change as in that of the testis. The gubernaculum in the female lies in contact with the fundus of the uterus and contracts adhesions to this organ, and thus the ovary is prevented from descending below this level. The part of the gubernaculum between the ovary and the uterus becomes ultimately the proper ligament of the ovary, while the part between the uterus and the labium majus forms the round ligament of the uterus. A pouch of peritoneum analogous to the saccus vaginalis in the male accompanies it along the inguinal canal: it is called the **canal of Nuck**. In rare cases the gubernaculum may fail to contract adhesions to the uterus, and then the ovary descends through the inguinal canal into the labium majus, and under these circumstances its position resembles that of the testis.

The Metanephros and the Permanent Kidney.—The rudiments of the permanent kidneys make their appearance about the end of the first or the beginning of the second month. Each kidney has a two-fold origin, part arising from the metanephros, and part as a diverticulum from the hind-end of the Wolffian duct,

close to where the latter opens into the cloaca (Figs. 1115, 1116). The metanephros arises in the intermediate cell mass, caudal to the mesonephros, which it resembles in structure. The diverticulum from the Wolffian duct grows dorsalward and forward along the posterior abdominal wall, where its blind extremity expands and subsequently divides into several buds, which form the rudiments of the pelvis and calyces of the kidney; by continued growth and subdivision it gives

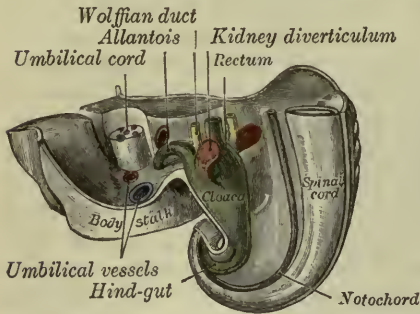


FIG. 1115.—Tail end of human embryo twenty-five to twenty-nine days old. (From model by Keibel.)

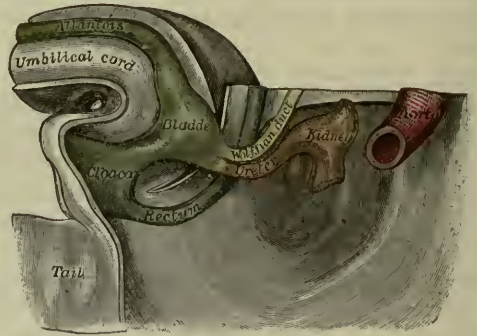


FIG. 1116.—Tail end of human embryo thirty-two to thirty-three days old. (From model by Keibel.)

rise to the collecting tubules of the kidney. The proximal portion of the diverticulum becomes the ureter. The secretory tubules are developed from the metanephros, which is moulded over the growing end of the diverticulum from the Wolffian duct. The tubules of the metanephros, unlike those of the pronephros and mesonephros, do not open into the Wolffian duct. One end expands to form a glomerulus, while the rest of the tubule rapidly elongates to form the convoluted and straight tubules, the loops of Henle, and the connecting tubules; these last

join and establish communications with the collecting tubules derived from the ultimate ramifications of the diverticulum from the Wolffian duct. The mesoderm around the tubules becomes condensed to form the connective tissue of the kidney. The ureter opens at first into the hind-end of the Wolffian duct; after the sixth week it separates from the Wolffian duct, and opens independently into the part of the cloaca which ultimately becomes the bladder (Figs. 1117, 1118).

The secretory tubules of the kidney become arranged into pyramidal masses or lobules, and the lobulated condition of the kidneys exists for some time after birth, while traces of

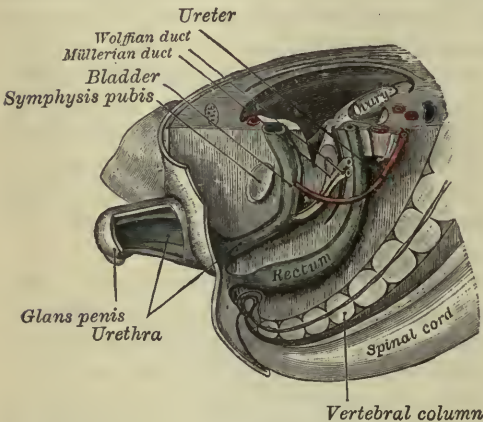


FIG. 1117.—Tail end of human embryo; from eight and a half to nine weeks old. (From model by Keibel.)

it may be found even in the adult. The kidney of the ox and many other animals remains lobulated throughout life.

The Urinary Bladder.—The bladder is formed partly from the entodermal cloaca and partly from the ends of the Wolffian ducts; the allantois takes no share in its formation. After the separation of the rectum from the dorsal part of the cloaca (p. 1109), the ventral part becomes subdivided into three portions: (1) an anterior **vesico-urethral portion**, continuous with the allantois—into this portion the Wolffian ducts open; (2) an intermediate narrow channel, the **pelvic portion**; and

(3) a posterior **phallic portion**, closed externally by the urogenital membrane (Fig. 1118). The second and third parts together constitute the **urogenital sinus**. The vesico-urethral portion absorbs the ends of the Wolffian ducts and the associated ends of the renal diverticula, and these give rise to the trigone of the bladder and part of the prostatic urethra. The remainder of the vesico-urethral portion forms the body of the bladder and part of the prostatic urethra; its apex is prolonged to the umbilicus as a narrow canal, which later is obliterated and becomes the medial umbilical ligament (urachus).

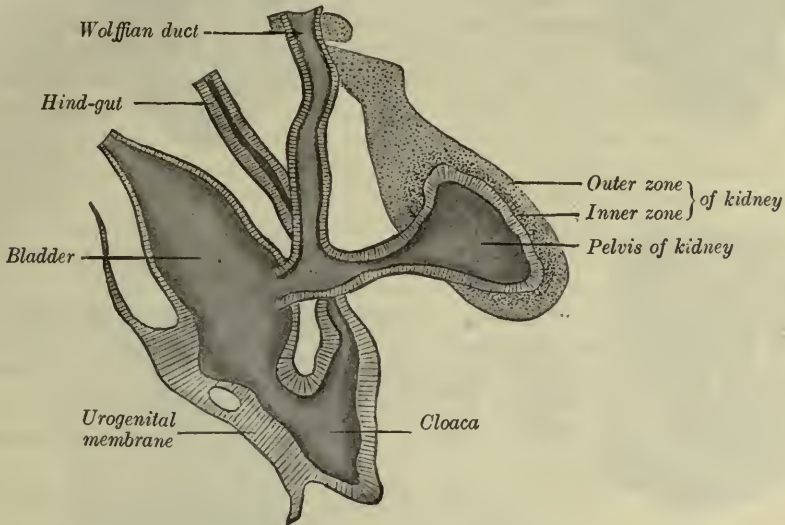


FIG. 1118.—Primitive kidney and bladder, from a reconstruction. (After Schreiner.)

The Prostate.—The prostate originally consists of two separate portions, each of which arises as a series of diverticular buds from the epithelial lining of the urogenital sinus and vesico-urethral part of the cloaca, between the third and fourth months. These buds become tubular, and form the glandular substance of the two lobes, which ultimately meet and fuse behind the urethra and also extend on to its ventral aspect. The isthmus or middle lobe is formed as an extension of the lateral lobes between the common ejaculatory ducts and the bladder. **Skene's ducts** in the female urethra are regarded as the homologues of the prostatic glands.

The **bulbo-urethral glands of Cowper** in the male, and **greater vestibular glands of Bartholin** in the female, also arise as diverticula from the epithelial lining of the urogenital sinus.

The External Organs of Generation (Fig. 1119).—As already stated (page 1109), the cloacal membrane, composed of ectoderm and entoderm, originally reaches from the umbilicus to the tail. The mesoderm extends to the midventral line for some distance behind the umbilicus, and forms the lower part of the abdominal wall; it ends below in a prominent swelling, the **cloacal tubercle**. Behind this tubercle the urogenital part of the cloacal membrane separates the ingrowing sheets of mesoderm.

The first rudiment of the penis (or clitoris) is a structure termed the **phallus**; it is derived from the phallic portion of the cloaca which has extended on to the end and sides of the under surface of the cloacal tubercle. The terminal part of the phallus representing the future glans becomes solid; the remainder, which is hollow, is converted into a longitudinal groove by the absorption of the urogenital membrane.

In the female a deep groove forms around the phallus and separates it from the rest of the cloacal tubercle, which is now termed the **genital tubercle**. The sides of

the genital tubercle grow backward as the **genital swellings**, which ultimately form the labia majora; the tubercle itself becomes the mons pubis. The labia minora arise by the continued growth of the lips of the groove on the under surface of the phallus; the remainder of the phallus forms the clitoris.

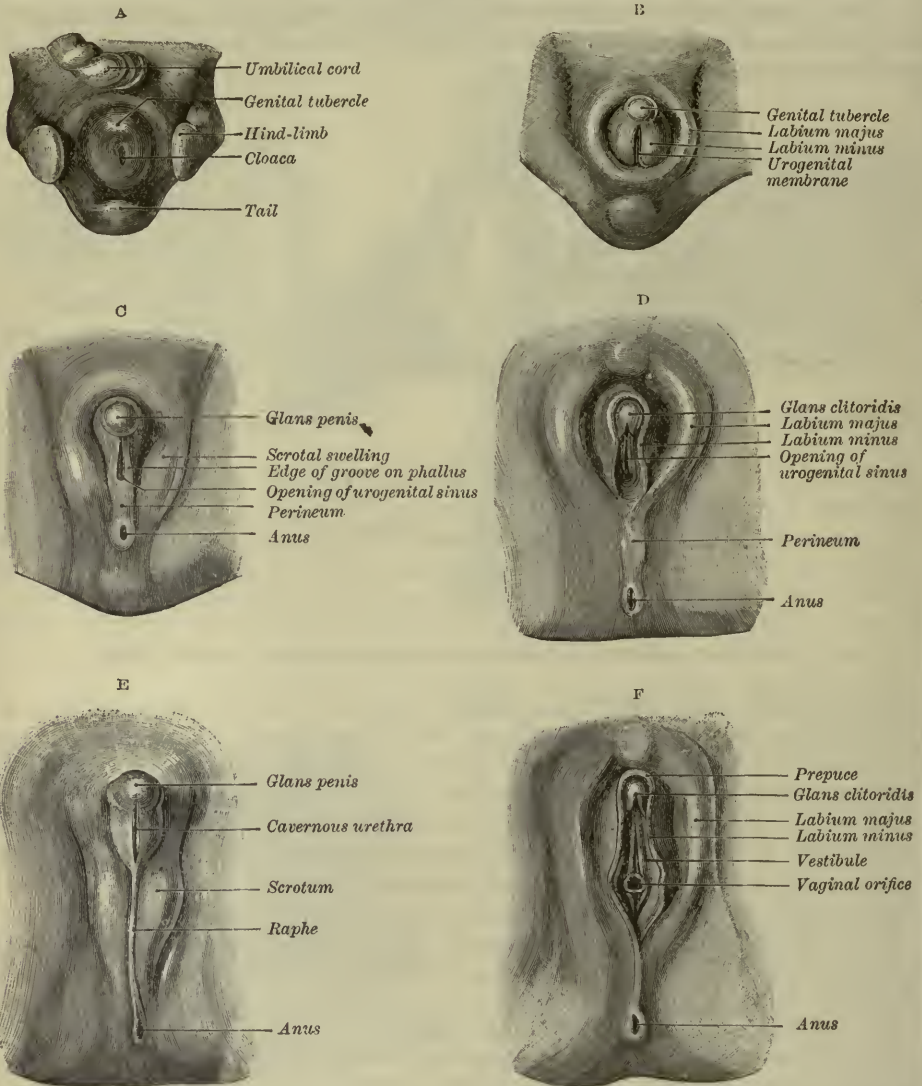


FIG. 1119.—Stages in the development of the external sexual organs in the male and female. (Drawn from the Ecker-Ziegler models.)

In the male the early changes are similar, but the pelvic portion of the cloaca undergoes much greater development, pushing before it the phallic portion. The genital swellings extend around between the pelvic portion and the anus, and form a scrotal area; during the changes associated with the descent of the testes this area is drawn out to form the scrotal sacs. The penis is developed from the phallus. As in the female, the urogenital membrane undergoes absorption, forming a channel on the under surface of the phallus; this channel extends only as far forward as the corona glandis.

The **corpora cavernosa** of the penis (or clitoris) and of the urethra arise from the

mesodermal tissue in the phallus; they are at first dense structures, but later vascular spaces appear in them, and they gradually become cavernous.

The **prepuce** in both sexes is formed by the growth of a solid plate of ectoderm into the superficial part of the phallus; on coronal section this plate presents the shape of a horseshoe. By the breaking down of its more centrally situated cells the plate is split into two lamellæ, and a cutaneous fold, the prepuce, is liberated and forms a hood over the glans. "Adherent prepuce is not an adhesion really, but a hindered central desquamation" (Berry Hart, *op. cit.*).

The Urethra.—As already described, in both sexes the phallic portion of the cloaca extends on to the under surface of the cloacal tubercle as far forward as the apex. At the apex the walls of the phallic portion come together and fuse, the lumen is obliterated, and a solid plate, the **urethral plate**, is formed. The remainder of the phallic portion is for a time tubular, and then, by the absorption of the urogenital membrane, it establishes a communication with the exterior; this opening is the **primitive urogenital ostium**, and it extends forward to the corona glandis.

In the female this condition is largely retained; the portion of the groove on the clitoris broadens out while the body of the clitoris enlarges, and thus the adult urethral opening is situated behind the base of the clitoris.

In the male, by the greater growth of the pelvic portion of the cloaca a longer urethra is formed, and the primitive ostium is carried forward with the phallus, but it still ends at the corona glandis. Later it closes from behind forward. Meanwhile the urethral plate of the glans breaks down centrally to form a median groove continuous with the primitive ostium. This groove also closes from behind forward, so that the external urethral opening is shifted forward to the end of the glans.

THE URINARY ORGANS.

The urinary organs comprise the **kidneys**, which secrete the urine, the **ureters**, or ducts, which convey urine to the **urinary bladder**, where it is for a time retained; and the **urethra**, through which it is discharged from the body.

The Kidneys (**Renes**).

The **kidneys** are situated in the posterior part of the abdomen, one on either side of the vertebral column, behind the peritoneum, and surrounded by a mass of fat and loose areolar tissue. Their upper extremities are on a level with the upper border of the twelfth thoracic vertebra, their lower extremities on a level with the third lumbar. The right kidney is usually slightly lower than the left, probably on account of the vicinity of the liver. The long axis of each kidney is directed downward and lateralward; the transverse axis backward and lateralward.

Each kidney is about 11.25 cm. in length, 5 to 7.5 cm. in breadth, and rather more than 2.5 cm. in thickness. The left is somewhat longer, and narrower, than the right. The weight of the kidney in the adult male varies from 125 to 170 gm., in the adult female from 115 to 155 gm. The combined weight of the two kidneys in proportion to that of the body is about 1 to 240.

The kidney has a characteristic form, and presents for examination two surfaces, two borders, and an upper and lower extremity.

Relations.—The **anterior surface** (*facies anterior*) (Figs. 1120 and 1122) of each kidney is convex, and looks forward and lateralward. Its relations to adjacent viscera differ so completely on the two sides that separate descriptions are necessary.

Anterior Surface of Right Kidney.—A narrow portion at the upper extremity is in relation with the right suprarenal gland. A large area just below this and involving about three-fourths of the surface, lies in the renal impression on the inferior

surface of the liver, and a narrow but somewhat variable area near the medial border is in contact with the descending part of the duodenum. The lower part of

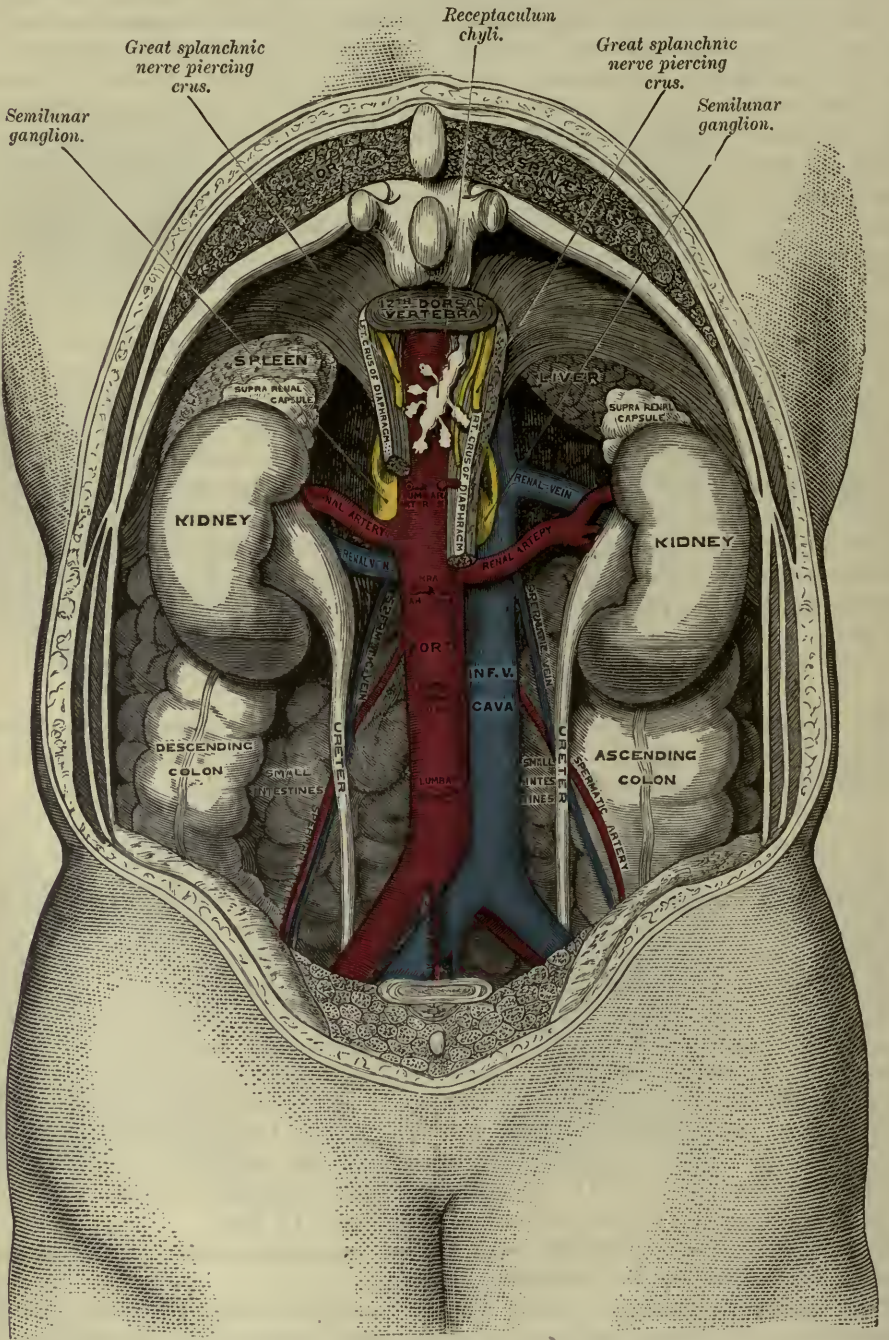


FIG. 1120.—The relations of the viscera and large vessels of the abdomen. (Seen from behind, the last thoracic vertebra being well raised.)

the anterior surface is in contact laterally with the right colic flexure, and medially, as a rule, with the small intestine. The areas in relation with the liver and small

intestine are covered by peritoneum; the suprarenal, duodenal, and colic areas are devoid of peritoneum.

Anterior Surface of Left Kidney.—A small area along the upper part of the medial border is in relation with the left suprarenal gland, and close to the lateral border is a long strip in contact with the renal impression on the spleen. A somewhat quadrilateral field, about the middle of the anterior surface, marks the site of contact with the body of the pancreas, on the deep surface of which are the lienal vessels. Above this is a small triangular portion, between the suprarenal and splenic areas, in contact with the postero-inferior surface of the stomach. Below the pancreatic area the lateral part is in relation with the left colic flexure,

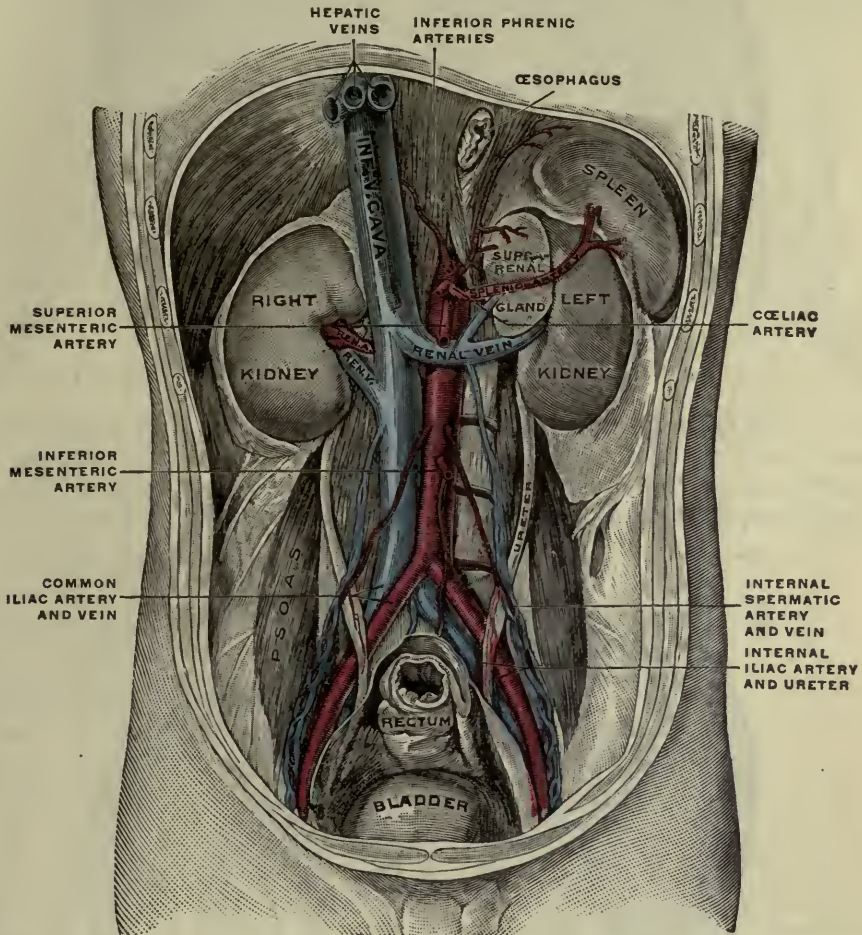


FIG. 1121.—Posterior abdominal wall, after removal of the peritoneum, showing kidneys, suprarenal capsules, and great vessels. (Corning).

the medial with the small intestine. The areas in contact with the stomach and spleen are covered by the peritoneum of the omental bursa, while that in relation to the small intestine is covered by the peritoneum of the general cavity; behind the latter are some branches of the left colic vessels. The suprarenal, pancreatic, and colic areas are devoid of peritoneum.

The **Posterior Surface** (*facies posterior*) (Figs. 1123, 1124).—The posterior surface of each kidney is directed backward and medialward. It is imbedded in areolar and fatty tissue and entirely devoid of peritoneal covering. It lies upon the diaphragm, the medial and lateral lumbocostal arches, the Psoas major, the Quadratus

lumborum, and the tendon of the Transversus abdominis, the subcostal, and one or two of the upper lumbar arteries, and the last thoracic, iliohypogastric, and ilioinguinal nerves. The right kidney rests upon the twelfth rib, the left usually on the eleventh and twelfth. The diaphragm separates the kidney from the

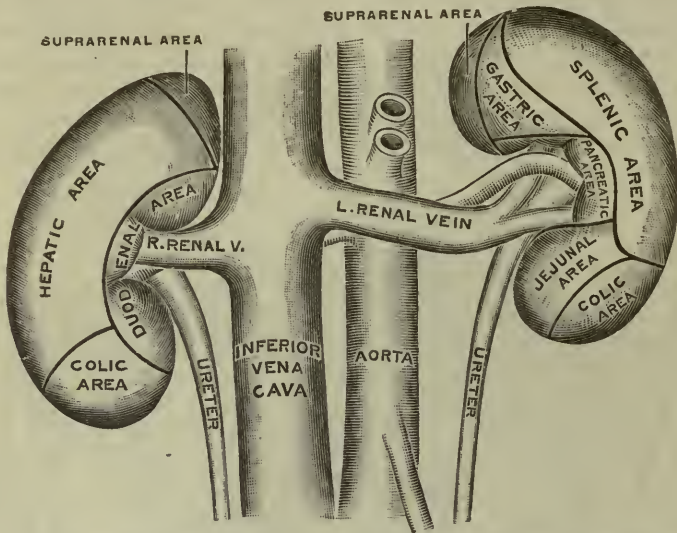


FIG. 1122.—The anterior surfaces of the kidneys, showing the areas of contact of neighboring viscera.

pleura, which dips down to form the phrenicocostal sinus, but frequently the muscular fibers of the diaphragm are defective or absent over a triangular area immediately above the lateral lumbocostal arch, and when this is the case the perinephric areolar tissue is in contact with the diaphragmatic pleura.

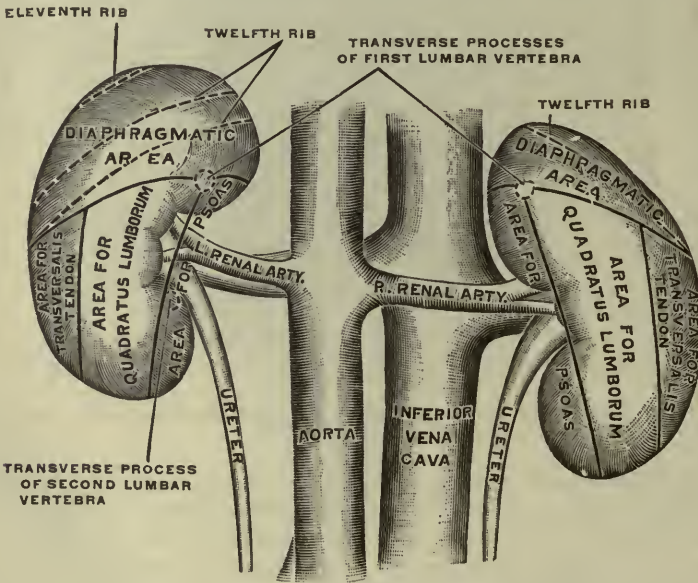


FIG. 1123.—The posterior surfaces of the kidneys, showing areas of relation to the parietes.

Borders.—The lateral border (*margo lateralis; external border*) is convex, and is directed toward the postero-lateral wall of the abdomen. On the left side it is in contact at its upper part, with the spleen.

The medial border (*margo medialis; internal border*) is concave in the center and convex toward either extremity; it is directed forward and a little downward.

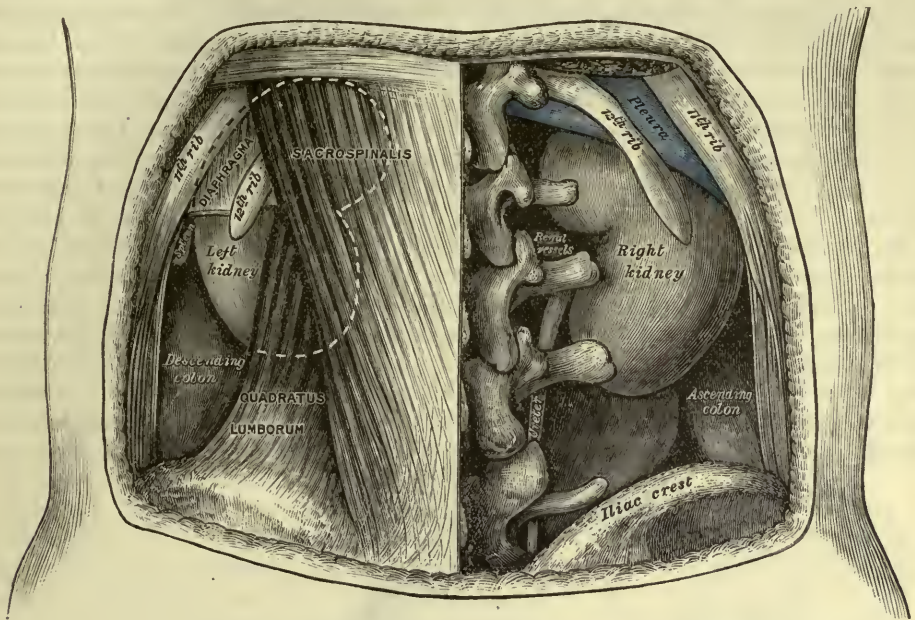


FIG. 1124.—The relations of the kidneys from behind.

Its central part presents a deep longitudinal fissure, bounded by prominent overhanging anterior and posterior lips. This fissure is named the **hilum**, and transmits the vessels, nerves, and ureter. Above the hilum the medial border is in relation with the suprarenal gland; below the hilum, with the ureter.

Extremities.—The superior extremity (*extremitas superior*) is thick and rounded, and is nearer the median line than the lower; it is surmounted by the suprarenal gland, which covers also a small portion of the anterior surface.

The inferior extremity (*extremitas inferior*) is smaller and thinner than the superior and farther from the median line. It extends to within 5 cm. of the iliac crest.

The relative position of the main structures in the hilum is as follows: the vein is in front, the artery in the middle, and the ureter behind and directed downward. Frequently, however, branches of both artery and vein are placed behind the ureter.

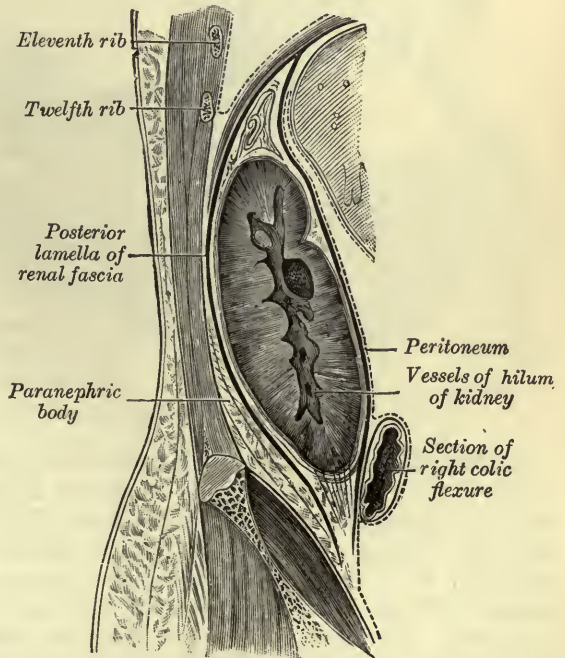


FIG. 1125.—Sagittal section through posterior abdominal wall, showing the relations of the capsule of the kidney. (After Gerota).

Fixation of the Kidney (Figs. 1125, 1126).—The kidney and its vessels are imbedded in a mass of fatty tissue, termed the **adipose capsule**, which is thickest at the margins of the kidney and is prolonged through the hilum into the renal sinus. The kidney and the adipose capsule are enclosed in a sheath of fibrous tissue continuous with the subperitoneal fascia, and named the **renal fascia**. At the lateral border of the kidney the renal fascia splits into an anterior and a posterior layer. The anterior layer is carried medialward in front of the kidney and its vessels, and is continuous over the aorta with the corresponding layer of the opposite side. The posterior layer extends medialward behind the kidney and blends with the fascia on the *Quadratus lumborum* and *Psoas major*, and through this fascia is attached to the vertebral column. Above the suprarenal gland the two layers of the renal fascia fuse, and unite with the fascia of the diaphragm; below they remain separate, and are gradually lost in the subperitoneal fascia of the iliac fossa. The renal fascia is connected to the fibrous tunic of the kidney by numerous trabeculæ, which traverse the adipose capsule, and are strongest near the lower end of the organ. Behind the fascia renalis is a considerable quantity of fat, which constitutes the **paranephric body**. The kidney is held in position partly through the attachment of the renal fascia and partly by the apposition of the neighboring viscera.

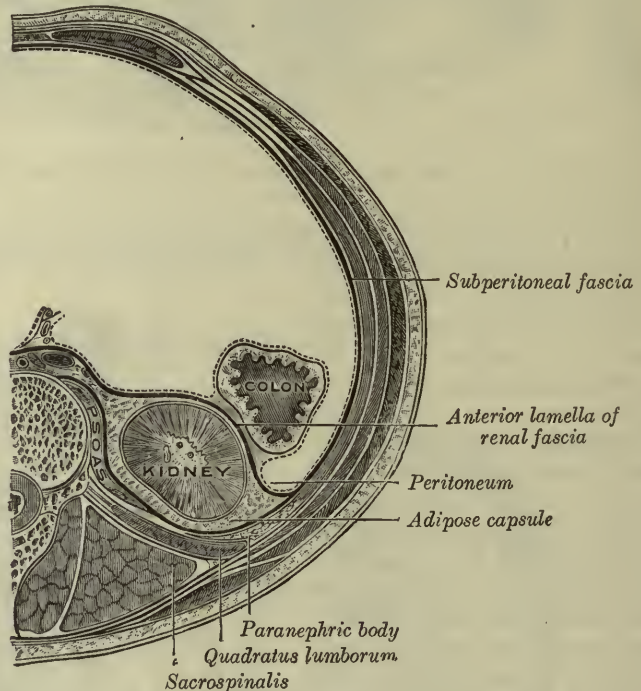


FIG. 1126.—Transverse section, showing the relations of the capsule of the kidney. (After Gerota.)

General Structure of the Kidney.—The kidney is invested by a fibrous tunic, which forms a firm, smooth covering to the organ. The tunic can be easily stripped off, but in doing so numerous fine processes of connective tissue and small bloodvessels are torn through. Beneath this coat a thin, wide-meshed net-work of unstriped muscular fiber forms an incomplete covering to the organ. When the capsule is stripped off, the surface of the kidney is found to be smooth and even and of a deep red color. In infants fissures extending for some depth may be seen on the surface of the organ, a remnant of the lobular construction of the gland. The kidney is dense in texture, but is easily lacerable by mechanical force. If a vertical section

of the kidney be made from its convex to its concave border, it will be seen that the hilum expands into a central cavity, the **renal sinus**, this contains the upper part of the renal pelvis and the calyces, surrounded by some fat in which are imbedded the branches of the renal vessels and nerves. The renal sinus is lined by a prolongation of the fibrous tunic, which is continued around the lips of the hilum. The **renal calyces**, from seven to thirteen in number, are cup-shaped tubes, each of which embraces one or more of the renal papillæ; they unite to form two or three short tubes, and these in turn join to form a funnel-shaped sac, the **renal pelvis**. The renal pelvis, wide above and narrow below where it joins the ureter, is partly outside the renal sinus. The renal calyces and pelvis form the upper expanded end of the excretory duct of the kidney.

The kidney is composed of an internal **medullary** and an external **cortical substance**.

The **medullary substance** (*substantia medullaris*) consists of a series of red-colored striated conical masses, termed the **renal pyramids**, the bases of which are directed toward the circumference of the kidney, while their apices converge toward the renal sinus, where they form prominent papillæ projecting into the interior of the calyces.

The **cortical substance** (*substantia corticalis*) is reddish brown in color and soft and granular in consistence. It lies immediately beneath the fibrous tunic, arches over the bases of the pyramids, and dips in between adjacent pyramids toward the renal sinus. The parts dipping in between the pyramids are named the **renal columns** (Bertini), while the portions which connect the renal columns to each other and intervene between the bases of the pyramids and the fibrous tunic are called the **cortical arches** (indicated between *A* and *A'* in Fig. 1127). If the cortex be examined with a lens, it will be seen to consist of a series of lighter-colored, conical areas, termed the radiate part, and a darker-colored intervening substance, which from the complexity of its structure is named the convoluted part. The rays gradually taper toward the circumference of the kidney, and consist of a series of outward prolongations from the base of each renal pyramid.

Minute Anatomy.—The **renal tubules** (Fig. 1028), of which the kidney is for the most part made up, commence in the cortical substance, and after pursuing a very circuitous course through the cortical and medullary substances, finally end at the apices of the renal pyramids by open mouths, so that the fluid which they contain is emptied, through the calyces, into the pelvis of the kidney. If the surface of one of the papillæ be examined with a lens, it will be seen to be studded over with minute openings, the orifices of the renal tubules, from sixteen to twenty in number, and if pressure be made on a fresh kidney, urine will be seen to exude from these orifices. The tubules commence in the convoluted part and renal columns as the **renal corpuscles**, which are small rounded masses of a deep red color, varying in size, but of an average of about 0.2 mm. in diameter. Each of these little bodies is composed of two parts: a central glomerulus of vessels, and a membranous envelope, the **glomerular capsule** (*capsule of Bowman*), which is the small pouch-like commencement of a renal tubule.

The **glomerulus** is a lobulated net-work of convoluted capillary bloodvessels, held together by scanty connective tissue. This capillary net-work is derived from a small arterial twig, the *afferent vessel*, which enters the capsule, generally at a point opposite to that at which the latter is connected with the tubule; and the resulting vein, the *efferent vessel*, emerges from the capsule at the same point. The afferent vessel is usually the larger of the two

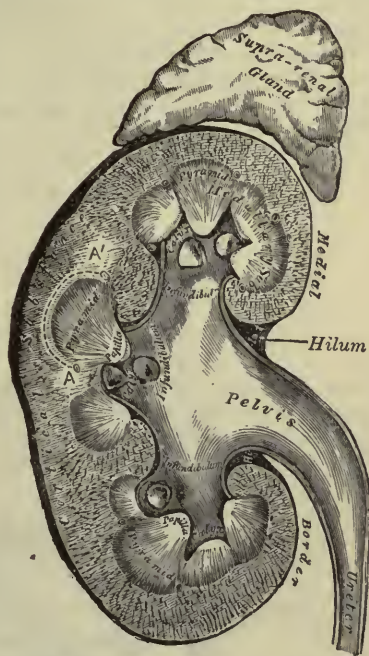


FIG. 1127.—Vertical section of kidney.

(Fig. 1129). The glomerular or Bowman's capsule, which surrounds the glomerulus, consists of a basement membrane, lined on its inner surface by a layer of flattened epithelial cells.

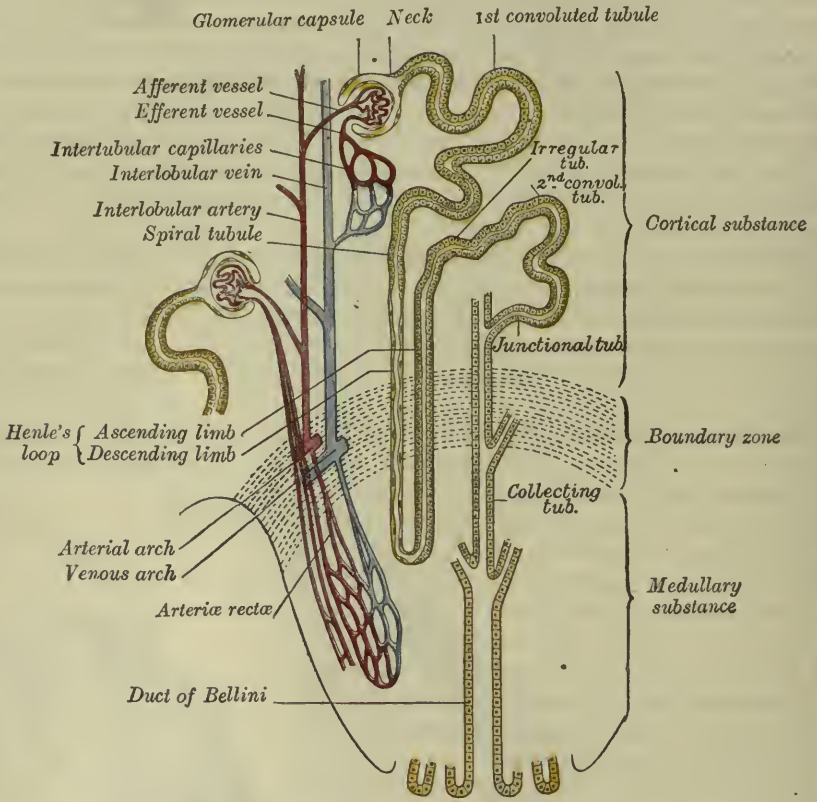


FIG. 1128.—Scheme of renal tubule and its vascular supply.

which are reflected from the lining membrane on to the glomerulus, at the point of entrance or exit of the afferent and efferent vessels. The whole surface of the glomerulus is covered with a continuous layer of the same cells, on a delicate supporting membrane (Fig. 1130). Thus between the glomerulus and the capsule a space is left, forming a cavity lined by a continuous layer of

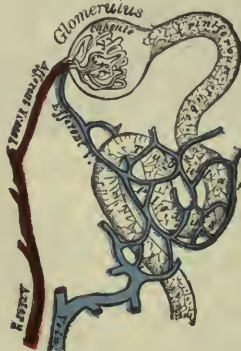

FIG. 1129.—Distribution of blood vessels in cortex of kidney.

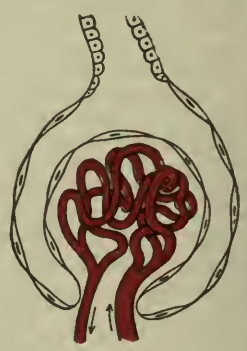

FIG. 1130.—Glomerulus.

squamous cells; this cavity varies in size according to the state of secretion and the amount of fluid present in it. In the fetus and young subject the lining epithelial cells are polyhedral or even columnar.

The **renal tubules**, commencing in the renal corpuscles, present, during their course, many changes in shape and direction, and are contained partly in the medullary and partly in the cortical substance. At their junction with the glomerular capsule they exhibit a somewhat constricted portion, which is termed the **neck**. Beyond this the tubule becomes convoluted, and pursues a considerable course in the cortical substance constituting the **proximal convoluted tube**. After a time the convolutions disappear, and the tube approaches the medullary substance in a more or less spiral manner; this section of the tubule has been called the **spiral tube**. Throughout this portion of their course the renal tubules are contained entirely in the cortical substance, and present a fairly uniform caliber. They now enter the medullary substance, suddenly become much smaller, quite straight in direction, and dip down for a variable depth into the pyramids, constituting the **descending limb of Henle's loop**. Bending on themselves, they form what is termed the **loop of Henle**, and reascending, they become suddenly enlarged, forming the **ascending limb of Henle's loop**, and reënter the cortical substance. This portion of the tubule ascends for a short distance, when it again becomes dilated, irregular, and angular. This section is termed the **zigzag tubule**; it ends in a convoluted tube, which resembles the proximal convoluted tubule, and is called the **distal convoluted tubule**. This again terminates in a narrow **junctional tube**, which enters the straight or collecting tube.

The **straight or collecting tubes** commence in the radiate part of the cortex, where they receive the curved ends of the distal convoluted tubules. They unite at short intervals with one another, the resulting tubes presenting a considerable increase in caliber, so that a series of comparatively large tubes passes from the bases of the rays into the renal pyramids. In the medulla the tubes of each pyramid converge to join a central tube (*duct of Bellini*) which finally opens on the summit of one of the papillæ; the contents of the tube are therefore discharged into one of the calyces.

Structure of the Renal Tubules.—The renal tubules consist of a basement membrane lined with epithelium. The epithelium varies considerably in different sections of the tubule. In the neck the epithelium is continuous with that lining the glomerular capsule, and like it consists of flattened cells each containing an oval nucleus (Fig. 1132). The two convoluted tubules, the spiral and zigzag tubules and the ascending limb of Henle's loop, are lined by a type of epithelium which is histologically the same in all. The cells are somewhat columnar in shape and dovetail into one another of their lateral aspect. Each has a striated border next the lumen of the tube, its inner part is granular and its outer portion vertically striated. The nucleus is spherical and situated about the center of the cell. In the descending limb of Henle's loop the epithelium resembles that found in the glomerular capsule and the commencement of the tube, consisting of flat, clear epithelial plates, each with an oval nucleus (Fig. 1131). The nuclei alternate on opposite surfaces of the tubule so that the lumen remains fairly constant.

In the straight tube the epithelium is clear and cubical: in its papillary portion the cells are distinctly columnar and transparent (Fig. 1132).

The Renal Bloodvessels.—The kidney is plentifully supplied with blood (Fig. 1133) by the renal artery, a large branch of the abdominal aorta. Before it enters the kidney, each artery divides into four or five branches which at the hilum lie mainly between the renal vein and ureter, the vein being in front, the ureter behind; one branch usually lies behind the ureter. Each vessel gives off some small branches to the suprarenal glands, to the ureter, and to the surrounding cellular tissue and muscles. Frequently a second renal artery, termed the **inferior renal**, is given off from the abdominal aorta at a lower level, and supplies the lower portion of the kidney, while occasionally an additional artery enters the upper part of the kidney. The branches of the renal artery, while in the sinus, give off a few twigs for the nutrition of the surrounding tissues, and end in the **arteriæ propriæ renales**, which enter the kidney proper in the renal columns. Two of these pass to each renal pyramid, and run along its sides for its entire length, giving off in their course the afferent vessels of the renal corpuscles in the renal columns. Having arrived at the bases of the pyramids, they form arterial arches or arcades which lie in the boundary zone between the bases of the pyramids and the cortical arches, and break up into two distinct sets of branches devoted to the supply of the remaining portions of the kidney.

The **first set**, the *interlobular arteries* (Fig. 1128), are given off at right angles from the side of the arterial arcade looking toward the cortical substance, and pass directly outward between the medullary rays to reach the fibrous tunic, where they end in the capillary net-work of this part. These vessels do not anastomose with each other, but form what are called **end-arteries**.



FIG. 1131.—Longitudinal section of descending limb of Henle's loop. a. Membrana propria. b. Epithelium.

In their outward course they give off lateral branches; these are the *afferent vessels* for the renal corpuscles (see page 1221); they enter the capsule, and end in the glomerulus. From each tuft the corresponding *efferent vessel* arises, and, having made its egress from the capsule near to the point where the afferent vessel enters, breaks up into a number of branches, which form a dense *plexus* around the adjacent urinary tubes.

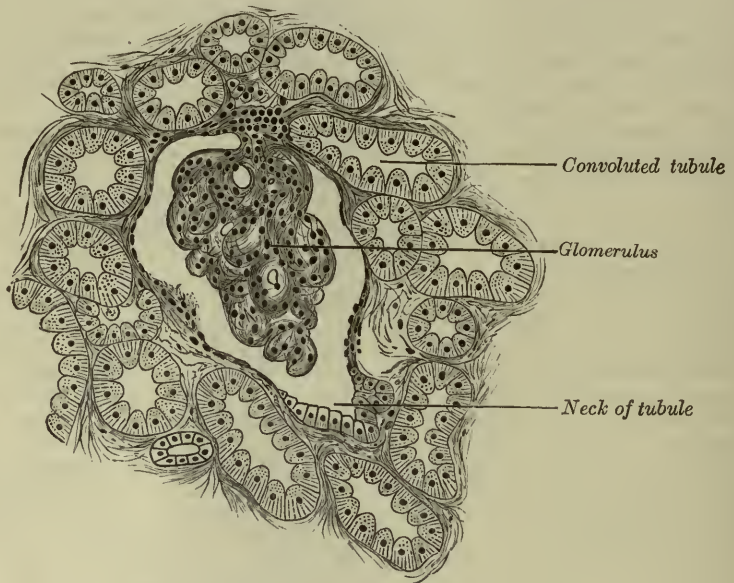


FIG. 1132.—Section of cortex of human kidney.

The **second set of branches** from the arterial arcades supply the renal pyramids, which they enter at their bases; and, passing straight through their substance to their apices, terminate in the venous plexuses found in that situation. They are called the *arteriæ rectæ*. The efferent vessels from the glomeruli nearest the medulla break up into leashes of straight vessels (*false arteriæ rectæ*) which pass down into the medulla and join the plexus of vessels there (Fig. 1128).

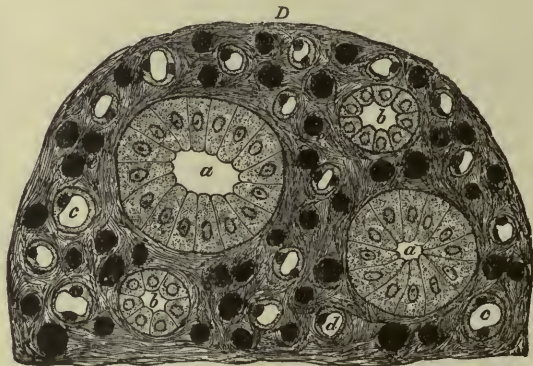


FIG. 1133.—Transverse section of pyramidal substance of kidney of pig, the bloodvessels of which are injected. *a*. Large collecting tube, cut across, lined with cylindrical epithelium. *b*. Branch of collecting tube, cut across, lined with cubical epithelium. *c*, *d*. Henle's loops cut across. *e*. Bloodvessels cut across. *D* Connective tissue ground substance.

The **renal veins** arise from three sources, viz., the veins beneath the fibrous tunic, the plexuses around the convoluted tubules in the cortex, and the plexuses situated at the apices of the renal pyramids. The veins beneath the fibrous tunic (*venæ stellatæ*) are stellate in arrangement, and are derived from the capillary net-work, into which the terminal branches of the interlobular arteries break up. These join to form the **interlobular veins**, which pass inward between the rays, receive branches from the plexuses around the convoluted tubules, and, having arrived at the bases of the renal pyramids, join with the *venæ rectæ*, next to be described.

The *venæ rectæ* are branches from the plexuses at the apices of the medullary pyramids, formed by the terminations of the *arteriæ rectæ*. They run outward in a straight course between the tubes of the medullary substance, and joining, as above stated, the interlobular veins, form venous arcades; these in turn unite and form veins which pass along the sides of the pyramids (Fig. 1128).

These vessels, *venæ propriæ renales*, accompany the arteries of the same name, running along the entire length of the sides of the pyramids, and quit the kidney substance to enter the sinus. In this cavity they join the corresponding veins from the other pyramids to form the *renal vein*, which emerges from the kidney at the hilum and opens into the inferior vena cava; the left vein is longer than the right, and crosses in front of the abdominal aorta.

The *lymphatics* of the kidney are described on page 712.

Nerves of the Kidney.—The nerves of the kidney, although small, are about fifteen in number. They have small ganglia developed upon them, and are derived from the renal plexus, which is formed by branches from the celiac plexus, the lower and outer part of the celiac ganglion and aortic plexus, and from the lesser and lowest splanchnic nerves. They communicate with the spermatic plexus, a circumstance which may explain the occurrence of pain in the testis in affections of the kidney. They accompany the renal artery and its branches, and are distributed to the bloodvessels and to the cells of the urinary tubules.

Connective Tissue (*intertubular stroma*).—Although the tubules and vessels are closely packed, a small amount of connective tissue, continuous with the fibrous tunic, binds them firmly together and supports the bloodvessels, lymphatics, and nerves.

Variations.—Malformations of the kidney are not uncommon. There may be an entire absence of one kidney, but, according to Morris, the number of these cases is "excessively small": or there may be congenital atrophy of one kidney, when the kidney is very small, but usually healthy in structure. These cases are of great importance, and must be duly taken into account when nephrectomy is contemplated. A more common malformation is where the two kidneys are fused together. They may be joined together only at their lower ends by means of a thick mass of renal tissue, so as to form a horseshoe-shaped body, or they may be completely united, forming a disk-like kidney, from which two ureters descend into the bladder. These fused kidneys are generally situated in the middle line of the abdomen, but may be misplaced as well. In some mammals, *e. g.*, ox and bear, the kidney consists of a number of distinct lobules; this lobulated condition is characteristic of the kidney of the human fetus, and traces of it may persist in the adult. Sometimes the pelvis is duplicated, while a double ureter is not very uncommon. In some rare instances a third kidney may be present.

One or both kidneys may be misplaced as a congenital condition, and remain fixed in this abnormal position. They are then very often misshapen. They may be situated higher, though this is very uncommon, or lower than normal or removed farther from the vertebral column than usual; or they may be displaced into the iliac fossa, over the sacroiliac joint, on to the promontory of the sacrum, or into the pelvis between the rectum and bladder or by the side of the uterus. In these latter cases they may give rise to very serious trouble. The kidney may also be misplaced as a congenital condition, but may not be fixed; it is then known as a *floating kidney*. It is believed to be due to the fact that the kidney is completely enveloped by peritoneum which then passes backward to the vertebral column as a double layer, forming a mesonephron which permits movement. The kidney may also be misplaced as an acquired condition; in these cases the kidney is mobile in the tissues by which it is surrounded, moving with the capsule in the perinephric tissues. This condition is known as *movable kidney*, and is more common in the female than in the male. It occurs in badly nourished people, or in those who have become emaciated from any cause. It must not be confounded with the *floating kidney*, which is a congenital condition due to the development of a mesonephron. The two conditions cannot, however, be distinguished until the abdomen is opened or the kidney explored from the loin.

The Ureters.

The *ureters* are the two tubes which convey the urine from the kidneys to the urinary bladder. Each commences within the sinus of the corresponding kidney as a number of short cup-shaped tubes, termed *calyces*, which encircle the renal papillæ. Since a single calyx may enclose more than one papilla the calyces are generally fewer in number than the pyramids—the former varying from seven to thirteen, the latter from eight to eighteen. The calyces join to form two or three short tubes, and these unite to form a funnel-shaped dilatation, wide above and narrow below, named the *renal pelvis*, which is situated partly inside and partly outside the renal sinus. It is usually placed on a level with the spinous process of the first lumbar vertebra.

The **Ureter Proper** measures from 25 to 30 cm. in length, and is a thick-walled narrow cylindrical tube which is directly continuous near the lower end of the kidney with the tapering extremity of the renal pelvis. It runs downward and medialward in front of the Psoas major and, entering the pelvic cavity, finally opens into the fundus of the bladder.

The **abdominal part** (*pars abdominalis*) lies behind the peritoneum on the medial part of the Psoas major, and is crossed obliquely by the internal spermatic vessels. It enters the pelvic cavity by crossing either the termination of the common, or the commencement of the external, iliac vessels.

At its origin the *right* ureter is usually covered by the descending part of the duodenum, and in its course downward lies to the right of the inferior vena cava, and is crossed by the right colic and ileocolic vessels, while near the superior aperture of the pelvis it passes behind the lower part of the mesentery and the terminal part of the ileum. The *left* ureter is crossed by the left colic vessels, and near the superior aperture of the pelvis passes behind the sigmoid colon and its mesentery.

The **pelvic part** (*pars pelvina*) runs at first downward on the lateral wall of the pelvic cavity, along the anterior border of the greater sciatic notch and under cover of the peritoneum. It lies in front of the hypogastric artery medial to the obturator nerve and the umbilical, obturator, inferior vesical, and middle hemorrhoidal arteries. Opposite the lower part of the greater sciatic foramen it inclines medialward, and reaches the lateral angle of the bladder, where it is situated in front of the upper end of the seminal vesicle and at a distance of about 5 cm. from the opposite ureter; here the ductus deferens crosses to its medial side, and the vesical veins surround it. Finally, the ureters run obliquely for about 2 cm. through the wall of the bladder and open by slit-like apertures into the cavity of the viscus at the lateral angles of the trigone. When the bladder is distended the openings of the ureters are about 5 cm. apart, but when it is empty and contracted the distance between them is diminished by one-half. Owing to their

oblique course through the coats of the bladder, the upper and lower walls of the terminal portions of the ureters become closely applied to each other when the viscus is distended, and, acting as valves, prevent regurgitation of urine from the bladder.

In the **female**, the ureter forms, as it lies in relation to the wall of the pelvis, the posterior boundary of a shallow depression named the **ovarian fossa**, in which the ovary is situated. It then runs medialward and forward on the lateral aspect of the cervix uteri and upper part of the vagina to reach the fundus of the bladder. In this part of its course it is accompanied for about 2.5 cm. by the uterine artery, which then crosses in front of the ureter and ascends between the two layers of the broad ligament. The ureter

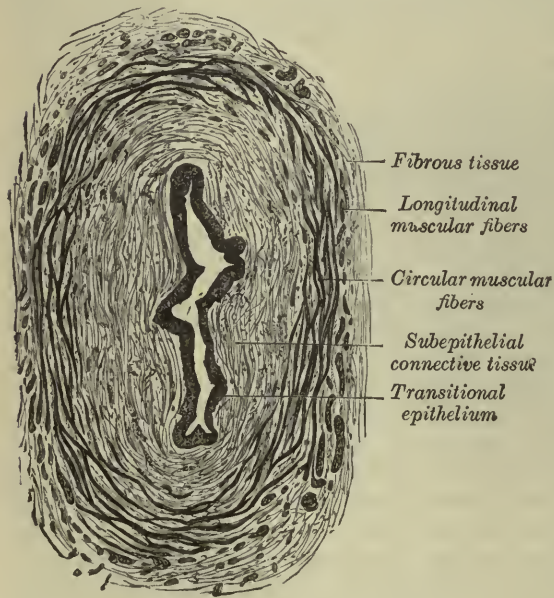


FIG. 1134.—Transverse section of ureter.

is distant about 2 cm. from the side of the cervix of the uterus. The ureter is sometimes duplicated on one or both sides, and the two tubes may remain

distinct as far as the fundus of the bladder. On rare occasions they open separately into the bladder cavity.

Structure (Fig. 1134).—The ureter is composed of three coats: **fibrous, muscular, and mucous coats.**

The **fibrous coat** (*tunica adventitia*) is continuous at one end with the fibrous tunic of the kidney on the floor of the sinus; while at the other it is lost in the fibrous structure of the bladder.

In the renal pelvis the **muscular coat** (*tunica muscularis*) consists of two layers, longitudinal and circular: the longitudinal fibers become lost upon the sides of the papillæ at the extremities of the calyces; the circular fibers may be traced surrounding the medullary substance in the same situation. In the ureter proper the muscular fibers are very distinct, and are arranged in three layers: an external longitudinal, a middle circular, and an internal, less distinct than the other two, but having a general longitudinal direction. According to Kölliker this internal layer is found only in the neighborhood of the bladder.

The **mucous coat** (*tunica mucosa*) is smooth, and presents a few longitudinal folds which become effaced by distension. It is continuous with the mucous membrane of the bladder below, while it is prolonged over the papillæ of the kidney above. Its epithelium is of a transitional character, and resembles that found in the bladder (see Fig. 1141). It consists of several layers of cells, of which the innermost—that is to say, the cells in contact with the urine—are somewhat flattened, with concavities on their deep surfaces into which the rounded ends of the cells of the second layer fit. These, the intermediate cells, more or less resemble columnar epithelium, and are pear-shaped, with rounded internal extremities which fit into the concavities of the cells of the first layer, and narrow external extremities which are wedged in between the cells of the third layer. The external or third layer consists of conical or oval cells varying in number in different parts, and presenting processes which extend down into the basement membrane. Beneath the epithelium, and separating it from the muscular coats, is a dense layer of fibrous tissue containing many elastic fibers.

Vessels and Nerves.—The **arteries** supplying the ureter are branches from the renal, internal spermatic, hypogastric, and inferior vesical.

The **nerves** are derived from the inferior mesenteric, spermatic, and pelvic plexuses.

Variations.—The upper portion of the ureter is sometimes double; more rarely it is double the greater part of its extent, or even completely so. In such cases there are two openings into the bladder. Asymmetry in these variations is common.

The Urinary Bladder (*Vesica Urinaria*; **Bladder**) (Fig. 1135).

The **urinary bladder** is a musculomembranous sac which acts as a reservoir for the urine; and as its size, position, and relations vary according to the amount of fluid it contains, it is necessary to study it as it appears (*a*) when *empty*, and (*b*) when *distended*. In both conditions the position of the bladder varies with the condition of the rectum, being pushed upward and forward when the rectum is distended.

The Empty Bladder.—When hardened *in situ*, the empty bladder has the form of a flattened tetrahedron, with its vertex tilted forward. It presents a fundus, a vertex, a superior and an inferior surface. The **fundus** (Fig. 1152) is triangular in shape, and is directed downward and backward toward the rectum, from which it is separated by the rectovesical fascia, the vesiculæ seminales, and the terminal portions of the ductus deferentes. The **vertex** is directed forward toward the upper part of the symphysis pubis, and from it the middle umbilical ligament is continued upward on the back of the anterior abdominal wall to the umbilicus. The peritoneum is carried by it from the vertex of the bladder on to the abdominal wall to form the middle umbilical fold. The **superior surface** is triangular, bounded on either side by a lateral border which separates it from the inferior surface, and behind by a posterior border, represented by a line joining the two ureters, which intervenes between it and the fundus. The lateral borders extend from the ureters to the vertex, and from them the peritoneum is carried to the walls of the pelvis. On either side of the bladder the peritoneum shows a depression, named the **para-vesical fossa** (Fig. 1037). The superior surface is directed upward, is covered by peritoneum, and is in relation with the sigmoid colon and some of the coils of the small intestine. When the bladder is empty and firmly contracted, this surface is convex

and the lateral and posterior borders are rounded; whereas if the bladder be relaxed it is concave, and the interior of the viscus, as seen in a median sagittal section, presents the appearance of a V-shaped slit with a shorter posterior and a longer anterior limb—the apex of the V corresponding with the internal orifice of the urethra. The **inferior surface** is directed downward and is uncovered by peritoneum. It may be divided into a posterior or prostatic area and two infero-lateral surfaces. The prostatic area is somewhat triangular: it rests upon and is in direct continuity with the base of the prostate; and from it the urethra emerges. The infero-lateral portions of the inferior surface are directed downward and lateralward: in front, they are separated from the symphysis pubis by a mass of fatty tissue which is named the **retropubic pad**; behind, they are in contact with the fascia which covers the Levatores ani and Obturatores interni.

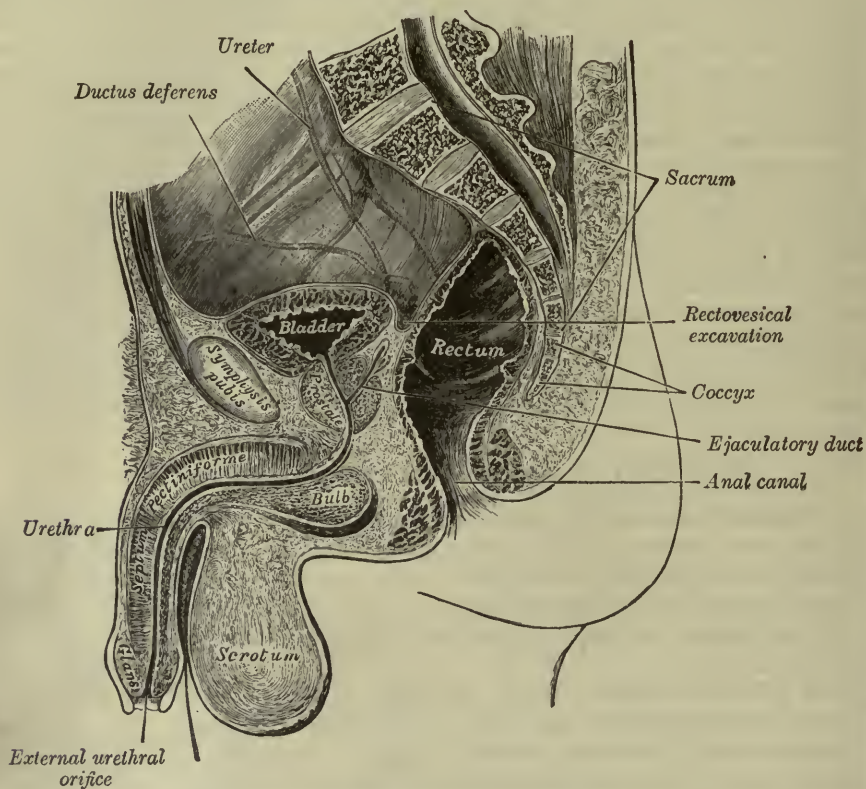


FIG. 1135.—Median sagittal section of male pelvis.

When the bladder is empty it is placed entirely within the pelvis, below the level of the obliterated hypogastric arteries, and below the level of those portions of the ductus deferentes which are in contact with the lateral wall of the pelvis; after they cross the ureters the ductus deferentes come into contact with the fundus of the bladder. As the viscus fills, its fundus, being more or less fixed, is only slightly depressed; while its superior surface gradually rises into the abdominal cavity, carrying with it its peritoneal covering, and at the same time rounding off the posterior and lateral borders.

The Distended Bladder.—When the bladder is moderately full it contains about 0.5 liter and assumes an oval form; the long diameter of the oval measures about 12 cm. and is directed upward and forward. In this condition it presents a postero-superior, an antero-inferior, and two lateral surfaces, a fundus and a

summit. The **postero-superior surface** is directed upward and backward, and is covered by peritoneum: behind, it is separated from the rectum by the rectovesical excavation, while its anterior part is in contact with the coils of the small intestine. The **antero-inferior surface** is devoid of peritoneum, and rests, below, against the pubic bones, above which it is in contact with the back of the anterior abdominal wall. The lower parts of the lateral surfaces are destitute of peritoneum, and are in contact with the lateral walls of the pelvis. The line of peritoneal reflection from the lateral surface is raised to the level of the obliterated hypogastric artery. The **fundus** undergoes little alteration in position, being only slightly lowered. It exhibits, however, a narrow triangular area, which is separated from the rectum merely by the rectovesical fascia. This area is bounded below by the prostate, above by the rectovesical fold of peritoneum, and laterally by the ductus deferentes.

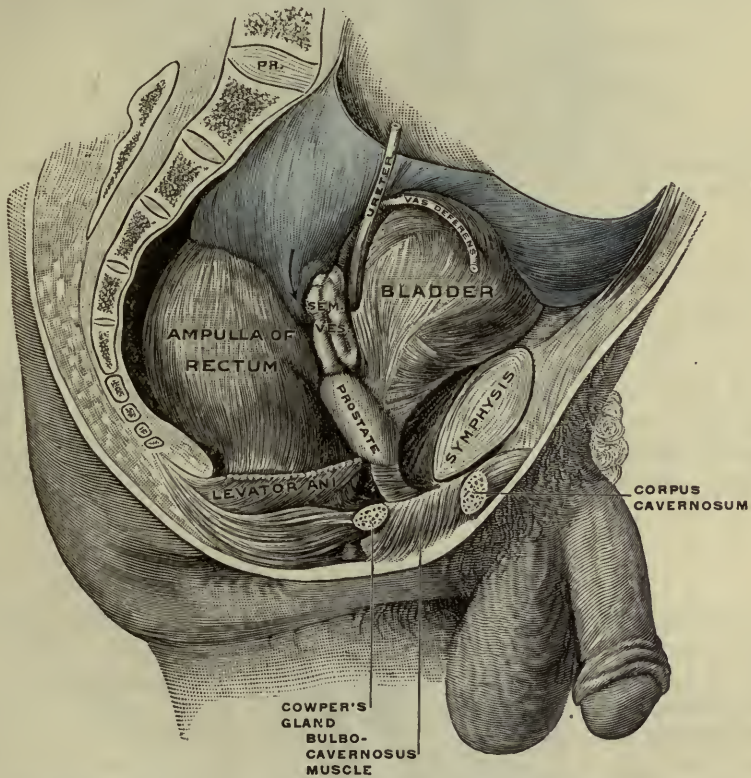


Fig. 1136.—Male pelvic organs seen from right side. Bladder and rectum distended; relations of peritoneum to the bladder and rectum shown in blue. The arrow points to the rectovesical pouch.

The ductus deferentes frequently come in contact with each other above the prostate, and under such circumstances the lower part of the triangular area is obliterated. The line of reflection of the peritoneum from the rectum to the bladder appears to undergo little or no change when the latter is distended; it is situated about 10 cm. from the anus. The **summit** is directed upward and forward above the point of attachment of the middle umbilical ligament, and hence the peritoneum which follows the ligament, forms a pouch of varying depth between the summit of the bladder, and the anterior abdominal wall.

The Bladder in the Child (Figs. 1137, 1138).—In the newborn child the internal urethral orifice is at the level of the upper border of the symphysis pubis; the bladder therefore lies relatively at a much higher level in the infant than in the adult. Its anterior surface “is in contact with about the lower two-thirds of that

part of the abdominal wall which lies between the symphysis pubis and the umbilicus" (Symington¹). Its fundus is clothed with peritoneum as far as the level of the internal orifice of the urethra. Although the bladder of the infant is usually described as an abdominal organ, Symington has pointed out that only about

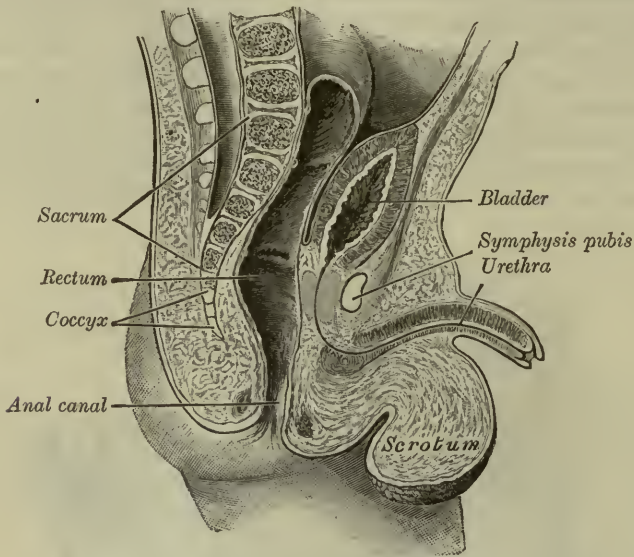


FIG. 1137.—Sagittal section through the pelvis of a newly born male child.

one-half of it lies above the plane of the superior aperture of the pelvis. Disse maintains that the internal urethral orifice sinks rapidly during the first three years, and then more slowly until the ninth year, after which it remains stationary until puberty, when it again slowly descends and reaches its adult position.

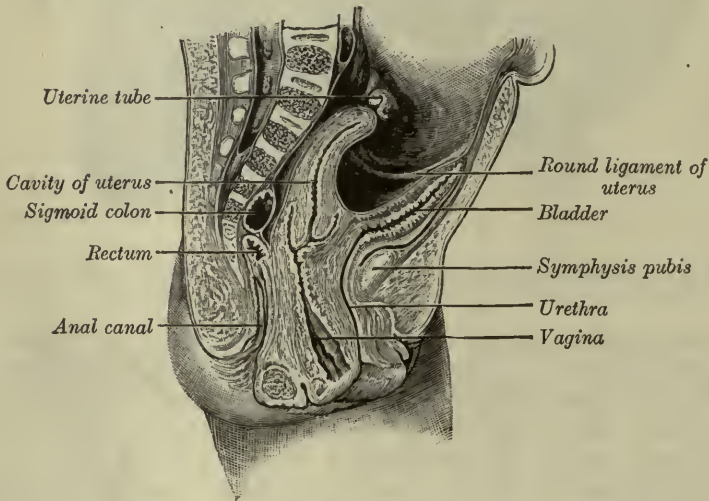


FIG. 1138.—Sagittal section through the pelvis of a newly born female child.

The Female Bladder (Fig. 1139).—In the female, the bladder is in relation behind with the uterus and the upper part of the vagina. It is separated from the anterior surface of the body of the uterus by the vesicouterine excavation, but

¹ The Anatomy of the Child.

below the level of this excavation it is connected to the front of the cervix uteri and the upper part of the anterior wall of the vagina by areolar tissue. When the bladder is empty the uterus rests upon its superior surface. The female bladder is said by some to be more capacious than that of the male, but probably the opposite is the case.

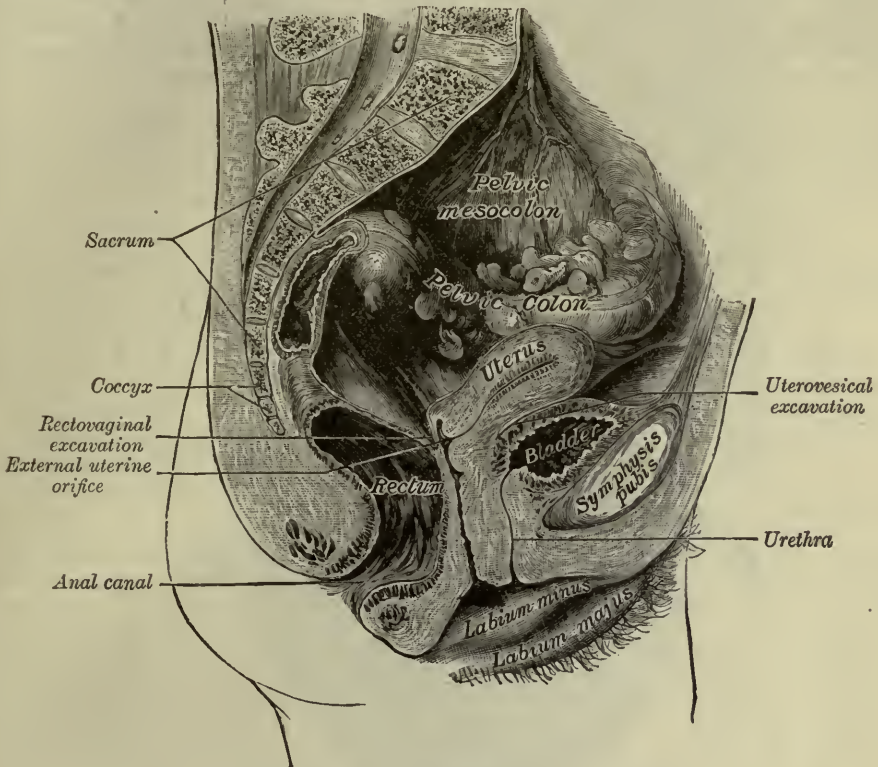


FIG. 1139.—Median sagittal section of female pelvis.

Ligaments.—The bladder is connected to the pelvic wall by the fascia endo-pelvina. In front this fascial attachment is strengthened by a few muscular fibers, the **Pubovesicales**, which extend from the back of the pubic bones to the front of the bladder; behind, other muscular fibers run from the fundus of the bladder to the sides of the rectum, in the sacrogenital folds, and constitute the **Rectovesicales**.

The vertex of the bladder is joined to the umbilicus by the remains of the urachus which forms the **middle umbilical ligament**, a fibromuscular cord, broad at its attachment to the bladder but narrowing as it ascends.

From the superior surface of the bladder the peritoneum is carried off in a series of folds which are sometimes termed the **false ligaments of the bladder**. Anteriorly there are three folds: the **middle umbilical fold** on the middle umbilical ligament, and two **lateral umbilical folds** on the obliterated hypogastric arteries. The reflections of the peritoneum on to the side walls of the pelvis form the lateral false ligaments, while the sacrogenital folds constitute posterior false ligaments.

Interior of the Bladder (Fig. 1140).—The mucous membrane lining the bladder is, over the greater part of the viscus, loosely attached to the muscular coat, and appears wrinkled or folded when the bladder is contracted: in the distended condition of the bladder the folds are effaced. Over a small triangular area, termed the **trigonum vesicæ**, immediately above and behind the internal orifice of the urethra, the mucous membrane is firmly bound to the muscular coat, and is always smooth.

The anterior angle of the trigonum vesicæ is formed by the internal orifice of the urethra: its postero-lateral angles by the orifices of the ureters. Stretching behind the latter openings is a slightly curved ridge, the **torus uretericus**, forming the base of the trigone and produced by an underlying bundle of non-striped muscular fibers. The lateral parts of this ridge extend beyond the openings of the ureters, and are named the **plicæ uretericæ**; they are produced by the terminal portions of the ureters as they traverse obliquely the bladder wall. When the bladder is illuminated the torus uretericus appears as a pale band and forms an important guide during the operation of introducing a catheter into the ureter.

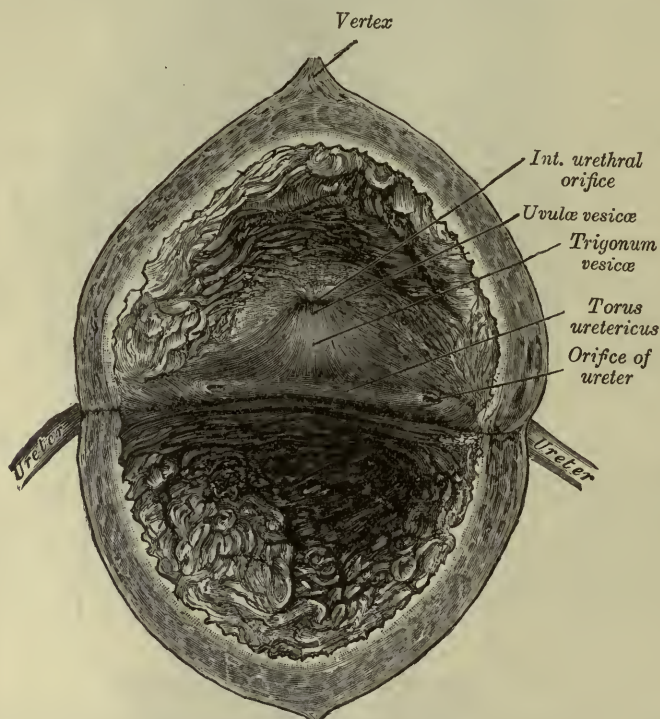


FIG. 1140.—The interior of bladder.

The **orifices of the ureters** are placed at the postero-lateral angles of the trigonum vesicæ, and are usually slit-like in form. In the contracted bladder they are about 2.5 cm. apart and about the same distance from the internal urethral orifice; in the distended viscus these measurements may be increased to about 5 cm.

The **internal urethral orifice** is placed at the apex of the trigonum vesicæ, in the most dependent part of the bladder, and is usually somewhat crescentic in form; the mucous membrane immediately behind it presents a slight elevation, the **uvula vesicæ**, caused by the middle lobe of the prostate.

Structure (Fig. 1141).—The bladder is composed of the four coats: **serous, muscular, sub-mucous, and mucous coats.**

The **serous coat** (*tunica serosa*) is a partial one, and is derived from the peritoneum. It invests the superior surface and the upper parts of the lateral surfaces, and is reflected from these on to the abdominal and pelvic walls.

The **muscular coat** (*tunica muscularis*) consists of three layers of unstriped muscular fibers: an external layer, composed of fibers having for the most part a longitudinal arrangement; a middle layer, in which the fibers are arranged, more or less, in a circular manner; and an internal layer, in which the fibers have a general longitudinal arrangement.

The **fibers of the external layer** arise from the posterior surface of the body of the pubis in both sexes (*musculi pubovesicales*), and in the male from the adjacent part of the prostate and its

capsule. They pass, in a more or less longitudinal manner, up the inferior surface of the bladder, over its vertex, and then descend along its fundus to become attached to the prostate in the male, and to the front of the vagina in the female. At the sides of the bladder the fibers are arranged obliquely and intersect one another. This layer has been named the **Detrusor urinæ muscle**.

The fibers of the middle circular layer are very thin and irregularly scattered on the body of the organ, and, although to some extent placed transversely to the long axis of the bladder, are for the most part arranged obliquely. Toward the lower part of the bladder, around the internal urethral orifice, they are disposed in a thick circular layer, forming the **Sphincter vesicæ**, which is continuous with the muscular fibers of the prostate.

The internal longitudinal layer is thin, and its fasciculi have a reticular arrangement, but with a tendency to assume for the most part a longitudinal direction. Two bands of oblique fibers, originating behind the orifices of the ureters, converge to the back part of the prostate, and are inserted by means of a fibrous process, into the middle lobe of that organ. They are the **muscles of the ureters**, described by Sir C. Bell, who supposed that during the contraction of the bladder they serve to retain the oblique direction of the ureters, and so prevent the reflux of the urine into them.

The **submucous coat** (*tela submucosa*) consists of a layer of areolar tissue, connecting together the muscular and mucous coats, and intimately united to the latter.

The **mucous coat** (*tunica mucosa*) is thin, smooth, and of a pale rose color. It is continuous above through the ureters with the lining membrane of the renal tubules, and below with that of the urethra. The loose texture of the submucous layer allows the mucous coat to be thrown into folds or *rugæ* when the bladder is empty. Over the trigonum vesicæ the mucous membrane is closely attached to the muscular coat, and is not thrown into folds, but is smooth and flat. The epithelium covering it is of the transitional variety, consisting of a superficial layer of polyhedral flattened cells, each with one, two, or three nuclei; beneath these is a stratum of large club-shaped cells, with their narrow extremities directed downward and wedged in between smaller spindle-shaped cells, containing oval nuclei (Fig. 1141). The epithelium varies according as the bladder is distended or contracted. In the former condition the superficial cells are flattened and those of the other layers are shortened; in the latter they present the appearance described above. There are no true glands in the mucous membrane of the bladder, though certain mucous follicles which exist, especially near the neck of the bladder, have been regarded as such.

Vessels and Nerves.—The arteries supplying the bladder are the superior, middle, and inferior vesical, derived from the anterior trunk of the hypogastric. The obturator and inferior gluteal arteries also supply small visceral branches to the bladder, and in the female additional branches are derived from the uterine and vaginal arteries.

The veins form a complicated plexus on the inferior surface, and fundus near the prostate, and end in the hypogastric veins.

The lymphatics are described on page 712.

The nerves of the bladder are (1) fine medullated fibers from the third and fourth sacral nerves, and (2) non-medullated fibers from the hypogastric plexus. They are connected with ganglia in the outer and submucous coats and are finally distributed, all as non-medullated fibers, to the muscular layer and epithelial lining of the viscus.

Abnormalities.—A defect of development, in which the bladder is implicated, is known under the name of *extroversion of the bladder*. In this condition the lower part of the abdominal wall and the anterior wall of the bladder are wanting, so that the fundus of the bladder presents on the abdominal surface, and is pushed forward by the pressure of the viscera within the abdomen, forming a red vascular tumor on which the openings of the ureters are visible. The penis, except the glans, is rudimentary and is cleft on its dorsal surface, exposing the floor of the urethra, a condition known as *epispadias*. The pelvic bones are also arrested in development.

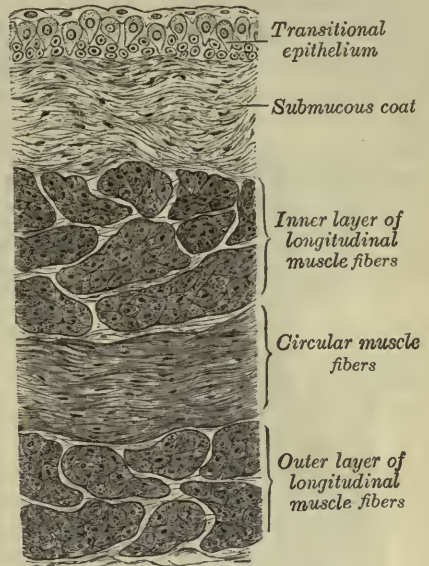


FIG. 1141.—Vertical section of bladder wall.

The Male Urethra (Urethra Virilis) (Fig. 1142).

The male urethra extends from the internal urethral orifice in the urinary bladder to the external urethral orifice at the end of the penis. It presents a double curve in the ordinary relaxed state of the penis (Fig. 1137). Its length varies from 17.5 to 20 cm.; and it is divided into three portions, the **prostatic**, **membranous**, and

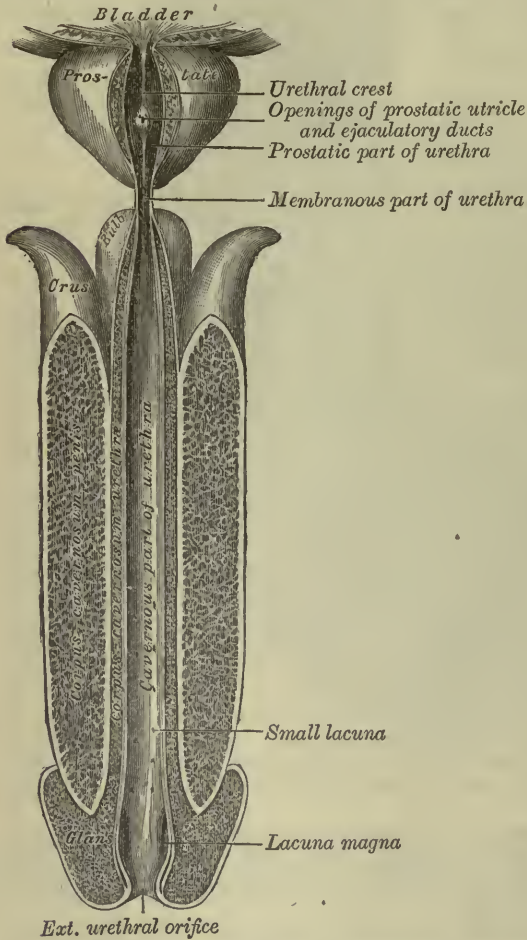

FIG. 1142.—The male urethra laid open on its anterior (upper) surface.

cavernous, the structure and relations of which are essentially different. Except during the passage of the urine or semen, the greater part of the urethral canal is a mere transverse cleft or slit, with its upper and under surfaces in contact; at the external orifice the slit is vertical, in the membranous portion irregular or stellate, and in the prostatic portion somewhat arched.

The **prostatic portion** (*pars prostatica*), the widest and most dilatable part of the canal, is about 3 cm. long. It runs almost vertically through the prostate from its base to its apex, lying nearer its anterior than its posterior surface; the form of the canal is spindle-shaped, being wider in the middle than at either extremity, and narrowest below, where it joins the membranous portion. A transverse section of the canal as it lies in the prostate is horse-shoe-shaped, with the convexity directed forward.

Upon the posterior wall or floor is a narrow longitudinal ridge, the **urethral crest** (*verumontanum*), formed by an elevation of the mucous membrane and its subjacent tissue. It is from 15 to 17 mm. in length, and about 3 mm. in height, and

contains, according to Kobelt, muscular and erectile tissue. When distended, it may serve to prevent the passage of the semen backward into the bladder. On either side of the crest is a slightly depressed fossa, the **prostatic sinus**, the floor of which is perforated by numerous apertures, the **orifices of the prostatic ducts** from the lateral lobes of the prostate; the ducts of the middle lobe open behind the crest. At the forefront of the urethral crest, below its summit, is a median elevation, the **colliculus seminalis**, upon or within the margins of which are the orifices of the prostatic utricle and the slit-like openings of the ejaculatory ducts. The **prostatic utricle** (*sinus pocularis*) forms a cul-de-sac about 6 mm. long, which runs upward and backward in the substance of the prostate behind the middle lobe. Its walls are composed of fibrous tissue, muscular fibers, and mucous

membrane, and numerous small glands open on its inner surface. It was called by Weber the *uterus masculinus*, from its being developed from the united lower ends of the atrophied Müllerian ducts, and therefore homologous with the uterus and vagina in the female.

The **membranous portion** (*pars membranacea*) is the shortest, least dilatable, and, with the exception of the external orifice, the narrowest part of the canal. It extends downward and forward, with a slight anterior concavity, between the apex of the prostate and the bulb of the urethra, perforating the urogenital diaphragm about 2.5 cm. below and behind the pubic symphysis. The hinder part of the urethral bulb lies in apposition with the inferior fascia of the urogenital diaphragm, but its upper portion diverges somewhat from this fascia: the anterior wall of the membranous urethra is thus prolonged for a short distance in front of the urogenital diaphragm; it measures about 2 cm. in length, while the posterior wall which is between the two fasciæ of the diaphragm is only 1.25 cm. long.

The membranous portion of the urethra is completely surrounded by the fibers of the Sphincter urethræ membranacæ. In front of it the deep dorsal vein of the penis enters the pelvis between the transverse ligament of the pelvis and the arcuate pubic ligament; on either side near its termination are the bulbourethral glands.

The **cavernous portion** (*pars cavernosa; penile or spongy portion*) is the longest part of the urethra, and is contained in the corpus cavernosum urethræ. It is about 15 cm. long, and extends from the termination of the membranous portion to the external urethral orifice. Commencing below the inferior fascia of the urogenital diaphragm it passes forward and upward to the front of the symphysis pubis; and then, in the flaccid condition of the penis, it bends downward and forward. It is narrow, and of uniform size in the body of the penis, measuring about 6 mm. in diameter; it is dilated behind, within the bulb, and again anteriorly within the glans penis, where it forms the *fossa navicularis urethræ*.

The **external urethral orifice** (*orificium urethræ externum; meatus urinarius*) is the most contracted part of the urethra; it is a vertical slit, about 6 mm. long, bounded on either side by two small labia.

The lining membrane of the urethra, especially on the floor of the cavernous portion, presents the orifices of numerous mucous glands and follicles situated in the submucous tissue, and named the **urethral glands** (*Littre*). Besides these there are a number of small pit-like recesses, or *lacunæ*, of varying sizes. Their orifices are directed forward, so that they may easily intercept the point of a catheter in its passage along the canal. One of these *lacunæ*, larger than the rest, is situated on the upper surface of the *fossa navicularis*; it is called the *lacuna magna*. The bulbo-urethral glands open into the cavernous portion about 2.5 cm. in front of the inferior fascia of the urogenital diaphragm.

Structure.—The urethra is composed of mucous membrane, supported by a submucous tissue which connects it with the various structures through which it passes.

The **mucous coat** forms part of the genito-urinary mucous membrane. It is continuous with the mucous membrane of the bladder, ureters, and kidneys; externally, with the integument covering the glans penis; and is prolonged into the ducts of the glands which open into the urethra, viz., the bulbo-urethral glands and the prostate; and into the ductus deferentes and vesiculæ seminales, through the ejaculatory ducts. In the cavernous and membranous portions the mucous membrane is arranged in longitudinal folds when the tube is empty. Small papillæ are found upon it, near the external urethral orifice; its epithelial lining is of the columnar variety except near the external orifice, where it is squamous and stratified.

The **submucous tissue** consists of a vascular erectile layer; outside this is a layer of unstriped muscular fibers, arranged in a circular direction, which separates the mucous membrane and submucous tissue from the tissue of the corpus cavernosum urethræ.

Congenital defects of the urethra occur occasionally. The one most frequently met with is where there is a cleft on the floor of the urethra owing to an arrest of union in the middle line. This is known as *hypospadias*, and the cleft may vary in extent. The simplest and by far the

most common form is where the deficiency is confined to the glans penis. The urethra ends at the point where the extremity of the prepuce joins the body of the penis, in a small valve-like opening. The prepuce is also cleft on its under surface and forms a sort of hood over the glans. There is a depression on the glans in the position of the normal meatus. This condition produces no disability and requires no treatment. In more severe cases the cavernous portion of the urethra is cleft throughout its entire length, and the opening of the urethra is at the point of junction of the penis and scrotum. The under surface of the penis in the middle line presents a furrow lined by a moist mucous membrane, on either side of which is often more or less dense fibrous tissue stretching from the glans to the opening of the urethra, which prevents complete erection taking place. Great discomfort is induced during micturition, and sexual connection is impossible. The condition may be remedied by a series of plastic operations. The worst form of this condition is where the urethra is deficient as far back as the perineum, and the scrotum is cleft. The penis is small and bound down between the two halves of the scrotum, so as to resemble an hypertrophied clitoris. The testes are often retained. The condition of parts, therefore, very much resembles the external organs of generation of the female, and many children the victims of this malformation have been brought up as girls. The halves of the scrotum, deficient of testes, resemble the labia, the cleft between them looks like the orifice of the vagina, and the diminutive penis is taken for an enlarged clitoris. There is no remedy for this condition.

A much more uncommon form of malformation is where there is an apparent deficiency of the upper wall of the urethra; this is named *epispadias*. The deficiency may vary in extent; when it is complete the condition is associated with extroversion of the bladder. In less extensive cases, where there is no extroversion, there is an infundibuliform opening into the bladder. The penis is usually dwarfed and turned upward, so that the glans lies over the opening. Congenital stricture is also occasionally met with, and in such cases multiple strictures may be present throughout the whole length of the cavernous portion.

The Female Urethra (Urethra Muliebris) (Fig. 1139).

The female urethra is a narrow membranous canal, about 4 cm. long, extending from the internal to the external urethral orifice. It is placed behind the symphysis pubis, imbedded in the anterior wall of the vagina, and its direction is obliquely downward and forward; it is slightly curved with the concavity directed forward. Its diameter when undilated is about 6 mm. It perforates the fasciæ of the urogenital diaphragm, and its external orifice is situated directly in front of the vaginal opening and about 2.5 cm. behind the glans clitoridis. The lining membrane is thrown into longitudinal folds, one of which, placed along the floor of the canal, is termed the **urethral crest**. Many small urethral glands open into the urethra.

Structure.—The urethra consists of three coats: **muscular, erectile, and mucous.**

The **muscular coat** is continuous with that of the bladder; it extends the whole length of the tube, and consists of circular fibers. In addition to this, between the superior and inferior fasciæ of the urogenital diaphragm, the female urethra is surrounded by the Sphincter urethræ membranaceæ, as in the male.

A **thin layer of spongy erectile tissue**, containing a plexus of large veins, intermixed with bundles of unstriped muscular fibers, lies immediately beneath the mucous coat.

The **mucous coat** is pale; it is continuous externally with that of the vulva, and internally with that of the bladder. It is lined by stratified squamous epithelium, which becomes transitional near the bladder. Its external orifice is surrounded by a few mucous follicles.

THE MALE GENITAL ORGANS (ORGANA GENITALIA VIRILIA).

The male genitals include the **testes**, the **ductus deferentes**, the **vesiculæ seminales**, the **ejaculatory ducts**, and the **penis**; together with the following accessory structures, viz., the **prostate** and the **bulbourethral glands**.

The Testes and Their Coverings. (Figs. 1143, 1144, 1145).

The **testes** are two glandular organs, which secrete the semen; they are suspended in the scrotum by the spermatic cords. At an early period of fetal life the testes are contained in the abdominal cavity, behind the peritoneum. Before birth they

descend to the inguinal canal, along which they pass with the spermatic cord, and, emerging at the subcutaneous inguinal ring, they descend into the scrotum, becoming invested in their course by coverings derived from the serous, muscular, and fibrous layers of the abdominal parietes, as well as by the scrotum.

The coverings of the testes are, the

Skin } Scrotum.
 Dartos tunic }
 Intercrural fascia.

Cremaster.
 Infundibuliform fascia.
 Tunica vaginalis.

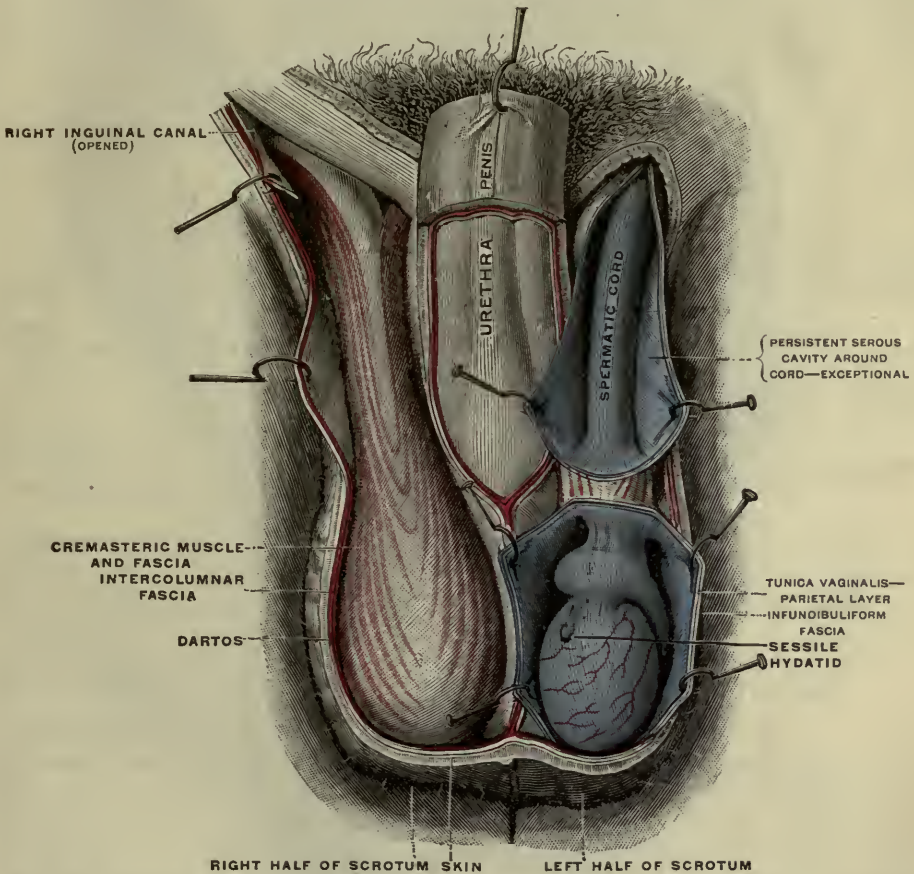


FIG. 1143.—The scrotum. On the left side the cavity of the tunica vaginalis has been opened; on the right side only the layers superficial to the Cremaster have been removed. (Testut.)

The **Scrotum** is a cutaneous pouch which contains the testes and parts of the spermatic cords. It is divided on its surface into two lateral portions by a ridge or **raphé**, which is continued forward to the under surface of the penis, and backward, along the middle line of the perineum to the anus. Of these two lateral portions the left hangs lower than the right, to correspond with the greater length of the left spermatic cord. Its external aspect varies under different circumstances: thus, under the influence of warmth, and in old and debilitated persons, it becomes elongated and flaccid; but, under the influence of cold, and in the young and robust, it is short, corrugated, and closely applied to the testes.

The scrotum consists of two layers, the **integument** and the **dartos tunic**.

The **Integument** is very thin, of a brownish color, and generally thrown into folds or rugæ. It is provided with sebaceous follicles, the secretion of which has a

peculiar odor, and is beset with thinly scattered, crisp hairs, the roots of which are seen through the skin.

The **Dartos Tunic** (*tunica dartos*) is a thin layer of non-striped muscular fibers, continuous, around the base of the scrotum, with the two layers of the superficial fascia of the groin and the perineum; it sends inward a septum, which divides the scrotal pouch into two cavities for the testes, and extends between the raphe and the under surface of the penis, as far as its root.

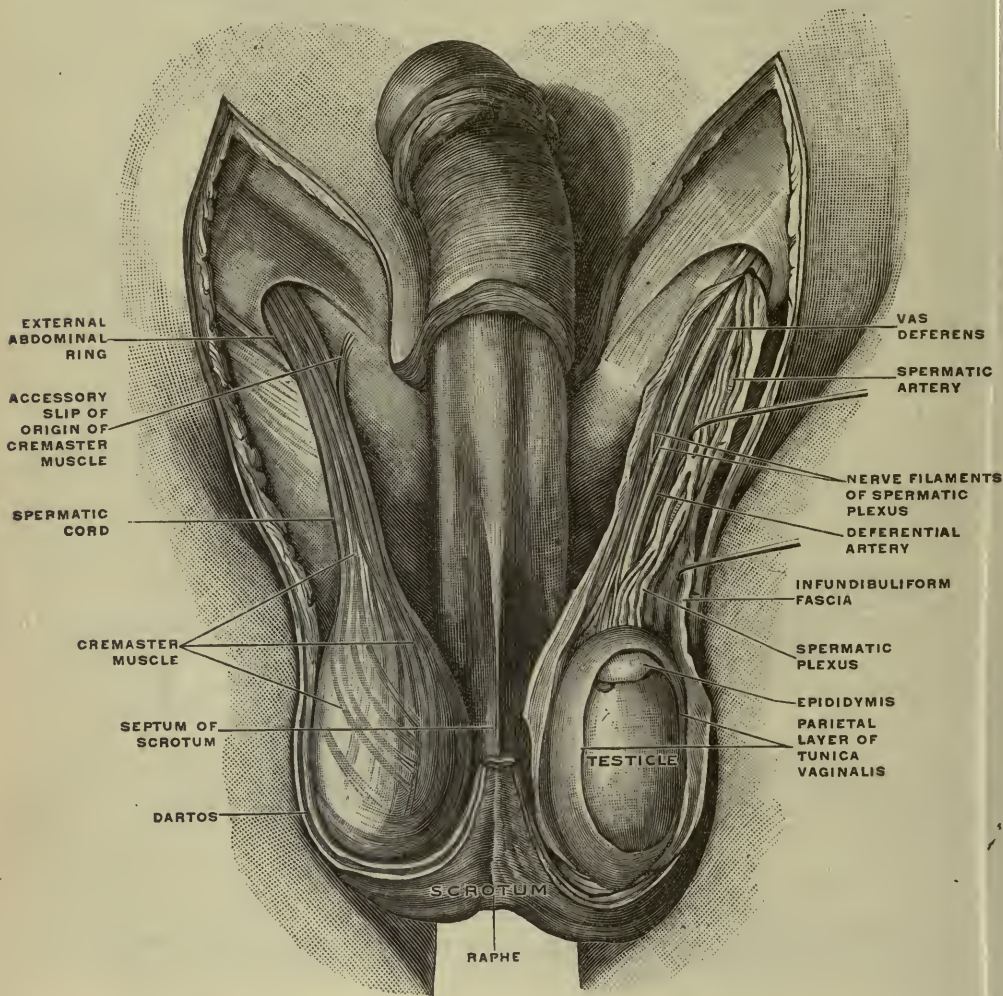


FIG. 1144.—The scrotum. The penis has been turned upward, and the anterior wall of the scrotum has been removed. On the right side, the spermatic cord, the infundibuliform fascia, and the Cremaster muscle are displayed; on the left side, the infundibuliform fascia has been divided by a longitudinal incision passing along the front of the cord and the testicle, and a portion of the parietal layer of the tunica vaginalis has been removed to display the testicle and a portion of the head of the epididymis, which are covered by the visceral layer of the tunica vaginalis. (Toldt.)

The **dartos tunic** is closely united to the skin externally, but connected with the subjacent parts by delicate areolar tissue, upon which it glides with the greatest facility.

The **Intercrural Fascia** (*intercolumnar or external spermatic fascia*) is a thin membrane, prolonged downward around the surface of the cord and testis (see page 411). It is separated from the dartos tunic by loose areolar tissue.

The **Cremaster** consists of scattered bundles of muscular fibers connected together into a continuous covering by intermediate areolar tissue (see page 414).

The **Infundibuliform Fascia** (*tunica vaginalis communis* [*testis et funiculi spermatici*]) is a thin layer, which loosely invests the cord; it is a continuation downward of the transversalis fascia (see page 418).

The **Tunica Vaginalis** is described with the testes.

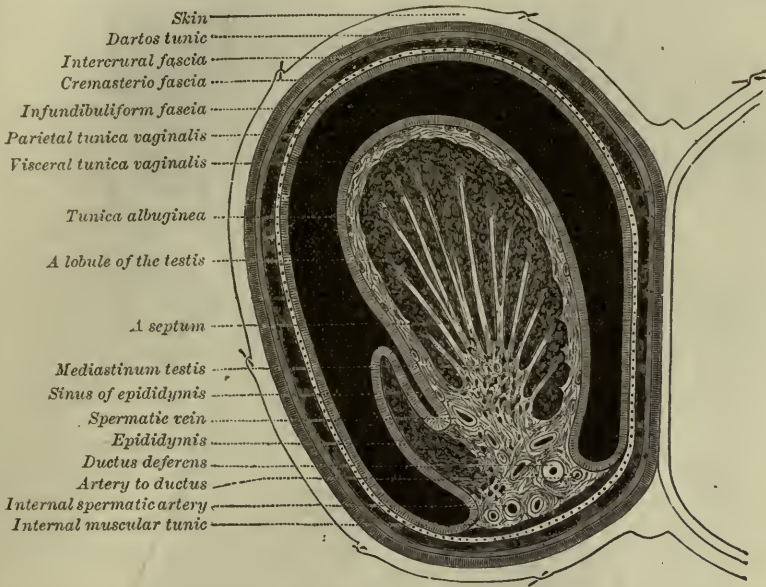


FIG. 1145.—Transverse section through the left side of the scrotum and the left testis. The sac of the tunica vaginalis is represented in a distended condition. (Diagrammatic.) (Delépine.)

Vessels and Nerves.—The **arteries** supplying the coverings of the testes are: the superficial and deep external pudendal branches of the femoral, the superficial perineal branch of the internal pudendal, and the cremasteric branch from the inferior epigastric. The **veins** follow the course of the corresponding arteries. The **lymphatics** end in the inguinal lymph glands. The **nerves** are the ilioinguinal and lumboinguinal branches of the lumbar plexus, the two superficial perineal branches of the internal pudendal nerve, and the pudendal branch of the posterior femoral cutaneous nerve.

The **Inguinal Canal** (*canalis inguinalis*) is described on page 418.

The **Spermatic Cord** (*funiculus spermaticus*) (Fig. 1146) extends from the abdominal inguinal ring, where the structures of which it is composed converge, to the back part of the testis. In the abdominal wall the cord passes obliquely along the inguinal canal, lying at first beneath the Obliquus internus, and upon the fascia transversalis; but nearer the pubis, it rests upon the inguinal and lacunar ligaments, having the aponeurosis of the Obliquus externus in front of it, and the inguinal falx behind it. It then escapes at the subcutaneous ring, and descends nearly vertically into the scrotum. The left cord is rather longer than the right, consequently the left testis hangs somewhat lower than its fellow.

Structure of the Spermatic Cord.—The spermatic cord is composed of arteries, veins, lymphatics, nerves, and the excretory duct of the testis. These structures are connected together by areolar tissue, and invested by the layers brought down by the testis in its descent.

The **arteries of the cord** are: the internal and external spermatics; and the artery to the ductus deferens.

The **internal spermatic artery**, a branch of the abdominal aorta, escapes from the abdomen at the abdominal inguinal ring, and accompanies the other constituents of the spermatic cord along the inguinal canal and through the subcutaneous inguinal ring into the scrotum. It then descends, to the testis, and, becoming tortuous, divides into several branches, two or three of which accompany the ductus deferens and supply the epididymis, anastomosing with the artery of the ductus deferens: the others supply the substance of the testis.

The *external spermatic artery* is a branch of the inferior epigastric artery. It accompanies the spermatic cord and supplies the coverings of the cord, anastomosing with the internal spermatic artery.

The *artery of the ductus deferens*, a branch of the superior vesical, is a long, slender vessel, which accompanies the ductus deferens, ramifying upon its coats, and anastomosing with the internal spermatic artery near the testis.

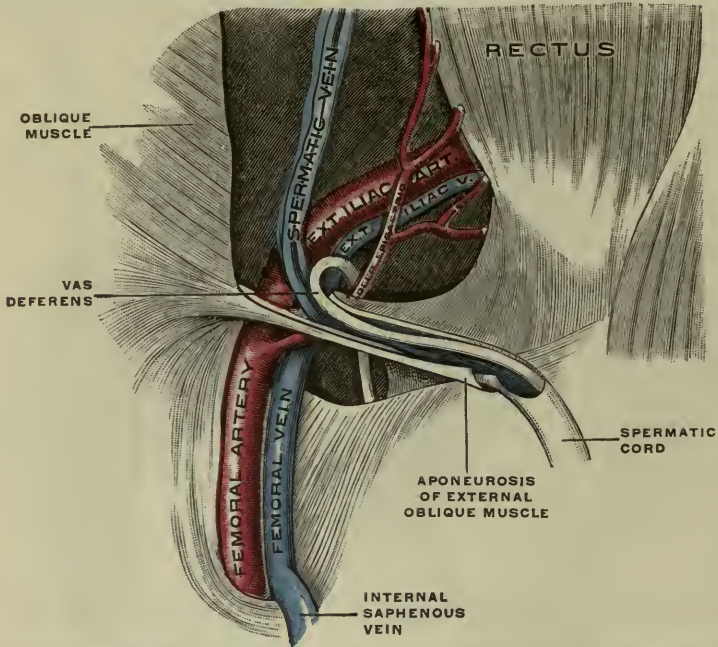


FIG. 1146.—The spermatic cord in the inguinal canal. (Poirier and Charpy.)

The **spermatic veins** (Fig. 1147) emerge from the back of the testis, and receive tributaries from the epididymis: they unite and form a convoluted plexus, the **plexus pampiniformis**, which forms the chief mass of the cord; the vessels composing this plexus are very numerous, and ascend along the cord in front of the ductus deferens; below the subcutaneous inguinal ring they unite to form three or four veins, which pass along the inguinal canal, and, entering the abdomen through the abdominal inguinal ring, coalesce to form two veins. These again unite to form a single vein, which opens on the right side into the inferior vena cava, at an acute angle, and on the left side into the left renal vein, at a right angle.

The **lymphatic vessels** are described on page 713.

The **nerves** are the spermatic plexus from the sympathetic, joined by filaments from the pelvic plexus which accompany the artery of the ductus deferens.

The scrotum forms an admirable covering for the protection of the testes. These bodies, lying suspended and loose in the cavity of the scrotum and surrounded by serous membrane, are capable of great mobility, and can therefore easily slip about within the scrotum and thus avoid injuries from blows or squeezes. The skin of the scrotum is very elastic and capable of great distension, and on account of the looseness and amount of subcutaneous tissue, the scrotum becomes greatly enlarged in cases of edema, to which this part is especially liable as a result of its dependent position.

The **Testes** are suspended in the scrotum by the spermatic cords, the left testis hanging somewhat lower than its fellow. The average dimensions of the testis are from 4 to 5 cm. in length, 2.5 cm. in breadth, and 3 cm. in the antero-posterior diameter; its weight varies from 10.5 to 14 gm. Each testis is of an oval form (Fig. 1148), compressed laterally, and having an oblique position in the scrotum; the upper extremity is directed forward and a little lateralward; the lower, backward and a little medialward; the anterior convex border looks forward and downward, the posterior or straight border, to which the cord is attached, backward and upward.

The anterior border and lateral surfaces, as well as both extremities of the organ, are convex, free, smooth, and invested by the visceral layer of the tunica vaginalis.

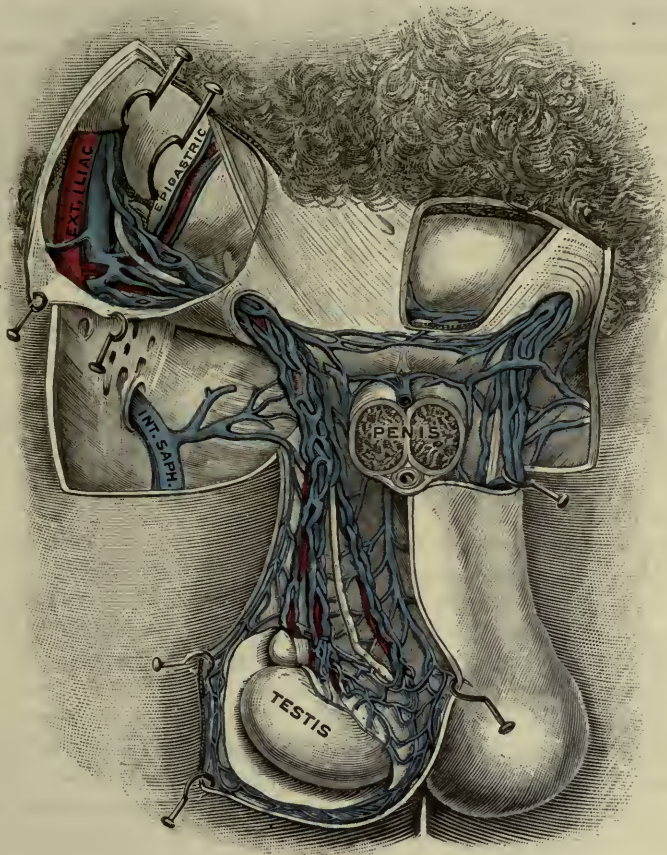


FIG. 1147.—Spermatic veins. (Testut.)

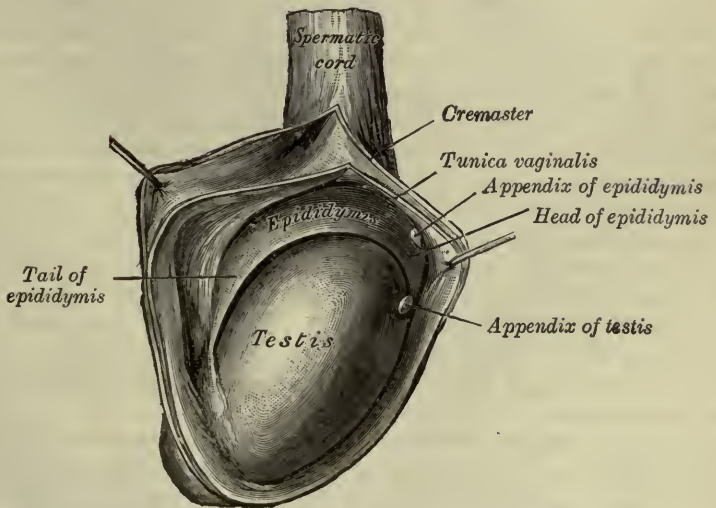


FIG. 1148.—The right testis, exposed by laying open the tunica vaginalis.

The posterior border, to which the cord is attached, receives only a partial investment from that membrane. Lying upon the lateral edge of this posterior border is a long, narrow, flattened body, named the **epididymis**.

The **epididymis** consists of a central portion or **body**; an upper enlarged extremity, the **head** (*globus major*); and a lower pointed extremity, the **tail** (*globus minor*), which is continuous with the ductus deferens, the **duct of the testis**. The head is intimately connected with the upper end of the testis by means of the efferent ductules of the gland; the tail is connected with the lower end by cellular tissue, and a reflection of the tunica vaginalis. The lateral surface, head and tail of the epididymis are free and covered by the serous membrane; the body is also completely invested by it, excepting along its posterior border; while between the body and the testis is a pouch, named the **sinus of the epididymis** (*digital fossa*). The epididymis is connected to the back of the testis by a fold of the serous membrane.

Appendages of the Testis and Epididymis.—On the upper extremity of the testis, just beneath the head of the epididymis, is a minute oval, sessile body, the **appendix of the testis** (*hydatid of Morgagni*); it is the remnant of the upper end of the Müllerian duct. On the head of the epididymis is a second small stalked appendage (sometimes duplicated); it is named the **appendix of the epididymis** (*pedunculated hydatid*), and is usually regarded as a detached efferent duct.

The testis is invested by three tunics: the **tunica vaginalis**, **tunica albuginea**, and **tunica vasculosa**.

The **Tunica Vaginalis** (*tunica vaginalis propria testis*) is the serous covering of the testis. It is a pouch of serous membrane, derived from the saccus vaginalis of the peritoneum, which in the fetus preceded the descent of the testis from the abdomen into the scrotum. After its descent, that portion of the pouch which extends from the abdominal inguinal ring to near the upper part of the gland becomes obliterated; the lower portion remains as a shut sac, which invests the surface of the testis, and is reflected on to the internal surface of the scrotum; hence it may be described as consisting of a **visceral** and a **parietal lamina**.

The **visceral lamina** (*lamina visceralis*) covers the greater part of the testis and epididymis, connecting the latter to the testis by means of a distinct fold. From the posterior border of the gland it is reflected on to the internal surface of the scrotum.

The **parietal lamina** (*lamina parietalis*) is far more extensive than the visceral, extending upward for some distance in front and on the medial side of the cord, and reaching below the testis. The inner surface of the tunica vaginalis is smooth, and covered by a layer of endothelial cells. The interval between the visceral and parietal laminae constitutes the cavity of the tunica vaginalis.

The obliterated portion of the saccus vaginalis may generally be seen as a fibro-cellular thread lying in the loose areolar tissue around the spermatic cord; sometimes this may be traced as a distinct band from the upper end of the inguinal canal, where it is connected with the peritoneum, down to the tunica vaginalis; sometimes it gradually becomes lost on the spermatic cord. Occasionally no trace of it can be detected. In some cases it happens that the pouch of peritoneum does not become obliterated, but the sac of the peritoneum communicates with the tunica vaginalis. This may give rise to one of the varieties of oblique inguinal hernia (page 1187). In other cases the pouch may contract, but not become entirely obliterated; it then forms a minute canal leading from the peritoneum to the tunica vaginalis.

The **Tunica Albuginea** is the fibrous covering of the testis. It is a dense membrane, of a bluish-white color, composed of bundles of white fibrous tissue which interlace in every direction. It is covered by the tunica vaginalis, except at the points of attachment of the epididymis to the testis, and along its posterior border, where

the spermatic vessels enter the gland. It is applied to the tunica vasculosa over the glandular substance of the testis, and, at its posterior border, is reflected into the interior of the gland, forming an incomplete vertical septum, called the **mediastinum testis** (*corpus Highmori*).

The **mediastinum testis** extends from the upper to near the lower extremity of the gland, and is wider above than below. From its front and sides numerous imperfect septa (*trabeculae*) are given off, which radiate toward the surface of the organ, and are attached to the tunica albuginea. They divide the interior of the organ into a number of incomplete spaces which are somewhat cone-shaped, being broad at their bases at the surface of the gland, and becoming narrower as they converge to the mediastinum. The mediastinum supports the vessels and duct of the testis in their passage to and from the substance of the gland.

The **Tunica Vasculosa** is the vascular layer of the testis, consisting of a plexus of bloodvessels, held together by delicate areolar tissue. It clothes the inner surface of the tunica albuginea and the different septa in the interior of the gland, and therefore forms an internal investment to all the spaces of which the gland is composed.

Structure.—The glandular structure of the testis consists of numerous lobules. Their number, in a single testis, is estimated by Berres at 250, and by Krause at 400. They differ in size according to their position, those in the middle of the gland being larger and longer. The lobules (Fig. 1149) are conical in shape, the base being directed toward the circumference of the organ, the apex toward the mediastinum. Each lobule is contained in one of the intervals between the fibrous septa which extend between the mediastinum testis and the tunica albuginea, and consists of from one to three, or more, minute convoluted tubes, the **tubuli seminiferi**. The tubules may be separately unraveled, by careful dissection under water, and may be seen to commence either by free cecal ends or by anastomotic loops. They are supported by loose connective tissue which contains here and there groups of "interstitial cells" containing yellow pigment granules. The total number of tubules is estimated by Lauth at 840, and the average length of each is 70 to 80 cm. Their diameter varies from 0.12 to 0.3 mm. The tubules are pale in color in early life, but in old age they acquire a deep yellow tinge from containing much fatty matter. Each tubule consists of a basement layer formed of laminated connective tissue containing numerous elastic fibers with flattened cells between the layers and covered externally by a layer of flattened epithelioid cells. Within the basement membrane are epithelial cells arranged in several irregular layers, which are not always clearly separated, but which may be arranged in three different groups (Fig. 1150). Among these cells may be seen the **spermatozoa** in different stages of development. (1) Lining the basement membrane and forming the outer zone is a layer of cubical cells, with small nuclei; some of these enlarge to become **spermatogonia**. The nuclei of some of the spermatogonia may be seen to be in process of indirect division (*karyokinesis*, page 37), and in consequence of this daughter cells are formed, which constitute the second zone. (2) Within this first layer is to be seen a number of larger polyhedral cells, with clear nuclei, arranged in two or three layers; these are the **intermediate cells** or **spermatocytes**. Most of these cells are in a condition of karyokinetic division, and the cells which result from this division form those of the next layer, the **spermatoblasts** or **spermatids**. (3) The third layer of cells consists of the spermatoblasts or spermatids, and each of these, without further subdivision, becomes a **spermatozoön**. The spermatids are small polyhedral cells, the nucleus of each of which contains half the usual number of chromosomes. In addition to these three layers of cells others are seen, which are termed the **supporting cells** (*cells of Sertoli*). They are elongated and columnar, and project inward from the basement membrane toward the lumen of the tube. As development of the spermatozoa proceeds the latter group themselves around the inner extremities of the supporting cells. The nuclear portion of the spermatid, which is partly

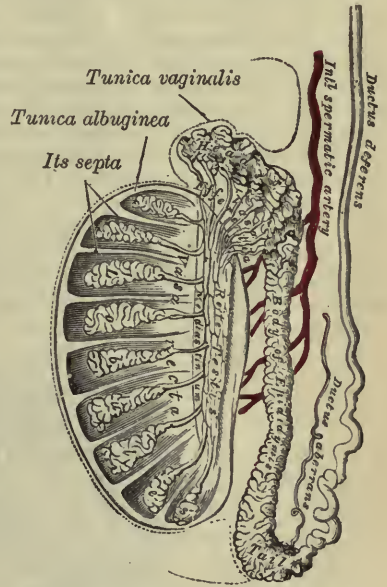


FIG. 1149.—Vertical section of the testis, to show the arrangement of the ducts.

imbedded in the supporting cell, is differentiated to form the head of the spermatozoön, while part of the cell protoplasm forms the middle piece and the tail is produced by an outgrowth from the double centriole of the cell. Ultimately the heads are liberated and the spermatozoa are set free. The structure of the spermatozoa is described on pages 42, 43.

In the apices of the lobules, the tubules become less convoluted, assume a nearly straight course, and unite together to form from twenty to thirty larger ducts, of about 0.5 mm. in diameter, and these, from their straight course, are called **tubuli recti** (Fig. 1149).

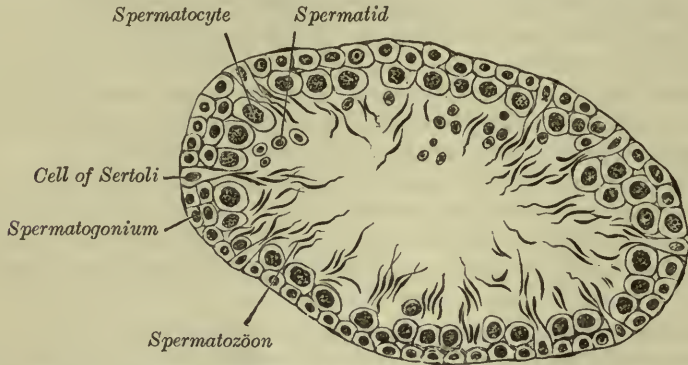


FIG. 1150.—Transverse section of a tubule of the testis of a rat. $\times 250$.

The **tubuli recti** enter the fibrous tissue of the mediastinum, and pass upward and backward, forming, in their ascent, a close net-work of anastomosing tubes which are merely channels in the fibrous stroma, lined by flattened epithelium, and having no proper walls; this constitutes the **rete testis**. At the upper end of the mediastinum, the vessels of the rete testis terminate in from twelve to fifteen or twenty ducts, the **ductuli efferentes**; they perforate the tunica albuginea, and carry the seminal fluid from the testis to the epididymis. Their course is at first straight; they then become enlarged, and exceedingly convoluted, and form a series of conical masses, the **coni vasculosi**, which together constitute the head of the epididymis. Each cone consists of a single convoluted duct, from 15 to 20 cm. in length, the diameter of which gradually decreases from the testis to the epididymis. Opposite the bases of the cones the efferent vessels open at narrow intervals into a single duct, which constitutes, by its complex convolutions, the body and tail of the epididymis. When the convolutions of this tube are unravelled, it measures upward of 6 meters in length; it increases in diameter and thickness as it approaches the ductus deferens. The convolutions are held together by fine areolar tissue, and by bands of fibrous tissue.

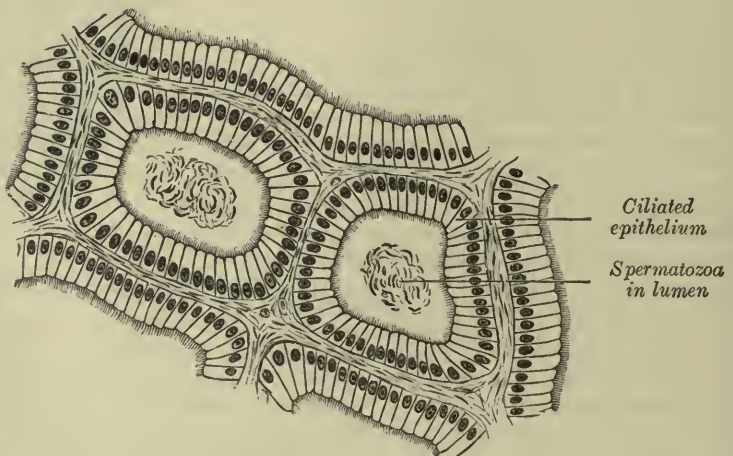


FIG. 1151.—Section of epididymis of guinea-pig. $\times 255$.

The **tubuli recti** have very thin walls; like the channels of the rete testis they are lined by a single layer of flattened epithelium. The ductuli efferentes and the tube of the epididymis have walls of considerable thickness, on account of the presence in them of muscular tissue, which is principally arranged in a circular manner. These tubes are lined by columnar ciliated epithelium (Fig. 1151).

Peculiarities.—The testis, developed in the lumbar region, may be arrested or delayed in its transit to the scrotum (*cryptorchism*). It may be retained in the abdomen; or it may be arrested at the abdominal inguinal ring, or in the inguinal canal; or it may just pass out of the subcutaneous inguinal ring without finding its way to the bottom of the scrotum. When retained in the abdomen it gives rise to no symptoms, other than the absence of the testis from the scrotum; but when it is retained in the inguinal canal it is subjected to pressure and may become inflamed and painful. The retained testis is probably functionally useless; so that a man in whom both testes are retained (*anorchism*) is sterile, though he may not be impotent. The absence of one testis is termed *monorchism*. When a testis is retained in the inguinal canal it is often complicated with a congenital hernia, the funicular process of the peritoneum not being obliterated. In addition to the cases above described, where there is some arrest in the descent of the testis, this organ may descend through the inguinal canal, but may miss the scrotum and assume some abnormal position. The most common form is where the testis, emerging at the subcutaneous inguinal ring, slips down between the scrotum and thigh and comes to rest in the perineum. This is known as *perineal ectopia testis*. With each variety of abnormality in the position of the testis, it is very common to find concurrently a congenital hernia, or, if a hernia be not actually present, the funicular process is usually patent, and almost invariably so if the testis is in the inguinal canal.

The testis, finally reaching the scrotum, may occupy an abnormal position in it. It may be inverted, so that its posterior or attached border is directed forward and the tunica vaginalis is situated behind.

Fluid collections of a serous character are very frequently found in the scrotum. To these the term *hydrocele* is applied. The most common form is the ordinary *vaginal hydrocele*, in which the fluid is contained in the sac of the tunica vaginalis, which is separated, in its normal condition, from the peritoneal cavity by the whole extent of the inguinal canal. In another form, the *congenital hydrocele*, the fluid is in the sac of the tunica vaginalis, but this cavity communicates with the general peritoneal cavity, its tubular process remaining pervious. A third variety, known as an *infantile hydrocele*, occurs in those cases where the tubular process becomes obliterated only at its upper part, at or near the abdominal inguinal ring. It resembles the vaginal hydrocele, except as regards its shape, the collection of fluid extending up the cord into the inguinal canal. Fourthly, the funicular process may become obliterated both at the abdominal inguinal ring and above the epididymis, leaving a central unobliterated portion, which may become distended with fluid, giving rise to a condition known as the *encysted hydrocele of the cord*.

The Ductus Deferens (Vas Deferens; Seminal Duct).

The *ductus deferens*, the excretory duct of the testis, is the continuation of the canal of the epididymis. Commencing at the lower part of the tail of the epididymis it is at first very tortuous, but gradually becoming less twisted it ascends along the posterior border of the testis and medial side of the epididymis, and, as a constituent of the spermatic cord, traverses the inguinal canal to the abdominal inguinal ring. Here it separates from the other structures of the cord, curves around the lateral side of the inferior epigastric artery, and ascends for about 2.5 cm. in front of the external iliac artery. It is next directed backward and slightly downward, and, crossing the external iliac vessels obliquely, enters the pelvic cavity, where it lies between the peritoneal membrane and the lateral wall of the pelvis, and descends on the medial side of the obliterated umbilical artery and the obturator nerve and vessels. It then crosses in front of the ureter, and, reaching the medial side of this tube, bends to form an acute angle, and runs medialward and slightly forward between the fundus of the bladder and the upper end of the seminal vesicle. Reaching the medial side of the seminal vesicle, it is directed downward and medialward in contact with it, gradually approaching the opposite ductus. Here it lies between the fundus of the bladder and the rectum, where it is enclosed, together with the seminal vesicle, in a sheath derived from the rectovesical portion of the fascia endopelvina. Lastly, it is directed downward to the base of the prostate, where it becomes greatly narrowed, and is joined at an acute angle by the duct of the seminal vesicle to form the ejaculatory duct, which traverses the prostate behind its middle lobe and opens into the prostatic portion of the urethra, close to the orifice of the prostatic utricle. The *ductus deferens* presents a hard and cord-like sensation to the fingers, and is of cylindrical form; its

walls are dense, and its canal is extremely small. At the fundus of the bladder it becomes enlarged and tortuous, and this portion is termed the *ampulla*. A small triangular area of the fundus of the bladder, between the ductus deferentes laterally and the bottom of the rectovesical excavation of peritoneum above, is in contact with the rectum.

Ductuli Aberrantes.—A long narrow tube, the *ductulus aberrans inferior* (*vas aberrans of Haller*), is occasionally found connected with the lower part of the canal of the epididymis, or with the commencement of the ductus deferens. Its length varies from 3.5 to 35 cm., and it may become dilated toward its extremity; more commonly it retains the same diameter throughout. Its structure is similar to that of the ductus deferens. Occasionally it is found unconnected with the epididymis. A second tube, the *ductulus aberrans superior*, occurs in the head of the epididymis; it is connected with the rete testis.

Paradidymis (*organ of Giralde's*).—This term is applied to a small collection of convoluted tubules, situated in front of the lower part of the cord above the head of the epididymis. These tubes are lined with columnar ciliated epithelium, and probably represent the remains of a part of the Wolffian body.

Structure.—The ductus deferens consists of three coats: (1) an **external or areolar coat**; (2) a **muscular coat** which in the greater part of the tube consists of two layers of unstriated muscular fiber: an outer, longitudinal in direction, and an inner, circular; but in addition to these, at the commencement of the ductus, there is a third layer, consisting of longitudinal fibers, placed internal to the circular stratum, between it and the mucous membrane; (3) an **internal or mucous coat**, which is pale, and arranged in longitudinal folds. The mucous coat is lined by columnar epithelium which is non-ciliated throughout the greater part of the tube; a variable portion of the testicular end of the tube is lined by two strata of columnar cells and the cells of the superficial layer are ciliated.

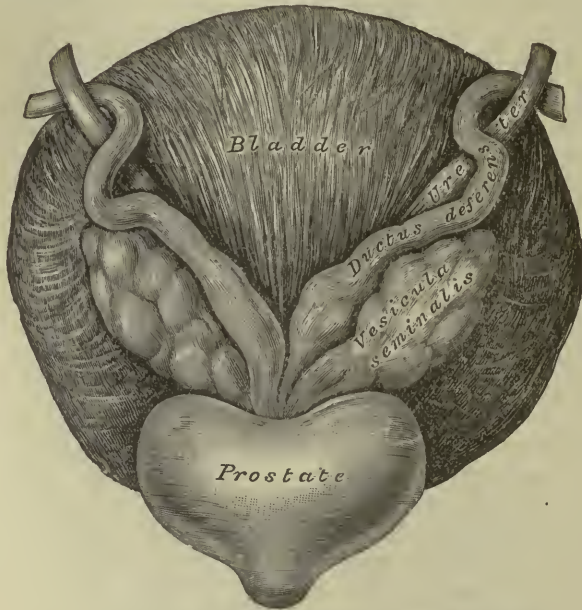


FIG. 1152.—Fundus of the bladder with the vesiculæ seminales.

The Vesiculæ Seminales (Seminal Vesicles) (Fig. 1152).

The *vesiculæ seminales* are two lobulated membranous pouches, placed between the fundus of the bladder and the rectum, serving as reservoirs for the semen, and secreting a fluid to be added to the secretion of the testes. Each sac is somewhat pyramidal in form, the broad end being directed backward, upward and lateralward. It is usually about 7.5 cm. long, but varies in size, not only in different individuals, but also in the same individual on the two sides. The **anterior surface** is in contact with the fundus of the bladder, extending from near the termination of the ureter

to the base of the prostate. The **posterior surface** rests upon the rectum, from which it is separated by the rectovesical fascia. The **upper extremities** of the two vesicles diverge from each other, and are in relation with the ductus deferentes and the terminations of the ureters, and are partly covered by peritoneum. The **lower extremities** are pointed, and converge toward the base of the prostate, where each joins with the corresponding ductus deferens to form the ejaculatory duct. Along the medial margin of each vesicle runs the ampulla of the ductus deferens.

Each vesicle consists of a single tube, coiled upon itself, and giving off several irregular cecal diverticula; the separate coils, as well as the diverticula, are connected together by fibrous tissue. When uncoiled, the tube is about the diameter of a quill, and varies in length from 10 to 15 cm.; it ends posteriorly in a cul-de-sac; its anterior extremity becomes constricted into a narrow straight duct, which joins with the corresponding ductus deferens to form the ejaculatory duct.

Structure.—The vesiculæ seminales are composed of three coats: an **external or areolar coat**; a **middle or muscular coat** thinner than in the ductus deferens and arranged in two layers, an outer longitudinal and inner circular; an **internal or mucous coat**, which is pale, of a whitish brown color, and presents a delicate reticular structure. The epithelium is columnar, and in the diverticula goblet cells are present, the secretion of which increases the bulk of the seminal fluid.

Vessels and Nerves.—The arteries supplying the vesiculæ seminales are derived from the middle and inferior vesical and middle hemorrhoidal. The **veins** and **lymphatics** accompany the arteries. The **nerves** are derived from the pelvic plexuses.

The Ejaculatory Ducts (Ductus Ejaculatorii) (Fig. 1153).

The **ejaculatory ducts** are two in number, one on either side of the middle line. Each is formed by the union of the duct from the vesicula seminalis with the ductus deferens, and is about 2 cm. long. They commence at the base of the prostate, and run forward and downward between its middle and lateral lobes, and along the sides of the prostatic utricle, to end by separate slit-like orifices close to or just within the margins of the utricle. The ducts diminish in size, and also converge, toward their terminations.

Structure.—The coats of the ejaculatory ducts are extremely thin. They are: an **outer fibrous layer**, which is almost entirely lost after the entrance of the ducts into the prostate; a **layer of muscular fibers** consisting of a thin outer circular, and an inner longitudinal, layer; and **mucous membrane**.

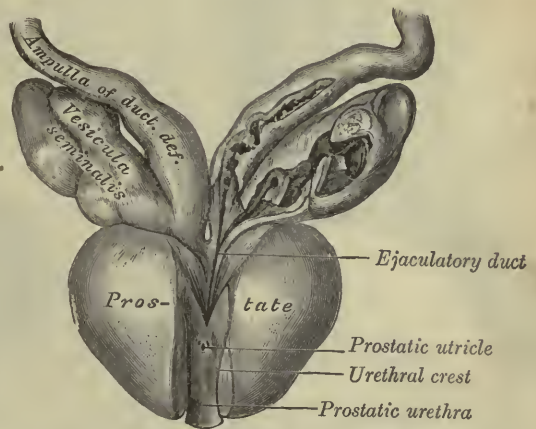


FIG. 1153.—Vesiculæ seminales and ampullæ of ductus deferens, seen from the front. The anterior walls of the left ampulla, left seminal vesicle, and prostatic urethra have been cut away.

The Penis.

The **penis** is a pendulous organ suspended from the front and sides of the pubic arch and containing the greater part of the urethra. In the flaccid condition it is cylindrical in shape, but when erect assumes the form of a triangular prism with rounded angles, one side of the prism forming the dorsum. It is composed of three cylindrical masses of cavernous tissue bound together by fibrous tissue and covered with skin. Two of the masses are lateral, and are known as the **corpora cavernosa penis**; the third is median, and is termed the **corpus cavernosum urethræ** (Figs. 1154, 1155).

The **Corpora Caverosa Penis** form the greater part of the substance of the penis. For their anterior three-fourths they lie in intimate apposition with one another, but behind they diverge in the form of two tapering processes, known as the **crura**, which are firmly connected to the rami of the pubic arch. Traced from behind forward, each crus begins by a blunt-pointed process in front of the tuberosity of the ischium. Just before it meets its fellow it presents a slight enlargement, named by Kobelt the **bulb of the corpus cavernosum penis**. Beyond this point the crus undergoes a constriction and merges into the corpus cavernosum proper,

which retains a uniform diameter to its anterior end. Each corpus cavernosum penis ends abruptly in a rounded extremity some distance from the point of the penis.

The corpora cavernosa penis are surrounded by a strong fibrous envelope consisting of superficial and deep fibers. The superficial fibers are longitudinal in direction, and form a single tube which encloses both corpora; the deep fibers are arranged circularly around each corpus, and form by their junction in the median plane the **septum of the penis**. This is thick and complete behind, but is imperfect in front, where it consists of a series of vertical bands arranged like the teeth of a comb; it is therefore named the **septum pectiniforme**.

The **Corpus Caverosum Urethrae** (*corpus spongiosum*) contains the urethra.

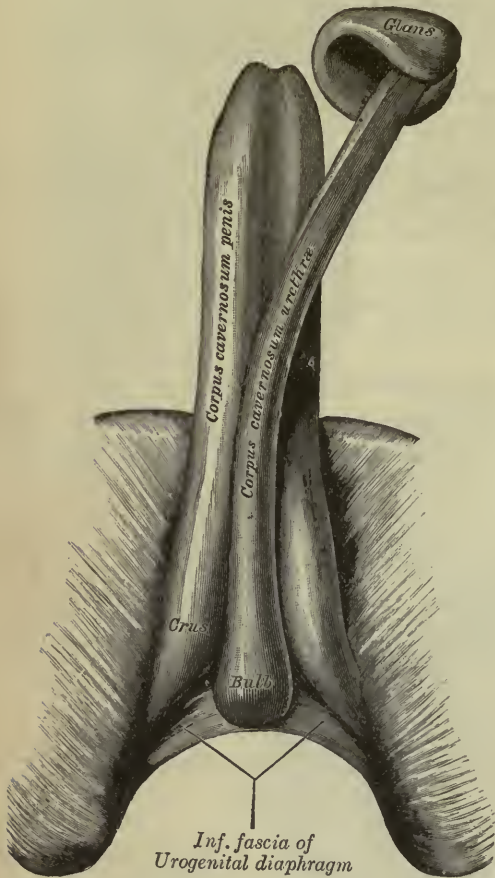


FIG. 1154.—The constituent cavernous cylinders of the penis. The glans and anterior part of the corpus cavernosum urethrae are detached from the corpora cavernosa penis and turned to one side.

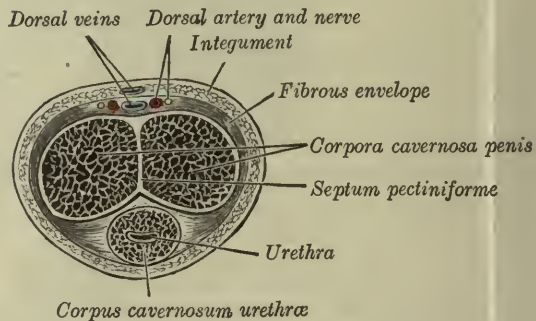


FIG. 1155.—Transverse section of the penis.

Behind, it is expanded to form the urethral bulb, and lies in apposition with the inferior fascia of the urogenital diaphragm, from which it receives a fibrous investment. The urethra enters the bulb nearer to the upper than to the lower surface. On the latter there is a median sulcus, from which a thin fibrous septum projects into the substance of the bulb and divides it imperfectly into two lateral **lobes** or **hemispheres**.

The portion of the corpus cavernosum urethrae in front of the bulb lies in a groove on the under surface of the conjoined corpora cavernosa penis. It is cylindrical in form and tapers slightly from behind forward. Its anterior end is expanded in the form of an obtuse cone, flattened from above downward. This expansion, termed the **glans penis**, is moulded on the rounded ends of the corpora cavernosa

penis, extending farther on their upper than on their lower surfaces. At the summit of the glans is the slit-like vertical external urethral orifice. The circumference of the base of the glans forms a rounded projecting border, the **corona glandis**, overhanging a deep **retroglandular sulcus**, behind which is the **neck** of the penis.

For descriptive purposes it is convenient to divide the penis into three regions: the **root**, the **body**, and the **extremity**.

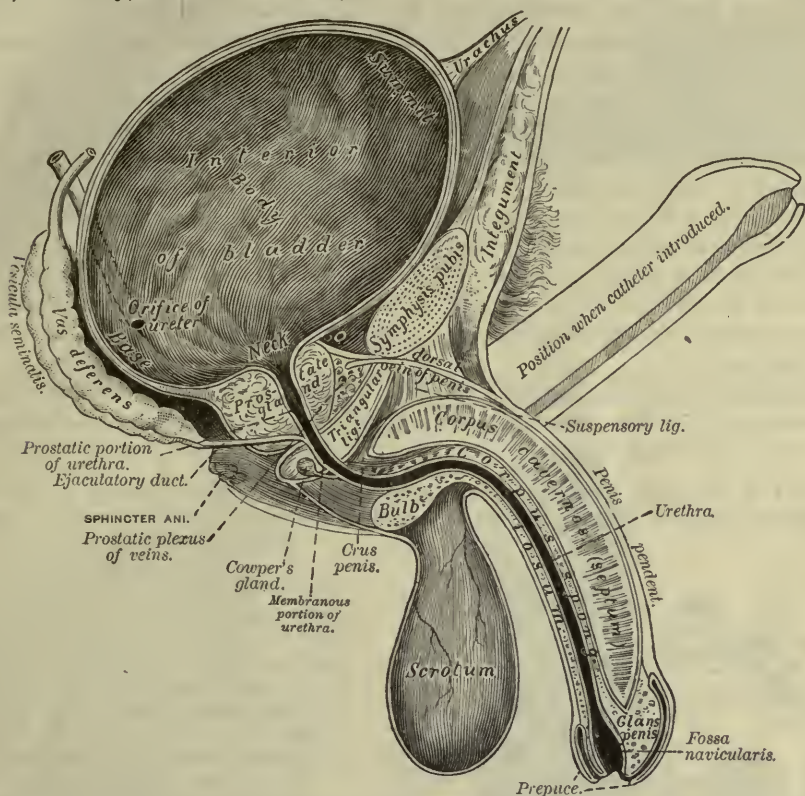


FIG. 1156.—Vertical section of bladder, penis, and urethra.

The **root** (*radix penis*) of the penis is triradiate in form, consisting of the diverging crura, one on either side, and the median urethral bulb. Each crus is covered by the Ischioavernosus, while the bulb is surrounded by the Bulbo-cavernosus. The root of the penis lies in the perineum between the inferior fasciæ of the urogenital diaphragm and the fascia of Colles. In addition to being attached to the fasciæ and the pubic rami, it is bound to the front of the symphysis pubis by the fundiform and suspensory ligaments. The **fundiform ligament** springs from the front of the sheath of the Rectus abdominis and the linea alba; it splits into two fasciculi which encircle the root of the penis. The upper fibers of the **suspensory ligament** pass downward from the lower end of the linea alba, and the lower fibers from the symphysis pubis; together they form a strong fibrous band, which extends to the upper surface of the root, where it blends with the fascial sheath of the organ.

The **body** (*corpus penis*) extends from the root to the ends of the corpora cavernosa penis, and in it these corpora cavernosa are intimately bound to one another. A shallow groove which marks their junction on the upper surface lodges the deep dorsal vein of the penis, while a deeper and wider groove between them on the under surface contains the corpus cavernosum urethrae. The body is ensheathed by fascia, which is continuous above with the fascia of Scarpa, and below with the dartos tunic of the scrotum and the fascia of Colles.

The **extremity** is formed by the glans penis, the expanded anterior end of the corpus cavernosum urethræ. It is separated from the body by the constricted neck, which is overhung by the corona glandis.

The integument covering the penis is remarkable for its thinness, its dark color, its looseness of connection with the deeper parts of the organ, and its absence of adipose tissue. At the root of the penis it is continuous with that over the pubes, scrotum, and perineum. At the neck it leaves the surface and becomes folded upon itself to form the **prepuce** or **foreskin**. The internal layer of the prepuce is directly continuous, along the line of the neck, with the integument over the glans. Immediately behind the external urethral orifice it forms a small secondary reduplication, attached along the bottom of a depressed median raphé, which extends from the meatus to the neck; this fold is termed the **frenulum** of the prepuce. The integument covering the glans is continuous with the urethral mucous membrane at the orifice; it is devoid of hairs, but projecting from its free surface are a number of small, highly sensitive papillæ. Scattered glands on the corona, neck, glans and inner layer of the prepuce, the **preputial glands**, have been described.¹ They secrete a sebaceous material of very peculiar odor, which probably contains casein, and readily undergoes decomposition; when mixed with discarded epithelial cells it is called smegma.

The prepuce covers a variable amount of the glans, and is separated from it by a potential sac—the **preputial sac**—which presents two shallow fossæ, one on either side of the frenulum.

Structure of the Penis.—From the internal surface of the fibrous envelope of the corpora cavernosa penis, as well as from the sides of the septum, numerous bands or cords are given off,

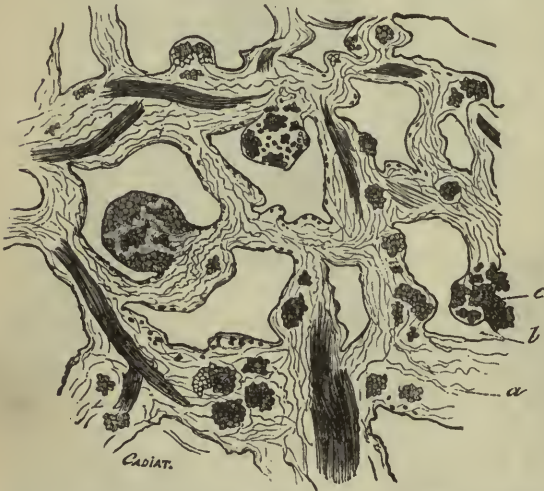

FIG. 1157.—Section of corpus cavernosum penis in a non-distended condition. (Cadiat.) *a*. Trabeculae of connective tissue, with many elastic fibers and bundles of plain muscular tissue, some of which are cut across (*c*). *b*. Blood sinuses.

which cross the interior of these corpora cavernosa in all directions, subdividing them into a number of separate compartments, and giving the entire structure a spongy appearance (Fig. 1157). These bands and cords are called **trabeculae**, and consist of white fibrous tissue, elastic fibers, and plain muscular fibers. In them are contained numerous arteries and nerves. The component fibers which form the trabeculae are larger and stronger around the circumference than at the centers of the corpora cavernosa; they are also thicker behind than in front. The interspaces (cavernous spaces), on the contrary, are larger at the center than at the circumference, their long diameters being directed transversely. They are filled with blood, and are lined by a layer of flattened cells similar to the endothelial lining of veins.

The fibrous envelope of the corpus cavernosum urethræ is thinner, whiter in color, and more elastic than that of the corpora cavernosa penis. The trabeculae are more delicate, nearly uniform in size, and the meshes between them smaller than in the corpora cavernosa penis: their long diameters, for the most part, corresponding with that of the penis. The external envelope or outer coat of the corpus cavernosum urethræ is formed partly of unstriated muscular fibers, and a layer of the same tissue immediately surrounds the canal of the urethra.

Vessels and Nerves.—The arteries bringing the blood to the cavernous spaces are the deep arteries of the penis and branches from the dorsal arteries of the penis, which perforate the fibrous capsule, along the upper surface, especially near the forepart of the organ. On entering the

¹ Stieda (Comptes-rendus du XII Congrès International de Médecine, Moscow, 1897) asserts that glands are never found on the corona glandis, and that what have hitherto been mistaken for glands are really large papillæ.

cavernous structure the arteries divide into branches, which are supported and enclosed by the trabeculæ. Some of these arteries end in a capillary net-work, the branches of which open directly into the cavernous spaces; others assume a tendril-like appearance, and form convoluted and somewhat dilated vessels, which were named by Müller *helicine arteries*. They open into the

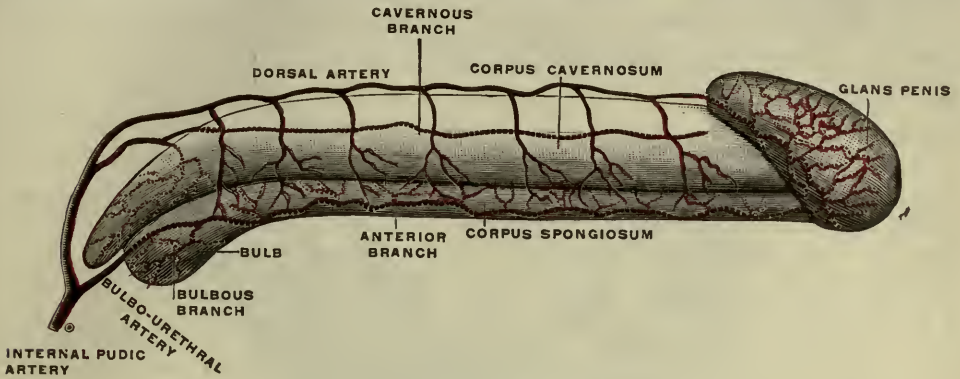


Fig. 1158.—Diagram of the arteries of the penis. (Testut.)

spaces, and from them are also given off small capillary branches to supply the trabecular structure. They are bound down in the spaces by fine fibrous processes, and are most abundant in the back part of the corpora cavernosa (Fig. 1157).

The blood from the cavernous spaces is returned by a series of vessels, some of which emerge in considerable numbers from the base of the glans penis and converge on the dorsum of the organ to form the deep dorsal vein; others pass out on the upper surface of the corpora cavernosa and join the same vein; some emerge from the under surface of the corpora cavernosa penis and receiving branches from the corpus cavernosum urethræ, wind around the sides of the penis to end in the deep dorsal vein; but the greater number pass out at the root of the penis and join the prostatic plexus.

The lymphatic vessels of the penis are described on page 713.

The nerves are derived from the pudendal nerve and the pelvic plexuses. On the glans and bulb some filaments of the cutaneous nerves have Pacinian bodies connected with them, and, according to Krause, many of them end in peculiar end-bulbs (see page 1060).

The Prostate (Prostata; Prostate Gland). (Fig. 1160.)

The prostate is a firm, partly glandular and partly muscular body, which is placed immediately below the internal urethral orifice and around the commencement of the urethra. It is situated in the pelvic cavity, below the lower part of the symphysis pubis, above the superior fascia of the urogenital diaphragm, and in front of the rectum, through which it may be distinctly felt, especially when enlarged. It is about the size of a chestnut and somewhat conical in shape, and presents for examination a base, an apex, an anterior, a posterior, and two lateral surfaces.



Fig. 1159.—Veins of the penis. (Testut.)

The **base** (*basis prostatae*) is directed upward, and is applied to the inferior surface of the bladder. The greater part of this surface is directly continuous with the bladder wall; the urethra penetrates it nearer its anterior than its posterior border.

The **apex** (*apex prostatae*) is directed downward, and is in contact with the superior fascia of the urogenital diaphragm.

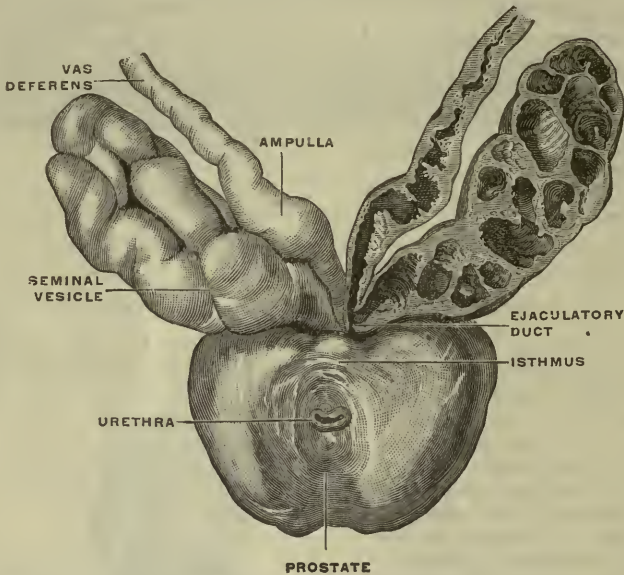


FIG. 1160.—Prostate with seminal vesicles and seminal ducts, viewed from in front and above. (Spalteholz.)

Surfaces.—The **posterior surface** (*facies posterior*) is flattened from side to side and slightly convex from above downward; it is separated from the rectum by its sheath and some loose connective tissue, and is distant about 4 cm. from the anus. Near its upper border there is a depression through which the two ejaculatory ducts enter the prostate. This depression serves to divide the posterior surface into a lower larger and an upper smaller part. The upper smaller part constitutes the **middle lobe** of the prostate and intervenes between the ejaculatory ducts and the urethra; it varies greatly in size, and in some cases is destitute of glandular tissue. The lower larger portion sometimes presents a shallow median furrow, which imperfectly separates it into a **right** and a **left lateral lobe**: these form the main mass of the gland and are directly continuous with each other behind the urethra. In front of the urethra they are connected by a band which is named the **isthmus**: this consists of the same tissues as the capsule and is devoid of glandular substance.

The **anterior surface** (*facies anterior*) measures about 2.5 cm. from above downward but is narrow and convex from side to side. It is placed about 2 cm. behind the pubic symphysis, from which it is separated by a plexus of veins and a quantity of loose fat. It is connected to the pubic bone on either side by the puboprostatic ligaments. The urethra emerges from this surface a little above and in front of the apex of the gland.

The **lateral surfaces** are prominent, and are covered by the anterior portions of the Levatores ani, which are, however, separated from the gland by a plexus of veins.

The prostate measures about 4 cm. transversely at the base, 2 cm. in its antero-posterior diameter, and 3 cm. in its vertical diameter. Its weight is about 8 gm. It is held in its position by the puboprostatic ligaments; by the superior fascia of

the urogenital diaphragm, which invests the prostate and the commencement of the membranous portion of the urethra; and by the anterior portions of the Levatores ani, which pass backward from the pubis and embrace the sides of the prostate. These portions of the Levatores ani, from the support they afford to the prostate, are named the *Levatores prostatae*.

The prostate is perforated by the urethra and the ejaculatory ducts. The urethra usually lies along the junction of its anterior with its middle third. The ejaculatory ducts pass obliquely downward and forward through the posterior part of the prostate, and open into the prostatic portion of the urethra.

Structure.—The prostate is immediately enveloped by a thin but firm fibrous capsule, distinct from that derived from the fascia endopelvina, and separated from it by a plexus of veins. This capsule is firmly adherent to the prostate and is structurally continuous with the stroma of the gland, being composed of the same tissues, viz.: non-striated muscle and fibrous tissue. The substance of the prostate is of a pale reddish-gray color, of great density, and not easily torn. It consists of glandular substance and muscular tissue.

The **muscular tissue** according to Kölliker, constitutes the proper stroma of the prostate; the connective tissue being very scanty, and simply forming between the muscular fibers, thin trabeculae, in which the vessels and nerves of the gland ramify. The muscular tissue is arranged as follows: immediately beneath the fibrous capsule is a dense layer, which forms an investing sheath for the gland; secondly, around the urethra, as it lies in the prostate, is another dense layer of circular fibers, continuous above with the internal layer of the muscular coat of the bladder, and blending below with the fibers surrounding the membranous portion of the urethra. Between these two layers strong bands of muscular tissue, which decussate freely, form meshes in which the glandular structure of the organ is imbedded. In that part of the gland which is situated in front of the urethra the muscular tissue is especially dense, and there is here little or no gland tissue; while in that part which is behind the urethra the muscular tissue presents a wide-meshed structure, which is densest at the base of the gland—that is, near the bladder—becoming looser and more sponge-like toward the apex of the organ.

The **glandular substance** is composed of numerous follicular pouches the lining of which frequently shows papillary elevations. The follicles open into elongated canals, which join to form from twelve to twenty small excretory ducts. They are connected together by areolar tissue, supported by prolongations from the fibrous capsule and muscular stroma, and enclosed in a delicate capillary plexus. The epithelium which lines the canals and the terminal vesicles is of the columnar variety. The prostatic ducts open into the floor of the prostatic portion of the urethra, and are lined by two layers of epithelium, the inner layer consisting of columnar and the outer of small cubical cells. Small colloid masses, known as **amyloid bodies** are often found in the gland tubes.

Vessels and Nerves.—The **arteries** supplying the prostate are derived from the internal pudendal, inferior vesical, and middle hemorrhoidal. Its veins form a plexus around the sides and base of the gland; they receive in front the dorsal vein of the penis, and end in the hypogastric veins. The **nerves** are derived from the pelvic plexus.

The Bulbourethral Glands (*Glandulae Bulbourethrales*; Cowper's Glands).

The **bulbourethral glands** are two small, rounded, and somewhat lobulated bodies, of a yellow color, about the size of peas, placed behind and lateral to the membranous portion of the urethra, between the two layers of the fascia of the urogenital diaphragm. They lie close above the bulb, and are enclosed by the transverse fibers of the Sphincter urethrae membranacea. Their existence is said to be constant: they gradually diminish in size as age advances.

The excretory duct of each gland, nearly 2.5 cm. long, passes obliquely forward beneath the mucous membrane, and opens by a minute orifice on the floor of the cavernous portion of the urethra about 2.5 cm. in front of the urogenital diaphragm.

Structure.—Each gland is made up of several lobules, held together by a fibrous investment. Each lobule consists of a number of acini, lined by columnar epithelial cells, opening into one duct, which joins with the ducts of other lobules outside the gland to form the single excretory duct.

THE FEMALE GENITAL ORGANS (ORGANA GENITALIA MULIEBRIA).

The female genital organs consist of an internal and an external group. The **internal organs** are situated within the pelvis, and consist of the **ovaries**, the **uterine tubes**, the **uterus**, and the **vagina**. The **external organs** are placed below the urogenital diaphragm and below and in front of the pubic arch. They comprise the **mons pubis**, the **labia majora et minora pudendi**, the **clitoris**, the **bulbus vestibuli**, and the **greater vestibular glands**.

The Ovaries (Ovaria).

The **ovaries** are homologous with the testes in the male. They are two nodular bodies, situated one on either side of the uterus in relation to the lateral wall of the pelvis, and attached to the back of the broad ligament of the uterus, behind and below the uterine tubes (Fig. 1161). The ovaries are of a grayish-pink color, and present either a smooth or a puckered uneven surface. They are each about 4 cm. in length, 2 cm. in width, and about 8 mm. in thickness, and weigh from 2

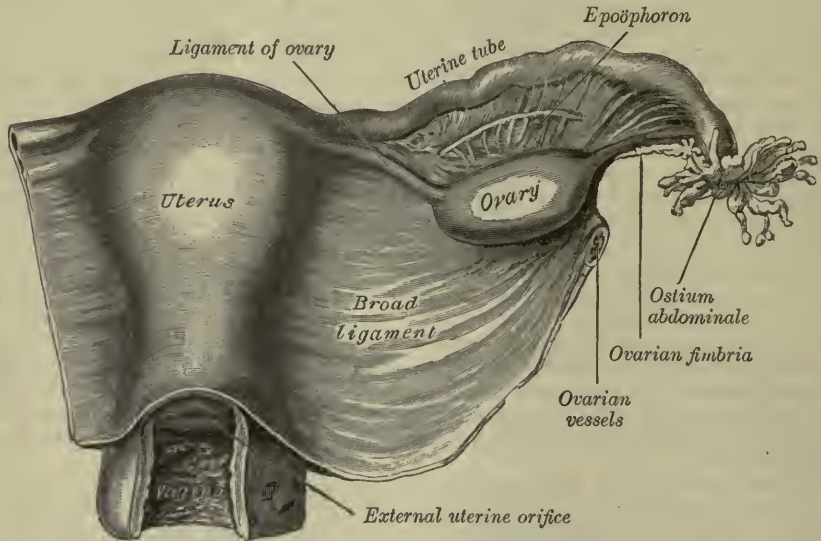


FIG. 1161.—Uterus and right broad ligament, seen from behind. The broad ligament has been spread out and the ovary drawn downward.

to 3.5 gm. Each ovary presents a lateral and a medial surface, an upper or tubal and a lower or uterine extremity, and an anterior or mesovarium and a posterior free border. It lies in a shallow depression, named the **ovarian fossa**, on the lateral wall of the pelvis; this fossa is bounded above by the external iliac vessels, in front by the obliterated umbilical artery, and behind by the ureter. The exact position of the ovary has been the subject of considerable difference of opinion, and the description here given applies to the ovary of the nulliparous woman. The ovary becomes displaced during the first pregnancy, and probably never again returns to its original position. In the erect posture the long axis of the ovary is vertical. The *tubal extremity* is near the external iliac vein; to it are attached the ovarian fimbria of the uterine tube and a fold of peritoneum, the **suspensory ligament of the ovary**, which is directed upward over the iliac vessels and contains the ovarian vessels. The *uterine end* is directed downward toward the pelvic floor, it is usually narrower than the tubal, and is attached to the lateral angle of the uterus, immediately behind the uterine tube, by a rounded cord termed the **ligament of the ovary**, which lies within the broad ligament and contains some non-stripped muscular

fibers. The *lateral surface* is in contact with the parietal peritoneum, which lines the ovarian fossa; the *medial surface* is to a large extent covered by the fimbriated extremity of the uterine tube. The *mesovarian border* is straight and is directed toward the obliterated umbilical artery, and is attached to the back of the broad ligament by a short fold named the **mesovarium**. Between the two layers of this fold the bloodvessels and nerves pass to reach the hilum of the ovary. The *free border* is convex, and is directed toward the ureter. The uterine tube arches over the ovary, running upward in relation to its mesovarian border, then curving over its tubal pole, and finally passing downward on its free border and medial surface.

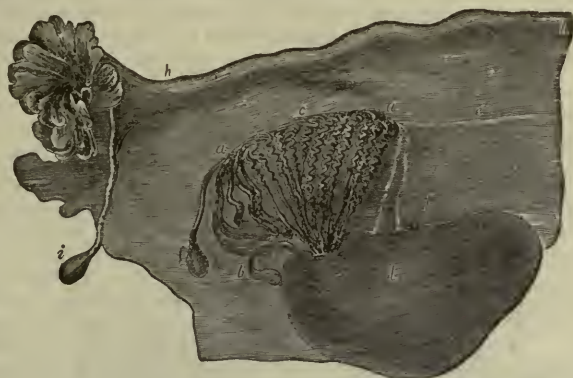


FIG. 1162.—Adult ovary, epoöphoron, and uterine tube. (From Farre, after Kobelt.) *a, a.* Epoöphoron formed from the upper part of the Wolffian body. *b.* Remains of the uppermost tubes sometimes forming hydatids. *c.* Middle set of tubes. *d.* Some lower atrophied tubes. *e.* Atrophied remains of the Wolffian duct. *f.* The terminal bulb or hydatid. *h.* The uterine tube. *i.* Hydatid attached to the extremity. *l.* The ovary.

Epoöphoron (*parovarium; organ of Rosenmüller*) (Figs. 1161, 1162).—The epoöphoron lies in the mesosalpinx between the ovary and the uterine tube, and consists of a few short tubules (**ductuli transversi**) which converge toward the ovary while their opposite ends open into a rudimentary duct, the **ductus longitudinalis epoöphori** (*duct of Gärtner*).

Paroöphoron.—The paroöphoron consists of a few scattered rudimentary tubules, best seen in the child, situated in the broad ligament between the epoöphoron and the uterus.

The ductuli transversi of the epoöphoron and the tubules of the paroöphoron are remnants of the tubules of the Wolffian body or mesonephros; the ductus longitudinalis epoöphori is a persistent portion of the Wolffian duct.

In the fetus the ovaries are situated, like the testes, in the lumbar region, near the kidneys, but they gradually descend into the pelvis (page 1211).

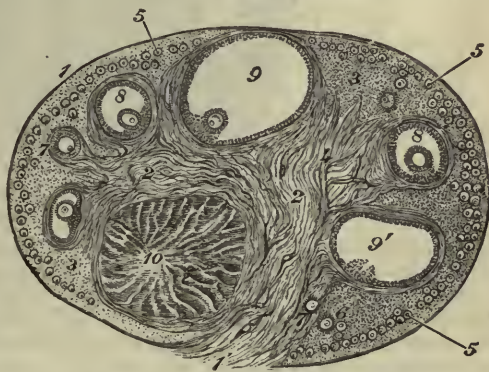


FIG. 1163.—Section of the ovary. (After Schrön.) 1. Outer covering. 1'. Attached border. 2. Central stroma. 3. Peripheral stroma. 4. Bloodvessels. 5. Vesicular follicles in their earliest stage. 6, 7, 8. More advanced follicles. 9. An almost mature follicle. 9'. Follicle from which the ovum has escaped. 10. Corpus luteum.

Structure (Fig. 1163).—The surface of the ovary is covered by a layer of columnar cells which constitutes the **germinal epithelium of Waldeyer**. This epithelium gives to the ovary a dull gray color as compared with the shining smoothness of the peritoneum; and the transition between the squamous epithelium of the peritoneum and the columnar cells which cover the ovary is usually marked by a line around the anterior border of the ovary. The ovary consists of a number of vesicular ovarian follicles imbedded in the meshes of a stroma or frame-work.

The **stroma** is a peculiar soft tissue, abundantly supplied with bloodvessels, consisting for the most part of spindle-shaped cells with a small amount of ordinary connective tissue. These cells have been regarded by some anatomists as unstriated muscle cells, which, indeed, they most resemble; by others as connective-tissue cells. On the surface of the organ this tissue is much condensed, and forms a layer (**tunica albuginea**) composed of short connective-tissue fibers, with fusiform cells between them. The stroma of the ovary may contain interstitial cells resembling those of the testis.

Vesicular Ovarian Follicles (*Graafian follicles*).—Upon making a section of an ovary, numerous round transparent vesicles of various sizes are to be seen; they are the follicles, or ovisacs containing the ova. Immediately beneath the superficial covering is a layer of stroma, in which are a large number of minute vesicles, of uniform size, about 0.25 mm. in diameter. These are the follicles in their earliest condition, and the layer where they are found has been termed the **cortical layer**. They are especially numerous in the ovary of the young child. After puberty, and during the whole of the child-bearing period, large and mature, or almost mature follicles are also found in the cortical layer in small numbers, and also "corpora lutea," the remains of follicles which have burst and are undergoing atrophy and absorption. Beneath this superficial stratum, other large and more or less mature follicles are found imbedded in the ovarian stroma. These increase in size as they recede from the surface toward a highly vascular stroma in the center of the organ, termed the **medullary substance** (*zona vasculosa of Waldeyer*). This stroma forms the tissue of the hilum by which the ovary is attached, and through which the bloodvessels enter: it does not contain any follicles.

The larger follicles (Fig. 1164) consist of an external fibrovascular coat, connected with the surrounding stroma of the ovary by a net-work of bloodvessels; and an internal coat, which consists of several layers of nucleated cells, called the **membrana granulosa**.

At one part of the mature follicle the cells of the **membrana granulosa** are collected into a mass which projects into the cavity of the follicle. This is termed the **discus proligerus**, and in it the ovum is imbedded.¹ The follicle contains a transparent albuminous fluid.

The development and maturation of the follicles and ova continue uninterruptedly from puberty to the end of the fruitful period of woman's life, while their formation commences before birth. Before puberty the ovaries are small and the follicles contained in them are disposed in a comparatively thick layer in the cortical substance; here they present the appearance of a large number of minute closed vesicles, constituting the early condition of the follicles; many, however, never attain full develop-

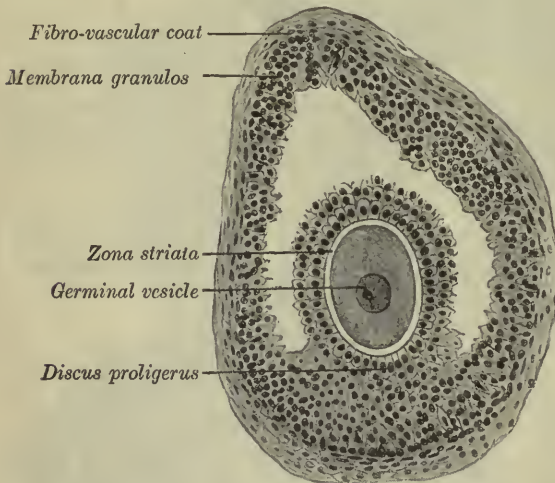


FIG. 1164.—Section of vesicular ovarian follicle of cat. $\times 50$.

ment, but shrink and disappear. At puberty the ovaries enlarge and become more vascular, the follicles are developed in greater abundance, and their ova are capable of fecundation.

Discharge of the Ovum.—The follicles, after attaining a certain stage of development, gradually approach the surface of the ovary and burst; the ovum and fluid contents of the follicle are liberated on the exterior of the ovary, and carried into the uterine tube by currents set up by the movements of the cilia covering the mucous membrane of the fimbriæ.

Corpus Luteum.—After the discharge of the ovum the lining of the follicle is thrown into folds, and vascular processes grow inward from the surrounding tissue. In this way the space is filled up and the corpus luteum formed. It consists at first of a radial arrangement of yellow cells with bloodvessels and lymphatic spaces, and later it merges with the surrounding stroma.

Vessels and Nerves.—The **arteries** of the ovaries and uterine tubes are the ovarian from the aorta. Each anastomoses freely in the mesosalpinx, with the uterine artery, giving some branches to the uterine tube, and others which traverse the mesovarium and enter the hilum of the ovary. The **veins** emerge from the hilum in the form of a plexus, the **pampiniform plexus**; the ovarian vein is formed from this plexus, and leaves the pelvis in company with the artery. The **nerves** are derived from the hypogastric or pelvic plexus, and from the ovarian plexus, the uterine tube receiving a branch from one of the uterine nerves.

¹ For a description of the ovum, see page 33.

The Uterine Tube (Tuba Uterina [Fallopian]; Fallopian Tube; Oviduct).
(Figs. 1161, 1165).

The uterine tubes convey the ova from the ovaries to the cavity of the uterus. They are two in number, one on either side, situated in the upper margin of the broad ligament, and extending from the superior angle of the uterus to the side of the pelvis. Each tube is about 10 cm. long, and is described as consisting of three portions: (1) the *isthmus*, or medial constricted third; (2) the *ampulla*, or intermediate dilated portion, which curves over the ovary; and (3) the *infundibulum* with its abdominal ostium, surrounded by *fimbriæ*, one of which, the *ovarian fimbria*

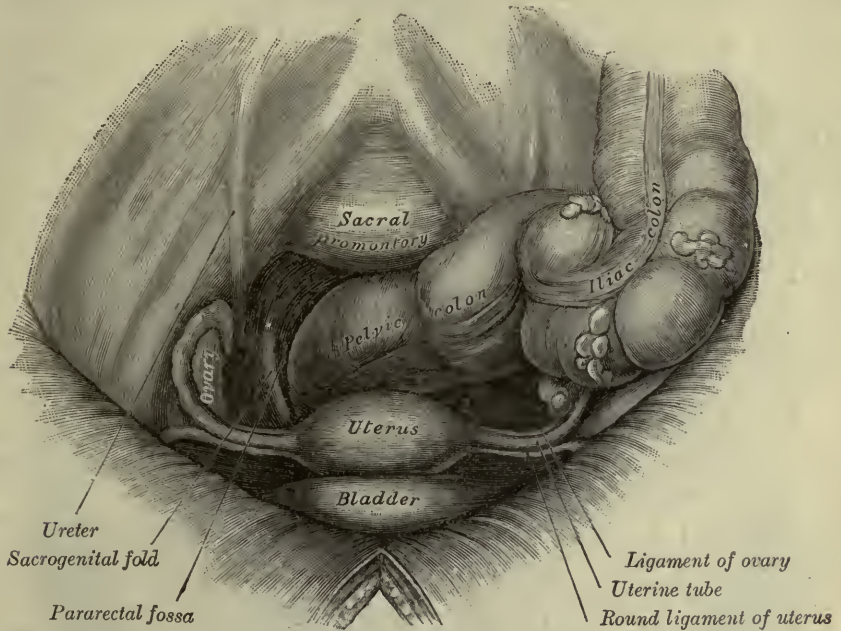


FIG. 1165.—Female pelvis and its contents, seen from above and in front.

is attached to the ovary. The uterine tube is directed lateralward as far as the uterine pole of the ovary, and then ascends along the mesovarian border of the ovary to the tubal pole, over which it arches; finally it turns downward and ends in relation to the free border and medial surface of the ovary. The uterine opening is minute, and will only admit a fine bristle; the abdominal opening is somewhat larger. In connection with the fimbriæ of the uterine tube, or with the broad ligament close to them, there are frequently one or more small pedunculated vesicles. These are termed the *appendices vesiculosæ* (*hydatids of Morgagni*).

Structure.—The uterine tube consists of three coats: **serous**, **muscular**, and **mucous**. The **external** or **serous coat** is peritoneal. The **middle** or **muscular coat** consists of an external longitudinal and an internal circular layer of non-stripped muscular fibers continuous with those of the uterus. The **internal** or **mucous coat** is continuous with the mucous lining of the uterus, and, at the abdominal ostium of the tube, with the peritoneum. It is thrown into longitudinal folds, which in the ampulla are much more extensive than in the isthmus. The lining epithelium is columnar and ciliated. This form of epithelium is also found on the inner surface of the fimbriæ, while on the outer or serous surfaces of these processes the epithelium gradually merges into the endothelium of the peritoneum.

Fertilization of the ovum is believed (page 44) to occur in the tube, and the fertilized ovum is then normally passed on into the uterus; the ovum, however, may adhere to and undergo development in the uterine tube, giving rise to the commonest variety of *ectopic gestation*. In such cases the amnion and chorion are formed, but a true decidua is never present; and the gestation usually

ends by extrusion of the ovum through the abdominal ostium, although it is not uncommon for the tube to rupture into the peritoneal cavity, this being accompanied by severe hemorrhage, and needing surgical interference.

The Uterus (Womb) (Figs. 1161, 1165, 1166).

The uterus is a hollow, thick-walled, muscular organ situated deeply in the pelvic cavity between the bladder and rectum. Into its upper part the uterine tubes open, one on either side, while below, its cavity communicates with that of

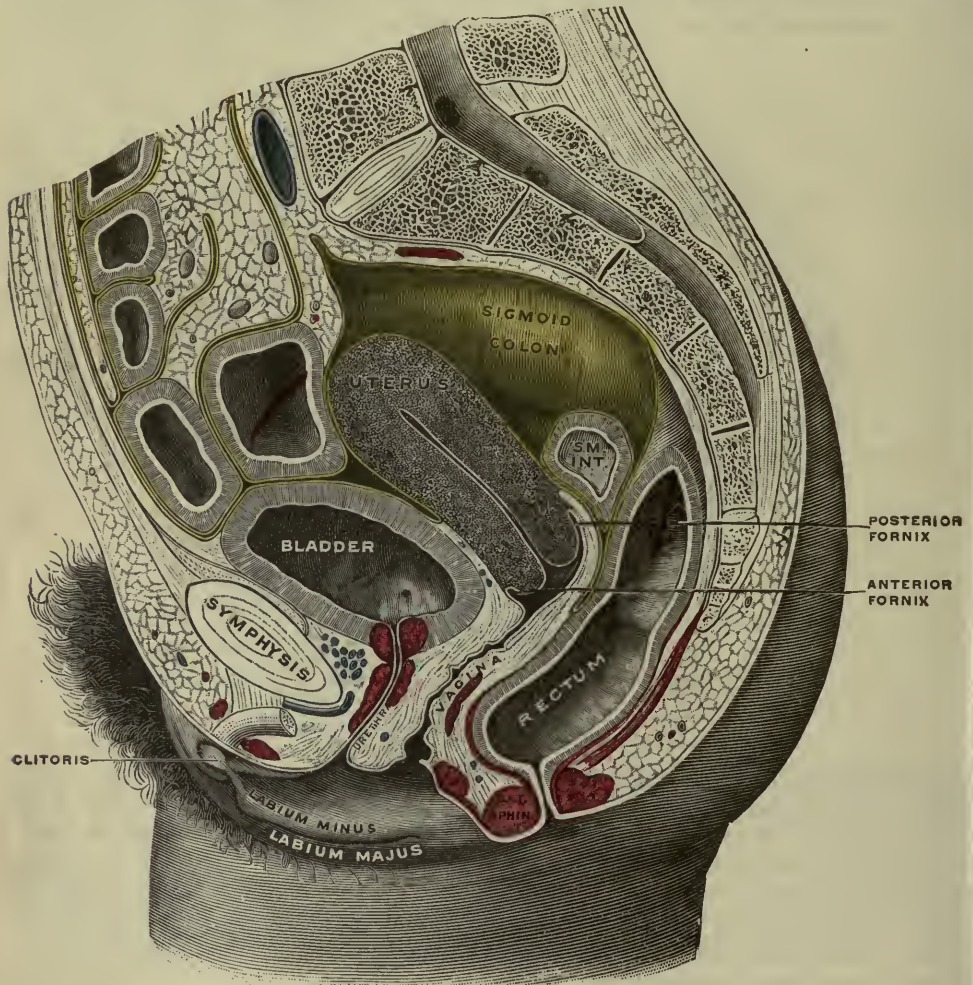


FIG. 1166.—Sagittal section of the lower part of a female trunk, right segment. *SM. INT.* Small intestine. (Testut.)

the vagina. When the ova are discharged from the ovaries they are carried to the uterine cavity through the uterine tubes. If an ovum be fertilized it imbeds itself in the uterine wall and is normally retained in the uterus until prenatal development is completed, the uterus undergoing changes in size and structure to accommodate itself to the needs of the growing embryo (see page 59). After parturition the uterus returns almost to its former condition, but certain traces of its enlargement remains. It is necessary, therefore, to describe as the type-form the adult virgin uterus, and then to consider the modifications which are effected as a result of pregnancy.

In the virgin state the uterus is flattened antero-posteriorly and is pyriform in shape, with the apex directed downward and backward. It lies between the bladder in front and the pelvic or sigmoid colon and rectum behind, and is completely within the pelvis, so that its base is below the level of the superior pelvic aperture. Its upper part is suspended by the broad and the round ligaments, while its lower portion is imbedded in the fibrous tissue of the pelvis.

The long axis of the uterus usually lies approximately in the axis of the superior pelvic aperture, but as the organ is freely movable its position varies with the state of distension of the bladder and rectum. Except when much displaced by a fully distended bladder, it forms a forward angle with the vagina, since the axis of the vagina corresponds to the axes of the cavity and inferior aperture of the pelvis.

The uterus measures about 7.5 cm. in length, 5 cm. in breadth, at its upper part, and nearly 2.5 cm. in thickness; it weighs from 30 to 40 gm. It is divisible into two portions. On the surface, about midway between the apex and base, is a slight constriction, known as the **isthmus**, and corresponding to this in the interior is a narrowing of the uterine cavity, the **internal orifice** of the uterus. The portion above the isthmus is termed the **body**, and that below, the **cervix**. The part of the body which lies above a plane passing through the points of entrance of the uterine tubes is known as the **fundus**.

Body (*corpus uteri*).—The body gradually narrows from the fundus to the isthmus.

The **vesical** or **anterior surface** (*facies vesicalis*) is flattened and covered by peritoneum, which is reflected on to the bladder to form the vesicouterine excavation. The surface lies in apposition with the bladder.

The **intestinal** or **posterior surface** (*facies intestinalis*) is convex transversely and is covered by peritoneum, which is continued down on to the cervix and vagina. It is in relation with the sigmoid colon, from which it is usually separated by some coils of small intestine.

The **fundus** (*fundus uteri*) is convex in all directions, and covered by peritoneum continuous with that on the vesical and intestinal surfaces. On it rest some coils of small intestine, and occasionally the distended sigmoid colon.

The **lateral margins** (*margo lateralis*) are slightly convex. At the upper end of each the uterine tube pierces the uterine wall. Below and in front of this point the round ligament of the uterus is fixed, while behind it is the attachment of the ligament of the ovary. These three structures lie within a fold of peritoneum which is reflected from the margin of the uterus to the wall of the pelvis, and is named the **broad ligament**.

Cervix (*cervix uteri; neck*).—The cervix is the lower constricted segment of the uterus. It is somewhat conical in shape, with its truncated apex directed downward and backward, but is slightly wider in the middle than either above or below. Owing to its relationships, it is less freely movable than the body, so that the latter may bend on it. The long axis of the cervix is therefore seldom in the same straight line as the long axis of the body. The long axis of the uterus as a whole presents the form of a curved line with its concavity forward, or in extreme cases may present an angular bend at the region of the isthmus.

The cervix projects through the anterior wall of the vagina, which divides it into an upper, supravaginal portion, and a lower, vaginal portion.

The **supravaginal portion** (*portio supravaginalis [cervicis]*) is separated in front from the bladder by fibrous tissue (**parametrium**), which extends also on to its sides and lateralward between the layers of the broad ligaments. The uterine arteries reach the margins of the cervix in this fibrous tissue, while on either side the ureter runs downward and forward in it at a distance of about 2 cm. from the cervix. *Posteriorly*, the supravaginal cervix is covered by peritoneum, which is prolonged

below on to the posterior vaginal wall, when it is reflected on to the rectum, forming the rectouterine excavation. It is in relation with the rectum, from which it may be separated by coils of small intestine.

The **vaginal portion** (*portio vaginalis [cervicis]*) of the cervix projects free into the anterior wall of the vagina between the anterior and posterior fornices. On its rounded extremity is a small, depressed, somewhat circular aperture, the **external orifice of the uterus**, through which the cavity of the cervix communicates with that of the vagina. The external orifice is bounded by two lips, an anterior and a posterior, of which the anterior is the shorter and thicker, although, on account of the slope of the cervix, it projects lower than the posterior. Normally, both lips are in contact with the posterior vaginal wall.

Interior of the Uterus (Fig. 1167).—The cavity of the uterus is small in comparison with the size of the organ.

The **Cavity of the Body** (*cavum uteri*) is a mere slit, flattened antero-posteriorly. It is triangular in shape, the base being formed by the internal surface of the fundus between the orifices of the uterine tubes, the apex by the internal orifice of the uterus through which the cavity of the body communicates with the canal of the cervix.

The **Canal of the Cervix** (*canalis cervicis uteri*) is somewhat fusiform, flattened from before backward, and broader at the middle than at either extremity. It communicates above through the internal orifice with the cavity of the body, and below through the external orifice with the vaginal cavity. The wall of the canal presents an anterior and a posterior longitudinal ridge, from each of which proceed a number of small oblique columns, the **palmate folds**, giving the appearance of branches from the stem of a tree; to this arrangement the name **arbor vitæ uterina** is applied. The folds on the two

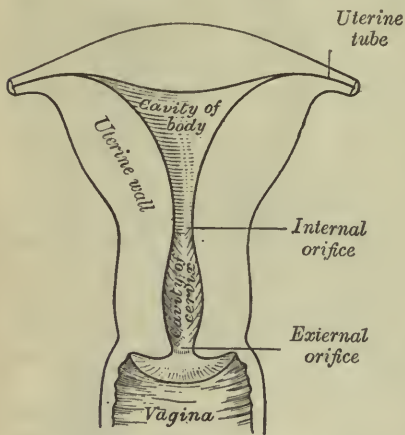


FIG. 1167.—Posterior half of uterus and upper part of vagina.

walls are not exactly opposed, but the fit between one another so as to close the cervical canal.

The total length of the uterine cavity from the external orifice to the fundus is about 6.25 cm.

Ligaments.—The ligaments of the uterus are eight in number: one anterior; one posterior; two lateral or broad; two uterosacral; and two round ligaments.

The **anterior ligament** consists of the vesicouterine fold of peritoneum, which is reflected on to the bladder from the front of the uterus, at the junction of the cervix and body.

The **posterior ligament** consists of the rectovaginal fold of peritoneum, which is reflected from the back of the posterior fornix of the vagina on to the front of the rectum. It forms the bottom of a deep pouch called the **rectouterine excavation**, which is bounded in front by the posterior wall of the uterus, the supravaginal cervix, and the posterior fornix of the vagina; behind, by the rectum; and laterally by two crescentic folds of peritoneum which pass backward from the cervix uteri on either side of the rectum to the posterior wall of the pelvis. These folds are named the **sacrogenital** or **rectouterine folds**. They contain a considerable amount of fibrous tissue and non-striped muscular fibers which are attached to the front of the sacrum and constitute the **uterosacral ligaments**.

The **two lateral or broad ligaments** (*ligamentum latum uteri*) pass from the sides of the uterus to the lateral walls of the pelvis. Together with the uterus they form

a septum across the female pelvis, dividing that cavity into two portions. In the anterior part is contained the bladder; in the posterior part the rectum, and in certain conditions some coils of the small intestine and a part of the sigmoid colon. Between the two layers of each broad ligament are contained: (1) the uterine tube superiorly; (2) the round ligament of the uterus; (3) the ovary and its ligament; (4) the epoöphoron and paroöphoron; (5) connective tissue; (6) unstriped muscular fibers; and (7) bloodvessels and nerves. The portion of the broad ligament which stretches from the uterine tube to the level of the ovary is known by the name of the **mesosalpinx**. Between the fimbriated extremity of the tube and the lower attachment of the broad ligament is a concave rounded margin, called the **infundibulopelvic ligament**.

The **round ligaments** (*ligamentum teres uteri*) are two flattened bands between 10 and 12 cm. in length, situated between the layers of the broad ligament in front of and below the uterine tubes. Commencing on either side at the lateral angle of the uterus, this ligament is directed forward, upward, and lateralward over the external iliac vessels. It then passes through the abdominal inguinal ring and along the inguinal canal to the labium majus, in which it becomes lost. The round ligaments consists principally of muscular tissue, prolonged from the uterus; also of some fibrous and areolar tissue, besides bloodvessels, lymphatics; and nerves, enclosed in a duplicature of peritoneum, which, in the fetus, is prolonged in the form of a tubular process for a short distance into the inguinal canal. This process is called the **canal of Nuck**. It is generally obliterated in the adult, but sometimes remains pervious even in advanced life. It is analogous to the saccus vaginalis, which precedes the descent of the testis.

In addition to the ligaments just described, there is a band named the **ligamentum transversalis colli** (Mackenrodt) on either side of the cervix uteri. It is attached to the side of the cervix uteri and to the vault and lateral fornix of the vagina, and is continuous externally with the fibrous tissue which surrounds the pelvic bloodvessels.

The form, size, and situation of the uterus vary at different periods of life and under different circumstances.

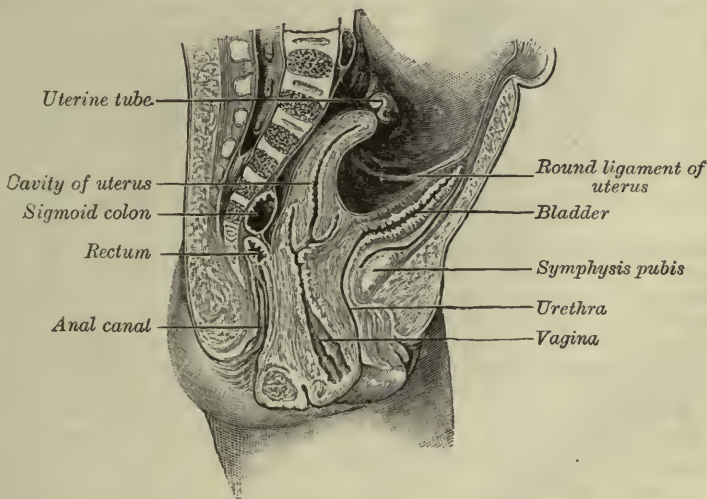


FIG. 1168.—Sagittal section through the pelvis of a newly born female child.

In the fetus the uterus is contained in the abdominal cavity, projecting beyond the superior aperture of the pelvis (Fig. 1168). The cervix is considerably larger than the body.

At puberty the uterus is pyriform in shape, and weighs from 14 to 17 gm. It has descended into the pelvis, the fundus being just below the level of the superior aperture of this cavity. The palmate folds are distinct, and extend to the upper part of the cavity of the organ.

The position of the uterus *in the adult* is liable to considerable variation, depending chiefly on the condition of the bladder and rectum. When the bladder is empty the entire uterus is directed forward, and is at the same time bent on itself at the junction of the body and cervix, so that the body lies upon the bladder. As the latter fills, the uterus gradually becomes more and more erect, until with a fully distended bladder the fundus may be directed backward toward the sacrum.

During menstruation the organ is enlarged, more vascular, and its surfaces rounder; the external orifice is rounded, its labia swollen, and the lining membrane of the body thickened, softer, and of a darker color. According to Sir J. Williams, at each recurrence of menstruation, a molecular disintegration of the mucous membrane takes place, which leads to its complete removal, only the bases of the glands imbedded in the muscle being left. At the cessation of menstruation, a fresh mucous membrane is formed by a proliferation of the remaining structures.

During pregnancy the uterus becomes enormously enlarged, and in the eighth month reaches the epigastric region. The increase in size is partly due to growth of preëxisting muscle, and partly to development of new fibers.

After parturition the uterus nearly regains its usual size, weighing about 42 gm.; but its cavity is larger than in the virgin state, its vessels are tortuous, and its muscular layers are more defined; the external orifice is more marked, and its edges present one or more fissures.

In old age the uterus becomes atrophied, and paler and denser in texture; a more distinct constriction separates the body and cervix. The internal orifice is frequently, and the external orifice occasionally, obliterated, while the lips almost entirely disappear.

Structure.—The uterus is composed of three coats: an **external** or **serous**, a **middle** or **muscular**, and an **internal** or **mucous**.

The **serous coat** (*tunica serosa*) is derived from the peritoneum; it invests the fundus and the whole of the intestinal surface of the uterus; but covers the vesical surface only as far as the junction of the body and cervix. In the lower fourth of the intestinal surface the peritoneum, though covering the uterus, is not closely connected with it, being separated from it by a layer of loose cellular tissue and some large veins.

The **muscular coat** (*tunica muscularis*) forms the chief bulk of the substance of the uterus. In the virgin it is dense, firm, of a grayish color, and cuts almost like cartilage. It is thick opposite the middle of the body and fundus, and thin at the orifices of the uterine tubes. It consists of bundles of unstriated muscular fibers, disposed in layers, intermixed with areolar tissue, blood-vessels, lymphatic vessels, and nerves. The layers are three in number: external, middle, and internal. The external and middle layers constitute the muscular coat proper, while the inner layer is a greatly hypertrophied *muscularis mucosæ*. During pregnancy the muscular tissue becomes more prominently developed, the fibers being greatly enlarged.

The external layer, placed beneath the peritoneum, is disposed as a thin plane on the vesical and intestinal surfaces. It consists of fibers which pass transversely across the fundus, and, converging at each lateral angle of the uterus, are continued on to the uterine tube, the round ligament, and the ligament of the ovary: some passing at each side into the broad ligament, and others running backward from the cervix into the sacrouterine ligaments. The middle layer of fibers presents no regularity in its arrangement, being disposed longitudinally, obliquely, and transversely. It contains more bloodvessels than either of the other two layers. The internal or deep layer consists of circular fibers arranged in the form of two hollow cones, the apices of which surround the orifices of the uterine tubes, their bases intermingling with one another on the middle of the body of the uterus. At the internal orifice these circular fibers form a distinct sphincter.

The **mucous membrane** (*tunica mucosa*) (Fig. 1169) is smooth, and closely adherent to the subjacent tissue. It is continuous through the fimbriated extremity of the uterine tubes, with the peritoneum; and, through the external uterine orifice, with the lining of the vagina.

In the body of the uterus the mucous membrane is smooth, soft, of a pale red color, lined by columnar ciliated epithelium, and presents, when viewed with a lens, the orifices of numerous tubular follicles, arranged perpendicularly to the surface. The structure of the corium differs from that of ordinary mucous membranes, and consists of an embryonic nucleated and highly cellular form of connective tissue in which run numerous large lymphatics. In it are the tube-like **uterine glands**, lined by ciliated columnar epithelium. They are of small size in the unimpregnated uterus, but shortly after impregnation become enlarged and elongated, presenting a contorted or waved appearance (see page 60).

In the cervix the mucous membrane is sharply differentiated from that of the uterine cavity. It is thrown into numerous oblique ridges, which diverge from an anterior and posterior longitudinal raphé. In the upper two-thirds of the canal, the mucous membrane is provided with numerous deep glandular follicles, which secrete a clear viscid alkaline mucus; and, in addition, extending through the whole length of the canal is a variable number of little cysts, presumably follicles which have become occluded and distended with retained secretion. They are called the **ovula Nabothi**. The mucous membrane covering the lower half of the cervical canal presents numerous papillæ. The epithelium of the upper two-thirds is cylindrical and ciliated, but below

this it loses its cilia, and gradually changes to stratified squamous epithelium close to the external orifice. On the vaginal surface of the cervix the epithelium is similar to that lining the vagina, viz., stratified squamous.

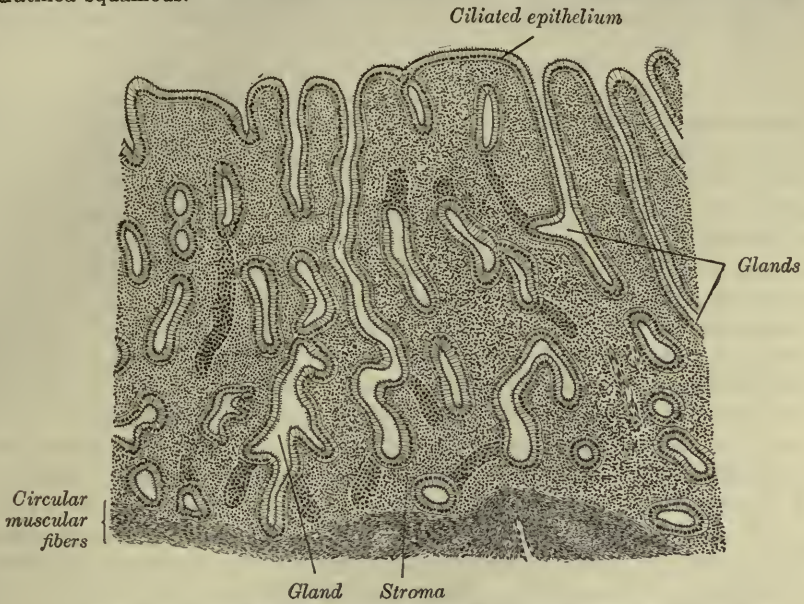


FIG. 1169.—Vertical section of mucous membrane of human uterus. (Sobotta.)

Vessels and Nerves.—The arteries of the uterus are the uterine, from the hypogastric; and the ovarian, from the abdominal aorta (Fig. 1170). They are remarkable for their tortuous

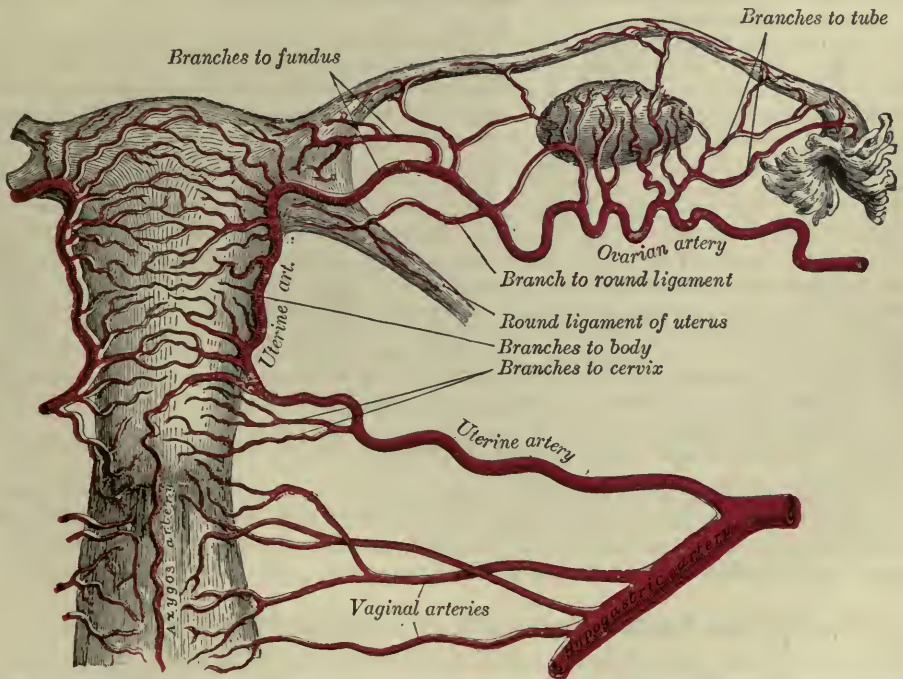


FIG. 1170.—The arteries of the internal organs of generation of the female, seen from behind. (After Hyrtl.)

course in the substance of the organ, and for their frequent anastomoses. The termination of the ovarian artery meets that of the uterine artery, and forms an anastomotic trunk from which branches are given off to supply the uterus, their disposition being circular. The veins are of

large size, and correspond with the arteries. They end in the uterine plexuses. In the impregnated uterus the arteries carry the blood to, and the veins convey it away from, the intervillous space of the placenta (see page 63). The **lymphatics** are described on page 714. The **nerves** are derived from the hypogastric and ovarian plexuses, and from the third and fourth sacral nerves.

The Vagina (Fig. 1166).

The **vagina** extends from the vestibule to the uterus, and is situated behind the bladder and in front of the rectum; it is directed upward and backward, its axis forming with that of the uterus an angle of over 90° , opening forward. Its walls are ordinarily in contact, and the usual shape of its lower part on transverse section is that of an H, the transverse limb being slightly curved forward or backward, while the lateral limbs are somewhat convex toward the median line; its middle part has the appearance of a transverse slit. Its length is 6 to 7.5 cm. along its anterior wall, and 9 cm. along its posterior wall. It is constricted at its commencement, dilated in the middle, and narrowed near its uterine extremity; it surrounds the vaginal portion of the cervix uteri, a short distance from the external orifice of the uterus, its attachment extending higher up on the posterior than on the anterior wall of the uterus. To the recess behind the cervix the term **posterior fornix** is applied, while the smaller recesses in front and at the sides are called the **anterior** and **lateral fornices**.

Relations.—The **anterior surface** of the vagina is in relation with the fundus of the bladder, and with the urethra. Its **posterior surface** is separated from the rectum by the rectouterine excavation in its upper fourth, and by the rectovesical fascia in its middle two-fourths; the lower fourth is separated from the anal canal by the perineal body. Its sides are enclosed between the Levatores ani muscles. As the terminal portions of the ureters pass forward and medialward to reach the fundus of the bladder, they run close to the lateral fornices of the vagina, and as they enter the bladder are slightly in front of the anterior fornix.

Structure.—The vagina consists of an **internal mucous lining** and a **muscular coat** separated by a layer of erectile tissue.

The **mucous membrane** (*tunica mucosa*) is continuous above with that lining the uterus. Its inner surface presents two longitudinal ridges, one on its anterior and one on its posterior wall. These ridges are called the **columns of the vagina** and from them numerous transverse ridges or rugæ extend outward on either side. These rugæ are divided by furrows of variable depth, giving to the mucous membrane the appearance of being studded over with conical projections or papillæ; they are most numerous near the orifice of the vagina, especially before parturition. The epithelium covering the mucous membrane is of the stratified squamous variety. The submucous tissue is very loose, and contains numerous large veins which by their anastomoses form a plexus, together with smooth muscular fibers derived from the muscular coat; it is regarded by Gussenbauer as an erectile tissue. It contains a number of mucous crypts, but no true glands.

The **muscular coat** (*tunica muscularis*) consists of two layers: an external longitudinal, which is by far the stronger, and an internal circular layer. The longitudinal fibers are continuous with the superficial muscular fibers of the uterus. The strongest fasciculi are those attached to the rectovesical fascia on either side. The two layers are not distinctly separable from each other, but are connected by oblique decussating fasciculi, which pass from the one layer to the other. In addition to this, the vagina at its lower end is surrounded by a band of striped muscular fibers, the **Bulbocavernosus** (see page 430).

External to the muscular coat is a layer of connective tissue, containing a large plexus of bloodvessels.

The **erectile tissue** consists of a layer of loose connective tissue, situated between the mucous membrane and the muscular coat; imbedded in it is a plexus of large veins, and numerous bundles of unstriped muscular fibers, derived from the circular muscular layer. The arrangement of the veins is similar to that found in other erectile tissues.

The External Genital Organs (Partes Genitales Externæ Muliebres)

(Fig. 1171).

The **external genital organs** of the female are: the **mons pubis**, the **labia majora et minora pudendi**, the **clitoris**, the **vestibule of the vagina**, the **bulb of the vestibule**, and the **greater vestibular glands**. The term **pudendum** or **vulva**, as generally applied, includes all these parts.

The Mammæ (Mammary Gland; Breasts).

The **mammæ** secrete the milk, and are accessory glands of the generative system. They exist in the male as well as in the female; but in the former only in the rudimentary state, unless their growth is excited by peculiar circumstances. In the female they are two large hemispherical eminences lying within the superficial fascia and situated on the front and sides of the chest; each extends from the second rib above to the sixth rib below, and from the side of the sternum to near the mid-axillary line. Their weight and dimensions differ at different periods of life, and in different individuals. Before puberty they are of small size, but enlarge as the generative organs become more completely developed. They increase during pregnancy and especially after delivery, and become atrophied in old age. The left mamma is generally a little larger than the right. The deep surface of each is nearly circular, flattened, or slightly concave, and has its long diameter directed upward and lateralward toward the axilla; it is separated from the fascia covering the Pectoralis major, Serratus anterior, and Obliquus externus abdominis by loose connective tissue. The subcutaneous surface of the mamma is convex, and presents, just below the center, a small conical prominence, the **papilla**.

The **Mammary Papilla** or **Nipple** (*papilla mammæ*) is a cylindrical or conical eminence situated about the level of the fourth intercostal space. It is capable of undergoing a sort of erection from mechanical excitement, a change mainly due to the contraction of its muscular fibers. It is of a pink or brownish hue, its surface wrinkled and provided with secondary papillæ; and it is perforated by from fifteen to twenty orifices, the apertures of the lactiferous ducts. The base of the mammary papilla is surrounded by an **areola**. In the virgin the areola is of a delicate rosy hue; about the second month after impregnation it enlarges and acquires a darker tinge, and as pregnancy advances it may assume a dark brown or even black color. This color diminishes as soon as lactation is over, but is never entirely lost throughout life. These changes in the color of the areola are of importance in forming a conclusion in a case of suspected first pregnancy. Near the base of the papilla, and upon the surface of the areola, are numerous large sebaceous glands, the **areolar glands**, which become much enlarged during lactation, and present the appearance of small tubercles beneath the skin. These glands secrete a peculiar fatty substance, which serves as a protection to the integument of the papilla during the act of sucking. The mammary papilla consists of numerous vessels, intermixed with plain muscular fibers, which are principally arranged in a circular manner around the base: some few fibers radiating from base to apex.

Development.—The mamma is developed partly from mesoderm and partly from ectoderm—its bloodvessels and connective tissue being derived from the former, its cellular elements from the latter. Its first rudiment is seen about the third month, in the form of a number of small inward projections of the ectoderm, which invade the mesoderm; from these, secondary tracts of cellular elements radiate and sub-
sequently arise to the epithelium of the glandular follicles, and nearly parallel with, each other. Together with the connecting skin between them, they form the **posterior labial commissure** or posterior boundary of the pudendum. The interval between the posterior commissure and the anus, from 2.5 to 3 cm. in length, constitutes the **perineum**. The labia majora correspond to the scrotum in the male.

The **Labia Minora** (*labia minora pudendi; nymphæ*) are two small cutaneous folds, situated between the labia majora, and extending from the clitoris obliquely downward, lateralward, and backward for about 4 cm. on either side of the orifice of the vagina, between which and the labia majora they end; in the virgin the posterior ends of the labia minora are usually joined across the middle line by a fold of skin, named the **frenulum of the labia** or **fourchette**. Anteriorly, each labium

large size, and correspond with the arteries. They end in the uterine plexuses. In the impregnated uterus the arteries carry the blood to, and the veins convey it away from, the intervillous space of the placenta (see page 63). The **lymphatics** are described on page 714. The **nerves** are derived from the hypogastric and ovarian plexuses, and from the third and fourth sacral nerves.

The Vagina (Fig. 1166).

The **vagina** extends from the vestibule to the uterus, and is situated behind the bladder and in front of the rectum; it is directed upward and backward, its axis forming with that of the uterus an angle of over 90° , opening forward. Its walls are ordinarily in contact, and the usual shape of its lower part on transverse section is that of an H, the transverse limb being slightly curved forward or backward, while the lateral limbs are somewhat convex toward the median line; its middle part has the appearance of a transverse slit. Its length is 6 to 7.5 cm. along its anterior wall, and 9 cm. along its posterior wall. It is constricted at its commencement, dilated in the middle, and narrowed near its uterine extremity; it surrounds the vaginal portion of the cervix uteri, a short distance from the external orifice of the uterus, its attachment extending higher up on the posterior than on the anterior wall of the uterus. To the recess behind the cervix the term **posterior fornix** is applied, while the smaller recesses in front and at the sides are called the **anterior** and **lateral fornices**.

Relations.—The **anterior surface** of the vagina is in relation with the fundus of the bladder, and with the urethra. Its **posterior surface** is separated from the rectum by the rectouterine excavation in its upper fourth, and by the rectovesical fascia in its middle two-fourths; the lower fourth is separated from the anal canal by the perineal body. Its sides are enclosed between the Levatores ani muscles. As the terminal portions of the ureters pass forward and medialward to reach the fundus of the bladder, they run close to the lateral fornices of the vagina, and as they enter the bladder are slightly in front of the anterior fornix.

Structure.—The vagina consists of an **internal mucous lining** and a **muscular coat** separated by a layer of erectile tissue.

The **mucous membrane** (*tunica mucosa*) is continuous above with that lining the uterus. Its inner surface presents two longitudinal ridges, one on its anterior and one on its posterior wall. These ridges are called the **columns of the vagina** and from them numerous transverse ridges or rugæ extend outward on either side. These rugæ are divided by furrows of variable depth, giving to the mucous membrane the appearance of being studded over with conical projections or papillæ; they are most numerous near the orifice of the vagina, especially before parturition. The epithelium covering the mucous membrane is of the stratified squamous variety. The submucous tissue is very loose, and contains numerous large veins which by their anastomoses form a plexus, together with smooth muscular fibers derived from the muscular coat; it is regarded by Gussenbauer as an erectile tissue. It contains a number of mucous crypts, but no true glands.

The **muscular coat** (*tunica muscularis*) consists of two layers: an external longitudinal, which is by far the stronger, and an internal circular layer. The longitudinal fibers are continuous with the superficial muscular fibers of the uterus. The strongest fasciculi are those attached to the rectovesical fascia on either side. The two layers are not distinctly separable from each other, but are connected by oblique decussating fasciculi, which pass from the one layer to the other. In addition to this, the vagina at its lower end is surrounded by a band of striped muscular fibers, the **Bulbocavernosus** (see page 430).

The **external muscular coat** is a layer of connective tissue, containing a large plexus of

the **pars intermedia**. Their posterior ends are expanded and are in contact with the greater vestibular glands; their anterior ends are tapered and joined to one another by the pars intermedia; their deep surfaces are in contact with the inferior fascia of the urogenital diaphragm; superficially they are covered by the Bulbocavernosus.

The **Greater Vestibular Glands** (*glandula vestibularis major* [Bartholini]; *Bartholin's glands*) are the homologues of the bulbo-urethral glands in the male. They consist of two small, roundish bodies of a reddish-yellow color, situated one on either side of the vaginal orifice in contact with the posterior end of each lateral mass of the bulb of the vestibule. Each gland opens by means of a duct, about 2 cm. long, immediately lateral to the hymen, in the groove between it and the labium minus.

The Mammæ (Mammary Gland; Breasts).

The **mammæ** secrete the milk, and are accessory glands of the generative system. They exist in the male as well as in the female; but in the former only in the rudimentary state, unless their growth is excited by peculiar circumstances. In the female they are two large hemispherical eminences lying within the superficial fascia and situated on the front and sides of the chest; each extends from the second rib above to the sixth rib below, and from the side of the sternum to near the mid-axillary line. Their weight and dimensions differ at different periods of life, and in different individuals. Before puberty they are of small size, but enlarge as the generative organs become more completely developed. They increase during pregnancy and especially after delivery, and become atrophied in old age. The left mamma is generally a little larger than the right. The deep surface of each is nearly circular, flattened, or slightly concave, and has its long diameter directed upward and lateralward toward the axilla; it is separated from the fascia covering the Pectoralis major, Serratus anterior, and Obliquus externus abdominis by loose connective tissue. The subcutaneous surface of the mamma is convex, and presents, just below the center, a small conical prominence, the **papilla**.

The **Mammary Papilla** or **Nipple** (*papilla mammæ*) is a cylindrical or conical eminence situated about the level of the fourth intercostal space. It is capable of undergoing a sort of erection from mechanical excitement, a change mainly due to the contraction of its muscular fibers. It is of a pink or brownish hue, its surface wrinkled and provided with secondary papillæ; and it is perforated by from fifteen to twenty orifices, the apertures of the lactiferous ducts. The base of the mammary papilla is surrounded by an **areola**. In the virgin the areola is of a delicate rosy hue; about the second month after impregnation it enlarges and acquires a darker tinge, and as pregnancy advances it may assume a dark brown or even black color. This color diminishes as soon as lactation is over, but is never entirely lost throughout life. These changes in the color of the areola are of importance in forming a conclusion in a case of suspected first pregnancy. Near the base of the papilla, and upon the surface of the areola, are numerous large sebaceous glands, the **areolar glands**, which become much enlarged during lactation, and present the appearance of small tubercles beneath the skin. These glands secrete a peculiar fatty substance, which serves as a protection to the integument of the papilla during the act of sucking. The mammary papilla consists of numerous vessels, intermixed with plain muscular fibers, which are principally arranged in a circular manner around the base: some few fibers radiating from base to apex.

Development.—The mamma is developed partly from mesoderm and partly from ectoderm—its bloodvessels and connective tissue being derived from the former, its cellular elements from the latter. Its first rudiment is seen about the third month, in the form of a number of small inward projections of the ectoderm, which invade the mesoderm; from these, secondary tracts of cellular elements radiate and subsequently give rise to the epithelium of the glandular follicles and ducts. The development of the follicles, however, remains imperfect, except in the parous female.

Structure (Figs. 1172, 1173).—The mamma consists of gland tissue; of fibrous tissue, connecting its lobes; and of fatty tissue in the intervals between the lobes. The gland tissue, when freed from fibrous tissue and fat, is of a pale reddish color, firm in texture, flattened from before backward and thicker in the center than at the circumference. The subcutaneous surface of the mamma presents numerous irregular processes which project toward the skin and are joined to it by bands of connective tissue. It consists of numerous lobes, and these are composed of lobules, connected together by areolar tissue, bloodvessels, and ducts. The smallest lobules consist of a cluster of rounded alveoli, which open into the smallest branches of the lactiferous ducts; these ducts unite to form larger ducts, and these end in a single canal, corresponding with one of the chief subdivisions of the gland. The number of excretory ducts varies from fifteen

to twenty; they are termed the **tubuli lactiferi**. They converge toward the areola, beneath which they form dilatations or **ampullæ**, which serve as reservoirs for the milk, and, at the base

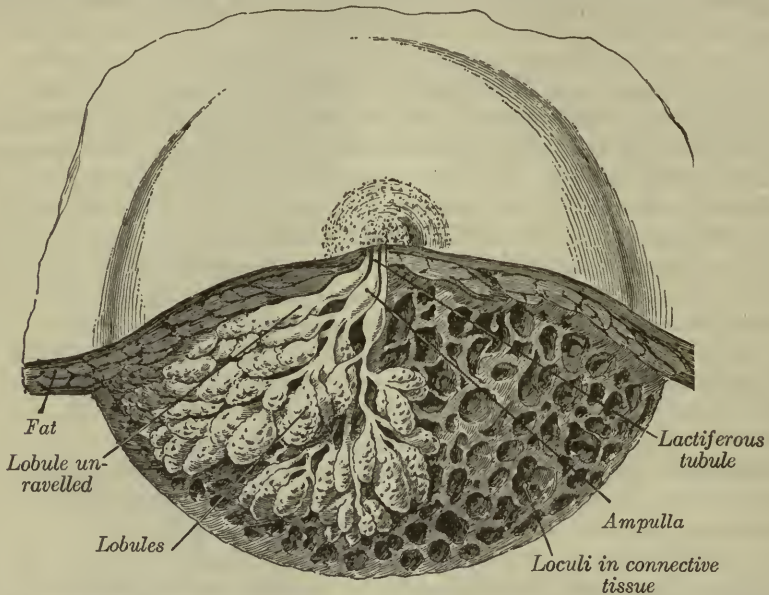


FIG. 1172.—Dissection of the lower half of the mamma during the period of lactation. (Luschka.)

of the papillæ, become contracted, and pursue a straight course to its summit, perforating it by separate orifices considerably narrower than the ducts themselves. The ducts are composed of areolar tissue containing longitudinal and transverse elastic fibers; muscular fibers are entirely

absent; they are lined by columnar epithelium resting on a basement membrane. The epithelium of the mamma differs according to the state of activity of the organ. In the gland of a woman who is not pregnant or suckling, the alveoli are very small and solid, being filled with a mass of granular polyhedral cells. During pregnancy the alveoli enlarge, and the cells undergo rapid multiplication. At the commencement of lactation, the cells in the center of the alveolus undergo fatty degeneration, and are eliminated in the first milk, as **colostrum corpuscles**. The peripheral cells of the alveolus remain, and form a single layer of granular, short columnar cells, with spherical nuclei, lining the basement membrane. The cells, during the

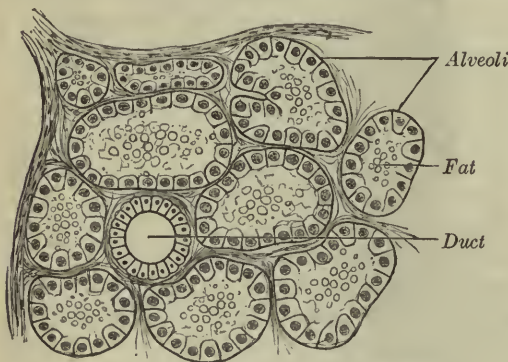


FIG. 1173.—Section of portion of mamma.

state of activity of the gland, are capable of forming, in their interior, oil globules, which are then ejected into the lumen of the alveolus, and constitute the milk globules. When the acini are distended by the accumulation of the secretion the lining epithelium becomes flattened.

The **fibrous tissue** invests the entire surface of the mamma, and sends down septa between its lobes, connecting them together.

The **fatty tissue** covers the surface of the gland, and occupies the interval between its lobes. It usually exists in considerable abundance, and determines the form and size of the gland. There is no fat immediately beneath the areola and papilla.

Vessels and Nerves.—The **arteries** supplying the mammae are derived from the thoracic branches of the axillary, the intercostals, and the internal mammary. The **veins** describe an anastomotic circle around the base of the papilla, called by Haller the **circulus venosus**. From this, large branches transmit the blood to the circumference of the gland, and end in the axillary and internal mammary veins. The **lymphatics** are described on page 715. The **nerves** are derived from the anterior and lateral cutaneous branches of the fourth, fifth, and sixth thoracic nerves.

THE DUCTLESS GLANDS.

There are certain organs which are very similar to secreting glands, but differ from them in one essential particular, viz., they do not possess any ducts by which their secretion is discharged. These organs are known as **ductless glands**. They are capable of *internal secretion*—that is to say, of forming, from materials brought to them in the blood, substances which have a certain influence upon the nutritive and other changes going on in the body. This secretion is carried into the blood stream, either directly by the veins or indirectly through the medium of the lymphatics.

These glands include the **thyroid**, the **parathyroids** and the **thymus**; the **pituitary body** and the **pineal body**; the **chromophil** and **cortical systems** to which belong the **suprarenals**, the **paraganglia** and **aortic glands**, the **glomus caroticum** and perhaps the **glomus coccygeum**. The **spleen** is usually included in this list and sometimes the **lymph** and **hemolymph nodes** described with the lymphatic system. Other glands as the **liver**, **pancreas** and **sexual glands** give off internal secretions, as do the **gastric** and **intestinal mucous membranes**.

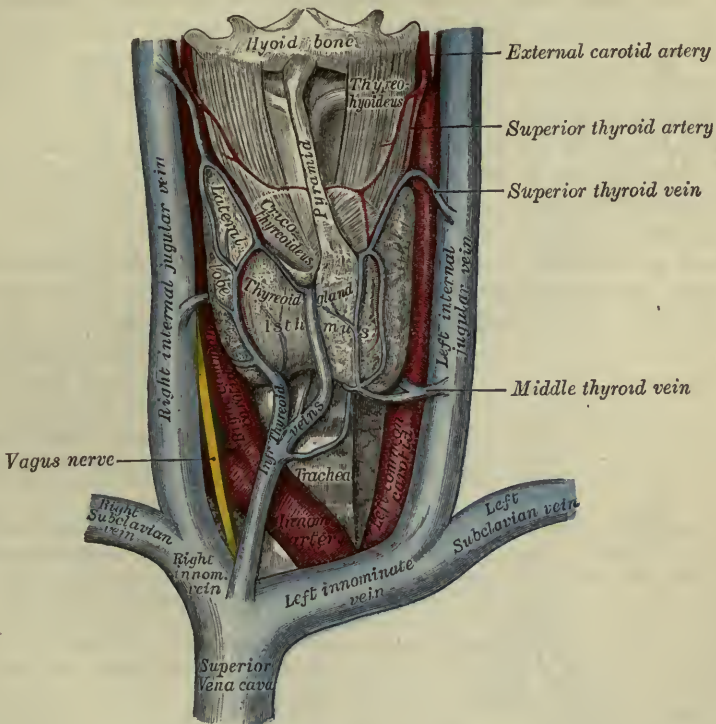


FIG. 1174.—The thyroid gland and its relations.

THE THYROID GLAND (GLANDULA THYREIODEA; THYROID BODY)
(Fig. 1174).

The **thyroid gland** is a highly vascular organ, situated at the front and sides of the neck; it consists of right and left lobes connected across the middle line by a narrow portion, the **isthmus**. Its weight is somewhat variable, but is usually about 30 grams. It is slightly heavier in the female, in whom it becomes enlarged during menstruation and pregnancy.

The **lobes** (*lobuli gl. thyreoidæ*) are conical in shape, the apex of each being directed upward and lateralward as far as the junction of the middle with the lower

third of the thyroid cartilage; the base looks downward, and is on a level with the fifth or sixth tracheal ring. Each lobe is about 5 cm. long; its greatest width is about 3 cm., and its thickness about 2 cm. The **lateral or superficial surface** is convex, and covered by the skin, the superficial and deep fasciæ, the Sternocleidomastoideus, the superior belly of the Omohyoideus, the Sternohyoideus and Sternothyroideus, and beneath the last muscle by the pretracheal layer of the deep fascia, which forms a capsule for the gland. The **deep or medial surface** is moulded over the underlying structures, viz., the thyroid and cricoid cartilages, the trachea, the Constrictor pharyngis inferior and posterior part of the Cricothyroideus, the esophagus (particularly on the left side of the neck), the superior and inferior thyroid arteries, and the recurrent nerves. The **anterior border** is thin, and inclines obliquely from above downward toward the middle line of the neck, while the **posterior border** is thick and overlaps the common carotid artery, and, as a rule, the parathyroids.

The **isthmus** (*isthmus gl. thyreoidea*) connects together the lower thirds of the lobes; it measures about 1.25 cm. in breadth, and the same in depth, and usually covers the second and third rings of the trachea. Its situation and size present, however, many variations. In the middle line of the neck it is covered by the skin and fascia, and close to the middle line, on either side, by the Sternothyroideus. Across its upper border runs an anastomotic branch uniting the two superior thyroid arteries; at its lower border are the inferior thyroid veins. Sometimes the isthmus is altogether wanting.

A third lobe, of conical shape, called the **pyramidal lobe**, frequently *arises* from the upper part of the isthmus, or from the adjacent portion of either lobe, but most commonly the left, and ascends as far as the hyoid bone. It is occasionally quite detached, or may be divided into two or more parts.

A fibrous or muscular band is sometimes found attached, above, to the body of the hyoid bone, and below to the isthmus of the gland, or its pyramidal lobe. When muscular, it is termed the **Levator glandulæ thyroideæ**.

Small detached portions of thyroid tissue are sometimes found in the vicinity of the lateral lobes or above the isthmus; they are called **accessory thyroid glands** (*glandulæ thyroideæ accessoriæ*).

Development.—The thyroid gland is developed from a median diverticulum (Fig. 1175), which appears about the fourth week on the summit of the tuberculum impar, but later is found in the furrow immediately behind the tuberculum (Fig. 979). It grows downward and backward as a tubular duct, which bifurcates and subsequently subdivides into a series of cellular cords, from which the isthmus and lateral lobes of the thyroid gland are developed. The ultimo-branchial bodies from the fifth pharyngeal pouches are enveloped by

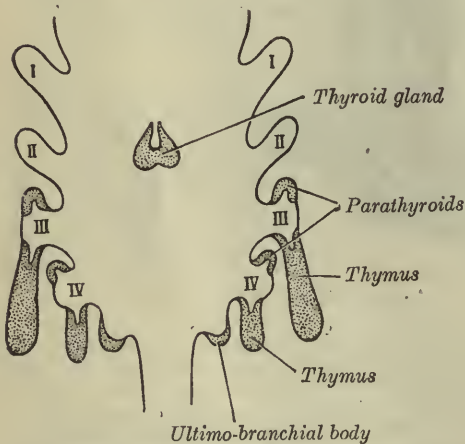


FIG. 1175.—Scheme showing development of branchial epithelial bodies. (Modified from Kohn.) I, II, III, IV. Branchial pouches.

the lateral lobes of the thyroid gland; they undergo atrophy and do not form true thyroid tissue. The connection of the diverticulum with the pharynx is termed the **thyroglossal duct**; its continuity is subsequently interrupted, and it undergoes degeneration, its upper end being represented by the foramen cecum of the tongue, and its lower by the pyramidal lobe of the thyroid gland.

Structure.—The thyroid gland is invested by a thin capsule of connective tissue, which projects into its substance and imperfectly divides it into masses of irregular form and size. When the organ is cut into, it is of a brownish-red color, and is seen to be made up of a number of closed vesicles, containing a yellow glairy fluid, and separated from each other by intermediate connective tissue (Fig. 1176).

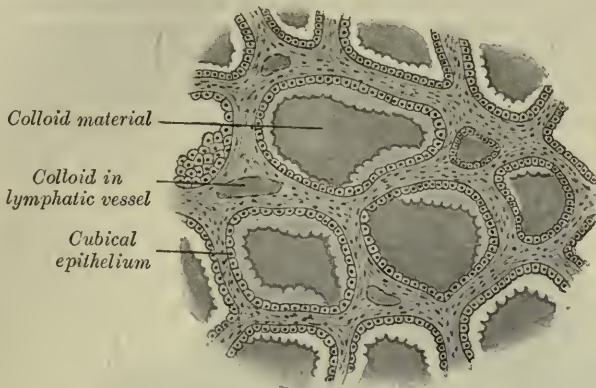


FIG. 1176.—Section of thyroid gland of sheep. $\times 160$.

The vesicles of the thyroid of the adult animal are generally closed spherical sacs; but in some young animals, *e. g.*, young dogs, the vesicles are more or less tubular and branched. This appearance is supposed to be due to the mode of growth of the gland, and merely indicates that an increase in the number of vesicles is taking place. Each vesicle is lined by a single layer of cubical epithelium. There does not appear to be a basement membrane, so that the epithelial cells are in direct contact with the connective-tissue reticulum which supports the acini. The vesicles are of various sizes and shapes, and contain as a normal product a viscid, homogeneous, semifluid, slightly yellowish, colloid material; red corpuscles are found in it in various stages of disintegration and decolorization, the yellow tinge being probably due to the hemoglobin, which is thus set free from the colored corpuscles. The colloid material contains an iodine compound, *iodothyryn*, and is readily stained by eosin. According to Bensley¹ the thyroid gland prepares and secretes into the vascular channels a substance, formed under normal conditions in the outer pole of the cell and excreted from it directly without passing by the indirect route through the follicular cavity. In addition to this direct mode of secretion there is an indirect mode which consists in the condensation of the secretion into the form of droplets, having high content of solids, and the extension of these droplets into the follicular cavity. These droplets are formed in the same zone of the cell as that in which the primary or direct secretion is formed.

This internal secretion of the thyroid is supposed to contain a specific hormone which acts as a chemical stimulus to other tissues, increasing their metabolism.

Vessels and Nerves.—The arteries supplying the thyroid gland are the superior and inferior thyroids and sometimes an additional branch (*thyroidea ima*) from the innominate artery or the arch of the aorta, which ascends upon the front of the trachea. The arteries are remarkable for their large size and frequent anastomoses. The veins form a plexus on the surface of the gland and on the front of the trachea; from this plexus the superior, middle, and inferior thyroid veins arise; the superior and middle end in the internal jugular, the inferior in the innominate vein. The capillary bloodvessels form a dense plexus in the connective tissue around the vesicles, between the epithelium of the vesicles and the endothelium of the lymphatics, which surround a greater or smaller part of the circumference of the vesicle. The lymphatic vessels run in the interlobular connective tissue, not uncommonly surrounding the arteries which they accompany, and communicate with a net-work in the capsule of the gland; they may contain colloid material. They end in the thoracic and right lymphatic trunks. The nerves are derived from the middle and inferior cervical ganglia of the sympathetic.

THE PARATHYROID GLANDS (Fig. 1177).

The parathyroid glands are small brownish-red bodies, situated as a rule between the posterior borders of the lateral lobes of the thyroid gland and its capsule. They differ from it in structure, being composed of masses of cells arranged in a more or less columnar fashion with numerous intervening capillaries. They meas-

¹ American Journal of Anatomy, 1916. xix.

ure on an average about 6 mm. in length, and from 3 to 4 mm. in breadth, and usually present the appearance of flattened oval disks. They are divided, according to their situation, into **superior** and **inferior**. The superior, usually two in number, are the more constant in position, and are situated, one on either side, at the level of the lower border of the cricoid cartilage, behind the junction of the pharynx and esophagus. The inferior, also usually two in number, may be applied to the lower edge of the lateral lobes, or placed at some little distance below the thyroid gland, or found in relation to one of the inferior thyroid veins.¹

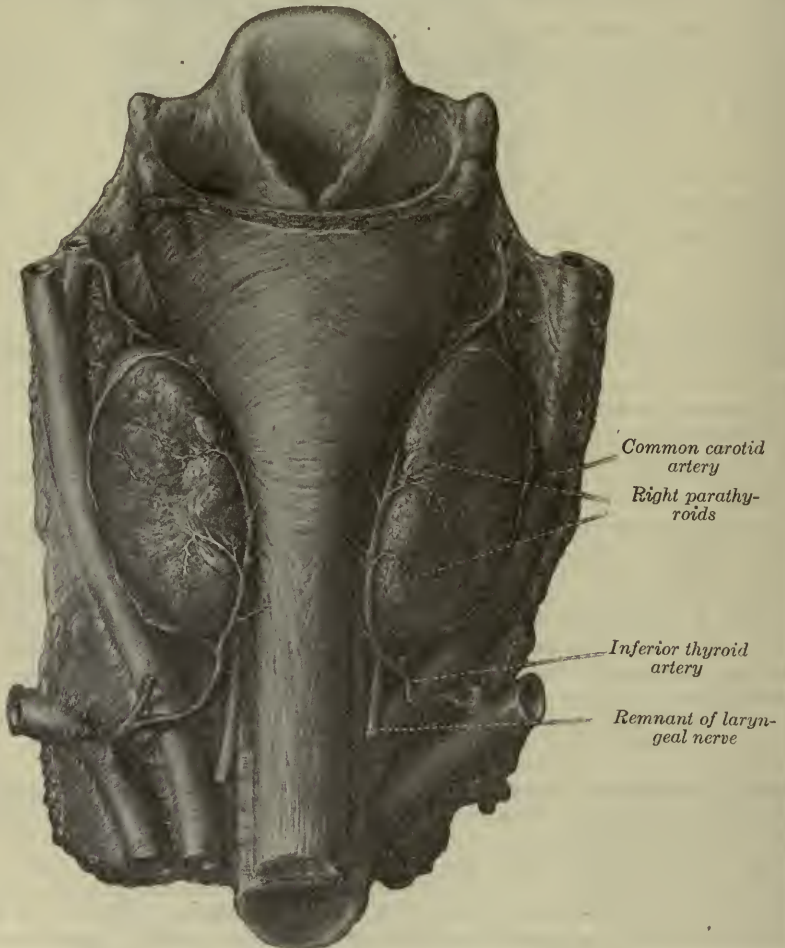


FIG. 1177.—Parathyroid glands. (Halsted and Evans.)

In man, they number four as a rule; fewer than four were found in less than 1 per cent. of over a thousand persons (Peperé²), but more than four in over 33 per cent. of 122 bodies examined by Civalleri. In addition, numerous minute islands of parathyroid tissue may be found scattered in the connective tissue and fat of the neck around the parathyroid glands proper, and quite distinct from them.

Development.—The parathyroid bodies are developed as outgrowths from the third and fourth branchial pouches (Fig. 1175).

A pair of diverticula arise from the fifth branchial pouch and form what are termed the **ultimo-branchial bodies** (Fig. 1175): these fuse with the thyroid gland, but probably contribute no true thyroid tissue.

¹ Consult an article "Concerning the Parathyroid Glands," by D. A. Welsh, *Journal of Anatomy and Physiology*, vol. xxxii.

² Consult *Le Ghiandole paratiroidee*, by A. Peperé, Turin, 1906.

Structure.—Microscopically the parathyroids consist of intercommunicating columns of cells supported by connective tissue containing a rich supply of blood capillaries. Most of the cells are clear, but some, larger in size, contain oxyphil granules. Vesicles containing colloid have been described as occurring in the parathyroid, but the observation has not been confirmed.

No doubt the parathyroid glands produce an internal secretion essential to the well-being of the human economy; but it is still a matter of dispute what symptoms of disease are produced by their removal and suppression of their secretion. Peperé believes that they show signs of exceptional activity during pregnancy, and that parathyroid insufficiency is a main factor in the production of tetany in infants and adults, of eclampsia, and of certain sorts of fits. It is probable that the tetany following parathyroidectomy is due to the accumulation of ammonium carbonate and Kendall has suggested that the function of the parathyroid is to convert ammonium carbonate into urea.

THE THYMUS GLAND (Fig. 1178).

The **thymus** is a temporary organ, attaining its largest size at the time of puberty (Hammar), when it ceases to grow, gradually dwindles, and almost disappears. If examined when its growth is most active, it will be found to consist of two lateral lobes placed in close contact along the middle line, situated partly in the thorax, partly in the neck, and extending from the fourth costal cartilage upward, as high as the lower border of the thyroid gland. It is covered by the sternum, and by the origins of the Sternohyoidei and Sternothyroidei.

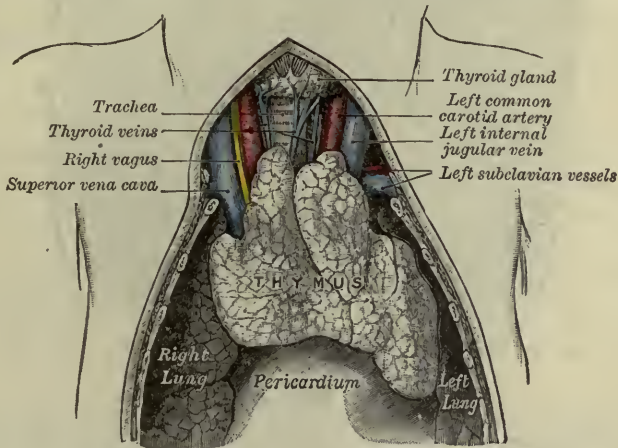


FIG. 1178.—The thymus of a full-time fetus, exposed *in situ*.

Below, it rests upon the pericardium, being separated from the aortic arch and great vessels by a layer of fascia. In the neck it lies on the front and sides of the trachea, behind the Sternohyoidei and Sternothyroidei. The two lobes generally differ in size; they are occasionally united, so as to form a single mass; and sometimes separated by an intermediate lobe. The thymus is of a pinkish-gray color, soft, and lobulated on its surfaces. It is about 5 cm. in length, 4 cm. in breadth below, and about 6 mm. in thickness. At birth it weighs about 15 grams, at puberty it weighs about 35 grams; after this it gradually decreases to 25 grams at twenty-five years, less than 15 grams at sixty, and about 6 grams at seventy years.

Development.—The thymus appears in the form of two flask-shaped entodermal diverticula, which arise, one on either side, from the third branchial pouch (Fig. 1175), and extend lateralward and backward into the surrounding mesoderm in front of the ventral aortæ. Here they meet and become joined to one another by connective tissue, but there is never any fusion of the thymus tissue proper. The pharyngeal opening of each diverticulum is soon obliterated, but the neck of the flask persists for some time as a cellular cord. By further proliferation of the cells lining the flask, buds of cells are formed, which become surrounded and isolated by the invading mesoderm. In the latter, numerous lymphoid cells make their

appearance, and are aggregated to form lymphoid follicles. These lymphoid cells are probably derivatives of the entodermal cells which lined the original diverticula and their subdivisions. Additional portions of thymus tissue are sometimes developed from the fourth branchial pouches. Thymus continues to grow until the time of puberty and then begins to atrophy.

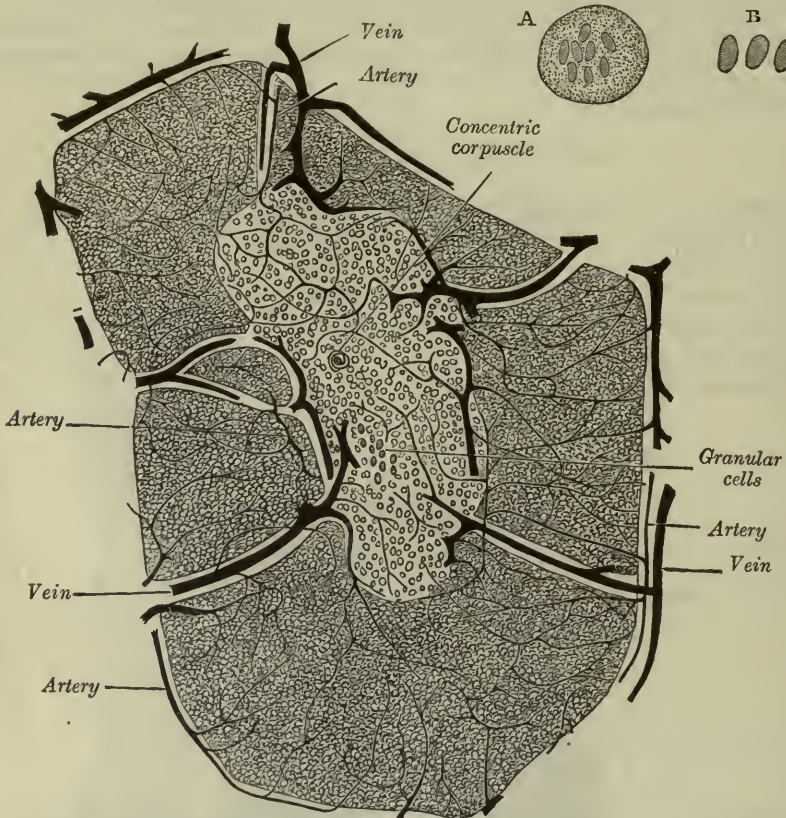


FIG. 1179.—Minute structure of thymus. Follicle of injected thymus from calf, four days old, slightly diagrammatic, magnified about 50 diameters. The large vessels are disposed in two rings, one of which surrounds the follicle, the other lies just within the margin of the medulla. (Watney.) A and B. From thymus of camel, examined without addition of any reagent. Magnified about 400 diameters. A. Large colorless cell, containing small oval masses of hemoglobin. Similar cells are found in the lymph glands, spleen, and medulla of bone. B. Colored blood corpuscles.

Structure.—Each lateral lobe is composed of numerous lobules held together by delicate areolar tissue; the entire gland being enclosed in an investing capsule of a similar but denser structure. The primary lobules vary in size from that of a pin's head to that of a small pea, and are made up of a number of small nodules or follicles, which are irregular in shape and are more or less fused together, especially toward the interior of the gland. Each follicle is from 1 to 2 mm. in diameter and consists of a medullary and a cortical portion, and these differ in many essential particulars from each other. The **cortical portion** is mainly composed of lymphoid cells, supported by a network of finely branched cells, which is continuous with a similar network in the medullary portion. This network forms an adventitia to the bloodvessels. In the **medullary portion** the reticulum is coarser than in the cortex, the lymphoid cells are relatively fewer in number, and there are found peculiar nest-like bodies, the concentric corpuscles of Hassall. These concentric corpuscles are composed of a central mass, consisting of one or more granular cells, and of a capsule which is formed of epithelioid cells (Fig. 1179). They are the remains of the epithelial tubes which grow out from the third branchial pouches of the embryo to form the thymus.

Each follicle is surrounded by a vascular plexus, from which vessels pass into the interior, and radiate from the periphery toward the center, forming a second zone just within the margin of the medullary portion. In the center of the medullary portion there are very few vessels, and they are of minute size.

Watney has made the important observation that hemoglobin is found in the thymus, either in cysts or in cells situated near to, or forming part of, the concentric corpuscles. This hemoglobin occurs as granules or as circular masses exactly resembling colored blood corpuscles. He

has also discovered, in the lymph issuing from the thymus, similar cells to those found in the gland, and, like them, containing hemoglobin in the form of either granules or masses. From these facts he arrives at the conclusion that the gland is one source of the colored blood corpuscles. More recently Schaffer has observed actual nucleated red-blood corpuscles in the thymus. The function of the thymus is obscure. It seems to furnish during the period of growth an internal secretion concerned with some phases of body metabolism, especially that of the sexual glands.

Vessels and Nerves.—The arteries supplying the thymus are derived from the internal mammary, and from the superior and inferior thyroids. The veins end in the left innominate vein, and in the thyroid veins. The lymphatics are described on page 698. The nerves are exceedingly minute; they are derived from the vagi and sympathetic. Branches from the descendens hypoglossi and phrenic reach the investing capsule, but do not penetrate into the substance of the gland.

THE HYPOPHYSIS CEREBRI.

The hypophysis (*pituitary body*) (Fig. 1180) is a small reddish-gray body, about 1 cm. in diameter, attached to the end of the infundibulum of the brain and resting in the hypophyseal fossa.

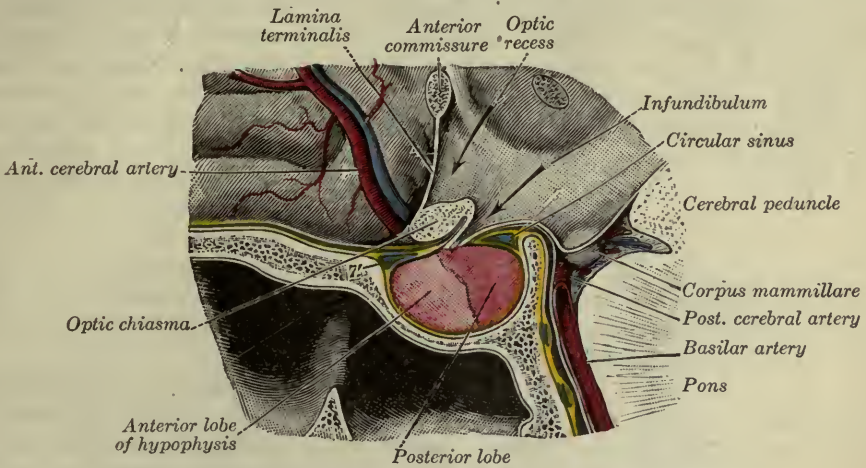


FIG. 1180.—The hypophysis cerebri in position. Shown in sagittal section.

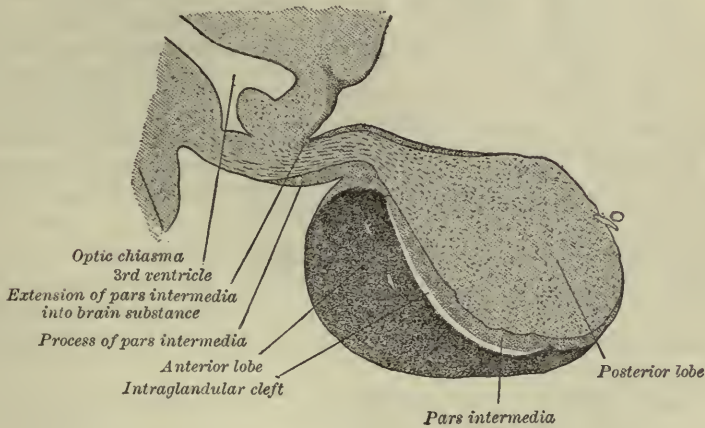


FIG. 1181.—Median sagittal section through the hypophysis of an adult monkey. Semidiagrammatic. (Herring.)

The hypophysis consists of an anterior and a posterior lobe, which differ from one another in their mode of development and in their structure (Fig. 1181). The anterior lobe is the larger and is somewhat kidney-shaped, the concavity being directed backward and embracing the posterior lobe. It consists of a pars anterior

and a pars intermedia, separated from each other by a narrow cleft, the remnant of the pouch or diverticulum. The pars anterior is extremely vascular and consists of epithelial cells of varying size and shape, arranged in cord-like trabeculae or alveoli and separated by large, thin-walled bloodvessels. The pars intermedia is a thin lamina closely applied to the body and neck of the posterior lobe and extending onto the neighboring parts of the brain; it contains few bloodvessels and consists of finely granular cells between which are small masses of colloid material. The pars intermedia in spite of the fact that it arises in common with the pars anterior from the ectoderm of the primitive buccal cavity is often considered as

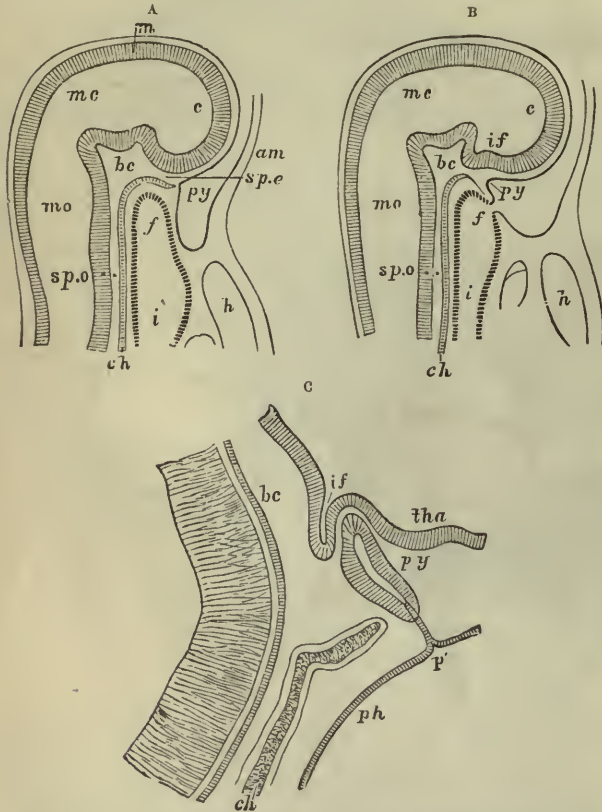


FIG. 1182.—Vertical sections of the heads of early embryos of the rabbit. Magnified. (From Mihalkovics.) A. From an embryo 5 mm. long. B. From an embryo 6 mm. long. C. Vertical section of the anterior end of the notochord and hypophysis, etc., from an embryo 16 mm. long. In A the buccopharyngeal membrane is still present. In B it is in the process of disappearing, and the stomodeum now communicates with the primitive pharynx. *am.* Amnion. *c.* Fore-brain. *ch.* Notochord. *f.* Anterior extremity of fore-gut. *i.* *h.* Heart. *i.f.* Infundibulum. *m.* Wall of brain cavity. *mc.* Mid-brain. *mo.* Hind-brain. *p.* Original position of hypophyseal diverticulum, *py.* *ph.* Pharynx. *sp.e.* Sphenoccephal parts of basis cranii. *tha.* Thalamus.

the general metabolism of the carbohydrates by accelerating the process of glycogenolysis in the liver.

The pars anterior exercises a stimulating effect on the growth of the skeleton and probably on connective tissues in general.

Enlargement of the hypophysis and of the cavity of the sella turcica are found in the rare disease *acromegaly*, which is characterized by gradual enlargement of the face, hands, and feet, with headache and often a peculiar type of blindness. This blindness is due to the pressure of the enlarging hypophysis on the optic chiasma (Fig. 1180).

Development of the Hypophysis Cerebri.—This in the adult consists of a large anterior, consisting of the pars anterior and the pars intermedia, and a small pos-

a part of the posterior lobe which arises from the floor of the third ventricle of the brain. Although of nervous origin the posterior lobe contains no nerve cells or fibers. It consists of neuroglia cells and fibers and is invaded by columns which grow into it from the pars intermedia; imbedded in it are large quantities of a colloid substance histologically similar to that found in the thyroid gland. In certain of the lower vertebrates, *e. g.*, fishes, nervous structures are present, and the lobe is of large size.

From the pars intermedia a substance, no doubt an internal secretion, causes constriction of the bloodvessels with rise of arterial blood-pressure. This substance seems to have a stimulating effect on most of the smooth muscles, acting directly upon the muscle causing contraction. It also increases the secretion of the urine; of the mammary glands when in functional activity; and of the cerebrospinal fluid. Extracts of this lobe also influ-

terior lobe: the former is derived from the ectoderm of the stomodeum, the latter from the floor of the fore-brain. About the fourth week there appears a pouch-like diverticulum of the ectodermal lining of the roof of the stomodeum. This diverticulum, **pouch of Rathke** (Fig. 1182), is the rudiment of the anterior lobe of the hypophysis; it extends upward in front of the cephalic end of the notochord and the remnant of the buccopharyngeal membrane, and comes into contact with the under surface of the fore-brain. It is then constricted off to form a closed vesicle, but remains for a time connected to the ectoderm of the stomodeum by a solid cord of cells. Masses of epithelial cells form on either side and in the front wall of the vesicle, and by the growth between these of a stroma from the mesoderm the development of the anterior lobe is completed. The upwardly directed hypophyseal involution becomes applied to the antero-lateral aspect of a downwardly directed diverticulum from the base of the fore-brain (page 744). This diverticulum constitutes the future infundibulum in the floor of the third ventricle while its inferior extremity becomes modified to form the posterior lobe of the hypophysis. In some of the lower animals the posterior lobe contains nerve cells and nerve fibers, but in man and the higher vertebrates these are replaced by connective tissue. A canal, **craniopharyngeal canal**, is sometimes found extending from the anterior part of the fossa hypophyseos of the sphenoid bone to the under surface of the skull, and marks the original position of Rathke's pouch; while at the junction of the septum of the nose with the palate traces of the stomodeal end are occasionally present (Frazer).

THE PINEAL BODY.

The **pineal body** (*epiphysis*) is a small reddish-gray body, about 8 mm. in length which lies in the depression between the superior colliculi. It is attached to the roof of the third ventricle near its junction with the mid-brain. It develops as an outgrowth from the third ventricle of the brain.

In early life it has a glandular structure which reaches its greatest development at about the seventh year. Later, especially after puberty, the glandular tissue gradually disappears and is replaced by connective tissue.

Structure.—The pineal body is destitute of nervous substance, and consists of follicles lined by epithelium and enveloped by connective tissue. These follicles contain a variable quantity of gritty material, composed of phosphate and carbonate of calcium, phosphate of magnesium and ammonia, and a little animal matter.

It contains a substance which if injected intravenously causes fall of blood-pressure. It seems probable that the gland furnishes an internal secretion in children that inhibits the development of the reproductive glands since the invasion of the gland in children, by pathological growths which practically destroy the glandular tissue, results in accelerated development of the sexual organs, increased growth of the skeleton and precocious mentality.

THE CHROMAPHIL AND CORTICAL SYSTEMS.

Chromaphil or chromaffin cells, so-called because they stain yellow or brownish with chromium salts, are associated with the ganglia of the sympathetic nervous system.

Development.—They arise in common with the sympathetic cells from the neural crest, and are therefore ectodermal in origin. The chromaphil and sympathetic cells are indistinguishable from one another at the time of their migration from the spinal ganglia to the regions occupied in the adult. Differentiation of chromaphil cells begins in embryos about 18 mm. in length but is not complete until about birth. The chromaphiloblasts increase in size more than the sympathoblasts and stain less intensely with ordinary dyes. Later the chrome reaction develops. The aortic bodies differentiate first and are prominent in 20 mm. embryos. The paraganglia of the sympathetic plexuses differentiate next and last of all the paraganglia of the sympathetic trunk. The carotid body is completely differentiated

in 30 mm. embryos. After birth the chromaphil organs degenerate but the paraganglia can be recognized with the microscope in sites originally occupied by them.

The **paraganglia** are small groups of chromaphil cells connected with the ganglia of the sympathetic trunk and the ganglia of the celiac, renal, suprarenal, aortic and hypogastric plexuses. They are sometimes found in connection with the ganglia of other sympathetic plexuses. None have been found with the sympathetic ganglia associated with the branches of the trigeminal nerve.

The **aortic glands** or **bodies** are the largest of these groups of chromaphil cells and measure in the newborn about 1 cm. in length. They lie one on either side of the aorta in the region of the inferior mesenteric artery. They decrease in size with age and after puberty are only visible with the microscope. About forty they disappear entirely. Other groups of chromaphil cells have been found associated with the sympathetic plexuses of the abdomen independently of the ganglia.

The medullary portions of the suprarenal glands and the glomus caroticum belong to the chromaphil system.

The Suprarenal Glands (*Glandulæ Suprarenalis*; Adrenal Capsule) (Figs. 1183, 1184).

The **suprarenal glands** are two small flattened bodies of a yellowish color, situated at the back part of the abdomen, behind the peritoneum, and immediately above and in front of the upper end of each kidney; hence their name. The right one is somewhat triangular in shape, bearing a resemblance to a cocked hat; the left is more semilunar, usually larger, and placed at a higher level than the right. They vary in size in different individuals, being sometimes so small as to be scarcely detected: their usual size is from 3 to 5 cm. in length, rather less in width, and from 4 to 6 mm. in thickness. Their average weight is from 1.5 to 2.5 gm. each.

Development.—Each suprarenal gland consists of a cortical portion derived from the celomic epithelium and a medullary portion originally composed of sympatho-chromaffin tissue. The cortical portion is first recognizable about the beginning of the fourth week as a series of buds from the celomic cells at the root of the mesentery. Later it becomes completely separated from the celomic epithelium and forms a suprarenal ridge projecting into the celom between the mesonephros and the root of the mesentery. Into this cortical portion cells from the neighboring masses of sympatho-chromaffin tissue migrate along the line of its central vein to reach and form the medullary portion of the gland.

Relations.—The relations of the suprarenal glands differ on the two sides of the body.

The **right suprarenal** is situated behind the inferior vena cava and right lobe of the liver, and in front of the diaphragm and upper end of the right kidney. It is roughly triangular in shape; its base, directed downward, is in contact with the medial and anterior aspects of the upper end of the right kidney. It presents two surfaces for examination, an anterior and a posterior. The *anterior surface* looks forward and lateralward, and has two areas: a medial, narrow, and non-peritoneal, which lies behind the inferior vena cava; and a lateral, somewhat triangular, in contact with the liver. The upper part of the latter surface is devoid of peritoneum, and is in relation with the bare area of the liver near its lower and medial angle, while its inferior portion is covered by peritoneum, reflected onto it from the inferior layer of the coronary ligament; occasionally the duodenum overlaps the inferior portion. A little below the apex, and near the anterior border of the gland, is a short furrow termed the **hilum**, from which the suprarenal vein emerges to join the inferior vena cava. The *posterior surface* is divided into upper and lower parts by a curved ridge: the upper, slightly convex, rests upon the diaphragm; the lower, concave, is in

contact with the upper end and the adjacent part of the anterior surface of the kidney.

The **left suprarenal**, slightly larger than the right, is crescentic in shape, its concavity being adapted to the medial border of the upper part of the left kidney. It presents a medial border, which is convex, and a lateral, which is concave; its upper end is narrow, and its lower rounded. Its *anterior surface* has two areas: an

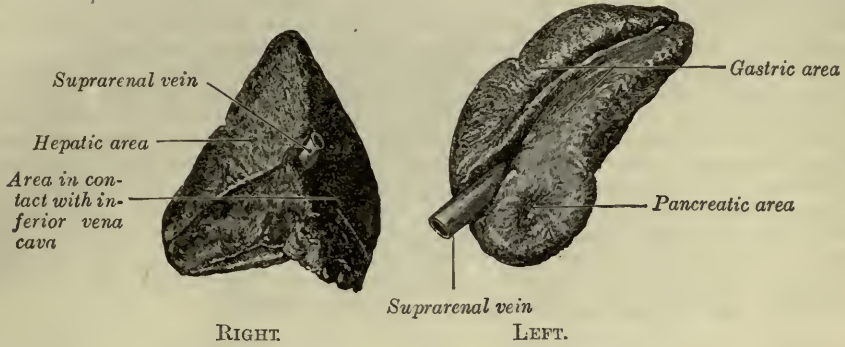


FIG. 1183.—Suprarenal glands viewed from the front.

upper one, covered by the peritoneum of the omental bursa, which separates it from the cardiac end of the stomach, and sometimes from the superior extremity of the spleen; and a lower one, which is in contact with the pancreas and lienal artery, and is therefore not covered by the peritoneum. On the anterior surface, near its lower end, is a furrow or hilum, directed downward and forward, from which the suprarenal vein emerges. Its *posterior surface* presents a vertical ridge, which divides it into two areas; the lateral area rests on the kidney, the medial and smaller on the left crus of the diaphragm.

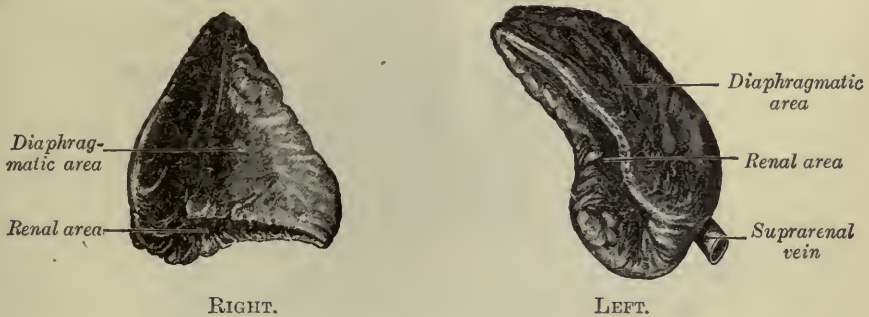

FIG. 1184.—Suprarenal glands viewed from behind.

The surface of the suprarenal gland is surrounded by areolar tissue containing much fat, and closely invested by a thin fibrous capsule, which is difficult to remove on account of the numerous fibrous processes and vessels entering the organ through the furrows on its anterior surface and base.

Small **accessory suprarenals** (*glandulæ suprarenales accessoriæ*) are often to be found in the connective tissue around the suprarenals. The smaller of these, on section, show a uniform surface, but in some of the larger a distinct medulla can be made out.

Structure.—On section, the suprarenal gland is seen to consist of two portions (Fig. 1185): an **external** or **cortical** and an **internal** or **medullary**. The former constitutes the chief part of the organ, and is of a deep yellow color; the medullary substance is soft, pulpy, and of a dark red or brown color.

The **cortical portion** (*substantia corticalis*) consists of a fine connective-tissue network, in which is imbedded the glandular epithelium. The epithelial cells are polyhedral in shape and possess rounded nuclei; many of the cells contain coarse granules, others lipid globules. Owing to differences in the arrangement of the cells, three distinct zones can be made out: (1) the **zona glomerulosa**, situated beneath the capsule, consists of cells arranged in rounded groups, with here and there indications of an alveolar structure; the cells of this zone are very granular, and stain deeply. (2) The **zona fasciculata**, continuous with the zona glomerulosa, is composed of columns of cells arranged in a radial manner; these cells contain finer granules and in many instances globules of lipid material. (3) The **zona reticularis**, in contact with the medulla, consists of cylindrical masses of cells irregularly arranged; these cells often contain pigment granules which give this zone a darker appearance than the rest of the cortex.

The **medullary portion** (*substantia medullaris*) is extremely vascular, and consists of large chromophil cells arranged in a network. The irregular polyhedral cells have a finely granular cytoplasm that are probably concerned with the secretion of adrenalin. In the meshes of the cellular network are large anastomosing venous sinuses (sinusoids) which are in close relationship with the chromophil or medullary cells. In many places the endothelial lining of the blood sinuses is in direct contact with the medullary cells. Some authors consider the endothelium absent in places and here the medullary cells are directly bathed by the blood. This intimate relationship between the chromophil cells and the blood stream undoubtedly facilitates the discharge of the internal secretion into the blood. There is a loose meshwork of supporting connective tissue containing non-striped muscle fibers. This portion of the gland is richly supplied with non-medullated nerve fibers, and here and there sympathetic ganglia are found.

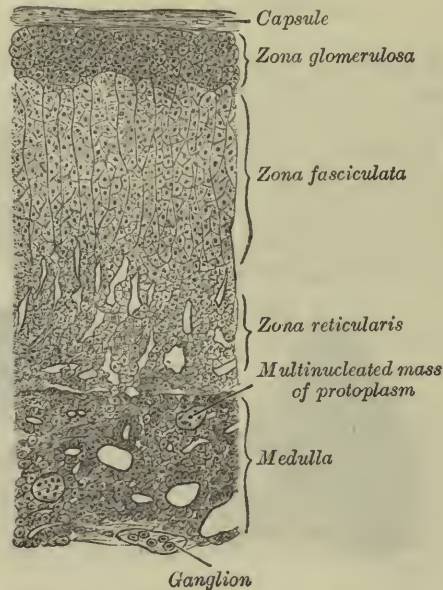

FIG. 1185.—Section of a part of a suprarenal gland. (Magnified.)

Vessels and Nerves.—The arteries supplying the suprarenal glands are numerous and of comparatively large size; they are derived from the aorta, the inferior phrenic, and the renal. They subdivide into minute branches previous to entering the cortical part of the gland, where they break up into capillaries which end in the venous plexus of the medullary portion.

The **suprarenal vein** returns the blood from the medullary venous plexus and receives several branches from the cortical substance; it emerges from the hilum of the gland and on the right side opens into the inferior vena cava, on the left into the renal vein.

The **lymphatics** end in the lumbar glands.

The **nerves** are exceedingly numerous, and are derived from the celiac and renal plexuses, and, according to Bergmann, from the phrenic and vagus nerves. They enter the lower and medial part of the capsule, traverse the cortex, and end around the cells of the medulla. They have numerous small ganglia developed upon them in the medullary portion of the gland.

In connection with the development of the medulla from the sympathochromaffin tissue, it is to be noted that this portion of the gland secretes a substance, *adrenalin*, which has a powerful influence on those muscular tissues which are supplied by sympathetic fibers.

Glomus Caroticum (Carotid Glands; Carotid Bodies).

The carotid bodies, two in number, are situated one on either side of the neck, behind the common carotid artery at its point of bifurcation into the external and internal carotid trunks. They are reddish brown in color and oval in shape, the long diameter measuring about 5 mm.

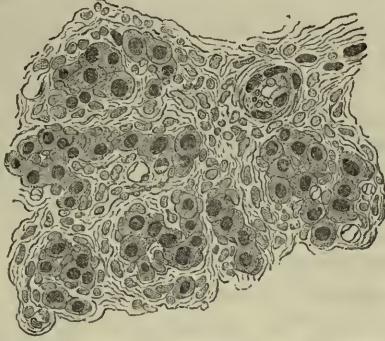


FIG. 1186.—Section of part of human glomus caroticum. (Schaper.) Highly magnified. Numerous bloodvessels are seen in section among the gland cells.

Each is invested by a fibrous capsule and consists largely of spherical or irregular masses of cells (Fig. 1186), the masses being more or less isolated from one another by septa which extend inward from the deep surface of the capsule. The cells are polyhedral in shape, and each contains a large nucleus imbedded in finely granular protoplasm, which is stained yellow by chromic salts. Numerous nerve fibers, derived from the sympathetic plexus on the carotid artery, are distributed throughout the organ, and a net-work of large sinusoidal capillaries ramifies among the cells.

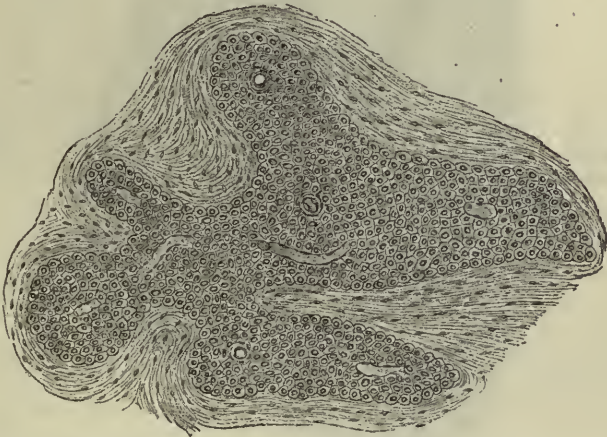


FIG. 1187.—Section of an irregular nodule of the glomus coccygeum. (Sertoli.) $\times 85$. The section shows the fibrous covering of the nodule, the bloodvessels within it, and the epithelial cells of which it is constituted.

Glomus Coccygeum (Coccygeal Gland or Body; Luschka's Gland).

The glomus coccygeum is placed in front of, or immediately below, the tip of the coccyx. It is about 2.5 mm. in diameter and is irregularly oval in shape; several smaller nodules are found around or near the main mass.

It consists of irregular masses of round or polyhedral cells (Fig. 1187), the cells

of each mass being grouped around a dilated sinusoidal capillary vessel. Each cell contains a large round or oval nucleus, the protoplasm surrounding which is clear, and is not stained by chromic salts.¹

THE SPLEEN (LIEN).

The **spleen** is situated principally in the left hypochondriac region, but its superior extremity extends into the epigastric region; it lies between the fundus of the stomach and the diaphragm. It is the largest of the ductless glands, and is of an oblong, flattened form, soft, of very friable consistence, highly vascular, and of a dark purplish color.

Development.—The spleen appears about the fifth week as a localized thickening of the mesoderm in the dorsal mesogastrum above the tail of the pancreas. With the change in position of the stomach the spleen is carried to the left, and comes to lie behind the stomach and in contact with the left kidney. The part of the dorsal mesogastrum which intervened between the spleen and the greater curvature of the stomach forms the gastrosplenic ligament.

Relations.—The **diaphragmatic surface** (*facies diaphragmatica*; *external or phrenic surface*) is convex, smooth, and is directed upward, backward, and to the left, except at its upper end, where it is directed slightly medialward. It is in relation with the under surface of the diaphragm, which separates it from the ninth, tenth, and eleventh ribs of the left side, and the intervening lower border of the left lung and pleura.

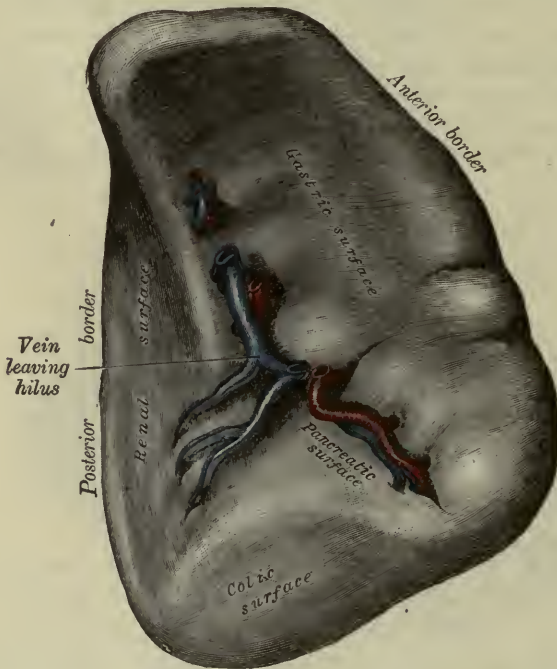


FIG. 1188.—The visceral surface of the spleen.

The **visceral surface** (Fig. 1188) is divided by a ridge into an **anterior or gastric** and a **posterior or renal portion**.

The **gastric surface** (*facies gastrica*), which is directed forward, upward, and medialward, is broad and concave, and is in contact with the posterior wall of the stomach;

¹ Consult the following article: "Über die menschliche Steissdrüse," von J. W. Thomson Walker, *Archiv für mikroskopische Anatomie und Entwicklungsgeschichte*, Band 64, 1904.

and below this with the tail of the pancreas. It presents near its medial border a long fissure, termed the hilum. This is pierced by several irregular apertures, for the entrance and exit of vessels and nerves.

The **renal surface** (*facies renalis*) is directed medialward and downward. It is somewhat flattened, is considerably narrower than the gastric surface, and is in relation with the upper part of the anterior surface of the left kidney and occasionally with the left suprarenal gland.

The **superior extremity** (*extremitas superior*) is directed toward the vertebral column, where it lies on a level with the eleventh thoracic vertebra. The **lower extremity** or **colic surface** (*extremitas inferior*) is flat, triangular in shape, and rests upon the left flexure of the colon and the phrenicocolic ligament, and is generally in contact with the tail of the pancreas. The **anterior border** (*margo anterior*) is free, sharp, and thin, and is often notched, especially below; it separates the diaphragmatic from the gastric surface. The **posterior border** (*margo posterior*), more rounded and blunter than the anterior, separates the renal from the diaphragmatic surface; it corresponds to the lower border of the eleventh rib and lies between the diaphragm and left kidney. The intermediate margin is the ridge which separates the renal and gastric surfaces. The **inferior border** (*internal border*) separates the diaphragmatic from the colic surface.

The spleen is almost entirely surrounded by peritoneum, which is firmly adherent to its capsule. It is held in position by two folds of this membrane. One, the **phrenicolienal ligament**, is derived from the peritoneum, where the wall of the general peritoneal cavity comes into contact with the omental bursa between the left kidney and the spleen; the lienal vessels pass between its two layers (Fig. 1039). The other fold, the **gastrolienal ligament**, is also formed of two layers, derived from the general cavity and the omental respectively, where they meet between the spleen and stomach (Fig. 1039); the short gastric and left gastroepiploic branches of the lienal artery run between its two layers. The lower end of the spleen is supported by the phrenicocolic ligament (see page 1155).

The size and weight of the spleen are liable to very extreme variations at different periods of life, in different individuals, and in the same individual under different conditions. *In the adult* it is usually about 12 cm. in length, 7 cm. in breadth, and 3 or 4 cm. in thickness, and weighs about 200 grams. *At birth* its weight, in proportion to the entire body, is almost equal to what is observed in the adult, being as 1 to 350; while in the adult it varies from 1 to 320 and 400. *In old age* the organ not only diminishes in weight, but decreases considerably in proportion to the entire body, being as 1 to 700. The size of the spleen is increased during and after digestion, and varies according to the state of nutrition of the body, being large in highly fed, and small in starved animals. In malarial fever it becomes much enlarged, weighing occasionally as much as 9 kilos.

Frequently in the neighborhood of the spleen, and especially in the gastrolienal ligament and greater omentum, small nodules of splenic tissue may be found, either isolated or connected to the spleen by thin bands of splenic tissue. They are known as **accessory spleens** (*lien accessorius; supernumerary spleen*). They vary in size from that of a pea to that of a plum.

Structure.—The spleen is invested by two coats: an **external serous** and an **internal fibro-elastic coat**.

The **external or serous coat** (*tunica serosa*) is derived from the peritoneum; it is thin, smooth, and in the human subject intimately adherent to the fibroelastic coat. It invests the entire organ, except at the hilum and along the lines of reflection of the phrenicolienal and gastrolienal ligaments.

The **fibroelastic coat** (*tunica albuginea*) invests the organ, and at the hilum is reflected inward upon the vessels in the form of sheaths. From these sheaths, as well as from the inner surface of the fibroelastic coat, numerous small fibrous bands, **trabeculae** (Fig. 1189), are given off in all directions; these uniting, constitute the frame-work of the spleen. The spleen therefore consists

of a number of small spaces or **areolæ**, formed by the trabeculæ; in these areolæ is contained the **splenic pulp**.

The fibroelastic coat, the sheaths of the vessels, and the trabeculæ, are composed of white and yellow elastic fibrous tissues, the latter predominating. It is owing to the presence of the elastic tissue that the spleen possesses a considerable amount of elasticity, which allows of the very great variations in size that it presents under certain circumstances. In addition to these




FIG. 1189.—Transverse section of the spleen, showing the trabecular tissue and the splenic vein and its tributaries.

constituents of this tunic, there is found in man a small amount of non-striped muscular fiber; and in some mammalia, *e. g.*, dog, pig, and cat, a large amount, so that the trabeculæ appear to consist chiefly of muscular tissue.

The **splenic pulp** (*pulpa lienis*) is a soft mass of a dark reddish-brown color, resembling grumous blood; it consists of a fine reticulum of fibers, continuous with those of the trabeculæ, to which are applied flat, branching cells. The meshes of the reticulum are filled with blood, in which,

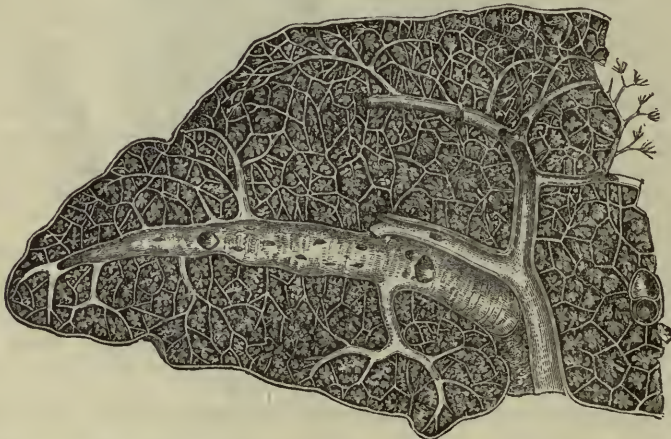

FIG. 1190.—Transverse section of the human spleen, showing the distribution of the splenic artery and its branches.

however, the white corpuscles are found to be in larger proportion than they are in ordinary blood. Large rounded cells, termed **splenic cells**, are also seen; these are capable of amoeboid movement, and often contain pigment and red-blood corpuscles in their interior. The cells of the reticulum each possess a round or oval nucleus, and like the splenic cells, they may contain pigment granules in their cytoplasm; they do not stain deeply with carmine, and in this respect differ from the cells of the Malpighian bodies. In the young spleen, giant cells may also be found.

each containing numerous nuclei or one compound nucleus. Nucleated red-blood corpuscles have also been found in the spleen of young animals.

Bloodvessels of the Spleen.—The **lienal artery** is remarkable for its large size in proportion to the size of the organ, and also for its tortuous course. It divides into six or more branches, which enter the hilum of the spleen and ramify throughout its substance (Fig. 1190), receiving sheaths from an involution of the external fibrous tissue. Similar sheaths also invest the nerves and veins.

Each branch runs in the transverse axis of the organ, from within outward, diminishing in size during its transit, and giving off in its passage smaller branches, some of which pass to the anterior, others to the posterior part. These ultimately leave the trabecular sheaths, and terminate in the proper substance of the spleen in small tufts or pencils of minute arterioles, which open into the interstices of the reticulum formed by the branched sustentacular cells. Each of the larger branches of the artery supplies chiefly that region of the organ in which the branch ramifies, having no anastomosis with the majority of the other branches.

The **arterioles**, supported by the minute trabeculae, traverse the pulp in all directions in bundles (*pencilli*) of straight vessels. Their trabecular sheaths gradually undergo a transformation, become much thickened, and converted into adenoid tissue; the bundles of connective tissue becoming looser and their fibrils more delicate, and containing in their interstices an abundance of lymph corpuscles (W. Müller).

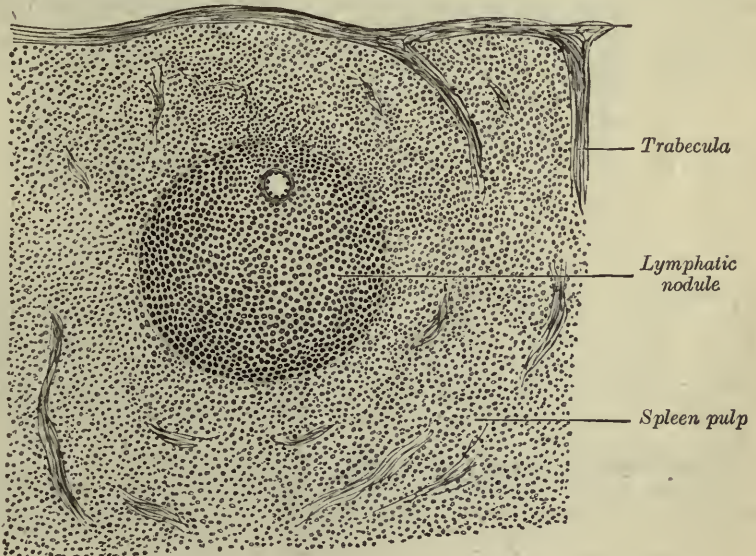


FIG. 1191.—Transverse section of a portion of the spleen.

The altered coat of the arterioles, consisting of adenoid tissue, presents here and there thickenings of a spheroidal shape, the **lymphatic nodules** (*Malpighian bodies of the spleen*). These bodies vary in size from about 0.25 mm. to 1 mm. in diameter. They are merely local expansions or hyperplasiae of the adenoid tissue, of which the external coat of the smaller arteries of the spleen is formed. They are most frequently found surrounding the arteriole, which thus seems to tunnel them, but occasionally they grow from one side of the vessel only, and present the appearance of a sessile bud growing from the arterial wall. In transverse sections, the artery, in the majority of cases, is found in an eccentric position. These bodies are visible to the naked eye on the surface of a fresh section of the organ, appearing as minute dots of a semiopaque whitish color in the dark substance of the pulp. In minute structure they resemble the adenoid tissue of lymph glands, consisting of a delicate reticulum, in the meshes of which lie ordinary lymphoid cells (Fig. 1191). The reticulum is made up of extremely fine fibrils, and is comparatively open in the center of the corpuscle, becoming closer at its periphery. The cells which it encloses are possessed of amoeboid movement. When treated with carmine they become deeply stained, and can be easily distinguished from those of the pulp.

The arterioles end by opening freely into the splenic pulp; their walls become much attenuated, they lose their tubular character, and the endothelial cells become altered, presenting a branched appearance, and acquiring processes which are directly connected with the processes of the reticular cells of the pulp (Fig. 1192). In this manner the vessels end, and the blood flowing through them finds its way into the interstices of the reticulated tissue of the splenic pulp. Thus

the blood passing through the spleen is brought into intimate relation with the elements of the pulp, and no doubt undergoes important changes.

After these changes have taken place the blood is collected from the interstices of the tissue by the rootlets of the veins, which begin much in the same way as the arteries end. The connective-tissue corpuscles of the pulp arrange themselves in rows, in such a way as to form an elongated space or sinus. They become elongated and spindle-shaped, and overlap each other at their extremities, and thus form a sort of endothelial lining of the path or sinus, which is the radicle of a vein. On the outer surfaces of these cells are seen delicate transverse lines or markings, which are due to minute elastic fibrillæ arranged in a circular manner around the sinus. Thus the channel obtains an external investment, and gradually becomes converted into a small

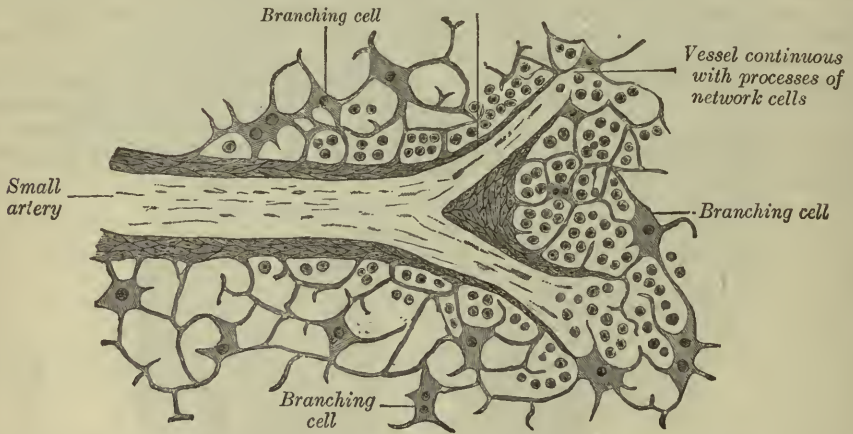


FIG. 1192.—Section of the spleen, showing the termination of the small bloodvessels.

vein, which after a short course acquires a coat of ordinary connective tissue, lined by a layer of flattened epithelial cells which are continuous with the supporting cells of the pulp. The smaller veins unite to form larger ones; these do not accompany the arteries, but soon enter the trabecular sheaths of the capsule, and by their junction form six or more branches, which emerge from the hilum, and, uniting, constitute the lienal vein, the largest radicle of the portal vein.

The **veins** are remarkable for their numerous anastomoses, while the arteries hardly anastomose at all.

The **lymphatics** are described on page 711.

The **nerves** are derived from the celiac plexus and are chiefly non-medullated. They are distributed to the bloodvessels and to the smooth muscle of the capsule and trabeculæ.

SURFACE ANATOMY AND SURFACE MARKINGS.

SURFACE ANATOMY OF THE HEAD AND NECK.

Bones (Fig. 1193).—Various bony surfaces and prominences on the skull can be easily identified by palpation. The **external occipital protuberance** is situated behind, in the middle line, at the junction of the skin of the neck with that of the head. The **superior nuchal line** runs lateralward from it on either side, while extending downward from it is the **median nuchal crest**, situated deeply at the bottom of the nuchal furrow. Above the superior nuchal lines the vault of the cranium

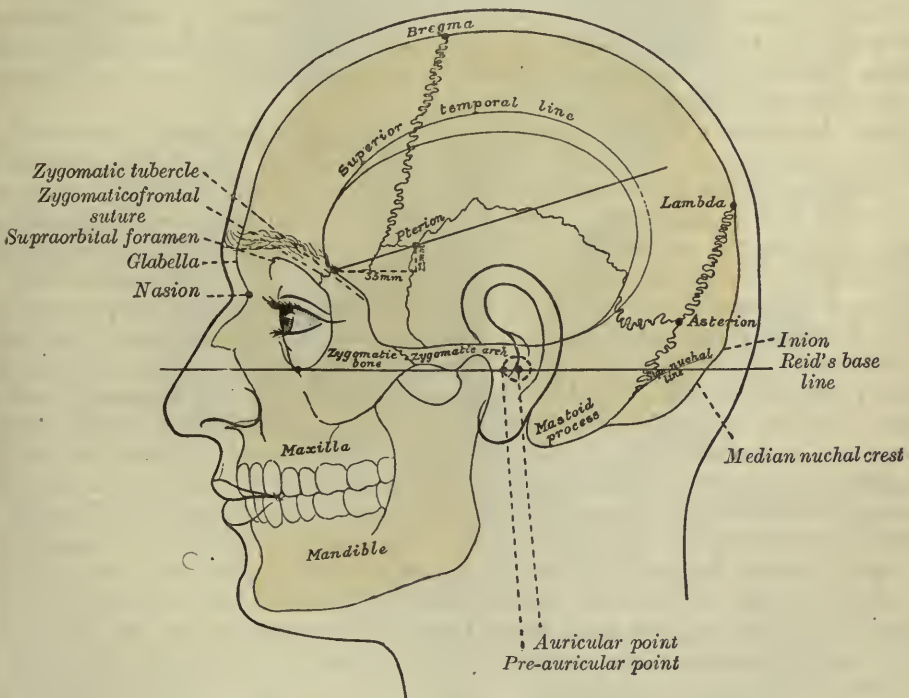


FIG. 1193.—Side view of head, showing surface relations of bones.

is thinly covered with soft structures, so that the form of this part of the head is almost that of the upper portion of the occipital, the parietal, and the frontal bones. The superior nuchal line can be followed lateralward to the mastoid portion of the temporal bone, from which the **mastoid process** projects downward and forward behind the ear. The anterior and posterior borders, the apex, and the external surface of this process are all available for superficial examination. The anterior border lies immediately behind the concha, and the apex is on a level

with the lobule of the auricula. About 1 cm. below and in front of the apex of the mastoid process, the **transverse process of the atlas** can be distinguished. In front of the ear the **zygomatic arch** can be felt throughout its entire length; its posterior end is narrow and is situated a little above the level of the tragus; its anterior end is broad and is continued into the zygomatic bone. The lower border of the arch is more distinct than the upper, which is obscured by the attachment of the temporal fascia. In front, and behind, the upper border of the arch can be followed into the **superior temporal line**. In front, this line begins at the zygomatic process of the frontal bone as a curved ridge which runs at first forward and upward on the frontal bone, and then curving backward separates the forehead from the temporal fossa. It can then be traced across the parietal bone, where, though less marked, it can generally be recognized. Finally, it curves downward, and forward, and passing above the external acoustic meatus, ends in the posterior root of the zygomatic arch. Near the line of the greatest transverse diameter of the head are the **parietal eminences**, one on either side of the middle line; further forward, on the forehead, are the **frontal eminences**, which vary in prominence in different individuals and are frequently unsymmetrical. Below the frontal eminences the **superciliary arches**, which indicate the position of the frontal sinuses, can be recognized; as a rule they are small in the female and absent in children. In some cases the prominence of the superciliary arches is related to the size of the frontal sinuses, but frequently there is no such relationship. Situated between, and connecting the superciliary ridges, is a smooth, somewhat triangular area, the **glabella**, below which the **nasion** (*frontonasal suture*) can be felt as a slight depression at the root of the nose.

Below the nasion the **nasal bones**, scantily covered by soft tissues, can be traced to their junction with the nasal cartilages, and on either side of the nasal bone the complete outline of the **orbital margin** can be made out. At the junction of the medial and intermediate thirds of the supraorbital margin the **supraorbital notch**, when present, can be felt; close to the medial end of the infraorbital margin is a little tubercle which serves as a guide to the position of the lacrimal sac. Below and lateral to the orbit, on either side, is the **zygomatic bone** forming the prominence of the cheek; its posterior margin is easily palpable, and on it just above the level of the lateral palpebral commissure is the **zygomatic tubercle**. A slight depression, about 1 cm. above this tubercle, indicates the position of the **zygomaticofrontal suture**. Directly below the orbit a considerable part of the anterior surface of the maxilla and the whole of its alveolar process can be palpated. The outline of the **mandible** can be recognized throughout practically its entire extent; in front of the tragus and below the zygomatic arch is the condyle, and from this the posterior border of the ramus can be followed to the angle; from the angle to the symphysis the lower rounded border of the mandible can be easily traced; the lower part of the anterior border of the ramus and the alveolar process can be made out without difficulty. In the receding angle below the chin is the **hyoid bone**, and the finger can be carried along the bone to the tip of the greater cornu, which is on a level with the angle of the mandible: the greater cornu is most readily appreciated by making pressure on one side, when the cornu of the opposite side will be rendered prominent and can be felt distinctly beneath the skin.

Joints and Muscles.—The **temporomandibular articulation** is quite superficial, and is situated below the posterior end of the zygomatic arch, in front of the external acoustic meatus. Its position can be ascertained by defining the condyle of the mandible; when the mouth opens, the condyle advances out of the mandibular fossa on to the articular tubercle, and a depression is felt in the situation of the joint.

The outlines of the muscles of the head and face cannot be traced on the surface except in the case of the Masseter and Temporalis. The muscles of the scalp

are so thin that the outline of the bone is perceptible beneath them. Those of the face are small, covered by soft skin, and often by a considerable layer of fat, and their outlines are therefore concealed; they serve, however, to round off and smooth prominent borders, and to fill up what would otherwise be unsightly angular depressions. Thus the **Orbicularis oculi** rounds off the prominent margin of the orbit, and the **Procerus** fills in the sharp depression below the glabella. In like manner the **labial muscles** converging to the lips, and assisted by the superimposed fat, fill up the sunken hollow of the lower part of the face. When in action the facial muscles produce the various expressions, and in addition throw the skin into numerous folds and wrinkles. The **Masseter** imparts fulness to the hinder part of the cheek; if firmly contracted, as when the teeth are clenched, its quadrilateral outline is plainly visible; the anterior border forms a prominent vertical ridge, behind which is a considerable fulness especially marked at the

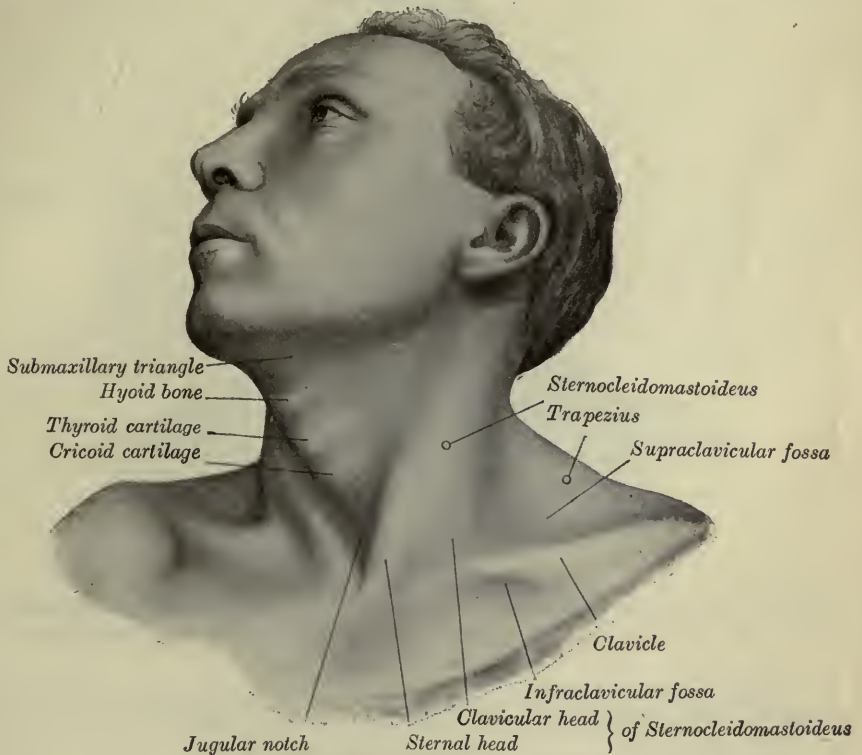

FIG. 1194.—Anterolateral view of head and neck.

lower part of the muscle. The **Temporalis** is fan-shaped and fills the temporal fossa, substituting for the concavity a somewhat convex swelling, the anterior part of which, on account of the absence of hair on the overlying skin, is more marked than the posterior, and stands out in strong relief when the muscle is in action.

In the neck, the **Platysma** when contracted throws the skin into oblique ridges parallel with the fasciculi of the muscle. The **Sternocleidomastoideus** has the most important influence on the surface form of the neck (Figs. 1194, 1195). When the muscle is at rest its anterior border forms an oblique rounded edge ending below in the sharp outline of the sternal head; the posterior border is only distinct for about 2 or 3 cm. above the middle of the clavicle. During contraction, the sternal head stands out as a sharply defined ridge, while the clavicular head is flatter and less prominent; between the two heads is a slight depression: the fleshy middle portion

of the muscle appears as an oblique elevation with a thick, rounded, anterior border, best marked in its lower part. The sternal heads of the two muscles are separated by a V-shaped depression, in which are the **Sternohyoideus** and **Sternothyreoideus**.

Above the hyoid bone, near the middle line, the anterior belly of the **Digastricus** produces a slight convexity.

The anterior border of the **Trapezius** presents as a faint ridge running from the superior nuchal line, downward and forward to the junction of the intermediate and lateral thirds of the clavicle. Between the Sternocleidomastoideus and the Trapezius is the posterior triangle of the neck, the lower part of which appears as a shallow concavity—the **supraclavicular fossa**. In this fossa, the inferior belly of the **Omo-hyoideus**, when in action, presents as a rounded cord-like elevation a little above, and almost parallel to, the clavicle.

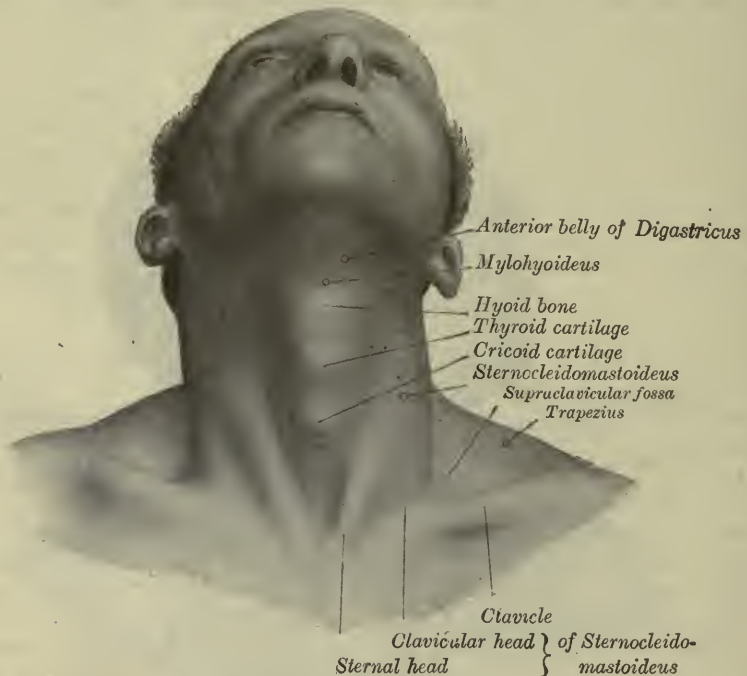


FIG. 1195.—Front view of neck.

Arteries.—The positions of several of the larger arteries can be ascertained from their pulsations.

The **subclavian artery** can be felt by making pressure downward, backward, and medialward behind the clavicular head of the Sternocleidomastoideus; its **transverse cervical branch** may be detected parallel to, and about a finger's breadth above, the clavicle. The **common and external carotid arteries** can be recognized immediately beneath the anterior edge of the Sternocleidomastoideus. The **external maxillary artery** can be traced over the border of the mandible just in front of the anterior border of the Masseter, then about 1 cm. lateral to the angle of the mouth, and finally as it runs up the side of the nose. The pulsation of the **occipital artery** can be distinguished about 3 or 4 cm. lateral to the external occipital protuberance; that of the **posterior auricular** in the groove between the mastoid process and the auricula. The course of the **superficial temporal artery** can be readily followed across the posterior end of the zygomatic arch to a point about 3 to 5 cm. above this, where it divides into its frontal and parietal branches; the pulsation of the frontal branch is frequently visible on the side of the forehead. The **supraorbital artery** can usually be detected immediately above the supraorbital notch or foramen.

SURFACE MARKINGS OF SPECIAL REGIONS OF HEAD AND NECK.

The Cranium.—Scalp.—The soft parts covering the upper surface of the skull form the scalp and comprise the following layers (Fig. 1196): (1) *skin*, (2) *subcutaneous tissue*, (3) *Occipitalis frontalis* and *galea aponeurotica*, (4) *subaponeurotic tissue*, (5) *pericranium*. The subcutaneous tissue consists of a close mesh-work of fibers, the meshes of which contain fatty tissue; the fibers bind the skin and galea aponeurotica firmly together, so that when the Occipitalis or the Frontalis is in action the skin moves with the aponeurosis. The subaponeurotic tissue, which intervenes between the galea aponeurotica and the pericranium, is much looser in texture, and permits the movement of the aponeurosis over the underlying bones.

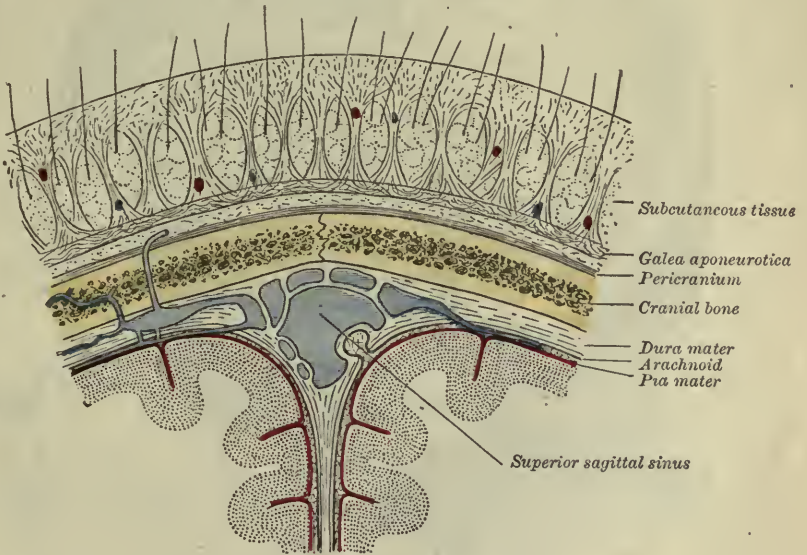


FIG. 1196.—Diagrammatic section of scalp.

Bony Landmarks (Fig. 1193).—In addition to the bony points already described which can be determined by palpation, the following are utilized for surface markings:

Auricular Point.—The center of the orifice of the external acoustic meatus.

Preauricular Point.—A point on the posterior root of the zygomatic arch immediately in front of the external acoustic meatus.

Asterion.—The point of meeting of the lambdoidal, mastoöccipital, and masto-parietal sutures; it lies 4 cm. behind and 12 mm. above the level of the auricular point.

Pterion.—The point where the great wing of the sphenoid joins the sphenoidal angle of the parietal; it is situated 35 mm. behind, and 12 mm. above, the level of the frontozygomatic suture.

Inion.—The external occipital protuberance.

Lambda.—The point of meeting of the lambdoidal and sagittal sutures; it is in the middle line about 6.5 cm. above the inion.

Bregma.—The meeting-point of the coronal and sagittal sutures; it lies at the point of intersection of the middle line of the scalp with a line drawn vertically upward through the preauricular point.

A line passing through the inferior margin of the orbit and the auricular point is known as **Reid's base line**. The lambdoidal suture can be indicated on either

side by the upper two-thirds of a line from the lambda to the tip of the mastoid process. The **sagittal suture** is in the line joining the lambda to the bregma. The position of the **coronal suture** on either side is sufficiently represented by a line joining the bregma to the center of the zygomatic arch.

The floor of the middle fossa of the skull is at the level of the posterior three-fourths of the upper border of the zygomatic arch; the articular eminence of the temporal bone is opposite the foramen spinosum and the semilunar ganglion.

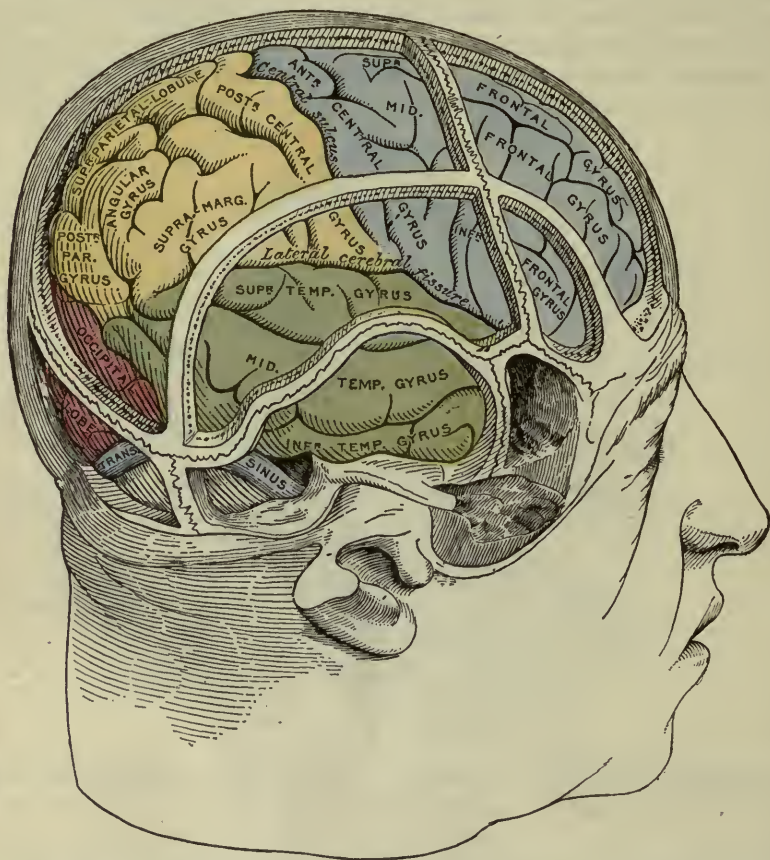


FIG. 1197.—Drawing of a cast by Cunningham to illustrate the relations of the brain to the skull.

Brain (Figs. 1197, 1198).—The general outline of the **cerebral hemisphere**, on either side, may be mapped out on the surface in the following manner. Starting from the nasion, a line drawn along the middle of the scalp to the inion represents the superior border. The line of the lower margin behind is that of the transverse sinus (see page 1294), or more roughly a line convex upward from the inion to the posterior root of the zygomatic process of the temporal bone; thence along the posterior two-thirds of the upper border of the zygomatic arch where the line turns up to the pterion; the front part of the lower margin extends from the pterion to the glabella about 1 cm. above the supraorbital margin. The **cerebellum** is so deeply situated that there is no reliable surface marking for it; a point 4 cm. behind and 1.5 cm. below the level of the auricular point is situated directly over it.

The relations of the principal fissures and gyri of the cerebral hemispheres to the surface of the scalp are of considerable practical importance, and several methods of indicating them have been devised. Necessarily these methods can

only be regarded as approximately correct, yet they are all sufficiently accurate for surgical purposes. The **longitudinal fissure** corresponds to the medial line of the scalp between the nasion andinion. In order to mark out the **lateral cerebral (Sylvian) fissure** a point, termed the Sylvian point, which practically corresponds to the pterion, is defined 35 mm. behind and 12 mm. above the level of the frontozygomatic suture; this point marks the spot where the lateral fissure divides. Another method of defining the Sylvian point is to divide the distance between the nasion andinion into four equal parts; from the junction of the third and fourth parts (reckoning from the front) draw a line to the frontozygomatic suture; from the junction of the first and second parts a line to the auricular point. These two lines intersect at the Sylvian point and the portion of the first line behind this point overlies the posterior ramus of the lateral cerebral fissure. The position

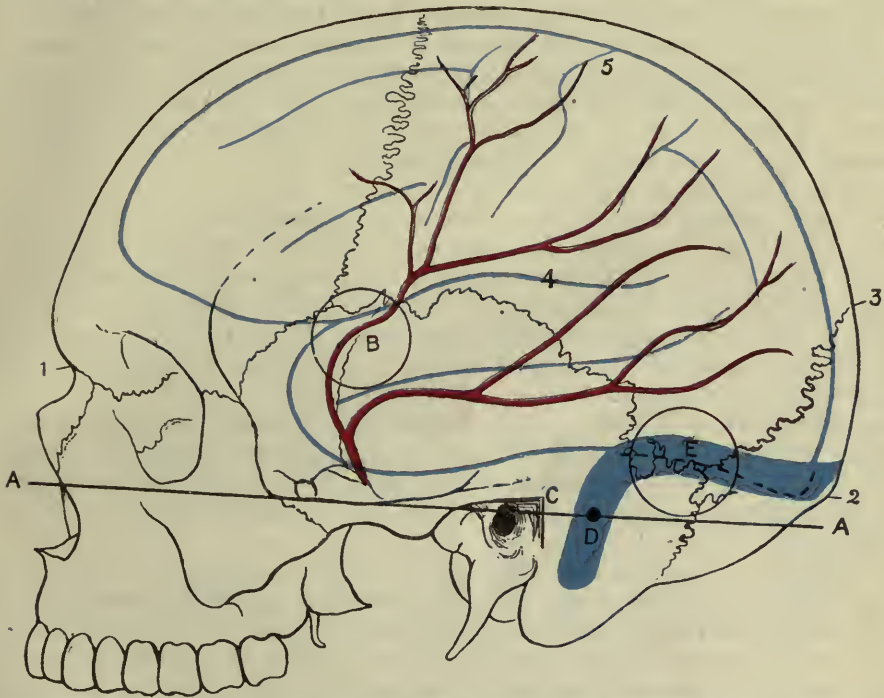


FIG. 1198.—Relations of the brain and middle meningeal artery to the surface of the skull. 1. Nasion. 2. Inion. 3. Lambda. 4. Lateral cerebral fissure. 5. Central sulcus. AA. Reid's base line. B. Point for trephining the anterior branch of the middle meningeal artery. C. Suprameatal triangle. D. Sigmoid bend of the transverse sinus. E. Point for trephining over the straight portion of the transverse sinus, exposing dura mater of both cerebrum and cerebellum. Outline of cerebral hemisphere indicated in blue; course of middle meningeal artery in red.

of the posterior ramus can otherwise be obtained by joining the Sylvian point to a point 2 cm. below the summit of the parietal eminence. The anterior ascending ramus can be marked out by drawing a line upward at right angles to the line of the posterior ramus for 2 cm. and the anterior horizontal ramus by a line of the same length drawn horizontally forward—both from the Sylvian point. To define the **central sulcus (fissure of Rolando)** two points are taken; one is situated 1.25 cm. behind the center of the line joining the nasion andinion; the second is at the intersection of the line of the posterior ramus of the lateral cerebral fissure with a line through the preauricular point at right angles to Reid's base line. The upper 9 cm. of the line joining these two points overlies the central sulcus and forms an angle, opening forward, of about 70° with the middle line of the scalp. An alternative method is to draw two perpendicular lines from Reid's base line to the top of the head; one from the preauricular point and the other from the posterior

border of the mastoid process at its root. A line from the upper end of the posterior line to the point where the anterior intersects the line of the posterior ramus of the lateral fissure indicates the position of the central sulcus. The **precentral** and **postcentral sulci** are practically parallel to the central sulcus; they are situated respectively about 15 mm. in front of, and behind, it. The **superior frontal sulcus** can be mapped out by a line drawn from the junction of the upper and middle thirds of the precentral sulcus, in a direction parallel with the longitudinal sulcus, to a point midway between the middle line of the forehead and the temporal line, 4 cm. above the supraorbital notch. The **inferior frontal sulcus** begins at the junction of the middle and lower thirds of the precentral sulcus, and follows the course of the superior temporal line.

The horizontal limb of the **intraparietal sulcus** begins from the junction of the lower with the middle third of the postcentral sulcus and curves backward parallel to the longitudinal fissure, midway between it and the parietal eminence; it then curves downward to end midway between the lambda and the parietal eminence. The external part of the **parietoöccipital fissure** runs lateralward at right angles to the longitudinal fissure for about 2.5 cm. from a point 5 mm. in front of the lambda. If the line of the posterior ramus of the lateral cerebral fissure be continued back to the longitudinal fissure, the last 2.5 cm. of it will indicate the position of the parietoöccipital fissure.

The **lateral ventricle** may be circumscribed by a quadrilateral figure. The upper limit is a horizontal line 5 cm. above the zygomatic arch; this defines the roof of the ventricle. The lower limit is a horizontal line 1 cm. above the zygomatic arch; it indicates the level of the end of the inferior horn. Two vertical lines, one through the junction of the anterior and middle thirds of the zygomatic arch, and the other 5 cm. behind the tip of the mastoid process, indicate the extent of the anterior horn in front and the posterior horn behind.

Vessels.—The line of the anterior division of the **middle meningeal artery** is equidistant from the frontozygomatic suture and the zygomatic arch; it is obtained by joining up the following points: (1) 2.5 cm., (2) 4 cm., and (3) 5 cm. from these two landmarks. The posterior division can be reached 2.5 cm. above the auricular point.

The position of the **transverse sinus** is obtained by taking two lines: the first from the inion to a point 2.5 cm. behind the auricular point; the second from the anterior end of the first to the tip of the mastoid process. The second line corresponds roughly to the line of reflection of the skin of the auricula behind, and its upper two-thirds represents the sigmoid part of the sinus. The first part of the sinus has a slight upward convexity, and its highest point is about 4 cm. behind and 1 cm. above the level of the auricular point. The width of the sinus is about 1 cm.

The Face.—Air Sinuses (Fig. 1199).—The frontal and maxillary sinuses vary so greatly in form and size that their surface markings must be regarded as only roughly approximate. To mark out the position of the **frontal sinus** three points are taken: (1) the nasion, (2) a point in the middle line 3 cm. above the nasion, (3) a point at the junction of the lateral and intermediate thirds of the supraorbital margin. By joining these a triangular field is described which overlies the greater part of the sinus. The outline of the **maxillary sinus** is irregularly quadrilateral and is obtained by joining up the following points: (1) the lacrimal tubercle, (2) a point on the zygomatic bone at the level of the inferior and lateral margins of the orbit, (3) and (4) points on the alveolar process above the last molar and the second premolar teeth respectively.

External Maxillary Artery.—The course of this artery on the face may be indicated by a line starting from the lower border of the mandible at the anterior margin of the Masseter, and running at first forward and upward to a point 1 cm. lateral

to the angle of the mouth, thence to the ala of the nose and upward to the medial commissure of the eye (Fig. 1200).

Trigeminal Nerve.—Terminal branches of this nerve, viz., the supraorbital branch of the ophthalmic, the infraorbital of the maxillary, and the mental of the mandibular emerge from corresponding foramina on the face (Fig. 1200). The supraorbital foramen is situated at the junction of the medial and intermediate thirds of the supraorbital margin. A line drawn from this foramen to the lower border of the mandible, through the interval between the two lower premolar teeth, passes over the infraorbital and mental foramina; the former lies about 1 cm. below the margin of the orbit, while the latter varies in position according to the age of the individual; in the adult it is midway between the upper and lower borders of the mandible, in the child it is nearer the lower border, while in the edentulous jaw of old age it is close to the upper margin.

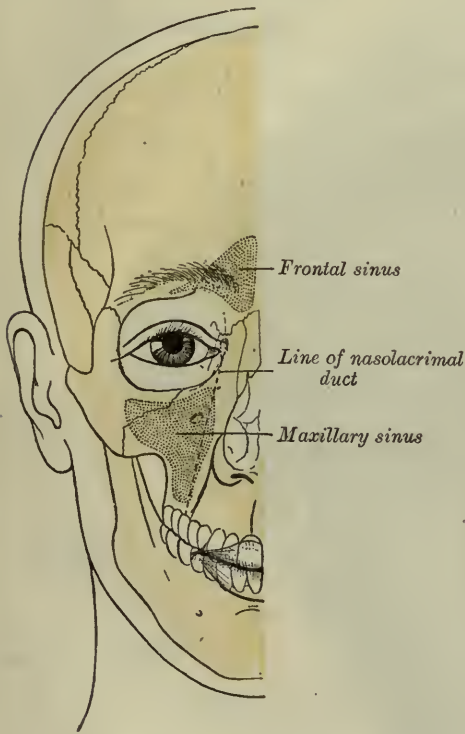


FIG. 1199.—Outline of bones of face, showing position of air sinuses.

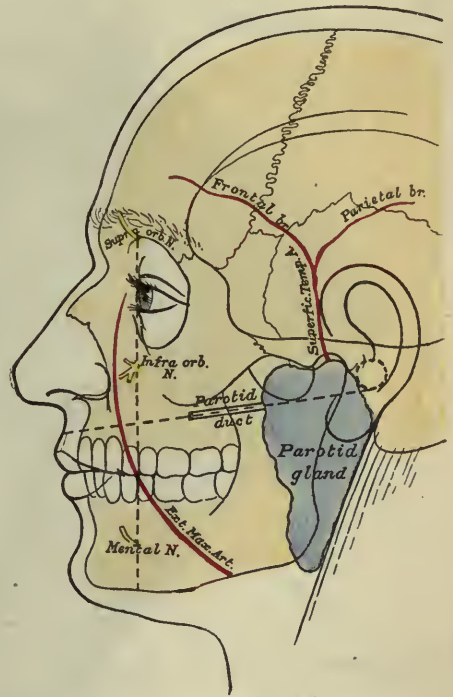


FIG. 1200.—Outline of side of face, showing chief surface markings.

The position of the sphenopalatine ganglion is indicated from the side by a point on the upper border of the zygomatic arch, 6 mm. from the margin of the zygomatic bone.

Parotid Gland (Fig. 1200).—The upper border of the parotid gland corresponds to the posterior two-thirds of the lower border of the zygomatic arch; the posterior border to the front of the external acoustic meatus, the mastoid process, and the anterior border of Sternocleidomastoideus. The inferior border is indicated by a line from the tip of the mastoid process to the junction of the body and greater cornu of the hyoid bone. In front, the anterior border extends for a variable distance on the superficial surface of the Masseter. The surface marking for the parotid duct is a line drawn across the face about a finger's breadth below the zygomatic arch, *i. e.*, from the lower margin of the concha to midway between the red margin

of the lip and the ala of the nose; the duct ends opposite the second upper molar tooth and measures about 5 cm. in length.

The Nose.—The outlines of the nasal bones and the cartilages forming the external nose can be easily felt. The mobile portion of the nasal septum, formed by the medial crura of the greater alar cartilages and the skin, is easily distinguished between the nares. When the head is tilted back and a speculum introduced through the naris, the floor of the nasal cavity, the lower part of the nasal septum, and the anterior ends of the middle and inferior nasal conchæ can be examined. The opening of the nasolacrimal duct, which lies under cover of the front of the inferior nasal concha, is situated about 2.5 cm. behind the naris and 2 cm. above the level of the floor of the nasal cavity.

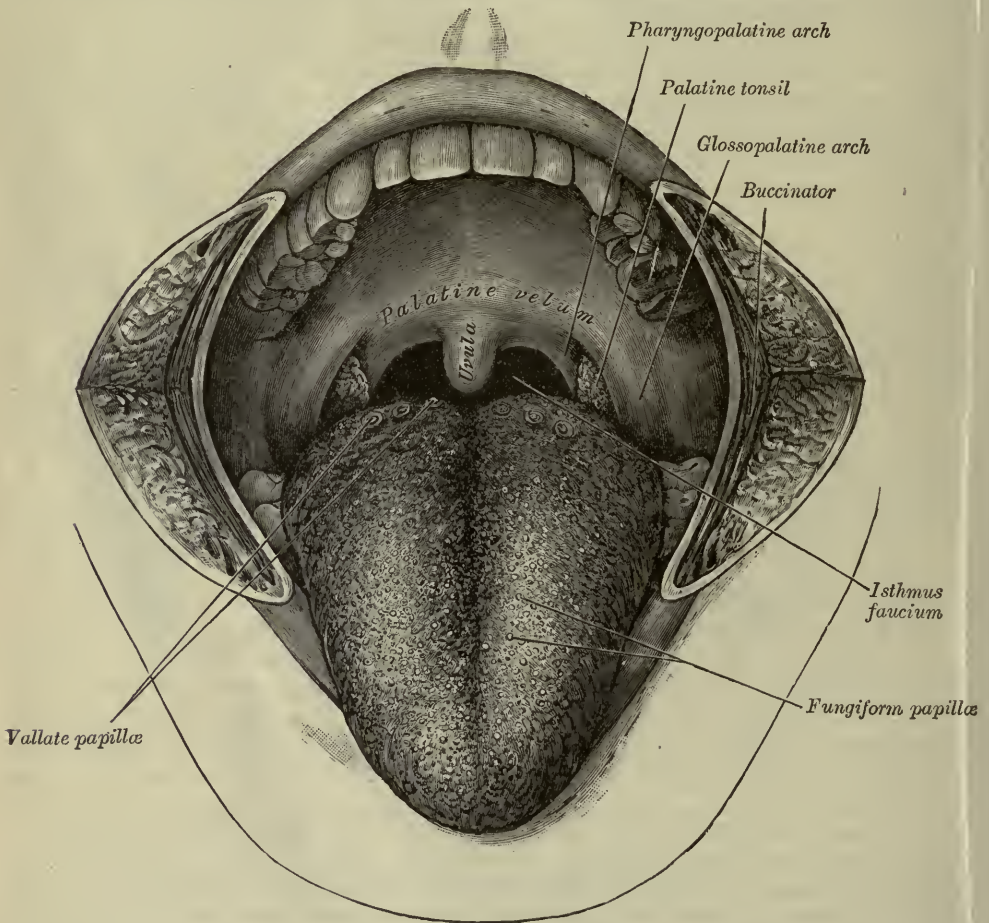


FIG. 1201.—The mouth cavity. The cheeks have been slit transversely and the tongue pulled forward.

The Mouth.—The orifice of the mouth is bounded by the lips, which are covered externally by the whitish skin and internally by the red mucous membrane. The size of the orifice varies considerably in different individuals, but seems to bear a close relationship to the size and prominence of the teeth; its angles usually correspond to the lateral borders of the canine teeth. Running down the center of the outer surface of the upper lip is a shallow groove—the **philtrum**. If the lips be everted there can be seen, in the middle line of each, a small fold of mucous membrane—the **frenulum**—passing from the lip to the gum. By pulling the angle of the

mouth outward the mucous membrane of the cheek can be inspected, and on this, opposite the second molar tooth of the maxilla, is the little papilla which marks the orifice of the parotid duct.

In the floor of the mouth is the **tongue** (Fig. 1201). Its upper surface is convex and is marked along the middle line by a shallow sulcus; the anterior two-thirds are rough and studded with papillæ; the posterior third is smooth and tuberculated. The division between the anterior two-thirds and the posterior third is marked by a V-shaped furrow, the **sulcus terminalis**, which is situated immediately behind the line of the vallate papillæ.

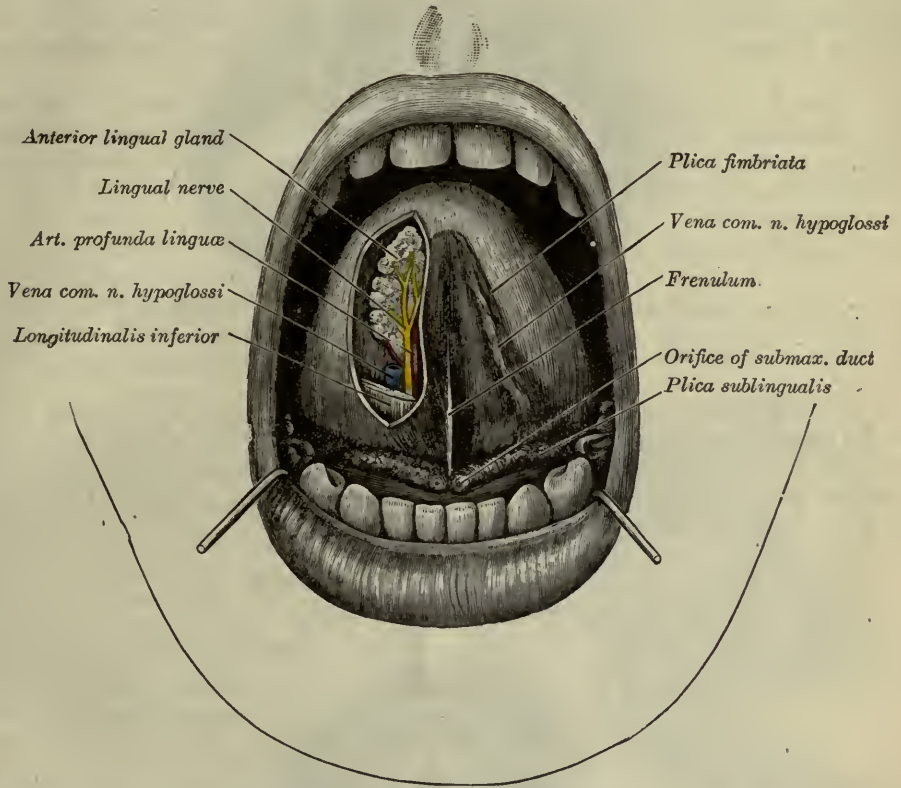


FIG. 1202.—The mouth cavity. The apex of the tongue is turned upward, and on the right side a superficial dissection of its under surface has been made.

On the under surface of the tongue (Fig. 1202) the mucous membrane is smooth and devoid of papillæ. In the middle line, the mucous membrane extends to the floor of the mouth as a distinct fold—the **frenulum**—the free edge of which runs forward to the **symphysis menti**. Sometimes the **ranine vein** can be seen immediately beneath the mucous membrane, a little lateral to the frenulum. Close to the attachment of the frenulum to the floor of the mouth, the slit-like orifice of the **submaxillary duct** is visible on either side: Running backward and lateralward from the orifice of the submaxillary duct is the **plica sublingualis**, produced by the projection of the sublingual gland which lies immediately beneath the mucous membrane. The plica serves also to indicate the line of the submaxillary duct and of the lingual nerve. At the back of the mouth is the **isthmus faucium**, bounded above by the **palatine velum**, from the free margin of which the **uvula** projects downward in the middle line. On either side of the isthmus are the two **palatine arches**, the anterior formed by the **Glossopalatinus** and the posterior by the **Pharyn-**

gopalatinus. Between the two arches of either side is the palatine tonsil, above which is the small supratonsillar recess; the position of the tonsil corresponds to the angle of the mandible. When the mouth is opened widely, a tense band—the pterygomandibular raphé—can be seen and felt lateral to the glossopalatine arch. Its lower end is attached to the mandible behind the last molar tooth, and immediately below and in front of this the lingual nerve can be felt; the upper

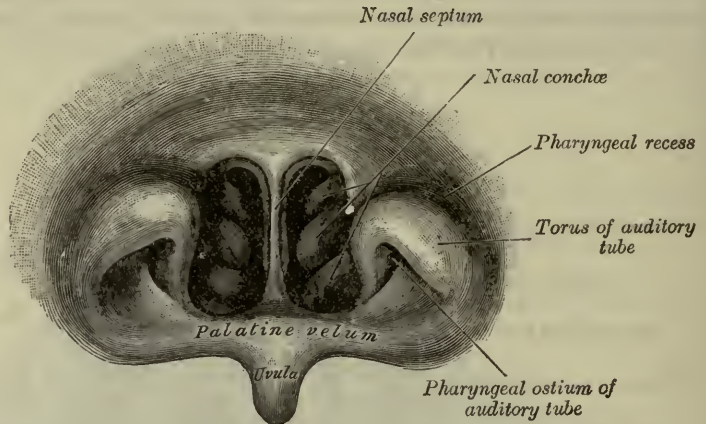


FIG. 1203.—Front of nasal part of pharynx, as seen with the laryngoscope.

end of the ligament can be traced to the pterygoid hamulus. About 1 cm. in front of the hamulus and 1 cm. medial to the last molar tooth of the maxilla is the greater palatine foramen through which the descending palatine vessels and the anterior palatine nerve emerge. Behind the last molar tooth of the maxilla the coronoid process of the mandible is palpable.

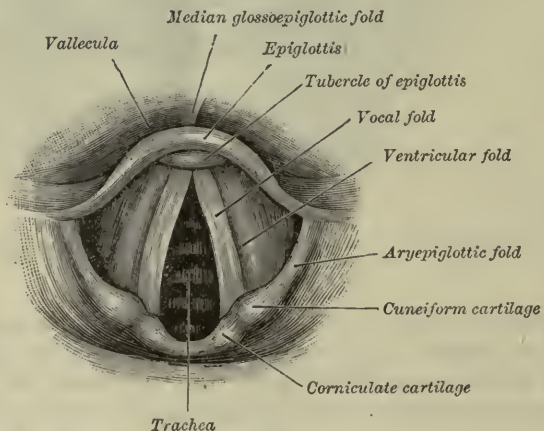


FIG. 1204.—Laryngoscopic view of interior of larynx

By tilting the head well back a portion of the posterior pharyngeal wall, corresponding to the site of the second and third cervical vertebræ, can be seen through the isthmus faucium. On introducing the finger the anterior surfaces of the upper cervical vertebræ can be felt through the thin muscular wall of the pharynx; if the finger be hooked round the palatine velum, the choanæ can be distinguished in front, and the pharyngeal ostium of the auditory tube on either side. The level of the choanæ is that of the atlas, while the palatine velum is opposite the body of the axis.

With the laryngoscope many other structures can be seen. In the nasal part of the pharynx (Fig. 1203), the choanæ, the nasal septum, the nasal conchæ, and the pharyngeal ostia of the auditory tubes can all be examined. Further down, the base of the tongue, the anterior surface of the epiglottis with the glossoepiglottic and pharyngoepiglottic folds bounding the valleculæ, and the piriform sinuses, are readily distinguished. Beyond these is the entrance to the larynx, bounded on either side by the aryepiglottic folds, in each of which are two rounded eminences corresponding to the corniculate and cuneiform cartilages.

Within the larynx (Fig. 1204) on either side are the ventricular and vocal folds (false and true vocal cords) with the ventricle between them. Still deeper are seen the cricoid cartilage and the anterior parts of some of the cartilaginous rings of the trachea, and sometimes, during deep inspiration, the bifurcation of the trachea.

The Eye.—The palpebral fissure is elliptical in shape, and varies in form in different individuals and in different races of mankind; normally it is oblique, in a direction upward and lateralward, so that the lateral commissure is on a slightly higher level than the medial. When the eyes are directed forward as in ordinary vision the upper part of the cornea is covered by the upper eyelid and its lower margin corresponds to the level of the free margin of the lower eyelid, so that usually the lower three-fourths are exposed.

At the medial commissure (Fig. 1205) are the *caruncula lacrimalis* and the *plica semilunaris*. When the lids are everted, the tarsal glands appear as a series of nearly straight parallel rows of light yellow granules. On the margins of the lids about 5 mm. from the medial commissure are two small openings—the **lacrimal puncta**; in the natural condition they are in contact with the conjunctiva of the bulb of the eye, so that it is necessary to evert the eyelids to expose them. The position of the lacrimal sac is indicated by a little tubercle which can be plainly felt on the lower margin of the orbit; the sac lies immediately above and medial to the tubercle. If the eyelids be drawn lateralward so as to tighten the skin at the medial commissure a prominent core can be felt beneath the tightened skin; this is the medial palpebral ligament, which lies over the junction of the upper with the lower two-thirds of the sac, thus forming a useful guide to its situation. The direction of the nasolacrimal duct is indicated by a line from the lacrimal sac to the first molar tooth of the maxilla; the length of the duct is about 12 or 13 mm.

On looking into the eye, the iris with its opening, the **pupil**, and the front of the lens can be examined, but for investigation of the **retina** an ophthalmoscope is necessary. With this the **lens**, the vessels of the **retina**, the **optic disk**, and the **macula lutea** can all be inspected (Fig. 1206).

On the lateral surface of the nasal part of the frontal bone the pulley of the **Oblíquus superior** can be easily reached by pushing the finger backward along the roof of the orbit; the tendon of the muscle can be traced for a short distance backward and lateralward from the pulley.

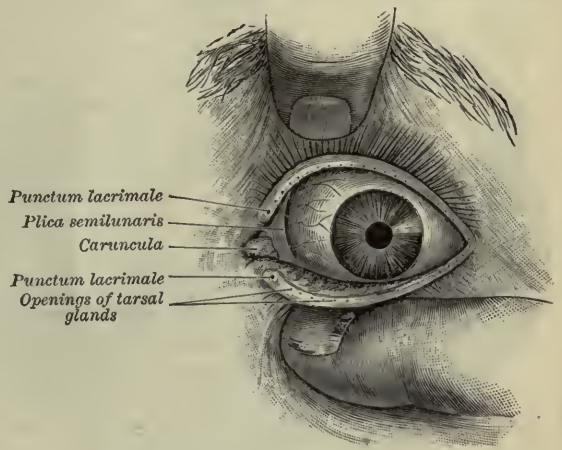


FIG. 1205.—Front of left eye with eyelids separated to show medial canthus.

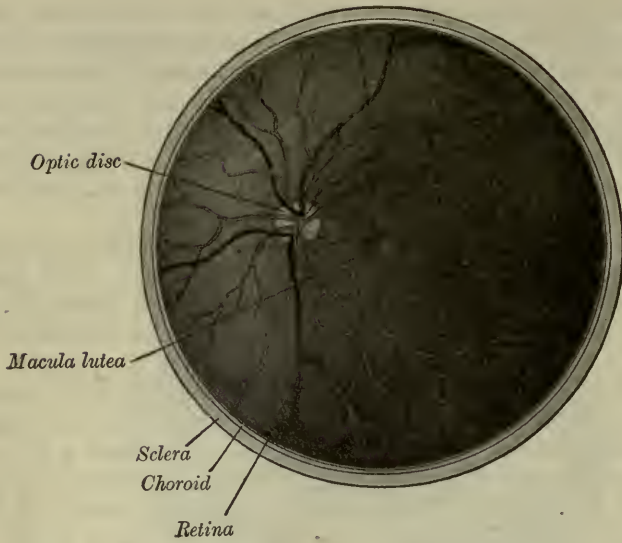


FIG. 1206.—The interior of the posterior half of the left eyeball.

The Ear.—The various prominences and fossæ of the auricula (see page 1034) are visible (Fig. 1207). The opening of the **external acoustic meatus** is exposed by

drawing the tragus forward; at the orifice are a few short crisp hairs which serve to prevent the entrance of dust or of small insects; beyond this the secretion of the **ceruminous glands** serves to catch any small particles which may find their way into the meatus. The interior of the meatus can be examined through a speculum. At the line of junction of its bony and cartilaginous portions an obtuse angle is formed which projects into the antero-inferior wall and produces a narrowing of the lumen in this situation. The cartilaginous part, however, is connected to the bony part by fibrous tissue which renders the outer part of the meatus very movable, and therefore by drawing the auricula upward, backward, and slightly outward, the canal is rendered almost straight. In children the meatus is very short, and this should be remembered in introducing the speculum.

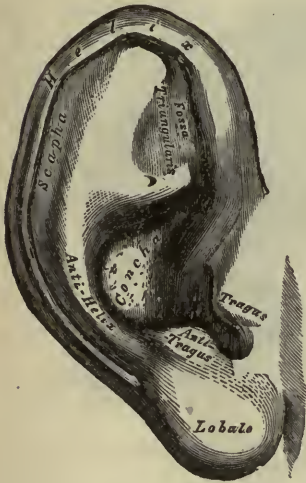

FIG. 1207.—The auricula or pinna. Lateral surface.

Through the speculum the greater part of the **tympanic membrane** (Fig. 1208) is visible. It is a pearly-gray membrane slightly glistening in the adult, placed

obliquely so as to form with the floor of the meatus an angle of about 55° . At birth it is more horizontal and situated in almost the same plane as the base of the skull. The membrane is concave outward, and the point of deepest concavity—the **umbo**—is slightly below the center. Running upward and slightly forward from the umbo is a reddish-yellow streak produced by the manubrium of the malleus. This streak ends above just below the roof of the meatus at a small white rounded prominence which is caused by the lateral process of the malleus projecting against the membrane. The anterior and posterior **malleolar folds** extend from the prominence to the circumference of the membrane and enclose the **pars flaccida**. Behind the streak caused by the manubrium of the malleus a second streak, shorter and very faint, can be distinguished; this is the **long crus**

of the incus. A narrow triangular patch extending downward and forward from the umbo reflects the light more brightly than any other part, and is usually described as the cone of light.

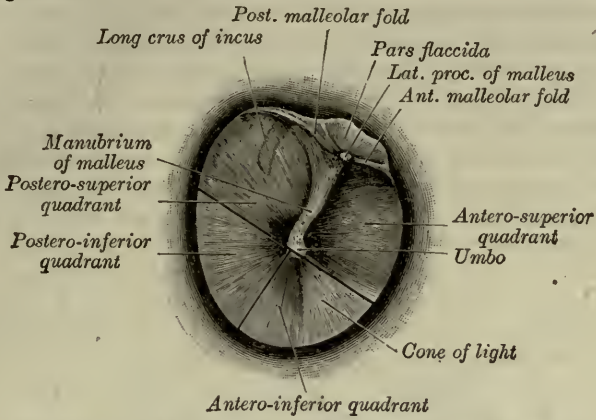


FIG. 1208.—The right tympanic membrane as seen through a speculum.

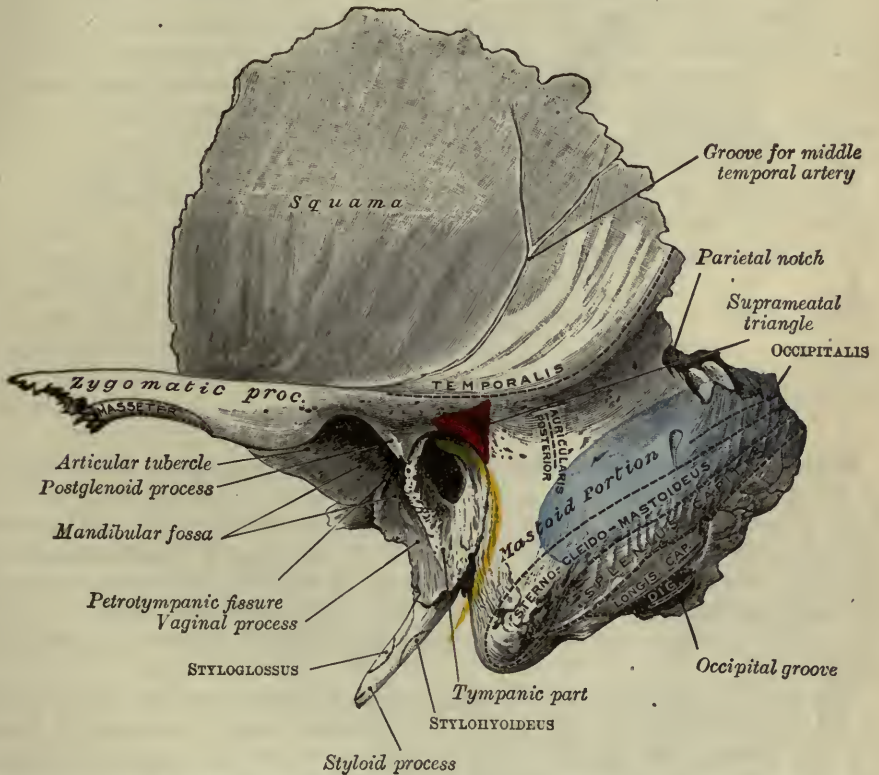


FIG. 1209.—Left temporal bone showing surface markings for the tympanic antrum (red), transverse sinus (blue), and facial nerve (yellow).

Tympanic Antrum.—The site of the tympanic antrum is indicated by the supra-meatal triangle (Fig. 1209). This triangle is bounded above by the posterior root of the zygomatic arch; behind by a vertical line from the posterior border of the external acoustic meatus; in front and below by the upper margin of the meatus.

The Neck (Fig. 1210).—**Larynx and Trachea.**—In the receding angle below the chin, the hyoid bone (page 1288), situated opposite the fourth cervical vertebra, can easily be made out. A finger's breadth below it is the laryngeal prominence of the

thyroid cartilage; the space intervening between the hyoid bone and the thyroid cartilage is occupied by the **hyothyroid membrane**. The outlines of the thyroid cartilage are readily palpated; below its lower border is a depression corresponding to the middle **cricothyroid ligament**. The level of the vocal folds corresponds to the middle of the anterior margin of the thyroid cartilage. The anterior part of the cricoid cartilage forms an important landmark on the front of the neck; it lies opposite the sixth cervical vertebra, and indicates the junctions of pharynx with esophagus, and larynx with trachea. Below the cricoid cartilage the **trachea** can be felt, though it is only in thin subjects that the separate rings can be distinguished; as a rule there are seven or eight rings above the jugular notch of the sternum, and of these the second, third, and fourth are covered by the isthmus of the thyroid gland.

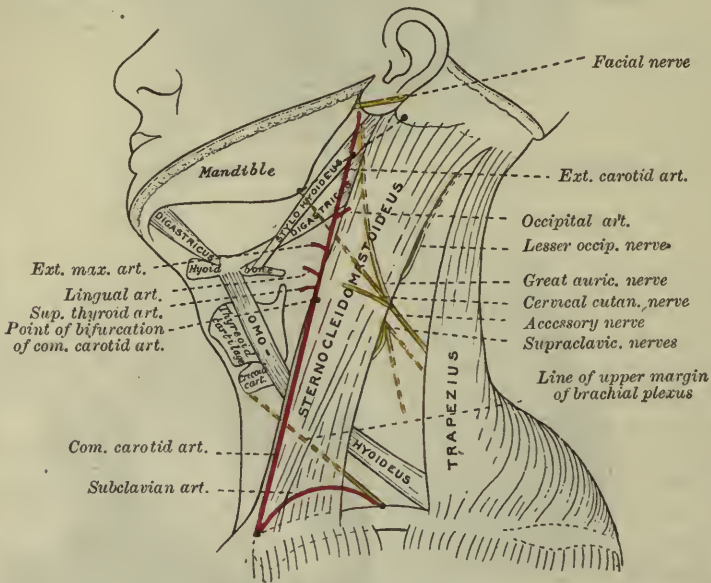


FIG. 1210.—Side of neck, showing chief surface markings.

Muscles.—The posterior belly of **Digastricus** is marked out by a line from the tip of the mastoid process to the junction of the greater cornu and body of the hyoid bone; a line from this latter point to a point just lateral to the symphysis menti indicates the position of the anterior belly. The line of **Omohyoideus** begins at the lower border of the hyoid bone, curves downward and lateralward to cross **Sternocleidomastoideus** at the junction of its middle and lower thirds, *i. e.*, opposite the cricoid cartilage, and then runs more horizontally to the acromial end of the clavicle.

Arteries.—The position of the **common carotid** artery in the neck is indicated by a line drawn from the upper part of the sternal end of the clavicle to a point midway between the tip of the mastoid process and the angle of the mandible. From the clavicle to the upper border of the thyroid cartilage this line overlies the common carotid artery, beyond this it is over the external carotid. The **external carotid** artery may otherwise be marked out by the upper part of a line from the side of the cricoid cartilage to the front of the external acoustic meatus, arching the line slightly forward.

The points of origin of the main branches of the external carotid in the neck are all related to the tip of the greater cornu of the hyoid bone as follows: (1) the **superior thyroid**, immediately below it; (2) the **lingual**, on a level with it; (3) the **facial**, and (4) the **occipital** a little above and behind it.

The **subclavian artery** is indicated on the surface by a curved line, convex upward, from the sternoclavicular articulation to the middle of the clavicle. The highest point of the convexity is from 1 to 3 cm. above the clavicle.

Veins.—The surface marking for the **internal jugular vein** is slightly lateral and parallel to that for the common carotid artery. The position of the **external jugular vein** is marked out by a line from the angle of the mandible to the middle of the clavicle. A point on this line about 4 cm. above the clavicle indicates the spot where the vein pierces the deep fascia. The line of the **anterior jugular vein** begins close to the symphysis menti, runs downward parallel with and a little to one side of the middle line and, at a variable distance above the jugular notch, turns lateralward to the external jugular.

Nerves.—The **facial nerve** at its exit from the stylomastoid foramen is situated about 2.5 cm. from the surface, opposite the middle of the anterior border of the mastoid process; a horizontal line from this point to the ramus of the mandible overlies the stem of the nerve. To mark the site of the **accessory nerve** a line is drawn from the angle of the mandible to a point on the anterior border of Sternocleidomastoideus about 3 to 4 cm. below the apex of the mastoid process, or to the midpoint of the posterior border of the muscle; the line is continued across the posterior triangle to Trapezius.

The cutaneous branches of the cervical plexus as they emerge from the posterior border of Sternocleidomastoideus may be indicated as follows: the **lesser occipital** begins immediately above the midpoint of the border and runs along the border to the scalp; the **great auricular** and **cervical cutaneous** both start from the middle of the border, the former running upward toward the lobule of the auricula, the latter crossing Sternocleidomastoideus at right angles to its long axis; the **supra-clavicular** nerves emerge from immediately below the middle of the posterior border and run down over the clavicle. The **phrenic** nerve begins at the level of the middle of the thyroid cartilage and runs behind the clavicle about midway between the anterior and posterior borders of Sternocleidomastoideus.

The upper border of the **brachial plexus** is indicated by a line from the side of the cricoid cartilage to the middle of the clavicle.

Submaxillary Gland.—On either side of the neck the superficial portion of the submaxillary gland, as it lies partly under cover of the mandible, can be palpated.

SURFACE ANATOMY OF THE BACK.

Bones.—The only subcutaneous parts of the vertebral column are the apices of the spinous processes. These are distinguishable at the bottom of a furrow which runs down the middle line of the back from the external occipital protuberance to the middle of the sacrum. In the **cervical region** the furrow is broad and ends below in a conspicuous projection caused by the spinous processes of the seventh cervical and first thoracic vertebræ. Above this, the spinous process of the sixth cervical vertebra sometimes forms a projection; the other cervical spinous processes are sunken, but that of the axis can be felt. In the **thoracic region** the furrow is shallow and during stooping disappears, and then the spinous processes become more or less visible; the markings produced by them are small and close together. In the **lumbar region** the furrow is deep and the situations of the spinous processes are frequently indicated by little pits or depressions, especially when the muscles in the loins are well-developed. In the **sacral region** the furrow is shallower, presenting a flattened area which ends below at the most prominent part of the dorsal surface of the sacrum, *i. e.*, the spinous process of the third sacral vertebra. At the bottom of the sacral furrow the irregular dorsal surface of the bone may be felt, and below this, in the deep groove running to the anus, the **coccyx**.

The only other portions of the vertebral column which can be felt from the surface are the transverse processes of the first, sixth, and seventh cervical vertebræ.

Muscles.—The muscles proper of the back are so obscured by those of the upper extremity (Fig. 1211) that they have very little influence on surface form. The **Splenii** by their divergence serve to broaden out the upper part of the back of the neck and produce a fulness in this situation. In the loin the **Sacrospinales**, bound

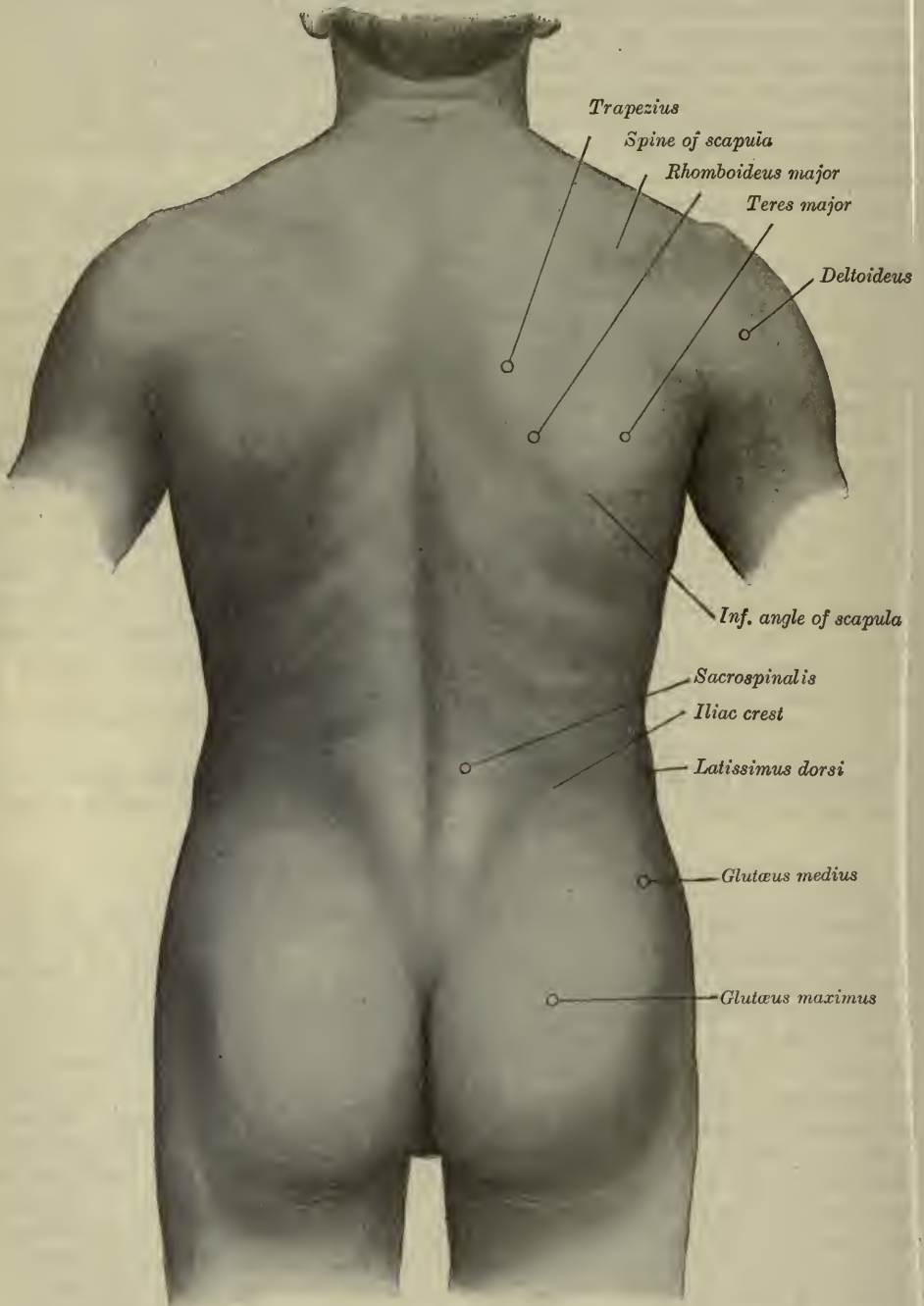


FIG. 1211.—Surface anatomy of the back.

down by the lumbodorsal fascia, form rounded vertical eminences which determine the depth of the spinal furrow and taper below to a point on the dorsal surface of the sacrum. The continuations of the **Sacrospinales** in the lower thoracic region form flattened planes which are gradually lost on passing upward.

SURFACE MARKINGS OF THE BACK.

Bony Landmarks.—In order to identify any particular spinous process it is customary to count from the prominence caused by the seventh cervical and first

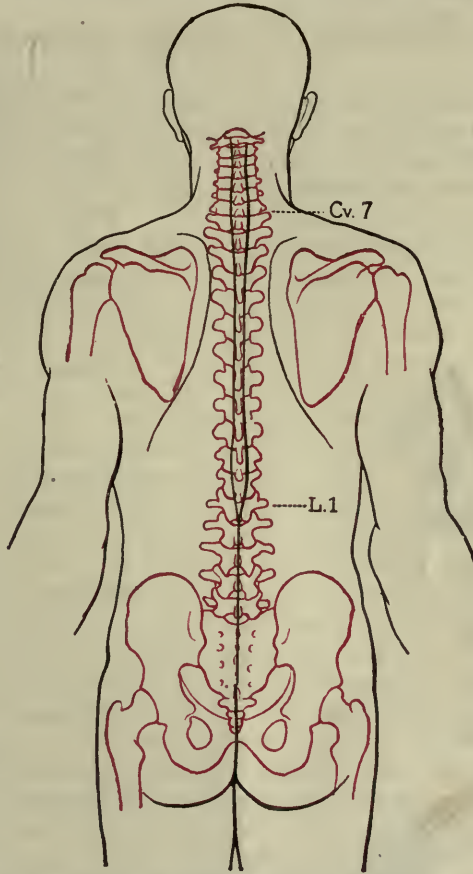


FIG. 1212.—Diagram showing the relation of the medulla spinalis to the dorsal surface of the trunk. The bones are outlined in red.

Level of body of	No. of nerve.	Level of tip of spine of	Level of body of	No. of nerve.	Level of tip of spine of
C. 1	C. 1	..	T. 8	T. 9	7 T.
2	{ 2	..	9	10	8
3	{ 3	1 C.	10	11	9
4	4	2	..	12	10
5	5	3	11	L. 1	11
6	6	4	..	{ 2	..
7	7	5	12	{ 3	..
..	8	6	..	{ 4	12
T. 1	T. 1	7	..	{ 5	..
2	2	1 T.	L. 1	{ S. 1	..
3	3	{ 2	..
4	4	2	..	{ 3	..
5	5	3	..	{ 4	1 L.
6	6	4	..	{ 5	..
7	7	5	..	C. 1	..
..	8	6	L. 2

thoracic; of these the latter is the more prominent. The root of the spine of the scapula is on a level with the tip of the spinous process of the third thoracic vertebra, and the inferior angle with that of the seventh. The highest point of the iliac crest is on a level with the spinous process of the fourth lumbar, and the posterior superior iliac spine with that of the second sacral.

The transverse process of the atlas is about 1 cm. below and in front of the apex of the mastoid process. The transverse process of the sixth cervical vertebra is opposite the cricoid cartilage; below it is the transverse process of the seventh and occasionally a cervical rib.

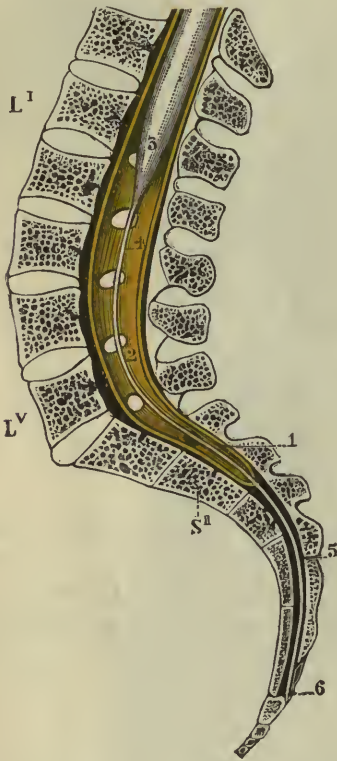


FIG. 1213.—Sagittal section of vertebral canal to show the lower end of the medulla spinalis and the filum terminale. (Testut.) *Li, Lc.* First and fifth lumbar vertebrae. *Sii.* Second sacral vertebra. 1. Dura mater. 2. Lower part of subarachnoid cavity. 3. Lower extremity of medulla spinalis. 4. Filum terminale internum, and 5, Filum terminale externum. 6. Attachment of filum terminale to first segment of coccyx.

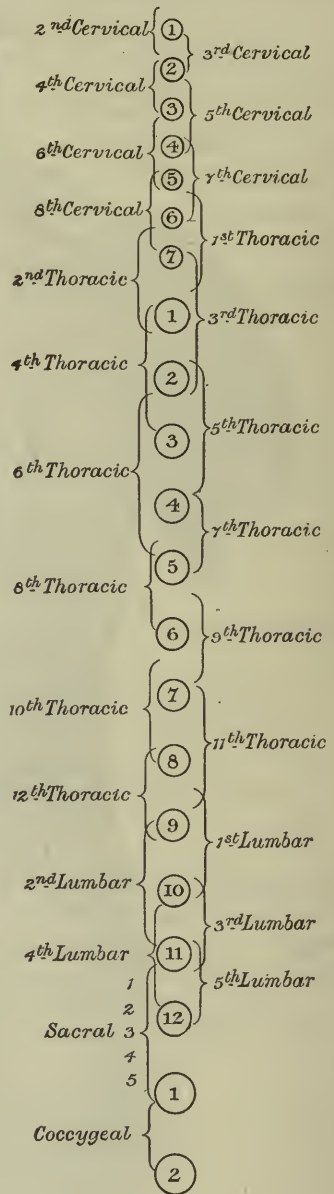


FIG. 1214.—Scheme showing the relations of the regions of attachment of the spinal nerves to the vertebral spinous processes. (After Reid.)

Medulla Spinalis.—The position of the lower end of the medulla spinalis varies slightly with the movements of the vertebral column, but, in the adult, in the upright posture it is usually at the level of the spinous process of the second lumbar vertebra (Fig. 1212); at birth it lies at the level of the fourth lumbar.

The subdural and subarachnoid cavities end below opposite the spinous process of the third sacral vertebra (Fig. 1213).

Spinal Nerves (Fig. 1214).—The table on page 1305, after Macalister, shows the relations which the places of attachment of the nerves to the medulla spinalis present to the bodies and spinous processes of the vertebræ.

SURFACE ANATOMY OF THE THORAX.

Bones.—The skeleton of the thorax is to a very considerable extent covered by muscles, so that in the strongly developed muscular subject it is for the most part concealed. In the emaciated subject, however, the **ribs**, especially in the lower and lateral regions, stand out as prominent ridges with the sunken intercostal spaces between them.

In the middle line, in front, the superficial surface of the **sternum** can be felt throughout its entire length at the bottom of a furrow, the sternal furrow, situated between the *Pectorales majores*. These muscles overlap the anterior surface somewhat, so that the whole width of the sternum is not subcutaneous, and this overlapping is greatest opposite the middle of the bone; the furrow, therefore, is wide at its upper and lower parts but narrow in the middle. At the upper border of the manubrium sterni is the **jugular notch**: the lateral parts of this notch are obscured by the tendinous origins of the *Sternocleidomastoidei*, which appear as oblique cords narrowing and deepening the notch. Lower down on the subcutaneous surface is a well-defined transverse ridge, the **sternal angle**; it denotes the junction of the manubrium and body. From the middle of the sternum the sternal furrow spreads out and ends at the junction of the body with the xiphoid process. Immediately below this is the **infrasternal notch**; between the sternal ends of the seventh costal cartilages, and below the notch, is a triangular depression, the epigastric fossa, in which the **xiphoid process** can be felt.

On either side of the sternum the costal cartilages and ribs on the front of the thorax are partly obscured by the *Pectoralis major*, through which, however, they can be felt as ridges with yielding intervals between them corresponding to the intercostal spaces. Of these spaces, that between the second and third ribs is the widest, the next two are somewhat narrower, and the remainder, with the exception of the last two, are comparatively narrow.

Below the lower border of the *Pectoralis major* on the front of the chest, the broad flat outlines of the ribs as they descend, and the more rounded outlines of the costal cartilages, are often visible. The lower boundary of the front of the thorax, which is most plainly seen by bending the body backward, is formed by the xiphoid process, the cartilages of the seventh, eighth, ninth, and tenth ribs, and the ends of the cartilages of the eleventh and twelfth ribs.

On either side of the thorax, from the axilla downward, the flattened external surfaces of the ribs may be defined. Although covered by muscles, all the ribs, with the exception of the first, can generally be followed without difficulty over the front and sides of the thorax. The first rib being almost completely covered by the clavicle can only be distinguished in a small portion of its extent.

At the back, the angles of the ribs lie on a slightly marked oblique line on either side of, and some distance from, the spinous processes of the vertebræ. The line diverges somewhat as it descends, and lateral to it is a broad convex surface caused by the projection of the ribs beyond their angles. Over this surface, except where covered by the scapula, the individual ribs can be distinguished.

Muscles.—The surface muscles covering the thorax belong to the musculature of the upper extremity (Figs. 1215, 1219), and will be described in that section (page 1325). There is, however, an area of practical importance bounded by these muscles. It is limited above by the lower border of *Trapezius*, below by the upper border of *Latissimus dorsi*, and laterally by the vertebral border of the scapula; the

floor is partly formed by *Rhomboideus major*. If the scapula be drawn forward by folding the arms across the chest, and the trunk bent forward, parts of the sixth and seventh ribs and the interspace between them become subcutaneous and available for auscultation. The space is therefore known as the **triangle of auscultation**.

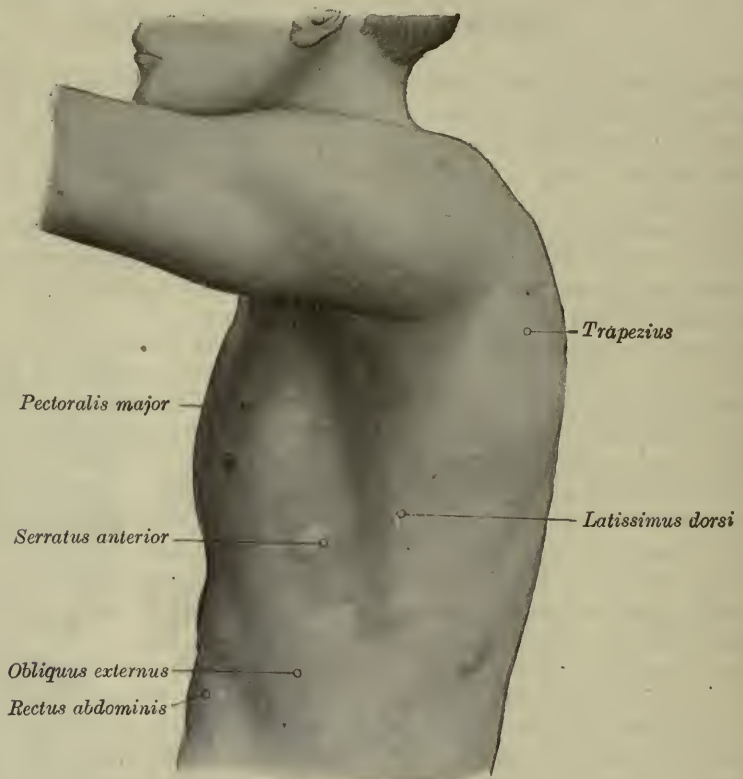


FIG. 1215.—The left side of the thorax.

Mamma.—The size of the mamma is subject to great variations. In the adult nulliparous female, it extends vertically from the second to the sixth rib, and transversely from the side of the sternum to the midaxillary line. In the male and in the nulliparous female the **mammary papilla** is situated in the fourth interspace about 9 or 10 cm. from the middle line, or 2 cm. from the costochondral junction.

SURFACE MARKINGS OF THE THORAX.

Bony Landmarks.—The second costal cartilage corresponding to the sternal angle is so readily found that it is used as a starting-point from which to count the ribs. The lower border of the *Pectoralis major* at its attachment corresponds to the fifth rib; the uppermost visible digitation of *Serratus anterior* indicates the sixth rib.

The jugular notch is in the same horizontal plane as the lower border of the body of the second thoracic vertebra; the sternal angle is at the level of the fifth thoracic vertebra, while the junction between the body and xiphoid process of the sternum corresponds to the fibrocartilage between the ninth and tenth thoracic vertebræ.

The influence of the obliquity of the ribs on horizontal levels in the thorax is well shown by the following line. "If a horizontal line be drawn around the body at the level of the inferior angle of the scapula, while the arms are at the sides, the

line would cut the sternum in front between the fourth and fifth ribs, the fifth rib in the nipple line, and the ninth rib at the vertebral column." (Treves).

Diaphragm.—The shape and variations of the diaphragm as seen by skiagraphy have already been described (page 407).

Surface Lines.—For clinical purposes, and for convenience of description, the surface of the thorax has been mapped out by arbitrary lines (Fig. 1220). On the front of the thorax the most important vertical lines are the **midsternal**, the middle line of the sternum; and the **mammary**, or, better **midclavicular**, which runs vertically downward from a point midway between the center of the jugular notch and the tip of the acromion. This latter line, if prolonged, is practically continuous with the lateral line on the front of the abdomen. Other vertical lines on the front of the thorax are the **lateral sternal** along the ternal margin, and the **parasternal** midway between the lateral sternal and the mammary.

On either side of the thorax the **anterior** and **posterior axillary lines** are drawn vertically from the corresponding axillary folds; the **midaxillary line** runs downward from the apex of the axilla.

On the posterior surface of the thorax the **scapular line** is drawn vertically through the inferior angle of the scapula.

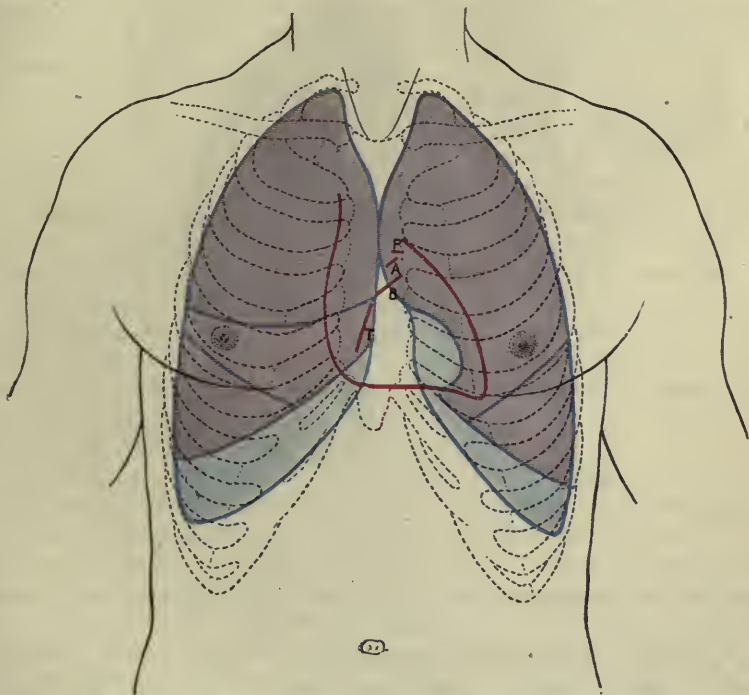


Fig. 1216.—Front of thorax, showing surface relations of bones, lungs (purple), pleura (blue), and heart (red outline). P. Pulmonary valve. A. Aortic valve. B. Bicuspid valve. T. Tricuspid valve.

Pleuræ (Figs. 1216, 1217).—The lines of reflection of the pleuræ can be indicated on the surface. On the *right* side the line begins at the sternoclavicular articulation and runs downward and medialward to the midpoint of the junction between the manubrium and body of the sternum. It then follows the midsternal line to the lower end of the body of the sternum or on to the xiphoid process, where it turns lateralward and downward across the seventh sternocostal articulation. It crosses the eighth costochondral junction in the mammary line, the tenth rib in the midaxillary line, and is prolonged thence to the spinous process of the twelfth thoracic vertebra.

On the *left* side, beginning at the sternoclavicular articulation, it reaches the midpoint of the junction between the manubrium and body of the sternum, and extends down the midsternal line in contact with that of the opposite side to the level of the fourth costal cartilage. It then diverges lateralward and is continued downward slightly lateral to the sternal border, as far as the sixth costal cartilage. Running downward and lateralward from this point it crosses the seventh costal cartilage, and from this onward it is similar to the line on the right side, but at a slightly lower level.

Lungs (Figs. 1216, 1217).—The **apex** of the lung is situated in the neck above the medial third of the clavicle. The height to which it rises above the clavicle varies very considerably, but is generally about 2.5 cm. It may, however, extend as high as 4 or 5 cm., or, on the other hand, may scarcely project above the level of this bone.

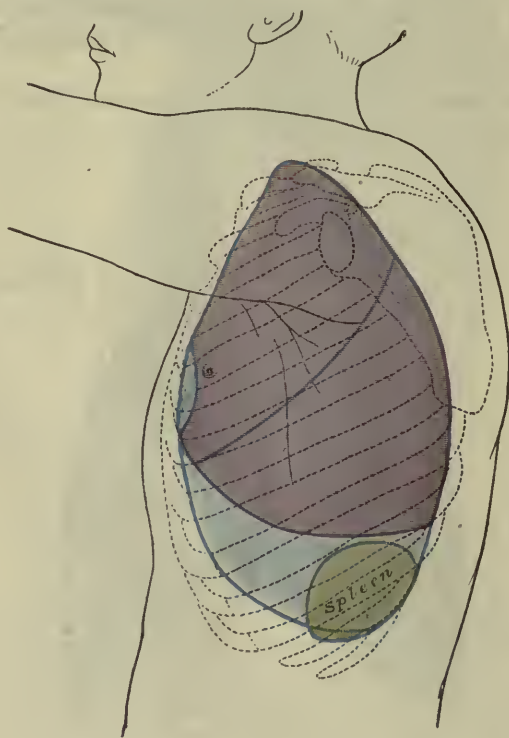

FIG. 1217.—Side of thorax, showing surface markings for bones, lungs (purple), pleura (blue), and spleen (green).

In order to mark out the **anterior borders** of the lungs a line is drawn from each apex point—2.5 cm. above the clavicle and rather nearer the anterior than the posterior border of Sternocleidomastoideus—downward and medialward across the sternoclavicular articulation and manubrium sterni until it meets, or almost meets, its fellow of the other side at the midpoint of the junction between the manubrium and body of the sternum. From this point the two lines run downward, practically along the midsternal line, as far as the level of the fourth costal cartilages. The continuation of the anterior border of the *right* lung is marked by a prolongation of its line vertically downward to the level of the sixth costal cartilage, and then it turns lateralward and downward. The line on the *left* side curves lateralward and downward across the fourth sternocostal articulation to reach the parasternal line at the fifth costal cartilage, and then turns medialward and downward to the sixth sternocostal articulation.

In the position of expiration the **lower border** of the lung may be marked by a slightly curved line with its convexity downward, from the sixth sternocostal junction to the tenth thoracic spinous process. This line crosses the mid-clavicular line at the sixth, and the midaxillary line at the eighth rib.

The **posterior borders** of the lungs are indicated by lines drawn from the level of the spinous process of the seventh cervical vertebra, down either side of the vertebral column, across the costovertebral joints, as low as the spinous process of the tenth thoracic vertebra.

The position of the **oblique fissure** in either lung can be shown by a line drawn from the spinous process of the second thoracic vertebra around the side of the thorax to the sixth rib in the mid-clavicular line; this line corresponds roughly to the line of the vertebral border of the scapula when the hand is placed on the top of the head. The **horizontal fissure** in the right lung is indicated by a line drawn from the midpoint of the preceding, or from the point where it cuts the midaxillary line, to the midsternal line at the level of the fourth costal cartilage.

Trachea.—This may be marked out on the back by a line from the spinous process of the sixth cervical to that of the fourth thoracic vertebra where it bifurcates; from its bifurcation the two bronchi are directed downward and lateralward. In front, the point of bifurcation corresponds to the sternal angle.

Esophagus.—The extent of the esophagus may be indicated on the back by a line from the sixth cervical to the level of the ninth thoracic spinous process, 2.5 cm. to the left of the middle line.

Heart.—The outline of the heart in relation to the front of the thorax (Figs 1216, 1218) can be represented by a quadrangular figure. The apex of the heart is first determined, either by its pulsation or as a point in the fifth interspace, 9 cm. to the left of the midsternal line. The other three points are: (a) the seventh right sternocostal articulation; (b) a point on the upper border of the third right costal cartilage 1 cm. from the right lateral sternal line; (c) a point on the lower border of the second left costal cartilage 2.5 cm. from the left lateral sternal line. A line joining the apex to point (a) and traversing the junction of the body of the sternum with the xiphoid process represents the lowest limit of the heart—its acute margin. The right and left borders are represented respectively by lines joining (a) to (b) and the apex to (c); both lines are convex lateralward, but the convexity is more marked on the right where its summit is 4 cm. distant from the midsternal line opposite the fourth costal cartilage.

A portion of the area of the heart thus mapped out is uncovered by lung, and therefore gives a dull note on percussion; the remainder being overlapped by lung gives a more or less resonant note. The former is known as the area of superficial cardiac dulness, the latter as the area of deep cardiac dulness. The area of superficial cardiac dulness is somewhat triangular; from the apex of the heart two lines are drawn to the midsternal line, one to the level of the fourth costal cartilage, the other to the junction between the body and xiphoid process; the portion of the midsternal line between these points is the base of the triangle. Latham lays down the following rule as a sufficient practical guide for the definition of the area of superficial dulness. "Make a circle of two inches in diameter around a point midway between the nipple and the end of the sternum."

The **coronary sulcus** can be indicated by a line from the third left, to the sixth right, sternocostal joint. The **anterior longitudinal sulcus** is a finger's breadth to the right of the left margin of the heart.

The position of the various orifices is as follows: The **pulmonary orifice** is situated in the upper angle of the third left sternocostal articulation; the **aortic orifice** is a little below and medial to this, close to the articulation. The **left atrioventricular opening** is opposite the fourth costal cartilage, and rather to the left of the midsternal line; the **right atrioventricular opening** is a little lower, opposite

the fourth interspace of the right side. The lines indicating the atrioventricular openings are slightly below and parallel to the line of the coronary sulcus.

Arteries.—The line of the **ascending aorta** begins slightly to the left of the mid-sternal line opposite the third costal cartilage and extends upward and to the right to the upper border of the second right costal cartilage. The beginning of the **aortic arch** is indicated by a line from this latter point to the midsternal line about 2.5 cm. below the jugular notch. The point on the midsternal line is opposite the summit of the arch, and a line from it to the right sternoclavicular articulation represents the site of the **innominate artery**, while another line from a point slightly to the left of it and passing through the left sternoclavicular articulation indicates the position of the **left common carotid artery** in the thorax.

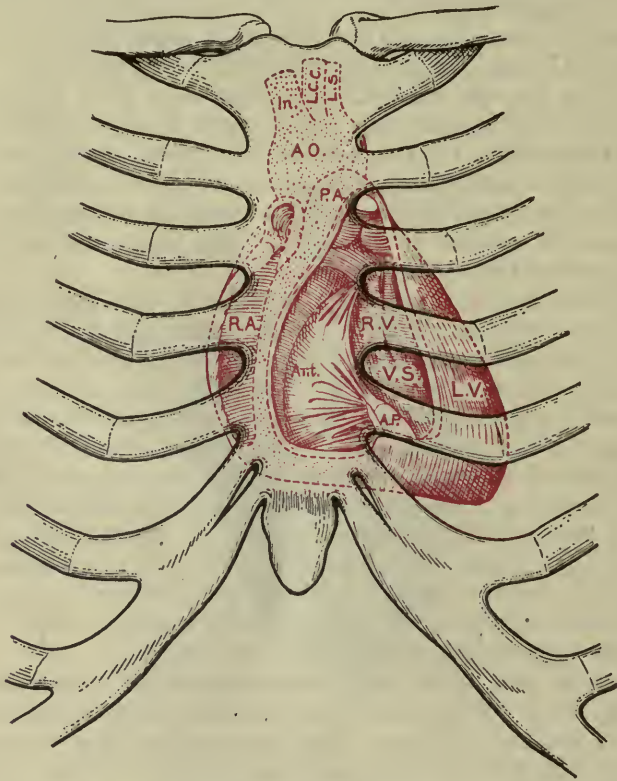


FIG. 1218.—Diagram showing relations of opened heart to front of thoracic wall. *Ant.* Anterior segment of tricuspid valve. *A.O.* Aorta. *A.P.* Anterior papillary muscle. *In.* Innominate artery. *L.C.C.* Left common carotid artery. *L.S.* Left subclavian artery. *L.V.* Left ventricle. *P.A.* Pulmonary artery. *R.A.* Right atrium. *R.V.* Right ventricle. *V.S.* Ventricular septum.

The **internal mammary artery** descends behind the first six costal cartilages about 1 cm. from the lateral sternal line.

Veins.—The line of the **right innominate vein** crosses the right sternoclavicular joint and the upper border of the first right costal cartilage about 1 cm. from the lateral sternal line; that of the **left innominate vein** extends from the left sternoclavicular articulation to meet the right at the upper border of the first right costal cartilage. The junction of the two lines indicates the origin of the **superior vena cava**, the line of which is continued vertically down to the level of the third right costal cartilage. The end of the **inferior vena cava** is situated opposite the upper margin of the sixth right costal cartilage about 2 cm. from the mid-sternal line.

SURFACE ANATOMY OF THE ABDOMEN.

Skin.—The skin of the front of the abdomen is thin. In the male it is often thickly hair-clad, especially toward the lower part of the middle line; in the female the hairs are confined to the pubes. Just below the line of the iliac crest, especially marked in fat subjects, is a shallow groove termed the **iliac furrow**, while in the site of the inguinal ligament a sharper fold known as the **fold of the groin** is easily distinguishable.

After distension of the abdomen from pregnancy or other causes the skin commonly presents transverse white lines which are quite smooth, being destitute of papillæ; these are known as **striæ gravidarum** or **striæ albicantes**. The **linea nigra** of pregnancy is often seen as a pigmented brown streak in the middle line between the umbilicus and symphysis pubis.

In the middle line of the front of the abdomen is a shallow furrow which extends from the junction between the body of the sternum with the xiphoid process to a short distance below the umbilicus; it corresponds to the **linea alba**. The umbilicus is situated in the middle line, but it varies in position as regards its height; in an adult subject it is always placed above the middle point of the body, and in a normal well-nourished subject is from 2 to 2.5 cm. above the level of the tubercles of the iliac crests.

Bones.—The bones in relation with the surface of the abdomen are (1) the lower part of the vertebral column and the lower ribs and (2) the pelvis; the former have already been described (page 1303), the latter will be considered with the lower limb.

Muscles (Fig. 1219).—The only muscles of the abdomen which have any considerable influence on surface form are the **Obliquus externus** and the **Rectus**. The upper digitations of origin of **Obliquus externus** are well-marked in a muscular subject, interdigitating with those of **Serratus anterior**; the lower digitations are covered by the border of **Latissimus dorsi** and are not visible. The attachment of the **Obliqui externus** and **internus** to the crest of the ilium forms a thick oblique roll which determines the **iliac furrow**. Sometimes on the front of the lateral region of the abdomen an undulating line marks the passing of the muscular fibers of the **Obliquus externus** into its aponeurosis. The lateral margin of the **Obliquus externus** is separated from that of the **Latissimus dorsi** by a small triangular interval—the **lumbar triangle**—the base of which is formed by the iliac crest, and its floor by **Obliquus internus**.

The lateral margin of **Rectus abdominis** is indicated by the **linea semilunaris**, which may be exactly defined by putting the muscle into action. The surface of the **Rectus** presents three transverse furrows, the **tendinous inscriptions**: the upper two of these, viz., one opposite, or a little below, the tip of the xiphoid process, and the other midway between this point and the umbilicus, are usually well-marked; the third, opposite the umbilicus, is not so distinct. Between the two **Recti** the **linea alba** can be palpated from the xiphoid process to a point just below the umbilicus; it is represented by a distinct dip between the muscles: beyond this the muscles are in apposition.

Vessels.—In thin subjects the pulsation of the **abdominal aorta** can be readily felt by making deep pressure in the middle line above the umbilicus.

Viscera.—Under normal conditions the various portions of the **digestive tube** cannot be identified by simple palpation. Peristalsis of the coils of small intestine can be observed in some persons with extremely thin abdominal walls when some degree of constipation exists. In cases of constipation it is sometimes possible to trace portions of the great intestine by feeling the fecal masses within the gut. In thin persons with relaxed abdominal walls the iliac colon can be felt in the left

iliac region—rolling under the fingers when empty and forming a distinct tumor when distended.

The greater part of the liver lies under cover of the lower ribs and their cartilages, but in the epigastric fossa it comes in contact with the abdominal wall. The

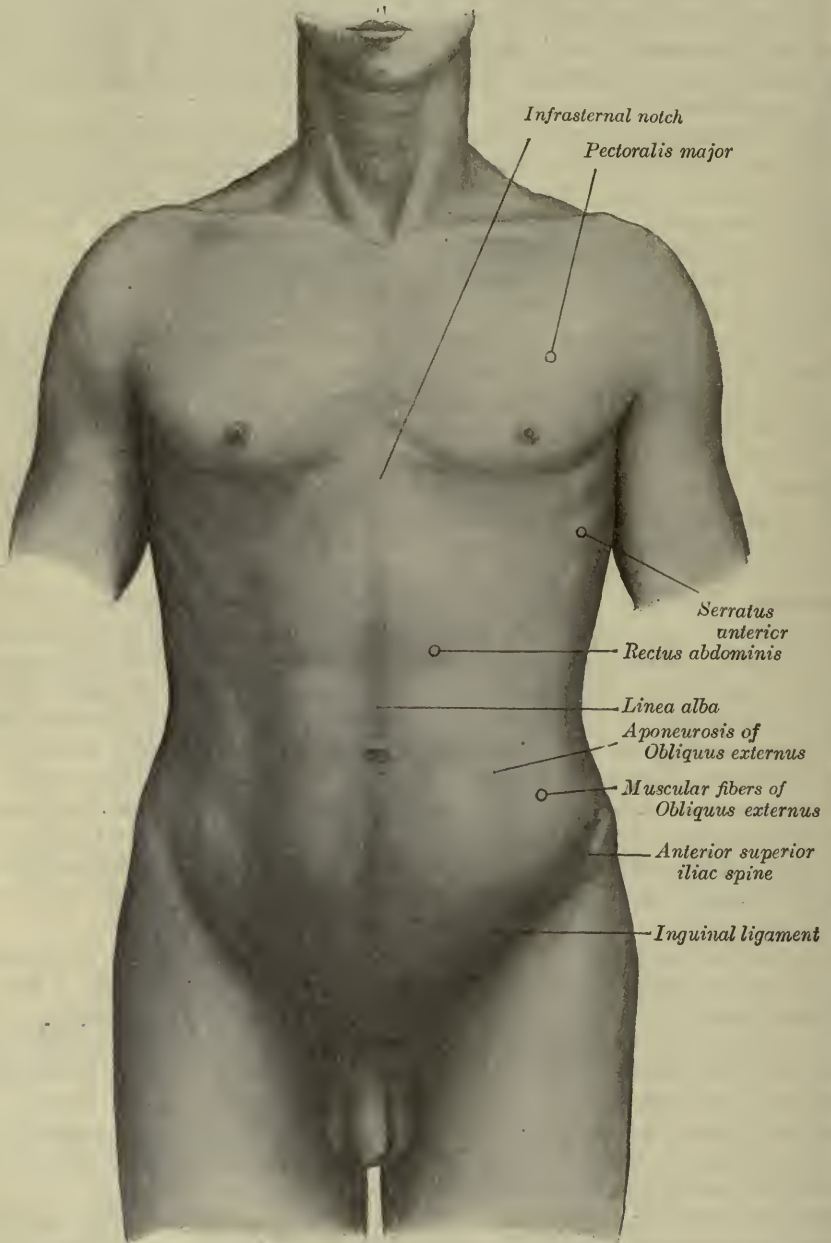


FIG. 1219.—Surface anatomy of the front of the thorax and abdomen.

position of the liver varies according to the posture of the body. In the erect posture in the adult male the edge of the liver projects about 1 cm. below the lower margin of the right costal cartilages, and its inferior margin can often be felt in this situation if the abdominal wall is thin. In the supine position the liver

recedes above the margin of the ribs and cannot then be detected by the finger; in the prone position it falls forward and is then generally palpable in a patient with loose and lax abdominal walls. Its position varies with the respiratory movements; during a deep inspiration it descends below the ribs; in expiration it is raised. Pressure from without, as in tight lacing, by compressing the lower part of the chest, displaces the liver considerably, its anterior edge frequently extending as low as the crest of the ilium. Again its position varies greatly with the state of the stomach and intestines; when these are empty the liver descends, when they are distended it is pushed upward.

The **pancreas** can sometimes be felt, in emaciated subjects, when the stomach and colon are empty, by making deep pressure in the middle line about 7 or 8 cm. above the umbilicus.

The **kidneys** being situated at the back of the abdominal cavity and deeply placed cannot be palpated unless enlarged or misplaced.

SURFACE MARKINGS OF THE ABDOMEN.

Bony Landmarks.—Above, the chief bony markings are the xiphoid process, the lower six costal cartilages, and the anterior ends of the lower six ribs. The junction between the body of the sternum and the xiphoid process is on the level of the tenth thoracic vertebra. Below, the main landmarks are the symphysis pubis and the pubic crest and tubercle, the anterior superior iliac spine, and the iliac crest.

Muscles (Fig. 1227).—The **Rectus** lies between the linea alba and the linea semilunaris; the former is indicated by the middle line, the latter by a curved line, convex lateralward, from the tip of the cartilage of the ninth rib to the pubic tubercle; at the level of the umbilicus the linea semilunaris is about 7 cm. from the middle line. The line indicating the junction of the muscular fibers of **Obliquus externus** with its aponeurosis extends from the tip of the ninth costal cartilage to a point just medial to the anterior superior iliac spine.

The **umbilicus** is at the level of the fibrocartilage between the third and fourth lumbar vertebræ.

The **subcutaneous inguinal ring** is situated 1 cm. above and lateral to the pubic tubercle; the **abdominal inguinal ring** lies 1 to 2 cm. above the middle of the inguinal ligament. The position of the **inguinal canal** is indicated by a line joining these two points.

Surface Lines.—For convenience of description of the viscera and of reference to morbid conditions of the contained parts, the abdomen is divided into nine regions, by imaginary planes, two horizontal and two sagittal, the edges of the planes being indicated by lines drawn on the surface of the body (Fig. 1220). In the older method the upper, or subcostal, horizontal line encircles the body at the level of the lowest points of the tenth costal cartilages; the lower, or intertubercular, is a line carried through the highest points of the iliac crests seen from the front, *i. e.*, through the tubercles on the iliac crests about 5 cm. behind the anterior superior spines. An alternative method is that of Addison, who adopts the following lines:

(1) An upper transverse, the **transpyloric**, halfway between the jugular notch and the upper border of the symphysis pubis; this indicates the margin of the transpyloric plane, which in most cases cuts through the pylorus, the tips of the ninth costal cartilages and the lower border of the first lumbar vertebra; (2) a lower transverse line midway between the upper transverse and the upper border of the symphysis pubis; this is termed the **transtubercular**, since it practically corresponds to that passing through the iliac tubercles; behind, its plane cuts the body of the fifth lumbar vertebra.

By means of these horizontal planes the abdomen is divided into three zones named from above, the **subcostal**, **umbilical**, and **hypogastric zones**. Each of these is further subdivided into three regions by the two sagittal planes, which are indicated on the surface by a right and a left lateral line drawn vertically through points halfway between the anterior superior iliac spines and the middle line. The middle region of the upper zone is called the **epigastric**, and the two lateral regions

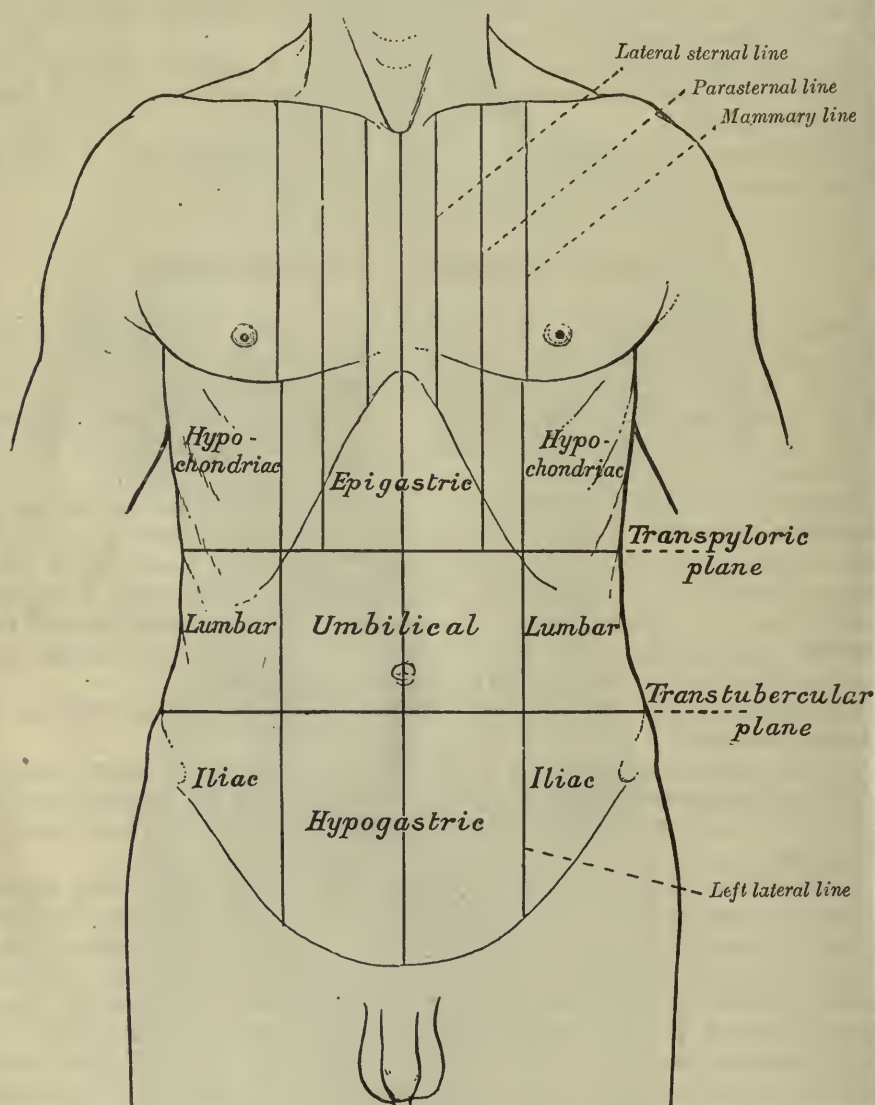


FIG. 1220.—Surface lines of the front of the thorax and abdomen.

the **right** and **left hypochondriac**. The central region of the middle zone is the **umbilical**, and the two lateral regions the **right** and **left lumbar**. The middle region of the lower zone is the **hypogastric** or **pubic**, and the lateral are the **right** and **left iliac** or **inguinal**. The middle regions, viz., **epigastric**, **umbilical**, and **pubic**, can each be divided into right and left portions by the middle line. In the following description of the viscera the regions marked out by Addison's lines are those referred to.

Stomach (Fig. 1223).—The shape of the stomach is constantly undergoing alteration; it is affected by the particular phase of the process of gastric digestion, by

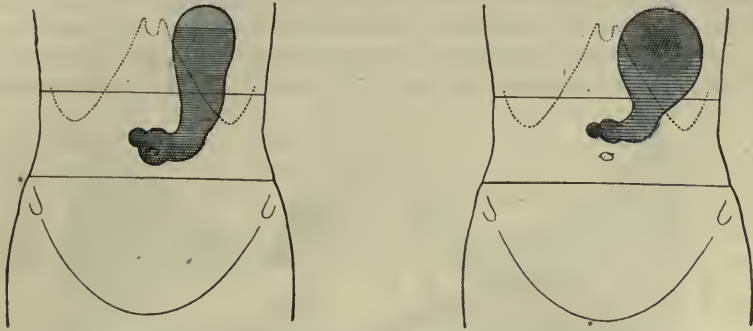


FIG. 1221.—With the patient in the erect posture. FIG. 1222.—With the patient lying down.
Figs. 1221 and 1222.—Radiographs of a moderately distended stomach, showing the influence of posture.
(Modified from Hertz.)

the state of the surrounding viscera, and by the amount and character of its contents. Its position also varies with that of the body (Figs. 1221, 1222), so

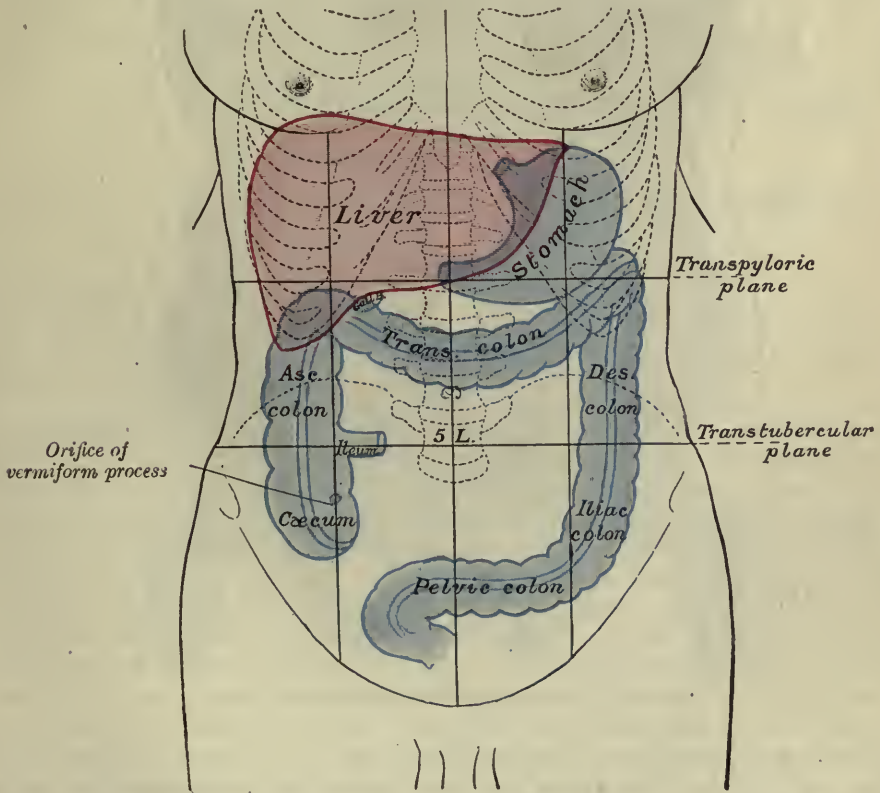


FIG. 1223.—Front of abdomen, showing surface markings for liver, stomach, and great intestine.

that it is impossible to indicate it on the surface with any degree of accuracy. The measurements given refer to a moderately filled stomach with the body in the supine position.

The cardiac orifice is opposite the seventh left costal cartilage about 2.5 cm. from the side of the sternum; it corresponds to the level of the tenth thoracic vertebra. The pyloric orifice is on the transpyloric line about 1 cm. to the right of the middle line, or alternately 5 cm. below the seventh right sternocostal articulation; it is at the level of the first lumbar vertebra. A curved line, convex downward and to the left, joining these points indicates the lesser curvature. In the left lateral line the fundus of the stomach reaches as high as the fifth interspace or the sixth

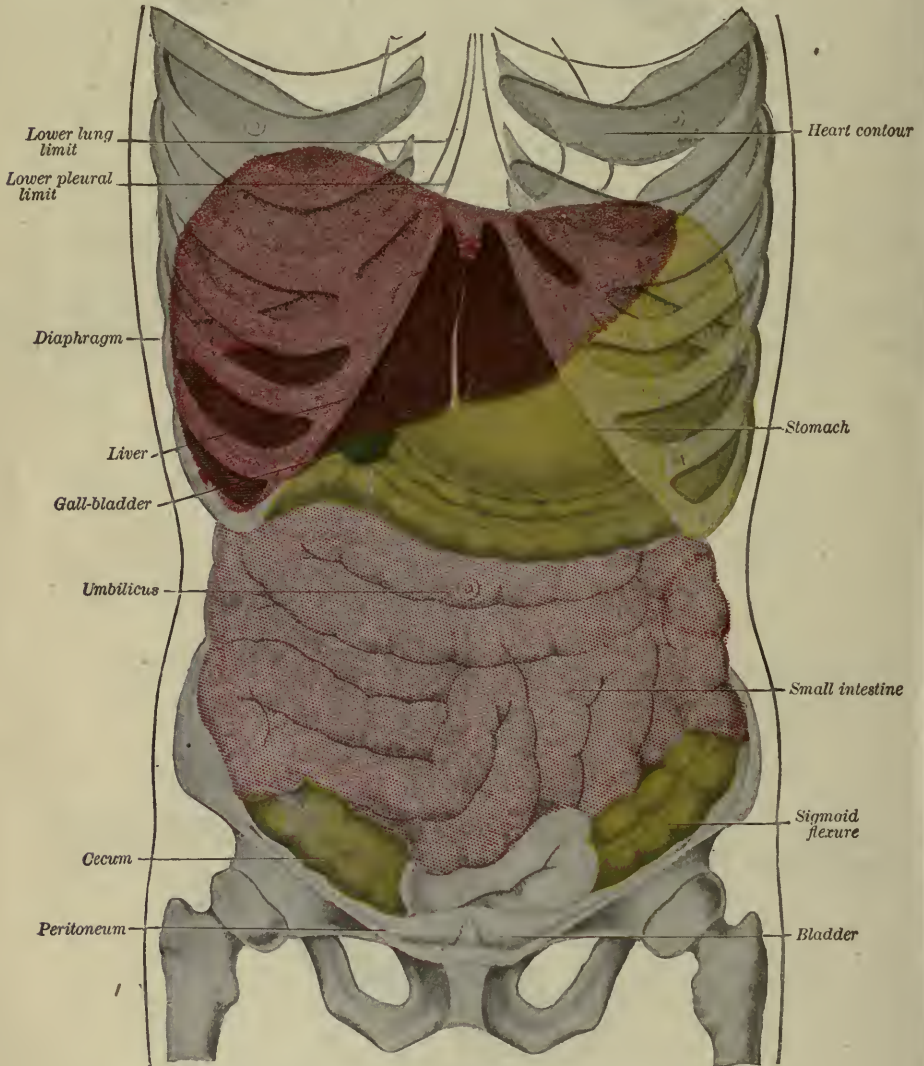


FIG. 1224.—Topography of thoracic and abdominal viscera.

costal cartilage, a little below the apex of the heart. To indicate the greater curvature a curved line is drawn from the cardiac orifice to the summit of the fundus, thence downward and to the left, finally turning medialward to the pyloric orifice, but passing, on its way, through the intersection of the left lateral with the transpyloric line. The portion of the stomach which is in contact with the abdominal wall can be represented roughly by a triangular area the base of which is formed by a line drawn from the tip of the tenth left costal cartilage to the tip of the ninth

right cartilage, and the sides by two lines drawn from the end of the eighth left costal cartilage to the ends of the base line.

A space of some clinical importance—the **space of Traube**—overlies the stomach and may be thus indicated. It is semilunar in outline and lies within the following boundaries: the lower edge of the left lung, the anterior border of the spleen, the left costal margin and the inferior margin of the left lobe of the liver.

Duodenum (Fig. 1225).—The superior part is horizontal and extends from the pylorus to the right lateral line; the descending part is situated medial to the right lateral line, from the transpyloric line to a point midway between the transpyloric and transtuberular lines. The horizontal part runs with a slight upward slope from the end of the descending part to the left of the middle line; the ascending part is vertical, and reaches the transpyloric line, where it ends in the duodeno-jejunal flexure, about 2.5 cm. to the left of the middle line.

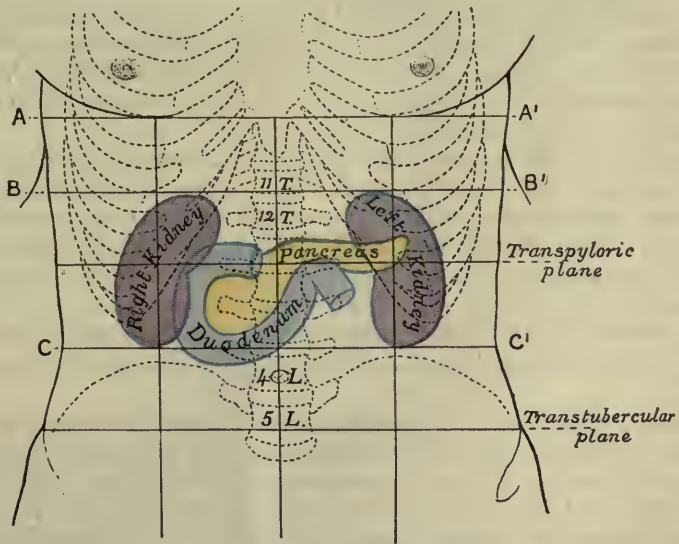


FIG. 1225.—Front of abdomen, showing surface markings for duodenum, pancreas, and kidneys. *A A'*. Plane through joint between body and xiphoid process of sternum. *B B'*. Plane midway between *A A'* and transpyloric plane. *C C'*. Plane midway between transpyloric and transtuberular planes.

Small Intestine.—The coils of small intestine occupy the front of the abdomen. For the most part the coils of the jejunum are situated on the left side, *i. e.*, in the left lumbar and iliac regions, and in the left half of the umbilical region. The coils of the ileum lie toward the right in the right lumbar and iliac regions, in the right half of the umbilical region, and in the hypogastric region; a portion of the ileum is within the pelvis. The end of the ileum, *i. e.*, the **ileocolic junction**, is slightly below and medial to the intersection of the right lateral and transtuberular lines.

Cecum and Vermiform Process.—The cecum is in the right iliac and hypogastric regions; its position varies with its degree of distension, but the midpoint of a line drawn from the right anterior superior iliac spine to the upper margin of the symphysis pubis will mark approximately the middle of its lower border.

The position of the base of the **vermiform process** is indicated by a point on the lateral line on a level with the anterior superior iliac spine.

Ascending Colon.—The ascending colon passes upward through the right lumbar region, lateral to the right lateral line. The **right colic flexure** is situated in the upper and right angle of intersection of the subcostal and right lateral lines.

Transverse Colon.—The transverse colon crosses the abdomen on the confines of the umbilical and epigastric regions, its lower border being on a level slightly

above the umbilicus, its upper border just below the greater curvature of the stomach.

Descending Colon.—The left colic flexure is situated in the upper left angle of the intersection between the left lateral and transpyloric lines. The descending colon courses down through the left lumbar region, lateral to the left lateral line, as far as the iliac crest (see footnote p. 1181).

Iliac Colon.—The line of the iliac colon is from the end of the descending colon to the left lateral line at the level of the anterior superior iliac spine.

Liver (Fig. 1223).—The upper limit of the right lobe of the liver, in the middle line, is at the level of the junction between the body of the sternum and the xiphoid process; on the right side the line must be carried upward as far as the fifth costal cartilage in the mammary line, and then downward to reach the seventh rib at the side of the thorax. The upper limit of the left lobe can be defined by continuing this line downward and to the left to the sixth costal cartilage, 5 cm. from the middle line. The lower limit can be indicated by a line drawn 1 cm. below the lower margin of the thorax on the right side as far as the ninth costal cartilage, thence obliquely upward to the eighth left costal cartilage, crossing the middle line just above the transpyloric plane and finally, with a slight left convexity, to the end of the line indicating the upper limit.

According to Birmingham the limits of the normal liver may be marked out on the surface of the body in the following manner. Take three points: (*a*) 1.25 cm. below the right nipple; (*b*) 1.25 cm. below the tip of the tenth rib; (*c*) 2.5 cm. below the left nipple. Join (*a*) and (*c*) by a line slightly convex upward; (*a*) and (*b*) by a line slightly convex lateralward; and (*b*) and (*c*) by a line slightly convex downward.

The fundus of the gall-bladder approaches the surface behind the anterior end of the ninth right costal cartilage close to the lateral margin of the Rectus abdominis.

Pancreas (Fig. 1225).—The pancreas lies in front of the second lumbar vertebra. Its head occupies the curve of the duodenum and is therefore indicated by the same lines as that viscus; its neck corresponds to the pylorus. Its body extends along the transpyloric line, the bulk of it lying above this line to the tail which is in the left hypochondriac region slightly to the left of the lateral line and above the transpyloric.

Spleen (Figs. 1217, 1226).—To map out the spleen the tenth rib is taken as representing its long axis; vertically it is situated between the upper border of the ninth and the lower border of the eleventh ribs. The highest point is 4 cm. from the middle line of the back at the level of the tip of the ninth thoracic spinous process; the lowest point is in the midaxillary line at the level of the first lumbar spinous process.

Kidneys (Figs. 1225, 1226).—The right kidney usually lies about 1 cm. lower than the left, but for practical purposes similar surface markings are taken for each.

On the front of the abdomen the upper pole lies midway between the plane of the lower end of the body of the sternum and the transpyloric plane, 5 cm. from the middle line. The lower pole is situated midway between the transpyloric and intertubercular planes, 7 cm. from the middle line. The hilum is on the transpyloric plane, 5 cm. from the middle line. Round these three points a kidney-shaped figure 4 cm. to 5 cm. broad is drawn, two-thirds of which lies medial to the lateral line. To indicate the position of the kidney from the back, the parallelogram of Morris is used; two vertical lines are drawn, the first 2.5 cm., the second 9.5 cm. from the middle line; the parallelogram is completed by two horizontal lines drawn respectively at the levels of the tips of the spinous process of the eleventh thoracic and the lower border of the spinous process of the third

lumbar vertebra. The hilum is 5 cm. from the middle line at the level of the spinous process of the first lumbar vertebra.

Ureters.—On the front of the abdomen, the line of the ureter runs from the hilum of the kidney to the pubic tubercle; on the back, from the hilum vertically downward, passing practically through the posterior superior iliac spine (Fig. 1226).

Vessels (Fig. 1227).—The **inferior epigastric artery** can be marked out by a line from a point midway between the anterior superior iliac spine and the pubic symphysis to the umbilicus. This line also indicates the lateral boundary of **Hesselbach's triangle**—an area of importance in connection with inguinal hernia; the other boundaries are the lateral edge of Rectus abdominis, and the medial half of the inguinal ligament. The line of the **abdominal aorta** begins in the middle line about 4 cm. above the transpyloric line and extends to a point 2 cm. below and to the left of the umbilicus—

or more accurately to a point 2 cm. to the left of the middle line on a line which passes through the highest points of the iliac crests (A A', Fig. 1227). The

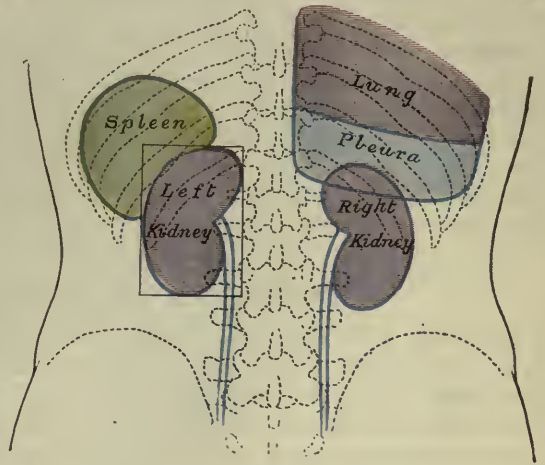


FIG. 1226.—Back of lumbar region, showing surface markings for kidneys, ureters, and spleen. The lower portions of the lung and pleura are shown on the right side.

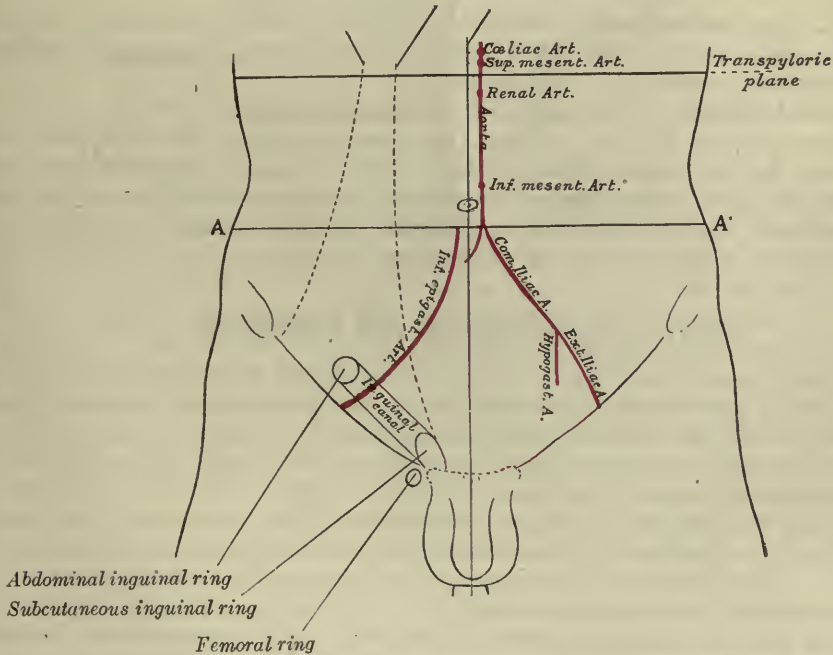


FIG. 1227.—Front of abdomen, showing surface markings for arteries and inguinal canal.

point of termination of the abdominal aorta corresponds to the level of the fourth lumbar vertebra; a line drawn from it to a point midway between the anterior superior iliac spine and the symphysis pubis indicates the common and external

iliac arteries. The **common iliac** is represented by the upper third of this line, the **external iliac** by the remaining two-thirds.

Of the larger branches of the abdominal aorta, the **celiac artery** is 4 cm., the **superior mesenteric** 2 cm. above the transpyloric line; the **renal arteries** are 2 cm. below the same line. The **inferior mesenteric artery** is 4 cm. above the bifurcation of the abdominal aorta.

Nerves.—The thoracic nerves on the anterior abdominal wall are represented by lines continuing those of the bony ribs. The termination of the seventh nerve is at the level of the xiphoid process, the tenth reaches the vicinity of the umbilicus, the twelfth ends about midway between the umbilicus and the upper border of the symphysis pubis. The first lumbar is parallel to the thoracic nerves; its iliohypogastric branch becomes cutaneous above the subcutaneous inguinal ring; its ilioinguinal branch at the ring.

SURFACE ANATOMY OF THE PERINEUM.

Skin.—In the middle line of the posterior part of the perineum and about 4 cm. in front of the tip of the coccyx is the anal orifice. The junction of the mucous membrane of the anal canal with the skin of the perineum is marked by a white line which indicates also the line of contact of the external and internal Sphincters. In the anterior part of the perineum the external genital organs are situated. The skin covering the scrotum is rough and corrugated, but over the penis it is smooth; extending forward from the anus on to the scrotum and penis is a median ridge which indicates the scrotal raphé. In the **female** are seen the skin reduplications forming the labia majora and minora laterally, the frenulum of the labia behind, and the prepuce of the clitoris in front; still more anteriorly is the mons pubis.

Bones.—In the antero-lateral boundaries of the perineum, the whole outline of the pubic arch can be readily traced ending in the ischial tuberosities. Behind in the middle line is the tip of the coccyx.

Muscles and Ligaments.—The margin of the **Glutæus maximus** forms the postero-lateral boundary, and in thin subjects, by pressing deeply, the sacrotuberous ligament can be felt through the muscle. The only other muscles influencing surface form are the **Ischiocavernosus** covering the crus penis, which lies on the side of the pubic arch, and the **Sphincter ani externus**, which, in action, closes the anal orifice and causes a puckering of the skin around it.

SURFACE MARKINGS OF THE PERINEUM.

A line drawn transversely across in front of the ischial tuberosities divides the perineum into a posterior or rectal, and an anterior or urogenital, triangle. This line passes through the central point of the perineum, which is situated about 2.5 cm. in front of the center of the anal aperture or, in the male, midway between the anus and the reflection of the skin on to the scrotum.

Rectum and Anal Canal.—A finger inserted through the anal orifice is grasped by the Sphincter ani externus, passes into the region of the Sphincter ani internus, and higher up encounters the resistance of the Puborectalis; beyond this it may reach the lowest of the transverse rectal folds. In front, the urethral bulb and membranous part of the urethra are first identified, and then about 4 cm. above the anal orifice the prostate is felt; beyond this the vesiculæ seminales, if enlarged, and the fundus of the bladder, when distended, can be recognized. On either side is the ischio-rectal fossa. Behind are the anococcygeal body, the pelvic surfaces of the coccyx and lower end of the sacrum, and the sacrospinous ligaments (Fig. 1228).

In the female the posterior wall and fornix of the vagina, and the cervix and body of the uterus can be felt in front, while somewhat laterally the ovaries can just be reached.

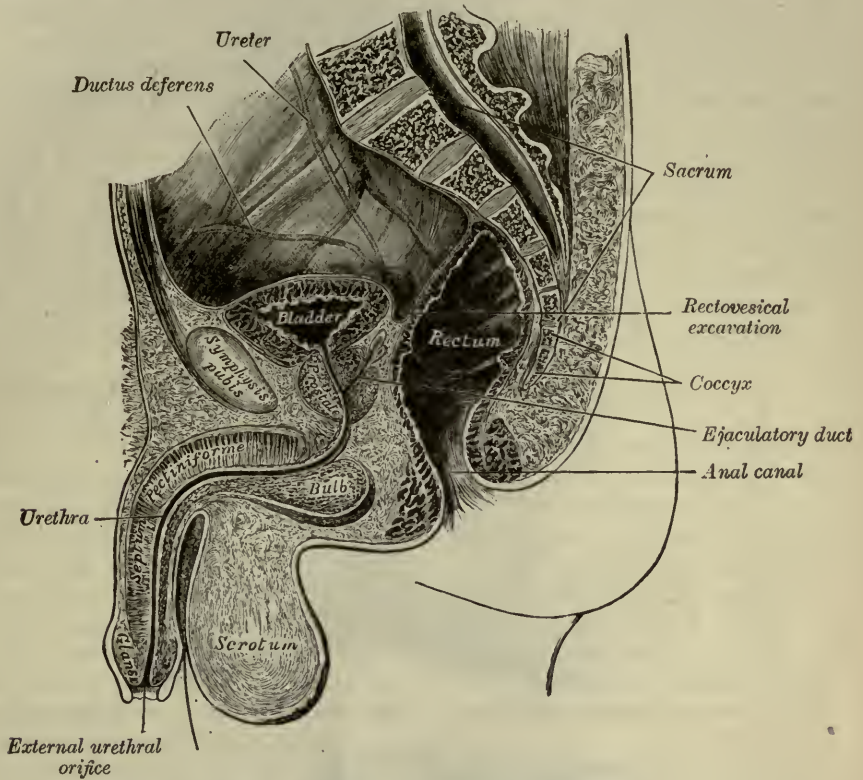


FIG. 1228.—Median sagittal section of male pelvis.

Male Urogenital Organs.—The *corpora cavernosa penis* can be followed backward to the *crura* which are attached to the sides of the pubic arch. The *glans penis*, covered by the prepuce, and the external urethral orifice can be examined, and the course of the urethra traced along the under surface of the penis to the bulb which is situated immediately in front of the central point of the perineum. Through the wall of the *scrotum* on either side the *testis* can be palpated; it lies toward the back of the scrotum, and along its posterior border the *epididymis* can be felt; passing upward along the medial side of the epididymis is the *spermatic cord*, which can be traced upward to the subcutaneous inguinal ring.

By means of a sound the general topography of the urethra and bladder can be investigated; with the urethroscope the interior of the urethra can be illuminated and viewed directly; with the cystoscope the interior of the bladder is in a similar manner illuminated for visual examination. In the bladder the main points to which attention is directed are the *trigone*, the *torus uretericus*, the *plicæ uretericæ*, and the openings of the *ureters* and *urethra* (see Fig. 1240).

Female Urogenital Organs.—In the *puddendal cleft* (Fig. 1229) between the *labia minora* are the openings of the *vagina* and *urethra*. In the virgin the vaginal opening is partly closed by the *hymen*—after coitus the remains of the hymen are represented by the *carunculæ hymenales*. Between the hymen and the *frenulum* of the labia is the *fossa navicularis*, while in the groove between the hymen and the *labium minus*, on either side, the small opening of the *greater vestibular (Bartholin's) gland* can be seen. These glands when enlarged can be felt on either side of the

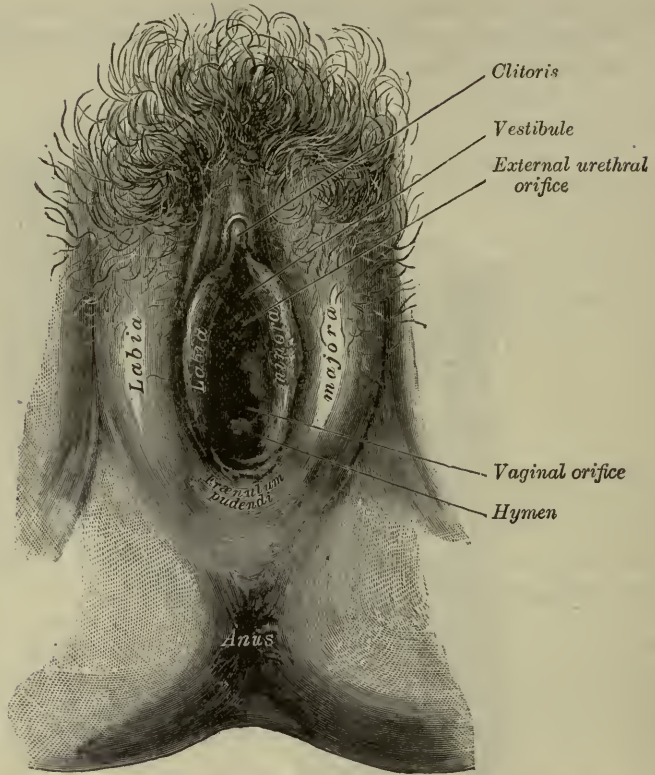


FIG. 1229.—External genital organs of female. The labia minora have been drawn apart.

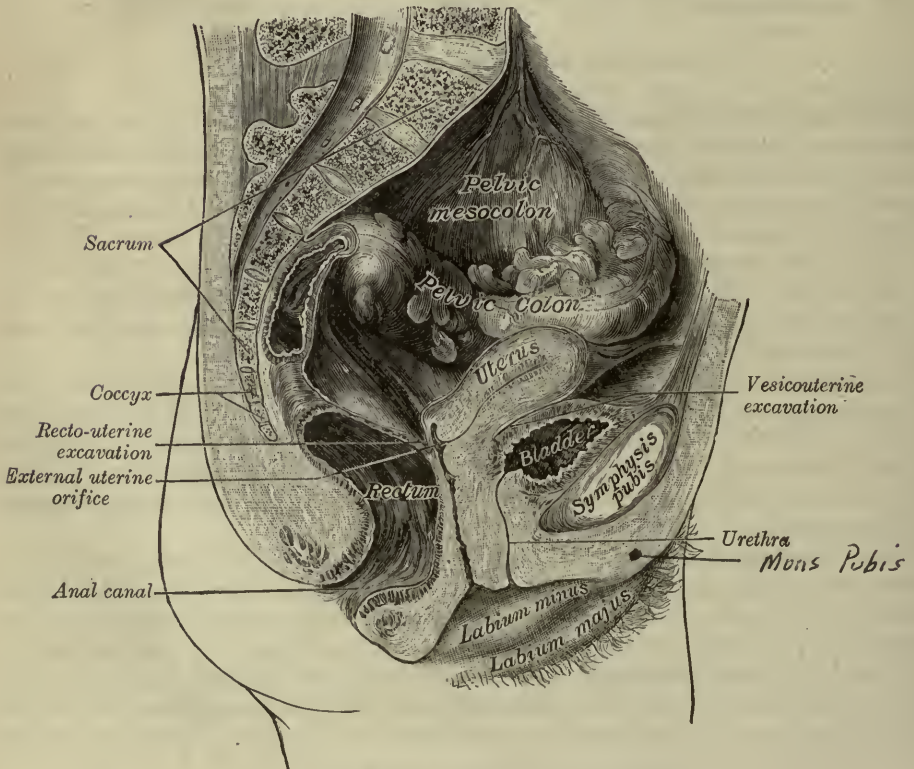


FIG. 1230.—Median sagittal section of female pelvis.

posterior part of the vaginal orifice. By inserting a finger into the vagina the following structures can be examined through its wall (Fig. 1230). Behind, from below upward, are the **anal canal**, the **rectum**, and the **rectouterine excavation**. Projecting into the roof of the vagina is the vaginal portion of the cervix uteri with the external uterine orifice; in front of and behind the cervix the anterior and posterior **vaginal fornices** respectively can be examined. With the finger in the vagina and the other hand on the abdominal wall the whole of the **cervix** and **body of the uterus**, the **uterine tubes**, and the **ovaries** can be palpated. If a speculum be introduced into the vagina, the walls of the passage, the vaginal portion of the cervix, and the external uterine orifice can all be exposed for visual examination.

The external urethral orifice lies in front of the vaginal opening; the angular gap in which it is situated between the two converging labia minora is termed the **vestibule**. The urethral canal in the female is very dilatable and can be explored with the finger. About 2.5 cm. in front of the external orifice of the urethra are the **glans** and **prepuce of the clitoris**, and still farther forward is the **mons pubis**.

SURFACE ANATOMY OF THE UPPER EXTREMITY.

Skin.—The skin covering the shoulder and arm is smooth and very movable on the underlying structures. In the axilla there are numerous hairs and many sudoriferous and sebaceous glands. Over the medial side and front of the forearm the skin is thin and smooth, and contains few hairs but many sudoriferous glands; over the lateral side and back of the arm and forearm it is thicker, denser, and contains more hairs but fewer sudoriferous glands. In the region of the olecranon it is thick and rough, and is very loosely connected to the underlying tissue so that it falls into transverse wrinkles when the forearm is extended. At the front of the wrist there are three transverse furrows in the skin; they correspond respectively from above downward to the positions of the styloid process of the ulna, the wrist-joint, and the midcarpal joint.

The skin of the palm of the hand differs considerably from that of the forearm. At the wrist it suddenly becomes hard and dense and covered with a thick layer of epidermis; on the thenar eminence these characteristics are less marked than elsewhere. In spite of its hardness and density the skin of the palm is exceedingly sensitive and very vascular, but it is destitute of hairs and sebaceous glands. It is tied down by fibrous bands along the lines of flexion of the digits, exhibiting certain furrows of a permanent character. One of these, starting in front of the wrist at the tuberosity of the navicular bone, curves around the thenar eminence and ends on the radial border of the hand a little above the metacarpophalangeal joint of the index finger. A second line begins at the end of the first and extends obliquely across the palm to reach the ulnar border about the middle of the fifth metacarpal bone. A third line begins at the ulnar border about 2.5 cm. distal to the end of the second and extends across the heads of the fifth, fourth, and third metacarpal bones. The proximal segments of the fingers are joined to one another on the volar aspect by folds of skin constituting the "web" of the fingers; these folds extend across about the level of the centers of the proximal phalanges and their free margins are continuous with the transverse furrows at the roots of the fingers. Since the web is confined to the volar aspect the fingers appear shorter when viewed from in front than from behind.

Over the fingers and thumb the skin again becomes thinner, especially at the flexures of the joints (where it is crossed by transverse furrows) and over the terminal phalanges; it is disposed on numerous ridges in consequence of the arrangement of the papillæ in it. These ridges form, in different individuals, distinctive and permanent patterns which can be used for purposes of identification. The superficial fascia in the palm of the hand is made up of dense fibro-fatty tissue which

binds the skin so firmly to the palmar aponeurosis that very little movement is permitted between the two.

On the back of the hand and fingers the subcutaneous tissue is lax, so that the skin is freely movable on the underlying parts. Over the interphalangeal joints the skin is very loose and is thrown into transverse wrinkles when the fingers are extended.

Bones.—The **clavicle** can be felt throughout its entire length. The enlarged sternal extremity projects above the upper margin of the sternum at the side of the jugular notch, and from this the body of the bone can be traced lateralward immediately under the skin. The medial part is convex forward, but the surface is partially obscured by the attachments of Sternocleidomastoideus and Pectoralis major; the lateral third is concave forward and ends at the acromion of the scapula in a slight enlargement. The clavicle is almost horizontal when the arm is lying by the side, although in muscular subjects it may incline a little upward at its acromial end, which is on a plane posterior to the sternal end.

The only parts of the **scapula** that are truly subcutaneous are the spine and acromion, but the coracoid process, the vertebral border, the inferior angle, and to a lesser extent the axillary border can also be readily defined. The acromion and spine are easily recognizable throughout their entire extent, forming with the clavicle the arch of the shoulder. The acromion forms the point of the shoulder; it joins the clavicle at an acute angle—the acromial angle—slightly medial to, and behind the tip of the acromion. The spine can be felt as a distinct ridge, marked on the surface as an oblique depression which becomes less distinct and ends in a slight dimple a little lateral to the spinous processes of the vertebræ. Below this point the vertebral border can be traced downward and lateralward to the inferior angle, which can be identified although covered by Latissimus dorsi. From the inferior angle the axillary border can usually be traced upward through its thick muscular covering, forming with its enveloping muscles the posterior fold of the axilla. The coracoid process is situated about 2 cm. below the junction of the intermediate and lateral thirds of the clavicle; it is covered by the anterior border of Deltoides, and thus lies a little lateral to the infraclavicular fossa or depression which marks the interval between the Pectoralis major and Deltoides.

The **humerus** is almost entirely surrounded by muscles, and the only parts which are strictly subcutaneous are small portions of the medial and lateral epicondyles; in addition to these, however, the tubercles and a part of the head of the bone can be felt under the skin and muscles by which they are covered. Of these, the greater tubercle forms the most prominent bony point of the shoulder, extending beyond the acromion; it is best recognized when the arm is lying passive by the side, for if the arm be raised it recedes under the arch of the shoulder. The lesser tubercle, directed forward, is medial to the greater and separated from it by the intertubercular groove, which can be made out by deep pressure. When the arm is abducted the lower part of the head of the humerus can be examined by pressing deeply in the axilla. On either side of the elbow-joint and just above it are the medial and lateral epicondyles. Of these, the former is the more prominent, but the medial supracondylar ridge passing upward from it is much less marked than the lateral, and as a rule is not palpable; occasionally, however, the hook-shaped supracondylar process (page 211) is found on this border. The position of the lateral epicondyle is best seen during semiflexion of the forearm, and is indicated by a depression; from it the strongly marked lateral supracondylar ridge runs upward.

The most prominent part of the **ulna**, the olecranon, can always be identified at the back of the elbow-joint. When the forearm is flexed the upper quadrilateral surface is palpable, but during extension it recedes into the olecranon fossa. During extension the upper border of the olecranon is slightly above the level of the medial

epicondyle and nearer to this than to the lateral; when the forearm is fully flexed the olecranon and the epicondyles form the angles of an equilateral triangle. On the back of the olecranon is a smooth triangular subcutaneous surface, and running down the back of the forearm from the apex of this triangle the prominent dorsal border of the ulna can be felt in its whole length: it has a sinuous outline, and is situated in the middle of the back of the limb above; but below, where it is rounded off, it can be traced to the small subcutaneous surface of the styloid process on the medial side of the wrist. The styloid process forms a prominent tubercle continuous above with the dorsal border and ending below in a blunt apex at the level of the wrist-joint; it is most evident when the hand is in a position midway between supination and pronation. When the forearm is pronated another prominence, the head of the ulna, appears behind and above the styloid process.

Below the lateral epicondyle of the humerus a portion of the head of the **radius** is palpable; its position is indicated on the surface by a little dimple, which is best seen when the arm is extended. If the finger be placed in this dimple and the semiflexed forearm be alternately pronated and supinated the head of the radius will be felt distinctly, rotating in the radial notch. The upper half of the body of the bone is obscured by muscles; the lower half, though not subcutaneous, can be readily examined, and if traced downward is found to end in a lozenge-shaped convex surface on the lateral side of the base of the styloid process; this is the only subcutaneous part of the bone, and from its lower end the apex of the styloid process bends medialward toward the wrist. About the middle of the dorsal surface of the lower end of the radius is the dorsal radial tubercle, best perceived when the wrist is slightly flexed; it forms the lateral boundary of the oblique groove for the tendon of *Extensor pollicis longus*.

On the front of the wrist are two subcutaneous eminences, one, on the radial side, the larger and flatter, produced by the tuberosity of the **navicular** and the ridge on the **greater multangular**; the other, on the ulnar side, by the **pisiform**. The tuberosity of the navicular is distal and medial to the styloid process of the radius, and is most clearly visible when the wrist-joint is extended; the ridge on the greater multangular is about 1 cm. distal to it. The pisiform is about 1 cm. distal to the lower end of the ulna and just distal to the level of the styloid process of the radius; it is crossed by the uppermost crease which separates the front of the forearm from the palm of the hand. The rest of the volar surface of the bony carpus is covered by tendons and the transverse carpal ligament, and is entirely concealed, with the exception of the hamulus of the **hamate bone**, which, however, is difficult to define. On the dorsal surface of the carpus only the **triangular bone** can be clearly made out.

Distal to the carpus the dorsal surfaces of the **metacarpal bones**, covered by the Extensor tendons, except the fifth, are visible only in very thin hands; the dorsal surface of the fifth is, however, subcutaneous throughout almost its whole length. Slightly lateral to the middle line of the hand is a prominence, frequently well-marked, but occasionally indistinct, formed by the styloid process of the third metacarpal bone; it is situated about 4 cm. distal to the dorsal radial tubercle. The heads of the metacarpal bones can be plainly seen and felt, rounded in contour and standing out in bold relief under the skin when the fist is clenched; the head of the third is the most prominent. In the palm of the hand the metacarpal bones are covered by muscles, tendons, and aponeuroses, so that only their heads can be distinguished. The base of the metacarpal bone of the thumb, however, is prominent dorsally, distal to the styloid process of the radius; the body of the bone is easily palpable, ending at the head in a flattened prominence, in front of which are the sesamoid bones.

The enlarged ends of the **phalanges** can be easily felt. When the digits are bent the proximal phalanges form prominences, which in the joints between the

first and second phalanges are slightly hollow, but flattened and square-shaped in those between the second and third.

Articulations.—The **sternoclavicular joint** is subcutaneous, and its position is indicated by the enlarged sternal extremity of the clavicle, lateral to the long cord-like sternal head of *Sternocleidomastoideus*. If this muscle be relaxed a depression between the end of the clavicle and the sternum can be felt, defining the exact position of the joint.

The position of the **acromioclavicular joint** can generally be ascertained by determining the slightly enlarged acromial end of the clavicle which projects above the level of the acromion; sometimes this enlargement is so considerable as to form a rounded eminence.

The **shoulder-joint** is deeply seated and cannot be palpated. If the forearm be slightly flexed a curved crease or fold with its convexity downward is seen in front of the elbow, extending from one epicondyle to the other; the **elbow-joint** is slightly distal to the center of the fold. The position of the **radiohumeral joint** can be ascertained by feeling for a slight groove or depression between the head of the radius and the capitulum of the humerus, at the back of the elbow-joint.

The position of the **proximal radioulnar joint** is marked on the surface at the back of the elbow by the dimple which indicates the position of the head of the radius. The site of the **distal radioulnar joint** can be defined by feeling for the slight groove at the back of the wrist between the prominent head of the ulna and the lower end of the radius, when the forearm is in a state of almost complete pronation.

Of the three transverse skin furrows on the front of the wrist, the middle corresponds fairly accurately with the **wrist-joint**, while the most distal indicates the position of the **midcarpal articulation**.

The **metacarpophalangeal** and **interphalangeal joints** are readily available for surface examination; the former are situated just distal to the prominences of the knuckles, the latter are sufficiently indicated by the furrows on the volar, and the wrinkles on the dorsal surfaces.

Muscles (Figs. 1194, 1231, 1232).—The anterior border of the **Trapezius** presents as a slight ridge running downward and forward from the superior nuchal line of the occipital bone to the junction of the intermediate and lateral thirds of the clavicle. The inferior border of the muscle forms an undulating ridge passing downward and medialward from the root of the spine of the scapula to the spinous process of the twelfth thoracic vertebra.

The lateral border of the **Latissimus dorsi** (Fig. 1215) may be traced, when the muscle is in action, as a rounded edge starting from the iliac crest and slanting obliquely forward and upward to the axilla, where it takes part with the *Teres major* in forming the posterior axillary fold.

The **Pectoralis major** (Fig. 1219) conceals a considerable part of the thoracic wall in front. Its sternal origin presents a border which bounds, and determines the width of the sternal furrow. The upper margin is generally well-marked medially and forms the medial boundary of a triangular depression, the **infraclavicular fossa**, which separates the *Pectoralis major* from the *Deltoides*; it gradually becomes less marked as it approaches the tendon of insertion and is closely blended with the *Deltoides*. The lower border of *Pectoralis major* forms the rounded anterior axillary fold. Occasionally a gap is visible between the clavicular and sternal parts of the muscle.

When the arm is raised the lowest slip of origin of **Pectoralis minor** produces a fulness just below the anterior axillary fold and serves to break the sharp outline of the lower border of *Pectoralis major*.

The origin of the **Serratus anterior** (Figs. 1215, 1219) causes a very characteristic surface marking. When the arm is abducted the lower five or six serrations form

a zigzag line with a general convexity forward; when the arm is by the side the highest visible serration is that attached to the fifth rib.

The **Deltoideus** with the prominence of the upper end of the humerus produces the rounded contour of the shoulder; it is rounded and fuller in front than behind, where it presents a somewhat flattened form. Above, its anterior border presents a slightly curved eminence which forms the lateral boundary of the infraclavicular fossa; below, it is closely united with the **Pectoralis major**. Its posterior border is thin, flattened, and scarcely marked above, but is thicker and more prominent below. The insertion of **Deltoideus** is marked by a depression on the lateral side of the middle of the arm.

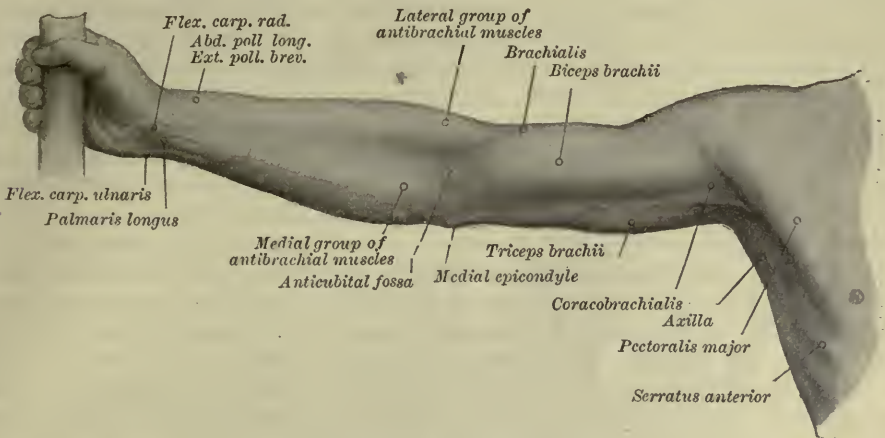


FIG. 1231.—Front of right upper extremity.

Of the scapular muscles the only one which influences surface form is the **Teres major**; it assists the **Latissimus dorsi** in forming the thick, rounded, posterior axillary fold.

When the arm is raised the **Coracobrachialis** reveals itself as a narrow elevation emerging from under cover of the anterior axillary fold and running medial to the body of the humerus.

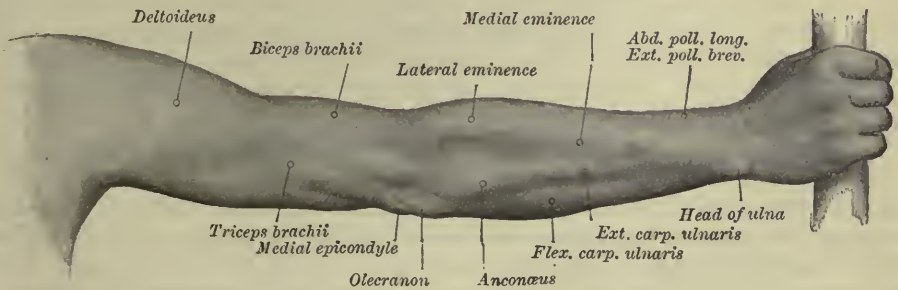


FIG. 1232.—Back of right upper extremity.

On the front and medial aspects of the arm is the prominence of the **Biceps brachii**, bounded on either side by an intermuscular depression. It determines the contour of the front of the arm and extends from the anterior axillary fold to the bend of the elbow; its upper tendons are concealed by the **Pectoralis major** and **Deltoideus**, and its lower tendon sinks into the anticubital fossa. When the muscle is fully contracted it presents a globular form, and the **lacertus fibrosus** attached

to its tendon of insertion becomes prominent as a sharp ridge running downward and medialward.

On either side of the *Biceps brachii* at the lower part of the arm the *Brachialis* is discernible. Laterally it forms a narrow eminence extending some distance up the arm; medially it exhibits only a little fullness above the elbow.

On the back of the arm the long head of the *Triceps brachii* may be seen as a longitudinal eminence, emerging from under cover of *Deltoides* and gradually passing into the flattened plane of the tendon of the muscle at the lower part of the back of the arm. When the muscle is in action the medial and lateral heads become prominent.

On the front of the elbow are two muscular elevations, one on either side, separate above but converging below so as to form the medial and lateral boundaries of the anticubital fossa. The medial elevation consists of the *Pronator teres* and the *Flexors*, and forms a fusiform mass, pointed above at the medial epicondyle and gradually tapering off below. The *Pronator teres* is the most lateral of the group, while the *Flexor carpi radialis*, lying to its medial side, is the most prominent and may be traced downward to its tendon, which is situated nearer to the radial than to the ulnar border of the front of the wrist and medial to the radial artery. The *Palmaris longus* presents no surface marking above, but below, its tendon stands out when the muscle is in action as a sharp, tense cord in front of the middle of the wrist. The *Flexor digitorum sublimis* does not directly influence surface form; the position of its four tendons on the front of the lower part of the forearm is indicated by an elongated depression between the tendons of *Palmaris longus* and *Flexor carpi ulnaris*. The *Flexor carpi ulnaris* determines the contour of the medial border of the forearm, and is separated from the *Extensor* group of muscles by the ulnar furrow produced by the subcutaneous dorsal border of the ulna; its tendon is evident along the ulnar border of the lower part of the forearm, and is most marked when the hand is flexed and adducted.

The elevation forming the lateral side of the anticubital fossa consists of the *Brachioradialis*, the *Extensors* and the *Supinator*; it occupies the lateral and a considerable part of the dorsal surface of the forearm in the region of the elbow, and forms a fusiform mass which is altogether on a higher level than that produced by the medial elevation. Its apex is between the *Triceps brachii* and *Brachialis* some distance above the elbow-joint; it acquires its greatest breadth opposite the lateral epicondyle, and below this shades off into a flattened surface. About the middle of the forearm it divides into two diverging longitudinal eminences. The lateral eminence consists of the *Brachioradialis* and the *Extensores carpi radiales longus* and *brevis*, and descends from the lateral supracondylar ridge in the direction of the styloid process of the radius. The medial eminence comprises the *Extensor digitorum communis*, *Extensor digiti quinti proprius*, and the *Extensor carpi ulnaris*; it begins at the lateral epicondyle of the humerus as a tapering mass which is separated above from the *Anconæus* by a well-marked furrow, and below from the *Pronator teres* and *Flexor* group by the ulnar furrow. The medial border of the *Brachioradialis* starts as a rounded elevation above the lateral epicondyle; lower down the muscle forms a prominent mass on the radial side of the upper part of the forearm; below it tapers to its tendon, which may be traced to the styloid process of the radius. The *Anconæus* presents as a triangular slightly elevated area, immediately lateral to the subcutaneous surface of the olecranon and differentiated from the *Extensor* group by an oblique depression; the upper angle of the triangle is at the dimple over the lateral epicondyle.

At the lower part of the back of the forearm in the interval between the two diverging eminences is an oblique elongated swelling; full above but flattened and partially subdivided below; it is caused by the *Abductor pollicis longus* and the *Extensor pollicis brevis*. It crosses the dorsal and lateral surfaces of

the radius to the radial side of the wrist-joint, whence it is continued on to the dorsal surface of the thumb as a ridge best marked when the thumb is extended.

The tendons of most of the Extensor muscles can be seen and felt on the back of the wrist. Laterally is the oblique ridge produced by the Extensor pollicis longus. The Extensor carpi radialis longus is scarcely palpable, but the Extensor carpi radialis brevis can be identified as a vertical ridge emerging from under the ulnar border of the tendon of the Extensor pollicis longus when the wrist is extended. Medial to this the Extensor tendons of the fingers can be felt, the Extensor digiti quinti proprius being separated from the tendons of the Extensor digitorum communis by a slight furrow.

The muscles of the hand are principally concerned, as regards surface form, in producing the thenar and hypothenar eminences, and cannot be individually distinguished; the thenar eminence, on the radial side, is larger and rounder than the hypothenar, which is a long narrow elevation along the ulnar side of the palm. When the *Palmaris brevis* is in action it produces a wrinkling of the skin over the hypothenar eminence and a dimple on the ulnar border. On the back of the hand the *Interossei dorsales* give rise to elongated swellings between the metacarpal bones; the first forms a prominent fusiform bulging when the thumb is adducted, the others are not so marked.

Arteries.—Above the middle of the clavicle the pulsation of the *subclavian artery* can be detected by pressing downward, backward, and medialward against the first rib. The pulsation of the *axillary artery* as it crosses the second rib can be felt below the middle of the clavicle just medial to the coracoid process; along the lateral wall of the axilla the course of the artery can be easily followed close to the medial border of *Coracobrachialis*. The *brachial artery* can be recognized in practically the whole of its extent, along the medial margin of the *Biceps*; in the upper two-thirds of the arm it lies medial to the humerus, but in the lower third is more directly on the front of the bone. Over the lower end of the radius, between the styloid process and *Flexor carpi radialis*, a portion of the *radial artery* is superficial and is used clinically for observations on the pulse.

Veins.—The superficial veins of the upper extremity are easily rendered visible by compressing the proximal trunks; their arrangement is described on pages 660 to 662.

Nerves.—The uppermost trunks of the *brachial plexus* are palpable for a short distance above the clavicle as they emerge from under the lateral border of *Sternocleidomastoideus*; the larger nerves derived from the plexus can be rolled under the finger against the lateral axillary wall but cannot be identified. The *ulnar nerve* can be detected in the groove behind the medial epicondyle of the humerus.

SURFACE MARKINGS OF THE UPPER EXTREMITY.

Bony Landmarks.—The bony landmarks as described above are so readily available for surface recognition that no special measurements are required to indicate them. It may be noted, however, that the medial angle of the scapula is applied to the second rib, while the inferior angle lies against the seventh. The intertubercular groove of the humerus is vertically below the acromioclavicular joint when the arm hangs by the side with the palm of the hand forward.

Articulations.—The *acromioclavicular joint* is situated in a plane passing sagittally through the middle line of the front of the arm. The line of the *elbow-joint* is not straight; the radiohumeral portion is practically at right angles to the long axis of the humerus and is situated about 2 cm. distal to the lateral epicondyle; the ulnohumeral portion is oblique, and its medial end is about 2.5 cm. distal to the medial epicondyle. The position of the *wrist-joint* can be indicated by drawing a

curved line, with its convexity upward, between the styloid processes of the radius and ulna; the summit of the convexity is about 1 cm. above the center of a straight line joining the two processes.

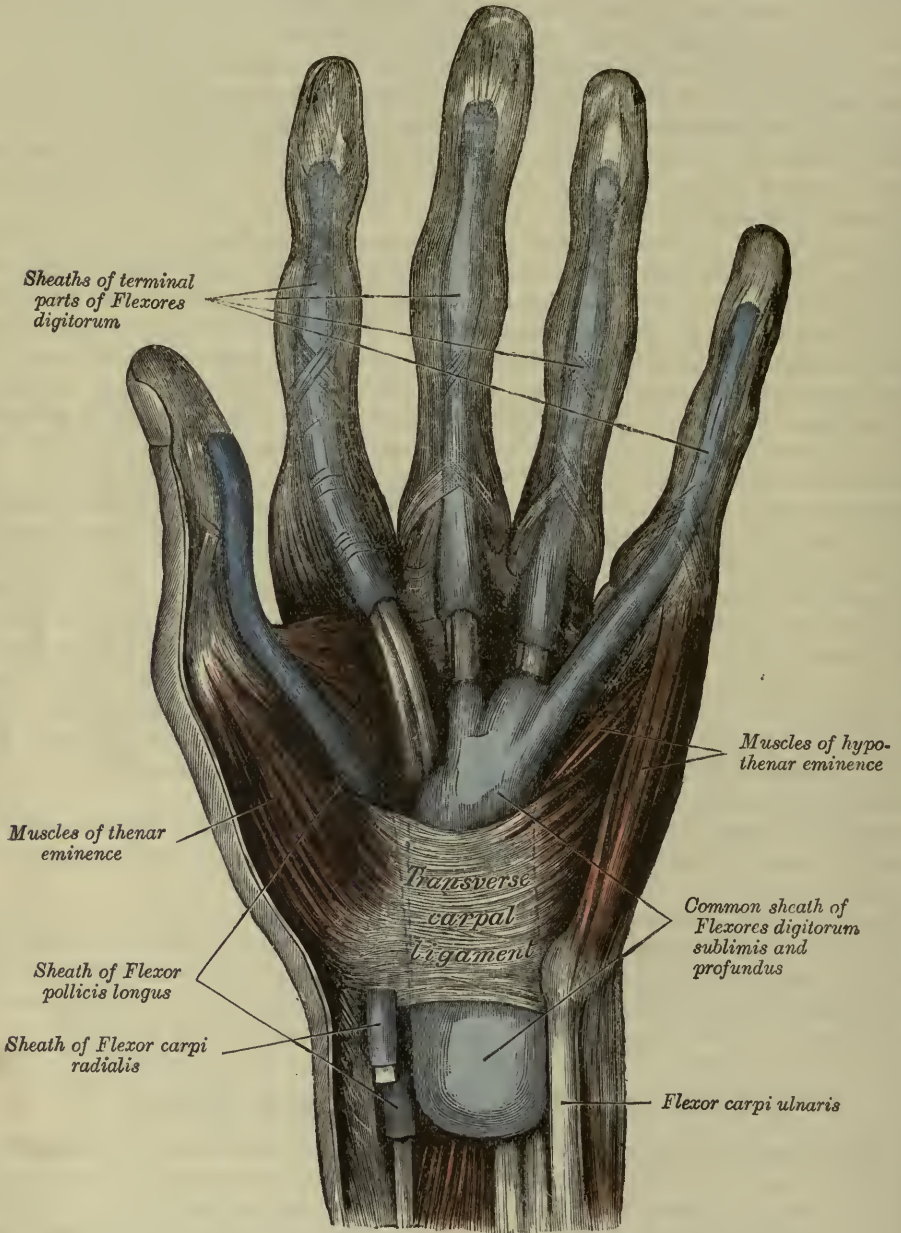


FIG. 1233.—The mucous sheaths of the tendons on the front of the wrist and digits.

Muscles.—The only muscles of the upper extremity which occasionally require definition by surface lines are the Trapezius, the Latissimus dorsi, and the Pectorales major and minor. The antero-superior border of **Trapezius** is indicated by a line from the superior nuchal line about 3 cm. lateral to the external occipital protuberance to the junction of the intermediate and lateral thirds of the clavicle; the line of the lower border extends from the spinous process of the twelfth thoracic vertebra to the vertebral border of the scapula at the root of the spine. The upper border

of *Latissimus dorsi* is almost horizontal, running from the spinous process of the seventh thoracic vertebra to the inferior angle of the scapula and thence somewhat obliquely to the intertubercular sulcus of the humerus; the lower border corresponds roughly to a line drawn from the iliac crest about 2 cm. from the lateral margin of

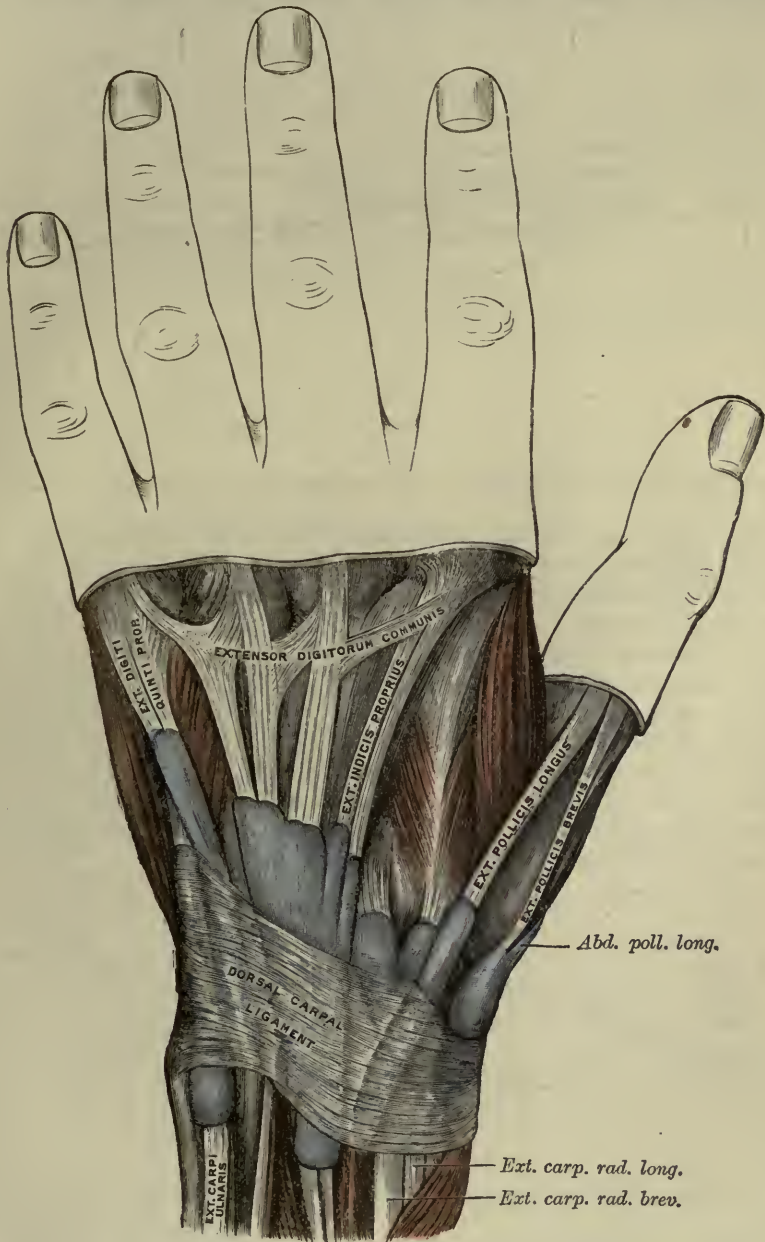

FIG. 1234.—The mucous sheaths of the tendons on the back of the wrist.

the Sacrospinalis to the intertubercular sulcus. The upper margin of **Pectoralis major** extends from the middle of the clavicle to the surgical neck of the humerus; its lower border is practically in the line of the fifth rib and reaches from the fifth costochondral junction to the middle of the anterior border of *Deltoides*. The two lines indicating the borders of **Pectoralis minor** begin at the coracoid process

of the scapula and extend to the third and fifth ribs respectively, just lateral to the corresponding costal cartilages. On the front of the elbow-joint a triangular space—the **antecubital fossa**—is mapped out for convenience of reference. The base of the triangle is a line joining the medial and lateral epicondyles, while the sides are formed respectively by the salient margins of the Brachioradialis and Pronator teres.

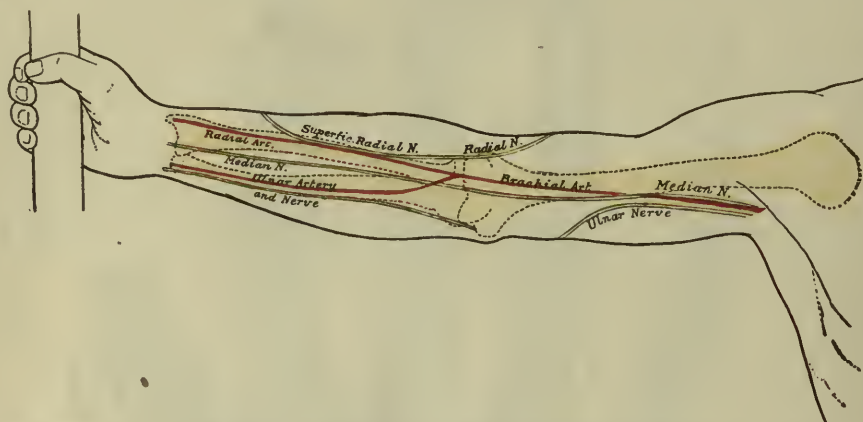


FIG. 1235.—Front of right upper extremity, showing surface markings for bones, arteries, and nerves.

Mucous Sheaths.—On the volar surfaces of the wrist and hand the mucous sheaths of the Flexor tendons (Fig. 1233) can be indicated as follows. The sheath for Flexor pollicis longus extends from about 3 cm. above the upper edge of the transverse carpal ligament to the terminal phalanx of the thumb. The common sheath for the Flexores digitorum reaches about 3.5 to 4 cm. above the upper edge of the transverse carpal ligament and extends on the palm of the hand to about the level of the centers of the metacarpal bones. The sheath for the tendons to the little finger is continued from the common sheath to the base of the terminal phalanx of this finger; the sheaths for the tendons of the other fingers are separated from the common sheath by an interval; they begin opposite the necks of the metacarpal bones and extend to the terminal phalanges. The mucous sheaths of the Extensor tendons are shown in Fig. 1234 (see also page 459).

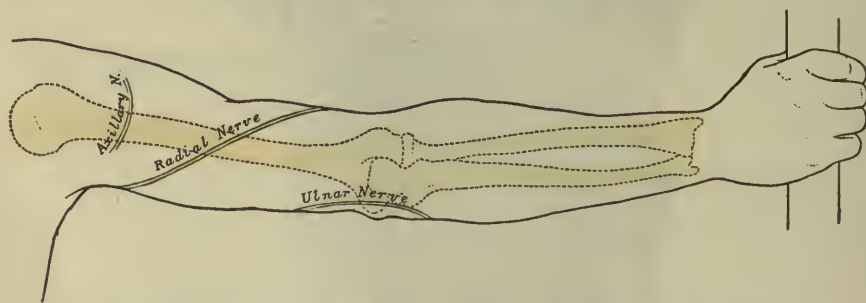

FIG. 1236.—Back of right upper extremity, showing surface markings for bones and nerves.

Arteries (Fig. 1235).—The course of the **axillary artery** can be marked out by abducting the arm to a right angle and drawing a line from the middle of the clavicle to the point where the tendon of the Pectoralis major crosses the prominence of the Coracobrachialis. Of the branches of the axillary artery, the origin of the **thoracoacromial** corresponds to the point where the artery crosses the upper border of Pectoralis minor; the **lateral thoracic** takes practically the line of the lower border of Pectoralis minor; the **subscapular** is sufficiently indicated by

the axillary border of the scapula; the **scapular circumflex** is given off the subscapular opposite the midpoint of a line joining the tip of the acromion to the lower edge of the deltoid tuberosity, while the **humeral circumflex** arteries arise from the axillary about 2 cm. above this. The position of the **brachial artery** is marked by a line drawn from the junction of the anterior and middle thirds of the distance between the anterior and posterior axillary folds to a point midway between the epicondyles of the humerus and continued distally for 2.5 cm., at which point the artery bifurcates. With regard to the branches of the brachial artery—the **profunda** crosses the back of the humerus at the level of the insertion of *Deltoideus*; the **nutrient** is given off opposite the middle of the body of the humerus; a line from this point to the back of the medial condyle represents the **superior ulnar collateral**; the **inferior ulnar collateral** is given off about 5 cm. above the fold of the elbow-joint and runs directly medialward.

The position of the **radial artery** in the forearm is represented by a line from the lateral margin of the *Biceps* tendon in the center of the antecubital fossa to the medial side of the front of the styloid process of the radius when the limb is in the position of supination. The situation of the distal portion of the artery is indicated by continuing this line around the radial side of the wrist to the proximal end of the first intermetacarpal space.

On account of the curved direction of the **ulnar artery**, two lines are required to indicate its course; one is drawn from the front of the medial epicondyle to the radial side of the pisiform bone; the lower two-thirds of this line represents two-thirds of the artery; the upper third is represented by a second line from the center of the hollow in front of the elbow-joint to the junction of the upper and middle thirds of the first line.

The **superficial volar arch** (Fig. 1237) can be indicated by a line starting from the radial side of the pisiform bone and curving distalward and lateralward as far as the base of the thumb, with its convexity toward the fingers. The summit of the arch is usually on a level with the ulnar border of the outstretched thumb. The **deep volar arch** is practically transverse, and is situated about 1 cm. nearer to the carpus.

Nerves (Figs. 1235, 1236).—In the arm the line of the **median nerve** is practically the same as that for the brachial artery; at the bend of the elbow the nerve is medial to the artery. The course of the nerve in the forearm is marked by a line starting from a point just medial to the center of one joining the epicondyles, and extending to the lateral margin of the tendon of *Palmaris longus* at the wrist.

The **ulnar nerve** follows the line of the brachial artery in the upper half of the

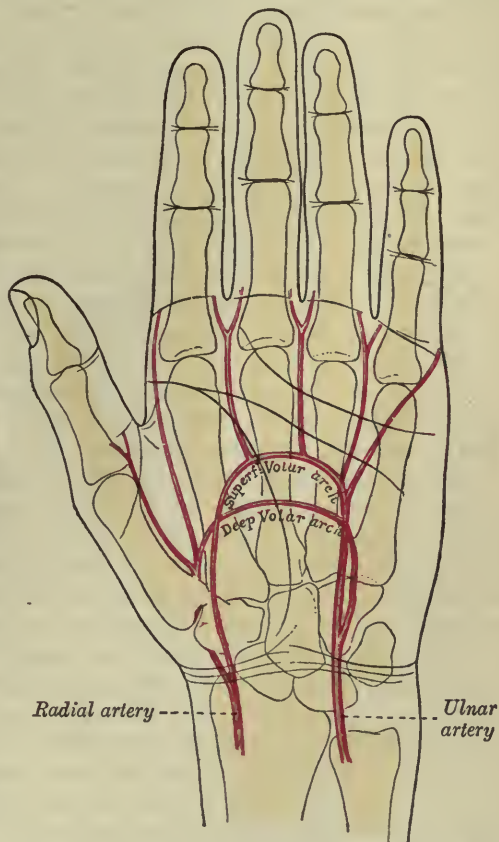


FIG. 1237.—Palm of left hand, showing position of skin creases and bones, and surface markings for the volar arches.

arm, but at the middle of the arm it diverges and descends to the back of the medial epicondyle. In the forearm it is represented by a line from the front of the medial epicondyle to the radial side of the pisiform bone.

The course of the **radial nerve** can be indicated by a line from just below the posterior axillary fold, to the lateral side of the humerus at the junction of its middle and lower thirds; thence it passes vertically downward on the front of the arm to the level of the lateral epicondyle. The course of the **superficial radial nerve** is represented by a continuation of this line downward to the junction of the middle and lower thirds of the radial artery; it then crosses the radius and runs distalward to the dorsum of the base of the first metacarpal bone.

The **axillary nerve** crosses the humerus about 2 cm. above the center of a line joining the tip of the acromion to the lower edge of the deltoid tuberosity.

SURFACE ANATOMY OF THE LOWER EXTREMITY.

Skin.—The skin of the thigh, especially in the hollow of the groin and on the medial side, is thin, smooth and elastic, and contains few hairs except on the neighborhood of the pubis. Laterally it is thicker and the hairs are more numerous. The junction of the skin of the thigh with that on the front of the abdomen is marked by a well-defined furrow which indicates the site of the inguinal ligament; the furrow presents a general convexity downward, but its medial half, which is the better marked, is nearly straight. The skin over the buttock is fairly thick and is characterized by its low sensibility and slight vascularity; as a rule it is destitute of conspicuous hairs except toward the post-anal furrow, where in some males they are abundantly developed. An almost transverse fold—the **gluteal fold**—crosses the lower part of the buttock; it practically bisects the lower margin of the *Glutæus maximus* and is most evident during extension of the hip-joint. The skin over the front of the knee is covered by thickened epidermis; it is loose and thrown into transverse wrinkles when the leg is extended. The skin of the leg is thin, especially on the medial side, and is covered with numerous large hairs. On the dorsum of the foot the skin is thin, loosely connected to subjacent parts, and contains few hairs, on the plantar surface, and especially over the heel, the epidermis is of great thickness, and here, as in the palm of the hand, there are neither hairs nor sebaceous glands.

Bones.—The **hip bones** are largely covered with muscles, so that only at a few points do they approach the surface. In front the anterior superior iliac spine is easily recognized, and in thin subjects stands out as a prominence at the lateral end of the fold of the groin; in fat subjects its position is indicated by an oblique depression, at the bottom of which the bony process can be felt. Proceeding upward and backward from this process the sinuously curved iliac crest can be traced to the posterior superior iliac spine, the site of which is indicated by a slight depression; on the outer lip of the crest, about 5 cm. behind the anterior superior spine, is the prominent iliac tubercle. In thin subjects the pubic tubercle is very apparent, but in the obese it is obscured by the pubic fat; it can, however, be detected by following up the tendon of origin of *Adductor longus*. Another part of the bony pelvis which is accessible to touch is the ischial tuberosity, situated beneath the *Glutæus maximus*, and, when the hip is flexed, easily felt, as it is then uncovered by muscle.

The **femur** is enveloped by muscles, so that in fairly muscular subjects the only accessible parts are the lateral surface of the greater trochanter and the lower expanded end of the bone. The site of the greater trochanter is generally indicated by a depression, owing to the thickness of the *Glutæi medius* and *minimus* which project above it; when, however, the thigh is flexed, and especially if it be crossed over the opposite one, the trochanter produces a blunt eminence on the surface.

The lateral condyle is more easily felt than the medial; both epicondyles can be readily identified, and at the upper part of the medial condyle the sharp adductor tubercle can be recognized without difficulty. When the knee is flexed a portion of the patellar surface is uncovered and is palpable.

The anterior surface of the **patella** is subcutaneous. When the knee is extended the medial border of the bone is a little more prominent than the lateral, and if the **Quadriceps femoris** be relaxed the bone can be moved from side to side. When the joint is flexed the patella recedes into the hollow between the condyles of the femur and the upper end of the tibia, and becomes firmly applied to the femur.

A considerable portion of the **tibia** is subcutaneous. At the upper end the condyles can be felt just below the knee; the medial condyle is broad and smooth, and merges into the subcutaneous surface of the body below; the lateral is narrower and more prominent, and on it, about midway between the apex of the patella and the head of the fibula, is the tubercle for the attachment of the iliotibial band. In front of the upper end of the bone, between the condyles, is an oval eminence, the tuberosity, which is continuous below with the anterior crest of the bone. This crest can be identified in the upper two-thirds of its extent as a flexuous ridge, but in the lower third it disappears and the bone is concealed by the tendons of the muscles on the front of the leg. Medial to the anterior crest is the broad surface, slightly encroached on by muscles in front and behind. The medial malleolus forms a broad prominence, situated at a higher level and somewhat farther forward than the lateral malleolus; it overhangs the medial border of the arch of the foot; its anterior border is nearly straight, its posterior presents a sharp edge which forms the medial margin of the groove for the tendon of **Tibialis posterior**.

The only subcutaneous parts of the **fibula** are the head, the lower part of the body, and the lateral malleolus. The head lies behind and lateral to the lateral condyle of the tibia, and presents as a small prominent pyramidal eminence slightly above the level of the tibial tuberosity; its position can be readily located by following downward the tendon of **Biceps femoris**. The lateral malleolus is a narrow elongated prominence, from which the lower third or half of the lateral surface of the body of the bone can be traced upward.

On the dorsum of the tarsus the individual bones cannot be distinguished, with the exception of the head of the **talus**, which forms a rounded projection in front of the ankle-joint when the foot is forcibly extended. The whole dorsal surface of the foot has a smooth convex outline, the summit of which is the ridge formed by the head of the talus, the navicular, the second cuneiform, and the second metatarsal bone; from this it inclines gradually lateralward, and rapidly medialward. On the medial side of the foot the medial process of the tuberosity of the **calcaneus** and the ridge separating the posterior from the medial surface of the bone are distinguishable; in front of this, and below the medial malleolus, is the **sustenaculum tali**. The tuberosity of the **navicular** is palpable about 2.5 to 3 cm. in front of the medial malleolus.

Farther forward, the ridge formed by the base of the **first metatarsal bone** can be obscurely felt, and from this the body of the bone can be traced to the expanded head; beneath the base of the first phalanx is the medial sesamoid bone. On the lateral side of the foot the most posterior bony point is the lateral process of the tuberosity of the calcaneus, with the ridge separating the posterior from the lateral surface of the bone. In front of this the greater part of the lateral surface of the calcaneus is subcutaneous; on it, below and in front of the lateral malleolus, the trochlear process, when present, can be felt. Farther forward the base of the **fifth metatarsal bone** is prominent, and from it the body and expanded head can be traced.

As in the case of the metacarpals, the dorsal surfaces of the **metatarsal bones**

are easily defined, although their heads do not form prominences; the plantar surfaces are obscured by muscles. The **phalanges** in their whole extent are readily palpable.

Articulations.—The **hip-joint** is deeply seated and cannot be palpated.

The interval between the tibia and femur can always be easily felt; if the **knee-joint** be extended this interval is on a higher level than the apex of the patella, but if the joint be slightly flexed it is directly behind the apex. When the knee is semiflexed, the medial borders of the patella and of the medial condyle of the femur, and the upper border of the medial condyle of the tibia, bound a triangular depressed area which indicates the position of the joint.

The **ankle-joint** can be felt on either side of the Extensor tendons, and during extension of the joint the superior articular surface of the talus presents below the anterior border of the lower end of the tibia.

Muscles.—Of the muscles of the thigh, those of the anterior femoral region (Fig. 1238) contribute largely to surface form. The **Tensor fasciæ latæ** produces a broad elevation immediately below the anterior part of the iliac crest and behind the anterior superior iliac spine; from its lower border a groove caused by the iliotibial band extends downward to the lateral side of the knee-joint. The upper portion of **Sartorius** constitutes the lateral boundary of the femoral triangle, and, when the muscle is in action, forms a prominent oblique ridge which is continued below into a flattened plane and then gradually merges into a general fulness on the medial side of the knee-joint. When the Sartorius is not in action, a depression exists between the Quadriceps femoris and the Adductores, and extends obliquely downward and medialward from the apex of the femoral triangle to the side of the

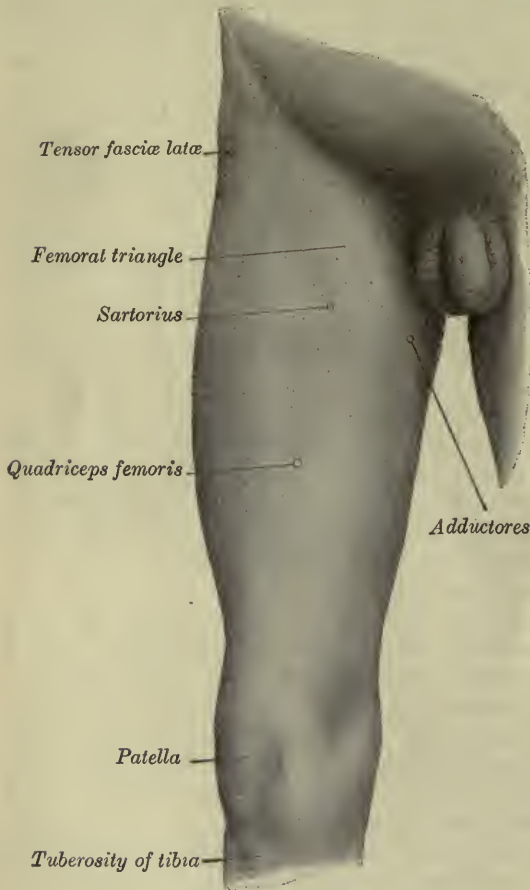


FIG. 1238.—Front and medial aspect of right thigh.

knee. In the angle formed by the divergence of Sartorius and Tensor fasciæ latæ, just below the anterior superior iliac spine, the **Rectus femoris** appears, and in a muscular subject its borders can be clearly defined when the muscle is in action. The **Vastus lateralis** forms a long flattened plane traversed by the groove of the iliotibial band. The **Vastus medialis** gives rise to a considerable prominence on the medial side of the lower half of the thigh; this prominence increases toward the knee and ends somewhat abruptly with a full curved outline. The **Vastus intermedius** is completely hidden. The Adductores cannot be differentiated from one another, with the exception of the upper tendon of Adductor longus and the lower tendon of Adductor magnus. When the **Adductor longus** is in action its

upper tendon stands out as a prominent ridge running obliquely downward and lateralward from the neighborhood of the pubic tubercle, and forming the medial border of the femoral triangle. The lower tendon of **Adductor magnus** can be distinctly felt as a short ridge extending downward between the Sartorius and Vastus medialis to the adductor tubercle. The adductores fill in the triangular space at the upper part of the thigh, between the femur and the pelvis, and to them is due the contour of the medial border of the thigh, the **Gracilis** contributing largely to the smoothness of the outline.

The **Glutæus maximus** (Fig. 1239) forms the full rounded outline of the buttock; it is more prominent behind, compressed in front, and ends at its tendinous insertion in a depression immediately behind the greater trochanter; its lower border crosses the gluteal fold obliquely downward and lateralward. The upper is part of **Glutæus medius** visible, but its lower part with **Glutæus minimus** and the external rotators are completely hidden. From beneath the lower margin of **Glutæus maximus** the hamstrings appear; at first they are narrow and not well-defined, but as they descend they become more prominent and eventually divide into two well-marked ridges formed by their tendons; these constitute the upper boundaries of the popliteal fossa. The tendon of **Biceps femoris** is a thick cord running to the head of

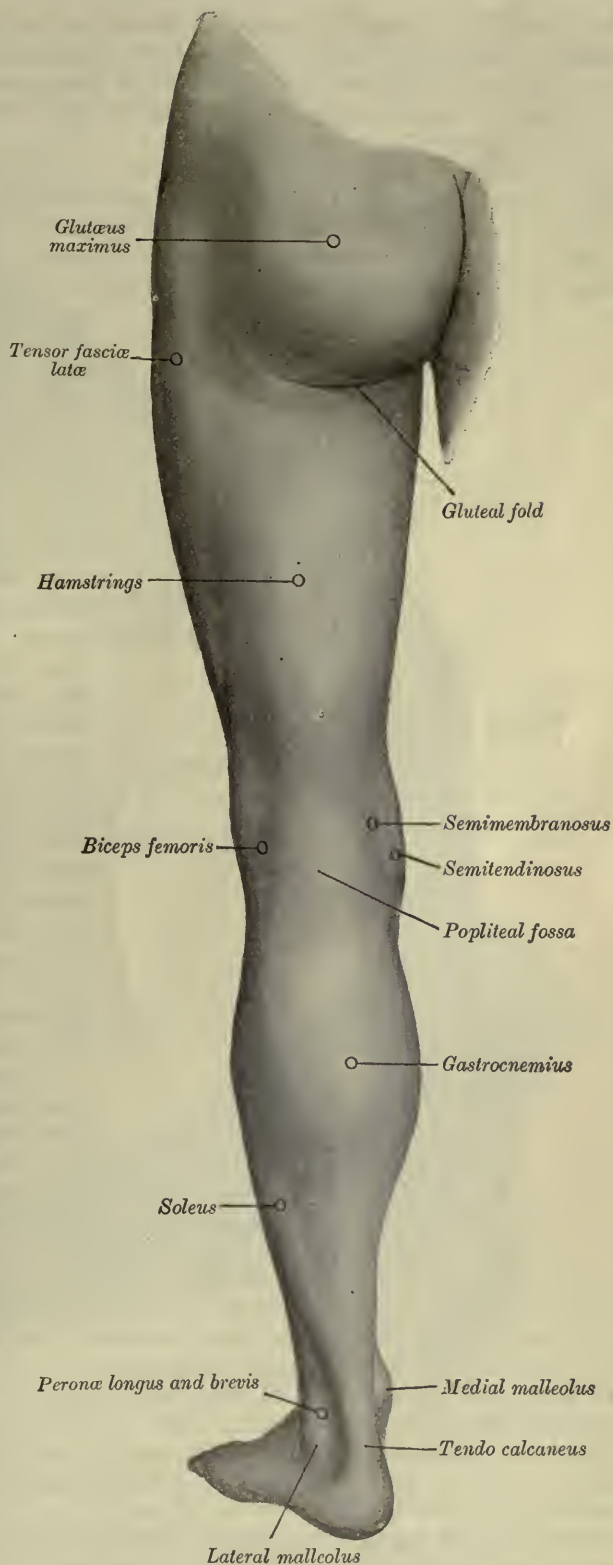

FIG. 1239.—Back of left lower extremity.

the fibula; the tendons of the **Semimembranosus** and **Semitendinosus** as they run medialward to the tibia are separated by a slight furrow; the **Semitendinosus** is the more medial, and can be felt in certain positions of the limb as a sharp cord, while the **Semimembranosus** is thick and rounded. The **Gracilis** is situated a little in front of them.

The **Tibialis anterior** (Fig. 1240) presents a fusiform enlargement at the lateral side of the tibia and projects beyond the anterior crest of the bone; its tendon can be traced on the front of the tibia and ankle-joint and thence along the medial side of the foot to the base of the first metatarsal bone. The fleshy fibers of **Peronæus longus** are strongly marked at the upper part of the lateral side of the leg; it is

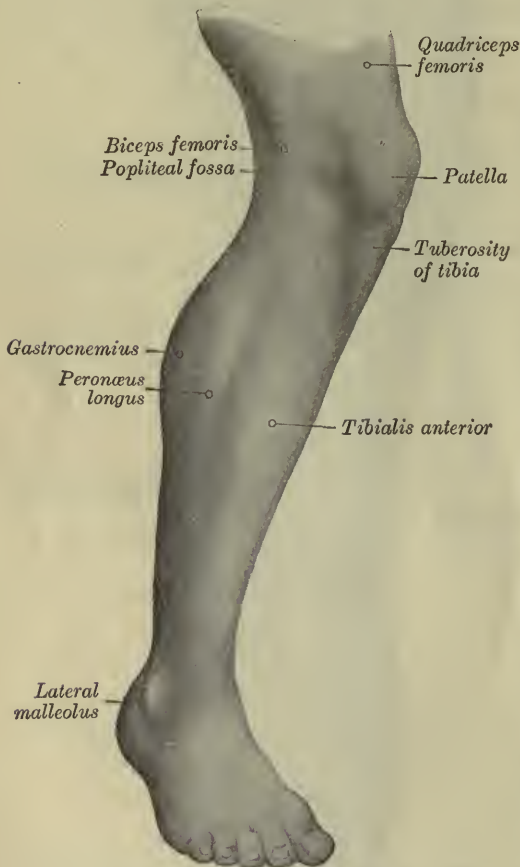


FIG. 1240.—Lateral aspect of right leg.

separated by furrows from **Extensor digitorum longus** in front and **Soleus** behind. Below, the fleshy fibers end abruptly in a tendon which overlaps the more flattened elevation of **Peronæus brevis**; below the lateral malleolus the tendon of **Peronæus brevis** is the more marked.

On the dorsum of the foot (Fig. 1241) the tendons emerging from beneath the transverse and cruciate crural ligaments spread out and can be distinguished as follows: the most medial and largest is **Tibialis anterior**, the next is **Extensor hallucis proprius**, then **Extensor digitorum longus** dividing into four tendons, to the second, third, fourth, and fifth toes, and lastly **Peronæus tertius**. The **Extensor digitorum brevis** produces a rounded outline on the dorsum of the foot and a fulness in front of the lateral malleolus. The **Interossei dorsales** bulge between the metatarsal bones.

At the back of the knee is the popliteal fossa, bounded above by the tendons of the hamstrings and below by the **Gastrocnemius**. Below this fossa is the prominent fleshy mass of the calf of the leg produced by **Gastrocnemius** and **Soleus** (Fig.

1239). When these muscles are in action the borders of **Gastrocnemius** form two well-defined curved lines which converge to the tendocalcaneus; the medial border is the more prominent. At the same time the edges of **Soleus** can be seen forming, on either side of **Gastrocnemius**, curved eminences, of which the lateral is the longer. The fleshy mass of the calf ends somewhat abruptly in the tendocalcaneus, which tapers in the upper three-fourths of its extent but widens out slightly below. Behind the medial border of the lower part of the tibia (Fig. 1242) a well-defined ridge is produced by the tendon of **Tibialis posterior** during contraction of the muscle.

On the sole of the foot the **Abductor digiti quinti** forms a narrow rounded elevation on the lateral side, and the **Abductor hallucis** a lesser elevation on the medial

side. The **Flexor digitorum brevis**, bound down by the plantar aponeurosis, is not very apparent; it produces a flattened form, and the thickened skin underlying it is thrown into numerous wrinkles.

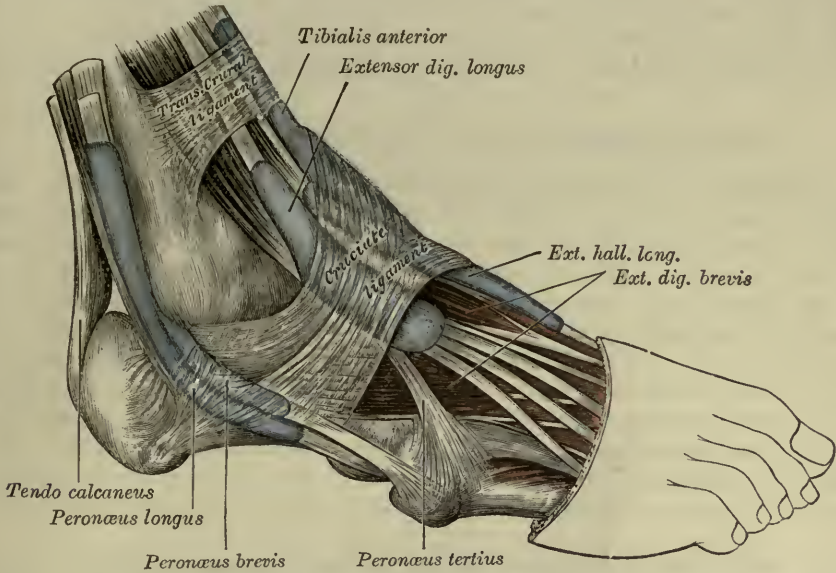


FIG. 1241.—The mucous sheaths of the tendons around the ankle. Lateral aspect.

Arteries.—The **femoral artery** as it crosses the brim of the pelvis is readily felt; in its course down the thigh its pulsation becomes gradually more difficult of recognition. When the knee is flexed the pulsation of the **popliteal artery** can easily be detected in the popliteal fossa.

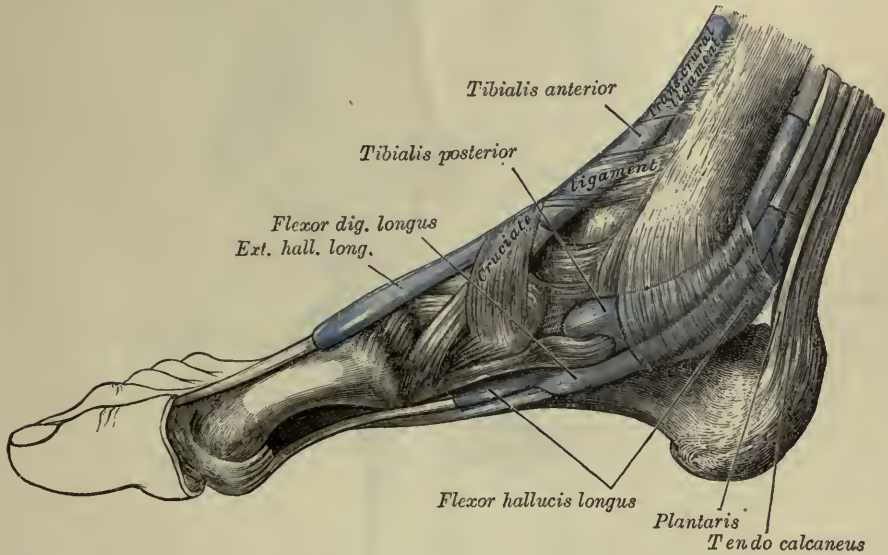


FIG. 1242.—The mucous sheaths of the tendons around the ankle. Medial aspect.

On the lower part of the front of the tibia the **anterior tibial artery** becomes superficial and can be traced over the ankle into the **dorsalis pedis**; the latter can be followed to the proximal end of the first intermetatarsal space. The pulsation

of the **posterior tibial artery** becomes evident near the lower end of the back of the tibia, and is easily detected behind the medial malleolus.

Veins.—By compressing the proximal trunks, the venous arch on the dorsum of the foot, together with the great and small saphenous veins leading from it (see page 669), are rendered visible.

Nerves.—The only nerve of the lower extremity which can be located by palpation is the **common peroneal** as it winds around the lateral side of the neck of the fibula.

SURFACE MARKINGS OF THE LOWER EXTREMITY.

Bony Landmarks.—The anterior superior iliac spine is at the level of the sacral promontory—the posterior at the level of the spinous process of the second sacral vertebra. A horizontal line through the highest points of the iliac crests passes also through the spinous process of the fourth lumbar vertebra, while, as already pointed out (page 1315), the transtubercular plane through the tubercles on the iliac crests cuts the body of the fifth lumbar vertebra. The upper margin of the greater sciatic notch is opposite the spinous process of the third sacral vertebra, and slightly below this level is the posterior inferior iliac spine. The surface markings of the posterior inferior iliac spine and the ischial spine are both situated in a line which joins the posterior superior iliac spine to the outer part of the ischial tuberosity; the posterior inferior spine is 5 cm. and the ischial spine 10 cm. below the posterior superior spine; the ischial spine is opposite the first piece of the coccyx.

With the body in the erect posture the line joining the pubic tubercle to the top of the greater trochanter is practically horizontal; the middle of this line overlies the acetabulum and the head of the femur.

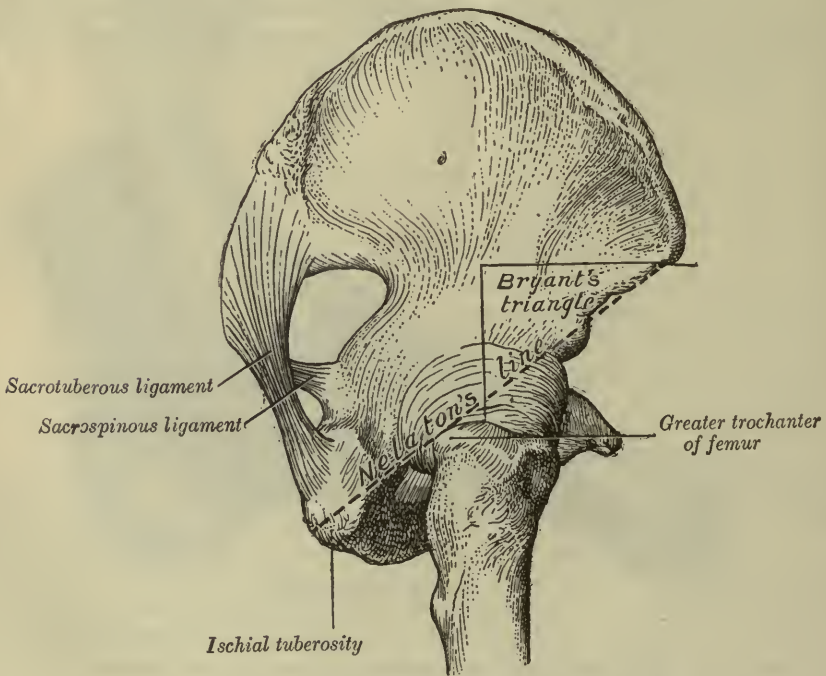


FIG. 1243.—Nélaton's line and Bryant's triangle.

A line used for clinical purposes is that of Nélaton (Fig. 1243), which is drawn from the anterior superior iliac spine to the most prominent part of the ischial

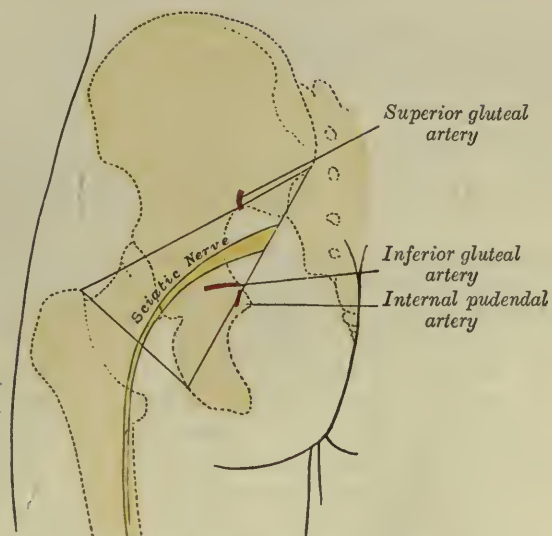


FIG. 1244.—Left gluteal region, showing surface markings for arteries and sciatic nerve.

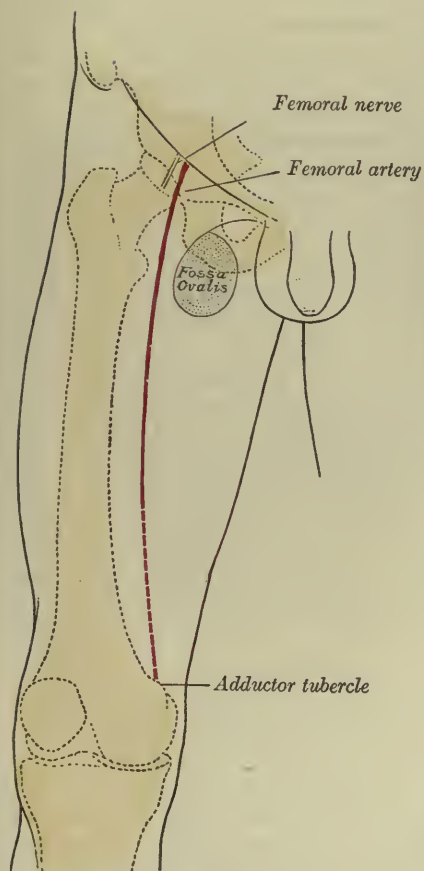


FIG. 1245.—Front of right thigh, showing surface markings for bones, femoral artery and femoral nerve.

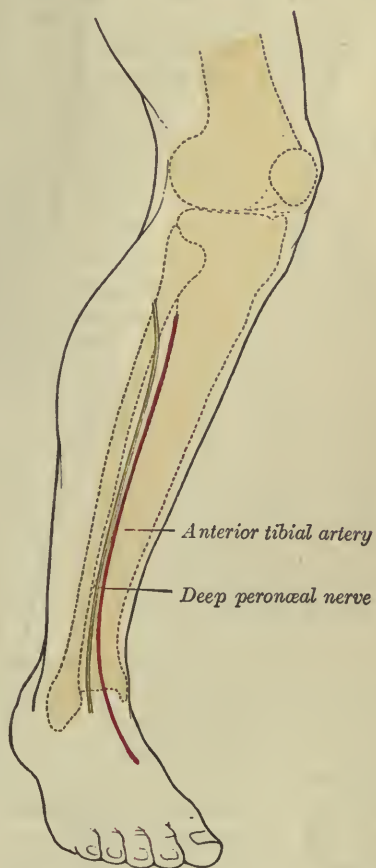


FIG. 1246.—Lateral aspect of right leg, showing surface markings for bones, anterior tibial and dorsalis pedis arteries, and deep peroneal nerve.

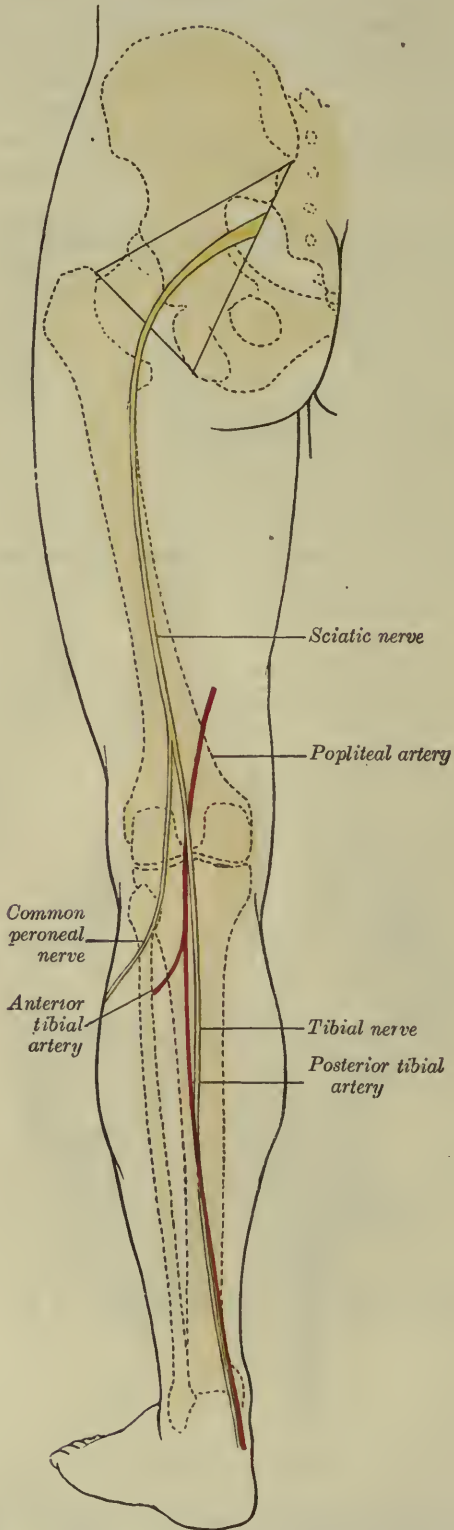


FIG. 1247.—Back of left lower extremity, showing surface markings for bones, vessels, and nerves

tuberosity; it crosses the center of the acetabulum and the upper border of the greater trochanter. Another surface marking of clinical importance is **Bryant's triangle**, which is mapped out thus: a line from the anterior superior iliac spine to the top of the greater trochanter forms the base of the triangle; its sides are formed respectively by a horizontal line from the anterior superior iliac spine and a vertical line from the top of the greater trochanter.

Articulations.—The posterior superior iliac spine overlies the center of the **sacroiliac articulations**.

The **hip-joint** may be indicated, as described above, by the center of a horizontal line from the pubic tubercle to the top of the greater trochanter; or more generally, it is below and slightly lateral to the middle of the inguinal ligament. The **knee-joint** is superficial and requires no surface marking. The level of the **ankle-joint** is that of a transverse line about 1 cm. above the level of the tip of the medial malleolus. If the foot be forcibly extended, the head of the talus appears as a rounded prominence on the medial side of the dorsum; just in front of this prominence and behind the tuberosity of the navicular is the **talonavicular joint**. The **calcaneocuboid joint** is situated midway between the lateral malleolus and the prominent base of the fifth metatarsal bone; the line indicating it is parallel to that of the **talonavicular joint**. The line of the **fifth tarsometatarsal joint** is very oblique; it starts from the projection of the base of the fifth metatarsal bone, and if continued would pass through the head of the first metatarsal. The lines of the **fourth and third tarsometatarsal joints** are less oblique. The **first tarsometatarsal joint** corresponds to a groove which can be felt by making firm pressure on the medial border of the foot 2.5 cm. in front of the tuberosity of the navicular bone; the position of the **second tarsometatarsal joint** is 1.25 cm. behind this. The **metatarsophalangeal joints** are about 2.5 cm. behind the webs of the corresponding toes.

Muscles.—None of the muscles require any special surface lines to indicate them, but there are three intermuscular spaces which occasionally require definition, viz., the femoral triangle, the adductor canal, and the popliteal fossa.

The **femoral triangle** is bounded above by the inguinal ligament, laterally by the medial border of Sartorius, and medially by the medial border of Adductor longus. In the triangle is the fossa ovalis, through which the great saphenous vein dips to join the femoral; the center of this fossa is about 4 cm. below and lateral to the pubic tubercle, its vertical diameter measures about 4 cm. and its transverse about 1.5 cm. The femoral ring is about 1.25 cm. lateral to the pubic tubercle.

The **adductor canal** occupies the medial part of the middle third of the thigh; it begins at the apex of the femoral triangle and lies deep to the vertical part of Sartorius. The **popliteal fossa** is bounded: above and medially by the tendons of Semimembranosus and Semitendinosus; above and laterally by the tendon of Biceps femoris; below and medially by the medial head of Gastrocnemius; below and laterally by the lateral head of Gastrocnemius and the Plantaris.

Mucous Sheaths.—The positions of the mucous sheaths around the tendons about the ankle-joints are sufficiently indicated in Figs. 1241, 1242 (see also page 489).

Arteries.—The points of emergence of the three main arteries on the buttock, viz., the superior and inferior gluteals and the internal pudendal, may be indicated in the following manner (Fig. 1244). With the femur slightly flexed and rotated inward, a line is drawn from the posterior superior iliac spine to the posterior superior angle of the greater trochanter; the point of emergence of the **superior gluteal artery** from the upper part of the greater sciatic foramen corresponds to the junction of the upper and middle thirds of this line. A second line is drawn from the posterior superior iliac spine to the outer part of the ischial tuberosity; the junction of its lower with its middle third marks the point of emergence of the **inferior gluteal and internal pudendal arteries** from the lower part of the greater sciatic

foramen. The course of the **femoral artery** (Fig. 1245) is represented by the upper two-thirds of a line from a point midway between the anterior superior iliac spine and the symphysis pubis to the adductor tubercle, with the thigh abducted and rotated outward; the **profunda femoris** arises from it about 1 to 5 cm. below the inguinal ligament. The course of the upper part of the **popliteal artery** (Fig. 1247) is indicated by a line from the lateral margin of Semimembranosus at the junction of the middle and lower thirds of the thigh, obliquely downward to the middle of the popliteal fossa; from this point it runs vertically downward for about 2.5 cm. or to the level of a line through the lower part of the tibial tuberosity. The line indicating the **anterior tibial artery** (Fig. 1246) is drawn from the medial side of the head of the fibula to a point midway between the malleoli; the artery begins about 3 cm. below the head of the fibula. The **dorsalis pedis artery** is represented on the dorsum of the foot by a line from the center of the interval between the malleoli to the proximal end of the first intermetatarsal space.

The course of the **posterior tibial artery** (Fig. 1247) can be shown by a line from the end of the popliteal artery, *i. e.*, 2.5 cm. below the center of the popliteal fossa, to midway between the tip of the medial malleolus and the center of the convexity of the heel; its main branch, the **peroneal artery**, begins about 7 or 8 cm. below the level of the knee-joint and follows the line of the fibula to the back of the lateral malleolus. The **medial** and **lateral plantar arteries** begin from the end of the posterior tibial; the medial extends to the middle of the plantar surface of the ball of the great toe, the lateral to within a finger's breadth of the tuberosity of the fifth metatarsal bone; from this latter point the **plantar arch** crosses the foot transversely to the proximal end of the first intermetatarsal space.

Veins.—The line of the **great saphenous vein** is from the front of the medial malleolus to the center of the fossa ovalis; the **small saphenous vein** runs from the back of the lateral malleolus to the center of the popliteal fossa.

Nerves.—The course of the **sciatic nerve** (Fig. 1247) can be indicated by a line from a point midway between the outer border of the ischial tuberosity and the posterior superior angle of the greater trochanter to the upper angle of the popliteal fossa. The continuation of this line vertically through the center of the popliteal fossa represents the position of the **tibial nerve**, while the **common peroneal nerve** follows the line of the tendon of Biceps femoris. The lines for the **deep peroneal nerve** and the continuation of the **tibial nerve** correspond respectively to those for the anterior and posterior tibial arteries.

INDEX.

A

- ABDOMEN**, 1147
 apertures in walls of, 1147
 boundaries of, 1147
 fascia of, 408
 triangular, 412
 lymph glands of, 703
 muscles of, 408
 actions of, 417
 nerves of, 417
 regions of, 1147
 surface anatomy of, 1313
 markings of, 1315
Abdominal aorta, 603
 branches of, 603
 surface markings of, 1321
aortic plexus, 987
 muscles, 408
 ring, deep, 418
 external, 410
 inguinal, 418
 internal, 418
 wall, lymphatic vessels of, 706
Abducent nerve, 899
 composition and central connections of, 861
Abductor digiti quinti muscle
 (foot), 492
 actions of, 496
 nerves of, 495
 variations of, 492
 (hand), 463
 actions of, 464
 nerves of, 464
 variations of, 464
 hallucis muscle, 491
 actions of, 495
 nerves of, 495
 variations of, 491
 indicis muscle, 464
 minimi digiti muscle, 463
 pollicis brevis muscle, 461
 actions of, 462
 nerves of, 462
 variations of, 462
 longus muscle, 455
 actions of, 456
 nerves of, 456
 variations of, 455
 muscle, 461
Aberrant ducts of testis, 1246
Abnormalities of vertebral column, 116
Accelerator urinæ muscle, 428
Accessory hemiazygos vein, 667
 nerve, 913
 composition and central connections of, 855
 cranial part of, 913
 spinal part of, 913
 obturator nerve, 955
 olivary nuclei, 781
 organs of digestive tube, 1100
 of eye, 1021
 pancreatic duct, 1202
 part of parotid gland, 1134
 processes, 106
 pudendal artery, 618
 sinuses of nose, 998
 Accessory spleens, 1283
 thyroid glands, 1270
 Acetabular fossa, 237
 notch, 237
 Acetabulum, 237
 Achromatic spindle, 37
 Acoustic meatus, external, 145,
 183, 1036
 development of, 1033
 internal, 143, 193
 nerve, 905, 1035
 composition and central connections of, 857
 development of, 1033
 nuclei of, 788, 906
Acromioclavicular joint, 315
 movements of, 316
 surface anatomy of, 1328,
 1331
Acromion, 203
Acromiothoracic artery, 588
Adamantoblasts, 1123
Adductor brevis muscle, 473
 actions of, 474
 nerves of, 474
 variations of, 474
 canal, 627
 hallucis muscle, 493
 actions of, 496
 nerves of, 495
 variations of, 494
 longus muscle, 472
 actions of, 474
 nerves of, 474
 variations of, 474
 magnus muscle, 473
 actions of, 474
 nerves of, 474
 variations of, 474
 minimus muscle, 474
 obliquus hallucis muscle, 493
 pollicis muscle, 462
 pollicis muscles, actions of, 462
 nerves of, 462
 variations of, 462
 obliquus muscle, 462
 transversus muscle, 462
 transversus pollicis muscle, 462
 tubercle, 246
 Adipose capsule of kidney, 1220
 Adminiculum lineæ albæ, 417
 Adrenal capsule, 1278
 gland, lymphatic capillaries in,
 686
 Adrenalin, 1280
 Afferent nerves, 729
 vessels of kidney, 1224
 After-birth, 64
 Agger nasi, 161
 Aggregated lymphatic nodules,
 1176
 Agminated follicles, 1176
 Air cells, ethmoidal, 154, 998
 mastoid, 142
 sinuses of nose, 998
 of skull, 80
 Ala cinerea, 800
 lobuli centralis, 789
 nasi, 992
 oss. illi, 232
 Alæ of ethmoid, 153
 of sacrum, 110
 of vomer, 170
 Alar cartilages of nose, 993
 lamina, 735
 Alcock, canal of, 421
 Alimentary canal, 1100
 lymphatic capillaries in, 684
 Allantoic vessels, 54
 Allantois, 54
 Alveolar arch, 161
 arteries, 561
 border of mandible, 173
 canals, 158
 index, 199
 nerves, 890, 891, 896
 point, 161, 198
 process of maxilla, 161
 Alveoli, formation of, 1124
 Alveus, 833, 840
 Ammacrine cells of retina, 1017
 Amnion, 56
 false, 56
 Amniotic cavity, 56
 ectoderm, 56
 fold, 56
 Amphiarthroses, 284
 Ampulla of ductus deferens, 1246
 rectal, 1183
 of uterine tube, 1257
 of Vater, 1199
 Ampullæ of semicircular canals,
 1049
 of tubuli lactiferi, 1268
 Amygdala, 835
 Amygdaline nucleus, 791
 Amygdaloid nucleus, 869
 Anal canal or anal part of rectum,
 1184
 development of, 1108
 lymphatic vessels of, 711
 membrane of, 1110
 valves of, 1184
 fascia, 421
 Anaphase of karyokinesis, 37
 Anastomoses of arteries, 543
 around elbow-joint, 592
 knee-joint, 634
 crucial, 630
 Anastomotic branch of inferior
 gluteal artery, 620
 Anastomotic magna of brachial
 artery, 592
 of femoral artery, 631
 Anatomical neck of humerus, 209
 Anconæus muscle, 454
 actions of, 456
 nerves of, 456
 Angiology, 497
 Angle of Louis, 121, *note*
 iridial or filtration, 1007
 of mandible, 174
 of pubis, 236
 of rib, 124
 sacrovertebral, 106
 of sternum, 121
 subscapular, 203
 Angular artery, 556
 gyrus, 823
 movement, 286

- Angular vein, 645
 Angulus Ludovici, 121
 Animal cell, 35
 Ankle bone, 266
 Ankle-joint, 349
 movements of, 351
 relations of tendons and vessels to, 351
 surface anatomy of, 1338
 markings of, 1343
 Annular ligament, 456, 458
 of ankle, 488, 489
 of radius, 324
 of wrist, anterior, 456
 posterior, 458
Annulus fibrosus [of intervertebral fibrocartilage], 289
inguinalis abdominis, 418
subcutaneus, 410
ovalis, 531
tendineus communis, 1022
 Anococcygeal body, 1184
 nerves, 968
 raphé, 426
Ansa hypoglossi, 928
lentiformis, 835, 837
subclavia [Viessent], 981
 Anterior annular ligament, 456, 488
 basis bundle, 760
 calcaneoastragaloid ligament, 352
 circumflex artery, 589
 common ligament, 287
 condyloid foramen, 131
 cornu of medulla spinalis, 753
 costovertebral ligament, 299
 crural nerve, 955
 inferior ligament, 348
 intercostal arteries, 584
 interosseous artery, 596
 nerve, 938
 ligament, 327
 perforated substance, 869
 peroneal artery, 638
 pillar of fauces, 1137
 pillars of fornix, 838
 pulmonary nerves, 913
 radial carpal artery, 594
 radioulnar ligament, 325
 superior dental nerve, 891
 ligament, 301, 348
 talotibial ligament, 351
 temporal artery, 559
 tibial nerve, 965
 ulnar carpal artery, 598
 Antero-lateral fasciculus, superficial, 854
 ganglionic arteries, 573
 muscles of abdomen, 408
 Antero-medial ganglionic arteries, 571
 Antibrachial fascia, 445
 cutaneous nerve, dorsal, 944
 lateral, 935
 medial, 937
 Anticubital fossa, 589
 Antihelix, 1033
 Antitragicus muscle, 1035
 Antitragus, 1034
Antrum cardiacum, 1161
 of Highmore, 159, 999
 pyloric, 1162, 1163
 tympanic, 142, 1042
 entrance to, 1042
 Anus, 1100, 1184
 lymphatic vessels of, 711
 Aorta, 545
 abdominal, 602
 branches of, 603
abdominalis, 602
 arch of, 547
 branches of, 548
 peculiarities of, 548
 of branches of, 548
 Aorta *ascendens*, 545
 ascending, 545
 bulb of, 545
 coarctation of, 547
 descending, 598
thoracalis, 598
rami mediastinales, 600
pericardiaci, 600
 thoracic, 598
 branches of, 600
 transverse, 547
 Aortæ, anterior ventral, 516
 dorsal, 517
 primitive, 506
 Aortic arches, 516
 bodies, 1278
 glands, 1269, 1278
 isthmus, 406
 isthmus, 517, 546
 lymph glands, 705
 opening of heart, 534
 plexus, 987
 semilunar valves, 534
 septum, 514
 sinuses, 534
 spindle, 547
 vestibule, 534
 Aorticorenal ganglion, 985
Apertura pelvis [minoris] inferior, 240
superior, 239
tympanica canaliculi chordæ, 1038
 Aperture, anterior nasal, 196
 Apertures in walls of abdomen, 1147
Apeæ cordis, 527
 of fibula, 260
 of heart, 527
linguæ, 1125
 of nose, 992
oss. sacri, 110
prostatæ, 1252
pulmonis, 1094
 Aponeurosis, 376
 epicranial, 380
 lumbar, 397
 of obliquus externus, 410
 palatine, 1139
 palmar, 460
palmaris, 460
 pharyngeal, 1143
 plantar, 490
plantaris, 490
 suprahyoid, 392
Apparatus digestorius, 1100
lacrimalis, 1028
respiratorius, 1071
urogenitalis, 1204
 Appendages of testis, 1242
Appendices epiploicæ, 1158
vesiculosæ, 1257
 Appendicular artery, 607
 skeleton, 79
 Appendix, auricular, left, 533
 right, 529
 ensiform, 121
 of epididymis, 1242
 of testis, 1242
 of ventricle of larynx, 1080
ventriculi laryngis, 1080
 vermiform, 1178
 xiphoid, 121
Aqueductus cerebri, 806
cochleæ, 144, 181
Fallopîi, 143
vestibuli, 143
 Aqueduct, cerebral, 806
 of cochlea, 144
 of Sylvius, 766, 806
 Aqueous humor, 1018
 Arachnoid, 876
 granulations, 878
 structure of, 876
 villi, 878
Arachnoidea encephali, 876
spinalis, 876
 Arantii, corpus, 533, 535
Arbor vitæ [of cerebellum], 791
uterina, 1260
 Arch, alveolar, 161
 of aorta, 547
 branches of, 548
 peculiarities of, 548
 of atlas, 99
 axillary, 434
 carotid, 516
 crural, deep, 419
 glossopalatine, 1137
 lumbocostal, 405
 palmar, deep, 595
 superficial, 598
 pharyngopalatine, 1137
 plantar, 639
 pubic, 240
 of a vertebra, 96
 volar, deep, 595
 superficial, 598
 zygomatic, 183
 Arches, aortic, 506, 516
 branchial or visceral, 65
 of fauces, 1137
 of foot, 360
 superiliary, 135, 178, 183
 Architecture of femur, 248
 Arcuate artery, 637
 fibers, 782, 783
 ligaments, 404
 line of ilium, 234
 nucleus, 782
Arcus aortæ, 547
cartilaginis cricoideæ, 1074
glossopalatinus, 1137
lumbocostalis lateralis [Halleri], 405
medialis [Halleri], 404
parietooccipitalis, 823
pharyngopalatinus, 1137
volaris profundus, 595
superficialis, 598
 Area *acustica*, 800
cribrosa media, 143
superior, 143
facialis, 143
 olfactory, 67
 oval, of Flechsig, 764
parolfactoria, 827
 pericardial, 47
 postrema, 800
 proamniotic, 47
 Areas of cerebral cortex, 849
 of Cohnheim, 374
 vascular, 505
 Areola of mamma, 1267
 Areolæ of bone, 93, 94
 Areolar glands, 1267
 Arm bone, 209
 fascia of, 442
 muscles of, 442
 development of, 371
 Arnold's nerve, 911
 Arrectores pilorum muscle, 1069
Arteria alveolaris inferior, 561
superior posterior, 562
angularis, 556
anonyma, 548
arcuata, 637
auditiva interna, 580
auricularis posterior, 557
ramus auricularis, 556
occipitalis, 557
profundus, 560
axillaris, 586
basilaris, 580
rami ad pontem, 580
brachialis, 589
rami musculares, 592
buccinatoria, 561
bulbi urethræ, 619
canalis pterygoidei, 562, 568

- Arteria carotis communis*, 549
externa, 551
interna, 566
ramus caroticotypanicus, 568
centralis retinae, 571, 1018
cerebelli inferior anterior, 580
posterior, 580
superior, 580
cerebri anterior, 571
media, 572
posterior, 580
cervicalis ascendens, 581
profunda, 585
chorioidea, 574
circumflexa femoris lateralis, 630
medialis, 630
humeri anterior, 589
posterior, 589
ilium profunda, 623
superficialis, 629
scapulae, 588
caliaca, 603
colica dextra, 609
media, 609
sinistra, 610
collateralis ulnaris inferior, 592
superior, 591
comes nervi phrenici, 583
comitans nervi ischiadici, 620
communicans anterior, 572
posterior, 573
coronaria [cordis] dextra, 546
sinistra, 547
cystica, 605
dorsalis hallucis, 637
nasi, 571
pedis, 636
ramus plantaris profundus, 637
epigastrica inferior, 623
superficialis, 629
superior, 585
femoralis, 623
rami musculares, 629
frontalis, 570
gastrica dextra, 604
sinistra, 603
gastroduodenalis, 604
gastroepiploica dextra, 604
sinistra, 606
genu media, 633
suprema, 631
glutæa inferior, 620
ramus iliacus, 621
tumbalis, 621
superior, 622
hemorrhoidalis inferior, 619
media, 615
superior, 610
hepatica, 603
hypogastrica, 614
ileocolica, 607
iliaca externa, 622
iliolumbalis, 621
infraorbitalis, 562
interossea communis, 596
dorsalis, 596
volaris, 596
labialis inferior, 555
superior, 555
lacrimalis, 569
laryngea inferior, 581
superior, 552
lienal, 605
rami pancreatici, 606
lingualis, 553
rami dorsales linguae, 553
ramus hyoideus, 553
malleolaris anterior lateralis, 635
medialis, 635
posterior medialis, 639
mammaria interna, 583
rami intercostales, 584
perforantes, 584
- Arteria mammaria interna, rami*
sternales, 584
massesterica, 561
maxillaris externa, 553
rami glandulares, 555
ramus tonsillaris, 555
interna, 559
rami pterygoidei, 561
ramus meningeus accessorius, 561
mediana, 596
meningea anterior, 568
media, 560
mesenterica inferior, 609
superior, 606
musculophrenica, 584
nutricia fibulae, 638
humeri, 591
tibiae, 638
obturatoria, 616
occipitalis, 556
rami musculares, 556
ramus auricularis, 556
descendens, 557
meningeus, 557
ophthalmica, 568
palatina ascendens, 555
descendens, 562
pancreatica magna, 606
pancreaticoduodenalis inferior, 607
superior, 605
perforans prima, 631
secunda, 631
tertia, 631
pericardiophrenica, 583
perinei, 619
peronæa, 638
ramus calcaneus lateralis, 638
communicans, 638
perforans, 638
pharyngea ascendens, 557
rami pharyngei, 558
plantaris lateralis, 639
medialis, 639
poplitea, 632
princeps cervicis, 557
hallucis, 640
pollicis, 595
profunda brachii, 591
femoris, 629
penis, 620
putenda externa profunda, 629
superficialis, 629
interna, 617
pulmonalis, 543
ramus dexter, 545
sinister, 545
radialis, 592
rami musculares, 594
perforantes, 595
ramus carpus dorsalis, 594
volaris, 594
volaris superficialis, 594
recurrens radialis, 594
tibialis anterior, 635
posterior, 635
recurrentes ulnaris anterior, 596
posterior, 596
sacralis lateralis, 621
media, 613
sphenopalatina, 562
spinalis anterior, 579
posterior, 579
sternocleidomastoidea, 556
stylomastoidea, 557
subclavia, 575
sublingualis, 553
submental, 555
subscapularis, 588
supraorbitalis, 569
tarsæ lateralis, 637
temporalis media, 558
superficialis, 558
- Arteria temporalis superficialis, rami*
auriculares anteriores, 559
ramus frontalis, 559
parietalis, 559
thoracalis lateralis, 588
suprema, 587
thoracoacromialis, 588
thyreoidea ima, 549
inferior, 581
rami œsophagei, 581
tracheales, 581
superior, 552
ramus cricothyreoideus, 552
hyoideus, 552
sternocleidomastoideus, 552
tibialis anterior, 634
rami musculares, 635
posterior, 637
rami calcanei mediales, 639
ramus communicans, 639
transversa colli, 582
ramus ascendens, 582
descendens, 582
faciei, 558
scapulae, 582
tympánica anterior, 560
inferior, 558
ulnaris, 595
rami musculares, 598
ramus carpus dorsalis, 598
volaris, 598
volaris profundus, 598
urethralis, 619
uterina, 615
vaginalis, 616
vertebralis, 578
rami spinales, 579
ramus meningeus, 579
vesicalis inferior, 615
medialis, 615
superior, 615
volaris indicis radialis, 595
- Arteriæ bronchiales*, 600
ciliares, 571
digitales volares communes, 598
proprie, 598
gastricæ breves, 606
genu inferiores, 633
superiores, 633
iliacæ communes, 613
intercostales, 600
intestinales, 607
lumbales, 612
metacarpeæ volares, 595
metatarseæ plantares, 640
œsophageæ, 600
ovaricæ, 611
palpebrales mediales, 570
phrenicæ inferiores, 612
proprie renales, 1223
rectæ, 1224
renales, 610
sigmoidæ, 610
spermaticæ internæ, 611
suprarenales media, 610
surales, 633
tarsæ mediales, 637
tunica adventitia, 499
intima, 498
media, 498
- Arterial mesocardium*, 526
Arterioles, 497
Artery or Arteries, abdominal
aorta, 602
accessory pudendal, 618
meningeal, 561
acromiothoracic, 588
alveolar, 561
anastomoses of, 543
anastomotic branch of inferior gluteal, 620
anastomotica magna, of brachial, 592

- Artery or Arteries, anastomotica
 magna of femoral, 631
 angular, 556
 anterior cerebral, 571
 choroidal, 574
 ciliary, 571
 communicating, 571
 humeral circumflex, 589
 inferior cerebellar, 580
 meningeal, 568
 spinal, 579
 tibial, 634
 tympanic, 560
 antero-lateral ganglionic, 573
 antero-medial ganglionic, 561
 aorta, 545
 abdominal, 602
 arch of, 547
 ascending, 545
 descending, 598
 thoracic, 598
 appendicular, 607
 arcuate, 637
 articular, 633
 ascending cervical, 581
 palatine, 555
 pharyngeal, 557
 auditory, 580
 internal, 580
 auricular, anterior, 559
 deep, 560
 of occipital, 557
 posterior, 557
 axillary, 586
 azygos, of knee, 633
 of vagina, 616
 basilar, 580
 brachial, 589
 brachiocephalic, 548
 of brain, 574
 bronchial, 600, 1100
 buccal, 561
 buccinator, 561
 bulbar, 580
 calcaneal, 638, 639
 capsular, middle, 610
 caroticotympanic, 568
 carotid, common, 549
 external, 551
 internal, 566
 carpal, dorsal, 594
 radial, 594
 ulnar, 598
 volar, 594, 598
 cavernous, 568
 cecal, of ileocolic, 607
 central, of retina, 571, 1018
 cerebellar, 580
 cerebral, anterior, 571
 middle, 572
 posterior, 580
 of cerebral hemorrhage, 573
 cervical, ascending, 581
 deep, 585
 superficial, 582
 transverse, 582
 choroid, 574
 choroidal, 574, 581
 ciliary, 571
 circle of Willis, 574
 circumflex, femoral, 630
 humeral, 589
 coccygeal of inferior gluteal, 620
 cochlear, 1059
 coeliac, 603
 colic, 609, 610
 comitans nervi ischiadici, 620
 phrenici, 583
 common carotid, 549
 iliac, 613
 interosseous, 596
 communicating, anterior, 571
 of dorsalis pedis, 637
 posterior, 573
 coronary, of heart, 546
- Artery or Arteries, coronary, of
 lips, 555
 of stomach, 603
 of corpus cavernosum, penis,
 620
 costocervical trunk, 585
 cremasteric, 623
 cricothyroid, 552
 cystic, 605
 deep auricular, 560
 epigastric, 623
 external pudendal, 629
 iliac circumflex, 623
 palmar arch, 595
 of penis, 617
 plantar, 637
 temporal, 561
 volar branch of ulnar, 598
 dental, inferior, 561
 posterior, 562
 descending aorta, 598
 development of, 505, 514
 branch of occipital, 557
 palatine, 562
 digital, foot, 640
 hand, 598
 volar, 598
 distribution of, 543
 dorsal carpal of radial, 594
 of ulnar, 598
 interosseous, 596
 metacarpal, 594
 nasal, 571
 of penis, 620
 dorsales linguae, 553
 dorsalis hallucis, 637
 pedis, 636
 scapulae, 588
 of ductus deferens, 615
 epigastric, deep or inferior, 623
 superficial, 629
 superior, 585
 esophageal, of aorta, 600
 of inferior thyroid, 581
 ethmoidal, 570
 external carotid, 551
 iliac, 622
 maxillary, 553
 plantar, 639
 pudendal, 629
 facial, 553
 transverse, 558
 femoral, 623
 circumflex, 630
 fibular, 635
 frontal, 570
 ganglionic, 571, 573, 581
 gastric, 603, 604, 606
 gastroduodenal, 604
 gastroepiploic, 604, 606
 genicular, 631, 633, 634
 gluteal, 620
 of head and neck, 549
 helicine, 1251
 hemorrhoidal, inferior, 619
 middle, 615
 superior, 610
 hepatic, 603
 highest genicular, 631
 intercostal, 585
 thoracic, 587
 humeral circumflex, 589
 hypogastric, 614
 obliterated, 615
 ileal, of ileocolic, 607
 ileocolic, 607
 iliac circumflex, deep, 623
 superficial, 629
 common, 613
 external, 622
 internal, 614
 iliolumbar, 621
 inferior alveolar, 561
 articular, of knee, 633
 cerebellar, 580
- Artery or Arteries, inferior epi-
 gastric, 623
 genicular, 633
 gluteal, 620
 hemorrhoidal, 619
 labial, 555
 laryngeal, 581
 mesenteric, 609
 pancreaticoduodenal, 607
 phrenic, 612
 profunda, 591
 thyroid, 581
 tympanic, 558
 ulnar collateral, 592
 infrahyoid, 552
 infraorbital, 562
 infrascapular, 588
 innominate, 548
 intercostal, 600, 601
 branches of internal mam-
 mary, 583
 highest, 585
 superior, 585
 interlobular, of kidney, 1223
 internal auditory, 580, 1059
 carotid, 566
 iliac, 614
 mammary, 583
 maxillary, 559
 palpebral, 570
 plantar, 639
 pudendal or pudic, 617
 spermatic, 611
 interosseous, anterior, 596
 common, 596
 dorsal, 596
 palmar, 595
 posterior, 596
 volar, 596
 intestinal, 607
 labial, 555
 of labyrinth, 1059
 lacrimal, 569
 laryngeal, inferior, 581
 superior, 552
 lateral calcaneal, 638
 femoral circumflex, 630
 nasal, 556
 palpebral, 569
 sacral, 621
 tarsal, 637
 left colic, 610
 gastric, 603
 gastroepiploic, 606
 lienal, 605
 lingual, 553
 deep, 553
 long ciliary, 571
 thoracic, 588
 of lower extremity, 623
 lumbar, 612
 malleolar, 635
 internal, 639
 mammary, internal, 583
 masseteric, 561
 maxillary, external, 553
 internal, 559
 medial palpebral, 570
 mediana, 596
 mediastinal, from aorta, 600
 from internal mammary, 583
 medullary, 560
 medullary, 580
 meningeal, accessory, 561
 anterior, 568
 of ascending pharyngeal, 558
 middle, 560
 of occipital, 557
 small, 561
 of vertebral, 579
 mesenteric, inferior, 609
 superior, 606
 metatarsal, 637
 middle cerebral, 572
 genicular, 633

- Artery or Arteries, middle hemor-
rhoidal, 615
meningeal, 560
sacral, 612
mode of division of, 543
of origin of branches, 543
musculophrenic, 583
mylohyoid, 561
nasal, 571
dorsal, 571
lateral, 556
nasopalatine, 562
nerves of, 499
obturator, 616
occipital, 556
ophthalmic, 568
ovarian, 611
palatine, ascending, 555
of ascending pharyngeal, 557
descending, 562
palmar arch, deep, 595
superficial, 598
palpebral, 569, 570
internal, 570
pancreatic, of lienal, 606
pancreaticoduodenal, 605
parvidural, 561
perforating, of foot, 640
of hand, 595
of internal mammary, 584
of thigh, 631
pericardiophrenic, 584
pericardial, 584, 600
perineal, 619
superficial, 619
peroneal, 638
anterior, 638
pharyngeal, ascending, 557
of internal maxillary, 562
phrenic, inferior, 612
superior, 601
plantar, deep, 637
lateral (external), 639
medial (internal), 639
metatarsal, 640
pontine, 580
popliteal, 632
posterior auricular, 557
cerebral, 580
communicating, 573
humeral circumflex, 589
inferior cerebellar, 580
meningeal, from vertebral,
579
scapular, 582
scrotal, 619
superior alveolar, 562
tibial, 637
postero-medial ganglionic, 574,
581
princeps cervicis, 557
pollicis, 595
profunda, 591
brachii, 591
cervicalis, 585
femoris, 629
linguae, 553
superior, 591
of pterygoid canal, 562, 568
pudendal, external, 629
internal, 617
in female, 620
in male, 617
pudic, external, 629
internal, 617
pulmonary, 543
pyloric, 604
radial, 592
recurrent, 594
radialis indicis, 595
ranine, 553
recurrent, of hand, 595
interosseous, 597
radial, 594
tibial, 635
- Artery or Arteries, recurrent
ulnar, 596
renal, 610
right colic, 609
gastric, 604
gastroepiploic, 606
sacral, lateral, 621
middle, 613
scapular circumflex, 588
posterior, 582
transverse, 582
sciatic, 620
scrotal, posterior, 619
sheaths of, 499
short ciliary, 571
gastric, 606
sigmoid, 610
spermatic, 611
external, 623
internal, 611
sphenopalatine, 562
spinal, 579
splenic, 605
sternocleidomastoid, 552, 556
sternomastoid, 552, 556
striate, 573
structure of, 498
stylomastoid, 557
subclavian, 575
subcostal, 601
sublingual, 553
submaxillary, 555
submental, 555
subscapular, 588
superficial cervical, 582
epigastric, 629
external pudendal, 629
iliac circumflex, 629
palmar arch, 598
temporal, 558
volar, 594
arch, 598
superior articular, of knee, 633
cerebellar, 580
epigastric, 585
gluteal, 622
hemorrhoidal, 610
intercostal, 585
labial, 555
laryngeal, 552
mesenteric, 606
phrenic, 601
profunda, 591
thoracic, 587
thyroid, 552
tympanic, 561
ulnar collateral, 591
vesical, 615
superhyoid, 553
supraorbital, 569
suprarenal, 610, 612
suprascapular, 582
sural, 633
systemic distribution of, 543
tarsal, 637
temporal, 558
deep, 561
middle, 558
superficial, 558
thoracic, 587, 588
aorta, 598
axis, 588
highest, 587
lateral, 588
superior, 587
thoracoacromial, 588
thyroidea ima, 549
thyrocervical trunk, 581
thyroid axis, 581
inferior, 581
superior, 552
tibial, anterior, 634
posterior, 637
recurrent, 635
tonsillar, 555
- Artery or Arteries, transversa
colli, 582
transverse cervical, 582
facial, 558
perineal, 619
scapular, 582
transversalis colli, 582
of trunk, 598
tympanic, 558, 560
ulnar, 595
recurrent, 596
umbilical, in fetus, 540
of upper extremity, 575
urethral, 619
of urethral bulb, 619
uterine, 615
vaginal, 616
vasa aberrantia, 590
brevia, 606
intestini tenuis, 607
vertebral, 578
vesical, 615
vestibular, 1059
Vidian, 562, 568
volar arch, deep, 595
superficial, 598
carpal, 594
digital, common, 598
interosseous, 596
metacarpal, 595
proper, 598
volaris indicis radialis, 595
Arthrodia, 286
Articular arteries, 633
capsules, 279
cartilage, 282
disk of acromioclavicular joint,
315
of distal radioulnar joint, 325
of sternoclavicular joint, 314
of temporomandibular joint,
258
lamella of bone, 279
meniscus, 298
processes of vertebræ, 96
tubercle of temporal bone, 139,
180
Articulatio acromioclavicularis, 315
atlantoepistrophica, 292
calcaneocuboidea, 354
coxa, 333
cubiti, 321
cuneonavicularis, 356
ellipsoidea, 286
genu, 339
humeri, 317
mandibularis, 297
radiocarpea, 327
radioulnaris, 324
distalis, 325
proximalis, 324
sacroiliaca, 306
sellaris, 286
sternoclavicularis, 313
talocalcanea, 352
talocalcaneonavicularis, 353
talocruralis, 349
tibiofibularis, 348
trochoidea, 285
Articulation or Articulations, 279
acromioclavicular, 315
amphiarthroses, 285
of ankle, 349
atlantococcipital, 295
of atlas with axis or epistro-
pheus, 292
with occipital bone, 295
calcaneocuboid, 354
of calcaneus and astragalus, 352
with the cuboid, 354
carpometa-carpal, 330
of carpus, 328
of cartilages of ribs with each
other, 304
classification of, 284

- Articulation or Articulations, con-
dyloid, 285
costocondral, 299
costochondral, 304
costosternal, 302
costotransverse, 300
costovertebral, 299
coxal, 333
cuboideonavicular, 356
cuneocuboid, 357
cuneonavicular, 356
diarthroses, 285
of digits, 333
of elbow, 321
gomphosis, 284
of hip, 333
humeral, 317
immovable, 284
inferior, 325
intercarpal, 328
interchondral, 304
intercuneiform, 357
intermetacarpal, 331
intermetatarsal, 358
intertarsal, 352
of knee, 339
of lower extremity, 333
of mandible, 297
metacarpophalangeal, 332
metatarsophalangeal, 359
movable, 285
movements of, 286
of navicular with cuneiform
bones, 356
of pelvis, 306
with vertebral column, 306
of phalanges of foot, 359
of hand, 333
of pubic bones, 310
symphysis, 310
radiocarpal, 327
radioulnar, 324, 325
by reciprocal reception, 286
sacrocoxygeal symphysis, 309
sacroiliac, 306
of sacrum and coccyx, 309
scapuloclavicular, 315
schindylesis, 284
of shoulder, 317
sternoclavicular, 313
sternocostal, 302
of sternum, 304
sutura, 284
symphysis, 285
pubis, 310
synarthroses, 284
synchondrosis, 284
syndesmosis, 285
talocalcaneal, 352
talocalcaneonavicular, 353
talocrural, 349
tarsometatarsal, 358
of tarsus, 352
temporomandibular, 297
tibiofibular, 348
syndesmosis, 348
tibiotarsal, 349
of trunk, 287
of upper extremity, 313
of vertebral arches, 289
bodies, 287
column, 287
with cranium, 295
with pelvis, 306
of wrist, 327
- Articulationes capitulorum*, 299
carpometacarpæ, 330
pollicis, 330
costotransversaria, 300
costovertebrales, 299
digitorum manus, 333
pedis, 359
intercarpæ, 328
interchondrales, 304
intermetacarpeæ, 331
- Articulationes intermetatarsea*, 358
intertarsæ, 352
metatarsophalangeæ, 359
ossiculorum auditus, 1045
sternocostales, 302
tarsometatarsea, 358
- Aryepiglottic fold, 1079
Aryepiglotticus muscle, 1083
Arytenoideus muscle, 1082
Arytenoid cartilages, 1075
glands, 1084
swellings, 1071
- Ascending aorta, 545
cervical artery, 582
colon, 1180
frontal convolution, 821
lumbar vein, 667
oblique muscle, 412
palatine artery, 555
parietal convolution, 823
pharyngeal artery, 557
ramus of ischium, 235
of os pubis, 235
- Association fibers of cerebral
hemispheres, 843
neurons, 755
- Asterion, 183, 198
- Astragalus, 266
ossification of, 275
- Atavistic epiphyses, 95
- Atlantoöccipital articulation, 295
- Atlas, 99
development of anterior arch
of, 82
ossification of, 113
- Atresia, congenital, of pupil, 1003
- Atria of bronchi, 1098
- Atrial canal, 508
- Atrioventricular bundle of His,
537
opening, left, 533, 534
right, 531
- Atrium dextrum*, 529
of heart, left, 533
primitive, 508
right, 529
of nasal fossa, 994
sinistrum, 533
- Attic or epitympanic recess, 142,
1038
- Attolens aurem muscle, 1035
- Attrahens aurem muscle, 1035
- Auditory artery, 580
internal, 580
canal, external, 1036
meatus, external, 1036
nerve, 905
ossicles, 1044
development of, 1033
pit, 1029
plate, 1029
teeth of Huschke, 1055
tube, 1042
cartilaginous portion of, 1043
cushion of, 1043, 1147
isthmus of, 1043
osseous portion of, 1043
pharyngeal ostium of, 1141
tonsil of, 1043
torus tubarius, 1043
veins, 1059
vesicle, 1030
- Auerbach's plexus, 1177
- Auricle, left, 533
right, 523
- Auricula dextra*, 529
of ear, 1033
cartilage of, 1034
development of, 1033
ligaments of, 1035
muscles of, 1035
vessels and nerves of, 1036
- of heart, left, 533
right, 529
sinistra, 533
- Auricular appendix, left, 533
right, 529
- artery, anterior, 559
deep, 560
of occipital, 557
posterior, 557
lymph glands, 693
nerve, anterior, 895
great, 926
posterior, 905
of vagus, 911
point, 198
surface of ilium, 234
of sacrum, 108
tuberle of Darwin, 1033
vein, posterior, 646
- Auricularis muscles, 1035
- Auriculotemporal nerve, 895
- Auriculoventricular groove, 527
- Auris interna*, 1047
- Auscultation, triangle of, 434
- Axes of pelvis, 240
- Axial filament of spermatozoön, 43
skeleton, 79
- Axilla, 585
fascia of, 436
- Axillary arch, 434
artery, 586
branches of, 587
surface markings of, 1331
lymph glands, 699
nerve, 934
sheath, 586
vein, 663
- Axis, celiac, 603
of lens, 1019
optic, 1001
thoracic, 588
thyroid, 581
of vertebra, 100
ossification of, 113
- Axis-cylinder process, 723
- Axon of nerve cells, 723
- Azygos arteries of vagina, 616
artery, articular, 633
uvulæ muscle, 1139
vein, 667

B

- BACK, muscles of, 396
- Baillarger, band of, 835, 845
- Ball-and-socket joint, 285
- Band of Baillarger, 835, 845
of Bechterew, 846
of Gennari, 846
of Giacomini, 827
iliotibial, 468
moderator, 532
- Bare area of liver, 1150
- Bartholin, duct of, 1136
glands of, 1213, 1266
- Basal column, posterior, 758
lamina, 735
optic nucleus of Meynert, 513
plate of placenta, 63
ridge, or cingulum of tooth, 1116
vein, 653
- Base of cerebral peduncle, 802
of heart, 527
of sacrum, 109
of skull, inferior surface, 179
upper surface of, 190
- Basichromatin, 37
- Basihyal of hyoid bone, 177
- Basilar artery, 580
crest, 1054
membrane, 1056
part of occipital bone, 132
plexus of veins, 660
sinus, 660
- Basilic vein, 662
median, 661
- Basion, 181, 198

- Basis bundle, anterior, 760
 lateral, 762
cordis, 527
oss. sacri, 109
pedunculi, 802
prostate, 1252
pulmonis, 1094
- Basivertebral veins, 668
- Basket cells of cerebellum, 794
- Bechterew, band of, 846
 nucleus of, 788
 pontospinal fasciculus of, 872
- Bed of stomach, 1162
- Bell, nerve of, 928, 933
- Bellini, duct of, 1223
- Bertin, ligament of, 335
- Betz, giant cells of, 845
- Biceps brachii muscle, 443
 actions of, 444
 nerves of, 444
 variations of, 444
 femoris muscle, 478
 actions of, 480
 nerves of, 480
 variations of, 479
 flexor cubiti muscle, 443
 muscle, 443
- Bicipital fascia, 444
 groove, 209
 ridges, 209
- Bicuspid teeth, 1118
 valve, 534
- Bigelow, Y-shaped ligament of, 335
- Bile capillaries, 1197
 ducts, 1197, 1198
 lymphatic capillaries in, 686
 structure of, 1199
- Bipolar cells of retina, 1016
- Bird's nest of cerebellum, 791
- Biventer cervicis muscle, 400
- Biventral lobes of cerebellum, 791
- Bladder, 1227
 gall, 1197
 urinary, 1227
 in child, 1229
 development of, 1212
 distended, 1228
 empty, 1227
 female, 1230
 interior of, 1231
 ligaments of, 1231
 lymphatic vessels of, 712
 structure of, 1232
 trigone of, 1231
 vessels and nerves of, 1233
- Blandin, glands of, 1131
- Blastodermic vesicle, 46
- Blastopore, 47
- Blood, composition of, 503
 corpuscles, 503
 development of, 505
 origin of, 505
 course of, in an adult, 497
 in fetus, 540
 islands, 506
 liquor sanguinis, 503
 plasma, 503
 platelets, 505
- Boehdalek, cornucopia of, 798
- Body or Bodies, anococcygeal, 1184
 aortic, 1278
 carotid, 1281
 ciliary, 1010
 coccygeal, 1281
 geniculate, 811
 Malpighian, of kidney, 1221
 of spleen, 1285
 olivary, 769
 of penis, 1249
 perineal, 1184
 pineal, 1277
 pituitary, 814, 1275
 polar, 40
- Body or Bodies, restiform, 793
 of stomach, 1163
 thyroid, 1269
 trapezoid, 787
 of uterus, 1259
 of a vertebra, 96
- Body-stalk, 53, 57
- Bone or Bones, 86
 ankle, 266
 arm, 209
 articular lamella of, 279
 astragalus, 266
 atlas, 99
 axis, 100
 breast, 119
 calcaneus, 263
 calf, 260
 canaliculi of, 91
 cancellous tissue of, 86
 capitate, 226
 carpal, 221
 cells, 91
 chemical composition of, 91
 classes of, viz., long, flat, mixed
 or irregular, short, 79
 clavicle, 280
 coccyx, 111
 collar, 200
 compact tissue of, 86
 cranial, 129
 cuboid, 269
 cuneiform, of carpus, 224
 of tarsus, 270
 development of, 86
 diploë of, 80
 of ear, 1044
 of elbow, 214
 eminences and depressions of, 80
 epistropheus, 100
 ethmoid, 153
 facial, 156
 femur, 242
 fibula, 260
 flat, 79
 of foot, 262
 frontal, 135
 hamate, 227
 of hand, 221
 Haversian canals of, 89
 systems of, 89
 hip, 231
 humerus, 209
 hyoid, 177
 ilium, 231
 incus, 1044
 inferior nasal conchæ, 169
 innominate, 231
 interparietal, 132
 ischium, 234
 lacrimal, 163
 lesser, 164
 lacunæ of, 90
 lamellæ of, 90
 lingual, 177
 long, 79
 of lower extremity, 231
 jaw, 172
 lunata, 221
 lymphatics of, 89
 malar, 164
 malleus, 1044
 mandible, 172
 marrow of, 87
 maxillæ, 157
 medullary artery of, 88
 membrane of, 87
 metacarpal, 227
 metatarsal, 272
 minute anatomy of, 89
 multangular, greater, 225
 lesser, 225
 nasal, 156
 navicular, of carpus, 221
 of tarsus, 270
- Bone or Bones, nerves of, 88
 number of, in body, 79
 nutrient artery of, 88
 occipital, 129
 os calcis, 263
 coxæ, 231
 magnum, 226
 ossification of, 91
 palate, 166
 palatine, 166
 parietal, 133
 patella, 255
 pelvic, 238
 perforating fibers of, 90
 periosteum of, 87
 lymphatic capillaries in, 684
 phalanges of foot, 275
 of hand, 230
 pisiform, 225
 pubis, 236
 radius, 219
 ribs, 123
 sacrum, 106
 scaphoid, 221, 270
 scapula, 202
 semilunar, 224
 sesamoid, 277
 shin, 256
 short, 79
 sphenoid, 147
 sphenoidal conchæ, 152
 stapes, 1045
 sternum, 119
 strength of, compared with
 other materials, 87
 structure and physical prop-
 erties of, 86
 surfaces of, 80
 sutural, 156
 talus, 266
 tarsal, 263
 temporal, 138
 thigh, 242
 tibia, 256
 trapezium, 225
 trapezoid, 225
 triangular, 224
 turbinate, 169
 ulna, 214
 unciform, 227
 of upper extremity, 200
 jaw, 157
 vertebra prominens, 101
 vertebræ, cervical, 97
 coccygeal, 106
 lumbar, 104
 thoracic, 102
 sacral, 106
 vessels of, 88
 vomer, 170
 Wormian, 156
 zygomatic, 164
- Bowman, capsule of, 1222
 glands of, 996
 membrane of, 1008
 muscle of, 1011
- Brachia conjunctiva of cere-
 bellum, 792
 of corpora quadrigemina, 805
 pontis, 793
- Brachial artery, 589
 branches of, 590
 peculiarities of, 590
 surface marking of, 1335
 cutaneous nerve, lateral, 934
 medial, 937
 posterior, 943
 fascia, 442
 plexus, 930
 veins, 663
- Brachialis anticus muscle, 444
 muscle, 444
 actions of, 444
 nerves of, 444
 variations of, 444

- Brachiocephalic artery, 548
veins, 664
- Brachioradialis muscle, 451
actions of, 456
nerves of, 456
variations of, 451
- Brain, arteries of, 574
commissures of, 809
development of, 736
divisions of, 766
dura of, 872
meninges of, 872
pathways from, to spinal cord, 870
pia of, 878
sensory pathways from spinal cord to, 851
surface markings of, 1292
veins of, 652
weight of, 848
- Branchial arches, 65
grooves, 65
- Breadth index of skull, 198
- Breast bone, 119
- Breasts or mammae, 1267
development of, 1267
- Bregma, 178, 198
- Bregmatic fontanelle, 196
- Bridge of nose, 992
- Brim of pelvis, 238
- Broad ligaments of uterus, 1154, 1260
- Broca, cap of, 822
diagonal band of, 869
gyrus of, 822
limbic lobe of, 825
parolfactory area of, 826
- Bronchi, 1084
divisions of, 1097
eparterial, 1097
hyparterial, 1097
intrapulmonary, 1098
left, 1085
lymphatic capillaries in, 686
right, 1085
- Bronchial arteries, 600, 1100
nerves, 913
veins, 667, 1100
- Bronchomediastinal trunks, 717, 718
- Bronchus dexter*, 1085
sinister, 1085
- Brunner's glands, 1176
- Bryant's triangle, 1343
- Buccae*, 1112
- Buccal artery, 561
branches of facial nerve, 905
cavity, 1110
glands, 1112
nerve, long, 895
- Buccinator artery, 561
muscle, 384
relations of, 384
nerve, 895
- Buccoanal membrane, 70
- Buccopharyngeal fascia, 390
membrane, 47
- Bulb of aorta, 545
of corpus cavernosum penis, 1248
of eye, 1000
olfactory, 826, 848
of posterior cornu, 831
spinal, 767
vaginal, 1266
of vestibule, 1266
- Bulbar arteries, 580
- Bulbocavernosus muscle, 428, 430
actions of, 428, 430
- Bulbospinal fasciculus, 854
- Bulbourethral glands of Cowper, 1215, 1253
- Bulbs of internal jugular vein, 648
- Bulbus cordis*, 508
oculi, 1000
ofactorius, 826
- Bulbus vestibuli*, 1266
- Bulla ethmoidalis*, 195, 995
- Bundle of His, 537
oval, 735
of Vicq d'Azyr, 810, 813, 839, 869
- Burdach, tract of, 752, 763
- Burns' space, 389
- Bursa, omental, 1152, 1155
development of, 1106
omentalis, 1155
pharyngeal, 1141
prepatellar, 471
- Bursæ beneath glutæus maxi-
mus, 474
mucosæ, 283
near knee-joint, 345
shoulder-joint, 319
- C**
- CACUMINAL lobe, 790
- Calamus scriptorius*, 799
- Calcaneal arteries, 638, 639
lateral, 638
medial, 639
nerve, internal, 963
medial, 963
sulcus, 263
tuberosity, 266
- Calcaneostragaloid articulation, 352
ligaments, 352
- Calcaneocuboid ligaments, 354
- Calcaneonavicular ligaments, 355
- Calcaneotibial ligament, 350
- Calcaneus, 263
ossification of, 275
- Calcar avis*, 831
- Calcarine fissure, 820
- Calf bone, 260
- Calices of kidney, 1221, 1225
- Callosal convolution, 825
fissure, 825, 828
- Callosomarginal fissure, 820
- Camper, fascia of, 408
- Canaliculi of bone, 89
dental, 1119
- Canaliculus, inferior tympanic, 144, 181
mastoid, 144, 181
- Canalis centralis cochleæ*, 143
craniopharyngeus, 153
reunians [of Hensen], 1052, 1054
- Canal or Canals, adductor, 627
Alcock's, 421
alimentary, 1100
alveolar, 158
atrial, 508
auditory, external, 1036
carotid, 143, 181
central, of medulla spinalis, 754
of cervix of uterus, 1260
condyloid, 131
craniopharyngeal, 153, 1277
ethmoidal, 138, 154
femoral, 625
Haversian, of bone, 89
of Huguier, 141, 904, 1039
Hunter's, 627
hyaloid, 1018
hypoglossal, 131
incisive, 162, 180
infraorbital, 159
inguinal, 418
lacrimal, 1028
mandibular, 173
neural, 50
neurenteric, 50
of Nuck, 1211, 1261
of Petit, 1019
pharyngeal, 180
pterygoid, 181
pterygopalatine, 159, 168
- Canal or Canals, sacral, 110
of Schlemm, 1005
semicircular, 1049
membranous, 1052
spermatic, 418
spiral, of modiolus, 1051
vertebral, 110
- Canales semicirculares ossei*, 1049
- Canaliculus innominatus of Arnold, 150, note
- Canalis adductorius*, 627
centralis [medulla spinalis], 754
cervicis uteri, 1260
inguinalis, 418, 1239
sacralis, 110
semicircularis lateralis, 1049
posterior, 1049
superior, 1049
- Cancellous tissue of bone, 86
- Canine eminence, 158
fossa, 158
teeth, 1117
- Caninus muscle, 383
actions of, 383
nerves of, 383
- Canthi of eyelids, 1025
- Cap of Broca, 822
- Capillaries, 499
bile, 1179
lymphatic, 684
structure of, 500
- Capitate bone, 226
- Capitulum fibulæ*, 260
humeri, 212
mallet, 1044
stapedis, 1045
- Capsula articularis*. See Individual joints.
cricoarytanoidea, 1087
externa, 837
extrema, 835
interna, 836
lentis, 1019
vasculosa lentis, 1003
- Capsular artery, middle, 610
- Capsule, adipose, of kidney, 1220
adrenal, 1278
of Bowman, 1221
of brain, 835, 836, 837
of Glisson, 1157, 1194
of lens, 1019
of Ténon, 1024
- Caput cæcum coli*, 1177
femoris, 243
humeri, 209
pancreatis, 1200
tabi, 267
- Cardiac cycle, 538.
ganglion of Wrisberg, 984
glands of stomach, 1166
muscular tissue, 536
nerves, cervical, 912
from sympathetic, 979
from vagus, 912
great, 979
inferior, 912
middle, 979
superior, 912
thoracic, 912
notch, 1096
orifice of stomach, 1161
plexus of nerves, 984
veins, 642
- Cardinal veins, 520
- Caroticoclinoid foramen, 151, 191
ligament, 153
- Caroticotympanic artery, 568
nerve, 1047
- Carotid arch, 516
artery, common, 549
branches of (occasional), 551
peculiarities of, 551
surface markings of, 1302
external, 551

- Carotid artery, external branches
of, 552
surface markings of, 1302
internal, 566
branches of, 568
peculiarities of, 567
bodies, 1281
canal, 143, 181
ganglion, 977
glands, 1281
groove, 148, 191
nerve, internal, 977
nerves from glossopharyngeal,
909
plexus, 977
internal, 977
sheath, 389
triangles, 564
Carpal arteries from radial, 594
from ulnar, 598
bones, 221
net-work, 594
Carpometacarpal articulations,
330
Carpus, 221
articulations of, 328
ossification of, 230
surface form of, 1327
Cartilage or Cartilages, articular,
280
arytenoid, 1075
of auricula, 1034
cells, 279
corniculate, 1075
costal, 127, 281
cricoid, 1074
cuneiform, 1075
of epiglottis, 1075
epiphysial, 93
ethmovermerine, 171
histology of, 279
hyaline, 279
intrathyroid, 1074
lacunæ, 280
of larynx, 1073
structure of, 1076
lateral, 993
of nose, 992, 993
Meckel's, 66, 174
parachordal, 84
permanent, 279
of pinna, 1034
of Santorini, 1075
of septum of nose, 993
sesamoid, 993
temporary, 280
thyroid, 1073
trabeculae cranii, 84
of trachea, 1086
vomeronasal, 996
white fibro-, 279, 281
of Wrisberg, 1075
Cartilaginee alares minores, 993
arytanoideæ, 1075
corniculatæ, 1075
costales, 127
cuneiformes, 1075
laryngis, 1073
nasi, 992
Cartilaginous ear capsules, 85
vertebral column, 82
Cartilago alaris major, 993
crus laterale, 993
mediale, 993
auriculæ, 1034
cricoidea, 1074
epiglottica, 1075
nasi lateralis, 993
septi nasi, 992
thyreoidea, 1073
triticca, 1077
Caruncula lacrimalis, 1028
Carunculae hymenales, 1266
Cauda equina, 750
helicis, 1034
Cauda pancreatis, 1201
Caudal fold of embryo, 53
Caudate lobe of liver, 1192
nucleus, 833
process of liver, 1192
Caudatum, 833
Cavernous arteries, 568
nerves of penis, 989
plexus, 978
portion of urethra, 1235
sinuses, 658
nerves in, 900
spaces of penis, 1250
Cavity or Cavities, amniotic, 56
body or celom, 50
buccal, 1110
cotyloid, 237
glenoid, 207
of lesser pelvis, 239
mediastinal, 1090, 1092
of mouth proper, 1110
nasal, 194, 994
oral, 1110
peritoneal, 1150
of septum pellucidum, 840
sigmoid, of radius, 220
of ulna, 215
subarachnoid, 876
subdural; 875
of thorax, 524
tympenic, 1038
of uterus, 1260
Cavum conchæ, 1034
laryngis, 1078
Meckelii, 886
nasi, 194, 994
oris, 1110
proprium, 1110
septi pellucidi, 840
subarachnoideale, 876
tympani, paries carotica, 1042
labyrinthica, 1040
mastoidea, 1042
tympanicum, 1037
paries jugularis, 1038
membranacca, 1038
tegmentalis, 1038
uteri, 1260
Cecal arteries, 607
fossæ, 1160
Cecum, 1177
lymphatic vessels of, 710
Celiac artery, 603
axis, 603
branches of vagus nerve, 913
ganglion, 985
plexus, 985
Cell or Cells, animal, 35
basket, of cerebellum, 796
of Betz, 845
of bone, 91
centro-acinar, of Langerhans,
1204
chromaffin, 1277
clasmotocytes, 377
of Claudius, 1058
definition of, 35
of Deiters, 1058
divisions of, 37
of Dogiel, 921
enamel, 1123
germinal, of medulla spinalis,
733
giant, 88
of Betz, 845
of Golgi, 845
of fundus glands, 1166
granule, 377
gustatory, 991
of Hensen, 1058
lamellar, 377
of Martinotti, 845
mass, inner, 46
intermediate, 50
Mastzellen, 377
Cell or Cells, membrane, 36
nerve, 721
nucleus of, 36
olfactory, 996
pigment, 377
plasma, 377
of Purkinje, 794
reproduction of, 37
of Sertoli, 1243
of spinal ganglia, 730, 919
splenic, 1284
structure of, 35
wandering, 377
Cells, 829
Cellulae ethmoidales, 998
Cement of teeth, 1120
formation of, 1124
Centers of ossification, 93
visual, 814
Central artery of retina, 571
canal of medulla spinalis, 754
cells of fundus glands, 1166
fissure, 819
gray stratum of cerebral aque-
duct, 806
ligament of medulla spinalis,
879
lobe, 825
nervous system, 721
part of lateral ventricle, 829
sulcus, 819
tendinous point of perineum, 427
tendon of diaphragm, 406
tract of cranial nerves, 805
of trigeminal nerves, 805
Centrifugal nerve fibers, 729
Centriole, 37
bodies of ovum, 40
of spermatozoön, 42, 43
Centripetal nerve fibers, 729
Centroacinar cells of Langerhans,
1204
Centrosome, 37
Centrosphere, 37
Centrum ovale majus, 828
minus, 827
Cephalic flexure of embryonic
brain, 737
fold of embryo, 53
index, 198
portion of sympathetic system,
977
vein, 661
accessory, 662
Ceratohyal of hyoid bone, 178
Cerebellar arteries, 580
fasciculus, direct, 788
notches, 788
peduncles, 793
tract, direct, 761, 778
of Flechsig, 761
veins, 652
Cerebellum, 788
brachia conjunctiva, 792
pontis, 793
development of, 740
fibrae propriae, 794
gray substance of, 794
lobes of, 788
nucleus dentatus, 796
peduncles of, 793
structure of, 791
surfaces of, 789, 790
vermis of, 788
white substance of, 791
Cerebral arteries, anterior, 571
middle, 572
posterior, 580
aqueduct, 806
cortex, nerve cells of, 845
fibers of, 846
structure of, 845
types of, 847
fissure, lateral, 819
hemispheres, 817

- Cerebral hemispheres, borders of, 818
 development of, 744
 fibers of, association, 843
 commissural, 843
 projection, 843
 transverse, 843
 fissures of, 819
 gray substance of, 845
 gyri of, 821
 interior of, 827
 lobes of, 821, 822
 localization of, 849
 nerves, 881. See Cranial nerves.
 poles of, 818
 structure of, 842
 sulci of, 819, 820, 821
 surfaces of, 818
 white substance of, 842
 peduncles, 800
 structure of, 800
 veins, 652
 ventricles, 797, 815, 829
- Cerebrospinal fasciculus, 759, 760
 fibers of internal capsule, 836
 fluid, 880
- Ceruminous glands, 1037
- Cervical artery, ascending, 581
 deep, 585
 superficial, 582
 transverse, 582
 branch of facial nerve, 905
 cardiac nerves, 912
 enlargement of medulla spin-
 alis, 752
 fascia, 388
 flexure of embryonic brain, 131
 ganglion, 978, 979, 980
 lymph glands, 697
 muscles, lateral, 388
 nerve, cutaneous or transverse,
 927
 of facial, 905
 nerves, 921
 divisions of, anterior, 925
 posterior, 921
 pleura, 1088
 plexus, 925
 branches of, 926, 927
 portion of sympathetic, 978
 rib, 102, 128
 veins, 651
 vertebræ, 97
- Cervicalis ascendens muscle, 399
- Cervix uteri*, 1259
portio supravaginalis, 1259
vaginalis, 1260
 of uterus, 1259
- Chambers of eye, 1012
- Check ligaments, 296
 of eye, 1024
- Cheeks, 1112
- Chest, 117
- Chiasma, optic, 814, 883
opticum, 814, 883
- Chiasmatic groove, 147, 190
- Choanae, 180, 196, 994
- Chondrin, 282
- Chondrocranium, 84
- Chondro-epitrochlearis muscle,
 437
- Chondroglossus muscle, 1130
- Chondromucoid, 282
- Chondrosternal ligament, 302
 intra-articular, 303
- Chondroxiphoid ligaments, 304
- Chorda obliqua*, 325
 tympani nerve, 904
- Chordæ tendineæ* [left ventricle],
 535
 [right ventricle], 532
 Willis, 655
- Chordal furrow, 52
 portion of base of skull, 84
- Chorioidea*, 1009
lamina choriocapillaris, 1010
vasculosa, 1010
- Chorion, 60
 frondosum, 62
 laeve, 61
- Chorionic villi, 60
- Choroid artery, 574
 coat of eyeball, 1009
 structure of, 1010
 plexuses of fourth ventricle, 798
 of lateral ventricle, 840
 of third ventricle, 815
 vein, 653
- Choroidal artery, anterior, 574
 posterior, 581
 fissure, 841, 1002
- Chromaffin cells, 1277
- Chromaphil and cortical systems,
 1277
 development of, 1277
- Chromatin, 36
- Chromatolysis, 724
- Chromosomes, 37
- Chyle, 683
- Chyliferous vessels, 683
- Cilia*, 1025
- Ciliaris muscle, 1010
- Ciliary arteries, 571
 body, 1010
 ganglion, 888
 glands, 1025
 muscle, 1011
 nerves, 888
 processes, 1010
- Cingulate gyrus, 825
 sulcus, 820
- Cingulum of cerebral hemisphere,
 843
 of teeth, 1116
- Circle, arterial, of Willis, 574
- Circular folds of small intestine,
 1173
 sinus, 659
 sulcus, 821, 825
- Circulating fluids, 503
- Circulation of blood in adult, 497
 in fetus, 540
- Circulus arteriosus major*, 1014
minor, 1014
major [iris], 571, 1014
minor [iris], 571, 1014
venosus [mammary], 1268
- Circumduction, 286
- Circumferential fibrocartilage, 282
- Circumflex arteries, femoral, 630
 humeral, 589
 nerve, 934
- Circuminsular fissure, 821
- Circumvallate papillæ, 1126
- Cisterna basalis*, 876
chylæ, 691
cerebellomedullaris, 876
chiasmatis, 877
fossæ cerebri lateralis, 877
interpeduncularis, 876
magna, 876
pontis, 876
venæ magnæ cerebri, 877
- Cisternæ subarachnoid, 876
subarachnoidales, 876
- Clarke's column, 758
- Clastmatocytes, 377
- Claudius, cells of, 1058
- Clastrum, 835
- Clava, 774
- Clavicle, 200
 ossification of, 202
 peculiarities of, in sexes, 202
 structure of, 202
 surface anatomy of, 1326
- Clavicula*, 200
- Clavipectoral fascia, 437
- Cleft palate, 199
- Cleidothyoideus muscle, 393
- Clinging fibers of cerebellum, 796
- Clinoid processes, anterior, 151,
 190
 middle, 147, 190
 posterior, 147, 190
- Clitoris, 1266
 frenulum of, 1266
 glans of, 1266
 nerves of, 968
 prepuce of, 1266
- Clivus of sphenoid, 148
 monticuli of cerebellum, 790
- Cloaca, ectodermal, 1109
 endodermal, 1109
 pelvic portion of, 1212
 phallic portion of, 1213
 vesicourethral portion of, 1212
- Cloacal duct, 1109
 membrane, 1109
 tubercle, 1213
- Cloquet, lymph gland of, 703
- Closing membranes, 65
- Coarctation of aorta, 547
- Coccygeal arteries, 620
 body, 1281
 cornua, 111
 gland, 1281
 nerve, division of, anterior, 957
 posterior, 925
 plexus, 968
- Coccygeus muscle, 424
 actions of, 424
 nerves of, 424
- Coccyx, 111
 ossification of, 114
- Cochlea, 1050
 aqueduct of, 144, 181
 cupula of, 1050, 1051
hamulus laminae spiralis, 1051
 helicotrema of, 1051
 modiolus of, 1050
 scalæ of, 1051
 spiral canal of, 1051
 lamina of, 1051
 vessels of, 1059
- Cochlear artery, 1059
 nerve, 906, 1059
 composition and central con-
 nections of, 857
 nuclei, 788, 906
 root of acoustic nerve, 906
- Cochleariform process, 145, 1042
- Cog-tooth of malleus, 1044
- Cohnheim, areas of, 374
- Colic arteries of ileocolic, 609
 left, 610
 middle, 609
 right, 609
 flexures, right and left, 1180
 impression, 1189
 valve, 1179
- Collar bone, 200
- Collateral circulation, 543
 eminence, 833
 fissure, 820
 ganglia, 977
- Collecting tubes of kidney, 1223
- Colles, fascia of, 235, 409, 426
- Colliculi, inferior, 805, 806
 superior, 805, 806
- Colliculus of arytenoid cartilage,
 1075
facialis, 799
inferior, 806
nervi optici, 1015
superior, 806
- Collum anatomicum*, 209
femoris, 243
mallei, 1044
tali, 269
- Coloboma, 1002
- Colon, 1180
ascendens, 1180
 ascending, 1180
descendens, 1181

- Colon, descending, 1181
 iliac, 1182
 left or splenic flexure of, 1181
 pelvic, 1182
 right or hepatic flexure of, 1180
 sigmoid, 1182
 sigmoideum, 1182
 structure of, 1184
 tela submucosa, 1186
 transverse, 1180
 transversum, 1180
 tunica mucosa, 1186
 muscularis, 1185
 serosa, 1184
 vessels and nerves of, 1187
 Colored lines of Retzius, 1120
 or red corpuscles, 503
 Colorless corpuscles, 504
 Colostrum corpuscles, 1268
 Columna anterior [*medulla spin-*
 alis], 753
 fornicis, 838
 lateralis [*medulla spinalis*], 753
 nasi, 992
 posterior [*medulla spinalis*], 753
 vertebralis, 96
 Columnæ carneæ, 532
 Columns of Clarke, 758
 of fornx, 838
 of medulla spinalis, 756, 757,
 758
 rectal, of Morgagni, 1185
 renal, 1221
 of vagina, 1264
 vertebral, 96, 114
 Comes nervi phrenici, 584
Comitans nervi ischiadici, 620
 Comma-shaped fasciculus, 764
 Commissura laborium anterior,
 1265
 palpebrarum lateralis, 1025
 medialis, 1025
 Commissural fibers of cerebral
 hemispheres, 843
 Commissure of brain, 809
 anterior, 747, 840
 middle or gray, 809
 posterior, 743, 812
 of corpus callosum, 747
 habenular, 812
 hippocampal, 838, 869
 of Gudden, 814
 of labia majora, 1265
 of medulla spinalis, anterior
 and posterior gray, 754
 anterior white, 752
 optic, 814
 Commissures, palpebral, 1025
 Common bile duct, 1198
 lymphatics of, 711
 carotid artery, 549
 dental germ, 1122
 iliac arteries, 613
 glands, 704
 veins, 677
 integument, 1062
 interosseous artery, 596
 peroneal nerve, 694
 Communicans fibularis nerve, 694
 tibialis nerve, 962
 Communicantes cervicales nerves,
 928
 Communicating artery, anterior,
 571
 from dorsalis pedis, 637
 posterior, 573
 Compact tissue of bone, 86
 Comparison of bones of hand and
 foot, 276
 Complexus muscle, 400
 Composition and central connec-
 tions of cranial nerves,
 855
 of spinal nerves, 849
 Compressor naris muscle, 382
 Concha of auricula, 1034
 nasal, inferior, 169
 articulations of, 170
 ossification of, 170
 middle, 156
 superior, 156
 nasalis inferior, 169
 Conchæ, sphenoidal, 152
 sphenoidales, 152
 Conchal crest, 160, 167
 Condyle of mandible, 174
 Condyles of femur, 247
 occipital, 131
 of tibia, 256
 Condylloid articulation, 286
 canal, 131
 foramen, anterior, 131
 fossa, 131, 181
 process of mandible, 174
 Cone of attraction, 45
 bipolars of retina, 1017
 granules of retina, 1017
 of origin of axon, 724
 Cones of retina, 1017
 Confluence of sinuses, 131, 658
Confluens sinuum, 658
Coni vasculosi, 1244
 Conical papillæ, 1127
 Conjoined tendon of internal
 oblique and transversalis
 muscles, 414
 Conjugate diameter of pelvis, 239
 Conjunctiva, 1026
 Connecting fibrocartilages, 282
 Connective tissue, extraperitoneal,
 418
 Conoid ligament, 315
 tubercle, 200
 Constriction, duodenopyloric, 1162
 Constrictor muscles, 1142
 pharyngis inferior muscle, 1142
 medius muscle, 1143
 superior muscle, 1143
 urethra muscle, 429, 431
Conus arteriosus, 531
 elasticus [larynx], 1078
 medullaris, 749
 Convoluted tubes of kidney, 1223
 Convolution, callosal, 825
 frontal, ascending, 821
 occipitotemporal, 823
 parietal, ascending, 823
 Cooper, ligament of, 412
 Copula, 1103
 Cor, 526
 Coracoacromial ligament, 316
 Coracobrachialis muscle, 443
 actions of, 444
 nerves of, 444
 variations of, 443
 Coracoclavicular fascia, 437
 Coracohumeral ligament, 317
 Coracoid process, 207
 tuberosity, 200
 Cord, gangliated, 976
 spermatic, 1239
 spinal, 749
 umbilical, 57
 vocal, false, 1079
 inferior, 1080
 superior, 1079
 true, 1080
 Corium or cutis vera, 1065
 layers of, 1065
 stratum papillare, 1065
 reticulare, 1065
 Cornea, 1006
 structure of, 1007
 Corneal corpuscles, 1008
 endothelium, 1009
 epithelium, 1007
 spaces, 1008
 Corniculate cartilages, 1075
Cornu anterius, 830
 inferior, 831
 Cornu of medulla spinalis, 753
 posterius, 831
 Cornua of coccyx, 111
 of hyoid bone, 178
 of lateral ventricles, 830, 831
 majora [os *hyoidei*], 178
 minora [os *hyoidei*], 178
 of sacrum, 108
 of thyroid cartilage, 1073, 1074
 Cornucopia of Bochdalek, 798
Corona glandis, 1249
 radiata [brain], 837
 [ovum], 40
 Coronal suture, 178, 183
 Coronary artery of heart, 546
 peculiarities of, 547
 of lips, 555
 of stomach, 603
 ligament of liver, 1150
 ligaments of knee, 343
 plexuses, 985, 987
 sinus, 642
 opening of, 530
 sulcus of heart, 526
 veins, 642
 of stomach, 682
 Coronoid fossa, 212
 process of mandible, 174
 of ulna, 214
Corpora cavernosa clitoridis, 1266
 penis, 1248
 bulbs of, 1248
 crura of, 1248
 mammillaria, 813
 quadrigemina, 805
 brachia of, 805, 806
 structure of, 806
Corpus albicans, 813
 Aranii, 533
 callosum, 818, 828
 development of, 747
 genu of, 828
 peduncle of, 827
 rostrum of, 828
 splenium of, 828
 cavernosum, artery to, 620
 urethra, 1247
 ciliare, 1010
 femoris, 246
 fibula, 260
 fornicis, 838
 geniculatum laterale, 811
 mediale, 811
 Highmori, 1243
 humeri, 209
 incudis, 1044
 luteum, 1256
 maxilla, 158
 oss. hyoidei, 177
 ilii, 231
 ischii, 234
 pubis, 235
 pancreatis, 1201
 papillare [corium], 1065
 penis, 1249
 pineale, 812
 radix, 219
 sphenoidale, 147
 spongiosum, 1248
 sterni, 120
 striatum, 833
 vein of, 838
 subthalamicum, 812
 tabi, 267
 tibia, 257
 ulnae, 215
 uteri, 1259
 vertebrae, 96
 vitreum, 1018
 Corpuscles, colored, 503
 development of, 503
 colorless, 504
 genital, 1060
 of Golgi and Mazzoni, 1061
 of Grandry, 1060

- Corpuscles of Hassall, 1274
 of Herbst, 1061
 Pacinian, 1060
 of Ruffini, 1061
 of Wagner and Meissner, 1061
 Corrugator cutis ani muscle, 425
 muscle, 381
 actions of, 381
 nerves of, 381
 supercilii muscle, 381
 Cortex of cerebellum, 794
 of cerebrum 845
 Corti, ganglion of, 1051, 1059
 organs of, 1056
 pillars or rods of, 1056
 spiral organ of, 1056
 tunnel of, 1057
 Cortical arches of kidney, 1221
 arterial system of brain, 574
 portion of suprarenal gland, 1280
 substance of kidney, 1221
 of lens, 1020
 visual center, 882
 Corticostriate fibers, 835
Costæ, 123
 Costal cartilages, 127, 280
 element or process, 98
 groove, 124
 pleura, 1088
 tuberosity, 202
 Costocephalic articulation, 299
 Costocervical trunk, 585
 Costochondral articulations, 304
 Costocoracoid ligament, 437
 membrane, 528
 Costocoracoid muscle, 437
 Costomediastinal sinus, 1090
 Costosternal articulations, 302
 Costotransverse articulations, 300
 ligaments, 302
 Costovertebral articulations, 299
 ligament, anterior, 299
 Cotyloid cavity, 237
 ligament, 237, 436
 Covering bones, 85
 Coverings of ovum, 40
 of testes, 1236
 Cowper's glands, 1213, 1253
 Coxal articulation, 333
 movements of, 338
 muscles in relation to, 338
 Cranial arachnoid, 876
 bones, 129
 dura mater, 872
 fossa, anterior, 190
 middle, 190
 posterior, 190, 192
 nerves, 881
 abducent, 899
 accessory, 913
 acoustic, 905
 composition and central connections of, 855
 development of, 748
 facial, 901
 glossopharyngeal, 906
 hypoglossal, 914
 oculomotor, 884
 olfactory, 881
 optic, 882
 tracts of, 804, 805
 trigeminal, 886
 trochlear, 885
 vagus, 910
 pia mater, 879
 sympathetics, 970
 Craniology, 197
 Craniopharyngeal canal, 1277
 Cranium, 128
 bones of, 128, 129
 breadth of, 198
 development of, 83
 height of, 198
 Cranium, horizontal circumference of, 198
 length of, 198
 longitudinal arc of, 198
 Cremaster muscle, 414
 Cremasteric artery, 623
 fascia, 414
 Crescents of Gianuzzi, 1136
 Crest or Crests, basilar, 1054
 conchal, 159, 167
 ethmoidal, 161, 167
 frontal, 136
 of ilium, 234
 incisor, 163
 infratemporal, 150, 183
 internal occipital, 131, 193
 intertrochanteric, 246
 lacrimal, 161, 164
 nasal, 163, 167
 neural, 51, 736
 obturator, 236
 of pubis, 236
 of right atrium, 529
 sphenoidal, 149
 supramastoid, 139
 of tibia, 257
 of tubercles of humerus, 209
 urethral, in female, 1236
 in male, 1234
 Cribriform plate of ethmoid, 153
 Cricarytenoideus lateralis muscle, 1082
 posterior muscle, 1082
 Cricarytenoid ligament, 1078
 muscles, 1082
 Cricoid cartilage, 1074
 Cricothyreoid muscle, 1081
 Cricothyroid artery, 552
 ligament, middle, 1078
 membrane, 1078
 muscle, 1081
 Cricotracheal ligament, 1077
Crista arcuata [arytenoid cartilage], 1075
 colli costæ, 123
 falciformis, 143
 galli, 153
 terminalis [of His], 509
 vestibuli, 1047
 Crossed commissural fibers, 755
 pyramidal tract, 760
 Crosses of Ranvier, 727
 Crown of a tooth, 1117
 Crucial anastomosis, 630
 ligaments, 342
 Cruciate crural ligament, 488
 eminence of occipital bone, 130
 ligament of atlas, 295
 ligaments of knee, 342
 Crura cerebri, 800
 of diaphragm, 405
 of fornix, 840
 of penis, 1248
 of stapes, 1045
 of subcutaneous inguinal ring, 410
 Crural arch, deep, 419
 nerve, anterior, 955
 septum, 626
 sheath, 625
 Crureus muscle, 471
 Crus cerebri, 800
 communis [semicircular canals], 1049
 fornicis, 840
 helicis, 1034
 penis, 1248
 Crusta or pes of cerebral peduncle, 802
 petrosa of teeth, 1120
 formation of, 1120
 Cruveilhier, glenoid ligaments of, 332, 359
 Crypts of Lieberkühn, 1174
 Crystalline lens, 1019
 Crystalline lens, cortical substance of, 1020
 development of, 1002
 nucleus of, 1020
 Cuboid bone, 269
 Cuboideonavicular articulation, 356
Culmen monticuli [cerebellum], 789
 Concave nucleus, 774
 tubercle, 774
 Cuneiform bone of carpus, 225
 of tarsus, first, 270
 second, 271
 third, 271
 cartilages, 1075
 tubercle, 1079
 Cuneocuboid articulation, 357
 Cuneonavicular articulation, 356
 Cuneus, 823
 Cup, optic, 1001
 Cupula of cochlea, 1051
 of pleura, 1088
Curvatura ventriculi major, 1162
 minor, 1162
 Curvatures of stomach, 1162
 Curved lines of ilium, 232, 233
 Curves of vertebral column, 114
 Cushion of auditory tube, 1141
 of epiglottis, 1076
 Cushions, endocardial, 512
 Cusps of bicuspid valve, 534
 of tricuspid valve, 531
 Cutaneous cervical nerve, 927
 nerve, external, 953
 internal, 937, 955
 lesser, 937
 middle, 955
 Cuticle, 1062
Cuticula dentis, 1123
 Cutis plate, 80
 vera or corium, 1065
 Cutting teeth, 1115
 Cuvier, ducts of, 520
 Cycle, cardiac, 538
Cymba conchæ, 1034
 Cystic artery, 605
 duct, 1198
 vein, 682
 Cyton, 723
 Cytoplasm, 35
 Cytotrophoblast, 47

D

- DACRYON, 189, 1198
 Dartos tunic, 1238
 Darwin, auricular tubercle of, 1033
 Daughter chromosomes, 37
 Decidua, 59
 basalis, 60
 capsularis, 60
 parietalis, 60
 placentalis, 60
 stratum compactum of, 59
 spongiosum of, 60
 unaltered or boundary layer of, 60
 Decidual cells, 59
 Decussation of lemniscus, 777
 of optic nerves, 883
 pyramidal, 767
 sensory, 777
 Deep abdominal ring, 418
 artery of penis, 617
 auricular artery, 560
 cerebral veins, 653
 cervical artery, 585
 fascia, 388
 lymph glands, 697
 vein, 651
 crural arch, 419
 epigastric artery, 623
 vein, 672

- Deep external pudic artery, 629
 fascia of arm, 442
 of forearm, 445
 femoral artery, 629
 iliac circumflex vein, 673
 lingual artery, 553
 muscles of back, 396
 palmar arch, 595
 peroneal nerve, 965
 petrosal nerve, 892
 plantar artery, 637
 Sylvian vein, 653
 temporal arteries, 561
 nerves, 895
 transverse fascia of leg, 483
 Degeneration, Wallerian, 759
 Deglutition, 1140
 Deiters, cells of, 1058
 nucleus of, 788, 803
 Deltoid ligament, 350
 muscle, 439
 tuberosity, 211
 Deltoid muscle, 439
 actions of, 440
 nerves of, 440
 variations of, 440
 Demilunes of Heidenhain, 1136
 Demours, membrane of, 1008
 Dendrons of nerve cells, 723
 Dens, or odontoid process of axis, 99
 serotinus, 1118
 Dental artery, inferior, 561
 posterior, 562
 canaliculi, 1119
 formulæ, 1114
 furrow, 1122
 germs, 1122
 lamina, 1122
 nerve, inferior, 896
 pulp, 1118
 sac, 1123
 Dentate fissure, 826
 gyrus, 827, 868
 ligament, 880
 Dentés, 1112
 canini, 1116
 decidui, 1118
 incisivi, 1115
 molares, 1118
 permanentes, 1115
 præmolares, 1118
 Dentin, 1119
 formation of, 1123
 intertubular, 1120
 secondary, 1120
 Dental canaliculi, 1119
 fibers, 1119
 matrix, 1119
 sheath of Neumann, 1119
 tubules, 1109
 Depressions for arachnoid granulations, 134
 Depressor alæ nasi muscle, 382
 anguli oris muscle, 381
 labii inferioris muscle, 383
 septi muscle, 382
 actions of, 382
 nerves of, 382
 Dermal bones, 85
 Dermic coat of hair follicle, 1076
 Dermis, 1065
 Descemet, membrane of, 1008
 Descendens cervicalis nerve, 928
 Descending aorta, 598
 colon, 1181
 comma-shaped fasciculus, 764
 oblique muscle, 409
 palatine artery, 562
 process of lacrimonal bone, 164
 ramus of hypoglossal nerve, 918
 of ischium, 235
 of os pubis, 237
 Descent of testis, 1210
 Detrusor urinæ muscle, 1233
 Deutoplasm, 39
 Development of allantois, 54
 of amnion, 56
 of anal canal, 1108
 of arteries, 515
 of body cavities, 72
 of bone, 86
 of brain, 736
 of branchial or visceral arches, 65
 of chorion, 60
 of chromaphil and cortical systems, 1277
 of cranial nerves, 748
 of deciduous teeth, 1122
 of diencephalon, 742
 of digestive tube, 1101
 of ear, 1029
 of external organs of generation, 1213
 of eye, 1001
 of face, 67
 of fetal membranes, 54
 of heart, 506
 of hypophysis cerebri, 1276
 of joints, 283
 of kidney, 1211
 of limbs, 71
 of liver, 1193
 of lymphatic system, 768
 of mammae, 1101
 of medulla spinalis, 749
 of mouth, 1101
 of muscles, 371
 of nervous system, 733
 of neural groove and tube, 50
 of nose, 67
 of notochord, 52
 of ovaries, 1207
 of palate, 70
 of palatine tonsils, 1103
 of pancreas, 1202
 of parathyroid glands, 1272
 of permanent teeth, 1124
 of pharyngeal pouches, 65
 of placenta, 62
 of primitive segments, 52
 streak, 47
 of prostate, 1213
 of rectum, 1108
 of respiratory organs, 1071
 of ribs, 82
 of salivary glands, 1102
 of skeleton, 80
 of skin, 1066
 of skull, 83
 of spinal nerves, 735
 of spleen, 1282
 of sternum, 83
 of suprarenal glands, 1278
 of teeth, 1121
 of testis, 1210
 of thymus, 1273
 of thyroid gland, 1270
 of tongue, 1102
 of umbilical cord, 57
 of urethra, 1215
 of urinary bladder, 1212
 and generative organs, 1205
 of vascular system, 505
 of veins, 518
 of venous sinuses of dura mater, 522
 of vertebral column, 80
 of visceral arches, 65
 of yolk-sac, 54
 Diagonal band of Broca, 869
 Diameters of pelvis, 239, 240
 Diaphragm, lymphatic vessels of, 717
 muscles of, 404
 actions of, 406
 nerves of, 406
 variations of, 406
 pelvic, 420, 1147
 Diaphragm, urogenital, 428
Diaphragma sellæ, 874
 Diaphragmatic lymph glands, 715
 part of pelvic fascia, 421
 pleura, 1088
 surface of heart, 529
 Diarthroses, 285
 Diaster, 37
 Diencephalon, 807
 development of, 742
 Digastric fossa, 141
 muscle, 391
 nerve from facial, 905
 triangle, 564
 Digastric muscle, 391
 actions of, 393
 nerves of, 393
 variations of, 392
 Digestion, organs of, 1100
 Digestive apparatus, 1100
 development of, 1101
 tube, 1100
 Digital arteries of foot, 640
 from superficial volar arch, 598
 of hand, 598
 fossa of epididymis, 1242
 of femur, 244
 nerves of lateral plantar, 963
 of medial plantar, 963
 of median, 938
 of musculocutaneous, 937
 of radial, 943
 of ulnar, 939
 vaginal ligaments, 449
 veins of foot, 669
 of hand, 660
 Digits, articulations of, 333
 Dilator naris anterior muscle, 382
 action of, 382
 nerves of, 382
 posterior muscle, 382
 action of, 382
 nerves of, 382
 pupillæ muscle, 1013
 tubæ muscle, 1044
 Diploë, 80
 Diploic veins, 651, 652
 Direct cerebellar fasciculus, 758
 tract, 778
 of Flechsig, 761
 pyramidal tract, 759
 Discharge of ovum, 1256
Discus articularis, 298
 proligerus, 1256
 Disk, interpubic, 311
 optic, 1015
 Disks, tactile, of Merkel, 1059
Diverticulum ilei, 1172
 Meckel's, 54, 1172
 Divisions of bronchi, 1197
 of cells, 37
 Dobie's line, 375
 Dogiel, cells of, 921
 Dorsal aortæ, 517
 artery of penis, 620
 carpal artery, of radial, 594
 of ulnar, 598
 ligament, 458
 cutaneous nerves, 963, 966
 fissure of medulla oblongata, 767
 interossei muscles, 464, 495
 interosseous artery, 596
 nerve, 944
 lamina, 735
 mesogastrum, 1103
 metacarpal arteries, 594
 veins, 663
 nasal artery, 571
 nerve of penis, 968
 peripheral band, 764
 pulmonary nerves, 913
 scapular nerve, 932
 spinal artery, 579

- Dorsal veins of penis, 676
venous arch of foot, 669
net-work of hand, 660
vestibular nucleus, 788
- Dorsalis hallucis artery*, 637
- linguæ artery*, 555
- pedis artery*, 636
branches of, 637
peculiarities of, 636
relations, 636
surface markings of, 1346
- scapulae artery*, 588
- Dorsoepitrochlearis brachii muscle, 434
- Dorsomedian fissure of medulla oblongata, 767
- Dorsum ili*, 232
- lingua*, 1125
- nasi*, 992
- selle*, 147, 190
- of tongue, 1125
- Douglas, pouch of, 1152
- Drum, 1037
- Duct or Ducts, accessory pancreatic, 1202
- of Bartholin, 1136
- of Bellini, 1223
- of bulbourethral glands, 1253
- cloacal, 1109
- common bile, 1198
- of Cuvier, 520
- cystic, 1198
- ejaculatory, 1247
- frontonasal, 138
- of Gärtner, 1255
- hepatic, 1197
- lacrimal, 1028
- lactiferous, 1268
- of liver, 1197
- lymphatic, right, 691
- Müllerian, 1206
- nasolacrimal or nasal, 1029
- pancreatic, 1202
- parotid, 1134
- pronephric, 1205
- prostatic, 1253
- orifices of, 1234
- of Rivinus, 1136
- of Santorini, 1202
- semicircular, 1052
- seminal, 1245
- Skene's, 1213
- Stensen's, 1134
- sublingual, 1136
- submaxillary, 1135
- thoracic, 690
- thyroglossal, 1126, 1270
- vitelline, 54
- Wharton's, 1135
- of Wirsung, 1202
- Wolffian, 1205
- Ductless glands, 1269
- parathyroids, 1271
- spleen, 1282
- suprarenals, 1278
- thymus, 1273
- thyroid, 1269
- Ductuli aberrantes* [testis], 1246
- effervescentes* [testis], 1244
- transversi* [epoöphoron], 1255
- Ductus arteriosus*, 540
- choledochus*, 1198
- cochlearis*, 1054
- cysticus*, 1198
- deferens*, 1245
- ampulla of, 1246
- structure of, 1246
- ejaculatorii*, 1247
- endolymphaticus*, 1048, 1052
- hepaticus*, 1197
- lacrimalis*, 1028
- longitudinalis epoöphori*, 1255
- lymphaticus dexter*, 691
- nasolacrimalis*, 1029
- pancreaticus* [Wirsungi], 1202
- Ductus parotideus*, 1134
- Santorini*, 1202
- semicirculares*, 1052
- submaxillaris*, 1135
- thoracicus*, 690
- utriculosaccularis*, 1052
- venosus*, 519, 542
- development of, 519
- fossa for, 1191
- obliterated, 681
- Duodenal fossæ, 1159
- glands, 1176
- impression, 1190
- Duodenojejunal flexure, 1169
- fold, 1159
- fossa, 1159
- Duodenomesocolic fold, 1159
- Duodenopyloric constriction, 1162
- Duodenum, 1168
- ascending portion, 1169
- descending portion, 1169
- horizontal portion, 1169
- lymphatic vessels of, 710
- superior portion, 1169
- suspensory muscle of, 1170
- vessels and nerves of, 1170
- Dura mater, cranial, 872
- arteries of, 872
- endosteal layer of, 875
- meningeal layer of, 875
- nerves of, 875
- processes of, 873
- veins of, 875
- encephali*, 872
- spinal, 875
- structure of, 876
- spinalis*, 875
- venous sinuses of, development of, 522
- Dural nerve, 911
- E**
- EAR, 1029
- auricula of, 1033
- muscles of, 1035
- cartilaginous capsules of, 85
- cochlea, 1050
- development of, 1029
- external, 1033
- internal, or labyrinth, 1047
- meatus acusticus externus, 1036
- membranous labyrinth, 1051
- middle, 1037
- osseous labyrinth, 1047
- pinna of, 1033
- semicircular canals of, 1049
- tympenic cavity of, 1037
- muscles of, 1046
- ossicles of, 1044
- vessels and nerves of, 1046
- vestibule of, 1047
- Eberstaller, medial frontal sulcus of, 822
- Ectoderm, 47
- Ectodermal cloaca, 1109
- Efferent nerves, 729
- Eighth nerve, 905
- Ejaculator urinæ muscle, 428
- Ejaculatory ducts, 1247
- Elastic fibrocartilage, 282
- laminae of cornea, 1008
- membrane of larynx, 1077
- Elbow bone, 214
- Elbow-joint, 321
- anastomoses around, 592
- movements of, 322
- surface anatomy of, 1328
- markings of, 1331
- vessels and nerves of, 322
- Eleventh nerve, 313
- Embryo, form of, at different stages, 74
- separation of, 53
- Embryology, 38
- Embryonic disk, 47
- pole, 46
- Eminence, canine, 158
- collateral, 833
- cruciate, 130
- frontal, 135, 178, 183
- hypothenar, 456
- iliopectineal, 234
- intercondyloid, of tibia, 256
- medial, of rhomboid fossa, 799
- parietal, 133, 178, 183
- pyramidal, of pons, 785
- of tympanic cavity, 1042
- thenar, 456
- Eminences and depressions of bones, 80
- Eminentia arcuata*, 142
- articularis*, 139
- collateralis*, 833
- pyramidalis*, 1042
- saccularis*, 813
- Emissary veins, 660
- Enamel cells, 1123
- droplet, 1123
- epithelium, 1123
- fibers or prisms, 1120
- organ, 1123
- of teeth, 1120
- formation of, 1123
- Enarthrosis, 286
- Encephalon, 766
- End-arteries, 1223
- End-bulbs of Krause, 1060
- End-plates, motor, of Kühne, 730
- Endocardial cushions, 512
- Endocardium, 535
- Endognathion, 199
- Endolymph, 1051
- Endomysium, 373
- Endoneurium, 728
- Endosteal layer of dura mater, 875
- Endothelium, corneal, 1009
- Enlargements of medulla spinalis, 751
- Ensiform appendix, 121
- Entoderm, 47
- Entodermal cloaca, 1109
- Entrance of larynx, 1079
- Eosinophil corpuscles, 504
- Eparterial branch of right bronchus, 1085, 1097
- Ependymal layer, 733
- Epicardium, 535
- Epicondyles of humerus, 212
- Epicranial aponeurosis, 380
- Epidermic coat of hair follicle, 1068
- Epidermis, development of, 1066
- structure of, 1062
- Epididymis, 1242
- Epidural space, 875
- Epigastric artery, deep or inferior, 623
- peculiarities of, 623
- surface markings of, 1321
- superficial, 629
- superior, 585
- lymph glands, 704
- region, 1149
- vein, deep, 762
- inferior, 672
- Epiglottis, 1075
- tubercle or cushion of, 1076
- Epimysium, 373
- Epineurium, 728
- Epitotic center of temporal bone, 146
- Epiphyses, atavistic, 95
- pressure, 95
- traction, 95

- Epiphysal cartilage, 93
 Epiphysis, 35, 812, 1277
 Epiploic foramen, 1156
 Epitrochleo-anconaeus muscle, 448
Epistropheus, 100
Epithalamus, 743, 812
fasciculus retroflexus [of Meynert], 812
ganglion habenule, 812
 pineal body, 812
 structure of, 812
 posterior commissure, 812
 nucleus of, 812
trigonum habenule, 812
 Epithelium, enamel, 1123
 germinal, of Waldeyer, 1209, 1255
 stratified, of cornea, 1007
 transitional, 1223
 Eptympanic recess, 142, 1038
 Eponychium, 1067
 Epöphoron, 1206, 1255
 Equator of lens, 1019
 Erector clitoridis muscle, 430
 penis muscle, 428
 spinæ or sacrospinalis muscle, 397
 Eruption of teeth, 1124
 Erythroblasts, 88
 Esophageal arteries, 581, 600
 glands, 1146
 hiatus in diaphragm, 466
 nerves, 913
 plexus, 913
 Esophagus, 1144
 abdominal portion of, 1146
 cervical portion of, 1145
 lymphatic vessels of, 719
 nerves of, 1146
 structure of, 1146
 tela submucosa, 1146
 thoracic portion of, 1145
 tunica mucosa, 1146
 mucularis, 1146
 vessels of, 1146
 Ethmoid bone, 153
 articulations of, 156
 cribriform plate of, 153
 crest, 161, 167
 foramina, 189
 horizontal lamina of, 153
 labyrinth or lateral mass of, 154
 lamina papyracea of, 155
 os planum of, 155
 ossification of, 155
 perpendicular plate of, 153
 uncinate process of, 155
 vertical plate, 154
 Ethmoidal arteries, 570
 canals, 138, 154
 cells, 154, 998
 notch, 137
 plate, 85
 process of inferior nasal concha, 169
 spine, 147, 190
 Ethmovomerine cartilage, 171
 Eustachian tube, 1042
 valve, 530
 Excavation, rectouterine, 1152
 retrovesical, 1152
 vesicouterine, 1152
 Exner, plexus of, 846
 Exognathion, 200
 Extensor carpi radialis accessorius muscle, 452
 brevis muscle, 452
 actions of, 456
 nerves of, 456
 variations of, 452
 intermedius muscle, 452
 longus muscle, 452
 actions of, 456
 nerves of, 456
 Extensor carpi radialis longus muscle, variations of, 452
 ulnaris muscle, 454
 actions of, 456
 nerves of, 456
 variations of, 454
 coccygis muscle, 401
 digiti quinti proprius muscle, 454
 actions of, 456
 nerves of, 456
 variations of, 454
 digitorum brevis muscle, 488
 actions of, 488
 nerves of, 488
 variations of, 488
 communis muscle, 452
 actions of, 456
 nerves of, 456
 variations of, 454
 longus muscle, 481
 actions of, 482
 nerves of, 482
 variations of, 482
 hallucis longus muscle, 481
 actions of, 482
 nerves of, 482
 variations of, 481
 indicis proprius muscle, 456
 actions of, 456
 nerves of, 456
 variations of, 456
 minimi digiti muscle, 454
 ossis metacarpi pollicis muscle, 455
 metatarsis hallucis muscle, 481
 pollicis brevis muscle, 455
 actions of, 456
 nerves of, 456
 variations of, 455
 longus muscle, 455
 actions of, 456
 nerves of, 456
 primi internodii pollicis muscle, 455
 proprius hallucis muscle, 481
 secundi internodii pollicis muscle, 455
 Exterior of skull, 178
 External abdominal ring, 410
 arcuate ligament, 405
 auditory canal, 1036
 meatus, 1036
 calcaneal artery, 638
 calcaneostragaloid ligament, 352
 canthus of eyelids, 1025
 circumflex artery, 630
 cutaneous nerve, 953
 geniculate body, 811
 intercostal muscles, 403
 lateral ligament, 297, 322, 328
 ligament of malleus, 1045
 malleolar artery, 635
 oblique muscle, 409
 plantar artery, 639
 nerve, 963
 popliteal nerve, 964
 pterygoid muscle, 386
 pudic arteries, 629
 respiratory nerve of Bell, 933
 saphenous vein, 670
 semilunar fibrocartilage, 343
 spermatic fascia, 1238
 sphincter ani muscle, 425
 Extraspinal veins, 668
Extremitas acromialis [clavicular], 202
 sternalis [clavicular], 202
 Extremity of penis, 1250
 Extrinsic muscles of tongue, 1129
 Eye, 1000
 Eyeball or bulb of eye, 1000
 Eyeball, accessory organs of, 1021
 aqueous humor, 1018
 capsule of Tënon, 1024
 chambers of, 1012
 choroid, 1009
 ciliary body, 1010
 muscle, 1011
 processes, 1010
 conjunctiva, 1026
 cornea, 1006
 crystalline lens, 1019
 development of, 1001
 fascia bulbi, 1024
 fibrous tunic, 1005
 hyaloid membrane, 1018
 iris, 1012
 obliculus ciliaris, 1010
 pupil, 1012
 pupillary membrane, 1003
 refracting media, 1018
 retina, 1014
 pigmented layer of, 1015
 proper, 1015
 supporting frame-work of, 1017
 sclera, 1005
 tunics of, 1005
 vascular, 1009
 uvea, 1013
 vessels and nerves of, 1021
 vitreous body, 1018
 Eyebrows, 1025
 Eyelashes, 1025
 Eyelids, 1025
 canthus of, 1025
 development of, 1005
 structure of, 1025
 surface anatomy of, 1299
 tarsi of, 1025
 Eye-teeth, 1117
- F**
- FACE, bones of, 156
 development of, 67
 lymphatics of, 692
 surface anatomy of, 1294
 Facial artery, 553
 transverse, 558
 bones, 156
 canal, 142
 hiatus of, 142
 prominence of, 1042
 lymph glands, 694
 nerve, 901
 composition and central connections of, 861
 sympathetic efferent fibers of, 970
 vein, anterior, 645
 common, 645
 deep, 645
 posterior, 645
 transverse, 645
 Falciform ligament of liver, 1150
 1192
 margin of fossa ovalis, 469
 process of sacrotuberous ligament, 309
 Fallopian tubes, 1257
 Fallopius, aqueduct of, prominence of, 1042
 False ligaments of bladder, 1231
 pelvis, 239
 ribs, 123
 vocal cords, 1079
Falx aponeurolica inguinalis, 414
 cerebelli, 873
 cerebri, 873
 Fascia or Fasciæ, 376
 of abdomen, 408
 triangular, 412
 anal, 421
 of ankle, 488

- Fascia or Fasciæ, antibrachial, 445
antibrachii, 445
 of arm, 442
 axillary, 436
 bicapital, 444
 brachial, 442
brachii, 442
 buccopharyngeal, 390
 bulb, 1204
 of Camper, 408
 cervical, 387, 388
 clavipectoral, 437
 of Colles, 235, 409, 426
 colli, 388
 coracoclavicular, 437
coracoclavicularis, 437
 cremasteric, 414
 cribrosa, 468
 cruris, 480
 deep, 378
 of deltoideus, 439
dentata hippocampi, 827
 diaphragmatic part of pelvic, 421
 dorsal, of foot, 490
 endopelvic, 422
 of forearm, 445
 general description of, 376
 of hand, 456
iliaca, 466
 iliopectineal, 466
infraspinata, 441
 infraspinatus, 441
 infundibuliform, 418
 intercolumnar, 1238
 intercostal, 402
 intercrural, 411
 lata, 468
 falciform margin of, 469
 fossa ovalis of, 469
 iliotibial tract or band of, 468
 of leg, 480
 deep transverse, 483
 lumbar, 397
 masseteric, 385
 of obturator internus, 420
 orbital, 1025
 palmar, 460
 parotideomasseteric, 385
 pectoral, 435
 pelvic, 420
 plantar, 490
 pretracheal, 390
 prevertebral, 390
 of piriformis, 421
 of psoas and iliacus, 466
 of quadratus lumborum, 419
 rectal, 422
 rectovesical, 422
 renal, 1220
 of Scarpa, 408
 Sibson's, 1089
 spermatic, external, 411, 1238
 subscapular, 440
subscapularis, 440
 superficial, 377
supraspinata, 440
 suprassinatus, 440
 temporal, 386
 of thigh, 467
 of thoracic region, 435
transversalis, 418
 triangular, of abdomen, 412
 of upper extremity, 431
 of urogenital diaphragm, 428, 429, 430
 region, 426
 vesical, 422
- Fasciculi, intrafusal, 1061
longitudinales, 785
- Fasciculus, bulbospinal, 854
 cerebelloolivary, 781
 cerebrospinal, 759, 760
cerebrospinalis anterior, 759
- Fasciculus, cerebrospinalis lateralis*, 760
 comma-shaped, 764
 cuneatus, 762
 gracilis, 762
 lateral proper, 762
 spinothalamic, 762
lateralis proprius, 762
 of Lissauer, 762
 longitudinal, inferior, 844
 medial, 762, 784, 803
 posterior, 803
 superior, 844
mammillotegmentalis, 867
 mammillo-thalamic, 869
 occipitofrontal, 844
 olfactory, 840
 olivospinal, 761, 854
 perpendicular, 844
 pontospinal, 872
 posterior proper, 764
 retroflexus of Meynert, 812
 rubrospinal, 761, 870
 secondary sensory, 762
 solitarius, 785
 spinocerebellar, dorsal, 761, 778
 ventral, 761
 spinoolivary, 854
 spinotectal, 762
 spinothalamic, 762
 superficial antero-lateral, 854
 tectospinal, 760, 871
 thalamomammillary, 839
 uncinata, 843
 ventral spinothalamio, 854
 vestibulospinal, 760, 803, 872
- Fasciola cinerea*, 827
- Fauces, arches or pillars of, 1137
 isthmus of, 1137
 muscles of, actions of, 1140
- Female genital organs, 1254
 bulb of vestibule, 1264
 carunculæ hymenales, 1266
 clitoris, 1266
 development of, 1205
 epoöphoron, 1255
 fourchette, 1265
 glands of Bartholin, 1266
 greater vestibular, 1266
 hymen, 1266
 labia majora, 1265
 minora, 1265
 mons pubis, 1265
 navicular fossa, 1266
 ovaries, 1254
 uterine tubes, 1257
 uterus or womb, 1258
 vagina, 1264
 vestibule, 1266
 pronucleus, 42
 urethra, 1236
- Femoral artery, 623
 branches of, 629
 peculiarities of, 629
 surface marking of, 1346
 canal, 625
 circumflex arteries, 630
 cutaneous nerve, anterior, 955
 lateral, 951
 posterior, 959
 fossa, 626
 nerve, 955
 ring, 625
 septum, 626
 sheath, 625
 triangle, 626
 vein, 672
- Femur, 242
 architecture of, 248
 inner, of upper, 249
 of distal portion, 253
 condyles of, 247
 head of, 243
 neck of, 243
 ossification of, 255
- Femur, spiral line of, 245
 surface anatomy of, 1336
 trochanters of, 243, 244
- Fenestra cochleæ*, 1040
ovalis, 1040
rotunda, 1040
vestibuli, 1040
- Fertilization of ovum, 44
- Fetal membranes, 54
- Fetus, circulation in, 540
 foramen ovale in, 512, 539
 valve of inferior vena cava in, 540
 vascular system in, peculiarities of, 539
- Fibers, arcuate, 782
 dental, 1119
 intercolumnar, 410
 intercrural, 410
 intrafusal, 1061
 of muscles, 373
 nerve, 721
 non-medullated, 728
 olfactory projections, 869
 of Purkinje, 536
 of Remak, 728
 sustentacular, of Müller, 1017
 of tactile discrimination, 854
 taste, 861
 of Tomes, 1119
 touch, 854
- Fibræ intercrurales*, 410
pontis profundæ, 785
superficiales, 785
proprie [cerebellum], 794
- Fibrocartilage, 281
 circumferential, 282
 connecting, 282
 interarticular, 281
 intervertebral, 289
 semilunar, of knee, 342, 343
 stratiform, 282
 yellow or elastic, 282
- Fibrocartilaginous lamina, interpubic, 311
- Fibrous capsule of Glisson, 1194
 pericardium, 525
 rings of heart, 536
 sheaths of flexor tendons of fingers, 449
 of toes, 492
 tunic of kidney, 1220
- Fibula, 260
 ossification of, 262
 surface form of, 1337
- Fibular artery, 635
 collateral ligament of knee-joint, 341
- Fifth metacarpal bone, 228
 metatarsal bone, 274
 nerve, 886
 ventricle, 840
- Filiform papillæ of tongue, 1127
- Fillet, medial, 803
- Filtration angle of eye, 1007
- Filum terminale*, 750
- Fimbria hippocampi*, 840
 ovarian, 1257
 Fimbriæ of uterine tube, 1257
- Fimbriodentate fissure, 827, 840
- First cuneiform bone, 270
 dorsal metacarpal artery, 595
 metatarsal artery, 636
 metacarpal bone, 228
 metatarsal bone, 272
 nerve, 881
- Fissura antitragohelicina*, 1034
calcarina, 820
cerebri lateralis [*Sylvii*], 819
longitudinalis, 818
collateralis, 820
hippocampi, 826
mediana anterior [medullæ oblongatæ], 767
 spinalis], 752

- Fissura mediana posterior* [medullæ oblongatæ], 767
parietooccipitalis, 820
petrotympanica, 1038
prima [cerebellum], 740
 [rhinencephalon], 827
secunda [cerebellum], 740
- Fissure or Fissures, anterior median of medulla spinalis, 752
 callosomarginal, 820
 of cerebellum, 788, 789
 development of, 741
 floccular, 741
 horizontal, 789
 postcentral, 789
 postnodular, 741, 790
 postpyramidal, 790
 precentral, 789
 preclival, 789
 prepyramidal, 790
 of cerebrum, 819
 calcarine, 820
 callosal, 825, 828
 central, 819
 collateral, 820
 development of, 747
 external rhinal, 744
 fimbriodentate, 827, 840
 hippocampal, 746, 826
 interlobular, 819
 lateral, 746, 819
 longitudinal, 818
 parietooccipital, 820
 of Rolando, 819
 of Sylvius, 819
 transverse, 842
 choroidal, 841, 1002
 circuminsular, 821
 dentate, 826
 Glaserian, 140, 1038
 of liver, 1191
 longitudinal, 818
 of lungs, 1096
 of medulla oblongata, 767
 orbital, inferior, 184, 189
 superior, 151, 189, 192
 petrooccipital, 181, 193
 petrosphenoidal, 181
 petrotympanic, 140, 180, 1038
 pterygoid, 151
 pterygomaxillary, 185
 of Rolando, 819
 sphenomaxillary, 184
 of Sylvius, 747, 819
 tympanomastoid, 181
 vestibular, 1051
- Fixation of kidney, 1220
 of muscles, 362
- Flat bones, 79
- Flechsig, cerebellar tract of, 761
 oval area of, 764
- Flexor accessorius longus digitorum muscle, 485
 muscle, 493
 brevis minimi digiti muscle, 464, 494
 carpi radialis muscle, 446
 actions of, 450
 nerves of, 450
 variations of, 446
 ulnaris muscle, 447
 actions of, 450
 nerves of, 450
 variations of, 448
 digiti quinti brevis muscle of foot, 494
 actions of, 496
 nerves of, 495
 of hand, 464
 actions of, 464
 nerves of, 464
 digitorum brevis muscle, 491
 actions of, 496
 nerves of, 495
 variations of, 492
- Flexor digitorum longus muscle, 485
 actions of, 486
 nerves of, 486
 variations of, 485
 profundus muscle, 448
 actions of, 450
 nerves of, 450
 variations of, 449
 sublimis muscle, 448
 actions of, 450
 nerves of, 450
 variations of, 448
 hallucis brevis muscle, 493
 actions of, 496
 nerves of, 495
 variations of, 493
 longus muscle, 485
 actions of, 486
 nerves of, 486
 variations of, 485
 pollicis brevis muscle, 461
 actions of, 462
 nerves of, 462
 variations of, 462
 longus muscle, 449
 actions of, 450
 nerves of, 450
 variations of, 449
- Flexure, cervical, 737
 colic, left, 1181
 right, 1180
 hepatic, 1180
 pontine, 737
 splenic, 1181
 ventral cephalic, 737
- Floating ribs, 123
- Floccular fissure, 741
- Flocculus, 791
- Floor of fourth ventricle, 798
- Floor-plate of medulla spinalis, 733
- Fluid, cerebrospinal, 877
- Fluids, circulating, 503
- Fold or Folds, amniotic, 56
 aryepiglottic, 1079
 caudal, 53
 cephalic, 53
 duodenojejunal, 1159
 gastropancreatic, 1156
 glossoepiglottic, 1075
 ileocecal, 1160
 malleolar, 1039
 rectouterine, 1260
 sacrogenital, 1154, 1260
 salpingopalatine, 1142
 salpingopharyngeal, 1142
 transverse, of rectum, 1183
 of Treves, 1160
 umbilical, 1231
 ventricular, of larynx, 1079
 vestigial, of Marshall, 522, 526
 vocal, of larynx, 1080
- Folium cacuminis*, 790
vermis, 790
- Follicle of hair, 1067
- Follicles, agminated, 1176
 Graafian, or vesicular ovarian, 1256
- Fontana, spaces of, 1009
- Fontanelles, 196
- Foot, arches of, 360
 fascia of, 490
 muscles of, 490
 ossification of bones of, 275
 phalanges of, articulations of, 359
 skeleton of, 262
 surface anatomy of, 1337
- Foramen, caroticoelinoïd, 151, 191
 cecum of frontal bone, 137
 of medulla oblongata, 767
 of tongue, 1103, 1125
 condyloid, anterior, 131
 epiploicum, 1103, 1156
- Foramen of Huschke, 145, 147
 incisive, 162, 180
 infraorbital, 158, 187
 interventricular, 816, 840
 intervertebral, 96
 jugular, 181, 193
 lacerum, 181, 192
 magnum, 129, 132, 192
 Majendii, 798
 mandibular, 173
 mastoid, 141, 183
 mental, 172, 188
 of Monro, 816, 840
 obturator, 237
 optic, 147, 151, 190
 ovale of heart, 512, 539
 of sphenoid, 150, 180, 192
 palatine, 180
 parietal, 178
 rotundum, 150, 192
 sciatic, 309
 singulare, 143
 sphenopalatine, 168
 spinosum, 150, 180, 192
 sternal, 121
 stylomastoid, 144, 181
 supraorbital, 136, 186, 189
 supratrochlear, 212
 thyroid, 237
 transversarium, 98
 vena-caval, 406
 vertebral, 96
 Vesalii, 150, 192
 of Winslow, 603, 1156
 zygomaticofacial, 164, 187
 zygomaticoörbital, 165
 zygomaticotemporal, 164, 183
- Foramina, ethmoidal, 189
 intervertebral, 96
 of Luschka, 798, 877
 for olfactory nerves, 153
 in roof of fourth ventricle, 799
 sacral, 106, 108
 of Scarpa, 162, 180
 of Stensen, 162, 180
 Thebesii, 530
venarum minimarum, 530
- Forceps, anterior, 829
 posterior, 829
- Forearm, fascia of, 445
 muscles of, 445
- Fore-brain, 51, 741, 807
- Foregut, 53, 1101
- Foreskin, 1250
- Form of embryo at different stages, 74
- Formatio reticularis alba*, 784
grisea, 784
 of medulla spinalis, 754
- Fornicolumns, 838
- Fornix of brain, 838
 body of, 838
 columns of, 838
 crura of, 840
 development of, 747
 pillars of, 838, 840
 of conjunctiva, 1027
- Fossa or Fossæ, acetabular, 237
 anticubital, 589
 canine, 158
 cecal, 1160
 cochlearis, 1048
 condyloid, 131, 181
 coronoid, 212
cranii anterior, 190
media, 190
posterior, 192
 digastric, 141
 digital, of epididymis, 1242
 of femur, 244
 for ductus venosus, 1191
 duodenal, 1159
 duodenojejunal, 1159
 femoral, 626
 for gall-bladder, 1191

- Fossa or Fossæ, glenoid, 140
 hyaloid, 1018
 hypophyseos, 147, 190
 ileocecal, 1160
 iliac, 234
 incisive, 158, 172, 188
 incedis, 1042
 for inferior vena cava, 1191
 infraspinal, 203
 infratemporal, 184
infratemporalis, 184
 intercondyloid, of femur, 247
 of tibia, 256
 interpeduncular, 800, 816
 intersigmoid, 1161
 ischio-rectal, 425
ischio-rectalis, 425
 jugular, 144
 lacrimal, 137, 188
 of liver, 1191
 mandibular, 140, 180, 183
 mastoid, 140
 nasal, 994
navicularis [urethra], 1235
 [vulva], 1266
 occipital, inferior, 193
 olecranon, 212
 ovalis of fascia lata, 469
 of heart, 531
 ovarian, 1154, 1254
 pararectal, 1154
 paravesical, 1154
 pericecal, 1160
 peritoneal, 1158
 popliteal, 631
 pterygoid, 151
pterygopalatina, 185
 pterygopalatine, 185
 radial, 212
 retrocecal, 1161
 retroperitoneal, 1158
 rhomboid, 798
rhomboidca, 798
 of Rosenmüller, 1141, 1142
sagittalis sinistra [liver], 1141
 scaphoid, 151, 180
 of skull, anterior, 190
 middle, 190
 posterior, 192
 sphenomaxillary, 185
 subarcuate, 143
 subscapular, 202
 supraspinatus, 203
 supratornsillar, 1138
 Sylvian, 747
 temporal, 183
temporalis, 183
triangularis, 1034
 trochanteric, 244
 for umbilical vein, 1191
venæ cavae, 1191
 vermian, 131
vesicæ felleæ, 1191
- Fountain decussation of Meynert, 806
- Fourchette, 1265
- Fourth metacarpal bone, 228
 metatarsal bone, 274
 nerve, 885
 ventricle, 797
 floor of, 798
- Fovea capitis femoris*, 243
centralis retinae, 1015, 1017
 structure of, 1017
dentis, 99
 of rhomboid fossa, 800
 trochlear, 137, 188
- Foveolæ, Howship's, 88
- Free nerve-endings, 1059
- Freely movable joints, 285
- Frenula of colic valve, 1179
 of lips, 1111
- Frenulum of clitoris, 1266
 of labia minora, 1265
 linguæ, 1125
- Frenulum of prepuce, 1250
 veli, 805
- Frommann's lines, 727
- Frontal air sinuses, 138, 998
 artery, 750
 bone, 135
 articulations of, 138
 orbital or horizontal part of, 137
 ossification of, 138
 squama of, 135
 structure of, 138
 convolution, ascending, 821
 crest, 136
 eminences, 135, 178, 183
 gyri, 821, 822
 lobe, 821
 nerve, 887
 operculum, 825
 process of maxilla, 161
 sulci, 821
 suture, 135, 178
 vein, 644
- Frontalis muscle, actions of, 380
 nerves of, 380
 variations of, 380
- Frontoethmoidal suture, 190
- Frontomaxillary suture, 189
- Frontonasal duct, 138
 process, 97
- Frontopontine fibers, 802
- Frontosphenoidal process of zygomatic bone, 164
- Fundiform ligament of penis, 1249
- Fundus glands of stomach, 1166
 tympani, 1038
 of uterus, 1259
- Fungiform papillæ of tongue, 1126
- Funiculi of medulla spinalis, 758, 759
- Funiculus separans*, 800
spermaticus, 1239
- Furcal nerve, 949
- Furcula, 1071, 1103
- Furrow, chordal, 52
 dental, 1122
 naso-optic, 69, 1005
- Furrowed band of cerebellum, 971
- Fusiform gyrus, 823, 824
- G**
- Galea aponeurotica*, 380
- Galen, veins of, 653
- Gall-bladder, 1197
 fossa for, 1191
 lymphatic capillaries in, 686
 vessels of, 711
 structure of, 1198
- Gangliated cord, 976
- Ganglion or Ganglia, 730
 aorticorenal, 985
 cardiac, of Wrisberg, 984
 carotid, 977
 celiac, 985
 cervical, 978, 980
cervicale inferius, 980
medium, 979
superius, 978
 ciliary, 888
caliaca, 985
 collateral, 976
 of Corti, 1051, 1059
 Gasserian, 886
 genicular, 902
geniculi, 902
 of glossopharyngeal, 906
habenulae, 812
 impar, 984
 inferior, 908
 interpeduncular, 800, 802, 868
 jugular, 908, 911
jugularæ, 911
- Ganglion or Ganglia, Langley's, 1137
 lenticular, 888
 Meckel's, 891
nodosum, 911
 ophthalmic, 888
 otic, 897
oticum, 897
petrosum, 908
 petrous, 908
 phrenicum, 986
 ridge or neural crest, 51, 736
 of Scarpa, 1058
 semilunar, of abdomen, 985
 of trigeminal nerve, 886
semilunare [Gasser], 886
 sphenopalatine, 891
rami nasales posteriores inferiores, 893
superiores, 893
orbitales, 893
 spinal, 918
spinale, 918
 spiral, of cochlea, 1059
 splanchnic, 981
submaxillare, 898
 submaxillary, 898
 superior, of glossopharyngeal, 908
 mesenteric, 987
superius, 908
 of vagus, 910
 vestibular, 1058
 of Wrisberg, 984
- Ganglionic arterial system of brain, 574
 arteries, anterolateral, 573
 antero-medial, 571
 postero-lateral, 581
 postero-medial, 574, 581
 layer of retina, 1016
- Gärtner, duct of, 1206, 1255
- Gasserian ganglion, 886
- Gaster, 1161
- Gastric arteries, short, 606
 artery, left, 603
 right, 604
 glands, 1166
 impression, 1189
 lymph glands, 706
 nerves from vagus, 913
 plexuses from sympathetic, 986, 987
 from vagus, 913
 veins, short, 681
- Gastrocnemius muscle, 482
 actions of, 483
 nerves of, 483
 variations of, 483
- Gastrocolic ligament, 1153
 omentum, 1157
- Gastroduodenal artery, 604
- Gastroepiploic arteries, 604, 606
 gland, right, 706
 veins, 681, 682
- Gastrohepatic omentum, 1156
- Gastrointestinal ligament, 1155
- Gastropancreatic fold, 1156
- Gastrophrenic ligament, 1162
- Gemelli muscles, actions of, 478
 nerves of, 478
- Gemellus inferior muscle, 477
 superior muscle, 477
- General sensations, peripheral terminations of nerve of, 1059
- Generation, development of external organs of, 1213
- Genicular arteries, 631, 633
 ganglion of facial nerve, 902
- Geniculate bodies, 811
- Geniculum of facial nerve, 902
 of internal capsule, 836
- Genioglossus muscle, 1129
- Geniohyoglossus muscle, 1129
- Geniohyoid muscle, 393

- Geniohyoideus muscle, 393
 action of, 393
 nerves of, 393
 variations of, 393
- Genital cord, 1207
 corpuscles, 1060
 organs of female, 1254
 external, 1264
 of male, 1236
 glands, 1207
 ridge, 1207
 swellings, 1214
 tubercle, 1213
- Genitocrural nerve, 953
 Genitofemoral nerve, 953
 Gennari, band of, 845, 847
- Genu of corpus callosum, 828
 of internal capsule, 836
- Gerlach, tube tonsil of, 1043
- Germ centers, 689
 dental, 1122
- Germinal cells, 35
 epithelium, 1207, 1255
 path, 1210
 spot, 39
 vesicle, 39
- Giacomini, band of, 827
- Giant cells, 88
 of Betz, 845
- Gianuzzi, crescents of, 1136
- Gimbernat's ligament, 412
- Gingivæ, 1112
- Ginglymus, 285
- Giraldès, organ of, 1246
- Girdle of inferior extremity, 200
 pelvic, 200
 shoulder, 200
 of superior extremity, 200
- Glabella, 135, 178, 198
- Gladiolus, 120
- Gland or Glands, accessory, of
 mouth, 1137
 part of parotid, 1134
 anterior lingual, 1131
 aortic, 1269
 areolar, 1267
 arytenoid, 1084
 of Bartholin, 1266
 of Blandin, 1131
 of Bowman, 996
 Brunner's, 1176
 buccal, 1112
 bulbourethral, 1253
 cardiac, 1166
 carotid, 1281
 ceruminous, 1037
 ciliary, 1025
 coccygeal, 1281
 Cowper's, 1253
 ductless, 1269
 duodenal, 1176
 esophageal, 1146
 fundus, 1166
 gastric, 1166
 gastro-epiploic, right, 706
 genital, 1207
 intestinal, 1174
 labial, 1111
 lacrimal, 1028
 of larynx, 1084
 lenticular, of stomach, 1167
 of Littré, 1235
 Luschka's, 1281
 mammae, 1267
 mammary, 1267
 Meibomian, 1026
 molar, 1112
 mucous, of tongue, 1131
 of Nuhn, 1131
 oxyntic, 1166
 parathyroid, 1271
 parotid, 1132
 Peyer's, 1176
 preputial, 1250
 prostate, 1251
- Gland or Glands, pyloric, 1166
 salivary, 1132
 sebaceous, 1069
 serous, of tongue, 1137
 solitary, 1176
 sublingual, 1136
 submaxillary, 1135
 sudoriferous, 1070
 suprarenal, 1278
 sweat, 1070
 tarsal, 1026
 thymus, 1273
 thyroid, 1269
 of tongue, 1131
 trachoma, 1028
 urethral, 1235
 uterine, 1262
 vestibular, greater, 1266
- Glandula lacrymalis*, 1028
parotis, 1132
sublingualis, 1136
submaxillaris, 1135
suprarenalis, 1278
thyroidea, 1269
vestibularis major [Bartholini], 1266
- Glandulæ bulbourethrales*, 1253
duodenales [Brunneri], 1176
intestinales [Lieberkuhni], 1174
labiales, 1111
esophageæ, 1146
 Pacchioni, 878
sebaceæ, 1069
sudoriferæ, 1070
suprarenales accessoriae, 1279
tarsales [Meibomi], 1026
thyroideæ accessoriae, 1270
- Glans clitoridis*, 1266
penis, 1248
- Glaserian fissure, 140, 1038
- Glenohumeral ligaments, 318
- Glenoid cavity, 207
 fossa, 104
 ligament of Cruveilhier, 332, 359
 of shoulder, 319
- Glenoidal labrum of hip-joint, 336
 of shoulder-joint, 319
- Gliding joints, 285
 movement, 286
- Glisson's capsule, 1157, 1194
- Globular processes of His, 68
- Globus major* [epididymis], 1242
minor [epididymis], 1242
pallidus, 834
- Glomera carotica*, 1281
- Glomus caroticum*, 1281
coccygeum, 1281
- Glossoepiglottic folds, 1075, 1125
- Glossopalatine arch, 1137
- Glossopalatinus muscle, 1129, 1139 note
- Glossopharyngeal nerve, 906
 composition and central connections of, 856
 sympathetic afferent fibers of, 972
- Glottis respiratoria*, 1080
vocalis, 1080
 rima of, 1080
- Glutæus maximus muscle, 474
 actions of, 478
 nerves of, 478
 medius muscle, 474
 actions of, 478
 nerves of, 478
 variations of, 475
 minimus muscle, 475
 actions of, 478
 nerves of, 478
 variations of, 475
- Gluteal artery, inferior, 620
 superior, 622
- lines of ilium, 232
- Gluteal muscles, 474
 nerves, 959
 tuberosity, 246
 veins, 674
- Gnathic index, 246
- Golgi, cells of, 845
 organs of, 1061
- Golgi and Mazzoni, corpuscles of, 1061
- Goll, tract of, 752, 762
- Gomphosis, 284
- Gonion, 198
- Gower's, tract of, 761, 854
- Graafian follicles, 1256
 structure of, 1256
- Gracile nucleus, 774
- Gracilis muscle, 471
 actions of, 474
 nerves of, 474
- Grandry, tactile corpuscles of, 1060
- Granular layer of dentin, 1119
- Granulationes arachnoideales*, 878
- Granulations, arachnoid, 878
- Granule cells, 377
- Gray commissure of brain, 809
 commissures of medullaspiralis, 754
 or gelatinous nerve fibers, 728
 substance of cerebellum, 794
 of cerebral hemispheres, 845
 of cortex, 794
 of medulla oblongata, 779
 spinalis, 753
- Great auricular nerve, 926
 cardiac nerve, 979
 vein, 642
 cerebral vein, 653
 longitudinal fissure, 818
 omentum, 1157
 sacrosciatic ligament, 309
 saphenous vein, 669
 splanchnic nerve, 981
 transverse fissure of brain, 842
 wings of sphenoid, 149
- Greater cavernous nerve, 989
 curvature of stomach, 1162
 multangular bone, 225
 occipital nerve, 923
 omentum, 1157
 palatine foramen, 180
 pelvis, 238
 peritoneal sac, 1150
 sciatic foramen, 309
 notch, 235
 sigmoid cavity, 215
 splanchnic nerve, 981
 superficial petrosal nerve, 892, 903
 trochanter, 244
 vestibular glands, 1213, 1266
- Groove, auriculoventricular, 526
 bicipital, 209
 carotid, 148, 191
 chiasmatic, 147, 190
 costal, 124
 infraorbital, 159
 interatrial, 527
 intertubercular, of humerus, 209
 lacrimal, 159, 189
 musculospiral, 211
 mylohyoid, 173
 neural, 50
 obturator, 237
 occipital, 141
 optic, 147
 primitive, 47
 pterygopalatine, 151
 for radial nerve, 211
 vertebral, 115
- Gubernaculum dentis*, 1124
testis, 1211
- Gudden, commissure of, 883
 mammillo-tegmental bundle of, 867

- Gullet, 1144
Gums, 1112
Gustatory calyculi, 991
 cells, 991
 hair, 992
 pore, 991
Gyre, medifrontal, 822
 precentral, 821
 subfrontal, 822
 superfrontal, 821
Gyri of brain, 821
 angular, 823
 of Broca, 822
 central, anterior, 821
 posterior, 823
 cingulate, 826
 cuneus, 823
 dentate, 827, 868
 frontal, 821, 822
 fusiform, 823
 hippocampal, 826
 of insula, 825
 of limbic lobe, 825
 lingual, 823
 occipital, 823
 orbital, 822
 precuneus, 823
 quadrate, 823
 straight, 822
 subcallosal, 827, 869
 superior parietal lobule, 823
 supracallosal, 827
 supramarginal, 823
 temporal, 824
 transverse, of Heschl, 824
 uncus, 826
Gyrus of Broca, 822
 centralis anterior, 821
 posterior, 823
 cinguli, 825
 dentatus, 827
 epicallosus, 827
 frontalis inferior, 822
 medius, 822
 superior, 821
 hippocampi, 826
 marginal, 822
 subcallosus, 827, 869
- H**
- HABENULAR commissure, 812
Hair cells of spiral organ of Corti, 1057
Hairs, 1067
 cuticle of, 1069
 follicle of, 1067
 gustatory, 992
 olfactory, 996
 roots of, 1067
 scapus or shaft of, 1069
 structure of, 1068
Haller, vas aberrans of, 1246
Hamate bone, 227
Hamstring muscles, 478
Hamulus of hamate bone, 227
 lacrimar, 164
 laminae spiralis, 1051
 pterygoid, 150, 180
Hand, muscles of, 456
 phalanges of, articulations of, 333
 skeleton of, 221
 surface anatomy of, 1327
 markings of, 1330
Hard palate, 1112
Harrison's sulcus, 128
Hasner, plica lacrimalis of, 1029
Hassal, corpuscles of, 1274
Haversian canals of bone, 89
 systems of bone, 89
Head, arteries of, 549
 lymphatics of, 692
 muscles of, 378
 Head, muscles of, development of, 372
 veins of, 644
 Head-cap of spermatozoön, 42
 Hearing, organ of, 1029
 Heart, 526
 arteries of, 538
 atrioventricular bundle of His, 537
 node, 537
 atrium, left, 533
 right, 529
 component parts of, 526
 development of, 506
 endocardium, 535
 fibers of atria, 537
 of ventricles, 537
 fibrous rings of, 536
 lymphatic capillaries of, 687
 vessels of, 718
 nerves of, 538
 sinoatrial node of, 537
 size and weight of, 526
 structure of, 535
 surface marking of, 1311
 trigonum fibrosum, 536
 veins of, 642
 ventricle, left, 534
 right, 531
 Heidenhain, demilunes of, 1136
 Height index of skull, 198
 Helicine arteries, 1251
 Helicis major muscle, 1035
 minor muscle, 1035
 Helicotrema, 1050
 Helix, 1033
 Helwig's bundle, 854
 Hemiazzygos vein, 667
 accessory, 667
 Hemispheres, cerebellar, 788
 cerebral, 817
 Hemorrhoidal artery, inferior, 619
 middle, 615
 superior, 610
 nerve, inferior, 968
 plexuses of nerves, 987, 988
 vein, middle, 676
 superior, 681
 venous plexus, 676
 Henle, loop of, 1223
 Henle's layer of hair follicle, 1068
 Hensen, canalis reuniens of, 1054
 knot of, 47
 stripe of, 1058
 supporting cells of, 1058
 Hepar, 1188
 capsula fibrosa [Glissoni], 1195
 facies inferior, 1189
 posterior, 1190
 superior, 1189
 margo anterior, 1191
 tunica serosa, 1195
 Hepatic artery, 603
 branches of vagus nerve, 913
 cells, 1196
 cylinders, 1193
 duct, 1197
 flexure of colon, 1180
 lymph glands, 706
 plexus, 986
 veins, 680
 Hepatoduodenal ligament, 1151, 1157
 Hepatogastric ligament, 1151, 1157
 Hepatorenal ligament, 1150
 Herbst, corpuscles of, 1061
 Hernia, congenital, complete, 1187
 incomplete, 1188
 into funicular process, 1189
 Herophilus, torcular of, 658
 Heschl, gyri of, 824
 Hesselbach, interfoveolar ligament of, 415
 triangle of, 1221
 Hiatus, aortic, 406
 esophageal, 406
 of facial canal, 142
 semilunaris, 195, 995
 Higher or cortical visual centers, 814
 Highest intercostal artery, 585
 veins, 666
 nuchal line, 129
 thoracic artery, 587
 Highmore, antrum of, 159, 999
 Hilum of kidney, 1219
 Hilus of lung, 1095
 of spleen, 1283
 Hind-brain, 738, 767
 Hind-gut, 53, 1101
 Hinge-joint, 285
 Hip bone, 231
 articulations of, 238
 ossification of, 237
 structure of, 237
 surface anatomy of, 1336
 Hip-joint, 333
 movements of, 338
 muscles in relation with, 338
 surface marking of, 1343
 Hippocampal commissure, 838, 869
 fissure, 746, 826
 gyrus, 826
 Hippocampus, 746, 832
 major, 832
 His, atrioventricular bundle of, 537
 globular processes of, 68
 Holoblastic ova, 45
 Horizontal cells of retina, 1017
 part of palatine bone, 167
 semicircular canal, 1049
 sulcus of cerebellum, 789
 Houston's valves of rectum, 1183
 Howship's foveolæ, 88
 Huguier, canal of, 141, 904, 1039
 Humeral articulation, 317
 bursæ in relation to, 319
 movements of, 319
 vessels and nerves of, 319
 circumflex arteries, 589
 Humerus, 209
 ossification of, 213
 structure of, 212
 surface anatomy of, 1326
 Humer, aqueous, 1018
 Hunter's canal, 627
 Huschke, auditory teeth of, 1055
 foramen of, 145, 147
 Huxley's layer of hair follicle, 1068
 Hyaline cartilage, 279
 cell, 504
 Hyaloid canal, 1018
 fossa, 1018
 membrane of eye, 1018
 Hyaloplasm, 36
 Hydatid of Morgagni, 1207, 1242, 1257
 pedunculated, of epididymis, 1242
 Hymen, 1266
 Hyoepiglottic ligament, 1077
 Hyo-glossal membrane, 1132
 Hyo-glossus muscle, 1129
 Hyoid arteries, 552, 553
 bone, 177
 body of, 177
 cornua of, 177
 ossification of, 178
 Hyothyroid ligaments, 1077
 membrane, 1076
 Hyparterial bronchi, 1085, 1097
 Hypochondriac regions, 1149
 Hypochordal bar or brace, 82
 Hypogastric artery, 614
 branches of, 615
 in fetus, 540

- Hypogastric artery, obliterated, 615
 peculiarities of, 615
 lymph glands, 704
 plexus, 987
 region, 1149
 vein, 673
 zone, 1148
- Hypoglossal nerve, 914
 composition and central connections of, 855
 nucleus of, 779
- Hypophysis cerebri*, 814, 1275
 development of, 1276
- Hypothalami, pars mammillaria*, 743
optica, 744
- Hypothalamus, 812
 corpora mammillaria, 813
 hypophysis or pituitary body, 814, 1275
 infundibulum, 813
 optic chiasma, 814
 subthalamic tegmental region, 812
 corpus subthalamicum, or nucleus of Luys, 812
 stratum dorsale, 812
 zona incerta, 812
 tuber cinereum, 813
- Hypothenar eminence, 456
- I
- ILEOCECAL fold, 1160
 fossæ, 1160
 valve, 1179
- Ileocolic artery, 607
 lymph glands, 709
- Ileum, 1170
 lymphatic vessels of, 710
- Iliac arteries, common, 613
 peculiarities of, 614
 surface markings of, 1322
 external, 622
 surface markings of, 1322
 internal, 614
 peculiarities of, 614
- circumflex artery, deep, 623
 superficial, 629
 vein, deep, 673
 superficial, 669
- colon, 1182
 fascia, 466
 fossa, 234
 furrow, 1313
 lymph glands, 703, 704
 region, 1149
 spines, 234
 tuberosity, 234
 vein, common, 677
 peculiarities of, 677
 external, 672
 internal, 673
- Iliacus muscle, 467
 actions of, 467
 fascia of, 466
 vocal cords, of, 467
 variations of, 467
- Iliocapsularis muscle, 467
 Iliococcygeus muscle, 424
 Iliocostalis cervicis muscle, 399
 dorsi muscle, 399
 lumborum muscle, 399
- Iliofemoral ligament, 334
 Iliohypogastric nerve, 950
 Ilioinguinal nerve, 952
 Iliolumbar artery, 621
 ligament, 306
 vein, 678
- Iliopectineal eminence, 234
 fascia, 466
- Iliosacralis muscle, 424
 Iliotibial band or tract, 468
- Iliotrochanteric ligament, 335
- Ilium, 231
 ala of, 232
 body of, 231
 crest of, 234
 dorsum of, 232
 gluteal lines of, 233
 spines of, 234
- Imbedding or implantation of ovum, 58
- Immovable articulations, 284
- Impression, colic, 1189
 duodenal, 1190
 gastric, 1189
 renal, 1189
 rhomboid, 202
 suprarenal, 1191
 trigeminal, 143
- Incisive bone, 162
 canals, 162, 180
 foramen, 162, 180
 fossa, 158, 172, 188
 teeth, 1115
- Incisor crest, 163
 teeth, 1115
- Incisura angularis*, 1162
apicis cordis, 527
cardiaca, 1162
fastigii, 741
radialis, 215
semilunaris, 215
temporalis, 826
tenorii, 874
- Incremental lines of Salter, 1120
- Incus, 1044
crus breve, 1044
longum, 1045
 development of, 1033
 ligaments of, 1045, 1046
 process of, long, 1045
 short, 1044
- Index, cephalic or breadth, 198
 gnathic or alveolar, 199
 nasal, 198
 orbital, 198
 vertical or height, 198
- Indusium griseum*, 827, 865
- Inferior articular arteries, 633
 articulation, 325
 calcaneonavicular ligament, 355
 cerebellar peduncles, 793
 constrictor muscle, 1142
 dental artery, 561
 nerve, 896
 epigastric vein, 672
 ganglion, 908, 911
 laryngeal nerve, 912
 longitudinal sinus, 655
 maxillary nerve, 893
 medullary velum, 794
 oblique muscle, 1023
 profunda artery, 591
 pubic ligament, 310
 quadrigeminal body, 806
 semilunar lobule, 791
 tarsal plate, 1025
 thyroarytenoid ligaments, 1080
 vocal cords, 1080
- Infraclavicular branches of brachial plexus, 933
- Infracostales muscle, 403
- Infraglenoid tuberosity, 205
- Infrahyoid artery, 552
 muscles, 391
- Infraorbital artery, 562
 canal, 159
 foramen, 158, 187
 groove, 159
 nerve, 889 *note*
 plexus of nerves, 891
- Infrapatellar pad of fat, 344
- Infrascapular artery, 588
- Infraspinatus fascia, 441
 fossa, 203
- Infraspinatus muscle, 441
 actions of, 442
 nerves of, 442
- Infrasternal notch, 1307
- Infratemporal crest, 150, 183
 fossa, 184
 surface of maxilla, 158
- Infratrochlear nerve, 888
- Infundibuliform fascia, 418
- Infundibulopelvic ligament, 1261
- Infundibulum of brain, 813
 of ethmoid bone, 156, 195, 995
- Inguinal aponeurotic falx, 414
 canal, 418
 glands, 702
 ligament, 411
 reflected, 412
 regions, 1149
 ring, abdominal, 418
 subcutaneous, 410
- Inion, 185, 198
- Inlet of pelvis, 239
- Inner cell-mass, 46
- Innominate artery, 548
 bone, 231
 articulations of, 238
 ossification of, 237
 veins, 664
 peculiarities of, 666
- Inscriptions, tendinous, of rectus abdominis, 416
- Insertion of muscles, 362
- Insula, 825
 circular sulcus of, 825
 development of, 825
 gyri of, 825
 opercula of, 825
- Integument, common, 1062
- Interalveolar cell-islets, 1204
- Interarticular chondrosternal ligament, 303
 costocentral ligaments, 300
 fibrocartilages, 281
 sternocostal ligaments, 303
- Interatrial groove, 527
- Intercalatum, 802
- Intercapital veins, 661, 669
- Intercarpal articulations, 328
 movements of, 330
- Intercavernous sinuses, 659
- Intercellular biliary passages, 1197
- Intercentral ligaments, 287
- Interchondral ligaments, 304
- Interclavicular ligament, 314
- Interclinoid ligament, 153
- Intercolumnar fascia, 1238
 fibers, 410
- Intercondyloid eminence of tibia, 256
 fossa of femur, 247
 of tibia, posterior, 256
- Intercostal arteries from aorta, 600
 highest, 585
 from internal mammary, 583
 superior, 585
 fasciæ, 402
 lymph glands, 715
 membranes, 403
 muscles, 403
 nerves, 945
 spaces, 123
 veins, 666
- Intercostales externi muscles, 403
 variations of, 403
- interni muscles, 403
 variations of, 403
- Intercostobrachial nerve, 946, 947
- Intercrural fascia, 411
 fibers, 410
- Intercuneiform articulations, 357
- Interfoveolar ligament of Hesselbach, 415
- Interglobular spaces, 1120

- Interior of bladder, 1231
 of larynx, 1078
 of skull, 189
 of uterus, 1260
 Interlobular arteries of kidney, 1223
 Intermediate cell-mass, 50
 Intermetacarpal articulations, 331
 Intermetatarsal articulations, 358
 Internal abdominal ring, 418
 acoustic meatus, 143
 arcuate ligament, 404
 calcaneal arteries, 639
 nerves, 963
 calcaneostragaloid ligament, 352
 calcaneonavicular ligament, 355
 canthus of eyelids, 1025
 capsule of brain, 836
 circumflex artery, 630
 cutaneous nerve, 937, 955
 lesser, 937
 geniculate body, 811
 iliac artery, 614
 glands, 704
 vein, 673
 intercostals muscle, 403
 lateral ligament, 297, 322, 328
 malleolar artery, 635, 639
 mammary artery, 583
 gland, 715
 maxillary glands, 694
 oblique muscle, 412
 palpebral arteries, 570
 plantar artery, 639
 nerve, 963
 popliteal nerve, 960
 pterygoid muscle, 387
 pudendal artery, 617
 veins, 674
 pudic artery, 617
 nerve, 967
 veins, 674
 respiratory nerve of Bell, 928
 saphenous nerve, 956
 vein, 669
 semilunar fibrocartilage, 343
 sphincter ani muscle, 426
 Internodal segments of nerves, 727
 Interosseal muscles of foot, 495
 actions of, 495
 nerves of, 495
 of hand, 464
 actions of, 465
 nerves of, 465
 Interosseous arteries, 595, 596, 597
 ligament, 302
 membrane of forearm, 325
 of leg, 348
 nerve, dorsal or posterior, 944
 volar or anterior, 938
 Interparietal bone, 132
 Interpeduncular fossa, 816
 ganglion, 800, 802, 868
 Interphalangeal articulations, 333, 359
 Interpleural space, 1090
 Interpubic disk, 311
 fibrocartilaginous lamina, 311
 Intersegmental neurons, 755
 septâ, 80
 Intersigmoid fossa, 1167
 Interspinal ligaments, 291
 Interspinales muscles, 400
 actions of, 402
 nerves of, 402
 Interspinous ligament, 291
 Intersternal ligaments, 304
 Intertarsal articulations, 352
 Intertragie notch, 1034
 Intertransversales muscle, 401
 Intertransversarii muscles, 401
 actions of, 402
 nerves of, 402
 Intertransverse ligaments, 291
 Intertrochanteric crest, 246
 line, 245
 Intertubercular plane, 1147
 Intertubular dentin, 1120
 Intervenous tubercle, 531
 Interventricular foramen, 816, 840
 septum, 534
 Intervertebral fibrocartilages, 289
 foramina, 96
 veins, 669
 Intervillous space, 59
 Intestinal arteries, 607
 glands, 1174
 villi, 1174
 Intestine, development of, 1101
 large, 1177
 lymphatic nodules of, 1176
 lymphatics of, 710
 small, 1168
 structure of, 1172
 vessels and nerves of, 1176
 surface markings of, 1319
Intestinum cæcum, 1177
 crassum, 1177
 ileum, 1171
 jejunum, 1170
 rectum, 1183
 tenue, 1168
 tela submucosa, 1172
 tunica mucosa, 1173
 muscularis, 1172
 serosa, 1172
 Intra-articular ligament, 300
 Intra-cartilaginous ossification, 93
 Intra-epithelial plexus of cornea, 1009
 Intrafusal fasciculi, 1061
 fibers, 1061
 Intrajugular process, 131
 Intralobular veins, 1196
 Intramembranous ossification, 91
 Intraparietal sulcus, 822
 Intrapulmonary bronchi, 1098
 Intraspinal veins, 668
 Intra-thyroid cartilage, 1074
 Intrinsic muscles of tongue, 1130
 spinal reflex paths, 850
 Iodothyryl, 1271
 Iridial angle, 1007
 Iris, 1012
 structure of, 1013
 vessels and nerves of, 1014
 Irregular bones, 80
 Ischio capsular ligament, 334
 Ischiocavernosus muscle, 428, 430
 action of, 428, 430
 Ischio-rectal fossa, 425
 Ischium, 234
 body of, 234
 rami of, 235
 spine of, 235
 tuberosity of, 235
 Island of Reil, 825
 Islands, blood, 506
 of Langerhans, 1204
 Isthmus, aortic, 517, 547
 of external acoustic meatus, 1043
 faucium, 1137
 glandula thyreoidea, 1270
 of limbic lobe, 825
 rhombencephali, 738
 of thyroid gland, 1269
 of uterine tube, 1257
Iter chordæ arterius, 1039
 posterius, 1038
 Ivory of teeth, 1119

J

 JACOB'S membrane, 1017
 Jacobson, nerve of, 909, 1047
 vomeronasal organs of, 71, 996
 Jejunum, 1170
 lymphatic vessels of, 710
 Jelly of Wharton, 58
 Joint capsules, lymphatic capillaries in, 684
 Joints. *See* Articulations.
 development of, 283
 Jugular foramen, 181, 193
 fossa, 144
 ganglion of glossopharyngeal nerve, 908
 of vagus nerve, 911
 nerve, 978
 notch, 120, 131
 process, 131, 181
 surface of temporal bone, 144
 tubercle, 131
 vein, anterior, 647
 external, 646
 internal, 648
 bulbs of, 648
 posterior external, 647
Jugum sphenoidale, 153
 Junctional tube, 1223

K

 KARYOKINESIS, 37
 Karyomitome, 36
 Karyomitosi, 37
 Karyoplasm, 36
 Kerckring, ossific center of, 133
 Kerckring, valves of, 1173
 Kidneys, 1215
 calyces of, 1221, 1225
 cortical substance of, 1221
 development of, 1211
 fixation of, 1220
 hilum of, 1219
 lymphatic capillaries in, 687
 vessels of, 712
 Malpighian bodies of, 1221
 capsule, 1221
 medullary substance of, 1221
 minute anatomy of, 1221
 nerves of, 1225
 paranephric body, 1220
 renal artery, 610
 fascia, 1220
 pelvis, 1221
 sinus, 1221
 tubules, 1221
 structure of, 1220
 surface marking of, 1320
 veins of, 679, 1224
 weight and dimensions of, 1215
 Knee cap, 255
 Knee-joint, 339
 bursa of, 345
 movements of, 346
 surface anatomy of, 1338
 Krause, end-bulbs of, 1060
 membrane of, 375
 Kühne, motor end-plates of, 730

L

 LABBÉ, posterior anastomotic vein of, 652
Labia cerebri, 827
 majora, 1265
 minora, 1265
 oris, 1111
 Labial arteries, 555
 commissures, 1265
 glands, 1111
 grooves, 1102
 Labiodental lamina, 1122
Labrum glenoidale, 319, 336
 Labyrinth, membranous, 1051
 development of, 1032
 vessels of, 1059
 osseous, 1047

- Labyrinthus ethmoidalis*, 154
membranaceus, 1051
osseus, 1047
- Lacertus fibrosus*, 444
- Laciniate ligament, 489
- Lacrimal apparatus, 1028
artery, 569
bone, 163
articulations of, 164
lesser, 164
ossification of, 164
canals, 1028
caruncula, 1028
crest, posterior, 164
ducts or canals, 1028
ampullæ of, 1028
fossa, 137, 188
glands, 1028
groove, 159, 189
hamulus, 164
nerve, 887
notch, 159
papilla, 1025
process of inferior nasal concha, 169
punctum, 1025
sac, 1028
tubercle, 161
- Lacteals, 683
- Lactiferous ducts, 1268
- Lacuna magna* [of urethra], 1235
- Lacunæ of bone, 89, 90
of cartilage, 280
of urethra, 1235
venous, 655
- Lacunar ligament, 412
- Lacus lacrimalis*, 1025, 1028
- Lagena, 1054
- Lambda, 178, 198
- Lambdoidal suture, 132, 135, 183
- Lamellæ of bone, 89
articular, 279
circumferential, 89
interstitial, 89
primary or fundamental, 90
secondary or special, 90
- Lamellar cells, 377
- Lamina affixa*, 838
basalis, 1010
cartilaginæ cricoideæ, 1047
choriocapillaris, 1010
cribrosa scleræ, 1005
dorsal or alar, 735
elastic, of cornea, 1008
elastica anterior, 1008
posterior, 1008
fibrocartilaginea interpubica, 311
labiodental, 1122
lingual, 1122
medullary, 810
nasal, 68
reticular, 1058
spiral, of cochlea, 1051
spiralis ossea, 1051
suprachorioidea, 1005, 1010
terminalis, 742, 816
vasculosa, 1010
ventral or basal, 735
of vertebræ, 96
- Lancisi, nerves of, 868
- Langerhans, centro-acinar cells of, 1204
islands of, 1204
- Langhans, layer of, 47
- Langley's ganglion, 1137
- Lantermann, segments of, 727
- Large deep petrosal nerve, 892
intestine, 1177
cecum, 1177
colic valve, 1179
colon, 1180
ascending, 1180
descending, 1181
iliac, 1182
sigmoid or pelvic, 1182
- Large intestine, colon, transverse, 1180
rectum, 1183
superficial petrosal nerve, 892, 903
- Laryngeal artery, inferior, 581
superior, 552
nerves, 912
part of pharynx, 1142
prominence, 1073
sacculæ, 1080
sinus, 1080
- Larynx, 1072
cartilages of, 1073
conus elasticus of, 1078
elastic membrane of, 1077
glands of, 1084
interior of, 1078
ligaments of, 1076
lymphatic vessels of, 698, 1084
mucous membrane of, 1083
muscles of, 1081
actions of, 1083
nerves of, 1084
rima glottidis of, 1080
surface marking of, 1301
ventricle of, 1080
ventricular folds of, 1079
vessels of, 1084
vestibule of, 1078
vocal folds of, 1080
- Lateral cartilages, 993
cricoarytenoid muscle, 1081
sinuses, 657
spinothalamic fasciculus, 762
thyrohyoid ligament, 1077
- Latissimus dorsi muscle, 432
actions of, 435
nerves of, 434
variations of, 434
- Layer of Langhans, 47
of rods and cones, 1017
- Layers of cerebral cortex, 845
- Least splanchnic nerve, 981
- Left atrium, 533
auricle, 533
auricular appendix, 533
coronary plexus, 985
vein, 642
lobe of liver, 1192
ventricle, 534
- Leg, fascia of, 480
deep transverse, 483
muscles of, 480
development of, 372
- Lemniscus, lateral, 805
lateralis, 805
medial, 804
medialis, 804
spinal, 762
- Lens, capsule of, 1019
vascular, 1003
changes produced in, by age, 1021
crystallina, 1019
crystalline, 1019
development of, 1002
equator of, 1019
poles of, 1019
structure of, 1020
suspensory ligament of, 1018
vesicle, 1001
- Lenticula, 834
- Lenticular ganglion, 888
glands of stomach, 1167
nucleus, 834
process of incus, 1045
- Lentiform nucleus, 834
- Lesser cavernous nerve, 989
curvature of stomach, 1162
internal cutaneous nerve, 937
lacrimal bone, 164
multangular bone, 225
omentum, 1156
pelvis, 239
- Lesser peritoneal sac, 1152, 1155
sac or omental bursa of peritoneum, 1155
boundaries of, 1156
sciatic foramen, 309
notch, 235
sigmoid cavity, 215
splanchnic nerve, 981
trochanter, 245
- Leucocytes, 504
- Levator anguli oris muscle, 383
scapulæ muscle, 435
ani muscle, 422
actions of, 424
nerves of, 424
claviculæ muscle, 435
glandulæ thyreoidæ muscle, 1270
menti muscle, 383
palati muscle, 1139
palpebræ superioris muscle, 1021
actions of, 1023
nerves of, 1023
prostatæ muscle, 424
scapulæ muscle, 435
actions of, 435
nerves of, 435
variations of, 435
veli palatini muscle, 1139
- Levatores costarum muscle, 403
- Lieberkühn, crypts of, 1174
- Lien, 1228
accessorius, 1283
extremilæ inferior, 1283
superior, 1283
faciæ gastrica, 1282
renalis, 1283
margo anterior, 1283
posterior, 1283
- Lienal artery, 605
plexus of nerves, 986
vein, 681
- Ligament or Ligaments, acromio-clavicular, 315
alar, 296
of ankle, 349, 350, 351
annular, of ankle, 488, 489
of radius, 324
of stapes, 1046
of wrist, 456, 458
anterior, 327
inferior, 348
longitudinal, 287
superior, 301, 348
apical odontoid, 296
arcuate, 405
atlantoaxial, 293
atlantooccipital, 296
membrane, posterior, 296
of auricula or pinna, 1035
of Bertin, 335
bifurcated, 354, 355
of Bigelow, 335
of bladder, 1231
broad, of uterus, 1260
calcaneoastagaloid, 352
calcaneocuboid, 354
calcaneofibular, 351
calcaneonavicular, plantar, 355
calcaneotibial, 350
capsular. *See* Individual Joints.
caroticochloind, 153
carpometaacarpal, 331
of carpus, 328, 329
central, of medulla spinalis, 879
check, 296
of eye, 1024
chondrosteral, 302
intra-articular, 303
chondroxiphoid, 304
common, anterior, 287
posterior, 288
conoid, 315
of Cooper, 412

- Ligamentous action of muscles, 287
- Ligamentum acromioclaviculare*, 315
- annulare baseos stapedis*, 1046
- radii*, 324
- arcuatum pubis*, 310
- bifurcatum*, 354
- calcaneocuboideum dorsale*, 354
- plantare*, 354
- calcaneofibulare*, 351
- calcaneonavicular plantare*, 355
- capituli costæ interarticulare*, 300
- radiatum*, 299
- capitulum* [oss. *metacarpalium*]
- transversum*, 331
- carpi dorsale*, 458
- transversum*, 456
- volare*, 456
- collaterale fibulare*, 341
- radiale*, 322, 328
- tibiale*, 341
- ulnare*, 322, 328
- colli costæ*, 302
- conoideum*, 315
- coracoacromiale*, 316
- coracoclaviculare*, 315
- coracohumerale*, 317
- coronarium hepatis*, 1192
- costoclaviculare*, 314
- costotransversarium anterius*, 301
- posterius*, 301
- cricoarytenoideum posterius*, 1078
- cricothyreoideum medium*, 1078
- cricotracheale*, 1077
- cruciatum anterius*, 342
- posterius*, 342
- cuboideonavicular dorsale*, 357
- plantare*, 357
- deltoidaleum*, 350
- denticulatum*, 879
- falciforme hepatis*, 1192
- hyoepiglotticum*, 1077
- hyothyreoideum laterale*, 1077
- medium*, 1077
- iliofenorale*, 335
- iliolumbale*, 306
- incudis posterius*, 1045
- superius*, 1046
- inguinale* [Poupartii], 411
- reflexum* [Colleri], 412
- interclaviculare*, 314
- ischiocapsulare*, 335
- lacunare* [Gimbernati], 412
- latum pulmonis*, 1090
- uteri*, 1260
- longitudinale anterius*, 287
- posterius*, 288
- mallei anterius*, 1045
- laterale*, 1045
- superius*, 1045
- malleoli lateralis anterius*, 348
- posterius*, 348
- mucosum*, 344
- nuchæ*, 290
- patellæ*, 340
- plantare longum*, 354
- popliteum obliquum*, 340
- pubicum superius*, 310
- pubocapsulare*, 335
- pulmonale*, 1090
- radiocarpeum dorsale*, 328
- volare*, 327
- sacrocoxygeum anterius*, 309
- laterale*, 310
- posterius*, 309
- sacroiliacum anterius*, 307
- interosseum*, 308
- posterius*, 307
- sacrospinosum*, 309
- sacro tuberosum*, 309
- sphenomandibulare*, 297
- sternoclaviculare*, 313
- Ligamentum sternocostale inter-articulare*, 303
- stylomandibulare*, 298
- supraspinale*, 290
- talocalcaneum anterius*, 352
- interosseum*, 353
- laterale*, 352
- mediale*, 353
- posterius*, 352
- talofibulare anterius*, 351
- posterius*, 352
- talonaviculare dorsale*, 354
- temporomandibulare*, 297
- teres femoris*, 336
- hepatis*, 1193
- uteri*, 1261
- thyroepiglotticum*, 1078
- transversalis colli uteri*, 1261
- transversum acetabuli*, 336
- atlantis*, 293
- crus inferius*, 295
- superius*, 295
- cruris*, 488
- geni*, 343
- scapule inferius*, 317
- superius*, 317
- trapezoideum*, 315
- triangulare dextrum*, 1192
- sinistrum*, 1193
- tuberculi costæ*, 302
- venosum*, 1193
- Ligature of arteries. See each Artery.
- Ligula*, 797
- Limbic lobe*, 825
- Limbs*, development of, 71
- Limbus fossæ ovalis*, 513
- lamina spiralis*, 1055
- Limiting membranes of retina 1017
- Line or Lines*, arcuate, of ilium, 234
- colored, of Retzius, 1120
- curved, of ilium, 232
- gluteal, of ilium, 232
- incremental, of Salter, 1120
- intercondyloid, 247
- intertrochanteric, 245
- mylohyoid, 173
- nuchal, 129, 182
- oblique, of fibula, 261
- of mandible, 172
- of radius, 219
- pectineal, 246
- popliteal, of tibia, 258
- of Schreger, 1120
- spiral, of femur, 245
- temporal, 134, 136, 178, 183
- Linea alba*, 416
- aspera*, 246
- quadrata*, 246
- semicircularis*, 416
- splendens*, 879
- Lineæ semilunares*, 417
- Lingua*, 1125
- facies inferior*, 1125
- tunica mucosa*, 1131
- Lingual artery*, 553
- deep, 553
- bone, 177
- branches of glossopharyngeal nerve, 909
- gyrus, 823
- lamina, 1122
- lymph glands, 694
- nerve, 895
- tonsil, 1131
- veins, 648
- Lingula cerebelli*, 789
- of cerebellum, 789
- of mandibula, 173
- of sphenoid, 148, 192
- Linin*, 36
- Lip*, tympanic, 1055
- vestibular, 1055
- Lips*, 1111
- Liquor amnii*, 56
- sanguinis*, 503
- Lissauer*, fasciculus of, 762
- tract of, 762
- Littre*, urethral glands of, 1235
- Liver*, 1188
- bare area of, 1150
- bile ducts of, 1197
- common, 1198
- cystic duct, 1198
- development of, 1193
- excretory apparatus of, 1197
- fixation of, 1193
- fossæ of, 1191
- gall-bladder, 1197
- hepatic artery, 603, 1196
- cells, 1196
- duct, 1197
- veins, 680
- ligaments of, 1192
- lobes of, 1191, 1192
- lobules of, 1195
- longitudinal fissures of, 1191
- lymphatic capillaries in, 685
- vessels of, 711
- nerves of, 1194
- portal vein, 681, 1196
- structure of, 1195
- surface markings of, 1320
- surfaces of, 1188
- vessels of, 1194
- Lobe or Lobes*, acuminal, 790
- of cerebellum, 788
- of cerebral hemisphere, 821
- frontal, 821
- insula, 825
- limbic, 825
- occipital, 823
- olfactory, 826
- parietal, 822
- precuneus, 823
- quadrate, 823
- temporal, 823
- of liver, 1191, 1192
- of lung, 1097
- nodular, 791
- Spigelian, 1192
- of thymus, 1273
- of thyroid gland, 1269
- tuberal, 791
- uvular, 791
- Lobule of auricula*, 1034
- biventral, 791
- inferior semilunar, 791
- paracentral, 822
- parietal, 823
- postero-inferior, 790
- postero-superior, 791
- Lobules of liver*, 1195
- of testes, 1243
- Lobuli glandulæ thyreoideæ*, 1269
- hepatis*, 1195
- Lobulus centralis*, 790
- parietalis inferior*, 823
- superior*, 823
- semilunaris inferior*, 791
- superior*, 790
- Lobus caudatus*, 1192
- clivi*, 790
- culminis*, 790
- frontalis*, 821
- hepatis dexter*, 1191
- sinister*, 1192
- noduli*, 791
- occipitalis*, 823
- olfactorius*, 826
- parietalis*, 822
- pyramidis*, 791
- quadratus*, 1192
- semilunaris*, 790
- temporalis*, 823
- tuberus*, 791
- uvulæ*, 791
- Localization, cerebral, 849

- Lockwood, tendon of, 1022
Locus cæruleus, 800
 Loewenthal's tract, 872
 Long bones, 79
 buccal nerve, 895
 calcaneocuboid ligament, 354
 ciliary nerves, 888
 external lateral ligament, 341
 or internal saphenous nerve, 956
 root of ciliary ganglion, 888
 saphenous nerve, 956
 vein, 669
 subscapular nerve, 934
 thoracic artery, 588
 nerve, 933
 Longissimus capitis muscle, 399
 cervicis muscle, 399
 dorsi muscle, 399
 Longitudinal fasciculus, inferior, 844
 posterior, 803
 superior, 844
 fissure, cerebral, 818
 great, 818
 of liver, 1191
 sinuses, 654, 655
 striae, lateral and medial, 827
 sulci of heart, 527
 Longitudinalis linguæ inferior muscle, 1130
 superior muscle, 1130
 Longus capitis muscle, 349
 actions of, 396
 nerves of, 395
 colli muscle, 394
 action of, 396
 nerves of, 396
 Loop of Henle, 1223
 Lower extremity, arteries of, 623
 articulations of, 333
 bones of, 231
 lymphatic glands of, 701
 vessels of, 701
 muscles of, 465
 surface anatomy of, 1336
 markings of, 1342
 veins of, 669
 jaw, bones of, 172
 lateral cartilage, 993
 visual centers, 814
 Lower, tubercle of, 531
 Lumbar aponeurosis, 397
 arteries, 612
 enlargement of medulla spinalis, 752
 fascia, 397
 lymph glands, 705
 nerves, anterior, 948
 posterior, 924
 plexus of nerves, 949
 regions of abdomen, 1149
 triangle, 434
 vein, ascending, 667, 678
 veins, 678
 vertebra, 104
 Lumbocostal arch, 404
 Lumbodorsal fascia, 397
 Lumbosacral plexus, 948
 trunk, 948
 Lumbricales muscles of foot, 493
 actions of, 496
 nerves of, 495
 variations of, 493
 of hand, 464
 actions of, 465
 nerves of, 465
 variations of, 464
 Lunate bone, 224
 surface of acetabulum, 237
 Lung-buds, 1071
 Lungs, 1093
 development of, 1071
 fissures and lobes of, 1096
 nerves of, 1100
 root of, 1097
 Lungs, structure of, 1098
 surface markings of, 1310
 vessels of, 1100
 Lunule of nails, 1066
 of semilunar valves, 533
 Luschka, foramina of, 877
 gland of, 1281
 Luys, nucleus of, 812
 Lymph Gland or Glands of abdomen, 703
 aortic, 705
 auricular, 693
 axillary, 699
 buccinator, 694
 cervical, 697
 of Cloquet, 703
 deltoideopectoral, 699
 diaphragmatic, 715
 epigastric, 704
 of face, 692
 facial, 694
 gastric, 706
 gastroepiploic, right, 706
 of head, 692
 hepatic, 706
 hypogastric, 704
 iliac, 703, 704
 ileocolic, 709
 infraorbital, 694
 inguinal, 702
 intercostal, 715
 internal mammary, 715
 lingual, 694
 of lower extremity, 701
 lumbar, 705
 mastoid, 693
 maxillary, 694
 mediastinal, 717
 mesenteric, 709, 710
 mesocolic, 709
 of neck, 697
 obturator, 704
 occipital, 692
 pancreaticoduodenal, 710
 pancreaticolienal, 706
 pararectal, 710
 paratracheal, 697
 parietal, 703
 parotid, 693
 of pelvis, 703
 popliteal, 701
 preauricular, 693
 retropharyngeal, 694
 of Rosenmüller, 703
 sacral, 704
 splenic, 706
 Stahr, middle gland of, 697
 sternal, 715
 structure of, 688
 subinguinal, 702
 submaxillary, 697
 submental, 697
 suprahyoid, 697
 supramandibular, 694
 supratrochlear, 699
 of thorax, 715
 tibial, anterior, 701
 of tongue, 696
 tracheobronchial, 717
 of upper extremity, 699
 visceral, of abdomen and pelvis, 706
 path, 688
 sinus, 689
 Lymphatic capillaries, 684
 distribution of, 684
 duct, right, 691
 nodules, aggregated, 1176
 solitary, 1176
 of spleen, 1285
 system, 683
 trunks, bronchomediastinal, 691, 692, 717
 intestinal, 691
 jugular, 691, 692
 Lymphatic trunks, lumbar, 691
 subclavian, 691, 692
 vessels, 687
 of abdominal viscera, 710
 wall, 706
 of anal canal and anus, 711
 of auricular and external acoustic meatus, 694
 of bladder, 712
 of cecum, 710
 of colon, 711
 of common bile-duct, 711
 development of, 768
 of diaphragm, 717
 of ductus deferens, 713
 of duodenum, 710
 of esophagus, 719
 of external genitals, 706
 of face, 695
 of gall-bladder, 711
 of gluteal region, 703
 of heart, 718
 of ileum, 710
 of jejunum, 710
 of kidney, 712
 lacteals, 683
 of larynx, 698
 of liver, 711
 of lower extremity, 703
 of lungs, 718
 of mamma, 715
 of mouth, 695
 of nasal cavities, 695
 of neck, 698
 of ovary, 714
 of palatine tonsil, 695
 of pancreas, 711
 of pelvic viscera, 710
 of pelvis, 706
 of perineum, 706
 of pharynx, 698
 of pleura, 719
 of prostate, 713
 of rectum, 711
 of reproductive organs, 713
 of scalp, 694
 of spleen, 711
 of stomach, 710
 structure of, 687
 of suprarenal glands, 711
 of testes, 713
 of thoracic viscera, 718
 wall, 715
 of thymus, 719
 of thyroid gland, 698
 of tongue, 696
 of upper extremity, 700
 of ureter, 712
 of urethra, 713
 of urinary organs, 712
 of uterine tube, 714
 of uterus, 714
 of vagina, 714
 of vermiform process, 710
 of vesiculæ seminales, 713
 Lymphocyte, 504
Lymphoglandulae, 688
 auriculares, 693
 axillares, 699
 cervicales, 697
 epigastricae, 704
 faciales profundae, 694
 gastricae, 706
 hepatica, 706
 hypogastricae, 704
 inguinales, 702
 intercostales, 715
 linguales, 694
 lumbales, 705
 mediastinales, 717
 mesentericae, 709
 mesocolicae, 709
 occipitales, 692
 pancreaticolienales, 706
 popliteae, 701

- Lymphoglandula, sternales*, 715
subinguinales, 702
submaxillares, 697
tibialis anterior, 701
 Lyra of fornix, 838, 869
- M**
- MACEWEN, suprameatal triangle of, 140
 Mackenrodt, ligament of, 1261
Macula acustica sacculi, 1052
utriculi, 1051
cribrosa media, 1047
superior, 1048
lytea, 1015, 1017
 structure of, 1017
 Majendie, foramen of, 798, 877
 Malar bone, 164
 process of maxilla, 161
 Male genital organs, 1236
 bulbourethral glands, 1213, 1253
ductus deferens, 1245
 ejaculatory duct, 1247
 penis, 1247
 prostate, 1251
 testes and their coverings, 1236
vesiculae seminales, 1246
 pronucleus, 45
 urethra, 1234
 Malleolar arteries, 635
 folds, 1039
 sulcus, 260
 Malleolus, lateral, 260
 medial, 259
 Malleus, 1044
 development of, 1033
 ligaments of, 1045
 Malpighian bodies, kidney, 1221
 of spleen, 1285
 capsules of kidney, 1221
 Mammæ, 1267
 development of, 1267
 lymphatic vessels of, 715
 nerves of, 1268
 papilla or nipple of, 1267
 structure of, 1267
 vessels of, 1268
 Mammary arteries, 583, 588
 gland, 1267
 internal, 715
 veins, internal, 666
 Mamillary process, 106
 Mamnillo-thalamic fasciculus, 869
 Mandible, 172
 angle of, 174
 articulations of, 175
 body of, 172
 changes in, due to age, 175
 condyloid process of, 174
 coronoid process of, 174
 ossification of, 174
 ramus of, 173
Mandibula, 172
 Mandibular arch, 66
 branches of facial nerve, 905
 canal, 173
 foramen, 173
 fossa, 140, 180, 183
 nerve, 893
 notch, 174
 Mantle layer, 733
 Manubrium of malleus, 1044
 of sternum, 119
 Margin, supraorbital, 135
 Marginal gyrus, 822
 layer, 733
 veins of foot, 669
 Margins of heart, 529
 Marrow of bone, 87
 Marshall, oblique vein of, 522, 526, 643
 vestigial fold of, 522, 526, 643
 Martinotti, cells of, 845
Massa intermedia, 809, 816
 Masses, lateral, of atlas, 99
 Masseter muscle, 385
 action of, 387
 nerves of, 387
 Masseteric artery, 561
 fascia, 385
 nerve, 894
 Mastoid canaliculus, 144, 181
 cells, 142
 foramen, 141, 183
 fossa, 140
 glands, 693
 notch, 141, 181
 portion of temporal bone, 141
 process, 141
 Mastzellen, 377
 Matrix of nail, 1066
 Maturation of ovum, 40
 Maxilla, 157
 articulations of, 163
 changes in, due to age, 163
 ossification of, 163
 Maxillary artery, external, 553
 peculiarities of, 556
 internal, 559
 glands, internal, 694
 nerve, 889
 inferior, 893
 process of inferior nasal concha, 169
 of palatine bone, 168
 of zygomatic bone, 166
 processes of fetus, 66
 sinus, 159, 999
 tuberosity, 159
 vein, internal, 646
Meatus acusticus externus, 1036
cartilagineus, 1036
osseus, 1036
 auditory, external, 1036
 external acoustic, 145, 183, 1036
 internal, 146, 193
 urinarius, 1235
 urinary, 1266
 Meatuses of nose, 195, 994, 995
 Mechanics of muscle, 362
 Mechanism of pelvis, 311
 of respiration, 407
 of thorax, 304
 Meckel's cartilages, 66, 174
 diverticulum, 54, 1172
 ganglion, 891
 Media, refracting, of bulb of eye, 1018
 Medial geniculate body, 811
 lemniscus, 804
 longitudinal fasciculus, 803
 wall of nasal cavity, 995
 Median antibrachial vein, 662
 basilic vein, 661
 nerve, 938
 Mediastinal arteries from aorta, 600
 from internal mammary, 583
 lymph glands, 717
 pleura, 1088
 Mediastinum, 1090
 testis, 1243
 Medicornu, 831
 Medidural artery, 560
 Medifrontal gyre, 822
 Medulla of hair, 1069
oblongata, 767
 anterior district of, 768
 arcuate fibers of, 782
 development of, 739
fasciculus cuneatus, 776
gracilis, 776
 fissures and sulci of, 767, 768
 gray substance of, 779
Medulla oblongata, formatio reticularis, 784
 lateral district of, 769
 olive of, 769
 posterior district of, 774
 pyramid of, 768
 restiform bodies of, 782
 structure of, 775
spinalis, 749
 central canal of, 754
 columns of, 753
 development of, 749
 distribution of nerve cells in, 755
 enlargements of, 751
 fissures of, 752
 gray commissures of, 754
 substance of, 753
ligamentum denticulatum, 877
 meninges of, 872
 neuroglia of, 872
 sulci of, 752
 veins of, 669
 white commissure of, 752
 substance of, 758
 Medullary artery of bone, 88
 lamina, 810
 laminae of lentiform nucleus, 834
 membrane of bone, 87
 portion of suprarenal gland, 1280
 segments of nerves, 727
 sheath of nerve-fibers, 725, 726
 spaces of bone, 94
 substance of kidney, 1221
 velum, 793, 797
 Medullated nerve-fibers, 724
 Meibomian glands, 1026
 Meissner's plexus, 1177
 tactile corpuscles, 1061
Membrana atlantooccipitalis, Anterior, 295
posterior, 296
granulosa [of Graafian follicle], 1256
hyothyreoidea, 1076
interossea antebrachii, 325
cruris, 348
pupillaris, 1014
tectoria [of atlas and occipital bone], 296
 Membrane, anal, 1110
 arachnoid, 876
 atlantooccipital, 295, 296
 basilar, 1054, 1056
 of Bowman, 1008
 costocoracoid, 437
 cricothyroid, 1078
 of Demours, 1008
 of Descemet, 1008
 elastic, of larynx, 1077
 fenestrated, 498
 hyaloid, 1018
 hyoglossal, 1132
 hyothyroid, 1076
 intercostal, 403
 interosseous, of forearm, 325
 of leg, 348
 Jacob's, 1017
 of Krause, 375
 limiting, 1017
 medullary, of bone, 87
 of Nasmyth, 1123
 nuclear, 36
 obturator, 476
 pharyngeal, 1101
 pupillary, 1003, 1014
 of Reissner, 1054
 tectorial, of ductus cochlearis, 1053
 thyrohyoid, 1076
 tympanic, 1039
 vestibular, 1054
 vitelline, 45

- Membranes of brain and medulla
 spinalis, 872
 fetal, 54
 synovial, 279
 Membranous cochlea, 1054
 cranium, 84
 labyrinth, 1015
 portion of urethra, 1235
 semicircular canals, 1052
 vertebral column, 81
 Meningeal artery, accessory, 561
 anterior, 568
 from ascending pharyngeal,
 558
 middle, 560
 surface marking of, 1294
 from occipital, 557
 from vertebral, 579
 branch of spinal nerve, 921
 layer of dura mater, 875
 nerve from hypoglossal, 918
 from maxillary, 889
 Meninges of brain and medulla
 spinalis, 872
 Menisci, 281
 of knee-joint, 342
 Meniscus, articular, 298
 Mental foramen, 172, 188
 nerve, 897
 point, 198
 protuberance, 172
 spines, 172
 tubercle, 172
 Mentalis muscle, 383
 Mentohyoideus muscle, 392
 Merkel, tactile disks of, 1059
 Meroblastic ova, 45
 Mesencephalon, 51, 741, 800
 Mesenteric arteries, 606, 609
 lymph glands, 709
 plexuses of nerves, 987
 veins, 681, 682
 Mesenteries, 1157
 mesentery proper, 1157
 sigmoid mesocolon, 1153, 1157
 transverse mesocolon, 1157
 Mesenteriole of vermiform pro-
 cess, 1178
Mesenterium, 1157
 Mesocardium, arterial, 526
 venous, 526
 Mesocolic lymph glands, 709
 Mesocolon, sigmoid, 1153, 1157
 transverse, 1157
 Mesoderm, 49
 formation of, 47
 Mesogastrium, 1103
 Mesognathion, 199
 Mesonephros, 1205
 Mesorchium, 1207
 Mesosalpinx, 1261
 Mesovarium, 1207, 1255
 Metacarpal bones, 227
 articulations of, 230
 characteristics of, 228
 ossification of, 230
 Metacarpophalangeal articula-
 tions, 332
 Metacarpus, 227
 Metanephros, 1205
 Metaphase of karyokinesis, 37
 Metatarsal arteries, 637
 bones, 272
 characteristics of, 272
 veins, 672
 Metatarsophalangeal articula-
 tions, 359
 Metatarsus, 272
 ossification of, 275
 Metathalamus, 743, 811
 Metencephalon, 738
 Metopic suture, 135
 Meynert, basal optic nucleus of,
 813
 fasciculus retroflexus of, 812
 Meynert, fountain decussation
 of, 806
 substantia innominata of, 837
 Microcytes, 503
 Mid-brain, 54, 741, 800
 Mid-carpal joint, 329
 Middle capsular artery, 610
 cerebellar peduncles, 793
 commissure of brain, 809
 constrictor muscle, 1143
 costotransverse ligament, 302
 cutaneous nerve, 955
 dental nerve, 891
 subscapular nerve, 934
 thyrohyoid ligament, 1077
 tibiofibular ligament, 348
 Milk teeth, 1118
 Mitochondria sheath, 43
 Mitral cells, 848, 997
 orifice, 534
 valve, 534
 Moderator band, 532
 Modiolus of cochlea, 1050
 Molar glands, 1112
 teeth, 1118
 Molecular layer of cortex of
 cerebellum, 794
 of cerebrum, 845
 Monakow, rubrospinal fasciculus
 of, 761
 Monaster or mother star, 37
 Monroe, foramen of, 816, 840
 sulcus of, 741, 816
Mons pubis, 1265
 Veneris, 1265
 Morgagni, hydatid of, 1207, 1242,
 1257
 rectal columns of, 1184
 sinus of, 1143
 Morula, 46
 Moss fibers, 796
 Mother star or monaster, 37
 Motor areas of cerebral cortex,
 847
 end-plates, 730
 nerves, 730
 neurons, lower and upper, 870
 tract, 870
 Mott, spino-quadrigenal sys-
 tem of, 762
 Mouth, 1110
 development of, 1101
 lymphatics of, 695
 mucous membrane of, 1110
 muscles of, 382
 variations of, 385
 Movable articulations, 285
 Movements admitted in joints,
 286
 Mucous glands of tongue, 1131
 sheaths, 283
 of tendons around ankle, 489
 on back of wrist, 459
 on front of wrist, 457
 Müller, orbitalis muscle of,
 1024
 sustentacular fibers of, 1017
 Müllerian duct, 1206
 eminence, 1207
 Multangular bones, 225
 Multicuspid teeth, 1118
 Multifidus muscle, 400
 action of, 402
 nerves of, 402
 spine muscle, 400
 Muscle or Muscles of abdomen,
 408
 abductor hallucis, 491
 digiti quinti (foot), 492
 (hand), 463
 indicus, 464
 minimi digiti, 463
 pollicis, 461
 brevis, 461
 longus, 455
 Muscle or Muscles, accelerator
 urine, 428
 accessorius, 399
 of foot, 493
 action of, on joints, 368
 abductor brevis, 473
 hallucis, 493
 longus, 472
 magnus, 473
 minimus, 474
 obliquus hallucis, 493
 pollicis, 462
 pollicis obliquus, 462
 transversus, 462
 of anal region, 424
 anconaeus, 454
 anterior crural, 480
 femoral, 467
 vertebral, 394
 anterolateral of abdomen, 405
 antitragicus, 1035
 of arm, 442
 development of, 371
 arrectores pilorum, 1069
 articularis genu or *subcrureus*,
 471
 aryepiglotticus, 1083
 arytenoideus, 1082
 attollens aurem, 1035
 attrahens aurem, 1035
 of auricula or pinna, 1035
 auricularis, 1035
 axillary arch, 434
 azygos uvulae, 1139
 of back, 396
 biceps, 433
 brachii, 433
 femoris, 478
 flexor cubiti, 443
 biventer cervicis, 400
 Bowman's, 1011
 brachialis, 444
 anticus, 444
 brachioradialis, 451
 buccinator, 384
 bulbocavernosus, 428, 430
 caninus, 383
 cardiac, 536
 cervical, 387, 388
 cervicalis ascendens, 399
 chondro-epitrochlearis, 437
 chondroglossus, 1130
 ciliaris, 1010
 cleidohyoideus, 393
 coccygeus, 424
 columns, 374
 complexus, 400
 compressor naris, 382
 urethrae, 429, 431
 constrictors of pharynx, 1142
 urethrae, 429, 431
 coracobrachialis, 443
 corrugator, 381
 cutis ani, 425
 supercilii, 381
 costocoroides, 437
 cremaster, 414
 cricoarytenoideus, 1082
 cricoarytenoid, 1082
 cricothyroideus, 1081
 cricothyroid, 1081
 crureus, 471
 deltoid, 439
 deltoides, 439
 depressor *alae nasi*, 382
 anguli oris, 383
 labii inferioris, 383
 septi, 382
 detrusor urinae, 1233
 development of, 371
 diaphragm, 404
 digastric, 391
 digastricus, 391
 dilatator naris, 382
 pupillae, 1013

- Muscle or Muscles, *dilatator tubæ*, 1044
dorsal antibrachial, 451
dorsoepitrochlearis brachii, 434
ejaculator urinae, 428
epicranius, 378
epitrochleo-anconæus, 448
erector clitoridis, 430
penis, 428
spinæ, 397
extensor carpi radialis acces-
sorius, 452
brevior, 452
brevis, 452
intermedius, 452
longior, 452
longus, 452
ulnaris, 454
coccygis, 401
digiti quinti proprius, 454
digitorum brevis, 490
communis, 452
longus, 481
hallucis longus, 481
indicis, 456
proprius, 456
minimi digiti, 454
ossis metacarpi hallucis, 481
pollicis, 455
pollicis brevis, 455
longus, 455
primi internodii pollicis, 455
proprius hallucis, 481
secundi internodii pollicis, 455
external sphincter ani, 425
of eyelids, 380
fasciculi of, 373
fibers of, 373
fixation, 362
flexor accessorius, 493
longus digitorum, 485
brevis minimi digiti, 464, 494
carpi radialis, 446
ulnaris, 447
digiti quinti brevis [foot], 494
[of hand], 464
digitorum brevis, 491
longus, 485
profundus, 448
sublimis, 448
hallucis brevis, 493
longus, 485
pollicis brevis, 461
longus, 449
of foot, 490
of forearm, 445
form of, 361
frontalis, 379
gastrocnemius, 482
gemellus, 477
genioglossus, 1129
geniohyoglossus, 1129
geniohyoid, 393
geniohyoideus, 393
glossopalatinus, 1129, 1139 note
glutæus maximus, 474
medius, 474
minimus, 475
of gluteal region, 474
gracilis, 471
hamstring, 478
of hand, 456
of head, 378
development of, 372
helicis major, 1035
minor, 1035
hyoglossus, 1129
of iliac region, 466
iliacus, 467
minor, 467
ilio capsularis, 467
iliococcygeus, 424
iliocostalis, 399
cervicis, 399
dorsi, 399
- Muscle or Muscles, *iliocostalis*
lumborum, 399
iliosacralis, 424
incisivus labii, 385
infracostal, 403
infrahyoid, 391
infraspinatus, 441
insertion of, 362
intercostal, 402, 403
intercostales, 402, 403
intermediate volar, 465
internal sphincter ani, 426
interossei, dorsal, 495
of foot, 495
of hand, 464
plantar, 495
interspinales, 400
intertransversales, 401
intertransversarii, 401
ischioavernosus, 428, 430
of larynx, 1081
lateral cervical, 388
crural, 486
vertebral, 396
volar, 461
latissimus dorsi, 432
of leg, 480
development of, 372
levator anguli oris, 383
scapulae, 435
ani, 422
claviculae, 435
glandulae thyroideae, 1270
menti, 383
palati, 1139
palpebrae superioris, 1021
prostatae, 424
scapulae, 435
veli palatini, 1139
levatores costarum, 403
lingualis, 1130
longissimus capitis, 399
cervicis, 399
dorsi, 399
longitudinalis linguae, 1130
longus capitis, 395
colli, 394
of lower extremity, 465
lumbricales [of foot], 493
[of hand], 464
lymphatics of, 376
masseter, 385
of mastication, 385
mechanics of, 362
medial femoral, 471
volar, 462
mentalis, 383
mentochoideus, 392
of mouth, 382
multifidus, 400
spinæ, 400
mylohyoid, 393
mylohyoideus, 393
nasalis, 382
nasolabialis, 385
nerves and vessels of,
376
of nose, 382
oblique, 409, 412
inferior, 1023
superior, 1022
obliquus auriculæ, 1035
capitis, 402
externus abdominis, 410
inferior, 402
internus abdominis, 412
oculi, 1022, 1023
superior, 402
obturator externus, 477
internus, 477
occipitalis, 379
occipitofrontalis, 378
ocular, 1021
omohyoid, 394
omohyoideus, 394
- Muscle or Muscles, *opponens digiti*
quinti [of foot], 494
[of hand], 464
minimi digiti, 464
pollicis, 461
orbicularis oculi, 380
oris, 384
palpebrarum, 380
orbitalis of H. Müller, 1024
origin of, 362
of palate, 1139
palatoglossus, 1129, 1139 note
palatopharyngeus, 1139
palmaris brevis, 463
longus, 446
pectineus, 472
pectoralis major, 436
minimus, 438
minor, 438
of pelvis, 420
perineal, superficial transverse,
427, 430
of perineum, 424
peroneus accessorius, 487
brevis, 487
longus, 486
quartus, 487
quinti digiti, 487
tertius, 482
peroneocalcaneus externus,
487
internus, 485
peroneocuboideus, 487
peroneotibialis, 485
pharyngopalatinus, 1139
of pharynx, 1142
of pinna or auricula, 1035
piriformis, 476
pisiformularis, 464
pisimetacarpus, 464
pisuncinatus, 464
plantar, first layer, 491
fourth layer, 495
second layer, 493
third layer, 493
plantaris, 483
plate, 80
platysma, 388
popliteus, 484
minor, 485
posterior crural, 482
femoral, 478
procerus, 382
pronator quadratus, 449
teres, 446
psoas magnus, 467
major, 467
minor, 467
parvus, 467
pterygoid, 386
pterygoideus externus, 386
internus, 387
pubococcygeus, 424
puborectalis, 424
pubovesicales, 1231
pull, action of, on tendon, 364
direction of, 363
pyramidalis abdominis, 416
nasi, 382
quadratus femoris, 477
labii, 383
lumborum, 420
menti, 383
planta, 493
quadriceps extensor, 470
femoris, 470
recti [of eyeball], 1022
rectococcygeal, 1186
rectovesicales, 1231
rectus abdominis, 415
capitis anterior, 395
lateralis, 395
posterior, 401
anticus, 395
posticus, 401

- Muscle or Muscles, *rectus femoris*, 470
retrahens aurem, 1035
rhomboideus major, 434
minor, 434
occipitalis, 435
risorius, 385
rotatores, 400
spinæ, 400
sacrospinalis, 397
salpingopharyngeus, 1143
sarcous elements of, 375
sartorius, 470
scalenus anterior, 396
anticus, 396
medius, 396
pleuralis, 396
posterior, 396
posticus, 396
 of scalp, 378
semimembranosus, 479
semispinalis capitis, 400
cervicis, 400
colli, 400
dorsi, 400
semilendinosus, 479
sense, impulses of, 851
serratus anterior, 438
magnus, 529
posterior, 404
posticus, 404
soleus, 493
sheaths, lymphatic capillaries in, 684
 of shoulder-girdle, development of, 371
sphincter ani, 425
externus, 425
internus, 426
pupilla, 1013
recti, 424
urethra membranacea, 429, 431
vagina, 430
vesicæ, 1233
spinalis capitis, 400
cervicis, 400
colli, 400
dorsi, 399
splenius capitis, 397
cervicis, 397
colli, 397
stapedius, 1046
sternalis, 437
sternoclavicularis, 438
sternocleidomastoideus, 390
sternohyoid, 393
sternohyoideus, 393
sternomastoid, 390
sternothyroideus, 393
sternothyroid, 393
strength of, 364
striped, 373
styloglossus, 1130
stylohyoid, 392
stylohyoideus, 392
stylopharyngeus, 1143
subanconæus, 445
subclavius, 438
subcostales, 403
suberureus, 471
suboccipital, 401
subscapularis, 440
superficial cervical, 387
supinator, 454
brevis, 454
longus, 451
suprahyoid, 391
supraclavicularis, 390
supracostalis, 403
supraspinatus, 440
suspensory, of duodenum, 1170
synergic, 362
temporal, 386
temporalis, 386
tendons of, 376
- Muscle or Muscles, *tensor palati*, 1139
tarsi, 380
tympani, 1046
veli palatini, 1139
teres major, 442
minor, 441
 of thigh, 467
 of thorax, 402
tibiofacialis anterior, 480
thyroarytenoideus, 1082
thyrocoepiglotticus, 1083
thyrohyoideus, 394
thyroarytenoid, 1083
thyrohyoid, 394
tibialis anterior, 480
anticus, 480
posterior, 485
 of tongue, 1128
trachealis, 1087
trachelomastoid, 399
tragicus, 1035
transversalis, 414
cervicis, 399
transversus abdominis, 414
auriculæ, 1035
linguae, 1130
menti, 383
nuchæ, 380
pedis, 493
perinæi, 427, 429
profundus, 429, 431
superficialis [in female], 430
 [in male], 427
thoracis, 403
trapezius, 432
triangularis, 383
sterni, 403
triceps, 444
brachii, 444
extensor cubiti, 444
suræ, 483
 of trunk, 396
 of tympanic cavity, 1046
 of upper extremity, 432
 of ureters, 1232
 urogenital region [female], 430
 [male], 426
 of uvula, 1139
vastus externus, 470
intermedius, 471
internus, 471
lateralis, 470
medialis, 471
ventricularis, 1083
 ventrolateral, of neck, development of, 371
 vertebral, 394, 396
verticalis linguae, 1131
vocalis, 1083
volar antibrachial, 445
voluntary, 373
 work accomplished by, 365
zygomaticus, 383
 major, 383
- Muscular fibers of heart, 535
 process of arytenoid cartilage, 1075
 triangle, 394, 563
Muscularis mucosæ, 1173
Musculi oculi, 1021
ossiculorum auditus, 1046
papillares [of left ventricle], 534
 [of right ventricle], 532
pectinati [of left auricle], 534
 [of right auricle], 529
pubovesicales, 1232
- Musculocutaneous nerve of arm, 935
 of leg, 966
 musculophrenic artery, 583
 musculospiral groove, 211
 nerve, 943
 Myelencephalon, 738
 Myelocytes, 88
- Myeloplaxes, 88
 Mylohyoid artery, 561
 groove, 173
 line, 173
 muscle, 393
 nerve, 896
 Mylohyoideus muscle, 393
 action of, 393
 nerves of, 393
 variations of, 393
 Myocardium, 535
 Myocel, 52
 Myology, 361
- N
- NAILS, 1066
 Nares, 992, 994
 Nasal aperture, anterior, 196
 artery, 571
 lateral, 556
 bones, 156
 articulations of, 157
 ossification of, 157
 cartilages, 992, 993
 cavities, 194, 994
 arteries of, 996
 lymphatic capillaries in, 686
 vessels of, 695
 mucous membrane of, 996
 nerves of, 996, 997
 veins of, 997
 vestibule of, 994
concha, inferior, 169
 middle, 156
 superior, 156
crest, 163, 167
 duct, 1029
fossa, 994
 index, 198
 lamina, 68
 mucous membrane, 996
 nerve from ophthalmic, 888
 nerves from nasopalatine ganglion, 893
 notch of frontal bone, 136
 of maxilla, 158
 part of frontal bone, 136
 of pharynx, 1141
 process of frontal bone, 136
 of maxilla, 161
 processes of fetus, 67
 septum, 194, 995
 spine, anterior, 158, 163
 of frontal bone, 136
 posterior, 167, 180
- Nasalis muscle, 382
 action of, 382
 nerves of, 382
- Nasion, 136, 186, 198
 Nasmyth's membrane, 1123
 Nasociliary nerve, 888
 Nasofrontal vein, 659
 Nasolabial muscle, 385
 Nasolacrimal duct, 1029
 Nasoöptic furrow, 69, 1005
 Nasopalatine nerve, 893
 recess, 996
 Nasopharynx, 1141
Nasus externus, 992
 Navicular bone of carpus, 221
 of tarsus, 270
 fossa, 1266
- Neck, lymphatic glands of, 697
 vessels of, 698
 muscles of, 387
 development of, 371
 triangles of, 562
 veins of, 646
- Nélaton's line, 1342
 Neopallium, 744
 Nerve cells, 721
 of cerebellar cortex, 794
 of cerebral cortex, 845

- Nerve cells of medulla spinalis, 755, 757
 endings, free, 1059
 fasciculi of medulla spinalis, 759
 fibers of cerebral cortex, 846
 medullated, 724
 non-medullated, 728
 roots, 916, 948
- Nerve or Nerves, abducent, 899
 accessory, 913
 acoustic, 905, 1058
 alveolar, 890, 891
 inferior, 895
 anococcygeal, 968
 anterior crural, 953
 interosseous, 938
 superior alveolar, 891
 thoracic, 933
 tibial, 965
- antibrachial cutaneous, 936, 937
- Arnold's, 911
- auditory, 905
- auricular of auriculotemporal, 895
 great, 926
 posterior, 905
 of vagus, 911
- auriculotemporal, 895
- axillary, 934
- brachial cutaneous, lateral, 934
 medial, 937
 posterior, 943
- bronchial, 913
- buccal, of facial, 905
 long, 895
- buccinator, 895
- calcaneal, medial, 963
- cardiac, cervical, 912
 great, 979
 of sympathetic, 979
 thoracic, 912
 of vagus, 912
- caroticotympanic, 978, 1047
- carotid of glossopharyngeal, 909
- cavernous, of penis, 989
- celiac, of vagus, 913
- cerebral, 881. *See* Cranial.
- cerebrospinal, structure of, 728
- cervical, 928
 cutaneous, 927
 divisions of, 921, 925
 of facial, 905
 transverse, 927
- chorda tympani, 904, 1047
- ciliary, 888, 889
- circumflex, 934
- of clitoris, 968
- coccygeal, division of, 925, 957
- cochlear, 906, 1059
- cranial, 881
 abducent, 899
 accessory, 913
 acoustic, 905
 central tract of, 804
 composition and central connections of, 855
 facial, 901
 glossopharyngeal, 906
 hypoglossal, 914
 oculomotor, 884
 olfactory, 881
 optic, 882
 thalamic tract of, 805
 trigeminal, 886
 trochlear, 885
 vagus, 910
- crural, anterior, 955
- cutaneous cervical, 927
 external, 953
 internal, 937, 955
 lesser, 937
 middle, 955
 deep branch of radial, 944
- Nerve or Nerves, deep branch of
 ulnar, 943
 peroneal, 965
 petrosal, 892
 temporal, 894
- descending ramus of hypoglossal, 918
- development of, 735, 747
- digastric, from facial, 905
- digital, of lateral plantar, 963
 of medial plantar, 963
 of median, 938
 of radial, 944
 of superficial peroneal, 966
 of ulnar, 943
- dorsal antibrachial cutaneous, 944
 branch of ulnar, 942
 cutaneous, 963, 966
 digital, 965
 of penis, 968
 scapular, 932
- of dura mater, 875
- dural, 911
- eighth, 905
- eleventh, 913
- end-organs of, 1059
- endoneurium of, 728
- epineurium of, 728
- esophageal, 913
- external nasal, 891
 plantar, 963
 popliteal, 964
 saphenous, 963
 spermatic, 953
- facial, 901
- femoral, 955
 cutaneous, anterior, 955
 lateral, 953
 posterior, 959
- fifth, 886
- first, 881
- fourth, 885
- frontal, 887
- ganglia of, 730
- gastric branches of vagus, 913
- genitocrural, 953
- genitofemoral, 953
- glossopharyngeal, 906
- gluteal, 959, 960
- great auricular, 926
- greater occipital, 923
 splanchnic, 981
 superficial petrosal, 892
- hemorrhoidal, inferior, 968
- hepatic branches of vagus, 913
- hypoglossal, 914
- iliohypogastric, 950
- ilioinguinal, 952
- incisive, 897
- inferior dental, 897
- infraorbital, 889 *note*
- infrapatellar, 956
- infratrochlear, 888
- intercostal, 945
- intercostobrachial, 946
- intermedius of Wrisberg, 901
- internal calcaneal, 963
 cutaneous of arm, 937
 carotid, 977
 plantar, 963
 popliteal, 960
 saphenous, 956
- interosseous, dorsal, 944
 volar, 938
- Jacobson's, 909, 1047
- jugular, 978
- labial posterior, 968
 superior, 891
- lacrimal, 887
- of Lancisi, 868
- laryngeal, 912
- laryngopharyngeal of sympathetic, 978
- Nerve or Nerves, lateral anti-brachial cutaneous, 935, 936
 brachial cutaneous, 934
 femoral cutaneous, 953
 plantar, 963
 sural cutaneous, 964
- lesser splanchnic, 891
- lingual, 895
 of glossopharyngeal, 909
- long ciliary, 888
 saphenous, 956
 subscapular, 934
 thoracic, 933
- lowest splanchnic, 981
- lumbar, divisions of, 924, 948
- lumbosacral trunk, 948
- mandibular, 893
 of facial, 905
- masseteric, 894
- maxillary, 889
 inferior, 893
- medial antibrachial cutaneous, 937
 brachial cutaneous, 937
 sural cutaneous, 962
 plantar, 963
- median, 938
- meningeal, of hypoglossal, 918
 of maxillary, 889
 middle, 889
 of spinal, 916
 of vagus, 911
- mental, 897
- motor, 730
- musculocutaneous, of arm, 935
 of leg, 966
- musculospiral, 943
- mylohyoid, 896
- nasal, of ophthalmic, 888
 from sphenopalatine ganglion, 893
- nasociliary, 888
- nasopalatine, 893
- ninth, 906
- obturator, 953
 accessory, 955
- occipital, greater, 923
 smaller, 926
 third, 923
- oculomotor, 884
- olfactory, 881
- ophthalmic, 887
- optic, 882
- orbital, 893
- origins of, 729
- palatine, 893
- palmar cutaneous, of median, 938
 of ulnar, 942
- palpebral, inferior, 891
- perforating cutaneous, 967
- perineal, 968
- perineurium of, 728
- plexus of, 728
 annular, 1009
- aortic abdominal, 987
- Auerbach's, 1177
- brachial, 930
- cardiac, 984
- carotid, 977
- cavernous, 978
- celiac, 985
- cervical, 925
 posterior, 921, 922, 923
- choroid, of fourth ventricle, 798
 of lateral ventricle, 840
 of third ventricle, 815
- coccygeal, 968
- of cornea, 1009
- coronary, 985, 987
- esophageal, 910, 913
- of Exner, 846

- Nerve or Nerves, plexus of, gastric, 913, 987
 hemorrhoidal, 987
 hepatic, 986
 hypogastric, 987
 infraorbital, 891
 lial, 986
 lumbar, 948
 lumbosacral, 948
 Meissner's, 1177
 mesenteric, 987
 myenteric, 1177
 ovarian, 987
 parotid, 902
 patellar, 953, 956
 pelvic, 987
 pharyngeal, 909, 912, 979
 phrenic, 985
 prostatic, 988
 pudendal, 966
 pulmonary, 910, 913
 renal, 987
 sacral, 957
 solar, 985
 spermatic, 987
 splenic, 986
 of submucosa, 1177
 subsartorial, 956
 suprarenal, 987
 tonsillar, 909
 tympanic, 1047
 uterine, 989
 vaginal, 989
 vesical, 988
- peroneal, 964, 965, 968
 petrosal, deep, 892, 977
 external, 978
 greater superficial, 892
 smaller superficial, 1047
 large, deep, 892
 superficial, 892, 903
- pharyngeal, of glossopharyngeal, 909
 of sphenopalatine ganglion, 893
 of vagus, 911
 phrenic, 928
 plantar, 963
 pneumogastric, 910
 popliteal, 960, 694
 of pterygoid canal, 892, 977
 to pterygoideus externus, 895
 internus, 894
 pterygopalatine, 893
 pudendal, 967
 inferior, 960
 pudic, internal, 967
 pulmonary, 913
 radial, 943
 rami communicantes, gray and white, 902, 976
 recurrent, 912
 reflexes, trigeminal, 899
 respiratory, of Bell, 928, 933
 to rhomboids, 932
 roots, 764, 918
 sacral, 957
 saphenous, 956, 963
 sciatic, 960
 scrotal, posterior, 968
 second, 882
 seventh, 901
 short ciliary, 889
 sixth, 899
 smaller occipital, 926
 spermatic, external, 953
 sphenopalatine branches of maxillary, 890
 spinal, 916
 accessory, 913
 composition and central connections of, 849
 development of, 735
 divisions of, 921, 925
 roots of, 764, 916
- Nerve or Nerves, splanchnic, 981
 to stapedius, 904
 stylohyoid, 905
 to subclavius, 933
 subscapular, 933, 934
 superior labial, 891
 superficial branch of radial, 944
 of ulnar, 942
 supra-acromial, 928
 supraclavicular, 928
 supraorbital, 888
 suprascapular, 932
 suprasternal, 928
 supratrochlear, 888
 sural, 963
 lateral cutaneous, 964
 sympathetic, 968
 cranial, 970
 sacral, 973
 structure of, 729
 thoracolumbar, 974
 of taste, 992
 temporal, deep, 895
 of facial, 905
 temporo-malar, 889
 tenth, 910
 terminations of, 729
 third, 884
 thoracic, divisions of, 923, 933
 thoracodorsal, 934
 thyrohyoid, 918
 tibial, 960
 anterior, 965
 of tongue, 1132
 tonsillar, 909
 transverse cervical, 927
 trifacial, 886
 trigeminal, 886
 central tract of, 805
 trochlear, 885
 twelfth, 914
 tympanic, of glossopharyngeal, 909, 1047
 ulnar, 939
 collateral, 943
 of urethral bulb, 968
 vagus, 910
 vestibular, 906, 1058
 Vidian, 892
 volar digital, 938
 interosseous, 938
 of Wisberg, 937
 zygomatic, 889
 of facial, 905
 zygomaticofacial, 890
 zygomaticotemporal, 890
- Nervi anococcygei*, 968
auriculares anteriores, 895
carotici externi, 979
cavernosi penis minores, 989
cerebrales, 881
cervicales, 921, 925
ciliares longi, 888
clunium inferiores, 960
coccygeus, 925, 957
communicantes cervicales, 928
hypoglossi, 928
digitales dorsales hallucis, 965
plantares communes, 963
proprii, 963
ethmoidales, 888
intercostales, 945
lumbales, 924
 anteriores, 948
 posteriores, 924
nerorum, 728
olfactorii, 881
palatini, 893
sacrales, 924, 957, 968
sphenopalatini, 890
spinales, 916
 rami anteriores, 925
 posteriores, 928
subscapulares, 933
supraclaviculares, 928
- Nervi temporales profundi*, 895
thoracales, 923
 anteriores, 933, 944
 Nervous system, description of, 721
 development of, 733
- Nervus abducens*, 899
accessorius, 913
 rami externus, 913
 internus, 913
acusticus, 1058
alveolaris inferior, 896
auricularis magnus, 926
 posterior, 905
auriculotemporalis, 895
axillaris, 934
buccinatorius, 905
canalis pterygoidei, 892
cardiacus inferior, 981
 medius, 979
 superior, 979
caroticotympanicus inferior, 909
 superior, 909
cavernous penis major, 989
cochlearis, 1059
clunium inferior medialis, 967
 inferiores, 960
communicans fibularis, 964
tibialis, 962
cutaneus antebrachii dorsalis, 944
 lateralis, 936
 medialis, 937
brachii medialis, 937
 posterior, 943
colli, 927
dorsalis intermedius, 966
 medialis, 966
femoralis lateralis, 953
 posterior, 959
suræ lateralis, 964
 medialis, 962
descendens cervicales, 928
dorsalis clitoridis, 968
penis, 968
scapula, 932
facialis, 901
 rami buccales, 905
 temporales, 905
 zygomatici, 905
ramus colli, 905
digastricus, 905
marginalis mandibularis, 905
stylohyoideus, 905
femoralis, 955
frontalis, 887
furcalis, 949
geniofemoralis, 953
glossopharyngeus, 906
 ganglion petrosus, 908
 superior, 908
 rami linguales, 909
 pharyngei, 909
 tonsillares, 909
 ramus stylopharyngeus, 909
glutæus inferior, 959
 superior, 959
hemorrhoidalis inferior, 968
hypoglossus, 914
 ramus descendens, 916
 thyrohyoideus, 916
iliohypogastricus, 950
ilioinguinalis, 952
infratrochlearis, 888
intermedius [of Wisberg], 901
interosseus dorsalis, 944
 volaris, 938
ischiadicus, 960
lacrimalis, 887
laryngeus superior, 912
 lingualis, 895
lumboinguinalis, 953
mandibularis, 893
massetericus, 894
maxillaris, 889

- Nervus maxillaris, rami alveolares superiores posteriores*, 890
labialis superiores, 891
nasales externi, 891
palpebrales inferiores, 819
ramus alveolaris superior anterior, 891
medius, 891
meatus auditorii externi, 895
medianus, 938
meningeus medius, 889
musculocutaneus, 935
mylohyoideus, 896
nasociliaris, 888
obturatorius, 953
accessorius, 955
occipitalis major, 923
minor, 926
oculomotorius, 884
ophthalmicus, 887
opticus, 882
palatinus, 893
perineci, 968
peroneus communis, 964
profundus, 965
petrosus profundus, 892
superficialis major, 892
phrenicus, 928
plantaris lateralis, 963
medialis, 963
pterygoideus externus, 895
internus, 894
pudendus, 967
radialis, 943
recurrens, 912
saphenus, 956
spermaticus externus, 953
spinousus, 894
splanchnicus, 881
stapedius, 904
subclavius, 933
subscapularis, 932
supraorbitalis, 888
supratrochlearis, 888
suralis, 963
thoracalis longus, 933
thoracodorsalis, 934
tibialis, 960, 962, 963
trigeminus, 886
trochlearis, 885
tympanicus, 909
ulnaris, 938
rami musculares, 942
ramus cutaneus palmaris, 942
dorsalis manus, 942
profundus, 943
superficialis, 942
volaris manus, 942
vagus, 910
rami bronchiales, 913
cardiaci, 912
caeliaci, 913
gastrici, 913
hepatica, 913
oesophagei, 913
ramus auricularis, 911
meningeus, 911
pharyngeus, 911
vestibularis, 1058
zygomaticus, 889
 Net-work, carpal, 594
 malleolar, 636
 Neumann, dental sheath of, 1119
 Neural arch, 96
 canal, 50
 crest, 51, 736
 folds, 50
 groove, 50
 tube, 50
 Neurenteric canal, 50
 Neuroblasts, 733
 Neurocentral synchondrosis, 112
 Neuroglia, 722
 Neuroglia of cord, 754, 755
 Neurokeratin, 725
 Neurolemma, 725
 Neurology, 721
 Neuromeres, 750
 Neuromuscular spindles, 1061
 Neuron theory, 732
 Neurons, motor, 870
 Neurotendinous spindles, 1061
 Neutrophil colorless corpuscles, 504
 Nidus avis of cerebellum, 791
 Ninth nerve, 906
 Nipple or papilla of mamma, 1267
 Nissl's granules, 723
 Node, atrioventricular, 537
 sinoatrial, 537
 Nodes of Ranvier, 727
 Nodular lobe, 790
 Nodule of cerebellum, 790
Noduli lymphatici aggregati, 1176
solitarii, 1176, 1187
Nodus vermis, 790
 Non-medullated nerve fibers, 728
 Normæ of skull, basalis, 179
 frontalis, 185
 lateralis, 182
 occipitalis, 185
 verticalis, 178
 Normoblasts, 88
 Nose, 992
 accessory sinuses of, 998
 alar cartilages of, 993
 arteries of, 993, 996
 cartilage of septum of, 992
 cartilaginous frame-work of, 992
 cavities of, 994
 development of, 67
 external, 992
 lateral cartilage of, 993
 lymphatics of, 695
 mucous membrane of, 996
 muscles of, 382
 variations of, 382
 nerves of, 997
 veins of, 997
 Notch, acetabular, 237
 cardiac, 1096
 cerebellar, 788
 ethmoidal, 137
 intertragic, 1034
 jugular, 131
 lacrimal, 159
 mandibular, 174
 mastoid, 141, 181
 nasal, of frontal, 136
 of maxilla, 158
 parietal, 141
 preoccipital, 818
 presternal, 120
 of Rivinus, 1038
 scapular, 204
 sciatic, 234
 sphenopalatine, 169
 superior thyroid, 1073
 supraorbital, 136, 186, 189
 ulnar, of radius, 220
 umbilical, of liver, 1191
 vertebral, 97
 Notochord, 52
 Nuchal line, 129, 182
 Nuck, canal of, 1211, 1261
 Nuclear layer of cerebellar cortex, 795
 layers of retina, 1016
 matrix, 36
 membrane, 36
 substance, 36
 Nucleated sheath of Schwann, 725
 Nuclei of cochlear nerve, 788, 906
 of glossopharyngeal and vagus nerves, 779, 780
 of oculomotor nerve, 884
 Nuclei, olivary, 781
 of origin of motor nerves, 881
pontis, 786
 of termination of sensory nerves, 908
 of trigeminal nerve, 787, 807
 of vestibular nerve, 788, 881
 Nucleoli, 37
 Nucleus of abducent nerve, 787
 of accessory nerve, 913
ambiguus, 779
amygdala, 835
 amygdaline, 791
 amygdaloid, 869
arcuatus, 782
 of Bechterew, 788
caudate, 833
caudatus, 833
 of a cell, 36
 of Darkschewitsch, 812
 of Deiters, 788, 803
dentatus [of cerebellum], 796
dorsalis, 758
emboliformis, 796
 of facial nerve, 787, 902
fastigii, 796
globosus, 796
 of hypoglossal nerve, 779
 inferior central, 784
intercalatus, 799
 of lateral lemniscus, 906
lateralis, 784
 of lens, 1020
 lenticular, 834
 lentiform, 834
lentiformis, 834
 of Luys, 812
 of medial longitudinal fasciculus, 803
nervus abducentis, 787
facialis, 787
trigeminus, 787
 of oculomotor nerve, 807, 884
olivaris superior, 787
 olivary, 781, 787
 of posterior commissure, 812
 pulposus, 82
 red, 802
 of Roller, 784
 segmentation, 45
 sensory, 902
 trapezoid, 787
 of trochlear nerve, 807, 885
 of vagus nerve, 780
 Nuel, space of, 1058
 Nuhn, glands of, 1131
 Nutrient artery of bone, 88
 Nutritive yolk, 39
 Nymphæ, 1265
- O
- OBELION, 178, 198
 Obex, 798
 Oblique cord, 325
 ligament, 325
 line of fibula, 261
 of mandible, 172
 of radius, 219
 muscles, 409, 412
 inferior, 1023
 superior, 1022
 popliteal ligament, 340
 ridge of clavicle, 200
 sinus of pericardium, 526
 vein of left atrium, 526, 643
 of Marshall, 526, 643
 Obliquus oculi muscles, actions of, 1023
 nerves of, 1023
 Obliquus auriculæ muscle, 1035
 capitis inferior muscle, 402
 action of, 402
 nerves of, 402

- Obliquus capitis superior muscle, 402
 action of, 402
 nerves of, 402
 externus abdominis muscle, 409
 variations of, 412
 inferior muscle, 402
 internus abdominis muscle, 412
 variations of, 414
 oculi inferior muscle, 1023
 superior muscle, 1022
 superior muscle, 402
 Obliterated ductus venosus, 681
 hypogastric artery, 615
 umbilical vein, 681, 1150
 Obturator artery, 616
 crest, 236
 externus muscle, 477
 actions of, 478
 nerves of, 478
 foramen, 237
 groove, 237
 internus muscle, 477
 actions of, 478
 fascia of, 420
 nerves of, 478
 lymph gland, 704
 membrane, 476
 nerve, 953
 accessory, 955
 tubercle, 237
 vein, 676
 Occipital artery, 556
 bone, 129
 articulations of, 133
 basilar part of, 132
 lateral parts of, 131
 ossification of, 132
 squama of, 129
 structure of, 123
 condyles, 131
 crest, internal, 131, 193
 fossa, 131
 groove, 141, 181
 lobe, 823
 lymph glands, 692
 nerve, 923, 926
 point, 198
 protuberance, 129, 130, 182, 183
 sinus, 658
 sulcus, 823
 triangle, 394, 565
 vein, 646
 Occipitalis muscle, actions of, 380
 nerves of, 380
 variations of, 380
 Occipitotemporal convolution, 823
 Occipitofrontal fasciculus, 844
 Occipitofrontalis muscle, 378
 Occipitomastoid suture, 183
 Occipitotemporal convolution, 823
 Ocular muscles, 1021
 Oculomotor sulcus, 801
 nerve, 884
 composition and central connections of, 863
 sympathetic efferent fibers of, 970
 Odontoblasts, 1118, 1123
 Odontoid ligaments, 296
 process of axis, 100
 Olecranon, 214
 fossa, 212
 Olfactory areas, 67
 bulb, 826, 848
 structure of, 848
 cells, 996
 fasciculus, 840
 hair, 996
 lobe, 826
 nerves, 881
 composition and central connections of, 866
 development of, 1001
 Olfactory pits, 68
 projection fibers, 869
 sulcus, 822
 tract, 826
 trigone, 827
 Oliva, 769
 Olive, 769
 peduncle of, 781
 Olivary body, 769
 nucleus, 781, 787
 Clivospinal fasciculus, 854
 Omental bursa, 1152, 1155
 recess, 1156
 Omentum, gastrocolic, 1157
 gastrohepatic, 1156
 greater, 1157
 lesser, 1156
 small, 1156
 Omohyoid muscle, 394
 Omohyoideus muscle, 394
 action of, 394
 nerves of, 394
 variations of, 394
 Ontogeny, 35
 Oocytes, 38, 41
 Oögonia, 34
 Oöplasm, 39
 Opening of aorta in left ventricle, 534
 aortic, in diaphragm, 406
 caval, in diaphragm, 406
 of coronary sinus, 530
 esophageal, in diaphragm, 406
 of inferior vena cava, 530
 of pulmonary artery, 531
 veins, 533
 saphenous, 468
 of superior cava, 529
 of thorax, 524
 Openings, atrioventricular, 531, 534
 in roof of fourth ventricle, 798
 Opercula of insula, 825
 Ophryon, 198
 Ophthalmic artery, 568
 ganglion, 888
 nerve, 887
 veins, 658
 Opisthion, 181, 198
 Opisthotic center of temporal bone, 164
 Opponens digiti quinti muscle, 464
 actions of, 464
 nerves of, 464
 minimi digiti muscle, 464
 pollicis muscle, 461
 actions of, 462
 nerves of, 462
 variations of, 462
 Optic axis, 1001
 chiasma, 814, 883
 commissure, 814
 cup, 1001
 disk, 1015
 foramen, 147, 151, 190
 groove, 147
 nerve, 882
 composition and central connections of, 864
 radiations, 814
 recess, 816
 stalk, 742, 1001
 thalamus, 808
 tracts, 814, 884
 vesicle, 742, 1001
 Ora serrata, 1014, 1018
 Oral cavity, 1110
 part of pharynx, 1142
 Orbicular ligament, 342
 Orbicularis oculi muscle, 380
 actions of, 381, 385
 lacrimal part, 380
 nerves of, 381, 385
 orbital part, 380
 Orbicularis oculi muscle, palpebral part, 380
 oris muscle, 384
 palpebrarum muscle, 380
 Orbicularis ciliaris muscle, 1010
 Orbita, 188
 Orbits, 188
 relation of nerves in, 900
 Orbital fascia, 1025
 fissures, 151, 184, 189, 192
 gyri, 822
 index, 198
 nerve, 889
 operculum, 825
 plates, 137
 process of palatine bone, 168
 of zygomatic bone, 165
 septum, 1026
 sulcus, 822
 vein, 645
 Orbitalis muscle of H. Müller, 1024
 Orbitosphenoids, 151
 Organ, enamel, 1123
 of Giralaldès, 1246
 of hearing, 1029
 of Rosenmüller, 1206, 1255
 of sight, 1000
 of smell, 992
 spiral, of Corti, 1056
 Organa genitalia muliebris, 1254
 virilia, 1236
 oculi accessoria, 1021
 Organon auditus, 1029
 gustus, 991
 olfactorius, 992
 spirale [Corti], 1056
 visus, 1000
 Organs of digestion, 1100
 genital, of female, 1254
 of male, 1236
 of Golgi, 376
 of the senses, 991
 of taste, 991
 urogenital, 1204
 vomeronasal, of Jacobson, 71, 996
 Orifice, atrioventricular, 531, 533
 cardiac, of stomach, 1161
 mitral, 534
 of mouth, 1110
 pyloric, of stomach, 1162
 urethral, 1232, 1235, 1266
 of uterus, 1259, 1260
 vaginal, 1266
 Orifices of ureters, 1232
 Origin of muscles, 362
 Os acetabuli, 238
 calcis, 263
 capitulum, 226
 coccygis, 111
 cordis, 536
 coxae, 231
 articulations of, 238
 ossification of, 237
 structure of, 237
 cuboideum, 269
 cuneiforme primum, 270
 secundum, 271
 tertium, 271
 ethmoidale, 153
 frontale, 135
 hamatum, 227
 hyoideum, 177
 iliä, 231
 incisivum, 162
 innominatum, 231
 ischii, 234
 lacrimal, 163
 lunatum, 224
 magnum, 227
 multangulum, 225
 naviculare manus, 221
 pedis, 270
 occipitale, 129

- Os palatinum*, 166
parietale, 133
pisiforme, 225
planum, 155
pubis, 236
sacrum, 106
sphenoidale, 147
alæ magna, 149
parva, 151
temporale, 138
trigonum, 269
triquetrum, 225
zygomaticum, 164
Ossa carpi, 221
cranii, 129
extremilitatis inferioris, 231
superioris, 200
faciei, 156
metacarpalia, 228
metatarsalia, 272
nasalia, 156
sesamoidea, 277
tarsi, 263
Ossein, 91
Ossicles, auditory, 1044
development of, 1033
ligaments of, 1045
Ossicula auditus, 1044
Ossification of atlas, 113
of axis, 113
of clavicle, 202
of coccyx, 114
of ethmoid, 156
of femur, 255
of fibula, 262
of foot, 275
of frontal, 138
of hand, 230
of hip bone, 237
of humerus, 213
of hyoid, 178
of inferior nasal concha, 170
intra-cartilaginous, 93
intramembranous, 91
of lacrimal, 164
of lumbar vertebrae, 113
of mandible, 174
of maxilla, 163
of nasal, 157
of occipital, 132
of os coxæ or innominatum, 237
of palatine, 169
of parietal, 135
of patella, 256
of radius, 220
of ribs, 127
of sacrum, 113
of scapula, 208
of seventh cervical vertebra, 113
of sphenoid, 152
of sternum, 121
of temporal, 145
of tibia, 260
of ulna, 219
of vertebral column, 111
of vomer, 171
of zygomatic, 166
Osteoblasts, 87
Osteoclasts, 88, 1124
Osteodentin, 1120
Osteogenetic fibers, 92
Osteology, 79
Ostium, abdominal, of uterine tube, 1257
mazillare, 995
pharyngeal, of auditory tube, 1141
primitive urogenital, 1215
primum [heart], 512
secundum [heart], 512
Otic ganglion, 897
Otoconia, 1054
Outlet of pelvis, 240
Ova, primitive, 1207

Oval area of Flechsig, 764
bundle, 735
Ovaria, 1254
Ovarian arteries, 611
fossa, 1154, 1254
plexus of nerves, 987
veins, 679
Ovaries, 1254
descent of, 1207
development of, 1207
ligaments of, 1254
lymphatic capillaries of, 687
vessels of, 714
nerves of, 1256
structure of, 1255
vesicular or Graafian follicles of, 1256
vessels of, 1256
Oviduct, 1257
Ovula Nabothi, 1262
Ovum, 35, 38
corona radiata of, 39
coverings of, 40
discharge of, 1256
fertilization of, 44
germinal spot of, 39
vesicle of, 39, 40
implantation or imbedding of, 58
maturation of, 40
mature, 40
segmentation of, 45
structure of, 38
yolk of, 39
zona pellucida or radiata of, 40
Oxyntic cells, 1167
glands, 1167
Oxyphil colorless corpuscles, 504

P
PACCHIONIAN glands, 878
Pacinian corpuscles, 1060
Pad, retropubic, 1228
Pain, impulses of, 853
Palatal process of maxilla, 162
Palate, 1112
arches of, 1112
bone, 166
development of, 70
hard, 1112
soft, 1112
Palatine aponeurosis, 1139
artery, ascending, 555
of ascending pharyngeal, 557
descending, 562
bone, 166
articulations of, 169
horizontal part of, 167
orbital process of, 168
ossification of, 169
pyramidal process or tuberosity of, 168
sphenoidal process of, 169
vertical part of, 167
foramen, 180
nerves, 893
process of maxilla, 162
processes of fetus, 70
tonsils, 1137
uvula, 1112
velum, 1112
Palatoglossus muscle, 1129, *note*, 1139
Palatopharyngeus muscle, 1139
Palatum, 1112
durum, 1112
molle, 1112
Palmar aponeurosis, 460
arch, deep, 595
superficial, 598
cutaneous branch of median nerve, 938

Palmar cutaneous branch of ulnar nerve, 942
fascia, 460
interossei muscles, 465
interosseous arteries, 596
ligaments, 328, 331
nerves of ulnar, 942, 943
Palmaris brevis muscle, 463
actions of, 464
nerves of, 464
variations of, 464
longus muscle, 446
actions of, 450
nerves of, 450
variations of, 446
Palpebræ, 1025
Palpebral arteries, 569, 570
commissures or canthi, 1025
fissure, 1025
ligament, 1026
medial, 381
nerves from maxillary, 891
raphé, lateral, 381
Pampiniform plexus of spermatic cord, 678
Pancreas, 1199
accessory duct of, 1202, 1203
body of, 1201
development of, 1203
duct of, 1022, 1203
head of, 1200
lymphatic vessels of, 711
neck of, 1201
nerves of, 1204
structure of, 1203
surface marking of, 1320
tail of, 1201
uncinate process of, 1200
vessels of, 1204
Pancreatic arteries, 606
duct, 1202
accessory, 1202, 1203
veins, 681
Pancreatica magna artery, 606
Pancreaticoduodenal arteries, 604, 607
lymph glands, 710
veins, 682
Pancreaticolienal lymph glands, 706
Papilla, lacrimal, 1025
foliata, 1132
mammaria, 1267
Papillæ, circumvallate, 1126
conical, 1127
filiform, 1127
fungiform, 1126
of skin, 1065
of tongue, 1126
Papillary layer of skin, 1065
process, 1191
Paracentral lobule, 822
Parachordal cartilages, 84
Paradidymis, 1246
Paraganglia, 1269, 1278
Parallel striæ of Retzius, 1120
Paramastoid process, 131
Paramedial sulcus, 822
Parametrium, 1259
Paranephric body, 1220
Paranucleus, 1204
Paraplasma, 36
Paraplexus, 840
Pararectal fossa, 1154
lymph glands, 710
Parathyroid glands, 1271
development of, 1272
structure of, 1273
Paravesical fossa, 1154
Paraxial mesoderm, 50
Parietal bone, 133
articulations of, 135
ossification of, 233
cells of fundus glands, 1167
convolution, ascending, 823

- Parietal eminence, 133, 178, 183
 foramen, 134, 178
 lobe, 822
 gyri of, 823
 notch, 141
 operculum, 825
 pleura, 1087
 veins, 520
 Parietomastoid suture, 183
 Parietooccipital fissure, 820
 Parietotemporal artery, 573
 Parolfactory area of Broca, 827
 Paroöphoron, 1206, 1255
 Parotid duct, 1134
 gland, 1132
 accessory part of, 1134
 nerves of, 1134
 structure of, 1134
 surface marking of, 1295
 vessels of, 1134
 lymph glands, 693
 plexus, 902
 Parotideomasseteric fascia, 385
 Parovarium, 1255
Partes genitales externæ mulie-
bres, 1264
 Parumbilical veins, 682
 Patella, 255
 articulation of, 256
 movements of, 346
 ossification of, 256
 structure of, 256
 surface anatomy of, 1337
 Patellar plexus, 953, 956
 retinacula, 340
 surface of femur, 248
 Pathways from brain to spinal
 cord, 870
 Pectinate ligament of iris, 1009
 Pectineal line, 246
 Pectineus muscle, 472
 actions of, 474
 nerves of, 474
 variations of, 474
 Pectiniforme septum, 1248
 Pectoralis major muscle, 436
 actions of, 439
 nerves of, 439
 variations of, 438
 minimus muscle, 438
 minor muscle, 438
 actions of, 439
 nerves of, 439
 variations of, 438
 Peculiar thoracic vertebræ, 104
 Pedicles of a vertebra, 96
 Peduncle of corpus callosum, 827
 of olive, 781
 Peduncles of cerebellum, 792
 cerebral, 800
Pedunculus cerebri, 800
 Pelvic colon, 1182
 diaphragm, 420
 fascia of, 420
 fascia, 420
 endopelvic part of, 422
 girle, 200
 plexuses, 987
 portion of sympathetic system,
 984
 Pelvis, 238, 1149
 articulations of, 306
 axes of, 240
 boundaries of, 238
 brim of, 238
 cavity of lesser, 239
 diameters, 239, 240
 in fetus, 242
 greater or false, 238
 inferior aperture or outlet of,
 240
 lesser or true, 239
 ligaments of, 307, 308
 linea terminalis of, 238
 lymph glands of, 703
 Pelvis, *major*, 238
 male and female, differences
 between, 241
 mechanism of, 311
 minor, 239
 position of, 241
 renal, 1221
 superior aperture or inlet of,
 239
 surface anatomy of, 1336
 Penis, 1247
 body of, 1249
 corona glandis, 1249
 corpora cavernosa, 1248
 corpus cavernosum urethræ, or
 corpus spongiosum, 1248
 crura of, 1248
 deep artery of, 620
 dorsal artery of, 620
 veins of, 676
 extremity of, 1250
 fundiform ligament of, 1249
 glands, 1248
 nerves of, 1250
 prepuce or foreskin of, 1250
 root of, 1249
 septum pectiniforme, 1248
 structure of, 1250
 suspensory ligament of, 1249
 Perforated substance, 800, 827
 Perforating arteries, of hand, 595
 from internal mammary, 584
 from plantar, 640
 from profunda femoris, 631
 cutaneous nerve, 967
 fibers of Sharpey, 90
 Perforator of spermatozoön, 42
 Pericardiacophrenic artery, 584
 Pericardial area, 46
 lymphatic capillaries in, 684
 arteries, 584, 600
 pleura, 1089
 Pericardium, 524
 fibrous, 526, 526
 nerves of, 526
 oblique sinus of, 526
 relations of, 525
 serous, 525
 structure of, 525
 transverse sinus of, 526
 vessels of, 526
 vestigial fold of, 526
 Pericecal folds, 1160
 fossæ, 1160
 Perichondrium, 279
 Perilymph, 1051
 Perimysium, 373
 Perineal artery, 619
 body, 1185
 branch of fourth sacral nerve,
 968
 muscle, superficial transverse,
 427, 430
 nerve, 968
 Perineum, boundaries of, 424
 central tendinous point of, 427
 lymphatic vessels of, 706
 muscles of, 424
 Perineurium, 728
 Periosteum, 87
 of bone, lymphatic capillaries
 in, 684
 Peripheral end-organs, 1059
 nervous system, 728
 organs of special senses, 991
 terminations of nerves of
 general sensations, 1059
 Periscleral lymph space, 1024
 Peritoneal cavity, 1150
 lymphatic capillaries in, 684
 fossæ or recesses, 1158
 sacs, 1150, 1152, 1155
 Peritoneum, 1149
 epiploic foramen of, 1156
 lesser sac of, 1155
 Peritoneum, ligaments of, 1156
 main cavity or greater sac of,
 1150
 horizontal disposition of,
 1153, 1154, 1155
 vertical disposition of, 1150
 mesenteries, 1157
 omenta, 1156
 omental bursa of, 1155
 vertical disposition of, 1152
 parietal portion of, 1150
 visceral portion of, 1150
 Permanent cartilage, 279
 choanæ, 70
 kidney, 1211
 teeth, 1115
 development of, 1124
 Peronæi muscles, actions of, 488
 nerves of, 487
 variations of, 487
 Peronæus accessorius muscle, 487
 brevis muscle, 487
 longus muscle, 486
 quartus muscle, 487
 quinti digiti muscle, 487
 tertius muscle, 482
 actions of, 482
 nerves of, 482
 Peroneal arteries, 638
 nerves, 964, 965
 retinacula, 489
 septa, 480
 Peroneocalcaneus externus mus-
 cle, 487
 internus muscle, 485
 Peroneocuboideus muscle, 487
 Peroneotibialis muscle, 485
 Perpendicular fasciculus, 844
 line of ulna, 218
 plate of ethmoid, 154
Pes or base of cerebral peduncle,
 802
 hippocampi, 833
 Petit, canal of, 1019
 triangle of, 434
 Petroöccipital fissure, 181
 Petrosal nerve, deep, 892
 external, 979
 large deep, 892
 superficial, 892, 903
 superficial, greater, 892, 903
 smaller, 1047
 process, 147
 sinuses, 648, 659
 Petrosphenoidal fissure, 181
 Petrosquamous sinus, 658
 suture, 142, 145
 Petrotympanic fissure, 140, 180
 Petrous ganglion, 908
 portion of temporal bone, 142
 Peyer's glands, 1176
 patches, 1176
 Phalangeal processes of Corti's
 rods, 1058
Phalanges digitorum manus, 230
 pedis, 275
 of foot, 275
 articulations of, 359
 ossification of, 275
 of hand, 230
 articulations of, 333
 ossification of, 231
 ungual, 275
 Pharyngeal aponeurosis, 1143
 artery, ascending, 557
 bursa, 1142
 grooves, 65
 membrane, 1101
 nerve from glossopharyngeal,
 909
 from sphenopalatine gan-
 glion, 893
 from vagus, 911
 ostium of auditory tube, 1141
 plexus of nerves, 909, 912, 979

- Pharyngeal pouches, 65
 recess, 1142
 tonsil, 1142
 tubercle, 132, 180
 veins, 649
- Pharyngopalatine arch, 1137
- Pharyngopalatinus muscle, 1139
- Pharynx, 1141
 aponeurosis of, 1143
 development of, 1103
 laryngeal part of, 1142
 lymphatic vessels of, 698
 mucous coat of, 1144
 muscles of, 1142
 actions of, 1143
 nerves of, 1143
 nasal part of, 1141
 oral part of, 1142
 structure of, 1143
- Philtrum, 385
- Phrenic arteries, 601, 612
 nerve, 928
 plexus of nerves, 985
 veins, 666, 679
- Phrenicocolic ligament, 1158
- Phrenicocostal sinus, 1089
- Phrenicolicorn ligament, 1155
- Phrenicopericardiac ligament, 678
- Phylogeny, 35
- Pia of brain, 879
 of cord, 879
 mater, cranial, 879
encephali, 879
 spinal, 879
spinialis, 879
- Pigment of iris, 1013
 of skin, 1064
- Pigmented layer of retina, 1015
- Pili*, 1067
- Pillars of Corti, 1056
 of external abdominal ring, 410
 of fauces, 1112
 of fornix, 838, 840
- Pineal body, 812, 1277
 structure of, 1277
 recess, 743, 816
- Pinna, 1033
 cartilage of, 1034
 ligaments of, 1035
- Piriformis muscle, 476
 actions of, 478
 fascia of, 421
 nerves of, 478
 variations of, 476
- Pisiannularis muscle, 464
- Pisiform bone, 225
- Pisimetacarpus muscle, 464
- Pisiuncinatus muscle, 464
- Pisohamate ligament, 329
- Pisometacarpal ligament, 329
- Pits, olfactory, 68
- Pituitary body, 814, 1257
- Pivot-joint, 285
- Placenta, 62
 circulation through, 63, 540
 cotyledons of, 63
 fetal portion of, 62
 maternal portion of, 62
 previa, 64
 separation of, 64
- Plane, intertubercular, 1147
 subcostal, 1148
 transpyloric, 1147
- Plantar aponeurosis, 490
 arch, 639
 arteries, 639
 cutaneous venous arch, 669
 digital veins, 671
 fascia, 490
 interossei muscles, 495
 ligament, long, 354
 metatarsal arteries, 640
 nerves, 963
- Plantaris muscle, 483
 actions of, 483
- Plantaris muscle, nerves of, 483
- Planum nuchale*, 120
occipitale, 130
- Plasma cells, 377
- Plate or Plates, cribriform, of ethmoid, 153
 ethmoidal, 85
 orbital, of frontal, 137
 perpendicular, of ethmoid, 154
 pterygoid, of sphenoid, 151
 tarsal, 1025
- Platelets of blood, 505
- Platysma muscle, 388
 action of, 388
 nerves of, 388
- Pleura, 1087
 cavity of, 1088
 cervical, 1088
 costal, 1088
 cupula of, 1088
 diaphragmatic, 1088
 lymphatic vessels of, 719
 mediastinal, 1088
 nerves of, 1090
 parietal, 1087
 pericardial, 1088
 pulmonary, 1087
 reflections of, 1088
 structure of, 1090
 surface markings of, 1309
 vessels of, 1090
- Pleural cavity, lymphatic capillaries in, 684
- Plexiform layers of retina, 1016
- Plexus of nerves, annular, 1009
 aortic abdominal, 987
 Auerbach's, 1177
 brachial, 930
 cardiac, 984
 cavernous, 978
 celiac, 985
 cervical, 925
 posterior, 912, 922, 923
 choroid, of fourth ventricle, 798
 of lateral ventricle, 840
 of third ventricle, 815
 coccygeal, 968
 of cornea, 1009
 coronary, 985, 987
 esophageal, 913
 of Exner, 846
 gastric, 987
 hemorrhoidal, 987
 hepatic, 986
 hypogastric, 987
 infraorbital, 891
 internal carotid, 977
 lienal, 986
 lumbar, 948
 lumbosacral, 948
 Meissner's, 1177
 mesenteric, 987
 myenteric, 1177
 ovarian, 987
 parotid, 902
 patellar, 953, 956
 pelvic, 987
 pharyngeal, 909, 912, 979
 phrenic, 985
 prostatic, 988
 pudendal, 966
 pulmonary, 910, 913
 renal, 987
 sacral, 957
 solar, 985
 spermatic, 987
 splenic, 986
 subsartorial, 956
 suprarenal, 987
 tonsillar, 909
 tympanic, 1047
 uterine, 989
 vaginal, 989
 vesical, 988
- Plexus of veins, basilar, 660
 hemorrhoidal, 676
 pterygoid, 645
 pudendal, 676
 uterine, 676
 vertebral, 668
 vesical, 676
 vesicoprostatic, 676
- Plexus aorticus abdominalis*, 987
arteria ovarica, 987
brachialis, 930
cardiacus, 984
caroticus internus, 977
cavernosus, 978
cervicalis, 925
chorioideus ventriculi, 840, 841
celiacus, 985
coronarius, 985
gastricus superior, 987
hepaticus, 986
hypogastricus, 987
lienalis, 986
lumbalis, 949
lumbosacralis, 948
mesentericus inferior, 987
phrenicus, 985
prostaticus, 988
puddendalis, 966
renalis, 987
sacralis, 957
spermaticus, 987
suprarenalis, 987
venosi basilaris 660
hemorrhoidalis, 676
pterygoideus, 645
pudendalis, 676
vertebrales, 668
vesicalis, 676
- Plica circulares* [Kerkrings], 1173
- Plica fimbriata* [tongue], 1125
- gubernatrix*, 1211
- lacrimalis of Hasner, 1029
- semilunaris* [conjunctiva], 1028
 [tonsil], 1138
sublingualis, 1136
triangularis [tonsil], 1138
vascularis, 1211
vesicalis transversa, 1154
- Plica ureterica*, 1232
- ventriculares* [laryngis], 1079
 vocales, 1080
- Pneumogastric nerve, 910
- Polar bodies or polocytes, 40
- Poles of cerebral hemispheres, 818
 of eyeball, 1001
 of lens, 1019
- Polymorphonuclear leucocytes, 504
- Polyspermy, 45
- Pomum Adami*, 1073
- Pons, 785
 development of, 740
 hepatic, 1191
 structure of, 785
 Varoli, 785
- Ponticulus* [auricula], 1034
- Pontine arteries, 580
- Pontospinal fasciculus, 872
- Popliteal artery, 632
 branches of, 633
 peculiarities of, 633
 surface marking of, 1346
 fossa or space, 631
 line of tibia, 258
 lymph glands, 701
 nerves, 960, 964
 surface of femur, 246
 vein, 672
- Popliteus muscle, 484
 actions of, 486
 minor, 485
 nerves of, 486
 variations of, 485
- Pore, gustatory, 991

- Porta of liver, 1191
 Portal vein, 681
 development of, 681
 Postanal gut, 1110
 Postaxial borders of limbs, 71
 Postcentral sulcus, 822
 Postcornu, 831
 Posterior annular ligament, 458
 basis bundle, 764
 calcaneostragaloid ligament, 352
 circumflex artery, 589
 common ligament, 288
 cornu of medulla spinalis, 753
 costotransverse ligament, 302
 cricoarytenoid muscle, 1082
 deep cervical vein, 651
 dental artery, 562
 ground bundle, 764
 inferior ligament, 348
 interosseous artery, 596
 nerve, 944
 ligament, 327
 pillar of fauces, 1137
 proper fasciculus, 764
 pulmonary nerves, 913
 radial carpal artery, 594
 radioulnar ligament, 325
 sacrosciatic ligament, 309
 scapular artery, 582
 nerve, 932
 superior ligament, 348
 talotibial ligament, 350
 temporal artery, 559
 ulnar carpal artery, 598
 vertebral vein, 651
 Postero-lateral ganglionic arteries, 581
 Postero-medial ganglionic arteries, 547, 581
 Postgemina, 806
 Postnodular fissure, 790
 Postpartum hemorrhage, 64
 Postpyramidal fissure, 790
 Postsphenoid part of sphenoid, 152
 Pouch of Douglas, 1152
 of Prussak, 1046
 of Rathke, 1277
 Pouches, pharyngeal, 65
 Poupart's ligament, 411
Præputium clitoridis, 1266
 Preauricular lymph glands, 693
 point, 1291
 sulcus of ilium, 234
 Preaxial borders of limbs, 71
 Precentral gyre, 821
 sulcus, 821
 Prechordal portion of base of fetal skull, 84
 Precommisure, 840
 Precornu, 830
 Precuneus, 823
 Pregemina, 806
 Premaxilla, 126
 Premolar teeth, 1118
 Preoccipital notch, 818
 Prepatellar bursa, 471
 Prepuce of clitoris, 1266
 of penis, 1250
 development of, 1215
 Preputial glands, 1250
 sac, 1250
 Prepyramidal fissure, 790
 tract, 761
 Presphenoid, 152
 Pressure epiphyses, 95
 Presternal notch, 120
 Pretracheal fascia, 390
 Prevertebral fascia, 389
 part of base of skull, 84
 Primary areolæ of bone, 93
 ocytes, 38
 spermatocytes, 43
 Primitive aortæ, 506
 Primitive atrium, 508, 512
 costal arches, 82
 digestive tube, 53
 fibrillæ of Schultze, 725
 groove, 47
 jugular veins, 520
 ova, 1209
 palate, 70
 segments, 52
 sheath of nerve fiber, 727
 streak, 47
 urogenital ostium, 1215
 ventricle of heart, 508
 Princeps cervicis artery, 557
 pollicis artery, 595
Prismata adamantina, 1120
 Proamnion, 47
 Procerus muscle, 382
 action of, 382
 nerves of, 382
 Process or Processes, alveolar, 161
 articular, of vertebrae, 96
 ciliary, 1010
 clinoid, 147, 151, 190
 condyloid, of mandible, 174
 coracoid, 207
 coronoid, of mandible, 174
 of ulna, 214
 costal, 98
 descending, of lacrimal, 164
 of dura mater, 873
 frontal, of maxilla, 161
 frontonasal, 67
 frontosphenoidal, of zygomatic, 164
 globular, of His, 68
 of inferior nasal concha, 169
 intrajugular, 131
 jugular, 131, 181
 lateral nasal, 68
 lenticular, of incus, 1045
 malar, of maxilla, 161
 mastoid, 141
 maxillary, of fetus, 69
 of inferior nasal concha, 169
 of palatine bone, 168
 of zygomatic bone, 166
 muscular, of arytenoid, 1075
 nasal, of frontal bone, 136
 of maxilla, 161
 odontoid, of axis or epistropheus, 100
 orbital, of palatine bone, 168
 of zygomatic bone, 165
 palatal, of maxilla, 162
 palatine, of fetus, 70
 of maxilla, 162
 papillary, of liver, 1491
 paramastoid, 131
 petrosal, 147
 phalangeal, of Corti's rods, 1057
 pterygoid, of sphenoidal bone, 151
 pyramidal, of palatine bone, 168, 180
 sphenoidal, of palatine bone, 169
 of septal cartilage of nose, 993
 turbanated, 152
 spinous, of ilium, 234
 of vertebrae, 96
 styloid, of fibula, 260
 of radius, 220
 of temporal bone, 145, 181
 of ulna, 218
 temporal, of zygomatic, 166
 transverse, of vertebrae, 96
 trochlear, of calcaneus, 266
 uncinate, of ethmoid, 155
 vaginal, of sphenoid, 151
 of temporal, 144, 145
 vermiform, 1178
 of vertebrae, 106
 vocal, of arytenoid, 1075
 Process or Processes, xiphoid, 121
 zygomatic, of frontal, 136
 of maxilla, 161
 of temporal bone, 139
Processus alveolaris [maxillæ], 161
 brevis [malleus], 1044
 ciliares, 1010
 cochleariformis, 145, 1042
 condyloideus [mandibulæ], 174
 coracoideus [scapulæ], 207
 coronoideus [mandibulæ], 174
 [ulnare], 214
 frontalis [maxillæ], 161
 gracilis [malleus], 1044
 orbitalis [os palatinum], 168
 palatinum [maxillæ], 162
 pterygoidei, 151
 pyramidalis [os palatinum], 168
 spinousus, 97
 sphenoidalis [os palatinum], 169
 transversi, 97
 tubarius, 152
 vermiformis, 1178
 xiphoides, 121
 zygomaticus, 161
 Proctodeum, 1110
 Prodentia, 1123
 Profunda arteries, 591
 brachii artery, 591
 cervicalis artery, 585
 femoris artery, 629
 vein, 672
 linguæ artery, 553
 Projection fibers of cerebral hemispheres, 842
 Prominence of aqueduct of Fallopius, 1042
 of facial canal, 1042
 laryngeal, 1073
Prominentia canalis facialis, 1042
Promontorium, 1042
 Promontory of tympanic cavity, 1042
 Pronator quadratus muscle, 449
 actions of, 450
 nerves of, 450
 variations of, 450
 teres muscle, 446
 actions of, 450
 nerves of, 450
 variations of, 446
 Pronephric duct, 1205
 Pronephros, 1205
 Pronucleus, female, 42
 male, 45
 Proötic center of temporal bone, 146
 Prophase of karyokinesis, 37
 Proencephalon, 51, 807
Prostata, 1251
 Prostate, 1251
 development of, 1213
 gland, 1251
 lobes of, 1252
 lymphatic capillaries of, 687
 vessels of, 713
 nerves of, 1253
 structure of, 1253
 vessels of, 1253
 Prostatic ducts, orifices of, 1234
 plexus of nerves, 988
 portion of urethra, 1234
 sinus, 1234
 utricle, 1234
 Prosthion, 198
 Prothrombin, 505
 Protoplasm, 35
 Protoplasmic process of nerve cells, 723
 Protuberance, mental, 172
 occipital, 129, 130, 183
 Prussak, pouch of, 1046
 Psalterium, 838
 Pseudocele, 840
 Pseudonucleoli, 37

- Pseudopodium, 505
 Psoas magnus muscle, 467
 major muscle, 467
 actions of, 467
 fascia covering, 466
 nerves of, 467
 minor muscle, 467
 actions of, 467
 nerves of, 467
 parvus muscle, 467
 Pterion, 151, 182, 198
 ossicle, 156
 Pterotic center of temporal bone, 146
 Pterygoid canal, 151, 180
 fissure, 151
 fossa of sphenoid, 151
 hamulus, 151, 180
 muscles, 386
 plates, 151
 plexus of veins, 645
 processes of sphenoid, 151
 tubercle, 152
 Pterygoideus externus muscle, 386
 action of, 387
 nerves of, 387
 internus muscle, 387
 action of, 387
 nerves of, 387
 Pterygomandibular ligament, 384
 Pterygomaxillary fissure, 185
 Pterygopalatine canal, 159, 168
 fossa, 185
 groove, 151
 nerve, 893
 Pterygospinosus ligament, 153, 388
 Pubic arch, 240
 bones, articulation of, 309
 ligaments, 310
 region, 1149
 tubercle or spine, 236
 vein, 673
 Pubis, 236
 angle of, 236
 body of, 236
 crest of, 236
 iliopectineal eminence of, 236
 obturator crest of, 236
 rami of, 236
 symphysis of, 310
 tubercle or spine of, 236
 Pubocapsular ligament, 334
 Pubococcygeus muscle, 424
 Pubofemoral ligament, 335
 Puborectalis muscle, 424
 Pubovesicales muscles, 1231
 Pudendal artery, accessory, 618
 internal, in female, 620
 in male, 617
 cleft or rima, 1256
 nerve, 967
 inferior, 960
 plexus, nervous, 966
 venous, 676
 veins, internal, 673
 Pudendum, 1264
 Pudic arteries, 617, 629
 nerve, internal, 967
 veins, internal, 674
 Pulmonary artery, 543
 opening of, in right ventricle, 531
 ligaments, 1088, 1090
 nerves, 913
 pleura, 1087
 semilunar valves, 532
 veins, 642
 openings of, in left atrium, 533
Pulmones, 1093
 facies costalis, 1094
 mediastinalis, 1095
 margo anterior, 1096
 margo inferior, 1096
 posterior, 1096
 Pulp cavity of teeth, 1118
 dental, 1118
 of spleen, 1284
 Pulvinar, 808
 Puncta lacrimalia, 1028
 vasculosa, 827
 Pupil, 1012
 congenital atresia of, 1003
 pupillary membrane, 1003, 1014
 Purkinje, cells of, 794
 fibers of, 536
 Putamen, 834
 Pyloric antrum, 1162, 1163
 artery, 604
 glands, 1166
 orifice of stomach, 1162
 part of stomach, 1162, 1163
 valve, 1164
 vein, 682
 Pyramid, 1042
 of cerebellum, 791
 of medulla oblongata, 768
 of temporal bone, 142
 of vestibule, 1048
 Pyramidal cells of cerebral cortex, 845
 decussation, 768
 eminence of tympanic cavity, 1042
 lobe of thyroid gland, 1270
 process of palatine bone, 168, 180
 tracts, 759, 760
 Pyramidalis muscle, 416
 variations of, 417
 nasi muscle, 382
 Pyramids, renal, 1221
Pyramis medullæ oblongatæ, 768
- Q**
- QUADRATE lobe of liver, 1192
 Quadratus femoris muscle, 477
 actions of, 478
 nerves of, 478
 labii inferioris muscle, 383
 action of, 383
 nerves of, 383
 superioris muscle, 383
 action of, 383
 nerves of, 383
 lumborum muscle, 420
 actions of, 420
 fascia covering, 419
 nerves of, 420
 variations of, 420
 menti muscle, 383
 plantæ muscle, 493
 actions of, 496
 nerves of, 496
 variations of, 496
 Quadriceps extensor muscle, 470
 femoris muscle, 470
 actions of, 471
 nerves of, 471
 Quadrigeminal bodies, 805
- R**
- RADIAL artery, 592
 branches of, 594
 carpal, 594
 peculiarities of, 594
 recurrent, 594
 surface marking of, 1335
 fibers of cerebral cortex, 846
 fossa, 212
 nerve, 943
 sulcus, 211
 tuberosity, 219
 Radialis indicis artery, 595
 Radiate ligament, 299
 sternocostal ligaments, 302
 Radiocarpal articulation, 327
 movements of, 328
 Radioulnar articulations, 324, 325
 ligaments, 325
 union, middle, 325
 Radius, 219
 grooves on lower end of, 220
 oblique line of, 219
 ossification of, 220
 sigmoid cavity of, 220
 structure of, 220
 surface anatomy of, 1327
 tuberosity of, 219
 ulnar notch of, 220
Radix arcus vertebræ, 97
 linguæ, 1125
 penis, 1249
 pili, 1067
 pulmonis, 1097
 Rami of ischium, 235
 of pubis, 236
 Ramus of mandible, 173
 Ranine artery, 553
 vein, 648, 649
 Ranvier, crosses of, 727
 nodes of, 727
 Raphé, anococcygeal, 426
 lateral palpebral, 381
 of palate, 1112
 pterygomandibular, 384
 of scrotum, 1237
 Rathke, pouch of, 1277
Receptaculum chyli, 691
 Recess, epitympanic, 142, 1038
 nasopalatine, 996
 omental, 1156
 optic, 816
 pharyngeal, 1141, 1142
 pineal, 743, 816
 sphenothmoidal, 195, 994
 Recesses, lateral, of fourth ventricle, 797
 peritoneal, 1158
 of Tröbtsch, 1046
Recessus ellipticus, 1048
 infundibuli, 816
 intersigmoideus, 1161
 pinealis, 743, 816
 sacciformis, 326
 sphericus, 1047
 suprapinealis, 816
 Reciprocal reception, articulation by, 286
 Rectal ampulla, 1183
 columns of Morgagni, 1185
 layer of pelvic fascia, 422
 Recti muscles, actions of, 1023
 nerves of, 1023
 Rectococcygeal muscles, 1186
 Rectouterine folds, 1260
 Rectovesical excavation, 1152
 folds, 1154
 layer of pelvic fascia, 422
 Rectovesicales muscles, 1231
 Rectum, 1183
 ampulla of, 1183
 anal part of, 1184
 development of, 1108
 Houston's valves of, 1183
 lymphatic vessels of, 711
 relations of, 1184
 Rectus abdominis muscle, 415
 sheath of, 416
 capitis anterior muscle, 395
 action of, 396
 nerves of, 395
 anticus major muscle, 395
 minor muscle, 395
 lateralis muscle, 395
 action of, 396
 nerves of, 395
 posterior major muscle, 401
 action of, 402

- Rectus capitis posterior major muscle, nerves of, 402
 minor muscle, 401
 action of, 402
 nerves of, 402
 femoris muscle, 470
 actions of, 471
 nerves of, 471
 muscles of eyeball, 1022
 Recurrent artery, interosseous, 597
 radial, 594
 tibial, 635
 ulnar, 596
 branches from deep volar arch, 595
 laryngeal nerve, 912
 nerve, 912
 Red corpuscles, 503
 nucleus, 802
 Reflected inguinal ligament, 412
 Reflections of pleuræ, 1088
 Reflex paths, spinal intrinsic, 850
 Refracting media of eye, 1018
 Regions of abdomen, 1147
 Reil, island of, 825
 Reissner, vestibular membrane of, 1054
 Renal arteries, 610
 columns, 1221
 fascia, 1220
 impression, 1189
 pelvis, 1221, 1225
 plexus, 987
 pyramids, 1221
 sinus, 1221
 tubules, 1221
 veins, 679
 vessels, afferent and efferent, 1221, 1224
Renes, 1215
 Reproduction of cells, 37
 Respiration, mechanism of, 407
 Respiratory apparatus, 1071
 development of, 1071
 nerve of Bell, 928, 933
 system, 1071
 Restiform bodies of medulla, 973
Rete canalis hypoglossi, 660
 foraminis ovalis, 660
 testis, 1244
Retia venosa vertebrarum, 668
 Reticular lamina, 1058
 layer of skin, 1065
Reticularis alba, 784
 grisea, 784
 Retina, 1014
 central artery of, 571
 development of, 1002
 fovea centralis, 1015
 layers of, 1015
 macula lutea, 1015
 membrana limitans, 1017
 ora serrata, 1014
 structure of, 1015
 supporting frame-work of, 1017
 Retinacula of hip-joint, 334
 patellar, 340
 peroneal, 489
 Retrahens aurem muscle, 1035
 Retrocecal fossa, 1161
 Retroglanular sulcus of penis, 1249
 Retroperitoneal fossæ, 1158
 Retropharyngeal lymph glands, 694
 space, 390
 Retropubic pad, 1228
 Retrovesical excavation, 1152
 Retzius, colored lines of, 1120
 Rhinal fissure, external, 744
 Rhinencephalon, 744, 826
 Rhombencephalon, 51, 738, 767
 Rhombic grooves, 740
 lip, 739
 Rhomboid fossa, 798
 impression, 202
 ligament, 314
 Rhomboidei muscles, actions of, 435
 nerves of, 435
 variations of, 435
 Rhomboideus major muscle, 434
 minor muscle, 434
 occipitalis muscle, 435
 Rhomboids, nerve to, 932
 Ribs, 123
 common characteristics of, 123
 development of, 82
 false, 123
 floating or vertebral, 123
 ossification of, 127
 peculiar, 125
 structure of, 125
 true, 123
 vertebrochondral, 123
 vertebrosternal, 123
 Ridge, ganglion, 51, 736
 supracondylar, 211
 trapezoid or oblique, 200
 Ridges, bicipital, 209
 Right atrium, 529
 auricle, 529
 auricular appendix, 529
 coronary plexus, 985
 veins, 642
 gastroepiploic glands, 706
 ventricle, 531
Rima glottidis, 1080
 of mouth, 1110
 palpebrarum, 1025
 pudendal, 1265
 Ring, femoral, 625
 subcutaneous, 410
 tympanic, 146
 Rings, abdominal, 410, 418
 fibrous, of heart, 536
 Risorius muscle, 385
 action of, 385
 nerves of, 385
 Rivinus, ducts of, 1136
 notch of, 1038
 Rod-bipolars of retina, 1017
 Rod-granules of retina, 1017
 Rods and cones, layer of, 1017
 of Corti, 1056
 of retina, 1017
 Rolando, fissure of, 819
 substantia gelatinosa of, 753
 tubercle of, 775
 Roller, nucleus of, 784
 Roof plate of medulla spinalis, 133
 Root of lung, 1097
 of penis, 1249
 Root-sheaths of hair, 1068
 Roots of spinal nerves, 764, 916
 of teeth, 1114
 of zygomatic process, 139
 Rosenmüller, fossa of, 1141, 1142
 lymph gland of, 703
 organ of, 1206, 1255
 Rostrum of corpus callosum, 828
 sphenoidal, 149
 Rotary joint, 285
 Rotation, movement of, 286
 Rotator muscles, 400
 action of, 402
 nerves of, 402
 spinæ muscle, 400
 Round ligament of liver, 1192
 of uterus, 1261
 Rubrospinal fasciculus, 870
 Ruffini, corpuscles of, 1061
 Rust-colored layer of cerebellar cortex, 795

S

 SAC, dental, 1123
 lacrimal, 1028
 Sac, preputial, 1250
 Sacs of peritoneum, 1150, 1152
 Saccule, laryngeal, 1080
 of vestibule, 1051, 1052
Sacculus, 1052
Saccus lacrimonalis, 1028
 vaginalis, 1211
 Sacral arteries, lateral, 621
 artery, middle, 613
 canal, 110
 cornua, 108
 crests, 107, 108
 foramina, 106, 108
 groove, 107
 hiatus, 107
 lymph glands, 704
 nerves, divisions of, 924, 957
 nucleus of medulla spinalis, 758
 plexus, 957
 sympathetics, 973
 tuberosity, 108
 veins, 673, 677
 Sacrococcygeal ligaments, 309
 Sacrogenital folds, 1154, 1260
 Sacroiliac articulation, 306
 ligaments, 307, 308
 Sacrosiatic ligaments, 309
 Sacrospinalis muscle, 397
 Sacrovertebral angle, 106
 Sacrum, 106
 ala of, 110
 apex of, 110
 articulations of, 111
 auricular surface of, 108
 base of, 109
 ossification of, 113
 structure of, 111
 variations of, 111
 Saddle-joint, 286
 Sagittal fossa of liver, 1191
 sinuses, 654, 655
 sulcus, 131, 134, 136
 suture, 134, 178
 Salivary glands, 1132
 development of, 1102
 parotid, 1132
 structure of, 1136
 sublingual, 1136
 submaxillary, 1135
 Salpingopalatine fold, 1142
 Salpingopharyngeal fold, 1142
 Salpingopharyngeus muscle, 1143
 Salter, incremental lines of, 1120
 Santorini, cartilages of, 1075
 duct of, 1202
 Saphenous nerves, 956, 963
 opening, 469
 veins, 669, 670
 Sarcolemma, 373
 Sarcomere, 375
 Sarcoplast, 374
 Sarcostyles, 374
 Sarcous elements of muscles, 375
 Sartorius muscle, 470
Scala media [cochlear], 1054
 tympani, 1051
 vestibuli, 1051
 Scalene tubercle, 125
 Scaleni muscles, actions of, 396
 nerves of, 396
 variations of, 396
 Scalenus anterior muscle, 396
 anticus muscle, 396
 medius muscle, 396
 pleuralis muscle, 396
 posterior muscle, 396
 posticus muscle, 396
 Scalp, lymphatic vessels of, 694
 skin of, 378
 Scapha, 1034
 Scaphoid bone, 221, 270
 fossa of sphenoid, 151, 180
 Scapula, 202
 acromion of, 203
 coracoid process of, 207

- Scapula, glenoid cavity of, 207
ligaments of, 316
ossification of, 208
surface of, 203
structure of, 207
surface anatomy of, 1326
- Scapular arteries, 582
circumflex artery, 588
nerve, posterior, 932
notch, 204
- Scapuloclavicular articulation, 315
- Scapus or shaft of hair, 1069
pili, 1069
- Scarpa, fascia of, 408
foramina of, 162, 180
ganglion of, 1058
triangle of, 626
- Schindylesis, 284
- Schlemm, canal of, 1005
- Schreger, lines of, 1120
- Schultze, primitive fibrillæ of, 725
- Schwann, white matter of, 726
- Sciatic artery, 620
foramen, 309
nerves, 959, 960
notch, 235
veins, 674
- Sclera, 1005
structure of, 1006
Scleral spur, 1007
- Sclerocorneal junction, 1005
- Sclerogenous layer, 80
- Sclerotome, 80
- Scrotal arteries, posterior, 619
nerves, posterior, 968
- Scrotum, 1237
dartos tunic of, 1238
integument of, 1237
nerves of, 1239
raphé of, 1237
vessels of, 1239
- Sebaceous glands, 1069
- Second cuneiform bone, 271
metacarpal bone, 228
metatarsal bone, 271
nerve, 882
- Secondary arcola of bone, 94
dentin, 1120
óocytes, 41
sensory fasciculus, 762
spermatocytes, 43
tympenic membrane, 1040
- Secretion, internal, 1269
- Segment, internodal, 727
of Lantermann, 727
medullary, 727
- Segmentation of cells, 37
of fertilized ovum, 45
nucleus, 45
- Segments, primitive, 52
spinal, 750
- Sella turcica*, 147, 190
- Semicanalis n. tensoris tympani*, 145, 1042
tubæ auditivæ, 145, 1042
- Semicircular canals, 1047, 1052
ducts, 1052
- Semilunar bone, 224
fibrocartilages of knee, 342, 343
ganglion of abdomen, 985
of trigeminal nerve, 886
lobules of cerebellum, 790
- Semimembranosus muscle, 479
actions of, 480
nerves of, 480
variations of, 479
- Seminal duct, 1245
vesicles, 1246
- Semispinalis capitis muscle, 400
cervicis muscle, 400
colli muscle, 400
dorsi muscle, 400
muscles, actions of, 402
nerves of, 402
- Semitendinosus muscle, 479
actions of, 480
nerves of, 480
- Sensations, peripheral termina-
tions of nerves of, 1059
- Senses, organs of, 991
special, peripheral organs of,
991
- Sensory areas of cerebral cortex,
849
decussation, 777
pathways from spinal cord to
brain, 851
- Septum, aortic, 514
canalis musculotubarii, 145,
1042
crural, 626
femorale, 626
inferius of heart, 512
intermedium, 512
interventricular, 534
lucidum, 840
mobile nasi, 993
nasi, 194
of nose, 194, 995
orbital, 1026
pectiniforme penis, 1248
pellucidum, 840
primum, 512
secundum, 512
spurium, 510
subarachnoid, 877
of tongue, 1132
transversum, 72
of semicircular ducts, 1052
urorectal, 1109
ventricular, 512, 535
ventriculorum, 535
- Serosa, or false amnion, 56
- Serous glands of tongue, 1131
pericardium, 526
- Serratus anterior muscle, 438
actions of, 439
nerves of, 439
variations of, 439
magnus muscle, 438
posterior inferior muscle, 404
variations of, 404
superior muscle, 404
variations of, 404
posticus muscles, 404
- Sertoli, cells of, 1243
- Sesamoid bones, 277
cartilages, 993
- Seventh nerve, 901
- Shaft of hair, 1069
- Sheath or Sheaths of arteries, 499
carotid, 389
crural, 625
dentinal, of Neumann, 1119
femoral, 625
of flexor tendons of fingers, 449
of toes, 492
mucous, 283
of tendons around ankle, 489
on back of wrist, 459
in front of wrist, 457
of rectus abdominis muscle, 416
- Shin bone, 256
- Short bones, 79
calcaneocuboid ligament, 354
gastric veins, 681
plantar ligament, 354
saphenous nerve, 963
vein, 670
- Shoulder blade, 202
girdle, 200
muscles of, 439
development of, 371
- Shoulder-joint, 317
bursæ near, 319
movements of, 319
vessels and nerves of, 319
- Sibson's fascia, 1089
- Sight, organ of, 1000
- Sigmoid arteries, 610
cavity of radius, 220
of ulna, 215
colon, 1182
flexure, 1182
mesocolon, 1153
sinus, 657
sulcus, 142
- Sinus or Sinuses, aortic, 534
basilar, 660
cavernous, 658
cervicalis, 67
circular, 659
confluence of, 658
coronary, 642
costomediastinal, 1090
cranial, 135 *note*
of dura mater, 654
of epididymis, 1242
of external jugular vein, 647
frontal, 138, 998
intercavernous, 659
laryngeal, 1080
lateral, 657
longitudinal, 654, 655
maxillary, 159, 999
of Morgagni, 1143
of nose, 998
occipital, 658
of pericardium, 526
petrosal, 659
petrosquamous, 658
phrenicocostal, 1089
pocularis, 1234
prostatic, 1234
pyriformis, 1142
renal, 1221
rhomboidalis, 51
sagittal, 654, 655
septum, 511
sigmoid, 657
sphenoidal, 149, 998
sphenoparietal, 658
straight, 655
tentorial, 655
tonsillar, 67
transverse, 657, 660
urogenital, 1213
of Valsalva, 533, 534
venarum, 528
venosus, 508
- Sinus or Sinuses, cavernosus*, 658
coronarius, 642
dura matris, 654
frontales, 998
intercavernosi, 659
maxillaris, 159, 999
occipitalis, 658
paranasales, 998
petrosus, 648, 659
rectus, 655
sagittalis, 654, 655
sphenoidales, 998
tarsi, 267
transversus, 657
venosus, 529
scelere, 1005
- Sinusoids of Minot, 501
- Sixth nerve, 899
- Skein, or spirem, 37
- Skeleton, 79
development of, 80
- Skene's duct, 1213
- Skin, 1062
appendages of, 1066
hairs, 1067
nails, 1066
sebaceous glands, 1069
sudoriferous or sweat glands,
1070
arteries of, 1066
corium or cutis vera, 1065
development of, 1066
epidermis or cuticle, 1062
furrows of, 1062

- Skin, lymphatic capillaries in, 684
 nerves of, 1066
 papillary layer of, 1065
 reticular layer of, 1065
stratum corneum, 1062
mucosum, 1062
 true 1065
- Skull, 128
 development of, 83
 differences in, due to age, 196
 exterior of, 178
 fossa of, 190, 192
 interior of, 189
norma basalis, 178, 179
frontalis, 185
lateralis, 182
occipitalis, 185
verticalis, 178
 sexual differences in, 197
 surface anatomy of, 1278
 tables of, 195
 upper surface of base of, 190
 Skull-cap, inner surface of, 189
 Slightly movable joints, 285
 Small cardiac vein, 642
 cavernous nerves, 989
 intestine, 1168
 areolar or submucous coat
 of, 1172
 circular folds of, 1173
 duodenum, 1168
 glands of, 1176
 ileum, 1170
 jejunum, 1170
 lymphatic nodules of, 1176
 vessels of, 710
 Meckel's diverticulum of,
 1172
 mucous membrane of, 1173
 muscular coat of, 1172
 nerves of, 1176
 Peyer's glands of, 1176
 serous coat of, 1172
valvula conniventes of, 1173
 vessels of, 1176
 villi of, 1174
 saphenous vein, 670
 sciatic nerve, 959
 wings of sphenoid, 151
 Smaller occipital nerve, 926
 Smallest cardiac veins, 643
 Smell, organ of, 992
 Soft palate, 1112
 aponeurosis of, 1139
 arches or pillars of, 1112
 muscles of, 1139
 Solar plexus, 985
 Sole of foot, muscles of, first
 layer, 491
 fourth layer, 495
 second layer, 493
 third layer, 493
 Soleus muscle, 483
 actions of, 483
 nerves of, 483
 variations of, 483
 Solitary cells of medulla spinalis,
 758
 glands, 1176
 Somatic cells, 35
 fibers of spinal nerves, 920
 layer of mesoderm, 50
 Somatopleure, 50
 Space or Spaces, of angle of iris,
 1009
 of Burns, 389
 corneal, 1008
 interpleural, 1090
 of Fontana, 1009
 intercostal, 123
 interglobular, 1120
 of Nuel, 1058
 popliteal, 631
 retropharyngeal, 390
 subarachnoid, 876
 Space or Spaces, suprasternal, 389
Spatia zonularis, 1019
Spatium perichorioideale, 1005
 Spermatic artery, internal, 611
 canal, 418
 cord, 1239
 structure of, 1239
 fascia, external, 411, 1238
 plexus of nerves, 987
 veins, 678
 Spermatids, 43, 1243
 Spermatoblasts, 1243
 Spermatoocytes, 43, 1243
 Spermatogonia, 43, 1243
 Spermatozoön 42, 1243
 body or connecting piece of, 42
 formation of, 1243
 head of, 42
 neck of, 42
 perforator of, 42
 tail of, 43
 Sphenothmoidal recess, 195, 994
 suture, 190
 Sphenofrontal suture, 182, 190
 Sphenoid bone, 147
 articulations of, 153
 body of, 147
 ossification of, 152
 pterygoid processes of, 151
 wings of, 149, 151
 Sphenoidal air sinuses, 149, 998
 conchæ, 152
 crest, 149
 process of palatine bone, 169
 of septal cartilage of nose,
 993
 rostrum, 149
 spine, 150, 180
 turbinated processes, 152
 Sphenomandibular ligament, 297,
 388
 Sphenomaxillary fissure, 184
 fossa, 185
 Sphenopalatine artery, 562
 foramen, 168
 ganglion, 891
 nerves, 890
 notch, 169
 Sphenoparietal sinus, 658
 suture, 182
 Sphenosquamosal suture, 182
 Sphenozygomatic suture, 182
 Spincter ani externus muscle,
 425
 internus muscle, 426
 pupillæ muscle, 1013
 recti muscle, 424
 urethræ membranaceæ muscle,
 429, 431
 vaginæ muscle, 430
 Spigelian lobe of liver, 1192
 Spina heliæ, 1034
scapula, 203
vestibuli, 510
 Spinal accessory nerve, 913
 arteries, 579
 bulb, 767
 column, 96
 cord, 749
 dura of, 875
 pathways from brain to, 870
 pia of, 879
 sensory pathways from, to
 brain, 851
 ganglia, 917
 lemniscus, 762
 nerves, 916
 composition and central con-
 nections of, 849
 connections with sympa-
 thetic, 920
 development of, 119
 divisions of, 921, 925
 fibers of, 920
 points of emergence of, 916
 Spinal nerves, roots of, 764, 916
 size and direction of, 917
 structure of, 920
 reflex paths, intrinsic, 850
 segments, 750
 Spinalis capitis muscle, 400
 cervicis muscle, 400
 colli muscle, 400
 dorsi muscle, 399
 Spindle, achromatic, 37
 aortic, 547
 neuromuscular, 1061
 neurotendinous, 1061
 Spine or Spines, ethmoidal, 147,
 190
 of frontal bone, 136
 iliac, 234
 ischial, 235
 mental, 172
 nasal, 158, 163, 167, 180, 187
 pubic, 236
 of scapula, 203
 sphenoidal, 150, 180
 suprarental, 145, 183
 of tibia, 256
 trochlear, 137
 Spinoglenoid ligament, 317
 Spinoölivary fasciculus, 854
 Spinoquadrigeminal system of
 Mott, 762
 Spinotectal fasciculus, 762, 854
 Spinothalamic fasciculus, 762
 Spinous process of a vertebra, 96
 Spiral canal of modiolus, 1051
 ligament, 1054
 line of femur, 245
 organ of Corti, 1056
 thread of spermatozoön, 43
 tube of kidney, 1223
 Spirem or skein, 37
 Splanchnic fibers of spinal
 nerves, 920
 layer of mesoderm, 50
 nerves, 981
 Splanchnology, 1071
 Splanchnopleure, 50
 Spleen or lien, 1282
 accessory, 1283
 bloodvessels of, 1285
 development of, 1282
 lymphatic capillaries in, 686
 nodulus of, 1285
 vessels of, 711
 Malpighian bodies of, 1285
 relations of, 1282
 size and weight of, 1283
 structure of, 1283
 supernumerary, 1283
 surface marking of, 1320
 Splenic center of ossification, 175
 Splenic artery, 605
 distribution of, 1285
 cells, 1284
 glands, 706
 flexure of colon, 1180
 plexus, 986
 pulp, 1284
 vein, 681
 Splenii muscles, actions of, 397
 nerves of, 397
 Splenium of corpus callosum, 828
 Splenius capitis muscle, 397
 cervicis muscle, 397
 variations of, 397
 colli muscle, 397
 Spongioblasts, 733
 Spongioplasm, 36
 Spring ligament, 356
 Spur of malleus, 1044
 scleral, 1007
 Squama, frontal, 135
 occipital, 129
 temporal, 139
 Squamosal suture, 183
 Stahr, middle gland of, 697

- Stalks, optic, 742, 1001
of thalamus, 811
- Stapedius muscle, 1046
- Stapes, 1045
annular ligament of, 1043
development of, 1033
- Stellate ligament, 299
veins of kidney, 1224
- Stensen, duct of, 1134
foramina of, 126, 180
- Stephanion, 183, 198
- Sternal angle, 121
end of clavicle, 202
foramen, 121
furrow, 1307
glands, 715
plate, 83
- Sternalis muscle, 437
- Sternebræ, 120
- Sternoclavicular articulation, 313
surface anatomy of, 1328
- Sternoclavicularis muscle, 438
- Sternocleidomastoid artery, 552, 556
- Sternocleidomastoid muscle, 390
variations of, 390
- Sternocostal ligaments, 302
surface of heart, 528
- Sternohyoid muscle, 393
- Sternohyoideus muscle, 393
variations of, 393
- Sternomastoid artery, 552, 556
muscle, 390
- Sternopericardiac ligaments, 526
- Sternothyreoides muscle, 393
variations of, 394
- Sternothyroid muscle, 393
- Sternum, 119
articulations of, 123
development of, 83
ossification of, 121
structure of, 121
- Stomach, 1161
bed, 1162
body of, 1163
cardiac glands of, 1166
orifice of, 1161
component parts of, 1163
curvatures of, 1162
development of, 1103
fundus of, 1163
glands of, 1166
incisura angularis, 1162
interior of, 1162
lymphatic vessels of, 710
mucous membrane of, 1166
muscular coat of, 1164
nerves of, 1167
openings of, 1161
position of, 1163
pyloric antrum, 1162, 1163
glands, 1166
orifice, 1162
valve, 1164
serous coat of, 1164
shape and position of, 1161
structure of, 1164
subdivisions of, 1163
sulcus intermedius, 1162
surface marking of, 1317
surfaces of, 1162
teeth, 1117
vessels of, 1167
- Stomodeum, 1101
- Stratiform fibrocartilage, 282
- Stratum cinereum*, 806
compactum [decidua], 59
corneum, 1062
dorsale, 812
germinativum, 1063
granulosum, 1063
intermedium [choroid], 1010
lemnisci, 806
lucidum, 1063
- Stratum opticum* [retina], 1015
[superior colliculus], 806
spongiosum [decidua], 60
zonale, 806
- Streak, primitive, 47
- Stria, longitudinal, 827
- Striate arteries, 573
veins, inferior, 653
- Striated muscle, lymphatic capillaries in, 684
- Stripe of Hensen, 1058
- Striped muscle, 373
- Stroma of iris, 1013
of kidney, 1225
of ovary, 1256
- Styloglossus muscle, 1130
- Stylohyal part of styloid process, 145
- Stylohyoid ligament, 392
muscle, 392
nerve, from facial, 905
- Stylohyoideus muscle, 392
variations of, 392
- Styloid process of fibula, 260
of radius, 220
of temporal bone, 145, 181
of ulna, 218
- Stylomandibular ligament, 388
- Stylomastoid artery, 557
foramen, 144, 181
- Stylopharyngeus muscle, 1143
- Subanconeus muscle, 445
- Subarachnoid cavity, 876
cisternæ, 876
septum, 877
space, 876
- Subarcuate fossa, 143
- Subcallosal gyrus, 827, 869
- Subcardinal veins, 520
- Subclavian arteries, 575
first part of left, 577
of right, 576
second portion of, 577
surface anatomy of, 1290
marking of, 1303
third portion of, 577
- triangle, 394, 565
vein, 664
- Subclavius muscle, 438
variations, 438
- Subcostal arteries, 601
zone, 1148
- Subcostales muscles, 403
- Subcrureus or articularis genu muscle, 471
- Subcutaneous inguinal ring, 410
- Subdural cavity, 875
- Subepithelial plexus of cornea, 1009
- Subfrontal gyre, 822
- Sublingual lymph glands, 702
- Sublingual artery, 553
gland, 1136
- Sublobular veins, 1196
- Submaxillary artery, 555
duct, 1135
ganglion, 898
gland, 1135
lymph glands, 697
triangle, 392, 564
- Submental artery, 555
lymph glands, 697
triangle, 392
- Subnasal point, 198
- Suboccipital muscles, 401
triangle, 402, 578
- Subparietal sulcus, 823
- Subperitoneal connective tissue, 418
- Subpleural mediastinal plexus, 584
- Subpubic ligament, 310
- Subsartorial plexus, 956
- Subscapular angle, 203
artery, 588
- Subscapular fascia, 440
fossa, 202
nerves, 933
- Subscapularis muscle, 440
- Subserous areolar tissue, 1150
- Substantia adamantina*, 1120
alba, 758
eburnea, 1119
ferruginea, 800
gelatinosa centralis, 754
of Rolando, 753
nerve cells in, 758
grisea centralis, 753
innominate of Meynert, 837
nigra, 802
ossea, 1120
perforata anterior, 827
propria [cornea], 1007
- Subthalamie tegmental region, 812
- Suctorial pad, 384
- Sudoriferous glands, 1070
- Sulci and fissures of cerebral hemisphere, 819
development of, 747
of medulla oblongata, 767
spinalis, 752
- Suleus, anterior longitudinal, of heart, 527
antihelicis transversus, 1034
arteriæ vertebralis, 99
basilaris, 785
calcaneal, 263
central, 819
centralis [Roland], 819
cingulate, 820
cinguli, 820
circular, 821, 825
circularis, 821
corneæ, 1007
coronary, of heart, 526
frontal, 821
horizontal, of cerebellum, 789
intermedius [stomach], 1162
intraparietal, 822
lateral cerebral, 801
limitans [rhomboid fossa], 799
lunatus, 823 *note*
malleolar, 262
medial frontal, of Eberstaller, 822
median, of rhomboid fossa, 799
of tongue, 1125
medianus posterior, 752
of Monro, 741, 742, 816
occipital, 823
oculomotor, 801
olfactory, 822
orbital, 822
paramedial, 822
postcentral, 822
posterior longitudinal, of heart, 527
preauricular, of ilium, 234
precentral, 821
radial, 211
retroglangular, 1249
sagittalis, 131, 134, 136
sigmoid, 142
spirales, 1055
subparietal, 823
tal, 267
temporal, 824
terminal, of right atrium, 529
of tongue, 1125
tubæ auditivæ, 150, 181
tympenic, 145, 1037, 1039
valleculæ, 790
Supercilia, 1025
- Superciliary arches, 135, 178, 183
- Superficial antero-lateral fasciculus, 854
cervical artery, 582
lymph glands 697
muscle, 387

- Superficial cervical nerve, 927
 epigastric artery, 629
 external pudendal artery, 629
 pudic artery, 623
 iliac circumflex artery, 629
 long plantar ligament, 354
 palmar arch, 598
 perineal artery, 619
 peroneal nerve, 966, 968
 Sylvian vein, 652
 temporal artery, 558
 vein, 645
 transverse ligament of fingers,
 461
 perineal muscle, 427, 430
 volar artery, 594
 Superficialis volæ artery, 594
 Superfrontal gyre, 821
 Superior articular arteries, 633
 calcanocuboid ligament, 354
 cerbellar peduncles, 792
 constrictor muscle, 1143
 dental nerve, 890
 intercostal artery, 585
 lingualis muscle, 1130
 longitudinal sinus, 654
 maxillary nerve, 889
 medullary velum, 793
 nasal concha, 156
 nuchal line, 130
 oblique muscle, 1022
 orbital fissure, 151, 189
 petrosal sinus, 659
 profunda artery, 591
 sagittal sinus, 654
 semicircular canal, 1049
 tarsal plate, 1025
 thoracic artery, 587
 tibiofibular articulation, 348
 tympenic artery, 561
 vesical artery, 615
 vocal cords, 1079
 Supernumerary spleen, 1283
 Supinator brevis muscle, 454
 longus muscle, 451
 Supra-acromial nerves, 928
 Supporting cells of Hensen, 1058
 of Sertoli, 1243
 frame-work of retina, 1017
 Supracallosal gyrus, 827
 Supraclavicular branches of
 brachial plexus, 932
 nerves, 928
 Supraclavicularis muscle, 390
 Supracondylar process, 212 *note*
 ridges, 211
 Supracostalis muscle, 403
 Supraglenoid tuberosity, 207
 Suprahyoid aponeurosis, 392
 artery, 553
 lymph glands, 697
 muscles, 391
 triangle, 392, 565
 Supramarginal gyrus, 823
 Supramastoid crest, 139
 Suprameatal spine, 145, 183
 triangle, 140, 183
 Supraorbital artery, 569
 foramen, 136, 186, 189
 margin, 135
 nerve, 887
 notch, 136, 186, 189
 vein, 644
 Suprarenal arteries, 610, 612
 glands, 1278
 development of, 1278
 lymphatic vessels of, 711
 nerves of, 1280
 vessels of, 1280
 impression, 1191
 plexus, 987
 veins, 679
 Suprascapular artery, 582
 ligament, 317
 Suprascapular nerve, 932
 Supraspinal ligament, 290
 Supraspinatous fascia, 440
 fossa, 203
 Supraspinatus muscle, 440
 Supraspinous ligament, 290
 Suprasternal nerves, 298
 space, 389
 Supratonsillar fossa, 1138
 Supratrochlear foramen, 212
 nerve, 888
 Sural arteries, 633
 cutaneous nerve, medial, 962
 nerve, 963
 Surface anatomy and surface
 markings of abdomen, 1315
 accessory nerve, 1303
 acromioclavicular joint, 1328,
 1331
 adductor canal, 1343
 ankle-joint, 1338, 1343
 anterior tibial artery, 1341,
 1346
 aorta, abdominal 1313, 1321
 ascending, 1312
 aortic arch, 1312
 axillary artery, 1331, 1334
 nerve, 1336
 back, 1303
 bones of cranium, 1291
 of lower extremity, 1336
 of thorax, 1308
 of upper extremity, 1325
 brachial artery, 1331, 1335
 plexus, 1303, 1331
 brain, 1292
 Bryant's triangle, 1343
 calcaneus, 1337
 carpal bones, 1327
 caruncula lacrimalis, 1299
 cecum, 1319
 celiac artery, 1322
 cerebellum, 1292
 cerebral hemisphere, 1292
 cervical cutaneous nerve,
 1303
 clavicle, 1326
 colon, ascending, 1319
 descending, 1320
 iliac, 1320
 transverse, 1319
 common carotid artery, 1302
 iliac artery, 1322
 peroneal nerve, 1342, 1346
 deep peroneal nerve, 1346
 deltoideus muscle, 1329
 diaphragm, 1309
 dorsalis pedis artery, 1341,
 1346
 duodenum, 1319
 ear, 1300
 elbow-joint, 1331
 esophagus, 1311
 external carotid artery, 1302
 iliac artery, 1322
 maxillary artery, 1294
 eye, 1299
 facial nerve, 1303
 femoral artery, 1341, 1346
 triangle 1343
 femur, 1336
 fibula, 1337
 fissures of brain, 1293
 fold of groin, 1313
 frontal sinus, 1294
 gall-bladder, 1320
 gluteal arteries, 1343
 fold, 1336
 great auricular nerve, 1303
 head and neck, 1287
 heart, 1311
 coronary sulcus, 1311
 longitudinal sulcus, 1311
 orifices of, 1311
 Hesselbach's triangle, 1321
 Surface anatomy and surface
 markings of hip bones,
 1336
 hip-joint, 1338, 1343
 humeral circumflex artery,
 1335
 humerus, 1326
 hyoid bone, 1301
 ileocolic junction, 1319
 iliac arteries, 1322
 furrow, 1313
 inferior, epigastric artery,
 1321
 vena cava, 1312
 infrasternal notch, 1307
 inguinal rings and canal
 1315
 innominate artery, 1312
 veins, 1312
 internal mammary artery,
 1312
 pudendal artery, 1343
 intestines, 1319, 1320
 joints of fingers, 1328
 of foot, 1343
 jugular notch, 1307
 veins, 1303
 kidneys, 1320
 knee-joint, 1338
 lacrimal puncta, 1299
 sac, 1299
 larynx, 1299, 1301
 lateral plantar artery, 1346
 thoracic artery, 1334
 ventricle of brain, 1294
 latissimus dorsi, 1328, 1333
 left common carotid artery
 in thorax, 1312
 lesser occipital nerve, 1303
 linea semilunaris, 1313
 liver, 1314, 1320
 lower extremity, 1336
 lumbar triangle, 1313
 lungs, 1310
 mammary, 1308
 maxillary sinus, 1294
 medial plantar artery, 1346
 median nerve, 1335
 medulla spinalis, 1306
 mesenteric arteries, 1322
 metacarpal bones, 1327
 middle meningeal artery,
 1294
 mouth, 1296
 mucous sheaths around
 ankle, 1343
 of wrist and hand, 1334
 muscles of abdomen, 1315
 of arm, 1328
 of buttock, 1338
 of foot, 1340
 of forearm, 1329
 of head and neck, 1288,
 1289, 1301
 of hand, 1331
 of leg, 1340
 of thigh, 1338
 nasal part of pharynx, 1299
 nasolacrimal duct, 1299
 neck, 1301
 Nélaton's line, 1342
 nose, 1296
 palatine arches, 1297
 palmar or volar arches, 1335
 palpebral fissure, 1299
 pancreas, 1315, 1320
 parotid duct, 1295
 gland, 1295
 patella, 1337
 pectoralis muscles, 1328, 1333
 pelvis, 1336
 perineum, 1322
 peroneal artery, 1346
 nerves, 1346
 phalanges of foot, 1338

- Surface anatomy and surface markings of phalanges of hand, 1327
 phrenic nerve, 1303
 plantar arch, 1346
 arteries, 1346
 pleuræ, 1309
 plica semilunaris, 1299
 popliteal artery, 1341
 fossa, 1343
 posterior tibial artery, 1342, 1346
 profunda brachii artery, 1335
 femoris artery, 1346
 pupil, 1299
 radial artery, 1331, 1335
 nerve, 1336
 radioulnar joints, 1328
 radius, 1327
 rectum and anal canal, 1322
 Reid's base line, 1291
 renal arteries, 1322
 sacroiliac joint, 1343
 saphenous veins, 1346
 scapula, 1326
 scapular circumflex artery, 1335
 sciatic nerve, 1346
 serratus anterior muscle, 1328
 shoulder-joint, 1328
 spinal nerves, 1307
 spleen, 1320
 sternal angle, 1307, 1309
 sternoclavicular joint, 1328
 sternocleidomastoid muscle, 1289
 stomach, 1317
 striæ gravidarum or albicantes, 1313
 subclavian artery, 1303, 1331
 subdural and subarachnoid cavities, 1306
 submaxillary gland, 1303
 subscapular artery, 1334
 supraclavicular nerves, 1303
 superior vena cava, 1312
 talus, 1337
 tarsus and foot, 1337
 temporomandibular joint, 1288
 tendinous inscriptions of rectus abdominis, 1313
 thoracoacromial artery, 1334
 thorax, 1307
 tibia, 1337
 tibial nerve, 1346
 tongue, 1297
 tonsil, 1298
 trachea, 1301, 1311
 transverse sinus, 1294
 trapezius, 1332
 trigeminal nerve, 1295
 tympanic antrum, 1301
 membrane, 1300
 ulna, 1326
 ulnar artery, 1335
 collateral arteries, 1335
 nerve, 1331, 1335
 umbilicus, 1313, 1315
 upper extremity, 1325
 urogenital organs, female, 1323
 male, 1323
 vermiform process, 1319
 vertebral column, 1303
 volar or palmar arches, 1335
 wrist and hand, 1327
 wrist-joint, 1327, 1331
- Suspensory ligament of axilla, 436
 of eye, 1025
 of lens, 1018
 of ovary, 1254
 of penis, 1249
- Sustentacular fibers of Müller, 1017
- Sustentaculum lienis*, 1158
talii, 266
Sutura dentata, 284
harmonia, 284
limbosa, 284
notha, 284
serrata, 284
squamosa, 284
vera, 284
- Sutural bones, 156
 Suture, coronal, 178, 183
 frontal, 178
 frontoethmoidal, 190
 frontomaxillary, 189
 lambdoidal, 132, 135, 178, 183
 metopic, 135
 occipitomastoid, 183
 parietomastoid, 183
 petroöccipital, 193
 petrosquamous, 142, 145
 sagittal, 178
 sphenoethmoidal, 190
 sphenofrontal, 182, 190
 sphenoparietal, 182
 sphenopetrosal, 190
 sphenosquamosal, 182
 sphenozygomatic, 182
 squamous, 183
 zygomaticofrontal, 182
 zygomaticomaxillary, 189
 zygomaticotemporal, 182
- Sweat glands, 1070
 Sylvian fissure, 747
 fossa, 747
 veins, 652, 653
 Sylvius, aqueduct of, 766, 767, 806
 fissure of, 819
- Sympathetic fibers of spinal nerves, 920
 nerves, 968
 connections with spinal nerves, 976
 plexuses, 984, 985, 987
 system, cephalic portion of, 977
 cephalic portion of, 977
 cervical portion of, 978
 pelvic portion of, 984
 thoracic portion of, 981
 trunks, 976
- Symphysis of mandible, 127
ossium pubis, 310
 pubis, 310
sacrococcygea, 309
- Synarthroses, 286
 Synchondrosis, 284
 neurocentral, 112
- Syncytiotrophoblast, 47
 Syncytium, 47
 Syndesmology, 279
 Syndesmosis, 285
tibiofibularis, 348
- Synergic muscles, 362
 Synovia, 283
 Synovial membrane, 282. *See also* Individual Joints.
- Systemic circulation, 497
 veins, 641
- T**
- TABLES of the skull, 79
 Tactile corpuscles of Golgi and
 Mazzoni, 1061
 of Grandry, 1060
 of Pacini, 1060
 of Ruffini, 1061
 of Wagner and Meissner, 1061
 discrimination, fibers of, 854
- Tania pontis*, 785
semicircularis, 837, 869
thalami, 809
ventriculi quarti, 797
Taniæ coli, 1185
- Taniæ of fourth ventricle, 797
 of muscular coat of large intestine, 1177
- Talocalcaneal articulation, 352
 Talocalcaneonavicular articulation, 353
 Talotibial ligaments, 351
 Talus, 266
 ossification of, 275
- Tangential fibers of cerebral cortex, 846
 Tapetum of choroid, 1010
 of corpus callosum, 829
- Tarsal arteries, 637
 bones, 263
 glands, 1026
 plates, 1025
- Tarsi of eyelids, 1025
 Tarsometatarsal articulations, 358
- Tarsus, 263
 articulations of, 352
 inferior, 1025
 ossification of, 275
 superior, 1025
 surface markings of, 1343
 synovial membranes of, 358
- Taste fibers, 867
 nerves of, 992
 organ of, 991
- Taste-buds, 991
 Tectorial membrane of ductus cochlearis, 1058
- Tectospinal fasciculus, 871
- Teeth, 1112
 bicuspid, 1118
 canine, 1117
 cement or crusta petrosa of, 1120
 crown of, 1116, 1117
 cutting, 1115
 deciduous, 1118
 dental canaliculi of, 1119
 dentin of, 1119
 development of, 1121
 enamel of, 1120
 eruption of, 1124
 eye, 1117
 general characters of, 1114
 incisive, 1115
 incisors, 1115
 ivory of, 1119
 milk, 1118
 molar, 1118
 multicuspid, 1118
 necks of, 1114
 permanent, 1115
 successional, 1124
 superadded, 1124
 premolar, 1118
 pulp cavity of, 1118
 roots of, 1114
 stomach, 1117
 structure of, 1118
substantia adamantina of, 1120
 eburnea of, 1119
 ossea of, 1120
 temporary, 1118
 wisdom, 1118
- Tegmen tympani, 124, 1038
 Tegmental part of pons, 786
 Tegmentum, 802
Tela chorioidea [fourth ventricle], 798
 [third ventricle], 841
- Telencephalon, 743, 817
 Telophase of karyokinesis, 38
 Temperature, impulses of, 853
 Temporal arteries, 558, 561
 bone, 138
 articulations of, 147
 mastoid portion of, 141
 ossification of, 145
 petrous portion of, 142
 pyramid of, 142

- Temporal bone, squama of, 139
 structure of, 145
 tympanic part of, 145
 fascia, 385
 fossa, 183
 gyri, 824
 lines, 134, 136, 178, 183
 lobe, 823
 muscle, 386
 nerves of auriculotemporal, 895
 deep, 895
 of facial, 905
 operculum, 825
 process of zygomatic bone, 166
 veins, 645
 Temporalis muscle, 386
 Temporary teeth, 1118
 Temporomalar nerve, 889
 Temporomandibular articulation, 297
 surface anatomy of, 1288
 Temporomaxillary vein, 646
 Tendinous arch of pelvic fascia, 422
 inscriptions of rectus abdominis muscle, 416
 Tendo Achillis, 483
 calcaneus, 483
 oculi, 468
 Tendon, action of muscle pull on, 364
 central, of diaphragm, 406
 conjoined, of internal oblique and transversalis muscles, 414
 of conus arteriosus, 531
 superior, of Lockwood, 1022
 of Zinn, 1022
 Tendons, 376
 on back of wrist, relations of, 458
 Tendril fibers of cerebellum, 796
 Tenon, capsule of, 1037
 Tensor fasciæ lata muscles, actions of, 478
 nerves of, 478
 palati muscle, 1139
 tarsi muscle, 380
 tympani muscle, 1046
 semicanal for, 145, 1042
 veli palatini muscle, 1139
 Tenth nerve, 910
 Tentorial sinus, 655
 Tentorium cerebelli, 874
 Teres major muscle, 442
 minor muscle, 441
 variations of, 442
 Terminal crest of right atrium, 529
 sulcus of right atrium, 529
 vein, 653
 ventricle, 735, 754
 Testes, 1236, 1240
 appendages of, 1242
 coni vasculosi of, 1244
 coverings of, 1236
 descent of, 1210
 development of, 1210
 ductuli efferentes, 1244
 ductus deferens, 1245
 gubernaculum testis, 1211
 lobules of, 1243
 lymphatic capillaries of, 687
 vessels of, 713
 mediastinum testis, 1243
 rete testis, 1244
 structure of, 1243
 tubuli recti, 1244
 seminiferi, 1243
 tunica albuginea, 1242
 vaginalis, 1242
 vasculosa, 1242
 Thalamecephalon, 808
 Thalami, 742, 808
 connections of, 810
 development of, 742
 Thalami, intermediate mass of, 742, 743, 809
 stalks of, 811
 structure of, 810
 surfaces of, 808, 809
 Thalamic tract of cranial nerves, 805
 Thalamomammillary fasciculus, 839
 Thebesius, foramina of, 530
 valve of, 530, 642
 veins of, 643
 Thenar eminence, 456
 Thigh bone, 242
 fascia lata of, 468
 superficial, 468
 muscles of, 467
 Third cuneiform bone, 271
 metacarpal bone, 228
 metatarsal bone, 274
 nerve, 884
 trochanter, 246
 ventricle of brain, 815
 Thoracic aorta, 598
 peculiarities of, 599
 arteries, 587, 588
 axis, 588
 cardiac nerves, 912
 duct, 690
 nerves, divisions of, 923, 944
 portion of gangliated cord, 981
 vertebræ, 102
 Thoracoacromial artery, 588
 Thoracodorsal nerve, 934
 Thoracoepigastric vein, 670
 Thoracolumbar sympathetics, 974
 Thorax, 117
 boundaries of, 117
 cavity of, 524
 lymph glands of, 715
 lymphatic vessels of, 715, 716
 mechanism of, 304
 muscles of, 402
 openings of, 117, 118, 524
 parts passing through, 524
 skeleton of, 117
 surface anatomy of, 1307
 markings of, 1308
 Thromboplastin, 505
 Thumb, carpometacarpal articulation of, 330
 Thymus, 1273
 development of, 1273
 glands, 1273
 lymphatic capillaries in, 686
 vessels of, 719
 nerves of, 1275
 structure of, 1274
 vessels of, 1275
 Thyreoarytænoideus muscle, 1083
 Thyreohyoideus muscle, 394
 action of, 394
 nerves of, 394, 916
 Thyreoidæ ima artery, 549
 Thyroarytenoid ligaments, 1080
 muscle, 1083
 Thyrocervical trunk, 581
 Thyroepiglottic ligament, 1078
 muscle, 1083
 Thyroglossal duct, 1126
 Thyrohyals of hyoid bone, 178
 Thyrohyoid ligaments, 1077
 membrane, 1076
 muscle, 394
 Thyroid arteries, 552, 581
 axis, 581
 body, 1269
 cartilage, 1073
 foramen, 237
 gland, 1269
 development of, 1270
 isthmus of, 1270
 lobes of, 1269
 lymphatic capillaries in, 686
 Thyroid gland, lymphatic vessels of, 697
 nerves of, 1271
 pyramidal lobe of, 1270
 structure of, 1271
 vessels of, 1271
 notch, superior, 1073
 veins, 649, 666
 Thyroids, accessory, 1270
 Tibia, 256
 condyles of, 256
 ossification of, 260
 spine of, 256
 surface anatomy of, 1337
 tuberosity of, 256
 Tibial artery, anterior, 634
 branches of, 635
 peculiarities of, 635
 surface marking of, 1337
 posterior, 637
 branches of, 638
 peculiarities of, 638
 surface marking of, 1346
 recurrent, 635
 collateral ligament of knee-joint, 341
 nerve, 960
 anterior, 965
 surfaces of femur, 248
 veins, 672
 Tibialis anterior muscle, 480
 anticus muscle, 480
 posterior muscle, 485
 Tibiofacialis muscle, 480
 Tibiofibular articulation, 348
 ligament, middle, 348
 syndesmosis, 348
 Tibionavicular ligament, 350
 Tibiotarsal articulation, 349
 Tomes' fibers, 1119
 Tongue, 1125
 development of, 1102
 dorsum of, 1125
 frenulum of, 1125
 glands of, 1131
 lymph gland of, 696
 lymphatic vessels of, 696
 mucous membrane of, 1131
 muscles of, 1128
 actions of, 1131
 nerves of, 1132
 papillæ of, 1126
 septum of, 1132
 structure of, 1131
 vessels of, 1132
Tonsilla cerebelli, 791
Tonsillæ intestinales, 1176
 palatina, 1137
 Tonsillar artery, 555
 nerves from glossopharyngeal, 909
 sinus, 1138
 Tonsils, 1137
 lingual, 1131
 palatine, 1137
 development of, 1103
 lymphatic vessels of, 695
 nerves of, 1139
 structure of, 1139
 vessels of, 1139
 pharyngeal, 1142
 Torcular Herophili, 131, 658
 Torus of auditory tube, 1141
 uretericus, 1232
 uterinus, 1154
 Touch fibers, 854
Trabecula carnea, 532, 535
 crani, 84
 of penis, 1250
 of spleen, 1283
 of testis, 1243
 Trachea, 1084
 lymphatic capillaries in, 686
 nerves of, 1087
 relations of, 1084

- Trachea, structure of, 1086
vessels of, 1087
- Trachealis muscle, 1087
- Trachelomastoid muscle, 399
- Tracheobronchial glands, 717
- Trachoma glands, 1028
- Tract or Tracts, anterior basis
bundle, 760
of Burdach, 752, 763
central, of cranial nerves, 804
of trigeminal nerve, 805
cerebellar, of Flechsig, 761
comma, 764
dorsal peripheral band, 764
of Goll, 752, 762
of Gowers, 761, 754
lateral basis bundle, 762
of Lissauer, 762
olfactory, 826
optic, 814, 884
prepyramidal, 761
pyramidal, 759, 760
thalamic, of cranial nerves, 805
- Traction epiphyses, 95
- Tractus iliotibialis*, 468
- olfactomesencephalicus*, 867
- olfactorius*, 826
- peduncularis transversus*, 802
note
- spiralis foraminosus*, 143, 1050
- Tractus muscle, 1035
- Tragus, 1034
- Transpyloric plane, 1147
- Transversa colli artery, 582
- Transversalis cervicis muscle, 399
colli artery, 582
fascia, 418
muscle, 414
- Transverse acetabular ligament
of hip-joint, 336
- aorta, 547
- carpal ligament, 456
- cervical arteries, 582
nerve, 927
- colon, 1180
- crural ligament, 488
- facial artery, 558
vein, 645
- fibers of cerebral hemispheres,
841, 842
- fissure of brain, 842
of liver, 1191
- folds of rectum, 1183
- ligament of atlas, 293
- of fingers, 461
- humeral, 319
- of knee, 343
- metacarpal, 331
- metatarsal, 359
- of pelvis, 429
- ligaments of scapula, 317
- lingualis muscle, 1130
- mesocolon, 1157
- occipital sulcus, 823
- process of a vertebra, 96
- scapular artery, 582
- sinus, 660
of pericardium, 526
- temporal gyri, 824
- Transversus abdominis muscle,
414
variations of, 414
auriculæ muscle, 1035
linguæ muscle, 1130
menti muscle, 383
nuchæ muscle, 380
pedis muscle, 493
perinei muscle, 427
profundus muscle in female,
431
in male, 429
superficialis muscle, actions
of, 428, 430
in female, 430
in male, 427
- Transversus thoracis muscle, 403
- Trapezium, 225
- Trapezium muscle, 432
actions of, 435
nerves of, 434
variations of, 432
- Trapezoid, 225
body, 787
ligament, 315
nucleus, 787
ridge, 200
- Treves, bloodless fold of, 1160
- Triangle of auscultation, 434
Bryant's, 1343
carotid, 392, 394, 564
digastric, 564
femoral, 626
of Hesselbach, 1321
lumbar, 434
muscular, 394, 563
of neck, 562
occipital, 394, 565
of Petit, 434
Scarpa's, 626
subclavian, 394, 565
submaxillary, 392, 564
submental, 392
suboccipital, 402, 578
suprahyoid, 392, 565
suprameatal, 140, 183
- Triangular articular disk, 325
bone, 224
fascia of abdomen, 412
ligament, 428
of liver, 1150, 1151
- Triangularis muscle, 383
- sterni muscle, 403
- Triceps brachii muscle, 444
extensor cubiti muscle, 444
muscle, 444
suræ muscle, 483
- Tricuspid valve, 531
- Trifacial nerve, 886
- Trigeminal impression, 143
nerve, 886
central tract of, 805
composition and central con-
nections of, 862
reflexes, 899
surface marking of, 1295
- Trigone, olfactory, 827
- Trigonum collaterale*, 833
fenorale, 626
habenulæ, 812
hypoglossi, 799
olfactorium, 827
vagi, 781
vestiæ, 1231
- Trochanter, greater, 244
lesser, 245
third, 246
- Trochanteric fossa, 244
- Trochlea of humerus, 212
- Trochlear fovea, 137, 188
nerve, 885
composition and central con-
nections of, 863
process of calcaneus, 266
spine, 137
- Trochoid joint, 285
- Trolard, anastomotic vein of, 652
- Trörltsch, recess of, 1046
- Trophoblast, 46
- Truc nucleoli, 37
pelvis, 239
skin, 1065
vocal cords, 1080
- Truncus arteriosus*, 508, 514
costocervicalis, 585
sympathicus, 976
thyrocervicalis, 581
- Trunk, arteries of, 598
articulations of, 287
costocervical, 585
thyrocervical, 581
- Tuba auditiva*, 1042
uterina [Fallopia], 1257
- Tube, auditory, 1042
digestive, 1100
Eustachian, 1042
Fallopian, 1257
neural, 50
uterine, 1257
- Tuber cinereum*, 775
frontale, 135
omentale [liver], 1189
[pancreas], 1201
parietale, 133
valvule, 791
vermis [cerebellum], 791
- Tuberæ lobe, 791
- Tubercle, adductor, 246
articular, of temporal bone,
139, 180
auricular, of Darwin, 1033
conoid, 200
cuneate, 774
cuneiform, 1079
of epiglottis, 1076
of femur, 245
of humerus, 209
intervenous, 531
jugular, 131
lacrimal, 161
of Lower, 531
mental, 172
obturator, 273
peroneal, 266
pharyngeal, 132, 180
posterior, 99
pterygoid, 152
pubic, 236
of rib, 124
of Rolando, 775
scalene, 125
- Tuberculum acusticum*, 800, 906
impar, 1102
intervenosum, 531
majus [humeri], 209
minus [humeri], 209
sella, 147, 190
- Tuberosity, calcaneal, 266
coracoid, 200
costal, 202
of cuboid, 269
deltoid, 211
of fifth metatarsal bone, 274
gluteal, 246
iliac, 234
infraglenoid, 205
of ischium, 235
maxillary, 159
of navicular bone, 270
of palatine bone, 168
radial, 219
supraglenoid, 207
of tibia, 256
of ulna, 214
- Tubules, renal, 1223
- Tubuli lactiferi*, 1268
recti [testis], 1244
seminiferi, 1243
- Tunic, dartos, 1238
fibrous, of kidney, 1220
- Tunica adventitia*, 499
albuginea [ovary], 1256
[testis], 1242
conjunctiva bulbi, 1027
dartos, 1238
elastica externa, 499
fibrosa oculi, 1005
intima, 498
media, 498
serosa, 1149
vaginalis, 1242
*communis [testis et funiculi
spermatice]*, 1239
propria testis, 1242
vasculosa [testis], 1243

- Tunica vasculosa oculi*, 1009
 Tunics of eyeball, 1005
 Tunnel of Corti, 1057
 Turbinate bone, 169
 processes, sphenoidal, 152
 Turner, intraparietal sulcus of, 822
 Twelfth nerve, 914
 Tympanic antrum, 142
 artery, 560
 from ascending pharyngeal, 558
 from internal maxillary, 560
 canaliculus, inferior, 144, 181
 cavity, 1037
 arteries of, 1046
 attic or epitympanic recess of, 1038
 carotid or anterior wall of, 1042
 jugular wall or floor of, 1038
 labyrinthine or median wall of, 1040
 mastoid or posterior wall of, 1042
 membranous or lateral wall of, 1038
 mucous membrane of, 1046
 muscles of, 1046
 nerves of, 1046
 ossicles of, 1044
 tegmental wall or roof of, 1038
 vessels of, 1046
 lip, 1055
 membrane, 1039
 nerve (Jacobson's), 909, 1047
 plexus, 909, 1047
 ring, 146
 sulcus, 145, 1037, 1039
 Tympanohyal part of styloid process, 145
 Tympanomastoid fissure, 144, 181
 Tympanum, 1037
- U**
- ULNA, 214
 articulations of, 219
 coronoid process of, 214
 radial notch of, 215
 semilunar notch of, 215
 sigmoid cavities of, 215
 styloid process of, 218
 surface anatomy of, 1326
 Ulnar artery, 595
 surface marking of, 1335
 notch of radius, 220
 Ultimobranchial bodies, 1273
 Umbilical arteries in fetus, 61, 540
 cord, 57
 folds, 1231
 fossa of liver, 1191
 notch of liver, 1191
 veins, 61, 507, 519
 obliterated, 681, 1150
 zone, 1148, 1149
 Umbilicus, 417
 Umbo of membrana tympani, 1039
 Unciform bone, 227
 Uncinate fasciculus, 843
 Unconscious muscle sense, impulses of, 851
 Uncus, 826
 Ungual phalanges, 230, 275
Unques, 1066
 Urachus, 1213
 Ureter, 1225
 arteries of, 1227
 lymphatic vessels of, 712
 muscles of, 1233
 Ureter, nerves of, 1227
 orifices of, 1232
 Urethra, development of, 1215
 female, 1236
 male, 1234
 crest or verumontanum of, 1234
 lymphatic vessels of, 713
 muliebris, 1236
 virilis, 1234
 Urethral artery, 619
 bulb, 1235
 crest, in female, 1236
 in male, 1234
 glands, 1235
 orifices, 1232, 1235, 1266
 plate, 1215
 Urinary bladder, female, 1230
 lymphatic capillaries in, 687
 male, 1227
 meatus, 1266
 organs, 1215
 Urogenital apparatus, 1204
 diaphragm, 428
 fold, 1206
 organs, 1204
 ostium, primitive, 1215
 Urorectal septum, 1109
 Uterine artery, 615
 glands, 1262
 plexus of nerves, 989
 plexuses of veins, 676
 tube, 1257
 Uterosacral ligaments, 1260
 Uterus, 1258
 in adult, 1262
 after parturition, 1262
 cervix of, 1259
 development of, 1207
 during menstruation, 1262
 pregnancy, 1262
 in fetus, 1261
 form, size, and situation of, 1261
 fundus of, 1259
 interior of, 1260
 isthmus of, 1259
 ligaments of, 1260
 lymphatic capillaries of, 687
 vessels of, 714
 masculinus, or prostatic utricle, 1234, 1235
 nerves of, 1263
 in old age, 1262
 at puberty, 1261
 virgin state of, 1259
 Utricle, prostatic, 1234
 of vestibule, 1051
Utriculus, 1051
 Uvea, 1013
 Uvula of cerebellum, 791
 palatine, 1112
 vermis, 791
 vesica, 1232
 Uvular lobe, 791
- V**
- VAGINA, 1264
 lymphatic vessels of, 714
Vagina mucosa, 283
 Vaginal artery, 616
 bulb, 1266
 orifice, 1266
 plexus of nerves, 989
 plexuses of veins, 677
 process of temporal bone, 144, 145
 processes of sphenoid bone, 151
 Vagus nerve, 910
 composition and central connections of, 855
 sympathetic afferent fibers, 973
 efferent fibers of, 972
- Vallecula cerebelli*, 788
 Vallecule of tongue, 1075
 Vallum, 1126
 Valsalva, sinuses of, 533, 534
 Valve, bicuspid, 534
 colic, 1179
 of coronary sinus, 530, 642
 Eustachian, 530
 ileocecal, 1179
 of inferior vena cava, 530, 678
 mitral, 534
 pyloric, 1164
 Thebesian, 530, 642
 tricuspid, 531
 of Viussens, 793
 Valves, anal, 1184
 of heart, development of, 514
 of Houston, 1183
 of Kerkring, 1173
 of lymphatics, 687
 right and left venous, 510
 semilunar aortic, 534
 pulmonary, 532
 of veins, 501
Valvula bicuspidalis [metralis], 534
 coli, 1179
 sinus coronarii [Thebesii], 531
 tricuspidalis, 531
 venæ cavæ inferioris, 530
Valvula conniventes, 1173
 Vas aberrans of Haller, 1240
 deferens, 1245
 spirale, 1056
Vasa aberrantia [from brachial artery], 590
 brevia arteries, 606
 intestini tenuis arteries, 607
 vasorum [arteries], 499
 [veins], 502
 Vascular areas of yolk-sac, 505
 capsule of lens, 1003
 system, changes in, at birth, 542
 development of, 505
 peculiarities in fetus, 539
 Vasomotor nerve fibers, 728
 Vastus externus muscle, 470
 intermedius muscle, 471
 internus muscle, 471
 lateralis muscle, 470
 medialis muscle, 471
 Vater, ampulla of, 1199
 Vein or Veins, of abdomen, 672
 anastomotic, of Labbe, 652
 angular, 645
 auditory, 1059
 auricular, 646
 axillary, 663
 azygos, 667
 basal, 653
 basilic, 662
 median, 661
 basivertebral, 668
 brachial, 663
 brachiocephalic, 664
 of brain, 652
 bronchial, 697, 1100
 cardiac, 642, 643
 cardinal, 520
 cephalic, 661
 accessory, 662
 cerebellar, 653
 cerebral, 652, 653
 choroid, 653
 coats of, 501
 common facial, 645
 iliac, 677
 coronary, 642
 of stomach, 682
 of corpus striatum, 838
 cystic, 682
 deep cerebral, 653
 cervical, 651
 epigastric, 672
 facial, 645

- Vein or Veins, deep, of forearm, 663
 of hand, 663
 of lower extremity, 671
 of upper extremity, 663
 development of, 518
 digital, of foot, 669
 of hand, 660
 diploic, 651
 dorsal digital, 660
 metacarpal, 660, 663
 of penis, 676
 emissary, 660
 epigastric, 672
 extraspinal, 668
 facial, 645
 femoral, 672
 frontal, 644
 of Galen, 653
 gastroepiploic, 681
 gluteal, 673
 of hand, 660, 663
 of head and neck, 643
 of heart, 642
 hemiazygos, 667
 hemorrhoidal, 676, 681
 hepatic, 680
 histology of, 501
 hypogastric, 673
 iliac, 672, 673, 677, 678
 iliolumbar, 678
 inferior vena cava, 677
 innominate, 666
 intercapitular, 661, 669
 intercostal, highest, 666
 interlobular, of kidney, 1224
 of liver, 1196
 intervertebral, 669
 intralobular, of liver, 1197
 intraspinal, 668
 jugular, 646, 647, 648
 primitive, 520
 of Labbé, posterior anastomotic, 652
 labial, 645
 lateral sacral, 673
 of left atrium, 526
 lienal or splenic, 681
 lingual, 648
 of lower extremity, 669
 lumbar, 678
 ascending, 667
 mammary, internal, 666
 marginal, of foot, 669
 masseteric, 645
 maxillary, internal, 646
 median antibrachial, 662
 basilic, 661
 of medulla spinalis, 669
 mesenteric, 682
 metatarsal, 672
 nasofrontal, 659
 of neck, 646
 oblique, of left atrium [Marshall], 522, 526, 643
 obturator, 673
 occipital, 646
 ophthalmic, 658
 orbital, 645
 ovarian, 679
 palpebral, 645
 pancreatic, 681
 pancreaticoduodenal, 682
 parumbilical, 682
 of pelvis, 672
 penis, dorsal of, 676
 peroneal, 672
 pharyngeal, 649
 phrenic, inferior, 679
 superior, 666
 plantar, 671
 plexus of, basilar, 660
 hemorrhoidal, 676
 prostatic, 676
 pterygoid, 645
 pudendal, 676
- Vein or Veins, plexus of, uterine, 676
 vaginal, 677
 vertebral, 668
 vesical, 676
 vesicoprostatic, 676
 popliteal, 672
 portal, 680
 posterior of left ventricle, 643
 primitive jugular, 520
 profunda femoris, 672
 pubic, 673
 pudendal, internal, 674
 pudic, 674
 pulmonary, 642
 pyloric, 682
 ranine, 648
 renal, 679, 1224
 sacral, 673, 677
 saphenous, 670
 sciatic, 674
 short gastric, 681
 spermatic, 678
 of spinal cord, 669
 splenic or lienal, 681
 striate, inferior, 653
 structure of, 501
 subcardinal, 520
 subclavian, 664
 sublobular, of liver, 1197
 superficial, 641
 of lower extremity, 669
 of upper extremity, 660
 superior cerebral, 652
 mesenteric, 682
 phrenic, 666
 vena cava, 666
 supraorbital, 645
 suprarenal, 679
 Sylvian, 652, 653
 systemic, 642
 temporal, 645
 temporomaxillary, 646
 terminal, 653
 of Thebesius, 643
 thoracoepigastric, 670
 of thorax, 664
 thyroid, inferior, 666
 middle, 649
 superior, 649
 tibial, 672
 transverse facial, 645
 Trolard, great anastomotic of, 652
 umbilical, 62, 507
 obliterated, 681, 1150
 of upper extremity, 660
 valves of, 501
 vena azygos major, 667
 minor, 667
 cava, inferior, 667
 superior, 666
 vertebral, 651
 of vertebral column, 667
 visceral, 518
 vitelline, 506, 518
 volar, 661, 663
- Velamentous insertion of umbilical cord, 65
- Velum interpositum*, 841
medullaræ, 793, 794
medullary, 793, 794, 797
palatine, 1112
- Vena angularis*, 645
anonyma dextra, 664
sinistra, 666
auricularis posterior, 646
axillaris, 663
azygos, 667
basilica, 662
cava inferior, 677
superior, 666
 surface marking of, 1312
 caval foramen in diaphragm, 406
cephalica accessoria, 662
- Vena cerebri magna*, 653
media, 652
cervicalis profunda, 651
circumflexa alium profunda, 673
cordis, 642, 643
coronaria ventriculi, 682
corporis striata, 653
cystica, 682
epigastrica inferior, 672
facialis anterior, 645
posterior, 646
femoralis, 672
frontalis, 644
gastroepiploica, 681, 682
hemorrhoidalis media, 676
hemiazygos, 677
accessoria, 677
hypogastrica, 673
iliaca externa, 672
jugularis anterior, 647
externa, 646
interna, 648
posterior, 647
linealis, 681
magna [Galen], 653, 842
maxillaris interna, 646
mediana antibrachii, 662
cubiti, 661
mesenterica inferior, 681
superior, 682
obliqua atriis sinistri [Marshall], 643
obturatoria, 676
occipitalis, 646
ophthalmica, 659
poplitea, 672
portæ, 681
posterior ventriculi sinistri, 643
profunda femoris, 672
saphena magna, 669
parva, 670
subclavia, 664
supraorbitalis, 645
temporalis superficialis, 645
terminalis, 653
thyreoidea superioris, 649
vertebralis, 649
- Vena advehentes*, 519
anonymæ, 664
basivertebrales, 668
brachiales, 663
bronchiales, 667
cerebelli, 653
cerebri, 652, 653
comitantes, 641
cordis, 642
minimæ, 530
digitales plantares, 671
diploicæ, 651
dorsales penis, 676
 Galeni, 842
gastricæ breves, 681
gluteæ, 674
hepaticæ, 680
iliacæ communes, 677
intercostales suprema, 666
intervertebrales, 669
linguales, 648
lumbales, 678
mammariæ internæ, 666
ovariæ, 679
pancreaticæ, 681
pancreaticoduodenales, 682
parumbilicales, 682
pharyngææ, 649
phrenicæ inferiores, 679
propriæ renales, 1225
pulmonales, 642
rectæ [kidney], 1224
renales, 679
revehentes, 519
sacrales, 676, 677
spermaticæ, 678
spinales, 669
stellatæ [kidney], 1224

- Vena suprarenales*, 669
thyreoidæ inferiores, 666
tibiales, 672
vorticosa, 1010, 1021
 Venous arches, 669
 lacunæ of dura mater, 655
 mesocardium, 526
 plexus, hemorrhoidal, 676
 ovarian, 679, 1256
 pampiniform, 678, 1240, 1256
 pharyngeal, 649
 pterygoid, 645
 pudendal, 676
 spermatic, 678, 1240
 uterine, 676
 vaginal, 677
 vesical, 676
 sinuses, 641
 of dura mater, 654
 development of, 522
 valves, right and left, 510
 Ventral cochlear nucleus, 788
 fissure of medulla oblongata, 767
 lamina, 735
 longitudinal bundle, 803
 mesogastrium, 1103
 psalterium, 869
 pulmonary nerves, 193
 spinal artery, 579
 spinothalamic fasciculus, 854
 Ventricle of fornix, 838
 of mid-brain, 806
 terminal, of medulla spinalis, 754
 of Verga, 838
 Ventricles of brain, 797, 798, 815, 829
 of heart, 508, 531, 534
 of larynx, 1080
 Ventricular folds of larynx, 1079
 ligament of larynx, 1080
 septum, 512, 534
 Ventricularis muscle, 1083
Ventriculus, 1161
 dexter, 531
 laryngis [Morgagni], 1080
 lateralis, 829
 quartus, 797
 tertius, 815
 Ventromedian fissure of medulla oblongata, 767
 Verga, ventricle of, 838
 Vermian fossa, 131
 Vermiform process or appendix, 1178
 Vermis of cerebellum, 788, 790
 Vertebra prominens, 101
 Vertebrae, 96
 cervical, 97
 coccygeal, 106
 ligaments of, 287-291
 lumbar, 104
 sacral, 106
 thoracic, 102
 Vertebral arch, 96
 arches, articulations of, 289
 artery, 578
 canal, 116
 column, 96, 114
 articulations of, 287
 surface form of, 1305
 veins of, 667
 foramen, 96
 groove, 115
 notches, 97
 part of base of skull, 84
 ribs, 123
 veins, 651
 venous plexuses, 668
 Vertical index of skull, 198
 lingualis muscle, 1131
 part of palatine bone, 167
 Verticalis linguæ muscle, 1131
 Verumontanum, 1234
Vesica fellea, 1197
 urinaria, 1227
 Vesical artery, 615
 layer of pelvic fascia, 422
 plexus of nerves, 988
 of veins, 676
 Vesicle, auditory, 1030
 blastodermic, 46
 germinal, 39
 lens, 1001
 optic, 742, 1001
 Vesicoprostatic plexus of veins, 676
 Vesicouterine excavation, 1152
Vesiculæ seminales, 1246
 Vesicular ovarian follicles, 1256
 Vestibular arteries, 1059
 bulb, 1266
 fissure, 1051
 ganglion, 1058
 glands, greater, 1266
 lip, 1055
 membrane, 1054
 nerve, 906, 1058
 composition and central connections of, 860
 nuclei of, 788
 Vestibule, aortic, 534
 of internal ear, 1047
 of larynx, 1078
 of mouth, 1110
 of nasal cavity, 994
 of omental bursa, 1156
 of vagina, 1266
 Vestibulospinal fasciculus, 803, 872
 tract, 760
Vestibulum, 1047
 oris, 1110
 raginæ, 1266
 Vestigial fold of Marshall, 643
 of pericardium, 526
 Vicq d'Azyr, bundle of, 810, 813, 839, 869
 Vidian artery, 562, 568
 nerve, 892
 Vieussens, valve of, 793
 Villi, arachnoid, 878
 of chorion, 60
 of intestine, 1174
 Visceral arches, 65
 veins, 518
 Visual area of cortex, 847
 centres, 814
 purple, 1015
 Visuopsychic, area, 847
 Visuosensory area, 847
 Vitelline circulation, 54, 507
 duct, 1103
 fluid, 54
 membrane, 45
 veins, 506, 518
 Vitreous body of eye, 1018
 table of skull, 79
 Vocal cords, 1079, 1080
 folds, 1080
 process of arytenoid cartilage, 1075
 Vocalis muscle, 1083
 Voice, organs of, 1072
 Volar arches, 595, 598
 surface markings of, 1335
 branch of ulnar nerve, 942
 carpal artery, 594
 ligament, 456
 net-work, 594
 digital arteries, 598
 nerves, 938
 interosseous artery, 596
 nerve, 938
 metacarpal arteries, 595
 veins, 663
 venous arches, 663
 Volaris indicis radialis artery, 595
 Vomer, 170
 Vomeronasal cartilage, 996
 organs, 71, 996
 Vulva, 1264

W

 WAGNER and Meissner, corpuscles of, 1061
 Waldeyer, germinal epithelium of, 1029
 odontoblasts of, 1118
 zona vasculosa of, 1256
 Wallenburg, basal olfactory bundle of, 867
 Wallerian degeneration, 759
 Wandering cells, 377
 Wharton, duct of, 1135
 jelly of, 58
 Willis, circle of, 574
 Windpipe, 1084
 Winslow, foramen of, 603, 1106, 1156
 Wirsung, duct of, 1202
 Wisdom teeth, 1118
 Wolffian body, 1205
 duct, 1205
 tubules, 1205
 Womb, 1258
 Wormian bones, 156
 Wrisberg, cardiac ganglion of, 984
 cartilages of, 1075
 ligament of, 343
 nerve of, 937
 nervus intermedius of, 901
 Wrist-joint, 327
 surface anatomy of, 1331

X


 XIPHOID appendix, 121
 process, 121

Y

 Y-SHAPED cartilage of acetabulum, 237
 ligament of Bigelow, 335
 Yolk, formative, 39
 nutritive, 39
 Yolk-sac, 54
 Yolk-stalk, 1103

Z

 ZIGZAG tubule, 1223
 Zinn, ligament or tendon of, 1022
 zonule of, 1018
 Zones of abdomen, 1148, 1149
Zonula ciliaris, 1018
 Zonule of Zinn, 1018
 Zygomatic arch, 183
 bone, 164
 branch of facial nerve, 905
 nerve, 889
 process of frontal bone, 136
 of maxilla, 161
 of temporal bone, 139
 Zygomaticofacial foramen, 164, 187
 nerve, 889
 Zygomaticofrontal suture, 182
 Zygomaticoörbital foramina, 165
 Zygomaticotemporal foramen, 164, 183
 nerve, 989, 890
 suture, 182
 Zygomaticus muscle, 383



**THIS BOOK IS DUE ON THE LAST DATE
STAMPED BELOW**

Books not returned on time are subject to a fine of 50c per volume after the third day overdue, increasing to \$1.00 per volume after the sixth day. Books not in demand may be renewed if application is made before expiration of loan period.

AUG 23 1938

SEP 24 1939

FEB 2 - 1939

MAR 28 1939

OCT 6 1939

NOV 14 1939

JUL 20 1940

FEB 27 1941

DEC 7 - 1942

DEC 21 1942

14 DAY

APR 5 1961

APR 1 1961

14 DAY

RETURNED
OCT 25 1967

OCT 25 1967

half of 50 cents
...

