




Presented by  
the Author.



22102101872

Med

K32237

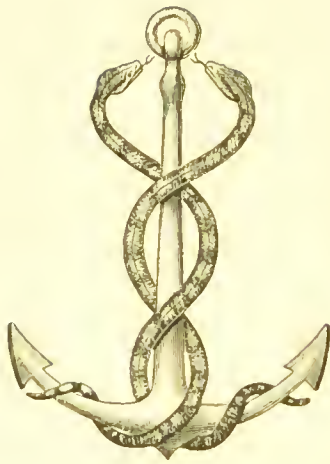


Digitized by the Internet Archive  
in 2016

<https://archive.org/details/b28067149>

HERNIA, HYDROCELE, AND  
VARICOCELE.





NUNQUAM ALIUD NATURA, ALIUD SAPIENTIA DIGIT.

THE RADICAL CURE OF  
HERNIA, HYDROCELE,  
AND  
VARICOCELE.

BY

CHARLES BARRETT LOCKWOOD, F.R.C.S.,

ASSISTANT SURGEON AND LECTURER UPON SURGICAL AND DESCRIPTIVE  
ANATOMY, ST. BARTHOLOMEW'S HOSPITAL; SURGEON TO THE  
GREAT NORTHERN CENTRAL HOSPITAL, LONDON.

*WITH ILLUSTRATIONS.*

EDINBURGH & LONDON:  
YOUNG J. PENTLAND.

1898.

EDINBURGH: PRINTED FOR YOUNG J. PENTLAND, 11 TEVIOT PLACE, AND  
38 WEST SMITHFIELD, LONDON, E.C., BY MORRISON AND GIBB LIMITED.

14785570

WELLCOME INSTITUTE LIBRARY	
Coll.	wel10mec
Call No.	
	W1

B1



## PREFACE.



It is now unnecessary to defend the operation for the radical cure of hernia. That operation is, perhaps, performed more often than any other. Nevertheless, surgeons are still in doubt as to which of the various methods is the best. This question can only be decided by the results of those who have performed many operations of the kind. I have endeavoured to record my experience in these pages. The closely allied operations for the radical cure of hydrocele and varicocele are added, and, I trust, with sufficient reason. Should this endeavour meet with approval, it is my intention to continue with other abdominal operations.

C. B. LOCKWOOD.

19 UPPER BERKELEY STREET,  
PORTMAN SQUARE, W.,  
*October 1898.*



# CONTENTS.



PAGE

## CHAPTER I.

Introductory . . . . . 1

## CHAPTER II.

Radical Cure of Inguinal Hernia . . . . . 37

## CHAPTER III.

Radical Cure of Inguinal Hernia—the Operation . . . . . 56

## CHAPTER IV.

Contents of the Sac—Malpositions of the Testicles—Hernia of  
the Ovary and Fallopian Tube—Congenital Hydrocele . . . . . 79

## CHAPTER V.

Separation of the Sac—Peculiarities of the Sac—Hernia of the  
Bladder . . . . . 100

## CHAPTER VI.

Contents of the Inguinal Canal—Lipoma of the Cord—Inguinal  
Varix . . . . . 110

	PAGE
CHAPTER VII.	
Ligature and Transplantation of the Stump of the Sae—Restoration and Closure of the Inguinal Canal . . . . .	123
CHAPTER VIII.	
Inguinal Hernia in Females . . . . .	139
CHAPTER IX.	
The Dressing—After-Treatment—Complications—Immediate Results . . . . .	144
CHAPTER X.	
Ultimate Results of the Operation for the Radical Cure of Non-Strangulated Inguinal Hernia . . . . .	160
CHAPTER XI.	
Radical Cure of Femoral Hernia . . . . .	176
CHAPTER XII.	
Radical Cure of Ventral Hernia, Congenital and Acquired—Traumatic Ventral Hernia . . . . .	207
CHAPTER XIII.	
Radical Cure of Umbilical Hernia . . . . .	221
CHAPTER XIV.	
Radical Cure of Hydrocele . . . . .	234
CHAPTER XV.	
Radical Cure of Varicocele—Exploration of the Inguinal Canal .	259

## LIST OF ILLUSTRATIONS.



FIG.	PAGE
1. Acquired hernia . . . . .	25
2. Blunt-pointed herniotomy needle . . . . .	42
3. Outside dressing for inguinal or femoral hernia . . . . .	49
4. Outside dressing for double radical cure of inguinal or femoral hernia . . . . .	50
5. Skin incisions for radical cure of femoral and inguinal herniæ . . . . .	61
6. Polypoid bodies pendent from wall of sac . . . . .	65
7. Relation of polypoid bodies to wall of sac . . . . .	65
8. Method of securing the omentum with interlocking sutures . . . . .	69
9. Testicle retained within the abdomen . . . . .	83
10. Section of undescended testicle . . . . .	84
11. Hernia of ovary and Fallopian tube, with torsion of the pedicle . . . . .	96
12. Varieties of infantile hernia . . . . .	106
13. Mode of applying a Staffordshire knot to the stump of the sac . . . . .	124
14. A normal inguinal canal . . . . .	129
15. Inguinal canal in case of hernia . . . . .	130
16. Method of inserting deep sutures . . . . .	133
17. Cooper's ligament . . . . .	188

FIG.	PAGE
18. Mode of suturing the femoral canal . . . . .	193
19. Closure of femoral canal completed . . . . .	194
20. Method of applying sutures in the radical cure of ventral and umbilical herniæ . . . . .	209
21. The separation of the recti and stretching of the linea alba in acquired umbilical hernia . . . . .	225
22. Showing how much of the parietal part of the tunica vaginalis is removed . . . . .	248
23. The mode of dressing scrotal wounds . . . . .	249

HERNIA, HYDROCELE, AND  
VARICOCELE.





# HERNIA, HYDROCELE, AND VARICOCELE.



## CHAPTER I.

### INTRODUCTORY.

THE success of operations for the radical cure of hernia depends so much upon the selection of cases, that I propose to begin by stating the principles by which I have been guided. It will be found that the cases are divisible into congenital, traumatic, and acquired. Nearly all of my operations have been done upon the congenital and traumatic. The acquired have only been attempted for special reasons. A brief reference to the differences betwixt congenital and acquired hernia shows the reason for this discrimination. Many of the following facts were given in the Hunterian Lectures, which I delivered in 1889 before the Royal College of Surgeons of

England.<sup>1</sup> Since then other opportunities have occurred of investigating the morbid anatomy and pathology of hernia, and these have confirmed the views I then expressed. A more extensive clinical experience has also helped to establish the earlier investigations.

In this brief account of the causation of hernia, I propose to consider, first, the condition of the abdominal wall; second, the condition of the abdominal contents; and, third, the physiological relation of these to one another, during respiration and exertion. It is hardly necessary to dwell upon the importance of a correct knowledge of each of these points. As I proceed, it will be seen that in some types of hernia the abdominal wall is healthy and well suited for reparative operations, whilst in others its tissues are degenerate and relaxed. Further, in some types of hernia, the abdominal contents are healthy and normally situated, but in others they are prolapsed, and calculated by their pressure to overcome the most elaborate operation upon the abdominal wall.

#### CONGENITAL HERNIA.

*The abdominal wall.*—In congenital hernia of young

<sup>1</sup> Hunterian Lectures, "On the Morbid Anatomy, Pathology, and Treatment of Hernia," London, 1889.

adults, the tissues of the abdominal wall are healthy. The skin is supple, with but little subcutaneous fat. The lineæ semilunares and the digitations of such muscles as the serratus magnus and external oblique are quite distinct. The hypogastric fossæ do not bulge. Generally speaking, the abdomen is flat. The muscles feel hard and elastic, and resist pressure; or, in other words, their tone is good. Their movements are rapid and forcible. When an incision is made, the subcutaneous fat is firm and free from oiliness; the aponeurosis of the external oblique muscle is white, glistening, and on the stretch, so that its fibres spring together again when pulled apart. The muscular fibres of the internal oblique and transversalis are firm, red, and well developed, and not infiltrated with fat; the hernial apertures are small and tight; the inguinal canal is long and narrow, and when the patient coughs or vomits it closes and forcibly ejects the finger; and, last, the peritoneum is tough and elastic, and does not bulge. The hernial sac is long and narrow, and very closely adherent to the spermatic cord; its mouth is small and tight, and flush with the rest of the peritoneum. Its walls are usually thick and opaque. The hypogastric fossæ do not bulge, and are not like funnels leading into the mouth of the sac. In fact, in congenital hernia,

although the fault is in the abdominal wall, nevertheless it is local and purely developmental, and consists in the non-closure of the processus vaginalis. Presently it will be seen that no fault whatever can be found in the abdominal viscera or their suspensory apparatus. The gap in the abdominal wall is comparable to a hare-lip or branchial fistula, and is just as compatible with perfect general health. The congenital defect is frequently associated with others, especially with malpositions of the testicles.

*The abdominal contents—The mesentery—Its length.*  
—For many years surgeons thought that all herniæ were caused by an elongation of the mesentery. This erroneous supposition did much to retard the operation. Obviously, if hernia originated in elongation of the mesentery, an operation on the abdominal wall would not remove the cause of the disease.

The average length of the mesentery, including the width of the bowel, is 8 in.<sup>1</sup> But most extraordinary variations occur. In three individuals, æt. 40 years, it was 5, 7, and 10 in. long. Compared with the height of the individual, it is longest in infancy, and in those who have protuberant abdomens. For in-

<sup>1</sup> This refers to one hundred measurements. Twelve additional measurements gave an average length of 8½ in. Most of the subjects were over 40.

stance, a very stout woman with a protuberant abdomen, but no ruptures, had a mesentery 11 in. long. In five cases of congenital hernia, the mesentery measured 3 in., 6 in.,  $6\frac{1}{2}$  in.,  $7\frac{1}{2}$  in., and  $8\frac{3}{4}$  in. in length. In fact, they were rather below the average.

*The height of the mesentery in congenital hernia—*  
*The suspension of the mesentery.*—It is obvious that the height at which the mesentery is attached to the vertebral column has to be considered as well as its length. The mesentery of a young and healthy person has such strong attachments at its root, that it cannot be dragged downwards. It is fixed by a firm fibro-muscular band, which springs mainly from the right crus of the diaphragm. This muscle is inserted, as Treitz has shown, into the flexura duodeno-jejunalis. But, in addition, I have traced its fibres into the mesentery, where they spread out with the branches of the superior mesenteric artery. Thus it is in reality the suspensory muscle of the duodenum and mesentery.

The suspensory muscle is far stronger than is needed to support the weight of the intestines and mesentery, which, together with the contents of the former, is only 26 oz. Its chief function is to resist the downward displacement of the intestines during the descent

of the diaphragm, and probably to assist the abdominal muscles in restoring their position during expiration. The other attachments of the mesentery are not of such importance. When they are absent, owing to developmental arrest, the root is still properly suspended.

The highest part of the mesentery—measured to the top of the flexura duodeno-jejunalis—is from 3 to 4 in. above a base line drawn across the body at the level of the top of the iliac crests. After 40 years of age it tends to be lower. In congenital hernia the mesentery is fixed by a strong suspensory muscle at its proper height. In five cases it was 4,  $4\frac{1}{2}$ , 4, 4, and  $3\frac{1}{2}$  in. above the base line.

*The excursion of the intestines.*—The range of movement of the intestines depends upon the length of the mesentery, and upon the height of its attachment. The ileum is the most displaceable part of the intestines. The crural arches and spines and crests of the pubic bones are used as landmarks to judge how far the intestines can be displaced. It is usual in those without hernial sacs, or without bulgings of the hypogastric fossa, to find that the ileum passes  $1\frac{1}{2}$  in. beyond the right crural arch, 1 in. beyond the spines of the pubic bones, and that it just touches the left crural arch. The long mesentery of infancy and

childhood permits a relatively greater excursion of the intestines. In twelve out of a hundred measurements of normal subjects, the mesentery was so short and was attached so high that the ileum just touched the lower abdominal walls, and could not be drawn from the abdomen without stretching or displacing the mesentery. The youngest of these was 14 years old, the oldest was 75. Doubtless this is the ideal type. It is found in healthy, vigorous adults with flat abdomens, and in spare, active people in extreme age. But even in this class I have often seen the intestine strangulated in the mouth of the processus vaginalis.

The average excursion of the small intestines may be exceeded without any bulging of the hypogastric fossæ, or without the formation of hernial sacs. In 11 per cent. of my measurements of those without herniæ or bulgings, the ileum reached 3 in. beyond the right crural arch.

We have seen that in congenital hernia the mesentery is not elongated, and also that it is held at the right height. We shall now find that the excursion of the intestines is not increased in congenital hernia. In an infant 10 weeks old, with a congenital hernia, the ileum reached 1 in. beyond the right crural arch, and touched the spine of the pubes. In a youth of

18, the ileum reached, but could not be pulled beyond, the right erural arch. The sigmoid flexure, however, had a long mesentery, and could be drawn  $1\frac{1}{2}$  in. beyond the left erural arch, and into a congenital sac which he happened to have upon the same side. This illustrates very well how impossible it is to find anyone in whom a hernia could not occur. Presently the mobility of the cæcum and of the omentum will be considered. A young man, æt. 24, died of strangulated hernia. Although the ileum just touched the crural arches and back of the pubic bone, nevertheless it had become strangulated in the mouth of an open proecessus vaginalis. In another man of the same age, who also died of a strangulated inguinal hernia, the ileum could be drawn  $1\frac{1}{2}$  in. beyond the right crural arch, as far as the pubic crest, and as far as the left erural arch. It easily passed into a congenital hernial sac of the right side, in which it had been so tightly strangulated that it gangrened. In a man, æt. 28, with a funicular hernia, the ileum passed 2 in. beyond the right erural arch, 1 in. beyond the pubic spine, and 2 in. beyond the left erural arch. The cæcum was very movable, and lay in the pelvis. It went 2 in. beyond the right crural arch, and touched the spine of the pubes. Finally, in a man, æt. 31, the ileum passed 2 in. beyond the right erural arch,



1 in. beyond the spine of the pubes, and the jejunum just touched the left pubic spine.

Thus every case of congenital hernia which has hitherto been measured had a mesentery of the usual length and height, and intestines with the usual excursion or range of movement.

*The great omentum and other viscera.*—The great omentum is the commonest of the contents of hernial sacs. Whilst operating upon inguinal and femoral herniæ, I found it forty-nine times in 155 cases, of which I have an explicit note. Intestine was only found twenty times, and nearly always in strangulated ruptures. In non-strangulated, it usually slips back when the patient lies down. The omentum, on the other hand, is often adherent, especially in femoral ruptures. Eighty-three out of the 155 sacs were empty. Three contained fluid. Three of the ommental herniæ also contained fluid. Although it is generally supposed that epiploecæ are more often met with on the left side, the proportion in these cases was almost the same. It was found in thirty-one out of ninety-six right inguinal or femoral sacs, and in eighteen out of fifty-nine left.

These figures include operations upon both congenital and acquired ruptures. But it is obvious that the sac of a congenital hernia is not caused by

the omentum. The latter might possibly be caught in the mouth of the processus vaginalis and prevent its closure; but in infancy the great omentum is so short and rudimentary, that this is quite unlikely to happen. In adults, it is exceptional to find a great omentum which could not enter the mouth of an inguinal or femoral sac.

The distance to which the great omentum can descend depends both upon its own length and upon the length of the transverse mesocolon. The transverse mesocolon resembles the mesentery. In infancy and childhood it is relatively long, in youth and early manhood it is short, and then becomes longer.<sup>1</sup>

The length of the great omentum is very variable at all ages. Together with the transverse mesocolon, it measured 7 in. in a child *æt.* 2 years,  $14\frac{1}{2}$  in a youth of 21, and 8 in. in an octogenarian. The average combined length of the great omentum and transverse mesocolon in twenty-three subjects, *æt.* from 2 to 80 years, was  $10\frac{1}{4}$  in.

The cæcum and sigmoid flexure are seldom found in hernial sacs. When either of them is present in a congenital sac, there is usually a peritoneal fold

<sup>1</sup> In seven subjects, *æt.* from 4 weeks to 16 years, its average length was  $4\frac{7}{8}$  in.; in twelve, *æt.* from 4 weeks to 28 years, it was 6 in.; in sixteen, *æt.* from 31 to 50, it was 7 in.; and nine, *æt.* from 54 to 80, it was almost  $7\frac{1}{2}$  in.

which I named the *plica vascularis*,<sup>1</sup> uniting the bowel to the testis. This fold contains the spermatic vessels and upper part of the gubernaculum. As the testis passes into the scrotum, it occasionally pulls the bowel after it by means of the *plica*. Sometimes the cæcum and ascending colon retain their primitive mesentery, and are quite free and movable within the abdomen. A floating cæcum of this kind may find its way into an inguinal or femoral hernia of the left side.

The sigmoid flexure is, as I have just said, rare in hernial sacs. Its mesentery and attachments are too variable for it to be a constant factor in causing hernia. The positions and attachments of the other abdominal viscera are also normal in congenital hernia. The pylorus lies at its proper height under the right eighth costal cartilage. The kidneys are firmly fixed in the lumbar region, and do not descend too far beyond the last rib. Their suspensory ligaments are firm and not elongated. Presently we shall see how different all these are in acquired hernia.

The clinical history of congenital hernia often shows that it is caused by a developmental defect and not by any pathological change in the abdominal wall or mesentery. Whilst operating on children and youths

<sup>1</sup> "The Morbid Anatomy and Pathology of Encysted and Infantile Hernia," *Med.-Chir. Trans.*, London, 1836, vol. xlix. p. 479 *et seq.*

for radical cure, it is the rule to find evidences of the developmental origin of the rupture. Femoral ruptures, which are acquired, are so rare in children that I have only operated upon two. Both occurred in boys,<sup>1</sup> and as they had had them for some years, they were, as a matter of fact, probably of developmental origin. The following is a common history:—

A. B., æt. 28, had had no sign of rupture until ten days before the operation for radical cure was done. Whilst he was lifting a heavy weight, a rupture suddenly appeared on the right side, and became acutely strangulated. It was reduced by taxis with much difficulty. At the operation for radical cure, it was found that the tunica vaginalis communicated with the abdomen by a long, narrow canal with rather thick walls. Since I have explored the inguinal canal more freely, peritoneal sacs have often been found where there has been no history of the descent of bowel or omentum.

The interpretation of such cases as this is clear. Obviously the mesentery had neither grown long suddenly, nor slipped down the spine. As a matter of fact, the processus vaginalis had always been open and ready for the bowel or omentum to enter.

<sup>1</sup> I have also operated for radical cure of femoral hernia upon a young man, æt. 22.

Why they did not do so at an earlier age is quite unknown. The measurements which I have given in my lectures show that their range of movement would always permit their entrance. Perhaps the valvular arrangement of the mouth of the open process is the safeguard.

Cases of congenital hernia possess other characteristic features. In most the long and narrow hernial sac, when full of bowel or omentum, can be seen to extend upwards and outwards along the inguinal canal, which has preserved its obliquity. In such a case, the finger may enter the inguinal canal, but cannot pass beyond it into the abdomen. This is only possible when the hernia has been neglected, and allowed to distend the inguinal canal, and displace its posterior wall. The spermatic cord is always closely adherent to the sac of a congenital hernia. Indeed, this close adhesion is one of the difficulties of the operation. Sometimes when the hernia is a true congenital one, and not funicular, its contents descend far enough to surround the testicle, and are obviously within the tunica vaginalis.

#### ACQUIRED HERNIA.

In acquired hernia, there is a widespread deteriora-

tion of the tissues, which not only makes the abdominal walls more liable to bulge and form hernial sacs, but also weakens the attachments of the mesentery and of the other abdominal viscera. As the suspensory ligaments elongate, the various organs gravitate into the lower part of the abdomen, and at the same time the relaxed abdominal walls bulge below, and may yield at the inguinal or femoral canals. Coincidentally the physiological conditions of the abdomen alter, particularly the intra-abdominal pressure, and the retentive power which the late Dr. Matthews Duncan described. These points have so much influence upon the selection of cases for radical cure, that I propose to consider them more in detail before describing the operations.

*The abdominal wall.*—For reasons which will soon be given, curative operations upon acquired hernia are to be avoided. Sometimes, however, they are undertaken for the relief of pain, or because of frequent strangulation, or to enable a truss to be worn, so that we have frequent opportunities of comparing them with the congenital. The patients with acquired hernia are usually beyond the meridian of life, and have lost their youthful vigour and elasticity. During the operation, this is shown by the tissues. The skin is loose and flabby, also the subcutaneous fat. The

aponeurosis of the external oblique is flaccid and hardly tense during coughing or vomiting. The hernial apertures are large and lax. The inguinal canal, if it exists, has little tendency to close during the contraction of the muscles. The fingers can be thrust through the hernial aperture straight into the abdomen. The muscular fibres of the internal oblique and transversalis abdominis are, as a rule, thinned out, pale, and flabby, and infiltrated with fat. The finger can easily be pushed beneath the arciform fibres,<sup>1</sup> and raise them from the peritoneum. Without care, the muscular fibres are also apt to come apart.

The fascia transversalis is flaccid and easily stretched, and the subperitoneal fat is loose and oily. The peritoneum is thin and very slack. The hernial sac has a wide and capacious mouth, communicating by a funnel-like approach with the general peritoneal cavity. When the abdominal wall of a typical case of acquired hernia is viewed from within, it may be seen that the hernial sac is not the only place where it has given way. First, it is quite common to find that the peritoneum is beginning to protrude at all the inguinal and femoral apertures.

<sup>1</sup> The fibres of the internal oblique and transversalis, which arise from Poupart's ligament and cross the inguinal canal, to be inserted into the conjoined tendon.

Second, the hypogastric fossæ are bulged throughout their whole extent, but most in their lower parts, opposite the inguinal rings and canals. This bulging always accompanies acquired hernia, and, I believe, precedes its occurrence. The contour of the abdomen is altered by this bulging of the abdominal wall, in a manner which will be described presently. In women, the pelvic peritoneum and fasciæ undergo changes during the child-bearing period which cause them to relax, and which render them more liable to be protruded by the intra-abdominal pressure at that weak spot, the femoral ring.

*The mesentery.*—In undoubted cases of acquired hernia, the length of the mesentery is the same as in unruptured people of the same age. In twenty-one ruptured subjects, whose ages ranged from 31 to 85 years, the average length of the mesentery was  $7\frac{1}{4}$  in.; in fact, less than the average length in those without ruptures. Twenty-one is too small a number to strike an average from. It happened to include several subjects with unusually short mesenterics. In six additional cases of acquired hernia, the average length of the mesentery was  $9\frac{1}{2}$  in. I think it is probable that in acquired hernia the mesentery may, like the rest of the tissues, be rather relaxed and flabby, and therefore easily stretched. When the



bowel and mesentery have been prolapsed for years into an enormously deep hernial sac, the herniated part of the mesentery becomes elongated and rope-like. In one such case the mesentery in the sac was 11 in. long, although the rest measured only  $7\frac{1}{2}$  in.<sup>1</sup> In another, a large inguinal sac contained a loop of intestine, with a mesentery 11 in. long, the rest of the mesentery measuring barely 9 in.

In acquired hernia the transverse mesocolon and great omentum are usually longer than in congenital hernia, simply because the subjects are older. Moreover, as I have shown elsewhere, the transverse mesocolon is often prolapsed, so that the great omentum hangs lower.

*The attachments and suspension of the mesentery.*— In typical cases of acquired hernia, the suspensory apparatus of the abdominal viscera is relaxed as well as the abdominal walls. In a severe case a mere glance is enough to show that the abdominal viscera have glided down towards the pelvis. It is no exaggeration to say that, in the case which first drew my attention to this point, the root of the mesentery sprang from the promontory of the sacrum. But, ordinarily, the prolapse is not obvious until the height of the flexura duodeno-jejunalis is measured from the

<sup>1</sup> Mentioned in Hunterian Lectures on "Hernia," p. 22.

base line drawn across the highest part of the iliac crests. In twenty-one cases of acquired hernia the average height of the duodeno-jejunal flexure above that base line was  $1\frac{1}{4}$  in., instead of being at least 3 in., as in normal subjects. In five additional measurements of cases of acquired hernia its average height was  $1\frac{1}{2}$  in. In acquired hernia the intra-abdominal condition is variable, whilst in congenital it is constant, being always that of a normal subject. In inguinal hernia the arrangement of the hernial sacs is exactly the reverse, for the acquired are simple and differ but slightly from one another; whilst the congenital sacs are very variable, and often complicated by abnormalities of the testicle, by folds, such as the plica vasularis, by constrictions, or by additional sacs, as in infantile hernia. In a certain number of cases of acquired hernia the mesentery is prolapsed, without any obvious failure in the suspension of the other abdominal viscera. But, as a rule, the prolapse of the mesentery is merely part of a widespread defect of the tissues. Thus I have found in acquired hernia, that—(a) Only the mesentery was prolapsed, all the rest appearing to be normal; (b) that the mesentery and transverse mesocolon, together with the hepatic and splenic flexures, were prolapsed; (c) that the mesentery, transverse mesocolon, the right and left

colons, and the kidneys, were prolapsed; (*d*) that the mesentery, transverse mesocolon, kidneys, and other organs were prolapsed. The same relaxation of the tissues conduces to prolapse of the rectum and uterus. In prolapse of the mesentery the other organs are prolapsed in the following order of frequency—(1) The transverse mesocolon; (2) the hepatic flexure of the colon; (3) the right kidney; (4) the splenic flexure of the colon; and (5) the left kidney. The prolapse of the rectum and of the uterus are not seen at post-mortem examinations.

The peculiar looseness of the viscera in severe cases of acquired hernia is very obvious when looked for in the dead-house. The root of the mesentery offers hardly any resistance, and is easily pulled down. The kidneys are often movable, and may lie upon the iliac crests. The pylorus is sometimes close to the umbilicus, the gastro-hepatic omentum having elongated. In truth, there is a kind of landslip of the viscera attached to the back of the abdomen.

The cæcum and sigmoid flexure may also descend when the other organs are prolapsed, but I think there is no doubt but that this only occurs in the most exaggerated examples. Many cases of cæocele or of sigmocele are congenital. In some the cæcum or sigmoid flexure was pulled into the hernial sac

along with the peritoneum of the iliac fossa, the latter having been displaced as the pressure of the small intestine or omentum distended the hernial sac.

*The excursion of the intestines.*—Prolapse of the mesentery, as might be expected, permits a greater excursion or range of movement to the intestines. But, in calculating this, the varying length of the mesentery has to be taken into account. For instance, a woman, æt. 58, with acquired hernia, had a mesentery 5 in. long, whilst a man, æt. 40, had one 9 in. long.<sup>1</sup> It may be remembered that an excursion of 3 in. was the greatest met with in normal subjects. This was found in 11 per cent. In twenty-seven people with acquired hernia, six had an excursion of 3 in., two of  $3\frac{1}{2}$  in., and seven of 4 in., and one of  $4\frac{1}{2}$  in. Two had the average excursion; that is to say, the ileum passed  $1\frac{1}{2}$  in. beyond the right crural arch, 1 in. beyond the spines of the pubic bones, and as far as the left crural arch. In all the rest this excursion was exceeded.

In six additional measurements one had the average excursion, one of  $2\frac{1}{2}$  in., one of 3, one of  $3\frac{1}{2}$ , one of 4, and one of  $5\frac{1}{2}$ . In this last, the mesentery was

<sup>1</sup> The breadth of the intestine has always been included in the measurement of the mesentery.

12 in. long and its root only  $\frac{1}{2}$  in. above the base line.

*Physiological considerations.*—Prolapse of the mesentery, as I have said elsewhere, is only *one* of the predisposing causes of inguinal and femoral hernia.<sup>1</sup> It allows the intestines to gravitate into the lower part of the abdomen. But it is not to be thought that the mere weight of the intestines, together with the weight of their contents, is enough either to bulge the abdominal wall or to produce a hernial sac. Intra-abdominal pressure is an abstruse and ill-understood subject, but it is evident that the prolapsed viscera would, during any exertion, press with greater severity upon the lower walls of the abdomen, and especially upon the hypogastric fossæ, and upon the ill-guarded inguinal and femoral rings. Further, as I have already pointed out, the abdominal walls share in the tissue changes which permit the prolapse of the mesentery and of the other viscera, and are therefore ill fitted to resist any additional pressure. Both the anatomical and the clinical evidence are in favour of the view that bulging of the hypogastric fossæ precedes the formation of the hernial sacs.

<sup>1</sup> My colleague, Mr. Macready, in his admirable book on hernia, whilst doing the fullest justice to my work, has evidently thought that I wished to say that prolapse of the mesentery was *THE cause of hernia*. However, such was not my intention.

The late Dr. Matthews Dunean,<sup>1</sup> a man of unusual sagacity, also argued that in acquired hernia the retentive power of the abdomen was diminished. There can, I think, be no doubt but that the healthy abdomen has a physiological property by which its contents are maintained in position, and prevented from falling. It owes this to the resiliency of the thoracic walls, to the tone of the diaphragm and abdominal muscles, and to the condition of the viscera and their supports, particularly of the suspensory muscle of the duodenum and mesentery. When these are impaired, the pressure of the atmosphere no longer helps to support the viscera, and they all descend towards the pelvis and hernial apertures. Glenard has also written upon a peculiar kind of prolapse of the abdominal viscera, but not in connection with hernia; and my friend Mr. Bruce Clarke<sup>2</sup> has added to our knowledge of this important subject.

*Clinical history and diagnosis.*—If in so many cases of acquired hernia the rupture is but a local manifestation of a widespread tissue change, then it is clear that no operation upon the abdominal

<sup>1</sup> "Researches in Obstetrics," 1868, p. 410 *et seq.* Also "Clinical Lectures on Diseases of Women," 4th edition, 1889.

<sup>2</sup> An address "On Some Effects of a Lack of Muscular Development," *Brit. Med. Journ.*, London, 1896, vol. ii. p. 1493.

wall could cure the disease. Such operations are doomed to failure. But nevertheless they are, I regret to say, frequently done, and bring surgery into much discredit. Within a week I saw the following cases:—

A man, *æt.* 46, came with typical acquired inguinal herniæ of both sides. He had had double radical cure done twice by the same surgeon, and had twice relapsed. The desire of the ruptured to be cured is so great, that they will submit to anything, if a prospect of cure is held forth. A ship's stoker, *æt.* 49, with typical acquired herniæ, came because of suppuration and extrusion of silk, after double radical cure. His hypogastric fossæ bulged, and both sides had relapsed. Next week another case of the same kind appeared. Such disasters tend to bring an excellent operation and surgery in general into disrepute. The recognition of typical cases of acquired hernia is easy, if attention be paid to the clinical history, to the general condition of the patient, and to the characters of the rupture or ruptures. Besides the typical cases of acquired hernia, there are others in which it is difficult to say whether the rupture is traumatic and not due to any alterations in the tissues themselves. Other acquired herniæ are due to pathological conditions, but of a kind which

are purely local and remediable by operation. Examples of both of these will be given hereafter.

The history of an acquired hernia is usually as follows. Sometimes it comes down so quietly and slowly that its presence is unknown. But more often its advent is preceded by many months of pain at the internal abdominal or femoral rings, or referred to the distribution of the ilio-inguinal or genito-erural nerves. This pain is probably caused either by the pressure on the nerves, or by the gradual stretching of the peritoneum. It is described as being of a burning or stabbing character. If no truss be worn, the rupture gradually increases in length and girth. The sac is seldom a long narrow tube, as in congenital hernia.

Generally speaking, acquired hernia is a disease of middle and advanced age. The information afforded by dissection and by operations leads me to think that true acquired hernia, that is to say hernia due to tissue change, is rare before 40 years of age. The patients with acquired hernia are often overworked and worn, and their movements devoid of vigour and elasticity. When stripped and told to stand erect, the abdominal walls are usually thin and flaccid. The hypogastric fossæ bulge at either side of the rectus abdominis, like funnels leading towards the inguinal rings. In addition, the whole of the lower and front



part of the abdominal walls bulges over the iliac

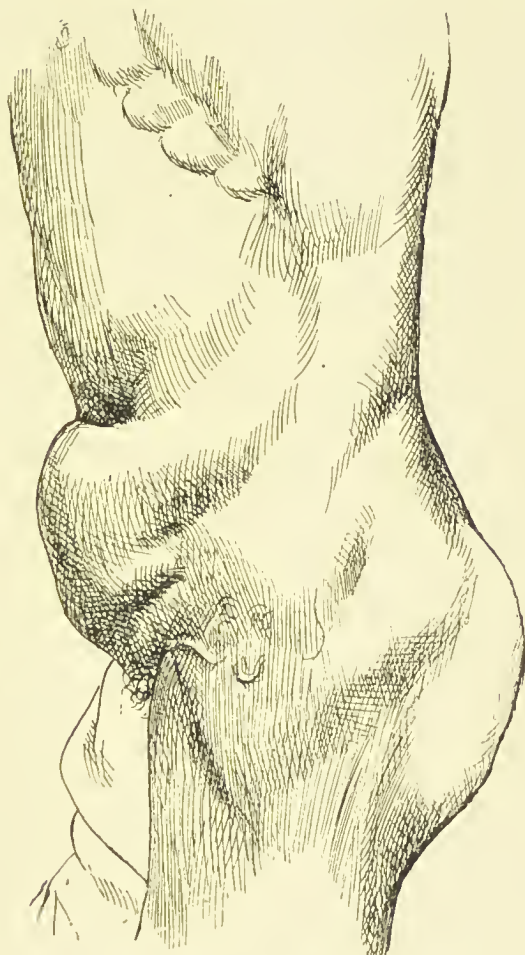


FIG. 1. —Acquired hernia. The bulging of the abdominal walls due to prolapse of the mesentery.<sup>1</sup>

crests and crural arches; whilst the part above the umbilicus, and beneath the ensiform cartilage and

<sup>1</sup> I am indebted to Mr. Macready for this photograph.

seventh and eighth costal cartilages, falls in. This sign of prolapse of the mesentery is easily overlooked, unless the patient be made to stand erect with his attention distracted from the abdominal muscles (Fig. 1). Exaggerated examples are not very frequent, but minor degrees are exceedingly common when properly looked for. Occasionally the kidneys, especially the right, can be felt movable and displaced on to the ilium. Other organs, such as the uterus and rectum, may be prolapsed. Affections indicative of debility may co-exist. A very severe case of irreducible inguinal hernia, upon which I had to operate, had *genu valgum*. As a rule both sides are ruptured. The protrusions may be femoral on one side and inguinal on the other, or both kinds may be present on the same side. When the rupture is single, an attentive search reveals the bulging of both hypogastric fossæ, and usually a localised impulse at the opposite inguinal or femoral rings. The impulse is more easily seen than felt.

An acquired hernia usually opens into the abdomen by a large and direct aperture, and is therefore rather less liable to become strangulated than one which is congenital. As the rupture increases, the fascia transversalis and conjoined tendon, which form the back of the inguinal canal, are dragged inwards by the herniated viscera, so that the inguinal canal no

longer exists. When this has taken place, the hand can be thrust straight into the abdomen.

But many acquired herniæ are of the direct variety. I have dissected a number of these, and have always found the conjoined tendon stretched by the rupture, and pushed before it into the scrotum. I have never seen it split. In this class the hernial aperture is loose and capacious, and the hand can be thrust straight into the abdomen.

When the hernia is direct, the spermatic cord is not displaced. Sometimes it may be easily felt separate from the hernial sac, and running upwards and outwards towards the internal abdominal ring.

*Herniæ of doubtful origin.*—Besides the undoubted congenital and acquired herniæ, there remains a third class, the exact pathology of which is by no means clear. So little attention has hitherto been paid to the general morbid state of the abdomen in acquired hernia, that many points are still in need of elucidation. Great progress would be achieved, if careful clinical histories were collated with thoroughly executed post-mortem examinations. The third class includes such cases as the following.

Whilst operating upon an irreducible femoral hernia, a group of at least four closed sacs full of straw-coloured fluid was found. In another case the hernia con-

sisted of a mass of fat, with a small sac in its centre. It seems unlikely that these had been caused otherwise than by a local morbid condition, nor could they be altogether due to pressure from the interior of the abdomen. It is probable that they were produced by local causes, and were therefore favourable for the curative operation. Unfortunately, an unknown proportion of femoral herniæ are associated with that widespread relaxation of tissues which leads to bulging of the abdominal wall, to prolapse of the mesentery, and of other organs.

It is clear that the pathology of femoral hernia is very complicated, and its causes hard to discriminate. My own results after radical cure of femoral hernia are not quite so good as after inguinal, because it is so much harder to make a scientific selection. I have twice operated for the cure of femoral hernia in boys. One was 12 years old, and the other 15. I thought their ruptures were probably congenital. One was well four years, and the other two and a half years afterwards.

In operating upon inguinal hernia, local conditions conducing to hernia are often met with. For instance, a female had a hernia which pierced the conjoined tendon, and protruded at the external ring. It consisted mainly of a lump of fat, with a small

blind sac in its centre. It reminded one of those fatty herniæ which occasionally pierce the linea alba or lineæ semilunares.

Not infrequently the inguinal canal contains fat, which seems to have conduced to the hernia. A soldier with double inguinal hernia had each of the canals distended by a lipoma, which lay below the fundus of the sac. These lipomata looked like the advanced guard of the hernia.

Inguinal varicocele, too, is a common complication of hernia. The veins of the cord are often large enough to distend the inguinal canals, and interfere with its automatic valve action.

#### TRAUMATIC HERNIA.

I do not propose to refer to ruptures which follow open wounds, whether made by accident or design, but rather to such as these. A policeman, æt. 31, had a violent struggle whilst arresting a soldier. A rupture appeared, and three days afterwards became strangulated. This was relieved by operation, and a so-called radical cure was done at a London hospital. Six months later the hernia had relapsed, and a second operation had to be done, otherwise he had to leave the force. He

was a perfectly healthy man, with excellent tissues. At the first operation a wound had been made in the scrotum, and the sac merely tied near the external abdominal ring. This futile proceeding was followed by suppuration. He was cured by the open operation, which I am about to describe. Owing to the previous operation, I could not tell for certain whether this was a traumatic rupture, or whether it might not have been one of those cases in which the hernia descends suddenly into a congenital sac. But the thinness of the sac, and the looseness of its connections with the cord, seemed to render this improbable. The conditions met with in a horse-artilleryman seemed much more conclusive. He became suddenly ruptured whilst galloping upon his gun over Aldershot Heath. No strangulation ensued, but he had radical cure done to enable him to remain in the army.<sup>1</sup> At the operation I found all the tissues exceedingly good. The rupture had escaped by a small hole, almost a slit, in the conjoined tendon. I afterwards operated upon another artilleryman, whose hernia was almost the same.<sup>2</sup> It is obviously most important to distinguish cases of this kind from those in which widespread morbid

<sup>1</sup> This patient was well two years after the operation.

<sup>2</sup> This patient is well more than two years after the operation.

conditions are present, such as those which I have just described in acquired hernia. Care is required in weighing the history, because patients usually attribute their ruptures to strains or injuries. In some instances they are undoubtedly right, but in many the predisposing morbid condition of the tissues is unsuspected. It is so natural to lay stress upon the exciting cause which seems so obvious, and to overlook the predisposing cause which is hidden.

Cases such as the following are also rather difficult to classify. A man, *æt.* 35, came with several urethral strictures, of which the narrowest admitted an 11-mm. bougie. When I performed internal urethrotomy, they were exceedingly tough, and had evidently existed some years. There was a slight impulse at the right inguinal canal. On the left side radical cure of inguinal hernia had been done twice over. The first operation speedily relapsed; the second threatened to relapse. It seems probable that in cases such as this some weakness of the inguinal canal predisposes to rupture, but that the protrusion is actually caused by the straining consequent upon the stricture. It is rather remarkable that the latter should have been overlooked by two surgeons. I think it is probable that radical cure would succeed after the strictures had been divided.

## CONCLUSIONS.

Judged from the standpoint of anatomy and pathology, the congenital herniæ of young adults are the best for radical cure, whilst the acquired herniæ of later life are unsuitable. The traumatic herniæ of healthy adults are likewise favourable, and also such as originate in local conditions, especially those in which a piece of fat or varix of the cord precedes the sac. As I continue, it will be seen that these conclusions are borne out by the results of curative operations. In practice, however, the operation is not entirely restricted by the above considerations. Radical cure is nearly always done after operations for the relief of strangulated hernia. The mere ligature and removal of the sac has a favourable influence upon the mortality of the operation; whilst the repair of the abdominal wall is often strong enough to allow a light truss to be worn during exertion, but renders it unnecessary at other times. The records of St. Bartholomew's Hospital<sup>1</sup> show that in former days the omission of ligature of the neck of the sac, or of an efficient radical cure, was followed by an immediate recurrence of the hernia,

<sup>1</sup> C. B. Lockwood, "On the Importance of Performing the Radical Cure after Operations for Strangulated Hernia," *Brit. Med. Journ.*, London, July 18, 1891.



protrusion of the sac from the wound, suppuration in the sac, sloughing of the sac, infection of the peritoneum from the sac, and relapse of the hernia into the sac when the patient began to walk about again.

Radical cure is also called for in cases of acquired hernia which are painful, irreducible, unmanageable, or liable to frequent attacks of strangulation. Three years ago I operated upon a lady in her seventieth year for the relief of a huge femoral enterocele. Twenty years before, it became strangulated, and was operated upon. It relapsed, and had been strangulated, according to her account, forty or fifty times. She made a good recovery, and now wears a light truss during the day. Many of these painful and irreducible herniæ contain adherent omentum. The operation of radical cure is a great boon to these cases, and often gives better results than the age of the patient and the condition of the abdomen seem to promise. These were the contents of one hundred consecutive inguinal sacs opened by myself:—

Empty . . . . .	62
Adherent omentum . . . . .	20
Omentum . . . . .	14
Intestine . . . . .	3
Omentum and bowel . . . . .	1
	—
Total . . . . .	100

Not a few of these patients with adherent omentum had been ordered to wear trusses.

Many of the operations referred to in these pages have been done upon men who wished to enter or remain in the army, navy, or police; also upon prison warders, asylum attendants, many post-office officials, candidates for the missionary service, engineers to Indian railways, and others who wished to go to the colonies or to hot climates. Young females with inguinal hernia eagerly avail themselves of an operation which dispenses with such an embarrassment as a truss, and in them the results are exceedingly good. As increasing experience has made the operation safer, and, as its results are better known, the patients themselves request to have it done in preference to wearing a truss. Those appliances are expensive, troublesome, and frequently inefficient. They are apt to fail just at the moment when their support is most needed. The wearer of a truss is always anxious to conceal the fact, and by many a truss is looked upon as a social disadvantage. Also, an increasing number of medical students request to have radical cure performed.

RADICAL CURE IN CHILDREN.

Children are not, from an anatomical point of view, ideal subjects for radical cure. My measurements show that during infancy and childhood the mesentery is relatively long, and the excursion of the intestines relatively great.<sup>1</sup> But still, in spite of this, the fact remains that in infancy and childhood ruptures usually get well if properly treated with a truss. Obviously, a truss should, when practicable, be tried before an operation is done.

<sup>1</sup> The following are a few measurements of infants, but more are needed :—

Age.	Length of Mesentery.	Excursion beyond Right Crural Arch.
3 weeks . . .	4 in.	1½ in.
4 ,, . . .	3 ,,	1½ ,,
2 years . . .	5 ,,	2½ ,,
2 ,, . . .	4¼ ,,	2¼ ,,
2 ,, . . .	6½ ,,	1¾ ,,
3 ,, . . .	4½ ,,	2 ,,
3 ,, . . .	5 ,,	1½ ,,
3 ,, . . .	5 ,,	1¼ ,,
5 ,, . . .	5 ,,	1 ,,
5 ,, . . .	5½ ,,	1½ ,,

The delicacy of the tissues, especially of the vas deferens and spermatic vessels, is an additional reason for avoiding all but necessary operations in infancy. Those structures are usually adherent to the sac, and, in the attempt at separation, I have more than once seen the vas deferens divided, and the vessels torn. Nevertheless the operation is attended with such slight danger to life, and usually succeeds so well in children, that I do not hesitate to perform it when an adequate reason exists. I usually advise that the operation should be done before the boy or girl goes to boarding-school. Children are greatly handicapped if they cannot join in the sports and amusements of their fellows. At the age of 8 or 9 years the tissues are well formed, and can be safely manipulated.

So far, what has been said mainly applies to inguinal and femoral hernia. Umbilical and ventral have also been operated upon, and in due course these will be described. But it is hardly necessary to remark that the same general principles of pathology apply to them as to the other kinds. I propose to describe the operations upon inguinal herniæ first, and afterwards those upon femoral, umbilical, and ventral.

## CHAPTER II.

### RADICAL CURE OF INGUINAL HERNIA.

THE patient ought to be under observation for a day or two before the operation, and the rupture seen by the surgeon or by some other competent observer. Last year I operated for radical cure of inguinal hernia upon a young woman who was positive that she had ruptures which descended on both sides. Both inguinal canals were opened. The right contained a hernial sac, the left was normal. The thoracic and abdominal viscera should also be examined. This step should never be omitted in these or other cases. A little time since, mitral disease, which had been overlooked, caused me much anxiety after an operation for radical cure.

Any disease of the lungs is most objectionable. At the operation the anæsthetic is taken badly, and afterwards a cough adds to the pain, and diminishes the chances of cure. Once a patient, upon whom I operated, concealed the existence of a cough. Bronchitis is aggravated by anæsthetics, especially by

ether, and sometimes ends fatally. If a patient with bronchitis must be operated upon, it is best to choose, if possible, the summer. It is probable that chloroform and A.C.E. mixture are the safest anæsthetics. The abdomen should be carefully examined. A young woman who had had a femoral hernia operated upon, afterwards complained of discomfort, although the hernia was cured. We then ascertained that she had a displaced and movable kidney on the right side. The urine should always be examined. Another woman, with what was guessed to be an irreducible epiplocele, had to be rejected because she had albuminuria. This was found to be associated with an enlarged and tender right kidney. She was most anxious for the operation. In children a hernial sac full of fluid is sometimes associated with tuberculous peritonitis. I have thrice seen tubercle of the sac during radical cure. Not long since I declined to operate upon a patient of Dr. Hurford's, because we discovered that he had tuberculous peritonitis with much free fluid in his peritoneum and processus vaginalis. His scrotum was tense, and rather hot and tender. The fluid was easily squeezed into the abdomen, where more was discovered. He also had a high temperature each night.

Now and then young females conceal the fact that they are pregnant. Under these circumstances I

have once operated upon a girl who was three months pregnant. She made a perfect recovery. The patient may be in a state which renders suppuration very likely to follow the operation. Radical cure, with removal of a retained and atrophied testis, was done upon a patient whose wound began to suppurate from the first day. When endeavouring to find the cause, he remarked, for the first time, that he had had a suppurating sore upon the finger. He was just recovering from that kind of paronychia which is such a close relation to pemphigus.

Sometimes operations must be undertaken, although the circumstances are unfavourable. A woman with large fibroids of the uterus had double radical cure done for very painful and irreducible femoral herniæ. After the operation, uterine hæmorrhage was restrained with ergotine. A man with albuminuria, and who was much debilitated by residence in the tropics, was operated on for the relief of a huge irreducible epiplocele, complicated with hydrocele.

#### PREPARATION OF THE PATIENT.<sup>1</sup>

The night before the operation, a warm bath is

<sup>1</sup> The reasons for these precautions and additional details are given in "Aseptic Surgery," by C. B. Lockwood, Edinburgh and London, 1896.

given, with a thorough soaping and scrubbing. The hair is shaved at least 6 in. round the site of the incision. The skin is afterwards disinfected by first extracting the fat with ether or turpentine, and then soaking it for three minutes with a solution of biniodide of mercury and methylated spirit, 1 part of biniodide in 500 parts of spirit. This is washed away with biniodide of mercury lotion,—1 part in 2000 parts of water,—and an antiseptic dressing is applied to keep it aseptic until the operation. For this purpose I use a dressing which consists of a layer of 5 per cent. carbolic gauze, well soaked and wrung out in the 1 in 2000 biniodide lotion, next the skin, then a layer of alembroth wool, and last an eight-fold outside Listerian dressing, properly bandaged on. It is advantageous to add some glycerin to the lotion in which the gauze is soaked. By that means the dressing is kept moist, and the chemical penetrates further into the skin. It is best to shave the skin before the operation, but sometimes it is advisable to wait until nervous patients are anaesthetised. But the skin of cleanly people is now easy to disinfect, and this method gives good results, although it may have to be carried out when the patient lies on the table. As a rule, if the skin has been ulcerated by a truss, the operation ought to be put off. In a case in which



the rupture was strangulated, this could not be done. Therefore the ulcer was scraped, swabbed with pure carbolic acid, and the wound afterwards drained. Healing took place by first intention.

In another case a truss had caused an abscess. Before proceeding, this was cleaned out with a sharp spoon, and disinfected with pure carbolic acid. A drainage tube was used, and there was slight superficial suppuration. This did not cause any of the deep sutures to come out. The ultimate result was excellent. A drain is used in these cases, because no certain way is known of disinfecting the septic sinus or ulcer.

It is also advisable to give a mild purge the day before the operation; if necessary, followed by an enema. This saves a good deal of discomfort during the first two days.

A little clear soup may be taken four hours before the anæsthetic; but if the operation is done in the earlier part of the day, healthy young adults do not require any. If vomiting occurs, it adds greatly to the pain and discomfort.<sup>1</sup>

When both sides are ruptured, a double operation is done, and causes but slight additional shock or

<sup>1</sup> For most judicious remarks on this subject, see Hewitt, "Anæsthetics and their Administration," London, 1893.

suffering. Usually the ruptures are both femoral, or both inguinal. Once a man, *æ*t. 26, was operated upon for right inguinal hernia, and a left femoral.



FIG. 2.—Blunt-pointed herniotomy needle.

#### INSTRUMENTS REQUIRED—THEIR PREPARATION.

A pair of blunt-pointed herniotomy needles are the only special instruments needed for the operation. Messrs. Arnold & Son have made some for me, which others and myself prefer to Professor Maewen's original model. Their curve is rather less and shorter; the metal in the curved part is distributed so as to make them more rigid, and the hole is made much easier for threading, by making it run across the point of the needle, so that it can be threaded from right to left (*vide* Fig. 2).

The other instruments which are required are a scalpel, seissors, dissecting forceps, eight or twelve pairs of pressure forceps, also a straight and a medium-size curved Hagedorn's needle. The same instruments

serve for umbilical and inguinal hernia, whether strangulated or not; they also serve for non-strangulated femoral hernia. For strangulated femoral hernia I still use, in addition, a broad shallow-grooved director and a blunt-pointed herniotomy knife.

These instruments are sterilised by boiling them for fifteen to twenty minutes in a solution of ordinary washing soda and water.<sup>1</sup> From this they are transferred, without contamination, into a flat sterilised dish, containing enough 2½ per cent. solution of carbolic acid to cover them. The carbolic acid ought to melt at a temperature not lower than 40° C. If it is necessary to carry the instruments away to a private house, they are wrapped in 5 per cent. carbolic gauze, and folded in an eight-fold outside dressing.

#### LIGATURES AND SUTURES.

For more than ten years I have used twisted silk for ligatures and buried sutures. As a rule, silk-worm gut, or, as it is often called, fishing-gut, is used for skin sutures. For ligaturing vessels, No. 0 or No. 1 twisted silk is sufficiently strong, and No. 4 or 5 for buried sutures. These materials are sterilised by boiling them for twenty minutes. For this purpose

<sup>1</sup> A teaspoonful of washing soda to a pint of water.

it is convenient to wind the silk upon a glass reel, or glass microscope slide. The hank of silk-worm gut is secured with a piece of medium-sized drainage tube. After having been sterilised, the silk and the fishing-gut are kept in a 5 per cent. solution of carbolic acid; but just before use they are put into a bowl of 2½ per cent. solution.

Our latest tests show that silk and fishing-gut, treated in this way, are always sterile. It also behaves well in wounds. Out of forty-five operations for the cure of inguinal, femoral, or umbilical hernia, done betwixt January 1895 and July 1896, one case parted with one suture, and one parted with several; the rest healed by first intention.<sup>1</sup> Also, I have had a consecutive series of forty-two operations without a suppuration.

In 1896, radical cure was done twenty-nine times upon twenty-six inguinal, two ventral, and one femoral hernia. One of these suppurated after the operation. It was the man who had paronychia when the operation was done. However, curiously enough, no sutures came away, and the wound was soundly healed at the end of a month. In another case of an old man with an enormous

<sup>1</sup> C. B. Lockwood, "Further Report on Aseptic and Septic Surgical Cases, with special reference to the Disinfection of Materials and the Skin," *Brit. Med. Journ.*, London, 11th July 1896.

inguinal hernia, complicated with hydrocele, a suture came away about three months after the operation. His wound had been drained, and he had worn a truss as soon as he got up. Although I have had opportunities of judging, I have not seen better results than these from any kind of prepared catgut, kangaroo tendon, or other materials.

#### THE SPONGES AND LOTIONS.

Fine Turkey sponges are used. The following method of sterilisation gives perfect results, if carried out by a conscientious person. The new sponges are beaten and shaken in a linen bag, to knock out the sand. To remove bits of shell or of coral they are soaked all night in a solution of strong nitric or hydrochloric acid and water, one part of acid to ten parts of water. When the effervescence has ceased, and no more shell or grit can be felt, the acid is washed away with water which has been boiled and allowed to cool. Then the sponges are soaked for twelve hours in a solution of washing soda in hot water, to take away the remains of the acid, and also any animal matter left by the rotiferæ. The soda is washed away with sterilised water, and the sponges immersed in one part of a saturated solution of sulphurous acid in four parts of

water. This is again washed away with sterilised water, and the sponges dropped into a solution of one part of carbolic acid in twenty parts of water, until they are to be used. After having been used, the sponges are prepared in exactly the same way, except that they require no beating or immersion in acid, but go at once into the soda solution.

When the sterilised sponges are to be carried away to an operation, they are folded in a new piece of jaconet the size of a pocket-handkerchief. This jaconet is secured with string or with an indiarubber band. After having been used a few times, the jaconet can be burnt. It is discarded at once if it touches anything septic.

In addition to carbolic acid lotion for the instruments and ligatures, I use a solution of 1 part of biniodide of mercury in 2000 parts of water, for cleansing the sponges and rinsing the wound. For ordinary purposes, it is convenient to carry tabloids of biniodide of mercury and iodide of potash.<sup>1</sup> As a rule, three sponges suffice. The biniodide removes the blood so easily that they are cleansed by the assistant in a bowl of lotion, handed by the nurse. Thus the number of persons engaged in

<sup>1</sup> Each tabloid should make a pint of lotion—strength, 1 in 1000. Messrs. Burroughs, Wellcome, & Co. now make tabloids of this size, which are perfectly soluble.

the operation is diminished, and a source of error eliminated.

### THE DRESSING.

The dressing is prepared before the operation. Some finely powdered crystals of iodoform are placed in a sterilised flask with a perforated cover.<sup>1</sup> This is handed to the surgeon, immersed up to the neck in a small basin of 1 in 50 carbolic lotion. The iodoform powder is used to dust upon the skin after the wound has been sutured. It seems to prevent blistering and irritation; it is also an antiseptic, and prevents the growth of any bacteria from the mouths of the sebaceous glands, sweat glands, or hair follicles, in case they escape being killed during the process of disinfection. Some 5 per cent. carbolic gauze, in layers of six or eight thicknesses, is cut into 4-in. squares, and soaked in 1 in 2000 biniodide lotion for about twelve hours before the operation. These squares of gauze are wrung out and placed next the wound, so as to cover a considerable area of skin. They are sterile, and contain a small store of antiseptic; moreover, they protect the skin from the next layer. Since the amount of antiseptic in the carbolic gauze is so small, the next layer of the dressing consists of

<sup>1</sup> A small cheap glass pepper-pot is very convenient.

2 per cent. alembroth wool. This is a most efficient antiseptic, but must not be allowed to touch the skin, otherwise it causes a very acute dermatitis, with blistering. For the exclusion of free air, and for the distribution of any blood or fluid from the wound throughout the dressing, an eight-fold outside gauze dressing is prepared. This consists of eight layers of carbolie gauze, covered with a layer of indiarubber jaeonet. A paper pattern is cut by the surgeon the day before the operation. This has to cover the groin, and fit accurately at the root of the penis or fold of the pudenda, because at this point the wound is rather close to the edge of the dressing.

The paper pattern reaches as high as the groove below the anterior superior spine of the ilium, and as low as the junction of the upper with the middle third of the thigh; its outer margin lies on the front of the great trochanter of the femur; its inner margin reaches across the pubes, as far as the line of the external iliac artery; and below the pubes its margin corresponds to the tendon of the adductor longus (Fig. 3).

The eightfold outside dressing is cut to this pattern, and two buckles are sewn upon its two outside corners. To prevent pressure-sores, these buckles should lie well upon the dressing itself, and not overlap the edge so



as to touch the skin. A strap made of a broad soft water bandage is sewn to each of the inner angles; the upper one to go round the pelvis, and the lower one

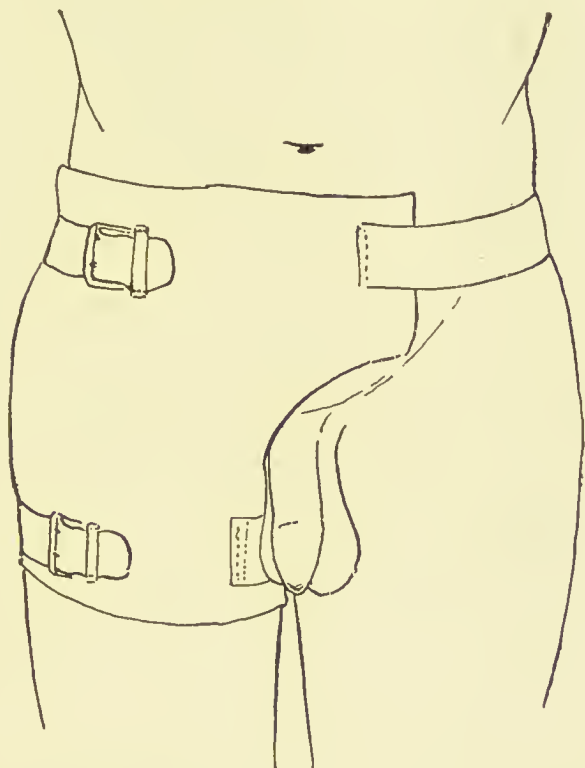


FIG. 3.—Outside dressing for inguinal or femoral hernia, or for exploration of the inguinal canal.

round the thigh. After these straps have been fastened, a spica bandage is put on. For this purpose at least two wide elastic bandages are required. This bandaging begins round the thigh, and is carried from

without inwards. By this means the outside dressing is drawn over towards the middle line, and the weak spot at the pubes guarded against. The wound is of

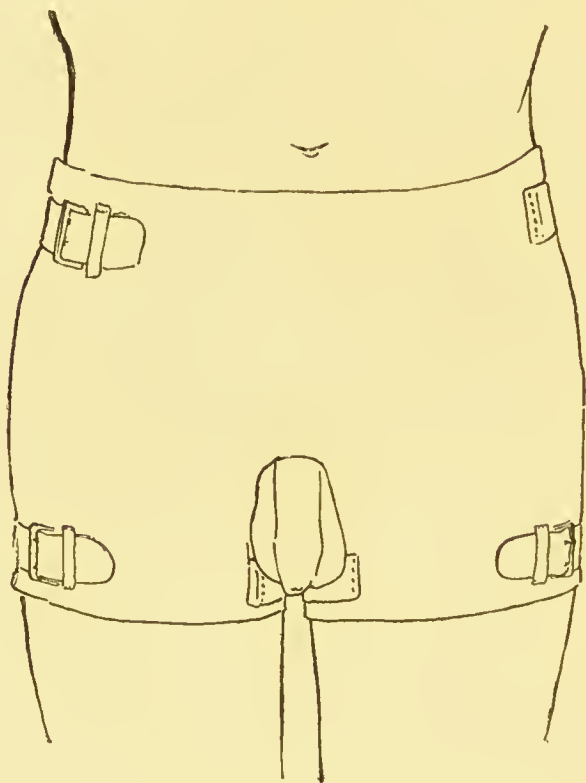


FIG. 4.—Outside dressing for double radical cure of inguinal or femoral hernia, or for exploration of both inguinal canals.

necessity very close to the edge of the dressing where it curves round the root of the penis or the pudenda. Efficient bandaging prevents the patient scratching beneath the dressing, or exploring the

wound with the fingers. Quite recently a radical cure of inguinal hernia suppurated because of this indiscretion.

For operations on both sides at the same time, a double outside dressing is made after the same fashion. It is fastened on with similar straps and buckles, and with a double spica. It is shown in the accompanying illustration (Fig. 4).

#### THE NURSE AND ASSISTANTS.

One nurse is enough. She is told to prepare six sterilised basins for the operation, and six sterilised towels. Just before the operation several large cans of water should be boiled for twenty minutes, and left to cool. At the operation the nurse touches none of the instruments, materials, or appliances, but merely hands fresh basins of lotion to the assistant. The assistant is not allowed to put his fingers into the wound. The nurse hands him a sponge in a basin of biniodide of mercury lotion, 1 in 2000. In this lotion it is so easy for him to squeeze the blood out of the sponge that one has done for a double operation.

STERILISATION OF THE HANDS OF THE SURGEON  
AND OF HIS ASSISTANT.

It is probable that the hands are one of the commonest sources of wound infection. Judged by culture media tests, the following method has given us of late quite 90 per cent. of sterility.<sup>1</sup> First, the nails are cut off quite close, so as to leave no preventible chink or cranny; second, the hands and arms are scrubbed with hot water and soap and a sterilised nail-brush for three minutes; third, they are soaked for two minutes in a solution of biniodide of mercury in methylated spirit, 1 part of biniodide in 500 parts of spirit; and, fourth, the spirit is washed off with biniodide of mercury lotion, 1 in 2000, and the operation begun. During the operation the hands are frequently rinsed in the same kind of lotion. For this purpose the nurse places a bowl of it near the instruments.

<sup>1</sup> Of late we have taken care to remove all trace of the mercuric salt from the bits of skin, sponge, towel, or ligature, by dipping them into sulphide of ammonium and then into sterilised distilled water, before placing them in the culture broth. These precautions have made no appreciable difference, thus showing that the minute quantity of chemical conveyed into the broth in our earliest experiments had not vitiated the result. For further details see "Aseptic Surgery," p. 13 *et seq.*

## THE OPERATION ROOM.

These operations were done in hospitals, nursing homes, and private houses. When efficient nursing and attendance can be obtained, the patient's home is usually the quietest and best. The room has to be examined to guard against any sanitary defect. In modern houses the sanitation has nearly always had attention. To avoid dust, the curtains and carpets should be taken away the day before the operation, and all the ledges and wood-work wiped down with a cloth wet with an antiseptic, such as 1 in 20 carbolic lotion. A fire should be lighted and the window thrown open.

A wooden table, 6 ft. long, 3 ft. high, and 2 ft. 6 in. wide, or thereabouts, should be scrubbed clean with soap and water, and covered, after having been dried, with a blanket or two. A small table is required for the surgeon's instruments and bowls. This is covered all over with a sterilised towel.

## THE ANÆSTHETIC.

When the anæsthetic is skilfully given, the patient suffers much less from sickness and coughing after the operation. It is unnecessary to point out the

importance of this in all operations upon the abdominal wall. As a rule, pain is felt for twelve to twenty-four hours after the operation, in the back, beneath the floating ribs, and in the wound during straining, coughing, or vomiting. The latter are usually due to the way in which the anæsthetic is given. Ether is probably safer during anæsthesia, but is more irritating to the air passages. Chloroform is easier to give and less irritating, but rather more dangerous during anæsthesia. Both are followed by a good deal of vomiting. The anæsthetist is informed of any peculiarities in the case, and selects and administers whatever he deems best. The chest and extremities should be warmly clad, and kept covered during the anæsthesia.

#### THE FIELD OF OPERATION.

To prevent the contamination of instruments or ligatures, an aseptic field of operation is prepared as soon as anæsthesia is established. The clothing having been drawn aside and the protective dressing (see p. 47) removed, a thin Mackintosh or a dry towel is spread over the clothing. Four disinfected towels are then arranged around the site of the incision, so as to cover all the clothes and blankets and all the undisinfected skin. An extra towel may be required

betwixt the basins and the wound, lest, by inadvertence, a ligature or instrument should be infected.

The skin area surrounded by the towels receives a final disinfection with the 1 in 500 solution of spirit and biniodide of mercury. This is washed away with the lotion used throughout the operation, namely, 1 part of biniodide in 2000 parts of water.

The organs of generation are shut out of the field of operation by covering them with a layer of carbolic gauze, wrung out in 1 in 2000 biniodide lotion. This "Phallic shield" is of great importance in all operations for hernia, hydrocele, or varicocele.

## CHAPTER III.

### RADICAL CURE OF INGUINAL HERNIA— THE OPERATION.

MY earliest operations upon inguinal ruptures were done by a method which closely resembled that of Professor Macewen. It aimed at the obliteration of the sac and the repair of the abdominal wall, without any division of the aponeurosis of the external oblique muscle.<sup>1</sup> The cases were selected with all the precautions which I have described, and the results have been exceedingly good. I have recently seen patients who were operated upon more than six years ago, and found that they were cured and able to do whatever they desired. But by degrees it became evident to me that the operation could not be done with certainty, unless each step was guided by the vision. For instance, a youth was operated upon under the most favourable conditions. Within six months he had

<sup>1</sup> C. B. Lockwood, "The Radical Cure of Femoral and Inguinal Hernia," *Lancet*, London, November 25, 1893.



relapsed, but asked for a second operation. On the second occasion the aponeurosis of the external oblique was incised, and the neck of the sac exposed to view. Then it was seen that the first operation had not obliterated the upper part of the sac, so that the intestine entered it again. Further, I have come to the conclusion that the sutures needed to restore the inguinal canal cannot be efficiently passed unless the manipulation be guided by vision. Moreover, other observations showed that unless the inside of the neck of the sac was actually seen, the operator might overlook adherent omentum. A little time since I operated upon a gentleman in whom this had happened. At the first operation an incision had been made over the external abdominal ring, and the fundus of the sac opened. The hernia came down again before the patient was out of bed. At the second operation the aponeurosis of the external oblique was divided, and the whole interior of the sac exposed. The neck of the sac contained omentum, which was adherent to its mouth, and almost within the abdomen. Even when the canal is opened and the interior of the sac displayed to view, it is sometimes most difficult to recognise altered and adherent omentum. In a recent case the omentum had become smooth and polished, and incorporated with the fundus of the sac.

I only recognised it when the incision reached the mouth of the sac.

There is also another cogent reason for opening the inguinal canal. In a rather considerable proportion of cases it contains small fatty tumours. The presence of these is usually unsuspected until the inguinal canal has been laid open. The reasons which render their removal imperative will be given later. But, besides fat, the inguinal canal often contains varicose spermatic veins. These, too, must be overlooked when the aponeurosis is not divided. Their treatment is described hereafter.

Contrary to what used to be thought, the division of the external oblique aponeurosis leaves no permanent weakness of the abdominal wall. Experience shows that it unites quickly and well. I have been in the habit, whilst operating, of showing that its fibres are arranged parallel to one another, so that they spring together when taut, and can only be separated when slack. Obviously this minimises the risk of non-union. It is quite usual to find that the external abdominal ring feels tight and strong again six weeks after the aponeurosis has been divided and sewn together.

Unfortunately, all the layers of the abdominal wall do not possess such valuable properties. The muscular

fibres of the internal oblique and transversalis abdominis muscles cannot be relied upon to unite after they have been divided. I have watched patients in whom this error has been committed. The point of division had become a gap in the abdominal wall, with extensive hernial protrusion. Any division of muscular fibres is quite unnecessary. It offers no advantage whatever, and has been scrupulously avoided in all my operations.

But besides the obliteration of the sac, the operation for the radical cure of hernia aims at the repair of the abdominal wall. After the inguinal canal has been opened, it is easy to see how far its valvular arrangement has been destroyed, and what is needed for its repair. In my later operations this has been done by the method of Bassini. The inguinal valve will be described presently.

Thus the first aim of the operation for the radical cure of hernia is to obliterate the hernial sac, so as to leave no depression at its mouth. This step is guided by vision and accomplished with the least possible division of muscles. The second aim is the repair and restoration of the abdominal wall, so that the inguinal canal again functions as a valve.

## SKIN INCISION.

The skin incision is made over the centre of the inguinal canal, parallel to the inner half of Poupart's ligament (see Fig. 5, B). Formerly, when the neck of the sac and the inguinal canal were reached through the external abdominal ring,<sup>1</sup> the cut was made in the upper part of the scrotum. By transferring it altogether to the groin, the operation is safer and easier, and asepsis is more certain.<sup>2</sup> Moreover, a fair amount of pressure can be applied to the groin. This prevents any oozing of blood or inflammatory effusion into the tissues, and helps to protect the wound from the entrance of air. The inner end of the skin incision should not be carried inside the spine of the pubes, otherwise it lies dangerously near the inner edge of the dressing, and may become exposed during the movements of the patient. If more room is needed, the incision should be carried upwards and outwards; but a 2-in. incision is usually long enough for an uncomplicated case. As skill and experience increases the incision tends to become shorter. I

<sup>1</sup> Macewen, "On the Radical Cure of Oblique Inguinal Hernia by Internal Abdominal Peritoneal Pad, and the Restoration of the Valved Form of the Inguinal Canal," *Brit. Med. Journ.*, London, December 10, 1887, Fig. 2.

<sup>2</sup> Of late we have succeeded in disinfecting the skin of the scrotum almost as well as that of other regions.

always use the inguinal incision now in cases of strangulated inguinal hernia.<sup>1</sup> The operation is, in fact, exactly the same as that of radical cure, except that the contents of the sac are strangulated.

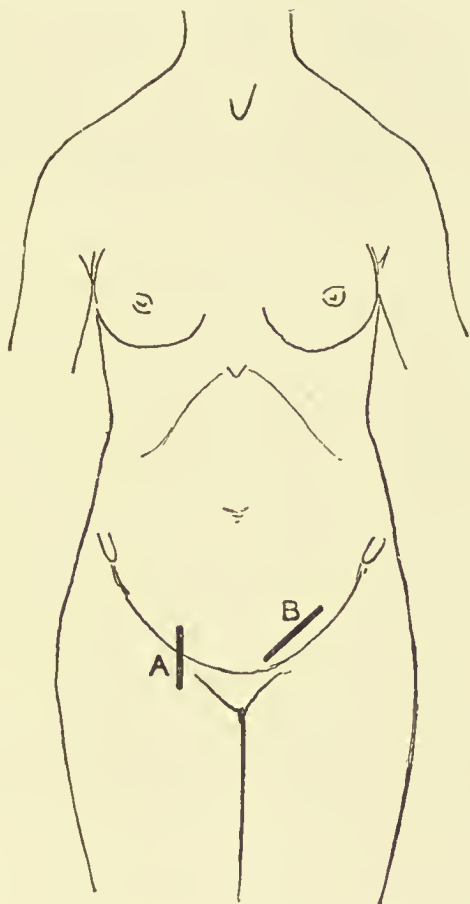


FIG. 5.—Skin incisions for the radical cure of—A, femoral, and B, inguinal hernia. The same are used in the operation for the relief of strangulation.

once to prevent the tissues becoming infiltrated with blood.

Sometimes I have met with bursal spaces in the

<sup>1</sup> C. B. Lockwood, "The Operation for Strangulated Inguinal Hernia considered in relation to Recent Advances in Surgery," *Lancet*, London, March 28, 1896, p. 833.

subcutaneous tissues. In the case of a youth, they had such distinct walls that at first it was thought that the hernial sac had been opened. These spaces are probably caused by trusses. They might be embarrassing to an inexperienced operator.

#### THE INGUINAL CANAL.

The aponeurosis of the external oblique muscle is split three-quarters of an inch above Poupart's ligament. None of its fibres is cut across. Whenever the patient strains, the lips of the wound in the aponeurosis close together. The inner end of the cut opens the external abdominal ring, whilst its outer end lays bare the muscular fibres of the internal oblique muscle of the abdomen. I again repeat that it is of the greatest importance not to divide any of these muscular fibres, otherwise a weak abdominal wall will ensue.

#### THE HERNIAL SAC—POSITION OF SPERMATIC CORD.

The hernial sac is difficult to find, especially when it is small, thin, and diaphanous, as in children. It is nearly always hidden by the cremaster muscle, which has to be cut through or parted where it springs from

internal oblique and transversalis muscles. In one of my cases the cremaster is noted to have been exceedingly thick and strong, and to have quite hidden the sac. Beneath the cremaster is a layer of transversalis fascia, which forms one of the coverings of the sac, and is easily mistaken for it. In the inguinal canal the vas deferens and spermatic vessels almost invariably lie behind and below the hernial sac, and are not endangered when the cremaster muscle and transversalis fascia are divided. The sac may be recognised by its opaque white colour, by its outline, or by its shining and smooth interior, from which a little serous fluid may escape. In truth, in many operations the sac is not recognised until it has been laid open. But the position of the cord is not taken for granted. Whilst operating upon a youth for an incomplete inguinal hernia of the left side, I found the cord above and in front of the sac. Again, in another case, in which the hernia was likewise in the left side, the sac was exceedingly long and narrow, and situated right behind all the constituents of the cord. Therefore it is always necessary to divide the cremaster muscles and transversalis fascia with care, the fingers being used to ascertain the position of the vas deferens. After the sac has been opened, its extent is learnt

with the finger or probe, and if it contains any fluid, bowel, omentum, or the testis or ovary, they are at once dealt with. It is convenient, therefore, to proceed with those cases which have something in the sac.

#### CONTENTS OF HERNIAL SAC—TUBERCLE.

The sac usually contains a little serous fluid. Twice I have seen the fluid rather abundant and turbid. In both cases the interior of the sac was studded with tubercle, which had been overlooked. Recently I refused to operate upon a case of this kind. As I said before, the tunica vaginalis contained fluid which could be reduced into the abdomen. The serotum was hot and slightly tender; the patient was not well, and had an increased temperature at night; the abdomen was a little distended, and contained free fluid, and some thickening and induration of the peritoneum could be felt. Once I quite unexpectedly found pus in a femoral sac.

#### CONTENTS OF HERNIAL SAC—FLUID AND CYSTS.

Once straw-coloured fluid in the sac was associated with a growth of pedunculated bodies from the wall



of the sac (Figs. 6 and 7). These slipped out when

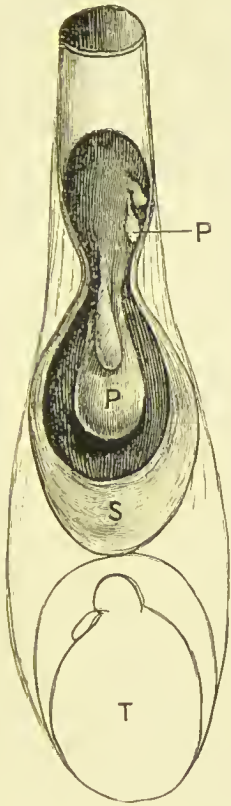


FIG. 6.—Polypoid bodies pendent from the wall of a hernial sac. S, hernial sac; P, polypi; T, testis.

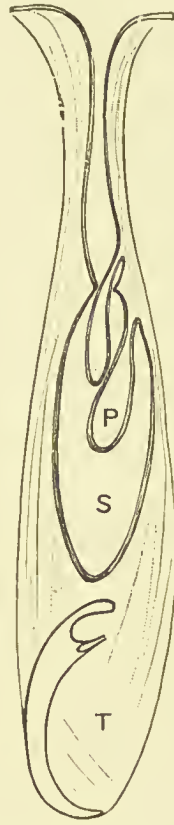


FIG. 7.—Diagram to show the relation of the polypoid bodies to the wall of the sac. Letters the same as Fig. 6.

the sac was opened, and looked like ordinary mucous nasal polypi.<sup>1</sup>

<sup>1</sup> For full account, see *Trans. Path. Soc. London*, 1896, vol. xlvii. p. 61, Figs. 3 and 4.

On another occasion, similar growths were met with unaccompanied with fluid in the sac. Before the operation the hernia felt like a tense cyst.

In a third case a boy was supposed to have a hydrocele of the cord. When the inguinal canal was opened, a peculiar long irregular sac was found. It did not collapse; and when an opening was made a number of these curious polypoid bodies slipped out. They lay in an unobliterated processus vaginalis, which communicated with the general peritoneal cavity above, but was irregularly constricted below. In this case the spermatic veins were also varicose and required removal.

Jacobson<sup>1</sup> describes a case from the practice of the late Sir George Humphry, in which a similar state of things was discovered. A cystic swelling of the cord was drawn down from the inguinal canal. It contained clear fluid and several thin-walled cysts, bearing blood vessels and containing fluid. At its lower part the main cyst seemed to be formed by part of the tunica vaginalis.

My colleague, Mr. Harrison Cripps, has shown a specimen at the Pathological Society, which proves that similar bodies may grow from the omentum, and cause ascites.<sup>2</sup>

<sup>1</sup> "Diseases of the Male Organs of Generation," London, 1893, p. 126.

<sup>2</sup> *Trans. Path. Soc. London*, vol. xlviii. p. 85.

When the neck of a congenital hernia is plugged with adherent omentum, hydrocele fluid not infrequently collects in the lower part of the sac. These cases will hereafter be described more fully.

*Omentum.*—The great omentum is one of the commonest contents of hernial sacs. When the sac is congenital and full of omentum, the prospects of a permanent cure are most favourable, because the operation repairs the developmental defect in the abdominal wall, and at the same time gets rid of a considerable part of the omentum. The great omentum ought to be treated with extreme care. Two of the deaths which I have seen after this operation were due to the great omentum.<sup>1</sup> In one, the ligature slipped off the omental stump, and the abdomen filled with blood. In the other, a vein was torn through near the greater curvature of the stomach, whilst the omentum was being pulled down into the wound. It is obvious how this last accident may be avoided. No anxiety need be felt about the omental stump, if it be treated like all other pedicles and secured with a ligature which transfixes its substance.

One of the blunt herniotomy needles (Fig. 2) is threaded with rather thick twisted silk (No. 4 or 5),

<sup>1</sup> Both were mentioned along with another case in my Hunterian Lectures, cf. "The Morbid Anatomy, Pathology, and Treatment of Hernia," London, 1889, p. 128.

and thrust through the omentum half an inch above the place where it is to be cut through.

In transfixing the omentum, the usual precautions are taken to avoid its veins. Whilst operating upon a man with a very vascular omentum, a vessel was transfixed and bled freely into the omentum, so that it became filled with a large hæmatoma. Fortunately, it was possible to put ligatures above the hæmatoma and cut it all away.

When the needle is withdrawn, the loop of the silk is either tied with a Staffordshire knot, or it is cut, and after its two halves have been intertwined they are tightly tied round the right and left edges of the omentum. Finally, if there be any oozing, two of the ends may be tied round the whole omentum as an additional safeguard. Or, to save time, the omentum may be secured with a Staffordshire knot (*vide* Fig. 13, p. 124). I find this the easiest and quickest way, and quite safe. It may be made as follows:—After the needle has been thrust through the omentum and withdrawn, the loop of the silk which is left is carried over the end of the omentum until it is opposite the two free ends of the silk; then the loop is put between the two ends, and they are pulled tight and tied. For small pedicles the Staffordshire knot is hard to beat. When the omen-

tum is very bulky, it cannot be simply transixed and tied, because when too much is included in the ligature it cannot be pulled tight enough to constrict all the vessels. The lump, moreover, is so large that it may be impossible to force it into the abdomen. To avoid this, the omentum is laeed in the following way with a series of interlocking sutures. A blunt needle is armed with twisted silk, and thrust through the omentum half an inch from its edge. The needle is withdrawn, leaving the loop, which is cut through so as to make two ligatures. These are interlaeed, and

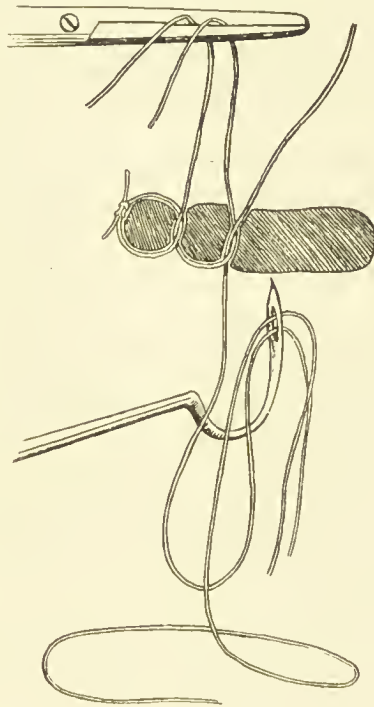


FIG. 8.—Method of securing the omentum with interlocking sutures.

one of them tied around the edge of the omentum. The ligature which remains is threaded through the blunt needle, and one end of it carried through the omentum again a little further on. The needle is previously armed with a fresh ligature, which is also

left in the omentum when it is withdrawn. The original ligature is intertwined with this new one and tied. The process is repeated as often as is needed with fresh pieces of silk (Fig. 8). When the section is high up, great care has to be taken not to include a bit of colon in the ligature. Bull<sup>1</sup> mentions a case in which a constriction which lasted for fifteen minutes was followed by perforation and death from suppurative peritonitis. I have never known the omental stump give any trouble. Sometimes I have thought that its position in the abdomen was marked for a time by a tender place, which soon got well. I have not seen such disasters as are described by Lucas Championnière,<sup>2</sup> who more than once performed laparotomy for suppuration around the omental stump.

Sometimes the omentum is chronically inflamed and indurated. When this condition is met with, I have always endeavoured to remove as much as possible of the altered omentum. There is reason to suppose that it may give rise to pain, and even to peritonitis, when it is put back into the abdomen.

Occasionally, after a large piece of omentum has been taken away, more continues to descend into the

<sup>1</sup> *Ann. Surg.*, St. Louis, March 1893, p. 269.

<sup>2</sup> "Cure radicale des hernies," Paris, 1892, p. 396 *et seq.*

sac, and will not keep back in the abdomen. This is either due to adhesions just within the abdomen, or, as in a recent operation, to the descent of a fresh bit of omentum, which required to be removed.

### MALIGNANT DISEASE AND HERNIA.

Twice I have seen the herniated omentum infiltrated with malignant disease. Whilst helping Mr. Bruce Clarke to operate upon a woman for a very large and irreducible umbilical hernia, we found the omentum very thick, indurated, and adherent. It looked as if it was infiltrated with new growth, and the histological examination showed that it was carcinomatous. On another occasion I helped Mr. Butlin to operate upon an irreducible femoral epiplocele. Here, again, it was afterwards ascertained that the induration was due to carcinoma. These two cases have always seemed to me to be very mysterious. It is difficult to imagine a primary carcinoma of a mesoblastic structure, such as the great omentum. Nevertheless no primary growth could be discovered in either of them. In the Museum of the London Hospital is the sac of an inguinal hernia, with nodules of malignant disease in its interior.<sup>1</sup>

<sup>1</sup> Specimen 1290.

## ADHERENT OMENTUM.

Adherent omentum is one of the commonest reasons for the performance of radical cure. The following is a typical history:—C. B., æt. 22, thinks he has been ruptured since a child. Rupture goes back, but has been painful for the last four years. Has been to several truss-makers, and had about eight different kinds of trusses, but all were uncomfortable or uncertain. At the operation the sac contained omentum, which was adherent, and could not be quite reduced. The slenderest slip of omentum may prevent a truss being worn. Such a strip of adherent omentum can only be diagnosed by opening the sac. In a little boy, who could not wear a truss, all the omentum could be reduced except one long delicate strip, which was found at the operation. Exactly the same condition was found in one of our students. At ordinary times his truss kept the rupture up, but if he danced or exerted himself, it came down, and he had to return home to reduce it. Such adhesions may be suspected in those who have tried all kinds of trusses, which failed on account of pain, or because they did not retain the hernia. As Petit and Lawrence<sup>1</sup> have said,

<sup>1</sup> "A Treatise on Ruptures," 5th edition, p. 51.



only the rash think they know the contents of hernial sacs.

The omental adhesions may be so slight as to come apart when the finger is swept round the sac; or they may be very firm, and cause the greatest difficulty to the operator. On one occasion the omental adhesions took nearly an hour's hard work before they were overcome. When the adhesions are firm, not easily undone, and near the bottom of the sac, it is convenient to ligature the omentum at the internal abdominal ring,<sup>1</sup> and, after it has been divided, to remove the adherent part along with the sac.

When the omentum has been thoroughly freed, it usually slips back into the abdomen, and at once ascends towards the epigastrium. Should it linger about the mouth of the sac, adhesions ought to be suspected and sought for. It may be necessary to detach adhesions from the very mouth of the sac, and almost within the abdomen. By pulling down and incising the sac, this can be done in such a way as to allow any bleeding vessels to be seen and ligatured. The omental stump ought not to be allowed to slip back into the abdomen, but should be held within range by means of the ligature, or by a pair of pressure

<sup>1</sup> I merely use the term internal abdominal ring to indicate a locality, and not with reference to an anatomical entity.

forceps, until it is absolutely certain that it will not bleed. I have already mentioned cases in which hæmorrhage from the omentum caused a fatal ending.

Irreducible omentum is not always adherent. A young man had a large acquired inguinal hernia, with a mass of irreducible omentum. No adhesions were found, but the omentum could not be reduced, because the part in the fundus of the sac was far too big to pass through the neck. I have several times met with this impacted omentum, and generally associated with hydrocele of the sac.

#### CONTENTS OF THE SAC—INTESTINE.

As a rule, no intestine is seen during the operation of radical cure. If any presents, it can usually be returned quite easily into the abdomen. Sometimes the sacs of very large inguinal herniæ contain many feet of small intestine, usually ileum. Once I saw the operator fail to get the intestine back into the abdomen. I have heard of cases in which it was resected. I attribute the absence of difficulty in my own cases to the case with which the bowel can be thrust back into the abdomen when the sac is opened by the inguinal incision. Once returned, it is easily kept back with

a sponge<sup>1</sup> until the neck of the sac is secured. The reduction of the intestine is rather a knack. The bowel bears a good deal of vigorous handling when it has not been strangulated, and the hinder part is easiest to reduce first.

The small intestine may be fixed to the sac by inflammatory adhesions. As a rule, these can be separated; but in a case of femoral hernia they were so firm that I left the piece of sac upon the intestine, with which it was reduced into the abdomen. It was as far as possible covered with peritoneum, drawn over it with fine sutures. This is a wise precaution when the intestine has been denuded of serous covering, otherwise troublesome adhesions are formed. It also stops any oozing of blood from the vascular intestine.

In very large inguinal ruptures, the sac grows bigger at the expense of the peritoneum which lines the iliac fossa. The serous membrane, together with the cæcum and ileum or the sigmoid flexure, is displaced bodily down the back of the sac, to which the viscera continue fastened by their original folds of serous membrane.

Great care should be taken not to injure these so-

<sup>1</sup> Secured with a string or tape, or pair of clamp forceps. It is very easy to lose sponges within the abdomen.

called "natural fleshy adhesions." When I have met with this condition, it has been overcome by dividing the sac half an inch below the adherent cæcum, ileum, or sigmoid flexure, so as to allow the bowel and peritoneum to be pushed back again into the iliac fossa, thus reversing their descent, and without any danger to their vascular supply. After reduction, the sac is sutured in the manner described hereafter.

In congenital herniæ a peritoneal fold often runs along the back of the sac, and unites the epididymis to the cæcum, ileum, mesentery, vermiform appendix, or sigmoid flexure. This is the upper fold of the mesorchium, which I have elsewhere named the *plica vascularis*.<sup>1</sup> I gave it this name to indicate that it carries the vascular supply of the testicle. Obviously, it has to be divided with care, otherwise the testicle may be deprived of nourishment, and slough or become atrophied.

The occasional persistence of the *plica vascularis* explains those cases of congenital hernia in which the cæcum, ileum, vermiform appendix, or sigmoid flexure is dragged down the back of the sac into the scrotum, following the testis in its transit.

<sup>1</sup> Hunterian Lectures "On the Development and Transition of the Testicles," p. 109.

The vermiform appendix is occasionally found in hernial sacs. In cases where this has occurred, I have seen it either pushed back or removed. As the removal is such a slight addition to the operation, and as the herniated appendix is so often abnormal,<sup>1</sup> it ought generally to be taken away. In the case of a youth, I found a long appendix in the sac of a congenital inguinal hernia of the right side. It contained several concretions. The removal was done in the usual way, which is as follows:—When a meso-appendix is present, it is transfixed and tied; next, a peritoneal flap is cut out to cover the stump of the appendix; then the muscular and mucous coats of the appendix are bared by stripping back the peritoneal flaps; and, last, the bared muscular and mucous coats are encircled with a fine silk ligature, and cut across. It is as well, before closing the peritoneal flap over the stump, to touch the interior of the mucous coat with an actual cautery, or with pure carbolic acid.

He who undertakes the operation of radical cure must be prepared for the most difficult and dangerous complications. I saw my colleague, Mr. Bruce Clarke, operate upon a boy upon whom a radical cure had

<sup>1</sup> For more information see an excellent paper by Mr. Eccles, "On Hernia of the Vermiform Appendix," *St. Barth. Hosp. Rep.*, London, 1896, vol. xxxii. p. 93 *et seq.*

been attempted before, but abandoned, because the bowel could not be reduced. He was obliged to resect the cæcum and adjacent intestines, and after this brilliant procedure the boy made a rapid recovery.<sup>1</sup> On another occasion, I also saw my colleague, Mr. Howard Marsh, meet with a Meckel's diverticulum in the sac of a congenital inguinal hernia of the right side. It was adherent to the sac and to the testicle. This patient ultimately died of peritonitis. An operation had been attempted elsewhere, and had left a septic sinus, probably communicating with the interior of the bowel.

<sup>1</sup> "A Case of Excision of the Cæcum, etc.," *Trans. Clin. Soc. London*, 1893, vol. xvi. p. 200.

## CHAPTER IV.

### CONTENTS OF THE SAC—MALPOSITIONS OF THE TESTICLES — HERNIA OF THE OVARY AND FALLOPIAN TUBE—CONGENITAL HYDROCELE.

At this stage we have often to decide what ought to be done with a retained testis. I have met with this complication twenty-eight times,<sup>1</sup> in 149 male patients operated on for the cure of non-strangulated inguinal hernia—

Both testes retained	4
Right only	9
Left only	14
Doubtful	1
Total	28

In these operations the retained testis was treated as follows—

Pushed back into the abdomen	1
Removed	3
Placed in scrotum	24
Total	28

---

<sup>1</sup> Five of these cases were mentioned in the *Lancet*, 25th November 1893.

The testicle may be arrested in any part of its transition, but most frequently it is in the inguinal canal, where it is apt to get nipped, and is in the way of a truss. Sometimes, however, it easily slips back from the inguinal canal into the abdomen. Another common place for the testicle is just outside the external ring, lying upon the aponeurosis of the external oblique and in front of the inguinal canal. Here it may also hinder the wearing of a truss, and may be otherwise uncomfortable. It is very difficult at times to tell whether the testicle is outside or inside the canal. In the case of a boy of 11, with retained testicle, the general opinion was that the gland was in the canal, and could be pushed into the abdomen. As a matter of fact, it lay in a closed sac upon the aponeurosis of the external oblique. The external abdominal ring was small, and when the inguinal canal was explored, it contained a funicular sac. This case is rather significant when we remember that trusses are ordered for such cases. The effect upon the retained testicle is quite ignored, and it is supposed "to return into the abdomen and take care of itself."

Whilst operating upon a young gentleman who had the left testicle upon the aponeurosis of the external oblique, and over the canal, a very large varicocele



was also found. This gave rise to troublesome hæmorrhage at the operation, and would probably have interfered with the wearing of a truss.

Cases in which the testicle is retained outside the canal are particularly favourable, because the organ is well grown, and can easily be transplanted into the scrotum. It is also favourable if the testicle lies in the canal but has been known at times to pass into the scrotum.

The statements of patients on this point cannot be relied upon, because I have known them to be deceived by the descent of the omentum.

When the testicle is retained in the inguinal canal, the processus vaginalis, in which the testicle lies, usually communicates with the general peritoneal cavity. In some cases the opening is large, in others none exists. For instance, in a man with both testicles retained in the inguinal canals, I found the left in a capacious sac, which did not communicate. But a hernial sac was found behind the upper end of this testicular sac, like that of infantile hernia (*vide* Fig. 12, *f*, p. 106).

When the testicle is retained outside the canal, I have sometimes failed to find a communication, or have only found a long slender canal. But the presence of a hernial sac within the canal is to be sus-

peeted in every case, even although the testicle itself is in a closed sac. Therefore in these cases I always explore the inguinal canal as a precautionary measure. A case has just been mentioned in which a funicular sac was found.

The extent of the processus vaginalis varies a good deal when the testicle is ill-deseended.<sup>1</sup> Sometimes it does not reach beyond the external abdominal ring, and, being expanded within the inguinal canal, pushes itself betwixt the muscles of the abdominal wall, thus giving rise to interstitial hernia. When the processus vaginalis stops in the canal, the corresponding side of the serotum is not, as a rule, properly developed. Or the processus vaginalis may emerge at the external abdominal ring, and then expand and turn upwards over the aponeurosis, upon which, as I have just said, the testicle lies.

Or the processus vaginalis may reach the bottom of the serotum, although the testicle has remained in the inguinal canal. In this case, both sides of the serotum are properly developed. The patient may say that at times he feels the testicle pass into the serotum. At the operation it is usually found that this was impossible, and that he had mistaken the omentum for the

<sup>1</sup> As the fetus is upside down when the testicle enters the serotum, the word descent is hardly correct, although sanctioned by custom.

testicle. Once the bottom of the processus vaginalis was full of turbid fluid mixed with blood. The testicle was retained and complicated with intestine which was strangulated and gangrenous.<sup>1</sup>

The retained testicle is fastened to the back of the processus vaginalis by the mesorchium. Its mobility mainly depends upon the length and looseness of this fold or mesentery. The upper fold of

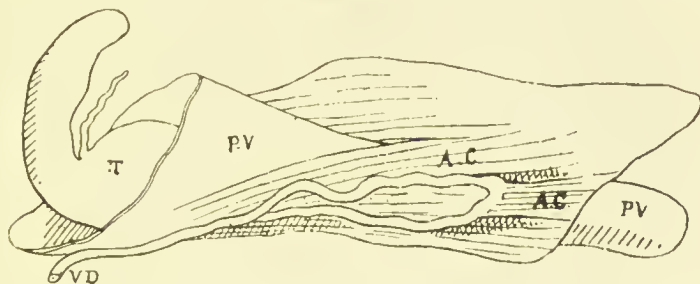


FIG. 9.—The testicle retained within the abdomen. The vas deferens loops down towards the external abdominal ring. See Hunterian Lectures, Fig. 17, p. 48. AC, ascending cremaster; PV, processus vaginalis; T, testicle; VD, vas deferens.

the mesorchium, the plia vasularis, as I have just said, contains the spermatic vessels, and therefore has to be divided with great care. The vas deferens lies behind the processus vaginalis. Its course is variable, and not infrequently it loops down the back of the processus towards the serotum, reaching some distance beyond the testicle (Fig. 9).

<sup>1</sup> C. B. Lockwood, "A Case of Resection and Immediate Suture of Intestine," *Med.-Chir. Trans.*, London, 1874, vol. lxxvii.

At other times it is tortuous. Both of these conditions are favourable, because they allow the testicle to go into the serotum when the sac has been cut across.

More information is wanted about the functional

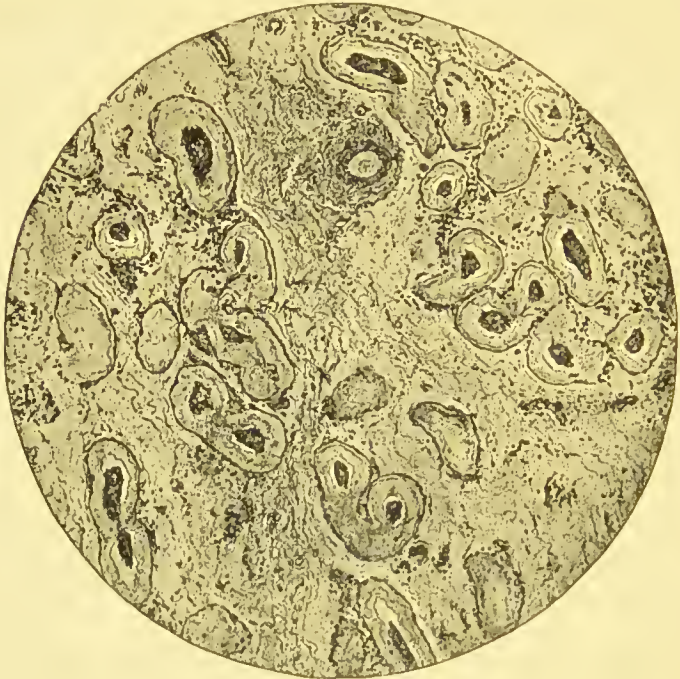

FIG. 10.—From a Microphotograph of section of undescended testicle. See also *Trans. Path. Soc. London*, vol. xlviii. Fig. 6, p. 187.

value of these undescended testes. As a rule, they are only half grown, and feel much softer than the normal gland. Sometimes the epididymis is separated from the body of the testis. Their histological structure has lately been investigated by Griffiths,<sup>1</sup> Shat-

<sup>1</sup> *Journ. Anat. and Physiol.*, London, vol. xxviii. pp. 209-221.

tock,<sup>1</sup> and myself.<sup>2</sup> The epididymis is normal, but the body of the testicle contains too much connective tissue, and too little secreting substance.<sup>3</sup> The seminiferous tubules are small, and contain ill-developed spermatoblasts and no spermatozoa. But all these observations have been made upon testicles which were removed from adults. I am watching with interest the boys whose testicles have been transplanted into the scrotum.

In one case the organ has certainly grown bigger since I placed it there. It seems possible that some of these retained testicles may develop when they have been put into their proper place.

When the testicle is retained in the abdomen, it cannot always be transplanted into the scrotum. Several times I have dissected the bodies of these cryptorchids, and found the spermatic vessels and vas deferens too short to allow the testicle to be dragged further than the inguinal canal. Nevertheless, in one of my operations, I found that, although the testicle was within the abdomen, yet its mesorchium, vessels, and vas were so loose and so long, that it

<sup>1</sup> *Brit. Med. Journ.*, London, 20th February 1897, p. 460.

<sup>2</sup> *Trans. Path. Soc. London*, 1897, vol. xlviii. p. 137, Fig. 6.

<sup>3</sup> Owing to Mr. Curling, the London Hospital Museum is rich in specimens of this kind. One retained testis is said to be fibrous, No. 1980. In another case the vesicula seminalis on the side of the retained testis contained no spermatozoa, No. 1983.

could be got into the scrotum. It is probable that in this case the testicle used to enter the canal at times. This distinguishes it from a case of true cryptorchismus, in which the testicle is always in the abdomen. When the testicle is in the inguinal canal, it may be—(a) Pushed back into the abdomen; (b) excised; (c) transplanted into the scrotum. I have only pushed the testicle back into the abdomen in one case. The patient had both testicles in the inguinal canals. The right was brought down into the upper part of the scrotum, but with difficulty, the cord being very tight. The left was so ill-developed, with a wide separation of the epididymis from the body, that I had no alternative but to push it back into the abdomen, or take it away. Lest the right testicle might have been injured in dragging it down, the first alternative was chosen. This man was examined two and a half years after. Both the ruptures had been cured by the operation. The left testicle had caused no inconvenience whatever. The right had reascended to the external abdominal ring. It was smaller than an ordinary testicle, but felt normal. It was out of the way of a truss, had one been necessary.

In 1893 I helped my friend and colleague, Mr. Bowlby, to operate for the radical cure of a right

inguinal hernia, complicated with retained testis. The latter was pushed back into the abdomen, whither it went with great ease. For a few months the testicle could be felt in that position, and was a little swollen and tender. At about the end of a year it became quite painless and comfortable. The hernia, too, had been cured.

More information is needed upon this question, but, on the whole, it seems as if it might be better not to push the testicle back, unless there was some strong reason for so doing, as, for instance, in such a case as that of the double retained testis which has just been mentioned.

Griffiths returned dogs' testicles into the abdomen, and found that those of puppies' underwent little change until puberty; that after puberty the pushed-back testes grew a little; whilst, when adult testes were pushed back, they soon dwindled to half their previous size.<sup>1</sup>

When the other testicle is in the scrotum, it is less imperative to try and preserve that which is retained in the inguinal canal. But in young adults it seems possible that the gland may grow after it has been put in the scrotum, and therefore every attempt should be made to place it there. It is otherwise with

<sup>1</sup> *Journ. Anat. and Physiol.*, London, vol. xxviii. p. 218.

the ill-developed retained testicles of adults. After transplantation, they either waste or remain the same size. I therefore ask for permission to perform excision, should transplantation prove to be impossible. After the testicle has been taken away, it is much easier to close the inguinal canal. But patients are naturally most reluctant to part with a retained testicle, and are much gratified if nothing better than an atrophied organ can be preserved.

The testicle was removed thrice in the twenty-eight cases; twice because it was so atrophied; once because it was atrophied and painful, with vessels and vas deferens very short. A very abnormal testicle, with a wide separation betwixt the body and epididymis, might also require removal.

The removal of the ill-developed testicle seems to make no appreciable difference in the shock of the operation.

The spermatic vessels and vas deferens were merely included in the ligature which secured the neck of the sac. I have not yet seen pain or unusual symptoms follow this method.

The ease with which the testicle can be transplanted from the groin into the scrotum depends upon the place where it has stopped. As I have said, the easiest cases are those in which the testicle has passed



beyond the external abdominal ring, and then turned up again on to the aponeurosis of the external oblique. In four I have found the spermatic vessels and vas deferens quite long enough to let the testicle be shifted to the bottom of the scrotum without inversion. After this has been done, the communication with the abdomen is searched for with a probe, and more than once I have found a long narrow canal. Then all the redundant sac is removed, as in the operation for hydrocele, and the testicle fixed, as will be described presently, in the scrotum. Afterwards, the inguinal canal is opened, and a careful search made for the upper part of the processus vaginalis. I have sometimes found it open, although a hernia had never occurred.

But when the testicle is in the inguinal canal, the spermatic vessels and vas deferens are usually too short to allow the testicle to descend much further than the pubic crest, if so far. However, it can be got a little further down by cautiously dividing the peritoneal sac and the tissues round the globus major, and then down each side of the epididymis. This cut passes through the plica vascularis, and exposes the spermatic vessels and vas deferens, as well as the muscular fibres of the internal cremaster, which envelop them. Some of these latter may require division. The good effects of this treatment of the sac and fibres

are often very marked. But if it should not suffice, the testicle can be inverted.<sup>1</sup> As is well known, the vas deferens and spermatic vessels run downwards behind the epididymis to enter below at the globus minor. By separating the cord from the epididymis, the testicle can be inverted, so that the globus major becomes its lowest part. A fishing-gut suture is passed through the serous covering of the globus major. The two ends of this are carried by a needle through the bottom of the scrotum, so that they emerge half an inch apart. Finally, they are pulled tight, to draw the testicle into the serotum, and tied over a roll of iodoform gauze. In from twenty-four to forty-eight hours this suture is easily cut and pulled out. The punctures are protected by dusting them with iodoform powder.

In separating the cord from the back of the epididymis, the branch of the spermatic artery to the epididymis is cut through, but I have been surprised to see how much can be done without cutting off all the blood supply of the testicle. It continues to bleed freely, when hardly anything is left except the vas deferens and its artery.

I have inverted the testicle fifteen times, in order to

<sup>1</sup> Inversion of the testicle was, I believe, first practised by Mr. John Wood. My knowledge of this ingenious device was derived from Mr. Bidwell.

transplant it from the groin into the serotum. Seven of these have been examined after intervals of six months (two cases) and ten months (two cases), and of one, two, and three years. The transplanted testicle had not atrophied in any. In that which was seen after three years it felt quite natural, and both the patient and myself thought that it had grown.

Transplantation of the testicle is usually followed by orchitis.<sup>1</sup> Probably this complication is of little consequence. It occurred in a case which was seen after an interval of ten months. This testicle was half the size of its fellow, and felt quite natural. It lay half-way down the serotum. The patient was exceedingly pleased that it had been preserved. In all the other cases, the transplanted testicle lay far enough down the serotum to be out of the way of a truss, had one been required.

Transplantation of the testicle does not seem to add to the risks of radical cure. It is true that I have had the first misfortune to have a fatality in this class, but the boy's death was due to the anæsthetic. The operation was done because the omentum was adherent to the sac, and irreducible.

<sup>1</sup> Recently I ordered a young gentleman with a retained testicle to wear a horse-shoe truss. The organ suddenly descended into the serotum and underwent a sharp attack of orchitis.

In each of the seven cases which came to be seen, the hernia was cured.

Cases of hernia which are complicated with retained testis are not always the most favourable for a curative operation, because the back of the inguinal canal is sometimes ill-developed and exceedingly difficult to repair. However, the retained testis often renders treatment by a truss too painful to be borne,—a disability which a proper operation is sure to overcome.

In operating upon a man, *æt.* 22, I found it rather difficult to find room for the testicles in the scrotum, because that receptacle had only partially grown. This suggests another reason why the operation should not be put off too long.

Hitherto I have seldom operated before 12 years of age. It seems reasonable to choose a time a little before the gland begins its normal growth and evolution, that is to say, just before puberty. In younger children the organ itself and the vas deferens and spermatic vessels are so small as to be in danger of injury. Nevertheless special reasons may exist for operating earlier. My youngest patient was 7 years old.

In infants I have succeeded in getting the testicle to descend into the scrotum by teaching the nurse to

push it down, and then applying an indiarubber truss with a horseshoe-shaped pad.<sup>1</sup> This, however, requires much care and intelligence on the part of the nurse.

All the foregoing are cases of arrest of development. Two others have been met with in which, by too great action of the perineal fibres of the gubernaculum, the testis had been dragged into the perineum.<sup>2</sup> Neither required an operation. One was an infant, sent by my friend Mr. Stephen Paget. The other was a man who came because he had gonorrhœal epididymitis in the displaced organ, and could not sit down. In many of these cases the processus vaginalis is patent, and accompanies the testis into the perineum. More than once septic peritonitis has followed attempts to replace the testis in the scrotum.

#### HERNIA OF THE OVARY AND FALLOPIAN TUBE.

At this stage of the operation it may also be necessary to decide what should be done with a herniated ovary and Fallopian tube. I have met with this complication twice in thirty-four operations done on thirty-two females, the rupture being double in two. As a rule, the herniated ovary cannot be

<sup>1</sup> With care and attention an indiarubber truss can be fitted to the youngest infant and worn without pain or injury, and with a fair prospect of a cure.

<sup>2</sup> For an account of perineal fibres of gubernaculum, see Hunterian Lectures "On the Development and Transition of the Testis," London, 1888, p. 103 *et seq.*

diagnosed until it has been exposed to view. I have seen that which was confidently stated to be the ovary, prove a bit of indurated omentum, or a piece of fat on the exterior of the sac.

When the ovary and tube are met with in the sac, the question arises whether they ought to be excised or pushed back into the abdomen. Our knowledge of these herniated ovaries is very incomplete, and still less is known as to their behaviour when returned to the abdomen. A herniated ovary is not analogous to a retained testis. An excess of development rather than an arrest is concerned in its production.

One of my patients was a girl, *æt.* 18. The ovary itself was small. The Fallopian tube was completely severed in two about 1 in. from the fimbriated end, and was obviously unable to transmit ova.<sup>1</sup> It seemed possible to return the ovary and tube into the abdomen, but as they were so abnormal I did not do so but cut them both away.

The Fallopian tube and ovary are not always malformed when they are herniated. Sir James Paget placed a specimen in the Museum of St. Bartholomew's Hospital,<sup>2</sup> in which the ovary is almost its normal

<sup>1</sup> The specimen is preserved in the Museum of St. Bartholomew's Hospital, No. 2113A.

<sup>2</sup> No. 2113. I am indebted to Sir James for having very kindly sent me his original notes of this specimen.

size, and the Fallopian tube well formed and pervious. Under these circumstances it would seem more reasonable to return the organs to their proper place than to remove them. Whether an ill-grown ovary<sup>1</sup> would grow after having been put into the abdomen is quite unknown. Lejars met with pus in a herniated tube which was strangulated. He opened the bladder in dissecting up the sac, and a urinary fistula ensued.<sup>2</sup>

On the second occasion I met with a herniated ovary and Fallopian tube under very unusual circumstances. An infant, 6 months old, seemed to have an inflamed or strangulated inguinal hernia. When the sac was opened, the ovary and tube, both intensely engorged with blood, came into view. Their condition was due to a twist in the pedicle<sup>3</sup> (Fig. 11). They were excised, being too much damaged for replacement within the abdomen. I also helped

<sup>1</sup> Professor Milling returned herniated ovaries and tubes on both sides. The patient was *æt.* 19, and had not menstruated. *Epitome, Brit. Med. Journ.*, London, January 7, 1892. Brünner pursued the same course.

<sup>2</sup> *Rev. de chir.*, Paris, January 1893. Abstracted in *Brit. Med. Journ.*, London, March 11, 1893.

<sup>3</sup> C. B. Lockwood, "Hernia of the Ovary in an Infant, with Torsion of the Pedicle," *Brit. Med. Journ.*, London, June 13, 1896, p. 1442. Mr. Edmund Owen has described a similar case, *Lancet*, London, March 21, 1896, p. 765. Surgeon-Captain Hornby has also mentioned a case with like characters, *Brit. Med. Journ.*, London, January 4, 1896, p. 17.

Mr. Butlin to remove a herniated ovary and tube. The sac was full of blood-stained fluid, and an

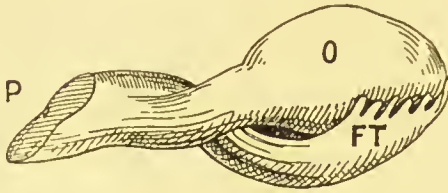


FIG. 11.—Hernia of ovary and Fallopian tube, with torsion of the pedicle. FT, Fallopian tube; O, ovary; P, pedicle.

attempt at reduction had been made, the local symptoms having simulated strangulated hernia. The ovary was small, and the inflamed and

the swollen Fallopian tube possessed no fimbriæ.

#### INGUINAL HERNIA AND HYDROCELE.

Inguinal hernia may be complicated by various kinds of hydrocele. A patient over 50 years of age, who came from South America, had upon the right side both a huge acquired inguinal hernia and a very large hydrocele of the tunica vaginalis. The sacs of these had no communication whatever, and it was a mere coincidence that they should have occurred together. So far as concerns the hydrocele, the treatment was very simple, and hardly any addition to the danger of the operation. It was cured by removing the parietal layer of the tunica vaginalis in the manner described hereafter, and the hernia was reduced and made amenable to



a truss by excision of a huge lump of adherent omentum, by removal of the sac, and suture of the abdominal opening. Owing to the great size of the hernia, and the tropical life of the patient, this was a formidable proceeding.

The sac of a congenital hernia may contain hydrocele fluid in its testicular part, and bowel or omentum in its upper. Both of these combinations have been met with. A man seemed to have an ordinary hydrocele. The tunica vaginalis was full of translucent fluid, which was free from impulse. The cord above the testicle was thick and hard. At the operation the neck of the sac was, as I had suspected before the operation, tightly packed with adherent and indurated omentum, which was most difficult to separate and remove. The operation lasted nearly an hour and a half. Doubtless the hydrocele is caused by changes in the omentum, which from a state of passive engorgement becomes at last chronically inflamed within the hernial sac. In another similar case of fluid in the sac, the omentum was strangulated with non-passage of flatus or feces, but without vomiting, only nausea. Another case of congenital hernia had strangulated intestine in the neck of the sac, and grumous fluid in the testicular. The day before, a medical man had drawn off a quantity of hydrocele fluid which, from

thè history, had been there for some time, and was not the ordinary effusion seen in the sacs of strangulated herniæ. Fortunately in this case the puncture had been made below the bowel, and no harm had ensued, beyond perhaps some hæmorrhage into the sac.

Hydrocele fluid in the sac of a congenital hernia, or in a tunica vaginalis which does not communicate with the hernial sac, is cured by a slight addition to the ordinary operation of radical cure. It is merely necessary to remove the parietal layer of the tunica vaginalis. This can sometimes be done by pulling the hydrocele up into the inguinal incision. But when the hydrocele is large, the usual scrotal incision has to be made, in the manner described on page 245.

A hydrocele of the cord may complicate inguinal hernia. A youth came with a small tense hydrocele of the cord. It was above the tunica vaginalis, and just outside the external abdominal ring. He stated, however, that at times another protrusion appeared above the hydrocele. After a few days in bed, this hydrocele disappeared. At the operation its sac was opened, and found to have a long and narrow tube leading into the abdomen.

Congenital hydroceles in boys are to be suspected. I now unhesitatingly explore the inguinal canal when

curing the hydrocele. The following case illustrates the advantages of this step:—

A boy, æt. 12, had a hydrocele of the cord. It reached from just above the testicle to the external ring. Its sac did not communicate with either the tunica vaginalis or the abdomen, but a little serous canal,  $\frac{3}{4}$  in. long, ran up the cord from its highest part, and when the inguinal canal was explored a large hernial sac was found. He said he thought that he had worn a truss when an infant. In neither of these cases were any sutures put in the back of the inguinal canal, as it seemed almost perfect. The aponeurosis of the external oblique was closed in the usual way.

## CHAPTER V.

### SEPARATION OF THE SAC—PECULIARITIES IN THE SAC—HERNIA OF THE BLADDER.

IN congenital inguinal hernia the sac and spermatic cord will be found closely adherent to one another. Generally the spermatic vessels run along the back of the sac in the *pliega vascularis*. They are least adherent at the internal abdominal ring, and most adherent at the lower part of the inguinal canal and near the testes. Within the abdomen the vas deferens and spermatic vessels run apart from one another. The vas is not adherent to the peritoneum, but moves about quite freely. The spermatic vessels are merely fastened to the peritoneum by a little loose connective tissue and by a few recurrent branches. At the internal abdominal ring the vas and vessels converge, and enter the inguinal canal together with the hernial sac, to which they do not for the first half inch attach themselves at all closely. I am therefore accustomed to begin the separation of the hernial sac from the

spermatie cord as high up as can be done without dividing any of the muscular fibres of the internal oblique and transversalis muscles. If cutting instruments be used for this purpose, the small vessels which supply the sac are apt to bleed, and therefore it is easiest to pull the cord and its constituents gently away from the sac with a pair of dissecting forceps. At the same time the sac itself is steadied by holding the edge of the opening in the grip of a pair of pressure forceps. When the sac is small it may be stripped entirely from the cord, but when it is long the separation is much facilitated by cutting it across about an inch from the internal abdominal ring. This is done by dividing the sac bit by bit, as the cord is separated from it. When a truss has been worn, this part of the operation is harder, because all the structures are matted together.

As a rule, when the sac has been cut across, its lower end requires no further attention.<sup>1</sup> But if it does not fall back into the scrotum, or if it be at all bulky, the part of it within the inguinal canal ought to be taken away by continuing to strip the cord off

<sup>1</sup> It is quite unnecessary to sew up the lower end of the sac. If that is done fluid may accumulate in its interior. I have lately had a case in which blood accumulated in the lower part of the sac, although no sutures had been inserted. A cyst was formed which had to be removed.

it until it can be entirely removed, or cut off at the level of the external abdominal ring.

#### ACTION OF THE INGUINAL CANAL.

*Sphincter action.*—A little consideration will show that it is essential to leave nothing in the inguinal canal which can with safety be removed. If during an operation the patient vomits or strains, the action of the inguinal canal is clearly revealed. In a muscular subject it closes with considerable force, and pushes out the finger. This happens because the front and back walls are forcibly brought together, and at the same moment the arciform fibres (*vide* Figs. 14 and 15, pp. 129, 130) of the internal oblique and transversalis shorten and descend upon the spermatic cord, press it down upon Poupart's ligament, and so obliterate the gap which would otherwise remain betwixt them and that structure. Poupart's ligament also takes a share in closing the inguinal canal. At rest, it forms a slight curve, with its convexity towards the thigh. When the external oblique contracts, it becomes straighter and more rigid, and is nearer to the arciform fibres.

Obviously the spermatic cord is at all times a bar to the complete closure of the inguinal canal. Much more, then, is it undesirable to leave anything addi-

tional, such as a hernial sac, varicose veins, or a lipoma of the cord.

When the testicle is taken away, it is quite unnecessary to separate the lower part of the sac from the cord, as they can be taken away together. Thus castration makes the operation easier, and also improves the chances of a permanent cure, because it empties the inguinal canal. In some enormous congenital inguinal herniæ upon which I have operated, and in others which I have dissected, the testicle has been so flattened out and atrophied by pressure that it could not have had much functional value. Before undertaking these huge herniæ, I always ask for leave to remove the testicle, if that step should seem desirable. Furthermore, the vas deferens and spermatic vessels sometimes suffer severely during their separation from the back of the sac. Whilst doing this, it is well to remember that the vas deferens lies nearer the middle line of the body than the vessels, from which it may be separated by a wide interval.<sup>1</sup>

#### PECULIARITIES IN THE CONSTRUCTION OF THE SAC.

*Constrictions.*—The sac of an inguinal hernia may be constricted in any part of its length. These constrictions

<sup>1</sup> For an explanation, see "Development and Transition of Testis," p. 116, Fig. 56.

tions are either developmental, and a kind of attempt at the natural process of closure of the processus vaginalis, or they may be acquired. The ring of peritoneum round the mouth of the hernial sac has a curious tendency to thicken and contract by a process of chronic inflammation. Sometimes the hernia pushes this thickened and contracted ring down the inguinal canal, until it is some distance away from its original position,—the internal abdominal ring.

A constriction of this kind might be mistaken for the mouth of the sac. Whilst operating upon an epiplocele this error was made. The omentum had been tied in the usual way, but, when pushed through what was supposed to be the mouth of the sac, it refused to disappear into the abdomen. When the sac was slit up, the omental stump was found still in the upper part of the sac, lying betwixt its real mouth and the constriction, which was about an inch lower down.

#### REDUPLICATION OF THE SAC.

These constrictions also give rise to another variation of the sac, an example of which was met with during an operation upon the left inguinal hernia of a man, *æt.* 36. He had an ordinary acquired hernia with a capacious sac. About half-way down the back



of this was a small circular aperture, which led into a second sac that ran downwards behind the hernial sac.<sup>1</sup> The explanation of this second sac, as Cloquet and others have pointed out, is probably as follows:—The usual ring is formed at the mouth of the sac, and gradually contracts, until, at last, the hernial protrusion finds it hard to pass through. Then it continues to push the peritoncum onwards, and to make a new sac by the side of the ring, which of course leads into the new sac.

The hernial sac may have other kinds of protrusions, probably of the same nature as that which has just been described. During an operation by one of my colleagues, I saw a considerable offset spring from the front of the sac of a right inguinal hernia. It arose opposite the external abdominal ring, and then ran for about  $1\frac{1}{2}$  or 2 in. upwards and outwards upon the aponeurosis of the external oblique, lying superficial to the inguinal canal.

#### INFANTILE HERNIA.

Sometimes the hernia is into an infantile sac.<sup>2</sup> In this condition the processus vaginalis remains un-

<sup>1</sup> This specimen is in the Museum of St. Bartholomew's Hospital.

<sup>2</sup> I have given an account of infantile hernia in "Hunterian Lectures on Hernia," p. 153 *et seq.*, and in *Med.-Chir. Trans.*, London, vol. lxi. p. 479 *et seq.*

obliterated, either wholly or in part (*vide* Fig. 12), and a second peritoneal pouch or additional sac is pulled down behind it by the gubernaculum testis. This curious arrangement has sometimes proved very embarrassing, and, being unrecognised, has on more than one

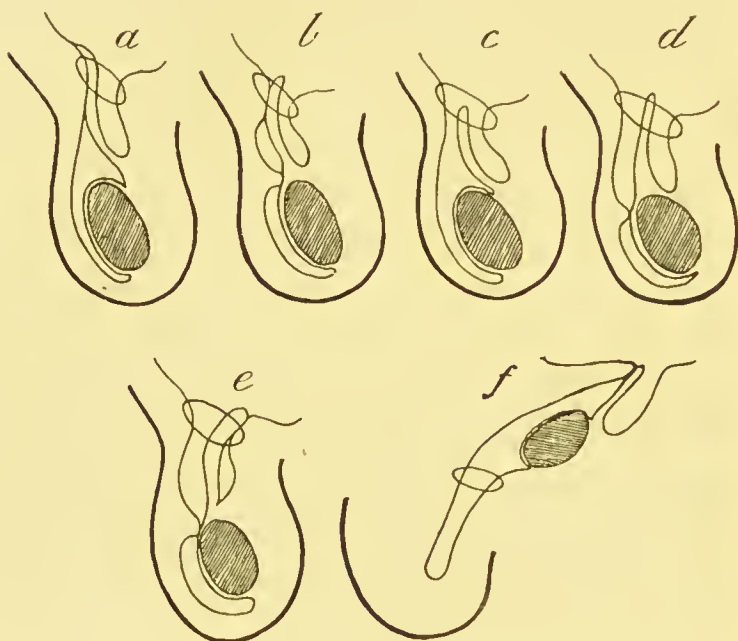


FIG. 12.—The varieties of infantile hernia.

occasion, when the hernia was strangulated, led to the death of the patient, the operator having failed to find the hernia.

I once met with an infantile sac under rather unusual circumstances. A young man had double

inguinal herniæ, with retained testes in both sides. Whilst operating upon the left, I found the testis projecting into a large sac, which reached from the scrotum as high as the peritoneum, but had no communication with the abdominal cavity. Behind its upper part, and closely connected with the spermatic cord, was a hernial sac about  $2\frac{1}{2}$  in. long (Fig. 12, *f*).

A sac closely allied to that of an infantile hernia was found whilst operating upon a boy for a large left inguinal hernia. The testis lay in a normal tunica vaginalis, but the upper part of the processus vaginalis was unobliterated, and formed the sac of a funicular hernia. Behind this was a blind sac, with rather thick walls of serous membrane, and containing a little hydroecle fluid (Fig. 12, *e*). The vas deferens and spermatic vessels were closely adherent to this sac, and this made the operation very long and tedious.

#### HERNIA OF BLADDER.

The urinary bladder, or a diverticulum of it, may be met with in the operations upon either congenital or acquired herniæ. This organ adheres to the outside of the sac, and seems very hard to recognise. As

a rule, it is not known that it has been opened until urine begins to flow,<sup>1</sup> although the appearance of muscular fibres has saved Krönlein, Kummer, and Walter from this accident. A youth upon whom I operated had a strange history. Wishing to enter the army, he had a right inguinal rupture operated upon by Mr. Johnson Smith. At this operation Mr. Johnson Smith (to whom I am indebted for kindly writing to me about the man), in detaching an unusually large piece of fat, opened the bladder, or rather, as he says, a finger-like prolongation of that organ. The aperture just admitted the little finger, and had to be closed again with two or three silk sutures. Some months afterwards, the same patient came to me to have a radical cure done upon an inguinal hernia of the left side. The operation did well, but he complained of increased frequency of micturition, and pus was found in his urine. With an endoscope, two small calculi were seen in the bladder, and I cured him by performing lithotrity. No bits of silk could be found in the detritus. There was no evidence in this case to show whether the bladder

<sup>1</sup> In Michel's case the accident was recognised by the passage of blood with the urine. Thirty hours after the operation, the wound and the abdomen were opened, and the bladder successfully sutured. —“A Case of Extraperitoneal Vesical Hernia,” *Med.-Chir. Trans.* London, 1894, vol. lxxvii. p. 229 *et seq.*

had been pulled down with the peritoneum during the formation of the sac of an acquired hernia, or whether it had been pulled down by the gubernaculum during the transition of the testis. I saw my colleague, Mr. Maeready, unwittingly ligature a bit of the wall of the bladder whilst operating upon a femoral hernia. No leakage occurred at first, but afterwards some urine ran from the wound, but ceased of its own accord. Obviously this must have been an acquired condition. Should the bladder be wounded, it is clear, from the teaching of my case, that the sutures must be passed with great care, so as to prevent them from entering the bladder. They ought to be inserted by Lembert's method into the muscular coat, and be tied upon the outside of the bladder. Properly prepared raw catgut would be the safest material for the sutures.<sup>1</sup>

<sup>1</sup> Raw catgut prepared as follows is always sterile, and makes excellent sutures and ligatures. Wind the raw catgut on a board, and scrub with soap and water; extract with ether the fat and grease put on by the manufacturer; disinfect by soaking for not less than seventy-two hours in 1 in 250 watery solution of biniodide of mercury. The prepared catgut is kept in a bottle of the same solution, and is quite strong and good months after it has been prepared.

## CHAPTER VI.

### CONTENTS OF THE INGUINAL CANAL—LIPOMA OF THE CORD—INGUINAL VARIX.

I HAVE already said that one of the chief objects of the operation of radical cure of inguinal hernia is to take away anything which interferes with the valve or sphincter-like action of the inguinal canal. At this stage of the operation it is easy to see how the inguinal canal closes whenever the muscles contract. The descent of the arciform fibres of the internal oblique and transversalis upon Poupart's ligament is exceedingly forcible. The importance of this action is too obvious to need pointing out, and it is evident that anything which prevents it ought to be taken away. Removal of the spermatic cord is out of the question, although, as I have said, when castration is practised, the operation is easier, and probably gives better results. But in about 3 per cent. of my cases the inguinal canal was occupied by a considerable mass of fat, or, in other words, by a lipoma of the

spermatic cord. In a rather larger proportion, about 5 per cent., there was considerable dilatation of the spermatic veins, or varix of the cord. This will be described presently. As regards lipomata of the cord, there can be no doubt but that they are not infrequently mistaken for ruptures, and are sometimes treated with trusses. A postman was refused for promotion until he had had double inguinal ruptures cured. On the right side I found the sac of an incomplete inguinal hernia, with some varix of the spermatic veins. The usual operation for radical cure was done, and the veins excised. On the left side he had an impulse on coughing, and a swelling, which could be reduced into the abdomen, and was thought to be an incomplete hernia. When the left inguinal canal was opened, a lipoma of the cord, with varix of the spermatic veins, was found, but no hernial sac. The fat and the veins were excised. For some years this man had worn a double inguinal truss. Two years after the operation his right side was perfect. On the left he had occasional pain in the testis, which however, felt quite normal.

Another youth was operated upon, after having been rejected for the army because he had hernial impulses in both inguinal canals. When the inguinal canals were opened, I found a small hernial sac in the

left, and a small lipoma in the right. Eight months after, he was quite well, but had not, having changed his mind, reapplied for admission into the army.

Yet another man had radical cure done on each side, to enable him to remain in the army. Unlike the two others, he had hernial sacs on both sides, together with lipomata. After the operation he returned to the army. In one of my earlier cases I omitted to remove a fair amount of fat from the inguinal canal of a youth who was operated upon for a left inguinal epiplocele. On reflection, this omission was much regretted. It is obvious that its removal would have involved no danger whatever, whilst its presence would interfere with the valvular closure of the inguinal canal. These lipomata are easily removed, either alone, or with the sac. They have hardly any adhesions with the constituents of the cord.

I have twice found fatty tumours in the inguinal canal of young women. In one the mass was clearly continuous with the subperitoneal fat, and had a thin-walled hernial sac in its interior. Neither the fatty tumour nor the sac was connected with the round ligament of the uterus. The patient had been able to wear a truss, but had radical cure done because she was about to be married. In the other the mass of fat was adherent to the sac and round ligament.



I have elsewhere<sup>1</sup> discussed the pathology of these lipomata of the cord. They usually arise from subperitoneal fat, which accompanies the processus vaginalis in its transition. But recently, my colleague, Dr. F. W. Andrewes, has examined a case microscopically, and found distinct adrenal structures. Evidently we have here Wolffian remains, which have undergone fatty changes.

The relationship of fatty tumours to the causation of rupture is, I believe, unknown. They are often situated at the lowest part of the sac, and it seems reasonable to think that by distending the inguinal canal, and by preventing its closure, they may act as a kind of advanced guard of the rupture, and help its descent.

The by no means infrequent occurrence of these lipomata is an additional argument in favour of always opening and exploring the inguinal canal when operating for the radical cure of hernia. It is probable that their presence can only be learned in that way. Many have been mistaken for ruptures, and trusses applied to them. Some of the patients may, as in one of my cases, have been in danger of losing appointments because of the mistaken diagnosis.

<sup>1</sup> Hunterian Lectures, "On the Development and Transition of the Testis," p. 96.

All my own cases occurred in adults. I have not yet seen a lipoma of the cord in a child, apart from hernia. Whilst helping a colleague to operate upon a little boy, a hernial sac and a lipoma were found in the inguinal canal. The lipoma was large enough to form at least a medium-sized bubonocele.

#### INGUINAL VARICOCELE.

When scrotal varicocele complicates inguinal hernia, it is nearly always on the left side. In one case a right inguinal hernia was complicated with a left varicocele. Both were operated upon at the same time. The varicocele operation will be described hereafter. In other cases the varicocele is on the same side as the hernia.

A left inguinal epiplocele was complicated with a large scrotal varicocele of the same side. The dilated veins were easily pushed up into the inguinal incision, and excised. The same course was pursued when a left scrotal varicocele was met with at the lower end of the sac of a congenital hernia. Thus a scrotal varicocele on the same or opposite side to the hernia is easily dealt with. As the operation which I do for scrotal varicocele differs slightly from that which is ordinarily practised, its details will be given later.

In a proportion of cases of radical cure of inguinal hernia the spermatic veins in the inguinal canal are varicose, although those in the serotum are quite natural. I propose to describe this complication forthwith, because it has to be dealt with at this stage of the operation.

Hitherto inguinal varicoceles have been mistaken for incomplete ruptures. This is easily done, because the swelling in the inguinal canal appears when the patient stands up, disappears when he lies down, has an impulse on coughing, is increased by exertion, and causes a pain which closely simulates that of a hernia; but, as I have just said, a scrotal varicocele is nearly always absent, and now that the condition is recognised, I am hopeful that we shall learn to diagnose it. Once I began to operate upon a youth for the cure of what was thought to be double inguinal hernia. The right inguinal canal contained a group of enormously dilated spermatic veins, exactly like a large scrotal varicocele. The left contained a similar group, together with a small empty hernial sac. These veins were excised, and the sac treated in the usual way. I regret to say that this proved to be one of the very few cases of radical cure which has caused me any anxiety. On the third day I found this youth blanched, and with

a rapid pulse and distended abdomen. As there was much induration about the left inguinal region, together with a swelling in the iliac fossa, an anæsthetic was given, and I explored the wound. A huge blood clot was removed from the iliac fossa. More blood was found in the peritoneal cavity, which was drained with a glass tube above the pubes. The source of the hæmorrhage was not discovered. He made a complete recovery, after an anxious illness. The right side healed by first intention; the left was packed with antiseptic gauze. This is the only case of mine which has been complicated with hæmorrhage. How far it was related to the varicose veins I do not know. In another case an inguinal varicocele was found under the following circumstances:—A youth, æt. 21, had a small reducible hernia of the right side. It was painful, and difficult to manage. On the left side he had a decided impulse and a bulging of the inguinal canal. We could not, however, satisfy ourselves that he had a rupture there, and the question was discussed as to whether an operation ought to be done on that side. I decided, however, to explore the canal. First, because exploration is such a harmless proceeding; and next, because I feared to overlook a hernial sac, or lipoma, or varicocele. On the right side a hernial sac was found, together with con-

siderable varix of the spermatic veins. As soon as the left inguinal canal was opened, a huge bunch of varicose veins bulged out. It was quite obvious that they were actually distending the inguinal canal. No hernial sac was found. The veins were clamped with pressure forceps above and below, removed with scissors, and each end transfixed and tied with a Staffordshire knot. In another case an inguinal varix was met with in the right inguinal canal of a young man. When, during the operation, he coughed or strained, the veins swelled up and bulged in an extraordinary manner.

A very large scrotal and inguinal varicocele was unexpectedly encountered in a case of congenital hernia. The patient was a youth in whom the left testicle and left side of the scrotum had not grown properly, and were only half the size of the right. The left testicle usually lay in the scrotum, but was frequently retracted into the inguinal canal. The congenital sac was very thin, with a huge varicocele adherent to its back part, and bulging the upper part of the scrotum, as well as the inguinal canal. This was tied at the internal ring and below, and then excised. When the operation was finished, the testicle seemed to hang by nothing but the vas; it certainly did not alter as long as the youth was under observation. On the contrary, it seemed to grow a

little bigger. Recently, I operated upon a compositor who had worn a double inguinal truss for three years. When I saw him no rupture was to be found, but, after admission, the house surgeon found, as he thought, an incomplete one upon the right side. At the operation a double inguinal varix was found. On inquiring, it was found that the lower end of the right varicocele could be felt when the testicle was pulled down.

It is not unlikely but that varix of the cord may have some relationship to the causation of inguinal hernia. Another youth was operated upon for the cure of a right inguinal epiplocele. A large varix of the cord was likewise found, and whenever he coughed or strained during the operation the veins filled with blood, and became so huge that they seemed well calculated, not only to distend the inguinal canal, but also to prevent its closure during expiratory efforts.

A youth had a congenital inguinal hernia of the left side. The testicle was ill, grown and could be retracted into the abdomen. The left side of the scrotum was also ill developed. For no obvious reason he was unable to wear a truss. At the operation a large varicocele was found in the inguinal canal and behind the sac. It was excised.

It is probable that at least two kinds of inguinal varix or varicocele may be met with. Sometimes the veins of the cord are merely dilated and more conspicuous than normal. Their walls are thin, so that the blood shows easily through, and they are easily lacerated, especially as they adhere closely to the cord and its coverings, or to the hernial sac when it exists; but although they fill the inguinal canal, they do not seem much inclined to crowd out when the aponeurosis of the external oblique is incised. Indeed, their presence is not always obvious until the later stages of the operation, when the hernial sac is being taken away and separated from the cord. Briefly, they give the impression of being a dilatation of already existing spermatic veins. In other cases, as soon as the inguinal canal is incised, a bunch of dilated veins, exactly like a serotal varicocele, hasten to protrude. These veins are numerous, have thick walls, and are not very adherent. They evidently distend the inguinal canal and prevent its proper closure during exertion. This inguinal varicocele is exactly like the serotal variety. It is doubtless of congenital origin, and is due to an overgrowth of some of the original Wolffian veins. All embryologists are familiar with the extraordinary vascularity of the Wolffian body, and are aware that at

one time that organ extends from the suprarenals to the epididymis.

I have hitherto treated all the inguinal varicoceles that I have met with in the same way as if they had been serotal. The danger of ligatures slipping and allowing hæmorrhage into the museular planes and iliae fossa has to be clearly borne in mind. The rope of veins is therefore separated from the vas and elamped as it emerges from beneath the internal oblique and transversalis museles, and below at the external abdominal ring. The intervening bit is then exeised. The spermatie artery is probably included, but I have seen no ill result follow, although I have examined many of the cases at intervals after the operation. The attempt to save the artery by disentangling it from amongst the veins has always failed. Next the two stumps are transfixed and tied with silk above and below the pairs of forceps. This is expeditiously done with a Staffordshire knot.

The removal of the varicocele leaves the inguinal canal almost empty. The vas deferens and a few accompanying vessels are all that remain. The latter seem enough to carry on the circulation of the testicle. So far no case of atrophy has occurred, and the proceeding does not seem to cause orchitis.<sup>1</sup>

<sup>1</sup> Halsted, *Johns Hopkins Hosp. Bull.*, Baltimore, No. 29, March 1893, vol. iv., has advocated free removal of spermatic veins.



Should the inguinal varicocele be unaccompanied by a hernial sac, the operation is completed by closing the inguinal canal, and dressing the wound in the manner described below.

In endeavouring to diagnose inguinal varicocele, the following points may be of assistance. First, a doubt usually exists as to the presence of a rupture; second, the rupture is incomplete; third, a truss is painful; fourth, throbbing and pain may be felt;<sup>1</sup> fifth, by pulling down the testicle the lower end of the varicocele may be felt.

Should an inguinal varicocele be diagnosed, the propriety of an operation will depend upon the amount of pain and discomfort which it causes. The fact that it may also predispose to hernia should be taken into consideration.

Once I found an inguinal and a scrotal varicocele on the same side. The swelling in the inguinal canal was so marked and had so much impulse that it was mistaken for a rupture. These symptoms were, however, caused by a continuation of the scrotal varicocele upwards into the abdomen. The veins were all excised, the ligatures being placed at the internal ring and

<sup>1</sup> An intelligent medical student upon whom I operated had a congenital hernia and an inguinal varicocele in the right side. He said he had had much throbbing in the canal. A truss was difficult to wear, and inefficient.

above the testicle; that organ being easily pulled up into the inguinal wound. This case ended in suppuration. We attributed this to imperfect disinfection of the skin, owing to injuries inflicted upon it by a careless barber. Nevertheless it is possible that, owing to their liability to bleed, this class of case may have a larger percentage of suppuration than others, such as radical cure of hydrocele.

Inasmuch as the more conservative school of surgeons apply trusses to all who complain of pain in the inguinal canal, accompanied with impulse, it is likely that a good many individuals are wearing trusses upon inguinal varicoceles, or upon fatty tumours of the cord. Perhaps I should add that in women the veins of the round ligament of the uterus are sometimes enlarged in a similar way, as will be presently described (see p. 141).

Mr. Pearce Gould<sup>1</sup> has described the case of a man, æt. 34, in whom he found a dermoid cyst of the spermatic cord simulating hernia. The patient had worn a truss for fourteen years.

<sup>1</sup> *Lancet*, London, November 4, 1893, p. 1127.

## CHAPTER VII.

### LIGATURE AND TRANSPLANTATION OF THE STUMP OF THE SAC—RESTORATION AND CLOSURE OF THE INGUINAL CANAL.

#### LIGATURE OF THE SAC.

THE sac having been cut across about half an inch from its mouth, is held in pressure forceps and thoroughly separated from the cord until its junction with the peritoneum is seen. A little pad of fat or fibrous tissue often marks that point. It lies below in the angle where the sac and the peritoneum join. Next, the stump and the neck of the sac are ligatured as follows:—One of the herniotomy needles is armed with about two feet of No. 4 or 5 twisted silk. The stump of the sac is pulled down a little, being held for the purpose by one or more pairs of pressure forceps. A few gentle twists given to the stump ensure a thorough obliteration, and prevent intestines getting into the way of the needle, which, although blunt, might do

harm. The needle is now thrust through the neck of the sac at its junction with the peritoneum, and then withdrawn, leaving the loop of silk in the neck of the sac. This loop is now pulled over the stump of the sac and tied in a Staffordshire knot, one end going above and the other below the loop (*vide*

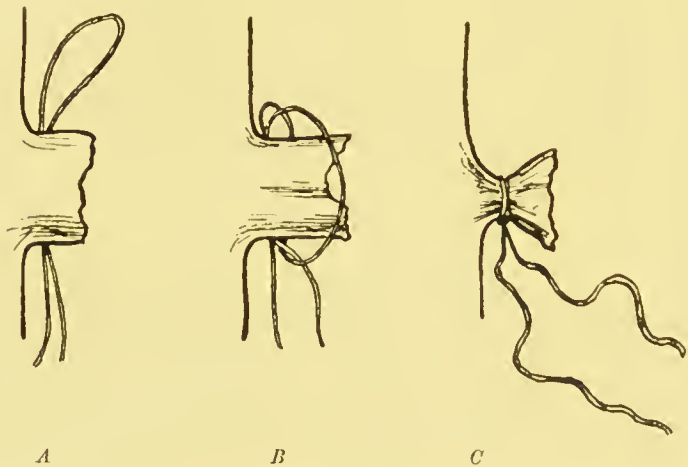


FIG. 13.—Mode of applying a Staffordshire knot to the stump of the sac—*A*, after withdrawal of the needle; *B*, loop carried over neck of sac, and ready for completion by pulling tight; and *C*, knotting the two ends.

Fig. 13). This knot cannot slip off the stump, is very easy and expeditious, and leaves two ends of silk for the next stage,—the transplantation of the neck of the sac. The transfixion is very important. Edwards<sup>1</sup> has, with great honesty and candour, narrated a case in which the ligature slipped

<sup>1</sup> *Ann. Surg.*, St. Louis, vol. i. p. 120.

off the neck of the sac, leaving a huge gap, through which the intestines gushed. In one of my cases the ligature broke, but I was able to seize the stump and apply a new ligature.

A Staffordshire knot can only be applied when the neck of the sac is of moderate dimensions. It is, however, remarkable how the largest sacs shrink when they have been emptied. Should the neck of the sac be enormous, it is laced with a series of transfixing sutures in exactly the same way as the omentum (Fig. 8, p. 69). Two, three, or even four transfixions have been required in some of my operations. In these severe and neglected ruptures the inguinal canal does not exist, and the operation has to be modified to meet the exigencies of the case. Such severe procedures are not, as a rule, undertaken to cure, but to enable the patient to wear a truss.

#### TRANSPLANTATION OF THE STUMP OF THE SAC.

After the neck of the sac has been ligatured, the stump is transplanted so as to lie underneath the arciform fibres of the internal oblique and transversalis muscle,<sup>1</sup> and well away from the inguinal canal; but

<sup>1</sup> The internal abdominal ring, of which so many operators make so much, does not exist as a surgical entity. It is a mere landmark.

first the finger is pushed a little way underneath the fibres, to make room for the stump. The skin and subcutaneous tissue are also displaced with the finger, so as to expose the aponeurosis of the external oblique muscle above and external to the incision.

After these preparations the stump is drawn beneath the areiform fibres, and fixed there by threading first one end of its ligature, and afterwards the other, through one of the herniotomy needles, which is then thrust from within outwards, through the fascia transversalis, through the fibres of the internal oblique and transversalis abdominis muscles, and through the aponeurosis of the external oblique. The point of the needle ought to emerge about an inch above and an inch external to the centre of Poupart's ligament. As it emerges the assistant pulls the skin and subcutaneous tissue upwards and outwards, so that the operator can disengage the threads. The two punctures are made about half an inch apart, so that the threads, being pulled moderately tight, and knotted with a jam knot (*vide* p. 132), hold the stump against the inner surface of the transversalis muscle, or, more correctly, against the transversalis fascia, which adheres to and forms the sheath of that muscle. The threads are not fastened too tightly lest they might constrict the tissues, and make a

little gap in the abdominal wall. As soon as they have been tied, the skin is allowed to slip back into position so as to cover the knot. By this device the stump of the sac no longer lies opposite the inguinal canal, along which it might afterwards be propelled, but against powerful muscles and aponeuroses. These, it is obvious, afford the greatest support to the stump when it is most wanted, because they are rigid and unyielding during exertion, such as coughing, vomiting, lifting, and so forth. It is also clear that by this device there is no chance of leaving a peritoneal depression at the place where the mouth of the sac had been.

Many ways of treating the sac have been devised. It is unnecessary to refer to any of the subcutaneous methods. They are now abandoned. About 1876, Mitchell Banks in this country, and Czerny abroad, led the way with an open operation, and used a simple ligature of the sac as high up as possible, followed by suture of the external abdominal ring. Next, about 1887, Macewen carried a suture along the sac from top to bottom, and then through the abdominal wall. Traction upon the thread pleats the sac into a pad, and fixes it within the so-called internal abdominal ring. Thus he claims that he not only does away with any chance of a peritoneal depression, but also makes an elevation to turn aside the intestinal impact. C. B. Ball<sup>1</sup> advocated twisting

---

<sup>1</sup> Dr. Ball's paper is in the *Brit. Med. Journ.*, London, for 10th December 1887, along with others by Macewen, Kendal Franks, Barker, and others.

the sac by four or five turns. This is a useful procedure, and I often avail myself of it to make quite sure of obliterating the whole sac. E. Stanmore Bishop<sup>1</sup> has modified Macewen's method, by passing the thread all round the periphery of the sac, and then through the abdominal wall. He claims that this makes a better pad than Macewen's operation.

A number of plans have been used for invaginating the sac into the inguinal canal. I do not propose to mention these, because it seems to me most undesirable that anything should be left in the canal.

Instead of ligaturing the sac, surgeons have transplanted it in various ways. Koehler's operation is a type of these proceedings. He separates the sac without opening the inguinal canal, and then pulls it through a hole in the aponeurosis of the external oblique. This hole is made external to the neck of the sac, so that the direction of the sac is reversed, being pulled directly outwards. Twisting, as in Ball's operation, is also applied in Koehler's proceeding. After it the patients used to be allowed to rise on the eighth day. Halsted and Bassini merely close the neck of the sac with sutures, before repairing the inguinal canal. It may be remarked that most of these methods require a thorough separation of the fundus of the sac, a point which I have already commented upon. In children, the sac, after separation, is usually so thin and torn, that no pad of the slightest use could be made out of it. To me there always seems a danger lest these pads should interfere with the action of the muscles, and tend to keep open the inguinal canal. It is unnecessary to say more upon the subject of opening

<sup>1</sup> *Internal. Clin.*, Phila., vol. iv. p. 218.



the inguinal canal and the reasons why that step is imperative.

### REPAIR OF THE INGUINAL CANAL.

The stump of the sac having been transplanted, the condition of the inguinal canal is ascertained. In the normal state the spermatic cord runs along the floor of the inguinal canal, in contact with the inner surface of Poupart's ligament. The arciform fibres of the internal oblique and transversalis muscle<sup>1</sup> spring from Poupart's ligament

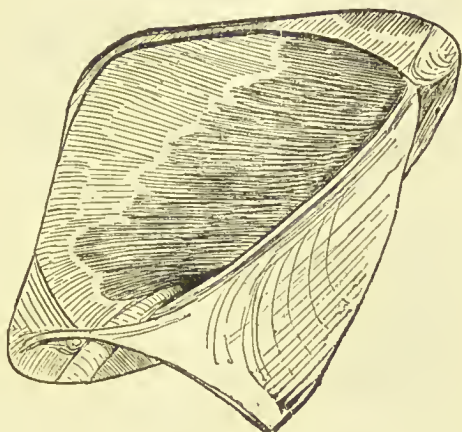


FIG. 14.—A normal inguinal canal. Arciform fibres compressing the cord against Poupart's ligament.<sup>2</sup>

in front of the beginning of the spermatic cord, and immediately arch over it to unite with the conjoined tendon, which is behind the cord (*vide* Fig. 14).

<sup>1</sup> At this point nearly all the fibres belong to the internal oblique muscle, but it is convenient to take them together.

<sup>2</sup> For this and several other drawings I am indebted to Mr. Compton. Some of them have also appeared in my chapter in Mr. Harrison Cripps' work on "Abdominal Surgery."

The interval betwixt the arching fibres and Poupart's ligament is just sufficient for the passage of the cord (*vide* Fig. 14). The cord is hidden by the cremaster. Whilst the abdominal wall is flaccid, the finger-tip can be thrust along the upper surface of the cord towards the abdomen. When the abdominal muscles contract,

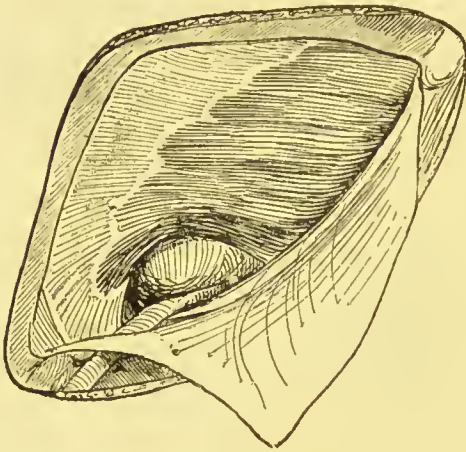


FIG. 15.—Inguinal canal in case of hernia. The arciform fibres displaced upwards.

the finger is pushed out by the arciform fibres descending; and at the same time the cord is forced down upon the inner surface of Poupart's ligament. This sphincter or valve-like action is well calculated to prevent the escape of abdominal contents. It is aided, too, by the simultaneous coming together of the front and back walls of the inguinal canal. This important safeguard is quite done away with by the intrusion of a hernia into the inguinal canal. As is well known, the hernia always descends above and in front of the spermatic cord. As it grows bigger it pushes the cord down against Poupart's ligament, and lifts the arei-

form fibres up, so that they cannot descend and exercise their sphincter or valve action. Thus it is obvious, as I have already said, that the first step in radical cure is to entirely remove the sac, so as to leave the arciform fibres free to descend. In some of my cases the sac has been so narrow that after its removal the arciform fibres at once applied themselves closely to the cord, and therefore no further step was needed to restore their function. But, as a rule, the hernial protrusion has lifted the arciform fibres so far off the cord, that, when the stump of the sac has been transplanted, a distinct semilunar gap is left above and behind its upper end (*vide* Fig. 15, p. 130).

The size of this gap is now estimated, and diminished by the insertion of sutures, after the fashion of Bassini and Halsted. The number of sutures depends upon the size of the gap. My cases have required one, two, three, or four sutures; as a rule, two have sufficed. It is probable that much has yet to be learnt about this proceeding, for it has only been used since about 1890. I myself merely use the sutures to restore the arciform fibres to their normal position. It is my intention that in the future any strain shall be borne by the muscular fibres, and not by the sutures, which therefore need not be very numerous or very strong. I, moreover, endeavour to tie them so

that they do not constrict or cut through the muscle fibres. They are passed as follows:—First, the spermatic cord is lifted off the inner surface of Poupart's ligament, and a loop of silk passed under it to allow the assistant to raise it up without putting his fingers into the wound. Next, one of the blunt herniotomy needles is threaded with about a foot of No. 4 or No. 5 twisted silk, and thrust from within outwards, through the deep edge of Poupart's ligament (*vide* Fig. 16). The first suture pierces the ligament just above the femoral vein, but that vessel is not endangered if the needle be kept close to the ligament, and if its point be turned forwards and upwards. When a sufficient number of sutures have been passed through Poupart's ligament, they are carried with the second blunt needle beneath the spermatic cord and through the areiform fibres. To avoid wounding the peritoneum or epigastric vessels, the needle is passed beneath the muscular fibres and transfixes them from within outwards. To do this it is usually necessary to push the tip of the left index finger beneath the areiform fibres. When these sutures are tightened, the areiform fibres descend into their original position, and the gap is obliterated. To avoid constricting the muscle fibres, the sutures are tied with a jam knot. This is made by pulling the suture sufficiently tight, and giving

the ends two turns on each other (instead of one turn as in making an ordinary knot), then, by pulling the cords in reverse directions the double turns jam, so that the loop, which contains the muscle fibres and Poupart's ligament, cannot become smaller when a final knot of the ordinary kind is tied.

In repairing the inguinal canal, another effect of the hernial protrusion has often to be remedied. When the rupture has been neglected and is of long duration, the constant traction of the bowel or omentum gradually drags the posterior wall of the inguinal canal inwards, until it arrives opposite

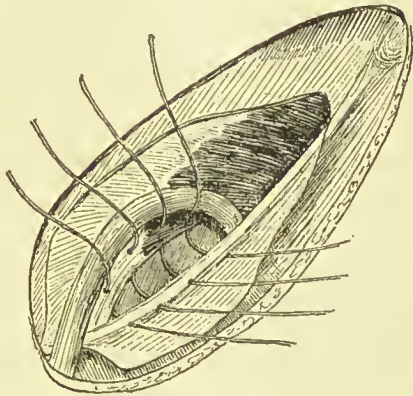


FIG. 16.—To show the method of inserting the deep sutures, the spermatic cord having been lifted up.

the outer edge of the rectus abdominis. When this has happened, the finger can be thrust through the external abdominal ring, past the edge of the rectus, straight into the abdomen.

The epigastric artery is also displaced, and can be felt with the finger-tip close to the edge of the rectus.

The posterior wall of the inguinal canal is formed

by the conjoined tendon of the internal oblique and transversalis abdominis muscles, fascia transversalis, and an additional band of fibres derived from the deeper layers of the internal oblique and transversalis, and called Hesselbach's band. The conjoined tendon and fascia transversalis are so intimately blended that it is almost impossible to say where one begins and the other ends. Hesselbach's band strengthens the fascia transversalis at the outer third of the inguinal canal, and therefore abuts upon the inner side of the neck of the sac.

When this displacement of the back of the inguinal canal is recognised, it is remedied by carrying some of the stitches through the conjoined tendon, so as to pull it outwards again towards Poupart's ligament.

I have sometimes had to alter the way in which the hinder wall of the inguinal canal is repaired. A woman had a small elastic swelling, like a marble, in the right inguinal canal. This proved to be a small sac full of fluid. Its neck pierced the conjoined tendon, just outside the rectus abdominis. After the sac had been treated in the usual way, the small hole was easily closed. Three years afterwards, this woman requested me to operate upon a swelling which had appeared on the left side. She had a small blind sac, surrounded by a quantity of fat, protruding through

the conjoined tendon, and straight out of the external abdominal ring. The same operation was done as upon the right side.

Direct inguinal hernia is probably rare in women. Whilst operating upon a young woman for the radical cure of a right inguinal hernia, the opening was found close to the edge of the rectus. The deep epigastric artery was felt outside the neck of the sac. Care was taken to avoid it in passing the ligatures, and extra sutures were used to repair the back of the canal.

An artilleryman ruptured himself suddenly. The hernia was direct, and had escaped through an oval gap in the conjoined tendon. The deep epigastric artery and veins were seen running outside this opening. The gap in the conjoined tendon was closed with three stitches. I had no doubt but that this rupture was traumatic. Two years afterwards he wrote to say he was as well and strong as ever,—able to ride bare-back and do his artillery work.

It is by no means easy to replace the arciform fibres, and repair the back of the inguinal canal even when its front wall has been incised, and its interior freely exposed to view. I doubt, therefore, the efficacy of any operations which aim at repairing the canal through the external abdominal ring.

When the testicle is retained in the inguinal canal,

I have occasionally met with a deficiency of the arciform fibres of the internal oblique and transversalis muscles. This of course makes the operation harder, and success more uncertain.

The presence of the spermatic cord is considered by some to be one of the great bars to an efficient closure of the hernial gap. Halsted<sup>1</sup> therefore transplants it by passing it between the fibres of the internal oblique and transversalis, and out through the outer end of the incision in the aponeurosis of the external oblique. The abdominal wall is then sutured beneath the cord, so that it is left lying upon the aponeurosis, and beneath the skin of the groin. Halsted evidently relies more upon suturing than upon the restoration of the inguinal valve.

Wölfler<sup>2</sup> dislocates the spermatic cord by lifting it from the inguinal canal, and pushing it, together with the testicle, which is displaced for the purpose, through a slit in the rectus abdominis muscle. This device seems to have met with little favour in this country.

#### RECLOSURE OF THE INGUINAL CANAL, AND SUTURE OF THE SKIN INCISION.

The loop of silk having been taken off, the spermatic cord falls back into its place. Any blood is

<sup>1</sup> "A New Operation for Radical Cure of Hernia," *Ann. Surg.*, St. Louis, March 1890, p. 234 *et seq.*; also *Johns Hopkins Hosp. Bull.*, Baltimore, No. 29, vol. iv. p. 17.

<sup>2</sup> Epitome, *Brit. Med. Journ.*, London January 7, 1893, p. 2.



thoroughly washed out of the inguinal canal with lotion. Too much care cannot be taken to see that all the bleeding has ceased. If a hæmatoma forms, it is almost certain to suppurate. Then the aponeurosis of the external oblique is brought together again with about six points of interrupted suture. These consist of No. 3 or 4 twisted silk, and are passed with a curved Hagedorn's needle. It is easiest to pass all the sutures before finally knotting them. The lowest suture needs extra care, because it adjusts the size of the external abdominal ring. Enough room is left for the easy passage of the cord. The external ring has little to do with the causation of hernia, but it is a point towards which those who examine for the army and navy direct their attention.

Whilst closing the opening in the aponeurosis of the external oblique, another effect of the hernial protrusion has to be rectified. In about a quarter of my cases the aponeurosis in front of the inguinal canal had been stretched and bulged, so that the edges of the incision in it did not spring together when the muscle was in action. This defect, however, is easily remedied by including all the slack part of the aponeurosis in the sutures.

The inguinal canal being thus completed, any bleeding from the superficial vessels is arrested by

tying them with fine (No. 00) silk ligatures or by twisting them. Then the skin incision is brought together with scrupulous accuracy with sutures of fine fishing-gut, or of horse-hair. Too much pains cannot be lavished upon this step. When the edges of the skin are accurately apposed to one another, they adhere in a few hours, and help to prevent infection from the outside. A better æsthetic effect is also obtained, and the scar may be almost invisible,—a thing which always gratifies the patient.

## CHAPTER VIII.

### INGUINAL HERNIA IN FEMALES.

YOUNG females with inguinal hernia eagerly avail themselves of the radical cure, the alternative treatment by a truss being very repugnant. They are in every respect most excellent subjects for operation. The hernia is due to a local developmental defect. Its sac is formed by the canal of Nuck, which, instead of being small, rudimentary, and easily obliterated has grown and remained open. The hernial sac seldom reaches beyond the external abdominal ring. It usually has thick walls, and its mouth is narrow. The round ligament of the uterus adheres to it, and fixes it to the crest of the pubes, and to the labium major. This ligament, however, interferes very little with the operation. It has not to be carefully detached from the sac like the spermatic cord, and need hardly be taken into consideration during the passage of sutures which repair the canal. As a rule, moreover, the sac is empty. Adherent omentum

was only met with once in forty-three operations; non-adherent omentum twice; and the ovary twice. I have operated thrice on both sides, twenty-two times on the right side only, and fifteen on the left. The youngest patient was 9 years old. One patient had very slight suppuration without extrusion of sutures; another had more severe suppuration, and parted with all the sutures.

In addition, the operation for the radical cure of inguinal hernia is easier in the female, because of the smallness of the inguinal canal. I have not yet met with a case in which the arciform fibres and posterior wall had become much disturbed, or required more than two or three sutures for their readjustment. An old woman with a large enterocele is excepted, but she was only operated upon to enable her to wear a truss.

The operation upon a female is exactly the same as that upon a male, except that there is no spermatic cord to cause embarrassment. The inguinal canal is laid open by the same incision,<sup>1</sup> and the sac, together with the round ligament of the uterus adherent to the back, is lifted from its bed. Near the external abdominal ring it is held by the fibres of the round

<sup>1</sup> An incision  $1\frac{1}{2}$  in. long is enough; one of 2 in. is seldom required. Radical cure of hernia is, in my opinion, often done through far too long an incision.

ligament of the uterus, which are nearly always especially adherent to its lower end. Small branches of the external pudic arteries run upwards along these fibres. Before they are divided, it therefore is best to seize them in a pair of clamp forceps, and put on a fine silk ligature. During pregnancy, the round ligament becomes much hypertrophied and more vascular. I have operated once unwittingly and once intentionally during pregnancy. In both, the round ligament was very thick and vascular. One of these patients was seen just before her confinement. The side which had been operated upon was perfect, but the opposite side had become ruptured. The other woman remains perfectly well, although she has had three more children. Sometimes the veins of the round ligament are varicose, exactly like inguinal varix in the male. Varix of the round ligament resembles varix of the spermatic cord, in being mistaken for hernia. This has happened thrice within my recollection. But I do not know whether the patients had been wearing trusses; they were not under my own care.

The sac and its contents are dealt with in the same way as in the male. The treatment of a herniated ovary has been already considered. In females the inguinal canal is also repaired in the same way as

in the male, and with sutures pressed after the manner of Bassini and Halsted. The inguinal canal is closed, the skin adjusted, and the wound dressed in exactly the same manner as in the male.

Direct inguinal hernia is rare in females; nevertheless, whilst operating upon a girl, æt. 18, I found that the hernia had escaped through the back of the inguinal canal by an elongated opening, which corresponded to the gap beneath the arciform fibres. The finger thrust through this opening felt the epigastric artery beating at its outer side. The gap was easily closed with two sutures. The rupture had existed a year, and the history threw no light upon its origin.

Another female, a married woman with a family, also had rather a curious kind of direct hernia. In May 1891 she came with a small tense hernia like a marble protruding from the right external abdominal ring. This was a small sac piercing the conjoined tendon. In June 1894 she returned quite cured by the operation three years before, and with an almost invisible scar on the right side, but with another small rupture on the left. It was almost exactly like the one which had been cured three years before, and consisted of two small sacs with a good deal of fat about them. One opened into the general peritoneal

eavity, and the other was blind. They protruded through the conjoined tendon. The neck of the sacs was transfixed, tied, and secured in the usual way, and the hole sutured without opening the inguinal canal.

The operation of radical cure of inguinal hernia is well borne by females. The only serious complication in the forty patients was an attack of scarlet fever which one had. The wound, however, did not suppurate, and she soon recovered. Another female had an attack of cystitis. Suppuration occurred thrice,<sup>1</sup>—once owing to non-disinfection of the skin, and once to non-disinfection of ligatures.

<sup>1</sup> Unfortunately the non-disinfected ligatures were used for a double operation, so that the three cases of suppuration occurred in two patients.

## CHAPTER IX.

### THE DRESSING—AFTER-TREATMENT— COMPLICATIONS—RESULTS.

#### THE DRESSING.

THE dressing is one of the most important details of the operation of radical cure of either inguinal, femoral, umbilical, or ventral hernia. The method which I use for disinfecting the skin is so efficient,<sup>1</sup> that infection of the wound from that source has become exceedingly rare. I nevertheless still guard against the possibility of it by dusting the skin around the wound with a layer of finely powdered iodoform crystals. The efficiency of the iodoform as an antiseptic is greatly increased by its being finely powdered. Besides preventing skin infection, the iodoform has other advantages. It helps to prevent infection should the dressing become displaced. I have two or three times

<sup>1</sup> Recently the skin of the hands of the surgeon, of the house surgeon, and of the patient, was aseptic sixty-three times out of sixty-four.



seen the wound exposed to view, but protected from the air by the layer of iodoform. Next, the iodoform seems to prevent the other chemicals in the dressing from irritating and blistering the skin. It also prevents the dressing from sticking to the skin and edges of the wound. Any fear of the iodoform itself infecting the wound may be dismissed. Together with Dr. Black Jones, I endeavoured to cultivate bacteria from various specimens of iodoform, but we could never succeed. Then the wound and the skin around are covered with a layer of 5 per cent. carbolic gauze, which has been soaked and wrung out in biniodide of mercury lotion 1 in 2000. All kinds of antiseptic dressings have been tried, but this has been clung to, because it is quite non-irritating, and can be left untouched until the tenth day, when the wound is healed. Inasmuch as it contains but a comparatively weak store of antiseptic, the whole is covered with a layer of alembroth wool. This is impregnated with 2 per cent. of sal alembroth. Any fluid from the wound has to pass through this layer of sal alembroth wool, and by mingling with the sal alembroth becomes strongly antiseptic. The same applies to fluids which endeavour to enter the dressing from the outside. There are, however, limits to the amount of urine which the wool can disinfect or

render antiseptic. Particular care is taken not to allow the alembroth wool to touch the skin, otherwise it inevitably causes dermatitis and blistering. An eight-fold Listerian dressing of carbolic gauze and jaconet is next applied. This has already been described (see Figs. 3 and 4). During struggling, coughing, or vomiting, this aids in preventing air getting to the wound. It also arrests the progress of any blood from the wound, distributes it in the sal alembroth wool, and helps to guard against the entrance of urine. This dressing almost keeps in place without further bandaging. A certain amount of pressure upon the wound is highly advantageous, because it prevents any oozing of blood, and limits the amount of inflammatory effusion. A spica bandage is therefore applied over the whole. It is obvious that the weakest point in this dressing is where it turns round the root of the penis. At this point the wound is not more than an inch distant from the edge of the dressing, and consequently from the open air. To help to guard this point, the spica is carried from without inwards, round the thigh and round the pelvis. This pulls the edge of the dressing towards the root of the penis instead of away from it. This angle is rendered more secure by stitching the bandage with a needle and thread, or by

tightly applied strapping. A well-applied spica also prevents stupid and reckless patients from exploring the wound with their fingers. This was the cause of suppuration in at least one of my cases.

When both sides are operated upon, either two separate dressings can be applied, or the single dressing, which has been already described (*vide* Fig. 4).

I have laid some stress upon this dressing, and upon its adjustment, because the safety and comfort of the patient depend so much upon attention to these details. Two faults are commonly committed in the making of these dressings. First, the buckles are sewn at the edge instead of upon the dressing. In consequence, they are apt to hurt the patient. Second, the upper part of the dressing is made too big, so that it fits round the abdomen, instead of round the pelvis.

#### AFTER-TREATMENT.

The after-treatment of operations for the radical cure of hernia is simple and uneventful. After shock has passed away, like most operation cases, the patients complain of a pain in the back, and very often of pain beneath the costal margins. An opiate is seldom needed for this pain; but should it be really severe, it is safest to give 10 or 15 minims of

tincture of opium by the rectum, in a little starch solution. I have seen several disasters when morphia has been given after ether anæsthesia, and therefore that drug is seldom or never given to my patients. The abdominal wall about the wound is also sore, and is usually held very quiet. It is probable that at this stage a certain amount of bruising of muscles and of extravasation of blood betwixt the muscular fibres would be found if the vicinity of the wound were examined. Until the anæsthetic is quite recovered from, nothing is given by the mouth, for fear of vomiting. Should this complication ensue, it is best met by rectal feeding. If it be accompanied with constipation, as in the case of a man with bilious vomiting, a determined attempt should be made to open the bowels with purges and enemata. Enormous quantities of aperients may be required. If all goes well, however, I usually give a mild aperient about thirty-six hours after the operation; and as soon as it has acted, the patient recovers his appetite, and is allowed any ordinary light diet.

Constipation is rather common after the operation of radical cure. It is possible that the wound and the bruising of the abdominal wall cause pain during expulsive efforts, which, therefore, are not attempted. A medical man was operated upon for a small left

inguinal hernia, with a lipoma of the cord, and some varix of the spermatic veins. The sac was empty. After the operation, he had rather more pain in the back and beneath the ribs than is usual. Afterwards, although he seemed very well, his bowels refused to act until he had had castor-oil, calomel, white mixture, croton-oil, and numerous enemata. A strange thing happened to this gentleman six weeks later. After walking some distance, he vomited for some hours, and passed no flatus. At the same time he had abdominal pain. In my opinion this was due to an error in diet, causing some cerebral obstruction, and had nothing whatever to do with the operation. He is now very well, and much gratified with the result.

This surmise is to some extent confirmed by another case, in which a very severe abdominal pain came on two months after the radical cure of a left inguinal epiplocele. This caused great alarm, but was almost certainly caused by copaiba, which the patient had taken for a recent attack of gonorrhœa.

Retention of urine is a rare complication of radical cure of hernia, and merely requires to be relieved with a catheter passed with aseptic precautions.

Smoking is allowed in moderation, and a small quantity of beer, or of light wine, may be drunk.

The dressing is watched, lest the bandages become loosened. With very rare exceptions, the dressing which was put on at the operation is taken off on the tenth day. The skin incision is dry and devoid of redness or swelling. The stitches are cut and removed with sterilised seissors and forceps. As the uniting material is still delicate, the wound is protected with a little iodoform collodion, or with a scrap of iodoform gauze fastened on with a spiral bandage. A sufficient time must be allowed for the reunion of the aponeurosis of the external oblique. In three weeks the union is moderately strong, and in six it is exceedingly firm and fibrous. Therefore the patients are kept three weeks in bed, three weeks on a couch, and then have six weeks' gentle exercise. During the second three weeks they can lie about in a garden, or drive in an easy carriage. During the six weeks' gentle exercise it is undesirable that they should strain or lift heavy weights.

My own observations lead me to think that, after the sac has been removed, the arciform fibres soon begin to function, and guard the inguinal canal against a fresh hernial protrusion. The muscle fibres, however, will not contract well and descend forcibly upon Ponpart's ligament, until the inflammatory action set up by the operation has had time to subside.

Some surgeons allow cases of radical cure to get up within the fortnight, and in these I cannot but think that relapses would be more common, if it were not for the protection afforded by the sphincter-like action of the arciform fibres.

The same applies to the conjoined tendon and back of the inguinal canal, which are apt to be drawn inwards by the traction of the rupture. When that force is removed, the muscular fibres inserted into the conjoined tendon help to draw it outwards again. The intra-abdominal pressure, moreover, forces the conjoined tendon forwards against the front wall of the inguinal canal. Thus it is evident that the sutures which drew the conjoined tendon and back of the inguinal outwards into their normal position are not called upon to bear any considerable strain. Indeed, I do not suppose that they do more than hold those structures in position until the muscles have readapted themselves to their normal position and function.

#### COMPLICATIONS.

In hospital practice all kinds of operations are apt to be complicated by intercurrent complaints. A young woman had scarlet fever, which she had caught

just before admission. She soon recovered, and her wound healed by first intention. A youth had a slight attack of pneumonia, probably associated with influenza, and another had a slight attack of rheumatism. On the whole, very little pain or inconvenience is experienced when the operation is done expeditiously, and with proper precautions.

A youth had mental disturbance and delusions for a time after the radical cure of an inguinal hernia, but got quite well after leaving the hospital. Another patient, whose case is given at length (see p. 174), had a similar complication. In hospital practice, the unstable mental equilibrium of the patients is apt to be upset after all kinds of surgical procedures.

Except in elderly people with acquired hernia, I do not order a truss after the operation of radical cure. After an efficient operation, a relapse is so rare in well selected cases that a truss is quite unnecessary, and it might be harmful to the newly-developed reparative material. In those who have worn a truss for any length of time, the subcutaneous tissue is absorbed, the external abdominal ring feels larger, and the whole abdominal wall thinner; in other words, the continuous pressure has caused an atrophy of the abdominal wall. Its effect upon young and newly-



formed connective tissue might be expected to be greater and more rapid.

### IMMEDIATE RESULTS.

*Mortality.*—Out of a total of 190 patients, upon whom 202 operations for the radical cure of non-strangulated inguinal hernia were done, one died from the effects of chloroform. He was a youth upon whom operation was a necessity, as he had a retained testis and a strip of adherent omentum, in consequence of which a truss could not be worn.

Thirteen additional operations were done after strangulation of the intestine had been relieved. All of these recovered, although some of the ruptures were of the most formidable dimensions. Owing to the urgency of the symptoms, elaborate methods of preparation were out of the question. Indeed, when some of them were done, the perfect methods of disinfecting the skin, which we now use, had not been invented. In some, moreover, the hernial sac contained fluid which was obviously septic, and in others this may have also been the case. It is not, therefore, surprising that four out of the thirteen had some degree of suppuration, though never of a severe or prolonged kind. The other nine healed by first intention.

In one case the suppuration was confined to the scrotum, which had had to be incised. The fluid in the hernial sac was obviously septic at the time of operation. In another the suppuration was very slight, and occurred during an attack of delirium tremens, in course of which the patient pulled off his dressings. It is probable that the other two cases were caused by imperfect disinfection of the skin.

Most of the strangulated ruptures were acquired, and required trusses after the operation. The addition of radical cure to the operation for the relief of strangulation, not only lessens the dangers, but also enables a truss to be worn with greater ease and comfort.<sup>1</sup>

The following case has, I find, been omitted. It is rather remarkable. A man had had a strangulated inguinal hernia of the left side reduced by taxis by one of my colleagues. Afterwards, he had persistent vomiting, but inasmuch as he was suffering from nephritis, and had had a uræmic convulsion, it was thought to be uræmic in its origin. I saw him on the fifth day, and found that he passed no flatus, and was continuously sick. The abdomen was slightly distended, although nothing could be felt in the left

<sup>1</sup> C. B. Lockwood "On the Importance of Performing the Radical Cure after Operations for Strangulated Hernia," *Brit. Med. Journ.*, London, 18th July 1891.

inguinal canal. Nevertheless the abdomen was opened, and a loop of strangulated small intestine was withdrawn from a hernial sac which lay in its upper part. After this had been done, the abdomen was rapidly closed, the left inguinal canal opened, and the sac ligatured at its neck, lest it should strangulate another loop of intestine. The inguinal canal and the incision in the skin were afterwards closed in the usual way. In spite of the nephritis, the patient recovered without any bad symptoms, and both the wounds healed by first intention.

*Suppuration.*—Although I have not had a really serious or anxious case of suppuration, nevertheless this complication has been more frequent than is creditable. All the cases I have ever had are included in the following statistics of non-strangulated inguinal hernia, and the minutest drop of pus has been recorded. Most of the patients in whom suppuration occurred were never at all ill, and, in some of them, it was so slight and superficial that no deep sutures were lost.

It is only right, in considering the amount of suppuration, to recall the way in which the cases are managed. Our hospitals are educational establishments, and much of the work is done by gentlemen who hold office for comparatively short periods. They

have, of course, very little practical experience of the methods which they are called upon to carry out, and therefore it is not uninteresting to note, that on four occasions suppuration occurred in the first case which the new house surgeon was called upon to prepare. Inasmuch as the total suppuration after the radical cure of non-strangulated inguinal hernia is eighteen out of 202 wounds, four is a high proportion. In these eighteen suppuration wounds are included such as the following:—(1) One in which there was a septic sinus at the time of operation, and in which any slight suppuration continued for a few days afterwards. (2) One in which an inexperienced house surgeon removed the dressing on the fifth day, and took out the stitches, leaving the wound unprotected, because he thought it had healed. It suppurated, with extrusion of deep sutures. (3) One in which the patient, in spite of repeated warnings, passed his fingers under the dressing. (4) One in which the patient concealed the fact that at the time of operation he was suffering from whitlow of the finger, and had been having similar suppurations elsewhere. I have also since learnt that he drank rather freely. (5) A case in which both sides were operated upon simultaneously, and in which both simultaneously suppurated, with extrusion of silk. The house surgeon had not

disinfected the silk according to his directions. This is counted as two cases of suppuration. (6) A case in which only one of the stitch-holes suppurated slightly. This was before we began to use our present more perfect system of disinfecting the skin. To this earlier period also belongs a case in which a bit of the patient's skin was cut off at the operation, and put into nutrient broth. It gave rise to a growth of *Staphylococcus aureus*. The wound afterwards suppurated, and the pus contained the same microbe.

This skin suppuration is now so mild and sub-acute, that its presence is not discovered until the dressing is taken off on the eighth or ninth day. The wound may then seem to be healed, and the skin natural. There is, however, usually some suspicious fulness, with slight pain on pressure. A director pushed into one end of the wound lets out some thick, curdy pus. The deep sutures are usually extruded, but sometimes they never appear, and the sinus rapidly closes.

My earlier operations were done as far back as 1886, and since then we have made great improvements in the disinfection of the hands of the surgeon and of his assistants, as well as of the skin of the patient. The distribution of these cases of sup-

putation, in four series of fifty consecutive operations, is as follows:—

First . . . . .	50	wounds,	7	suppurated.
Second . . . . .	50	„	4	„
Third . . . . .	50	„	5	„
Fourth . . . . .	50	„	2	„
	<hr/>		<hr/>	
Total . . . . .	200	„	18	suppurations. <sup>1</sup>

The cases of suppuration may also be tabulated as follows:—

Slight superficial, without extrusion of sutures . . . . .	2
Subacute; fate of sutures doubtful . . . . .	2
Subacute, with loss of one or more deep sutures . . . . .	11
Acute, with loss of no sutures . . . . .	1
Acute, with loss of sutures . . . . .	2
	<hr/>
Total . . . . .	18

I have omitted from these statistics the case of double hernia and varix of the cord in which the wound was opened up, and the abdomen drained, because of hæmorrhage (*vide* p. 115). The wound on the right side healed by first intention, but that on the left was packed with iodoform gauze. Even then the evidences of sepsis were so trivial that they might reasonably have been ignored.

<sup>1</sup> According to Talliens, the proportion of suppuration after radical cure of inguinal hernia in Roux's clinic was sixty-seven out of 324 (*Rev. méd. de la Suisse Rom.*, Genève, July 20, 1897, quoted in *Epitome, Brit. Med. Journ.*, London, October 23, 1897, p. 66). Sheild (*Lancet*, London, August 14, 1897, p. 379) enumerates thirty-one cases of radical cure of non-strangulated hernia, and mentions four cases of suppuration; one of the latter died.

*Orchitis—Atrophy of the testicle.*—Inflammation of the testicle is unusual after the open operation for the radical cure of hernia. It occurred after an operation upon the left inguinal hernia of a young man. Three months afterwards the left testicle was atrophied. The operation was quite uncomplicated, and no cause whatever could be found to account for the orchitis.

This, too, is the only atrophy of the testicle which I have found amongst my own cases, but it ought not necessarily to be attributed to the orchitis. After the retained testicle is brought down from the inguinal canal into the scrotum, an orchitis always ensues, and is not, as we have seen, followed by atrophy. An injury to the vas deferens is a much more likely cause of the atrophy, but that duct was certainly not divided at the operation, and I am not conscious that it got caught in any of the sutures. Orchitis seems common after other operations. O'Connor<sup>1</sup> did 129 cures by Halsted's method, and had 80 per cent. of orchitis, and 20 per cent. of atrophy of the testicle.

<sup>1</sup> *Glasgow Med. Journ.*, February 1898.

## CHAPTER X.

### ULTIMATE RESULTS OF THE OPERATION FOR THE RADICAL CURE OF NON-STRANGULATED INGUINAL HERNIA.

THE ultimate results of operations for the radical cure of hernia depend upon a variety of circumstances. My own experience shows that when an efficient operation is done upon selected cases, a cure may be relied on.

At the same time, I would remark that as yet we are not in possession of all the information which is required for a proper selection. Amongst the few relapses which I have had, two at least were genuine disappointments. All the conditions before, at, and after the operation seemed to promise a successful result. When a relapse, however, occurs, through faults committed by a careless patient, the operation itself ought not to be blamed. Some of my hospital patients have been known to climb trees and walls within a month of their operation, and



others have at once gone back to laborious occupations. Besides, any individual may produce a rupture when engaged in efforts beyond his strength. One of my patients has had to continue to lift enormous bales of carpet, in spite of my warnings; his operation, however, has borne this for four years. Cases occur in which the operation has to be done upon those who are clearly unfavourable subjects.

In some of my own cases the abdominal walls were so thin and relaxed, with bulging of the hypogastric fossæ, that the prospects of a cure were not very good. For a variety of reasons the operation cannot be withheld in every dubious case. For instance, an anæmic young man, whose case has just been mentioned, had a painful varicocele upon the left side, and an inguinal rupture upon the right. His abdominal walls were thin, with some bulging of the hypogastric fossæ. He desired, whilst the varicocele was being cured, that an attempt should also be made to cure the hernia. This was done, and although his work is heavy lifting, he has had no return of the rupture on the right side during the four years which have elapsed. His left inguinal canal does not seem to be very strong, but he says that if a rupture comes there, he would have it operated upon. This case also illustrates another point. There

can be little doubt but that surgeons have different views as to what is a "cure." About a year after the operation, this patient was seen by a surgeon, who at that time was hostile to radical cure. He came from the interview in great distress, under the impression that his rupture had returned. My colleague, Mr. Bowlby, kindly examined him, and, without knowing what had occurred, said he could discern no trace of a rupture, and that the result was excellent.

In some of my cases both the hypogastric fossæ were slightly bulged before the operation, and gave a marked impulse on coughing. I have little doubt but that this general impulse has been occasionally mistaken for the local impulse of a developing rupture, and that, after so many silk sutures have been buried in the abdominal wall, a distinct lump sometimes remains at the site of the operation. This lump projects a little, and transmits an impulse when the patient coughs. Obviously, a careless or prejudiced observer might easily think that the rupture had recurred. Rather more than a year ago I operated upon a youth who had had radical cure done during his infancy, but, unfortunately, the wound had suppurated, and the hernia had soon relapsed. Under the circumstances, I inserted rather more

sutures than usual. A lump, such as I have just described, was the result; but for a year this has undergone no alteration. It projects and has a decided impulse each time the patient coughs.

I have also operated upon patients to enable them to enter a club, or the army, navy, police, or post-office. Some of these were close on 40 years of age, and apparently not very good subjects. The results, however, have been better than might have been anticipated, in spite of adverse circumstances, although some have been put to the severest tests.

Dr. A., æt. 28, was operated upon nearly four years ago for the radical cure of an inguinal hernia. Six weeks afterwards he passed the army medical examination and went to India. Here he lived the usual life, and learnt to ride upon horseback. He had two attacks of dysentery, and one of typhoid fever, but there has been no return of his rupture, and he is most gratified with the result.

Some years since a soldier in the horse artillery was sent by my friend Surgeon-Captain Risk, to be operated upon for the radical cure of inguinal hernia. Two years after it was done, he was quite well, and sent one of his fellow-artillerymen to have the same operation performed. This second man wrote to say

that he was quite well two years after his operation, and did not require a truss. I believe that in both of these cases the rupture was traumatic. A third patient wrote that he was well after he had been enlisted in the artillery for a year. He had had an inguinal rupture operated upon. Artillery work and riding upon gun-carriages must be a very severe test.

A young man was enlisted in the infantry after he had had radical cure of inguinal hernia done. Three years later he wrote from India to say that the army-surgeon considered his rupture to be cured. I find that seven of the patients upon whom I have operated have been accepted for the army; that one was accepted for the police, another for prison warden, and a third for asylum attendant. Many have entered the postal service.

The statements which patients make themselves are to be taken with great caution. A man had radical cure done for right and left inguinal herniæ, complicated with retained testes. A year after, he wrote to say the left rupture was well, but that the right had relapsed. When examined, it was found that he had mistaken the right testicle for a rupture. Before the operation, that organ had lain almost within the abdomen. In the case of a woman who

was operated upon for the cure of a femoral hernia, the symptoms of supposed relapse were due to a movable right kidney.

Provided a rupture can be managed with a truss, life insurance companies do not, I believe, make any addition to the premiums. It is, however, not without interest to note that one of my patients was accepted as a first-class life three years after he had been operated upon for radical cure of inguinal hernia, and although he had not worn a truss.

Medical men, too, sometimes arrive at hasty conclusions. One day I was told that a woman, upon whom I had operated for radical cure of a left inguinal hernia, was in the hospital for a relapse of the rupture, and that it had become strangulated, and needed operation. The inguinal canals on both sides were perfect, but she had a strangulated femoral hernia on the right side.

An effort has been made to trace the cases. At least 200 reply post-cards were sent out. About one-half of them remained unanswered, and twenty-seven came back through the dead-letter office. On the other hand, nearly a hundred of the patients showed their gratitude, by coming, at great inconvenience in some cases, to be examined. The results are as follows:—

TABULAR STATEMENT OF CASES SEEN AT INTERVALS AFTER  
CONVALESCENCE—INGUINAL HERNIA.

	Total.	Cured.	Relapsed.	Number of Females included in Total. All Cured.
Under 6 months . . . . .	16	13	3 males	1
"  12  "  .  .  .  .	12	10	2  "	2
"  18  "  .  .  .  .	7	7	...	...
"  2  years  .  .  .	7	7	...	1
"  2½  "  .  .  .  .	12	12	...	2
"  3  "  .  .  .  .	9	9	...	...
"  3½  "  .  .  .  .	12	12	...	4
"  4  "  .  .  .  .	5	5	...	1
"  4½  "  .  .  .  .	4	4	...	...
"  5  "  .  .  .  .	1	1	...	...
"  5½  "  .  .  .  .	3	3	...	...
"  6  "  .  .  .  .	1	1	...	...
"  6½  "  .  .  .  .	1	1	...	1 <sup>1</sup>
"  7  "  .  .  .  .	1	1	...	...
Total . . . . .	91	86	5	12

These figures refer to patients, and not to opera-

<sup>1</sup> Same woman is included in 3½ years. Right side done, 1891; left, 1894. Both well, 1897.

tions. The majority of the ninety-one had only one side operated upon, but a few had both.

Much is to be learnt from cases which relapse. Judging from my own and those of other surgeons, I should say the chief causes of relapse are—(1) Operating on improper cases; (2) inefficient or bad operating; (3) suppuration; (4) exertion too soon after operation; (5) accident.

In my earlier cases of radical cure of inguinal hernia, I operated without opening the canal. Two of these speedily relapsed, and thenceforth I always divided the aponeurosis, and saw what I was doing. The details of these two cases are as follow:—

A youth, G. S., æt. 18, had radical cure of a right inguinal hernia done, without any division of the aponeurosis of the external oblique. A hydrocele of the cord had distended the canal, which was therefore more difficult to repair. The wound suppurated, and the deep stitches had to be removed under nitrous oxide. I believe that the sutures had not been properly sterilised before use. Within six months the rupture had returned, and he required a truss. He was, however, much gratified, because, before the operation, he suffered considerable pain, and was unable to wear a truss, or follow his occupation.

Although it is possible that the operation may not

have been quite efficient, I have now seen so many cases of relapse after suppuration, that I should have little hesitation in saying that that was the real cause.

Halsted had six relapses in fifty-eight cases, and all of them after suppuration.<sup>1</sup> In Coley's operations on children, primary union took place in thirty-three, and two suppurated. Both of these latter relapsed.<sup>2</sup> Taillens'<sup>3</sup> statistics give 15·2 per cent. of relapse after healing by first intention, and 22·4 per cent. after suppuration.

A youth, V. F., æt. 18, was operated upon for the cure of a right inguinal rupture. The inguinal canal was not opened. The wound healed by first intention. Six months after, the rupture suddenly came down whilst he was lifting a cask of beer. He requested a second operation. Whilst performing this, I found that the ligature had not been properly applied at the neck of the sac, so that the upper inch of the old sac had not been obliterated. This case decided me in future always to open the inguinal canal.

The other three cases of relapse were operated on by the open method:—

1. A man, R. D., æt. 24, was operated upon for

<sup>1</sup> *Johns Hopkins Hosp. Bull.*, Baltimore, 1893, No. 29, vol. iv. p. 17.

<sup>2</sup> *Medical Week*, 17th March 1893.

<sup>3</sup> *Vide ante*, p. 158.



double acquired inguinal hernia. The sac on the left side contained much omentum; the right was empty. The spermatic veins were varicose, and were excised. The back of each inguinal canal was repaired with three sutures. Both wounds healed by first intention. He came back in three months with a slight relapse on the right side. In this case it is to be remarked that, first, the ruptures were acquired; and, second, that he began to work too soon. Unless the double ruptures are known to be congenital, they are in themselves a bad sign, because they are likely to be due to some general cause, quite unaffected by the operation, which persists and produces another rupture, in spite of the surgeon's efforts.

2. A youth, W. L., æt. 17, a wood-carver, was operated on for right inguinal hernia. One stitch was placed in the back of the inguinal canal. Eight months later he had a small hernial protrusion through the back of the inguinal canal. The left side had almost the same amount of impulse in the inguinal canal, and he wore a double truss. Here, again, the rupture was probably acquired, and associated with some general cause unaffected by the operation. Perhaps a single stitch was insufficient.

3. In the following case the cause of the relapse was quite inscrutable. The patient, Mr. D., æt. 20,

was a healthy young man, a clerk, who had a small acquired rupture of the right side. The operation seemed thoroughly efficient, and the wound healed by first intention. Within two months he was accepted for life insurance as a first-class life, but six months later the rupture relapsed. Before the operation he had worn a truss with pain and difficulty. Afterwards a light instrument could be worn with comfort. In this case the abdominal walls were thin, with some bulging of the hypogastric fossæ.

It is noteworthy that each of these cases relapsed within six months or a year of the operation. Anderegg<sup>1</sup> says that he saw forty-one relapses out of 105 cases of radical cure. Three-fourths occurred during the first year, and two during the second.

Amongst my cases is that of a rather delicate man who had a left inguinal rupture operated upon when he was 30 years old. Three years afterwards that side was perfect, but he had developed a small incomplete inguinal hernia on the right. He was pale and anæmic, with relaxed tissues. He desired to undergo another operation, because he found a truss so irksome. He, however, was not a favourable subject, inasmuch as his ruptures were

<sup>1</sup> "Die Radicaloperation der Hernien, etc.," *Deutsche Ztschr. f. Chir.*, Stuttgart, Bd. xxiv. Hefte 3 and 4.

probably acquired, and therefore associated with more than a mere local defect in the abdominal wall.

We have also to consider whether the operation upon the left side helped to cause the rupture upon the right. As I have just remarked, the ruptures being acquired, were associated with a general weakness and relaxation of the tissues; therefore the right rupture might have appeared even if the left had not been cured.

A truss is not ordered after the operation of radical cure. If a person wishes to wear a truss, he might as well wear it without having undergone the discomfort and irksomeness of an operation. Besides, the results so far seem to me to show that in the vast majority of cases a truss is quite unnecessary. Why should every case of radical cure wear a truss because a small percentage has relapsed? and how shall we ever learn the results if every patient wears a truss? So far as I can see, it is time enough to order a truss when signs of recurrence appear. After radical cure has been done, the relapse seldom occurs suddenly. When the sac has been thoroughly obliterated by the operation, the hernial protrusion has to make for itself a new one; this is usually a slow process, and accompanied with pain from the beginning. Also, inasmuch

as the pressure of a truss causes some absorption of the subcutaneous tissue, it seems reasonable to suspect its effect upon the material which repairs the aponeurosis of the external oblique muscle. Under certain circumstances, however, it is probably better to order a light truss than to run the risk of a relapse. For instance, a young man who had been cured for four years was allowed to wear a truss whilst bicycling, because the exertion caused a feeling of discomfort at the site of the operation. This may have been due to various causes, but the precaution seemed to be a wise one. Another patient was ordered a light double inguinal truss to wear during exertion, because the whole abdominal wall was weak, with bulging of the hypogastric fossæ. He had the operation done with the view of entering the army. Another man with a weak abdominal wall, who was occasionally doing work beyond his strength, was advised to wear a truss during his efforts. He had had no relapse, although he had undergone excessive labour for eighteen months. These cases are included amongst the cured.

Females are more reluctant than males to come for examination, and therefore I only know the result in twelve cases. All of these were cured. A girl who had had both sides done at the same time, and in whom both wounds suppurated, afterwards complained

of pain, but I could find no relapse. One woman had a small direct hernia operated on in the year 1891, and a similar one on the opposite side in 1894. Both were well in 1897, in spite of the birth of children. I have already mentioned another woman who was well four years afterwards, although she had had four confinements. Some of the most perfect results which I have seen have been in girls of 10 to 12 years of age, who had had small congenital inguinal ruptures.

In five cases of non-strangulated inguinal hernia the operation of radical cure was done merely to enable the patient to wear a truss. All these operations were of a formidable kind, and only undertaken after much consideration. In four of them the inguinal canal had ceased to exist, and the sac opened straight into the abdomen by a capacious mouth. When, after much toil and difficulty, the neck of the sac had been separated and secured with a chain of interlocking sutures, a huge gap remained in the abdominal wall. This gap was closed, as well as the circumstances would permit, with a series of buried silk sutures, which fastened the conjoined tendon to Poupart's ligament. Then the aponeurosis of the external oblique was brought together with another layer of buried sutures, so as to overlap and cover in the first

layer. Owing to the free oozing of blood from the spermatic veins, and from the vessels of the abdominal wall, a drainage tube had to be used in most for the first twenty-four hours.

The details of these cases are briefly as follow:—

J. H., æt. 40, toymaker, but unable to wear a truss, or to work. Both sides ruptured. Right sac very big, and contained ileum, cæcum, and vermiform appendix. Left side a very large empty sac. Had also an umbilical rupture. A typical case of prolapse of the mesentery. The operation enabled him to wear a truss, and earn his living again.

H., æt. 63. Huge irreducible epiploecle of right side, together with an enlarged and chronically inflamed testis. Had been ruptured for thirty years. Testis removed. Much adherent omentum taken away. As he had a small incomplete rupture on the left side, a double truss was ordered.

J. W., æt. 54. Very large irreducible right inguinal rupture, with hydrocele and œdema of serotum. Radical cure of hydrocele and hernia at same time. He had lived nearly all his life in the tropics, and his general condition was indifferent. He had chronic dysentery, his urine was of low specific gravity, and contained a trace of albumin. He made a good recovery, but was demented for several days. Some

months after, one or two of his deep sutures came out, but very quietly, and without pain or discomfort. During his dementia he urinated into his dressings, but the wound did not suppurate at the time.

J. P., farm labourer, æt. 40, who had a very large right inguinal hernia with adherent omentum and hydrocele of the sac. The usual incision for radical cure sufficed. The patient was afterwards able to wear a truss, and earn his living in comfort.

The fifth case was that of a man, æt. 51, with a right inguinal rupture. Thirty years before he had been operated upon by the late John Wood. A huge adherent epiplocele afterwards developed on the same side. The wound was drained, and united by first intention.

The risks in these cases of very large rupture are but little greater than in the ordinary run, because the dangers of sepsis<sup>1</sup> are now overcome by the precautions which I have described. It is, however, to be remembered that many of those with large chronic ruptures are unsound in other respects. For instance, one of those which I have just described had chronic nephritis. His miseries, however, were so great that he chose to run the risk of the operation.

<sup>1</sup> See W. Mitchell Banks, "Some Statistics of the Operation for the Radical Cure of Hernia," *Brit. Med. Journ.*, London, 10th December 1887, p. 1259.

## CHAPTER XI.

### RADICAL CURE OF FEMORAL HERNIA.

I HAVE already said that femoral hernia differs from inguinal in that it seldom, perhaps never, has a developmental origin. I have only operated twice upon femoral ruptures which might possibly have been congenital.<sup>1</sup> They occurred in boys, *æt.* 12 and 15, and had existed for years. It is also possible that another young man, *æt.* 21, had a congenital femoral rupture. In all of these patients, the muscles, fasciæ, and aponeuroses of the abdominal walls seemed perfect, and the rupture was clearly the only defect, and quite local in its origin. In the other cases a great many different morbid conditions seem to have been concerned in the causation of the ruptures. What was found in some seemed to show that no widespread alteration of the peritoneum or tissues, or prolapse of the mesentery, had caused

<sup>1</sup> The word congenital is used, both here and elsewhere, to imply a developmental cause.



the rupture. For instance, one patient had a number of cysts full of fluid. Others had sacs full of fluid, the neck being plugged with omentum, so-called femoral hydrocele. In two, the bulk of the tumour consisted of fat with a small narrow peritoneal sac in its centre. Half contained omentum,<sup>1</sup> which was usually adherent. It is possible that in these the omentum caused the rupture; and if this be true, the latter would not recur when the omentum was removed. The results of some of the cases certainly bear out this suggestion. In January 1891 a cook was operated upon for double femoral epiploceles, which were both irreducible. She remains well, after an interval of more than seven years.

The operation of radical cure was also done for an enterocele which was irreducible on account of adhesions. A huge femoral enterocele was operated upon although the patient was an old lady in her seventieth year, because it was quite unmanageable, and had been strangulated forty or fifty times. She made an excellent recovery. As a matter of fact, a very large femoral rupture is easier to operate upon than a small one, because, owing to the dilatation of the femoral canal and ring, it is so much easier to pass the deep sutures.

<sup>1</sup> Twelve of the twenty-four non-strangulated femoral ruptures.

I have declined to operate in a number of cases of femoral hernia, and have ordered trusses, because the patients were suffering from a general fault of the tissues, with, in many cases, the usual signs of prolapse of the mesentery and of other organs. In some women the rupture is associated with a relaxation of the peritoneum and fasciæ of the pelvis, as is evidenced by prolapse of the uterus, bladder, rectum, or vagina. These are obviously ill-advised to undergo a curative operation. But when all these are set aside, a great many cases of irreducible and painful femoral hernia remain, in which an operation is a great boon. They are either cured, or enabled to wear a light truss with reasonable comfort. But I never make light of this operation. It is true that it is borne exceedingly well by boys or young women, but they are only a very small proportion of the operation cases. The majority are elderly women with painful irreducible ruptures, who are by no means good subjects for operation. My own experience in this class has been rather painful. A middle-aged woman was operated upon for an unmanageable femoral hernia. She died of ether bronchitis on the sixth day, with the wound healed. Another woman was operated upon for an irreducible epiplocele. The operation was simple and uncomplicated, and did not last more than thirty-five

minutes. Although apparently doing well and comfortable, she died quite suddenly at ten at night. Nothing was found to account for her death. I give such stringent orders against the dangerous practice of administering morphia after operations, that I do not think any had been given to her by the house surgeon.

The diagnosis of femoral hernia is not quite so easy as inguinal. One of the boys with femoral hernia was wearing an inguinal truss. Once I cut down upon a swelling which had been taken for a femoral hernia, but which proved to be a varix of the saphenous vein. I have seen others fall into the same error. The vein was tied, and the patient cured. In another case, that which had been diagnosed as an irreducible femoral epiplocele, proved to be a lymphatic gland full of growth, with a stalk running into the femoral canal. Once the hernial sac was full of pus, but shut off from the peritoneal cavity. In many, the hernial sac had ascended so high that the swelling closely simulated an incomplete inguinal hernia, for which I have seen it mistaken.

It is unnecessary to repeat the details of the preparation of the instruments or materials. They are all exactly the same as for the inguinal operation. The preparation of the patient is likewise the same.

Discretion is needed in disinfecting the skin, and sometimes it is well to leave certain steps, such as the shaving, until the patient is anaesthetised. The field of operation is likewise prepared in the same way, the genitalia being shut off with a screen of antiseptic gauze.

#### SKIN INCISION.

A vertical skin incision is made over the most prominent part of the hernial swelling. It begins an inch above Poupart's ligament, and extends 2 in. down the thigh (Fig. 5. This is enough to facilitate the introduction of the deep sutures. If the patient is fat, it may be carried a little lower. The proximity of the pudenda is taken into consideration. In a case which suppurated, we thought the wound had been infected by a vaginal discharge. Incision, therefore, is kept as far outwards as seems feasible. Consequently, it often lies rather to the outer-side of the hernial swelling, and over the course of the common femoral vessels.

The incision is carried boldly down to the sac. As a rule, no blood vessels require to be clamped, but occasionally branches of the superficial epigastric or superficial external pudic have to be secured. Once a vein at the lower end of the wound bled smartly

for a time. It was either the internal saphenous itself or a large branch of that vessel. In making the skin incision, inflamed femoral or inguinal lymphatic glands are sometimes met with; when large, or in the way, I have usually excised them.<sup>1</sup>

## FINDING THE SAC.

The sac of a femoral hernia may be easily found, but now and then it is very small, and hidden in the fat of the groin. Inasmuch as a small sac is often enveloped in a rather thick layer of subperitoneal fat, it is not at all easy to distinguish from its surroundings. Under these circumstances the spine of the pubes is a guide to its position. It will be found three-quarters of an inch external to it; and the sac, together with its fat, feels rather firmer than the fat in which it lies. The finger easily separates it from its surroundings, so that it can be lifted up like a small fatty tumour, with a stalk running into the femoral canal. If the small lump of fat be cautiously divided from below upwards with the scissors or knife,

<sup>1</sup> A skin incision along the curve in the skin parallel to Poupart's ligament leaves a less conspicuous scar. This incision is, however, followed by a good deal more hæmorrhage, and its inner end is rather near the pudenda. It also seems to me to endanger the common femoral vein.

a little sac is found in its centre. In many of my cases the sac was thin, and had to be opened with great caution. As a rule, too, the hernial swelling had mounted directly upwards over Poupart's ligament, but not infrequently prolongations were met with which ran outwards towards the anterior superior spine of the ilium, inwards towards the pubes, or downwards along the saphenous vein. In an enormous sac, removed from an old lady in her seventieth year, each of these prolongations was found. Usually the sacs of femoral herniæ are loose and non-adherent, like ordinary fatty tumours, but these prolongations may be rather tightly held. I have, however, not yet had much difficulty in detaching them through the small skin incision.

The fat upon the outside of the sac may be so abundant as to form a real fatty tumour. Recently I operated upon a case in which such a mass of fat had been diagnosed as a herniated ovary. The serous sac seemed a mere appanage to the mass of fat, and contained a small knuckle of strangulated intestine.

#### OPENING THE SAC.

The sacs of femoral ruptures vary in size, shape, and thickness. Those which are irregular may have a

single cavity, as in the very old lady with a huge femoral enterocele, or several closed cavities filled with straw-coloured albuminous fluid. These serous sacs should be cautiously opened, until at last one is met with opening by a narrow canal into the general peritoneal cavity. This indicates the neck of the sac, which should be slit up with knife or scissors lest a strip of adherent omentum be overlooked. It is most desirable that the omentum should be set quite free, because omental bands within the abdomen are a cause of intestinal obstruction.

In opening the sac of a femoral hernia, it is to be remembered that it may be very thin, and also that it may contain adherent intestine. This only happened once in my non-strangulated cases. It is, of course, the rule to meet with intestine in strangulated femoral hernia; therefore, to avoid injuring the bowel, the sac is pinched up in the usual way, and opened with the flat surface of the knife held towards it.

Sometimes it is hard to tell when the sac has been opened. The fat outside, and the omentum inside, are much alike. When the latter fills the sac, and is adherent, it is not easy to see the smooth polished interior. Under these circumstances the cut is carried cautiously upwards towards the femoral ring,

until the neck of the sac is opened. The neck of the sac is usually thicker, and the omentum in its interior is more rope-like and less adherent than that in the sac itself.

#### CONTENTS OF THE FEMORAL SAC.

*Intestine.*—Intestine, as I have just said, is seldom found in the sac of a non-strangulated femoral rupture. The huge femoral rupture in the old lady in her seventieth year contained a large quantity; but the femoral ring and the neck of the sac were both capacious, so that reduction was easy. In another case the intestine was irreducible because of inflammatory adhesions, which were hard to undo, and left a large raw surface upon the intestine. To prevent fresh adhesions forming within the abdomen, this was covered with a small flap of peritoneum, secured with fine silk sutures. In helping others I have seen the vermiform appendix in a femoral sac of the right side. I have not yet met with mesenteric adhesions in femoral ruptures.

*Omentum.*—The omentum is one of the commonest contents of irreducible femoral ruptures, and is nearly always adherent. When the adhesions are slight, they are easily separated with the finger until the neck



and mouth of the sac are quite free, and some fresh omentum can be gently pulled down and ligatured. As I have elsewhere pointed out, this is to be done with the greatest care and gentleness. The omental veins are exceedingly thin, and a patient with inguinal epiploecle once died because they had been torn through near the great curve of the stomach. It is unnecessary to waste time in separating adhesions betwixt the omentum and the fundus of the sac, because they can be removed together after the omentum has been separated from the neck of the sac and divided. In clearing the neck of the sac, troublesome adhesions may be met with, but nevertheless all should be separated, so that the omentum can ascend towards the stomach as soon as its stump is returned. The intestines have not infrequently been strangulated by adherent omental bands. By slitting up the neck of the sac, and by pulling it down with pressure forceps, the highest limits of the adhesions can be reached. When the omentum is slender, it is transfixed at the femoral ring with a ligature of twisted silk (No. 3 or 4), and tied with a Staffordshire knot. The omentum below the knot having been removed, the stump is pushed back into the abdomen. More than once, when the omentum has been tied with a single Staffordshire knot, I have found the

stump too bulky to pass through the neck of the sac or through the femoral ring, both being very narrow. A vigorous push sometimes reduced the stump, the neck of the sac being steadied with pressure forceps; but often I have found it necessary to pull down more omentum, and lace it with a series of ligatures which transfix and interlocked.<sup>1</sup>

A loop of intestine may lurk behind the omentum, and be enclosed within it, as if within an omental sac. I have more than once met with this arrangement in strangulated femoral ruptures, but not in the non-strangulated. The peculiarity ought, however, to be borne in mind, and the omentum always examined before it is transfixed or divided.

The fluid which oftentimes accompanies femoral epiplocele calls for no further remark.

Once whilst helping a colleague to operate upon an irreducible femoral epiplocele of the left side, the sac was full of indurated and adherent omentum. This afterwards proved to be infiltrated with carcinoma. The patient was a woman, æt. 40. She had had the rupture for four years, and it had grown much bigger for four months before the operation.

<sup>1</sup> This method has already been described.

LIGATURE OF THE NECK OF THE SAC, AND FIXATION  
OF THE STUMP.

When the neck of the sac has been emptied, it is ready to be freed from its surroundings and secured with a silk ligature. Fortunately, the neck of the sac, like the sac itself, lies loosely in its bed, and can therefore be easily separated with the tip of the finger or any blunt instrument. The common femoral vein lies close to its outer side, but with part of the femoral sheath and some cellular tissue intervening. At this stage of the operation the vein could only be injured by carelessness. The sac is also easily separated from the ligaments of Hey and Gimbernat, and from the pectineal fascia and Cooper's ligament, upon both of which it lies. After this has been done, the finger can be passed behind the neck of the sac into the pelvis, so as to feel distinctly the *linea ilio-pectinea*.

Inasmuch as the ligament named "Cooper's ligament," after Sir Astley Cooper, is of importance in the subsequent stages of the operation, and inasmuch as it seems comparatively unknown to surgeons, I propose to give a short account of it. Briefly, it is a very strong band of fibrous tissue which runs along the *linea ilio-pectinea*, and gives origin to some of the fibres of the *pectineus* muscle, which spring from it almost at a right angle and run downwards in the floor of Scarpa's triangle, towards their insertion into the

femur. The inner end of Cooper's band is attached to the back of the spine and body of the pubes, being closely con-

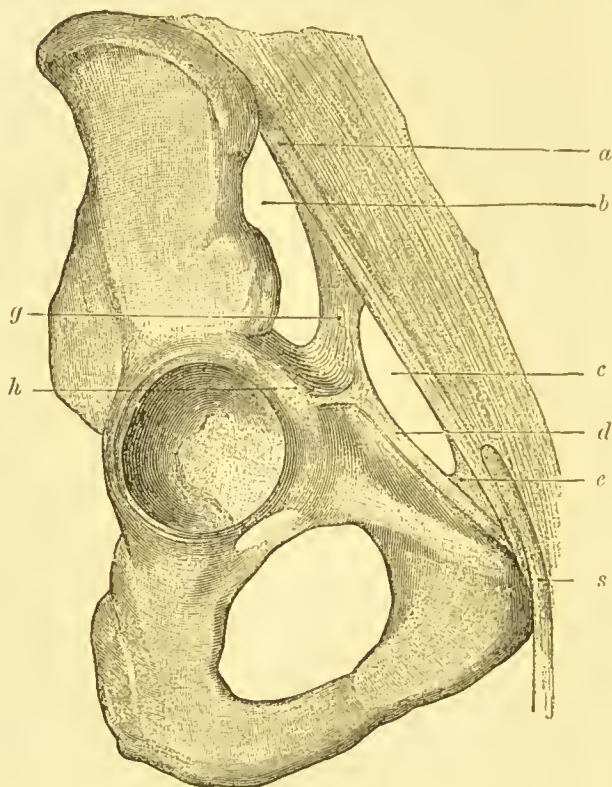


FIG. 17.—Cooper's ligament.—After Macalister.<sup>1</sup> *a*, Poupart's ligament; *b*, lacuna muscularis; *c*, lacuna vascularis; *d*, Cooper's ligament; *e*, Gimbernat's ligament; *g*, ilio-pectineal ligament; *h*, ilio-pectineal eminence; *s*, spermatic cord.

netted with Gimbernat's ligament; its outer end is lost upon the brim of the pelvis at the pectineal eminence (*vide* Fig.

<sup>1</sup> See "A Text-Book of Human Anatomy," by Prof. Alexander Macalister, 1889, Fig. 261, p. 160. See also Sappey, "Traité d'anatomie descriptive," p. 405 *et seq.*

17). Between these attachments, and especially where it lies behind the femoral ring, Cooper's ligament is but loosely fastened to the bone. Indeed, it is merely connected by the pelvic fascia where the latter lines the inside of the body and horizontal ramus of the pubes. The thin and diaphanous pectineal fascia which covers the pectineus muscle is attached to its front edge. At the femoral ring a blunt hook can easily be thrust betwixt Cooper's ligament and the linea ilio-pectinea. As I have often demonstrated to others, the ligament is so strong that it can hardly be torn asunder, and with the help of a hook I have almost lifted the buttocks off the table without any sign of its yielding.

Hey's ligament also calls for some remark. So far as I can gather Hey may have intended to describe some fibres which run across in the substance of the femoral sheath, a little below and parallel to Poupart's ligament. These fibres are seen by dissecting away the continuation of the falciform process of Burns, which sweeps upwards and inwards round the upper part of the saphenous opening, to reach the pubic spine. But nowadays the part of this process of the deep fascia of the thigh which runs parallel to Poupart's ligament, and which crosses the femoral sheath, is usually called "Hey's ligament," and as such will be referred to in this book.

Hence it follows that Cooper's ligament is behind the femoral canal, and Hey's ligament in front of it.

The neck of the sac having been separated from its surroundings as far as its junction with the peritoneum, its interior is finally examined to see that it contains neither bowel nor omentum. Then it

is transfixed at its junction with the peritoneum with one of the blunt herniotomy needles, armed with about 2 ft. of No. 3 or 4 twisted silk. To enable the needle to be thrust through the highest part of the neck of the sac, it is pulled down with pressure forceps. The herniotomy needle having been withdrawn, the loop of silk is carried over the sac, and the ends tied with a Staffordshire knot. The sac is now cut off half an inch below this ligature, unless this may have been done before.

#### FIXATION OF THE STUMP OF THE SAC.

If the neck of the sac has been thoroughly freed all round, its stump is now easily pushed up the femoral canal into the abdomen, or it may slip up of its own accord. It now lies just within the femoral ring, and has hardly any tendency at all to re-enter the femoral canal. But it is wise to make certain of its fixation within the abdomen in the following way. The ends of the ligature on the stump having been left long for the purpose, are threaded through one of the herniotomy needles, and then carried one after the other up through the femoral canal, until the point of the needle is half an inch above Poupart's ligament, and opposite the middle of the inguinal canal. At

this point the needle is thrust through the abdominal wall, until it emerges through the aponeurosis of the external oblique muscle. At this stage the skin and subcutaneous tissue are pulled upwards and inwards by the assistant, to expose the point of the needle, and to permit of its being unthreaded and withdrawn.

When both ends of the ligature have been carried through the abdominal wall, they are gently tightened, and securely knotted upon the aponeurosis of the external oblique. As soon as the assistant leaves go of the skin, it slips back into position and covers the knot. The stump of the sac is now firmly fixed inside the abdomen, and just within the femoral ring. The ligature which holds it pierces Hesselbach's triangle, and is internal to the deep epigastric artery and veins, and a little above the round ligament of the uterus or the spermatic cord where they lie in the hollow of Poupart's ligament. When operating upon males, it seems very easy to avoid including the vas deferens, because that structure lies so close to Poupart's ligament.

#### CLOSURE OF THE FEMORAL CANAL.

The stump of the sac having been fixed within the abdomen, the finger can still be thrust into the

femoral canal, which has now to be closed. This is rather a difficult problem. On the inner side, Gimbernat's ligament cannot be utilised for the purpose, and, on the outer side, the common femoral vein must neither be injured nor compressed.

For many years I have closed the femoral canal by suturing Hey's ligament to Cooper's. By proceeding in the following way, an exceedingly strong and permanent closure is obtained. As a matter of convenience, a sufficient number of sutures are first passed betwixt Cooper's ligament and the linea ilio-pectinea. For this purpose the index finger of the left hand is pushed up the femoral canal so that it lies with its dorsum against the common femoral vein, and its tip upon, and a little within, the ilio-pectineal ridge. The finger is intended to protect the vein from the point of the herniotomy needle, and to guide the latter as its point is thrust beneath Cooper's ligament. In cases in which the femoral canal has been distended and stretched, the needle can be guided by vision.

The herniotomy needle is passed in the following manner:—Having been armed with about  $1\frac{1}{2}$  ft. of No. 4 or 5 twisted silk, its point is guided up the femoral canal until it rests against the inside of the linea ilio-pectinea, opposite the outer edge of Gim-



bernat's ligament. The needle is then rotated so that its point serapes over the linea ilio-pectinea and picks up Cooper's ligament. Finally, the point emerges through the upper part of the pectineal

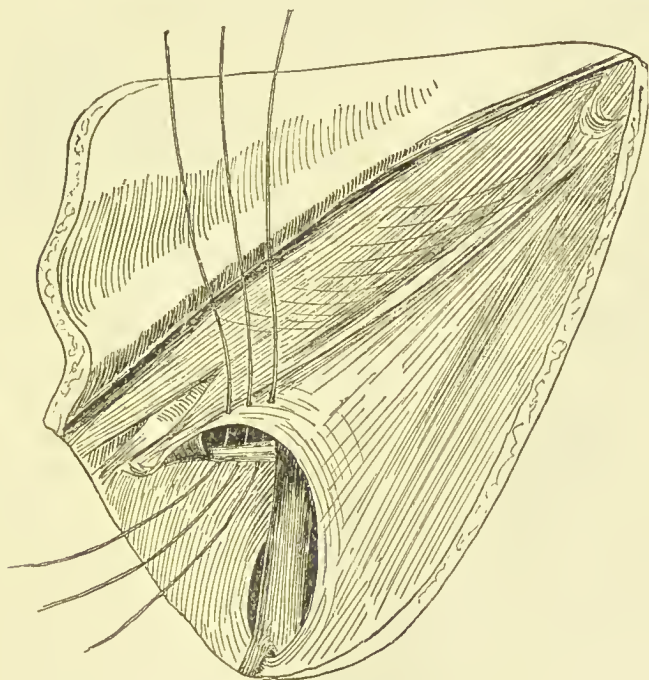


FIG. 18.—Mode of suturing the femoral canal.

fascia, where it is unthreaded and withdrawn, leaving the suture beneath Cooper's ligament (*vide* Fig. 18). Additional sutures are passed in exactly the same way, but each a little farther outwards, until the last lies at the inner edge of the common femoral vein. Two or three sutures generally suffice, but I have

used as many as five. The next step is to again thread the upper end of each ligature in turn through the herniotomy needle, and by pushing the point of the needle half-way up the femoral canal and rotating it forwards, pass the thread from within outwards

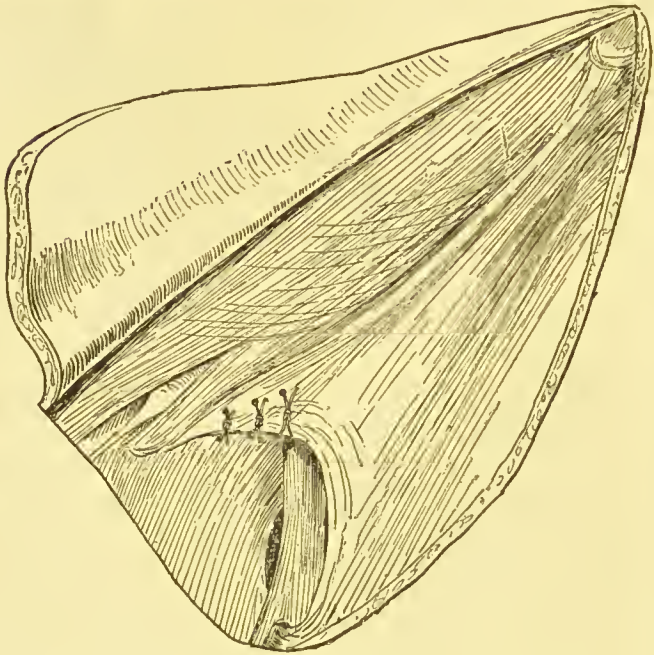


FIG. 19.—Closure of the femoral canal completed.

through Hey's ligament, close to its junction with Poupart's ligament (*vide* Fig. 18). Before knotting these threads, they are pulled tight, to see whether enough have been passed to make a thorough and firm closure of the femoral canal, but without compressing the femoral vein (*vide* Fig. 19).

In my experience this operation is very efficient. The only step in it which presents much difficulty is that of picking Cooper's ligament off the linea ilio-pectinea. But, after a little practice, it is easily scraped away from the bone with the point of the needle.

I have not hitherto endeavoured, as some operators say they have done,<sup>1</sup> to place any sutures with the idea of closing the saphenous opening. - It seems to me to be unnecessary to do so, and unlikely to afford any resistance against relapse.

#### DRESSING AND AFTER-TREATMENT.

The final stages of the operation are the same as in the radical cure of inguinal hernia. The wound is irrigated by squeezing into it biniodide lotion (1 in 2000) from a sponge; and then it is accurately closed with fishing-gut sutures. By this stage there is usually a distinct hollow in the place where the hernial swelling used to be. Finally, the skin is dusted with finely powdered crystallised iodoform, and a dressing is applied, consisting, first, of a layer of 5 per cent. carbolic gauze, wrung out in 1 in 2000 biniodide

<sup>1</sup> Francis T. Heuston, "A Case of Radical Cure of Femoral Hernia," *Brit. Med. Journ.*, London, December 2, 1887, p. 1206.

of mercury lotion; next is a covering of alembroth wool; and over all an outside dressing, like that used for radical cure of inguinal hernia. This is applied in exactly the same way, with straps and bandages (*vide* Fig. 3).

As a rule, the after-progress of a case of radical or femoral hernia is uneventful. A pain in the back is usually complained of, also a pain beneath the costal cartilages. The urine is passed naturally, and the bowels are easily moved with some simple aperient upon the second or third day. When all goes well, the wound is dressed on the eighth or ninth day, and the skin sutures removed. Afterwards a protective dressing of iodoform gauze, fixed with collodion, or with a spica bandage, is all that is needed. To prevent sickness after the anæsthetic, nothing is given by the mouth for the first four hours but a little hot water to relieve thirst. Afterwards a tablespoonful of mutton essence is given, and in an hour a little tea and peptonised milk. After the bowels have acted, any light diet is allowed, with wine or beer in moderation. The period of recumbency is the same as in radical cure of inguinal hernia, or in other suturing operations upon the abdominal walls, namely, three weeks in bed, three weeks on a couch, and six weeks' gentle exer-

cise. This has to be impressed upon the patient's mind, especially if belonging to the lower grades of society. The second three weeks' recumbency can be passed to some extent in the open air or in an easy conveyance.

The above method of treating the stump of the sac is the same as that which is used by most surgeons. Mr. Rushton Parker<sup>1</sup> thinks it better not to tie both ends of the ligature to fasten it within the abdomen, but only to secure one, as Macewen recommends. Mr. Parker believes that the double ligature constricts the tissues, and causes suppuration. I cannot myself attribute suppuration to this cause, but I take care not to pull the ligatures too tight, in order to avoid strangulating the tissues, and so making a weak place in the abdominal wall. I have not practised Professor Macewen's method of preserving and folding up the sac. The sac of a femoral hernia is a morbid structure, with rather peculiar characters, as is shown by its tendency to inflame and form serous cysts, and it is therefore better away.

So far as I can learn, other operators have not utilised Cooper's ligament for the closure of the femoral canal. Many have, however, proceeded in a very similar manner. Tuffier<sup>2</sup> closes the crural ring by stitching Poupart's ligament to the pectineal fascia. He operates through the inguinal canal,—quite an unnecessary complication.

Fabricius,<sup>3</sup> who does not seem to have actually operated

---

<sup>1</sup> *Brit. Med. Journ.*, London, November 11, 1893, p. 1037.

<sup>2</sup> *Rev. de chir.*, Paris, March 1896. Also *Epitome, Brit. Med. Journ.*, London, April 25, 1896, p. 66.

<sup>3</sup> *Centralbl. f. Chir.*, Leipzig, 1893, S. 95.

upon patients, proposed to clear the femoral canal, and then fasten Poupart's ligament to the periosteum of the horizontal ramus of the pubes.

Salzer<sup>1</sup> endeavours, in cases of large femoral rupture, to close the femoral canal with a flap of pectineal fascia turned up from below, and fixed with sutures to the middle third of Poupart's ligament. The pectineal fascia is so thin and diaphanous, that this method has little to commend it.

Watson Cheyne<sup>2</sup> has gone a step further than Salzer, and used a flap of pectineal fascia and muscle to fill the femoral canal. "Although its muscular elements may atrophy, a dense mass of fibrous tissue will be left behind." This method has more to commend it, but nevertheless it has not been extensively used. I know of a case in which it was attempted by one who had made the radical cure of hernia his special study, and who had to abandon it on account of hæmorrhage.

When I have seen it done, it has seemed to me a much more severe operation than the mere suture of Hey's and Cooper's ligaments, and not, in my judgment, likely to afford a more perfect closure.

#### IMMEDIATE RESULTS.

Owing to the age of the patients, and the state of their tissues, it is known at the time of operation that a cure cannot be counted upon with anything

<sup>1</sup> *Centralbl. f. Chir.*, Leipzig, August 20, 1892.

<sup>2</sup> "The Radical Cure of Hernia, with a Description of a Method of Operating for Femoral Hernia," *Lancet*, London, November 5, 1892.

like the same degree of certainty in femoral as in congenital inguinal hernia. Nevertheless, a great many cases are rightly undertaken, because of omental adhesions, hydrocele of the sac, painfulness, or for other reasons. In these it is always worth while to aim at a permanent cure, although the tissues of the abdominal wall are relaxed, with obvious prolapse of the mesentery, and of other organs. Even under such conditions as these, I have sometimes found that the operation closes the femoral canal so firmly that it has not given way under the slight strains of a woman's occupation. It is a great boon to a woman to be able to put aside her truss for a time each day.

Twenty-four operations have been done upon non-strangulated femoral hernia. In two of the patients both sides were done at the same time. One had a left femoral and a right inguinal hernia done at the same time. Nineteen of the wounds healed by first intention, and three wounds had some degree of suppuration. An aged woman, whose health was bad and who had uterine fibroids and a vaginal discharge, had double irreducible femoral epiploceles operated upon at her own urgent request, because they were so painful and troublesome. Both wounds supplicated, but not enough to lead to the loss of the

buried sutures. The second case of suppuration was also subacute and superficial, and was not followed by the loss of the deep sutures.

As I have already said, two patients died after the operation for the radical cure of non-strangulated femoral hernia. In one the fatality was due to acute bronchitis after the ether. The patient succumbed on the sixth day. The wound was almost healed by first intention, and it was clear that the operation had firmly closed the femoral canal and ring, without leaving a peritoneal depression. It was impossible to force the finger down the femoral canal into the thigh. Although I blame the ether for this most unfortunate calamity, I have to add that severe bronchitis occurred in another case after the administration of chloroform, in an operation for the radical cure of both an inguinal and of a femoral hernia in the same person, and at the same time. The operation was therefore a prolonged one, and the chloroform had to be given for over an hour. In the case of ether bronchitis, the operation was brief, but a history of a winter cough was afterwards obtained.

The second fatality occurred in a stout woman, who had a small irreducible femoral epiplocele. The operation was quite uncomplicated, and she seemed to be doing perfectly, when, about five hours after, she



suddenly became faint and died. At the examination nothing whatever could be found to account for this disastrous result. Clots were diligently sought for in the heart and pulmonary vessels.

Of the cases which remained, I am unable to recall one which gave rise to any anxiety. Taught by these fatalities, I look upon these middle-aged women as objects of suspicion, and only operate upon them when there is a good reason, and after mature consideration.

A complete and satisfactory radical cure was done ten times after the relief of strangulated femoral hernia. Nine of these recovered, and their wounds healed by first intention. The details of the fatal cases are as follows:—

A woman, æt. 67, had had a right femoral hernia strangulated for fifty-six hours. At the operation the gut was in good condition, and was replaced, a radical cure being afterwards effected. For two days there was complete relief, with the passage of flatus and cessation of vomiting. The symptoms of strangulation then recurred, and were attributed to peritonitis, as a tender and indurated swelling could be felt in the iliac fossa. The patient died, and a knuckle of gangrenous intestine was found prolapsed through a rent in the peritoneum, not far from the

original neck of the sac. I greatly regret that I did not perform an exploratory laparotomy in this case as soon as these symptoms of strangulation recurred.

So far as could be ascertained, the radical cure had not caused the hole in the peritoneum. With my recent favourable experience of the operative treatment of peritonitis,<sup>1</sup> I should now unhesitatingly explore such a case.

One in ten is a low mortality after strangulated femoral hernia, but the radical cure was only done under favourable conditions. When the patient was critically ill, when the bowel was ulcerated, or when the tissues were septic, a thin silk ligature was merely tied round the neck of the sac. Such cases as these have been omitted. It is clear, however, that the addition of the radical cure certainly does not increase the mortality after strangulated hernia. Indeed, as I have shown elsewhere,<sup>2</sup> it must tend to diminish it, because (a) it prevents a protrusion of the sac from the wound; (b) sloughing of the sac; (c) suppuration of the sac; (d) infection of the peritoneum; (e) immediate return of the rupture; (f) ultimate return of the rupture.

<sup>1</sup> "The Surgical Treatment of Diffuse Septic Peritonitis, with Successful Cases," *Med.-Chir. Trans.*, London, 1895, vol. lxxviii.

<sup>2</sup> "On the Importance of Performing the Radical Cure after Operations for Strangulated Hernia," *Brit. Med. Journ.*, London, 18th July 1891.

## SUMMARY.

NON-STRANGULATED FEMORAL HERNIA—RESULT OF  
RADICAL CURE.

Died . . . . .	2 patients.
Recovered . . . . .	20 ,,
	<hr/>
Total . . . . .	<u>22</u> ,,

Healed by first intention . . . . .	19 wounds.
Suppurated slightly, and with- out loss of sutures . . . . .	3 ,,
	<hr/>
Total . . . . .	<u>22</u> wounds in 20 patients.

Two double operations, one of which suppurated on both sides.

Although the percentage of suppuration seems to be high, nevertheless, from my experience of the cases, and of others which I have had the opportunity of seeing, I am inclined to think that this complication is less serious after the radical cure of femoral than after the radical cure of inguinal hernia. First, the wound is smaller; next, it does not involve any large muscular planes; and, last, the buried sutures are fewer, and more easily taken out in case of necessity.

The cases of radical cure of femoral hernia have been difficult to follow up, because, as I have already said, women are most reluctant to return for examination. Mr. Henry Fraser Stokes has kindly examined a cook, who was operated upon for double irreducible epiploccles. Although she is now 48 years old, and

seven years have elapsed since the operation, she had no relapse. A woman, who was found at the operation to have pus in the interior of the sac, was well two and a half years afterwards. A boy, æt. 12, who had a right femoral hernia operated upon, was quite well three and a half years afterwards. Two maid-servants were both well two years after their operations. One of them was 46 years of age, and the radical cure was done after strangulation.<sup>1</sup> A man, æt. 37 years, was well more than a year after the radical cure of a right femoral hernia. A housewife, æt. 43, was well a year after her operation; also, another woman, æt. 56, died a year after a radical cure, following kelotomy, without any signs of relapse.

When we consider that femoral ruptures are acquired, and seldom due to a mere local developmental defect, like congenital inguinal hernia, it is difficult not to be struck with the small number of relapses which have been found amongst those who have returned for examination.

A woman, æt. 41, had radical cure of a left femoral hernia done after strangulation. A truss was not ordered. Six months afterwards the rupture

<sup>1</sup> Her rupture became strangulated whilst she was wearing one of the old-fashioned and dangerous trusses with a hollow pad.

suddenly relapsed whilst she was lifting a sick child. Doubtless this woman ought to have worn a light truss.

By far the greatest proportion of the operations done upon femoral ruptures were operations of necessity.

There can be no question but that the patients considered it a great boon to be relieved of their irreducible epiploceles, or femoral hydroceles, even if a light truss had afterwards to be worn during the day-time.

The operation for strangulated femoral hernia is the same as that which has just been described, except that the contents of the sac are strangulated. It is necessary to recognise that in most cases the fluid in the sacs of strangulated ruptures is septic, and contains various kinds of intestinal bacteria. As soon, therefore, as the sac has been opened, and before any attempt at division of the constriction, a methodical attempt should be made to disinfect the interior of the sac and its contents. I am accustomed to use a quantity of 1 in 1000 biniodide of mercury lotion for this purpose. Fortunately, as the results show, the intestinal bacteria seem easy to kill.

As I have already stated, no suppuration occurred in the nine cases which recovered. After the dis-

infection of the sac, the constriction is divided and the bowel gently pulled down and examined. If it has not been ulcerated by Gimbernat's ligament, it is gently squeezed to empty it of blood or other contents, and then is quietly returned within the abdomen. If any omentum is present, it is removed. After this the other steps of the operation are the same as if the rupture had not been strangulated. I have observed, however, that especial care has to be taken to ligature the neck of the sac at a higher level than the hole which the knife makes in it when the constriction is divided. This is easily accomplished by pulling the sac well down before transfixing its neck with the herniotomy needle.

## CHAPTER XII.

### RADICAL CURE OF VENTRAL HERNIA, CONGENITAL AND ACQUIRED; TRAUMATIC VENTRAL HERNIA.

#### RADICAL CURE OF CONGENITAL VENTRAL HERNIA.

VENTRAL herniæ are seldom caused by developmental faults in the abdominal wall, but the following probably began in that way:—

A boy, æt. 6, had a small circular hole in the linea alba, about an inch above the umbilicus. It just admitted the tip of the index finger, and allowed the abdominal contents to protrude. The rupture caused hardly any inconvenience, but the child was about to proceed to India, where the heat renders a truss irksome, and he was also intended for the Government service, into which the ruptured are not admitted. The boy seemed to be well grown and healthy, and all the rest of the abdominal wall was thick and strong. The following operation, therefore, was done to close

the gap in the linea alba, by bringing together each stratum of the abdominal wall with a separate row of buried silk sutures. This operation will be described in detail, because it is a type of that which is done upon ventral and umbilical ruptures, whenever the conditions permit of such an elaborate procedure.

A small vertical incision was made over the hernia, until its peritoneal sac was seen. A little pad of fat, which overlay the sac, was taken away. It is possible that these small lipomata, so often met with in ventral herniæ, may have something to do with their formation. The peritoneal sac seemed quite shallow, and was not opened. The falciform ligament of the liver lies behind the upper part of the linea alba, so that, even had I taken away the sac, plenty of peritoneum was at hand for the formation of a new one. Next, the linea alba was split until the muscular fibres of the inner edge of the rectus could be seen on either side. Then the posterior layers of the sheaths of the recti were fastened together; next, the inner edges of the recti; and, finally, the front layers of the sheaths of the recti.

My own experience of operations upon the abdomen has led me to the conclusion that this is the most reliable way of closing apertures. In the lower and front part of the abdomen, and in recent operation



wounds, good results can oftentimes be obtained with a single row of fishing-gut sutures; but it is very doubtful whether such a simple method gives a sufficiently thick and strong cicatrix in cases of ventral hernia.

For additional strength, it is better not to fasten together the sheaths of the recti by their edges, but to make them overlapped, in the manner which Lucas-

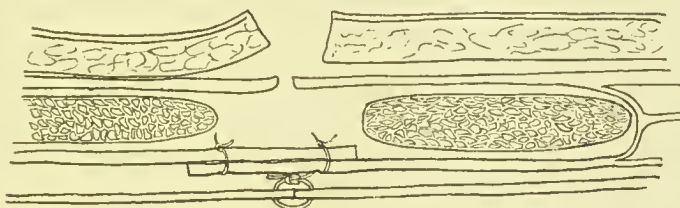


FIG. 20.—Method of applying sutures in the radical cure of ventral and umbilical hernia. For the sake of clearness the other rows of sutures are omitted.

Championnière uses to unite the aponeurosis of the external oblique, in his operation for the radical cure of inguinal hernia<sup>1</sup> This is done with two vertical rows of interrupted buried silk sutures. These transfix and fasten together the edges and bases of the aponeurotic flaps (*vide* Fig. 20). The recti are brought together with a row of simple interrupted sutures, the number of which depends upon the size of the gap. They are placed about  $\frac{1}{3}$  in. apart, and in this

<sup>1</sup> "Cure radicale des hernies," Paris, 1892, p. 194, Fig. 37.

boy two pairs were required. I have found that a defect in this method of suturing has to be guarded against. In the middle, where the flaps completely overlap, a very strong buttress is formed, but above and below, where the flaps begin to overlap, there is always a weak spot. I have hitherto overcome this defect by inserting an additional suture above and below, at the junction of the flaps. Obviously, in this method, all the sutures of each layer have to be inserted before they are tied. In the case of the boy, only the posterior sheath of the rectus was overlapped in this way. The result seemed so satisfactory, that the anterior sheath was merely united with a row of sutures. When this had been done, the skin wound was closed in the usual way, and healed by first intention. Six months afterwards I could find no hernia.

#### ACQUIRED VENTRAL HERNIA.

The acquired type of ventral hernia was exemplified by the case of a labouring man, who was sent to me by my friend Dr. Tanner of Farnham. The patient was strong and healthy, and about 50 years of age. The rupture had been forming for several years, and lately had interfered with his work, having become painful. At the right edge of the linea alba, midway

betwixt the umbilicus and the ensiform cartilage, he had a lump as big as a pigeon's egg. It was irreducible, and very like a fatty tumour. It had a pedicle, however, which went into the abdomen, and a slight impulse could be felt when he coughed.

This tumour proved to be a mass of fat, with a small narrow peritoneal sac in its centre. In removing this fat and its contained sac, a second one of the same kind, but smaller, was found piercing the linea alba, about  $\frac{3}{4}$  in. higher up. The two openings were united by a vertical incision. The sacs were then removed, together with their envelope of fat. At this stage some small vessels at the base of the falciform ligament had to be tied, the incision having to be enlarged for the purpose. A little serous fluid was found in the sacs. Next, the hole in the abdominal wall was closed as follows:—(1) The peritoneum was united with a continuous suture; (2) the posterior sheath of the rectus was sutured beneath the linea alba; (3) the inner edge of the rectus was pulled over the opening, and sutured to the linea alba; (4) the anterior sheath of the rectus was joined with a row of interrupted sutures; and, finally, the skin wound was closed,—five rows of sutures in all.

The wound was not drained, and healed by first

intention. Dr. Tanner informs me that this man was quite well and able to work more than a year after the operation. Ventral hernia seems to be not uncommon above the umbilicus, and opposite the attachment of the falciform ligament. I have had under my care four cases similar to the above, but as the ruptures caused no inconvenience, I left them alone. Ventral herniæ occur in this position because it is a place where various small vessels from the falciform ligament pierce the linea alba and sheath of the rectus abdominis.

Acquired ventral herniæ of this type occur by the side of the umbilicus, and in the lineæ semilunares. In my Hunterian Lectures on "Hernia" <sup>1</sup> is given an instance of one of the appendices epiploicæ passing into a very delicate peritoneal sac, which protruded through the linea semilunaris.<sup>2</sup>

In women who have borne children in rapid succession, the recti may be separated from each other throughout the linea alba, but especially below the umbilicus. The normal linea alba is from  $\frac{1}{2}$  to  $\frac{2}{3}$  in. wide at the umbilicus; 2 in. lower down the inner edges of the recti come together, and are merely separated by a delicate septum of connective tissue. In

<sup>1</sup> Page 137, Fig. 31.

<sup>2</sup> This specimen is preserved in the Museum of St. Bartholomew's Hospital.

the case of a young married lady, who had had several children in rapid succession, the recti was at least 2 in. apart, midway betwixt the pubes and umbilicus, with an elongated ventral hernia protruding through the gap. A suitable abdominal belt was fitted.

As yet I have not operated upon a congenital or acquired ventral hernia in the lower part of the linea alba. Below the level of the anterior superior iliac spines the posterior aponeurotic sheath of the rectus is absent, its place being taken by the transversalis fascia. This arrangement might necessitate some modifications in the suturing.

#### TRAUMATIC VENTRAL HERNIA.

Wounds in any part of the abdomen may be followed by ventral hernia, but the risk seems greater in the lower and front part. Within the last seven or eight years I have seen ventral herniæ after ovariotomy, inguinal eolotomy, cholecystostomy, excision of the vermiform appendix, nephrectomy by lateral incision, lumbar nephrotomy, laparotomy for septic peritonitis, and laparotomy for pancreatic cyst.

Small traumatic ventral herniæ may cause little inconvenience, and merely require suitable abdominal

belts and pads. But presently I shall mention eases in which they made life a burden, and compelled the unfortunate victims to encounter the gravest risks in the hope of being eured.

As a rule, more than one cause is concerned in the production of a traumatic ventral rupture. Amongst the commonest are—(1) Inefficient suturing of incisions; (2) too short a period of reeumbency and rest; (3) the omission of an abdominal belt during the first year after the operation; (4) suppuration; (5) ill-planned incisions; and (6) relaxation and degeneration of the muscles and tissues of the abdominal wall. The hernia which results has nearly always a wide mouth, with fibrous tissue around, but not, as a rule, with sharp edges. The body of the sac is very capacious, with secondary sacs protruding from its sides in amongst the abdominal fat. The coverings are usually loose skin, a little scar-tissue, and peritoneum. This thinness has to be remembered during the operation, and also the frequency with which the intestinal and omental contents are adherent.

I have already discussed some of these causes of ventral hernia whilst describing the operations for the radical cure of inguinal, femoral, and ventral hernia. As regards the suturing of abdominal wounds, the

advantages of buried sutures which unite layer to layer have already been pointed out.<sup>1</sup> The use of buried sutures is, however, inadmissible where the wound is likely to suppurate, as, for instance, after laparotomy for septic peritonitis.

As regards the time needed for repair, some surgeons make a great point of the shortness of the time needed, but it is clearly unreasonable to expect the reparative material to grow strong and fibrous in a short time. I am accustomed, therefore, to give those upon whom I have performed laparotomy the same rules as for radical cure of hernia, namely, three weeks in bed, three weeks on a couch, and six weeks' gentle exercise. A small well-sutured wound does not require an abdominal belt, but it is wise to order one if it is over 3 in. long. Especial care is needed after suppuration. This misfortune usually leads to the extrusion of the deep sutures. It is not always recognised that after suppuration a longer time is needed for thorough cicatrisation, and the patient is sometimes allowed to begin work too soon. Some suppurating abdominal wounds, such as occur after

<sup>1</sup> Mr. Alban Doran, in his excellent paper in the *Lancet*, London, November 27, 1897, p. 1379, entitled "Hernia of the Abdominal Cicatrix, and Operations for its Cure," describes, p. 1380, Case 3, a case which relapsed after a continuous suture of the peritoneum and single row of interrupted gut sutures in the rest of the abdominal wall.

septic peritonitis, gape in the most threatening way, and their edges are too far apart for efficient repair.

In planning an abdominal incision, its subsequent closure ought to be taken into consideration. For instance, for removal of the appendix, an incision above and parallel to the outer half of Poupart's ligament does not divide the nerves of the rectus abdominis. It can be made, as M'Burney suggested, so as to split the fibres of the external oblique aponeurosis, and then the muscular fibres of the internal oblique and transversalis, which run in the opposite direction, can be pulled apart and the peritoneum opened. When these layers are united with buried sutures, the advantages of this mode of incision are obvious. A similar method is applicable to the loin and other regions of the abdomen. Long incisions in the semilunar lines interfere very much with the nerves which supply the recti, and are not so well adapted for closure by layers of buried sutures.<sup>1</sup>

Degeneration and relaxation of the abdominal muscles and aponeuroses is a cause of ventral hernia which is likely to be overlooked. Whilst operating upon middle-aged women for intractable ventral

<sup>1</sup> Lennander, *Centralbl. f. Chir.*, Leipzig, 1898, Bd. iv., describes a method of median and of lateral laparotomy in which the edge of the rectus is pulled aside before the hinder sheath is incised. I have seen my colleague Mr. Bowlby use the same device.



hernia, and whilst watching the operations of other surgeons, I have particularly noticed the condition of the muscles, aponeuroses, and tissues of the abdominal walls. Their looseness and fattiness are sometimes very marked; the subcutaneous fat is soft and oily; the aponeuroses are limp and slaek; the fibres of the muscles are pale, yellow, and friable; and the periton-eum is redundant and easily displaced. Clearly these conditions cannot be affected by an operation; and if one be done, they still persist, and may produce a fresh rupture. In addition, the heart, kidneys, and lungs may participate in the morbid changes, and thus render an operation all the more inadvisable.

Operations cannot always be withheld even in unfavourable cases. Six years ago, a woman came under my care for an enormous ventral hernia. Seven years before, she had had an operation done upon a small umbilical rupture, which soon relapsed and grew into a tumour about a foot in diameter, containing a considerable part of the bowels and omentum. Her life was a great burden to her, and she longed for an operation; but that had to be deferred because she was pregnant, and because the surface of the huge tumour was superficially ulcerated and very septic. Having had a miscarriage, she returned, but the operation was again deferred because she had bronchitis.

When this had subsided, the hernia was partially reduced under an anæsthetic, and its interior laid open by a longitudinal incision. It contained the cæcum and vermiform appendix, the right and transverse colons, the whole of the great omentum, and about 2 ft. of ileum. It communicated with the abdomen by an opening about  $2\frac{1}{2}$  in. in diameter. The hernial aperture had to be enlarged upwards to enable the cæcum to be reduced, after which the great omentum was secured with a row of about thirty interlocking sutures, and removed. Next, the peritoneal sac was separated and cut away, its mouth being closed with a row of sutures. The margins of the opening in the linea alba were then split until the edges of the recti came into view. The posterior layers were superimposed with a series of sutures, in the manner described in the operation for congenital ventral hernia. The recti were so thin and fatty that it seemed useless to try to suture them together. As the operation had lasted a long time,—it took an hour and forty minutes from beginning to end,—the front sheath of the rectus was closed with a continuous suture; and, finally, the redundant skin was cut away and the wound closed. This operation was followed by less shock than might have been anticipated. On the sixth day some blood was let out

of the wound. Afterwards she improved; but an attack of bronchitis, which the ether had brought on, began to trouble her. Her heart, too, became rapid, and beat over 150 per minute. She died on the ninth day from bronchitis. The wound was nearly healed, and she had no trace of peritonitis.

Since this time I have usually drained the wounds after operations upon ventral or umbilical herniæ. Owing to their position, to the looseness of the subcutaneous tissues, and the impossibility of making adequate pressure, a hæmatoma easily forms. The drain is not needed for more than twenty-four or forty-eight hours.

I also operated upon another woman for a very large ventral hernia, following laparotomy below the umbilicus. The tumour was resonant, and all the contents could not be reduced. The sac, therefore, was opened at some distance from the scar, and contained two adherent coils of small intestine. As these could not be detached, the sac was cut so as to enable them to be returned adherent to its walls. The abdominal opening was closed with the usual precautions, and drained for the first forty-eight hours. Although this patient disturbed her dressings, and took her discharge before the wound was soundly healed, she nevertheless made an excellent recovery,

and the wound healed by first intention. Six weeks afterwards her abdominal wall was very firm and strong.

Another woman, æt. 29, was operated upon in the same way for a large ventral hernia following laparotomy for the cure of a pancreatic cyst. The wound healed by first intention, and two years after she was well. An important question was raised by this case. Within a year of the operation she became pregnant, but the risk of a recurrence of the ventral hernia seemed so considerable that abortion was procured. Dr. Matthews tells me that afterwards she bore a child without causing a relapse.

Each of these two patients wore an abdominal belt after the operation, but their comfort was much increased, and they ceased to be invalids.

## CHAPTER XIII.

### RADICAL CURE OF UMBILICAL HERNIA.

INFANTS born with congenital umbilical hernia are often deformed in other ways. In Marjantschik's case the sac contained most of the liver and intestines. Laparotomy was done, and the infant died on the fifth day, of peritonitis and gastro-colitis. The spleen was found to be ill-developed.<sup>1</sup>

Exaggerated cases of umbilical hernia, and of ectopium abdominis, such as are sometimes associated with anencephalus, clubbing of the hands and feet, congenital absence of the margin of the acetabulum, extroversion of the bladder, and so forth, do not come within the range of practical surgery.<sup>2</sup>

These congenital umbilical ruptures are usually

<sup>1</sup> *Centrallbl. f. Gynäk.*, Leipzig, 1896, No. 13 ; *Epitome, Brit. Med. Journ.*, London, April 25, 1896, p. 67.

<sup>2</sup> *E.g.*, see specimens in the Museum of St. Bartholomew's Hospital. For description, see paper by author in *Trans. Path. Soc. London*, 1887, vol. xxxviii. p. 303.

very large, with thin, transparent sac walls, devoid of proper skin, and chiefly consisting of the mucous tissue of the umbilical cord. These coverings are prone to inflame, ulcerate, and slough. Last year I did not operate upon a case placed under my care by my friend Mr. Herbert Newton, because the surface of the sac was superficially ulcerated and septic, and because the surrounding abdominal wall seemed thin and unfavourable.

In America, congenital umbilical herniæ have been successfully operated upon by Macdonald,<sup>1</sup> Barton, and others. If an operation be done, it should be undertaken before the cord has had time to gangrene, and before the sac has inflamed or ulcerated. Macdonald gives a table of nineteen recorded cases, with seventeen recoveries; but of twelve cases treated by bandages and compresses, nine died, and three recovered. According to Lindfors,<sup>2</sup> eight cases out of thirteen recovered after operation. Cold was, as might be expected, very fatal to these new-born infants.

Bergen<sup>3</sup> has also described a success in a female child operated on thirty hours after birth, although

<sup>1</sup> *Am. Journ. Obst.*, N. Y., January 1890.

<sup>2</sup> *Samml. klin. Vortr.*, Leipzig, January 1893.

<sup>3</sup> *N. Arch. d'obst. et de gynéc.*, Paris, June 25, 1893; Abstract, *Brit. Med. Journ.*, London, September 23, 1893.

the operation occupied an hour and a quarter. The sac, as is often the case, contained the cæcum, vermiform appendix, and colon, all adherent to the membranes of the cord. The opening was closed by uniting the peritoneum, the aponeurosis, and the skin with separate rows of sutures. Without doubt, this is the best method to attempt when the operation has to be done. In infants with less vitality, reliance might, however, have to be placed upon a single row of fishing-gut sutures. On the whole, and after making due allowance for unpublished fatalities, the weight of evidence is in favour of operation in bad cases of congenital umbilical hernia.

#### INFANTILE UMBILICAL HERNIA.

The infantile form of umbilical hernia is very common, and is caused by the yielding of the umbilical cicatrix. It occurs about the sixth month, or a little later. It never strangulates, and has a strong tendency to undergo spontaneous cure. This may be assisted by a properly applied bandage, and small *flat* pad to cover the hole. Instrument makers oftentimes provide a convex pad, which fits into the hole, and hinders it from closing. I have not yet met with an infantile umbilical rupture which failed to

get well without an operation. In troublesome cases I have usually found, like Mr. Arbuthnot Lane, that as soon as the child was placed under proper observation, its evacuations were unhealthy, and contained undigested food. The child's abdomen is at the same time swollen with wind, and very tight. A proper diet and a little mild purgative usually cures this condition, and renders the hernia easier to retain within the abdomen.

RADICAL CURE OF ACQUIRED UMBILICAL HERNIA,  
STRANGULATED AND NON-STRANGULATED.

It is probable that in most cases of acquired umbilical hernia, the rupture is but a part of the morbid condition, the recti being widely separated from one another, and the linea alba thinned and weakened by stretching. In an aged woman with an umbilical rupture 3 in. in diameter, the recti were  $2\frac{1}{2}$  in. apart half an inch below the umbilicus, and their muscular fibres were coarse and friable and infiltrated with fat. The accompanying sketch<sup>1</sup> (Fig. 21) shows the excessive width of the linea alba. Large acquired umbilical ruptures occur oftenest in women who are

<sup>1</sup> Hunterian Lectures on "Hernia," p. 133, Fig. 30. The specimen is in the Museum of St. Bartholomew's Hospital.



obese and emphysematous, and in whom the heart, too, may be dilated and infiltrated with fat. A woman upon whom I recently operated for a pendulous and ulcerated umbilical rupture had probably all of these, with glycosuria in addition. During the operation, it was evident that the great omentum was laden with soft and oily fat, and, together with the intestines, seemed too large for the abdominal cavity.

Both the local and the general conditions in acquired umbilical hernia are therefore not at all favourable for curative operations. My own ex-

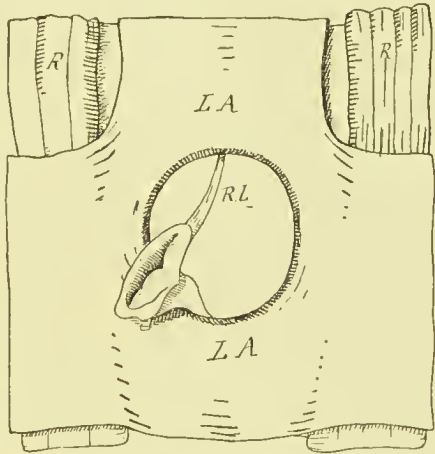


FIG. 21.—The separation of the recti and stretching of the linea alba in acquired umbilical hernia. *LA*, linea alba; *R*, rectus abdominis; *RL*, round ligament of the liver (obliterated umbilical vein).

perience has been mainly confined to attempts which I have made to close the umbilical ring after operating for the relief of strangulation. But circumstances often justify palliative operations upon non-strangulated umbilical herniæ. Their omental and intestinal contents are often adherent to each other and to the sac, so as to cause attacks of obstruction or of

strangulation ; or, owing to the size of the tumour, the skin over it may have become stretched and shining, or red and inflamed, with superficial ulceration or sloughing.<sup>1</sup> The digestion and the functions of the intestines may be interfered with. Not infrequently the irreducible umbilical hernia forms a long pendulous tumour which cannot be managed with any kind of belt, and is most uncomfortable and even dangerous. Under such circumstances, one of my patients preferred to risk an operation rather than lie in misery, although she also had glycosuria and an indifferent heart.

After operations for the relief of strangulated umbilical hernia, the propriety of an attempt to close the hernial aperture cannot be questioned. It is a great gain if the hernial sac can be removed and the general cavity of the peritoneum shut off from the wound. Also, it adds much to the security of the patient if the hernial aperture can be sutured in such a manner as to prevent an immediate recurrence of the rupture during vomiting or coughing, and afterwards to render it more amenable to treat-

<sup>1</sup> Although the sac may be very thin and tense, it seldom bursts. Mr. Henry Pilkington has, however, recorded a case of spontaneous laceration of the sac of an enormous umbilical hernia. Mr. Pilkington sutured the rent, and the patient recovered (*Lancet*, London, May 10, 1890, p. 1007).

ment. An ideal operation would be that which has already been described for the other varieties of ventral hernia. It ought to provide for the closure of the hernial aperture by uniting, first, the peritoneum; second, the posterior layers of the sheaths of the recti; third, the recti; fourth, the anterior layers of the sheaths of the recti; and, fifth, the skin. But unfortunately it often happens that the linea alba is so thin, and the recti so far apart, that this operation is impracticable. Moreover, the general condition of patients with strangulated umbilical ruptures will not always allow of time being given to such an efficient closure. Obese and plethoric, with weak hearts and emphysematous lungs, they take anæsthetics badly, and suffer severely from shock and other after-effects, especially bronchitis. Owing to these circumstances, I have on five occasions had to content myself with the complete removal of the sac, and a rapid suturing together of the peritoneum and sides of the hernial aperture with seven or eight buried sutures of twisted silk. One of the cases treated in this way is known to have relapsed about a year after the operation, and the patient afterwards wore a belt. I now order a suitable abdominal belt after operations upon acquired umbilical hernia, and do not allow the patient to get up or walk about until the wound is sufficiently healed

to allow the belt to be worn without pain or discomfort. I am also determined in the future to try and unite the peritoneum separately with a row of interrupted sutures, or with a continuous suture, because without a separate suture it is very difficult not to include too much of the peritoneum betwixt the edges of the fibrous layers, and so prevent them growing together. A continuous suture has several faults. If one part gives way, the whole becomes slack; judging from skin wounds, it is apt to strangle the tissues; and, finally, in case of suppuration the whole is extruded. It is unusual for the whole of the interrupted sutures to be lost, even in acute suppuration.

An umbilical hernia is likely to relapse if the thin edges of the umbilical ring be merely sutured together. But often the patient is too ill to allow them to be split, and the front and back layers of the sheaths of the rectus united, as in the radical cure of ventral hernia. I have nevertheless obtained an efficient closure by a modified procedure which takes but little time. It simply consists in splitting the margins of the umbilical ring all round for a depth of about one-third of an inch, and then suturing the split surfaces together. This, of course, brings a considerable area of fibrous tissue in contact.

In operating upon a non-strangulated umbilical rupture, I found it easier to suture together the upper and lower margins of the ring instead of the right and left sides. As the tension is transverse, the advantages of this course are obvious.

After all kinds of anæsthetics, and especially after an acutely strangulated hernia, vomiting may be rather violent. In these circumstances an efficient series of sutures is a great safeguard. This vomiting is best met by rectal feeding, the thirst may be relieved by enemata of tepid water, and by washing the mouth out with hot water, none of which should be swallowed.

After operations upon umbilical herniæ, I usually place a small drainage tube in the lower angle of the wound, because, owing to its position, neither blood nor serous effusion easily escape from it, and the application of pressure is out of the question. Besides, owing to the intertrigo, eczema, or ulceration of the skin, the asepticity of the operation is less to be depended upon, even although the greatest efforts may have been made to disinfect the skin. The drainage tube need not be left in for more than twenty-four to forty-eight hours.

The radical cure of umbilical hernia is safer and more likely to succeed when the rupture is not strangu-

lated but reducible, or merely irreducible. In the absence of urgent symptoms, there is time to regulate the patient's diet, evacuate the intestines, and ascertain the state of the organs.

It is also advantageous to wait until any inflammation or ulceration of skin has got well. The disinfection of the skin is a more certain process when it can be done in a leisurely fashion.

The fluid in the sacs of strangulated ruptures is septic, and contains intestinal bacteria. It might therefore be expected that suppuration would be more common after strangulation. I know, however, of no conclusive evidence on this point; but my own statistics of strangulated inguinal hernia show that suppuration is twice as frequent in them as in non-strangulated. Hence, when radical cure is done after strangulation, there is rather more chance of the deep sutures coming out again. The septicity of the sac fluid is an additional reason for the use of a drainage tube.

The anatomical arrangement of large umbilical ruptures is nearly always the same, whether the contents are strangulated or merely irreducible. The sac is always thin, consisting of a layer of stretched or shiny skin, a very thin layer of fibrous tissue, and the peritoneum. This sac is usually full of omentum,

which is adherent to its interior. It may also contain part of the transverse colon, or of the jejunum, or coils of both large and small intestine. As a rule, the bowels lie behind the omentum, in the position which they occupy within the abdomen, and they may be enveloped in a kind of omental sac. Sometimes the intestines elude the omentum, and lie in contact with and perhaps adherent to the sac wall. Thus the thin sac needs to be opened with caution. A small non-strangulated umbilical rupture upon which I operated consisted of a small empty sac, enveloped in a mass of fat, and causing considerable pain and discomfort.

If the rupture is small, the skin may be reflected by a single vertical incision in the median line; but when the sac is large, and the skin likely to be redundant, then it saves time to make an incision along either side, so as to leave just enough skin to close the wound. After the incision I nearly always begin by separating the skin from the sac, and in most cases this can be rapidly done with the finger and scissors. The sac should be opened by pinching up a bit of it in the dissecting forceps, and cutting it through with the knife held on the flat.

Besides being very thin, the sacs of umbilical herniæ are often sacculated. This peculiarity must be understood, otherwise a loop of intestine, or a piece of

omentum, might be overlooked. Whilst operating upon an enormous and acutely strangulated umbilical hernia in a very stout man, I opened a sac containing omentum, by the side of which was another sac, and when the partition was divided the strangulated bowel came into view. A specimen to which I have already referred shows how these saeculations are formed (see Fig. 21). In it the sac has been dissected away, leaving the obliterated umbilical vein, which lay in a deep groove between the two halves of the sac. The urachus and obliterated hypogastric arteries usually remain in their proper position, attached to the lower margin of the umbilical ring, so that the sac protrudes above them; but they too may cross the sac wall, and cause depressions in it. Owing to adhesions and sacculations, an operation upon an umbilical hernia may prove to be a very formidable and difficult undertaking. It is hardly necessary to repeat how the omentum ought to be managed. The ligatures applied to it ought all to transfix and interlock. The stump should not be returned until it is absolutely dry. Intestinal adhesions should be undone, or, if this cannot be accomplished without danger to the bowel, the adherent part of the sac may be returned into the abdomen along with the bowel. When the sac has been emptied, the redundant part of it is cut away,



care being taken to leave enough serous membrane to bring it together behind the umbilical ring. A small narrow sac merely requires to be transfixed and tied like an inguinal or femoral sac.

The fibrous covering of the sac may be freely removed, as it is of no use for the closure of the hernial aperture, a step which has already been described. During all these manipulations, care should be taken to prevent blood running back into the abdomen. This is done by pushing a sponge into the mouth of the rupture as soon as its contents have been returned. This sponge must be secured with a string, or with a pair of pressure forceps, otherwise it may get lost in the abdomen. The presence of blood clot within the abdomen causes pain by setting up a kind of chronic peritonitis.

## CHAPTER XIV.

### THE RADICAL CURE OF HYDROCELE.

A PROPORTION of non-strangulated inguinal ruptures are complicated by chronic hydrocele, either congenital or acquired. I have met with the following combinations of a congenital kind:—(a) Congenital inguinal hernia, with hydrocele of the testicular part of the processus vaginalis. (b) Congenital funicular hernia, and an encysted hydrocele of the cord; the latter was betwixt the hernial sac and the tunica vaginalis. (c) Hydrocele of the sac of a congenital funicular hernia, with polypoid growths into the sac; three cases. (d) Hydrocele of the sac of a congenital funicular hernia.

The following have been met with in cases of acquired hernia:—(a) An acquired hernial sac, and an ordinary hydrocele of the tunica vaginalis, the sacs, of course, being distinct from one another; (b) acquired hernial sac, with its neck packed with omentum and its fundus full of hydrocele fluid.

I have not yet met with an infantile hernia combined with hydrocele, or hernia and encysted hydrocele of the epididymis; nor have I seen hydrocele of the processus vaginalis in cases of undescended testis.

In some cases of hernia and hydrocele it was possible to deal with both the hernia and the hydrocele through the usual inguinal incision. As I have already pointed out, a small encysted hydrocele of the cord can easily be pulled up into the inguinal incision, and dissected out. The same can also be done in congenital herniæ when the hydrocele is caused by a strip of omentum which plugs the funicular part of the processus vaginalis. Under these circumstances, it suffices to remove the omentum, and then pull the rest of the sac into the inguinal wound, snipping away its front part. This leaves the tunica vaginalis vera in contact with the cellular tissue of the serotum. The plug of omentum is, in some way or another, the cause of the hydrocele, and when both it and the sac have been cut away a recurrence is impossible.

A kind of hydrocele fluid occasionally accumulates in the sac of an acquired hernia when its mouth and neck are plugged with omentum. I have hitherto been able to deal with this complication through the inguinal incision, either by cutting the fundus of the sac freely open, or by taking it away, and at the

same time removing the omentum. In a case in which the sac was not freely opened, a hæmatoma formed, and had to be excised. But sometimes, when the tunica vaginalis contains hydrocele fluid, the operation has to be begun through the serotal incision. Then, as it proceeds, something suspicious is met with, and the incision has to be prolonged upwards into the groin, so as to explore the interior of the inguinal canal.

For instance, a boy, æt. 5, had a serotal hydrocele for some years. When the sac was opened by a serotal incision, a long, narrow, serous canal was found running up the inguinal canal towards the abdomen. The aponeurosis of the external oblique was divided, the canal dissected out, and tied at its junction with the peritoneum. The parietal layer of the tunica vaginalis was then cut away, so as to make sure of curing the hydrocele. This began as an operation for hydrocele, and ended with a radical cure of hernia.

In another case, which has already been described at length, a very large acquired hernia was dealt with through the usual inguinal incision. The wound had afterwards to be prolonged into the serotum for the cure of a large passive hydrocele. Thus it happens that anyone who undertakes to cure a rupture may at the same time have to cure a hydrocele. The converse also holds good, and whoever begins to operate

for the cure of a hydrocele may have to proceed to radical cure of hernia.

It is needless to say that chronic hydrocele seldom gets well without surgical measures. Mere tapping is of no avail. I have, however, met the following instances of spontaneous cure:—

A man, æt. 65, came under my care with a chronic hydrocele of two years' duration. It had been tapped five times. He had bronchitis, so I tapped it again, and told him to come in the summer to be cured. He returned in the summer with no trace of hydrocele, and said that after the tapping it had rapidly refilled, and then got quickly well. He attributed his cure to some spirits of camphor which he was taking.

A gentleman, æt. 51, had a left inguinal rupture and hydrocele fluid in both the right and left tunica vaginalis. This also disappeared spontaneously, but without any tapping.

I have dealt elsewhere<sup>1</sup> with the question of the radical cure of hydrocele by the injection of irritants, such as tincture of iodine, pure carbolic acid, black wash, port wine, and so forth. With the help of my friend, Mr. E. G. B. Adams, I made an abstract of the notes of seventy-four patients who had been treated in

<sup>1</sup> "The Operation for the Radical Cure of Hydrocele by Excision of the Sac, illustrated by a Series of Cases," *Lancet*, London, October 19, 1895; *Trans. Med. Soc. London*, 1896, vol. xix. p. 17 *et seq.*

St. Bartholomew's Hospital in the preceding ten years, by various kinds of injections, usually the Edinburgh tincture of iodine. The seventy-four patients had had ninety-three injections. In six, the result was doubtful; they were not cured when last seen. In twenty-four, the injection had undoubtedly failed. The fate of the rest was unknown. The proportion of known failures was thus very high. Their histories were remarkable: ten failed after one injection; eleven had two injections; one had three injections; and two had four. In those which had two, three, or four injections, the result is in many cases unknown, but some were ultimately treated by excision of the sac. Of the two cases which were tapped four times, one, a medical man, tells me that he now, after much suffering, has a spermatocele; the other seems to have been cured with carbolic acid after three injections with iodine. The patient who was injected three times had a most remarkable career. His hydrocele, which is said to have followed a blow, was tapped, thrice injected with iodine, twice incised and drained, and finally laid open, painted with liquor iodi, and packed with iodoform gauze.<sup>1</sup> Excision of the parietal layer of the tunica vaginalis was not performed.

<sup>1</sup> Mr. Willett referred to this case in a discussion at the Royal Medical and Chirurgical Society, *Lancet*, London, March 3, 1888.

Besides being very uncertain,—according to the statistics of St. Bartholomew's Hospital the chances of failure are 32 per cent.,—the treatment by injection is objectionable on other grounds. Whatever enthusiastic surgeons may say, there can be no doubt but that it is very painful. Although cocaine was freely used, pain which needed morphia for its alleviation was quite common in the St. Bartholomew's cases, and occasionally the pain was so severe that the patients vomited. I have now operated upon four patients who had previously had injections of iodine or carbolic acid. They were unanimous in saying that the operation of excision of the parietal layer of the tunica vaginalis was far less painful than injection, and was in fact a comparatively comfortable proceeding.

But, besides being uncertain, the so-called cure by injection gives the patient an additional disease. I have now operated four times after it had been done: in three the testicle was enlarged and chronically inflamed months afterwards, and in the fourth there was still a nodular condition of the testicle and epididymis.

In two out of these four cases treated by injection, no adhesions had formed. In one of the others the visceral and parietal layers of the tunica vaginalis had become irregularly adherent, so that the hydrocele

fluid was contained in three sacs instead of one. In another, slight adhesions had formed in the lower part of the tunica vaginalis, and amongst these was a thin-walled cyst containing about 2 drms. of clear and yellow fluid.

Before operating, particular attention should be given to the condition of the spermatic cord. In nearly all cases of ordinary passive hydrocele the cord above the swelling is normal, and its various contents can be felt with the finger and thumb separate and distinct from one another. Any hardness or thickening is a suspicious circumstance. In the case of a boy with hydrocele of the funicular part of the processus vaginalis, closely simulating a hydrocele of the tunica vaginalis, the cord was slightly thickened and very hard. It contained a serous canal, which led upwards towards the abdomen and ended above in quite a large hernial sac, which was treated by the usual operation of radical cure. In the case of a young man the cord was slightly thickened and very hard. It contained a long narrow canal, filled with a strip of chronically inflamed omentum. Hard nodules in the cord may be indicative of tubercle. In malignant disease of the testis associated with hydrocele the growth may have extended into the cord, so as to hide its constituents and make it thicker.



The operation for the radical cure of chronic hydrocele of the tunica vaginalis is one of the safest and most satisfactory in surgery, and I know of hardly any class of patients who are so profuse in their expressions of gratitude. It is not, however, justifiable, unless the most stringent precautions be taken. At the outset the condition of the great organs ought to be ascertained. The patient, instruments, sponges, towels, and materials should all be prepared exactly in the same way as for radical cure of hernia. The instruments required are of the simplest kind,—a knife, seissors, dissecting forceps, a dozen pairs of pressure forceps, and a small straight Hagedorn needle, are all that are required. The numerous small vessels which bleed are secured with fine sterilised catgut or No. 0 twisted silk. Silk is easiest to prepare, and is probably the safest. Then some thin fishing-gut is used for suturing the wound. This is best sterilised by boiling it in water for twenty minutes. A rubber drainage tube,  $\frac{1}{4}$  in. in diameter and 6 in. long, is sterilised in the same way.

Before anæsthesia, the condition of the heart, lungs, and kidneys ought to be ascertained. In the oldest patient upon whom I have hitherto operated, a man in his seventieth year, the anæsthetic caused the pulse to become slow and intermittent for some days,

although before it had been thought normal. The operation was quite uncomplicated, and I am told that it only took seven minutes. But cases cannot always be selected. A man, *æt.* 41, had been a heavy drinker. His face was covered with *acne rosacea*. He had a high tension pulse, and probably some aortic stenosis. His urine contained a trace of albumin. He took ether well, and suffered no apparent harm from the operation. A man, *æt.* 63, also had aene, and admitted that he drank; another, who was a plumber, suffered from lead-poisoning; several had chronic bronchitis; another case has been mentioned, in which hernia and hydrocele were combined with chronic dysentery and albuminuria.

A correct estimate of the local condition should be made. Hydrocele is a symptom of a disease of the tunica vaginalis alone, or of the tunica vaginalis and also of the testis and epididymis. In most of my cases the one testicle was rather larger than its fellow, but now and then the long-continued pressure of the fluid had flattened it out and caused it to atrophy. It is therefore usually necessary to warn the patient that the organ will still continue slightly enlarged after the hydrocele has been cured. In very long-standing cases, in which the hydrocele is large, it is wise to have permission to remove the testicle, in

case it is much spread out and wasted. But whilst the tunica vaginalis is full of fluid it is not always possible to ascertain the condition of the testicle. Sometimes a strong light determines its position, and that it is not enlarged. But, as a rule, it is better not to express any opinion as to its condition until the fluid has been drawn off through a small cannula.<sup>1</sup> I have met with hydroceles in which the testicle has been the seat of gumma, syphilitic inflammation, tubercle, chronic abscess, malignant growth. The last was mistaken for tubercle. The organ was removed very widely; the cord being severed at its exit from the external abdominal ring. More than four years have elapsed without any recurrence.

The radical cure of hydrocele by excision of the sac is obviously a certain cure for encysted hydrocele of the cord. It is also, I believe, a certain cure in ordinary passive hydrocele of the tunica vaginalis. On October 15, 1895, I showed fourteen out of my first twenty-three cases to the Fellows of the Medical Society of London. They were all perfectly well at varying periods after the operation. I have, however,

<sup>1</sup> A cannula 1 mm. or 1.5 mm. in diameter is large enough to draw off hydrocele fluid. Although suppuration is almost unknown after this operation, the usual precautions ought to be taken to prevent infection. The old-fashioned trocar and cannula are much too large and clumsy.

had a failure in the case of a man who had an unusual and complicated hydrocele. Before the operation he was thought to have an ordinary passive hydrocele of the tunica vaginalis. He had a stricture at the meatus urinarius which measured 9 mm., another at 1 in. which measured 9 mm., and another at  $4\frac{1}{4}$  in. which measured 10 mm. On July 27, 1895, I operated upon the hydrocele. The tunica vaginalis contained some ounces of ordinary hydrocele fluid; but at the head of the epididymis, and apparently distending it, was a second sac, also filled with the same kind of fluid. Both of these sacs were treated by the operation which I am about to describe. A slight inflammation of the testis and epididymis ensued, but the recovery was so rapid, that on August 3 I was able to perform internal urethrotomy and divide his strictures. I saw this man at a later date, and thought that a fresh cyst was growing in the head of the epididymis. It is obvious that if the epididymis can develop one cyst it may develop another. But fortunately it is probable that this kind of cystic disease of the epididymis is exceedingly rare. Inasmuch as the contents are not milky, and as the clinical characters of the tumour may be those of an ordinary hydrocele, it must be exceedingly difficult to diagnose without an incision. As re-

gards the character, of the fluid contents of hydroceles, it is to be noted that in one case the tunica vaginalis was full of milky fluid, although no lesion of the testicle or epididymis could be seen at the operation.

The patient is prepared for the radical cure of hydrocele in exactly the same way as for the radical cure of hernia. But after the parts have been thoroughly shaved, the serotal skin is defatted and disinfected with as little scrubbing as possible, because it is often thin and delicate, and easily inflamed and blistered by rough treatment or strong chemicals.

The patient is anaesthetised, lying comfortably upon his back. The trunk and limbs should be warmly clad. The garments and coverings are protected with thin Mackintoshes, which are themselves covered with sterilised towels. The towel which covers the thighs is drawn up under the hydrocele so as to keep it from sinking between the thighs. The penis is carefully wrapped up in a thick layer of 5 per cent. carbolic gauze, wrung out in 1 to 2000 biniodide of mercury lotion.

The operation itself is very simple, and is performed in the following way. An incision is made down to the hydrocele sac, from its uppermost limits down-

wards as far as its lowest. In an average case this begins at the pubic crest and ends where the serotum begins to turn upwards again towards the perineum. This incision should lie about 1 in. outside the root of the penis, so as not to be too near the hole in the outside dressing. The bleeding from the scrotal vessels is trifling, and is stopped with pressure foreeps. The deep external pudic artery, near the pubes, is usually the largest artery that is cut. As soon as the bluish-looking tunica vaginalis is reached, it is separated with the fingers and scissors, until the spermatic vessels are almost brought into view. This step is easiest whilst the sac is full of fluid. Sometimes the hydrocele, together with the testicle, slips out of the serotum, but this does not matter, because the testicle is so easily put back again at the end of the operation. It is merely necessary to see that it is replaced without any torsion of the spermatic cord.

The hydrocele fluid is let out by thrusting the knife into the sac. At this stage it is to be remembered that the testicle and epididymis and the spermatic cord may be in front. I have not myself operated upon a case of anterior inversion, but once the epididymis was separated from the body of the testis, and lay upon the front of the sac just beneath

the skin incision.<sup>1</sup> The testis and epididymis may be avoided by puncturing the thin and translucent part of the sac. In case of doubt, an incision should be cautiously made. The spermatic vessels run upon the outside of the sac, and are easily seen and avoided. But the vas deferens is not infrequently separated from the spermatic vessels, and lies to their inner side. Therefore, the hole in the sac having been made larger, the finger is introduced so as to learn the positions of the testis, epididymis, and vas deferens. The hard and cord-like vas is easily felt, and, when not behind, is displaced inwards, and the spermatic vessels outwards.

The sac having been emptied, the whole of the parietal part of the tunica vaginalis is cut away to within a quarter of an inch of the testicle and epididymis. These organs are left in the condition shown in the accompanying sketch (*vide* Fig. 22).

The cavity of a large hydrocele may extend a long way up the spermatic cord. This upward prolongation should be sought for and dissected out. A number

<sup>1</sup> A man was under my care who had the following history :—He had a scrotal swelling, which a medical man attempted to tap. The operation was done with a large trocar and cannula, and was very painful. Nothing came out but blood, and he says he was told that the swelling was a tumour. A strong light showed that the testicle was in front of the sac, and exactly beneath the puncture. The hydrocele fluid was painlessly withdrawn through a fine cannula.

of small vessels, derived from the spermatic and cremasteric, bleed at the cut edge of the tunica vaginalis; they should be clamped and afterwards tied. When all the hæmorrhage has been arrested, the testis and

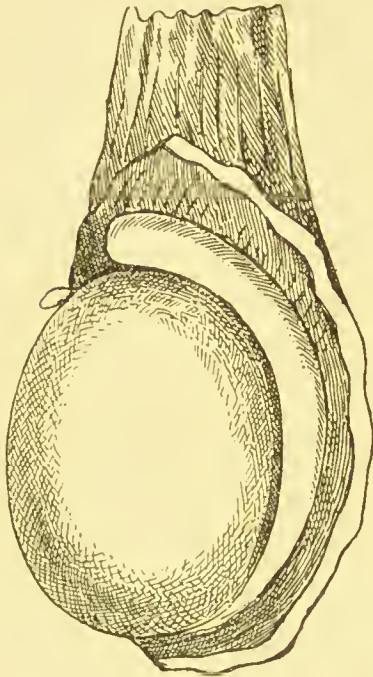


FIG. 22.—To show how much of the parietal part of the tunica vaginalis is removed.

epididymis are pushed back into the serotum. It is, I believe, quite unnecessary to paint the tunica vaginalis vera with chemical irritants or to injure it mechanically. The wound is closed with a series of interrupted sutures. A drainage tube about a third of an inch in diameter, and long enough to reach to the whole length of the wound, is introduced and fastened with a suture. This precaution is required because a little blood nearly always escapes from the serotal vessels, and if not let out forms a hæmatoma in the loose cellular tissues of the serotum. This tube is sutured into the upper angle of the wound. This is not the most dependent part, but the fluids of

are pushed back into the serotum. It is, I believe, quite unnecessary to paint the tunica vaginalis vera with chemical irritants or to injure it mechanically. The wound is closed with a series of interrupted sutures. A drainage tube about a third of an inch in diameter, and long enough to reach to the whole length of the wound, is introduced and fastened with a suture. This precaution is required because



wounds do not always obey the laws of gravitation. Furthermore, when the tube is placed below, the fluids more easily soak beyond the lower edge of the dressing, and allow infection to spread from the anus to the wound.

The wound is dressed in the same way as that for

the radical cure of hernia. First, a layer of finely-powdered iodoform is dusted on; second, the whole scrotum is enveloped in a layer of 5 per cent. carbolic gauze, wrung out in 1 in 2000 biniodide of mercury lotion; third, a layer of alcambroth wool; and

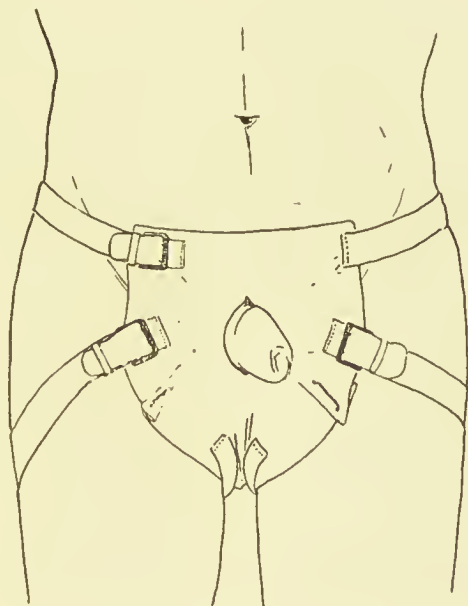


FIG. 23.—The mode of dressing scrotal wounds.

fourth, an outside dressing. The last is made in the following way, and, when properly fitted, adds immensely to the comfort and safety of the patient. It consists of the usual eightfold dressing of carbolic gauze and jaconet. It is accurately cut to pattern, and fitted to suit the case. It is triangular, with an

aperture near the base for the penis to pass through (*vide* Fig. 23), and is pleated a little on either side, and at the apex, so as to form a hollow for the serotum and dressing.

To the apex of the triangle two strong bands of some soft material are sewn. When the dressing is in position, these bands fix its apex against the perineum, and are carried round the thighs to meet the pelvic band in front. This is a similar band of soft material which passes round the pelvis, and is fastened to the upper angles of the dressing. The straps are best made of stout bandages or webbing. It is convenient to have buckles sewn upon the upper angles of the dressing, so as to allow of the straps being pulled tight from time to time. If buckles be used, they should be sewn upon the dressing, and not at the edge, otherwise they cause pain and discomfort. By pulling upon these straps, and stuffing a little alembroth wool under the dressing, a fair amount of pressure can be applied to the serotum. No other bandages are required. The patient is told to turn upon his side when he desires to pass urine. After the drainage tube has been taken out, he can turn about freely in bed, and sleep upon his side. If necessary, he can get up with it on.

The after-treatment is very simple. When the

effects of the anæsthetic have passed away, any light diet may be given, and the minor indulgences need not be stopped. The drainage tube is removed at the end of twenty-four hours. It may be left in for forty-eight hours without ill effect; but as a rule the carbolic gauze and most of the alembroth wool are soaked with blood by the end of twenty-four hours. It is removed with the same precautions as those used at the operation. A pair of sterilised scissors and a pair of sterilised dissecting forceps are used to cut the stitch and remove the tube. Then the wound is dusted with finely-powdered iodoform, thoroughly covered with 5 per cent. carbolic gauze, wrung out in 1 to 2000 biniodide of mercury lotion, covered with alembroth wool, and finally protected from exposure to air by the outside dressing.

At the end of a week the stitches are removed, and the line of incision protected with collodion-iodoform. Next day the patient gets up, the scrotum being supported in a linen suspender. At the end of a fortnight he can return to work.

I have operated forty-four times for the radical cure of hydrocele upon forty-one patients. In three, the hydrocele was double, and both sides were done at the same time. The ages of the patients ran from 5 years to 69 years. Many of them were far from

being ideal subjects. Nevertheless, suppuration only occurred once. It was slight, and due to the patient passing urine into his dressing.

The operation for the radical cure of hydrocele is not at all painful. So far as I am aware, only one patient had pain of any degree of severity, and this was caused by a rather sharp inflammation of the testis and epididymis; this, however, soon subsided, and left no ill effects.

Five other patients had slight attacks of orchitis and epididymitis, but in all it was subacute, and lasted but a short time. Traumatic orchitis of this kind is quite unlike that due to gonorrhœal<sup>1</sup> or other infection.

When the hydrocele is double, both sides can be operated upon at the same time. In three of my cases a double operation was performed. All the patients made the usual rapid recovery, and suffered in no way from the additional proceeding.

Various complications may be met with during the operation for the radical cure of hydrocele. Some of the most important have already been described in connection with the radical cure of hernia (*vide* p. 151). But, in addition, the following have been met with. Amongst the commonest were cysts in

<sup>1</sup> At a recent operation the epididymis was inflamed and enlarged. The patient said the hydrocele had followed an attack of gonorrhœa which he had had two years before I saw him.

connection with the epididymis, hydatids of Morgagni, or tunica vaginalis. These cysts are easily cured by cutting away their most projecting part, so as to leave their interior exposed.

Passive hydrocele of the tunica vaginalis is often attributed to a blow—very often to a blow from a cricket-ball. A young gentleman was struck with a cricket-ball. A hæmatocele formed, and was tapped by Dr. Sydenham, but a hydrocele followed the hæmatocle. When I operated upon the hydrocele, the body of the testis had clearly been ruptured by the blow, because there was a large semilunar rent in the tunica vaginalis vera. A month afterwards the testicle was soft, but a little enlarged. The ultimate result was perfect.

It is not always possible to tell a hydrocele with thickened walls from a hæmatocele, because neither transmits any light. But should a hæmatocele be met with, as in one of my cases, the treatment and the result are exactly the same. It is merely necessary to remove all the clot and fibrin, and cut away the parietal layer of the tunica vaginalis. The result is as satisfactory, and the recovery as rapid, as in an ordinary case of hydrocele. The tunica vaginalis reflexa is best taken away in cases of hæmatocle, because it is usually rough, rigid, and chronically

inflamed. Besides, its removal is quite harmless, and afterwards its loss cannot be detected.

The hydrocele may also be multilocular. A case has been mentioned in which a hydrocele of the tunica vaginalis was complicated by an equally large one in the head of the epididymis. In another case, in which the so-called radical cure by injection had been tried six years before, the tunica vaginalis had been converted into three distinct sacs by adhesions. Only one of them was full of fluid. In this case a big varicocele was also found. It lay in front, and was simply tied and taken away at the same time as the sac wall. A youth who was operated upon for a small, thick-walled hydrocele of the tunica vaginalis, said that a year before a varicocele on the same side had been cured by operation. It is improbable that these varicoceles had any causal relationship to the hydroceles.

A chronic abscess of the globus major of the epididymis was unexpectedly met with in the case of a man with double hydrocele. On the right side the tunica vaginalis contained much fluid, and was crossed by bands of adhesions. A thin-walled cyst, full of translucent yellow fluid, hung like a grape from the head of the epididymis. This cyst was removed, and the hydrocele treated in the usual way. The left tunica

vaginalis did not contain so much fluid, but there was a hard lump about  $\frac{3}{4}$  in. in diameter in the globus major. It was surrounded by thickened and indurated tunica vaginalis. Pus escaped when it was punctured, so half of its wall was cut away, and its interior scraped out, and filled with iodoform. This was followed by a slight attack of orchitis and epididymitis, which soon subsided.

A considerable thickening of the tunica vaginalis vera was also met with in the case of a young man, who was known to have had a chronic inflammation of the testicle for more than eighteen months, which had ended in the formation of a hydrocele. The tunica vaginalis covering the lower part of the body of the testicle was opaque and thickened, and projected as though an abscess, or gumma, or tubercle lay beneath. However, after cutting through at least a quarter of an inch of thickened tunica vaginalis, normal testicular substance was reached. This patient was given mercury and iodide of potassium, and in a month his testicle was quite soft, although still rather larger than its fellow.

Various conditions of the tunica vaginalis are met with during operations upon passive hydroceles. In some cases it seems to have been stretched and thinned, but usually it is decidedly thickened, and its

interior rough and tubercular. The thickening is the result of chronic inflammation.

The small projections look so like tubercles that I have frequently had them examined for tubercle bacilli, but neither Professor Kanthack, nor my colleague, Dr. F. W. Andrewes, has succeeded in finding that microbe.

In some old hydroceles I have found plates of fibrous tissue in the tunica vaginalis, which were quite rigid, and cut like cartilage. Sometimes these plates undergo calcification.<sup>1</sup>

Serious complications do not occur after this radical cure of hydrocele, and minor ones are by no means common. Orchitis and epididymitis have already been mentioned. They occur, separately or together, in about 10 per cent. of the cases. But this traumatic inflammation is mild and of short duration, and not at all comparable to the orchitis and epididymitis caused by gonorrhœal or other infection.

In spite of the drainage tube, some blood may collect in the loose tissues of the serotum. This may be mistaken for a swelling of the testicle. It causes hardly any pain, and quickly disappears, leaving no ill effects.

<sup>1</sup> For similar plates in the walls of a hernial sac, see Hunterian Lectures on "Hernia," p. 126, Fig. 29.



When the scrotum is long and loose, it is exceedingly liable to œdematous swellings, especially if any part of it slips below the dressings. The treatment is simple, and consists in elevating the scrotum with a small hard pillow pushed betwixt the thighs.

Eczema of the skin of the scrotum sometimes occurs. This complication is annoying, because of the itching. A dressing of iodoform, and of iodoform gauze, has a soothing effect, and does not jeopardise the healing of the wound.

After six weeks or two months, a faint scar upon the scrotum is the only trace of the operation. The one testicle is usually a little larger than its fellow, but it slips about painlessly and naturally in the scrotum. Nothing whatever remains to show that the parietal layer of the tunica vaginalis has been removed.

These operations for the radical cure of hydrocele, and also those for the radical cure of hernia, prove that the testicle is very tolerant of surgical interference. I am therefore now accustomed to explore tuberculous or doubtful swellings much more freely than hitherto.<sup>1</sup>

Sometimes the tumour is so placed in the epididymis that it can be reached without opening the tunica vaginalis. As a rule, that serous sac has to be laid

<sup>1</sup> On one occasion a doubtful tumour proved to be a psammoma.

open. When this has been done, the operation is completed by snipping away the parietal layer of the tunica vaginalis, the same as in the operation for the radical cure of hydrocele. It is hardly necessary to enumerate the objections to sewing the incision up again, but a hæmatocele, hydrocele, or a purulent collection may easily supervene. Also, the absence of the parietal layer is quite unknown and unfelt.

## CHAPTER XV.

### RADICAL CURE OF VARICOCELE—EXPLORATION OF THE INGUINAL CANAL.

INGUINAL ruptures are often associated with serotal varicocele, or with inguinal varicocele. Inasmuch as the varicocele has usually to be cured at the same time as the rupture, I propose to give a brief description of the operation. But, first, the radical cure of varicocele is by no means so simple and easy as it seems to be. After it has been done, I have seen much suffering caused by orchitis, hæmorrhage, supuration, and have heard of cases in which the testicle has sloughed. Apart from chloroform and ether, the only severe complication in my cases of radical cure of inguinal hernia occurred in one in which there was an inguinal varicocele. The man had hæmorrhage into the iliac fossa and peritoneal cavity. It was not proved that this came from the stump of the varicocele, but nevertheless such may have been the case.

Two kinds of varicocele are met with, the serotal

and the inguinal. The former is so well known and so easily recognised that it hardly calls for a detailed account; the latter, on the other hand, has hitherto had little attention given to it, and is, moreover, very difficult to diagnose, so that I have referred to it rather fully whilst describing the treatment of the contents of the inguinal canal.

Cases have been mentioned in which the scrotal varicocele was upon the same side as the inguinal rupture. In these it was easily cured through the ordinary inguinal incision, by pulling up the cord and testicle. When the scrotal varicocele is on the opposite side, a fresh incision is of course required. I have also referred to a case in which a scrotal varicocle complicated an ordinary passive hydrocele of the tunica vaginalis. It was easily dealt with at the same time as the hydrocele, and through the same incision. Once a very large varicocele complicated an undescended testicle. It gave rise to very troublesome hæmorrhage at the operation.

The patient is prepared for the radical cure of varicocele in the same way as for the radical cure of hernia. A bath is given the night before, and the scrotum and pubes are thoroughly shaved and disinfected, and protected with an antiseptic dressing. Inasmuch as the scrotal skin is delicate and easily blistered, dis-

cretion must be used according to the class of case. The scrotum of a cleanly gentleman need not be treated with as much vigour as that of an out-patient. It is advisable to give a purge the night before the operation. All the instruments, appliances, sponges, and silk are prepared the same as for radical cure of hernia. After having observed the behaviour of various kinds of ligature, I use sterilised twisted silk (No. 3 or 4). The pedicle which is left after the excision of the varicose veins is very treacherous, because it contains muscular tissue, and therefore shrinks. On more than one occasion I have seen troublesome recurrent hæmorrhage after the pedicles have merely been encircled and tied with prepared catgut. Sterilised twisted silk behaves remarkably well, and, excepting a small hæmatoma, I have never had hæmorrhage after using it, and can hardly recall a case in which it has been extruded. No. 00 twisted silk is used for ligaturing any small vessels, and is sterilised by boiling. A little fine fishing-gut or horse-hair should be sterilised in the same way for suturing the wound. A  $\frac{1}{4}$ -inch rubber drainage tube should also be sterilised.

However dry the wound is left, the scrotal vessels are apt to ooze a little during reaction. It is hardly possible to use pressure to control this; and if no pro-

vision is made to allow the blood to run into the dressing, it collects in the loose cellular tissue of the serotum. This hæmatoma usually suppurates, and delays convalescence.

The instruments needed are a knife, scissors, dissecting forceps, half a dozen pressure forceps, a small straight sewing-needle, and a pair of blunt-pointed herniotomy needles (*vide* Fig. 2, p. 42). The latter are wanted to transfix the pedicles after excision of the varicose veins. An outside dressing, the same as that which is used after the radical cure of hydrocele, is also got ready. The lotions are the same as for radical cure of hernia, namely, 1 in 2000 biniodide of mercury lotion for the sponges, and 1 in 50 carbolic for the instruments and ligatures.

The object of the operation is to excise 1 in. to 1½ in. of the dilated spermatic veins, and at the same time shorten the spermatic cord. In many cases of varicocele the spermatic cord is too long, and the testicle, in consequence, too dependent.

It is, of course, impossible to shorten the cord by a subcutaneous operation. Nevertheless the latter seems to have an attraction for some surgeons. My own observations, however, have led me to conclude that it is followed by an undue proportion of failures. Even when the veins are clearly exposed to view, one

has to be careful to see that a sufficient quantity of the spermatic veins is obliterated. After the main bulk has been excised, I have often demonstrated another group near the back of the spermatic cord. Had these been overlooked, an efficient operation would not have been done, and the varicocele might not have been cured. It is difficult to see how a subcutaneous operation could ensure the obliteration of this posterior group. Moreover, now that asepsis is so much better understood, the subcutaneous proceeding is robbed of any advantages that it may have been thought to possess.

The following operation is slightly different from that which is usually described, some modifications having been introduced to guard against recurrent hæmorrhage. The patient is anaesthetised lying comfortably upon his back. The field of operation is prepared the same as for the radical cure of hernia or hydrocele. The sterilised towel which covers the thighs is pulled up under the scrotum. The penis is covered with a layer of 5 per cent. gauze, wrung out in biniodide of mercury lotion (1 in 2000). The operator usually stands upon the same side as the varicocele. The upper limit of the varicocele having been previously noted whilst the patient stood up, a vertical incision  $1\frac{1}{2}$  in. long is made into the scrotum,

so as to begin over the upper part of the varicocele, and usually reaching as high as the level of the pubic crest. During this stage, either the surgeon or his assistant squeezes the spermatic cord and the upper part of the varicocele into the wound, by grasping the back of the scrotum with the left hand.

The incision is continued through the sheath of the spermatic cord until the varicose veins protrude from the wound. If the veins have been thoroughly exposed, it is now easy to separate them in a bundle from the vas deferens and spermatic artery, which lie behind. If the cord be unduly long, quite 2 in. of the veins should be separated. Whilst this is being done, the vas deferens usually comes into view, and care has to be taken lest it be pinched with the pressure forceps, or caught in the ligatures. Sometimes the vas makes a loop, which is rather deceptive. Its position ought to be accurately ascertained at each stage of the operation. Fortunately, it is easily felt.

When the bundle of veins has been separated, it is clamped with pressure forceps at its lower part, where it is beginning to swell out into the varicocele, and also at its upper part, about 1 in. below the external abdominal ring. At that situation the bundle is smaller, and composed of fewer veins. The



piece betwixt the pressure forceps is excised with the scissors. It is usually above  $1\frac{1}{2}$  in. long.

To prevent hæmorrhage from the pedicles, they are transfixcd and tied in the following way. One of the blunt-pointed herniotomy needles is armed with 2 ft. of No. 3 twisted silk, and is thrust through the bundle of veins just beyond both the upper and lower pairs of pressure forceps. The needle is withdrawn, leaving a loop, which is carried back again over the pressure forceps and pedicle, and tied in a Staffordshire knot. The knot should be very tight, otherwise, when the pedicle shrinks, it becomes loose. Generally it will be found best, as the knot is being pulled tight, to gently remove the pressure forceps from the pedicles. The ends of the ligatures are left long.

Both the stumps ought to be absolutely dry. If any blood oozes out, a fresh ligature is applied a little higher up or a little lower down. In passing the blunt needle through the pedicle, the veins themselves ought not to be pierced; an interval can generally be found; but if one be transfixcd, it ceases to bleed when the ligature is tightened. However, before this can be done, a hæmatoma may have formed in the cellular tissue of the spermatic cord, because the blood collects there with surprising celerity. The next step is to fasten the pedicles together, so as to shorten the

cord and prevent a gap. This is done by knotting the ends of the ligatures, which were left long for that purpose. But before doing so it is advisable to take the precaution of looking at the hinder part of the cord, near the vas deferens, to see whether any of the veins in that situation need ligaturing. As I have already said, a second bundle is discovered in a sixth of the cases at the back of the principal group.<sup>1</sup> If any additional varicose veins be found, they ought to be clamped, excised, and tied. As a rule, they do not afford a pedicle large enough to allow of transfixion.

The veins having been tied and the stumps fastened together, a drainage tube  $\frac{1}{4}$  in. diameter and 1 in. long is put into the wound and fixed with a point of suture. Then the small wound is closed with two or three additional sutures, dusted with iodoform, dressed with a layer of 5 per cent. carbolic gauze wrung out in biniodide of mercury lotion (1 in 2000), and a layer of alembroth wool, and the whole covered with the triangular outside dressing which I use for all scrotal operations (*vide* Fig. 23, p. 249).

The after-treatment is quite simple. A catheter is seldom needed; but as retention occasionally occurs, it ought to be borne in mind. The drainage tube is

<sup>1</sup> In twenty-four consecutive operations the second group occurred four times.

taken out with aseptic precautions at the end of twenty-four hours. Its tract closes at once, and heals like the rest of the wound by first intention. If it be left in for forty-eight hours, a small gap is apt to be left, which is longer in healing. The rest of the stitches are taken out on the eighth day, when the wound is healed, and merely wants a little protection with a layer of collodion and carbolic gauze. The patient gets up at the end of a fortnight, and in three weeks can return to his usual avocations. For a week or more after the operation, the testicle and epididymis are rather tender and hypersensitive. The presence of the remains of the varicocele, which is filled with blood clot and in a state of plastic inflammation, is enough to account for this condition. The pain gradually departs as the clot organises. During this stage a lincn suspender ought to be worn. For a time a small hard mass can be felt around the ligatures. This inflammatory exudation fastens the ends of the spermatic cord together, and ultimately removes the silk ligatures. Patients are sometimes anxious about this small lump, unless reassured.

Various other ways of obliterating the varicose veins have been devised ; they all aim at preventing hæmorrhage, sepsis, and the reappearance of the ligature. Dr. Ball crushes the veins with a pile clamp. Mr. Henry Lee, whose predilection

for the actual cautery will be remembered, used to burn the veins through. Mr. Gould recommends that this be done subcutaneously with the galvanic *écraseur*. It will be noted that these procedures do not shorten the cord. A great variety of materials are used for ligatures.

The majority of these cases of operation for scrotal varicocele have been accepted after the operation for one or other of the public services, and were therefore presumably cured. Nor have I ever, myself, seen a failure after the open operation, although I have after the subcutaneous. I can, however, recall a case occurring before the above series began, in which a testicle that was small before the operation afterwards underwent decided wasting.

In all these cases of scrotal varicocele the dilated veins were in the usual place just above the *globus major* of the epididymis. I have once met with one in which they were situated below and behind the lowest part, without any evidence of inversion of the testicle and epididymis.

Before 1894 I kept no systematic notes of my operations for varicocele, but since then I have done twenty-four. These were done on account of neuralgic or aching pain, or to allow the patient to enter the army, navy, post-office service, Indian railway service, and so forth. It seems that in tropical climates vari-

cocceles are apt to become painful, and incapaeitate for marching or other duty. All were drained for about twenty-four hours, and all healed by first intention. In four, the second posterior group of veins had to be tied. In one, a hæmatoma of the scrotum formed, but soon went away. In one case circumcision was done at the same time, and in two a hernia on the right side was cured at the same time as a hydrocele on the left. I have not included in the twenty-four cases two in which the scrotal varicocele was on the same side as an inguinal hernia. In these the spermatic veins were pulled up into the inguinal wound, and excised the same as if the incision had been in the scrotum. It is best to deal with the varicocele after the hernial sac has been excised and its stump transplanted, and before any attempt is made to restore the inguinal canal. A drainage tube was not used in these two cases. In addition, I have not included a case in which a varicocele was found upon the front wall of a multilocular hydrocele. It was excised together with the wall of the hydrocele.

#### EXPLORATION OF THE INGUINAL CANAL.

Hitherto the inguinal canal has seldom been explored to see whether it contained a congenital

peritoneal sac, an inguinal varix, or a lipoma of the cord. The fear of non-union of the external oblique aponeurosis has doubtless deterred surgeons. But it is evident that non-union of the aponeurosis is very rare, and in case of doubt the risk is far outweighed by that of leaving a hernial sac, an inguinal varix, or a lipoma in the canal. In my own cases there was always an indication for the exploration, such, for instance, as pain and impulse in the inguinal canal, undue patency of the external abdominal ring, slight bulging of the inguinal canal, some variety of congenital hydrocele, or a congenital defect in the position or growth of the testicle. The following case shows how easily a hernial sac may be overlooked when exploration is not practised. A young gentleman, who belonged to the colonies, had a congenital inguinal hernia on the left side. It had been acutely strangulated once, and he was unable to wear a truss. The hernial sac was of the congenital variety, contained omentum just beginning to be adherent, and had a very tight and narrow mouth. On the right side he had never had a hernia, or any symptoms of one, but the external abdominal ring was large, the inguinal canal rather patulous, and with a slight impulse on coughing. When the canal was laid open, it seemed at first glance to be normal, but

a cut through the cremaster and sheath of the cord revealed a serous sac about 2 in. long, and large enough to admit the first joint of the finger. The spermatic veins were also varicose. Clearly, unless the inguinal canal had been explored, this patient would have continued in a state of danger, for such sacs as he had give rise to the acutest and most dangerous kind of strangulated inguinal hernia.

Exploratory operations become unnecessary as soon as we possess the indications for a proper diagnosis. With more experience we shall ultimately learn how to diagnose inguinal varix and lipoma of the cord. Cases will then be treated on their merits, and either left alone or operated upon according to circumstances.





# INDEX.



	PAGE
Abdominal belts . . . . .	227
,, incisions . . . . .	216
,, wall in acquired hernia . . . . .	14
,, ,, congenital hernia . . . . .	3
Abscess in double hydrocele . . . . .	254
Age in relation to hernia . . . . .	14, 24, 198
Albuminuria, operation inadvisable in cases of . . . . .	38
Anæsthetic, choice of . . . . .	54
ANDEREGG, relapses . . . . .	170
ANDREWES, lipoma of cord . . . . .	113
Appendix, vermiform, in hernia sacs . . . . .	77
Asepsis, precautions to secure . . . . .	54, 241
Assistant, duties of . . . . .	51
Bacteria, intestinal, in sac fluid . . . . .	230
BALL, treatment of sac . . . . .	127
,, ,, varicocele . . . . .	267
BANKS (Mitchell), treatment of sac . . . . .	127
BASSINI, treatment of sac . . . . .	128
BISHOP (Stanmore), treatment of sac . . . . .	128
Bladder, hernia of . . . . .	107
BOWLBY, retained testis . . . . .	87
Boys, hydroceles in . . . . .	99
Bronchitic cases, unsuitable for operation . . . . .	37, 200, 219
BRUNNER, herniated ovary . . . . .	95
BUTLIN, herniated ovary . . . . .	96
Cæcocele, congenital . . . . .	19
Cæcum, rare in hernial sacs . . . . .	10
,, resection of . . . . .	78
Causation of hernia . . . . .	11
CHEYNE, closure of femoral canal . . . . .	198

	PAGE
Children, length of mesentery in . . . . .	35
,,    radical cure in . . . . .	35
CLARKE (Bruce), muscular development . . . . .	22
,,    resection of caecum . . . . .	78
COLEY, relapses . . . . .	168
Cord, spermatic, in relation to hernia . . . . .	100
,,    ,,    lipoma of . . . . .	110
CRIPPS (Harrison), polypoid bodies in omentum . . . . .	66
Cure, radical, of hernia, complications . . . . .	151
,,    ,,    ,,    during pregnancy . . . . .	39, 141
,,    ,,    ,,    femoral . . . . .	176
,,    ,,    ,,    in children . . . . .	35
,,    ,,    ,,    inguinal . . . . .	37, 56
,,    ,,    ,,    umbilical . . . . .	221
,,    ,,    ,,    ventral . . . . .	207
,,    ,,    of hydrocele . . . . .	235
,,    ,,    of varicocele . . . . .	259
CURLING, retained testes . . . . .	85
Cysts complicating hydrocele . . . . .	252
CZERNY, treatment of sac . . . . .	127
Dementia complicating radical cure . . . . .	152, 174
Diagnosis of acquired hernia . . . . .	22
,,    femoral hernia . . . . .	179
DORAN (Alban), hernia of abdominal cicatrix . . . . .	215
Drainage tube, use of, indicated . . . . .	229
Dressing, mode of preparing . . . . .	47, 144, 195, 249
DUNCAN (Matthews), retentive power of abdomen . . . . .	14, 22
Eczema of skin of scrotum . . . . .	257
Euterocele, femoral . . . . .	33, 177
Epididymitis complicating hydrocele . . . . .	256
Epiplocele, femoral . . . . .	177
,,    statistics of . . . . .	9
,,    with varicocele . . . . .	114
FABRICIUS, closure of femoral canal . . . . .	197
Fallopian tube, hernia of . . . . .	93
Fatal cases . . . . .	201
Females, inguinal hernia in . . . . .	139, 142
,,    radical cure in pregnant . . . . .	39, 141
,,    umbilical hernia in . . . . .	224
Femoral canal, closure of . . . . .	191
,,    hernia . . . . .	12, 28, 176
,,    ,,    non-strangulated, results of operation . . . . .	203

	PAGE
GLENARD, prolapse of viscera . . . . .	22
Globus major, abscess of . . . . .	254
GOULD (Pearce), dermoid cyst of cord . . . . .	122
„ „ varicocele . . . . .	268
GRIFFITHS, experiments on dogs' testicles . . . . .	87
Hæmatocœle, treatment of . . . . .	253
Hæmorrhage, precautions against . . . . .	263
HALSTED, treatment of the sac . . . . .	131
„ „ „ cord . . . . .	136
„ „ relapses . . . . .	168
Hernia, acquired . . . . .	13
„ „ cases unsuited for operation . . . . .	23, 32
„ „ congenital . . . . .	2
„ „ causation . . . . .	11
„ „ diagnosis . . . . .	13
„ of bladder . . . . .	107
„ of doubtful origin . . . . .	27
„ of Fallopian tube . . . . .	93
„ femoral . . . . .	12, 28, 176
„ „ causation . . . . .	21
„ infantile . . . . .	95, 105
„ inguinal . . . . .	28, 37
„ „ causation . . . . .	21
„ „ complications . . . . .	71, 96, 143, 234
„ „ direct, rare in females . . . . .	142
„ ovarian . . . . .	93
„ „ infantile . . . . .	95
„ umbilical . . . . .	221
„ „ in women . . . . .	224
„ ventral . . . . .	207
Herniotomy needles . . . . .	42
HESSELBACH, band of . . . . .	134
HEUSTON, femoral hernia . . . . .	195
HEY, ligament of . . . . .	189
HORNBY, infantile herniated ovary . . . . .	95
HUMPHRY (Sir G. M.), polypoid bodies in sac . . . . .	66
Hydrocœle and inguinal hernia . . . . .	96, 174
„ „ in boys . . . . .	98
„ „ multilocular . . . . .	254
„ „ radical cure of . . . . .	234
„ „ „ cases . . . . .	243
Infants, herniated ovary in . . . . .	95
Inguinal canal, action of . . . . .	102

	PAGE
Inguinal canal, exploration of . . . . .	269
"    "    reclosure of . . . . .	136
"    "    repair of . . . . .	129
"    hernia . . . . .	28, 37
"    "    causation . . . . .	21
"    "    complications . . . . .	71, 96, 143, 234
"    "    direct, rare in females . . . . .	142
Injection treatment of hydrocele . . . . .	237
Intestines, in hernial sac . . . . .	9, 74, 184
"    range of movement . . . . .	6, 20
"    weight of . . . . .	5
JACOBSON, <i>quoted</i> . . . . .	66
Kidney, complications in hernia cases . . . . .	38, 154
"    prolapsed . . . . .	19
KOCHER, treatment of sac . . . . .	128
KRONLEIN, hernia of bladder . . . . .	108
KUMMER,    "    "    . . . . .	108
LAWRENCE, <i>quoted</i> . . . . .	72
LEE, treatment of varicocele . . . . .	269
LEJARS, <i>quoted</i> . . . . .	95
LENNANDER, laparotomy . . . . .	216
Life assurance, operation no bar to . . . . .	165
Ligatures used in operations . . . . .	43, 187
Lipoma of the cord . . . . .	110
LUCAS-CHAMPIONNIÈRE, radical cure of hernia . . . . .	209
M'BURNEY, abdominal incision . . . . .	216
MACEWEN, operation of . . . . .	56
"    treatment of sac . . . . .	127
MACREADY, hernia of bladder . . . . .	109
Malignant disease and hernia . . . . .	71
MARSH (Howard), operation by . . . . .	178
MECKEL'S diverticulum in sac . . . . .	78
Mesentery, height of . . . . .	5, 6, 9
"    length of . . . . .	4, 16, 35
"    prolapsed . . . . .	18, 174
"    suspension of . . . . .	5, 17
Mesocolon, transverse, in acquired hernia . . . . .	17, 18
"    "    in congenital hernia . . . . .	10
MICHEL, hernia of bladder . . . . .	107
MILLING, herniated ovary . . . . .	95

	PAGE
Mitral disease associated with hernia . . . . .	37
Mortality statistics . . . . .	153
Needles, herniotomy . . . . .	42
Nephritis complicating hernia . . . . .	154
Nurse, duties of . . . . .	51
O'CONNOR, statistics of orchitis . . . . .	159
Orchitis, complicating hydrocele . . . . .	256
"    "    radical cure . . . . .	159
"    "    varicocele . . . . .	259
Omentum, adherent . . . . .	9, 72, 184
"    in acquired hernia . . . . .	17
"    in congenital hernia . . . . .	10
"    in hernial sac . . . . .	9, 67, 184
"    method of suturing . . . . .	69
"    polypoid bodies in . . . . .	65
Operation for radical cure described . . . . .	56
"    room, requisites for . . . . .	53
"    treatment after . . . . .	147, 197
Ovary, herniated . . . . .	93
OWEN (Edmund), infantile herniated ovary . . . . .	95
PAGET (Sir James), herniated ovary . . . . .	94
PARKER (Rushton), treatment of stump of sac . . . . .	197
Patients for operation, preparation of . . . . .	39, 179, 245, 260
"    "    selection of . . . . .	38, 178
PETIT, <i>quoted</i> . . . . .	72
Phallic shield . . . . .	55
PILKINGTON, spontaneous laceration of sac . . . . .	226
Plica vascularis . . . . .	11
Polypoid bodies in hernial sac . . . . .	65
Pregnancy, radical cure during . . . . .	39, 141
Relapse, cases of . . . . .	23, 29, 31, 56, 168, 170
"    chief causes of . . . . .	167
Rest after operation, period of . . . . .	150, 196, 215
Results of operation, immediate . . . . .	153, 198
"    "    statistical . . . . .	153, 166
"    "    ultimate . . . . .	160
Sac, hernial, constriction of . . . . .	104
"    "    contents of . . . . .	33, 64, 79, 184, 231
"    "    fixation of stump of . . . . .	190
"    "    ligature of . . . . .	123, 187

	PAGE
Sae, hernial, laceration of . . . . .	226
"  "  opening of . . . . .	182
"  "  polypoid bodies in . . . . .	65
"  "  position of . . . . .	62, 181
"  "  reduplication of . . . . .	104
"  "  separation of . . . . .	100
"  "  tuberulous . . . . .	64
SALZER, closure of femoral canal . . . . .	198
Scarlet fever, complicating radical cure . . . . .	143
Serotum, eczema of skin of . . . . .	257
"  varicocele of . . . . .	114
SHEILD, statistics of cases . . . . .	158
Sigmoecele, congenital . . . . .	19
Sigmoid flexure rarely found in hernial sacs . . . . .	10
Skin incisions in radical cure . . . . .	61, 180
"  "  "  suture of . . . . .	136
SMITH (Johnson), hernia of bladder . . . . .	108
Spermatic cord. <i>See</i> Cord. . . . .	100
Sponges, mode of sterilising . . . . .	45
Staffordshire knot . . . . .	124
<i>Staphylococcus aureus</i> in pns . . . . .	157
Suppuration after operation . . . . .	155, 168, 203
Sutures used in operations . . . . .	43, 69, 209
TALLIENS, cases of suppuration . . . . .	158
Tapping, senseless in chronic hydrocele . . . . .	23
Testis, inflammation of . . . . .	159, 239
"  inversion of . . . . .	90
"  retained, complicating inguinal hernia . . . . .	87
"  "  statistics of cases . . . . .	79
"  transplantation of . . . . .	91
"  undescended section of . . . . .	84
TREITZ, suspensory muscles of mesentery . . . . .	5
Trusses, objected to by females . . . . .	34
"  "  in cases of adherent omentum . . . . .	72
"  "  "  retained testis . . . . .	80
"  unnecessary in most cases after operation . . . . .	52, 171
Tubercle complicating radical cure . . . . .	38
TUFFIER, closure of femoral canal . . . . .	197
Tunica vaginalis, thickening of . . . . .	255
Umbilical hernia, acquired . . . . .	224
"  "  infantile . . . . .	223
Urine examination, essential . . . . .	38

*INDEX.*

279

	PAGE
Varicocele, inguinal, complicating hernia . . . . .	29, 115
"          "    diagnosis of . . . . .	121
"          "    radical cure of . . . . .	259
"    scrotal . . . . .	114
Varix mistaken for hernia . . . . .	141
Ventral hernia, acquired . . . . .	210
"    "    causation of . . . . .	216
"    "    congenital . . . . .	207
"    "    traumatic . . . . .	213
Viscera in acquired hernia, variable . . . . .	18
"    congenital hernia, normal . . . . .	11
Vision of field of operation . . . . .	56
WALTER, hernia of bladder . . . . .	108
WÖFLER, dislocation of cord . . . . .	136







# YOUNG J. PENTLAND'S PUBLICATIONS.

---

**SYSTEM of GYNECOLOGY and OBSTETRICS.** By AMERICAN AUTHORS. Edited by MATTHEW D. MANN, A.M., M.D., Professor of Obstetrics and Gynecology in the Medical Department of the University of Buffalo, N.Y.; and BARTON COOKE HIRST, M.D., Associate Professor of Obstetrics in the University of Pennsylvania; Obstetrician to the Philadelphia Maternity Hospital; Gynecologist to the Orthopædic Hospital. In 8 very handsome volumes, Royal 8vo, Cloth, of about 400 pages each, fully Illustrated with Engravings and Coloured Plates. Price 12s. 6d. each, nett. For sale by Subscription only.

**TEXT-BOOK of GENERAL BOTANY.** By Dr. W. J. BEHRENS. Translation from the Second German Edition. Revised by PATRICK GEDDES, F.R.S.E., Professor of Botany in the University of Dundee. 8vo, Cloth, pp. viii., 374, with 408 Illustrations, finely engraved on Wood, and 4 Analytical Tables, New Edition. Price 5s. (1893.)

**THE ELEMENTS OF OPHTHALMOSCOPIC DIAGNOSIS.** FOR THE USE OF STUDENTS ATTENDING OPHTHALMIC PRACTICE. By GEORGE A. BERRY, M.B., F.R.C.S.ED., Ophthalmic Surgeon, Edinburgh Royal Infirmary; Lecturer on Ophthalmology, Royal College of Surgeons, Edinburgh. Crown 8vo, Cloth, pp. xii., 83. Price 3s. 6d. (1891.)

**DISEASES of the EYE.** A PRACTICAL TREATISE FOR STUDENTS OF OPHTHALMOLOGY. By GEORGE A. BERRY, M.B., F.R.C.S.ED., Ophthalmic Surgeon, Edinburgh Royal Infirmary; Senior Surgeon, Edinburgh Eye Dispensary; Lecturer on Ophthalmology, Royal College of Surgeons, Edinburgh. Second Edition revised and enlarged. 8vo, Cloth, gilt top, pp. xvi., 730, Illustrated with many Coloured Plates and Wood Engravings. Price 25s. (1893).

*(Pentland's Medical Series, Volume Second.)*

**THE NATIONAL MEDICAL DICTIONARY.** INCLUDING ENGLISH, FRENCH, GERMAN, ITALIAN, AND LATIN TECHNICAL TERMS USED IN MEDICINE AND THE COLLATERAL SCIENCES, AND

A SERIES OF TABLES OF USEFUL DATA. By JOHN S. BILLINGS, A.M., M.D., LL.D., Harv. and Edin., D.C.L., Oxon., Member of the National Academy of Sciences, Surgeon, U.S.A., &c. With the collaboration of W. O. ATWATER, M.D., FRANK BAKER, M.D., JAMES M. FLINT, M.D., R. LORINI, M.D., S. M. BURNETT, M.D., J. H. KIDDER, M.D., H. C. YARROW, M.D., WILLIAM LEE, M.D., C. S. MINOT, M.D., WASHINGTON MATTHEWS, M.D., W. T. COUNCILMAN, M.D. In Two very handsome Imperial 8vo volumes, containing about 1600 pages. Price 50s. nett. (1890.)

**DISEASES of the HEART and THORACIC AORTA.** By BYROM BRAMWELL, M.D., F.R.C.P.ED., Lecturer on the Principles and Practice of Medicine, and on Practical Medicine and Medical Diagnosis, in the Extra-Academical School of Medicine, Edinburgh; Assistant Physician, Edinburgh Royal Infirmary. Large 8vo, Cloth, pp. xvi., 783. Illustrated with 226 Wood Engravings, and 68 pages of Lithograph Plates, exhibiting 91 Figures—317 Illustrations in all. Price 25s. (1884.)

**INTRACRANIAL TUMOURS.** By BYROM BRAMWELL, M.D., F.R.C.P.ED., Lecturer on the Principles and Practice of Medicine in the Extra-Academical School of Medicine, Edinburgh; Assistant Physician to the Edinburgh Royal Infirmary. 8vo, Cloth, pp. xvi., 270, with 116 Illustrations. Price 14s. (1888.)

**ILLUSTRATIONS of the NERVE TRACTS in the MID AND HIND BRAIN, AND THE CRANIAL NERVES ARISING THEREFROM.** By ALEXANDER BRUCE, M.D., F.R.C.P.ED., Lecturer on Pathology in the School of Medicine, Edinburgh; Assistant Physician (formerly Pathologist), Edinburgh Royal Infirmary; Pathologist to the Royal Hospital for Sick Children. Oblong 4to, Cloth, in a series of 27 Coloured Plates from Original Drawings, with Descriptive Letterpress, and 27 Engravings throughout the Text. Price 50s. nett. (1892.)

**DISEASE in CHILDREN: A MANUAL FOR STUDENTS AND PRACTITIONERS.** By JAMES CARMICHAEL, M.D., F.R.C.P.ED., Physician, Royal Hospital for Sick Children; University Lecturer on Disease in Children, Edinburgh. Crown 8vo, Cloth, pp. xvi., 520. Illustrated with Charts. Price 10s. 6d. (1892.)

*(Pentland's Students' Manuals.*

**TUBERCULOUS DISEASE of the BONES and JOINTS.**

By W. WATSON CHEYNE, M.B., F.R.S., F.R.C.S., Professor of Surgery, King's College, London. 8vo, Cloth, pp. xvi., 374. Illustrated with numerous Wood Engravings throughout the Text. Price 14s. nett. (1895.)

**SUPPURATION and SEPTIC DISEASES. THREE LECTURES DELIVERED AT THE ROYAL COLLEGE OF SURGEONS OF ENGLAND.**

By W. WATSON CHEYNE, M.B., F.R.S., F.R.C.S., Professor of Surgery, King's College, London. 8vo, Cloth, pp. xii., 102, with 4 Illustrations. Price 5s. (1889.)

**THE TREATMENT of WOUNDS, ABSCESSSES, and ULCERS.**

By W. WATSON CHEYNE, M.B., F.R.S., F.R.C.S., Professor of Surgery, King's College, London. Second Edition. Crown 8vo, Cloth, pp. xvi., 200. Price 3s. 6d. (1897.)

**ATLAS of the DISEASES of the SKIN.**

By H. RADCLIFFE CROCKER, M.D., F.R.C.P., Physician to the Department for Diseases of the Skin, University College Hospital, London. In 16 Fasciculi, containing 96 plates, exhibiting 238 Figures in colours from Original Drawings specially prepared for the work, with Descriptive Letterpress. Price 21s. each nett. Or in Two large handsome Folio Volumes, Half Morocco, gilt tops. Price £18, 18s. nett. (1897.)

\* \* *Subscribers' Names can be received for the Parts.*

**MANUAL OF PRACTICAL ANATOMY.**

By D. J. CUNNINGHAM, M.D., Professor of Anatomy and Chirurgery, University of Dublin. Second Edition. In two Vols., Crown 8vo, Cloth. Volume First—Upper and Lower Limb; Abdomen. Volume Second—Thorax; Head and Neck. Illustrated with 372 Engravings and 2 full-page Plates. Price 12s. 6d. each. (1896.)

*(Pentland's Students' Manuals.)*

**HYGIENE AND DISEASES OF WARM CLIMATES,**

IN A SERIES OF ARTICLES BY EMINENT AUTHORITIES. Edited by ANDREW DAVIDSON, M.D., F.R.C.P.ED., late Visiting and Superintending Surgeon, Civil Hospital; Professor of Chemistry, Royal College, Mauritius; Author of "*Geographical Pathology.*" Royal 8vo, Cloth, pp. xvi., 1016. Illustrated with Engravings throughout the Text and full-page Plates. Price 31s. 6d. (1893.)

**GEOGRAPHICAL PATHOLOGY.** AN INQUIRY INTO THE GEOGRAPHICAL DISTRIBUTION OF INFECTIVE AND CLIMATIC DISEASES. By ANDREW DAVIDSON, M.D., F.R.C.P.ED., late Visiting and Superintending Surgeon, Civil Hospital; Professor of Chemistry, Royal College, Mauritius. Two vols. Large 8vo, Cloth. pp. xvi., 1008. Illustrated with Maps and Charts. Price 31s. 6d. (1891.)

**TEXT-BOOK of NERVOUS DISEASES.** By AMERICAN AUTHORS. Edited by FRANCIS X. DERGUM, M.D., PH.D., Clinical Professor of Nervous Diseases in the Jefferson Medical College of Philadelphia. Royal 8vo, pp. xvi., 1056, with 341 Engravings in the Text, and 7 Coloured Plates. Price 25s. nett. (1895.)

## THE "COMPEND" SERIES.

*A Series of Handbooks to assist Students preparing for Examinations.*

**COMPEND of HUMAN ANATOMY,** INCLUDING THE ANATOMY OF THE VISCERA. By SAMUEL O. L. POTTER, M.A., M.D., Cooper Medical College, San Francisco. Fifth Edition, revised and enlarged, Crown 8vo, Cloth, pp. 233, with 117 Engravings and 16 full-page Plates. Price 5s.

**COMPEND of the PRACTICE of MEDICINE.** By DANIEL E. HUGHES, M.D., late Demonstrator of Clinical Medicine in the Jefferson Medical College of Philadelphia. Fourth Edition, revised and enlarged, Crown 8vo, Cloth, pp. 328. Price 7s. 6d.

**COMPEND of OBSTETRICS.** By HENRY G. LANDIS, A.M., M.D., late Professor of Obstetrics and Diseases of Women in Starling Medical College. Fourth Edition, thoroughly revised, enlarged, and improved, Crown 8vo, Cloth, pp. 118, with 17 Illustrations. Price 4s. 6d.

**COMPEND of SURGERY.** By ORVILLE HORWITZ, B.S., M.D., Chief of the Outdoor Surgical Department, Jefferson Medical College Hospital. Fourth Edition, revised, Crown 8vo, Cloth, pp. 272, with 136 Illustrations. Price 5s.

**COMPEND of GENERAL PATHOLOGY and MORBID ANATOMY.** By H. NEWBERRY HALL, Ph.G., M.D., Professor of Pathology and Medical Chemistry, Post-Graduate Medical School; Surgeon to the Emergency Hospital, &c., Chicago. Crown 8vo, Cloth, pp. 204, with 91 Illustrations. Price 4s. 6d.

**COMPEND of DISEASES of CHILDREN.** By MARCUS P. HATFIELD, A.M., M.D., Professor of Diseases of Children, Chicago Medical College. Crown 8vo, Cloth, pp. 186, with Coloured Plate. Price 4s. 6d.

**COMPEND of DENTAL PATHOLOGY and DENTAL MEDICINE.** By GEO. W. WARREN, D.D.S., Clinical Chief, Pennsylvania College of Dental Surgery. Crown 8vo, Cloth, pp. 109, Illustrations. Price 4s. 6d.

**CYCLOPÆDIA of the DISEASES of CHILDREN, MEDICAL AND SURGICAL.** The Articles written especially for the Work by American, British, and Canadian Authors. Edited by JOHN M. KEATING, M.D. In 8 Vols., Royal 8vo, of about 500 pages each, Illustrated with Wood Engravings in the Text, and numerous full-page Plates. Price 12s. 6d. per Volume nett, Carriage Free.

\* \* \* *Detailed Prospectus on application.*

**A TREATISE on OBSTETRICS, FOR STUDENTS AND PRACTITIONERS.** By EDWARD P. DAVIS, A.M., M.D., Professor of Obstetrics and Diseases of Infancy in the Philadelphia Polyclinic; Clinical Professor of Obstetrics, Jefferson Medical College, Philadelphia. Large 8vo, Cloth, pp. 533, Illustrated with 217 Engravings, and 30 Plates in colours and monochrome. Price 16s. *nett.* (1897.)

**EDINBURGH HOSPITAL REPORTS.** PUBLISHED UNDER THE SUPERVISION OF AN EDITORIAL COMMITTEE ELECTED BY THE MEDICAL AND SURGICAL OFFICERS OF THE ROYAL INFIRMARY, ROYAL HOSPITAL FOR SICK CHILDREN, AND ROYAL MATERNITY AND SIMPSON MEMORIAL HOSPITAL. Edited by G. A. GIBSON, M.D., D.Sc., C. W. CATHCART, M.A., M.B., JOHN THOMSON, M.D., and D. BERRY HART, M.D. To be issued annually, 8vo, pp. xvi., 650 or thereby, handsomely printed, illustrated with full-page Plates and Engravings. Price per Volume, 12s. 6d. *nett.* Carriage free. Volumes I. to V. now ready.

**DISEASES of the STOMACH.** By DR. C. A. EWALD, Extraordinary Professor of Medicine at the University of Berlin; Director of the Augusta Hospital. Authorised Translation, with Special Additions by the Author, by MORRIS MANGES, A.M., M.D., Attending Physician, Mount Sinai Hospital, New York City, 8vo, Cloth, pp. xvi., 498, with 30 Illustrations. Price 16s. (1892.)

**THE EDINBURGH MEDICAL JOURNAL.** Edited by G. A. GIBSON, M.D., D.Sc., F.R.C.P.Ed., Assistant Physician, Edinburgh Royal Infirmary. Issued monthly. Price 2s. each part; Subscription 21s. per annum (in advance), post free. For the Colonies and Abroad, 24s. per annum (in advance), post free.

**EXAMINATION QUESTIONS, SET FOR THE PROFESSIONAL EXAMINATIONS IN EDINBURGH UNIVERSITY DURING THE PAST TEN YEARS, SELECTED FROM THE CALENDARS.** By W. RAMSAY SMITH, M.B., C.M., B.Sc., Formerly Demonstrator of Anatomy, Edinburgh School of Medicine, Minto House; late Senior Assistant to the Professor of Natural History, University of Edinburgh. \*

NATURAL HISTORY, arranged and annotated. Price 1s.

BOTANY, arranged and annotated. Price 1s. 6d.

CHEMISTRY, answered and annotated. Price 2s.

ANATOMY, answered and annotated. Price 2s.

PHYSIOLOGY, answered and annotated. Price 2s.

MATERIA MEDICA, answered and annotated. Price 2s.

MIDWIFERY AND GYNECOLOGY, answered and annotated.

Price 1s. 6d.

SURGERY, answered and annotated. Price 1s. 6d.

PRACTICE OF PHYSIC, answered and annotated. Price 1s. 6d.

MEDICAL JURISPRUDENCE AND PUBLIC HEALTH, answered and annotated. Price 2s.

**THE FUNDUS OCULI, with an OPHTHALMOSCOPIC ATLAS, ILLUSTRATING ITS PHYSIOLOGICAL AND PATHOLOGICAL CONDITIONS.** By W. ADAMS FROST, F.R.C.S., Ophthalmic Surgeon, St. George's Hospital; Surgeon to the Royal Westminster Ophthalmic Hospital, London. In one handsome 4to Volume, extra Cloth, gilt top, with 47 Plates, exhibiting 107 beautifully Coloured Figures and numerous Engravings in the Text. Price £3, 3s. nett. (1896.)

**PHYSICAL DIAGNOSIS: A GUIDE TO METHODS OF CLINICAL INVESTIGATION.** By G. A. GIBSON, M.D., D.Sc., F.R.C.P.Ed., Assistant Physician, Edinburgh Royal Infirmary; Lecturer on the Principles and Practice of Medicine in the Edinburgh Medical School; and WILLIAM RUSSELL, M.D., F.R.C.P.Ed., Assistant Physician, Edinburgh Royal Infirmary. Second Edition, thoroughly revised, Crown 8vo, Cloth, pp. xvi., 383, with 109 Illustrations, some Coloured. Price 10s. 6d. (1893.)

(*Pentland's Students' Manuals.*)

**HYDATID DISEASE IN ITS CLINICAL ASPECTS.**

By JAMES GRAHAM, M.A., M.D., late Demonstrator of Anatomy, Sydney University; Medical Superintendent, Prince Alfred Hospital, Sydney. 8vo, Cloth, gilt top, pp. xvi., 204, with 34 full-page Coloured Plates. Price 16s. (1891.)

**A SYSTEM OF PRACTICAL THERAPEUTICS.** By

Various Authors. Edited by HOBART AMORY HARE, M.D., Clinical Professor of Diseases of Children, and Demonstrator of Therapeutics in the University of Pennsylvania; Physician to St. Agnes's Hospital, Philadelphia. 3 Vols., Royal 8vo, of about 1000 pages each. Price per vol. 22s. 6d. *nett*, carriage free.

**HANDBOOK OF OBSTETRIC NURSING.** By F. W. N.

HAULTAIN, M.D., F.R.C.P.ED., Physician to the Royal Dispensary; late Clinical Assistant to Physician for Diseases of Women, Royal Infirmary, Edinburgh; and J. HAIG FERGUSON, M.D., F.R.C.P.ED., Physician to the New Town Dispensary; late Resident Physician, Royal Maternity Hospital, Edinburgh. Second Edition, Revised and Enlarged, Crown 8vo, Cloth, pp. xvi., 244, with Coloured Plate and 33 Wood Engravings. Price 5s. (1894.)

**HUMAN MONSTROSITIES.** By BARTON COOKE HIRST, M.D.,

Professor of Obstetrics in the University of Pennsylvania; and GEORGE A. PIERSOL, M.D., Professor of Embryology and Histology in the University of Pennsylvania. In 4 Fasciculi, folio size, Illustrated with Engravings and full-page Photographic Plates from Nature. Price 25s. each Fasciculus. *Sold only by Subscription.*

**THE URINE AND THE COMMON POISONS, MEMORANDA, CHEMICAL AND MICROSCOPICAL, FOR LABORATORY USE.**

By J. W. HOLLAND, M.D., Professor of Medical Chemistry and Toxicology, Jefferson Medical College, Philadelphia. Second, Edition, Revised and Enlarged, oblong Crown 8vo, Cloth, pp. 65, with 28 Illustrations. Price 4s. (1889.)

**DISEASES OF THE SKIN: A MANUAL FOR STUDENTS AND PRACTITIONERS.** By W. ALLAN JAMIESON, M.D., F.R.C.P.ED., Extra Physician for Diseases of the Skin, Edinburgh Royal

Infirmary; Consulting Physician, Edinburgh City Hospital; Lecturer on Diseases of the Skin, School of Medicine, Edinburgh. Fourth Edition, Revised and Enlarged, 8vo, Cloth, pp. xvi., 676, with Coloured Illustrations. Price 21s. (1894.)

*(Pentland's Medical Series, Volume First.)*

**BOTANY: A CONCISE MANUAL FOR STUDENTS OF MEDICINE AND SCIENCE.** By ALEXANDER JOHNSTONE, F.G.S., Lecturer on Botany, School of Medicine, Edinburgh. Crown 8vo, Cloth, pp. xvi., 260, with 164 Illustrations and a series of Floral Diagrams. Price 6s. (1891.)

*(Pentland's Students' Manuals.)*

**A NEW PRONOUNCING DICTIONARY of MEDICAL TERMS.** By JOHN M. KEATING, M.D., Fellow of the College of Physicians of Philadelphia, Visiting Obstetrician to the Philadelphia Hospital, and Lecturer on Diseases of Women and Children. Handsome 8vo, Cloth, pp. 818. Price 18s. (1892.)

**CLINICAL GYNÆCOLOGY, MEDICAL and SURGICAL.** By AMERICAN AUTHORS. Edited by JOHN M. KEATING, M.D., LL.D., and HENRY C. COE, M.D., M.R.C.S., Professor of Gynecology, New York Polyclinic. Two Volumes, Royal 8vo, Cloth, pp. xviii., 994, Illustrated with Full-page Plates and Engravings in the Text. Price 25s. nett. (1895.)

**TEXT-BOOK of ABDOMINAL SURGERY: A CLINICAL MANUAL FOR PRACTITIONERS AND STUDENTS.** By SKENE KEITH, F.R.C.S.Ed.; assisted by GEORGE E. KEITH, M.B. 8vo, Cloth, gilt top, pp. xvi., 508. Price 16s. (1894.)

*(Pentland's Medical Series, Volume Fourth.)*

**THE ESSENTIALS of MEDICAL ANATOMY.** By H. R. KENWOOD, M.B., C.M., L.R.C.P. (Lond.) 12mo, Cloth, pp. 52. Price 2s. (1889.)

**THE PARASITES of MAN, AND THE DISEASES WHICH PROCEED FROM THEM.** A TEXT-BOOK FOR STUDENTS AND PRACTITIONERS. By RUDOLF LEUCKART, Professor of Zoology and Comparative Anatomy in the University of Leipsic. Translated from the German, with the Co-operation of the Author, by WILLIAM E. HOYLE, M.A. (Oxon.), M.R.C.S., F.R.S.E., Curator of the Museums, Owens College, Manchester. NATURAL HISTORY OF



PARASITES IN GENERAL—SYSTEMATIC ACCOUNT OF THE PARASITES INFESTING MAN—PROTOZOA—CESTODA. Large 8vo, Cloth, pp. xxviii., 772, Illustrated with 404 Engravings. Price 31s. 6d. (1886.)

**FIRST AID to the INJURED and MANAGEMENT of the SICK.** By E. J. LAWLESS, M.D., Surgeon-Major, 4th V.B., E. Surrey Regiment. Crown 8vo, Cloth, pp. xvi., 262, Illustrated with numerous Wood Engravings. Price 3s. 6d. (1894.)

**TRAUMATIC INFECTION.** HUNTERIAN LECTURES DELIVERED AT THE ROYAL COLLEGE OF SURGEONS OF ENGLAND. By CHARLES BARRETT LOCKWOOD, F.R.C.S., Hunterian Professor, Royal College of Surgeons of England; Assistant Surgeon to St. Bartholomew's Hospital; Surgeon to the Great Northern Central Hospital. Crown 8vo, Cloth, pp. xii., 138, Illustrated with 27 Wood Engravings in the Text. Price 3s. (1896.)

**ASEPTIC SURGERY.** By CHARLES BARRETT LOCKWOOD, F.R.C.S. Crown 8vo, Cloth, pp. xvi., 233. Price 4s. (1896.)

**STUDENTS' POCKET MEDICAL LEXICON,** GIVING THE CORRECT PRONUNCIATION AND DEFINITION OF ALL WORDS AND TERMS IN GENERAL USE IN MEDICINE AND THE COLLATERAL SCIENCES. By ELIAS LONGLEY. New Edition, 18mo, Cloth, pp. 303. Price 4s. (1891.)

**DISEASES of the THROAT, NOSE, and EAR.** By P. M'BRIDE, M.D., F.R.C.P.Ed., Lecturer on the Diseases of the Ear and Throat, Edinburgh School of Medicine; Aural Surgeon and Laryngologist, Royal Infirmary, Edinburgh; Surgeon, Edinburgh Ear and Throat Dispensary. Second Edition, thoroughly revised. 8vo, Cloth, pp. xvi., 682, with Coloured Illustrations from Original Drawings. Price 25s. (1894.)

*(Pentland's Medical Series, Volume Third.)*

**REGIONAL ANATOMY** IN ITS RELATION TO MEDICINE AND SURGERY. By GEORGE MCCLELLAN, M.D., Lecturer on Descriptive and Regional Anatomy at the Pennsylvania School of Anatomy. In Two Handsome Volumes, large 4to, Illustrated with 100 full-page facsimile Chromo-lithographic Plates, reproduced from Photographs taken by the Author of his own Dissections, expressly designed and prepared for this work, and coloured by him after nature. Price 42s. each nett.

**ATLAS of VENEREAL DISEASES.** A SERIES OF ILLUSTRATIONS FROM ORIGINAL PAINTINGS, WITH DESCRIPTIONS OF THE VARIED LESIONS, THEIR DIFFERENTIAL DIAGNOSIS AND TREATMENT. By P. H. MACLAREN, M.D., F.R.C.S. ED., Surgeon, Edinburgh Royal Infirmary; Formerly Surgeon in Charge of the Lock Wards, Edinburgh Royal Infirmary; Examiner in the Royal College of Surgeons, Edinburgh. In one handsome Royal 4to Volume, Extra Cloth. Price 63s. nett.

**FUNCTIONAL and ORGANIC DISEASES of the STOMACH.** By SIDNEY MARTIN, M.D., F.R.S., F.R.C.P., Assistant Physician and Assistant Professor of Clinical Medicine at University College Hospital; Assistant Physician to the Hospital for Consumption and Diseases of the Chest, Brompton. 8vo, Cloth, pp. xvi., 506, Illustrated with numerous Engravings throughout the Text. Price 16s. (1895.)

*(Pentland's Medical Series, Volume Fifth.)*

**A SYSTEM OF GENITO - URINARY DISEASES, SYPHILOLOGY, AND DERMATOLOGY.** Edited by PRINCE A. MORROW, M.D. 6 Vols., large 8vo, of about 550 pages each, fully Illustrated. Price per vol. 14s. carriage free.

**MANUAL of BACTERIOLOGY.** By ROBERT MUIR, M.D., F.R.C.P. ED., Lecturer on Pathological Bacteriology, Edinburgh University; Pathologist to the Royal Infirmary, Edinburgh; and JAMES RITCHIE, M.D., B.Sc., Lecturer in Pathology, University of Oxford. Crown 8vo, Cloth, pp. xvi., 500, with 108 Illustrations in the Text. Price 12s. 6d. [*Pentland's Students' Manuals.*]

**PRESCRIBING and TREATMENT IN THE DISEASES OF INFANTS AND CHILDREN.** By PHILIP E. MUSKETT, L.R.C.P. & S. ED., late Surgeon to the Sydney Hospital; formerly Senior Resident Medical Officer, Sydney Hospital. Third Edition. Revised and Enlarged. 18mo, pp. xx., 336, in Flexible Leather binding for the pocket. Price 6s. 6d. (1894.)

**PRACTICAL TREATISE on MEDICAL DIAGNOSIS.** By JOHN H. MUSSER, M.D., Assistant Professor of Clinical Medicine in the University of Pennsylvania; Physician to the Philadelphia and the Presbyterian Hospitals. Royal 8vo, Cloth, pp. viii., 881, Illustrated with 162 Woodcuts and 2 Coloured Plates. Price 24s. (1894.)

- MALIGNANT DISEASE of the THROAT and NOSE.** By DAVID NEWMAN, M.D., Laryngologist to the Glasgow Royal Infirmary; Assistant Surgeon to the Western Infirmary; Examiner in Pathology in the University of Glasgow. 8vo, pp. xvi., 212, with 3 Illustrations. Price 8s. 6d. (1892.)
- TEXT-BOOK of OPHTHALMOLOGY.** By W. F. NORRIS, A.M., M.D., and C. A. OLIVER, A.M., M.D. Royal 8vo, pp. viii., 622, Illustrated with 5 Coloured Plates and 357 Woodcuts. Price 25s. (1893.)
- LEAD POISONING, ACUTE AND CHRONIC. BEING THE GOULSTONIAN LECTURES DELIVERED AT THE ROYAL COLLEGE OF PHYSICIANS.** By THOMAS OLIVER, M.D., F.R.C.P., Physician Royal Infirmary, Newcastle-on-Tyne; Professor of Physiology, University of Durham; Honorary Physician, Newcastle-on-Tyne Dispensary and Industrial Schools. 8vo, Cloth, pp. xii., 121, with Coloured Illustrations. Price 10s. 6d. (1891.)
- THE PRINCIPLES and PRACTICE of MEDICINE, DESIGNED FOR THE USE OF PRACTITIONERS AND STUDENTS OF MEDICINE.** By WILLIAM OSLER, M.D., F.R.C.P., Professor of Medicine in the Johns Hopkins University, and Physician-in-Chief to the Johns Hopkins Hospital, Baltimore. Second Edition, thoroughly Revised and partly Re-written. Large 8vo, Cloth, pp. xvi., 1080, Illustrated with Charts. Price 24s.
- LECTURES on ANGINA PECTORIS and ALLIED STATES.** By WILLIAM OSLER, M.D., F.R.C.P., Professor of Medicine in the Johns Hopkins University, Baltimore. 8vo, Cloth, pp. viii., 160. Price 6s. *nett.* (1897.)
- TREATISE on SURGERY.** By AMERICAN AUTHORS. FOR STUDENTS AND PRACTITIONERS OF SURGERY AND MEDICINE. Edited by ROSWELL PARK, A.M., M.D., Professor of the Principles and Practice of Surgery and of Clinical Surgery in the Medical Department of the University of Buffalo, Buffalo, New York; Surgeon to the Buffalo General Hospital, etc. Two Volumes. Large 8vo, Cloth, pp. 1603, with 707 Engravings and 38 full-page Plates in Colours and Monochrome. Price 34s. *nett.* (1897.)
- THE SCIENCE and ART of OBSTETRICS.** By THEOPHILUS PARVIN, M.D., LL.D., Professor of Obstetrics and Diseases of Women and Children in Jefferson Medical College, Phila-

delphia, and one of the Obstetricians to the Philadelphia Hospital. Third Edition, thoroughly revised, large 8vo, Cloth, pp. 701, with 269 Wood Engravings, and 2 Coloured Plates. Price 18s. (1895.)

**BERI BERI :** RESEARCHES CONCERNING ITS NATURE AND CAUSE AND THE MEANS OF ITS ARREST. By C. A. PEKELHARING, Professor in the Faculty of Medicine, University of Utrecht ; and C. WINKLER, Lecturer in the University of Utrecht. Translated by JAMES CANTLIE, M.A., M.B., F.R.C.S. 8vo, Cloth, pp. xvi., 160, Illustrated with full-page Coloured Plates from Original Drawings. Price 10s. 6d. nett. (1893.)

**REPORTS from the LABORATORY of the ROYAL COLLEGE OF PHYSICIANS, EDINBURGH.** Edited by J. BATTY TUKE, M.D., G. SIMS WOODHEAD, M.D., and D. NOEL PATON, M.D.

VOLUME FIRST, 8vo, Cloth, pp. 212, with 23 full-page Plates, and 19 Engravings. Price 7s. 6d. nett.

VOLUME SECOND, 8vo, Cloth, pp. xiv., 280, with 43 full-page Plates, consisting of Lithographs, Chromo-Lithographs, and Micro-Photographs. Price 10s. 6d. nett.

VOLUME THIRD, 8vo, Cloth, pp. xii., 304, with 11 Plates and Folding Charts. Price 9s. nett.

VOLUME FOURTH, 8vo, Cloth, pp. xii., 254, with 25 Plates and Folding Charts. Price 10s. 6d. nett.

**PEDIATRICS :** THE HYGIENIC AND MEDICAL TREATMENT OF CHILDREN. By THOMAS MORGAN ROTCH, M.D., Professor of Diseases of Children, Harvard University. Two Vols., large 8vo, pp. 1124, with 450 Illustrations in the Text, and 8 full-page Coloured Plates. Price 25s. nett. (1896.)

**TEXT-BOOK of PHYSIOLOGY.** By BRITISH PHYSIOLOGISTS. Edited by E. A. SCHAFER, F.R.S., Jodrell Professor of Physiology, University College, London. Two Volumes, Royal 8vo, each pp. xxiv., 950 or thereby, with numerous Illustrations in the Text. *In Press.*

\* \* The following, among others, will contribute :—Professor BURDON SANDERSON (Oxford), Professor GAMGEE, Dr. GASKELL (Cambridge), Professor GOTCH (Oxford), Professor SHERRINGTON (Liverpool), Professor M'KENDRICK (Glasgow), Professor HALLIBURTON (King's College), Professor HAYCRAFT (Cardiff), Dr.

PEMBREY (Charing Cross), Dr. STARLING (Guy's), Dr. RIVERS (Cambridge), J. N. LANGLEY (Cambridge), the EDITOR, etc. etc.

**DISEASES of the MOUTH, THROAT, and NOSE**, including RHINOSCOPY AND METHODS OF LOCAL TREATMENT. By PHILIP SCHECH, M.D., Lecturer in the University of Munich. Translated by R. H. BLAIKIE, M.D., F.R.S.E., formerly Surgeon. Edinburgh Ear and Throat Dispensary; late Clinical Assistant. Ear and Throat Department, Royal Infirmary, Edinburgh. 8vo, Cloth, pp. xii., 302, with 5 Wood Engravings. Price 9s. (1886.)

**ELEMENTS of PHARMACOLOGY**. By Dr. OSWALD SCHMIEDEBERG, Professor of Pharmacology, University of Strasbourg. Translated by THOMAS DIXSON, M.B., Lecturer on Materia Medica in the University of Sydney, N.S.W. 8vo, Cloth, pp. xii. 223, with 7 Illustrations. Price 9s. (1887.)

**SURGICAL ANATOMY. A MANUAL FOR STUDENTS**. By A. MARMADUKE SHEILD, M.B. (Cantab.), F.R.C.S., Senior Assistant Surgeon, Aural Surgeon and Teacher of Operative Surgery, Charing Cross Hospital. Crown 8vo, Cloth, pp. xvi., 212. Price 6s. (1891.)  
(*Pentland's Students' Manuals.*)

**MEDICAL GYNECOLOGY: A TREATISE ON THE DISEASES OF WOMEN FROM THE STANDPOINT OF THE PHYSICIAN**. By ALEXANDER J. C. SKENE, M.D., Professor of Gynecology in the Long Island College Hospital, Brooklyn, New York. 8vo, Cloth, pp. vi., 530, with Illustrations in the Text. Price 21s.

**ILLUSTRATIONS of ZOOLOGY, INVERTEBRATES AND VERTEBRATES**. By WILLIAM RAMSAY SMITH, B.Sc., and J. STEWART NORWELL, B.Sc. New and Cheaper Edition. Crown 4to, extra Cloth, gilt top, with 70 Plates, exhibiting over 400 Figures. Price 7s. 6d.

**EXAMINATION of the EYE**. By SIMEON SNELL, F.R.C.S.ED., Ophthalmic Surgeon, Sheffield General Infirmary. Crown 8vo, pp. 150 or thereby, with numerous Illustrations. *In Press.*

**DISEASES of the DIGESTIVE ORGANS in INFANTS AND CHILDREN**. WITH CHAPTERS ON THE INVESTIGATION OF DISEASE AND ON THE GENERAL MANAGEMENT OF CHILDREN. By LOUIS STARR, M.D., late Clinical Professor of Diseases of Children in the Hospital of the University of Pennsylvania; Physician to

the Children's Hospital, Philadelphia. Second Edition, Post 8vo, Cloth, pp. 396, with Illustrations. Price 10s. (1891.)

**EPIDEMIC OPHTHALMIA: ITS SYMPTOMS, DIAGNOSIS, AND MANAGEMENT.** By SYDNEY STEPHENSON, F.R.C.S.Ed., Surgeon, Ophthalmic School, Hanwell. 8vo, Cloth, pp. xvi., 278, Illustrated throughout the Text. Price 9s. nett. (1895.)

**APPENDICITIS and PERITYPHLITIS.** By CHARLES TALAMON, Physician to the Tenon Hospital, Paris. Translated from the French by RICHARD J. A. BERRY, M.B., C.M., late President of the Royal Medical Society, Edinburgh. Crown 8vo, Cloth, pp. viii., 239. Price 6s. (1893.)

**THE PATHOLOGY and TREATMENT of VENEREAL DISEASES.** By ROBERT W. TAYLOR, M.D., Clinical Professor of Venereal Diseases at the College of Physicians and Surgeons (Columbia College) New York; Surgeon to Bellevue Hospital; and Consulting Surgeon to the City (Charity) Hospital, New York. Royal 8vo, Cloth, pp. 1002, Illustrated with 230 Engravings in the Text, and 7 Coloured Plates. Price 22s. nett. (1896.)

**MINOR SURGERY and BANDAGING. INCLUDING THE TREATMENT OF FRACTURES AND DISLOCATIONS, ETC. ETC.** By HENRY R. WHARTON, M.D., Demonstrator of Surgery and Lecturer on Surgical Diseases of Children in the University of Pennsylvania. Post 8vo, Cloth, pp. 496, with 403 Engravings. Price 12s. 6d. (1891.)

**OUTLINES of ZOOLOGY.** By J. ARTHUR THOMSON, M.A., Lecturer on Zoology, School of Medicine, Edinburgh. Second Edition, Revised and Enlarged. Crown 8vo, Cloth, pp. xx., 820, with 266 Illustrations in the Text. Price 15s. (1895.)

*(Pentland's Students' Manuals.)*

**CLINICAL TEXT-BOOK of MEDICAL DIAGNOSIS, BASED ON THE MOST RECENT METHODS OF EXAMINATION.** By OSWALD VIERORDT, M.D., Professor of Medicine at the University of Heidelberg. Translated, with additions from the second enlarged German edition, with the Author's permission. By FRANCIS H. STUART, M.D., Member of the Medical Society of the County of Kings, New York. Large 8vo, Cloth, pp. xvi., 700, with 178 fine Engravings, many in Colour. Price 18s. (1891.)

**PRACTICAL GUIDE to MEAT INSPECTION.** By THOMAS WALLEY, M.R.C.V.S., formerly Principal of the Edinburgh Royal (Dick) Veterinary College ; Professor of Veterinary Medicine and Surgery, &c. Third Edition, thoroughly Revised, pp. xvi., 198, with 44 Figures, mostly in Colours. Price 10s. 6d. (1896.)

**DISEASES of the LIVER, GALL BLADDER and BILIARY SYSTEM: THEIR PATHOLOGY, DIAGNOSIS, AND SURGICAL TREATMENT.** By H. J. WARING, M.S., B.Sc., F.R.C.S., Demonstrator of Operative Surgery and Senior Demonstrator St. Bartholomew's Hospital ; Senior Assistant Surgeon, Metropolitan Hospital ; Surgeon to the Belgrave Hospital for Children, London. 8vo, Cloth, pp. xvi., 386, with 58 Illustrations. Price 12s. 6d. nett. (1897.)

**MANUAL of OPERATIVE SURGERY.** By H. J. WARING, M.S., B.Sc., F.R.C.S., Demonstrator of Operative Surgery and Senior Demonstrator of Anatomy, St. Bartholomew's Hospital ; Surgeon, Metropolitan Hospital ; Surgeon to the Belgrave Hospital for Children, London. Crown 8vo, pp. 550 or thereby, with 400 Illustrations in the Text. *In Press.* (*Pentland's Students' Manuals.*)

**ECTOPIC PREGNANCY.** By J. CLARENCE WEBSTER, M.D., F.R.C.P.Ed., Formerly Assistant to the Professor of Midwifery and Diseases of Women and Children in the University of Edinburgh. 8vo, Cloth, pp. xvi., 374, with 22 pages of Plates and Figures throughout the Text. Price 12s. 6d. nett. (1895.)

**RESEARCHES in FEMALE PELVIC ANATOMY.** By J. CLARENCE WEBSTER, B.A., M.D., M.R.C.P.Ed., Demy 4to, Cloth. Illustrated with 26 full-page Coloured Plates from Original Drawings. Price 30s. nett. (1892.)

**TUBO-PERITONEAL ECTOPIC GESTATION.** By J. CLARENCE WEBSTER, B.A., M.D., M.R.C.P.Ed. Demy 4to Cloth, Illustrated with 11 full-page Plates, several Coloured, exhibiting numerous Figures. Price 16s. nett. (1892.)

**PRACTICAL and OPERATIVE GYNECOLOGY.** By J. CLARENCE WEBSTER, M.D., F.R.C.P.Ed., formerly Assistant to the Professor of Midwifery and Diseases of Women, University of Edinburgh. Crown 8vo, Cloth, pp. xvi., 296, with 54 Illustrations. Price 7s. 6d. (1896.) (*Pentland's Students' Manuals.*)

- MANUAL of DISEASES of WOMEN.** By J. CLARENCE WEBSTER, B.A., M.D., F.R.C.P.ED., Demonstrator of Gynecology, McGill University; Assistant Gynecologist, Royal Victoria Hospital, Montreal. Crown 8vo, pp. 650 or thereby, with 300 Illustrations. *In Press.* (*Pentland's Students' Manuals.*)
- DIABETES MELLITUS: ITS SYMPTOMS, PATHOLOGY, AND TREATMENT.** By RICHARD T. WILLIAMSON, M.D., M.R.C.P., M.R.C.S., Medical Registrar, Manchester Royal Infirmary. 8vo. pp. xvi., 400 or thereby. *In Press.*
- TEXT-BOOK of OBSTETRICS, INCLUDING THE PATHOLOGY AND THERAPEUTICS OF THE PUERPERAL STATE. DESIGNED FOR PRACTITIONERS AND STUDENTS OF MEDICINE.** By Dr. F. WINCKEL, Professor of Gynæcology and Director of the Royal Hospital for Women. Translated under the supervision of J. CLIFTON EDGAR, A.M., M.D., Adjunct Professor of Obstetrics, University of the City of New York. Royal 8vo, Cloth, pp. 927, Illustrated with 190 Engravings, mostly Original. Price 28s. (1890.)
- PRACTICAL PATHOLOGY. A MANUAL FOR STUDENTS AND PRACTITIONERS.** By G. SIMS WOODHEAD, M.D., F.R.C.P.ED., Director of the Laboratories of the Royal Colleges of Physicians (London) and Surgeons (England). Third Edition, Revised and Enlarged, 8vo. Cloth, pp. xxiv., 652, with 195 Coloured Illustrations, mostly from Original Drawings. Price 25s. (1892.)
- THE JOURNAL of PATHOLOGY and BACTERIOLOGY.** Edited, with the collaboration of distinguished British and Foreign Pathologists, by GERMAN SIMS WOODHAD, M.D., Director of the Laboratories of the Royal Colleges of Physicians (London) and Surgeons (England). Assisted in special departments by SIDNEY MARTIN, M.D., Lond. (*Pathological Chemistry*); G. E. CARTWRIGHT WOOD, M.D., Edin. (*Bacteriology*); C. S. SHERRINGTON, M.D., Cantab. (*Experimental Pathology*); S. G. SHATTOCK, F.R.C.S. (*Morbid Anatomy and Histology*). Issued at Quarterly Intervals. Subscription 21s. per Volume (in advance) post free.

YOUNG J. PENTLAND,  
 EDINBURGH: 11 TEVIOT PLACE.  
 LONDON: 38 WEST SMITHFIELD, E.C.









