


Handwritten text, possibly a signature or name, located at the top of the page.



E. BARCLAY - SMITH, M.D.



22101348118

Med

K8409

46518

THE
DISSECTOR'S MANUAL
OF
PRACTICAL AND SURGICAL
ANATOMY.

BY
ERASMUS WILSON, F.R.S.

SECOND EDITION,
ILLUSTRATED WITH WOOD ENGRAVINGS.

LONDON:
LONGMAN, BROWN, GREEN, AND LONGMANS.
1853.

849 451

WELLCOME INSTITUTE LIBRARY	
Coll.	weIMOmec
Call	
No.	Q5

LONDON :
SPOTTISWOODES and SHAW,
New-street-Square.

TO

JONES QUAIN, M.D.

THIS

THE AUTHOR'S FIRST WORK

IS DEDICATED,

IN EVER GRATEFUL REMEMBRANCE.



Digitized by the Internet Archive
in 2016

<https://archive.org/details/b28134886>

P R E F A C E.

INSTRUCTION in Anatomy is conveyed to the student in two ways; *firstly*, by a systematic arrangement which analyses the component structures of the body, and treats of them in physiological order, as Bones, Joints, Muscles, Vessels, Nerves, and Organs; *secondly*, by demonstration, which displays the component structures in their relations to each other, and their complicity in the injuries and surgical operations to which the body may be subjected. To this latter branch of the subject the present book is devoted; while the former is treated of in my other anatomical work, the ANATOMIST'S VADE-MECUM.

The opportunity of revision afforded by the demand for a second edition of this book I have faithfully taken advantage of, by re-writing such parts as I thought could be improved, and by the addition of twenty-five new illustrations, engraved on wood by Bagg, the greater part from drawings made by myself.

It remains for me further only to hope that the book may prove an useful and favoured companion with those

for whom it was written, maintaining its character of *manual* by being always at hand when not in the hand of the student, and a not unworthy member of the shelf of reference of those students of an older growth, who having discharged the immediate labours of their education, still find a pleasure in refreshing the knowledge of early and retrospective days.

17. Henrietta Street, Cavendish Square,
January, 1853.

ERRATA.

THE Reader is requested to correct immediately the following :—

- Page 49. line 2., *for* “communicans peronei, cutaneous and articular,” *read* “anterior tibial and musculo-cutaneous.”
- 59., line 17., from bottom, *after* “anterior tibial,” *insert* “artery.”
97. line 9., *for* “vein and artery,” *read* “vein and nerve.”
134. line 12., *for* “abductor,” *read* “adductor.”
- 269., between lines 3 and 4., *insert*—“The *infra-orbital* artery would appear from its size to be the proper continuation of the internal maxillary. It runs along the infra-orbital canal with the superior maxillary nerve, sending branches upwards into the orbit ; and downwards, through canals in the bone, to supply the mucous membrane of the antrum, and the teeth of the upper jaw, and emerging on the face at the infra-orbital foramen. A branch sent to the incisor teeth is the *anterior dental* ; and on the face the infra-orbital inosculates with the facial and transverse facial artery.”
- 311., between lines 22 and 23., *insert*—“The *choroidean artery* is a small branch given off by the internal carotid, near the origin of the posterior communicating : it passes beneath the edge of the middle lobe of the brain to enter the descending cornu of the lateral ventricle, and is distributed to the choroid plexus.”
- 330., between the last two lines *insert* the word “ventricle.”
- 484., line 10. from bottom, *for* “œsophagial,” *read* “œsophageal.”

C O N T E N T S.

INTRODUCTION; GENERAL ANATOMY	-	-	Page
			1

CHAPTER I.

LOWER EXTREMITY.

Surgical observations	-	-	-	-	7
Anterior femoral region	-	-	-	-	11
Internal femoral region	-	-	-	-	18
Vessels of the thigh	-	-	-	-	20
Operations on the femoral artery	-	-	-	-	21
Nerves of the thigh	-	-	-	-	28
Femoral hernia	-	-	-	-	31
Gluteal region	-	-	-	-	35
Posterior femoral region	-	-	-	-	43
Popliteal region	-	-	-	-	45
Operation on the popliteal artery	-	-	-	-	46
Anatomy of the leg	-	-	-	-	49
Anterior tibial region	-	-	-	-	51
Operations on the anterior tibial artery	-	-	-	-	54
Dorsal region of the foot	-	-	-	-	55
Operation on the dorsalis pedis artery	-	-	-	-	56
Fibular region	-	-	-	-	58
Posterior tibial region	-	-	-	-	59
Operations on the posterior tibial artery	-	-	-	-	64
Operations on the peroneal artery	-	-	-	-	66
Sole of the foot	-	-	-	-	68
Actions of muscles of the lower extremity	-	-	-	-	74

CHAPTER II.

UPPER EXTREMITY.

	Page
General anatomy - - - - -	76
Table of muscles - - - - -	77
Anterior thoracic region - - - - -	81
Mammary gland - - - - -	82
Operations on the axillary artery ; upper part - - - - -	86
Anatomy of the axilla - - - - -	88
Operations on the axillary artery ; lower part - - - - -	89
Brachial plexus of nerves - - - - -	93
Anatomy of the walls of the thorax - - - - -	95
Anatomy of the shoulder and scapula - - - - -	99
Anterior brachial region - - - - -	104
Veins of the bend of the elbow - - - - -	105
Accidents from venesection - - - - -	106
Operations on the brachial artery - - - - -	112
Anatomy of the fore-arm - - - - -	115
Operations on the radial artery - - - - -	121
Operations on the ulnar artery - - - - -	124
Palm of the hand - - - - -	132

CHAPTER III.

THORAX.

Boundaries of the thorax - - - - -	140
Pleuræ ; mediastinum - - - - -	141
Phrenic nerves - - - - -	143
Lungs - - - - -	143
Heart - - - - -	150
Great vessels of the heart - - - - -	162
Nerves of the thorax - - - - -	166
Pneumogastric nerve - - - - -	166
Sympathetic nerve - - - - -	168
Intercostal nerves - - - - -	170
Trachea - - - - -	171
Œsophagus - - - - -	172
Thoracic aorta - - - - -	173
Azygos veins - - - - -	175
Thoracic duct - - - - -	176

CHAPTER IV.

REGION OF THE BACK.

	Page
Table of muscles - - - - -	179
Cutaneous nerves of the back - - - - -	180
Nerves and vessels of the back - - - - -	187
Table of origins and insertions of muscles - - - - -	194

CHAPTER V.

HEAD AND NECK.

Muscles of the head and face - - - - -	198
Vessels and nerves of the cranium - - - - -	201
Parotid gland - - - - -	209
Vessels and nerves of the face - - - - -	212
Facial nerve - - - - -	212
Facial artery - - - - -	216
Anatomy of the orbit - - - - -	217
Muscles of the neck - - - - -	229
Thyroid gland - - - - -	235
Tracheotomy and laryngotomy - - - - -	236
Submaxillary gland - - - - -	238
Sublingual gland - - - - -	239
Vessels and nerves of the neck - - - - -	242
External jugular vein ; operation - - - - -	243
Posterior triangular space - - - - -	244
Cervical nerves - - - - -	244
Brachial plexus of nerves - - - - -	247
Subclavian artery and branches - - - - -	248
Operation on the subclavian artery - - - - -	250
Common carotid artery - - - - -	253
Operations on the common carotid artery - - - - -	254
Operation on the arteria innominata - - - - -	255
Thoracic duct - - - - -	258
External carotid artery and branches - - - - -	258
Fifth pair of nerves - - - - -	270
Internal carotid artery - - - - -	281
Facial nerve ; deep portion - - - - -	284
Eighth pair of nerves - - - - -	285
Hypoglossal nerve - - - - -	290
Sympathetic nerve - - - - -	291

	Page
Prævertebral region - - - - -	295
Pharynx - - - - -	296
Soft palate - - - - -	300
Œsophagus - - - - -	304

CHAPTER VI.

BRAIN AND SPINAL CORD.

Membranes of the brain - - - - -	305
Vessels of the brain - - - - -	310
Cerebrum - - - - -	314
Cerebellum - - - - -	327
Base of the brain - - - - -	329
Medulla oblongata - - - - -	333
Fibres of the brain - - - - -	335
Cranial nerves - - - - -	338
Sinuses of the cranium - - - - -	345
Spinal cord - - - - -	349

CHAPTER VII.

ORGANS OF SENSE.

Nose and nasal fossæ - - - - -	357
Appendages of the eye - - - - -	364
Lachrymal apparatus - - - - -	367
Eye-ball - - - - -	369
Ear - - - - -	380
Mouth and tongue - - - - -	395
Larynx - - - - -	398
Skin - - - - -	408
Appendages of the skin - - - - -	413

CHAPTER VIII.

ABDOMEN.

Superficial anatomy - - - - -	417
Muscles of the abdomen - - - - -	420
Vessels and nerves of the parietes - - - - -	426
Spermatic cord - - - - -	431
Anatomy of hernia - - - - -	433
Cavity of the abdomen - - - - -	438

	Page
Regions and position of viscera - - -	438
Peritoneum - - -	440
Stomach - - -	446
Intestines - - -	447
Vessels and nerves of the alimentary canal - - -	455
Liver - - -	463
Gall bladder - - -	474
Pancreas - - -	475
Spleen - - -	476
Supra-renal capsules - - -	478
Kidneys - - -	479
Deep vessels and nerves of the abdomen - - -	483
Abdominal aorta - - -	483
Common and external iliac arteries - - -	487
Inferior vena cava - - -	488
Sympathetic nerve and plexuses - - -	490
Lymphatic vessels and glands - - -	492
Receptaculum chyli - - -	493
Deep muscles of the abdomen - - -	493
Diaphragm - - -	494
Lumbar nerves and plexus - - -	497

CHAPTER IX.

PELVIS AND ORGANS OF GENERATION.

Viscera of the pelvis - - -	501
Pelvic fascia - - -	502
Muscles of the cavity of the pelvis - - -	503
Rectum - - -	504
Urinary bladder - - -	505
Prostate gland - - -	509
Vesiculæ seminales - - -	510
Vessels of the pelvis - - -	511
Nerves of the pelvis - - -	516
Male organs of generation - - -	518
Penis - - -	518
Urethra - - -	521
Testes - - -	524
Female pelvis - - -	529
Female organs of generation - - -	529
Uterus - - -	530
External organs - - -	536

CHAPTER X.

ANATOMY OF THE PERINEUM.

	Page
General considerations - - - - -	539
Internal pudic artery - - - - -	547
Operation of lithotomy - - - - -	552
Female perineum - - - - -	554

CHAPTER XI.

ANATOMY OF THE FŒTUS.

Exterior anatomy of the fœtus - - - - -	556
Fœtal circulation - - - - -	557
Fœtal thymus gland - - - - -	560
Fœtal heart - - - - -	563
Viscera of the abdomen - - - - -	564
Viscera of the pelvis - - - - -	565
Fœtal testes, their descent - - - - -	566

CHAPTER XII.

LIGAMENTS.

General anatomy - - - - -	568
Ligaments of the trunk - - - - -	572
Ligaments of the upper extremity - - - - -	586
Ligaments of the lower extremity - - - - -	598

DISSECTOR'S MANUAL.

INTRODUCTION.

THE human body is composed of certain principal structures, which occupy the same relative position to each other, wheresoever they be examined. To obtain a good knowledge of these, is the first duty of the dissector; the more particularly, that a just conception of their nature and position will greatly facilitate the future progress of his studies. These parts may be thus arranged, in the order of their superposition:—

Integument.

Superficial fascia.

Deep fascia.

Muscles.

Vessels, { Arteries.
 { Veins.
 { Lymphatics.

Nerves.

Bones and ligaments,

and cellular tissue, the common connecting medium of the body, by which they are all held together.

The business of dissection, therefore, consists in dividing and turning aside the integument, the superficial fascia, and the deep fascia; in freeing the muscles from their enveloping cellular tissue; in separating them, so as to display the vessels and nerves which lie between them; and in following the latter to their ultimate ramifications.

In the same manner the performance of an operation with the aid of the knife, as, for example, the tying of an artery, requires the division of the integument, super-

ficial fascia, and deep fascia, the separation of the muscles, and the finding and securing of the vessel. So again, in amputation, the same structures are to be divided, and in precisely the same order. Thus the student will perceive that one principal object of dissection is the practice of his knife in the division and separation of these parts, so as to enable him to accomplish his end with ease and dexterity. All the operations of dissection should be conducted with the same delicacy that is observed in the treatment of the living subject. The result of such practice must be obvious—the attainment of that confidence and precision in surgical manipulations, which is so necessary to the successful surgeon.

Now, let us inquire into the nature of the structures composing the preceding table.

The **INTEGUMENT** (integere, to cover in,) is the investing covering of the entire body; in common parlance, the skin: it consists of the epiderma and derma.

The *Epiderma* (cuticle, scarfskin) is the thin, horny layer which forms the surface of the integument. It is produced by the derma, upon which it is exactly moulded; is dense and hard on the outer surface, but softer within; hence it has been described as consisting of two layers, of which the inner and deeper layer is called *rete mucosum* (*rete*, because the depressions caused by the papillæ of the derma give it the appearance of a net; *mucosum*, from its softness). In intimate structure the epiderma is composed of nucleated cells, which are thick in the part called *rete mucosum*, but flattened into thin *scales* in the outer layer. These cells are the seat of the pigment of the skin; which has a deeper hue in the thick and newly-formed cells than in the scales of the horny layer where it is pale and almost lost, from drying. The epiderma is very thick in the palms of the hands and soles of the feet, and, in a state of increased density, constitutes the nails.

The *Derma* or cutis, or true skin, also presents a superficial and a deep layer. The former constituting the surface of the derma, and, formed into numberless minute papillæ, is termed the *papillary* layer. The latter, being the chief bulk of the derma, is the *corium*. The papillary layer contains the capillaries and ultimate nervous plexuses of the skin; the corium is composed of

fibres and strands of fibrous tissue, which form meshes of extreme fineness in the superficial portion of the layer, and coarser meshes in its deeper part. The meshes of the corium are occupied by fat, and give passage to the vessels and nerves of the papillary layer.

The SUPERFICIAL FASCIA (fascia, a bandage), placed immediately beneath the tegument over every part of the body, is the medium of connection between that layer and the deeper parts. It consists of fibro-cellular tissue, in which is deposited an abundance of adipose tissue. The fat, being a bad conductor of caloric, serves to retain the warmth of the body; while it forms at the same time a yielding medium, through which the minute vessels and nerves pass to the papillary layer of the skin, without incurring the risk of obstruction from injury or pressure. By dissection, the superficial fascia may be separated into *two layers*, between which are found the superficial or cutaneous vessels and nerves; as the superficial epigastric artery, the saphenous veins, the radial and ulnar veins, the superficial lymphatic vessels, or the cutaneous nerves, and in one instance a muscle, platysma myoides.

The DEEP FASCIA is a dense and resisting layer, found chiefly in the extremities and in the neck, where large vessels are carrying onwards the circulating fluids in opposition to the laws of gravity, and where muscles are often acting with prodigious force. In other situations, as over the trunk of the body or upon the head, this layer cannot be said to exist. The deep fascia in the limbs (aponeurotic fascia) is a white fibrous membrane, formed by a close interlacement of glistening fibres, which cross each other in various directions. To the eye it presents a brilliant, nacreous lustre. It is strong and unyielding, enclosing the entire limb, and is prolonged into its substance so as to form distinct sheaths to all the muscles. Upon the inner side of the limb it is thin; on the outer and less protected side it is dense and thick. It is connected to the prominent points about the limb, as to the pelvis, knee, and ankle, in the lower extremity, and to the clavicle, scapula, elbow, and wrist, in the upper extremity. Its tension is regulated in some situations by muscular action, as by the tensor vaginæ femoris and gluteus maximus in the thigh, and by the biceps and palmaris longus in the arm. The deep fascia of the neck

(cellulo-fibrous fascia) is thinner and has none of the resplendency of that of the limbs, although composed, like the latter, of white fibrous tissue.

The **MUSCLES** (*musculus*, from *movere*, to move) are the moving organs of the body: they are made up of fibres disposed parallel to each other in a framework of cellular tissue. Towards the extremities of the muscles the fibres cease, and the cellular framework is condensed into a rounded cord, called *tendon* (*tendo*, a sinew), by which it is attached to the bones. The more fixed extremity of a muscle is called the "*origin*;" its more moveable end the "*insertion*." The muscles which enclose cavities, as the abdominal, are broad and extensive; and their tendon is flattened out into a thin expansion, which is called "*aponeurosis*" (*απο*, longé; *νευρον*, *nervus*; a nerve widely spread out). This derivation demands some explanation. The ancients named all the white fibres of the body *νευρα*, or nerves.

The **VESSELS** are of three kinds, arteries, veins, and lymphatics. *Arteries* are cylindrical tubes, composed of three layers, an *external*, formed of condensed cellular tissue, the *cellulo-fibrous* coat; a *middle*, of fibres analogous to those of organic muscle, the *contractile* coat; and a lining membrane, the *internal* or serous coat. After death they are usually found empty, but preserve their cylindrical form by reason of the thickness of their coats; hence their name (*αηρ τηρειν*, to contain air), from a supposition of the ancients that they were intended to confine the vital spirits. Their office is to convey the vital fluid to every part of the system; and their ultimate terminations are denominated, from their extreme minuteness, *capillaries* (*capillus*, hair).

The *veins* are found in company with the arteries; with the exception of the superficial veins. They return the blood from the capillary vessels of the arteries to the right side of the heart, to be then circulated through the lungs. They are larger than the arteries, and after death are found filled with dark-coloured blood. The coats are the same as those of the arteries, but much thinner; and the internal coat is reflected inwards at various points, so as to form valves. The position of these valves is evidently marked on the exterior of the tube, by the swellings on that part of the vessel which immediately precedes them.

The *lymphatics* (lymp^ha, water) are small, delicate vessels which accompany the veins, and present many points of resemblance with them. They return a limpid fluid to the venous circulation, and are provided with a number of valves placed at short distances, which, with the corresponding swellings, give them a knotted appearance. Their coats are the same as those of veins and arteries. Near the flexures of the joints they enter small red bodies, called *glands*, from which they emerge fewer in number, and larger in size. They are too minute to be seen in an ordinary dissection, unless the subject be anasarcaous.

The NERVES (*νευρα*, nerves) are white flattened cords, composed of fibres, which are connected by one extremity with the cerebro-spinal axis; and, by the other, are distributed to all the textures of the body, communicating to them sensibility and power of motion. The smallest nerve is made up of a number of tubular fibres, enclosed in a peculiar transparent sheath, called *neurilemma*; which, when freshly exposed, presents a continuous zigzag line along its cylinder. The nerves are usually found accompanying the arteries, and, in the extremities, are placed nearer the integument than those vessels, as if to be ready to apprise the neighbouring muscles of the first approach of injury, that they may withdraw the more immediately important organs, the arteries, from its consequences.

The BONES are the organs of support to the animal frame. They give firmness and strength to the entire fabric, afford points of connection to the numerous muscles, and bestow general form upon the body. In the limbs they are hollow cylinders, calculated by their form and structure to support weight, and resist violence. In the trunk and head, they are flattened and arched, to protect cavities and provide extensive surfaces of attachment. In many situations they present projections of considerable length that serve as levers; and smooth surfaces that possess all the mechanical advantages of the pulley. While strength and solidity are the principal objects sought for in the shaft of the bone, the extremities are expanded into broad surfaces, that they may transmit the weight of the body with perfect security to the bones below.

In the formation of a joint a new organ is introduced, the *ligament* (ligare, to bind). It consists of short strata of fibres passing from bone to bone, in order to connect them together. The different varieties of joint demand a different arrangement of these ligaments. Thus the *hinge joint*, as the elbow, wrist, knee, ankle, moving in one direction only, has necessarily a squareness of form, and is provided with a ligament to each of its four sides. These are named from their position, anterior, posterior, and lateral. A great proportion of the joints of the body are constructed upon this simple principle. When more extensive movements are demanded, the ball and socket joint is provided, and to accommodate its circular form, the four ligaments are, as it were, united into one, which completely surrounds the ends of the two bones. Hence the capsular ligaments of the hip, the shoulder, and the thumb. And when repose and solidity are the great objects, as in the vertebral column, the pelvis, the carpus, and tarsus, small slips of ligaments are seen passing from bone to bone in every direction in which these straight bands can be arranged, without inconvenience to the general plan.

These then are the structures of which, with the exception of the viscera, the whole animal frame is composed; and it is incumbent upon the student of anatomy to possess a clear and distinct idea of all these parts, their uses, and natural dependencies, before he can hope to display and examine them in the body with advantage.

CHAPTER I.

THE LOWER EXTREMITY.

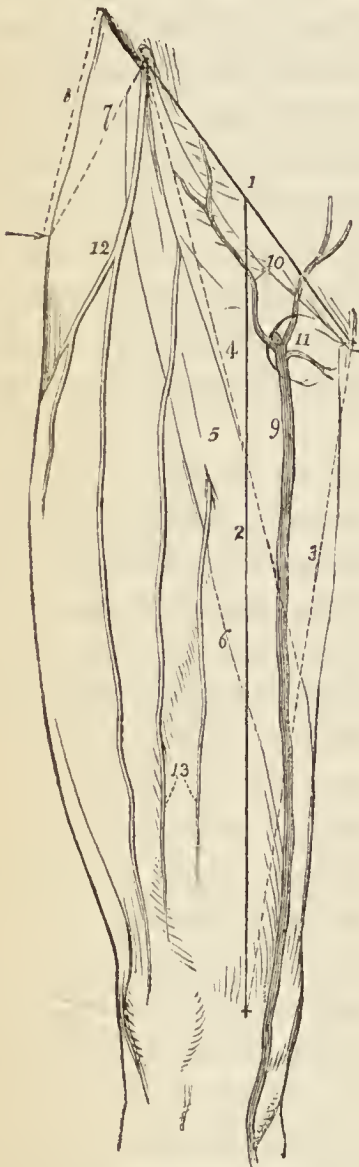BEFORE commencing the dissection of the lower extremity, the student will carefully reflect upon the objects of his proposed dissection, and particularly upon the practical application of the information which he is seeking to acquire. The *lower extremity* comprises all that portion of the body which forms the lower limb, and is bounded above by the external surface of the pelvis. It consists of a thigh, leg, and foot; of the hip, knee, ankle, tarsal, metatarsal, and digital joints; of a complicated apparatus of muscles; of the femoral, popliteal, tibial, pedal, and plantar arteries; of veins, lymphatics, nerves, bones, and ligaments.

Now all these structures are liable to injury; and the surgeon, upon such an occurrence, is called upon to remedy the accident, to apply the knowledge that he shall have gained, through the aid of his eyes and hands, in the dissecting room. Suppose the accident be one involving deep and important parts without affecting the surface, or exposing to the eyes the structure which may be injured: in such a case the surgeon has recourse to the comparative form and position of the adjoining limb; but circumstances may render this comparison unavailing; and he is then obliged to recall the observations he may chance to have made during his anatomical studies. Depend upon it, that a sound knowledge of the relations of the different portions of the limbs will ever be found of the highest possible value to the man who is suddenly called to the aid of a wounded fellow-creature. Indeed such a knowledge should be considered as the leading characteristic of the accomplished surgeon.

Starting with reflections such as these, the student will perceive that other observations are necessary to him in addition to those which arise out of the mere dissection

of the component parts of the limb which he is about to study. The thigh may be dislocated at the hip, or at the knee; the muscles, or their tendons, may be ruptured; the arteries may be wounded or diseased, requiring that incisions of considerable extent or depth should be made in their course, and a ligature placed around them; or nerves may be ganglionated, and demand removal; lastly, the whole limb may be disorganised, and call for amputation. In each and every of these circumstances, relief is simply and effectually bestowed, if the operator be well acquainted with the situation and dissection of the various structures implicated in the

Fig. 1.*



accident or disease; and these are to be learnt only in the dissecting room by careful observation and manipulation.

Having the lower extremity extended on the table before him, and the leg everted, let the student carry a line (*fig. 1. 1.*) from the extreme point of the anterior superior spinous process of the ilium to the symphysis pubis, and then another, 2., from the middle of the preceding to that projection upon the inner condyle of the femur, which gives attachment to the internal lateral ligament of the knee-joint; this will mark the course of the femoral artery. If the leg be perfectly straight, without inversion or eversion, the line must be carried to the apex of the patella. Again, if a line, 3., be drawn from the spinous process of the pubis along the

* *Fig. 1.* The thigh turned upon its outer side as in dissecting it.

No. 1. A line drawn from the anterior superior spine of the ilium to the spine of the pubes; these two points are represented by crosses. The curved line below line 1 is Poupart's ligament. 2. A second line extended from the middle of the preceding to the tubercle on

inner border of the thigh to the projection on the internal condyle, a second line, 4., drawn from the anterior superior spinous process of the ilium, and crossing the former at the middle of the thigh, will mark the direction of the upper margin of the sartorius muscle, and enclose a triangular space (Scarpa's), which is bounded above by Poupart's ligament. Within this triangle, which corresponds with the axillary space in the upper limb, the position of the femoral artery may be distinguished by a groove, and may be laid bare and secured, in any part of the line 2, which marks its course; the usual situation for ligature of the femoral artery (Scarpa's operation), in popliteal aneurism, being at the point where the upper margin of the sartorius crosses its course, the border of this muscle forming the natural guide for the direction of the incision. At the pubic angle of this triangular space, is situated the saphenous opening, 11., through which the sac of femoral hernia is protruded. In rare cases, the femoral artery is tied below the lower border of the sartorius muscle (Hunter's operation); under such circumstances, a space, varying from one inch to one inch and a half, and parallel to the oblique line, should be allowed for the breadth of the sartorius, and the incision commenced immediately below this border, 6., still following the original line of its course.

Besides these, there is another point of importance to

the inner condyle of the femur. This line marks the direction of the femoral artery. 3. A third line, drawn from the spine of the pubes to the tubercle on the inner condyle of the femur. 4. A fourth line drawn from the spine of the ilium to the middle of line 3.; this line marks the upper border of the sartorius muscle, and is the direction for the incision in securing the artery in the upper third of its course. The triangular hollow space, bounded by the curved line of Poupart's ligament above, and lines 3, 4, at the sides, is the triangular space of Scarpa, in the hollow of which are situated the femoral vessels. 5. The outline of the sartorius muscle. 6. The direction of the incision in operating upon the femoral artery, below the sartorius muscle. 7. A line drawn from the trochanter major to the spine of the ilium. 8. Another line drawn from the trochanter major to the crest of the ilium. 9. The internal saphenous vein. 10. The superficial epigastric and superficial circumflexa ilii veins, converging to open into it previously to its entrance into the saphenous opening. 11. The saphenous opening in the fascia lata. 12. The external cutaneous nerve. 13. The middle cutaneous nerves, branches of the anterior crural.

the surgeon, in the consideration of the proper projections on the surface of the limb, viz., the apophysis named trochanter major. For it is this prominence that marks the altered position of the limb in dislocations or diseases of the hip-joint, or fractures about the neck of the femur. It is a point little liable to variation from strength or muscularity of the limb; but is necessarily more prominent and more sharply defined in an emaciated person. A line, 8., drawn from the upper point of the trochanter major to the most convex part of the crest of the ilium, and another, 7., extended from the same point to the anterior superior spinous process, may be compared with the same admeasurements on the opposite limb.

An important measurement of the thigh, for the detection of dislocation, is obtained by extending a line from the anterior superior spinous process of the ilium to the apex of the patella, and comparing its length with that on the opposite limb. If shortening be found to exist, whilst the distance, 8., between the trochanter major and the crest of the ilium is the same on both sides of the body, then the cause of the diminution of length must exist in the bone, and be the result of fracture. This may be determined by another measurement, made between the apex of the trochanter major and the lower point of the patella.

Let it not be said that these directions are too obvious to deserve attention: they must be followed carefully; and before the student commences his dissection, he should have himself made and repeated the observations here advised; have impressed well upon his memory the relative position of each landmark; and have cut down upon the artery at various points. By such means he will gain confidence in his knowledge and precision in the performance of surgical operations. Again, in displacement of the ends of the bone from fracture of the femur, it is of the greatest importance to their proper adjustment, that he be well acquainted with the position of the patella in relation to the spines of the ilium and pubes.

The lower extremity is divided anatomically into several distinct compartments or regions, the separate and relative study of which serves materially to facilitate the student's apprehension of the whole. The regions of the thigh are, the anterior femoral, internal femoral, gluteal,

posterior femoral, and popliteal; of the leg, the anterior tibial, fibular, sural or superficial posterior tibial, and deep posterior tibial; of the foot, the dorsal and plantar regions.

ANTERIOR FEMORAL REGION.

The dissection of the anterior femoral region is best commenced by making an incision (*fig. 1. 1.*) from the anterior superior spinous process of the ilium along the line of Poupart's ligament to the spinous process of the pubis, then carrying a second, 2. along the course of the femoral artery to the inner condyle of the femur, and bounding it inferiorly by a third, carried transversely across the head of the tibia. It may be convenient to make a fourth incision across the middle of the thigh so as to diminish the extent of surface opened at once, and enable the student to concentrate his attention in the first instance upon the most important part of the front of the thigh, namely, the triangular hollow space which contains the femoral vessels and the saphenous opening. The student then nips up the integument with his forceps at the upper angle, and dissects back that layer so as to expose the superficial fascia beneath, and form a flap upon the outer side of the limb. He then turns to the opposite side, and repeats the same proceeding.

But the student who handles a scalpel for the first time, will not find its application so easy as this description would lead him to infer. If he examine the edge of his blade attentively with a lens, he will perceive that it is actually a microscopic saw. Now a saw divides by being drawn across the material to be cut; and no direct force applied to the saw, would carry it through the substance without this motion. Let him apply this reasoning to his scalpel, it must be handled lightly, and drawn without pressure across the textures to be divided: if he use force and pressure, the best edge would be useless in his hands. The art of dissecting with neatness and operating with dexterity, owes much to the good understanding existing between the knife and the hand; and the best operators have ever been the best dissectors.

If the student have reflected the integument *well*, he will have exposed the superficial fascia, which may be known by its soft yellow surface, studded with lobules of fat, surrounded by the white areolæ of cellular tissue in which they are contained. The under surface of the integument, the corium of the skin, will appear quite white, and present a number of depressions, corresponding with the fatty depositions in the superficial fascia.

The SUPERFICIAL FASCIA is composed of two layers, between which are situated the cutaneous vessels and nerves. To examine these an incision should be made by the side of the saphenous vein, and the superficial

layer dissected outwards and upwards towards Poupart's ligament, over which it may be traced into the subcutaneous covering of the abdomen. This dissection is comparatively easy in the groin, from the number of superficial vessels, nerves, and lymphatics which are found in that region, but lower down the thigh, the separation of the layers is impracticable. The deep layer is interposed between the superficial vessels and the fascia lata, and closes the saphenous opening; the perforation of the latter portion of the superficial fascia by numerous lymphatic vessels has gained for it the appellation of *cribriform fascia*.

The parts to be examined in the superficial fascia are, the inguinal glands, the three small arteries, superficial circumflexa ilii, superficial epigastric and superior external pudic, the internal saphenous vein and its tributaries, the crural portions of the ilio-inguinal and genito-crural nerves, the external, middle, and internal cutaneous nerves, and in the lower part of the thigh the superficial branch of the anastomotica magna artery, the internal saphenous nerve, and the extensive nervous interlacement situated around the front of the knee, the plexus patellæ.

The *inguinal glands* are situated along the line of Poupart's ligament, and near the termination of the saphenous vein; the former receive the lymphatic vessels from the abdomen and genital organs; the latter, of larger size, receive the lymphatics of the lower limb.

The three small *arteries*, the *superficial circumflexa ilii*, the *superficial epigastric*, and the *superior external pudic*, are the first branches of the femoral artery. They pierce the deep fascia immediately beneath Poupart's ligament, and are distributed to the skin, superficial fascia, and inguinal glands: the circumflexa ilii taking its course along Poupart's ligament towards the crest of the ilium; the epigastric ascending upon the abdomen towards the umbilicus; and the pudic passing inwards to the scrotum, or labia pudendi.

The *internal saphenous vein*, *fig. 1. 9.*, (*σαφήνης*, perspicuous, obvious) of considerable size, sometimes consisting of two parallel trunks, receives its current of blood from the superficial veins of the inner side of the foot, leg, and thigh, along which it runs, and terminates in the

femoral vein near the pubic extremity of Poupart's ligament, by passing through an aperture in the deep fascia, named, from its office, *saphenous opening*, 11. Just as the vein curves inwards to enter this opening, it receives a number of small veins, 10., which converge from the abdomen, hip, and genital organs. These vessels play a conspicuous part in femoral hernia, and, therefore, must not be passed over without remark. The saphenous vein is accompanied by superficial lymphatic vessels throughout the whole of its course.

The *cutaneous nerves* will be found: the ilio-inguinal to the inner side of the saphenous opening; the genito-crural just externally to the saphenous opening; the two branches of the middle cutaneous nerve in the middle of the front of the thigh; the internal cutaneous, its three branches, in the line of the internal saphenous vein; and the external cutaneous along the outer border of the thigh.

The *crural* portion of the *ilio-inguinal nerve* is the continuation of that nerve, after it has escaped with the spermatic cord from the external abdominal ring. It terminates in the integument of the upper part of the thigh, internally to the saphenous opening, after having supplied the scrotum. The ilio-inguinal nerve proceeds from the first lumbar nerve.

The *crural* branch of the *genito-crural nerve* pierces the fascia lata a little below Poupart's ligament, and just externally to the femoral artery from the sheath of which it escapes. It is distributed to the integument as far as the middle of thigh, and communicates with the middle cutaneous nerve. The genito-crural nerve proceeds from the second lumbar nerve.

The *middle cutaneous nerve* is a branch of the anterior crural; it pierces the fascia lata about three inches below Poupart's ligament, and divides into two branches, which are distributed to the integument of the front of the thigh as far as the knee. One or both of these branches sometimes pierce the sartorius muscle.

The *internal cutaneous nerve*, also a branch of the the anterior crural, passes inwards in front of the sheath of the femoral artery, and after giving off three cutaneous filaments, which pierce the fascia lata and follow the course of the internal saphenous vein, divides into an

anterior and an inner branch. The *anterior* branch pierces the fascia lata at the lower third of the thigh, near the internal saphenous vein, which it follows to the inner side of the knee and divides into two terminal twigs. The *inner* branch pierces the fascia lata on the inner side of the knee, and is distributed to the integument along the inner side of the leg.

The *external cutaneous nerve*, *fig. 1. 12.* is derived from the second lumbar nerve, and pierces the fascia lata about two inches below the anterior superior spine of the ilium, where it divides into two branches, one of which (*posterior*) crosses the tensor vaginæ femoris muscle to the outer and posterior side of the thigh, and is distributed to the integument in that region; the *anterior* branch, after passing downwards for several inches in a sheath of the fascia lata, divides into two twigs, which are distributed to the integument of the outer border of the thigh, and to the knee joint.

The *long saphenous nerve* pierces the deep fascia and becomes superficial at the side of the knee, it is accompanied by the superficial branch of the anastomotica magna artery.

The *cutaneus patellæ*, a branch of the long saphenous, becomes superficial a little higher than the parent trunk, and assists in the formation of the *plexus patellæ* by means of its communications with the other cutaneous nerves of the knee.

When these structures have been well examined, the deep layer of superficial fascia may be removed, in order to bring into view the deep fascia.

The DEEP FASCIA of the thigh, from being the most extensive in the body, is named *fascia lata*. It is an extremely dense membrane, consisting of glistening tendinous fibres, disposed longitudinally and circularly around the limb; is thickest on the outer side of the thigh, and thinner on its inner side. The fascia lata envelopes the whole of the muscles of the thigh, and sends processes inwards, which form distinct sheaths for each. It is attached *above* to the prominent points about the pelvis, viz., to the pubes, Poupart's ligament, crest of the ilium, sacrum, and ischium; *below*, to the heads of the tibia and fibula; and *behind*, to the linea aspera. Besides these, it has two muscular attachments, one by means of the

tensor vaginæ femoris; the other, through the gluteus maximus. It is perforated at several points for the passage of the cutaneous nerves, and near the pubes is the saphenous opening.

The existence of this opening, *fig. 1. 11.*, causes the division of the upper part of the fascia lata into two portions, an iliac portion situated towards the ilium, and a pubic portion towards the pubes. The *iliac portion* is attached along Poupart's ligament, as far as the spine of the pubes; from this point it is reflected downwards, in a curved direction, forming a sharp edge, called the *falciform process*. The edge of the falciform process immediately overlays and is reflected upon the sheath of the femoral vessels; and the lower extremity of the curve is continuous with the pubic portion. The *pubic portion* is also attached to the spine of the pubes, and along the pectineal line, as far as the inner border of the psoas muscle: here it divides into two layers, which embrace that muscle and the iliacus, and are then lost in the fascial coverings surrounding the muscles on the outer side of the thigh.

From this description, it will be obvious that the *iliac portion*, being attached to Poupart's ligament, must be on a plane considerably anterior to the *pubic portion* which is attached to the bone; and it is between the two that the femoral vessels are placed, enclosed in their sheath. It follows also from this disposition that the saphenous opening is oblique in its direction with regard to these two layers of fascia. It is, moreover, closed by some dense bands of cellular tissue, which are perforated by a number of minute openings for the transmission of the superficial lymphatic vessels of the lower extremity, and are hence named *cribriform fascia* (cribrum, a sieve.) This cribriform fascia would be altogether unworthy the notice of the dissector, were it not for the arbitrary importance attached to every fibre of membrane or process of fascia that may possess the slightest relation to the protrusion of intestine from the cavity of the abdomen. For this reason it is that the saphenous opening is so urgently recommended to the student's attention; and the cribriform fascia, from its position, must necessarily form one of the coverings of the femoral hernia.

The student may now remove the fascia lata, by dissecting it from its loose cellular attachment to the muscles,

following always the course of their fibres. If the student would dissect well, he must treasure this rule as a golden maxim,—“*muscles must always be dissected in the course of their fibres.*” And, let us remind him again (for we cannot too strenuously insist upon the application of the principles of dissection to the operations of surgery) that, in the living body, the same rule must be rigidly adhered to, if a successful issue be desired.

Muscles of the Anterior Femoral Region.

The muscles of the anterior femoral region are arranged in two groups, an *anterior group*, consisting of six muscles; and an *internal group* of seven: as follows—

<i>Anterior group.</i>	<i>Internal group.</i>
Tensor vaginæ femoris.	Iliacus internus.
Sartorius.	Psoas magnus.
Rectus.	Pectineus.
Vastus internus.	Adductor longus.
Vastus externus.	Adductor brevis.
Crureus.	Adductor magnus.
	Gracilis.

As soon as these two tables are got by heart, the student may commence the dissection of the muscles which they represent.

The TENSOR VAGINÆ FEMORIS (stretcher of the sheath of the thigh) is a short flat muscle, situated on the outer side of the hip. It *arises* from the crest of the ilium, near its anterior superior spinous process, and is *inserted* between two layers of the fascia lata at about one fourth down the thigh.

The SARTORIUS (tailor's muscle) is a long riband-like muscle, *arising* from the anterior superior spinous process of the ilium and from the notch immediately below that process; it crosses obliquely the upper third of the thigh, descends behind the inner condyle of the femur, and is *inserted* by an aponeurotic expansion into the inner tuberosity of the tibia. This expansion covers in the insertion of the tendons of the gracilis and semitendinosus muscles. The inner border of the sartorius muscle is the guide to the operation for tying the femoral artery in the middle of its course; and the outer boundary of Scarpa's triangular space.

The RECTUS (straight) muscle is fusiform in its shape and bipenniform in the disposition of its fibres: it *arises* by two round tendons; one from the anterior inferior spinous process of the ilium, the other from the upper lip of the acetabulum. It is *inserted* by a broad and strong tendon into the upper border of the patella. It is more correct to consider the patella as a sesamoid bone, developed within the tendon of the rectus; and the ligamentum patellæ as the continuation of the tendon to its insertion into the tubercle of the tibia.

The rectus must now be divided through its middle, and the two ends turned aside, to bring clearly into view the next muscles.

The three next muscles are generally considered collectively under the name of triceps extensor cruris. Adopting this view, the muscle surrounds the whole of the femur, except the rough line (linea aspera) upon its posterior aspect. Its division into three parts is not well defined; the fleshy mass upon each side being distinguished by the names of vastus internus and externus, the middle portion by that of crureus.

The VASTUS EXTERNUS, narrow below and broad above, *arises* from the base of the trochanter major, the outer surface of the femur and outer lip of the linea aspera and from the intermuscular fascia; and passes down to be *inserted* into the outer border of the patella; or rather, by means of the ligamentum patellæ, into the tubercle of the tibia, conjointly with the rectus and two following muscles.

The VASTUS INTERNUS, broad below and narrow above, *arises* from the anterior intertrochanteric line, inner surface of the femur, inner lip of the linea aspera, and intermuscular fascia, and is *inserted* into the inner border of the patella. By its mesial border it is blended with the crureus.

The CRUREUS (crus, the leg) *arises* from the anterior intertrochanteric line and anterior surface of the femur to within two inches of the patella. It is continuous by its inner border with the vastus internus, and is *inserted* into the upper border of the patella; its tendon occupying its cutaneous aspect.

When the crureus is divided from its insertion, a small muscular fasciculus is often seen upon the lower part of the femur; this fasciculus is *inserted* into the pouch of

synovial membrane that extends upwards from the knee-joint behind the patella, and is named, from its situation, *sub-crureus*. It would seem to be intended to support the synovial membrane.

ACTIONS.—The tensor vaginæ femoris renders the fascia lata tense, and slightly inverts the limb. The sartorius flexes the leg upon the thigh, and, continuing to act, the thigh upon the pelvis, at the same time carrying the leg across that of the opposite side, into the position in which tailors sit; hence its name. Taking its fixed point from below, it assists the extensor muscles in steadying the leg for the support of the trunk. The other four muscles have been collectively named *quadriceps extensor*, from their similarity of action. They extend the leg upon the thigh, and obtain a great increase of power by their attachment to the patella, which acts as a fulcrum. Taking their fixed point from the tibia, they steady the femur upon the leg; and the rectus, by being attached to the pelvis, serves to balance the trunk upon the lower extremity.

Internal Femoral Region.

The origins of the iliacus and psoas muscles being situated within the abdomen, the entire muscles cannot be seen in this dissection; but as a part of them quits that cavity to be inserted into the femur, that portion necessarily belongs to the anatomy of the thigh.

The **ILIACUS INTERNUS** is a flat, radiated muscle: it *arises* from the inner concave surface of the ilium, and, after joining with the tendon of the psoas, is *inserted* into the trochanter minor of the femur. A few fibres of this muscle proceed from the sacrum, and others from the capsular ligament of the hip-joint.

The **PSOAS MAGNUS** (*ψοα*, lumbus, a loin,) situated by the side of the vertebral column in the loins, is a long fusiform muscle. It *arises* from the bodies and bases of the transverse processes of the last dorsal and all the lumbar vertebræ. It also takes its origin from the intervertebral substances and from a series of tendinous arches attached to the vertebræ, and intended for the protection of the lumbar vessels and branches of the sympathetic nerve, in their passage between the muscle and the bone. The tendon of the psoas magnus unites with that of the iliacus, and the conjoined tendon is *inserted* into the posterior part of the trochanter minor.

Two synovial bursæ are found in relation with the last two muscles: the first, of considerable size, is situated between their under surface and the capsule of the hip-joint;

the other, much smaller, is interposed between the conjoined tendon and the anterior part of the trochanter minor.

The PECTINEUS is a flat and quadrangular muscle; it *arises* from the pectineal line (pecten, a crest) of the os pubis, and from the surface of bone in front of that line; and is *inserted* into the line leading from the anterior intertrochanteric line to the linea aspera of the femur.

The ADDUCTOR LONGUS (adducere, to draw to), the most superficial of the three adductors, *arises* by a round and thick tendon from the front surface of the os pubis, immediately below the angle of that bone; and, assuming a flattened and expanded form as it descends, is *inserted* into the middle third of the linea aspera.

The pectineus and adductor longus form the inner boundary of the triangular space of Scarpa, in which the femoral vessels and nerves are lodged. They must be divided, the pectineus near its origin and turned outwards, and the adductor longus through its middle, turning its ends to either side, to bring into view the adductor brevis.

The ADDUCTOR BREVIS, placed behind the pectineus and adductor longus, is fleshy, and thicker than the adductor longus: it *arises* from the body of the os pubis, and is *inserted* into the line leading from the trochanter minor to the linea aspera. It is pierced by the middle perforating artery, and supports the anterior branch of the obturator nerve and artery.

The adductor brevis may now be divided from its origin and turned outwards, or its inner two thirds may be cut away entirely, after separating the anterior branch of the obturator artery and nerve from its surface. This exposes the entire extent of the adductor magnus, and a fleshy mass of muscle which covers in the obturator foramen, the obturator externus.

The OBTURATOR EXTERNUS muscle (obturare, to stop up) *arises* from the obturator membrane, and from the surface of bone immediately surrounding it anteriorly, viz. from the ramus of the os pubis and ischium: its tendon passes behind the neck of the femur, to be *inserted* with the external rotator muscles, into the trochanteric fossa of the femur.

Although this muscle belongs properly to another group (glutæal region), it has been deemed consistent with the object of this work to describe every organ which may come beneath the observation of

the student in the progress of his dissection, in the situation which it actually occupies.

The ADDUCTOR MAGNUS is a broad triangular muscle, forming a septum of division between the muscles situated on the anterior and those on the posterior aspect of the thigh. It *arises* by fleshy fibres from the ramus of the os pubis and ischium and from the side of the tuber ischii; and radiating in its passage outwards, is *inserted* into the whole length of the linea aspera, and inner condyle of the femur. The adductor magnus is pierced by five openings: the three superior, for the three perforating arteries; and the fourth, for the termination of the profunda. The fifth is the large oval opening, in the tendinous portion of the muscle, that gives passage to the femoral vessels.

The GRACILIS (slender) is situated along the inner border of the thigh: it *arises* by a broad, but very thin, tendon, from the body of the os pubis along the edge of the symphysis, and from the margin of the ramus of the pubes and ischium; and is *inserted* by a rounded tendon into the inner tuberosity of the tibia, beneath the expansion of the sartorius.

ACTIONS. — The illacus, psoas, pectineus, and adductor longus muscles bend the thigh upon the pelvis, and, at the same time, from the obliquity of their insertion into the lesser trochanter and linea aspera, rotate the entire limb outwards: the pectineus and adductors adduct the thigh powerfully; and, from the manner of their insertion into the linea aspera, they assist in rotating the limb outwards: the gracilis is likewise an adductor of the thigh, but contributes also to the flexion of the leg, by its attachment to the inner tuberosity of the tibia.

VESSELS OF THE THIGH.

The *arteries* of the anterior aspect of the thigh are next to be examined: they are best dissected by following the branches through their ramifications from the main trunk. The scalpel may be carried along the side of their cylinder without danger of dividing their coats; but if it be turned in the opposite direction, they must inevitably be cut across. They are easily separated from the cellular tissue and adipose substance, and from the smaller veins which surround them. All the veins, excepting the main trunks, had better be removed at once, otherwise their intricacy and bleeding will greatly interfere with the student's progress, and confuse his dissection.

FEMORAL ARTERY.

The arteries situated on the anterior aspect of the thigh are the femoral and its branches: the latter are as follows:—

Superficial circumflexa ilii.
 ————— epigastric.
 Superior external pudic.
 Inferior external pudic.
 Profunda { External circumflex.
 { Internal circumflex.
 { Three perforating.
 Muscular.
 Anastomotica magna.

The femoral artery and vein are inclosed in a sheath, the *femoral sheath*, which is broad and funnel-shaped at Poupart's ligament, but narrows to the size of the vessels two inches below that point. The infundibular portion of the sheath is aponeurotic in structure, and is continuous with the transversalis and iliac fasciæ; but lower down, where it closely invests the vessels, it consists of condensed cellular tissue. In the infundibuliform portion of the sheath, the artery and vein lie side by side, separated by a septum; and to the inner side of the vein, also separated by a septum, is a space occupied by a lymphatic gland and some loose cellular tissue; the *femoral* or *crural canal*. Above, the femoral canal opens into the abdomen by an aperture which is termed the *femoral* or *crural ring*; below, it is lost in the contraction of the sheath.

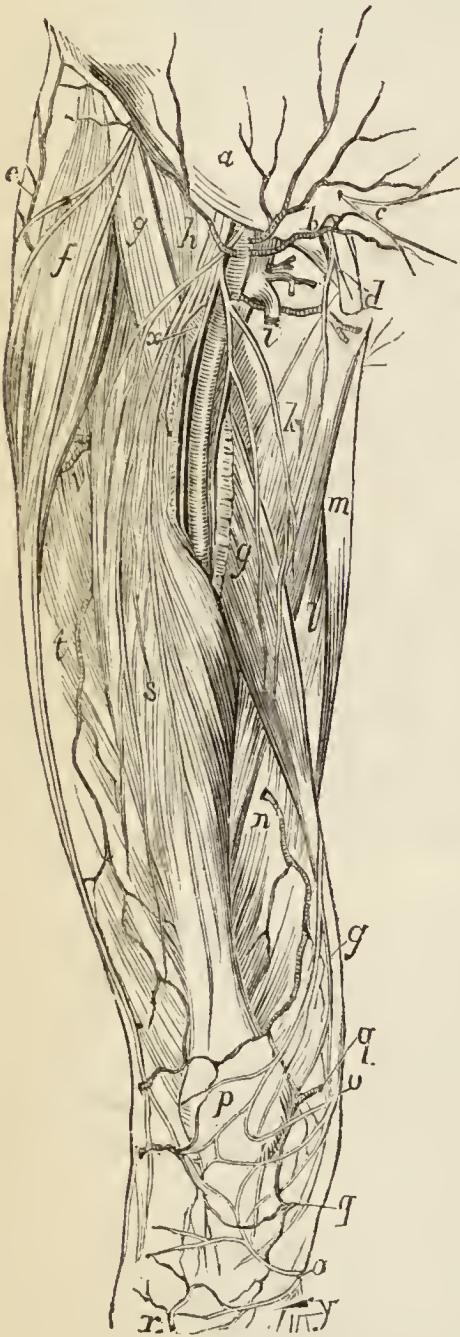
Below the infundibular portion of the femoral sheath, two nerves, the *long saphenous* and *muscular branch* to the vastus internus, both branches of the anterior crural, are found in relation with the vessels. Above, they lie to the outer side; but lower down, the long saphenous passes in front of the artery and enters the aponeurotic sheath which encloses the vessels.

These nerves are to be borne in mind in the operation for tying the femoral artery in the upper third of the thigh (Scarpa's operation). In this operation the incision (about three inches in length) is made along the upper and inner edge of the sartorius muscle, and crosses obliquely the direction of the vessels. The *integument* is first divided, then the *superficial fascia*; next the *deep fascia*, or fascia

lata; the edge of the sartorius muscle is then to be drawn aside and the sheath of the vessels exposed; the operator opens the sheath with care, to avoid injuring the two nerves just referred to, and the needle is placed around the artery, taking care to separate it as little as possible from its connections. In making the first incision the saphenous vein must be remembered, lest it be divided, and the point of the artery selected for the application of the ligature should be between four and five inches below Poupart's ligament. The femoral vein is here altogether behind the artery.

In the operation below the sartorius (Hunter's operation) the incision, three inches in length, is made along the lower and outer border of the sartorius, in the groove between that muscle and the vastus internus. The parts cut through are the same as in Scarpa's operation; the sartorius must be drawn upwards and inwards; and the artery secured where it lies under cover of the aponeurotic fascia stretched across it between the adductor longus and magnus on the one side, and the vastus internus on the other.

Fig. 2.*



The FEMORAL ARTERY runs down the inner side of the thigh, from Poupart's ligament, at a point exactly midway between the anterior superior spinous process of the ilium and symphysis pubis, to the hole in the adductor magnus, at the junction of the middle with the inferior third of the thigh, where it becomes the popliteal artery. The femoral vein is at first to the inner side, and upon the same plane with the artery, but lower down; the vein becomes placed behind and rather to the outer side of the artery, and retains that relation throughout the rest of its course.

* Vessels and nerves of the front of the thigh. — *a*. Aponeurosis of the external oblique muscle. The small artery to the outer side

Relations. — The upper third of the femoral artery is superficial, being covered only by the integument, superficial fascia, fascia lata, and some lymphatic glands. The lower two thirds are covered by the sartorius muscle. To its *outer* side the artery rests against the psoas and vastus internus, and is separated from the anterior crural nerve by the breadth of the former muscle. *Behind*, it has the psoas muscle which intervenes between it and the hip-joint; it is next separated from the pectineus by the femoral vein, profunda vein and artery, and then lies on the adductor longus to its termination. While beneath

of the letter is the superficial circumflexa ilii; that, to its inner side (between *a* and *b*) is the superficial epigastric; and the artery immediately under *b* is the superior external pudic. *b* marks the external abdominal ring. *c*. The ilio-hypogastric nerve. *d*. The spermatic cord issuing from the external abdominal ring; the nerve lying on the cord and descending to the thigh is the ilio-inguinal; the artery immediately below the spermatic cord is the inferior external pudic. *e*. The gluteus medius muscle, the artery ascending upon the anterior border of this muscle, is a branch of the external circumflex. *f*. The tensor vaginæ femoris muscle; the large nerve lying on this muscle is the external cutaneous. *g, g*. The sartorius; this muscle is cut through and a portion removed over the femoral vessels; the three nerves crossing the sartorius muscle above the section, are the genito-crural and two middle cutaneous nerves; the two small nerves crossing it below the section are the branches of the internal cutaneous, which take the course of the long saphenous vein. *h*. The iliacus muscle. *i*. The pectineus. The nerves and vessels situated between *h* and *i* are the anterior crural nerve, femoral artery, and femoral vein. The divided venous trunk directly above *i* is the long saphenous vein and the smaller veins above it, the superficial epigastric and external pudic. *h*. The adductor longus. *l*. The adductor magnus. *m*. The gracilis. *n*. The vastus internus; the artery piercing this muscle and descending to the knee joint is a branch of the anastomotica magna; the nerve crossing the muscle is the anterior branch of the internal cutaneous. *o, o*. Branches of the long saphenous nerve to the knee joint, where they form the patellar plexus. *p*. The patella. *q, q*. The internal articular arteries. *r*. The recurrent tibial artery. *s*. The rectus muscle; the two nerves between which the letter is placed are the middle cutaneous. *t*. The vastus externus muscle; the artery crossing this muscle in its course to the knee is the descending branch of the external circumflex. *v*. The external circumflex artery. *x*. The profunda artery; the nerve crossing it and lying to the outer side of the femoral artery is the long saphenous; this nerve conceals the femoral vein. The nerve crossing the femoral artery and then running along its inner side is the internal cutaneous nerve. *y*. The long saphenous nerve below the knee.

the sartorius muscle it is placed in an aponeurotic sheath, or canal formed by tendinous fibres extended like a bridge from the adductor longus and magnus to the vastus internus; this is the aponeurotic sheath through which the long saphenous nerve takes its course.

Branches.—The superficial circumflexa ilii, superficial epigastric, superior external pudic, and inferior external pudic, are four small arteries given off from the femoral, immediately below Poupart's ligament.

The *superficial circumflexa ilii* passes outwards beneath the fascia lata, and piercing that structure near the anterior superior spine of the ilium becomes cutaneous and is distributed to the integument. In its course it sends off several twigs which pierce the fascia to reach the inguinal glands.

The *superficial epigastric*, after piercing the fascia lata, ascends towards the umbilicus and inosculates with branches of the deep epigastric.

The *superior external pudic* artery passes inwards across the spermatic cord, and is distributed to the penis and scrotum in the male, and labia in the female. It inosculates with the internal pudic artery.

The two latter arteries are important in their connection with hernial tumours occurring in this region: I have seen both of them crossing an inguinal, and the latter ramifying upon a femoral hernia. In the operation they are liable to division; but, from their small size, would cause very little inconvenience.

The *inferior external pudic* is given off from the femoral a little below and sometimes in common with the superior external pudic; it crosses the femoral vein immediately below the termination of the internal saphenous vein and resting on the pectineus reaches the inner border of the thigh; it then pierces the fascia lata and is distributed to the integument of the external organs of generation and perineum, communicating with branches of the internal pudic.

The PROFUNDA FEMORIS artery is given off from the outer side of the femoral, about one inch and a half below Poupart's ligament. From its large size, it may be considered as a division of the femoral rather than a branch: and, in this view, the short trunk has been called the common femoral (*femoralis communis*), and its two divisions, *femoralis superficialis* and *femoralis profunda*; the

superficial femoral being intended for the supply of the knee and leg, while the profunda is distributed to the thigh. The profunda artery is best examined by drawing aside or removing the superficial femoral, and dissecting away the femoral and profunda veins, that conceal the artery from view. The adductor longus would also be dissected from its insertion with advantage.

The *Course* of the profunda artery is downwards and backwards, and a little outwards, behind the adductor longus muscle; it then pierces the adductor magnus, and is distributed to the flexor muscles of the posterior part of the thigh.

Relations.—The profunda artery rests successively upon the pectineus, the conjoined tendon of the psoas and iliacus, adductor brevis, and adductor magnus muscles. To its *outer* side, the tendinous insertion of the vastus internus muscle intervenes between it and the femur, and *in front* it is separated from the femoral artery above by the profunda vein and femoral vein; and below by the adductor longus muscle.

The *branches* of the profunda artery are the external circumflex, internal circumflex, and three perforating arteries.

The *External circumflex* artery passes outwards beneath the sartorius and rectus, and in front of the crureus muscle, passing between the divisions of the crural nerve, and divides into three sets of branches; *ascending*, which pass upwards beneath the sartorius rectus and tensor vaginæ femoris, and inosculate with the terminal branches of the gluteal artery; *descending*, which pass downwards beneath the rectus muscle to inosculate with the superior articular arteries of the popliteal; and *middle*, which continue the original course of the artery around the thigh, pierce the vastus externus, and anastomose with branches of the ischiatic, internal circumflex, and superior perforating artery. It supplies the muscles on the anterior and outer side of the thigh.

The *Internal circumflex* artery winds around the inner side of the neck of the femur, passing between the pectineus and psoas, and over the upper border of the adductor brevis to the tendon of the obturator externus, which it accompanies to the space between the quadratus femoris and upper border of the adductor magnus. While

on the obturator externus it gives off a branch which is distributed to that muscle, the adductor brevis and gracilis, and anastomoses with the obturator artery. It next gives off an *articular* branch which enters the hip-joint through the notch in the acetabulum; and terminates in several branches which inosculate with the ischiatic, external circumflex, and superior perforating arteries.

The *Superior perforating* artery passes backwards near the lower border of the pectineus, pierces the adductor brevis and magnus near the femur, and is distributed to the posterior muscles of the thigh; inosculating freely with the circumflex and ischiatic arteries, and with the branches of the middle perforating artery.

The *Middle perforating* artery pierces the tendons of the adductor brevis and magnus, and is distributed like the superior; inosculating with the superior and inferior perforantes. From this branch is given off the *nutritious* artery of the femur.

The *Inferior perforating* artery is given off below the adductor brevis, and pierces the tendon of the adductor magnus, supplying it and the flexor muscles, and inosculating with the middle perforating artery above, and with the articular branches of the popliteal below.

It is through the medium of the branches of the profunda, which inosculate above with branches of the internal iliac, and below with those of the popliteal artery, that the collateral circulation is maintained in the limb after ligation of the femoral artery.

We now return to the superficial femoral. It gives off *muscular branches* throughout the whole of its course, which supply the muscles in immediate proximity with the artery, particularly those of the anterior aspect of the thigh. One of these branches, larger than the rest, arises from the femoral immediately below the origin of the profunda, and passing outwards between the rectus and sartorius, divides into branches, which are distributed to all the muscles of the anterior aspect of the thigh. This may be named the *superior muscular artery*.

The *Anastomotica magna* arises from the femoral, near to its termination at the opening in the adductor magnus, and divides into a superficial and deep branch. The *superficial branch* accompanies the internal saphenous nerve to the knee, and piercing the fascia lata is distributed to the

integument. The *deep branch* passes onwards through the substance of the vastus internus muscle, and resting on the tendon of the adductor magnus to the knee, where it inosculates with the internal articular branches of the popliteal, and the recurrent of the anterior tibial. It also sends a branch to the vastus internus, which supplies the synovial membrane of the joint, and inosculates with the superior external articular artery and external circumflex.

When the pectineus muscle is divided through its origin and turned down, a small artery will be seen issuing from the opening in the upper part of the obturator membrane; this is the obturator artery, a branch of the internal iliac.

The OBTURATOR artery, after passing through the obturator foramen, divides into two branches, internal and external. The *internal* branch curves inwards around the bony margin of the obturator foramen, and distributes branches to the obturator and adductor muscles, inosculating with the internal circumflex artery of the femoral. The *external* branch winds around the outer margin of the obturator foramen to the space between the gemellus inferior and quadratus femoris, where it inosculates with the ischiatic artery. In its course it inosculates also with the internal circumflex artery, and sends a small branch through the notch in the acetabulum, to supply the ligamentum teres.

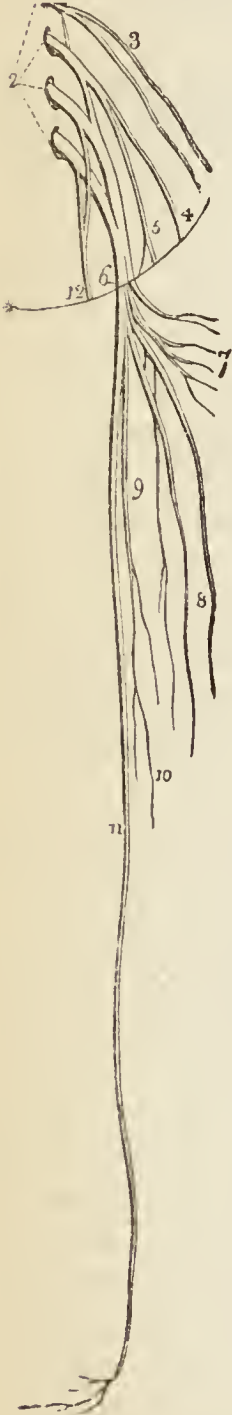
The VEINS of the anterior femoral region are superficial and deep. The *superficial*, are the internal saphenous, and its tributaries. The *deep*, are the femoral and profunda, with their tributaries. The *femoral vein* commences at the hole in the adductor magnus, and ascends behind the artery to within two inches of Poupart's ligament, where it receives the profunda vein; it then becomes placed to the inner side of the artery, and continues in that position to Poupart's ligament. After passing beneath the ligament, it receives the name of external iliac vein. The *profunda vein*, commencing with the ultimate ramifications of the profunda artery, ascends in front of that vessel to its origin from the common femoral artery, where it joins the femoral vein. The tributary veins are those accompanying the branches of the main arteries. They are usually two to each branch, one on either side: hence they are called *venæ comites*. They

communicate freely across the cylinder of the artery by short transverse trunks. Veins are considerably larger than the arteries which they accompany.

Nerves of the Anterior Femoral Region.

The student will now direct his attention to the nerves of this region, They are derived from the lumbar plexus : and are the

Fig. 3. *



External cutaneous,
Genito-crural,

Anterior crural { Middle cutaneous,
Internal cutaneous,
Long saphenous,
Muscular,

Obturator.

The EXTERNAL CUTANEOUS NERVE, 4., is described with the superficial fascia at page 14. The *crural* portion of the genito-crural nerve; and the crural distribution of the ilio-inguinal nerve have also been described in the same place.

The ANTERIOR CRURAL OR FEMORAL NERVE, 6., is the largest of the branches from the lumbar plexus. It is formed by the union of the second, third, and fourth lumbar nerves, passes beneath the outer border of the psoas magnus muscle, and runs downwards in the groove between that muscle and the iliacus internus to Poupart's ligament. It is there separated from the femoral artery by the breadth of the psoas muscle, usually not more than half an inch wide; and immediately below Poupart's ligament divides into superficial and deep branches: while within the pelvis it gives off several twigs to the iliacus muscle, and sends down a branch to supply the femoral artery.

* The lumbar plexus with its branches.

No. 1. The dorsi-lumbar nerve. 2. The four upper lumbar

The *superficial branches* are the middle cutaneous, internal cutaneous and internal saphenous; the *deep branches* are the muscular and articular.

The middle and internal cutaneous nerves have been already described; page 13.

The *long saphenous* or internal saphenous nerve inclines inwards to the sheath of the femoral vessels, and passes downwards in front of the sheath and beneath the aponeurotic expansion which covers the sheath, to the opening in the adductor magnus. It then quits the femoral vessels, and, continuing to descend, passes between the tendons of the sartorius and gracilis, and reaches the internal saphenous vein. By the side of the latter it passes down the inner side of the leg, in front of the inner ankle and along the inner side of the foot as far as the great toe. The *branches* of the internal saphenous are, one or two in the thigh to communicate with the obturator nerve and internal cutaneous, the three together forming a plexus; one, at the knee, the *cutaneus patellæ*, which pierces the sartorius muscle and is distributed to the front of the knee, assisting, by its communications with other cutaneous nerves of the knee, to form the *plexus patellæ*; and several cutaneous twigs below the knee.

Of the *deep branches* of the anterior crural nerve the *muscular* supply all the muscles of the anterior femoral region (excepting one) and the pectineus. The excepted muscle is the tensor vaginæ femoris which receives its nerves from the superior gluteal. The *sartorius* muscle receives three or four branches, which arise with the cutaneous nerves, and frequently are supplied by the latter. The branch to the *vastus externus* accompanies the descending branch of the external circumflex artery. The branch to the *vastus internus* muscle (short saphenous, of some authors, from arising frequently in common with the long saphenous, and pursuing a parallel course

nerves. 3. The ilio-hypogastric and ilio-inguinal nerves proceeding from the first lumbar nerve. 4. The genito-crural nerve. 5. The external cutaneous nerve. 6. The anterior crural nerve. 7. Its muscular branches. 8. The middle and internal cutaneous nerves. 9. 10. The long muscular branch to the vastus internus muscle and knee joint. 11. The internal saphenous nerve. 12. The obturator nerve. * The line of Poupert's ligament.

in the upper part of the thigh) descends upon the sheath of the femoral vessels, and beneath the aponeurotic fascia of the sheath. It is of large size, and sends off several twigs to the vastus internus, and a long articular filament to the synovial membrane of the knee-joint. This latter accompanies the deep branch of the *anastomotica magna*.

The OBTURATOR NERVE is formed by a branch from the third and another from the fourth lumbar nerve, and, passing downwards through the psoas muscle and bifurcation of the common iliac vessels, runs along the inner border of the brim of the pelvis to the obturator foramen, where it joins the obturator artery. Having escaped from the pelvis it divides into an anterior and a posterior branch.

The *anterior branch* passes in front of the adductor brevis and supplies that muscle, the pectineus, gracilis, and adductor longus, and, at the lower border of the latter, unites with the internal cutaneous nerve and internal saphenous to form a plexus. In its course this nerve gives off an *articular* twig to the hip-joint, a *cutaneous* branch which pierces the fascia lata at the knee; and after communicating with the internal saphenous nerve is distributed to the integument as far as the middle of the leg; and a twig from its termination to the femoral artery.

The *posterior branch* pierces the obturator externus muscle, and sends twigs for its supply as well as the adductor magnus muscle; it also sends down an *articular* filament which accompanies the popliteal artery to the knee-joint.

A portion of the obturator nerve is sometimes given off in an irregular manner, and proceeds in an irregular course. When it exists it is either a high division of the obturator, or takes its origin by separate cords from the third and fourth lumbar nerves. It is called the *accessory obturator nerve*; passes down along the inner border of the psoas muscle to the front of the pelvis, crosses the body of the os pubis, and gets beneath the pectineus. It gives branches to the pectineus muscle and hip-joint, and joins the anterior branch of the obturator, forming, when of large size, the *cutaneous* branch of that nerve.

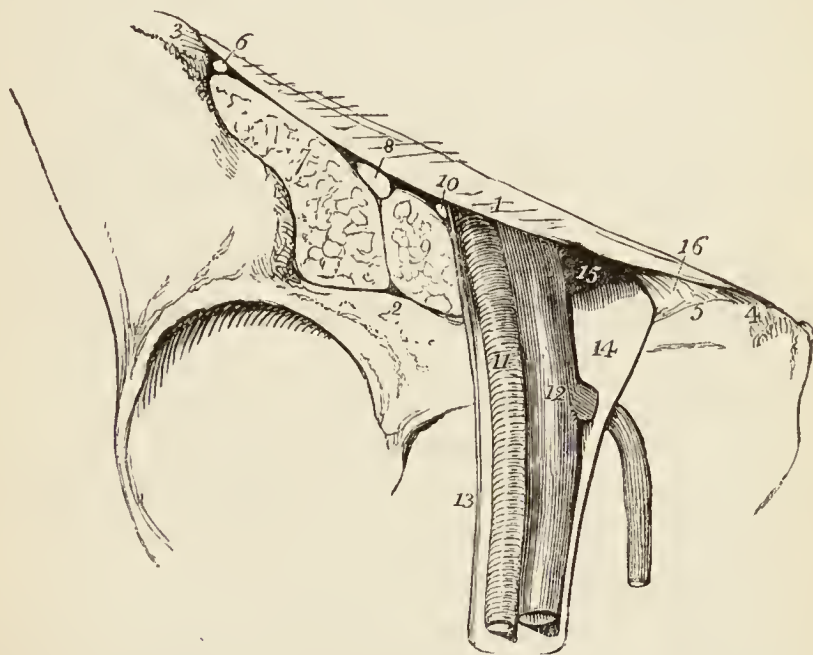
We advise the student to have made himself thoroughly master of

this region and of each, before he venture to direct his attention to another, and to proceed methodically, following with care every line of proceeding here pointed out, unless, indeed, he can himself suggest a better or one more familiar to his mode of study, for we are well convinced that the same plan will not be found advantageous to all. Let him question his knowledge upon each of the preceding sections, and remark the adage "Memoria augetur ex colendo."

FEMORAL HERNIA.

After proceeding, as we have here directed, with the common anatomy of the anterior femoral region, the student may now turn his attention to the special anatomy of that portion of the region through which the intestine finds its way in femoral hernia. With this object the sheath of the vessels should have been left undisturbed.

Fig. 4.*



The sheath may now be opened, and the parts contained within the sheath and adjacent parts examined.

* A section of the structures which leave the pelvis through the femoral arch;— the vessels and their sheath only, being left.

No. 1. Poupart's ligament, the upper boundary of the femoral arch. 2. Its lower boundary, the border of the pubes and ilium. 3. The anterior superior spine of the ilium. 4. The spine of the pubes. 5. The pectineal line of the pubes. 6. The external cutaneous nerve. 7. The iliacus muscle. 8. The anterior crural nerve. 9. The psoas magnus muscle. 10. The crural branch of the genito-crural nerve. 11. The femoral artery. 12. The femoral vein, receiv-

Stretching across from the anterior superior spinous process of the ilium to the spine of the pubes is Poupart's ligament, which forms an arch over the concave border of the pelvis, the *crural* or *femoral arch*. Beneath this arch will be seen to pass a number of important structures, which are disposed in the following order, from without inwards:— external cutaneous nerve, 6.; iliacus internus muscle, 7.; anterior crural nerve, 8.; psoas magnus muscle, 9.; crural division of the genito-crural nerve, 10.; femoral artery, 11.; femoral vein, 12.; lymphatic vessels; — the four latter being enclosed in a common sheath.

The *sheath*, 13. 14., of the femoral vessels is the fibrous covering which invests the artery and vein during their passage beneath the femoral arch. It is formed by the internal lining of the abdomen; and as this has received various names, according to the situations it may occupy, as *transversalis fascia*, *iliac fascia*, *pelvic fascia*, although actually but one and the same membrane, so the sheath is said to be formed in front by the transversalis fascia, to the outer side, by the iliac fascia, and to the inner side by the pelvic fascia; for Poupart's ligament is the line of union of these three regions of the internal abdominal fascia; and in escaping immediately beneath Poupart's ligament the vessels necessarily carry with them a part of each.

The breadth of the sheath of the vessels at Poupart's ligament is two inches, and in the female more; but at two inches below the ligament, the sheath has diminished to three quarters of an inch, and merges into the common cellular covering of the vessels.

Now it is obvious that the artery and vein, placed side by side, cannot occupy an area two inches in breadth, and therefore that there must be either some other structure situated within the sheath, or an imperfectly filled

ing the internal saphenous vein, which pierces the sheath to open into it. 13. The external portion of the sheath of the femoral vessels, lying in contact with the artery. 14. The large funnel-shaped cavity in the sheath, to the inner side of the vein, which receives the sac of femoral hernia, this is the crural canal. 15. The crural ring, bounded in front by Poupart's ligament, behind by the pubes, externally by the femoral vein, and internally by (16.) Gimbernat's ligament.

space. The latter is the fact; for, if we open the sheath, we shall see a space, 14., to the inner side of the vein, which is only occupied by *cellular tissue, lymphatic vessels,* and a *lymphatic gland*. So that the inner wall of the sheath is separated by a considerable interval from the vein, while the outer wall, 13., is in close contact, and adherent to the artery: moreover, the sheath is divided by septa into three parts, one septum being placed between the artery and vein, and another between the vein and the space to its inner side; this space being the *crural* or *femoral canal*.

The lymphatic gland is placed immediately under Poupart's ligament, and may be easily pushed into the cavity of the abdomen by using very slight pressure with the finger.

The *opening*, 15., thus produced by the finger is the *crural* or *femoral ring*: it is bounded in front by Poupart's ligament, 1., behind by the body of the pubes, 2., to the outer side by the femoral vein, 12., and to the inner side by Gimbernat's ligament, 16. This ligament is one insertion of Poupart's ligament, which expands in a radiated manner to be attached along the sharp edge of the pectineal line.

If the student, before passing his finger through the femoral ring from the sheath, should attempt to press it from within the abdomen, after tearing away the peritoneum, he will find an obstacle in a thin cellular membrane which is spread across the opening at its entrance: this is the *septum crurale*.

Now the *course* which the intestine follows in femoral hernia may be thus described. It *first* descends through the femoral ring into the crural canal, carrying with it the peritoneum and septum crurale. *Secondly*, it advances forwards through the saphenous opening in the fascia lata, this being the weakest side of the sheath of the vessels. In this part of its course it gains two additional coverings, viz. the sheath of the vessels called "*fascia propria*," and the perforated cellular tissue before described (page 15.) as forming the *cribriform fascia*. *Thirdly*, it turns upwards over Poupart's ligament.

To return it again to the cavity of the abdomen we must pursue the converse of the direction which is followed in its descent, i.e. we must press it first *downwards*

below Poupart's ligament, then *backwards* through the saphenous opening, then *upwards* through the femoral ring; having previously flexed and rotated the thigh inwards, in order to relax the structures concerned in the hernia.

But should the intestine be strangulated, that is, nipped in its passage, so as to arrest the progress of the aliment, and by distension and pressure cause obstruction to the circulation of the blood, and endanger the life of the patient, we must have recourse to an operation for its relief. This operation consists in dividing carefully all the structures covering the hernia, down to the intestine. The surgeon must, therefore, know well what parts are likely to meet his knife in the living dissection. Two of these are common to the whole body, and must be divided in every operation; the others are peculiar to the region: they are six in number, — namely, integument; superficial fascia; cribriform fascia; fascia propria (sheath of the vessels); septum crurale; peritoneal sac.

After opening the peritoneal sac, the surgeon examines the intestine and feels for the stricture. This is generally the margin of the femoral ring; or it may be the upper curve of the saphenous opening; if the former, Gimbernat's ligament is the probable cause of the stricture, and should be divided horizontally; if the latter, the incision necessary for the liberation of the intestine should be made upwards and inwards.

This is the anatomical principle of practice in every case of femoral hernia; and the incision required for the relief of the stricture is very slight. But if the operator be a bad dissector, and, by a necessary consequence, a bad operator, he may, instead of loosening the ring, carry his incision altogether through Poupart's ligament, or very likely still farther, and cut across the spermatic or epigastric artery, and so complete the operation with the life of his patient.

Such an operator should be forewarned that a variety in the distribution of the arteries sometimes occurs in the vicinity of the femoral ring; and unless he be guarded, his reputation may be for ever destroyed by an unfortunate complication of this kind. The variety consists in the origin of the obturator artery, from the epigastric immediately above the femoral ring. The artery arising

in this situation, descends most frequently in contact with the external iliac vein, and would therefore be placed to the *outer* side of the hernial sac, and be comparatively safe. But sometimes the obturator encircles the ring in its course to the obturator foramen, winding along near the margin of Gimbernat's ligament, and would necessarily occupy a very dangerous position in the operation, actually *encircling the neck of the hernial sac*, and might be wounded by the most skilful operator. Therefore the safety of the patient demands that the surgeon should always conduct his operation as if his patient were the subject of this anomalous distribution, and he may then reflect upon his conduct even after an unsuccessful issue without self reproach.*

GLUTEAL REGION.

The subject being turned on its face, and a block placed beneath the pubes to support the pelvis, the student commences the dissection of this region, by carrying an incision from the apex of the coccyx along the crest of the ilium to its anterior superior spinous process, or vice versâ, if he be on the left side. He then makes an incision from the posterior fifth of the crest of the ilium, to the apex of the trochanter major: this marks the upper border of the gluteus maximus; and a third incision from the apex of the coccyx along the fleshy margin of the lower border of the gluteus maximus, to the outer side of the thigh, about four inches below the apex of the trochanter major. He then reflects the integument, superficial fascia, and deep fascia, which latter is very thin over this muscle, from the gluteus maximus, following rigidly the course of its fibres; and having exposed the muscle in its entire extent, he dissects the integument and superficial fascia from off the deep fascia which binds down the gluteus medius, the other portion of this region. The more advanced student may wish to dissect the cutaneous nerves in this region; in which case he removes only the integument and then proceeds to seek for the nerves and follow them in their course.

The CUTANEOUS NERVES distributed to this region are :
 1. *Branches* of the *external cutaneous* which turn back from a little below the anterior superior spine of the

* The author has met with five or six instances of this dangerous distribution in about 300 bodies, which is a large average. In a preparation now before him, a large branch of communication between the epigastric and obturator artery takes that remarkable course along the margin of Gimbernat's ligament, leaving the femoral ring to its outer side.

ilium. 2. The *lateral cutaneous branch* of the *last dorsal* nerve, which crosses the crest of the ilium just behind the origin of the tensor vaginae femoris muscle and supplies the integument as low as the trochanter major. 3. The *iliac branch* of the *ilio-hypogastric* nerve, which crosses the crest of the ilium a little beyond its middle, and is of small size. 4. *Two or three branches*, given off by the posterior division of the *lumbar* nerves; these cross the crest of the ilium farther back than the preceding. 5. *Two or three branches* from the posterior *sacral* nerves. Besides these, the integument covering the lower border of the gluteus maximus receives a few cutaneous branches from the lesser sciatic nerve.

The MUSCLES of the *gluteal* region are,

Gluteus maximus,	Obturator internus,
——— medius,	Gemellus inferior,
——— minimus,	Obturator externus,
Pyramiformis,	Quadratus femoris.
Gemellus superior,	

The GLUTEUS MAXIMUS ($\gamma\lambda\omicron\upsilon\tau\omicron\varsigma$, nates) is the thick, fleshy mass of muscle, of a quadrangular shape, which forms the convexity of the nates. In structure, it is extremely coarse, being made up of large fibres, which are collected into fasciculi, and these again into distinct muscular masses, separated by deep cellular furrows. It *arises* from the posterior fifth of the crest of the ilium, from the posterior surface of the sacrum and coccyx, and from the great sacro-ischiatic ligament. It passes obliquely outwards and downwards, to be *inserted* into the rough line leading from the trochanter major to the linea aspera, and is continuous by means of its tendon with the fascia lata covering the outer side of the thigh. Several bursæ are situated between this muscle and subjacent parts; one upon the tuberosity of the ischium, one between its tendon and the trochanter major, and one between it and the tendon of the vastus externus.

After this muscle has been sufficiently studied, it must be turned down from its origin. Its dissection, however, from the parts beneath demands considerable care, as a number of arteries and nerves are situated immediately below it.

The GLUTEUS MEDIUS is placed in front of rather than beneath the gluteus maximus, and is covered in by a pro-

cess of the deep fascia, which is very thick and dense. It *arises* from the outer lip of the crest of the ilium for four fifths of its length, from the surface of bone between that border, and the superior curved line on the dorsum ilii, and from the dense fascia above mentioned. Its fibres converge to the outer part of the trochanter major, into which its tendon is *inserted*.

This muscle should now be removed from its origin and turned down, so as to expose the next which is situated beneath it; a bursa will be found between its tendon and the trochanter.

The GLUTEUS MINIMUS (*fig. 5. 1.*) is a radiated muscle, *arising* from the surface of the dorsum ilii, between the superior and inferior curved lines: its fibres converge to the anterior border of the trochanter major, into which it is *inserted* by means of a rounded tendon. There is no distinct separation between the gluteus medius and minimus anteriorly.

The gluteus minimus should be divided through its tendon and turned upwards in order to show that head of the rectus muscle which proceeds from the upper lip of the acetabulum.

To understand the exact relations and origins of the next muscles, the student should consult his skeleton. Upon the posterior and lateral aspect of the pelvis, he will find a considerable vacuity. This is broken in upon by a sharp spinous process projected from the border of the ischium, the *spine* of the ischium: the excavated sweep immediately above this spine is called the *great sacro-ischiatic notch*, in contra-distinction to another sweep beneath the spine, named the *lesser sacro-ischiatic notch*; and the lesser sacro-ischiatic notch is bounded inferiorly by a thick tubercle, the tuberosity of the ischium. In the subject, the narrow extremity of a radiated ligament is attached to the spine of the ischium, while its expanded end is connected to the side of the sacrum and coccyx: hence it is named *sacro-ischiatic*, and is further known by the cognomina, *lesser* and *anterior*, which serve to distinguish it from another ligament, radiated at each extremity, attached by the broader end to the posterior spinous process of the ilium, the side of the sacrum and coccyx, and by its smaller end to the inner border of the tuberosity of the ischium. This ligament is necessarily longer than the former, and more posterior: hence it is named the *posterior* or *great sacro-ischiatic* ligament. These two ligaments convert the notches into foramina, which are thence called the *superior* or *great sacro-ischiatic foramen*, and the *inferior* or *lesser sacro-ischiatic foramen*. Let us now return to the muscles.

The PYRIFORMIS muscle (*fig. 5. 3.* *pyrum*, a pear, i.e. pear-shaped) *arises* from the anterior surface of the sacrum, by little slips interposed between the anterior sacral fora-

mina from the first to the fourth. It passes out of the pelvis, through the great sacro-ischiatic foramen, and is *inserted* by a rounded tendon into the posterior border of the trochanter major.

Immediately below the pyriformis is a small slip of muscle, the GEMELLUS SUPERIOR (gemellus, double, twin): it *arises* from the spine of the ischium, and is *inserted* into the upper border of the tendon of the obturator internus, and into the digital fossa of the trochanter major.

The OBTURATOR INTERNUS *arises* from the inner surface of the anterior wall of the pelvis, being attached to the margin of bone around the obturator foramen, and to the obturator membrane. It passes out of the pelvis through the lesser sacro-ischiatic foramen, and is *inserted* by a flattened tendon into the digital fossa of the trochanter major. The lesser sacro-ischiatic notch, over which this muscle plays as through a pulley, is faced with cartilage, and provided with a synovial bursa to facilitate its movements. The tendon of the obturator is supported on each side by the gemelli muscles (hence their names), which are inserted into the sides of the tendon, and appear to be auxiliaries or superadded portions of the obturator internus.

The GEMELLUS INFERIOR *arises* from the posterior point of the tuberosity of the ischium, and is *inserted* into the lower border of the tendon of the obturator internus, and into the digital fossa of the trochanter major.

Placed deeply between the gemellus inferior and the quadratus femoris, may be seen the tendon of the obturator externus, becoming more superficial as it passes outwards to its *insertion* into the digital fossa of the trochanter major: it *arises* from the external surface of the obturator ligament, and from the margin of bone immediately surrounding it. (Page 19.)

The QUADRATUS FEMORIS, 5. (square-shaped) *arises* from the external border of the tuberosity of the ischium, and is *inserted* into a rough line on the posterior border of the trochanter major, which is thence named *linea quadrati*.

ACTIONS.—The glutei muscles are abductors of the thigh, when they take their fixed point from the pelvis. Taking their fixed point from the thigh, they steady the pelvis on the head of the femur; this action is peculiarly obvious in standing on one leg: they assist also in carrying the leg forward, in progression. The gluteus

minimus being attached to the anterior border of the trochanter major, rotates the limb slightly inwards. The gluteus medius and maximus, from their insertion into the posterior aspect of the bone, rotate the limb outwards: the latter is, moreover, a tensor of the fascia of the thigh. The other muscles rotate the limb outwards, everting the knee and foot; hence they are named external rotators.

Vessels and Nerves of the Gluteal Region.

<i>Arteries.</i>		<i>Nerves.</i>			
Gluteal	{	Superficial branch.	Gluteal	{	Superior branch.
		Deep superior branch.			Inferior branch.
		Deep inferior branch.	Lesser Ischi- atic	{	Inferior gluteal.
Ischi- atic	{	Coccygeal.			Cutaneous external.
		Comes nervi ischiatici.			— middle.
Muscular.	— internal.				
Internal pudic.		Great Ischiatic.		Internal pudic.	

The gluteal artery and nerve (*fig. 5. 11.*) are found immediately above the pyriformis muscle; the other vessels and nerves, 12. 14., immediately beneath that muscle.

The GLUTEAL ARTERY is the continuation of the posterior trunk of the internal iliac; it passes out of the pelvis through the great sacro-ischiatic foramen, above the pyriformis muscle, and divides into three branches; *superficial*, *deep superior*, and *deep inferior*.

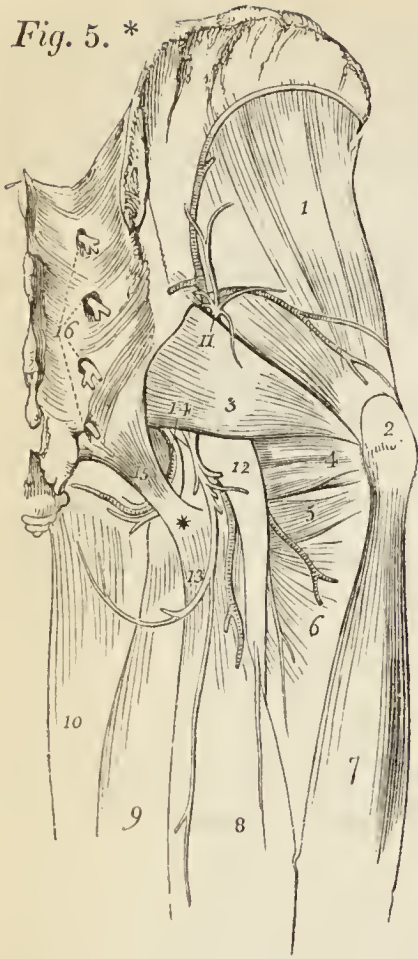
The *superficial branch* passes backwards between the gluteus maximus and medius, and is distributed to the gluteus maximus and to the integument of the gluteal and sacral region.

The *deep superior branch* passes forwards along the superior curved line of the ilium, between the gluteus medius and minimus to the anterior superior spinous process of the ilium where it inosculates with the superficial circumflexa ilii and external circumflex. There are frequently two arteries occupying the place of this branch.

The *deep inferior branches*, two or three in number, cross the gluteus minimus obliquely to the trochanter major where they inosculate with branches of the external circumflex and ischiatic arteries, and send branches through the muscle for the supply of the hip-joint.

The arteries in this region are all branches of the internal iliac within the pelvis, and the nerves are derived from the sacral plexus; hence, a part of their course cannot, at present, be seen. They all quit the pelvis through the great sacro-ischiatic foramen.

Fig. 5. *



The ISCHIATIC ARTERY, one of the terminal branches of the anterior trunk of the internal iliac, escapes from the pelvis beneath the piriformis muscle, and passing downwards with the ischiatic nerves, in the interval between the tuberosity of the ischium and the trochanter major divides into several branches, the principal of which are the *coccygeal*, *comes nervi ischiatici* and *muscular*.

The *coccygeal branch* pierces the great sacro-ischiatic ligament and is distributed to the coccygeus and levatorani muscles, and to the integument of the anal and coccygeal region.

The *comes nervi ischiatici* is a slender branch which accompanies the great ischiatic nerve, extending as far as the lower part of the thigh.

The *muscular branches* supply the muscles of the posterior part of the hip and thigh, and send twigs to the hip joint. They inosculate with the internal and external circumflex arteries, obturator, and superior perforating.

* A deep posterior view of the anatomy of the hip; showing the muscles, vessels, and nerves, which are exposed by the removal of the gluteus maximus muscle.

No. 1. The gluteus minimus muscle. 2. The trochanter major of the femur. 3. The piriformis muscle. 4. The tendon of the obturator internus muscle, bounded above by the gemellus superior, and below by the gemellus inferior. 5. The quadratus femoris muscle. 6. The adductor magnus. 7. The vastus externus muscle. 8. The long head of the biceps. 9. The semitendinosus. 10. The gracilis. 11. The superior gluteal artery and nerve, escaping from the pelvis above the piriformis muscle. 12. The great ischiatic nerve. 13. The lesser ischiatic nerve, and between the two the ischiatic artery. 14. The pudic artery and nerve. All these vessels and nerves pass out from the pelvis below the piriformis muscle. 15. The great or posterior sacro-ischiatic ligament. * The tuberosity of the ischium. 16. The posterior divisions of the sacral nerves.

The INTERNAL PUDIC ARTERY, the other terminal branch of the anterior trunk of the internal iliac, also issues from the pelvis through the great ischiatic foramen below the pyriformis, to disappear immediately beneath the great sacro-ischiatic ligament, and pursue its course within the pelvis.

From the description usually given of this artery, the student might imagine that its course was extremely eccentric, going out of the pelvis and then going in. But if he refer to his skeleton and to the subject, he will see that the artery forms the most gentle curve imaginable in this part of its course; and that its various relation to the pelvis depends upon the projection inwards of the spine of the ischium, upon which the artery, with its veins and nerve, rest in this region.

Upon entering, the lesser ischiatic foramen, the internal pudic artery crosses the lower part of the obturator internus muscle to the ramus of the ischium, along which, and the ramus of the pubes, it ascends to the symphysis. Its branches are distributed to the perineum.

The VEINS, as in all the secondary arteries of the body, are placed by the side of the arteries in pairs, which are called "*venæ comites.*"

Nerves of the Gluteal Region.

The GLUTEAL NERVE (superior gluteal; *fig. 5. 11.*; *fig. 8. 2.*) is a branch of the lumbo-sacral or fifth lumbar nerve. It passes out of the pelvis with the gluteal artery through the great sacro-ischiatic foramen, and divides into a *superior* and *inferior* branch.

The *superior branch* follows the direction of the superior curved line of the ilium, accompanying the deep superior branch of the gluteal artery, and sends filaments to the gluteus medius and minimus.

The *inferior branch* passes obliquely downwards and forwards between the gluteus medius and minimus to the tensor vaginae femoris, and is distributed to all the three muscles.

The LESSER ISCHIATIC NERVE (*fig. 5. 13.*; *fig. 8. 6.*) one of the branches of the sacral plexus, passes out of the pelvis through the great sacro-ischiatic foramen below

the pyriformis muscle, and continues its course downwards through the middle of the thigh to the lower part of the popliteal region where it pierces the fascia and becomes subcutaneous. It then associates itself with the external saphenous vein, and descends to the lower part of the leg, communicating with the external saphenous nerve. The branches of the lesser ischiatic nerve are *muscular* and *cutaneous*.

The *muscular* or *inferior gluteal* are several large branches distributed to the gluteus maximus.

The *cutaneous branches* are divisible into external, internal, and middle. The *external cutaneous branches* are several filaments which turn around the lower border of the gluteus maximus, and are distributed to the integument over the hip and outer side of the thigh. The *internal cutaneous branches* are distributed to the integument of the upper and inner part of the thigh. One of these branches, larger than the rest, *inferior pudendal*, (*fig. 74.*) curves around the tuberosity of the ischium, pierces the fascia lata near the ramus of that bone, and, after communicating with the superficial perineal nerve, is distributed to the integument of the scrotum and penis. The *middle cutaneous branches*, two or three in number, are derived from the lesser ischiatic in its course down the thigh and are distributed to the integument.

The GREAT ISCHIATIC NERVE (*fig. 5. 12., fig. 8. 7.*) is the largest nervous cord in the body; it is formed by the sacral plexus, or rather is a prolongation of the plexus; and at its exit from the great sacro-ischiatic foramen, beneath the pyriformis, measures three quarters of an inch in breadth. It descends through the middle of the space between the trochanter major and tuberosity of the ischium, and along the posterior part of the thigh to its lower third, where it divides into two large terminal branches, *internal* and *external popliteal*. This division sometimes takes place at the plexus, and the two nerves descend side by side; sometimes one passes out of the pelvis above the pyriformis, or even pierces that muscle. In its course downwards the nerve rests on the gemellus superior, tendon of the obturator internus, gemellus inferior, quadratus femoris, and then gets between the flexor muscles and adductor magnus, a few muscular

twigs are given off by the nerve while in the gluteal region.

The INTERNAL PUDIC NERVE (*fig. 5. 14., fig. 8. 5.*) may be seen lying by the side of the internal pudic artery. It proceeds from the lower part of the sacral plexus and passing out of the pelvis through the great sacro-ischiatic foramen below the pyriformis muscle, enters it again through the lesser sacro-ischiatic foramen and accompanies the internal pudic artery in its course.

POSTERIOR FEMORAL REGION.

Carry an incision along the middle of the posterior aspect of the thigh, as far as the bend of the knee. Bound it in this situation by a transverse incision, and reflect the integument to either side. In the superficial fascia will be seen the cutaneous branches of the lesser ischiatic nerve.

Upon removing the superficial fascia, the *deep fascia* will be found to be extremely thin; and, on turning it aside, we bring into view the three muscles of this region, the flexors of the leg —

Biceps.

Semi-tendinosus.

Semi-membranosus.

The BICEPS FLEXOR CRURIS (bis double, — κεφαλη, head) *arises* by two heads, one by a common tendon with the semi-tendinosus from the upper and back part of the tuberosity of the ischium; the other, muscular, and much shorter, from the lower two thirds of the external border of the linea aspera. This muscle forms the outer ham-string, and is *inserted* by a strong tendon into the head of the fibula; a portion of the tendon being continued into the fascia of the leg.

The SEMI-TENDINOSUS, remarkable for its long tendon, *arises* in common with the long head of the biceps from the upper and back part of the tuberosity of the ischium. It is *inserted* into the inner tuberosity of the tibia; and sends an expansion to the fascia of the leg.

These two muscles must be dissected from the tuberosity of the ischium to bring into view the origin of the next.

The SEMI-MEMBRANOSUS, remarkable for the tendinous expansion upon its anterior and posterior surfaces *arises* from the tuberosity of the ischium, in front of the common origin of the two preceding muscles. It is *inserted* into the posterior part of the inner tuberosity of the tibia; at its insertion, the tendon splits into three portions, one of which is inserted in a groove on the inner side of the head of the tibia, beneath the internal lateral ligament. The second is continuous, with an aponeurotic expansion which binds down the popliteus muscle, the popliteal fascia; and the third turns upwards and outwards to the external condyle of the femur, forming the middle portion of the posterior ligament of the knee-joint (*ligamentum posticum Winslowii*).

The tendons of the two last muscles, viz., the semi-tendinosus and semi-membranosus, with those of the gracilis and sartorius, form the inner ham-string.

If the semi-membranosus muscle be turned down from its origin, the student will bring into view the broad and radiated expanse of the adductor magnus, upon which the great ischiatic nerve and the three flexor muscles above described rest.

ACTIONS.—These three ham-string muscles are the direct flexors of the leg upon the thigh; and, by taking their origin from below, they balance the pelvis on the lower extremities.

Arteries and Nerves of the Posterior Femoral Region.

The ARTERIES of this region are the external and internal circumflex, three perforating, the termination of the profunda femoris and the popliteal.

The middle branch of the *external circumflex* is seen piercing the upper part of the vastus externus, to inosculate with the internal circumflex, ischiatic, and superior perforating artery. The *internal circumflex* makes its appearance between the upper border of the adductor magnus, and the lower border of the quadratus femoris. It inosculates with the external circumflex, ischiatic, and superior perforating artery.

The *three perforating arteries* emerge on the posterior aspect of the thigh, by passing through tendinous arches between the adductor magnus and the linea aspera. They anastomose with each other, with the circumflex and ischiatic arteries above, and with the articular branches of the popliteal below. The *profunda artery*

passes through the adductor magnus, close to the linea aspera, and is protected from pressure by a tendinous arch, thrown across the bone. It makes its appearance at about an inch above the commencement of the popliteal artery.

The NERVES in this region are the greater and lesser ischiatic. The continuation of the *lesser ischiatic* is seen upon the semi-tendinosus muscle.

The *Great ischiatic nerve* (*fig. 8. 7.*) runs down the middle of the posterior femoral region, being situated between the flexor muscles and the adductor magnus. At the lower third of the thigh it divides into two nerves of nearly equal size, the *internal popliteal*, 9., and *external popliteal*, 8. Its branches are *muscular* and *articular*. The *muscular branches* are distributed to the biceps, semi-tendinosus, semi-membranosus and adductor magnus. The *articular branch* descends to the external condyle of the femur and is distributed to the knee-joint.

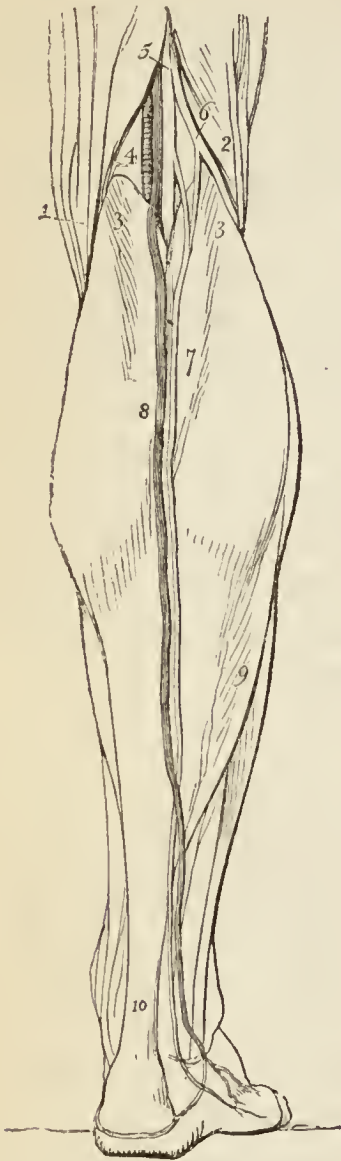
POPLITEAL REGION.

The lower part of the posterior femoral region is a surgical region of some importance, the popliteal (*fig. 6.*). It is a diamond-shaped space, bounded above on each side by the two ham-strings 1. 2., and below by the two heads, 3. 3., of the great muscle of the calf, the gastrocnemius. On dissecting back the integument, a large vein, 8., which runs up the middle of the posterior part of the leg, the *external saphenous*, is seen between the layers of the superficial fascia. To this several cutaneous veins converge, which must be divided in making an incision for the purpose of reaching the artery. If the superficial fascia be dissected away, the external saphenous vein will be seen passing through an oval foramen in the deep popliteal fascia, to terminate in the popliteal vein. Some cutaneous branches of nerves from the lesser ischiatic and internal cutaneous of the anterior crural may also be found in the superficial fascia.

The *deep popliteal fascia* is thin, and will be removed without being observed, unless the dissector proceed cautiously. It is a part of the common deep fascia (*fascia lata*) investing the entire limb. Beneath the deep fascia is a quantity of adipose substance which fills up the whole

popliteal space, from the bone and joint to the surface, and protects and supports the popliteal vessels and nerves.

Fig. 6.*



It will be recollected, that at the upper part of this popliteal space the great ischiatic nerve divides into two branches of nearly equal size, the internal and external popliteal. The internal popliteal, 4., runs along the middle line of this space, from apex to apex of its diamond-shaped area. It is placed near the surface, and is easily found on slightly separating the adipose tissue. This nerve divides the region into two equal halves: in the external one will be found a large branch of the internal popliteal, the external saphenous nerve, and the external popliteal nerve, 6., lying along the tendon of the biceps muscle.

To the *inner* side of the internal popliteal nerve, at a variable depth, is the *popliteal vein*, to which the external saphenous vein will serve as a guide, and to the *inner* side of the vein, and still deeper, resting on the femur, is the *popliteal artery*.

If therefore it were necessary to place a ligature around the popliteal artery, we should make a longitudinal incision along the middle of the popliteal space, which should divide the *integument*, the *superficial fascia*, remembering the external saphenous vein, the *deep fascia*, then cautiously make our way through the adipose substance,

* The popliteal region, and the superficial anatomy of the calf of the leg.

No. 1. The inner ham-string. 2. The outer ham-string. 3. 3. The two heads of the gastrocnemius muscle. 4. The popliteal artery, vein, and nerve, in their relative position from within outwards; the artery being the deepest, next the vein, and the nerve quite superficial. 5. The termination of the ischiatic nerve dividing into the internal popliteal nerve, and 6. the external popliteal. 7. The external saphenous nerve. 8. The external saphenous vein. 9. The outer border of the soleus muscle. 10. The tendo Achillis.

a little to the inner side of the middle line, down to the artery, and hook around it the aneurismal needle.

In the upper part of the popliteal space, the artery lies comparatively superficially; and is altogether to the inner side of the internal popliteal nerve. In the middle portion it is deepest: and between the heads of the gastrocnemius, it again becomes superficial, but is crossed by numerous muscular branches, both of the artery and nerve, which would interfere with the progress of an operation.

The *floor* of the popliteal space is formed by the expanded inferior extremity of the femur, by the knee-joint, and by the popliteal muscle immediately below the joint.

The POPLITEAL ARTERY (*fig. 6. 4. fig. 9.*) runs obliquely outwards, through the middle of the popliteal space, *from* the opening in the adductor magnus, *to* the lower border of the popliteus muscle, where it divides into the anterior and posterior tibial artery.

In this course it rests first on the femur, then on the posterior ligament of the knee-joint, then on the fascia covering the popliteal muscle: superficial and external to it is the popliteal vein, and still more superficial and external, the internal popliteal nerve. It has, also, in relation with it, four or five lymphatic glands which lie near its cylinder.

The branches of the popliteal artery are, the

Superior external articular,
Superior internal articular,
Azygos articular,
Inferior external articular,
Inferior internal articular,
Sural.

The *Superior articular* arteries, *external* and *internal*, wind around the femur immediately above the condyles, to the front of the knee-joint, anastomosing with each other, with the external circumflex, the anastomotica magna, the inferior articular and the recurrent of the anterior tibial. The external passes beneath the tendon of the biceps, and the internal through an arched opening beneath the tendon of the adductor magnus. They supply the knee-joint and lower part of the femur, and give branches to the vasti muscles.

The *Azygos articular* artery pierces the posterior ligament of the joint, the ligamentum posticum Winslowii,

and supplies the crucial ligaments and synovial membrane.

The *Inferior articular* arteries wind around the head of the tibia, immediately below the joint, and anastomose with each other, the superior articular arteries, and the recurrent of the anterior tibial. The external passes beneath the two external lateral ligaments of the joint, and the internal beneath the internal lateral ligament.

The *Sural* arteries (sura, the calf) are two muscular branches of large size, distributed to the two heads of the gastrocnemius muscle. Other muscular branches are given off from the upper part of the popliteal to supply the ham-string muscles.

The INTERNAL POPLITEAL NERVE (*fig. 6. 4., fig. 8. 9.*) runs through the middle of the popliteal space, from the division of the great ischiatic nerve to the lower border of the popliteus muscle, where it passes with the artery beneath the arch of the soleus, and becomes the posterior tibial nerve. It is superficial in the whole of its course, and lies externally to the vein and artery.

The *branches* of the internal popliteal nerve are, muscular or sural, articular, and a cutaneous branch — the external saphenous nerve.

The *Muscular branches*, of considerable size, and four or five in number, are distributed to the gastrocnemius, soleus, plantaris, and popliteus muscles.

The *Articular branches*, two or three in number, supply the knee-joint; two of the twigs accompanying the internal articular arteries.

The *External* or *short saphenous nerve* (communicans poplitei, vel tibialis) proceeds from the middle of the internal popliteal, and descends in the groove between the two bellies of the gastrocnemius muscle to the middle of the leg; it then pierces the fascia, and, after receiving the communicans peronei, comes into relation with the external saphenous vein, and follows the course of that vein to the outer ankle, to which and to the integument of the heel and foot it distributes branches.

The EXTERNAL POPLITEAL NERVE (peroneal; *fig. 6. 6., fig. 8. 8.*), one half smaller than the internal, passes downwards by the side of the tendon of the biceps, and crosses the internal head of the gastrocnemius and the head of the soleus to the neck of the fibula; it then pierces the

peroneus longus muscle and divides into two branches, *communicans peronei*, cutaneous and articular.

The *branches* of the external popliteal nerve are the *communicans peronei*, *cutaneous* and *articular*.

The *Communicans peronei*, proceeding from the external popliteal near the head of the fibula, crosses the external origin of the gastrocnemius muscle, and, piercing the deep fascia, descends to the middle of the leg, where it joins the external saphenous nerve. It gives off one or two cutaneous filaments in its course.

The *Cutaneous branch* descends the outer side of the leg, supplying the integument.

The *Articular branches* take the course of the external articular arteries to the knee-joint, to which they are distributed.

Dissection of the Leg.

The leg is naturally divided into three regions, *anterior tibial*, *fibular*, and *posterior tibial*. Each region is composed of its appropriate muscles, vessels, and nerves. Those of the anterior tibial region may be thus arranged :

Superficial to the fascia.

Tibial recurrent artery,
Internal saphenous vein,
Internal saphenous nerve,
Musculo-cutaneous nerve.

Beneath the fascia.

Tibialis anticus,
Extensor longus digitorum,
Peroneus tertius,
Extensor proprius pollicis,
Anterior tibial artery,
Anterior tibial nerve.

The student will find it convenient, before commencing the dissection of the leg, to separate the limb from the rest of the body, by dividing the muscles, and sawing across the femur at about its middle. This step is better than disarticulating at the hip-joint, as it gives him an opportunity, at an after period, of studying the ligaments of the hip. The dissection of the anterior tibial region is to be commenced by carrying an incision along the middle of the leg, midway between the tibia and the fibula, from the knee to the ankle, and bounding it inferiorly by a transverse incision, extending from one malleolus to the other. And to expose the tendons on the dorsum of the foot, the longitudinal incision may be carried onwards to the outer side of the base of the great toe, and terminated by another incision directed across the heads of the metatarsal bones.

When the integument of these two regions has been turned aside, a small artery must be sought for near the

head of the tibia, it pierces the deep fascia, and turns upwards upon the knee-joint, to inosculate with the articular arteries. This is the *recurrent branch* of the *anterior tibial* artery.

In dissecting the *superficial fascia* from the anterior tibial region, it is desirable to commence by finding the situation of the superficial vessels and nerves, and take them as a point of departure, and a guide to the direction in which the dissection should be pursued. Unless this be done there is a danger of cutting away branches of vessels or filaments of nerves without perceiving them. Although this advice is suggested by the dissection of the present region, it is equally applicable to all the regions of the body. The young dissector must apply to one of his seniors or to the Demonstrator to have the precise spot pointed out to him, where superficial vessels or nerves are to be found. The following remarks will aid him in his search.

On the inner side of the leg will be found the *internal saphenous vein*, and the numerous branches which empty themselves into it in its course. This vein commences on the inner side of the dorsum of the foot, where it receives the inner termination of a venous arch which lies across the metatarsal bones. It then runs in front of the inner malleolus and ascends the inner side of the leg; passes behind the inner condyle of the femur, and is continued upwards along the inner side of the thigh to the saphenous opening.

In company with the internal saphenous vein is the *internal saphenous nerve*, a branch of the anterior crural. This nerve pierces the fascia lata at the knee, and gives off several cutaneous filaments in its course downwards. Below the ankle it is distributed to the inner side of the foot and great toe. In the neighbourhood of the long saphenous nerve may be found the *cutaneous branch of the obturator nerve*, which unites with the internal saphenous, and supplies the integument of the inner side of the leg as far as its middle.

Taking its course along the outer border of the anterior tibial region, is the *cutaneous branch of the external popliteal nerve*; and, at the lower third of the leg and close to the fibula, the *musculo-cutaneous nerve* will be found piercing the deep fascia, and dividing into its two cutaneous branches. These branches pass downwards in front of the ankle to the dorsum of the foot and toes, to which they are distributed; the *external branch*, the

larger of the two supplying three toes and a half; the *internal branch* one toe and a half.

The DEEP FASCIA is strong and tendinous, and firmly attached to the tibia and fibula. By its internal surface it gives origin to the muscles of this region, and between the two malleoli it forms a dense band, called *anterior annular ligament*, which binds down the tendons of the extensor muscles, and forms separate canals for them in their passage forwards to the dorsum of the foot. The anterior annular ligament consists of two portions, upper and lower; — the *upper* portion is the broad band connected with the tibia and fibula, now described. The *lower* portion is placed on the dorsum of the foot, extending between the inner malleolus and the outer surface of the os calcis: the inner extremity has, besides, a second attachment to the plantar fascia, with which it is continuous.

An incision may now be made through the deep fascia, in the course of a line drawn from the midpoint between the head of the fibula and spine of the tibia, to midway between the inner and outer malleolus. This will mark the course of the anterior tibial artery: and an incision made in any part of this line will expose that vessel in its course between the muscles. The structures to be divided are the same as in any other part of the body. (Vide Introduction, page 1.)

The deep fascia is easily separated from the muscles in the lower part of the leg, but above it is closely connected to them, and cannot be removed without dividing some of their fibres. When removing the deep fascia, the anterior annular ligament should be left uninjured.

Muscles of the Anterior Tibial Region.

Tibialis anticus,
Extensor longus digitorum,
Peroneus tertius,
Extensor proprius pollicis.

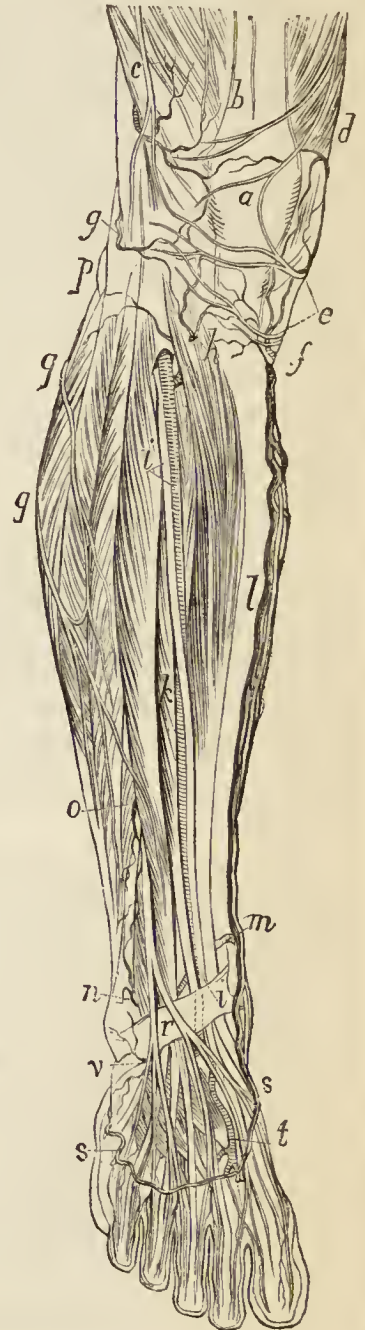
The TIBIALIS ANTICUS muscle (*flexor tarsi tibialis*) arises from the outer tuberosity and upper two thirds of the tibia, from the interosseous membrane, intermuscular fascia, and deep fascia; its tendon passes through a distinct sheath in the annular ligament, and is *inserted* into the inner and under side of the internal cuneiform bone, and base of the metatarsal bone of the great toe.

The *EXTENSOR LONGUS DIGITORUM* arises from the outer tuberosity of the tibia, from the head and upper three-fourths of the fibula, from the interosseous membrane, intermuscular fascia, and deep fascia. Below it divides into four tendons, which pass beneath the annular ligament, to be *inserted* into the second and third phalanges of the four lesser toes. The mode of insertion of the extensor tendons, both in the hand and in the foot, is remarkable (*fig. 17.*); each tendon spreads into a broad aponeurosis, which is situated over the first phalanx, and receives on its borders the insertion of the lumbricales and interossei: this aponeurosis divides into three slips; the middle slip is inserted into the base of the second phalanx, and the two lateral slips are continued onwards to be inserted into the base of the third.

The *PERONEUS TERTIUS* (flexor tarsi fibularis) arises from the lower fourth of the fibula, and intermuscular fascia; it is *inserted* into the base of the metatarsal bone of the little toe. Although it appears to be merely a part of the extensor longus digitorum, it may be looked upon as analogous to the flexor carpi ulnaris of the fore-arm. Sometimes it is altogether wanting.

The *EXTENSOR PROPRIUS POLLICIS* lies between the tibialis anticus and extensor longus digitorum. It arises from the lower two-thirds of the fibula and interosseous membrane. Its tendon passes through a distinct sheath in the annular ligament, and is *inserted* into the base of the last phalanx of the great toe.

Fig. 7.*



* Vessels and nerves of the front of the leg.—*a.* The patella. *b.* The tendon of the rectus muscle; the nerves, one on either side of the letter, are the middle cutaneous. *c.* The vastus externus muscle; the nerve lying on this muscle is the external cutaneous; and the

ACTIONS. — The tibialis anticus and peroneus tertius are direct flexors of the tarsus upon the leg; acting in conjunction with the tibialis posticus, and peroneus longus and brevis, they direct the foot either inwards or outwards, and preserve its flatness in progression. The extensor longus digitorum, and extensor proprius pollicis, are direct extensors of the phalanges: but continuing their action, they assist the tibialis anticus and peroneus tertius, in flexing the entire foot upon the leg. Taking their origin from below, they increase the stability of the ankle.

Vessels and Nerves of the Anterior Tibial Region.

We have seen in a previous section that the popliteal artery divides into the anterior and posterior tibial.

The ANTERIOR TIBIAL passes forwards between the two heads of the tibialis posticus muscle, then through the opening in the upper part of the interosseous membrane, to the anterior tibial region. From this point it runs down the anterior aspect of the leg to the ankle joint, where it becomes the dorsalis pedis. In its course it rests upon the interosseous membrane, the lower part of the tibia, and the anterior ligament of the joint. In the upper third of its course it is situated between the tibialis anticus and extensor longus digitorum; lower down between the tibialis anticus and extensor proprius pollicis; and just before it reaches the ankle it is crossed

artery, the superior external articular. *d.* The vastus internus muscle; the nerve lying upon it is the anterior branch of the internal cutaneous; the artery, the superior internal articular. *e.* Patellar branches of the long saphenous nerve. *f.* The inferior internal articular artery. *g.* The inferior external articular artery. *h.* The recurrent articular, a branch of the anterior tibial artery; the letter is placed on the upper part of the tibialis anticus muscle. *i, i.* The anterior tibial artery and nerve; the upper letter is placed on the extensor longus digitorum muscle; the lower on the anterior annular ligament. *k.* The extensor proprius pollicis muscle. *l.* The tibia; the vein lying to the inner side of this letter is the long saphenous, with its accompanying nerve. *m.* The internal malleolar artery. *n.* The external malleolar artery; its trunk is seen just above the annular ligament. *o.* The anterior peroneal artery. *p.* The external popliteal nerve piercing the head of the peroneus muscle. *q, q.* Cutaneous branches of the external popliteal nerve; the three muscles crossed by these nerves are the gastrocnemius and the two peronei. *r.* The musculo-cutaneous nerve, separating into its two divisions for the supply of the foot. *s, s.* The venous arch of the dorsum of the foot, from which the long and short saphenous veins arise. *t.* The dorsalis pedis artery accompanied by the anterior tibial nerve. *v.* The tarsea artery.

by the tendon of the extensor proprius pollicis, and becomes placed between that tendon and the tendons of the extensor longus digitorum. Its immediate relations are, the venæ comites, and the anterior tibial nerve: the latter lies at first to its outer side; about the middle of the leg it becomes placed in front of the artery; and at the ankle is again at its outer side.

Operations. — The anterior tibial artery may be tied in any part of its course (after it has escaped through the opening in the interosseous membrane), by making an incision in the direction of a line drawn from the midpoint, between the anterior borders of the tibia and fibula in the upper third of the leg, to the middle of the ankle.

The operation in the *upper third* of the course of the artery is one of considerable difficulty. — 1st. On account of the absence of any positive guide to the interspace between the tibialis anticus and extensor longus digitorum muscles; 2d. On account of the great depth of the artery; and 3dly. On account of the unyielding nature of the deep fascia, which constricts the external orifice of the wound. In consequence of these impediments, the artery is never operated upon in this situation, excepting for the purpose of securing both ends of the vessel in accidental wounds. The incision in the integument and deep fascia must be four inches in length. The artery has a vein to either side, *venæ comites*; the nerve lies to its outer side.

In the *middle third* of the leg, the incision is to be made in the same direction, and about three inches in length. The structures to be divided are the *integument, superficial fascia, and deep fascia*. Then the interspace between the tibialis anticus and extensor proprius pollicis is to be found, and the two muscles separated. Lying at the bottom of the interval between them, and supported by the interosseous membrane, will be seen the artery, accompanied by its venæ comites, and having the anterior tibial nerve resting upon it. The nerve is to be drawn carefully aside, the sheath of the vessels opened, and the ligature conveyed, by means of the aneurism needle, around the artery.

In the *lower third* of the leg, an incision in the same direction but two inches in length will suffice. The structures to be cut through are the same as in the former operation. The artery will be found resting on the bone, between the tendons of the tibialis anticus and extensor longus digitorum, or, nearer to the ankle, between the tendons of the extensor longus digitorum and extensor proprius pollicis. The relations to the veins are the same; the nerve lies to its outer side.

The *branches* of the anterior tibial artery are the

Recurrent,	External malleolar,
Muscular,	Internal malleolar.

The *recurrent* branch passes upwards to the front of the knee-joint upon which it is distributed, anastomosing

with the articular arteries. It pierces the origin of the tibialis anticus muscle.

The *muscular* branches supply the muscles of the anterior tibial region.

The *malleolar arteries* are distributed to the ankle joint; the *external* passing beneath the tendons of the extensor longus digitorum and peroneus tertius, and inosculating with the anterior peroneal artery and dorsalis pedis; the *internal* beneath the tendons of the extensor proprius pollicis and tibialis anticus, inosculates with branches of the posterior tibial and internal plantar artery.

The ANTERIOR TIBIAL NERVE (*interosseous*, *fig. 8. 13.*) commences at the bifurcation of the external popliteal upon the neck of the fibula, and passes beneath the upper part of the extensor longus digitorum, to reach the outer side of the anterior tibial artery, just as that vessel has passed through the opening in the interosseous membrane. It descends with the artery, lying at first to its outer side, and then in front of it, and near the ankle becomes again placed to its outer side. It supplies the muscles of the anterior tibial region, and on the foot accompanies the dorsalis pedis artery to the space between the great and second toe.

Dorsal Region of the Foot.

The deep fascia in this region is extremely thin, and can hardly be said to exist: the muscles on the dorsum of the foot are,

Extensor brevis digitorum,

4 Dorsal interossei { bicipital { 1 adductor,
3 abductors.

The EXTENSOR BREVIS DIGITORUM muscle *arises* from the outer side of the os calcis, crosses the foot obliquely, and terminates in four tendons, the innermost of which is *inserted* into the base of the first phalanx of the great toe, and the other three into the sides of the long extensor tendons of the second, third, and fourth toes.

The DORSAL INTEROSSEI muscles are placed between the metatarsal bones; they resemble the analogous muscles of the hand in *arising* by two heads from the adjacent sides of the metatarsal bones; their tendons are *inserted*

into the base of the first phalanx, and into the digital expansion of the tendons of the long extensor.

The *first dorsal interosseous* is *inserted* into the inner side of the second toe, and is therefore an *adductor*; the other three are *inserted* into the outer side of the second, third, and fourth toes, and are therefore *abductors*.

Communicating arteries (posterior perforantes), between the dorsum and sole of the foot, pass between the bifid origins of these muscles.

The ARTERY of the dorsum of the foot, DORSALIS PEDIS, is the continuation of the anterior tibial; it runs along the dorsum of the foot, from the ankle to the base of the first metatarsal space, where it gives off a branch, the *dorsalis pollicis*, and then dips between the two heads of the first dorsal interosseous muscle into the sole of the foot, and becomes continuous with the deep plantar arch. In its course along the foot it gives off the *tarsea* and *metatarsea*, and is placed on the outer side of the tendon of the extensor proprius pollicis; on its fibular side it has the tendon of the extensor longus digitorum, and near its termination is crossed by the inner tendon of the extensor brevis digitorum.

Operation. — The dorsalis pedis artery is to be exposed, by making an incision two inches in length along the external border of the tendon of the extensor proprius pollicis muscle, beginning at the ankle joint. The artery, accompanied by its two veins and nerve, rests upon the bones of the tarsus, between the tendons of the extensor proprius pollicis and extensor longus digitorum. Near the base of the metatarsal bones it is crossed by the innermost tendon of the extensor brevis digitorum.

The *tarsea* crosses the dorsum of the foot in an arched direction, beneath the extensor brevis digitorum muscle. It supplies the articulations of the tarsal bones, and inosculates at the outer border of the foot with the external malleolar, peroneal arteries, and external plantar.

The *metatarsea* forms a similar arch across the bases of the metatarsal bones, and terminates on the outer side of the foot by inosculating with the *tarsea*, and external plantar artery. From its convex side the *metatarsea* gives off three branches, the *interosseæ*, which pass forwards on the interossei muscles and divide into branches (dorsal collateral) which supply the sides of the toes between which they are placed. Near their origin the

interosseæ receive the posterior perforating branches from the plantar arch; and at their bifurcation they are joined by the anterior perforating branches from the digital arteries. The interosseous artery of the fourth interosseous space, in addition to the two dorsal collateral branches into which it bifurcates, sends a third to the outer side of the little toe.

The *dorsalis pollicis* runs forward upon the first dorsal interosseous muscle, and at the base of the first phalanx divides into two branches, *one* of which passes beneath the tendon of the extensor proprius pollicis, and is distributed to the inner border of the great toe; the *other* bifurcates into two collateral branches, which supply the adjacent sides of the great and second toe.

While in the metatarsal space the dorsalis pedis artery gives off another branch, *magna pollicis*, which sends a digital branch to the inner border of the great toe, and then bifurcates to supply the collateral digital branches of the great and second toe.

The VEINS of the dorsum of the foot are a *venous arch* which lies across the metatarsus, and the *internal* and *external saphenous veins*. The venous arch receives the digital veins by its convex side, and terminates in the saphenous veins.

The *internal saphenous vein*, taking its origin by the veins of the great toe and inner termination of the venous arch, passes upwards along the inner border of the foot, and in front of the inner ankle to the side of the leg, whence it is continued to the saphenous opening.

The *external saphenous vein* commences in a similar manner on the outer side of the little toe and side of the foot; it receives the outer termination of the venous arch, passes behind the outer ankle, and ascends along the back of the leg to the popliteal region, where it enters an opening in the deep fascia and joins the popliteal vein.

The NERVES distributed upon the dorsum of the foot are five in number, namely, the *internal* and *external branches* of the *musculo-cutaneous* nerve; the *internal* and *external saphenous* nerves, and the *anterior tibial*.

The *cutaneous branches* of the *musculo-cutaneous nerve* divide into a leash of branches which spread out upon the dorsum of the foot in their course to the toes.

The *internal branch*, the smaller of the two, is distributed to the inner side of the foot and great toe, and communicates with the anterior tibial and internal saphenous. The *external*, or larger branch, supplies the adjacent sides of the second and third, third and fourth, and fourth and fifth toes, and communicates with the external saphenous.

The *internal* or *long saphenous nerve* passes along the inner side of the foot as far as the base of the metatarsus, and communicates with the internal cutaneous nerve.

The *short* or *external saphenous nerve* advances along the outer border of the foot from behind the outer ankle. It is distributed to the outer side of the little toe, and sometimes its inner side and the adjacent side of the next. It communicates with the external cutaneous nerve.

The *anterior tibial nerve* gives off a large branch to the extensor brevis digitorum muscle, and becoming superficial on the first interosseous muscle, is distributed to the adjacent sides of the great and second toe; while on the interosseous muscle it receives a branch of communication from the internal cutaneous nerve, and sometimes this branch is so large as to supersede the anterior tibial in its distribution. The branch to the extensor brevis digitorum, after supplying the muscle, becomes gangliiform and distributes branches to the articulations of the tarsus.

Fibular Region.

If the leg be turned upon its inner side and the deep fascia removed from over the fibula, two muscles will be exposed which arise from that bone: these are the peroneus longus and brevis. They are separated from the muscles before and behind by intermuscular septa, from which they partly take their origin. At the outer ankle the deep fascia is thickened, and extending from the external malleolus to the side of the os calcis constitutes the *external annular ligament*. This ligamentous band forms a sheath for the peronei muscles in their passage behind the outer ankle; the sheath is lined by synovial membrane.

The PERONEUS LONGUS (*περοννη*, fibula, extensor tarsi fibularis longior) arises from the head and upper half of the fibula; also from the deep fascia and intermuscular septa: its tendon passes behind the outer malleolus to a groove in the cuboid bone, through which it proceeds obliquely across the foot to be *inserted* into the base of

the metatarsal bone of the great toe. The tendon is thickened where it passes behind the external malleolus, and a sesamoid bone is developed in that part which is lodged in the groove of the cuboid bone.

The PERONEUS BREVIS (extensor tarsi fibularis brevior) arises from the lower half of the fibula and from the intermuscular septa; its tendon passes behind the external malleolus, with the tendon of the preceding muscle, and through a groove in the os calcis to be inserted into the base of the metatarsal bone of the little toe.

ACTIONS. — The peronei muscles are extensors of the foot conjointly with the tibialis posticus. They antagonise the tibialis anticus and peroneus tertius, which are flexors of the foot. The whole of these muscles acting together tend to maintain the flatness of the foot, so necessary to security in walking.

There is no artery in this region, but if the peroneus longus muscle be carefully turned aside from its origin, the external popliteal or peroneal nerve will be seen to give off a small *recurrent branch*, which takes the course of the recurrent tibial artery to the front of the knee; and then divides into its two terminal branches, the *anterior tibial nerve* and *musculo-cutaneous*.

The *anterior tibial nerve* may now be seen piercing the head of the extensor longus digitorum to reach the anterior tibial; its course has already been described, page 55.

The *musculo-cutaneous*, the proper nerve of the region, passes downwards in the substance of the peroneus longus; it then gets between the peroneus longus and brevis; then between the peronei and the extensor longus digitorum; and at the lower third of the leg pierces the deep fascia and divides into the internal and external cutaneous nerves of the foot. In its course among the muscles the nerve gives several branches to the peronei. The cutaneous branches have been already described, page 57.

Posterior Tibial Region.

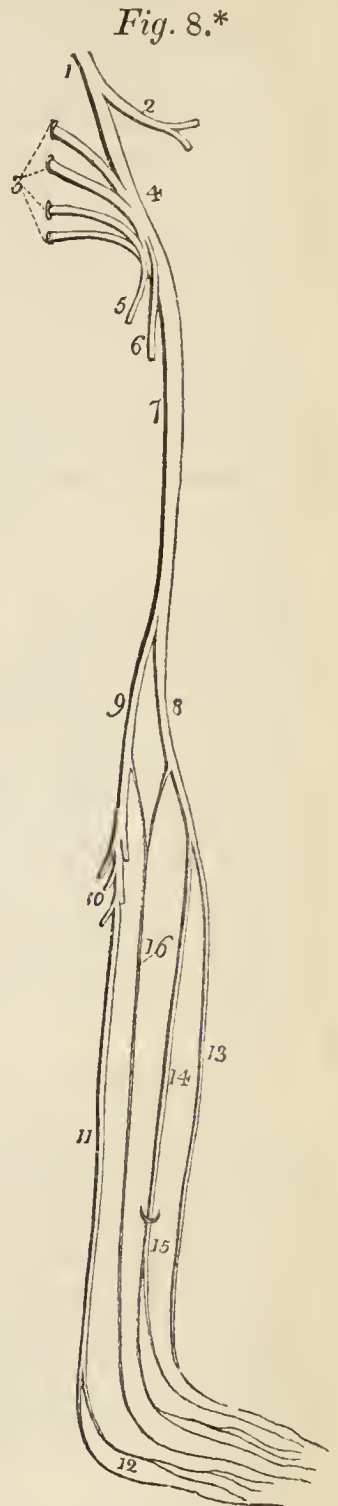
This region is best dissected by making an incision from the middle of the popliteal space, down the middle of the posterior part of the leg, to the tuberosity of the os calcis, bounding it inferiorly by a transverse incision to each malleolus. Turning aside the two flaps

of integument, the superficial fascia is brought into view, and between its two layers will be found the superficial vessels and nerves. In the middle line is the external saphenous vein, accompanied above by the lesser ischiatic nerve, and below, by the external saphenous nerve. On the inner side of the leg is the internal saphenous vein and nerve, with the termination of the internal cutaneous nerve. On the outer side are several cutaneous branches from the external popliteal, one of which is the *communicans peronei*.

The *external saphenous vein* (*fig. 6. 8.*) commences on the outer side of the little toe, and after receiving the external termination of the venous arch, passes along the outer side of the foot, behind the external malleolus, and up the middle of the back of the leg to the popliteal region. In its course along the leg it lies in the groove between the two bellies of the gastrocnemius muscle, and in the ham pierces the deep fascia to join the popliteal vein.

The *lesser ischiatic nerve* pierces the popliteal fascia and descends by the side of the external saphenous vein to the point of emergence of the external saphenous nerve, with which it joins, after giving off several cutaneous twigs.

The *short or external saphenous nerve* (*fig. 6. 7. ; fig. 8. 16.*) will be found lying by the side of the external saphenous vein; in the lower part of the leg it pierces the deep fascia just below the gastrocnemius groove, and descends with the external saphenous vein; passes be-



* *Fig. 8.* A diagram showing the formation and branches of the sacral plexus.

No. 1. The lumbo-sacral nerve, descending to join the sacral plexus, and giving off a large branch. 2. The gluteal nerve. 3. The anterior branches of the four upper sacral nerves. 4. The sacral plexus. 5. The internal pudic nerve. 6. The lesser ischiatic

hind the external malleolus and along the outer border of the foot. It is distributed to the outer part of the foot and little toe, and communicates with the external cutaneous nerve.

The *internal saphenous vein and nerve* have been described with the dissection of the anterior tibial region. The *internal cutaneous* branches of the anterior crural are distributed to the integument of the inner side of the calf behind the internal saphenous vein.

The *communicans peronei*, a branch of the external popliteal nerve, pierces the deep fascia near the head of the fibula, and descends to the external saphenous nerve, which it joins; in its course it gives off cutaneous filaments. Along the outer border of the leg are other *cutaneous branches*, derived from the external popliteal nerve.

The DEEP FASCIA, in the upper part of this region, is thin: below it is thicker; on the inner side it is connected with the tibia, and externally is continuous with the deep fascia of the front of the leg. If the deep fascia be turned aside, the three muscles forming the superficial group of the posterior tibial region will be brought into view; they are —

Gastrocnemius,
Plantaris,
Soleus.

The GASTROCNEMIUS (*γαστροκνημιον*, the bellied part of the leg) *arises* by two heads from the two condyles of the femur, the inner head being the longest. They unite to form the beautiful muscle so characteristic of this region of the limb. It is *inserted*, by means of the tendo Achillis, into the lower part of the posterior tuberosity of the os calcis, a synovial bursa being placed between the tendon and the upper part of the tuberosity. The gastrocnemius must be removed from its origin, and turned down, in order to expose the next muscle.

The PLANTARIS (*planta*, the sole of the foot), an extremely diminutive muscle, situated between the gas-

nerve. 7. The great ischiatic nerve. 8. The external popliteal nerve. 9. The internal popliteal nerve. 10. Its sural branches. 11. The posterior tibial nerve, dividing inferiorly into the two plantar nerves, 12. 13. The anterior tibial nerve. 14. The musculocutaneous nerve, its muscular portion. 15. Its cutaneous portion, consisting of two branches. 16. The external saphenous nerve.

trocnemius and soleus, *arises* from the outer condyle of the femur, and is *inserted*, by its long and delicately slender tendon, into the posterior tuberosity of the os calcis, by the side of the tendo Achillis. It crosses between the gastrocnemius and soleus in its descent.

The SOLEUS (solea, a sole) is the broad muscle upon which the plantaris rests. It *arises* from the head and upper third of the fibula, from the oblique line, and middle third of the tibia. Its fibres converge to the tendo Achillis, by which it is *inserted* into the posterior tuberosity of the os calcis.

Between the fibular and tibial origins of this muscle is a tendinous arch, beneath which the popliteal vessels and nerve pass into the leg. The soleus muscle must now be divided along its extensive origin, and turned down.

ACTIONS.—The three muscles of the calf draw powerfully on the os calcis, and lift the heel; continuing their action, they raise the entire body. This action is attained by means of a lever of the *second* power, the fulcrum (the toes) being at one end, the weight (the body supported on the tibia) in the middle, and the power (these muscles) at the other extremity.

They are therefore the walking muscles, and perform all movements that require the support of the whole body from the ground, as dancing, leaping, &c. Taking their fixed point from below, they steady the leg upon the foot.

An *intermuscular fascia* serves to separate the superficial from the deep group, and by its strong attachments to the bones at each side, binds down the muscles closely in their places. On removing this fascia, the muscles of the *deep group* are brought clearly into view; they are—

Popliteus,
Flexor longus pollicis,
Flexor longus digitorum,
Tibialis posticus.

The POPLITEUS muscle (poples, the ham of the leg) forms the floor of the popliteal region at its lower part, and is bound tightly down by a strong fascia derived from the middle slip of the tendon of the semi-membranosus muscle (page 44.). It *arises* by a rounded tendon from a deep groove on the outer side of the external condyle of the femur, beneath the external lateral ligament and within the capsular ligament of the joint. It spreads obliquely over the head of the tibia, and is *inserted* into the surface of bone above its oblique line. This line is

often called, from being the limit of insertion of the popliteus muscle, popliteal line.

The next three muscles in their course into the sole of the foot pass under cover of an aponeurosis extended between the inner malleolus and the side of the os calcis, the *internal annular* ligament. This ligament is narrow at its attachment to the tibia and broad where it is connected with the os calcis; above it is continuous with the deep fascia of the leg, and below gives origin to one of the muscles of the sole of the foot. Towards the bone it sends inwards partitions for the separation of the tendons and vessels.

The FLEXOR LONGUS POLLICIS is the most superficial of the three muscles. It *arises* from the lower two-thirds of the fibula, passes through a groove in the astragalus and os calcis, which is converted by tendinous fibres into a distinct sheath lined by synovial membrane, into the sole of the foot, and is *inserted* into the base of the last phalanx of the great toe.

The FLEXOR LONGUS DIGITORUM (*perforans*) *arises* from the surface of the tibia, immediately below the popliteal line. Its tendon passes through a sheath common to it and the tibialis posticus behind the inner malleolus; it then passes through a second sheath which is connected with a groove in the astragalus and os calcis, into the sole of the foot, where it divides into four tendons, which are *inserted* into the base of the last phalanx of the four lesser toes, perforating the tendons of the flexor brevis digitorum.

The flexor longus pollicis must now be removed from its origin, and the flexor longus digitorum drawn aside, to bring into view a fascia which is attached on either side to the tibia and fibula, and which binds down the tibialis posticus. The two preceding muscles take part of their origin from this fascia.

The TIBIALIS POSTICUS (*extensor tarsi tibialis*) lies upon the interosseous membrane, between the two bones of the leg. It *arises* by two heads from the adjacent sides of the tibia and fibula their whole length, from the interosseous membrane, and from the aponeurosis which binds it in its place. Its tendon passes inwards beneath the tendon of the flexor longus digitorum, and runs in the same sheath; it then passes through a proper sheath over

the deltoid ligament and beneath the calcaneo-scapoid articulation to be *inserted* into the tuberosity of the scaphoid and internal cuneiform bone; a process of its tendon being prolonged outwards to the external cuneiform.

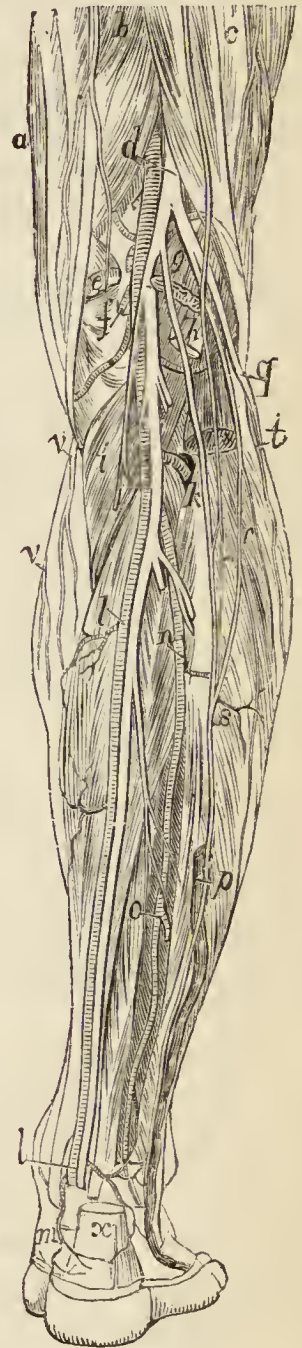
The student will observe that the two latter muscles change their relative position to each other in their course. Thus, in the leg, the position of the three muscles from within outwards, is flexor longus digitorum, tibialis posticus, flexor longus pollicis. At the inner malleolus, the relation of the tendons is tibialis posticus, flexor longus digitorum, both in the same sheath; then a broad groove, which lodges the posterior tibial artery, venæ comites, and nerve; and lastly, the flexor longus pollicis.

The ARTERIES of the posterior tibial region are the posterior tibial and its branches.

The POSTERIOR TIBIAL ARTERY passes obliquely downwards along the tibial side of the leg from the lower border of the popliteus muscle to the concavity of the os calcis, where it divides into the internal and external plantar artery. In its course, it rests upon the tibialis posticus, flexor longus digitorum, and tibia, and is covered in by the intermuscular fascia. It is accompanied by venæ comites, and the posterior tibial nerve, which lies to its inner side above, and to the outer side in the rest of its course.

Operation.— One of the most difficult operations in the entire body is the ligation of the posterior tibial artery, in the *upper third* of its course. It is happily one rarely required, except

Fig. 9.*



* Vessels and nerves of the posterior aspect of the leg.— *a*. The muscles of the inner hamstring. *b*. The semi-tendinosus; the nerve lying upon this muscle is the inner branch of the internal cutaneous. *c*. The biceps muscle; the nerve lying upon this muscle is the lesser sciatic; and the smaller nerve externally to the letter *a* a branch of the external cutaneous. *d*. The popliteal artery and great ischiatic

ing in the case of accidental wound, where both extremities of the vessel must be secured. An incision four or five inches in length, is made parallel with the inner border of the tibia, and about half an inch distant. This will divide the *integument, superficial fascia,* and *deep fascia*; the border of the gastrocnemius is then to be held aside, and another incision of the same extent made through the soleus down to the intermuscular fascia. When the intermuscular fascia is clearly exposed, it may be slit up. The artery, with its venæ comites and nerve, lie immediately beneath it, near the middle line of the leg, and resting upon the tibialis posticus muscle. The nerve lies upon the artery, or directly to its outer side.

In the *middle third* of the course of the artery a longitudinal incision two inches and a half in length should be made parallel with the internal border of the tibia and tendo Achillis, and midway between them. The *integument, superficial* and *deep fascia,* should be divided and the sheath of the vessels opened upon a director. The artery lies between the venæ comites, and the nerve is to the outer side.

At the ankle, an incision two inches in length is sufficient. It must be directed obliquely from the inner border of the tendo Achillis, to the point of the internal malleolus, or in the opposite

nerve; the latter is dividing into the external and internal popliteal nerve. The letter is placed on the semi-membranosus muscle. *e.* The internal head of the gastrocnemius muscle; the artery crossing the popliteal space above this muscle is the superior internal articular. *f.* The popliteal artery; the branch near the letter is the azygos articular, and that which crosses the popliteal space below the letter is the inferior internal articular. *g.* The external head of the gastrocnemius muscle; above this head is seen the superior external articular artery. *h.* The plantaris muscle; the artery crossing below it is the inferior external articular. *i.* The popliteus muscle. *k.* The anterior tibial artery passing between the two heads of the tibialis posticus and through the interosseous membrane to the front of the leg. *l, l.* The posterior tibial artery; the upper letter rests on the flexor longus digitorum; the line leading to the lower letter crosses the tendons of the tibialis posticus and flexor longus digitorum. *m.* A calcanean branch of the posterior tibial artery. *n.* The peroneal artery; the letter rests on the tibialis posticus. *o.* The point of division of the peroneal artery; the letter rests on the inner part of the flexor longus pollicis muscle, a piece of which is cut away in order to show the artery. *p.* The short saphenous vein and nerve; this nerve may be seen arising from the internal popliteal nerve under the name of *communicans tibialis* at *g.* *q.* The external popliteal nerve. *r.* Its *communicans peronei* branch, which communicates at *s* with the *communicans tibialis.* *t.* A cutaneous branch of the external popliteal nerve. *v.* Branches of the long saphenous nerve. *x.* The tendo Achillis cut across just above its insertion into the os calcis. The internal popliteal nerve accompanies the popliteal artery, and the posterior tibial nerve the posterior tibial artery.

direction, as may be most convenient. It will divide the *integument*, *superficial fascia*, and *deep fascia*. The next step, in the living subject, would be to feel for the pulsation of the artery; but, in the dead, the student will find the sheath containing the vessels at about three quarters of an inch from the edge of the malleolus. The nerve lies to the outer side of the artery. If the student open a sheath lying immediately under cover of the malleolus, he will find it to contain the tendons of the flexor longus digitorum and tibialis posticus muscles. And if he get too near the tendo Achillis, he will open the sheath of the tendon of the flexor longus pollicis.

The *branches* of the posterior tibial artery are the

Peroneal,	Internal calcanean,
Nutritious,	Internal plantar,
Muscular,	External plantar.

The *peroneal artery* is given off from the posterior tibial at about two inches below the lower border of the popliteus muscle; it is nearly as large as the anterior tibial artery, and passes obliquely outwards to the fibula. It then runs downwards along the inner border of the fibula to its lower third, where it divides into the anterior and posterior peroneal artery. At the upper part of its course it rests upon the tibialis posticus, but soon gets under cover of the flexor longus pollicis, having the fibula to its outer side. The peroneal artery previously to its division gives off *muscular branches* and a *nutrient branch* to the fibula.

Operation.—From the very deep position of the fibular artery beneath the flexor longus pollicis muscle, and behind the fibula, this is a very difficult operation. This may well be conceived, when it is recollected that it has been proposed to saw away a portion of the bone to reach the artery. Like the operation on the upper part of the tibial arteries, it is not likely to be required except in the case of accidental wound. The operation is performed in the middle third of the leg, previously to the division of the artery into the anterior and posterior peroneal. An incision, four inches in length, must be made parallel with and at about an inch distant from the fibula. The integument, superficial and deep fascia, being drawn aside, the soleus and intermuscular fascia must be divided to the same extent. The flexor longus pollicis is then to be separated from the fibula, and drawn outwards. Beneath this muscle, by the side of the fibula, will be found the artery. It has no accompanying nerve.

The *anterior peroneal artery*, at the lower third of the leg, pierces the interosseous membrane, and is distributed on the front of the outer malleolus, anastomosing with the external malleolar and tarsal artery.

The *posterior peroneal* continues onwards along the posterior aspect of the outer malleolus to the side of the os calcis, to which, and to the muscles arising from it, it distributes *external calcanean* branches. It anastomoses with the anterior peroneal, tarsal, external plantar, and posterior tibial artery—with the latter by means of a small *transverse* branch.

The *nutritious artery* of the tibia arises from the trunk of the tibial, frequently above the origin of the peroneal, and proceeds to the nutritious canal, which it traverses obliquely from below upwards.

The *muscular branches* of the posterior tibial artery are distributed to the soleus and deep muscles on the posterior aspect of the leg. One branch is deserving of notice, a *recurrent branch*, which arises from the posterior tibial above the origin of the peroneal artery, pierces the soleus, and is distributed upon the inner side of the head of the tibia, anastomosing with the inferior internal articular.

The *internal calcanean branches*, three or four in number, proceed from the posterior tibial artery immediately before its division; they are distributed to the inner side of the os calcis, to the integument, and to the muscles which arise from its inner tuberosity, and anastomose with the external calcanean branches of the posterior peroneal, and with all the neighbouring arteries.

The POSTERIOR TIBIAL VEINS receive the veins which accompany the numerous branches of the posterior tibial and peroneal arteries, and terminate in the popliteal vein.

The POSTERIOR TIBIAL NERVE is continued along the posterior aspect of the leg from the lower border of the popliteus muscle to the posterior part of the inner ankle, where it divides into the internal and external plantar nerve. In the upper part of its course it lies to the inner side of the posterior tibial artery; it then becomes placed to its outer side; in the lower third of the leg it lies parallel with the inner border of the tendo Achillis.

The *branches* of the posterior tibial nerve are *muscular* twigs to the deep muscles of the posterior aspect of the leg, the branch to the flexor longus pollicis accompanies the fibular artery; one or two filaments which entwine around the artery and then terminate in the integument; and a *plantar cutaneous* branch which is distributed to

the integument of the heel, and inner border of the sole of the foot.

SOLE OF THE FOOT.

Dissection.—The sole of the foot is to be dissected by carrying a longitudinal incision along the middle of the foot from the heel to the base of the toes, and crossing it in the latter situation by a transverse incision. The integument is next to be dissected off the superficial fascia, so as to make an inner and an outer flap. Each of the toes is then to be treated in a similar manner, being laid open by a longitudinal incision.

The SUPERFICIAL FASCIA is closely adherent to the integument, and must be raised in the same manner, turning the flaps to either side. In so doing, the cutaneous nerve of the sole of the foot is to be sought for near the heel; and near the front of the foot, the digital arteries and nerves to the outer sides of the great and little toes. When turned up and examined on its under surface, the superficial fascia has the appearance of a dense cushion of fat held down at numerous points by strong cellular tissue.

The DEEP, or PLANTAR, FASCIA is a strong aponeurotic structure stretched between the under surface of the tuberosities of the calcaneum and the heads of the metatarsal bones. It thus serves a double purpose, being mainly instrumental in preserving the convexity of the arch of the foot, while it protects from injurious pressure the soft parts between it and the bones. This fascia is divided into three portions, a middle and two lateral. The *middle portion* is very dense, and is made up of strong tendinous fibres, closely interlaced with each other. It occupies the middle of the sole, and terminates towards the toes in five slips, which are held firmly together by transverse bands of fibres passing between and interlacing them. Each of the slips embraces the base of the corresponding toe, and is attached in the middle to the sheath of the flexor tendons, and at either side to the head of the metatarsal bone. Between the slips at their base, the transverse bands of fibres already described form a kind of arch of protection to the digital vessels and nerves. The *lateral portions* of the plantar fascia cover in the muscles of the borders of the foot; the *inner* portion being continuous with the fascia of the dorsum of the

foot, and the *outer* one attached to the os calcis and base of the metatarsal bone of the little toe. Between these latter points the fascia forms a thick band, which gives origin to a part of the abductor minimi digiti muscle. At the junction of the middle with the lateral portions of the fascia lata, two septa are sent inwards, which separate the three superficial muscles, and form a complete sheath for the middle muscle, the flexor brevis digitorum.

The lateral portions of the plantar fascia are easily removed from the muscles. The middle portion must be divided through its middle, and each extremity raised separately; the anterior towards the toes, from which it may be divided; the posterior towards the os calcis: this latter dissection cannot, however, be effected without dividing many of the muscular fibres of the flexor brevis digitorum, which arise from the surface of the fascia. When the fascia is removed the lateral septa may be seen, together with two digital nerves which perforate the septa, and the tendon of the flexor longus pollicis.

The MUSCLES of the sole of the foot may be arranged in four layers: —

First Layer.

Abductor pollicis,	Flexor brevis digitorum.
Abductor minimi digiti,	

Second Layer.

Tendon of the flexor longus pollicis,	Accessorius,
Tendons of the flexor longus digitorum,	Lumbricales (4).

Third Layer.

Flexor brevis pollicis,	Flexor brevis minimi digiti,
Adductor pollicis,	Transversus pedis.

Fourth Layer.

Three plantar interossei (all adductors).

The ABDUCTOR POLLICIS lies along the inner border of the foot; it *arises* by two heads, between which the tendons of the long flexors, arteries, veins, and nerves enter the sole of the foot. One head *arises* from the inner tuberosity of the os calcis, the other from the internal annular ligament and plantar fascia. *Insertion*, into the base of the first phalanx of the great toe, and internal sesamoid bone.

The ABDUCTOR MINIMI DIGITI lies along the outer border of the sole of the foot. It *arises* from the outer tuberosity of the os calcis, and from the plantar fascia, as far forward as the base of the metatarsal bone of the little toe, and is *inserted* into the base of the first phalanx of the little toe.

The FLEXOR BREVIS DIGITORUM (*perforatus*) is placed between the two preceding muscles. It *arises* from the under surface of the os calcis, plantar fascia, and intermuscular septa, and is *inserted* by four tendons into the base of the second phalanx of the four lesser toes. Each tendon divides, previously to its insertion, to give passage to the tendon of the long flexor: hence its cognomen *perforatus*.

Dissection.— These muscles are to be divided posteriorly from their origin, and anteriorly through their tendons, and removed. This will bring into view the second layer, and the external plantar artery and nerve, which lie obliquely across it. At the point where the tendons of the long flexors cross each other, a communicating slip is sent between them, which associates their action.

The MUSCULUS ACCESSORIUS *arises* by two slips from either side of the under surface of the os calcis; the inner slip being fleshy, the outer tendinous and blended with the ligamentum longum plantæ. It is *inserted* into the outer side and upper surface of the tendon of the flexor longus digitorum.

The LUMBRICALES (*lumbricus*, an earthworm) are four little muscles *arising* from the tendons of the flexor longus digitorum at their point of bifurcation, and *inserted* into the expansion of the extensor tendons, and into the base of the first phalanx of the four lesser toes on their tibial side. The innermost lumbricalis is connected with only one tendon.

Dissection.— To expose the third layer of muscles without disturbing the vessels, cut the tendons of the long flexors across through the insertion of the accessorius, draw that muscle with the tendons backwards by means of hooks, and snip off the digital extremities of the tendons. A little cleaning of fat and cellular tissue will then bring clearly into view the third layer of muscles. In this dissection the branches of the internal plantar nerve will run considerable risk, unless the student be careful.

The FLEXOR BREVIS POLLICIS *arises* by a pointed tendinous process from the side of the cuboid, the external

cuneiform bone, and the expanded tendon of the tibialis posticus; it is *inserted* by two heads into the base of the first phalanx of the great toe, the inner head being conjoined with the insertion of the abductor pollicis, the outer head with the adductor pollicis and transversus pedis. Two sesamoid bones are developed in the tendons of insertion of these two heads, and the tendon of the flexor longus pollicis lies in the groove between them.

The ADDUCTOR POLLICIS *arises* from the cuboid bone, from the sheath of the tendon of the peroneus longus, and from the base of the third and fourth metatarsal bones. It is *inserted* into the base of the first phalanx of the great toe, in conjunction with the outer head of the flexor brevis pollicis.

The FLEXOR BREVIS MINIMI DIGITI *arises* from the base of the metatarsal bone of the little toe, and from the sheath of the tendon of the peroneus longus. It is *inserted* into the base of the first phalanx of the little toe, on its outer side.

The TRANSVERSUS PEDIS *arises* by fleshy slips from the heads of the metatarsal bones of the four lesser toes. Its tendon is *inserted* into the base of the first phalanx of the great toe, being blended with that of the adductor pollicis.

The plantar interossei muscles (page 74.) must be left until the arteries and nerves have been dissected and studied.

ACTIONS.—The actions of the muscles in the sole of the foot are implied in their names. See analysis (page 75.).

The ARTERIES of the sole of the foot are the *internal* and *external plantar*, the terminal branches of the posterior tibial artery at the inner malleolus. Their distribution may be thus expressed in a tabular form:—

Posterior tibial	{	internal plantar	{	muscular	{	anterior perforating.
		external plantar		articular		collateral.
				digital		posterior perforating.
				posterior perforating.		

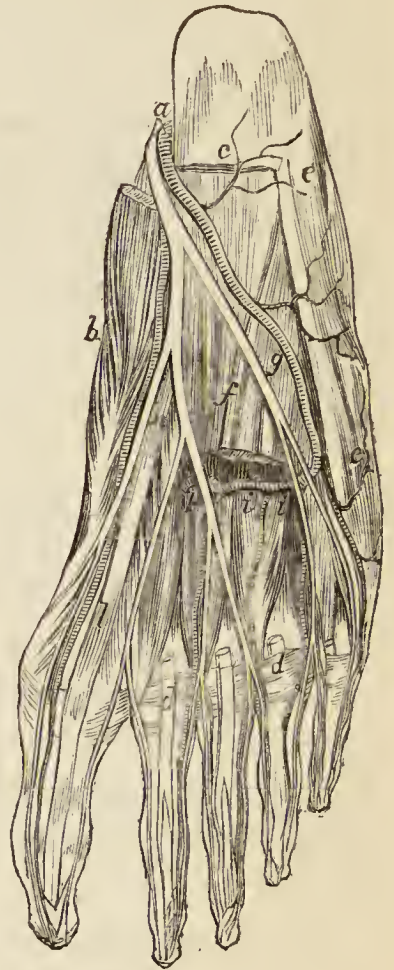
The INTERNAL PLANTAR ARTERY passes along the inner border of the foot beneath the abductor pollicis, and distributes branches to the inner border of the foot and great toe.

The **EXTERNAL PLANTAR ARTERY**, much larger than the internal, passes obliquely outward^a between the first and second layers of the plantar muscles, to the fifth metatarsal space. It then turns horizontally inwards between the second and third layers, to the first metatarsal space, where it inosculates with the *dorsalis pedis*. The horizontal portion of the artery describes a slight curve, having the convexity forwards; this is the plantar arch.

The *muscular* and *articular branches* of the external plantar artery are distributed to the muscles in the sole of the foot and to the articulations of the tarsus.

The *digital branches* are four in number; the first is distributed to the outer side of the little toe; the three others pass forwards to the cleft between the toes, and divide into collateral branches, which supply the adjacent sides of the three external toes, and the outer side of the second. At the bifurcation of the toes, a small branch is sent upwards from each digital artery, to inosculate with the interosseous branches of the metatarsæ; these are the *anterior perforating arteries*.

Fig. 10.*



* Vessels and nerves of the sole of the foot.—*a*. The plantar artery and nerve. *b*. The abductor pollicis; a part of the origin of this muscle has been removed in order to bring into view the plantar artery and nerve. *c*. The origin of the flexor brevis digitorum; the cut tendons of this muscle are seen at *d, d*. *e, e*. The abductor minimi digiti muscle. *f*. The musculus accessorius muscle. *g*. The external plantar artery and nerve. *h*. The internal plantar artery and nerve. *i, i*. The external plantar artery in the deep part of the foot, where it forms the plantar arch: the branches proceeding forwards from the plantar arch are the digital; the short branches passing backwards are the posterior perforating. The muscles on which the letters *i, i* are placed are the interossei. *k*. The external plantar artery passing upwards to the dorsum of the foot to become continuous with the communicating branch of the *dorsalis pedis*. *l*. The tendon of the flexor longus pollicis.

The *posterior perforating* are three small branches which pass upwards between the heads of the three external dorsal interossei muscles, to inosculate with the arch formed by the metatarsal artery.

The NERVES of the sole of the foot are, like the arteries, the *internal* and *external plantar* (*fig. 8. 12.*), terminal branches of the posterior tibial.

The INTERNAL PLANTAR NERVE, larger than the external, crosses the posterior tibial vessels to enter the sole of the foot, and becomes placed between the abductor pollicis and flexor brevis digitorum; it then enters the sheath of the latter muscle, and divides opposite the bases of the metatarsal bones into three digital branches; *one* to supply the adjacent sides of the great and second toe; the *second* the adjacent sides of the second and third toe; and the *third* the corresponding sides of the third and fourth toe. This distribution is precisely similar to that of the digital branches of the median nerve.

In its course the internal plantar nerve gives off *cutaneous branches* to the integument of the inner side and sole of the foot; *muscular* branches; a *digital* branch to the inner border of the great toe; and *articular* branches to the articulations of the tarsal and metatarsal bones.

The EXTERNAL PLANTAR NERVE, the smaller of the two, follows the course of the external plantar artery to the outer border of the musculus accessorius, beneath which it sends several deep branches to supply the adductor pollicis, interossei, transversus pedis and the articulations of the tarsal and metatarsal bones. It then gives branches to the integument of the outer border and sole of the foot, and sends forward two digital branches to supply the little toe and half the next.

When the arteries and nerves have been examined, the transversus pedis and other muscles may be removed which impede the view of the plantar interossei. They are covered in by a thin aponeurotic fascia which is attached in front to a ligamentous band passing between the heads of the metatarsal bones, the *transverse ligament*. This ligament as well as the fascia must be divided in order to bring the full extent of the interossei into view.

The PLANTAR INTEROSSEI muscles are three in number, and are placed *upon* rather than between the metatarsal

bones. They *arise* from the base of the metatarsal bones of the three outer toes, and are *inserted* into the inner side of the extensor tendon and base of the first phalanx of the same toes. In their action they are all *adductors*.

When the anatomy of the muscles, vessels, and nerves of the sole of the foot is completed, and the student is preparing to study the ligaments, he should lay open the groove in the cuboid bone by dividing the ligamentous sheath in which it is contained, and expose the tendon of the peroneus longus in its passage across the foot, to its insertion into the base of the metatarsal bone of the great toe. In that portion of the tendon which lies in contact with the cuboid, he will find a sesamoid bone. In some instances the deposit of bone has not taken place, and the thickening of the tendon is merely fibro-cartilaginous. The insertion of the tendon of the tibialis posticus may also be examined at the same time with advantage.

Analysis of the Arrangement and Actions of the Muscles of the lower Extremity.

The lower extremity is composed of, 1st. the femur; 2d. the tibia and fibula; 3d. the tarsus; 4th. the toes. The trunk is the fixed point from which arise the muscles that move the thigh. The articulation of the hip is an universal joint; hence the movements are very numerous, but they may all be referred to the four primary directions, *forwards, backwards, inwards, outwards*, to which is added *rotation* on its axis.

The articulation of the femur with the tibia is a hinge joint, and is therefore applicable only to *flexion* and *extension*: the muscles performing these actions arise from the pelvis and femur. But as we descend, we find the length of the bones diminishing while their numbers increase. The foot is a compound organ made up of a number of parts, each part performing distinct movements. We are therefore prepared to find a number of muscles destined to supply these demands. But numerous as they really are, they may, by a careful analysis, be arranged and grouped under a few simple actions.

The movements of the tarsus may be referred to four heads, *flexion, extension, adduction, abduction*, the two latter actions being very imperfect. The muscles performing these movements are the following:—

Flexion.

Tibialis anticus,
Peroneus tertius.

Extension.

Tibialis posticus,
Peroneus longus,
———— brevis, and where
forcible action is required
as in walking,
Gastrocnemius,
Plantaris,
Soleus.

Adduction.

Tibialis anticus,
———— posticus.

Abduction.

Peroneus longus,
———— brevis.

The movements of the toes may in the same manner be reduced to precisely the same simplicity of action, thus : —

Flexion.

Flexor longus digitorum,
———— brevis digitorum,
———— accessorius,
———— minimi digiti.

Extension.

Extensor longus digitorum,
———— brevis digitorum.

Adduction.

Interossei, { 1 dorsal.
 { 3 plantar.

Abduction.

Interossei, 3 dorsal.
Abductor minimi digiti.

The great toe, like the thumb in the hand, enjoys an independence of action, and is therefore provided with distinct muscles to perform its movements. But even here the direction of the actions is nothing more than is possessed by each of the other toes, and may be referred to the same plan, thus : —

Flexion.

Flexor longus pollicis,
———— brevis pollicis.

Extension.

Extensor proprius pollicis,
———— brevis digitorum.

Adduction.

Adductor pollicis.

Abduction.

Abductor pollicis.

The only muscles excluded from this table are the lumbricales, four small muscles, which, from their attachments to the tendons of the long flexor, appear to be assistants to their action ; and the transversus pedis, a small muscle placed transversely in the foot across the heads of the metatarsal bones, which has for its office the drawing together of the toes.

CHAP. II.

THE UPPER EXTREMITY.

THE upper extremity is the member developed from the upper part of the thoracic arch, as the lower extremity is the member developed from the pelvic arch. It consists of an apparatus of bones, joints, muscles, vessels, and nerves, and is covered by the common investments of the entire body, viz. the deep and superficial fascia and the integument.

The *bones* of the upper extremity are the clavicle, scapula, humerus, radius and ulna, carpal, metacarpal, and phalanges. The *clavicle* is the medium of connection between the upper extremity and the rest of the skeleton; it is the fulcrum of action of the entire limb, and is prominently characteristic of animals possessing great power in the arms, as man, the bat, the mole, birds, &c. The *scapula* is a flat bone, and affords by its construction peculiar advantages; giving origin, by its extensive surface, to a number of muscles, and being itself moveable on the convexity of the thorax. This is the bone which secures the connection of the arm with the trunk, and provides for all the diversity of movement so characteristic of the upper extremity, and which entitles it to the designation of an "universal joint." The next bones, the *humerus*, *radius*, and *ulna*, have for their office the extension of the limb, for the purpose of supplying to the beautiful apparatus of the hand the advantages which are to be obtained by a voluntary approximation or extension from the body. They are, therefore, denominated *long* bones, and like all bones of this class are divisible into a shaft, an upper and a lower extremity. The shaft is more or less cylindrical and smooth, whilst the extremities are projected into processes which serve as levers for the attachment and action of muscles. The *carpus* is an assemblage of small bones belonging to the class of *short* bones. They are all slightly movable upon each other, and bestow pliancy and strength by means of the mutual yielding which exists between them. The *metacarpal bones* and *phalanges* are *long* bones, of a length proportionate to the arm and to the moving powers intended for their action; they give breadth and extent to

the hand, and facility in all the movements which that important organ is destined to perform.

The *muscles* are naturally divided into groups, which concur mutually in certain actions necessary to the effective movements of the limb. The distribution of these groups, with their corresponding duties, will be best seen in a tabular analysis, thus :—

Anterior Thoracic Group.

Pectoralis major.
Pectoralis minor.
Subclavius.
Serratus magnus.

Posterior Thoracic Group.

Trapezius.
Levator anguli scapulæ.
Rhomboides major.
Rhomboides minor.

Humeral Group.

Subscapularis.
Supra-spinatus.
Infra-spinatus.
Teres minor.
Teres major.

Latissimus dorsi.
Pectoralis major.
Deltoid.
Coraco-brachialis.

Anterior Brachial Group.

Biceps.
Brachialis anticus.

Posterior Brachial Group.

Triceps.
Anconeus.

FORE-ARM.

Anterior Group.

Pronator radii teres
Pronator radii quadratus.
Flexor carpi radialis.
Flexor carpi ulnaris.
Flexor digitorum sublimis.
Flexor digitorum profundus.
Flexor pollicis longus.
Palmaris longus.

Posterior Group.

Supinator radii longus.
Supinator radii brevis.
Extensor carpi radialis longior.
Extensor carpi radialis brevior.
Extensor carpi ulnaris.
Extensor communis digitorum.
Extensor minimi digiti.
Extensor pollicis ossis metacarpi.
Extensor pollicis primi internodii.
Extensor pollicis secundi internodii.
Extensor indicis.

HAND.

Radial Group.

Flexor ossis metacarpi.
Flexor brevis pollicis.
Abductor pollicis.
Adductor pollicis.

Ulnar Group.

Palmaris brevis.
Flexor ossis metacarpi.
Flexor brevis minimi digiti.
Abductor minimi digiti.

Palmar Group.

Lumbricales.
Interossei palmares.
Interossei dorsales.

The *anterior* and *posterior thoracic groups* preserve the fixity and steadiness of the shoulder, and render it capable of supporting heavy weights and becoming the point of resistance to the actions of the humeral muscles. They also move the scapula freely on the chest, and afford all the advantages of the strongest articulation by bone. The *humeral* group carries the arm throughout all that circle of motion which is so necessary to an universal joint, and so valuable in application to its extensive uses. The muscles of the *anterior brachial group* are the flexors of the elbow, the perfect flexion of the joint being procured by an advantageous attachment to both the radius and ulna. The *posterior brachial group* is the antagonist to the former, and extends the fore-arm. Now, it is fair to anticipate, that as the bones increase in number, and the limb is carried farther from the centre, the movements will increase in proportionate ratio. The movements of the *shoulder* were those of totality: the motions of the *scapulo-humeral joint* were of the most simple kind, such as would result from the application of a round ball against a shallow socket; those of the *elbow* were in one direction only, flexion and extension; but the *wrist* requires an apparatus for the action of the powerful twist which is so remarkable in that joint. And this is provided for by two pairs of the muscles of the fore-arm, the *pronators* and *supinators*, the former throwing the wrist and hand inwards, the latter outwards. Now this action could not be effectively produced without the exertion of muscular force upon the axis of support to the wrist; and we therefore find that the radius alone articulates with the wrist, and administers to all its movements, while the ulna is reserved as the especial agent in the motions of the elbow. Besides pronation and supination, the wrist possesses powerful flexion and extension, and to this office are assigned the next muscles, *flexores* and *extensores carpi*. The fingers are simply supplied for all their numerous movements of flexion and extension, by three *flexors* situated in the fore-arm, and six *extensors*; one flexor and three extensors being intended for the especial use of the thumb. The remaining muscle, the palmaris longus, is an extensor of the palmar fascia, which provides by its strength and elasticity for a powerful resistance to shocks received upon the surface of the hand. The

muscles of the *hand* are *flexors*, *abductors*, and *adductors*. The short flexors of the thumb and little finger are necessary to the strength of grip so characteristic of the human hand. All the remaining muscles are abductors and adductors (see *fig. 19.*), with the exception of the *palmaris brevis*, which contracts the integument on the side of the hand, and the *lumbricales*, which are accessory in their actions to the deep flexor. The abductor and adductor of the thumb are known by those names; the analogous muscles of the index finger are the first dorsal and first palmar interosseous; of the middle finger the two next dorsal interossei; of the ring finger the fourth dorsal and second palmar; and of the little finger the abductor *minimi digiti* and third palmar interosseous. These movements of abduction and adduction are highly valuable in the grasp of large or irregular bodies, or in the contraction of the bulk of the hand in various important surgical manipulations.

The main *artery* for the supply of the upper extremity commences within the thorax, and, arching over its brim, passes *beneath* the *clavicle*; hence it is named *subclavian*. On quitting the side of the chest, it is received into the space which intervenes between the scapula and ribs, and acquires the name of that space—*axillary*. It then runs along the *arm* to the bend of the elbow, under the name of *brachial*. Now it is an established principle in the distribution of arteries, that they always select the most protected situations for their course. Thus they are constantly placed on the inner side of the limb, and avoid the convexities of joints, where they would be subjected to injury, both from external pressure and over extension. The brachial artery is therefore placed along the inner side of the arm, as is the femoral in the thigh; the brachial dips deeply into the space of the elbow, as does the popliteal into the space of the ham.

Arrived at the bend of the elbow, the brachial artery accommodates itself to the augmented lateral breadth of the fore-arm, and its increased number of components, the *radius*, the *ulna*, and *intermediate space*, by dividing into three branches corresponding with these three parts, the two bones and the interosseous space. Its branches, therefore, are radial, ulnar, and interosseous; as in the leg we find the posterior tibial and fibular corresponding

with the two bones, and the anterior tibial with the interosseous space.

The *radial artery* supplies all the parts placed upon the *radial* side of the fore-arm, and passing between the two heads of the first dorsal interosseous muscle, is distributed to the thumb and deep structures in the hand, under the name of the *deep palmar arch*. The *ulnar* supplies all the parts placed upon the *ulnar* side of the fore-arm, and in the hand forms the *superficial palmar arch*, from which the branches pass off, which are distributed to the fingers.

In the supply of branches, the *muscles* necessarily come in for a large share, which receive no names unless they assume a remarkable magnitude, as the profunda arteries. Other named branches owe their names to peculiarity of structure, and are, therefore, easily remembered. But the *joints* which are exposed to pressure and are uncovered, except by integument, derive an abundant supply of branches from all the surrounding sources. For instance, the elbow joint is provided with eight nutrient branches, the superior profunda and its posterior articular branch, inferior profunda, anastomotica magna, radial recurrent, anterior and posterior ulnar recurrenents, and interosseous recurrent. The knee has seven named branches, the wrist three, and the ankle four.

Thus it may be shown that the principle of arrangement of the arteries, as of the muscles and the rest of the systems, is the same throughout the entire body : the exceptions are individualities that associate objects of importance and interest with their existence.

The *veins* of the upper extremity are the superficial and the deep : the former are placed between the two layers of the superficial fascia, the latter are associated with the arteries. All the arteries of the limbs and trunk which are below the second magnitude are accompanied by two veins, named "*Venæ comites*;" thus the radial, ulnar, interosseous, and brachial arteries, with their branches, have each their corresponding *venæ comites*. The axillary and subclavian have each a single vein.

The *lymphatic vessels* are rarely seen in an ordinary dissection, excepting under very favourable circumstances, as in anasarca, when they are sometimes observed, as white opaque threads, traversing the transparent jelly-like cellular substance, and entering the lymphatic glands at

all points of their circumference. They follow in their course the direction of the veins to which they bear an analogy. The *lymphatic glands* are accumulated in the loose cellular tissue of the axilla, and two or three may be met with in the course of the basilic vein.

The *nerves* of the upper extremity are derived from the brachial plexus which is formed by the last four cervical and first dorsal nerve. A *plexus* is the means by which nervous branches destined to a single apparatus are associated in their structure previously to distribution, so that the sensations of each filament may harmonise with all the rest, and produce the unity of impulse which is necessary to perfect action. For it is evident that if an impression were received by the terminal filament of any one nerve, and excited a reflex movement, without a simultaneous impression upon the other nerves of the same limb and consequent muscular movement, that an opposition of action would result; which is inconsistent with natural and healthy function. We are, therefore, interested in the complex interlacements and union of a number of nerves in the formation of a plexus, when we reflect upon the important benefits which such a disposition confers.

The branches which are given off by the brachial or axillary plexus are, 1st, those distributed to the shoulder and neighbouring part of the chest; and 2d, those destined to the arm. The former are named *thoracic* and *scapular*: the latter consist of six nerves;—one, which supplies the muscles about the shoulder joint, the *circumflex*; two, going to the integument of the arm, *external* and *internal cutaneous*; and three, like the three arteries, supplying the fore-arm and hand, *musculo-spiral*, *ulnar*, and *median*.

Let us now proceed to the *dissection* of the upper extremity, beginning with the —

ANTERIOR THORACIC REGION.

Dissection. — Make an incision along the line of the clavicle, from its sternal extremity, for about two-thirds of its length; carry a second incision longitudinally along the middle of the sternum to its lower extremity, and a third along the lower border of the pectoralis major muscle and anterior border of the axilla to the arm. Dissect back the integument from the area included within these incisions. Then, in order further to expose the side of the chest and the axilla, carry a fourth incision from the angle of the preceding

at the lower end of the sternum horizontally outwards to the side of the chest, three or four inches below the axilla, and reflect the integument as before. The dissector should next proceed to seek for the cutaneous nerves situated in the superficial fascia, and in the upper part of the region he will find a thin stratum of muscular fibres, a part of the cutaneous muscle of the side of the neck, *platysma myoides*. He may then study the mammary gland, and, after this has been completed, dissect off the deep fascia from the whole of the region and examine the muscles. In removing the deep fascia, the student must be reminded of the necessity of dissecting in the course of the fibres of the muscles, and his progress will be facilitated by putting the muscles on the stretch.

The *cutaneous nerves* of the anterior thoracic region are, several cutaneous branches from the cervical plexus, which pass down over the clavicle and are distributed to the integument covering the pectoralis major muscle; *anterior-cutaneous* of the thorax, which pierce the pectoralis major muscle near the sternum, and are reflected outwards to the integument and mammary gland; and *lateral-cutaneous nerves* of the thorax, which issue from the intercostal spaces on the side of the chest, and proceed upwards and forwards around the lower border of the pectoralis major to the integument covering that muscle, and to the mammary gland. On the side of the chest in and below the axilla are several cutaneous nerves, proceeding from the lateral cutaneous branches of the intercostal nerves: these are the posterior branches of the lateral cutaneous nerves. Some pass backwards over the posterior border of the axilla, and are distributed to the integument covering the *latissimus dorsi* muscle and lower part of the scapula; and two, proceeding from the second and third intercostal nerves, are distributed to the integument of the inner side of the arm under the name of *intercosto-humeral nerves*.

Mammary gland. — The mamma may be best studied in the female, although it exists also in the male. It is situated in the pectoral region, being separated from the pectoralis major muscle by the deep fascia; and occupies a circular space which extends longitudinally from the third to the sixth rib, and horizontally from near the sternum to the axilla. Its base is somewhat elliptical, the long diameter corresponding with the direction of the fibres of the pectoralis major muscle; and the left mamma is generally a little larger than the right.

Near the centre of the convexity of each mamma is a

small prominence of the integument, called the *nipple* (mamilla), which is surrounded by an areola having a coloured tint. In females of fair complexion, before impregnation, the colour of the areola is a delicate pink; after impregnation, it assumes a brownish hue, which deepens in colour as pregnancy advances; and after the birth of a child, the brownish tint continues through life.

The areola is furnished with a considerable number of *sebiparous glands*, which secrete a peculiar fatty substance for the protection of the delicate integument around the nipple. During suckling these glands are increased in size, and have the appearance of small pimples, projecting from the skin. At this period they serve by their increased secretion to defend the nipple and areola from the excoriating action of the mouth of the infant.

In *structure*, the mamma is a conglomerate gland, and consists of lobes, which are held together by a dense and firm cellular tissue; the lobes are composed of lobules, and the lobules of minute cæcal vesicles, the ultimate terminations of the excretory ducts.

The excretory ducts (tubuli lactiferi, galactophori), from fifteen to twenty-five in number, commence by small openings at the apex of the nipple, and pass inwards, parallel with each other, towards the central part of the gland, where they form dilatations (ampullæ), and give off numerous branches to ramify through the gland to their ultimate terminations in the minute lobules.

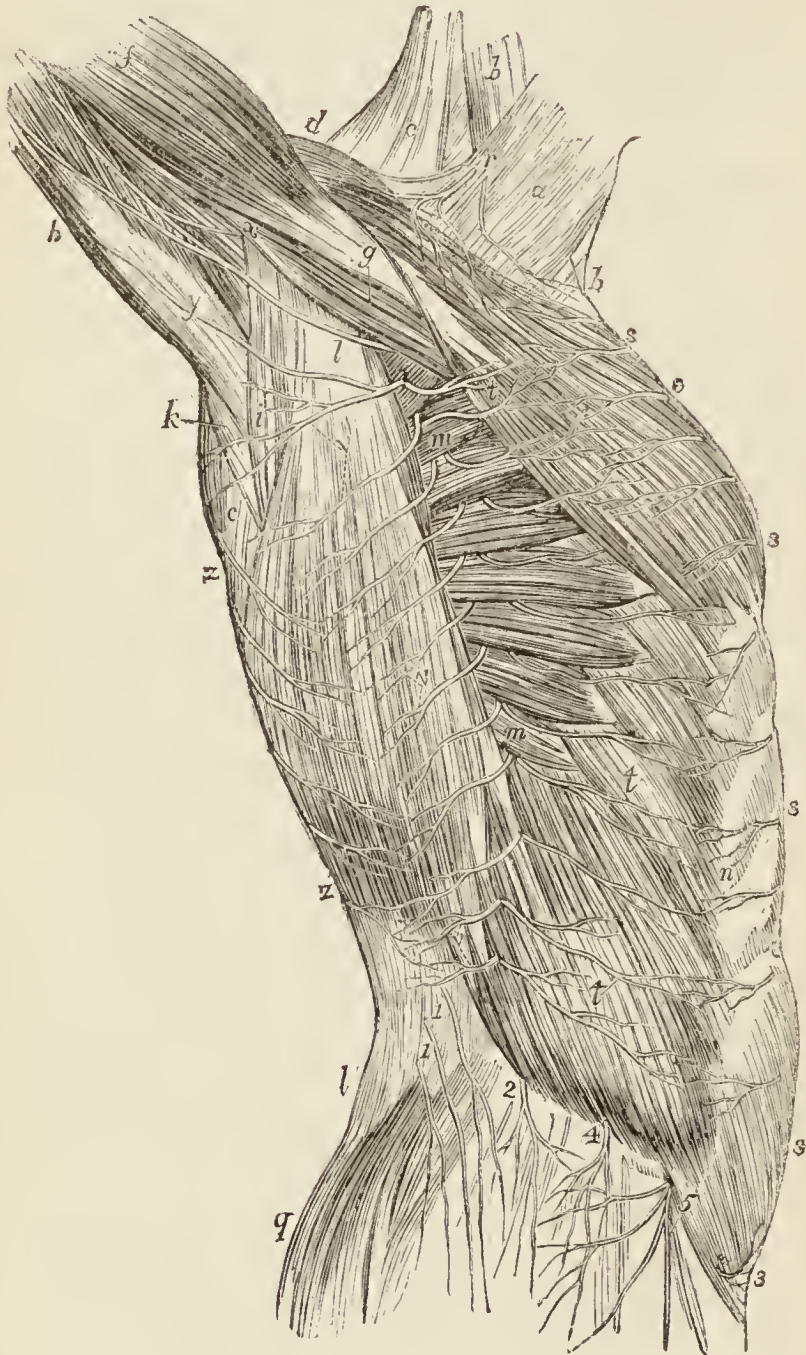
The ducts and cæcal vesicles are lined, throughout, by a mucous membrane, which is continuous at the apex of the nipple with the integument.

In the nipple the excretory ducts are surrounded by a tissue analogous to the dartos of the scrotum, to which the power of erectility of the nipple seems due. There is no appearance of any structure resembling erectile tissue.

The mammæ are supplied with *arteries* from the thoracic branches of the axillary, from the intercostals, and from the internal mammary. The *veins* form an incomplete circle around the base of the nipple (circulus venosus Halleri), from which larger veins conduct the blood to the circumference of the gland, and by their communications form a plexus on its surface. They terminate in

the axillary vein, the internal mammary, the intercostals and the jugular veins.

*Fig. 11.**



The *lymphatics* take the course of the veins, inwards, to the anterior mediastinal glands; and outwards along the border of the pectoralis major to the axillary glands.

* Superficial nerves and muscles of the trunk. — *a*. The platysma myoides muscle. *b, b*. The sterno-mastoid. *c, c*. The trapezius. *d*. Part of the deltoid. *e*. The pectoralis major. *f*. The biceps. *g*. The coraco-brachialis. *h*. The triceps. *i*. The teres major.

The *nerves* of the mammary gland are derived from the anterior cutaneous branches of the third, fourth, and fifth intercostal nerves; and from the lateral cutaneous branches of the same nerves.

The MUSCLES of the anterior thoracic region are the

Pectoralis major.

Pectoralis minor.

Subclavius.

The PECTORALIS MAJOR muscle *arises* from the sternal half of the clavicle, half the sternum its whole length, the cartilages of all the true ribs, excepting the first and last, and the aponeurosis of the external oblique muscle of the abdomen. It is *inserted* by a broad tendon into the anterior bicipital ridge of the humerus.

That portion of the muscle which arises from the clavicle, is separated from that connected with the sternum by a distinct cellular interspace; hence we speak of the *clavicular* portion and *sternal* portion of the pectoralis major. The fibres from this very extensive origin converge towards a narrow insertion, giving the muscle a radiated appearance. But there is a peculiarity about the formation of its tendon which must be carefully noted. The whole of the lower border is folded inwards upon the upper portion, so that the tendon is doubled upon itself. Another peculiarity results from this arrangement: the fibres of the upper portion of the muscle are inserted into the lower part of the ridge, and those of the lower portion into the upper part.

k. The teres minor. *l, l.* The latissimus dorsi. *m, m.* The serratus magnus. The upper *m* is situated in the lower part of the cavity of the axilla. *n.* The external oblique muscle; the letter is placed on the linea semilunaris. *q.* The gluteus maximus. *r.* Supraclavicular branches of the cervical plexus: the anterior branch is the sternal; the posterior the acromial. *s, s.* Anterior cutaneous nerves. *t, t.* Anterior branches of the lateral cutaneous nerves. *v, v.* Posterior branches of the lateral cutaneous nerves. *w.* The intercostohumeral nerve; which communicates with *x*, a branch of the nerve of Wrisberg. *y.* The branch of the lateral cutaneous branch of the third intercostal nerve to the arm. *z, z.* Posterior cutaneous nerves. 1, 1. Cutaneous branches derived from the lumbar nerves. 2. The iliac branch of the ilio-hypogastric nerve. 3. Its hypogastric branch. 4. The lateral cutaneous branch of the last dorsal nerve. 2. and 4, are placed on the crest of the ilium. 5. The external cutaneous nerve of the thigh, giving off cutaneous branches to the hip.

The pectoralis major muscle is separated from the deltoid by a deep cellular interspace, in which are seen the cephalic vein and the descending branch of the thoracica-acromialis artery. (*Fig. 12. 11.*)

Operations.—The pectoralis major forms the ground plan of three operations required for the ligature of the axillary artery in the upper part of its course.

The *first* and more usual operation is to make an incision parallel with and about three quarters of an inch below the clavicle. The incision should be three inches in length, and extend a little beyond the interspace of the deltoid and pectoralis muscle. It should divide the *integument, superficial fascia, platysma myoides*, and clavicular portion of the pectoralis major. The posterior layer of the sheath of the pectoralis must be divided on a director, and the sheath of the axillary vessels opened with care. The axillary vein of large size lies in front, and conceals the artery: behind the artery are the nerves of the brachial plexus. In this operation the cephalic vein is endangered, and several branches of the superior thoracic artery and thoracica-acromialis cut across.

Another operation, rarely practised, is that of Desault. It consists in making an incision two inches and a half long in the line of the interspace between the pectoralis major and deltoid. The cephalic vein is drawn aside and the muscles separated so as to expose the tendon of the pectoralis minor, which is to be cut across, and the vessels brought into view by raising them on the finger. The descending branch, and one or two of the thoracic branches of the thoracica-acromialis artery, are necessarily divided.

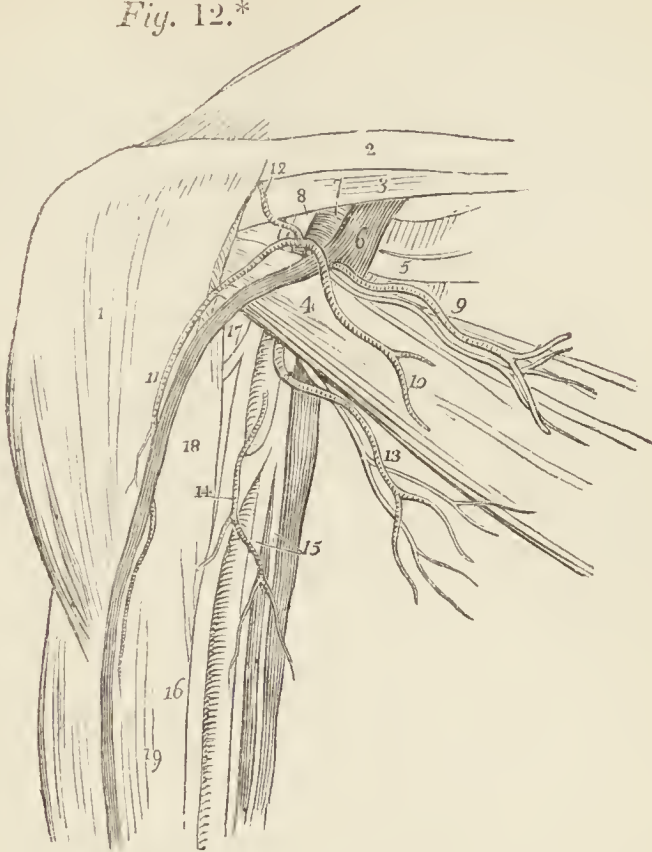
The third operation (Lisfrancs) is equally objectionable. The incision, three inches in length, is made in the direction of the line of separation of the sternal and clavicular portions of the pectoralis major, and the two portions of the muscle separated in order to reach the artery.

Dissection.—The pectoralis major is now to be removed by dividing its fibres along the lower border of the clavicle, and then carrying the incision perpendicularly downwards, parallel to the sternum, and at about three inches from its border. Divide some loose cellular tissue, and several small branches of the thoracic arteries, and reflect the muscle outwards. We thus bring into view a region of considerable interest, from which the fat and cellular tissue must be carefully removed.

In the middle of this region is the pectoralis minor muscle (*fig. 12. 4.*), and above it a triangular space bounded superiorly by the costo-coracoid membrane, 3., which covers in the subclavius muscle, and by the second rib and two adjoining interspaces internally. In this triangular space, 5., are found, the subclavian vein, 6., the subclavian artery, 7., and the brachial plexus of nerves, 8., all resting on the first rib; the acromial thoracic, 10., and

superior thoracic artery, 9., with their veins and nerves, and the cephalic vein, 11. Below the pectoralis minor,

*Fig. 12.**



the axillary artery is seen embraced by the two heads of the median nerve, 16., having to its inner side the axillary vein, and in front the inferior thoracic, 13., and axillary thoracic, 14., branches.

* *Fig. 12.* The vessels and nerves of the deep pectoral region. — No. 1. The deltoid muscle. 2. The clavicle. 3. The subclavius muscle, covered in by the costo-coracoid membrane. 4. The pectoralis minor muscle. 5. The second rib; immediately above it is the first intercostal space and first rib. 6. The axillary vein receiving the termination of the cephalic vein. 7. The axillary artery. 8. The triangular space which intervenes between the brachial artery on its outer side, and the brachial plexus of nerves. 9. The superior thoracic artery and nerve. 10. The thoracic branch of the thoracica-acromialis artery. 11. The descending branch of the thoracica acromialis, descending by the side of the cephalic vein. 12. The acromial branch of the thoracica acromialis. 13. The long thoracic artery and nerve. 14. The thoracica alaris branch of the axillary artery. 15. The internal cutaneous and ulnar nerves resting on the axillary vein. 16. The median nerve, embracing the axillary artery, with its two heads. 17. The external cutaneous nerve, piercing the coraco-brachialis muscle. 18. The coraco-brachialis. 19. The biceps muscle.

The PECTORALIS MINOR *arises* by three digitations from the third, fourth, and fifth ribs, and is *inserted* into the anterior border of the coracoid process of the scapula by a broad tendon.

The SUBCLAVIUS muscle *arises* by a round tendon from the cartilage of the first rib, and is *inserted* into the under surface of the clavicle for nearly half its length. This muscle is concealed by the costo-coracoid membrane, an extension of the deep cervical fascia, by which it is invested.

The upper part of the axillary space above the pectoralis minor, and the larger portion of the space below it, should now be carefully cleared of cellular tissue and fat, and the vessels and nerves made out which occupy the axillary space and give branches to the surrounding parts. In the loose cellular tissue of the axilla, at its lower part and lying nearer to the thorax than the arm, is a cluster of ten or twelve *lymphatic glands*, which receive the lymphatic vessels from the front and back of the chest and mammary gland. The efferent vessels from these glands pass upwards by the side of the subclavian vessels to the root of the neck, and terminate in the great lymphatic ducts. To facilitate the dissection of the axilla, the pectoralis minor muscle may be drawn aside, or even divided across.

The AXILLA or armpit is the space between the side of the chest and the arm. In form it resembles a triangular cone, the apex being above at the clavicle, the base below at the lower borders of the pectoralis major and latissimus dorsi. It is broad from before backwards near the thorax, but narrows towards the humerus; and is bounded *in front* by the pectoralis major and minor muscles; *behind* by the subscapularis, teres major, and latissimus dorsi; *internally* by the four upper ribs with their intercostal muscles and part of the serratus magnus muscle; and *externally* by the biceps, coraco-brachialis, and humerus.

The parts contained within the axilla are the axillary artery and vein, with their branches; the brachial plexus of nerves, with its branches; the two intercosto-humeral nerves; the external respiratory nerve of Bell, which lies upon the serratus magnus muscle; and from ten to twelve lymphatic glands.

The axillary vessels at their point of emergence from beneath the subclavius muscle, are invested for a short distance by a thin sheath derived from the costo-coracoid membrane. The thoracica-acromialis artery and ante-

rior thoracic nerve are seen to perforate this sheath in their course forward; the sheath must be removed in order to bring the axillary vessels completely into view.

The AXILLARY ARTERY passes outwards and downwards with a gentle curve, through the axillary space from the lower border of the first rib, to the lower border of the tendons of the latissimus dorsi and teres major, where it becomes the brachial.

Relations.— In its course it is in relation *in front* with the pectoralis major, pectoralis minor, and again with the pectoralis major, being immediately invested with the aponeurotic sheath derived from the costo-coracoid membrane; *internally*, it has the first intercostal muscle, the first serration of the serratus magnus, the axillary vein, and at its lower part the brachial plexus; *externally* and *posteriorly* it is approached by the brachial plexus, a cellular interval existing between them above; then it is in relation with the subscapularis, the coraco-brachialis, the teres major and latissimus dorsi. The brachial plexus of nerves lies to the outer side of the artery above, being separated from it by a cellular interspace, but approaches it in the middle of its course, and then completely surrounds the artery; the median and external cutaneous nerve lying to its outer side; the ulnar, the internal cutaneous and internal cutaneous of Wrisberg to its inner side, and the musculo-spiral and circumflex behind.

A slight inspection of this artery and its numerous relations, will serve to show that its ligature would be an extremely injudicious and dangerous operation, warranted only by the pressure of extreme circumstances. But the student may be called upon to give the steps of the operation: he must, therefore, reflect upon the position, depth, and relations of the artery. A superficial vessel requires only a short incision, the length increasing with the depth of the artery.

Operations.— The operations on the axillary artery in the upper part of its course have been already examined (page 86.); we have now to consider the mode of tying it in its lower part. An incision, two inches in length, is to be made along the hollow of the axilla, at one third from its anterior border. This incision should divide the *integument* and *superficial fascia*; in the next place the *deep fascia* should be cut through along the border of the coraco-brachialis muscle, when the median nerve will be brought into view; behind the median nerve is situated the axillary artery. When the

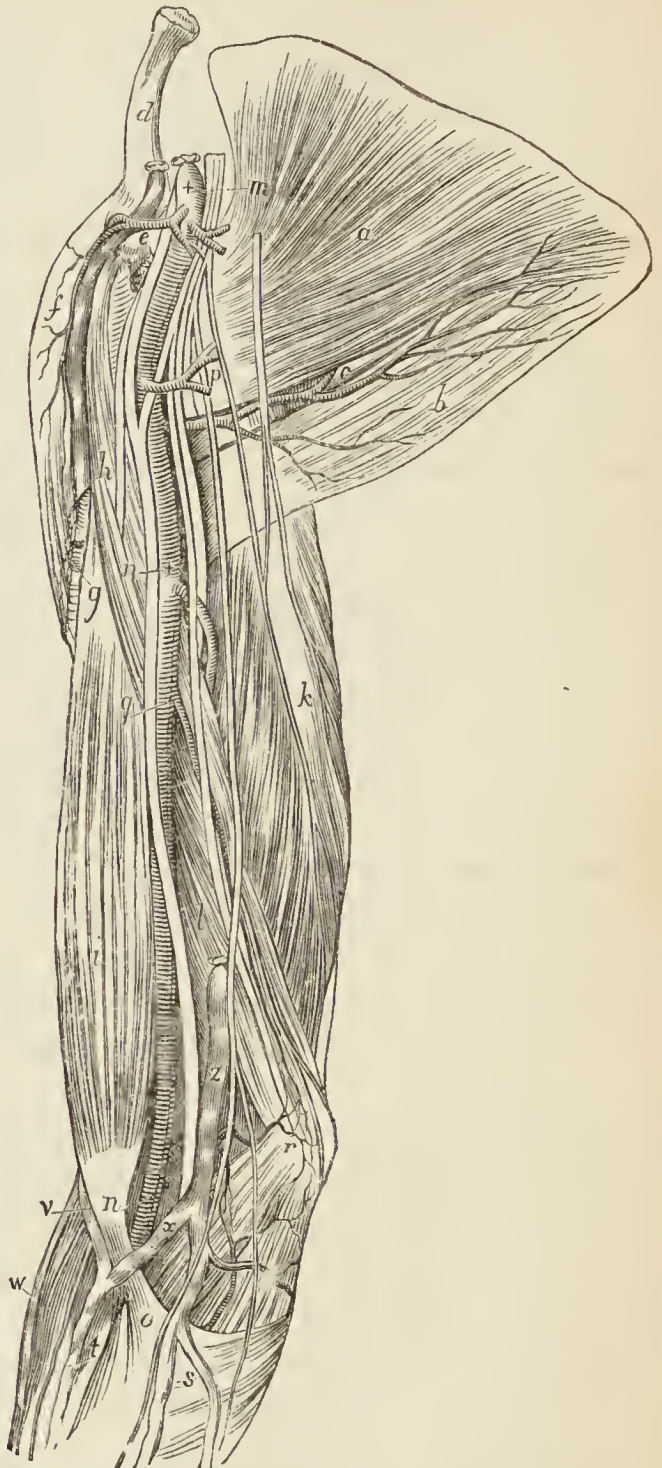deep fascia is divided, the axillary vein must be drawn inwards and the fore-arm bent to relax the nerves ; the operator then pushes aside the median nerve and carries the needle around the artery. The objections to this operation are numerous. The breaking up of the loose cellular tissue may give rise to suppuration and sinuses. Nerves may be injured or tied, the vein or veins may be wounded, and, even when the artery is reached, it is tied in the midst of a number of branches.

Branches. — The branches of the *axillary artery* are seven in number : —

Superior thoracic,
 Thoracica acromialis
 Long thoracic,
 Thoracica alaris,
 Subscapular,
 Circumflex anterior,
 Circumflex posterior.

The superior thoracic and thoracica acromialis are found in the triangular space above the pectoralis minor ; the long thoracic and thoracica alaris, below the pectoralis minor ; and the three remaining branches below the lower border of the subscapularis.

Fig. 13.*



* The axillary and brachial vessels and nerves. — *a.* The subscapularis muscle occupying the anterior surface of the scapula. *b.* The teres major ; the artery resting on this muscle is the subscapularis.

The *superior thoracic*, the highest of the branches of the axillary, and sometimes derived from the next, passes inwards to the chest in front of the pectoralis minor muscle, and is distributed to the pectoral muscles and walls of the chest. It anastomoses with the intercostal and mammary arteries.

The *thoracica acromialis* is a short trunk which proceeds from the axillary in the space above the pectoralis minor muscle, and divides into three sets of branches, — *thoracic*, which are distributed to the pectoral muscles,

pular; and *c* is the dorsalis scapulæ branch. *d*. The clavicle. *e*. The coracoid process of the scapula. *f*. The deltoid. *g*. The tendon of the pectoralis major. *h*. The coraco-brachialis muscle, and external cutaneous nerve. *i*. The biceps. *k*. The long head of the triceps. *l*. Its short or internal head. *m*. The axillary artery. *n, n*. The brachial artery. The upper *n* rests on the coraco-brachialis muscle; the lower on the tendon of the biceps. *o*. The aponeurosis of the tendon of the biceps which crosses the brachial artery to become continuous with the fascia of the fore-arm. The two branches of the axillary artery immediately below the cross at *m*, are the *thoracica-acromialis* and *superior thoracic*: and the nerves crossed by the leading line are the inner cord of the brachial plexus. Between the axillary artery and *e*, is the outer cord of the plexus: and to the left of *e* is the cephalic vein, and the division of the *thoracica acromialis* artery into its acromial and descending branch. *p*. The long thoracic artery. The five nerves crossed by this artery are (from the artery to the letter), the internal head of the median, ulnar, musculo-spiral, circumflex, and internal cutaneous; the nerve to the right of the letter is the lesser internal cutaneous; and the nerve beyond the latter the intercosto-humeral. The letter *h* denotes the musculo-cutaneous nerve as well as the coraco-brachialis muscle which it is seen to pierce; *n* denotes the median nerve. The large branch given off by the brachial artery just below the cross *n*, is the *superior profunda*; it is crossed in front by the ulnar nerve, behind by the musculo-spiral, and is seen sinking between the long and the short heads of the triceps to reach the back of the humerus. *q*. The *inferior profunda* artery. *r*. The *anastomotica magna*. The letter rests on the internal condyle of the humerus; the large nerve to the right of the letter is the ulnar, and the small nerve the posterior branch of the internal cutaneous; the small nerve to the left of the letter is the anterior branch of the internal cutaneous; next follows the basilic vein, then the median nerve. *s*. The anterior and posterior ulnar vein uniting to form the common ulnar vein. *t*. The median vein. The vein (*x*) between *n* and *o* is the median basilic. *v*. The median cephalic. *w*. The radial vein. The nerves between *t* and *w* are branches of the external cutaneous. *z*. The basilic vein.

serratus magnus, and mammary gland; *acromial*, which pass outwards to the acromion, and inosculate with branches of the supra-scapular artery; and *descending* a single branch, which follows the interspace between the deltoid and pectoralis major muscles, and is in relation with the cephalic vein.

The *long thoracic* (external mammary) follows the lower border of the pectoralis minor to the side of the chest. It is distributed to the pectoralis major and minor, serratus magnus, and mammary gland; inosculating with the superior thoracic, intercostal, and mammary arteries.

The *thoracica alaris* is a small branch distributed to the plexus of nerves and glands in the axilla. It is frequently wanting, its place being supplied by a branch from one of the other thoracic arteries.

The *subscapular artery*, the largest of the branches of the axillary, runs along the lower border of the subscapularis muscle, to the inferior angle of the scapula, where it inosculates with the posterior scapular, a branch of the subclavian. It supplies the muscles on the under surface and inferior border of the scapula, and side of the chest. At about an inch and a half from the axillary, it gives off a large branch, the *dorsalis scapulae*, which passes backwards through the triangular space bounded by the teres minor, teres major, and scapular head of the triceps, and beneath the infra-spinatus to the dorsum of the scapula, where it is distributed, inosculating with the supra-scapular and posterior scapular arteries.

The *circumflex arteries* wind around the neck of the humerus. The *anterior*, very small, passes beneath the coraco-brachialis and short head of the biceps, and sends a branch upwards along the bicipital groove to supply the shoulder-joint.

The *posterior circumflex*, of larger size, passes backwards through the quadrangular space bounded by the teres minor and major, the scapular head of the triceps and the humerus, and is distributed to the deltoid muscle and joint: sometimes this artery is a branch of the superior profunda of the brachial. It then ascends behind the tendon of the teres major, and is distributed to the deltoid without passing through the quadrangular

space. The posterior circumflex artery sends branches to the shoulder-joint.

The AXILLARY VEIN lies to the inner side of the artery throughout its course, and from its large size partly conceals it from view. It is the continuation of the basilic vein. At its commencement it receives the large trunk resulting from the junction of the brachial veins, and in its course, the veins returning the blood from the branches of the axillary artery; in the space above the pectoralis minor it receives the cephalic vein.

The *dissection* of the nerves of the axilla will be facilitated by the division of the axillary artery, by turning it down, and removing its smaller branches; the smaller branches of the plexus may then be followed to their destination.

The BRACHIAL PLEXUS OF NERVES formed in the root of the neck by the last four cervical and first dorsal nerve, enters the axillary space as two cords, from which a third, formed by a branch from each of the others, soon proceeds. The three cords partly surround the artery, one lying to its outer side, one to the inner side, and one behind. A branch from the inner cord and one from the outer cord then unite in front of the artery to form the median nerve, and complete the circle around it.

The *branches* of the brachial plexus are: — from the *outer cord*, one of the anterior thoracic nerves, the external cutaneous nerve, and the outer head of the median; from the *inner cord*, the other anterior thoracic nerve, the other head of the median, the internal cutaneous, the lesser internal cutaneous of Wrisberg, and the ulnar; and from the *posterior cord*, the subscapular nerves, the circumflex, and musculo-spiral.

Besides the above branches, the brachial plexus, while in the neck, gives off several *superior muscular branches*: one to the subclavius muscle, one to the rhomboid muscles and levator anguli scapulæ; one, of large size, the *suprascapular*; and a long and slender nerve which passes down the thoracic wall of the axilla, the *posterior thoracic*, or external respiratory nerve of Bell.

In reference to their distribution, the branches of the brachial plexus may be arranged in three groups, *thoracic*, *scapular*, and *brachial*, as follows: —

Thoracic.

Anterior thoracic,
Posterior thoracic.

Scapular.

Superior muscular,
Suprascapular,
Subscapular.

Brachial.

External or musculo-cutaneous,
Internal cutaneous,
Lesser internal cutaneous,
Median,
Ulnar,
Musculo-spiral,
Circumflex.

The *anterior thoracic nerves* proceed, the one from the external cord of the plexus, the other from the internal cord. The former, the *external* or superficial branch, crosses the axillary artery in the space above the pectoralis minor to the front of the chest, and is distributed to the pectoralis major muscle. The *internal* or deeper branch issues from between the axillary artery and vein, and after forming a loop of communication with the preceding is distributed to the under surface of the pectoralis minor and major.

The *posterior thoracic*, or external respiratory of Bell, is formed by the junction of two offsets, one from the fifth, the other from the sixth cervical nerve; it crosses behind the brachial plexus to reach the side of the chest, and descends upon the serratus magnus to the lower part of that muscle, to which it is distributed.

The *suprascapular nerve* arises from the fifth cervical nerve, and proceeds obliquely outwards to the suprascapular notch; it then passes through the notch, crosses the supra-spinous fossa beneath the supra-spinatus muscle, and running in front of the concave margin of the spine of the scapula enters the infra-spinous fossa. It is distributed to the supra-spinatus and infra-spinatus muscle, and sends two or three filaments to the shoulder-joint.

The *subscapular nerves* are three in number; one supplies the upper part of the subscapularis muscle; the second (*long subscapular*) follows the course of the subscapular artery, and is distributed to the latissimus dorsi; the third is distributed to the lower part of the subscapularis muscle and teres major.

The brachial group of nerves must be left until the dissection of the arm is proceeded with. At present, and until the time arrives for the inspection of the cavity of the thorax, the student may examine that portion of the latissimus dorsi which is visible from the front, the serratus magnus, and the muscles and vessels of the parietes of the chest.

The LATISSIMUS DORSI muscle covers the whole of the lower part of the back and loins. It *arises* from the spinous processes of the six inferior dorsal vertebræ, from all the lumbar and sacral spinous processes, from the posterior third of the crest of the ilium, and from the three lower ribs; the latter origin takes place by muscular slips which indigitate with the external oblique muscle of the abdomen. The fibres from this extensive origin converge as they ascend, and cross the inferior angle of the scapula; they then curve around the lower border of the teres major muscle, and terminate in a short quadrilateral tendon, which lies in front of the tendon of the teres, and is *inserted* into the bicipital groove. A synovial bursa is interposed between the muscle and the lower angle of the scapula, and another between its tendon and that of the teres major. The muscle frequently receives a small fasciculus from the scapula as it crosses its inferior angle.

The SERRATUS MAGNUS (serratus, indented like the edge of a saw,) *arises* by fleshy serrations from the nine upper ribs excepting the first, and extends backwards upon the side of the chest, to be *inserted* into the whole length of the base of the scapula upon its anterior aspect. In structure, the muscle is composed of three portions, a superior portion, formed by two serrations attached to the second rib, and inserted into the inner surface of the superior angle of the scapula, — a middle portion, composed of the serrations connected with the third and fourth ribs, and inserted into the greater part of the posterior border, — and an inferior portion, consisting of the last five serrations which indigitate with the obliquus externus, they form a thick muscular fasciculus, which is inserted into the scapula near its inferior angle.

The intercostal muscles are two planes of muscular and tendinous fibres directed obliquely between the adjacent ribs and closing the intercostal spaces.

The INTERCOSTALES EXTERNI, eleven on each side,

commence posteriorly at the tubercles of the ribs, and advance forwards to the costal cartilages, where they terminate in a thin aponeurosis which is continued onwards to the sternum. Their fibres are directed obliquely downwards and inwards, pursuing the same line with those of the external oblique muscle of the abdomen. They are thicker than the internal intercostals.

The INTERCOSTALES INTERNI, also eleven on each side, commence anteriorly at the sternum, and extend backwards as far as the angles of the ribs, whence they are prolonged to the vertebral column by a thin aponeurosis. Their fibres are directed obliquely downwards and backwards, and correspond in direction with those of the internal oblique muscle of the abdomen. The two muscles cross each other in the direction of their fibres.

In structure the intercostal muscles consist of an admixture of muscular and tendinous fibres. They *arise* from the two lips of the lower border of the ribs, the external from the outer lip, the internal from the inner, and are *inserted* into the upper border.

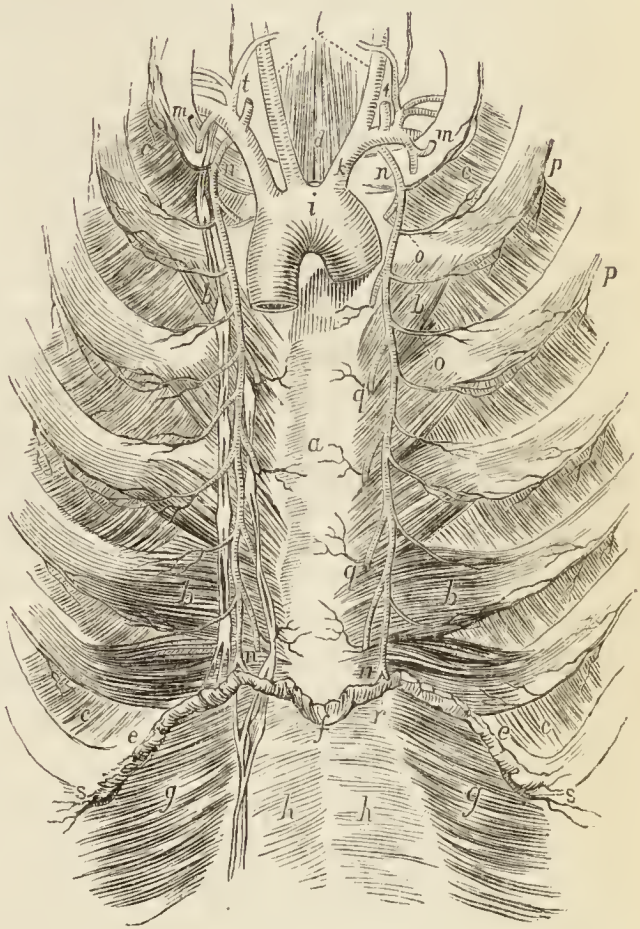
When the anterior wall of the thorax is removed for the purpose of examining the contents of that cavity, a muscle will be found upon its inner surface connected on the one hand with the border of the sternum, and on the other with the cartilages of the ribs: this is the triangularis sterni. In making the dissection necessary for the examination of this muscle, the sternum should be cut across on a level with the lower border of the first rib, and again at the upper border of the articulation of the seventh; the knife should then be carried along the corresponding borders of these ribs, and through the cartilages and intercostal muscles as far outwards as possible. The segment of the chest included by the section should next be carefully raised and the cellular tissue divided, which serves to connect it on the middle line with the mediastinum. The triangularis muscle lying against the cartilages of the ribs on either side of the sternum may now be seen together with the internal mammary arteries, and the surface of the muscle may be cleaned by the removal of some cellular tissue and fat.

The TRIANGULARIS STERNI, situated upon the inner wall of the front of the chest, *arises* by a thin aponeurosis from the side of the sternum, ensiform cartilage, and sternal extremities of the costal cartilages; and is *inserted* by fleshy digitations into the cartilages of the third, fourth, fifth, and sixth ribs, and often into that of the second.

The VESSELS of the walls of the chest are the intercostal arteries proceeding from the aorta, and the internal mammary arteries, branches of the subclavians.

The *intercostal arteries* lie between the two planes of intercostal muscle, in company with the intercostal vein and artery, the former being above and the latter below. The artery is placed near the lower border of each rib, and, at about the middle of the space, divides into two branches, which run along the borders of contiguous ribs, and in the front of the chest anastomose with the anterior intercostal branches of the internal mammary.

Fig. 14.*



* The internal aspect of the anterior wall of the chest, showing the internal mammary arteries.—*a*. The internal surface of the sternum. *b, b*. The triangularis sterni muscles. *c, c*. The intercostales interni muscles. *d*. The sterno-thyroid muscles. *e, e*. The cut edge of the diaphragm. *f*. The ensiform cartilage; the letter is placed on the linea alba. *g, g*. The transversalis abdominis muscle. *h, h*. The posterior wall of the sheath of the recti muscles. *i*. The arch of the aorta. *k*. The arteria innominata. *l*. The common carotid arteries. *m, m*. The subclavian arteries. *n, n*. The internal mammary arteries. On the left side the lymphatic vessels and glands in relation with the internal mammary vessels are seen. *o, o*. Anterior intercostal branches which inosculate with *p, p*, the aortic intercostals. *q, q*. Perforating branches. *r*. The division of the internal mammary artery into superior epigastric and musculo-phrenic. *s, s*. The musculo-phrenic arteries. *t, t*. The two ascending branches of the subclavian artery, vertebral, and thyroid axis. *v, v*. The superior intercostal arteries, giving off the profunda cervicis.

If the external intercostal muscle be carefully raised, this distribution of the intercostal artery may be seen, and at the same time the intercostal nerve by which the artery is accompanied.

The INTERCOSTAL NERVES are the anterior divisions of the dorsal nerves. The nerve takes the same course as the artery, lying by its side, but inferiorly to it in position. Beyond the middle of the ribs, the nerve is embedded in the substance of the anterior intercostal muscle, and then gets to its inner surface lying in contact with the pleura. Near the sternum the nerve pierces the anterior intercostal and pectoralis major, to be distributed to the integument of the front of the chest under the name of *anterior cutaneous*. Midway between the vertebral column and the sternum, and while between the intercostal muscles, the nerve gives off the *lateral cutaneous branch*, which pierces the external intercostal muscle and serratus magnus, and divides into an anterior and posterior twig for the supply of the integument of the side of the thorax, page 82.

The INTERNAL MAMMARY ARTERY, a branch of the subclavian, passes down the anterior wall of the chest, by the side of the sternum, and resting against the cartilages of the ribs and intercostal muscles, to the sheath of the rectus abdominis muscle, where, under the name of *superior epigastric*, it inosculates with the epigastric artery, a branch of the external iliac. It is covered by the pleura and triangularis sterni muscle, and accompanied by the internal mammary veins and a chain of lymphatic glands.

The *branches* of the internal mammary artery within the chest are as follows:—

The *comes nervi phrenici*, a long and slender branch given off by the artery as it enters the chest, descends by the side of the phrenic nerve to the diaphragm.

Several small *mediastinal* and *pericardiac* branches distributed to the anterior mediastinum, pericardium, thymus gland, and triangularis sterni muscle.

Anterior intercostals, which supply the intercostal muscles of the front of the chest, and inosculate with the aortic intercostals; to each space there are two arteries which run along the borders of the rib. Besides supplying the intercostal muscles, they send branches to the pectoral muscles and mammary gland.

Perforating arteries (mammary), which pass forwards

to the front of the chest through the first six intercostal spaces; they then turn outwards, and after giving some branches to the front of the sternum, are distributed to the pectoral muscles and mammary gland. Those intended for the mammary gland are of larger size than the rest.

The *musculo-phrenic* artery, which proceeds from the internal mammary at the interspace between the sixth and seventh ribs, and passes downwards and outwards over the cartilages of the false ribs to the last intercostal space. It pierces the diaphragm at the attachment of that muscle to the eighth rib, and sends branches to its muscular structure, and others to the intercostal spaces of the false ribs.

The student must now proceed to the examination of the contents of the thorax, and for a description of the viscera of that cavity may turn to Chapter III. After the thorax has been studied, the subject is to be turned, and the muscles of the back dissected and examined; the description of these muscles is contained in Chapter IV. We may now suppose that these dissections have been completed, and the student is anxious to continue the dissection of the arm. For this purpose he must saw the clavicle across at about its middle, and cut away, at a short distance from their insertion, those muscles of the scapula and shoulder which still retain the arm in connexion with the body. These muscles are, the trapezius, levator anguli scapula and omohyoideus above; rhomboideus minor and major, behind; latissimus dorsi below; and serratus magnus in front. The above muscles may now be examined more attentively in reference to their attachments, and the shoulder placed in a favourable position for the dissection of its proper muscles, beginning with the deltoid.

Dissection of the Shoulder and Scapula.

Acromial Region.

The integument should now be raised from off the deltoid muscle, beginning at its anterior border, and reflecting it outwards as far as the base of the scapula, and downwards to the insertion of the deltoid and the inferior angle of the scapula.

In the *superficial fascia* covering the upper part of the muscle will be found some nervous filaments, *supra-acromiales*, from the cervical plexus; and spreading over the lower half of the muscle from its posterior border,

several *cutaneous* branches of the *circumflex* nerve. Along its anterior border lies the cephalic vein and accompanying branch of the thoracica-acromialis artery.

The *deep fascia* covering the deltoid muscle, like that of its analogue the gluteus maximus, is thin, and the muscle beneath coarse, and made up of numerous fasciculi separated by tendinous intersections. The deep fascia must be dissected off in the course of the muscular fibres.

The DELTOID muscle (Δ , delta; εἶδος, resemblance) *arises* from the outer third of the clavicle, from the acromion process, and from the whole length of the spine of the scapula. The fibres from this broad origin converge to the middle of the outer side of the humerus, where they are *inserted* into a rough triangular elevation.

The deltoid muscle may now be cut away from its extensive origin and turned down. In so doing the posterior circumflex vessels and circumflex nerve will be found connected by numerous branches to its under surface, and a large bursa over the head of the humerus will be exposed. The vessels and nerves should be cleaned, and the cellular tissue removed from the tendons and muscles which are now brought into view. In front will be seen the broad tendon of the subscapularis; crossing the head of the bone that of the supra-spinatus conjoined externally with the infra-spinatus, and below the latter the teres minor. The three latter muscles proceeding from the dorsum of the scapula, as well as the subscapularis from its ventral surface, should now be dissected and cleaned. To see the supra-spinatus it will be further necessary to divide the trapezius muscle from its insertion into the upper border of the spine of the scapula and from the clavicle. The circumflex vessels and nerve which impede this dissection should now be studied and cut across.

The POSTERIOR CIRCUMFLEX ARTERY, proceeding from the lower part of the axillary, reaches the under surface of the deltoid, after passing through a quadrangular interval, bounded by the teres minor above, teres major below, the neck of the humerus in front, and the long head of the triceps behind. It supplies branches to these muscles in its course; is then distributed to the deltoid and shoulder joint, and inosculates with the *anterior circumflex*, which, now that the deltoid is turned down, may be seen winding around the neck of the humerus from the front.

The CIRCUMFLEX NERVE takes the same course as the posterior circumflex artery, from the lower part of the axilla, and having reached the back of the humerus, separates

into an upper and a lower division ; the upper division, continuing onwards beneath the deltoid, is distributed to the anterior part of that muscle ; the lower division sends a branch (remarkable for a gangliform swelling) to the teres minor, several branches to the posterior part of the deltoid, and mounting over the border of the muscle becomes *cutaneous*, supplying the integument over its lower half by means of several filaments. Besides its muscular and cutaneous branches, the trunk of the nerve gives off an *articular* branch, which enters the shoulder-joint at its posterior and under part.

Posterior Scapular Region.

The muscles of this region are the

Supra-spinatus,	Teres minor,
Infra-spinatus,	Teres major.

The supra-spinatus muscle is covered in by a strong fascia, which must be removed in order to bring the muscle into view. At an after part of the dissection, when the ligaments have been examined, the acromion process may be sawn through, in order to lay bare the entire extent of the muscle ; this proceeding is not, however, indispensable. In the preparation of the supra-spinatus, the student should direct his attention to the boundaries of the hollow in which the muscle is contained. To the upper border of the scapula he will find inserted the small muscle from the neck, omohyoideus. In front of the attachment of this muscle is the transverse ligament which converts the notch in the upper border of the scapula into a foramen, the supra-scapular nerve enters the supra-spinous fossa through this foramen, while the supra-scapular artery passes over it. To the angle of the scapula, and that portion of the posterior border which corresponds with the supra-spinatus fossa, is attached the levator anguli scapulæ, and from the upper border of the spine of the scapula the trapezius has already been removed.

The SUPRA-SPINATUS muscle *arises* from the supra-spinous fossa, the spine of the scapula and deep fascia ; and is *inserted* into the uppermost depression on the greater tuberosity of the humerus.

The INFRA-SPINATUS muscle *arises* from the whole extent of the infra-spinous fossa, excepting a small portion near the neck of the bone, from the spine of the scapula and from its investing fascia. The muscle is *inserted* into the middle depression on the greater tuberosity of the humerus, its tendon being blended with that of the supra-spinatus above, and the teres minor below.

In studying the connexions of this muscle the student should direct his attention to a muscle attached to the posterior border of the scapula, the rhomboideus major, and above this the small band of muscle, rhomboideus minor, which is attached to that portion of the border which corresponds with the base of the triangular expansion of the spine of the scapula over which the trapezius glides. The next two muscles are connected with the lower or anterior border of the scapula.

The TERES MINOR (*teres*, round) muscle *arises* from the posterior surface of the lower border of the scapula for about the middle third of its extent. It is closely connected with the lower border of the preceding muscle, and is *inserted* into the inferior depression of the greater tuberosity of the humerus.

The tendons of the three preceding muscles, with that of the subscapularis, are in immediate contact with the joint, and form part of its ligamentous capsule, thereby preserving the solidity of the articulation. They are therefore the structures most frequently ruptured in dislocation of the shoulder-joint with violence.

The TERES MAJOR muscle *arises* from the dorsal surface of the inferior angle of the scapula, and from its inferior border. It is *inserted* conjointly with the tendon of the latissimus dorsi into the posterior bicipital ridge of the humerus. At its origin this muscle is covered by the latissimus dorsi, but the latter shortly afterwards curves around its lower border, and becomes placed in front. The two tendons at their insertion, one lying behind the other, are separated by a bursa.

The VESSELS and NERVES of the posterior scapular region are the supra-scapular artery and nerve, and the dorsalis scapulæ branch of the subscapular artery.

The *supra-scapular artery*, a branch of the thyroid axis of the subclavian, crosses the root of the neck to the superior border of the scapula; it then passes over the transverse ligament of the supra-scapular notch, and enters the supra-spinous fossa, getting beneath the supra-spinatus muscle. After giving branches to that muscle and the shoulder-joint, the artery passes in front of the spine of the scapula into the infra-spinous fossa, where it inosculates with dorsalis scapulæ and posterior scapular.

The *supra-scapular nerve*, a branch of the brachial plexus, enters the supra-spinous fossa through the supra-

scapular notch, and after supplying the muscle and shoulder-joint, passes with the artery into the infra-spinous fossa, and is distributed to the infra-spinatus muscle.

The *dorsalis scapulæ artery*, a branch of the subscapular, curves around the inferior border of the scapula through the triangular space bounded by the teres minor above, teres major below, and long head of the triceps in front, and passing beneath the teres minor enters the infra-spinous fossa, and is distributed to its muscle, inosculating with the termination of the supra-scapular artery. While in the triangular space it gives off a branch which runs between the teres minor and major to the angle of the scapula, and inosculates with the posterior scapular artery.

The *posterior circumflex artery* and nerve which supply the teres muscles will be found in the quadrangular space in front of the long head of the triceps; and along the posterior border of the scapula may be seen the twigs of distribution of another scapular artery, the posterior scapular.

The *posterior scapular artery* is a branch of the transversalis colli of the subclavian; it descends along the posterior border of the scapula under cover of the levator anguli scapulæ and rhomboid muscles to the inferior angle. In its course it gives branches to both surfaces of the scapula, and inosculates in the infra-spinous fossa with supra-scapular and dorsalis scapulæ arteries, and at its termination with the subscapular artery.

Anterior Scapular Region.

The only muscle situated in the anterior scapular region is the subscapularis, which is bound down by a thin process of aponeurotic fascia. To this aspect, along the posterior border of the scapula, is attached the serratus magnus muscle. The vessels and nerves of the region are the subscapular; the posterior scapular artery may be seen uncovered by muscle lying along its posterior border.

The SUBSCAPULARIS muscle *arises* from the whole of the under surface of the scapula excepting the superior and inferior angles, and terminates by a broad and thick tendon, which is *inserted* into the lesser tuberosity of the humerus, and by muscular fibres into the surface of bone

immediately below that process. The substance of the muscle is traversed by several intersecting membranous layers, from which muscular fibres arise, the intersections being attached to the ridges on the surface of the scapula. Its tendon forms part of the capsule of the joint, glides over a large bursa which separates it from the base of the coracoid process, and is lined by a prolongation of the synovial membrane of the articulation.

The SUBSCAPULAR ARTERY, lying along the lower border of the scapula, sends branches to the subscapularis muscle, and inosculates with the posterior scapular. A branch (infra-scapular) from the dorsalis scapulæ passes beneath the muscle, and on the surface of the bone, inosculates with the supra-scapular above, and the posterior scapular behind.

The *subscapular nerves* have been already described; page 94.

Anterior Brachial Region.

Having placed the arm in a convenient position for dissection, an incision should be made through the integument, along the middle of the biceps muscle, to about three inches below the elbow, and bounded at its extremity by a transverse incision. The integument is next to be dissected carefully back, and the superficial fascia exposed. The superficial vessels and nerves are then to be sought for in the superficial fascia, and examined.

Lying along the outer side of the convexity formed by the biceps is a large vein, the *cephalic*, which may be traced upwards to the interspace between the deltoid and pectoralis major, and downwards to the outer side of the elbow joint; below the elbow joint it is the *radial vein*. On the inner side of the convexity of the biceps is another large vein, *basilic*, which at the elbow is formed by the union of the *anterior* and *posterior ulnar* veins. In the middle line of the fore-arm, between the radial and ulnar veins is the *median* vein, which just below the elbow divides into two branches, one to join the cephalic vein, *median cephalic*, and one to the basilic vein, *median basilic*.

Behind the cephalic vein, and commencing at the middle of the arm, are two *cutaneous* branches from the *musculo-spiral* nerve; and in the groove to the outer side of the tendon of the biceps at the bend of the elbow the

external cutaneous nerve pierces the deep fascia. On the inner side of the arm immediately below the axilla, may be found the *intercosto-humeral nerve* and a *cutaneous* branch of the musculo-spiral; at about the middle of the upper arm the *internal cutaneous nerve* pierces the fascia and runs down the arm by the side of the basilic vein; and at the lower third of the upper arm, and behind the preceding, is the *lesser internal cutaneous nerve*, or nerve of Wrisberg.

CUTANEOUS VEINS.—The *median vein* is so named from its position in the middle of the fore-arm. It receives the returning blood from the front of the hand and fore-arm, and near the elbow forms a trunk of moderate size, which is increased by a communicating branch, 9., from the deep veins. Just below the bend of the elbow, the median divides into two branches—the median basilic and median cephalic.

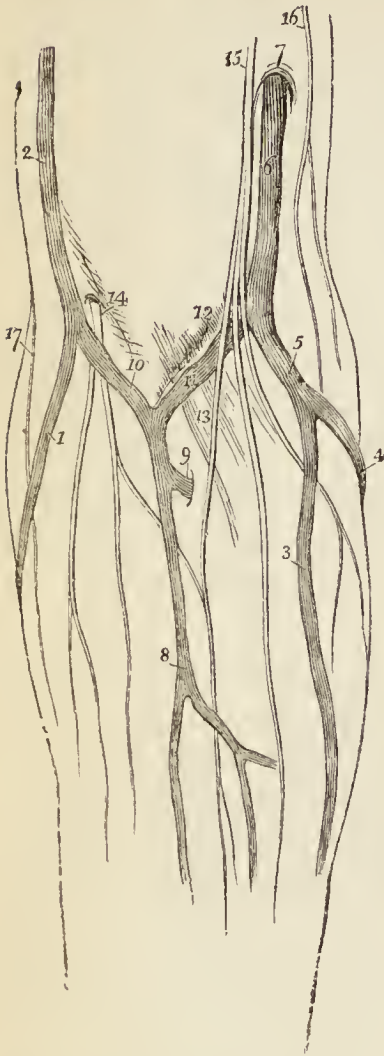The *median basilic vein*, the larger of the two, passes obliquely inwards along the border of the biceps, and unites with the common trunk of the ulnar veins to form the basilic vein. It crosses the brachial artery, being separated from it by the deep fascia, which is here strengthened by an aponeurotic slip, given off by the edge of the tendon of the biceps. The vein has one or two filaments of the internal cutaneous nerve passing in front, and others passing behind it. The relations of this vein should be carefully studied, in reference to the operation of bleeding, this being the vein the best suited for the purpose.

The *median cephalic vein*, longer and somewhat smaller than the preceding, inclines outwards in the groove between the biceps and the supinator longus, to unite with the radial vein, and form the cephalic vein. The branches of the external cutaneous nerve pass behind it. From the depth of the groove in which this vein is placed, and its smaller size, it is not usually selected for the operation of bleeding.

In the best performed operations on these veins, inconvenience sometimes arises from the wound or division of the cutaneous nerves. This accident is most likely to occur in opening the median basilic, because the internal cutaneous nerves pass *in front* of that vein; the external cutaneous nerves being *behind* the median cephalic vein.

The results of such an accident may be slight or serious, in proportion to the dexterity of the operator, or the condition of the lancet. A sharp blade and a clean wound can never do amiss.

Fig. 15.*



Occasionally the median basilic is completely transfixed, and the process of fascia derived from the edge of the biceps tendon injured. Inflammation may supervene and be followed by contraction of the fascia, causing great pain and deformity to the patient.

But this is not all; the brachial artery is sometimes wounded also. The lancet has transfixed the entire cylinder of the vein, the process of fascia, and the coats of the artery. The consequences of this accident cannot be too strongly impressed upon the student's recollection, they are as follows:—

1. "*False aneurism* is the *most common* form of disease following the accidental wound of the artery at the bend of the arm." † In this case the blood rushing from the

wounded vessel forms for itself a sac by the condensation of the surrounding tissues.

* The superficial anatomy of the bend of the elbow.—No. 1. The radial vein. 2. The cephalic vein. 3. The anterior ulnar vein. 4. The posterior ulnar vein. 5. The common ulnar vein. 6. The basilic vein. 7. The point at which the basilic vein pierces the deep fascia. 8. The median vein. 9. A deep vein joining the median just before its bifurcation. 10. The median cephalic vein. 11. The median basilic. 12. A prominence of the deep fascia caused by the brachial artery. 13. The tendinous band proceeding from the tendon of the biceps to the deep fascia of the fore-arm. 14. The cutaneous portion of the musculo-cutaneous nerve perforating the deep fascia. 15. The internal cutaneous nerve. 16. The lesser internal cutaneous or nerve of Wrisberg. 17. The external cutaneous branch of the musculo-spiral nerve.

† The passages between inverted commas are quotations from Liston's "Practical Surgery."

2. *Aneurismal varix* is the accident next in frequency: “the coats of the vein and artery become firmly agglutinated,” and “the arterial blood is poured into the vein at each contraction in a small and forcible stream, occasioning a peculiar shrill sound.”

3. The third variety, “*Varicose aneurism*,” is rare. It consists in the formation of a false aneurism between the artery and vein, and communicating with both.

Thus it may be shown that this operation, so apparently simple and easy of execution, that is constantly entrusted to the hands of the tyro apprentice, often before he has ever opened a manual of anatomy, is attended with dangers, if caution be not used, equal to those of many of the greater operations of surgery. We therefore advise the dissector not to pass hastily over this region, but consider well its relations and appliances. If other reasons for his attention were needed, he should recollect that every man is a judge of so common a proceeding.

The *radial vein* collects the venous blood from the thumb and outer aspect of the hand and fore-arm; it is often of small size. Its junction with the median cephalic constitutes the cephalic vein.

The *cephalic vein* (κεφαλή, the head) ascends the outer side of the arm to the groove between the pectoralis major and deltoid, where it is in relation with the descending branch of the thoracica-acromialis artery, and terminates beneath the clavicle in the axillary vein. A large communicating branch sometimes crosses the clavicle between the external jugular and this vein, which gives it the appearance of being derived directly from the head—hence its appellation.

The *ulnar veins*, anterior and posterior, unite near the bend of the elbow to form a common ulnar trunk, and the latter, after receiving the median basilic, becomes the basilic vein.

The *basilic vein* (βασιλικός, royal, or principal) ascends from the common ulnar vein formed by the two preceding, along the inner side of the upper arm, and near its middle pierces the fascia; it then passes upwards to the axilla, and becomes the axillary vein. In its course it lies to the inner side of the brachial artery.

The *lymphatic vessels* of the upper arm follow the

course of the basilic and cephalic veins, those accompanying the former being the most numerous. Just above the elbow, to the inner side of the basilic vein, may be found a lymphatic gland.

CUTANEOUS NERVES.—The *external cutaneous* nerves are derived from the musculo-spiral and musculo-cutaneous. The *cutaneous branches* of the *musculo-spiral*, two in number, pierce the deep fascia, the one (*upper*) just below the insertion of the deltoid, the other (*lower*) at about the middle of the upper arm. The *upper* branch descends by the side of the cephalic vein, and supplies the integument as far as the elbow. The *lower* branch passes down in front of the elbow, and along the outer side of the forearm to the back of the wrist; supplying the integument in its course.

The *cutaneous* portion of the *musculo-cutaneous nerve*, emerging from beneath the tendon of the biceps, pierces the deep fascia at the bend of the elbow, and passing behind the median cephalic vein, divides into two branches, which are distributed to the outer side of the forearm, as far as the hand.

The *internal cutaneous nerves* are derived from the internal cutaneous, the lesser internal cutaneous, the intercosto-humeral, and the musculo-spiral.

The *internal cutaneous nerve* pierces the fascia by the side of the basilic vein at about the middle of the upper arm, and divides into two branches, external and internal. The *external* branch passes in front of, and sometimes behind, the median basilic vein, and along the inner side of the forearm to the wrist. The *internal* branch passes inwards behind the internal condyle, and, after giving filaments to the region of the olecranon, descends along the forearm to the wrist. While in the axilla, the internal cutaneous nerve gives off a cutaneous branch, which pierces the fascia, and descends along the inner side of the arm to the elbow.

The *lesser internal cutaneous nerve*, or nerve of Wrisberg, passes down the upper arm, lying to the inner side of the brachial vessels and internal cutaneous nerve, and pierces the deep fascia at about the middle of its posterior aspect, to be distributed to the integument of the lower third of the upper arm, as far as the olecranon. While in the axilla, the nerve of Wrisberg communicates

with the intercosto-humeral nerve, and sometimes its place is taken by the latter.

The *intercosto-humeral nerve* (*fig. 13.*), the lateral cutaneous branch of the second intercostal nerve, communicates with the nerve of Wrisberg in the axilla, and, piercing the fascia, is distributed to the integument of the inner and posterior aspect of the upper half of the upper arm. Besides communicating with the nerve of Wrisberg, one of its branches unites with the internal cutaneous branch of the musculo-spiral nerve.

The *internal cutaneous* branch of the *musculo-spiral nerve* passes backwards beneath the intercosto-humeral nerve, and, after communicating with one of its branches, is distributed to the integument of the middle of the posterior aspect of the upper arm, as far as the olecranon.

The DEEP FASCIA of the upper arm is continuous above with the thin aponeurosis which covers in the pectoralis major and deltoid, and forms the lower boundary of the axilla. It receives, at its upper part, an addition of fibres from the tendons of the pectoralis major, teres major, and latissimus dorsi, sends inwards sheaths for the muscles, and is attached on either side to the condyloid ridges and condyles; inferiorly, it is continuous with the fascia of the fore-arm, and at the elbow receives a strong band of fibres from the inner border of the tendon of the biceps. The attachment of the deep fascia to the condyloid ridges constitutes the *intermuscular septa*, between the muscles of the anterior and posterior brachial region.

The deep fascia should be laid open by means of an incision made along the middle of the biceps to the bend of the elbow, and crossed at that point by a transverse incision. The fascia should then be reflected to either side, when the muscles, vessels, and nerves of the anterior brachial region will be brought into view.

The MUSCLES of the anterior brachial region are three in number; namely, the

Coraco-brachialis,
Biceps,
Brachialis anticus.

The CORACO-BRACHIALIS — a name composed of its points of origin and insertion — *arises* from the coracoid process in common with the short head of the biceps,

and is *inserted* into a rough line on the inner side of the middle of the humerus. The muscle is pierced from within outwards by the musculo-cutaneous nerve.

The BICEPS (*bis*—κεφαλαί, two heads) *arises* by two tendons, one the *short head*, from the coracoid process in common with the coraco-brachialis; the other the *long head*, from the upper part of the glenoid cavity. The muscle is *inserted* by a rounded tendon into the back part of the tubercle of the radius. The long head, a long slender tendon, passes through the capsular ligament of the shoulder-joint enclosed in a sheath of the synovial membrane; after leaving the cavity of the joint it is lodged in the deep groove that separates the two tuberosities of the humerus, the bicipital groove. A small synovial bursa is interposed between the tendon of insertion and the tubercle of the radius. *At the bend of the elbow*, the tendon of the biceps gives off from its inner side a tendinous band (*fig. 15. 13.*), which protects the brachial artery, and is continuous with the fascia of the fore-arm.

To see the next muscle, the biceps must be drawn aside; it covers the entire breadth of the humerus at its lower part, and extends for a short distance beyond the biceps on either side.

The BRACHIALIS ANTICUS muscle *arises* by two fleshy serrations from the depressions on either side of the insertion of the deltoid, from the anterior surface of the humerus, and from the inner intermuscular septum. Its fibres converge to be *inserted* into the coronoid process of the ulna, between two processes of the flexor longus digitorum.

As some convenience will arise to the student from possessing a knowledge of the triceps muscle, the muscle of the posterior brachial region, before studying the brachial artery and nerves, he may now turn the arm and bring the muscle into view by detaching the deep fascia in the manner practised for the anterior muscles.

The TRICEPS, or triceps extensor cubiti muscle (τρεις κεφαλαί, three heads), *arises* by three heads—external, middle, and internal. The *external* head *arises* from the whole length of the external and posterior aspect of the humerus, from the insertion of the teres minor at the greater tuberosity to the external condyle, and also from the external intermuscular septum. The *internal* head

arises from the inner and posterior aspect of the humerus, from the insertion of the *teres major* to the internal condyle, and from the internal intermuscular septum. The *middle* or long head *arises* from the lower part of the head and adjoining part of the border of the scapula, to the extent of about an inch. The three heads, passing downwards in different directions, unite to form a broad muscle, which is *inserted* into the olecranon process of the ulna, and sends an expansion to the deep fascia of the fore-arm. A small bursa is situated between the tendon of the muscle and the upper part of the olecranon.

ACTIONS.—We may now inquire into the actions of the muscles of the shoulder and upper arm. The *pectoralis major* draws the arm against the thorax, while its upper fibres assist the upper part of the *trapezius* in raising the shoulder, as in supporting weights. The lower fibres depress the shoulder with the aid of the *latissimus dorsi*. Taking its fixed point from the shoulder, the *pectoralis major* assists the *pectoralis minor*, *subclavius*, and *serratus magnus*, in drawing up and expanding the chest. The *pectoralis minor*, in addition to this action, draws upon the coracoid process, and assists in rotating the scapula upon the chest. The *subclavius* draws the clavicle downwards and forwards, and thereby assists in steadying the shoulder. The *serratus magnus* is the great external inspiratory muscle, raising the ribs when the shoulders are fixed, and thereby increasing the cavity of the chest. Acting upon the scapula, it draws the shoulder forwards, as we see to be the case in diseased lungs, where the chest has become almost fixed from apprehension of the expanding action of the respiratory muscles. The *trapezius* muscle carries the entire shoulder upwards and backwards, and is assisted in this action by the *levator anguli scapulæ*, *rhomboideus minor*, and *rhomboideus major*. Acting in the opposite direction, they flex the vertebral column towards the shoulder. The lower fibres of the *trapezius* unite with the *latissimus dorsi*, in drawing the shoulder and arm downwards and backwards. When the arms are fixed, as by crutches, or seizing the branch of a tree, the *latissimi dorsi* muscles lift the entire trunk and carry it forwards.

The *supra-spinatus*, *infra-spinatus*, *teres minor*, and *subscapularis* are the circumductor muscles of the arm; they regulate the movements of the head of the humerus against the glenoid cavity. The *deltoid* is the elevator muscle of the arm in a direct line, and, by means of its extensive origin, can carry the arm forwards or backwards so as to range with the hand a considerable segment of a large circle. The arm, raised by the *deltoid*, is a good illustration of a lever of the *third* power, so common in the animal machine, by which velocity is gained at the expense of power. In this lever the weight (hand) is at one extremity, the fulcrum (the glenoid cavity) at the opposite end, and the power (the insertion of the muscle) between the two, but nearer the fulcrum than the weight.

The muscles of the anterior brachial region are flexors; the

coraco-brachialis flexing the humerus on the scapula, and carrying it inwards. The biceps and brachialis anticus flex the fore-arm upon the arm. The former possesses also the additional action of supinating the fore-arm, by means of the obliquity of its insertion into the tuberosity of the radius. The triceps is an extensor of the fore-arm; hence its title, *triceps extensor cubiti*.

BRACHIAL ARTERY.—The *brachial artery*, the continuation of the axillary, passes down the inner side of the arm, from the lower border of the tendons of the *latissimus dorsi* and *teres major*, to a little below the bend of the elbow, where it divides into the radial and ulnar arteries.

In its course downwards, it is placed at first to the inner side of the humerus, but soon gets in front of the bone. It rests successively on the triceps, coraco-brachialis, and brachialis anticus. To its *outer* side is the coraco-brachialis and biceps, the latter somewhat overlapping it; to its *inner* side is the internal cutaneous and ulnar nerve. In *front* it has the basilic vein, the deep fascia, and the median nerve; the latter lies to its outer side above, crosses it at its middle, and lower down gets to its inner side. In immediate relation with the artery, and lying in the same sheath, are the brachial *venæ comites*.

Operations.—The *brachial artery* may be tied in the middle or upper part of the arm, or at the bend of the elbow. In the former situation an incision two inches and a half in length is made along the inner border of the coraco-brachialis and biceps. This should divide the *integument*, *superficial* and *deep fascia*. The basilic vein, which lies in front of the sheath of the vessels in the middle of the arm, should be drawn aside, as also should the median nerve which crosses the artery from without inwards at the middle of its course. The sheath must then be carefully opened, and a needle passed beneath the artery, taking care to avoid the two veins (*venæ comites*) by which it is accompanied. The only difficulty the student will experience in this operation is the finding of the sheath, which is placed beneath the edge of the biceps; it is therefore necessary to pronate the arm in performing the operation. At the bend of the arm, an incision two inches in length should be made along the inner border of the tendon of the biceps to the outer side of the median basilic vein; the *integument* and *superficial fascia* should be divided; next the *deep fascia*, strengthened in this situation by the aponeurotic band given off from the tendon of the biceps. The sheath of the vessels may then be opened, and the artery secured, as it lies between its two veins. The median nerve lies nearly an inch to the inner side of the artery at this point.

The *branches* of the brachial artery are the

Superior profunda,	Anastomotica magna,
Inferior profunda,	Muscular and nutrient.

The *superior profunda* arises opposite the lower border of the tendon of the latissimus dorsi, and winds around the humerus, between the triceps and the bone, to the space between the brachialis anticus and supinator longus, where it inosculates with the radial recurrent artery. It accompanies the musculo-spiral nerve. In its course it gives off the posterior articular artery, which descends to the elbow-joint, and a more superficial branch which descends by the side of the external intermuscular septum, and inosculates with the interosseous articular artery. The inferior muscular branches of the superior profunda inosculate with the inferior profunda, anastomotica magna, and ulnar recurrent arteries.

The *inferior profunda* arises from about the middle of the brachial artery, and descends to the space between the inner condyle and olecranon in company with the ulnar nerve, where it inosculates with the posterior ulnar recurrent. In its course it pierces the intermuscular septum.

The *anastomotica magna* is given off nearly at right angles from the brachial, at about two inches above the joint. It passes directly inwards upon the brachialis anticus muscle, pierces the intermuscular septum, and winds around the humerus to inosculate with the superior profunda. On the brachialis anticus it divides into two branches, which inosculate with the anterior and posterior ulnar recurrent arteries and with the inferior profunda.

The *muscular branches* are distributed to the muscles in the course of the artery—viz. to the coraco-brachialis, biceps, deltoid, brachialis anticus, and triceps. The *nutrient* branch is given off at about the middle of the arm, and passes into the medullary foramen situated near the insertion of the coraco-brachialis muscle.

The NERVES of the upper arm may now be followed in their course as far as the elbow, and their branches examined; but they cannot be completely studied until after the dissection of the fore-arm.

The MUSCULO-CUTANEOUS NERVE (external cutaneous, perforans Casserii) arises from the brachial plexus in

common with the external head of the median; pierces the coraco-brachialis muscle, and passes between the biceps and brachialis anticus to the outer side of the bend of the elbow, where it perforates the fascia, and divides into two branches, which are distributed to the integument of the outer side of the fore-arm as far as the hand. In the muscular part of its course it gives branches to the coraco-brachialis, biceps, and brachialis anticus.

The **MEDIAN NERVE** arises by two heads which proceed from the outer and inner cords of the brachial plexus, and embrace the axillary artery. The nerve lies at first to the outer side of the brachial artery, but crosses it in the middle, sometimes in front and sometimes behind, and getting to its inner side descends to the bend of the elbow. It gives off no branch in the upper arm.

The **ULNAR NERVE**, somewhat smaller than the median, arises from the inner cord of the plexus in common with the inner head of that nerve; and descends upon the inner side of the brachial artery to about its middle. It then pierces the intermuscular septum, and passes down upon, and partly embedded in, the inner portion of the triceps to the groove between the internal condyle and the olecranon; having in company the inferior profunda artery. It gives off no branch in the upper arm.

The **INTERNAL CUTANEOUS NERVE** arises with the ulnar from the inner cord of the brachial plexus. It lies at first to the inner side of the brachial artery, but shortly gets in front of it, and at the middle of the arm pierces the fascia, and divides into its two cutaneous branches (page 108.). Soon after its origin it gives off a cutaneous branch, which pierces the fascia immediately below the axilla.

The **LESSER INTERNAL CUTANEOUS NERVE** (Wrisberg's) arises, with the two preceding, from the inner cord of the plexus, and, issuing from beneath the axillary vein, descends the inner side of the arm to the middle of its posterior aspect, where it pierces the deep fascia and becomes cutaneous. In the axilla it communicates with the intercosto-humeral nerve.

The **CIRCUMFLEX NERVE** proceeds from the posterior cord of the brachial plexus, and lies behind the axillary artery; its course and branches have been already described (page 100.).

The MUSCULO-SPIRAL NERVE, the largest branch of the brachial plexus, arises from its posterior trunk in common with the circumflex, and, descending behind the axillary and brachial artery, winds around the humerus between the triceps and the bone, and in company with the superior profunda artery to the space between the brachialis anticus and supinator longus, and thence onwards to the bend of the elbow, where it divides into two branches, radial and posterior interosseous.

The *branches* of the musculo-spiral nerve in the upper arm are muscular and cutaneous.

The *muscular* branches are distributed to the triceps, anconeus, brachialis anticus, supinator longus, and extensor carpi radialis longior.

The *cutaneous* branches are three in number—internal, and two external. The *internal* branch arises from the nerve in the axilla, and pierces the deep fascia in the upper third of the arm on its posterior aspect (page 109.). The *external* branches pass through the substance of the external head of the triceps, and pierce the deep fascia; one (*upper*) near the insertion of the deltoid, the other or *lower* branch at about the middle of the upper arm.

ANATOMY OF THE FORE-ARM.

An incision may now be carried along the front of the fore-arm, from the elbow to the wrist, and terminated in the latter situation by a transverse incision. The integument should then be dissected back on either side, and the dissection carried completely around the arm. Furthermore, the integument should be raised in the same manner from the back of the hand and fingers, leaving the palm of the hand for subsequent dissection.

In the superficial fascia of the front of the fore-arm will be found a number of superficial veins, which may be followed downwards to the hand, and some cutaneous nerves.

CUTANEOUS VEINS.—The *radial vein* commences on the dorsum of the hand, in the radial termination of a *venous arch*, which receives the veins of the fingers. This origin is increased by the junction of some small veins from the thumb. The radial vein ascends the dorsal side of the fore-arm to a little below its middle, then lies on its anterior aspect to the bend of the elbow, where it receives the median cephalic, and becomes the cephalic vein.

The *posterior ulnar vein* begins in the ulnar extremity of the venous arch, and, after receiving a large vein — the *vena salvatella* — from the little finger, ascends along the posterior aspect of the fore-arm to the bend of the elbow, where it turns forward and terminates in the anterior ulnar vein.

The *anterior ulnar vein*, beginning at the wrist, ascends along the anterior aspect of the inner side of the fore-arm to the bend of the elbow, where it receives the median basilic, and becomes the basilic vein.

The *median* vein begins upon the front of the wrist by the junction of branches from the palm of the hand, and passing upwards along the front of the fore-arm, terminates just below the bend of the elbow by dividing into the median cephalic and median basilic.

CUTANEOUS NERVES. — The superficial nerves situated upon the *outer* side of the front of the fore-arm are the musculo-cutaneous, the external cutaneous of the musculo-spiral, and, a little above the wrist, the radial nerve in its course to the back of the hand. Those on the *inner* side of the fore-arm are the internal cutaneous, and, lower down, a cutaneous branch of the ulnar. On the *middle*, a little above the wrist, is the palmar cutaneous branch of the median; and on the *back of the hand* is the radial nerve and a branch of the ulnar.

The *musculo-cutaneous nerve*, after becoming superficial at the elbow, divides into an anterior and a posterior branch. The *anterior branch* passes along the outer border of the fore-arm, and, at its lower part, overlies the radial artery. At the wrist it gives several filaments to the ball of the thumb, and pierces the deep fascia to accompany the radial artery to the back of the wrist. The *posterior branch*, smaller than the anterior, follows the outer border of the fore-arm on its posterior aspect, and is distributed to the integument as far as the wrist; it communicates with the radial nerve and with the external cutaneous branch of the musculo-spiral.

The *cutaneous branch* of the *musculo-spiral nerve* passes down the outer side of the fore-arm, and, at about the middle, reaches its posterior aspect, and is continued to the wrist; it communicates with the posterior branch of the musculo-cutaneous nerve.

The *internal cutaneous nerve* reaches the fore-arm by

two branches; the *anterior* branch is that which passes in front of the median basilic vein, and descends along the fore-arm to the wrist. The *posterior* branch enters the fore-arm behind the internal condyle of the humerus, and passes down the posterior aspect of the ulnar border of the fore-arm to its lower third.

The *radial nerve* pierces the deep fascia about two inches above the wrist on the posterior aspect of the fore-arm, and divides into two branches, which are distributed to the integument of the radial half of the hand. The *external branch* communicates with the cutaneous branch of the musculo-cutaneous nerve, and is distributed to the radial border of the thumb. The *internal branch* divides into filaments, which are distributed to the ulnar border of the thumb, to the index and middle fingers, and the radial border of the ring finger. This branch communicates with the musculo-cutaneous nerve, and with the ulnar. On the fingers, the digital branches communicate with those of the median nerve.

The *dorsal branch* of the *ulnar nerve* pierces the deep fascia on the wrist, and divides into branches, one of which forms an arch on the back of the hand by communicating with the radial nerve, while the others are distributed to the little finger and half the ring finger.

The DEEP FASCIA of the fore-arm is dense and thick, particularly on its posterior aspect. It is continuous above with the corresponding fascia of the upper arm; below, it is connected with the anterior annular ligament in front, and behind forms the posterior annular ligament, and is prolonged onwards to the back of the hand and fingers. At the elbow it receives an augmentation of fibres from the tendon of the biceps, from the brachialis anticus, and muscles arising from the internal condyle, and from the triceps behind. It surrounds all the muscles of the fore-arm, forming septa, from which part of the muscles arise; and constitutes an aponeurosis of separation between the superficial and deep muscles. Posteriorly it is attached to the ulna; and at its lower part in front gives passage to the tendon of the palmaris longus muscle.

When the deep fascia has been examined, an incision should be made along the front of the fore-arm from the elbow to the wrist, and crossed in the latter situation by a transverse section. Before

this is done, it is proper to note two small nerves, which should be spared in the removal of the fascia. One of these is the palmar cutaneous branch of the median; it pierces the fascia just above the wrist, and crosses the middle of the annular ligament to reach the hand. The other is a cutaneous branch of the ulnar nerve, which pierces the fascia at about the middle of the fore-arm, and passes down in front of the ulnar artery to the palm of the hand. The deep fascia is to be raised from the muscles and turned to either side; in doing which the septa between the muscles should be observed. The attachment of the fibres of the muscles to the fascia at their upper part will render the dissection troublesome, and will spoil the appearance of the muscles.

The MUSCLES of the anterior aspect of the fore-arm consist of a *superficial* and a *deep* group, and are eight in number, five in the superficial layer, and three in the deep; they are all *flexors* and *pronators*. The superficial group is as follows:—

Pronator radii teres,
Flexor carpi radialis,
Palmaris longus,
Flexor carpi ulnaris,
Flexor sublimis digitorum.

The PRONATOR RADII TERES *arises* by two heads, one from the inner condyle of the humerus, deep fascia, and intermuscular septum; the other from the coronoid process of the ulna; the median nerve passing between them. Its tendon is flat, and is *inserted* into the middle third of the oblique ridge of the radius. The two heads of this muscle are best seen by cutting away that which arises from the inner condyle, and turning it aside. The second head will then be seen with the median nerve lying across it.

The pronator radii teres forms the inner border of a triangular space, bounded externally by the supinator longus and above by the brachialis anticus, which contains the termination of the brachial artery, where it bifurcates into the radial and ulnar artery, the median nerve, the tendon of the biceps, and the musculo-spiral nerve. The latter lies under cover of the supinator longus.

The FLEXOR CARPI RADIALIS *arises* from the inner condyle, deep fascia, and intermuscular septa. Its tendon passes through a groove in the trapezium bone, to be

inserted into the base of the metacarpal bone of the index finger.

The PALMARIS LONGUS muscle *arises* from the inner condyle, deep fascia, and intermuscular septa. Its tendon pierces the deep fascia and crosses the annular ligament, to be *inserted* into the palmar fascia.

The FLEXOR CARPI ULNARIS *arises* by two heads, one from the inner condyle and intermuscular septa, the other from the olecranon, and by means of a strong aponeurosis from two thirds of the inner border of the ulna. The ulnar nerve passes between its two heads. Its tendon is *inserted* into the pisiform bone, and base of the metacarpal bone of the little finger.

The flexor carpi radialis and palmaris longus should now be divided near their origin, and the flexor carpi ulnaris drawn aside in order to bring into view the flexor sublimis digitorum which lies beneath them.

The FLEXOR SUBLIMIS DIGITORUM (*perforatus*) *arises* from the inner condyle, intermuscular septa, internal lateral ligament, coronoid process of the ulna, and oblique line of the radius. The median nerve and ulnar artery pass between its origins. It divides into four tendons, which pass beneath the annular ligament, and are *inserted* into the base of the second phalanges of the fingers, splitting at their terminations to give passage to the tendons of the deep flexors; thence its designation *perforatus*.

The *deep layer* of muscles is brought into view by dividing the flexor sublimis through its tendons, and drawing the muscle upwards and outwards, and at the same time drawing aside the pronator radii teres. These muscles should be as little disturbed as possible, in order to avoid dislocating the blood vessels and nerves, and when the latter are studied they should be replaced. The *deep* muscles of the fore-arm are the

Flexor profundus digitorum,
Flexor longus pollicis,
Pronator quadratus.

The FLEXOR PROFUNDUS DIGITORUM (*perforans*) *arises* from the inner border and anterior surface of the ulna for three-fourths of its extent, from the inner side of the olecranon, and one half the interosseous membrane. The muscle terminates in four tendons, which pass beneath

the annular ligament, and on the fingers, between the two slips of the flexor sublimis (hence its designation *perforans*), to be *inserted* into the base of the last phalanges. The tendon for the index finger is distinct from the rest, the other three being more or less connected by cellular tissue and tendinous slips.

The FLEXOR LONGUS POLLICIS *arises* from anterior surface of the radius for two-thirds of its extent, and from one half of the interosseous membrane. Its tendon passes beneath the annular ligament, to be *inserted* into the base of the last phalanx of the thumb.

The PRONATOR QUADRATUS lies across the radius and ulna for the lower fourth of their extent; it *arises* from the anterior and inner side of the ulna, and is *inserted* into the front of the radius. The muscle is broader at its origin than at its insertion.

Actions.—The pronator radii teres and pronator quadratus muscles rotate the radius upon the ulna, and render the hand prone. The remaining muscles are flexors: two flexors of the wrist, flexor carpi radialis and ulnaris; two of the fingers, flexor sublimis and profundus, the former flexing the second phalanges, the latter the last; one flexor of the last phalanx of the thumb, flexor longus pollicis. The palmaris longus is primarily a tensor of the palmar fascia, and secondarily a flexor of the wrist and fore-arm.

The VESSELS of the anterior region of the fore-arm are the radial and ulnar, with their veins and branches.

The RADIAL ARTERY, one of the divisions of the brachial, passes down the radial side of the fore-arm from the bend of the elbow to the wrist; it then turns backwards around the base of the thumb, and passing through the first interosseous space between the two heads of the first dorsal interosseous muscle, enters the palm of the hand and becomes the deep palmar arch.

In the upper half of its course, the radial artery is placed between the supinator longus, by which it is slightly overlapped, and the pronator radii teres; in the lower half, between the tendons of the supinator longus and flexor carpi radialis. It rests in succession on the supinator brevis, pronator radii teres, radial origin of the flexor sublimis, flexor longus pollicis, and pronator quadratus; and is covered in by the integument and fasciæ. At the wrist it is in contact with the external lateral ligament, and beneath the extensor tendons of the thumb.

It is accompanied by venæ comites, and is in close relation by its middle third with the radial nerve which lies to its outer side.

Operations. — The radial artery may be tied in any part of its course, either above, where it is placed between the supinator longus and pronator teres, or below, between the tendons of the supinator longus and flexor carpi radialis. In either case the border of the supinator longus is the guide for the incision (two inches long); and the same parts are to be divided in both, viz., the *integument, superficial, and deep fascia.* The operation, at the upper part of the arm, will require the longer incision on account of the greater depth of the vessel, though the difference in that particular is very trifling. In the middle third of its course the radial artery is accompanied by the radial nerve.

The radial artery may likewise be tied where it is winding around the root of the thumb, to enter the palm of the hand. In this operation the incision should be made along the middle of the space between the tendons of the extensor primi and secundi internodii. In dividing the superficial fascia, one or two branches of veins may be wounded, and a branch of the dorsal division of the radial nerve which crosses the space. The artery is placed deeply upon the trapezium bone, and is accompanied by its two venæ comites.

The *branches* of the radial artery in the fore-arm and at the wrist are the —

Radial recurrent,	Posterior carpal,
Muscular,	Metacarpal,
Superficialis volæ,	Dorsales pollicis,
Anterior carpal,	Dorsalis indicis.

The *radial recurrent* branch, given off just below the elbow, passes outwards to the supinator longus muscle and gives off several branches for the supply of the muscles arising from the external condyle; it then ascends in the space between the supinator longus and brachialis anticus, and inosculates with the superior profunda.

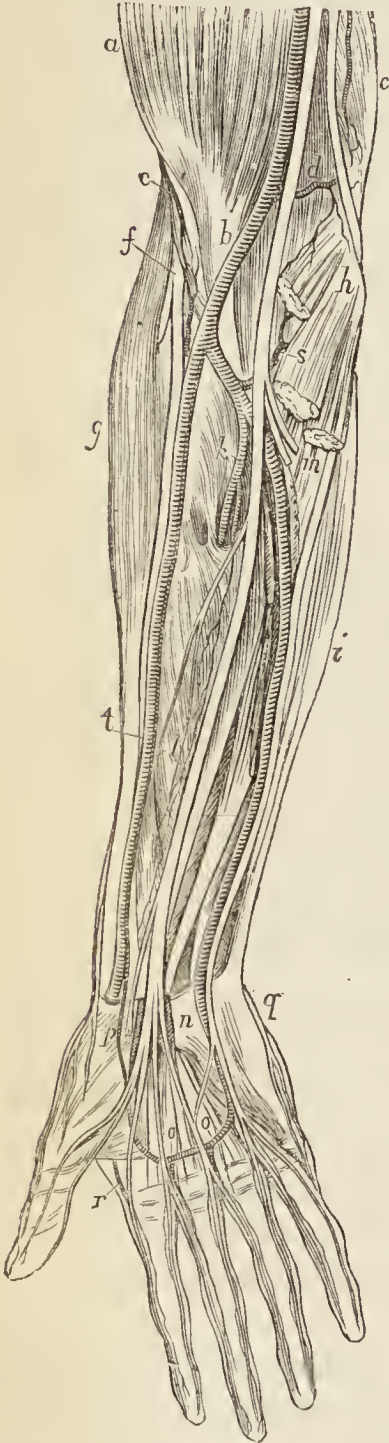
The *muscular* branches are distributed to the muscles of the radial border of the fore-arm.

The *superficialis volæ* arises from the radial at the wrist and crosses the ball of the thumb, generally piercing the abductor pollicis muscle, to inosculate with the ulnar artery and complete the superficial palmar arch. This artery varies much in size, being sometimes a mere twig and sometimes a bifurcation of the radial.

The *anterior carpal* branch passes inwards along the lower border of the pronator quadratus, and forms an arch

by inosculating with the anterior carpal branch of the ulnar artery. From this arch twigs are given off to supply the wrist joint.

Fig. 16.*



The *posterior carpal* branch proceeding from the radial while in relation with the wrist, crosses the carpus transversely, and inosculates with the posterior carpal branch of the ulnar artery. From this arch are given off the *dorsal interosseous* branches of the third and fourth metacarpal spaces. The latter are joined over the heads of the interossei muscles by the perforating branches of the deep palmar arch.

The *metacarpal* or *first dorsal interosseous* branch passes forwards to the metacarpal space between the index and middle finger. At the cleft of the fingers it inosculates with the palmar digital artery, and gives off dorsal collateral branches. It is joined over the heads of the interosseous muscle by the perforating branch from the deep palmar arch.

The *dorsales pollicis* are two small branches which run along the sides of the dorsal aspect of the thumb.

The *dorsalis indicis* is a small branch which runs along the radial border of the metacarpal bone and phalanges of the index finger.

The ULNAR ARTERY, the other and larger division of the brachial

* Vessels and nerves of the front of the fore-arm. — *a*. The biceps. *b*. Its tendon crossed by the brachial artery. *c*. The triceps; the ulnar nerve accompanied by the inferior profunda artery rests on the triceps; externally to the ulnar nerve are the median nerve and brachial artery. *d*. The anastomotica magna artery; the letter is

artery, crosses the fore-arm obliquely to the commencement of its middle third; it then runs down its ulnar side to the wrist, crosses the annular ligament, and forms the superficial palmar arch, which terminates by inosculating with the superficialis volæ.

In the upper or oblique portion of its course, the ulnar artery lies upon the brachialis anticus and flexor profundus digitorum, and is covered in by the superficial layer of muscles of the fore-arm and by the median nerve. In the second part of its course, it is placed upon the flexor profundus and pronator quadratus, lying between the flexor carpi ulnaris and flexor sublimis digitorum. While crossing the annular ligament it is protected from injury by a strong tendinous arch, thrown over it from the pisiform bone. It is accompanied in its course by the venæ comites, and is in relation with the ulnar nerve for the lower two-thirds of its extent; the nerve lying to its ulnar side.

placed on the brachialis anticus muscle. *e.* The outer part of the brachialis anticus, and superior profunda artery. *f.* The musculospiral nerve, dividing into the radial and posterior interosseous nerve; the small artery by its side is the recurrent radial. *g.* The supinator longus muscle; along the inner border of which lies the radial artery and nerve. *h.* The internal condyle of the humerus; the three muscles arising from it and cut across are the pronator radii teres, flexor carpi radialis and palmaris longus. *i.* The flexor carpi ulnaris muscle; along its inner border are seen the ulnar artery and nerve. *k.* The interosseous artery. The letter rests on the supinator brevis muscle; above the letter is the bifurcation of the brachial artery into the radial and ulnar; to its left is the radial artery and nerve; to its right, the interosseous artery, the median nerve, the ulnar artery, and further inwards the ulnar nerve. *l.* The median nerve accompanied by the median artery; the letter rests on the flexor sublimis digitorum. *m.* The flexor sublimis digitorum; a portion of the muscle is cut away in order to bring into view the ulnar artery. *n.* The annular ligament cut through in order to bring into view the median nerve in its passage beneath it; to the right of the letter lies the ulnar artery and nerve. *o, o.* The superficial palmar arch. *p.* The superficialis volæ artery, which completes the palmar arch; the letter rests on the muscles of the ball of the thumb, and the nerve to its left is a branch of the radial. *q.* A branch of the dorsal division of the ulnar nerve. *r.* The radialis indicis artery. *s.* The anterior ulnar recurrent artery, passing upwards to inosculate with the anastomotica magna. *t.* The radial nerve passing beneath the tendon of the supinator longus muscle to the back of the fore-arm.

Operations.—The ulnar artery is usually tied in three situations:—1st. At the commencement of the middle third of the fore-arm, where it emerges from beneath the flexor sublimis. 2nd. In the lower third. 3rd. As it crosses the annular ligament. In the first two operations the border of the flexor carpi ulnaris muscle and tendon is the guide for the incision, in the latter the pisiform bone. The high operation is the most difficult, on account of the depth of the artery and the danger of separating the wrong muscles. The lower operations are simple and easy, the artery lying quite superficially. The ulnar nerve lies immediately to the ulnar side of the artery from the commencement of the middle third to the wrist, and therefore is not endangered in the upper operation. The venæ comites are one at each side. The structures to be cut through are the *integument, superficial fascia, deep fascia, the sheath of the vessels,* and, at the wrist, the palmaris brevis muscle and tendinous band. The length of incision for the upper operation is three inches, and for the lower two.

In wounds of arteries, wherever they occur, both extremities of the vessel are to be tied; and this is the rule of practice for wounds in the palm of the hand.

The *branches* of the ulnar artery in the fore-arm are the —

Anterior ulnar recurrent,	Anterior carpal,
Posterior ulnar recurrent,	Posterior carpal,
Interosseous,	Metacarpal.
Muscular,	

The *anterior ulnar recurrent* arises immediately below the elbow, and ascending between the pronator radii teres and brachialis anticus gives branches to the muscles and inosculates with the inferior profunda and anastomotica magna. This artery frequently arises from a common trunk with the following.

The *posterior ulnar recurrent*, larger than the preceding, passes beneath the flexor sublimis digitorum muscle to the notch between the inner condyle and the olecranon, where it is in relation with the ulnar nerve, and inosculates with the inferior profunda and anastomotica magna.

The *interosseous artery* is a short trunk, which arises opposite the tuberosity of the biceps, and passes backwards to the interosseous membrane, where it divides into the anterior and posterior interosseous.

The *anterior interosseous* artery passes down the front of the interosseous membrane, between the flexor profundus digitorum and flexor longus pollicis, and behind

the pronator quadratus ; it then passes through an opening in the interosseous membrane to the back of the wrist, where it inosculates with the posterior carpal branches of the radial and ulnar. The anterior interosseous artery gives off several *muscular* branches ; *nutrient* branches to the radius and ulna ; a *companion branch* to the *median* nerve ; and at the upper border of the pronator quadratus, a small branch, which descends behind that muscle to inosculate with the anterior carpal arteries.

The *posterior interosseous* artery passes backwards through an opening between the upper part of the interosseous membrane and the oblique ligament, and descends between the superficial and deep layer of muscles of the back of the fore-arm to the wrist, where it inosculates with the posterior carpal arteries, and with the termination of the anterior interosseous. The posterior interosseous artery gives off at its upper part a *recurrent* branch, which ascends between the supinator brevis and extensor carpi ulnaris, and enters the anconeus, where it inosculates with a branch of the superior profunda.

The *muscular branches* of the ulnar artery are distributed to the muscles of the ulnar border of the fore-arm.

The *anterior carpal* branch crosses in front of the wrist joint, and inosculates with the anterior carpal branch of the radial artery, forming an *anterior carpal arch*.

The *posterior carpal* branch, taking a similar course across the back of the wrist, forms, with a similar inosculation, a *posterior carpal arch*.

The *metacarpal* branch, often a branch of the preceding, passes along the inner border of the metacarpal bone of the little finger, and forms the dorsal collateral branch of that finger.

The NERVES of the fore-arm are the radial, ulnar, and median, which belong to its anterior aspect ; and the interosseous, the nerve of its posterior region.

The RADIAL NERVE, one of the terminal branches of the musculo-spiral (page 115.), passes downwards along the outer side of the radial artery, and overlapped by the supinator longus to the lower third of the fore-arm, where it turns beneath the tendon of that muscle, and piercing the deep fascia is distributed to the back of the hand, the thumb, and two fingers and a half (page 117.).

The **MEDIAN NERVE** (page 114.), lying in the hollow of the bend of the elbow, passes between the two heads of the pronator radii teres. It next gets beneath the flexor sublimis digitorum and descends the middle of the fore-arm, lying between that muscle and the flexor profundus to its lower fourth. There it becomes superficial, and running along the outer border of the tendons of the flexor sublimis, passes beneath the annular ligament, and enters the palm of the hand.

The *branches* of the median nerve in the fore-arm are, muscular, anterior interosseous, and superficial palmar.

The *muscular* branches are distributed to all the muscles of the superficial layer, except the flexor carpi ulnaris, and to one of the deep layer, the flexor profundus digitorum, its radial half.

The *anterior interosseous* nerve, of large size, accompanies the anterior interosseous artery, and supplies the deep layer of muscles of the front of the fore-arm.

The *superficial palmar* branch leaves the median nerve at the lower part of the fore-arm, and piercing the deep fascia, crosses the annular ligament, and is distributed to the integument of the palm of the hand.

The **ULNAR NERVE** (page 114.), entering the fore-arm in the groove behind the internal condyle between the two heads of the flexor carpi ulnaris, comes into relation with the ulnar artery at the commencement of its middle third. It then descends along the inner side of the artery to the wrist, crosses with it the annular ligament, and divides into two palmar branches.

The *branches* of the ulnar nerve in the fore-arm are, articular, muscular, cutaneous, and dorsal cutaneous.

The *articular* branches are given to the elbow joint, while the nerve lies in the groove between the internal condyle and the olecranon.

The *muscular* branches are distributed to the flexor carpi ulnaris, and inner half of the flexor profundus digitorum.

The *cutaneous* branch proceeds from about the middle of the nerve, and descends upon the ulnar artery to the hand, giving twigs to the integument in its course. One branch from its upper part, sometimes a separate offset from the nerve, and sometimes absent, pierces the fascia, and communicates with the internal cutaneous nerve.

The *dorsal cutaneous* branch passes backwards, beneath

the tendon of the flexor carpi ulnaris, at the lower third of the fore-arm, and piercing the deep fascia, supplies the ulnar side of the back of the hand, and one finger and a half (page 117.).

The POSTERIOR INTEROSSEOUS, the other division of the musculo-spiral nerve at the bend of the elbow, pierces the supinator brevis muscle, and is distributed to the back of the fore-arm. Its further examination must therefore be reserved until the posterior aspect of the fore-arm is dissected.

Posterior Region of the Fore-arm.

The deep fascia may now be dissected from the posterior aspect of the fore-arm in a manner similar to that practised on the anterior aspect; the longitudinal incision should be bounded by a transverse incision made along the upper border of the posterior annular ligament, and the fascia turned to either side. The posterior annular ligament is attached externally to the radius, and internally to the pisiform bone, and forms separate sheaths for the passage of the tendons of muscles to the hand.

The MUSCLES of the posterior region of the fore-arm are a superficial and a deep group; the *superficial group* or layer consists of seven muscles, namely:

Supinator longus,
 Extensor carpi radialis longior,
 ——— carpi radialis brevior,
 ——— communis digitorum,
 ——— minimi digiti,
 ——— carpi ulnaris,
 Anconeus.

The SUPINATOR LONGUS muscle is placed along the radial border of the fore-arm. It *arises* from the external condyloid ridge of the humerus, nearly as high as the insertion of the deltoid, and from the intermuscular septum; and is *inserted* into the base of the styloid process of the radius.

This muscle must be divided through the middle, and the two ends turned to either side to expose the next muscle.

The EXTENSOR CARPI RADIALIS LONGIOR *arises* from the external condyloid ridge below the preceding, and from the intermuscular septum. Its tendon passes through a groove in the radius, immediately behind the styloid

process, to be inserted into the base of the metacarpal bone of the index finger.

The *EXTENSOR CARPI RADIALIS BREVIOR* is seen by drawing aside the former muscle. It *arises* from the external condyle of the humerus and intermuscular septa, and is *inserted* into the base of the metacarpal bone of the middle finger. Its tendon is lodged in the same groove on the radius with that of the *extensor carpi radialis longior*.

The *EXTENSOR COMMUNIS DIGITORUM* *arises* from the external condyle by a common tendon with the preceding and two following muscles, from the intermuscular septa and deep fascia; and divides into four tendons, which are *inserted* into the second and third phalanges of the fingers. At the metacarpo-phalangeal articulation each tendon becomes narrow and thick, and sends a thin fasciculus upon each side of the joint. It then spreads out, and receiving the tendon of the *lumbricalis* and some tendinous fasciculi from the *interossei*, forms a broad aponeurosis, which covers the whole of the posterior aspect of the finger. At the first phalangeal joint the aponeurosis divides into three slips. The middle slip is inserted into the base of the second phalanx, and the two lateral portions are continued onwards on each side of the joint, to be inserted into the last. Little oblique tendinous slips connect the tendons of the ring with the middle and little finger as they cross the back of the hand.

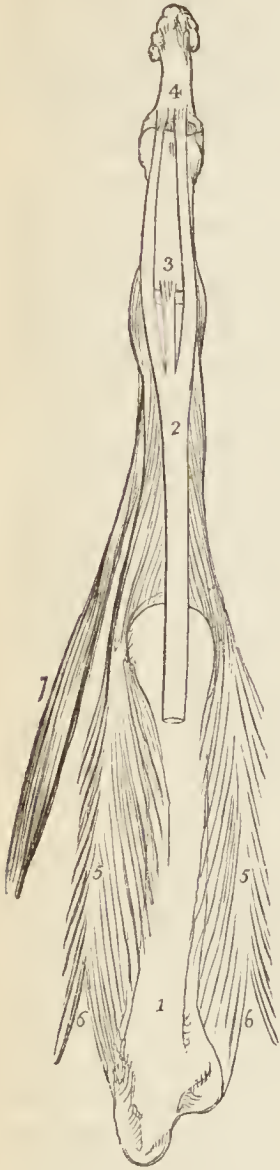
The *EXTENSOR MINIMI DIGITI (auricularis)* is an off-set from the *extensor communis*. It assists in forming the tendinous expansion on the back of the little finger, and is *inserted* into the last two phalanges. It is to this muscle that the little finger owes its power of separate extension; and from being called into action when the point of the finger is introduced into the meatus of the ear, the muscle was called by the older writers "*auricularis*."

The *EXTENSOR CARPI ULNARIS* *arises* from the external condyle by the common tendon, from the border of the ulna, and from the deep fascia. Its tendon passes through the posterior groove in the ulna, to be *inserted* into the base of the metacarpal bone of the little finger.

The *ANCONIUS* is a small triangular muscle, having the appearance of being a continuation of the *triceps*; it

arises from the outer condyle, and is *inserted* into the olecranon and triangular surface of the upper extremity of the ulna.

Fig. 17.*



When these muscles have been examined, the extensor communis digitorum, extensor minimi digiti, and extensor carpi ulnaris should be divided, and the ends drawn aside, to bring into view the deep layer, which consists of five muscles :

Supinator brevis,
 Extensor ossis metacarpi pollicis,
 ———— primi internodii pollicis,
 ———— secundi internodii pollicis,
 ———— indicis.

The SUPINATOR BREVIS cannot be seen in its entire extent, until the radial extensors of the carpus are divided from their origin. It *arises* from the external condyle, external lateral and orbicular ligament, and from the ulna; it winds around the upper part of the radius to be inserted into the upper third of its oblique line. The posterior interosseous artery and nerve are seen perforating the lower border of this muscle.

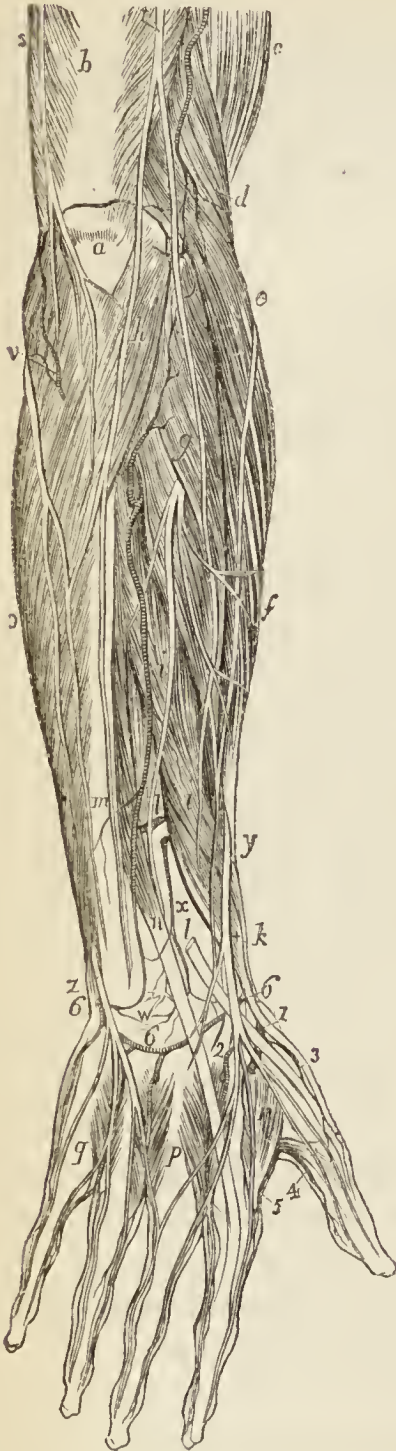
The EXTENSOR OSSIS METACARPI POLLICIS is placed immediately below the supinator brevis. It *arises* from the ulna, interosseous membrane, and radius, and is *inserted*, as its name implies, into the base of the metacarpal bone of the thumb. Its tendon passes through the groove immediately in front of the styloid process of the radius.

* The arrangement of the extensor tendon on the dorsal surface of a finger.

No. 1. The metacarpal bone of the middle finger. 2. The extensor tendon expanding into a broad aponeurosis, which divides into three slips. 3. The middle slip, inserted into the base of the second phalanx. 4. The two lateral slips inserted into the base of the third phalanx. 5, 5. Two dorsal interossei, showing their bifid origin, 6, 6.; inserted by an aponeurotic expansion into the sides of the extensor tendon. 7. The second lumbricalis muscle, also inserted into the side of the extensor tendon.

The EXTENSOR PRIMI INTERNODII POLLICIS, the smallest

Fig. 18.*



of the muscles in this layer, *arises* from the interosseous membrane and radius, and passes through the same groove with the extensor ossis metacarpi, to be *inserted* into the base of the first phalanx of the thumb.

The EXTENSOR SECUNDI INTERNODII POLLICIS *arises* from the ulna and interosseous membrane. Its tendon passes through a distinct groove in the radius, and is *inserted* into the base of the last phalanx of the thumb.

The EXTENSOR INDICIS *arises* from the ulna as high up as the extensor ossis metacarpi pollicis, and inferiorly from the interosseous membrane. Its tendon is *inserted* into the aponeurosis formed by the common extensor tendon of the index finger.

When the posterior surface of the lower extremities of the radius and ulna is examined, a number of grooves will be seen, through which the tendons of the muscles of the posterior region of the fore-arm pass to their destination upon the hand. In the subject, the posterior annular ligament forms for them a number of distinct sheaths. Their relative position from radius to ulna must be attentively studied. Into the base of the styloid process of the radius is inserted the tendon of the supinator longus. Im-

* Nerves and vessels of the back of the fore-arm and hand. — a. The olecranon. b. The triceps. c. The biceps. d. The supinator longus. e. The extensor carpi radialis longior. f. The extensor carpi radialis brevior. g. The supinator brevis. h. The anconeus. i, i. The extensor ossis metacarpi pollicis. k. The extensor primi internodii pollicis. l, l. The extensor secundi internodii; the portion of this muscle between the two letters has been cut away.

mediately in front of the styloid process is a groove which lodges the tendons of the extensor ossis metacarpi and primi internodii; immediately behind it another, broad and shallow, for the tendons of the extensor carpi radialis longior and brevior, which are crossed obliquely by a superficial sheath in the annular ligament for the extensor secundi internodii. Farther inwards is a small groove for the tendon of the extensor indicis, and a large one for the extensor communis. Upon the ulna is a groove for the extensor minimi digiti and extensor carpi ulnaris.

ACTIONS. — The anconeus is associated in its action with the triceps extensor cubiti: it assists in extending the fore-arm upon the arm. The supinator longus and brevis effect the supination of the fore-arm, and antagonize the two pronators. The extensores carpi radialis, longior, and brevior, and ulnaris extend the wrist in opposition to the two flexors of the carpus. The extensor communis digitorum restores the fingers to the straight position, after being flexed by the two flexors, sublimis and profundus. The extensor ossis metacarpi, primi internodii, and secundi internodii pollicis, are the especial extensors of the thumb, and serve to balance the actions of the flexor ossis metacarpi, flexor brevis, and flexor longus pollicis. The extensor indicis gives the character of extension to the index finger, and is hence named *indicator*, and the extensor minimi digiti supplies that finger with the power of exercising a distinct extension.

The **VESSELS** and **NERVES** of the posterior region of the fore-arm are, the posterior interosseous artery and nerve.

m. The ulna. *n.* The extensor indicis muscle. *o.* The flexor carpi ulnaris. *p, q.* Dorsal interossei muscles. *r.* The abductor indicis. *s.* The lesser internal cutaneous nerve. *t.* The external cutaneous branch of the musculo-spiral nerve. The artery by the side of this nerve is a branch of the superior profunda; inosculating with the recurrent interosseous *u*, and across the elbow with the posterior ulnar recurrent, *v.* The nerve immediately below *e* is the posterior branch of the external cutaneous; and the nerve below *v* the posterior branch of the internal cutaneous. The nerve piercing the supinator muscle just below *g*, and the artery issuing from beneath the lower edge of the same muscle, are the posterior interosseous. *w* is the ganglion on the back of the wrist joint formed by the posterior interosseous nerve. *x.* The termination of the anterior interosseous artery, forming a loop of inosculation with the posterior interosseous. *y.* The radial nerve descending upon the back of the hand. *z.* The posterior branch of the ulnar nerve. Below the letter *w* is the posterior carpal arch (6, 6.) formed by the posterior carpal arteries, radial and ulnar.

1. The radial artery passing beneath the extensor tendons of the thumb. 2. The metacarpal branch. 3. One of the dorsales pollicis branches. 4. The princeps pollicis artery. 5. The radialis indicis artery. 6, 6. The posterior carpal arch formed by the posterior carpal arteries.

The *posterior interosseous artery* may now be seen issuing from between the contiguous borders of the supinator brevis and extensor ossis metacarpi pollicis, or piercing the fibres of the former. Its course and distribution will be found described at page 125.

The *posterior interosseous nerve*, commencing at the bifurcation of the musculo-spinal, in front of the external condyle of the humerus (page 115.), pierces the supinator brevis on its anterior aspect, and passes through the substance of the muscle to its lower part. It then escapes from the muscle, and after giving off several muscular branches, dips between the extensor primi and secundi internodii, to reach the interosseous membrane upon which it descends to the wrist joint. On the wrist it forms a gangliform enlargement, which distributes filaments to the numerous articulations of the carpus. The posterior interosseous nerve supplies all the muscles of the posterior region of the fore-arm, with the exception of the supinator longus, extensor carpi radialis longior, and anconeus.

PALM OF THE HAND.

To dissect the palm of the hand, make an incision from the wrist to the root of the middle finger, and bound it by a transverse incision carried across the roots of the fingers. Raise the integument by beginning at the angles, and in dissecting the ulnar flap be careful not to injure or remove the palmaris brevis muscle. Afterwards carry an incision along the middle of each finger, and turn the integument aside.

The palmaris brevis muscle and the cutaneous branches of the median and ulnar nerve should now be examined.

The PALMARIS BREVIS is a thin plane of muscular fibres, about an inch in width, which *arises* from the annular ligament and palmar fascia, and passes transversely inwards to be *inserted* into the integument of the inner border of the hand.

The superficial branch of the median nerve, and the cutaneous palmar branch of the ulnar nerve, have been already described at page 126. The former, besides supplying the palm of the hand, sends a few filaments to the ball of the thumb.

The *palmar fascia*, which is brought into view by the removal of the superficial fascia and fat, consists of three

portions, central and two lateral. The lateral portions are thin, and enclose the muscles of the borders of the hand. The *central* portion occupies the middle of the palm, and is strong and tendinous: it is narrow at the wrist, where it is attached to the annular ligament and receives the insertion of the tendon of the palmaris longus, and broad over the heads of the metacarpal bones, where it divides into four processes, each of which subdivides to embrace the root of the corresponding finger. These processes are attached upon the middle line to the sheath of the tendons, and at the side of each finger to the lateral and transverse ligaments. The fascia is strengthened at its point of division into slips by strong fasciculi of transverse fibres, and the arched interval left between each pair of slips gives passage to the tendons of the flexor muscles. The arches between the fingers transmit the digital vessels and nerves, and lumbricales muscles.

The palmar fascia may now be removed, in doing which, care should be taken to avoid dividing the superficial palmar arch or its branches, and these latter, with their accompanying branches of the median nerve, may be cleared by the removal of the cellular tissue and fat. This dissection brings into view the muscles of the palm.

The MUSCLES of the palm of the hand are arranged in three groups: a radial or thenar group belonging to the thumb; an ulnar or hypothenar group to the little finger; and a palmar group situated in the middle of the palm.

The muscles of the *radial group* are the

Abductor pollicis,
Flexor ossis metacarpi (opponens),
Flexor brevis pollicis,
Adductor pollicis.

The ABDUCTOR POLLICIS is a small, thin muscle, which *arises* from the trapezium bone and annular ligament. It is *inserted* into the base of the first phalanx of the thumb.

This muscle must be divided from its origin, and turned aside, in order to see the next.

The FLEXOR OSSIS METACARPI (opponens pollicis) *arises* from the trapezium and annular ligament, and is *inserted* into the whole length of the metacarpal bone.

The flexor ossis metacarpi may now be divided from its origin and turned aside, in order to show the next muscle.

The FLEXOR BREVIS POLLICIS consists of two portions, between which lies the tendon of the flexor longus pollicis. The external portion *arises* from the trapezium and annular ligament; the internal portion from the trapezoides and os magnum. They are both *inserted* into the base of the first phalanx of the thumb, having a sesamoid bone in each of their tendons to protect the joint.

The next muscle is brought into view by drawing aside the flexor brevis pollicis on the one side, and the tendons of the long flexors on the other. It cannot be fully seen until the latter have been removed at a subsequent part of the dissection.

The ABDUCTOR POLLICIS is a triangular muscle; it *arises* by a broad origin from the metacarpal bone of the middle finger; and the fibres converge to its insertion into the base of the first phalanx of the thumb conjointly with the inner head of the flexor brevis.

The muscles of the *ulnar group* are the

Abductor minimi digiti,
Flexor brevis minimi digiti,
Adductor ossis metacarpi (opponens).

The ABDUCTOR MINIMI DIGITI is a small tapering muscle which *arises* from the pisiform bone, where it is continuous with the tendon of the flexor carpi ulnaris; and is *inserted* into the base of the first phalanx of the little finger, and the expansion of the extensor tendon.

This muscle may be divided through the middle and its ends turned aside, which will bring into view the two next muscles.

The FLEXOR BREVIS MINIMI DIGITI is a small muscle *arising* from the unciform bone and annular ligament, and *inserted* into the base of the first phalanx. It is sometimes wanting.

The ADDUCTOR OSSIS METACARPI, or adductor minimi digiti (opponens), *arises* from the unciform bone and annular ligament, and is *inserted* into the whole length of the metacarpal bone of the little finger.

The muscles of the *middle palmar* region are the

Lumbricales,
Interossei.

To bring the lumbricales into view, the tendons of the flexor sublimis should be snipped across at the annular ligament, and drawn from under the superficial palmar arch towards the fingers;

the tendons of the deep flexor are then exposed, with which the lumbricales are connected.

The LUMBRICALES, four in number, are accessories to the deep flexor muscles. They *arise* from the radial side of the tendons of the deep flexor, and are *inserted* into the aponeurotic expansion of the extensor tendons on the radial side of the fingers. These small muscles often present varieties of origin, such as arising by two heads, or being connected with other than the radial border of the tendons.

The tendons of the deep flexor may now be cut through at the annular ligament, and drawn towards the fingers. In making this section, a loose synovial membrane which encloses the tendons of both flexors in their passage beneath the annular ligament, and extends for a short distance above and below that ligament, will be divided. When these tendons are removed, the palmar interossei will be brought into view. Before examining them, however, it may be convenient to study the vessels and nerves.

The PALMAR INTEROSSEI, three in number, are placed upon the metacarpal bones, rather than between them. They *arise* from the base of the metacarpal bone of one finger, and are *inserted* into the base of the first phalanx and aponeurotic expansion of the extensor tendon of the same finger. The first belongs to the index finger, the second to the ring finger, and the third to the little finger, the middle finger being omitted.

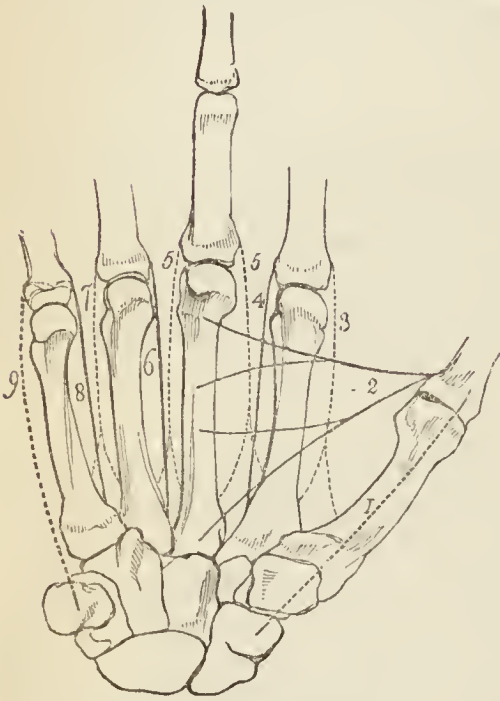
The dorsal interossei are seen from the palmar side of the hand, occupying the spaces between the metacarpal bones; but they are best examined by turning to the dorsal side.

The DORSAL INTEROSSEI, four in number, are situated in the four spaces between the metacarpal bones. They are bipenniform muscles, and *arise* by two heads, from adjoining sides of the bases of the metacarpal bones. They are *inserted* into the base of the first phalanges, and into the aponeurosis of the extensor tendons.

The first is inserted into the index finger, and from its use is called *abductor indicis*; the second and third are inserted into the middle finger, compensating its exclusion from the palmar group; the fourth is attached to the ring finger; so that each finger is provided with two interossei, with the exception of the little finger, as may be shown by means of a table, thus:—

Index finger, { one dorsal (abductor indicis),
 { one palmar.
Middle finger, two dorsal.
Ring finger, { one dorsal,
 { one palmar.
Little finger, remaining palmar.

Fig. 19.*



The radial artery passes into the palm of the hand between the two heads of the first dorsal interosseous muscle and the perforating branches of the deep palmar arch, between the heads of the other dorsal interossei.

ACTIONS.—The actions of the muscles of the hand are expressed in their names. Those of the radial group belong to the thumb, and provide for three of its movements, *abduction*, *adduction*, and *flexion*. The ulnar group, in like manner, are subservient to the same motions of the little finger; and the interossei are abductors and adductors of the several fin-

gers. The lumbricales are accessory in their actions to the deep flexors: they were called by the earlier anatomists *fidicini*, i. e. fiddlers' muscles, from an idea that they might effect the fractional movements by which the performer is enabled to produce the various notes on that instrument.

In relation to the axis of the hand (*fig. 19.*), the four *dorsal* interossei are *abductors*, and the three palmar *adductors*. It will therefore be seen that each finger is provided with its proper adductor and abductor, two flexors, and (with the exception of the middle and ring fingers) two extensors. The thumb has moreover a flexor and extensor of the metacarpal bone; and the little finger a flexor of the metacarpal bone without an extensor.

* *Fig. 19.* A diagram showing the abductor and adductor muscles of the hand, and the attachments and actions of the interossei. The middle finger is made longer than the rest, in order to mark the central axis of the hand, to which the movements of abduction and adduction are referrible. The dotted lines represent the six abductor muscles, and the plain lines the four adductors.

No. 1. The abductor pollicis, arising from the trapezium bone.
 2. The adductor pollicis, arising from the middle metacarpal bone.
 3. The first dorsal interosseous, the abductor of the index finger: all

The **VESSELS** of the palm of the hand are the termination of the ulnar, forming the superficial palmar arch, and the termination of the radial forming the deep palmar arch, with their companion veins (*venæ comites*).

The **ULNAR ARTERY** crosses the annular ligament by the side of the pisiform bone, and curves across the middle of the palm to the ball of the thumb, where it terminates by inosculating with the *superficialis volæ*, a branch of the radial.

The *branches* of the ulnar artery are, a communicating branch and four digital arteries.

The *communicating* or deep branch arises close to the annular ligament, and dips between the abductor minimi digiti and flexor brevis to inosculate with the termination of the deep palmar arch. It is accompanied by the deep palmar branch of the ulnar nerve.

The *digital* branches, four in number, are given off from the convexity of the superficial palmar arch. The first and smallest is distributed to the ulnar side of the little finger. The other three are short trunks, which divide between the heads of the metacarpal bones, and form the collateral branch of the radial side of the little finger, the collateral branches of the ring and middle fingers, and the collateral branch of the ulnar side of the index finger. On the last phalanx, the collateral arteries communicate and form an arch, from which numerous branches are given off to the tip of the finger.

The **RADIAL ARTERY** enters the palm of the hand between the two heads of first dorsal interosseous muscle, and crossing the palmar interossei to the base of the metacarpal bone of the little finger, terminates by inosculating with the communicating branch of the ulnar. It thus constitutes the deep palmar arch which lies near the basis of the metacarpal bones, while the superficial arch lies

the dorsal interossei arise by two heads, as in the diagram. 4. The first palmar interosseous, the adductor of the index finger. 5, 5. The second and third dorsal interossei muscles, both abductors of the middle finger. 6. The second palmar interosseous, adductor of the ring finger. 7. The fourth dorsal interosseous, abductor of the ring finger. 8. The third palmar interosseous, adductor of the little finger. 9. The abductor of the little finger, arising from the pisiform bone.

over the distal third of those bones, the two arches being separated by the tendons of the superficial and deep flexors, the lumbricales, and the median nerve.

The *branches* of the radial artery in the palm of the hand are the

Princeps pollicis,	Perforantes,
Radialis indicis,	Recurrentes.
Interosseæ,	

The *princeps pollicis*, the great artery of the thumb, passes along the metacarpal bone of the thumb, between the first dorsal interosseous (abductor indicis) and flexor brevis pollicis to the base of the first phalanx; and, between the two heads of the latter muscle, in the groove of the tendon of the flexor longus, it divides into two collateral branches for the palmar borders of the thumb.

The *radialis indicis*, the digital branch of the radial side of the index finger, is directed inwards between the abductor indicis and the flexor brevis and adductor pollicis to the side of the finger, along which it is distributed, forming its radial collateral artery. Near its origin it gives off a small branch (more frequently a direct branch of the radial), which inosculates with the superficial palmar arch.

The *interosseæ palmares*, three or four in number, are branches of the deep palmar arch; they pass forward upon the interossei muscles, and inosculate with the digital branches of the superficial arch, opposite the heads of the metacarpal bones.

The *perforantes*, three in number, pass directly backwards between the heads of the dorsal interossei muscles, and inosculate with the dorsal interosseous arteries.

The *recurrent* branches of the deep palmar arch pass upwards in front of the wrist joint, and inosculate with the arterial arch formed by the anterior carpal arteries.

The NERVES of the palm of the hand are the ulnar and median.

The ULNAR NERVE, crossing the annular ligament with the ulnar artery, immediately divides into a superficial and deep branch.

The *superficial palmar branch*, after giving some filaments to the palmaris brevis and inner border of the hand, divides into three branches, which are distributed,

one to the ulnar side of the little finger, *one* to the adjoining borders of the little and ring fingers, and a communicating branch to join the median nerve.

The *deep palmar branch* passes between the abductor and flexor minimi digiti, to the deep palmar arch, supplying the muscles of the little finger, the interossei palmar and dorsal, the two ulnar lumbricales, adductor pollicis, and inner head of the flexor brevis pollicis.

The MEDIAN NERVE, after passing beneath the annular ligament, is spread out and flattened, and divides into a muscular and five digital branches.

The *muscular* branch is distributed to the abductor pollicis, flexor ossis metacarpi, and external head of the flexor brevis.

The five *digital* nerves are thus disposed: *two* pass outwards to the thumb and supply its borders; the *third* passes along the radial side of the index finger, sending a twig to the first lumbricalis in its course; the *fourth* subdivides for the supply of the adjacent sides of the index and middle fingers, and gives a twig to the second lumbricalis; the *fifth* receives a filament of communication from the ulnar nerve, and supplies the collateral branches of the middle and ring fingers.

On the fingers, the digital nerves lie to the inner side of, and superficially to, the arteries, and terminate by dividing into numerous twigs for their sentient extremities, and the structures engaged in the production of the nails. Near the base of the first phalanx each nerve gives off a *dorsal* branch, which takes its course along the dorsal border of the finger.

CHAP. III.

THORAX.

THE THORAX is the conical cavity situated at the upper part of the trunk of the body. It is narrow above and broad below, and is bounded, *in front*, by the sternum, six superior intercostal cartilages, ribs, and intercostal muscles; *laterally*, by the ribs and intercostal muscles; and *behind* by the ribs, intercostal muscles, and vertebral column, as low down as the upper margin of the last rib and first lumbar vertebra.

To examine the contents of the thorax, the anterior and lateral wall of the chest must be removed. This dissection is effected by sawing across the sternum immediately below the articulation of the first ribs, and again immediately above the articulation of the cartilages of the sixth ribs. From these points carry the knife along the lower edge of the first rib above, and upper edge of the sixth rib below, as far back as may be convenient, and connect the ends of the incisions by a section of the ribs and intercostal muscles, from the second to the fifth, inclusive. Then raise the piece at one angle, and remove it with as little disturbance to the parts beneath as possible.

In the skeleton, the superior aperture of the thorax is bounded by the sternum and first dorsal vertebra, before and behind, and by the first ribs in the rest of its circumference. It is broader from side to side than from before backwards, and gives passage in the subject to the trachea, œsophagus, subclavian and carotid arteries and veins, the thoracic duct, and several large nerves; the interstices being closed by the thoracic fascia. The inferior boundary or floor of the thorax is formed by the diaphragm, which extends obliquely from the ensiform cartilage across the six lower ribs to the first lumbar vertebra. This aperture of the thorax is also broader from side to side than from before backwards, and from the obliquity of the diaphragm the chest is much deeper behind than before. The diaphragm gives passage to the inferior vena cava, œsophagus, aorta, thoracic duct, the azygos veins, and some large nerves.

The contents of the thorax are the *lungs* and the *heart* with their investing membranes, *pleuræ* and *pericardium*, and great vessels; together with the œsophagus and some large nerves.

PLEURÆ.

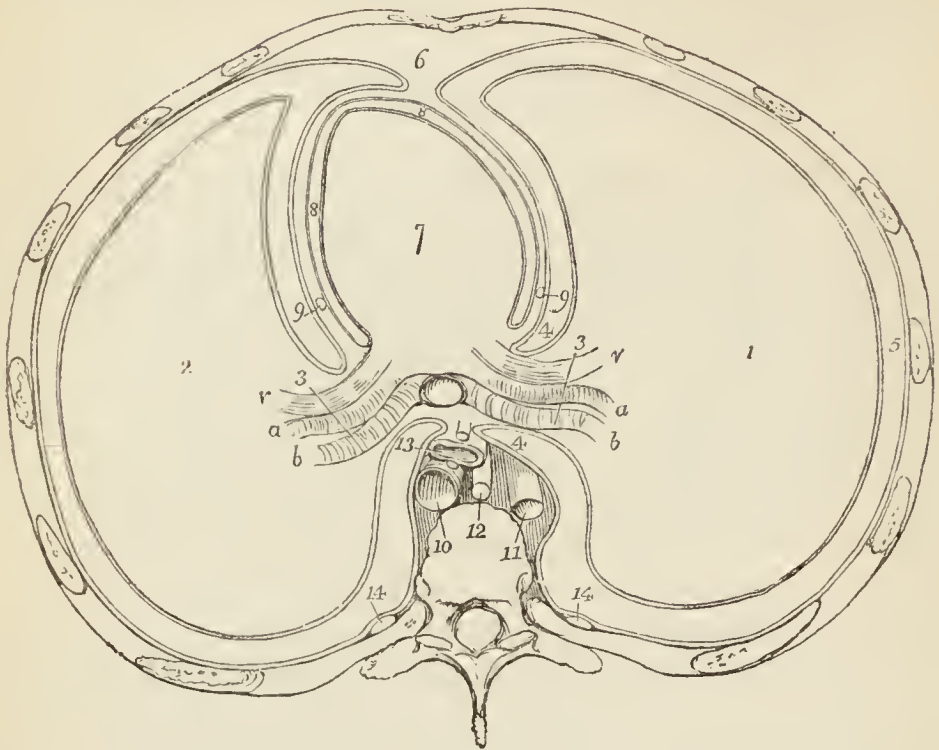
The PLEURÆ are two serous membranes which invest the lungs and form the lining of the cavity of the chest on either side. That portion of the membrane which covers the lung is termed *pleura pulmonalis*, and that which lines the parietes *pleura costalis*. Besides forming the internal lining of the ribs and intercostal muscles, the reflected portion of the membrane covers the upper surface of the diaphragm and the thoracic surface of the vessels at the root of the neck, extending for somewhat more than an inch above the margin of the first rib. At the lower border of the root of the lung is a fold of the pleura which extends down the side of the posterior mediastinum to the diaphragm: this is the broad ligament of the lung, *ligamentum latum pulmonis*. On its external surface, where the pleura is connected with surrounding parts, it is rough; on its inner surface, smooth. On the right side, where the diaphragm is pressed upwards by the liver, the pleura is shorter than on the left, but extends higher into the neck; while the left pleura, in consequence of the encroachment of the heart upon the left side of the chest, is narrower than the right.

MEDIASTINUM. — The approximation of the two reflected pleuræ in the middle line of the thorax forms a septum which divides the chest into the two pulmonary cavities. This is the mediastinum. The two pleuræ are not, however, in contact with each other at the middle line in the formation of the mediastinum, but have a space between them which contains all the viscera of the chest excepting the lungs. The mediastinum is divided into the *anterior*, *middle*, and *posterior*.

The *anterior mediastinum* (*fig. 20. 6.*) is a triangular space, bounded in front by the sternum, and on either side by the pleura. It contains a quantity of loose cellular tissue, in which are found some lymphatic vessels passing upwards from the liver; the remains of the thymus gland, the origins of the sterno-hyoid, sterno-thyroid, and

left triangularis sterni muscle, and the left internal mammary vessels.

*Fig. 20.**



The *middle mediastinum* (*fig. 20. 7.*) contains the heart enclosed in its pericardium; the ascending aorta; the superior vena cava; the pulmonary vessels; the bifurcation of the trachea; and the phrenic nerves.

The *posterior mediastinum* is bounded behind by the vertebral column, in front by the pericardium, and on each side by the pleura. It contains the descending aorta (*fig. 20. 10.*); the greater and lesser azygos veins, and superior intercostal vein; the thoracic duct; the œsophagus and pneumogastric nerves; and the great splanchnic nerves.

* A diagram representing a transverse section of the chest, and the relative position of the viscera.

No. 1. The right lung. 2. The left lung. 3. The root of the lungs, with the order of vessels, from before backwards, shown. *v.* The pulmonary vein. *a.* The pulmonary artery. *b.* The bronchus. 4, 4. The point of reflection of the pleura, from the root of the lung upon the parietes. 5. The cavity of the pleura: that which is in contact with the lung is the pleura pulmonalis, and that with the wall of the chest, pleura costalis. 6. The anterior mediastinum, bounded by the sternum in front, and by the pleura at each side. 7. The heart, in the middle mediastinum. 8. The cavity of the pericardium. 9, 9. The phrenic nerves lying between the pleura

The pleura should now be carefully dissected away from the side of the pericardium, and from the root of the lung before and behind, and also removed from the side of the posterior mediastinum in order to bring into view the vessels which it contains. On the side of the pericardium will be found the phrenic nerve, which, from its whiteness, is seen through the pleura before that membrane is removed. On the front of the root of the lungs is the anterior pulmonary plexus, behind the root of the lungs the posterior pulmonary plexus and pneumogastric nerves; while the root of the lungs itself is composed of the pulmonary artery, pulmonary veins and bronchus, with their divisions.

The PHRENIC NERVES, the nerves of the diaphragm, proceed from the cervical nerves (3rd, 4th, 5th), and pass in front of the anterior scalmi muscles to enter the chest. The nerve, on either side, then passes between the subclavian artery and vein, and descends by the side of the pericardium in front of the root of the lungs to the diaphragm, to which it is distributed. The right phrenic nerve in the upper part of the thorax lies along the outer side of the vena innominata and superior vena cava. The left crosses the arch of the aorta, and, having to follow the convexity of the heart, is somewhat longer than the right. Each nerve at its entrance into the chest crosses in front of the internal mammary artery and while in relation with that vessel is joined by a long and slender arterial branch, the *comes nervi phrenici*, which accompanies the nerve to the diaphragm. The phrenic nerve gives one or two small filaments to the pericardium.

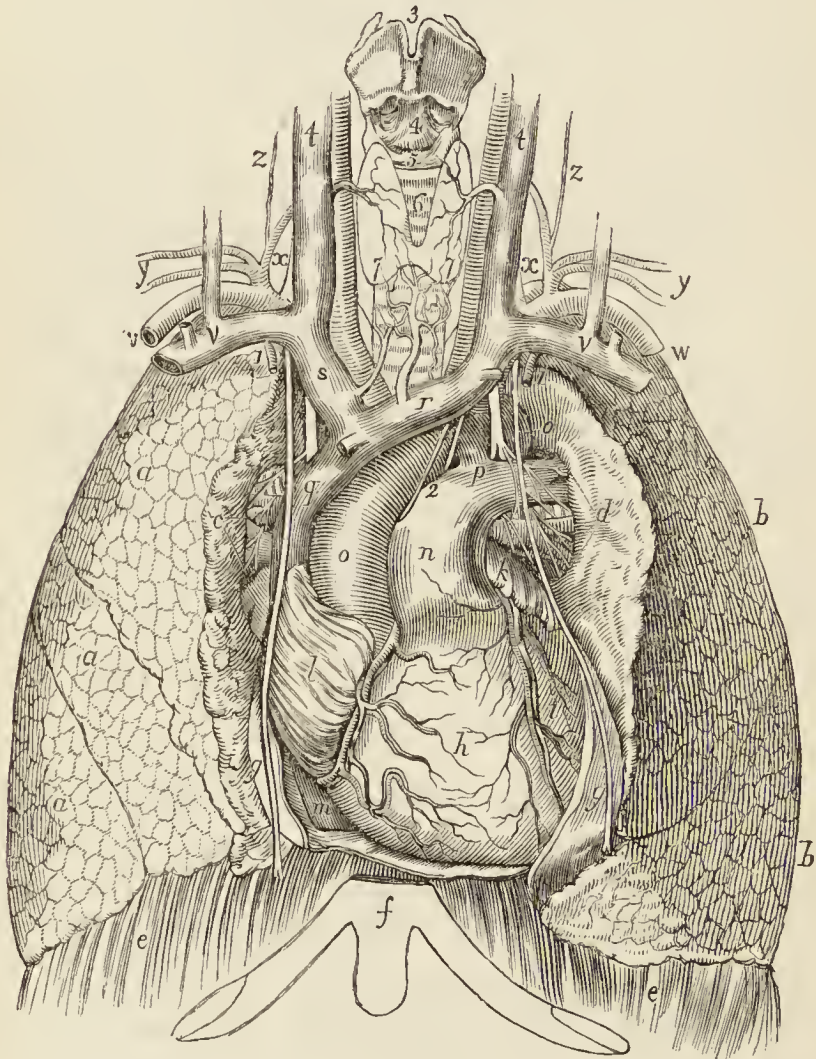
THE LUNGS.

The lungs are two conical organs, situated one on each side of the chest, embracing the heart, and separated from each other by that organ and by a membranous partition, the mediastinum. On the external or thoracic side they are convex, and correspond with the form of the cavity of the chest; internally they are concave, to

and pericardium, in front of the root of the lungs. 10. The descending aorta. 11. The vena azygos. 12. The thoracic duct. 13. The œsophagus, accompanied by the two pneumogastric nerves. These parts, from No. 10. to 13., are all within the posterior mediastinum, which is bounded on each side by the pleura, and behind by the vertebral column. 14. The sympathetic nerve at each side.

receive the convexity of the heart. Superiorly they terminate in a tapering cone, which extends above the level of the first rib into the root of the neck; and inferiorly they are broad and concave, and rest on the convex surface of the diaphragm. Their posterior border is rounded, broad and long, the anterior sharp, short, and marked by one or two deep fissures; and the inferior border which surrounds the base is also sharp. The colour of the lungs is pinkish-grey, mottled, and variously marked with black. The surface is figured with irregularly polyhedral outlines, which represent the

* *Fig. 21.*



* The lungs and heart, with the great vessels of the latter, viewed from the front.

a, a, a. The right lung; its three lobes. *b, b.* The left lung; its two lobes. *c.* The root of the right lung, the bronchus being highest, the pulmonary artery next, and the pulmonary vein below. *d.* The root of the left lung, the pulmonary artery being highest,

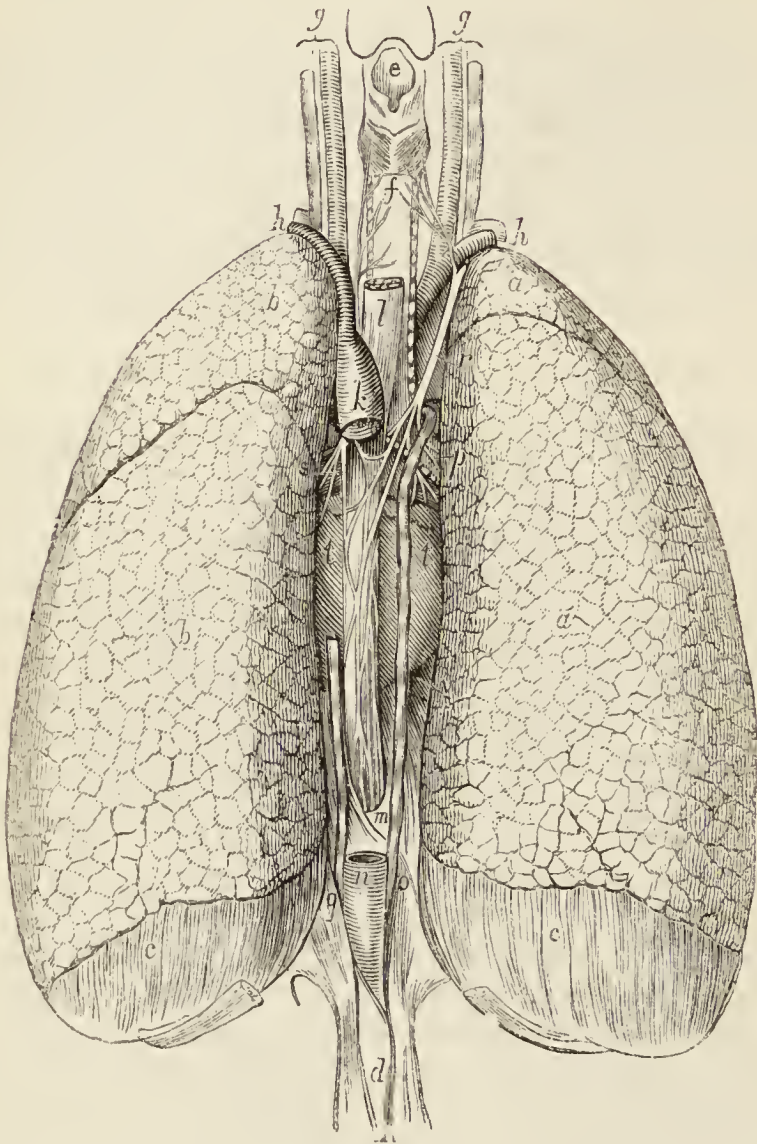
lobules of the organ, and the area of each of these polyhedral spaces is crossed by lighter lines representing smaller lobules. The weight of the lungs is about forty ounces, the right lung being two ounces heavier than the left.

Each lung is divided into two lobes, by a long and deep fissure, which extends from the posterior surface of the organ, downwards and forwards, to near the anterior angle of its base. In the right lung the upper lobe is subdivided by a second fissure, which runs obliquely forward from the middle of the preceding to the anterior border of the organ, and marks off a small triangular

next the bronchus, then the pulmonary vein. *e, e.* The diaphragm. *f.* The lower end of the sternum, and ensiform cartilage. *g, g.* The pericardium. The nerves lying on the pericardium and descending in front of the roots of the lungs are the phrenic. *h.* The heart; its right ventricle. *i.* The left ventricle. The apex is concealed behind the pericardium, *g.* *h.* The left auricle. *l.* The right auricle. *m.* The inferior vena cava, contained within the cavity of the pericardium. The vessels between *h* and *i* are the left coronary; those between *h* and *l* the right coronary. *n.* The pulmonary artery. *o, o.* The arch of the aorta. *p.* The cord of the ductus arteriosus. *q.* The superior vena cava. *r.* The left vena innominata, receiving one of the inferior thyroid veins. *s.* The right vena innominata, also receiving an inferior thyroid vein. The large artery immediately above the vein is the arteria innominata. *t, t.* The internal jugular veins. The large artery lying to the inner side of each is the common carotid. *v, v.* The subclavian veins. The two veins opening into the subclavian, near the latter, are the external jugular (the larger) and anterior jugular. *w, w.* The subclavian arteries. *x, x.* The letter is placed between the vertebral artery internally, the thyroid axis externally, the apex of the lung below, and the inferior thyroid artery above. *y, y.* The transverse cervical and suprascapular arteries. *z.* The cervicalis ascendens artery. 1. The internal mammary artery. The nerve to the inner side of this artery is the phrenic, and the larger nerve more internally the pneumogastric. From the latter, branches are seen passing upon the root of the lungs to form the anterior pulmonary plexus; and at *p* the recurrent nerve is seen winding around the arch of the aorta. 2. The left superficial cardiac of the sympathetic, and inferior cardiac of the left pneumogastric nerve, crossing the arch of the aorta to reach the superficial cardiac plexus. 3. The thyroid cartilage. 4. The crico-thyroidean membrane. 5. The cricoid cartilage. 6. The trachea. 7, 7. The two lobes of the thyroid gland, connected by a narrow isthmus. The veins of the gland are seen passing outwards to the internal jugulars, and downwards to the innominate veins.

lobe. The left lung presents a deep notch in its anterior border at a point corresponding with the apex of the heart.

*Fig. 22.**



* The lungs and contents of the posterior mediastinum viewed from behind.

a, a. The right lung; its superior and inferior lobe. *b, b.* The left lung; its two lobes. *c, c.* The greater muscle of the diaphragm, upon which the lungs rest. *d.* The crura of the diaphragm. *e.* The epiglottis and aperture of the larynx. *f.* The trachea. The pair of muscles immediately above the letter are the crico-arytænoidei postici; the nerve at each side, the recurrent laryngeal. *g, g.* The common carotid artery and internal jugular vein, the pneumogastric nerve lying between them. *h, h.* The subclavian artery and vein. The recurrent laryngeal nerve is seen turning around the right subclavian artery. *i.* The arteria innominata. *k.* The descending portion of the arch of the aorta. *l.* The œso-

The right lung is larger than the left in consequence of the inclination of the heart to the left side. It is also shorter from the great convexity of the liver, which presses the diaphragm upwards on the right side of the chest considerably above the level of the left; and it has three lobes. The left lung is smaller, has but two lobes, but is longer than the right.

Each lung is retained in its place by its *root*, which is formed by the pulmonary artery, pulmonary veins, and bronchial tubes, together with the bronchial vessels and pulmonary plexuses of nerves. The groove on the surface of the lung where the vessels enter its substance is the *hilum pulmonis*, and the position of the large vessels in the root of the lung as follows: from before backwards they are placed in a similar order on both sides, viz.

Pulmonary veins, Pulmonary artery, Bronchus.

From above downwards, on the *right* side, this order is exactly reversed; but on the *left* side, the bronchus has to stoop beneath the arch of the aorta, which alters its position to the vessels. They are thus disposed on the two sides:—

<i>Right.</i>	<i>Left.</i>
Bronchus,	Artery,
Artery,	Bronchus,
Veins.	Veins.

The special relations of the roots of the lung are, for the right, the descending cava, which lies in front, and the vena azygos, which arches over it from behind to terminate in the superior vena cava. The root of the left lung has the descending aorta lying behind it.

phagus, surrounded lower down by the œsophageal plexus of nerves, and passing, at *m*, through its opening in the diaphragm. *n*. The thoracic aorta, passing through the aortic opening of the diaphragm together with *o*, the greater vena azygos, which crosses the right bronchus, *p*, to terminate in the superior vena cava. *q*. The lesser vena azygos. *r*. The right pneumogastric nerve, descending behind the root of the right lung to the posterior aspect of the œsophagus, and giving off branches to the posterior pulmonary plexus in its course. *s*. The left pneumogastric nerve, descending behind the root of the left lung, to the front of the œsophagus. *p*, *s*. also refer to the roots of the lungs. *t*, *t*. The heart. *v*. The inferior vena cava, passing through the diaphragm to enter the right auricle of the heart.

Structure.—The lungs are composed of the ramifications of the bronchial tubes (*bronchia*), which terminate in intercellular passages and air-cells, of the ramifications of the pulmonary artery and veins, bronchial arteries and veins, lymphatics and nerves. The whole of these structures, being held together by cellular tissue, constitute the *parenchyma*. The *parenchyma* of the lungs, when examined on the surface, or by means of a section, is seen to consist of small polyhedral divisions, or lobules, which are connected to each other by an interlobular cellular tissue. These lobules, again, consist of smaller lobules; and the latter are formed by a cluster of air-cells, in the parietes of which the capillaries of the pulmonary artery and pulmonary veins are distributed. Each lobule, taken alone, is provided with its separate bronchial tube, pulmonary artery and vein, and is isolated from surrounding lobules by a process of cellular membrane derived from the subserous tissue; and the entire lung is an assemblage of these lobules, so separated and so connected, held together by the pleura.

The serous-investing membrane of the lungs or pleura is connected with the surface of the lobules by means of a *subserous cellular tissue*, which forms a distinct layer, and being prolonged between the lobules, is the bond of adhesion between them. This layer contains elastic tissue, and is a chief source of the elasticity of the lungs; its interstices are moistened by a serous secretion, and are unincumbered with fat.

Bronchial Tubes.—The two bronchi proceed from the bifurcation of the trachea opposite the third dorsal vertebra to their corresponding lungs. The right, about an inch long, takes its course nearly at right angles with the trachea, and enters the upper part of the right lung; while the left, two inches in length, and smaller than the right, passes obliquely beneath the arch of the aorta, and enters the lung at about the middle of its root. Upon entering the lungs, they divide into two branches, and each of these divides and subdivides dichotomously to their ultimate termination in the intercellular passages and air-cells.

According to Mr. Rainey, the bronchial tubes continue to diminish in size until they attain a diameter of $\frac{1}{50}$ to $\frac{1}{30}$ of an inch, and arrive within $\frac{1}{8}$ of an inch of the surface of the lung. They then become changed in structure, and are continued onwards in the midst of air-cells, under the name of *intercellular passages*. Lastly, the intercellular passages, after several bifurcations, terminate, each by a cæcal extremity or air-cell. The intercellular passages are at first cylindrical, like the bronchial tubes, but soon become irregular in shape from the great number of air-cells which open into them on all sides. The *air-cells*, in the adult lung, measure between $\frac{1}{200}$ and $\frac{1}{70}$ of an inch; they are irregular in shape, most frequently four-sided cavities, separated by thin septa, and communicating freely with the intercellular passages, and sparingly with the bronchial tubes.

In structure the bronchial tubes are composed of fibro-cartilages, fibrous membrane, muscular fibres, elastic fibres, and mucous membrane. The *fibro-cartilages* of the primary divisions of the trachea are six or eight in number in the right, and ten or twelve in the left

branch. Within the lung the bronchial tubes are cylindrical, and the fibro-cartilage assumes the form of thin plates of irregular shape and size. These plates are found entering into the structure of the bronchial tubes, until the latter attain a very minute size ($\frac{1}{4}$ of a line in diameter), and are then entirely lost. The *fibrous membrane*, which enters largely into the formation of the trachea and bronchial tubes, is the principal coat of the smallest tubes, and is continued to their terminations in the intercellular passages and air-cells.

The *muscular fibres*, belonging to the class of non-striated or organic muscle, are arranged in circles around the tube, and form a muscular coat which is continued as far as the tubes themselves, being absent in the intercellular passages and cells. The *elastic fibres*, arranged in longitudinal fasciculi, form a thin stratum situated next the mucous lining; this elastic coat is prolonged to the ends of the tubes, and scattered fibres are found around the intercellular passages and cells. The *mucous membrane*, lining the bronchial tubes, is provided with a ciliated columnar epithelium as far as their termination; but in the intercellular passages and air-cells it is altered in its characters, is thin and transparent, and coated with a squamous epithelium.

The capillaries of the lungs form plexuses which occupy the walls and septa of the air-cells and the walls of the intercellular passages, but are not continued into the bronchial tubes. The septa between the cells consist of a single layer of the capillary plexus enclosed in a fold of the mucous lining membrane. The cells of the central parts of the lung are most vascular, and at the same time smallest, while those of the periphery are less vascular and larger.

The pigmentary matter of the lungs is contained in the air-cells, as well as in the cellular tissue of the interlobular spaces and of the blood-vessels; it is composed chiefly of carbon.

The *pulmonary artery*, conveying the dark and impure venous blood to the lungs, terminates in capillary vessels, which form a minute network in the parietes of the intercellular passages and air-cells, and then converge to form the pulmonary veins, by which the arterial blood, purified in its passage through the capillaries, is returned to the left auricle of the heart.

The *bronchial arteries*, branches of the thoracic aorta, ramify on the parietes of the bronchial tubes, and terminate partly in bronchial veins which convey the venous blood to the vena azygos on the right side, and the superior intercostal vein on the left; and partly in the pulmonary capillaries.

The *lymphatics*, commencing on the surface and in the substance of the lungs, terminate in the bronchial glands. These glands, very numerous, and often of large size, are placed at the roots of the lungs, around the bronchi, and at the bifurcation of the trachea. In early life they resemble lymphatic glands in other situations; but in old age, and often in the adult, are black and filled with carbonaceous matter, and occasionally with calcareous deposits.

The *nerves* of the lungs are derived from the pneumogastric and sympathetic. They form two plexuses: *anterior pulmonary plexus*, situated upon the front of the root of the lungs, and composed chiefly of filaments from the great cardiac plexus; and *posterior*

pulmonary plexus, on the posterior aspect of the root of the lungs, composed principally of branches from the pneumogastric. The branches from these plexuses follow the course of the bronchial tubes, and are distributed to the intercellular passages and air-cells.

Dissection.—After the pulmonary plexuses, anterior and posterior, have been dissected, and the relative position of the vessels composing the root of the lung examined; the latter may be removed, and the branches followed for some distance into the substance of the lung, in order to see their mode of division, and the structure of the bronchial tubes.

THE HEART.

The central organ of circulation, the heart, is situated between the two layers of pleura which constitute the mediastinum, and is enclosed in a proper membrane, the pericardium.

PERICARDIUM.—The pericardium is a fibro-serous membrane like the dura mater, and resembles that membrane, also, in deriving its serous layer from the reflected serous membrane of the viscus which it encloses. It consists, therefore, of two layers, an external fibrous and an internal serous. The *fibrous* layer is attached, above, to the great vessels at the root of the heart, and adds to their strength by contributing a fibrous sheath; below, it is connected with the tendinous portion of the diaphragm. The serous membrane invests the heart, and surrounding the great vessels which proceed from its root, is then reflected on the inner surface of the fibrous layer.

The *pericardium* may be laid open from the front by means of a crucial incision, and after its relation to the heart and great vessels has been examined, the latter may be cleared of fat and cellular tissue, in order to see the nerves and nervous plexuses situated at the root of the heart. Crossing the arch of the aorta, to reach the pericardium, is the *left phrenic nerve*. Further to the left is a large nerve which crosses the aorta to the back of the root of the lungs; this is the *left pneumogastric nerve*. Between these are two smaller nerves, especially destined for the heart, the *left superficial cardiac nerve*, a branch of the sympathetic, and the *inferior cardiac branch* of the *left pneumogastric*. These nerves should be traced to the concavity of the arch of the aorta, where they unite with the *superficial cardiac plexus*. The latter receives from behind an offset from the deep cardiac plexus, and descends in the groove between the trunk of the pulmonary artery and aorta to the anterior coronary artery, where it becomes the *anterior coronary plexus*. In following these plexuses in the course now described, the pericardium must be divided and turned aside in the direction taken by the nerves.

The *arteries* of the pericardium are derived from the numerous vessels which surround it: thus in front it receives branches from the internal mammary arteries; on the sides from the bronchial arteries; behind from the descending aorta; and below from the phrenic arteries.

The HEART is placed obliquely in the chest, the *base* being directed upwards and backwards towards the right shoulder; the *apex* forwards and to the left, pointing to the space between the fifth and sixth ribs, at about two or three inches from the sternum.* Its *under side* is flattened, and rests upon the tendinous portion of the diaphragm; its *upper side* is rounded and convex, and formed principally by the right ventricle, and partly by the left. Surmounting the ventricles are the corresponding auricles, whose auricular appendages are directed forwards, and slightly overlap the root of the pulmonary artery. The pulmonary artery is the large anterior vessel at the root of the heart; it crosses obliquely the commencement of the aorta.

The heart consists of two auricles and two ventricles, which are respectively named, from their position, right and left. The right is the venous side of the heart; it receives into its auricle the venous blood from every part of the body, by the superior and inferior cava and coronary vein. From the auricle the blood passes into the ventricle, and from the ventricle through the pulmonary artery, to the capillaries of the lungs. From these it is returned as arterial blood to the left auricle; from the left auricle it passes into the left ventricle; and from the left ventricle is carried through the aorta, to be distributed to every part of the body, and again returned to the heart by the veins. This constitutes the course of the *adult circulation*.

The heart is best studied *in situ*. If, however, it be removed from the body, it should be placed in the position indicated in the above description of its situation. A transverse incision should then be made along the ventricular margin of the right auricle, from the appendix to its right border, and crossed by a perpendicular incision, carried from the side of the superior to the inferior cava.

* The size of the heart is about five inches in length, three inches and a half in greatest breadth, and two and a half in thickness. Its weight is about eleven ounces in the male, and nine ounces in the female.

The blood must then be removed. Some fine specimens of white fibrin are frequently found with the coagula; occasionally they are yellow and gelatinous. This appearance deceived the older anatomists, who called these substances "polypus of the heart:" they are frequently found in the right ventricle, and sometimes in the left cavities.

The RIGHT AURICLE is larger than the left, and consists of a principal cavity or sinus, and an appendix auriculæ. The interior of the sinus presents for examination five openings; two valves; two relicts of foetal structure; and two peculiarities in the proper structure of the auricle. To facilitate remembrance they may be thus arranged:—

Openings.

Superior cava,
Inferior cava,
Coronary vein,
Foramina Thebesii,
Auriculo-ventricular opening.

Valves.

Eustachian valve,
Coronary valve.

Relicts of foetal Structure.

Annulus ovalis,
Fossa ovalis.

Structure of the Auricle.

Tuberculum Loweri,
Musculi pectinati.

The *superior cava* returns the blood from the upper half of the body, and opens into the upper and back part of the auricle.

The *inferior cava* returns the blood from the lower half of the body, and opens through the lower and posterior wall, close to the partition between the auricles (*septum auricularum*). The direction of these two vessels is such, that a stream forced through the superior cava would be directed towards the auriculo-ventricular opening. In like manner, a stream rushing upwards by the inferior cava would force its current against the *septum auricularum*; this is the proper direction of the two currents during foetal life.

The *coronary vein* returns the venous blood from the substance of the heart; it opens into the auricle between the inferior cava and the auriculo-ventricular opening, under cover of the coronary valve.

The *foramina Thebesii* are minute pore-like openings of small veins which issue directly from the muscular structure of the heart without entering the general venous current. These openings are also found in the left

auricle, and in the right and left ventricles, but are generally believed to be mere cæcal depressions.

The *auriculo-ventricular opening* is the large opening of communication between the auricle and ventricle.

The *Eustachian valve* is a part of the apparatus of fœtal circulation, and serves to direct the placental blood from the inferior cava, through the foramen ovale into the left auricle. In the adult it is a mere vestige and imperfect, though sometimes it remains of large size. It is formed by a fold of the lining membrane of the auricle, containing some muscular fibres, is situated between the aperture of the inferior cava and the auriculo-ventricular opening, and is generally connected with the coronary valve.

The *coronary valve* is a semilunar fold of the lining membrane, stretching across the mouth of the coronary vein, and preventing the reflux of blood in the vein during the contraction of the auricle.

The *annulus ovalis* is situated on the septum auricularum, opposite the termination of the inferior cava. It is the rounded margin of the septum, which occupies the place of the foramen ovale of the fœtus.

The *fossa ovalis* is an oval depression corresponding with the foramen ovale of the fœtus. This opening is closed at birth by a thin valvular layer, which is continuous with the left margin of the annulus, and is frequently imperfect at its upper part. The depression or fossa in the right auricle results from this arrangement. There is no fossa ovalis in the left auricle.

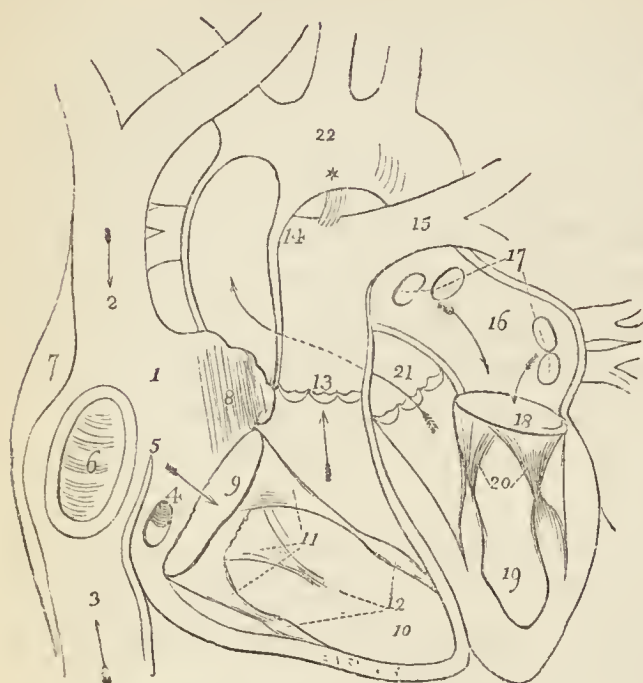
The *tuberculum Loweri* is the portion of auricle intervening between the openings of the superior and inferior cava. Being thicker than the walls of the veins, it forms a projection, which was supposed by Lower to direct the blood from the superior cava into the auriculo-ventricular opening.

The *musculi pectinati* are small muscular columns situated in the appendix auriculæ. They are numerous, and arranged parallel with each other; hence their cognomen, "*pectinati*," like the teeth of a comb.

The RIGHT OR ANTERIOR VENTRICLE is triangular and prismoid in form. Its anterior side is convex, and forms the larger portion of the front of the heart. The posterior side, which is also inferior, is flat, and rests on the

diaphragm ; the inner side corresponds with the partition

Fig. 23.*



between the two ventricles, septum ventriculorum. Superiorly, where the pulmonary artery arises, there is a dilatation of the ventricle, termed the *infundibulum* or *conus arteriosus*.

The right ventricle is to be laid open by making an incision parallel with, and a little to the right of, the anterior longitudinal furrow, from the pulmonary artery in front to the apex of the heart, and thence by the side of the posterior longitudinal

furrow behind to the auriculo-ventricular opening.

It contains, to be examined, two openings, the auriculo-

* The cavities of the heart. — No. 1. The right auricle. 2. The entrance of the superior cava. 3. The entrance of the inferior cava. 4. The opening of the coronary vein, half closed by its valve. 5. The Eustachian valve. 6. The fossa ovalis, surrounded by the annulus ovalis. 7. The tuberculum Loweri. 8. The muscoli pectinati. 9. The auriculo-ventricular opening. 10. The right ventricle. 11. The tricuspid valve, attached by the chordæ tendineæ to the carneæ columnæ, 12. 13. The pulmonary artery, guarded at its commencement by three semilunar valves. 14. The right pulmonary artery, passing beneath the arch and behind the ascending aorta. 15. The left pulmonary artery, crossing in front of the descending aorta. *The remains of the ductus arteriosus, acting as a ligament between the pulmonary artery and arch of the aorta. The arrows mark the course of the venous blood through the right side of the heart. Entering the auricle by the superior and inferior cavæ, it passes through the auriculo-ventricular opening into the ventricle, and thence through the pulmonary artery to the lungs. 16. The left auricle. 17. The openings of the four pulmonary veins. 18. The auriculo-ventricular opening. 19. The left ventricle. 20. The mitral valve, attached by its chordæ tendineæ to two large columnæ carneæ, which project from the walls of the ventricle. 21. The commencement and course of the ascending aorta behind the pulmonary artery, marked by an arrow. The entrance of the vessel is guarded by three semilunar valves. 22. The arch of the aorta. The comparative thickness of the two ventricles is shown in the diagram. The course of the pure blood through the left side of the heart is marked by arrows.

ventricular and that of the pulmonary artery; two apparatus of valves, the tricuspid and semilunar; and a muscular and tendinous apparatus belonging to the tricuspid valves. They may be thus arranged, —

Auriculo-ventricular opening,	Tricuspid valves,
Opening of the pulmonary artery,	Semilunar valves,
	Chordæ tendineæ,
	Columnæ carneæ.

The *auriculo-ventricular opening* is surrounded by a fibrous ring, covered by the lining membrane (endocardium) of the heart. It is the opening of communication between the right auricle and ventricle.

The *opening of the pulmonary artery* is situated at the summit of the conus arteriosus, close to the septum ventriculorum, on the left side of the right ventricle, and upon the anterior aspect of the heart.

The *tricuspid valves* are three triangular folds of the lining membrane, strengthened by a thin layer of fibrous tissue. They are connected by their base around the auriculo-ventricular opening; and by their sides and apices, which are thickened, they give attachment to a number of slender tendinous cords, called chordæ tendineæ. The *chordæ tendineæ* are the tendons of the thick muscular columns (*columnæ carneæ*) which stand out from the walls of the ventricle, and serve as muscles to the valves. A number of these tendinous cords converge to a single muscular attachment. The tricuspid valves prevent the regurgitation of blood into the auricle during the contraction of the ventricle, and they are prevented from being themselves driven back by the chordæ tendineæ and their muscular attachments.

This connection of the muscular columns of the heart to the valves has caused their division into active and passive. The *active* valves are the tricuspid and mitral; the *passive*, the semilunar and coronary.

The valves consist, according to Mr. King*, of *curtains*,

The blood is brought from the lungs by the four pulmonary veins into the left auricle, and passes through the auriculo-ventricular opening into the left ventricle, from whence it is conveyed by the aorta to every part of the body.

* "Essay on the Safety-Valve Function in the Right Ventricle of the Human Heart," by T. W. King. Guy's Hospital Reports, vol. ii.

cords, and *columns*. The *anterior valve* or *curtain* is the largest, and is so placed as to prevent the filling of the pulmonary artery during the distention of the ventricle. The *right valve* or *curtain* is of smaller size, and is situated on the right side of the auriculo-ventricular opening. The third valve, or "*fixed curtain*," is connected by its cords to the septum ventriculorum. The *cords* (*chordæ tendineæ*) of the anterior curtain are attached, principally, to a long *column* (*columna carnea*), which is connected with the "right or thin and *yielding wall* of the ventricle." From the lower part of this column a transverse muscular band, the "*long moderator band*," is stretched to the septum ventriculorum, or "*solid wall*" of the ventricle. The right curtain is connected, by means of its *cords*, partly with the long column, and partly with its own proper column, the *second column*, which is also attached to the "*yielding wall*" of the ventricle. A third and smaller column is generally connected with the right curtain. The "*fixed curtain*" is so named from its attachment to the "*solid wall*" of the ventricle, by means of cords only, without fleshy columns.

From this arrangement of the valves it follows, that if the right ventricle be over distended, the thin or "*yielding wall*" will give way, and carry with it the columns of the anterior and right valves. The cords connected with these columns will draw down the edges of the corresponding valves, and produce an opening between the curtains, through which the superabundant blood may escape into the auricle, and the ventricle be relieved from over-pressure. This mechanism is therefore adapted to fulfil the function of a *safety valve*.

The *columnæ carneæ* (fleshy columns) is a name expressive of the appearance of the internal walls of the ventricles, which, with the exception of the infundibulum, seem formed of muscular columns interlacing in almost every direction. They are divided, according to the manner of their connection, into three sets. 1. The greater number are attached by the whole of one side, and merely form convexities into the cavity of the ventricle. 2. Others are connected by both extremities, being free in the middle. 3. A few (*columnæ papillares*) are attached by one extremity to the walls of the heart, and by the other give insertion to the *chordæ tendineæ*.

The *semilunar valves*, three in number, are situated

around the commencement of the pulmonary artery, being formed by a folding of its lining membrane, strengthened by a thin layer of fibrous tissue. They are attached by their convex borders, and free by the concave, which are directed upwards in the course of the vessel, so that, during the current of the blood along the artery, they are pressed against the sides of the cylinder; but if any attempt at regurgitation ensue, they are immediately expanded, and effectually close the entrance of the tube. The margins of the valves are thicker than the rest of their extent, and each valve presents in the centre of this margin a small fibro-cartilaginous tubercle or nodule, called *corpus Arantii*, which locks in with the other two during the closure of the valves, and secures the triangular space which would otherwise be left by the approximation of three semilunar folds. On either side of the nodule the edge of the valve is folded and thin, and to this part the term *lunula* has been applied. When the valves are closed, the lunulæ are brought in contact with each other by their surfaces.

Between the semilunar valves and the cylinder of the artery are three pouches, called the *pulmonary sinuses* (sinuses of Valsalva). Similar sinuses are situated behind the valves at the commencement of the aorta, and are larger and more capacious than those of the pulmonary artery.

The *pulmonary artery* commences by a scalloped border, corresponding with the three valves which are attached along its edge. It is connected to the ventricle by muscular fibres, and by the lining membrane of the heart.

THE LEFT OR POSTERIOR AURICLE is somewhat smaller, but thicker, than the right; of a cuboid form, and situated more posteriorly. The *appendix auriculæ* is constricted at its junction with the auricle, and has a foliated appearance; it is directed forwards towards the root of the pulmonary artery, to which the auriculæ of both sides appear to converge.

The left auricle is to be laid open by a \perp shaped incision, the horizontal section being made along the border which is attached to the base of the ventricle.

It presents for examination five openings, and the muscular structure of the appendix; the fossa ovalis, as pre-

viously observed, is not seen on the left side of the septum auricularum. The parts to be examined are —

Four pulmonary veins,
Auriculo-ventricular opening,
Musculi pectinati.

The *pulmonary veins*, two from the right and two from the left lung, open into the corresponding sides of the auricle. The two left pulmonary veins terminate frequently by a common opening.

The *auriculo-ventricular opening* is the aperture of communication between the auricle and ventricle.

The *musculi pectinati* are fewer in number than in the right auricle, and are situated only in the appendix auriculæ.

LEFT VENTRICLE. — The left ventricle is to be opened by making an incision a little to the left of the septum ventriculorum, and continuing it around the apex of the heart to the auriculo-ventricular opening behind.

The left ventricle is conical, both in external figure and in the form of its internal cavity. It forms the apex of the heart, by projecting beyond the right ventricle, while the latter has the advantage in length towards the base. Its walls are about seven lines in thickness, those of the right ventricle being about two lines and a half.

It presents for examination, in its interior, two openings, two valves, and the tendinous cords and muscular columns; they may be thus arranged :—

Auriculo-ventricular opening,	Mitral valves,
Aortic opening,	Semilunar valves,
Chordæ tendineæ,	
Columnæ carneæ.	

The *auriculo-ventricular opening* is a dense fibrous ring, covered by the endocardium, but smaller in size than that of the right side. Its fibrous structure is closely connected with that of the right auriculo-ventricular and aortic rings; and at the junction of the three there is a fibro-cartilaginous mass, and, in some animals, a portion of bone.

The *mitral valves* are attached around the auriculo-ventricular opening, as are the tricuspid in the right ventricle. They are thicker than the tricuspid, and consist of two segments, of which the larger is placed

between the auriculo-ventricular opening and the commencement of the aorta, and acts the part of a valve to that foramen during the filling of the ventricle. The difference in size of the two valves, both being triangular, and the space between them, has given rise to the idea of a "*bishop's mitre*," after which they were named. These valves, like the tricuspid, are furnished with an apparatus of tendinous cords, *chordæ tendineæ*, which are attached to two very large *columnæ carneæ*.

The *columnæ carneæ* admit of the same arrangement, into three kinds, as on the right side. Those which are free by one extremity, the *columnæ papillares*, are two in number, and larger than those on the opposite side; one being placed on the left wall of the ventricle, and the other at the junction of the septum ventriculorum with the posterior wall.

The *semilunar valves* are placed around the commencement of the aorta, like those of the pulmonary artery; they are similar in structure, and are attached to the scalloped border by which the aorta is connected with the ventricle. The nodule in the centre of each fold is larger than those in the pulmonary valves, and it was these that Arantius particularly described; but the term "*corpora Arantii*" is now applied indiscriminately to both. The fossæ between the semilunar valves and the cylinder of the artery are larger than those of the pulmonary artery; they are called the "*sinus aortici*" (sinuses of Valsalva).

Structure.—The heart is composed of muscular fibres, which are interposed between two membranes—the pericardium externally, and endocardium within—and are attached to the fibrous rings which surround the four great openings in the root of the heart,—the auriculo-ventricular openings, and those of the pulmonary artery and aorta.

The *fibres of the ventricles*, taking their origin from these rings, wind spirally around each ventricle, to the apex of the heart, and then turn abruptly inwards so as to form an internal layer to the preceding. The greater part of these recurrent fibres proceed to the fibrous rings, into which they are inserted, while some constitute the *columnæ papillares*. A superficial set of fibres forms a thin stratum, which winds around both ventricles and binds them together.

The *fibres of the auricles*, like those of the ventricles, arise from the fibrous rings, and, after winding more or less obliquely and transversely around the auricles—some passing between the two to form the septum auricularum,—return to be *inserted* into the fibrous rings. Some of the fibres are disposed in circles around the openings of the large veins.

The *endocardium* is the serous lining membrane of the heart. It is thin and transparent, but somewhat thicker and less transparent on the left side than on the right. It forms the folds which, thickened by fibrous tissue, constitute the valves of the heart, and is continuous, at the apertures, with the internal coat of the arteries and veins.

VESSELS OF THE HEART.—The vessels of the heart may be examined either before or after the dissection of the organ, as may best suit the convenience of the student. This might be done on the subject; but as there are many more important things to study, and decay is rapid in its march, the student would do well to obtain a heart specially for the dissection of the vessels, and prepare them for that purpose by injection with coloured tallow.

The **CORONARY ARTERIES** arise from the aortic sinuses at the commencement of the ascending aorta, immediately above the free margin of the semilunar valves. The *left*, or *anterior coronary*, passes forwards between the pulmonary artery and left appendix auriculæ, and divides into two branches; one of which winds around the base of the left ventricle in the auriculo-ventricular groove, and inosculates with the right coronary, forming an arterial circle around the base of the heart; while the other passes along the line of union of the two ventricles, upon the anterior aspect of the heart, to its apex, where it anastomoses with the descending branch of the right coronary. It supplies the left auricle and the anterior surface of both ventricles.

The *right* or *posterior coronary* passes forward between the root of the pulmonary artery and the right auricle, and winds along the auriculo-ventricular groove to the posterior longitudinal furrow, where it descends upon the posterior aspect of the heart to its apex, and inosculates with the left coronary. It is distributed to the right auricle, and to the posterior surface of both ventricles, and sends a large branch along the sharp margin of the right ventricle to the apex of the heart.

Cardiac Veins.—The veins returning the blood from the substance of the heart are the

Great cardiac vein,	Anterior cardiac veins,
Posterior cardiac veins,	Venæ Thebesii.

The *great cardiac vein* (coronary) commences at the apex of the heart, and ascends along the anterior longitudinal groove to the base of the ventricles; it then

curves around the left auriculo-ventricular groove to the posterior part of the heart, where it terminates in the right auricle. It receives in its course the left cardiac veins from the left auricle and ventricle, and the posterior cardiac veins from the posterior longitudinal groove.

The *posterior cardiac vein*, frequently two in number, commences also at the apex of the heart, and ascends along the posterior longitudinal groove, to terminate in the great cardiac vein. It receives the veins from the posterior aspect of the two ventricles.

The *anterior cardiac veins* collect the blood from the anterior surface of the right ventricle; one larger than the rest runs along the right border of the heart and joins the trunk formed by these veins, which curves around the right auriculo-ventricular groove, to terminate in the great cardiac vein near its entrance into the right auricle; others cross the groove, and open directly into the auricle.

The *venæ Thebesii* (venæ minimæ) are numerous minute venules which convey the venous blood directly from the substance of the heart into the right auricle. Their existence is denied by some anatomists.

NERVES OF THE HEART.—The heart is supplied with nerves by the superficial and deep cardiac plexuses.

The *superficial cardiac plexus* is situated immediately beneath the arch of the aorta and in front of the right pulmonary artery. It receives the superficial cardiac nerve of the left side and the inferior cardiac branch of the left pneumogastric nerve, both of which cross the arch of the aorta between the left phrenic and pneumogastric nerve. It receives besides numerous filaments from the deep cardiac plexus, and sometimes a cardiac branch from the right pneumogastric nerve. Connected with the plexus is a small ganglion (sometimes wanting), the cardiac ganglion of Wrisberg, which lies close to the right side of the fibrous cord of the ductus arteriosus. The superficial cardiac plexus gives off filaments which pass along the front of the left pulmonary artery to the root of the left lung, where they communicate with the anterior pulmonary plexus; while the principal part of the plexus descends in the groove between the pulmonary artery and the aorta to the anterior longitudinal sulcus of the heart, where it comes into relation with the anterior

coronary artery, and becomes the *anterior coronary plexus*. At the base of the heart the anterior coronary plexus receives several filaments from the deep cardiac plexus. Its branches are distributed to the substance of the heart in the course of the anterior coronary artery.

The *deep cardiac plexus* (great cardiac plexus) is situated in a triangular space, bounded in front by the arch of the aorta, behind by the trachea, its point of bifurcation, and below by the right pulmonary artery.

The dissection of this plexus requires the removal of the arch of the aorta, and, like the examination of the coronary arteries, had better be made on a heart procured specially for the purpose.

The deep cardiac plexus receives all the cardiac branches of the sympathetic with the exception of the *nervus superficialis cordis* of the left side; and all the cardiac branches of the pneumogastric excepting the left inferior branch. It gives off numerous filaments; some, proceeding from its *right* side, pass in front of the right pulmonary artery to reach the right anterior pulmonary plexus; others descend along the trunk of the pulmonary artery to join the anterior coronary plexus; and a third set pass behind the pulmonary artery to the posterior coronary plexus and right auricle. The filaments proceeding from its *left* side are directed, some forwards beneath the arch of the aorta to join the superficial cardiac plexus, some outwards to the left anterior pulmonary plexus, and some to the left auricle; while the great bulk are continued downwards to the posterior coronary artery, and become the *posterior coronary plexus*, which supplies the muscular structure of the posterior aspect of the heart.

GREAT VESSELS OF THE HEART.

The great vessels connected with the heart are the pulmonary artery, aorta, superior and inferior cava, and four pulmonary veins.

PULMONARY ARTERY.—The pulmonary artery is the most anterior of the vessels at the root of the heart. It arises from the left side of the base of the right ventricle, that part termed the infundibulum; and ascends for the space of two inches to the under side of the arch of the aorta, where it divides into two branches of nearly equal

size, the right and left pulmonary arteries; the left branch, just at its point of division, being connected with the aorta by a fibrous cord, the remains of the ductus arteriosus of the fœtus. At its origin the pulmonary artery is in relation on either side with an appendix auriculæ and one of the coronary arteries; and behind it has the commencement of the aorta and left auricle. It is enclosed by the pericardium for nearly the whole of its length, its trunk and that of the aorta being contained in the same sheath of *serous* membrane.

The *right pulmonary artery*, longer and somewhat larger than the left, passes transversely outwards behind the ascending aorta and superior vena cava to the root of the right lung, where it divides into three branches for the three lobes. In its course it lies parallel with and in front of the right bronchus.

The *left pulmonary artery*, shorter and smaller than the right, crosses the descending aorta and left bronchus to the root of the left lung, where it divides into two branches for the two lobes.

AORTA.—The aorta, the great arterial trunk of the body, arises from the left ventricle at the middle of the root of the heart. It ascends at first forwards and to the right, next curves backwards and to the left, and then descends on the left side of the vertebral column to the fourth lumbar vertebra. The aorta within the thorax is therefore divided into the arch and thoracic aorta. At its commencement the vessel presents three dilatations, the *sinus aortici*, which correspond with the spaces occupied by the three semilunar valves.

The *arch of the aorta*, commencing at a point corresponding with the articulation of the cartilage of the fourth rib with the sternum on the left side, crosses behind and near the sternum to a point corresponding with the upper border of the articulation of the second rib with the sternum on the right side. It then curves backwards and to the left, and descends to the left side of the body of the third dorsal vertebra, and at the lower border of the latter vertebra becomes the thoracic aorta.

The first or *ascending* portion of the arch, a little more than two inches in length, is almost wholly contained within the pericardium. It is crossed *in front* by the pulmonary artery: on its *left* side it has the left auricle

and pulmonary artery; on its *right* the right auricle and superior vena cava; and *behind* the right pulmonary artery and veins.

The second or *transverse* portion of the arch is crossed *in front* by the left phrenic nerve, left nervus superficialis cordis, left inferior cardiac of the pneumogastric, and left pneumogastric nerve. *Behind* it is in relation with the trachea, œsophagus, thoracic duct, the nerves to the deep cardiac plexus, and the left recurrent nerve. *Above* it gives off the arteria innominata, left carotid and left subclavian artery, and supports the left vena innominata; and *below* is in relation with the superficial cardiac plexus, the bifurcation of the pulmonary artery, cord of the ductus arteriosus, left bronchus, and left recurrent nerve.

The third or *descending* portion of the arch lies against the third dorsal vertebra, and is partially covered by the left pleura.

The ARTERIA INNOMINATA, the first and largest branch given off by the arch of the aorta, is an inch and a half in length. It ascends obliquely to the right sterno-clavicular articulation, where it divides into the right carotid and right subclavian artery.

It is in *relation in front* with the left vena innominata, the sternum, and origin of the sterno-hyoid and sterno-thyroid muscles. *Behind* it has at first the trachea, and then the right pneumogastric nerve. To the *right* it is in relation with the right vena innominata and pleura; and on the *left* with the left common carotid artery, and the remains of the thymus gland.

The arteria innominata usually gives off no branch; but sometimes a small vessel proceeds from it which ascends upon the front of the trachea to the thyroid gland. This is the *middle thyroid artery* of Harrison, the *thyroidea ima* of Neubauer.

The LEFT COMMON CAROTID ARTERY, the second branch from the arch of the aorta, ascends obliquely to the left sterno-clavicular articulation, and thence passes onwards to the side of the neck. It is in relation *in front* with the left vena innominata, which crosses it near its origin; the remains of the thymus gland, and the origins of the sterno-hyoid and sterno-thyroid muscles. *Behind*, it rests in succession on the trachea, œsophagus, and thoracic

duct. To its *inner* side is the arteria innominata; and *externally* the left pneumogastric nerve and pleura.

The LEFT SUBCLAVIAN ARTERY, the third branch given off by the arch of the aorta, ascends perpendicularly to the inner border of the first rib, where it turns outwards over the rib and behind the scalenus anticus muscle. In consequence of the antero-posterior direction of the arch of the aorta, the left subclavian artery rests on the vertebral column and longus colli muscle. In *front* it has the pleura, the pneumogastric and phrenic nerve; and to its *inner* side the trachea, œsophagus, and thoracic duct.

SUPERIOR VENA CAVA.—This large vein, about three inches in length, is formed by the union of the two venæ innominatæ. It commences immediately to the right of the arch of the aorta; at about its middle becomes enclosed in the pericardium; and terminates in the upper part of the right auricle.

It is *in relation* in *front* with the pericardium; *behind* with the right pulmonary artery; to its *inner* side with the ascending aorta; and *externally* with the pleura and right phrenic nerve.

In the upper half of its course the superior vena cava receives several small veins from the mediastinum, and just before its entrance into the pericardium it is joined from behind by the great azygos vein.

The VENÆ INNOMINATÆ are formed by the union of the internal jugular and subclavian vein at each side.

The *right vena innominata*, about an inch and a quarter in length, descends almost vertically by the side of the arteria innominata to unite with its fellow of the opposite side in the formation of the superior vena cava. It is in relation by its outer side with the pleura and right phrenic nerve. This vein receives at its origin the trunk of the ductus lymphaticus dexter, which opens into it from behind; and in its course it is joined by the right vertebral, right inferior thyroid, and right internal mammary vein.

The *left vena innominata*, considerably longer than the right, crosses obliquely the three great arteries arising from the arch of the aorta to its junction with the right vena innominata. It is *in relation* in *front* with the left sterno-clavicular articulation, and the remains of the thymus gland, which separate it from the sternum.

Behind, it has the upper border of the arch of the aorta, the large arteries arising from it, and the nerves which pass in front of the arch.

The veins opening into the left vena innominata are the left vertebral, left inferior thyroid, left mammary, superior intercostal, and several small veins from the anterior mediastinum. At its origin it receives the thoracic duct, which opens into it from behind.

INFERIOR VENA CAVA.—The inferior vena cava, the large trunk from the lower half of the body, after passing through the tendinous portion of the diaphragm, opens immediately into the posterior part of the right auricle. It receives no branches within the thorax.

PULMONARY VEINS.—The pulmonary veins returning the pure blood from the lungs to the left auricle lie in front of the other vessels in the roots of the lungs. There are two on each side, those of the left lung being the veins of its two lobes; while on the right side the veins of the superior and middle lobe are united into a single trunk. The *right* pulmonary veins are longer than the left, and pass behind the right auricle. The *left* pulmonary veins pass in front of the descending aorta.

NERVES OF THE THORAX.

The nerves found in the thorax are the phrenic, pneumogastric, and sympathetic. The first of these merely pass through the thorax in their way to the diaphragm: they have been already described, page 143. The pneumogastric and sympathetic supply the viscera of the thorax in their course through its cavity.

The **PNEUMOGASTRIC NERVE**, the largest of the three nerves of the eighth pair, after descending the neck in the sheath of the carotid vessels, enters the chest, and, passing backwards and inwards behind the root of the lungs, reaches the œsophagus, along which it takes its course to the stomach. As the two nerves of opposite sides of the chest differ in their course, it becomes necessary to examine each separately.

The *right* nerve enters the chest after passing between the subclavian artery and vein; it then passes inwards and backwards by the side of the trachea to the posterior aspect of the root of the lungs, where it forms the pos-

terior pulmonary plexus. From the root of the lungs it proceeds as a double cord to the œsophagus, and takes its course along the *posterior* aspect of the œsophagus to the corresponding aspect of the stomach, to which it is distributed. At the lower part of the œsophagus the two cords reunite.

The *left* nerve enters the chest between the left common carotid and subclavian artery, and behind the left vena innominata. It crosses the arch of the aorta, around which the recurrent takes its course, and passes backwards to the posterior aspect of the root of the lungs, where, like the right, it forms the posterior pulmonary plexus. From the root of the lung it passes by one or two cords to the *anterior* aspect of the œsophagus, along which it takes its course to the corresponding aspect of the stomach.

The *branches* of the pneumogastric nerves within the thorax are the *recurrent* or *inferior laryngeal*, *cardiac*, *pulmonary* anterior and posterior, and *œsophageal*.

The *recurrent laryngeal* nerve curves around the subclavian artery on the right side and the arch of the aorta on the left, and ascends in the groove between the trachea and œsophagus to the larynx. As it curves around its respective artery, the nerve gives off one or two cardiac branches to the deep cardiac plexus.

The *cardiac* branches are the inferior cardiac given off from the pneumogastric just as that nerve is about to enter the chest; and some cardiac branches given off within the thorax.

The *inferior cardiac branch* of the right side passes down by the side of the arteria innominata to the deep cardiac plexus, and joins one of the cardiac branches of the sympathetic. The *left inferior cardiac* branch has been already described (page 150.); it takes its course in front of the arch of the aorta to the superficial cardiac plexus.

The *cardiac branches*, given off within the thorax, are several small nerves to the deep cardiac plexus. On the right side they proceed from the trunk of the nerve; on the left, from the recurrent laryngeal.

The *anterior pulmonary* are two or three small branches which pass forwards to the anterior aspect of the root of the lungs, and form, by their communications with fila-

ments from the cardiac plexuses, the anterior pulmonary plexus.

The *posterior pulmonary branches*, larger and more numerous than the anterior, proceed from the nerve where it is flattened and split into several cords. These branches are joined by filaments from the third and fourth thoracic ganglia of the sympathetic, and form the posterior pulmonary plexus.

Œsophageal branches are given off by the pneumogastric nerves above the root of the lungs: below that point, the trunks of the nerves, divided into several cords, form a plexus around the œsophagus, the right and left nerves communicating with each other. This plexus accompanies the œsophagus to the stomach, and is the œsophageal plexus (*plexus gulæ*).

SYMPATHETIC NERVE.—The sympathetic nerve within the thorax consists of two portions; one, *prevertebral*, composed of nerves descending from the neck, and forming the *superficial* and *deep cardiac plexus*; the other, the *vertebral* portion, being the trunk of the gangliated cord, situated on the heads of the ribs by the side of the vertebral column.

The superficial cardiac plexus, situated beneath the arch of the aorta, has been already examined (p. 161). To see the *deep cardiac plexus*, it is necessary to draw aside the arch of the aorta, behind which it lies. This may be best effected by dividing the aorta through each extremity of the transverse portion of the arch, cutting through the ligament of the ductus arteriosus, and drawing the severed parts of the vessel, with its large branches, upwards. By the removal of some cellular tissue and lymphatic glands, the deep cardiac plexus and lower part of the trachea, with its bifurcation, will be brought into view.

The *deep* or *great cardiac plexus* is situated on the bifurcation of the trachea above the right pulmonary artery, and behind the transverse portion of the arch of the aorta. It receives, on the *right* side, the three cardiac nerves of the sympathetic of the same side, and the cardiac branches of the right pneumogastric and right recurrent nerve. On the *left* side it receives the middle and inferior cardiac nerves of the sympathetic of the left side; the cardiac branches of the left pneumogastric (excepting the inferior), and several cardiac branches from the left recurrent nerve. In other words, it receives all

the cardiac filaments of the sympathetic, pneumogastric, and recurrent nerves, with the exception of the left superior cardiac of the sympathetic (*nervus superficialis cordis*) and the inferior cervical cardiac of the left pneumogastric, these two nerves being destined to the superficial cardiac plexus.

The cardiac nerves being situated on a plane posterior to that of the arteries, are found in that situation at their entrance into the chest. The nerves of the right side pass for the most part behind (but sometimes in front of) the subclavian artery; those of the left side enter the chest between the carotid and subclavian artery. The *nervus superficialis cordis* of the right side runs by the side of the *arteria innominata*; that of the left side takes the left common carotid for its guide; while the other nerves, in their course to the deep plexus, pass inwards to the side of the trachea.

The *branches* of the deep cardiac plexus, proceeding from its right and left division, pass downwards to join the coronary arteries, and outwards to the pulmonary plexuses. From the *right division* of the plexus the branches proceed before and behind the right pulmonary artery. Those which pass in front descend upon the trunk of the pulmonary to the left coronary artery, and constitute the *anterior coronary plexus*; those which pass behind the right pulmonary artery are distributed to the right auricle; a third set of filaments, proceeding from the right division of the deep cardiac plexus follow the course of the right pulmonary artery to the anterior pulmonary plexus.

From the *left division* of the plexus branches proceed beneath the arch of the aorta immediately to the right of the ligament of the ductus arteriosus to join the superficial cardiac plexus; others pass outwards with the pulmonary artery to the pulmonary plexus; a few descend to the left auricle; but the chief bulk pass on to the right coronary artery and form the posterior coronary plexus.

The *vertebral portion of the sympathetic nerve* is the trunk of the sympathetic in its course through the cavity of the thorax. It lies by the side of the vertebral column upon the heads of the ribs and intercostal spaces; but at its lowest part comes into relation with the sides of the bodies of the last two dorsal vertebræ.

To see the nerve distinctly, the pleura should be stripped from the sides of the vertebral column, and any fat which may impede the view of the nerve and its branches removed.

The thoracic portion of the great sympathetic nerve consists of twelve ganglia with their connecting cords. The ganglia are flat, of a pearly hue, and somewhat triangular shape; and each ganglion overlies the head of the corresponding rib. The first two ganglia are larger than the rest.

The *branches* of the thoracic ganglia are external, or *communicating*, two or three in number, to communicate with each intercostal nerve; and internal or *visceral*.

The *visceral branches*, arising from the five or six upper ganglia, are of small size, and are distributed to the aorta, œsophagus, vertebral column, and lungs. The branches to the lungs proceed from the third and fourth ganglia, and go to join the posterior pulmonary plexus. The visceral branches of the six lower ganglia unite to form the three splanchnic nerves.

The *great splanchnic* nerve proceeds from the sixth dorsal ganglion, and receiving the branches of the seventh, eighth, ninth, and tenth, passes downwards upon the front of the vertebral column, and, piercing the crus of the diaphragm, terminates in the semilunar ganglion.

The *lesser splanchnic nerve* is formed by filaments which issue from the tenth and eleventh ganglia; it pierces the crus of the diaphragm, and joins the solar plexus near the middle line.

The *third or renal splanchnic* nerve proceeds from the last thoracic ganglion, and, piercing the diaphragm, terminates in the renal plexus. When absent, the place of this nerve is supplied by the lesser splanchnic.

The process by which the sympathetic nerve was brought into view—namely, that of stripping off the pleura—exposes also the intercostal spaces, with the intercostal nerves and vessels. The relation of these parts may now be examined, and one of the intercostal nerves traced through its course.

The INTERCOSTAL NERVES are twelve in number on each side of the thorax; the eleven superior nerves lie in the intercostal spaces, the twelfth below the lower border of the last rib. Each nerve lies upon an external intercostal muscle, but soon gets under cover of the in-

ternal intercostal, and then passes between the two planes of muscle to the front part of the chest. Near its origin the nerve receives two or three filaments from the neighbouring ganglion of the sympathetic, in its course it gives twigs to the intercostal muscles, and at the middle of the arch of the rib sends off the lateral cutaneous branch.

The *first intercostal nerve* ascends from the intercostal space, and crosses the neck of the first rib to join the brachial plexus. It sends off a small intercostal branch, which takes the course of the other nerves to the front of the chest; but the latter gives no lateral cutaneous branch.

The *second intercostal nerve* is remarkable for the large size of its lateral cutaneous nerve, the *intercosto-humeral*.

The *six inferior intercostal nerves* at the termination of the intercostal spaces continue their course to the middle line of the body between the abdominal muscles.

CONTENTS OF THE POSTERIOR MEDIASTINUM.

Returning now to the middle line, the student may examine and dissect the parts which are usually enumerated as being contained in the posterior mediastinum. They are the œsophagus, aorta, venæ azygos, and thoracic duct. In front of them, at the upper part of the chest, and for the first time fully brought into view, is the trachea.

TRACHEA.—The trachea or wind-pipe extends from the larynx to the lungs; it lies over the vertebral column, and is about four inches in length. Its commencement corresponds in position with the fifth cervical vertebra, and its termination, where it divides into the two bronchi with the third dorsal vertebra. It is cylindrical for three-fourths of its circumference, but flattened behind, where it is in relation with the œsophagus. The bronchi have the same shape as the trachea, but the bronchial tubes into which the bronchi divide are perfectly cylindrical. The *right bronchus*, about an inch in length, is horizontal in direction, occupies the upper part of the root of the lung; and divides into three bronchial tubes for the three lobes of the lung. The *left*

bronchus, two inches in length, is oblique in direction, smaller than the right, and descends to the middle of the root of the lung. It divides into two bronchial tubes for the two lobes of the lung.

In *structure* the trachea and bronchi are composed of fibro-cartilaginous rings, connected by a fibrous membrane; they have also entering into their composition, muscular fibres, a coat of elastic tissue, mucous membrane and mucous glands.

The *fibro-cartilaginous rings* are from fifteen to twenty in number, and extend for two-thirds around the cylinder of the trachea. The lowest ring differs in shape from the rest, being prolonged to a V-shaped point between the bronchi at the bifurcation of the trachea.

The *fibrous membrane* encloses the rings completely, and forms a distinct layer over their outer surface.

The *muscular fibres* form a thin stratum, extending transversely between the cartilaginous rings behind.

The *elastic coat* is composed of fibres of elastic tissue disposed longitudinally. Where they invest the cartilages they form a thin layer, but behind, in the flat part of the tube between the cartilages, the fibres are gathered into strong fasciculi.

The *mucous membrane* is closely adherent to the elastic coat, and is continuous above with the lining of the larynx, and below with that of the bronchial tubes.

The *mucous glands* are small ovoid bodies situated externally to the fibrous membrane, and between that membrane and the muscular layer behind, and in the substance of the fibrous membrane between the rings. Their ducts open upon the mucous membrane.

ŒSOPHAGUS.—The œsophagus commences in the neck opposite the fifth cervical vertebra, and pursues a slightly flexuous course through the posterior mediastinum to the œsophageal opening of the diaphragm. Through the neck it inclines slightly to the left side; having entered the thorax it bends a little to the right, and reaches the midline of the vertebral column opposite the fifth dorsal vertebra; it then turns again to the left, gets in front of the aorta, and passes through the œsophageal opening in front of that vessel.

In the upper part of the thorax the œsophagus lies behind the trachea, projecting a little on its left side; it then passes behind the arch of the aorta, the left bronchus, and the pericardium. Laterally, it is in relation with the pleura; on the right with great vena azygos, and on the left with the aorta. It rests in its course downwards on the longus colli muscles, the right intercostal arteries, thoracic duct, and lower down on the aorta.

In *structure* the œsophagus is composed of three coats, *muscular*, *cellular*, and *mucous*.

The *muscular coat* consists of two layers of fibres, longitudinal and circular. The *longitudinal fibres* are connected above with the cricoid cartilage and muscular structure of the pharynx, and form a thick stratum around the tube; inferiorly they expand upon the stomach. The *circular fibres* forming the internal layer are continuous above with the muscular structure of the pharynx, and are also attached to the cricoid cartilage; inferiorly they enlarge and surround the stomach.

The muscular fibres of the upper part of the œsophagus are of the striated kind, the muscle of animal life; and those of the lower part the non-striated kind, the muscle of organic life.

The *cellular coat* is a moderately thick layer of cellular tissue, which connects together the muscular and the mucous coat; it is loosely adherent to the former, but closely to the latter.

The *mucous coat* is thick, and presents upon its surface a few minute and scattered papillæ. It is arranged in longitudinal plicæ, and is covered by a thick whitish epithelium of the squamous or tessellated kind. It is but loosely connected with the muscular coat.

The *mucous glands* of the œsophagus (œsophageal glands) are most abundant at the lower part of the tube; they are small lobulated bodies, situated in the cellular coat, and opening on the surface of the mucous membrane by means of long excretory tubes.

THORACIC AORTA.—The thoracic aorta commencing at the lower border and left side of the third dorsal vertebra curves gently towards the right as it descends, and as it passes through the aortic opening of the diaphragm lies upon the middle line of the vertebral column.

The *branches* of the thoracic aorta are, the pericardiac, bronchial, œsophageal, posterior mediastinal, and intercostal.

The *bronchial arteries*, generally three in number, one for the right lung and two for the left, vary both in size and origin; the right often proceeding from a short trunk common to it and one of the left bronchial branches, or from the first aortic intercostal. They take their course to the back of the root of the lung, and accompany the ramifications of the bronchial tubes through its substance. They give twigs also to the bronchial glands, œsophagus, and pericardium.

The *œsophageal arteries*, four or five in number, arise from the anterior part of the aorta, and are distributed to the œsophagus, establishing a chain of anastomoses along that tube: the superior inosculate with the bronchial

arteries, and with œsophageal branches of the inferior thyroid arteries; and the inferior with similar branches of the phrenic and gastric arteries.

The *posterior mediastinal* arteries are small twigs distributed to the lymphatic glands and cellular tissue of the posterior mediastinum.

The *intercostal arteries*, nine in number on each side, the two superior spaces being supplied by the superior intercostal artery, a branch of the subclavian, arise from the posterior part of the aorta. The right intercostals are longer than the left on account of the position of the aorta. They ascend somewhat obliquely from their origin, and cross the vertebral column behind the thoracic duct, vena azygos major, and sympathetic nerve to the intercostal spaces; the left passing beneath the superior intercostal vein, vena azygos minor, and sympathetic.

In the intercostal space, the artery comes into relation with the vein and nerve, the former being above, and the latter immediately below it. It is covered in by a thin fascia, continued from the free edge of the internal intercostal muscle to the vertebra; and rests upon the external intercostal muscle.

On first entering the intercostal space, the intercostal artery gives off a *dorsal branch*, which passes back close to the vertebræ and between their transverse processes, to be distributed to the muscles and integument of the back, and by means of a small *spinal* twig to the interior of the vertebral column. The artery next takes its course along the middle of the intercostal space, and gradually ascends to the lower border of the rib above, with which it comes into relation at about its angle; the artery then follows the lower border of the rib, lying between the two planes of intercostal muscles to the front of the chest, where it inosculates with the corresponding anterior intercostal branch of the internal mammary artery.

Besides the dorsal branch, and several small muscular branches, the intercostal artery, at about the middle of its course, gives off a *large branch*, which runs along the upper border of the rib below, to the front part of the chest, and inosculates with an anterior intercostal branch of the internal mammary.

The upper pair of aortic intercostal arteries inosculate with the superior intercostals of the subclavians; the

lower pair anastomose with the lumbar and epigastric arteries in the parietes of the abdomen.

SUPERIOR INTERCOSTAL ARTERIES.—Supplying the upper two intercostal spaces on each side is the superior intercostal artery. It arises from the subclavian artery, and descends over the necks of the first and second ribs externally to the sympathetic nerve, and inosculates with the first aortic intercostal. It sends off branches to the first and second intercostal spaces, and *dorsal* branches to the muscles and integument of the back.

VEINS OF THE POSTERIOR MEDIASTINUM.—The venæ azygos major and minor and left superior intercostal vein constitute a small prevertebral system of veins, interposed between the superior and inferior vena-cava, and communicating with both.

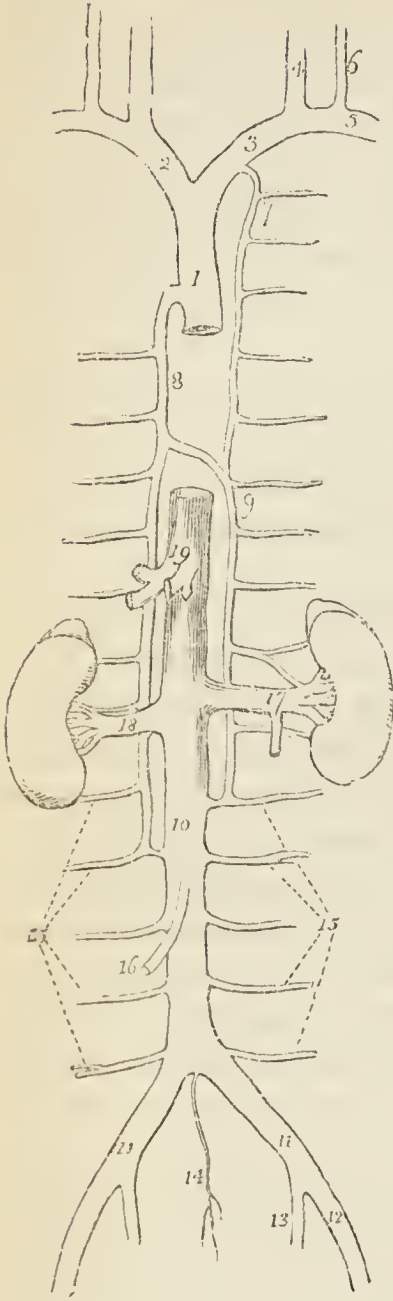
The **VENA AZYGOS MAJOR** commences in the lumbar region by a communication with the right lumbar veins. It passes through the aortic opening of the diaphragm, ascends along the right side of the vertebral column, and opposite the third dorsal vertebra arches forward over the root of the right lung, to terminate in the superior vena cava at its entrance into the pericardium. In its course it lies superficially to the right intercostal arteries, having the thoracic duct on its left and the pleura on its right side. It receives all the intercostal veins of the right side (with the exception of those of the first and second spaces), the vena azygos minor, and the right bronchial vein.

The **VENA AZYGOS MINOR** commences in the lumbar region by a communication with one of the left lumbar veins, or with the left renal; it enters the chest through the aortic opening, or, more frequently, through the crus of the diaphragm, and ascends the left side of the vertebral column to the fifth or sixth vertebra, which it crosses to terminate in the vena azygos major. It receives the six or seven lower intercostal veins of the left side. The azygos veins have no valves.

The *right superior intercostal vein* receives the veins of the first and second intercostal spaces, and opens into the subclavian vein of the same side.

The *left superior intercostal vein* receives the veins from all the intercostal spaces (five or six) of the left side above the vena azygos minor and the left bronchial vein.

Fig. 24.*



It communicates below with the vena azygos minor, and crosses the arch of the aorta to terminate in the left vena innominata.

THORACIC DUCT.—The thoracic duct is the great trunk of the lymphatic and chylous system. It commences in the abdomen on the second lumbar vertebra by an enlargement of considerable size termed *receptaculum chyli*; enters the chest through the aortic opening, ascends upon the vertebral column between the aorta and vena azygos major, and terminates at the root of the neck on the left side by opening into the angle of junction between the internal jugular and subclavian vein. At the aortic opening the thoracic duct lies close to the right crus of the diaphragm, in the thorax it rests upon the right intercostal arteries, and opposite the fourth dorsal vertebra inclines to the left side. A little higher it passes behind the arch of the aorta and reaches the left side of the œsophagus along which it takes its course, lying behind the left subclavian artery, to the root of the neck. It there makes a

* The veins of the trunk. — No. 1. The superior vena cava. 2. The right vena innominata. 3. The left vena innominata. 4. The internal jugular vein of the left side. 5. The subclavian vein of the left side. 6. The external jugular vein. 7. The left superior intercostal vein. 8. The great vena azygos, communicating inferiorly with one of the lumbar veins. 9. The lesser vena azygos, communicating inferiorly with a lumbar and with the left renal vein. 10. The inferior vena cava. 11, 11. The two common iliac veins. 12. The right external iliac. 13. The internal iliac vein. 14. The vena sacra media. 15, 15. The lumbar veins. 16. The right spermatic vein. 17. The left renal vein, into which is seen opening from below the left spermatic vein. 18. The right renal vein. 19. The hepatic veins.

hook-like bend from behind forwards, to its termination.

The thoracic duct is about eighteen or twenty inches in length, and near its origin as large as a goose quill; as it ascends it diminishes in size, and near its termination again becomes dilated. At about the middle of the thorax it frequently divides into two branches, which soon after reunite; sometimes it forms a kind of plexus in this situation; and occasionally divides into two branches near its termination.

The thoracic duct within the thorax receives the lymphatics of the left side of the chest, and from the left side of its contained viscera. The lymphatics of the right side of the chest and right half of the thoracic viscera terminate in a short trunk, the *ductus lymphaticus dexter* situated in the root of the neck of the right side, and terminating in the junction of the right internal jugular and right subclavian vein.

The thoracic duct and *ductus lymphaticus dexter* are both provided with valves, and at their termination is a large valve which prevents the regurgitation of blood from the veins.

LYMPHATIC GLANDS.—The lymphatic glands of the thorax are the anterior mediastinal, intercostal, œsophageal, bronchial, and cardiac.

The *anterior mediastinal glands* are situated along the course of the internal mammary arteries; they are six or seven in number on each side, and receive the lymphatic vessels from the anterior wall of the chest, the mediastinum, thymus gland, and pericardium.

The *intercostal glands* are situated near the intercostal arteries on each side of the vertebral column. They receive the lymphatics from the intercostal spaces and posterior wall of the thorax.

The *œsophageal glands*, fifteen or twenty in number, are situated in the course of the œsophagus, and receive the lymphatics of that tube.

The *bronchial glands*, ten or twelve in number, are placed near the bifurcation of the trachea and the roots of the lungs. They receive the lymphatics of the lungs both superficial and deep.

The *cardiac glands* are three or four in number, and

placed near the arch of the aorta ; they receive the lymphatics of the heart.

All the lymphatics of the chest terminate eventually in the thoracic duct or ductus lymphaticus dexter.

Internal Parietes of the Thorax. — The intercostal muscles, which have already been examined, upon the exterior of the chest (page 95.) may now be studied from within. The internal intercostal is seen to terminate by an abrupt border, from which a thin aponeurosis is continued onwards over the intercostal vessels and nerve to the side of the vertebral column.

In the *dome* of the chest may be examined the relative position of the parts which pass to and from the chest ; and in its *floor* the unequally convex surface of the diaphragm, with the openings which give passage to parts passing to and from the abdomen.

In the superior opening of the thorax will be seen, from before backwards, the sterno-hyoid and sterno-thyroid muscles ; remains of the thymus gland ; venæ innominatæ ; phrenic and pneumogastric nerves ; arteria innominata and left carotid artery ; cardiac nerves ; trachea ; left recurrent nerve ; œsophagus ; left subclavian artery ; thoracic duct ; longus colli muscles ; superior intercostal arteries ; first dorsal nerve ; and sympathetic. Besides these parts, which are in the state of transit, there is at each side the pouch of pleura for the reception of the summit of the corresponding lung.

The apertures in the floor of the thorax, and the parts to which they give passage, are, the *quadrilateral opening* in the tendinous centre of the diaphragm for the inferior vena cava ; the *elliptical opening* in the muscular structure of the diaphragm for the œsophagus and pneumogastric nerves, and the *musculo-fibrous arch* behind the central part of the diaphragm, the *aortic opening*, for the aorta, thoracic duct, and right vena azygos. The left vena azygos, sympathetic, and splanchnic nerves, pass through irregular intervals in the muscular structure of the crura of the diaphragm.

After completing the thorax, the student must turn his attention to the dissection of the back and its muscles.

CHAPTER IV.

REGION OF THE BACK.

It is customary in most dissecting-rooms to turn the body upon its face after the lapse of a few days, that the student may have an opportunity of studying the muscles of the back and the posterior parts of the limbs. The student must therefore endeavour to accommodate his dissection to these rules. The most appropriate time for making this dissection is that referred to at page 99; when the examination of the front of the shoulder and contents of the thorax has been completed.

The *region of the back* is, from its extent, common to the neck, the upper extremities, and the abdomen. The muscles of which it is composed are numerous, and may be arranged into six layers.

First Layer.

Trapezius,
Latissimus dorsi.

Transversalis colli,
Trachelo-mastoideus,
Complexus.

Second Layer.

Levator anguli scapulæ,
Rhomboides minor,
Rhomboides major.

Fifth Layer.

(Dorsal Group.)

Semi spinalis dorsi,
Semi spinalis colli.

Third Layer.

Serratus posticus superior,
Serratus posticus inferior,
Splenius capitis,
Splenius colli.

(Cervical Group.)

Rectus anticus major,
Rectus anticus minor,
Rectus lateralis,
Obliquus inferior,
Obliquus superior.

Fourth Layer.

(Dorsal Group.)

Sacro-lumbalis,
Longissimus dorsi,
Spinalis dorsi.

Sixth Layer.

Multifidus spinæ,
Inter-spinales,
Inter-transversales.
Levatores costarum.

(Cervical Group.)
Cervicalis ascendens,

For the *dissection* of the back, an incision should be made along the middle of the spine, from the tubercle on the occipital bone to the sacrum. From the upper extremity of this incision, carry a *second* transversely outwards to the back of the ear; and from its lower end a *third*, along the crest of the ilium to about its middle. As the flap included by these incisions is too large to be conveniently manageable, a *fourth* incision should be made from the middle of the back, transversely outwards to the tip of the acromion. The two flaps should then be dissected carefully off from the whole of this surface, when the superficial fascia will be exposed.

The student should now seek for the superficial cutaneous vessels and nerves of the back. The former are small, and, taking their course usually in company with the nerves, are useful as guides to the situation of the latter. The superficial cutaneous nerves of the neck and upper half of the back pierce the trapezius close to the spine, and pass outwards in their distribution to the integument. Those of the lower half of the back issue from the latissimus dorsi, at a point corresponding with the angle of the ribs; and those proceeding from the lumbar nerves reach the surface in the situation of the outer border of the sacro-lumbalis.

The *cutaneous nerves* of the back are derived from the posterior divisions of the spinal nerves. Each posterior division of a spinal nerve divides into an *internal* and *external* branch. The internal branch is directed inwards towards the middle of the spine, and becoming cutaneous near the spinous processes of the vertebræ, is then reflected outwards to supply the integument.

The *internal* branch of the posterior division of the *first cervical*, or suboccipital nerve, is distributed, when it exists, to the integument of the back of the head.

The *internal* branch of the posterior division of the *second cervical* is the occipitalis major nerve, which pierces the origin of the trapezius muscle in its course to the back of the head to join the occipital artery.

The *internal* branch of the *third cervical* nerve, when it arrives at the surface, gives off a small cutaneous branch to the integument of the head, before it takes its reflected course on the back of the neck.

The *cutaneous branches* in the cervical region are derived from the third, fourth, and fifth cervical nerves;—the *internal* branches of the three remaining nerves being intended for the supply of the muscles.

The *cutaneous nerves* in the thoracic region are derived: the *six upper* from the *internal* branches of the posterior division; the *six lower* from the *external* branches of the

posterior division. The former pierce the trapezius near the spinous processes, and are directed outwards. The latter pierce the latissimus dorsi over the angles of the ribs, and are directed downwards over the side of the trunk.

The *cutaneous nerves*, in the lumbar region, are derived from the *external* branches of the posterior division of the three upper lumbar nerves, they reach the surface in a line with the outer border of the sacro-lumbalis, and descend over the crest of the ilium to the integument of the gluteal region.

The *cutaneous nerves* in the sacral region, derived from the *external* branches of the three upper sacral nerves, are distributed to the integument of the sacral and posterior part of the gluteal region; and those of the last two sacral nerves to the integument over the coccyx.

When the cutaneous nerves have been studied, the superficial fascia should be removed from the muscles in the direction of their fibres, and the muscles of the superficial layer brought into view; they are the trapezius and latissimus dorsi.

FIRST LAYER.

The TRAPEZIUS muscle (*trapezium*, a quadrangle with unequal sides) *arises* from the superior curved line of the occipital bone, ligamentum nuchæ, and supraspinous ligament and spinous processes of the last cervical and all the dorsal vertebræ. The fibres converge from these various points, and are *inserted* into the scapular third of the clavicle, acromion, and the whole length of the upper border of the spine of the scapula. The inferior fibres become tendinous near the scapula, and glide over the triangular surface at the posterior extremity of its spine, upon a bursa mucosa. When the trapezius is dissected on both sides, the two muscles resemble a trapezium, or diamond-shaped quadrangle, on the posterior part of the shoulders: hence the muscle was formerly named cucullaris (cucullus, a monk's cowl). The cervical and upper part of the dorsal portion of the muscle is tendinous at its origin, and forms, with the muscle of the opposite side, a kind of tendinous ellipse.

The anterior border of the cervical portion of the trapezius forms the posterior boundary of the posterior

triangle of the neck. The *spinal accessory nerve*, which crosses this triangle, passes beneath the border of the trapezius, and is distributed to the under-surface of the muscle as far as its lower portion. There is also connected with the anterior border of the muscle in the neck a small artery, the *superficialis cervicis*, a branch of the *transversalis colli*.

The trapezius muscle should be divided by a longitudinal incision directed along the middle of the back, and the two portions turned aside. By turning the muscle back from its cervical origin, the *ligamentum nuchæ* will be brought into view; and lower down, the removal of the muscle will enable the student to see the upper portion of the *latissimus dorsi*.

The *ligamentum nuchæ* is a thin fibrous band extended from the tubercle and spine of the occipital bone to the spinous process of the seventh cervical vertebra, where it is continuous with the *supraspinous ligament*. It is connected with the spinous processes of all the cervical vertebræ, excepting the atlas, by means of a series of small fibrous slips. It is the analogue of an important elastic ligament in animals.

The *LATISSIMUS DORSI* muscle covers the whole of the lower part of the back and loins. It *arises* from the spinous processes of the six inferior dorsal vertebræ, from all the lumbar and sacral spinous processes, from the posterior third of the crest of the ilium, and from the three lower ribs; the latter origin takes place by muscular slips, which indigitate with the external oblique muscle of the abdomen. The fibres from this extensive origin converge as they ascend, and cross the inferior angle of the scapula; they then curve around the inferior border of the *teres major* muscle, and terminate in a short quadrilateral tendon which lies in front of the tendon of the *teres* and is inserted into the bicipital groove. A synovial bursa is interposed between the muscle and the lower angle of the scapula, and another between its tendon and that of the *teres major*. The muscle frequently receives a small fasciculus from the scapula as it crosses its inferior angle.

The *latissimus dorsi* may be divided by a longitudinal incision directed across the lower ribs to the posterior part of the crest of the ilium, and the two portions of the muscle turned aside. In making this dissection, care must be taken to avoid injuring a small muscle which lies beneath, the *serratus posticus inferior*.

SECOND LAYER.

The second layer of muscles consists of the levator anguli scapulæ, rhomboideus minor and rhomboideus major.

The LEVATOR ANGULI SCAPULÆ *arises* by tendinous slips, from the posterior tubercles of the transverse processes of the four upper cervical vertebræ, and is *inserted* into the upper angle and posterior border of the scapula, as far as the triangular smooth surface at the root of its spine.

The RHOMBOIDEUS MINOR (rhombus, a parallelogram with four equal sides) is a narrow slip of muscle, detached from the rhomboideus major by a slight cellular interspace. It arises from the spinous process of the last cervical vertebra and ligamentum nuchæ, and is *inserted* into the edge of the triangular surface, on the posterior border of the scapula.

The RHOMBOIDEUS MAJOR *arises* from the spinous processes of the four upper dorsal vertebræ and from the interspinous ligaments; it is *inserted* into the posterior border of the scapula as far as its inferior angle. The upper and middle portion of the insertion is effected by means of a tendinous band, which is attached in a longitudinal direction to the posterior border of the scapula.

The *transversalis colli artery*, a branch of the thyroid axis of the subclavian, will be seen, at this stage of the dissection, crossing the posterior triangle of the neck, a short distance above the clavicle, to the levator anguli scapulæ, where it divides into two branches, the *superficialis cervicis*, which has been already examined in connection with the anterior border of the trapezius, and the *posterior scapular artery*. The latter, which is the proper continuation of the transversalis colli, passes beneath the levator anguli scapulæ; it then turns down and runs along the base of the scapula, under cover of the rhomboid muscles, to its inferior angle, where it inosculates with the subscapular artery. When the rhomboid muscles are divided and turned aside, the artery will be seen accompanied by a nerve (the rhomboid) which distributes branches to the levator anguli scapulæ and rhomboidei muscles.

THIRD LAYER.

The *third layer* of muscles is brought into view when the rhomboidei and levator anguli scapulæ are divided through the middle and turned aside. To make them more clear, the spinous attachment of the rhomboid muscles may be removed altogether. The third layer consists of the serratus posticus superior, serratus posticus inferior, and splenius.

The SERRATUS POSTICUS SUPERIOR is situated at the upper part of the thorax; it *arises* from the ligamentum nuchæ, the spinous process of the last cervical and those of the two upper dorsal vertebræ. The muscle passes obliquely downwards and outwards, and is *inserted* by four serrations into the upper border of the second, third, fourth, and fifth ribs.

The SERRATUS POSTICUS INFERIOR *arises* from the spinous processes and interspinous ligaments of the last two dorsal and two upper lumbar vertebræ, and passing obliquely upwards, is *inserted* by four serrations into the lower border of the four lower ribs. Both muscles are constituted by a thin aponeurosis for about half their extent.

The upper border of the serratus posticus inferior is continuous with a thin tendinous layer, the *vertebral aponeurosis*. This aponeurosis is a thin membranous expansion composed of longitudinal and transverse fibres, and extending the whole length of the thoracic region. It is attached mesially to the spinous processes of the dorsal vertebræ, and externally to the angles of the ribs; superiorly it is continued upwards beneath the serratus posticus superior, with the lower border of which it is sometimes connected. It serves to bind down the erector spinæ, and separate it from the superficial muscles.

The serratus posticus superior must be removed from its origin and turned outwards, to bring into view the whole extent of the splenius muscle.

The SPLENIUS MUSCLE is single at its origin, but divides soon after into two portions, which are destined to distinct insertions. It *arises* from the lower half of the ligamentum nuchæ, the spinous process of the last cervical, and the spinous processes and interspinous ligaments of the six upper dorsal vertebræ; it divides as it ascends

the neck into the splenius capitis and colli. The *splenius capitis* is *inserted* into the rough surface of the occipital bone between the two curved lines, and into the mastoid portion of the temporal bone. The *splenius colli* is *inserted* into the posterior tubercles of the transverse processes of the three or four upper cervical vertebræ.

Returning to the serratus posticus inferior, its thin tendon of origin will be found inseparably united with that of the latissimus dorsi, and both are connected by their under surface with another aponeurotic expansion, the *fascia lumborum*. The fascia lumborum is the posterior aponeurosis of the transversalis abdominis muscle, and occupies the space between the crest of the ilium and last rib; it also gives attachment to the internal oblique muscle of the abdomen, and binds down the lumbar portion of the large muscles of the next layer, the erector spinæ.

FOURTH LAYER.

The *fourth layer* is to be brought into view by removing from its origin the splenius muscle, and dividing and turning aside the vertebral aponeurosis and fascia lumborum. This layer consists of the sacro-lumbalis, longissimus dorsi and spinalis dorsi in the lumbar and dorsal region, and the cervicalis ascendens, transversalis colli, trachelo-mastoideus and complexus in the cervical region.

The SACRO-LUMBALIS and LONGISSIMUS DORSI *arise* by a common origin from the posterior third of the crest of the ilium, from the posterior surface of the sacrum, and from the lumbar vertebræ: opposite the last rib a line of separation begins to be perceptible between the two muscles. The *sacro-lumbalis* is *inserted* by separate tendons into the angles of the six lower ribs. On turning the muscle a little outwards, a number of tendinous slips will be seen taking their origin from the ribs, and terminating in a muscular fasciculus, by which the sacro-lumbalis is prolonged to the upper part of the thorax. This is the *musculus accessorius ad sacro-lumbalem*; it *arises* from the angles of the six lower ribs, and is *inserted* by separate tendons into the angles of the six upper ribs.

The *longissimus dorsi* is *inserted* into the transverse processes of all the lumbar and dorsal vertebræ, and into the six or eight lower ribs, between their tubercles and angles.

The SPINALIS DORSI *arises* from the spinous processes of the two upper lumbar and two lower dorsal vertebræ, and is *inserted* into the spinous processes of all the upper dorsal vertebræ. The two muscles form an ellipse, which appears to enclose the spinous processes of all the dorsal vertebræ.

The CERVICALIS ASCENDENS is the continuation of the sacro-lumbalis upwards into the neck. It *arises* from the angles of the four upper ribs, and is *inserted* by slender tendons into the posterior tubercles of the transverse processes of the four lower cervical vertebræ.

The TRANSVERSALIS COLLI would appear to be the continuation upwards into the neck of the longissimus dorsi; it *arises* from the transverse processes of the third, fourth, fifth, and sixth dorsal vertebræ, and is *inserted* into the posterior tubercles of the transverse processes of the four or five inferior cervical vertebræ.

The TRACHELO-MASTOID is likewise a continuation upwards from the longissimus dorsi. It is a slender and delicate muscle, *arising* from the transverse processes of the four upper dorsal and four lower cervical vertebræ, and *inserted* into the mastoid process to the inner side of the digastric fossa.

The COMPLEXUS is a large muscle, and with the splenius forms the great bulk of the back of the neck. It crosses the direction of the splenius, *arising* from the transverse processes of the four upper dorsal, and from the transverse and articular processes of the four lower cervical vertebræ, and is *inserted* into the rough surface on the occipital bone between the two curved lines, near the occipital spine. A large fasciculus of the complexus is so distinct from the principal mass of the muscle as to have led to its description as a separate muscle under the name of *biventer cervicis*. This appellation is not inappropriate, for the muscle consists of a central tendon, with two fleshy bellies. The complexus is marked in the upper part of the neck by a transverse tendinous intersection.

The posterior divisions of the spinal nerves and some arteries are brought into view with this layer. These nerves and vessels are now to be examined; for which purpose the complexus should be cut across its middle, and its ends turned aside; or so much of the muscles removed as may be necessary to bring the next layer fully into view.

CERVICAL NERVES.—The posterior divisions of the *cervical nerves* issue from between the transverse processes, and divide into an internal and external branch. The *internal* branch is directed inwards to the spinous processes of the vertebræ, and after supplying the muscles of the inner portion of the vertebral groove becomes *cutaneous*, and is distributed to the integument of the neck (page 180.). The *external* branch is smaller than the internal, and is distributed to the muscles of the outer portion of the vertebral groove.

There are certain exceptions to this general idea of the distribution of the posterior divisions of the cervical nerves which may now be mentioned.

The *first* or *suboccipital nerve* has no external branch; it appears in the space between the recti and obliqui muscles, and is distributed to those muscles and the complexus. It also sends a branch downwards to communicate with the internal branch of the second cervical nerve.

The *internal branch* of the second cervical nerve is the *occipitalis major nerve*; it pierces the complexus and trapezius, and is distributed to the integument of the scalp, taking the direction of the occipital artery.

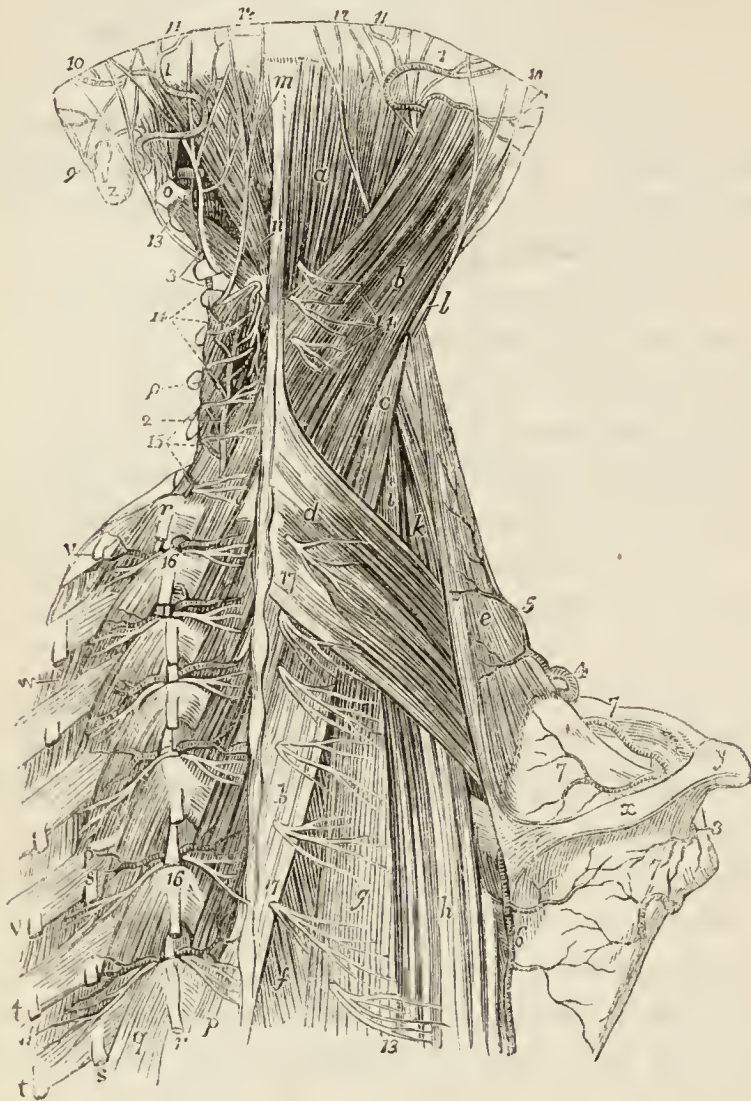The *internal branches* of the *second, third, fourth* and *fifth* nerves lie upon the semispinalis colli muscle, and are closely connected with a fascia which separates that muscle from the complexus. The second and third, with a branch from the first, constitute the *posterior cervical plexus*; and all the branches in their course to the surface pierce the complexus and trapezius and some the splenius.

The *internal branches* of the *sixth, seventh* and *eighth* nerves pass beneath the semispinalis colli, and are lost in the muscles without reaching the integument.

DORSAL NERVES.—The posterior divisions of the twelve dorsal nerves appear between the transverse processes, and, like the cervical, divide into an *internal* and *external* branch. The *internal branches* diminish in size from the first to the last. The six upper branches pass inwards beneath the semispinalis dorsi, between that muscle and the multifidus spinæ, and, piercing the rhomboid, trapezius and latissimus dorsi muscles, become cutaneous close to the spinous processes, and are reflected outwards

to supply the integument (page 180.). The six lower branches are lost in the muscles of the spine.

Fig. 25.*



* Vessels and nerves of the back of the neck and thorax.—
a. The complexus muscle. *b, b.* The splenius capitis. *c.* The splenius colli. *d.* The serratus posticus superior. *e.* The levator anguli scapulæ. *f.* The spinalis dorsi. *g.* The longissimus dorsi. *h.* The sacro-lumbalis. *i.* The transversalis colli. *k.* The cervicalis ascendens. *l.* The trachelo-mastoideus. *m.* The rectus posticus minor. *n.* Rectus posticus major. *o.* The transverse process of the atlas, with the obliquus capitis superior and inferior muscles. *p, p.* The multifidus spinæ muscle. *q, q.* The levatores costarum. *r, r.* The tendons of insertion of the longissimus dorsi muscles into the transverse processes of the dorsal vertebræ. *s, s.* Its tendons of insertion into the ribs. *t, t.* The two upper insertions, of the sacro-lumbalis into the angles of the ribs. *v, v.* The insertions of the musculus accessorius ad sacro-lumbalem. *w, w.* The external intercostal muscles. *x.* The spine of the scapula. *y.* The acromion process. *z.* The mastoid process.

1, 1. The occipital artery; on the left side it is seen giving off

The *external branches* increase in size from above downwards, and make their appearance in the line of separation between the longissimus dorsi and sacrolumbalis. The six upper branches are distributed to those muscles and levatores costarum. The six lower, after supplying the same muscles, pierce the serratus posterior inferior and latissimus dorsi in a line with the angles of the vertebræ and become *cutaneous* (page 181).

LUMBAR NERVES.—The posterior divisions of these nerves, five in number, also appear between the transverse processes in the muscular interspace between the longissimus dorsi and multifidus spinæ. Like the cervical and dorsal nerves, they divide into an internal and external branch.

The *internal branches* are distributed to the muscles lying close to the spinous processes, and chiefly to the multifidus spinæ.

The *external branches* supply the muscles lying upon the transverse processes, and the three upper pierce the aponeurosis of the latissimus dorsi, and become cutaneous (page 181.).

VESSELS OF THE BACK.—The arteries brought into view by the dissection of the deep muscles of the back are—the princeps cervicis, a branch of the occipital; the vertebral artery; the profunda cervicis; and the dorsal branches of the intercostal and lumbar arteries.

The OCCIPITAL ARTERY is seen issuing from beneath

its princeps cervicis branch, which descends near *o* to inosculate with—2. The profunda cervicis artery. 3. The vertebral artery. 4. The transversalis colli artery. 5. Its superficialis cervicis branch. 6. The posterior scapular artery. 7, 7, 8. The supra-scapular artery; the upper 7 is on the clavicle; the middle in the supraspinous fossa; the lower in the infraspinous fossa; below the latter is the dorsalis scapulæ branch of the subscapular artery. 9. The posterior auricular branch of the facial nerve. 10, 10. The occipitalis minor nerve. 11, 11. The occipitalis major. 12. The occipital branch of the third cervical nerve. 13. The posterior division of the first cervical nerve. 14, 14. The posterior divisions of the third, fourth, and fifth cervical nerves. 15. The posterior divisions of the sixth, seventh, and eighth cervical nerves. 16, 16. The posterior divisions of the dorsal nerves; each dividing into an internal and external branch, and accompanied by corresponding arteries. 17, 17. The posterior cutaneous branches of the six upper dorsal nerves. 18. The posterior cutaneous branch of the seventh dorsal nerve, piercing the longissimus dorsi muscle.

the sterno-mastoid and splenius muscle; passing over the origin of the complexus, and then piercing the trapezius in its course to the back of the head.

The *princeps cervicis*, a branch of the occipital, passes downwards between the complexus and semispinalis colli muscle, supplies the muscles in its course, and inosculates with branches of the vertebral and with the profunda cervicis.

The VERTEBRAL ARTERY is seen in the space bounded by the recti and obliqui muscles; where it is making its curve behind the articular process of the atlas, previously to passing through the opening in the posterior occipito-atloid ligament. The suboccipital nerve may also be seen issuing from beneath the artery. The vertebral artery gives off a few muscular twigs, which inosculate with the princeps cervicis and profunda cervicis.

The PROFUNDA CERVICIS artery is a branch of the superior intercostal of the subclavian: it appears on the back of the neck, between the transverse processes of the last cervical and first dorsal vertebra, and takes its course upwards between the complexus and semispinalis colli. It supplies the muscles in its way, and inosculates with the princeps cervicis and branches of the vertebral.

The INTERCOSTAL ARTERIES, at the commencement of the intercostal spaces, give off a *dorsal branch*, which passes backwards, between the transverse processes and between the body of the vertebra and the anterior costo-transverse ligament, to the posterior aspect of the trunk. Each dorsal branch accompanies the dorsal branch of the intercostal nerve, and like it divides into an *internal* and *external* branch, which take a similar course to the branches of the nerve. The *internal branch* is distributed to the muscles lying near the spinous processes, one twig becoming cutaneous with the corresponding branch of the nerve. The *external branch* supplies the longissimus dorsi, sacro-lumbalis, and levatores costarum; twigs of the lower dorsal branches becoming cutaneous with the nerves which they accompany.

As the dorsal branch of the intercostal artery passes near the intervertebral foramen, it gives off a *spinal branch*, which is distributed to the membranes of the spinal cord and to the vertebræ.

The *dorsal branches* of the *lumbar arteries* have a similar distribution to those of the intercostals.

The *veins of the back* correspond with the arteries, and pass forwards, between the transverse processes of the vertebræ, to open into the vertebral veins in the neck, and the intercostal and lumbar veins in the rest of the trunk. In the cervical regions the veins are large and communicate freely, constituting a kind of plexus.

FIFTH LAYER.

The fifth layer consists of the semispinales, situated in the cervical and dorsal regions, and the small group of recti and obliqui at the upper part of the cervical region.

The recti and obliqui and semispinalis colli are already exposed by the removal of the muscles of the preceding layer; the semispinalis dorsi is brought into view by the removal of the longissimus dorsi and spinalis dorsi.

The SEMISPINALES muscles are connected with the transverse and spinous processes of the vertebræ, spanning one-half the vertebral column; hence their name semispinales.

The *semispinalis dorsi* arises from the transverse processes of the dorsal vertebræ from the sixth to the tenth; and is *inserted* into the spinous processes of the four upper dorsal and two lower cervical vertebræ.

The *semispinalis colli* arises from the transverse processes of the five or six upper dorsal vertebræ, and is *inserted* into the spinous processes of the cervical vertebræ from the second to the fifth.

The RECTUS POSTICUS MAJOR arises from the spinous process of the axis, and is *inserted* into the inferior curved line of the occipital bone.

The RECTUS POSTICUS MINOR arises from the spinous tubercle of the atlas, and is *inserted* into the rough surface on the occipital bone, beneath the inferior curved line.

The RECTUS LATERALIS is extended between the transverse process of the atlas and the occipital bone; it arises from the transverse process of the atlas, and is *inserted* into the rough surface of the occipital bone, externally to the condyle.

The OBLIQUUS INFERIOR arises from the spinous process

of the axis, and is *inserted* into the extremity of the transverse process of the atlas.

The OBLIQUUS SUPERIOR *arises* from the extremity of the transverse process of the atlas, and passes obliquely inwards, to be *inserted* into the rough surface of the occipital bone between the curved lines.

SIXTH LAYER.

The *sixth* layer of the muscles of the back includes a muscle lying beneath the semispinales, multifidus spinæ, the small muscles passing between the spinous processes, others passing between the transverse processes, and some small muscles extended between the transverse processes and the ribs, the levatores costarum.

No other dissection is required for the demonstration of these muscles, than the removal of the semispinales and some cellular tissue.

The MULTIFIDUS SPINÆ consists of a great number of fleshy fasciculi extending between the transverse and spinous processes of the vertebræ, from the sacrum to the axis. Each fasciculus *arises* from a transverse process, and is *inserted* into the spinous process of the first or second vertebra above. The lowest fibres of origin proceed from the sacrum, and in the lumbar and cervical regions from the articular processes. Some deep fasciculi of this muscle have been described by Theile under the name of *rotatores spinæ*.

The INTERSPINALES are small muscular slips arranged in pairs, and situated between the spinous processes of the vertebræ. In the *cervical region* there are six pairs of these muscles, the first being placed between the axis and third vertebra, and the sixth between the last cervical and first dorsal. In the *dorsal region*, rudiments of these muscles are occasionally met with between the upper and lower vertebræ, but are absent in the rest. In the *lumbar region* there are six pairs of interspinales, the first pair occupying the interspinous space between the last dorsal and first lumbar vertebra, and the last the space between the fifth lumbar and sacrum. They are thin and imperfectly developed. Rudimentary interspinales are occasionally met with between the lower part of the sacrum and the coccyx; these are the analogues of the caudal

muscles of brutes; in man they have been named collectively the *extensor coccygis* [sacro-coccygeus posticus].

The INTERTRANSVERSALES are small quadrilateral muscles situated between the transverse processes of the vertebræ. In the *cervical region* they are arranged in pairs corresponding with the double conformation of the transverse processes, the vertebral artery and anterior division of the cervical nerves lying between them. The *rectus anticus minor* and *rectus lateralis* represent the intertransversales between the atlas and cranium. In the *dorsal region* the anterior intertransversales are represented by the intercostal muscles, while the posterior are mere tendinous bands, muscular only between the first and last vertebræ. In the *lumbar region*, the anterior intertransversales are thin, and occupy only part of the space between the transverse processes. Analogues of posterior intertransversales exist in the form of small muscular fasciculi (*interobliqui*) extended between the rudimentary posterior transverse processes of the lumbar vertebræ.

The LEVATORES COSTARUM, twelve in number on each side, *arise* from the transverse processes of the dorsal vertebræ, and pass obliquely outwards and downwards to be *inserted* into the rough surface between the tubercle and angle of the rib below them. The first of these muscles arises from the transverse process of the last cervical vertebra, and the last from that of the eleventh dorsal. The levatores of the inferior ribs, besides the distribution here described, send a fasciculus downwards to the second rib below their origin, and consequently are inserted into two ribs. There are four of these *levatores costarum longi*, for the four inferior ribs.

With regard to the origin and insertion of the muscles of the back, the student should be informed that no exact regularity attends their attachments. At the best, a knowledge of their precise connections, even were it possible to retain it, would be but a barren information, if not absolutely injurious, as tending to exclude more valuable learning. I have therefore endeavoured to arrange a plan, by which they may be more easily recollected, by placing them in a tabular form (p. 194.), that the student may see, at a glance, the origin and insertion of each, and compare the natural grouping and similarity of attachments of the various layers. In this manner, also, their actions will be better comprehended, and learnt with greater facility.

ORIGIN.				
Layers.	Spinous Processes.	Transverse Processes.	Ribs.	Additional.
<i>1st Layer.</i>				
Trapezius - -	last cervical, 12 dorsal	- -	- -	occipital bone, and ligamentum nuchæ - -
Latissimus dorsi -	6 lower dorsal, 5 lumbar	- -	3 lower	sacrum and ilium -
<i>2nd Layer.</i>				
Levator anguli scapulæ - -	- -	4 upper cervical	- -	- - -
Rhomboideus min. -	lig. nuchæ, and last cervical	- -	- -	- - -
Rhomboideus major	4 upper dorsal	- -	- -	- - -
<i>3rd Layer.</i>				
Serratus posticus superior - -	lig. nuchæ, last cervical, 2 upper dorsal	- -	- -	- - -
Serratus posticus inferior - -	2 lower dorsal, 2 upper lumbar	- -	- -	- - -
Splenius capitis -	lig. nuchæ, last cervical, 6 upper dorsal	- -	- -	- - -
Splenius colli -	- -	- -	- -	- - -
<i>4th Layer.</i>				
Sacro lumbalis -	- -	- -	- -	sacrum and ilium -
— accessorius ad sacro-lumbalem	- -	- -	angles of 6 lower	- - -
Longissimus dorsi -	- -	- -	- -	sacrum and lumbar vertebræ -
Spinalis dorsi -	2 lower dorsal, 2 upper lumbar	- -	- -	- - -
Cervicalis ascendens	- -	- -	angles of 4 upper	- - -
Transversalis colli -	- -	3rd, 4th, 5th, and 6th dorsal	- -	- - -
Trachelo-mastoideus	- -	4 upper dorsal, 4 lower cervical	- -	- - -
Complexus - -	- -	4 upper dorsal, 4 lower cervical	- -	- - -
<i>5th Layer.</i>				
Semi-spinalis dorsi -	- -	6th to 10th dorsal	- -	- - -
Semi-spinalis colli -	- -	5 or 6 upper dorsal	- -	- - -
Rectus posticus maj.	axis	- -	- -	- - -
Rectus posticus min.	atlas	- -	- -	- - -
Rectus lateralis -	- -	atlas	- -	- - -
Obliquus inferior -	axis	- -	- -	- - -
Obliquus superior -	- -	axis	- -	- - -
<i>6th Layer.</i>				
Multifidus spinæ -	- -	from sacrum to 3d cervical	- -	- - -
Inter-spinales -	{ cervical and lumbar - }	- -	- -	- - -
Inter-transversales -	- -	{ cervical and lumbar - }	- -	- - -
Levatores costarum	- -	last cervical and 11 dorsal	- -	- - -

INSERTION.			
Spinous Processes.	Transverse Processes.	Ribs.	Additional.
- - -	- -	- - -	{ clavicle and spine of the scapula.
- - -	- -	- - -	{ bicipital groove of the humerus.
- - -	- -	- - -	{ angle and base of the scapula.
- - -	- -	- - -	base of the scapula.
- - -	- -	- - -	base of the scapula.
- - -	- -	2d, 3d, 4th, and 5th.	
- - -	- -	4 lower ribs.	
- - -	- -	- - -	{ occipital and temporal bone.
- - -	4 upper cervical.		
- - -	- -	angles of 6 lower.	
- - -	- -	angles of 6 upper.	
- - -	{ all the lumbar and dorsal -	{ 6 or 8 lower ribs between tubercles and angles.	
8 upper dorsal.			
- - -	4 lower cervical.		
- - -	4 lower cervical.		
- - -	- -	- - -	mastoid process.
- - -	- -	- - -	{ occipital bone between the curved lines.
{ 4 upper dorsal, 2 lower cervical, 2d to 5th cervical.			
- - -	- -	- - -	occipital bone.
- - -	- -	- - -	occipital bone.
- - -	atlas.	- - -	occipital bone.
- - -	- -	- - -	occipital bone.
{ from last lumbar to axis. cervical and lumbar.			
- - -	{ cervical and lumbar.		
- - -	- -	{ all the ribs between the tubercles and angles.	

In examining the foregoing table, the student will observe the constant recurrence of the number *four* in the origin and insertion of the muscles. Sometimes the *four* occurs at the top or bottom of a region of the spine, and frequently includes a part of two regions, and takes two from each, as in the case of the serrati. Again, he will perceive that the muscles of the upper half of the table take their origin from spinous processes, and pass outwards to transverse, whereas the lower half arise mostly from transverse processes. To the student we commit these reflections, and leave it to the peculiar tenor of his own mind to make such arrangements as will be best retained by his memory.

ACTIONS.— The upper fibres of the trapezius draw the shoulder upwards and backwards; the middle fibres, directly backwards; and the lower, downwards and backwards. The lower fibres also act by producing rotation of the scapula upon the chest. If the shoulder be fixed, the upper fibres will flex the spine towards the corresponding side. The latissimus dorsi is a muscle of the arm, drawing it backwards and downwards, and at the same time rotating it inwards; if the arm be fixed, the latissimus dorsi will draw the spine to that side, and, raising the lower ribs, be an inspiratory muscle; and if both arms be fixed, the two muscles will draw the whole trunk forwards, as in climbing or walking on crutches. The levator anguli scapulæ lifts the upper angle of the scapula, and with it the entire shoulder, and the rhomboidei carry the scapula and shoulder upwards and backwards.

The serrati are respiratory muscles acting in opposition to each other, the *serratus posticus superior* drawing the ribs upwards, and thereby expanding the chest, and the *inferior* drawing the lower ribs downwards, and diminishing the cavity of the chest. The former is an inspiratory, the latter an expiratory muscle. The splenii muscles of one side draw the vertebral column backwards and to one side, and rotate the head towards the corresponding shoulder. The muscles of opposite sides, acting together, will draw the head directly backwards. They are the natural antagonists of the sterno-mastoid muscles.

The *sacro-lumbalis* with its *accessory muscle*, the *longissimus dorsi*, and the *spinalis dorsi*, are known by the general term of *erectores spinæ*, which sufficiently expresses their action. They keep the spine supported in the vertical position by their broad origin from below, and by means of their insertion, by distinct tendons, into the ribs and spinous processes. Being made up of a number of distinct fasciculi which alternate in their actions, the spine is kept erect without fatigue, even when they have to counterbalance a corpulent abdominal development. The continuations upwards of these muscles into the neck preserve the steadiness and uprightness of that region. When the muscles of one side act alone, the neck is rotated upon its axis. The *complexus*, by being attached to the occipital bone, draws the head backwards, and counteracts the muscles on the anterior part of the neck. It assists also in the rotation of the head.

The *semi-spinales* and *multifidus spinæ* muscles act directly on the vertebræ, and contribute to the general action of supporting the vertebral column erect.

The four little muscles situated between the occiput and the first two vertebræ effect the various movements between these bones, the *recti* producing the antero-posterior actions, and the *obliqui* the rotatory motions of the atlas on the axis.

The actions of the remaining muscles of the spine — the *inter-spinales* and *inter-transversales* — are expressed in their names. They approximate their attachments, and assist the more powerful muscles in preserving the erect position of the body.

The *levatores costarum* raise the posterior parts of the ribs, and are probably more serviceable in preserving the articulation of the ribs from dislocation than in raising them in inspiration.

CHAPTER V

HEAD AND NECK.

THE *head* may be considered as an expansion of the superior part of the vertebral column, for the reception of the brain and the principal organs of sense.

The *neck* is the medium of communication and connection between the head and the rest of the body:—*communication*, by means of the trachea and œsophagus, with the internal organs; *connection*, by means of the muscles and vertebral column, with the superficies and osseous fabric of the trunk.

The head may be divided into the *cranium* and *face*; the former being the osseous recipient of the brain, and the latter the apparatus for the development and protection of the principal organs of sense.

The exterior of the *cranium* presents for examination its convex surface, and on its sides the external organ of hearing. The *face* is more varied, comprehending, the orbits for the organs of vision; the nose or external organ of smell; the mouth, containing the organ of taste; and the jaws or apparatus of mastication.

We shall commence the dissection of the head and neck, by devoting one side to the examination of the muscles, reserving the other for the study of the vessels and nerves.

The MUSCLES are associated into certain natural groups, which correspond with the divisions of the head and face above established: thus we find a—

Cranial group,	Superior labial group,
Auricular group,	Inferior labial group,
Orbital group,	Maxillary group.
Nasal group,	

The muscles belonging to each of these groups may be thus arranged:—

- | | |
|--|---|
| <p>1. <i>Cranial group.</i>
Occipito-frontalis.</p> <p>2. <i>Auricular group.</i>
Attollens aurem,
Attrahens aurem,
Retrahens aurem.</p> <p>3. <i>Orbital group.</i>
Orbicularis palpebrarum,
Corrugator supercilii,
Tensor tarsi.</p> <p>4. <i>Nasal group.</i>
Pyramidalis nasi,
Compressor nasi,
Dilatator naris,
Depressor alæ nasi.</p> <p>5. <i>Superior labial group.</i>
(* Orbicularis oris),</p> | <p>Levator labii superioris
alæque nasi,
Levator labii superioris
proprius,
Levator anguli oris,
Zygomaticus major,
Zygomaticus minor.</p> <p>6. <i>Inferior labial group.</i>
(* Orbicularis oris),
Depressor labii inferioris,
Depressor anguli oris,
Levator labii inferioris.</p> <p>7. <i>Maxillary group.</i>
Masseter,
Buccinator,
Temporalis,
Pterygoideus externus,
Pterygoideus internus.</p> |
|--|---|

The surface of the cranium is to be dissected by making a longitudinal incision along the vertex of the head from the tubercle on the occipital bone to the root of the nose ; and a second incision along the lower part of the forehead to the temporal ridge ; carry this incision downwards to the zygoma, and follow the direction of the zygoma to the ear ; then make a sweep around the lobe of the ear, and cross the mastoid process to the commencement of the longitudinal incision over the occipital tubercle. Dissect the integument and superficial fascia carefully back as far as the ear, so as to form an anterior flap ; and the posterior portion forwards from behind to meet the preceding : then divide the integument close to the ear, and remove it completely. This dissection requires care, for the muscles are thin, and without attention would be raised with the integument. There is no deep fascia on the face and head, nor is it required, for here the muscles are closely applied against the bones upon which they depend for support, whilst in the extremities the support is derived from the dense layer of fascia by which they are invested, and which forms for each a distinct sheath.

1. *Cranial Group.*—The OCCIPITO-FRONTALIS is a broad musculo-aponeurotic layer, which covers the whole of the

* The orbicularis, from encircling the mouth, belongs necessarily to both the superior and inferior labial regions ; therefore, to prevent misconception, we have enclosed it in both within brackets.

side of the vertex of the skull, from the occiput to the eyebrow. It *arises* by tendinous fibres from the outer two-thirds of the superior curved line of the occipital, and from the mastoid portion of the temporal bone. Its *insertion* takes place by means of the blending of the fibres of its anterior portion with those of the orbicularis palpebrarum, corrugator supercilii, levator labii superioris alæque nasi, and pyramidalis nasi. The muscle is fleshy in front over the frontal bone and behind over the occipital, the two portions being connected by a broad aponeurosis. The two muscles together with their aponeurosis cover the whole of the vertex of the skull, hence their designation *galea capitis*; they are loosely adherent to the pericranium, but very closely to the integument, particularly over the forehead.

The *action* of the occipito-frontalis is to raise the eyebrows thereby throwing the integument of the forehead into transverse wrinkles. Some persons have the power of moving the entire scalp upon the pericranium by means of these muscles.

2. *Auricular Group*.—Attollens aurem,
Attrahens aurem,
Retrahens aurem.

The dissection of these three small and superficial muscles requires the careful removal of the integument from around the pinna; their exact position is shown by drawing the pinna from the side of the head, and they may be conveniently dissected by taking the prominent lines which they thus form as a guide for the incision.

The ATTOLLENS AUREM (superior auriculæ), the largest of the three, is a thin triangular plane of muscular fibres *arising* from the edge of the aponeurosis of the occipito-frontalis, and *inserted* into the convexity of the fossa triangularis and scaphoidea.

The ATTRAHENS AUREM (anterior auriculæ), also triangular, *arises* from the edge of the aponeurosis of the occipito-frontalis in front of the preceding, and is *inserted* into the spine of the helix.

The RETRAHENS AUREM (posterior auriculæ) *arises* by two muscular slips from the root of the mastoid process. They are *inserted* into the posterior surface of the concha.

The *actions* of the auricular muscles are expressed in their names; they have but little power in man, but are important muscles in brutes.

Beneath the *attrahens* and *attollens* muscles is a white glistening fascia which may now be examined.

The TEMPORAL FASCIA is a strong aponeurotic membrane, which covers in the temporal muscle at each side of the head, and gives origin by its internal surface to some of its fibres. It is attached to the whole extent of the temporal ridge above, and to the zygomatic arch below; in the latter situation it is thick, and consists of two layers, the external being connected to the upper border of the arch, and the internal to its inner surface. Some fat is found between these two layers, and also the orbital branch of the temporal artery.

Separate the temporal fascia from the temporal ridge, and turn it downwards; the temporal muscle will then be exposed in the greater part of its extent. Above, the muscle is rough, from the necessity of dividing its fibres in the removal of the fascia; below, some fat and cellular tissue require removal to make it clean.

The TEMPORAL MUSCLE, broad and radiating, occupies the temporal fossa, and expands over the side of the head. It *arises* by tendinous fibres from the temporal ridge, and by muscular fibres from the surface of bone constituting the temporal fossa, and from the temporal fascia. Its fibres converge to a strong and narrow tendon, which is *inserted* into the apex and internal surface of the coronoid process of the lower jaw.

Having now examined the muscles of the cranium, with the view to a speedy opening of the skull for the examination of the brain, the student should next proceed to study the vessels and nerves distributed upon the exterior of the cranium, and which would be destroyed by the removal of the calvarium. For this purpose the integument covering one side of the head has been left undisturbed. This may now be dissected in the manner directed for the dissection of the muscles (page 199.), the integument alone being removed, and the superficial fascia in which the vessels and nerves are embedded exposed to view.

Vessels and Nerves of the Cranium.—The arteries of the cranium are the supra-orbital and frontal from the ophthalmic; the temporal artery; posterior auricular and occipital.

The *supra-orbital artery* escapes from the orbit through the supra-orbital notch in company with the supra-orbital nerve, and divides into a superficial and deep branch, which are distributed to the integument and muscles of the forehead and to the pericranium.

The *frontal artery*, one of the terminal branches of the ophthalmic, emerges from the orbit at its inner angle and ascends the middle of the forehead, to which it is distributed, anastomosing with its fellow of the opposite side.

The *temporal artery*, one of the terminal branches of the external carotid, ascends in front of the ear and divides into an anterior and a posterior branch. The *anterior temporal** arches forwards upon the temple, and is distributed to the integument and muscles of the scalp, inosculating with the supra-orbital and frontal artery.

The *posterior temporal* curves upwards and backwards over the ear and inosculates with its fellow of the opposite side, and with the occipital and posterior auricular arteries.

The *posterior auricular artery* ascends in front of the mastoid process, and divides into two branches, one of which supplies the pinna and anastomoses with the posterior temporal, while the other crosses the mastoid process to the posterior portion of the occipito-frontalis, and inosculates with the occipital artery.

The *occipital artery*, emerging from between the splenius and complexus, and piercing the trapezius muscle, ascends upon the occipito-frontalis muscle, and divides into branches which supply that muscle, the pericranium, and integument, and inosculate with its fellow of the opposite side, the posterior temporal and the posterior auricular artery.

The *veins of the scalp* are found by the side of the arteries. The *frontal vein*, descending the mid-line of the forehead to the inner angle of the orbit, receives the supra-orbital vein, and becomes the facial vein. The *temporal* and *posterior auricular* veins terminate in the external jugular, and the *occipital* veins in the internal jugular.

* This is the vessel which is selected for the operation of arteriotomy.

The NERVES distributed to the cranium are the supra-orbital and supra-trochlear branches of the first division of the fifth pair ; temporal branches from the second and third divisions of the fifth and from the facial nerve ; posterior auricular from the facial ; auricularis magnus and occipitalis minor, from the anterior cervical plexus ; and occipitalis major, from the posterior division of the second cervical nerve.

The *supra-orbital nerve*, issuing from the orbit through the supra-orbital notch with the artery of the same name, gives filaments to the eyelids, the muscles of the forehead and pericranium, and divides into two cutaneous branches, internal and external. The *internal* branch pierces the occipito-frontalis, and is distributed to the integument as far as the summit of the head. The *external* branch, of larger size, communicates with the facial nerve, and piercing the occipito-frontalis, is distributed to the integument as far back as the occiput.

The *supra-trochlear nerve* emerges from the orbit at its inner angle, and piercing the muscle, is distributed to the integument in the middle line of the forehead.

The *temporal branch* of the second division of the fifth or superior maxillary nerve pierces the temporal fascia a little above the zygoma, and is distributed to the integument of the front of the temple. It communicates with the facial nerve.

The *temporal branches*, anterior and posterior, of the auriculo-temporal nerve, a branch of the third division of the fifth or inferior maxillary nerve, ascend upon the temple in front of the ear. The *anterior* branch is distributed to the integument as far as the summit of the head. The *posterior* branch is directed backwards over the external ear, and supplies the integument, after giving twigs to the *attrahens aurem* and to the pinna.

The *temporal branches* of the facial nerve, two or three in number, pass in a radiated manner over the temple, and are distributed to the *attrahens aurem*, occipito-frontalis, and orbicularis palpebrarum muscle. They communicate with the temporal branch of the superior maxillary, and with the supra-orbital nerve.

The *posterior auricular nerve* is a branch of the facial ; taking its origin at the stylo-mastoid foramen, it ascends in front of the mastoid process to the back of the ear,

and divides into an anterior and a posterior branch. The *anterior branch* (auricular) is distributed to the *retrahens aurem* and to the pinna. The *posterior branch* (occipital) communicates with the *auricularis magnus* nerve, and is distributed to the *occipito-frontalis*.

The *auricularis magnus nerve*, derived from the cervical plexus, divides below the ear into branches, which are distributed to the back of the pinna; and a *mastoid branch*, which communicates with the preceding nerve, and is distributed to the integument over the mastoid process.

The *occipitalis minor nerve*, also a branch of the cervical plexus, reaches the occiput at the posterior border of the *sterno-mastoid* muscle, and mounting the back of the head, sends branches to the *occipito-frontalis* and *attollens aurem* (*auricular* branch), and communicates with the posterior auricular nerve, and with the *occipitalis major*.

The *occipitalis major nerve*, a branch of the posterior division of the second cervical (p. 188.), pierces the *trapezius* muscle close to the occipital artery, and lies by the side of that vessel. Soon after its emergence from the *trapezius*, it receives a branch from the third cervical, and divides into numerous branches, which are distributed to the *occipito-frontalis* and integument as far as the summit of the head. It communicates with the *occipitalis minor* nerve, and sends an *auricular* branch to the back of the ear.

The student may now open the skull, and examine the contents of that cavity; for this purpose the brain must be removed. He will find instructions for conducting this operation in Chapter VI., which is devoted to the anatomy of the brain and spinal cord.

After the brain and spinal cord have been studied, the dissector may return to the anatomy of the face. If he be studying the right side of the face, an incision should be made from the front of ear along the ramus of the lower jaw to its angle, and thence onwards along the margin of the jaw to the chin. The integument should be raised with care, and towards the middle line. If the student have the left side of the face, he should carry an incision from the middle line of the forehead along the ridge of the nose, the upper and the lower lip, to the chin, and then backward along the lower jaw, dissecting the flap from the middle line to the ear. The muscles may then be made clear by the removal of the cellular tissue and fat: in dissecting them they should be put gently on the stretch, and cleaned in the direction of their fibres.

3. *Orbital Group*.—Orbicularis palpebrarum,
Corrugator supercilii,
Tensor tarsi.

The ORBICULARIS PALPEBRARUM is a sphincter muscle, surrounding the orbit and eyelids. It *arises* from the internal angular process of the frontal bone, from the nasal process of the superior maxillary, and from a short tendon (*tendo oculi*) which extends between the nasal process of the superior maxillary bone, and the inner extremities of the tarsal cartilages of the eyelids. The fibres encircle the orbit and eyelids, forming a broad and thin muscular plane, which is *inserted* into the lower border of the *tendo oculi*, and into the nasal process of the superior maxillary bone. That portion of the muscle which occupies the eyelids (*ciliaris*) is composed of fibres, which are thin and pale*, and possess an involuntary action. The *tendo oculi*, in addition to its insertion into the nasal process of the superior maxillary bone, sends a process inwards, which expands over the lachrymal sac, and is attached to the ridge of the lachrymal bone: this is the reflected aponeurosis of the *tendo oculi*.

The CORRUGATOR SUPERCILII is a small narrow and pointed muscle, situated immediately above the orbit and beneath the upper segment of the orbicularis palpebrarum. It *arises* from the inner extremity of the superciliary ridge, and is *inserted* into the under surface of the orbicularis palpebrarum at a point corresponding with the middle of the superciliary arch.

The TENSOR TARSII (Horner's † muscle) is a thin plane of muscular fibres, about three lines in breadth and six in length. It is best dissected by separating the eyelids

* Mr. Haynes Walton has shown that the margin of the *ciliaris* is thick, and its fibres redder than the rest of the ciliary muscle; furthermore, that its thickness is augmented by the addition of the tensor tarsi muscle. This portion of the muscle he conceives to be the agent in the production of Entropium.—*Med. Times and Gazette*, May, 1852.

† W. E. Horner, M. D., Professor of Anatomy in the University of Pennsylvania. The notice of this muscle is contained in a work published in Philadelphia in 1827, entitled "Lessons in Practical Anatomy."

from the eye, and turning them over the nose without disturbing the tendo oculi; then dissect away the small fold of mucous membrane called *plica semilunaris*, and some loose cellular tissue under which the muscle is concealed. It *arises* from the orbital surface of the lachrymal bone, and passing across the lachrymal sac, divides into two slips, which are continuous with the margin of the ciliaris along the edges of the lids*, some few of its fibres being attached to the lachrymal canals as far as the puncta.

ACTIONS.—The palpebral portion of the orbicularis [ciliaris] acts involuntarily in closing the lids, and from the greater curve of the upper lid, upon that principally. The entire muscle acts as a sphincter, drawing at the same time, by means of its osseous attachment, the integument and lids inwards towards the nose. The *corrugatores superciliarum* draw the eyebrows downwards and inwards, and produce the vertical wrinkles of the forehead. The *tensor tarsi*, or lachrymal muscle, is an auxiliary to the orbicularis, and draws the extremities of the lachrymal canals inwards, so as to place the puncta in the best position for receiving the tears. It serves also to keep the lids in relation with the surface of the eye, and compresses the lachrymal sac. Dr. Horner is acquainted with two persons who have the voluntary power of drawing the lids inwards by these muscles so as to bury the puncta in the angle of the eye.

4. *Nasal Group.*—Pyramidalis nasi,
Compressor nasi,
Dilatator naris,
Depressor alæ nasi.

The PYRAMIDALIS NASI is a small pyramidal slip of muscular fibres sent downwards upon the bridge of the nose by the occipito-frontalis. It is *inserted* into the tendinous expansion of the compressores nasi.

The COMPRESSOR NASI is a thin and triangular muscle; it *arises* by its apex from the canine fossa of the superior maxillary bone, and spreads out upon the side of the nose into a thin tendinous expansion, which is continuous across its ridge with the muscle of the opposite side. It is connected at its origin with a muscular fasciculus which is attached to the nasal process of the superior maxillary bone immediately below the origin of the levator labii superioris alæque nasi. This muscular slip

* Mr. Haynes Walton, loc. cit.

was termed by Albinus *musculus anomalus*, from its attachment to the bone by both ends; and by Santorini, *musculus rhomboideus*.

The DILATATOR NARIS is a thin and indistinct muscular apparatus expanded upon the ala of the nostril, and consisting of an anterior and posterior slip. The anterior slip (levator proprius alæ nasi anterior) *arises* from the upper border and surface of the alar cartilage, and is *inserted* into the integument of the border of the nostril. The posterior slip (levator alæ nasi posterior) *arises* from the nasal process of the superior maxillary bone and from the sesamoid cartilages, and is *inserted* into the integument of the border of the nostril for the posterior half of its extent.

The dilatator naris muscle is difficult of dissection, from the close adhesion of the integument to the nasal cartilages.

The DEPRESSOR ALÆ NASI (myrtiformis) is brought into view by drawing upwards the upper lip and raising the mucous membrane. It *arises* from the superior maxillary bone in front of the roots of the second incisor and canine teeth (myrtiform fossa), and passes upwards and inwards to be *inserted* into the posterior part of the column and ala nasi. It is closely connected with the deep surface of the orbicularis.

ACTIONS. — The pyramidalis nasi, as a point of attachment of the occipito-frontalis, assists that muscle in its action: it also draws down the inner angle of the eyebrow, and by its insertion fixes the aponeurosis of the compressores nasi, and tends to elevate the nose. The compressores nasi appear to act in expanding rather than in compressing the nares; hence probably the compressed state of the nares from paralysis of these muscles in the last moments of life, or in compression of the brain. The dilatator naris is a dilator of the nostril, and the depressor alæ nasi draws downwards both the ala and column of the nose, the depression of the latter being assisted by the naso-labialis.

5. Superior Labial Group. —

Orbicularis oris,
 Levator labii superioris alæque nasi,
 Levator labii superioris proprius,
 Levator anguli oris,
 Zygomaticus major,
 Zygomaticus minor.

The ORBICULARIS ORIS is a sphincter muscle, completely surrounding the mouth, and possessing consequently neither origin nor insertion. It is composed of two thick semicircular planes of fibres, which embrace the rima of the mouth, and interlace at their extremities, where they are continuous with the fibres of the buccinator, and of the other muscles connected with the angle of the mouth. The upper segment is attached by means of a small muscular fasciculus (naso-labialis) to the columna of the nose; and other fasciculi connected with both segments, and attached to the maxillary bones, are termed "accessorii."

The LEVATOR LABII SUPERIORIS ALÆQUE NASI is a thin triangular muscle; it *arises* from the upper part of the nasal process of the superior maxillary bone; and, becoming broader as it descends, is *inserted* by two distinct portions into the ala of the nose and upper lip.

The LEVATOR LABII SUPERIORIS PROPRIUS is a thin quadrilateral muscle; it *arises* from the lower border of the orbit, and passing obliquely downwards and inwards, is *inserted* into the integument of the upper lip, its deep fibres being blended with those of the orbicularis.

The LEVATOR ANGULI ORIS *arises* from the canine fossa of the superior maxillary bone, and passes outwards to be *inserted* into the angle of the mouth, intermingling its fibres with those of the orbicularis, zygomatici, and depressor anguli oris.

The ZYGOMATIC muscles are two slender fasciculi of fibres which *arise* from the malar bone, and are *inserted* into the angle of the mouth, where they are continuous with the other muscles attached to this part. The zygomaticus minor is situated in front of the major, and is continuous at its insertion with the levator labii superioris proprius: it is not unfrequently wanting.

ACTIONS.—The orbicularis oris produces the direct closure of the lips by means of its continuity, at the angles of the mouth, with the fibres of the buccinator. When acting singly in the forcible closure of the mouth, the integument is thrown into wrinkles, in consequence of its firm connection with the surface of the muscle; its naso-labial fasciculus draws downwards the columna nasi. The levator labii superioris alæque nasi lifts the upper lip with the ala of the nose, and expands the opening of the nares. The levator labii superioris proprius is the proper elevator of the upper lip;

acting singly, it draws the lip a little to one side. The levator anguli oris lifts the angle of the mouth and draws it inwards, while the zygomatici pull it upwards and outwards, as in laughing.

6. *Inferior Labial Group.*—

Depressor labii inferioris,
Depressor anguli oris,
Levator labii inferioris.

The DEPRESSOR LABII INFERIORIS (*quadratus menti*) arises from the oblique line by the side of the symphysis of the lower jaw, and passing upwards and inwards, is inserted into the orbicularis muscle and integument of the lower lip.

The DEPRESSOR ANGULI ORIS (*triangularis oris*) is a triangular plane of muscle arising by a broad base from the external oblique ridge of the lower jaw, and inserted by its apex into the angle of the mouth, where it is continuous with the levator anguli oris and zygomaticus major, and with a subcutaneous muscle called risorius Santorini. The risorius Santorini arises by two or three fasciculi from the fascia covering the masseter muscle, and is inserted into the angle of the mouth.

The LEVATOR LABII INFERIORIS (*levator menti*) is a small conical slip of muscle arising from the incisive fossa of the lower jaw, and inserted into the integument of the chin. It is in relation with the mucous membrane of the mouth, with its fellow, and with the depressor labii inferioris.

7. *Maxillary Group.*—Masseter,
Buccinator,
Temporalis,
Pterygoideus externus,
Pterygoideus internus.

Before proceeding to the dissection of the masseter muscle, the parotid gland, which overlaps and partly conceals the muscle and sends its excretory duct across it, should be examined. The gland is bound down by a strong fascia, which may be removed.

The PAROTID GLAND (*παρά, near, οὖς, ὠτός, the ear*) is the largest of three salivary glands situated on each side of the face in the neighbourhood of the mouth. The parotid, as its name implies, is placed immediately in front of the external ear, extends superficially for a short

distance over the masseter muscle, and deeply behind the ramus of the lower jaw. It reaches inferiorly to below the level of the angle of the jaw, and posteriorly to the mastoid process, slightly overlapping the insertion of the sterno-mastoid muscle. Embedded in its substance, are the external carotid artery, the temporo-maxillary vein, and facial nerve; emerging from its anterior border, the transverse facial artery and branches of the facial nerve; and above, the temporal artery and auriculo-temporal nerve.

The duct of the parotid gland (Stenon's duct), about two inches in length and about the diameter of a crow's-quill, issues from the anterior part of the gland, just below the zygoma, and crosses the masseter muscle; it then curves inwards over the anterior border of the muscle, and pierces the buccinator opposite the second molar tooth of the upper jaw; its opening in the mouth being indicated by a prominent papilla. A small glandular appendage, the *socia parotidis*, is connected with the upper part of the duct on the masseter muscle.

Structure.—The salivary are conglomerate glands, consisting of lobes, which are made up of polyhedral lobules, and these of smaller lobules.

The smallest lobule is apparently composed of granules, which are minute cæcal pouches, formed by the dilatation of the extreme ramifications of the ducts. These minute ducts unite to form lobular ducts, and the lobular ducts constitute by their union a single excretory duct. The cæcal pouches are connected by cellular tissue, so as to form a minute lobule; the lobules are held together by a more condensed cellular layer; and the larger lobes are enveloped by a dense fibrous capsule, which is firmly attached to the deep cervical fascia. The submaxillary and sublingual glands are looser in structure, and their lobules are larger than those of the parotid gland.

The duct of the parotid gland may now be cut across, when the small size of its area, as compared with the thickness of its wall, will be observed. The gland may then be drawn back, or so much of it removed as shall interfere with the examination of the masseter muscle.

The MASSETER (*μασσάομαι*, to chew) is a short, thick, and somewhat quadrilateral muscle, composed of two planes of fibres, superficial and deep. The *superficial* layer *arises* by a strong aponeurosis from the tuberosity of the superior maxillary bone, the lower border of the malar bone, and the zygoma, and passes backwards to be

inserted into the ramus and angle of the inferior maxilla. The *deep* layer *arises* from the posterior part of the zygoma, and passes forwards, to be *inserted* into the upper half of the ramus. This muscle is tendinous and muscular in its structure.

The buccinator muscle is in a great measure concealed from view by a lobulated mass of fat, which fills up the hollow in front of the masseter. Through this mass of fat the duct of the parotid gland makes its way. The fat is now to be removed in order to bring the muscle into view; and the operation is to be conducted with care, in order to avoid disturbing the facial artery and vein. The muscle is invested by a thin fascia.

The BUCCINATOR MUSCLE (*buccina*, a trumpet), the trumpeter's muscle, *arises* from the alveolar process of the superior maxilla, from the external oblique line of the inferior maxilla as far forward as the second bicuspid tooth, and from the pterygo-maxillary ligament. This ligament is the *raphé* of union between the buccinator and superior constrictor muscle, and is attached by one extremity to the hamular process of the internal pterygoid plate, and by the other to the extremity of the molar ridge. The fibres of the muscle converge towards the angle of the mouth, where they cross each other, the superior being continuous with the inferior segment of the orbicularis oris, and the inferior with the superior segment.

The next step in the dissection necessary to display the remaining muscles of this group requires the section of the zygoma at both extremities, and its removal, turning it down with the masseter. This brings into view the lower part of the temporal muscle, which has been already described (page 201.). The coronoid process may then be cut across with a saw, and drawn upwards with the tendon of the temporal muscle. In the next place, that portion of the ramus of the jaw between its neck and the angle must be sawn through and removed, when the two pterygoid muscles will become visible, and may be dissected. This preparation will also display the origin of the buccinator muscle from the pterygo-maxillary ligament.

The EXTERNAL PTERYGOID is a short and thick muscle, broader at its origin than at its insertion. It *arises* by two heads, *one* from the pterygoid ridge on the greater ala of the sphenoid; the *other* from the external pterygoid plate and tuberosity of the palate bone. The fibres pass backwards to be *inserted* into the neck of the lower jaw

and the interarticular fibro-cartilage. The internal maxillary artery frequently passes between the two heads of this muscle.

The external pterygoid muscle must now be removed, and the head of the lower jaw dislocated from its socket and withdrawn, for the purpose of seeing the pterygoideus internus.

The INTERNAL PTERYGOID is a thick quadrangular muscle. It *arises* from the pterygoid fossa and descends obliquely backwards, to be *inserted* into the ramus and angle of the lower jaw: it resembles the masseter in appearance and direction, and was named by Winslow the internal masseter.

ACTIONS.—The maxillary muscles are the active agents in mastication, and form an apparatus beautifully fitted for that office. The buccinator circumscribes the cavity of the mouth, and with the aid of the tongue keeps the food under the immediate pressure of the teeth. By means of its connection with the superior constrictor, it shortens the cavity of the pharynx from before backwards, and becomes an important auxiliary in deglutition. The temporal, the masseter, and the internal pterygoid are the bruising muscles, drawing the lower jaw against the upper with great force. The two latter, from the obliquity of their direction, assist the external pterygoid in grinding the food, by carrying the lower jaw forward upon the upper; the jaw being brought back again by the deep portion of the masseter and posterior fibres of the temporal. The whole of these muscles, acting in succession, produce a rotatory movement of the teeth upon each other, which, with the direct action of the lower jaw against the upper, effects the proper mastication of the food.

Vessels and Nerves of the Face.

The vessels and nerves may now be dissected on the opposite side of the face. The integument should be removed with care, in the manner already pointed out for the examination of the muscles (page 204.), and the vessels and nerves sought for and followed through their course. As a preparatory step, the branches of the facial nerve should be found as they issue from beneath the anterior border of the parotid gland, and traced backwards through the gland to their trunk; they may then be traced in their distribution over the face.

The FACIAL NERVE (*portio dura*), the motor nerve of the face, issues from the cranium through the stylo-mastoid foramen, passes forward through the parotid gland to the ramus of the jaw, and divides into two trunks, *temporo-facial* and *cervico-facial*. These trunks divide into numerous branches which escape from the anterior

border of the parotid gland and are distributed in a radiated manner over the side of the face, from the temple to below the lower jaw; on the masseter muscle the branches communicate and form loops, and the whole arrangement over the side of the face has been termed *pes anserinus*.

The *branches* of the facial nerve, at its exit from the stylo-mastoid foramen, are three in number, namely, the *posterior auricular*, a *stylo-hyoid* branch for the muscle of that name, and a *digastric* branch for the digastricus.

The *posterior auricular branch* ascends in front of the mastoid process to the back of the ear, and divides into an anterior or auricular, and a posterior or occipital branch. The *auricular* branch communicates with the auricular branch of the pneumogastric nerve, and is distributed to the retrahens aurem and pinna. The *occipital* branch communicates with the auricularis magnus and occipitalis minor, and is lost in the occipito-frontalis muscle (page 203.).

The *stylo-hyoid branch* supplies the stylo-hyoideus muscle, and communicates with the sympathetic plexus of the external carotid artery.

The *digastric branch* enters the posterior belly of the digastricus muscle, and communicates with the glosso-pharyngeal and pneumogastric nerve.

The *temporo-facial division*, while in the parotid gland, sends a branch of communication along the carotid artery to the auriculo-temporal nerve, and divides into temporal, malar, and infra-orbital branches.

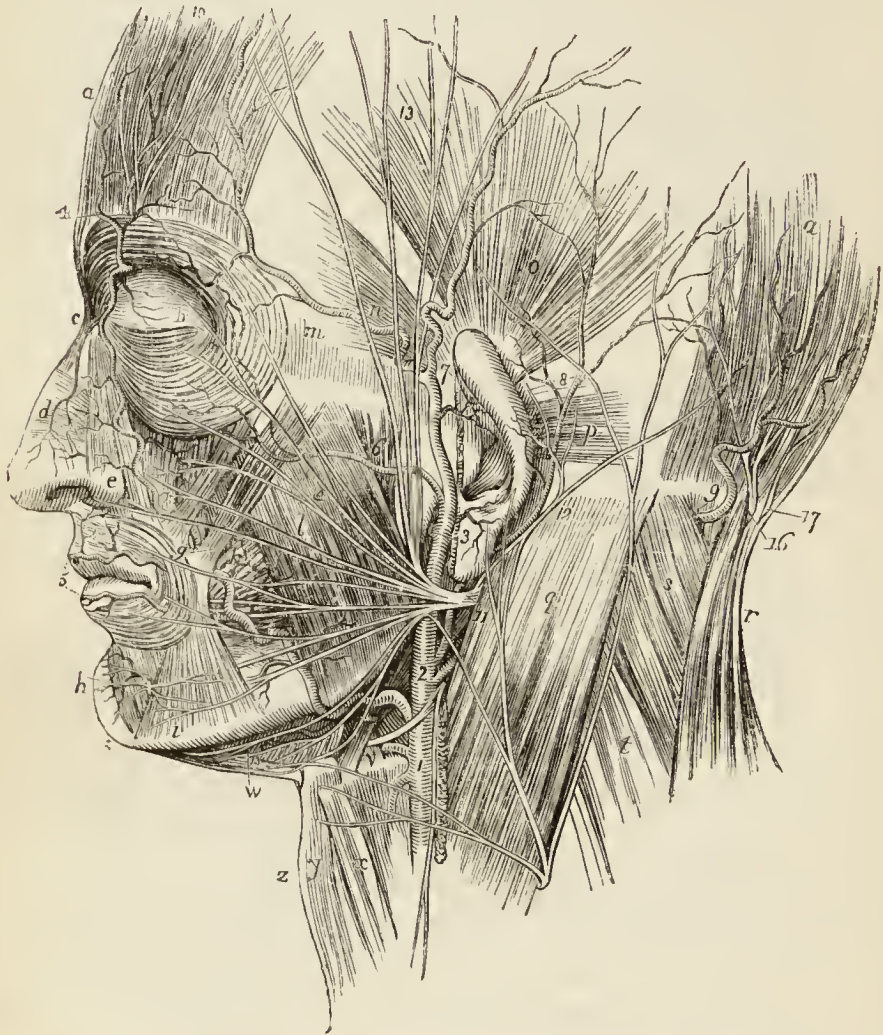The *temporal branches* ascending over the temporal region supply the attrahens aurem, occipito-frontalis, and orbicularis palpebrarum; and communicate with the supra-orbital nerve and the temporal branch of the superior maxillary (page 203.).

The *malar branches* cross the malar bone to the outer angle of the eye, and supply the orbicularis palpebrarum, corrugator supercilii, and eyelids. They communicate with the subcutaneous malæ branch of the superior maxillary nerve, and with branches of the ophthalmic nerve in the eyelids.

The *infra-orbital branches* cross the masseter muscle, and are distributed to the buccinator, elevator muscles of the upper lip, and orbicularis oris. They communicate

with the terminal branches of the infra-orbital nerve, the infra-trochlear and nasal nerve. Two or more of these branches are found by the side of Stenon's duct.

*Fig. 26.**



* Anatomy of the face.—*aa*. The occipito-frontalis muscle. *b*. The orbicularis palpebrarum. *c*. The pyramidalis nasi. *d*. The compressor nasi. *e*. The levator labii superioris alæque nasi. *f*. The levator labii superioris. *g*. The two zygomatic muscles, major and minor; the letter rests on the orbicularis oris. *h*. The depressor labii inferioris. *i*. The depressor anguli oris. *k*. The buccinator. *l*. The masseter. *m*. The temporal fascia. *n*. The attrahens aurem muscle. *o*. The attollens aurem. *p*. The retrahens aurem. *q*. The sterno-mastoid muscle. *r*. The trapezius. *s*. The splenius capitis. *t*. The levator anguli scapulæ. *v*. The stylohyoid, posterior belly of the digastricus (both cut across), and hyoglossus muscle; the letter rests immediately on the great cornu of the os hyoides, the muscles being above it. *w*. The anterior belly of the digastricus and mylo-hyoid muscle. *x*. The omo-hyoideus. *y*. The sterno-hyoideus. *z*. The pomum Adami.

1. The external carotid artery; the three arteries passing from its anterior aspect are the thyroid, lingual, and facial. 2. The occipital and posterior auricular artery. 3. The bifurcation of the ex-

The *cervico-facial division*, smaller than the temporo-facial, communicates in the parotid gland with the auricularis magnus nerve, and divides into branches which admit of arrangement into three sets: buccal, supra-maxillary, and infra-maxillary.

The *buccal branches* pass forwards across the masseter muscle towards the mouth, and distribute branches to the orbicularis oris and buccinator. They communicate with the branches of the temporo-facial, and with the buccal branch of the inferior maxillary nerve.

The *supra-maxillary branches* are destined to the muscles of the lower lip, and take their course along the body of the lower jaw. They have a plexiform communication with the inferior dental nerve beneath the depressor anguli oris.

The *infra-maxillary branches* (*subcutanei colli*) take their course below the lower jaw, pierce the deep cervical

artery into temporal and internal maxillary. The facial artery is seen passing over the lower jaw, crossing the buccinator (*h*) muscle, appearing between the zygomatic muscles (*g*), and thence proceeding onwards by the side of the nose to the inner angle of the eye, where, under the name of angular artery, it anastomoses with the nasal branch of the ophthalmic (*c*). 4. The frontal artery. The small artery (*d*) is the dorsalis nasi. 5. The coronary arteries. The inferior labial artery is seen passing beneath the muscle (*i*). The sub-mental artery is seen meandering on the mylo-hyoid muscle (*w*). 6. The transverse facial artery. 7. The temporal artery bifurcating into the anterior and posterior temporal. 8. The posterior auricular artery. 9. The occipital artery issuing from between the splenius and complexus.

10. The supra-orbital nerve and artery. A twig of the infra-orbital nerve and artery is seen at *f*. The inferior dental nerve and artery are seen on the chin (*h*). These nerves are branches of the fifth pair. 11. The facial nerve. 12. Its posterior auricular branch. 13. Its temporal branches. 14. Its malar branches; the infra-orbital branches are seen proceeding towards *f*. These three sets constitute the temporo-facial division of the facial nerve. The buccal branches are seen on the buccinator muscle. The supra-maxillary branches are seen passing along the jaw to communicate with the inferior dental nerve (*h*). The infra-maxillary branches are seen passing down below the jaw. The three latter sets are the cervico-facial division of the facial nerve; the radiation of all the branches over the face being the pes anserinus. The nerve between 1 and 2 is the hypoglossal, which gives off the descendens noni. 15. The three ascending branches of the cervical plexus of nerves, viz., cervicalis superficialis, auricularis magnus, and occipitalis minor. 16. The occipitalis major nerve. 17. The occipital branch of the third cervical nerve.

fascia, and are distributed to the platysma and integument. They communicate with the superficialis colli nerve.

The facial nerve has been called the *sympatheticus minor*, on account of its numerous communications with other nerves. Thus, within the cranium it communicates with the auditory nerve, sphenopalatine ganglion, and pneumogastric nerve; at its exit, with the glosso-pharyngeal, sympathetic, and cervical nerves; and on the face with the three divisions of the fifth nerve.

The FACIAL ARTERY, a branch of the external carotid, enters upon the face by curving around the body of the lower jaw at the anterior inferior angle of the masseter muscle. It then passes forwards in a more or less tortuous course to the angle of the mouth, and ascends by the side of the nose to the inner angle of the eye, where it is named the *angular artery*; it terminates by inosculating with the nasal and frontal branches of the ophthalmic artery. In its course over the jaw it is covered by the platysma myoides, and at the angle of the mouth by the depressor anguli oris and zygomatic muscles. It rests on the buccinator and elevator muscles of the lip.

The *branches* of the facial artery are, twigs to the masseter muscle (masseteric), inferior labial, inferior coronary, superior coronary, and lateral nasal.

The *inferior labial branch* passes forwards beneath the depressor anguli oris muscle, and is distributed to the muscles of the lower lip, inosculating with the labial branch of the inferior dental, and with the inferior coronary.

The *inferior coronary branch* is given off at the angle of the mouth, and passes inwards near the edge of the lower lip, lying between the orbicularis and the mucous membrane: it inosculates with its fellow of the opposite side.

The *superior coronary branch*, arising close to, or in common with, the preceding, takes its course in the same manner along the upper lip, inosculating with its fellow of the opposite side. At the middle of the lip it sends a small branch upwards to the septum of the nose (artery of the septum).

The *lateral nasal branch* is given off near the ala nasi, and passes beneath the levator labii superioris alæque nasi, to be distributed to the nose. It inosculates with the nasal branch of the ophthalmic artery.

The **FACIAL VEIN** commences at the inner angle of the eye, where, under the name of angular vein, it receives the frontal vein from the forehead; the frontal veins of opposite sides being united across the bridge of the nose by a transverse branch. The facial vein passes outwards beneath the zygomatic muscles to the anterior border of the masseter muscle, along which it descends to the lower jaw, where it joins the facial artery. Passing over the jaw it pierces the deep cervical fascia, and terminates in the internal jugular vein.

The **TRANSVERSE FACIAL ARTERY**, a branch of the temporal artery, emerges from beneath the anterior border of the parotid gland, and runs transversely across the face a little above Stenon's duct. It supplies the muscles in its course, and inosculates with the facial and infraorbital artery.

ANATOMY OF THE ORBIT.

To open the orbit (the calvarium and brain having been removed) the frontal bone must be sawn through at the inner extremity of the orbital ridge; and externally, at its outer extremity. The roof of the orbit may then be comminuted with the hammer; a process easily performed, on account of the thinness of the orbital plate of the frontal bone and lesser wing of the sphenoid. The superciliary portion of the orbit may now be driven forwards by a smart blow, and the broken fragments of the roof of the orbit removed. The periosteum will then be exposed unbroken and undisturbed.

The **PERIOSTEUM** is a moderately thick white membrane, only slightly connected with the surface of the bones of the orbit on account of their smoothness and density, but firmly at the different sutures, or at the points of transit of vessels and nerves. It is continuous through the optic foramen and sphenoidal fissure with the dura mater, and at the margins of the orbit with the pericranium and periosteum of the face.

Remove the periosteum from the whole of the upper surface of the exposed orbit, and the muscles, vessels, and nerves may then be examined

The contents of the orbit are, 1st. The globe of the eye appended to the extremity of the optic nerve. 2nd. The six muscles which move the eyeball, four recti, two obliqui, and the elevator muscle of the upper eyelid. 3rd. The ophthalmic artery with its branches. 4th. The ophthalmic vein with its tributaries. 5th. The nerves, which

consist of three branches of the ophthalmic—frontal, lachrymal, and nasal; the third, fourth, and sixth, to the muscles; and the ciliary ganglion with its branches. 6th. The lachrymal gland.

In the middle line is the levator palpebræ muscle, and resting upon it the frontal nerve, with its accompanying artery, the supra-orbital. To the inner side is the obliquus superior, and running along its border the fourth nerve posteriorly, and the infra-trochlear branch in front. To the outer side is the upper border of the external rectus supporting the lachrymal artery and nerve, and in front the lachrymal gland.

If the levator palpebræ muscle, and with it the frontal nerve and supraorbital artery, be divided through the middle and turned aside, the superior rectus will be seen occupying the middle place; and if the obliquus superior be also divided and its ends thrown aside, the upper margin of the internal rectus will occupy the inner side supporting the infra-trochlear nerve.

Next divide the superior rectus through the middle, and draw its ends asunder, in doing which a branch of the third nerve may be seen entering its under surface, and a third plane will be brought into view. This requires to be freed of a large quantity of fat, before the structures situated in it can be fully seen. The student must work cautiously and unweariedly, until he has removed every particle of this fat, which is not difficult to do from its being contained in areolæ of loose cellular tissue.

In the middle line he will now perceive the optic nerve, crossed from without inwards by the ophthalmic artery and nasal nerve, and having to its outer side the ascending branch of the third nerve, the ciliary ganglion with its branches, the ciliary arteries, and a little more externally, in contact with the external rectus muscle, the sixth nerve.

Next divide the optic nerve through its middle, and draw it forwards, when a layer will be observed, which is formed by the inferior rectus muscle supporting the long branch of the third nerve in the middle line; and in front, the inferior oblique muscle connected with the globe of the eye.

The MUSCLES of the orbit are seven in number; namely—

Levator palpebræ,	Rectus externus,
Rectus superior,	Obliquus superior,
Rectus inferior,	Obliquus inferior.
Rectus internus,	

The dissection of the muscles of the orbit may be facilitated by drawing the globe of the eye forwards; or, if it be desired, the muscles may be made tense by injecting the globe of the eye with tallow or wax. For this purpose a probe should be pushed along the optic nerve, so as to break down the cribriform plate of the sclerotic coat, and an injecting pipe introduced into the neurilemma of the nerve. By similar means the globe of the eye may be distended with air.

The *LEVATOR PALPEBRÆ* is a long, thin, and triangular muscle, situated in the upper part of the orbit on the middle line; it *arises* from the upper margin of the optic foramen, and from the fibrous sheath of the optic nerve, and is *inserted* into the upper border of the superior tarsal cartilage.

The *RECTUS SUPERIOR* (*attollens*) *arises* from the upper margin of the optic foramen, and from the fibrous sheath of the optic nerve, and is *inserted* into the upper surface of the globe of the eye at a point somewhat more than three lines from the margin of the cornea.

The *RECTUS INFERIOR* (*depressor*) *arises* from the inferior margin of the optic foramen by a tendon (ligament of Zinn) which is common to it, the internal and the external rectus, and from the fibrous sheath of the optic nerve; it is *inserted* into the inferior surface of the globe of the eye, a little more than two lines from the margin of the cornea.

The *RECTUS INTERNUS* (*adductor*), the thickest and shortest of the straight muscles, *arises* from the common tendon and from the fibrous sheath of the optic nerve, and is *inserted* into the inner surface of the globe of the eye at two lines from the margin of the cornea.

The *RECTUS EXTERNUS* (*abductor*), the longest of the straight muscles, *arises* by two distinct heads, one from the common tendon, the other, with the origin of the superior rectus, from the margin of the optic foramen; the nasal third and sixth nerves passing between its heads. It is *inserted* into the outer surface of the globe of the eye, a little more than two lines from the margin of the cornea.

The recti muscles present several characters which are common to all; thus, they are thin, have each the form of an isosceles triangle, bear the same relation to the globe of the eye, and are inserted in a similar manner into the sclerotica at about two lines from the circumference of the cornea. The points of difference relate to thickness and length; the internal rectus is the thickest and shortest, the external rectus the longest of the four, and the superior rectus the most thin. The insertion of the four recti muscles into the globe of the eye forms a tendinous expansion, which is continued as far as the margin of the cornea, and is called the tunica albuginea.

The *OBLIQUUS SUPERIOR* (*trochlearis*) is a fusiform muscle *arising* from the margin of the optic foramen and

from the fibrous sheath of the optic nerve; it passes forwards to the pulley beneath the internal angular process of the frontal bone; its tendon is then reflected beneath the superior rectus muscle, to the outer and posterior part of the globe of the eye, where it is inserted into the sclerotic coat near the entrance of the optic nerve.

The *trochlea* or *pulley* of the superior oblique muscle is a fibro-cartilaginous ring attached to the depression beneath the internal angular process of the frontal bone. The ring is flat, about a line in width, and provided with a synovial membrane, which is continued together with a fibrous sheath, for a short distance, upon the tendon. Sometimes the ring is supported, or in part formed, by a process of bone.

The OBLIQUUS INFERIOR, a thin and narrow muscle, *arises* from the inner margin of the superior maxillary bone, immediately external to the lachrymal groove, and passes beneath the inferior rectus, to be *inserted* into the outer and posterior part of the eyeball at about two lines from the entrance of the optic nerve.

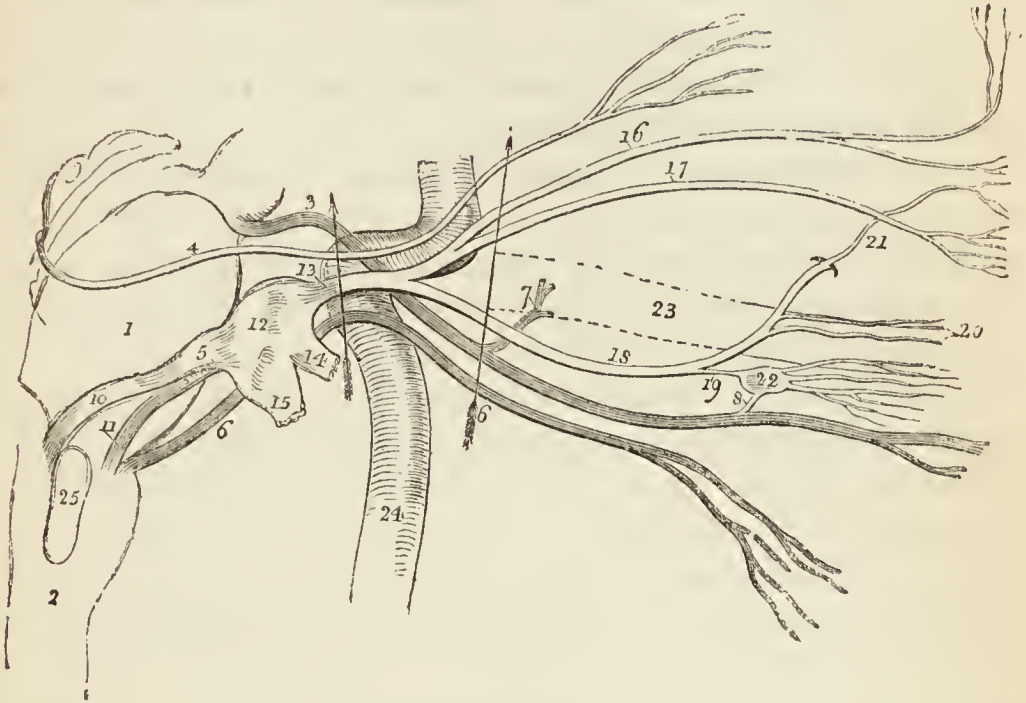
ACTIONS.—The levator palpebræ raises the upper eyelid. The four recti, acting singly, pull the eyeball in the four directions; upwards, downwards, inwards, and outwards. Acting by pairs, they carry the eyeball in the diagonal of these directions, viz. upwards and inwards, upwards and outwards, downwards and inwards, or downwards and outwards. Acting all together, they directly retract the globe within the orbit. The superior oblique muscle, acting alone, rolls the globe inwards and forwards, and carries the pupil outwards and downwards to the lower and outer angle of the orbit. The inferior oblique acting alone, rolls the globe outwards and backwards, and carries the pupil outwards and upwards to the upper and outer angle of the eye. Both muscles acting together, draw the eyeball forwards, and give the pupil that slight degree of eversion which enables it to admit the largest field of vision.

Nerves of the Orbit.

The dissection of the nerves of the orbit may be prosecuted either on the same side as the muscles, if the parts have not been too much disturbed, or the opposite orbit may be taken expressly for the purpose. The outer wall of the orbit should be broken away with the chisel and bone-nippers, to bring the apex of the orbit well into view, and the anterior clinoid process should also be removed. Furthermore, a thin layer of the dura mater should be raised from the side of the sella turcica, in order to bring into view the trunks of the nerves in their course to the orbit, and the parts situated in the cavernous sinus.

The NERVES of the orbit are the third, fourth, first division of the fifth, sixth, and the ophthalmic or ciliary ganglion, with its branches.

Fig. 27.*



* The origin, course, and distribution of the nerves of the orbit. The pons Varolii and medulla oblongata are in outline, and the horizontal portion of the carotid artery marks the situation of the cavernous sinus.

No. 1. The pons Varolii. 2. The medulla oblongata. 3. The third nerve, arising from the crus cerebri. 7. Its ascending branch. 8. Its communication with the ciliary ganglion. 4. The fourth nerve, arising from the valve of Vieussens, immediately below the corpora quadrigemina, 9. 5. The fifth nerve, arising by two roots. 10. The posterior root from the posterior part of the medulla oblongata. 11. The anterior root from the anterior part of the medulla oblongata. 12. The Casserian ganglion. 13. Its ophthalmic division. 14. Its superior maxillary division. 15. Its inferior maxillary division. 16. The frontal branch of the ophthalmic nerve. 17. The lachrymal branch. 18. The nasal. 19. Its communication with the ophthalmic ganglion; the superior or long root. 20. Its ciliary branches. 21. The infra-trochlear branch, given off just as the nerve enters the anterior ethmoidal foramen. 6, 6. The sixth nerve, arising from the corpus pyramidale. 22. The ophthalmic ganglion, giving off ciliary nerves. 23. The outline of the optic nerve. 24. The internal carotid artery. 25. The corpus olivare. The arrow at 3. marks the relative situation of the four nerves of the orbit, as they enter the cavernous sinus. The third is the highest, then the fourth, next the ophthalmic division of the fifth, and then the sixth. The arrow at 6. marks the relation

The **THIRD NERVE** (*motores oculorum*) pierces the dura mater immediately in front of the posterior clinoid process, and passing obliquely forwards and downwards, divides into two branches, which enter the orbit through the sphenoidal fissure, and between the two heads of the external rectus muscle.

The *superior branch* ascends and supplies the superior rectus and levator palpebræ.

The *inferior branch* sends a branch beneath the optic nerve to the internal rectus, another to the inferior rectus, and a long branch to the inferior oblique muscle. From the latter a short thick branch is given to the ophthalmic ganglion, forming its inferior root.

The **FOURTH NERVE** (*patheticus, trochlearis*), the smallest of the cerebral nerves, pierces the dura mater below the third nerve, and passes obliquely upwards to enter the orbit through the upper part of the sphenoidal fissure; it therefore crosses the third nerve. Entering the orbit, the nerve passes across the levator palpebræ near its origin, and is distributed to the superior oblique or *trochlearis* muscle, spreading out, contrary to the mode of distribution of the other nerves, on the orbital surface of the muscle.

The fourth nerve communicates in the cavernous sinus with the ophthalmic nerve and the carotid plexus of the sympathetic; it also sends off a *recurrent* filament, which, in conjunction with a similar offset of the ophthalmic, is distributed to the tentorium cerebelli. Sometimes the communication with the ophthalmic takes place in the orbit, in which case the lachrymal nerve has the appearance of arising by two roots.

The **OPHTHALMIC NERVE**, the upper branch of the Casserian ganglion, passes along the outer wall of the cavernous sinus, below the fourth nerve, and divides into three branches, *frontal, lachrymal, and nasal*. The nerve communicates, while in the sinus, with the carotid plexus and fourth nerve, and sends off a recurrent branch to the tentorium cerebelli.

of the six nerves as they enter the sphenoidal fissure;—the three superior, fourth, frontal, and lachrymal enter the orbit above the origin of the levator palpebræ;—the three inferior, nasal, third, and sixth, pass between the two heads of the external rectus.

The **FRONTAL NERVE** enters the orbit immediately to the outer side of the fourth nerve, and passing forwards, for some distance, upon the levator palpebræ muscle, divides into a supra-orbital and supra-trochlear branch.

The *supra-orbital* branch, which is the proper continuation of the nerve, passes out of the orbit through the supra-orbital notch, and mounts upon the forehead, supplying the integument, muscles, and pericranium (p. 203.). While in the notch it sends filaments to the upper eyelid.

The *supra-trochlear* branch passes inwards to the angle of the orbit, above the pulley of the superior oblique muscle, and is distributed to the inner angle of the eye, the root of the nose, and middle line of the forehead (p. 203.). It communicates with the infra-trochlear branch of the nasal nerve.

The **LACHRYMAL NERVE**, the smallest of the three branches of the ophthalmic, enters the orbit on the outer side of the frontal, but enclosed in a separate sheath of dura mater; and passes forwards, above the upper border of the external rectus muscle, to the lachrymal gland, where it divides into two branches, superior and inferior. The *superior branch* passes over the gland which it supplies on the upper surface, and traversing a foramen in the malar bone, communicates with the subcutaneous malæ and facial nerve. The *inferior branch* supplies the under surface of the gland, and supplies the upper lid and outer angle of the eye.

The lachrymal nerve sometimes receives the branch of the fourth nerve destined for the ophthalmic, and appears to arise by two roots.

The **NASAL NERVE** (naso-ciliaris) enters the orbit between the two heads of the external rectus and between the two branches of the third nerve. It crosses the optic nerve in company with the ophthalmic artery, and passing over the internal rectus, enters the anterior ethmoidal foramen, by which it is conducted to the cribriform plate of the ethmoid bone. It then passes through the slit-like opening by the side of the crista galli, and descends into the nose, where it divides into an internal and an external branch. The *internal branch* is distributed to the mucous membrane; and the *external branch*, passing

outwards between the nasal bone and cartilage, supplies the integument of the exterior of the nose as far as its tip.

The *branches* of the nasal nerve are the *ganglionic*, *ciliary*, and *infra-trochlear*.

The *ganglionic branch*, about half an inch in length and of small size, enters the upper angle of the ophthalmic ganglion, and constitutes its superior or long root.

The *long ciliary branches* are two or three filaments given off from the nerve as it crosses the optic nerve. They pierce the sclerotic coat near the short ciliary nerves, and passing through the globe of the eye between the sclerotic and choroid, are distributed to the iris.

The *infra-trochlear branch* is given off close to the anterior ethmoidal foramen. It passes forwards along the upper border of the internal rectus to the inner angle of the eye, where it communicates with the supra-trochlear nerve, and is distributed to the lachrymal sac and inner angle of the orbit.

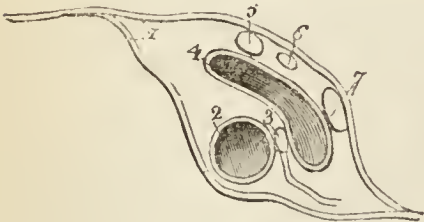
The SIXTH NERVE (*abducens oculi*) pierces the dura mater on the body of the sphenoid bone, and passes along the inner wall of the cavernous sinus, below the other nerves, and resting against the internal carotid artery to the sphenoidal fissure. It enters the sphenoidal fissure above the ophthalmic vein, and passing between the two heads of the external rectus, is distributed to that muscle.

In the cavernous sinus the sixth nerve receives several filaments from the carotid plexus.

The four nerves just described are situated, previously to their entry into the orbit, in the cavernous sinus; the first three, namely, third, fourth, and three branches of the fifth, in the outer wall of the

sinus, each nerve being enclosed in a separate sheath of dura mater; the remaining nerve, the sixth, in the internal wall of the sinus, that is, between the sinus and the internal carotid artery. Another relation of the nerves is that from above downwards; at their entrance into the sinus they are placed in the order of their numbers,

Fig. 28.*



* A transverse section of the cavernous sinus of the right side.— No. 1. The dura mater, splitting to enclose the vessels and nerves. 2. The internal carotid artery. 3. The sixth nerve, receiving a branch from the carotid plexus of the sympathetic. 4. The cavernous sinus. 5. The third nerve. 6. The fourth nerve. 7. The ophthalmic division of the fifth nerve.

namely, third, fourth, fifth, sixth; but at the ethmoidal fissure, the fourth, frontal, and lachrymal are the highest, these three entering the orbit above the origin of the levator palpebræ; the others lie in the following relative position,—upper branch of the third, nasal, lower branch of the third and sixth. The three latter all pass between the two heads of the external rectus. Below the sixth nerve, at the sphenoidal fissure, is the ophthalmic vein.

The OPTHALMIC GANGLION (ciliary; lenticular) is a small quadrangular and flattened body of a reddish colour, situated between the optic nerve and external rectus.

Its *branches* of communication are three in number: *one*, the *long root*, which proceeds from its superior angle and joins the nasal nerve; a short and thick branch, the *short root*, which proceeds from its inferior angle and joins the inferior branch of the third nerve; and a slender filament from the carotid plexus, the *sympathetic root*.

Its *branches of distribution* are the *short ciliary nerves*; they proceed from the anterior angles of the ganglion in two groups, the upper group consisting of about four filaments, and the lower of five or six. They accompany the ciliary arteries in a waving course, and divide into a number of filaments which pierce the sclerotic around the optic nerve, and supply the tunics of the eyeball.

Vessels of the Orbit.

The vessels of the orbit are the ophthalmic artery and vein with their branches.

The OPTHALMIC ARTERY arises from the internal carotid, just as the latter vessel pierces the dura mater, and enters the orbit through the optic foramen lying externally to the optic nerve. It then crosses the optic nerve to the inner wall of the orbit, and at the inner angle of the eye divides into two terminal branches, frontal and nasal.

The *branches* of the ophthalmic artery, ten in number, may be arranged in two groups, the first group including the vessels distributed to the circumference of the orbit; and the second, those which supply the eyeball and its muscles.

First Group.

Lachrymal,	Palpebral,
Supra-orbital,	Frontal,
Posterior ethmoidal,	Nasal.
Anterior ethmoidal,	

Second Group.

Muscular,—anterior ciliary,
Ciliary short and long,
Centralis retinae.

The *lachrymal* is the first branch of the ophthalmic artery, and is usually given off immediately before that artery enters the optic foramen. It follows the course of the lachrymal nerve, above the upper border of the external rectus muscle, and is distributed to the lachrymal gland. The small branches which escape from the gland supply the conjunctiva and upper eyelid. The lachrymal artery gives off a *malar branch*, which passes through the malar bone into the temporal fossa, and inosculates with the deep temporal arteries, while some of its branches become subcutaneous on the cheek, and anastomose with the transverse facial.

The *supra-orbital artery* follows the course of the frontal nerve, resting on the levator palpebræ muscle; it passes through the supra-orbital foramen, and divides into a superficial and deep branch, which are distributed to the muscles and integument of the forehead, and to the pericranium. At the supra-orbital foramen it sends a branch inwards to the diploë.

The *ethmoidal* arteries, *posterior* and *anterior*, pass through the ethmoidal foramina, and are distributed to the falx cerebri and to the ethmoidal cells and nasal fossæ. The latter accompanies the nasal nerve, and sends a branch to the frontal sinus.

The *palpebral* arteries, *superior* and *inferior*, are given off from the ophthalmic, near the inner angle of the orbit; they encircle the eyelids, forming a superior and an inferior arch near the borders of the lids, between the orbicularis palpebrarum and tarsal cartilage. At the outer angle of the eyelids, the superior palpebral inosculates with the orbital branch of the temporal artery. The inferior palpebral sends a branch to the nasal duct.

The *frontal* artery, one of the terminal branches of the ophthalmic, emerges from the orbit at its inner angle, and ascends along the middle of the forehead. It is distributed to the integument, muscles, and pericranium.

The *nasal* artery, the other terminal branch of the ophthalmic, passes out of the orbit above the tendo oculi,

and divides into two branches; one of which inosculates with the angular artery, while the other, the *dorsalis nasi*, runs along the ridge of the nose, and is distributed to the integument of that organ. The nasal artery sends a small branch to the lachrymal sac.

The *muscular branches*, usually two in number, *superior* and *inferior*, supply the muscles of the orbit; and upon the anterior aspect of the globe of the eye give off the *anterior ciliary* arteries, which pierce the sclerotic near its margin of connection with the cornea, and are distributed to the iris. It is the congestion of these vessels that gives rise to the vascular zone around the cornea in iritis.

The *ciliary arteries* are divisible into three groups, short, long, and anterior.

The *short ciliary* (posterior), from ten to fifteen in number, pierce the sclerotic around the entrance of the optic nerve, and supply the choroid coat and ciliary processes. The *long ciliary*, two in number, pierce the sclerotic on opposite sides of the globe of the eye, and pass forwards between it and the choroid to the iris. They form an arterial circle around the circumference of the iris by inosculating with each other, and from this circle branches are given off which ramify in the substance of the iris, and form a second circle around the pupil. The *anterior ciliary* are branches of the muscular arteries; they terminate in the great arterial circle of the iris.

The *centralis retinæ* artery pierces the optic nerve obliquely, and passes forwards in the centre of its cylinder to the retina, where it divides into branches, which ramify in the inner layer of that membrane. It supplies the retina, hyaloid membrane, and zonula ciliaris; and, by means of a branch sent forwards through the centre of the vitreous humour in a tubular sheath of the hyaloid membrane, the capsule of the lens.

The OPHTHALMIC VEIN commences at the inner angle of the eye, where it communicates with the angular vein and takes the course of the ophthalmic artery, receiving the veins corresponding with its branches. It quits the orbit through the sphenoidal fissure, after passing between the two heads of the external rectus, and opens into the

cavernous sinus. At the sphenoidal fissure it lies beneath the sixth nerve.

LACHRYMAL GLAND.—The *lachrymal gland* is situated at the upper and outer angle of the orbit, and consists of two portions, orbital and palpebral. The *orbital portion*, about three quarters of an inch in length, is flattened and oval in shape, and occupies the lachrymal fossa in the orbital plate of the frontal bone. It is in contact superiorly with the periosteum, with which it is closely connected by its upper and convex surface; by its inferior or concave surface it is in relation with the globe of the eye, and the superior and external rectus; and by its anterior border with the broad tarsal ligament. By the posterior border it receives its vessels and nerves. The *palpebral portion*, smaller than the preceding, is situated in the upper eyelid, extending downwards to the superior margin of the tarsal cartilage. It is continuous with the orbital portion above, and is enclosed in an investment of dense fibrous membrane. The secretion of the lachrymal gland is conveyed away by from eight to twelve small ducts which run for a short distance beneath the conjunctiva, and open upon its surface by a series of pores, about one-twentieth of an inch apart, situated in a curved line a little above the upper border of the tarsal cartilage.

For the anatomy of the appendages of the eye, and the rest of the lachrymal apparatus, the student is referred to Chapter VII.

ANATOMY OF THE NECK.

The *neck*, as before stated, is the medium of *communication* and *connection*, between the head and the trunk of the body.

Connection is established by means of the integument and sterno-mastoid muscle, the muscles of the prevertebral region, vertebral column, and muscles of the back.

Communication is effected by means of apparatuses connected with respiration and deglutition. Associated with *respiration* is the larynx, and with *deglutition* the os hyoides, the tongue, the soft palate, and the pharynx. These may be considered as the elements of the neck, and form so many regions, by which the muscles may be grouped and arranged.

Thus we find the—

1. Superficial group.
2. Depressors of the os hyoides and larynx.
3. Elevators of the os hyoides and larynx.
4. Lingual group.
5. Soft palate group.
6. Pharyngeal group.
7. Prevertebral group.
8. Proper muscles of the larynx.

These eight groups, therefore, will form so many distinct ideas, by which the composition of the neck and the arrangement of its muscles may be associated in the mind. To facilitate still more the learning of these muscles, the student is informed that, with the exception of the first two, each group consists of five muscles. This is better shown in the following table:—

<p>1. <i>Superficial group.</i> Platysma myoides, Sterno-cleido-mastoideus.</p>	<p>Tensor palati, Azygos uvulæ, Palato-glossus, Palato-pharyngeus.</p>
<p>2. <i>Depressors of the os hyoides and larynx.</i> Sterno-hyoideus, Sterno-thyroideus, Thyro-hyoideus, Omo-hyoideus.</p>	<p>6. <i>Muscles of the pharynx.</i> Constrictor inferior, Constrictor medius, Constrictor superior, Stylo-pharyngeus, Palato-pharyngeus.</p>
<p>3. <i>Elevators of the os hyoides and larynx.</i> Digastricus, Stylo-hyoideus, Mylo-hyoideus, Genio-hyoideus, Genio-hyo-glossus.</p>	<p>7. <i>Prevertebral group.</i> Rectus anticus major, Rectus anticus minor, Scalenus anticus, Scalenus posticus, Longus colli.</p>
<p>4. <i>Muscles of the tongue.</i> Genio-hyo-glossus, Hyo-glossus, Lingualis, Stylo-glossus, Palato-glossus.</p>	<p>8. <i>Muscles of the larynx.</i> Crico-thyroid, Crico-arytænoid, posticus, Crico-arytænoid, lateralis, Thyro-arytænoid, Arytænoid.</p>
<p>5. <i>Muscles of the soft palate.</i> Levator palati,</p>	

After this arrangement of the muscles has been well considered, and, we may add, *learnt by heart*, the student should commence the dissection of one side of the neck with a view to see their connections and relations. With this object an incision should be made along the middle line of the neck from the chin to the sternum, and bounded superiorly and inferiorly by two transverse incisions; the superior one carried along the margin of the lower jaw, and across the mastoid process to the tubercle on the occipital bone, the inferior one along the clavicle to the acromion process. The square flap of integument thus included should be turned back from the entire side of the neck, which brings into view the superficial fascia.

The *superficial fascia* consists of two layers, between which is placed the platysma myoides muscle. The external layer must therefore be reflected from off its fibres, to the same extent with the flap of integument, observing to dissect always in the course of the fibres.

The PLATYSMA MYOIDES (πλατύς, μῦς, εἶδος, broad muscle-like lamella) is a thin plane of muscular fibres, situated between the two layers of the superficial cervical fascia; it *arises* from the superficial fascia over the pectoralis major and deltoid muscles, and passes obliquely upwards and inwards along the side of the neck to be *inserted* into the side of the chin, oblique line of the lower jaw, the angle of the mouth, and into the cellular tissue of the face. The most anterior fibres are continuous beneath the chin with the muscle of the opposite side; the next interlace with the depressor anguli oris and depressor labii inferioris; and the most posterior fibres are disposed in a transverse direction across the side of the face, arising from the fibrous covering of the parotid gland, and inserted into the angle of the mouth, constituting the risorius Santorini (page 209.). The entire muscle is analogous to the cutaneous muscle of brutes, the panniculus carnosus.

Upon removing the platysma, and with it the deep layer of superficial fascia, we bring into view the external jugular vein, and ascending branches of the cervical plexus of nerves. The jugular vein is lying obliquely along the neck, parallel with the fibres of the platysma myoides, while it crosses the direction of the sternomastoid muscle.

The sterno-mastoid is as yet concealed from view by a layer of fascia, which covers in the whole of the side of the neck. This is

the deep cervical fascia, the reflections of which we have next to examine.

The *deep cervical fascia* is a strong cellulo-fibrous membrane, which invests the neck, forming sheaths for the various muscles, and retaining and supporting the vessels and nerves. It is attached posteriorly along the middle line to the ligamentum nuchæ, being overlapped by the trapezius muscle; passes forwards to the posterior border of the sterno-mastoid, and divides into two layers which embrace that muscle, and unite again at its anterior border. It is then directed onwards to the middle line, where it becomes continuous with the deep fascia of the opposite side of the neck. The *anterior layer*, that which is superficial to the sterno-mastoid, is prolonged upwards on the side of the jaw and parotid gland, to the zygoma, and downwards over the clavicle and pectoralis major muscle. The *posterior layer*, which can only be examined by removing or drawing aside the sterno-mastoid muscle, is attached superiorly to the styloid process of the temporal bone, and is thence reflected to the angle of the jaw, forming the *stylo-maxillary ligament*. Inferiorly it forms a loop, which acts as a pulley to the omo-hyoid muscle, and is then continued downwards behind the clavicle, so as to enclose the subclavius muscle. The extremities of the latter portion are attached firmly to the cartilage of the first rib and coracoid process: hence it is named *costo-coracoid membrane* or *ligament*. In the middle line the deep fascia is connected with the sternum.

This fascia is of great importance in a surgical point of view. In its normal condition, it binds down firmly all the structures of the neck, and preserves their natural position. When, however, tumours form beneath it, as bronchocele, enlargements of the lymphatic glands, aneurism, &c., the pressure which it then exerts may be fatal to the patient, from compression of the trachea, larynx, and nerves, unless the tension be relieved by incision.

If the deep fascia be divided in the direction of the sterno-mastoid muscle, and turned aside, that muscle will be brought into view, and the posterior part of its sheath examined.

The STERNO-CLEIDO-MASTOIDEUS is the large oblique muscle of the neck. It *arises*, as implied by its name, from the sternum and clavicle (*κλειδίον*), and passes obliquely upwards and backwards to be *inserted* into the

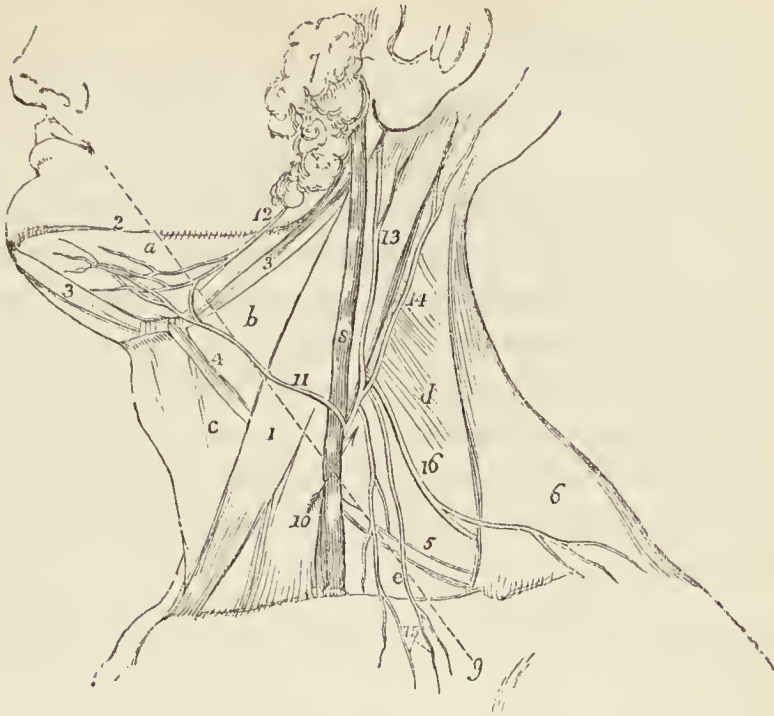mastoid process of the temporal, and into the superior curved line of the occipital bone. The sternal portion arises by a rounded tendon, increases in breadth as it ascends, and spreads out to a considerable extent at its insertion. The clavicular portion is broad and fleshy, and separate from the sternal portion below, but becomes gradually blended with the posterior surface of the latter as it ascends.

ACTIONS.—The platysma produces a muscular traction on the integument of the neck, which prevents it from falling so flaccid in old persons as it would if the extension of the skin were the mere result of elasticity. It draws also upon the angle of the mouth, and is one of the depressors of the lower jaw. The sterno-mastoid muscles are the great anterior muscles of connection between the thorax and the head. Both muscles acting together bow the head directly forwards. The clavicular portions, acting more forcibly than the sternal, give stability and steadiness to the head in supporting great weights. Either muscle acting singly would draw the head towards the shoulder of the same side, and carry the face towards the opposite side.

The sterno-mastoid muscle, stretching obliquely across the side of the neck, divides the latter into two great triangles, *anterior* and *posterior*; each of which is subdivided into smaller triangles. The *great anterior triangle*, having its base at the lower jaw and apex at the sternum, is bounded in front by the mid-line of the neck, behind by the sterno-mastoid, and above by the body of the lower jaw. This triangular space contains the carotid arteries, internal jugular vein, and large nerves of the neck; the anterior border of the sterno-mastoid being the guide for the incision in ligature of the common carotid artery.

The *posterior triangle*, having its base at the clavicle and apex at the occiput, is bounded in front by the sterno-mastoid muscle; behind by the trapezius, and below by the clavicle; it contains in its lower part the subclavian artery and vein, with some of their branches, and the brachial plexus of nerves. Both triangular spaces are covered in by the deep cervical fascia and platysma myoides muscle; and the external jugular vein, in its vertical course down the neck, passes from the anterior triangle across the sterno-mastoid muscle to the posterior triangle.

Fig. 29.*



The sterno-mastoid may now be removed by dividing it through the middle and turning aside its ends. The upper end will be found to be perforated by a large nerve, the spinal accessory of the eighth pair, which, after supplying the sterno-mastoid, takes its course across the posterior triangle to the under part of the trapezius. The deep layer of fascia is then to be dissected from off the side of the larynx and trachea towards the mid-line, when the second group of muscles, the depressors of the os hyoides and larynx, will be brought into view.

* The triangles of the neck, with the external jugular vein and superficial branches of the cervical plexus.

No. 1. The sterno-mastoid muscle, which divides the side of the neck into two great triangles, anterior and posterior. *a.* The submaxillary triangle. *b.* The superior carotid triangle. *c.* The inferior carotid triangle. *d.* The sub-occipital triangle. *e.* The subclavian triangle. 2. The border of the lower jaw. 3, 3. The digastric muscle. 4. The superior belly of the omohyoid muscle. 5. Its inferior belly. 6. The trapezius muscle. 7. The parotid gland. 8. The external jugular vein. 9. A dotted line, marking the direction of the fibres of the platysma myoides muscle. 10. A small arrow, showing the direction of the incision for opening the jugular vein. 11. The superficialis colli nerve, which forms a plexus with (12.) an inframaxillary branch of the facial nerve, over the submaxillary triangle. 13. The auricularis magnus nerve. 14. The occipitalis minor. 15. The descending superficial branches [supraclavicular] of the plexus. 16. The spinal accessory nerve.

Second Group. — Depressors of the os hyoides and larynx.

Sterno-hyoid,
Sterno-thyroid,

Thyro-hyoid,
Omo-hyoid.

The STERNO-HYOIDEUS is a narrow, riband-like muscle, *arising* from the posterior surface of the first bone of the sternum, and from the posterior sterno-clavicular ligament (sometimes from the inner extremity of the clavicle, and sometimes from the cartilage of the first rib). It is *inserted* into the lower border of the os hyoides. The sterno-hyoidei are separated by a considerable interval at the root of the neck, but approach each other as they ascend; they are frequently traversed below by a tendinous intersection.

The sterno-hyoideus may be divided through the middle, and its ends turned aside.

The STERNO-THYROIDEUS, broader than the preceding, beneath which it lies, *arises* from the posterior surface of the upper bone of the sternum, and from the cartilage of the first rib; it is *inserted* into the oblique line on the great ala of the thyroid cartilage. The inner borders lie in contact along the middle line, and the muscles are marked by a tendinous intersection at their lower part.

The THYRO-HYOIDEUS is the continuation upwards of the sterno-thyroid muscle. It *arises* from the oblique line on the thyroid cartilage, and is *inserted* into the lower border of the body, and into the great cornu of the os hyoides for one half its length.

The OMO-HYOIDEUS ($\omega\mu\omicron\varsigma$, shoulder) is a double-bellied muscle passing obliquely across the neck from the scapula to the os hyoides; it forms an obtuse angle behind the sterno-mastoid muscle, and is retained in that position by means of a process of the deep cervical fascia which is connected to the inner border of its tendon. It *arises* from the upper border of the scapula, and from the transverse ligament of the supra-scapular notch, and is *inserted* into the os hyoides at the junction of the body and great cornu.

ACTIONS. — The four muscles of this group are depressors of the os hyoides and larynx. The three former drawing these parts downwards in the middle line, and the two omo-hyoidei regulating

their traction to the one or other side of the neck, according to the position of the head. The omo-hyoid muscles, by means of their connexion with the cervical fascia, are rendered tensors of that portion of the deep cervical fascia which covers the lower part of the neck, between the two sterno-mastoid muscles.

The omo-hyoid muscle, crossing the neck obliquely in a direction opposite to that of the sterno-mastoid, and crossing also the anterior and posterior triangular spaces, subdivides the latter into smaller triangles. The inferior angle of the great anterior triangle, cut off by the upper belly of the omo-hyoideus, is the *inferior carotid triangle*, while the space above is the *superior carotid triangle*. The apical portion of the great posterior triangular space is the *occipital triangle*; while the space between the omo-hyoid and the clavicle is the *subclavian triangle*. The latter contains the subclavian artery and vein, and brachial plexus of nerves; and is bounded in front by the sterno-mastoid, above by the omo-hyoid, and below by the clavicle. The external jugular vein enters this space to join the subclavian vein, and it is here that the operation of tying the subclavian artery is performed.

If the sterno-hyoid and sterno-thyroid muscles be divided, and the ends turned aside, the thyroid gland will be brought into view, lying upon the trachea, the two lobes being connected by a transverse portion which crosses the air-tube.

THYROID GLAND. — The thyroid gland consists of two lobes, which are placed one on each side of the trachea, and are connected with each other by means of an *isthmus*, which crosses its upper rings, usually the third and fourth; but in this respect there is some variety, a point necessary to be remembered in operations on the trachea. The lobes are somewhat conical in shape, being larger below than above, and the smaller end is continued upwards to the side of the thyroid cartilage. The isthmus is connected with the lower third of the two lobes, and often gives origin to a process of variable length and size, called the *pyramid* or third lobe. The pyramid is generally situated on the left side of the isthmus, and is sometimes derived from the left lobe. The left lobe is somewhat smaller than the right, the weight of the entire gland being about one ounce and a half. It is, however, larger in young persons and females than in adult males, and

undergoes a slight increase during menstruation. Its permanent enlargement constitutes bronchocele, goître, or the Derbyshire neck.

The structure of the thyroid is of a brownish-red colour, and is composed of a dense aggregation of minute and independent membranous cavities enclosed by a plexus of capillary vessels, and connected together by cellular tissue. The cavities are filled with a yellowish fluid, in which are found cytoblasts and cells; the latter measuring $\frac{1}{1400}$ of an inch in diameter. In young animals the cytoblasts lie in contact with the internal wall of the cavities, and constitute a kind of tessellated epithelium.

A muscle is occasionally found connected with its isthmus, or with the pyramid, and is attached, superiorly, to the body of the os hyoides, or to the thyroid cartilage. It was named by Soemmering the "*levator glandulæ thyroideæ*."

Vessels and Nerves.—It is abundantly supplied with blood by the superior and inferior thyroid arteries. Sometimes an additional artery is derived from the arteria in-nominata, and ascends upon the front of the trachea to be distributed to the gland. The wounding of the latter vessel, in tracheotomy, might be fatal to the patient. The *nerves* are derived from the superior laryngeal, and from the middle and inferior cervical ganglia of the sympathetic.

The TRACHEA may now be examined with reference to the operation of tracheotomy.

Operation.—Next to bleeding, *tracheotomy* is one of the most important operations on the human body, from the emergency of the circumstances under which the surgeon is called upon to act, and from the liability of their occurrence to every practitioner and at any moment. The student should not omit to perform this operation while dissecting the neck, for, although trifling in itself, it might be the instant means of saving, if not of restoring, life. If called unexpectedly to a patient labouring under symptoms of threatened suffocation, he would not hesitate to perform it with his penknife; therefore he must familiarise himself with its steps.

An incision is to be made to the extent of an inch and a half along the middle line of the neck, just above the sternum. This may divide the integument and superficial fascia. The next incision takes him to the space between the two sterno-thyroid muscles: these are to be separated, an opening made into the trachea, and a canula, or writing quill, inserted into it. This is the only part of the operation that requires care; for some large veins, the inferior thyroid, and occasionally an inferior thyroid artery from the inno-

minata, lie immediately upon the trachea. The bleeding resulting from the wound of any of these vessels might be fatal from pouring into the trachea. In the case of the artery it would be necessary to tie the divided extremities.

LARYNGOTOMY is practised a little higher in the neck, immediately below the thyroid cartilage. The structures are to be divided as in the previous operation, and the point of a bistoury introduced into the larynx through the crico-thyroid membrane, in the space left by the divergence of the two crico-thyroid muscles. A small branch of communication between the two superior thyroid arteries (inferior laryngeal) crosses this ligament, the division of which, as it might give rise to disagreeable hæmorrhage, must be carefully avoided.

Third Group.—Elevators of the os hyoides.

Digastricus,
Stylo-hyoid,
Mylo-hyoid,
Genio-hyoid,
Genio-hyo-glossus.

To dissect these muscles the neck should be supported by a high block and the head thrown backwards. The deep fascia should be carefully removed, together with any cellular tissue or fat which may impede the view.

The DIGASTRICUS ($\delta\iota\varsigma$, twice, $\gamma\alpha\sigma\tau\eta\rho$, belly) is a small muscle situated immediately beneath the side of the body of the lower jaw; it is fleshy at each extremity, and tendinous in the middle. It *arises* from the digastric fossa and anterior border of the mastoid process of the temporal bone, and is *inserted* into a depression on the inner side of the lower jaw, close to the symphysis. The middle tendon is held in connexion with the body of the os hyoides by an aponeurotic loop, through which it plays as through a pulley; the loop being lubricated by a synovial membrane. A thin layer of aponeurosis is given off from the tendon of the digastricus at each side, which is connected with the body of the os hyoides, and forms a strong plane of fascia between the anterior portions of the two muscles. This fascia is named the *supra-hyoidean*.

The digastricus muscle encloses on two sides, the lower jaw being the third, a small triangular space which is named, from its situation, *submaxillary triangle*; while it constitutes the upper boundary of the *superior carotid triangle*, the other two sides of the latter being the omo-

hyoid below, and the sterno-mastoid behind. The student has now before him the three subdivisions of the anterior triangular space of the neck, namely, *submaxillary*, *superior carotid*, and *inferior carotid*.

In the *submaxillary triangle* he will find the submaxillary gland, facial artery, and submental artery, the floor of the triangular space being formed by the mylo-hyoideus muscle.

In the *superior carotid triangle* is the common carotid artery, dividing into the external and internal carotid, the internal jugular vein, the hypoglossal nerve, descendens noni, pneumogastric, and, behind the sheath of the carotid vessels, the sympathetic nerve.

In the *inferior carotid triangle* is the sheath of the common carotid artery, the internal jugular vein and pneumogastric nerve being enclosed in the sheath with the artery.

SUBMAXILLARY GLAND.—This salivary gland, situated in the submaxillary triangle, is of a rounded form. It rests on the mylo-hyoideus, hyo-glossus, and stylo-glossus muscles, and is separated from the parotid gland by the stylo-maxillary ligament. Its lateral boundaries are the lower jaw, against which it lies, and the digastricus muscle, and it is covered in by the deep cervical fascia and platysma. Its excretory duct (Wharton's), about two inches in length, issues from the middle of the gland and passes between the mylo-hyoideus and hyo-glossus to the frænum linguæ, by the side of which it terminates at the apex of a papilla. A process of the gland is prolonged with the duct for a short distance behind the mylo-hyoideus.

The structure of the submaxillary gland is similar to that of the parotid already described (page 210.), but its lobes are larger and less firmly held together by cellular tissue. Its duct also is thinner, being composed only of a fibrous coat lined by mucous membrane.

The submaxillary gland has lying in a groove upon its upper surface the facial artery.

The **STYLO-HYOIDEUS** is a small and slender muscle situated in immediate relation with the posterior belly of the digastricus muscle, by which it is pierced. It *arises* from the middle of the styloid process, and is *inserted* into the body of the os hyoides near the middle line.

The digastricus must be divided at its insertion into the lower jaw, its attachment to the os hyoides with that of the stylo-hyoideus separated, and the muscles turned aside in order to bring the next muscle into view. The supra-hyoidean fascia, and any cellular tissue and fat which may disfigure the muscle, should also be dissected away.

The MYLO-HYOIDEUS (*μύλη*, mola, *i. e.* attached to the molar ridge of the lower jaw) is a broad and triangular plane of muscular fibres, forming, with its fellow of the opposite side, the inferior wall or floor of the mouth. It *arises* from the molar ridge of the lower jaw, and proceeds obliquely inwards to be *inserted* into the *raphé* of the two muscles and body of the os hyoides: the *raphé* is sometimes deficient at its anterior part.

After the mylo-hyoideus has been examined, it should be cut away from its origin and insertion, and completely removed. The view of the next muscles would also be greatly improved by dividing the lower jaw a little to the side of the symphysis, and drawing it outwards or removing it altogether, if the ramus have been already cut across in dissecting the internal pterygoid muscle. The tongue may then be drawn out of the mouth by means of a hook.

The GENIO-HYOIDEUS (*γένειον*, the chin) *arises* from a small tubercle on the inner side of the symphysis of the lower jaw, and is *inserted* into the body of the os hyoides. It is a short and slender muscle, very closely connected with its fellow and with the border of the following.

The GENIO-HYO-GLOSSUS (*γλωσσα*, the tongue) is a triangular muscle, narrow and pointed at its origin from the lower jaw, broad and fan-shaped at its attachment to the tongue. It *arises* from a tubercle immediately above that of the genio-hyoideus, and spreads out to be *inserted* into the whole length of the tongue, from its base to the apex, and into the os hyoides.

The whole of this group of muscles acts upon the os hyoides when the lower jaw is closed, and upon the lower jaw when the os hyoides is drawn downwards and fixed by the depressors of the os hyoides and larynx. The genio-hyo-glossus is moreover a muscle of the tongue.

The removal of the mylo-hyoideus brings into view, besides the last two muscles, the duct of the submaxillary gland, and the third and smallest of the salivary glands, the sublingual.

SUBLINGUAL GLAND.—The sublingual is a long and flattened gland situated in the floor of the mouth by the

side of the frænum linguæ and tongue, and covered on this aspect by the mucous membrane. At the frænum it is in relation with its fellow of the opposite side, and in the rest of its course lies between the lower jaw and genio-hyo-glossus, being bounded below by the mylo-hyoideus. It is in relation also with the duct of the sub-maxillary gland and the hypoglossal nerve.

The sublingual gland in essential structure is similar to the other salivary glands; but the lobules are more loosely connected, and in some instances lie apart from each other. Its secretion is poured into the mouth by from seven to twenty short ducts (ductus Riviniani), which open upon the ridge made by the gland in the floor of the mouth; the larger openings being situated by the side of the frænum linguæ. One of the ducts longer than the rest, and opening close to Wharton's duct, has been named ductus Bartholini.

Fourth Group.—Muscles of the Tongue.

Genio-hyo-glossus,
Hyo-glossus,
Lingualis,
Stylo-glossus,
Palato-glossus.

These muscles are already exposed by the preparation of the last group; the student has therefore only to clean them, to bring them more clearly into view.

The genio-hyo-glossus is repeated with this group, as belonging in action to the present set of muscles as well as the last.

The HYO-GLOSSUS is a square-shaped plane of muscle, *arising* from the whole length of the great cornu and from the body of the os hyoides, and *inserted* between the stylo-glossus and lingualis into the side of the tongue. The direction of the fibres of that portion of the muscle which arises from the body is obliquely backwards, and that from the great cornu obliquely forwards; hence they are described by Albinus as two distinct muscles, under the names of basio-glossus and cerato-glossus, to which he added a third fasciculus, arising from the lesser cornu, and spreading along the side of the tongue, the chondro-glossus. The basio-glossus slightly overlaps the cerato-glossus at its upper part, and is separated from it by the transverse portion of the stylo-glossus.

The hyo-glossus muscle is crossed by two large nerves, and the duct of the submaxillary gland. The gustatory nerve is the highest of the three, the hypoglossal nerve the lowest, Wharton's duct and the deep process of the submaxillary gland lying between them.

The LINGUALIS. — The fibres of this muscle (lingualis inferior) may be seen towards the apex of the tongue, issuing from the interval between the hyo-glossus and genio-hyo-glossus; it is best examined by removing the preceding muscle. It consists of a small fasciculus of fibres, running longitudinally from the base, where it is attached to the os hyoides, to the apex of the tongue. By the outer border its fibres reach the plane of longitudinal fasciculi of the stylo-glossus; and by its under surface it is in relation with the ranine artery.

The STYLO-GLOSSUS *arises* from the apex of the styloid process and from the stylo-maxillary ligament; it divides upon the side of the tongue into a transverse and longitudinal portion: the *transverse* portion dips into the substance of the tongue between the two parts of the hyo-glossus; the *longitudinal* portion spreads out upon the side of the tongue, and is prolonged forward as far as its tip.

The PALATO-GLOSSUS passes between the soft palate and the side of the base of the tongue, forming a projection of the mucous membrane, which is called the anterior pillar of the soft palate. Its fibres are lost superiorly among the muscular fibres of the palato-pharyngeus, and inferiorly among the fibres of the stylo-glossus upon the side of the tongue. This muscle with its fellow constitutes the constrictor isthmi faucium.

ACTIONS. — The genio-hyo-glossus muscle effects several movements of the tongue. When the tongue is steadied and pointed by the other muscles, the posterior fibres of the genio-hyo-glossus would dart it from the mouth, while its anterior fibres would restore it to its original position. The whole length of the muscle acting upon the tongue, would render it concave along the middle line, and form a channel for the current of fluid towards the pharynx, as in sucking. The apex of the tongue is directed to the roof of the mouth, and rendered convex from before backwards by the linguales. The hyo-glossi, by drawing down the sides of the tongue, render it convex along the middle line. It is drawn upwards at its base by the palato-glossi, and backwards or to either side by the stylo-glossi. Thus the whole of the complicated movements of the tongue may be explained, by reasoning upon the direction of the

fibres of the muscles, and their probable actions. The palato-glossi muscles, assisted by the uvula, have the power of closing the fauces completely, an action which takes place in deglutition.

VESSELS AND NERVES OF THE NECK.

Having thus far studied the muscles, the dissector should turn to the opposite side of the neck, with the view of examining the vessels and nerves. The integument and superficial fascia having been dissected back, the platysma is brought into view, and may be carefully raised. Beneath it, in the anterior triangle, will be found the inframaxillary branches of the cervico-facial division of the facial nerve (page 215.), and the superficialis colli nerve; lying upon the sheath of the sterno-mastoid muscle is the auricularis magnus nerve and external jugular vein, with one or two lymphatic glands; and in the lower part of the posterior triangle will be seen the clavicular and acromial branches of the cervical plexus.

The SUPERFICIALIS COLLI nerve, one of the three superficial ascending branches of the cervical plexus, arises from the second and third cervical nerves, and curving around the posterior border of the sterno-mastoid at about its middle, crosses that muscle to its anterior border; it then pierces the deep cervical fascia, and divides into an *ascending* and *descending* branch. There are sometimes two nerves in place of this division into two branches.

The *ascending branch* divides into several filaments, one of which ascends by the side of the external jugular vein; others communicate with the inframaxillary branches of the facial nerve, forming a kind of plexus; and a third set piercing the platysma are distributed to the integument of the anterior triangle as high as the lower jaw. These latter supply the platysma and communicate with the branches of the facial through that muscle.

The *descending branch* pierces the platysma and is distributed to the integument of the front of the neck as far downwards as the sternum.

The AURICULARIS MAGNUS, the largest of the three branches of the cervical plexus, proceeds from the second and third cervical nerves. It pierces the deep fascia at the posterior border of the sterno-mastoid, and ascends beneath the platysma and parallel with the external

jugular vein to the parotid gland, where it divides into an *anterior* and *posterior* branch.

The *anterior branch* distributes filaments to the integument of the face over the parotid gland, and communicates with the facial nerve.

The *posterior branch* ascends to the back of the ear, and divides into filaments which are distributed to the pinna; and a *mastoid branch* which supplies the integument behind the ear, and communicates with the posterior auricular branches of the pneumogastric and facial nerve, and with the occipitalis minor.

The OCCIPITALIS MINOR nerve, arising from the second cervical nerve, ascends along the posterior border of the sterno-mastoid, pierces the deep fascia near the occiput, and is distributed to the occipito-frontalis and attollens aurem (*auricular branch*), and to the lateral and posterior part of the head, communicating with the occipitalis major and posterior auricular branch of the facial.

The EXTERNAL JUGULAR VEIN, formed by the union of the posterior auricular and temporo-maxillary vein in the parotid gland, descends over the sterno-mastoid muscle, lying between the deep cervical fascia and the platysma, to the posterior border of the sterno-mastoid, at its lower part, where it pierces the deep fascia and terminates in the subclavian vein. It communicates with the internal jugular vein in the parotid gland, and in the lower part of the neck with the anterior jugular. It also communicates occasionally with the cephalic vein, by a branch from the latter which crosses the clavicle. The external jugular vein receives several superficial veins from the back part of the head and neck.

Operation.—The external jugular vein is generally opened, where it lies on the sterno-mastoid muscle. The finger should be placed on the vessel, below the point selected for incision, with the double object of rendering the vein tense, and preventing the admission of air. The incision should be directed obliquely upwards and backwards (*fig. 29.*, No 10.), so as to cross the direction of the fibres of the platysma, otherwise the fibres, by drawing the edges of the wound together, might prevent the flow of blood. The parts cut through will be the integument, the platysma with the two layers of the superficial fascia, between which it is placed, and the coats of the vein.

The ANTERIOR JUGULAR VEIN is formed by branches which commence in the fore part of the neck. It passes

along the anterior border of the sterno-mastoid, and turning outwards behind the tendon of that muscle, terminates in the subclavian vein near the external jugular. It communicates with the external and internal jugular vein, and with its fellow of the opposite side of the neck.

Superficial lymphatic Glands. — The superficial lymphatic glands of the neck are two or three beneath the chin and in the submaxillary triangle, and three or four in the course of the external jugular vein. The largest of the latter are situated at the lower part of the vein, at the posterior border of the sterno-mastoid muscle.

POSTERIOR TRIANGULAR SPACE.

The sheath of the sterno-mastoid may now be laid open by means of a longitudinal incision, and dissected back to the posterior border of the muscle. In the next place, the deep fascia covering the posterior triangular space should be carefully removed, in order to bring into view the nerves and vessels which it contains. Turning around the posterior border of the sterno-mastoid from behind, are the three ascending branches of the cervical plexus already described, namely, superficialis colli, auricularis magnus, and occipitalis minor; crossing the space below these, is the spinal accessory nerve in its course from the sterno-mastoid to the trapezius; lower down are the descending branches of the cervical plexus, elavieulares, and acromiales; beneath the latter is the posterior belly of the omo-hyoid muscle, which marks the lower boundary of the occipital triangle, and the upper boundary of the subclavian triangle. On a level with this muscle is the transversalis colli artery, and lower down, behind the elaviele, the suprascapular artery. Moreover, lying deeply in the subclavian triangle, is the subclavian artery and brachial plexus of nerves.

The subclavian triangle varies in its extent in different subjects; the posterior belly of the omo-hyoideus, usually an inch and a half above the elaviele, may descend nearer to that bone; or the sterno-mastoid and trapezius, instead of having between them a space equal to one-third the length of the elaviele, may approach each other, or even meet.

The floor of the posterior triangle is formed by the muscles of the back of the neck, and by the middle and posterior scalenus.

After studying the relative position of the contents of the posterior triangle, the sterno-mastoid may be divided through the middle, and its ends turned upwards and downwards. The spinal accessory nerve may then be seen piercing the upper part of the muscle, and the cervical nerves and cervical plexus may be dissected.

CERVICAL NERVES. — The cervical nerves are eight in number, the first passing out of the vertebral canal above

the atlas, and the last between the seventh cervical and first dorsal vertebra. Each nerve, at its issue from the vertebral canal, splits into an *anterior* and *posterior* division. The posterior divisions have been already described (page 188.).

The anterior division of the *first cervical*, or sub-occipital nerve, proceeds from its trunk, while the latter is placed on the posterior arch of the atlas; and passing forwards, beneath the vertebral artery, curves downwards, in front of the transverse process of the atlas, to form a loop of communication with an ascending branch of the second cervical nerve.

This nerve supplies the rectus lateralis and rectus anticus minor muscle, and its loop receives branches of communication from the pneumogastric, hypoglossal, and sympathetic nerve.

The anterior division of the *second cervical nerve* quits its trunk of origin by passing over the lamina of the axis; it then passes forwards externally to the vertebral artery and intertransverse muscles, and divides into an *ascending* branch, which completes the loop with the first nerve, and two *descending* branches, which form loops with corresponding branches of the third.

The *third* and *fourth* cervical nerves, immediately on their exit from between the intertransverse muscles, divide in a similar manner into branches which form loops with the nerve above and below.

Cervical Plexus. — The communications so established between the anterior divisions of the four upper cervical nerves, constitute the cervical plexus. The plexus is situated behind the sterno-mastoid muscle, and rests on the levator anguli scapulæ, posterior and middle scalenus, and splenius colli muscle.

The *branches* of the cervical plexus admit of a primary division into *superficial* and deep; and the superficial set are further divisible into *ascending* and *descending*. The following table exhibits this arrangement: —

Superficial .	{	<i>Ascending</i> ,	{	Superficialis colli,
				Auricularis magnus,
				Occipitalis minor.
		<i>Descending</i> ,	{	Acromiales,
				Claviculares.

Deep { Communicating branches,
 Communicans noni,
 Muscular,
 Phrenic.

The *ascending superficial branches* proceed from the second and third cervical nerves, and pass forwards to the posterior border of the sterno-mastoid muscle (p. 242.).

The *descending superficial branches*, two or three in number, proceed from the fourth cervical nerve, and pass downwards in the triangular space; they then pierce the deep fascia, and crossing the clavicle, are distributed to the integument of the front of the chest from the sternum to the acromion: hence their designation, *claviculares* and *acromiales*. The most anterior of the branches is named *sternal*, from its destination, and the outermost branch passes over the clavicular attachment of the trapezius, to reach the shoulder.

Deep Branches. — The *communicating branches* are filaments of communication passing between the loop of the first cervical nerve and the pneumogastric, hypoglossal, and sympathetic nerve, and communications between the other nerves and the sympathetic.

The *communicans noni* is a long and slender branch of communication between the cervical plexus and the descendens noni. It arises from the second and third cervical nerves, and passing downwards, by the side of the internal jugular vein to the middle of the neck, reaches the front of the sheath of the carotid vessels, and forms a loop with the descendens noni of the hypoglossal nerve.

The *muscular branches* of the cervical plexus are distributed to the muscles of the front of the vertebral column and side of the neck. From the loop, between the *first* and second nerve, branches are given to the anterior recti. From the *second* cervical nerve a branch is given to the sterno-mastoid. From the *third* and *fourth* nerves branches are given off to the trapezius, levator anguli scapulæ, and scalenus posticus. The branch to the trapezius communicates with the spinal accessory nerve.

The *phrenic nerve* (internal respiratory of Bell) is formed by the union of filaments from the third, fourth, and fifth cervical nerve. It passes downwards, resting on the scalenus anticus muscle, and at the root of the

neck receives a filament from the sympathetic. The nerve next passes between the subclavian artery and vein, and crossing the origin of the internal mammary artery, enters the chest. It then descends through the chest, between the pleura and pericardium, and in front of the root of the lung, to the diaphragm (page 143.).

BRACHIAL PLEXUS. — The anterior divisions of the four lower cervical nerves and the first dorsal, constitute, by their communications, the brachial plexus. The mode of formation of the plexus is as follows:—the fifth and sixth nerves unite to form a common trunk; the last cervical and first dorsal also unite as soon as they meet, to form a single trunk; the seventh cervical nerve lies for some distance apart from the rest, and then divides into two branches, which join the other cords. At this point the plexus consists of two cords, from which a third is given off, and the three cords become placed, one to the inner side of the axillary artery, one behind, and one to its outer side (page 93.).

The brachial plexus communicates with the cervical plexus by means of a branch from the fourth to the fifth nerve; and receives branches from the two inferior cervical ganglia of the sympathetic.

The *branches* of the brachial plexus in the neck are some small branches to the longus colli and scalmi; branches to the rhomboidei and subclavius muscle, the suprascapular, and posterior thoracic.

The *rhomboïd branch* proceeds from the fifth cervical nerve, and passing backwards through the fibres of the scalenus medius, and beneath the levator anguli scapulæ, is distributed to the under surface of the rhomboid muscles. In its course it sometimes gives a branch to the levator anguli scapulæ.

The *subclavian branch* proceeds from the cord formed by the fifth and sixth nerves, and descends in front of the subclavian artery to the subclavius muscle. This nerve usually communicates with the phrenic at its entrance into the chest.

The *posterior thoracic nerve* (long thoracic; external respiratory of Bell) arises by two roots from the fifth and sixth cervical nerves, and passing between the fibres of the middle scalenus, descends behind the brachial

plexus to the serratus magnus, along which it is distributed to the lower border of that muscle (page 94.).

The *suprascapular nerve* proceeds from the fifth cervical nerve, and descends, beneath the trapezius, to the suprascapular fossa (page 102.).

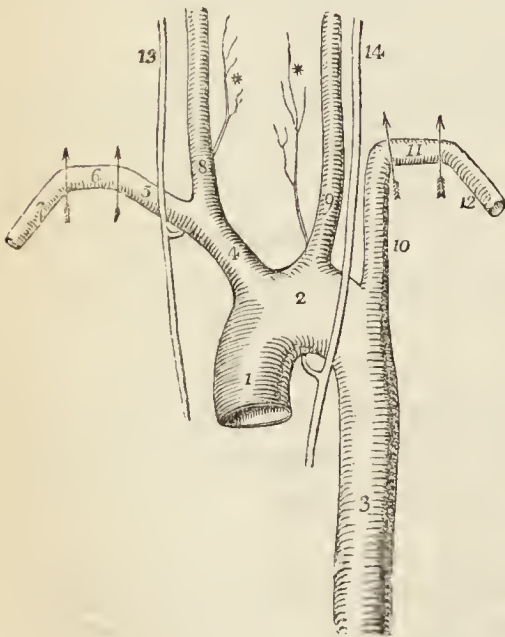
Before proceeding to the study of the subclavian artery and its branches, the dissector should define and examine a group of muscles forming a pyramidal mass at the root of the neck, the scaleni. These muscles are connected with the transverse processes of the cervical vertebræ above, and the first and second ribs below. According to different authors, they are two, three, or more in number.

The *SCALENUS ANTICUS* arises from the anterior tubercles of the transverse processes of the third, fourth, fifth, and sixth cervical vertebræ, and is *inserted* into the tubercle upon the upper and inner border of the first rib. It is a triangular muscle, and at its origin is continuous with the *rectus anticus major*.

The *SCALENUS POSTICUS* (*scalenus medius* and *posticus*) arises from the posterior tubercles of all the cervical vertebræ excepting the first. It is inserted by two fleshy fasciculi into the first and second ribs. The *anterior* of the two fasciculi (*scalenus medius*) is large, and occupies all the surface of the first rib between the groove for the subclavian artery and the tuberosity. The *posterior* (*scalenus posticus*) is small, and is attached to the second rib between its tubercle and angle.

SUBCLAVIAN ARTERY and its Branches. — The subclavian artery differs in its origin on the two sides of the body, and consequently in that portion of its course which is in relation with the cavity of the thorax. On its escape from the chest its course is alike on both sides. The course of the artery is divided into three parts.

Fig. 30.*



* The arch of the aorta, with its branches, and the course of the subclavian arteries.

No. 1. The ascending portion of the arch of the aorta. 2. The

First Part.—On the right side the subclavian artery commences at the bifurcation of the arteria innominata, opposite the sterno-clavicular articulation, and passes obliquely outwards to the inner border of the scalenus anticus, where the second portion of its course begins.

On the left side the subclavian artery proceeds from the posterior part of the arch of the aorta, and therefore lies more deeply in the chest, and is longer in its course. It ascends perpendicularly to the inner border of the scalenus anticus. From this point the arteries correspond on both sides.

Second Part.—The artery next passes horizontally outwards behind the scalenus anticus; and (third part) then curves outwards and downwards to become, opposite the lower border of the first rib, the axillary artery.

Relations.—The *first* part of the artery is crossed *in front* by the internal jugular vein, vertebral vein, pneumogastric nerve, phrenic nerve, and one or two branches of the sympathetic; *behind* it has the sympathetic nerve, on the right side the recurrent nerve, and on the left the thoracic duct; *below*, on the right side is the pleura; that membrane being to its outer side on the left.

The *second portion* of the artery has the scalenus anticus *in front*; the scalenus medius and two lower nerves of the brachial plexus *behind*; the upper nerves of the plexus *above*, and the pleura *below*. The scalenus anticus separates it from the phrenic nerve and subclavian vein, which latter is rather below the level of the artery.

The *third portion* of the artery is situated in the subclavian triangle, and is more superficial than the rest. In front it is covered by the integument, platysma, and deep fascia, and crossed by the supraclavicular nerves. Lower down it is crossed by the suprascapular artery and vein,

transverse part of the arch. 3. The thoracic aorta. 4. The arteria innominata. 5. The right subclavian, the first, or obliquely ascending portion of its course. 6. The second, or transverse portion. 7. The third, or obliquely descending portion. 8. The right carotid artery. 9. The left carotid. 10. The left subclavian artery; the first, or perpendicular portion. 11. The second, or transverse. 12. The third, or oblique portion. 13. The right pneumogastric nerve, giving off the recurrent * around the subclavian artery. 14. The left pneumogastric, sending its recurrent branch * around the arch of the aorta. * * The two recurrent laryngeal nerves.

and gets behind the subclavius muscle and clavicle. *Behind*, it has the scalenus medius; *above*, the brachial plexus; and *below*, the first rib and subclavian vein.

Operation.—Ligature of the subclavian artery is performed on that vessel in the third part of its course, just after its issue from between the scalmi muscles, and where it rests on the first rib.

An incision is made along the upper border of the clavicle, from the sternal portion of the sterno-mastoid muscle to the edge of the trapezius. This should divide the integument, superficial fascia, platysma, and deep fascia; and more or less of the clavicular portion of the sterno-mastoid muscle, according to its breadth or the depth of the artery. Then lay aside the knife, introduce a finger into the wound behind the vein, and feel for the tubercle on the first rib: immediately behind it is the cylinder of the artery, which may be recognised by its roundness and elasticity, and by its pulsation beneath the finger. One of the chief difficulties in the performance of the operation is the position of the vein, in front of the artery; and when of large size and distended with blood it may present an inconvenient obstacle. Occasionally another impediment arises from the termination of the external jugular vein in the middle of the space. The operator has to guard against wounding these veins, or placing his ligature around any of the nerves of the brachial plexus. The parts cut through in the operation are the *integument, superficial fascia, platysma, supraclavicular nerves, clavicular origin of the sterno-mastoid muscle, deep fascia, cellular tissue.*

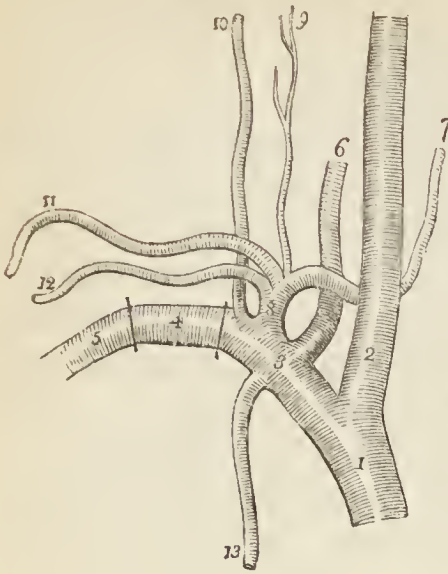
Branches.—The branches of the subclavian artery are four, and sometimes five, in number. Three are given off from the *first portion* of the artery; one, the superior intercostal, from the *second portion*; and when a fifth artery exists, it arises from the third portion, and is the suprascapular. In a tabular form the branches are as follows:—

Vertebral,	
Internal mammary,	
Thyroid axis	{
	Inferior thyroid,
	Suprascapular,
	Transversalis colli.
Superior intercostal	— Profunda cervicis.

The VERTEBRAL ARTERY, the first and largest of the branches of the subclavian artery, arises from the posterior aspect of that trunk; it ascends through the foramina in the transverse processes of all the cervical vertebræ, excepting the last; then winds backwards around the articulating process of the atlas; and, piercing

the dura mater, enters the skull through the foramen magnum. The two arteries unite at the lower border of the pons Varolii, to form the *basilar artery*. In the foramina of the transverse processes of the vertebræ the artery lies in front of the cervical nerves, and on the left side the artery is crossed by the thoracic duct.

Fig. 31.*



The *branches* of the vertebral artery in the neck are *lateral spinal branches*, which enter the intervertebral foramina, and are distributed to the vertebræ and spinal cord.

The INTERNAL MAMMARY ARTERY arises from the under side of the subclavian, and passes down behind the subclavian vein to the cartilage of the first rib. It then descends by the side of the sternum, resting on the cartilages of the ribs, to the sheath of the rectus, where, under the name of superior epigastric, it terminates by inosculating with the epigastric branch of the external iliac. As the artery enters the chest it is crossed by the phrenic nerve.

The relations and branches of the internal mammary artery have been already described at page 98.

The THYROID AXIS is a short trunk which arises from the front of the subclavian, close to the inner border of the anterior scalenus, and divides almost immediately into three branches; inferior thyroid, suprascapular, and transversalis colli.

The INFERIOR THYROID ARTERY ascends obliquely in a serpentine course behind the sheath of the carotid vessels,

* The right subclavian artery, with its branches.

No. 1. The arteria innominata, dividing into, 2. The right common carotid artery, and 3. The right subclavian artery, the first part of its course. 4. The second part of its course. 5. The third part of its course. 6. The vertebral artery. 7. The inferior thyroid artery. 8. The thyroid axis. 9. The cervicalis ascendens. 10. The profunda cervicis; the superior intercostal artery from which it arises is concealed by the trunk of the subclavian. 11. The transversalis colli artery. 12. The suprascapular artery. 13. The internal mammary artery.

and in front of the longus colli, to the inferior and posterior part of the thyroid gland, to which it is distributed. It is in relation with the middle cervical ganglion of the sympathetic, which lies in front of it; and sends branches to the trachea, larynx, and œsophagus.

Near its origin the inferior thyroid artery gives off a large branch, the *cervicalis ascendens*, which passes up the neck, resting on the anterior tubercles of the transverse processes of the cervical vertebræ, and occupying the groove between the scalenus anticus and rectus anticus major. It is distributed to the deep muscles and glands of the neck, and sends branches through the intervertebral foramina to supply the spinal cord and its membranes.

The SUPRASCAPULAR ARTERY (*transversalis humeri*) passes obliquely outwards behind the clavicle, and over the ligament of the suprascapular notch, to the supraspinatus fossa. It crosses in its course the scalenus anticus muscle, phrenic nerve, and subclavian artery, is distributed to the muscles of the dorsum of the scapula, and inosculates with the posterior scapular, and beneath the acromion process with the dorsal branch of the subscapular artery (page 92).

The TRANSVERSALIS COLLI ARTERY passes transversely across the subclavian triangle at the root of the neck to the anterior border of the levator anguli scapulæ, where it divides into two terminal branches, the superficialis cervicis and posterior scapular. In its course it lies above the suprascapular artery, and crosses the scaleni muscles and brachial plexus of nerves, often passing between the latter. At its bifurcation it is covered in by the edge of the trapezius.

The *superficialis cervicis* artery, its ascending branch, passes upwards under cover of the anterior border of the trapezius, and is distributed to the superficial muscles of the neck and deep cervical glands.

The *posterior scapular* artery, the proper continuation of the transversalis colli, passes backwards to the superior angle of the scapula, and then descends along the posterior border of that bone to its inferior angle, where it inosculates with the subscapular artery (page 92.).

The SUPERIOR INTERCOSTAL ARTERY arises from the upper and back part of the subclavian artery behind the scalenus anticus, and passes down behind the pleura to the

neck of the first rib, whence it descends to supply the first two intercostal spaces (page 175.).

The *profunda cervicis* artery arises by a common trunk with the preceding, or, more properly, is a branch of the superior intercostal, corresponding with the posterior branch of the other intercostal arteries. It passes backwards between the transverse processes of the seventh cervical and first dorsal vertebra, and ascends among the muscles at the back of the neck, to which it is distributed, inosculating with the princeps cervicis, a branch of the occipital (page 190.).

The SUBCLAVIAN VEIN, the continuation upwards of the axillary vein, commences opposite the lower border of the first rib, and ascends in front of the rib and scalenus anticus and behind the clavicle and subclavius muscle to opposite the sterno-clavicular articulation, where it joins with the internal jugular vein to form the vena innominata. The subclavian vein is placed in front of, but rather below, the level of the subclavian artery, and is separated from the artery by the scalenus anticus, and by the phrenic and pneumogastric nerve.

The *branches* which open into the subclavian vein are the *external* and *anterior jugular* externally to the scalenus anticus, and the *vertebral* internally to that muscle.

Carotid Artery and its Branches.

The COMMON CAROTID ARTERY differs in its origin and length on the two sides of the neck. On the *right* side it proceeds from the bifurcation of the arteria innominata opposite the sterno-clavicular articulation; on the *left* it arises from the arch of the aorta, and ascending to a parallel position in the neck, takes a course similar to the right.

The common carotid artery ascends the neck by the side of the trachea and larynx to a point corresponding with the upper border of the thyroid cartilage, where it divides into the external carotid and internal carotid.

In its course it is enclosed in a fibrous sheath, which also contains the internal jugular vein, lying to the outer side of the artery; and the pneumogastric nerve, which lies between and behind both. The sheath rests upon the vertebral column, having interposed the sympathetic

nerve and the muscles of the anterior surface of the vertebral column, namely, the longus colli and rectus anticus major. In front of the sheath, at its middle, is the loop formed between the descendens noni nerve and the communicating branch of the cervical plexus, with the filaments given off by the loop.

With regard to the surface of the neck, the sheath of the carotid is deeply seated in the lower two-thirds of its extent and superficially in its upper third. It is covered in below by the sterno-mastoid, sterno-hyoid, and sterno-thyroid muscles, and crossed at about its middle by the omo-hyoid. Above, it has in front only the platysma and deep fascia. It is also crossed, both its superficial and deep part, by the thyroid veins.

Lying *internally* to the sheath is the trachea and larynx, with the inferior thyroid artery and recurrent laryngeal nerve, the two latter reaching that situation after having passed behind the sheath. On the left side of the neck, there is in addition the œsophagus. Externally to the sheath is a chain of lymphatic vessels and glands, the concatenated glands of the neck.

The special relations of the left common carotid while within the chest have been already described (page 165.). It is crossed by the left vena innominata, and in its course to the side of the neck rests upon the trachea, œsophagus, and thoracic duct.

The common carotid artery gives off no branch in its course.

The sheath of the carotid artery may now be carefully opened, and the relative positions of the internal jugular vein and pneumogastric nerve examined.

Operations.—The *common carotid* artery may be secured either in the upper or the lower carotid triangle. In the former, the *high* operation, the artery is comparatively superficial, and the operation proportionately simple. The incision is to be made along the anterior border of the sterno-mastoid, commencing an inch below the angle of the jaw, and carrying it half way down the neck. It should divide the integument, superficial fascia, platysma, and deep fascia. We then expose the sheath of the vessels, upon which lies the descendens noni nerve. Leave this nerve undisturbed, and open the sheath to its inner side, immediately above the omo-hyoid muscle; then turn the needle around the artery *from without inwards*, guarding against including the pneumogastric nerve by keeping the point of the instrument close to the cylinder of the artery. The parts to be cut through are the *integument, superficial fascia,*

platysma, superficialis colli nerve, *deep fascia*, and *sheath* of the vessels.

In the inferior carotid triangle the *low* operation is practised. The sterno-mastoid is still the guide for the incision, and the layers to be cut through are precisely the same as in the high operation. The sterno-mastoid is to be drawn aside, and the sheath will be found concealed by the sterno-thyroid muscle. This muscle is to be divided, and the sheath opened as in the previous operation. The descendens noni, if it extend so low, lies to the inner side of the sheath. The anterior jugular vein is situated along the inner border of the sterno-mastoid muscle, and should be looked for and avoided. The parts to be cut through are the same as in the previous operation, with the addition of the sterno-thyroid muscle.

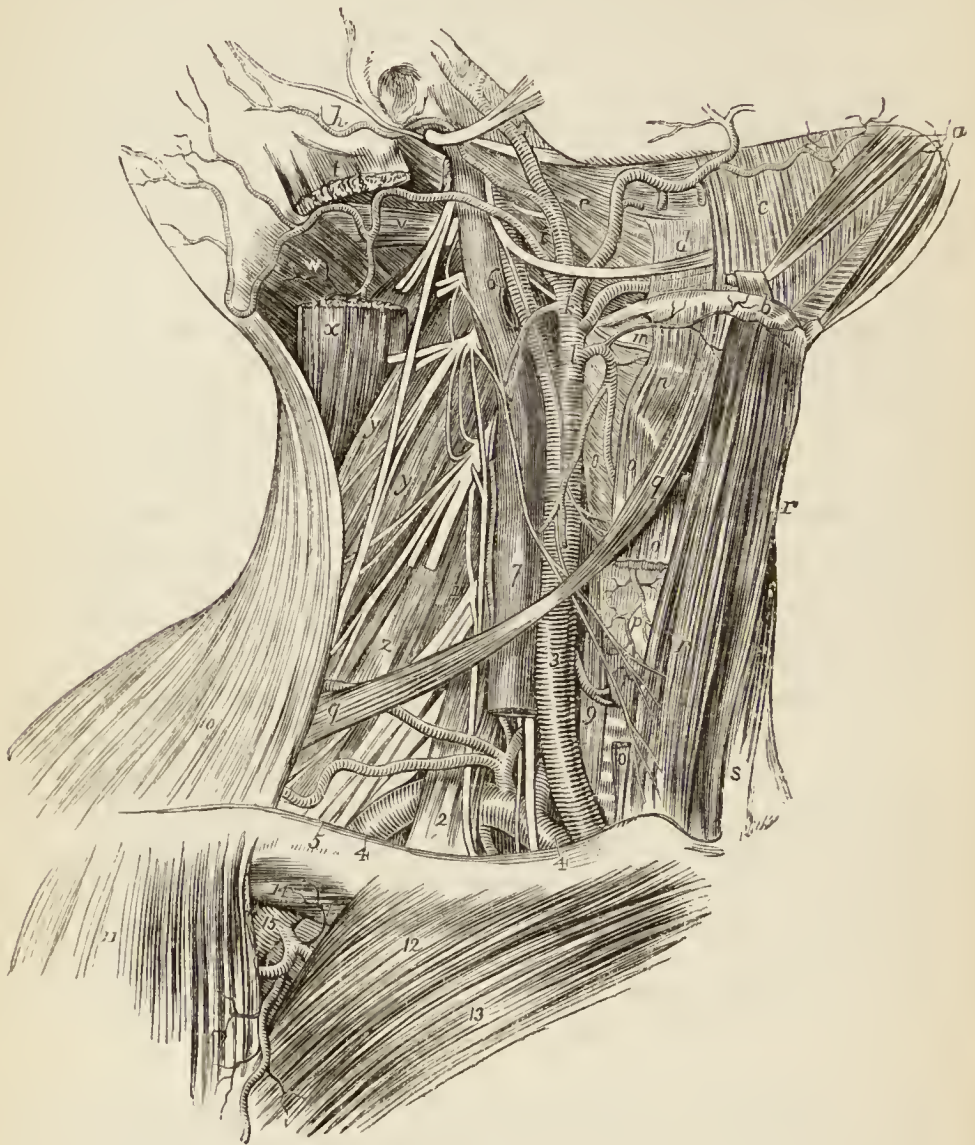The *arteria innominata* is also tied in the lower carotid triangle, on the right side. The incision, three inches in length, should be made obliquely across the space between the two sterno-mastoid muscles, immediately above the sternum. It should commence over the right sterno-clavicular articulation, and be carried obliquely upwards to the sterno-mastoid muscle of the opposite side, dividing the integument, superficial, and deep fascia. The operator then separates the two sterno-thyroid muscles; and, following the course of the trachea, reaches that artery as it crosses that tube to the right side. In the injected subject the student will find this by no means a difficult operation: the artery is much more superficial than might be expected, and the practice of the operation on the subject will not only familiarise him with the natural position of the artery, but also with the proximity of the arch of the aorta, and the possibility of aneurism of that vessel making its appearance above the sternum. The inferior thyroid veins are very much in the way of this operation, and care must be taken not to wound them. An inferior thyroid artery, from the innominata, is also occasionally met with. The layers to be cut through are simply the integument, and superficial and deep fascia.

The INTERNAL JUGULAR VEIN, larger than the common carotid artery, is the great venous trunk by which the blood from the sinuses of the cranium reaches the heart. It commences at the jugular foramen in the base of the skull, and passing down the front of the vertebral column becomes enclosed in the sheath of the common carotid artery lying to the outer side and parallel with that vessel. At the root of the neck on the *right* side the vein diverges from the artery, and a triangular space is formed between them, through which the pneumogastric nerve may be seen; on the left side no such separation exists. The internal jugular vein unites with the sub-clavian vein to form the vena innominata.

The *branches* which the internal jugular vein receives,

while situated in the carotid sheath, are the superior and middle thyroid veins.

*Fig. 32.**



* Anatomy of the neck. — *a*. The anterior bellies of the digastric muscles; their tendinous pulleys are seen to be attached to the os hyoides, *b*. *c*. The mylo-hyoideus muscle, on which is seen the submental branch of the facial artery. *d*. The hyo-glossus muscle; the artery above the letter is the facial; the nerve below it, the hypoglossal; the dotted lines below the nerve indicate the course of the lingual artery behind the muscle. *e*. The stylo-glossus muscle. *f*. The styloid process and muscles proceeding therefrom; the white band above *f* is the stylo-maxillary ligament. The artery in front of *f* is the external carotid; that behind it is the posterior auricular; the large nerve crossing these arteries is the facial. *g*. The bifurcation of the external carotid artery into the temporal and internal maxillary. *h*. The posterior auricular branch of the facial nerve, and posterior auri-

Lymphatic Glands and Vessels.—The deep lymphatic glands and vessels of the neck are situated along the

cular artery. *i* rests on the middle constrictor and stylo-pharyngeus muscle; the latter is crossed by the glosso-pharyngeal nerve, which is seen just above *i*. The large artery in front of *i* is the external carotid; the artery behind it the occipital, and the large nerve below it the hypoglossal. *k*. The mastoid branch of the external carotid. The small nerve seen in the space above this branch is the superior laryngeal; and the smaller nerve descending behind it, upon the carotid artery, the descendens noni. *l*. The superior thyroid artery; just below the letter, the common carotid bifurcates into the external and internal carotid. *m*. The thyro-hyoidean membrane, on which are seen the superior laryngeal nerve and artery below, and the hyoidean branch of the superior thyroid above the letter. *n*. The thyro-hyoid muscle. *o, o*. The sterno-thyroid. *p*. The thyroid gland. *q, q*. Omo-hyoid muscle. *r, r*. The sterno-hyoid muscles. *s*. The left sterno-mastoid muscle. *t*. The origin of the right sterno-mastoid muscle. *v*. The superior obliquus capitis muscle; the artery meandering over this muscle is the occipital; the nerve to its right is the spinal accessory. *w*. The complexus muscle; the small artery crossing it from the occipital, is the princeps cervicis. *x*. The splenius capitis. *y, y*. The levator anguli scapulæ muscle. *z*. The scalenus posticus. 1. The scalenus medius. 2. The scalenus anticus. The two arteries crossing this muscle are the suprascapular (the lower) and transversalis colli (the upper); the trunk from which they proceed is the thyroid axis, which is also seen giving off the inferior thyroid artery; the latter, after crossing behind the common carotid artery, 3, enters the lower part of the thyroid gland, *p*. 4, 4. The subclavian artery. The large artery between the thyroid axis and common carotid is the vertebral, and the nerves crossing the subclavian in this situation, the pneumogastric (the larger) and a branch of the sympathetic. The artery proceeding from the subclavian below the thyroid axis, is the internal mammary, and the nerve near it, and lying on the scalenus anticus (2), is the phrenic. 5. The brachial plexus of nerves. 6, 7. The internal jugular vein. The portion 6 accompanies the internal carotid artery; the portion 7 the common carotid. The opening just below 6 is the divided trunk of the facial vein; the slender nerve to the right of 6 is the descendens noni; the slender nerve to the left, which descends to join the descendens noni, is the communicating branch. The short trunk to the left of 6 is the second cervical nerve; the third and fourth cervical nerves are seen lower down, and the cervical plexus resting on the levator anguli scapulæ and scalenus posticus muscle, *y y, z*. The little artery to the left of the internal jugular vein, at 7, is the cervicalis ascendens branch of the inferior thyroid. 8. The inferior constrictor muscle; the figure is placed between the trunk of the superior thyroid artery, and its muscular branch. 9. The œsophagus; the artery immediately above the figure is the inferior

course of the internal jugular vein, chiefly on its outer side, while a few are found by the side of the pharynx, œsophagus, and trachea. The lymphatic vessels terminate, on the right side, in the ductus lymphaticus dexter, and on the left in the thoracic duct.

The *ductus lymphaticus dexter* is a short trunk formed by the union of the lymphatic vessels of the right side of the head, right upper extremity, and right side of the thorax. It is situated at the root of the neck on the right side, and terminates at the point of junction of the internal jugular with the subclavian vein, on the posterior aspect of the vessel. At its termination it is provided with a pair of semilunar valves.

The *thoracic duct* (p. 176.) ascends into the left side of the root of the neck, behind the first portion of the subclavian artery, as high as the last cervical vertebra. It then curves downwards and forwards in front of the scalenus anticus and phrenic nerve, and terminates by opening into the posterior aspect of the junction of the internal jugular and subclavian vein. In the root of the neck it receives the lymphatics of the left side of the head and neck, left upper extremity, and left half of the thorax. At its opening into the vein, the thoracic duct is provided with a pair of semilunar valves.

The student should now proceed to dissect the external carotid artery and its branches, taking care not to divide the nerves which cross it in its course.

The EXTERNAL CAROTID ARTERY ascends nearly perpendicularly from a point opposite the upper border of the thyroid cartilage to the space between the neck of the lower jaw and meatus auditorius, where it divides into two terminal branches, the temporal and internal maxillary.

In the beginning of its course it is superficial, being covered in only by the platysma and deep fascia, and crossed by the hypoglossal nerve; a little higher it is crossed by the digastricus and stylo-hyoid muscle; and higher still it enters the substance of the parotid gland,

thyroid. 10. The trapezius muscle. 11. The deltoid. 12. The clavicular portion of the pectoralis major. 13. Its sternal portion. 14. The subclavius muscle. 15. The axillary artery, giving off the thoracico-acromialis artery.

and has in front of it the facial nerve and temporo-maxillary vein. Crossing *behind* it, and separating it from the internal carotid, is the stylo-pharyngeus and styloglossus muscle, the glosso-pharyngeal nerve, and the deep part of the parotid gland. The internal carotid artery lies at first to the outer side of the external carotid, but soon gets behind it.

The *branches* of the external carotid (ten in number) are divided into three sets — anterior, posterior, and ascending. They are as follows:—

<i>Anterior.</i>	<i>Posterior.</i>
Superior thyroid,	Sterno-mastoid,
Lingual,	Occipital,
Facial.	Posterior auricular.
<i>Ascending.</i>	
Ascending pharyngeal,	
Parotidean,	
Temporal,	
Internal maxillary.	

1. The SUPERIOR THYROID ARTERY, the first of the branches of the external carotid, arises from that trunk just below the great cornu of the os hyoides, and curves downwards to the thyroid gland. It is distributed by several large branches to the anterior part of the gland, and anastomoses with its fellow of the opposite side, and with the inferior thyroid arteries. In its course it passes beneath the omo-hyoid, sterno-thyroid, and sterno-hyoid muscles.

The *branches* of the superior thyroid artery are the

Hyoid,	Inferior laryngeal,
Superior laryngeal,	Muscular.

The *hyoid* branch passes forwards beneath the thyro-hyoideus, and is distributed to the depressor muscles of the os hyoides near their insertion.

The *superior laryngeal* pierces the thyro-hyoidean membrane, in company with the superior laryngeal nerve, and supplies the mucous membrane and muscles of the larynx, sending a branch upwards to the epiglottis.

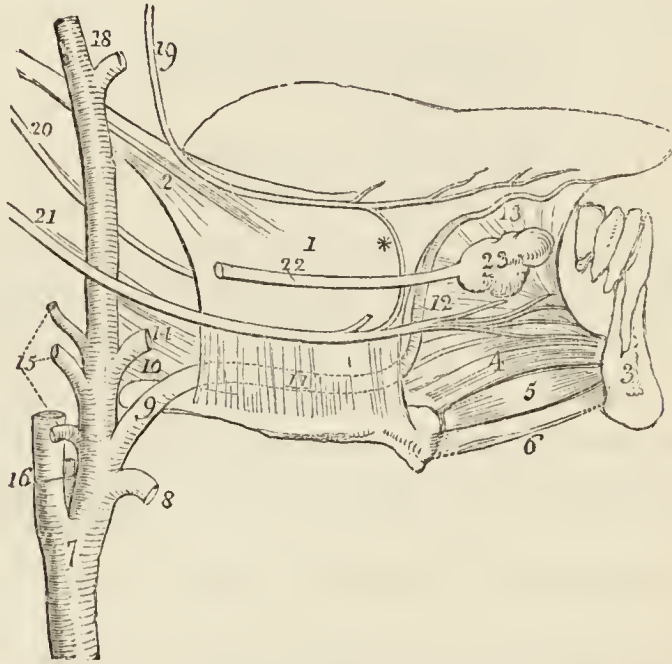
The *inferior laryngeal* (crico-thyroid) is a small branch which crosses the crico-thyroid membrane near the lower border of the thyroid cartilage. It sends

branches through that membrane to supply the mucous lining of the larynx, and inosculates with its fellow of the opposite side.

The *muscular* branches are distributed to the depressor muscles of the os hyoides and larynx. One of these branches crosses the sheath of the common carotid to the under surface of the sterno-mastoid muscle.

The LINGUAL ARTERY arises just above the superior thyroid, and, bending upwards over the great cornu of the os hyoides, runs forward nearly parallel with that bone; it then ascends to the under surface of the tongue, and passes onwards, in a serpentine course, to the tip of the organ, under the name of *ranine* artery.

Fig. 33.*



* The anatomy of the side of the tongue, with the relations of the vessels and nerves.

No. 1. The hyo-glossus muscle, arising from the side of the os hyoides below, and inserted into the side of the tongue, where it mingles its fibres with those of the stylo-glossus muscle, 2. 3. A section of the lower jaw at the symphysis. 4. The genio-hyo-glossus muscle. 5. The genio-hyoideus muscle. 6. The cut edge of the mylo-hyoideus. 7. The common carotid artery, dividing into the external and internal carotid. 8. The trunk of the superior thyroid artery. 9. The lingual artery; the first, or oblique portion of its course, resting upon the great cornu of the os hyoides, and upon (10.) the middle constrictor muscle. 11. The second, or horizontal portion of the lingual artery; its course beneath the hyo-glossus muscle is marked by dotted lines. 12. The third, or oblique por-

The first portion of the artery is superficial, although crossed by the digastricus and stylo-hyoid muscle and by the hypoglossal nerve. In its horizontal and oblique course it lies beneath the hyo-glossus, being at first placed between that muscle and the middle constrictor, and then between it and the genio-hyo-glossus. In its course along the under surface of the tongue, it lies between the lingualis and mucous membrane. The hyo-glossus muscle separates it from the hypoglossal nerve.

Operation. — The *lingual artery* is tied in the upper angle of the *superior carotid triangle*. The external incision should be made parallel with the lower border of the posterior belly of the digastricus muscle. It should cut through the integument, superficial fascia, platysma, and deep fascia. The hyo-glossus will then form the floor of the wound, upon which rests the lingual nerve; this must be carefully avoided by making the incision through the muscle below the nerve. The artery will then be exposed in the second part of its course.

The structures to be cut through are the *integument, superficial fascia, platysma, superficialis colli nerve, deep fascia, and hyo-glossus muscle.*

The *branches* of the lingual artery are the

Hyoid,
Dorsalis linguæ,
Sublingual.

The *hyoid* branch runs along the upper border of the os hyoides, and is distributed to the elevator muscles of the os hyoides, near their origin, inosculating with its fellow of the opposite side.

The *dorsalis linguæ* ascends along the posterior border of the hyo-glossus muscle, to the dorsum of the tongue, and is distributed to the tongue, the fauces, and epiglottis, anastomosing with its fellow of the opposite side.

tion of the lingual artery. 13. Its termination, the ranine artery. 14. The trunk of the facial artery. 15. The three posterior branches of the external carotid artery; they are from below upwards, the mastoid, occipital, and posterior auricular. 16. The trunk of the ascending pharyngeal artery. 18. The two terminal branches of the external carotid, the internal maxillary and temporal. 19. The gustatory branch of the fifth nerve. * Its communication with the lingual nerve. 20. The glosso-pharyngeal nerve. 21. The hypoglossal nerve. 22. Wharton's duct. 23. The sublingual gland.

The *sublingual* branch runs forwards on the genio-hyo-glossus muscle, and is distributed to the sublingual gland and to the muscles of the tongue. It is situated between the mylo-hyoideus and genio-hyo-glossus, generally accompanies Wharton's duct for a part of its course, and sends a branch to the frænum linguæ. It is the latter branch which affords the considerable hæmorrhage which sometimes follows the operation of snipping the frænum in children.

The *ranine artery* (the continuation of the lingual beyond the origin of the sublingual) terminates at the tip of the tongue by inosculating with its fellow of the opposite side.

The FACIAL ARTERY arises immediately above the lingual and a little above the great cornu of the os hyoides, and passes forwards to the submaxillary gland, in which it lies embedded. It then curves around the body of the lower jaw, close to the anterior inferior angle of the masseter muscle, ascends to the angle of the mouth, and thence to the angle of the eye, where it is named the *angular artery*.

In its course to the lower jaw it is crossed by the digastricus and stylo-hyoid muscle, and then becomes lodged in the submaxillary gland, wherein it makes a considerable bend. Its course and relations on the face have been already described (p. 216.).

Operation. — The *facial artery* is usually tied while resting on the body of the lower jaw, close to the anterior inferior angle of the masseter muscle. It is here superficial, and may be felt and seen pulsating immediately beneath the integument. It is covered by the *integument, superficial fascia, and platysma*. If it were necessary to tie the artery below the jaw, the upper border of the posterior belly of the digastric muscle would be the guide to the vessel. The ligature might then be passed around it just before it entered the submaxillary gland, whilst resting against the stylo-maxillary ligament. The structures to be cut through are the *integument, superficial fascia, platysma, cervical branches of the facial nerve, and deep fascia*.

The *branches* of the facial artery below the lower jaw are the

Inferior palatine,
Tonsillar,

Submaxillary,
Submental.

The *inferior palatine* branch ascends between the stylo-glossus and stylo-pharyngeus muscle, to be distributed to the tonsil and soft palate, and anastomoses with the posterior palatine branch of the internal maxillary artery.

The *tonsillar* branch ascends upon the side of the pharynx, and pierces the superior constrictor muscle, to be distributed to the tonsil.

The *submaxillary* (glandular) are four or five branches which supply the submaxillary gland.

The *submental* branch runs forward upon the mylo-hyoid muscle, under cover of the body of the lower jaw, and anastomoses with branches of the sublingual and inferior dental artery.

The STERNO-MASTOID ARTERY turns downwards from its origin, to be distributed to the sternoc-mastoid muscle and lymphatic glands of the neck. Sometimes there are two branches.

The OCCIPITAL ARTERY, smaller than the anterior branches, passes backwards behind the parotid gland and beneath the posterior belly of the digastricus, trachelo-mastoid, and sterno-mastoid muscle, to the occipital groove in the mastoid portion of the temporal bone. It then ascends between the splenius and complexus, pierces the trapezius, and is distributed to the back of the head (p. 202.). Opposite the angle of the jaw, the hypoglossal nerve curves forward around the artery.

Besides muscular branches to the muscles near which it passes, the occipital artery gives off but one named artery in the front of the neck; namely, the *inferior meningeal*, which ascends by the side of the internal jugular vein, and passes through the foramen lacerum posterius to be distributed to the dura mater.

Its posterior branch, the *arteria princeps cervicis*, has been already described (p. 190.).

The POSTERIOR AURICULAR ARTERY arises from the external carotid, above the level of the digastric and stylo-hyoid muscles, and ascends by the side of the styloid process, and behind the parotid gland, to the back part of the concha. It is distributed by two branches to the external ear and side of the head, anastomosing with the occipital and temporal arteries; some of its branches pass through fissures in the fibro-cartilage, to reach the

anterior surface of the pinna. The anterior auricular arteries are branches of the temporal.

The posterior auricular sends a branch to the digastricus muscle, and several to the parotid gland; it then gives off the *stylo-mastoid*, which enters the stylo-mastoid foramen, to be distributed to the aquæductus Fallopii, labyrinth, mastoid cells, and tympanum.

The ASCENDING PHARYNGEAL ARTERY, the smallest of the branches of the external carotid, arises from that trunk near its bifurcation, and ascends between the internal carotid and the side of the pharynx to the base of the skull, where it divides into two branches,—*meningeal*, which enters the foramen lacerum posterius, to be distributed to the dura mater, and *pharyngeal*. It supplies the pharynx, tonsils, soft palate, and Eustachian tube.

The PAROTIDEAN ARTERIES are four or five large branches which are given off from the external carotid whilst that vessel is situated in the parotid gland. They are distributed to the structure of the gland, their terminal branches reaching the integument of the side of the face.

The TEMPORAL ARTERY is one of the two terminal branches of the external carotid. It ascends over the root of the zygoma, and, at about an inch and a half above the zygomatic arch, divides into an anterior and a posterior temporal branch. The *anterior temporal* is distributed over the front of the temple and arch of the skull, and anastomoses with the opposite anterior temporal and with the supraorbital and frontal artery. The *posterior temporal* curves upwards and backwards, and inosculates with its fellow of the opposite side, with the posterior auricular and occipital artery.

The trunk of the temporal artery is covered by the parotid gland and by the attrahens aurem muscle, and rests on the temporal fascia.

The *branches* of the temporal artery are: some small offsets to the parotid gland, articulation of the lower jaw, external ear and orbit; and two of larger size—the *transverse facial* and *middle temporal*.

The branches to the external ear (*anterior auricular*) are two in number, and are distributed to the anterior portion of the pinna.

The branch to the orbit (*orbital*) passes forward, im-

mediately above the zygoma, between the two layers of the temporal fascia, and inosculates beneath the orbicularis with a branch of the lachrymal artery.

The *transversalis faciei* arises from the temporal immediately below the zygoma, and runs transversely across the face, resting on the masseter muscle, and lying parallel with and a little above Stenon's duct. It anastomoses with the facial and infra-orbital artery.

The *middle temporal branch* passes through an opening in the temporal fascia immediately above the zygoma, and supplies the temporal muscle, inosculating with the deep temporal arteries.

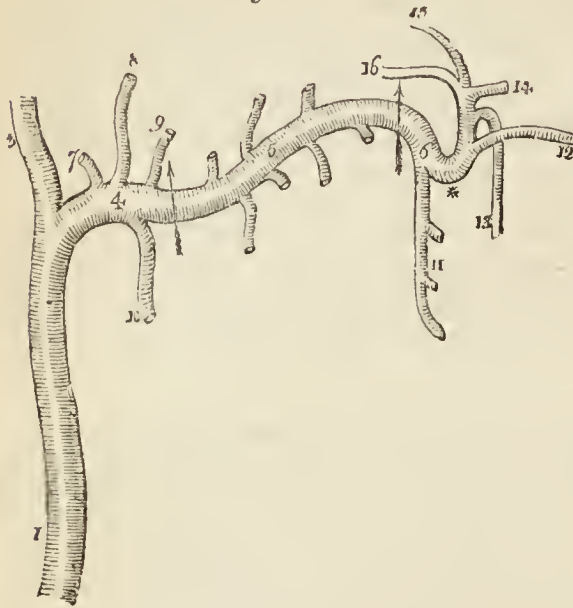
The examination of the next artery, the internal maxillary, requires the preparation already described (page 211.) for the study of the pterygoid muscles. The temporal fascia should be divided along the upper border of the zygoma; the zygoma cut through with the saw at both ends, and turned down with the masseter muscle; noting in this part of the dissection the *masseteric artery* and *nerve*, which cross the sigmoid notch of the lower jaw, to enter the under surface of that muscle. The coronoid process of the lower jaw should then be sawn through, and drawn upwards with the temporal muscle. Next the neck of the lower jaw should be cut across; and then the ramus, down to the dental foramen. The fat and cellular tissue may then be cleared away, carefully preserving any branches of nerves, and the internal maxillary artery and such of its branches as are visible at this stage of the dissection may be followed in their course.

The INTERNAL MAXILLARY ARTERY, one of the terminal branches of the external carotid, commences in the substance of the parotid gland opposite the meatus auditorius. It passes forwards behind the neck of the lower jaw, curves around the lower border of the external pterygoid muscle, and ascends obliquely forwards upon the outer aspect of that muscle to the space between its two heads. It then passes horizontally inwards between the two heads of the external pterygoid, and enters the speno-maxillary fossa, where it divides into its terminal branches.

The artery admits of a natural division into three parts; first, that situated behind the neck of the lower jaw, *maxillary portion*; second, that in relation with the external pterygoid muscle, *pterygoid portion*; third, that situated in the speno-maxillary fossa, *spheno-maxillary portion*.

The *maxillary portion* is situated between the neck of the jaw and the internal lateral ligament and inferior

Fig. 34.*



dentul nerve, and lies parallel with the auriculo-temporal nerve. The *pterygoid portion* lies between the external pterygoid and the masseter and temporal muscle, and is crossed by the masseteric nerve.

Having thus far examined the internal maxillary artery and its relations, the head of the lower jaw should be dislocated and drawn forwards with the external pterygoid muscle, in order to be able to

dissect the branches of the artery which lie behind. Before disturbing the muscle, however, the student should observe the nerves and vessels which are in relation with it. At its upper border he will find the temporal nerve, the deep temporal arteries, and the masseteric nerve. Piercing the muscle at its anterior part is the buccal nerve. Lying against the superior maxillary bone, just in front of its attachment, is the superior dental nerve, accompanied by its artery. Issuing from below the muscle are two large nerves, the gustatory and inferior dental; and, passing backwards behind its condyloid attachment, is the auriculo-temporal nerve.

* The internal maxillary artery, with its branches.

No. 1. The external carotid artery, 3, 4. The two terminal branches of the external carotid. 3. The temporal artery; and 4. The internal maxillary, the first or *maxillary portion* of its course: the limit of this portion is marked by an arrow. 5. The second, or *muscular portion*, of the artery; the limits are bounded by the arrows. 6. The third, or *spheno-maxillary portion*. The branches of the maxillary portion are—7. Tympanic branch. 8. The arteria meningea media. 9. The arteria meningea parva. 10. The inferior dental artery. The branches of the second portion are wholly muscular, the ascending ones being distributed to the temporal, and the descending to the four other muscles of the intermaxillary region, viz. the two pterygoids, the masseter and buccinator. The branches of the spheno-maxillary portion of the artery are, 11. The superior dental artery. 12. The infra-orbital artery. 13. The descending palatine. 14. The spheno-palatine, or nasal. 15. The pterygo-palatine. 16. The Vidian. * The remarkable bend which the third portion of the artery makes as it turns inwards to enter the spheno-maxillary fossa.

When the external pterygoid muscle is drawn forwards, these nerves may be traced to their origin from the inferior maxillary nerve. They should be cleared of fat and cellular tissue, as well as the arterial branches of the internal maxillary. Numerous veins, part of a plexus, will be found between the two pterygoid muscles ; these must be removed. The auriculo-temporal nerve may then be followed in its course backward, and a small nerve observed, — the chorda tympani, which joins the gustatory nerve at an acute angle on the internal pterygoid muscle.

The *branches* of the internal maxillary artery, grouped into three sets in correspondence with the divisions of the trunk of the artery, are as follows :—

<i>Maxillary portion.</i>	<i>Pterygoid portion.</i>
Tympanic,	Deep temporal,
Inferior dental,	Pterygoid,
Arteria meningea media,	Masseteric,
Arteria meningea parva.	Buccal.

Pterygo-maxillary portion.

Superior dental,
 Infra-orbital,
 Pterygo-palatine,
 Spheno-palatine,
 Descending palatine,
 Vidian.

The *tympanic* branch passes into the tympanum through the fissura Glaseri, and is distributed to the laxator tympani and membrana tympani ; on the latter it inosculates with the stylo-mastoid artery.

The *inferior dental* descends to the dental foramen, and enters the canal of the lower jaw in company with the dental nerve. Opposite the bicuspid teeth it divides into two branches, one of which is continued onwards within the bone as far as the symphysis, to supply the incisor teeth, while the other escapes with the nerve at the mental foramen, and anastomoses with the inferior labial and submental branch of the facial. It supplies the teeth of the lower jaw, sending small branches along the canals in their roots. At the inferior dental foramen, it gives off a *mylo-hyoid* branch, which accompanies the mylo-hyoidean nerve.

The *arteria meningea media* ascends, behind the temporo-maxillary articulation, to the foramen spinosum

in the spinous process of the sphenoid bone, and, entering the cranium, divides into an anterior and a posterior branch, which are distributed to the dura mater and bone.

The *meningea parva* is a small branch which ascends to the foramen ovale, and passes into the skull to be distributed to the Casserian ganglion and dura mater. It gives off a twig to the nasal fossæ and soft palate.

The *muscular branches* are distributed, as their names imply, to the five muscles of the maxillary region; the *temporal* branches (*temporales profundæ*) are two in number; they inosculate with branches of the superficial temporal. The *pterygoid* branches are distributed to both the muscles of that name. The *masseteric* artery passes outwards, behind the tendon of the temporal muscle and over the sigmoid notch, to the masseteric muscle. The *buccal* branch, arising over the anterior part of the pterygoid muscle, passes downwards with the buccal nerve to the buccinator muscle. It inosculates with the facial and transverse facial artery.

The *superior dental artery* (alveolar, superior maxillary) is given off from the internal maxillary, just as that vessel is about to make its turn inwards to reach the spheno-maxillary fossa. It descends upon the tuberosity of the superior maxillary bone, and sends its branches through several small foramina to supply the posterior teeth of the upper jaw and the antrum. The terminal branches are continued forwards upon the alveolar process, to be distributed to the gums and sockets of the teeth.

To see the remaining branches of the internal maxillary artery, the outer wall of the orbit must be divided with the saw, to the level of the cheek, and removed.

The saw should then be carried through the great ala of the sphenoid bone, the dura mater having been stripped from its surface, to the foramen rotundum. Another section must be made through the squamous portion of the temporal bone to the foramen spinosum, and the extremities of the sections connected by means of the chisel. The piece of bone included by these incisions is then to be broken outwards, and any pieces of bone removed which may interfere with the view of the inferior and superior maxillary nerves, passing through their respective openings, and spheno-maxillary fossa. For the present, the student must be satisfied with tracing the branches as far as the openings through which they pass, and not

attempt to follow them in their course. He should also disturb the neighbouring parts as little as possible, in order to avoid injury to Meckel's ganglion and its branches.

The *pterygo-palatine* is a small branch which passes backwards through the pterygo-palatine canal, and supplies the upper part of the pharynx, Eustachian tube, and sphenoidal cells.

The *spheno-palatine*, or nasal, enters the superior meatus of the nose through the spheno-palatine foramen in company with the nasal branches of Meckel's ganglion, and divides into two or three branches. One branch (*artery of the septum*) is distributed to the mucous membrane of the septum, and inosculates in the anterior palatine canal with a terminal branch of the descending palatine. Another branch supplies the mucous membrane of the lateral wall of the nares, antrum, sphenoid and ethmoid cells.

The *superior* or *descending palatine* artery (posterior palatine) descends along the posterior palatine canal, in company with the palatine branches of Meckel's ganglion, to the posterior palatine foramen. It then bends forward, lying in a groove upon the bone, and is distributed to the palate. While in the posterior palatine canal it sends a branch backwards, through the small posterior palatine foramen, to supply the soft palate, and anteriorly it distributes a branch to the anterior palatine canal, which reaches the nares and inosculates with the branches of the spheno-palatine artery.

The *Vidian branch* passes backwards along the pterygoid canal, and is distributed to the sheath of the Vidian nerve, and to the Eustachian tube.

VEINS OF THE EXTERNAL CAROTID.—The veins of the branches of the external carotid artery follow the direction of their respective vessels. The *internal maxillary vein* commences by the union of veins returning the blood from the zygomatic and pterygoid fossa, where they are so numerous and communicate so freely with each other as to constitute a *pterygoid plexus*. Behind the neck of the lower jaw the internal maxillary vein unites with the *temporal* vein, and the two together constitute the *temporo-maxillary vein*. The temporo-maxillary vein descends through the substance of the parotid gland, receiving in its course the transverse facial, anterior

auricular, and parotid veins. At the lower part of the gland it is joined by the *posterior auricular vein*, and becomes the external jugular. The *external jugular vein* communicates with the internal jugular in the parotid gland, and after receiving a cutaneous branch from the occipital region takes its course down the neck, across the sterno-mastoid muscle, to the subclavian vein.

The *facial*, the *occipital*, the *lingual*, and *superior thyroid veins* open into the internal jugular vein.

Fifth Pair of Nerves.

The preparation already made for the examination of the internal maxillary artery and its branches, is that which is best suited for the display of the two maxillary divisions of the fifth nerve, superior and inferior. Within the cranium, the dura mater should be stripped off the bones of the middle fossa, so as to expose the Casserian ganglion, and the ganglion may be carefully raised from its bed in order to see the anterior root of the nerve, in its course beneath the ganglion to join the inferior maxillary nerve. In the present dissection it will be more convenient to study the inferior maxillary nerve before the superior.

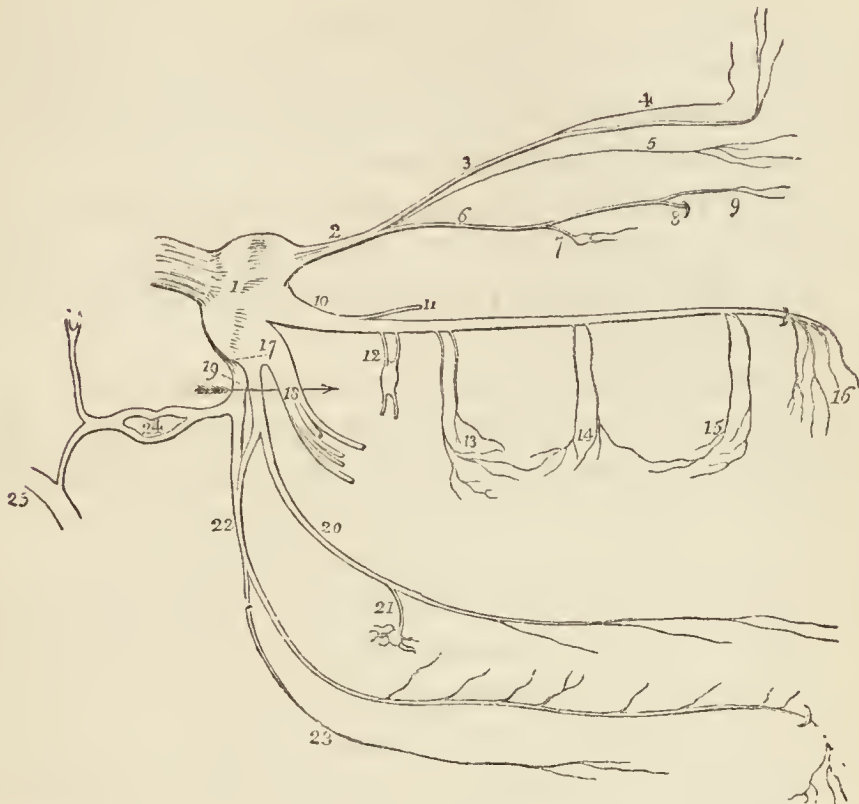
The FIFTH NERVE (*trifacial*; *trigeminus*) is the great sensitive nerve of the head and face, and the largest of the cranial nerves. It is a flattened cord, composed of a number of filaments held together by a sheath of the arachnoid membrane. It passes through an oval opening in the dura mater, near the extremity of the petrous portion of the temporal bone, resting in a groove upon that bone, and spreads out into a large flattened semi-lunar ganglion,—the Casserian. The Casserian ganglion occupies a considerable extent of space immediately in front of the extremity of the petrous bone, and upon the base of the great wing of the sphenoid, and divides into three branches,—*ophthalmic*, *superior maxillary*, and *inferior maxillary*.

The *ophthalmic nerve*, the smallest of the three, is about three quarters of an inch in length; it is situated in the outer wall of the cavernous sinus, externally to the other nerves in the sinus, and divides into three branches,—*frontal*, *lachrymal*, and *nasal*, which enter the orbit through the sphenoidal fissure (page 222.).

The *superior maxillary nerve* passes forwards to the foramen rotundum, through which it escapes from the cranium.

The INFERIOR MAXILLARY NERVE, the largest of the three, proceeds from the posterior angle of the Casserian

Fig. 35.*



ganglion, and passes out of the cranium through the foramen ovale. It then divides into two portions — *external* and *internal*.

* The branches of the fifth nerve.—No. 1. The Casserian ganglion. 2. The ophthalmic nerve. 3. The frontal nerve. 4. Its supra-trochlear branch. 5. The lachrymal nerve. 6. The nasal nerve. 7. Its branch of communication with the ophthalmic ganglion. 8. The passage of the nerve through the anterior ethmoidal foramen. 9. The infra-trochlear nerve. 10. The superior maxillary nerve. 11. Its orbital branch. 12. The sphenopalatine branches, communicating with Meckel's ganglion. 13. The posterior dental branches. 14. Middle dental branches. 15. The anterior dental branches. 16. The infra-orbital branches. 17. The inferior maxillary nerve. 18. Its external or muscular division. 19. The internal division of the inferior maxillary nerve. The arrow marks the separation of these two divisions of the nerve by the external pterygoid muscle. 20. The gustatory nerve. 21. The branch of communication with the submaxillary ganglion. 22. The inferior dental nerve, receiving a branch from the gustatory. 23. Its mylo-hyoidean branch. 24. The auriculo-temporal nerve communicating with, 25, the facial nerve.

The EXTERNAL DIVISION, into which nearly the whole of the motor root may be traced, separates into five or six branches for the supply of the muscles of the temporo-maxillary region.

The *masseteric branch*, passing over the external pterygoid muscle and behind the tendon of the temporal, crosses the sigmoid notch with the masseteric artery, and is distributed to the masseter muscle.

The *deep temporal branches*, two in number, *anterior* and *posterior*, pass between the external pterygoid muscle and the side of the cranium, to be distributed to the temporal muscle.

The *buccal branch* is of large size, and pierces the lower fibres of the external pterygoid muscle at its anterior part. It sends a branch to the external pterygoid muscle, and is then distributed to the buccinator, where it communicates with the facial nerve.

The *internal pterygoid branch* is a long and slender nerve, which passes inwards to the internal pterygoid muscle, and gives filaments in its course to the tensor palati and tensor tympani. This nerve is remarkable for its connection with the otic ganglion, to which it is closely attached.

The *external pterygoid branch* is commonly derived from the buccal nerve.

The examination of some of the preceding nerves will have required the drawing aside of the external pterygoid, and even, as in the case of the buccal nerve, the division of some of its fibres. The muscle must now be entirely removed, in order to see the branches of the internal division of the inferior maxillary nerve, which lie behind it.

The INTERNAL DIVISION splits into three branches,—*auriculo-temporal*, *inferior dental*, and *gustatory*.

The AURICULO-TEMPORAL NERVE passes backwards behind the articulation of the lower jaw, and enters the parotid gland, where it divides into two temporal branches. It generally consists of two cords, between which the arteria meningeae media takes its course to the foramen spinosum.

Its *branches* are, a small branch to the temporo-maxillary articulation; two or three small branches to the parotid gland; two branches to the meatus auris, which enter the canal between the fibro-cartilage and the pro-

cessus auditorius ; two auricular branches to the pinna ; a communicating branch to the otic ganglion ; two communicating branches to the facial nerve ; and the temporal branches.

The *auricular* branches, *superior* and *inferior*, are distributed to the pinna above and below the meatus. The inferior branch communicates with the sympathetic.

The branches which communicate with the facial nerve embrace the external carotid artery in their course.

The *temporal branches* are anterior and posterior. The *anterior* accompanies the temporal artery, and supplies the integument of the temporal region, communicating with the branches of the facial and supra-orbital nerve ; the latter is distributed to the upper part of the pinna, the *attrahens aurem* muscle, and the integument of the posterior part of the temple.

The INFERIOR DENTAL NERVE, the largest of the three branches of the internal division of the inferior maxillary, passes downwards with the inferior dental artery, at first between the two pterygoid muscles, and then between the internal lateral ligament and the ramus of the lower jaw, to the dental foramen. It then runs along the canal in the inferior maxillary bone, distributing branches (inferior maxillary plexus) to the teeth and gums, and divides into two terminal branches,—*incisive* and *mental*.

The *branches* of the inferior dental nerve, besides those given to the teeth, are the mylo-hyoidean and the two terminal branches.

The *mylo-hyoidean branch* quits the nerve just as it is about to enter the dental foramen. This branch pierces the insertion of the internal lateral ligament, and descends along a groove in the bone to the inferior surface of the mylo-hyoid muscle, to which, and to the anterior belly of the digastricus, it is distributed.

The *incisive branch* is continued forwards to the symphysis of the jaw, to supply the incisor teeth.

The *mental* or *labial branch* emerges from the jaw at the mental foramen, beneath the depressor anguli oris, and divides into branches which supply the muscles and integument of the lower lip and chin, and communicate with the facial nerve.

The mylo-hyoidean nerve is seen in the dissection of the mylo-hyoideus muscle, when the submaxillary region is turned upwards.

It is, however, better seen when a section is made through the body of the lower jaw a little to the side of the symphysis, and the jaw is drawn aside, after the detachment of the mylo-hyoideus muscle and buccinator, together with the pterygo-maxillary ligament and that portion of the superior constrictor which is connected with the lower jaw. If this preparation is not made for the mylo-hyoidean nerve, it is necessary in tracing the course of the following nerve.

The GUSTATORY NERVE descends between the two pterygoid muscles, and makes a gentle curve forwards to the side of the tongue, along which it takes its course to the tip. On the side of the tongue it is flattened, and gives off numerous branches, which are distributed to the mucous membrane and papillæ.

In the upper part of its course the gustatory nerve lies between the external pterygoid muscle and the pharynx, next between the two pterygoid muscles, then between the internal pterygoid and ramus of the jaw, and between the stylo-glossus muscle and the submaxillary gland; lastly, it runs along the side of the tongue, resting against the hyo-glossus muscle, and crossing the duct of the submaxillary gland, and is covered in by the mylo-hyoideus and mucous membrane.

The gustatory nerve, while between the pterygoid muscles, often receives a communicating branch from the inferior dental; lower down it is joined at an acute angle by the chorda tympani, a small nerve which, arising from the facial in the aqueductus Fallopii, crosses the tympanum, and escapes from that cavity through the fissura Glaseri. Having joined the gustatory nerve, the chorda tympani is continued downwards in its sheath to the submaxillary ganglion.

One or two *branches* are given by the gustatory nerve to the submaxillary ganglion.

On the hyo-glossus muscle several *branches* of communication join with branches of the hypo-glossal nerve, and others are sent to the sublingual gland and Wharton's duct.

The SUBMAXILLARY GANGLION, of small size and reddish colour, is situated on the submaxillary gland, in close relation with the gustatory nerve, and near the posterior border of the mylo-hyoideus muscle.

Its *branches of distribution*, six or eight in number, divide into many filaments, which supply the side of the

tongue, the submaxillary and sublingual glands, and Wharton's duct.

Its *branches of communication* are two or three from and to the gustatory nerve; one from the chorda tympani; two or three which form a plexus with branches of the hypoglossal nerve; and one or two filaments which pass to the facial artery, and communicate with the *nervi molles* from the cervical portion of the sympathetic.

If the student cut across the inferior maxillary nerve at its origin from the Casserian ganglion, and after breaking away the bone at the outer side of the foramen ovale draw the nerve outwards, he may find lying against the nerve, close to its exit from the foramen ovale, a small oval-shaped body,—the otic ganglion. Another guide to this small ganglion is the internal pterygoid nerve, upon which the ganglion is placed. Unless the subject be fresh, the dissector may fail to discover the ganglion, which, to make it out clearly with its branches, requires a fresh subject and a special dissection. If the latter can be obtained, the ganglion is best found by dissecting from within; taking the Eustachian tube, against which it lies, and the internal pterygoid nerve, as guides to its position.

The OTIC GANGLION (Arnold's) is a small oval-shaped and flattened ganglion, situated upon the internal pterygoid nerve, and appearing like a swelling of that nerve. It lies against the inner surface of the inferior maxillary nerve, close to the foramen ovale, and is in relation internally with the Eustachian tube and tensor palati muscle, and behind with the arteria meningea media.

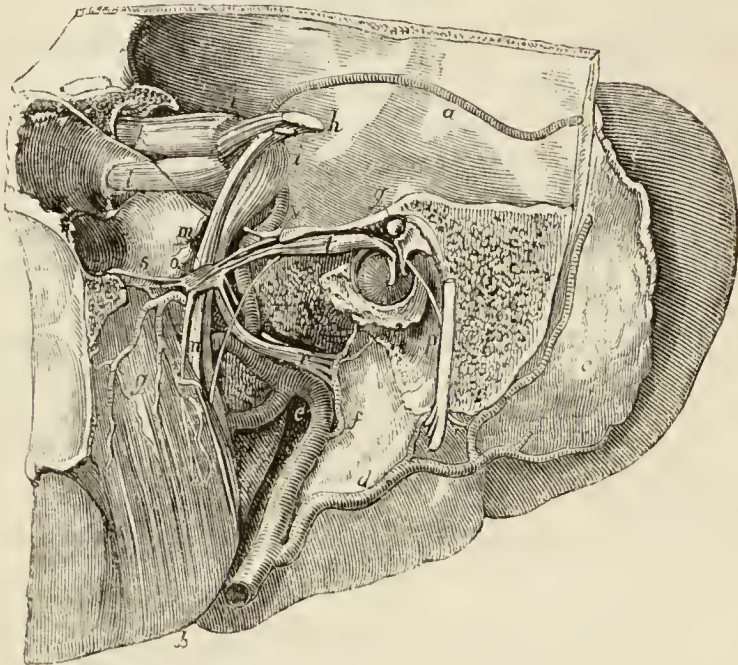
The *branches* of the otic ganglion are seven in number; two of distribution, and five of communication.

The *branches of distribution* are, a small filament to the tensor tympani muscle, and one or two to the tensor palati muscle.

The *branches of communication* are, one or two filaments from the inferior maxillary nerve (short root); one or two filaments from the auriculo-temporal nerve; filaments from the *nervi molles* of the arteria meningea media and the *nervus petrosus superficialis minor* (long root). The latter nerve ascends from the ganglion to a small canal situated between the foramen ovale and foramen spinosum, and passes backwards on the petrous bone to the hiatus Fallopii, where it divides into two filaments. One of these filaments enters the hiatus and

joins the intumescencia gangliformis of the facial; the other passes to a minute foramen nearer the base of the petrous bone, and enters the tympanum, where it communicates with a branch of Jacobson's nerve.

*Fig. 36.**



* The otic ganglion: after Arnold. *a*. The internal surface of the temporal bone, crossed by the posterior branch of the arteria meningea media. *b*. The internal pterygoid muscle, attached to the ramus and angle of the lower jaw. *c*. The divided integument of the back of the pinna, on which are seen ramifying the branches of the posterior auricular artery. *d*. The parotid gland: the artery below the letter is the trunk of the posterior auricular; the small artery to its right, the stylo-mastoid; the large artery to its left, the external carotid. *e*. The internal maxillary artery, giving off the inferior dental; and a little further on the arteria meningea media; of which *a* is a branch. *f*. The tympanic branch of the internal maxillary artery. *g*. The internal pterygoid artery. *h*. The fifth nerve, its two roots. *i*. The Casserian ganglion, the artery near the letters *ii* is the arteria meningea media. *k*. The ophthalmic nerve. *l*. The superior maxillary nerve. *m*. The inferior maxillary nerve: the motor root of the fifth joins the inferior maxillary at this point, and forms a plexiform enlargement. *n*. The inferior dental and gustatory nerve; the nerve to the left of the letter is the internal pterygoid: it pierces the otic ganglion, *o*, in its way to the muscle. The small nerve to the right of *n* is the chorda tympani proceeding to join the gustatory nerve; its origin from the facial nerve is seen at *p*, and its subsequent course between the malleus and incus at *q*. *p*. The facial nerve, situated in the

The SUPERIOR MAXILLARY NERVE, issuing from the middle of the Casserian ganglion, passes through the foramen rotundum, then crosses the sphe-no-maxillary fossa, and enters the canal in the floor of the orbit, along which it runs to the infra-orbital foramen. Emerging on the face, beneath the levator labii superioris muscle, it divides into a number of branches, which form a plexus with the facial nerve.

The *branches* of the superior maxillary nerve are divisible into three groups:—Those which are given off in the sphe-no-maxillary fossa; those in the infra-orbital canal; and those on the face. They may be thus arranged:—

Spheno-maxillary fossa,	{	Orbital, or temporo-malar,
		Spheno-palatine,
		Posterior dental.
Infra-orbital canal,	{	Middle dental,
		Anterior dental.
On the face,	{	Muscular,
		Cutaneous.

The *orbital* or *temporo-malar* branch enters the orbit through the sphe-no-maxillary fissure, and divides into two branches,—temporal and malar: the *temporal branch* ascends along the outer wall of the orbit, and after receiving a branch from the lachrymal nerve, passes through a canal in the malar bone, and enters the temporal fossa; it then pierces the temporal muscle and fascia, and is distributed to the integument of the temple and side of the forehead, communicating with the facial and anterior temporal nerve. In the temporal fossa it communicates with the deep temporal nerves. The *malar*, or inferior,

aqueductus Fallopii. *r.* The auriculo-temporal nerve, embracing the arteria meningea media in its course backwards: this nerve receives two branches from the otic ganglion. *s.* Two branches of the otic ganglion to the tensor palati muscle. *t.* The tensor tympani muscle, receiving from the front two small nerves, one from the otic ganglion, and one from the internal pterygoid nerve. *v.* The long root of the otic ganglion, the nervus petrosus superficialis minor; the short root is a small branch proceeding from the trunk of the inferior maxillary to the ganglion. *x.* The membrana tympani, on which is seen the handle of the malleus.

branch (*subcutaneus malæ*) takes its course along the lower angle of the outer wall of the orbit, and emerges upon the cheek through an opening in the malar bone, passing between the fibres of the *orbicularis palpebrarum* muscle. It communicates with branches of the infra-orbital and facial nerve.

The *spheno-palatine* branches, two in number, pass downwards to the spheno-palatine, or Meckel's ganglion.

The *posterior dental* branches, two in number, pass downwards upon the tuberosity of the superior maxillary bone, where, *one* enters a canal in the bone and is distributed to the molar teeth and lining membrane of the antrum, and communicates with the anterior dental nerve; while the other, lying externally to the bone, is distributed to the gums and buccinator muscle.

The *middle* and *anterior dental* branches descend to the corresponding teeth and gums; the former beneath the lining membrane of the antrum, the latter through distinct canals in the walls of the bone. Previously to their distribution, the dental nerves form a plexus (*superior maxillary plexus*) in the outer wall of the superior maxillary bone, immediately above the alveolus. From this plexus the filaments are given off which supply the pulps of the teeth, gums, mucous membrane of the floor of the nares and the palate.

The *muscular* and *cutaneous branches* are the terminating filaments of the nerve; they supply the muscles, integument, and mucous membrane of the lower eyelid, cheek, nose, and lip, and form a plexus by their communications with the facial nerve.

The student may now proceed to examine the small ganglion connected with the superior maxillary nerve, and situated in the spheno-maxillary fossa. To ascertain the precise position of the ganglion and the direction of its branches, he should refer to the skull, and make such observations with regard to the removal of parts of the bones as will enable him to obtain a good view of the contents of the cavity. The branches proceeding downwards from the superior maxillary nerve are the proper guide to the ganglion; the nasal branches, which pass into the nose through the spheno-palatine foramen, can only be followed on a section of the skull, and must be left for a later period of the dissection: the same remark applies to the palatine nerves; but the Vidian may be traced backwards through the pterygoid canal, by cutting away with care the root of the pterygoid process, and may then be followed to the

petrous portion of the temporal bone, where it joins the facial nerve.

The SPHENO-PALATINE, or MECKEL'S GANGLION is situated in the spheno-maxillary fossa, at a short distance below the superior maxillary nerve, with which it is connected by the two spheno-palatine nerves. It is of small size, triangular in shape, of a reddish-grey colour, and is placed on the posterior part of the spheno-palatine nerves, which it only partially involves.

Its *branches* are divisible into four groups, ascending, descending, internal, and posterior.

The *ascending* branches are three or four small filaments which are distributed to the periosteum of the orbit.

The *descending* branches are the three palatine nerves, anterior, middle, and posterior.

The *anterior* or *large palatine nerve* descends from the ganglion through the posterior palatine canal, and emerges at the posterior palatine foramen. It then passes forwards in the substance of the hard palate to which it is distributed, and communicates with the naso-palatine nerve. While in the posterior palatine canal, this nerve gives off several branches (*inferior nasal*), which enter the nose through openings in the palate bone, and are distributed to the middle and inferior meatus, the inferior spongy bone, and the antrum.

The *middle* or *external palatine nerve* descends, externally to the preceding, to the posterior palatine foramen, and distributes branches to the tonsil, soft palate, and uvula.

The *posterior* or *small palatine nerve* passes down through a separate canal, and emerges through a separate opening behind the posterior palatine foramen. It is distributed to the hard palate and gums, near its point of exit, as also to the tonsil, soft palate, and uvula.

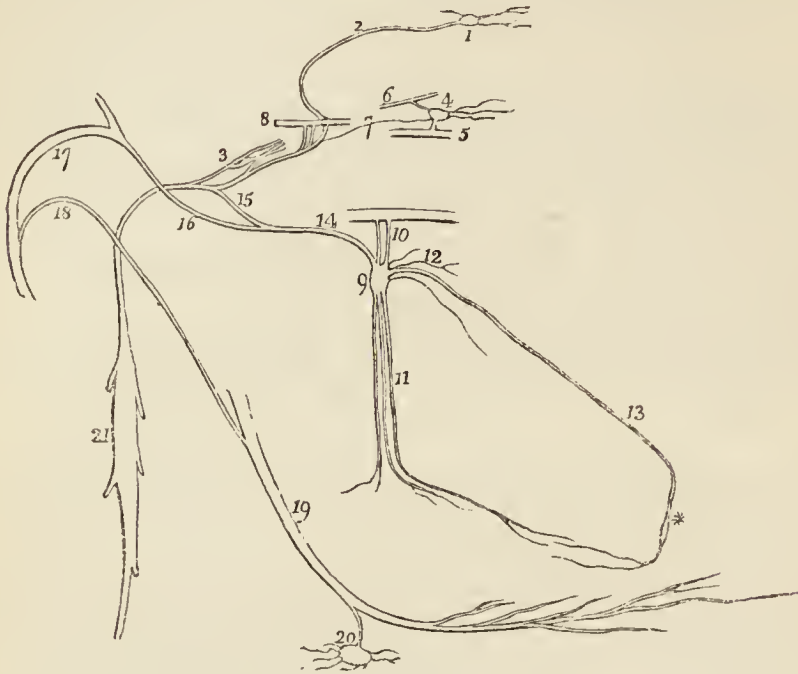
The *internal* branches are the superior nasal and the naso-palatine.

The *superior nasal*, four or five in number, enter the nasal fossa through the spheno-palatine foramen, and are distributed to the mucous membrane of the superior meatus and superior and middle spongy bones.

The *naso-palatine nerve* enters the nasal fossa with the

nasal nerves, and crosses the roof of the nares to reach the septum, to which it gives filaments. It then curves

*Fig. 37.**



downwards and forwards to the naso-palatine canal, and passes through that canal to the palate, to which and to

* The cranial ganglia of the sympathetic nerve. — No. 1. The ganglion of Ribes. 2. The filament by which it communicates with the carotid plexus (3.). 4. The ophthalmic or ciliary ganglion, giving off ciliary branches for the supply of the globe of the eye. 5. Part of the inferior division of the third nerve, receiving the inferior root of the ganglion. 6. Part of the nasal nerve, receiving the superior root of the ganglion. 7. A slender filament sent directly backwards from the ganglion to the sympathetic branches in the cavernous sinus. 8. Part of the sixth nerve in the cavernous sinus, receiving two branches from the carotid plexus. 9. Meckel's ganglion (spheno-palatine). 10. The spheno-palatine nerves sent to the ganglion by the superior maxillary nerve. 11. The descending palatine nerves. 12. The nasal branches. 13. The naso-palatine branch, one of the nasal branches. * The point where Cloquet supposed the naso-palatine ganglion to be situated. 14. The posterior branch of the ganglion, the Vidian nerve. 15. Its carotid branch, communicating with the carotid plexus. 16. Its petrosal branch, joining the angular bend of the facial nerve. 17. The facial nerve. 18. The chorda tympani nerve, which descends to join the gustatory nerve. 19. The gustatory nerve. 20. The submaxillary ganglion, receiving the chorda tympani nerve from the gustatory. 21. The superior cervical ganglion of the sympathetic.

the papilla behind the incisor teeth it is distributed. This nerve was described by Cloquet as uniting with its fellow in the anterior palatine canal, and constituting the *naso-palatine ganglion*. The existence of this ganglion is disputed.

The *posterior* branches are the Vidian or pterygoid nerve and the pharyngeal.

The *Vidian* nerve passes directly backwards from the spheno-palatine ganglion, through the pterygoid or Vidian canal, to the foramen lacerum basis cranii, where it divides into two branches, the *carotid* and *petrosal*. The *carotid branch* (n. petrosus profundus) crosses the foramen lacerum, surrounded by the cartilaginous substance which closes that opening, and enters the carotid canal to join the carotid plexus. The *petrosal branch* (nervus petrosus superficialis major) enters the cranium through the foramen lacerum basis cranii, piercing the cartilaginous substance, and passes backwards beneath the Casserian ganglion and dura mater, embedded in a groove on the anterior surface of the petrous bone, to the hiatus Fallopii. In the hiatus Fallopii it receives a branch from Jacobson's nerve, and terminates in the intumescencia gangliformis of the facial nerve.

The *pharyngeal* nerve is a small branch which passes backwards through the pterygo-palatine canal with the pterygo-palatine artery, to be distributed to the mucous membrane of the Eustachian tube and neighbouring part of the pharynx.

While examining the nerves proceeding from Meckel's ganglion, the dissector will observe the branches of the internal maxillary artery by which they are accompanied: the spheno-palatine artery enters the nose with the superior nasal nerves; the descending palatine artery passes down to the palate with the palatine nerves; and the Vidian artery accompanies the Vidian nerve.

INTERNAL CAROTID ARTERY.

The student may now proceed to examine the internal carotid artery, with which view he may remove any structure that conceals the artery. The internal jugular vein lies to its outer side; it is crossed in front by the stylo-glossus and stylo-pharyngeus muscle and stylo-hyoid ligament, and higher up it has the parotid gland; to its inner side is the pharynx and ascending pharyngeal artery

(page 264.), and behind it has the vertebral column, the rectus anticus major muscle, and some important nerves.

As the student may wish to remove the styloid process, he should observe the relative position of the parts connected with it. Passing forward from the apex of this process to the angle of the jaw is the *stylo-maxillary ligament*, a process of the deep cervical fascia which separates the submaxillary from the parotid gland. Proceeding also from the apex of the process and partly from this ligament, is the *stylo-glossus*, the highest of the three styloid muscles. Arising from the middle of the styloid process, and coming forwards to the body of the os hyoides, is the *stylo-hyoides* muscle, middle in position to the others—but the most superficial of the three. Next the *stylo-pharyngeus* may be seen arising from the inner side of the base of the styloid process, and passing downwards almost vertically to the middle of the pharynx, the lowest and deepest of the three muscles. Lastly, there is the *stylo-hyoid* ligament, a fibrous cord extending from the apex of the styloid process to the lesser cornu of the os hyoides. This ligament is sometimes cartilaginous or even osseous, and may be jointed with the styloid process above and the lesser cornu of the os hyoides below. At its lower part it is behind the hyo-glossus muscle, and gives origin to part of the middle constrictor muscle.

The INTERNAL CAROTID ARTERY curves slightly outwards at its origin from the common carotid, and ascends nearly perpendicularly by the side of the pharynx to the carotid foramen in the petrous portion of the temporal bone. It then passes *inwards* along the carotid canal; *forwards* by the side of the sella turcica; and *upwards* by the anterior clinoid process, where it pierces the dura mater, and divides into three terminal branches.

The course of this artery is remarkable for the number of angular curves which it forms; one or two of these flexures are sometimes seen in the cervical portion, near the base of the skull; by the side of the sella turcica, it resembles the Italic letter *S* placed horizontally.

The internal carotid, which at first lies on the same plane with the external carotid, soon gets behind the latter, and higher up is separated from it by the stylo-glossus, stylo-pharyngeus, stylo-hyoid ligament, and parotid gland; and is crossed by the glosso-pharyngeal nerve. To its *inner* side is the pharynx, tonsil, and ascending pharyngeal artery; to its *outer* side, the internal jugular vein; between the vein and artery near the base of the skull, the glosso-pharyngeal, pneumogastric, and hypoglossal nerve; and externally to the vein, the loop between the first and second cervical nerves. *Behind*,

the artery rests on the rectus anticus major, the superior cervical ganglion of the sympathetic, the pharyngeal and superior laryngeal nerves being interposed.

To follow the internal carotid artery through the petrous portion of the temporal bone, it is necessary to make a section of the skull from the back part of the mastoid process to the carotid foramen, keeping close to the outside of the styloid-mastoid foramen. This piece of bone may then be broken away and preserved for the subsequent examination of the membrana tympani, ossicula auditus, and chorda tympani nerve. The anterior wall of the carotid canal is to be furthermore broken away by the chisel.

The petrous portion of the artery is in close contact with the periosteal lining of the carotid canal derived from the dura mater, and is embraced by the nerves of the carotid plexus. At the extremity of the canal, the artery is in relation with the under surface of the Casserian ganglion.

By the side of the sella turcica the internal carotid artery is situated in the inner wall of the cavernous sinus, and is in relation by its outer side with the lining membrane of the sinus, the sixth nerve, and the ascending branches of the carotid plexus. The third, fourth, and ophthalmic nerve are placed in the outer wall of the sinus, and are separated by the latter from the artery.

The cerebral portion of the artery is invested by a sheath of the arachnoid, and is in close relation with the optic nerve.

The *branches* of the internal carotid artery are derived from its cranial portion, and are as follows:—

Tympanic,	Anterior cerebral,
Anterior meningeal,	Middle cerebral,
Ophthalmic,	Posterior communicating,
	Choroidean.

The *tympanic* is a small branch given off in the carotid canal; it enters the tympanum, and inosculates with the tympanic branch of the internal maxillary and with the stylo-mastoid artery.

The *anterior meningeal*, arising from the artery after its escape from the carotid canal, is distributed to the Casserian ganglion and dura mater of the middle fossa of the cranium.

The *ophthalmic artery* is given off close to the anterior

clinoid process, and passes through the optic foramen lying to the outer side of the optic nerve. Its distribution within the orbit has been already described (page 225.).

The *anterior* and *middle cerebral* artery, and the *posterior communicating*, the terminal branches of the internal carotid, will be described with the anatomy of the brain in the next Chapter.

INTERNAL JUGULAR VEIN.—The vein corresponding with the internal carotid artery, and which, lower in the neck, accompanies the common carotid, is the internal jugular. It commences at the jugular fossa, in the foramen lacerum posterius basis cranii, where it receives the blood from the sinuses of the dura mater. At its origin, the internal jugular vein is posterior to the internal carotid artery, but soon gets to its outer side, and keeps that position in relation to the common carotid artery in its course through the neck. The eighth pair of nerves, at its exit from the cranium, lies in front and to the inner side of the vein; the hypoglossal nerve being behind its inner border. The glosso-pharyngeal and hypoglossal nerves then pass forwards, between the inner side of the vein and the internal carotid artery; the pneumogastric, and superior cervical ganglion of the sympathetic, are placed at its inner side; and the spinal accessory nerve crosses behind, and sometimes in front of it, at its upper part.

The internal jugular vein receives the facial, occipital, lingual, pharyngeal, and superior and middle thyroid veins.

FACIAL NERVE.

The section already prescribed (page 281.) for the demonstration of the internal carotid may be made subservient to the examination of the facial nerve in its course through the petrous bone. With this object the saw should not be carried too far or too deeply, and used only to divide such parts as may not be conveniently broken away with the chisel and hammer. The outer boundary of the stylo-mastoid foramen being laid open, the wall of the aqueductus Fallopii may be broken away in its course along the internal boundary of the tympanum to the anterior surface of the petrous bone, and thence backwards to the meatus.

The **FACIAL NERVE** (portio dura of the seventh pair) passes into the meatus auditorius internus, with the

auditory nerve or portio mollis, lying at first to the inner side and then upon the latter. At the bottom of the meatus it enters the aqueductus Fallopii, and takes its course forwards to the hiatus Fallopii, in the anterior surface of the petrous bone; it then curves backwards towards the tympanum, and descends in the inner wall of that cavity to the stylo-mastoid foramen, through which it emerges.

While in the meatus auditorius, the facial nerve communicates with the auditory nerve by one or two filaments. At the angular bend of the aqueductus Fallopii, where the nerve is close to the anterior surface of the petrous bone, it presents a gangliform swelling (*intumescencia gangliformis: ganglion geniculare*), which receives the petrosal branch of the Vidian nerve and that of the otic ganglion, and sends a filament back to the auditory nerve. Behind the tympanum it is joined by one or two twigs from the auricular branch of the pneumogastric; and lower down it gives off a *tympanic branch* to the stapedius muscle, and the *chorda tympani nerve*.

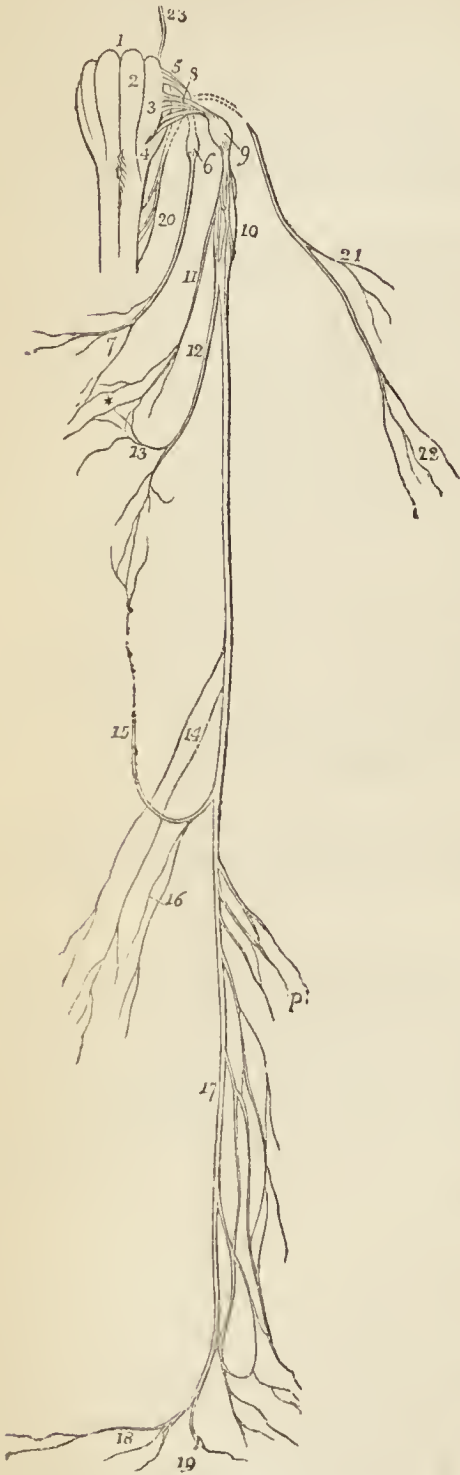
The chorda tympani nerve may now be sought for on the removed section of the bone previously made, and may be traced across the tympanum.

The *chorda tympani* nerve quits the facial just above the stylo-mastoid foramen, and ascends by a distinct canal to the upper part of the posterior wall of the tympanum, which it enters through an opening situated between the base of the pyramid and the attachment of the membrana tympani. It then crosses the tympanum, between the handle of the malleus and long process of the incus to the anterior inferior angle of the cavity, and escapes through a distinct opening in the fissura Glaseri, to join the gustatory nerve at an acute angle between the two pterygoid muscles (page 274.). In its course through the tympanum it is enclosed within a sheath of mucous membrane.

EIGHTH PAIR OF NERVES. — The eighth pair consists of three nerves, — *glosso-pharyngeal*, *pneumogastric*, and *spinal accessory*, — which escape from the cranium at the foramen lacerum posterius, internally and anteriorly to the internal jugular vein. At their point of exit the

glosso-pharyngeal is in front of the other two, and has a separate sheath of dura mater. The pneumogastric and spinal accessory are enclosed in the same sheath.

Fig. 38.*



The GLOSSO-PHARYNGEAL NERVE, the smallest of the three, advances forwards between the internal carotid artery and jugular vein, and crosses the artery to the lower border of the stylo-pharyngeus muscle; it then turns forwards across the stylo-pharyngeus, and, getting behind the hyoglossus muscle, is distributed to the mucous membrane of the tongue, the pharynx, and the tonsil.

While in the jugular fossa the nerve presents two gangliform swellings; one, *superior*, of small size, and involving only the posterior fibres of the nerve,—the *ganglion jugulare* (Muller); the other, *inferior*, of larger size, nearly half an inch below the superior, and occupying the whole diameter of the nerve, the *ganglion petrosum*, or ganglion of Andersch.

The *branches* of the glosso-pharyngeal nerve are, branches of communication and branches of distribution.

* Origin and distribution of the eighth pair of nerves of the left side.—No. 1. The medulla oblongata. 2. The corpus pyramidale of the left side. 3. The corpus olivare. 4. The corpus restiforme. 5. The origin of the glosso-pharyngeal nerve. 6. The inferior ganglion of the glosso-pharyngeal nerve, ganglion petrosum or

The *branches of communication* proceed chiefly from the ganglion of Andersch; they are, one to join the auricular branch of the pneumogastric; one to the ganglion of the pneumogastric; one to the superior cervical ganglion of the sympathetic; and one, which arises below the ganglion, and pierces the posterior belly of the digastricus muscle, to join the facial nerve.

The *branches of distribution* are:—

Tympanic,	Pharyngeal,
Carotid,	Tonsillitic,
Muscular,	Lingual.

The *tympanic* branch (Jacobson's nerve) proceeds from the ganglion of Andersch, or from the trunk of the nerve immediately above the ganglion; it enters a small bony canal in the jugular fossa, and divides into six branches, which are distributed upon the inner wall of the tympanum, and establish a plexiform communication (tympanic plexus) with the sympathetic and fifth pair of nerves. The *branches of distribution* supply the fenestra rotunda, fenestra ovalis, and Eustachian tube: those of communication join the carotid plexus in the carotid canal, the petrosal branch of the Vidian nerve, and the otic ganglion.

The *carotid* branches are several filaments which follow the trunk of the internal carotid artery, and communicate with the *nervi molles* of the sympathetic.

The *muscular* branch divides into filaments, which are distributed to the posterior belly of the digastricus, stylohyoideus, stylo-pharyngeus, and constrictor muscles.

ganglion of Andersch. 7. A branch from the glosso-pharyngeal nerve to the pharyngeal plexus. 8. The origin of the pneumogastric nerve. 9. The upper or jugular ganglion of the pneumogastric. 10. The lower, or plexiform ganglion of the nerve. 11. The pharyngeal nerve, descending to form the pharyngeal plexus*. 12. The superior laryngeal nerve. 13. A branch to the pharyngeal plexus. 14. Cardiac nerves. 15. The recurrent laryngeal nerve. 16. Cardiac branches from the recurrent. 17. Œsophageal plexus. 18. Branches to the stomach. 19. A branch which joins the solar plexus. 20. The origin of the spinal accessory nerve. 21. Its branches to the sterno-mastoid muscle. 22. Terminal branches to the trapezius. 23. The origin of the facial nerve. *p.* The branches forming the pulmonary plexuses.

The *pharyngeal* branches are two or three filaments, which are distributed to the pharynx and unite with the pharyngeal branches of the pneumogastric and sympathetic nerve to form the *pharyngeal plexus*.

The *tonsillitic* branches proceed from the glosso-pharyngeal nerve near its termination; they form a plexus (*circulus tonsillaris*) around the base of the tonsil, from which numerous filaments are given off to the mucous membrane of the fauces and soft palate. These filaments communicate with the descending palatine branches of Meckel's ganglion.

The *lingual* branches enter the substance of the tongue beneath the hyo-glossus and stylo-glossus muscle, and are distributed to the mucous membrane of the side and base of the tongue, and to the epiglottis and fauces.

The PNEUMOGASTRIC OR VAGUS NERVE, the largest of the three divisions of the eighth pair, at its escape from the jugular foramen, is enclosed in a sheath of dura mater, which is common to it and the spinal accessory. The nerve takes its course down the side of the neck, lying at first between the internal carotid artery and jugular vein, and then between and behind the common carotid artery and jugular vein, enclosed in the same sheath, to the superior opening of the thorax, through which it passes to the lungs and stomach.

In the jugular foramen the pneumogastric nerve presents a small round ganglion, the *superior* or *jugular ganglion*; and, immediately at its exit, a gangliform swelling nearly an inch in length, the *inferior ganglion* (*plexus gangliformis*).

The *branches* of the pneumogastric nerve are, the branches of communication and the branches of distribution.

The *branches of communication* proceed from the ganglia: from the superior ganglion one or two branches pass to the spinal accessory; one or two to the superior ganglion of the sympathetic; and one to the inferior ganglion of the glosso-pharyngeal. From the inferior ganglion there pass off branches to the hypoglossal; branches to the superior cervical ganglion of the sympathetic; and branches to the loop between the first and second cervical nerves.

The *branches of distribution* are : —

Auricular,	Superior laryngeal,
Pharyngeal,	Cardiac,
	Inferior laryngeal.

The *auricular* nerve is given off from the lower part of the jugular ganglion, or from the trunk of the nerve immediately below it, and receives immediately after its origin a small branch of communication from the glosso-pharyngeal. It then passes outwards behind the jugular vein, and on the outer side of that vessel enters a small canal in the petrous portion of the temporal bone near the stylo-mastoid foramen. Guided by this canal it reaches the descending part of the aqueductus Fallopii and joins the facial nerve. In the aqueductus Fallopii the auricular nerve gives off two small filaments, one of which communicates with the posterior auricular branch of the facial, while the other is distributed to the pinna.

The *pharyngeal* nerve arises from the upper part of the superior ganglion, and crosses behind the internal carotid artery to the upper border of the middle constrictor, upon which it forms the *pharyngeal plexus*, assisted by branches from the glosso-pharyngeal, superior laryngeal, and sympathetic. The pharyngeal plexus is distributed to the muscles and mucous membrane of the pharynx.

The *superior laryngeal nerve* arises from the inferior ganglion, and descends behind the internal carotid artery to the opening in the thyro-hyoidean membrane, through which it passes with the superior laryngeal artery, and is distributed to the mucous membrane of the larynx and arytenoideus muscle. On the latter, and behind the cricoid cartilage, it communicates with the recurrent laryngeal nerve. Behind the internal carotid it gives off the *external laryngeal branch*, which sends a twig to the pharyngeal plexus, and then descends to supply the inferior constrictor and crico-thyroid muscle and thyroid gland. This branch communicates inferiorly with the recurrent laryngeal and sympathetic nerve.

The *cardiac branches*, two or three in number, arise from the upper and lower part of the nerve. Those from above communicate with cardiac branches of the sympa-

thetic. One large branch is given off just before the nerve enters the chest; on the *right* side this nerve descends by the side of the arteria innominata to the deep cardiac plexus; and on the *left* it passes in front of the arch of the aorta to the superficial cardiac plexus.

The *inferior laryngeal*, or recurrent laryngeal nerve, curves around the subclavian artery on the right, and the arch of the aorta on the left side. It ascends in the groove between the trachea and œsophagus, and piercing the lower fibres of the inferior constrictor muscle enters the larynx close to the articulation of the inferior cornu of the thyroid with the cricoid cartilage. It is distributed to all the muscles of the larynx, with the exception of the crico-thyroid, and communicates on the arytenoideus muscle with the superior laryngeal nerve. As it curves around the subclavian artery and aorta it gives branches (cardiac) to the heart and root of the lungs; and as it ascends the neck it distributes filaments to the œsophagus and trachea, and communicates with the external laryngeal nerve and sympathetic.

The SPINAL ACCESSORY NERVE in its passage through the jugular foramen is contained in the same sheath of dura mater as the pneumogastric nerve, and is applied against the posterior aspect of its superior ganglion. Quitting the opening the nerve passes outwards behind and sometimes in front of the jugular vein to the upper part of the sterno-mastoid muscle, whence it is continued obliquely across the posterior triangular space of the neck to the trapezius.

The *branches of communication* of the spinal accessory are one or two small branches from the superior ganglion of the pneumogastric, and a large branch which joins the pneumogastric between the two ganglia.

Its *branches* of distribution are *muscular* branches to the sterno-mastoid and trapezius.

The HYPOGLOSSAL NERVE [ninth] passes out of the cranium through the anterior condyloid foramen, where it is situated behind the internal carotid artery and internal jugular vein; it then advances forwards between the artery and vein, and opposite the angle of the lower jaw curves around the occipital artery, and crosses the external carotid artery to the hyo-glossus muscle. Resting on the hyo-glossus muscle at its lower part, it becomes flattened,

and divides into a number of branches which are distributed to the muscles of the tongue.

The *branches of communication* of the hypoglossal nerve are, several to the pneumogastric, with which nerve it is closely united; one or two with the superior cervical ganglion of the sympathetic; and one or two with the loop between the first and second cervical nerves.

Its *branches of distribution* are the descendens noni, thyro-hyoidean, and muscular.

The *descendens noni* is a long and slender nerve, which quits the hypoglossal just as it is about to form its arch around the occipital artery, and descends upon the sheath of the carotid vessels. Just below the middle of the neck, it forms a loop with a long branch from the second and third cervical nerves. From the convexity of this loop branches are sent to the sterno-hyoideus, sterno-thyroideus, and both bellies of the omo-hyoideus; sometimes also a twig is given off to the cardiac plexus, and occasionally one to the phrenic nerve.

The *thyro-hyoidean* nerve is a small branch distributed to the thyro-hyoideus muscle. It is given off from the trunk of the hypoglossal near the posterior border of the hyo-glossus muscle, and descends obliquely over the great cornu of the os hyoides.

The *muscular* branches are given off where the nerve is covered in by the mylo-hyoideus muscle, and rests on the hyo-glossus; several large branches take their course across the fibres of the genio-hyo-glossus to reach the substance of the tongue. Moreover, on the hyo-glossus muscle, the branches of the hypoglossal nerve communicate with those of the gustatory nerve.

SYMPATHETIC NERVE.

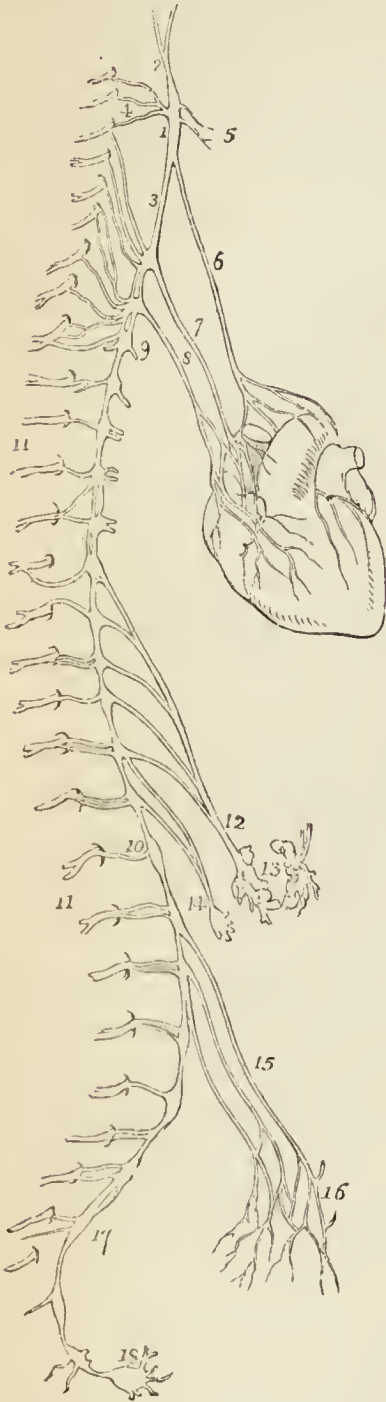
The sympathetic nerve is brought into view by dividing the internal carotid artery and internal jugular vein, and drawing them aside together with the pneumogastric nerve.

The cervical portion of the sympathetic nerve consists of three ganglia with their connecting cords and branches.

The SUPERIOR CERVICAL GANGLION is long and fusiform, of a reddish-grey colour, smooth, and of considerable thickness, extending from within an inch of the carotid fora-

men in the petrous bone to opposite the lower border of the third cervical vertebra. It rests on the rectus anticus major muscle, and lies behind and to the inner side of the internal carotid artery.

Fig. 39.*



Its *branches*, like those of all the sympathetic ganglia are divisible into *superior*, *inferior*, *external*, and *internal*; to which may be added, as proper to this ganglion, *anterior*.

The *superior* (carotid nerve) is a single branch which ascends by the side of the internal carotid, and divides into two branches; one lying to the outer, the other to the inner side of that vessel. The two branches enter the carotid canal, and by their communications with each other, and with the petrosal branch of the Vidian, constitute the *carotid plexus*. The continuation of the carotid plexus onwards with the artery by the side of the sella turcica is the *cavernous plexus*, and from the latter branches having a plexiform distribution are given off with each branch of the artery.

The carotid plexus, moreover, is the means of communication of the greater number of the cranial nerves with the rest of the sympathetic. It sends branches to the third

* The sympathetic nerve, its entire length. — No. 1. The superior cervical ganglion. 2. Its ascending or carotid branch, which divides into two branches. 3. Its descending branch. 4. Its external branches, communicating with the first, second, and third cervical nerves. 5. Internal branches to communicate with the facial, eighth and ninth nerves, and with the pharyngeal plexus. 6. The superior cardiac nerve, superficialis cordis. 7. The middle or great cardiac nerve, arising from the second cervical ganglion.

nerve, the ophthalmic, the Casserian ganglion; two large branches join the sixth nerve in the cavernous sinus; it sends a branch to the ophthalmic ganglion; it communicates with the superior maxillary, the facial, and auditory nerve by means of the Vidian; with the inferior maxillary by a branch from the otic ganglion; and with the glosso-pharyngeal by means of two filaments to the tympanic nerve.

The *inferior* or descending branch, sometimes two, is the cord of communication with the middle cervical ganglion.

The *external branches* are numerous, and may be divided into two sets: those which communicate with the glosso-pharyngeal, pneumogastric, and hypoglossal nerve; and those which communicate with the first four cervical nerves.

The *internal branches* are three in number: *pharyngeal*, to assist in forming the pharyngeal plexus; *laryngeal*, to join the superior laryngeal nerve and its branches; and the *superior cardiac nerve*, or *nervus superficialis cordis*.

The *anterior branches* accompany the external carotid artery with its branches, around which they form plexuses, and here and there small ganglia; they are called, from the softness of their texture, *nervi molles*, and from their reddish hue, *nervi subrufi*. The branches accompanying the facial artery are conducted by that vessel to the sub-maxillary ganglion, and those which accompany the internal maxillary artery reach the otic ganglion through the medium of the *arteria meningea media*.

The MIDDLE CERVICAL GANGLION (thyroid ganglion) is of small size, and sometimes altogether wanting. It is situated opposite the fifth cervical vertebra, and rests against the inferior thyroid artery. This relation is so constant as to have induced Haller to name it the "thyroid ganglion."

Its *superior branch*, or branches, ascend to communicate with the superior cervical ganglion.

Its *inferior branches* descend to join the inferior cervical

-
8. The inferior cardiac nerve, from the inferior cervical ganglion. 9. The first dorsal ganglion. 10. The last dorsal ganglion. 11, 11. Spinal nerves. 12. Great splanchnic nerve. 13. The two semilunar ganglia, which form by their communication the solar plexus. 14. The lesser splanchnic nerve, forming the renal plexus. 15. Branches from the lumbar ganglia. 16. The hypogastric plexus. 17. Sacral ganglion. 18. The last ganglion of the sympathetic, ganglion impar.

ganglion; one of these frequently passes in front of the subclavian artery, the other behind it.

Its *external branches* communicate with the fifth and sixth cervical nerves.

Its *internal branches* are filaments which accompany the inferior thyroid artery, the inferior thyroid plexus; and the *middle cardiac nerve*, *nervus cardiacus magnus*.

The INFERIOR CERVICAL GANGLION (vertebral ganglion) is much larger than the preceding, and is constant in its existence. It is of a semilunar form, and is situated on the base of the transverse process of the seventh cervical vertebra immediately behind the vertebral artery; hence its designation "vertebral ganglion."

Its *superior branches* communicate with the middle cervical ganglion.

The *inferior branches* pass, some before and some behind the subclavian artery, to join the first thoracic ganglion (p. 170).

The *external branches* consist of two sets; one which communicates with the sixth, seventh, and eighth cervical and first dorsal nerve, and one which accompanies the vertebral artery along the vertebral canal, forming the *vertebral plexus*. This plexus sends filaments to all the branches given off by the artery, and communicates in the cranium with the filaments of the carotid plexus accompanying the branches of the internal carotid artery.

The internal branch is the *inferior cardiac nerve*, *nervus cardiacus minor*.

CARDIAC NERVES. — The cardiac nerves are three in number on each side of the neck; namely, superior, middle, and inferior.

The *superior cardiac nerve* (*nervus superficialis cordis*) arises from the lower part of the superior cervical ganglion, and descends the neck behind the sheath of the common carotid artery to the chest; crossing in its course the inferior thyroid artery and recurrent laryngeal nerve. The nerve of the *left* side follows the course of the carotid artery, and crossing the arch of the aorta terminates in the superficial cardiac plexus. The nerve of the *right* side crosses the subclavian artery sometimes in front and sometimes behind, and follows the posterior border of the *arteria innominata* to the deep cardiac plexus. The superficial cardiac nerve receives filaments from the pneumo-

gastric nerve, and distributes branches to the thyroid gland and trachea.

The *middle cardiac nerve* (nervus cardiacus magnus) proceeds from the middle cervical ganglion, or, in its absence, from the cord of communication between the superior and inferior ganglion. It is the largest of the three nerves, and lies parallel with the recurrent laryngeal. At the root of the neck it divides into several branches which pass, some before and some behind, the subclavian artery, communicates with the superior and inferior cardiac, the pneumogastric, and recurrent nerve, and descends to the deep cardiac plexus.

The *inferior cardiac nerve* (nervus cardiacus minor) arises from the inferior cervical ganglion, communicates with the recurrent laryngeal and middle cardiac nerve, and descends to the deep cardiac plexus (p. 168.).

PRÆVERTEBRAL REGION.

The student should now cut through the trachea and œsophagus, with the vessels and nerves of the neck opposite the first rib, and draw them forwards; he should divide with the scalpel the loose cellular tissue which connects the back part of the pharynx with the vertebral column, and continue the separation to the base of the skull. He should then make a section of the cranium on each side behind the mastoid process, directing the saw towards the basilar process, and then break through the basilar process with the chisel and hammer. This preparation should be made with care, and the eighth pair of nerves at their exit from the cranium as much as possible preserved. Having accomplished this section, he may proceed to examine the muscles lying on the front of the vertebral column in the cervical region.

The *muscles* of the prævertebral region are, the rectus anticus major and minor, longus colli, and two muscles which have been already examined, the scaleni.

The RECTUS ANTICUS MAJOR, broad and thick above, and narrow and pointed below, *arises* from the anterior tubercles of the transverse processes of the third, fourth, fifth, and sixth cervical vertebræ, and is *inserted* into the basilar process of the occipital bone.

The RECTUS ANTICUS MINOR *arises* from the anterior border of the lateral mass of the atlas, and is *inserted* into the basilar process, its fibres being directed obliquely upwards and inwards.

The LONGUS COLLI is a long and flat muscle, consisting of two portions. The *upper* *arises* from the anterior

tubercle of the atlas, and is *inserted* into the transverse processes of the third, fourth, and fifth cervical vertebræ. The *lower* portion *arises* from the bodies of the second, third, and fourth, and transverse processes of the fifth and sixth, and passes down the neck, to be *inserted* into the bodies of the three lower cervical and three upper dorsal vertebræ. We should thus arrange these attachments in a tabular form:—

	<i>Origin.</i>	<i>Insertion.</i>
Upper portion	} Atlas	} 3rd, 4th, and 5th transverse processes.
Lower portion.	} 2nd, 3rd, & 4th bodies 5th & 6th transverse processes	} 3 lower cervical vertebræ, bodies. 3 upper dorsal, bodies.

In general terms, the muscle is attached to the bodies and transverse processes of the six superior cervical vertebræ above, and to the bodies of the last three cervical and first three dorsal below.

The student should also examine in this region the *rectus lateralis*, which is presented by its anterior face, and in the dissection of the back was seen only from behind; and the *anterior inter-transversales*. The anterior division of the cervical nerves will be found between the anterior and posterior inter-transversales.

If the anterior inter-transversales be removed, the vertebral artery will be seen taking its course upwards through the foramina in the transverse processes of the vertebræ. It lies in front of the cervical nerves, and is accompanied by the vertebral vein and vertebral plexus of nerves. Opposite each inter-vertebral foramen, the vertebral artery sends a *spinal* branch into the vertebral canal to supply the spinal cord.

ACTIONS.—The *rectus anticus major* and *minor* preserve the equilibrium of the head upon the atlas; and, acting conjointly with the *longus colli*, flex and rotate the head and the cervical portion of the vertebral column.

ANATOMY OF THE PHARYNX.

Turning now to the portion which has been removed from the front of the vertebral column, the student may proceed to its dissection. By the removal of the cellular tissue from the nerves, he will be enabled to see the communications which take place between the eighth and ninth nerves and sympathetic; and make out the origin

of the upper branches of the pneumogastric, and particularly the branches distributed to the pharynx and larynx.

Preparatory to dissecting the muscles of the pharynx, its cavity should be distended with tow or wool. The student should then remove the cellular tissue from off the muscles on one side, reserving the other for the examination of the vessels and nerves.

The PHARYNX is a musculo-membranous sac resting against the vertebral column, and extending from the base of the skull to opposite the cricoid cartilage and fifth cervical vertebra. It is composed of muscles, mucous membrane, and a strong aponeurosis, and communicates in front with the cavity of the nose, mouth, and larynx. Above it is attached partly by muscle, but chiefly by aponeurosis, to the basilar process of the occipital bone and petrous portion of the temporal, and below it is continuous with the œsophagus.

The MUSCLES of the pharynx are the superior, middle, and inferior constrictor, the stylo-pharyngeus, and palato-pharyngeus.

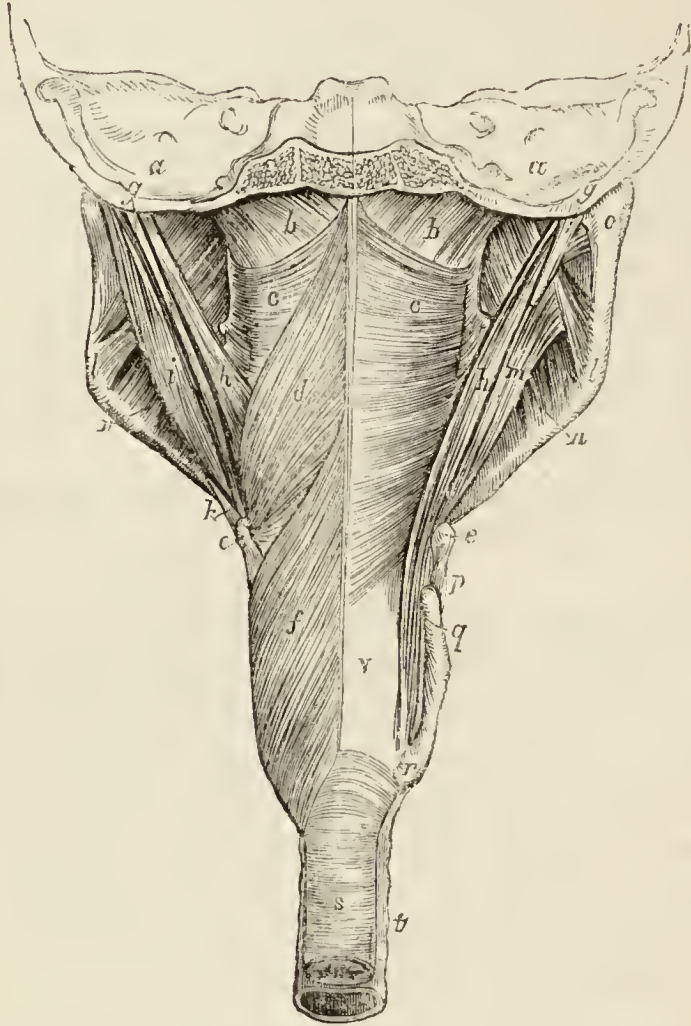
The CONSTRICTOR INFERIOR, the thickest of the three muscles, *arises* from the cricoid cartilage and the oblique line of the thyroid. Its fibres spread out and are *inserted* into the fibrous *raphé* of the middle of the pharynx, the inferior fibres being almost horizontal, and the superior oblique and overlapping the middle constrictor. The upper border of the muscle is in relation with the superior laryngeal nerve, and the lower border near its origin with the inferior laryngeal or recurrent.

Detach the upper portion of the inferior constrictor from its attachment to the raphé, and turn it downwards to bring the lower part of the next muscle into view.

The CONSTRICTOR MEDIUS *arises* from the great cornu of the os hyoides, from the lesser cornu, and from the stylo-hyoidean ligament. It radiates, from its origin, upon the side of the pharynx, the lower fibres descending and being overlapped by the constrictor inferior; and the upper fibres ascending, so as to cover in the constrictor superior. It is *inserted* into the raphé, and by a fibrous aponeurosis into the basilar process of the occipital bone. The lower border of the muscle is in relation with the superior laryngeal nerve, and its upper border is separated from the superior constrictor by the stylo-pharyngeus muscle and glosso-pharyngeal nerve.

The upper portion of this muscle must be turned down, to bring the whole of the superior constrictor into view; in so doing, the stylo-pharyngeus muscle will be seen passing behind its upper border.

*Fig. 40.**



* Muscles of the pharynx. — *a, a*. Transverse section of the posterior fossa of the base of the cranium. *b, b*. The fibrous membrane of the bag of the pharynx. *c, c*. The superior constrictor muscle; its origin from the internal pterygoid plate of the pterygoid process is seen. *d*. The middle constrictor muscle. *e*. The extremity of the great cornu of the os hyoides. *f*. The inferior constrictor muscle. *g*. The styloid process. *h, h*. The stylo-pharyngeus muscle. *i*. The posterior belly of the digastricus muscle. *k*. The stylo-hyoid muscle pierced by the tendon of the digastricus. *l, l*. The stylo-maxillary ligament attached to the angle of the lower jaw. *m*. The stylo-glossus muscle. *n*. The internal pterygoid muscle. *o*. Part of the external pterygoid muscle: the letter is placed on the neck of the lower jaw. *p*. The thyro-hyoidean ligament. *q*. The superior cornu of the thyroid cartilage. *r*. The inferior cornu. *s*. The œsophagus surrounded by its circular fibres. *t*. The trachea. *v*. The lining membrane of the pharynx.

The CONSTRUCTOR SUPERIOR is a thin and quadrilateral plane of muscular fibres, *arising* from the extremity of the molar ridge of the lower jaw, from the pterygo-maxillary ligament, and from the lower third of the internal pterygoid plate, and *inserted* into the *raphe* and basilar process of the occipital bone. Its superior fibres are arched, and leave a concave interspace between its upper border and the basilar process; some of its lower fibres are continuous with those of the genio-hyo-glossus on the side of the tongue; and it is overlapped inferiorly by the middle constrictor.

Between the side of the pharynx and the ramus of the lower jaw is a triangular interval, the *maxillo-pharyngeal space*, which is bounded on the *inner* side by the superior constrictor muscle; on the *outer* side by the internal pterygoid muscle; and *behind* by the rectus anticus major and vertebral column. In this space are situated the internal carotid artery, the internal jugular vein, and the glosso-pharyngeal, pneumogastric, spinal accessory, and hypoglossal nerve.

The STYLO-PHARYNGEUS is a long and slender muscle, *arising* from the inner side of the base of the styloid process; it descends between the superior and middle constrictor muscles, and spreads out beneath the mucous membrane of the pharynx; it is *inserted* partly into the posterior border of the thyroid cartilage, and partly into the internal face of the inferior constrictor. Along its lower border is seen the glosso-pharyngeal nerve which crosses it, opposite the root of the tongue, to pass between the superior and middle constrictor and behind the hypoglossus.

When the muscles of the exterior of the pharynx have been studied, the sac should be opened along the middle line, and the sides drawn apart in order to examine its interior.

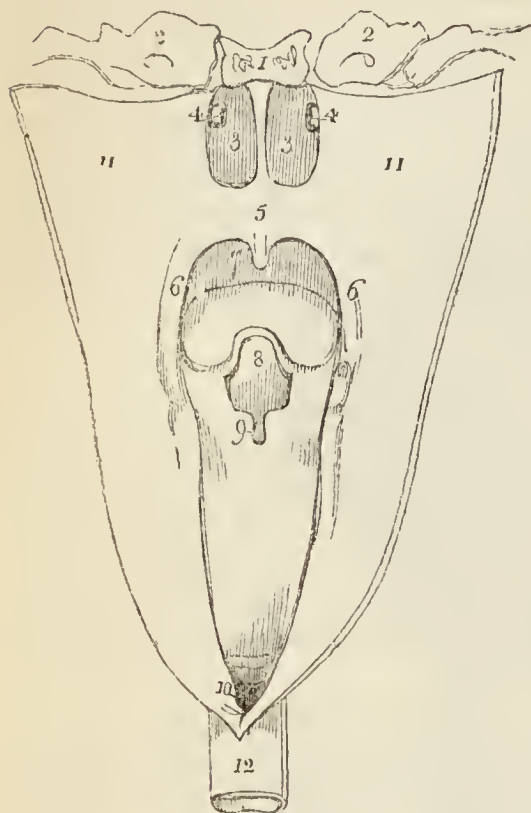
The pharynx presents *seven* openings, two at its upper and front part, the posterior nares; one on each side of the posterior nares, the aperture of the Eustachian tube; below the posterior nares, the opening of the mouth, or isthmus faucium; lower down, the opening of the larynx; and inferiorly, the œsophagus.

The *posterior nares* are oval in shape, and separated from each other by the vomer.

The apertures of the *Eustachian tubes* are two slit-like openings, situated one at each side of the fauces, and

in a line with the posterior extremity of the inferior spongy bone. The Eustachian tube is a fibro-cartilaginous and osseous canal,

Fig. 41.*



which extends obliquely outwards and upwards to the tympanum, and is the medium of communication between that cavity and the external air. If the mucous membrane be removed from around the aperture, the fibro-cartilage will be found to be about an inch in length, broad at the extremity, and narrower as it proceeds outwards. It is lined by mucous membrane which is continuous with that of the tympanum, and is provided around the aperture with numerous mucous glands.

Between the posterior nares and the opening of the mouth is a musculo-membranous fold, which forms a kind of curtain at the back of the mouth, the *soft palate* or *velum pendulum palati*. Hanging from the middle of its inferior border is a small rounded process, the *uvula*; and passing outwards from the uvula on each side are two curved folds of the mucous membrane, the arches or pillars of the palate. The *anterior pillar* is continued downwards to the side of the base of the tongue, and is formed by the prominence of the palato-glossus muscle. The *posterior pillar* is prolonged downwards and backwards into the pharynx, and is formed by the convexity

* The openings of the pharynx. — No. 1. The basilar process of the occipital bone. 2, 2. The petrous portion of the temporal bone. 3, 3. The posterior nares, separated by the vomer. 4, 4. The openings of the Eustachian tubes. 5. The soft palate. 6, 6. The posterior pillars of the soft palate. 7. The cavity of the mouth; the convex line below the figure represents the tongue. 8. The epiglottis. 9. The opening of the larynx. 10. The opening of the oesophagus. 11, 11. The sides of the pharynx drawn open. 12. The oesophagus.

of the palato-pharyngeus muscle. These two pillars, closely united above, are separated below by a triangular interval or niche, in which the tonsil is lodged.

The TONSILS (*amygdalæ*) are two glandular organs, shaped like almonds, and situated between the anterior and posterior pillar of the soft palate, on each side of the fauces. They are composed of an assemblage of mucous follicles, which open upon the surface of the gland by about twelve apertures. Externally, they are invested by the pharyngeal fascia, which separates them from the superior constrictor muscle and internal carotid artery, and prevents an abscess from opening in that direction. In relation to surrounding parts, each gland corresponds with the angle of the lower jaw.

The space included between the soft palate and the root of the tongue is the *isthmus of the fauces*. It is bounded *above* by the soft palate, on each *side* by the pillars of the soft palate and tonsils, and *below* by the root of the tongue. It is the opening between the mouth and pharynx.

The opening into the larynx is broad in front and narrow behind. It is bounded in front by the epiglottis, and on the sides by the fold of mucous membrane stretched between the sides of the epiglottis and the arytenoid cartilages. In front of the epiglottis is the root of the tongue.

The opening into the œsophagus corresponding with the lower border of the inferior constrictor and the commencement of the circular muscular fibres, has the appearance of the aperture of a sphincter, the mucous membrane, paler than that of the pharynx, being thrown into folds.

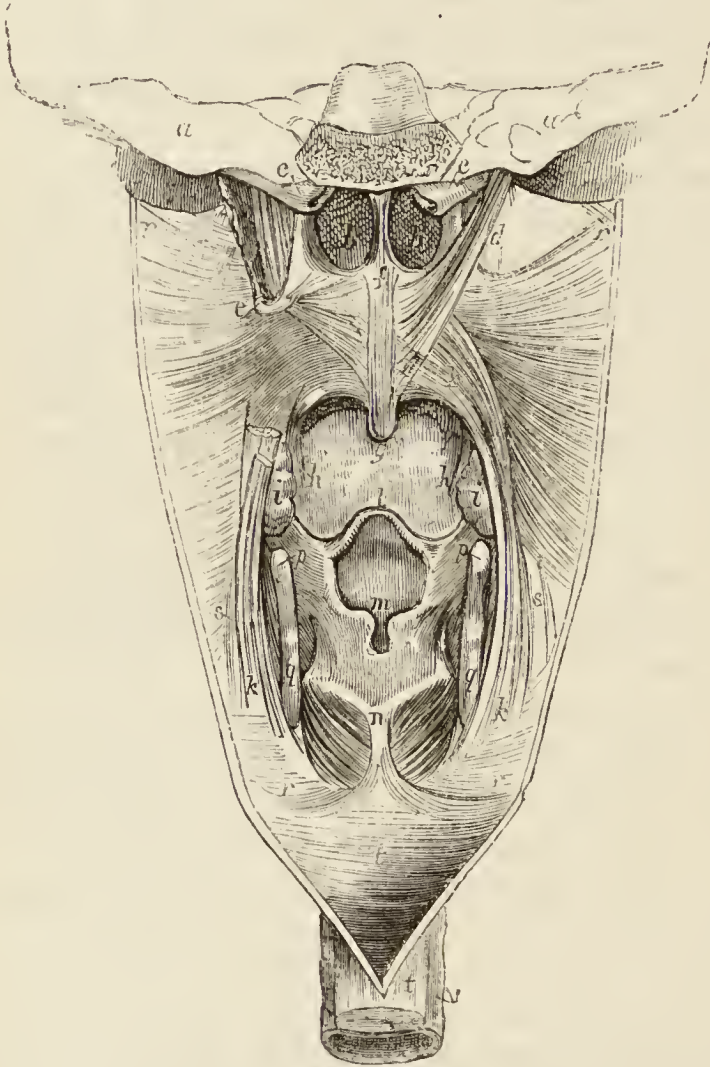
The student may now proceed to the removal of the mucous membrane from the posterior surface and pillars of the palate, and for some little distance on the side of the pharynx. On the middle line he will find a pair of small muscles which descend into the uvula; these are the *azygos uvulæ*. On the side of the soft palate, and coming down from the base of the cranium, is the *levator palati*. The attachment of the superior constrictor to the internal pterygoid plate should now be defined and divided in order to bring into view a muscle which lies under cover of that plate, the *tensor palati*. In the posterior pillar of the soft palate is the palato-pharyngeus muscle, and in the anterior pillar the palato-glossus.

The MUSCLES of the soft palate are ;—

Levator palati,	Azygos uvulæ,
Tensor palati,	Palato-glossus,
Palato-pharyngeus.	

The AZYGOS UVULÆ is a pair of small muscles situated along the midline of the soft palate. They *arise* from the spine of the palate bone, and are *inserted* into the uvula.

*Fig. 42.**



* Muscles of the soft palate and interior of the pharynx. — *a*. Section of the base of the skull. *b, b*. Posterior nares, separated by the vomer. *c, c*. The Eustachian tubes. *d*. The levator palati muscle. The muscle winding around the hamular process *e*, and spreading out in the soft palate is the tensor palati. *f*. The azygos uvulæ. *g*. The uvula. *h, h*. The anterior pillars of the palate formed by the palato-glossus muscles. The letters *g, h, h*, are placed on the tongue. *i, i*. The tonsils. *k, k*. The palato-pharyngeus muscle; on the right side its origin by two fasciculi, between which the levator palati passes, is

The *LEVATOR PALATI* *arises* from the extremity of the petrous portion of the temporal bone, and from the posterior aspect of the Eustachian tube, and passing down by the side of the posterior naris, spreads out between the fasciculi of origin of the palato-pharyngeus and is *inserted* into the raphé, where it is overlaid by the *azygos uvulæ*.

The *TENSOR PALATI* (*circumflexus*) *arises* from the scaphoid fossa at the base of the internal pterygoid plate, from the adjacent part of the sphenoid bone, and from the anterior aspect of the Eustachian tube. It lies between the internal pterygoid muscle and internal pterygoid plate, and winding around the hamular process of the latter, expands into a tendinous aponeurosis which is *inserted* into the transverse ridge on the horizontal portion of the palate bone and into the raphé.

The *PALATO-PHARYNGEUS* forms the posterior pillar of the fauces; it *arises* by two fasciculi from the raphé of the soft palate, where its fibres are continuous with those of the muscle of the opposite side; and is *inserted* into the inner surface of the pharynx and posterior border of the thyroid cartilage. This muscle is broad above where it forms the whole thickness of the lower half of the soft palate, narrow in the posterior pillar, and again broad and thin in the pharynx, where it spreads out previously to its insertion. The levator palati passes to its insertion between the two fasciculi of origin of the muscle.

The *PALATO-GLOSSUS* (*constrictor isthmi faucium*) is a small fasciculus of fibres which *arises* in the soft palate, and descends to be *inserted* into the side of the tongue. It is the projection of this small muscle, covered by mucous membrane, that forms the anterior pillar of the soft palate. It has been named *constrictor isthmi faucium*,

seen : on the left side the upper part of the muscle has been removed. This muscle forms the posterior pillar of the soft palate. *l.* The epiglottis. *m.* The superior aperture of the larynx; the two rounded prominences below the letter are formed by the *cornicula laryngis*. *n.* The cricoid cartilage; the muscle on each side of the letter is the *crico-arytenoideus posticus*. *p.* The extremity of the great cornu of the *os hyoides*. *q.* The posterior border of the thyroid cartilage. *r, r.* The bag of the pharynx drawn aside. *s, s.* The *stylo-pharyngeus* muscle, issuing from beneath the lower border of the middle constrictor. *t, t.* The *œsophagus*. *v.* The *trachea*.

from a function it performs in common with the palato-pharyngeus, viz. of constricting the opening of the fauces.

ACTIONS.—The azygos uvulæ shortens the uvula. The levator palati raises the soft palate, while the tensor spreads it out laterally so as to form a septum between the pharynx and posterior nares. Taking its fixed point from below, the tensor palati will dilate the Eustachian tube. The palato-glossus and palato-pharyngeus constrict the opening of the fauces, and by drawing down the soft palate, they serve to press the mass of food from the dorsum of the tongue into the pharynx.

The **ÆSOPHAGUS** commences at the lower border of the cricoid cartilage, and in its course down the neck rests on the vertebral column, inclining to the left so as to project beyond the border of the trachea on that side. It is composed of three coats, muscular, cellular, and mucous.

The *muscular coat* consists of two layers of fibres, of which the external are longitudinal, and the internal circular. The longitudinal fibres commence by three fasciculi, anterior and two lateral: the anterior fasciculus is attached to the longitudinal ridge on the posterior surface of the cricoid cartilage; the lateral fasciculi are connected with the inferior constrictor of the pharynx. The internal layer of circular fibres is continuous with the inferior constrictor.

The *mucous coat* is covered by a thick, whitish epithelium, and is thrown into longitudinal folds.

The anatomy of the nose, mouth, and larynx are contained in a subsequent Chapter (VII.), in which they are associated with the organs of vision and hearing.

CHAPTER VI.

BRAIN AND SPINAL CORD.

THE brain is a collective term which signifies those parts of the nervous system, exclusive of the nerves themselves, which are contained within the cranium: they are the cerebrum, cerebellum, and medulla oblongata. These are invested and protected by the membranes of the brain, and the whole together constitute the encephalon (ἐν κεφαλῇ), within the head).

To examine the encephalon with its membranes, the upper part of the skull must be removed by sawing through the external table, and breaking the internal table with the chisel and hammer. After the calvarium has been loosened all round, it will require a considerable degree of force to tear the bone away from the dura mater. This adhesion is particularly firm at the sutures, where the dura mater is continuous with a membranous layer interposed between the edges of the bones; in other situations, the connection results from numerous vessels which permeate the inner table of the skull. The adhesion subsisting between the dura mater and bone is greater in the young subject than in the adult.

Upon being torn away, the internal table will present the deeply grooved and ramified channels corresponding with branches of the arteria meningea media. Along the middle line will be seen a groove corresponding with the superior longitudinal sinus, and on either side may be frequently observed some depressed fossæ, corresponding with the Pacchionian bodies.

The MEMBRANES of the encephalon and spinal cord are the *dura mater*, *arachnoid membrane*, and *pia mater*.

The DURA MATER* is the firm, whitish or greyish layer which is brought into view when the calvarium is removed. It is a strong fibrous membrane, somewhat laminated in texture, and composed of white fibrous tissue. Lining the interior of the cranium, it serves as the internal periosteum of that cavity; it is prolonged also into the spinal column, under the name of theca

* So named from a supposition that it was the source of all the fibrous membranes of the body.

vertebralis, but is not adherent to the bones in that canal as in the cranium. From the internal surface of the dura mater, processes are directed inwards for the support and protection of parts of the brain; while from its exterior, other processes are prolonged outwards to form sheaths for the nerves as they quit the skull and spinal column. Its external surface is rough and fibrous, and corresponds with the internal table of the skull. The internal surface is smooth, and lined by the thin varnish-like lamella of the arachnoid membrane. The latter is a serous membrane. Hence the dura mater becomes a *fibro-serous* membrane, being composed of its own proper fibrous structure, and the serous layer derived from the arachnoid. There are two other instances of fibro-serous membrane in the body, formed in the same way, namely, the pericardium and tunica albuginea of the testicle.

On the external surface of the dura mater the branches of the middle meningeal artery may be seen ramifying; and in the middle line is a depressed groove, formed by the subsidence of the upper wall of the superior longitudinal sinus. If the sinus be opened along its course, it will be found to be a triangular channel, crossed at its lower angle by numerous white bands, called chordæ Willisii; granular bodies are also occasionally seen in its interior, these are glandulæ Pacchioni.

The GLANDULÆ PACCHIONI* are small, round, whitish granulations, occurring singly or in clusters, and forming small groups of various size along the margins of the longitudinal fissure of the cerebrum, and more particularly near the summit of the latter. These bodies would seem to be of morbid origin; they are absent in infancy, increase in numbers in adult life, and are abundant in the aged. They are generally associated with opacity of the arachnoid around their bases, but in some instances are wanting even in the adult. They have their point of attachment in the pia mater, from which they seem to spring, carrying with them the arachnoid membrane, and then, in proportion to their size, producing various effects upon contiguous parts. For example, when small, they

* These bodies are incorrectly described as conglobate glands by Pacchioni, in an epistolary dissertation, "De Glandulis conglobatis Duræ Meningis indeque ortis Lymphaticis ad Piam Matrem productis," published at Rome, in 1705.

remain free or constitute a bond of adhesion between the visceral and parietal layer of the arachnoid: when of larger size they produce absorption of the dura mater, and as the degree of absorption is greater or less, they protrude through that membrane, and form depressions on the inner surface of the cranium, or simply render the dura mater thin and cribriform. Sometimes they cause absorption of the wall of the longitudinal sinus, and projecting into its cavity, give rise to the granulations described in connection with that channel.

If the student cut through one side of the dura mater, in the direction of his incision through the skull, and turn it upwards towards the middle line, he will observe the smooth internal surface of this membrane. He will perceive also the large veins of the hemispheres filled with dark blood, and passing from behind forwards to open into the superior longitudinal sinus; and the firm connection, by means of these veins and the Pacchionian bodies, between the opposed surfaces of the arachnoid membrane. If he separate these adhesions with his scalpel, he will see a vertical layer of dura mater descending between the hemispheres; and if he draw one side of the brain a little outwards, he will be enabled to perceive the extent of the process of membrane, which is called the *falx cerebri*.

The processes of dura mater which are sent inwards towards the interior of the skull, are the *falx cerebri*, *tentorium cerebelli*, and *falx cerebelli*.

The *falx cerebri* (*falx*, a sickle), so named from its sickle-like appearance, narrow in front, broad behind, and forming a sharp curved edge below, is attached in front to the crista galli process of the ethmoid bone, and behind to the tentorium cerebelli.

The *tentorium cerebelli* (*tentorium*, a tent) is a roof of dura mater, thrown across the cerebellum and attached at each side to the margin of the petrous portion of the temporal bone; behind, to the transverse ridge of the occipital bone, which lodges the lateral sinuses; and to the clinoid processes in front. It supports the posterior lobes of the cerebrum and prevents their pressure* on the cerebellum, leaving only a small opening anteriorly, for the transmission of the crura cerebri.

The *falx cerebelli* is a small process, generally double,

* In leaping animals, as the feline and canine genera, the tentorium forms a bony tent.

attached to the vertical ridge of the occipital bone beneath the lateral sinus, and to the tentorium. It is received into the indentation between the two hemispheres of the cerebellum.

The student cannot see the tentorium and falx cerebelli until the brain is removed; but he should consider the attachments of the former on the dried skull, for he will have to incise it in the removal of the brain. He should now proceed to that operation, for which purpose the dura mater is to be divided all round, on a level with the section through the skull, and the scissors are to be carried deeply between the hemispheres of the brain in front to cut through the anterior part of the falx; then draw the dura mater backwards, and leave it hanging by its attachment to the tentorium. Raise the anterior lobes of the brain carefully with the hand, and lift the olfactory bulbs from the cribriform fossæ with the handle of the scalpel. Then cut across the two optic nerves and internal carotid arteries. Next divide the infundibulum and third nerves, and carry the knife along the margin of the petrous bone at each side, so as to divide the tentorium near its attachment. Cut across the fourth, fifth, sixth, seventh, and eighth nerves in succession with a sharp knife, and pass the scalpel as far down as possible into the vertebral canal, to sever the spinal cord, cutting first to one side and then to the other, in order to divide the vertebral arteries and first cervical nerves. Then let him press the cerebellum gently upwards with the fingers of the right hand, the hemispheres being supported with the left, and the brain will roll into his hand.

The student may now direct his attention to the anatomy of the brain, and the two membranes which form its immediate investment; namely, the arachnoid and pia mater; leaving the dura mater in the base of the cranium, the exit of the cranial nerves, and the sinuses of the dura mater for subsequent examination. The brain should be placed upon a plate, and supported by a towel, disposed like a turban within the margin of the plate. When the upper surface has been examined, the organ should be carefully turned in order to display the under surface or base.

The ARACHNOID MEMBRANE (*ἀράχνη, εἶδος*, like a spider's web), so named from its extreme tenuity, is the serous membrane of the cerebro-spinal centre; and, like other serous membranes, a shut sac. It envelopes the brain and spinal cord (visceral layer), and is reflected on the inner surface of the dura mater (parietal layer), giving to that membrane its serous investment.

On the upper surface of the hemispheres the arachnoid is transparent, but may be demonstrated as it passes across the sulci from one convolution to another, by injecting with a blow-pipe, a stream of air beneath it. At the base of the brain the membrane is opalescent and thicker than

in other situations, and more easily demonstrable from the circumstance of stretching across the interval between the middle lobes of the hemispheres. The space which is included between this layer of membrane and those parts of the base of the brain which are bounded by the optic commissure and fissures of Sylvius in front, and the pons Varolii behind, is termed the *anterior sub-arachnoidean space*. Another space formed in a similar manner, between the under part of the cerebellum and the medulla oblongata, is the *posterior sub-arachnoidean space*; and a third space, situated over the corpora quadrigemina, may be termed the *superior sub-arachnoidean space*. These spaces communicate freely with each other, the anterior and posterior across the crura cerebelli, the anterior and the superior around the crura cerebri, and the latter and the posterior across the cerebellum in the course of the vermiform processes. They communicate also with a still larger space formed by the loose disposition of the arachnoid around the spinal cord, the *spinal sub-arachnoidean space*. The whole of these spaces, with the lesser spaces between the convolutions of the hemispheres, constitute one large and continuous cavity, which is filled with a limpid, serous secretion, the *sub-arachnoidean* or *cerebro-spinal fluid*, a fluid which is necessary to the maintenance and protection of the cerebro-spinal mass. The quantity of the cerebro-spinal fluid is determined by the relative size of the cerebro-spinal axis and that of the containing cavity, and is consequently very variable. It is smaller in youth than in old age, and in the adult has been estimated at about two ounces. The visceral layer of the arachnoid is connected to the pia mater by a delicate cellular tissue, which in the sub-arachnoidean spaces is loose and filamentous. The serous secretion of the true cavity of the arachnoid is very small in quantity as compared with the sub-arachnoidean fluid.

The arachnoid does not enter into the ventricles of the brain, as imagined by Bichât, but is reflected inwards upon the venæ Galeni for a short distance only, and returns upon those vessels to the dura mater of the tentorium. It surrounds the nerves as they originate from the brain, and forms a sheath around them to their point of exit from the skull. It is then reflected back upon the inner surface of the dura mater.

According to Mr. Rainey*, *vessels* of considerable size, but few in number, and branches of cranial *nerves*, are found in the arachnoid. He also describes, in this membrane, numberless plexuses and ganglia, which he considers to be analogous to those of the sympathetic nerve. The fibres proceeding from this source are distributed on the arteries and nerves of the cerebro-spinal axis, but particularly on the former.

The PIA MATER is a vascular membrane composed of innumerable vessels held together by a thin layer of cellular tissue. It invests the whole surface of the brain, dipping into the sulci between the convolutions, and forming a fold in its interior called *velum interpositum*. It also forms folds in other situations, as in the third and fourth ventricles, and in the longitudinal fissures of the spinal cord.

This membrane differs in structure in different parts of the cerebro-spinal axis. Thus, on the surface of the cerebrum, in contact with the soft grey matter of the brain, it is extremely vascular, forming remarkable loops of anastomoses in the interspaces of the convolutions, and distributing multitudes of minute straight vessels (*tomentum cerebri*) to the grey substance. In the *substantia perforata*, again, and *locus perforatus*, it gives off tufts of small arteries, which pierce the white matter to reach the grey substance in the interior. But upon the *crura cerebri*, *pons Varolii*, and spinal cord, its vascular character seems almost lost. It has become a *dense fibrous membrane*, difficult to tear off, and forming the proper sheath of the spinal cord.

The pia mater is the nutrient membrane of the brain, and derives its blood from the internal carotid and vertebral arteries. Its nerves are the minute filaments of the sympathetic, which accompany the branches of the arteries. At the base of the brain the arteries maintain a remarkable communication, the *circle of Willis*. If the arachnoid membrane be removed, and the connections of the pia mater gently separated, these vessels may be examined.

The INTERNAL CAROTID ARTERY at the fissure of Sylvius divides into three branches, namely, anterior cerebral, middle cerebral, and posterior communicating.

* Medico-Chirurgical Transactions, vol. xxix.

The *anterior cerebral artery* passes forwards in the great longitudinal fissure between the two hemispheres of the brain; then curves backwards along the corpus callosum to its posterior extremity. It gives branches to the olfactory and optic nerves, to the under surface of the anterior lobes, the third ventricle, the corpus callosum, and the inner surface of the hemispheres. The two anterior cerebral arteries are connected soon after their origin by a short anastomosing trunk, the *anterior communicating artery*.

The *middle cerebral artery*, larger than the preceding, passes outwards along the fissure of Sylvius, and divides into three principal branches, which supply the anterior and middle lobes of the brain, and the island of Reil. Near its origin it gives off the numerous small branches which enter the substantia perforata, to be distributed to the corpus striatum.

The *posterior communicating artery*, very variable in size, sometimes double, and sometimes altogether absent, passes backwards and inosculates with the posterior cerebral, a branch of the basilar artery. Occasionally it is so large as to take the place of the posterior cerebral artery.

The VERTEBRAL ARTERY pierces the dura mater on the side of the spinal canal between the atlas and occipital bone, and enters the cranium through the foramen magnum. Opposite the lower border of the pons Varolii, it unites with its fellow of the opposite side to form the basilar artery.

The BASILAR ARTERY passes forwards, resting in the groove on the midline of the pons Varolii; and at the anterior border of the pons divides into four ultimate branches, two to either side.

The *branches* of the vertebral artery within the cranium and of the basilar are as follows:—

<i>Vertebral.</i>	<i>Basilar.</i>
Posterior meningeal,	Inferior cerebellar.
Anterior spinal,	Transverse,
Posterior spinal,	Superior cerebellar,
Posterior cerebral.	

The *posterior meningeal* are one or two small branches which enter the cranium through the foramen magnum,

to be distributed to the dura mater of the cerebellar fossæ, and to the falx cerebelli. One branch, described by Soemmering, passes into the cranium along the first cervical nerve.

The *anterior spinal* is a small branch which unites with its fellow of the opposite side, on the front of the medulla oblongata. The artery formed by the union of these two vessels descends along the anterior aspect of the spinal cord, to which it distributes branches.

The *posterior spinal* winds around the medulla oblongata to the posterior aspect of the cord, and descends on either side to the cauda equina. It communicates very freely with the spinal branches of the intercostal and lumbar arteries, and near its origin sends a branch upwards to the fourth ventricle.

The *inferior cerebellar* arteries wind around the upper part of the medulla oblongata to the under surface of the cerebellum, to which they are distributed. They pass between the filaments of origin of the hypoglossal nerve in their course, and anastomose with the superior cerebellar arteries.

The *transverse* branches of the basilar artery supply the pons Varolii, and adjacent parts of the brain. One of these branches, larger than the rest, passes along the crus cerebelli to be distributed to the anterior border of the cerebellum (*middle cerebellar artery*).

The *superior cerebellar* arteries, two of the terminal branches of the basilar, wind around the crus cerebri on each side, lying in relation with the fourth nerve, and are distributed to the upper surface of the cerebellum, inosculating with the inferior cerebellar. This artery gives off a small branch (internal auditory) which accompanies the seventh pair of nerves into the meatus auditorius internus: the auditory branch may be derived directly from the basilar.

The *posterior cerebral* arteries, the other two terminal branches of the basilar, wind around the crus cerebri at each side, and are distributed to the posterior lobes of the cerebrum. They are separated from the superior cerebellar arteries, near their origin, by the third pair of nerves, and are in close relation with the fourth pair in their course around the crura cerebri. Anteriorly, near their origin, they give off a tuft of small vessels which

enter the locus perforatus, and they receive the posterior communicating arteries from the internal carotid. They also send a branch to the velum interpositum and plexus choroides, *posterior choroid*.

The communications established between the anterior cerebral arteries in front, and the internal carotids and posterior cerebral arteries behind, by the communicating arteries, constitute the circle of Willis. This remarkable vascular communication at the base of the brain is formed by the anterior communicating branch, anterior cerebrals, and internal carotid arteries in front, and by the posterior communicating, posterior cerebrals, and basilar artery behind.

The VEINS of the brain are also situated in the pia mater, and pour their contents into the sinuses of the dura mater. They are remarkable for the absence of valves and extreme tenuity of their coats, and are divisible into cerebral and cerebellar veins, the former being further divided into superficial and deep.

The *superficial cerebral veins* are situated on the surface of the hemispheres lying in the grooves formed by the convexities of the convolutions. They are named, from the position which they may chance to occupy upon the surface of the organ, either superior or inferior, internal or external, anterior or posterior.

The *superior cerebral veins*, seven or eight in number on each side, pass obliquely forwards and terminate in the superior longitudinal sinus, in the opposite direction to the course of the stream of blood in the sinus.

The *deep* or *ventricular veins* commence within the lateral ventricles by the veins of the corpora striata and those of the *choroid plexus*, which unite to form the two venæ Galeni.

The *venæ Galeni* pass backwards in the structure of the velum interpositum, and, escaping through the fissure of Bichât, terminate in the straight sinus.

The *cerebellar veins* are disposed, like those of the cerebrum, on the surface of the lobes of the cerebellum. They are situated, some upon the superior, and some on the inferior surface, while others occupy the borders of the organ. They terminate in the lateral and petrosal sinuses.

CEREBRUM.

The *cerebrum* presents on its surface a number of slightly convex elevations, the convolutions (*gyri*), which are separated from each other by sulci of various depth.* It is divided superiorly into two hemispheres by the great longitudinal fissure which lodges the falx cerebri, and marks the original development of the brain by two symmetrical halves.

Each hemisphere, upon its under surface, admits of a division into three lobes, anterior, middle, and posterior. The *anterior lobe* rests on the roof of the orbit, and is separated from the middle by the fissure of Sylvius. The *middle lobe* is received into the middle fossa of the base of the skull, and is separated from the posterior by a slight impression produced by the ridge of the petrous bone. The *posterior lobe* is supported by the tentorium.

If the upper part of one hemisphere, at about one-third from its summit, be removed with a scalpel, a centre of white substance will be observed, surrounded by a narrow border of grey, which follows the line of the sulci and convolutions, and presents a zigzag form. This section, from exhibiting the largest surface of medullary substance demonstrable in a single hemisphere, is called *centrum ovale minus*. It is spotted by numerous small red points (*puncta vasculosa*), which are produced by the escape of blood from the cut ends of minute arteries and veins.

Separate carefully the two hemispheres of the cerebrum, and a broad band of white substance (*corpus callosum*) will be seen to connect them; it will be seen also that the surface of the hemisphere, where it comes in contact with the *corpus callosum*, is bounded by a large convolution (*gyrus fornicatus*) which lies horizontally on that body, and may be traced forwards and backwards to the base of the brain, terminating by each extremity at

* In estimating the surface of the brain, which, according to Baillarger, averages in round numbers 670 square inches, these convolutions and the laminae of the cerebellum are supposed to be unfolded.

the fissure of Sylvius. The sulcus between this convolution and the corpus callosum has been termed, very improperly, the "ventricle of the corpus callosum;" and some longitudinal fibres (*striæ longitudinales laterales*), which are brought into view when the convolution is raised, were called by Reil the "covered band." If the upper part of each hemisphere be removed to a level with the corpus callosum, a large expanse of medullary matter, surrounded by a zigzag line of grey substance corresponding with the convolutions and sulci of the two hemispheres, will be seen. This is the *centrum ovale majus* of Vieussens.

The *corpus callosum* (callosus, hard) is a thick layer of medullary fibres passing transversely between the two hemispheres, and constituting the *great commissure* (*trabs cerebri*, beam of the brain). It is situated in the middle line of the *centrum ovale majus*, but nearer the anterior than the posterior part of the brain, and terminates anteriorly in a rounded border (*genu*), which may be traced downwards to the base of the brain in front of the commissure of the optic nerves. Posteriorly it forms a thick rounded fold (*splenium*), which is continuous with the fornix. The length of the corpus callosum is about four inches.

Beneath the posterior rounded border of the corpus callosum is the *transverse fissure* of the cerebrum, which extends between the hemispheres and *crura cerebri* from near the fissure of Sylvius on one side, to the same point on the opposite side of the brain. It is through this fissure that the pia mater communicates with the *velum interpositum*. And it was here that Bichât conceived the arachnoid to enter the ventricles; hence it is also named the *fissure of Bichât*.

Along the middle line of the corpus callosum is the *raphé*, a linear depression between two slightly elevated longitudinal bands (*chordæ longitudinales*, Lancisii); and, on either side of the *raphé*, may be seen the *lineæ transversæ*, which mark the direction of the fibres of which the corpus callosum is composed. These fibres may be traced into the hemispheres on either side, and they will be seen to be crossed at about an inch from the *raphé* by the longitudinal fibres of the covered band of

Reil. Anteriorly and posteriorly the fibres of the corpus callosum curve into their corresponding lobes.

If a superficial incision be made through the corpus callosum on either side of the *raphé*, two irregular cavities will be opened, which extend from one extremity of the hemispheres to the other: these are the *lateral ventricles*. To expose them completely, their upper boundary should be removed with the scissors. In making this dissection, the thin and diaphanous membrane of the ventricles may frequently be seen.

LATERAL VENTRICLES.—Each lateral ventricle is divided into a *central cavity*, and three smaller cavities called *cornua*. The *anterior cornu* curves forwards and outwards in the anterior lobe; the *middle cornu* descends into the middle lobe; and the *posterior cornu* passes backwards in the posterior lobe, converging towards its fellow of the opposite side. The central cavity is triangular in form, being bounded above (*roof*) by the corpus callosum; internally by the septum lucidum, which separates it from the opposite ventricle; and below (*floor*) by the following parts, taken in their order of position from before backwards:—

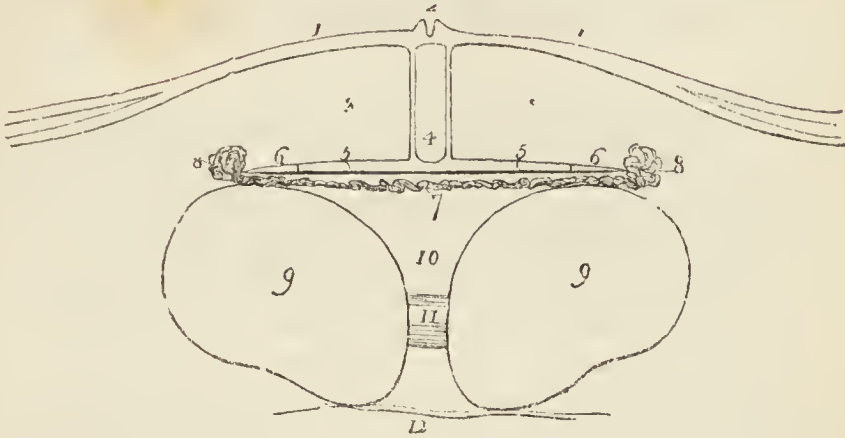
Corpus striatum,	Choroid plexus,
Tenia semicircularis,	Corpus fimbriatum,
Thalamus opticus,	Fornix.

The *corpus striatum* is named from the striated lines of white and grey matter which are seen upon cutting into its substance. It is grey on the exterior, and of a pyriform shape. The broad end, directed forwards, rests against the corpus striatum of the opposite side: the small end, backwards, is separated from its fellow by the interposition of the thalami optici. The corpora striata are the superior ganglia of the cerebrum.

The *tenia semicircularis* (*tenia*, a fillet) is a narrow band of medullary substance, extending along the posterior border of the corpus striatum, and serving as a bond of connection between that body and the thalamus opticus. It is transparent and dense at the surface, and received from Tarinus the name of *horny band*. The tenia is partly concealed by a large vein (*vena corporis striati*), which receives numerous small veins from the corpus striatum and thalamus opticus, and terminates in the vena Galeni of its own side.

The *thalamus opticus* (thalamus, a bed) is an oblong body, having a thin coating of white substance on its

Fig. 43.*



surface; it has received its name from giving origin to one root of the optic nerve. It is the inferior ganglion of the cerebrum. Part only of the thalamus is seen in the floor of the lateral ventricle; we must therefore defer its further description until we can examine it in its entire extent.

The *choroid plexus* (*χόριοις*, *εἶδος*, resembling the chorion †) is a vascular fringe extending obliquely across the floor of the lateral ventricle, and sinking into the middle cornu. Anteriorly, it is small and tapering, and communicates with the choroid plexus of the opposite ventricle, through a large oval opening, the *foramen of Monro*, or *foramen commune anterius*. This foramen may be distinctly seen by pulling slightly on the plexus,

* A diagram, representing a transverse section of the brain. — Nos. 1, 1. The corpus callosum, or great commissure of the hemispheres, extending transversely into each hemisphere. 2. The raphé, a linear depression between two slightly elevated ridges. 3, 3. The lateral ventricles. 4. The space between the two layers of the septum lucidum, called the fifth ventricle. 5, 5. The fornix. 6, 6. The thin edges of the fornix, called corpora fimbriata. 7. The velum interpositum. 8, 8. The plexiform borders of the velum interpositum, called choroid plexuses. 9, 9. The thalami optici. 10. The space between the two thalami, called third ventricle. 11. The grey commissure of the thalami optici, called middle commissure, or *commissura mollis* of the third ventricle. 12. The line of the base of the brain.

† See the note appended to the description of the choroid coat of the eyeball.

and pressing aside the septum lucidum with the handle of the knife. It is situated between the under surface of the fornix and the anterior extremities of the thalami optici, and forms a communication transversely between the lateral ventricles, and perpendicularly with the third ventricle.

The choroid plexus presents upon its surface a number of minute vascular processes, which are termed *villi*. They are invested by a very delicate epithelium, surmounted by cilia, which have been seen in active movement in the embryo. In their interior the plexuses not unfrequently contain particles of calcareous matter, and are sometimes covered by small clusters of serous cysts.

The *corpus fimbriatum* is a narrow white band, situated immediately behind the choroid plexus, and extending with it into the descending cornu of the lateral ventricle. It is, in fact, the lateral thin edge of the fornix, and being attached to the hippocampus major in the descending horn of the lateral ventricle, it is also termed *tenia hippocampi*.

The *fornix* is a white layer of medullary substance, of which a portion only is seen in this view of the ventricle.

The *anterior cornu* is triangular in its form, sweeping outwards, and terminating by a point in the anterior lobe of the brain, at a short distance from its surface.

The *posterior cornu* or *digital cavity* curves inwards, as it extends back into the posterior lobe of the brain, and likewise terminates near the surface. An elevation (corresponding with a deep sulcus between two convolutions) projects into the area of this cornu, and is called the *hippocampus minor*.

The *middle* or *descending cornu*, in descending into the middle lobe of the brain, forms a very considerable curve, and alters its direction several times as it proceeds. Hence it is described as passing backwards and outwards and downwards, and then turning forwards and inwards.* It is the largest of the three cornua, and terminates close to

* This complex expression of a very simple curve has given origin to a symbol formed by the primary letters of these various terms; and by means of this the student recollects with ease the course of the cornu, BODEL.

the fissure of Sylvius, after having curved around the crus cerebri.

The middle cornu should now be laid open, by inserting the little finger into its cavity, and making it serve as a director for the scalpel in cutting away the side of the hemisphere, so as to expose it completely.

The *superior boundary* of the middle cornu is formed by the under surface of the thalamus opticus, upon which are the two projections called corpus geniculatum internum and externum; and the *inferior wall* by the following parts: —

Hippocampus major,	Choroid plexus,
Pes hippocampi,	Fascia dentata,
Pes accessorius,	Transverse fissure.
Corpus fimbriatum,	

The *hippocampus major* or *cornu Ammonis*, so called from its resemblance to a ram's horn, the famous crest of Jupiter Ammon, is a considerable projection from the inferior wall, and extends the whole length of the middle cornu. Its extremity is likened to the foot of an animal, from its presenting a number of knuckle-like elevations upon the surface, and is named *pes hippocampi*. The hippocampus major is the internal surface of the convolution (gyrus fornicatus) of the lateral edge of the hemisphere, the convolution which has been previously described as lying upon the corpus callosum and extending downwards to the base of the brain to terminate at the fissure of Sylvius. If it be cut across, the section will be seen to resemble the extremity of a convoluted scroll, consisting of alternate layers of white and grey substance. The hippocampus major is continuous superiorly with the fornix and corpus callosum, and derives its medullary layer from the corpus fimbriatum.

The *pes accessorius* (eminentia collateralis) is a swelling somewhat resembling the hippocampus major, but smaller in size, and situated in the angular interval between it and the hippocampus minor. Like the latter, it is formed by the protrusion of one of the sulci of the convolutions.

The *corpus fimbriatum* (tenia hippocampi) is the narrow white band which is prolonged from the central cavity of the ventricle, and is attached along the inner border of

the hippocampus major. It is lost inferiorly on the hippocampus.

Fascia dentata.—If the corpus fimbriatum be carefully raised, a narrow serrated band of grey substance, the margin of the grey substance of the middle lobe, will be seen beneath it; this is the fascia dentata. Beneath the corpus fimbriatum will be likewise seen the *transverse fissure* of the brain, which has been before described as extending from near the fissure of Sylvius on one side, across to the same point on the opposite side of the brain. It is through this fissure that the pia mater communicates with the *choroid plexus*, and the latter obtains its supply of blood. The fissure is bounded on one side by the corpus fimbriatum, and on the other by the under surface of the thalamus opticus.

The internal boundary of the lateral ventricle is the *septum lucidum*. This septum is thin and semi-transparent, and consists of two laminae of cerebral substance attached above to the under surface of the corpus callosum at its anterior part, and below to the fornix. Between the two layers is a narrow space, the *fifth ventricle*, which is lined by a proper membrane. The *fifth ventricle* may be shown, by snipping through the septum lucidum transversely with the scissors.

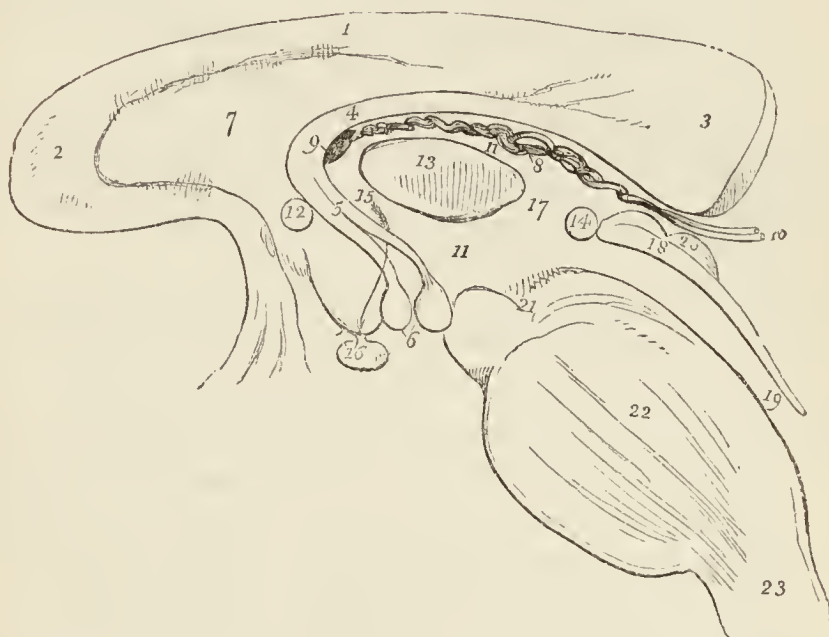The corpus callosum should now be cut across towards its anterior extremity, and the two ends carefully dissected away. The anterior portion will be retained only by the septum lucidum, but the posterior will be found incorporated with the white layer beneath which is the fornix.

FORNIX.—The fornix (arch) is a triangular lamina of white substance, broad behind, and extending into each lateral ventricle: narrow in front, where it terminates in two crura, which arch downwards to the base of the brain. The two crura descend in a curved direction to the base of the brain, embedded in grey substance in the lateral walls of the third ventricle, and lying directly behind the anterior commissure. At the base of the brain they make a sudden curve upon themselves and constitute the corpora albicantia, from which they may be traced upwards to their origin in the thalami optici. Opening transversely beneath these two crura, just as they are about to arch downwards, is the foramen of com-

munication between the lateral and the third ventricle, the *foramen of Monro*; or *foramen commune anterius*. The choroid plexuses communicate, and the veins of the corpora striata pass through this opening.

The lateral thin edges of the fornix are continuous *posteriorly* with the concave border of the hippocampus

Fig. 44.*



* A diagram representing the longitudinal section of the brain between the two hemispheres. — No. 1. The corpus callosum. 2. Its anterior extremity (genu) turning downwards to terminate at the base of the brain. 3. Its posterior extremity (splenium) much larger than the anterior, forms a rounded border, which is continuous with — 4. The fornix. 5. The two crura of the fornix, terminating in—6. The two corpora albicantia. 7. The septum lucidum. 8. The velum interpositum. 9. The opening of communication between the lateral and third ventricle. 10. The venæ Galeni, escaping through the fissure of Bichât to enter the straight sinus. 11, 11. The third ventricle. 12. Section of the anterior commissure. 13. Section of the middle commissure, commissura mollis. 14. Section of the posterior commissure. 15. The foramen commune anterius, or space between the anterior and middle commissure, leading downwards in the direction of the arrow, between the crura of the fornix to the infundibulum: hence it is also named, iter ad infundibulum. 16. The pituitary gland. 17. The foramen commune posterius. 18. The cut edge of the corpora quadrigemina, which forms the superior boundary of the iter à tertio ad quartum ventriculum, leading from the third (11.) into the fourth ventricle, 19. 20. The corpora quadrigemina. 21. The crus cerebri of the right side. 22. Section of the pons Varolii. 23. Section of the medulla oblongata.

major at each side, and form the narrow white band called *corpus fimbriatum* (posterior crus of the fornix). In the middle line the fornix is continuous with the corpus callosum, and at each side with the hippocampus major and minor. Upon the under surface of the fornix towards its posterior part, some transverse lines are seen passing between the diverging corpora fimbriata: this appearance is termed the *lyra* (*corpus psalloides*), from a fancied resemblance to the strings of a harp.

The fornix may now be removed by dividing it across anteriorly and turning it backwards, at the same time separating its lateral connections with the hippocampi. If the student examine its under surface, he will perceive the *lyra* above described.

Beneath the fornix is the *velum interpositum* (*tela choroidea*), a duplicature of pia mater introduced into the interior of the brain, through the transverse fissure. The velum is continuous at each side with the choroid plexus, and contains in its inferior layer two large veins (*venæ Galeni*) which receive the blood from the corpora striata and choroid plexuses, and terminate posteriorly, after uniting into a single trunk, in the straight sinus. Upon the under surface of the velum interpositum are two fringe-like bodies, which project into the third ventricle. These are the *choroid plexuses* of the *third ventricle*; posteriorly these fringes enclose the pineal gland.

If the velum interpositum be raised and turned back, an operation which must be conducted with care, particularly at its posterior part where it invests the pineal gland, the thalami optici and the cavity of the third ventricle will be brought into view.

THALAMI OPTICI.—The thalami optici are two oblong, square-shaped bodies, of a white colour superficially, inserted between the two diverging portions of the corpora striata. In the middle line a fissure exists between them which is called the *third ventricle*. Posteriorly and inferiorly, they form the superior wall of the descending cornu of the lateral ventricle, and present two rounded elevations called *corpus geniculatum externum* and *internum*. The *corpus geniculatum externum* is the larger of the two, and of a greyish colour; it is the principal origin of the optic nerve. Anteriorly, the thalami are

connected with the corpora albicantia by means of two white bands, which appear to originate in the white substance (*tenia semicircularis*) uniting the thalami to the corpora striata. Externally they are in relation with the corpora striata and hemispheres. In their interior the thalami are composed of white fibres mixed with grey substance. They are essentially the *inferior ganglia of the cerebrum*.

THIRD VENTRICLE.—The third ventricle is the fissure between the two thalami optici. It is bounded above by the under surface of the velum interpositum, from which are suspended the choroid plexuses of the third ventricle. Its *floor* is formed by the grey substance of the anterior termination of the corpus callosum, called lamina cinerea, the tuber cinereum, corpora albicantia, and locus perforatus. *Laterally* it is bounded by the thalami optici; *anteriorly* by the anterior commissure and crura of the fornix; and *posteriorly* by the posterior commissure and the iter à tertio ad quartum ventriculum. The third ventricle is crossed by three commissures, anterior, middle, and posterior; and between these are two spaces, called foramen commune anterius and foramen commune posterius.

The *anterior commissure* is a small rounded white cord, which enters the corpus striatum at either side, and spreads out in the substance of the hemispheres; the *middle* or *soft commissure* consists of grey matter, which is continuous with the grey lining of the ventricle, it connects the adjacent sides of the thalami optici; the *posterior commissure*, smaller than the anterior, is a flattened white cord, connecting the two thalami optici posteriorly.

The space between the anterior and middle commissure is called the *foramen commune anterius*, and is that to which Monro has given his name (foramen of Monro). It is the medium of communication between the two lateral and third ventricle, and transmits superiorly the choroid plexus and venæ corporum striatorum. The foramen commune anterius is also termed *iter ad infundibulum*, from leading downwards to the funnel-shaped cavity of the infundibulum. The crura of the fornix are embedded in the lateral walls of the foramen commune, and are concealed from view in this situation by the layer of grey

substance which lines the interior of the third ventricle. If the crura be slightly separated, the anterior commissure will be seen immediately in front of them, crossing from one corpus striatum to the other. The space between the middle and posterior commissure is the *foramen commune posterius*; it is much shallower than the preceding, and is the origin of a canal, the aqueduct of Sylvius or *iter à tertio ad quartum ventriculum*, which leads backwards beneath the posterior commissure and through the base of the corpora quadrigemina to the upper part of the fourth ventricle.

CORPORA QUADRIGEMINA. — The corpora quadrigemina, or optic lobes, are situated immediately behind the third ventricle and posterior commissure; and beneath the posterior border of the corpus callosum. They form, indeed, at this point, the inferior boundary of the transverse fissure of the hemispheres, the fissure of Bichât. The anterior pair of these bodies are grey in colour, and are named *nates*: the posterior pair are white and much smaller than the anterior: they are termed *testes*. From the nates on each side may be traced a rounded process (brachium anterius) which passes obliquely outwards into the thalamus opticus; and from the testis a similar but smaller process (brachium posterius) which has the same destination. The corpus geniculatum internum lies in the interval of these two processes, where they enter the thalamus; and behind the brachium posterius is a prominent band (laqueus) which marks the course of the superior division of the fasciculus olivaris. The corpora quadrigemina are perforated longitudinally through their base by the aqueduct of Sylvius; they are covered in partly by the pia mater and partly by the velum interpositum, and the nates support the pineal gland.

PINEAL GLAND. — The pineal gland is a small reddish-grey body of a conical form (hence its synonym *conarium*), situated on the anterior part of the nates and invested by a duplicature of pia mater derived from the under part of the velum interpositum. The pineal gland, when pressed between the fingers, is found to contain a gritty matter (acervulus) composed chemically of phosphate and carbonate of lime, and phosphate of magnesia and ammonia, and is sometimes hollow in the interior. It is connected to the brain by means of two medullary cords called *pe-*

duncles, and a thin lamina derived from the posterior commissure; the peduncles of the pineal gland are attached to the thalami optici, and may be traced along the upper and inner margin of those bodies to the crura of the fornix, with which they become blended. From the close connection subsisting between the pia mater and the pineal gland, and the softness of texture of the latter, the gland is liable to be torn away in the removal of the pia mater.

Behind the corpora quadrigemina is the cerebellum, and beneath the cerebellum, the fourth ventricle. The student must therefore divide the cerebellum down to the fourth ventricle, and turn its lobes aside to examine that cavity.

FOURTH VENTRICLE. — The fourth ventricle (*sinus rhomboidalis*) is the ventricle of the cerebellum. It is situated on the posterior surface of the medulla oblongata and pons Varolii, is lozenge-shaped in its form, and *bounded on each side* by a thick cord passing between the cerebellum and corpora quadrigemina, called the *processus e cerebello ad testes*, and by the *corpus restiforme*. It is covered in *behind* by the cerebellum, and by a thin lamella of medullary substance, stretched between the two *processus e cerebello ad testes*, termed the *valve of Vieussens*.

That portion of the cerebellum which forms the posterior boundary of the fourth ventricle, presents four small prominences or lobules, and a thin layer of medullary substance, the *velum medullare posterius*. Of the lobules two are placed in the middle line, the *nodulus* and *uvula*, the former being before the latter; the remaining two are named *amygdalæ*, or tonsils, and are situated one on either side of the uvula. They all project into the cavity of the fourth ventricle, and the *velum medullare posterius* is situated in front of them. The *valve of Vieussens* or *velum medullare arterius* is an extremely thin lamella of medullary substance, prolonged from the white matter of the cerebellum to the testes, and attached on each side to the *processus e cerebello ad testes*. This lamella is overlaid for a short distance by a thin, transversely-grooved lobule of grey substance (*linguetta laminosa*) derived from the anterior border of the cerebellum, and its junction with the testes is strengthened by a narrow slip given off by the commissure of those bodies,

the *frænulum veli medullaris anterioris*. The *anterior wall*, or *floor* of the fourth ventricle, is formed by two slightly convex bodies, *fasciculi teretes* (innominati), separated by a longitudinal groove which is continuous inferiorly with the posterior median fissure of the spinal cord. On these bodies the grey substance (*fasciolæ cinereæ*) derived from the interior of the medulla is spread out, and at the lower part of the ventricle forms several eminences or nuclei, from which, according to Stilling, the eighth and ninth nerves, and probably also the fifth, take their origin. Higher up the *fasciculi teretes* are crossed by several white *striae* (*lineæ transversæ*), the origin of the auditory nerves. Upon the lower part of the floor of this ventricle is an impression resembling the point of a pen, and hence named *calamus scriptorius*; the lateral boundaries of the *calamus* are the *processus clavati* of the posterior pyramids. *Above*, the fourth ventricle is bounded by the *corpora quadrigemina* and aqueduct of Sylvius; and *below* by a layer of pia mater and arachnoid, called the valve of the arachnoid. Beneath this valve a communication exists between the ventricles of the brain and the sub-arachnoidean space. Within the fourth ventricle, and lying against the uvula and tonsils, are two small vascular fringes formed by the pia mater, the *choroid plexuses* of the fourth ventricle.

LINING MEMBRANE OF THE VENTRICLES.

The lining membrane of the ventricles is a serous layer distinct from the arachnoid; it lines the whole of the interior of the lateral ventricles, and is connected above and below with the attached border of the choroid plexus, so as to exclude all communication between the lateral ventricles and the exterior of the brain. From the lateral ventricles it is reflected through the foramen of Monro, on each side, into the third ventricle, which it invests throughout. From the third it is conducted into the fourth ventricle, through the *iter à tertio ad quartum ventriculum*, and, after lining its interior, becomes continuous inferiorly with the subarachnoidean space of the spinal cord. The lining membrane of the ventricles is provided with a ciliated epithelium, and is the source of the secretion which moistens and lubricates their interior. The fifth ventricle has a separate lining membrane.

CEREBELLUM.

The *cerebellum*, seven times smaller than the cerebrum, is situated beneath the posterior lobes of the latter, being lodged in the posterior fossa of the base of the cranium, and protected from the superincumbent pressure of the cerebrum by the tentorium cerebelli. Like the cerebrum, it is composed of grey and white substance, the former occupying the surface, the latter the interior; and its surface is formed of parallel lamellæ separated by sulci, and here and there by deeper sulci. In form, the cerebellum is oblong and flattened, its greater diameter being from side to side, its two surfaces looking upwards and downwards, and its borders being anterior, posterior, and lateral. In consideration of its shape, the cerebellum admits of a division into two hemispheres, into certain prominences termed processes and lobules, and into certain divisions of its substance called lobes, formed upon the hemispheres by the deeper sulci above referred to. The two hemispheres are separated from each other on the upper surface of the cerebellum by a longitudinal ridge, which is termed the *superior vermiform process*, and which forms a commissure between them. On the anterior border of the organ there is a semilunar notch, *incisura cerebelli anterior*, which encircles the corpora quadrigemina posteriorly. On the posterior border there is another notch, *incisura cerebelli posterior*, which receives the upper part of the falx cerebelli: and on the under surface of the cerebellum is a deep fissure corresponding with the medulla oblongata, and termed the *vallecula* (valley).

Each hemisphere of the cerebellum is divided by means of a fissure (sulcus horizontalis) which runs along its free border, into an upper and a lower portion; and upon each of these portions certain lobes are marked out. Thus on the upper portion there are two such lobes separated by a sulcus, somewhat more strongly marked than the rest, and extending deeper into the substance of the cerebellum. They are the *lobus superior anterior* and *lobus superior posterior*. Upon the under portion of the hemisphere there are three such lobes, namely, *lobus inferior anterior*, *medius*, and *posterior*, and two additional ones of peculiar form, the *lobus inferior internus*, or *tonsil*, and the *flocculus*. The tonsil (amygdala) is situated on

the side of the vallecule, and projects into the fourth ventricle. The flocculus, or pneumogastric lobule, long and slender, extends from the side of the vallecule, around the corpus restiforme to the crus cerebelli, lying behind the filaments of the eighth pair of nerves.

The commissure between the two hemispheres is termed the *worm* (vermis), that portion of the worm which occupies the upper surface of the cerebellum as far back as the horizontal fissure being the processus vermiformis superior, and that which is lodged within the vallecule being the processus vermiformis inferior. The *superior vermiform process* is a prominent longitudinal ridge, extending from the incisura anterior to the incisura posterior cerebelli. In imitation of the hemispheres, it is divided into lobes, of which three have received names, namely, the *lobulus centralis*, which is a small lobe situated in the incisura anterior; the *monticulus cerebelli*, a longer lobe, having its peak and declivity; and a small lobe near the incisura posterior, the *commissura simplex*. The lobes of the *inferior vermiform process* are four in number, namely, the *commissura brevis*, situated in the incisura posterior, below the horizontal fissure; the *pyramid*, a small, obtusely-pointed eminence; a larger prominence, the *uvula*, situated between the tonsils, and connected with them by means of a commissure; and in front of the uvula the *nodulus*. In front of the nodulus is a thin lamina of medullary substance, consisting of a central and two lateral portions, the *velum medullare posterius* (valvula Tarini); and between this velum and the nodulus and uvula is a deep fossa, which is known as the *swallow's nest* (nidus hirundinis). The *velum medullare anterius* is the valve of Vieussens, described with the fourth ventricle. Both these vela proceed from the same point in the roof of that ventricle, and separate from each other at an angle, the one passing obliquely forwards, the other obliquely backwards.

When a vertical incision is made into the cerebellum, that appearance is seen which has been denominated *arbor vitæ cerebelli*. The white substance in the centre of such a section resembles the trunk of a tree, from which the branches are given off, and from the branches branchlets and leaves, the two latter being coated by a moderately thick and uniform layer of grey substance.

If the incision be made somewhat nearer the commissure than to the lateral border of the organ, a yellowish-grey dentated line, enclosing medullary substance traversed by the openings of numerous vessels, will be seen in the centre of the white substance. This is the ganglion of the cerebellum, the *corpus rhomboideum* or dentatum, from which the peduncles of the cerebellum proceed. The grey line is dense and horny in structure, and is the cut edge of a thin capsule, open towards the medulla oblongata.

The cerebellum is associated with the rest of the encephalon by means of three pairs of rounded cords or peduncles, superior, middle, and inferior. The superior peduncles, or *processus e cerebello ad testes*, proceed from the cerebellum forwards and upwards to the testes, in which they are lost. They form the anterior part of the lateral boundaries of the fourth ventricle, and give attachment by their inner borders to the valve of Vieussens, which is stretched between them. At their junction with the testes they are crossed by the fourth pair of nerves. The middle peduncles, or *crura cerebelli ad pontem*, the largest of the three, issue from the cerebellum through the anterior extremity of the sulcus horizontalis, and are lost in the pons Varolii. The inferior peduncles, or *crura ad medullam oblongatam*, are the corpora restiformia which descend to the posterior part of the medulla oblongata and form the inferior portion of the lateral boundaries of the fourth ventricle.

BASE OF THE BRAIN.

The student should now prepare to study the base of the brain : for this purpose the organ should be turned upon its incised surface ; and if the dissection have hitherto been conducted with care, he will find the base uninjured. The arachnoid membrane, some parts of the pia mater, and the circle of Willis, must be carefully cleared away, in order to expose all the parts to be examined. These he will find arranged in the following order from before backwards :

Longitudinal fissure,	Infundibulum ;
Olfactory nerves,	Corpora albicantia,
Fissure of Sylvius,	Locus perforatus,
Substantia perforata ;	Crura cerebri ;
Commencement of the trans-	Pons Varolii,
verse fissure,	Crura cerebelli,
Optic commissure,	Medulla oblongata.
Tuber cinereum,	

The *longitudinal* fissure is the space separating the two hemispheres : it is continued downwards to the base of the brain, and divides the two anterior lobes. In this fissure the anterior cerebral arteries ascend towards the corpus callosum: and, if the two lobes be slightly drawn asunder, the anterior border (genu) of the corpus callosum will be seen descending to the base of the brain. Arrived at the base of the brain, the corpus callosum terminates by a concave border, which is prolonged to the commissure of the optic nerves by a thin layer of grey substance, the *lamina cinerea*. The lamina cinerea is the anterior part of the inferior boundary of the third ventricle. On each side of the lamina cinerea the corpus callosum is continued into the substantia perforata and crura cerebri, and upon the latter forms a narrow medullary band lying externally to, and slightly overlapping, the optic tract, the *medulla innominata*.

Upon the under surface of each anterior lobe, on either side of the longitudinal fissure, is the *olfactory nerve*, with its bulb.

The *fissure of Sylvius* bounds the anterior lobe posteriorly, and separates it from the middle lobe; it lodges the middle cerebral artery. If this fissure be followed outwards, a small isolated cluster of five or six convolutions (gyri operati) will be observed; these constitute the *island of Reil*. The island of Reil, together with the substantia perforata, form the base of the corpus striatum.

The *substantia perforata* (locus perforatus anticus) is a triangular plane of white substance, situated at the inner extremity of the fissure of Sylvius. It is named *perforata*, from being pierced by a number of openings for small arteries, which enter the brain in this situation to supply the grey substance of the corpus striatum.

Passing backwards on each side beneath the edge of the middle lobe, is the commencement of the *great transverse fissure*, which extends beneath the hemisphere of one side to the same point on the opposite side. A probe passed into this fissure between the crus cerebri and middle lobe would enter the middle cornu of the lateral

The *optic commissure* is situated on the middle line;

it is the point of communication between the two optic nerves.

The *tuber cinereum* is an eminence of grey substance situated immediately behind the optic commissure, and in front of the corpora mammillaria. From its centre there projects a small conical body of grey substance, apparently a prolongation of the tuber cinereum, the *infundibulum*. The infundibulum is hollow in its interior, enclosing a short caecal canal, which communicates with the cavity of the third ventricle; and below the termination of the canal, the conical process becomes connected with the pituitary gland. The infundibulum and tuber cinereum form part of the floor of the third ventricle.

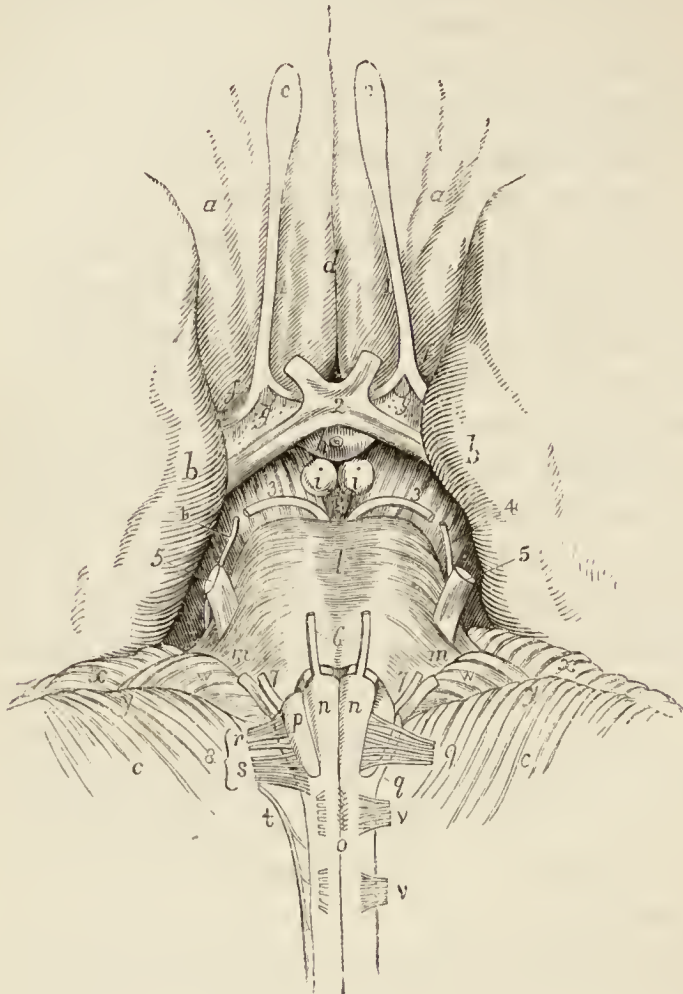
The *pituitary gland* (hypophysis cerebri) is a small, flattened, reddish-grey body situated in the sella turcica, and closely retained in that situation by the dura mater and arachnoid. It consists of two lobes, closely pressed together, the anterior lobe being the larger of the two and oblong in shape, the posterior round. Both lobes are connected with the infundibulum, but the latter is so soft in texture as to be generally torn through in the removal of the brain. Indeed, for the purposes of the student, it is better to effect this separation with the knife, and leave the pituitary body *in situ*, to be examined with the base of the cranium.

The *corpora albicantia* (mammillaria, pisiformia, bulbi fornicis) are two white convex bodies, having the shape and size of peas, situated behind the tuber cinereum, and between the crura cerebri. They are a part of the crura of the fornix, which after their origin from the thalami optici, descend to the base of the brain, and making a sudden curve upon themselves previously to their ascent to the lateral ventricles, constitute the corpora albicantia. When divided by section, these bodies will be found to be composed of a capsule of white substance, containing grey matter, the grey matter of the two corpora being connected by means of a commissure.

The *locus perforatus* (posticus) is a layer of whitish-grey substance, connected in front with the corpora albicantia, behind with the pons Varolii, and on each side with the crura cerebri, between which it is situated. It is perforated by several thick tufts of arteries, which are distributed to the thalami optici and third ventricle, of

which latter it assists in forming the floor. It is also called the pons Tarini.

*Fig. 45.**



* Anatomy of the base of the brain. — *a, a.* The anterior lobes of the cerebrum. *b, b.* The middle lobes. *c, c.* The cerebellum. *d.* The longitudinal fissure of the cerebrum. *1, 1.* The first pair, or olfactory nerves. *e, e.* The bulbi olfactorii. *f, f.* The three roots of origin of the olfactory nerve; externally to the letter is the fissure of Sylvius. *g, g.* The substantia perforata. *2.* The second pair, or optic nerves; the figure rests on the optic commissure. *h.* The tuber cinereum, on the summit of which is seen the infundibulum cut across. *i, i.* The corpora albicantia. *k.* The locus perforatus. *3, 3.* The third pair of nerves: the figures are placed on the crura cerebri. *l.* The pons Varolii. *m, m.* The crura cerebelli. *4, 4.* The fourth pair of nerves. *5, 5.* The fifth pair, issuing from the crura cerebelli. *6.* The sixth pair. *7, 7.* The seventh pair; the smaller nerve is the portio dura. *n, n.* The corpora pyramidalia of the medulla oblongata. *o.* The medulla spinalis; just above the letter is seen the decussation of the fibres of the corpora pyramidalia. *p.* One of the corpora olivaria;

The *crura cerebri* (peduncles of the cerebrum) are two thick white cords, which issue from the anterior border of the pons Varolii, and diverge to each side to enter the thalami optici. By their outer side the *crura cerebri* are continuous with the corpora quadrigemina, and, above, they constitute the lower boundary of the aqueduct of Sylvius. In their interior, they contain grey matter, which has a semilunar shape when the crus is divided transversely, and has been termed the *locus niger*. The third nerve will be observed to arise from the inner side of each crus, and the fourth nerves wind around their outer border from above.

The *pons Varolii* (*protuberantia annularis, nodus encephali*) is the broad transverse band of white fibres which arches like a bridge across the upper part of the medulla oblongata; and, contracting on each side into a thick rounded cord, enters the substance of the cerebellum under the name of *crus cerebelli*. There is a groove along its middle which lodges the basilar artery. The pons Varolii is the commissure of the cerebellum, and associates the two lateral lobes in their common functions. Resting against the pons, near its posterior border, is the sixth pair of nerves. On the anterior border of the *crus cerebelli*, at each side, is the thick bundle of filaments belonging to the fifth nerve, and, lying against its posterior border, the seventh pair of nerves. The upper surface of the pons forms a part of the floor of the fourth ventricle.

MEDULLA OBLONGATA.

The medulla oblongata (*bulbus rhachidicus*) is the upper enlarged portion of the spinal cord. It is somewhat conical in shape, and a little more than an inch in length, extending from the pons Varolii to a point corre-

the other is concealed by the filaments of the ninth nerve. *q*. One of the corpora restiformia; the other is concealed by the filaments of the eighth nerve. 8. The eighth nerve; consisting of *r*, the glosso-pharyngeal; *s*, the pneumogastric; *t*, the spinal accessory. 9. The ninth, or hypoglossal nerve. *v, v*. The anterior roots of the two upper spinal nerves. *w, w*. The pneumogastric lobules of the cerebellum. *x, x*. The border of the lobus superior of the cerebellum. *y, y*. The border of the lobus inferior anterior. The fissure between *x* and *y* is the sulcus horizontalis.

sponding with the upper border of the atlas. On the middle line, in front and behind, the medulla oblongata is marked by two vertical fissures, the anterior and posterior median fissures, which divide it superficially into two symmetrical lateral cords or columns; whilst each lateral column is subdivided by minor grooves into three smaller cords, namely, the corpora pyramidalia, corpora olivaria, and corpora restiformia.

The *corpora pyramidalia* are two narrow convex cords, tapering slightly from above downwards, and situated one on either side of the anterior median fissure. At about an inch below the pons the corpora pyramidalia communicate very freely across the fissure by a decussation of their fibres, and at their point of entrance into the pons they are constricted into round cords. The fissure is somewhat enlarged by this constriction, and the enlarged space has received the name of foramen cæcum (Vicq d'Azyr) of the medulla oblongata.

The *corpora olivaria* (named from some resemblance to the shape of an olive) are two oblong, oval-shaped, convex bodies, of about the same breadth with the corpora pyramidalia, about half-an-inch in length, and somewhat larger above than below. The corpus olivare is situated immediately external to the corpus pyramidale, from which, and from the corpus restiforme, it is separated by a well-marked groove. In this groove some longitudinal fibres are seen which enclose the base of the corpus olivare, and have been named *funiculi siliquæ*, those which lie to its inner side being the funiculus internus, and those to its outer side the funiculus externus. Besides these there are other fibres which cross the corpus olivare obliquely, these are the *fibræ arciformes*. When examined by section, the corpus olivare is found to be a ganglion deeply embedded in the medulla oblongata, and meeting its fellow at the middle line behind the corpus pyramidale. The ganglion of the corpus olivare (corpus dentatum, nucleus olivæ), like that of the cerebellum, is a yellowish-grey dentated capsule, open behind, and containing medullary substance from which a fasciculus of fibres proceeds upwards to the corpora quadrigemina and thalami optici. The nervous filaments which spring from the groove on the anterior border of the corpus olivare, are those of the hypoglossal nerve; and those on

its posterior border are the glosso-pharyngeal and pneumogastric.

The *corpora restiformia* (restis, a rope) comprehend the whole of the posterior half of each lateral column of the medulla oblongata. They are separated from the corpora olivaria by the grooves already spoken of; posteriorly, they are divided from each other by the posterior median fissure and the fourth ventricle, and superiorly they diverge and curve backwards to enter the cerebellum, and constitute its inferior peduncles. Along the posterior border of each corpus restiforme, and marked off from that body by a groove, is a narrow white cord, separated from its fellow by the posterior fissure. This pair of narrow cords are termed the *posterior pyramids* (fasciculi graciles). Each fasciculus forms an enlargement (processus clavatus) at its upper end, and is then lost in the corresponding corpus restiforme. The processus clavati are the lateral boundaries of the nib of the calamus scriptorius. The corpus restiforme is crossed near its entrance into the cerebellum by the auditory nerve, the choroid plexus of the fourth ventricle, and the pneumogastric lobule.

The remaining portion of the medulla oblongata visible from the exterior, are the two slightly convex columns which enter into the formation of the floor of the fourth ventricle. These columns are the fasciculi teretes (in-nominati).

DIVERGING FIBRES.—The fibres composing the columns of the medulla oblongata have a special arrangement on reaching the upper part of that body; those of the corpora pyramidalia and olivaria enter the pons Varolii, and are thence prolonged through the crura cerebri, thalami optici, and corpora striata to the cerebral hemispheres; but those of the corpora restiformia are reflected backwards into the cerebellum, and form its inferior peduncles.

From pursuing this course, and spreading out as they advance, these fibres have been termed by Gall the *diverging fibres*. While situated within the pons the fibres of the *corpus pyramidale* and *olivare* separate and spread out, and have grey substance interposed between them; and they quit the pons, much increased in number and bulk, so as to form the *crus cerebri*. The fibres of the *crus cerebri* again are separated in the thalamus opticus, and are intermingled with grey matter, and they also quit that body greatly increased in number and bulk. Precisely the same change takes place in the corpus striatum, and the fibres are now so extraordinarily multiplied as to be capable of forming a large proportion of the hemispheres.

Observing this remarkable increase in the white fibres, apparently from the admixture of grey substance, Gall and Spurzheim considered the latter as the material of increase or formative substance to the white fibres, and they are borne out in this conclusion by several collateral facts, among the most prominent of which is the great vascularity of the grey substance; the larger proportion of the nutrient fluid circulating through it is fully capable of effecting the increased growth and nutrition of the structures by which it is surrounded. For a like reason, the bodies in which this grey substance occurs, are called by the same physiologists "*ganglia of increase*," and by other authors simply ganglia. Thus, the thalami optici and corpora striata are the ganglia of the cerebrum; or, in other words, the *formative ganglia* of the hemispheres.

The fibres of the corpora pyramidalia are not all of them destined to the course above described; several fasciculi curve outwards to reach the corpora restiformia, some passing in front and some behind the corpus olivare on each side. These are the *arciform fibres*; they are distinguished by Mr. Solly into the *superficial* and *deep cerebellar fibres*. In the pons Varolii the continued or cerebral fibres (Solly) of the corpus pyramidale are placed between the superficial and deep layers of transverse fibres, and, escaping from the pons, constitute the inferior and inner segment of the crus cerebri. From the crus cerebri they pass for the most part beneath the thalami optici into the corpora striata.

The fibres which enclose the corpus olivare, under the name of fasciculi siliquæ, are separated by that body into two bands; the innermost of the two bands, *funiculus siliquæ internus*, accompanies the fibres of the corpus pyramidale into the crus cerebri. The *funiculus siliquæ externus* unites with a fasciculus proceeding from the nucleus olivæ, and the combined column ascending behind the crus cerebelli divides into a superior and an inferior band. The inferior band proceeds with a fasciculus presently to be described, the fasciculus innominatus, into the upper segment of the crus cerebri. The superior band (laqueus) ascends by the side of the processus cerebelli ad testes, and, crossing the latter obliquely, enters the corpora quadrigemina, in which many of its fibres are distributed, while the rest are continued onwards into the thalamus opticus.

The corpora restiformia derive their fibres from the anterior as well as from the posterior columns of the medulla oblongata; they diverge as they approach the cerebellum, and leaving between them the cavity of the fourth ventricle, enter the substance of the cerebellum, under the form of two rounded cords. These cords envelop the corpora rhomboidea, or ganglia of increase, and then expand on all sides so as to constitute the cerebellum.

Besides the fibres here described, there are, in the interior of the medulla oblongata, behind the corpora olivaria, and more or less apparent between these bodies and the corpora restiformia, two large bundles of fibres, the *fasciculi innominati*. These fasciculi ascend behind the deep transverse fibres of the pons Varolii, and become apparent in the floor of the fourth ventricle, under the name of *fasciculi teretes*. From this point they are prolonged upwards be-

neath the corpora quadrigemina into the crura cerebri, of which they form the upper and outer segment, and are thence continued through the thalami optici and corpora striata into the hemispheres. The locus niger of the crus cerebri is a septum of grey matter interposed between these fasciculi and those of the corpora pyramidalia.

CONVERGING FIBRES. — In addition to the diverging fibres which are thus shown to constitute both the cerebrum and cerebellum, by their increase and development, another set of fibres are found to exist, which have for their office the association of the symmetrical halves and distant parts of the same hemispheres.

These are called from their direction *converging fibres*, and from their office *commissures*. The commissures of the cerebrum and cerebellum are the —

Corpus callosum,	Middle commissure,
Fornix,	Posterior commissure,
Septum lucidum,	Peduncles of pineal gland,
Anterior commissure,	Pons Varolii.

The *corpus callosum* is the commissure of the hemispheres. It is therefore of moderate thickness in the middle, where its fibres pass directly from one hemisphere to the other; thicker in front (genu), where the anterior lobes are connected; and thickest behind (splenium), where the fibres from the posterior lobes are assembled. The fibres which curve backwards into the posterior lobes from the splenium of the corpus callosum have been termed *forceps*, those which pass directly outwards into the middle lobes from the same point, *tapetum*, and those which curve forwards and inwards from the genu to the anterior lobes, *forceps anterior*.

The *fornix* is an antero-posterior commissure, and serves to connect a number of parts. Below, it is associated with the tenia semicircularis, thalami optici, and peduncles of the pineal gland; on each side, by means of the corpora fimbriata, with the middle lobes of the brain; and, above, with the corpus callosum, and consequently with the hemispheres.

The *septum lucidum* is a perpendicular commissure between the fornix and corpus callosum.

The *anterior commissure* traverses the corpus striatum, and connects the anterior and middle lobes of opposite hemispheres. The *middle commissure* is a layer of grey substance, uniting the thalami optici. The *posterior commissure* is a white rounded cord, connecting the thalami optici.

The *peduncles of the pineal gland* must also be regarded as commissures, assisted in their function by the grey substance of the gland.

The *pons Varolii* is the commissure to the two hemispheres of the cerebellum. It consists of transverse fibres, which are split into two layers by the passage of the fasciculi of the corpora pyramidalia and corpora olivaria. These two layers, the superior and inferior, are collected together on each side, in the formation of the crura cerebelli.

CRANIAL NERVES.

Having studied the parts constituting the base of the brain, the dissector may now proceed to examine the origins of the cranial nerves, and, where necessary, trace them through the substance of the brain to their real source.

There are *nine pairs* of cranial nerves, which, taken in their order from before backwards, are as follows:—

- 1st. Olfactory.
- 2nd. Optic.
- 3rd. Motores oculorum.
- 4th. Pathetici (trochleares).
- 5th. Trifacial (trigemini).
- 6th. Abducentes.
- 7th. { Facial (portio dura).
Auditory (portio mollis).
- 8th. { Glosso-pharyngeal.
Pneumogastric (vagus, par vagum).
Spinal accessory.
- 9th. Hypoglossal (lingual).

Functionally or physiologically the cranial nerves admit of division into three groups, namely, nerves of special sense, nerves of motion, and compound nerves, that is, nerves which contain fibres both of sensation and motion. The nerves belonging to these groups are the following:—

Special sense	{	1st. Olfactory. 2nd. Optic. 7th. Auditory.
Motion	{	3rd. Motores oculorum. 4th. Pathetici. 6th. Abducentes. 7th. Facial. 9th. Hypoglossal.
Compound	{	5th. Trifacial. 8th. Glosso-pharyngeal. Pneumogastric. Spinal accessory.

FIRST PAIR: OLFACTORY.—The olfactory nerve arises by three roots; an *inner root* from the inner and posterior part of the anterior lobe close to the substantia perforata; a *middle root* from a papilla of grey matter (caruncula mamillaris) embedded in the anterior lobe;

and an *external root*, which may be traced as a white streak along the fissure of Sylvius into the corpus striatum, where it is continuous with some of the fibres of the anterior commissure. The nervous cord formed by the union of these three roots is soft in texture, prismoid in shape, and embedded in a sulcus between two convolutions on the under surface of each anterior lobe of the brain, lying between the pia mater and the arachnoid. As it passes forwards it increases in breadth and swells at its extremity into an oblong mass of grey and white substance, the *bulbus olfactorius*, which rests upon the cribriform lamella of the ethmoid bone. From the under surface of the bulbus olfactorius are given off the nerves which pass through the cribriform foramina and supply the mucous membrane of the nares.

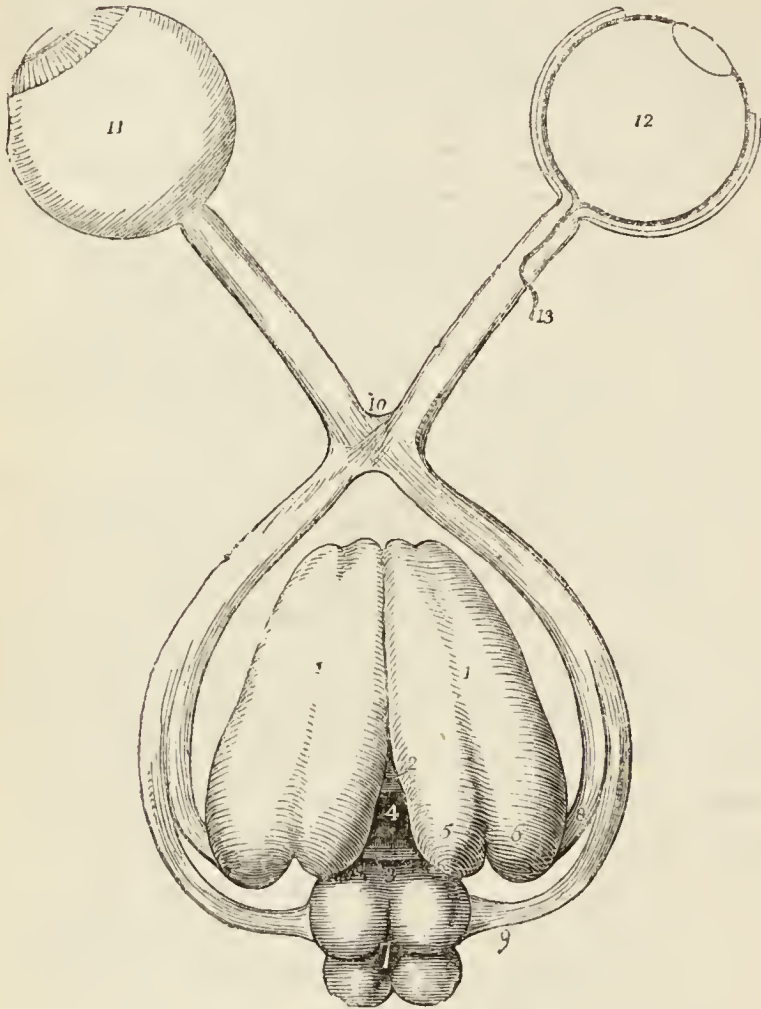
SECOND PAIR: OPTIC.—The optic nerve, a nerve of large size, arises from the corpora geniculata on the posterior and inferior aspect of the thalamus opticus from the thalamus itself and from the nares. Proceeding from this origin it winds around the crus cerebri as a flattened band, under the name of *tractus opticus*, and joins with its fellow in front of the tuber cinereum to form the *optic commissure* (chiasma). The tractus opticus is united with the crus cerebri and tuber cinereum, and is covered in by the pia mater; the commissure is also connected with the tuber cinereum, from which it receives fibres, and the nerve beyond the commissure diverges from its fellow, becomes rounded in form, and is enclosed in a sheath derived from the arachnoid. The commissure rests on the processus olivaris of the sphenoid bone, and is composed of the fibres of the two nerves; the innermost fibres cross each other to pass to opposite eyes, while the outer fibres continue their course uninterruptedly to the eye of the corresponding side. The neurilemma of the commissure, as well as that of the nerves, is formed by the pia mater.

THIRD PAIR: MOTORES OCULORUM.—The motor oculi, a nerve of moderate size, arises from the inner side of the crus cerebri, close to the pons Varolii, and passes forward between the posterior cerebral and superior cerebellar artery.

The fibres of origin of this nerve may be traced into

the grey substance of the crus cerebri*, into the motor tract †, and as far as the corpora quadrigemina and valve of Vieussens. In the cavernous sinus it receives one or

Fig. 46. †



* Mayo.

† Solly.

‡ The origin and distribution of the optic nerves. — Nos. 1, 1. The thalami optici, their upper surface. 2. The middle commissure of the third ventricle, connecting the two thalami. 3. The posterior commissure of the third ventricle. 4. The foramen commune posterius. 5. The corpus geniculatum internum. 6. The corpus geniculatum externum. 7. The corpora quadrigemina: the anterior pair are the nates, the posterior the testes. 8. One root of the optic nerve, arising from the corpora geniculata. 9. The other root, arising from the nates. 10. The commissure. 11. The expansion of the optic nerve into the retina. 12. A section of the retina, showing its three layers: the external is Jacob's membrane, the next the nervous, and the internal the vascular, formed by the ramifications of the arteria centralis retinae, which is seen at 13, piercing the optic nerve, and running forward through its centre.

two filaments from the carotid plexus, and one from the ophthalmic nerve.

FOURTH PAIR: PATHETICI (trochlearis).—The fourth is the smallest cerebral nerve; it arises from the valve of Vieussens close to the testis, and winds around the crus cerebri to the base of the brain.

FIFTH PAIR: TRIFACIAL (trigeminus.)—The fifth nerve, the great sensitive nerve of the head and face, and the largest cranial nerve, is analogous to the spinal nerves in its origin by two roots from the anterior and posterior columns of the spinal cord, and in the existence of a ganglion on the posterior root. It arises* from a tract of yellowish-white matter situated in front of the floor of the fourth ventricle and the origin of the auditory nerve, and behind the crus cerebelli. This tract divides inferiorly into two fasciculi which may be traced downwards into the spinal cord, one being continuous with the fibres of the anterior column, the other with the posterior column. Proceeding from this origin, the two roots of the nerve pass forward, and issue from the brain upon the anterior part of the crus cerebelli, where they are separated by a slight interval. The anterior is much smaller than the posterior, and the two together constitute the fifth nerve, which, in this situation, consists of seventy to a hundred filaments held together by pia mater.

SIXTH PAIR: ABDUCENTES.—The abducens nerve, about half the size of the motor oculi, arises by several filaments from the upper constricted part of the corpus pyramidale, close to the pons Varolii. Proceeding forwards from this origin, it lies parallel with the basilar artery. Mr. Mayo traced the origin of this nerve between the fasciculi of the corpora pyramidalia to the posterior part of the medulla oblongata; and Mr. Grainger pointed out its connection with the grey substance of the spinal cord.

SEVENTH PAIR.—The seventh pair consists of two nerves which lie side by side on the posterior border of the crus cerebelli. The smaller and most internal of

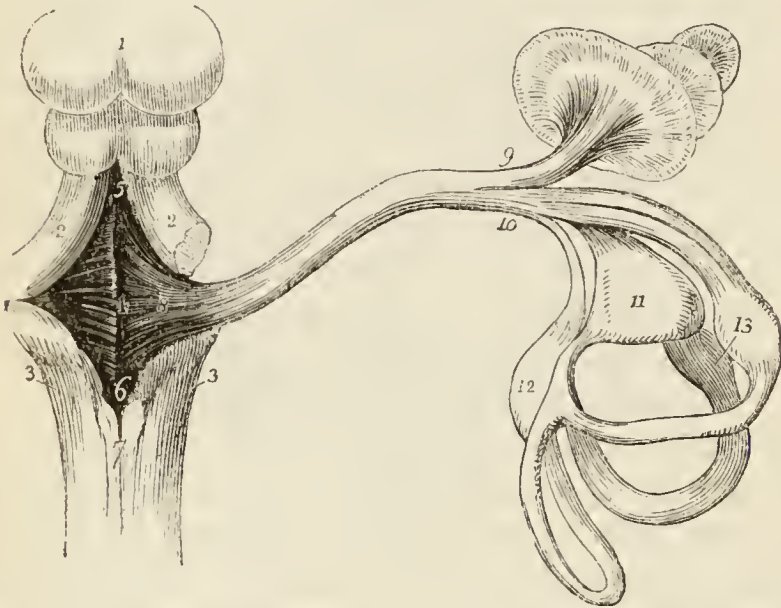
* I have adopted the origin of this nerve given by Dr. Alcock, of Dublin, in the Cyclopædia of Anatomy and Physiology, as the result of his dissections. Mr. Mayo also traces the anterior root of the nerve to a similar origin.

these, and, at the same time, the most dense in texture, is the facial nerve, or portio dura. The external nerve, which is soft and pulpy, and often grooved by contact with the preceding, is the auditory nerve, or portio mollis of the seventh pair.

FACIAL NERVE (portio dura).—The facial nerve, the motor nerve of the face, arises from the upper part of the groove between the corpus olivare and the corpus restiforme, close to the pons Varolii, from which point its fibres may be traced deeply into the corpus restiforme. The nerve then passes forwards, resting on the crus cerebelli, and comes into relation with the auditory nerve, with which it enters the meatus auditorius internus.

AUDITORY NERVE (portio mollis).—The auditory nerve

*Fig. 47.**



* The origin and distribution of the auditory nerve.—No. 1. The corpora quadrigemina. 2, 2. The processus e cerebello ad testes at each side. 3, 3. The corpora restiformia. 4. The space included between these four bodies, the fourth ventricle. 5. The opening of the canal of communication which leads from the third ventricle, the iter à tertio ad quartum ventriculum. 6. The calamus scriptorius. 7. The posterior median columns of the spinal cord, which form by their divergence the point of the calamus, also called the ventricle of Arantius. 8. The lineæ transversæ of the fourth ventricle, the lines of origin of the auditory nerve. 9. The anterior branch of the auditory nerve, distributed to the cochlea. 10. The posterior, or vestibular branch. 11. The utricle communis, which conceals the sacculus proprius from view. 12. The ampulla of the oblique semicircular canal. 13. The ampullæ of the perpendicular and horizontal semicircular canals.

takes its origin in the *lineæ transversæ* (*striæ medullares*) of the anterior wall or floor of the fourth ventricle, and winds around the *corpus restiforme*, from which it receives fibres, to the posterior border of the *crus cerebelli*, where it comes into relation with the facial nerve. From the softness of texture of the nerve, it presents a groove on its superior surface for the reception of the *portio dura*. The auditory nerve is the eighth pair of Sœmmering.

EIGHTH PAIR.—The eighth pair consists of three nerves, the glosso-pharyngeal, pneumogastric, and spinal accessory: these are the ninth, tenth, and eleventh pairs of Sœmmering.

GLOSSO-PHARYNGEAL NERVE.—This nerve arises by five or six filaments from the groove between the *corpus olivare* and *restiforme*, or rather from the anterior border of the latter. The filaments unite to form a nerve of moderate size. The fibres of origin may be traced through the fasciculi of the *corpus restiforme* to the grey substance in the floor of the fourth ventricle.

PNEUMOGASTRIC NERVE (vagus).—The pneumogastric arises by ten or fifteen filaments from the groove between the *corpus olivare* and *corpus restiforme*, or rather from the anterior border of the latter, immediately below the glosso-pharyngeal. The fibres of origin may be traced, like those of the glosso-pharyngeal, to the grey substance in the floor of the fourth ventricle.

SPINAL ACCESSORY.—The spinal accessory nerve arises by several filaments from the side of the spinal cord, as low down as the fifth or sixth cervical nerve, and ascends behind the *ligamentum denticulatum* and between the anterior and posterior roots of the spinal nerves to the side of the *medulla oblongata*, where it comes into relation with the two preceding nerves.

NINTH PAIR: HYPOGLOSSAL NERVE (lingual).—The hypoglossal nerve arises from the groove between the *corpus pyramidale* and *corpus olivare* by ten or fifteen filaments, which are collected into two bundles. The bundles unite and form a nerve of considerable size.

At its origin, the hypoglossal nerve sometimes communicates with the posterior root of the first cervical nerve. Its deep origin may be traced to the grey substance in the floor of the fourth ventricle.

The student may now return to the cranium to examine the nerves in their passage through the dura mater and the foramina in the base of the skull.

The *olfactory bulb* sends its numerous small nerves through the cribriform foramina of the ethmoid bone, in the sulcus situated on either side of the attachment of the falx cerebri to the crista galli.

The *optic nerve* passes through the optic foramen, and receives in its passage a sheath from the dura mater. The dura mater at this point divides into two layers, one being continuous with the periosteum of the orbit, the other being the sheath of the optic nerve. The ophthalmic artery enters the orbit through the optic foramen with the optic nerve, lying to its outer side.

The *third, or motor oculi nerve*, passes through an opening in the dura mater situated immediately in front of the posterior clinoid process, and takes its course through the outer wall of the cavernous sinus to the sphenoidal fissure through which it enters the orbit (page 222.).

The *fourth nerve* passes through the dura mater a little further back, and externally to the third nerve. It also takes its course through the outer wall of the cavernous sinus to the sphenoidal fissure, by which it enters the orbit (p. 222.).

The *fifth nerve* passes through a large oval opening in the dura mater, immediately behind and to the outer side of the fourth nerve. This opening is situated in the anterior part of the tentorium cerebelli at its insertion into the petrous bone, and the nerve lies in a groove on the border of that bone near its extremity. After passing through this opening, the nerve enters the Casserian ganglion; and if the ganglion be gently raised, the anterior root of the fifth nerve will be seen passing beneath the ganglionic mass to join with the inferior maxillary nerve.

The *sixth nerve* enters an opening in the dura mater behind and to the inner side of the opening for the fifth nerve, and ascends upon the body of the sphenoid bone to reach the cavernous sinus below the other nerves. It lies in the inner wall of the sinus, between the sinus and the internal carotid artery, and passes into the orbit through the sphenoidal fissure.

The *seventh pair* of nerves, consisting of the facial and auditory, enter the meatus auditorius internus, which is lined by the dura mater. The facial nerve lies in front of

the auditory ; and a small artery, the internal auditory, a branch of the superior cerebellar, enters with them to be distributed to the internal ear. At the bottom of the meatus auditorius internus the facial nerve enters its special canal, the aqueductus Fallopii, and the auditory nerve divides into a number of small branches which pass into the cochlea and vestibule.

The *eighth pair of nerves*, the glosso-pharyngeal, pneumogastric, and spinal accessory, pass through the dura mater and jugular foramen, behind and to the inner side of the seventh pair. The glosso-pharyngeal pierces the dura mater separately, and in front of the other two, and receives a sheath from that membrane in its passage. The pneumogastric and the spinal accessory also receive a sheath, which is common to the two nerves.

The *ninth, or hypoglossal nerve*, pierces the dura mater by two or three separate filaments to the inner side of the eighth pair, and near the foramen magnum. Having passed through the dura mater, the filaments unite into a single nerve at the anterior condyloid foramen ; and the nerve receives a sheath from the dura mater.

Immediately behind, and to the inner side of the optic foramen, the internal carotid artery will be seen emerging from the dura mater. And just below the margin of the foramen magnum, on either side, is the trunk of the vertebral artery penetrating the dura mater.

The pituitary gland will be seen occupying the sella turcica, and surrounded by that portion of the dura mater which stretches between the clinoid processes.

To dissect the gland, the dura mater surrounding it must be turned aside and the posterior clinoid processes broken off ; but as this preparation would injure the parts contained in the cavernous sinuses, it may be omitted until the cavernous sinuses have been examined and are completed.

The gland is composed of two lobes, and the remains of the infundibulum will be seen attached to its upper surface (page 331.).

SINUSES OF THE CRANIUM.

The sinuses of the dura mater are irregular channels, formed by the splitting of the layers of that membrane,

and lined upon their inner surface by a continuation of the internal coat of the veins. They may be divided into two groups:—1. Those situated at the upper and back part of the skull. 2. The sinuses at the base of the skull. The former are, the

Superior longitudinal sinus,	Occipital sinuses,
Inferior longitudinal sinus,	Lateral sinuses.
Straight sinus,	

The only dissection required for the sinuses, with the exception of the cavernous sinus, is to lay them open with the scissors or scalpel. The cavernous requires to be isolated after the examination of the nerves which occupy its external wall.

The *superior longitudinal sinus* is situated in the attached margin of the falx cerebri, and extends along the middle line of the arch of the skull, from the foramen cæcum in the frontal, to the inner tuberosity of the occipital bone, where it divides into the two lateral sinuses. It is triangular in form, is small in front, and increases gradually in size as it passes backwards; it receives the superior cerebral veins which open into it obliquely, numerous small veins from the diploë, and near the posterior extremity of the sagittal suture the *parietal veins*, from the pericranium and scalp. Examined in its interior, it presents numerous transverse fibrous bands (trabeculæ), the chordæ Willisii, which are stretched across its inferior angle; and some small white granular masses, the glandulæ Pacchioni; the oblique openings of the cerebral veins, with their valve-like margin, are also seen on the walls of the sinus.

The termination of the superior longitudinal sinus in the two lateral sinuses forms a considerable dilatation, into which the straight sinus opens from the front, and the occipital sinuses from below. This dilatation is named the *torcular Herophili**, and is the point of communication of six sinuses, the superior longitudinal, two lateral, two occipital, and the straight.

The *inferior longitudinal sinus* is situated in the free margin of the falx cerebri; it is cylindrical in form, and

* Torcular (a press), from a supposition entertained by the older anatomists that the columns of blood, coming in different directions, compressed each other at this point.

extends from near the crista galli to the anterior border of the tentorium, where it terminates in the straight sinus. It receives in its course several veins from the falx.

The *straight*, or *fourth sinus*, is the sinus of the tentorium: it is situated at the line of union of the falx with the tentorium; is prismoid in form, and extends across the tentorium, from the termination of the inferior longitudinal sinus to the torcular Herophili. It receives the venæ Galeni, the cerebral veins from the inferior part of the posterior lobes, and the superior cerebellar veins.

The *occipital sinuses* are two canals of small size, situated in the attached border of the falx cerebelli; they commence by several small veins around the foramen magnum, and terminate by separate openings in the torcular Herophili. They not unfrequently communicate with the termination of the lateral sinuses.

The *lateral sinuses*, commencing at the torcular Herophili, pass horizontally outwards, in the attached margin of the tentorium, and then curve downwards and inwards along the base of the petrous portion of the temporal bone, at each side, to the foramina lacera posteriora, where they terminate in the internal jugular veins. Each sinus rests in its course on the transverse groove of the occipital bone, posterior inferior angle of the parietal, mastoid portion of the temporal, and again on the occipital bone. They receive the cerebral veins from the inferior surface of the posterior lobes, the inferior cerebellar veins, the superior petrosal sinuses, the mastoid and posterior condyloid veins, and, at their termination the inferior petrosal sinuses. These sinuses are often unequal in size, the right being larger than the left.

The sinuses of the base of the skull are the—

Cavernous,	Superior petrosal,
Inferior petrosal,	Transverse.
Circular,	

The *cavernous sinuses* are named from presenting a structure similar to that of the corpus cavernosum penis. They are situated on each side of the sella turcica, receiving, anteriorly, the ophthalmic veins through the sphenoidal fissures, and terminating posteriorly in the inferior petrosal sinuses. In the internal wall of each cavernous sinus is the internal carotid artery, accompanied

by several filaments of the carotid plexus, and crossed by the sixth nerve; and, in its external wall, the third, fourth, and ophthalmic nerves. These structures are separated from the blood flowing through the sinus, by the tubular lining membrane. The cerebral veins from the under surface of the anterior lobes open into the cavernous sinuses. They communicate by means of the ophthalmic with the facial veins, by the circular sinus with each other, and by the superior petrosal with the lateral sinuses.

The *inferior petrosal sinuses* are the continuations of the cavernous sinuses backwards along the lower border of the petrous portion of the temporal bone at each side of the base of the skull, to the foramina lacera posteriora, where they terminate with the lateral sinuses in the commencement of the internal jugular veins.

The *circular sinus* (sinus of Ridley) is situated in the sella turcica, surrounding the pituitary gland, and communicating on each side with the cavernous sinus. The posterior segment is larger than the anterior.

The *superior petrosal sinuses* pass obliquely backwards along the attached border of tentorium on the upper margin of the petrous portion of the temporal bone, and establish a communication between the cavernous and lateral sinus at each side. They receive one or two cerebral veins from the inferior part of the middle lobes, and a cerebellar vein from the anterior border of the cerebellum. Near the extremity of the petrous bone these sinuses cross the oval aperture which transmits the fifth nerve.

The *transverse sinus* (basilar, anterior occipital) passes transversely across the basilar process of the occipital bone, forming a communication between the two inferior petrosal sinuses. Sometimes there are two sinuses in this situation.

The ARTERIES of the dura mater are the *anterior meningeal*, from the ethmoidal, ophthalmic, and internal carotid; the *middle* and *small meningeal*, from the internal maxillary; the *inferior meningeal*, from the ascending pharyngeal and occipital; and the *posterior meningeal*, from the vertebral.

If the dura mater be stripped up in the middle fossa of the cranium, the arteria meningeae media will be seen

issuing from the foramen spinosum and dividing into two branches. The *anterior* branch crosses the great ala of the sphenoid to the groove or canal in the anterior inferior angle of the parietal bone, and gives off branches which ramify upon the external surface of the dura mater, and anastomose with corresponding branches from the opposite side. The *posterior* branch crosses the squamous portion of the temporal bone to the posterior part of the dura mater and cranium. The arteria meningea media gives branches to the Casserian ganglion and a small branch which enters the hiatus Fallopii to supply the facial nerve. Its other branches are destined to the bones of the cranium and dura mater.

The NERVES of the dura mater are derived from the sympathetic, and accompany the arteries. Some filaments are also given to it by the Casserian ganglion; and a large recurrent branch arises from the ophthalmic, and sometimes from the fourth nerve, in the cavernous sinus, and takes its course between the layers of the tentorium to the lateral sinus. Purkinje describes a nervous plexus as being situated around the trunk of the vena Galeni, and distributing filaments to the tentorium.

SPINAL CORD.

The dissection of the spinal cord requires that the spinal column should be opened throughout its entire length by sawing through the laminae of the vertebrae, close to the roots of the transverse processes, and raising the arches with a chisel; the muscles of the back having been removed as a preliminary step.

The *spinal column* contains the *spinal cord*, or medulla spinalis; the *roots* of the *spinal nerves*; and the membranes of the cord, viz. the *dura mater*, *arachnoid*, *pia mater*, and *membrana dentata*.

The *dura mater spinalis* (theca vertebralis) is a cylindrical sheath of fibrous membrane, identical in structure with the dura mater of the skull, and continuous with that membrane. At the margin of the occipital foramen it is closely adherent to the bone; by its anterior surface it is attached to the posterior common ligament, and below, by means of its pointed extremity, to the coccyx. In the rest of its extent it is comparatively free, being connected, by a loose cellular tissue, to the walls of the spinal canal. In this cellular tissue there exists a quantity

of reddish, oily, adipose substance, somewhat analogous to the marrow of long bones. On either side, and below, the dura mater forms a sheath for each of the spinal nerves, to which it is closely adherent. Upon its inner surface it is smooth, being lined by the arachnoid; and on its sides may be seen double openings for the two roots of each of the spinal nerves.

The *arachnoid* is a continuation of the serous membrane of the brain. It encloses the cord very loosely, being connected to it only by long slender filaments* of cellular tissue, and by a longitudinal lamella which is attached to the posterior aspect of the cord. The cellular tissue is most abundant in the cervical region, and diminishes in quantity from above downwards; and the longitudinal lamella is complete only in the dorsal region. The arachnoid passes off from the cord on either side with the spinal nerves, to which it forms a sheath; and is then reflected on the dura mater, to constitute its serous surface. A connection exists in several places between the arachnoid of the cord and that of the dura mater. The space between the arachnoid and the spinal cord is identical with that already described as existing between the same parts in the brain, the *sub-arachnoidean space*. It is occupied by a serous fluid, sufficient in quantity to expand the arachnoid and fill completely the cavity of the theca vertebralis. The *sub-arachnoidean* or *cerebro-spinal fluid* keeps up a constant and gentle pressure on the entire surface of the brain and spinal cord, and yields with the greatest facility to the various movements of the cord, giving to those delicate structures the advantage of the principles so usefully applied by Dr. Arnott in the hydrostatic bed.

The *pia mater* is the immediate investment of the cord; and, like the other membranes, is continuous with that of the brain. It is not, however, like the *pia mater cerebri*, a vascular membrane; but is dense and fibrous in structure, and contains but few vessels. It invests the cord closely, and sends a duplicature into the *fissura longitudinalis anterior*, and another, extremely delicate, into the *fissura longitudinalis posterior*. It forms a sheath for

* According to Mr. Rainey, these filaments are nervous fasciuli, having their origin in the arachnoid, and passing to the arteries of the cord. See p. 309.

each of the filaments of the nerves, and for the nerves themselves; and, inferiorly, at the conical termination of the cord, is prolonged downwards as a slender ligament (*filum terminale*), which descends through the centre of the cauda equina, and is attached to the dura mater lining the canal of the coccyx. This attachment is a rudiment of the original extension of the spinal cord into the canal of the sacrum and coccyx. The pia mater has, distributed to it, a number of nervous plexuses derived from the sympathetic.

The *membrana dentata* (ligamentum dentatum) is a thin process of pia mater sent off from each side of the cord throughout its entire length, and separating the anterior from the posterior roots of the spinal nerves. The number of serrations on each side is about twenty, the first being situated on a level with the occipital foramen, and having the vertebral artery and hypoglossal nerve passing in front, and the spinal accessory nerve behind it, and the last opposite the first or second lumbar vertebra. Below this point, the *membrana dentata* is lost in the *filum terminale* of the pia mater. The use of this membrane is to maintain the position of the spinal cord in the midst of the fluid by which it is surrounded.

The *spinal cord* of the adult, somewhat less than eighteen inches in length, extends from the pons Varolii to opposite the first or second lumbar vertebra, where it terminates in a rounded point; in the child, at birth, it reaches the middle of the third lumbar vertebra, and in the embryo is prolonged as far as the coccyx. It presents a difference of diameter in different parts of its extent, and exhibits three enlargements. The uppermost of these is the *medulla oblongata*; the next corresponds with the origin of the nerves destined to the upper extremities (brachial); and the lower enlargement (lumbar) is situated near its termination, and corresponds with the attachment of the nerves which are intended for the supply of the lower limb. The brachial enlargement is flattened from before backwards, and extends from the third cervical vertebra to the first dorsal; the lumbar enlargement is flattened from side to side, and is smaller than the brachial. The spinal cord gives off near its termination that assemblage of nerves which has received the name of *cauda equina*.

In form, the spinal cord is a flattened cylinder, and presents on its anterior surface a fissure, which extends into the cord to the depth of one-third of its diameter. This is the *anterior median fissure*. If the sides of the fissure be gently separated, they will be seen to be connected at the bottom by a layer of medullary substance, the *anterior white commissure*.

On the posterior surface another fissure exists, which is so narrow between the second cervical and second lumbar nerve, as to be hardly perceptible. This is the *posterior median fissure*. It extends more deeply into the cord than the anterior fissure, and terminates in the grey substance of the interior.* These two fissures divide the medulla spinalis into two lateral cords, which are connected to each other by the white commissure which forms the bottom of the anterior fissure, and by a commissure of grey matter situated behind the former. On either side of the posterior median fissure is a slight line which bounds on each side the posterior median columns. These columns are most apparent at the upper part of the cord, in the medulla oblongata, where they have received the name of posterior pyramids.

Two other lines are observed on the medulla, the anterior and posterior lateral sulci, corresponding with the attachment of the anterior and posterior roots of the spinal nerves. The *anterior lateral sulcus* is a mere trace, marked only by the attachments of the filaments of the anterior roots. The *posterior lateral sulcus* is more evident, and is a narrow greyish line, derived from the greyish substance of the interior.

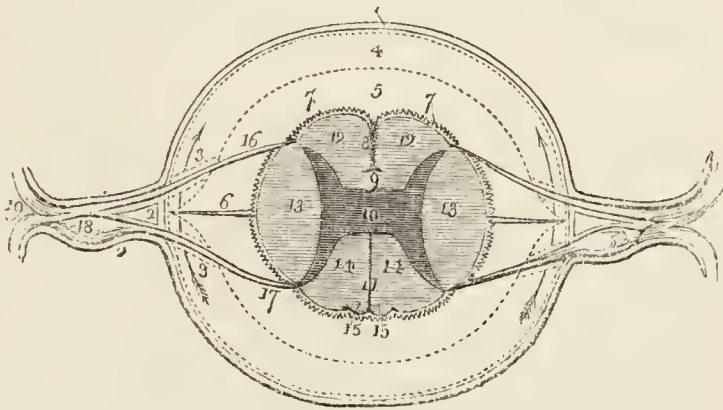
Although these fissures and sulci indicate a division of the spinal cord into three pairs of columns, namely, anterior, lateral, and posterior, the posterior median columns being regarded as a part of the posterior columns, it is customary to consider each half of the spinal cord as consisting of two columns only, the antero-lateral and the posterior. The *antero-lateral columns* are the columns of motion, and comprehend all that part of the cord situated between the *fissura longitudinalis anterior* and the posterior lateral sulcus, the grey line of origin of

* According to some anatomists, there exists a *posterior white commissure* at the bottom of the posterior median fissure.

the posterior roots of the spinal nerves. The *posterior columns* are the columns of sensation.

If a transverse section of the spinal cord be made, its internal structure may be seen and examined. It will then appear to be composed of two hollow cylinders of white matter, placed side by side, and connected by a narrow *white commissure*. Each cylinder is filled with grey substance, which is connected by a commissure of the same matter (*grey commissure*). The form of the grey substance, as observed in the section, is that of two irregularly curved or crescentic lines joined by a transverse band. The extremities of the curved lines correspond with the sulci of origin of the anterior and posterior roots of the nerves. The anterior extremities, larger than the posterior, do not quite reach this surface; but the posterior appear upon the surface, and form a narrow grey line, the *sulcus lateralis posterior*.

Fig. 48.*



* Section of the spinal cord with its membranes.—No. 1. The dura mater. 2, 2. The dura mater, forming a sheath for each of the roots of a spinal nerve, and afterwards a sheath for the nerve itself. The dotted line represents the arachnoid membrane. 3, 3. A sheath formed by the arachnoid around each of the roots of the spinal nerve, during its passage through that membrane. 4. The space between the two layers of the arachnoid: an arrow at each side shows that this space is continuous all around the spinal cord, and that the disposition of the membrane at 3, 3. is a mere sheath. 5. The space between the arachnoid and pia mater, the sub-arachnoidean space, in which is lodged the sub-arachnoidean fluid. 6. One of the dentations of the ligamentum denticulatum. 7, 7. The pia mater of the cord. 8. The anterior median fissure. 9. The white commissure, connecting the two lateral halves of the cord. 10. The grey commissure, connecting the two semilunar processes of grey substance. 11. The posterior median fissure.

The white substance of the spinal cord is composed of parallel fibres, which are collected into longitudinal laminæ and extend throughout the entire length of the cord. These laminæ are various in breadth, and are arranged in a radiated manner; one border being thick and corresponding with the surface of the cord, while the other is thin and lies in contact with the grey substance of the interior. According to Rolando, the white substance constitutes a simple nervous membrane, which is folded into longitudinal plaits, having the radiated disposition above described. The anterior commissure, according to his description, is merely the continuation of this nervous membrane from one lateral cord across the middle line to the other. Moreover, Rolando considers that a thin lamina of pia matter is received between each of the folds from the exterior, while a layer of the grey substance is prolonged between them from within. Cruveilhier is of opinion that each lamella is completely independent of its neighbours, and he believes this statement to be confirmed by pathology, which shows that a single lamella may be injured or atrophied, and at the same time be surrounded by others perfectly sound.

SPINAL NERVES.—The nerves proceeding from the spinal cord are thirty-one pairs. Each nerve arises by two roots, an anterior or motor root, and a posterior or sensitive root.

The anterior roots proceed from a narrow white line, anterior lateral sulcus, on the antero-lateral column of the spinal cord, and gradually approach towards the anterior median fissure as they descend.

The posterior roots, more regular than the anterior, proceed from the posterior lateral sulcus, a narrow grey stria formed by the internal grey substance of the cord. They are larger, and the filaments of origin more numerous than those of the anterior roots. In the intervertebral foramina there is a ganglion on each of the posterior roots. The first cervical nerve forms an exception to these characters; its posterior root is smaller than the anterior; it often joins in whole or in part with

12, 12. The antero-lateral columns of the spinal cord. 13, 13. The two lateral columns. 14. The posterior columns. 15, 15. The posterior median columns, bounded by two shallow fissures. 16. The origin of the anterior or motor root of a spinal nerve, from the anterior lateral sulcus. 17. The origin of its posterior or sensitive root, from its posterior lateral sulcus. 18. The ganglion on the posterior root. 19. The spinal nerve separating into its two primary divisions, anterior and posterior.

the spinal accessory nerve, and sometimes with the hypoglossal: there is frequently no ganglion upon it, and when the ganglion exists, it is often situated within the dura mater, the latter being the usual position of the ganglia of the last two pairs of spinal nerves.

After the formation of a ganglion, the two roots unite, and constitute a spinal nerve, which escapes through the intervertebral foramen, and separates into an anterior division for the supply of the front aspect of the body, and a posterior division for the posterior aspect. In the first cervical and last sacral and coccygeal nerve this separation takes place within the dura mater, and in the upper four sacral nerves externally to that cavity, but within the sacral canal. The anterior divisions, with the exception of the first two cervical nerves, are larger than the posterior; an arrangement which is proportioned to the larger extent of surface they are required to supply.

The spinal nerves are classed as follows:—

Cervical	-	-	-	8 pairs.
Dorsal	-	-	-	12
Lumbar	-	-	-	5
Sacral	-	-	-	5
Coccygeal	-	-	-	1

The cervical nerves pass off transversely from the spinal cord; the dorsal are oblique in their direction; and the lumbar and sacral, vertical; the latter form the large assemblage of nerves at the termination of the cord, called *cauda equina*. The *cauda equina* occupies the lower third of the spinal canal.

The ARTERIES of the spinal cord are, the anterior, posterior, and lateral spinal, which are derived from the vertebral; and branches from the intercostal and lumbar arteries, which enter the canal through the intervertebral foramina.

The VEINS of the vertebral column and spinal cord form a complex venous plexus within and around the vertebral canal, and are divisible into three sets:—

Dorsi-spinal,
Meningo-rachidian,
Medulli-spinal.

The *dorsi-spinal* form a plexus around the spinous, transverse and articular processes and arches of the ver-

tebræ. They receive the returning blood from the dorsal muscles and surrounding structures, and transmit it, in part to the meningo-rachidian, and in part to the vertebral, intercostal, lumbar, and sacral veins.

The *meningo-rachidian veins* are situated between the theca vertebralis and the vertebræ. They communicate freely with each other by means of a complicated plexus. In front they form two longitudinal trunks (*longitudinal spinal sinuses*), which extend the whole length of the column one on each side of the posterior common ligament, and are joined on the body of each vertebra by transverse trunks, which pass beneath the ligament, and receive the large basi-vertebral veins from the interior of each vertebra. The meningo-rachidian veins communicate superiorly through the anterior condyloid foramina with the internal jugulars; in the neck they pour their blood into the vertebral veins; in the thorax, into the intercostals; and in the loins and pelvis into the lumbar and sacral veins, the communications being established through the intervertebral foramina.

The *medulli-spinal veins* are situated between the pia mater and arachnoid; they communicate freely with each other to form plexuses, and send branches through the intervertebral foramina with each of the spinal nerves, to join the veins of the trunk.

CHAPTER VII.

ORGANS OF SENSE.

The Nose and Nasal Fossæ.

THE organ of smell consists essentially of two parts: one external, *the nose*; the other internal, the *nasal fossæ*.

The dissection of the nose and nasal fossæ is to be made on that piece of the face which has been already used in the examination of the pharynx and soft palate (page 295). If the cartilages of the nose be dry, they should be softened by steeping in water and brought into a state fit for dissection. Any integument which may have been left on the nose should then be removed, together with cellular tissue, fat, and the remains of muscles. The dissection will be facilitated by stuffing the nostrils with cotton wool.

THE NOSE is the triangular pyramid projecting from the centre of the face, immediately above the upper lip. Superiorly, it is connected with the forehead, by means of a narrow bridge; inferiorly, it presents two openings, the *nostrils*, which overhang the mouth, and are so constructed that the odour of all substances must be received by the nose, before they can be introduced within the lips. The septum between the openings of the nostrils is called the *columna*. Their entrance is guarded by a number of stiff hairs (*vibrissæ*), which project across the openings, and act as a filter in preventing the introduction of foreign substances, such as dust, or insects, with the current of air intended for respiration.

The anatomical elements of which the nose is composed are,—1. The integument; 2. Muscles; 3. Bones; 4. Fibro-cartilages; 5. Mucous membrane; 6. Vessels and nerves.

1. The *integument* forming the tip (*lobulus*) and wings (*alæ*) of the nose is extremely thick and dense, so as to be with difficulty separated from the fibro-cartilage. It is furnished with an abundance of *sebiferous follicles*,

which by their oily secretion protect the extremity of the nose in excessive alternations of temperature. The sebaceous matter of these follicles becomes of a dark colour near the surface, from altered secretion and also from attraction of the carbonaceous matter floating in the atmosphere: hence the spotted appearance which the tip of the nose presents in large cities. When the integument is firmly compressed, the inspissated sebaceous secretion is squeezed out from the follicles, and taking the cylindrical form of their excretory ducts, has the appearance of small white maggots with black heads.

2. The *muscles* are brought into view by reflecting the integument; they are, the pyramidalis nasi, compressor nasi, dilator naris, levator labii superioris alæque nasi, and depressor labii superioris alæque nasi. They have been already described with the muscles of the face.

3. The *bones* of the nose are, the nasal, and nasal processes of the superior maxillary.

4. The *fibro-cartilages* give form and stability to the outwork of the nose, providing, at the same time, by their elasticity, against injuries. They are five in number, namely, the —

Fibro-cartilage of the septum,
Two lateral fibro-cartilages,
Two alar fibro cartilages.

The *fibro-cartilage of the septum*, somewhat triangular in form, divides the nose into its two nostrils. It is connected above with the nasal bones and lateral fibro-cartilages; behind, with the ethmoidal septum and vomer; and below, with the palate processes of the superior maxillary bones. The alar fibro-cartilages and columna move freely upon the fibro-cartilage of the septum, being but loosely connected with it by perichondrium.

The *lateral fibro-cartilages* are also triangular; they are connected, *in front*, with the fibro-cartilage of the septum; *above*, with the nasal bones; *behind*, with the nasal processes of the superior maxillary bones; and *below* with the alar fibro-cartilages.

Alar fibro-cartilages. — Each of these cartilages is curved in such a manner as to correspond with the walls

of the nostril, to which it forms a kind of rim. The inner portion is loosely connected with the same part of the opposite cartilage, so as to form the *columna*. It is expanded and thickened at the point of the nose to constitute the *lobe*; and on the side makes a curve corresponding with that of the ala. This curve is prolonged downwards and forwards in the direction of the posterior border of the ala by three or four small fibro-cartilaginous plates (sesamoid cartilages, cartilaginee minores), which are appendages of the alar fibro-cartilage.

The whole of these fibro-cartilages are connected with each other and to the bones by perichondrium, which, from its membranous structure, permits of the freedom of motion existing between them.

5. The *mucous membrane*, lining the interior of the nose, is continuous with the skin externally, and with the pituitary membrane of the nasal fossæ within. Around the entrance of the nostrils it is provided with the *vibrissæ*.

6. *Vessels and Nerves*.—The *arteries* of the nose are the lateralis nasi from the facial, and the nasalis septi from the superior coronary.

Its *nerves* are the facial, infra-orbital, and nasal branch of the ophthalmic.

NASAL FOSSÆ.

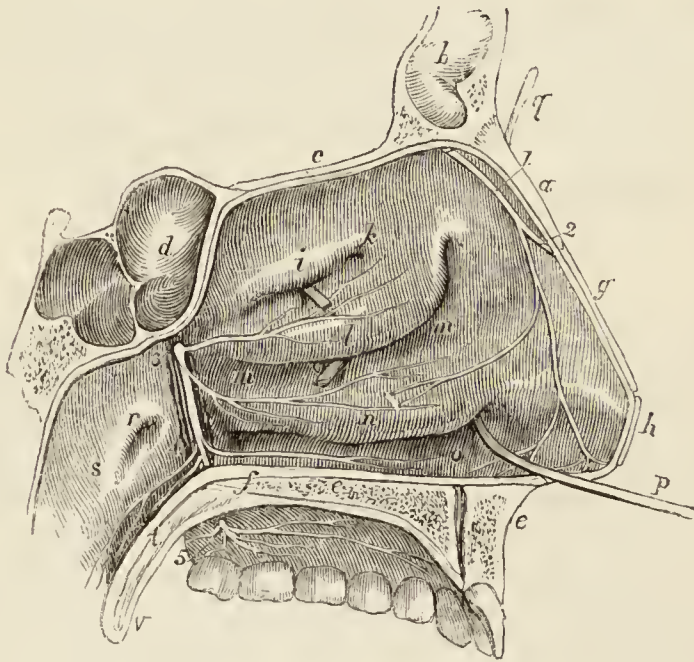
To obtain a view of the *nasal fossæ*, the face must be divided through the nose by a vertical incision a little to one side of the middle line. This incision should be made with the scalpel through the nose, and with the saw through one nasal bone, the frontal bone, the cribriform plate of the ethmoidal, and body of the sphenoid *above*; and through the palatal process of the superior maxillary and palate bone *below*. When the section is made, the turbinated bones, with the spaces between them, will be exposed on one side, and the septum narium on the other: both are covered by mucous membrane.

The *nasal fossæ* are two irregular, compressed cavities extending backwards from the nose to the pharynx. They are bounded *superiorly* by the lateral cartilage of the nose, and by the nasal, sphenoid, and ethmoid bones; *inferiorly* by the hard palate; and, in the *middle* line, they are separated from each other by a bony and fibro-cartilaginous septum.

Upon the outer wall of each fossa, in the dried skull, are three projecting processes, termed spongy bones. The two superior belong to the ethmoid; the inferior is a separate bone. In the fresh fossæ these are covered with mucous membrane, and serve to increase the surface of that membrane by their prominence and convoluted form. The space intervening between the superior and middle spongy bone is the *superior meatus*; the space between the middle and inferior, the *middle meatus*; and that between the inferior and the floor of the fossa, the *inferior meatus*.

These *meatuses* are passages which extend from before backwards, and it is in circulating through and amongst these that the atmosphere deposits its odorant particles upon the mucous membrane. There are several *openings* into the nasal fossæ: thus, in the *superior meatus* are the openings of the sphenoidal and posterior ethmoidal cells; in the *middle* the anterior ethmoidal cells, the frontal

Fig. 49.*



* Section of the nasal fossæ, showing the outer wall of the left naris.—*a*. The nasal bone. *b*. The frontal sinus in the frontal bone. *c*. The ethmoid bone. *d*. The sphenoidal sinus in the sphenoid bone. *e*. The superior maxillary bone. *f*. The palate bone. *g*. The lateral cartilage of the nose. *h*. The alar cartilage. *i*. The prominence formed by the superior turbinated bone. *k*. The superior meatus; behind the letter *a* a portion of a probe is seen, introduced into the posterior ethmoid cells; the dark hollow behind the probe leads into the sphenoid sinus. *l*. The middle spongy

sinuses, and the antrum maxillare; and, in the inferior meatus, the termination of the nasal duct. In the dried bone there are two additional openings, the sphenopalatine and the anterior palatine foramen; the former being situated in the superior, and the latter in the inferior meatus.

The *mucous membrane* of the nasal fossæ is called *pituitary*, or *Schneiderian*; the former name being derived from the nature of its secretion, the latter from Schneider, who was the first to show that the secretion of the nose proceeded from the mucous membrane, and not from the brain, as was formerly imagined. It is closely adherent to the periosteum, constituting what is called a fibro-mucous membrane, and is continuous with the general gastro-pulmonary mucous membrane. From the nasal fossæ it may be traced through the openings in the meatuses, into the sphenoidal and ethmoidal cells; into the frontal sinuses; into the antrum maxillare; through the nasal duct to the surface of the eye, where it is continuous with the conjunctiva; along the Eustachian tubes into the tympanum and mastoid cells, to which it forms the lining membrane; and through the posterior nares into the pharynx and mouth, and thence through the lungs and alimentary canal.

The surface of the membrane is furnished with a laminated epithelium near the apertures of the nares, and in the rest of its extent with a columnar epithelium supporting innumerable vibratile cilia.

The ARTERIES of the nasal fossæ are the anterior and posterior ethmoidal and sphenopalatine.

bone. *m, m.* The middle meatus; the probe is passed up into the anterior ethmoid cells and frontal sinus; directly behind the probe is seen the opening into the maxillary antrum. *n.* The inferior spongy bone. *o.* The inferior meatus. *p.* A probe passed upwards through the nasal duct; the extremity of the probe is seen at *q.* *r.* The aperture of the Eustachian tube. *s.* The cavity of the pharynx. *t.* The soft palate. *v.* The uvula. 1. The nasal nerve, dividing into its internal and external branch. 2. The external branch escaping from the cavity of the nose. 3. Meckel's ganglion. 4. The palatine nerves, brought into view by the removal of the mucous membrane and bone. The branches to the nose and palate proceed from the great palatine nerve, which is seen issuing upon the palate at 5.

The *ethmoidal* arteries are branches of the ophthalmic, and enter the nasal fossæ through the foramina in the cribriform plate. They supply the mucous membrane of the upper part of the fossæ.

The *spheno-palatine* artery is a branch of the internal maxillary. It enters the nasal fossæ with the nasal nerves through the spheno-palatine foramen at the posterior part of the superior meatus, and divides into several branches which are distributed to the mucous membrane of the spongy bones, posterior ethmoidal cells, and antrum. One branch, the *artery of the septum*, crosses the roof of the fossa, and passes downwards and forwards beneath the mucous membrane of the septum to the anterior palatine canal, where it inosculates with branches of the descending palatine artery.

The NERVES of the nose and nasal fossæ are the olfactory, the nasal and naso-palatine from Meckel's ganglion, and the nasal branch of the ophthalmic.

The *olfactory nerve* is distributed to the mucous membrane of the nasal fossæ by means of a number of branches which pass through the foramina in the cribriform plate of the ethmoid bone. The branches are arranged in three groups, an inner group, reddish in colour and soft, spread out upon the upper part of the septum; an outer group, whiter and more firm, which descend through bony canals in the outer wall of the nares, and are distributed on the superior and middle spongy bones; and a middle group, which supply the mucous membrane of the roof of the nasal fossæ.

The *nasal branches* of Meckel's ganglion enter the nasal fossæ through the spheno-palatine foramen, and are distributed to the mucous membrane of the superior and middle spongy bones, the posterior ethmoidal cells, and the upper part of the septum.

The *naso-palatine* nerve, also a branch of Meckel's ganglion, enters the nasal fossæ with the nasal nerves, and, crossing the roof of the fossæ, descends upon the septum beneath the mucous membrane to the naso-palatine canal. Passing through the naso-palatine canal, it enters the anterior palatine canal, and is distributed to the papilla behind the incisor teeth, communicating with its fellow of the opposite side and with the anterior palatine nerves. In its course the naso-palatine nerve gives several

branches to the mucous membrane of the septum; and the naso-palatine canal of the left side is in front of that of the right.

The naso-palatine nerve, and also the inner group of branches of the olfactory, are best seen by cutting away the osseous portion of the septum, and tearing it away from the mucous membrane. Before this is done, the extent and relations of the cartilage of the septum should be examined. The outer group of branches of the olfactory nerve are to be sought for on the outer wall of the nasal fossæ, and the nasal branch of the ophthalmic on the anterior part of its roof beneath the nasal bone.

The *nasal branch* of the ophthalmic nerve enters the nasal fossæ by the most anterior of the openings in the cribriform plate of the ethmoid bone, and divides into an internal and external branch. The *internal branch* is distributed to the mucous membrane of the septum as far as the aperture of the nostril. The *external branch* continues its course onwards, in a groove, upon the under surface of the nasal bone, passes between the nasal bone and lateral cartilage, and is distributed to the exterior of the nose, as far as the aperture of the nostril. In the nasal fossæ this branch gives off several filaments to the internal surface of the outer wall of the nose.

Practical Observations.—The mucous membrane is rendered an organ of smell by contact of the odorant particles. If the secretion be deficient, the contact is not appreciable, and there is loss of smell. Or if the membrane be swollen and thickened, there is likewise loss of smell. Both of these conditions are consequences of common cold.

When hæmorrhage occurs from the mucous membrane, it may proceed to so great an extent as to endanger life. In such a case the nasal fossæ must be stopped from behind, by drawing a piece of sponge against the posterior nares. This is effected by introducing an instrument carrying a curved spring with an eye at its extremity along the inferior meatus to the pharynx. The spring is then pressed onwards, and is directed by its curve into the posterior part of the mouth; the thread bearing the sponge is passed through the eye of the spring, and the instrument with the thread is withdrawn through the nose. The sponge is then carefully directed beneath the soft palate, and drawn gently against the posterior openings of the nose.

Growths of various kinds (polypi) proceed from the mucous membrane, and increase to a great size, impeding nasal respiration, forcing the bones out of their places, and doing great mischief. They are generally attached by a narrow pedicle, and may be removed with the polypus forceps. In performing this operation, the

direction of the meatuses must be recollected; otherwise there would be danger of entangling the instrument, and pulling away one of the spongy bones.

When the tube of the stomach-pump cannot be passed through the mouth, it may be introduced into that viscus by passing it along the inferior meatus of the nose. Patients with extensive injury to the jaws have been nourished for a long time solely by liquid food poured into the stomach in this way.

In obstruction of the nasal duct, it is often necessary to introduce a probe into it from the inferior meatus (Fig. 49.). This operation should therefore be practised upon the subject.

THE EYE, WITH ITS APPENDAGES.

The appendages of the eye, consisting of the eyelids, conjunctiva, and lachrymal apparatus, are to be examined from the exterior; and the dissection necessary for the purpose may be made either during the progress of the dissection of the face or at a later period, for example, after the examination of the nose, one orbit being reserved for the purpose. To expose the tarsal cartilages, all that is necessary is to remove the orbicularis palpebrarum muscle. To reach the lachrymal gland, and study the lachrymal canals and nasal duct, the eyelids must be separated from their connexions above and below, and turned inwards.

The *appendages of the eye* (*tutamina oculi*) are, the eyebrows, eyelids, eyelashes, conjunctiva, *caruncula lachrymalis*, and the lachrymal apparatus.

The EYEBROWS (*supercilia*) are two projecting arches of integument, covered with short thick hairs, which form the upper boundary of the orbits. They are connected beneath with the orbiculares, occipito-frontales, and *corrugatores superciliarum* muscles; their use is to shade the eyes from too vivid a light, or protect them from particles of dust and moisture floating over the forehead.

The EYELIDS (*palpebræ*) are two valvular layers placed in front of the eye, serving to defend it from injury by their closure. When drawn open, they leave between them an elliptical space (*fissura palpebrarum*), the angles of which are called *canthi*. The outer canthus is formed by the meeting of the two lids at an acute angle. The inner canthus is prolonged for a short distance inwards, towards the nose, and a triangular space is left between the lids in this situation, which is called the *lacus lachrymalis*. At the commencement of the *lacus lachrymalis*, upon each of the two lids, is a small angular projection, the *lachrymal papilla* or *tubercle*; and at the apex of

each papilla a small orifice (punctum lachrymale), the commencement of the lachrymal canal.

The eyelids have, entering into their structure, *integument, orbicularis muscle, tarsal cartilages, Meibomian glands, and conjunctiva.*

The tegumentary cellular tissue of the eyelids is remarkable for its looseness, and for the absence of adipose substance ; it is particularly liable to serous infiltration. The fibres of the orbicularis muscle covering the eyelids are extremely thin and pale.

The *tarsal cartilages* are two thin lamellæ of fibro-cartilage, about an inch in length, which give form and support to the eyelids. The *superior* is of a semilunar form, about one-third of an inch in breadth at its middle, and tapering to each extremity. Its lower border is broad and flat ; its upper is thin, and gives attachment to the levator palpebræ and to the fibrous membrane of the lids.

The *inferior fibro-cartilage* is an elliptical band, narrower than the superior, and situated in the substance of the lower lid. Its upper border is flat, and corresponds with the flat edge of the upper cartilage. The lower is held in its place by the fibrous membrane. Near the inner canthus the tarsal cartilages terminate, at the commencement of the lacus lachrymalis, and are attached to the margin of the orbit by the tendo oculi. At their outer extremity they terminate at a short distance from the angle of the canthus, and are retained in their position by means of a decussation of the fibrous structure of the broad tarsal ligament, called the *external palpebral or tarsal ligament.*

The *fibrous membrane* of the lids is firmly attached to the periosteum, around the margin of the orbit, by its circumference, and to the tarsal cartilages by its central margin. It is thick and dense on the outer half of the orbit, but becomes thin to its inner side. Its use is to retain the tarsal cartilages in their place, and give support to the lids ; hence it has been named the *broad tarsal ligament.*

The *Meibomian glands* are embedded in the internal surface of the cartilages, and are very distinctly seen on examining the inner aspect of the lids. They have the appearance of parallel strings of pearls, about thirty in number in the upper cartilage, and somewhat fewer in

the lower ; and open by minute foramina on the edges of the lids. They correspond in length with the breadth of the cartilage, and are consequently longer in the upper than in the lower lid.

Each gland consists of a single lengthened follicle or tube, into which a number of small clustered follicles open ; the latter are so numerous as almost to conceal the tube by which the secretion is poured out upon the margin of the lids. Occasionally an arch is formed between two of them, and produces a very graceful appearance.

The edges of the eyelids are furnished with a triple row of long thick hairs, which curve upwards from the upper lid, and downwards from the lower, so that they may not interlace with each other in the closure of the eyelids, and prove an impediment to the opening of the eyes. These are the *eyelashes (cilia)*, important organs of defence to the sensitive surface of so delicate an organ as the eye.

The *conjunctiva* is the mucous membrane of the eye. It covers the whole of its anterior surface, and is then reflected upon the lids so as to form their internal layer. The duplicatures formed between the globe of the eye and the lids, are called the superior and inferior palpebral sinuses, of which the former is much deeper than the inferior. Where it covers the cornea the conjunctiva is very thin, and closely adherent, and no vessels can be traced into it. Upon the sclerotica it is thicker, and less adherent ; but upon the inner surface of the lids is very closely connected, and exceedingly vascular. It is continuous with the general gastro-pulmonary mucous membrane, and sympathises in its affections, as may be observed in various diseases. From the surface of the eye it may be traced, through the lachrymal ducts, into the lachrymal gland ; along the edges of the lids it is continuous with the mucous lining of the Meibomian glands, and, at the inner angle of the eye, may be followed through the lachrymal canals into the lachrymal sac, and thence downwards, through the nasal duct, into the inferior meatus of the nose.

The *caruncula lachrymalis* is the small reddish body which occupies the lacus lachrymalis at the inner canthus of the eye. In health, it presents a bright pink tint ; in

sickness, it loses its colour, and becomes pale. It consists of an assemblage of follicles similar to the Meibomian glands, embedded in a fibro-cartilaginous tissue, and is the source of the whitish secretion which so constantly forms at the inner angle of the eye. It is covered with minute hairs, which are sometimes so long as to be visible to the naked eye.

Immediately to the outer side of the caruncula is a slight duplicature of the conjunctiva, called *plica semilunaris*, which contains a minute plate of cartilage, and is the rudiment of the third lid of animals, the *membrana nictitans* of birds.

Vessels and Nerves.—The palpebræ are supplied internally with *arteries* from the ophthalmic, and externally from the facial and transverse facial. Their *nerves* are branches of the fifth, and of the facial.

LACHRYMAL APPARATUS.

The *lachrymal apparatus* consists of the lachrymal gland, with its excretory ducts; the puncta lachrymalia, and lachrymal canals; the lachrymal sac and nasal duct.

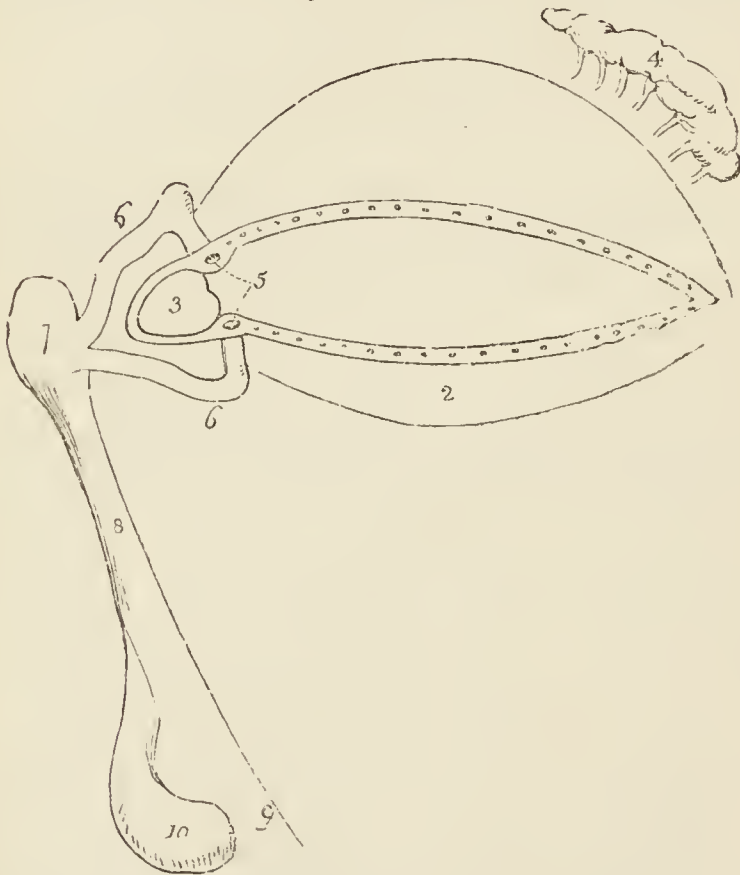
The lachrymal gland is brought into view by detaching the broad tarsal ligament from its connexion with the upper margin of the orbit, and removing some cellular tissue and fat. The gland has been already described with the dissection of the orbit (p. 228.). At the present time the relations of the palpebral portion may be more accurately observed together with the excretory ducts.

The *lachrymal gland* consists of two portions, orbital and palpebral. The *orbital portion*, the larger of the two, is flattened in form, and lies against the periosteum of the orbit, its anterior border being in relation with the broad tarsal ligament. The *palpebral portion* is connected with the anterior border of the orbital portion, by means of the dense fibrous membrane, which invests both portions. It is oblong in shape, lies in contact with the broad tarsal ligament, and is in relation, by its lower border, with the tarsal cartilage of the upper lid. The excretory ducts of the lachrymal gland are eight to twelve in number. They open upon the conjunctiva, in the direction of a curved line, situated a little above the tarsal cartilage at the outer part of the upper lid.

Lachrymal Canals.—The lachrymal canals commence

at the minute openings, *puncta lachrymalia*, seen upon the lachrymal papillæ of the lids at the outer extremity of the lacus lachrymalis, and proceed inwards to the lachrymal sac, where they terminate beneath a valvular semilunar fold of the lining membrane of the sac. The *superior* duct at first ascends, and then turns suddenly inwards towards the sac, forming an abrupt angle. The inferior duct forms the same kind of angle, by descending at first, and then turning abruptly inwards. They are dense and elastic in structure, and remain constantly open, so that they act like capillary tubes, in absorbing the tears from the surface of the eye. The two fasciculi of the tensor tarsi muscle are inserted into these ducts, and serve to draw them inwards.

*Fig. 50.**



* The lachrymal apparatus and tarsal cartilages of the eyelids.—
 No. 1. The tarsal cartilage of the upper lid. 2. The tarsal cartilage of the lower lid; the openings along the edges of the lids are those of the Meibomian ducts. 3. The caruncula lachrymalis. 4. The lachrymal gland pouring out its secretion by a number of small ducts. 5. The lachrymal tubercles, with the openings of the lachrymal ducts called *puncta lachrymalia*. 6, 6. The lachrymal ducts. 7. The lachrymal sac. 8. The nasal duct. 9. Its termination in the inferior meatus of the nose. 10. The inferior turbinate bone.

The *lachrymal sac* is the upper extremity of the nasal duct, and is scarcely more dilated than the rest of the canal. It is lodged in the groove of the lachrymal bone, and is often distinguished, internally, from the nasal duct, by a semilunar or circular valve. The sac consists of mucous membrane, but is covered in, and retained in its place by a fibrous expansion, derived from the tendon of the orbicularis, which is inserted into the ridge on the lachrymal bone; it is also covered by the tensor tarsi muscle, which arises from the same ridge, and in its action upon the lachrymal canals may serve to compress the lachrymal sac.

The *nasal duct* is a short canal, about three quarters of an inch in length, directed downwards, backwards, and a little outwards to the inferior meatus of the nose, where it terminates by an expanded orifice. It is lined by mucous membrane, which is continuous with the conjunctiva above, and with the pituitary membrane of the nose below. Obstruction, from inflammation and supuration of this duct, constitutes the disease called *fistula lachrymalis*.

Vessels and Nerves.—The lachrymal gland is supplied with blood by the lachrymal branch of the ophthalmic artery; and with nerves, by the lachrymal branch of the ophthalmic nerve.

THE EYEBALL.

The form of the eyeball is that of a sphere, of about one inch in diameter, having the segment of a smaller sphere engrafted upon its anterior surface, which increases its antero-posterior diameter. The axes of the two eyeballs are parallel with each other, but do not correspond with the axes of the orbits, which are directed outwards. The optic nerves follow the direction of the orbits, and therefore enter the eyeballs to their nasal side.

For the dissection of the eyeball, the student must procure some sheep's eyes from the butcher; the eyes in his own subject will be too far advanced in decomposition to be made use of by the time he is able to give his attention to them. Should he be able to procure a fresh human eye, the difficulty will be removed; but for all the purposes of dissection, the sheep's or bullock's eye is preferable. For external form, he must study the human eye. To examine the exterior of the eyeball, the muscles, fat, and cellular tissue which invest it must be carefully dissected away.

The globe of the eye is composed of *tunics*, and of refracting media called *humours*. The *tunics* are three in number, the

1. Sclerotic and cornea,
2. Choroid, iris, and ciliary processes,
3. Retina and zonula ciliaris.

The *humours* are also three —

Aqueous, Crystalline (lens), Vitreous.

FIRST TUNIC.—The sclerotic and cornea form the external tunic of the eyeball, and give it its peculiar form. Four-fifths of the globe are invested by the sclerotic, the remaining fifth by the cornea.

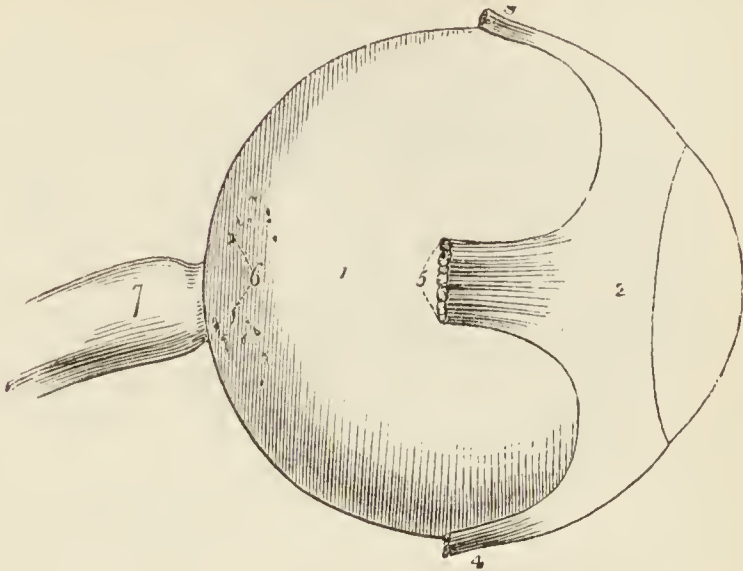
The *sclerotic* (*σκληρός*, hard) is a dense fibrous membrane, thicker behind than in front. It is continuous, posteriorly, with the sheath of the optic nerve, which is derived from the dura mater, and is pierced by that nerve as well as by the ciliary nerves and arteries. Anteriorly it presents a bevelled edge, which receives the cornea in the same way that a watch-glass is received by the groove in its case. Its anterior surface is covered by a thin tendinous layer, the *tunica albuginea*, derived from the expansion of the tendons of the four recti muscles. By its posterior surface it gives attachment to the two oblique muscles. The *tunica albuginea* is covered, for a part of its extent, by the mucous membrane of the front of the eye, the conjunctiva; and, by reason of the brilliancy of its whiteness, gives occasion to the common expression, “the white of the eye.”

At the entrance of the optic nerve, the sclerotic forms a thin *cribriform lamella* (*lamina cribrosa*), which is pierced by a number of minute openings for the passage of the nervous filaments. One of these openings, larger than the rest, and situated in the centre of the lamella, is the *porus opticus*, through which the *arteria centralis retinae* enters the eyeball.

The *cornea* (*corneus*, horny) is the transparent projecting layer that constitutes the anterior fifth of the globe of the eye. In its form it is circular, concavo-convex, and resembles a watch-glass. It is received by its edge, which is sharp and thin, within the bevelled border of the sclerotic, to which it is very firmly attached,

and it is somewhat thicker than the anterior portion of that tunic. When examined from the exterior, its ver-

*Fig. 51.**



tical diameter is seen to be about one-sixteenth shorter than the transverse, in consequence of the overlapping above and below, of the margin of the sclerotica; on the interior, however, its outline is perfectly circular.

The cornea is composed of four layers: namely, of the conjunctiva, of the cornea proper (which consists of several thin lamellæ connected together by an extremely fine cellular tissue), of the cornea elastica (a “fine, elastic, and exquisitely transparent membrane, exactly applied to the inner surface of the cornea proper”), and of the lining membrane of the anterior chamber of the eyeball. The cornea elastica is remarkable for its perfect transparency even when submitted for many days to the action of water or alcohol, while the cornea proper is rendered opaque by the same immersion. To expose this membrane, Dr. Jacob suggests that the eye should be placed in water for six or eight days, and then that all the opaque cornea should be removed layer after layer. Another character of the cornea elastica is its great elasticity, which causes it to roll up when divided or torn, in the same manner as the capsule of the lens. The use of this layer, according to Dr. Jacob, is “to preserve the requisite permanent correct curvature of the flaccid cornea proper.”

* The external tunic of the eye.—No. 1. The sclerotic coat. 2. The tunica albuginea, formed by the expansion of the tendons of the four recti muscles. 3. The insertion of the superior rectus. 4. The insertion of the inferior rectus. 5. The insertion of the external rectus. 6. Small openings in the sclerotic for the passage of the ciliary arteries and nerves. 7. The optic nerve, which becomes constricted at its point of entrance into the globe of the eye. 8. The cornea.

The opacity of the cornea, produced by pressure on the globe, results from infiltration of fluid into the cellular tissue connecting its layers. This appearance cannot be produced in a sound living eye, although a small quantity of serous fluid (liquor corneæ) is said to occupy the areolæ of the cellular tissue.

Dissection.—The sclerotic and cornea are now to be dissected away from the second tunic. This, with care, may be easily performed, the only firm connexions subsisting between them being at the circumference of the iris, the entrance of the optic nerve, and the perforation of the ciliary nerves and arteries. Pinch up a fold of the sclerotic near its anterior circumference, and make a small opening into it; then raise the edge of the tunic, and, with a pair of fine scissors having a probe point, divide the entire circumference of the sclerotic, and cut it away bit by bit. Then separate it from its attachment around the circumference of the iris by a gentle pressure with the edge of the knife. The dissection of the eye must be conducted under water.

In the course of this dissection the *ciliary nerves* and *long ciliary arteries* will be seen passing forwards between the sclerotic and choroid, to be distributed to the iris.

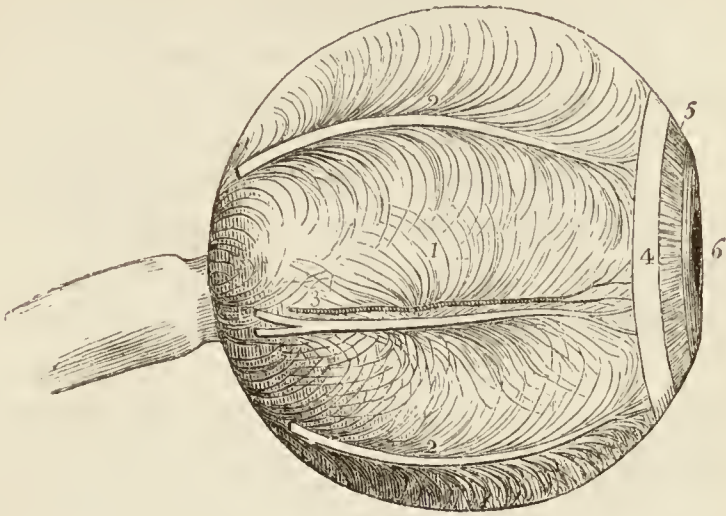
SECOND TUNIC.—The second tunic of the eyeball is formed by the *choroid*, *ciliary ligament*, and *iris*, the *ciliary processes* being an appendage developed from its inner surface.

The *choroid** is a vascular membrane of a rich chocolate-brown colour upon its external surface, and of a deep black colour within. It is connected to the sclerotic, externally, by an extremely fine cellular tissue (*membrana fusca*), and by nerves and vessels. Internally it is in simple contact with the third tunic of the eye, the retina. It is pierced posteriorly for the passage of the optic nerve, and is connected anteriorly with the iris, ciliary processes, and with the line of junction of the cornea and sclerotic, by a dense white structure, the *ciliary ligament*, which surrounds the circumference of the iris like a ring.

* The word *choroid* has been very much abused in anatomical language. It was originally applied to the membrane of the fœtus called chorion, from the Greek word *χόριον* (*domicilium*), that membrane being, as it were, the abode or receptacle of the fœtus. *Χόριον* comes from *χαρῆω*, to take or receive. Now it so happens that the chorion in the ovum is a vascular membrane of peculiar structure. Hence the term *choroid* (*χόριον* — *εἶδος*, like the chorion) has been used indiscriminately to signify vascular structures (as in the choroid membrane of the eye, the choroid plexus, &c.); and we find Cruveilhier (in his work on *Anatomy*, vol. iii. p. 463.) saying, in a note, “*Choroïde est synonyme de vasculaire.*”

The choroid membrane is composed of three layers, an *external* or *venous* layer, which consists principally of veins arranged in

Fig. 52.*



a peculiar manner: hence they have been named *venæ vorticosæ*. The marking on the surface of the membrane produced by these veins resembles so many centres to which a number of curved lines converge. It is this layer which is connected with the ciliary ligament. The *middle* or *arterial layer* (*tunica Ruyschiana*) is formed principally by the ramifications of minute arteries. It is reflected inwards at its junction with the ciliary ligament, so as to form the ciliary processes. The *internal layer* is a delicate membrane (*membrana pigmenti*) composed of several laminæ of nucleated hexagonal cells, which contain the granules of pigmentum, and are arranged so as to resemble a tessellated pavement.

In animals, the pigmentum nigrum, on the posterior wall of the eyeball, is replaced by a layer of considerable extent and of metallic brilliancy, called the tapetum.

The *ciliary ligament*, or circle (*annulus albidus*), is the bond of union between the external and middle tunics of the eyeball, and serves to connect the cornea and sclerotic, at their line of junction, with the iris and external layer of the choroid. It is also the point to which the ciliary nerves and vessels proceed previously to their distribution, and it receives the anterior ciliary arteries through the anterior margin of the sclerotic. A minute vascular

* The second tunic of the eye.—No. 1. The choroid membrane, upon which are seen the curved lines marking the arrangement of the *venæ vorticosæ*. 2, 2. Ciliary nerves. 3. A long ciliary artery and nerve. 4. The ciliary ligament. 5. The iris: the two sets of fibres are very distinctly seen—the external radiating towards the centre, and the internal, circular, surrounding the pupil, 6.

canal is situated within the ciliary ligament, called the ciliary canal, or the canal of Fontana, from its discoverer.

The *iris* (iris, a rainbow) is so named from its variety of colour in different individuals: it forms a septum between the anterior and posterior chambers of the eye, and is pierced somewhat to the nasal side of its centre by a circular opening, which is called the *pupil*. By its periphery it is connected with the ciliary ligament, and by its inner circumference forms the margin of the pupil; its anterior surface looks towards the cornea, and the posterior towards the ciliary processes and lens.

The iris is composed of two layers, *anterior* or *muscular*, consisting of *radiating* fibres, which converge from the circumference towards the centre, and have the power of dilating the pupil, and *circular*, which surround the pupil like a sphincter, and by their action produce contraction of its area. The posterior layer is of a deep purple tint, and is thence named *uvea*, from its resemblance in colour to a ripe grape.

The *ciliary processes* (*corpus ciliare*) may be seen in two ways, either by removing the iris from its attachment to the ciliary ligament, when a front view of the processes will be obtained, or by making a transverse section through the globe of the eye, when they may be examined from behind. They consist of a number of triangular folds, formed apparently by the plaiting of the middle and internal layer of the choroid. According to Zinn, they are about sixty in number, and may be divided into large and small, the latter being situated in the spaces between the former. Their periphery is connected with the ciliary ligament, and is continuous with the middle and internal layer of the choroid. The central border is free, and rests against the circumference of the lens. The anterior surface corresponds with the uvea; the posterior receives the folds of the zonula ciliaris between its processes, and thus establishes a connexion between the choroid and the third tunic of the eye. The ciliary processes are covered with a thick layer of pigmentum nigrum, which is more abundant upon them, and upon the anterior part of the choroid, than upon the posterior part of the latter. When the pigment is washed off, the processes are of a whitish colour.

THIRD TUNIC. — The third tunic of the eye is the

retina, which is prolonged forwards to the lens by the *zonula ciliaris*.

Dissection.—If, after the preceding dissection, the choroid membrane be carefully raised and removed, the eye being kept under water, the retina may be seen very distinctly.

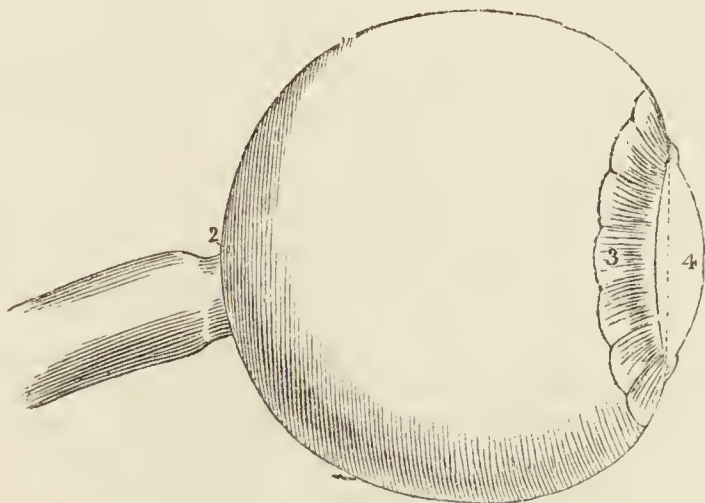
The *retina* is composed of three layers :—

<i>External</i> ,	or Jacob's membrane,
<i>Middle</i> ,	Nervous membrane,
<i>Internal</i> ,	Vascular membrane.

Jacob's membrane is extremely thin, and is seen as a mere film when the freshly dissected eye is suspended in water. Examined by the microscope, it is found to be composed of cells having a tessellated arrangement. Dr. Jacob considers it to be a serous membrane.

The *nervous membrane* is the expansion of the optic nerve, and forms a thin semi-transparent bluish-white layer, which envelopes the vitreous humour, and extends forwards to the commencement of the ciliary processes, where it terminates by an abrupt scalloped margin. According to Treviranus, this layer is composed of cylindrical fibres, which proceed from the optic nerve, and, near their termination, bend abruptly inwards, to form the internal papillary layer, which lies in contact with the hyaloid membrane; each fibre constituting by its extremity a distinct papilla.

Fig. 53.*



* The third tunic of the eye.—No. 1. The retina, terminating anteriorly in a scalloped border. 2. The foramen of Soemmering. 3. The zonula ciliaris. 4. The lens.

The *vascular membrane* consists of the ramifications of a minute artery, the *arteria centralis retinæ*, and its accompanying vein: the artery pierces the optic nerve, and enters the globe of the eye through the *porus opticus*, in the centre of the *lamina cribrosa*. This artery may be seen very distinctly by making a transverse section of the eyeball. Its branches are continued anteriorly into the *zonula ciliaris*. The vascular layer forms distinct sheaths for the nervous papillæ, which constitute the inner surface of the retina.

In the centre of the posterior part of the globe of the eye the retina presents a circular spot, which is called the *foramen of Soemmering*; it is surrounded by a yellow halo, the *limbus luteus*, and is frequently obscured by an elliptical fold of the retina, which has been regarded as a normal condition of the membrane. The term *foramen* is misapplied to this spot, for the vascular layer and the *membrana Jacobi* are continued across it; the nervous substance alone appearing to be deficient. It exists only in animals having the axes of the eyeballs parallel with each other, as man, quadrumana, and some saurian reptiles, and is said to give passage to a small lymphatic vessel.

The *zonula ciliaris* (*zonula of Zinn*) is a thin vascular layer, which connects the anterior margin of the retina with the anterior surface of the lens near its circumference. It presents upon its surface a number of small folds corresponding with the ciliary processes, between which they are received. These processes are arranged in the form of rays around the lens, and the spaces between them are stained by the *pigmentum nigrum* of the ciliary processes. They derive their vessels from the vascular layer of the retina. The under surface of the *zonula* is in contact with the *hyaloid membrane*, and around the lens forms the anterior fluted wall of the *canal of Petit*.

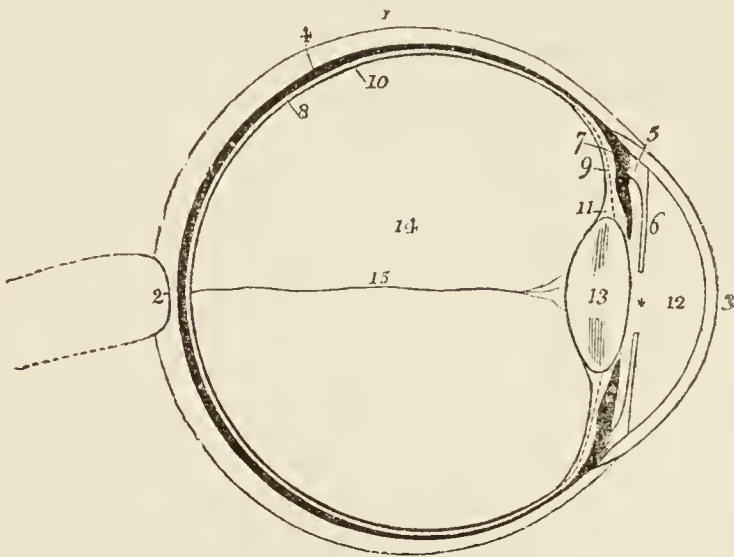
The connexion between these folds and the ciliary processes may be demonstrated by dividing an eye transversely into two portions, then raising the anterior half and allowing the vitreous humour to fall out by its own weight. The folds of the *zonula* will then be seen to be drawn out from between the folds of the ciliary processes.

HUMOURS.—The *aqueous humour* is situated in the anterior and posterior chambers of the eye; it is a weakly

albuminous fluid, with an alkaline reaction, and a specific gravity very little greater than that of distilled water. According to Petit, it scarcely exceeds four or five grains in weight.

The *anterior chamber* is the space intervening between the cornea in front, and the iris and pupil behind. The *posterior chamber* is the narrow space, less than half a line in depth*, bounded by the posterior surface of the iris and pupil in front, and by the ciliary processes, zonula

Fig. 54.†



* Winslow and Lieutaud thought the iris to be in contact with the lens. It frequently adheres to the capsule of the latter in iritis. The depth of the posterior chamber is greater in old than in young persons.

† A longitudinal section of the globe of the eye.—No. 1. The sclerotic, thicker behind than in front. 2. The lamina cribrosa; the thin layer of the sclerotic, which is pierced with holes for the passage of the nervous substance of the optic nerve. 3. The cornea, which is seen to be inserted into the border of the sclerotic coat. 4. The choroid membrane (the dark layer). 5. The ciliary ligament. 6. The iris. * The pupil. 7. The ciliary processes. 8. The retina (the white layer). 9. The dotted line represents the zonula ciliaris, which is continued from the anterior border of the retina to the capsule of the lens. 10. The innermost line is the hyaloid membrane, which may be followed behind the lens. 11. The canal of Petit. 12. The anterior chamber of the eye. The narrow space between the iris and the ciliary processes and lens is the posterior chamber. 13. The lens enclosed in its capsule. 14. The posterior cavity of the globe, in which the vitreous humour is lodged. 15. A minute artery, a branch of the arteria centralis retinae, which traverses the centre of the vitreous humour to reach the capsule of the lens.

ciliaris, and lens behind. The two chambers are lined by a thin layer, the *secreting membrane of the aqueous humour*.

The *vitreous humour* forms the principal bulk of the globe of the eye. It is an albuminous and highly transparent fluid, enclosed in a delicate membrane, the *hyaloid*. From the inner surface of this membrane, numerous thin lamellæ are directed inwards, and form compartments in which the fluid is contained. According to Hanover, these lamellæ have a radiated arrangement, like those on the transverse section of an orange, and are about 180 in number. In the centre of the vitreous humour is a tubular canal, through which a minute artery is conducted from the arteria centralis retinae to the capsule of the lens. This vessel is injected without difficulty in the fœtus.

The *crystalline humour* or *lens* is situated immediately behind the pupil, and is surrounded by the ciliary processes, which slightly overlap its margin. It is more convex on the posterior than on the anterior surface, and is embedded in the anterior part of the vitreous humour, from which it is separated by the hyaloid membrane. It is invested by a peculiarly transparent and elastic membrane, the capsule of the lens, which contains a small quantity of fluid, called *liquor Morgagni*, and is retained in its place by the attachment of the zonula ciliaris. Dr. Jacob is of opinion that the lens is connected to its capsule by means of cellular tissue, and that the liquor Morgagni is the result of a cadaveric change.

The lens consists of concentric layers, of which the external are soft, the next firmer, and the central form a hardened nucleus. These layers are best demonstrated by boiling, or by immersion in alcohol, when they separate easily from each other. Another division of the lens takes place at the same time: it splits into three triangular segments, which have the sharp edge directed towards the centre, and the base towards the circumference. The concentric lamellæ are composed of minute parallel fibres, which are united with each other by means of scalloped borders, the convexity on the one border fitting into the concave scallop upon the other.

Immediately around the circumference of the lens is a triangular canal, the *canal of Petit*, about a line and a half in breadth. It is bounded, in front, by the flutings of the zonula ciliaris; behind, by the hyaloid membrane; and within, by the border of the lens.

The VESSELS of the globe of the eye are the long and short, and anterior ciliary arteries, and the *arteria centralis retinae*. The *long ciliary arteries*, two in number, pierce the posterior part of the sclerotic, and pass forward on each side, between that membrane and the choroid, to the ciliary ligament, where they divide into two branches, which are distributed to the iris. The *short ciliary arteries* pierce the posterior part of the sclerotic coat, and are distributed to the middle layer of the choroid membrane. The *anterior ciliary* are branches of the muscular arteries. They enter the eye through the anterior part of the sclerotic, and are distributed to the iris. It is the increased number of these latter arteries, in iritis, that gives rise to the peculiar red zone around the circumference of the cornea.

The *arteria centralis retinae* enters the optic nerve at about half an inch from the globe of the eye, and, passing through the *porus opticus*, is distributed upon the inner surface of the retina, forming its vascular layer; one branch pierces the centre of the vitreous humour and supplies the capsule of the lens.

The *nerves* of the eyeball are the optic, two ciliary nerves from the nasal branch of the ophthalmic, and the ciliary nerves from the ophthalmic ganglion.

Observations. — The sclerotic is a tunic of protection, and the cornea a medium for the transmission of light. The choroid supports the vessels destined for the nutrition of the eye, and by its *pigmentum nigrum* absorbs all loose and scattered rays that might confuse the image impressed upon the retina. The iris, by means of its powers of expansion and contraction, regulates the quantity of light admitted through the pupil. If the iris be thin, and the rays of light pass through its substance, they are immediately absorbed by the uvea; and if that layer be insufficient, they are taken up by the black pigment of the ciliary processes. In Albinos, where there is an absence of *pigmentum nigrum*, the rays of light traverse the iris, and even the sclerotic, and so overwhelm the eye with light, that sight is destroyed, except in the dimness of evening, or at night. In the manufacture of optical instruments, care is taken to colour their interior black, with the same object, the absorption of scattered rays.

The transparent lamellated cornea and the humours of the eye have for their office the refraction of the rays in such proportion as to direct the image in the most favourable manner upon the retina. Where the refracting medium is too great, as in over convexity of the cornea and lens, the image falls short of the retina (myopia, near-sightedness); and where it is too little, the image is thrown beyond the nervous membrane (presbyopia, far-sightedness). These conditions are rectified by the use of spectacles, which provide a differently refracting medium externally to the eye, and thereby correct the transmission of light.

THE ORGAN OF HEARING.

The apparatus of hearing is composed of three parts, the external ear, middle ear or tympanum, and internal ear or labyrinth.

The EXTERNAL EAR consists of two portions, the *pinna* and *meatus*; the former representing a kind of funnel which collects the vibrations of the atmosphere, producing sounds, and the latter a tube which conveys the vibrations to the tympanum.

The PINNA presents a number of folds and hollows upon its surface, which have different names assigned to them. Thus, the external folded margin is called the *helix* (ἑλιξ, a fold). The elevation parallel to and in front of the helix is called *antihelix* (ἀντι, opposite). The pointed process, projecting like a valve over the opening of the ear from the face, is called the *tragus* (τράγος, a goat), probably from being sometimes covered with bristly hair like that of a goat; and a tubercle opposite to this is the *antitragus*. The lower dependent and fleshy portion of the pinna, is the *lobulus*. The space between the helix and antihelix is named the *fossa innominata* (*scaphoidea*). Another depression is observed at the upper extremity of the antihelix, which bifurcates and leaves a triangular space between its branches, called the *fossa triangularis* (ovalis); and the large central space, to which all the channels converge, is the *concha*, which opens directly into the *meatus*.

The pinna is composed of *integument*, *fibro-cartilage*, *ligaments*, and *muscles*.

The *integument* is thin, contains an abundance of sebiparous glands, and is closely connected with the fibro-cartilage.

The integument should be dissected off from the fibro-cartilage, a task of some difficulty, in consequence of the close adhesion which subsists between them, in order to bring into view the cartilage with its ligaments and muscles. Over the muscles the integument must be raised with care, as, from their paleness, they might otherwise be dissected away.

The *fibro-cartilage* gives form to the pinna, and is folded so as to produce the various convexities and grooves which have been described upon its surface. The *helix* commences in the concha, and partially divides that cavity into two parts ; on its anterior border, where it commences its curve upwards, is a tubercle or *spine*, and a little above this a small vertical fissure, the *fissure of the helix*. The termination of the helix and antihelix forms a lengthened process, the *processus caudatus*, which is separated from the concha by an extensive fissure. Upon the anterior surface of the tragus is another fissure, the *fissure of the tragus*, and, in the lobulus, the fibro-cartilage is wholly deficient. The fibro-cartilage of the meatus is divided from the concha by several fissures (fissures of Santorinus), and at the upper and anterior part of the cylinder there is a considerable space, which is closed by ligamentous fibres ; it is firmly attached at its termination to the *processus auditorius*.

The *ligaments* of the external ear are those which attach the pinna to the side of the head, viz. the anterior, posterior, and ligament of the tragus ; and those of the fibro-cartilage, which serve to preserve its folds and connect the opposite margins of the fissures. The latter are two in number, the ligament between the concha and the *processus caudatus*, and the broad ligament which extends from the upper margin of the fibro-cartilage of the tragus to the helix, and completes the meatus.

The proper *muscles* of the pinna are the—

Major helicis,	Antitragicus,
Minor helicis,	Transversus auriculæ,
Tragicus,	Obliquus auris.

The *major helicis* is a narrow band of muscular fibres situated upon the anterior border of the helix. It arises

from the spine of the helix, and is inserted into the anterior border of that fold.

The *minor helix* is placed upon the anterior extremity (crus) of the helix, at its commencement in the fossa of the concha.

The *tragicus* is a thin quadrilateral layer of muscular fibres, situated upon the tragus.

The *antitragicus* arises from the antitragus, and is inserted into the posterior surface of the processus caudatus of the helix.

The *transversus auriculæ*, partly tendinous and partly muscular, extends transversely from the convexity of the concha to that of the helix, on the posterior surface of the pinna.

The *obliquus auris* (Tod) is a small band of fibres passing between the upper part of the convexity of the concha and the convexity immediately above it.

Mr. Tod* describes, besides, a contractor meatûs, or trago-helicus muscle.

The MEATUS AUDITORIUS is a canal, partly cartilaginous and partly osseous, about an inch in length, which extends inwards and a little forwards from the concha to the tympanum. It is narrower in the middle than at each extremity, forms an oval cylinder, the long diameter being vertical, and is slightly curved upon itself, the concavity looking downwards.

It is lined by an extremely thin pouch of epithelium, which, when withdrawn after maceration, preserves the form of the meatus. Some stiff short hairs are also found in its interior, which stretch across the tube, and prevent the ingress of insects and dust. In the substance of its lining membrane are a number of *ceruminous glands*, which secrete the wax of the ear.

Vessels and Nerves.—The pinna is plentifully supplied with *arteries*,—by the anterior auricular from the temporal; by the posterior auricular from the external carotid; and by a branch from the occipital artery.

Its *nerves* are derived from the auriculo-temporal of the fifth, the posterior auricular of the facial, and the auricularis magnus of the cervical plexus.

* "The Anatomy and Physiology of the Organ of Hearing," by David Tod. 1832.

MIDDLE EAR OR TYMPANUM.

The tympanum is an irregular bony cavity, compressed from without inwards, and situated within the petrous bone. It is bounded, *externally*, by the meatus and membrana tympani; *internally*, by the base of the petrous bone; *behind*, by the mastoid cells; and, throughout the rest of its circumference, by the thin osseous layer which connects the petrous with the squamous portion of the temporal bone.

The *membrana tympani* is a thin and semi-transparent membrane of an oval shape, its long diameter being vertical. It is inserted into a groove situated around the circumference of the meatus, near its termination, and is placed obliquely across the area of that tube, the direction of the obliquity being downwards and inwards. It is concave towards the meatus, convex towards the tympanum, and composed of *three layers*, *external*, or epithelial; *middle*, fibrous and muscular; and *internal*, mucous, derived from the mucous lining of the tympanum.

The tympanum contains three small bones, *ossicula auditûs*, viz. the malleus, incus, and stapes.

The *malleus* (*hammer*) consists of a head, neck, handle (*manubrium*), and two processes, *long* (*processus gracilis*) and *short* (*processus brevis*). The manubrium is connected with the membrana tympani by its whole length, extending below the central point of that membrane. It lies beneath the mucous layer of the membrane, and serves as a point of attachment to which the radiating fibres of the fibrous layer converge. The long process descends to a groove near the fissura Glaseri, and gives attachment to the laxator tympani muscle. Into the short process is inserted the tendon of the tensor tympani, and the head of the bone articulates with the incus.

The *incus* (*anvil*) is named from an imagined resemblance to an anvil. It has also been likened to a bicuspid tooth, having one root longer than, and widely separated from, the other. It consists of two processes, which unite nearly at right angles, and at their junction form a flattened body, which articulates with the head of the malleus. The short process is attached to the margin of the opening of the mastoid cells by means of a ligament; the long

process descends nearly parallel with the handle of the malleus, and curves inwards, near its termination. At its extremity is a small globular projection, the *os orbiculare*, which in the fœtus is a distinct bone, but becomes ankylosed to the long process of the incus in the adult: this process articulates with the head of the stapes.

The *stapes* is shaped like a stirrup, to which it bears a close resemblance. Its head articulates with the *os orbiculare*, and the two branches (*crura*) are connected by their extremities with a flat, oval-shaped plate, representing the foot of the stirrup. The foot of the stirrup is received into the fenestra ovalis, to the margin of which it is connected by means of a ligament: it is in contact, by its surface, with the *membrana vestibuli*, and is covered in by the mucous lining of the tympanum. The neck of the stapes gives attachment to the *stapedius* muscle.

The *ossicula auditûs* are retained in their position and moved upon themselves by means of ligaments and muscles.

The *ligaments* are three in number, the suspensory ligament of the malleus, which is attached by one extremity to the upper wall of the tympanum, and by the other to the head of the malleus; the posterior ligament of the incus, a short and thick band, which serves to attach the extremity of the short process of that bone to the margin of the opening of the mastoid cells; and the annular ligament which connects the margin of the foot of the stapes with the circumference of the fenestra ovalis. These ligaments have been described as muscles, by Mr. Tod, under the names of *superior capitis mallei*, *obliquus incudis externus posterior*, and *musculus vel structura stapedii inferior*. Arnold adds as a fourth a suspensory ligament of the incus.

The *muscles* of the *tympanum* are four in number, the—

Tensor tympani,
Laxator tympani,
Laxator tympani minor,
Stapedius.

The *tensor tympani* (*musculus internus mallei*) arises from the spinous process of the sphenoid, from the petrous portion of the temporal bone, and from the Eustachian

tube, and passes forwards in a distinct canal, separated from the tube by the *processus cochleariformis*, to be *inserted* into the handle of the malleus, immediately below the root of the *processus gracilis*.

The *laxator tympani* (*musculus externus mallei*) *arises* from the spinous process of the sphenoid bone, and passes through an opening in the *fissura Glaseri*, to be *inserted* into the neck of the malleus, just above the root of the *processus gracilis*. This is regarded as a ligament (anterior ligament of the malleus) by some anatomists.

The *laxator tympani minor* (posterior ligament of the malleus) *arises* from the upper margin of the meatus, and is *inserted* into the handle of the malleus, and the *processus brevis*. This is regarded as a ligament by some anatomists.

The *stapedius* *arises* from the interior of the pyramid, and escapes from its summit to be *inserted* into the neck of the stapes.

Foramina.—The openings in the tympanum are ten in number, *five large* and *five small*; they are—

<i>Large Openings.</i>	<i>Small Openings.</i>
Meatus auditorius,	Entrance of chorda tympani,
Fenestra ovalis,	Exit of the chorda tympani,
Fenestra rotunda,	For the laxator tympani,
Mastoid cells,	For the tensor tympani,
Eustachian tube.	For the stapedius.

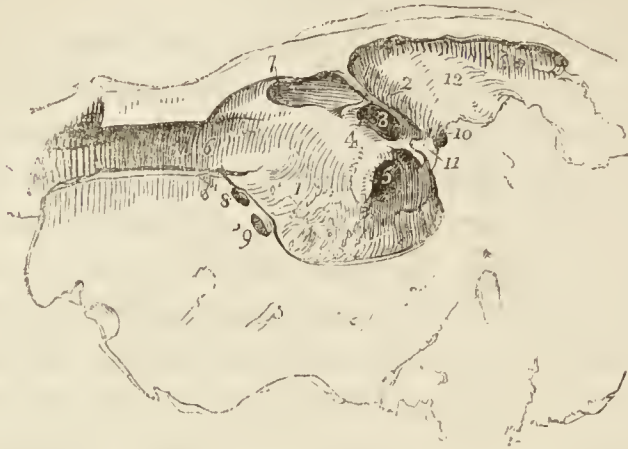The opening of the *meatus auditorius* has been already described.

The *fenestra ovalis* (*fenestra vestibuli*) is a reniform opening, situated at the bottom of a small oval fossa (the *pelvis ovalis*), in the upper part of the inner wall of the tympanum, directly opposite the meatus. The long diameter of the fenestra is directed horizontally, and its convex borders upwards. It is the opening of communication between the tympanum and vestibule, and is closed by the foot of the stapes and by the lining membranes of both cavities.

The *fenestra rotunda* (*fenestra cochleæ*) is somewhat triangular in its form, and situated in the inner wall of the tympanum, below and rather posteriorly to the fenestra ovalis, from which it is separated by a bony elevation,

called the *promontory*. It serves to establish a communication between the tympanum and the cochlea. In the

*Fig. 55.**



fresh subject it is closed by a proper membrane (*m. tympani secundaria*), as well as by the lining of both cavities.

The *mastoid cells* are numerous, and occupy the whole of the interior of the mastoid process and part of the petrous bone. They communicate by a large irregular opening with the upper and posterior circumference of the tympanum.

The *Eustachian tube* is a short canal about an inch and three quarters in length, extending obliquely between the pharynx and the anterior circumference of the tympanum. In structure it is partly fibro-cartilaginous and partly osseous, is broad and expanded at its pharyngeal extremity, and narrow and compressed at the tympanum.

The *smaller openings* serve for the transmission of the chorda tympani nerve, and three of the muscles of the tympanum.

* The tympanum of the left ear.—No. 1. Its inner wall. 2. A convex ridge marking the situation of the aquæductus Fallopii: the star shows its termination on the face of the section in its course downwards to the stylo-mastoid foramen. 3. The fenestra ovalis. 4. The promontory. 5. The fenestra rotunda. Anteriorly (6.) is the entrance of the Eustachian tube. 7. The opening for the tensor tympani. 8. The opening for the laxator tympani; and (9.) the opening of exit for the chorda tympani nerve. Posteriorly (10.) is the opening of entrance for the chorda tympani; and (11.) the pyramid with the small opening at its apex which gives passage to the tendon of the stapedius muscle. Superiorly is a large opening (12.) leading backwards to the mastoid cells.

The *opening* by which the *chorda tympani* enters the tympanum is at about the middle of its *posterior wall*, and near the root of the pyramid. The *opening of exit* for the *chorda tympani* is at the *fissura Glaseri* in the *anterior wall* of the tympanum.

The *opening* for the *laxator tympani* muscle is also situated in the *fissura Glaseri*, in the *anterior wall* of the tympanum. The *opening* for the *tensor tympani* muscle is in the *inner wall*, immediately above the opening of the Eustachian tube. The *opening* for the *stapedius* muscle is at the apex of a conical bony eminence, called the pyramid, which is situated on the *posterior wall* of the tympanum, immediately behind the fenestra ovalis.

Directly *above* the fenestra ovalis is a *rounded ridge* formed by the projection of the *aquæductus Fallopii*. *Beneath* the fenestra ovalis and separating it from the fenestra rotunda is the *promontory*, a rounded prominence formed by the projection of the first turn of the cochlea. It is channelled upon its surface by three small grooves, which lodge the three tympanic branches of Jacobson's nerve.

The *foramina* and *processes of the tympanum* may be arranged, according to their situation, into four groups.

1. In the *external wall* is the *meatus auditorius*, closed by the *membrana tympani*.

2. In the *inner wall*, from above downwards, are the—
 Opening for the tensor tympani,
 Ridge of the aquæductus Fallopii,
 Fenestra ovalis,
 Promontory, with the grooves for Jacobson's nerve,
 Fenestra rotunda.

3. In the *posterior wall* are the—
 Opening of the mastoid cells,
 Pyramid, and opening for the stapedius,
 Opening for Jacobson's nerve.
 Apertura chordæ (entrance).

4. In the *anterior wall* are the—
 Eustachian tube,
 Fissura Glaseri,
 Opening for laxator tympani,
 Apertura chordæ (exit).

The tympanum is lined by a *vascular mucous membrane*, which invests the ossicula and chorda tympani, and forms the internal layer of the membrana tympani. From the tympanum it is reflected into the mastoid cells, which it lines throughout, and it passes through the Eustachian tube to become continuous with the mucous membrane of the pharynx. In the Eustachian tube it is furnished with vibratile cilia.

Vessels and Nerves.—The *arteries* of the tympanum are derived from the internal maxillary, internal carotid, and posterior auricular.

Its *nerves* are—1. Minute branches from the *facial*, which are distributed to the stapedius muscle. 2. The *chorda tympani*, which leaves the facial nerve near the stylo-mastoid foramen, and arches upwards to enter the tympanum at the root of the pyramid; it then passes forwards between the handle of the malleus and long process of the incus, to its proper opening in the fissura Glaseri. 3. The *tympanic branches of Jacobson's nerve*, which are distributed to the membranes of the fenestra ovalis and fenestra rotunda, and to the Eustachian tube, and form a plexus by communicating with the carotid plexus, otic ganglion, and Vidian nerve. 4. A filament from the otic ganglion to the tensor tympani muscle.

INTERNAL EAR.

The *internal ear* is called *labyrinth*, from the complexity of its communications; it consists of a membranous and an osseous portion. The osseous labyrinth presents a series of cavities, which are channelled through the substance of the petrous bone, and is situated between the cavity of the tympanum and the meatus auditorius internus. It is divisible into the —

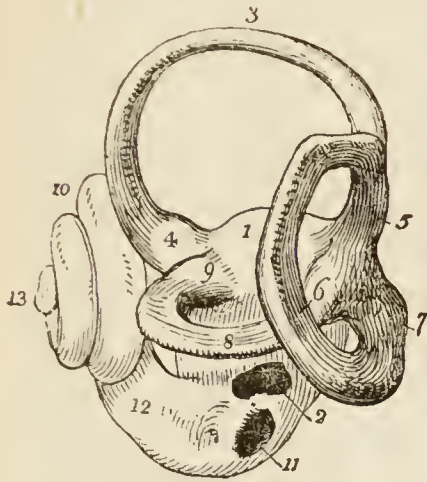
Vestibule, Semicircular canals, Cochlea.

The VESTIBULE is a small three-cornered cavity, compressed from without inwards, and situated immediately within the inner wall of the tympanum. The three corners, which are named ventricles or cornua, are placed, one anteriorly, one superiorly, and one posteriorly.

The anterior ventricle receives the oval aperture of the scala vestibuli; the superior, the ampullary openings of the superior and horizontal semicircular canals; the pos-

terior, the ampullary opening of the oblique semicircular canal, the common aperture of the oblique and perpendicular canals, the termination of the horizontal canal,

Fig. 56.*



and the aperture of the aquæductus vestibuli. In the *anterior ventricle* is a small depression, which corresponds with the posterior segment of the cul-de-sac of the meatus auditorius internus; it is called the *fovea hemispherica*, and is pierced by a cluster of small openings, the *macula cribrosa*. In the *superior ventricle* of the vestibule is another small depression, the *fovea elliptica*, which is separated from

the fovea hemispherica by a projecting crest, the *eminentia pyramidalis*. The latter is pierced by numerous minute openings for the passage of nervous filaments. The *posterior ventricle* presents a third small depression, the *fovea sulciformis*, which leads upwards to the ostium aquæductûs vestibuli. The *internal wall* of the vestibule corresponds with the bottom of the cul-de-sac of the meatus auditorius internus, and is pierced by numerous small openings for the transmission of nervous filaments. In the *external* or *tympanic wall* is the reniform opening of the fenestra ovalis (fenestra vestibuli), the margin of which presents a prominent rim towards the cavity of the vestibule.

The openings of the vestibule may be arranged, like those of the tympanum, into *large* and *small*.

* The labyrinth of the left ear.—No. 1. The vestibule. 2. The fenestra ovalis, in its natural position, looking from the meatus auditorius externus, the entrance into the vestibule from the tympanum. 3. The perpendicular semicircular canal. 4. Its ampulla. 5. Its union with the oblique canal. 6. The oblique semicircular canal. 7. Its ampulla. 8. The horizontal semicircular canal. 9. Its ampulla. 10. The cochlea, internal to and rather in front of the vestibule. 11. The fenestra rotunda, the entrance into the scala tympani of the cochlea. 12. The canal of the cochlea leading from the fenestra rotunda to make its first turn. 13. The extremity of the canal called the cupola.

The *large openings* are seven in number, viz. the —

Fenestra ovalis,

Scala vestibuli,

Five openings of the three semicircular canals.

The *small openings* are the —

Aquæductus vestibuli,

Openings for small arteries,

Openings for branches of the auditory nerve.

The *fenestra ovalis* has already been described; it is the opening from the tympanum.

The opening of the *scala vestibuli* is the oval termination of the vestibular canal of the cochlea.

The *aquæductus vestibuli* (canal of Cotunnus) is the commencement of the small canal which opens under the osseous scale on the posterior surface of the petrous bone. It gives passage to a process of membrane (which is continuous internally with the lining membrane of the vestibule, and externally with the dura mater), and to a small vein.

The *openings* for *arteries* and *nerves* are situated in the internal wall of the vestibule, and correspond with the termination of the meatus auditorius internus.

The SEMICIRCULAR CANALS are three bony passages communicating with the vestibule, into which they open by both extremities. Near one extremity of each of the canals is a dilatation of its cavity, which is called the *ampulla* (sinus ampullaceus). The *superior*, or perpendicular canal (canalis semicircularis verticalis superior), is directed transversely across the petrous bone, forming a projection on the anterior face of the latter. It commences, by means of an ampulla, in the superior ventricle of the vestibule, and terminates posteriorly by joining with the oblique and forming a common canal which opens into the upper part of the posterior ventricle. The *middle* or *oblique* canal (canalis semicircularis verticalis posterior) corresponds with the posterior part of the petrous portion of the temporal bone; it commences by an ampullary dilatation in the posterior ventricle, and curves nearly perpendicularly upwards to terminate in the common canal. In the ampulla of this canal are numerous minute openings for nervous filaments. The *inferior* or *horizontal* canal (canalis semicircularis hori-

zontalis) is directed outwards towards the base of the petrous bone, and is shorter than the two preceding. It commences by an ampullary dilatation in the superior ventricle, and terminates in the posterior ventricle.

The COCHLEA (*snail-shell*) forms the anterior portion of the labyrinth, corresponding by its apex with the anterior wall of the petrous bone, and by its base with the anterior depression at the bottom of the cul de sac of the meatus auditorius internus. It consists of an osseous and gradually tapering canal, about one inch and a half in length, which makes two turns and a half spirally around a central axis, called the modiulus.

The central axis, or *modiulus*, is large near its base, where it corresponds with the first turn of the cochlea, and diminishes in diameter towards its extremity. At its base, it is pierced by numerous minute openings, which transmit the filaments of the cochlear nerve. These openings are disposed in a spiral manner: hence they have received, from Cotunnus, the name of tractus spiralis foraminulentus. The modiulus is everywhere traversed, in the direction of its length, by minute canals, which proceed from the tractus spiralis foraminulentus, and terminate upon the sides of the modiulus, by opening into the canal of the cochlea or upon the surface of its lamina spiralis. The central canal of the tractus spiralis foraminulentus is larger than the rest, and is named the tubulus centralis modioli; it is continued onwards to the extremity of the modiulus, and transmits a nerve and small artery (*arteria centralis modioli*).

The interior of the canal of the cochlea is partially divided into two passages (*scalæ*) by means of a thin and porous lamina of bone (*zonula ossea laminae spiralis*), which is wound spirally around the modiulus, in the direction of the canal. The bony septum extends for about two-thirds across the diameter of the canal, and in the fresh subject is prolonged to the opposite wall by means of a membranous layer, so as to constitute a complete partition, the *lamina spiralis*. This osseous lamina spiralis consists of two thin lamellæ of bone, between which, and through the perforations on their surfaces, the filaments of the cochlear nerve reach the membrane of the cochlea. At the apex of the cochlea, the lamina spiralis terminates by a pointed, hook-shaped process, the *hamulus laminae*

spiralis. The two scalæ of the cochlea, which are completely separated throughout their length in the living ear, communicate superiorly, over the hamulus laminae spiralis, by means of an opening common to both, which has been termed by Breschet *helico-trema* (ἑλιξ, ἐλίσσω, volvere—τροῖμα). Inferiorly, one of the two scalæ, the scala vestibuli, terminates by means of an oval aperture in the anterior ventricle of the vestibule; while the other, the scala tympani, becomes somewhat expanded, and opens into the tympanum through the fenestra rotunda (fenestra cochleæ). Near the termination of the scala tympani is the small opening of the aquæductus cochleæ.

The internal surface of the osseous labyrinth is lined by a *fibro-serous membrane*, which is analogous to the dura mater in performing the office of a periosteum by its exterior, whilst it fulfils the purpose of a serous membrane by its internal layer, secreting a limpid fluid, the aqua labyrinthi (perilymph, liquor Cotunnii), and sending a reflection inwards upon the nerves distributed to the membranous labyrinth. In the cochlea, the membrane of the labyrinth invests the two surfaces of the bony lamina spiralis, and being continued from its border across the diameter of the canal to its outer wall, forms the membranous lamina spiralis, and completes the separation between the scala tympani and scala vestibuli. The fenestra ovalis and fenestra rotunda are closed by an extension of this membrane across them, assisted by the membrane of the tympanum, and a proper intermediate layer. Besides lining the interior of the osseous cavity, the membrane of the labyrinth sends two delicate processes along the aqueducts of the vestibule and cochlea, to the internal surface of the dura mater, with which they are continuous. These processes are the remains of a communication originally subsisting between the dura mater and the cavity of the labyrinth.*

* Cotunnus regarded these processes as tubular canals through which the superabundant aqua labyrinthi might be expelled into the cavity of the cranium. Wharton Jones, in the article "Organ of Hearing," in the Cyclopædia of Anatomy and Physiology, also describes them as tubular canals which terminate beneath the dura mater of the petrous bone in a small dilated pouch. In the ear of a man deaf and dumb from birth, he found the termination of the aqueduct of the vestibule of unusually large size in consequence of irregular development.

The MEMBRANOUS LABYRINTH is smaller in size, but a perfect counterpart, with respect to form, of the vestibule and semicircular canals. It consists of a small elongated sac, *sacculus communis* (*utricle communis*); of three semicircular membranous canals, which correspond with the osseous canals, and communicate with the *sacculus communis*; and of a small round sac (*sacculus proprius*), which occupies the anterior ventricle of the vestibule, and lies in close contact with the external surface of the *sacculus communis*. The membranous semicircular canals are two-thirds smaller in diameter than the osseous canals.

The membranous labyrinth is retained in position by means of the numerous nervous filaments which are distributed to it from the openings in the inner wall of the vestibule, and is separated from the lining membrane of the labyrinth, by the *aqua labyrinthi*. In structure it is composed of four layers; an external or serous layer, derived from the lining membrane of the labyrinth; a vascular layer, in which an abundance of minute vessels are distributed; a nervous layer, formed by the expansion of the filaments of the vestibular nerve; and an internal and serous membrane, by which the limpid fluid which fills its interior is secreted. Some patches of pigment have been observed by Wharton Jones, in the tissue of the membranous labyrinth of man. Among animals such spots are constant.

The membranous labyrinth is filled with a limpid fluid, first well described by Scarpa, and thence named *liquor Scarpæ* (*endolymph*, vitreous humour of the ear), and contains two small calcareous masses, called *otoconites*. The *otoconites* (*ὄττις, ὠτὸς, κότις*, the ear-dust) consist of an assemblage of minute, crystalline particles of carbonate and phosphate of lime, held together by animal substance, and probably retained in form by a reflection of the lining membrane of the membranous labyrinth. They are found suspended in the *liquor Scarpæ*; one in the *sacculus communis*, the other in the *sacculus proprius*, from that part of each sac with which the nerves are connected.

The AUDITORY NERVE divides into two branches at the bottom of the cul-de-sac of the *meatus auditorius internus*; a vestibular nerve, and a cochlear nerve. The *vestibular nerve*, the posterior of the two, divides

into three branches, superior, middle, and inferior. The superior vestibular branch gives off a number of filaments which pass through the minute openings of the eminentia pyramidalis and superior ventricle of the vestibule, and are distributed to the sacculus communis and ampullæ of the perpendicular and horizontal semicircular canals. The middle vestibular branch sends off numerous filaments, which pass through the openings of the macula cribrosa in the anterior ventricle of the vestibule, and are distributed to the sacculus proprius. The inferior and smallest branch takes its course backwards to the posterior wall of the vestibule, and gives off filaments, which pierce the wall of the ampullary dilatation of the oblique canal, to be distributed upon its ampulla. According to Stiefensand, there is in the situation of the point of entrance of the nervous filaments into the ampulla, a deep depression upon the exterior of the membrane, and upon the interior a corresponding projection, which forms a kind of transverse septum, partially dividing the cavity of the ampulla into two chambers. In the substance of the sacculi and ampullæ, the nervous filaments radiate in all directions, anastomosing with each other, and forming interlacements and loops; and they terminate upon the inner surface of the membrane in minute papillæ, resembling those of the retina.

The *cochlear nerve* divides into numerous filaments which enter the foramina of the tractus spiralis foraminulentus in the base of the cochlea, and passing upwards in the canals of the modiolus, bend outwards at right angles, to be distributed in the tissue of the lamina spiralis. The central portion of the nerve passes through the tubulus centralis of the modiolus, and supplies the apical portion of the lamina spiralis. In the lamina spiralis, the nervous filaments, lying side by side, on an even plane, form numerous anastomosing loops, and spread out into a nervous membrane. According to Treviranus and Gottsche, the ultimate terminations of the filaments assume the form of papillæ.

The *arteries* of the labyrinth are derived from the internal auditory branch of the superior cerebellar or basilar artery, and from the stylo-mastoid.

MOUTH AND TONGUE.

In the section of the nasal fossæ the incision was carried through the roof of the mouth, and the division of the soft palate was completed by an incision made with a scalpel. Care was taken not to disturb the cavity of the mouth any more than was necessary. We have now to study that cavity, together with the tongue, for which purpose any fragments of the preceding dissection, which may obscure the view, should be removed; and that side of the mouth selected for examination which has been least injured.

The *mouth* is the irregular cavity which contains the organ of taste, and the principal instruments of mastication. It is bounded, *in front*, by the lips; on either *side*, by the internal surface of the cheeks; *above*, by the hard palate and teeth of the upper jaw; *below*, by the tongue, by the mucous membrane stretched between the arch of the lower jaw and the under surface of the tongue, and by the teeth of the inferior maxilla; and, *behind*, by the soft palate and fauces.

The *lips* are two fleshy folds formed externally by common integument, and internally by mucous membrane, and containing between these two layers, muscles, a quantity of fat, and numerous small *labial glands*. They are attached to the surface of the upper and lower jaw; and each lip is connected to the gum in the middle line by a fold of mucous membrane, the *frænum labii superioris*, and *frænum labii inferioris*, the former being the larger of the two.

The *cheeks* (buccæ) are continuous on either hand with the lips, and form the sides of the face; they are composed of integument, a large quantity of fat, muscles, mucous membrane, and *buccal glands*.

The mucous membrane lining the cheeks is reflected above and below upon the sides of the jaws, and is attached posteriorly to the anterior margin of the ramus of the lower jaw. At about its middle, opposite the second molar tooth of the upper jaw, is a papilla, upon which may be observed a small opening, the aperture of the duct of the parotid gland.

The *hard palate* is a dense structure, composed of mucous membrane, palatal glands, fibrous tissue, vessels, and nerves, and firmly connected to the palate processes of the superior maxillary and palate bones. It is bounded

in front and on each side by the alveolar processes and gums, and is continuous behind with the soft palate. Along the middle line it is marked by an elevated raphé, and presents, upon each side of the raphé, a number of transverse ridges and grooves. Near its anterior extremity, and immediately behind the middle incisor teeth, is a papilla which corresponds with the termination of the anterior palatine canal, and receives the naso-palatine nerves.

The *vessels* and *nerves* of the hard palate are the descending palatine artery (page 269.), and nerves (page 279.), which emerge at the posterior palatine foramina and pass forwards, and the naso-palatine nerve (page 280.), and artery of the septum (page 269.), in front.

If the mucous membrane be torn away from the side of the nasal fossa, at its posterior part, so as to expose the ascending portion of the palate bone and sphenopalatine foramen, the descending palatine artery and accompanying nerves may be seen through the thin plate of bone. This plate should be removed and the artery and nerve followed in their course downwards to the posterior palatine foramen, and from that point forwards in the substance of the palate. The artery and nerve lie deeply in the palate, and for a part of their course in a groove on the bone. At the same time the two other palatine nerves, *middle* and *posterior* (page 279.), may be dissected and traced to their distribution, the *middle* to the tonsil and soft palate; the *posterior* to the posterior part of the palate as well as to the soft palate and tonsil.

The *gums* are composed of a thick and dense mucous membrane, which is closely adherent to the periosteum of the alveolar processes, and embraces the necks of the teeth. They are remarkable for their hardness and insensibility; and for their close contact, without adhesion, to the surface of the tooth. From the neck of the tooth they are reflected into the alveolus, and become continuous with the periosteal (peridental) membrane of that cavity.

TONGUE.—The *tongue* is invested by mucous membrane, which is reflected from its under part upon the inner surface of the lower jaw, and constitutes, with the muscles beneath, the floor of the mouth. Upon the under surface of the tongue, near its anterior part, the mucous membrane forms a considerable fold, which is called the *frænum linguæ*; and on each side of the frænum is a large papilla, the commencement of the duct of the sub-

maxillary gland (Wharton's duct). Running back from this papilla is a ridge, occasioned by the prominence of the sublingual gland; and opening upon the summit of this ridge, a number of small openings, the apertures of the excretory ducts of the gland. Posteriorly the tongue is connected with the os hyoides by muscle, and to the epiglottis by three folds of mucous membrane, called the *fræna epiglottidis*.

The *mucous membrane* of the mouth is continuous with the derma along the margin of the lips. On either side of the *frænum linguæ* it may be traced through the sublingual ducts, and along Wharton's ducts into the submaxillary glands. From the sides of the cheeks it passes through the opening of Stenon's ducts to the parotid glands. In the fauces it forms the assemblage of follicles called tonsils, and may thence be traced downwards into the larynx and pharynx, where it is continuous with the general gastro-pulmonary mucous membrane.

Beneath the mucous membrane are a number of small *glandular granules*, which pour their secretion upon the surface. A considerable number of these bodies are situated within the lips, in the palate, and in the floor of the mouth. They are named, according to their position, *labial* glands, *palatal* glands, and *buccal* glands.

The surface of the tongue is covered by a dense layer, analogous to the corium of the skin, which gives support to papillæ. A *raphé* marks the middle line of the organ, and divides it into symmetrical halves.

The *papillæ* of the *tongue* are the—

Papillæ circumvallatæ,	Papillæ filiformes,
Papillæ conicæ,	Papillæ fungiformes.

The *papillæ circumvallatæ* (p. lenticulares) are of large size, and from fifteen to twenty in number. They are situated on the dorsum of the tongue, near its root, and form a row on each side, which meets its fellow at the middle line, like the two branches of the letter A. Each papilla resembles a cone, attached by its apex to the bottom of a cup-shaped depression: hence they are also named *papillæ calyciformes*. This cup-shaped cavity forms a kind of fossa around the papilla, whence their name, *circumvallatæ*. At the meeting of the two rows of these papillæ upon the middle of the root of the tongue, is a deep mucous follicle, called *foramen cæcum*.

The *papillæ conicæ* and *filiformes* cover the whole surface of the tongue in front of the *circumvallatæ*, but are most abundant towards its anterior part. They are conical and filiform in shape, and many of them are pierced at the extremity by a minute aperture. Hence they may be regarded as follicles, rather than sentient organs; the true sentient papillæ being extremely minute, and occupying their surface as they do that of the other papillæ of the tongue.

The *papillæ fungiformes* (p. capitatæ) are irregularly dispersed over the dorsum of the tongue, and are easily recognised among the other papillæ by their rounded heads, larger size, and red colour. A number of these papillæ will generally be observed at the tip of the tongue.

Behind the papillæ *circumvallatæ*, at the root of the tongue, are a number of mucous glands (*lingual*) which, open upon the surface. There is also a small cluster beneath the tip of the tongue.

In structure the tongue is composed of muscular fibres, which are distributed in layers arranged in various directions : thus, some are disposed *longitudinally* (*lingualis superficialis*); others *transversely* (*lingualis transversus*); others, again, *obliquely* and *vertically*. Between the muscular fibres is a considerable quantity of adipose substance, and in the middle of the organ a vertical septum of fibrous tissue.

Vessels and Nerves.—The tongue is abundantly supplied with blood by the lingual arteries.

The *nerves* are three in number, and of large size: the *gustatory* branch of the inferior maxillary, which is distributed to the papillæ, and is the nerve of common sensation and taste; the *glosso-pharyngeal*, which is distributed to the mucous membrane, glands, and papillæ *circumvallatæ*; and the *hypoglossal*, which is the motor nerve of the tongue, and is distributed to the muscles.

THE LARYNX.

The *larynx* is situated at the fore-part of the neck, between the trachea and the base of the tongue. It is a short tube, having an hour-glass form, and is composed of *cartilages*, *ligaments*, *muscles*, *vessels*, *nerves*, and *mucous membrane*.

The *cartilages* are the —

Thyroid,	Two cornicula laryngis,
Cricoid,	Two cuneiform,
Two arytenoid,	Epiglottis.

The *thyroid* (θυρεός — εἶδος, like a shield) is the largest cartilage of the larynx: it consists of two lateral portions, or *alæ*, which meet at an angle in front, and form the projection which is known by the name of *pomum Adami*. In the male, after puberty, the angle of union of the two alæ is acute; in the female, and before puberty in the male, it is obtuse. Where the pomum Adami is prominent, a bursa mucosa is often found between it and the skin.

Each ala is quadrilateral in shape, and forms a rounded border posteriorly, which terminates above, in the *superior cornu*, and below, in the *inferior cornu*. Upon the side of the ala is an *oblique line*, or *ridge*, directed downwards and forwards, and bounded at each extremity by a tubercle. Into this line the sterno-thyroid muscle is inserted; and from it the thyro-hyoid and inferior constrictor take their origin. In the *receding angle*, formed by the meeting of the two alæ upon the inner side of the cartilage, and near its lower border, are attached the epiglottis, the chordæ vocales, the thyro-arytenoid, and thyro-epiglottidean muscles.

The *cricoid* (κρίκος — εἶδος, like a ring) is a ring of cartilage, narrow in front, and broad behind, where it is surmounted by *two rounded surfaces*, which articulate with the arytenoid cartilages. At the middle line, posteriorly, is a *vertical ridge*, which gives attachment to the œsophagus, and on each side of the ridge are the depressions which lodge the crico-arytenoidei postici muscles. On either side of the ring is a *glenoid cavity*, which articulates with the inferior cornu of the thyroid cartilage.

The *arytenoid cartilages* (ἀρυταινα*, a pitcher), two in number, are triangular and prismoid in form. They are broad and thick below, where they articulate with the

* This derivation has reference to the appearance of both cartilages taken together and covered by mucous membrane. In animals, which were the principal subjects of dissection among the ancients, the opening of the larynx with the arytenoid cartilages bears a striking resemblance to the mouth of a pitcher having a large spout.

upper border of the cricoid cartilage; pointed above, and prolonged by two small pyriform fibro-cartilages, *cornicula laryngis* (capitula Santorini), which are curved inwards and backwards; and they each present three surfaces, anterior, posterior, and internal. The posterior surface is concave, and lodges part of the arytenoideus muscle; the internal surface is smooth, and forms part of the lateral wall of the larynx; the anterior or external surface is rough and irregular, and gives attachment to the chorda vocalis, thyro-arytenoideus, crico-arytenoideus lateralis and posticus, and, above these, to the base of the cuneiform cartilage.

The *cuneiform cartilages* are two small cylinders of yellow fibro-cartilage, about seven lines in length, and enlarged at each extremity. By the lower end, or base, the cartilage is attached to the middle of the external surface of the arytenoid; and, by its upper extremity, forms a prominence in the border of the aryteno-epiglottidean fold of membrane. They are sometimes wanting.

In the male, the cartilages of the larynx are more or less ossified, particularly in old age.

The *epiglottis* (ἐπιγλωττίς, upon the tongue) is a fibro-cartilage of a yellowish colour, studded with a number of small mucous glands, which are lodged in shallow pits upon its surface. It is shaped like a cordate leaf, and is placed immediately in front of the opening of the larynx, which it closes completely when the larynx is drawn up beneath the base of the tongue. It is attached by its point to the *receding angle* between the two alæ of the thyroid cartilage.

Ligaments.—The *ligaments* of the larynx are numerous, and may be arranged into four groups: 1. Those which articulate the thyroid with the os hyoides. 2. Those which connect it with the cricoid. 3. Ligaments of the arytenoid cartilages. 4. Ligaments of the epiglottis.

1. The ligaments which connect the thyroid cartilage with the os hyoides are three in number.

The two *thyro-hyoidean ligaments* pass between the superior cornua of the thyroid, and the extremities of the greater cornua of the os hyoides: a sesamoid bone or cartilage is found in each.

The *thyro-hyoidean membrane* is a broad membranous layer, occupying the entire space between the upper

border of the thyroid cartilage, and the upper border of the os hyoides. It is pierced by the superior laryngeal nerve and artery.

2. The ligaments connecting the thyroid to the cricoid cartilage are also three in number:—

Two *capsular ligaments*, with their synovial membranes, which form the articulation between the inferior cornua of the thyroid and the sides of the cricoid; and the crico-thyroidean membrane. The *crico-thyroidean membrane* is a fan-shaped layer of yellow elastic tissue, thick in front (middle crico-thyroidean ligament) and thinner at each side (lateral crico-thyroidean ligament). It is attached by its apex to the lower border and receding angle of the thyroid cartilage, and by its expanded margin to the upper border of the cricoid and base of the arytenoid cartilages. Superiorly it is continuous with the inferior margin of the chorda vocalis. The front of the crico-thyroidean membrane is crossed by a small artery, the inferior laryngeal, and is the spot selected for the operation of laryngotomy. Laterally it is covered in by the crico-thyroidei and crico-arytenoidei laterales muscles.

3. The ligaments of the arytenoid cartilages are eight in number:—

Two *capsular ligaments*, with synovial membranes, which articulate the arytenoid cartilages with the cricoid, strengthened behind by two *posterior crico-arytenoid bands*, or ligaments; and the superior and inferior thyro-arytenoid ligaments. The *superior thyro-arytenoid ligaments* are two thin bands of yellow elastic tissue, which are attached in front to the receding angle of the thyroid cartilage, and behind to the anterior and inner border of each arytenoid cartilage. The lower border of this ligament constitutes the upper boundary of the ventricle of the larynx, and the fold of mucous membrane caused by its projection has been called the superior or false chorda vocalis. The *inferior thyro-arytenoid ligaments*, or true *chordæ vocales*, are thicker than the superior, and, like them, composed of yellow elastic tissue. Each ligament is attached in front to the receding angle of the thyroid cartilage, and behind to the anterior angle of the base of the arytenoid. The inferior border of the chorda vocalis is continuous with the lateral expansion of the crico-

thyroid ligament. The superior border forms the lower boundary of the ventricle of the larynx. The space between the two chorda vocales is the glottis, or rima glottidis.

4. The ligaments of the epiglottis are five in number, namely, three glosso-epiglottic, hyo-epiglottic, and thyro-epiglottic.

The *glosso-epiglottic* ligaments (fræna epiglottidis) are three folds of mucous membrane, which connect the anterior surface of the epiglottis with the root of the tongue. The middle of these contains elastic tissue. The *hyo-epiglottic* ligament is a band of yellow elastic tissue, passing between the anterior aspect of the epiglottis near its apex, and the upper margin of the body of the os hyoides. The *thyro-epiglottic* ligament is a long and slender fasciculus of yellow elastic tissue, which embraces the apex of the epiglottis, and is inserted into the receding angle of the thyroid cartilage, immediately below the anterior fissure, and above the attachment of the chordæ vocales.

Muscles.—The muscles of the larynx are eight in number: the five larger are the muscles of the chordæ vocales and rima glottidis; the three smaller are muscles of the epiglottis.

The five muscles of the chordæ vocales and rima glottidis are, the—

Crico-thyroid,	Thyro-arytenoideus,
Crico-arytenoideus posticus,	Arytenoideus.
Crico-arytenoideus lateralis,	

The *crico-thyroid* muscle *arises* from the anterior surface of the cricoid cartilage, and passes obliquely outwards and backwards, to be *inserted* into the lower and inner border of the ala of the thyroid, from its tubercle as far back as the inferior cornu.

The *crico-arytenoideus posticus* *arises* from the depression on the posterior surface of the cricoid cartilage, and passes upwards and outwards, to be *inserted* into the outer angle of the base of the arytenoid.

The *crico-arytenoideus lateralis* *arises* from the upper border of the side of the cricoid, and passes upwards and backwards, to be *inserted* into the outer angle of the base of the arytenoid cartilage.

The *thyro-arytenoideus* arises from the receding angle of the thyroid cartilage, close to the outer side of the chorda vocalis, and passes backwards, parallel with the cord, to be *inserted* into the base and outer surface of the arytenoid cartilage.

The *arytenoideus* muscle occupies the posterior concave surface of the arytenoid cartilages, between which it is stretched. It consists of three planes of transverse and oblique fibres; hence it was formerly considered as several muscles, under the names of *transversi* and *obliqui*.

The three muscles of the epiglottis are the —

Thyro-epiglottideus,
Aryteno-epiglottideus superior,
Aryteno-epiglottideus inferior.

The *thyro-epiglottideus* appears to be formed by the upper fibres of the thyro-arytenoideus muscle; they spread out upon the external surface of the sacculus laryngis, and in the aryteno-epiglottidean fold of mucous membrane, on which they are lost; a few of the anterior fibres being continued onwards to the side of the epiglottis (depressor epiglottidis).

The *aryteno-epiglottideus superior* consists of a few scattered fibres, which pass forwards in the fold of mucous membrane, forming the lateral boundary of the entrance into the larynx, from the apex of the arytenoid cartilage to the side of the epiglottis.

The *aryteno-epiglottideus inferior*. — This muscle, described by Mr. Hilton, and closely connected with the sacculus laryngis, may be found by raising the mucous membrane immediately above the ventricle of the larynx. It *arises*, by a narrow and fibrous origin, from the arytenoid cartilage, just above the attachment of the chorda vocalis; and, passing forwards, and a little upwards, expands over the upper half, or two-thirds of the sacculus laryngis, and is *inserted* by a broad attachment into the side of the epiglottis.

ACTIONS. — From a careful examination of the muscles of the larynx, Mr. Bishop* concludes, that the crico-arytenoidei postici open the glottis, while all the rest close it. The arytenoideus approximates the arytenoid cartilages

* Cyclopædia of Anatomy and Physiology, art. LARYNX.

posteriorly, and the crico-arytenoidei laterales and thyro-arytenoidei anteriorly; the latter, moreover, close the glottis mesially. The crico-thyroidei are tensors of the chordæ vocales, and these muscles, together with the thyro-arytenoidei, regulate the tension, position, and vibrating length of the vocal cords.

The crico-thyroid muscles effect the tension of the chordæ vocales by rotating the cricoid on the inferior cornua of the thyroid; by this action, the anterior portion is drawn upwards, and made to approximate the inferior border of the thyroid, while the posterior and superior border of the cricoid, together with the arytenoid cartilages, is carried backwards. The crico-arytenoidei postici separate the chordæ vocales, by drawing the outer angles of the arytenoid cartilages outwards and downwards. The crico-arytenoidei laterales, by drawing the outer angles of the arytenoid cartilages forwards, approximate the anterior angles, to which the chordæ vocales are attached. The thyro-arytenoidei draw the arytenoid cartilages forwards, and, by their connexion with the chordæ vocales, act upon the whole length of those cords.

The thyro-epiglottideus acts principally by compressing the glands of the sacculus laryngis, and the sac itself: by its attachment to the epiglottis, it would act feebly upon that valve. The aryteno-epiglottideus superior serves to keep the mucous membrane of the sides of the opening of the glottis tense, when the larynx is drawn upwards, and the opening closed by the epiglottis. Of the aryteno-epiglottideus, the "functions appear to be," writes Mr. Hilton, "to compress the subjacent glands which open the pouch; to diminish the capacity of that cavity, and change its form; and to approximate the epiglottis and the arytenoid cartilage."

Mucous Membrane. — The aperture of the larynx is a triangular or cordiform opening, broad in front and narrow behind; bounded anteriorly by the epiglottis, posteriorly by the arytenoideus muscle, and on either side by a fold of mucous membrane stretched between the side of the epiglottis and the apex of the arytenoid cartilage. On the margin of this *aryteno-epiglottidean* fold the cuneiform cartilage forms a prominence more or less distinct. The cavity of the larynx is divided into two

parts by an oblong constriction, produced by the prominence of the chordæ vocales. That portion of the cavity which lies above the constriction is broad and triangular above, and narrow below; that which is below it, is narrow above and broad and cylindrical below, the circumference of the cylinder corresponding with the ring of the cricoid; while the space included by the constriction is a narrow, triangular fissure, the *glottis*, or *rima glottidis*. The form of the glottis is that of an isosceles triangle, bounded on the sides by the chordæ vocales and inner surface of the arytenoid cartilages, and behind by the arytenoideus muscle. Its length is greater in the male than in the female; and, in the former, measures somewhat less than an inch. Immediately above the prominence caused by the chorda vocalis, and extending nearly its entire length on each side of the cavity of the larynx, is an elliptical fossa, the *ventricle of the larynx*. This fossa is bounded below by the chorda vocalis, which it serves to isolate; and above, by a border of mucous membrane folded upon the lower edge of the superior thyro-arytenoid ligament (superior or false chorda vocalis). The whole of the cavity of the larynx, with its prominences and depressions, is lined by mucous membrane, which is continuous, superiorly, with that of the mouth and pharynx; and inferiorly, is prolonged through the trachea and bronchial tubes into the lungs. In the ventricles of the larynx the mucous membrane forms a cæcal pouch of variable size, termed by Mr. Hilton the *sacculus laryngis*.* The

* This sac was described by Mr. Hilton before he was aware that it had already been pointed out by the older anatomists. I myself made a dissection, which I still possess, of the same sac in an enlarged state, during the month of August, 1837, without any knowledge either of Mr. Hilton's labours or Morgagni's account. The sac projected considerably above the upper border of the thyroid cartilage, and the extremity had been snipped off on one side in the removal of the muscles. The larynx was presented to me by Dr. George Moore of Camberwell; he had obtained it from a child who died of bronchial disease; and he conceived that this peculiar disposition of the mucous membrane might possibly explain some of the symptoms by which the case was accompanied. Cruveilhier made the same observation in equal ignorance of Morgagni's description, for we read in a note at p. 677, vol. ii. of his *Anatomie*

sacculus laryngis is directed upwards, sometimes extending as high as the upper border of the thyroid cartilage, and occasionally above that border. When dissected from the interior of the larynx, it is found covered by the aryteno-epiglottideus muscle and a fibrous membrane, which latter is attached to the superior thyro-arytenoid ligament below; to the epiglottis in front; and to the upper border of the thyroid cartilage above. If examined from the exterior of the larynx, it will be seen to be covered by the thyro-epiglottideus muscle. On the surface of its mucous membrane are the openings of sixty or seventy small follicular glands, which are situated in the sub-mucous tissue, and give to its external surface a rough and ill-dissected appearance. The secretion from these glands is intended for the lubrication of the chordæ vocales, and is directed upon them by two small valvular folds of mucous membrane, which are situated at the entrance of the sacculus. The mucous membrane is closely connected to the epiglottis, and to the chordæ vocales; on the latter, being remarkable for its thinness. It is invested by a columnar ciliated epithelium as high up as the superior folds of the ventricle of the larynx and the lower half of the epiglottis.

Glands.—The mucous membrane of the larynx is furnished with an abundance of mucous glands; many of these are situated on the epiglottis, in the sacculus laryngis, and in the aryteno-epiglottidean folds, where they are termed *arytenoid*. The body known as the epiglottic gland is merely a mass of cellular and adipose tissue, situated in the triangular space between the front surface of the apex of the epiglottis, the hyo-epiglottidean ligament, and the thyro-hyoidean membrane.

Vessels and Nerves.—The *arteries* of the larynx are derived from the superior and inferior thyroid. The

Descriptive.—“J’ai vu pour la première fois cette arrière cavité chez un individu affecté de phthisie laryngée, où elle était très-développée. Je fis des recherches sur le larynx d’autres individus, et je trouvai que cette disposition était constante. Je ne savais pas alors que Morgagni avait indiqué et fait représenter la même disposition.” Cruveilhier compares its form very aptly to a “*Phrygian casque*,” and Morgagni’s figure, *Advers.* 1. *Epist.* *Anat.* 3. plate 2. fig. 4, has the same appearance. But neither of these anatomists notice the follicular glands described by Mr. Hilton.

nerves are the superior laryngeal and recurrent laryngeal, both branches of the pneumogastric. The two nerves communicate with each other freely, but the superior laryngeal is distributed principally to the mucous membrane at the entrance of the larynx; the recurrent to the muscles.

TRACHEA.—The trachea or wind-pipe is cylindrical for about two-thirds of its circumference, and flattened on the posterior third, where it rests on the œsophagus. It is about four inches in length, and extends from opposite the fifth cervical vertebra to opposite the third dorsal vertebra, where it divides into two bronchi. Its area is somewhat larger in the male than in the female, and its diameter from side to side about an inch.

It is composed of fibro-cartilaginous rings, fibrous membrane, muscular fibres, fibres of elastic fibrous tissue, and is lined by mucous membrane.

The fibro-cartilaginous rings are from fifteen to twenty in number, and extend for two-thirds around its cylinder, being deficient at the posterior part. The first ring is received within the lower margin of the cricoid cartilage, and is broader than the rest; the last is broad at the middle in consequence of the prolongation of the lower border into a triangular process which curves backwards at the point of bifurcation. The posterior extremities of the rings are rounded, and occasionally one or two rings will be found to bifurcate.

The *fibrous membrane* connects the rings and forms a thin covering to them on the outer surface. Internally it does not reach the surface, and the rings have in consequence an appearance of greater prominence. It also stretches across between the rings on the posterior part of the trachea.

The *muscular fibres* are disposed transversely across the space, between the extremities of the fibro-cartilages behind. They are placed internally to the fibrous membrane.

The *elastic fibrous tissue* is disposed in longitudinal bundles, within the fibro-cartilages; and, behind, internally to the muscular layer.

The *mucous membrane*, which is pale, forms the internal lining of the tube, and has opening upon its surface the excretory tubes of numerous mucous glands.

These glands are situated for the most part between the layers of membrane in the back part of the tube (page 172.).

ORGAN OF TOUCH.

The *skin* is the exterior investment of the body, which it serves to cover and protect. It is continuous at the apertures of the internal cavities with the lining membrane of those cavities, the internal skin or mucous membrane, and is composed essentially of two layers, *derma* and *epiderma*.

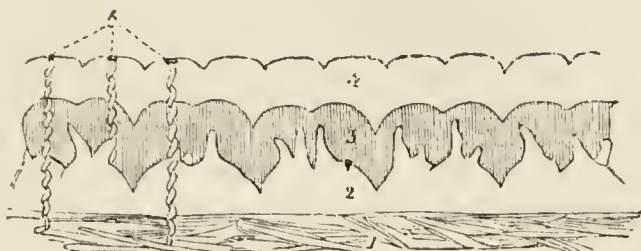
The *DERMA*, or cutis, is chiefly composed of cellulo-fibrous tissue, besides which it has entering into its structure elastic and contractile fibrous tissue, together with blood-vessels, lymphatic vessels, and nerves. The cellulo-fibrous tissue exists in greatest abundance in the deeper stratum of the derma, which is consequently dense, white, and coarse; the superficial stratum, on the other hand, is fine in texture, reddish in colour, soft, raised into minute papillæ, and highly vascular and sensitive. These differences in structure have given rise to a division of the derma into the deep stratum, or *corium*, and the superficial, or *papillary* layer.

In the *corium* the cellulo-fibrous tissue is collected into fasciculi, which are small and closely interwoven in the superficial strata, large and coarse in the deep strata; in the latter forming an areolar net-work with large areolæ, which are occupied by adipose tissue. These areolæ are the channels by which the branches of vessels and nerves find a safe passage to the papillary layer, in which and in the superficial strata of the corium they are principally distributed. The yellow elastic tissue is found chiefly in the superficial strata, the red contractile tissue in the deep. It is to the latter that the nipples and scrotum owe their contractile powers, and the general surface of the skin the contraction which is known by the name of *cutis anserina*. The corium presents some variety in thickness in different parts of the body. Thus in the more exposed regions, as the back, the outer sides of the limbs, the palms, and the soles, it is remarkable for its thickness; while on protected parts it is comparatively thin. On the eyelids, the penis, and the scrotum it is peculiarly delicate. It is connected by its

under surface with the common superficial fascia of the body.

The *papillary* layer of the derma is raised in the form of conical prominences or papillæ. On the general

Fig. 57.*



surface of the body the papillæ are short and exceedingly minute ; but in other situations, as the palmar surface of the hands and fingers, and the plantar surface of the feet and toes, they are long and of large size. They also differ in arrangement ; for, on the general surface, they are distributed at unequal distances and without order ; whereas, on the palms and soles, and on the corresponding surfaces of the fingers and toes, they are collected into little square clumps, containing from ten to twenty papillæ ; and these little clumps are disposed in parallel rows. It is this arrangement in rows that gives rise to the characteristic parallel ridges and furrows which are met with on the hands and feet. The papillæ in these little square clumps are for the most part uniform in size and length, but every here and there one papilla may be observed which is longer than the rest. The largest papillæ of the derma are those which produce the nail ; in the dermal follicle of the nail they are long and filiform, while beneath its concave surface they form longitudinal and parallel plications which extend for nearly the entire length of that organ. In structure each papilla is composed of a more or less convoluted capillary and a more or less convoluted nervous loop.

The EPIDERMA or cuticle (scarfskin) is a product of the derma, which it serves to envelope and defend.

* A section of the skin. — No. 1. The corium. 2. The papillary layer of the cutis. 3. The rete mucosum modelled upon the papillæ. 4. The cuticle. 5. Spiral perspiratory ducts, opening at the pores upon the ridges of the cuticle.

That surface of the epiderma which is exposed to the influence of the atmosphere and exterior sources of injury is hard and horny in texture, while that which lies in contact with the papillary layer is soft and cellular. Hence the epiderma, like the derma, is divisible into two layers, external and internal, the latter being termed the *rete mucosum*. Moreover, the epiderma is laminated in structure, and the laminae present a progressively increasing tenuity and density as they advance from the inner to the outer surface. This difference of density is dependent on the mode of growth of the epiderma, for as the external surface is constantly subjected to destruction from attrition and chemical action, so the membrane is continually reproduced on its internal surface ; new layers being successively formed on the derma to take the place of the old.

The theory of growth of the epiderma, deduced from the observations of Schwann, is as follows : — A stratum of plastic lymph (liquor sanguinis) is poured out upon the surface of the derma. This fluid, by virtue of the vital force inherent in itself, and communicated to it by contact with a living tissue, is converted into granules, which are termed cell-germs, or *cytoblasts*. By endosmosis, these cytoblasts imbibe serum from the plastic lymph and adjacent tissues, and the outermost layer or pellicle of the cytoblast becomes gradually distended by the imbibed fluid. The cytoblast has now become a cell, and the solid portion of the cytoblast, which always remains adherent to some one point of the internal surface of the cell-membrane, is the *nucleus* of the cell. Moreover, within the nucleus, one or several nuclei are formed, which are termed *nucleoli*. By a continuance of the process of imbibition, the cell becomes more or less spherical ; so that, after a time, every part of the surface of the papillary layer of the derma is coated by a thin and membranous stratum, consisting of spherical cells lying closely pressed together, and corresponding with every irregularity which the papillae present. But, as this production of cells is a function constantly in operation, a new layer is formed before the first is completed, and the latter is separated by subsequent formations farther and farther from the surface of the papillary layer. As a consequence of loss of contact with the

derma, the vital force is progressively diminished; the cell becomes subject to the influence of physical laws, and evaporation of its fluid slowly ensues. In consequence of this evaporation the cell becomes collapsed and flattened, and assumes an elliptical form; the latter is by degrees converted into the flat cell with parallel and contiguous layers, and an included nucleolated nucleus; and, lastly, the flattened cell desiccates into a thin membranous scale, in which the nucleus is no longer apparent.

My own investigations* have shown that, after the original granules of the liquor sanguinis have become aggregated into a granular nucleus, other granules are formed in successive circles around the circumference of the nucleus, until the entire breadth of the epidermal scale is attained; that the cell never acquires a greater thickness than that of the original nucleus; and that the formation of the scale results from the desiccation of the cell, as it is gradually pushed outwards from the derma towards the surface. Consequently, the cell never possesses any other than the flattened form; all its phases of growth are perfected in the deepest layer of the epiderma; and, in its internal structure, it is a parent cell containing secondary and tertiary cells and granules, its growth being the result of the growth of these secondary formations.

The under surface of the epiderma is accurately modelled on the papillary layer of the derma, each papilla having its appropriate sheath in the newly-formed epiderma or rete mucosum, and each irregularity of surface of the former having its representative in the soft tissue of the latter. On the external surface, this character is lost; the minute elevations corresponding with the papillæ are, as it were, polished down, and the surface is rendered smooth and uniform. The palmar and plantar surfaces of the hands and feet are, however, an exception to this rule; for here, in consequence of the large size of the papillæ and their peculiar arrangement in rows, ridges corresponding with the papillæ are strongly marked on the superficial surface of the epi-

* Diseases of the Skin, 2nd edit. p. 5.

derma. The epiderma is remarkable for its thickness in situations where the papillæ are large, as in the palms and soles. In other situations, it assumes a character which is also due to the nature of the surface of the derma; namely, that of being marked by a network of linear furrows, which trace out the surface into small polygonal and lozenge-shaped areæ. These lines correspond with the folds of the derma produced by its movements, and are most numerous where those movements are the greatest, as in the flexures and on the convexities of joints.

The dark colour of the skin among the natives of the South is due to the coloration of the primitive granules of which the cell is composed, especially the nucleus. As the cells desiccate, the colour of the granules is lost; hence the deeper hue of the rete mucosum.

The *pores* of the epiderma are the openings of the perspiratory ducts, hair follicles, and sebiparous glands.

Vessels and Nerves.—The *arteries* of the derma which enter its structure through the areolæ of the under surface of the corium, divide into innumerable intermediate vessels, which form a rich capillary plexus, in the superficial strata of the skin, and in its papillary layer. In the papillæ of some parts of the derma, as in the longitudinal plications beneath the nail, the capillary vessels form simple loops, but in other papillæ they are convoluted to a greater or less degree in proportion to the size and importance of the papillæ. The *lymphatic* vessels probably form, in the superficial strata of the derma, a plexus, the meshes of which are interwoven with those of the capillary and nervous plexus. No lymphatics have as yet been discovered in the papillæ.

The *nerves* of the derma, after entering the areolæ of the deeper part of the corium, divide into minute fasciculi, which form a terminal plexus in the upper strata of the corium. From this plexus the primitive fibres pass off to their distribution, as loops, in the papillæ. In the less sensitive parts of the skin the loops are simple and more or less acute in their bend, in conformity with the figure of the papillæ. In the sensitive parts, however, and especially in the tactile papillæ of the pulps of the fingers, the loop is convoluted to a greater or less extent, and acts as a multiplier of sensation.

APPENDAGES OF THE SKIN.

The appendages of the skin are the nails, hairs, sebiparous glands, and perspiratory glands and ducts.

The NAILS are horny appendages of the skin, identical in formation with the epiderma, of which they are a part. A nail is convex on its external surface, concave within, and implanted by means of a thin margin or root in a fold of the derma, which is nearly two lines in depth, and acts the part of a follicle to the nail. At the bottom of the groove of the follicle are a number of filiform papillæ, which produce the margin of the root, and, by the successive formation of new cells, push the nail onwards in its growth. The concave surface of the nail is in contact with the derma, and the latter is covered by papillæ, which perform the double office of retaining the nail in its place, and giving it increased thickness by the addition of newly-formed cells to its under surface. It is this constant change occurring in the under surface of the nail, co-operating with the continual reproduction taking place along the margin of the root, which ensures the growth of the nail in the proper direction. The nail derives a peculiarity of appearance from the disposition and form of the papillæ on the unguis surface of the derma (matrix). Thus, beneath the root, and for a short distance onwards towards its middle, the derma is covered by papillæ which are more minute, and consequently less vascular than the papillæ somewhat farther on. This patch of papillæ is bounded by a semilunar line, and the part of the nail covering it being lighter in colour than the rest, has been termed *lunula*. Beyond the lunula the papillæ are raised into longitudinal plaits, which are exceedingly vascular, and give a deeper tint of redness to the nail. These plait-like papillæ of the derma are well calculated by their form to offer an extensive surface both for the adhesion and formation of the nail. The granules and cells are developed on every part of their surface, both in the grooves between the plaits and on their sides, and a horny lamina is formed between each pair of plaits. When the under surface of a nail is examined, these longitudinal laminae, corresponding with the longitudinal papillæ of the unguis portion of the derma, are distinctly apparent, and if the nail be forcibly

detached, the laminae may be seen in the act of parting from the grooves of the papillae. It is this structure that gives rise to the ribbed appearance of the nail. The papillary surface of the derma which produces the nail is continuous around the circumference of the attached part of that organ with the derma of the surrounding skin, and the horny structure of the nail is consequently continuous with that of the epiderma.

HAIRS are horny appendages of the skin produced by the involution and subsequent evolution of the epiderma; the involution constituting the follicle in which the hair is inclosed, and the evolution the shaft of the hair. Hairs vary much in size and length in different parts of the body; in some they are so short as not to appear beyond the follicle; in others they grow to a great length, as on the scalp; while along the margins of the eyelids and in the whiskers and beard, they are remarkable for their thickness. Hairs are generally more or less flattened in form, and when the extremity of a transverse section is examined, it is found to possess an elliptical or reniform outline. This examination also demonstrates that the centre of the hair is porous and loose in texture, while its periphery is dense; thus affording ground for its division into a cortical and a medullary portion. The free extremity of a hair is generally pointed, and sometimes split into two or three filaments. Its attached extremity is implanted deeply in the integument extending through the derma into the subcutaneous cellular tissue, where it is surrounded by adipose cells. The central extremity of a hair is larger than its shaft, and is called the root or bulb. It is rounded or conical in its shape.

The process of formation of a hair by its follicle is identical with that of the formation of the epiderma by the papillary layer of the derma. Plastic lymph is in the first instance exuded by the capillary plexus of the follicle, the lymph undergoes conversion, first into granules, then into cells, and the latter are elongated into fibres. The cells which are destined to form the surface of the hair go through a different process. They are converted into flat scales, which inclose the fibrous structure of the interior. These scales, as they are successively produced, overlap those which precede and give rise to the pro-

minent and waving lines which may be seen around the circumference of a hair. It is this overlapping line that is the cause of the roughness which we experience in drawing a hair, from its point to its bulb, between the fingers. The bulb is the newly-formed portion of the hair: its expanded form is due to the greater bulk of the fresh cells compared with the fibres and scales into which they are subsequently converted in the shaft.

The colour of the hair, like that of the epiderma, is due to the coloration of the primitive granules of the cells.

The SEBIPAROUS GLANDS are sacculated glandular organs embedded in the substance of the derma, and presenting every variety of complexity, from the simplest pouch-like follicle to the sacculated and lobulated gland. In some situations, the excretory ducts of these glands open independently on the surface of the epiderma; while in others, and the most numerous, they terminate in the follicles of the hairs. The sebiparous glands associated with the hairs are racemiform and lobulated in structure, consisting of sacculi which open by short pedunculated tubuli into a common excretory duct, and the latter, after a short course, terminates in the hair-follicle. In the scalp there are two of these glands to each hair-follicle. On the nose and face the glands are of large size, distinctly lobulated, and constantly associated with small hair-follicles. In the meatus auditorius the sebiparous (ceruminous) glands are also large and lobulated, but the largest are those of the eyelids, the Meibomian glands. The excretory ducts of sebiparous glands offer some diversity in different parts of the body; thus, in many situations they are short and straight, while in others, as in the palms of the hands and soles of the feet, where the epiderma is thick, they assume a spiral arrangement. The sebiferous ducts are lined by an inversion of the epiderma, which forms a thick and funnel-shaped cone at its commencement, but soon becomes uniform and soft. Sebiparous glands are met with in all parts of the body, but are most abundant in the skin of the face, and in those situations which are naturally exposed to the influence of friction.

The sebaceous substance, when it collects in inordinate quantities within the excretory ducts, becomes the habitat

of a very remarkable parasitic animal, the *steatozoon folliculorum*.

The SUDORIPAROUS GLANDS are situated deeply in the corium and also in the subcutaneous cellular tissue, where they are surrounded by adipose cells. They are small, oblong bodies, composed of one or more convoluted tubuli, or of a congeries of globular sacs, which open into a common efferent duct. The latter ascends from the gland through the derma and epiderma, and terminates on the surface by a funnel-shaped and oblique aperture or pore. The efferent duct presents some variety in its course upwards: thus within the derma it is curved and serpentine, and if the epiderma be thin, it proceeds more or less directly to the excreting pore. Sometimes it is spirally curved within the derma, and having passed the latter, is regularly and beautifully spiral in its passage through the epiderma, the last turn forming an oblique and valvular opening on the surface. The spiral course of the duct is especially remarkable in the thick epiderma of the palm of the hand and sole of the foot. On those parts of the skin where the papillæ are irregularly distributed, the efferent ducts of the sudoriparous glands open on the surface also irregularly, while on the palmar and plantar surfaces of the hands and feet, the pores are situated at regular distances along the ridges, at points corresponding with the intervals of the small, square-shaped, clumps of papillæ. Indeed the apertures of the pores, seen upon the surface of the epidermal ridges, give rise to the appearance of small transverse furrows, which intersect the ridges from point to point.

The efferent duct and the component sacs and tubuli of the sudoriparous gland are lined by an inflection of the epiderma. This inflection is thick and infundibiliform in the upper stratum of the derma, but soon becomes uniform and soft. The infundibiliform projection is drawn out from the duct when the epiderma is removed, and may be perceived on the under surface of the latter as a nipple-shaped cone. A good view of the sudoriferous ducts is obtained by gently separating the epiderma of a portion of decomposing skin; or they may be better seen by scalding a piece of skin, and then withdrawing the epiderma from the derma. In both cases it is the lining sheath of epiderma which is drawn out from the duct.

CHAPTER VIII.

ABDOMEN.

THE dissection of the abdomen is to be commenced by making three incisions:—the first, *vertical*, in the middle line from over the lower part of the sternum to the pubes; the second, *oblique*, from the umbilicus, upwards and outwards to the outer side of the chest as high as the fifth or sixth rib; and the third, *oblique*, from the umbilicus downwards and outwards to the crest of the ilium, and along the crest to its middle. The three flaps of integument included by these incisions should then be dissected back, when the *superficial fascia* will be brought into view. The student should next proceed to seek out and dissect the superficial vessels and nerves, and three or four lymphatic glands situated in the neighbourhood of the groin.

The *superficial fascia* of the abdomen, like that in other parts of the body, is composed of cellular and adipose tissue. The quantity of fat varies considerably in different subjects. Near the groin the fascia is separable into two layers, between which are situated the superficial vessels and some inguinal glands. The superficial layer, in which the fat is chiefly found, is continuous over Poupart's ligament with the superficial fascia of the thigh. The deep layer is attached to Poupart's ligament, and is lost on the upper part of the fascia lata. It contains but little fat, and is cellulofibrous in structure. The superficial fascia, divested of its fat, forms a sheath for the spermatic cord, and is prolonged over the penis and scrotum into the perineum, where it is continuous with the superficial fascia of that region.

The *superficial arteries* of the abdomen are the superior external pudic, superficial epigastric, and superficial circumflexa ilii, all situated in the groin and branches of the femoral artery; and cutaneous branches which accompany the lateral cutaneous and anterior cutaneous nerves; the latter being derived from the intercostals, deep epigastric, and internal mammary artery.

The *superior external pudic artery* crosses the external abdominal ring and spermatic cord, and is distributed to the integument of the pubes and external organs of generation.

The *superficial epigastric* lies externally to the external abdominal ring, and ascends towards the umbilicus, supplying the integument in its course, and inguinal glands.

The *superficial circumflexa ilii* sends one or two small branches to the integument near the iliac extremity of Poupart's ligament.

The *veins* accompanying these arteries terminate in the internal saphenous vein.

The *superficial nerves* of the abdomen are the lateral cutaneous, anterior cutaneous, ilio-hypogastric, and ilio-inguinal.

The *lateral cutaneous nerves*, five or six in number, are derived from the intercostal nerves. They pierce the muscles in a line with the thoracic branches, and divide like them into an anterior and posterior branch. The *anterior branch* is continued forwards as far as the linea semilunaris. The *posterior branch*, smaller than the anterior, turns backward over the latissimus dorsi muscle.

The *lateral cutaneous* branch of the last dorsal nerve is an exception to the rest. It does not divide after piercing the external oblique muscle, but is directed downwards over the crest of the ilium, and is distributed to the integument of the hip as low down as the trochanter major. The nerve crosses the crest of the ilium just behind the origin of the tensor vaginae femoris. (page 36.)

The *anterior cutaneous nerves* are the terminations of the intercostal nerves; they pierce the sheath of the rectus near the linea alba, and are reflected outwards to be distributed to the integument. Like the lateral cutaneous nerves, they are accompanied by small arteries.

The *ilio-hypogastric nerve*, derived from the first lumbar nerve, divides into an iliac and hypogastric branch. The *iliac branch* pierces the muscles just above the crest of the ilium and behind its middle point, and is distributed to the integument of the gluteal region. The *hypogastric branch* pierces the aponeurosis of the external oblique above the external abdominal ring,

and is distributed to the integument of the hypogastric region.

The *ilio-inguinal nerve*, also derived from the first lumbar nerve, emerges at the external abdominal ring, and is distributed to the scrotum and upper part of the thigh, internally to the saphenous opening.

The *lymphatic glands*, three or four in number, are situated between the two layers of the superficial fascia above Poupart's ligament. They receive the lymphatics from the abdomen, upper and outer part of the thigh, and genital organs; and their efferent ducts descend to the saphenous opening to enter the stream of lymphatics of the lower limb.

The superficial fascia should now be dissected off the external oblique muscle on both sides, taking the direction of the fibres of the muscle and of the aponeurosis as a guide. The dissection should be carried upwards to the origin of the muscle from the ribs, backwards to its free border, and downwards to Poupart's ligament and the front of the pubes. On the one side a thin fascia which surrounds the spermatic cord at the abdominal ring, the *intercolumnar fascia*, should be displayed; on the other side it should be removed, and the boundaries of the external abdominal ring made evident.

The MUSCLES of the abdomen are the

External oblique,	Rectus,
Internal oblique,	Pyramidalis,
Transversalis,	Quadratus lumborum.

When the external oblique muscle is dissected on both sides, a white tendinous line will be seen along the middle of the abdomen, extending from the ensiform cartilage to the pubes: this is the *linea alba*. A little external to it, on each side, two curved lines will be observed extending from the eighth rib to the spine of the pubes, and bounding the recti muscles: these are the *lineæ semilunares*. Some transverse lines, *lineæ transversæ*, three in number, connect the *lineæ semilunares* with the *linea alba* at and above the umbilicus.

The *linea semilunaris* was the situation formerly chosen for the operation of tapping the abdomen in dropsy, *paracentesis abdominis*. But being merely the outer margin of a muscle, it is liable to alter its position with the expansion to which the whole of the abdominal muscles are subjected in that disease. The rectus may, in this way, be spread over the whole anterior half of the abdomen, and

the *linea semilunaris* become so much displaced as hardly to be discerned by external examination. Again, the sheath of the rectus contains a large artery (*epigastric*); and with the increased breadth of the muscle, this also changes its course. In a few instances the artery has been wounded in consequence of this change of position, and the operation in the *linea semilunaris* is therefore abandoned. *Ventral hernia* may occur in the course of this line.

The *linea alba* is now selected for the operation of *paracentesis abdominis*. Being in the middle line it cannot change its place by distension, and there is no risk of wounding an artery. The spot selected for the operation is usually midway between the umbilicus and pubes. It is performed by making a small incision with a bistoury through the integument and superficial fascia, and then introducing the trochar. This line is also the seat of operation for *puncturing the bladder* above the pubes; which is performed in the same manner as *paracentesis abdominis*.

The *high operation for lithotomy*, a practice disused in this country, has also its seat in the *linea alba*.

The *Cæsarian section*, for opening the uterus and removing the fœtus, an operation which is now becoming frequent in consequence of success; and the operation for the removal of a part or the whole of the cyst in ovarian dropsy, is also practised in the *linea alba*.

Moreover, a weakening of the *linea alba*, from over-distension, or congenital deficiency, gives rise to the protrusion of intestine at the umbilicus, called *umbilical hernia*.

Deficiencies of development also occur in this line, in which some of the abdominal viscera are exposed; the most frequent instance of this arrest is in the case where the mucous membrane of the bladder is protruded through the integument.

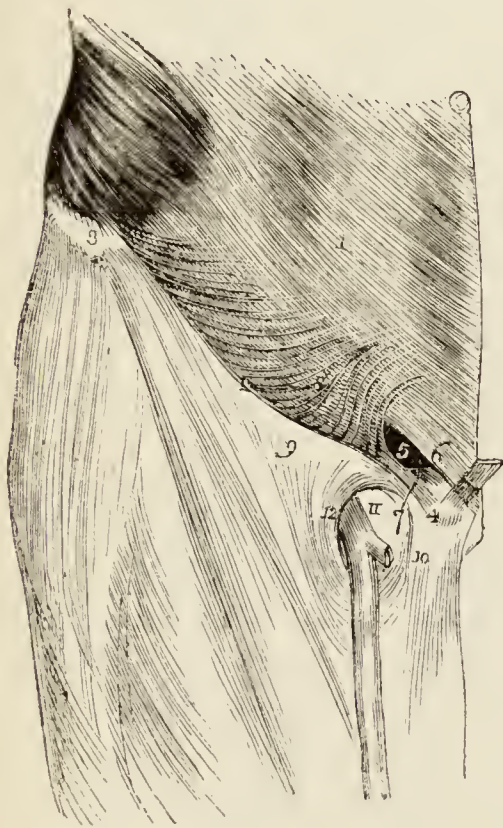
The EXTERNAL OBLIQUE MUSCLE (*obliquus externus abdominis descendens*) is the external flat muscle of the abdomen. Its name is derived from the obliquity of its direction, and the descending course of its fibres. It *arises* by fleshy digitations from the external surface of the eight inferior ribs; the five upper digitations being received between corresponding processes of the serratus magnus, and the three lower of the latissimus dorsi. Soon after its origin it spreads out into a broad aponeurosis, and is *inserted* into the outer lip of the crest of the ilium for one half its length, the anterior superior spine of the ilium, spine of the os pubis, pectineal line, front of the os pubis, and *linea alba*.

The superior border of the *obliquus externus* is continuous with the lower border of the *pectoralis major*, and its fibres of origin with those of the external intercostal muscles. Its posterior border is separated from the anterior border of the *latissimus dorsi* by a cellular interval, but is sometimes overlapped by that muscle.

The lower border of the aponeurosis, which is stretched between the anterior superior spinous process of the ilium and the spine of the os pubis, is round from being folded inwards, and forms *Poupart's ligament*. Poupart's ligament is round at its outer part, but flattened from above downwards nearer the pubes, forming a groove which supports the spermatic cord. It is curved in its course, from its attachment to the fascia lata; and its insertion into the pectineal line is *Gimbernat's ligament*. The attachment of Gimbernat's ligament to the pectineal line is about three quarters of an inch in length, and from this insertion some tendinous fibres are directed upwards and inwards behind the rectus muscle to the linea alba, and have received the name of *triangular ligament*.

Just above the crest of the os pubis is the *external abdominal ring*, a triangular opening formed by the

Fig. 58.*



separation of the fibres of the aponeurosis of the external oblique. It is oblique in its direction, and corresponds with the course of the fibres of the aponeurosis. It is bounded below by the crest of the os pubis; on either side, by the borders of the aponeurosis, which are called *pillars*; and above by some curved fibres (*inter-columnar*) which originate from Poupart's ligament, and cross the upper angle of the ring, so as to give it strength. The *external pillar*, which is at the same time *inferior* from the obliquity of the opening, is inserted into the spine of

* The anatomy of inguinal hernia, the right inguinal region. — No. 1. The lower part of the aponeurosis of the external oblique muscle of the abdomen. 2. Poupart's ligament, the lower border of the aponeurosis. 3. The anterior superior spinous process of the ilium. 4. The spine of the pubis. 5. The external abdominal

the os pubis; the internal or superior pillar forms an interlacement with its fellow of the opposite side over the front of the symphysis pubis. The external abdominal ring gives passage to the spermatic cord in the male, and the round ligament in the female: they are both invested in their passage through it by a thin fascia derived from the edges of the ring, and called *intercolumnar fascia*, or *fascia spermatica*. The pouch of inguinal hernia, in passing through this opening, receives the *inter-columnar fascia* as one of its coverings.

The external oblique is now to be removed by making an incision across the ribs, just below its origin, to its posterior border; and another along the crest of the ilium to the anterior superior spine, and thence transversely onwards to the linea alba. The muscle may then be turned forwards to the linea alba, or removed altogether. The lower portion of the aponeurosis should now be turned downwards, and left for subsequent examination.

The INTERNAL OBLIQUE MUSCLE (*obliquus internus abdominis ascendens*) is the middle flat muscle of the abdomen. It *arises* from the outer half of Poupart's ligament, from the middle of the crest of the ilium for two-thirds its length, and by a thin aponeurosis from the spinous processes of the lumbar vertebræ. Its fibres diverge from their origin, so that those from Poupart's ligament curve downwards, those from the anterior part of the crest of the ilium pass transversely, and the rest ascend obliquely. The muscle is *inserted* into the pectineal line and crest of the os pubis, linea alba, and lower borders of the five inferior ribs.

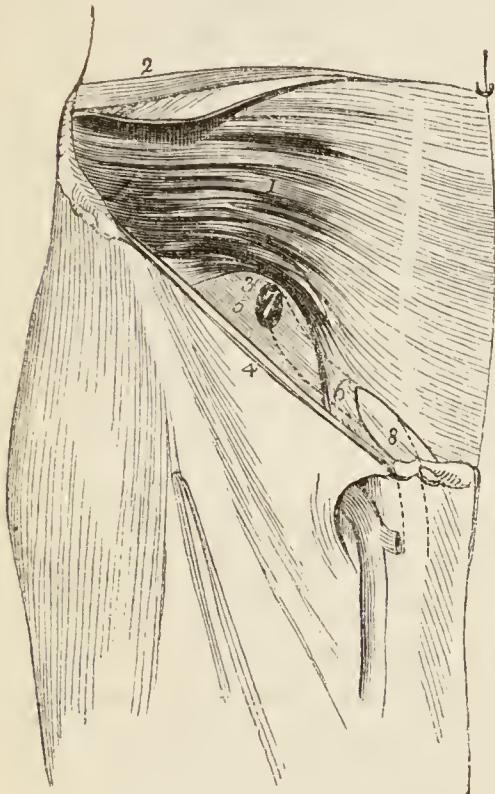
Along the upper three-fourths of the linea semilunaris, the aponeurosis of the internal oblique separates into two lamellæ, which pass one in front and the other behind the rectus muscle to the linea alba, where they are inserted; along the lower fourth, the aponeurosis passes altogether in front of the rectus without separation. The

ring. 6. The internal and superior pillar of the ring, passing down over the front of the pubes, and decussating with the same pillar of the opposite side. 7. The external and inferior pillar of the ring attached to the spine of the pubes. 8. The semilunar fibres which curve inwards from Poupart's ligament, and strengthen the upper angle of the ring. 9. The iliac portion of the fascia lata. 10. Its pubic portion. 11. The saphenous opening, with the saphenous vein passing through it. 12. The falciform border of the saphenous opening.

two layers, which thus enclose the rectus, form for it a partial sheath.

The lowest fibres of the internal oblique are inserted into the pectineal line of the os pubis in common with those of the transversalis muscle. Hence the tendon of this insertion is called the *conjoined tendon of the internal oblique and transversalis*. This structure corresponds

Fig. 59.*



with the external abdominal ring, and forms a protection to what would otherwise be a weak point in the abdomen. Sometimes the tendon is insufficient to resist the pressure from within, and becomes forced through the external ring; it then forms the distinctive covering of *direct inguinal hernia*.

The spermatic cord passes beneath the arched border of the internal oblique muscle, between it and Poupart's ligament. During its passage some fibres are given off from the lower border of the muscle, which accompany the cord downwards to the testicle, and form loops around it; this is the cremaster muscle. In the descent of oblique inguinal hernia, which travels the same course as the spermatic cord, the cremaster muscle forms one of its coverings.

forms one of its coverings.

* The internal oblique and transversalis muscles in the inguinal region, with the boundaries of the inguinal canal. — No. 1. The internal oblique muscle. 2. A part of the transversalis muscle seen by drawing down the internal oblique. 3. The lower arched border of the two muscles, forming the upper boundary of the canal. 4. Poupart's ligament, forming the lower boundary of the canal. 5. The fascia transversalis. 6. The conjoined tendon of the internal oblique and transversalis descending behind Poupart's ligament, to be inserted into the pectineal line. Numbers 5 and 6 form the posterior boundary of the canal, the anterior boundary being formed by the aponeurosis of the external oblique muscle which is removed. 7. The internal abdominal ring, an opening in the transversalis fascia, the commencement of the canal. 8. A dark outline marking the situation of the external abdominal ring. The dotted lines between the two rings show the situation and course of the spermatic cord.

The CREMASTER, considered as a distinct muscle, *arises* from the middle of Poupart's ligament, and forms a series of loops upon the spermatic cord. A few of its fibres are inserted into the tunica vaginalis; the rest ascend along the inner side of the cord, to be *inserted*, with the conjoined tendon, into the pectineal line of the os pubis.

The internal oblique muscle is to be removed by separating it from its attachments to the ribs above, and the crest of the ilium and Poupart's ligament below. It should be divided behind by a vertical incision extending from the last rib to the crest of the ilium, as its lumbar attachment cannot at present be examined. The muscle is then to be turned forwards. Some degree of care will be required in performing this dissection, from the difficulty of distinguishing between this muscle and the one beneath. A thin layer of cellular tissue is all that separates them for the greater part of their extent. There will also be found between them branches of the intercostal arteries and nerves, the ilio-inguinal and ilio-hypogastric nerves, and near the crest of the ilium the circumflexa ilii artery which ascends between the two muscles, and forms a valuable guide to their separation. Just above Poupart's ligament they are so closely connected, that it is impossible to divide them.

The TRANSVERSALIS is the internal flat muscle of the abdomen; it is transverse in the direction of its fibres, as is implied in its name. It *arises* from the outer third of Poupart's ligament, from the internal lip of the crest of the ilium, its anterior two-thirds; from the spinous and transverse processes of the lumbar vertebræ, and from the inner surface of the six inferior ribs, indigitating with the diaphragm. Its lower fibres curve downwards, to be *inserted*, with the lower fibres of the internal oblique, into the pectineal line, and form the conjoined tendon. Throughout the rest of its extent it is inserted into the crest of the os pubis and linea alba. The *lower fourth* of its aponeurosis passes in front of the rectus to the linea alba; the upper *three-fourths*, with the posterior lamella of the internal oblique behind it.

The *posterior aponeurosis* of the transversalis divides into three lamellæ; *anterior*, which is attached to the bases of the transverse processes of the lumbar vertebræ; *middle*, to the apices of the transverse processes; and *posterior*, to the apices of the spinous processes. The anterior and middle lamella inclose the quadratus lumborum muscle; the middle and posterior, the erector spinæ. The union of the posterior lamella with the

posterior aponeurosis of the internal oblique, serratus posticus inferior, and latissimus dorsi, constitutes the lumbar fascia (page 186.).

To dissect the *rectus* muscle, its sheath should be opened by a vertical incision extending from over the cartilages of the lower ribs to the front of the os pubis. The sheath may then be dissected off and turned to either side; this is easily done excepting at the lineæ transversæ, where a close adhesion subsists between the muscle and the external boundary of the sheath. The sheath contains the rectus and pyramidalis muscle.

The RECTUS MUSCLE *arises* by a double tendon from the front and crest of the os pubis, and is *inserted* into the cartilages of the fifth, sixth, and seventh ribs. It is traversed by several tendinous intersections, called lineæ transversæ. One of these is situated at the umbilicus, one over the ensiform cartilage, and one midway between these points; when a fourth exists, it is situated below the umbilicus. They are vestiges of the abdominal ribs of reptiles, and very rarely extend completely through the muscle.

The PYRAMIDALIS MUSCLE *arises* from the crest of the os pubis in front of the rectus, and is *inserted* into the linea alba about midway between the umbilicus and os pubis. It is inclosed in the same sheath with the rectus, and rests against the lower part of that muscle. It is sometimes wanting.

The rectus may now be divided across the middle, and the two ends drawn aside for the purpose of examining the mode of formation of its sheath.

The *sheath of the rectus* is formed, *in front*, for the upper three-fourths of its extent, by the aponeurosis of the external oblique and the anterior lamella of the internal oblique, and *behind* by the posterior lamella of the internal oblique and the aponeurosis of the transversalis. At the commencement of the lower fourth, the posterior wall of the sheath terminates in a thin curved margin, the aponeuroses of the three muscles passing altogether in front of the rectus.

ACTIONS.—The external oblique muscle, acting singly, would draw the thorax towards the pelvis, and twist the body to the opposite side. Both muscles, acting together, would flex the thorax directly on the pelvis. The internal oblique of one side draws the chest downwards and outwards: both together bend it directly for-

wards. Either transversalis muscle, acting singly, will diminish the size of the abdomen on its own side, and both together will constrict the entire cylinder of the cavity. The recti muscles, assisted by the pyramidales, flex the thorax towards the pelvis, and, through the medium of the lineæ transversæ, are enabled to act when their sheath is curved inwards by the action of the transversales. The pyramidales are tensors of the linea alba. The abdominal are expiratory muscles, and the chief agents of expulsion; by their action the fœtus is expelled from the uterus, the urine from the bladder, fæces from the rectum, bile from the gall-bladder, ingesta from the stomach and bowels in vomiting, and mucus and irritating substances from the bronchial tubes, trachea, and nasal passages during coughing and sneezing. To produce these efforts, they all act together. Their violent and continued action produces hernia; and, acting spasmodically, they may occasion rupture of the viscera.

Vessels and Nerves. — The VESSELS of the abdominal parietes are, the intercostal and lumbar arteries; circumflexa ilii; and, in the sheath of the rectus, the epigastric and internal mammary.

The *intercostal arteries* continue their course from the lower intercostal spaces between the internal oblique and transversalis muscle; they are distributed to the muscles, and inosculate with the lumbar arteries, internal mammary, and epigastric.

The *lumbar arteries*, four in number on each side, are branches of the abdominal aorta. Their course and distribution is similar to that of the intercostals. Each artery, between the transverse processes of the vertebræ, divides into a dorsal and abdominal branch. The *dorsal branch* passes backwards for the supply of the spine and muscles of the vertebral column. The *abdominal branch* advances between the transversalis and internal oblique muscle to supply the parietes of the abdomen. These branches inosculate with the intercostal arteries above, the ilio-lumbar and circumflexa ilii below, and the internal mammary and epigastric in front.

The *circumflexa ilii artery* arises from the external iliac artery close to Poupart's ligament, and passes outwards behind that ligament to the crest of the ilium, and along the crest to its posterior part, where it inosculates with the ilio-lumbar artery. In its course, the artery pierces the crural sheath, and then lies between the transversalis muscle and fascia; near its termination it

pierces the transversalis, and becomes placed between it and the internal oblique. An *ascending branch* is given off near the anterior superior spine of the ilium; this branch ascends in the cellular interval between the internal oblique and transversalis, and inosculates with the other arteries of the parietes.

The *epigastric artery* arises from the front of the external iliac artery a little above the circumflexa ilii; it bends inwards, and then ascends obliquely between the transversalis fascia and peritoneum to the lower margin of the sheath of the rectus. Piercing the transversalis fascia it enters the sheath and ascends behind the rectus muscle to its upper part, where (in the substance of the muscle) it inosculates with the internal mammary artery. In the first part of its course the artery lies internally to the internal abdominal ring, below the spermatic cord, and above the femoral ring. When the abdominal parietes are examined from within, the epigastric artery will be seen to form a prominent ridge, which divides the iliac fossa into an internal and external portion. It is in the former that direct inguinal hernia occurs; in the latter oblique inguinal hernia.

The *branches* of the epigastric artery are:—

A *cremasteric* branch which accompanies the spermatic cord, and after supplying the cremaster muscle inosculates with the spermatic artery.

A *pubic* branch, which is distributed behind the pubes, and sends a small branch of communication downwards to the obturator artery.

Muscular branches, which pass outwards between the abdominal muscles, and inosculate with the circumflexa ilii, lumbar, and intercostal arteries.

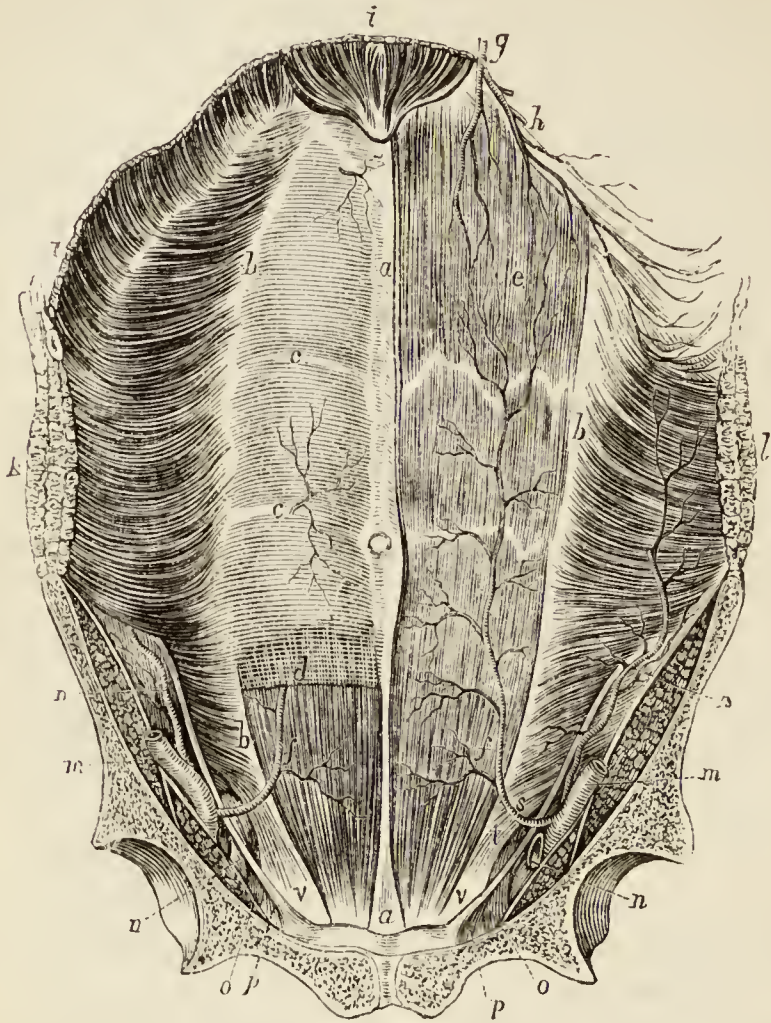
Superficial branches, which are distributed to the integument of the abdomen.

The *internal mammary artery*, a branch of the subclavian, is situated in the sheath of the rectus. It supplies the upper part of that muscle, and inosculates with the epigastric, intercostals, and lumbar arteries. (page 98.)

The **VEINS** accompanying the arteries of the abdominal parietes take the course of their respective arterial branches; the intercostal veins terminate in the venæ

azygos, the lumbar in the inferior vena cava, and the circumflexa ilii and epigastric in the external iliac.

Fig. 60.*



* Anterior wall of the abdomen ; internal aspect.— *a, a*. Linea alba. *b, b*. Linea semilunaris. *c, c*. Lineæ transversæ. The letters *c, c* are placed on the posterior surface of the sheath of the rectus. *d*. The lower border of this sheath, under which the epigastric artery is seen passing. *e, f*. The rectus muscle: *e* refers also to the superior epigastric artery, a branch of the internal mammary; and *f, f* to the proper epigastric artery. *g*. The internal mammary artery. *h*. Its musculo-phrenic branch. *i, i*. Part of the diaphragm. *k*. Section of the three abdominal muscles. *l*. Section of the external and internal oblique; the transversalis having been removed. *m*. The external iliac artery. *n*. The circumflexa ilii artery, seen in its whole course on the right side in consequence of the removal of the transversalis muscle; the leading line crosses the iliacus muscle. *o*. The external iliac vein. *p*. The crural ring. *q*. Gimbernat's ligament. *s, t* refer to the arch formed between the lower borders of the internal oblique and transversalis muscle and Poupart's ligament; the arch is crossed by the epigastric artery: the space *s* above the artery corresponds with the internal abdominal ring, and gives passage to oblique inguinal hernia: in this space is seen

The NERVES of the abdominal parietes are, the six lower intercostals, and two branches of the first lumbar nerve, namely, the ilio-hypogastric, and ilio-inguinal.

The *intercostal nerves* pass from the intercostal spaces, between the internal oblique and transversalis muscle, to the front of the abdomen, where they enter the sheath of the rectus. Near the linea alba they terminate by piercing the sheath, and becoming the *anterior cutaneous nerves* (page 418.).

Midway between the vertebral column and linea alba, each intercostal nerve gives off its *lateral cutaneous branch*, which pierces the internal and external oblique muscles to reach the surface (page 418.).

The *last intercostal*, or, rather, the last dorsal nerve, lies below the last rib; its lateral cutaneous branch does not divide like the rest, but is continued over the crest of the ilium, to the integument of the hip (page 36.).

The *ilio-hypogastric nerve* pierces the transversalis just above the crest of the ilium, and a little posterior to its mid-point, and divides into its two branches, iliac and hypogastric. The *iliac* branch pierces the internal and external oblique muscles, and descends over the crest of the ilium, to be distributed to the integument of the gluteal region (page 36.).

The *hypogastric branch* continues its course forward, a little above the crest of the ilium; and, near the anterior superior spine, communicates with the ilio-inguinal nerve. It then pierces the internal oblique muscle, and, near the linea alba, the aponeurosis of the external oblique, and is distributed to the integument of the hypogastric region.

The *ilio-inguinal nerve*, smaller than the preceding, and inferior to it in position, pierces the transversalis muscle in front of the anterior superior spine of the ilium, and communicates with the hypogastric branch of the ilio-hypogastric nerve. It then pierces the internal oblique muscle, and, passing through the external abdominal ring with the spermatic cord, is distributed to

a part of the internal oblique muscle, which extends lower on Poupart's ligament than the transversalis. Through the space *t* is seen the aponeurosis of the external oblique muscle. *v.* The conjoined tendon of the internal oblique and transversalis.

the integument of the upper and inner part of the thigh, and to the neighbouring part of the scrotum or pudendum (page 13.).

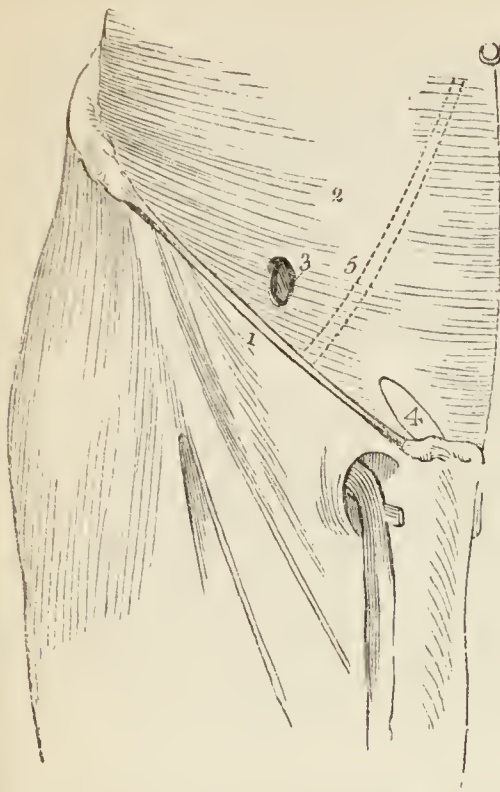
The vessels and nerves of the abdominal parietes having been carefully studied, the dissector should examine the lower border of the transversalis muscle, and its relations to the internal oblique muscle (which has been already turned aside, but may be replaced for this examination) and to the spermatic cord. The latter will be found issuing from beneath the lower border of the muscle between it and Poupart's ligament. Following the curve formed by the lower border of the muscle, he will find it descend behind the spermatic cord and Poupart's ligament, to be inserted, in conjunction with the internal oblique muscle, into the pectineal line of the pubes behind Gimbernat's ligament. The membranous structure which occupies the interval between the lower border of the transversalis and Poupart's ligament is the *transversalis fascia*, which is next to be examined. For this purpose the transversalis should be separated from its attachment to Poupart's ligament, and the crest of the ilium, and turned upwards and forwards; the muscle should then be divided by an incision carried from the middle of the crest of the ilium to the last rib, and another bordering the lower margin of the thorax. The muscle may then be turned over entirely to the middle line, and the transversalis fascia will be exposed.

The *fascia transversalis* (*fascia Cooperi*, — from its important relation to inguinal hernia being first particularly described by Sir Astley Cooper) is a thin fibrous membrane which lines the internal surface of the transversalis muscle, and is interposed between that muscle and the peritoneum. It is thickest at the lower part of the abdomen, where the muscular structure is weak, and becomes thinner as it ascends, until it is lost in the subserous cellular tissue. It is attached inferiorly to the reflected margin of Poupart's ligament, and to the crest of the ilium; internally, to the pectineal line and border of the rectus muscle; and, at the inner part of the femoral arch, is continued beneath Poupart's ligament, and forms the anterior segment of the crural canal, or sheath of the femoral vessels.

The internal abdominal ring is situated in this fascia, at about midway between the symphysis pubis and the anterior superior spine of the ilium, and half an inch above Poupart's ligament; it is oval in form, and bounded on its inner side by a well-marked falciform border, but is ill-defined around its outer margin. From the circumference of the ring is given off an *infundibuliform*

process, which surrounds the testicle and spermatic cord,

Fig. 61.*



constituting the fascia propria of the latter, and forms the first investment to the sac of oblique inguinal hernia.

When the fascia propria has been carefully examined, it should be laid open by a longitudinal incision; this will bring into view a layer of subserous fat, of variable thickness. When the fat is pushed aside with the handle of the scalpel, the peritoneum will be found to bulge at this point, and at the most prominent part of the bulge may be detected the fibrous remains of the obliterated process of the peritoneum, which originally surrounded the testis during its descent in the fœtus. This fibrous structure may present every degree of degradation; sometimes it is scarcely discernible, at other

times it is a fibrous band of some bulk; in another series of cases it is sacculated, or the tube of peritoneum may still be pervious.

SPERMATIC CORD.—The spermatic cord, composed of the vessels, nerves, and excretory duct of the testicle, and inclosed by certain coverings, takes its course from the internal abdominal ring, between the layers constituting the parietes of the abdomen, to the external abdominal ring. The space so occupied by the spermatic cord is denominated the *spermatic canal*, and is about one inch and a half in length. It is bounded *in front* by the aponeurosis of the external oblique muscle; *behind*, by the transversalis fascia, and the conjoined tendon of the internal oblique and transversalis; *above*, by the arched borders of the internal oblique and transversalis; *below*, by the grooved border of Poupart's ligament: and at

* The transversalis fascia, the abdominal muscles being removed.—No. 1. Poupart's ligament. 2. The transversalis fascia. 3. The internal abdominal ring, an opening in the transversalis fascia. 4. The situation of the external abdominal ring. 5. A dotted line marking the course of the epigastric artery between the two rings.

each extremity by one of the abdominal rings, the internal ring at the internal termination, the external ring at the outer extremity.

The *coverings* of the spermatic cord, while situated in the spermatic canal, are the *fascia propria*, derived from the fascia transversalis; and the *cremaster muscle*, derived from the lower border of the internal oblique. On emerging at the external abdominal ring, it receives the *intercolumnar fascia* from the borders of the ring, and is then inclosed in a sheath of *superficial fascia*; lastly, it is covered by the integument.

The *fascia propria*, derived from the fascia transversalis, is an infundibuliform sheath, loosely connected with the cord by cellular tissue, in which adipose matter is deposited. The fibres of the cremaster muscle, held together by cellular tissue, and thus forming a cellulomuscular layer, has received the name of *cremasteric fascia*; and the intercolumnar fascia is also known as the *spermatic fascia*.

The coverings of the cord may now be divided longitudinally, and turned aside, in order to bring into view its other components, the vessels, nerves, and excretory duct.

The **ARTERIES** of the spermatic cord are the cremasteric, spermatic, and deferential.

The *cremasteric artery* is a small branch of the epigastric, and is distributed to the cremasteric fascia.

The *spermatic artery*, a branch of the aorta, enters the internal abdominal ring, and accompanies the cord to the testicle, to which it is distributed.

The *deferential artery* is a small branch of the superior vesical artery, which accompanies the vas deferens to the testicle.

The **VEINS** of the cord, the *spermatic veins*, ascend from the posterior border of the testicle. They form a *plexus* which constitutes the chief bulk of the cord, and unite in a single vein, which accompanies the spermatic artery to terminate on the right side in the inferior vena cava, and on the left in the left renal vein.

The *lymphatic vessels* of the spermatic cord terminate in the lumbar glands.

The **NERVES** of the spermatic cord are the scrotal branch of the ilio-inguinal; the genital branch of the

genito-crural which enters the internal abdominal ring and accompanies the cremasteric artery to be distributed to the cremasteric fascia; and the spermatic plexus. The *spermatic plexus* is derived from the aortic and renal plexus, and accompanies the spermatic artery.

The VAS DEFERENS, the excretory duct of the testis, is situated along the posterior border of the cord, where it may be distinguished by the hard and cordy sensation which it communicates to the fingers. On reaching the internal abdominal ring it lies internally to the spermatic vessels, and turns inwards behind the epigastric artery to the side and base of the bladder, where it terminates in the urethra. It is accompanied by its proper artery.

In the *female*, the place of the spermatic cord is occupied by the *round ligament* of the uterus, which takes exactly the same course as the cord, has the same relations and coverings, with the exception of the cremaster, and, after passing through the external abdominal ring, terminates in the superficial fascia of the groin.

ANATOMY OF HERNIA.

The herniæ occurring in the parietes of the abdomen have been divided by Sir Astley Cooper into four species; namely, *umbilical*, *ventral*, *inguinal*, and *femoral*: to which may be added, as occasionally taking place, *phrenic*, *obturator*, *ischiatric*, *gluteal*, *perineal*, and, in the female, *vaginal*.

Umbilical hernia occurs at the umbilicus from weakening of the linea alba, either by over distension, as in utero-gestation, or from congenital deficiency. Its coverings are, the integument, superficial fascia, distended aponeurosis, and peritoneum.

Ventral hernia occurs chiefly in the linea semilunaris, and, from the same causes: its coverings are the same, but it has usually three layers of aponeurosis.

Inguinal hernia is of two kinds, *oblique* and *direct*: the former takes the course of the spermatic canal, descending by the side of the spermatic cord. The latter (*direct*) pushes directly through the external abdominal ring, carrying before it the conjoined tendon of the internal oblique and transversalis muscles.

One side of the abdomen having been reserved for the study of hernia, an incision should be made through the aponeurosis of the

external oblique from the anterior superior spine of the ilium to the linea alba, and another along the margin of Poupart's ligament to the external pillar of the external abdominal ring. The aponeurosis should then be drawn down, and the internal oblique muscle and transversalis dissected separately and turned aside in a similar manner. The transversalis fascia and peritoneum should next be divided in the direction of the transverse incision from the crest of the ilium to the linea alba. The student may now follow the description of inguinal hernia, and examine the layers concerned in its course.

In **OBLIQUE INGUINAL HERNIA** the intestine escapes from the cavity of the abdomen into the spermatic canal, through the *internal abdominal ring*, pressing before it a pouch of peritoneum, which constitutes the *hernial sac*, and distending the infundibiliform process of the transversalis fascia. After emerging through the internal abdominal ring it passes *first* beneath the lower and arched border of the transversalis muscle; *then* beneath the lower border of the internal oblique muscle; and *finally* through the external abdominal ring in the aponeurosis of the external oblique. From the transversalis muscle it receives no investment; while passing beneath the lower border of the internal oblique, it obtains the cremaster muscle; and, upon escaping at the external abdominal ring, receives the intercolumnar fascia. So that the coverings of an oblique inguinal hernia, after it has emerged through the external abdominal ring, are, from the surface to the intestine, the

Integument,
Superficial fascia,
Intercolumnar fascia,
Cremaster muscle,
Transversalis, or infundibiliform fascia,
Peritoneal sac.

There are three* varieties of oblique inguinal hernia: common, congenital, and encysted.

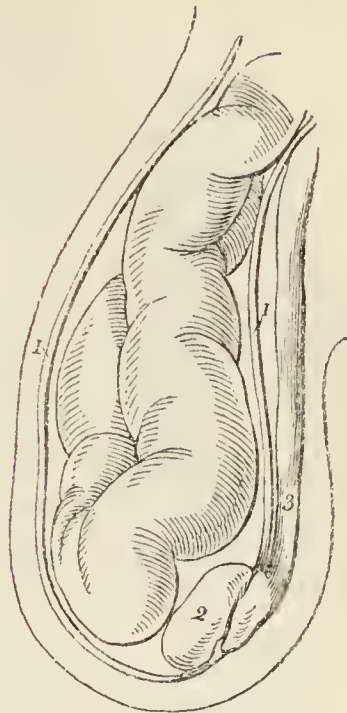
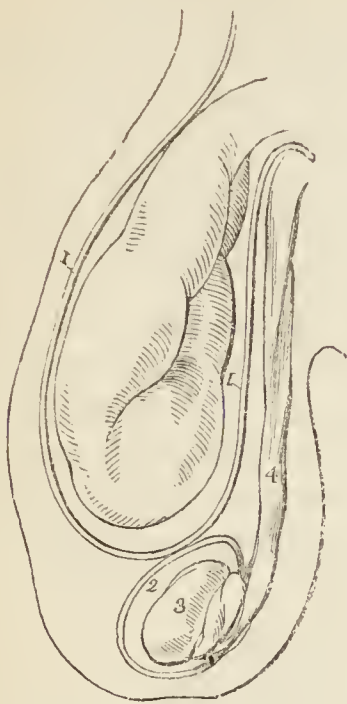
Common oblique hernia is that which has been described above.

* Velpeau describes a fourth, in which the protrusion takes place between the edge of the rectus and the umbilical ligament, and then takes the course of the spermatic canal.

Congenital hernia results from the non-closure of the pouch of peritoneum carried downwards into the scrotum

Fig. 62.*

Fig. 63.†



by the testicle during its descent in the foetus. In consequence of this defect, the intestine at some period of life is forced into the peritoneal canal, and descends through it into the tunica vaginalis, where it lies in contact with the testicle; so that congenital hernia has no proper sac, but is contained within the tunica vaginalis. The other coverings are the same as those of common inguinal hernia.

Encysted hernia (*hernia infantilis* of Hey) is that form of protrusion in which the pouch of peritoneum forming the tunica vaginalis, being only partially closed, and remaining open externally to the abdomen, admits of the hernia passing into the scrotum, behind the tunica

* Common oblique inguinal hernia. The intestine in a distinct sac of peritoneum, and separated from the testicle by the tunica vaginalis.

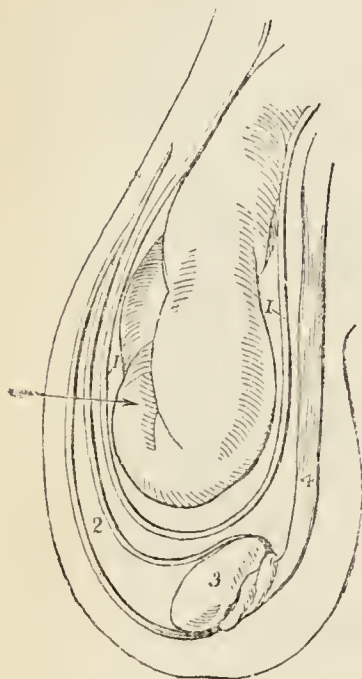
Nos. 1, 1. The sac of the hernia. 2. The tunica vaginalis enclosing the testicle, 3. 4. The spermatic cord.

† Congenital hernia; the intestine being in contact with the testicle; the tunica vaginalis of the testicle forming the sac of the hernia.

Nos. 1, 1. The tunica vaginalis testis, continuous superiorly with the peritoneum, of which it is a part. 2. The testicle. 3. The spermatic cord.

vaginalis. So that the surgeon, in operating upon this variety, requires to divide three layers of serous membrane;

Fig. 64.*



the first and second layers being those of the tunica vaginalis, and the third the true sac of the hernia.

DIRECT INGUINAL HERNIA has received its name from passing *directly* through the external abdominal ring, and forcing before it the opposing parietes. This portion of the wall of the abdomen is strengthened by the conjoined tendon of the internal oblique and transversalis muscle, which is pressed before the hernia, and forms one of its investments. Its coverings are, the

Integument,
Superficial fascia,
Intercolumnar fascia,
Conjoined tendon,
Transversalis fascia,
Peritoneal sac.

Direct inguinal hernia differs from oblique, firstly, in never attaining the same bulk, in consequence of the resisting nature of the conjoined tendon of the internal oblique and transversalis, and of the transversalis fascia; secondly, in its direction, having a tendency to protrude *from* the middle line, rather than towards it; thirdly, in making for itself a new passage through the abdominal parietes, instead of following a natural channel; and fourthly, in the relation of the neck of its sac to the epigastric artery, that vessel lying to the outer side of the opening of the sac of direct hernia, and to the inner side of that of oblique hernia.

All the forms of inguinal hernia are designated *scrotal*, when they have descended into that cavity.

* Encysted hernia; the hernial sac containing the intestine being behind the tunica vaginalis.

Nos. 1. 1. The hernial sac. 2. The cavity of the tunica vaginalis. 3. The testicle. 4. The spermatic cord. The arrow shows that three layers of serous membrane must be divided before the intestine can be reached.

Oblique inguinal hernia, in its course through the spermatic canal, lies above the spermatic cord. In rare cases the hernial protrusion may separate the components of the cord, so that some of them may lie in front of the tumour: hence one of many reasons for extreme care and caution in operating for strangulated hernia. Direct inguinal hernia often carries the spermatic cord before it, so that the vessels of which it is composed become spread over the front of the hernial sac, or slip to one side.

In operating upon inguinal hernia, the importance of knowing the layers which cover it, and which are to be cut through before reaching the bowel, is obvious; the oblique and direct hernia differ from each other in this respect only in the composition of the fourth layer, the cremaster occupying that place in oblique hernia, and the conjoined tendon in direct. If the oblique inguinal hernia had reached no farther than the spermatic canal, then the aponeurosis of the external oblique muscle would take the place of the intercolumnar fascia. This form of oblique inguinal hernia is termed *bubonocoele*.

The *seat of stricture* is commonly the neck of the sac in all the varieties of inguinal hernia, and the direction of the incision for its liberation should be *directly upwards*, by which means any danger to the epigastric artery is avoided. Sometimes the stricture of oblique inguinal hernia is occasioned by the lower border of the internal oblique muscle, and sometimes by the external abdominal ring. In old and large hernia, the internal ring is dragged down so as to become placed opposite the external, and the two together form the neck of the sac. In direct hernia, the fascia transversalis with the border of the conjoined tendon are the structures forming the neck of the sac.

When the layers of the abdominal parietes concerned in inguinal hernia have been examined, an incision should be made from the umbilicus to the anterior superior spine of the ilium at each side, and the triangular flap included by these incisions turned down. On the surface of this flap will be seen several prominences and depressions which require to be noted.

In the middle line behind the linea alba is a prominence caused by a fibrous cord called *urachus*, which

ascends from the apex of the bladder to the umbilicus; on either side of the middle line, and converging from the sides of the bladder to the urachus in their course to the umbilicus, is another prominence caused by a fibrous cord (umbilical ligament), the remains of the hypogastric artery of the fœtus. This cord, at its lower part, lies in the direction of the epigastric artery, and divides the lower part of the anterior wall of the abdomen into two fossæ, which correspond with the seat of protrusion of the oblique and direct inguinal hernia; the former passing through the outer fossa, and the latter through the inner, between the epigastric artery and the edge of the rectus.

CAVITY OF THE ABDOMEN.

The cavity of the abdomen may now be laid open by means of an incision made parallel with, but a little to the left of, the linea alba from the ensiform cartilage to the umbilicus, and another on each side from the umbilicus to the last rib. The flaps included by these incisions should then be turned back.

The cavity of the abdomen is bounded *in front* and *at the sides* by the lower ribs and abdominal muscles; *behind*, by the vertebral column and abdominal muscles; *above*, by the diaphragm; and, *below*, by the pelvis; and contains, the alimentary canal, the organs subservient to digestion, viz. the liver, pancreas, and spleen; and the organs of excretion, the kidneys, with the supra-renal capsules.

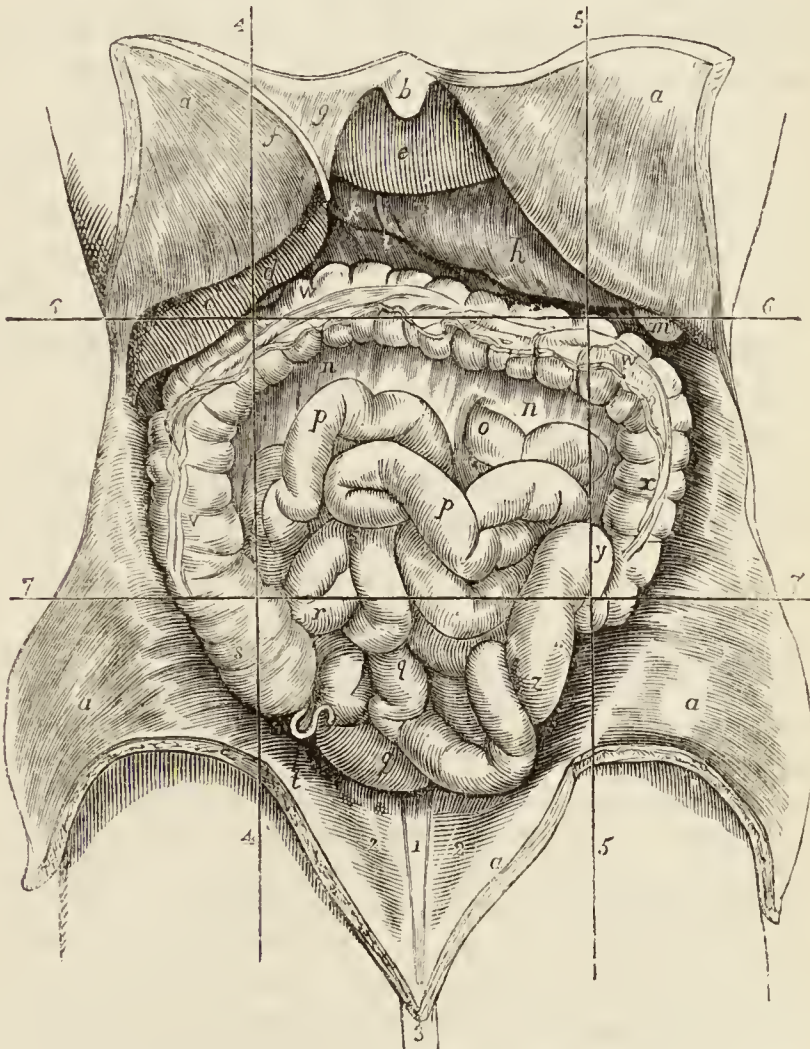
Regions. — For convenience of description of the viscera, and of reference to the morbid affections of this cavity, the abdomen is divided into certain districts or regions. Thus, if two transverse lines be carried around the body, the one parallel with the cartilage of the eighth rib, the other with the highest point of the crests of the ilia, the abdomen will be divided into three zones. Again, if a perpendicular line be drawn, at each side, from the cartilage of the eighth rib to the middle of Poupart's ligament, the three primary zones will each be subdivided into three compartments or regions, a middle and two lateral.

The middle region of the upper zone being immediately over the small end of the stomach, is called *epigastric* (ἐπί γαστήρ, over the stomach). The two lateral regions, being under the cartilages of the ribs, are called *hypochondriac* (ὑπὸ χόνδροι, under the cartilages). The

middle region of the middle zone is the *umbilical*; the two lateral, the *lumbar*. The middle region of the inferior zone is the *hypogastric* (ὕπὸ γαστήρ , below the stomach); and the two lateral, the *iliac*. In addition to these divisions, we employ the term *inguinal region*, in reference to the vicinity of Poupart's ligament.

Position of the Viscera.—In the *upper zone* will be seen the liver, extending across from the right to the left side; the stomach and spleen on the left, and the pancreas and duodenum behind. In the *middle zone* is the transverse portion of the colon, with the upper part of the ascending and descending colon, omentum, small

Fig. 65.*



* Cavity and viscera of the abdomen.—*a, a.* Flaps of the abdominal parietes turned back. *b.* The ensiform cartilage. *c.* The right lobe of the liver. *d.* The fundus of the gall-bladder. *e.* The left lobe of the liver. *f.* The round ligament of the liver. *g.* The broad ligament of the liver. *h.* The stomach. *i.* The pylorus.

intestines, mesentery; and, behind, the kidneys and supra-renal capsules. In the *inferior zone* is the lower part of the omentum and small intestines, the cæcum, ascending and descending colon, with the sigmoid flexure, and ureters.

The smooth and polished surface which the viscera and parietes of the abdomen present, is due to the peritoneum.

PERITONEUM. — The peritoneum (*περιτείνειν*, to extend around) is a serous membrane, and therefore a shut sac: a single exception exists in the human subject to this character, namely, in the female, where the peritoneum is perforated by the open extremities of the Fallopian tubes, and is continuous with their mucous lining.

The simplest idea that can be given of a serous membrane which may apply equally to all, is, that it invests the viscus or viscera, and is then reflected upon the parietes of the containing cavity. If the cavity contain only a single viscus, the consideration of the serous membrane is extremely simple. But in the abdomen, where there are a number of viscera, the serous membrane passes from one to the other until it has invested the whole, before it is reflected on the parietes. Hence its reflections are a little more complicated.

In tracing the reflections of the peritoneum in the middle line, we commence with the diaphragm, which is

k. The first portion of the duodenum. *m.* The spleen. *n, n.* The transverse meso-colon. *o.* The jejunum, commencing at the under surface of the transverse meso-colon near the vertebral column. *p, p.* Jejunum. *q, q.* Ileum. *r.* The ileum near its termination in *s*, the cæcum. *t.* The appendix vermiformis cæci. *v.* The ascending colon. *w.* The transverse colon. The cut edge of the omentum is seen on this portion of the intestine. *x.* The descending colon. *y.* The sigmoid flexure of the colon. *z.* Its lower part, just before it becomes the rectum. 1. The prominence caused by the urachus. 2, 2. The prominences caused by the umbilical ligaments of the bladder, the remains of the hypogastric arteries. 3. The umbilicus. 4, 5, 6, 7 are lines which mark the division of the abdomen into regions; *e* is placed in the epigastric region; *c*, in the right hypochondriac region; the left hypochondriac region is the space between 5 and 6. *n, o, p* are situated in the umbilical region; *v* in the right lumbar region; and *x* in the left. *q* is situated in the hypogastric region; *s* in the right iliac region; while the lines 7 and 5 mark the left iliac region.

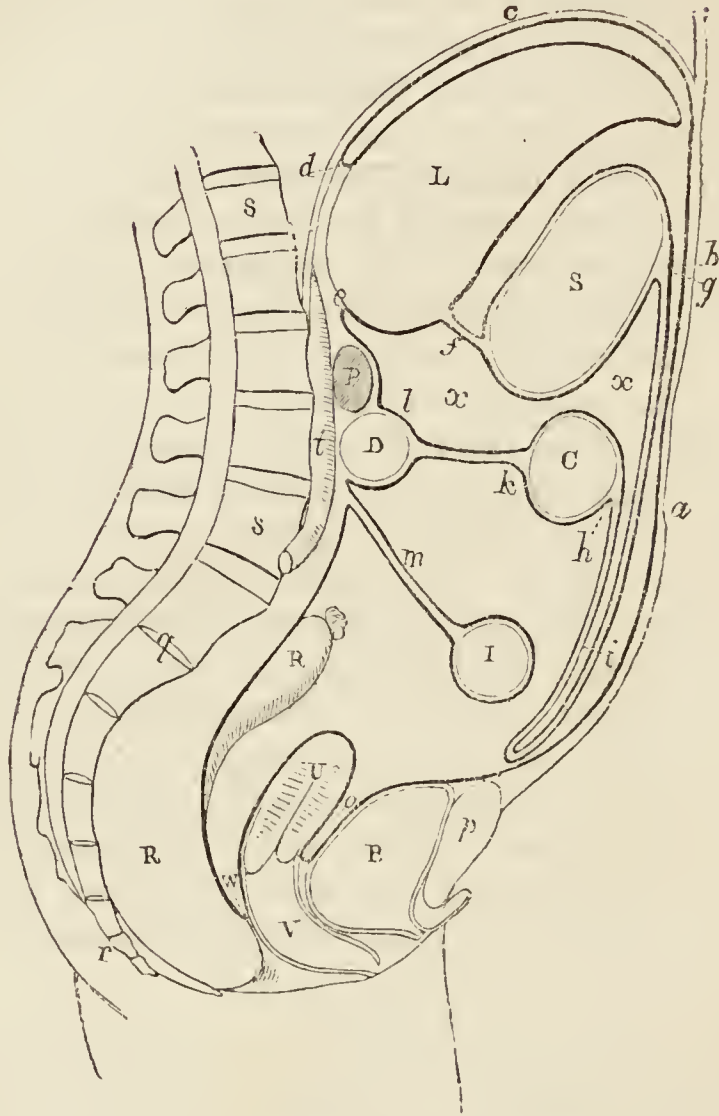
lined by two layers, one from the parietes in front, *anterior*, and one from the parietes behind, *posterior*. These two layers of the same membrane, at the posterior part of the diaphragm, descend to the upper surface of the liver, forming the *coronary* and *lateral ligaments* of the liver. They then surround the liver, one going in front, the other behind that viscus, and, meeting at its under surface, pass to the stomach, forming the *lesser omentum*. They then, in the same manner, surround the stomach, and, meeting at its lower border, descend for some distance in front of the intestines, and return to the transverse colon, forming the *great omentum*; they then surround the transverse colon, and pass directly backwards to the vertebral column, forming the transverse *meso-colon*. Here the two layers separate; the *posterior* ascends in front of the pancreas and aorta, and returns to the posterior part of the diaphragm, where it becomes the posterior layer with which we commenced. The *anterior* descends, invests all the small intestines, and returning to the vertebral column, forms the *mesentery*. It then descends into the pelvis in front of the rectum, which it holds in its place by means of a fold called *meso-rectum*, forms a pouch, the *recto-vesical fold*, between the rectum and bladder, ascends upon the posterior surface of the bladder, forming its false ligaments, and returns upon the anterior parietes of the abdomen to the diaphragm, whence we first traced it.

In the female, after descending into the pelvis in front of the rectum, it is reflected upon the posterior surface of the vagina and uterus. It then descends on the anterior surface of the uterus, and forms at either side the broad ligaments of that organ. From the uterus it ascends upon the posterior surface of the bladder and anterior parietes of the abdomen, and is continued, as in the male, to the diaphragm.

In this way the continuity of the peritoneum, as a whole, is distinctly shown, and it matters not where the examination commence or where it terminate, still the same continuity of surface will be discernible throughout. If we trace it from side to side of the abdomen, we may commence at the umbilicus; we then follow it outwards, lining the inner side of the parietes, to the ascending colon; it surrounds that intestine; it then surrounds the

small intestine, and, returning on itself, forms the mesentery. It then invests the descending colon, and

*Fig. 66.**



* Reflections of the peritoneum; the dark line represents the peritoneum, and the Roman capitals the viscera which it envelopes. Starting from the umbilicus *a*, the peritoneum may be traced upwards on the abdominal parietes *b*, along the diaphragm *c*, to the point *d*, whence it descends to the liver *L*. The liver at *d* is in contact with the diaphragm, and the extension of the peritoneum *d, e* from the walls of the abdomen to the liver constitutes its ligaments. The peritoneum *d, e* is now to be traced around the liver to the under part of the liver at *f*, and thence to the stomach *S*. *f* is the gastro-hepatic or lesser omentum. Inclosing the stomach the two layers meet along the greater curve of the stomach at *g*, and descend together in front of the abdominal viscera into the abdomen. The two layers then return upon themselves to the point where they embrace the transverse colon *C*. The two layers

reaches the parietes on the opposite side of the abdomen, whence it may be traced to the exact point from which we started.

The viscera which are thus shown to be invested by the peritoneum in its course downwards are the —

Liver,	Small intestines,
Stomach,	Pelvic viscera.
Transverse colon,	

The folds, formed between these and between the diaphragm and the liver, are —

(Diaphragm.)

Broad, coronary, and lateral ligaments.

(Liver.)

Lesser omentum.

(Stomach.)

Greater omentum.

(Transverse colon.)

Transverse meso-colon.

Mesentery,

Meso-rectum,

Recto-vesical fold,

False ligaments of the bladder.

from *g* to *h*, are the gastro-colic or great omentum, which, examined at *i*, necessarily consists of four layers of membrane. Having surrounded the colon, the two layers meet at *k*, and passing backwards towards the vertebral column separate to embrace the transverse portion of the duodenum, *D*. *k* is the transverse meso-colon; the upper of its two layers ascends in front of the pancreas *P*, and is continuous with the membrane at *e*, whence one layer of the description commenced. The lower layer of the meso-colon *k*, having reached the vertebral column, advances forward and surrounds the small intestines *I*, and returns to the vertebral column, forming the fold *m*, which is the mesentery. It then descends upon the rectum *R*, into the pelvis, then over the uterus *U*, next over the bladder *B*, and thence upwards upon the abdominal parietes to the point *a*, where the description commenced. *n* is the recto-vaginal fold of the peritoneum; *V* being the vagina. *o* is the utero-vesical fold. *p*. The symphysis pubis. *q*. The sacrum. *r*. The coccyx. *s, s*. The five lumbar vertebræ. *t*. The aorta. *x, x*. The lesser cavity of the peritoneum, which communicates with the greater cavity at the foramen of Winslow.

And in the female, the —

Broad ligaments of the uterus.

The ligaments of the liver will be described with that organ.

The *lesser omentum* (gastro-hepatic) is the duplicature which passes between the liver and the upper border of the stomach. It is extremely thin, excepting at its right border, where it is free, and contains between its layers, the —

Hepatic artery,
Ductus communis choledochus,
Lymphatics,
Portal vein,
Hepatic plexus of nerves.

These structures are inclosed in a loose cellular tissue, called *Glisson's capsule*. The relative position of the three vessels is, the artery to the left, the duct to the right, and the vein between and behind.

If the finger be introduced behind this right border of the lesser omentum, it will be situated in an opening called the *foramen of Winslow*. In *front* of the finger will lie the right border of the lesser omentum; *behind* it the diaphragm, covered by the ascending or posterior layer of the peritoneum; *below*, the hepatic artery, curving forwards from the cæliac axis; and *above*, the lobus Spigelii. These, therefore, are the *boundaries of the foramen of Winslow*, which is nothing more than a constriction of the general cavity of the peritoneum at this point, arising out of the necessity for the hepatic and gastric arteries to pass forwards from the cæliac axis to reach their respective viscera.

If air be blown through the foramen of Winslow, it will descend behind the lesser omentum and stomach to the space between the descending and ascending pair of layers, forming the great omentum. This is sometimes called the lesser cavity of the peritoneum, and that external to the foramen the greater cavity; in which case the foramen is considered as the means of communication between the two. There is a great objection to this division, as it might lead the inexperienced to believe that there were really two cavities. There is but one only, the foramen of Winslow being merely a constrict-

tion of that one, to facilitate the communication between the nutrient arteries and the viscera of the upper part of the abdomen.

The *great omentum* (gastro-colic) consists of *four layers of peritoneum*, the two which descend from the stomach, and the same two, returning upon themselves to the transverse colon. A quantity of adipose substance is deposited around the vessels which ramify through its structure. It would appear to perform a double function in the economy: 1st. Protecting the intestines from cold; and, 2ndly, Facilitating the movement of the intestines upon each other during their vermicular action.

The *transverse meso-colon* (μέσος, middle, being attached to the middle of the cylinder of the intestine) is the medium of connection between the transverse colon and the posterior wall of the abdomen. It affords to the nutrient arteries a passage to reach the intestine, and incloses between its layers, at the posterior part, the transverse portion of the duodenum. It also forms a transverse septum across the abdominal cavity.

The *mesentery* (μέσον έντερον, being connected to the middle of the cylinder of the small intestine) is the medium of connection between the small intestines and the posterior wall of the abdomen. It is oblique in its direction, being attached to the posterior wall, from the left side of the second lumbar vertebra to the right iliac fossa. It retains the small intestines in their places, and gives passage to the mesenteric arteries, veins, nerves, and lymphatics.

The *meso-rectum*, in like manner, retains the rectum in connection with the front of the sacrum. Besides this, there are some minor folds in the pelvis, as the *recto-vesical* fold, the *false ligaments of the bladder*, and the *broad ligaments of the uterus*.

The *appendices epiploicæ* are small irregular pouches of the peritoneum, filled with fat, and situated like fringes upon the large intestine.

Three other duplicatures of the peritoneum are situated in the sides of the abdomen; they are, the *gastro-phrenic* ligament, the *gastro-splenic omentum*, the *ascending and descending meso-colon*. The *gastro-phrenic ligament* is a small duplicature of the peritoneum, which descends from the diaphragm to the extremity of the œsophagus

and lesser curve of the stomach. The *gastro-splenic omentum* is the duplicature which connects the spleen to the stomach. The *ascending meso-colon* is the fold which connects the upper part of the ascending colon with the posterior wall of the abdomen; and the *descending meso-colon*, that which retains the sigmoid flexure in connection with the abdominal wall.

ALIMENTARY CANAL.

The alimentary canal is a musculo-membranous tube, extending from the mouth to the anus. It is variously named in the different parts of its course, as, for example, in its upper part, mouth, pharynx, œsophagus; the remaining part is situated within the abdomen, and consists of the stomach, the small intestine, and large intestine. The small intestine is subdivided into three portions, duodenum, jejunum, and ileum; and the large intestine also into three, cæcum, colon, and rectum.

THE STOMACH.

The stomach is an expansion of the alimentary canal, situated in the left hypochondriac and epigastric region, and, for a small extent, in the right hypochondriac region. It is directed somewhat obliquely from above downwards, from left to right, and from behind forwards; and in the female, where the injurious system of tight-lacing has been pursued, is longer than in the male. On account of the peculiarity of its form, it is divided into a *greater* or *splenic*, and a *lesser* or *pyloric*, end; a *lesser curvature* above, and a *greater curvature* below; an *anterior* and a *posterior surface*; a *cardiac orifice*, and a *pyloric orifice*. The great end (fundus) is not only of large size, but expands beyond the point of entrance of the œsophagus, and is embraced by the concave surface of the spleen. The pylorus is the small and contracted extremity of the organ; it is situated on a plane anterior and inferior to the cardiac orifice, and lies in contact with the under surface of the liver, often reaching to the gall-bladder. Near the lesser end of the stomach is a small dilatation, called by Willis the antrum of the pylorus. The two curvatures give attachment to the peritoneum; the upper curve to the lesser omentum, and

the lower to the greater omentum. The anterior surface looks upwards and forwards, and is in relation with the diaphragm (which separates it from the viscera of the thorax, and from the six lower ribs), with the left lobe of the liver; and, in the epigastric region, with the abdominal parietes. The posterior surface looks downwards and backwards, and is in relation with the diaphragm, the pancreas, the third portion of the duodenum, the transverse meso-colon, the left kidney, and left suprarenal capsule; this surface forms the anterior boundary of that cul-de-sac of the peritoneum which is situated behind the lesser omentum, and extends into the greater omentum. In a state of distension, as after a meal, the anterior surface becomes superior, and the greater curvature is directed forwards against the abdominal parietes.

SMALL INTESTINES.

The small intestine is about twenty or twenty-five feet in length, and is divisible into three portions, *duodenum*, *jejunum*, and *ileum*.

The *duodenum* (called *δωδεκαδάκτυλον* by Herophilus) is somewhat larger than the rest of the small intestines, and has received its name from being about equal in length to the breadth of twelve fingers (eight or ten inches). Commencing at the pylorus, it ascends *obliquely* backwards to the under surface of the liver; it next descends *perpendicularly* in front of the right kidney, and then passes nearly *transversely* across the third lumbar vertebra; terminating in the jejunum on the left side of the second lumbar vertebra, where it is crossed by the superior mesenteric artery and vein. The *first* or *oblique portion* of its course, between two and three inches in length, is completely inclosed by the peritoneum; it is in relation, *above*, with the liver and neck of the gall-bladder; *in front*, with the great omentum and abdominal parietes; and *behind*, with the right border of the lesser omentum and its vessels. The *second* or *perpendicular portion* is situated altogether behind the peritoneum; it is in relation, by its *anterior surface*, with the commencement of the arch of the colon; by its *posterior surface*, with the concave margin of the right kidney, the inferior vena cava, and ductus communis choledochus; by its *right border*, with the ascending colon; and by its *left border*,

with the pancreas. The ductus communis choledochus and pancreatic duct open into the internal and posterior side of the perpendicular portion, a little below its middle. The *third* or *transverse portion* of the duodenum lies between the diverging layers of the transverse meso-colon, with which and with the stomach it is in relation *in front*; *above*, it is in contact with the lower border of the pancreas, the superior mesenteric artery and vein being interposed; and, *behind*, it rests upon the inferior vena cava and aorta.

The *jejunum* (jejunus, empty) is named from being generally found empty. It forms the upper two-fifths of the small intestine; commencing at the duodenum on the left side of the second lumbar vertebra, and terminating in the ileum. It is thicker to the touch than the rest of the intestine, and has a pinkish tinge from containing more mucous membrane than the ileum.

The *ileum* (ἔϊλειν, to twist, to convolute) includes the remaining three-fifths of the small intestine. It is somewhat smaller in calibre, thinner in texture, and paler than the jejunum; but there is no mark by which to distinguish the termination of the one, or the commencement of the other. It terminates in the right iliac fossa, by opening at an obtuse angle into the colon.

The jejunum and ileum are surrounded, above and at the sides, by the colon; in front, they are in relation with the omentum and abdominal parietes; they are retained in their position by the mesentery, which connects them with the posterior wall of the abdomen; and below they descend into the cavity of the pelvis. At about the lower third of the ileum a pouch-like process or diverticulum of the intestine is occasionally seen. This is a vestige of embryonic structure, and is formed by the obliteration of the vitelline duct at a short distance from the cylinder of the intestine.

LARGE INTESTINE.

The large intestine, about five feet in length, is sacculated in appearance, and is divided into the *cæcum*, *colon*, and *rectum*.

The *cæcum* (cæcus, blind) is the blind pouch, or cul-de-sac, at the commencement of the large intestine. It is situated in the right iliac fossa, and is retained in its

place by the peritoneum which passes over its anterior surface; its posterior surface is connected by loose cellular tissue with the iliac fascia. Attached to its extremity is the appendix vermiformis, a long worm-shaped tube, the rudiment of the lengthened cæcum found in all mammiferous animals except man and the higher quadrumana. The appendix varies in length from one to five or six inches; it is about equal in diameter to a goose-quill, and is connected with the posterior and left aspect of the cæcum, near the extremity of the ileum. It is usually more or less coiled upon itself, and retained in that coil by a falciform duplicature of peritoneum. Its canal is extremely small, and the orifice by which it opens into the cæcum not unfrequently provided with an incomplete valve. Occasionally the peritoneum invests the cæcum so completely as to constitute a meso-cæcum, which permits of an unusual degree of movement in this portion of the intestine, and serves to explain the occurrence of hernia of the cæcum upon the right side. The cæcum is the most dilated portion of the large intestine.

The *colon* is divided into *ascending*, *transverse*, and *descending*. The *ascending colon* passes upwards from the right iliac fossa, through the right lumbar region, to the under surface of the liver. It then bends inwards (hepatic flexure), and crosses the upper part of the umbilical region, under the name of *transverse colon*; and, on the left side (splenic flexure), descends (*descending colon*) through the left lumbar region to the left iliac fossa, where it makes a remarkable curve upon itself, which is called the *sigmoid flexure*.

The *ascending colon*, the most dilated portion of the large intestine, next to the cæcum, is retained in its position in the abdomen either by the peritoneum passing simply in front of it, or by a narrow meso-colon. It is in relation, *in front*, with the small intestine and abdominal parietes; *behind*, with the quadratus lumborum muscle and right kidney; *internally*, with the small intestine and the perpendicular portion of the duodenum; and, by its *upper extremity*, with the under surface of the liver and gall-bladder. The *transverse colon*, the longest portion of the large intestine, forms a curve across the cavity of the abdomen, the convexity of which looks forwards and sometimes downwards. It is in rela-

tion, by its *upper surface*, with the liver, gall-bladder, stomach, and lower extremity of the spleen; by its *lower surface*, with the small intestine; by its *anterior surface*, with the anterior layers of the great omentum and the abdominal parietes; and, by its *posterior surface*, with the transverse meso-colon. The *descending colon* is smaller in calibre, and is situated more deeply than the ascending colon: its relations are precisely similar. The *sigmoid flexure* is the narrowest part of the colon; it curves in the first place upwards and then downwards, and to one or the other side, and is retained in its place by a meso-colon. It is in relation, *in front*, with the small intestine and abdominal parietes; *behind*, with the iliac fossa; and, on either *side*, with the small intestine.

The *rectum*, the termination of the large intestine, is seven or eight inches in length. It has received its name, not so much from the direction of its course, as from the straightness of its form in comparison with the colon. It descends, from opposite the left sacro-iliac symphysis, in front of the sacrum, forming a gentle curve to the right side, and then returning to the middle line; opposite the extremity of the coccyx it curves backwards to terminate at the anus at about an inch in front of the apex of that bone. The rectum, therefore, forms a double flexure in its course, the one being directed from side to side, the other from before backwards. It is smaller in calibre at its upper part than the sigmoid flexure, but becomes gradually larger as it descends, and at its lower extremity, previously to its termination at the anus, forms a dilatation of considerable but variable magnitude.

With reference to its relations, the rectum is divided into three portions; the *first*, including half its length, extends to about the middle of the sacrum, is completely surrounded by peritoneum, and connected to the sacrum by means of the meso-rectum. It is in relation, above, with the left sacro-iliac symphysis; and, below, with the branches of the internal iliac artery, sacral plexus of nerves, and left ureter; one or two convolutions of the small intestine are interposed between the front of the rectum and the bladder, in the male; and between the rectum and the uterus with its appendages in the female. The *second portion*, about three inches in length, is closely attached to the surface of the sacrum, and

covered by peritoneum only in front ; it is in relation by its lower part with the base of the bladder, vesiculæ seminales, and prostate gland, and in the female with the vagina. The *third portion* curves backwards from opposite the prostate gland and tip of the coccyx, to terminate at the anus ; it is embraced by the levatores ani, and is about one inch and a half in length. It is separated from the membranous portion of the urethra by a triangular space ; in the female this space intervenes between the vagina and the rectum, and constitutes by its base the perineum.

The *anus* is situated at a little more than an inch in front of the extremity of the coccyx. The integument around it is covered with hairs, and is thrown into numerous radiated plaits, which are obliterated during the passage of fæces. The margin of the anus is provided with an abundance of sebiparous glands, and the epiderma may be seen terminating by a fringed and scalloped border at a few lines above the extremity of the opening.

Structure. — The alimentary canal within the abdomen possesses four coats ; serous, muscular, cellular, and mucous.

The *serous coat* is derived from the peritoneum. The stomach is completely surrounded by peritoneum, excepting along the line of attachment of the great and lesser omentum. The *first or oblique portion of the duodenum* is also completely included by the serous membrane, with the exception of the points of attachment of the omenta. The *descending portion* has merely a partial covering on its anterior surface. The *transverse portion* is also behind the peritoneum, being situated between the two layers of the transverse meso-colon, and has but a partial covering. The rest of the *small intestine* is completely invested by it, excepting along the concave border to which the mesentery is attached. The *cæcum* is more or less invested by the peritoneum, the more frequent disposition being that in which the intestine is surrounded for three-fourths only of its circumference. The *ascending* and the *descending colon* are covered by the serous membrane only in front. The *transverse colon* is invested completely, with the exception of the lines of attachment of the greater omentum and transverse meso-colon. And the *sigmoid flexure* is entirely surrounded, with the exception of the part corresponding with the junction of the left meso-colon. The upper third of the rectum is completely inclosed by the peritoneum ; the middle third has an anterior covering only, and the inferior third none whatsoever.

The *muscular coat* is composed of two planes of fibres, an external *longitudinal* and an internal *circular*.

On the *stomach* the longitudinal fibres are most apparent along the lesser curve, and the circular at the smaller end. At the

pylorus the latter are aggregated into a thick circular ring, which, with the spiral fold of mucous membrane found in this situation, constitutes the *pyloric valve*. At the great end of the stomach a new order of fibres is introduced, having for their object to strengthen and compress that extremity of the organ. They are directed more or less horizontally from the great end towards the lesser end, and are generally lost upon the sides of the stomach at about its middle; these are the *oblique fibres*. They are most numerous at the upper part of the cul-de-sac, near the cardiac orifice.

The *small intestine* is provided with both layers of fibres, pretty equally distributed over the entire surface; the longitudinal fibres being best marked along the free border. At the termination of the ileum the circular fibres are continued into the two folds of the ileo-cæcal valve, while the longitudinal fibres pass onwards to the large intestine. In the *large intestine* the longitudinal fibres commence at the appendix vermiformis, and are collected into three bands, an anterior, broad, and two posterior and narrower bands. These bands are nearly one-half shorter than the intestine, and serve to maintain the sacculated structure which is characteristic of the cæcum and colon. In the *descending colon* the posterior bands usually unite and form a single band. From this point the bands are continued downwards upon the sigmoid flexure to the rectum, around which they spread out and form a thick and very muscular longitudinal layer. The circular fibres in the cæcum and colon are exceedingly thin; in the rectum they are thicker, and near its lower extremity they are aggregated into the thick muscular band which is known as the internal sphincter ani. Between the latter and the mucous membrane are several narrow fasciculi of longitudinal muscular fibres, somewhat more than an inch in length, which have been described by Horner of Philadelphia.

The *cellular coat* (submucous, nervous) is a moderately thick stratum of fibro-cellular tissue which serves as the bond of connexion between the muscular and mucous coat. It gives support to the mucous membrane and affords a nidus to the vessels and nerves previously to their distribution to that membrane. It is firmly adherent to the mucous layer, but more loosely to the muscular coat.

The *mucous coat* in the stomach is thin at the great extremity, and thicker towards the pyloric extremity. It is of a pinkish colour, the depth of colour being greater in infancy than in the adult, and less in old age; and being increased under the excitement of digestion. It is, moreover, formed into plaits or *rugæ*, which are disposed for the most part in a longitudinal direction. The *rugæ* are most numerous towards the lesser end of the stomach; while around the cardiac orifice they assume a radiated arrangement. At the pylorus the mucous membrane forms a circular or spiral fold which constitutes a part of the apparatus of the *pyloric valve*. In the lower half of the duodenum, the whole length of the jejunum, and the upper part of the ileum, it forms valvular folds called *valvula conniventes*, which are several lines in breadth in the lower part of the duodenum and upper portion of the jejunum, and dimi-

nish gradually in size towards each extremity. These folds do not entirely surround the cylinder of the intestine, but extend for about one half or three-fourths of its circumference. In the lower half of the ileum the mucous lining is without folds; hence the thinness of the coats of this intestine as compared with the jejunum and duodenum. At the termination of the ileum in the cæcum, the mucous membrane forms two folds, which are strengthened by the muscular coat, and project into the cæcum. These are the *ileo-cæcal valve* (valvula Bauhini). In the cæcum and colon the mucous membrane is raised into crescentic folds, which correspond with the sharp edges of the sacculi; and, in the rectum, it forms three valvular folds*, one of which is situated near the commencement of the intestine; the second, extending from the side of the tube, is placed opposite the middle of the sacrum; and the third, which is the largest and most constant, projects from the anterior wall of the intestine opposite the base of the bladder. Besides these folds, the membrane in the empty state of the intestine is thrown into longitudinal plaits, somewhat similar to those of the œsophagus; these have been named the *columns* of the rectum. The mucous membrane of the rectum is connected to the muscular coat by a very loose cellular tissue, as in the œsophagus.

Structure of Mucous Membrane. — Mucous membrane is analogous to the cutaneous covering of the exterior of the body, and resembles that tissue very closely in its structure. It is composed of two layers, *epithelium* and *corium*.

The *epithelium* is the epiderma of the mucous membrane. Throughout the pharynx and œsophagus it resembles the epiderma, both in appearance and character. It is continuous with the epiderma of the skin at the margin of the lips, and terminates by an irregular border at the cardiac orifice of the stomach. At the opposite extremity of the canal it terminates by a scalloped border just within the verge of the anus. In the mouth it is composed of laminae of cytoblasts, cells, and polyhedral scales. Each cell and each scale possesses a central nucleus, and within the nucleus are one or more nucleus-corpuseles. According to Mr. Nasmyth†, the deepest lamina of the epithelium appears to consist of nuclei (cytoblasts) only; in the next the investing vesicle or cell is developed; the cells by degrees enlarge and become flattened, and in the superficial laminae are converted into thin scales. The nuclei, the cells, and the scales are connected together by a glutinous fluid of the consistence of jelly, which contains an abundance of minute opaque granules. The scales of the superficial layer overlap each other by their margins. During the natural functions of the mucous membrane the superficial scales exfoliate continually and give place to

* Mr. Houston, "On the Mucous Membrane of the Rectum." Dublin Hospital Reports, vol. v.

† "Investigations into the Structure of the Epithelium," presented to the medical section of the British Medical Association, in 1839, published in a work entitled "Three Memoirs on the Development of the Teeth and Epithelium," 1841.

the deeper layers. In the upper part of the pharynx near the posterior nares, and around the apertures of the Eustachian tubes, the epithelium is ciliated; in the pharynx and œsophagus it is squamous, and in the latter remarkable for its thickness. In the stomach and intestines the epithelial bodies are pyriform in shape, and have a columnar arrangement, the apices being applied to the papillary surface of the membrane, and the bases forming, by their approximation, the free intestinal surface. Each column is provided with a central nucleus and nucleus-corpuscle, which gives its middle a swollen appearance; and, from the transparency of its structure, the nucleus may be seen through the base of the column, when examined from the surface. Around the circular villi, the columns, from being placed perpendicularly to the surface, have a radiated arrangement. The columnar epithelium is produced, in the same manner with the laminated epithelium, in cytoblasts, cells, and columns, and the latter are continually thrown off to give place to successive layers.

The *corium* is analogous to the corium of the skin, and, like it, is the formative structure by which the epithelium is produced. Its surface presents several varieties of appearance when examined in different parts of its extent. In the stomach it forms minute polyhedral cells (*alveoli*), into the floor of which the gastric follicles open, and upon their margins at the pyloric end of the stomach are numerous small flat villi. In the small intestine it presents numerous minute, projecting papillæ, called villi. The villi are of two kinds, *cylindrical* and *laminated*, and so abundant, as to give to the entire surface a beautiful velvety appearance.* In the large intestine the surface is composed of a fine network of minute polyhedral cells, more numerous and minute than those of the stomach. The deeper layer of the corium is a cellulo-fibrous structure, in which the vessels and nerves ramify previously to their termination in the superficial layer.

Glands. — In the loose cellular tissue connecting the mucous with the fibrous layer, are situated the glands and follicles belonging to the mucous membrane: these are the —

- Gastric follicles,
- Duodenal glands (Brunner's),
- Glandulæ solitariae,
- Glandulæ aggregatae (Peyer's),
- Simple follicles (Lieberkühn's).

The *gastric follicles* are long tubular follicular glands, situated perpendicularly side by side in every part of the mucous membrane of the stomach. At their terminations they are dilated into small lateral pouches, which give them a clustered appearance. This character is more clearly exhibited at the pyloric than at the cardiac

* Krause estimates the number of villi in a square line in the upper part of the small intestine at fifty to ninety; and lower down, forty to seventy; the total for the whole length of the intestine being four millions.

end of the stomach. They are intended, very probably, for the secretion of the gastric fluid.

The *duodenal*, or *Brunner's glands*, are small flattened granular bodies, compared collectively by Von Brunn to a second pancreas. They resemble in structure the small salivary glands, so abundant beneath the mucous membrane of the mouth and lips; and, like them, they open upon the surface by minute excretory ducts. They are limited to the duodenum and commencement of the jejunum.

The *solitary glands* are of two kinds, those of the small and those of the large intestine. The former are small circular whitish and slightly prominent patches, surrounded by a zone or wreath of simple follicles. When opened, they are seen to consist of a small flattened saccular cavity, containing a mucous secretion, but having no excretory duct. They are found in all parts of the small intestines.

The solitary glands of the large intestine are most abundant in the cæcum and appendix cæci; they are small circular prominences, flattened upon the surface, and perforated in the centre by a minute excretory opening.

The *aggregate*, or *Peyer's glands*, are situated in the lower part of the jejunum and in the ileum, but chiefly in the lower part of the latter. They are collected into patches, which are small and circular, and few in number, in the upper part of the bowel, and large and oblong or oval below, and occupy that portion of the intestine which is opposite the attachment of the mesentery. To the naked eye they present the appearance of pale disks, covered with small irregular fissures; but with the aid of the microscope they are seen to be composed of numerous small circular patches, surrounded by simple follicles, like the solitary glands of the small intestine. Each patch corresponds with a flattened and closed sac, situated beneath the membrane, but having no excretory opening, and containing a small quantity of a whitish pulp. The interspace between the patches is occupied by villi.

The *Simple follicles*, or crypts of Lieberkühn, are small cæcal pouches of the mucous layer, dispersed in immense numbers over every part of the mucous membrane, and opening on the surface by round apertures. In the large intestine, they are longer and more numerous than in the small.

Vessels and Nerves.—The *arteries* of the abdominal portion of the alimentary canal form a chain of communications along the tube, which is continued upwards to the pharynx and mouth; they are, the gastric, hepatic, splenic, superior mesenteric and inferior mesenteric. The *veins* unite to form the vena portæ. The *lymphatics* and lacteals open into the thoracic duct.

The *nerves* of the stomach are the pneumo-gastric, and sympathetic branches from the solar plexus; those of the intestinal canal are the superior and inferior mesen-

teric, and hypogastric plexuses. The extremity of the rectum is supplied by the inferior sacral nerves from the spinal cord.

Dissection.—The student should now raise the transverse colon, and pin it upwards upon the chest. He should then draw the whole of the small intestines over to the left side. Then let him dissect the peritoneal layer from the middle line, opposite the third lumbar vertebra, and he will expose the superior mesenteric artery, and by its side the superior mesenteric vein. The branches of the artery should be carefully cleared of fat and cellular tissue. In the progress of the dissection nervous filaments, lacteals, and lymphatic glands will be exposed.

The SUPERIOR MESENTERIC ARTERY, the second of the single trunks given off by the abdominal aorta, and next in size to the cæliac axis, arises from the aorta immediately below the latter vessel, and behind the pancreas. It passes forwards between the pancreas and transverse duodenum, and descends within the layers of the mesentery, to the right iliac fossa, where it terminates, very much diminished in size. It forms a curve in its course, the convexity being directed towards the left, and the concavity to the right. It is in relation near its commencement with the portal vein; and is accompanied by two veins, and the superior mesenteric plexus of nerves.

The *branches* of the superior mesenteric artery are —

Vasa intestini tenuis,	Colica dextra,
Ileo-colica,	Colica media.

The *vasa intestini tenuis* arise from the convexity of the superior mesenteric artery. They vary from fifteen to twenty in number, and are distributed to the small intestine, from the duodenum to the termination of the ileum. In their course between the layers of the mesentery, they form a series of arches by the inosculation of their larger branches; from these are developed secondary arches, and from the latter a third series of arches, from which the branches arise which are distributed to the coats of the intestine. From the middle branches a fourth, and sometimes even a fifth series of arches is produced. By means of these arches a direct communication is established between all the branches given off from the convexity of the superior mesenteric artery; a superior branch (*inferior pancreatico-duodenalis*) supplies the pancreas and duodenum, and inosculates with

the pancreatico-duodenalis, and the inferior unites with the ileo-colica.

The *ileo-colic artery* is the last branch given off from the concavity of the superior mesenteric. It descends to the right iliac fossa, and divides into branches which communicate and form arches, from which branches are distributed to the termination of the ileum, the cæcum, and the commencement of the colon. This artery inosculates on the one hand with the termination of the mesenteric trunk, and on the other with the colica dextra.

The *colica dextra* arises from about the middle of the concavity of the superior mesenteric, and passing outwards behind the peritoneum, divides into branches which form arches, and are distributed to the ascending colon. Its descending branches inosculate with the ileo-colica, and the ascending with the colica media.

The *colica media* arises from the upper part of the concavity of the superior mesenteric, and passes forward between the layers of the transverse mesocolon, where it forms arches, and is distributed to the transverse colon. It inosculates on the right with the colica dextra; and on the left with the colica sinistra, a branch of the inferior mesenteric artery.

The SUPERIOR MESENTERIC VEIN is formed by branches which collect the venous blood from the capillaries of the superior mesenteric artery; they constitute, by their junction, a large trunk, which ascends by the side of the artery, crosses the transverse portion of the duodenum, and unites behind the pancreas with the splenic in the formation of the portal vein.

The LYMPHATIC VESSELS and GLANDS of the small intestine are situated between the layers of the mesentery. The glands occupy the meshes of the branches of the artery, and are named *mesenteric glands*. They are most numerous and largest superiorly, near the duodenum; and inferiorly, near the termination of the ileum. The lymphatic vessels are of two kinds: those of the structure of the intestines, which run upon its surface previously to entering the mesenteric glands; and those which commence in the villi, in the substance of the mucous membrane, and are named lacteals.

The *lacteals*, according to Henle, commence in the centre of each villus as a cæcal tubulus, which opens into

a fine network, situated in the submucous tissue. From this areolar network the lacteal vessels proceed to the mesenteric glands, and from thence to the thoracic duct, in which they terminate.

The NERVES of the small intestines are the *mesenteric plexus*.

Dissection. — The small intestines should now be removed by cutting through the mesentery near its intestinal border, and placing a ligature around the jejunum at its commencement, and another around the ileum near its termination. They may then be set aside for the purpose of examining their interior, and the arrangement of the mucous membrane, at a convenient moment. It would be desirable also that the student should inflate a portion of the upper part of the jejunum, and of the lower part of the ileum, that he may observe their appearance when dry. The valvulæ conniventes will thus form a pretty and useful preparation. Then dissect carefully the anterior layer of the left meso-colon; the inferior mesenteric artery, with its branches, will be brought into view.

The INFERIOR MESENTERIC ARTERY, smaller than the superior, arises from the abdominal aorta, about two inches below the origin of that vessel, and descends between the layers of the left meso-colon, to the left iliac fossa, where it divides into three *branches*:

Colica sinistra,	Sigmoid,
Superior hæmorrhoidal.	

The *colica sinistra* is distributed to the descending colon; it passes upwards and outwards behind the peritoneum, and divides into two branches, one of which ascends to inosculate with the colica media, while the other descends to communicate with the sigmoid branch. The inosculature of the colica sinistra with the colica media is the largest arterial anastomosis in the body.

The *sigmoid* artery passes obliquely outwards behind the peritoneum, and divides into branches which form arches, and are distributed to the sigmoid flexure of the colon. The superior branch inosculates with the colica sinistra, the inferior with the superior hæmorrhoidal artery.

The *superior hæmorrhoidal* artery is the continuation of the inferior mesenteric. It crosses the ureter and common iliac artery of the left side, and descends between the two layers of the meso-rectum as far as the middle

of the rectum to which it is distributed, anastomosing with the middle and external hæmorrhoidal arteries.

The INFERIOR MESENTERIC VEIN receives its blood from the rectum by means of the hæmorrhoidal veins, and from the sigmoid flexure and descending colon, and ascends behind the transverse duodenum and pancreas, to terminate in the splenic vein. Its hæmorrhoidal branches inosculate with branches of the internal iliac vein, and thus establish a communication between the portal and general venous system.

The LYMPHATIC GLANDS of the large intestines (mesocolic) are situated along the attached margin of the intestine, in the meshes formed by the colic and hæmorrhoidal arteries previously to their distribution. The *lymphatic vessels* take their course in two different directions; those of the cæcum, ascending and transverse colon, after traversing their proper glands, proceed to the mesenteric; and those of the descending colon and rectum, to the lumbar glands.

The NERVES of the descending colon, sigmoid flexure, and rectum are derived from the inferior mesenteric plexus, which proceeds chiefly from the aortic plexus.

Dissection.—The large intestines should now be removed altogether, and a ligature placed around the upper part of the rectum. The student should then pin up the liver and inflate the duodenum and stomach with a small quantity of air. The blowpipe may be inserted for this purpose into the upper part of the jejunum, which was left on the removal of the small intestines. Next remove the middle portion of the lesser omentum, and feel for the cæliac axis. The branches of the cæliac axis should then be dissected and followed to their distribution. It would be well to avoid disturbing the cæliac axis itself at present, as it is surrounded by the solar plexus, which must be afterwards examined.

The CÆLIAC AXIS (*κοιλία*, ventriculus) is the first single trunk given off from the abdominal aorta. It arises opposite the upper border of the first lumbar vertebra, is about half an inch in length, and divides into three large branches, gastric, hepatic, and splenic.

The GASTRIC ARTERY (*coronaria ventriculi*), the smallest of the three branches of the cæliac axis, ascends between the two layers of the lesser omentum to the cardiac orifice of the stomach, then runs along the lesser curvature to the pylorus, and inosculates with the pyloric branch of

the hepatic. It is distributed to the lower extremity of the œsophagus and lesser curve of the stomach, and anastomoses with the œsophageal arteries, and vasa brevia of the splenic artery.

The HEPATIC ARTERY curves forward, and ascends along the right border of the lesser omentum to the liver, where it divides into two branches (right and left), which enter the transverse fissure, and are distributed along the portal canals to the right and left lobes. It is in relation, in the right border of the lesser omentum, with the ductus communis choledochus and portal vein, and is surrounded by the hepatic plexus of nerves and numerous lymphatics. There are sometimes two hepatic arteries, in which case one is derived from the superior mesenteric artery.

The *branches* of the hepatic artery are, the

Pyloric,

Gastro-duodenalis, { Gastro-epiploica dextra,
Pancreatico-duodenalis,

Cystic.

The *pyloric branch*, given off from the hepatic near the pylorus, is distributed to the commencement of the duodenum and to the lesser curve of the stomach, where it inosculates with the gastric artery.

The *gastro-duodenalis artery* is a short but large trunk, which descends behind the pylorus, and divides into two branches, the gastro-epiploica dextra, and pancreatico-duodenalis. Previously to its division, it gives off some *inferior pyloric* branches to the small end of the stomach.

The *gastro-epiploica dextra* runs along the great curve of the stomach lying between the two layers of the great omentum, and inosculates at about its middle with the gastro-epiploica sinistra, a branch of the splenic artery. It supplies the great curve of the stomach, and great omentum; hence its name.

The *pancreatico-duodenalis* curves along the fixed border of the duodenum, partly concealed by the attachment of the pancreas, and is distributed to the pancreas and duodenum. It inosculates below with the inferior pancreatico-duodenalis and pancreatic branches of the superior mesenteric artery.

The *cystic artery*, generally a branch of the right

hepatic, is of small size, and ramifies between the coats of the gall-bladder, previously to its distribution to the mucous membrane.

The SPLENIC ARTERY, the largest of the three branches of the cœliac axis, passes horizontally to the left along the upper border of the pancreas, and divides into five or six large branches, which enter the hilus of the spleen, and are distributed to its structure. In its course it is tortuous and serpentine, and frequently makes a complete turn upon itself. It lies in a narrow groove in the upper border of the pancreas, and is accompanied by the splenic vein, which lies beneath it, and by the splenic plexus of nerves.

The *branches* of the splenic artery are, the—

Pancreaticæ parvæ,	Vasa brevia,
Pancreatica magna,	Gastro-epiploica sinistra.

The *pancreaticæ parvæ* are numerous small branches distributed to the pancreas, as the splenic artery runs along its upper border. One of these, larger than the rest, follows the course of the pancreatic duct, and is called *pancreatica magna*.

The *vasa brevia* are five or six branches of small size which pass from the extremity of the splenic artery and its terminal branches, between the layers of the gastro-splenic omentum, to the great end of the stomach, to which they are distributed, inosculating with branches of the gastric artery and gastro-epiploica sinistra.

The *gastro-epiploica sinistra* appears to be the continuation of the splenic artery; it passes forwards from left to right, along the great curve of the stomach, lying between the layers of the great omentum, and inosculates with the gastro-epiploica dextra. It is distributed to the greater curve of the stomach and to the great omentum.

The GASTRIC VEINS, corresponding with the gastric, gastro-epiploic, and vasa brevia arteries, terminate in the splenic vein.

The SPLENIC VEIN commences in the structure of the spleen, and quits that organ by several large veins; it is larger than the splenic artery, and perfectly straight in its course. It passes horizontally inwards behind the pancreas, and terminates near its greater end by uniting with the superior mesenteric and forming the portal vein.

It receives in its course the gastric and pancreatic veins, and near its termination the inferior mesenteric vein.

The NERVES which accompany the branches of the cœliac axis are derived from the solar plexus, and constitute the gastric, hepatic, and splenic plexus.

The relations of the vessels situated in the right border of the lesser omentum should now be examined more particularly. The hepatic artery will be found to the left, the ductus communis choledochus to the right, and the portal vein behind and between them. The student will also perceive how the lower boundary of the foramen of Winslow is formed by the hepatic artery.

The *ductus communis choledochus* (χολή, bilis, δέχομαι, recipio) is the common excretory duct of the liver and gall-bladder. It is about three inches in length, and is formed by the junction of the hepatic with the cystic duct. It descends through the right border of the lesser omentum, and behind the descending portion of the duodenum to the inner side of that intestine, where it terminates by passing obliquely between the muscular and mucous coat, and opening on the summit of a papilla which is common to it and the pancreatic duct. The papilla is situated near the lower part of the descending portion of the duodenum on its inner side; and the duct is constricted in size during its passage between the coats of the intestine.

The ductus communis choledochus, hepatic artery, and portal vein are surrounded and held together, while in the right border of the lesser omentum, by loose cellular tissue, which is continued with the vessels into the substance of the liver, and is termed *Glisson's capsule*. In this Glisson's capsule are also contained a number of large lymphatic vessels which are taking their course from the liver and gall-bladder to the lumbar glands.

If the hepatic artery and ductus communis choledochus be drawn aside, and the connecting cellular tissue removed, the portal vein will be brought into view, lying between and behind the duct and artery.

The VENA PORTÆ, formed by the union of the splenic and superior mesenteric vein behind the pancreas, is about three inches in length. It ascends through the right border of the lesser omentum to the transverse fissure of the liver, where it divides into two branches, one for each lateral lobe. In the right border of the lesser omentum it is situated behind and between the

hepatic artery and ductus communis choledochus, and is surrounded by the hepatic plexus of nerves and lymphatics. At the transverse fissure each primary branch divides into numerous secondary branches which ramify through the portal canals, and give off vaginal and interlobular veins, and the latter terminate in the lobular venous plexus of the lobules of the liver. The portal vein within the liver receives the venous blood from the capillaries of the hepatic artery.

The student may now proceed to examine the liver; firstly in situ, with a view to its connections and relations, afterwards on its removal from the body. In effecting its removal he will have to cut through the ligaments which connect it to the abdominal parietes and diaphragm above and in front, and the parts contained in the right border of the lesser omentum and inferior vena cava below and behind.

THE LIVER.

The liver is a conglomerate gland of large size, appended to the alimentary canal, and performing the double office of separating impurities from the venous blood of the chylopoietic viscera previously to its return into the general venous circulation, and of secreting a fluid necessary to chylicification, the bile. It is the largest organ in the body, weighing about four pounds, and measuring through its longest diameter about twelve inches. It is situated in the right hypochondriac region, and extends across the epigastrium into the left hypochondrium, frequently reaching, by its left extremity, the upper end of the spleen. It is placed obliquely in the abdomen; its convex surface looking upwards and forwards, the concave downwards and backwards. The anterior border is sharp and free, and marked by a deep notch, the posterior rounded and broad. It is in relation, superiorly and posteriorly, with the diaphragm; inferiorly, with the stomach, ascending portion of the duodenum, transverse colon, right supra-renal capsule, and right kidney; and corresponds, by its free border, with the lower margin of the ribs.

Ligaments. — The liver is retained in its place by five ligaments; four of which are duplicatures of the peritoneum, situated on the convex surface of the organ; the fifth is a fibrous cord which passes through a fissure

in its under surface, from the umbilicus to the inferior vena cava. They are the —

Longitudinal,
Two lateral,

Coronary,
Round.

The *longitudinal ligament* (broad, ligamentum suspensorium hepatis) is an antero-posterior fold of peritoneum, extending from the notch on the anterior margin of the liver to its posterior border. Between its two layers, in the anterior and free margin, is the round ligament.

The *lateral ligaments* are formed by the two layers of peritoneum, which pass from the under surface of the diaphragm to the posterior border of the liver; they correspond with its lateral lobes.

The *coronary ligament* is formed by the separation of the two layers forming the lateral ligaments near their point of convergence. The posterior layer is continued unbroken from one lateral ligament into the other; but the anterior quits the posterior at each side, and is continuous with the corresponding layer of the longitudinal ligament. In this way a large oval surface on the posterior border of the liver is left uncovered by peritoneum, and is connected to the diaphragm by cellular tissue. This space is formed principally by the right lateral ligament, and is pierced near its left extremity by the inferior vena cava, previously to the passage of that vessel through the tendinous opening in the diaphragm.

The *round ligament* is a fibrous cord resulting from the obliteration of the umbilical vein, and situated between the two layers of peritoneum in the anterior border of the longitudinal ligament. It may be traced from the umbilicus, through the longitudinal fissure of the under surface of the liver to the inferior vena cava, to which it is connected.

Fissures.— The under surface of the liver is marked by five fissures, which divide its surface into five compartments or lobes, two principal and three minor lobes; they are the —

Fissures.

Transverse fissure,
Fissure for the gall-bladder,
Longitudinal fissure,
Fissure of the ductus venosus,
Fissure for the vena cava.

Lobes.

Right lobe,	Lobus quadratus,
Left lobe,	Lobus Spigelii,
	Lobus caudatus.

The *longitudinal fissure* is a deep groove running from the notch upon the anterior margin of the liver, to the posterior border of the organ. At about one-third from its posterior extremity it is joined by a short but deep fissure, the transverse, which meets it transversely from the under part of the right lobe.

The longitudinal fissure in front of this junction lodges the fibrous cord of the umbilical vein, and is generally crossed by a band of hepatic substance called the *pons hepatis*.

The *fissure for the ductus venosus* is the shorter portion of the longitudinal fissure, extending from the junctional termination of the transverse fissure to the posterior border of the liver, and containing a small fibrous cord, the remains of the ductus venosus. This fissure is therefore but a part of the longitudinal fissure.

The *transverse fissure* is the short and deep fissure, about two inches in length, through which the hepatic ducts quit, and the hepatic artery and portal vein enter the liver. Hence this fissure was considered by the older anatomists as the gate (*porta*) of the liver; and the large vein entering the organ at this point, the portal vein. At their entrance into the transverse fissure the branches of the hepatic duct are the most anterior, next those of the artery, and most posteriorly the portal vein.

The *fissure for the gall-bladder* is a shallow fossa extending forwards, parallel with the longitudinal fissure, from the right extremity of the transverse fissure to the free border of the liver, where it frequently forms a notch.

The *fissure for the vena cava* is a deep and short fissure, occasionally a circular tunnel, which proceeds from a little behind the right extremity of the transverse fissure to the posterior border of the liver, and lodges the inferior vena cava.

These five fissures taken collectively resemble an inverted ∇ , the base corresponding with the free margin of the liver, and the apex with its posterior border. Viewing them in this way, the two anterior branches represent the longitudinal fissure on the left, and

the fissure for the gall-bladder on the right side ; the two posterior, the fissure for the ductus venosus on the left, and the fissure for the vena cava on the right side ; and the connecting bar, the transverse fissure.

Lobes.—The *right lobe* is four or six times larger than the left, from which it is separated, on the concave surface, by the longitudinal fissure, and, on the convex, by the longitudinal ligament. It is marked upon its under surface by the transverse fissure, and by the fissures for the gall-bladder and vena cava ; and presents three depressions, one, in front, for the curve of the ascending colon (*impressio colica*), and two, behind, for the right supra-renal capsule and kidney (*impressio renalis*).

The *left lobe* is small and flattened, convex upon its upper surface, and concave below, where it lies in contact with the anterior surface of the stomach. It is sometimes in contact by its extremity with the upper end of the spleen, and is in relation, by its posterior border, with the cardiac orifice of the stomach and left pneumogastric nerve.

The *lobus quadratus* is a quadrilateral lobe situated on the under surface of the right lobe : it is bounded, *in front*, by the free border of the liver ; *behind*, by the transverse fissure ; to the *right*, by the gall-bladder ; and to the *left*, by the longitudinal fissure.

The *lobus Spigelii* is a small triangular lobe, also situated on the under surface of the right lobe : it is bounded, *in front*, by the transverse fissure ; and, *on the sides*, by the fissures for the ductus venosus and vena cava.

The *lobus caudatus* is a small tail-like appendage of the lobus Spigelii, from which it runs outwards like a crest into the right lobe, and serves to separate the right extremity of the transverse fissure from the commencement of the fissure for the vena cava. In some persons this lobe is well marked, in others it is small and ill-defined.

Reverting to the comparison of the fissures with an inverted ∇ , it will be observed that the quadrilateral interval in front of the transverse bar represents the lobus quadratus ; the triangular space behind the bar, the lobus Spigelii ; and the apex of the letter the point of union between the inferior vena cava and the remains of the ductus venosus.

Vessels and Nerves.—The vessels entering into the structure of the liver are also *five* in number ; they are the

Hepatic artery,	Hepatic veins,	Lymphatics.
Portal vein,	Hepatic ducts,	

The *hepatic artery*, *portal vein*, and *hepatic duct* enter the liver at the transverse fissure, and ramify through portal canals to every part of the organ ; so that their general direction is from below upwards, and from the centre towards the circumference.

The *hepatic veins* commence at the circumference, and proceed from before backwards, to open into the vena cava, on the posterior border of the liver. Hence the branches of the two veins cross each other in their course.

The portal vein, hepatic artery, and hepatic duct are moreover enveloped in a loose cellular tissue (the capsule of Glisson) which permits them to contract upon themselves when emptied of their contents ; the hepatic veins, on the contrary, are closely adherent by their parietes to the surface of the canals in which they run, and are unable to contract. By these characters the anatomist is enabled, in any section of the liver, to distinguish at once the most minute branch of the portal vein from an hepatic vein ; the former will be found more or less collapsed, and always accompanied by an artery and duct, and the latter widely open and solitary.

The *lymphatics* of the liver are divisible into the deep and superficial. The former take their course through the portal canals and right border of the lesser omentum to the lymphatic glands situated in the course of the hepatic artery, and along the lesser curve of the stomach. The *superficial* lymphatics are situated in the cellular structure of the proper capsule, over the whole surface of the liver. Those of the convex surface are divided into two sets, one passing from before backwards, and one from behind forwards ; the former enter the lateral and coronary ligaments, pierce the diaphragm, and join the posterior mediastinal glands, or proceed to the glands situated around the inferior cava ; the latter also consists of two groups, one which ascends in the broad ligament, and perforates the diaphragm, to terminate in the anterior mediastinal glands, while the other curves around the anterior margin of the liver to its concave surface, and pursues its course to the glands in the right border of the lesser omentum. The lymphatics of the concave surface of the liver are variously distributed ; those from the right lobe terminate in the lumbar glands ; those from the gall-bladder, which are large, enter the glands in the right border of the lesser omentum ; and those from the left lobe converge to the glands situated along the lesser curve of the stomach.

The *nerves* of the liver are derived from the systems both of animal and organic life ; the former proceed from the right phrenic and right pneumogastric nerve, the latter from the hepatic plexus.

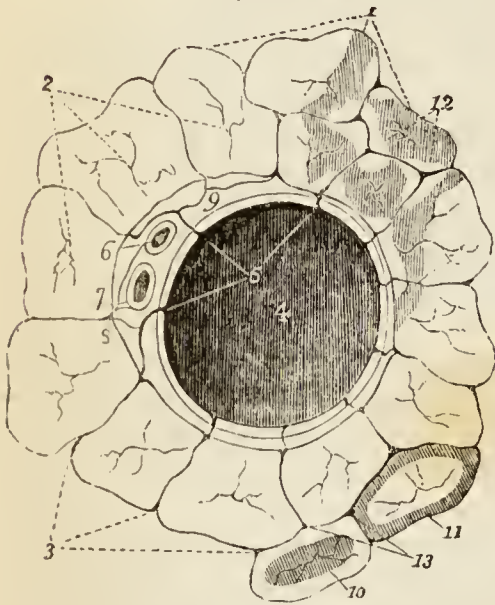
Structure and Minute Anatomy of the Liver.

The *liver* is composed of *lobules*, of a connecting medium called *Glisson's capsule*, of the ramifications of the *portal vein*, *hepatic duct*,

hepatic artery, hepatic veins, lymphatics, and nerves, and is enclosed and retained in its situation by the peritoneum.

The *lobules* are small granular bodies of about the size of a millet-seed, of irregular form, and presenting a number of rounded prominences on their surface. When divided longitudinally, they have a foliated appearance, and transversely, a polygonal outline, with sharp or rounded angles, according to the smaller or greater quantity of Glisson's capsule contained in the liver. Each lobule is divided upon its exterior into a base and a capsular surface. The *base* corresponds with one extremity of the lobule, is flattened, and rests upon an hepatic vein, which is thence named *sublobular*. The *capsular surface* includes the rest of the periphery of the lobule, and has received its designation from being enclosed in a cellular capsule derived from the capsule of Glisson. In the centre of each lobule is a small vein, the *intralobular*, which is formed by the convergence of six or eight minute venules from the rounded prominences of the periphery. The intralobular vein thus constituted takes its course through the centre of the longitudinal axis of the lobule, pierces the middle of its base, and opens into the sublobular vein. The periphery of the lobule, with the exception of its base, which is always closely attached to a sublobular vein, is connected

Fig. 67.*



by means of its cellular capsule with the capsular surfaces of surrounding lobules. The interval between the lobules is the *interlobular fissure*, and the angular interstices formed by the apposition of several lobules are the *interlobular spaces*.

The lobules of the centre of the liver are angular, and somewhat smaller than those of the surface, from the greater compression to which they are submitted. The superficial lobules are incomplete, and give to the surface of the organ the appearance and all the advantages resulting from an examination of a transverse section.

“Each lobule is *composed* of a plexus of biliary ducts, of a venous plexus, formed by branches of the portal vein, of a branch (intra-

* Transverse section of a small portal canal and its vessels, after Kiernan.

No. 1. Transverse sections of the lobules of the liver. 2. Intralobular hepatic veins in the centres of the lobules. 3. Interlobular fissures, in which ramify branches of the portal vein, hepatic artery, and hepatic ducts. 4. The portal vein, from which pass off on all sides interlobular veins (5, 5) which ramify in the interlobular fissures. 6. The hepatic artery. 7. The hepatic duct. 8. A branch from each of the three vessels seen entering one of the interlobular

lobular) of an hepatic vein, and of minute arteries; nerves and absorbents, it is to be presumed, also enter into their formation, but cannot be traced into them." "Examined with the microscope, a lobule is apparently composed of numerous minute bodies of a yellowish colour and of various forms, connected with each other by vessels. These minute bodies are the *acini* of Malpighi." "If an uninjected lobule be examined and contrasted with an injected lobule, it will be found that the acini of Malpighi in the former are identical with the injected lobular biliary plexus in the latter, and the blood-vessels in both will be easily distinguished from the ducts."*

Glisson's capsule is the cellulo-fibrous tissue which envelopes the hepatic artery, portal vein, and hepatic duct, during their passage through the right border of the lesser omentum, and which continues to surround them to their ultimate distribution in the substance of the lobules. It forms for each lobule a distinct capsule, which invests it on all sides with the exception of its base, connects all the lobules together, and constitutes the proper capsule of the entire organ. But Glisson's capsule is not mere cellular tissue; "it is to the liver what the pia mater is to the brain; it is a cellulo-vascular membrane, in which the vessels divide and subdivide to an extreme degree of minuteness; which lines the portal canals, forming sheaths for the larger vessels contained in them, and a web in which the smaller vessels ramify; which enters the interlobular fissures, and with the vessels forms the capsules of the lobules; and which finally enters the lobules, and with the blood-vessels expands itself over the secreting biliary ducts." Hence arises a natural division of the capsule into three portions, *vaginal*, *interlobular*, and *lobular*.

The vaginal portion is that which invests the hepatic artery, hepatic duct, and portal vein, in the portal canals; in the large canals it completely surrounds these vessels, but in the smaller is situated only on that side which is occupied by the artery and duct. The interlobular portion occupies the interlobular fissures and spaces, and the lobular portion forms the supporting tissue of the substance of the lobules.

The *portal vein*, entering the liver at the transverse fissure, ramifies through its structure in canals, which resemble, by their surfaces, the external superficies of the liver, and are formed by the

fissures. 9. The cellular tissue, Glisson's capsule, by which they are all surrounded. It will be observed that the boundaries of the canal in which the portal vein is lodged, are formed by the sides of the lobules and interlobular fissures, and not by the bases of the lobules, as are those of the sublobular veins. 10. A lobule in the state of "passive congestion," or "hepatic venous congestion." 11. A lobule in the state of portal venous congestion. 12. The mottled patches indicating the existence of "active congestion."

* The Anatomy and Physiology of the Liver, by Mr. Kiernan, Phil. Trans. 1833, from which this and the other paragraphs within inverted commas, on the structure of the liver, are quoted.

capsular surfaces of the lobules. These are the portal canals, and contain, besides the portal vein, with its ramifications, the artery and duct with their branches.

In the larger canals, the vessels are separated from the parietes by a web of Glisson's capsule; but, in the smaller, the portal vein is in contact with the surface of the canal for about two-thirds of its cylinder, the opposite third being in relation with the artery and duct and their investing capsule. If, therefore, the portal vein were laid open by a longitudinal incision in one of these smaller canals, the coats being transparent, the outline of the lobules, bounded by their interlobular fissures, would be as distinctly seen as upon the external surface of the liver, and the smaller venous branches would be observed entering the interlobular spaces.

The branches of the portal vein are, the vaginal, interlobular, and lobular. The *vaginal branches* are those which, being given off in the portal canals, have to pass through the sheath (vagina) of Glisson's capsule, previously to entering the interlobular spaces. In this course they form an intricate plexus, the *vaginal plexus*, which, depending for its existence on the capsule of Glisson, necessarily surrounds the vessels, as does that capsule in the larger canals, and occupies the capsular side only in the smaller canals. The *interlobular branches* are given off from the vaginal portal plexus where it exists, and directly from the portal veins, in that part of the smaller canals where the coats of the vein are in contact with the walls of the canal. They then enter the interlobular spaces and divide into branches, which cover with their ramifications every part of the surface of the lobules, with the exception of their bases and those extremities of the superficial lobules which appear upon the surfaces of the liver. The interlobular veins communicate freely with each other, and with the corresponding veins of adjoining fissures, and establish a general portal anastomosis throughout the entire liver. The *lobular branches* are derived from the interlobular veins; they form a plexus within each lobule, and converge from the circumference towards the centre, where they terminate in the minute radicles of the intralobular vein. "This plexus, interposed between the interlobular portal veins and the intralobular hepatic vein, constitutes the venous part of the lobule, and may be called the *lobular venous plexus*." The irregular islets of the substance of the lobules, seen between the meshes of this plexus by means of the microscope, are the acini of Malpighi, and are portions of the lobular biliary plexus.

The portal vein returns the venous blood from the chylopoietic viscera, to be circulated through the lobules; it also receives the venous blood, which results from the distribution of the hepatic artery.

The *hepatic duct*, entering the liver at the transverse fissure, divides into branches, which ramify through the portal canals, with the portal vein and hepatic artery, to terminate in the substance of the lobules. Its branches, like those of the portal vein, are vaginal, interlobular, and lobular.

The *vaginal branches* ramify through the capsule of Glisson, and form a *vaginal biliary plexus*, which, like the vaginal portal plexus,

surrounds the vessels in the large canals, but is deficient on that side of the smaller canals near which the duct is placed. The branches given off by the vaginal biliary plexus are interlobular and lobular. The *interlobular branches* proceed from the vaginal biliary plexus where it exists, and directly from the hepatic duct on that side of the smaller canals against which the duct is placed. They enter the interlobular spaces, and ramify upon the capsular surface of the lobules in the interlobular fissures, where they communicate freely with each other. The *lobular ducts* are derived chiefly from the interlobular; but to those lobules forming the walls of the portal canals, they pass directly from the vaginal plexus. They enter the lobule, and form a plexus in its interior, the *lobular biliary plexus*, which constitutes the principal part of the substance of the lobule. The ducts terminate either in loops or in caecal extremities.

The coats of the duct are very vascular, and are supplied with a number of mucous follicles, which are distributed irregularly in the larger, but are arranged in two parallel longitudinal rows in the smaller ducts.

The *hepatic artery* enters the liver with the portal veins and hepatic duct, and ramifies with those vessels through the portal canals. Its branches are the vaginal, interlobular, and lobular. The *vaginal branches*, like those of the portal vein and hepatic duct, form a *vaginal plexus*, which exists throughout the whole extent of the portal canals, with the exception of that side of the smaller canals which corresponds with the artery. The *interlobular branches*, arising from the vaginal plexus and from the parietal side of the artery (in the smaller canals), ramify through the interlobular fissures, and are principally distributed to the coats of the interlobular ducts.

“From the superficial interlobular fissures small arteries emerge, and ramify in the *proper capsule*, on the convex and concave surface of the liver, and in the ligaments. These are the *capsular arteries*.” Where the capsule is well developed, “these vessels cover the surfaces of the liver with a beautiful plexus,” and “anastomose with branches of the phrenic, internal mammary, and supra-renal arteries,” and with the epigastric.

The *lobular branches*, extremely minute and few in number, are the nutrient vessels of the lobules, and terminate in the lobular venous plexus.

All the venous blood resulting from the distribution of the hepatic artery, even that from the vasa vasorum of the hepatic veins, is returned into the portal vein.

The *hepatic veins* commence in the substance of each lobule by minute venules, which receive the blood from the lobular venous plexus, and converge to form the intralobular vein. The *intralobular vein* passes through the central axis of the lobule, and through the middle of its base, to terminate in a sublobular vein; and the union of the sublobular veins constitutes the hepatic trunks, which open into the inferior vena cava. The hepatic venous system consists, therefore, of three sets of vessels; intralobular veins, sublobular veins, and hepatic trunks.

The *sublobular veins* are contained in canals formed solely by the

bases of the lobules, with which, from the absence of Glisson's capsule, they are in immediate contact. Their coats are thin and transparent; and, if they be laid open by a longitudinal incision, the bases of the lobules will be distinctly seen, separated by interlobular fissures, and perforated through the centre by the opening of the intralobular vein.

The *hepatic trunks* are formed by the union of the sublobular veins; they are contained in canals (hepatic-venous), similar in structure to the portal canals, and lined by a prolongation of the proper capsule. They proceed from before backwards, and terminate, by two large openings (corresponding with the right and left lobes of the liver) and several smaller apertures, in the inferior vena cava.

Summary. — The liver has been shown to be composed of *lobules*; the lobules (excepting at their bases) are invested and connected together, the vessels supported, and the whole organ enclosed, by *Glisson's capsule*; and they are so arranged, that the base of every

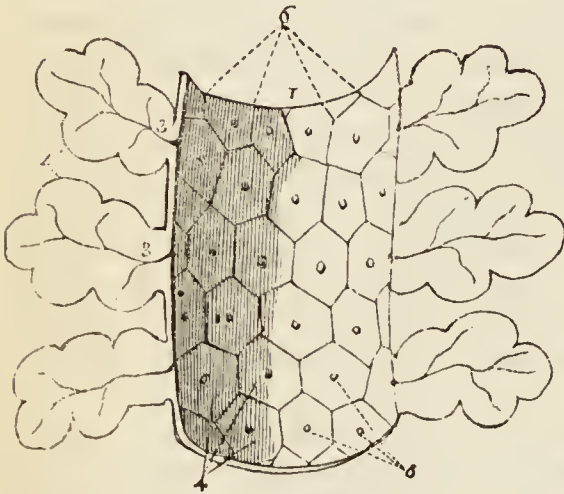
lobule in the liver is in contact with an hepatic vein (sublobular).

The *portal vein* distributes its numberless branches through portal canals, which are channelled through every part of the organ; it brings the returning blood from the chylopoietic viscera; it collects also the venous blood from the ultimate ramifications of the hepatic artery in the liver itself. It gives off branches in the canals, which are called *vaginal*, and form a venous *vaginal*

plexus; these give off *interlobular branches*, and the latter enter the lobules and form *lobular venous plexuses*, from the blood circulating in which, the bile is secreted.

The *bile* in the lobule is received by a network of minute ducts, the *lobular biliary plexus*; it is conveyed from the lobule into the *interlobular ducts*; it is thence poured into the *biliary vaginal plexus* of the portal canals, and thence into the excreting ducts, by which it is carried to the duodenum and gall-bladder, after being mingled in its course with the mucous secretion from the numberless muciparous follicles in the walls of the ducts.

Fig. 68.*



* The distribution of the hepatic veins, after Kiernan. — No. 1. A section of a sublobular vein. 2. Longitudinal sections of the lobules, presenting a foliated appearance. 3, 3. Intralobular veins. 4. "The bases of other lobules seen through the coats of the vein, and forming the canal in which the vein is contained." 5. The openings of intralobular veins, which issue from the centre of the base of each lobule. 6. The interlobular fissures separating the bases of the lobules.

The *hepatic artery* distributes branches through every portal canal; gives off *vaginal branches* which form a vaginal hepatic plexus, from which the *interlobular branches* arise, and these latter terminate ultimately in the lobular venous plexuses of the portal vein. The artery ramifies abundantly in the coats of the hepatic ducts, enabling them to provide their mucous secretion; and supplies the vasa vasorum of the portal and hepatic veins, and the nutrient vessels of the entire organ.

The *hepatic veins* commence in the centre of each lobule by minute radicles, which collect the impure blood from the lobular venous plexus and convey it into the *intra-lobular veins*; these open into the *sublobular veins*, and the sublobular veins unite to form the large hepatic trunks by which the blood is conveyed into the vena cava.

Physiological and pathological Deductions. — The physiological deduction arising out of this anatomical arrangement is, that the *bile is wholly secreted from venous blood*, and not from a mixed venous and arterial blood, as stated by Müller; for although the portal vein receives its blood from two sources, viz., from the chylopoietic viscera, and from the capillaries of the hepatic artery, yet the very fact of the blood of the latter vessel having passed through its capillaries into the portal vein, or in extremely small quantity into the capillary network of the lobular venous plexus, is sufficient to establish its venous character.*

The pathological deductions depend upon the following facts: — Each lobule is a perfect gland; of uniform structure, of uniform colour, and possessing the same degree of vascularity throughout. It is the seat of a double venous circulation, the vessels of the one (*hepatic*) being situated in the centre of the lobule, and those of the other (*portal*) in the circumference. Now the colour of the lobule, as of the entire liver, depends chiefly upon the proportion of blood contained within these two sets of vessels; and so long as the circulation is natural, the colour will be uniform. But the instant that any cause is developed which shall interfere with the free circulation of either, there will be an immediate diversity in the colour of the lobule.

Thus, if there be any impediment to the free circulation of the venous blood through the heart or lungs, the circulation in the hepatic veins will be retarded, and the sublobular and the intra-lobular veins will become congested, giving rise to a more or less extensive redness in the centre of each of the lobules, while the marginal or non-congested portion presents a distinct border of a yellowish white, yellow, or green colour, according to the quantity and quality of the bile it may contain. “This is ‘*passive congestion*’ of the liver, the usual and natural state of the organ after death;” and, as it commences with the hepatic vein, it may be called the first stage of *hepatic venous* congestion.

* For arguments on this contested question, see the article LIVER, in the “Cyclopædia of Anatomy and Physiology.”

But if the causes which produced this state of congestion continue, or be from the beginning of a more active kind, the congestion will extend through the lobular venous plexuses "into those branches of the portal vein situated in the *interlobular fissures*, but not to those in the *spaces*, which being larger, and giving origin to those in the fissures, are the last to be congested." In this second stage the liver has a mottled appearance, the non-congested substance is arranged in isolated, circular, and ramose patches, in the centres of which the spaces and parts of the fissures are seen. This is an extended degree of *hepatic venous congestion*; it is "*active congestion*" of the liver, and very commonly attends disease of the heart and lungs.

These are instances of *partial congestion*, but there is sometimes *general congestion* of the organ. "In general congestion the whole liver is of a red colour, but the central portions of the lobules are usually of a deeper hue than the marginal portions."

GALL-BLADDER.

The *gall-bladder* is the reservoir of the bile; it is a pyriform sac, situated in a fossa on the under surface of the right lobe of the liver, and extending from the right extremity of the transverse fissure to the free margin. It is divided into a body, fundus, and neck: the fundus or broad extremity in the natural position of the liver is placed downwards, and frequently projects beyond the free margin of the liver, while the neck, small and constricted, is directed upwards. This sac is composed of three coats, serous, fibrous, and mucous. The *serous coat* is partial, is derived from the peritoneum, and covers that side only which is unattached to the liver. The *middle* or *fibrous coat* is a thin but strong fibrous layer, connected on one side to the liver, and on the other to the peritoneum. The *internal* or *mucous coat* is but loosely attached to the fibrous layer; it is everywhere raised into minute rugæ, which give it a beautifully reticulated appearance, and forms, at the neck of the sac, a spiral valve. It is continuous through the hepatic duct with the mucous membrane lining all the ducts of the liver, and through the ductus communis choledochus with the mucous membrane of the alimentary canal.

The *biliary ducts* are, the hepatic, cystic, and ductus communis choledochus.

The *hepatic duct*, nearly two inches long, is formed in the transverse fissure of the liver by the junction of two ducts which proceed from the right and left lobes. It

joins the cystic duct at an acute angle, and the common duct resulting from their union is the ductus communis choledochus.

The *cystic duct*, about an inch in length, passes inwards from the neck of the gall-bladder, and unites at an acute angle with the preceding.

The *ductus communis choledochus* descends through the right border of the lesser omentum to the duodenum (page 462.).

The coats of the hepatic duct are an external or fibrous, and an internal or mucous coat. The *external coat* is composed of a contractile fibrous tissue, which is probably muscular; but its muscularity has not yet been demonstrated in the human subject. The *mucous coat* is continuous on the one hand with the lining membrane of the hepatic ducts and gall-bladder, and on the other with that of the duodenum.

Vessels and Nerves. — The gall-bladder is supplied with blood by the cystic artery, a branch of the hepatic. Its veins return their blood into the portal vein. The nerves are derived from the hepatic plexus.

The stomach having been examined in situ, may now be removed, after placing a ligature around the cardiac and pyloric orifices, and dividing the extremity of the œsophagus on the one hand, and the commencement of the duodenum on the other. The gastro-splenic omentum must also be divided, and any other connections which may impede the observation of the parts situated behind it. The duodenum should then be distended with air, and the student may proceed to examine the pancreas with the splenic artery and vein lying on its upper border, the superior mesenteric artery and vein and portal vein issuing from behind it, and the spleen lying at its small extremity and connected to it by the splenic artery and vein.

THE PANCREAS.

The pancreas is a long, flattened, conglomerate gland, analogous to the salivary glands. It is about six inches in length, and between three and four ounces in weight; is situated transversely across the posterior wall of the abdomen, behind the stomach; and rests on the aorta, vena portæ, inferior vena cava, the origin of the superior mesenteric artery, and the left kidney and supra-renal capsule; opposite the first and second lumbar vertebræ. It is divided into a body, a greater and a smaller extremity: the great end or head is placed towards the right, and is surrounded by the curve of the duodenum; the lesser end extends to the left as far as the spleen.

The anterior surface of the body of the pancreas is covered by the ascending posterior layer of peritoneum, and is in relation with the stomach, the first portion of the duodenum, and the commencement of the transverse arch of the colon. The posterior surface is grooved for the splenic vein, and tunnelled by a complete canal for the superior mesenteric and portal vein, and superior mesenteric artery. The upper border presents a deep groove, sometimes a canal, for the splenic artery and vein, and is in relation with the oblique portion of the duodenum, the lobus Spigelii, and cœliac axis. And the lower border is separated from the transverse portion of the duodenum by the superior mesenteric artery and vein. Upon the posterior part of the head of the pancreas is a lobular fold of the gland which completes the canal of the superior mesenteric vessels, and is called the *lesser pancreas*.

In structure, the pancreas is composed of reddish-yellow polyhedral lobules; these consist of smaller lobules, and the latter are made up of the arborescent ramifications of minute ducts, terminating in cæcal pouches.

The pancreatic duct commences at the small extremity of the organ by two branches, which converge and unite after a course of about one-third the length of the gland. The duct is then continued onwards from left to right, gradually increasing in size, and lying nearer the anterior than the posterior surface of the organ, to the lower part of the descending duodenum, where it terminates on the papilla of mucous membrane, common to it, and the ductus communis choledochus. The duct receives numerous branches which open into it on all sides from the lobules of the gland, and at its termination is slightly dilated, and passes obliquely between the muscular and mucous coat of the intestine to reach the papilla. The duct which receives the secretion from the lesser pancreas is called the *ductus pancreaticus minor*; it opens into the principal duct near the duodenum, and sometimes passes separately into that intestine. As a variety, two pancreatic ducts are occasionally met with.

Vessels and Nerves. — The arteries of the pancreas are branches of the splenic, hepatic, and superior mesenteric; the *veins* open into the splenic vein; the *lymphatics* terminate in the lumbar glands. The *nerves* are filaments of the splenic plexus.

THE SPLEEN.

The spleen is an oblong flattened organ, of a dark bluish-red colour, situated in the left hypochondriac region. It is variable in size and weight*, spongy and vascular in texture, and exceedingly friable. The external surface is convex, the internal slightly concave, indented along the middle line, and pierced by several large and irregular openings for the entrance and exit of vessels; this is the *hilum lienis*. The upper extremity is somewhat larger than the lower, and rounded; the inferior is flattened; the posterior border is obtuse, the anterior sharp, and marked by several notches. The spleen is in relation by its external or *convex* surface with the diaphragm, which separates it from the ninth, tenth, and eleventh ribs; by its *concave* surface, with the great end of the stomach, the extremity of the pancreas, the gastro-splenic omentum and its vessels, the left kidney and supra-renal capsule, and the left crus of the diaphragm; by its *upper end* with the diaphragm, and sometimes with the extremity of the left lobe of the liver; and, by its *lower end*, with the left extremity of the transverse arch of the colon. It is connected to the stomach by the gastro-splenic omentum, and to the diaphragm by a fold of the peritoneum called the *suspensory ligament*.

A second spleen (*lien succenturiatus*) is sometimes found appended to one of the branches of the splenic artery, near the great end of the stomach; when it exists, it is round and of small size, rarely larger than a hazel-nut. I have seen two, and even three of these bodies; there may be more.

The spleen is invested by the peritoneum and by a *tunica propria* of elastic tissue, which enables it to yield to the greater or less distension of its vessels. The elastic tunic forms sheaths for the vessels in their ramifications through the organ, and from these sheaths small fibrous bands (*trabeculæ*) are given off in all directions, which become attached to the internal surface of the elastic tunic, and constitute the areolar framework of the spleen. The substance occupying the interspaces of this tissue is soft, granular, and of a bright red colour, interspersed with small, white, soft corpuscles (*Malpighian bodies*). These corpuscles, according to the researches of Oesterlen and Simon, are aggregations of cytoblasts enclosed

* Its ordinary length is about five inches; and its weight, six ounces.

in a kind of capsule of capillary vessels. There are, besides, separate cytoblasts abundantly scattered through the red substance.

Vessels and Nerves. — The *splenic artery* is of very large size in proportion to the bulk of the spleen; it is a division of the cœliac axis. The branches which enter the spleen are distributed to distinct sections of the organ, and anastomose very sparingly with each other. The *veins* by their numerous dilatations constitute the principal part of the bulk of the spleen; they pour their blood into the splenic vein, which is one of the two great formative trunks of the portal vein. The *lymphatics* are remarkable for their number and large size; they terminate in the lumbar glands. The *nerves* are, the splenic plexus, derived from the solar plexus.

THE SUPRA-RENAL CAPSULES.

The supra-renal capsules are two small yellowish and flattened bodies surmounting the kidneys, and inclining inwards towards the vertebral column. The right is somewhat three-cornered in shape, the left semilunar; they are connected to the kidneys by the common investing cellular tissue, and each capsule is marked on its anterior surface by a fissure which appears to divide it into two lobes. The right supra-renal capsule is closely adherent to the posterior and under surface of the liver, the left lies in contact with the pancreas and spleen. Both capsules rest against the crura of the diaphragm on a level with the tenth dorsal vertebra, and, by their inner border, are in relation with the great splanchnic nerve and semilunar ganglion. They are larger in the fœtus than in the adult, and appear to perform some office connected with embryonic life. The anatomy of these organs in the fœtus will be found in a subsequent Chapter.

In structure they are composed of two substances, cortical and medullary. The cortical substance is of a yellowish colour, and consists of straight parallel columns placed perpendicularly side by side. The medullary substance is generally of a dark brown colour, double the quantity of the yellow substance, soft and spongy in texture, and contains within its centre the trunk of a large vein, the vena supra-renal. It is the large size of this vein that gives to the fresh supra-renal capsule the appearance of a central cavity: the dark-coloured pulpy or fluid contents of the capsule, at a certain period after death, are produced by softening of the medullary substance. Dr. Nagel* has shown, by his injections and micro-

* Müller's Archiv. 1836.

scopic examinations, that the appearance of columns in the cortical substance is caused by the direction of a plexus of capillary vessels. Of the numerous minute arteries, supplying the supra-renal capsule, he says, the greater number enter the cortical substance at every point of its surface, and, after proceeding for scarcely half a line, divide into a plexus of straight capillary vessels. Some few of the small arteries traverse the cortical layer, and give off, in the medullary substance, several branches which proceed in different directions, and re-enter the cortical layer, to divide into a capillary plexus in a similar manner with the first described. From the capillary plexus, composing the cortical layer, the blood is received by numerous small veins, which form a venous plexus in the medullary substance, and terminate at acute angles in the large central vein.

According to the more recent researches of Oesterlen and Simon, the appearance of columns is due to groups of small corpuscles or cytoblasts associated with elementary granules and fat-cells collected together in the form of parallel cylinders or cones, each group being inclosed in a tube of delicate membrane (limitary membrane). The medullary substance and intercolumnar spaces contain cytoblasts uniformly scattered and interspersed with granules and fat-cells. Oesterlen found also, occasionally, in the medullary substance, elongated spaces without lining membrane containing a thick greyish-white fluid.

Vessels and Nerves. — The supra-renal arteries are derived from the aorta, from the renal, and from the phrenic arteries; they are remarkable for the innumerable minute twigs into which they divide, previously to entering the capsule. The *supra-renal vein* collecting the blood from the medullary venous plexus, and receiving several branches which pierce the cortical layer, opens directly into the vena cava on the right side, and into the renal vein on the left.

The *lymphatics* are large and very numerous; they terminate in the lumbar glands. The *nerves* are derived from the renal and from the phrenic plexus.

THE KIDNEYS.

The kidneys, the secreting organs of the urine, are situated in the lumbar regions, behind the peritoneum, and on each side of the vertebral column, extending from the eleventh rib to near the crest of the ilium, and approaching the vertebral column by their upper ends. Each kidney is between four and five inches in length, about two inches and a half in breadth, somewhat more than one inch in thickness, and weighs between three and five ounces. The kidneys are usually surrounded by fat; they rest on the crura of the diaphragm, on the anterior lamella of the aponeurosis of the transversalis muscle, which

separates them from the quadratus lumborum, and on the psoas magnus. The *right kidney* is somewhat lower than the left, from the position of the liver; it is in relation, by its anterior surface, with the liver and descending portion of the duodenum, which rest against it; and is covered in by the ascending colon. The *left kidney*, higher than the right, is covered, in front by the great end of the stomach, by the spleen and descending colon. The anterior surface of the kidney is convex, while the posterior is flat; the superior extremity is in relation with the supra-renal capsule; the convex border is turned outwards towards the parietes of the abdomen; the concave border looks inwards towards the vertebral column, and presents a deep notch (*hilum renale*), which leads to a cavity, or *sinus*, within the organ. In the *sinus renalis* are situated the vessels and nerves of the kidney, and the expansion of the excretory duct called *pelvis renalis*. At the hilum these vessels are so placed that the renal vein is in front of the artery, and the pelvis and ureter behind.

The kidney is dense and fragile in texture, and invested by a proper fibrous capsule, which is easily torn from its surface. When divided by a longitudinal incision, carried from the convex to the concave border, it is found to present in its interior two structures, an external or vascular (cortical), and an internal or tubular (medullary) substance. The *tubular portion* is formed of pale reddish-coloured conical masses, corresponding by their bases with the vascular structure, and by their apices with the hilum of the organ; these bodies are named cones (pyramids of Malpighi), and are from eight to fifteen in number. The *vascular portion*, about two lines in thickness, is composed of blood-vessels and the plexiform convolutions of uriniferous tubuli, and not only constitutes the surface of the kidney, but dips between the cones and surrounds them nearly to their apices (*septula renum*).

The cones or pyramids of the tubular portion of the kidney are composed of minute straight tubuli uriniferi, of about the diameter of a fine hair. The tubuli commence at the apices of the cones, and pursue a parallel course towards the periphery of the organ, bifurcating from point to point, and separated only by minute straight blood-vessels, and a small quantity of parenchymatous substance. At the bases of the pyramids the tubuli collect into smaller conical fasciculi (*pyramids of Ferrein*), which are prolonged into the substance of the cortical portion of the kidney, and have interposed between them processes of the vascular structure. In the smaller pyramids the fasciculi separate into their component tubules, which, after a course marked by "tortuosities, plexuses,

convolutions, and dilatations," terminate, according to Mr. Bowman*, in small round bodies, the corpora Malpighiana, or, according to Krause, and the recent investigations of Mr. Toynebee †, by anastomoses and cæcal extremities. The average diameter of the tubuli uriniferi in the cortical portion of the kidney is $\frac{1}{480}$ th of an inch, of which about two-thirds are occupied by a nucleated epithelium, the remaining third representing the area of the tube. According to Mr. Bowman, the epithelium is ciliated in that part of the tubule which is near the Malpighian body, the tubule itself being very much constricted.

In the cortical portion of the kidney are contained a multitude of minute, red, globular bodies, the corpora Malpighiana, or glomeruli. Each Malpighian body, about $\frac{1}{100}$ of an inch in diameter, is composed of a plexus of capillary vessels, and in addition, according to Mr. Toynebee, of a coil of an uriniferous tubule; the tuft of capillaries and the coil of the tubule being both enclosed in a thin membranous capsule. According to Mr. Bowman, the capsule of the Malpighian body is the origin of the uriniferous tubule expanded into a globular form for the reception of the capillary tuft. The capillary vessels of the vascular tuft are arranged in loops closely packed together, and surrounded by an epithelium which is continuous with a similar structure lining the inner surface of the capsule. They are derived from a small artery, which, after piercing the capsule, immediately divides in a radiated manner into several branches. From the interior of this little vascular ball a vein proceeds, smaller than the corresponding artery, and pierces the capsule close by the artery, to communicate with the efferent vessels of other Malpighian bodies and constitute a venous plexus.

The cones or mamillary processes of the interior of the kidney are invested by mucous membrane, which is continuous at their apices with the uriniferous tubuli, and is reflected from their sides so as to form around each a cup-like pouch, or *calyx*. The calices communicate with a common cavity of larger size, situated at each extremity, and in the middle of the organ; and these three cavities, the *infundibula*, constitute by their union the large membranous sac, which emerges through the hilum renale, the *pelvis* of the kidney.

The kidney in the embryo and fœtus consists of lobules. See the anatomy of the fœtus in a succeeding Chapter.

The *ureter* (*οὔρον*, urine, *τηρεῖν*, to keep), the excretory duct of the kidney, is a membranous tube of about the diameter of a goose-quill, and nearly eighteen inches in length; it is continuous, superiorly, with the pelvis of the kidney, and is constricted inferiorly, where it lies in an oblique direction between the muscular and mucous coat of the base of the bladder, and opens upon

* On the Structure and Use of the Malpighian Bodies of the Kidney. Philosophical Transactions, 1842.

† On the intimate Structure of the Human Kidney, &c. Medico-Chirurgical Transactions, vol. xxix., 1846.

its mucous surface. Lying along the posterior wall of the abdomen, it is situated behind the peritoneum, and is crossed by the spermatic vessels; in its course downwards it rests against the anterior surface of the psoas, and crosses the common iliac artery and vein, and then the external iliac vessels. Within the pelvis it crosses the hypogastric cord and vas deferens in the male, and runs by the side of the cervix uteri and upper part of the vagina in the female. There are sometimes two ureters to one kidney. The ureter, the pelvis, the infundibula, and the calices are composed of two coats, an external or fibro-cellular coat, the tunica propria, and an internal mucous coat, which is continuous with the mucous membrane of the bladder inferiorly, and with that of the tubuli uriniferi above. The cells of the epithelium are spheroidal.

Vessels and Nerves. — The renal artery is derived from the aorta; it divides into several large branches before entering the hilum, and within the organ ramifies in an arborescent manner, terminating in nutrient twigs, and the small inferent vessels of the corpora Malpighiana. In the Malpighian bodies the inferent vessels divide into several primary twigs, which subdivide into capillaries, and the capillaries, after forming loops, converge to the efferent vein, which is generally smaller than the corresponding artery. The efferent veins proceed to, and form a capillary venous plexus, which surrounds the tortuous tubuli uriniferi, and from this venous plexus the blood is conveyed, by converging branches, into the renal vein.

“Thus,” remarks Mr. Bowman, “there are in the kidney two perfectly distinct systems of capillary vessels, through both of which the blood passes in its course from the arteries into the veins; the first, that” which forms the vascular tuft in the Malpighian bodies, and is “in immediate connection with the arteries; the second, that enveloping the convolutions of the tubes, and communicating directly with the veins. The efferent vessels of the Malpighian bodies, that carry the blood between these two systems, may collectively be termed the portal system of the kidney.” The inferences drawn by Mr. Bowman from his investigations are interesting; they are, that the capillary tufts of the Malpighian bodies are the part of the kidney specially acted on by diuretics; that they are the medium by which water, certain salts, and other substances, pass out of the system; that they are, moreover, the means of escape of certain morbid products, such as sugar, albumen, and the red particles of the blood. Respecting the capillary venous plexus, we have proof that the principal proximate constituents of urine, such as urea, lithic acid, &c., are, like the bile, derived from venous (portal) blood.

The *veins* of the kidney commence at the surface by minute converging venules, the *stellated vessels*, and proceed inwards, receiving in their course the veins of the cortical and tubular portions of the

organ. On arriving at the pelvis, they unite to form the branches of the renal vein, which terminates in the vena cava by a single large trunk on each side; the left renal vein receiving the left spermatic vein. Injections thrown into the renal artery, and returning by the tubuli uriniferi, make their way into those tubes by rupture. The *lymphatic vessels* terminate in the lumbar glands.

The *nerves* are derived from the renal plexus, which is formed partly by the solar plexus, and partly by the lesser splanchnic nerve. The renal plexus gives branches to the spermatic plexus, and branches which accompany the ureters: hence the morbid sympathies which exist between the kidney, the ureter, and the testicle; and by the communications with the solar plexus, with the stomach, and diaphragm, and indeed with the whole system. In the intimate structure of the kidney, the nerve-fibres are, according to Mr. Toynebee, continuous with the nucleated cells of the parenchyma of the organ.

DEEP VESSELS AND NERVES OF THE ABDOMEN.

The deep vessels and nerves of the abdomen are the abdominal aorta, inferior vena cava, thoracic duct, and sympathetic nerve.

The duodenum and pancreas may now be removed, together with any cellular tissue, membrane, or organ which may impede the view of the great vessels lying upon the vertebral column. In following the branches of the arteries and veins care should be taken to avoid destroying the nerves which lie upon the vessels and their numerous plexuses.

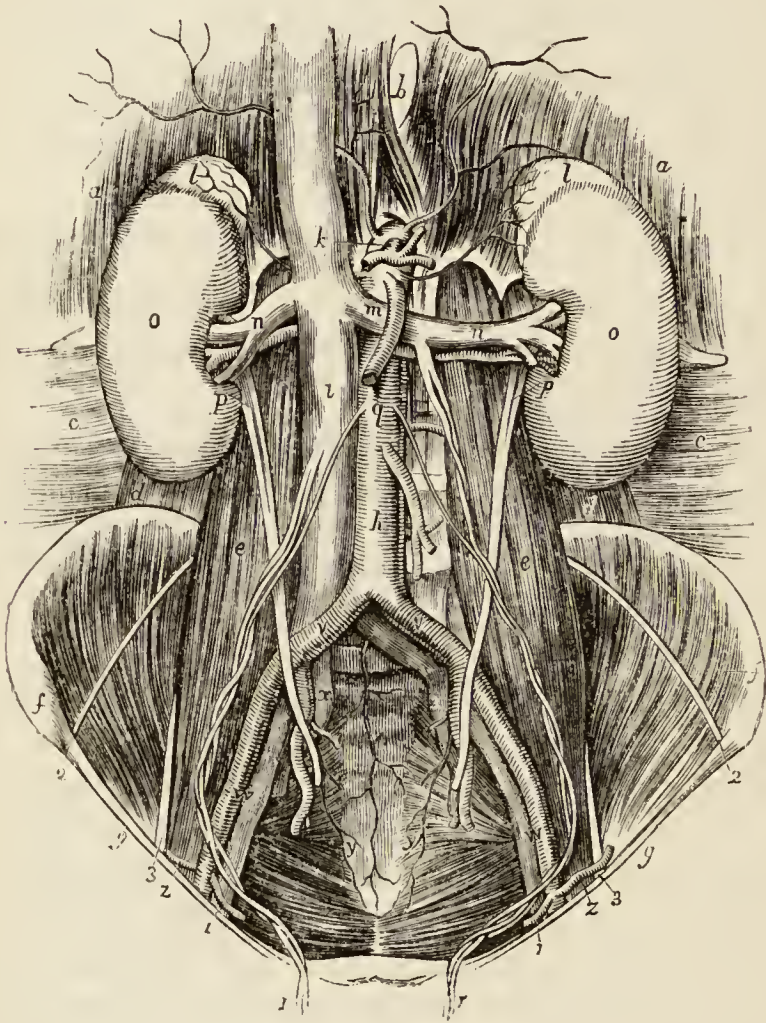
The ABDOMINAL AORTA enters the abdomen through the aortic opening of the diaphragm, and between the two pillars of that muscle. In its course downwards, it lies on the left of the vertebral column, and terminates on the fourth lumbar vertebra by dividing into the two common iliac arteries. It is crossed by the left renal vein, pancreas, transverse duodenum, and mesentery, and is in relation behind with the thoracic duct, receptaculum chyli, and left lumbar veins. On its left side is situated the left semilunar ganglion and sympathetic nerve, and on its right, the inferior vena cava, right semilunar ganglion, and the commencement of the vena azygos.

The branches of the abdominal aorta are the —

- | | | |
|----------------------|---|----------------------|
| Phrenic, | | Spermatic, |
| Cœliac axis | { | Gastric, |
| | | Hepatic, |
| | | Splenic, |
| Superior mesenteric, | | Inferior mesenteric, |
| | | Supra-renal, |
| | | Renal, |
| | | Lumbar, |
| | | Sacra media. |

The PHRENIC ARTERIES are given off (frequently by a common trunk) from the anterior part of the aorta, as soon as that vessel has passed through the aortic opening. Passing obliquely outwards upon the under surface of the diaphragm, each artery divides into two branches: an *internal branch*, which runs forward and inosculates with its fellow of the opposite side in front of the œsophagus

*Fig. 69.**



* The abdominal aorta, with its branches.—*a, a*. The diaphragm. *b*. Its œsophagial opening. *c, c*. The transversalis abdominis muscle. *d, d*. The quadratus lumborum. *e, e*. The psoas magnus. *f, f*. The iliacus muscle; the letters are placed on the crests of the ilium, near the anterior superior spinous process. *g, g*. Poupart's ligament. *h*. The aorta. *i, i*. The inferior vena cava. The phrenic arteries are seen ramifying on the under side of the diaphragm, between *a* and *b*. *k*. The cœliac axis; the letter is placed on the inferior vena cava. Immediately below the cœliac axis are seen the two small capsular arteries which pass outwards to *l, l*. The supra renal capsules. *m*. The superior mesenteric artery; the letter is placed

geal opening; and an *external branch*, which proceeds outwards towards the great circumference of the muscle, and sends branches to the supra-renal capsules. The phrenic arteries inosculate with branches of the internal mammary, intercostal, epigastric, œsophageal, gastric, hepatic, and supra-renal arteries. They are not unfrequently derived from the cœliac axis, or from one of its divisions; and sometimes they give off the supra-renal arteries.

The CÆLIAC AXIS is so named from giving off the three large arteries, gastric, hepatic, and splenic, which pass off from its summit as from a centre. The trunk of the cœliac axis is surrounded by a plexus of nerves, which has received the name of solar plexus; and in the substance of the solar plexus on each side is the semilunar ganglion. The artery cannot be cleaned without destroying these nerves.

The branches of the cœliac axis have been already described (page 459.); as have the superior and inferior mesenteric arteries (pages 456, 458.).

The SPERMATIC ARTERIES are two small vessels which arise from the front of the aorta, below the superior mesenteric. From this origin each artery passes obliquely outwards, and accompanies the corresponding ureter along the front of the psoas muscle to the border of the pelvis, where it is in relation with the external iliac artery. It is then directed outwards to the internal abdominal ring, and follows the course of the spermatic cord, along the spermatic canal and through the scrotum to the testicle, to which it is distributed. The right sper-

on the left renal vein, near its junction with the inferior vena cava. *n, n.* The renal vessels, artery and vein. *o, o.* The kidneys. *p, p.* The ureters descending to the pelvis. *q.* The spermatic arteries; these arteries join the spermatic veins, and form the spermatic cord. *r, r.* The right spermatic vein is seen opening into the inferior cava; the left, into the left renal vein between *m* and *n*. The large trunk between *q* and *h* is the inferior mesenteric artery. *s.* One of the lumbar arteries. *t.* The sacra media. *v, v.* The common iliac arteries; below the left is seen the corresponding vein. *w, w.* The external iliac artery and vein. *x, x.* The internal iliac artery and vein. *y, y.* The lateral sacral arteries. *z, z.* The circumflexa ilii artery. 1, 1. The epigastric artery. 2, 2. The external cutaneous nerve of the thigh. 3, 3. The anterior crural nerve.

matic artery lies in front of the vena cava; and both vessels are accompanied by their corresponding veins and by the spermatic plexuses of nerves.

The spermatic arteries in the female (*ovarian*) descend into the pelvis, and pass between the two layers of the broad ligaments of the uterus, to be distributed to the ovaries, Fallopian tubes, and round ligaments. Along the latter they are continued to the inguinal canal and labium at each side. They inosculate with the uterine arteries.

The SUPRA-RENAL ARTERIES (capsular) are two small vessels which arise from the aorta immediately above the renal arteries, and are distributed to the supra-renal capsules. They are sometimes branches of the phrenic or of the renal arteries.

The RENAL ARTERIES (emulgent) are two large trunks given off from the sides of the aorta, immediately below the superior mesenteric artery. The right is longer than the left, on account of the position of the aorta, and passes behind the vena cava to the kidney of that side. The left is somewhat higher than the right. They divide into several large branches previously to entering the kidney, and ramify very minutely in its vascular portion. The renal arteries supply several small branches to the supra-renal capsules, and one to the ureter.

The LUMBAR ARTERIES correspond with the intercostals in the chest. They are four or five in number on each side, curve around the bodies of the lumbar vertebræ beneath the psoas muscles, and divide into two branches; one of which passes backwards between the transverse processes, and is distributed to the vertebræ, spinal cord and muscles of the back, whilst the other, taking its course behind the quadratus lumborum, supplies the abdominal muscles, and inosculates with branches of the internal mammary and epigastric arteries. The first lumbar artery runs along the lower border of the last rib; and the last, along the crest of the ilium. In passing between the psoas muscle and the vertebræ, they are protected by a series of tendinous arches, which defend them and the communicating branches of the sympathetic nerve from pressure during the action of the muscle.

The SACRA MEDIA arises from the posterior part of the aorta at its bifurcation, and descends along the middle of

the anterior surface of the sacrum to the first piece of the coccyx, where it terminates by inosculating with the lateral sacral arteries. It distributes branches to the rectum and anterior sacral nerves, and inosculates on each side with the lateral sacral arteries.

Varieties in the Branches of the abdominal Aorta.—The phrenic arteries are very rarely both derived from the aorta. One or both may be branches of the celiac axis; one may proceed from the gastric artery, from the renal, or from the upper lumbar artery. There are occasionally three or more phrenic arteries. The celiac axis is very variable in length, and gives off its branches irregularly. There are sometimes two or even three hepatic arteries, one of which may be derived from the gastric or even from the superior mesenteric.

The colica media is sometimes derived from the hepatic artery. The spermatic arteries are very variable both in origin and number. The right spermatic may be a branch of the renal artery, and the left a branch of the inferior mesenteric. The supra-renal arteries may be derived from the phrenic or renal arteries. The renal arteries present several varieties in number; there may be three or even four arteries on one side, and one only on the other. When there are several renal arteries on one side, one may arise from the common iliac artery, from the front of the aorta near its lower part, or from the internal iliac.

COMMON ILIAC ARTERIES. — The bifurcation of the aorta usually takes place on the fourth lumbar vertebra. Sometimes it occurs as high as the third, and occasionally as low as the fifth. The common iliac arteries are about two inches in length. They diverge from the termination of the aorta, and pass downwards and outwards on each side to the margin of the pelvis opposite the sacro-iliac symphysis, where they divide into the external and internal iliac arteries. In old persons the common iliacs are more or less dilated and curved in their course.

The *right* artery is somewhat longer than the left, and forms a more obtuse angle with the termination of the aorta. The angle of bifurcation is greater in the female than in the male.

Both arteries are covered by peritoneum, and are crossed at their point of bifurcation by the ureter. The *left* is furthermore crossed by the rectum and superior hæmorrhoidal artery. Both are in relation, externally, with the psoas muscle, and behind with the common iliac vein, the *right* artery being also in relation with

the left common iliac vein, which crosses behind it, to terminate in the inferior vena cava.

The EXTERNAL ILIAC ARTERY passes obliquely downwards along the inner border of the psoas muscle, from opposite the sacro-iliac symphysis to the femoral arch, where it becomes the femoral artery. It is covered in by the peritoneum and by a thin layer of fascia derived from the iliac fascia, has lying upon it the spermatic vessels, and is crossed near its termination by the crural branch of the genito-crural nerve, and by the circumflexa ilii vein. Externally it is in relation with the psoas muscle, the iliac fascia being interposed; and posteriorly it has the external iliac vein, which at Poupart's ligament is placed to its inner side. The artery is surrounded by lymphatic vessels and several lymphatic glands.

The *branches* of the external iliac artery are two or three small twigs to the psoas muscle and lymphatic glands, the epigastric and circumflexa ilii artery; the two latter are given off close to Poupart's ligament.

The epigastric artery may now be seen taking its course beneath the peritoneum to the sheath of the rectus and forming the prominence of the internal wall of the abdomen, which determines the position of the two fossæ through which the two forms of inguinal hernia proceed. The relation of the artery to the two abdominal rings, internal and external, should be noted, and also its relation to the femoral ring above which it takes its course. It is crossed by the vas deferens; and in the female, by the round ligament of the uterus.

The course and distribution of the artery have been already given (page 427), as well as that of the circumflexa ilii.

The internal iliac artery will be described with the anatomy of the pelvis.

INFERIOR VENA CAVA. — The inferior vena cava is formed by the union of the two common iliac veins, upon the intervertebral substance of the fourth and fifth lumbar vertebræ. It ascends along the front of the vertebral column, on the right of the abdominal aorta; and passing through the fissure in the posterior border of the liver, and the quadrilateral opening in the tendinous centre of the diaphragm, terminates in the inferior and posterior part of the right auricle. There are no valves in this vein.

It is in *relation* from below upwards, *in front* with the mesentery, transverse duodenum, portal vein, pancreas,

and liver, which latter nearly and sometimes completely surrounds it; *behind* it rests on the vertebral column and right crus of the diaphragm, from which it is separated by the right renal and right lumbar arteries; to the *right* it has the peritoneum and sympathetic nerve; and to the *left*, the aorta.

The *branches* which the inferior cava receives in its course are the —

Lumbar,	Supra-renal,
Right spermatic,	Phrenic,
Renal,	Hepatic.

The *lumbar veins*, three or four in number on each side, collect the venous blood from the muscles and integument of the loins, and spinal veins; the left are longer than the right, on account of the position of the vena cava.

The *right spermatic vein* is formed by the two veins which return the blood from the venous plexus of the spermatic cord. These veins follow the course of the spermatic artery, and unite to form the single trunk which opens into the inferior vena cava. The *left spermatic vein* terminates in the left renal vein.

The *ovarian veins* represent the spermatic veins of the male, and collect the venous blood from the ovaries, round ligaments, Fallopian tubes, and communicate with the uterine sinuses. They terminate as in the male.

The *renal or emulgent veins* return the blood from the kidneys; their branches are situated in front of the divisions of the renal arteries, and the left opens into the vena cava somewhat higher than the right. The *left* is longer than the right in consequence of the position of the vena cava, and crosses the aorta immediately below the origin of the superior mesenteric artery. It receives the *left spermatic vein*, which terminates in it at right angles; hence the more frequent occurrence of varicocele on the left than on the right side.

The *supra-renal veins* terminate partly in the renal veins, and partly in the inferior vena cava.

The *phrenic veins* return the blood from the ramifications of the phrenic arteries; they open into the inferior cava.

The EXTERNAL ILIAC VEIN lies to the inner side of the

corresponding artery at the os pubis; but gradually gets behind it as it passes upwards along the brim of the pelvis, and terminates opposite the sacro-iliac symphysis, by uniting with the internal iliac, to form the common iliac vein. Immediately above Poupart's ligament it receives the epigastric and circumflexa ilii vein; it has no valves.

The INTERNAL ILIAC VEIN is formed by vessels which correspond with the branches of the internal iliac artery; it lies to the inner side of the internal iliac artery, and terminates by uniting with the external iliac vein, to form the common iliac.

The COMMON ILIAC VEINS are formed by the union of the external and internal iliac vein on each side of the pelvis. The *right* common iliac, shorter than the left, ascends obliquely behind the corresponding artery; and upon the intervertebral substance of the fourth and fifth lumbar vertebræ, unites with the vein of the opposite side, to form the inferior cava. The left common iliac, longer and more oblique than the right, ascends behind and a little internally to the corresponding artery, and passes beneath the right common iliac artery, near its origin, to unite with the right vein in the formation of the inferior vena cava. The right common iliac vein has no branch opening into it; the left receives the vena sacra media. These veins have no valves.

The SYMPATHETIC NERVE, within the abdomen, consists of a prevertebral portion which is distributed to the viscera, and a vertebral portion which is the proper continuation of the nerve on the vertebral column.

The prevertebral portion consists of the epigastric or solar, and the hypogastric plexus, with the numerous secondary plexuses to which the former gives origin.

The *epigastric*, or *solar plexus*, is an intricate interlacement of nervous cords and branches, situated around the cœliac axis and origin of the superior mesenteric artery, and resting upon the aorta and crura of the diaphragm. Laterally it extends on each side to the supra-renal capsules, and is covered in by the stomach, and on the right side by the inferior vena cava. Besides the nerves, the epigastric plexus has entering into its structure several nervous ganglia, and especially two of large size, the semilunar ganglia.

The *semilunar ganglion* is a large irregular gangliform body, pierced by numerous openings, and appearing like the aggregation of a number of smaller ganglia, having spaces between them. It is situated by the side of the cœliac axis and root of the superior mesenteric artery, and extends outwards to the supra-renal capsules. The ganglia communicate both above and below the cœliac axis, and constitute a gangliform circle from which branches pass off in all directions, like rays from a centre. Hence the appellation *solar plexus*.

The *epigastric plexus* receives the great splanchnic nerves; part of the lesser splanchnic nerves; the termination of the right pneumogastric nerve; some branches from the right phrenic nerve; and sometimes one or two filaments from the left. It sends forth numerous filaments which accompany, under the name of *plexuses*, all the branches given off by the abdominal aorta. Thus we have, derived from this plexus, the—

Phrenic, or diaphrag-	Supra-renal plexuses,
matic plexuses,	Renal plexuses,
Gastric plexus,	Superior mesenteric plexus,
Hepatic plexus,	Aortic plexus,
Splenic plexus,	Spermatic plexuses,
	Inferior mesenteric plexuses.

In connection with the *phrenic plexus* of the right side there is described a small *ganglion diaphragmaticum*, which is situated near the supra-renal capsule. In this ganglion branches of the right phrenic nerve communicate with those of the sympathetic.

The *supra-renal plexuses* are remarkable for their large size, and for a ganglion, which has received the name of ganglion supra-renale.

The *renal plexuses* are also large, and receive the third splanchnic nerve.

The *superior mesenteric plexus* has several small ganglia at the root of the artery and its nerves, which are whiter than those of the other plexuses, form a kind of nervous sheath to the artery and its branches.

The *aortic plexus* is a continuation of the solar plexus downwards on the aorta, for the supply of the inferior branches of that trunk; it receives also branches from the renal plexuses and from the lumbar ganglia. It is

the source or origin of the inferior mesenteric plexus, and part of the spermatic plexus, and it terminates below in the hypogastric plexus. It likewise distributes branches on the inferior vena cava.

The *spermatic plexus* is derived from the renal plexus, but receives filaments from the aortic plexus.

The *inferior mesenteric plexus* is derived chiefly from the aortic plexus.

The HYPOGASTRIC PLEXUS is formed by the termination of the aortic plexus, and by the union of branches from the lower lumbar ganglia. It is situated over the promontory of the sacrum, between the two common iliac arteries, and bifurcates inferiorly into two lateral portions, *inferior hypogastric plexuses*, which communicate with branches from the third and fourth sacral nerves. It distributes branches to all the viscera of the pelvis, and sends filaments which accompany the branches of the internal iliac artery.

The VERTEBRAL portion, or trunk of the sympathetic, is situated on the vertebral column, close to the anterior border of the psoas magnus muscle. It is continuous above, under the edge of the diaphragm, with the thoracic portion of the nerve, and below it descends upon the sacrum, in front of the anterior sacral foramina, to the coccyx. It presents four small lumbar ganglia which are fusiform in shape and of a pearly grey colour.

The branches given off by the ganglia are branches of communication and branches of distribution.

The *branches of communication* are ascending and descending to the ganglion above and below.

The *branches of distribution* are external and internal. The *external branches*, two or three in number, and longer than in the other regions, communicate with the lumbar nerves.

The *internal branches* consist of two sets; of which the upper pass inwards in front of the abdominal aorta, and join the *aortic plexus*; the lower branches cross the common iliac arteries, and unite over the promontory of the sacrum, to form the hypogastric plexus.

LYMPHATIC VESSELS AND GLANDS.—The *deep lymphatic glands of the abdomen* are the lumbar glands; they are very numerous, and are seated around the common iliac vessels, the aorta and vena cava.

The deep lymphatic glands of the pelvis are the external iliac, internal iliac, and sacral.

The *external iliac* are placed around the external iliac vessels, being in continuation by one extremity with the femoral lymphatics, and by the other with the lumbar glands.

The *internal iliac* glands are situated in the course of the internal iliac vessels, and the *sacral* glands are supported by the concave surface of the sacrum.

The *deep lymphatic vessels* are continued upwards from the thigh, beneath Poupart's ligament, and along the external iliac vessels to the lumbar glands, receiving in their course the epigastric, circumflexa ilii, and ilio-lumbar lymphatic vessels. Those from the parietes of the pelvis, and from the gluteal, ischiatic, and obturator vessels follow the course of the internal iliac arteries, and unite with the lumbar lymphatics. And the lumbar lymphatic vessels, after receiving all the lymphatics from the lower extremities, pelvis, and loins, terminate by several large trunks in the receptaculum chyli.

To see the receptaculum chyli and commencement of the thoracic duct, the inferior vena cava which was divided on the removal of the liver, and drawn aside for the examination of the right semi-lunar ganglion, should now be further drawn aside or turned down to reach the vertebral column. Any cellular tissue and fat which may impede the view, should be removed.

The *receptaculum chyli* is a triangular oblong sac, the reservoir of the lymphatics of the lower half of the body; it is situated on the front of the body of the second lumbar vertebra, behind and between the aorta and inferior vena cava, and close to the tendon of the right crus of the diaphragm. It receives, by its lower part, four or five large lymphatic trunks, and above, where it becomes narrowed, in order to constitute the thoracic duct, it is joined by the trunks of the lacteals. The upper part of the receptaculum chyli contracts its dimensions to the size of a small quill, and becomes the thoracic duct, which ascends through the aortic opening in the diaphragm, to terminate in the root of the neck at the junction of the left internal jugular with the left subclavian vein. In the aortic opening, and between the two crura of the diaphragm, it is situated between the aorta, which is to the left, and the vena azygos major, which is to the right.

DEEP MUSCLES OF THE ABDOMEN.

The deep muscles of the abdomen are the—

Diaphragm,	Psoas parvus,
Psoas magnus,	Iliacus internus,
Quadratus lumborum.	

The peritoneum should now be dissected carefully from the surface of the diaphragm, and any cellular tissue or fat removed which may in any way obscure it. Its border of attachment to the ribs, and particularly its posterior border and the lesser muscle, should also be carefully made out.

The DIAPHRAGM is the muscular septum between the thorax and abdomen, and is composed of two portions, a greater and a lesser muscle. The *greater muscle* arises from the ensiform cartilage; from the inner surface of the six inferior ribs, indigitating with the transversalis; and from the ligamentum arcuatum externum and internum. From these points, which form the internal circumference of the trunk, the fibres converge and are *inserted* into the central tendon.

The *ligamentum arcuatum externum* is the upper border of the anterior lamella of the aponeurosis of the transversalis; it arches across the origin of the quadratus lumborum muscle, and is attached, by one extremity, to the base of the transverse process of the first lumbar vertebra, and by the other, to the apex and lower margin of the last rib.

The *ligamentum arcuatum internum*, or *proprium*, is a tendinous arch thrown across the psoas magnus muscle as it emerges from the chest. It is attached by one extremity to the base of the transverse process of the first lumbar vertebra, and by the other is continuous with the tendon of the lesser muscle opposite the body of the second.

The *tendinous centre* of the diaphragm is shaped like a trefoil leaf, of which the central leaflet points to the ensiform cartilage, and is the largest; the lateral leaflets, right and left, occupy the corresponding portions of the muscle; the right being the larger and more rounded, and the left smaller and lengthened in its form.

Between the sides of the ensiform cartilage and the cartilages of the adjoining ribs, is a small triangular space where the muscular fibres of the diaphragm are deficient.

This space is closed only by peritoneum on the side of the abdomen, and by pleura within the chest. It is therefore a weak point, and a portion of the contents of the abdomen might, by violent exertion, be forced through it, producing phrenic, or diaphragmatic hernia.

The *lesser muscle* of the diaphragm takes its origin from the bodies of the lumbar vertebræ, by two tendons. The *right*, larger and longer than the left, arises from the anterior surface of the bodies of the second, third, and fourth vertebræ; and the *left*, from the side of the second and third. The tendons form two large fleshy bellies (*crura*, pillars), which ascend, to be inserted into the central tendon. The inner fasciculi of the two crura cross each other in front of the aorta, and again diverge, to surround the œsophagus, so as to present the appearance of a figure of eight. The anterior fasciculus of the decussation is formed by the right crus.

The *openings in the diaphragm* are three: one, quadrilateral, in the tendinous centre, at the union of the right and middle leaflets, for the passage of the *inferior vena cava*; a muscular opening of an elliptic shape formed by the two crura, for the transmission of the *œsophagus* and *pneumogastric nerves*; and a third, the *aortic*, which is formed by a tendinous arch thrown from the tendon of one crus to that of the other, beneath which pass the *aorta*, the *right vena azygos*, and the *thoracic duct*. The great splanchnic nerves pass through openings in the lesser muscle on each side; and the lesser splanchnic nerves, between the fibres which arise from the ligamentum arcuatum internum.

The diaphragm, being interposed between the viscera of the chest and abdomen, is important in its relations to the organs contained in the two cavities. Above it is in contact with the pleuræ, pericardium, heart, and lungs. By its *inferior surface*, with the peritoneum; on the left, with the stomach and spleen; on the right, with the convexity of the liver; and behind, with the kidneys, supra-renal capsules, duodenum, and solar plexus. By its *circumference*, with the ribs, intercostal muscles, and vertebral column.

To see the next muscle, the *psoas magnus*, a thin fascia must be laid open and turned aside. This fascia is a prolongation upwards of the iliac fascia, much attenuated in substance. It is attached to the bodies of the vertebræ leaving an arched space corresponding with the constricted portion of each vertebra, for the passage of the lumbar vessels and external branches of the sympathetic nerve. Externally it is connected with the aponeurosis of the transversalis

muscle; and above, with the ligamentum arcuatum internum. Lower down it is attached to the brim of the pelvis. The removal of the fascia brings into view the psoas magnus and parvus, and a nerve which pierces the muscle at about its middle and lies upon its anterior surface, the genito-crural; care must be taken not to injure this nerve in the dissection of the fascia.

The **PSOAS MAGNUS** ($\psi\acute{o}\alpha$, lumbus), situated by the side of the vertebral column in the loin, is a long fusiform muscle. It *arises* from the sides of the bodies of the last dorsal and all the lumbar vertebræ, from their intervertebral substances, transverse processes, and the tendinous arches which are thrown across the constricted portion of the vertebræ, to protect the lumbar arteries and external branches of the sympathetic nerve from pressure in their passage beneath the muscle. From this extensive origin the muscle passes along the brim of the pelvis and beneath Poupart's ligament to its *insertion* into the trochanter minor of the femur.

This muscle issues from beneath the ligamentum arcuatum internum above, and is in relation, by its anterior surface, with the psoas parvus, kidney, and genito-crural nerve which pierces it at about its middle and then lies on its anterior surface. By its inner border and surface it is in relation with the lumbar vessels, the sympathetic nerve with its external branches, and, lower down, with the iliac vessels. Its substance is traversed by the nerves constituting the lumbar plexus; and in the iliac fossa it has, escaping from beneath it and then lying along its outer border, the anterior crural nerve.

The **PSOAS PARVUS** is a small and infrequent muscle, which *arises* from the last dorsal and first lumbar vertebra, and from the intervertebral substance between them; it passes beneath the ligamentum arcuatum internum, and terminates in a long slender tendon which expands inferiorly and is *inserted* into the ilio-pectineal line and eminence. The tendon is continuous, by its outer border, with the iliac fascia.

To see the abdominal or pelvic portion of the iliacus internus muscle, the iliac fascia must be removed, and care must be taken to avoid injury to a nerve which crosses the iliacus muscle, the external cutaneous, and the anterior crural nerve which lies in the groove between the psoas and iliacus.

The *iliac fascia* is a thin aponeurosis which covers in the iliacus muscle, and is continued upwards upon the front of the psoas to the ligamentum arcuatum internum. It is attached to the inner lip of the crest of the ilium,

and passing behind the iliac vessels, is connected with the brim of the pelvis. Inferiorly, at Poupart's ligament, it is connected with the fascia transversalis, and at the inner third of that ligament forms the posterior part of the femoral sheath.

The ILIACUS MUSCLE *arises* from the whole extent of the inner concave surface of the ilium; and by a few fibres from the base of the sacrum. This muscle passes beneath Poupart's ligament, to be *inserted* with the psoas into the trochanter minor of the femur.

The QUADRATUS LUMBORUM muscle is concealed from view by the anterior lamella of the aponeurosis of the transversalis muscle, which is inserted into the bases of the transverse processes of the lumbar vertebræ. When this lamella is divided, the muscle will be seen to consist of two portions: one, the external, *arising* from the ilio-lumbar ligament and crest of the ilium for two inches in extent, and *inserted* into the apices of the transverse processes of the four upper lumbar vertebræ (sometimes also the last dorsal) and last rib; the other, the inner and anterior portion, *arises* by tendinous slips from the transverse processes of the three or four lower lumbar vertebræ, and passes upwards, to be *inserted* into the lower border of the last rib. If the muscle be cut across or removed, the middle lamella of the transversalis will be seen attached to the apices of the transverse processes; the quadratus being enclosed between the two lamellæ as in a sheath.

ACTIONS.—The diaphragm is an inspiratory muscle, the contraction of its fibres increasing the cavity of the chest. It acts also as a muscle of expulsion by pressing upon the abdominal viscera, as in the expulsion of the excretions, of the fœtus, &c. The spasmodic action of the muscle produces hiccup, sobbing, &c.

The psoas and iliacus muscles flex the trunk upon the lower extremities or the legs upon the pelvis, at the same time everting the foot. The quadratus lumborum is an expiratory muscle, and assists in fixing the chest.

The psoas magnus, if not previously removed for the examination of the quadratus lumborum, must now be carefully dissected from its origin, for the purpose of bringing into view the lumbar plexus of nerves, which is situated in the substance of the muscle.

LUMBAR NERVES.

There are five pairs of lumbar nerves, of which the first makes its appearance between the first and second

lumbar vertebræ, and the last between the fifth lumbar and the base of the sacrum. The *anterior* branches increase in size from above downwards. At their exit from the intervertebral foramina they receive the external branch of the lumbar ganglia of the sympathetic, and pass obliquely outwards behind the psoas magnus, or through its substance, sending twigs to that muscle and to the quadratus lumborum. In this situation each nerve divides into two branches: a superior branch which ascends, to form a loop of communication with the nerve above; and an inferior branch which descends, to join in like manner the nerve below. The communications and anastomoses which are thus established, constitute the lumbar plexus.

The *posterior* branches diminish in size from above downwards; they pass backwards between the transverse processes of the corresponding vertebræ, and each nerve divides into an internal and an external branch. The *internal* branch, the smaller of the two, passes inwards, to be distributed to the multifidus spinæ and interspinales; and becoming cutaneous, supplies the integument of the lumbar region on the middle line. The *external* branches communicate with each other by several loops; and after supplying the deeper muscles, pierce the sacro-lumbalis, to reach the integument to which they are distributed. The external branches of the three lower lumbar nerves (*nervi clunium superiores postici*) descend over the posterior part of the crest of the ilium, and are distributed to the integument of the gluteal region.

LUMBAR PLEXUS.—The lumbar plexus is formed by the communications and anastomoses which take place between the anterior branches of the four upper lumbar nerves, and between the latter and the last dorsal. It is narrow above, increases in breadth inferiorly, and is situated between the transverse processes of the lumbar vertebræ and quadratus lumborum behind, and the psoas magnus muscle in front.

The *branches* of the *lumbar plexus* are the—

Ilio-hypogastric,	External cutaneous,
Ilio-inguinal,	Obturator,
Genito-crural,	Anterior crural.

The ILIO-HYPOGASTRIC NERVE proceeds from the first lumbar nerve, and passes obliquely outwards between the

fibres of the *psoas magnus*, and across the *quadratus lumborum* to about the middle of the crest of the ilium. It then pierces the *transversalis* muscle, and between it and the internal oblique divides into its two terminal branches, iliac and hypogastric; the former being distributed to the integument of the hip; and the latter, to that of the hypogastric region and external organs of generation (pages 36, 418.).

The *ILIO-INGUINAL NERVE*, smaller than the preceding, also arises from the first lumbar nerve. It passes obliquely downwards and outwards below the ilio-hypogastric nerve, and crosses the *quadratus lumborum* and *iliacus* muscle in its course to the anterior part of the crest of the ilium: it then pierces the *transversalis* muscle; next, the internal oblique; and escaping at the external abdominal ring with the spermatic cord, is distributed to the scrotum and inner part of the thigh; in the female, to the pudendum (pages 13, 419.).

The *GENITO-CRURAL NERVE* proceeds from the second lumbar nerve, and by a few fibres from the loop between it and the first. It traverses the *psoas magnus* from behind forwards, and runs down the anterior surface of that muscle, lying beneath its fascia, to near Poupert's ligament, where it divides into a genital and a crural branch.

The *genital branch* (n. spermaticus, seu pudendus externus) crosses the external iliac artery to the internal abdominal ring, and descends along the posterior aspect of the spermatic cord to the scrotum. It is distributed to the cord and cremaster muscle; and in the female, to the round ligament and labium pudendi (page 432.).

The *crural branch* (*lumbo-inguinalis*) descends along the outer side of the external iliac artery, and crossing the origin of the *circumflexa ilii* artery enters the femoral sheath, in front of the femoral artery. It pierces the sheath below Poupert's ligament, and is distributed to the integument of the upper and inner part of the thigh (page 13.).

The *EXTERNAL CUTANEOUS NERVE* (*inguino-cutaneous*) proceeds from the second lumbar, and from the loop between it and the third. It pierces the posterior fibres of the *psoas* muscle; and crossing the *iliacus* lying upon the iliac fascia, to the anterior superior spinous process of

the ilium, passes into the thigh beneath Poupart's ligament. It is distributed to the integument of the outer aspect of the thigh as far as the knee (page 14.).

The ANTERIOR CRURAL NERVE is the largest of the divisions of the lumbar plexus: it is formed by the union of cords from the second, third, and fourth lumbar nerves. Emerging from beneath the psoas muscle, it passes downwards in the groove between the psoas and iliacus, and beneath Poupart's ligament, into the thigh. At Poupart's ligament it is separated from the femoral artery by the breadth of the psoas muscle, which at this point is scarcely more than half an inch in diameter, and by the iliac fascia beneath which it lies.

Its *branches* within the pelvis are three or four twigs to the iliacus muscle, and a long filament to the femoral artery.

The OBTURATOR NERVE is formed by a branch from the third, and another from the fourth lumbar nerve; it takes its course among the fibres of the psoas muscle, through the angle of bifurcation of the common iliac vessels, and along the inner border of the brim of the pelvis, to the obturator foramen, where it joins the obturator artery, and passes into the thigh. It is distributed to the muscles of the inner aspect of the thigh, and to the hip and knee joint, (page 30.).

A small nerve is sometimes met with in association with the obturator, termed the *accessory obturator nerve*. This nerve may be a high division of the obturator, or it may arise separately from the third and fourth lumbar nerves. It passes down the inner border of the psoas muscle, and crosses the os pubis, to enter the thigh (page 30.).

LUMBO-SACRAL NERVE.—The anterior division of the fifth lumbar nerve, conjoined with a branch from the fourth, constitutes the lumbo-sacral nerve, which descends over the base of the sacrum into the pelvis, and assists in forming the sacral plexus.

CHAPTER IX.

PELVIS AND ORGANS OF GENERATION.

THE cavity of the pelvis is that portion of the great abdominal cavity which is included within the bones of the pelvis below the level of the linea ilio-pectinea and the promontory of the sacrum. It is bounded by the cavity of the abdomen above, and by the perineum below. Its internal parietes are formed in front, below, and at the sides, by the peritoneum, pelvic fascia, levatores ani and obturator muscles; and behind by the coccygei muscles, sacro-ischiatic ligaments, pyriformis muscle, sacral plexus of nerves, sacrum, and coccyx.

The VISCERA of the pelvis in the male, are the urinary bladder, vesiculæ seminales, prostate gland, and rectum; and in the female, the urinary bladder, uterus, vagina, and rectum.

Viewed from above, the urinary bladder will be seen to form a convexity, pointed in the male, more obtuse in the female, behind the ossa pubis; the rectum, flexuous in its course, rests against the sacrum. In the male, the bladder and rectum are in contact; in the female, the uterus is interposed, and with its broad ligaments stretching out on each side forms a transverse septum, which divides the cavity of the pelvis into an anterior and a posterior part.

The *peritoneum* invests the pelvic viscera only partially; thus it forms a complete covering for the upper portion of the rectum, and connects it by a duplicature (meso-rectum) to the surface of the sacrum; lower down it covers only the anterior surface of the rectum, and is reflected from it upon the posterior surface of the bladder. The fold or pouch, formed between the rectum and the bladder, is the *recto-vesical*. In the female, the pouch intervenes between the rectum and the vagina, and is the *recto-vaginal*; and a second pouch is formed between the uterus and bladder, the *utero-vesical* fold. From the

sides of the bladder the peritoneum ascends upon the walls of the pelvis, and its reflection from the sides of the organ to the pelvis have been named *false ligaments of the bladder*.

The PELVIC FASCIA is an aponeurotic layer situated beneath the peritoneum, forming a covering to the walls of the pelvis, and reflected from its walls upon the viscera. The pelvic fascia is attached to the internal surface of the ossa pubis near the symphysis, to the body of the pubes above the origin of the obturator internus muscle, to the ilio-pectineal line of the brim of the pelvis as far back as the sacro-iliac articulation, and to the margin of the great sacro-ischiatic foramen. Having descended upon the wall of the pelvis as low as the pubic arch in front, and the spine of the ischium behind, it divides, in the direction of a line drawn between those points, into *two* layers, internal and external. The *internal* layer (recto-vesical) is continued downwards to the prostate gland, neck of the bladder, (vagina), and rectum, to which it is closely attached; and is reflected for a short distance upwards and downwards on these viscera. This layer is in contact, by its external surface, with the levator ani muscle and coccygeus; and is prolonged backwards over the sacral nerves to the lower part of the sacrum and the coccyx, to which it is attached, meeting on the middle line the layer of the opposite side. The *external* layer is the obturator fascia, it covers in the obturator muscle, and is attached to the ramus of the pubes and ischium in front, and to the tuberosity of the ischium and falciform border of the great sacro-ischiatic ligament below. The levator ani arises from the line of division of the two preceding layers, and the obturator layer sends off a thin aponeurotic expansion which covers the external surface of that muscle. The obturator fascia, together with this aponeurotic expansion, constitute, the *ischio-rectal fascia* which lines the ischio-rectal fossa, and is attached in front to the triangular ligament of the perineum.

The anterior part of the pelvic fascia is separated from its fellow of the opposite side by a narrow interval, and the fascia passing from the side of the symphysis to the upper part of the prostate gland and front of the neck of the bladder, constitutes the *anterior true ligament of the bladder* (pubio-vesical); a little further outwards, the

fascia passing to the side of the neck of the bladder, constitutes its *lateral true ligament*; and reflected forwards from the neck of the bladder upon the prostate, it forms a sheath for that gland which encloses the prostatic plexus of veins. Upon the rectum and vagina it also forms a sheath.

The student must now turn his attention to the study of the viscera of the pelvis; therefore, after examining their relative position from above, he should proceed to separate the os innominatum of the left side, so as to obtain a side view of these organs. For this purpose he must divide the pubes with the saw on the left side, a little external to the symphysis. Then let him cut through the psoas muscle and iliac vessels opposite the sacro-iliac symphysis, and divide the ligaments of that articulation. Next cut away with the scalpel the structures adhering to the inner surface of the pubes and ilium of the same side; taking care to separate the pelvic fascia from its connections and from the surface of the obturator muscle; then snip across the spine of the ischium, so as to leave the attachments of the levator ani, coccygeus, and lesser sacro-ischiatic ligament; and after cutting through the pyriformis muscle, remove the bone altogether.

The MUSCLES brought into view by this dissection are the coccygeus and levator ani.

The COCCYGEUS muscle is a thin triangular muscle. It *arises* from the spine of the ischium and lesser sacro-ischiatic ligament, and spreads out to be *inserted* into the side of the coccyx and lower part of the sacrum. The coccygeus rests upon the lesser sacro-ischiatic ligament, and is in relation, by its posterior border, with the pyriformis; and by the anterior, with the levator ani.

The LEVATOR ANI is a thin muscle, situated between the two layers (recto-vesical and obturator) of the pelvic fascia, and, forming, with its fellow of the opposite side, a movable boundary to the outlet of the pelvis. It *arises* from the inner surface of the os pubis, near the pubic arch, from the base and upper border of the spine of the ischium, and between these points from a tendinous arch, which occupies the line of division of the pelvic fascia. Its fibres descend, to be *inserted* into its fellow of the opposite side beneath the prostate gland, into the rectum, and behind the rectum, into its fellow of the opposite side and the side of the extremity of the coccyx.

The anterior and posterior borders of the levator ani are thicker than the rest of the muscle, from the larger

extent of origin of the muscular fibres; the anterior border arising in part from the ramus of the pubes, and the posterior from the posterior border of the spine of the ischium. The anterior border of the two muscles is separated by a space which gives passage to the urethra, and in the female, to the vagina. This space is closed within the pelvis by the pelvic fascia and anterior ligaments of the bladder. The anterior portion of the muscle forms a loop beneath the prostate gland with the corresponding portion of the opposite side; and this portion has been described under the names of *levator* or *compressor prostaticæ*.

The ACTION of the coccygeus muscle is to flex the coccyx; that of the levator ani, to lift the prostate gland, lower part of the anus and coccyx, and thus contract the space of the outlet of the pelvis. The levatores ani are antagonistic of the diaphragm and the rest of the expulsive muscles, and serve to support the rectum and vagina during their expulsive efforts. The levator ani acts in unison with the diaphragm, and rises and falls like that muscle in forcible respiration. Yielding to the propulsive action of the abdominal muscles, it enables the outlet of the pelvis to bear a greater force than a resisting structure, and on the remission of such action it restores the perineum to its original form.

When the coccygeus and levator ani muscle are removed, the recto-vesical layer of the pelvic fascia may be traced to its attachments to the neck of the bladder and rectum, and over the prostate gland, to which it forms a sheath.

The recto-vesical fascia may now be turned down, and the cellular tissue and fat removed from the side of the bladder, recto-vesical pouch of the peritoneum and rectum. The dissection may be facilitated by blowing air into the bladder, and placing a little cotton wool in the recto-vesical pouch of the peritoneum, and also into the rectum; but care should be taken to avoid over distention of these parts; it would be better to leave them flaccid than to stretch their coats. In the progress of this dissection the remains of the hypogastric artery should be followed forwards to the abdominal parietes, and the ureter to the side of the bladder; the vas deferens should also be traced downwards behind the vesicula seminalis to the base of the prostate.

The RECTUM.—The rectum, between seven and eight inches in length, commences at the sacro-iliac symphysis on the left side, and terminates at the anus. It is divided anatomically into three portions, upper, middle, and lower. The *upper* portion, comprising half its length, is completely surrounded by the peritoneum, which connects it to the wall of the pelvis by means of the meso-rectum.

It is in relation with the left internal iliac vessels, ureter, and sacral plexus of nerves. The *middle* portion, three inches in length, and extending from opposite the middle of the sacrum to the tip of the coccyx, is covered by peritoneum only in front and for two-thirds of its extent. It is in relation behind with the sacrum and coccyx, and in front with the vesiculæ seminales, the triangular portion of the bladder situated between those organs, and the prostate gland. The *lower* portion, an inch and a half in length, curves backwards from the prostate gland opposite the tip of the coccyx, to the anus. This portion is more or less dilated, and is supported by the levatores ani.

URINARY BLADDER.

The urinary bladder is a hollow membranous viscus, triangular and flattened against the pubes when empty, ovoid when distended, situated behind the pubes and in front of and upon the rectum. It is larger in its vertical diameter than from side to side, and its long axis is directed from above obliquely downwards and backwards.

The bladder is divided into body, fundus, base, and neck. The *body* comprehends the middle zone of the organ; the *fundus* (superior fundus), its upper segment; the *base* (inferior fundus) the lower broad extremity which rests on the rectum; and the *neck*, the narrow constricted portion which is applied against the prostate gland.

It is retained in position by *ligaments*, which are divisible into true and false. The *true* ligaments are five in number, two anterior, two lateral, and the cord of the urachus. The *false* ligaments are folds of the peritoneum, and are also five in number, two posterior, two lateral, and one superior.

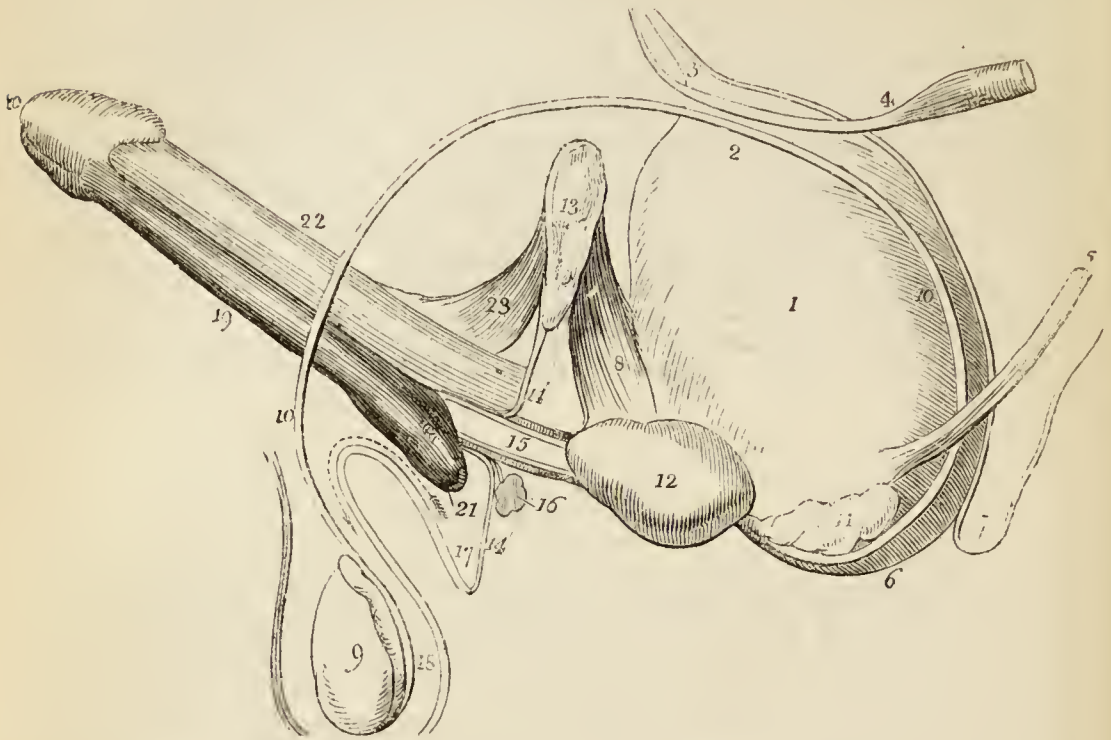
The *anterior ligaments* are formed by the recto-vesical fascia in its passage from the inner surface of the pubes on each side of the symphysis to the neck of the bladder and prostate gland.

The *lateral ligaments* are also formed by the recto-vesical fascia in its passage from the levatores ani muscles to the sides of the prostate gland and neck of the bladder.

The *ligament of the urachus* is a fibrous cord resulting

from the obliteration of a tubular canal (urachus) existing in the embryo. It proceeds from the summit of the

*Fig. 70.**



bladder, and ascends along the linea alba to the umbilicus.

* A side view of the male organs of generation, with a section of the perineum.—No. 1. The body of the bladder. 2. Its fundus. 3. The urachus, proceeding from the apex of the bladder, and covered by peritoneum. 4. The umbilical artery at the point where it becomes obliterated, and forms a fibrous cord which passes forwards by the side of the bladder, and then ascends to the umbilicus. 5. The ureter. 6. The base of the bladder. 7. The fold of peritoneum formed between the rectum and bladder. 8. The anterior ligaments of the bladder. 9. The testicle. 10, 10. The vas deferens. 11. The vesicula seminalis of the left side. 12. The prostate gland. 13. The symphysis pubis. 14, 14. The triangular ligament. 15. The membranous portion of the urethra. The dark bands immediately above and below this portion of the urethra, are the cut edges of the compressor urethrae muscle. 16. One of Cowper's glands. 17. The continuation of the triangular ligament, with the superficial fascia, which proceeds forwards upon the bulb, and is then lost in the dartos of the scrotum (18.). The space in which the number (17.) is situated, is that occupied by the muscles, vessels, and nerves of the perineum: the arrow marks the direction which urine would take when infiltrated into the perineum. 19. The corpus spongiosum penis. 20. The glans penis. 21. The bulb. 22. The corpus cavernosum of the left side. 23. The ligamentum suspensorium penis.

The *posterior false ligaments* are the fold of peritoneum formed on each side of the pelvis by the obliterated hypogastric artery; this fold also contains the ureter and the vessels and nerves of the bladder.

The *lateral false ligaments* are formed by the passage of the peritoneum, from the side of the pelvis to the side of the bladder. The obliterated hypogastric artery lies along the line of reflection of the membrane.

The *superior* or *suspensory* false ligament is the fold of peritoneum caused by the prominence of the cord of the urachus and the cords of the obliterated hypogastric arteries.

The bladder is composed of four coats, serous, muscular, cellular, and mucous.

The *serous coat* is partial and derived from the peritoneum, which invests the posterior surface and sides of the bladder from about opposite the point of termination of the ureters to its summit, whence it is guided to the anterior wall of the abdomen by the hypogastric cords and urachus.

The *muscular coat* consists of two layers: an external layer composed of longitudinal fibres, the detrusor urinæ; and an internal layer of oblique and circular fibres irregularly distributed. The longitudinal fibres arise from the anterior ligaments of the bladder (tendons of the detrusor urinæ), the neck of that organ, and the base of the prostate gland, and spread out as they ascend to the fundus; here a small fasciculus follows the course of the urachus, but the greater number converge upon the posterior surface of the organ and descend to its neck, where they are inserted into the isthmus of the prostate gland, and into a ring of muscular tissue, which surrounds the commencement of the prostatic portion of the urethra. In the female they are inserted into the vagina. The lateral fibres commence at the prostate gland and muscular ring of the urethra on one side, and spread out as they ascend upon the side of the bladder, to descend upon the opposite side, and be inserted into the prostate and opposite segment of the same ring. Two bands of oblique fibres are described by Sir Charles Bell, as originating at the terminations of the ureters, and converging to the neck of the bladder; the existence of these muscles is not well established. The fibres corresponding with the trigonum vesicæ are transverse.

Mr. Guthrie*, observes that there are no fibres at the neck of the bladder capable of forming a sphincter vesicæ; but Mr. Lane † has described a fasciculus of muscular fibres which surround the com-

* "On the Anatomy and Diseases of the Neck of the Bladder and of the Urethra."

† Lancet, vol. i. 1842-3, p. 670.

mencement of the urethra, and perform such an office. These fibres form a narrow bundle above the urethra, but spread out below, behind the prostate gland: they are brought into view by dissecting off the mucous membrane from around the orifice of the urethra.

Sir Astley Cooper has described around the urethra, within the prostate gland, a ring of elastic tissue, or, rather, according to Mr. Lane, of muscular fibres, which has for its object the closure of the urethra against the involuntary passage of the urine. It is into this ring that the longitudinal fibres of the detrusor urinæ are inserted, so that the muscle, taking a fixed point at the pubes, will not only compress the bladder, and thereby tend to force its contents along the urethra, but will at the same time, by means of its attachment to the ring, dilate the entrance of the urethra, and afford a free egress to the contents of the bladder.

The *cellular*, or submucous coat is the thick layer of cellular tissue, which is interposed between the mucous and muscular coat, and forms the bond of union between them.

The *mucous coat* is thin and smooth, of a pale rose colour, and exactly moulded on the muscular coat, to which it is connected by the cellular coat; its papillæ are very minute, and there are a number of mucous follicles, especially near the neck of the organ. This mucous membrane is continuous, through the ureters, with the lining membrane of the uriniferous ducts, and through the urethra, with that of the prostatic ducts, tubuli seminiferi, and Cowper's glands. The cells of the epithelium are of the spheroidal kind.

Upon the internal surface of the base of the bladder is a triangular smooth plane, of a paler colour than the rest of the mucous membrane, the trigonum vesicæ, or *trigone vesicale*. This is the most sensitive part of the bladder, and the pressure of calculi upon it gives rise to great suffering. It is bounded on each side by the raised ridge, corresponding with the muscles of the ureters, at each posterior angle by the openings of the ureters, and in front by a slight elevation of the mucous membrane at the entrance of the urethra, called *uvula vesicæ*.

The external surface of the base of the bladder corresponding with the trigonum, is also triangular, and is separated from the rectum by a thin layer of fibrous membrane, derived from the recto-vesical fascia. It is bounded behind by the recto-vesical fold of peritoneum; and on each side by the vas deferens and vesicula seminalis, which converge almost to a point at the base of the prostate gland. It is through this space that the opening is made in the recto-vesical operation for puncture of the bladder.

The *arteries* of the urinary bladder are the *superior vesical*, three or four small branches which proceed from the commencement of the hypogastric artery, previously to its complete obliteration; and the *inferior vesical*, from the internal iliac. The latter is distributed to the base of the bladder, vesiculæ seminales, and prostate gland. The *veins* are numerous and of large size, and form a plexus around the neck and at the base of the bladder; the plexus communicates with the prostatic plexus and with the hæmorrhoidal veins. The *nerves* of the bladder are derived from the inferior hypogastric plexuses and their communications with the third and fourth sacral nerves.

PROSTATE GLAND.

The prostate gland (*προΐστημι*, præponere) is situated in front of the neck of the bladder, behind the triangular ligament and pelvic fascia, and upon the rectum, through which latter it may be felt with the finger. It surrounds the commencement of the urethra for somewhat more than an inch of its extent, and resembles a Spanish chestnut both in size and form; the base being directed backwards towards the neck of the bladder, the apex forwards, and the convex side towards the rectum. It is retained firmly in position by the anterior and lateral ligaments of the bladder, and by a process of the recto-vesical fascia, which forms a sheath around it. It consists of three lobes, two lateral and a middle lobe or isthmus; the lateral lobes are distinguished by an indentation on the base of the gland, and a slight furrow on its upper and lower surface. The third lobe, or isthmus, is a small transverse band which passes between the two lateral lobes at the base of the organ.

In structure the prostate gland is composed of ramified ducts, terminating in lobules of follicular pouches, which are so closely compressed as to give to a thin section of the gland a cellular appearance. It is pale in colour and hard in texture, splits easily in the course of its ducts, and is surrounded by a proper fibrous covering, and by a plexus of veins which are enclosed by the sheath derived from the recto-vesical fascia. Its secretion is poured into the prostatic portion of the urethra by fifteen or twenty excretory ducts. The ducts of the lateral lobes open into the urethra on each side of the *veru montanum*; those of the third lobe open upon and behind the *veru*. The urethra, in passing through the prostate, lies one-third nearer its upper, than its lower surface.

The *arteries* of the prostate gland are small and derived from the inferior vesical and middle hæmorrhoidal. The *veins* form a plexus

around the gland, which receives from the front the veins of the penis, and terminates in the vesical plexus.

VESICULÆ SEMINALES.

On the under surface of the base of the bladder, and converging towards the base of the prostate gland, are two lobulated and somewhat pyriform bodies, about two inches in length, the vesiculæ seminales. Their upper surface is in contact with the base of the bladder; the under side rests on the rectum, separated only by a process derived from the recto-vesical fascia; the larger extremities are directed backwards and outwards, and the smaller ends almost meet at the base of the prostate. They enclose between them a triangular space, which is bounded posteriorly by the recto-vesical fold of peritoneum, and corresponds with the trigonum vesicæ on the interior of the bladder. Each vesicula is formed by the convolutions of a single tube, which gives off several irregular cæcal branches. It is enclosed in a fibrous membrane, derived from the recto-vesical fascia, and is constricted beneath the isthmus of the prostate gland into a small excretory duct. The vas deferens, somewhat enlarged and sacculated, lies along the inner border of each vesicula, and is included in its fibrous investment. It communicates with the duct of the vesicula, beneath the isthmus of the prostate, and forms the ejaculatory duct.

The ejaculatory duct is about three quarters of an inch in length, and running forwards, first between the base of the prostate and the isthmus, and then through the tissue of the veru montanum, opens on the mucous membrane of the urethra, by the side of, or within the aperture of the sinus pocularis.

In *structure* the vesiculæ seminales are composed of three coats: *external*, which is cellular; *middle*, fibrous and contractile; and *internal* or *mucous*, a thin mucous membrane, presenting a delicate reticular marking, like that of the gall-bladder, and invested by a squamous epithelium.

The bladder and rectum may now be turned down, and the peritoneum removed from the right wall of the pelvis. This will bring into view the pelvic fascia and its recto-vesical layer, which may be examined from the inside. In the next place the internal iliac artery should be sought for in the posterior false ligament of the

bladder, and the cellular tissue and fat which conceal it and its branches removed.

The ARTERIES of the pelvis are the internal iliac and its branches; the superior hæmorrhoidal, from the inferior mesenteric; and the arteria sacra media, from the aorta.

The INTERNAL ILIAC ARTERY is a short trunk between one and two inches in length. It proceeds from the common iliac artery, opposite the sacro-iliac symphysis, and passes obliquely downwards and forwards, to a level with the upper border of the sacro-ischiatic foramen, where it separates into an *anterior* and *posterior* division. From the extremity of the artery, a fibrous cord is continued onwards by the side of the bladder to near its summit, and thence onwards by the side of the linea alba to the umbilicus: this is the remains of the hypogastric artery of the fœtus.

In the fœtus the internal iliac artery, under the name of *hypogastric*, takes the course just indicated, and becomes the umbilical artery. After birth, the artery ceases to be pervious beyond the side of the bladder, where it gives off the superior vesical arteries.

The internal iliac artery is in relation in front with the ureter; behind, with the internal iliac vein; and towards the wall of the pelvis, with the sacral plexus and pyriformis.

The *branches* of the internal iliac are, from the anterior trunk, the —

Superior vesical,	Vaginal,
Inferior vesical,	Obturator,
Middle hæmorrhoidal,	Ischiatic,
Uterine,	Internal pudic;

from the posterior trunk, the —

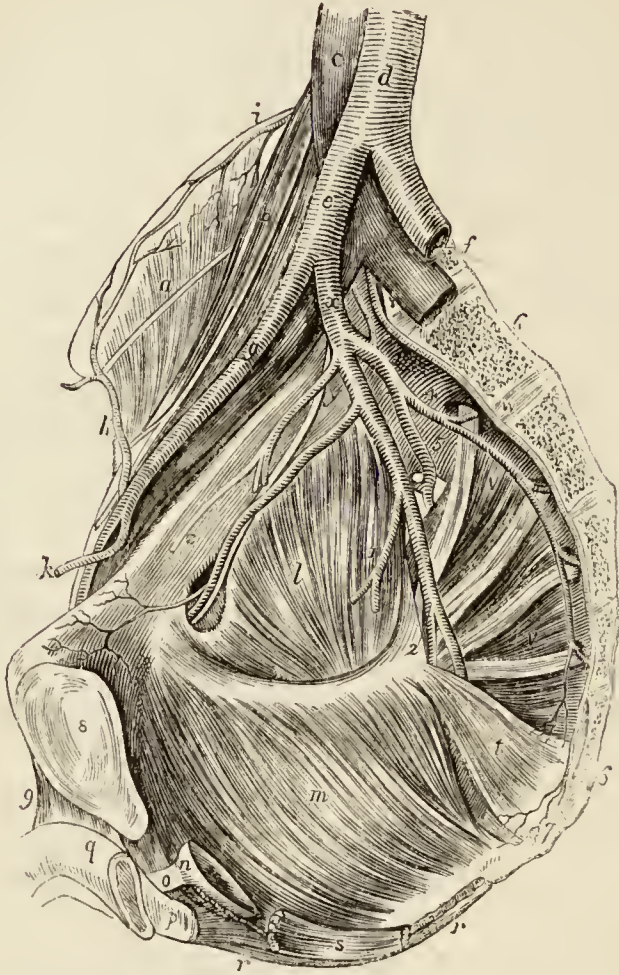
Ilio-lumbar,	Lateral sacral,
	Gluteal.

The *superior vesical* arteries are three or four small branches, which proceed from the pervious portion of the hypogastric cord. They are distributed to the upper and middle part of the bladder. From one of these there passes off a small artery, the *deferential*, which accompanies the vas deferens along the spermatic cord.

The inferior vesical, somewhat larger than the preceding, passes down upon the side of the bladder to its

base, and is distributed to that region, the vesiculæ seminales, and prostate gland.

Fig. 71.*



* Longitudinal section of the pelvis, showing its cavity and the internal iliac artery.—*a*. The iliacus internus muscle, crossed by the external cutaneous nerve. *b*. The psoas muscle, and genito-crural nerve. *c*. The inferior vena cava. *d*. The aorta. *e*. The right common iliac artery. *f*. The left common iliac artery and vein. *g*. The external iliac artery and vein. *h*. The circumflexa ilii artery inosculating with *i*, the ilio-lumbar artery. *k*. The epigastric artery. *l*. The obturator internus muscle. *m*. The levator ani. *n*. Part of the prostate gland supported by the levator ani. *o*. The membranous part of the urethra. *p*. The bulb. *q*. The corpus cavernosum penis. *r, r*. The sphincter ani. *s*. The lower extremity of the rectum. *t*. The coccygeus muscle. *v, v*. The pyriformis muscle, crossed by the sacral nerves. *w*. The arteria sacra media. *x*. The internal iliac artery. *y*. Its anterior trunk; the artery above the letter is the unobliterated portion of the hypogastric artery, which gives off the superior vesical arteries, and becomes converted into a fibrous cord, *z*. The artery below *y*, is the obturator, and the nerve above it the obturator nerve. A little further on the nerve and artery are seen passing through the ob-

The *middle hæmorrhoidal artery*, frequently a branch of the preceding, passes downwards to the rectum, to which it is distributed, inosculating with the superior and inferior hæmorrhoidal arteries. In the female, it distributes branches to the vagina.

The *uterine artery* passes downwards between the layers of the broad ligament, to the neck of the uterus, and then ascends in a tortuous course along its lateral border, between the layers of the broad ligament. It gives off branches to the vagina, the lower part of the bladder, the Fallopian tube, and round ligament, and inosculates with the spermatic or ovarian artery.

The *vaginal artery* corresponds in position with the inferior vesical, and is distributed to the vagina and neighbouring parts of the bladder and rectum.

The **OBTURATOR ARTERY**, sometimes a branch of the posterior division, passes forwards below the brim of the pelvis to the upper part of the obturator foramen, through which it escapes into the thigh (p. 27.).

Its *branches* within the pelvis are: an *iliac* branch, which supplies the bone of the iliac fossa, and inosculates with the ilio-lumbar artery; and a *pubic* branch which is given off close to the obturator foramen, and inosculates with its fellow of the opposite side, behind the pubes, and with the pubic branch of the epigastric artery.

The **ISCHIATIC ARTERY** is the larger of the two terminal branches of the anterior division of the internal iliac. It passes downwards in front of the pyriformis and sacral plexus of nerves, and internally to the pudic artery, to the lower part of the great ischiatic foramen, where it escapes from the pelvis between the lower border of the pyriformis and the coccygeus, to both of which it distributes branches.

The **INTERNAL PUDIC ARTERY**, the other terminal branch of the anterior division of the internal iliac, descends externally to the ischiatic artery to the lower part of the

turator foramen. 1. The inferior vesical artery, giving off the middle hæmorrhoidal. 2. The anterior trunk, dividing into internal pudic and ischiatic. 3. The ilio-lumbar artery. 4. The lateral sacral artery, sending branches into the anterior sacral foramina. 5. The gluteal artery. 6, 6. The sacrum. 7. The coccyx. 8. The symphysis pubis. 9. The suspensory ligament of the penis.

great ischiatic foramen, and passes through the foramen between the lower border of the pyriformis and coccygeus. It then crosses the spine of the ischium, and re-enters the pelvis through the lesser ischiatic foramen. In the next place it passes forward upon the obturator fascia, and above the tuberosity of the ischium, to the perineum, to which it is distributed.

The *branches* of the internal pudic artery within the pelvis are several small twigs to the levator ani and sacral nerves, and occasionally a branch which takes the place of the inferior vesical or middle hæmorrhoidal artery.

POSTERIOR DIVISION.—The ILIO-LUMBAR ARTERY ascends beneath the external iliac vessels and psoas muscle, to the posterior part of the crest of the ilium, where it divides into two branches: a *lumbar branch*, which supplies the psoas and quadratus lumborum muscles, and sends a ramuscule through the fifth intervertebral foramen to the spinal cord and its membranes; and an *iliac branch*, which passes across the iliac fossa to the crest of the ilium, where it inosculates with the lumbar and circumflexa ilii arteries. In its course it distributes branches to the iliacus and abdominal muscles.

The LATERAL SACRAL ARTERIES are generally two in number on each side, superior and inferior. The *superior* passes inwards to the first sacral foramen, and is distributed to the contents of the spinal canal, from which it escapes by the posterior sacral foramen, and supplies the integument on the dorsum of the sacrum. The *inferior* passes down by the side of the anterior sacral foramina, to the coccyx; it first pierces and then rests upon the origin of the pyriformis, and sends branches into the sacral canal, to supply the sacral nerves. Both arteries inosculate with each other and with the sacra media.

The GLUTEAL ARTERY is the continuation of the posterior trunk of the internal iliac: it passes backwards between the lumbo-sacral and first sacral nerve through the upper part of the great sacro-ischiatic foramen and above the pyriformis muscle. While within the pelvis it gives off some muscular twigs to the iliacus and pyriformis muscle; and at its escape from the pelvis, a *nutritious* artery to the ilium.

The *superior hæmorrhoidal artery* is the continuation

of the inferior mesenteric artery into the pelvis; it divides in the meso-rectum into two branches, which are distributed on each side of the rectum as far as its lower part, and inosculate with the middle and inferior hæmorrhoidal arteries.

The *arteria sacra media* descends along the middle of the sacrum from the bifurcation of the aorta. It gives off lateral branches, which inosculate with the lateral sacral arteries, and terminates on the coccyx.

The VEINS of the pelvis unite to form the internal iliac vein.

The INTERNAL ILIAC VEIN receives the returning blood by the gluteal, ischiatic, internal pudic, and obturator veins from the exterior of the pelvis, and by the vesical and uterine plexuses from within. It lies at first to the inner side and then behind the internal iliac artery, and terminates by uniting with the external iliac vein, to form the common iliac vein.

The *vesical* and *prostatic plexus* surrounds the neck and base of the bladder, the prostate gland, and membranous portion of the urethra. It receives the veins from the external organs of generation, the dorsal vein of the penis, after piercing the triangular ligament, dividing into two branches before joining it. The plexus is surrounded by the sheath of pelvic fascia which encloses the prostate gland, and spreads over the base of the bladder.

The *internal pudic vein*, besides the branches which accompany the internal pudic artery, receives a hæmorrhoidal vein from a plexus which surrounds the lower part of the rectum, the *hæmorrhoidal plexus*.

The *uterine* and *vaginal plexus* is situated around the vagina and upon the sides of the uterus; above, it is in communication with the ovarian plexus.

The *ilio-lumbar* and *lateral sacral veins* terminate in the common iliac vein; and the middle sacral vein, in the left common iliac vein.

The LYMPHATIC VESSELS of the pelvis are those proceeding from the deeper structures of the external organs of generation, the walls and viscera of the pelvis. They terminate in a chain of *glands*, situated in the course of the iliac vessels, and the efferent ducts of the latter unite with the lumbar glands.

The NERVES of the pelvis are the five sacral and coccygeal nerve derived from the spinal cord, the hypogastric plexus, and the trunk of the sympathetic.

The SACRAL NERVES are five in number on each side; the anterior divisions of the four upper nerves issue from the sacrum through the anterior sacral foramina, the fifth escapes between the sacrum and coccyx, and pierces the coccygeus muscle. The two upper nerves are of large size; the third is scarcely one fourth as large as the second; the fourth is much smaller than the third; and the fifth than the fourth. The first three nerves, with a part of the fourth and the lumbo-sacral nerve, unite to form the sacral plexus.

The *fourth sacral nerve* divides into two branches, one of which assists in forming the sacral plexus, the other separates into three branches: a *communicating* branch, to unite with the fifth sacral nerve; a *visceral* branch, to join with the hypogastric plexus and supply the bladder and prostate gland, and in the female, the vagina; and a *muscular* branch which sends filaments to the levator ani and coccygeus and an *hæmorrhoidal* branch to the sphincter ani and integument behind the anus.

The *fifth sacral nerve*, issuing from between the sacrum and coccyx, pierces the coccygeus muscle, and receives the communicating branch from the fourth; it then communicates with the coccygeal nerve, and piercing the coccygeus a second time, is distributed to the integument over the dorsal surface of the coccyx.

The *coccygeal nerve* pierces the coccygeus muscle, and unites with the fifth sacral nerve, in which it is lost.

Each of the anterior divisions of the sacral nerves receives a filament from the sympathetic at its point of escape from the sacral canal.

SACRAL PLEXUS.—The sacral plexus is formed by the union of the lumbo-sacral, the three upper sacral nerves, and one half the fourth. It is triangular in form, its base corresponding with the whole length of the sacrum, and its apex with the lower part of the great sacro-ischiatic foramen. It rests on the pyriformis muscle, and is crossed by the branches of the internal iliac vessels.

The *branches* of the sacral plexus are chiefly destined for the supply of the lower limb, and are given off ex-

ternally to the pelvis; those which proceed from the plexus within the pelvis, are some muscular branches to the pyriformis and obturator internus, the superior gluteal nerve, and pudic.

The branches to the *pyriformis* muscle are commonly two in number; the branch to the *obturator internus* passes out of the pelvis through the great sacro-ischiatic foramen, with the internal pudic vessels and nerve crosses the spine of the ischium, and re-enters the pelvis through the lesser sacro-ischiatic foramen, to be distributed to the muscle.

The SUPERIOR GLUTEAL NERVE arises from the lumbo-sacral nerve, near its junction with the first sacral nerve, and passes out of the pelvis through the upper part of the great sacro-ischiatic foramen, above the pyriformis muscle. It is distributed to the gluteal muscles (page 41.).

The PUDIC NERVE arises from the lower part of the sacral plexus, and passes out of the pelvis through the great sacro-ischiatic foramen, below the pyriformis muscle. It crosses the spine of the ischium, and re-entering the pelvis through the lesser sacro-ischiatic foramen, accompanies the internal pudic artery along the outer wall of the ischio-rectal fossa to the perineum. In its course along the ischio-rectal fossa, it lies below the artery, and divides into two branches, perineal and dorsal artery of the penis.

Near its origin the pudic nerve gives off the *inferior hæmorrhoidal nerve*, which passes through the lesser sacro-ischiatic foramen, and crosses the ischio-rectal fossa with one of the inferior hæmorrhoidal arteries, to be distributed to the sphincter ani and integument around the anus. This nerve sometimes proceeds directly from the sacral plexus.

SYMPATHETIC NERVE.—The sympathetic nerve within the pelvis consists of the trunk of the nerve, and the pre-vertebral portion.

The trunk of the nerve presents four or five small fusiform ganglia, situated on the sacrum close to the anterior sacral foramina; the uppermost ganglion communicates with the last of the lumbar ganglia; the lowest ganglion of each side communicates with a small ganglion situated on the first bone of the coccyx, the

ganglion impar, or *azygos*, which thus becomes the bond of union between the extremities of the two sympathetic nerves.

The *branches* of the sacral ganglia are, branches of communication, and branches of distribution.

The *branches of communication* are two from each ganglion, which pass *outwards*, to communicate with the anterior sacral nerves, and with the coccygeal nerve.

The *branches of distribution* pass *inwards* upon the front of the sacrum, and follow the course of the branches of the *arteria sacra media*. Other branches, proceeding from the first and second ganglia, join the hypogastric plexus; and a third set, issuing from the ganglion impar and its communicating cords, is distributed to the coccyx.

HYPOGASTRIC PLEXUS.—The pre-vertebral portion of the sympathetic system, within the pelvis, consists of the hypogastric plexus and its lateral divisions, the inferior hypogastric plexuses.

The *hypogastric plexus* is the prolongation of the aortic plexus into the pelvis. It is situated over the front of the sacrum at its upper part, and divides into two lateral portions, the *inferior hypogastric plexuses*, which descend to the sides of the base of the bladder, vagina, and rectum.

Each inferior hypogastric plexus receives branches from the third and fourth sacral nerves, and gives off plexuses, which accompany the branches of the internal iliac artery, and take the names of the respective arteries. The inferior hypogastric plexus supplies the bladder, prostate gland, vesiculæ seminales, corpus cavernosum penis, rectum; and, in the female, the vagina, uterus with its appendages, and ovaries.

MALE ORGANS OF GENERATION.

The organs of generation in the male are, the penis and testes, with their appendages.

PENIS.

The *penis* is divisible into a body, root, and extremity.

The *body* is surrounded by a thin integument, which is remarkable for the looseness of its cellular connection with the deeper parts of the organ, and for containing no

adipose tissue. The *root* is broad, and firmly adherent to the rami of the pubes and ischium by means of two strong processes, the *crura*, and is connected to the symphysis pubis by a fibrous membrane, the *ligamentum suspensorium*.

The *extremity*, or *glans penis*, resembles an obtuse cone, somewhat compressed from above downwards, and of a deeper red colour than the surrounding skin. At its apex is a small vertical slit, the *meatus urinarius*, which is bounded by two, more or less protuberant, *labia*; and, extending backwards from the meatus, is a depressed *raphé*, to which is attached a loose fold of mucous membrane, the *frænum præputii*. The base of the *glans* is marked by a projecting collar, the *corona glandis*, upon which are seen a number of small papillary elevations, the *glandulæ Tysoni* (*odoriferæ*).

Behind the *corona* is a deep *fossa* (*fossa glandis, cervix*), bounded by a circular fold of integument, the *præputium*, which, in the quiescent state of the organ, may be drawn over the *glans*, but, in its distended state, is obliterated, and serves to facilitate its enlargement. The internal surface of the *prepuce* is lined by mucous membrane, covered by a thin epithelium; this membrane is reflected over the *glans penis*, and, at the *meatus urinarius*, is continuous with the mucous lining of the *urethra*.

In dissecting the penis an incision should be made, along the middle of the *dorsum* of the organ, and the integument turned aside. Then the superficial fascia may be dissected back and the *ligamentum suspensorium* and dorsal vessels and nerves brought into view.

The *superficial fascia* is thin, and its cellular structure free from fat; it is continuous with the superficial fascia of the abdomen above, and with the *dartos* and superficial fascia of the *perineum* below.

The *ligamentum suspensorium penis* is a strong fibrous membrane of triangular form, attached by its apex to the symphysis pubis; and by its base, to the body of the penis. Near its attachment it separates into two layers, between which the dorsal vessels and nerves take their course.

The penis is composed of the *corpus cavernosum* and *corpus spongiosum*, and contains in its interior the longest portion of the *urethra*.

The *corpus cavernosum* is distinguished into two lateral portions (*corpora cavernosa*) by an imperfect septum, and by a superior and inferior groove, and is divided posteriorly into two *crura*. It is firmly adherent, by means of its *crura*, to the rami of the pubes and ischium; and each *crus*, previously to its junction with its fellow, presents a slight enlargement, which has been named by Kobelt the *bulb*. The *corpus cavernosum* forms, anteriorly, a single rounded extremity, which is received into a fossa in the base of the glans; the superior groove lodges the dorsal vessels of the organ, and the inferior receives the *corpus spongiosum*. Its fibrous tunic is thick, elastic, and extremely firm, and sends a number of fibrous bands and cords (*trabeculæ*) inwards from its inferior groove, which cross its interior in a radiating direction, and are inserted into the inner walls of the tunic. These *trabeculæ* are most abundant on the middle line, where they are ranged vertically, side by side, somewhat like the teeth of a comb, and constitute the imperfect partition of the *corpus cavernosum*, called *septum pectiniforme*. The septum is more complete at its posterior than towards its anterior part.

The tunic of the *corpus cavernosum* consists of strong longitudinal fibrous fasciculi, closely interwoven with each other. Its internal structure is composed of erectile tissue.

The *corpus spongiosum* is situated along the under surface of the *corpus cavernosum*, in its inferior groove. It commences by its posterior extremity between and beneath the *crura penis*, where it forms a considerable enlargement, the *bulb*, and terminates anteriorly by another expansion, the *glans penis*. Its middle portion, or body, is nearly cylindrical, and tapers gradually from its posterior towards its anterior extremity. The bulb is adherent to the triangular ligament by means of a prolongation of that membrane; in the rest of its extent the *corpus spongiosum* is attached to the *corpus cavernosum* by cellular tissue, and by veins which wind around that body to reach the dorsal vein.

It is composed of erectile tissue, enclosed by a dense fibrous layer, much thinner than that of the *corpus cavernosum*, and contains in its interior the spongy portion of the urethra, which lies nearer its upper than its

lower wall. The bulb exhibits a tendency to division into two lobes, an appearance which is due to the existence of a thin longitudinal septum in its internal structure.

Erectile tissue is a peculiar cellulo-vascular structure, entering in considerable proportion into the composition of the organs of generation. It consists essentially of a plexus of veins so closely convoluted and interwoven with each other, as to give rise to a cellular appearance when examined by means of a section. The veins forming this plexus are smaller in the glans penis, corpus spongiosum, and circumference of the corpus cavernosum, than in the central part of the latter, where they are large and dilated. They have no other coat than the internal lining prolonged from the neighbouring veins; and the interstices of the plexus are occupied by a peculiar reddish fibrous tissue. They receive their blood from the capillaries of the arteries in the same manner as veins in general, and not by means of vessels having a peculiar form and distribution, as described by Müller. The helicine arteries of that physiologist have no existence.

Vessels and Nerves. — The arteries of the penis are derived from the internal pudic; they are, the arteries of the bulb, arteries of the corpus cavernosum, and dorsales penis. Its *veins* are superficial and deep. The deep veins run by the side of the deep arteries, and terminate in the internal pudic veins. The superficial veins escape in considerable number from the base of the glans, and converge on the dorsum penis, to form a large dorsal vein, which receives other veins from the corpus cavernosum and spongiosum in its course, and passes backwards between two layers of the ligamentum suspensorium, and through the triangular ligament, beneath the arch of the pubes, to terminate in the prostatic plexus. Previously to its termination it divides into two trunks.

The *Lymphatics* terminate in the inguinal glands. The *nerves* are derived from the pudic nerve, sacral plexus, and hypogastric plexus.

URETHRA.

The urethra is the membranous canal, extending from the neck of the bladder to the meatus urinarius. It is curved in its course, and composed of two layers, a mucous coat and an elastic fibrous coat. The mucous coat is thin and smooth; it is continuous, internally, with the mucous membrane of the bladder; externally, with the investing membrane of the glans; and at certain points of its extent, with the lining membrane of the numerous ducts which open into the urethra, namely, those of Cowper's glands, the prostate gland, vasa deferentia, and vesiculæ seminales. The elastic fibrous coat varies in thickness in

different parts of the course of the urethra: it is thick in the prostate gland, forms a firm investment for the membranous portion of the canal, and is thin in the spongy portion, where it serves as a bond of connection between the mucous membrane and the corpus spongiosum. The urethra is about eight inches in length, and is divided into a prostatic, membranous, and spongy portion.

The *prostatic portion*, a little more than an inch in length, is situated in the prostate gland, about one third nearer its upper than its lower surface, and extending from its base to its apex. Upon its lower circumference or floor is a longitudinal ridge or crest, the *veru montanum*, or *caput gallinaginis*; and on each side of the veru, a depressed fossa, the *prostatic sinus*, in which are seen the numerous openings (fifteen to twenty) of the prostatic ducts. The veru montanum is most prominent in the centre; and immediately in front of the prominent part, is the opening of a small cæcal sac, the *sinus pocularis*, or *utriculus prostaticus*. This sac is the analogue of the uterus; it is nearly half an inch in length, and extends back beneath the third lobe of the prostate. It causes, by its approach to the surface, the prominence of the veru montanum, and is composed of two coats, mucous and fibrous. The fibrous coat is thick, and contains on each side the ejaculatory duct. The mucous coat is provided with an abundance of muciparous glands. The ejaculatory ducts terminate on each side within the aperture of the sinus pocularis, by slit-like openings.

When the sinus pocularis is of large size, it is capable of receiving the point of a small catheter, and by that means interfering with an important operation. In case of such interruption the point of the instrument must be carried along the upper wall of the urethra.

The prostatic portion of the urethra, when distended, is the most dilated part of the canal; but, excepting during the passage of urine, is completely closed, by means of a ring of muscular tissue, which encircles the urethra as far as the anterior extremity of the veru montanum. In the contracted state of the urethra, the veru montanum acts as a valve, being pressed upwards against the roof of the canal; but during the action of the detrusor muscle of the bladder, the whole ring is expanded by the longi-

tudinal muscular fibres which are inserted into it; and the veru is especially drawn downwards by two delicate tendons, which were traced by Mr. Tyrrell from the posterior fibres of the detrusor into the tissue of this process.

The *membranous portion*, the narrowest part of the canal, measures about three lines in diameter, and is somewhat less than an inch in length. It extends from the apex of the prostate gland to the bulb of the corpus spongiosum, and passes through the triangular ligament. Its coats are the mucous membrane, elastic fibrous tissue, and compressor urethræ muscle. The submucous tissue is richly supplied with vessels.

The *spongy portion*, about six inches in length, forms the rest of the extent of the canal, and is lodged in the corpus spongiosum from its commencement at the triangular ligament to the meatus urinarius. It is narrowest in the body, and becomes dilated at each extremity, posteriorly in the bulb, where it is named the bulbous portion, and anteriorly in the glans penis, where it forms the fossa navicularis. The meatus urinarius is the most constricted part of the canal; so that a catheter, which will enter that opening, may be passed freely through the whole extent of a normal urethra.

Opening into the bulbous portion are two small excretory ducts about an inch in length, which may be traced backwards, between the coats of the urethra and the bulb, to the under part of the membranous portion behind the triangular ligament, where they originate in two small lobulated and somewhat compressed glands, of about the size of peas. These are Cowper's glands: they are situated immediately beneath the membranous portion of the urethra, and are enclosed by the lower segment of the compressor urethræ muscle, so as to be subject to muscular compression. Upon the whole of the internal surface of the spongy portion of the urethra, and especially along its lower surface, are numerous small openings or *lacunæ*, which are the apertures of mucous glands situated in the submucous cellular tissue. The openings of these lacunæ are directed forwards, and are liable occasionally to intercept the point of a small catheter in its passage into the bladder. At about an inch and a half from the opening of the meatus, in the upper wall of the urethra,

one of these lacunæ is generally found much larger than the rest, and is named the *lacuna magna*. In a preparation of this lacuna, made by Sir Astley Cooper, the extremity of the canal presents several large primary ramifications.

TESTES.

The testes are two small glandular organs, suspended from the abdomen by the spermatic cords, and enclosed in an external tegumentary covering, the scrotum.

The SCROTUM is distinguished into two lateral halves or hemispheres by a *raphé*, which is continued anteriorly along the under surface of the penis, and posteriorly along the middle line of the perineum to the anus. Of these two lateral portions the left is somewhat longer than the right, and corresponds with the greater length of the spermatic cord on the left side.

The scrotum is composed of two layers, the integument, and a proper covering, the dartos; the integument is extremely thin, transparent, and abundant, and beset by a number of hairs, which issue obliquely from the skin, and have prominent roots. The dartos is a thin layer of contractile fibrous tissue, intermediate in properties between muscular fibre and elastic tissue; it forms the proper tunic of the scrotum, and sends inwards a septum (*septum scroti*), which divides it into two cavities for the two testes. The dartos is continuous around the base of the scrotum with the common superficial fascia of the abdomen and perineum.

The SPERMATIC CORD is the medium of communication between the testes and the interior of the abdomen: it is composed of arteries, veins, lymphatics, nerves, the excretory duct of the testicle, and investing tunics. It commences at the internal abdominal ring, where the vessels of which it is composed converge, and passes obliquely along the spermatic canal; the cord then escapes at the external abdominal ring, and descends through the scrotum to the posterior border of the testicle. The left cord is somewhat longer than the right, and permits the left testicle to reach a lower level than its fellow.

The TESTIS (testicle) is a small, oblong, and rounded gland, about an inch and a half in length, somewhat

compressed on the sides and behind, and suspended in the cavity of the scrotum by the spermatic cord.

Its position in the scrotum is oblique; so that the upper extremity is directed upwards and forwards, and a little outwards; the lower, downwards and backwards, and a little inwards; the convex border looks forwards and downwards; and the flattened border, to which the cord is attached, backwards and upwards. Lying against its outer and posterior border is a flattened body, which follows the course of the testicle, and extends from its upper to its lower extremity; this body is named, from its relation to the testis, *epididymis* (ἐπί, upon, δίδυμος, the testicle); it is divided into a central part or body, an upper extremity or *globus major*, and a lower extremity, *globus minor* (*cauda*) *epididymis*. The *globus major* is situated against the upper end of the testicle, to which it is closely adherent; the *globus minor* is placed at its lower end, is attached to the testis by cellular tissue, and curves upwards to become continuous with the *vas deferens*.

The testis is invested by three tunics, *tunica vaginalis*, *tunica albuginea*, and *tunica vasculosa*; and is connected to the inner surface of the *dartos* by a large quantity of extremely loose cellular tissue, in which fat is never deposited, but which is very susceptible of serous infiltration.

The *tunica vaginalis* is a pouch of serous membrane derived from the peritoneum in the descent of the testis, and afterwards obliterated, from the abdomen to within a short distance of the gland. Like other serous coverings, it is a shut sac, investing the organ, and thence reflected so as to form a bag around its circumference; hence it is divided into the *tunica vaginalis propria*, and *tunica vaginalis reflexa*. The *tunica vaginalis propria* covers the surface of the *tunica albuginea*, and surrounds the *epididymis*, connecting it to the testis by means of a distinct duplicature. The *tunica vaginalis reflexa* is attached by its external surface, through the medium of a quantity of loose cellular tissue, to the inner surface of the *dartos*. Between the two layers is the smooth surface of the shut sac, moistened by its proper secretion.

The *tunica albuginea* (*dura mater testis*) is a thick fibrous membrane of a bluish white colour, and the proper

tunic of the testicle. It is adherent externally to the tunica vaginalis propria, and, from the union of a serous with a fibrous membrane, is considered to be a fibro-serous membrane, like the dura mater and pericardium. After surrounding the testicle, the tunica albuginea is reflected from its posterior border into the interior of the gland, and forms a projecting longitudinal ridge, which is called the *mediastinum testis* (corpus Highmorianum*), from which numerous fibrous cords (trabeculæ, septula) are given off to be inserted into the inner surface of the tunic. The mediastinum serves to contain the vessels and ducts of the testicle in their passage into the substance of the organ; and the fibrous cords are admirably fitted, as has been shown by Sir Astley Cooper, to prevent compression of the gland. If a transverse section be made of the testis, and the surface of the mediastinum examined, it will be observed that the blood-vessels of the substance of the organ are situated near the posterior border of the mediastinum, while the divided ducts of the rete testis occupy a place nearer the free margin.

The *tunica vasculosa* (pia mater testis) is the nutrient membrane of the testis. It is situated immediately within the tunica albuginea, and encloses the substance of the gland, sending processes inwards between the lobules, in the same manner that the pia mater is reflected between the convolutions of the brain.

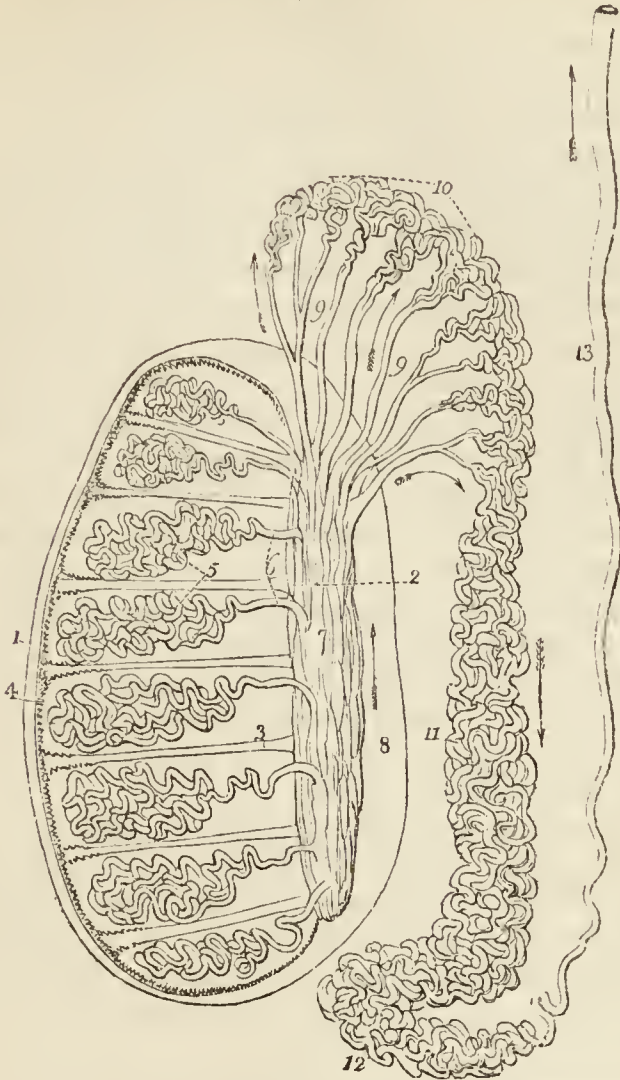
The substance of the testis consists of numerous conical flattened *lobules* (lobuli testis), the bases being directed towards the surface of the organ, and the apices towards the mediastinum. Krause found between four and five hundred of these lobules in a single testis. Each lobule is invested by a distinct sheath formed of two layers, one being derived from the tunica vasculosa, the other from the tunica albuginea. The lobule is composed of one or several minute tubuli, *tubuli seminiferi*†, exceedingly convoluted, anastomosing frequently with each other near their extremities, terminating

* Nathaniel Highmore, a physician of Oxford, in his "Corporis Humani Disquisitio Anatomica," published in 1651, considers the corpus Highmorianum as a duct formed by the convergence of the fibrous cords, which he mistakes for smaller ducts.

† Lauth estimates the whole number of tubuli seminiferi in each testis at 840, and their average length at 2 feet 3 inches. According to this calculation, the whole length of the tubuli seminiferi would be 1890 feet.

in loops or in free cæcal ends, and of the same diameter ($\frac{1}{170}$ of an inch, Lauth) throughout. The tubuli seminiferi are of a bright

Fig 72.*



* The anatomy of the testicle.—No. 1. The tunica albuginea. 2. The mediastinum testis, or corpus Highmorianum. 3. A fibrous cord passing between two of the lobules, from the mediastinum to the inner surface of the tunica albuginea. Similar cords are observed between the other lobules. 4. The tunica vasculosa or pia mater testis. 5. Two of the lobules of which the substance of the testicle is composed; they are seen to consist of the convolutions of minute tubes, tubuli seminiferi. 6 The small straight tubes by which the tubuli seminiferi terminate, vasa recta. 7. The rete testis, an aggregation of tubuli, situated in the anterior half of the mediastinum. The posterior half (8.) is occupied by the arteries and veins. 9, 9. The vasa efferentia. 10. The conical convolutions of tubuli called coni vasculosi; this portion of the organ being of large size, and situated externally to the testicle, is the globus major of the epididymis. 11. The body of the epididymis. 12. The globus minor of the epididymis. 13. The vas deferens, ascending to the external abdominal ring. The arrows mark the course of the secretion along the tubes.

yellow colour; they become less convoluted in the apices of the lobules, and terminate by forming between twenty and thirty small straight ducts of about twice the diameter of the tubuli seminiferi, the *vasa recta*. The *vasa recta* enter the substance of the mediastinum, and terminate in from seven to thirteen ducts, smaller in diameter than the *vasa recta*. These ducts pursue, a waving course from below upwards through the fibrous tissue of the mediastinum; they communicate freely with each other, and constitute the *rete testis*. At the upper extremity of the mediastinum, the ducts of the *rete testis* terminate in from nine to thirty small ducts, the *vasa efferentia**, which form by their convolutions a series of conical masses, the *coni vasculosi*; from the bases of these cones tubes of larger size proceed, which constitute, by their complex convolutions, the body of the epididymis. The tubes become gradually larger towards the lower end of the epididymis, and terminate in a single large and convoluted duct, the *vas deferens*.

The *Epididymis* is formed by the convolutions of the excretory seminal ducts, externally to the testis, and previously to their termination in the *vas deferens*. The more numerous convolutions, and the aggregation of the *coni vasculosi* at the upper end of the organ, constitute the *globus major*; the continuation of the convolutions downwards is the body, and the smaller number of convolutions of the single tube at the lower extremity, the *globus minor*. The tubuli are connected together by a very delicate cellular tissue, and are enclosed by the *tunica vaginalis*.

A small convoluted duct, of variable length, is generally connected with the duct of the epididymis immediately before the commencement of the *vas deferens*. This is the *vasculum aberrans* of Haller; it is attached to the epididymis by the cellular tissue in which that body is enveloped. Sometimes it becomes dilated towards its extremity, but more frequently retains the same diameter throughout.

The *vas deferens* may be traced upwards from the *globus minor* of the epididymis, along the posterior part of the spermatic cord, and along the spermatic canal to the internal abdominal ring. From the ring it is reflected inwards to the side of the fundus of the bladder, and descends along its posterior surface, crossing the direction of the ureter, to the inner border of the *vesicula seminalis*. In this situation it becomes somewhat larger in size, and sacculated, and terminates at the base of the prostate gland by uniting with the duct of the *vesicula seminalis* and constituting the ejaculatory duct. The ejaculatory duct, which is thus formed by the junction of the duct of

* Each *vas efferens* with its cone measures, according to Lauth, about 8 inches. The entire length of the tubes composing the epididymis, according to the same authority, is about 21 feet.

the vesicula seminalis with the vas deferens, passes forwards in the outer wall of the sinus pocularis, and terminates by a slit-like opening close to or just within the aperture of the sinus.

FEMALE PELVIS.

The boundaries of the pelvis in the female are the same as those of the male. The contents are, the bladder, vagina, uterus with its appendages, and the rectum. Some portion of the small intestine also occupies the upper part of its cavity.

The *bladder* is in relation with the ossa pubis in front, with the uterus behind (from which it is usually separated by a convolution of small intestine), and with the neck of the uterus and vagina beneath. The form of the female bladder corresponds with that of the pelvis, being broad from side to side and often bulging more on one side than on the other. This is particularly evident after frequent parturition. The *coats* of the bladder are the same as those of the male.

The *urethra*, about an inch and a half in length, is lodged in the upper and anterior wall of the vagina, in its course downwards and forwards, beneath the arch of the pubes, to the meatus urinarius. It is lined by mucous membrane disposed in longitudinal folds, and is continuous, internally with that of the bladder, and externally with that of the vulva. The mucous membrane is surrounded by a proper coat of elastic tissue (to which the muscular fibres of the detrusor urinæ are attached), by a plexus of blood-vessels, and by the fibres of the compressor urethræ. It is to the elastic tissue that is due the remarkable dilatibility of the female urethra, and its speedy return to its original diameter. The meatus is encircled by a ring of fibrous tissue, which prevents it from distending with the same facility as the rest of the canal; hence it is sometimes advantageous, in performing this operation, to divide the margin of the meatus with the knife.

VAGINA.

The *vagina* is a membranous canal leading from the vulva to the uterus, and corresponding in direction with the axis of the outlet of the pelvis. It is constricted at its

commencement, but near the uterus becomes dilated, and is closed by the contact of the anterior with the posterior wall. Its length is variable; but it is always longer upon the posterior than upon the anterior wall, the former being usually about five or six inches in length, and the latter four or five. It is attached to the cervix of the uterus, which latter projects into the upper extremity of the canal.

In *structure* the vagina is composed of a *mucous lining*, a layer of *erectile tissue*, and an external tunic of *contractile fibrous tissue*, resembling the dartos of the scrotum. The upper fourth of the posterior wall of the vagina is covered, on its pelvic surface, by the peritoneum; while in front the peritoneum is reflected from the upper part of the cervix of the uterus to the posterior surface of the bladder. On each side it gives attachment, superiorly, to the broad ligaments of the uterus; and inferiorly, to the pelvic fascia and levatores ani.

The *mucous membrane* presents a number of *transverse papillæ* or *rugæ* upon the upper and lower surface of the canal, the rugæ extending outwards on each side from a middle *raphé*. The transverse papillæ and *raphé* are more apparent upon the upper than upon the lower surface, and the two *raphé* are called the *columns of the vagina*. The mucous membrane is covered by thin cuticular epithelium, which is continued from the labia, and terminates by a fringed border at about the middle of the cervix uteri.

The *middle*, or *erectile layer* consists of *erectile tissue* enclosed between two layers of fibrous membrane; this layer is thickest near the commencement of the vagina, and becomes gradually thinner as it approaches the uterus.

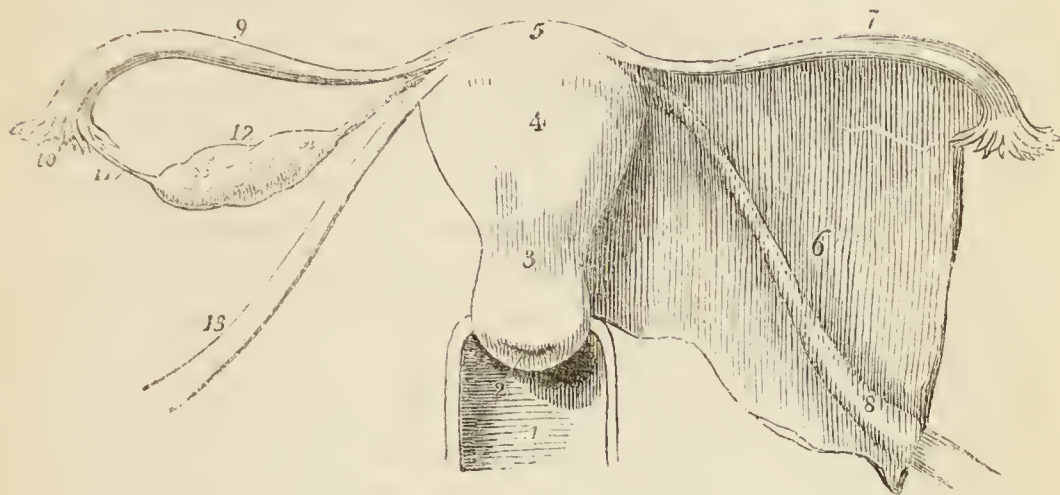
The *external*, or *dartoid layer* of the vagina serves to connect it to surrounding viscera. Thus it is very closely adherent to the under surface of the bladder, and drags that organ down with it, in prolapsus uteri. To the rectum it is less closely united, and that intestine is therefore less frequently affected in prolapsus.

UTERUS.

The *uterus* is a flattened organ of a pyriform shape, having the base directed upwards and forwards, and the apex downwards and backwards in the line of axis of the inlet of the pelvis, and forming a considerable angle with the course of the vagina. It is convex on its posterior surface, and somewhat flattened on its anterior aspect. In the unimpregnated state it is about three inches in length, two in breadth across its broadest part, and one in thickness; and is divisible into fundus, body, cervix, and os uteri. At the period of puberty the uterus

weighs about one ounce and a half; after parturition, from two to three ounces; and at the ninth month of utero-gestation, from two to four pounds.

*Fig. 73.**



The *fundus* and *body* are enclosed in a duplicature of peritoneum, which is connected with the sides of the pelvis, and forms a transverse septum between the bladder and rectum. The folds formed by this duplicature of peritoneum on each side of the organ are the *broad ligaments* of the uterus.

The *cervix* is the lower portion of the organ. It is distinguished from the body by a well marked constriction; around its circumference is attached the upper end of the vagina; and at its extremity is an opening which is nearly round in the virgin, and transverse after parturition, the *os uteri* (*os tinæ*), bounded before and behind by two labia, the anterior labium being the most thick, and the posterior somewhat the longer. The opening of the *os uteri* is of considerable size, and is named the *orificium uteri externum*; the canal then

* The female internal organs of generation.—No. 1. The upper part of the vagina. 2. The *os uteri*, projecting into the vagina; the posterior lip is seen to be longer and larger than the anterior. 3. The *cervix uteri*. 4. The body of the uterus. 5. Its *fundus*. 6. The broad ligament of the left side, having enclosed between its layers (7.) the Fallopian tube, and (8.) the round ligament; on the right side the broad ligament is removed, so as to bring more clearly into view the structures which it contains. 9. The Fallopian tube. 10. Its fimbriated extremity. 11. One of its fimbriæ, attached to the ovary. 12. The ovary attached by its ligament to the upper angle of the uterus. 13. The round ligament.

becomes narrowed, and at the upper end of the cervix is constricted into a smaller opening, the *orificium internum*.* At this point the canal of the cervix expands into the shallow triangular cavity of the uterus, the inferior angle corresponding with the *orificium internum*, and the two superior angles (which are funnel-shaped and represent the original bicornute condition of the organ) with the commencement of the Fallopian tubes. In the canal of the cervix uteri are two longitudinal folds, anterior and posterior to which numerous oblique folds converge so as to give the idea of branches from the stem of a tree; hence this appearance has been denominated the *arbor vitæ uterina*. Between these folds and around the os uteri are numerous mucous follicles. It is the closure of the mouth of one of these follicles, and the subsequent distention of the follicle with its proper secretion, that occasions those vesicular appearances so often noticed within the mouth and cervix of the uterus, called the *ovula of Naboth*.

Structure. — The uterus is composed of three tunics: of an *external* or *serous coat*, derived from the peritoneum, which constitutes the duplicatures on each side of the organ, called the broad ligaments; of a *middle* or *muscular coat*, which gives thickness and bulk to the uterus; and of an *internal* or *mucous membrane*, which lines its interior, and is continuous on the one hand with the mucous lining of the Fallopian tubes, and on the other with that of the vagina.

In the unimpregnated state the muscular coat is exceedingly condensed in texture, offers resistance to section with the scalpel, and appears to be composed of whitish fibres inextricably interlaced and mingled with blood-vessels. In the impregnated uterus the fibres are of large size, distinct, and disposed in two layers — superficial and deep. The *superficial layer* consists of fibres which pursue a vertical direction, some being longitudinal, and others oblique. The longitudinal fibres are found principally on the middle line, forming a thin plane upon the anterior and posterior face and fundus of the organ. The oblique fibres occupy chiefly the sides and the fundus. At the angles of the uterus the fibres of the superficial layer are continued outwards upon the Fallopian tubes, and into the round ligaments and ligaments of the ovaries. The *deep layer* consists of two hollow cones of circular fibres, having their apex at the openings of the Fallopian tubes, and intermingling

* The *orificium internum* is not unfrequently obliterated in old persons. Indeed, this obliteration is so common, as to have induced Mayer to regard it as normal.

with each other by their bases on the body of the organ. These fibres are continuous with the deep muscular layer of the Fallopian tubes, and indicate the primitive formation of the uterus by the blending of these two canals. Around the cervix uteri the muscular fibres assume a circular form, interlacing with and crossing each other at acute angles.

The *mucous membrane* presents on its surface numerous minute apertures corresponding with mucous glands, and is provided with a columnar ciliated epithelium, which extends from the middle of the cervix uteri to the extremities of the Fallopian tubes.

Vessels and Nerves.—The *arteries* of the uterus are the uterine from the internal iliac, and the ovarian from the aorta. The *veins* are large and remarkable; in the impregnated uterus they are called sinuses, and consist of canals channelled through the substance of the organ, being merely lined by the internal membrane of the veins. They terminate on each side of the uterus in the uterine plexuses. The *lymphatics* terminate in the lumbar glands.

The *nerves* of the uterus are derived from the hypogastric and spermatic plexuses, and from the sacral plexus. They have been made the subject of special investigation by Dr. Robert Lee, who has successfully repaired the omission made by Dr. William Hunter, in this part of the anatomy of the organ. In his numerous dissections, of the uterus, both in the unimpregnated and gravid state, Dr. Lee has made the discovery of several large nervous ganglia and plexuses. The principal of these, situated on each side of the cervix uteri immediately behind the ureter, he terms the *hypogastric ganglion*; it receives the greater number of the nerves from the hypogastric and sacral plexus, and distributes, branches to the uterus, vagina, bladder, and rectum. Of the branches to the uterus, a large fasciculus proceeds upwards by the side of the organ towards its angle, where they communicate with branches of the spermatic plexus, and form another large ganglion, which he designates the *spermatic ganglion*, and which supplies the fundus uteri. Besides these, Dr. Lee describes *vesical* and *vaginal ganglia*, and anterior and posterior *subperitoneal ganglia* and *plexuses*, which communicate with the preceding, and constitute an extensive nervous network over the entire uterus. Dr. Lee concludes his observations by remarking:—“These dissections prove that the human uterus possesses a great system of nerves, which enlarges with the coats, blood-vessels, and absorbents during pregnancy, and which returns after parturition to its original condition before conception takes place. It is chiefly by the influence of these nerves that the uterus performs the varied functions of menstruation, conception, and parturition, and it is solely by their means that the whole fabric of the nervous system sympathises with the different morbid affections of the uterus. If these nerves of the uterus could not be demonstrated, its physiology and pathology would be completely inexplicable.”*

* Philosophical Transactions for 1842.

APPENDAGES OF THE UTERUS.

The *appendages of the uterus* are enclosed by the lateral duplicatures of peritoneum, called the broad ligaments. They are the *Fallopian tubes* and *ovaries*.

The FALLOPIAN TUBES or oviducts, the uterine trumpets of the French writers, are situated in the upper border of the broad ligaments, and are connected with the superior angles of the uterus. They are somewhat trumpet-shaped, being smaller at the uterine than at the free extremity, and narrower in the middle than at either end. Each tube is about four or five inches in length, and more or less flexuous in its course. The canal of the Fallopian tube is exceedingly minute; its inner extremity opens by means of the *ostium uterinum* into the upper angle of the cavity of the uterus, and the opposite end into the cavity of the peritoneum. The free or expanded extremity of the Fallopian tube presents a double and sometimes a triple series of small processes or fringes, which surround the margin of the trumpet or funnel-shaped opening, the *ostium abdominale*. This fringe-like appendage to the end of the tube has gained for it the appellation of the fimbriated extremity; and the remarkable manner in which this circular fringe applies itself to the surface of the ovary during sexual excitement, the additional title of *morsus diaboli*. A short ligamentous cord proceeds from the fimbriated extremity, to be attached to the distal end of the ovary, and serves to guide the tube in its seizure of that organ.

The Fallopian tube is composed of three tunics: an external and loose investment derived from the peritoneum; a middle or *muscular* coat, consisting of circular [internal] and longitudinal [external] fibres, continuous with those of the uterus; and an internal or lining *mucous* membrane, which is continuous on the one hand with the mucous membrane of the uterus, and at the opposite extremity with the peritoneum. In the minute canal of the tube the mucous membrane is thrown into longitudinal folds or rugæ, which indicate the adaptation of the tube for dilatation.

The OVARIES (*testes muliebres*) are two oblong flattened and oval bodies of a whitish colour, and uneven surface, situated in the posterior layer of peritoneum of the broad ligaments. They are connected to the upper angles of the uterus at each side by means of a rounded cord, con-

sisting of fibrous tissue and a few muscular fibres derived from the uterus—the *ligament of the ovary*. By the opposite extremity they are connected by another and a shorter ligament to the fimbriated aperture of the Fallopian tube.

In *structure* the ovary is composed of a cellulo-fibrous parenchyma or *stroma*, traversed by blood-vessels, and enclosed in a capsule consisting of three layers: a vascular layer, which is situated most internally, and sends processes inwards to the interior of the organ; a middle or fibrous layer (*tunica albuginea*) of considerable density; and an external investment of peritoneum.

In the cells of the stroma of the ovary the small vesicles or ovisacs of the future ova, the Graafian vesicles, are developed. There are usually about fifteen fully formed Graafian vesicles in each ovary; and Dr. Martin Barry has shown that countless numbers of microscopic ovisacs exist in the parenchyma of the organ, but that very few are perfected so as to produce ova.

After conception, a yellow spot, the *corpus luteum*, is found in one or both ovaries. The corpus luteum is a globular mass of yellow spongy tissue, traversed by white areolar bands, and containing in its centre a small cavity, more or less obliterated, which was originally occupied by the ovum. The interior of the cavity is lined by a puckered membrane, the remains of the ovisac. In recent corpora lutea, the opening by which the ovum escaped from the ovisac through the capsule of the ovary is distinctly visible; when closed, a small cicatrix may be seen on the surface of the ovary, in the situation of the opening. A similar appearance to the preceding, but of smaller size, and without a central cavity, is sometimes met with in the ovaries of the virgin; this is a *false corpus luteum*.

Vessels and Nerves.—The *arteries* of the ovaries are the spermatic or ovarian; the *veins* form an *ovarian* plexus, which terminates in the uterine plexus. The *nerves* are derived from the spermatic plexus.

The ROUND LIGAMENTS are two muscular and fibrous cords between four and five inches long, situated within the layers of the broad ligaments, and extending from the upper angles of the uterus, and along the spermatic canals, to the labia majora, in which they are lost. They are accompanied by a small artery, by several filaments of the spermatic plexus of nerves, by a plexus of veins, and by a process of the peritoneum, which represents the serous membrane investing the spermatic cord in the male. In the young subject, this process extends for a short distance along the spermatic canal, and is denominated the *canal of Nuck*; it is occasionally pervious in

the adult. The plexus of veins occasionally becomes varicose, and forms a small tumour at the external abdominal ring, which has been mistaken for inguinal hernia. The round ligaments serve to retain the uterus in its proper position in the pelvis, and during utero-gestation, to draw the anterior surface of the organ against the abdominal parietes.

EXTERNAL ORGANS OF GENERATION.

The female organs of generation are divisible into the internal and external; the internal are contained within the pelvis, and have been already described; they are the vagina, uterus, ovaries, and Fallopian tubes. The external organs are the mons Veneris, labia majora, labia minora, clitoris, meatus urinarius, and the opening of the vagina.

The *mons Veneris* is the eminence of integument, situated upon the front of the ossa pubis. Its cellular tissue is loaded with adipose substance, and the surface covered with hairs.

The *labia majora* are two large longitudinal folds of integument, containing cellular tissue, fat, and a tissue resembling the dartos. They enclose an elliptical fissure, the common urino-sexual opening or *vulva*. The vulva receives the inferior opening of the urethra and vagina, and is bounded, anteriorly, by the commissura superior, and posteriorly, by the commissura inferior. Stretching across the posterior commissure is a small transverse fold, the *frænulum labiorum* or fourchette, which is ruptured during parturition; and immediately within this fold is a small cavity, the *fossa navicularis*. The length of the perineum is measured from the posterior commissure to the margin of the anus, and is usually not more than an inch. The external surface of the labia is covered with hairs: the inner surface is smooth, and lined by mucous membrane, which contains a number of sebiparous follicles, and is covered by a thin cuticular epithelium. The use of the labia majora is to favour the extension of the vulva during parturition; for, in the passage of the head of the fœtus, the labia are unfolded and completely effaced.

The *labia minora*, or *nymphæ*, are two smaller folds, situated within the labia majora. Superiorly, they are

divided into two processes, which surround the glans clitoridis, the superior fold forming the præputium clitoridis, the inferior its frænulum. Inferiorly, they diminish gradually in size, and are lost on the sides of the opening of the vagina. The nymphæ consist of mucous membrane, covered by a thin cuticular epithelium. They are provided with a number of mucous follicles, and contain, in their interior, a plexus of blood-vessels.

The *clitoris* is a small elongated organ, situated in front of the ossa pubis, and supported by a suspensory ligament. It is formed by a small body, which is analogous to the corpus cavernosum of the penis, and, like it, arises from the ramus of the os pubis and ischium on each side, by two *crura*. At the extremity of the clitoris is a small accumulation of erectile tissue, which is highly sensitive, and is termed the *glans*. The corpus cavernosum clitoridis, like that of the penis, is composed of erectile tissue, enclosed in a dense layer of fibrous membrane, and is susceptible of erection. Like the penis, also, it is provided with two small muscles, the *erectores clitoridis*.

At about an inch behind the clitoris is *the entrance of the vagina*, an elliptical opening, marked by a prominent margin. The entrance to the vagina is closed, in the virgin, by a membrane of a semilunar form, which is stretched across the opening; this is the *hymen*. Sometimes the membrane forms a complete septum, and gives rise to great inconvenience by preventing the escape of the menstrual effusion. It is then called an *imperforate hymen*. The *hymen* must not be considered a necessary accompaniment of virginity, for its existence is very uncertain. When present, it assumes a variety of appearances: it may be a membranous fringe, with a round opening in the centre; or a semilunar fold, leaving an opening in front; or a transverse septum, having an opening both in front and behind; or a vertical band with an opening at each side.

The rupture of the hymen, or its rudimentary existence, gives rise to the appearance of a fringe of papillæ around the opening of the vagina; these are the *carunculæ myrtiformes*.

The triangular smooth surface between the clitoris and the entrance of the vagina, which is bounded on each

side by the upper portions of the nymphæ, is the *vestibule*.

At the posterior part of the vestibule, and near the margin of the vagina, is the opening of the urethra — the *meatus urinarius*; and around the meatus an elevation of the mucous membrane, formed by the aggregation of numerous mucous glands. This prominence serves as a guide to finding the meatus, in the operation of introducing the female catheter.

Beneath the vestibule on each side, and extending from the clitoris to the side of the vagina, are two oblong or pyriform bodies, consisting of erectile tissue enclosed in a thin layer of fibrous membrane. These bodies are narrow above (*pars intermedia*), broad and rounded below, and are termed by Kobelt, who considers them analogous to the bulb of the male urethra, the *bulbi vestibuli*.

Behind these bodies, and lying against the outer wall of the vagina, are two small glands analogous to Cowper's glands in the male subject; these are the *glands of Bartholine*. Each gland opens, by means of a long duct, upon the inner side of the corresponding nymphæ.

CHAPTER X.

ANATOMY OF THE PERINEUM.

THE *perineum* is the inferior part of the trunk of the body, in which are situated the two great excretory outlets, the urethra and the termination of the alimentary canal. These are parts of delicate and complicated structure, and largely supplied with vessels and nerves. They are also peculiarly liable, from the nature of their functions, to causes of irritation and disease. Indeed, disease is more frequent and various in this region than in any other of the body. Nearly the whole of the affections admit of relief or cure from operative procedure. Hence the perineum is the most important surgical region of the entire system, and incisions are made through it to great depth and in various directions. A good knowledge of its component structures and relations is therefore highly necessary to the Surgeon, for a misdirected incision, by wounding important parts, would involve the most serious consequences, and probably prove fatal to the patient.

The anatomical composition of the perineum is the same as that of any other part of the body, consisting of *integument, superficial fascia, muscles, vessels, and nerves*. But to suit the peculiar functions of this region, they are somewhat differently distributed and arranged.

To obtain a clear and precise idea of the nature of the perineum, the student must take in his hand a pelvis in which the sacro-ischiatic ligaments have been left in their proper positions. Let him now turn to the outlet of the pelvis, and he will be enabled to trace the *boundaries of the perineum*. *In front* he will have the arch of the pubes, *on each side* the ramus and tuberosity of the ischium and great sacro-ischiatic ligaments, and *behind* the coccyx.

If he draw a line transversely across this outlet from the anterior extremity of one tuberosity of the ischium to the same point on the other, he will divide the opening

into two parts of nearly equal size. The *anterior space* belongs to the organs of generation; the *posterior*, to the termination of the alimentary canal. Let us first examine the *anterior* or *genital space*.

A thin aponeurosis is stretched across this anterior space, from the ramus of the pubes and ischium on one side, to the same part on the opposite side. This is the triangular ligament. It is a septum of division between the interior and exterior of the pelvis, between the internal organs of generation and the external.

Externally to the triangular ligament is the *penis*, which is composed of two lengthened bodies—the corpus cavernosum above, and the corpus spongiosum below. The corpus cavernosum is firmly attached to the ramus of the pubes and ischium on each side, by two diverging processes called *crura penis*. The corpus spongiosum is the medium of transmission for the urethra, which enters that body immediately on its escape from the triangular ligament, and takes its course through its interior to its termination at the meatus urinarius.

The extremity of the corpus spongiosum, which receives the urethra, is enlarged, and is called the *bulb*; at its opposite extremity it is again enlarged, and forms the *glans penis*.

The penis is moved by three pairs of muscles, which are the *muscles of the perineum*. It is supplied with blood-vessels and nerves from the internal pudic artery and nerve. The muscles, vessels, and nerves are in immediate relation with the commencement of the penis, and *directly external* to the triangular ligament.

Then the whole of these parts are covered in and held firmly in their places by the *superficial perineal fascia*, which is continuous with the triangular ligament posteriorly, and is firmly attached on each side to the ramus of the pubes and ischium, whilst, anteriorly, it is continuous with the cellular base of the common superficial fascia of the scrotum and abdomen.

So that the genital portion of the perineum consists of two layers of aponeurosis, which are connected posteriorly and at the sides, and enclose a triangular space, in which are contained the root of the penis, with its muscles, vessels, and nerves. Externally to the superficial perineal fascia, is the integument.

The *posterior* or *anal portion of the perineum*, instead of a resisting membranous partition, like the triangular ligament, is divided from the cavity of the pelvis by a convex muscular septum—the levator ani muscle, which arises from nearly the whole circumference of the interior of the pelvis, and is inserted around the extremity of the rectum. A broad band of muscular fibres embraces the lower end of the intestine, forming the internal sphincter; and superficially to it is the flat ellipse of the external sphincter, which is covered by the superficial fascia and integument. Externally to the sphincter, between it and the internal wall of the pelvis is the ischio-rectal fossa, which contains a large collection of fat.

Dissection.—To dissect the perineum the subject should be fixed in the position for lithotomy, that is, the hands should be bound to the soles of the feet, and the knees kept apart. An easier plan is the drawing of the feet upwards, by means of a cord passed through a hook in the ceiling. Both of these means of preparation have for their object the full exposure of the perineum. And as this is a dissection which demands some degree of delicacy and nice manipulation, a strong light should be thrown upon the part. Having fixed the subject, and drawn the scrotum upwards by means of a string or hook, carry an incision from the base of the scrotum along the ramus of the pubes and ischium and tuberosity of the ischium, to a point parallel with the apex of the coccyx; then describe a curve over the coccyx to the same point on the opposite side, and continue the incision onwards along the opposite tuberosity and ramus of the ischium, and ramus of the pubes, to the opposite side of the scrotum, where the two extremities may be connected by a transverse incision. This incision will completely surround the perineum, following very nearly the outline of its boundaries. Now let the student dissect off the integument carefully from the whole of the included space, and he will expose the fatty cellular structure of the common superficial fascia.

The *superficial fascia* of the perineum, like that of the groin, consists of two layers, of which the *external* is cellular, and contains adipose tissue in variable proportion; and the *internal* is membranous and divested of fat.

In the superficial layer is contained a cutaneous muscle — the sphincter ani, which has been already dissected, in the removal of the integument.

The SPHINCTER ANI is a thin and elliptical plane of muscle, closely adherent to the integument, and surrounding the opening of the anus. It *arises*, posteriorly, in the superficial fascia around the coccyx, and by a fibrous raphé from the apex of that bone; and is *inserted*, anteriorly, into the tendinous centre of the perineum, and into the raphé of the integument, nearly as far forward as the commencement of the scrotum.

The sphincter ani may now be turned back from its anterior part; in raising it some small vessels and a nerve will be found joining it from the ischio-rectal fossa, these are the inferior hæmorrhoidal vessels and nerve. In the next place the student should dissect off the superficial layer of the superficial fascia from the deep layer, and pick out with care all the fat from the ischio-rectal fossa, taking care to avoid injuring, the deep layer of the superficial fascia, and especially that portion of it which turns back to unite with the triangular ligament.

The deep or membranous layer of the superficial perineal fascia is a strong but thin fibrous layer, which binds down the root of the penis and muscles of the genital portion of the perineum. It is firmly attached at each side to the ramus of the pubes and ischium nearly as far back as the tuberosities of that bone. Across the middle of the perineum it turns backwards, to become continuous with the triangular ligament. In front, it is continuous with the dartos of the scrotum, the superficial fascia of the penis, and the deep layer of the superficial fascia of the abdomen. Moreover, it is connected on the middle line with the raphé of the muscles of the spongy portion of the urethra and septum scroti, and thus divides the perineum into two lateral cavities, more or less complete.

It follows, from this arrangement, that if urine had escaped from the urethra at the point where that tube had just traversed the triangular ligament, it would be unable to follow the laws of gravity, and pass backwards towards the anus, on account of the communication between the superficial perineal fascia and the ligament. It could not pass outwards into the thighs, on account of the connection of the superficial perineal fascia to the

ramus of the pubes and ischium. It would, therefore, burrow among the muscles at the root of the penis, and be constrained to follow the direction of the penis forwards into the scrotum, and thence upwards into the cellular tissue of the lower part of the abdomen.

An abscess in this situation is excessively painful, on account of the tension and resistance of the deep layer of the superficial perineal fascia; and, unless speedily opened by the Surgeon, might give rise to consequences dangerous to life.

Behind the posterior and folded border of the superficial fascia, is situated, at each side, the *ischio-rectal fossa*. This fossa interposed, as its name implies, between the lower part of the rectum, and the side of the ischium, is bounded, in front, by the folded border of the superficial perineal fascia and triangular ligament; behind, by the border of the gluteus maximus and great sacro-ischiatic ligament; internally, by the levator ani and sphincter ani; and externally, by the internal obturator muscle and obturator fascia. In this, the outer wall of the ischio-rectal fossa, at a little more than an inch from the surface, and enclosed in a special sheath of fascia, are the internal pudic vessels and nerve, and crossing the fossa to the anus, the inferior hæmorrhoidal vessels and nerve.

The width of the ischio-rectal fossa is about an inch, and its depth two inches.

The best manner of dissecting the superficial perineal fascia is to make an incision from the middle point of the upper incision to the tuberosity of the ischium on each side. We thus form a Λ shaped flap, which, on being turned downwards (*fig. 75. 4.*), displays very distinctly the continuity of this fascia with the triangular ligament. The two side flaps (*5, 5.*) are then to be dissected outwards, and the firm connection between this fascia and the ramus of pubes and ischium demonstrated.

When the student has thus satisfied himself of the connections of the superficial perineal fascia, he must proceed to remove the fat and cellular tissue, which conceal from view the muscles and superficial vessels of the perineum. In the middle line is the projection of the corpus spongiosum, and on each side the commencement of the corpus cavernosum (*crus penis*). Upon these bodies are situated two pairs of muscles; and, between them, the

If the external sphincter ani be raised at the side as far as its attachment to the anus, the rounded border of the internal sphincter will be brought into view.

The SPHINCTER ANI INTERNUS is a muscular band embracing the extremity of the intestine, and formed by an aggregation of the circular muscular fibres of the rectum.

Part of the levator ani may now be seen, forming the floor and inner boundary of the ischio-rectal fossa. Its fibres may be traced to their insertion into the extremity of the rectum, and the muscle will be seen to be covered by a thin fascia. The examination of the muscle in its entire extent must be left until the pelvis is examined from within. It arises within the pelvis, and is inserted into the coccyx, the raphé between the coccyx and rectum, the side of the rectum, the central tendinous point of the perineum, and into its fellow of the opposite side.

Actions.—The acceleratores urinæ being continuous at the middle line, and attached on each side to the triangular ligament by means of their posterior fibres, will support the bulbous portion of the urethra, and acting suddenly, will propel the semen, or the last drops of urine from the canal. The posterior and middle fibres, according to Krause*, contribute towards the erection of the corpus spongiosum, by producing compression of the venous structure of the bulb; and the anterior fibres, according to Tyrrell†, assist in the erection of the entire organ, by compressing the vena dorsalis by means of their insertion into the fascia penis. The erector penis becomes entitled to its name from spreading out upon the dorsum of the organ into a membranous expansion (fascia penis), which, according to Krause, compresses the dorsal vein during the action of the muscle, and especially after the erection of the organ has commenced. The transverse muscles serve to steady the tendinous centre, that the muscles attached to it may obtain a firm point of support. According to Cruveilhier, they draw the anus backwards during the expulsion of the fæces, and antagonise the levatores ani which carry the anus forwards. The *external sphincter*, being a cutaneous muscle, contracts the integument around the anus, and by its attachment to the tendinous centre and to the point of the coccyx, assists the levator ani in giving support to the opening during expulsive efforts. The *internal sphincter* contracts the extremity of the cylinder of the intestine.

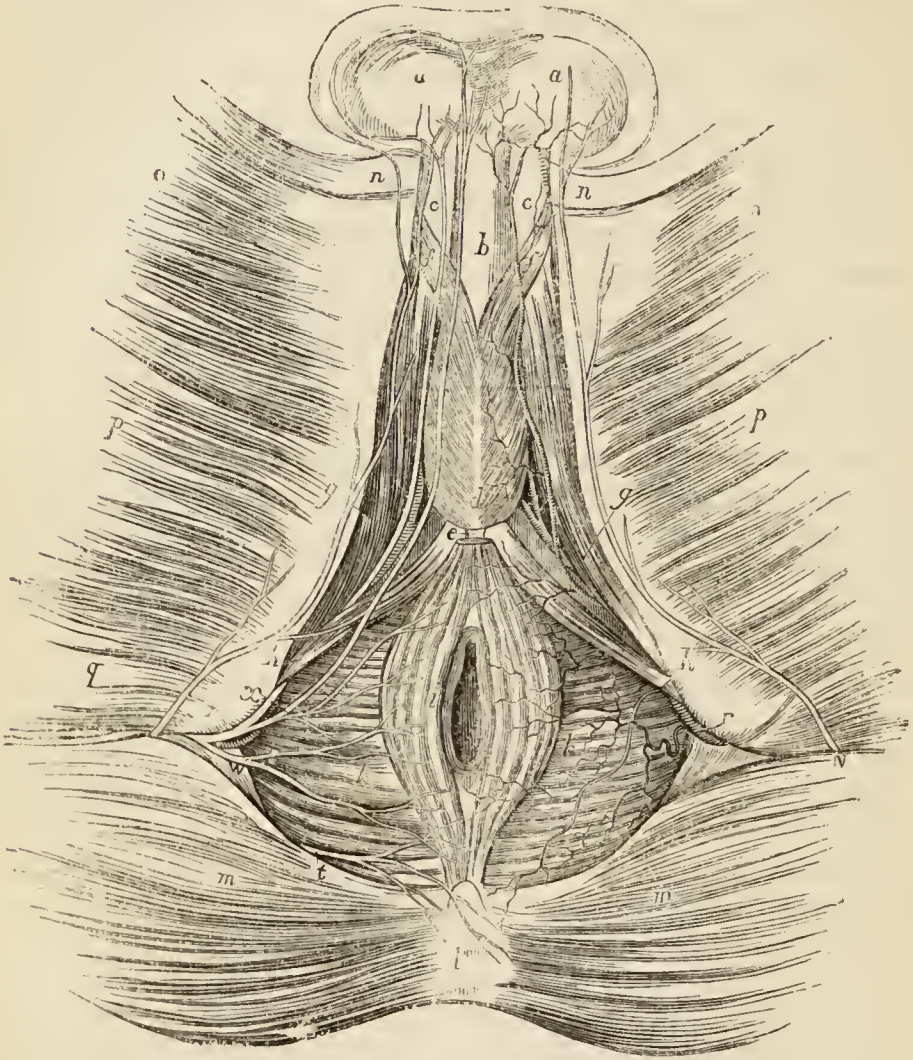
Now that the muscles of the perineum have been examined, the student should remove at one side the accelerator urinæ, transversus perinei and erector penis, and detach the crus penis from the bone, he will then bring into view a smooth shining aponeurotic layer which forms, as it were, the floor of the genital portion of the perineum. This is the external surface of the triangular ligament. By means of the handle of the scalpel it may be traced to its attach-

* Müller, Archiv für Anatomie, Physiologie, &c. 1837.

† Lectures in the College of Surgeons. 1839.

ment into the ramus of the pubes and ischium; on the middle line it is continuous with the covering of the penis behind the bulb, and below it is continuous with the folded border of the superficial

Fig 74.*



* Anatomy of the perineum.—*a, a*. The testes covered by cellular tissue, the scrotum being drawn up. *b*. The corpus spongiosum penis. *c, c*. The corpus cavernosum. *d, d*. The acceleratores urinæ muscles. *e*. The tendinous centre of the perineum. *f, f*. The slip of the accelerator urinæ, which surrounds the corpus cavernosum. *g, g*. The erector penis; the letter is placed on the ramus of the ischium. *h, h*. The transversus perinei muscle; the letter is placed on the tuberosity of the ischium. *i*. The sphincter ani. *k, k*. The levator ani. *l*. The coccyx. *m, m*. The gluteus maximus. *n*. The origin of the adductor longus. *o*. The gracilis. *p*. The adductor magnus. *q*. The conjoined head of the biceps and semitendinosus. *r, r*. The internal pudic artery, on the left side accompanied by the pudic nerve; the letters rest on the tuberosity of the ischium; the inferior hæmorrhoidal arteries are seen crossing the right ischio-rectal fossa (*k*) to reach the surface. *s*. The internal pudic artery giving off the artery of the bulb: the small artery lying superficially to the pudic at this point, and then running along the

perineal fascia. It is the internal boundary of the pouch of the genital portion of the perineum, which contains the root of the penis together with its muscles, vessels, and nerves.

The *triangular ligament*, or deep perineal fascia, is a thin layer of aponeurosis which is stretched across the anterior portion of the outlet of the pelvis; it is attached on each side to the pelvic border of the ramus of the pubes and ischium as far back as the origin of the erector penis muscle. Anteriorly, it is convex and closely connected with the subpubic ligament; while, posteriorly, it is concave, and turns forwards around the posterior border of the transversus perinei muscle, to become continuous with the superficial perineal fascia. At its middle, it is about an inch and a half in depth; at one inch below the pubic arch, it is pierced by the membranous portion of the urethra, and nearer the pubic arch, by the dorsal vein of the penis and internal pudic arteries.

Directly behind the ligament are situated the deep transversus perinei and compressor urethræ muscle, the arteries of the bulb, and Cowper's glands, and more deeply the pelvic fascia, which has been sometimes described as the posterior layer of the triangular ligament.

VESSELS AND NERVES OF THE PERINEUM.

The INTERNAL PUDIC ARTERY, one of the terminal branches of the internal iliac artery, in pursuing its course along the inner wall of the pelvis, crosses the spine of the ischium. Hence it is described as passing out of the pelvis through the great sacro-ischiatic foramen, and re-entering the pelvis through the lesser sacro-ischiatic foramen. It then passes forwards to the ramus of the ischium, resting against the obturator fascia and enclosed in a special sheath; and ascends along the inner border of the ramus of the ischium and pubes to near the arch

penis to *a.* is the superficial perineal; it is seen giving off a transversalis perinei branch, which crosses the transversus perinei muscle (*h.*); on the left side the nerves of the perineum are principally shown. *t.* The hæmorrhoidal branch of the fourth sacral nerve. *v, v.* The inferior pudendal nerve, a branch of the lesser sciatic. *w.* The inferior hæmorrhoidal nerve proceeding from the pudic. *x.* The superficial perineal nerve, posterior branch; the anterior branch is seen issuing from beneath the transversus perinei muscle, and running forwards by the side of the posterior branch, in the groove of the penis, to the scrotum at *y.*

of the pubes, where it perforates the triangular ligament and divides into two terminal branches;—the artery of the corpus cavernosum and dorsalis penis. While crossing the obturator muscle, the artery is situated in the outer wall of the ischio-rectal fossa, at somewhat more than an inch from the surface of the tuberosity.

The *branches* of the internal pudic artery in the perineum are the—

Inferior hæmorrhoidal,	Arteria corporis bulbosi,
Superficialis perinei,	Arteria corporis cavernosi,
Transversalis perinei,	Arteria dorsalis penis.

The *inferior hæmorrhoidal arteries* (external) are three or four small branches, given off by the internal pudic while behind the tuberosity of the ischium. They cross the ischio-rectal fossa, and are distributed to the anus, and to the muscles and integument of the anal region of the perineum.

The *superficial perineal artery* is given off near the attachment of the crus penis; it pierces the connecting layer of the superficial fascia and triangular ligament, and runs forward across the transversus perinei muscle, and along the groove between the accelerator urinæ and erector penis to the septum scroti, upon which it ramifies under the name of arteria septi. It distributes branches to the scrotum and to the perineum in its course forwards. One of the latter, larger than the rest, crosses the perineum, resting on the transversus perinei muscle, and is named the *transversalis perinei*. There are often two superficial perineal arteries.

The *artery of the bulb* is given off from the pudic, nearly opposite the opening for the transmission of the urethra; it passes almost transversely inwards behind the triangular ligament, and pierces that ligament, to enter the corpus spongiosum at its bulbous extremity. It is distributed to the corpus spongiosum.

The *artery of the corpus cavernosum*, one of the terminal branches of the internal pudic, pierces the crus penis, and runs forward in the interior of the corpus cavernosum, by the side of the septum pectiniforme. It ramifies in the parenchyma of the venous structure of the corpus cavernosum.

The *dorsal artery of the penis* ascends between the two

crura and symphysis pubis to the dorsum penis, and runs forward, through the suspensory ligament, in the groove of the corpus cavernosum, to the glans, distributing branches in its course to the body of the organ and integument.

The VEINS of the perineum, excepting the dorsal vein of the penis, unite to form the internal pudic vein, which follows the course of the artery, and terminates in the internal iliac vein.

The *dorsal vein of the penis*, after piercing the triangular ligament just beneath the subpubic ligament, divides into two trunks, and terminates in the prostatic plexus.

The NERVES of the perineum are, an hæmorrhoidal branch from the fourth sacral nerve, the inferior pudendal nerve a branch of the lesser ischiatic nerve, and the pudic.

The *hæmorrhoidal branch* of the fourth sacral nerve issues from between the coccygeus muscle and levator ani, and is distributed to the muscles and integument behind the anus.

The *inferior pudendal nerve* pierces the fascia lata near the ramus, and just in front of the tuberosity of the ischium, and passes forward in the superficial fascia of the perineum to the scrotum, to which and to the root of the penis it is distributed. In its course it communicates with the posterior superficial perineal nerve.

The PUDIC NERVE arises from the lower part of the sacral plexus, and passes out of the pelvis through the great sacro-ischiatic foramen below the pyriformis muscle. It then follows the course of the internal pudic artery along the wall of the ischio-rectal fossa, lying inferiorly to the artery and enclosed in the same sheath. Near its origin it gives off the *inferior hæmorrhoidal* nerve, and in the ischio-rectal fossa divides into a superior and an inferior branch.

The *inferior hæmorrhoidal nerve*, often a branch of the sacral plexus, passes through the lesser sacro-ischiatic foramen, and descends to the termination of the rectum, to be distributed to the sphincter ani and integument.

The *dorsalis penis nerve*, the superior division of the internal pudic, ascends along the posterior surface of the ramus of the ischium, pierces the triangular ligament,

and accompanies the *arteria dorsalis penis* to the glans, to which it is distributed. At the root of the penis the nerve gives off a cutaneous branch which runs along the side of the organ, gives filaments to the *corpus cavernosum*, and with its fellow of the opposite side supplies the integument of the upper two-thirds of the penis and prepuce.

The *perineal nerve*, or inferior terminal branch, larger than the preceding, pursues the course of the superficial perineal artery in the perineum, and divides into cutaneous and muscular branches. The cutaneous branches (*superficial perineal*), two in number, *posterior* and *anterior*, enter the ischio-rectal fossa, and pass forwards with the superficial perineal artery, to be distributed to the integument of the perineum, scrotum, and under part of the penis. The *posterior* superficial perineal nerve also sends a few filaments to the integument of the anus and sphincter ani; while the *anterior* gives off one or two twigs to the levator ani.

The *muscular* branches proceed from a single trunk which passes inwards behind the *transversus perinei* muscle; they are distributed to the *transversus perinei*, *accelerator urinæ*, and *erector penis*. The perineal nerve also sends two or three filaments to the *corpus spongiosum*.

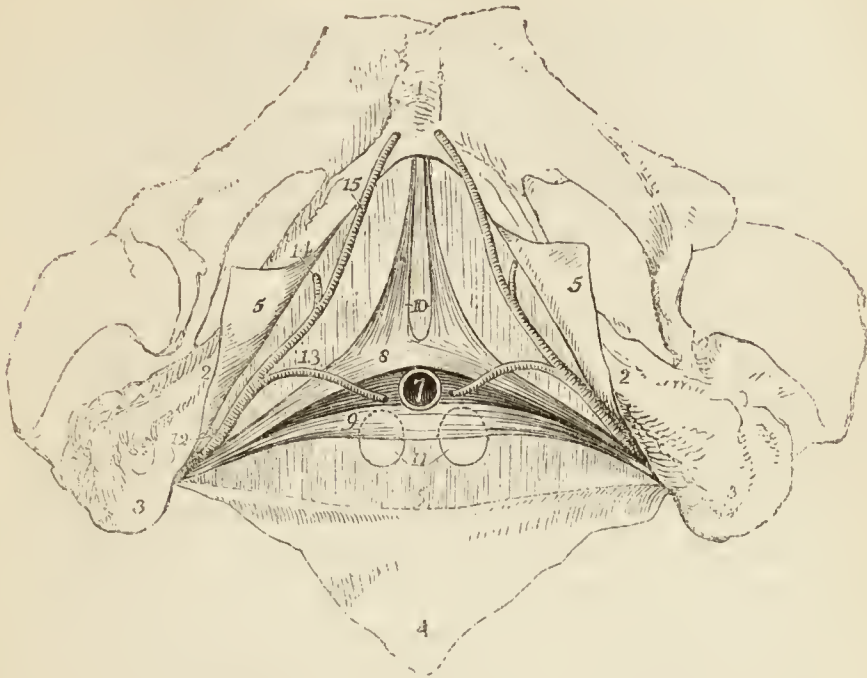
The student should now bring more completely into view the surface of the triangular ligament, for which purpose he should divide the *corpus spongiosum* at about an inch in front of the bulb, separate it from the *corpus cavernosum*, and turn it down. One crus of the *corpus cavernosum* has been already cut through, so that the penis may also be drawn aside. When the surface of the triangular ligament is fully exposed and cleaned, he should raise the triangular ligament carefully, and remove it, in order to bring into view the parts which lie behind. These are a pair of muscles, the deep *transversus perinei* and *compressor urethræ*, Cowper's glands, the membranous portion of the urethra and the arteries of the bulb.

The **TRANSVERSUS PERINEI PROFUNDUS** (*perinæus profundus*) is a thin muscle which *arises* from the ramus of the pubes and ischium by tendinous fibres, and passes inwards to the anterior extremity of the membranous portion of the urethra, where it is united, by means of a raphé, with its fellow of the opposite side, and is also inserted into the posterior part of the bulb.

The **COMPRESSOR URETHRÆ** (*constrictor urethræ membranaceæ*, *constrictor isthmi urethræ*) *arises* from the upper and lower surface of the anterior ligament of the

bladder, and passing inwards towards the middle line divides into two fasciculi, superior and inferior, which em-

Fig. 75.*



brace the membranous portion of the urethra. The *superior* fasciculus is continued forwards to the junction of the crura penis with which it is connected, and backwards to the prostate gland, upon the upper surface of which it is spread out. The *inferior* fasciculus is continued directly into its fellow of the opposite side, beneath the membranous portion of the urethra. A third fasciculus, closely united with the two preceding, consists of *circular* fibres, which enclose and form a muscular sheath for the membranous part of the urethra.

* The structures situated behind the triangular ligament.—No. 1. The symphysis pubis. 2, 2. The ramus of the pubes and ischium. 3, 3. The tuberosities of the ischia. 4. A triangular portion of the superficial fascia turned down, and shown to be continuous with the triangular ligament (6.) 5, 5. Two portions of the superficial perineal fascia, showing its connection to the ramus of the pubes and ischium. 7. The membranous portion of the urethra cut across. 8. The superior fasciculus of the compressor urethræ muscle of one side. 9. The inferior fasciculus of the compressor urethræ. The two fasciculi (8.) and (9.) constitute Guthrie's muscle of one side. 10. The pubic portions of the compressor urethræ, Wilson's muscles. 11. Cowper's glands. 12. The internal pudic artery, passing posteriorly to the crus of the compressor urethræ. 13. The artery of the bulb. 14. The artery of the corpus cavernosum. 15. The dorsalis penis artery.

Under the name of Wilson's museles, a fourth fasciculus has been described as descending vertically from the body of the pubes, near the symphysis, to unite with the superior fasciculus of the compressor urethræ. This fasciculus is inconstant and its existence is doubtful.

Actions. — The transversus perinei profundus draws the urethra and the bulb backwards; according to Santorinus, it also assists the accelerator urinæ in its action of compressing the bulb. The compressor urethræ, taking its fixed point from the ramus of the pubes and ischium at each side, can, says Mr. Guthrie, “compress the urethra, so as to close it, I conceive completely, after the manner of a sphincter.”

COWPER'S GLANDS are two small bodies of the size and shape of peas somewhat compressed, situated beneath the membranous portion of the urethra, immediately behind the bulb and triangular ligament, and between the deep transversus perinei muscle and deep segment of the compressor urethræ. The gland is lobulated in structure, and furnished with an excretory duct about an inch in length, which passes forwards by the side of the urethra, between it and the substance of the bulb, and terminates by opening into the bulbous portion of the urethra. Each gland is furnished with a small arterial twig from the artery of the bulb.

THE OPERATION OF LITHOTOMY, which especially gives interest to the anatomy of the perineum, requires the division of the different structures which enter into its composition. An incision has to be made through the perineum to the neck of the bladder. Another operation, the puncture of the bladder through the perineum, is also performed by incising in the same direction and through the same parts. In his second dissection, the student should practise the former operation, and afterwards examine the structures through which his incision has passed, and the liabilities that might ensue from proceeding ignorantly.

In lithotomy the patient is fixed by binding the palms of the hands against the soles of the feet, and holding apart the knees. The operator has thus the whole expanse of the perineum before his eyes; he observes the elevated line (*raphé*) which runs along the middle of the perineum to the anus, and he feels for the tuberosity of the ischium; he then commences an incision at the *raphé*, about an inch and a half, more or less, in front of the anus. The exact point for the commencement of the incision must always be left to the judgment of the operator, who will proportion the length of his incision to the size and age of his patient, his fatness, or emaciation; an inch and a half being about the average distance in an adult of ordinary condition.

The incision is carried obliquely downwards and outwards, to a point one-third nearer to the tuberosity of the ischium than to the

anus, and should terminate opposite the middle of the anus. The proportional distance between the tuberosity of the ischium and anus, is the Scylla and Charybdis of the operation; for approaching nearer the former would endanger the internal pudic artery; and the latter, the rectum; particularly if the surgeon have neglected the precaution of emptying that bowel previously to the operation.

The *first step*, then, of the operation is to make a steady incision from the raphé, an inch and a half in front of the anus, obliquely downwards and outwards to a point one-third nearer the tuberosity of the ischium than the anus, and opposite the middle of that opening. This incision should divide the integument, the superficial perineal fascia, the lower fibres of the accelerator urinæ, the transversus perinei muscle and artery, and some branches of the inferior hæmorrhoidal arteries and nerve. It may also divide the superficial perineal vessels and nerves.

The operator now inserts his finger into the upper part of the incision, drawing aside the bulb of the urethra, and presses his nail into the groove of the staff, just at the point where the urethra escapes from the triangular ligament: he then conveys the point of a knife, guided by his finger-nail, into the groove at the under part of the cylinder of the urethra, and carries it onwards, along the groove in the staff, into the bladder. In withdrawing the knife he depresses the handle, so as to divide but *slightly* the neck of the bladder, prostate gland, and triangular ligament, and more extensively any of the other textures which may have remained undivided by the first incision.

The form in the opening thus made must evidently be triangular, the base being at the integument, the apex at the neck of the bladder. The insertion of the knife into the under part of the cylinder of the urethra, is a precaution for avoiding the artery of the bulb*, which might otherwise be divided, and give rise to unpleasant hæmorrhage.

The *third step* of the operation consists in introducing the finger of the right hand through the wound into the bladder, dilating the neck of that viscus, and *breaking* the prostate gland in the direction of the incision, for the purpose of securing space for the removal of the calculus. Then passing the forceps along the finger, the calculus is seized by its short diameter, and must be withdrawn in the axis of the pelvis.

The structures cut through in this operation in their order of division, are the

Integument,
Superficial perineal fascia,
Bulbous portion of the accelerator urinæ muscle,
Transversus perinei muscle,

* The author has seen two or three instances of the early division of this artery, in which no precaution on the part of the surgeon could have availed, and the artery must have been inevitably divided.

Transversalis perinei artery,
 Triangular ligament,
 Membranous portion of the urethra,
 Lower segment of the deep transversus perinei muscle,
 Lower segment of the compressor urethræ,
 Some fibres of the levator ani,
 Prostate gland,
 Neck of the bladder.

The structures in the female perineum are the same as in the male, but somewhat modified to suit the difference of form in the organs of generation. The integument and superficial fascia are thrown into folds, called labia, to prepare for the enormous distension to which this part is submitted in parturition. The entrance of the vagina is encircled by a sphincter, which is not unlike the accelerator urinæ of the male. The clitoris is the penis of the female, composed of its corpus cavernosum, and therefore provided with erectores clitoridis, analogous to the erectores penis. The transversus perinei, sphincters, and levator ani, are precisely the same as in the male.

The dissection of the female perineum should be the same as that already prescribed for the male. The integument having been turned aside, the superficial fascia and superficial vessels should be examined and removed. The labia majora, being composed of integument and cellular tissue, should also be removed, and the muscles brought into view, and carefully cleaned.

The MUSCLES of the *female perineum* are the
 Constrictor vaginæ,
 Transversus perinei, superficial and deep,
 Erector clitoridis,
 Compressor urethræ,
 Sphincter ani.

The CONSTRICTOR VAGINÆ is analogous to the accelerator urinæ of the male : it *arises* from the tendinous centre of the perineum, where it is continuous with the sphincter ani and transversus perinei; and passes forwards on each side of the entrance of the vagina, to be *inserted* into the corpus cavernosum clitoridis.

The TRANSVERSUS PERINEI is a small muscle *arising* on each side from the ramus of the ischium, and *inserted* into the side of the constrictor vaginæ.

The TRANSVERSUS PERINEI PROFUNDUS is situated above the triangular ligament : as in the male, it is *inserted* into the urethra.

The **ERECTOR CLITORIDIS** *arises* from the ramus of the ischium, and is *inserted* on each side into the crus clitoridis.

The **COMPRESSOR URETHRÆ** has the same origin and insertion, and exercises the same functions in the female as in the male.

The **SPHINCTER ANI** surrounds the lower extremity of the rectum, as in the male.

The **LEVATOR ANI** is inserted into the side of the vagina and rectum.

The **TRIANGULAR LIGAMENT** is the same as in the male, but of less extent.

The **VESSELS** and **NERVES** of the perineum are identical with those of the male, with the exception that the artery of the bulb is distributed to the vagina. The nerve of the bulb has a similar distribution.

CHAPTER XI.

ANATOMY OF THE FŒTUS.

THE medium weight of a child of the full period, at birth, is seven pounds, and its length seventeen inches; the extremes of weight are four pounds and three quarters, and ten pounds; and the extremes of measurement, fifteen and twenty inches. The head is of large size, and lengthened from before backwards; the face small. The upper extremities are greatly developed, and the thorax expanded and full. The upper part of the abdomen is large, from the great size of the liver; the lower part is small and conical; and the lower extremities are very small in proportion to the rest of the body. The external genital organs are very large and fully developed; and the attachment of the umbilicus is one inch farther from the vertex of the head than from the soles of the feet, and one inch farther from the ensiform cartilage than from the symphysis pubis.

OSSEOUS SYSTEM.—The development of the osseous system is treated of in the Anatomists' Vade mecum. The ligamentous system presents no peculiarity deserving of remark.

MUSCULAR SYSTEM.—The muscles of the fœtus at birth are large and fully formed. They are of lighter colour than those of the adult, and softer texture. The transverse striæ on the fibres of animal life, are not distinguishable until the sixth month of fœtal life.

VASCULAR SYSTEM.—The circulating system presents several peculiarities: 1st, in the heart; there is a communication between the two auricles by means of the *foramen ovale*. 2ndly, in the arterial system; there is a communication between the pulmonary artery and descending aorta, by means of a large trunk—the *ductus arteriosus*. 3rdly, also in the arterial system; the internal iliac arteries, under the name of hypogastric and *umbilical*, are continued from the fœtus to the placenta, to which they return the blood which has circulated in the system

of the foetus. 4thly, in the venous system; there is a communication between the umbilical vein and the inferior vena cava, called the *ductus venosus*.

FŒTAL CIRCULATION.

The pure blood is brought from the placenta by the *umbilical vein*. The umbilical vein passes through the umbilicus, and enters the liver, where it divides into several branches, which may be arranged under three heads:—1st, two or three, which are distributed to the left lobe. 2dly, a single branch, which communicates with the portal vein in the transverse fissure, and supplies the right lobe. 3dly, a large branch, the *ductus venosus*, which passes directly backwards, and joins the inferior cava. In the inferior cava the pure blood becomes mixed with that which is returning from the lower extremities and abdominal viscera, and is carried through the right auricle (guided by the Eustachian valve) and through the *foramen ovale*, into the left auricle. From the left auricle it passes into the left ventricle, and from the left ventricle into the aorta, whence it is distributed, by means of the carotid and subclavian arteries, principally to the head and upper extremities. From the head and upper extremities, the impure blood is returned by the superior vena cava to the right auricle; from the right auricle it is propelled into the right ventricle, and from the right ventricle into the pulmonary artery. In the adult the blood would now be circulated through the lungs, and oxygenated; but in the foetus the lungs are solid, and almost impervious. Only a small quantity of the blood passes therefore into the lungs; the greater part rushes through the *ductus arteriosus* into the commencement of the descending aorta, where it becomes mingled with that portion of the pure blood which is not sent through the carotid and subclavian arteries.

Passing along the aorta, a small quantity of this mixed blood is distributed by the external iliac arteries to the lower extremities; the greater portion is conveyed by the internal iliac, hypogastric, and umbilical arteries to the placenta; the hypogastric arteries proceeding from the internal iliacs, and passing by the side of the fundus of the bladder, and upwards along the anterior wall of the

abdomen to the umbilicus, where they become the umbilical arteries.

From a careful consideration of this circulation, we perceive : —

1st. That the pure blood from the placenta is distributed in considerable quantity to the liver, before entering the general circulation. Hence arises the abundant nutrition of that organ, and its enormous size in comparison with other viscera.

2ndly. That the right auricle is the scene of meeting of a double current; the one coming from the inferior cava, the other from the superior, and that they must cross each other in their respective courses. How this crossing is effected the theorist will wonder; not so the practical anatomist; for a cursory examination of the foetal heart will show — 1. That the direction of entrance of the two vessels is so opposite, that they may discharge their currents through the same cavity without admixture. 2. That the inferior cava opens almost directly into the left auricle. 3. That by the aid of the Eustachian valve, the current in the inferior cava will be almost entirely excluded from the right ventricle.

3rdly. That the blood which circulates through the arch of the aorta, comes directly from the placenta; and, although mixed with the impure blood of the inferior cava, yet is propelled in so great abundance to the head and upper extremities, as to provide for the increased nutrition of those important parts, and prepare them, by their greater size and development, for the functions which they are required to perform at the instant of birth.

4thly. That the blood circulating in the descending aorta is very impure, being obtained principally from the returning current in the superior cava; a small quantity only being derived from the left ventricle. Yet it is from this impure blood that the nutrition of the lower extremities is provided. Hence we are not surprised at their insignificant development at birth; while we admire the providence of nature, which directs the nutrient current in abundance, to the organs of sense, prehension, and deglutition, organs so necessary, even at the instant of birth, to the safety and welfare of the creature.

After birth, the *foramen ovale* becomes gradually closed by a membranous layer, which is developed from the margin of the opening from below upwards, and

completely separates the two auricles. The situation of the foramen is seen in the adult heart, upon the septum auricularum, and is called the *fossa ovalis*; the prominent margin of the opening is the *annulus ovalis*.

As soon as the lungs have become inflated by the first act of inspiration, the blood of the pulmonary artery rushes through its right and left branches into the lungs, to be returned to the left auricle by the pulmonary veins. Thus the pulmonary circulation is established. Then the *ductus arteriosus* contracts and degenerates into an impervious fibrous cord, serving in after life simply as a bond of union between the left pulmonary artery and the concavity of the arch of the aorta.

The current through the umbilical cord being arrested, the *hypogastric arteries* likewise contract and become impervious. The *umbilical vein* and *ductus venosus*, also deprived of their circulating current, become reduced to fibrous cords, the former being the *round ligament* of the liver, and the latter a fibrous band which may be traced along the fissure for the ductus venosus to the inferior vena cava.

NERVOUS SYSTEM.—The brain is very soft, almost pulpy, and has a reddish tint throughout; its weight at birth, relatively to the entire body, is as one to six, and the difference between the white and grey substance is imperfectly marked. The nerves are firm and well developed.

FŒTAL ORGANS OF SENSE.

Eye.—The eyeballs are of large size and well developed at birth. The pupil is closed by a vascular membrane, called the *membrana pupillaris*, which disappears at about the seventh month. Sometimes it remains permanently, and produces blindness. It consists of two thin membranous layers, between which the ciliary arteries are prolonged from the edge of the iris, and form arches and loops by returning to it again, without anastomosing with those of the opposite side.

The removal of the membrane takes place by the contraction of these arches and loops, towards the edge of the pupil. The capsule of the lens is extremely vascular.

Ear.—The ear is remarkable for its early development; the labyrinth and ossicula auditûs are ossified at

an early period, and the latter are completely formed before birth. The only parts remaining incomplete are the mastoid cells, and the meatus auditorius. The membrana tympani in the foetal head is very oblique, occupying almost the basilar surface of the skull ; hence probably arises a deficient acuteness in the perception of sound. It is also extremely vascular.

Nose. — The sense of smell is imperfect in the infant, as may be inferred from the small capacity of the nasal fossæ, and the non-development of the ethmoid, sphenoid, frontal, and maxillary sinuses.

FCETAL THYROID GLAND.

The *thyroid gland* is of large size in the foetus, and is developed by two lateral halves, which approach and become connected at the middle line, so as to constitute a single gland. It is doubtful whether it performs any special function in foetal life.

FCETAL THYMUS GLAND.

The *thymus gland** consists “of a thoracic and a cervical portion on each side. The former is situated in the anterior mediastinum, and the latter is placed in the neck just above the first bone of the sternum, and behind the sterno-hyoidei and sterno-thyroidei muscles.” It extends upwards from the fourth rib as high as the thyroid gland, resting against the pericardium, and separated from the arch of the aorta and great vessels by the thoracic fascia in the chest, and lying on each side of the trachea in the neck.

Although described usually as a single gland, it consists actually of two lateral, almost symmetrical glands, connected with each other by cellular tissue only, and having no structural communication; they may therefore be “properly called, a right and left thymus gland.”

Between the second and third months of embryonic existence, the thymus is so small as to be only “just perceptible;” and continues gradually increasing with the

* In the description of this gland I have adhered closely to the history of it, given by Sir Astley Cooper, in his monograph “On the Anatomy of the Thymus Gland,” 1832.

growth of the fœtus until the seventh. At the eighth month, it is large; but, during the ninth, it undergoes a sudden change, assumes a greatly increased size, and at birth weighs 240 grains. After birth, it continues to enlarge until the expiration of the first year, when it ceases to grow, and gradually diminishes, until at puberty it has almost disappeared.

The thymus is a conglomerate gland, being composed of lobules disposed in a spiral form around a central cavity. The lobules are held together by a firm cellular tissue ("reticulated"), and the entire gland is enclosed in a coarse cellulo-fibrous capsule.

The *lobules* are very numerous, and vary in size from that of the head of a pin to a moderate-sized pea. Each lobule contains in its interior a small cavity, or "*secretory cell*," and several of these cells open into a small "*pouch*" which is situated at their base, and leads to the central cavity, the "*reservoir of the thymus*."

The *reservoir* is lined in its interior by a vascular mucous membrane, which is raised into ridges by a layer of ligamentous bands situated beneath it. The ligamentous bands proceed in various directions, and encircle the open mouths (*pores*) of the secretory cells and pouches. This ligamentous layer serves to keep the lobules together, and prevent the injurious distention of the cavity.

When either gland is carefully unravelled by removing the cellulo-fibrous capsule and vessels, and dissecting away the reticulated cellular tissue which retains the lobules in contact, the reservoir, from being folded in a serpentine manner upon itself, admits of being drawn out into a lengthened tubular *cord**, around which the lobules are clustered in a spiral manner, and resemble knots upon a cord, or a string of beads.

The reservoir, pouches, and cells, contain a white fluid "like chyle," or "like cream, but with a small admixture of red globules."

In an examination of the thymic fluid which I lately (1840) made, with a Powell microscope magnifying 600 times linear measure, I observed that the corpuscles were very numerous, smaller than the blood particles, globular

* See the plates in Sir Astley Cooper's work.

and oval in form, irregular in outline, variable in size, and provided with a small central nucleus.

In the human fœtus this fluid has been found by Sir Astley Cooper, in too small proportion to be submitted to chemical analysis. But the thymic fluid of the fœtal calf, which exists in great abundance, gave the following analytical results* ; 100 parts of the fluid contained sixteen parts of solid matter, which consisted of —

Incipient fibrine,
Albumen,
Mucus, and muco-extractive matter,
Muriate and phosphate of potass,
Phosphate of soda,
Phosphoric acid, a trace.

According to the researches of Simon† and Oesterlen, the thymus is composed of polygonal and mutually flattened membranous cells, measuring from half a line to two lines in diameter, and arranged in conical masses around a central cavity. Each cell is surrounded by a capillary plexus, and connected to neighbouring cells by cellular tissue intermingled with elastic fibres. The corpuscles found in the fluid of the thymus are dotted nuclei measuring $\frac{1}{3830}$ of an inch in diameter ; and are subject to conversion into nucleated cells and fat-cells.

The *arteries* of the thymus gland are derived from the internal mammary, superior and inferior thyroid.

The *veins* terminate in the left vena innominata, and some small branches in the thyroid veins.

The *nerves* are minute, and derived chiefly, through the internal mammary plexus, from the superior thoracic ganglion of the sympathetic. Sir Astley Cooper has also seen a branch from the junction of the pneumogastric and sympathetic pass to the side of the gland.

The *lymphatics* terminate in the general union of the lymphatic vessels, at the junction of the internal jugular and subclavian veins. Sir Astley Cooper has injected them only once in the human fœtus ; but in the calf he finds two large lymphatic ducts, which commence in the

* This analysis was conducted by Dr. Dowler, of Richmond.

† "A Physiological Essay on the Thymus Gland," 4to. 1845.

upper extremities of the glands, and pass downwards, to terminate at the junction of the jugular and subclavian vein at each side. These vessels he considers to be the “*absorbent ducts* of the glands; ‘*thymic ducts* ;’ they are the carriers of the fluid from the thymus into the veins.”

Sir Astley Cooper concludes his anatomical description of this gland with the following observations : —

“As the thymus secretes all the parts of the blood, viz. albumen, fibrine, and particles, is it not probable that the gland is designed to prepare a fluid well fitted for the foetal growth and nourishment from the blood of the mother before the birth of the foetus, and, consequently, before chyle is formed from food? —and this process continues for a short time after birth, the quantity of fluid secreted from the thymus gradually declining as that of chyfication becomes perfectly established.”

FŒTAL LUNGS.

The *lungs*, previously to the act of inspiration, are dense and solid in structure, and of a deep red colour. Their specific gravity is greater than water, in which they sink to the bottom; whereas lung which has respired will float upon that fluid. The specific gravity is, however, no test of the real weight of the lung, the respired lung being actually heavier than the foetal. Thus the weight of the foetal lung, at about the middle period of uterine life, is to the weight of the body as 1 to 60.* But, after respiration, the relative weight of the lung to the entire body is as 1 to 30.

FŒTAL HEART.

The *heart* of the foetus is large in proportion to the size of the body; it is also developed very early, representing at first a simple vessel, and undergoing various degrees of complication until it arrives at the compound character which it presents after birth. The two ventricles form, at one period, a single cavity, which is afterwards divided into two by the septum ventriculorum. The two auricles communicate up to the moment of birth,

* Cruveilhier, Anatomie Descriptive, vol. ii. p. 621.

the septum being incomplete, and leaving a large opening between them, the *foramen ovale* (foramen of Botal).*

The *ductus arteriosus* is another peculiarity of the fœtus, connected with the heart ; it is a communication between the left pulmonary artery and the aorta. It degenerates into a fibrous cord after birth, from the double cause of a diversion in the current of the blood towards the lungs, and from the pressure of the left bronchus, caused by its distention with air.

VISCERA OF THE ABDOMEN.

At an early period of uterine life, and sometimes at the period of birth, as I have twice observed in the imperfectly developed fœtus, two minute fibrous threads may be seen passing from the umbilicus to the mesentery. These are the remains of the omphalo-mesenteric vessels.

The *omphalo-mesenteric* are the first developed vessels of the germ : they ramify upon the vesicula umbilicalis, or yolk-bag, and supply the newly formed alimentary canal of the embryo. From them, as from a centre, the general circulating system is produced. After the establishment of the placental circulation they cease to carry blood, and dwindle to the size of mere threads, which may be easily demonstrated in the early periods of uterine life ; but are completely removed, excepting under peculiar circumstances, at a later period.

The *stomach* is of small size, and the great extremity but little developed. It is also more vertical in direction the earlier it is examined, a position that would seem due to the enormous magnitude of the liver, and particularly of its left lobe.

The *appendix vermiformis cæci* is long and of large size, and is continued directly from the central part of the cul-de-sac of the cæcum, of which it appears to be a constricted continuation. This is the character of the appendix cæci in the higher quadrumana.

The large intestines are filled with a dark green viscous secretion, called *meconium* (*μήκων*, poppy), from its resemblance to the inspissated juice of the poppy.

* Leonard Botal, of Piedmont, was the first of the moderns who gave an account of this opening, in a work published in 1565. His description is very imperfect. The foramen was well known to Galen.

The *pancreas* is comparatively larger in the fœtus than in the adult.

The *spleen* is comparatively smaller in the fœtus than in the adult.

FŒTAL LIVER.

The *liver* is the first formed organ in the embryo. It is developed from the alimentary canal, and at about the third week fills the whole abdomen, and is one half the weight of the entire embryo. At the fourth month, the liver is of immense size, in proportion to the bulk of the fœtus. At birth, it is of very large size, and occupies the whole upper part of the abdomen. The left lobe is as large as the right, and the falciform ligament corresponds with the middle line of the body. The liver diminishes rapidly after birth, probably from obliteration of the umbilical vein.

KIDNEYS AND SUPRA-RENAL CAPSULES.

The *kidneys* present a lobulated appearance in the fœtus, which is their permanent type among some animals, as the bear, the otter, and cetacea.

The *supra-renal capsules* are organs which appear, from their early and considerable development, to belong especially to the economy of the fœtus. They are distinctly formed at the second month of embryonic life, and are greater in size and weight than the kidneys. At the third or fourth month, they are equalled in bulk by the kidneys; and at birth, they are about one-third less than those organs.

VISCERA OF THE PELVIS.

The *bladder* in the fœtus is long and conical, and situated altogether above the upper border of the ossa pubis, which are as yet small and undeveloped. It is, indeed, an abdominal viscus, and is connected superiorly with a fibrous cord, called the *urachus*, of which it appears to be an expansion.

The *urachus* is continued upwards to the umbilicus, and becomes connected with the umbilical cord. In animals it is a pervious duct, and is continuous with one of the membranes of the embryo, the *allantois*. It has been found pervious in the human fœtus, and the urine

has been known to pass through the umbilicus. Calculous concretions have also been found in its course.

The *uterus*, in the early periods of embryonic existence, appears bifid, from the large size of the Fallopian tubes, and the small development of the body of the organ. At the end of the fourth month, the body assumes a larger bulk, and the bifid appearance is lost. The cervix uteri in the fœtus is larger than the body of the organ.

The *ovaries* are situated, like the testicles, in the lumbar region, near the kidneys, and descend from thence, gradually, into the pelvis.

FŒTAL TESTES.

The *testicles* in the embryo are situated in the lumbar regions, immediately in front of, and somewhat below the kidneys. They have, connected with them inferiorly, a peculiar structure, which assists in their descent, and is called the gubernaculum testis.

The *gubernaculum* is a soft conical cord, composed of cellular tissue, containing in its areolæ a gelatiniform fluid. In the abdomen, it lies in front of the psoas muscle, and passes along the spermatic canal, which it serves to distend for the passage of the testis. It is attached, by its superior and larger extremity, to the lower end of the testis and epididymis; and by the inferior extremity, to the bottom of the scrotum. The gubernaculum is surrounded by a thin layer of muscular fibres—the cremaster, which pass upwards upon this body, to be attached to the testis. Inferiorly, the muscular fibres divide into three processes, which, according to Mr. Curling*, are thus attached:—“The external and broadest is connected to Poupart’s ligament in the inguinal canal; the middle forms a lengthened band, which escapes at the external abdominal ring, and descends to the bottom of the scrotum, where it joins the dartos; the internal passes in the direction inwards, and has a firm attachment to the os pubis and sheath of the rectus muscle. Besides these, a number of muscular fibres are reflected from the internal oblique on the front of the gubernaculum.”

The *descent of the testicle* is gradual and progressive.

* “On the Structure of the Gubernaculum,” &c. by Mr. Curling, of the London Hospital. *Lancet*, vol. ii. 1840-41, p. 70.

Between the fifth and sixth month, it has reached the lower part of the psoas muscle; and during the seventh, it makes its way through the spermatic canal, and descends into the scrotum.

While situated in the lumbar region, the testis and gubernaculum are placed behind the peritoneum, by which they are invested upon their anterior surface and sides. As they descend, the investing peritoneum is carried downwards with the testes into the scrotum, forming a lengthened pouch, which by its upper extremity opens into the cavity of the peritoneum. The upper part of this pouch, being compressed by the spermatic canal, is gradually obliterated, the obliteration extending downwards along the spermatic cord nearly to the testis. That portion of the peritoneum which immediately surrounds the testis is, by the above process, cut off from its continuity with the peritoneum, and is termed the tunica vaginalis; and as this membrane must be obviously a shut sac, one portion of it investing the testis, and the other being reflected so as to form a loose bag around it, its two portions have received the appellations of tunica vaginalis propria, and tunica vaginalis reflexa.

The descent of the testes is effected by means of the traction of the muscle of the gubernaculum — the cremaster. “The fibres,” writes Mr. Curling, “proceeding from Poupart’s ligament, and the obliquus internus, tend to guide the gland into the inguinal canal: those attached to the os pubis, to draw it below the abdominal ring; and the process descending to the scrotum, to direct it to its final destination.” During the descent, “the muscle of the testis is gradually everted, until, when the transition is completed, it forms a muscular envelope external to the process of peritoneum, which surrounds the gland and the front of the cord. The mass composing the central part of the gubernaculum, which is so soft, lax, and yielding as in every way to facilitate these changes, becomes gradually diffused, and, after the arrival of the testicle in the scrotum, contributes to form the loose cellular tissue which afterwards exists so abundantly in this part.” The attachment of the gubernaculum to the bottom of the scrotum, is indicated throughout life by distinct traces.

CHAPTER XII.

OF THE LIGAMENTS.

THE bones are variously connected with each other in the construction of the skeleton, and the connection between any two bones constitutes a joint or articulation. If the joint be immovable, the surfaces of the bones are applied in direct contact; but if motion be intended, the opposing surfaces are expanded and coated by an elastic substance named cartilage; a fluid secreted by a membrane closed on all sides lubricates their surface, and they are firmly held together by means of short bands of glistening fibres, which are called ligaments (ligare, to bind). The study of the ligaments is termed syndesmology ($\sigma\upsilon\nu$, together, $\delta\epsilon\sigma\mu\acute{o}\varsigma$, bond), which, with the anatomy of the articulations, forms the subject of the present Chapter.

The forms of articulation met with in the human frame may be considered under three classes:—Synarthrosis, Amphiarthrosis, and Diarthrosis.

SYNARTHROSIS ($\sigma\upsilon\nu$, $\acute{\alpha}\rho\theta\rho\omega\sigma\iota\varsigma$, articulation) is expressive of the fixed form of joint, in which the bones are immovably connected with each other. The kinds of synarthrosis are four in number—*Sutura*, *Harmonia*, *Schindylesis*, *Gomphosis*. In the construction of sutures, the substance of the bones is not in immediate contact; but is separated by a layer of membrane, which is continuous, externally, with the pericranium and, internally, with the dura mater. It is the latter connection which gives rise to the great difficulty sometimes experienced in tearing the calvarium from the dura mater. Cruveilhier describes this interposed membrane as the *sutural cartilage*; I never saw any structure in the sutures which could be regarded as cartilage, and the history of the formation of the cranial bones would suggest a different explanation. Gomphosis ($\gamma\acute{o}\mu\phi\omicron\varsigma$, a nail), is expressive of the insertion of one bone into another, in the same

manner that a nail is fixed into a board ; this is illustrated in the articulation of the teeth with the alveoli of the maxillary bones.

AMPHI-ARTHROSIS (ἀμφί, both, ἄρθρωσις) is a joint intermediate in aptitude for motion, between the immovable synarthrosis and the movable diarthrosis. It is constituted by the approximation of surfaces partly coated with cartilage lined by synovial membrane, and partly connected by interosseous ligaments, or by the intervention of an elastic fibro-cartilage which adheres to the ends of both bones. Examples of this mode of articulation are seen in the union between the bodies of the vertebræ, of the sacrum with the coccyx, of the pieces of the sternum, the sacro-iliac and pubic symphysis (συμφύειν, to grow together), and, according to some, of the necks of the ribs, with the transverse processes.

DIARTHROSIS (διὰ, through, ἄρθρωσις) is the movable articulation, which constitutes by far the greater number of the joints of the body. The degree of motion in this class has given rise to a subdivision into three genera: Arthrodia, Ginglymus, and Enarthrosis.

Arthrodia is the movable joint in which the extent of motion is slight and limited, as in the articulations of the clavicle, of the ribs, articular processes of the vertebræ, axis with the atlas, radius with the ulna, fibula with the tibia, carpal and metacarpal, tarsal and metatarsal bones.

Ginglymus (γίγγλυμος, a hinge), or hinge-joint, is the movement of the bones upon each other in two directions only, viz. forwards and backwards; but the degree of motion may be very considerable. The instances of this form of joint are numerous; they comprehend the elbow, wrist, metacarpo-phalangeal and phalangeal joints in the upper extremity; and the knee, ankle, metatarso-phalangeal and phalangeal joints in the lower extremity. The lower jaw may also be admitted into this category, as partaking more of the character of the hinge-joint than of the less movable arthrodia.

The form of the ginglymoid joint is somewhat quadrilateral, and each of its four sides is provided with a ligament, which is named from its position, *anterior*, *posterior*, *internal*, or *external lateral*. The *lateral ligaments* are thick and strong, and the chief bond of union between the bones. The *anterior* and *posterior*

are thin and loose, in order to permit the required extent of movement.

Enarthrosis (ἐν, in, ἔρθρωσις) is the most extensive in its range of motion of all the movable joints. From the manner of connection and form of the bones in this articulation, it is called the ball-and-socket joint. There are two instances in the body, viz. the hip and the shoulder.

I have been in the habit of adding to the preceding the carpo-metacarpal articulation of the thumb, although not strictly a ball-and-socket joint, from the great extent of motion which it enjoys, and from the nature of the ligament connecting the bones. As far as the articular surfaces are concerned, it is rather a double than a single ball-and-socket; and the whole of these considerations remove it from the simple arthrodial and ginglymoid groups.

The ball-and-socket joint has a circular form; and, in place of the four distinct ligaments of the ginglymus, is enclosed in a bag of ligamentous membrane, called a *capsular ligament*.

The kinds of articulation may probably be conveyed in a more satisfactory manner in the tabular form, thus:—

Examples.

Synarthrosis.	{	Sutura -	-	bones of the skull.
		Harmonia	-	superior maxillary bones.
		Schindylesis	-	vomer with rostrum.
		Gomphosis	-	teeth with alveoli.
Amphi-arthrosis	-		-	{ bodies of the vertebræ. symphyses.
Diarthrosis.	{	Arthrodia	-	carpal and tarsal bones.
		Ginglymus	-	elbow, wrist, knee, ankle.
		Enarthrosis	-	hip, shoulder.

The motions permitted in joints may be referred to four heads; viz. Gliding, Angular movement, Circumduction, and Rotation.

1. *Gliding* is the simple movement of one articular surface upon another, and exists, to a greater or less extent, in all the joints. In the least movable joints, as in the carpus and tarsus, this is the only motion which is permitted.

2. *Angular movement* may be performed in four different directions: either forwards and backwards, as in

flexion and extension; or inwards and outwards, constituting adduction and abduction. Flexion and extension are illustrated in the ginglymoid joint, and exist in a large proportion of the joints of the body. Adduction and abduction, conjoined with flexion and extension, are met with complete, only in the most movable joints, as in the shoulder, hip, and thumb. In the wrist and ankle, adduction and abduction are only partial.

3. *Circumduction* is most strikingly exhibited in the shoulder and hip joints; it consists in the slight degree of motion which takes place between the head of a bone and its articular cavity, while the extremity of the limb is made to describe a large circle upon a plane surface. It is also seen, but in a less degree, in the carpo-metacarpal articulation of the thumb, metacarpo-phalangeal articulations of the fingers and toes, and in the elbow when that joint is flexed and the end of the humerus fixed.

4. *Rotation* is the movement of a bone upon its own axis, and is illustrated in the hip and shoulder, or better, in the rotation of the cup of the radius against the eminentia capitata of the humerus. Rotation is also observed in the movements of the atlas upon the axis, in which the odontoid process serves as a pivot, around which the atlas turns.

The structures entering into the composition of a joint are bone, cartilage, fibrous tissue, adipose tissue, and synovial membrane. Cartilage forms a thin coating to the articular extremities of bones, sometimes presenting a smooth surface which moves on a corresponding smooth surface of the articulating bone; sometimes forming a plate smooth on both surfaces and interposed between the cartilaginous ends of two bones, *interarticular*; and sometimes acting as the connecting medium between bones without any free surface, *interosseous*. Fibrous tissue enters into the construction of joints under the form of ligament, in one situation constituting bands of various breadth and thickness; in another, a layer which extends completely round the joint, and is then called a *capsular ligament*. All the ligaments of joints are composed of that variety of fibrous tissue termed white fibrous tissue; but in some situations ligaments are found, which consist of yellow fibrous tissue; for example, the ligamenta subflava of the arches of the vertebral column.

Adipose tissue exists in variable quantity in relation with joints, where it performs, among other offices, that of a valve or spring, which occupies any vacant space that may be formed during the movements of the joint, and effectually prevents the occurrence of a vacuum in those cavities. This purpose of adipose tissue is exemplified in the cushion of fat at the bottom of the acetabulum, and in the similar cushion behind the ligamentum patellæ. Synovial membrane constitutes the smooth and polished lining of a joint, and contains the fluid termed synovia, by means of which the adapted surfaces are enabled to move upon each other with perfect ease and freedom.

ARTICULATIONS.

The joints may be arranged, according to a natural division, into those of the trunk, those of the upper extremity, and those of the lower extremity.

LIGAMENTS OF THE TRUNK. — The articulations of the trunk are divisible into ten groups, viz. —

1. Of the vertebral column.
2. Of the atlas, with the occipital bone.
3. Of the axis, with the occipital bone.
4. Of the atlas, with the axis.
5. Of the lower jaw.
6. Of the ribs, with the vertebræ.
7. Of the ribs, with the sternum, and with each other.
8. Of the sternum.
9. Of the vertebral column, with the pelvis.
10. Of the pelvis.

1. *Articulation of the Vertebral Column.* — The ligaments connecting together the different pieces of the vertebral column, admit of the same arrangement as that of the vertebræ themselves. Thus the ligaments—

Of the <i>bodies</i> , are the —	Anterior common ligament, Posterior common ligament, Intervertebral substance.
Of the <i>arches</i> ,	Ligamenta subflava.
Of the <i>articular processes</i> ,	Capsular ligaments, Synovial membranes.

anterior surface, with the intervertebral substance, bodies of the vertebræ, and venæ basium vertebrarum; and by its *posterior surface*, with the dura mater of the spinal cord, some loose cellular tissue and numerous small veins being interposed.

The *intervertebral substance* is a lenticular disc of fibrous cartilage, interposed between each of the vertebræ from the axis to the sacrum, and retaining them firmly in connection with each other. It differs in thickness in different parts of the column, and varies in depth at different points of its extent; thus, it is thickest in the lumbar region, deepest in front in the cervical and lumbar regions, and behind in the dorsal region; and contributes to the formation of the natural curves of the cervical and lumbar portions of the vertebral column. The aggregate length of the intervertebral substance has been estimated at about one-fourth of that of the vertebral column, excluding the sacrum and coccyx.

When the intervertebral substance is bisected either horizontally or vertically, it is seen to be composed of a series of layers of dense fibrous tissue, separated by interstices filled with the softer kind. The central part of each intervertebral disc is wholly made up of this softer fibrous cartilage, which has the appearance of a pulp, and is so elastic as to rise above the level of the section as soon as its division is completed. When examined from the front, the layers are found to consist of fibres passing obliquely between the two vertebræ; in one layer passing from left to right, in the next from right to left, alternating in each successive layer.

ARCHES.—The *ligamenta subflava* are two thin planes, of yellow fibrous tissue, situated between the arches of each pair of vertebræ, from the axis to the sacrum. From the imbricated position of the laminæ they are attached to the posterior surface of the vertebra below, and to the anterior surface of the arch of the vertebra above, and are separated from each other at the middle line by a slight interspace. They counteract, by their elasticity, the efforts of the flexor muscles of the trunk; and by preserving the upright position of the spine, limit the expenditure of muscular force. They are longer in the cervical than in the other regions of the spine, and are thickest in the lumbar region.

The ligamenta subflava are in relation by both surfaces with the meningo-rachidian veins, and internally they are separated from the dura mater of the spinal cord by those veins and some loose cellular and adipose tissue.

ARTICULAR PROCESSES.—The *ligaments of the articular processes* of the vertebræ are thin layers of ligamentous fibres which surround and enclose the synovial membranes; the latter being looser in the cervical than in the other regions of the spine.

SPINOUS PROCESSES.—The *inter-spinous ligaments*, thin and membranous, are extended between the spinous processes in the dorsal and lumbar regions. They are thickest in the latter; and are in *relation* with the multifidus spinæ muscle, at each side.

The *supra-spinous ligament* is a strong fibrous cord, which extends from the apex of the spinous process of the last cervical vertebra to the sacrum, being attached to each spinous process in its course; like the anterior and posterior common ligaments, it is composed of fibres of unequal length, the deeper fibres passing from one vertebra to the next, the superficial fibres extending over several spinous processes; it is thickest in the lumbar region. The continuation of this ligament upwards to the tuberosity of the occipital bone, constitutes the rudimentary ligamentum nuchæ of man. The latter is strengthened, as in animals, by a thin slip from the spinous process of each cervical vertebra.

TRANSVERSE PROCESSES.—The *inter-transverse ligaments* are thin and membranous; they are found only between the transverse processes of the lower dorsal vertebræ.

2. *Articulation of the Atlas with the Occipital Bone.*
The ligaments of this articulation are *seven* in number,

Two anterior occipito-atloid,
Posterior occipito-atloid,
Lateral occipito-atloid,
Two capsular.

Of the two *anterior ligaments*, one is a *rounded* cord, situated in the middle line, and superficially to the other. It is attached, above, to the basilar process of the occipital bone; and, below, to the anterior tubercle of the atlas. The deeper ligament is a *broad* membranous layer,

attached, above, to the margin of the occipital foramen between the two condyles; and, below, to the whole length of the anterior arch of the atlas. It is in relation, in front, with the *recti antici minores*; and, behind, with the odontoid ligaments.

The *posterior ligament* is thin and membranous: it is attached, above, to the margin of the occipital foramen between the two condyles; and, below, to the posterior arch of the atlas. It is closely adherent to the dura mater by its inner surface; and forms a ligamentous arch at each side, for the passage of the vertebral arteries and first cervical nerves. It is in relation, posteriorly, with the *recti postici minores* and *obliqui superiores*.

The *lateral ligaments* are strong fasciculi of ligamentous fibres, attached, below, to the base of the transverse process of the atlas at each side, and above, to the transverse process of the occipital bone. With a ligamentous expansion derived from the vaginal process of the temporal bone, these ligaments form a strong sheath around the vessels and nerves which pass through the carotid and jugular foramina.

The *capsular ligaments* are the thin and loose ligamentous capsules, which surround the synovial membranes of the articulations between the condyles of the occipital bone and the superior articular processes of the atlas. The ligamentous fibres are most numerous upon the anterior and external part of the articulation.

The *movements* taking place between the cranium and atlas, are those of flexion and erection, giving rise to the forward nodding of the head. When this motion is increased to any extent, the whole of the cervical region concurs in its production.

3. *Articulation of the Axis with the Occipital Bone.* The ligaments of this articulation are *three* in number,

Occipito-axoid,

Two odontoid.

The *occipito-axoid ligament* (*apparatus ligamentosus colli*) is a broad band, which covers in the odontoid process and its ligaments. It is attached, below, to the body of the axis, where it is continuous with the posterior common ligament; superiorly, it is inserted by a broad expansion, into the basilar groove of the occipital

bone. It is firmly connected, opposite the body of the axis, with the dura mater; and sometimes is described as consisting of a central and two lateral portions; this, however, is an unnecessary refinement.

The *odontoid ligaments* (alar) are two short and thick fasciculi of fibres, which pass outwards from the apex of the odontoid process, to the sides of the occipital foramen and condyles. A third and smaller fasciculus (ligamentum suspensorium) proceeds from the apex of the odontoid process to the anterior margin of the foramen magnum.

These ligaments serve to limit the extent to which rotation of the head may be carried, hence they are termed *check ligaments*.

4. *Articulation of the Atlas with the Axis.*— The ligaments of this articulation are *five* in number:—

Anterior atlo-axoid,	Two capsular,
Posterior atlo-axoid,	Transverse.

The *anterior ligament* consists of ligamentous fibres, which pass from the anterior tubercle and arch of the atlas to the base of the odontoid process and body of the axis, where they are continuous with the commencement of the anterior common ligament.

The *posterior ligament* is a thin and membranous layer, passing between the posterior arch of the atlas and the laminæ of the axis.

The *capsular ligaments* surround the articular processes of the atlas and axis; they are loose, to permit of the freedom of movement which subsists between these vertebræ. The ligamentous fibres are most numerous on the outer and anterior part of the articulation, and the the synovial membrane usually communicates with the synovial cavity situated between the transverse ligament and the odontoid process.

The *transverse ligament* is a strong ligamentous band, which arches across the area of the ring of the atlas, from a rough tubercle upon the inner surface of one articular process to a corresponding tubercle on the other. It serves to retain the odontoid process of the axis, in connection with the anterior arch of the atlas. As it crosses the odontoid process some fibres are sent downwards, to be attached to the body of the axis, and others

pass upwards, to be inserted into the basilar process of the occipital bone ; hence the ligament has a cross-like appearance, and has been denominated *cruciform*. A synovial membrane is situated between the transverse ligament and the odontoid process ; and another, between that process and the inner surface of the anterior arch of the atlas.

ACTIONS.—It is the peculiar disposition of the transverse ligament in relation to the odontoid process, that enables the atlas, and with it the entire cranium, to rotate upon the axis ; the perfect freedom of movement between these bones being insured by the the synovial membranes. The lower part of the ring, formed by the transverse ligament with the atlas, is smaller than the upper, while the summit of the odontoid process is larger than its base ; so that the process is retained in its position by the transverse ligament, when the other ligaments are cut through. The extent to which the rotation of the head upon the axis can be carried, is determined by the odontoid ligaments. The odontoid process with its ligaments is covered in by the occipito-axoid ligament.

5. *Articulation of the Lower Jaw.*—The lower jaw has properly but one ligament, the *external lateral* ; the ligaments usually described are *three* in number ; to which may be added, as appertaining to the mechanism of the joint, an interarticular fibrous-cartilage, and two synovial membranes, thus:—

External lateral,	Inter-articular fibrous
Internal lateral,	cartilage,
Capsular,	Two synovial membranes.

The *external lateral ligament* is a short and thick band of fibres, passing obliquely backwards from the tubercle of the zygoma to the external surface of the neck of the lower jaw. It is in relation, externally, with the integument of the face, and, internally, with the two synovial membranes of the articulation and the interarticular cartilage. The external lateral ligament acts conjointly with its fellow of the opposite side of the head, in the movements of the jaw.

The *internal lateral ligament* has no connection with the articulation of the lower jaw, and is incorrectly named in relation to that joint ; it is a thin aponeurotic expansion, extending from the extremity of the spinous process of the sphenoid bone to the margin of the dental foramen ; and is pierced, at its insertion, by the mylo-hyoidean nerve.

A triangular space is left between the internal lateral ligament and the neck of the jaw, in which are situated the internal maxillary artery, auriculo-temporal nerve, inferior dental artery and nerve, and part of the external pterygoid muscle; internally, it is in relation with the internal pterygoid muscle.

The *capsular ligament* consists of numerous irregular ligamentous fibres, which pass from the edge of the glenoid cavity to the neck of the lower jaw, and surround the articulation; on the inner side of the joint, they form a pretty strong fasciculus.

The *inter-articular fibrous cartilage* is a thin oval plate, thicker at the edges than in the centre, and placed horizontally between the head of the condyle of the lower jaw and the glenoid cavity. It is connected by its outer border with the external lateral ligament, and in front receives some fibres of insertion of the external pterygoid muscle. Occasionally, it is incomplete in the centre. It divides the joint into two distinct cavities, the one being above and the other below the cartilage.

The *synovial membranes* are situated the one above, the other below the fibrous cartilage, the former being the larger of the two. When the fibrous cartilage is perforate, the synovial membranes communicate.

Besides the lower jaw, there are several other joints provided with a complete inter-articular cartilage, and, consequently, with two synovial membranes; they are, the *sterno-clavicular articulation*, the *acromio-clavicular*, and the *articulation of the ulna* with the *cuneiform bone*.

The inter-articular fibrous cartilages of the *knee joint* are partial, and there is but one synovial membrane.

The articulations of the heads of the ribs with the vertebræ have two synovial membranes separated by an inter-articular ligament without fibrous cartilage.

Connected with the lower jaw, though not with the joint, is the *stylo-maxillary ligament*, a process of the deep cervical fascia extended between the point of the styloid process and the angle of the jaw. It is attached to the jaw between the insertions of the masseter and internal pterygoid muscle, and separates the parotid, from the submaxillary gland.

ACTIONS.—The movements of the lower jaw are *depression*, by which the mouth is opened; *elevation*, by which it is closed; a *forward* and *backward* movement; and a movement from *side to side*.

In the movement of *depression*, the inter-articular cartilage glides forward on the eminentia articularis, carrying with it the condyle. If this movement be carried too far, the superior synovial membrane is ruptured, and dislocation of the fibro-cartilage with its condyle into the zygomatic fossa occurs. In *elevation* the fibrous cartilage and condyle are returned to their original position. The *forward* and *backward* movement is a gliding of the fibro-cartilage upon the glenoid articular surface, in the antero-posterior direction; and the movement from *side to side*, in the lateral direction.

Dislocations.—The dislocations of the lower jaw are *three*:—1. Complete; 2. Partial; and, 3. Subluxation.

In *Complete dislocation*, both condyles are thrown forwards into the zygomatic fossæ.

In *Partial dislocation*, one condyle is thrown forwards into the zygomatic fossa.

In *Subluxation*, the condyle is displaced from its interarticular fibro-cartilage.

6. *Articulation of the Ribs with the Vertebrae.*—The ligaments of these articulations are so strong as to render dislocation impossible; the neck of the rib would break before displacement could occur: they are divisible into two groups:—1. Those connecting the *head of the rib* with the bodies of the *vertebræ*; and 2. Those connecting the *neck and tubercle of the rib* with the *transverse processes*. They are—

1st Group.

Anterior costo-vertebral or stellate,
Capsular,
Inter-articular ligament.

Two synovial membranes.

2nd Group.

Anterior costo-transverse,
Middle costo-transverse,
Posterior costo-transverse.

The *anterior costo-vertebral* or *stellate ligament* consists of three short bands of ligamentous fibres that radiate from the anterior part of the head of the rib. The *superior band* passes upwards, and is attached to the vertebra above; the *middle fasciculus* is attached to the intervertebral substance; and the *inferior*, to the vertebra below.

In the *first, eleventh, and twelfth* ribs, the three fasciculi are attached to the body of the corresponding vertebra.

The *capsular ligament* is a thin layer of ligamentous fibres, surrounding the joint in the interval left by the an-

terior ligament; it is thickest above and below the articulation, and protects the synovial membranes.

The *inter-articular ligament* is a thin band which passes between the sharp crest on the head of the rib and the intervertebral substance. It divides the joint into two cavities, which are each furnished with a separate *synovial membrane*. The *first, eleventh, and twelfth* ribs have no interarticular ligament, and consequently but one synovial membrane.

The *anterior costo-transverse ligament* is a broad band composed of two fasciculi, which ascend from the crest-like ridge on the neck of the rib to the transverse process immediately above. This ligament separates the anterior from the dorsal branch of the intercostal nerve.

The *middle costo-transverse ligament* is a very strong interosseous ligament, passing directly between the posterior surface of the neck of the rib, and the transverse process against which it rests.

The *posterior costo-transverse ligament* is a small but strong fasciculus, passing obliquely from the tubercle of the rib to the apex of the transverse process. The articulation between the tubercle of the rib and the transverse process, is provided with a small synovial membrane.

There is no anterior costo-transverse ligament to the first or last rib; and only rudimentary posterior costo-transverse ligaments, to the eleventh and twelfth ribs.

ACTIONS. — The movements permitted by the articulations of the ribs are *upwards* and *downwards*, and slightly *forwards* and *backwards*; the movement increasing in extent from the head to the extremity of the rib. The forward and backward movement is very trifling in the seven superior, but greater in the inferior ribs; the eleventh and twelfth are very movable.

7. *Articulation of the Ribs with the Sternum, and with each other.* — The ligaments of the costo-sternal articulations are —

Anterior costo-sternal,	Superior costo-sternal,
Posterior costo-sternal,	Inferior costo-sternal.
Synovial membranes.	

The *anterior costo-sternal ligament* is a thin band of ligamentous fibres, passing in a radiated direction from the extremity of the costal cartilage to the anterior surface of the sternum, and intermingling its fibres with those of

the ligament of the opposite side, and with the tendinous fibres of origin of the pectoralis major muscle.

The *posterior costo-sternal ligament* is much smaller than the anterior; and consists of a thin fasciculus of fibres, situated on the posterior surface of the articulation.

The *superior* and *inferior costo-sternal ligaments* are narrow fasciculi, corresponding with the breadth of the cartilage, and connecting its superior and inferior borders with the side of the sternum.

The *synovial membrane* is absent in the articulation of the first rib, its cartilage being usually continuous with the sternum; that of the second rib has an inter-articular ligament, with two synovial membranes.

The *sixth* and *seventh* ribs have several fasciculi of strong ligamentous fibres, passing from the extremity of their cartilages to the anterior surface of the ensiform cartilage, which latter they are intended to support. They are named the *costo-xiphoid ligaments*.

The *sixth*, *seventh*, and *eighth*, and sometimes the *fifth* and the *ninth*, costal cartilages, have articulations with each other, and a perfect synovial membrane at each articulation. They are connected by ligamentous fibres which pass from one cartilage to the other, *external* and *internal ligaments*.

The *ninth* and *tenth* are connected at their extremities by ligamentous fibres, but have no synovial membranes.

ACTIONS. — The movements of the costo-sternal articulations are very trifling; they are limited to a slight degree of sliding motion. The first rib is the least, and the second the most movable.

8. *Articulation of the Sternum.* — The pieces of the sternum are connected by means of a thin plate of fibro-cartilage placed between each, and by an anterior and posterior ligament. The fibres of the *anterior sternal ligament* are longitudinal in direction, but so blended with the anterior costo-sternal ligaments, and the tendinous fibres of origin of the pectoral muscles, as scarcely to be distinguished as a distinct ligament. The *posterior sternal ligament* is a broad smooth plane of longitudinal fibres, placed upon the posterior surface of the bone, and extending from the manubrium to the ensiform cartilage. These ligaments contribute very materially to the strength of the sternum, and to the elasticity of the front of the chest.

9. *Articulation of the Vertebral Column with the Pelvis.* — The last lumbar vertebra is connected with the sacrum by the same ligaments with which the various vertebræ are connected to each other; viz., anterior and posterior common ligaments, intervertebral substance, ligamenta subflava, capsular ligaments, and inter- and supra-spinous ligaments.

There are, however, *two* proper ligaments connecting the vertebral column with the pelvis; these are, the —

Lumbo-sacral,

Lumbo-iliac.

The *lumbo-sacral* or *sacro-vertebral ligament* is a thick triangular fasciculus of ligamentous fibres, connected, above, with the transverse process of the last lumbar vertebra; and, below, with the posterior part of the upper border of the sacrum.

The *lumbo-iliac* or *ilio-lumbar ligament* passes from the apex of the transverse process of the last lumbar vertebra, to that part of the crest of the ilium which surmounts the sacro-iliac articulation. It is triangular in form.

10. *Articulations of the Pelvis.* — The ligaments belonging to the articulations of the pelvis are divisible into four groups:—(1.) those connecting the *sacrum* and *ilium*; (2.) those passing between the *sacrum* and *ischium*; (3.) between the *sacrum* and *coccyx*; and (4.) between the *two pubic bones*

1st. *Between the sacrum and ilium*:—

Sacro-iliac anterior,
Sacro-iliac posterior.

2nd. *Between the sacrum and ischium*:—

Sacro-ischiatric anterior (*short*),
Sacro-ischiatric posterior (*long*).

3rd. *Between the sacrum and coccyx*:—

Sacro-coccygean anterior,
Sacro-coccygean posterior.

4th. *Between the ossa pubis*:—

Anterior pubic,
Posterior pubic,
Superior pubic,
Subpubic,
Interosseous fibro-cartilage.

(1.) *Between the Sacrum and Ilium.*—The anterior

sacro-iliac ligament consists of numerous short ligamentous fibres, which pass from bone to bone on the anterior surface of the joint.

The *posterior sacro-iliac or interosseous ligament* is composed of numerous strong fasciculi of ligamentous fibres, which pass horizontally between the rough surfaces of the *posterior half* of the sacro-iliac articulation, and constitute the principal bond of connection between the sacrum and the ilium. One fasciculus of this ligament, longer and larger than the rest, is distinguished, from its direction, by the name of the *oblique sacro-iliac ligament*. It is attached by one extremity to the posterior superior spine of the ilium, and by the other to the third transverse tubercle on the posterior surface of the sacrum.

The surfaces of the two bones forming the sacro-iliac articulation are partly covered with cartilage, and partly rough and connected by the interosseous ligament. The *anterior or auricular half* is coated with cartilage, which is thicker on the sacrum than on the ilium. The surface of the cartilage is irregular and provided with a very delicate synovial membrane, which cannot be demonstrated in the adult, but is apparent in the young subject, and in the female during pregnancy.

(2.) *Between the Sacrum and Ischium.*—The *anterior or lesser sacro-ischiatic ligament* is thin, and triangular in form. It is attached by its apex to the spine of the ischium, and by its broad extremity to the side of the sacrum and coccyx, interlacing its fibres with the greater sacro-ischiatic ligament.

The anterior sacro-ischiatic ligament is *in relation*, in front with the coccygeus muscle, and behind with the posterior ligament, with which its fibres are intermingled. By its upper border it forms part of the lower boundary of the great sacro-ischiatic foramen; and by the lower, part of the lesser sacro-ischiatic foramen.

The *posterior or greater sacro-ischiatic ligament*, considerably larger, thicker, and more posterior than the preceding, is narrower in the middle than at each extremity. It is attached, by its smaller end, to the inner margin of the tuberosity and ramus of the ischium, where it forms a falciform process, which protects the internal pudic artery and is continuous with the obturator fascia. By its larger extremity it is inserted into the side of

the coccyx, sacrum, and posterior inferior spine of the ilium.

The posterior sacro-ischiatic ligament is *in relation*, in front with the anterior ligament, and behind with the gluteus maximus, to some of the fibres of which it gives origin. By its superior border it forms part of the boundary of the lesser ischiatic foramen, and by its lower border a part of the boundary of the perineum. It is pierced by the coccygeal branch of the ischiatic artery. The two ligaments convert the sacro-ischiatic notches into foramina.

(3.) *Between the Sacrum and Coccyx.*—The *anterior sacro-coccygean ligament* is a thin fasciculus passing from the anterior surface of the sacrum to the front of the coccyx.

The *posterior sacro-coccygean ligament* is a thick ligamentous layer, which completes the lower part of the sacral canal, and connects the sacrum with the coccyx posteriorly, extending as far as the apex of the latter bone.

Between the two bones is a thin disc of soft fibrous cartilage. In females there is frequently a small synovial membrane. This articulation admits of a certain degree of movement backwards during parturition.

The ligaments connecting the different pieces of the coccyx consist of a few scattered *anterior* and *posterior* fibres and a thin disc of fibro-cartilage. They exist only in the young subject; in the adult the pieces become ossified.

(4.) *Between the Ossa Pubis.*—The *anterior pubic ligament* is composed of ligamentous fibres, which pass obliquely across the union of the two bones from side to side, and form an interlacement in front of the symphysis.

The *posterior pubic ligament* consists of a few irregular fibres uniting the pubic bones posteriorly.

The *superior pubic ligament* is a thick band of fibres connecting the angles of the pubic bones superiorly, and filling the inequalities upon the surface of the bones.

The *subpubic ligament* is a thick arch of fibres connecting the two bones inferiorly, and forming the upper boundary of the pubic arch.

The *interosseous fibro-cartilage* unites the two surfaces of the pubic bones in the same manner as the interver-

tebral substance connects the bodies of the vertebræ. It resembles the intervertebral substance also in being composed of oblique fibres disposed in concentric layers, which are more dense towards the surface than near the centre. It is thick in front, and thin behind. A synovial membrane is sometimes found in the posterior half of the articulation.

This articulation becomes movable towards the latter term of pregnancy, and admits of a slight degree of separation of its surfaces.

The *obturator ligament* or *membrane* is not a ligament of articulation, but simply a fibrous membrane stretched across the obturator foramen. It gives attachment by its surfaces to the two obturator muscles, and leaves a space in the upper part of the foramen, for the passage of the obturator vessels and nerve.

The numerous vacuities in the walls of the pelvis, and their closure by ligamentous structures, as in the case of the sacro-ischiatic fissures and obturator foramina, serve to diminish very materially the pressure on the soft parts during the passage of the head of the fœtus through the pelvis in parturition.

LIGAMENTS OF THE UPPER EXTREMITY.

The *ligaments of the upper extremity* may be arranged in the order of the articulations between the different bones. They are the —

1. Sterno-clavicular articulation,
2. Scapulo-clavicular articulation,
3. Ligaments of the scapula,
4. Shoulder joint,
5. Elbow joint,
6. Radio-ulnar articulation,
7. Wrist joint,
8. Articulation between the carpal bones,
9. Carpo-metacarpal articulation,
10. Metacarpo-phalangeal articulation,
11. Articulation of the phalanges.

1. *Sterno-clavicular Articulation*.—The sterno-clavicular is an arthrodial articulation. Its ligaments are —

- Anterior sterno-clavicular,
- Posterior sterno-clavicular,
- Inter-clavicular,

Costo-clavicular (*rhomboid*).
 Inter-articular fibro-cartilage,
 Two synovial membranes.

The *anterior sterno-clavicular ligament* is a broad ligamentous layer extending obliquely downwards and inwards, covering the anterior aspect of the articulation. The ligament is *in relation* by its anterior surface with the integument and sternal origin of the sterno-mastoid muscle; behind with the interarticular fibro-cartilage and synovial membranes.

The *posterior sterno-clavicular ligament* is a broad fasciculus, covering the posterior surface of the articulation. It is *in relation* by its anterior surface with the inter-articular fibro-cartilage and synovial membranes, and behind with the sterno-hyoid and sterno-thyroid muscle.

The two ligaments are continuous at the upper and lower part of the articulation, so as to form a complete capsule around the joint.

The *inter-clavicular ligament* is a cord-like band which crosses from the extremity of one clavicle to that of the other, and is closely connected with the upper border of the sternum. It is separated by cellular tissue from the sterno-thyroid muscles.

The *costo-clavicular ligament (rhomboid)* is a thick fasciculus of fibres, connecting the sternal extremity of the clavicle with the cartilage of the first rib. It is situated obliquely between the rib and the under surface of the clavicle, and is *in relation* in front with the tendon of origin of the subclavius muscle, and behind with the subclavian vein.

It is the rupture of the rhomboid ligament in dislocation of the sternal end of the clavicle, that gives rise to the deformity peculiar to this accident.

The *inter-articular fibro-cartilage* is nearly circular in form, and thicker at the edges than in the centre. It is attached, above to the clavicle, below to the cartilage of the first rib, and throughout the rest of its circumference to the anterior and posterior sterno-clavicular ligaments. It divides the joint into two cavities, which are lined by distinct *synovial membranes*. This cartilage is sometimes pierced through its centre, and not unfrequently deficient, to a greater or less extent, at its lower part.

ACTIONS.—The movements of the sterno-clavicular articulation are, a *gliding movement* of the fibro-cartilage with the clavicle, upon the articular surface of the sternum, in the direction, forwards, backwards, upwards, and downwards; and *circumduction*. This articulation is the centre of the movements of the shoulder.

Dislocations.—The dislocations of the sternal extremity are *two*, forwards and backwards. The dislocation forwards may be partial.

The *Dislocation forwards*, if complete, is accompanied by the rupture of all the ligaments of the joint.

The *Dislocation backwards* is extremely rare. Sir Astley Cooper records only a single case, which occurred in consequence of distortion of the spine.

2. Scapulo-clavicular Articulation.—The ligaments of the scapular end of the clavicle are the —

- Superior acromio-clavicular,
- Inferior acromio-clavicular,
- Coraco-clavicular (*trapezoid* and *conoid*).
- Inter-articular fibro-cartilage,
- Two synovial membranes.

The *superior acromio-clavicular ligament* is a moderately thick plane of fibres passing between the extremity of the clavicle and acromion, on the upper surface of the joint.

The *inferior acromio-clavicular ligament* is a thin plane situated on the under surface. These two ligaments are continuous with each other in front and behind, and form a complete capsule around the joint.

The *coraco-clavicular ligament* (*trapezoid*, *conoid*) is a thick fasciculus of ligamentous fibres, passing obliquely between the base of the coracoid process and the under surface of the clavicle, and holding the end of the clavicle in firm connection with the scapula. When seen from *before*, it has a quadrilateral form; hence it is named *trapezoid*: and examined from *behind*, it has a triangular form, the base being upwards; hence another name, *conoid*.

The *inter-articular fibro-cartilage* is often indistinct, from having partial connections with the fibro-cartilaginous surfaces of the two bones between which it is placed; and is not unfrequently absent. When partial, it occupies the upper part of the articulation. The *synovial membranes* are very delicate. There is, of course, but one when the fibro-cartilage is incomplete.

ACTIONS.—The acromio-clavicular articulation admits of two

glenoid cavity, for the purposes of protecting its edges and deepening its cavity. It divides, superiorly, into two slips, which are continuous with the long tendon of the biceps; hence the ligament is frequently described as being formed by the splitting of that tendon. The cavity of the articulation is traversed by the long tendon of the biceps, which is enclosed in a sheath of synovial membrane in its passage through the joint.

The *synovial membrane* of the shoulder joint is extensive; it communicates, anteriorly, through an opening (foramen ovale) in the capsular ligament with a large bursal sac, which lines the under surface of the tendon of the subscapularis muscle. Superiorly, it frequently communicates through another opening in the capsular ligament, with a bursal sac belonging to the infra-spinatus muscle; and it, moreover, forms a sheath around that portion of the tendon of the biceps, which is included within the joint.

ACTIONS.—The shoulder joint is capable of every variety of motion; viz. of movement forwards and backwards, of abduction and adduction, of circumduction and rotation.

Dislocations.—The dislocations of the head of the humerus are *four* in number:—

1. *Downwards*, and *inwards*, into the axilla.
2. *Forwards*, under the pectoral muscles.
3. *Backwards*, on the dorsum of the scapula.
4. *Partial*, when the anterior part of the capsular ligament is torn through, and the head of the bone rests against the coracoid process.

The muscles immediately surrounding the shoulder joint are, the subscapularis, supra-spinatus, infra-spinatus, teres minor, long head of the triceps, and deltoid; the long tendon of the biceps is within the capsular ligament.

5. **Elbow Joint.**—The elbow is a ginglymoid articulation; its ligaments are *four* in number:—

Anterior,	Internal lateral,
Posterior,	External lateral.

The *anterior ligament* is a broad and thin membranous layer, descending from the anterior surface of the humerus, immediately above the joint, to the coronoid process of the ulna and orbicular ligament. On each side, it is connected with the lateral ligaments. It is composed of fibres which pass in three different directions; vertical,

transverse, and oblique, the latter being extended downwards and outwards to the orbicular ligament, into which they are attached inferiorly. This ligament is covered in by the brachialis anticus muscle.

The *posterior ligament* is a broad and loose layer, passing between the posterior surface of the humerus and the anterior surface of the base of the olecranon, and connected at each side with the lateral ligaments. It is covered in by the tendon of the triceps.

The *internal lateral ligament* is a thick triangular layer, attached above, by its apex, to the internal condyle of the humerus; and below, by its expanded border, to the margin of the greater sigmoid cavity of the ulna, extending from the coronoid process to the olecranon. At its insertion it is intermingled with some transverse fibres. The internal lateral ligament is in relation posteriorly with the ulnar nerve.

The *external lateral ligament* is a strong and narrow band, which descends from the external condyle of the humerus, to be inserted into the orbicular ligament, and into the ridge on the ulna, with which the posterior part of the latter ligament is connected. This ligament is closely united with the tendon of origin of the supinator brevis muscle.

The *synovial membrane* is extensive, and is reflected from the cartilaginous surfaces of the bones upon the inner surface of the ligaments. It surrounds, inferiorly, the head of the radius, and forms an articulating sac between it and the lesser sigmoid notch.

ACTIONS.—The movements of the elbow joint are, *flexion* and *extension*, which are performed with remarkable precision. The extent to which these movements are capable of being effected, is limited, in front by the coronoid process, and behind by the olecranon.

Dislocations.—The dislocations occurring at this articulation are *five* in number:—

1. Radius and ulna, backwards.
2. Radius and ulna, to either side.
3. Ulna, backwards.
4. Radius, forwards.
5. Radius, backwards. This is a very rare accident.

In the two latter dislocations, the annular ligament of the head of the radius is ruptured.

The muscles immediately surrounding, and in contact with the elbow joint are, *in front*, the brachialis anticus; to the *inner side*,

the pronator radii teres, flexor sublimis digitorum, and flexor carpi ulnaris; *externally*, the extensor carpi radialis brevis, extensor communis digitorum, extensor carpi ulnaris, anconeus, and supinator brevis; and *behind*, the triceps.

6. The *Radio-ulnar Articulation*.—The radius and ulna are firmly held together by ligaments which are connected with both extremities of the bones, and with the shaft; they are, the —

Orbicular,	Anterior inferior,
Oblique,	Posterior inferior,
Interosseous,	Inter-articular fibro-cartilage.

The *orbicular ligament* (*annular, coronary*) is a firm band several lines in breadth, which surrounds the head of the radius, and is attached by each end to an extremity of the lesser sigmoid cavity. It is strongest behind where it receives the external lateral ligament, and is lined on its inner surface by a reflection of the synovial membrane of the elbow joint.

The rupture of this ligament permits the dislocation of the head of the radius.

The *oblique ligament* (called also ligamentum teres, in contradistinction to the interosseous ligament) is a narrow slip of ligamentous fibres, descending obliquely from the base of the coronoid process of the ulna to the inner side of the radius, a little below its tuberosity.

The *interosseous ligament* is a broad and thin plane of aponeurotic fibres passing obliquely downwards, from the sharp ridge on the radius to that on the ulna. It is deficient superiorly, is broader in the middle than at each extremity, and is perforated at its lower part for the passage of the anterior interosseous artery. The posterior interosseous artery passes backwards, between the oblique ligament and the upper border of the interosseous ligament. This ligament affords an extensive surface for the attachment of muscles.

The interosseous ligament is *in relation, in front*, with the flexor profundus digitorum, flexor longus pollicis, pronator quadratus, and anterior interosseous artery and nerve; *behind*, with the supinator brevis, extensor ossis metacarpi pollicis, extensor primi internodii pollicis, extensor secundi internodii pollicis, extensor indicis; and near the wrist, with the anterior interosseous artery and posterior interosseous nerve.

The *anterior inferior ligament* is a thin fasciculus of fibres, passing transversely between the radius and ulna.

The *posterior inferior ligament* is also thin and loose, and has the same disposition on the posterior surface of the articulation.

The *inter-articular*, or *triangular fibro-cartilage*, acts the part of a ligament, between the lower extremities of the radius and ulna. It is attached, by its apex, to a depression on the inner surface of the styloid process of the ulna; and by its base, to the edge of the radius. This fibro-cartilage is lined, upon its upper surface, by a synovial membrane, which forms a duplicature between the radius and ulna, and is called the *membrana saciformis*. By its lower surface it enters into the articulation of the wrist-joint.

ACTIONS. — The movements taking place between the radius and the ulna are, the rotation of the former upon the latter; rotation forwards being termed *pronation*, and rotation backwards *supination*. In these movements the head of the radius turns upon its own axis within the orbicular ligament and lesser sigmoid notch of the ulna; while, inferiorly, the radius presents a concavity which moves upon the rounded head of the ulna. The movements of the radius are chiefly limited by the anterior and posterior inferior ligaments hence these are not unfrequently ruptured in great muscular efforts

Dislocations. — The dislocation of these two bones from each other at the upper end, have been indicated in the dislocations occurring at the elbow joint. They are, the displacement of the head of the radius forwards and backwards, and are accompanied with rupture of the annular ligament. At the lower end of the two bones, the ulna may be separated from the radius by the rupture of the connections of the inter-articular fibro-cartilage.

7. *Wrist Joint.* — The wrist is a ginglymoid articulation; the articular surfaces entering into its formation being the radius and under surface of the triangular fibro-cartilage above, and the rounded surfaces of the scaphoid, semilunar, and cuneiform bone below; its ligaments are *four* in number:—

Anterior,	Internal lateral,
Posterior,	External lateral.

The *anterior ligament* is a broad and membranous layer, consisting of three fasciculi, which pass between the lower part of the radius and the scaphoid, semilunar, and cuneiform bone.

The *posterior ligament*, also thin and loose, passes be-

tween the posterior surface of the radius, and the posterior surface of the semilunar and cuneiform bone.

The *internal lateral ligament* extends from the styloid process of the ulna to the cuneiform and pisiform bone.

The *external lateral ligament* is attached, by one extremity, to the styloid process of the radius, and by the other, to the side of the scaphoid bone, some of its fibres being prolonged to the trapezium. The radial artery rests on this ligament, as it passes backwards to the first metacarpal space.

The *synovial membrane* of the wrist-joint lines the under surface of the radius and inter-articular cartilage above, and the first row of bones of the carpus below.

The *relations* of the wrist-joint are, the flexor and extensor tendons by which it is surrounded, and the radial and ulnar artery.

ACTIONS.—The movements of the wrist-joint are, *flexion, extension, adduction, abduction, and circumduction*. In these motions the articular surfaces glide upon each other.

Dislocations. — The dislocations at the wrist-joint are of *three* kinds: —

1. Of both bones, *backwards* or *forwards*; a rare accident.
2. Of the *radius*, *forwards*.
3. Of the *ulna*, from its connection with the radius.

8. *Articulations between the Carpal Bones.*—These are amphi-arthrodial joints, with the exception of the conjoined head of the os magnum and unciforme, which is received into a cup formed by the scaphoid, semilunar, and cuneiform bone, and constitutes an enarthrosis. The ligaments are —

Dorsal,	Interosseous fibro-cartilages,
Palmar,	Anterior annular.

The *dorsal ligaments* are ligamentous bands, that pass transversely and longitudinally from bone to bone, upon the dorsal surface of the carpus.

The *palmar ligaments* are fasciculi of the same kind, but stronger than the dorsal, having the like disposition on the palmar surface.

The *interosseous ligaments* are fibro-cartilaginous lamellæ situated between the adjoining bones in each range: in the upper range, they close the upper part of the spaces between the scaphoid, semilunar, and cuneiform bones; in the lower range, they are stronger than in the upper, and connect the os magnum on the one side to the un-

ciforme, on the other to the trapezoides, and leave intervals through which the synovial membrane is continued to the bases of the metacarpal bones.

The *anterior annular ligament* is a firm ligamentous band, which connects the bones of the two sides of the carpus. It is attached, by one extremity, to the trapezium and scaphoid, and by the other, to the unciform process of the unciforme and base of the pisiform bone; it forms an arch over the anterior surface of the carpus, beneath which the tendons of the long flexors and the median nerve pass into the palm of the hand.

The *articulation of the pisiform bone* with the cuneiform is provided with a distinct synovial membrane, which is protected by fasciculi of ligamentous fibres, forming a kind of capsule around the joint; they are inserted into the cuneiforme, unciforme, and base of the metacarpal bone of the little finger.

Synovial Membranes.—There are *five* synovial membranes, entering into the composition of the articulations of the carpus:—

The *first* is situated between the lower end of the ulna and the inter-articular fibro-cartilage; it is called *sacciform*, from forming a sacculus between the lateral articulation of the ulna with the radius.

The *second* is situated between the lower surface of the radius and inter-articular fibro-cartilage *above*, and the first range of bones of the carpus *below*.

The *third* is the most extensive of the synovial membranes of the wrist; it is situated between the two rows of carpal bones, and passes between the bones of the second range, to invest the carpal extremities of the four metacarpal bones of the fingers.

The *fourth* is the synovial membrane of the articulation of the metacarpal bone of the thumb with the trapezium.

The *fifth* is situated between the pisiform and cuneiform bone.

ACTIONS.—Very little movement exists between the bones in each range, but more is permitted between the two ranges. The motions in the latter situation are those of flexion and extension.

Dislocations.—The dislocation of a carpal bone from violence is of very rare occurrence. The *os magnum* and *cuneiform* bones are sometimes partially dislocated from relaxation of their ligaments; this is more frequent in the former than in the latter bone.

9. The *Carpo-metacarpal Articulations*.—The second row of bones of the carpus articulates with the metacarpal bones of the four fingers, by *dorsal* and *palmar* ligaments; and the metacarpal bone of the thumb with the trapezium, by a true *capsular ligament*. There is also in the carpo-metacarpal articulation a thin interosseous band, which passes from the ulnar edge of the os magnum to the bases of the third and fourth metacarpal bones at their point of connection.

The *dorsal ligaments* are strong fasciculi which pass from the second range of carpal to the metacarpal bones; with the exception of the little finger there are two fasciculi to each bone; namely, to the index finger, one each from the trapezium and trapezoides; to the middle finger, one each from the trapezoides and os magnum; to the ring finger, one each from the os magnum and unciforme; and to the little finger, one from the unciforme.

The *palmar ligaments* are thin fasciculi, arranged upon the same plan on the palmar surface.

The *synovial membrane* is a continuation of the great synovial membrane of the two rows of carpal bones.

The *capsular ligament* of the thumb is one of the three true capsular ligaments of the skeleton; the other two being the shoulder joint and hip joint. The articulation has a proper *synovial membrane*.

The *metacarpal bones* of the four fingers are firmly connected at their bases by means of dorsal and palmar ligaments, which extend transversely from one bone to the other, and by interosseous ligaments, which pass between their contiguous surfaces. Their lateral articular facets are lined by a reflection of the great synovial membrane of the two rows of carpal bones.

ACTIONS.—The movements of the metacarpal on the carpal bones are restricted to a slight degree of sliding motion, with the exception of the articulation of the metacarpal bone of the thumb with the trapezium. In the latter articulation the movements are, *flexion*, *extension*, *adduction*, *abduction*, and *circumduction*.

Dislocations of these articulations only occur from great violence, as the bursting of a gun, or the crushing of the hand by a great weight. The kind of displacement depends therefore upon the nature of the injury, and not upon the peculiar conformation of the joint.

The metacarpal bone of the thumb may be dislocated from the trapezium, and thrown *inwards*, so as to rest between the trapezium and the base of the metacarpal bone of the index finger.

ACTIONS.—The movements of the phalangeal joints are, *flexion* and *extension*, these movements being more extensive between the first and second phalanges than between the second and third.

Dislocations.—The second phalanges are but rarely dislocated from the first. The last phalanges are dislocated from the second *backwards*; the base of the last phalanx resting upon the back of the second beneath the *extensor tendon*. The same dislocation occurs in the thumb.

In connection with the phalanges it may be proper to examine certain fibrous bands termed *thecae* or *vaginal ligaments*, which serve to retain the tendons of the flexor muscles in their position upon the flat surface of the bones. These fibrous bands are attached at each side to the lateral margins of the phalanges; they are thick in the interspaces of the joints, thin where the tendons lie upon the joints, and are lined upon their inner surface by synovial membrane.

LIGAMENTS OF THE LOWER EXTREMITY.

The *ligaments of the lower extremity*, like those of the upper, may be arranged in the order of the joints to which they belong; these are, the —

1. Hip joint.
2. Knee joint.
3. Articulation between the tibia and fibula.
4. Ankle joint.
5. Articulation of the tarsal bones.
6. Tarso-metatarsal articulation.
7. Metatarso-phalangeal articulation.
8. Articulation of the phalanges.

1. *Hip Joint.*—The articulation of the head of the femur with the acetabulum constitutes an enarthrosis, or ball-and-socket joint. The articular surfaces are the cup-shaped cavity of the acetabulum and the rounded head of the femur; the ligaments are *five* in number, viz. —

Capsular,	Teres,
Ilio-femoral,	Cotyloid,
Transverse.	

The *capsular ligament* is a strong ligamentous capsule, embracing the acetabulum superiorly, and inferiorly the neck of the femur, and connecting the two bones firmly together. It is much thicker upon the upper part of the

joint, where more resistance is required, than upon the under part, and extends farther upon the neck of the femur on the anterior and superior than on the posterior and inferior side, being attached to the inter-trochanteric line in front, to the base of the great trochanter above, and to the middle of the neck of the femur behind.

The *ilio-femoral ligament* is an accessory and radiating band, which descends obliquely from the anterior inferior spinous process of the ilium to the anterior inter-trochanteric line, and strengthens the anterior portion of the capsular ligament.

The *ligamentum teres*, triangular in shape, is attached, by a round apex, to the depression just below the middle of the head of the femur, and by its base, which divides into two fasciculi, into the borders of the notch of the acetabulum. It is formed by a fasciculus of fibres, of variable size, surrounded by synovial membrane; sometimes the synovial membrane alone exists, or the ligament is wholly absent.

The *cotyloid ligament* is a prismoid cord of fibro-cartilage, attached around the margin of the acetabulum, and serving to deepen that cavity and protect its edges. It is much thicker upon the upper and posterior border of the acetabulum than in front, and consists of fibres which arise from the whole circumference of the brim, and interlace with each other at acute angles. It is directed inwards towards the acetabulum.

The *transverse ligament* is a strong fasciculus of ligamentous fibres, continuous with the cotyloid ligament, and extended across the notch of the acetabulum. It converts the notch into a foramen, through which the articular branches of the internal circumflex and obturator arteries enter the joint.

The fossa at the bottom of the acetabulum is filled by a mass of fat covered by synovial membrane, which serves as an elastic cushion for the head of the bone during its movements. This was considered by Havers as the synovial gland.

The *synovial membrane* is extensive; it invests the head of the femur, and is continued around the ligamentum teres into the acetabulum, whence it is reflected upon the inner surface of the capsular ligament back to the head of the bone.

The muscles immediately surrounding and in contact with the hip joint are, *in front*, the psoas and iliacus, which are separated from the capsular ligament by a large synovial bursa; *above*, the short head of the rectus and the gluteus minimus; *behind*, the pyramidalis, gemellus superior, obturator internus, gemellus inferior, and quadratus femoris; and to the *inner side*, the obturator externus and pectineus.

ACTIONS. — The movements of the hip joint are very extensive; they are, *flexion, extension, adduction, abduction, circumduction, and rotation.*

Dislocations. — The dislocations of the hip joint are four in number: —

1. *Upwards*, upon the dorsum of the ilium.
2. *Downwards*, into the foramen ovale.
3. *Backwards and upwards*, into the ischiatic notch.
4. *Forwards and upwards*, upon the body of the pubes.

2. **Knee Joint.** — The knee is a ginglymoid articulation of large size, and is provided with numerous ligaments they are thirteen in number: —

Anterior or ligamentum patellæ,
 Posterior or ligamentum posticum Winslowii,
 Internal lateral,
 Two external lateral,
 Anterior or external crucial,
 Posterior or internal crucial,
 Transverse,
 Two coronary.
 Ligamentum mucosum, } *false ligaments,*
 Ligamenta alaria. }
 Two semilunar fibro-cartilages,
 Synovial membrane.

The first *five* are *external* to the articulation; the next *five* are *internal* to the articulation; the remaining three are mere folds of synovial membrane, and have no title to the name of ligaments. In addition to the ligaments, there are two fibro-cartilages, and a synovial membrane.

The *anterior ligament*, or *ligamentum patellæ*, is the prolongation of the tendon of the extensor muscles of the thigh downwards to the tubercle of the tibia. It is, therefore, no ligament; and, as the patella is simply a sesamoid bone developed in the tendon of the extensor muscles for the defence of the front of the knee joint, the ligamentum patellæ has no title to consideration, either as a ligament of the knee joint or as a ligament of the patella.

A small *bursa mucosa* is situated between the ligamentum patellæ near its insertion and the front of the tibia, and another of large size is placed between the anterior surface of the patella and the fascia lata. It is the latter which is inflamed in the "housemaid's knee."

The *posterior ligament, ligamentum posticum Winslowii*, is a broad expansion of ligamentous fibres, which covers the whole of the posterior part of the joint. It is divisible into two lateral portions, which invest the condyles of the femur, and a central portion which is depressed, and is formed by the interlacement of fasciculi passing in different directions. The strongest of these fasciculi is that which is derived from the tendon of the semi-membranosus; it passes obliquely upwards and outwards from the posterior part of the inner tuberosity of the tibia, to the external condyle of the femur. Other accessory fasciculi are given off by the tendon of the popliteus and by the heads of the gastrocnemius. The middle portion of the ligament supports the popliteal artery and vein, and is perforated by several openings for the passage of branches of the azygos articular artery and for the nerves of the joint.

The *internal lateral ligament* is a broad and trapezoid layer of ligamentous fibres, attached, above, to the tubercle on the internal condyle of the femur; and below, to the inner tuberosity of the tibia. It is crossed, at its lower part, by the tendons of the inner hamstring from which it is separated by a synovial bursa, and it covers in the anterior slip of the semi-membranosus tendon and the inferior internal articular artery.

External lateral Ligaments.—The *long* external lateral ligament is a strong rounded cord, which descends from the posterior part of the tubercle upon the external condyle of the femur, to the outer part of the head of the fibula. The *short* external lateral ligament is an irregular fasciculus situated behind the preceding, arising from the external condyle near the origin of the head of the gastrocnemius muscle, and inserted into the posterior part of the head of the fibula. It is firmly connected with the external semilunar fibro-cartilage, and appears principally intended to connect that cartilage with the fibula. The long external lateral ligament is covered in by the tendon of the biceps, and has passing beneath it the tendon of

origin of the popliteus muscle, and the inferior external articular artery.

The true ligaments *within the joint* are, the crucial, transverse, and coronary.

The *anterior, or external crucial ligament* arises from the depression upon the head of the tibia in front of the spinous process, and passes upwards and backwards, to be inserted into the inner surface of the outer condyle of the femur, as far as its posterior border. It is smaller than the posterior.

The *posterior, or internal crucial ligament* arises from the depression upon the head of the tibia, behind the spinous process, and passes upwards and forwards, to be inserted into the inner condyle of the femur. This ligament is less oblique and larger than the anterior.

The *transverse ligament* is a small slip of fibres, which extends transversely from the external semilunar fibro-cartilage, near its anterior extremity, to the anterior convexity of the internal cartilage.

The *coronary ligaments* are the short fibres by which the convex borders of the semilunar cartilages are connected to the head of the tibia, and to the ligaments surrounding the joint.

The *semilunar fibro-cartilages* are two falciform plates of fibro-cartilage, situated upon the margin of the head of the tibia, and serving to deepen the surface of articulation for the condyles of the femur. They are thick along their convex border, and thin and sharp along their concave edge.

The *internal semilunar fibro-cartilage* forms an oval cup for the reception of the internal condyle of the femur; it is connected, by its convex border, to the head of the tibia and to the internal and posterior ligaments, by means of its coronary ligament; and by its two extremities is firmly implanted into the depressions in front of and behind the spinous process. The *external semilunar fibro-cartilage* bounds a circular fossa for the external condyle; it is connected by its convex border with the head of the tibia, and to the external and posterior ligaments by means of its coronary ligament; by its two extremities it is inserted into the depression between the two projections which constitute the spinous process of the tibia. The two extremities of the external

cartilage being inserted into the same fossa, form almost a complete circle, and the cartilage being somewhat broader than the internal, nearly covers the articular surface of the tibia. The external semilunar fibro-cartilage, besides giving off a fasciculus from its anterior border to constitute the transverse ligament, is continuous by some of its fibres with the extremity of the anterior crucial ligament; posteriorly, it divides into three slips; one, a strong cord, ascends obliquely forwards, and is inserted into the anterior part of the inner condyle of the femur in front of the posterior crucial ligament; another is the fasciculus of insertion into the fossa of the spinous process; and the third, of small size, is continuous with the posterior part of the anterior crucial ligament.

The *ligamentum mucosum* is a slender conical process of synovial membrane, enclosing a few ligamentous fibres which proceed from the transverse ligament. It is connected, by its apex, with the anterior part of the condyloid notch; and by its base, is lost in the mass of fat which projects into the joint beneath the patella.

The *alar ligaments* are two fringed folds of synovial membrane, extending from the ligamentum mucosum, along the edges of the mass of fat, to the sides of the patella.

The *synovial membrane* of the knee joint is by far the most extensive in the skeleton. It invests the cartilaginous surface of the condyles of the femur, head of the tibia, and inner surface of the patella. It covers both surfaces of the semilunar fibro-cartilages, and is reflected upon the crucial ligaments, and inner surface of the ligaments which form the circumference of the joint. On each side of the patella, it lines the tendinous aponeuroses of the vastus internus and vastus externus muscles, and forms a pouch of considerable size between the extensor tendon and the front of the femur. It also forms the folds in the interior of the joint, called "*ligamentum mucosum*," and "*ligamenta alaria*." The superior pouch of the synovial membrane is supported and raised during the movements of the limb by a small muscle, the *subcrureus*, which is inserted into it.

Between the ligamentum patellæ and the synovial membrane is a considerable mass of fat, which presses the membrane towards the interior of the joint, and occupies the fossa between the two condyles.

Besides the proper ligaments of the articulation, the joint is protected, on its anterior part, by the fascia lata, which is thicker upon the outer than upon the inner side, by a tendinous expansion from the vastus internus, and by some scattered ligamentous fibres which are inserted into the sides of the patella. The expansion has been termed the *capsular ligament*.

ACTIONS.—The knee joint is one of the strongest of the articulations of the body, while at the same time it admits of the most perfect degree of movement in the directions of *flexion* and *extension*. During flexion, the articular surface of the tibia glides forward on the condyles of the femur; the lateral ligaments, the posterior, and the crucial ligaments are relaxed; while the ligamentum patellæ, being put upon the stretch, serves to press the adipose mass into the vacuity formed in the front of the joint. In *extension*, all the ligaments are put upon the stretch, with the exception of the ligamentum patellæ. When the knee is semi-flexed, a partial degree of *rotation* is permitted.

Dislocations.—The *patella* may be dislocated in three directions:—

1. *Outwards*, which is the most frequent.

2. *Inwards*, less frequent; in both these cases there will be rupture of the ligamentum patellæ, unless there has been previous weakness of the joint.

3. *Upwards*, accompanied with rupture of the ligamentum patellæ. The dislocations of the *knee joint* are *four* in number:—

1. Tibia, *forwards*.

2. Tibia, *backwards*.

3. Tibia, *to either side*.

The dislocations to either side are incomplete.

The *semilunar fibro-cartilages* may become displaced from relaxation of the ligaments of the knee, and become fixed between the condyles of the femur and the tibia, so as to render the joint immovable.

3. *Articulation between the Tibia and Fibula.*—The tibia and fibula are held firmly connected by means of *seven* ligaments, viz. —

Anterior, }
Posterior, } above.

Interosseous membrane,

Interosseous inferior,

Anterior, }
Posterior, } below.

Transverse.

The *anterior superior ligament* is a strong fasciculus of parallel fibres, passing obliquely downwards and outwards, from the outer tuberosity of the tibia to the anterior surface of the head of the fibula.

The *posterior superior ligament*, thicker and stronger

than the anterior, is disposed in a similar manner on the posterior surface of the joint.

Within the articulation there is a distinct *synovial membrane*, which is sometimes continuous with that of the knee joint.

The *interosseous membrane*, or *superior interosseous ligament*, is a broad layer of aponeurotic fibres, which pass obliquely downwards and outwards, from the sharp ridge on the tibia, to the inner edge of the fibula, and are crossed at an acute angle by a few fibres passing in the opposite direction. The ligament is deficient above, leaving a considerable interval between the bones, through which the anterior tibial artery takes its course forward to the anterior aspect of the leg, and near its lower third there is an opening for the anterior peroneal artery and vein.

The interosseous membrane is *in relation, in front*, with the tibialis anticus, extensor longus digitorum, extensor proprius pollicis, anterior tibial vessels and nerve, and anterior peroneal artery; *behind*, with the tibialis posticus, flexor longus digitorum, and posterior peroneal artery.

The *inferior interosseous ligament* consists of short and strong fibres, which hold the bones firmly together inferiorly, where they are nearly in contact. This articulation is so firm that the fibula is likely to be broken in the attempt to rupture the ligament.

The *anterior inferior ligament* is a broad band, consisting of two fasciculi of parallel fibres, which pass obliquely across the anterior aspect of the articulation of the two bones at their inferior extremity, from the tibia to the fibula.

The *posterior inferior ligament* is a similar band, upon the posterior surface of the articulation. Both ligaments project somewhat below the margin of the bones, and serve to deepen the cavity of articulation with the astragalus.

The *transverse ligament* is a narrow band of ligamentous fibres, continuous with the preceding, and passing transversely across the back of the ankle joint between the two malleoli.

The *synovial membrane* of the inferior tibio-fibular articulation, is a duplicature of the synovial membrane of

the ankle joint, reflected upwards for a short distance between the two bones.

ACTIONS. — Between the tibia and fibula there exists an obscure degree of movement, which is principally calculated to enable the latter to resist injury by yielding for a trifling extent to the pressure exerted.

4. *Ankle Joint.* — The ankle is a ginglymoid articulation; the surfaces entering into its formation are the under surface of the tibia with its malleolus and the malleolus of the fibula, above; and the surface of the astragalus with its two lateral facets, below. The ligaments are three in number: —

Anterior,	
Internal lateral,	External lateral.

The *anterior ligament* is a thin membranous layer, passing from the margin of the tibia to the astragalus in front of the articular surface. It is *in relation, in front*, with the extensor tendons of the great and lesser toes, tendons of the tibialis anticus and peroneus tertius, and anterior tibial vessels and nerve. *Posteriorly*, it lies in contact with the extra-synovial adipose tissue and synovial membrane.

The *internal lateral, or deltoid ligament* is a triangular layer of fibres, attached, superiorly, by its apex to the internal malleolus, and, inferiorly, by an expanded base to the astragalus, os calcis, and scaphoid bone. Beneath the superficial layer of this ligament is a much stronger and thicker fasciculus, which connects the apex of the internal malleolus with the side of the astragalus.

This internal lateral ligament is covered in, and partly concealed by the tendon of the tibialis posticus, and at its posterior part, is in relation with the tendons of the flexor longus digitorum, and flexor longus pollicis.

The *external lateral ligament* consists of three strong fasciculi, which proceed from the inner side of the external malleolus, and diverge in three different directions. The *anterior fasciculus* passes *forwards*, and is attached to the astragalus; the *posterior*, backwards, and is connected with the astragalus posteriorly; and the *middle*, longer than the other two, descends, to be inserted into the outer side of the os calcis.

is situated nearer the bones than the long plantar ligament, from which latter it is separated by adipose tissue; it is broad and extensive, and ties the under surface of the os calcis and cuboid bone firmly together.

The *interosseous ligaments* are five in number; they are short and strong ligamentous fibres situated between adjoining bones, and firmly attached to their rough surfaces. One of these, the *calcaneo-astragaloid*, is lodged in the groove between the upper surface of the os calcis and the lower of the astragalus. It is large and very strong, consists of vertical and oblique fibres, and serves to unite the os calcis and astragalus solidly together. The second interosseous ligament, also very strong, is situated between the sides of the scaphoid and cuboid bone; while the three remaining interosseous ligaments connect strongly together the three cuneiform bones and the cuboid.

The *synovial membranes* of the tarsus are four in number: *one*, for the posterior calcaneo-astragaloid articulation; a *second*, for the anterior calcaneo-astragaloid and astragalo-scaphoid articulation — occasionally an additional small synovial membrane is found in the anterior calcaneo-astragaloid joint; a *third*, for the calcaneo-cuboid articulation; and a *fourth*, the large tarsal synovial membrane, for the articulations between the scaphoid and three cuneiform bones, the cuneiform bones with each other, the external cuneiform bone with the cuboid, and the two external cuneiform bones with the bases of the second and third metatarsal bones. The prolongation which reaches the metatarsal bones passes forwards between the internal and middle cuneiform bones. A small synovial membrane is sometimes met with, between the contiguous surfaces of the scaphoid and cuboid bone.

ACTIONS. — The movements permitted by the articulation between the astragalus and os calcis, are a slight degree of gliding, in the directions *forwards* and *backwards*, and *laterally* from side to side. The movements of the second range of tarsal bones are very trifling, being greater between the scaphoid and three cuneiform bones than in the other articulations. The movements occurring between the first and second range are the most considerable: they are *adduction* and *abduction*, and in a minor degree *flexion*, which increases the arch of the foot, *extension*, which flattens the arch.

Dislocations. — The dislocations of these bones recorded by Sir Astley Cooper are:—

1. Dislocation of the astragalus: in this case the calcaneo-astragaloid interosseous ligament, must be ruptured.

2. Dislocation of the five anterior bones of the tarsus from the astragalus and os calcis.

3. Dislocation of the internal cuneiform bone.

6. *Tarso-metatarsal Articulation*.—The ligaments of this articulation are —

Dorsal,		Plantar,
Interosseous.		

The *dorsal ligaments* connect the metatarsal to the tarsal bones, and the metatarsal bones with each other. The precise arrangement of these ligaments is of little importance; but it may be remarked that the base of the second metatarsal bone, articulating with the three cuneiform bones, receives a ligamentous slip from each, while the rest, articulating with a single tarsal bone, receive only a single tarsal slip.

The *plantar ligaments* have the same disposition on the plantar surface.

The *interosseous ligaments* are situated between the bases of the metatarsal bones of the four lesser toes, and also between the bases of the second and third metatarsal bones and the internal and external cuneiform bones.

The metatarsal bone of the second toe is implanted by its base between the internal and external cuneiform bone, and is the most strongly articulated of all the metatarsal bones. This disposition must be recollected in amputation at the tarso-metatarsal articulation.

The *synovial membranes* of this articulation are three in number:—one for the metatarsal bone of the great toe, one for the second and third metatarsal bones (which is continuous with the great tarsal synovial membrane), and one for the fourth and fifth metatarsal bones.

ACTIONS.—The movements of the tarsal bones upon the tarsal and upon each other, are very slight; they are such only as contribute to the strength of the foot, by permitting a certain degree of yielding to opposing forces.

Dislocations.—These bones are not dislocated, except by extreme violence.

7. *Metatarso-phalangeal Articulation*.—The ligaments of this articulation, like those of the articulation between the first phalanges and metacarpal bones of the hand, are,

Inferior or plantar,	Two lateral,
Transverse.	

The *inferior* or *plantar ligaments* are thick and fibro-cartilaginous, and form part of the articulating surface of the joint.

The *lateral ligaments* are short and very strong, and situated one on each side of the joints.

The *transverse ligaments* are strong bands, which pass transversely between the anterior ligaments.

The expansion of the extensor tendon supplies the place of a dorsal ligament.

ACTIONS. — The movements of the first phalanges upon the rounded heads of the metatarsal bones, are *flexion*, *extension*, *adduction*, and *abduction*.

Dislocation of the first phalanges from the heads of the metacarpal bones, is extremely rare.

8. *Articulation of the Phalanges.*—The ligaments of the phalanges are the same as those of the fingers, and have the same disposition. Their actions are also similar. They are,

Inferior or plantar,

Two lateral.

INDEX.

Abdomen, 417.
 Abdominal regions, 438.
 Abdominal ring, 421.
 Abductor oculi, 219.
 Acervulus, 324.
 Acetabulum, 599.
 Acini, 469.
 Adductor oculi, 219.
 Air-cells, 148.
 Albino, 379.
 Alimentary canal, 446.
 Allantois, 565.
 Amphi arthrosis, 569.
 Ampulla, 390.
 Amygdalæ, 301.
 Andersch, ganglion of, 286.
 Aneurism, false, 106.
 varicose, 107.
 Aneurismal varix, 107.
 Annulus albidus, 373.
 ovalis, 153. 559.
 Antihelix, 380.
 Antitragus, 380.
 Antrum pylori, 446.
 Anus, 451.
 Aorta, 163. 173.
 Aortic sinuses, 159.
 Aponeurosis, 4.
 Apparatus ligamentosus colli, 576.
 Appendices epiploicæ, 445.
 Appendix auriculæ, 153. 157.
 vermiformis, 449. 564.
 Aqua labyriuthi, 392.
 Aquæductus cochleæ, 392.
 vestibuli, 390.
 Aqueduct of Sylvius, 324.
 Aqueous humour, 376.
 Arachnoid membrane, 308. 350.
 Arbor vitæ cerebelli, 323.
 uterina, 532.
 Arch, femoral, 32.
 palmar, superficial, 123. 137.
 Arciform fibres, 334. 336.
 Areola, 83.
 Arnold's ganglion, 275.
ARTERIES:
 general anatomy, 479.
 alveolar, 268.
 anastomotica brachialis, 113.
 femoralis, 26.
 angular, 216, 262.
 aorta, 163. 173. 483.
 articulares genû, 47.
 auricular anterior, 264. 382.
 posterior, 202. 263. 382.
 axillary, 89.
 azygos, 47.

ARTERIES—continued.
 basilar, 311.
 brachial, 112.
 bronchial, 149. 173.
 buccal, 268.
 bulbosi, 548.
 calcanean, 67.
 capsular, 486.
 carotid, common, 164. 253.
 external, 256.
 internal, 282. 310.
 carpal radial, 121.
 ulnar, 125.
 cavernosi, 548.
 centralis retinae, 227. 376. 379.
 cerebellar, 312.
 cerebral, 311.
 cervicalis ascendens, 252.
 choroidean, 313.
 ciliary, 227. 379.
 circumflex femoris, 25. 44.
 humeri, 92. 100.
 ili, 426.
 superficial, 12. 21. 418.
 coccygeal, 40.
 coeliac, 459. 485.
 colic, 457, 458.
 comes nervi ischiatici, 40.
 phrenici, 98.
 communicans cerebri, 311.
 coronaria cordis, 160.
 labii, 216.
 ventriculi, 459.
 corporis bulbosi, 548.
 cavernosi, 548.
 cremasteric, 427. 432.
 crico-thyroid, 259.
 cystic, 460. 475.
 deferential, 432. 511.
 dental, 267, 268.
 digitales manûs, 137.
 pedis, 72.
 dorsales pollicis, 122.
 dorsalis carpi, 121. 125.
 hallucis, 57.
 indicis, 122.
 linguæ, 261.
 nasi, 227.
 pedis, 56.
 penis, 548.
 pollicis, 57.
 scapulæ, 103.
 emulgent, 486.
 epigastric, 427.
 superficial, 12. 418.
 ethmoidal, 226. 362.
 facial, 216. 262.

ARTERIES—*continued.*

femoral, 22. 24.
 frontal, 202. 226.
 gastric, 459.
 gastro-duodenalis, 460.
 epiploica dextra, 460.
 sinistra, 461.
 gluteal, 39. 514.
 hæmorrhoidal, 458. 513. 515.
 external, 548.
 hepatic, 460. 471.
 hyoid, 259. 261.
 hypogastric, 511. 556.
 ileo-colic, 457.
 iliac, common, 487.
 external, 487.
 internal, 511.
 ilio-lumbar, 514.
 infra-orbital, see *Errata*, 627.
 innominata, 164.
 intercostal, 97. 174. 426.
 anterior, 98.
 superior, 175. 252.
 interosseous, 124. 132.
 intestini tenuis, 456.
 ischiatic, 40. 513.
 labial, 216.
 lachrymal, 226. 369.
 laryngeal, 259.
 lateralis nasi, 216. 359.
 lingual, 260.
 lumbar, 426. 486.
 magna pollicis, 57.
 malleolar, 55.
 mammary internal, 98. 251. 427.
 masseteric, 216. 263.
 mastoid, 263.
 maxillary internal, 265.
 superior, 268.
 mediastinal, 174.
 meningeal, anterior, 283. 348.
 inferior, 263. 348.
 media, 267. 348.
 parva, 268. 348.
 posterior, 311. 348.
 mesenteric, 456.
 inferior, 458.
 metacarpal, 122. 125.
 metatarsal, 56.
 musculo-phrenic, 99.
 mylo-hyoid, 267.
 nasal, 216. 226. 269. 359.
 obturator, 27. 513.
 occipital, 202. 263.
 œsophageal, 173.
 ophthalmic, 225. 283.
 orbital, 264.
 ovarian, 485.
 palatine, descending, 269.
 inferior, 263.
 posterior, 269.
 superior, 269.
 palpebral, 226. 367.
 pancreatica magna, 461.
 pancreaticæ parvæ, 461.
 pancreatico-duodenalis, 460.
 inferior, 456.
 parotidean, 264.
 perforantes, femoral, 26. 44.
 palmares, 138.
 plantares, 72. 73.
 pericardiac, 98. 173.

ARTERIES—*continued.*

perineal superficial, 548.
 peroneal, 66.
 pharyngea ascendens, 264.
 phrenic, 483.
 plantar, 71.
 popliteal, 47.
 princeps cervicis, 190. 263.
 pollicis, 138.
 profunda cervicis, 253.
 femoris, 24. 44.
 humeri, 113.
 pterygoid, 268.
 pterygo-palatine, 269.
 pubic, 427. 513.
 pudic, external, 12. 24. 418.
 internal, 41. 513. 547.
 pulmonary, 162.
 pyloric, 460.
 radial, 120.
 radialis indicis, 138.
 ranine, 260. 262.
 recurrens interosseæ, 125.
 radialis, 121.
 tibialis, 54.
 ulnaris, 124.
 renal, 482. 486.
 sacra lateralis, 514.
 media, 486. 515.
 scapular posterior, 103. 252.
 sigmoid, 458.
 spermatic, 432. 485.
 sphenopalatine, 269. 362.
 spinal, 312. 355.
 splenic, 461. 477.
 sterno-mastoid, 263.
 stylo-mastoid, 264.
 subclavian, 165. 248.
 sublingual, 262.
 submaxillary, 263.
 submental, 263.
 subscapular, 92. 104.
 superficialis cervicis, 252.
 volæ, 121.
 supra-orbital, 202. 226.
 supra-renal, 479. 486.
 scapular, 102. 252.
 sural, 48.
 tarsea, 56.
 temporal, 202. 264.
 temporales profundæ, 268.
 thoracic, 91.
 thyroidea inferior, 251.
 media, 164.
 superior, 259.
 tibialis antica, 53.
 postica, 64.
 tonsillar, 263.
 transversalis colli, 252.
 faciei, 217. 265.
 humeri, 252.
 perinei, 548.
 tympanic, 267. 283. 388.
 ulnar, 122.
 umbilical, 556.
 uterine, 513.
 vaginal, 513.
 vasa brevia, 461.
 intestini tenuis, 456.
 vertebral, 250. 311.
 vesical, 509. 511.
 Vidian, 269.

- Arthrodia, 569.
 Articulations, 572.
 Arytenoid cartilages, 399.
 glands, 406.
 Auricles of the heart, 152. 157.
 Auriculo-ventricular openings, 155. 158.
 Axilla, 88.
 Axis coeliac, 459. 485.
 thyroid, 251.

 Bartholine's duct, 240.
 glands, 538.
 Base of the brain, 329.
 Bauhini, valvula, 453.
 Bichât, fissure of, 315.
 Biliary ducts, 467. 470. 474.
 Bladder, 529. 565.
 Bones, general anatomy, 5.
 Botal, foramen of, 564.
 Brain, 305.
 Bronchi, 148. 171.
 Bronchial cells, 148.
 tubes, 148.
 Bronchocele, 236.
 Brunner's glands, 455.
 Bubonocele, 457.
 Bulb, corpus spongiosum, 520.
 Bulbi fornicis, 331.
 vestibuli, 538.
 Bulbous part of the urethra, 523.
 Bulbus olfactorius, 339.
 rachidicus, 333.

 Cæcum, 448.
 Calamus scriptorius, 326.
 Calices, 481.
 Camper's ligament, 547.
 Canal of Fontana, 374.
 Nuck, 535.
 Petit, 376. 378.
 Sylvius, 324.
 Canthi, 364.
 Capillaries, 4.
 Capitula laryngis, 400.
 Capsule of Glisson, 462. 467. 469.
 Capsules supra-renal, 478. 565.
 Caput gallinaginis, 522.
 Cardia, 446.
 Carpus, 594.
 Cartilage, inter-articular of clavicle,
 587, 588.
 inter-articular of jaw, 579.
 inter-articular of wrist, 593.
 semi-lunar, 602.
 Caruncula lachrymalis, 366.
 mamillaris, 338.
 Carunculæ myrtiformes, 537.
 Casserian ganglion, 270.
 Cauda equina, 351. 355.
 Cava vena, 165, 166. 488.
 Cells, development of, 410.
 Cellular tissue, 1.
 Centrum ovale, 314, 315.
 Cerebellum, 327.
 Cerebro-spinal fluid, 350.
 Cerebrum, 314.
 Ceruminous follicles, 382.
 Cervical ganglia, 291.
 Chambers of the eye, 377.
 Cheeks, 395.
 Chiasma nervorum opticorum, 339.
 Chordæ longitudinales, 315.

 Chordæ tendineæ, 155. 159.
 vocales, 401.
 Willisii, 346.
 Choroid membrane, 372.
 plexus, 317. 322. 326.
 Cilia, 366.
 Ciliary canal, 374.
 ligament, 373.
 processes, 374.
 Circle of Willis, 313.
 Circulation, adult, 151.
 fœtal, 557.
 Circulus tonsillaris, 288.
 venosus Halleri, 85.
 Clitoris, 537.
 Cochlea, 391.
 Cœliac axis, 459. 485.
 Colon, 449.
 Columna nasi, 357.
 Columnæ carneæ, 155. 159.
 papillares, 156.
 Columns of spinal cord, 352.
 Commissures, 323. 337.
 great, 315.
 Conarium, 324.
 Concha, 380.
 Congestion of the liver, 473.
 Coni renales, 480.
 vasculosi, 528.
 Conjunctiva, 366.
 Conus arteriosus, 154.
 Converging fibres, 337.
 Corium, 2. 408. 454.
 Cornea, 370.
 Cornicula laryngis, 400.
 Cornu Ammonis, 319.
 Cornua of the ventricles, 316.
 Corona glandis, 519.
 Coronary valve, 153.
 Corpora albicantia, 331.
 Arantii, 157. 159.
 cavernosa, 520.
 geniculata, 322.
 Malpighiana, 477. 481.
 mamillaria, 331.
 olivaria, 334.
 pisiformia, 331.
 pyramidalia, 334.
 quadrigemina, 324.
 restiformia, 335.
 striata, 316.
 Corpus callosum, 315.
 cavernosum, 520.
 ciliare, 374.
 dentatum, 329. 334.
 fimbriatum, 318, 319.
 geniculatum, 322.
 High morianum, 526.
 luteum, 535.
 psalloides, 322.
 rhomboideum, 329.
 spongiosum, 520.
 striatum, 316.
 Covered band of Reil, 315.
 Cowper's glands, 552.
 Cranial nerves, 338.
 Cribriform fascia, 12. 33.
 lamella, 370.
 Cricoid cartilage, 399.
 Crico-thyroid membrane, 401.
 Crura cerebelli, 329.
 Crura cerebri, 333.

- Crura penis, 520.
 Crural canal, 21. 33.
 ring, 21. 33
 Crystalline lens, 378.
 Cuneiform cartilages, 400.
 Cuticle, 2. 409.
 Cutis, 2. 408.
 Cystic duct, 475.
 Cytoblast, 410.

 Dartos, 524.
 Derbyshire neck, 236.
 Derma, 2. 406.
 Detrusor urinæ, 507.
 Diaphragm, 494.
 Diarthrosis, 569.
 Digital cavity, 318.
 DISLOCATIONS :
 ankle, 607.
 carpal bones, 595.
 carpo-metacarpal, 596.
 clavicle, 588, 589.
 elbow, 591.
 hip, 600.
 jaw, 580.
 knee, 604.
 metacarpo-phalangeal, 597.
 metatarso-phalangeal, 611.
 phalanges, 598.
 radius and ulna, 593.
 shoulder, 590.
 tarsal bones, 609.
 wrist, 594.
 Diverging fibres, 335.
 Dorsi-spinal veins, 355.
 Ductus ad nasum, 369.
 arteriosus, 556. 564.
 communis choledochus, 462.
 cysticus, 475.
 ejaculatorius, 528.
 hepaticus, 470. 474.
 lymphaticus dexter, 177. 258.
 pancreaticus, 476.
 prostatic, 509.
 thoracicus, 176. 253.
 venosus, 537.
 Duodenum, 447.
 Dura mater, 305. 349.

 Ear, 380.
 Ejaculatory duct, 528.
 Eminentia collateralis, 319.
 Enarthrosis, 570.
 Encephalon, 305.
 Endocardium, 160.
 Endolymph, 393.
 Entozoon folliculorum, 416.
 Epiderma, 2. 409.
 Epididymis, 525.
 Epigastric region, 438.
 Epiglottic gland, 406.
 Epiglottis, 400.
 Epiglottito-hyoidean ligament, 402.
 Epithelium, 453.
 Erectile tissue, 521.
 Eustachian tube, 300. 386.
 valve, 153.
 Eye, 364.
 Eye-brows, 364.
 globe, 369.
 lashes, 366.
 lids, 364.

 Falciform process, 15.
 Fallopian tubes, 534.
 Falx cerebelli, 307.
 cerebri, 307.
 FASCIA :
 general anatomy of, 3.
 cervical, 231.
 cremasteric, 432.
 cribriform, 12. 15.
 deep, 3.
 dentata, 320.
 iliaca, 496.
 intercolumnar, 422.
 lata, 14.
 lumbar, 185.
 obturator, 502.
 palmar, 132.
 pelvica, 502.
 perineal, 540. 547.
 plantar, 68.
 popliteal, 45.
 propria, 432.
 recto-vesical, 502.
 spermatic, 432.
 superficial, 3.
 temporal, 201.
 transversalis, 430.
 Fasciculi graciles, 335.
 innominati, 326. 335. 336.
 siliquæ, 334. 335.
 teretes, 326. 335. 336.
 Fauces, 301.
 Femoral arch, 32.
 canal, 21. 33.
 hernia, 31.
 ring, 21. 33.
 Fenestra ovalis, 385.
 rotunda, 385.
 Fibræ arciformes, 334. 336.
 Fibres of the brain, 335.
 heart, 159.
 Fibrous cartilage :
 inter-articular of the
 clavicle, 587, 588.
 jaw, 579.
 knee, 602.
 wrist, 593.
 Filum terminale, 351.
 Fimbriæ, Fallopian, 534.
 Fissure of Bichat, 315.
 brain, 315. 330.
 Sylvius, 330.
 Fissures of the liver, 464.
 spinal cord, 352.
 Flocculus, 328.
 Fœtal circulation, 557.
 Fœtus, anatomy of, 556.
 Follicles of Lieberkuhn, 455.
 Foramen, Botal, of, 564.
 cæcum, 334. 397.
 commune anterius, 317. 321. 323.
 posterius, 324.
 Monro, of, 317. 321. 323.
 ovale, 556. 564.
 saphenum, 15.
 Soemmering, of, 376.
 Winslow, of, 444.
 Foramina Thebesii, 152.
 Forceps cerebri, 337.
 Fornix, 320.
 Fossa innominata, 380.
 ischio-rectal, 543.

- Fossa navicularis urethræ, 523.
 navicularis pudendi, 536.-
 ovalis, 153. 380. 559.
 scaphoidea, 380.
 triangularis, 380.
 Fourchette, 536.
 Fræna epiglottidis, 397. 402.
 Frænulum labiorum, 536.
 Frænulum labii, 395.
 linguæ, 396.
 præputii, 519.
 Funiculi graciles, 335.
 siliquæ, 334.

 Galea capitis, 200.
 Gall-bladder, 474.
 Ganglia, cervical, 291.
 increase of, 336.
 lumbar, 492.
 sacral, 517.
 semilunar, 491.
 thoracic, 170.
 Ganglion of Andersch, 286.
 Arnold's, 275.
 azygos, 518.
 cardiac, 161.
 Casserian, 270.
 ciliary, 225.
 Cloquet's, 281.
 geniculare, 285.
 impar, 518.
 jugular, 286. 288.
 lenticular, 225.
 Meckel's, 279.
 Muller's, 286.
 naso-palatine, 281.
 ophthalmic, 225.
 otic, 275.
 petrous, 286.
 semi-lunar, 491.
 spheno-palatine, 279.
 submaxillary, 274.
 thyroid, 293.
 vertebral, 294.
 Wrisberg's, 161.
 Genu corporis callosi, 315.
 Gimbernat's ligament, 421.
 Ginglymus, 569.
 Gland, epiglottic, 406.
 pineal, 324.
 pituitary, 331.
 prostate, 509.
 thymus, 560.
 thyroid, 235. 560.
 Glands, aggregate, 455.
 arytenoid, 406.
 Bartholine's, 538.
 bronchial, 177.
 Brunner's, 455.
 buccal, 395.
 ceruminous, 382.
 concatenatæ, 257.
 Cowper's, 552.
 duodenal, 455.
 gastric, 454.
 inguinal, 12. 419.
 labial, 395.
 lachrymal, 228.
 Lieberkuhn's, 455.
 lingual, 398.
 lumbar, 492.
 lymphatic, 5.

 Glands, mammary, 82.
 mesenteric, 457.
 Meibomian, 365.
 oesophageal, 177.
 Pacchionian, 306.
 parotid, 209.
 Peyer's, 455.
 salivary, 209. 238. 239.
 sebiparous, 415.
 solitary, 455.
 sublingual, 239.
 submaxillary, 238.
 sudoriparous, 416.
 tracheal, 407.
 Glandulæ odoriferæ, 519.
 Pacchioni, 306.
 Tysoni, 519.
 Glans clitoridis, 537.
 penis, 519.
 Glisson's capsule, 462. 467. 469.
 Globus major epididymis, 525.
 minor epididymis, 525.
 Glomeruli, 481.
 Glottis, 405.
 Goitre, 236.
 Gomphosis, 568.
 Graafian vesicles, 535.
 Gubernaculum testis, 566.
 Gums, 296.
 Guthrie's muscle, 551.
 Gyri cerebri, 314.
 operti, 330.
 Gyrus fornicatus, 314. 319.

 Hair, 414.
 Harmonia, 568.
 Heart, 150. 563.
 Helicine arteries, 521.
 Helico-trema, 392.
 Helix, 380.
 Hepatic duct, 470. 474.
 Hernia, congenital, 435.
 diaphragmatic, 495.
 direct, 436.
 encysted, 435.
 femoral, 31.
 infantilis, 435.
 inguinal, 433.
 scrotal, 436.
 umbilical, 433.
 ventral, 433.
 Hilton's muscle, 403.
 Hilum lienis, 477.
 pulmonis, 147.
 renale, 490.
 Hippocampus major, 319.
 minor, 318.
 Horner's muscle, 205.
 Horny band, 316.
 Humours of the eye, 376.
 Hyaloid membrane, 378.
 Hymen, 537.
 Hypochondriac regions, 438.
 Hypogastric region, 439.
 Hypophysis cerebri, 331.

 Ileo-cæcal valve, 453.
 Ileum, 448.
 Iliac regions, 439.
 Incus, 383.
 Infundibula, 489.
 Infundibulum cerebri, 331.

Infundibulum cordis, 154.
 Inguinal region, 439.
 Integument, 2.
 Inter-articular cartilages of the clavicle, 587, 588.
 jaw, 579.
 wrist, 593.
 Inter-columnar fascia, 422.
 fibres, 421.
 Inter-vertebral substance, 574.
 Intestinal canal, 447.
 Intumescencia gangliiformis, 285.
 Iris, 374.
 Ischio-rectal fossa, 543.
 Isthmus of the fauces, 301.
 Iter ad infundibulum, 323.
 a tertio ad quartum ventriculum, 324.

 Jacob's membrane, 375.
 Jejunum, 448.
 Joint, ankle, 606.
 elbow, 590.
 hip, 598.
 lower jaw, 578.
 knee, 600.
 shoulder, 589.
 wrist, 593.

 Kidneys, 479. 565.

 Labia majora, 536.
 minora, 536.
 Labyrinth, 388.
 Lachrymal canals, 367.
 gland, 228. 367.
 papillæ, 364.
 puncta, 365. 368.
 sac, 369.
 tubercles, 364.
 Lacteals, 457.
 Lacunæ, 523.
 Lacus lachrymalis, 364.
 Lamina cinerea, 330.
 cribrosa, 370.
 spiralis, 391.
 Laqueus, 324.
 Laryngotomy, 237.
 Larynx, 398.
 Lateral ventricles, 316.
 Lens, 378.
 Lenticular ganglion, 225.
 Levers, 62. 111.
 Lieberkuhn's follicles, 455.
 Lien succenturiatus, 427.
 Ligament, 6.
 LIGAMENTS, 568.
 acromio-clavicular, 588.
 alar, 577. 603.
 ankle, of the, 606.
 annular, of the ankle, 51.
 radius, 592.
 wrist anterior, 595.
 posterior, 117.
 arcuatum externum, 494.
 internum, 494.
 atlo-axoid, 577.
 bladder, of the, 502.
 breve plantæ, 608.
 calcaneo-astragaloid, 609.
 cuboid, 608.
 scaphoid, 608.

LIGAMENTS—*continued.*
 capsular of the hip, 598.
 jaw, 779.
 rib, 580.
 shoulder, 589.
 thumb, 596.
 carpal, 594.
 carpo-metacarpal, 596.
 common anterior, 573.
 posterior, 573.
 conoid, 588.
 coracoid, 589.
 coraco-acromial, 589.
 clavicular, 588.
 humeral, 589.
 coronary, 592.
 coronary of the knee, 602.
 costo-clavicular, 587.
 coracoid, 231.
 sternal, 581.
 transverse, 581.
 vertebral, 580.
 xyphoid, 582.
 cotyloid, 599.
 crico-arytenoid, 401.
 crico-thyroidean, 401.
 crucial, 602.
 cruciform, 578.
 deltoid, 606.
 dentatum, 351.
 elbow, of the, 590.
 glenoid, 589.
 glosso-epiglottic, 402.
 hip-joint, of the, 598.
 hyo-epiglottic, 402.
 ilio-femoral, 599.
 inter-articular of ribs, 581.
 inter clavicular, 587.
 inter-osseous :
 calcaneo-astragaloid, 609.
 peroneo-tibial, 605.
 radio-ulnar, 592.
 inter-spinous, 575.
 inter-transverse, 575.
 inter-vertebral, 574.
 jaw, of the, 578.
 knee, of the, 600.
 larynx, of the, 400.
 lateral, of the ankle, 606.
 elbow, 590.
 jaw, 578.
 knee, 601.
 phalanges, foot, 611.
 phalanges, hand, 597.
 wrist, 594.
 liver, of the, 463.
 longum plantæ, 608.
 lumbo-iliac, 583.
 lumbo-sacral, 583.
 metacarpal, 597.
 metatarsal, 610.
 mucosum, 603.
 nuchæ, 182. 575.
 oblique, 592.
 obturator, 586.
 occipito-atloid, 575.
 axoid, 576.
 odontoid, 577.
 orbicular, 592.
 palpebral, 365.
 patellæ, 600.
 pelvis, of the, 583.

LIGAMENTS — *continued.*

- peroneo-tibial, 604.
 phalanges, of the foot, 611.
 of the hand, 597.
 plantar, long, 608.
 plantar, short 608.
 posticum Winslowii, 601.
 Poupart's, 421.
 pterygo-maxillary, 211, 299.
 pubic, 585.
 pulmonis, 141.
 radio-ulnar, 592.
 rhomboid, 587.
 rotundum, hepatis, 464.
 round, 433. 535.
 sacro-coccygean, 585.
 sacro-iliac, 584.
 sacro-ischiatic, 584.
 sacro-vertebral, 583.
 shoulder, of the, 589.
 stellate, 580.
 sternal, 582.
 sterno-clavicular, 587.
 stylo-maxillary, 231. 779.
 sub-flava, 574.
 sub-pubic, 585.
 supra-spinous, 575.
 suspensorium axis, 577.
 hepatis, 464.
 penis, 519.
 tarsal, 607.
 tarso-metatarsal, 610.
 teres, 599.
 thyroid-arytenoid, 401.
 thyro-epiglottic, 402.
 thyro-hyoidean, 400.
 tibio-fibular, 604.
 transverse :
 of the acetabulum, 599.
 of the ankle, 605.
 of the atlas, 577.
 of the knee, 602.
 of the metacarpus, 597.
 of the metatarsus, 611.
 of the scapula, 589.
 of the semilunar cartilages, 602.
 trapezoid, 588.
 tympanum, of the, 384.
 wrist, of the, 593.
 Zinn, of, 219.
 Ligamentum nuchæ, 182.
 Limbus luteus, 376.
 Linea alba, 419.
 Lineæ semilunares, 419.
 transversæ, 315. 419.
 Linguetta laminosa, 325.
 Lips, 395.
 Liquor Cotunnii, 392.
 Morgagni, 378.
 Scarpa, of, 393.
 Liver, 463. 565.
 Lobules of the liver, 468.
 Lobuli testis, 526.
 Lobulus auris, 380.
 centralis nasi, 357.
 pneumogastricus, 328.
 Lobus caudatus, 466.
 quadratus, 466.
 Spigelii, 466.
 Locus niger, 333.
 perforatus anticus, 330.
 posticus, 331.
 Lumbar fascia, 185.
 regions, 439.
 Lungs, 143. 563.
 Lunula, 157. 413.
 Lymphatic glands and vessels. 5.
 abdominal, 493.
 axillary, 88.
 bronchial, 177.
 cardiac, 177.
 cervical, 244. 257.
 iliac, 493.
 inguinal, 12. 419.
 intestines, 457. 459.
 kidneys, 483.
 lacteals, 457.
 liver, 467.
 lungs, 149.
 mediastinal, 177.
 mesenteric, 457.
 pelvis, 515.
 popliteal, 47.
 spleen, 478.
 testicle, 524.
 Lyra, 322.
 Malleus, 383.
 Malpighian bodies, 477. 481.
 Mamilla, 83.
 Mammæ, 82.
 Mammary gland, 82.
 Mastoid cells, 386.
 Matrix, 413.
 Maxillo-pharyngeal space, 299.
 Meatus, auditorius, 382.
 urinarius, female, 538.
 male, 519.
 Meatuses of the nares, 360.
 Meckel's ganglion, 279.
 Meconium, 564.
 Mediastinum, 141.
 testis, 526.
 Medulla innominata, 330.
 oblongata, 333.
 Meibomian glands, 365.
 Membrana dentata, 351.
 fusca, 372.
 nictitans, 367.
 pigmenti, 373.
 pupillaris, 559.
 sacciformis, 595.
 tympani, 383.
 Membrane, choroid, 372.
 hyaloid, 378.
 Jacob's, 375.
 of the ventricles, 326.
 Membranous urethra, 523.
 Mesenteric glands, 457.
 Mesentery, 445.
 Meso-cola, 445.
 Meso-rectum, 445.
 Metacarpus, 596.
 Metatarsus, 610.
 Mitral valve, 158.
 Modiolus, 391.
 Mons Veneris, 536.
 Monticulus cerebelli, 328.
 Morsus diaboli, 534.
 Mouth, 395.
 Mucous membrane, structure, 453.
 MUSCLES :
 general anatomy of, 4.
 abductor indicis, 135.

MUSCLES—*continued.*

- abductor minimi digiti, 70.
 oculi, 219.
 pollicis, 69. 133.
 accelerator urinæ, 544.
 accessorius, 70.
 adductor brevis, 19.
 longus, 18.
 magnus, 20.
 minimi digiti, 134.
 oculi, 219.
 pollicis, 71. 134.
 anconeus, 128.
 anomalus, 207.
 anterior auriculæ, 200.
 anti-tragicus, 382.
 arytenoidens, 403.
 aryteno-epiglottideus, 403.
 attollens aurem, 200.
 oculum, 219.
 attrahens aurem, 200.
 auricularis, 128.
 azygos uvulæ, 302.
 basio-glossus, 240.
 biceps flexor cruris, 43.
 cubiti, 110.
 biventer cervicis, 188.
 brachialis anticus, 110.
 buccinator, 211.
 bulbo-cavernosus, 544.
 cerato-glossus, 240.
 cervicalis ascendens, 187.
 ciliaris, 205.
 circumflexus palati, 303.
 coccygeus, 503.
 complexus, 187.
 compressor nasi, 206.
 prostatæ, 504.
 urethræ, 550. 555.
 constrictor isthmi faucium, 303.
 pharyngis, 297. 299.
 urethræ, 550.
 vaginæ, 554.
 coraco-brachialis, 109.
 corrugator supercillii, 205.
 crenaster, 424. 567.
 crico-arytenoid lateralis, 402.
 posticus, 402.
 thyroideus, 402.
 crureus, 17.
 cucullaris, 181.
 deltoid, 100.
 depressor alæ nasi, 207.
 anguli oris, 209.
 epiglottidis, 403.
 labii, 209.
 oculi, 219.
 detrusor urinæ, 507.
 diaphragm, 494.
 digastricus, 237.
 dilatator naris, 207.
 erector clitoridis, 555.
 penis, 544.
 spinæ, 196.
 extensor carpi radialis, 127.
 carpi ulnaris, 128.
 coccygis, 193.
 digiti minimi, 128.
 digitorum brevis, 55.
 digitorum communis, 128.
 digitorum longus, 52.
 indicis, 130.

MUSCLES—*continued.*

- extensor ossis metacarpi, 129.
 pollicis proprius, 52.
 internodii pollicis, 130.
 flexor accessorius, 70.
 brevis digiti min. 71. 134.
 carpi radialis, 118.
 ulnaris, 119.
 digitorum brevis, 70.
 profundus, 119.
 sublimis, 119.
 longus digitorum ped. 63.
 longus pollicis, 63.
 ossis metacarpi, 133.
 pollicis brevis, 70. 120. 134.
 longus, 63.
 gastrocnemius, 61.
 gemellus, 38.
 genio-hyo-glossus, 239.
 hyoideus, 239.
 gluteus maximus, 36.
 medius, 36.
 minimus, 37.
 gracilis, 20.
 helicus major, 381.
 minor, 382.
 hyo-glossus, 240.
 iliacus, 18. 497.
 indicator, 130.
 infra-spinatus, 101.
 inter-costales, 95.
 inter-obliqui, 193.
 inter-ossei, 55. 73. 135.
 inter-spinales, 192.
 inter-transversales, 193.
 ischio-cavernosus, 544.
 larynx, of the, 402.
 latissimus dorsi, 95.
 laxator tympani, 385.
 levator anguli oris, 208.
 scapulæ, 183.
 ani, 503.
 glandulæ thyroideæ, 236.
 labii, 208. 209.
 menti, 209.
 palati, 303.
 palpebræ, 219.
 prostatæ, 504.
 levatores costarum, 193.
 lingualis, 241.
 longissimus dorsi, 186.
 longus colli, 295.
 lumbricales, 70. 135.
 mallei externus, 385.
 internus, 384.
 masseter, 210.
 multifidus spinæ, 192.
 mylo-hyoideus, 239.
 myrtiformis, 207.
 naso-labialis, 208.
 obliquus abdominis, 420.
 auris, 382.
 capitis, 191.
 oculi, 219. 220.
 obturator externus, 19.
 internus, 38.
 occipito-frontalis, 199.
 omo-hyoideus, 234.
 opponens digiti minimi, 134.
 pollicis, 133.
 orbicularis oris, 208.
 palpebrarum, 205.

MUSCLES—*continued.*

palato-glossus, 241. 303.
 pharyngeus, 303.
 palmaris brevis, 132.
 longus, 119.
 pectineus, 19.
 pectoralis major, 85.
 minor, 88.
 perineus profundus, 550.
 peroneus brevis, 59.
 longus, 58.
 tertius, 52.
 plantaris, 61.
 platysma myoides, 230.
 popliteus, 62.
 posterior auriculæ, 200.
 pronator quadratus, 120.
 radii teres, 118.
 psoas magnus, 18. 496.
 parvus, 496.
 pterygoideus, 211.
 pyramidalis abdominis, 425.
 nasi, 206.
 pyriformis, 37.
 quadratus femoris, 38.
 lumborum, 497.
 menti, 209.
 quadriceps femoris, 38.
 rectus abdominis, 425.
 capitis anticus, 295.
 lateralis, 191.
 posticus, 191.
 femoris, 17.
 oculi externus, 219.
 inferior, 219.
 internus, 219.
 superior, 219.
 retrahens aurem, 200.
 rhomboideus, 183.
 risorius Santorini, 209. 230.
 sacro-lumbalis, 186.
 sartorius, 16.
 scalenus anticus, 248.
 medius, 248.
 posticus, 248.
 semi-spinalis, 191.
 semi-membranosus, 44.
 semi-tendinosus, 43.
 serratus magnus, 95.
 posticus, 184.
 soleus, 62.
 sphincter ani, 542. 545.
 vaginæ, 554.
 vesicæ, 507.
 spinalis dorsi, 187.
 splenius, 184.
 stapedius, 385.
 sterno-hyoideus, 234.
 mastoideus, 231.
 thyroideus, 234.
 stylo-glossus, 241.
 hyoideus, 238.
 pharyngeus, 299.
 subclavius, 88.
 subcrureus, 18.
 subscapularis, 103.
 superior auriculæ, 200.
 supinator brevis, 129.
 longus, 127.
 supra-spinatus, 101.
 temporal, 201.
 tensor-palati, 303.

MUSCLES—*continued.*

tensor tarsi, 205.
 tympani, 384.
 vaginæ femoris, 16.
 teres major, 102.
 minor, 102.
 thyro-arytenoideus, 403.
 epiglottideus, 403.
 hyoideus, 234.
 tibialis anticus, 51.
 posticus, 63.
 trachelo-mastoideus, 187.
 tragicus, 382.
 transversalis abdominis, 424
 colli, 187.
 transversus auriculæ, 382.
 pedis, 71.
 perinei, 544.
 profundus, 550. 554.
 trapezius, 181.
 triangularis oris, 209.
 sterni, 96.
 triceps extensor cruris, 17.
 cubiti, 116.
 trochlearis, 219.
 ureters, of the, 507.
 vastus externus, 17.
 internus, 17.
 Wilson's, 552.
 zygomaticus, 208.
 Musculi pectinati, 153. 158.
 Myopia, 380.
 Naboth, ovula of, 532.
 Nails, 413.
 Nares, 357.
 Nasal duct, 369.
 fossæ, 399.
 Nates cerebri, 324.
 NERVES :
 general anatomy, 5.
 abducentes, 224. 341.
 accessorius, 290. 343.
 acromiales, 246.
 auditory, 342. 393.
 auricularis anterior, 204.
 magnus, 204. 242.
 posterior, 203. 213.
 vagi, 289.
 auriculo-temporal, 272.
 brachial, 93.
 huccal, 272.
 cardiac, 167. 289. 294.
 carotid, 281. 287. 292.
 cervical anterior, 244.
 posterior, 188.
 cervico-facial, 212. 215.
 chorda tympani, 285.
 ciliary, 224. 225.
 circumflex, 100.
 claviculares, 246.
 coccygeal, 516.
 cochlear, 394.
 communicans noni, 246.
 peronei, 49. 61.
 poplitei, 48.
 tibialis, 48.
 cranial, 338.
 crural, 28.
 cutaneus dorsi, 180.
 externus brachialis, 108.
 113.

NERVES—*continued.*

cutaneus externus femoralis, 14.
 internus brachialis, 108. 114.
 femoralis, 13.
 medius femoralis, 13.
 patellæ, 14. 29.
 spiralis, 108. 116.
 dental, 273. 278.
 descendens noui, 291.
 digastric, 213.
 digital, 139.
 dorsal, 189.
 dorsalis penis, 549.
 eighth pair, 285. 343.
 facial, 212. 284. 342.
 femoral, 28.
 fifth pair, 270. 341.
 first pair, 338.
 fourth pair, 222. 341.
 frontal, 223.
 gastric, 462. 491.
 genito-crural, 13.
 glosso-pharyngeal, 286. 343.
 gluteal, 41.
 inferior, 42.
 gustatory, 274.
 hæmorrhoidal, 549.
 hypo-glossal, 290. 343.
 ilio-hypogastric, 498.
 ilio-inguinal, 13.
 inferior maxillary, 271.
 infra-trochlear, 224.
 inguino-cutaneous, 14. 499.
 intercostal, 98. 170.
 intercosto-humeral, 82. 109.
 inter-osseous anterior, 126.
 posterior, 132.
 ischiaticus major, 42.
 minor, 41. 60.
 Jacobson's, 287.
 labial, 273.
 lachrymal, 223.
 laryngeal inferior, 167. 290.
 recurrent, 167. 290.
 superior, 289.
 lingual, 343.
 lumbar anterior, 498.
 posterior, 189. 498.
 lumbo-inguinal, 499.
 sacral, 500.
 malar, 213.
 masseteric, 272.
 maxillaris inferior, 271.
 superior, 270. 277.
 median, 114. 126.
 mental, 273.
 molles, 293.
 motores.ocularum, 222. 339.
 musculo-cutaneous arm, 113. 116.
 leg, 49. 59.
 musculo-spiral, 115.
 mylo-hyoidean, 273.
 nasal, 223. 279. 362.
 naso-ciliaris, 223.
 naso-palatine, 279. 362.
 ninth pair, 290. 343.
 obturator, 30.
 occipitalis major, 188. 204.
 minor, 204. 243.
 œsophageal, 168.
 olfactory, 338. 362.
 ophthalmic, 222. 270.

NERVES—*continued.*

optic, 339. 375.
 orbital, 277.
 palatine, 279.
 palmar, 126. 138.
 pathetici, 222. 341.
 perforans Casserii, 113.
 perineal, 550.
 petrosal, 275. 281.
 pharyngeal, 281. 288. 289. 293.
 phrenic, 143. 246.
 plantar, 73.
 pneumo-gastric, 166. 288. 343.
 popliteal, 48.
 portio dura, 212. 284. 342.
 mollis, 342.
 pterygoid, 272.
 pudendalis inferior, 42. 549.
 pudendus externus, 499.
 pudic internal, 43.
 pulmonary, 167.
 radial, 117. 125.
 recurrent, 167.
 renal, 491.
 respiratory, external, 94. 247.
 sacral, 516.
 saphenous, external, 48. 58. 61.
 long or internal, 29. 58.
 short, 48. 58.
 sciatic, 41, 42. 60.
 second pair, 339.
 seventh pair, 341.
 sixth pair, 224. 341.
 spermatic, 492. 499.
 spheno-palatine, 278.
 spinal, 354.
 spinal accessory, 290. 343.
 splanchnic, 170.
 stylo-hyoid, 213.
 subcutaneous malæ, 278.
 sub-occipital, 188.
 sub-rufi, 293.
 subscapular, 94.
 superficialis colli, 242.
 cordis, 294.
 superior maxillary, 270. 277.
 supra-orbital, 203. 223.
 scapular, 94. 102.
 trochlear, 203. 223.
 sympatheticus major, 168. 291.
 minor, 216.
 temporal, 203. 213. 272. 273.
 temporo-facial, 212.
 malar, 277.
 third pair, 222. 339.
 thoracic, 94. 247.
 thyro-hyoidean, 291.
 tibialis, anterior, 55. 58.
 posterior, 67.
 tonsilitic, 288.
 trifacial, 270. 341.
 trigeminus, 270. 341.
 trochlearis, 222. 341.
 tympanic, 287.
 ulnar, 114. 126.
 vagus, 288. 343.
 vestibular, 394.
 Vidian, 281.
 Wrisberg, of, 108. 114.
 Neurilemma, 5.
 Nidus hirundinis, 328.
 Nipple, 83.

- Nodulus, 328.
 Nodus encephali, 333.
 Nose, 357.
 Nucleus olivæ, 334.
 Nuck, canal of, 535.
 Nymphæ, 536.
- Œsophagus, 172. 304.
 Omentum, gastro-hepatic, 444.
 gastro-splenic, 446.
 great, 445.
 lesser, 444.
 Omphalo-mesenteric vessels, 564.
- OPERATIONS :
 arteria innominata, 255.
 axillary artery, 86. 89.
 brachial artery, 112.
 Cæsarian section, 420.
 carotid artery, 254.
 crural hernia, 34.
 dorsalis pedis artery, 56.
 facial artery, 262.
 femoral artery, 21.
 hernia, 34.
 fibular artery, 66.
 hernia, crural, 34.
 femoral, 34.
 inguinal, 437.
 scrotal, 437.
 Hunter's, 22.
 inguinal hernia, 437.
 laryngotomy, 237.
 lingual artery, 261.
 lithotomy, 552.
 peracentesis abdominis, 419.
 peroneal artery, 66.
 plugging nares, 363.
 polypi narium, 363.
 popliteal artery, 46.
 radial artery, 121.
 Scarpa's, 21.
 scrotal hernia, 437.
 subclavian artery, 250.
 tibial artery, anterior, 54.
 posterior, 64.
 tracheotomy, 236.
 ulnar artery, 124.
 venesection, 106.
- Optic commissure, 339.
 thalami, 317. 322.
- Orbiculare, os, 384.
 Orbit, 217.
 Os tinæ, 531.
 Ossicula auditus, 383.
 Ostium abdominale, 534.
 uterinum, 534.
 Otoconites, 393.
 Ovaries, 534. 566.
 Oviducts, 534.
 Ovisacs, 535.
 Ovula Graafiana, 535.
 Naboth, of, 532.
- Pacchionian glands, 306.
 Palate, hard, 395.
 soft, 300.
 Palmar arch, 123. 137.
 Palpebræ, 364.
 Palpebral ligaments, 365.
 sinuses, 366.
 Pancreas, 475.
- Papillæ of the nail, 413.
 of the skin, 409.
 of the tongue, 397.
 calyciformes, 397.
 capitatæ, 398.
 circumvallatæ, 397.
 conicæ, 398.
 filiformes, 398.
 fungiformes, 398.
 lenticulares, 397.
- Parotid gland, 209.
 Peduncles of the cerebellum, 329.
 cerebrum, 333.
- Pelvis, viscera of, 501. 529.
 Penis, 518.
- Pericardium, 150.
 Perilymph, 392.
 Perineum, 539.
 Peritoneum, 440.
 Perspiratory ducts, 416.
- Pes accessorius, 319.
 anserinus, 213.
 hippocampi, 319.
- Peyer's glands, 455.
 Pharynx, 297.
- Pia mater, 310. 350.
 Pigmentum nigrum, 373.
 Pillars of the palate, 300.
 Pineal gland, 324.
 Pinna, 380.
- Pituitary gland, 331.
 membrane, 361.
- Pleura, 141.
- Plexus, aortic, 491.
 axillary, 93.
 brachial, 93. 247.
 cardiac, 61. 168.
 carotid, 292.
 cavernous, 292.
 cervical anterior, 245.
 posterior, 188.
 choroid, 317.
 cœliac, 490.
 coronary, 162.
 epigastric, 490.
 gangliiformis, 288.
 gastric, 491.
 hæmorrhoidal, 515.
 hepatic, 467. 491.
 hypogastric, 492.
 lumbar, 498.
 maxillary, 273. 278.
 mesenteric, 491. 492.
 œsophageal, 168.
 patellar, 29.
 pharyngeal, 288. 289. 293.
 phrenic, 491.
 prostatic, 509. 515.
 pterygoid, 269.
 pulmonary, 149. 167.
 renal, 491.
 sacral, 516.
 solar, 490.
 spermatic, 433. 492.
 splenic, 478. 491.
 submaxillary, 242.
 supra-renal, 491.
 tympanic, 388.
 uterine, 515.
 vaginal, 515.
 vertebral, 294.
 vesical, 509. 515.

- Plica semilunaris, 367.
 Plicæ, longitudinales, 452. 534.
 Pneumogastric lobule, 328.
 Polypus of the heart, 152.
 Pomum Adami, 399.
 Pons Tarini, 332.
 Varolii, 333.
 Pores, 416.
 Portal vein, 462. 467. 469.
 Portio dura, 212. 284. 342.
 Portio mollis, 342.
 Porus opticus, 370.
 Poupart's ligament, 421.
 Prepuce, 519.
 Presbyopia, 380.
 Processus e cerebello ad testes, 329.
 clavatus, 335
 vermiformes, 327, 328.
 Promontory, 387.
 Prostate gland, 509.
 Prostatic urethra, 522.
 Protuberantia annularis, 333.
 Pulmonary artery, 162.
 plexuses, 149. 167.
 sinuses, 157.
 veins, 166.
 Puncta lachrymalia, 365. 368.
 vasculosa, 314.
 Pupil, 374.
 Pylorus, 446.
 Pyramid, 328. 387.
 Pyramids, anterior, 334.
 Feirein, of, 480.
 Malpighi, of, 480.
 posterior, 335.
 Raphé, corporis callosi, 315.
 Receptaculum chyli, 176. 493.
 Rectum, 450. 504.
 Regions, abdominal, 438.
 Reil, island of, 300.
 Rete mucosam, 2. 410.
 testis, 528.
 Retina, 375.
 Ridley, sinus of, 348.
 Rima glottidis, 405.
 Ring, abdominal external, 421.
 internal, 430.
 femoral, 21. 33.
 Rivinian's ducts, 240.
 Rugæ, 452.

 Sacculus communis, 393.
 laryngis, 405.
 proprius, 393.
 Salivary glands, 209. 238, 239.
 Saphenous opening, 15.
 veins, 12. 45. 50. 576.
 Scala tympani, 392.
 vestibuli, 392.
 Scarf-skin, 2. 409.
 Schindylesis, 568. 570.
 Schneiderian membrane, 361.
 Sclerotic coat, 370.
 Scrotum, 524.
 Sebiparous glands, 415.
 Semicircular canals, 390.
 Semilunar fibro-cartilages, 602.
 valves, 156. 159.
 Septum auricularum, 152.
 crurale, 33.
 lucidum, 320.
 pectiniforme, 520.

 Septum scroti, 524.
 Sheath of the rectus, 425.
 Sigmoid flexure, 449.
 valves, 156. 159.
 Sinuses, structure, 345.
 Sinus ampullaceus, 390.
 aortic, 159.
 basilar, 348.
 cavernous, 347.
 circular, 347.
 fourth, 347.
 lateral, 347.
 longitudinal inferior, 346.
 superior, 346.
 occipital anterior, 348.
 posterior, 347.
 petrosal inferior, 348.
 superior, 348.
 pocularis, 522.
 prostatic, 522.
 pulmonary, 157.
 rectus or straight, 347.
 rhomboidalis, 325.
 spinal, 356.
 transverse, 348.
 Valsalva, of, 157. 159.
 Skin, 408.
 Socia parotidis, 210.
 Soft palate, 300.
 Spermatic canal, 431.
 cord, 431.
 Spheno-palatine ganglion, 279.
 Spinal cord, 349.
 nerves, 354.
 veins, 356.
 Spleen, 477.
 Splenium corporis callosi, 315.
 Spongy part of the urethra, 523.
 Stapes, 384.
 Stenon's duct, 210.
 Steatozoon folliculorum, 416.
 Stomach, 446, 564.
 Striæ laterales, 315.
 medullares, 343.
 Sub-arachnoidean fluid, 309. 350.
 space, 309. 350.
 tissue, 309.
 Sublingual gland, 239.
 Submaxillary gland, 238.
 Substantia perforata, 330.
 Sudoriferous ducts, 416.
 Sudoriparous glands, 416.
 Sulci of the spinal cord, 352.
 Supercilia, 364.
 Superficial fascia, 3.
 Supra-renal capsules, 478. 565.
 Suspensory ligament, liver, 464.
 penis, 519.
 Sutures, 568.
 Sympathetic system, 168. 291. 490.
 Symphysis, 569.
 Synarthrosis, 568.
 Syndesmology, 568.
 Synovia, 572.
 Synovial membrane, 572.

 Tapetum cerebri, 337.
 oculi, 373.
 Tarin, horny band of, 316.
 Tarsal cartilages, 365.
 Tarsus, 607.
 Tela choroidea, 322.

- Tendo Achilles, 61.
 oculi, 205.
 Tendon, 4.
 Tenia hippocampi, 318, 319.
 semicircularis, 316.
 Tarini, 316.
 Tentorium cerebelli, 307.
 Testes cerebri, 324.
 muliebres, 534.
 Testicles, 566.
 descent, 566.
 Thalami optici, 317. 322.
 Theca vertebralis, 349.
 Thecæ, 598.
 Thoracic duct, 176. 258.
 Thorax, 140.
 Thymus gland, 560.
 Thyro-hyoid membrane, 400.
 Thyroid axis, 251.
 Thyroid cartilage, 399.
 gland, 235.
 Tomentum cerebri, 310.
 Tongue, 396.
 Tonsils, 301.
 cerebelli, 327.
 Torcular Herophili, 346.
 Trachea, 171. 407.
 Tracheotomy, 236.
 Tractus motorius, 340.
 opticus, 339.
 spiralis, 391.
 Tragus, 380.
 Triangles of the neck, 232. 235.
 Triangular ligament, 547.
 Tricuspid valves, 155.
 Trigonum vesicæ, 508.
 Trochlearis, 219. 341.
 Tuber cinereum, 331.
 Tubercula quadrigemina, 324.
 Tuberculum Loweri, 153.
 Tubuli galactophori, 83.
 lactiferi, 83.
 seminiferi, 526.
 uriniferi, 480.
 Tunica albuginea oculi, 370.
 testis, 525.
 nervea, 452.
 Ruyschiana, 373.
 vaginalis, 525.
 vasculosa testis, 526.
 Tutamina oculi, 364.
 Tympanum, 383.
 Tyson's glands, 519.

 Umbilical region, 439.
 Urachus, 437. 565.
 Ureter, 481.
 Urethra, female, 529.
 male, 521.
 Uterus, 520. 566.
 Utriculus communis, 393.
 Uvea, 374.
 Uvula cerebelli, 328.
 palati, 300.
 vesicæ, 508.

 Vagina, 529.
 Vallecule, 327.
 Valsalva, sinuses of, 157. 159.
 Valve, arachnoid, 326.
 Bauhini, 453.
 coronary, 153.
 Eustachian, 153.
 ileo-cæcal, 453.
 mitral, 158.
 pyloric, 452.
 rectum, of the, 453.
 semilunar, 156. 159.
 Tarin, of, 328.
 tricuspid, 155.
 Vieussens, of, 325. 328.
 Valvula conniventes, 452.
 Vasa efferentia, 528.
 lactea, 83. 457.
 lymphatica, 5.
 recta, 528.
 Vasculum aberrans, 528.
 Vas deferens, 433. 528.
 VEINS:
 structure, 4.
 angular, 217.
 auricular, 202. 270.
 axillary, 93.
 azygos, 175.
 basilic, 107.
 cardiac, 160.
 cava inferior, 166. 488.
 superior, 165.
 cephalic, 107.
 cerebellar, 313.
 cerebral, 313.
 coronary, 160.
 corporis striati, 316.
 dorsalis penis, 549.
 dorsi-spinal, 355.
 emulgent, 489.
 facial, 217.
 femoral, 27.
 frontal, 202.
 Galenii, 322.
 gastric, 461.
 hepatic, 467. 471.
 iliac, 489.
 innominatæ, 165.
 intercostal superior, 175.
 jugular, anterior, 243.
 external, 243.
 internal, 255. 284.
 lumbar, 489.
 maxillary internal, 269.
 median, 105. 116.
 basilic, 105.
 cephalic, 105.
 medulli-spinal, 356.
 meningo-rachidian, 356.
 mesenteric, 457. 459.
 occipital, 202.
 ophthalmic, 227.
 ovarian, 489.
 parietal, 346.
 popliteal, 46.
 portal, 462.
 profunda femoris, 27.
 prostatic, 509. 515.
 pulmonary, 166.
 radial, 107. 115.
 renal, 489.
 salvatella, 116.
 saphenous external, 45. 57. 60.
 internal, 12. 50. 57.
 spermatic, 489.
 spinal, 356.
 splenic, 461.
 subclavian, 253.

VEINS — *continued.*

- temporal, 202. 269.
- temporo-maxillary, 269.
- Thebesii, 161.
- thyroid, 165. 256. 284.
- ulnar, 107. 116.
- uterine, 515.
- vertebral, 355.
- vesical, 515.
- Velum interpositum, 322.
- medullare, 328.
- pendulum palati, 300.
- Venæ comites, 80.
- Galenii, 313.
- vorticosa, 373.
- Ventricles of the brain :
 - fifth, 320.
 - fourth, 325.
 - lateral, 316.
 - third, 323.
 - of the corpus callosum, 315.

- Ventricles of the heart, 153. 158.
- of the larynx, 405.
- Vermiform processes, 327, 328.
- Vermis, 328.
- Vertebral aponeurosis, 184.
- Veru montanum, 522.
- Vesiculæ seminales, 510.
- Vestibule, 388.
- Vestibulum vaginæ, 538.
- Vibrissæ, 357.
- Villi, 454.
- Vitreous humour, 378.
- Vulva, 536.
- Wharton's duct, 238.
- Willis, circle of, 313.
- Wilson's muscles, 552.
- Wrisberg, nerve of, 93. 108.
- Zonula, ciliaris, 376.
- of Zinn, 376.

THE END.



LONDON :
 SPOTTISWOODES and SHAW,
 New-street-Square.

