

FENGER (C.)

---

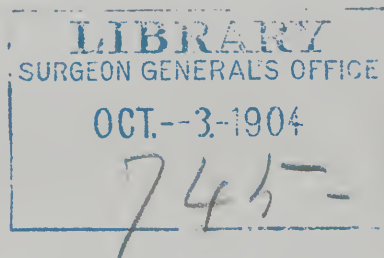
*Entero-Plastic Operation to Overcome or  
Prevent Stenosis,*

*With Especial Reference to the Spur in  
Preternatural Anus.*

BY

CHRISTIAN FENGER, M.D.,  
CHICAGO, ILL. ;

PROFESSOR OF SURGERY AND CLINICAL SURGERY, NORTHWESTERN  
UNIVERSITY MEDICAL SCHOOL.



FROM

THE AMERICAN JOURNAL OF THE MEDICAL SCIENCES,

APRIL, 1899.



ENTERO-PLASTIC OPERATION TO OVERCOME OR PREVENT  
STENOSIS, WITH ESPECIAL REFERENCE TO THE  
SPUR IN PRETERNATURAL ANUS.

BY CHRISTIAN FENGER, M.D.,  
CHICAGO, ILL.,

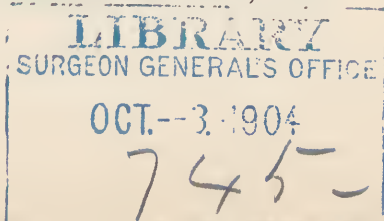
PROFESSOR OF SURGERY AND CLINICAL SURGERY, NORTHWESTERN UNIVERSITY MEDICAL SCHOOL.

THE principle of overcoming a stenosis of a canal by transverse union of a longitudinal incision, as applied by Heinecke-Mikulicz on the pylorus and by me on the ureter, is applicable in any portion of the intestinal tract below the duodenum wherever the mechanical conditions will permit.

The longitudinal incision or opening should be made in the middle of the convex surface—that is, equidistant from the two sides of the mesentery, so as not to interrupt blood-supply by the division of large vessels in the intestinal wall. Free mobility of the loops of intestine and intact peritoneal covering are desirable conditions, but the latter is not absolutely necessary. In places where the intestine has no mesentery and where there is a limit to the infolding or bringing into apposition of the convex surface or the surface of the intestine opposite the mesentery, as the cæcum, extraperitoneal border of the rectum or flexures of the colon, there is a limit to the length of the longitudinal incision. In an organ so free and movable as the small intestine, I see no reason why I could not unite the convex surface to an extent of five or six inches, or more, if this would be desirable. In fact, I see no other limit than that of the length of the mesentery, the time required for suturing, and the length of the wound. It is evident that the length of the longitudinal wound should not be unnecessarily great.

When there is no mesentery, and consequently only slight mobility, for folding in or apposition of the convex free surface of the intestine, or where the mobility is diminished or lost by diffuse inseparable adhesions, there is, of course, a limitation to the application of this principle.

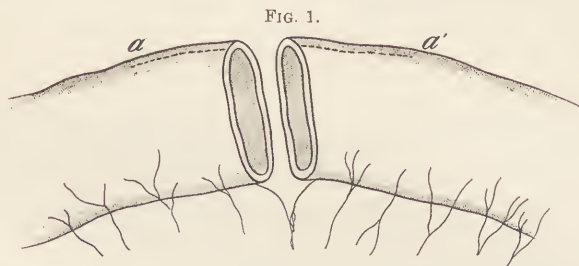
In one case of stenosis of the cæcum from tuberculosis, with remittent attacks of pain from incomplete occlusion, in which I did not deem excision of the cæcum advisable, I made this plastic operation, uniting transversely an incision of about four centimetres in length. The operation gave partial relief only, and a fecal fistula resulted, which



necessitated an ileo-colic anastomosis, which was followed by relief of the symptoms of the stenosis and left the fistula secreting mucus, as a rule, with, very rarely, some fecal matter.

Tension in the united wound and lack of free fecal passage at the place of operation are, when the sutures are applied correctly, undoubtedly the main cause of non-success—that is, of spontaneous reopening of the sutured intestine.

This plastic operation, when applied to resection and circular suture, will enable us to avoid narrowing of the intestine by folding in of its wall at the place of suture (Fig. 1). If, for the sake of additional safety,



it is deemed desirable to apply a second row of sero-muscular sutures at a distance of one-half centimetre from the first row, the advantage of having a larger amount of serous surface in contact is counterbalanced by the increase in size of the circular fold. The narrowing effect of a large fold can be overcome entirely by the plastic operation, because we can make the longitudinal division long enough to secure a circumference of any size desired.

The same principle is applicable when we wish to unite an intestine of small calibre end-to-end with one of large calibre. By longitudinal division of the smaller intestinal tube the line of union is easily made to correspond to that of the larger tube. If the lumen of the larger intestine is not deemed sufficiently wide to permit of so much folding in as is required, a longitudinal division is also here resorted to, until at last as large a line of union as we deem desirable is secured.

In artificial anus, whether this be the result of a premeditated operation or of an accident, where the mucosa of the intestine is finally united to the skin, it is commonly observed that the so-called spur forms a more or less complete obstruction to fecal passage from the proximal into the distal portion of the intestine. The spur, so to speak, leads the bowel-contents from the bowel out through the opening in the skin. The distal portion becomes small and retracted from non-use.

The spur is formed by a semicircular fold or group of folds located opposite to the opening through the abdominal wall at the place of the bend of the opened intestine. This semicircular fold may increase so

as to extend entirely around the lumen of the intestine, thus becoming a circular fold, and is then located at the end of the proximal portion of the intestine close to the opening in the skin, through which it may protrude as a prolapse of the mucosa or wall of the proximal bowel. When this spur is well developed it may form, even when the intestine is loosened from the abdominal wall, an impediment to free fecal passage that frustrates simple transverse or longitudinal suture of the intestinal opening, and consequently necessitates resection of the loop containing the spur.

As resection with subsequent circular suture is as yet an operation of some gravity, it would be an advantage to avoid resection and still overcome the stenosis and the influence of the spur with a more simple operation. That this can be done by application of the principle of the transverse union of a longitudinal wound I propose to show by the following case :

A. T., male, aged fourteen years, an American of German descent, entered the German-American Hospital, for operation, in my service, on April 2, 1898.

*Family history.* Father, mother, brothers, and two sisters living and healthy. One sister died of perityphlitic abscess. Grandparents, uncles, and aunts living and healthy, or cause of death unknown. Paternal grandfather died in old age of diphtheria. One paternal cousin had operation for appendicitis in 1894.

The patient's personal history was negative as regards disease or injury.

*Present illness.* On the evening of March 22, 1897, the patient was seized with acute pain in the abdomen below the level of the umbilicus ; the pain was generalized, very severe from the first, and of a severe aching, griping character, and was accompanied by vomiting and diarrhœa. He had elevation of temperature, but no chill until the following day. The pain lasted throughout the night, but in the morning it was not so severe and the patient walked about outdoors. At noon he had a chill and went to bed. Nausea and slight diarrhœa were present. Severe abdominal pain in the lower half of the abdomen came on at two o'clock the next morning and continued with remissions for two weeks, accompanied by daily elevation of temperature.

A physician was called on March 24th, who made a diagnosis of appendicitis. On April 5th the perityphlitic abscess was opened in narcosis. Fecal matter, with pus, escaped from around the appendix at the time of operation.

From this time until April 2, 1898, when I operated, a fecal fistula had existed, which has discharged a varying amount of feces daily. For the first eight weeks after the operation from one-fourth to one-eighth of the feces passed through the fistula and the remainder by the rectum. The rectal discharges were normal in color and occurred once daily. At the end of eight weeks the fecal discharge through the fistula decreased rapidly, so that it amounted only to a moistening of the dressings three times a day with fecal matter. About this time the wound was explored for gauze, which was supposed to have gotten into

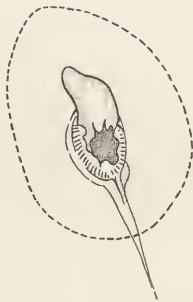
the intestine. After this exploration there was an immediate increase in the amount of fecal discharge through the fistula, which continued up to the time of operation. He has usually had about four to six evacuations daily through the fistula, varying from a drachm to three ounces, but ordinarily about one ounce. The feces were of normal color and soft, but not liquid. The amount of feces passed per rectum appears to be about the same as before the fistula was formed; the character is normal; the bowels are regular and there is no tendency to diarrhoea.

Relief from pain immediately followed the opening of the perityphlitic abscess and he has felt well ever since, with the exception of a few hours after the operation.

Operation, April 2, 1898. After the usual preparation, liquid diet and irrigation of the bowels through the fistula in another room, without using a rubber tube to push the spur back or down, he was brought to the operating-room. When he was put upon the table feces welled out. There were present at the operation the doctors from the Polyclinic. Drs. Haiselden and Buford assisted, and Dr. Gottschalk administered the ether.

The fistula was located in the right inguinal region, an inch to an inch and a half from Poupart's ligament, or from the anterior superior spine of the ilium. The opening was six centimetres in circumference, two centimetres in diameter, and would admit the little finger. The mucosa of the intestine was united to the skin, that is, the fistula was labiate. The mucosa bled when the finger was introduced. A tongue-shaped flap of mucosa, one centimetre square, protrudes when he strains. It comes out of the upper, outer corner of the fistula, and can be easily replaced. The fistula is surrounded by excoriated skin for an inch or more (Fig. 2).

FIG. 2.



Prolapse of tongue-shaped mucosa. Opening passable for the little finger. Dotted line indicates incision for cutaneous flap.

The fistula was now circumcised, one centimetre and a half from its border, through the skin, subcutaneous tissue, and abdominal muscles, down to the transversalis fascia (Fig. 2). This circular flap, like a collar, was loosened and closed tightly by a continuous silk suture so that none of the intestinal contents could pass out.

The abdomen was then disinfected and clean covers put on the table and the patient.

I now opened the peritoneal cavity one inch medial to and above the fistula, using great care to avoid adherent intestine. The omentum met with at first was ligated in portions. The isolation of the loop

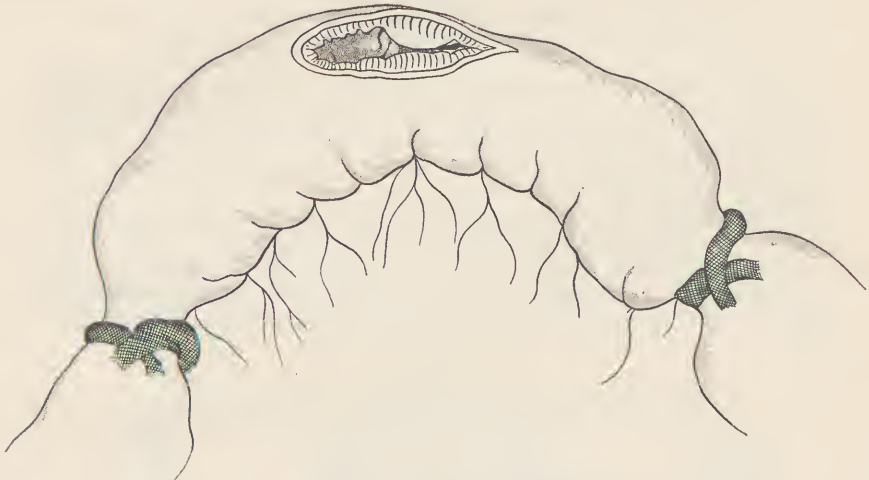with the fistula was relatively easy. It was found to be a loop of small intestine, and was surrounded by gauze sponges, freed from adherent omentum and held aside out of the abdominal wound while search was being made for the cæcum and appendix. The wound was packed with several sponges, the parietal peritoneum united to the skin, the branches of the inferior epigastric artery ligated, and the incision prolonged up and down in the sheath of the rectus muscle.

The cæcum was found to be free from adhesions and the appendix was adherent to the cæcum. The end of the appendix was dilated, fluctuating, and contained a fecal concretion.

The appendix was amputated and the stump buried under a musculo-serous circular flap.

I now proceeded to operate on the fecal fistula, which was found to be located two feet above the cæcum. The loop of the ileum containing

FIG. 3.



Proximal end of gut incised through prolapsed mucosa ; spur seen on mesenteric side, within gut.

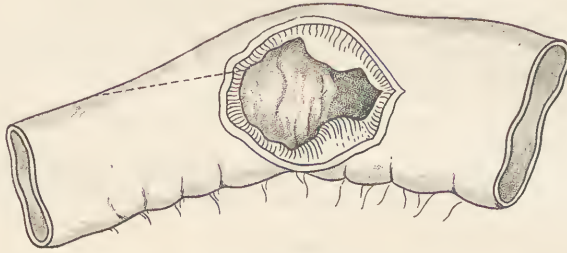
the fistula was pulled well out of the wound and surrounded by gauze. The loop was emptied and ligated by means of gauze strips, two to three inches on each side of the fistula (Fig. 3). The adherent omentum was dissected off from the intestine, which necessitated only a few ligatures. The abdominal-wall flap was then cut off from the border of the fistula.

The fistula appeared as a round or oval opening one-half to an inch in diameter on the convex surface of the ileum, half to three-quarters of an inch from the mesenteric border on each side (Fig. 3). The tongue-shaped flap of mucosa was found to be part of a circular fold hanging down from the proximal border of the fistula, continuous with the spur, and forming with this a circular prolapsed and invaginated valve or flap.

It was evident that a simple union of the fistulous opening either in a transverse or longitudinal direction would not do away with the stenosis caused by this ring-shaped valve of the mucosa, and conse-

quently would not remove the impediment to the passage of feces at this point, because this ring of mucosa would protrude into the lumen of the intestine and perhaps be the beginning of an invagination, or would at times at least impede fecal circulation.

FIG. 4.



Wound in ileum held out, showing spur, viz.: A counter fold or group of folds of mucosa. Line of incision 1 inch down into distal (smaller) portion of ileum.

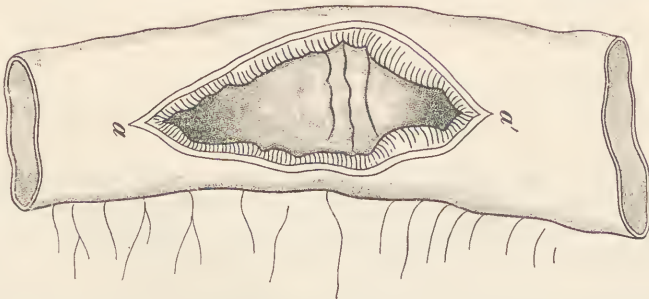
I believe that the spur or circular valve, by causing a disturbance of fecal circulation, is the cause of the common failure of permanent closure of the fistula following simple suturing of the intestinal opening.

The fistula reappears in a week or two and reopens because of the spur which remains.

I therefore decided to overcome the effect of the spur by the following plastic operation on the intestine:

1. A longitudinal incision at the convex border of the intestine one inch in length in the proximal end of the intestine through the tongue-shaped valve, up into the normal intestinal wall above it (Fig. 3).

FIG. 5.



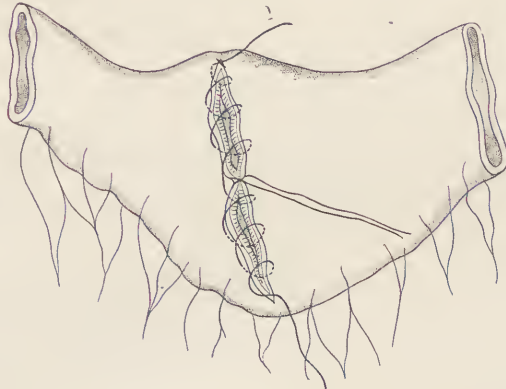
The whole of incision, viz.: the longitudinal wound in the ileum at middle of convex (opposite to mesentery) border. 1 inch up, 1 inch down; width of fistula  $\frac{1}{2}$  inch =  $2\frac{1}{2}$  inch. *a* lower and *a'* upper corner to be united by a guide suture left long.

2. A longitudinal incision, one inch long, into the distal or narrower portion of the intestine below the spur, thus making a longitudinal wound two inches in length on the convex border of the intestine (Fig. 4). As the original fistulous opening was two centimetres in diameter, the wound would be about three inches in total length. Upon making the incision at the upper end of the wound I saw a Peyer's patch.



The spur formed a circular valve of two or three parallel folds of mucosa, half an inch broad, most pronounced on the mesenteric side, extending around the entire circumference of the intestine, but smaller on the convex border (Fig. 5).

FIG. 6.



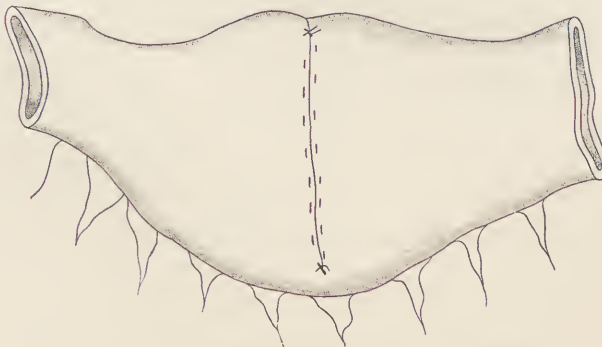
Continuous suture. Lies through whole thickness of wall, aided by the guide suture.

3. Transverse union of this longitudinal wound (Fig. 6).

*a.* Suture *a-a'* (Fig. 5) united the upper and lower corners and was left long for traction, dividing the wound into two transverse halves with the suture in the middle.

*b.* A continuous silk suture through all the layers of the intestine (Fig. 6).

FIG. 7.



Sero-muscularis continuous suture to bury the preceding suture.

*c.* A continuous serosa-muscularis suture, one centimetre outside of the former.

*d.* A second continuous serosa-muscularis suture to bury the former (Fig. 7).

4. Disinfection of the sutured loop with 1 : 1000 sublimate solution, and removal of the gauze ligatures around the loop of intestine.

5. Removal of the sponges and examination of the abdomen for hemorrhage.

6. Step sutures of the abdominal wall.

7. Gauze drain down to the appendix and over to the sutured loop of the ileum.

8. Injection of two quarts of physiological saline solution into the rectum.

The operation lasted three hours and a half. At its close the patient's pulse was good; no shock.

7.30 P.M. Gaseous distention of the abdomen. A little gas escaped after insertion of the rectal tube.

*April 3d.* Patient had a small dark-green and very thin bowel movement. Throughout the day he had considerable trouble on account of gaseous distention, for which injections of warm water and peppermint were made, but little gas passed. Temperature  $97.4^{\circ}$  to  $100.2^{\circ}$ . Pulse 120 to 130.

*4th.* A small amount of gas passed after injection of peppermint water. During the day he vomited several times, dressings were changed, half an ounce of bloody fluid, with some bright yellow pus, followed the removal of the packing. A drainage-tube was introduced. Temperature  $98.4^{\circ}$  to  $100^{\circ}$ . Pulse 100 to 108. During the day he had two small bowel movements.

*5th.* He passed considerable gas and had two dark green, thin bowel movements. Temperature,  $99.2^{\circ}$ . Pulse, 90.

*6th.* Slept well last night. Temperature  $99.6^{\circ}$ . Pulse 76. The drainage-tube was removed, half an inch cut off, and reinserted. Dressings were dry.

*7th.* Temperature  $99.6^{\circ}$ . Pulse 66. A large bowel movement followed the use of enemata.

*8th.* Temperature  $99.4^{\circ}$ . Pulse 56. Tube removed.

*11th.* Temperature  $98.4^{\circ}$ . Pulse 68. He has no pain. Eats and sleeps well.

*24th.* Only a granulating surface remains. The function of the bowels is normal.

*October.* Patient remains well.



# The Medical News.

Edited by J. RIDDLE GOFFE, M. D.

PUBLISHED WEEKLY, AT \$4.00 PER ANNUM.

THE practitioner who would give his patients the benefit of the latest and best knowledge, and thus most certainly ensure his own success, cannot afford to neglect the medical weeklies. Foremost among them, as well as cheapest, stands THE MEDICAL NEWS. Its 32 quarto pages of reading matter provide space each week to lay before its readers the latest advances in medicine, surgery, obstetrics, and the various specialties. This vast range of information is gathered from the whole civilized world by the perfect organization of THE NEWS. Its reputation brings to it the contributions of recognized leaders of medical thought and practice. It is a marvel of modern times that the immense body of the world's advancing knowledge in medicine can be laid each week upon the table of the subscriber at the comparatively trivial price of \$4 per annum. The secret of course lies in a circulation embracing the most progressive men in the United States and Canada as well as in many foreign countries.

# The American Journal of the Medical Sciences.

Edited by ALFRED STENGEL, M. D.

PUBLISHED MONTHLY, AT \$4.00 PER ANNUM.

BEING the medium chosen by the best minds of the profession during seventy-nine years for the presentation of their elaborate papers, THE AMERICAN JOURNAL has well earned the praise accorded it by an unquestioned authority—"from this file alone, were all other publications of the press for the last fifty years destroyed, it would be possible to reproduce the great majority of the real contributions of the world to medical science during that period." Original Articles, Reviews and Progress, the three main departments into which the contents of THE JOURNAL are divided, will be found to possess still greater interest than in the past. The brightest talent on both sides of the Atlantic is enlisted in its behalf, and no effort will be spared to make THE JOURNAL more than ever worthy of its position as the most useful and valuable of medical magazines.

# Progressive Medicine.

A Quarterly Digest of New Methods, Discoveries and Improvements in the Medical and Surgical Sciences.

Edited by HOBART AMORY HARE, M. D.

\$10.00 PER ANNUM.

"PROGRESSIVE MEDICINE" will be modelled upon an entirely novel plan and will present in an original, narrative form a clear statement of the practical advance made in every department of medicine and surgery during the year, each specialty being dealt with by a single authority whose reputation gives ample assurance of accuracy and completeness. The personal impress of the contributor will be upon each subject; his thoroughly digested narrative will present its data in due and instructive connection, enchaining the interest, economizing time, yet giving ample and detailed consideration to all matters which will prove of real value in actual practice.

Four volumes will be issued each year, the first appearing on March 1st, 1899, and the others following at intervals of three months. Each will contain from four to five hundred octavo pages, abundantly illustrated and handsomely bound in cloth.

Expecting appreciation of the self-evident utility of such a work to all practitioners, the publishers confidently anticipate a circulation so general as to justify the very moderate subscription price of ten dollars for the four volumes. All expenses of delivery will be prepaid.

## THE FOLLOWING FAVORABLE COMBINATION RATES ARE AVAILABLE.

	Alone	In Combination	
American Journal of the Medical Sciences.....	\$ 4.00	\$7.50	\$15.00
Medical News.....	4.00		
Progressive Medicine .....	10.00	\$15.75	\$16.00
Medical News Visiting List.....	1.25		
Medical News Formulary.....	1.50, net.		

In all \$20.75 for \$16.00

"Progressive Medicine," with the "American Journal" or "Medical News," will be supplied at \$13.00, or the "American Journal," "Medical News," "Visiting List" and "Formulary" at \$8.50.

LEA BROTHERS & CO., Publishers, { 706, 708 & 710 Sansom St., Philadelphia.  
111 Fifth Ave., New York.