

869

Mitchell, S.W. & Spiller,  
W.G.

LIBRARY  
SURGEON GENERAL'S OFFICE  
DEC 16 1911

*A Case of Erythromelalgia,*

*With Microscopical Examination of the Tissue from an  
Amputated Toe.*

BY

S. WEIR MITCHELL, M.D., LL.D.,

MEMBER OF THE NATIONAL ACADEMY OF SCIENCES; HONORARY FELLOW OF THE  
ROYAL MEDICO-CHIRURGICAL SOCIETY OF LONDON;

AND

WILLIAM G. SPILLER, M.D.,

PROFESSOR OF DISEASES OF THE NERVOUS SYSTEM IN THE PHILADELPHIA POLY-  
CLINIC; ASSOCIATE IN THE WILLIAM PEPPER LABORATORY OF CLINICAL  
MEDICINE, UNIVERSITY OF PENNSYLVANIA.

*(From the William Pepper Laboratory of Clinical Medicine,  
University of Pennsylvania.)*

FROM

THE AMERICAN JOURNAL OF THE MEDICAL SCIENCES,

JANUARY, 1899.



A CASE OF ERYTHROMELALGIA,

WITH MICROSCOPICAL EXAMINATION OF THE TISSUE FROM AN  
AMPUTATED TOE.<sup>1</sup>

BY S. WEIR MITCHELL, M.D., LL.D.,

MEMBER OF THE NATIONAL ACADEMY OF SCIENCES; HONORARY FELLOW OF THE ROYAL  
MEDICO-CHIRURGICAL SOCIETY OF LONDON;

AND

WILLIAM G. SPILLER, M.D.,

PROFESSOR OF DISEASES OF THE NERVOUS SYSTEM IN THE PHILADELPHIA POLYCLINIC; ASSOCIATE  
IN THE WILLIAM PEPPER LABORATORY OF CLINICAL MEDICINE, UNIVERSITY  
OF PENNSYLVANIA.

*(From the William Pepper Laboratory of Clinical Medicine, University  
of Pennsylvania.)*

---

It is known to neurologists that in 1872, and again later, one of the authors of this paper described cases of red neuralgia, and spoke of it as an unrecognized disease. Since then he has reported many cases. In this country the diagnosis has been disputed or the disease has been confused with Raynaud's malady. In the text-books it has frequently been hopelessly misunderstood. In France, however, a treatise (Lau-  
nois) was published upon it at an early date, and in England and, of late, in Germany it is fully accepted as a distinct malady by certain writers. It is now too well known to make a detailed description necessary. In its purity of type it must be seen in the younger adult. In older persons there are variations such as our present patient offers. In young cases there may be no pain and no flush when the limb is in a horizontal position, but the arteries throb, the temperature rises, and the redness becomes intense when the foot is pendent. In old cases and older people the temperature obeys the normal law and falls when the foot is down, and the flush and pain are less surely absent from the elevated foot. The tenderness, also, in these aberrant types is not so very much increased by pendency as is the case when the disease is more recent.

J. C., a merchant, married, aged sixty-one years, has had neither syphilis nor gonorrhœa. He is said to have had typhoid fever at the age of twenty, again in 1863, and once more in 1865. In June, 1863, he was in the army, was captured, and spent ten months in Libby prison. In August, 1864, he had a sunstroke, was unconscious eight hours, and has remained sensitive to the heat of the sun since that time.

<sup>1</sup> Read at the twenty-fourth annual meeting of the American Neurological Association, held in New York, May 26, 27, and 28, 1898.

He had fair health until 1897. In July of that year he began to have limited areas of savage pain in the right foot, with tenderness and intense flush when the limb hung down or was used. The disturbances were noted in various parts of the sole and toes, lasting for months in certain localities, and always with extensive flushes.

While the fourth and fifth toes were thus disordered, a small, deep, painful ulcer came on the outside of the fourth toe and healed slowly. After three months these toes seemed to be nearly well, and the second and third toes were furiously attacked. As, in turn, these parts improved, the great toe was similarly seized with violent pain, and has remained in this state, the former seats of disease having lost all active pain and nearly all tenderness. Cold relieved the pain, but heat made it worse. To raise the foot above a level eased the pain; to let the foot hang down made the pain worse; to stand or walk made it unendurable.

Dr. William A. Dickey, of Tiffin, Ohio, recognized the disorder and brought Mr. C. to consult one of us (Dr. Mitchell). He was examined by Dr. J. K. Mitchell, whose notes are used with those of Dr. Harrison, the resident at the Infirmary for Nervous Diseases.

The great toe was slightly red, but not swollen. More or less pain was felt at all times, and of late the pain was worse during the day. Handling, pressure, heat, pendency, walking, increased the pain enormously, and with it the redness. He was using morphine freely, but slept very little. He was very nervous, and feared to be touched anywhere on the painful foot. He did not seem to have any real discomfort from pressure except in the great toe.

The heart was very feeble. A faint rhythmic murmur was heard at the apex. The heart-beat was so feeble as to make the results of the study doubtful. The arteries were soft, and no excess of tension was noted. A slight arcus senilis was observed. The urine was negative.

The affected limb was strong and not wasted, and no tenderness was found over the trunks of the nerves. The right knee-jerk was ++, and successive hammer blows caused frequent repetition of response. The left knee-jerk was +, but no ankle clonus was obtained. The ankle-jerks were excessive. Urination and defecation were normal.

The patient could localize touch, could feel pain when stuck with a pin, and could distinguish extremes of temperature in all parts, even in the painful foot. It was impossible to examine him with the compasses, on account of the pain caused by the attempt. No disturbance of sensation for touch and pain could be found in the buttocks, perineum, external genitalia, and thighs. The pain experienced by the patient was intense, and many remedies had been tried in vain. The disease seemed to be limited to the great toe. The whole right foot appeared to be somewhat larger than the left, and the instep arch was less well formed. In the great toe alone all the symptom-peculiarities found in an advanced case and in a patient past middle age were observed. A small ulcer was present beneath the toe-nail of the great toe. The diagnosis was clear.

Little benefit has been obtained in cases of this disease until one of us (Dr. Mitchell) cured radically a case in a young man by stretching the posterior tibial nerve and cutting the musculo-cutaneous and the fillets of the external saphenous nerve. The result was a complete cure and permanent freedom from pain.

In the next case presenting itself an operation was decided on with entire confidence.

The patient was forty-two years old, and a man of good and active habits. Drs. Morris J. Lewis, J. K. Mitchell, and S. Weir Mitchell examined the man with unusual care, and found no reason to suspect organic disease. The details of this report have been given elsewhere.<sup>1</sup> Both of these cases were of traumatic origin. The operation in the second case was precisely like that in the successful one, but it resulted in gangrene. The patient was removed by his friends to a homœopathic hospital, and died there on the table while undergoing amputation. No satisfaction was given as to the pathological condition, but it was learned that the walls of the small arteries were much thickened. No information was obtained concerning the nerve-ends. The portions of the nerve-trunks removed by Dr. Morton, who operated, were in perfect health. No indications of truncal neuritis were observed.

The patient J. C. had this peculiarity: the circulation in the left leg was good, but in the right leg below the groin neither Dr. Morton nor Dr. Weir Mitchell could feel an arterial pulse. Dr. John K. Mitchell, while taking the notes, felt the beat of the posterior tibial artery, and tested it as compared with the ulnar pulse. The vessel certainly could not be normal, and this conclusion, drawn from clinical observation, has been fully confirmed by the high degree of arterio-sclerosis found at the microscopical examination. This condition of the arteries, with the fate of the patient just mentioned, rendered unwise a stretching of nerves which innervated a territory larger than that occupied at the time by the disease. It was resolved to amputate the toe and half of the metatarsal bone; this was done on April 3, 1898, by Dr. T. G. Morton, without tourniquet or rubber bandage. The arteries jetted freely. The wound was closed as usual.

Mr. C. complained next day of pain in the wound, but this gradually lessened. On April 8th the lower fourth of the wound opened with a slough half an inch long, but not deep. The dead part came away very slowly, and the wound healed tardily.

Ever since the operation he has complained at times of having some pain in the ball of the foot, and has certainly some reddening of the toes, with pain. He thinks the pain is "different," and that he is better. We are not so very sanguine as to his future freedom from pain, and the caution which limited the operative procedure was wise.

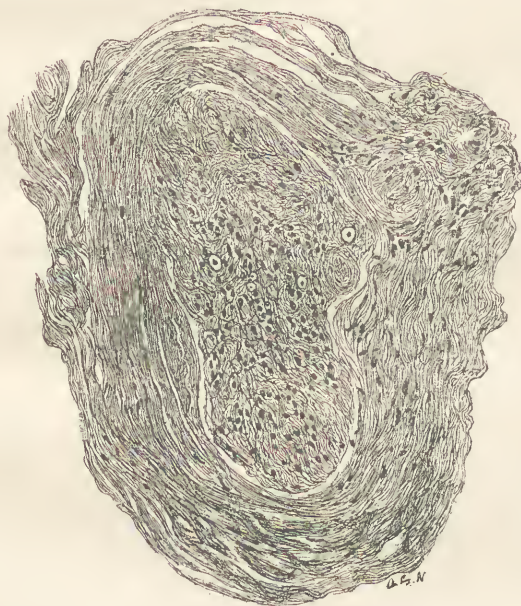
The report of this case has been given briefly, because the subject of operation has been discussed in the *Clinical Lessons*, and because Dr. Dickey will report the case more fully after some months have elapsed.

The findings in this case are of the most interesting character. The nerves of the great toe are intensely degenerated. Teased and stained in the fresh state with osmic acid, or stained with osmic acid and cut with the microtome, they show scarcely any nerve fibres; so few, indeed, that we hardly dared believe the findings could be correct until we had confirmed our observations by sections of nerve fibres hardened

<sup>1</sup> Mitchell. *Clinical Lessons on Nervous Diseases*.

in formalin and stained by Weigert's hæmatoxylin method. The nerve bundles are composed almost entirely of connective tissue; here and there in a longitudinal section one, two, or three fibres stand out distinctly from the light background of connective tissue, but even these nerve fibres exhibit irregular segmentation of the myelin. In transverse sections hardly more than three or four nerve fibres, with axis cylinders and medullary sheaths, may be seen in a nerve bundle, and in some bundles no nerve fibres at all are found. The connective tissue about these bundles is much thickened. The smallest fasciculi are entirely degenerated. This cannot be due to faulty technique, for the

FIG. 1.




Transverse section of a nerve bundle from the great toe. The connective-tissue sheath is thickened and the nerve fibres are almost entirely degenerated; only four or five normal nerve fibres are seen.

results obtained by osmic acid are the same as those obtained by Weigert's hæmatoxylin stain, and in using the latter method care has been taken to avoid too great decolorization. We have not been willing to depend on Pal's modification of Weigert's stain, as nerve fibres by the former method are frequently too much decolorized.

The vessels are no less interesting than the nerves. The media in the vessels of quite good size is thickened and the intima is intensely proliferated, so much so that it projects into the lumen of the vessels in great (microscopically speaking) masses of unequal size, and in some places nearly closes the lumen. In some of the smallest vessels also

the lumen is almost obliterated by the proliferated intima. In one vessel, the largest we could find, the fenestrated membrane is hypertrophied to several times its normal size and presents a hyaline appearance; in another section this membrane appears to be multiplied. In one place the overgrown intima projects into the vessel almost like a tumor, still attached only at one end. In another the lumen of the

FIG. 2.



Section from an artery of the great toe. The media is much thickened. The elastic membrane is wider than in normal arteries and shows hyaline degeneration.

vessel seems to be enlarged at the expense of one side of the vessel's walls, as though an attempt had been made to restore the normal space by lateral enlargement. In some portions of one vessel the media is much more thickened than the intima. The walls of the veins are also thickened.

The bones of the great toe are larger than those in a normal adult skeleton. Our attention has been directed to this, inasmuch as Staub<sup>1</sup> was able to observe in erythromelalgia acute, very painful swelling of the phalanges, and of the ends of the bones in the affected parts, and

<sup>1</sup> Staub. Monatshefte für praktische Dermatologie, 1894, vol. xix. p. 10.

after the acute stage had passed the enlargement of the bones was less noticeable, but still perceptible.

Lewin and Benda in 1894 collected all the cases of erythromelalgia they could find in the literature, numbering about forty-one; but none of these, as far as we can judge from the abstracts given by these writers, were with microscopical examination of tissue. From a study of these cases Lewin and Benda<sup>1</sup> concluded that the symptom-complex known as erythromelalgia is not a disease *sui generis*, but occurs with various cerebral and spinal maladies, in neurasthenia and hysteria, as

FIG. 3.



Longitudinal section of nerve bundles from the great toe. The nerve fibres are entirely degenerated, with the exception of the very few which are stained a deep black.

a manifestation of neuralgia or neuritis, or as a reflex disease. Most authors, they say, regard it as a vasomotor neurosis, but this seems to us to be a very insufficient explanation. We have directed our attention to the literature which has appeared since the date of this paper.

Heimann<sup>2</sup> reported two cases in which the disease was limited to

<sup>1</sup> Lewin and Benda. *Berliner klin. Wochenschrift*, 1894.

<sup>2</sup> Heimann. *Ibid.*, 1896, p 1135.



the distribution of the radial nerve. He believed that the cause was a vasomotor neuritis. No examination of tissue was made. The etiology of one case was alcoholism, exposure to cold, and hard manual labor; in the second case influenza may have played a rôle.

Eulenburg<sup>1</sup> regards erythromelalgia as a symptom-complex probably due to central disease, and not as an independent affection. The central origin does not exclude a simultaneous involvement of the peripheral nerves. The lesion is probably chiefly in the posterior and lateral portions of the spinal cinerea.

Bernhardt<sup>2</sup> speaks of the resemblance of erythromelalgia to acroparæsthesia. Paresthesia is common to both, but in the former the skin becomes red, and often swelling of the affected part is noted; the local temperature is elevated, and hyperidrosis and local bleeding are not rare. At times gastro-intestinal disturbance, migraine, ataxia, unconsciousness, organic ocular diseases, or muscular atrophies are observed, and the disease is more common in men. It differs very considerably, therefore, from acroparæsthesia.

Rost,<sup>3</sup> in presenting a case of erythromelalgia in the *Verein für innere Medicin in Berlin*, March 7, 1898, remarked that the disease is exceedingly rare, and that it has only received general recognition in Germany within the last few years, although it was described by Weir Mitchell in 1872. When Gerhardt, Senator, and Bernhardt each presented a case in 1892 at a meeting in Berlin, the subject attracted much attention. Rost is rather inclined to regard erythromelalgia as a *morbis sui generis*, although he had no microscopical findings to report.

Clinical cases of erythromelalgia have been reported since the publication of the paper by Lewin and Benda, by Nieden,<sup>4</sup> Staub,<sup>5</sup> Lévi<sup>6</sup> (one of whose cases was due to hysteria), Fischer,<sup>7</sup> Schenk,<sup>8</sup> Pezzoli,<sup>9</sup> Weir Mitchell,<sup>10</sup> Elsner,<sup>11</sup> Finger,<sup>12</sup> Pospeloff<sup>13</sup> (with syringomyelia), and Prentiss.<sup>14</sup> Other cases, references to which are given in the *Index Medicus* from 1894 to 1898, but which are not accessible to us in the

<sup>1</sup> Eulenburg. Deutsche med. Wochenschrift, 1893, p. 1325.

<sup>2</sup> Bernhardt. Die Erkrankungen der peripheren Nerven, Nothnagel's System, vol. xi., Part II., p. 446.

<sup>3</sup> Rost. Deutsche med. Wochenschrift, 1898, No. 13.

<sup>4</sup> Nieden. Archiv für Augenheilkunde, 1894, vol. xxviii.

<sup>5</sup> Staub. Monatshefte für praktische Dermatologie, 1894, vi. ix.

<sup>6</sup> Lévi. Archives de Neurologie, 1895, vol. xxix. p. 168. La Presse Méd., Sept. 15. 1897.

<sup>7</sup> Fischer. St. Petersburger med. Wochenschrift, 1895, p. 70.

<sup>8</sup> Schenk. Wiener medizinische Presse, 1896, No. 45, p. 1401.

<sup>9</sup> Pezzoli. Wiener klinische Wochenschrift, 1896, No. 53.

<sup>10</sup> Weir Mitchell. Clinical Lessons on Nervous Diseases.

<sup>11</sup> Elsner. Neurologisches Centralblatt, 1897, p. 1024.

<sup>12</sup> Finger. Annales de Dermatologie et de Syphiligraphie, 1897, third series, vol. viii. p. 91.

<sup>13</sup> Pospeloff. Idem. p. 922.

<sup>14</sup> Prentiss. A paper read before the Association of American Physicians, May 4, 1897.

original form, have been reported by Dünge, Bignone, Nolen, Christiani, Pajor, De Sanctis, and Vannini. It is likely that we have been unable to find all the cases reported, but the number as given is quite large.

Of considerable interest is the case reported by Dehio, inasmuch as a portion of the trunk of the ulnar nerve was examined. Dehio states that the hyperæmia, hyperidrosis, trophic disturbances of the skin, and the pain in the left hand of his patient suffering from erythromelalgia might have been due to peripheral disease of the nerves, but he is not inclined to accept the theory that only the most peripheral parts of the nerves of the hand were affected. If the symptoms were due to neuritis, muscular atrophy and reaction of degeneration should have been found, but were not. Muscular atrophy, however, was not observed in the great toe of our patient. He believes that the disease must have had its origin in the centres from which the nerves of the hand arise. A piece of the ulnar nerve 4 cm. long, and a piece of the ulnar artery of the same length, were excised, but not the slightest pathological change could be found in the nerve when this was examined microscopically. The adventitia and media of the ulnar artery were normal, but the elastic membrane formed a hyaline band, and the intima was thickened, reducing the lumen of the vessel to about half its normal size. These findings in the vessel are not unlike those in our case.

Dehio<sup>2</sup> thinks that erythromelalgia is the effect of abnormal irritation of the nervous system, and that the lesion is located in the posterior and lateral horns of the cord. It may be just as well to add that neither the most peripheral portions of the nerves nor the central nervous system were examined in Dehio's case.

About a year after the excision of a portion of the artery and nerve had been made above the wrist, Dehio's patient is said to have scarcely complained of pain at all, and to have been able to use the hand for light work. This result, it seems to us, could hardly have been attained if the symptoms had been due to disease of the posterior roots, and it seems to render the theory of a peripheral neuritis possible.

The case, with necropsy, reported by Auerbach<sup>3</sup> is certainly the most important in the literature of erythromelalgia since the disease was first described. Auerbach reports briefly two cases which he considers like the case reported by Dehio. He says they were due to arterio-sclerosis and should be separated from the nervous affection known as erythromelalgia, whether the latter is central or peripheral, organic or functional. In the very condensed report of these two cases we find no

<sup>1</sup> Dehio. *Berliner klin. Wochenschrift*, 1896, No. 37, p. 817.

<sup>2</sup> References to other cases may be found in the *Index Medicus* for 1898.

<sup>3</sup> Auerbach. *Deutsche Zeitschrift für Nervenheilkunde*, vol. xi. p. 142.

mention of a microscopical examination and no statement concerning the condition of the nerves.

In a case in which the lower limbs were involved, reported very fully by him, a suspicion of tabes arose. The microscopical study was made by Edinger. The nerves of the lower limbs were perfectly normal, even in the feet, but we cannot be perfectly sure from the text that the most peripheral parts of these nerves were examined, although it is presumable that they were. The media and intima of the vessels were somewhat thickened, but not excessively so. The upper sacral and lower lumbar posterior roots were much degenerated, but the roots above these were intact. The nerve roots supplying the affected parts were the only ones diseased.

Auerbach acknowledges that the posterior roots are frequently degenerated without causing the symptoms of erythromelalgia, and he thinks that in his case vasomotor fibres were involved which, since the investigations of Goltz, are known to be present in the posterior roots. More recently, he says, the studies of Gaule have shown that a portion of the trophic vasomotor apparatus is contained in the spinal ganglia or the sympathetic fibres passing to them. Other cases of erythromelalgia in which tabetic symptoms were present have been reported clinically. Auerbach says that Edinger informed him that one of his (Edinger's) patients recovering from a severe multiple neuritis presented deep redness of both legs and feet after they had been hanging motionless a few seconds. This is a very important statement in connection with our findings.

Auerbach justly says his case gives rise to the question: What must the nature of the disease of the roots be to produce erythromelalgia? This question he does not attempt to answer.

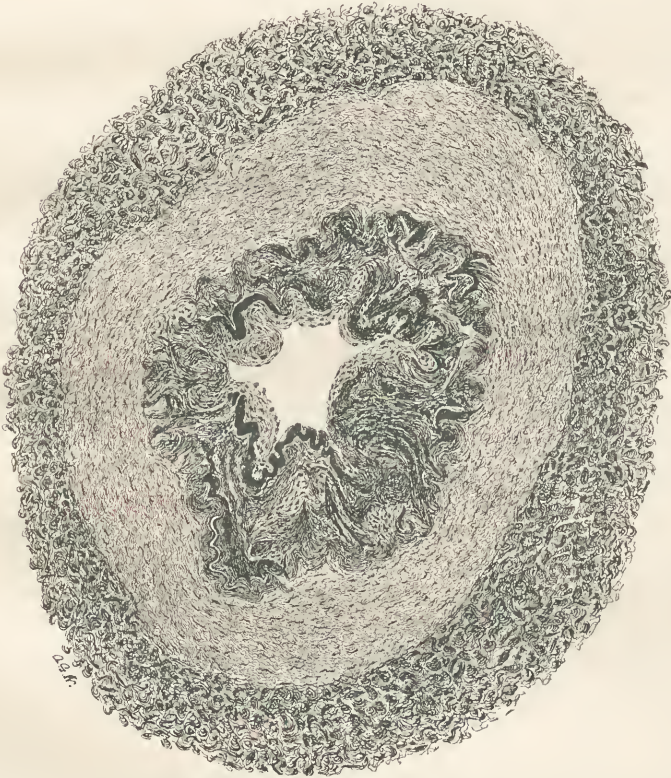Thoma<sup>1</sup> examined the vessels in a case of supra-orbital neuralgia, and found that the larger and smaller arterial branches from the supra-orbital region presented marked evidence of arterio-sclerosis, and that this sclerosis was much greater on the side where the neuralgia had existed. General arterio-sclerosis is usually attended by pain in different parts of the body. It is possible, therefore, according to Thoma, that the greater degree of the arterio-sclerosis in the supra-orbital region of the side on which the neuralgia had existed was the cause of the neuralgia, but it is just as probable that the neuralgia was the cause of the greater degree of arterio-sclerosis in the affected region. The vasomotor disturbances which accompany neuralgia cause a periodic change in the lumen of the vessels and the rapidity of the current of blood, and in course of time lead to localized endarteritis.

Thoma was not able to observe any difference in the nerves and

<sup>1</sup> Thoma. *Deutsches Archiv für klinische Medicin*, 1888, xliii. p. 409.

veins of the two supra-orbital regions. He mentions that attacks of supra-orbital neuralgia are accompanied by distinct hyperæmia of the painful region, and that this hyperæmia is due to the action of the vasomotor nerves. He has shown that when the lumen of an artery is too great for the amount of blood flowing through it, a compensatory connective-tissue thickening of the intima takes place, and the proper relations are restored. This may readily be seen in the stump after an

FIG. 4.



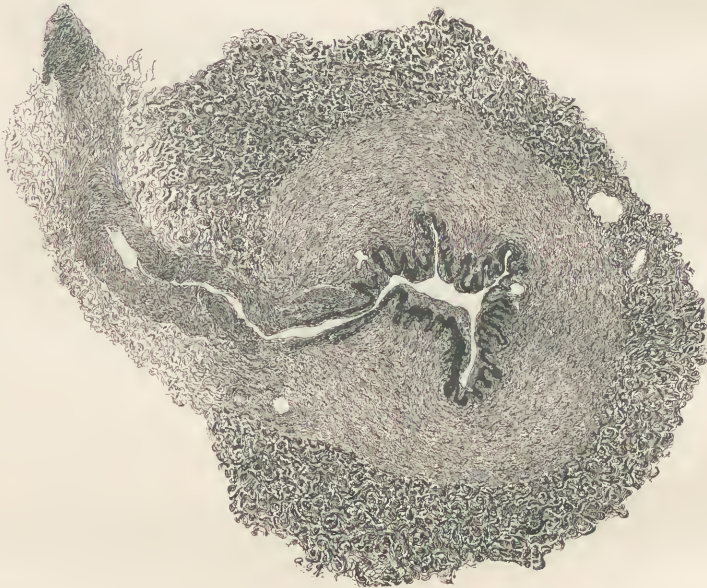
Section from an artery of the great toe. The intima is much thickened. The dark, wavy bands are probably reduplications of the elastic membrane.

amputation. The vessels, too large in the changed conditions, present contraction and concentric atrophy of the walls, or fibrous endarteritis, or both, and in this way the proper relations of artery and blood-current are restored. The less the contraction of the arterial wall, the greater the proliferation of the intima. This is a most ingenious explanation of the vascular alteration seen in cases of tic douloureux, and is applicable to the case of erythromelalgia reported in our paper.

We are, therefore, unable to say whether the arterio-sclerosis or the neuritis of the toe was the primary lesion, as it is exceedingly probable that such disease of the vessels causes malnutrition and degeneration of nerve fibres. On the other hand, Thoma's investigations seem to show that the neuritis may occur first, and cause the proliferation of the walls of the vessels. Bervoets found arterio-sclerosis in areas in which he had cut nerve fibres (cited by Dehio).

The case of interstitial hypertrophic and progressive neuritis of childhood published by Dejerine and Sottas<sup>1</sup> affords some similarity pathologically to this case of erythromelalgia. Through the kindness of these authors we have been able to examine sections from the peripheral

FIG. 5.



Section of an artery from the great toe. The media is thickened, and a new lumen seems to have been formed at the expense of the walls of the vessel.

nerves of their patient, and we find a nearly equal degeneration of nerve fibres in the two cases, and yet clinically the two diseases are very different. Dejerine and Sottas regarded the neuritis observed by them as ascending.

We shall not venture to express a positive opinion in regard to the primary seat of lesion in this case of erythromelalgia. Many investigations have shown that alteration of the cell-body occurs after periph-

<sup>1</sup> Dejerine and Sottas. *Mém. de la Soc. de Biologie*, 1893. Dejerine. *Revue de Médecine*, November, 1896.

eral lesion of the neuron, and Schaffer<sup>1</sup> recently has reversed this order. According to him, the changes in the peripheral portion of the motor neuron in tabes are secondary to a "partial degeneration," as he calls it, of the cell-body. The exaggerated knee-jerks in the present case would indicate that the roots of the mid-lumbar region of the cord were not degenerated.

The views held by one of us (Dr. Mitchell) for many years concerning the pathology of erythromelalgia seem to be justified by recent observations. So far as we are able to ascertain from the literature examined, the only distinctly pathological findings in this disease which could be considered in a causal relation are those of Auerbach and those which we now report. Dr. Mitchell<sup>2</sup> has always held that erythromelalgia may be due to some form of spinal disorder, and in his latest work (p. 180) stated that he still believed that this may be true of some of the cases. More recently, however, he has been inclined to attribute the symptoms of erythromelalgia to some form of neuritis, and has spoken of nerve-end neuritis. In two previous cases of Dr. Mitchell in which trunk nerves were examined, no changes were detected within them. These observations were made by Dr. D. Braden Kyle and Dr. Charles W. Burr, but in neither case could the peripheral nerve-ends be studied.

In one of the cases of erythromelalgia reported by Dr. Mitchell (*loc. cit.*, p. 192) exaggerated knee-jerks disappeared with the cessation of pain following excision and stretching of the nerves of the foot. This is an important fact, and seems to indicate that the exaggeration was due to pain, and warns us against placing too much value on exaggerated knee-jerks in these cases as a sign of spinal-cord disease. It is not improbable that the cells of the lumbar region controlling the knee-jerk are thrown into a state of hyperexcitability by inflammation of nerves having their reflex arc below the lumbar segment. It is uncommon to find exaggerated reflexes in neuritis, but it has been shown by one of us (Dr. Mitchell<sup>3</sup>) that certain forms of irritation of a nerve trunk may cause excessive irritability in the muscles supplied by the affected nerve, as was seen when a frozen nerve thawed.

We do not overlook the fact that the patient described in this paper was advanced in years, and that the arterio-sclerosis may have been largely or even entirely due to this fact. Arterio-sclerosis is not at all uncommon in the aged, and erythromelalgia is. We not infrequently find numbness and tingling in the fingers as a result of vascular disease, but we do not commonly find the grave signs of erythromelalgia. We believe, therefore, that we are justified in attributing the symptoms

<sup>1</sup> Schaffer. *Monatsschrift für Neurologie und Psychiatric*, 1898, vol. iii., No. 1.

<sup>2</sup> Mitchell. *Injuries of Nerves and their Consequences*, p. 60.

<sup>3</sup> Mitchell. *Clinical Lessons on Nervous Diseases*.

in this case to peripheral neuritis, but inasmuch as such neuritis was absent in Auerbach's case, we must conclude that involvement of the sensory fibres anywhere between the spinal cord—or possibly within the spinal cord—and the peripheral ramifications is capable, under certain circumstances, of causing erythromelalgia; hysteria, also, may present similar symptoms. It seems not improbable that the posterior roots and the peripheral terminations are the portions of the sensory nerves most liable to undergo degenerative changes. It is true that our microscopical examination has been limited to the tissues from one of the great toes, but we have not noted any symptoms indicating involvement of the posterior spinal roots. The sphincters were not involved, and sensation was preserved.

The preservation of sensation in the great toe, the nerves of which were so greatly degenerated, is a striking fact. Sensation seems to obey different laws from those on which motion is dependent. The few scattered undegenerated fibres must be regarded as the agents for the transmission of sensation, and it would appear that a few sensory fibres may be sufficient for this transmission. Inasmuch as the portions of the nerves examined were taken from the toe where little or no muscular tissue was present, it seems proper to regard these nerves as almost entirely sensory in character.

Our case is not the only one in which the preservation of sensation has seemed almost inexplicable after a histological examination has been made revealing intense degeneration. Brasch<sup>1</sup> reports such a case and explains the apparent contradiction by the supposition that even the most careful technique will not reveal all the nerve fibres.

<sup>1</sup> Brasch. Fortschritte der Medicin, 1898, No. 14, p. 553.











# The Medical News.

Edited by J. RIDDLE GOFFE, M. D.

PUBLISHED WEEKLY, AT \$4.00 PER ANNUM.

THE practitioner who would give his patients the benefit of the latest and best knowledge, and thus most certainly ensure his own success, cannot afford to neglect the medical weeklies. Foremost among them, as well as cheapest, stands THE MEDICAL NEWS. Its 32 quarto pages of reading matter provide space each week to lay before its readers the latest advances in medicine, surgery, obstetrics, and the various specialties. This vast range of information is gathered from the whole civilized world by the perfect organization of THE NEWS. Its reputation brings to it the contributions of recognized leaders of medical thought and practice. It is a marvel of modern times that the immense body of the world's advancing knowledge in medicine can be laid each week upon the table of the subscriber at the comparatively trivial price of \$4 per annum. The secret of course lies in a circulation embracing the most progressive men in the United States and Canada as well as in many foreign countries.

# The American Journal of the Medical Sciences.

Edited by ALFRED STENGEL, M. D.

PUBLISHED MONTHLY, AT \$4.00 PER ANNUM.

BEING the medium chosen by the best minds of the profession during seventy-nine years for the presentation of their elaborate papers, THE AMERICAN JOURNAL has well earned the praise accorded it by an unquestioned authority—"from this file alone, were all other publications of the press for the last fifty years destroyed, it would be possible to reproduce the great majority of the real contributions of the world to medical science during that period." Original Articles, Reviews and Progress, the three main departments into which the contents of THE JOURNAL are divided, will be found to possess still greater interest than in the past. The brightest talent on both sides of the Atlantic is enlisted in its behalf, and no effort will be spared to make THE JOURNAL more than ever worthy of its position as the most useful and valuable of medical magazines.

# Progressive Medicine.

A Quarterly Digest of New Methods, Discoveries and Improvements in  
the Medical and Surgical Sciences.

Edited by HOBART AMORY HARE, M. D.

\$10.00 PER ANNUM.

"PROGRESSIVE MEDICINE" will be modelled upon an entirely novel plan and will present in an original, narrative form a clear statement of the practical advance made in every department of medicine and surgery during the year, each specialty being dealt with by a single authority whose reputation gives ample assurance of accuracy and completeness. The personal impress of the contributor will be upon each subject; his thoroughly digested narrative will present its data in due and instructive connection, enchainning the interest, economizing time, yet giving ample and detailed consideration to all matters which will prove of real value in actual practice.

Four volumes will be issued each year, the first appearing on March 1st, 1899, and the others following at intervals of three months. Each will contain from four to five hundred octavo pages, abundantly illustrated and handsomely bound in cloth.

Expecting appreciation of the self-evident utility of such a work to all practitioners, the publishers confidently anticipate a circulation so general as to justify the very moderate subscription price of ten dollars for the four volumes. All expenses of delivery will be prepaid.

THE FOLLOWING FAVORABLE COMBINATION RATES ARE AVAILABLE.

	Alone	In Combination	
American Journal of the Medical Sciences.....	\$ 4.00	\$7.50	\$15.00
Medical News.....	4.00		
Progressive Medicine.....	10.00	1.25	\$16.00
Medical News Visiting List.....	1.25		
Medical News Formulary.....	1.50, net.		

In all \$20.75 for \$16.00

"Progressive Medicine," with the "American Journal" or "Medical News," will be supplied at \$13.00, or the "American Journal," "Medical News," "Visiting List" and "Formulary" at \$8.50.

LEA BROTHERS & CO., Publishers, { 706, 708 & 710 Sansom St., Philadelphia.  
111 Fifth Ave., New York.