




BOSTON MEDICAL LIBRARY

PURCHASED FROM THE INCOME OF THE

OLIVER F. WADSWORTH FUND

BOSTON MEDICAL LIBRARY  
in the Francis A. Countway  
Library of Medicine ~ *Boston*





Digitized by the Internet Archive  
in 2010 with funding from  
Open Knowledge Commons and Harvard Medical School

GYNÆCOLOGY  
FOR  
STUDENTS & PRACTITIONERS

*Also by*

T. W. EDEN, M.D., F.R.C.S., F.R.C.P.

**A MANUAL OF MIDWIFERY**

*Fourth Edition. 5 Plates and 354 Text-figures*

# GYNÆCOLOGY

FOR

## STUDENTS & PRACTITIONERS

BY

THOMAS WATTS EDEN

M.D., F.R.C.S., F.R.C.P. (Temp. Major, R.A.M.C.)

Obstetric Physician, Charing Cross Hospital; Joint Lecturer in Obstetrics and Gynæcology, Charing Cross Hospital Medical School; Surgeon, Chelsea Hospital for Women; Consulting Physician, Queen Charlotte's Lying-in Hospital; Late Examiner to the Universities of Oxford and Leeds, to the Royal College of Physicians and Surgeons, and to the War Office

AND

CUTHBERT LOCKYER


M.D., B.S., F.R.C.S., F.R.C.P.

Assistant Obstetric Physician, Charing Cross Hospital; Joint Lecturer in Obstetrics and Gynæcology, and Lecturer in Practical Obstetrics, Charing Cross Hospital Medical School; Surgeon to In-Patients, Samaritan Free Hospital for Women; Obstetric Physician to Out-Patients, Great Northern Central Hospital; Examiner to the University of London and to the Royal Colleges of Physicians and Surgeons; Late Physician to Out-Patients, British Lying-in Hospital

*With 513 Illustrations and 20 Coloured Plates*

NEW YORK  
THE MACMILLAN COMPANY

1916



14153 Wed. 6.80

*Printed in Great Britain*



## PREFACE

IN writing this book the object of the authors has been to set forth a comprehensive account of the special diseases of women, and to keep an even balance between the pathological and clinical aspects of the work. This balance, at all times difficult to maintain, is, we believe, reached more easily by collaboration between two writers than by the hand of one only. While it should satisfy the requirements of medical students of all classes, we believe that it will also assist the practitioner to elucidate and to deal with his difficult gynæcological cases.

Thanks to the generosity of our Publishers we have been able to illustrate fully all important pathological conditions, both in their naked-eye and microscopical features. With very few exceptions these illustrations have been prepared from material in our own collections, and most of the originals are to be seen in the Lockyer Collection in the museum of the Charing Cross Hospital Medical School. Use has also been made of a certain number of the illustrations which appeared in a former work on "Gynæcology" written by the senior author.

Coloured plates have been freely used where the presentation of colour was necessary for clearness of teaching.

With regard to the pathology of Chronic Endometritis and the results of Chronic Ovarian Inflammation, certain new views are advanced which may encounter criticism. We are ourselves convinced of their accuracy, and we believe that, when accepted, they will simplify and elucidate subjects upon which considerable confusion has hitherto prevailed.

The scope of the work is somewhat wider than that usually allotted to Gynæcology. Thus Appendicitis is included in the section dealing with Pelvic Infections, for reasons which are set forth in the text and need not be repeated here. Again, the results of Obstetric Infection are dealt with more fully than is usual, and in our opinion this is necessitated by the fact that such conditions so frequently come

under the care of the gynæcologist. A practical knowledge of Obstetrics forms an essential part of the training of a gynæcologist on account of the numerous points at which they overlap, and there is no doubt that Gynæcology has suffered in the past from the incursions of those who are not qualified by training to understand its clinical problems aright.

The classification which we have adopted will, we believe, be found to be convenient clinically, and to promote clearness in teaching. Pathological classifications we rejected because they involve to a greater or less extent the disassociation of conditions which are in close clinical relation. We therefore decided to apply the old Surgical Classification and speak of General Gynæcology, Regional Gynæcology and Operative Gynæcology. Under these main divisions anatomical subdivisions have been adopted as far as practicable. The first division includes Anatomy and Physiology, Methods of Examination, Prominent Symptoms, Disorders of Development and Function, and Pelvic Infections. We believe it is not inappropriate to speak of these subjects as comprising the *general* aspects of Gynæcology.

The Operative Section could not be made to embrace a full consideration of technical details without exceeding the space within which we desired to work. Operating cannot be learned from books and we believe that the section will be a sufficient guide for those readers who are accustomed to the general routine of modern surgical work.

To Messrs. Macmillan the Authors tender their grateful thanks for generously allowing them to borrow from the 'New System of Gynæcology,' in advance of its appearance, a considerable number of illustrations including coloured plates.

THOMAS WATTS EDEN.

CUTHBERT H. J. LOCKYER.

---

## ERRATA

- Page 313. Figure 151. Fourth line of legend, for pubes *read* tubes.  
 Page 317. Figure 153. For Teponema *read* Treponema.  
 Page 373. Line 11. For (see p. 445) *read* (see p. 845).

# CONTENTS

	PAGE
PREFACE	v
LIST OF COLOURED PLATES	xv

## PART I. GENERAL GYNÆCOLOGY

### SECTION I. ANATOMY AND PHYSIOLOGY

(1) GENERAL ANATOMY OF THE FEMALE PELVIC CAVITY	3
(2) THE PELVIC PERITONEUM AND CELLULAR TISSUE	5
(3) THE UTERUS	11
(4) THE FALLOPIAN TUBES	32
(5) THE OVARY AND EPOÖPHORON	36
(6) THE FUNCTIONS OF THE OVARY	49
(7) THE VAGINA	53
(8) THE VULVA	57
(9) THE URETHRA AND BLADDER	65
(10) PELVIC BLOOD-VESSELS, LYMPHATICS AND NERVES	68
(11) DEVELOPMENT OF THE FEMALE GENITO-URINARY TRACT	74
(12) PUBERTY, MENSTRUATION, AND THE MENOPAUSE	86

### SECTION II. METHODS OF EXAMINATION

(1) INTERROGATORY EXAMINATION	111
(2) ABDOMINAL EXAMINATION	112
(3) VAGINAL EXAMINATION	117
(4) EXAMINATION OF DISCHARGES, TISSUES, ETC.	129
(5) EXAMINATION OF THE URINARY SYSTEM	129

### SECTION III. PROMINENT GYNÆCOLOGICAL SYMPTOMS

(1) HÆMORRHAGE	130
(2) DISCHARGES	138
(3) PAIN	140
(4) DISTURBANCES OF MICTURITION	142
(5) DYSPAREUNIA	146
(6) STERILITY	147

## SECTION IV. DISORDERS OF DEVELOPMENT AND FUNCTION

	PAGE
(1) MALFORMATIONS	152
( <i>a</i> ) Malformations of the Ovaries	153
( <i>b</i> ) Malformations of the Fallopian Tubes	154
( <i>c</i> ) Malformations of the Uterus and Vagina	156
( <i>d</i> ) Atresic Conditions of the Genital Canal	163
( <i>e</i> ) Hermaphroditism and Pseudohermaphroditism	167
(2) DISORDERS OF MENSTRUATION	
( <i>a</i> ) Amenorrhœa, Primary	171
„          Secondary	178
( <i>b</i> ) Menorrhagia	180
( <i>c</i> ) Dysmenorrhœa	181
( <i>d</i> ) Menstrual Exfoliation	187
( <i>e</i> ) Intermenstrual Pain	190
(3) ECTOPIC PREGNANCY	
( <i>a</i> ) Ovarian Gestation	191
( <i>b</i> ) Tubal Gestation	194
( <i>c</i> ) Anatomy of Tubal Gestation	197
( <i>d</i> ) Clinical Features of Tubal Pregnancy	216
( <i>e</i> ) Treatment of Extra-uterine Pregnancy	227

## SECTION V. INFECTIONS OF THE FEMALE PELVIC ORGANS

(1) MICRO-ORGANISMS OF THE FEMALE GENITO-URINARY TRACT	232
(2) SEPTIC GENITAL INFECTIONS (NON-SPECIFIC)	236
( <i>a</i> ) Intoxication or Sapræmia	238
( <i>b</i> ) Infection or Septicæmia	242
( <i>c</i> ) Retained Products and Sub-involution	248
( <i>d</i> ) Senile Endometritis	251
( <i>e</i> ) Pelvic Cellulitis	252
( <i>f</i> ) Pelvic Peritonitis	259
( <i>g</i> ) Pyæmia	265
(3) SEPTIC URINARY INFECTIONS	
( <i>a</i> ) Cystitis	267
( <i>b</i> ) Pyelitis (Pyelonephritis)	274
(4) APPENDICITIS	277
(5) SPECIFIC INFECTIONS	
( <i>a</i> ) Gonorrhœa in Women	286
( <i>b</i> ) Tuberculosis of the Generative Organs	301
( <i>c</i> ) Syphilis in Women	317
( <i>d</i> ) Parasitic Affections of the Genitalia	324

## PART II. REGIONAL GYNÆCOLOGY

## SECTION I. DISEASES OF THE VULVA AND URETHRA

	PAGE
(1) ACUTE INFLAMMATORY CONDITIONS OF THE VULVA	337
(2) CHRONIC INFLAMMATORY CONDITIONS OF THE VULVA	340
(3) ULCERATION OF THE VULVA	348
(4) HYPERTROPHIC AND HYPERPLASTIC CONDITIONS OF THE VULVA	350
(5) NEW GROWTHS OF THE VULVA	353
(6) MORBID CONDITIONS OF BARTHOLIN'S GLAND	363
(7) LESIONS OF THE BLOOD- AND LYMPH-SYSTEMS	368
(8) LABIAL HERNIA	369
(9) PERINEAL INJURIES	369
(10) VAGINISMUS	371
(11) COCCYODYNIA	372
(12) DISEASES OF THE URETHRA	373

## SECTION II. DISEASES OF THE VAGINA

(1) INFLAMMATION OF THE VAGINA (VAGINITIS)	380
(2) ULCERATION OF THE VAGINA	383
(3) NEW GROWTHS OF THE VAGINA	384
(4) INJURIES TO THE VAGINA AND THEIR RESULTS	389

## SECTION III. DISEASES OF THE UTERUS

## A. INFLAMMATION AND ALLIED CONDITIONS

(1) ACUTE ENDOMETRITIS	391
(2) CHRONIC ENDOMETRITIS (CORPOREAL)	392
(3) ALLIED CONDITIONS	401
(4) CERVICAL ENDOMETRITIS : EROSION : NABOTH'S FOLLICLES	404
(5) CLINICAL FEATURES OF CHRONIC ENDOMETRITIS	413
(6) CHRONIC METRITIS AND ALLIED CONDITIONS	416

## B. NEW GROWTHS AND CASTS OF THE UTERUS

(7) FIBROID TUMOURS OF THE UTERUS	
( <i>a</i> ) General Pathological Anatomy of Fibroids	424
( <i>b</i> ) Secondary Changes in Fibroids	444
( <i>c</i> ) Fibroids and Pregnancy	460
( <i>d</i> ) Clinical Features of Fibroid Tumours	462
( <i>e</i> ) Symptoms of Fibroid Tumours	463
( <i>f</i> ) Physical Diagnosis of Fibroids	470
( <i>g</i> ) Pathological Diagnosis	475
( <i>h</i> ) Treatment of Fibroid Tumours	477

	PAGE
(8) UTERINE POLYPI	480
(9) UTERINE CASTS	487
(10) ADENOMYOMATA	489
( <i>a</i> ) Uterine Adenomyomata	489
( <i>b</i> ) Extra-uterine Adenomyomata	493
(11) BENIGN EPITHELIAL GROWTHS OF THE UTERUS	496
( <i>a</i> ) Simple Adenoma (Adenomatous Hyperplasia)	496
( <i>b</i> ) Papilliferous Adenoma (Villous Tumour of the Endometrium)	498
( <i>c</i> ) Simple Adenoma of the Cervix	500
(12) MALIGNANT GROWTHS OF THE UTERUS	
A MESOBLASTIC ; B. EPIBLASTIC	
(A) Sarcoma of the Uterus	501
Endothelioma and Perithelioma of the Uterus	514
(B) Cancer of the Uterus	514
( <i>a</i> ) Cancer of the Cervix	518
( <i>b</i> ) Cancer of the Body of the Uterus	531
( <i>c</i> ) Clinical Features of Cancer of the Cervix	537
( <i>d</i> ) Clinical Features of Cancer of the Body	547
( <i>e</i> ) Treatment of Uterine Cancer	549
(C) Chorionepithelioma	553
C LACERATIONS AND DISPLACEMENTS OF THE UTERUS	
( <i>a</i> ) LACERATIONS OF THE CERVIX	559
( <i>b</i> ) DISPLACEMENTS OF THE UTERUS	562
The Supports of the Uterus	562
Forward Displacement	568
Backward Displacement	570
( <i>c</i> ) CHRONIC INVERSION OF THE UTERUS	585
SECTION IV. 'PROLAPSE'	
(1) ANATOMY OF PROLAPSE	592
Hypertrophic Elongation of the Cervix	599
(2) SYMPTOMS OF PROLAPSE	600
(3) TREATMENT OF PROLAPSE	603
SECTION V. MORBID CONDITIONS OF THE FALLOPIAN TUBES	
I. TUBAL CYSTS	608
II. INFLAMMATION OF THE FALLOPIAN TUBE	608
A. Catarrhal Salpingitis	610
( <i>a</i> ) Hydrosalpinx	610
( <i>b</i> ) Hæmatosalpinx	613

	PAGE
B. Suppurative Salpingitis	614
( <i>a</i> ) Pyosalpinx	617
Contents of a Pyosalpinx	620
( <i>b</i> ) Rupture of a Sactosalpinx	621
( <i>c</i> ) Tubal Fistulæ	622
C. Interstitial Salpingitis	621
D. Chronic Salpingo-oöphoritis	626
Tubo-ovarian Cysts	627
E. Clinical Features of Inflammation of the Tubes and Ovaries	627
F. Treatment of Tubo-ovarian Inflammation	632
 III. NEW GROWTHS OF THE TUBES	 634
( <i>a</i> ) Primary Tubal Papilloma	635
Primary Tubal Papilliferous Carcinoma	637
Adenocarcinoma	637
( <i>b</i> ) Primary Tubal Chorionepithelioma	641
 SECTION VI. MORBID CONDITIONS OF THE OVARIES	
(1) CHRONIC OVARIAN PAIN	642
(2) DISPLACEMENTS OF THE OVARY	643
(3) INFLAMMATION OF THE OVARY	645
( <i>a</i> ) Perioöphoritis	645
( <i>b</i> ) Acute Interstitial Oöphoritis	646
Ovarian Abscess	646
( <i>c</i> ) Chronic Interstitial Oöphoritis	648
(1) " Small Cystic Degeneration " (Sclero-cystic Disease)	649
(2) Hydrops Folliculorum	650
(3) Simple Serous Cysts	652
(4) Theca-lutein Cysts	652
(5) Compound Theca-lutein Cysts	653
(6) Cysts of the Corpus Luteum	656
(7) Ovarian Hæmatomata	658
(4) NEW GROWTHS OF THE OVARY	659
( <i>a</i> ) Classification	661
( <i>b</i> ) Benign Epithelial Tumours	662
(1) Cystadenoma Pseudomucinosum	664
(2) Cystadenoma Serosum Papillare (Papilliferous Cyst)	669
( <i>c</i> ) Malignant Epithelial Tumours	
Carcinoma of the Ovary	673
( <i>d</i> ) Benign Connective-tissue Tumours of the Ovary	
Fibromata	682
Adenofibromata	684
Myofibromata and Myomata	684

	PAGE
(e) Malignant Connective-tissue Tumours	684
Sarcoma	684
Endothelioma	685
Perithelioma	688
(f) Ovarian Teratomata	
Teratomatous Cysts : ' Ovarian Dermoids '	689
Solid Ovarian Teratomata	695
(g) Compound Ovarian Tumours	697
(5) CYSTS ARISING IN THE BROAD LIGAMENT	
Fimbrial Cysts	698
Epoöphoritic Cysts (Parovarian)	701
Cysts of Kobelt's Tubes	702
Cysts of the Hydatid of Morgagni	702
(6) SECONDARY CHANGES IN OVARIAN TUMOURS	
Axial Rotation	702
Infection	703
Rupture	704
Adhesions	705
Malignant Degeneration	706
Degeneration Cysts in Solid Tumours	707
Psammomatous Degeneration	707
(7) CLINICAL FEATURES OF OVARIAN TUMOURS	707
Diagnosis of Secondary Changes	719
Ovarian Tumours and Pregnancy	721
(8) TREATMENT OF OVARIAN TUMOURS	722

### PART III. OPERATIVE GYNÆCOLOGY

#### SECTION I. TECHNIQUE

(a) PREPARATION OF THE PATIENT	725
(b) GENERAL CONDUCT OF THE OPERATION	726
(c) PREPARATION OF INSTRUMENTS, LIGATURES, ETC.	730
(d) ANÆSTHESIA	731
(e) GENERAL MEASURES FOR THE PREVENTION OF SHOCK	732
(f) THE OPERATOR AND ASSISTANTS	732
(g) GENERAL CONDUCT OF THE OPERATION	733

#### SECTION II. ABDOMINAL OPERATIONS

(a) MYOMECTOMY	740
(b) SUBTOTAL HYSTERECTOMY : SUPRA-VAGINAL AMPUTATION	742
(c) TOTAL ABDOMINAL HYSTERECTOMY (PANHYSTERECTOMY)	745



	PAGE
(d) SPECIAL METHODS OF HYSTERECTOMY	750
(1) Kelly's Method	750
(2) Doyen's Method	751
(3) Pryor's Method	751
(4) Wertheim's Method	752
(e) OVIOTOMY	758
(f) OPERATIONS ON THE UTERINE ADNEXA	762
(g) APPENDECTOMY	767
(h) VENTRISUSPENSION AND VENTRIFIXATION	769

## SECTION III. VAGINAL AND VULVAL OPERATIONS

(a) COLPOTOMY	777
(b) VAGINAL FIXATION AND INTERPOSITION OF THE UTERUS	781
(c) VAGINAL HYSTERECTOMY	782
(d) VAGINAL MYOMECTOMY	787
(e) DILATATION OF THE CERVIX AND CURETTING	793
(f) PLASTIC OPERATIONS ON THE UTERUS AND VAGINA	
(1) Trachelorrhaphy	799
(2) Amputation of the Cervix	804
(3) Pozzi's Operation for Sterility	805
(4) Radical Cure of Cystocele	806
(5) Perineorrhaphy	812
(6) Le Fort's Operation	824
(7) Operations for Fistulæ	825
(8) Operation for Restoration of an Inverted Uterus	831
(g) OPERATIONS ON THE VULVA	
(1) For Atresia	832
(2) For Urethral Caruncle	832
(3) For Prolapse of the Urethra	835
(4) For Urethrocele	835
(5) For Incontinence of Urine	835
(6) Excision of Bartholin's Cyst	836
(7) For Bartholin's Abscess	836
(8) For Hydrocele of the Canal of Nuck	836
(9) For Labial Hernia	837
(10) For Warts on the External Genitalia	837
(11) For Epithelioma of the Vulva	838
(h) OPERATIONS ON THE VAGINA	
(1) Operation for Vaginismus	840
(2) Operation for Partial Absence of Vagina	841
(3) Operation for Total Absence of Vagina	843
(4) Operation for Vaginal Septum	843

	PAGE
(5) Operation for Vaginal Cysts	843
(6) Operation for Solid Benign Tumours of the Vagina	844
(7) Operation for Carcinoma of the Vagina	845
(i) COCCYGECTOMY	845
©	
SECTION IV. THE AFTER-TREATMENT OF GYNÆCOLOGICAL OPERATIONS	
I. AFTER-TREATMENT OF A SIMPLE ABDOMINAL CASE	846
II. COMPLICATIONS AFTER ABDOMINAL OPERATIONS	850
(a) Shock	850
(b) Recurrent Hæmorrhage	853
(c) Acute Abdominal Distension	853
(d) Peritonitis	854
(e) Intestinal Obstruction	856
(f) Intestinal Paresis: Paralytic Ileus	857
(g) Acute Dilatation of the Stomach	858
(h) Suppression of Urine	859
(i) Cystitis	859
(j) Urinary Fistulæ	860
(k) Fæcal Fistulæ	860
(l) Infection of the Abdominal Wound	861
(m) Rupture of the Abdominal Wound	861
(n) Post-operative Parotitis and Phlebitis	861
(o) Pulmonary Embolism	862
III. AFTER-TREATMENT OF VAGINAL OPERATIONS	
Major Vaginal Operations	863
Minor Vaginal Operations	863
INDEX	865

## LIST OF COLOURED PLATES

PLATE	PAGE
I. NORMAL ENDOMETRIUM (PREMENSTRUAL PHASE)	<i>facing</i> 16
II. MUSCULATURE OF VIRGIN UTERUS AFTER PUBERTY	} „ 22
MUSCULATURE OF SENILE UTERUS AFTER MENOPAUSE	
MUSCULATURE OF PAROUS UTERUS BEFORE MENOPAUSE	
III. CORPUS LUTEUM OF PREGNANCY	„ 45
IV. HÆMATOCOLPOS	„ 173
V. UNRUPTURED TUBAL GESTATION	„ 197
VI. MICROSCOPIC SECTION THROUGH A CELLULITIC EXUDATION IN THE PELVIS	„ 254
VII. SCHEME OF GONORRHOËAL INFECTION OF THE FEMALE GENITAL TRACT	„ 287
VIII. ENDOMETRITIS SHOWING PLASMA-CELLS IN STROMA	„ 394
IX. THE UTERINE WALL IN TRUE CHRONIC METRITIS	„ 420
X. THE EFFECTS OF INVOLUTION ON THE ARTERIES IN THE UTERINE WALL	„ 421
XI. VESSELS IN A NORMAL PAROUS UTERUS	„ 421
XII. VESSELS IN A SUB-INVOLUTED UTERUS	„ 421
XIII. (a) VESSELS IN HYPERTROPHIED UTERUS	} „ 422
(b) VESSELS IN VIRGIN UTERUS	
XIV. DEGENERATIVE PROCESSES IN FIBROID TUMOURS	„ 446
XV. PREGNANCY IN A FIBROMYOMATOUS UTERUS (RED DEGENERATION)	„ 451
XVI. POLYPUS SHOWING VASCULAR ENGORGEMENT	„ 481
XVII. ADENOMYOMA UTERI	„ 492
XVIII. CHORIONEPITHELIOMA UTERI ET PULMONIS	„ 553
XIX. SUBACUTE PURULENT SALPINGITIS, SHOWING PLASMA-CELLS IN STROMA OF THE PLICÆ	„ 615
XX. OVARIAN CYST SHOWING EFFECTS OF ACUTE TORSION OF THE PEDICLE	„ 703



3  
9

# GYNÆCOLOGY

## PART I

### GENERAL GYNÆCOLOGY





## PART I : SECTION I

# ANATOMY AND PHYSIOLOGY : DEVELOPMENT : PUBERTY : MENSTRUATION AND THE MENOPAUSE

## THE ANATOMY AND PHYSIOLOGY OF THE FEMALE GENITAL ORGANS

### GENERAL ANATOMY OF THE FEMALE PELVIC CAVITY

THE true pelvic cavity forms the lowest part of the general abdominal or peritoneal cavity, and is limited above by the brim of the pelvis, below by the pelvic diaphragm. Within this cavity, and invested more or less completely by the peritoneum, lie the bladder, the uterus, the Fallopian tubes, the ovaries, and the upper part of the rectum ; the lowest part of the great or gastro-colic omentum, some coils of the ileum, and a loop of the pelvic colon also form part of its normal contents. It is further to be borne in mind that in a large proportion of cases the vermiform appendix overhangs the pelvic brim, and lies in close relation to the right ovary and to the outer part of the right Fallopian tube. Piercing the pelvic diaphragm to open upon the perineum are the urethra, the vagina, and the rectal ampulla with the anal canal ; these parts lie below the level of the peritoneal reflection, and represent respectively the urinary, genital, and intestinal tracts. A mesial sagittal section through the normal pelvis shows the general relations of the more important organs to one another (Figs. 1 and 2). Immediately behind the pubes lies the bladder, separated from the bone by a little loose and very vascular connective tissue. The urethra appears as a narrow channel which runs in its upper one-third directly downwards, and in its lower two-thirds curves downwards and forwards to end at the meatus urinarius. Behind the bladder lies the uterus ; these organs are separated from one another by a reflection of the peritoneum, but below the level of this reflection they are united, over a small area, by cellular tissue. The vagina runs downwards and forwards to end at the vulva ; it is united by a variable amount of cellular tissue to the bladder and urethra in front, and to the anterior rectal wall behind. The lower third of the anterior

vaginal wall is firmly welded to the posterior urethral wall, making the separation of these structures difficult. Planes of cellular tissue allow of the easy separation by dissection of the structures which

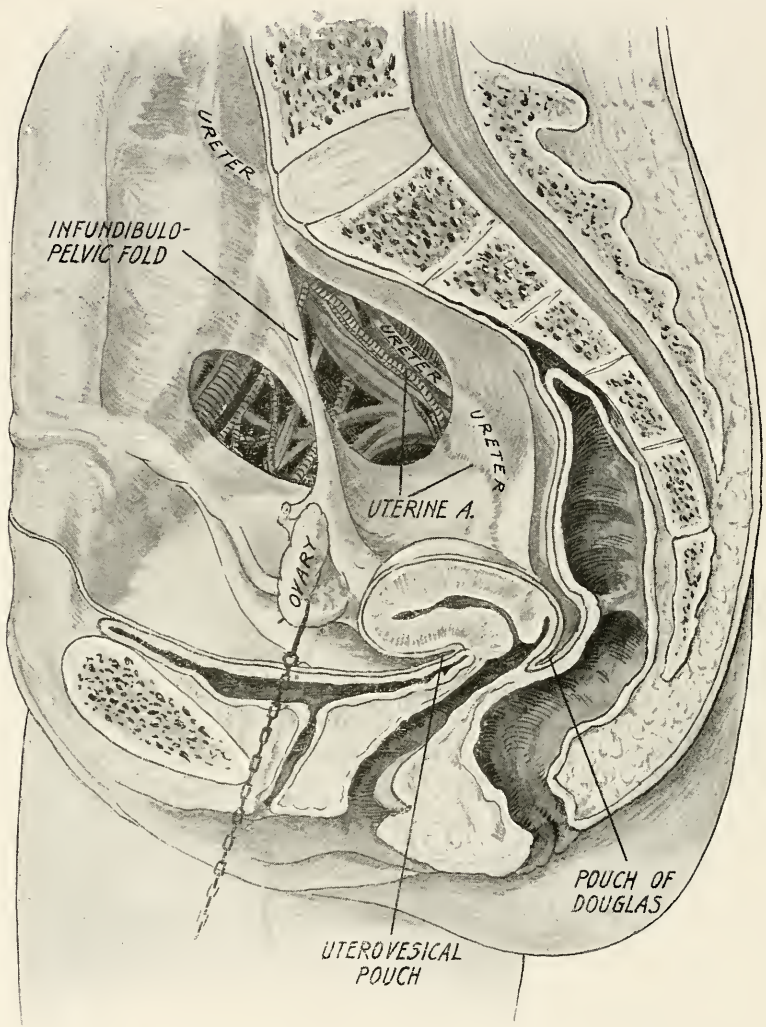


FIG. 1. MESIAL SAGITTAL SECTION THROUGH THE PELVIS OF AN ADULT NULLIPARA (Poirier).

they unite to one another; in positions where no cellular tissue is found, separation of the contiguous organs is more difficult and more likely to be attended by injury to the parts dealt with.

Behind the uterus lies a large peritoneal space which in Fig. 1 has been cleared of its contents—omentum, small intestine, and pelvic



colon. This space extends backwards to the anterior surface of the sacrum and is in relation inferiorly to the rectum. Placed between the rectum and the utero-vaginal junction in the lowest part of the

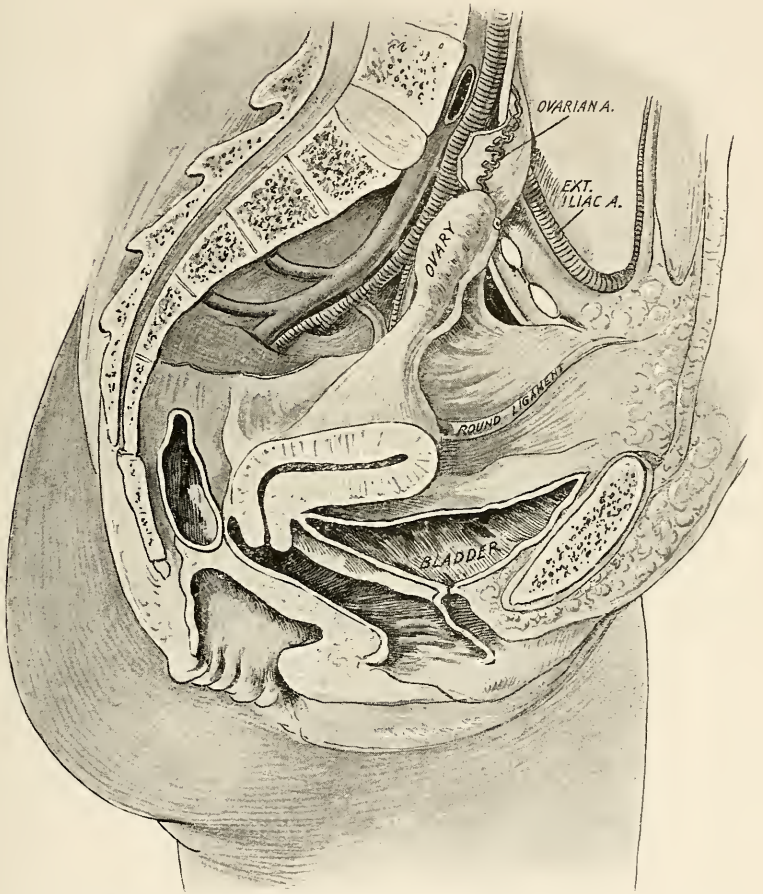


FIG. 2. MESIAL SAGITTAL SECTION THROUGH THE PELVIS OF AN ADULT PAROUS WOMAN (Poirier). Signs of parturition are seen in (a) the capacious vagina, (b) the enlarged ostium vaginae, (c) the laceration of the anterior part of the perineal body.

floor of this space, is a deep peritoneal fossa which anatomists call the *pouch of Douglas*.

### THE PELVIC PERITONEUM AND CELLULAR TISSUE

**Peritoneum.** In a mesial sagittal section (*see* Figs. 1 and 2) the peritoneum may be traced from the anterior abdominal wall to the spinal column. In Fig. 2 the bladder is nearly empty and is seen to lie entirely

below the level of the pelvic brim ; the peritoneum is seen coming first into relation with the back of the symphysis pubis, and then, rising gently, is reflected over the slightly curved fundus of the bladder to a point where the latter comes in contact with the anterior uterine wall. The peritoneum is separated from the bladder wall by a loose layer of connective tissue of considerable thickness, an arrangement which allows marked alterations to occur in the peritoneal relations of this organ when it becomes distended, and consequently rises upwards into the abdominal cavity proper. By the reflection of the peritoneum from the fundus of the bladder upon the uterus a peritoneal fossa or pouch is formed called the *utero-vesical* pouch ; when the bladder is completely empty this pouch is wide but shallow ; when the bladder becomes distended the pouch is made narrow but deep.

From the floor of the utero-vesical pouch the peritoneum passes upon the anterior uterine wall, and may be traced over the top of this organ and down its posterior wall to the floor of the pouch of Douglas, which forms the lowest point in the body at which peritoneum is met with. Before reaching this level the peritoneum leaves the uterus, and comes into relation with the upper  $\frac{1}{2}$  inch of the posterior vaginal wall, a considerable layer of connective tissue lying between them. To the wall of the uterus the peritoneum is closely united, no cellular tissue being found between them except over a small area of the anterior wall (*see* p. 25). From the floor of the pouch of Douglas the peritoneum is reflected upon the rectum investing first the anterior wall only, and higher up the anterior and both lateral walls ; at the level of the third sacral vertebra in the middle line it is reflected from the rectum upon the anterior surface of the sacrum, and passing upwards over the sacral promontory becomes continuous with the peritoneum covering the posterior abdominal wall. Over the whole of this area a considerable layer of cellular tissue is found beneath the peritoneum.

Examination from above of the pelvic organs (Fig. 3) shows that the pelvic cavity is roughly divided into an anterior and a posterior compartment by the uterus and certain structures directly attached to it, viz. the broad ligaments with the Fallopian tubes and ovaries, and the infundibulo-pelvic folds. These structures together form a curved transverse septum, convex in front, concave behind. The peritoneum covering the floor of the *anterior compartment* may be traced transversely from the pelvic brim over the lateral part of the pelvic wall to the side of the bladder, and over this organ to the pelvic wall and pelvic brim of the opposite side. Across the top of the bladder it forms a loose transverse fold known as the *transverse vesical fold* (*see* Fig. 3) ; external to the bladder the round ligament of the uterus crosses the floor of this compartment diagonally beneath the peritoneum to reach the internal abdominal ring. In the middle line the floor of this compartment corresponds with the utero-vesical pouch already

mentioned. This pouch is sometimes bounded laterally by two antero-posterior peritoneal folds running from the sides of the uterus to the sides of the bladder, and called the *utero-vesical ligaments*; they are, however, feebly developed and inconstant, and can seldom if ever be recognized during operative work. The utero-vesical pouch in normal conditions is only a potential space, for uterus and bladder lie in contact with one another. When the bladder is moderately distended a pair of shallow lateral fossæ may be observed, one on each side of the bladder, named the *lateral vesical pouches* or *para-vesical fossæ*.

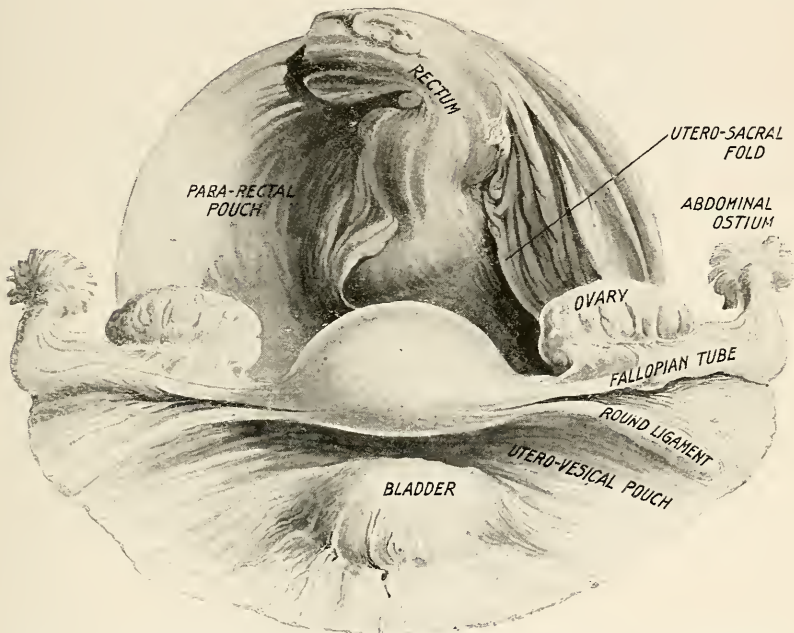


FIG. 3. THE PELVIC ORGANS SEEN FROM ABOVE; FROM A DISSECTION (Charing Cross Hospital Museum).

They are roughly divided into anterior and posterior segments by the round ligaments of the uterus.

The *posterior compartment* is much larger and deeper than the anterior (see Figs. 3, 4 and 20); in clinical usage this compartment is called the pouch of Douglas, although by the anatomist this name is reserved for the deep peritoneal fossa between the rectum and the cervico-vaginal junction. The peritoneal floor of this compartment may be traced transversely from the pelvic brim down the lateral pelvic wall to the line of origin of the pelvic diaphragm, and thence over the sloping pelvic diaphragm to the right utero-sacral ligament clearly discernible as a well-defined fold or ridge running backwards and outwards from the uterus to the sacrum (see Figs. 4 and 20). Over this fold the peritoneum dips nearly vertically downwards to form the anatomical pouch of Douglas, ascends the opposite side to reach

the left utero-sacral ligament, and so over the pelvic diaphragm to the opposite lateral pelvic wall and pelvic brim. The peritoneum which covers the anterior surface of the sacrum is reflected over the sides and anterior surface of the rectum, but does not form a complete

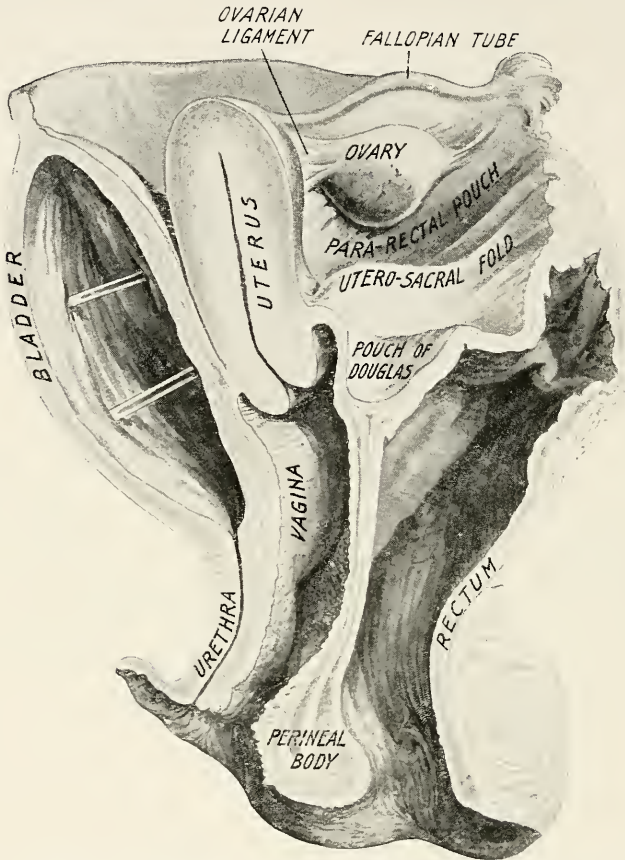


FIG. 4. THE PELVIC ORGANS; FROM A DISSECTION (Charing Cross Hospital Museum). The pelvic contents have been divided in mesial sagittal section. Note the effect on the position of the uterus due to distension of the bladder (see p. 66).

mesentery; at the level of the pouch of Douglas the anterior surface only of the rectum has a peritoneal covering.

The posterior compartment is divided by the utero-sacral folds into three fossæ—the anatomical pouch of Douglas, and the right and left *para-rectal fossæ* (see Figs. 3 and 4). The right para-rectal fossa is much more capacious than the left (see Fig. 3), the latter being largely filled up by the pelvic colon and the upper part of the rectum. The mesentery of the pelvic colon has an oblique attachment to the posterior wall of the left para-rectal fossa. Each para-rectal fossa is bounded in front by the posterior surface of the broad ligament, to which is attached the ovary (see Figs. 3 and 4). The depth of the pouch of Douglas

is variable ; its anterior wall usually corresponds to the upper half to  $\frac{3}{4}$  inch of the posterior vaginal wall, and its floor is situated about  $2\frac{1}{2}$  inches above the anus. Its upper limits are formed by the utero-sacral ligaments, which when strongly developed slightly constrict the entrance to it. Owing to the divergent direction of these ligaments, the entrance is wider behind than in front. It is obvious that the floor of the pouch of Douglas may be reached with the finger both through the vagina and the rectum, a much larger area being accessible through the latter canal than through the former (*see* Fig. 4). Under pathological conditions the size, position, and relations of this fossa are capable of wide alterations.

**Cellular Tissue.** The pelvic cellular tissue is continuous with the subperitoneal cellular tissue of the abdominal cavity ; comparatively thin in the upper part of the pelvis, it is most abundant on the pelvic floor, where it fills up all the intervals between the viscera, and forms the supporting medium for the large number of vessels, nerves, and lymphatics which pass to and from the viscera. Anteriorly the pelvic cellular tissue is continuous with the subperitoneal cellular tissue of the anterior abdominal wall, laterally with that of the iliac fossa ; it communicates with the extra-pelvic cellular tissue through the obturator and sacro-sciatic foramina ; investing the round ligament it connects, through the inguinal canal, with the subcutaneous fat of the labium majus, and through the mesentery of the pelvic colon it becomes continuous with the cellular tissue of the general abdominal cavity. It also surrounds the ureters, and through these it is connected with the fatty capsule of the kidney. Numerous lymphatic glands lie embedded in it, but these will be referred to more fully later on.

The cellular tissue is most abundant in relation to the cervix, where it forms the *parametrium* of Virchow ; on both sides, and in relation to the bladder, large masses of cellular tissue are found ; posteriorly in relation to the pouch of Douglas it is less abundant. The anterior and posterior surfaces of the uterine body have no cellular-tissue covering, the peritoneum resting upon the muscular layer.

The general distribution and relations will be followed in Fig. 5, from which it appears that the cellular tissue is located mainly in relation to the posterior pelvic compartment. Around the bladder only a thin layer is found, but at the sides of the uterus it is abundant, forming a thick lateral wedge of tissue interposed between the bladder and the sacro-sciatic notches. From this position the cellular tissue may be traced backwards to the anterior surface of the sacrum, which receives a thick covering, the rectum being completely surrounded. Anteriorly the cellular tissue is most abundant between the bladder and the posterior surface of the pubes. Embedded in the lateral masses of cellular tissue lie the ureters with the uterine arteries and veins, and the large veins of the pampiniform plexus.

The pelvic cellular tissue is for the most part a loose non-resistant

structure, but in certain directions it becomes condensed into strong fibrous tissue. This occurs chiefly in relation to the large venous plexuses and arteries, where it forms well-defined perivascular sheaths. Both arteries and veins are connected up with the internal iliac vessels on the one hand and with the viscera lying in the floor of the pelvis, on the other. The perivascular sheath thus becomes an important

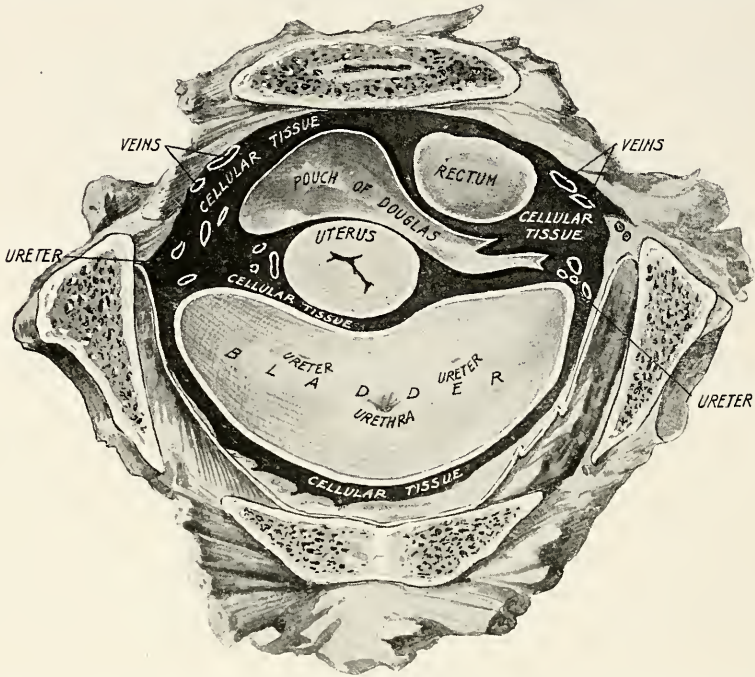


FIG. 5. HORIZONTAL SECTION THROUGH THE PELVIS TO SHOW THE CELLULAR TISSUE. It also shows the relation of the openings of the ureters and the urethra at the trigone of the bladder. (Martin.)

element in supporting the uterus and the other pelvic organs in their normal position (*see also* pp. 565, 566).

The pelvic course of the ureter lies entirely in the cellular-tissue planes and may be traced from the sacro-iliac synchondrosis, which it reaches in company with the ovarian artery, down the lateral pelvic wall to the broad ligament; here it runs at a deep level in close relation to the posterior layer of that ligament up to the posterior vaginal wall. Thence it passes to the base of the bladder in close relation to the cervico-vaginal attachment. It is enveloped in cellular tissue throughout, and carries its own nutritive vessels. The uterine vessels cross it obliquely in passing from without inwards to reach the cervix at about the level of the internal os, the artery being placed above the ureter (*see* Fig. 45). One or two small lymphatic glands, which may be found enlarged in operations for cancer of the cervix, are also present in the base of the broad ligament.

**Surgical Anatomy.** The pelvic peritoneal cavity may be reached from below, either through the utero-vesical pouch, or through the pouch of Douglas, by a vaginal incision. In opening the former (anterior colpotomy) the first structure to be cut is the anterior vaginal wall ; then by blunt dissection through the cellular tissue lying between the bladder and the cervix, the former organ is displaced and the floor of the utero-vesical pouch may be seized with forceps and divided. It will be borne in mind that in thus displacing the base of the bladder upwards, the ureters which pierce it will also be carried to a higher level, where injury to them may be more easily avoided. In opening the pouch of Douglas (posterior colpotomy), after the vaginal wall has been divided, a layer of cellular tissue of very variable thickness is encountered, and must be separated by blunt dissection in order to reach the peritoneum. No important viscus is here endangered (*see* Fig. 4). In a multipara the peritoneum is more easily reached both in front and behind than in a nullipara, owing to the stretching which results from pregnancy and labour.

Under pathological conditions the relations of the anterior and posterior peritoneal pouches may undergo great alteration. Thus in prolapse, the floor of the utero-vesical pouch may be outside the vulva (*see* Fig. 315) ; a tumour lying in the pouch of Douglas may depress it almost to the level of the anus, and at the same time displace the uterus forwards towards the pubes. An effusion in one of the lateral masses of cellular tissue will displace the uterus to the opposite side. Inflammation in any part of the pelvic cellular tissue may pass, by direct continuity, all round the pelvic cavity, and also extend to the anterior abdominal wall, to the iliac fossa, to the retroperitoneal abdominal cellular tissue, and so up to the kidney and the diaphragm ; or it may pass through the sacro-sciatic foramen into the buttock, and through the obturator foramen to the front of the thigh. Collections of pus in the pelvis may also be evacuated spontaneously into any of the hollow pelvic viscera, viz. the bladder, the vagina, and the large intestine.

## THE UTERUS

**General Anatomy and Relations.** When isolated from its attachments the uterus is seen to be a pyriform or pear-shaped organ consisting of an upper broad and a lower narrow portion. The lower portion is called the *cervix* ; the upper portion, the *body*. The junction of the two is indicated upon the outer surface by a slight constriction known as the *isthmus*. The cervix is cylindrical in shape and measures about 1 inch in length. The body is broader above than below and its transverse exceeds its antero-posterior measurement. The broad upper extremity is convex, markedly so in the sagittal plane, slightly in the coronal plane. The greatest transverse diameter of the body therefore lies a little below the top of the uterus, and the part above

this diameter is distinguished as the *fundus*. The curved outline, broad from side to side of this part of the uterus is characteristic, and is clearly recognizable by palpation on clinical examination. At the extremities of the greatest transverse diameter the Fallopian tubes join the body. This point is known as the *cornu* or *angle* of the uterus. Besides the Fallopian tubes two other structures are attached to the

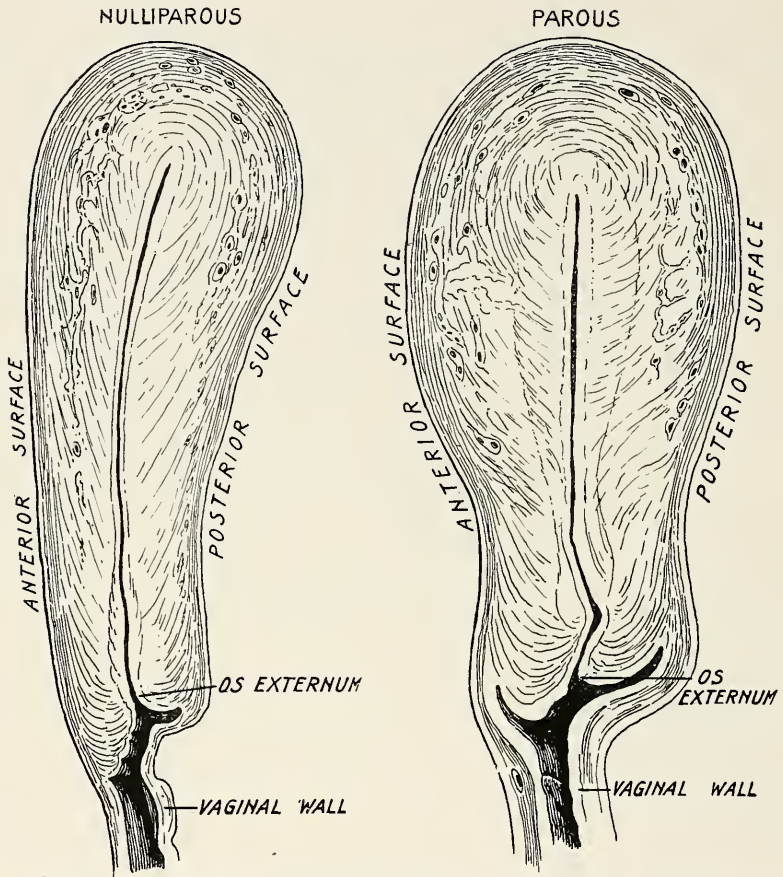


FIG. 6. THE UTERUS IN SAGITTAL SECTION ; post-mortem specimens.

uterine cornua, viz. the round ligaments and the ovarian ligaments. These three structures are not in the same plane but are arranged from above downwards in the order—tube, round ligament, ovarian ligament ; and from before backwards in the order—round ligament, Fallopian tube, ovarian ligament (*see* Fig. 23). In a nulliparous woman the anterior surface of the body is flat, the posterior distinctly convex. In women who have borne children, both are convex.

Externally the uterine body is covered with peritoneum (*vide infra*). In its interior is a potential cavity lined with a mucous membrane, the *endometrium*. The cavity contains only a small amount



of secretion produced by the mucous membrane. During menstruation, however, blood accumulates in it, and in pregnancy and in certain morbid conditions it increases greatly in size.

The uterine cavity communicates below with the vagina through an aperture in the cervix, called the *os externum*. Above it is continuous with the lumina of the Fallopian tubes, and through these channels the uterus communicates with the peritoneal sac. The genital tract—Fallopian tubes, uterus, and vagina—constitutes a continuous canal which forms a direct channel of communication between the surface of the body and the pelvic peritoneal cavity.

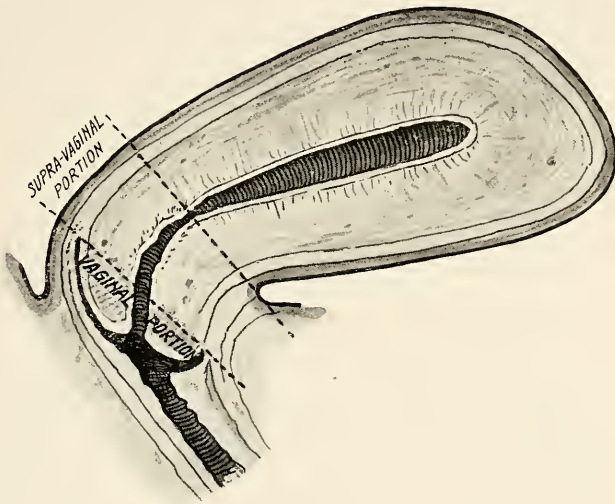


FIG. 7. THE DIVISIONS OF THE CERVIX (diagrammatic).

an anatomical arrangement which accounts for the extreme frequency with which infection of the pelvic peritoneum from without occurs in women. In men, such infection is, relatively speaking, of rare occurrence.

The cervix is divided for descriptive purposes into two parts; the lower part projects into the vagina and is called the *portio vaginalis*, the upper part lies above the cervico-vaginal attachment and is called the *supra-vaginal cervix*. The cervix is approximately cylindrical in shape and through its centre runs the cervical canal, a narrow channel with flattened walls, which communicates above with the body-cavity through the *os internum*, and opens below into the vagina through the external os. In a nullipara the vaginal portion or the *portio*, as it is commonly called, is shaped like an inverted cone upon the apex of which is the *os externum*, forming a circular or transverse aperture. After childbirth the external os is a long, more or less patulous, transverse slit, and often the *portio* is greatly modified in size and shape by laceration and certain resultant changes. The

external os may then present one or more deep lateral clefts (*see* Figs. 294 and 295), or from more numerous tears it may be cut up into several segments of unequal shape and size. Over the surface of the portio the vaginal mucosa is reflected and is firmly attached to the cervical tissues. The epithelial covering of this part of the cervix is therefore the same as that of the vaginal walls. In front the cervix is united

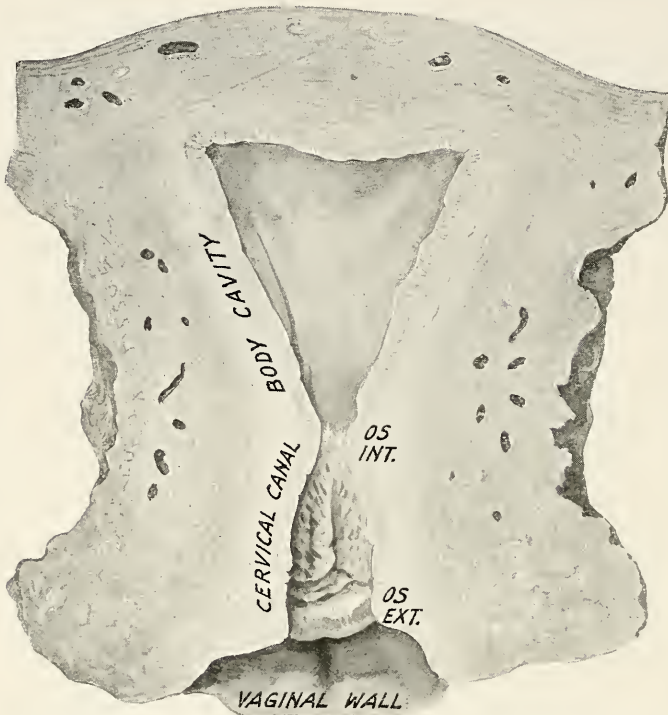


FIG. 8. NORMAL UTERUS OF A NULLIPARA. The uterus has been bisected in coronal section, along with the surrounding cellular tissue of the broad ligaments. The cavity of the body is triangular, that of the cervix is spindle-shaped. The large vessels seen laterally are in the cellular tissue of the broad ligament.

to the bladder by a layer of loose cellular tissue. At the sides it is in contact with the lateral masses of the pelvic cellular tissue.

In a nulliparous woman the length of the whole uterus from fundus to os externum is 3 inches, while the length of the cavity is  $2\frac{1}{2}$  inches. In a woman who has borne several children these measurements are usually exceeded by  $\frac{1}{4}$  to  $\frac{1}{2}$  inch. The length of the cervix is about 1 inch. The uterine wall is thickest at the fundus and thinnest where the cervix joins the body, varying from  $\frac{1}{2}$  to  $\frac{3}{4}$  inch. The uterus of a nullipara weighs from  $1\frac{1}{2}$  to 2 oz.; that of a multipara from 2 to  $2\frac{1}{2}$  oz.

When the whole of the uterus is laid open in coronal section its

cavity is seen to be funnel-shaped. The cavity of the body is triangular with the apex below, the upper angles being prolonged into the Fallopian tubes, the lower angle into the cervical canal. In a parous woman it is larger and more roomy than in a nullipara. The cavity of the cervix in a nullipara is spindle-shaped on coronal section. In a parous woman, the external os, being permanently widened by child-birth, is much larger than the internal os. Where the body-cavity is continued into the cervix there is a narrowing of the lumen which forms the *os internum*.

When examined *in situ* the body of the uterus will be seen to incline slightly forwards from the cervix so that the axis of the organ forms

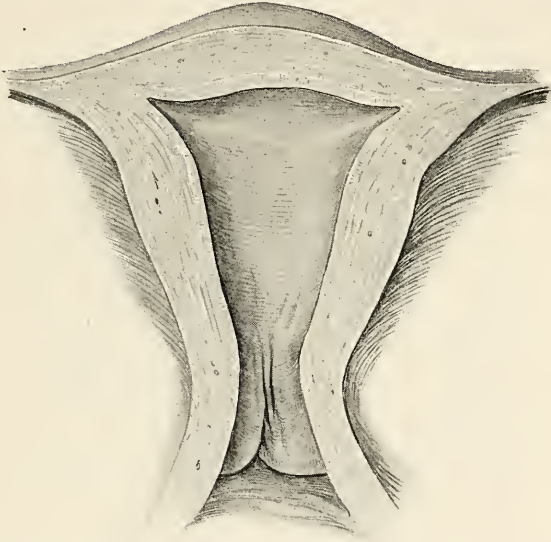


FIG. 9. NORMAL UTERUS OF A PAROUS WOMAN. The uterus has been freed from its attachments and bisected in coronal section.

a curve open widely in front, and equal to an obtuse angle of about  $160^\circ$ . In nulliparæ this angle is often much more acute and may be reduced even below  $90^\circ$ , but this modification is in nearly all cases associated with some other abnormality, such as deficiency in size (*see p. 568*). Sometimes the bend is backwards instead of forwards. In the foetus the uterine axis forms a straight line (*see Fig. 21*). As a rule the uterus is median in position in the pelvic cavity. Occasionally it has a lateral inclination, the body being directed towards one side, the cervix towards the other. In the erect attitude and with the bladder empty, the body of the uterus is strongly anteverted and lies nearly horizontal in the pelvis, the fundus being just below the level of the upper border of the pubes, the os externum at the level of the ischial spines. Distension of the bladder displaces the uterus upwards and backwards, carrying it farther away from the abdominal wall.

Distension of the rectum displaces it upwards and forwards. Variations of posture and muscular effort also affect its position. In bi-manual examination under anæsthesia, the uterus can be freely moved in all directions within the pelvis, and the cervix may be drawn down almost to the vulva with the volsella.

**Structure.** The mucous membrane lining the cavity of the uterus is the *endometrium*. In the body (corporeal endometrium) it

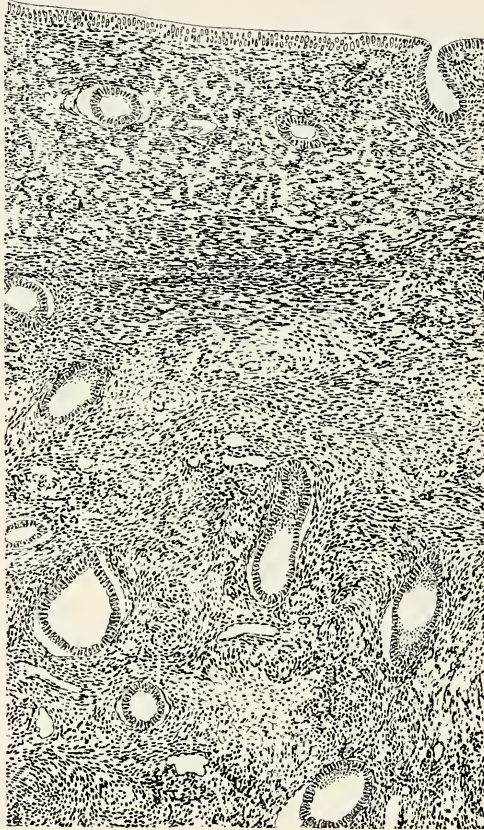
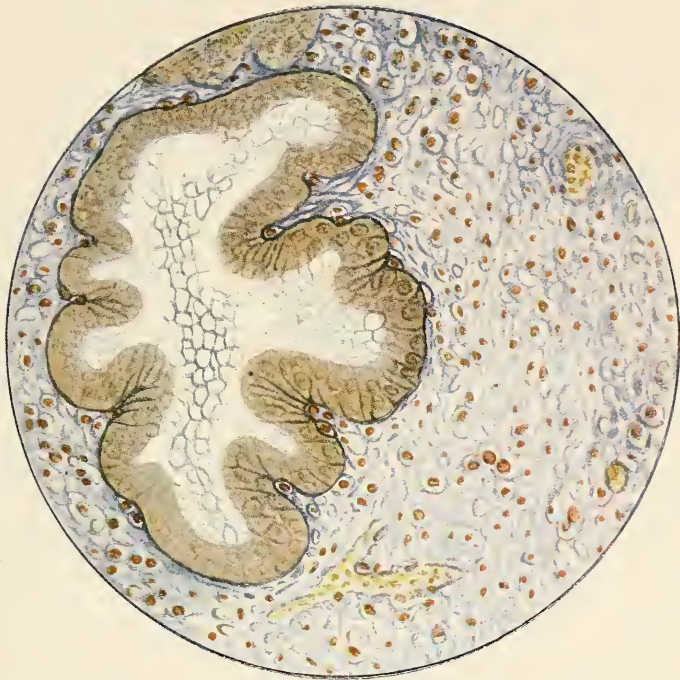


FIG. 10. THE ENDOMETRIUM OF A NULLIPARA (high power). The glands are relatively scanty, and no branchings are seen.

is smooth, polished, and pale yellowish-pink in colour; with a lens the openings of glands may be seen upon it. In the cervix (cervical endometrium) it is thrown into transverse folds with intervening sulci; a median ridge runs along the anterior and posterior walls, and at these ridges the transverse folds end. The whole arrangement roughly resembles the branchings of a tree, and the name *arbor vitæ* was given to it by the old anatomists. The average thickness of the endometrium in a healthy adult woman is about 2 mm. After the climacteric it undergoes shrinkage.



NORMAL ENDOMETRIUM (PREMENSTRUAL PHASE). Stained by Mallory's polychrome methylene blue. The basement-membrane of the gland-epithelium is stained deep blue; the network of collagen-fibres in the stroma is stained a paler blue, whilst the stroma-cells are orange-coloured. The blood-corpuscles in the capillaries are stained yellow. Note the fern-like projections into the gland, and the mucus (stained blue) in the gland-lumen.



The endometrium of the *body of the uterus* has no submucous layer, and its glands penetrate into the muscular wall, so that although it can be partially scraped away, it will not peel off. The structures

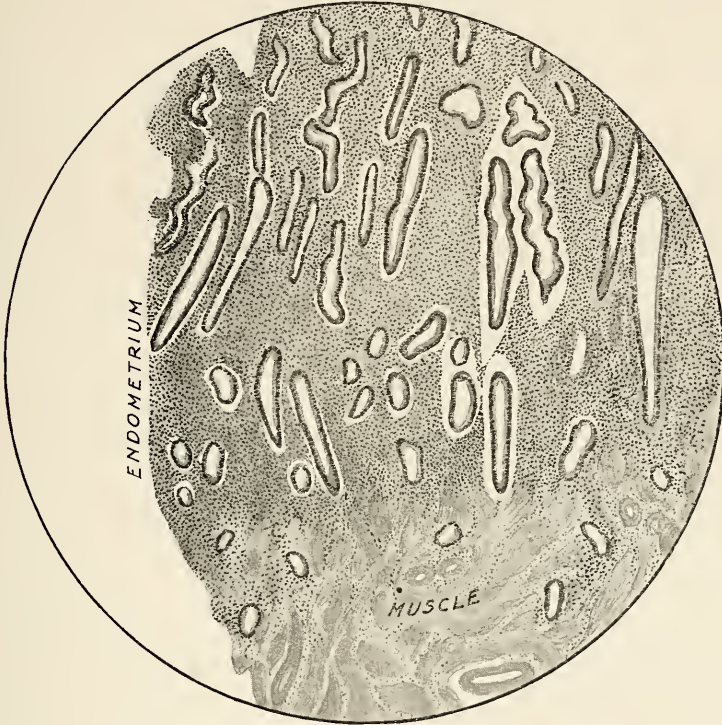


FIG. 11. NORMAL ENDOMETRIUM OF A PAROUS WOMAN (low power). The glands are numerous, fairly regular in outline, and some are slightly dilated. The deepest parts penetrate the muscular layer of the uterine wall.

which make up this membrane are (1) epithelium (surface and glandular) ; (2) stroma or interstitial tissue ; (3) blood-vessels and lymphatics.

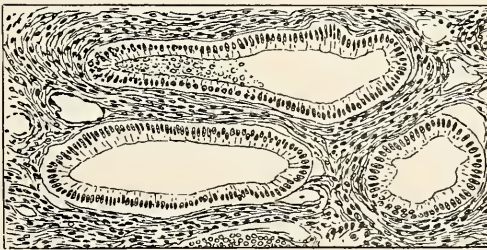


FIG. 12. THE GLANDS OF THE CORPOREAL ENDOMETRIUM (high power).

Nerve-endings cannot be demonstrated by our present methods of staining.

The *epithelium* of the corporeal endometrium consists of a single

layer of columnar ciliated cells resting on a basement membrane. The cilia are said to appear first at puberty and disappear at the climacteric. They are seldom well indicated in pathological conditions. The surface epithelium is invaginated at certain points, and these invaginations extend through the whole depth of the stroma and often into the superficial muscular strata. They form the glands of the corporeal endometrium. Their cells are of moderate height,

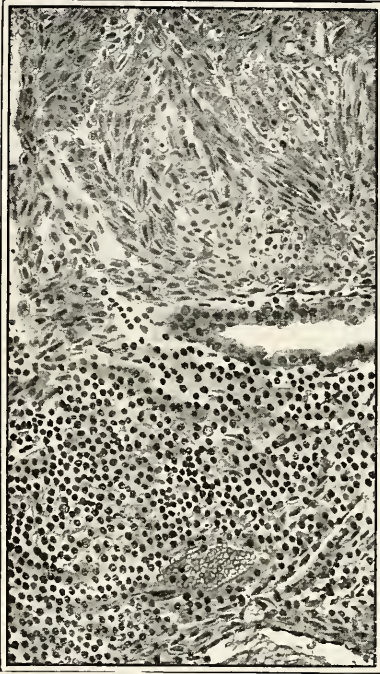


FIG. 13. THE STROMA OF THE CORPOREAL ENDOMETRIUM. In the lower part of the figure the lymphoid appearance of the stroma is well shown.

and the nuclei are unequally placed, being sometimes in the centre and sometimes in the basal third of the cell (see Fig. 12). They therefore differ from those of the cervical glands, where the cells are higher and the nuclei lie only at the base (see Fig. 14).

The glands are simple tubular structures, vertical in their superficial portion, slightly wavy, tortuous or spiral in the deeper part of their course. They are narrow where they open on to the surface, and become wider in the deeper parts, where they occasionally branch; but more common than branching is invagination of a portion of the gland-wall into the lumen, so that on section a small ring appears within a large one. The cilia of the cells may be traced into the upper part of the tubule, but they soon disappear and are not seen in the deeper portions. It has long been taught that the glands of the corporeal endometrium have no basement

membrane to their epithelium, but this is not correct. By suitable staining methods a basement membrane can be demonstrated as is shown in Pl. I (opposite p. 16). The cells secrete mucus. The amount of the secretion is very scanty, and goblet-cells are not usually found excepting when the membrane is inflamed and just before and during menstruation, when the mucus is abundant. Mucus therefore forms an important constituent of the menstrual fluid.

*The stroma or interstitial tissue* is composed of a network of embryonic mesoblastic tissue, in which are cells of irregular shapes and sizes. Their nuclei are relatively large, almost filling the cell-body, and contain one or more well-marked nucleoli. The usual shape of a stroma-cell is bluntly elliptical, but it may be round or



fusiform. There is no definite arrangement of the cells beyond the fact that they often aggregate in whorls around the gland-tubules and the blood-vessels. They appear to vary according to their position, being larger near the surface, where the network is more open, and smaller nearer the muscle. The network supporting the cells is composed of collagen-fibrils and is best seen in sections stained by Mallory's polychrome methylene blue (see Pl. I). In addition to the above irregular stroma-cells, there are others resembling round lymphocytes (see Fig. 13). To these the stroma owes its lymphoid appearance, and some authorities regard them as young formative connective-tissue cells. Whatever their origin they are present in great numbers, and from their resemblance to mononuclear and polynuclear leucocytes they make the diagnosis of a true inflammatory process difficult. In addition to the cells, the collagen-meshes often contain granular material which is probably coagulated serum.

*Blood-vessels.* Dilated capillaries, composed of a single layer of endothelium (see Pl. I), run through the whole thickness of the endometrium; some are placed vertically and may branch, others run a horizontal course. Deep in the stroma the vessels may become tortuous. The normal stroma, however, contains no vessels with fibromuscular walls.

As the structure of the corporeal endometrium varies with the menstrual cycle, no single picture can be made to present all its physiological characteristics, so that for further information on this important structure the student is referred to the section dealing with the Anatomy of Menstruation (see p. 89).

*The Cervical Endometrium.* Like that of the body of the uterus this membrane consists of a surface epithelium, with stroma and glands. The epithelium is again of columnar type and is continuous at the internal os with that investing the cavity of the uterine body.

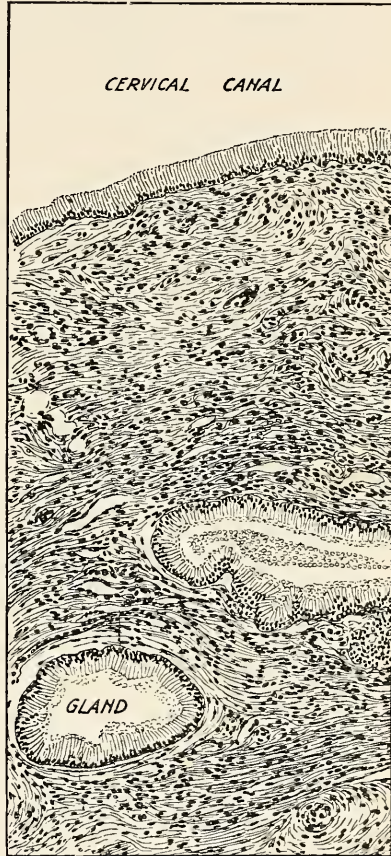

FIG. 14. SECTION THROUGH THE CERVICAL ENDOMETRIUM. The surface epithelium consists of a single layer of high palisade cells, the stroma is less cellular and contains much more fibrous tissue than that of the uterine body.

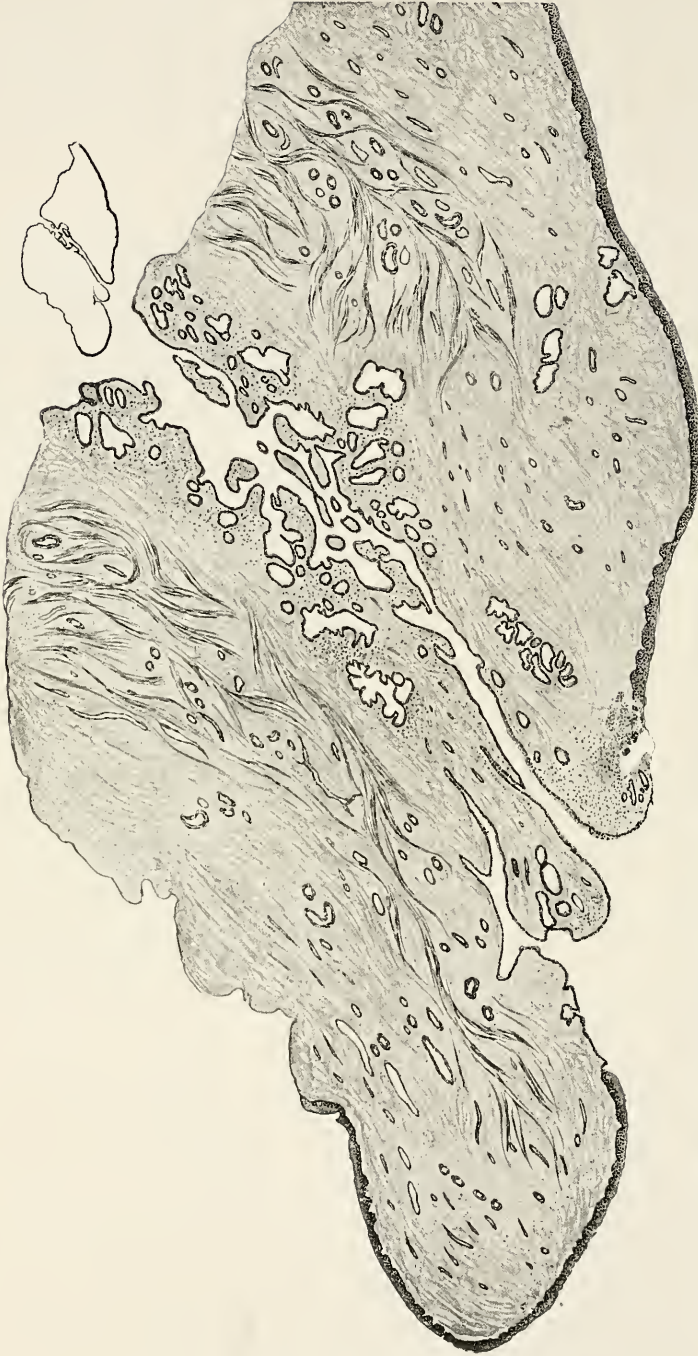

FIG. 15. SHOWING A SAGITTAL SECTION THROUGH THE VAGINAL PORTION OF THE CERVIX. The squamous epithelium of the vaginal surface is continuous at the margin of the external os with the columnar epithelium of the cervical canal. The appearance of the normal cervical endometrium should be specially noted. The anatomical folds resemble an archipelago when cut across. The inset shows the outline of the section cut for microscopic examination.

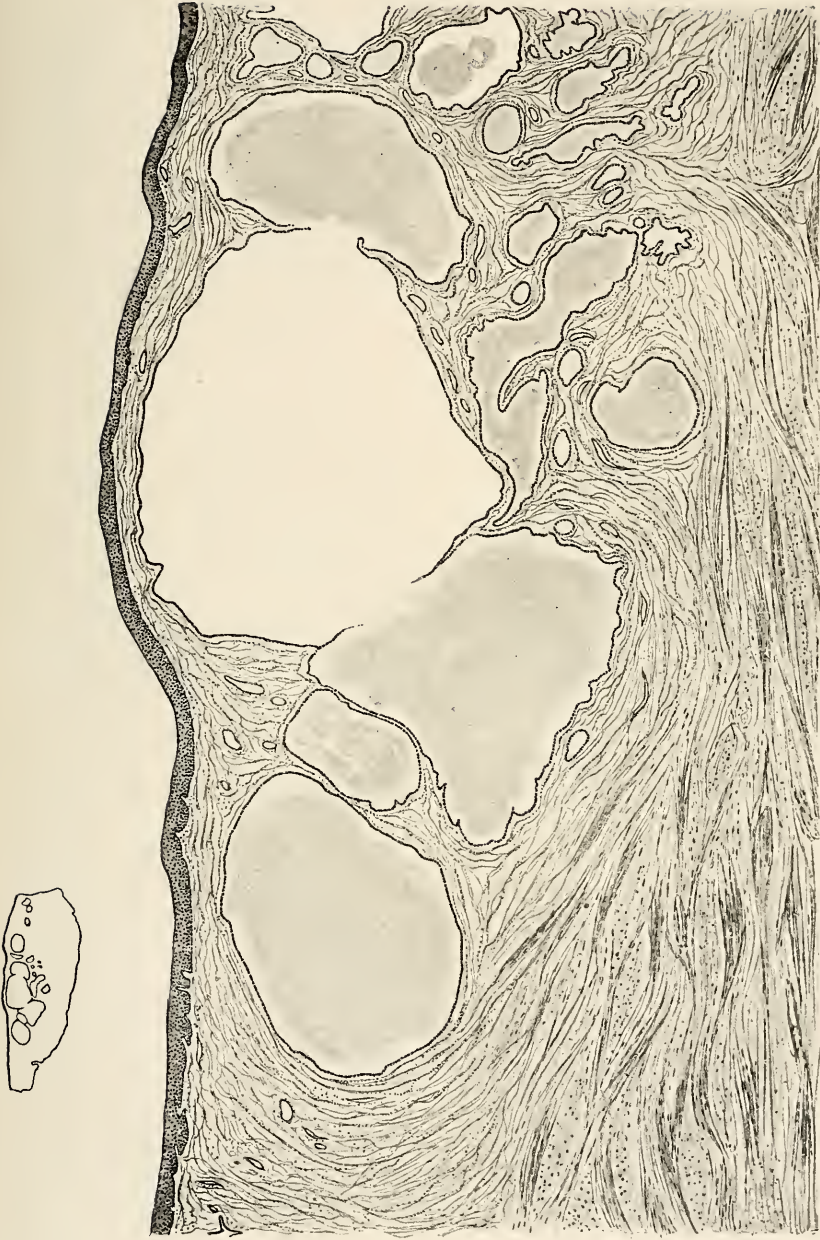

FIG. 16. SECTION OF THE VAGINAL PORTION OF THE CERVIX, showing dilatation of the glands and the formation of Naboth's ovules. The inset shows the naked-eye appearance of the section.

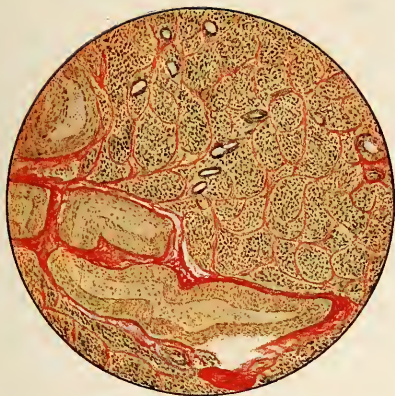The individual cells are much higher than those of the body, and their nuclei are basal, not centrally situated. The investing epithelium covers the elevations known as the *arbor vitæ*, and at the external os fuses with the squamous epithelium of the portio. It is also continuous with the epithelium of the glands which lie in great numbers in the stroma.

The stroma presents a striking contrast to that of the corporeal endometrium, since in the cervix there is no specialized arrangement required for menstruation. The glands do not expand and subside under the influence of an ovarian stimulus, and therefore there is no need for a soft expansile bed of embryonic tissue to surround them. The stroma, therefore, is composed of tissue closely resembling that of the general fibro-muscular wall of the cervix into which it insensibly passes (*see* Fig. 15).

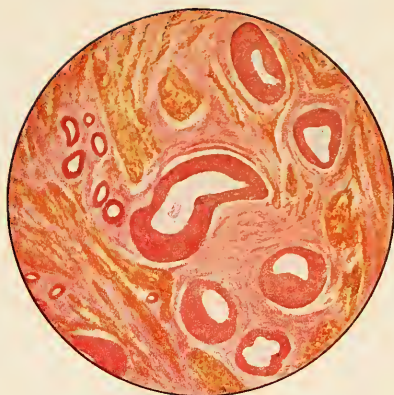The cervical glands are much more numerous than those of the body. Some are simple, but most are compound racemose structures which penetrate deeply into the fibro-muscular tissue and communicate with the surface upon which they pour their secretion. Dilatation of the terminal portions is frequently seen, and these dilated parts may enlarge, forming small retention cysts, visible and palpable upon the surface of the cervix, the so-called Naboth's ovules (*see* Fig. 16). Occasionally one of these follicles may be found to open upon the surface of the portio. The cervical glands produce an abundant secretion which is rich in mucin, alkaline in reaction, and to the naked eye resembles white-of-egg, being clear, colourless, viscid, and tenacious.

The point of transition between the cylindrical epithelium of the cervical mucosa and the squamous epithelium covering the portio is found, as already stated, at the external os (*see* Fig. 15). Exceptions may occur in the foetus, for the cylindrical epithelium may spread over the surface of the portio (Ruge). In the adult the same variation may occur in the pathological condition called cervical 'erosion.' In some cases, on the other hand, extension of the squamous epithelium into the cervical canal has been observed in the adult.

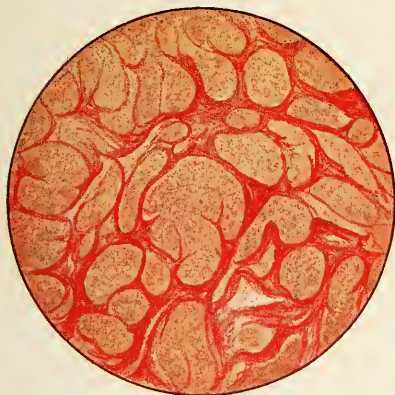
*The Musculature.* By far the greater part of the uterine wall consists of plain muscle and fibrous tissue. In the body the muscle-fibres are arranged in well-defined bundles separated by planes of well-developed fibrous tissue. The relative proportions of muscle and fibrous tissue vary with age; thus before puberty the proportion is as 2 to 3; after puberty a great relative increase of muscle occurs, the proportion being 3 to 2 (Pl. II*a*); after the climacteric the muscle gradually diminishes until the proportion of 2 to 3 is again reached (Pl. II*b*). The high proportion of muscle thus occurs during the period of sexual activity, when it is required for the control of menstrual bleeding, and to form the basis of uterine hypertrophy in pregnancy.



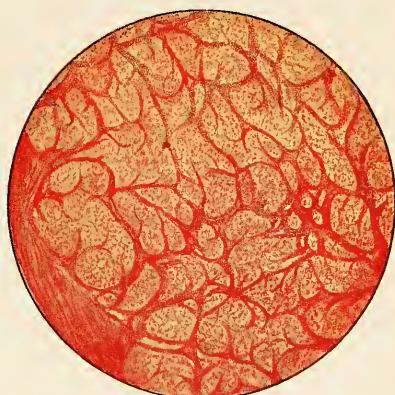
*a.*



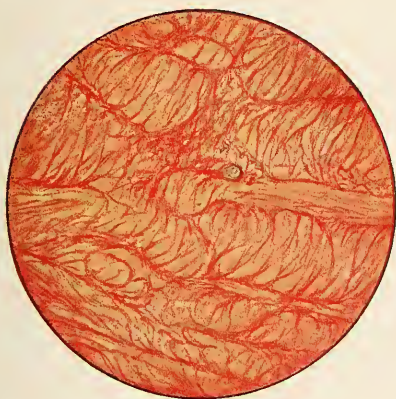*b.*



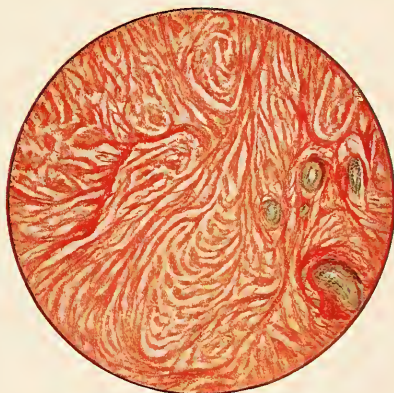*c.*



*d.*



*e.*



*f.*

*a.* MUSCULATURE OF VIRGIN UTERUS AFTER PUBERTY.  
*b.* MUSCULATURE OF SENILE UTERUS AFTER MENOPAUSE.  
*c, d, e, f.* MUSCULATURE OF PAROUS UTERUS BEFORE MENOPAUSE.



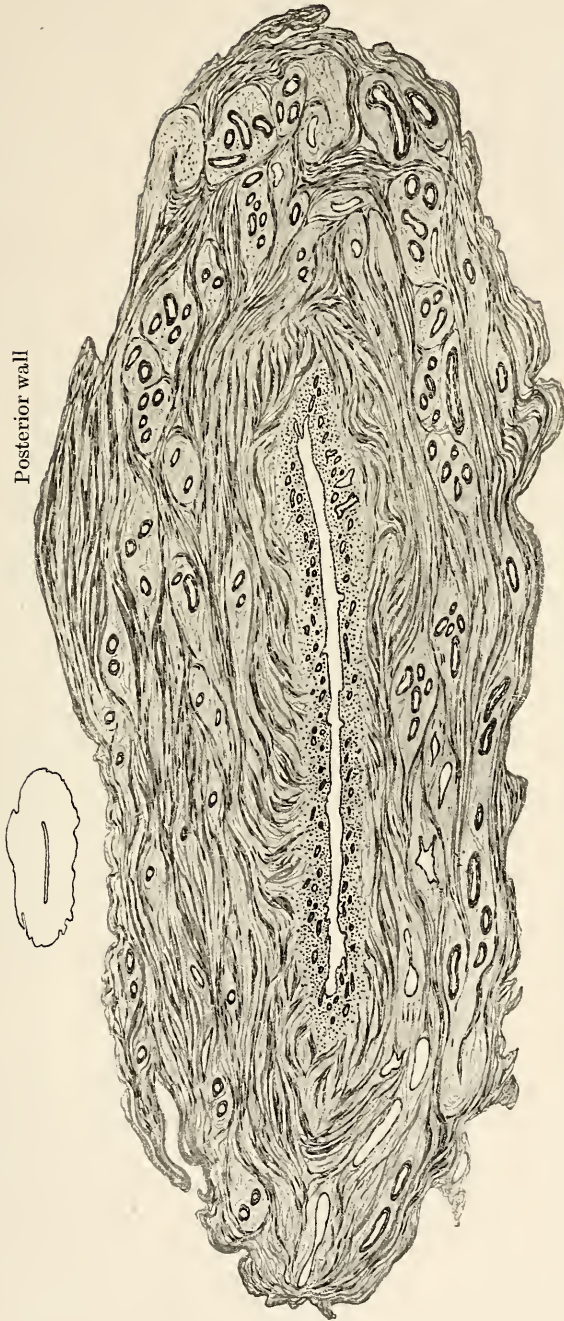


FIG. 17. TRANSVERSE SECTION THROUGH THE UTERINE BODY, showing the arrangement of the musculature. The submucous layer is the thickest. External to this, the vascular layer is represented by circular bundles around the blood-vessels; it is thicker posteriorly. The subserous (external) layer is thinnest of all.

In the cervix muscular and fibrous tissues are interwoven to form a dense reticulum in which individual bundles or planes cannot be distinguished. In the body the arrangement is more definite. Thus Tandler describes (1) a *subserous*, (2) a *vascular*, and (3) a *submucous* muscle layer, but states that these layers are difficult to separate one from another, and in places this is impossible, since they are so much interwoven. The best developed is the vascular layer, the arrangement of which is principally circular (in rings) (Pl. IIc).

Developmentally two layers of muscle are to be distinguished, one which develops around Müller's ducts, and a second which forms beneath the mucous membrane. The latter is described in Quain's "Anatomy" as the "muscularis mucosæ," and is there stated to be the thickest of all the layers. The vascular layer was regarded by Williams as the dividing-line between the "muscularis mucosæ" and the muscle-wall proper.

The musculature is best studied in the gravid uterus at term, when the fibres increase in length from  $\frac{1}{100}$  inch to  $\frac{1}{40}$  inch, and to this hypertrophy, hyperplasia, or increase in number, is probably added. The *subserous lamina* is then found to consist of a thin superficial sheet immediately beneath the peritoneum and of incomplete strata situated more deeply. This sheet begins as longitudinal bands at the cervix, which arch over the body and fundus, and pass into the broad ligaments at the sides, where they run on to the round ligaments, ovarian ligaments, and Fallopian tubes. Other fibres of this layer run from the cervix backwards beneath the utero-sacral folds of peritoneum. The *vascular lamina* (inner layer of Quain) is thickest posteriorly; it also arches over the fundus and runs irregularly or in circles around the blood-vessels, the position of the vessels corresponding to the submucous areolar tissue of other hollow viscera. The *submucous lamina*, termed by Quain the "muscularis mucosæ," consists of numerous concentric rings round the openings of the Fallopian tube, the widest circles of which meet in the middle of the uterus, whilst lower down they form the sphincters of the os internum and os externum.

*Elastic Tissue.* There is very little elastic tissue in the normal nulliparous uterus, but what exists is distributed as follows: (1) a thin lamina (*elastica interna*) in the inner coat of the arteries; (2) a certain amount in the middle coat of the veins; (3) a certain amount in the form of fine fibrils between the muscle-bundles. In cases of sub-involution a marked excess of elastic tissue is found, which forms one of the most characteristic features of this condition (see p. 421).

The *blood-vessels* penetrate all the fibro-muscular planes, but are best studied in the vascular lamina, where large arterial and venous channels are seen. The arteries run a spiral course, and for their size possess very thick walls. In the uterus of adults, vessels are



frequently found showing well-marked degenerative changes. It is probable that such changes form part of the normal process of involution, and being arrested at a certain point become permanent. After the climacteric hyaline degeneration occurs, involving all the coats of the arteries (Pl. IIb).

*The Lymphatics and Nerves.* The uterus is abundantly supplied with lymphatics and nerves. The former will be considered along with the other pelvic lymphatics. The nerves of the uterus come from the sympathetic system, through which the organ is brought into intimate relation with the central nervous system and also with the other abdominal viscera.

*The Peritoneum.* The peritoneal coat of the uterus completely covers the fundus and is reflected thence on to the round ligament and Fallopian tubes. The anterior and posterior surfaces of the body are completely covered with peritoneum, but upon the lateral aspect a considerable part has no peritoneal covering. This bare area is roughly triangular in shape, with the apex above, the base below at the level of the os internum (*see* Fig. 19). The cervix has no peritoneal covering on the front and sides, but the posterior surface of the supra-vaginal portion is covered by the peritoneum which passes from the back of the uterus down to the floor of the pouch of Douglas. Generally speaking, the peritoneum is firmly adherent to the subjacent muscle; but upon the lower part of the anterior wall, extending for about  $\frac{1}{2}$  inch above the internal os, there is an upward extension of cellular tissue beneath the peritoneum, which allows of its being stripped off the uterine wall. This area indicates the position in which the lower uterine segment is developed towards the end of pregnancy.

**The Uterine Attachments.** The attachments of the uterus may be enumerated as follows:

- (1) The broad ligaments.
- (2) The round ligaments.
- (3) The utero-sacral ligaments.
- (4) The transverse ligaments of the cervix.
- (5) The cervico-vaginal insertion.

*The Broad Ligaments.* These are double folds or duplications of peritoneum continuous with that covering the uterus, and reflected from it at its lateral borders. As seen in the living subject or in the cadaver, they form loose lateral folds which run from the uterus outwards and slightly backwards to the pelvic brim. When stretched, the broad ligament is roughly quadrilateral with upper, outer, lower and inner borders. The upper border is free and contains the Fallopian tube between its folds as far as the abdominal ostium, which is intra-peritoneal. From this point to the pelvic wall the upper border is free and is distinguished as the *infundibulo-pelvic fold*. The ovarian vessels run in the upper one-third of this fold. The outer border is

attached to the lateral pelvic wall along a line running obliquely from the external iliac vessels downwards, forwards and inwards to the pelvic floor. The inner border is attached to the sides of the uterus and is reflected on to the vaginal fornices. The lower border is short and unequal, the posterior peritoneal fold passing to a lower level than the anterior. In the normal position of the uterus the broad ligament is inclined forwards, so that its surfaces are directed, the one upwards and backwards, the other downwards and forwards (see Fig. 2).

The ovary is attached to the posterior peritoneal layer of the

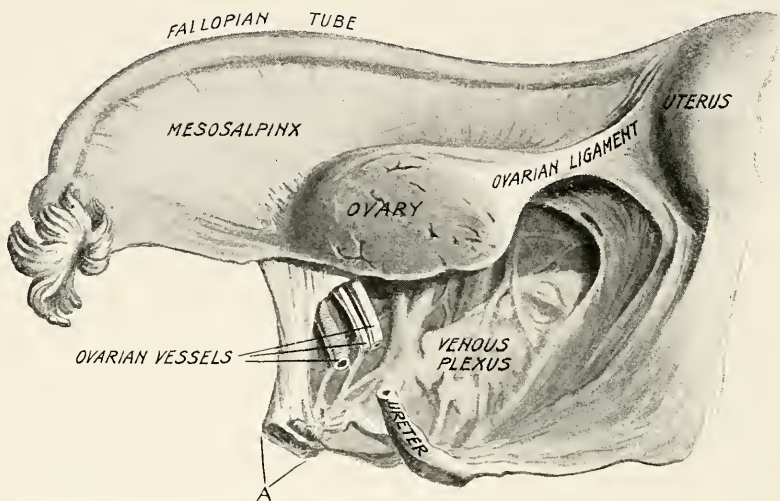


FIG. 18. THE POSTERIOR ASPECT OF THE BROAD LIGAMENT. A. Infundibulo-pelvic fold (Charing Cross Hospital Museum).

broad ligament; from the inner pole of the ovary to the cornu of the uterus runs the *ligamentum ovarii proprium*, a strong sub-peritoneal band of muscular and fibrous tissue (see Fig. 18). The infundibulo-pelvic fold is sometimes called the *suspensory ligament of the ovary*. The ovarian attachment divides the posterior surface of the broad ligament into an upper and a lower portion. The upper portion which lies between the Fallopian tube and the ovary is called the *mesosalpinx*; it is thin, translucent, contains little cellular tissue, and in it is found the parovarium (ep-oöphoron) with the beginning of the duct of Gartner. The lower part (*mesometrium*) is much thicker than the upper and widens rapidly as the pelvic floor is approached, so that the base contains a large amount of cellular tissue in which lie vessels and other important structures.

The anterior surface of the broad ligament is shallow and is crossed by the round ligament which runs obliquely beneath the peritoneum from the uterine angle to the internal abdominal ring. The peritoneum is reflected over the bladder and utero-vesical ligaments to the

anterior pelvic wall. The posterior surface of the broad ligament is much deeper than the anterior and is reflected over the utero-sacral ligaments and pararectal folds to the posterior pelvic wall, and is also continuous with the peritoneum covering the pouch of Douglas.

Morphologically the broad ligaments correspond with the mesentery

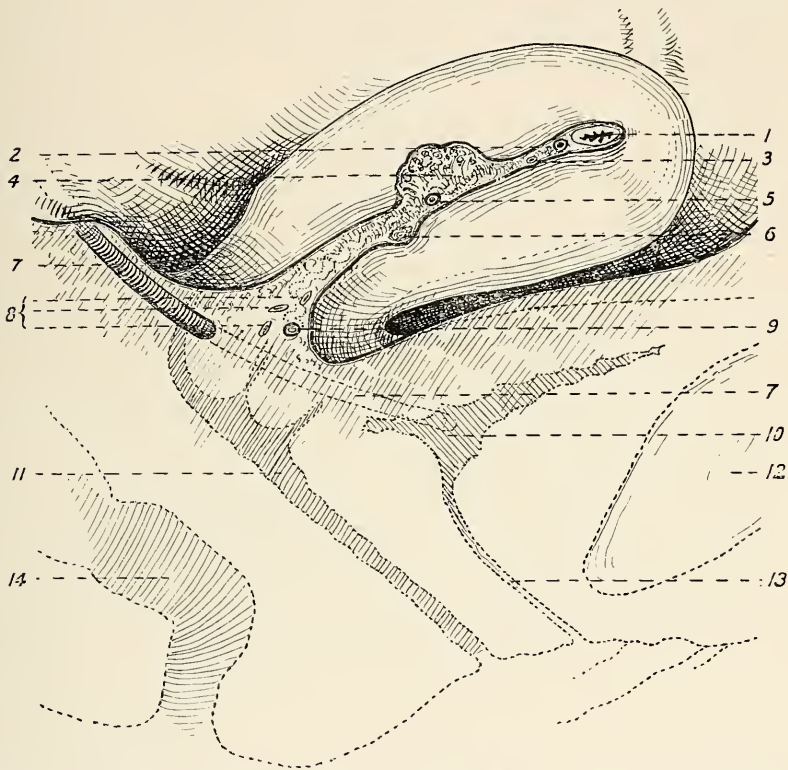


FIG. 19. SECTION THROUGH THE BROAD LIGAMENT ABOUT 1 INCH OUTSIDE THE UTERINE BORDER (diagrammatic). 1. Fallopian tube. 2. Tubal branch of ovarian artery. 3. Parovarian tubule. 4. Ovary. 5. Ovarian artery. 6. Round ligament. 7. Ureter. 8. Uterine veins. 9. Uterine artery. 10. Bladder. 11. Vagina. 12. Symphysis pubis. 13. Urethra. 14. Rectum.

of the intestine and are developed in a similar manner. They serve to tether the uterus while not impeding its mobility within a certain range. Between the layers of the broad ligament are enclosed a number of important structures. In the upper part are found the Fallopian tube, the round ligament, the ovarian ligament, the parovarium, and the anastomotic branch of the ovarian artery. In the lower part are found the ureter, the uterine vessels, the duct of Gartner, one or two small lymphatic glands, and a thick but variable mass of cellular tissue. The relations of these structures are illustrated diagrammatically in Fig. 19.

*The Round Ligaments.* These are a pair of slender cordlike structures, which arise from the anterior aspect of the uterine cornua and pass at first downwards and outwards beneath the anterior peritoneal layer of the broad ligament; then curving forwards and slightly upwards they cross to the internal abdominal ring. Passing down the inguinal canal they split up and become attached to the subcutaneous tissues of the labia majora. The peritoneal covering of the round ligament is lax and allows of the ligament being freely raised from its bed, so that it can be made use of in various surgical procedures.

The round ligaments are composed almost entirely of plain muscle. As seen in the living subject they are lax structures of variable thickness. They may in some instances be nearly as thin as a surgical probe; in others, nearly as thick as a lead pencil. Their course is curved, and they leave the abdominal cavity at a point which may be, and often is, on a plane posterior to that of the fundus of the normal anteverted uterus. These points indicate that they play but a subsidiary part as uterine supports. Developmentally, they are vestigial structures corresponding to the *gubernaculum testis* in the male (*see p. 85*). During pregnancy they undergo remarkable hypertrophy, from which it may be inferred that they are not entirely functionless structures.

*The Utero-sacral Ligaments.* These structures consist of a duplication of peritoneum containing a variable amount of firm, fibrous tissue with a little plain muscle. When divided during operative work they are seen to be firmer and stronger than the other 'ligaments' of the uterus (*see Fig. 20*). They run from the posterior aspect of the sides of the cervix at the level of the internal os, backwards to the anterior surface of the lower end of the sacrum, the rectum curving upwards over the ligament of the left side. As they run backwards, they diverge slightly from one another. They form the upper boundaries of the lateral walls of the pouch of Douglas and divide the posterior pelvic compartment into three fossæ (*see Figs. 2, 3, and 20*). In the living subject they vary greatly in thickness, being in some cases much better developed than others. They tether the cervix to the posterior pelvic wall, and when well developed may offer resistance to excessive forward displacement of the cervix. A small branch of the uterine artery accompanies each ligament. These ligaments can be palpated through the rectum, and when thickened by inflammatory or other morbid processes they will be readily felt.

*The Transverse Ligaments of the Cervix (ligamenta transversa collis).* These structures, described by Mackenrodt, are bands of firm, fibrous tissue which form specialized parts of the visceral layer of the pelvic fascia. Arising in the neighbourhood of the ischial spines, they pass through the pelvic cellular tissue and are attached to the sides of the cervix and vaginal walls. Unlike the other uterine liga-

ments, they have no special peritoneal covering. According to some anatomists they form part of the sheaths of the uterine arteries, which reach the uterus at about the same level.

*The Cervico-vaginal Insertion.* The uterus is attached more firmly

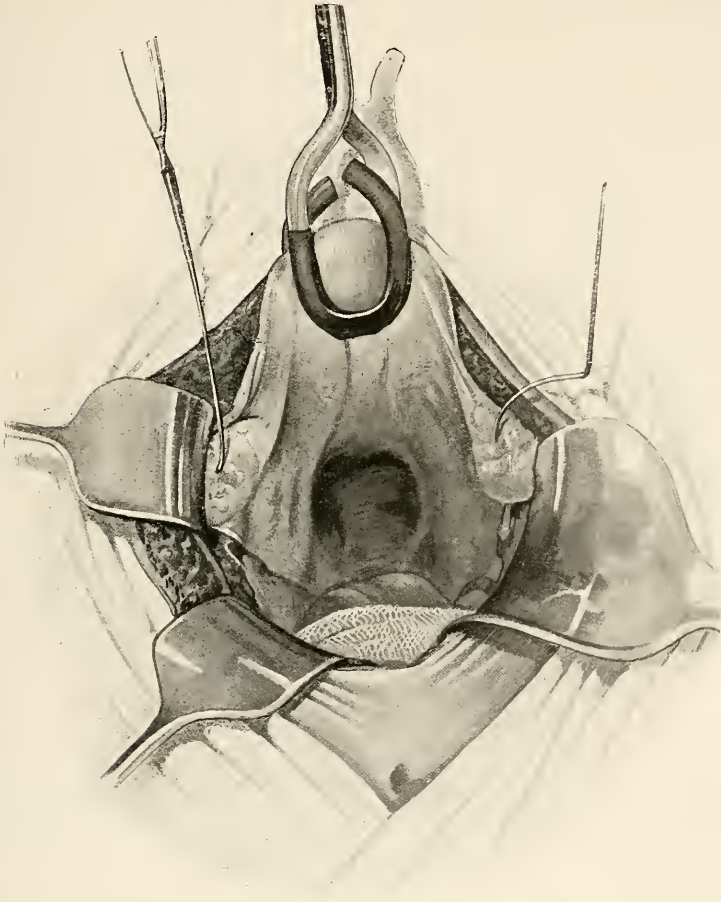


FIG. 20. SHOWING THE UTERUS DRAWN FORWARD AND THE OVARIES HELD ASIDE IN ORDER TO DEMONSTRATE THE POUCH OF DOUGLAS AND THE UTERO-SACRAL FOLDS, AS SEEN DURING OPERATION WITH THE PATIENT IN THE HIGH PELVIC POSTURE.

to the vagina than to any other structure. The upper end of the vagina is inverted, forming a cup-shaped depression which receives the vaginal portion of the cervix. The fibro-muscular tissues of the cervix and vagina are intimately blended, and the stratified epithelium of the latter is continued over the cervical surface up to the external os. Separation of the cervix from the vagina is impossible, except by cutting, as there is no intervening plane of cellular tissue, and the continuity of the two organs is complete. This intimate union

forms the principal support of the vaginal tube, which in the remainder of its course is surrounded by a sheath of loose cellular tissue.

**The Pelvic Floor.** The structures composing the pelvic floor and the general supports of the pelvic viscera will be more conveniently described in a later section dealing with Displacements (*see* p. 562).

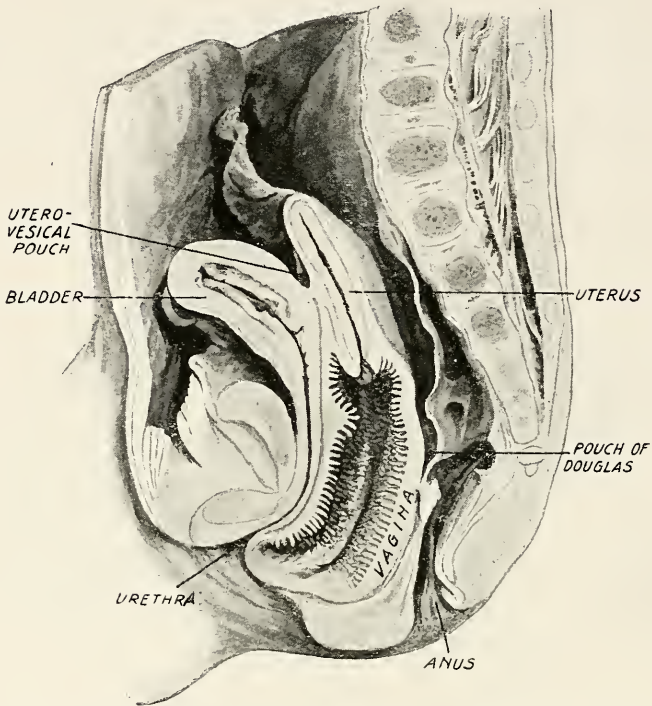


FIG. 21. SAGITTAL SECTION OF THE FŒTAL PELVIS OF SEVEN TO EIGHT MONTHS DEVELOPMENT (Charing Cross Hospital Museum). Both uterus and bladder extend above the pelvic brim; the cervix is equal in length to the body of the uterus; the vaginal rugæ are very prominent.

**The Uterus at Different Periods of Life.** In the *fœtus* at about the seventh month the uterus lies above the pelvic brim, *i.e.* at a higher level than in the adult. *The cervix is about equal to the body in length*, and the arrangement of the cervical endometrium, known as the arbor vitæ, has already appeared. The uterine axis is straight and nearly vertical. At *puberty* the uterus begins to grow rapidly, the body more rapidly than the cervix, until the adult proportions have been reached. The angle between the body and the cervix has now appeared; the whole organ has become anteverted and has sunk until it lies below the level of the pelvic brim. The proportion of muscle in the wall of the uterine body increases greatly, but this is not seen in the cervix to the same extent.

After *child-bearing* the uterus, as a rule, remains permanently enlarged; the cervix shows traces of more or less extensive lacerations, and the external os is enlarged (see Fig. 294, p. 559). The wall of the organ on section is seen to have increased in thickness, both mucous membrane and musculature participating in this change. The uterine cavity

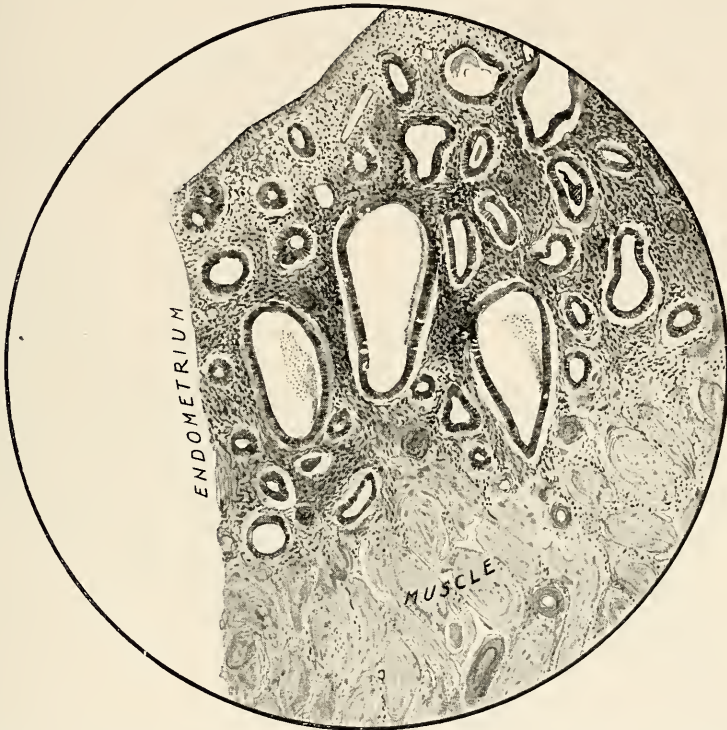


FIG. 22. THE ENDOMETRIUM AFTER THE CLIMACTERIC. Multipara, aged 68. The mucosa is thin, and many of the glands are dilated, but their epithelium is well preserved.

is also larger than in a nullipara. In the musculature, arteries with thickened walls are usually to be found; sometimes the chief thickening is in the intima, and vessels thus affected may become obliterated; in others the media and adventitia are the seat of the thickening. This thickening is due to a deposit of hyalin in the fibro-muscular tissue of the vessel-wall. Around the vessels the supporting fibrous tissue is largely replaced by elastic tissue which can be demonstrated by Weigert's elastic-tissue stain.

After the *menopause* the uterus shrinks in size and in weight. The shrinkage is especially evident in the cervix, for the *portio* usually disappears, leaving the os externum as a small aperture flush with the surface of the vaginal wall. The endometrium also atrophies, but this process is very slow, and in a woman who has passed the

menopause for several years a fairly thick endometrium with numerous glands and well-formed epithelium may be found (*see* Fig. 22). Many of the arteries in the musculature become obliterated, and patches of calcareous degeneration may appear in their coats (Pl. II*b*, opposite page 22). Much of the muscle in the uterine wall disappears, being replaced by fibrous tissue.

### THE FALLOPIAN TUBES

Representing morphologically the upper non-united portions of the Müllerian ducts, the Fallopian tubes are continuous with the uterus

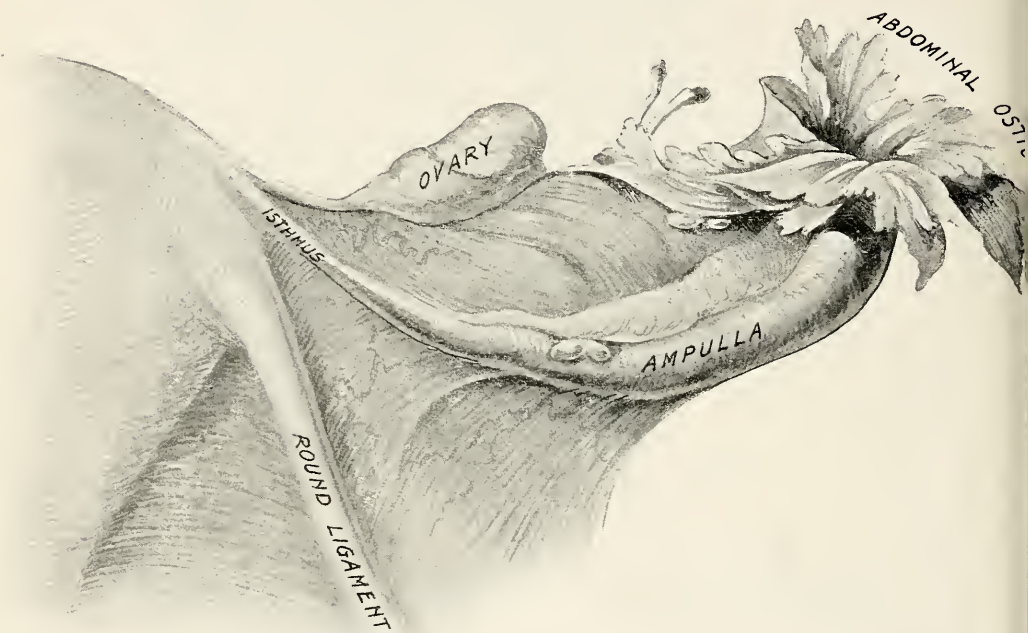


FIG. 23. THE FALLOPIAN TUBE (Richard). The figure also shows the relations of the three structures which are attached to the uterine cornu, viz. the ovarian ligament, the Fallopian tube, and the round ligament.

below, while the upper ends lie free in the pelvic peritoneal cavity. Each tube is attached to the corresponding cornu of the uterus, and measures from 4 to 4½ inches in length. At first it runs horizontally outwards from the uterus, then at the junction of its inner and middle thirds, it turns backwards and, describing a curve directed upwards, backwards and inwards, it surrounds the outer pole of the ovary. In infancy the tube is slightly convoluted, but this disappears by the time



puberty is reached. For descriptive purposes the tube is divided into three portions: the *interstitial* or *uterine* portion passing through the uterine wall, about  $\frac{1}{2}$  to  $\frac{3}{4}$  inch in length; then the *isthmus*, a narrow cylindrical portion corresponding to the inner third (see Fig. 23); lastly the *ampulla*, which corresponds to the curved portion, and has the shape of a very narrow funnel gradually widening to its termination. The upper free end of the tube forms the *abdominal ostium*; around it the tube-wall is divided in a digitate manner into a number of *fimbriæ* (see Fig. 23), one of which is longer than the rest, and usually reaches the ovary with its tip (*ovarian fimbria*). The interstitial portion is very narrow, having a lumen of 1 mm. in diameter; the isthmus is somewhat wider, while the ampulla gradually enlarges to a diameter of 4–5 mm. before reaching the abdominal ostium, which opens directly into the peritoneal cavity.

Structurally the tube consists of an outer peritoneal coat, a middle muscular coat, and a lining of mucous membrane. It lies between the layers of the broad ligament, the upper border of which forms its outer coat; accordingly the floor of the tube, corresponding to about one-sixth of its circumference, has no peritoneal covering, but lies in the interval between the layers of peritoneum (see Fig. 19). The part uncovered by peritoneum is greater in the isthmus than in the ampulla. Beneath the peritoneum is a thin layer of highly vascular and loose cellular tissue (the *subserosa*), which is most abundant along the floor of the tube.

The muscular wall is thicker in the outer than the inner part of the tube. The muscle is non-striated and arranged in three layers: a thin, outer longitudinal layer; a thick, middle circular layer, and an incomplete inner layer, which is also longitudinal and passes into the plicæ of the mucosa. There is no *submucosa*, so that the mucous membrane rests directly on the muscle.

The mucous membrane is continuous at one end of the tube with the endometrium, at the other with the peritoneum. It consists essentially of a single layer of columnar, ciliated epithelium, supported by a very thin layer of cellular tissue. There are no glands in the tubal mucosa. The general characters of the mucous membrane differ in different parts of the tube, but from end to end it is traversed by three well-defined longitudinal folds. In the interstitial portion these folds are simple and shallow; in the isthmus they are more numerous and not simple, but divided (see Fig. 24); in the ampulla they form a complex arborescent mass of curling, slender processes, known as the *plicæ* (see Fig. 25). The plicæ consist of a central core of finely interlaced connective tissue containing round and spindle cells; there are also a few elastic fibres and muscle-fibres. Some of these plicæ are simple, but the majority are compound, and some of the latter attain a considerable thickness; in the intervals between them the tube-wall is covered with but a thin layer of mucous membrane. The

lumen of this part of the tube accordingly consists of a complicated system of branching channels or interstices between the plicæ, with numerous *culs-de-sac* in all parts. When the abdominal end is reached the plicæ become smaller, the mucosa covering the fimbriæ showing comparatively few of them.

The tubal epithelium consists of a single layer of columnar ciliated cells ; the ciliæ are best developed in the ampullary portion, and

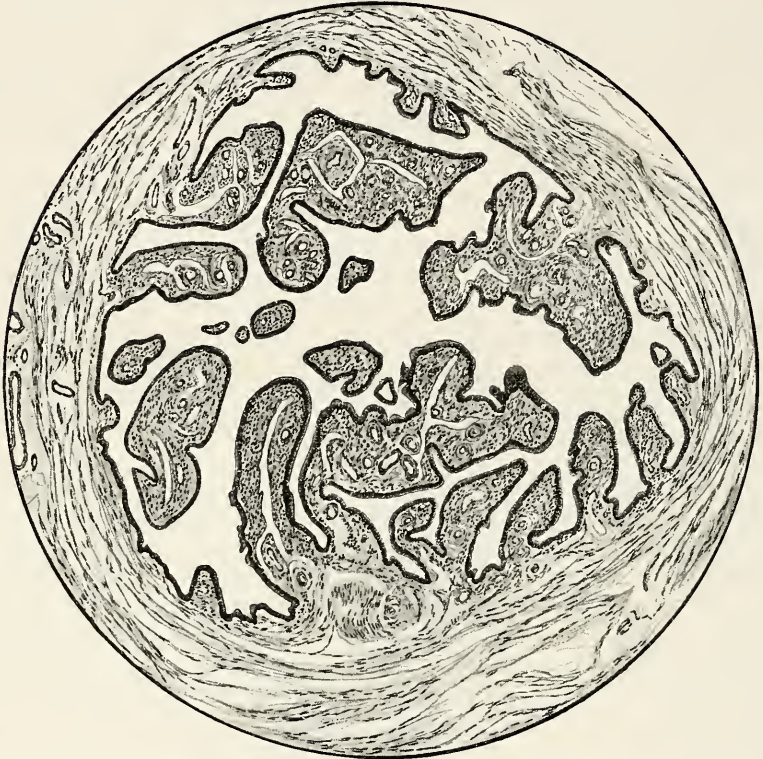

FIG. 24. TRANSVERSE SECTION THROUGH THE ISTHMUS OF THE FALLOPIAN TUBE.

their direction of movement is towards the uterus. Some of the cells are not ciliated but are concerned in the production of the tubal secretion, which is scanty, except in the premenstrual phase. Under normal conditions there is no tubal hæmorrhage during menstruation, but under pathological conditions it is said that this may occur.

Occasionally a second or *accessory abdominal ostium* surrounded by fimbriæ may be found upon the dorsal aspect of the ampullary portion (see Fig. 52). Occasionally, also, *diverticula* may be found in the same part of the tube, forming short tributaries of the main lumen ; they

are lined with a plicated mucous membrane, identical with the general tubal mucosa.

The tube is supplied with blood in the greater part of its extent from the tubal branches of the ovarian artery; the innermost part of the isthmus is supplied from the anastomotic branch of the uterine artery (see Fig. 44). The lymphatics pass in company with those from the uterine body to the iliac glands.

The continuity of its lumen with the uterine cavity below and the peritoneal cavity above, renders the tube liable to infection from both directions. Ascending infection is seen in gonorrhœa and sepsis, the morbid process spreading by direct continuity from the endometrium (see p. 287). Descending infection is seen in the case of tubercle (see p. 303), and possibly of malignant disease of the ovary or some other abdominal organ (see p. 638). Further, direct infection from the bowel or the vermiform appendix may occur when the tube becomes adherent to these organs. These considerations explain the extraordinary frequency with which the tubes become the seat of

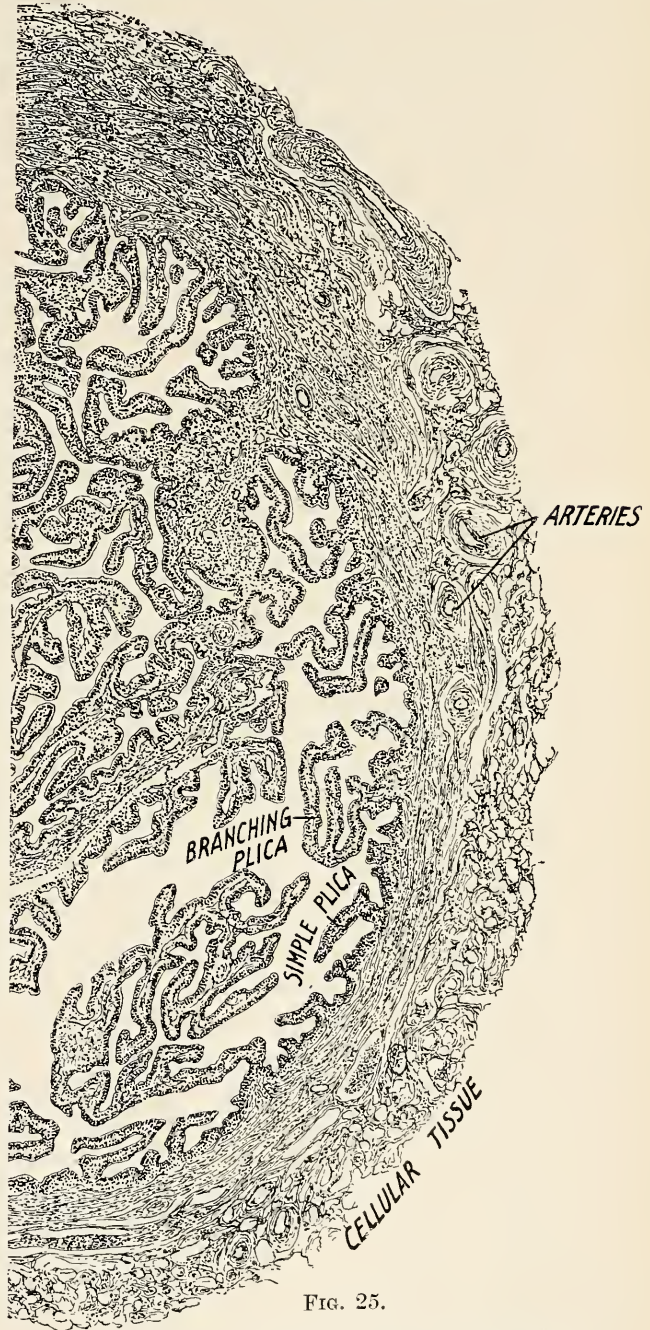

FIG. 25.

THE AMPULLA OF THE FALLOPIAN TUBE BISECTED

inflammatory changes. The anatomical conformation of the tubal mucosa favours the retention of infective material, and the development of the inflammatory process; and the small size of the uterine portion prevents anything like free drainage through the uterus from taking place. The numerous interstices between the tubal plicæ, and the occasional occurrence of diverticula, may help to explain the accidental detention of the fertilized ovum in the tube, which leads to tubal pregnancy.

## THE OVARY

The ovary is an organ which belongs to the class of ductless glands. In a young nullipara it is thin and flattened, resembling an almond; in older women it becomes larger, and more rounded in outline. Until ovulation begins its surface is smooth, later it becomes irregular from protrusion of ripening follicles and retention cysts. Scarring also occurs from repeated ruptures of ripe follicles; at the climacteric the ovary is often found so much roughened as to be likened to a peach-stone. Its general shape is oval. In an adult woman during the childbearing period of life, it varies a good deal in size and appearance. When seen during the maturation of a Gräafian follicle it is larger and more congested than during the resting stage. Its normal position is in the pelvic cavity, close to the lateral pelvic wall, where it is in relation in front with the external, and behind with the internal iliac artery. In multiparæ it is often found at a lower level than this, and may lie upon the floor of the pouch of Douglas.

The ovary is suspended from the back of the broad ligament (*see* Fig. 20) by a linear attachment corresponding to the *hilum* of the organ. Here the peritoneum ceases and gives place to the proper epithelial covering of the ovary, the line of transition being often recognizable to the naked eye as the *white line* of the ovary. To the uterine cornu it is slung by a well-developed, somewhat flattened, band of muscle and fibrous tissue, the *ligamentum ovarii proprium* (*see* Fig. 18). This ligament receives its blood-supply from the anastomotic branch of the uterine artery, which runs below it. The ovary has no peritoneal covering, and its attachments are such as to allow of a considerable range of mobility. One of the fimbriæ of the abdominal ostium of the tube—the *ovarian fimbria* usually touches the outer pole of the ovary, but does not afford it support. It is stated by Bland-Sutton that the ovary is sometimes furnished with a peritoneal hood, which is the homologue of the *tunica vaginalis testis*, but this statement lacks confirmation by other observers.

The exact position of the ovary, its inclination to the horizon, and the direction of its surfaces, though of interest to the anatomist, are questions which have no practical bearing, and therefore need not be discussed. The average size of the ovary in the adult is about

$1\frac{3}{4}'' \times 1'' \times \frac{1}{2}''$ , but healthy ovaries of nearly double this size are not uncommonly encountered.

The general characters of the ovary are best studied in specimens taken at some part of the child-bearing period of life (see Fig. 18 and Plate III). The outer surface is generally smooth and polished; not infrequently one or several small translucent cysts may be seen to protrude slightly from the surface; these are retention cysts formed by non-dehiscence or degeneration of Gräafian follicles. A mature follicle, or a recent corpus luteum may appear as a dark plum-coloured protrusion occupying a considerable area of the ovarian surface; or immediately after dehiscence it may be found collapsed, and possibly presenting a rent with slightly oozing edges.

When the ovary is bisected the cut surface is roughly oval in shape, the attached border (hilum) being straight (see Plate III, p. 44). The gland is usually divided for descriptive purposes into three areas: (a) *the cortex*; (b) *the medulla*; (c) *the hilum*. The *cortex* is the superficial area, crescentic in shape, forming the peripheral part of the gland. Immediately beneath the epithelial covering lies a layer of condensed fibrous tissue, often visible to the naked eye as a pale line, representing the *tunica albuginea*. The cortex contains the Gräafian follicles, and is, therefore, physiologically the most important part of the gland; morphologically it is distinguished as the *oöphoron* (egg-bearer). The *medulla* lies within the cortex, and is continuous with the hilum. It contains plain muscle, fibrous tissue, nerves, blood-vessels and lymphatics. The *hilum* attaches the ovary to the broad ligament. Through it pass the structures already mentioned as found in the medulla; they enter the ovary from the broad ligament. Upon the surface of the hilum is found the 'white line' of transition from peritoneum to ovarian epithelium already referred to.

The blood-supply is from the ovarian artery, which runs to the ovary along the outer free edge of the broad ligament, or infundibulopelvic fold. The vessels all enter at the hilum. The lymphatics drain into the lumbar chain of glands on the sides of the spinal column.

The nerve-supply of the ovary has been the subject of some dispute, but certain points are now definitely settled. The nerves arise from the sympathetic and enter at the hilum with the blood-vessels, being arranged in definite bundles. Within the ovary they break up into three sets of fibres. One set, *vascular fibres*, accompanies the vessels and are very numerous, forming a network around them. Another set proceeds direct to the follicles, *follicular fibres*, and is disposed concentrically around them, but does not penetrate further than the *theca interna*. The third set is distributed in the interstitial tissues—*interstitial fibres*, and groups of small cells, resembling ganglion cells, are found near them. The function of the ovarian nerves is probably, in the main vasomotor (Abel and McIlroy).

**Histology.** The surface of the ovary is covered with a single layer of cubical epithelium, the *capsular* or *germ-epithelium* (see Fig. 26). Although the direct representative of the embryonic hypoblast, its function is only protective. Careful preparation of the tissue is required to demonstrate the existence of these cells, which are very readily destroyed by preparation, but traces of them can be found in almost all cases up to the age of the menopause. The epithelium rests upon a basement membrane, which in turn rests upon the tunica albuginea, which encloses and protects the body of the gland. The tunica




FIG. 26. THE CAPSULAR EPITHELIUM OF THE OVARY IN THE ADULT, AND THE SUBJACENT TUNICA ALBUGINEA (high power)

albuginea is not clearly definable until puberty. At first it is thin, consisting only of three layers of cells. In later life it is thickened by the addition of two or three more laminæ of fibrous tissue. It cannot be stripped off, as its fibres are continuous with the connective tissue of the cortex.

At times there are found in the hilum small imperfect tubules lined with low cubical epithelium, often known as the *cords of Kölliker* or *rete ovarii*. These tubules are usually regarded as relics of the embryonic tubules of the Wolffian body, but according to certain recent writers they are derivatives of the embryonic hypoblast of the germ.

The cortex contains the essential elements of the ovary, the Gräafian follicles, embedded in a stroma, which has special characters. The number of Gräafian follicles present in the ovary of a foetus at term has been estimated at 30,000. Post-natal formation of follicles never occurs. The stroma is highly cellular; only in two portions, viz. beneath the germ-epithelium and along the lines of the vessels, are connective-tissue fibres to be found. The remainder of the cortex is not fibrillar, and consists of an aggregation of cells, some round, others fusiform, others polygonal, many of which show delicate processes. They contain large, round or oval nuclei, and are to be regarded as modified connective-tissue cells. Their varied characters

must be borne in mind in connection with the microscopical detection of certain new growths and inflammatory processes.

In lower mammals the interstitial (stroma) cells of the ovary are much larger and more numerous than in the human ovary. In the rabbit and rat their development has been traced to the germ-epithe-

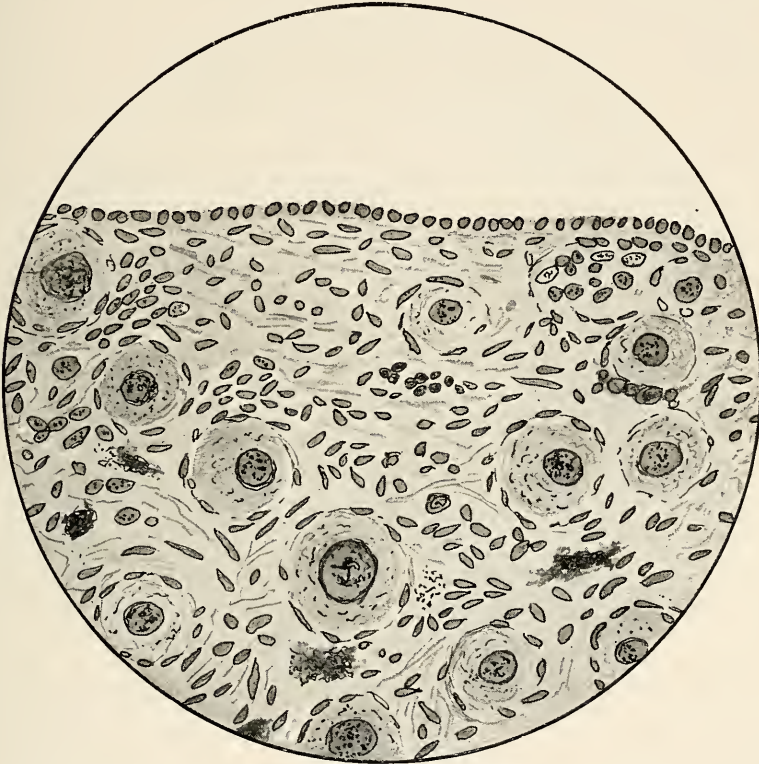


FIG. 27. THE CORTEX OF THE OVARY OF A CHILD (Stevens), showing the capsular epithelium, and the numerous primordial follicles, containing egg-cells.

lium (Lane Claypon), and they are probably of considerable physiological importance.

The cortex is divisible into four layers. Externally is the layer of capsular epithelial cells; underneath this comes the *tunica albuginea*; the third layer contains the *primordial* follicles, which are very irregularly arranged and exist in large numbers even in the adult; this gradually merges into the fourth layer, which contains the older follicles, some being visible to the naked eye.

**The Gräafian Follicle.** The structure of the Gräafian follicle will be best understood by tracing its development. There are three stages in the development of a follicle, viz. (1) the primordial follicle, *i.e.* the earlier stage; (2) the ripening follicle; (3) the mature follicle.

*Primordial follicles* are formed at an early period of embryonic

life by the downward growth of small processes from the germ-epithelium into the underlying mesoblast-cells. These processes are attacked by the mesoblast-cells and cut up into small portions, known as egg-nests. These again in turn become further broken up, until finally a large number of structures appear which consist of (1) a large central

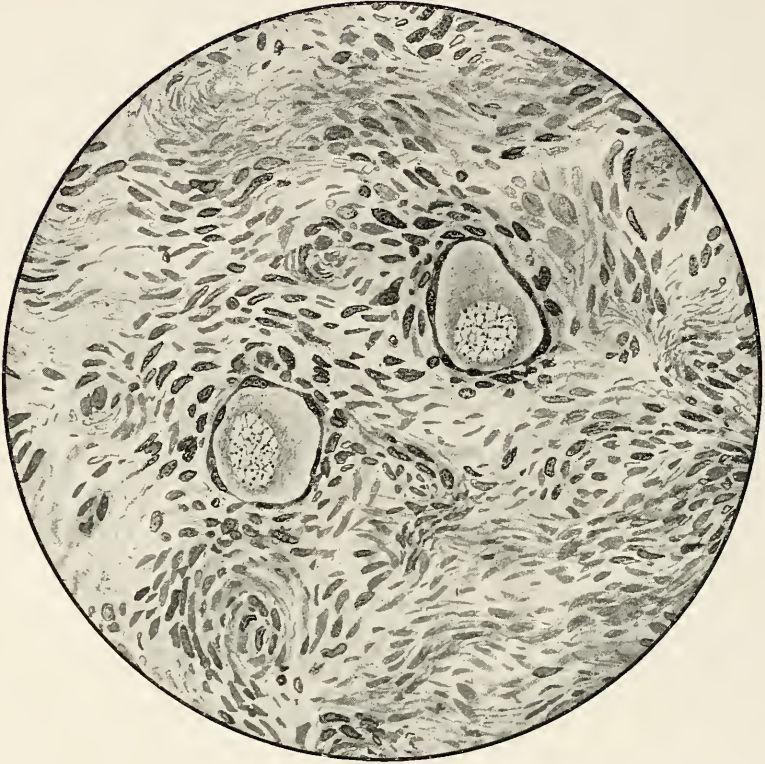


FIG. 28. THE CORTEX OF THE OVARY OF AN ADULT, showing two primordial follicles, containing egg-cells. The stroma is highly cellular.

cell, the ovum, or egg-cell ; (2) a single layer of flattened epithelial cells surrounding it ; (3) outside this a condensed layer of mesoblast-cells, which forms a rough capsule. This is the primordial follicle. Figs. 27 and 28 show that at this stage the follicle, which is not visible to the naked eye, contains no fluid and is not separated from the stroma by any clear space. The egg-protoplasm has no cell-membrane ; it is quite naked and shows a fine network on a clear ground-substance. The egg-nucleus, however, has a definite membrane and contains an eccentric nucleolus. Occasionally two egg-cells are found in a single follicle. In the foetal ovary none but primordial follicles are found. The primordial follicles lie immediately under the capsular epithelium, never in the medulla.

In childhood a further stage of development may be observed, viz.



*the ripening follicle.* The egg-cell enlarges but maintains its central position; the surrounding ring of flattened epithelial cells proliferates; the cells become cubical and arranged in many layers. They are sharply differentiated from the surrounding ovarian stroma. Soon liquefaction occurs in them, and at the same time the follicle sinks

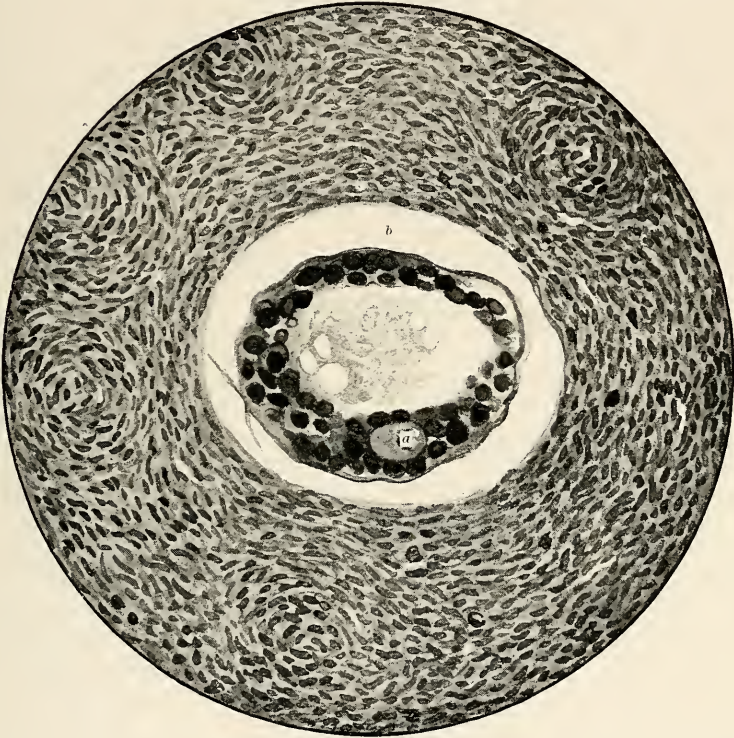


FIG. 29. GRÄAFIAN FOLLICLE FROM THE OVARY OF AN ADULT. The large clear cell (*a*) is the egg-cell; the central space is occupied by liquor folliculi. At (*b*) is seen the double layer of cells forming the membrana granulosa. The shrinkage from the wall of the follicle is the result of hardening the tissue.

deeper into the ovarian stroma. The fluid produced is called *liquor folliculi*. Although originally formed in the manner described, it is held by some authorities to be partly a transudation from the vessels of the *theca interna*. It is a thin, serous fluid containing albumen. Follicles, such as these, are present in large numbers after puberty. The greater number remain dormant, but some of them undergo a further process of maturation, ending in rupture, and upon this depends the important function of ovulation. Mature follicles are seldom found until after puberty: certainly no corpora lutea have ever been found before this age. It follows from what has been said that only in the adult ovary are all three kinds of follicles to be observed.

As a rule, a single Gräafian follicle ripens in one ovary at intervals of about four weeks. It is at present uncertain whether this process coincides with menstruation or not, but the physiological bearings will be again referred to in connection with the theories of menstrea-

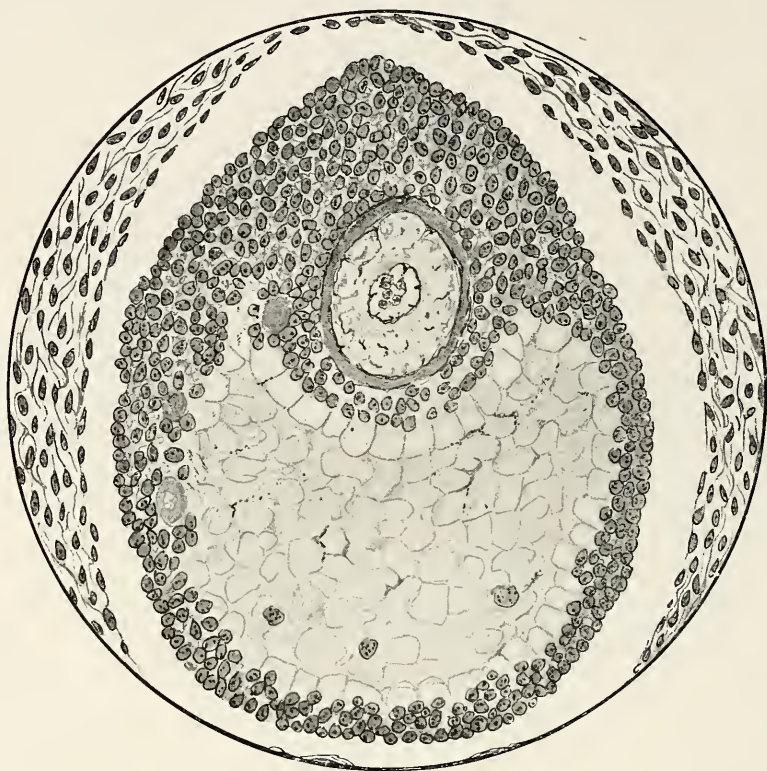


FIG. 30. RIPENING GRÄAFIAN FOLLICLE (Stevens). An early stage showing the formation of the liquor folliculi by liquefaction of the membrana granulosa-cells. The egg-cell has greatly increased in size, and the zona pellucida has developed around it.

tion. Occasionally two follicles ripen simultaneously, either in the same or it may be, one in each ovary.

*The Mature Follicle.* Starting with the dormant follicle the details of the ripening process are as follows : The central or egg-cell increases in size, and a uniform strong capsule, showing fine radial striation, called the *zona pellucida*, is developed around it (see Figs. 29 and 30). The *zona pellucida* is divided from the protoplasm of the egg-cell by the perivitelline space, in which the egg is free to move. The originally central nucleus is now pushed more and more towards the surface of the ovum by the development of its cytoplasm. The nucleolus is said to show amæboid movement. The cells derived from the follicular epithelium proliferate freely, forming at first a wall of many

cell-layers, and later a solid mass of closely packed cells surrounding the egg-cell. Liquefaction takes place among these cells, and an eccentric cavity filled with fluid is produced (see Fig. 30). The effect of this change is to divide the cells into two portions: (1) a cluster of protecting cells immediately surrounding the ovum so that it never comes into contact with the liquor folliculi, distinguished as

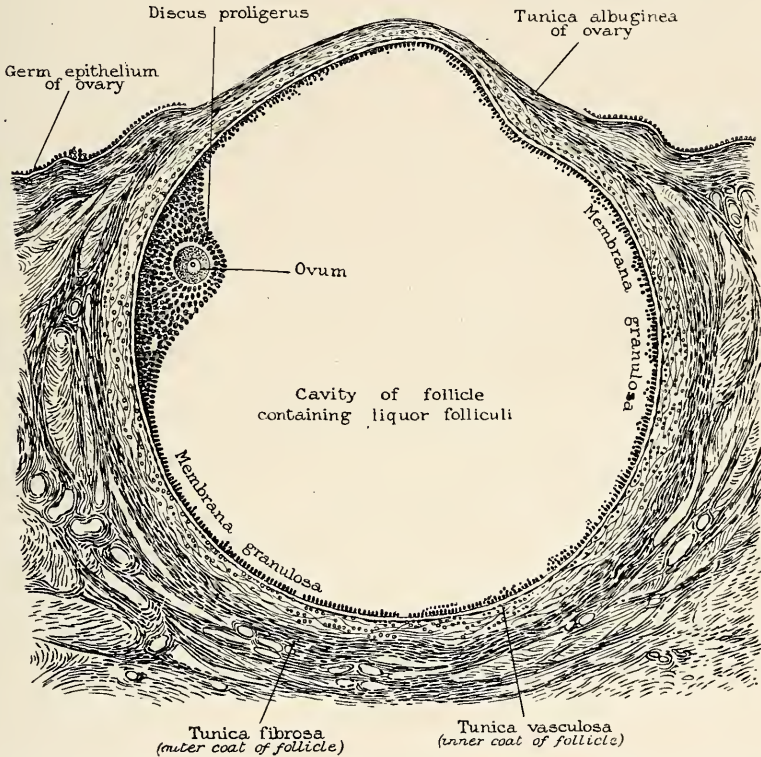


FIG. 31. RIPENING GRÄAFIAN FOLLICLE (LATER STAGE) PROTRUDING UPON THE SURFACE OF THE OVARY (Bumm).

the *discus proligerus* (see Fig. 31; (2) a stratified layer lining the wall of the follicle, called the *membrana granulosa*. An intra-epithelial network has been traced from the cells of the discus to the radial striæ of the zona pellucida, and this is thought to be concerned with the nutrition of the egg-cell.

The follicle now increases greatly in size, and the quantity of fluid it contains also rapidly increases. It is a thin serous fluid containing albumen. Around the follicle is now formed a capsule consisting of two layers, the outer called *theca externa* or *tunica fibrosa*; the inner, *theca interna* or *tunica vasculosa*. This capsule is formed from condensation of the ovarian stroma, which lies in contact with the follicular epithelium.

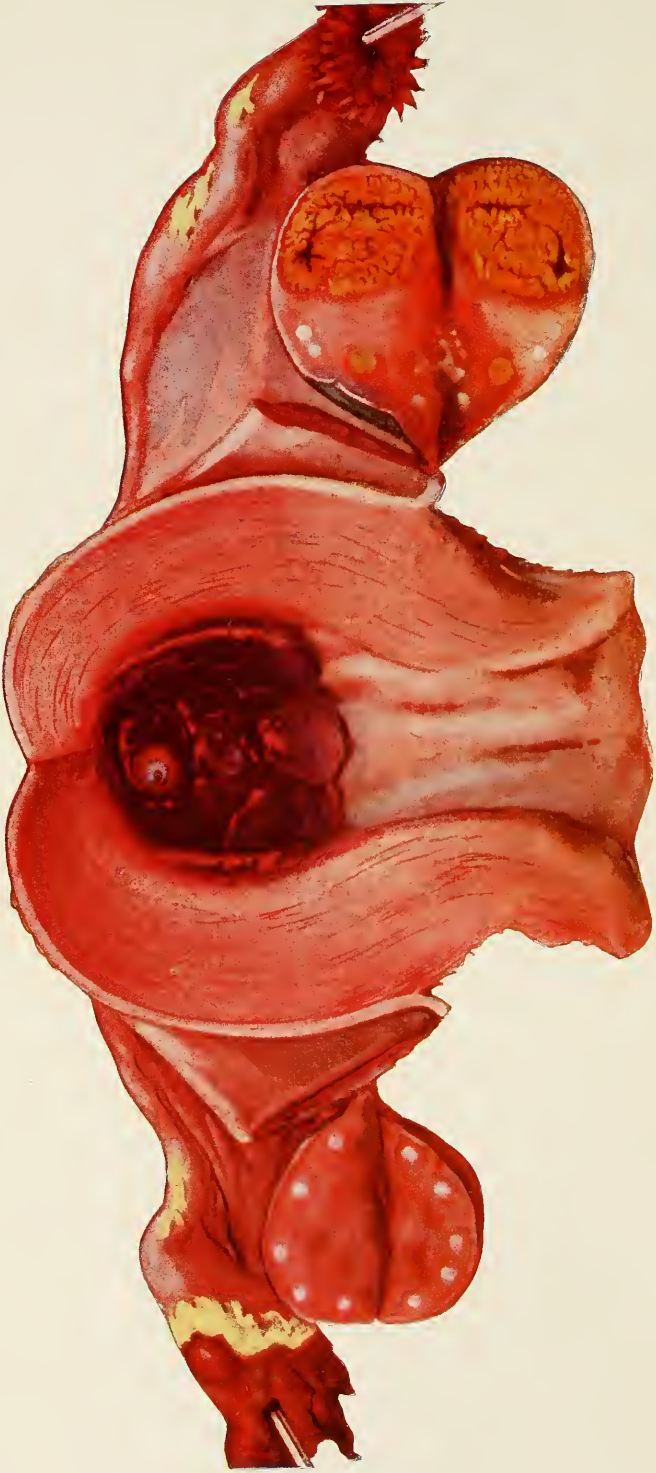
The ripe follicle has a diameter of 1–2 cm. It pushes its

way to the surface, where it bulges, forming a pale transparent spot known as the *stigma*. Rupture of the follicle now occurs, and the contents are discharged into the peritoneal cavity. Rupture appears to be mainly brought about by increased vascularity of the *theca interna*, which causes rapid production of liquor folliculi. In addition *lutein cells* appear (*vide infra*), which push their way like buds of new growth into the follicle even before rupture and escape of the ovum (Schroeder). Through this cell-growth the discus and the egg-cell are pushed towards the stigma, which then ruptures and allows the follicular contents to escape. Simultaneously with the appearance of the lutein cells fatty degeneration of the follicular epithelium sets in, and only the cells of the discus are preserved. Usually the discus is detached along with the egg-cell, which leaves the follicle surrounded by a protective covering of several layers of cells. The egg-cell may, however, remain in the follicle, and if fertilized there, ovarian pregnancy results.

The ruptured spot is soon cicatrized and a central space is formed, filled with degenerated cells and fluid. Blood escapes into this space from the vessels of the *theca interna*, and this with the investing lutein cells forms the *corpus luteum*.

Many Gräafian follicles at various stages of their development undergo degeneration and never mature. This process of degeneration is spoken of as *atresia* of the follicle, because a degenerate follicle never ruptures. The changes to be noted in this retrograde process are : (1) The membrana granulosa breaks up and can be seen as fragments floating in the liquor folliculi. The separated granulosa carries with it the ovum and discus proligerus. (2) The zona pellucida persists for some time ; the nucleus and nucleolus soon disappear, and leucocytes may be found within the collapsed zona pellucida before the ovum totally disappears. (3) From the theca interna, epithelioid cells containing a yellow lipid pigment develop ; these are called *theca-lutein* cells. They are smaller in size than the lutein-cells, which are found in a mature corpus luteum ; but in every other way the lutein cell of an atresic follicle resembles the lutein cell of the corpus luteum. The resemblance is so intimate that we are very sceptical as to the view which is held by German authors that the large lutein cells have a different source of origin from that of the small theca-lutein cell. German authorities speak of the former as the *granulosa-lutein* cells, attributing their origin to the stratum granulosum, *i.e.* to an origin from an epithelial source ; whereas, we are of opinion that the theca-lutein cell and the 'granulosa-lutein cell' are both derivatives of the theca interna, and are, therefore, in each case, of connective-tissue origin, just as is the decidual cell, which they closely resemble. (4) The atresic follicle ultimately becomes invaded by hyaline fibrous tissue and thus forms a *corpus albicans*, which in its turn is gradually broken up by young fibroblasts





and disappears. The last evidence of its existence is a tortuous strand of hyaline connective tissue, many of which are to be seen in every ovary. The final stage of an atresic follicle is therefore similar to that of a healthy corpus luteum (*vide infra*).

**The Corpus Luteum.** The appearance of this body is very striking and characteristic in virtue of the colour-contrast between the yellow investing convolutions and the dark-red central parts. It is circular or oval in shape, about 2 cm. in diameter ; it projects upon the surface of the ovary and may easily be shelled out of its bed. In addition to effused blood, it contains degenerated granulosa cells and the new elements known as *lutein cells* (see Fig. 32 and Pl. III). These cells closely

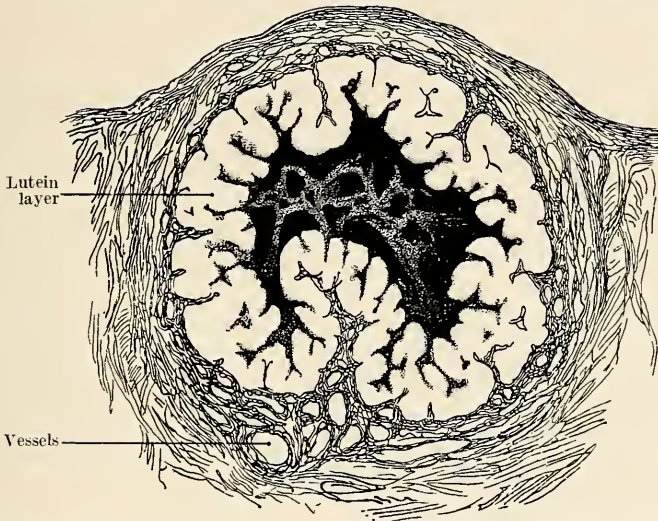


FIG. 32. CORPUS LUTEUM THREE WEEKS AFTER MENSTRUATION, showing the central clot and the convoluted lutein layer (Bumm).

resemble the decidual cells formed in the uterus during pregnancy. They are rich in clear protoplasm ; the nucleus is often vacuolated and contains finely divided chromatin, and the protoplasm contains yellow-coloured drop-like granules of a lipid substance called *lutein* (Plate III). Appearing first before rupture of the follicle, they increase greatly in size and number after rupture, and ultimately form sinuous folds of many cell-layers in thickness. The fibrous tissue and vessels pass into the centre of these folds from the follicular capsule, and by continued growth the convolutions become packed tightly together, and the individual cells become polygonal from pressure. When conception occurs the corpus luteum continues to grow, reaching its maximum size at the third month ; when conception does not occur, it rapidly disappears.

The origin of the lutein cells is still the subject of dispute. According to one view they are formed, together with the follicular epithelium,

from cells having a common origin in the germ-epithelium, and according to this view are epithelial cells. In common with many English and American authorities, however, we adhere, as previously stated, to the view that the lutein cells are derived from the connective tissue of the follicular capsule.

Subsequent changes in the corpus luteum consist in the absorption of the central blood-clot, complete occlusion of the cavity by proliferating lutein cells, and gradual shrinkage of the entire body. Soon the lutein cells undergo a kind of hyaline degeneration, losing their nuclei and cell-outlines, and becoming transformed into structureless masses. These are in turn replaced by connective tissue, which invades them from the surrounding ovarian stroma; at this stage the follicle is called the *corpus fibrosum* or *corpus albicans*. The corpus albicans ultimately becomes broken up by the invading connective tissue into sections, which may become widely separated from one another, and may persist as hyaline, homogeneous areas for a long period. Finally, all trace of lutein disappears, and only the depressed cicatrix remains upon the surface of the ovary to indicate the site of the corpus luteum. The length of time occupied by these changes is variable, becoming longer as age advances. Many weeks are always required for their completion.

The *function* of the corpus luteum is mainly that of a gland with an internal secretion; this point will be dealt with further in discussing the internal ovarian secretion. It may also be said to be instrumental in maintaining the ovarian blood-supply, which the cicatrization, following rupture of the follicles, would otherwise diminish.

The number of corpora lutea formed in both ovaries during the sexual life of an individual has been estimated at from 400 to 600, leaving some 29,000 follicles to find an immature termination. Many of these fail from defective blood-supply, or from being unfavourably placed for rupture. Pathological changes in the ovary, such as sclerosis, no doubt also favour this early retrogression. The result is an *atresic follicle* (Plate III), which may present as a *hydrops folliculorum* (see p. 650), or as a *theca-lutein cyst* (Fig. 359), according to the stage of development of the follicle at which the retrogression sets in.

**The Ovary at Different Periods of Life.** It has already been indicated that the structure of the ovary varies at different periods of life. Thus in *childhood* the organ is smooth, solid, about the size of an unshelled almond, and on microscopic examination is seen to contain enormous numbers of primordial follicles with some complete, and a few imperfectly ripened ones; but, as Stevens has shown, rupture of these follicles does not occur. In *adult life* the ovary is larger, pinkish in colour, often contains several small cysts which bulge upon its surface, and microscopically presents large numbers of complete follicles in various stages of the ripening process, in addition to recent or old corpora lutea. The stroma is highly cellular. In *advancing age* the



ovary is smaller than at any other period, hard in consistence, white and shrivelled ; on microscopic examination no follicles can be found in it, but hyaline areas representing old corpora albicantia may be seen ; the stroma consists largely of well-formed, wavy fibrous tissue, and the arteries show either thickening of their walls or complete

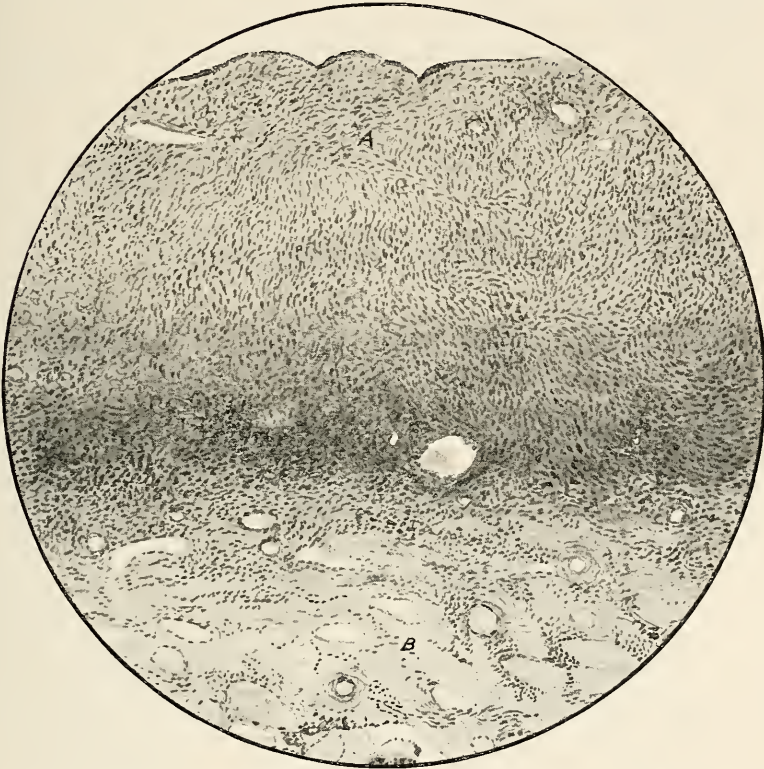

FIG. 33. THE OVARY OF A WOMAN OF 56. *A*, Cortex ; *B*, Medulla. The Gräafian follicles have entirely disappeared, and the cortex contains a large proportion of fibrous tissue.

obliteration from endarteritis. The capsular epithelium can sometimes be demonstrated even in old women, but the cells are then nearly flat instead of cubical.

**The Epoöphoron or Parovarium.** The parovarium or organ of Rosenmüller is a vestigial structure situated between the layers of the upper part of the broad ligaments, usually named the *mesosalpinx*. It corresponds to the epididymis and the vas deferens in the male, and is accordingly developed from part of the Wolffian body and the Wolffian duct. In the broad ligament of an adult woman it can readily be seen with the naked eye by separating tube and ovary from one another, and allowing a good light to pass through the translucent *mesosalpinx* (see Fig. 34). In the child it is ill-formed, but grows steadily

thereafter, until in middle life it reaches its highest point of development. It consists of a varying number of vertical tubules (usually

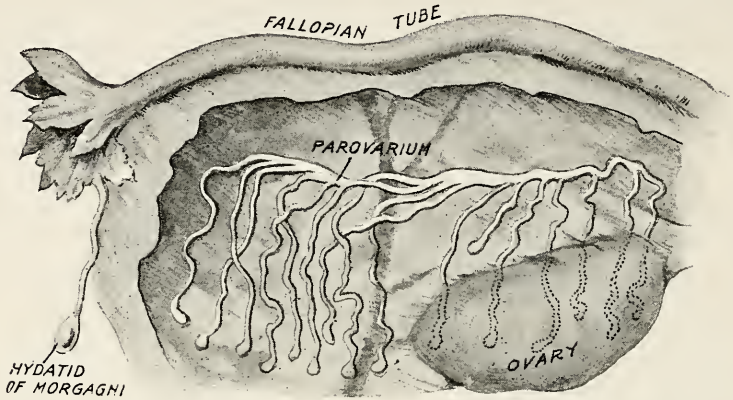


FIG. 34. THE PAROVARIUM OR ORGAN OF ROSENMÜLLER EXPOSED BY DISSECTION OF THE MESOSALPINX (Follin).

twelve) which, beginning in blind extremities near the hilum of the ovary, ascend towards the tube and then fuse with a larger horizontal

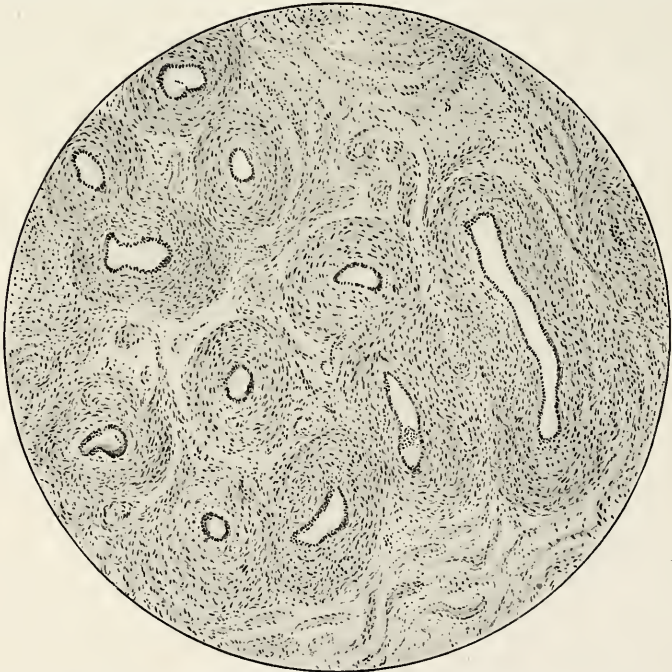

FIG. 35. THE NORMAL PAROVARIUM IN TRANSVERSE SECTION  $\times 105$ . Note the thickness of the muscular walls of the tubules.

tubule running at right angles to them. The outer end of the latter tubule is blind and sometimes divides into several branches which

are named *Kobelt's tubes* ; the inner part passing towards the uterus bends downwards, and running between the layers of the broad ligament reaches the vaginal fornices and may sometimes be traced along the anterior vaginal wall as far as the vulva. This long tube is the homologue of the vas deferens, and is named *Gartner's duct*.

The wall of the parovarian tubules consists of plain muscle, and a distinct lumen lined by columnar, ciliated epithelium persists (see Fig. 35). Cystic dilatations are not infrequently seen in the adult. The vertical and horizontal tubules of the parovarium proper can almost invariably be found ; the downward prolongation forming Gartner's duct is often absent. Attached to the mesosalpinx below the abdominal ostium of the tube is usually found a small pediculated cyst the size of a pea—the *Hydatid of Morgagni* (Fig. 34) ; it arises from the Wolffian duct and is the homologue of the structure of the same name in the testis.

### THE FUNCTIONS OF THE OVARY

The outstanding function of the ovary is that of *ovulation* ; the process includes the storage of ova in a condition of latency, the ripening of the protective Gräafian follicles, leading to their rupture and the consequent discharge of the ova into the peritoneal cavity. Upon this function depends the occurrence of gestation and the continuance of the species : it is therefore one of the most important functions of the body. The histology of the maturation and dehiscence of the follicles, and the subsequent repair of injury to the tissues has been already described. The formation of the corpus luteum is, however, something much more important than a reparative process ; lutein cells are elements as strongly characteristic of the ovary as are Gräafian follicles, for they occur in no other organ and their presence suffices for the recognition of the tissues in which they are found as ovarian tissue. The corpus luteum is only formed during the sexually mature period of life, and it is highly probable that it is physiologically correlated with the processes of menstruation and of reproduction. The epithelioid character of the lutein cells and their remarkable proliferative activity suggest that they may have a secretory function, but it is very difficult to isolate their special functions, if there are such, from those of the ovary in general. Certain data, however, exist which suggest that the corpus luteum may have a special function. Thus Fränkel, experimenting with pregnant rabbits, found that if the corpus luteum was destroyed by ignipuncture without injury to the rest of the ovary, abortion almost invariably occurred. From this he drew the conclusion that the corpus luteum produced an internal secretion, whose function it was to maintain the implantation and growth of the developing ovum *in utero*. His observation has been since repeatedly confirmed by others, and support for his theory has been found in a subsequent clinical observation which is also well established.

The new growth, known as chorionepithelioma, which arises from malignant transformation of the elements of the embryonic *syncytium*, is frequently associated with evidence of abnormal lutein activity in the ovaries, such as the formation of lutein cysts of large size, and the presence of a great excess of lutein cells in the ovarian tissue. This association of abnormal and perverted activity of the chorionic epithelium with lutein excess in the ovary may be fairly regarded as corroborative of Fränkel's theory.

Just as the possibility of gestation depends upon the presence of the activating ovary, so also does the process of menstruation. It has been established beyond dispute that menstruation does not occur unless ovaries are present which contain fully developed and ripening follicles and corpora lutea. Regularly before puberty, and occasionally after the menopause, the ovaries contain follicles which, however, are latent, and there are no corpora lutea at all. The essential change which takes place in the ovary at puberty is the ripening of the follicles and the consequent formation of corpora lutea; lutein cells therefore make their first appearance at puberty, and after the menopause, when their production ceases, they rapidly disappear. Their presence is accordingly characteristic of the sexually mature ovary, and is coincident in duration with that of menstruation. The cause of menstruation is therefore to be sought in the conditions which exist in the ovary during the sexually mature period of life when the follicles ripen and corpora lutea are produced. This matter will be referred to again later on.

**The Internal Ovarian Secretion.** The second great function of the ovary is the production of an internal secretion. It has for a long time been believed that the ovary produced such a secretion, and facts have gradually been accumulated which prove it beyond dispute. As a member of the class of endocrinous (ductless) glands, it was, of course, highly probable that the ovary would functionate in the same manner as others of its class, and the line of proof by which the existence of a thyroid secretion was demonstrated has been successfully followed in the case of the ovary. *Experimentally* it has been shown that total removal of both ovaries is regularly followed by certain definite changes affecting (a) the remaining genital organs; (b) the general metabolism; (c) other members of the class of endocrinous glands. Further, it has been shown that these changes can be to some extent modified or inhibited by (a) ovarian grafting, or (b) the administration of ovarian extracts to the castrated animals. *Clinically* it has been shown that ovarian grafting is practicable in women, and that it is successful, as long as the graft survives, in modifying the symptoms of the menopause; when the graft perishes these effects disappear. The clinical results of the administration of ovarian extract, in various forms of ovarian inactivity, have been contradictory and therefore inconclusive.

**Effects of Removal of both Ovaries.** These effects have been studied chiefly in rabbits and guinea-pigs, also to a less extent in cows, cats, dogs, and monkeys; they differ somewhat in different species, and also in individuals of the same species, but they may be generally stated as follows: As regards the *local* effects, the animals cease to go into heat periodically, or to show the periodic proœstrum (rut); the uterus undergoes well-marked atrophy, which affects chiefly the muscular coats, and to a less extent the endometrial glands; the cylindrical epithelium, however, persists. The mammæ also undergo atrophy in most animals. If the ovaries are removed during pregnancy there is a marked tendency to abortion in some animals (rabbits). As regards the *general metabolism*, the results obtained by different observers are not uniform, but *provisionally* it may be said that after removal of the ovaries calcium metabolism is affected, the excretion being reduced in rabbits to one-half, according to Blair Bell; and further, the excretion of phosphorus (as  $P_2O_5$ ) is somewhat reduced. The precise significance of these changes (if correctly stated) is not altogether clear. In addition it is generally agreed that there is a well-marked tendency to the excessive formation of adipose tissue.

If the experiment is performed upon young animals (before puberty) the genital organs tend to retain the infantile or premature type, and there is a marked tendency to overgrowth of the skeleton and of the adipose tissue of the body generally, the animals becoming abnormally large and abnormally fat.

As regards the effects upon the other *endocrinous glands*, the experimental work is still incomplete. Fairly definite results have been obtained in respect of the thyroid and the pituitary; in connection with the supra-renals, the thymus and the pineal gland, the work is less conclusive.

*Thyroid.* An enormous increase of colloid takes place, the staining reactions of which are not the same as those found in other enlargements, such as that which accompanies pregnancy and exophthalmic goitre. These changes are more marked in rodents than in carnivora.

*Pituitary.* Blair Bell claims to have observed indications of increased activity, *e.g.* an increase of the eosinophile cells in the *pars anterior*, and *pars intermedia*, but his results await confirmation. It therefore appears that the thyroid and the pituitary glands may possess a function which is in some way supplementary to the ovarian function, in consequence of which they all manifest an increased activity when the ovarian secretion has been withdrawn.

Details of the effects upon the other endocrinous glands cannot usefully be given at present.

Clinical observation of the results of the operative removal of both ovaries in women of sexually mature age confirms the experimental findings in several important points. First, complete amenorrhœa and sterility invariably occur if the removal of the ovaries has been

complete. Apparent exceptions have been from time to time recorded, and some of these have ultimately been explained by the discovery of a persistent piece of ovarian tissue, due either to the operation having been incomplete, or to the existence of accessory ovarian tissue in an abnormal situation. In all probability the same explanation holds good for all such cases. A minute portion of ovarian tissue remaining suffices to keep up the menstrual function. Secondly, atrophy of the uterus occurs, although this result appears to ensue much more slowly than in animals. Thirdly, there is often, although not always, a marked tendency to the excessive formation of adipose tissue ; but as in animals so in women, this change differs considerably in degree in different individuals.

**The Results of Ovarian Grafting.** Numerous observations have now been made, both experimentally and clinically, upon this subject, and the results are definite and uniform. The graft is made preferably with a portion of the ovary of the same individual (*autoplastic graft*) ; it may be made, however, with the ovary of another of the same species (*heteroplastic graft*) ; experiments with the ovary of a different species have been negative. A thin slice of tissue should be used, and it should be imbedded in the most vascular site available. In animals the subperitoneal tissue and the abdominal wall have been largely used ; in women the muscular layer of the parietes has been usually employed. A secondary blood-supply is rapidly formed which maintains the nutrition of the grafts ; nutrition in this artificial position is, however, defective, and degenerative changes soon set in which ultimately destroy the ovarian tissue. The Gräafian follicles are first affected, becoming cystic, and their epithelium degenerates ; in rabbits the interstitial cells, which are numerous and important, persist much longer than the follicles. That the grafts are functionally active is shown by a series of facts which have been demonstrated by various observers. Thus pregnancy has occurred both in animal experiments and in women (Morris) ; this is, of course, only possible when the site of the graft permits of the passage of the liberated ovum into the peritoneal cavity. Ovulation has been demonstrated in rabbits, and it has been shown that the uterus does not undergo atrophy as is usually the case after oöphorectomy. In animals previously castrated, ovarian grafts may arrest uterine and mammary atrophy, and even cause these organs to again increase in size, while in castrated monkeys recurrence of the proöstrum has been similarly induced. Clinically it has been shown that ovarian grafts diminish the severity of the climacteric symptoms after oöphorectomy, especially if the uterus has been left so that menstruation may continue (Tuffier). When the uterus has been removed as well, grafting has not much effect upon climacteric phenomena, which fact appears to indicate that these are due as much to the cessation of menstruation as to loss of the internal ovarian secretion.

The existence of an internal ovarian secretion may accordingly be regarded as a well-established physiological fact, and from what has been said, it is clear that this secretion plays an important part in the general physiology of the sexually mature female. Thus it initiates and controls the menstrual function, promotes the secondary development (*i e.* after puberty) of the other sexual organs and maintains them in a state of functional activity, influences the general metabolism of the body in certain definite directions, and is also probably correlated in its activities with the internal secretion of certain other members of the class of endocrinous glands.

Many questions, however, remain for investigation. Some attention has been devoted to the discovery of the particular elements in the ovary which produce it. In rabbits, as already mentioned, there is histological evidence that the interstitial cells are the active agents in its production. In the human ovary the interstitial cells are scanty and ill-developed, and it appears unlikely that they are secretory cells at all. Of the cellular elements in the human ovary the most active and important are the lutein cells; it will be recollected also that they first appear at puberty, and are afterwards to be found in the ovary until menstruation has ceased, or possibly later. It is accordingly reasonable to suppose that they are the chief seat of production of the internal secretion. Direct evidence is, however, lacking. Certain experiments first made by Fränkel, and since confirmed by others, indicate that the corpus luteum maintains the growth and development of the ovum *in utero*, but this does not justify us in attributing to it alone the production of the internal secretion. There are no means of differentiating the secretory functions of the different elements of the ovary, and the secretion must be regarded as the product of the whole gland.

The ovarian secretion has never been isolated and chemically examined, and nothing whatever is known about its composition and structure. It will be recollected that the same is true of the secretions of the other endocrinous glands.

## THE VAGINA

The vagina forms the lowest segment of the genital canal and extends from the vaginal portion of the cervix to the vulva. Normally its anterior and posterior walls fall in and come in contact with one another, so that the lumen is represented by a transverse slit wider at the sides than in the middle. When distended it becomes roughly cylindrical. The general direction of the vagina is from above downwards and forwards, with a slight anterior concavity. The posterior wall is accordingly rather longer than the anterior—4 inches and 3 inches respectively. The vagina is surrounded by a vascular connective-tissue sheath, which is thicker in a nulliparous than in a parous

woman. The upper extremity of the vagina, being closed by the cervico-vaginal junction, is often called the roof. It is partly inverted by the cervix, which projects into the centre of the canal. Round the cervix the vaginal walls are arched, *i.e.* concave, and four sections are distinguished, called respectively the anterior, posterior, right and left *vaginal fornices*. Of these, the posterior is the deepest and most capacious. The anterior is the shallowest, the lateral fornices being intermediate in depth. Immediately behind and above the posterior fornix lies the pouch of Douglas. Immediately above the anterior fornix lies the bladder (*see* Figs. 1 and 2). The lateral fornices are in contact with the masses of cellular tissue filling up the bases of the broad ligament.

The lower extremity is continuous with the vulva at the *ostium* or *introitus vaginae*. In the virgin this end is partly closed by the hymen which indicates the vulvo-vaginal junction. In the parous woman, the transition from vagina to vulva is not sharply defined, and the hymen has disappeared. As a rule the entrance to the vagina is concealed by apposition of the labia; when the perineal body has been extensively damaged, however, the lower end of the vagina remains open.

The anterior vaginal wall, in its upper half, comes into relation with the base of the bladder; in its lower half, the urethra is closely united to it. The bladder is usually separable from the vagina owing to the connective-tissue stratum which lies between them. The urethra, in its lower two-thirds, is closely incorporated with the outer layers of the vaginal wall and can only be separated by cutting. The posterior vaginal wall is related in its upper one-third to the floor of the pouch of Douglas (*see* Fig. 1); in the middle one-third to the rectal ampulla, and its lower one-third to the perineal body. Under normal conditions it is separated from all these structures by a layer of cellular tissue. In parous women, owing to infection of cellular tissue following obstetric lacerations, firm union may occur between the rectal and vaginal walls. The ureters lie in close relation to the lateral and anterior fornices (*see* Fig. 19). When thickened, as in tuberculous disease, they may be palpated in this situation. The uterine and vaginal arteries run close to the upper part of the lateral vaginal walls, where their pulsation may often be distinctly felt.

In the nulliparous woman both anterior and posterior walls are crossed on their mucous surface by transverse folds, or *rugæ*, which are most pronounced in the lower one-third of the anterior wall. After repeated childbearing, or when stretched from prolapse, these become wholly or partly obliterated. In some cases a median ridge runs vertically along both anterior and posterior walls. It is called the *median vaginal column*. In the foetus the transverse folds are more pronounced and more numerous than in the adult, and the median columns are well-marked (*see* Fig. 21).



*Structure.* The vaginal walls consist of three layers: (1) epithelium; (2) sub-epithelial connective tissue; (3) muscle (see Fig. 36).

The vaginal *epithelium* is of the stratified squamous type, resembling skin, and three layers of cells can be distinguished in it. The deepest layer consists of one or two rows of low columnar cells with single large nuclei. Above these lie several layers of typical prickle cells. Near the columnar layer these are small and closely packed together. Nearer the surface, they are larger and more definitely polygonal,

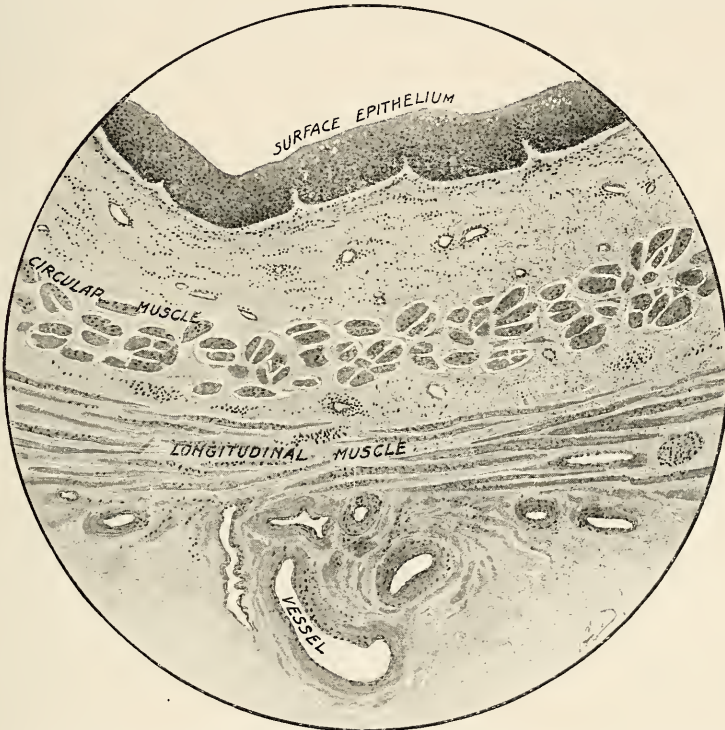

FIG. 36. LONGITUDINAL SECTION THROUGH THE VAGINAL WALL.  
Taken near the upper end of the canal.

with ladders between them, formed by the united processes of contiguous cells. The superficial layers consist of flattened cells with few nuclei and indistinct outlines, *i.e.* cells, that have undergone keratoid changes. Many layers of degenerated cells may be seen in process of separation from the surface. Many of the cells in this layer are vacuolated.

As a rule there are no glands to be found in the vaginal mucous membrane, but elementary glandular structures have in a few instances been detected by different observers. These may, however, have been derivatives of the lower part of the Wolffian duct, or may have been formed from the basal layer of the stratified epithelium in inflammatory conditions (see p. 384).

The sub-epithelial *connective tissue* is dense and fibrous in character, and from it well-marked digitate processes pass upwards into the deep layers of the epithelium. Sometimes, on the other hand, the deep surface of the epithelium sends out shallow digitate processes, which project into the sub-epithelial tissues. This is especially well-marked on the vaginal portion of the cervix (*see* Fig. 273, p. 522). This layer contains numerous vessels of large size.

The *muscular* layer consists in the main of circular fibres of plain muscle. Longitudinal fibres are also found outside these, but are relatively ill-developed. Outside the muscular wall is the loose sheath of connective tissue in which run the vaginal arteries and their companion veins.

**The Vaginal Secretion.** This consists mainly of a transudation through the epithelial layer from the blood-vessels. A certain amount of admixture of secretion from the uterus also takes place. Its naked-eye characters are variable. In children and in healthy nulliparous women it forms a whitish, flaky material of pultaceous consistence, which is especially abundant in the fornices, and resembles smegma. It is faintly acid in reaction. In parous women with a patulous vaginal ostium, this kind of secretion is not seen. In the case of most parous women the secretion is thin, yellowish-white in colour, and neutral or alkaline in reaction. On microscopical examination the secretion is seen to contain epithelial squames, leucocytes, bacteria, and *débris*.

The bacteriology of the vaginal secretion has been the subject of much dispute, but the following points appear to be now fairly well settled.

(1) In the white, flaky, acid secretion of children, virgins and healthy pregnant women, a specific bacillus can be found, the *Vaginal bacillus* of Döderlein. This organism grows only in acid media, and lactic acid can always be found in the secretion when it is present. Döderlein's view was that lactic acid was produced by the bacillus in its growth, by a fermentative process. Quite recently, however, Blair Bell has shown that this substance is present in the contents of a hæmatocolpos, which are sterile and contain no organisms whatever. This observation shows that lactic acid *may be* produced without the aid of bacterial action, but the conditions in a closed hæmatocolpos differ so widely from those of the open vagina that conclusions drawn from the one cannot be applied to the other.

(2) Pyogenic organisms are also sometimes found in the secretion of apparently healthy women; it is doubtful whether they are really pathogenic, they appear to exist as saprophytes, and to be incapable of producing infection when inoculated in animals.

(3) The healthy vaginal secretion probably plays a protective *rôle*, antagonizing such bacteria as the pyogenic cocci, either by destroying them or by paralyzing their activity. By its discoverer, the vaginal

bacillus was regarded as the active protective agent of the secretion, and to it was attributed bactericidal power, which was exerted by maintaining an acid reaction in the secretion. This view must now be modified, for the production of lactic acid in the secretion may be independent of the bacillus.

(4) Under certain circumstances, and especially when for any reason the secretion becomes alkaline, saprophytic organisms present may become capable of renewing their virulence, or other organisms introduced from without may grow, multiply, and perhaps spread to the upper parts of the genital tract. This in part accounts for the unusual liability of the genital tract to infection during menstruation, childbirth and the early puerperium.

From the bacteriological point of view the genital canal may be divided practically into two parts, one infected, and the other sterile. The former includes the vestibule, vagina, and lower part of the cervical canal; the latter the upper part of the cervical canal, the uterine cavity, and the tubal lumina. The sterile condition of the upper portion is explained by (1) the plug of mucus which lies in the cervical canal and which, owing to its poorness in albuminoids, furnishes no nutriment for micro-organisms; (2) the leucocytes which are found in great numbers in the cervical secretion at the level of the internal os, and act as destroyers of bacteria.

### THE VULVA

The following parts have to be described in connection with the vulva: the mons Veneris, the labia majora, the labia minora, the clitoris with its prepuce, the vestibule with the urinary meatus, the ostium vaginæ, the hymen and the perineal body.

The **labia majora** are antero-posterior folds developed by duplication of the skin at the sides of the cloaca; from the pubes they run backwards, and gradually become lost at the sides of the perineal body. They are only seen in their fully developed state in the period of life characterized by sexual activity, when they contain a large amount of subcutaneous fat. They then form thick folds, apposed to one another in the middle line, and passing anteriorly into a pad of skin and subcutaneous fat which covers the pubes, and is known as the *mons Veneris*. The outer surfaces of the labia and the whole of the mons Veneris are covered with hair, which first appears at puberty, and after the climacteric becomes grey and scanty, and may almost entirely have disappeared as old age is reached. The usual shape of the hirsute area is triangular, the base lying about  $\frac{1}{2}$  inch above the symphysis, the apex at the perineal body. Sometimes in brunettes the hair extends upon the anterior abdominal wall in triangular form nearly to the umbilicus, thus simulating the male type.

In children and old women the labia majora are thin, from lack

of subcutaneous fat, and the labia minora or the ostium vaginae may

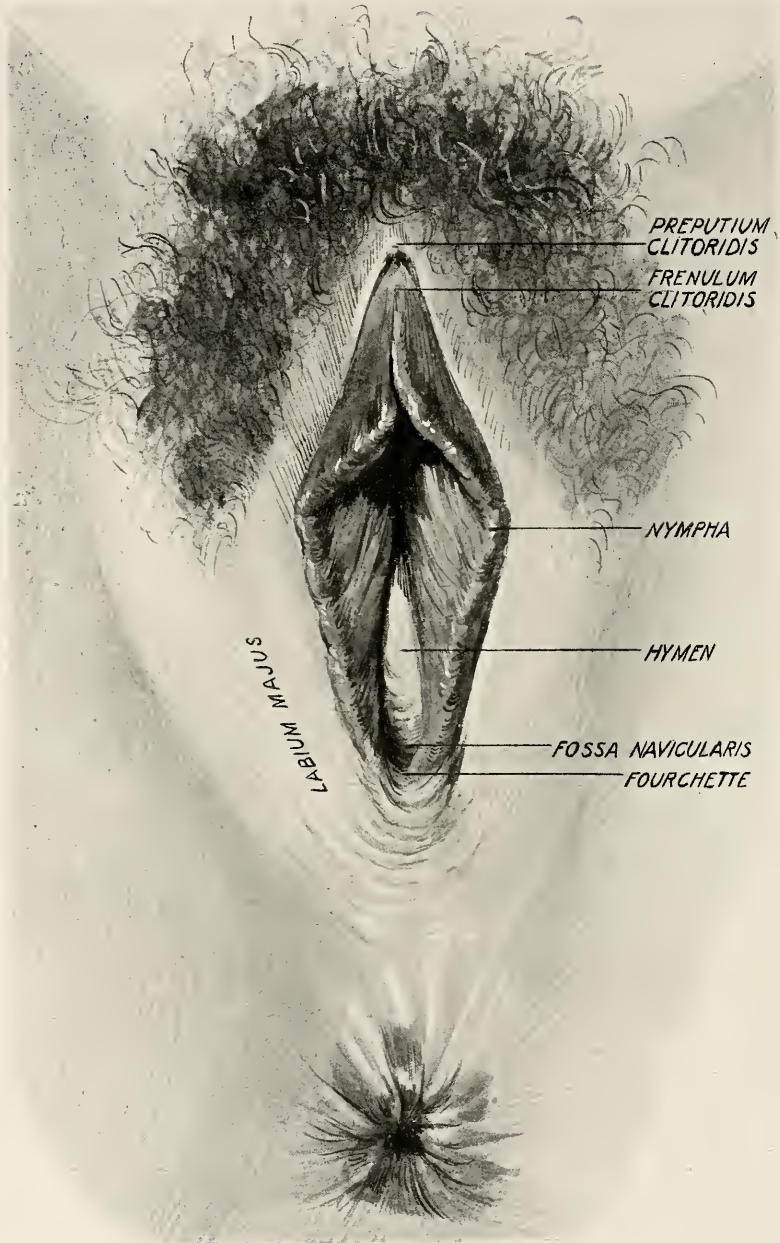


FIG. 37. THE VIRGIN VULVA. (From a photograph.)

then be exposed. In adult women the thighs may be widely abducted without separating the labia majora from one another. The inner

surfaces are covered with a thin soft skin which approximates to mucous membrane in naked-eye appearances.

In structure the labia closely resemble the general integument of the body. They are provided with large numbers of compound acinous sebaceous glands which are abundant even on the non-hairy

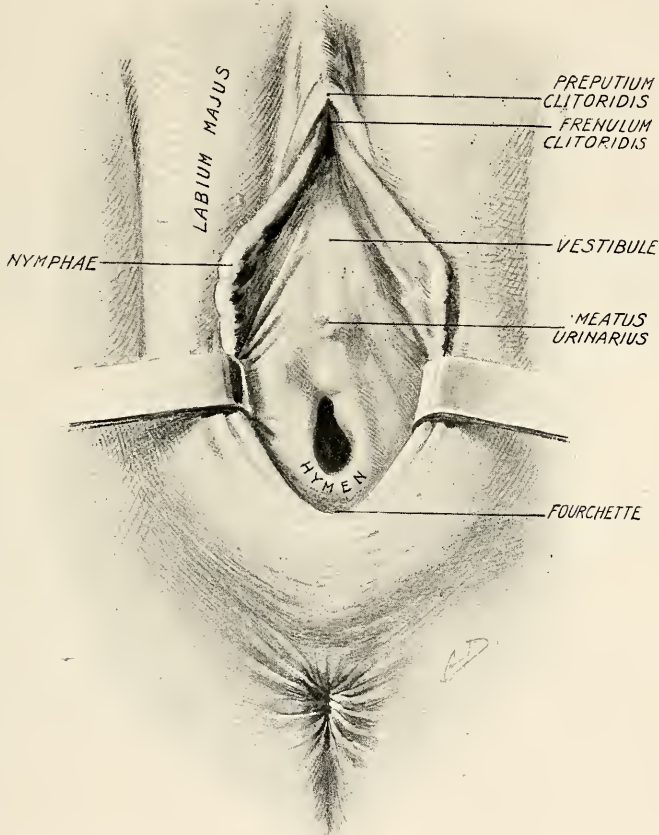


FIG. 38. THE VIRGIN VULVA AFTER SEPARATION OF THE LABIA.

parts, and are often visible there to the naked eye. There are also a few sweat-glands, which, however, are poorly developed.

The **labia minora** or **nymphæ** are a pair of thin folds of soft skin which lie within the greater labia, and form the lateral boundaries of the ostium vaginæ (see Fig. 37). They are crescentic in outline and are united posteriorly by a transverse fold, the *fourchette*. Anteriorly each nymphæ splits into two folds; the anterior pair of folds fuse and pass in front of the clitoris, forming its *preputium*; the posterior pair fuse and pass behind it, forming its *frenulum*. The nymphæ

are free from hair, and in brunettes they are often deeply pigmented ; in children they appear relatively large and prominent owing to the undeveloped condition of the greater labia. Structurally they consist of skin richly provided with sebaceous glands ; these are often visible to the naked eye in the form of pale, slightly elevated round areas.

The **vestibule** is the adult relic of the foetal *urogenital sinus* (Fig. 61, p. 85). It is a triangular area, the apex, directed anteriorly, being formed by the clitoris, the sides by the nymphæ, and the base by the

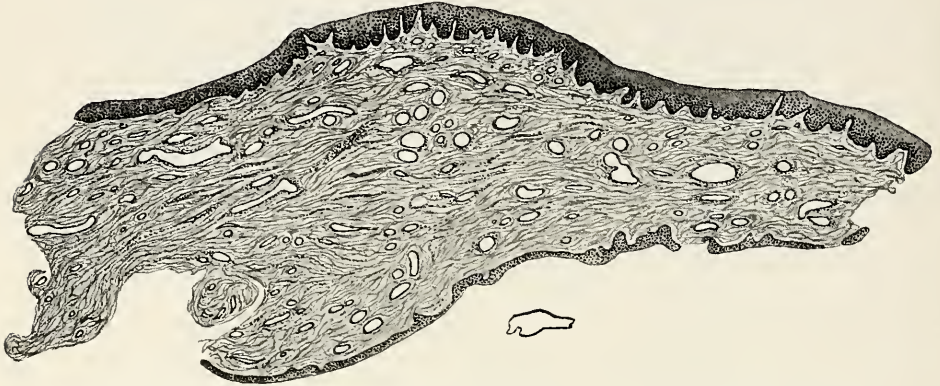

FIG. 39. SHOWING A SECTION OF THE HYMEN. On the vulval aspect there is a well-developed layer of stratified epithelium, and on the vaginal aspect a much thinner layer. Between the two epithelial surfaces there is a thick stratum of connective tissue carrying numerous blood-vessels and nerves.

The inset shows the actual thickness of the hymen.

anterior border of the ostium vaginæ (see Fig. 38). The urinary meatus lies near its base in the mesial plane. The depth of the vestibule from the surface depends upon the thickness and prominence of the labia, which always conceal it. In passing the catheter this area must be exposed so as to be clearly seen, and to do this it is necessary to hold the anterior portions of the labia apart.

The **clitoris** is the rudimentary homologue of the penis. It forms a small structure consisting of a *glans* about the size of a split pea, and a small body of variable length attached to the pubes by a pair of *crura*. Folds from the nymphæ form a hood which covers and sometimes entirely conceals the glans—the *preputium clitoridis*. The glans is composed of erectile tissue, abundantly supplied with sensory nerves ; it receives its blood-supply through the artery to the clitoris, a special branch of the internal pudic. This vessel may be the source of serious hæmorrhage when lacerated. Secretion may collect beneath the preputium causing local irritation, and sometimes the margins of the folds adhere to one another so that the clitoris cannot be exposed.

The **ostium** or **introitus vaginæ** is the entrance to the vaginal canal ; it lies at a deep but variable level from the surface of the apposed labia. In virgins the ostium is partly closed by the hymen (*see* Fig. 38) in married women the hymen is found lacerated or stretched, and

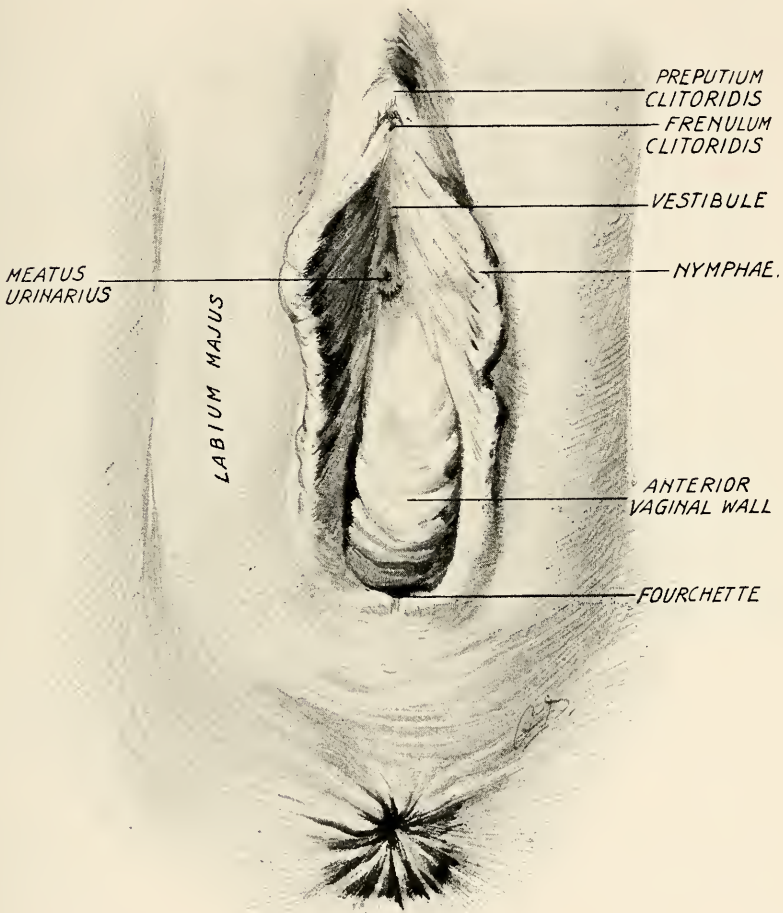


FIG 40. THE VULVA OF A MULTIPAROUS WOMAN. (From a photograph)  
The anterior vaginal wall is prolapsed (cystocele).

the ostium is easily dilatable ; in the case of women who have sustained local injury in child-birth the ostium is enlarged and patulous (*see* Fig. 40). The *hymen* is a membrane, of average thickness of about  $\frac{1}{8}$  inch, attached to the posterior one-half or two-thirds of the ostium vaginæ, and having usually a free, crescentic, anterior border which bisects the ostium. In front of this free border lies a space giving entrance to the vaginal canal (*see* Fig. 38). Between the posterior border of the hymen and the fourchette is a small

area which, when the nymphæ are separated, forms a shallow oval depression—the *fossa navicularis*. In parous women this fossa is not seen, for even slight puerperal lacerations destroy it.

Structurally the hymen is composed of well-developed but very vascular connective tissue. On both its vaginal and perineal surfaces it is covered with stratified squamous epithelium (see Fig. 39).

The shape and character of the hymen are very variable. It is sometimes attached all round the margins of the ostium vaginae ;

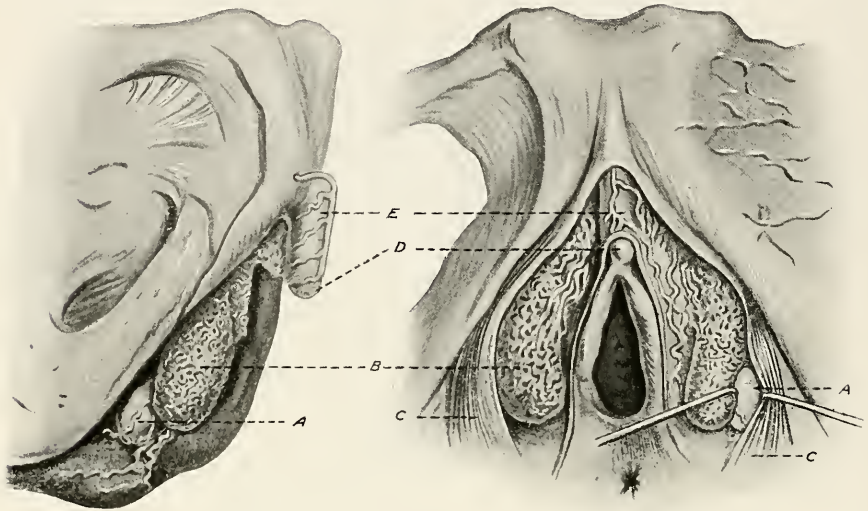


FIG. 41. LATERAL AND FRONT VIEWS OF THE GLAND OF BARTHOLIN AND OF THE ERECTILE STRUCTURES OF THE EXTERNAL ORGANS. A, Gland of Bartholin; B, Bulbus vestibuli; C, Sphincter vaginae muscle; D, Glans clitoridis; E, Body of clitoris.

it may then have either a central aperture, or two lateral apertures separated by an antero-posterior fold of membrane, or a number of small openings irregularly distributed—*cribriform* hymen. Sometimes no aperture at all exists, so that the vagina is completely closed by it below—*imperforate* hymen. The strength and dilatibility of the hymeneal membrane are variable; it may be so elastic as to stretch without lacerating during coitus; on the other hand, it may be so resistant that its removal is necessary before coitus can be completed. It follows that the presence of an entire hymen is not medico-legal evidence of virginity. In married women the hymen is, however, usually found divided by sulci into three or four portions, which have shrunk into small folds. In parous women these folds have further diminished, and appear as small sessile tubercles, four or five of which can be found around the ostium; they are called the *carunculæ myrtiformes*.



Certain muscles in relation to the ostium vaginae provide for it a kind of sphincter ; these are the anterior or pubic fibres of the

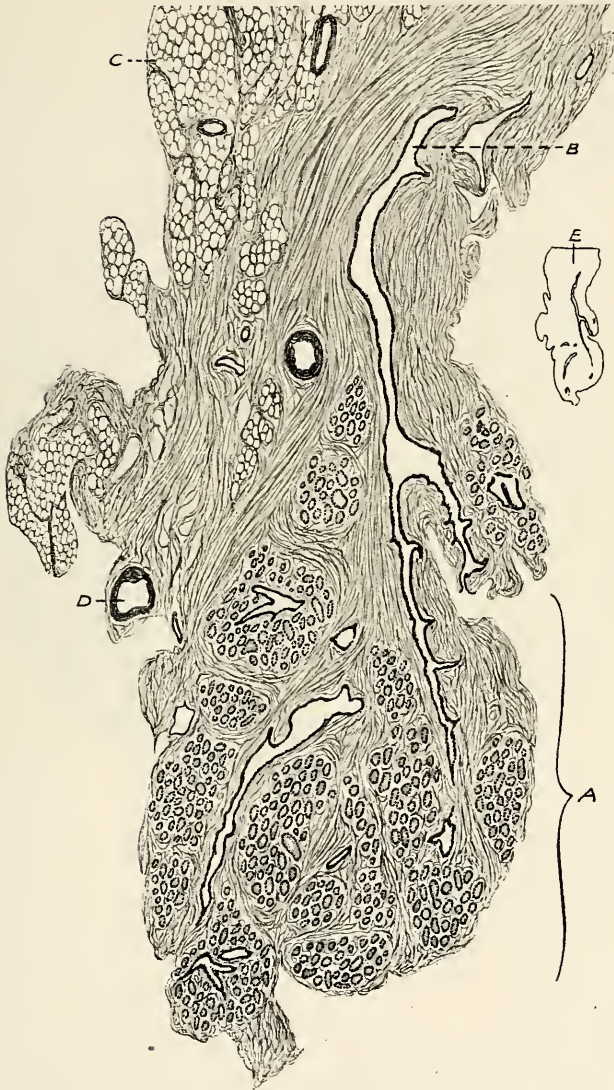

FIG. 42. A, Bartholin's gland ; B, Bartholin's duct ; C, fatty tissue of vulva ; D, branches of internal pudic artery, which correspond to the artery to the bulb in the male ; E, inset to show actual size of the microscopic slide. The portion forming the gland is about the size of a pea or small horse-bean.

levator ani, and the superficial perineal muscles. By voluntary action these muscles can constrict the ostium, and from reflex irritation, spasmodic contraction may occur, giving rise to the condition known clinically as *vaginismus* (see pp. 146 and 371).

**Bartholin's Glands.** Bartholin's glands are a pair of small, oval, glandular structures about  $\frac{1}{2}$  inch in diameter, lying at the sides of the lower end of the vagina beneath the superficial perineal fascia at the posterior end of each vestibular bulb (*see* Fig. 41). They are the homologue of Cowper's glands in the male.

Under normal conditions the Bartholin gland cannot be felt, but when indurated and enlarged by chronic inflammation, as frequently

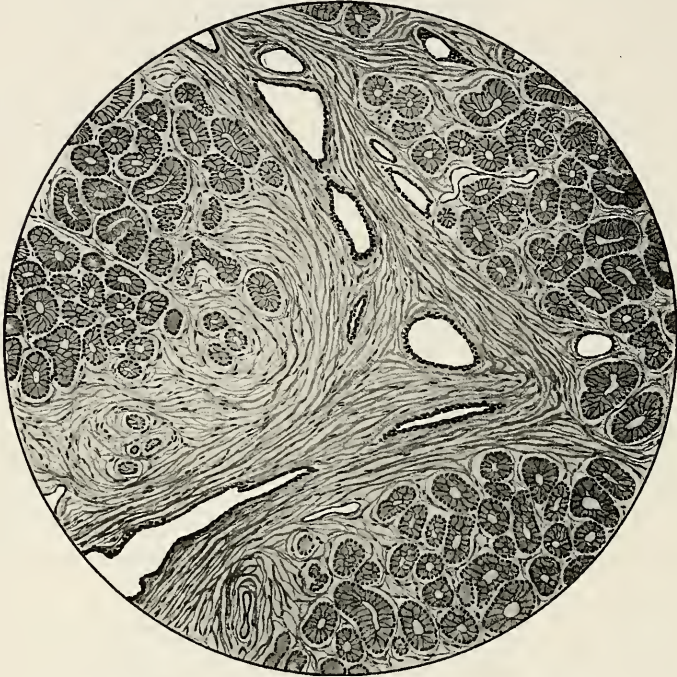

FIG. 43. TRANSVERSE SECTION THROUGH BARTHOLIN'S GLAND, showing tubules lined by columnar epithelium. The branching or racemose arrangement is shown in the section. The branches of the duct are lined by low cubical epithelium which, towards the commencement of the duct, becomes squamous.

occurs in gonorrhœa, it can be palpated by pinching up the tissues at the sides of the vulva between the finger passed inside and the thumb outside. The gland lies deeply, near the ascending ramus of the ischium (*see* Fig. 41), and can often there be felt as a hard, movable body, the size of a haricot bean. Each gland has a single, long narrow duct (*see* Fig. 42) which opens laterally at the base of the hymen. The mouth of the healthy duct may often be detected by the presence of a minute drop of clear secretion; otherwise it is very inconspicuous, unless reddened by inflammation.

The gland itself is a compound racemose structure enclosed in a fibrous capsule, from which arise numerous septa composed of well-formed fibrous tissue, subdividing the gland (*see* Fig. 43). Both

simple and compound tubules are present. The epithelium is columnar; the nuclei stain well and are situated at the base of the cells. There is a well-formed basement-membrane. In many tubules the epithelium is in more than one layer, but in the majority there is only one row of cells. The cell-protoplasm is very granular, but does not stain deeply. Many minute collecting ducts are seen among the tubules, and these are lined with several layers of epithelium of the low cubical type. In general appearance a section of the Bartholin gland is not unlike that of a salivary gland.

The main ducts have an epithelium of variable type. In the deeper parts it consists of a single row of well-formed columnar cells; in more superficial parts it is stratified and of the transitional type which is characteristic of the epithelium of the urinary passages. Sometimes the transition from one type of epithelium to the other is quite sharp. Into the deeper parts of the duct a few compound, racemose glands rich in goblet-cells may be seen to open. They no doubt produce mucus.

The secretion of the Bartholin glands is a clear, thin mucus of alkaline reaction. Its function is probably merely that of a lubricant of the vulva.

The **perineal body** is the mass of tissue which separates the vulva and lower part of the vagina on the one hand from the anal canal and rectum on the other, filling up the space left by the divergence of the lower ends of the alimentary and genital canals (*see* Figs. 1 and 2). It represents the lower part of the urorectal septum, which divides the cloaca into an anterior (genito-urinary) and a posterior (intestinal) segment (*see* Fig. 58). It is triangular in shape, the base being formed by the cutaneous surface, the apex passing upwards to the point at which the rectal and vaginal canals come into apposition, about  $1\frac{1}{2}$  inches above the anus. It is composed of muscular, fibrous, and fatty tissues; its base is covered with skin; its anterior wall is formed by the vagina, its posterior wall by the rectum. When intact the skin surface measures about  $1\frac{1}{2}$  inches from the anus to the fourchette.

## THE URETHRA

The urethra in the female is a short canal measuring  $1\frac{1}{2}$  inch in length, and of somewhat spindle-shape, being slightly constricted both at the meatus and at the neck of the bladder (*see* Fig. 1). Its general direction is downwards and forwards, with a slight anterior curve. In its lower two-thirds it is closely related to the anterior vaginal wall, so that a single thick stratum of tissue separates the lumen of the urethra from that of the vagina; in the upper one-third a layer of loose cellular tissue intervenes, allowing the two to be separated readily from one another by blunt dissection. Structurally the urethra consists of muscular, submucous, and mucous

coats. The *muscular coat* consists of plain muscle arranged in two layers, the outer circular, the inner longitudinal ; in addition, according to some anatomists, an external layer of striped muscle exists derived from the sphincter vaginæ muscles, and forms a urethral sphincter. The *submucosa* consists of highly vascular connective tissue containing a large proportion of elastic-fibres, and carrying the deep portions of the urethral glands. The *mucous membrane* is thrown into a number of longitudinal folds and consists of stratified epithelium resting directly upon the submucosa. The superficial cells are squamous near the extremities and columnar in the middle of the canal ; the deeper cells throughout are cubical and are arranged at right angles to the surface. The urethra is furnished with numerous glands which have been carefully described by Williamson and Attlee. They surround the urethra (peri-urethral), and are most numerous in the neighbourhood of the meatus. They are mostly compound racemose glands opening by a single duct upon the urethral mucosa, the deeper portions being lined by columnar epithelium. Near the meatus the ducts are often dilated, forming visible crypts. A specially developed pair of these glands, which open upon the floor of the urethra just within the meatus, are known as Skene's tubules. Morphologically the peri-urethral glands are the homologue of the prostate in the other sex.

An important characteristic of the urethra is its dilatability, which is mainly due to the large amount of elastic tissue in its walls and to the longitudinal folds of the mucosa, which become obliterated and so enlarge the superficies of the membrane during dilatation. The width to which the urethra can be dilated without laceration is variously estimated at from 13 to 30 mm. (roughly  $\frac{1}{2}$  to 1 inch).

## THE BLADDER

The position and relations of the bladder are subject to constant change owing to the ceaseless alternation of its systole and diastole. In the foetus and the young infant it is entirely an abdominal organ (*see* Fig. 21) and is somewhat spindle-shaped, tapering above into the urachus, below into the urethra. In the adult it is, when empty, entirely a pelvic organ. In distending within the normal limits it enlarges chiefly in the antero-posterior and transverse planes, displacing the uterus backwards, and filling the upper part of the pelvic cavity (*see* Fig. 4) ; when over-distended it also encroaches upon the abdominal cavity, and in extreme cases may form a swelling palpable *per abdomen* up to the level of the umbilicus. The average fluid-capacity of the bladder, tested in twenty-five normal individuals, was found by Guy L. Hanna to be 430 c.c. The internal urethral orifice lies about  $1\frac{1}{2}$  inches below the level of the pelvic brim.

The empty bladder is shown *in situ* in Fig. 1. It lies between the uterus and the symphysis pubis, and is covered above by the

peritoneum forming the floor of the utero-vesical pouch. The body of the uterus, when anteverted, rests upon the bladder. The bladder, commencing to distend, is shown in Fig. 2; the level of the utero-vesical pouch has risen, and even more apparent is the increase in the transverse dimensions of the organ.

The only part of the bladder which has firm attachments is the base, which is supported in its entire extent by the pelvic fascia, and at the sides receives support also from the pubic portions of the levator ani muscles (*pubo-coccygeus*). The base of the bladder has no peritoneal covering, but the peritoneum completely clothes the sides and upper part of the organ when empty. The base of the bladder is related in front to the back of the pubes, below to the anterior vaginal wall, and behind to the anterior uterine wall near the junction of the cervix and the body. Planes of loose cellular tissue are found in these situations, which allow of the easy operative separation of the base of the bladder from the adjacent organs. The relations of this part of the bladder are little affected by diastole and systole.

The relations of the top and sides of the bladder vary with the degree of distension. The lateral reflections of the peritoneum are raised considerably, so that a part of each side of the bladder is laid bare of peritoneum; behind and in front the peritoneal reflections are much firmer, so that a peritoneal pouch is maintained between the bladder and the abdominal wall in front and between the bladder and the uterus behind. In a case of extreme distension, however, the level of the anterior reflection may be raised from the abdominal wall for 2 inches, but it is not possible for the peritoneum to be stripped off the uterus to anything like this extent. In all conditions the base of the bladder can be reached through the upper one half of the anterior vaginal wall.

The wall of the bladder consists of mucous, submucous, and muscular coats, all three being readily distensible.

The mucous membrane, when the organ is empty, is thrown into numerous folds and rugæ; even when distended it appears rugose from the columnar arrangement of the subjacent muscular fibres. A portion of the base of the bladder is, however, smooth both in systole and diastole; this portion is triangular in shape and is outlined by the urethral aperture in front and the two ureteric apertures behind: it is called the *trigone* (see Fig. 5). The internal urethral opening forms a depression surrounded by a ring of mucous membrane, which is crossed by radiating folds. The ureteric apertures are narrow, oblique, valvular slits directed from behind forwards and towards the middle line. Between them runs a narrow ridge of mucous membrane called the *inter-ureteric fold*. At each side of the trigone is a shallow pouch, the *paratrigoal fossa*. The part of the base from which the urethra arises is sometimes called the *neck* of the bladder.

The epithelium of the bladder is of the transitional type, and

there are no glands. The submucous connective tissue is abundant except at the trigone, where the mucosa is firmly attached to the muscular layer. The bladder-muscle is arranged in three layers, the outer longitudinal, the inner circular, the middle reticulated.

The bladder-wall is very vascular and bleeds freely when cut or torn ; it is supplied by the superior and inferior vesical arteries from the internal iliac. The venous return is collected in plexuses ; the inferior vesical plexus, in relation with the base of the bladder, is very large and gives rise to free venous bleeding during operations on this part of the organ.

### PELVIC BLOOD-VESSELS, LYMPHATICS, AND NERVES

**Blood-vessels.** The arterial supply of the genital organs is derived from the following vessels, enumerated from above downwards :

1. The ovarian artery from the abdominal aorta or the renal artery.
  2. The uterine artery
  3. The vaginal arteries (3 or 4)
  4. The internal pudic artery
- } from the anterior division of the  
internal iliac.

The *ovarian* artery enters the pelvis posteriorly near the sacro-iliac joint, crossing obliquely in front of the ureter to pass into the infundibulo-pelvic fold of the broad ligament (*see* Figs. 2 and 18). Between the layers of the upper portion of the broad ligament it runs inwards to the uterine cornu, giving off many branches which supply the ovary and Fallopian tube (*see* Fig. 44). Near the uterine cornu it effects an anastomosis with the terminal branch of the uterine artery. It has two or more companion veins which freely communicate by tributaries.

The *uterine* artery enters the base of the broad ligament near the lateral pelvic wall and runs obliquely forwards and inwards through the abundant cellular tissue to reach the side of the uterus at about the level of the internal os. It crosses obliquely above the ureter just before reaching the side of the uterus (*see* Fig. 45). The main artery now turns abruptly upwards, keeping in close contact with the uterine wall. A numerous series of branches are given off at right angles to the main trunk which pass some over the anterior, some over the posterior surface of the uterus to anastomose, in the middle line, with corresponding branches from the artery of the opposite side (*see* Fig. 44). The first of these branches to be given off is of comparatively large size, and with its fellow of the opposite side forms the *circular artery of the cervix*. Near the uterine cornu the terminal portion of the uterine artery anastomoses with the ovarian (anastomotic branch). There are numerous companion veins throughout. In the broad ligament a large venous plexus (pampiniform

plexus) is formed which is drained by the ovarian veins, and communicates below with the vesical and hæmorrhoidal venous plexuses.

Both the ovarian and uterine arteries and their branches run a spiral or tortuous course which forms a strongly marked characteristic of these vessels (*see* Figs. 2 and 44). This peculiarity allows of the rapid elongation of these vessels which is required to meet the physiological

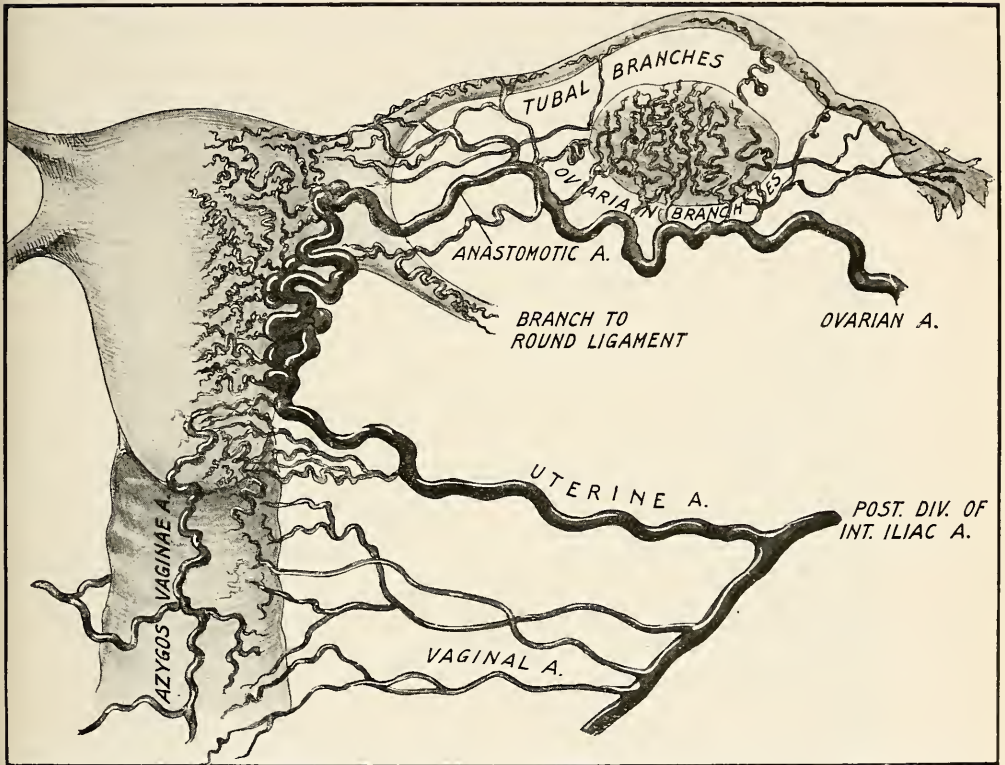


FIG. 44. THE ARTERIAL BLOOD-SUPPLY OF THE UTERUS AND VAGINA (His).  
 Note.—The uterine and vaginal arteries usually arise from the anterior, not the posterior division of the internal iliac.

enlargement of the uterus in pregnancy, and also permits of their return to the normal condition of tortuosity after the still more rapid shrinkage which succeeds delivery.

The *vaginal* arteries arise from the anterior division of the internal iliac below the uterine artery; sometimes one of them arises directly from the uterine, or from the middle hæmorrhoidal artery. They reach the sides of the vagina near its upper end, and branch irregularly, their general course being across the vaginal canal. Another artery is sometimes present, the *azygos vaginae*, which is derived partly from the circular artery of the cervix, and partly from the upper branches of the vaginal artery; it runs along the middle line both anteriorly and

posteriorly. In addition to this anastomosis, numerous direct communications are formed with the branches of the uterine arteries in the region of the vaginal fornices. The vaginal veins communicate freely with the hæmorrhoidal and vesical plexuses.

The internal *pubic arteries* supply the parts composing the vulva and the perineal body ; the trunk-vessel lies deeply beneath the edge

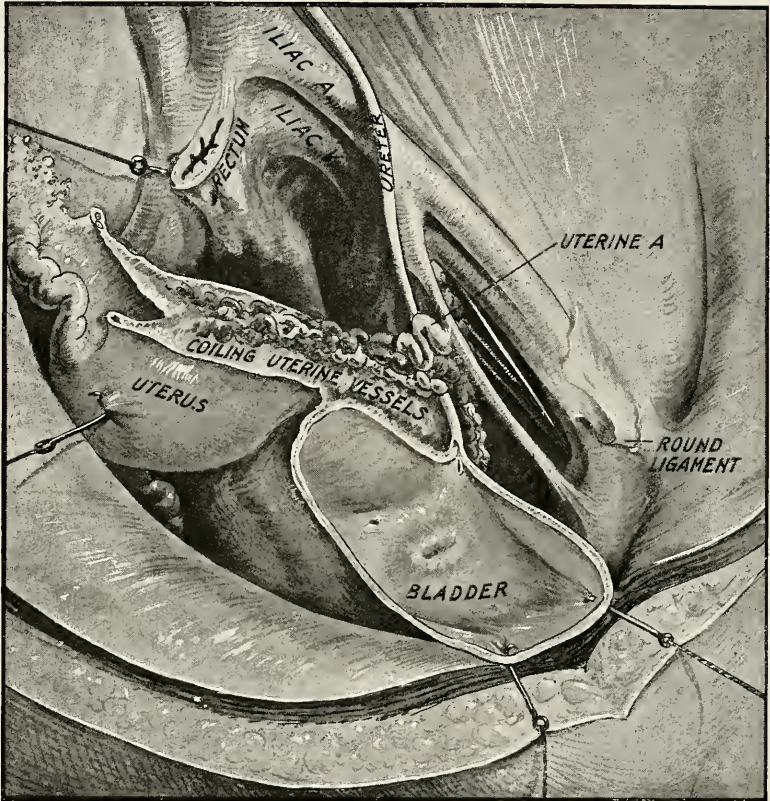


FIG. 45. DISSECTION OF THE LEFT BROAD LIGAMENT, showing the relation of the uterine artery to the ureter (Kelly).

of the pubic arch, and sends off numerous branches. Two of these are of some importance : (1) a large branch which reaches the posterior part of the vulva and supplies the Bartholinian gland (*see* Fig. 42 D) ; it corresponds to the *artery to the bulb* in the male ; (2) an anterior terminal branch which supplies the clitoris and vestibule—*artery to the clitoris*. The companion veins are numerous and pass, some into the inferior hæmorrhoidal, some into the inferior vesical plexus. The superficial labial branches frequently form varicosities of large size in pregnancy. The vulva is almost completely encircled by highly vascular erectile tissue, arranged in two crescentic lateral masses—the *vaginal bulbs* (*see* Fig. 41). The deep transverse perineal artery



and the artery to the clitoris supply them with blood. Deep laceration of the vulva may give rise to serious hæmorrhage, owing to the great vascularity of these parts.

**Lymphatics.** The lymphatics of the genital tract pass for the most part into certain deeply placed chains of glands. These are,

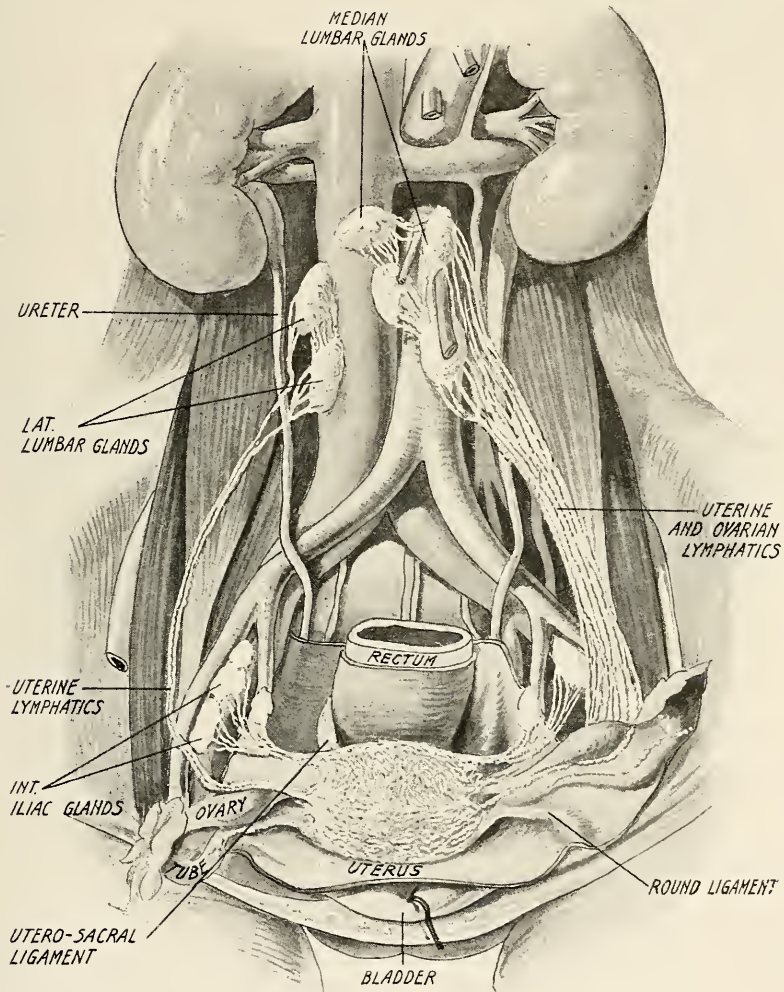


FIG. 46. GENERAL VIEW OF THE LYMPHATICS OF THE FEMALE INTERNAL SEXUAL ORGANS (Poirier).

firstly, the *internal iliac* or *hypogastric* chain consisting of two groups—the *superior*, placed upon the lateral pelvic wall in the angle formed by the bifurcation of the internal iliac artery, and the *inferior*, lying at a lower level in relation to the uterine artery (see Fig. 46); secondly, the *lumbar* chain of glands placed upon the lower part of the abdominal aorta and inferior vena cava, and consisting of a *median* and two

*lateral groups* (see Fig. 46). Other deeply placed glands which receive genital lymphatics are the *sacral group*, and one or two isolated glands lying between the rectum and the vagina. The only external glands which receive lymphatics from the pelvic organs are the *superior group* of the *superficial inguinal glands* placed in the groin. Accordingly, enlargements of lymphatic glands from disease cannot be recognized by clinical examination except in the case of certain areas of the genital tract.

From the *ovary* and *Fallopian tube* the lymphatics are collected into several trunk-vessels which accompany the ovarian artery and

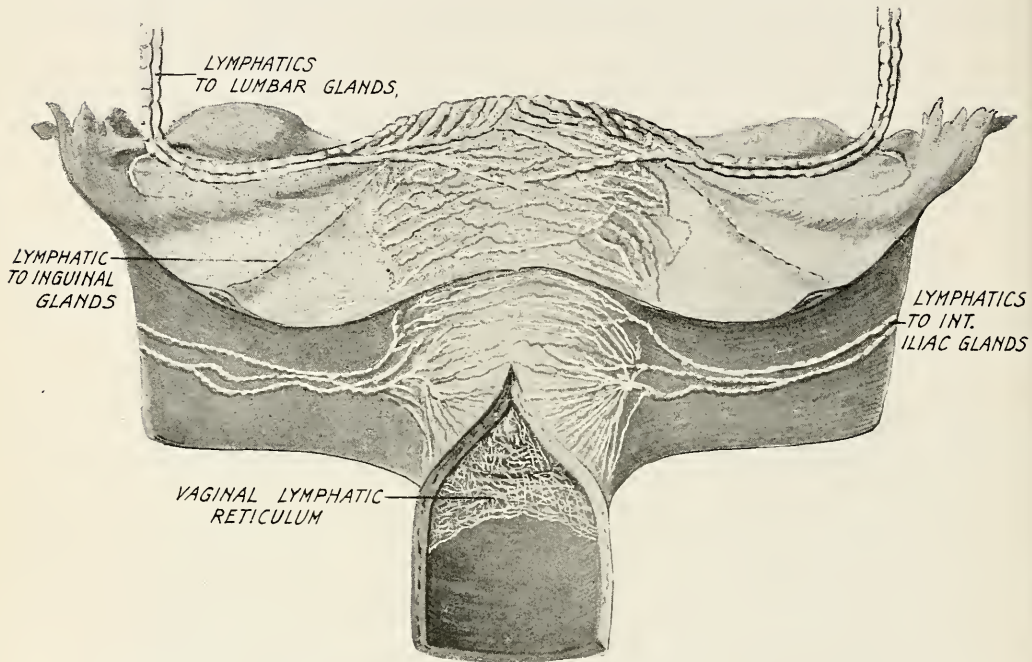


FIG. 47. THE UTERINE LYMPHATICS (Poirier).

veins and leave the broad ligament along with them (see Fig. 46). Thence they pass upwards over the pelvic brim in front of the ureter and finally join the lateral groups of the lumbar glands, those on the left lying upon the aorta, those on the right side upon the inferior vena cava.

From the *uterus* the course of the lymphatic trunks is not so simple. Those of the fundus and other parts of the uterine body anastomose to form two or three large trunk-vessels which pass outwards below the ovary, and run in company with the ovarian lymphatics of the same side to the same group of lumbar glands (see Fig. 47). From the fundus another small trunk passes forwards along the round ligament, leaves the abdominal cavity through the internal inguinal ring, and

finally joins the superior group of the superficial inguinal glands. The lymphatics of the cervix are collected into three or four large trunks which pass outwards in the lower part of the broad ligament, and join the superior group of the internal iliac chain of glands (see Fig. 47). Before reaching this group a small gland is often found lying in the base of the broad ligament at the level of the cervico-

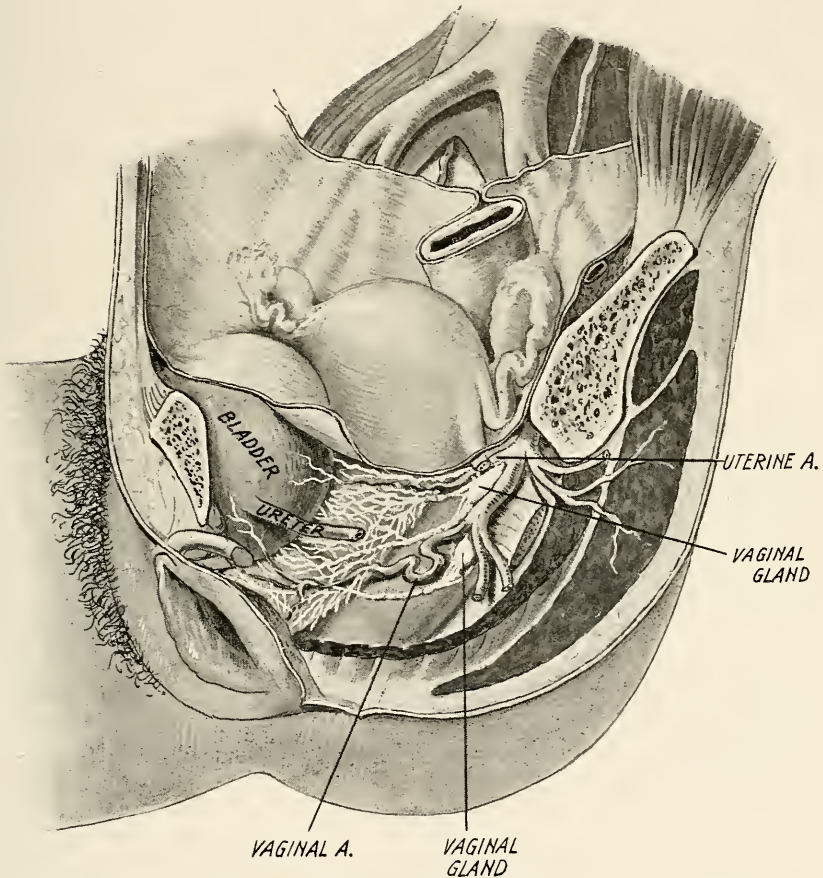


FIG. 48. THE VAGINAL LYMPHATICS AND THE GLANDS TO WHICH THEY PASS (Poirier).

vaginal insertion. A small lymphatic vessel is usually found in the utero-sacral ligament which joins the *sacral glands*. Free anastomoses exist between the lymphatics of the uterus, ovary and tube, and also with those coming from neighbouring pelvic organs.

The *vaginal* lymphatics are described by Poirier as consisting of three groups. Of the *superior* group, some join those of the cervix and pass into the superior group of the internal iliac glands ; the rest pass directly to the inferior group of glands of the same chain. The *median* vaginal lymphatics also pass into the inferior group of the

internal iliac glands, but one or two small trunks make their way into two glands lying upon each side of the rectum, and which are in communication with the superior hæmorrhoidal glands (Fig. 48). The *inferior* vaginal lymphatics, draining the parts down to the level of the hymen, according to Poirier, also pass into the inferior group of the internal iliac chain.

The *vulval* lymphatics, including those from the hymen, all pass into the superior group of the superficial inguinal chain. Free anastomoses exist between the lymphatics of one side and those of the other, so that both chains of glands may become infected from a unilateral or a median vulval lesion.

**Nerves.** The internal genital organs are freely supplied with sensory nerves from the pelvic sympathetic plexuses; these plexuses are connected with the eleventh and twelfth dorsal nerves, and with all the lumbar and sacral nerves. From this it follows that reflex pain arising from morbid conditions of these organs may have a very wide cutaneous distribution. The external organs are supplied by the pudic nerve (sacral plexus), the inferior pudendal nerve from the small sciatic, and the ilio-inguinal nerve from the upper part of the lumbar plexus.

The motor nerves to the levator ani and superficial perineal muscles are derived from the pudic nerve and the sacral and coccygeal plexuses.

### DEVELOPMENT OF THE FEMALE GENITO-URINARY TRACT

On the dorsal aspect of the cœlomic cavity and on either side of the spine, the mesoblast forms the *nephrogenic cord*, from which in the human subject three nephrogenic organs become differentiated. These organs are called the pronephros, mesonephros, and metanephros.

The *pronephros* is very rudimentary; it is represented by a glomerulus and a duct, both of which, according to Tandler, entirely disappear. Keith, however, considers that the cranial end of the pronephric duct forms the ampulla and the abdominal ostium of the Fallopian tube. Other observers also regard the hydatid of Morgagni and Kobelt's tubules as remnants of the pronephric duct.

The *mesonephros* and *metanephros* together form the Wolffian body and its duct (*see* Figs. 49, W.D., and 50, W.B.), which latter forms the primary urinary canal. The Wolffian body is divided into cranial and caudal sections. The cranial part corresponds to the mesonephros proper, and the caudal part to the metanephros; the latter forms a portion of the permanent kidney, and will receive no further mention. The mesonephros projects under the peritoneum of the dorsal cœlomic wall to which it becomes attached by a peritoneal fold called the *plica mesonephrica* (*see* Fig. 50, M.F.). After this fold is formed, the cœlomic entoderm of the medio-ventral surface of the mesonephros proliferates

to form the genital streak, which is the precursor of the sex-gland (*gonad*) (see Fig. 49, G.E.). The mesonephros is at first a large gland, but it soon undergoes atrophic changes which leave the upper part of the mesonephric fold empty. This upper empty fold then becomes the *plica diaphragmatica mesonephrica* (see Fig. 51, P.M.D.), which ultimately forms the free edge of the ovario-pelvic or infundibulo-pelvic fold and has received the name of *ligamentum suspensorium ovarii*.

The parts of the Wolffian system which persist in the human female are: (1) remains of the cranial or sexual segment (genital

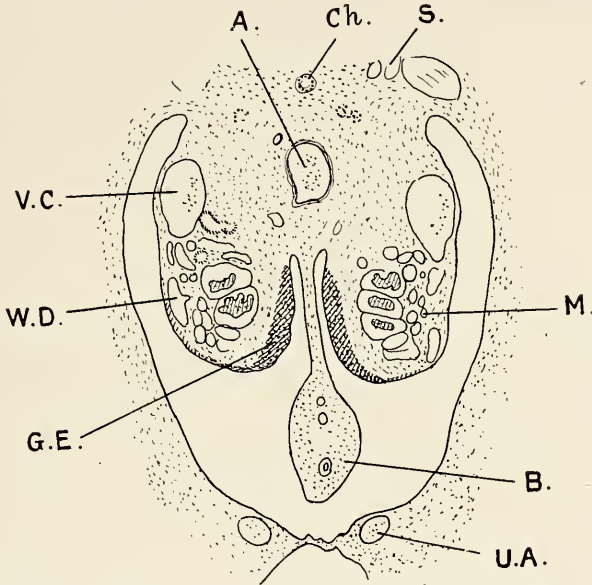


FIG. 49. SECTION THROUGH THE ABDOMINAL REGION OF A HUMAN EMBRYO 9.75 mm. LONG (after Tandler). A., aorta dorsalis; U.A., art. umbilicalis; Ch., chorda dorsalis; B., bowel; W.D., Wolffian duct; G.E., genital gland forming from germ-epithelium; S., sympathetic plexus; M., mesonephros with canals and glomeruli; V.C., vena cava.

tubules) which are represented by the *Epoöphoron*, a structure which lies in contact with the ovary, and which is sometimes called the par-ovarium or organ of Rosenmüller; this corresponds to the epididymis in the male (see Fig. 51, E.D.L., E.D.Tr.); (2) remains of the caudal or secretory (primitive renal) segment, which are preserved as the *paroöphoron* lying between the ovary and the uterus (see Fig. 51, P, p. 77); this corresponds to the paradidymus in the male; and (3) a portion of the primary urinary duct as the *duct of Gartner*. This is the homologue of the vas deferens of the male (see Fig. 51, G.D.).

**The Ovaries.** As already stated, the ovaries develop on the medio-ventral aspect of the mesonephros as the so-called *genital streaks* and extend for its whole length. In the human embryo these streaks arise relatively late. On transverse section the genital streak is seen

to be composed of several layers of epithelium—the *germ-epithelium*. In this are seen large cells rich in protoplasm and with a clear nucleus ; these are the *genital cells*. The latter are only found in the middle section of the genital streak ; at its head- and tail-ends the streak is not so raised, but forms a flat fold. The germ-epithelium grows rapidly into the underlying tissue in the form of *germinal cords*,

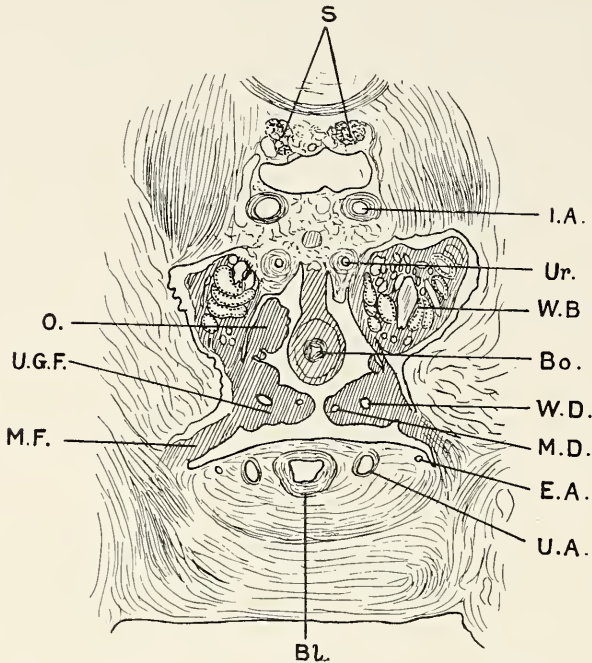


FIG. 50. SECTION THROUGH THE PELVIC REGION OF A HUMAN EMBRYO 28.5 mm. IN LENGTH (after Tandler). E.A., art. epigastrica ; U.A., art. umbilicalis ; BL., bladder ; Bo., bowel ; M.D., duct. Müllerii ; W.D., duct. Wolffii ; O., ovarium ; S., sympathetic plexus ; U.G.F., urogenital fold ; M.F., mesonephric fold ; W.B., Wolffian body ; Ur., ureter ; I.A., Iliac Artery.

which have only a slight significance in the development of the entire ovary, since after the formation of the primary follicles they disappear. The head-end of the genital streak does not develop, but the tail-end shows proliferation of its epithelium to form the *reticular cords* which are interposed between the mesonephros and the genital gland. The latter is not yet differentiated as ovary or testis ; this differentiation is first seen in embryos 14 mm. long (fifth to sixth week), when a testis begins to show a tunica albuginea and a marked development of genital cords. Absence of these structures at this stage marks the gland as an ovary. At this stage the ovary shows a development of connective tissue which grows from the depths into the germinal layer and divides the germ-epithelial cells and genital cells into groups (*egg-follicles*). In each such follicle we have a genital

cell surrounded by the germ-epithelial cells. No further increase of genital and epithelial cells takes place excepting for such cell-division as occurs in each individual group. Meanwhile the splitting-up of the groups by the stroma-tissue continues. This leads to the primordial egg-cells being scattered through the entire ovary, and these, surrounded by epithelial cells, constitute the *primordial follicles*. Those follicles

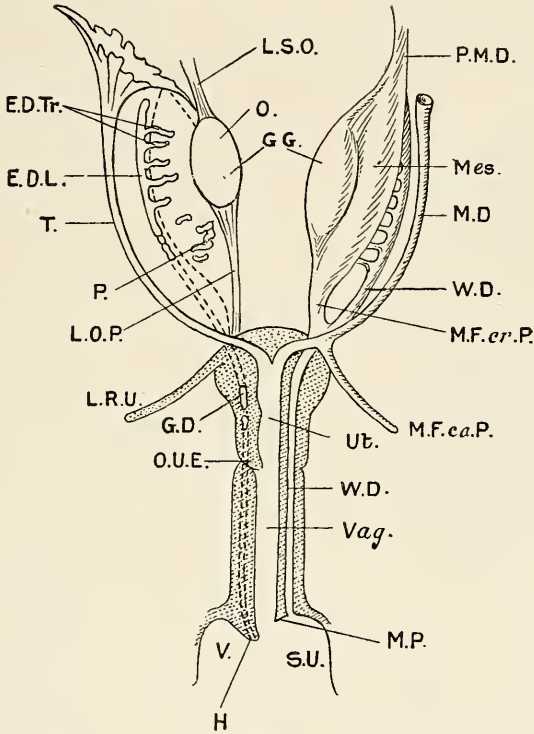


FIG. 51. SCHEME OF THE DEVELOPMENT OF THE FEMALE GENITALIA. On the left of the figure are shown the adult organs; on the right the embryonic structures are shown for comparison (after Tandler). E.D.L., Epoöphoron, longitudinal duct; E.D.Tr., Epoöphoron, transverse ducts; G.D., Gartner's duct; G.G., genital gland; H., hymen; L.O.P., Liq. ovarii proprium; L.R.U., liq. rotundum uteri; L.S.O., liq. suspensorium ovarii; Mes., Mesonephros; M.D., Müller's duct; M.F.ca.P., Mesonephric fold caudal portion; M.F.cr.P., mesonephric fold cranial portion; M.P., Müller's prominence; O.U.E., external os uteri; O., ovary; P., Paröphoron; P.M.D., Plica mesonephrica diaphragmatica; S.U., sinus urogenitalis; T., Fallopian tube; Ut., uterus; V., vestibulum vaginae; Vag., vagina; W.D., Wolffian duct.

which lie in the centre of the ovary begin to disappear in embryonic life, and by the end of the first year of life follicles are only found in the cortex. The follicles increase in size for a few weeks after birth and then remain at rest until puberty. The reticular cords, which were interposed between mesonephros and ovary, form part of the paröphoron which in the human ovary is rudimentary, but

supplies one source of origin for *small hilum cysts* which are often to be seen later in life. The external form of the ovary develops as follows: It consists of only the *middle third of the genital streak*, the head- and tail-ends are rudimentary or disappear. The middle part grows out more and more from the mesonephros until these structures are only connected by a fold of peritoneum. Its surface is flat as a whole, but with many furrows and knots. The foetal ovary is an elongated gland (*see Fig. 51, G.G.*), with its surface moulded by surrounding structures. The rounded form of the ovary is not assumed until after birth.

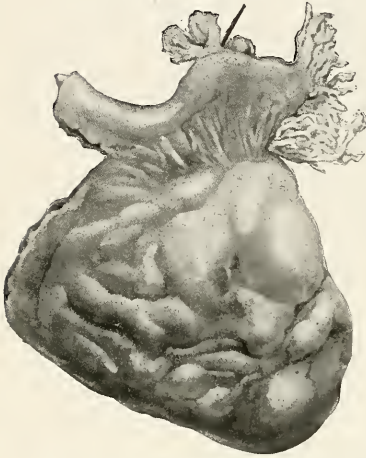

FIG. 52. TUBE SHOWING ACCESSORY ABDOMINAL OSTIUM.

**The Oviducts** (Fallopian Tubes) represent the upper non-fused portions of the Müllerian ducts; they appear relatively late in the human subject. In embryos 12 mm. long the oviducts arise on the lateral wall of the Wolffian duct as a shallow furrow in the coelomic epithelium. This develops into a tube, the cephalic segment of which is funnel-shaped. The narrow caudal end of the funnel is at first imperfectly united with the remainder of the tube, and at this point an accessory ostium often forms (*see Fig. 52*). Keith has advanced the view that the funnel-shaped segment of the oviduct is developed, not from Müller's duct, but from the *pronephros*.<sup>1</sup> The tail-part

of the Müllerian duct descends alongside the Wolffian duct, which it uses as a guide. These two ducts therefore lie in the same peritoneal fold (*see Fig. 50, W.D., M.D.*), which is derived from the mesonephric fold already described (*see Fig. 50, M.F.*). This is called the *urogenital fold* (*see Fig. 50, U.G.F.*); it lies on the posterior abdominal wall and on the lateral pelvic wall, whence it turns towards the mid-line rising up more and more from the floor of the pelvis as a transverse septum. Its median part is called the *genital fold* and contains four ducts—two Müllerian and two Wolffian—whilst its lateral parts form the *ligamentum latum*. At the level of the lower pole of the mesonephros the Müllerian ducts cross in front of the Wolffian ducts to meet each other in the mid-line (*see Fig. 51, W.D., M.D.*), and from thence they descend side by side to reach the dorsal wall of the urogenital sinus (*see Fig. 51, S.U.*), where they project and form a prominence. This prominence is clearly seen in embryos 28

<sup>1</sup> In the fourth month a simple longitudinal fold appears in the lumen of the tube, this is the primary mucous fold; secondary and tertiary folds, also longitudinal, appear about the seventh month. The fimbriae arise as blunt projections at the end of the tube.



mm. long and is called Müller's prominence (*see* Fig. 51, M.P.). Before the Müllerian ducts open at this prominence they *fuse to form a single canal*. The point where the fusion commences corresponds later to the external os uteri (*see* Fig. 51, O.U.E.). From thence the fusion spreads upwards and downwards to form the utero-vaginal canal. This is already seen in embryos 25 mm. long (end of second month).

**The Uterus and Vagina.** At this time the division between uterus and Fallopian tube is marked by the attachment to the Müllerian tubes of the mesonephric or urogenital fold (*see* Fig. 51, M.F.cr.P. (round ligament), L.R.U.); the part above this point is the Fallopian tube, that below it is the utero-vaginal canal. The differentiation between uterus and vagina is first seen in a distinction between the epithelial linings; that lining the uterus is simple cylindrical, that in the vagina is many layered.

Müller's ducts take a course which is concave forwards from the very beginning, and in the region of the utero-vaginal canal a bend appears corresponding to the boundary between vagina and uterus. In the fifth month the *portio vaginalis cervicis* and vaginal fornices are formed; at the same time, the lumen of the vagina is opened up, by the disappearance of the epithelial plug at its lower end. At this time also the *columnæ rugarum* appear in the vagina and the *arbor vitæ* in the cervix. The former appear at the vulval end of the vagina and spread upwards. In the seventh month glands form in the cervix, at the time of birth they appear in the uterus.

All the derivatives of Müller's ducts acquire a layer of muscle about the fifth month. It is circular in the region of the tube and uterus, longitudinal in the vagina. The vaginal musculature spreads itself out on the lips of the *portio vaginalis cervicis*. In the sixth and seventh months a strong submucous muscular stratum appears *parallel* to the long axis of Fallopian tube.

At the end of foetal life an additional muscular layer also appears in the subserous tissue. This increases until puberty. The subserous muscular layer develops simultaneously in the uterus, round ligament, ovarian ligament, and in the utero-sacral folds.

### **The Development of the Sinus Urogenitalis, the Fusion of the Urinary and Genital Tracts with each other and with the Sinus Urogenitalis**

As the sinus urogenitalis is derived from the cloaca, the latter must be first described.

The hind gut forms, in a 3 mm. embryo, a pouch which is flattened from side to side—the *cloaca* (*see* Fig. 53, Cl.). Into this the allantois opens at its upper and anterior aspect. The ventral wall of the cloaca lies against the ectoderm of the belly-wall extending from

the navel to the prominence of the tail so that the ectoderm and entoderm are here in immediate contact. These layers form a ventral boundary and constitute the *cloacal membrane* or plate (see Fig. 53, Cl.M.).

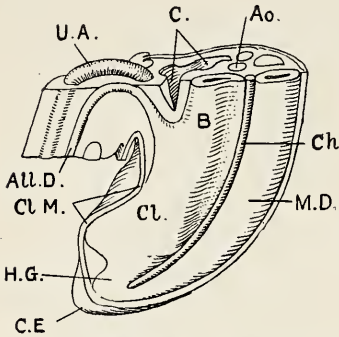


FIG. 53. MODEL OF THE CLOACAL REGION OF AN EMBRYO 3 MM. IN LENGTH (after Keibel). All.D., duct of allantois; Ao., aorta; U.A., umbilical artery; C., coelom; Ch., cord; Cl., cloaca; Cl.M., cloacal membrane; B., bowel; C.E., caudal extremity; H.G., hind gut; M.D., spinal canal.

the cloelom) is descending all the time and has now divided the cloacal space above the openings of the Wolffian ducts into two cavities. The ventral one, in direct continuation with the allantois, is the future

Quite early in development the cœlomic cavity protrudes downwards as a hollow spur between allantois and gut (see Figs. 53, 58 and 59, C.). This depression carries an investment of mesoblast before it, which by dipping into the cloaca forms the *urorectal septum* (see Fig. 58, S.Ur.). Later, the cloacal membrane in the median plane becomes depressed so as to form the ectodermal cloacal furrow.

At this stage the Wolffian ducts reach the lateral part of the ventral walls of the cloaca, which has widened out transversely at this level (see Fig. 54, Wf.D.). The mesodermal depression (urorectal septum from the

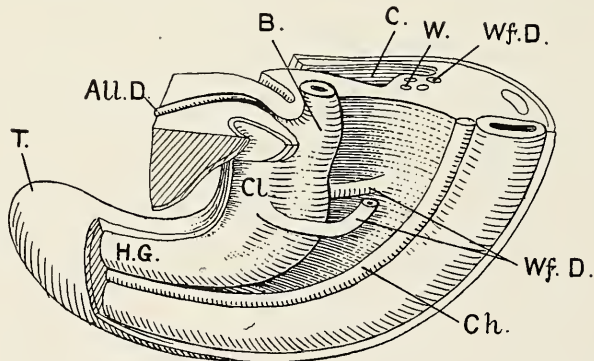


FIG. 54. CLOACAL REGION OF AN EMBRYO 4.2 mm. IN LENGTH (after Keibel). All.D., allantoic duct; C., coelom; Ch., cord; Cl., cloaca; B., bowel; T., tail; H.G., hind gut; W., Wolffian body; Wf.D., Wolffian duct.

bladder (see Fig. 57, B.L.), the other (dorsal) is in communication with the hind gut (see Fig. 57, B.O.). The openings of the Wolffian ducts in the ventral segment of the cloaca form the site of the future differentiation of bladder and ureters on the one hand, from the sinus

urogenitalis on the other. The upper part of the ventral portion of the cloaca is therefore appropriated by bladder and ureters, the lower part becomes the sinus urogenitalis (*see* Fig. 59, Bl., Sin. Ug.). Shortly after the Wolffian duct reaches the cloaca, there arises on

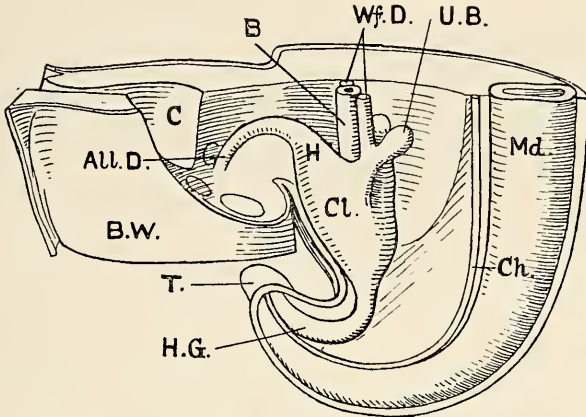


FIG. 55. MODEL OF CLOACAL REGION OF AN EMBRYO 6.5 MM. IN LENGTH (after Keibel). All.D., allantoic duct; B.W., belly wall; C., coelom; Ch., notochord; Cl., cloaca; B., bowel; H., bladder; Md., spinal canal; U.B., ureter; T., tail; H.G., hind gut; Wf.D., Wolffian ducts.

its dorsal wall, directly opposite its opening, the *renal or ureteric prominence*; this is seen in embryos 6½ mm. long (third to fourth week) (*see* Fig. 55, U.B.). The significance of this will be seen later.

The Müllerian ducts reach the sinus urogenitalis at a later stage than the Wolffian ducts. In the interval, two important developmental processes take place. The first concerns the development of the bladder and the vesical trigone, the second the complete separation of bowel from the sinus urogenitalis. Taking the latter first, we note that the urorectal septum by its continuous downgrowth divides the ventral cloacal segment (urogenital sinus) from the dorsal cloacal segment (the rectum). Finally the urorectal septum reaches the cloacal membrane, then the separation between bowel and urogenital sinus is completed (*see* Fig. 58, Cl.M., S.U.R.). This will again be referred to in dealing with the development of external genitals and rectum.

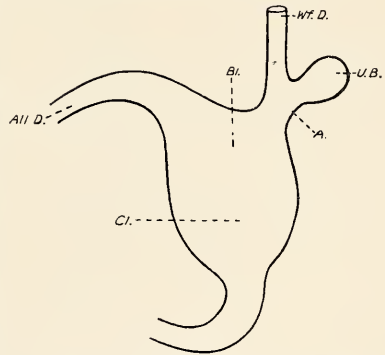


FIG. 56. Showing the portion of Wolffian duct (A) which forms part of the trigone of the bladder. All.D., allantoic duct; Bl., bladder; Cl., cloaca; U.B., ureteric bud; Wf.D., Wolffian duct.

As previously stated, there arises from the dorsal wall of the

Wolffian duct, just before it opens into the cloaca, the renal or ureteral bud (*see* Fig. 55, U.B.); this is the foundation of the ureter. The part of the Wolffian duct (A in Fig. 56) between its opening into the cloaca and the ureteral bud (*see also* Fig. 55) gets shorter and shorter and

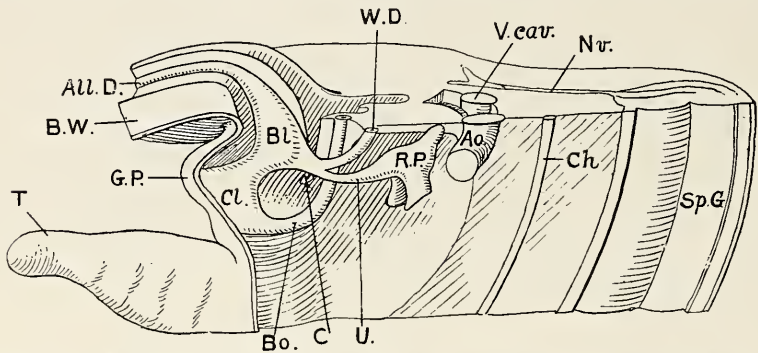


FIG. 57. MODEL OF CLOACAL REGION OF AN EMBRYO, 11.5 MM. IN LENGTH (after Keibel). All.D., allantoic duct; Ao., aorta; B.W., belly wall; C., coelom; Ch., notochord; Cl., cloaca; Bo., bowel; G.P., genital papilla; Bl., bladder; Sp.C., spinal canal; R.P., renal pelvis; Nv., nerve; T., tail; Sp.G., spinal ganglion; U., ureter; V.cav., vena cava; W.D., Wolffian duct.

it ultimately helps to form the trigone of the bladder and a part of the urethra (*see* Fig. 59, P.R.).

Meanwhile Müller's ducts have reached the sinus urogenitalis

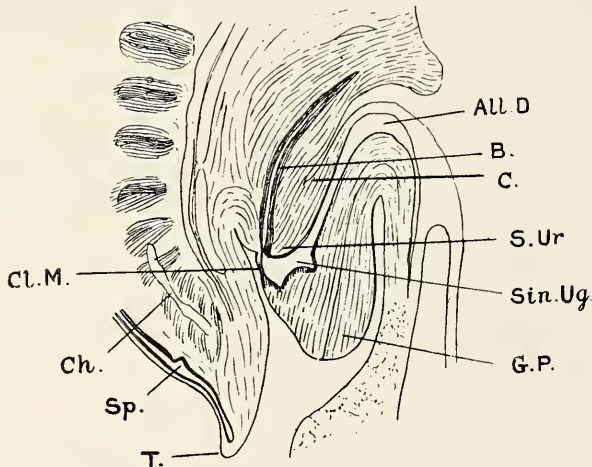


FIG. 58. SAGITTAL SECTION THROUGH THE PELVIC EXTREMITY OF AN EMBRYO 13 MM. IN LENGTH (after Keibel). All.D., allantoic duct; B., bowel; Ch., notochord; Cl.M., cloacal membrane; C., coelom (future pouch of Douglas); G.P., genital papilla; S.Ur., urorectal septum; Sin. Ug., sinus urogenitalis; Sp., spinal cord; T., tail.

(*see* Fig. 59, M.D.), and produced Müller's prominence on its dorsal wall; through this they open and their point of opening lies above that of the Wolffian ducts.

The bowel has been completely separated from the urogenital system by the urorectal septum (*see* Figs. 58 and 59). The upper part of the ventral cloacal segment has become the bladder and urachus. The sinus urogenitalis is at this stage an extremely long pouch (*see* Figs. 58 and 59, Sin.Ug.).

**Changes in the Cloacal Membrane.** Before describing the formation of the external genitals we must consider what has been going on with regard to the cloacal membrane.

This membrane, which reached from the navel to the tail, has been pushed inwards and invested by a thick mass of tissue which

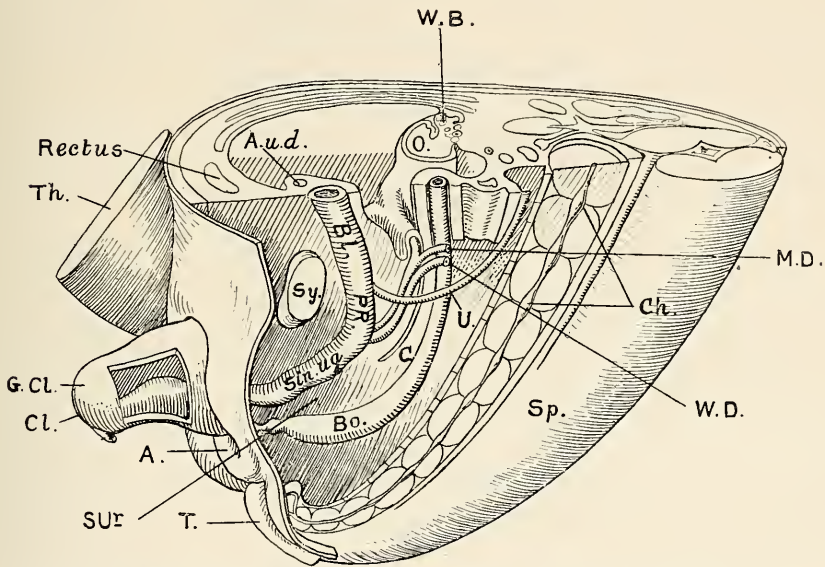


FIG. 59. MODEL OF THE PELVIC REGION OF A HUMAN EMBRYO 29 mm. IN LENGTH (after Keibel). A, Anus; A.u.d., art umbilicalis dextra; Bo., bowel; Bl., bladder; C., cœlom (pouch of Douglas); Ch., notochord; Cl., clitoris; G.Cl., glans clitoridis; L., liver; Lig. R., round ligament; M.D., Müller's duct; O., ovary; P.R., primary urethra; Sin. ug., sinus urogenitalis; Sy., symphysis; Sp., spinal cord; U., ureter; Th., thigh; T., tail; W.B., Wolffian body; W.D., Wolffian duct; S.Ur., urorectal septum.

forms a ventral papilla (*see* Figs. 57 and 58, G.P.). This cloacal or *genital papilla* partly covers the cloacal membrane. Partly through the growth of the genital papilla and partly through two lateral thick swellings—the *genital folds*—the cloacal membrane is pushed somewhat into the depths (backwards) (*see* Fig. 58, Cl.M.). By the union of the urorectal septum with the cloacal membrane the latter is divided into *urogenital membrane* anteriorly, and *anal membrane* posteriorly. The former is the first to dehisce, and thus the sinus urogenitalis opens externally prior to the gut. The genital papilla acquires a blunt free end, which is the future *glans clitoridis* (*see* Fig. 59, G.Cl.). Its surface, which looks towards the sinus urogenitalis,

becomes furrowed and presents two lateral borders. The groove between these borders is lined by epithelium and becomes the urethral groove, the borders themselves become the urethral lips.

From the genital folds the labia majora develop, whilst the urethral lips become the labia minora (*see* Fig. 60). The length of the urogenital sinus diminishes more and more, but the upper part, *i.e.* that between the opening of the ureter and the Müllerian promi-

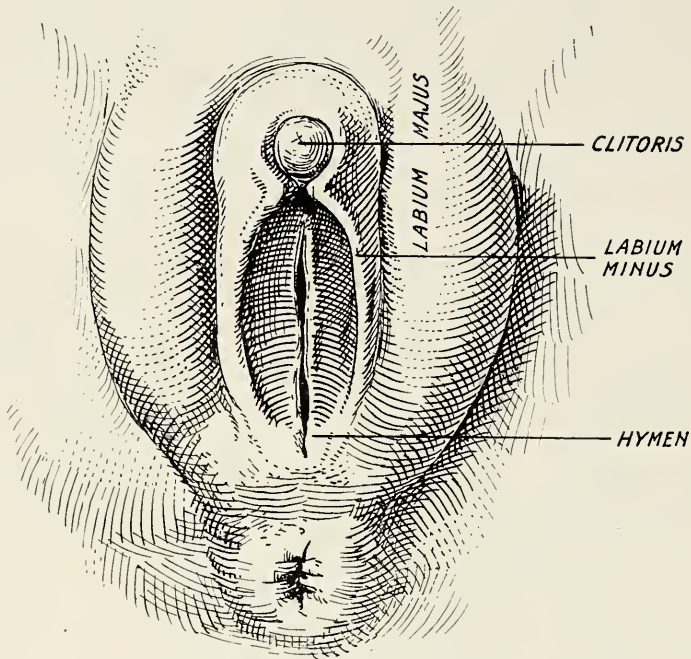


FIG. 60. DEVELOPMENT OF THE EXTERNAL GENITAL ORGANS (Kollmann). Female fœtus of the sixteenth week.

nence, stretches considerably in length (*see* Fig. 61, urethra). A circular furrow divides this section of the urogenital sinus into a proximal part, the *trigone*, and a distal part, the *urethra*. Through the reduction in length of the lower segment of the sinus urogenitalis and through the gradual increase in width of this portion of the canal, Müller's prominence recedes more and more upwards, and comes to lie finally in the floor of a short wide pouch. From the epithelium of Müller's prominence develops the *hymen*,<sup>1</sup> whilst the short pouch below, which is now the sole remaining part of the original sinus urogenitalis, becomes the *vestibule* and *fossa navicularis*. The former is much deeper in the newborn than in adults. The septum urorectale widens out to form the perineal body and perineum (*see* Fig. 60).

**The Ligaments.** At a certain stage of development we find on the posterior abdominal wall of the embryo a long Wolffian body

<sup>1</sup> Berry Hart and Keith regard the hymen as developing from the bulbous termination of the Wolffian ducts.

tapering at its caudal and cranial ends (see Fig. 51, Mes.) Internal to this is the ovary (see Fig. 51, G.G.), lateral to it and lying in the genital fold are the Wolffian and Müllerian ducts (see Fig. 51, W.D., M.D.). A fold develops from both the head- and the tail-ends of the Wolffian body; the former is the *plica diaphragmatica mesonephrica* (see Fig. 51, P.M.D.), which becomes the suspensory ligament of

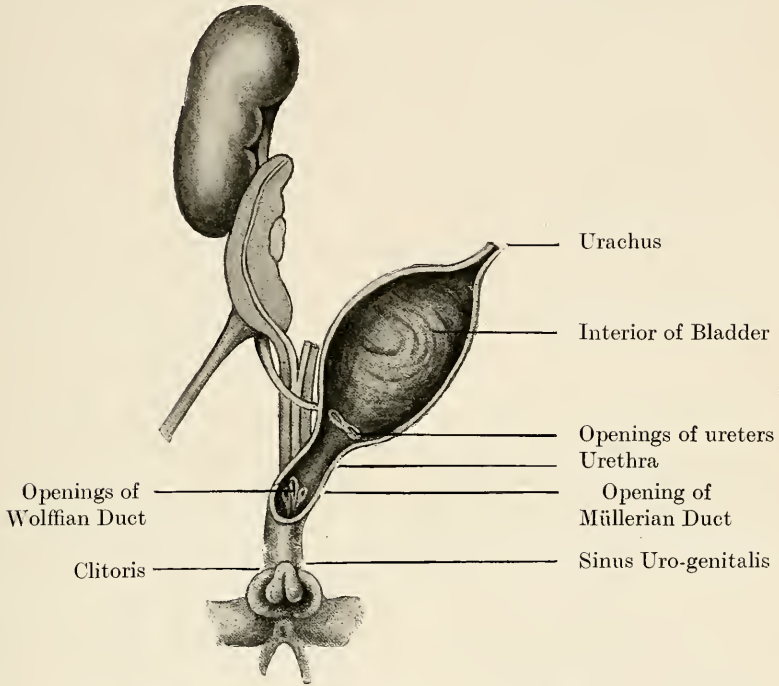


FIG. 61. (FROM MORRIS' "ANATOMY.") THE SINUS URO-GENITALIS HERE SEEN ULTIMATELY BECOMES SHORTENED AND FORMS THE VESTIBULE.

the ovary or infundibulo-pelvic fold; the latter is the *plica inguino-mesonephrica*, the upper part of which becomes the *ligamentum ovarii proprium* (see Fig. 51, M.F.cr.P.), and the lower part becomes *ligamentum rotundum* (see Fig. 51, M.F.ca.P.). The Wolffian and Müllerian ducts on each side lie in the urogenital fold (see Fig. 50, U.G.F.). These two folds fuse to form a transverse septum at the level of the lower pole of the Wolffian body. The *plica inguino-mesonephrica* crosses the urogenital fold (see Fig. 51); the part above the point of crossing becomes the ovarian ligament proper (see Fig. 51, L.O.P.), and the part below becomes the round ligament (see Fig. 51, L.R.U.). The external portions of the *plicæ urogenitalis* become the broad ligaments. The inner part becomes the mesosalpinx, and contains the remains of the Wolffian duct and body in the form of epoöphoron and paroöphoron (see Fig. 51, EO.Tr., E.O.L. and P.).

The following table sets forth the relations between the embryonic and adult structures (see Fig. 51) :

<i>Undeveloped Stage</i>	<i>Developed Genitalia</i>
Sex-gland (gonad).	Ovary.
Mesonephros.	Epoöphoron or parovarium.
Wolffian duct.	Gartner's duct.
Müller's duct.	Fallopian tube, utero-vaginal canal.
Müller's prominence. <sup>1</sup>	Hymen and orifice of vagina.
Plica inguino-mesonephrica (cranial part).	Ligamentum ovarii proprium.
Plica inguino-mesonephrica (caudal part).	Ligamentum rotundum.
Plica diaphragmatica mesonephrica.	Ligamentum suspensorium ovarii (infundibulo pelvic fold).
Plica urogenitalis.	Broad ligaments, mesosalpinx.
Sinus urogenitalis.	Vestibulum vaginæ and Fossa navicularis.

We have already referred to the change in situation of the embryonic folds or ligaments, but there is another point to which attention must finally be drawn. The genital gland (ovary), together with its ligaments, *descends* during the growth of the embryo. It arises in the lumbar region by the side of the vertebral column, but in the last weeks of intra-uterine life it comes to lie in the iliac fossa, and is found in a full term fœtus just above the pelvic brim. A short time before puberty the ovary descends into the true pelvis to take up its proper final position.

At any stage of growth of the embryo the descent of the ovary may be arrested. The ovary is then said to be *misplaced*; such misplacement is commonly associated with other developmental errors of the genitalia.

## PUBERTY, MENSTRUATION, AND THE MENOPAUSE

### Puberty ; Secondary Development

The change from childhood to adult age in both sexes is marked by widespread and important changes, which constitute a *secondary sexual development* of the individual, occurring at a period when the rapid growth which characterizes childhood has nearly spent itself. The effect of these changes is to bring into prominence the physical and mental characteristics of sex. Before puberty these characteristics are only lightly marked; although in most children the presence of masculine or feminine traits is recognizable, they do not become

<sup>1</sup> See footnote, p. 84.



pronounced until the age of puberty has been reached. Foundations of sex-characteristics are no doubt deeply laid at a very early period of intra-uterine existence. During life two powerful influences promote their further development. Firstly, the external influence of training and environment, especially association with others of the same sex; and, secondly, the inherent influence of the physiological changes which constitute puberty. The first-named influence may be very powerful, as is exemplified in the case of female pseudohermaphrodites (*see* p. 167), *i.e.* individuals with male gonads and female external genitalia. Such persons, brought up as girls, may display feminine qualities of mind and manner, and being married as women may fulfil the sexual rôle of the wife with apparent success. It must not, however, be forgotten that there are structural differences between male and female children quite apart from the genital system. The skeleton shows marked differences in the weight of the long bones, and in the shape of the pelvis, the special characters of the female pelvis being well marked in foetal life (Arthur Thomson). Possibly there are differences also in some of the endocrinous glands, although this cannot be definitely stated at present. The changes in the sexual glands at puberty are coincident in both sexes with atrophy of the thymus.

In the female, as already stated, the essential elements of the ovary do not reach their full structural development until puberty. Gräafian follicles then begin to mature and to rupture, leading to the liberation of ova and the formation of corpora lutea. In addition, the uterus develops, passing from the infantile to the adult type; the mammæ enlarge; the nipples become more prominent, and the areolæ more marked; hair appears in the axillæ, upon the mons Veneris and over the labia majora. A considerable development of subcutaneous fat occurs upon the mons Veneris and in the labia majora, which expand until they cover and nearly conceal the nymphæ. The latter are really the more prominent pair of labiæ in childhood, owing to the imperfect formation of the greater labia.

## MENSTRUATION

Menstruation is a periodic hæmorrhage from the corporeal endometrium which usually first appears coincident with puberty, and continues throughout the fertile period of life, *i.e.* until the climacteric has been reached. The age of commencement of menstruation in white women of the United States and Canada has been investigated by Englemann who, from the data of 20,000 cases, placed the average age at fourteen. Under the various climatic conditions found between Hudson Bay and the Gulf of Mexico, this writer found very little variation in the time of onset of menstruation. From Englemann's observations it appears that climate is of less importance than race,

and the often-expressed opinion that in cold countries women begin to menstruate later than in hot countries cannot be maintained. Thus the negresses of Somaliland begin at sixteen, the women of the Arctic Indians at twelve and a half ; but in India and Samoa menstruation begins early, and the first pregnancy often occurs at the age of twelve. In addition many factors of a general nature, such as nutrition, surroundings, heredity, etc., come into operation, some retarding, others advancing the process. While the average age for European races may be regarded as fourteen, the limits of normal puberty must be placed a good deal wider than this, viz. from twelve to sixteen years. Many instances of precocious menstruation at ages of five to eight years are on record, but few of them can be accepted as true examples of the menstrual function, due care not having been taken to exclude pathological conditions. It cannot be doubted, however, that true cases of precocious menstruation sometimes occur, for a recent case has been carefully recorded by Nacke, in which regular menstruation, at intervals of four weeks, was established at the age of three and a half years, and the signs of puberty were all fully developed at the age of five years.

Each menstrual period lasts on an average four to five days, but many individual variations, both in the duration and the amount of the hæmorrhage, are met with : less than two or more than seven days may be regarded as abnormal. No definite standard of amount can be applied, but for practical purposes increase or diminution from what is usual in any given individual is of more importance than the actual quantity of blood lost. An amount which is normal for one woman may be excess for another. As a rule menstrual blood does not clot, the formation of clots of large size is only seen when bleeding is excessive.

The hæmorrhage is usually scanty at first and reaches its acme on the second or third day. At first the discharge is pinkish and rather viscid, consisting of a large amount of mucus from the uterus and only a small amount of blood. Later it becomes bright red, and towards the end of the process it changes again to a brownish tint, from alteration in the blood-pigment. It is not infrequent for menstruation to become suspended for twenty-four hours or more, after which the flow returns and pursues its normal course.

The menstrual cycle averages about twenty-eight days, but here again variations are encountered ; in many healthy women it is twenty-one days only, in others it may be five weeks. The limits of the normal menstrual rhythm may therefore be placed at from three to five weeks. Departure from the rhythm normal to the individual in question is the more important point. From the first onset, a year or two frequently elapses before the rhythmical character of the process becomes established ; during this period the intervals

are usually prolonged ; sometimes, however, the early periods come too frequently, and are profuse and very painful.

### The Anatomy of Menstruation

The structure of the uterine mucosa varies at different parts of the menstrual cycle, therefore in dealing with the histology of men-

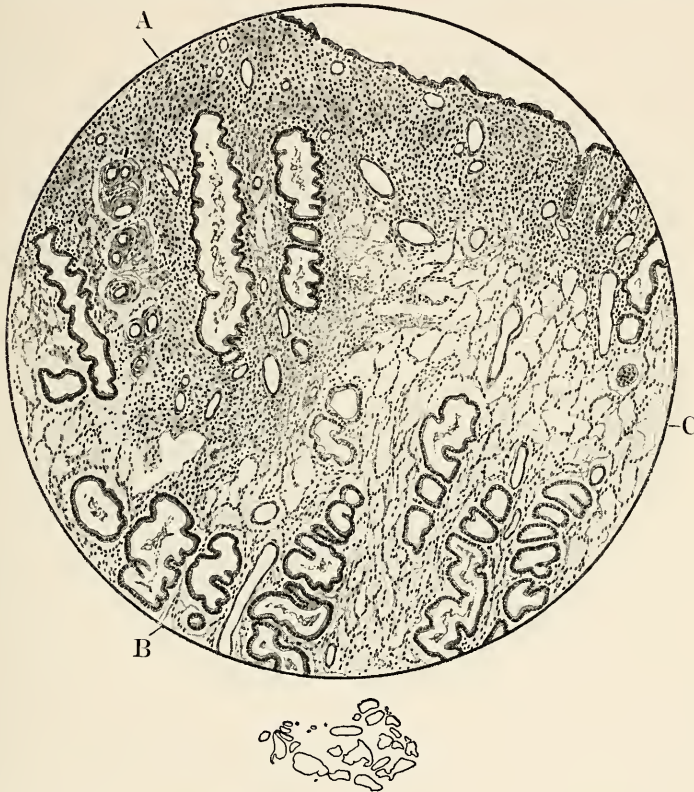

FIG. 62. SHOWING THE ENDOMETRIUM EIGHT DAYS BEFORE MENSTRUATION. A, Compact layer. B, Spongy layer of endometrium. C, Œdematous stroma.

struation it will be necessary to describe the entire cycle of changes. Hitschmann and Adler first drew attention to these physiological cyclic changes ; previously, the menstruating mucosa and the non-menstruating mucosa were studied apart, the idea being that the characters of the latter were constant, except when the mucosa was the seat of a pathological process, such as inflammation. These observers were the first to affirm that the cyclic changes in the uterine mucosa are so definite that, from the condition of the tissues, microscopists can tell, almost to a day, the date of the nearest period. In these cyclic changes all the elements of the endometrium take part.

The menstrual cycle may be studied in four *phases*: (1) the *premenstrual phase*; (2) the *menstrual phase*; (3) the *post-menstrual phase*, or *phase of involution and repair*; and (4) the *interval*.

(1) *The Premenstrual Phase*. Six or seven days before menstruation the glands increase rapidly in size and length, becoming convoluted. Fern-like processes project into the lumina, dividing the latter into deep bays. The epithelial cells become higher and wider,

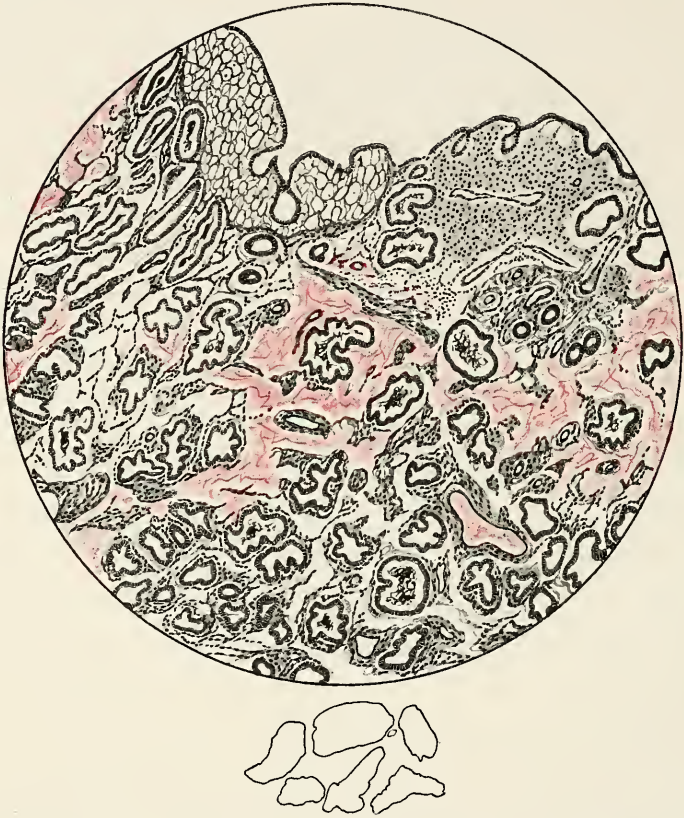

FIG. 63. SHOWING A LATER STAGE OF PREMENSTRUAL CONGESTION THAN THAT SEEN IN FIG. 62 AND PLATE I. The decidua-like appearance of the compact layer is more marked and diapedesis has led to interstitial hæmorrhage. The glands are full of mucus.  $\times 63$ .

and commence to secrete actively so that the interior of the enlarged tubules becomes filled with mucus. The connective-tissue stroma swells up and now consists of a superficial compact and a deep spongy layer. The former resembles an early stage of *decidua compacta*, the similarity being so marked in some instances that it is not always easy to exclude pregnancy. Figure 62 shows the division of the endometrium into compact and spongy layers. Plate I and Figure 62 show the so-called 'Opitz Gebhard's' gland, which was at one time regarded

as pathognomonic of pregnancy. It is, in fact, typical of the premenstrual phase of the periodic cycle. Figures 63 and 64 show still later stages of premenstrual congestion; actual interstitial hæmorrhage has now occurred due to diapedesis of red-blood corpuscles and serum from the delicate capillaries into the compact laminae and upper strata of the *decidua spongiosum*.

(2) *The Phase of Hæmorrhage.* Finally the surface-epithelium gives

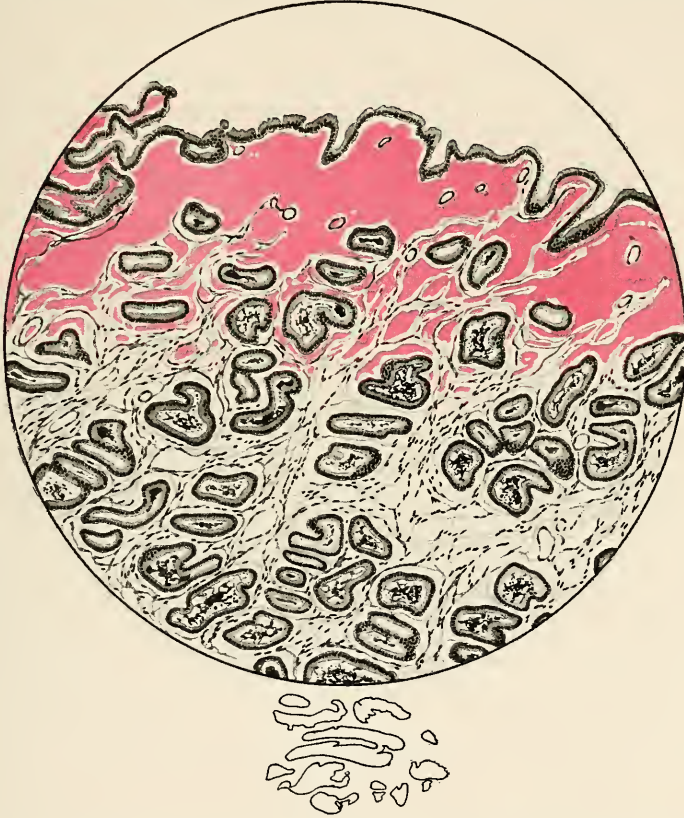

FIG. 64. SHOWING THE COMPACTA ENGORGED WITH BLOOD PRIOR TO THE ONSET OF MENSTRUATION. The red colour is excessive in the drawing.  $\times 65$ . The trabecular stroma and capillaries should both be visible as in Fig. 63.

way to hæmodynamic pressure and the contents of the subepithelial hæmatoma, or interstitial hæmorrhage, is poured out through a breach in the surface-continuity (see Figs. 65 and 66). Patches of the surface-cells become separated, but the amount of tissue lost in this way is very small.

(3) *The Phase of Involution and Repair.* Following the cessation of the menstrual flow of blood, the entire mucous membrane rapidly shrinks. The glands cease to secrete mucus; they collapse, lose their corkscrew appearance, and become narrow and straight. The

surface-epithelium is soon repaired, the stroma-cells shrink in size, and the tissue looks more fibrous. Figs. 67 and 68 show the state of the epithelium in the early stages of involution. The regeneration of the epithelium is commencing; the glands near the surface are straight and collapsed; the stroma is denser. Fig. 68 represents the deeper strata of the same section as Fig. 67, showing that the deep glands are still crenated although shrunken. Fig. 69

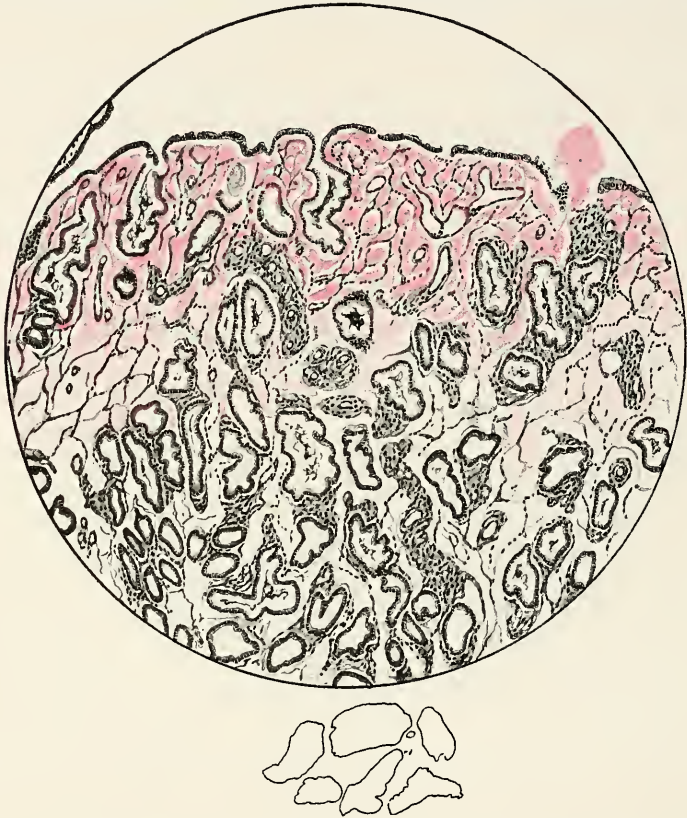

FIG. 65. SHOWING A POINT OF RUPTURE IN THE SURFACE-EPITHELIUM THROUGH WHICH BLOOD IS ESCAPING. The outlines of the engorged capillaries are well seen. The vessels are all intact showing that in this case the blood escaped by diapedesis. The faintly stained pink areas deeper in the section show exuded serum filling up connective-tissue spaces in the stroma. Note the patches of decidua-like cells around the crenated glands.  $\times 65$ .

shows the appearances three days after menstruation, and Fig. 70 shows that by the sixth day the continuity of the surface-epithelium in this particular case was completely restored.

(4) *The Interval*. This is the long phase which follows involution and precedes the premenstrual stage. It is not a resting stage; in fact there is probably no period of complete rest in the menstrual cycle. During the *interval* the epithelium of the surface and of the

glands has to be restored. In the epithelial cells mitotic division of nuclei is to be seen. When mitosis begins the postmenstrual phase of involution is at an end. This nuclear activity may be therefore said to start the *interval*. By the middle of the *interval* mitoses are numerous and the epithelial cells become larger and richer in protoplasm. In the late *interval* the epithelium is again well developed and commences to secrete. The lumina of the glands increase in

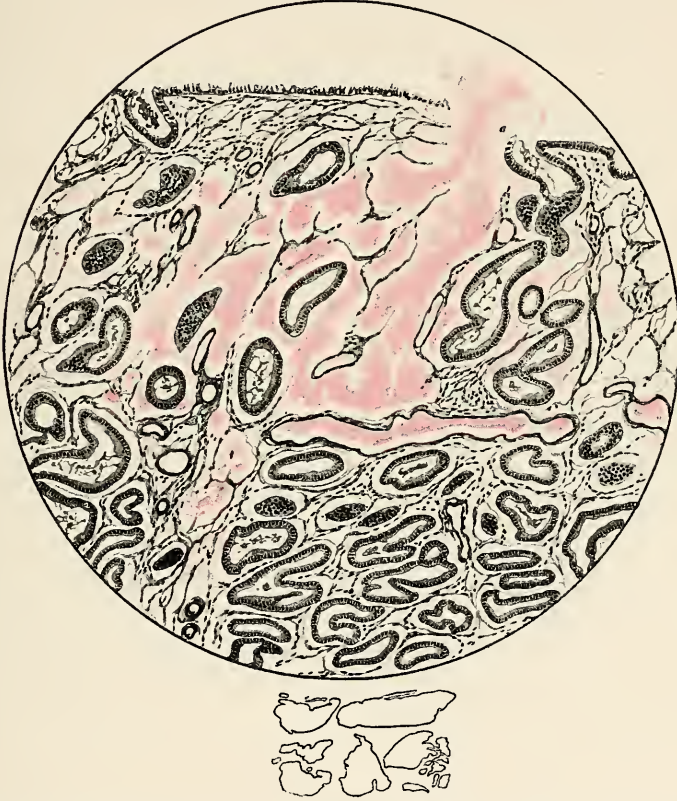

FIG. 66. ANOTHER EXAMPLE OF COMMENCING MENSTRUATION. The compact lamina is not so well marked as in the preceding figures. The open reticular appearance of the stroma is characteristic.  $\times 65$ .

size and contain a certain amount of mucus. As the epithelial cells continue to grow in width and length, the lining of the dilated glands becomes pleated and thrown into tufts, and the lumina become filled with mucus. With the appearance of the tufts the premenstrual phase begins and the *interval* ends.

The feature therefore of the *interval* is the restoration of the epithelial cell. The alterations in shape and size of the gland-tubules are initiated by the changes which occur in each individual epithelial cell.

Phases (3) and (4) make up about sixteen to eighteen days of the entire menstrual cycle, the duration of the different phases is however very variable.

The following important points should be borne in mind :

(1) *Glands.* (a) *Postmenstrual Phase.* The glands are narrow and straight (see Figs. 69 and 70).

(b) *In the interval.* The glands are tortuous.

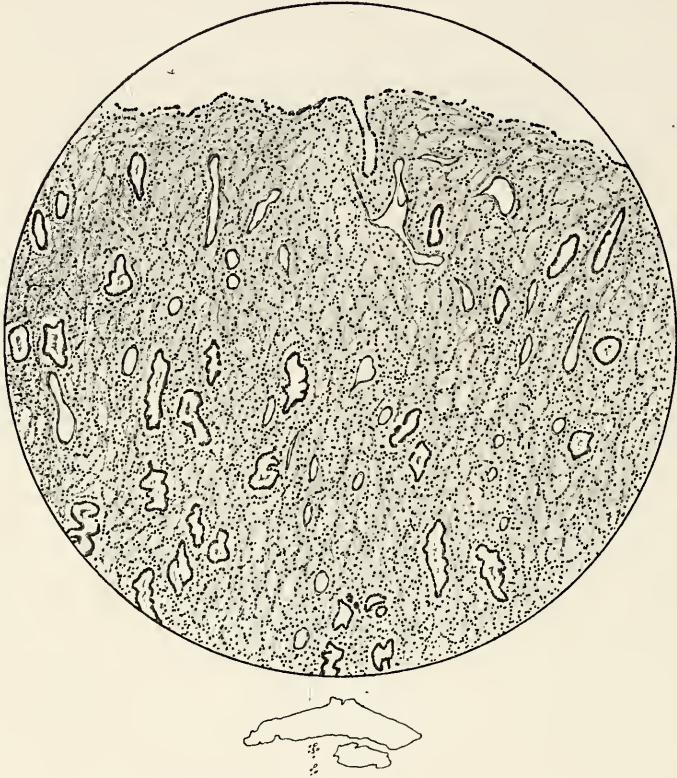

FIG. 67. THE ENDOMETRIUM IN THE EARLY STAGE OF INVOLUTION. The superficial glands are collapsed and straight. The surface-epithelium is just beginning to grow again.

(c) *Premenstrual Phase* (six days before the flow). The glands are wide, with fern-like spurs, so-called Opitz-Gebhard glands.

(d) *Menstruation.* Some glands still of the Opitz-Gebhard type, some collapsed and straight (see Figs. 65 and 66).

It should be observed that the gland-peculiarities noted above are really dependent upon the epithelial changes next to be described.

(2) *Epithelium.* (a) *Postmenstrual Phase.* The cells are low, the cytoplasm scanty, the nuclei lying side by side, the contour smooth (see Figs. 67 and 68).



(b) *In the Interval.* The cells are higher and richer in protoplasm. (see Fig. 62).

(c) *End of the Interval.* Fine granules appear in the cells, indicating commencing activity.

(d) *Premenstrual Phase.* The cells are secreting. They are wide and low; their walls have burst, and the nuclei are pale and wide apart (see Plate I).

(3) *Secretion.* The secretion consists of mucus, which is stained

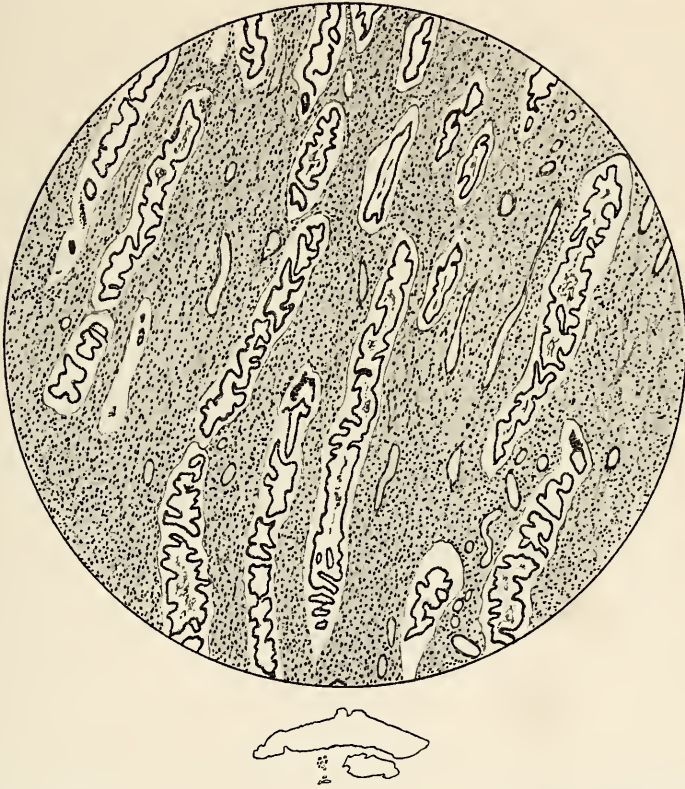

FIG. 68. DEEP STRATUM OF FIG. 67, SHOWING THAT THE DEEPER PARTS OF THE GLANDS ARE STILL CRENATED AND SOMEWHAT SPIRAL.

a deep blue in Plate I (Mallory's polychrome methylene blue). Note that no mucus appears in the cells. It is only seen in the lumina of the glands. Hitschmann and Adler first pointed out that under normal conditions cells distended with mucus (goblet-cells) occur in the cervical glands, while in the corporeal glands there are none.

(4) *Stroma.* (a) *Postmenstrual Phase.* Spindle-cells are formed (see Fig. 69).

(b) *The Interval.* Round cells are formed in greater abundance (see Fig. 62).

(c) *Premenstrual Phase.* The cells are rich in cytoplasm resembling young decidual cells (see Fig. 65 and Plate I, p. 16).

(d) *Immediately before Menstruation.* The cell-enlargement is even more marked.

(5) *The Mucosa, as a whole.* (a) *Postmenstrual Phase.* The glands are narrow, straight, and wide apart. The stroma is spindle-celled (see Fig. 69).

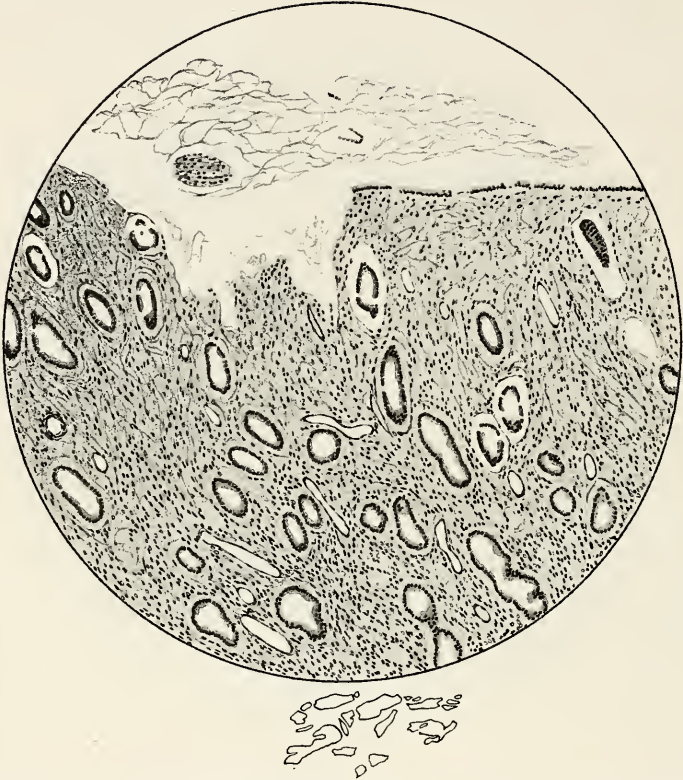


FIG. 69. SHOWING THE ENDOMETRIUM ON THE THIRD DAY AFTER A 'PERIOD.' The line of intact young epithelium is unusual so soon after menstruation. The glands are narrow and the absence of crenation shows that they are straightening out. The inset shows how thin the endometrium has become.

(b) *The Interval.* Glands are tortuous. The stroma-cells are rounder (see Fig. 62).

(c) *Premenstrual Phase.* The mucosa is divisible into compact and spongy layers (see Fig. 62). Opitz-Gebhard glands are present, lying close together, with active epithelium. The cells of the stroma are decidua-like. The lumen of the glands contains secretion (see Plate I).

(d) *First Day of Menstruation.* The surface-epithelium bulges irregularly from effusion of serum and blood. There are hæmorrhage and leucocytic infiltration into the compact layer. In the mid-layer of the mucosa Opitz-Gebhard glands preponderate. They are

regressive, being rounder and straighter, but secretion still persists (see Figs. 65 and 66).

*Third Day of Menstruation.* Patches of the surface-epithelium have disappeared and nearly all the glands are collapsed (see Fig. 69).

Coincident with the histological changes which precede menstruation, glycogen is said to be produced by the corporeal

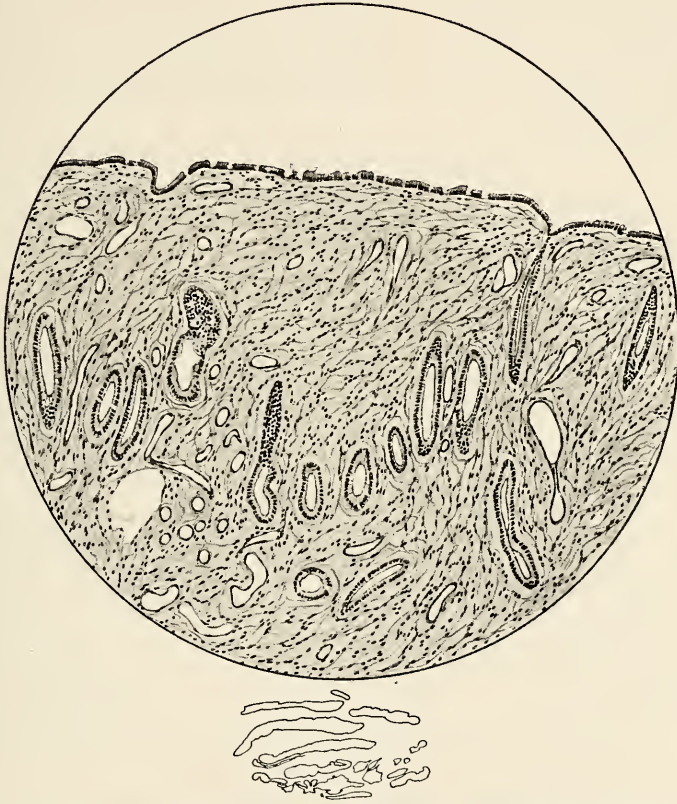

FIG. 70. SHOWING THE APPEARANCE OF THE ENDOMETRIUM SIX DAYS AFTER MENSTRUATION. Note the fibrotic appearance of the shrunken stroma and the still collapsed state of the glands. The inset shows the actual thickness of the section of hardened mucous membrane.

endometrium. It reaches its maximum quantity just before menstruation is established and subsides with the flow of menstrual blood. If menstruation does not occur, the Opitz-Gebhard glands go on enlarging, a true decidua is laid down from the stroma-cells, and the glycogen is retained for the nutrition of the ovum (Schroeder, Aschheim, and others). The cervical mucosa does not share in the menstrual changes seen in the corporeal endometrium, but some authorities maintain that the tubal-mucosa is capable of menstruating.

**The Composition of Menstrual Fluid.** A good deal of attention has recently been devoted to this subject by Blair Bell and others. The former has made use of the contents of a hæmatocolpos, which affords the opportunity of examining uncontaminated menstrual fluid in bulk, the chief alteration for which allowance must be made being loss of water by absorption. Hæmatocolpos-fluid contains a very high proportion of *mucin*, estimated by Blair Bell at 33 per cent.; the source of this substance is, of course, the uterine and cervical glands which are very active during mensuration. The blood is always fluid and has been shown to contain neither fibrinogen nor fibrin-ferment. Blair Bell claims to have proved by experiment that these bodies are removed from the blood by the endometrium during its passage through that membrane; they are not destroyed, as was formerly supposed, by the uterine and vaginal secretions. A considerable amount of lactic acid is present, and in this connection it is important to notice that the vaginal bacillus of Döderlein has never been found in hæmatocolpos-fluid. Lactic acid is a normal constituent of the healthy vaginal secretion (*see* p. 233), and Döderlein attributed its production to a process of fermentation set up by the vaginal bacillus, and this has been since confirmed by Schlutter. Blair Bell now suggests that it must be produced by an enzyme, but it is clear that conclusions drawn from an examination of hæmatocolpos-fluid cannot be applied to normal conditions; both methods of production of lactic acid may be possible under different circumstances. Lastly, it has been shown by Blair Bell that calcium salts are present in very large amount, and this observation has been repeatedly confirmed by the examination of fresh menstrual blood. This point will be referred to again, when discussing the causation of menstruation.

Other substances have been found in excess in menstrual blood, such as iodine (Gautres and Douser), phosphorus (Gautres), and arsenic (Ries), but these results await confirmation, and in the meantime their physiological significance need not be made the subject of speculation.

Microscopical examination of the menstrual discharge shows that at first it contains a large excess of leucocytes; later it consists of almost pure blood; towards the end, numerous epithelial elements from the uterus and vagina, in various stages of degeneration, are found. Occasionally shreds of tissue, visible to the naked eye, may be detected when the fluid is mixed with water.

When menstruation is normal in amount the discharge is almost entirely fluid, and the blood does not coagulate. Small clots of the size of a pea or a haricot bean are however not uncommonly found, and occasionally, in profuse bleeding, clots of large size may form in the vagina. The question of the coagulability of menstrual blood has recently been studied by Beckwith Whitehouse, and

certain experimental results which he has obtained are of suggestive interest.

The accepted view of the production of coagulation in the blood is as follows. Blood-plasma contains an albuminous substance—*fibrinogen*, *calcium salts*, and a body of unknown composition called *thrombogen*; these substances are all necessary to the production of a clot. The tissues of the body contain a hypothetical substance termed *thrombokinase*, which is also necessary to the formation of clotting within the body. When blood leaves the protection of the vessels and comes into actual contact with the tissues, thrombokinase, acting upon thrombogen in the presence of calcium salts, forms a new body, *thrombin* (fibrin-ferment). The latter acts upon fibrinogen so as to convert it into *fibrin*, which is the basis of blood-clot.

The observations of Whitehouse led him to the conclusion that *in the uterus* menstrual blood clots as soon as it is effused; this is in accordance with what has been observed by Heape in monkeys, for in these animals an intra-uterine menstrual clot is always formed. In the human uterus this clot is liquefied during its passage through the cervix and vagina, the effect being produced by admixture of the secretion of the uterine glands; this secretion, it is believed, is rich in a substance of the nature of an enzyme, which has the power of digesting blood-clot and which is named *thrombolysin*.

Whitehouse further believes that in the uterus blood clots with abnormal rapidity and completeness, and he suggests that this may be explained by the presence of an excess of *thrombokinase*, the production of which he attributes to the stroma-cells of the endometrium.

These observations suggest that some cases of excessive menstrual bleeding may be due to a chemical cause, viz. to deficient production of *thrombokinase* or excessive production of *thrombolysin* by the endometrium, since hæmorrhage from the damaged vessels of the mucous membrane is arrested mainly by the formation of thrombi. These conclusions must in the meantime await confirmation by further work.

**Clinical Features of Menstruation.** Certain recognizable changes occur *in the uterus itself*. Immediately before menstruation begins the uterus is unusually sensitive to pressure, and often feels softened; this is probably the result of the pre-menstrual congestion. Often the ovaries and Fallopian tubes also appear to be unduly sensitive. During the menstrual flow the cervix becomes definitely softened as in early pregnancy, and a little dilatation of the canal occurs; the uterine body is also soft, so that the local conditions simulate an early abortion. This may give rise to considerable difficulty in diagnosis in the case of menstrual irregularity, where a period occurs after an abnormally long interval. The diagnosis of abortion can then only be established by recognizing definite embryonic structures.

Menstrual dilatation of the cervix is no doubt occasioned by uterine contractions; these fulfil a double purpose by expelling the menstrual blood and at the same time facilitating its escape through the cervix. The contractions probably assist in arresting the bleeding by diminishing the calibre of the small vessels, and ultimately, as the contractions increase in strength, the uterus becomes firm and hard once more.

*Symptoms.* Hæmorrhage from the uterus is not the only symptom of menstruation. For several days preceding each period certain *premonitory* symptoms are often present, such as pelvic discomfort or actual pain, backache, headache, and more or less general malaise; in some cases excitability of temper or mental depression occurs; in others transient skin-eruptions appear regularly during the premenstrual phase. This train of symptoms is recognized by the patient as the precursor of the period. In other persons no premonitory symptoms occur, the period coming on without warning. In the first two or three days of the period the symptoms just described persist, and irritability of the bladder and sometimes painful micturition are also not infrequently met with.

It has been shown by numerous observations that during the premenstrual phase the pulse-rate and the temperature are slightly elevated, the blood-pressure is slightly raised, and the excretion of urea is slightly increased above the normal. During the menstrual period itself a fall occurs in each to slightly below the normal, and after the period is over a rapid return to the normal level sets in. These are indications of vaso-motor and, perhaps, of metabolic disturbances associated with the process.

The severity of the symptoms of menstruation is very variable in otherwise healthy women. Only a small minority appear to pass through the period without some suffering, and in many cases each menstrual period entails either a day or two of semi-invalidism, or at the least a good deal of restriction of activity.

The premonitory symptoms are probably due to the pelvic congestion induced by vaso-motor changes; it will be obvious that when local morbid conditions are present, especially those of an inflammatory nature, the symptoms which accompany them will tend to become aggravated before each monthly period, by the general premenstrual congestion of the pelvic organs.

**The Causation of Menstruation.** Facts which have been gradually accumulated in experimental and clinical work, during the last ten years, have influenced deeply the question of the causation of the menstrual process. The effect of recent work has not been to elucidate difficulties, but rather to indicate that the problem is even more complex than was supposed. And this result is mainly due to the correlation which has been shown to exist between the ovarian functions and those of the other endocrinous glands. Much of the

difficulty attending investigation of the subject is due to the fact that no process analogous to menstruation exists in the lower animals, with the exception of certain species of monkeys, in which a true menstruation occurs. The rut, or prooestrus, seen in many lower mammalian orders, is probably the physiological homologue of menstruation, but differs widely from it in character.

All theoretical considerations start from the well-established fact that menstruation in some way depends upon the presence of fully developed and active ovarian tissue. Complete removal of the ovaries before puberty prevents the establishment of the menstrual process, and in sexually mature women totally arrests it. Only one apparent exception to this rule is known, viz. that in female pseudo-hermaphrodites a periodic hæmorrhagic discharge may occur from the external genitalia, which are of the female type, although the gonads are of the male type. The explanation of this exception will be mentioned later.

The presence of ovaries does not alone suffice to excite menstruation: the ovarian tissue must be *fully developed and activating*. The first appearance of menstruation coincides with certain general physiological changes which collectively constitute *puberty*. These changes affect the external genitalia, the internal genitalia, the mammary glands, and the psychical characteristics of the individual; they will be found more fully described on p. 108. In their totality they make up the female sex-characteristics and differentiate the woman from the child. The changes which take place at puberty in the ovary are that follicles begin to ripen and to discharge their ova, while for the first time lutein tissue makes its appearance in the organ. Removal of the ovaries before puberty inhibits most, if not all, of the other changes, but it is doubtful whether the ovarian changes can be regarded as the sole exciting cause of puberty, for removal of the thyroid, and partial removal of the pituitary, in animals, causes retrogressive changes in the uterus and ovaries. It is therefore possible that puberty depends upon the healthy activity and physiological co-ordination of the ovaries with other endocrinous glands. A certain amount of support for this view may be found in the fact that female children often display marked physical and psychical characteristics widely different from those of boys; in them the ovaries are not fully developed and are inactive, and the presence of sex characters cannot be entirely attributed to their influence. Further, female pseudo-hermaphrodites possessing testes may yet, in external configuration and in psychical characters, present the appearance of attractive women.

Again, when the age of forty-eight to fifty is reached the menstrual process comes to an end, and coincident changes occur in the ovary, in the external and internal genitalia, in the mammary glands, in the general metabolism, and in the psychical characteristics of the

individual. These will be found more fully described on p. 107. All the climacteric changes are retrogressive, while those of puberty are progressive. The ovaries shrink, the Gräafian follicles cease to ripen and ultimately disappear *in toto*; fresh lutein tissue therefore ceases to be produced, and the ovary in the end entirely loses all its characteristic histological elements. Changes closely resembling those of the natural climacteric can be induced in younger women by removal of the ovaries, yet the conclusion cannot be safely drawn that the cessation of ovarian activity is the sole physiological cause of the cessation of menstruation, for ovarian and uterine atrophy may be induced in animals by removal of the thyroid or by partial removal of the pituitary (*vide infra*). Caution must be observed in applying experimental results to the problems of human physiology, but if due allowance be made it is still fair to conclude that the ovaries exert a preponderating influence upon the menstrual process.

If it be granted that the ovaries in some way initiate and maintain the process of menstruation, with which of the two great ovarian functions is it allied, ovulation or internal secretion? The difficulty of studying these functions separately has been already referred to, but certain clinical facts, which are well established, indicate that ovulation is probably not the exciting cause of menstruation. Thus pregnancy has been known to occur in girls before puberty, in adult women already pregnant (super-fœtation), or those in whom menstruation is suspended during lactation, and in women who have passed middle life and ceased to menstruate. Cases of pregnancy before puberty are not very uncommon; those occurring after the menopause may be regarded as abnormalities which prove nothing, but the instances cited in adult women are frequently met with and can be open to no objection; they must be accepted as showing that ovulation can occur under normal conditions without exciting menstruation. Further, clinical instances are not uncommon in which menstruation continues for a few months after complete removal of both ovaries, before ceasing finally. In such cases it is obvious that ovulation cannot be the exciting cause. Again clinical observation of ovaries during operative work indicates that ovulation, though periodic, has not the same incidence as menstruation, *i.e.* it does not regularly recur every three to four weeks. If these processes are not coincident, or if they have not the same periodicity, it is difficult to understand how they can be interdependent.

There remains the internal ovarian secretion, and in this is probably to be found the chief exciting cause of menstruation. This effect may be due partly to the production of an ovarian hormone which directly excites the menstrual changes in the endometrium; the first production of this hormone may then coincide with puberty and the appearance of menstruation. In part, its effect may be an



indirect one exerted through the general metabolism, and although some advance has been made in following the details of the process very much still remains to be discovered.

An important contribution to this difficult subject has been made by Blair Bell in relation to calcium metabolism. This observer first noted that menstrual fluid contains a very high percentage of calcium salts; he devised a clinical method of quantitatively estimating the calcium-content, by precipitating the salts in microscopic crystals which can be counted upon a hæmocytometer scale. He next made observations upon the calcium-content of systemic blood, and found that just before menstruation it is very high, falls rapidly when the bleeding begins, and gradually rises again to its previous level as the next period is approached. In laying-hens he observed also a marked fall in the calcium-content of the blood when an egg had been laid, and sometimes a preliminary rise. From these observations he suggests that periodic alterations in calcium-metabolism may be the exciting cause of menstrual bleeding. He believes that the excessive calcium-excretion is brought about by the uterine glands, and is an active function of their epithelium, the marked leucocytic diapedesis which occurs at the onset of menstruation assisting the process. The calcium-excretory function of the uterus, he suggests, is under the control of the ovaries, probably through the internal secretion.

Certain other considerations support the view that the ovaries are concerned in calcium-excretion generally. Thus the ovaries do not become active until a time at which the growth of the skeleton is practically complete, and the storage of calcium salts in the bones has ceased. Again, in the skeletal disease known as *osteomalacia*, in which extensive decalcification of bone occurs resulting in great deformities, removal of the ovaries frequently arrests the process, which may therefore be due to perverted ovarian activity leading to excessive calcium-excretion from absorption of lime salts from the bones.

Under this theory the uterine hæmorrhage may be partly accounted for by a deficiency of calcium in the systemic blood, impairing its coagulability. But whether or not it be accepted as a theory of menstruation, the fact that an increased output of calcium occurs through the medium of the menstrual fluid may be accepted as proved. This fact seems to revive in scientific form the old view that menstruation was a form of excretion which served the purpose of carrying off various waste substances from the body. This view of menstruation is embodied in the Hebraic laws and customs, which decreed that during menstruation a woman was 'unclean.' In some of the earliest extant medical writings this view also found expression and was currently maintained until recent years, when the process came to be regarded as a purely local phenomenon, the effect of which

was periodically to prepare the uterus for the implantation of a fertilized ovum. Within the last few years a fresh group of facts has come to light which indicate that the ovarian functions are clearly correlated with those of the other endocrinous glands, and therefore make it reasonable to suppose that menstruation is a process which influences and is influenced by the organism generally to an extent which had not hitherto been surmised.

The relations of the endocrinous glands to the ovaries and to the entire genital system have been investigated in four different directions ; *first*, it has been shown that certain definite changes occur in some of the endocrinous glands during pregnancy ; *secondly*, that removal of the ovaries induces changes in the endocrinous glands and, conversely, the removal, partially or entirely, of certain endocrinous glands leads to definite changes in the genital system ; *thirdly*, pathological conditions of certain of the endocrinous glands have been shown to be associated with morbid changes in the genital system ; *fourthly*, it has been shown that the effects of removal of the ovaries can be modified by the administration of extracts of certain endocrinous glands other than the ovary. Probably not all of these conclusions can be at present regarded as definitely established, and the experimental work upon which they are chiefly based requires confirmation. In regard to the thyroid, the pituitary and the suprarenals, the evidence is fairly satisfactory : in regard to the thymus and the pineal we have little information at present.

*The Thyroid.* The clinical fact has been well known for many years that the thyroid often enlarges appreciably during pregnancy, the enlargement subsiding after labour. In the rabbit it has been shown that an increase of colloid occurs during pregnancy, and that after oöphorectomy an enormous increase takes place. Further, goitre is a disease which affects women much oftener than men, and a certain number of cases are on record where Graves's disease (exophthalmic goitre) ensued with great rapidity after removal of the ovaries. Conversely, when the thyroid is removed in rabbits, which may survive for a considerable period, rapid atrophy of the uterus occurs, similar to that produced by oöphorectomy (Blair Bell). Clinically it has been observed that cases of obesity associated with amenorrhœa can often be successfully treated by administering thyroid extract.

*The Pituitary Gland.* During pregnancy histological changes, indicating increased cellular activity, have been found in rabbits, and after oöphorectomy somewhat similar changes have been seen. Partial removal of the pituitary in animals causes atrophy of the uterus, and disappearance of follicles from the ovary (Cushing). In young animals which survive this operation for some time, a condition supervenes which has received the name of *dystrophia adiposo-genitalis*, characterized by stunted growth, atrophy of the

genital organs, and general obesity. Blair Bell has shown that an extract of the infundibular portion of the pituitary exerts a powerful action on the muscle of the parturient uterus. This action, however, is not exerted only on the uterus, other forms of non-striated muscle are similarly affected, as is shown by an increase in intestinal peristalsis and a diminution in calibre of small blood-vessels.

*The Supra-renals.* In these organs also certain histological changes can be detected in pregnant animals. Removal of one gland does not affect the ovaries, but causes a certain amount of atrophy of the uterus (Blair Bell). Morbid conditions of the supra-renals have been observed in rare instances in children, in whom also abnormal conditions of the genitalia were present. In males precocious sexual development, and in females approximation to the male type, may apparently be produced by supra-renal disease, causing abnormal activity of the gland.

From these considerations it is clear that the functions of the genital system are interlocked with those of the other endocrinous glands; that some of the ovarian functions are shared by the thyroid and pituitary; that the supra-renals are possibly antagonistic to the ovaries; and, finally, that the causation of menstruation is to be sought not solely in the genital organs, but in the proper co-ordination of activity of widely separated and structurally diverse organs. And, further, it follows that menstruation serves more than a merely local purpose in connection with the process of reproduction; it is probably of the nature of a true excretion.

**General Management of Menstruation.** Menstruation, though a natural process, is one which readily passes the border line and becomes abnormal. The due and regular occurrence of this function is undoubtedly an indication of good bodily health, while marked departures from the normal unfavourably influence the general health in most cases. At puberty care is accordingly called for until the menstrual function becomes properly established and its rhythm defined. Especially to be avoided under these circumstances are overwork in school tasks, physical fatigue, and exposure to cold or wet during a menstrual period. In later life the same precautions, though desirable, are not in all classes of society practicable. A chill caught during menstruation sometimes causes sudden arrest of the hæmorrhage and, following upon this acute pelvic pain, probably from unrelieved congestion. Such an occurrence may perhaps become the starting-point of inflammatory changes in the internal pelvic organs. In women who are habitually constipated the daily use of a mild aperient is indicated during the menstrual period.

**Vicarious Menstruation (Xenomenia).** Gynæcological writers of a generation or more ago universally held the opinion that normal menstruation was sometimes replaced or supplemented by hæmorrhages from organs outside the genital tract, which recurred at

approximately regular monthly intervals. Writing in 1885, Routier succeeded in collecting the reports of 334 cases, most of which, however, had come from ancient literature. In the great majority of cases the hæmorrhage was described as occurring from a mucous membrane, the commonest sites being the stomach, the respiratory passages, the nose, the throat, and the intestine; sometimes the breasts and sometimes skin-surfaces were however affected. As a rule the periodic hæmorrhages were accompanied by the usual general symptoms associated with menstruation. In a large number of cases the organ from which the bleeding arose was the seat of some disease, such as gastric ulcer in cases of hæmatemesis, phthisis in cases of hæmoptysis, cancer in the breast, and ulceration in the case of skin-surfaces. Periodic bleeding from diseased surfaces in women who are at the same time menstruating naturally cannot possibly be regarded as instances of 'vicarious menstruation,' and practically the whole of such cases must be rejected.

A small number of cases remain however which require further consideration. These are cases of primary amenorrhœa associated with congenital defects which rendered normal menstruation impossible, and in which periodic monthly hæmorrhages occurred from apparently normal mucous membranes, and were attended with general symptoms similar to those of normal menstruation. A typical instance of this kind was published by Lloyd Thomas in 1888. At the age of seventeen a well-developed girl, who had never menstruated, began to suffer from attacks of violent headache, followed by vomiting, and terminating in abundant epistaxis; the attacks lasted for three to four days and recurred regularly every month, but there was no uterine bleeding at any time. This continued to the age of twenty-one, when she was examined and found to have complete atresia of the vagina; a small supra-pubic incision was then made, and the pelvic organs explored, when it was found that the uterus was absent, but a small nodular body, taken to be an ovary, was found on the left side. After the operation the monthly nasal hæmorrhages continued as before.

A similar case has been since recorded by de Sinéty, in which the bleeding occurred from the anal canal, the patient up to the age of thirty-one having never menstruated normally.

Cases such as these merit the name of 'vicarious menstruation,' and suggest the possibility that when menstruation is, from congenital defects, completely inhibited, periodic hæmorrhages may occur from other organs, which serve some physiological purpose. From what has just been said of the causation of menstruation, and the widespread systemic disturbances which attend it, it is not wholly improbable that under the influence of the internal ovarian secretion or the secretion of other endocrinous glands, such hæmorrhages may occur.

### THE MENOPAUSE OR CLIMACTERIC PERIOD

Menstruation generally ceases at some time between the ages of forty-five and fifty; it may, however, be delayed to the age of fifty-five or even later; in other cases it occurs earlier, between forty and forty-five. There are three modes in which the menstrual function may come to an end: (a) It may terminate suddenly and finally without any preceding change being observed; (b) the periods may occur at irregular and increasing intervals, with gradual reduction of the amount of bleeding, until it finally disappears completely; (c) during the period of irregularity occasional profuse or prolonged losses of blood may occur. The duration of the period of irregularity is variable, and may extend over several years.

Accompanying these alterations in the menstrual function certain general disturbances are very commonly met with. These disturbances may be divided into three groups: (a) *psychical*; (b) *vasomotor*; (c) *metabolic*.

The commonest *psychical* change is mental depression; although naturally of a cheerful disposition the woman may become morose, tearful, despondent. Changes of temperament in the direction of irritability and changes of affection are also common. Exaggeration or perversion of sexual feeling may occur, or sometimes sexual frigidity. The climacteric is not necessarily the precursor of senility; women often preserve the freshness of maturity for many years unless general ill-health or mental disturbances supervene. Loss of energy, of imagination and originality are sometimes found. Hallucinations are less common and should be regarded as prodromata of insanity. The climacteric is a time at which women are prone to become insane, and this liability is more marked in the statistics of private than of rate-paid asylums (Percy Smith), indicating a greater liability on the part of women of the better class.

Another *psychical* disturbance often found in sterile women who are approaching the menopause is *pseudocyesis*, or *spurious pregnancy*. In this condition amenorrhœa is associated with the presence of a *phantom* abdominal tumour and many of the minor signs and symptoms of pregnancy. The tendency to the deposition of fat in the abdominal walls at this time of life helps to simulate the presence of a growing abdominal tumour. The patient is, as a rule, herself entirely deceived, and often sincerely believes herself to be pregnant, so that it may be difficult to convince her of her error. So closely is the natural condition simulated that at the appropriate time a *false labour*, attended with severe abdominal pains, may occur. In order to avoid mistakes cases such as these should be examined under *anæsthesia* when the absence of pregnancy-changes in the uterus will be apparent.

The most characteristic *vasomotor* symptom consists in attacks of 'flushing.' The patient experiences the sensation of waves of heat passing over the whole body, often accompanied by visible congestion of the face and neck or other areas of the body, and followed in severe cases by profuse sweating. Each 'flushing' may last from fifteen to thirty minutes, or, on the other hand, may be almost momentary; several may occur in a day, or they may be much more infrequent than this; they appear to be especially severe at night. The mechanism of production of this vasomotor disturbance is not known. Headaches, neuralgia, sensations of tingling and numbness in the extremities, and sensory neuroses of the throat are also common.

The chief *metabolic* change is the marked tendency to obesity; often this is local, the abdominal wall being a frequent position where large deposits occur, leading to the suspicion of an abdominal tumour.

In rare instances women pass through the climacteric without suffering from any of the above-described disturbances. In others they are severe and prolonged, and may persist for several years after menstruation has ceased.

The *artificial* menopause which ensues upon operative removal of both ovaries during the sexually active period of life closely resembles the natural process, but the attendant symptoms are often unusually severe. Arrest of menstruation by removal of the uterus, if one or both of the ovaries are retained, is usually almost entirely free from the attendant symptoms just described, but when both ovaries have also been removed these symptoms, as a rule, are unusually severe.

Sometimes a *premature* menopause occurs apart altogether from operative interference, and a recent case has been recorded in which menstruation ceased naturally at the age of twenty-three, having begun at the age of eleven. A severe illness or a mental shock appears in some cases to have been the exciting cause; in others it has been due to lactational atrophy of the uterus; in others no cause has been discovered.

The general phenomena of the menopause are induced partly by the loss of the internal ovarian secretion, partly by the effects of the arrest of menstruation. The fact just alluded to, that hysterectomy with preservation of the ovaries is attended by less severe climacteric symptoms than total removal of the ovaries, indicates the importance of the ovarian secretion. This view is further supported by the results of ovarian grafting, with and without retention of the uterus, referred to on p. 52.

**Anatomical Changes.** Certain well-marked changes take place in the external and internal genital organs when the climacteric has been passed; they do not, however, appear immediately, and many women retain for a long time the outward signs of sexual activity. The labia majora slowly shrink from loss of subcutaneous fat, and

the labial and pubic hair become less abundant, gradually disappearing as old age is reached. The nymphæ become relatively prominent, and the skin of the vulva generally dry and somewhat polished in appearance. The stratified epithelium of the vulva and vagina atrophies, and small round patches of a dark-red colour, apparently due to exposure of the deep epithelium, are often seen. The vaginal portion of the cervix shrinks and becomes less prominent, or it may retreat until the lips of the external os are flush with the surface of the vaginal vault. The body of the uterus and the Fallopian tubes shrink; the endometrium in old women is found to be atrophied (see Fig. 194), and the greater part of the uterine muscle replaced by fibrous tissue (see Pl. II, Fig. *b*), but for several years after the cessation of menstruation the endometrium may be found to retain approximately its normal characters (see Fig. 31). The ovaries also shrink and completely lose all their Gräafian follicles, and then consist mainly of fibrous tissue. Gradual disappearance of the follicles can be traced long before menstruation ceases. The connective-tissue beneath the pelvic peritoneum to a great extent disappears, and the various ligaments become shortened and inelastic. The upper roomy part of the vagina becomes much diminished in capacity by shrinkage; sometimes irregular or concentric bands of dense fibrous tissue form in the vaginal wall, producing a constriction of the canal, or forming pockets in the vaginal vault. The mammary glands simultaneously atrophy and lose much of their fatty envelope.

The vaginal secretion of women past the menopause has no bactericidal properties, and owing to the imperfect closure of the ostium vaginæ, foreign matters enter more readily than in the case of younger women. Infection of the secretions is accordingly more prone to occur, and this change is probably the main factor in the causation of the condition described as *senile vaginitis* (see p. 382). The same changes may spread into the uterus, producing *senile endometritis* (see p. 251).

**Treatment.** The care of the general health in women who are passing through the change of life is of some importance. The attendant symptoms do not require treatment unless they are unusually severe or prolonged, and then it must be admitted that we do not possess any remedies which can be relied upon to relieve them. Ovarian extract, given in the form of tablets, or 'corpus luteum' tablets, or ovarian and mammary extract combined in capsules, sometimes appear to diminish the severity of the flushings; in other cases small doses of thyroid or thymus gland have proved useful. The use of sedatives, alcohol, and analgesic preparations is to be discouraged, especially in women of neurotic temperament, for drug habits are readily acquired under these conditions. The occasional exhibition of small doses of bromide combined with valerian or with a vegetable tonic, such as cinchona, is however often useful.

Hæmorrhage and discharges at or after the menopause must in all cases be regarded as indications of the possible occurrence of malignant disease, the most likely seat of the disease being the cervix or the body of the uterus. A careful and complete internal examination must in all cases be made without delay, for successful surgical intervention is possible only in the early stages. The necessity for submitting to such an examination must be explained to and urged upon the patient, who may, at first, be unwilling to allow it. In the great majority of cases a local cause will be found for irregular and protracted bleeding at the menopause, but sometimes, as has been already mentioned, this is not so. This matter will be again discussed in connection with the diagnosis of cancer of the uterus (p. 538).



## PART I: SECTION II

### METHODS OF EXAMINATION

#### INTERROGATORY EXAMINATION

**The Patient's Previous History.** In this connection there are certain points which are of especial significance in gynæcological cases. In the first place the menstrual function demands attention; the age of commencement, periodicity, degree of regularity, duration, amount, and attendant symptoms should be noted. Next the obstetric history, if any, should be taken, the chief points to be noted being the number of pregnancies, their dates, the occurrence of difficulties in delivery, and the length and character of the subsequent convalescence. The last-named point is of great practical importance, for a large number of cases of chronic pelvic inflammation arise from infection following either a confinement or miscarriage, and a prolonged or complicated lying-in period may be generally accepted as an indication of septic infection having occurred. The occurrence of a series of miscarriages is an important point in the obstetric history, for signs of systemic syphilis or local pelvic morbid conditions are not infrequently found in such cases; further, it must be remembered that a miscarriage is almost as frequently followed by septic infection as a confinement. Other points of etiological importance are the presence of hereditary or personal indications of tubercle, the recent occurrence of any of the acute exanthemata with complications and, lastly, the possibility of gonorrhœal infection.

**The History of the Present Illness.** Whenever it is possible to do so, a clear history of the *onset* of the illness should be elicited. In chronic cases of long standing this is seldom practicable, partly from the patient's recollection being at fault, and partly from her want of observation. In recent or acute cases the relation of the first symptoms to the last preceding menstrual period, or the last preceding pregnancy, should be established by dates. In many diseases, symptoms of considerable diagnostic importance appear at first, but being of brief duration, they are often not mentioned by the patient unless particular inquiry is made for them. As an example may be noted the scalding pain on micturition which accompanies the transitory acute urethritis of gonorrhœa (*see* p. 290). In cases characterized by attacks of acute pain, particular inquiry should be made as to their relation

to a menstrual period, and as to the occurrence of such menstrual alterations as delay, or increase in the amount of the hæmorrhage. The importance of these points will be obvious in cases of pelvic inflammation and of extra-uterine gestation.

It will be found that the symptomatology of gynæcological disease is somewhat restricted. There are three important symptoms, viz. *hæmorrhage*, *discharge*, and *pain*, which are met with either individually, or in various combinations, in a variety of different circumstances. The causation and significance of these cardinal symptoms will be considered in a later section; their incidence, their severity, their recurrence, and their special characters are subject to very numerous variations, the details of which should be noted in each individual case. Next in importance to these symptoms come disturbances of the function of menstruation, either in the form of alterations of rhythm, such as increased or diminished frequency, alterations of amount—either less or more, and alterations of duration. The effect, if any, of a menstrual period upon the symptoms complained of should also be inquired into. Many minor symptoms are also frequently met with, such as sterility, pain or difficulty in sexual intercourse (*dyspareunia*), and disturbances of the function of micturition, and, though of much less importance, of the function of defæcation.

The general health may be adversely influenced; thus severe hæmorrhage, sudden or prolonged, may lead to profound anæmia; malignant disease to wasting and cachexia; chronic pain to loss of sleep and appetite, to functional disturbances of the nervous system, or in some cases to aggravated forms of neurasthenia. It is to be borne always in mind that cases of the latter variety must be carefully discriminated from commencing *disseminated sclerosis*, a disease to which women are particularly prone, and which may on occasions be mistaken for hysteria, unless caution is exercised and the possibility of error recollected.

Care and judgment are required in estimating the value to be attached to the statements made by patients as to the severity of the symptoms of which they complain. This is especially the case with regard to pain, for many women unconsciously exaggerate this symptom; in many others it bears the complex and variable characters which are associated with 'functional' disturbances. In all cases less importance should be attached to the account of her sufferings given by the patient, than to the results of careful physical examination.

### ABDOMINAL EXAMINATION

The patient should lie upon her back with the body uncovered from the mammæ to the pubes. *Inspection* will detect the presence of enlargement of the abdomen, its distribution and extent, skin

markings, the condition of the navel and the degree of mobility of the parietes on respiration. Enlargement may be due to obesity, to the presence of fluid, to the presence of a tumour, to flatulent distension of the intestine, or it may be of the variety known as 'phantom' enlargement. In the case of obese patients great care is required; on the one hand a small tumour may easily be missed in such cases, while on the other the general enlargement may be wrongly attributed to a large tumour.

In some cases the presence of the signs of recent pregnancy must be sought for in the breasts; in cases of pain referred to the breast, a systematic surgical examination of both mammæ must be made.

**Palpation.** A certain amount of skill is required in successfully conducting an abdominal palpation. The hands should be warm, and in using them the whole hand should first be placed flat upon the abdomen, and lightly passed over the parietes, great gentleness being employed at first, especially in the case of nervous patients. The points of the fingers should not be used, but when pressure is required this should be applied with the whole hand or with all the fingers together. The patient meanwhile should breathe lightly and easily, keeping the mouth open. From nervousness many patients contract the recti muscles upon the lightest contact of the fingers, or maintaining the diaphragm in contraction, breathe solely with the thoracic muscles. To overcome the latter difficulty the patient may be directed to take rapid shallow respirations up to forty a minute, when the muscular tension is of necessity relaxed. An anæsthetic may, in some cases, be required before a satisfactory palpation can be made.

When the abdomen is not enlarged and its walls are thin, it is sometimes possible to recognize the body of the normal anteverted uterus on deep downward pressure behind the symphysis pubis. A soft, ill-defined swelling, dull on percussion, in the hypogastric region, which prevents the hand from being pressed into the pelvic brim, suggests the full or distended bladder. The cæcum and pelvic colon when distended form soft tympanitic swellings in either iliac region, which should not be mistaken for any abnormal condition; when contracted these portions of the gut, in thin patients, can be rolled beneath the fingers, and feel solid and cylindrical in shape. Tenderness on deep pressure at a point about 2 inches above the middle of Poupart's ligament is so frequently met with, especially upon the left side, that it can hardly be regarded as abnormal except in a severe form; it forms one of the well-known *stigmata* of hysteria, and though often referred to as 'ovarian tenderness,' its connection with the ovary is at least doubtful. On the right side its possible relation to appendicitis must be borne in mind.

The routine examination should also include palpation of the regions of the cæcum and appendix, the hepatic flexure, and gall-bladder, the splenic flexure and pelvic colon, and the renal region

on both sides. Movable kidney is very common in women, and when the abdominal walls are thin, it may be readily recognized by the following manœuvre. When examining the right kidney the examiner stands upon the patient's right side and places his left hand upon

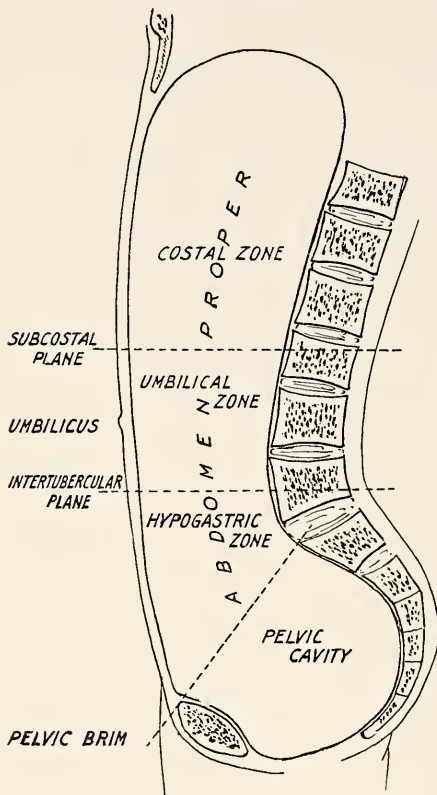


FIG. 71. THE ABDOMINO-PELVIC CAVITY (Cunningham).

the flank with the fingers behind in the ilio-costal space, the thumb in front along the costal margin. The patient is then directed to take a deep inspiration; when the kidney descends with the diaphragm the thumb is depressed deeply below the ribs, while the patient allows the chest to empty itself. The kidney is thus detained below the ribs and can be palpated with the right hand, and its size, contour, and sensibility determined. Afterwards the pressure of the left thumb is relaxed, when the kidney can be pushed up again into its bed. In examining the left kidney the examiner stands upon the left side and uses his right hand in the flank.

The position of swellings, or of areas of pain, increased sensibility or abnormal dulness, should be defined as accurately as possible for record, and here percussion is a useful aid. For this purpose the pelvi-abdominal cavity may be divided, as shown in Fig. 71, into four horizontal *zones* named from below upwards—the pelvis, the hypogastric zone, the umbilical zone, and the costal zone. The hypogastric zone is limited below by the pelvic brim, above by the inter-tubercular plane, a horizontal line drawn between the highest points of the iliac crest. The costal zone is limited below by the sub-costal plane, a horizontal line joining the tips of the tenth costal cartilages, and above by the dome of the diaphragm. The pelvic cavity may be further subdivided by the intersection of its anterior and posterior diameters into four sections, which are named right and left, anterior and posterior sections respectively. Each of the abdominal zones may be further subdivided into three *regions* by two vertical lines drawn one on each side from the middle of Poupart's ligament to the costal margin. Nine regions are thus marked out

the flank with the fingers behind in the ilio-costal space, the thumb in front along the costal margin. The patient is then directed to take a deep inspiration; when the kidney descends with the diaphragm the thumb is depressed deeply below the ribs, while the patient allows the chest to empty itself. The kidney is thus detained below the ribs and can be palpated with the right hand, and its size, contour, and sensibility determined. Afterwards the pressure of the left thumb is relaxed, when the kidney can be pushed up again into its bed. In examining the left kidney the examiner stands upon the left side and uses his right hand in the flank.

The position of swellings, or of areas of pain, increased sensibility or abnormal dulness, should be defined as accurately as possible for record, and here percussion is a useful aid. For

upon the anterior abdominal wall which are named as shown in Fig. 72. In the case of abdominal swellings of considerable size,

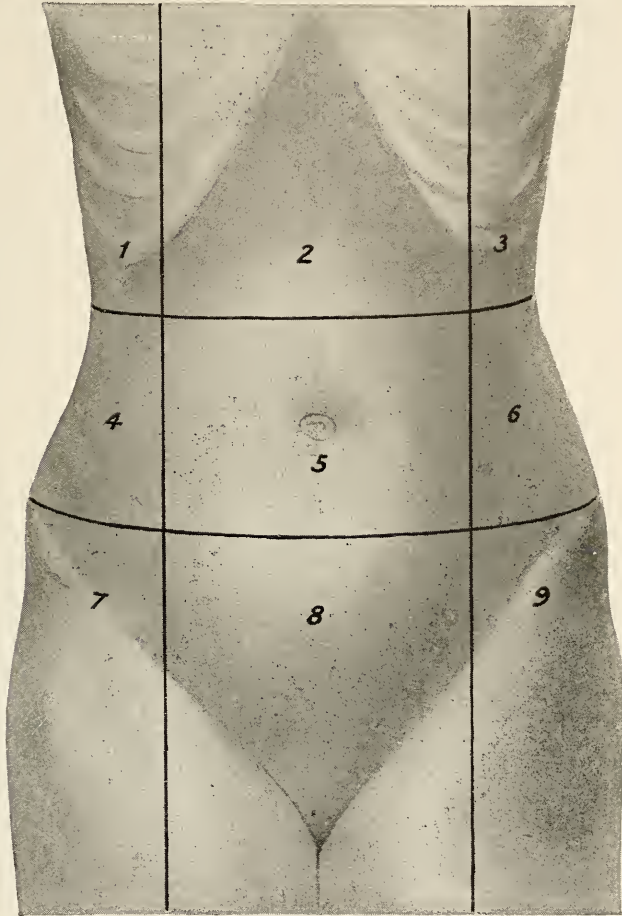


FIG. 72. THE REGIONS OF THE ABDOMEN (Cunningham). 1, Right hypochondriac region ; 2, epigastric region ; 3, left hypochondriac region ; 4, right lumbar region ; 5, umbilical region ; 6, left lumbar region ; 7, right iliac region ; 8, hypogastric region ; 9, left iliac region.

it is well to state the horizontal zones in which they lie, as well as the regions which they occupy.

When *general* enlargement of the whole abdomen is present the cause may be—(1) obesity ; (2) ascites ; (3) ‘phantom’ enlargements ; (4) a tumour. *Obesity* will be suspected if the adipose tissue of the body generally is in excess ; when giving rise to abdominal enlargement, the greater part of the excess of fat is in the abdominal parietes, the remainder in the omentum. The obese abdomen is flattened anteriorly, bulges in the flanks, shows no increase of tension, and the umbilical area is depressed to an unusual degree. The

presence of a thick layer of subcutaneous fat can be demonstrated by taking up the abdominal wall in folds between the fingers. Firm percussion is required to bring out a resonant note from the subjacent intestines. Small abdominal tumours, in such conditions, may be readily overlooked even when great care is exercised. When deep palpation is rendered difficult by obesity, or by rigidity of the abdominal muscles, it is convenient to employ both hands, one superimposed upon the other. The fingers of the lower hand are then used for palpating, while the upper hand presses it deeply into the abdomen so as to overcome the parietal resistance. *Ascites* causes general enlargement of the abdomen only when the amount of fluid is great. An area of resonance persists around the umbilicus, and extends upwards through the epigastric region into the costal angle, while the flanks and lower abdomen are dull; the area of dullness shifts on change of position, as may be demonstrated by turning the patient on her side, when the upper flank will become clear; a fluid thrill is readily obtained from side to side by gently flicking the abdominal wall in the flank. Small amounts of free fluid in the abdomen may be very difficult to recognize when the patient is corpulent or when some other morbid condition is also present. *Phantom* enlargement of the abdomen occurs in women of neurotic or hysterical temperament, and is always recognizable by its complete subsidence under anæsthesia. Comparatively few *tumours* attain a size large enough to cause *general* enlargement of the abdomen, at all similar to the conditions just mentioned; that most commonly met with is an ovarian cyst, more rarely a fibro-cystic tumour of the uterus; hydatid cysts, and malignant growths in their advanced stages, may also be mentioned.

When *localized* enlargement of the abdomen is met with, the possible causes are much more numerous and include morbid conditions of all the abdominal and pelvic viscera. Only those of pelvic origin can be referred to here. In the case of a tumour of *pelvic* origin rising into the abdominal cavity it is usually impossible to define its lower borders by abdominal examination; *i.e.* the fingers cannot be pressed down below it through the abdominal walls. Exceptions to this rule will be found in a pelvic tumour with a long pedicle which allows it to ride above the pelvic brim; such are either ovarian tumours, parovarian cysts, or subserous uterine fibroids. Pelvic abdominal swellings, as thus defined, may be fluid or solid, or in parts fluid, in other parts solid; the consistence of a soft solid tumour is not readily distinguishable from a cyst with thick walls or very viscid contents. Swellings of these characters may be due to over-distension of the bladder, to pregnancy, to new growths of the uterus, or ovaries, to distension of the Fallopian tubes or uterus, to fluid or solid effusions in the pelvic cellular tissue, or to encysted collections of fluid in the peritoneum. It must never be forgotten that the

commonest abdominal swelling in women is the gravid uterus, and unless the possibility is excluded by age or by the physical characters of the swelling, it should always be first considered. The over-distended bladder has also been the cause of innumerable diagnostic mistakes ; the catheter offers an easy means of recognizing it. The bladder being excluded, pelvi-abdominal tumours which yield a fluid thrill are in almost all cases ovarian or parovarian cysts ; occasionally fibro-cystic tumours of the uterus or hydatid cysts will be found to yield this sign. It is not in all cases, however, that fluid tumours yield a fluid thrill (*see* p. 710). As a rule the consistence of the gravid uterus is that of a soft solid ; occasionally, however, a fluid thrill may be detected (hydramnios).

Nearly all pelvi-abdominal tumours are dull to percussion. Exceptions will be found in cases of hæmatocele, and of encysted peritonitis, in which conditions coils of intestine always become incorporated by adhesions in the walls, giving a subresonant note over the greater part of its extent. In some instances also retro-peritoneal tumours displace the large gut forwards, giving a subresonant note over the position of the gut. Putrefaction, with production of gases, may occur in extra-uterine gestation, this giving rise to a greater or less degree of resonance in such tumours also.

All tumours of pelvic origin are dumb on auscultation, except the gravid uterus, an extra-uterine gestation, and certain uterine-fibroids which may yield a soufflé similar to that of pregnancy.

## VAGINAL EXAMINATION

A complete vaginal examination of the pelvic organs is conducted by inspection and palpation, and also requires the use of certain instruments. Parts of the examination are often unnecessary and may be omitted, but it will be convenient to describe the methods here in full. The hands should be washed immediately before making the internal examination, and the fingers to be introduced into the vagina should be lubricated with sterilized or carbolized glycerine or vaseline or some similar material. In cases of venereal or septic infection boiled rubber gloves *must* be worn, both to protect the fingers from contamination and to avoid the risk of carrying infective material to others. Under other conditions their use is a matter of choice, but there are many sound reasons for recommending their routine employment. It is not possible in all cases to exclude sepsis and gonorrhœa except by local examination, and contamination of the fingers may occur before the danger is recognized. To gynæcologists who are constantly operating, the preservation of the hands from contamination is a matter of the greatest importance, and equally to the practitioner engaged in midwifery. In hospital work, where a gynæcologist may examine a number of women in quick succession,

there is a further danger, viz. the possibility of carrying infection from one patient to another through inadequate disinfection of the hands after each examination. If gloves are not used, the examining fingers should be covered with a double rubber finger-stall provided with a wide collar, as shown in Fig. 73.

The position in which vaginal examination is usually made in this country is with the patient lying on her left side (*see* Fig. 80, page 126), with the thighs flexed on the abdomen. A high couch and a good light are useful aids. In cases of prolapse it is sometimes desirable to examine in the standing position ; in rare instances such postures

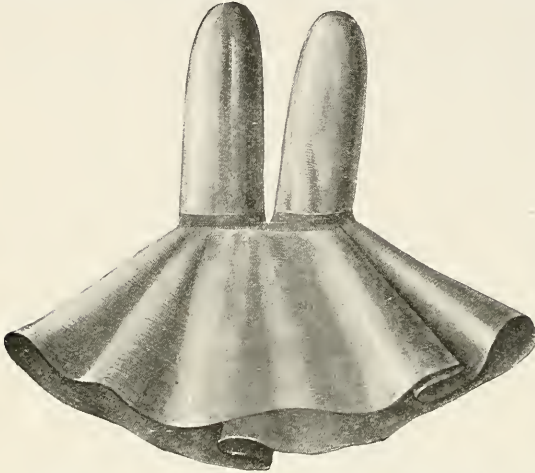


FIG. 73. DOUBLE RUBBER FINGER-STALL FOR USE IN MAKING VAGINAL EXAMINATION.

as the genu-pectoral may be adopted, but these are employed rather for treatment than for diagnostic examination. The examination can also be made with the patient lying on her back, with the thighs flexed, the feet supported on rests at the end of the couch, and the knees separated (*see* Fig. 74). In either position *inspection* of the vulva can be conveniently made, and this is the first part to which attention is directed.

The points which should be noted are the condition of the labia majora, labia minora, and clitoris ; then separating the labia with the fingers, the hymen, carunculæ myrtiformes, vestibule, meatus urinarius, and fossa navicularis should be examined in turn ; then, with the tip of the index finger introduced through the ostium vaginæ, pressure should be made upon the floor of the urethra towards the meatus, so as to reveal the presence, if any, of urethral discharge ; finally, the openings of the Bartholinian ducts may be inspected and the glands may be palpated, when enlarged, by taking the tissues at the base of each labium majus between the finger in the vagina and the thumb externally. Generally the mucous surfaces of the vulva are moist, but there is no visible discharge ; sometimes white curdy secretion or a thin opalescent fluid is present ; neither is abnormal.

The next step is the digital examination of the vagina, which is usually made with the index finger, or in a parous woman the index and middle fingers, of the right hand. It is a great convenience to learn to use either hand indifferently for the internal examination.



In introducing the fingers it will be remembered that the vulva presents an antero-posterior slit, while the lumen of the vagina is transverse ; the hand will therefore be rotated through a right angle as the fingers pass upwards towards the cervix.

The condition of the *vaginal walls* is the first point to be observed ; the transverse rugæ (*see p. 30*) can usually be felt on the anterior wall, but in women who have borne several children, or in cases of prolapse, they are often absent. The educated finger will at once detect such conditions as abnormal laxity of the walls (in prolapse), constrictions, cicatrices, warty excrescences, and new growths, either cystic or solid. The *vaginal portion of the cervix* must next be defined. It lies usually about the centre of the pelvic cavity, the os corresponding to the level of the ischial spine ; departure from this position is, however, by no means uncommon, and too much importance must not be attached to the slight displacements in one or another direction which may be met with, for the healthy uterus does not invariably lie in the middle line, nor at the same horizontal level. In nulliparous women the os forms either a small round aperture, or a narrow transverse slit ; in women who have borne children it is invariably either transverse if no laceration has occurred, or irregular if the cervix has been torn in delivery. Another condition which is not abnormal must also be borne in mind, viz. the presence of several low, smooth, round elevations upon the surface ; these are caused by retention cysts formed in the substance of the cervix by closure and dilatation of the deep portions of the cervical glands—the so-called *ovula Nabothi*. The educated finger will detect such abnormal conditions of the cervix as dilatation of the canal, hypertrophic elongation and ectropion, protruding polypi—either cervical or uterine, and ulcerations due to malignant growths or to other causes.

**Bimanual Examination.** The next step is the *bimanual examination*, and this is the most important from every point of view. Considerable experience of this method is necessary to acquire confidence and skill ; under favourable conditions it is easy and permits of a detailed examination of all the pelvic organs ; under unfavourable conditions, such as obesity, nervousness, etc., an experienced clinical observer may be obliged to suspend judgment until an examination under anæsthesia has been made, and even this in some instances may leave many points undetermined.

For a successful bimanual examination it is essential that the bladder should not be full nor the rectum loaded ; whenever possible a mild aperient should be administered in preparation for the examination, as a second visit to the doctor is thereby often avoided.

The only position in which the bimanual examination can be made is with the patient lying on her back, and the knees bent to an acute angle. When a special gynæcological couch, or operating table, is used the examiner stands between the patient's knees as in Fig. 74 ;

it is equally convenient, however, for the examiner to stand at the side of the couch, passing his right hand beneath the bent right knee of the patient (*see* Fig. 75), and for this method no special couch is required. The right hand is usually employed for the internal examination, the left is placed upon the hypogastrium, and with the fingers of the two hands working in conjunction, the pelvic organs

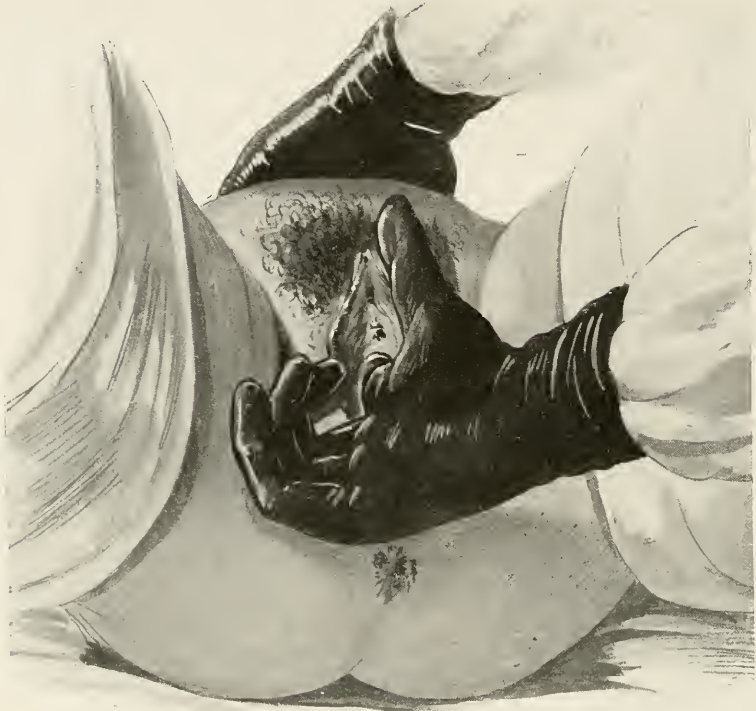

FIG. 74. METHOD OF MAKING THE BIMANUAL EXAMINATION, the examiner standing at the end of the couch. (From a photograph.)

can be palpated simultaneously from above and from below. It is advisable to become familiar with the use of either hand internally, for the right side of the pelvis can be explored more thoroughly with the right hand, the left side with the left hand. The examination should also be learned in both positions shown in Figs. 74 and 75; for the use of a couch or operating table is not always practicable, and in the case of patients confined to bed the position shown in Fig. 75 is more convenient and occasions less distress than the other.

The *body of the uterus* is first to be identified, and it is naturally first sought in its normal position of anteversion. The uterus usually lies roughly in the obstetric axis of the pelvic cavity. In thin subjects it will be readily felt in this position; if not found at once, the vaginal

finger should be used to push up the uterus towards the abdominal wall ; this is much more effectual than attempting forcibly to overcome the resistance of the powerful abdominal muscles, by pressure with the external hand. When the body of the uterus is thus held between the fingers of the two hands, it is possible to determine its position, size, shape, consistence, and mobility ; minor points also to be noted are sensitiveness to pressure, and pain provoked by movement. It is by no means easy to make a satisfactory bimanual examination of a retroverted uterus without first pushing it up to the




FIG. 75. METHOD OF MAKING THE BIMANUAL EXAMINATION, the examiner standing at the side of the couch. (From a photograph.)

level of the pelvic brim, and this can sometimes be done more effectually *per rectum* than *per vaginam*.

The *uterine appendages* should be identified next, and these are found by bimanual examination of the *lateral fornices*. In those subjects who have lax abdominal walls, and who tolerate the examination without difficulty, three structures may be made out. Anteriorly a thin cord which can be rolled between the fingers represents the round ligament ; behind this is a softer, cylindrical structure—the Fallopian tube ; tracing the latter outwards, the ovary may be felt in its usual position, *i.e.* close to the lateral pelvic wall ; it will be recognized by its round or oval shape, soft consistence, and ready mobility, slipping easily between the fingers of the two hands. If the ovary cannot be felt in its normal position, it may be found prolapsed into the pouch of Douglas. The most difficult of all to recognize is the unaltered Fallopian tube ; it is softer in consistence than the round ligament and difficult to distinguish unless thickened

or distorted by pathological changes. In cases of obesity, or rigidity of the abdominal walls, the unenlarged appendages may not be felt at all; when felt under such circumstances, they are probably of abnormally large size.

The *bladder* cannot be outlined by palpation when empty; the full bladder forms a soft fluctuating sac felt in the anterior fornix, which displaces the uterus backwards so that only its fundus can be felt. The *ureters* can in some cases be identified in the lateral vaginal fornices, a little to the outer side of the cervix. When thickened from tuberculous disease, or when a calculus is present, their detection is easy.

Many abnormal structures may be detected in the *lateral fornices*; a soft, cystic, movable swelling is generally an ovarian or a parovarian cyst; a hard, solid, movable swelling is generally a subperitoneal fibroid, but may be a solid tumour of the ovary; a firm or hard, fixed, tender swelling is generally inflammatory, and in the great majority of cases includes, as its nucleus, an inflamed tube or ovary, or both (salpingitis: oöphoritis); less commonly this kind of swelling is due to an inflammatory effusion into the broad ligament (cellulitis). A loop of the pelvic colon on the left side, or a portion of the cæcum on the right, may often be palpated in the lateral fornices, and may sometimes be felt to gurgle under the pressure of the fingers. It is, however, easy to mistake these parts of the intestine for pathological conditions such as cysts; they are always ill-defined in outline, and give an obscure sense of resistance rather than the impression of a definite mass. A second examination after an aperient has been taken usually shows that the swelling has disappeared.

Lastly, the *posterior fornix* is explored in the same manner. The pouch of Douglas is usually empty, but under normal conditions may sometimes contain a coil of small intestine, which may be felt to retreat or gurgle under the pressure of the finger. By pressing the internal finger upwards behind the cervix, a small portion of the posterior uterine wall in its lower part may be felt (*see Fig. 2*); the anterior rectal wall and the utero-sacral ligaments can also be felt, but the latter are not recognizable unless unusually well developed, or thickened by inflammatory or other changes. In all cases they can be examined much more effectually *per rectum* than *per vaginam*. Of all the structures which may, under abnormal conditions, be felt through the posterior fornix, the commonest is the body of the uterus in backward displacement, and next to this the ovary when prolapsed; other structures which may be encountered include such varied conditions as uterine fibroids, ovarian tumours (cystic or solid), inflamed or dilated tubes, intraperitoneal collections of blood or inflammatory fluids, displaced abdominal viscera such as the spleen or the kidney, new growths of abdominal origin such as carcinoma of the omentum or peritoneum, hydatid cysts of the pelvic

cellular tissue, faecal accumulations, and new growths or foreign bodies in the rectum.

In many cases great assistance will be obtained from conducting the examination both in the dorsal and in the lateral positions. The change of posture brings with it a change in the position of the principal pelvic organs, especially the uterus; in the lateral position this organ tends to fall forwards, and thus to allow a more complete examination of the region of the pouch of Douglas from below.

**Rectal, Recto-abdominal, and Recto-vagino-abdominal Examination.** Rectal examination is made with the index finger of the right hand protected by a glove and freely lubricated before being introduced. In a *virgo intacta* it is desirable to avoid vaginal examination if possible, and the recto-abdominal method then permits of approximately accurate results being obtained, especially as regards the size and position of the uterus. A history of hæmorrhage or pain accompanying defæcation necessitates a careful inspection of the anus before the finger is introduced, for a digital examination may be extremely painful when a fissure or a peri-anal abscess is present. Rectal examination allows of a more complete examination of the contents of the pouch of Douglas than does vaginal examination; the finger in the rectum passes far up the posterior wall of the pouch, while only its floor is accessible from the vagina (*see* Fig. 4). The nature of a retro-uterine swelling can often be elucidated in this way. Further, the utero-sacral ligaments are readily felt, and early infiltration, as in cancer of the cervix, may be detected, although not apparent from the vagina. Again, effusion into the pelvic cellular tissue sometimes tracks round the rectum, surrounding it more or less completely with a firm fixed ring of induration. Lastly, conditions such as rectal stricture or polypi, hæmorrhoids, faecal accumulations, and foreign bodies will also be detected. In the case of pelvic swellings it is sometimes useful to carry out a bimanual examination from the rectum (recto-abdominal), either alone, or even more conveniently with the index in the vagina, the second finger in the rectum (recto-vagino-abdominal). Slight degrees of impaired mobility may be thus detected, and the relation of a pelvic swelling to the uterus may be defined. Infiltration of the broad and utero-sacral ligaments in cancer of the cervix can be much better made out *per rectum* than *per vaginam*.

Unless the bowel has been recently and thoroughly emptied rectal examination is of little value; accordingly some preparation is often required before it can be carried out. But its usefulness under the conditions indicated above is very great.

**Visual Examination of the Vaginal Walls and Cervix.** With the aid of a vaginal speculum and a good light the vaginal canal and cervix can be conveniently inspected. There are many types of vaginal specula, but only two need be described: the most useful

is the *tubular* or Ferguson's speculum; next may be mentioned the *duck-bill* or Sims's speculum.

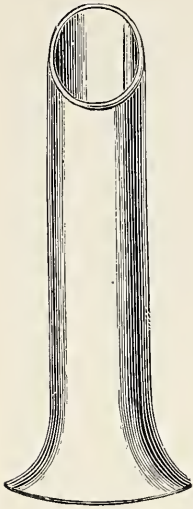


FIG. 76. FER-  
GUSON'S VAGINAL  
SPECULUM.

Ferguson's speculum is a tube of glass, porcelain or metal about 6 inches long, cut obliquely at its upper end, and furnished below with a shallow flange (see Fig. 76). It is made in different sizes; the smallest, suitable for a nullipara, having a diameter of about 1 inch. In introducing the instrument—surgically clean and smeared with a sterile or antiseptic lubricant, the fingers of the left hand are used to separate the labia minora until the ostium vaginae can be seen (see Fig. 77). The upper, oblique end is then applied to the vulva, the longer side being posterior, and with the edge the posterior vaginal wall, is gently pressed backwards; the lower end at the same time is so held that the instrument lies in the obstetric axis of the pelvic outlet. In this way the ostium vaginae is stretched until the short anterior side of the speculum will slip past the vestibule without the use of force. The instrument is then pushed gently inwards, the long side being directed behind the cervix into the posterior fornix; the cervix then lies exposed in the upper end of the speculum, and the

vaginal walls are not seen. In introducing or withdrawing the

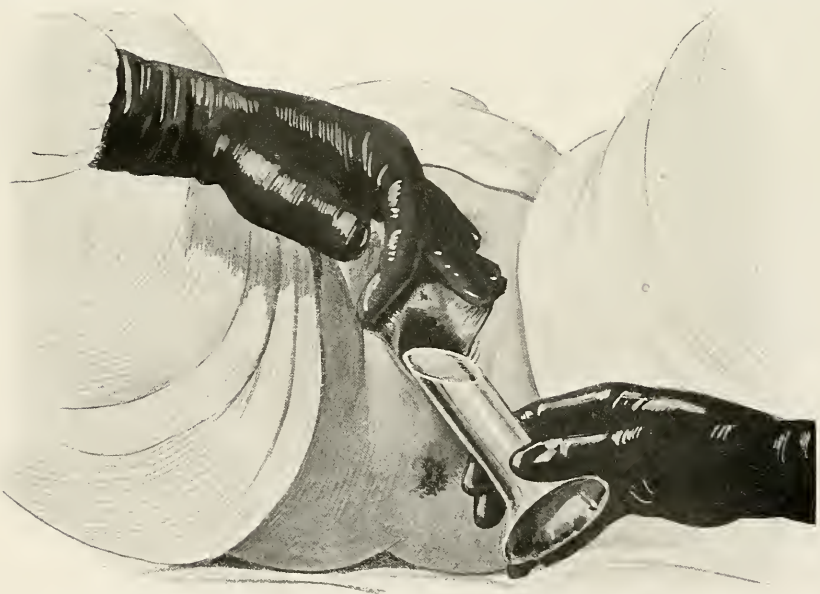


FIG. 77. METHOD OF INTRODUCING FERGUSON'S SPECULUM.  
(From a photograph.)

speculum the vaginal walls beyond it can be seen in contact with one another, and thus are open to examination in their whole extent, a small portion at a time.

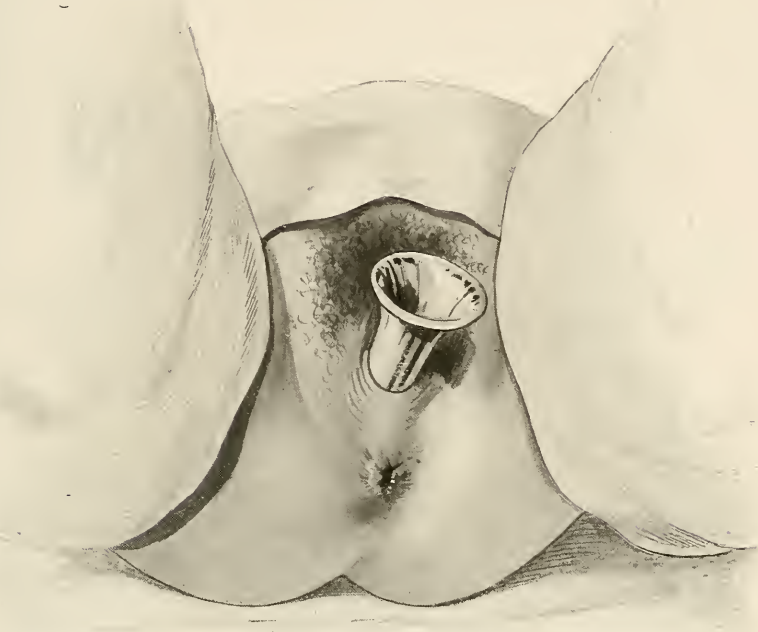


FIG. 78. FERGUSON'S SPECULUM AFTER INTRODUCTION. (From a photograph.)

This speculum can conveniently be used in either the dorsal or lateral position, and suffices for most of the purposes for which a speculum is required in clinical examination, or in the application of certain forms of treatment.

Sims's speculum is shown in Fig. 79; it is a double instrument, being held in the middle, and furnished with spoon-shaped ends of different sizes set transversely to the handle. According to the intention of its designer (Marion Sims), the instrument should be used in the *semi-prone*, or *Sims's* position, *i.e.* the patient lying on her left side, with the left arm carried behind her back and both thighs flexed, the right

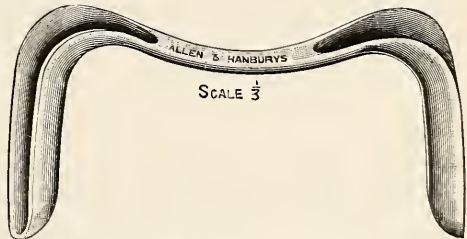


FIG. 79. SIMS'S VAGINAL SPECULUM.

more acutely than the left (Fig. 80). If, in this position, the ostium vaginae is opened, air enters the vagina and distends it, while the uterus falls forwards and downwards, *i.e.* towards the anterior

abdominal wall. The spoon-shaped end of the speculum is then introduced along the posterior vaginal wall, and being gently pulled backwards, the whole of the anterior vaginal wall and the cervix become exposed and can be inspected under good illumination. When the vaginal walls are lax, as in cases of prolapse, the anterior wall falls into the instrument and obscures the view unless pressed back with forceps. The speculum is less convenient for general use than the tubular one, and often necessitates the presence of an assistant to hold it in place. For vaginal operations it

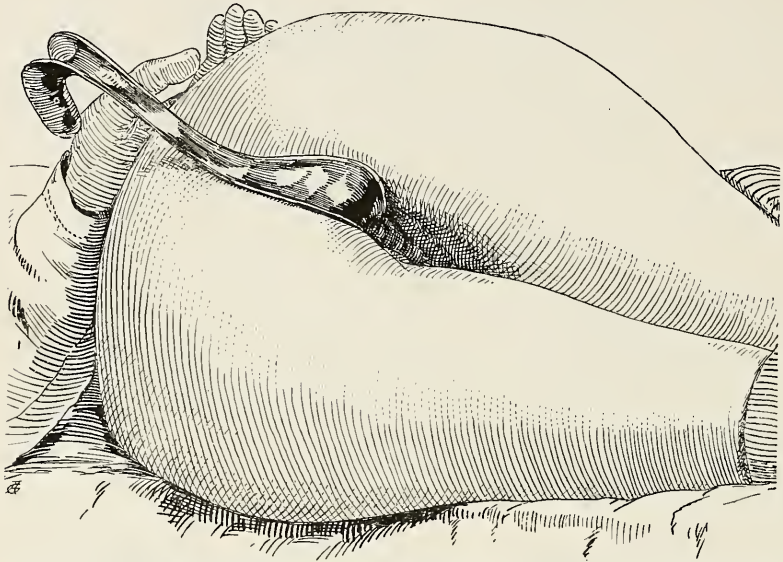


FIG. 80. SIMS'S POSITION, WITH THE SPECULUM INTRODUCED. The hand seen at the back is the left hand of the patient. (From a photograph.)

is in common use, being then employed in the modified lithotomy position. This speculum can be readily sterilized by dipping it in methylated spirit, and then igniting that which adheres to the instrument.

For operative purposes the other forms of vaginal speculum which are self-retracting are useful, viz. Jayle's vaginal retractor and Auvard's weighted speculum; they are, however, not required for purposes of ordinary clinical examination (*see* Fig. 81).

**The Uterine Sound.** This instrument is a probe specially designed for introduction into the cavity of the uterus (*see* Fig. 82). It is made of pliable metal so that it may be curved to suit abnormal conditions. At a point  $2\frac{1}{2}$  inches from the tip is a small knob, marking off the normal length of the uterine cavity; beyond the knob the sound is notched at intervals of 1 inch. Before being introduced into the uterus it must be surgically clean; this can be ensured by boiling



it or by dipping it in methylated spirit and then igniting the spirit which adheres.

Information can be obtained by the use of the sound with regard to: (1) The length and direction of the uterine cavity; (2) the




FIG. 81. SHOWING THE CERVIX EXPOSED BY THE USE OF JAYLE'S AND AUVARD'S SPECULA.

presence of dilatation (as distinct from elongation) of the cavity, by gently rotating the handle of the sound when introduced, so moving the point through the arc of a circle; (3) the presence of roughness or inequalities upon the uterine walls; (4) the approximate width of the corporeo-cervical angle; (5) the relation of the uterus to a pelvic tumour, when the position of the former cannot be made out by digital examination alone. The presence of a streak

of blood upon the sound on withdrawal does not indicate anything abnormal, but considerable hæmorrhage is a sign of disease.

The passage of the instrument through the cervical canal is generally painless, but a painful sensation is often produced by contact of the tip with the mucosa at the fundus.

Certain dangers attend the use of the sound which must be borne in mind. Primarily there is the risk of infection, either through a septic instrument, or through septic matter being picked up and carried from the vagina or the cervix into the uterine cavity. The latter is especially liable to occur in gonorrhœal or septic infection of the vagina or cervix ; and as a general rule the sound should not be used when an offensive discharge from those parts is present, or when gonorrhœal infection is suspected. If a menstrual period is overdue, suggesting the possibility of early pregnancy, the use of the sound should be avoided. In certain conditions, such as malignant tumours of the body of the uterus, the friable walls are easily per-

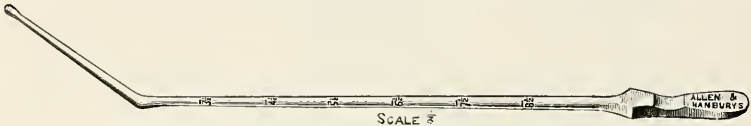

FIG. 82. THE UTERINE SOUND.

forated, and this accident under such conditions entails grave risks of septic peritonitis. Accidental perforation of the healthy uterus by a sterile sound has been known to occur without any harm resulting.

In consequence of the above-mentioned risks the sound is an instrument unsuited for general use. When employed, strict anti-septic precautions are called for which cannot well be carried out except in operative work or in examinations under anæsthesia. The sterilized sound must be manipulated so that it comes in contact with no part of the genital tract below the level of the cervix. The cervix should be first exposed with a speculum, and its surface cleansed with swabs ; if purulent cervical discharges are seen the instrument should not be used at all ; if the secretions appear healthy the sound may be carefully introduced into the os and carried gently up to the fundus. The position of the uterine body should, if possible, be ascertained by previous bimanual examination ; in some cases, however, this cannot be done, and one of the reasons for using the sound is to define the direction of the uterine body.

The sound is an instrument which is seldom employed by an experienced gynæcologist ; most of the information obtained by its use can also be gathered from a bimanual examination, and the more expert the practitioner becomes in the use of the latter method the less frequently will he resort to the use of the sound.

*The volsella* is a pair of long-handled, sharp-toothed forceps with which the cervix may be seized and drawn down towards the vulva

to facilitate its examination or to facilitate the introduction of the sound in difficult cases. In a healthy parous woman the cervix can be drawn down till the os externum lies at the level of the *introitus vaginae* without causing the patient much pain. Greatly increased mobility is present in prolapse; deficient mobility, up to complete fixation, may be met with in inflammatory conditions, in malignant infiltration of the broad ligaments, or in the presence of uterine tumours.

### EXAMINATION OF DISCHARGES, TISSUES, ETC.

It is obvious that the complete clinical examination of a gynaecological case may entail the microscopic and bacteriological examination of discharge, or of pieces of tissue removed for histological diagnosis. This work is best entrusted to a clinical laboratory, but the methods of obtaining the material must be referred to.

Discharges for bacteriological examination should be taken with careful technique. The source of the discharge having been determined, it is exposed with a speculum when necessary, and a flamed platinum wire used to take up a portion of the discharge. Two culture tubes, one of agar-agar and one of beef-tea, are then immediately inoculated, and a further portion of the discharge taken to make a smear preparation on a glass slide for staining purposes. The whole may then be sent to the laboratory for preparation and report. It is essential that culture-tubes be prepared immediately, as organisms of low virulence speedily die when taken from the body unless they are provided with a suitable culture-medium.

Pieces of tissue, such as curettings, should be placed immediately in saline solution to which formalin to make the strength of 1 per cent. has been added. In this solution they may remain without harm for two or three days. In the case of curetting *the whole* of the fragments removed should be sent to the laboratory.

**Examination of the Blood.** In infective and inflammatory conditions a complete differential blood-count is often of great value for diagnostic purposes (p. 628). Further, specific blood-reactions, such as the Wassermann test for syphilis, and the precipitation test for hydatid disease, and the von Pirquet reaction for tubercle, may be indicated under special conditions.

### EXAMINATION OF THE URINARY SYSTEM

Such conditions as functional disturbances of micturition, cystitis, pyelitis, foreign bodies in the bladder, prolapse of the bladder, vesical fistula, and movable kidney, come frequently under the notice of the gynaecologist, and are often associated with lesions of the genital canal itself. Such clinical methods of investigation as cystoscopy and catheterization of the ureters may then be required, but for a detailed description of these matters other works should be consulted.

## PART I: SECTION III

### PROMINENT GYNÆCOLOGICAL SYMPTOMS

CERTAIN symptoms which are of frequent occurrence under varied conditions may be conveniently considered individually as regards their clinical significance and treatment. Reference to them in connection with particular diseases can then be simplified and shortened. They are :

- (1) Hæmorrhage.
- (2) Discharges.
- (3) Pain.
- (4) Disturbances of micturition.
- (5) Dyspareunia.
- (6) Sterility.

#### HÆMORRHAGE

Hæmorrhage is a symptom frequently encountered in diseases of the female pelvic organs. In a preponderating majority of cases its source is the uterus ; it may, however, arise from disease of the vaginal walls, or the vulva. Severe bleeding is nearly always uterine in origin ; vaginal and vulval bleeding, except when due to traumatism, is always slight. Bleeding from the rectum is very seldom, if ever, due to disease of the genital organs, and therefore will not be considered here.

In hæmorrhage from the *body of the uterus* the actual source of the bleeding is usually the endometrium ; when it comes from the *cervix*, either the cervical endometrium or the stratified epithelial surface may be the actual source. Often polypi growing from the cervix cause bleeding, and sometimes growths which have come down from the uterine body and protrude through the cervix cause severe bleeding. In rare instances, blood escaping from the uterus may actually spring from the Fallopian tubes, as in tubal cancer (p. 640). Hæmorrhage from the endometrium may occur either as an excess of the regular menstrual loss, or as an irregular bleeding in the intervals. Thus has arisen the time-honoured distinction between *menorrhagia* (the former) and *metrorrhagia* (the latter). This distinction is, however, of little practical importance, for one variety passes insensibly into the other and the same conditions give rise to both. Before puberty and after the menopause all bleeding from the uterus is spoken of as metror-

rhagia. Bleeding from the cervix is characteristically intermenstrual, for the cervix takes no part in menstruation ; but excessive menstrual loss may also be met with in such cases, owing to the presence of associated lesions in the uterine body. Hæmorrhage following coitus, except a first coitus, is usually cervical, and in the majority of cases is due to carcinoma. The slight bleeding which usually attends a first coitus is due to laceration of the hymen ; sometimes serious bleeding occurs at coitus from laceration of the vaginal wall, and fatal results have from time to time been recorded.

*Hæmorrhage from the uterus* may be due to general or to local causes ; when severe it almost always has a local, not a general, cause.

**General Causes.** In all varieties of *anæmia* menstruation may be excessive ; in chlorosis this is exceptional, in pernicious anæmia it is said to be comparatively common. In *acute infectious diseases* excessive menstrual periods, or irregular hæmorrhages, often occur. *Nervous shock, fatigue,* and *occasional alcoholic excess* may all cause uterine hæmorrhage when the occurrence coincides with a menstrual period. Occasionally cases are met with in which slight bleeding from such causes occurs in the menstrual intervals.

It is often stated that *cardiac valvular disease* causes hæmorrhage, but a systematic examination of a series of heart-cases does not support this view (Gow). *Hæmophilia*, a disease very rare in women, may occasionally be the cause of uterine hæmorrhage. Severe menorrhagia is sometimes seen in women suffering from *myxædema*, without a recognizable local cause. It is possible that thyroid deficiency may explain it. Contradictory observations have, however, been recorded in which amenorrhæa has been attributed to myxædema. In the present state of our knowledge therefore the relation of thyroid activity to uterine hæmorrhage cannot be defined. *Puberty* and the *menopause* are often accompanied by profuse menstrual loss, and this without any discoverable sign of local lesions. After marriage an increase in the amount of menstrual loss is not uncommon, sometimes it becomes for a time profuse ; it is no doubt attributable to the effects of *sexual excitement* upon the pelvic circulation. Often the change from a temperate to a hot climate causes profuse menstruation, and is seen for example in Englishwomen who go to reside in India.

**Local Causes.** The subjoined list of morbid conditions, giving rise to hæmorrhage, is here given without detailed comment, as each will be considered in its place in a later section.

#### I. *Uterine* :

##### (A) *Body* (exclusive of uterine pregnancy)—

Extra-uterine pregnancy.

Chronic endometritis and allied conditions.

Acute (infective) endometritis.

Chronic metritis.

Mucous and fibroid polypi.  
 Submucous and interstitial fibroid tumours.  
 Adenomyoma.  
 Backward displacement.  
 Chronic inversion.  
 Carcinoma, sarcoma, chorionepithelioma.  
 Acute or chronic pelvic infection, *e.g.* salpingitis, peritonitis.  
 Increased intra-abdominal pressure, *e.g.* very large ovarian tumours.

(B) *Cervix*—

Mucous polypi.  
 Fibroid tumours.  
 Carcinoma and sarcoma.  
 Traumatic ulceration, as from a neglected pessary.  
 Tuberculous and syphilitic ulceration.  
 Pseudo-adenoma, 'erosion' (rarely).

- II. *Tubal* (in rare cases): Interstitial tubal pregnancy; tubal cancer.  
 III. *Vaginal*: Lacerations; carcinoma; traumatic ulceration.  
 IV. *Vulval*: Lacerations; ulcerations; rupture of varicose veins; carcinoma; urethral caruncle, urethral cancer.

In addition, it has already been pointed out that a certain amount of evidence has recently been adduced which appears to indicate that bleeding from the endometrium may occur as the result of some perversion or morbid alteration of the internal ovarian secretion, an excessive production, for example, of the ovarian hormone which induces menstrual changes in the endometrium. Such a condition may be evidenced anatomically by the presence of an excess of lutein tissue in the ovary. The possible influence of the normal internal ovarian secretion in inducing the recurrent bleeding of menstruation has been already mentioned; there is no great difficulty in supposing that abnormal bleeding may in the same way be set up by an abnormal or excessive ovarian secretion. In consideration, further, of the evidence which has now been obtained of a correlation in function between the ovaries and certain other endocrinous glands, it is not impossible that abnormal conditions, or perverted functions of these organs, may at times produce uterine hæmorrhage when the pelvic organs are normal. Certainly, cases of uterine hæmorrhage are not infrequent in which no definite general or pelvic cause can be discovered, and it may be that further observation will show that some of these cases may be due to such influences.

The clinical significance of hæmorrhage varies greatly at *different periods of life*, and it will be convenient to indicate the morbid con-

ditions which are most likely to be met with in the various phases of the development and decline of reproductive activity.

In *infancy* slight bleeding is not very uncommon in the first few weeks of life. Sometimes it is associated with mammary activity, the infant's breasts becoming tender, swollen, and full of secretion. It appears to be uterine in origin, and, except in premature infants, it is not of serious clinical import, and does not call for treatment.

In *childhood* hæmorrhage may indicate the precocious onset of menstruation (*see* p. 88); in other cases it may be due to malignant disease, the commonest forms at this period of life being sarcoma of the cervix and malignant growths of the ovary. It must also be recollected that pregnancy may occur before the establishment of menstruation, and may give rise to hæmorrhage.

In *adolescence* profuse hæmorrhage occasionally occurs at the onset of puberty, recurring with every period for several months. Occasionally more or less prolonged slight hæmorrhages occur, lasting for two or three weeks or even longer. No local corporeal cause of bleeding may be discovered in such cases, and medicinal measures are usually of no effect. Curetting may also fail. Eventually the periods become more normal in amount although in such cases menstruation, when regularly established, is often attended with more than the average loss. Sarcoma of the uterus and malignant ovarian growths may occur, and it must not be forgotten that hæmorrhage due to disturbances of pregnancy may be met with at an unexpectedly early age.

In the period of *reproductive activity* (fifteen to forty-five years) the commonest cause of hæmorrhage is some disturbance of pregnancy; the possibility of this occurrence should never be overlooked, even when general considerations would appear to warrant its exclusion. Next to pregnancy the commonest causes encountered are fibroid tumours (including polypi), malignant growths of the uterus, and pelvic inflammatory lesions. Any of the other local and general conditions mentioned in the preceding list may also be met with. It must be recollected that in pregnancy, traumatic laceration of the vulva or vagina produce much more severe bleeding than in the non-pregnant state.

At the *menopause* profuse and irregular periods occasionally occur without any present indication or later development of local disease (*see* p. 107). The liability at this time of life to the growth of cancer in the body or cervix of the uterus is, however, so clearly established that the most careful measures to exclude these conditions must in all cases be taken. Fibroid tumours sometimes occasion profuse climacteric hæmorrhages, owing to some degenerative change occurring in them. Chronic metritis is often met with at this period of life.

After the menopause, in the *post-climacteric period*, the reappearance of hæmorrhage generally indicates carcinoma or sarcoma of the uterus; more rarely the growth will be found in the vagina or vulva. Occasion

ally senile endometritis, or a degenerative change in an old fibroid tumour, is the cause. In elderly women an occasional slight uterine hæmorrhage may occur in connection with cardiac disease or arterio-sclerosis; the amount is not generally more than a *show*. Mucous polypi may first attract attention after the menopause, giving rise to a sanguineous discharge. It is improbable that they develop at this period; more probably they have been in existence for some time but give rise to no bleeding until some secondary change occurs in them, such as ulceration of their epithelial covering, to which the hæmorrhage is directly due. Such polypi should always be removed and submitted to microscopic examination, as a certain number of them will show malignant characters. Mucous polypi of the cervix may exist along with cancer of the body of the uterus: the uterine cavity should therefore always be explored with the curette at the time the polypus is removed. Malignant disease, quite unsuspected, may then be discovered.

A certain amount of difficulty often arises in determining the *degree of severity* of the hæmorrhage, unless the patient is under observation at the time the bleeding occurs. Rapid recovery may apparently be made from the effects of recurrent, profuse monthly losses, but unless a blood-count is made considerable degrees of anæmia may be overlooked; for the colour of the patient is but a fallacious guide in this respect. We should not wait until the patient is blanched before deciding that she is suffering from the constitutional effects of hæmorrhage, for chronic anæmia of moderate extent is often the starting-point of prolonged and intractable ill-health.

Generally speaking, *severe bleeding indicates the presence of a local cause, and calls for a local examination*. Slight and continuous, or irregular bleeding, is frequently due to a general cause; but in elderly women all hæmorrhages must be regarded as of grave significance, for they may be the earliest indication of the presence of a malignant growth. A glance over the conditions named above as local causes of hæmorrhage will show that bleeding, as a rule, must be accepted as indicating the necessity for a careful pelvic examination. It is better to examine and find no local disease than to delay while local disease is present and advancing.

Local examination will be directed to the exclusion (*a*) of pregnancy, (*b*) of new growths of the uterus, cervix or vagina, (*c*) of inflammatory lesions, (*d*) of uterine displacements, (*e*) of slight degrees of enlargement of the uterus, indicative of chronic endometritis and metritis, or an intra-uterine polypus. The exclusion of pregnancy is the first and essential step. After this, difficulty in diagnosis is usually restricted to cases in which there is slight enlargement of the uterus, and beyond this nothing abnormal is found. In such cases digital exploration of the uterine cavity (*see* p. 796) is often required to clear the matter up. In rare cases profuse, or even dangerous, bleeding may occur from the



uterus although no abnormality can be detected either on bimanual examination or digital exploration. These cases will be again referred to in connection with chronic metritis (*see* p. 417).

**Treatment.** The *arrest* of bleeding from the uterus is a problem which is frequently encountered by the medical practitioner. If the uterus is gravid, the treatment is that of threatened or inevitable abortion, as the case may be, and this subject is dealt with in text-books of midwifery. In all other circumstances the immediate treatment is governed more by the severity of the bleeding than by the local morbid conditions which may be present.

In all cases of *severe* bleeding from the uterus, rest in bed and free evacuation of the lower bowel are important, as by these means the pelvic circulation is to some extent relieved. Contraction of the uterine muscle is the principal factor in the natural mechanism for the arrest of bleeding from the uterine body, but it must be recollected that bleeding due to morbid conditions of the cervix cannot be checked in this way. Another possible factor, referred to on p. 99, is the influence of the uterine secretion in promoting coagulation, or in breaking up thrombi when formed. We know of no therapeutic means of influencing this function.

There are five chief methods of treating bleeding from the uterus : (1) drugs, (2) hot douches, (3) the vaginal or intra-uterine tampon, (4) radio-therapeutics, (5) operative measures.

*Drugs.* Two classes of remedies are employed in arresting uterine hæmorrhage : (a) general hæmostatics, which tend to control bleeding from any part of the body ; (b) uterine hæmostatics, which exert a special influence in controlling bleeding from the uterus.

(a) Among the former may be mentioned *salts of calcium* and preparations of the *adrenal glands*. It has been already stated that menstrual blood contains a high percentage of calcium salts ; therefore when menstruation is profuse and prolonged, the calcium-reserves of the body tend to become depleted. Upon the presence of calcium in the blood the property of coagulability in part depends, and when this constituent has fallen to below the normal the coagulability of the blood has probably been reduced. It can be shown clinically that the administration of calcium-salts increases coagulability, and such an increase will probably influence the amount of hæmorrhage by allowing thrombosis to occur with greater freedom. The action of calcium is therefore prophylactic, when taken in such manner as to cause an increase in the total calcium-content of the blood. To produce this effect calcium lactate may be given in doses of ten grains three times a day throughout the menstrual interval, or at least for ten days preceding each period. The treatment should be continued for several months and the effect will only be obtained so long as the excess of lime salts is maintained in the body-fluids.

Adrenalin, or other extracts of the adrenals, when taken internally,

accelerate the heart and produce a rise of blood-pressure due to vaso-constrictor action upon small arteries ; when applied locally they also produce a vaso-constrictor action which, while it lasts, diminishes or arrests local bleeding. It may thus be given internally in doses of 10 to 15 drops of a 1 in 1000 solution. It is, however, much more effective when applied directly to the endometrium or other bleeding surface (*see below*).

(b) The uterine hæmostatics which have been essayed in cases of hæmorrhage are very numerous.

It has been shown by Blair Bell that an *extract of the pituitary body* has a powerful effect on uterine muscle ; it greatly increases the length and strength of the contractions in labour, and has also a general vaso-constrictor action similar to that of adrenalin. As in the case of the latter, its effect is much less marked upon the non-gravid uterus than the gravid uterus, but it may be usefully given in uterine hæmorrhage. The dose for hypodermic injection is 1 c.c. of a 20 per cent. solution. As it raises blood-pressure very considerably its action must be carefully watched in the case of patients with an enfeebled or damaged heart or with degenerated arteries.

*Ergot* has been in common use for many years, and is the best known of all. Its influence upon the non-gravid uterus is, however, much less pronounced than that which is so readily produced by the obstetrician, and it must be admitted that only slight cases of bleeding can be controlled by its use. Further, in many slight cases, it appears to produce no decided effect, and must therefore be regarded as somewhat unreliable. Its effect is mainly due to the influence it exerts in causing contraction of the uterine muscle, but it is also to a certain extent a general vaso-constrictor. When given by the mouth large doses should be administered, *e.g.* 30 to 60 minims of the liquid extract three times a day, or 1 to 3 grains of ergotin in pill. It may be usefully combined with strychnine or with a dilute acid. Given by deep intra-muscular injection into the buttock or thigh, *e.g.* 10 minims of *Injectio Ergotini hypodermica B.P.*, its effect will be more quickly and certainly obtained. Many special preparations, or derivatives of ergot, are obtainable, and among these *Ernutin* may be mentioned ; it is best administered by deep intra-muscular injection. *Stypticine* (cotarnin hydrochloride) may also be favourably mentioned ; it is given hypodermically in doses of 1 to 2 minims of a 10 per cent. solution. *Hydrastis* may be given by the mouth as liquid extract (dose 30 to 60 minims), or in pill as 2 grains of the dry extract. *Hydrastis* and *ergot* may usefully be given in combination, either in mixture or pill, their administration being begun a day or two before the expected hæmorrhage. *Styptol* (cotarnin phthalate) and *Lodal*, another derivative of cotarnin, are given in doses of 1 to 1½ grains several times a day. In addition to hæmostatic action the two latter produce a slight sedative effect.

Besides their specific action on the uterus, these drugs are all vaso-constrictors, and produce some narrowing of the small arterial vessels of the body generally.

*Hot Douching.* Douching the vagina with hot water at a temperature of 115° to 120° F. is very commonly practised as a means of reducing hæmorrhage. It is doubtful if a hot douche is of much value as a uterine hæmostatic, unless applied to the interior of the uterus, when its effect becomes at once evident. This method can, however, seldom be used in gynæcological work, except after operative procedures and when the cervix is dilated. The vaginal douche is useful as a means of cleansing the canal, and if not markedly successful as a hæmostatic, it does no harm. Normal saline solution, or dilute solutions of antiseptics, or astringents should be used.

*Plugging.* Plugging the vaginal canal when properly applied is the most efficient means we possess of immediately controlling bleeding from the uterus. Sterilized gauze, either plain or impregnated with subgallate of bismuth, in a single long strip, is the best material for the purpose, and it should be passed, after douching, with the aid of Sims's speculum, by which the perineum is pulled back and the vulva opened. The strip is first pushed up along the posterior vaginal wall into the posterior fornix, which is tightly filled, and then the lateral and anterior fornices are filled in the same way; the lower part of the vagina is only loosely filled. The plug should not be allowed to remain for more than twenty-four hours, but it can be renewed after douching if necessary.

Plugging the *uterine cavity* is seldom practicable owing to the narrowness of the cervical canal. Sometimes, however, a strip of gauze can be pushed up to the fundus, and in such cases it is useful to soak the gauze previously in a 1 in 1000 sterile solution of adrenalin. The local hæmostatic action of this substance is then added to the excitant effect of the plug upon the uterine muscle.

*Radiation.* Within recent years much attention has been paid to the possibility of arresting uterine hæmorrhage by means of X-rays. It has now become well established that by the prolonged application of X-rays, of the hard or penetrating variety, menstruation can be completely and permanently arrested. This effect is produced in part by the action of the rays upon the ovaries, the Græafian follicles being completely destroyed and the subject rendered sterile, in part also by a direct effect upon the uterus causing it to undergo atrophy. It is, therefore, unsuitable for women under forty years of age. These effects can be produced when fibroid tumours are present or when the uterus is enlarged from causes other than tumour-formation. The technique is complicated and the treatment should be applied under the direction of a skilled radiologist. The matter will be referred to again in connection with the treatment of fibroid tumours (*see p. 478*).

*Operative treatment.* Curetting is a favourite remedy for all varieties of uterine hæmorrhage, but applied without discrimination it often

fails. The indications for this operation are referred to in detail later on (p. 797). Excision of a portion of the body of the uterus (utriculoplasty) has recently been practised but with disappointing results. If cases due to excessive ovarian activity could be clinically recognized they might be treated with success by partial resection of one ovary or of both. But the fact that the ovaries are found on clinical examination to be enlarged is not to be accepted as evidence of over-action, for the enlargement may be due to disease or to degenerative changes. It is obvious that ovarian resection, if used at all, must be applied with great caution.

## DISCHARGES

A discharge from the vagina is common, and is not in all cases a sign of disease. In some cases it is an important sign, and it will, therefore, be useful to consider the various kinds which may be met with in relation to their origin and their significance.

The characters of the *natural secretions* must first be borne in mind. The Bartholinian glands secrete a clear, colourless, slightly acid fluid, which in some cases can be observed welling up from the openings of the ducts on examination of the vulva. The vaginal walls produce a secretion which, even in healthy conditions, is variable in character. In nulliparous and virgin women it usually consists of a white semi-solid material of the consistence of smegma, flaky in appearance and acid in reaction. In parous women it is usually more fluid in consistence, milky in appearance, and neutral or alkaline in reaction. The cervical secretion is fairly abundant, and of the appearance and tenacious consistence of white of egg; it is definitely alkaline in reaction. The natural secretion from the endometrium and the tubal mucosa is scanty and unimportant.

**Types.** Four types of discharge may be described.

(1) *An excess of the natural secretions.* This may take the form of a thick, milky discharge, or of strings or pellets of thick, sticky, cervical mucus. It is usually more abundant immediately after menstruation than at other times. To these discharges the name of *leucorrhœa* (literally *a white flux*) may with accuracy be applied; this name is often, however, somewhat loosely used to indicate discharges different in nature from these. Excess of secretion may be the result of slight catarrhal inflammation, but frequently no definite sign of disease is present and the condition is of no clinical importance. It is frequently met with in anæmia and other depressed conditions of the general health.

(2) *Purulent and muco-purulent discharges* usually result from true inflammatory changes in the vulva, vagina or uterus; occasionally some neighbouring organ is its source; thus collections of pus from a pelvic abscess may be evacuated into the uterus or vagina. In the

acute stages of gonorrhœal infection a discharge of yellowish-green, highly irritating pus occurs; in the later, or chronic, stages the discharge is paler and muco-purulent. Other forms of vaginitis and endometritis, and ulcerative changes in the vagina or cervix, also set up discharges containing pus.

It is sometimes difficult to decide whether a small amount of a purulent discharge comes from the vaginal walls or from within the uterus. The *tampon test* may then be employed. It consists in placing a clean cotton-wool plug in contact with the external os, and leaving it in position for some hours; if a yellow discharge has come through the cervix, the plug will be stained where it lay in contact with the os, and not in other parts.

(3) *Thin serous, coloured* discharges are comparatively rare. They occur in the early stages of malignant disease of the cervix or uterine body; in the later stages of these diseases, hæmorrhage and necrotic changes in the tumour-tissues alter the characters of the discharge. Serous discharges are but rarely met with in any other conditions except pregnancy. The condition known as *intermitting hydrosalpinx* is said to give rise to this sign, but considerable uncertainty exists upon this point, which is referred to again on p. 612. In tubal papilloma and tubal cancer, a yellowish thin fluid often passes into the uterus and escapes as a vaginal discharge, but these diseases are very rare.

It must be borne in mind that attacks of urinary incontinence are sometimes mistaken by patients for a discharge. Whenever the local conditions fail to explain such a discharge, great care should be exercised, and if possible a small amount of the discharge obtained, which can be tested for urea; the presence of this substance can be detected in very small quantities, and may clear up a diagnostic difficulty. Urinary fistulæ must not be forgotten in this connection, although their nature is usually self-evident.

(4) *Offensive Discharges.* Discharges may become offensive from dirty personal habits, from the presence of foreign bodies in the vagina, from necrotic or ulcerative changes in tumour-tissues or in the walls of the genital canal; the pus from a pelvic abscess is usually offensive from the time of its first appearance. The discharge from an advanced case of cancer of the cervix is often extremely foul; the penetrating odour may be almost sickening to others but is hardly noticed by the patient herself. It results from putrescent changes set up in the necrotic cancer-tissues by bacterial invasion. It is often profuse in quantity and causes considerable irritation of the skin of the vulva and perineum, which cannot be kept clean. Cancer in the body of the uterus (*see* p. 532) is not so liable to undergo putrefactive changes as that in the cervix, owing to the better protection afforded by the closed cervix to bacterial infection from without. The morbid conditions most commonly associated with an offensive discharge are :

(1) cancer of the cervix or more rarely the body of the uterus ; (2) sloughing fibroids ; (3) retained and neglected pessaries ; (4) rupture of a pelvic abscess ; (5) urinary and fæcal fistulæ ; (6) in the puerperium, infection of the uterine cavity.

**Diagnosis.** When a discharge is complained of, its nature should be determined by direct observation, if there is any doubt as to which of the four types it belongs to. Those of the first class do not form indications for local examination, and they require no treatment. Those of the other classes all necessitate an examination in order to discover their source and the nature of the lesion to which they are due.

Indiscriminate treatment of discharges without exact diagnosis is quite unscientific and should be deprecated. Discharges either require no treatment at all or they call for careful preliminary investigation. In some instances the source and nature of a discharge are evident from its physical characters, the best instances being the very viscid colourless discharge which is met with in cervical catarrh and pseudo-adenoma. All purulent, or offensive discharges, require careful discrimination, and a routine investigation should be made in all cases.

First the vulva should be examined by inspection, and the condition of the urethra and Bartholinian glands noted. Next the vaginal walls should be inspected through a speculum, and then the cervix. Discharges tend to accumulate in the vaginal fornices, and before the condition of the cervix can be seen they must be cleared away with swabs. If the discharge comes from the cervix or body of the uterus, it will be seen issuing from the cervical canal ; if the discharge arises from below the uterus the cervical canal will show the usual viscid secretion, which is nearly colourless, and nearly transparent. Sinuses or fistulæ opening into the vaginal wall will be found with the speculum in the same way. If the discharge comes from the uterine body it is of much thinner consistence than the cervical discharge ; exact diagnosis is, however, impracticable without preliminary dilatation of the cervix.

In the case of a purulent discharge, it is often necessary to discover the organism to which it is due. This may involve both microscopic examination and cultures of the organisms. The gonococcus may be detected by its staining reaction alone, as described on p. 289. Other organisms usually require culture methods for their detection.

## PAIN

Pain arising from diseases of the internal sexual organs is not characteristic either in its distribution or general features ; it may be closely imitated in hysteria and neurasthenia even when, as far as can be ascertained, the pelvic organs are normal. Consequently pain is not as a rule a symptom of any great diagnostic significance in gynæcology.

The parts in which pain is most commonly felt are the hypogastric zone of the abdomen, the spine from the lower lumbar region to the coccyx, and the front and inner aspects of the thighs. The iliac regions, and more commonly the left, are common positions to which pain is referred, and often it is called on account of its position 'ovarian pain.' Its connection with the ovary is, however, very doubtful in the majority of cases; it may often be elicited or intensified by light pressure, and its seat is more probably in the nerves of the abdominal parietes. Epigastric pain, infra-mammary pain (especially frequent on the left side), and headaches are often regarded as referred or reflex pains of genital origin; the evidences in favour of this view are, however, not always convincing. Regions in which pain is felt are also often unduly sensitive or actually painful to pressure. Pain in the lower half of the trunk commonly attends the menstrual process; when occurring in the menstrual intervals its significance is greater than when occurring during menstruation.

The severity of the pain in any given case depends in great part upon the ability of the nervous system to resist painful impressions. Some women are so intolerant of pain that they unconsciously exaggerate, describing as "agonizing" a degree of pain which another would support with but little effort. Great care must accordingly be exercised in dealing with this symptom.

Certain characteristics of pain deserve notice. Thus uterine displacements, especially prolapse, give rise to a dragging, 'bearing-down' pain which is relieved by rest in the recumbent position. Pain due to inflammatory lesions is also relieved by rest and aggravated by exertion; another characteristic is its liability to exacerbations which frequently coincide with the menstrual periods.

The growth of tumours, whether innocent or malignant, is usually not attended by pain until, in the former case, the bulk of the tumour causes discomfort, or until, in the latter, ulceration of the primary growth, or secondary invasions, have occurred. Pain associated with new growths is not relieved by rest, and is, indeed, almost always worse at night than in the day, and, therefore, commonly induces insomnia. Attacks of colicky pains are associated with miscarriage, with tubal pregnancy in the early stages, and sometimes with intra-uterine polypi. Acute pain of sudden onset attends pelvic peritonitis from infection, as in a case of suppurative salpingitis, and hæmorrhage from rupture or leaking of a gravid Fallopian tube (*see* p. 217). The causes of pain located on the right side of the abdomen are very complex, for the organ at fault may be the Fallopian tube or the ovary, the vermiform appendix or the cæcum, the kidney, or the gall-bladder. Pain of neuralgic or neurasthenic origin is felt more often on the left side of the abdomen than the right, a clinical fact which it is very difficult to explain satisfactorily.

A movable kidney often gives rise to pain of an aching or dragging

character, felt more often on the right side than the left ; it is usually relieved by the recumbent position, and is sometimes associated with intermittent attacks of intense nauseating pain which are attributed to kinking of the ureter causing transient hydronephrosis ; they are known as Dietl's crises. Pain referred to the lower part of the back is very common in women, and is often very difficult to explain. Pain over the sacrum is often due simply to fatigue, and is almost invariably met with in neurasthenia ; displacements—backward and downward—of the uterus, 'erosion' of the cervix, inflammatory pelvic lesions, a tumour occupying the pouch of Douglas, and carcinoma of the cervix in its advanced stages, all cause pain in the same region. Pain localised to the region of the *coccyx* and felt chiefly when sitting, or in the act of rising from the sitting position, is sometimes met with (*coccygodynia*). Pain excited by movement at the sacro-coccygeal joint, or tenderness of the coccygeal ligaments, may also be present. *Coccygodynia* occurs almost exclusively in women, and according to Hirst three-fourths of the cases are due to obstetric injuries ; a few may be due to traumatism, others are of rheumatic origin.

Women who complain of pelvic pain not associated with any gross pelvic lesion, also usually complain of great sensitiveness of the organs on examination. This is sometimes so great as to prohibit satisfactory palpation of the uterus or adnexa. The condition is commonly attributed to 'congestion,' but no direct evidence of any circulatory disturbance has ever been advanced, and the cause of the tenderness is in point of fact unknown. It is especially marked in women of neurotic temperament.

Pain attending the menstrual process will be separately considered in the section dealing with *dysmenorrhœa* (p. 181).

### DISTURBANCES OF MICTURITION

The act of micturition may become abnormally frequent, or painful ; sudden or gradual retention may occur ; or urine may be passed involuntarily (incontinence), either continuously or occasionally, *e.g.* during coughing or sneezing. These symptoms, although usually due to disease in some part of the urinary tract or in the kidneys, are also frequently the result of injury or disease in some part of the genital canal.

**Pain and Frequency.** The number of times *per diem* the bladder is evacuated is to a great extent a matter of habit ; women of nervous temperament frequently present slight degrees of frequency in the day, but only rarely during the night ; indeed, persons who suffer from distressing frequency during the day, often sleep all night without interruption. Nocturnal frequency is therefore always of more serious import than daytime frequency. When associated with pain during, or during and after, the act, the significance of frequency is increased.



Mental influences are notoriously powerful agents in disturbing the functions of the bladder, and leading especially to irritability of that organ. Polyuria is one of the commonest signs of nervousness.

The first step in the investigation of such cases is an examination of the urine, which must always include the microscopic examination of the centrifugalized deposit. Uric acid, or urates, may be found, indicating a *gouty* condition, or albumen and casts may be found, indicating chronic *renal* changes, or sugar suggesting *diabetes*, or oxalates pointing to disturbance of *digestion*. The presence of pus may be due to urethritis, cystitis or pyelitis, or if the urine was passed naturally, to contamination by discharges from the vagina. Bacteriological examination and culture may be further necessitated in such cases.

Chronic bacterial infection may be present without any clinical evidence of cystitis or pyelitis being found ; consequently, if no other cause can be discovered, a specimen of urine should be taken with due antiseptic precautions against contamination, a sterile catheter being used, and a sterile tube into which the urine may be run. Bacteriological examination may then show that *bacillus coli* infection is present, and this condition, when chronic, may give rise to an aggravated form of frequent and painful micturition. It must be recollected that it is extremely rare to find the urine absolutely free from bacteria even when withdrawn by catheter. Bacteria are always present in the urethral mucosa, and may be carried into the bladder in the act of introducing the catheter. The numbers of such organisms are, however, small. It is only the detection of a definitely pathogenic organism in pure culture, or practically pure culture, that can be regarded as evidence of urinary infection. In nearly all cases pus and desquamated epithelium in abnormally large quantities are also found. The urine is acid in most forms of infection except that due to chronic cystitis. After a urinary infection has been clinically "cured" small numbers of the organism frequently persist in the urine.

It must be recollected that a movable kidney or a renal calculus, or certain diseases of the central nervous system, may also produce these symptoms in an aggravated form.

If nothing is found in the urine pointing to the presence of disease in the kidneys or any other part of the urinary tract, a local pelvic examination should be made, including a careful inspection of the vulva and urinary meatus and, if necessary, a cystoscopic examination of the bladder. The *local conditions* which may be present include the following : chronic cystitis or urethritis (usually gonorrhœal), a calculus in kidney, ureter, or bladder ; urethral caruncle, or prolapse of the urethral mucous membrane ; cystocele, or prolapse of the uterus ; pregnancy ; a pelvic or abdominal tumour ; and a pelvic inflammatory lesion. These conditions will all be described in later sections.

*Acute pain* on micturition is usually due either to acute cystitis or urethritis, to the passage of calculi, or to the presence of a vesical neoplasm.

The *treatment* of pain and frequency must obviously depend upon the causal conditions which may be present ; it is undesirable to endeavour to relieve these symptoms by sedative drugs until a thorough examination has been made in the endeavour to discover the cause.

**Retention.** Retention of urine may be due to hysteria, to the presence of some obstruction—usually outside the urinary tract altogether, or to reflex spasm of the sphincter or paralysis of the bladder.

*Hysteria* is a rare cause of retention of urine ; mental disturbances usually pervert the bladder-functions in the opposite direction. *Obstruction* causing retention of urine is seldom urethral, for stricture is very rare in the female. More often it is due to a pelvic tumour, the commonest conditions causing it being a retroverted gravid uterus, an impacted fibroid tumour, a pelvic hæmatocele, or a hæmatocolpos. These conditions will be considered in another place. *Reflex spasm* of the sphincter may be met with after the desire to evacuate the bladder has been too long resisted, after abdominal or vaginal operations, after child-birth, or from a very sensitive urethral caruncle which gives rise to severe pain during micturition. Post-operative retention sometimes persists until the patient leaves her bed, nervousness being probably largely responsible for its persistence. As soon as the patient can be allowed to get up, the bladder usually functions normally. The prolonged use of the catheter, which is necessary under such circumstances, is attended by definite risks of cystitis, even when the attendant nurse, to whom the duty usually falls, is careful and conscientious. It is quite possible that bacteria may be carried into the bladder from the urethra which are capable of setting up a mild form of cystitis. Prophylactic treatment should be instituted early in such cases, urotropin being given by the mouth, and the bladder irrigated daily with weak boric acid solution.

Cases of retention, for which no definite cause can be assigned and which are regarded as *hysterical*, should be relieved if possible by such measures as hot hip-baths, vaginal douches, and hot fomentations to the vulva ; the catheter being only used as the last resort.

**Incontinence of Urine.** This may be absolute in cases of paraplegia or of vesical fistula ; more often it is partial only, as in cases of unilateral ureteral fistula, or of weakening of, the sphincter of the bladder. Incontinence due to fistulæ will be referred to in connection with the latter subject ; that which depends upon abnormal conditions affecting the neck of the bladder may be due to a variety of different causes. In children, a form of incontinence occurring only during sleep, known as *nocturnal enuresis*, is met with, which will be separately considered. Occasional incontinence is commonly found in connection with epileptic fits.

*In adult women* the commonest cause of partial incontinence is child-bearing, and often, but not always, a more or less marked degree of prolapse is present. The nature of these parturient injuries will be understood when the subject of prolapse has been considered (p. 592). This form of incontinence is present only when the patient is up, and is immediately induced by some slight rise of intra-abdominal pressure, as from coughing, sneezing, straining, running, or walking. When she is resting the bladder is usually continent, and although there may be nocturnal frequency there is no nocturnal incontinence. This symptom is naturally aggravated by the supervention of pregnancy, or the presence of an abdominal tumour, etc. In marked cases it is very distressing, and is exaggerated by the morbid dread of its occurrence.

When definite signs of prolapse are present, treatment of this condition may be expected to cure the incontinence. When there is no local lesion to be discovered, treatment is much more difficult. Drugs are of little benefit, but the operation of urethroplasty, described on p. 835, is usually successful in giving at least a considerable degree of relief. The use of a portable rubber urinal is the last resort in cases of incurable incontinence.

*Nocturnal enuresis* in little girls may be due to some local irritation, such as uncleanness, thread-worms, skin-eruptions or vulvitis; hyperacidity of the urine and bladder-calculus may be found. The first consideration in such cases is to make a careful search for these conditions. Often, however, no local cause can be discovered, and the fault is to be referred to the innervation of the bladder. Often it can be cured by carefully educating the child, if this is begun before the condition has been long in existence. It must be recollected that the bladder-centre always requires education in children, which is not equally successful in every case, the age at which a child acquires control of the bladder being very variable. In some cases the removal of adenoids has cured it. Punishment of the child must always be avoided for there is no doubt that the evacuation of the bladder is quite involuntary. Nothing to drink should be allowed at night and the child should sleep lightly covered, and arrangements must be made for waking her at regular intervals so that she may be got out of bed for the purpose of emptying the bladder. The administration of belladonna is of great service in many cases, and the drug must be pushed to its physiological limits. Young children bear belladonna remarkably well, and a child of three or four years may be given 10 minims three times a day, and the dose gradually raised as far as 40 minims three times a day, without any of the ocular symptoms appearing which are so marked in adults. The use of the drug must be prolonged for a considerable time *after the incontinence has been relieved*. No operative treatment is possible.

### DYSPAREUNIA (PAINFUL OR DIFFICULT COITUS)

A variety of different conditions may render coitus painful and difficult to the female, and cases in which this symptom is present require careful investigation. The pain is seldom acute; usually it is described as of a dull aching character, and it may last for some hours after coitus has taken place. Dyspareunia is frequently associated with dislike or repugnance to sexual congress, to such an extent that in some cases nausea or even vomiting may be produced. Cases in which the dyspareunia commences at the beginning of married life have a different explanation from those in which this symptom supervenes after a period of normal married life. In the former case it is on account of the dyspareunia alone that the patient seeks advice; in the latter case other symptoms are commonly associated with it. Certain congenital abnormalities, such as an imperforate or abnormally resistant hymen, an imperforate vagina, or stenosis of the lower part of the canal, may render coitus impossible. A mechanical obstacle of a different kind is often met with in muscular spasm affecting the sphincter vaginae and probably the other superficial perineal muscles also. This condition is known as *vaginismus* and is usually set up originally as a protection against the pain caused by a local lesion. Often, however, it is well marked where no local cause can be detected. In women of neurotic temperament dyspareunia may occur without any local morbid condition being discovered to which it can be attributed. It is then probably psychical in origin, and is scarcely amenable to medical or surgical treatment.

In many cases, however, a *local cause* can be found for this troublesome symptom. The local causes of dyspareunia may be stated as follows:

#### *External Causes:*

- Acute and chronic vulvitis or vaginitis.
- Inflammation of the Bartholinian glands.
- Fissures and ulcers of the labia and ostium vaginae.
- Spasm of the ostium vaginae—*vaginismus*.
- Tenderness of the carunculæ myrtiformes.

#### *Internal Causes:*

- Inflammatory changes, acute or subacute, in the uterine appendages, peritoneum or cellular tissue.
- Backward displacement of the uterus, when complicated by adhesions, etc.
- Prolapse of the ovary.

When no local cause can be found the possibility of a serious disproportion in size between the male organ and the ostium vaginae should be recollected. In all cases of dyspareunia an interview should

be sought with the husband from whom more detailed information can usually be obtained than from the wife.

Cases of dyspareunia require a careful local examination, including inspection of the vulva ; if no external cause is discovered a careful bimanual examination should be made to exclude inflammatory conditions and prolapse of the ovaries. Vaginismus, although developed when attempts at coitus are made, may be absent when a gentle digital examination is made. If, however, backward pressure is exerted with the finger upon the lower part of the posterior vaginal wall the spasm can often be clearly observed.

The *treatment* of dyspareunia consists in the first place in the removal or relief of any local cause which may be present. An unruptured or imperforate hymen can be clipped away under anæsthesia, and the ostium vaginæ dilated. Fissures or tender *carunculae myrtiformes* can be excised. The treatment of vaginismus is dealt with in a later section (*see* p. 371). Internal causes require the treatment appropriate to the condition. When no local cause can be discovered a period of abstinence should be advised, and when marital intercourse is renewed the use of a 5 per cent. cocaine ointment a quarter of an hour beforehand may enable the difficulty to be overcome.

## STERILITY

Reproduction depends as much upon the normal sexual activity of the male as of the female ; sterility is therefore not due in all cases to the woman, although conditions which tend to produce it are much more common in the female than the male. Instances have occurred in which the marriage of perfectly healthy individuals has been unfruitful, yet in such cases the re-marriage of either has resulted in reproduction. Members of families with an average, or more than an average degree of fertility, are themselves more likely to have children than those characterized by a lesser or a declining degree of fertility. Certain families, like certain races, tend to die out, this process being due to a progressive failure of reproductive activity in some cases, to hereditary disease in others.

Sterility is usually described as of two kinds, *absolute* and *relative* : the former indicates persistent failure to conceive ; the latter, failure to carry pregnancy to a successful termination. Relative sterility is therefore an obstetric question and will not be further referred to here. The rule formulated by Matthews Duncan that the marriage of young persons between the ages of twenty and thirty cannot be regarded as sterile until four years have elapsed, should be observed in all cases. Instances have occurred in which a child has been born after from ten to fifteen years of sterile married life.

Absolute sterility is the consequence of a failure affecting the earliest stages of the reproductive process ; either fertilization does not

occur, or the fertilized ovum fails to make good its implantation and perishes at once. Non-fertilization probably implies that spermatozoa and oöcytes are not brought into contact with one another. This may be due (1) to inactivity of the sperm-cells preventing them from accomplishing their transit to the Fallopian tubes, where fertilization normally occurs; (2) to absence of spermatozoa from the semen (azoöspemia), or to destruction of the sperm-cells by abnormal discharges in the genital canal; (3) to mechanical obstacles in the canal which impede their progress, such as stenosis of the cervix, which prevents the entrance of the spermatozoa into the genital canal, or occlusion of the Fallopian tubes; (4) failure of the normal process of ovulation, *e.g.* the egg-cell may not be properly liberated from the ovary owing to surrounding adhesions or to abnormal thickness of the tunica albuginea. Failure of the fertilized ovum to become successfully embedded may be due to an unhealthy or abnormal endometrium, *e.g.* septic uterine infections, and exfoliative dysmenorrhœa. Absence or serious mal-development of any part of the genital canal is of course an absolute cause of sterility.

Some of these conditions constitute local causes capable of clinical detection. But sterility is not uncommon in persons in whom no local cause whatever can be discovered. It is, therefore, necessary to recognize also the *general conditions* which favour or impede the occurrence of conception. Of these age is one of the most important, and the age of the wife is of more weight than that of the husband. Women who marry between the ages of 20 and 30 show the highest degree of fertility; in those who marry after 40 Matthews Duncan found 85 per cent. were sterile.

Men of delicate health and sedentary occupation are less likely to procreate than robust men who lead an outdoor life; the influence of the general health in women is less important than in men. It is generally accepted that women who suffer from dysmenorrhœa are less fertile than those who menstruate without excessive pain, a view which rests upon the careful statistical observations of Matthews Duncan, Vedeler and others. Menstrual irregularities, and even marked degrees of amenorrhœa are not incompatible with an average fertility.

After passing these questions in review a *local cause* of the sterility may be sought for.

The local conditions previously mentioned as causes of dyspareunia tend to prevent conception by interfering with the natural course of sexual congress. Certain congenital abnormalities absolutely prevent conception, such as imperforate vagina (*see* p. 165), infantile uterus, hypospadias and hermaphroditism (p. 167); others are believed to hinder but do not absolutely prevent conception, such as conical cervix and hypertrophic elongation of the cervix (p. 599). Small size of the os externum (so-called pin-hole os) may perhaps also unfavourably

affect the prospects of conception. Uncomplicated displacements of the uterus do not form a serious hindrance to child-bearing, and numerous instances occur in which a retroverted uterus becomes gravid ; at the same time, the correction of a backward displacement in a childless woman has been frequently observed to be followed by conception. Chronic endometritis, and fibroid tumours of the uterus, stand in the same category as displacements, although their influence is much more unfavourable. The infective forms of endometritis, whether corporeal or cervical, form an almost absolute hindrance to conception. Occlusion of both Fallopian tubes renders conception impossible ; peritonitic adhesions involving the tube and ovary usually cause permanent sterility, but local recovery is not in these cases impossible. Bilateral ovarian tumours, when solid or malignant, may destroy all the ovarian cortical substance and render conception impossible by arresting ovulation.

When no local abnormality can be detected in the wife, it is quite possible that the fault is with the husband. In all such cases it is desirable to see the husband and determine the absence of sexual weakness or incompetence ; an examination of the semen should also be made, for sexual activity may co-exist with deficient vitality or absence of spermatozoa. Chronic orchitis of gonorrhœal origin is not infrequently a cause of sterility in the male.

**Treatment.** It must be understood that in all cases the condition of the husband requires attention as much as that of the wife. Apart from sexual competency and the absence of local disease, as a rule men of robust physique are better procreators than physically delicate men ; there are, however, many individual exceptions. Improvement of the physical condition of the husband often puts an end to a long period of sterility. Only when no fault can be found in the male partner is it right to submit the wife to operative procedures for the cure of sterility. In the female all local conditions which are, or which may possibly be causes of sterility, deserve careful treatment. Conditions which give rise to dyspareunia and so interfere with complete congress must be dealt with. Purulent or muco-purulent discharges, backward displacements, abnormal conditions of the cervix, such as ' pin-hole ' os, ' conical ' cervix and hypertrophic elongation should be dealt with by the operative methods which will be found described in another place. Inflammatory conditions affecting the tubes and ovaries are frequent causes, and are very difficult to deal with. Prolonged treatment by the palliative methods (*vide* p. 265) should always be carried out before resort to operation is advised. Inflammatory occlusion of the abdominal ostium of the Fallopian tube is, of course, an absolute bar to conception when bilateral ; an artificial ostium may be made (salpingostomy) when the inflammatory process has come to an end, and the amount of damage to the tube is not extensive. But the results of this operation are not uniformly favourable, on account of the

tendency of the artificial opening to become again occluded by adhesions. When no local cause can be discovered in either partner, the treatment of sterility becomes a much more difficult problem.

Certain general regulations are important in the treatment of sterility. Frequent sexual congress should be discouraged. It should further be pointed out that the ten days immediately following a menstrual period is the most favourable time for the occurrence of conception. In support of this statement sound anatomical reasons can be advanced. It is estimated that a period of eight to ten days (von Franqué) must elapse between the act of insemination and the arrival of the *fertilized ovum* in the uterus. If the act of insemination occurs a week after the cessation of menstruation, and conception follows, the fertilized ovum is due to arrive upon the endometrium when this membrane has entered the premenstrual phase. It is in this phase that the endometrium most closely resembles the decidua of pregnancy and has been called the *menstrual decidua* (see p. 89); it is reasonable to suppose that it is then best prepared for the embedding of the ovum. Very little change is required to convert the menstrual decidua into the true decidua of pregnancy.

A period of several weeks' separation of husband and wife is indicated if there has been excess, or if any sign of failure of sexual activity in the husband is detected. Abstinence from alcohol and tobacco should be prescribed, whenever there has been excessive indulgence in either. Apart from these general measures two other procedures deserve consideration, viz. dilatation of the cervix and artificial insemination of the uterus.

*Dilatation of the cervix* is useful not only in widening the canal but possibly also in stimulating the function of uterine polarity. Its effect is temporary and it should accordingly be performed at the most favourable moment; further it should be so carried out as to avoid injury to the uterine tissues, such as laceration by the use of unnecessarily large dilators. Dilatation should be performed at the close of a normal menstrual period; it is then practically certain that the patient is not at the moment pregnant, and it is agreed that the part of the menstrual cycle most favourable for the occurrence of conception is the week which immediately succeeds the period. The operation should be carried out with the most careful antiseptic precautions, and the dilatation should not be carried further than number 10 (see p. 793). An anæsthetic is necessary, but the patient can return to her husband after forty-eight hours.

*Artificial insemination* consists in the introduction of the semen into the uterus with a syringe. An old device of veterinary surgeons, it was first applied to women by Marion Sims (1860), but the results were unsatisfactory and the method fell into disrepute. Recently, with improved technique, occasional successes have been reported. Stringent precautions are required to preserved the vitality of the



spermatozoa. The best plan probably is to take the semen up into the syringe immediately after its deposition in the vagina and to introduce it at once into the uterus. A syringe with a special nozzle designed to pass through the internal os is required. There are few women who are willing to submit to this procedure, the indelicacy of which revolts their feelings, and the results are so uncertain that it cannot be urged with any degree of confidence.

## PART I: SECTION IV

# DISORDERS OF DEVELOPMENT AND FUNCTION

- (1) MALFORMATIONS.
- (2) DISORDERS OF MENSTRUATION.
- (3) ECTOPIC PREGNANCY.

### MALFORMATIONS

**Etiology.** The greater number of the malformations of the female generative organs are of congenital, *i.e.* pre-natal origin. Some are to be referred to the earlier months of gestation, such as pseudohermaphroditism and duplication of the uterus and vagina : others probably occur much later, for example the various kinds of occlusion of the vulva. Other malformations again are of post-natal origin, and are due to failure of the normal developmental changes which occur during childhood or at puberty ; examples of these are seen in the *uterus infantilis* and *uterus pubescens* in which the transition from foetal to adult characteristics is only imperfectly accomplished. Defects of development are not infrequently multiple and may affect different systems as well as different parts of the same system.

The etiological factors concerned in the production of malformations are quite unknown. Recent experimental work has shown that nutritional disturbances and slight traumatic influences can profoundly disturb the course of development of the ovum *in vitro*. Direct evidence of the operation of such conditions in the course of natural development is, of course, most difficult, if not impossible, to obtain. Clinical observation shows that heredity, and possibly parental syphilis, are the only conditions to which an unfavourable influence upon development can reasonably be attributed. The well-known influence of the latter condition in causing pre-natal death is the chief reason for regarding it as a possible cause of deflection of development from its normal course.

**MALFORMATIONS OF THE OVARIES**

These are uncommon and of minor clinical importance.

**Supernumerary and Accessory Ovaries.** A *supernumerary* ovary is one which is independent of, and of equal size with, the normal ovaries. The only satisfactorily demonstrated case is that of von Winckel in which the supernumerary ovary lay in front of the broad ligament and was attached to the uterine cornu by a definite ligamentous band. An *accessory* ovary is a piece of ovarian tissue of small size, present in addition to two normal ovaries; usually it is attached by a band to some portion of the normal ovary, and its formation is then attributed to the effects of constriction by peritonitic bands in early embryonic life. Sometimes it is found in an aberrant situation, but this is always upon the line of the normal descent of the ovary from the lumbar region to the pelvis (p. 86). Care is required in the diagnosis of an accessory ovary; unless the tissue under examination contains the characteristic histological elements, *i.e.* Gräafian follicles or lutein-cells, it cannot be regarded as ovarian. Many recorded cases have failed to comply with this test and it is probable that the condition is rarer than would appear from the literature. It is, however, possible that in some of the recorded cases of persistence of menstruation after double oöphorectomy, accessory ovarian tissue may have been present. Sometimes again accessory ovaries may become the seat of new growths, such as fibromata, or cysts, developing in unexpected situations. Except in these relations, however, supernumerary and accessory ovaries have no clinical importance.

**Absence and Rudimentary Development.** Complete absence of both ovaries only occurs in connection with such gross foetal monstrosities as the acardiac and sympodial foetuses, which are incapable of independent existence. Absence of the gonads in individuals of either sex is excessively rare, if indeed it ever occurs; confusion of sex may occur (hermaphroditism), but in such individuals sexual glands are always present though they may be of aberrant type. Complete absence of the ovaries can only be certainly recognized by post-mortem examination; operative records of the condition cannot be trusted, for it is easy for an ovary in an aberrant position to escape detection by an operator. By a 'rudimentary' ovary is meant an ovary which contains no Gräafian follicles, and properly recorded cases of this condition are almost as rare as those of absence of the glands. Owing to this uncertainty we are unable to say what would be the clinical effects of congenital absence of the ovaries upon an adult individual.

**Abnormal Situation: Ectopia Ovarii.** A number of cases have been recorded in which an ovary has been arrested in the abdomen at some point along the line of its normal descent. Further, in a few instances it has also been found in the sac of a congenital hernia. It will be recollected that hernia of the ovary is not uncommon in the acquired

variety also. An abdominal ovary gives rise to no clinical results; congenital ovarian hernia only becomes troublesome after puberty, when it gives rise to pain and tenderness which are aggravated with the menstrual periods.

### MALFORMATIONS OF THE FALLOPIAN TUBES

**Supernumerary Tubes and Accessory Abdominal Ostia.** A true *supernumerary* tube is an extremely rare occurrence, and it is doubtful if a satisfactory case is on record. Accessory ostia on the other hand are comparatively common, and occur, according to post-mortem

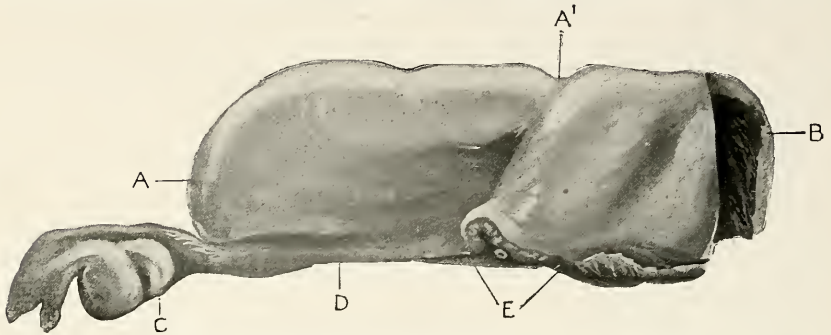


FIG. 83. ABSENCE OF THE INNER TWO-THIRDS OF THE FALLOPIAN TUBE. A, A', Ovary. B, Uterine horn. C, Ampullary portion of tube. D, Marks the site where tube terminated. E, Round ligament spread out. The above formed the contents of a right inguinal hernial sac.

records in from 4 to 10 per cent. of cases. The number of such accessory ostia varies up to six, although more than one is uncommon. They are usually situated on the dorsal surface (*see* Fig. 52, p. 78); the fringe of fimbriæ is always present, although variable in characters; in many instances there is no communication with the tube-lumen. An accessory ostium may become occluded, and cystic dilatation may then occur giving rise to one variety of tubal cyst (*see* p. 608). Apart from pathological changes, accessory ostia have no clinical significance.

**Defects of the Fallopian Tube.** Complete absence of both tubes is very rare, but two cases have been recorded by W. G. Spencer in which the tubes were represented only by a pea-like body upon each uterine cornu; the ovaries and the uterus were normal. Both these patients suffered from severe dysmenorrhœa, which was relieved by an operation which established a communication between the uterine cavity and the peritoneum.

*Rudimentary tubes* are not nearly so uncommon as the latter condition, and a number of cases are on record. In some the inner (uterine) portion has been deficient, and in a case recorded by one of us (C.L.) the abdominal ostium and infundibulum were the only portions represented (*see* Fig. 83). In others the inner half alone was present,

the tube ending abruptly about 2 inches from the uterine cornu. In *uterus bicornis unicollis*, the tube corresponding to the undeveloped horn is also often in a rudimentary condition (*vide infra*).

**Diverticula of the Tube.** In the latter half of foetal life the tube is normally tortuous, but it straightens out as the pelvis increases in size during childhood. As a foetal maldevelopment, a spiral tube is sometimes found associated with gross malformations of the genitalia, and in cases of infantilism. A persistence of the foetal tortuosity must not be confused with the convoluted state of the tube which is

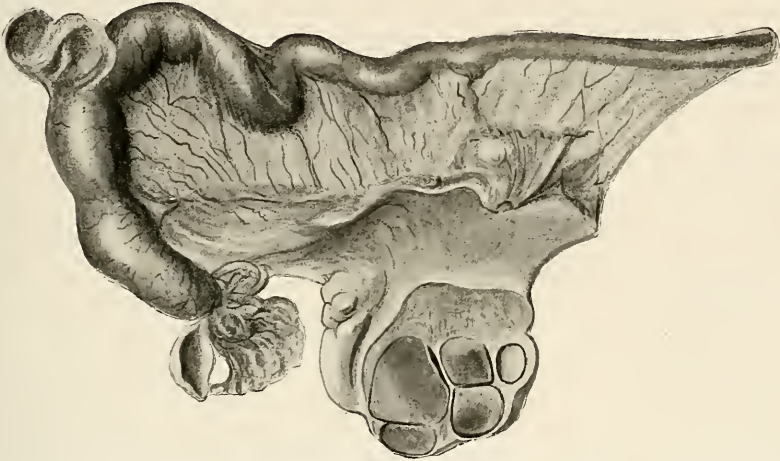


FIG. 84. HYPOPLASIA OF TUBE. The tortuosity is normal in the foetus, abnormal in adults. The walls are abnormally thin. There is a small cyst of the hydatid of Morgagni close to the fimbriae, also a small peritoneal cyst attached to the ampulla.

secondary to salpingitis, to which we shall have occasion later to refer.

Congenital diverticula include the entire wall of the tube and are not merely diverticula of the lumen into the tube-wall. When the mucous membrane is found to trespass into the muscularis of the tube it is a manifestation of chronic salpingitis and not a congenital abnormality.

Slighter developmental defects occasionally met with are persistence of the spiral convolutions which are normal in the foetus (*hypoplasia tubæ*, see Fig. 84), non-ciliation of the tubal epithelium, and very occasionally non-canalization of the tube, which remains as a solid cord.

*Displacements* of the tube sometimes occur; the greater number of examples are cases of hernia; one instance in which the tube with its companion ovary was situated in the right lumbar region has, however, been recorded. In this case the right half of the uterus was undeveloped, the organ being unicornute.

## MALFORMATIONS OF THE UTERUS AND VAGINA

The uterus is developed from the middle portions of the two Müllerian ducts which fuse to form a single tube; the vagina is similarly developed from the hinder portions of the same ducts. The greater number of malformations occur from arrest of the normal process of fusion at some stage or other, so that an intermediate arrangement becomes permanent. Such arrest may affect the whole of the uterine and vaginal sections of Müller's ducts, or may be limited to a portion of them. Further, unequal development of the two sides may occur, one being arrested, the other pursuing its normal course as far as may be without the full participation of its fellow. One of the commonest examples is the failure of one important factor only in development, viz. the fusion of the two ducts, the result being *duplication* of the whole or of certain parts of the uterus and vagina.

**Accessory Uterus.** This rare defect consists in the presence of a second uterus (corpus only) which is not furnished with adnexa or vagina; in this it is distinguished from the various forms of double uterus described below.

**Absence and Rudimentary Condition of the Uterus.** Complete absence of the uterus, if it ever occurs, is extremely rare, most of the cases recorded as such have probably been instances of pseudo-hermaphroditism (*vide infra*). The most marked defect of development is that known as the *uterus rudimentarius*, in which the organ is represented by a solid or very imperfectly canalized body composed of muscular and fibrous tissue. Sometimes the uterus permanently retains the characters which are normal at birth, *i.e.* development does not progress during infancy—*uterus fetalis* or *infantilis*. In this form the cervix is longer and thicker than the corpus and somewhat conical in shape; the total length of the organ is 1 to 1½ inches: the mucous membrane of both body and cervix is folded transversely. The Fallopian tubes and the vagina are also usually defective in development. Sometimes development is arrested before the changes normal at puberty have occurred; this gives rise to the *uterus pubescens*. Here body and cervix are of about equal length, and the whole organ is undersized; the tubes and the vagina usually participate in the defect.

Defects of development of the uterus give rise to loss, more or less complete, of the function of menstruation, and in all cases to complete loss of the function of reproduction. With the *uterus pubescens* a scanty and irregular menstrual function may be developed. The two more serious varieties of defect are attended with absolute amenorrhœa. In other respects the subjects of these defects may be normal and they often marry. Diagnosis can be made by careful examination under anæsthesia when the small size of the uterus can be shown by palpation and the use of the sound. It must be recollected that the

cervix in these cases may appear to be full-sized ; it is to the condition of the uterine body that attention must be chiefly directed.

**Duplication of the Uterus.** Six types of double uterus are known, which are diagrammatically represented in Figs. 85 to 90. Each Müllerian duct may develop independently, and remain distinct from its fellow, fusion being completely absent ; two uteri, independent of one another except at the cervico-vaginal insertion, result from this abnormality, the condition being called *uterus didelphys* (see Fig. 85).

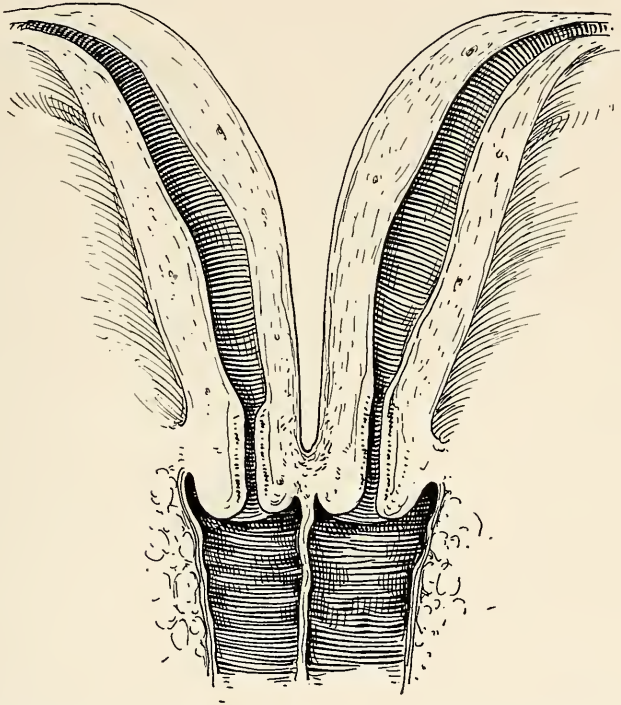


FIG. 85. UTERUS DIDELPHYS. Two uteri are formed, separated from one another by a deep sulcus which passes down to the cervico-vaginal insertion. Two distinct vaginal canals are present, in each of which lies a complete cervix.

The vagina in such cases also consists of two distinct canals separated by a median septum, a normal cervix and external os being found in each. The vulva is single and, as a rule, there is only one hymen. Through the deep cleft which persists between the two uteri, a fold of peritoneum often passes, the *vesico-rectal ligament*. Blair Bell has recorded a case of uterus didelphys in which each uterus had entered the sac of a bilateral inguinal hernia. Atresia is not uncommonly found in some part of the cervix or vagina of one or other side. Each half is roughly cylindrical, the characteristic pear-shape of the properly developed organ being the result of fusion of the two ducts.

In other cases the upper parts of the uterine portions of the Müllerian

ducts remain distinct, while the lower parts undergo imperfect fusion, so that the apposed walls unite while the lumina remain distinct. The cervix is single but divided by a median septum, and the vagina is usually duplicated also. This form is called the *uterus bicornis bicollis* (see Fig. 86) and differs in general outline from the *uterus didelphys* mainly in the lesser depth of the cleft between the two halves. Sometimes the process of fusion in the lower parts of the Müllerian ducts is carried a step further, an undivided cervix and vagina being formed,

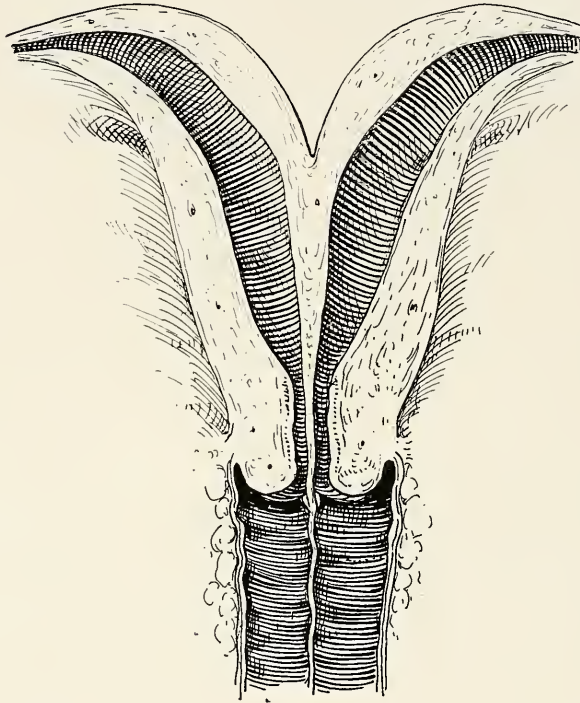


FIG. 86. UTERUS BICORNIS BICOLLIS. Fusion has occurred in the cervix and lower part of the uterine body, but it is incomplete, for the lumina are distinct. The vagina is divided by a median septum which is prolonged up into the cervix.

while from the level of the internal os upwards the uterine body is duplicated. On vaginal examination in such a case the cervix and vagina appear normal; the cleft between the uterine bodies is seldom so pronounced as to attract attention on bimanual examination; the presence of two divergent cavities may, however, sometimes be detected by the use of the sound. This form is the *uterus bicornis unicollis* (see Fig. 87).

In two other forms fusion has been carried to a point at which a single organ, having the characteristic pear-shape of the uterus, is formed, but the lumina remain wholly or partially separated from one



another by a median septum; these are the *uterus septus* and the *uterus subseptus* (see Figs. 88 and 89). In the former the septum extends from the fundus to the os externum, and may also be continued into the vagina; in the latter the septum ends at, or about, the level of the os internum, the cervix and the vagina being single. There is nothing in the shape of the uterine body in these cases to draw attention to the abnormality.

Lastly, one Müllerian duct may be entirely undeveloped, when a

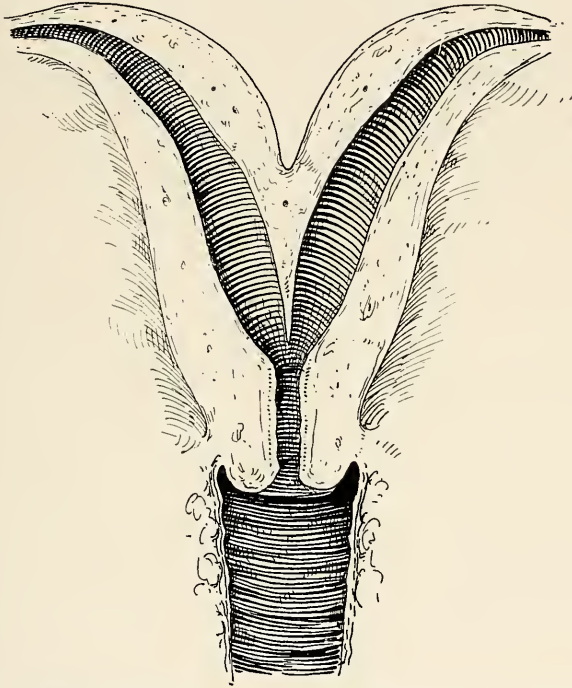


FIG. 87. UTERUS BICORNIS UNICOLLIS. The cavity of the uterine body is double; that of the cervix and vagina is single. Complete fusion has occurred in the lower half of the uterus.

tubular uterus having a strong lateral inclination is formed, *uterus unicornis*. More often, in such cases, however, a rudimentary condition of the opposite duct is found in the shape of a fibrous cord or band, usually only imperfectly canalized, which is attached to the side of the unicorn uterus (see Fig. 90). Sometimes in such cases the Fallopian tube itself on the side of the imperfection may be well developed; but the undeveloped horn rarely communicates with the uterine cavity. Such an imperfectly developed horn may become the seat of an ectopic pregnancy, the spermatozoa reaching it by migration from the opposite tube across the pouch of Douglas (external wandering). The mucous membrane of an undeveloped horn penetrates deeply into the muscular stroma (see Fig. 91).

These six recognized types of double uterus are clearly produced by arrest at some stage or other of the normal process of fusion of the apposed portions of the Müllerian ducts. Another type of duplication exists of which there is only one recorded instance (Gemmell and Pater-son); it is the most complete of all and arises at an earlier stage of development than any of the before-mentioned. In this the sole recorded instance the following developmental abnormalities were present : (a) partial bifurcation of the lower part of the vertebral column ;

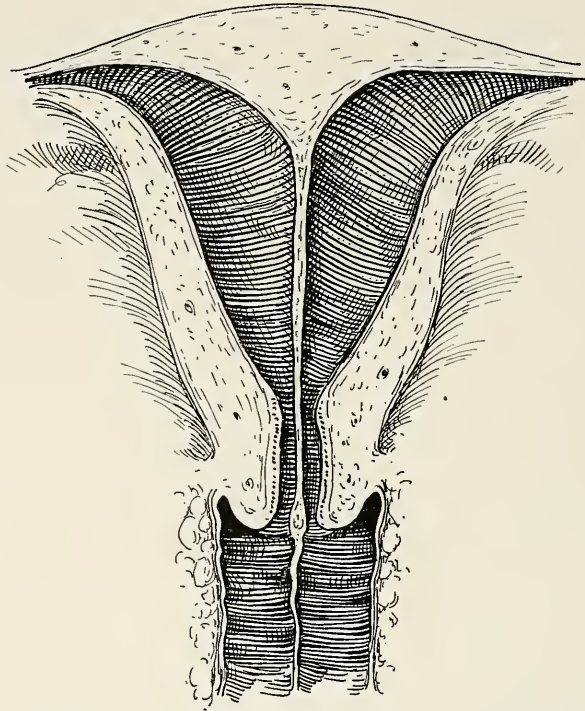


FIG. 88. UTERUS SEPTUS. Incomplete fusion has occurred throughout and the outward configuration of the uterus is normal. The cavity is divided by a median septum which extends into the vagina.

(b) a very large and wide bony pelvis ; (c) two uteri widely separated from one another by lateral inclination ; (d) two vaginae and two vulvæ ; (e) two urethræ and two bladders. This woman had given birth to a child from each of her distinct genital canals. These deformities were probably produced by partial dichotomy of the tail end of the early embryo (see Fig. 92, p. 164).

**Duplication of the Vagina.** The two vaginal canals when present almost always lie side by side, not in an antero-posterior relation ; a few exceptions have been recorded. The septum is composed of muscular tissue covered on each aspect with stratified epithelium. It is often incomplete, and the deficiency may be in the upper or lower

half, or in the middle. Occasionally complete or partial duplication of the vagina occurs with a single uterus, but in most cases the uterus is double also. The *uterus unicornis* usually goes with a single vagina which has a marked lateral inclination, and is abnormally small.

**Clinical Features of Duplication of the Uterus.** Double uteri, though of great developmental interest, are of small clinical importance. They are functionally entire organs, and menstruation and conception may proceed normally so as to arouse no suspicion

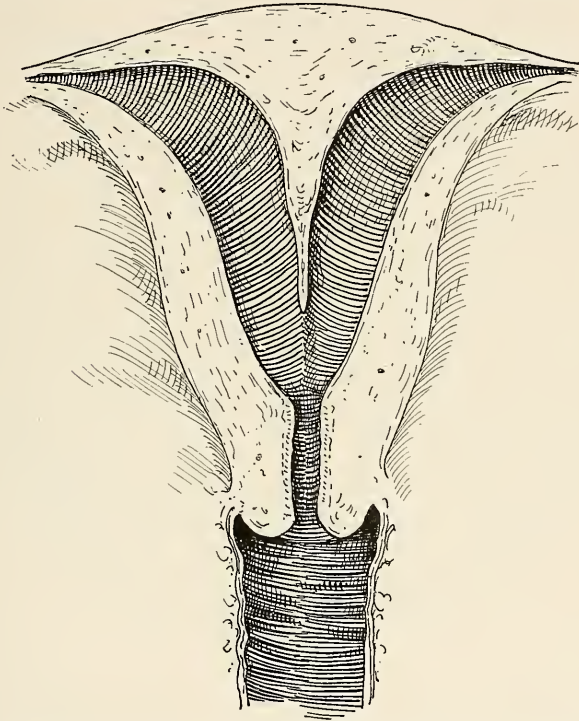


FIG. 89. UTERUS SUBSEPTUS. This differs from Fig. 88 only in respect of the septum, which ceases above the level of the internal os; the cervix and vagina are single.

of the imperfection. Menstruation occurs from both halves of the uterus; if pregnancy occurs in one half, menstruation is, as a rule, suppressed from both; exceptions have, however, been recorded. Twin pregnancy may occur from simultaneous lodgment of an ovum in each half and this condition offers a possible explanation of the occurrence of superfœtation. The Fallopian tubes and ovaries are usually normally developed. The condition is often first revealed by the accidental discovery during clinical examination of a double vagina. In married women one half of the vagina is usually found dilated, the other in its virginal condition; but sometimes both sides have been found dilated. The *septate uterus* is especially difficult

to recognize clinically on account of its normal configuration. The sound may indicate two cavities, but in applying this test it is better to use two sounds so that there may be no doubt of the presence of two cavities separated by a septum.

Double uteri are prone to the formation of fibroid tumours, just as normal uteri are, and many instances have been discovered in uteri removed for these growths. Sometimes duplication of the uterus is not

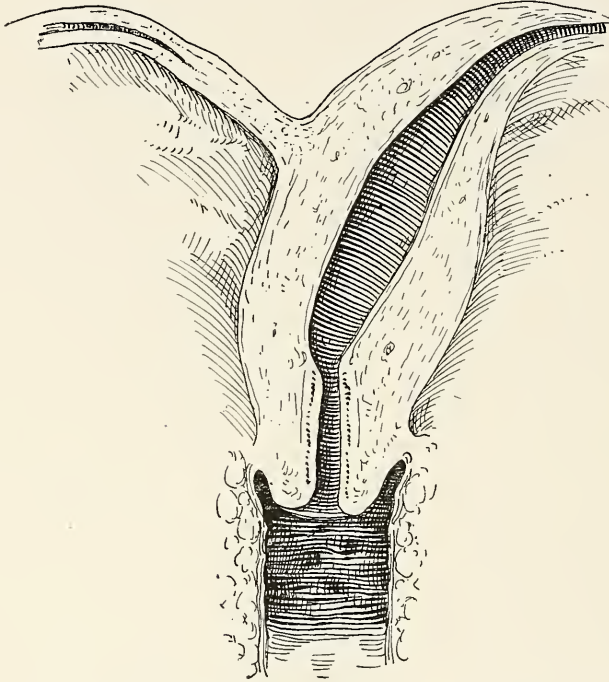


FIG. 90. UTERUS UNICORNIS, WITH AN IMPERFECTLY DEVELOPED SECOND CORNU.

the only developmental fault present; stenosis may also be found affecting either the cervix or some other part of the vagina upon one side but not upon the other. Accumulation of menstrual fluid will then occur above the obstruction (*cryptomenorrhœa*), and *lateral hæmatocolpos* or *hæmatometra* will then be formed. The clinical diagnosis of these conditions naturally presents great difficulty as there are no external signs of maldevelopment, and menstruation may be normal from the other side. Usually the dilated portion has been mistaken for a neoplasm, and its true nature has only become apparent when exposed by operation.

**ATRESIC CONDITIONS OF THE GENITAL CANAL**

These may affect the cervix, the vagina, or the vulva.

**Atresia of the Cervix.** This may take the form of complete failure of canalization, the cervix being represented by a solid block of fibrous and muscular tissue. More common are partial forms in which the canal is blocked only at one point, the commonest position for such a

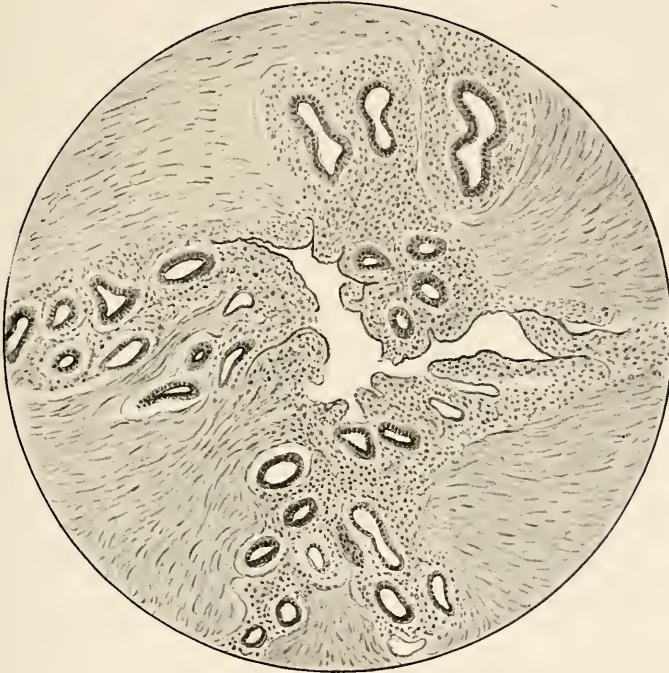

FIG. 91. TRANSVERSE SECTION THROUGH THE WALL OF A UTERUS UNICORNIS, showing a thick layer of uterine muscle into which the mucosa penetrates deeply. In this case only one Müllerian duct had developed, there was no accessory cornu as shown in Fig 90.

deformity being the region of the isthmus ; sometimes in partial atresia a canal exists large enough to admit a fine probe.

These conditions are important clinically, inasmuch as they give rise to *hæmatometra* and *hæmatosalpinx*. Attempts must therefore be made to correct the deformity. The procedure of choice is an abdominal operation exposing the isthmus by free separation of the bladder ; then the uterine cavity is opened above, and the vagina below the obstruction ; the intervening tissue is then excised, and the mucous membrane of the uterus united to that of the vagina. The alternative to this operation is removal of the uterus with conservation of the ovaries.

A minor form of cervical atresia is that known as the *pin-hole os*,

*with conical cervix.* In these cases the vaginal portion of the cervix instead of being cylindrical is smaller than normal, and shaped like an inverted cone, the os externum being upon the apex. This condition of the cervix is often associated with an anteflexed and under-sized uterine body; clinically dysmenorrhœa and sterility are usually present in such cases. The abnormal shape and size of the cervix are of

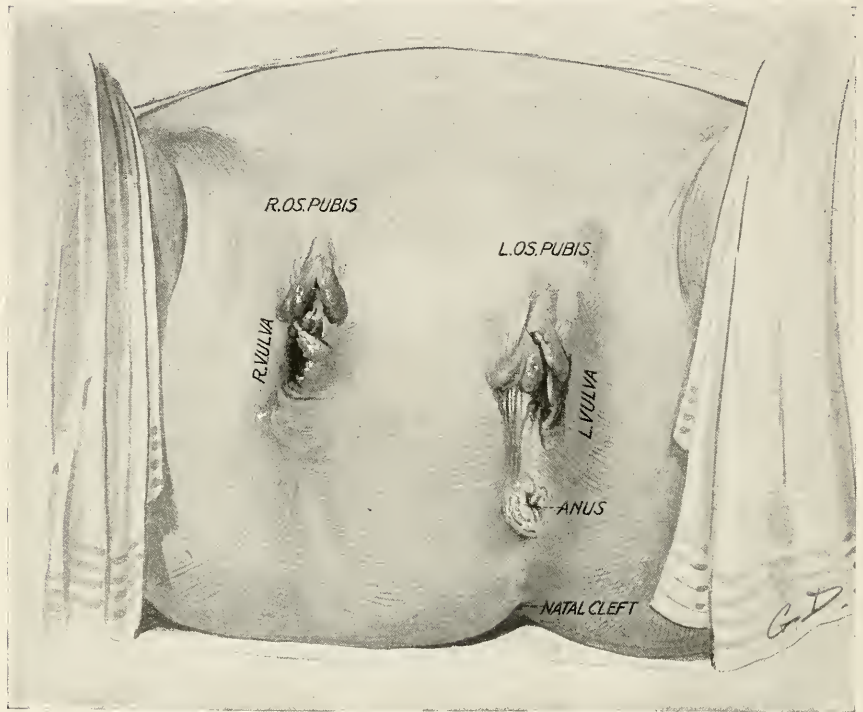


FIG. 92. DUPLICATION OF GENITALIA. (Gemmell and Paterson.)

little direct importance, but they point to the co-existence of a general condition of imperfect uterine development.

The os externum is, as a rule, abnormally small in these cases, and also in some instances where the vaginal portion of the cervix is otherwise normal. The abnormally small os is circular, and is often spoken of as the 'pin-hole' os; although its size exceeds that of a pin-prick, it is too small to admit the point of the uterine sound. Occasionally the internal os is also found to be abnormally small; as a rule, the point of the uterine sound will readily pass through it, but sometimes considerable difficulty is found, and the sound is tightly gripped in passing through the os. The operative treatment of this condition will be described in connection with other plastic operations (p. 805).

**Atresia of the Vagina and Vulva.** Three forms or degrees of *vaginal atresia* may be met with. In the first and most extreme form the organ is represented only by a fibrous band of variable dimensions. In the second degree a part only of the canal is imperforate, the remainder being normal; in the third degree a membranous septum, which may be complete or perforated, obstructs some part of the canal. The vulva below and the uterus and adnexa above, may in all these cases be normally developed, the vaginal defect being the only one present. On the other hand the uterus may be duplicated or rudimentary.

*Complete vaginal atresia* in any form, if the uterus and ovaries are normal, will lead to the phenomena of cryptomenorrhœa (*see* p. 172). Recognition is easy as the affected organ is well within reach, but the important point in diagnosis in such cases is to determine whether the uterus and ovaries are normally developed or not. If they are normal, complete restoration of the integrity of the genital canal can be effected by operation. If they are not normal it is questionable whether operative treatment of the vaginal obstruction is advisable. Operative reconstruction of the vagina has been undertaken in a few such cases, in order to render the woman marriageable, although the functions of menstruation and reproduction are irretrievably lost. The most successful method of dealing with cases of complete vaginal atresia is to utilize a loop of small intestine for the construction of a new vaginal tube; this operation is briefly described on p. 843.

Lesser degrees of atresia may be dealt with upon the same principle as that applied in cervical atresia, *i.e.* union of the normal mucous membranes situated above and below the defect.

**Vulval Atresia** is in comparison with the above extremely rare. Complete absence (*defectus vulvæ*) is only met with in foetal monstrosities which are incapable of independent existence.

*Superficial atresia* of the vulva is, however, fairly common; it consists in closure of the vulva by adhesion of the nymphæ and posterior parts of the labia majora to one another, as the result of an inflammatory process. This may occur either before birth or during infancy. The fossa navicularis is obliterated, the hymen concealed, and the vulval aperture almost entirely occluded (Fig. 93). Usually the clitoris can be seen anteriorly, and a narrow channel can be demonstrated immediately behind the clitoris, passing downwards and backwards into the vagina. Through this small channel the menstrual secretion may escape, and, in consequence, the deformity may remain unrecognized until adult life is reached or until coitus is found to be impossible. Occasionally the occlusion of the vulva is complete, and retention of menstrual fluid occurs.

The occluded portion of the vulva may be obviously cicatrized, as shown by the wrinkled and uneven condition of the surface, similar to that seen in Figure 93. The small anterior aperture leading into the vagina is also seen behind the clitoris. The treatment consists in

dividing the bridge of cicatricial tissue in the middle line from one end to the other. The flaps thus formed will be seen to have an inner mucous, and an outer cutaneous surface ; these surfaces are now united by sewing over the edges with catgut, as is shown in Fig. 507, p. 834.

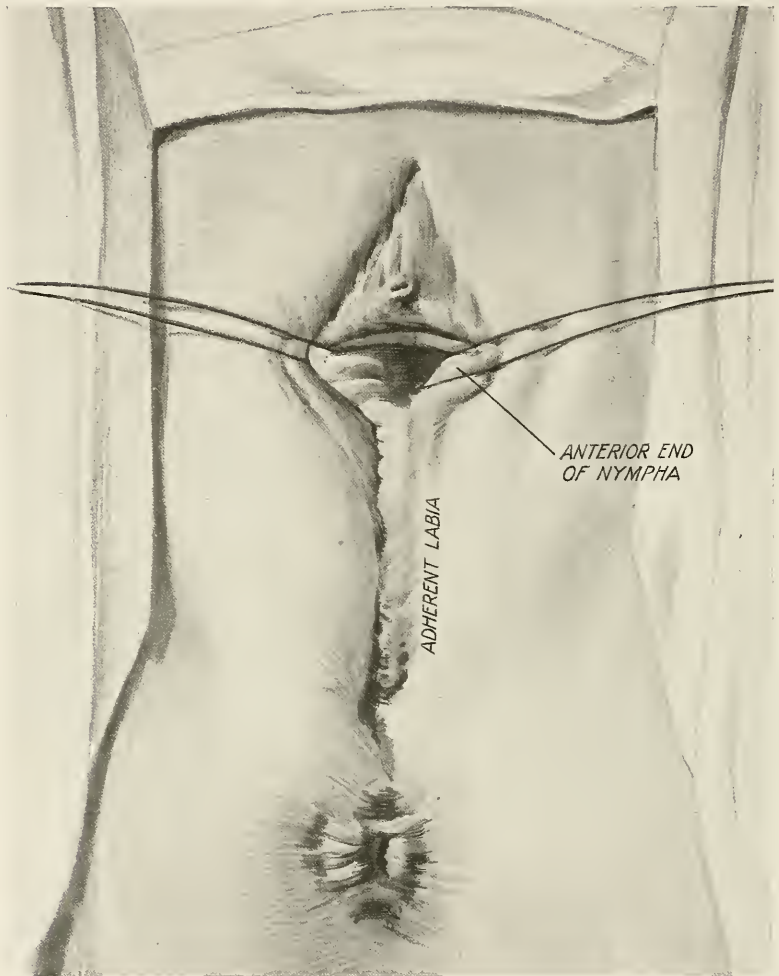


FIG. 93. SUPERFICIAL ATRESIA OF THE VULVA IN AN ADULT. The anterior extremities of the nymphæ have been drawn apart by ligatures, showing the narrow aperture leading to the vagina. The clitoris is seen to be unaffected. -  
See also Figure 507, p. 834.

The great depth at which the hymen lay in this figure (photographed immediately after the operation) became rapidly reduced by consolidation and retraction of the divided tissues.

Atresia involving the ostium vaginae may also be due to defects of development of the *hymen* or of the *lower end of the vaginal canal*. This subject will be dealt with in connection with cryptomenorrhœa,



and the variations in structure of the obstructing membrane described (*see* p. 173). In some cases the conditions are slightly different, for a distinct interval may occur between the imperforate hymen below and the lower end of the vaginal canal above; the intermediate area then represents the site of a vaginal atresia. In such cases the physical signs are modified for the marked bulging of the hymen and the impulse on coughing may be absent; the dilated condition of the vagina above will, however, be made out on rectal examination. The *treatment* consists in opening and draining the hæmatocolpos, and restoring the integrity of the vaginal canal. If the interval between the vagina and the vulva is considerable, a somewhat deep dissection may be required to reach the accumulation of blood. It is essential that the mucous membranes of the two segments should be united, for constriction or complete closure will gradually ensue if this is not accomplished. The vaginal wall must be freed from its connective tissue sheath for a sufficient distance so that it may be drawn down to the vulva and held there by stitches without tension. A wide glass or rubber tube is then introduced and held in position by dressings until union has taken place.

### HERMAPHRODITISM AND PSEUDOHERMAPHRODITISM

A *hermaphrodite* is an individual in whom the sexual glands or gonads characteristic of both sexes (ovary and testis) are represented. The essential characteristic of true hermaphroditism is the presence of both ovary and testis, either separate or in the form of a combined gland, and although there have been a number of reputed instances recorded in children and adults, in the great majority it remains open to doubt whether they can actually be accepted as such owing to the inconclusive nature of the evidence offered. An instance has been recorded in a fœtus of eight and a half months development by Blacker and Lawrence; a complete autopsy revealed on one side a uterus unicornis with an ovary and a Fallopian tube, and on the other a combined gland (ovo-testis) with an enlarged Wolffian duct, representing the epididymis and vas deferens, and a malformed Fallopian tube (Müller's duct).

Another instance has recently been recorded by Blair Bell (*see* Fig. 94) in which an individual 19 years of age, and reputed to be a female, was found to possess a genital gland which he claims contained structures representative of both ovary and testis. The genital gland of the other side was an ovary.

A *pseudohermaphrodite* is an individual with gonads characteristic of one sex, associated with external genitalia and secondary sexual characters resembling those of the opposite sex. This condition is not uncommon, and many undoubted examples have been recorded. Physiologically the sex of an individual is determined by the character

of the gonads : strictly speaking, therefore the condition under consideration is not hermaphroditism at all ; indeed there can be no such state as 'false hermaphroditism.' While the name is inexact,



FIG. 94. A CASE OF HERMAPHRODITISM. (Blair Bell.) The secondary sex characters were stated to be partly female (mammæ and pubic hair) and partly male (hair on legs and upper lip).

the convenience of retaining it in use must in the meantime outweigh the desire for terminological exactitude.

It will be recollected that in a normally developed man the essential female sex-organs, with the exception of the gonads, are represented in the form of vestigial structures ; thus the hydatid testis represents the remains of the Müllerian duct, and the prostatic utricle, the uterus. Again, in the normally developed female are to be found the epoöphoron and paroöphoritic tubules representing epididymis and paradidymis,

the clitoris representing the phallus, and the clitoridian folds representing the foreskin. The sex having been determined by the formation of an ovary or testis, in very early embryonic life, it is obvious that an aberrant course of later development might furnish the individual with some or all of the minor organs of the opposite sex.

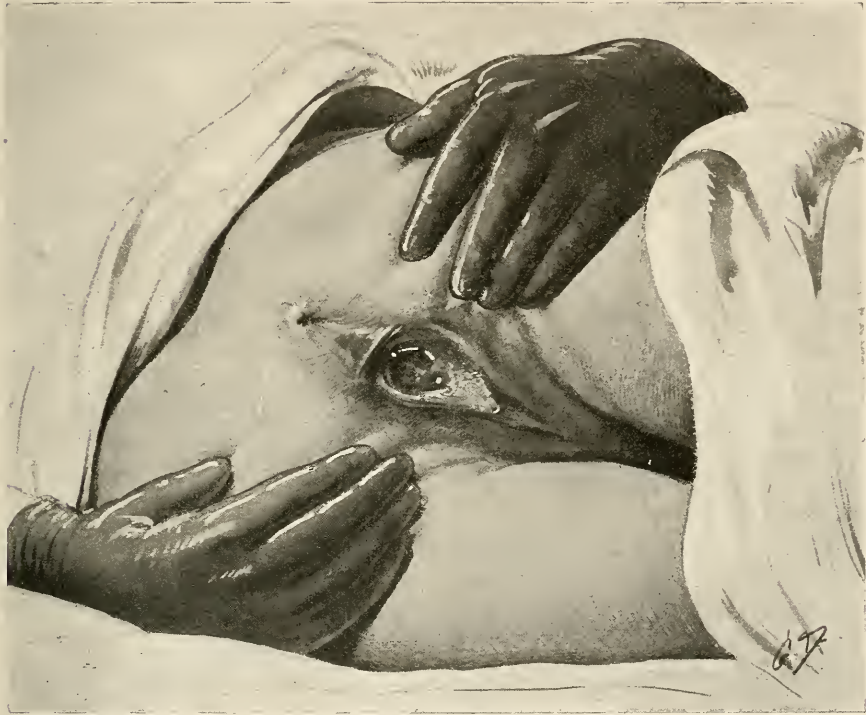


FIG. 95. A CASE OF MALE PSEUDOHERMAPHRODITISM, SHOWING THE EXTERNAL GENITALIA OF THE FEMALE TYPE. (Martin.)

The arrangement may be still further complicated by the well-known tendency of malformations to be multiple; combined malformations of the external and internal genitals are quite exceptionally frequent. The effect of certain of these malformations is to cause the external genitalia to assume the outward appearances of those of the opposite sex. Thus *hypospadias* in the male is brought about by non-union of the lateral halves of the penile urethra and of the scrotum; the result is that the separated halves of the scrotum resemble the labia majora, and leave between them a space, upon the floor of which opens the urethra. The penis is imperfectly developed and of small size. If normally descended testes were present there would be little difficulty in recognizing the malformation, for the glands would be felt in the apparent labia. Frequently, however, non-descent of the testes is

associated with hypospadias, and this greatly increases the difficulty of diagnosis. Thus an undoubted male may come to be regarded as a female, since in infancy sex is necessarily determined by examination of the external genitalia alone. Again, in a female, adhesion of the nymphæ may occur resulting in the forward prolongation of the urethra to the clitoris, the so-called 'clitoridian urethra'; this may be associated with hypertrophy of the clitoris, and double or single, labial ovarian hernia, when the *tout ensemble* will closely resemble the male genitalia.

In cases of malformation of the external genitalia, the major genital organs, in addition to the gonads, may be normally developed, *e.g.* the uterus and tubes in the female, and the epididymis and vas deferens in the male. Pseudohermaphrodites with gonads of the male, and external genitalia of the female type, are known as *male pseudohermaphrodites*, those with gonads of the female and external genitalia of the male type, as *female pseudohermaphrodites*. The former are much commoner than the latter.

A further complication is introduced in cases of pseudo-hermaphroditism by the development of *secondary sex characters* at puberty. Thus in male pseudohermaphrodites (hypospadiac male) development of the mammæ may occur, the development of hair may be of the female type, psychosexual feeling may be for the male; and the individual may take the place of a woman in society and may even marry. In a few instances a scanty periodic hæmorrhage from the genitalia has also been observed. Yet the individual is an undoubted male. In the same way a female pseudohermaphrodite (female with hypertrophy of the clitoris) may develop male characteristics and play the part of a man even to the extent of marrying. The process of development of the secondary sex-characters is not fully understood, but the facts suggest that environment and training in childhood may have more to do with the matter than has been suspected.

When mistakes in sex have been made in infancy and are not discovered until adult age has been reached, attempts to rectify the mistake are generally speaking inadvisable. The subjects of these malformations are necessarily sterile, and, of course, they should not marry. No operative treatment is practicable.

## DISORDERS OF MENSTRUATION

In this section will be considered the following conditions :

- (1) Amenorrhœa.
- (2) Menorrhagia.
- (3) Dysmenorrhœa.
- (4) Menstrual exfoliation.
- (5) Intermenstrual pain.

## AMENORRHŒA

Absence of the menstrual function is a natural condition before puberty, after the menopause, during pregnancy, and also, frequently, during lactation. This amenorrhœa of childhood, of age, and of reproduction, may be called *physiological* amenorrhœa. Another variety must also be specially distinguished, viz. that in which, owing to developmental faults, the menstrual discharge, although produced in normal amounts, is unable to find exit from the genital canal; this variety is known as *cryptomenorrhœa* (concealed menstruation). It is obvious that this condition differs widely from true amenorrhœa, in which there is an absence of menstrual bleeding, *i.e.* the essential menstrual changes in the uterus do not occur. It is convenient to divide cases of *pathological* amenorrhœa into two classes, viz. primary and secondary; the former class consists of cases in which the menstrual function has never been established, the latter includes all cases in which it is suppressed under abnormal conditions. Amenorrhœa is said to be *complete* when several months, or it may be years, elapse without the occurrence of a menstrual period; it is *incomplete* when the intervals are prolonged, it may be to eight or ten weeks, and the amount of the bleeding is scanty. Cryptomenorrhœa will be most conveniently considered as a variety of primary amenorrhœa due to developmental defects.

## PRIMARY AMENORRHŒA

This condition may be due to certain congenital defects, some of which are incurable, or to certain general disorders which, within limits, are capable of being cured.

## I. Developmental Causes

- (a) *Ovaries.* Absence or imperfect formation of the ovaries.
- (b) *Uterus.* Under-development, *e.g.* the condition *u. rudimentarius* and *u. infantilis* (p. 156).
- (c) *Cervix and vagina.* Atresic conditions leading to cryptomenorrhœa.

## II. General Causes

*Delayed Puberty.*

*Anæmia and chlorosis.*

*Tuberculosis*, either general or affecting the uterus and ovaries.

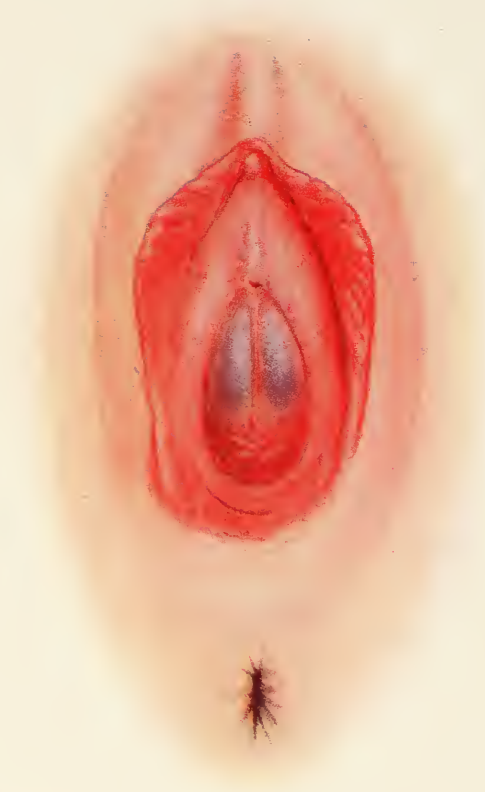**I. Developmental Causes.** These form an important and an interesting group of cases. Defects of the *ovaries* are very rare; absence of one ovary does not necessarily affect the process of menstruation at all; absence of both ovaries is extremely rare except in certain forms of foetal monstrosity incompatible with extra-uterine existence. Only by careful post-mortem examination can a diagnosis of this defect be established, for the ovaries may be misplaced and so remain unobserved during a clinical examination, or even a surgical exploration of the pelvis. A rudimentary condition of the ovaries in which no Græafian follicles are present occurs, though rarely; it may be congenital, or may be the result of disease during infancy, and in either case it is, of course, incurable. Another condition, the existence of which is at present theoretical, may also possibly occur, viz. defect or deficiency of the internal ovarian secretion, the organ being clinically normal. To this condition the name of *hypo-ööphorism* has been applied.

In the *rudimentary uterus* the organ is represented by a small fibrous body which is usually solid, but may contain a rudimentary cavity. In the *infantile uterus* the organ retains its foetal characters, viz. relatively small size of the body and large size of the cervix (see Fig. 21), but a cavity lined with a mucous membrane is always present. The former leads to incurable amenorrhœa; in the latter, development sometimes progresses to a certain extent leading to an imperfect menstrual function. Neither condition is amenable to treatment.

Another possible developmental cause of primary amenorrhœa must be mentioned, viz. defects of certain of the *endocrinous glands*. The only defect of this kind which has received much clinical attention is *cretinism*, resulting from imperfect development of the thyroid gland. This condition is commoner in girls than in boys, and leads to marked deficiency in mental and bodily growth. Amenorrhœa is a frequent, but not by any means an invariable, symptom, and when present it may be attributed, like the other features of the condition, to absence of the thyroid secretion. Cases of partial, primary amenorrhœa in which menstruation is scanty and occurs only at rare intervals occur sometimes in girls who present certain indications of hypothyroidism. They are fat, lethargic, and coarse-featured, although in other respects well developed. The dependence of such a condition upon thyroid defect is probable, but in the meantime hypothetical.

**Cryptomenorrhœa.** For the production of this condition it is necessary that the essential organs of menstruation, uterus, and





HEMATOCOLPOS. The obstructing membrane is pinkish in colour and presents a low median raphé.



ovaries, should be normal, and that some cause of obstruction should be present in the lower part of the genital canal which prevents the escape of the menstrual discharge. The obstruction may be found in any part of the canal below the internal os, the commonest situation being the *ostium vaginae*. The pent-up menstrual discharge will distend the canal above the site of the obstruction; thus in obstruction at the vulva, the vagina may become enormously distended; and in the presence of very large quantities of fluid the uterus may also fill up, and overflow may occur into the Fallopian tubes. Blood in the tubes leaks at first into the peritoneal cavity, but later the abdominal ostia become occluded, and accumulation also takes place in the tubes, which become more or less markedly dilated.

The commonest site of obstruction is the ostium vaginae; the middle third of the vagina and the cervix are occasional sites, but in comparison with the first-named they are very rare. At the ostium vaginae the lesion usually takes the form of an obstructing diaphragm, to which the name of *imperforate hymen* is applied. Under this designation are probably included two different conditions; both are characterized by the presence of a fleshy diaphragm in the position of the hymen, closing the lower end of the vagina; in other respects the vagina and vulva are normally developed. Thus the obstructing diaphragm may be formed, either by a septum representing the lower end of the imperforate Müllerian duct, or by non-perforation of the hymen, which then forms a complete transverse septum. It will be recollected that the hymen is developed from the Müllerian bulbs<sup>1</sup> which lie at the sides of the lower end of the Müllerian duct. In the first-named form of occlusion a normal hymen may be found lying behind and beneath, *i.e.* external to, the obstructing membrane; in the second variety no trace of the hymen can be found apart from the obstructing membrane. The membrane can be readily seen on separating the labia. It is pinkish in colour, like the adjacent mucous surfaces, and often presents a low median *raphé* (see Pl. IV). Its thickness is variable, and the thinner varieties, being semi-translucent, allow the dark colour of the blood filling the vagina to show through. Usually the membrane bulges slightly, and there is a distinct impulse on coughing. The structure of the membrane can be determined by taking a portion for microscopic examination and cutting sections at right angles to its surface. The nature of the epithelial covering is the point to which attention should be directed. The external surface is in all cases covered with stratified squamous cells of the same type as the vagina; the internal surface may show traces of columnar epithelium; and, according to Blair Bell, it does so in over 50 per cent. of cases. In some instances this epithelium forms a well-developed layer with small glands. According to the same authority such cells indicate that the membrane has been

<sup>1</sup> See footnote on page 84.

formed from the Müllerian duct, at any rate in part, for the hymen itself never contains columnar cells. If the membrane is covered with squamous cells on both surfaces it is a true imperforate hymen ; if columnar cells are found on the inner surface, the Müllerian duct has not been canalized at its lower extremity.

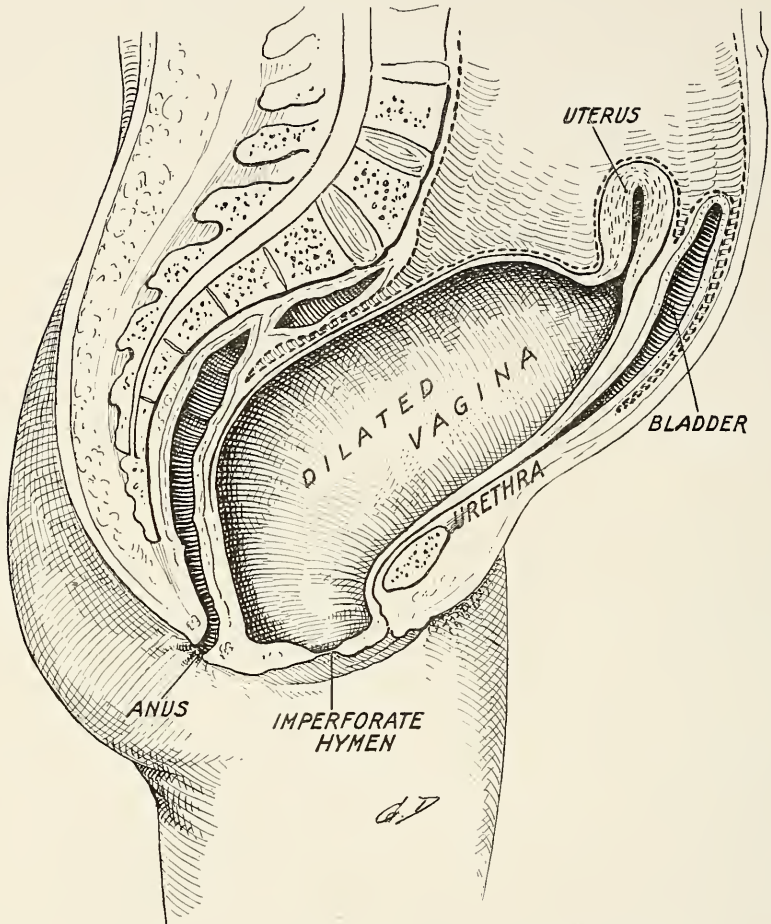


FIG. 96. HÆMATOCOLPOS (shown diagrammatically), after Cullingworth. The cervical canal is also dilated up to the level of the internal os. Note the elongation of the urethra and the elevation of uterus and bladder.

Occasionally occlusion of the ostium vaginae results from vaginitis in infancy, leading to adhesion of the apposed surfaces ; this form of occlusion is usually incomplete and does not lead to concealment of menstruation (*see* Fig. 93). Sometimes occlusion of the vagina or cervix may be acquired in adult life as the result of sloughing and subsequent cicatricial contraction ; but this again seldom leads to the occurrence of cryptomenorrhœa.

The accumulated menstrual blood distends the whole vagina

(hæmatocolpos), which may become gradually dilated until it contains from two to three pints of fluid. A large hæmatocolpos forms a dome-shaped swelling, palpable *per abdomen*, which may reach as high as the umbilicus, may fill the entire pelvic cavity compressing the rectum, and may even produce a certain amount of dilatation of the anal canal. The uterus, and with it the tubes and ovaries, become elevated, and can often be felt on external examination riding upon the summit of the abdominal swelling (*see* Fig. 96). As the anterior vaginal wall stretches, the urethra becomes elongated, while the bladder is carried upwards until it becomes wholly an abdominal organ. The lower part of the cervical canal is not uncommonly found dilated, but accumulation of menstrual blood in the uterus or the Fallopian tubes is only rarely met with. The possibility of this occurrence must, however, be borne in mind, for its clinical importance is considerable.

*Clinical Features.* The condition here described occurs in girls of about fifteen to eighteen years of age. The rate of accumulation of the fluid varies according to the amount of the menstrual flow. When the retained fluid accumulates slowly, no symptoms beyond the non-appearance of menstruation may be present, and the age of seventeen or eighteen may be attained before attention is directed to the state of affairs. When rapid accumulation occurs, periodic attacks of abdominal pain are generally met with, and such cases come under observation at an earlier age. The attacks of pain appear to correspond with the menstrual epochs, and are no doubt due to fresh hæmorrhage producing a rapid increase in tension in the already distended vagina. They do not, however, necessarily occur every month, but it may be at more or less prolonged and irregular intervals. Coincident rise of temperature is sometimes observed. Gradual enlargement of the abdomen is noticed in the chronic cases, and sometimes, though this is rare, there may be occasional attacks of retention of urine, which are explained by the changes in the bladder and urethra already mentioned. Rectal symptoms are practically never met with, as the position of this part of the intestine protects it from pressure from the front.

On abdominal examination a dome-shaped, elastic, fixed swelling may be felt in the hypogastric region, on the convex summit of which is a solid movable body which represents the uterus. The bladder, if distended, covers its anterior aspect; when this organ is empty the swelling is subresonant on percussion, owing to the presence of coils of intestine, between it and the abdominal wall. On vaginal examination the labia will be found normal, and the characters of the obstructing membrane are easily seen. The perineal body may bulge, and in cases of extreme distension of the vagina the anus may become slightly relaxed. On rectal examination the finger will detect a tense swelling more or less completely filling the pelvic cavity and perhaps compressing this part of the bowel.

*Congenital vaginal atresia* resulting in retention of menstrual fluid is much less common than occlusion at the vulva. Vaginal atresia is more often associated with other defects, incompatible with the establishment of the menstrual function, than is imperforate hymen, and accordingly these cases do not present the same clinical features. Atresia of the lower third of the vagina may, however, result in the formation of a hæmatocolpos, the lower end of which is separated from the vulval *cul-de-sac* by a septum of fibrous tissue of variable depth. Atresia of the upper part of the vagina will only result in retention of blood in the uterine cavity, if the development of the uterus and ovaries is normal.

Congenital atresia of the *cervix* is a rare condition ; it is sometimes met with in cases of duplication of the uterus (*see p. 157*), when the exit from one division of the uterine cavity may be obstructed, leading to the formation of a hæmatometra which exists side by side with a normal functional uterus. Unless the duplication of the organ has been detected, this form of hæmatometra is very difficult to recognize clinically, for menstruation may proceed normally from the other half of the uterus.

*Treatment* of imperforate hymen consists in incising the obstructing membrane under anæsthesia with strict antiseptic precautions, the incision being made with either knife or thermo-cautery. The retained fluid is dark red, or chocolate coloured, and of the consistence of treacle ; it flows slowly away, and owing to its viscosity it is difficult even with the aid of the douche to remove it completely. The remains of the hymen are then clipped away with scissors and the edges sewn over with catgut. As soon as the vagina is empty a careful bimanual examination should be made, and the degree of patency of the cervix, the size of the uterus, and the condition of the Fallopian tubes made out. If the *tubes* are found to be dilated abdominal section should be immediately performed, and the tubes removed. The ovaries should be left, as they are in practically all cases healthy. Removal of the tubes is necessary on account of the serious risks of their becoming involved either in an ascending infection or in an infection from the bowel. Their function has in any case been permanently destroyed, and their removal is a safeguard, but no further detriment to the patient than she has already suffered. If no accumulation in the uterus or tubes has occurred, the vaginal canal should be cleansed as thoroughly as possible with the douche, a sterile, alkaline solution being the most useful in removing the sticky fluid from the vaginal walls. During the next week great care is called for in keeping the vulva surgically clean, and in receiving the discharge into pads of antiseptic wool.

If accumulation of menstrual fluid in the *uterus* has occurred it will flow away spontaneously in time ; the uterine cavity should not be douched, owing to the risk of passage of the douche-fluid into the

tubes if these have become at all patulous. The risks of sepsis are much increased when there is hæmatometra, for it is impracticable to keep the vaginal canal sterile for long, and if pathogenic organisms obtain entrance, the conditions are peculiarly favourable for the development of an ascending infection.

## II. General Causes of Primary Amenorrhœa.

(a) *Delayed Puberty.* In this condition absence of the onset of menstruation is associated with absence, or imperfect completion, of the changes which are normally found at the epoch of puberty (*vide* p. 86). Thus the mammæ remain rudimentary, the pubic hair and the supra-pubic pad of fat (*mons Veneris*) do not appear, the labia majora do not become hirsute, and remain thin and slightly gaping in the middle line, allowing the nymphæ to appear. The age of twenty to twenty-five years may be attained before sexual maturity is reached, but unless some gross developmental defect is present the ultimate development of the individual will be normal.

Overwork, both mental and physical, is said to delay the onset of puberty, but nothing definite is known at present upon these points. Gross developmental defects, such as cretinism in their lesser degrees, may delay, without altogether inhibiting, the occurrence of puberty.

(b) *Anæmia and chlorosis* in severe forms inhibit the onset of menstruation which, however, will appear when these conditions are cured. Chlorosis is uncommon in girls before the age of puberty.

(c) *Tuberculosis* of the lungs in its advanced forms, and in many cases abdominal tuberculosis also, are associated with absence of the onset of menstruation. In the latter case the explanation may lie in destruction of the Græafian follicles by the disease or in advanced changes in the endometrium.

**Treatment of Primary Amenorrhœa.** When the average age of onset of menstruation has been exceeded by two or three years, a careful investigation of the case is called for. The condition of the general health, the presence of the changes characteristic of puberty, and the general development of the girl are the first points to consider. If this part of the examination is negative a local examination is required, and this should be conducted under anæsthesia if inspection shows that the vulva and ostium vaginæ are normal. The defects which have just been considered should be looked for one by one, and the prognosis depends entirely upon the nature and degree of the defect which may be present.

Anæmia, chlorosis, and tuberculosis call for the treatment appropriate to these conditions; deficiency of thyroid activity may be treated by the administration of full physiological doses of thyroid gland, the effects of which must be carefully watched. There are no *specific* remedies for primary amenorrhœa.

## SECONDARY AMENORRHŒA

### Causes.

- I. General debility from :
  - (a) Acute illness.
  - (b) During convalescence from illness or operation.
  - (c) Late stages of chronic disease, such as chronic nephritis, diabetes, tuberculosis, malaria, cancer.
- II. Severe form of anæmia.
- III. Some forms of chronic poisoning, *e.g.* alcohol, lead, morphia : other forms of the drug-habit.
- IV. Disorders of the nervous system—nervous shock, overwork, hysteria, insanity.
- V. General conditions, such as change of climate, imprisonment, etc.
- VI. Obesity, when rapidly advancing.
- VII. Chill.
- VIII. Disorders of certain endocrinous glands, *e.g.* thyroid.
- IX. Local conditions :
  - (a) Obliteration of the uterine cavity as from sloughing.
  - (b) Uterine atrophy, *e.g.* lactational atrophy.
  - (c) Bilateral solid ovarian tumours.
  - (d) Surgical removal of the uterus or both ovaries.

Any well-marked loss of vitality, either from acute illness or from chronic wasting disease, is usually accompanied by a temporary suspension of the menstrual function. The list given above is capable of considerable expansion, the instances mentioned being cited as examples only. There is probably no specific influence exerted on menstruation by disease; it appears rather that the menstrual function is one which may be readily arrested by marked depression of the level of the general health. It follows that no *specific* treatment is required, for restoration of health invariably results in the reappearance of menstruation.

Although all severe anæmias are usually accompanied by amenorrhœa, *chlorosis* is particularly liable to produce this effect. One of the commonest causes of amenorrhœa in girls of sixteen to twenty-five years of age is this disorder of the blood, which is characterized by a peculiar lemon-yellow tint of the skin, and by very marked deficiency of hæmoglobin, the number of hæmocytes being only slightly, and sometimes not at all, diminished. Owing to the exaggerated importance attached to cessation of the menses, these cases frequently come first under the notice of the gynæcologist, but specific treatment of the amenorrhœa is unnecessary, for when the chlorosis is cured the menstrual function will spontaneously reappear. The treatment consists, therefore, in attention to the teeth and the

condition of the digestive organs, the correction of constipation, and the administration of iron and arsenic internally; fresh air, good food, and cessation from work are most useful adjuncts, though not within the reach of all classes of patients.

Advanced stages of chronic poisoning by alcohol and lead, or of morphinism, characterized by profound disturbance of nutrition, are usually attended by amenorrhœa. Occasional alcoholic outbreaks often lead to menorrhagia, but habitual and long-continued tipping produces amenorrhœa.

Obesity is a fairly common accompaniment of amenorrhœa, but we have no knowledge of their inter-relationship. Such nervous disturbances as severe fright and hysteria may lead to prolonged periods of suspension of menstruation; as also may changes of environment, such as imprisonment or extreme changes of climate.

The local pelvic conditions mentioned in the list will not be here described, as they will come up for consideration in later sections.

It must be added that a certain number of cases of secondary amenorrhœa occur for which no explanation can be discovered. Sometimes such cases eventually declare themselves as instances of a premature menopause (p. 107); in others, after much apparently fruitless treatment, the menstrual function reappears and thenceforth pursues a normal course. In other cases, although menstruation recurs at prolonged intervals, it never regains the normal monthly periodicity. In the latter cases the general health may continue satisfactory, and one or two children may be borne, although these women never show a high degree of fertility.

In a certain number of cases of amenorrhœa, some of the attendant symptoms of menstruation may appear at the times corresponding to the menstrual epochs; these symptoms are then described as the *menstrual moliminia* (*molimen* = effort). Thus headache, pelvic pain, backache, and nausea, lasting for a day or two, may be complained of, and, perhaps, recognized by the patient as being similar to the troubles she experienced previously in connection with menstruation.

**Treatment of Secondary Amenorrhœa.** Amenorrhœa must, as a rule, be regarded as a *symptom*, not as a disease; treatment should, therefore, be directed to the underlying morbid condition, the successful management of which has the indirect effect of restoring the menstrual function. The class of drugs known as *emmenagogues* to which is attributed a specific influence in exciting menstruation, are disappointing in their effects, and indeed generally prove useless; none of them can with any confidence be recommended, but the following are harmless, and have sometimes, in the opinion of certain observers, proved useful. Apiol (essential oil of parsley; dose, 2-5 minims), either alone or in conjunction with ergot as *ergo-apiol*; manganese in the form of permanganate of potash (dose,  $\frac{1}{2}$ -2 grains); aloes in mild laxative doses; ovarian or thyroid

extract may also be given, in the form of tabloids, on the supposition that the amenorrhœa may be due to deficiency of the thyroid or ovarian secretions. The drug that will be found most serviceable is iron, either alone or in combination with arsenic ; even when there is no apparent anæmia, this combination will often prove successful after regular use for several weeks. In some cases the use of ferruginous natural waters, such as those of Plombières and Cauterets, may succeed where direct medicinal treatment has failed. Constipation must in all cases be carefully controlled. In cases where molimina are present, hot hip-baths, taken when these symptoms appear, may be tried. The internal use of electricity is not to be generally recommended ; exceptional cases in which it may be employed are cases of lactational atrophy or of infantile uterus.

### MENORRHAGIA : PROFUSE MENSTRUATION

This condition has been already dealt with in connection with the symptom of hæmorrhage from the genital canal (p. 130). It was there pointed out that a distinction between profuse menstrual bleeding and intermenstrual bleeding could not usefully be drawn because the one condition merged imperceptibly into the other ; the causes of both types of bleeding were often identical. No further general discussion is therefore required.

It is impossible to fix an arbitrary standard of the amount of bleeding which constitutes normal menstruation, and, consequently, profuse menstruation is difficult to define. It must be considered mainly in relation to two points, viz. the general effects, if any, produced by the monthly losses of blood, and the amount of increase above what is the average of the individual in question. These are the true criteria of excessive loss.

It must, however, be borne in mind that profuse menstruation may take the form of abnormal *frequency* instead of abnormal *amount*. Thus a woman who usually menstruates five days every four weeks ( $\frac{5}{4}$ ), may menstruate for the same number of days every three weeks ( $\frac{5}{3}$ ). To this form of profuse menstruation Blair Bell has applied the name of *epimenorrhœa*, and it is undoubtedly useful to have a name by which this form can be designated. It must, however, be clearly understood that epimenorrhœa is not a disorder in any way distinct from menorrhagia, for the conditions giving rise to them cannot be differentiated. In most marked cases of profuse menstruation, epimenorrhœa and menorrhagia are both present.

In cases of profuse menstruation some modification often occurs in the endometrial changes, as will be seen by comparing Fig. 97 with Fig. 66, which represents normal menstruation. These changes consist in the formation of large blood-lacunæ which may extend through the thickness of the mucous membrane down to the muscle.



## DYSMENORRHEA

A certain amount of pain usually accompanies menstruation even in women of normal health: only a very small proportion of the women of civilized races menstruate painlessly. A degree of pain which incapacitates the patient for a shorter or longer time from following her usual avocations is definitely abnormal and may be designated *dysmenorrhœa*. Excessive pain in menstruation may be

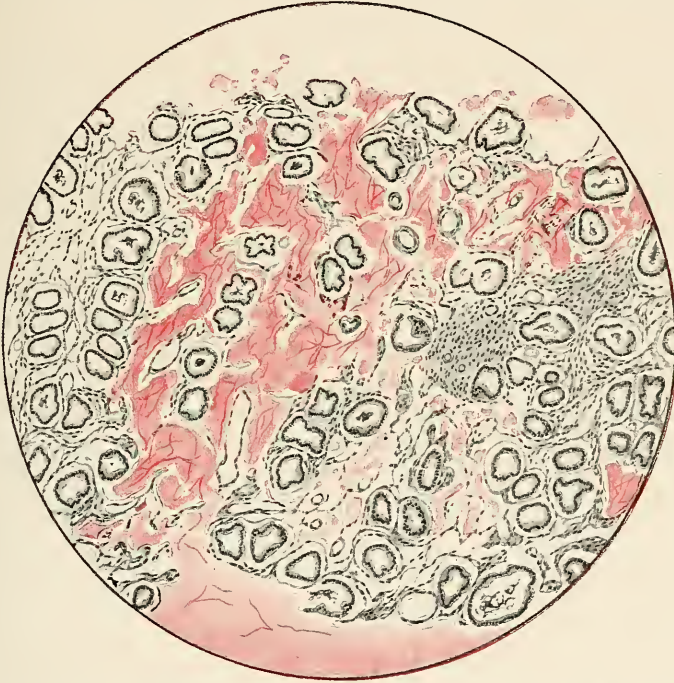


FIG. 97. CORPOREAL ENDOMETRIUM FROM A CASE OF FIBROMYOMA UTERI WITH MENORRHAGIA. Showing the formation of large blood-lacunæ extending through the whole thickness of the mucosa down to the muscle.

due to some disturbance of the menstrual process itself, or to some disease of the uterus or other pelvic organs, which is a source of pain independent of menstruation, and incidentally makes the menstrual process abnormally painful also. In the latter case dysmenorrhœa is *secondary*, and should be regarded as a symptom of the morbid condition to which it is due. In the former case the dysmenorrhœa is *primary* or *essential*, and in the menstrual intervals the patient is free from all symptoms; it is clearly of much greater clinical importance than the secondary form.

**Sources of Pain in Menstruation.** We must first consider with regard to the primary form what are the factors in the menstrual process which may possibly become sources of pain, and with regard

to the secondary form what morbid conditions of the pelvic organs are likely to make menstruation abnormally painful.

(a) *Uterine Contractions.* The part played by contractions of the uterine muscle in menstruation has been already explained (p. 100); efficient contraction is necessary to dilate the cervix, to expel the menstrual fluid into the vagina, and finally to assist in arresting the bleeding. Under normal conditions these contractions are probably rhythmical and not extremely painful. In some cases they may become spasmodic or tetanic, and as is the case with cramp in voluntary muscles, severe pain will be produced.

Spasmodic contractions may result either from faulty innervation, from inadequacy of the uterine musculature, or from the presence of some obstruction to the outflow of blood through the cervix.

Of the existence of faults in the *innervation of the uterus* nothing is definitely known. Inadequacy of the uterine muscle has been shown to exist in congenital under-development of the uterus, not only in the extreme form known as the infantile uterus, but in much less marked cases of abnormally small uteri. The proportion of muscle to fibrous tissue is low, and the arrangement of the fibres, according to Blair Bell, is also abnormal. To fulfil its menstrual function an abnormal effort will be required from such a uterus, and the contractions will become tetanic and extremely painful.

The existence of a *partial obstruction* would also induce an abnormal uterine effort. Such obstructions undoubtedly exist in the form of an abnormally acute bend at the isthmus of the uterus, an abnormally small external os uteri (*pin-hole os*), or a polypus blocking the cervical canal. Yet clinical evidence clearly shows that these conditions do not of themselves cause dysmenorrhœa, but when associated with inadequacy of the uterine muscle they are undoubtedly important. The obstacle they offer to the dilatation of the cervix and the expulsion of the menstrual blood can be overcome by a uterus of normal strength, but seriously embarrasses a congenitally weak organ. In the older nomenclature such cases were called *obstructive dysmenorrhœa*, but the true view is that the obstruction is too slight of itself to influence appreciably the menstrual process; it is of importance only when associated with muscular deficiency. Clinical experience shows that the most severe cases of primary dysmenorrhœa are those in which an abnormally small uterus is also acutely *flexed* or has an abnormally small os externum.

(b) *Intra-uterine Clotting.* Under normal conditions the probability is that menstrual blood does not coagulate in the uterus. The reasons for this have been already referred to (*see* p. 98). Women who menstruate freely, however, usually notice that clots are passed in the menstrual discharge, and these may be of large size when bleeding is excessive. They are formed in the vagina in almost all cases, and their expulsion is not necessarily attended by unusual pain. If, under

abnormal conditions, clots should be formed in the uterus, their expulsion through the cervix would undoubtedly cause great pain. In the severest known cases of dysmenorrhœa it is unusual for clots to be passed at all, and there is no clinical evidence that they are an important cause of menstrual pain. At the same time some women assert that bouts of severe pain in menstruation are often greatly relieved after clots have been passed, and it is, therefore, possible that intra-uterine clotting may be an occasional cause of dysmenorrhœa, but it must be regarded as of secondary importance in the production of pain.

(c) *Vaso-motor Disturbances.* General pelvic congestion forms an integral part of the menstrual process ; under normal conditions it is not of sufficient intensity to cause much pain, but the slight symptoms of the pre-menstrual phase may be due to it. An extreme degree of congestion would necessarily cause great pain, and might possibly be induced either by faulty innervation, or by local pathological conditions. Of the former there is no direct evidence ; of the latter there are numerous clinical examples. Inflammatory conditions, uterine displacements and uterine tumours all cause circulatory disturbances which take the form of local or general pelvic congestion. When the dilator action of the menstrual hormone is exerted upon the pelvic circulation in pathological conditions, the resultant effect may be an extreme degree of congestion sufficient to produce severe pain which can only be relieved by the local depletion of the menstrual hæmorrhage, and the cessation of the action of the menstrual hormone. These are the cases which were formerly described under the name of *congestive dysmenorrhœa* : the dysmenorrhœa is, however, as already pointed out, not a primary disorder but a symptom of another morbid condition.

**Clinical Types of Dysmenorrhœa.** From what has been already said it will be clear that the causation of extreme pain in menstruation may be complex, and in individual cases obscure. It is, therefore, useful to define two clinical types which can usually be identified without difficulty.

(a) *Primary (Spasmodic) Dysmenorrhœa.* This group will include nearly all the most severe examples of primary dysmenorrhœa. Irregular muscular contraction or 'spasm' is the chief factor in the production of the pain, and the name, which has been for long in use, is quite not appropriate. The great majority of cases of this disease occur in young women ; sometimes it continues till middle life or the menopause has been reached ; the greater number become cured by child-bearing. It may begin with the first onset of menstruation, but often it does not appear until some years later. Women who suffer from this disease may be otherwise in good health ; frequently they are either overworked, or of a pronounced neurotic temperament. It has, however, no definite association with disease in any other part of the body.

The menstrual periods are usually regular in rhythm, the flow moderate or scanty, and not unduly prolonged. Occasionally, irregularity with long intervals is met with, especially in cases where the uterus is imperfectly developed. The pain begins either some hours before, or at about the same time as, the hæmorrhage. It is in the hypogastric abdominal zone that the pain is chiefly felt, and often it radiates into the back and down the thighs; there are, of course, many gradations, but it may be of most intense and agonizing character, and after some hours may lead to fainting and collapse. It is often attended by severe headache and vomiting. It is usually spasmodic in character, with frequent exacerbations, but sometimes it continues without any remission for several hours. In either case the severe pains seldom continue for more than twelve to twenty-four hours, when a spontaneous remission occurs, and during the remainder of the period the pain is comparatively slight. While the severity of the pain is great the hæmorrhage is scanty; along with the remission there usually occurs a freer flow. During the period of severe pain vesical or rectal spasm may occur, leading in some cases to tenesmus of severe and prolonged character. During the first twenty-four to forty-eight hours the patient is often obliged by the severity of her pain, and the exhaustion which follows it, to remain in bed, but the recumbent position does not relieve her; in some cases it appears to aggravate the pain, and accordingly she keeps up as long as she possibly can.

On pelvic examination nothing abnormal may be found which will account for the pain. In many cases, however, the uterus will be found to be small and anteflexed; sometimes, in addition, the cervix is small, and the os externum of less than normal size (*see p. 148*). The association of these conditions may give rise to extreme menstrual suffering. Backward displacement is seldom found in dysmenorrhœa of this type. Generally speaking the pelvic organs are normal; absence of any gross lesion forms one of the most striking features of these cases.

It is the imperfect development of the uterus, and consequent inefficiency of its muscle, with perhaps deficiency in the function of *polarity*, which gives rise to the pain. In uteri which are apparently of normal size we must assume that there is a deficiency in the proportion of muscle to fibrous tissue similar to that which is known to exist in the under-developed uterus. Women of gouty tendencies are said to be more liable than others to this disease, and it is usually associated with sterility or with a low degree of fertility.

*Treatment.* Cases of spasmodic dysmenorrhœa call for careful local examination, and in unmarried women this should be carried out under anæsthesia. If the defects just described are present some form of operative treatment will probably alone prove effective. If the clinical findings are normal, there is hope of palliative treatment

proving successful. In all severe cases, therefore, local examination is required to avoid misdirection of effort.

*Palliative Treatment* is applied during the attacks. An aperient should be taken daily for two or three days before the period is expected. Although the recumbent position does not always relieve the pain, it is best to put the patient to bed and apply hot fomentations, frequently renewed, to the abdomen. A hot hip-bath at the beginning of the period often produces an effect even greater than that of the fomentations. Cases of moderate severity may be sufficiently relieved by administering, in addition, a diaphoretic, sedative mixture containing bromide of ammonia, liq. ammonii acetatis, spiritus etheris nitrosi, belladonna, and camphor water. Or large doses of bromide of ammonia (40–60 grs.), given in a small enema, will often afford relief.

In cases more severe than these, dry-cupping the loins, or the application of a mustard plaster to the dorsal spine may prove useful. But in addition analgesic or sedative remedies must also be resorted to. One of the most useful is phenazone (antipyrin) which may be given in doses of ten grains with a little sal-volatile, or 5 m. of tincture of capsicum, to counteract the depressing effect of this drug. An agreeable form in which it may be given is the effervescent granules. Other remedies of the same class, such as phenacetin, ammonal, pyramidon and aspirin, may be employed in similar doses; the latter often proves very useful in cases of moderate severity.

Alcohol, opium, and morphia should be withheld if possible, for the alcohol- or morphia-habit is too readily contracted in such cases. In pain of extreme severity morphia may be absolutely necessary, and is then best given in the form of a half-grain rectal suppository. General anæsthetics, such as chloroform, are, of course, unsuitable.

Attention to the general health and the administration of tonics are of benefit in the intervals. Child-bearing usually results in complete cure, but occasional exceptions are met with. It appears reasonable to suppose that the muscular hyperplasia of pregnancy is the main factor in effecting the cure; this may in fact permanently remedy the original muscular deficiency.

*Operative Treatment.* The first object of operative treatment is to assist the process of menstruation by providing a freer outflow through the cervix. This may be sought for either by simple dilatation of the cervix, combined with the use of an intra-uterine glass stem (*see* Fig. 466, p. 795), or with a plastic operation designed to enlarge the lower part of the canal permanently. The details of this operation are described in a later section.

The *rationale* of dilatation must be sought in the function of uterine polarity. Regular intermittent uterine contractions act upon the cervix, softening its tissues and dilating its canal, while tetanic contractions have no such effect. Conversely, artificial dilatation of the cervix acts upon the uterine body, producing contractions. These

phenomena may be observed both in the gravid and the non-gravid uterus. It appears that forcible dilatation, in cases of spasmodic dysmenorrhœa, exerts a more or less profound influence upon the mechanism of polarity, by which the contractions of menstruation are so regulated, that they lose their tetanic or spasmodic character.

Cases of spasmodic dysmenorrhœa are very exceptionally so intractable and so severe that these methods of treatment entirely fail to bring relief and the patient's life becomes burdensome on account of the severity of her sufferings, and the dread excited by the anticipation of their recurrence. Under these circumstances removal of the uterus may be practised in order permanently to suppress the menstrual function. Such an operation should not be undertaken except in cases of the greatest severity, and after a full trial has been given to all other methods. The ovaries should never be removed in these cases.

(b) *Secondary (Congestive) Dysmenorrhœa.* While spasmodic dysmenorrhœa is a disease *sui generis*, congestive dysmenorrhœa is a *symptom* of some other morbid condition, such as chronic pelvic inflammation affecting the tubes and ovaries and the pelvic peritoneum or cellular tissue, interstitial and submucous fibroid tumours, and backward displacement of the uterus, especially when complicated by adhesions or by subinvolution. All of these conditions are causes of chronic local congestion, and, accordingly, may excite more or less constant pelvic pain; when the phase of premenstrual congestion comes round, an exacerbation of pain occurs due to overdistension of the already congested pelvic vessels. The severity of the pain will depend upon (1) the extent of the inflammatory process or, as in the case of fibroids, the degree of interference with the pelvic circulation; (2) the nature and extent of the premenstrual congestion habitual to the individual in question, which is probably a variable factor. After the menstrual flow has been in progress for some time, varying with its amount, relief occurs by depletion of the congested vessels, and diminution of tension. It is probably not in all cases, however, that menstrual congestion reaches its acme before the appearance of bleeding; for in some cases the pain increases in severity during the first day or two, the flow being scanty or moderate, and on the third or fourth day relief occurs accompanied by a more abundant bleeding.

In these cases the pain is never of that acute or agonizing character often met with in the spasmodic form. It is continuous and not subject to marked exacerbations; it is usually relieved by rest in bed, the horizontal position being no doubt serviceable in assisting the pelvic circulation. This kind of dysmenorrhœa seldom, if ever, begins with the first onset of menstruation; often a history of some preceding pelvic trouble can be obtained, with which the onset of the dysmenorrhœa is connected. The amount of the bleeding is, as a rule, abundant or profuse; scanty bleeding is very rare with this variety of dysmenorrhœa; often the periods are prolonged or unduly frequent, or both.

The pain is referred chiefly to the back, thighs, and both iliac regions. Headache and vomiting are usually absent. On local pelvic examination, some morbid conditions, such as those already mentioned, will usually be met with.

*Treatment.* As this form of dysmenorrhœa is but a symptom of certain forms of pelvic disease, the most important part of the treatment is naturally directed to its cause. *Palliative treatment* during the periods is often necessary. It is always useful, in these cases, to keep the patient in bed until the severity of the pain has abated. Mild purgation each morning for a few days before and during the periods should be employed. Half a pint of warm saline solution injected into the rectum and retained, will often give great relief for a time, and can be repeated. Alcohol and belladonna tend to increase the pain; the coal-tar group of sedatives, such as antipyrin, are of little use; bromides and opium are the most successful, but should be administered with caution. Drugs, such as ergot and hydrastis, which check bleeding from the uterus, should be avoided, until the flow is freely established, since hæmorrhage is the natural channel of relief. Styptol acts both as a sedative and a uterine hæmostatic, and can be given with good effect in doses of  $1\frac{1}{2}$ –3 grs.

## MENSTRUAL EXFOLIATION

Under the designation ‘*membranous dysmenorrhœa*’ a condition has been long recognized in which pieces of membrane, so-called ‘casts,’ are expelled from the uterus. Experience has, however, shown that such casts may be passed without an abnormal amount of menstrual pain. The name, membranous dysmenorrhœa, is therefore inappropriate. The outstanding feature of the condition is the detachment and expulsion of portions of the superficial compact layer of the mucous membrane during menstruation. In the first edition of this work the title *exfoliative endometritis* was used, but we are now convinced that no histological evidences of inflammation can be found, and therefore this name is also inappropriate. We propose to use the term *menstrual exfoliation*, which accurately expresses all that is known of the process. The condition is sufficiently distinct from the other menstrual disorders to require its being classed by itself.

The pieces of discharged membrane usually occur in the form of narrow strips, or, more rarely, of pieces of large size representing the whole area of the anterior or posterior wall. Complete casts are never met with in this condition, although they do occur from other causes (p. 19). The free surface is smooth, and the attached surface shaggy and filamentous (see Fig. 98). Structurally, the membrane appears to consist of degenerated endometrium: the stroma-cells are shrunken and the interstitial tissue is infiltrated with blood, giving the appearance of degenerated fibrin. The glands are few, shrunken

and very small ; their cells, at the best, are cubical not columnar (*see* Fig. 99). In some instances the membrane is much thickened from hæmorrhagic infiltration, and then cells resembling decidual cells may be found in the stroma. There are no inflammatory changes in the membrane at all, nor is there any clinical evidence of its being due to

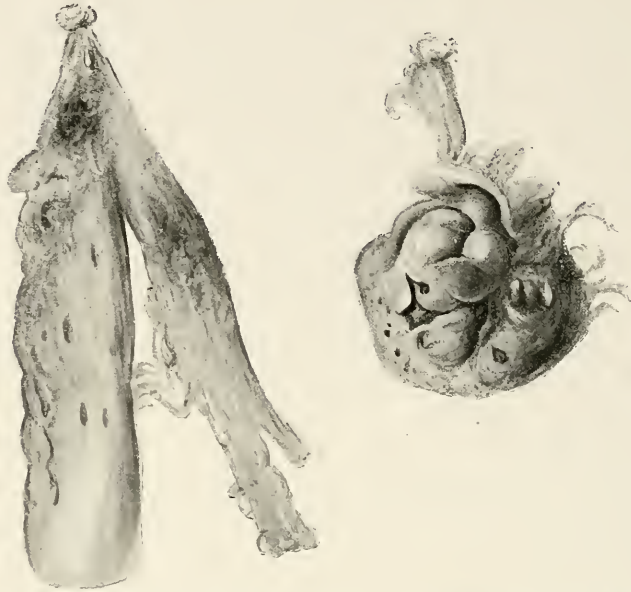


FIG. 98. EXFOLIATION THROWN OFF IN TWO PIECES DURING MENSTRUATION BY A VIRGIN AGED 19 YEARS.

infection. After the uterus has been curetted, portions of the same kind of membrane may be discharged at the next period.

Its causation is quite unknown ; its occurrence is rare and it is found chiefly in virgins and in sterile women ; sterility appears to be invariably associated with it, and it is practically incurable. In rare instances menstruation is not unduly painful, but usually extreme pain is present. Whitehouse has shown that in normal menstruation fragments of endometrium are often cast off large enough to be visible to the naked eye. The condition here described is, however, the exfoliation of an abnormal mucous membrane, and that it is a pathological condition there can be no doubt.

The menstrual disorder seldom begins at puberty. The period tends to be profuse in amount, and the pain may be excruciating in degree. It comes in attacks with remissions, and is relieved by the passage of the membrane, which usually occurs about the second or third day.

In order to recognize the condition the membrane must be sought



for in the menstrual discharge. The narrow strips may escape notice unless carefully looked for, as they are often rolled up into small bulk and concealed by blood-clot. All the pads used by the patient must therefore be examined, and all clots and pieces of tissue carefully inspected in water; the strips of membrane can then be unrolled and

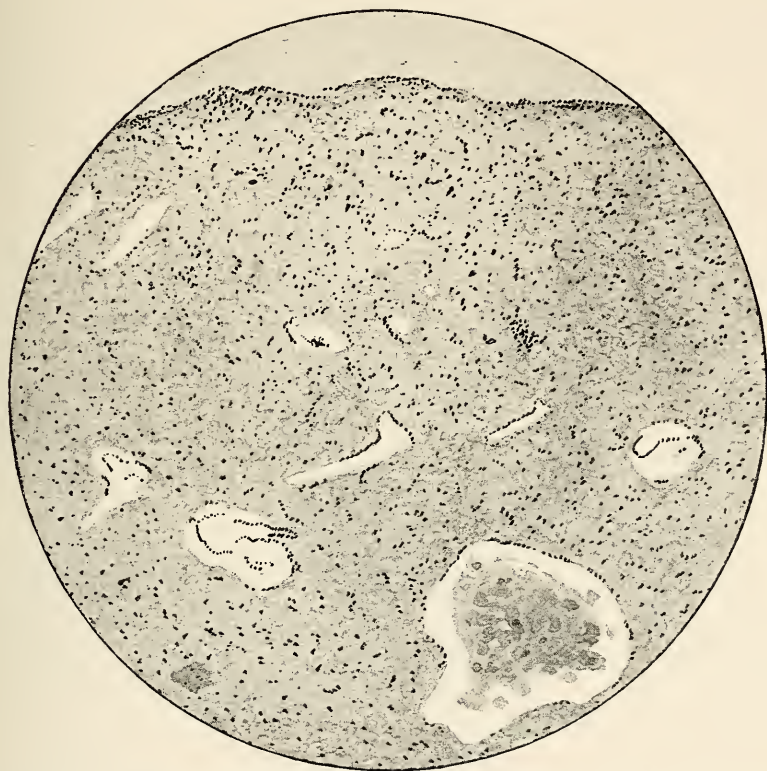


FIG. 99. VERTICAL SECTION THROUGH EXFOLIATION SHOWN IN FIG. 98.  
Several imperfect glands are seen in the section.

floated out. As a rule they are thin and semi-translucent in appearance, pale in colour and with one surface smooth, the other rough. In some instances a thick membrane, resembling decidua, is passed. The strips are about 1-2 inches in length, and quite narrow: often much smaller fragments are found.

*Treatment* is not encouraging. The formation of the membrane cannot be prevented by any medicinal or operative measures that we are acquainted with, and relief can only be given by analgesic remedies during the period. Curetting has been extensively employed with the result that its uselessness has been clearly shown.

## INTERMENSTRUAL PAIN

Although the causal relation of this affection to the menstrual process is not established, it is most convenient to consider it here. It consists of attacks of abdominal pain in the intermenstrual periods which recur at regular intervals ; as a rule the attacks occur about midway between two menstrual periods, but in other cases they may come on either earlier or later than this. In some cases they preserve a rhythm almost as regular as that of menstruation. The disease affects women during the time of full sexual development, and has not been observed at puberty. Subjects of this affection are nearly always sterile during its continuance, although a considerable proportion have been previously pregnant ; in some instances the disease has ensued upon a confinement or a miscarriage. The menstrual function itself is not in all cases abnormal, but a considerable proportion of patients suffer from dysmenorrhœa, and some from menorrhagia. In a few instances a watery or blood-stained discharge is regularly present during the attack of intermenstrual pain. — The pain is not acute, seldom indeed severe, but is usually described as aching or bearing-down in character. It bears no comparison with the pain of a severe case of spasmodic dysmenorrhœa.

A local lesion, recognizable by ordinary clinical examination, is present in the majority of cases. The lesion most frequently met with is inflammation, indicated by matting and enlargement of the tubes and ovaries upon one or both sides ; in other cases chronic endometritis, a small fibroid tumour, or a backward displacement may be found. It cannot in all cases be assumed that the morbid condition discovered in the pelvis is the cause of the pain.

The *causation* of intermenstrual pain is by no means clear. The theory that it is due to some abnormality of the function of ovulation offers the best explanation of the clinical facts. Thus it accounts for its periodic rhythm, for its varying relation to the menstrual period, and for the frequency with which it is associated with inflammatory lesions of the tubes and ovaries. It is possible that in inflamed or adherent ovaries the process of dehiscence of the Græafian follicle is interfered with, and rendered more difficult, and consequently painful. This may clearly be induced by general thickening of the tunica albuginea, or by previously existing adhesions of that part of the ovarian surface upon which the ripening follicle presents. The view advanced by certain writers that it is due to intermittent hydrosalpinx (*see* p. 612), while it may account for the occasional accompaniment of a watery discharge, does not explain the principal feature of the affection, *i.e.* its regular periodicity.

The *treatment* consists essentially in dealing with the local lesion which may be present. The attacks of pain may be relieved by the

same remedies as those employed in cases of dysmenorrhœa. The prospect of permanent cure is not hopeful.

## EXTRA-UTERINE (ECTOPIC) GESTATION

It is now well established that a fertilized ovum may become implanted not only in the uterus, but in the Fallopian tube, or in

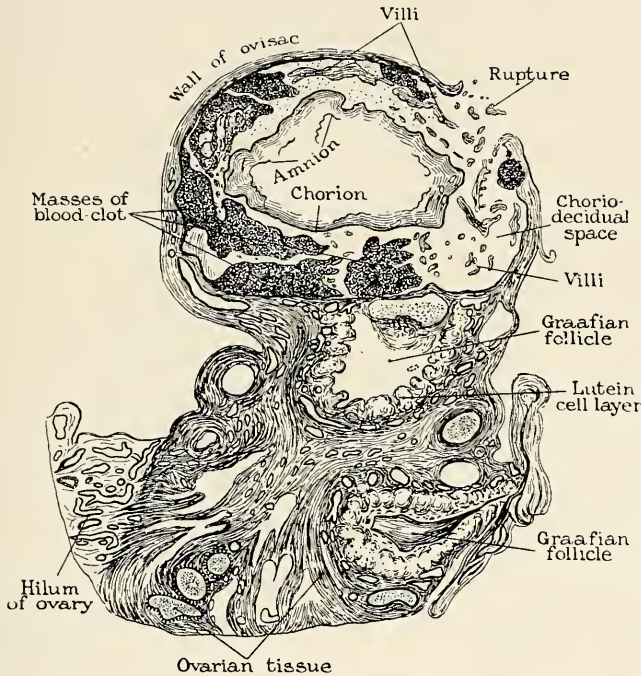


FIG. 100. OVARIAN PREGNANCY (Van Tussenbroek). The ovum has developed in a Graafian follicle; rupture has occurred on the free surface of the gestation-sac.

the ovary; in the two last-named positions the pregnancy is called extra-uterine or ectopic.

The possibility of the implantation of a fertilized ovum upon the peritoneum—*primary peritoneal pregnancy*—has been much discussed, but until the last year or two it cannot be said to have been satisfactorily demonstrated. Blair Bell now claims to have shown that it may occur in rodents, and its occurrence in the human species cannot be regarded as impossible. Further, a case has recently been recorded by Gröné (Sweden), which he asserts to be one of primary peritoneal pregnancy, the ovum having been implanted upon the peritoneum immediately behind the right round ligament. The case was submitted to operation, and as the patient recovered a detailed histo-

logical examination of the uterus and Fallopian tubes was not made. While there can be no inherent impossibility about the occurrence of primary peritoneal pregnancy, its actual demonstration is beset with great difficulties, and there can be no question that if it occurs

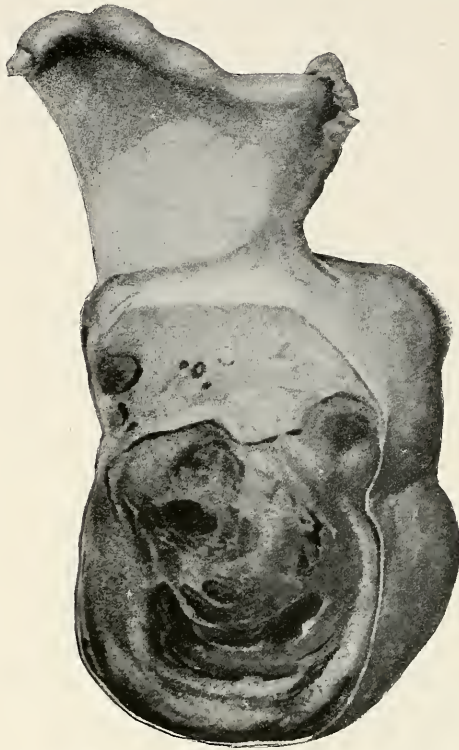


FIG. 101. OVARIAN PREGNANCY WHICH RESULTED IN THE FORMATION OF A MOLE; THE GESTATION-SAC WAS NOT RUPTURED (Giles and Lockyer).

at all in women it is very much rarer than the other two varieties of ectopic pregnancy.

### OVARIAN PREGNANCY

It is only within recent years that the occurrence of ovarian pregnancy has been satisfactorily proved, but the number of cases which can be accepted as reliable instances of the condition is now fairly large. There can be no doubt that it is very much less frequent than tubal pregnancy. In most cases the site of implantation appears to have been a Gräafian follicle, which may be entered by spermatozoa through the site of rupture, or possibly by direct penetration of the wall. It is, however, possible that the egg-cell may be impregnated when lying upon the surface of the ovary after its discharge from the follicle, and may afterwards excavate a bed

for itself in the ovarian tissues by its remarkable powers of erosion. Generally, however, the spermatozoa enter a Gräafian follicle and fertilize an egg-cell therein, which has not been discharged along with the fluid-contents of the follicle. In the cells which line the follicle the fertilized ovum finds its nidus, and the early stages of development pursue the usual course. Fig. 100 shows the formation of the *gestation-sac* or maternal covering of the ovum; this consists simply

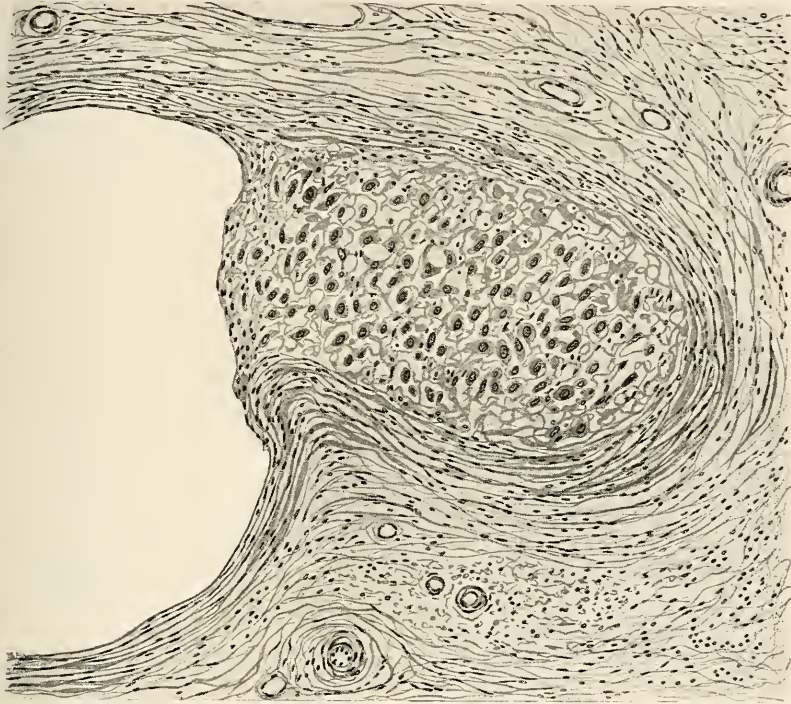


FIG. 102. Showing decidual reaction in the connective-tissue cells of the medulla of the ovary, from case shown Fig. 101 (Giles and Lockyer).

of the layers of tissue which normally compose the wall of the Gräafian follicle (*tunica interna* and *tunica externa*), and it will be seen that the greater part of the ovum is unsupported except by this delicate follicular wall. The features essential to the diagnosis of an ovarian pregnancy are shown in Fig. 101. It will be seen that the ovary contains a large blood-clot showing an amniotic cavity (chorionic villi were found in the clot by microscopic examination). There is a complete *capsule* composed of ovarian tissue; the ovary maintains its normal relations to the unaltered mesosalpinx and to the corresponding Fallopian tube.

A true decidua compacta is not formed in the ovary, but patches of decidual cells may be found both in the stroma of the medulla and

in that of the cortex (*see* Figs. 102 and 103). In most of the authentic cases pregnancy terminated at an early period by rupture (*see* Fig. 100), but in the case described by Giles and Lockyer a mole was formed and the ovarian capsule was never ruptured (*see* Fig. 101). The differential diagnosis by clinical methods from tubal pregnancy is impracticable

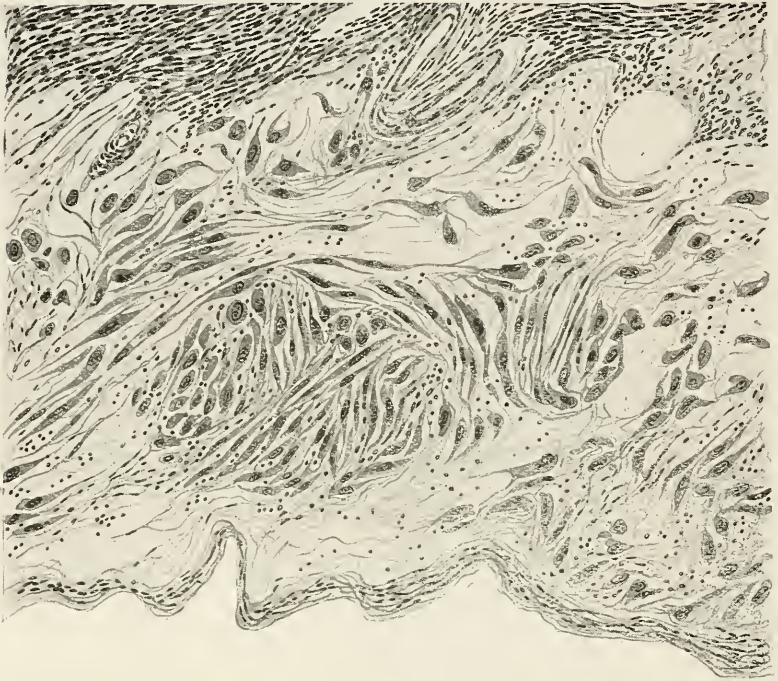

FIG. 103. Showing decidual reaction of the connective-tissue cells of the cortex of the ovary, from case shown Fig. 101 (Giles and Lockyer).

in the present state of our knowledge, careful examination of the complete specimen, after removal, being required to determine its true nature.

### TUBAL PREGNANCY

**Etiology.** The lodgment of a fertilized ovum in the Fallopian tube is not uncommon. The occurrence is of the nature of an accident the predisposing factors comprise many mechanical conditions relating to the tubes, and some authorities include anomalies of the fertilized ovum in the etiology of tubal pregnancy. With regard to the ovum it has been suggested that the preservation of the zona radiata (pellucida) during the time a fertilized ovum is in the tube prevents its implantation in this situation, and that premature disappearance of the zona radiata will favour immediate embedding. Normally the egg-cell is fertilized in the tube during its passage from the ruptured

Gräafian follicle to the uterus. By the time it has reached the uterus the zona pellucida has disappeared owing to the histolytic (destructive) faculty of the ectoderm, and the ovum, by means of its developing trophoblast, commences to burrow into the maternal tissues. If, owing to some delay the zona pellucida has disappeared before the ovum has entered the uterus, ectopic implantation is liable to occur. Failure to reach the uterus may be brought about (1) by *external wandering*; (2) by elongation of the tube itself, (3) by the presence of some obstacle in the lumen of the tube.

There are many conditions which may *delay the passage* of a fertilized ovum through the tube, foremost amongst these is a preceding inflammation, which is very frequently of gonorrhœal origin. In the section dealing with salpingitis it will be explained that there is a loss of cilia and of epithelium, with swelling of the mucosa and fusion of plicæ; thus the lumen is narrowed and rendered very complicated by the presence of polypoidal masses of adherent plicæ and pseudo-follicles. Later epithelial crypts and diverticula form in the muscularis, and kinking may produce septa in the lumen which add to the obstruction. It is thus clear that inflammation is capable of impairing the normal function of the tube, which is the transmission of the ovum into the uterine cavity, (1) by destruction of cilia, and (2) by the formation of mechanical barriers such as kinks, crypts, and diverticula. Rabinovitz, from an examination of 147 cases, came to the conclusion that gonorrhœal salpingitis is the most common cause of *repeated* tubal pregnancy. He lays stress on the view that mucosal changes may be present in tubes which appear normal to the naked eye, so that when a normal-looking tube is left *in situ* after the removal of a tubal gestation, it may, by reason of progressive inflammatory changes in its mucous membrane, become the seat of a second tubal gestation. The same author draws attention to the fact that in cases of tubal pregnancy, not infrequently the opposite tube is found to be the seat of hydrosalpinx, pyosalpinx, or hæmatosalpinx. Dührssen, in twenty-four out of thirty-five cases, found evidence of pre-existing disease in the tubes, and considered that in most of the cases this was due to gonorrhœa. In one of our own cases there was a mole in the wall of a pyosalpinx (*see* Fig. 104) which showed old interstitial thickening of the tube-wall in keeping with a history of chronic salpingitis. Prusmann found in twenty out of twenty-eight pregnant tubes adhesions between the folds of the mucosa in portions of the tube remote from the implantation of the ovum.

Old pelvic peritonitis may kink the tube and interfere with its muscular contractions and so lead to the retention of a fertilized ovum. The preponderance of inflammatory changes in the etiology is practically illustrated by the rare occurrence of tubal pregnancy in nulliparæ and by the circumstance that it happens very frequently

after a long period of sterility, and after the occurrence of an adnexal infection has been demonstrated clinically.

Nevertheless it is quite certain that there are other causes of delay of the fertilized ovum in the lumen of the tube besides those

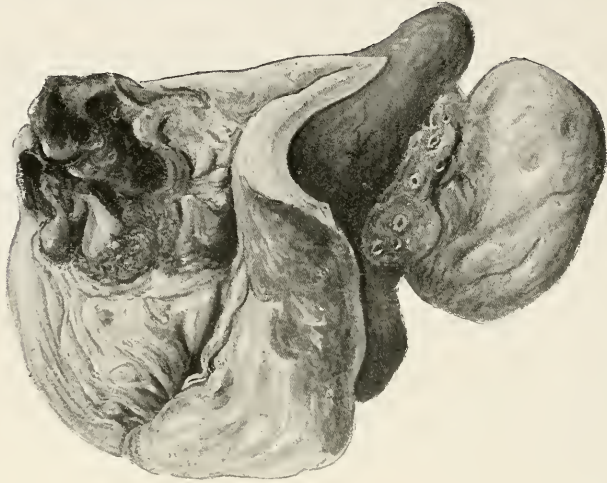


FIG. 104. TUBAL MOLE IN THE WALL OF A TUBE WHICH WAS THE SEAT OF CHRONIC SALPINGITIS PREVIOUS TO BECOMING GRAVID.

of an inflammatory origin, *e.g.* developmental errors. An ovum may find its way into a blind accessory tube and there become embedded. Congenital hypoplasia of the tubes, a condition in which the walls are thin and the tube tortuous, is said to favour tubal gestation. The

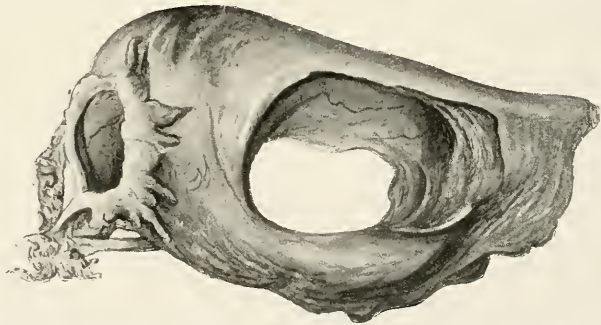
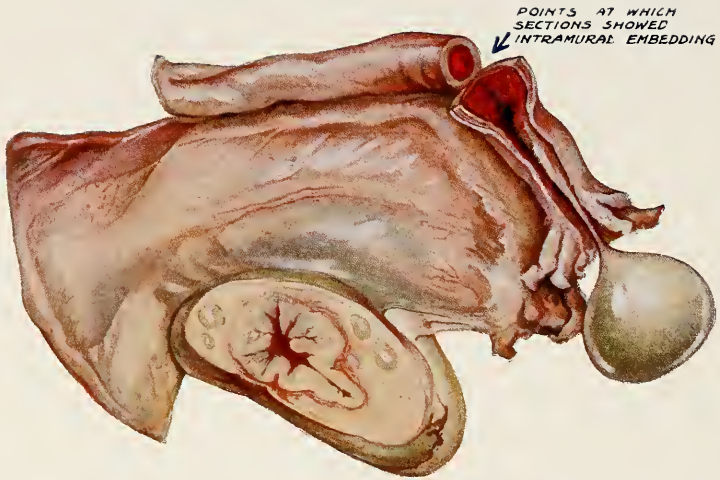


FIG. 105. GRAVID TUBE. Showing the dilated ostium through which the ovum escaped. The walls, which are ruptured, were so thin as to be nearly transparent, a condition due to congenital hypoplasia.

thin walls are thought to be lacking in the contractile power which is probably necessary for the propulsion of the ovum towards the uterus. The accompanying tortuosity is thought to offer an actual obstruction sufficient at any rate to delay the ovum until its tropho-







**INCOMPLETE TUBAL ABORTION.** The ampullary portion of the tube has been laid open to show the placental site, to which is attached the umbilical cord. The latter connects the extruded amniotic sac with the placenta. The arrow indicates the site from which the section was taken, which is shown in Fig. 108.

blast has had time to develop. Examples of hypoplasia are seen in Figs. 84 and 105. There is no fusion of plicæ in a tube which retains its infantile tortuosity, but when convolutions are produced by inflammation the plicæ will be found adherent also.

*Pregnancy in Anomalous Situations.* Pregnancy has occurred in the stump of a tube which has been removed, or in a tube left behind and ligatured after supravaginal amputation, and in the stump of the tube which had healed in the angle of the vaginal scar.

*Summary.* A tubal pregnancy is obviously due to more than one factor. It is always of the nature of an accident. The most probable *predisposing factor* would seem to be one of the mechanical conditions already described as interfering with the passage of the ovum along the tube, but it must be remembered that chronic salpingitis is certainly not present in many cases of tubal gestation. When it is present, however, it forms the most likely explanation of the accident. In 133 cases investigated by Finsterer, the course of childbed had previously been normal, and from this he concluded that an important factor in the causation must be anomalies in the fertilized ovum. The average interval between a normal pregnancy and tubal gestation was in this series seven years, so that it would seem quite impossible to exclude an intervening salpingitis.

## ANATOMY OF TUBAL PREGNANCY

Tubal pregnancy gives rise to a series of well-marked changes in the uterus, and in the affected Fallopian tube; the former are uniform and constant, the latter vary with the position of the ovum. The *uterus* always shows a certain amount of enlargement, accompanied with softening of its walls and softening of the cervix; both are recognizable clinically, although the softening of the lips of the external os is not so well marked as in uterine pregnancy. The endometrium is completely converted into a decidual membrane, indistinguishable from the decidua vera of normal uterine pregnancy (see Fig. 106). This change has been spoken of by Webster as the "decidual reaction" of the uterus. In the affected *tube* the changes are mainly confined to the neighbourhood of the ovum, distant parts showing practically no changes recognizable with the naked eye. The portion of the tube which encloses the ovum is usually called the *gestation-sac*, or *capsule*.

The fertilized ovum lodges most frequently in the *ampulla* of the tube (see Figs. 107 and 110, and Plate V), more rarely in the *isthmus* (see Fig. 111), and least frequently of all in the *interstitial* portion. Reference

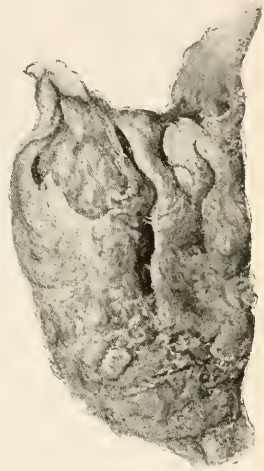

FIG. 106. DECIDUAL CAST FROM A CASE OF TUBAL PREGNANCY.

to Fig. 108 clearly shows that when lodged in the tube the fertilized ovum buries itself in the maternal tissues very much in the same manner as in uterine pregnancy. The depth to which penetration occurs varies; thus, the embedding may take place immediately

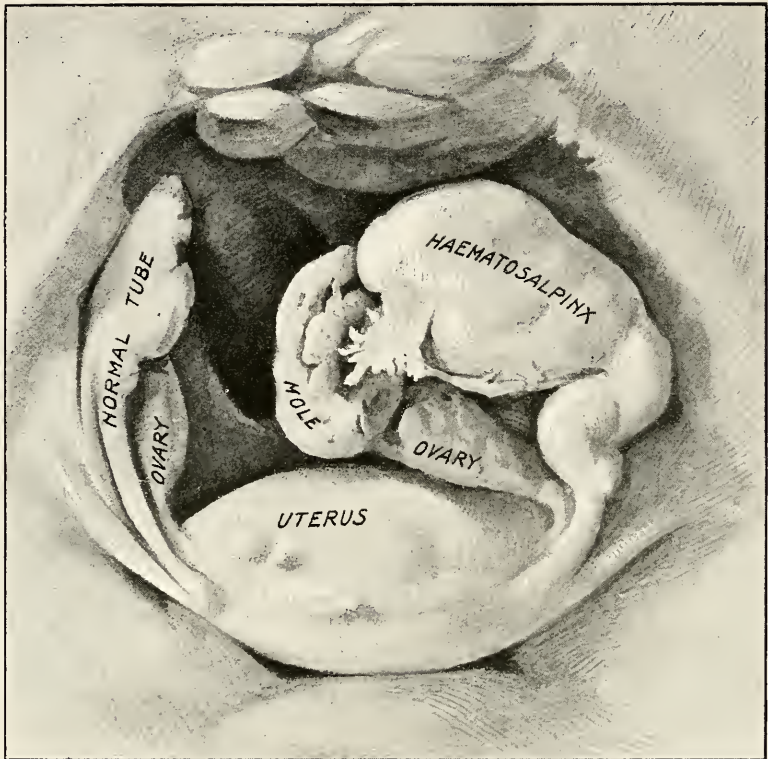


FIG. 107. TUBAL ABORTION WITH HÆMATOSALPINX (Bumm). The ovum, converted into a mole, has been expelled from the tube, the ampulla of which remains distended with blood. The gravid tube occupies the left posterior quarter of the pelvis, and is connected by a pedicle with the uterine cornu.

beneath the mucosa, *i.e.* between the latter and the muscularis, or, more commonly, the ovum burrows into the muscular wall (*see* Fig. 109). In either case the ovum develops external to the lumen, *i.e.* in the wall of the tube, and the tissues of the tube-wall form for it a *gestation-sac* or *capsule*.

In intra-uterine pregnancy the embedding is not deep; penetration never extends beyond the mucous membrane into the muscle; indeed, it does not reach very deeply into the mucosa, so that the growing embryo forms, almost from the first, a vesicular projection towards the uterine cavity. The more superficial the embedding in the tube, the more striking is the analogy of tubal pregnancy to uterine gestation. Fig. 108 shows the ovum surrounded towards the tube-lumen by

mucosa only, the latter corresponding to the decidua capsularis of uterine pregnancy. The site of the embedding in this specimen is in the *floor* of the tube, corresponding to the attachment of the mesosalpinx; this corresponds to what in uterine gestation would be called the *decidua basalis*. It must be pointed out, however, that no decidua is formed in the tube, a fact which is due to a deficiency of stroma-cells in the tubal mucosa, the latter being, as compared with the corporeal endometrium, a much thinner lining membrane. When penetration

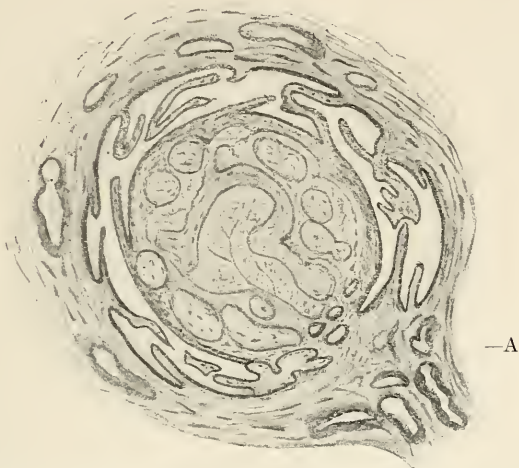


FIG. 108. Showing superficial embedding of the ovum, *i.e.* beneath the mucosa of the tube. The lumen of the tube surrounds the greater part of the ovum. The gestation-sac, or capsule, is in this case composed solely of mucous membrane. No muscle could be demonstrated in the sac, except at its attachment to the tube-wall opposite the mesosalpinx (A). This mode of embedding in the tube-wall more closely resembles the normal implantation in the uterus.

by the fertilized ovum reaches as far as the muscle-wall (*see* Fig. 109), the gestation-sac does not show a clear distinction between *capsularis* and *basalis*, and the strict analogy to uterine gestation breaks down.

As the embryo grows, the eroding trophoblast destroys the maternal tissues and eats its way into maternal blood-vessels. Hæmorrhage thus occurs within the gestation-sac or *capsule* and the latter ruptures in consequence at its weakest spot. In the majority of cases the gestation-sac or *capsules* is thinnest towards the lumen and hence hæmorrhage into the lumen is a common event; this accident is spoken of as *internal capsular hæmorrhage*. Less frequently the capsule gives way externally, *i.e.* through the peritoneum or into the layers of the broad ligament, and to this the term *external capsular hæmorrhage* is applied. The results of each type of hæmorrhage will be considered later on.

When the ovum lodges in the ampullary portion, the abdominal

ostium almost invariably becomes occluded before the end of the second month (eighth week); when the ovum lies in the isthmus or the interstitial portion, the abdominal ostium does not close (*see* Figs.

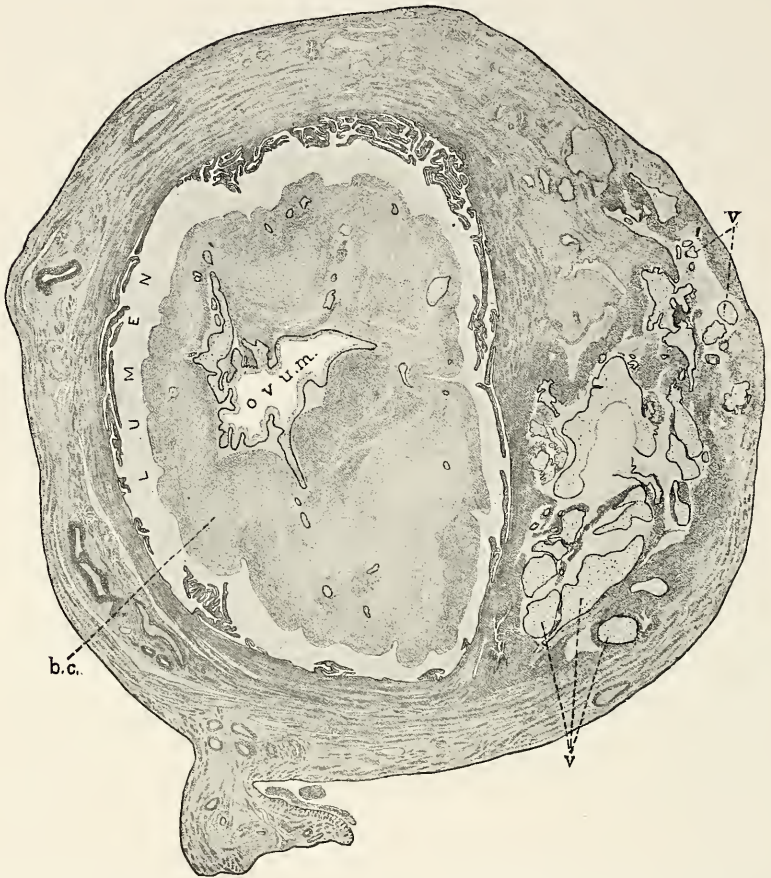

FIG. 109. SECTION THROUGH A GRAVID FALLOPIAN TUBE, ILLUSTRATING THE RESULTS OF INTERNAL CAPSULAR HÆMORRHAGE (Whitridge Williams). The ovum has escaped into the lumen of the tube; the site of the embedding in the tube-wall is shown to the right of the figure. V, Villi which have penetrated deeply into the wall of the tube; b.c., Blood clot containing chorionic villi seen in section; in the centre of the mass is an irregular space representing the amniotic sac.

110 and 111). The condition of the ostium, as will appear later, has an important clinical bearing.

The ability of the Fallopian tube to continue to accommodate the growing ovum is by no means certain; as a matter of fact it fails to do so except in extremely rare instances. It is, however, believed that genuine cases are on record of gestation continuing to term, or nearly to term, in an unruptured Fallopian tube. Failing this

event, either the ovum is destroyed, or it escapes from its cramped surroundings and pursues its development under more favourable conditions.

**I. Internal Capsular Hæmorrhage.** As a result of internal capsular hæmorrhage tubal pregnancy is terminated in one of the following

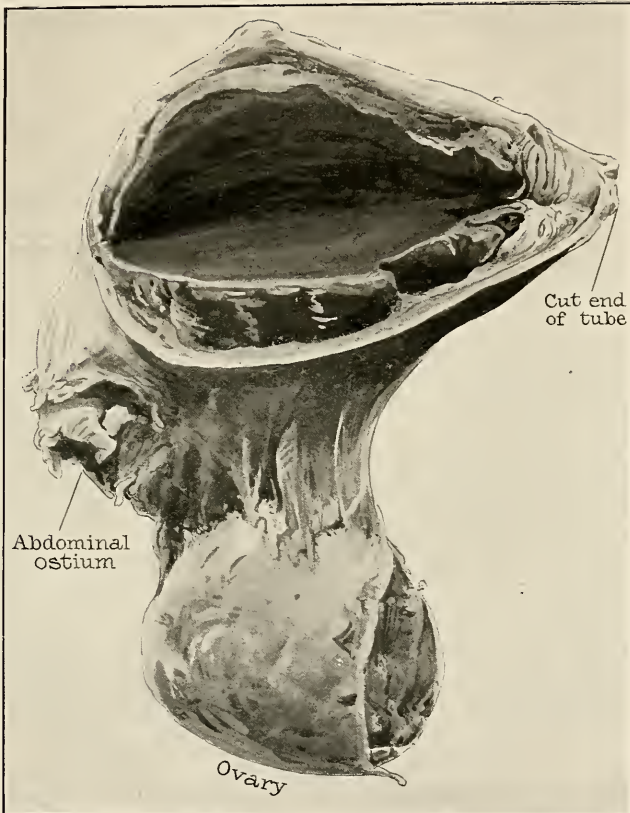

FIG. 110. TUBAL MOLE *in situ*, LAID OPEN BY LONGITUDINAL INCISION OF THE TUBE (Charing Cross Hospital Museum). The mole occupies the inner half of the ampullary portion of the tube. The abdominal ostium is patent.

ways: (1) The formation of a tubal mole; (2) tubal abortion; (3) the formation of a peritubal hæmatocele; (4) the formation of a diffuse hæmatocele.

(1) *The Tubal Mole.* This termination to a tubal pregnancy is brought about by the rupture of maternal blood-vessels caused by the eroding action of the proliferating trophoblastic investment of the chorionic villi. Blood is then poured into the ovum which, becoming over-distended, bursts through the *capsule*. Maternal and foetal blood, and finally the ovum itself, escape into the lumen of the tube. The result is a mole consisting of blood-clot, remains of the embryo, and fragments of chorionic villi, all of which form a solid mass which lies in,

and distends the lumen of the tube. The original site of implantation is marked by the presence of villi in the musculature of the tube-wall. The mode of formation of a tubal mole is well shown in Fig. 109, which represents a transverse section through a gravid Fallopian tube at the site of implantation of the ovum. The lumen of the tube is occupied by an oval mass of blood-clot detached completely from the wall; a cavity of irregular shape, representing the amniotic sac, is seen, placed somewhat eccentrically in the midst of the blood-clot. The effect of the hæmorrhage has clearly been to break up the chorion, which at this early period is covered in all parts with

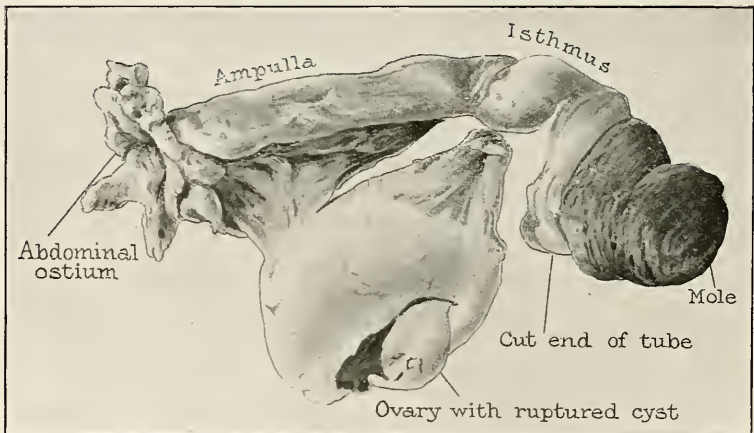


FIG. 111. TUBAL PREGNANCY OF FOUR TO FIVE WEEKS DURATION. Rupture has occurred in the isthmic portion of the tube and a small mole has been extruded. The abdominal ostium is patent, and the ampullary portion shows little alteration.

villi; many detached villi are seen in section in the blood-clot surrounding the ovum; a few are seen still retaining their attachment to the ovum; others are seen to be buried in the tube-wall and to be broken off entirely from the ovum. There is no appreciable thinning of the wall of the tube except at the right of the figure, where chorionic villi can be seen to have penetrated nearly as far as the peritoneal investment, thus breaking up the muscular wall of the tube. This area represents the position of the pit in which the ovum was originally imbedded. Remains of the branching plicæ of the tubal mucosa are also seen flattened out against the tube-wall, which indicate that the ovum has lodged in the ampullary portion of the tube. In Fig. 110 are seen the naked-eye appearances of a tubal mole *in situ* laid open by longitudinal section; the tube was removed on account of hæmorrhage through the unsealed abdominal ostium.

In tubal pregnancy the frequency with which moles occur is far greater than in the case of uterine pregnancy, probably on account



of the greater insecurity of the ovuline attachments in the former. The formation of a mole is usually accompanied by more or less hæmorrhage through the unsealed abdominal ostium. The ovum is, of course, destroyed by this process ; small moles may perhaps be retained in the tube and gradually disposed of by absorption ; larger moles are usually expelled by tubal rupture or abortion. Suppuration of a mole retained in the tube probably only occurs as the result

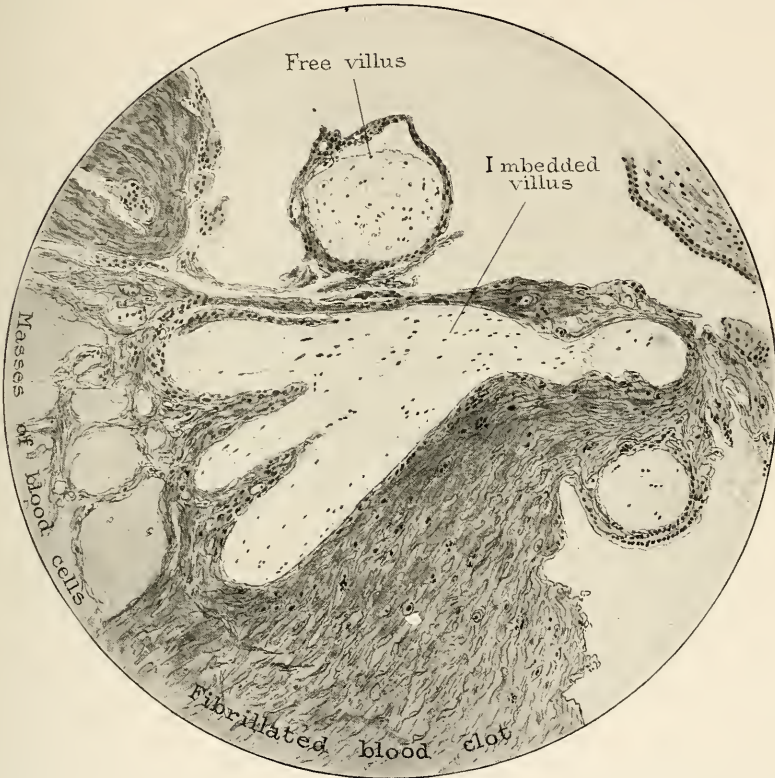


FIG. 112. CHORIONIC VILLI FROM A TUBAL MOLE. The large imbedded villus is seen to have lost its epithelial covering ; its stroma contains very few nuclei. The free villi have preserved their epithelium, which consists of a double row of cells. Syncytial buds in section are seen on the left side in the upper part of the figure.

of some form of infection, such as sepsis, gonorrhœa, or bowel-infection.

In operating on cases of tubal gestation, a mole is frequently found among the blood effused into the peritoneal cavity by rupture or abortion ; it exactly resembles a lump of blood-clot, and may remain unnoticed unless carefully looked for. Small moles are nearly globular (*see* Fig. 111) ; larger ones are oval in shape, heavier, and firmer than simple clotted blood (*see* Fig. 110) ; they often show remains of the amniotic sac on section, and on microscopic examination, after

suitable hardening, are found to contain chorionic villi imbedded in clotted blood. The embryo is very rarely discovered.

The recognition of chorionic villi under these conditions is a matter of some clinical importance. As shown in Fig. 112, some are free, others imbedded in the blood-clot. The former are covered by epithelium, definitely recognizable as that of the chorion, since it is composed of two layers—the outer layer consisting of irregularly nucleated plasmodium (the syncytium), the inner layer consisting of a single row of low columnar cells (Langhans' layer). The latter have almost completely lost their epithelium, while the stroma of all the villi has undergone considerable degeneration and appears structureless. After the destruction of the ovum the epithelium retains its vitality for a longer period than the stroma; this difference is due to the fact that the former is normally nourished directly by the maternal blood, with which it is always in contact, while the latter is normally nourished by the blood in the foetal capillaries. The epithelium can therefore draw nourishment from the effused blood in a mole, and thus survive, while the stroma, being suddenly cut off from its source of nutrition, perishes with the embryo. Owing to survival of the epithelium, villi can be recognized in a mole many weeks after its formation. Around the villi is seen blood-clot, in varying degrees of contraction, *i.e.* with a variable amount of fibrinous network. Sometimes quite fresh-looking villi may be found in a recent tubal mole.

(2) *Tubal abortion* occurs frequently in ampullary pregnancy, while the abdominal ostium remains patent, *i.e.* during the first two months of gestation; it is believed that it occurs almost as commonly as rupture in this variety of tubal pregnancy. In the isthmic and interstitial varieties, however, rupture is much more frequent than abortion; in the latter variety tubal abortion consists in the discharge of the ovum through the uterine ostium into the *uterine* cavity. An aborted tubal ovum, as a rule, has been previously converted into a mole, but this is not always the case. The process of abortion is seen in Fig. 113, which shows that the mole has been partly expelled through the dilated abdominal ostium. The main factor in its production is undoubtedly muscular contraction of the unaffected portions of the tube; the process constitutes a miniature labour, consisting of a stage of dilatation followed by a stage of expulsion, which again is succeeded by a stage of retraction. The developmental unity of the uterus and Fallopian tubes no doubt accounts for this physiological analogy. The contractions are perhaps reflexly excited by hæmorrhage into the ovum, causing sudden distension of the tube. The expulsion of the ovum may be *complete or incomplete*; in the latter the ovum is detained in the insufficiently dilated abdominal ostium, or a portion of it may remain attached to the original implantation-site of the ovum, the bulk of which has

been expelled. Here again the analogy with uterine abortion will be obvious. Tubal abortion may be attended by severe internal bleeding, equal in severity to that caused by rupture; when complete its result, as regards the ovum, is invariably to destroy it. After the expulsion of the ovum the tube usually remains considerably distended with blood (Fig. 113), but it is believed that it may rapidly retract and resume its normal shape and calibre, leaving no trace

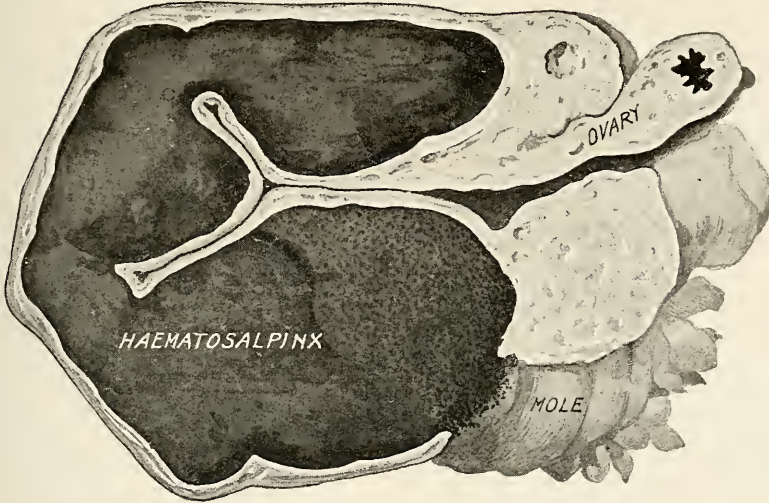


FIG. 113. TUBAL PREGNANCY, TERMINATING IN ABORTION. The tubal mole is seen partly extruded through the abdominal ostium. The tube is convoluted and its walls thickened from chronic salpingitis; its humen is dilated and full of blood.

to the naked eye of having been recently gravid. It is impossible to distinguish tubal abortion from tubal rupture by clinical diagnosis.

(3) *Peritubal Hæmatocele*. The abortion of the ovum seldom occurs with the first hæmorrhage, the whole process may take days or even weeks. The blood may at first escape from the ostium in small quantities, and mixed as it is with fragments of necrotic tissue, it may clot around the ostium and not be absorbed. The outer layers of the coagulum become organized into fibrous tissue. Thus an encapsulated clot is formed around the patent, fimbriated end of the tube, which increases in size by what Handley describes as the hæmodynamic pressure produced by recurring hæmorrhage within the tube. The term *peritubal hæmatocele* has been applied to the mass which is produced in this way. Fig. 114 shows a good example of the peritubal variety of discrete hæmatocele. The tube has been partially dissected from the false capsule which embraced its fimbriated extremity, in order to demonstrate the patent ostium into which a bristle has been passed. The ampullary segment of

the tube, which was the seat of the gestation, is seen to be distended, whilst the isthmic portion is normal.

Peritubal hæmatoceles form hard discrete tumours which are prone to acquire adhesions to the surrounding structures. When the clinical history is indefinite, they may be diagnosed as uterine myomata or solid tumours of the ovary, or more frequently as tubo-ovarian masses of inflammatory origin.

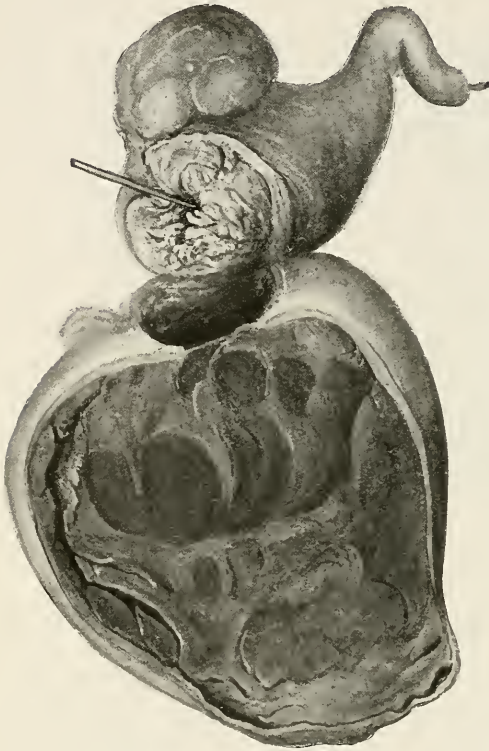


FIG. 114. PERITUBAL HÆMATOCELE.

(4) *Diffuse Hæmatocele.* A far more frequent occurrence than the formation of a peritubal hæmatocele is that of a diffuse or retro-uterine hæmatocele. The escape of blood is too extensive to allow of clotting and the formation of a capsule around the ostium of the tube, and the blood is therefore poured into, and fills, the pouch of Douglas. The clot thus formed is bounded below by the floor of Douglas' pouch, in front by the uterus and broad ligaments, whilst above it becomes shut off by a false membrane, adherent coils of intestine and omentum. The adhesions in these cases may be so dense as to resemble the capsule of a cyst. In such an encapsulated mass of blood lies the ovum in the form of a mole, or the latter may be found still detained in the dilated ostium of the tube.

**II. External Capsular Hæmorrhage.** The second possible ending to a tubal pregnancy is for the *capsule* to rupture, not into, but outside, the lumen of the tube. In these cases the muscularis has been so thinned by the eroding action of the trophoblast that the capsularis ruptures through the peritoneal coat of the tube, or into the broad ligament. This is called *external capsular hæmorrhage* or *tubal rupture*. The process by which this occurs is just the same as that which occasions internal capsular rupture or abortion, but here the eroding action of the trophoblast first destroys the muscularis right up to the peritoneum; then comes a time when the tube-wall is so eroded that the external boundary of the ovum is only composed of trophoblast and fibrinous tissue. When this stage is reached a sudden rent may occur externally (*tubal rupture*), and violent hæmorrhage may result. More

rarely, villi are seen to project here and there covered only with blood-clot, which overlies and encloses miniature leakages. This is spoken of as a *latent rupture*, and leads to the formation of a *paratubal hæmatocele*.

(1) *Paratubal Hæmatocele*. Leakages may occur at various points around the ovum, and by the resulting clot increasing in size a discrete or solitary hæmatocele is produced in the same way as was seen to happen in the case of tubal abortion. In this case a false capsule is formed which embraces the part of the tube surrounding the leaking point or points. As only a part of the circumference of the tube is enveloped by the encysted clot, the term *paratubal* is applied to this variety of hæmatocele. Fig. 115 shows this condition. The false capsule has ruptured, and its contents are seen in the upper drawing, the rupture occurred in the narrow portion of the tube internal to the ampulla.

(2) *Tubal Rupture*. In whatever part of the Fallopian tube the fertilized ovum may be lodged, there is a tendency to the occurrence of spontaneous rupture. In the isthmic and interstitial varieties rupture is apt to occur earlier than in the ampullary variety, owing to the fact that the lumen of the tube is larger and more dis-

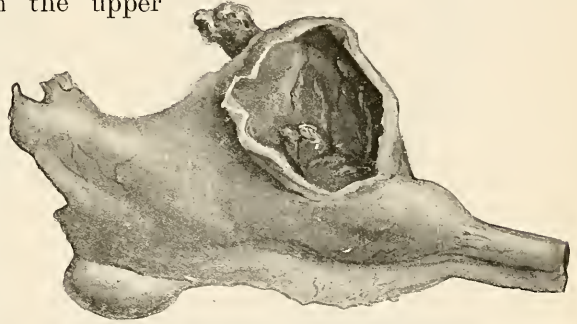


FIG. 115. PARATUBAL HÆMATOCELE. A false capsule has formed, around a leak, at the junction of the isthmic and ampullary portions of the tube.

tensible at the ampulla than it is in the interstitial and isthmic segments. Between the eighth and tenth weeks is the commonest time for rupture to occur, but it may be earlier or later than this. The conditions which predispose to rupture have been mentioned, viz. thinning of the tube-wall by distension, and the eroding action of the villi. In addition, there is probably a determining cause in most instances, such as a sudden increase in size of the ovum from hæmorrhage, or slight increase in vascular tension from some muscular effort on the part of the patient. Occasionally the eroding action of the villi alone will determine spontaneous perforation of the wall of the tube. Occlusion of the abdominal ostium is not an essential factor in the causation of rupture, for this accident frequently occurs without it (see Fig. 105, p. 196), even in the ampullary variety. Any part of the wall of the distended portion of the tube may burst.

The results of rupture, in so far as the life of the ovum is

concerned, depend to a great extent upon the position of the rent. If occurring upon the roof or sides of the tube the rupture will involve the peritoneal covering, and the blood effused will therefore be poured out into the general peritoneal cavity, while the mole may be completely expelled through the rent (*see* Figs. 116 and 117). If, on the other hand, the tear takes place in the floor of the tube, the

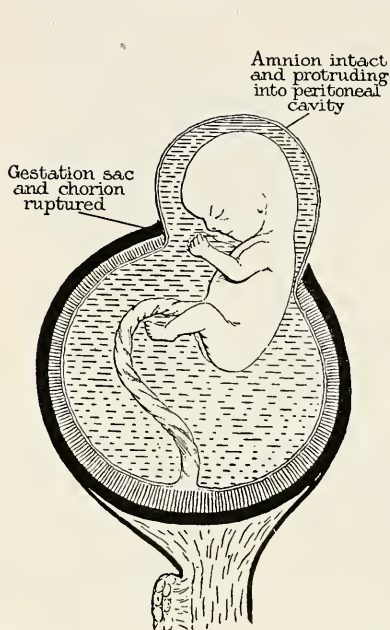

FIG. 116. INTRA-PERITONEAL RUPTURE OF THE TUBE (diagrammatic; after Giles). The chorion has been torn, but the amnion remains intact, the foetus contained within it; the placental portion of the chorion is uninjured. The foetus may survive.

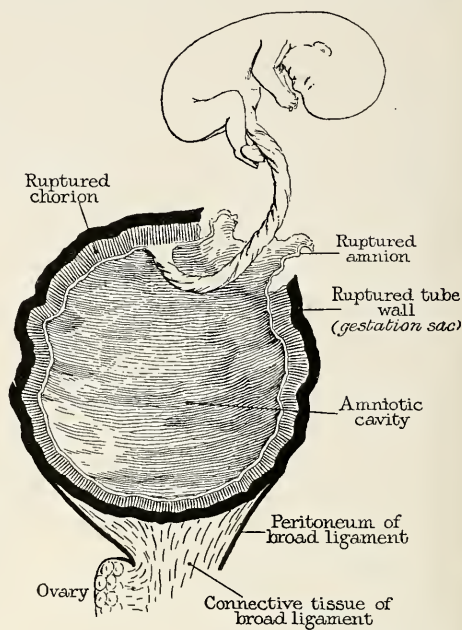


FIG. 117. INTRA-PERITONEAL RUPTURE OF THE TUBE (diagrammatic; after Giles). The chorion and amnion have both been torn, and the foetus has escaped from the gestation-sac; the placental portion of the chorion is injured. The foetus will perish.

peritoneal coat may escape, while the effused blood and the discharged ovum will make their way between the layers of the broad ligament, gradually separating these peritoneal folds and burrowing in the connective-tissue which this ligament contains (*see* Figs. 118 and 119). This form of rupture is very uncommon and occurs mainly in cases of isthmic pregnancy, since the lower wall of this portion of the tube is less completely invested by peritoneum than the ampulla. The former is known as *intra-peritoneal* rupture, the latter as *intra-ligamentary* or *extra-peritoneal* rupture. In both varieties the ovum is, as a rule, destroyed by previous hæmorrhage and converted into a mole. Apart from hæmorrhage, death of the ovum also inevitably follows (*a*) if the amnion is ruptured, or (*b*) if the placental portion of the chorion is lacerated or detached by the rupture (*see* Figs. 117 and

119). Occasionally, however, the ovum may continue its development, and in such cases it is observed that the amnion has remained intact, and that the placental chorion was so situated as to escape injury from the rupture (Figs. 116 and 118). In intra-peritoneal rupture the placenta then grows out of the rent in the tube and becomes attached to the neighbouring peritoneal surfaces, while layers of lymph

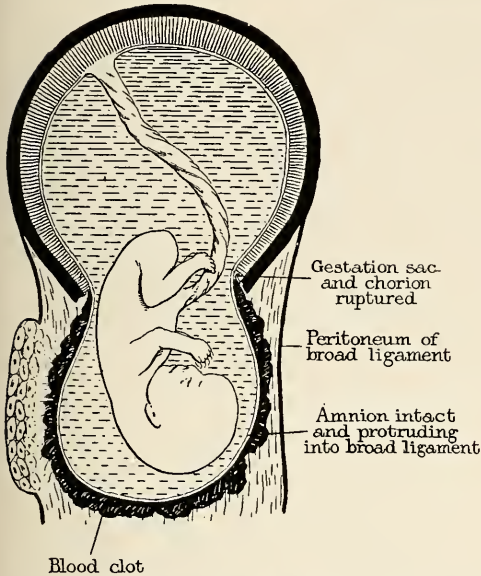


FIG. 118. INTRA-LIGAMENTARY RUPTURE OF THE TUBE (diagrammatic; after Giles). The amnion and the placental portion of the chorion are uninjured. The fœtus may survive.

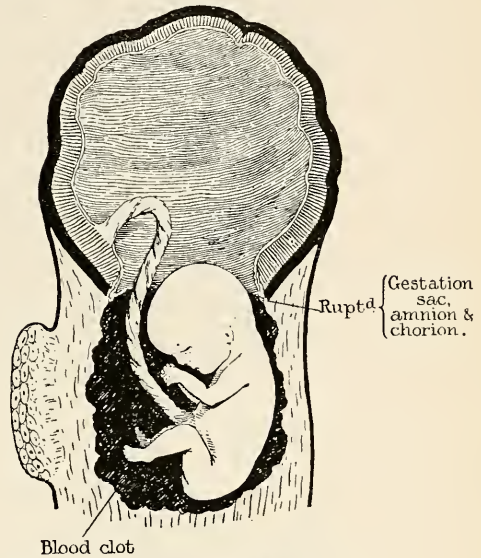


FIG. 119. INTRA-LIGAMENTARY RUPTURE OF THE TUBE (diagrammatic; after Giles). The chorion and amnion have both been torn, and the placental portion of the chorion is injured. The fetus will perish. Bleeding is intra-ligamentary.

are deposited upon the exposed amnion from the surrounding peritoneum, forming a false membrane, which constitutes a secondary gestation-sac (*tubo-abdominal gestation*). This secondary sac becomes further strengthened by adhesion to the neighbouring peritoneal surfaces, including omentum (see Figs. 120 and 121), coils of intestine, and the abdominal parietes. The ovum is now known as a *secondary abdominal (intra-peritoneal) pregnancy*. Precisely similar results may follow extra-peritoneal rupture, and for the same reasons; the condition is then described as *secondary abdominal (intra-ligamentary) pregnancy* (see Figs. 118 and 122). Intra-ligamentary pregnancy may undergo *secondary rupture* into the peritoneal cavity (Fig. 122); even then the ovum is not in all cases destroyed, but may continue to survive as also happens in the case of an intra-peritoneal pregnancy (see Figs. 120 and 123).

Both intra-peritoneal and intra-ligamentary pregnancy may continue to term; the patient then usually passes through a 'false

labour' and the foetus perishes. The occurrence of this false labour is a physiological point of great interest and importance, but we have no information as to its causation, or the mode in which it leads to the death of the foetus. False labour is attended with severe abdominal pain, which is mistaken by the patient for labour, but there

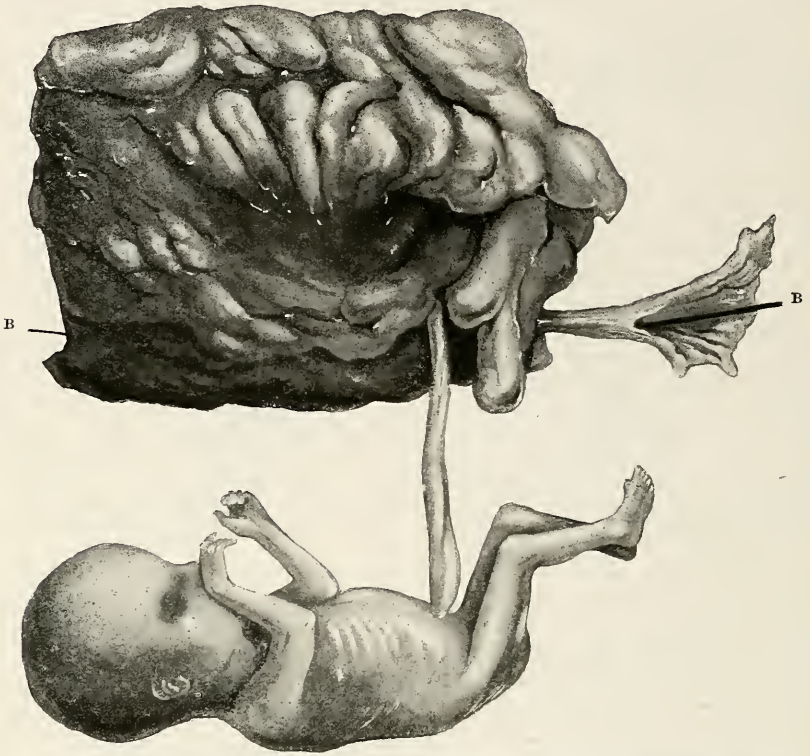


FIG. 120. MASS OF OMENTUM COILED AROUND A SECONDARY GESTATION-SAC ABOVE A RUPTURED FALLOPIAN TUBE. A bristle (B-B) has been passed along the tube. The foetus continued to develop for sixteen weeks after the primary rupture (Routh and Lockyer).

is no clinical evidence that uterine contractions play any part in its production.

In the intra-peritoneal form of secondary abdominal pregnancy the gestation sac consists of a membrane which is largely inflammatory in origin, and is composed of layers of lymph deposited upon the amnion, in which organization has proceeded to a variable extent. The membrane becomes closely adherent internally to the amnion, externally to the abdominal walls, and to the viscera, which structures support it and add to its strength. A great deal of the placental blood-supply is obtained from adherent omentum and mesentery. In this form of pregnancy the placenta generally lies below the foetus.

In the intra-ligamentary form the gestation-sac consists of the



tissues composing the broad ligament, which are progressively expanded as the foetus grows. This process involves great changes in the anatomical relations of the parts. Thus the peritoneum is raised from the pelvis, and stripped off the anterior abdominal wall, so that the reflection which corresponds to the floor of the utero-

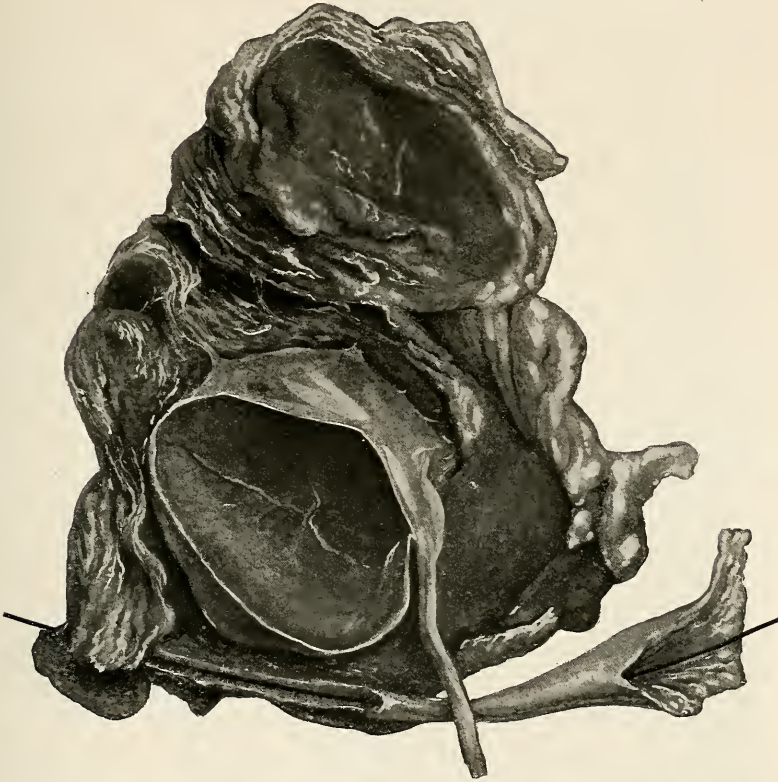


FIG. 121. The same specimen as shown in Fig. 120 (Routh and Lockyer). The omentum has been folded back to expose a secondary gestation-sac lying within it and above the Fallopian tube. The latter is seen to have ruptured through its isthmic portion.

vesical pouch may exceed the height of the umbilicus. To this condition the term *anterior subperitoneal pregnancy* is given. Posteriorly the foetus may be accommodated in a sac formed by the elevation of the peritoneum of the posterior layer of the broad ligament, and then that of the pouch of Douglas and that of the posterior pelvic wall. Finally, the mesocæcum or mesosigmoid may be opened up by this the so-called *posterior subperitoneal pregnancy*. An incidental result of these changes is that in the *anterior* cases the sac may be opened by an abdominal incision without traversing the peritoneal cavity at all, whilst in *posterior* cases the foetus may lie in a peritoneal sac which, on opening the abdomen, may be everted

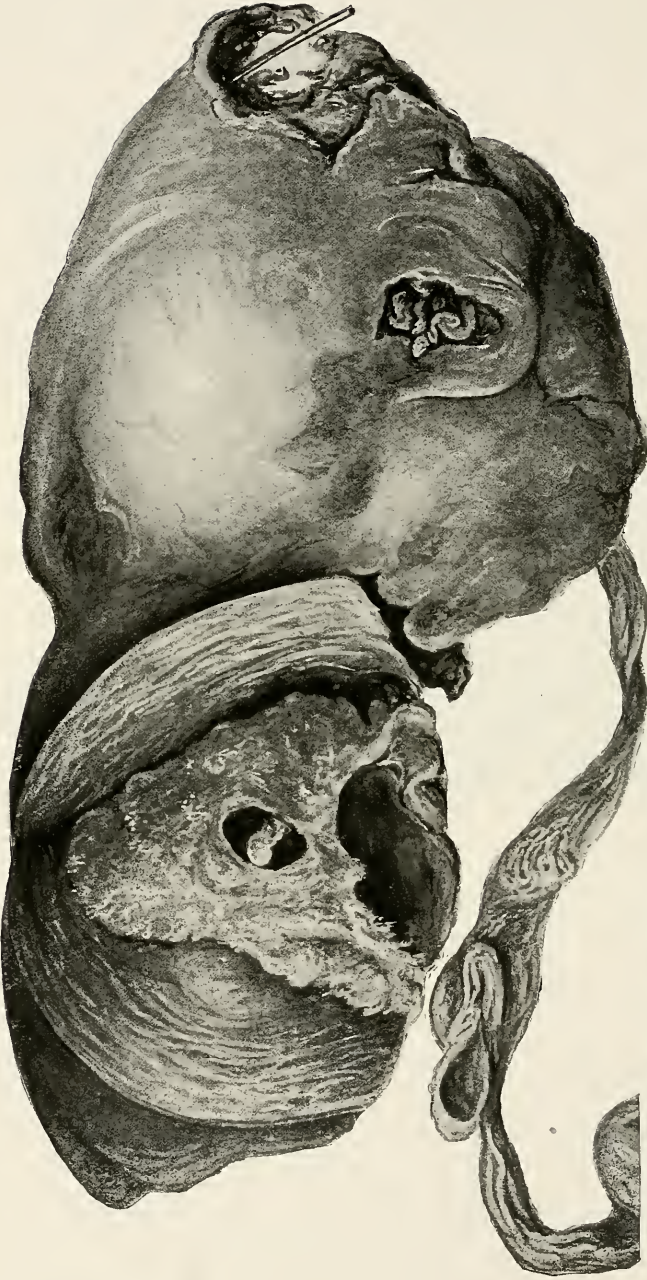

FIG. 122. Showing intra-ligamentary pregnancy of the right side. The uterus has been opened up from behind; it shows the decidua of pregnancy *in situ*. The fetus lay below the placenta and had escaped into the peritoneal cavity by secondary rupture of the gestation-sac. The umbilical cord is seen issuing from the bottom of the broad ligament. A bristle lies in the Fallopian tube at the top of the expanded broad ligament.

almost as freely as is possible with the gravid uterus, so that, as Taylor has pointed out, this variety of intra-ligamentary pregnancy is not entirely extra-peritoneal.

In cases of intra-ligamentary gestation the relation of the placenta to the fœtus is of importance. It was seen that in the secondary

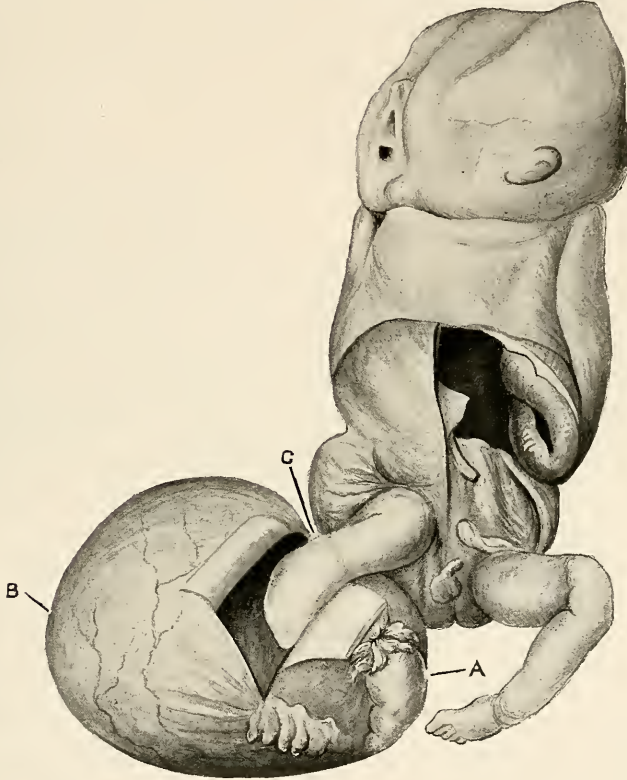


FIG. 123. TUBO-ABDOMINAL PREGNANCY, from a sketch by one of the authors of a specimen shown by Dr. J. B. Hellier. A, Ampulla of tube; B, Primary tubal gestation-sac; C, Foot of fœtus within gestation-sac. The rest of the fœtus had escaped into the peritoneal cavity.

abdominal (intra-peritoneal) pregnancy the fœtus generally lies above the placenta. In the intra-ligamentary variety the fœtus lies generally below the placenta (see Fig. 122). By the growth of the fœtus the placenta becomes displaced progressively upwards which causes its detachment from its original connections with consequent death of the fœtus. A point of importance in posterior subperitoneal gestation is the close relationship of the sac to the rectum, which leads to frequent infection. Hence it is that in this variety suppuration and the discharge of foetal bones *per rectum* is known to occur.

In a true broad-ligament gestation the ovary and its ligament will lie outside the sac, stretched out either on its posterior surface

or on the summit, or even on its anterior wall. The localization of the ovary is a matter of importance because a condition known as *pseudoligamentary* gestation is apt to be confused with and spoken of, as gestation between the layers of the broad ligament. In the false variety the fœtus is contained within the ampullary portion of the tube, which becomes adherent to the posterior surface of the broad ligament, the latter being stretched over the sac like a cap. In these cases the ovary lies in front of the gestation sac, between it and the posterior surface of the broad ligament.

Many cases are on record, both in ancient and in modern times, in which an extra-uterine fœtus has been retained within the abdominal

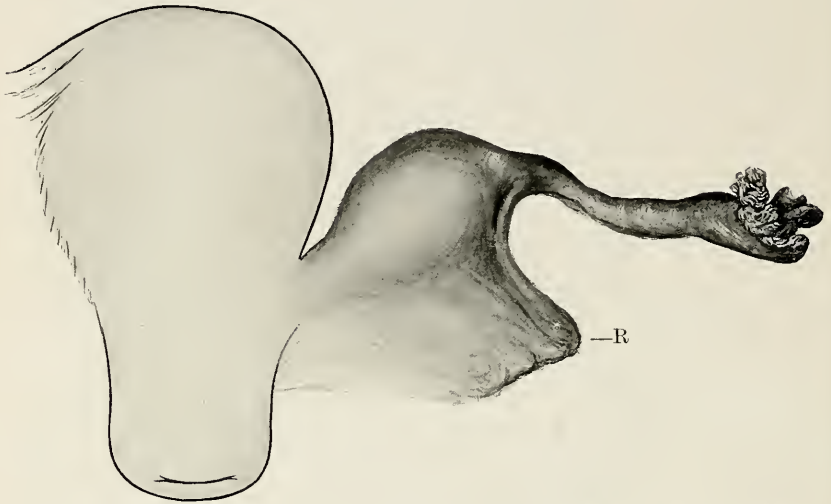


FIG. 124. ACCESSORY HORN ATTACHED TO THE LEFT SIDE OF A WELL-FORMED UTERUS. (Diagrammatic, the uterus was not removed.) The round ligament (R) is seen coming off from the outer side of the horn. There was no communication between the accessory horn and the normal uterine cavity.

cavity for many years after its death. In some of these cases the gestation-sac has become infected from the bowel or the uterus, and suppuration has occurred, resulting in the formation of fistulous communications with the exterior, or with the neighbouring hollow viscera—large intestine, bladder, and vagina. Through these fistulæ, fetal bones are from time to time discharged. When, however, the sac remains free from infection, the body of the fœtus shrinks by absorption of its fluid constituents, and upon the dried tissues lime-salts become freely deposited, converting it into a *lithopædion*. In this condition it may be retained for many years with little disturbance to the patient.

**Pregnancy in the Accessory Horn of a Uterus Bicornis.** This interesting phenomenon has been repeatedly mistaken for tubal pregnancy, from which it is distinguished by the different relation-

ship borne by the round ligament in the two conditions (see Fig. 124). In the case of tubal pregnancy the round ligament is attached to the inner side of the gestation-sac, whilst in cornual pregnancy it comes off the outer side of the sac.

In the majority of cases the band of union connecting the rudimentary or accessory horn to the uterus is solid, so that spermatozoa cannot enter this horn direct. In such cases external migration of the *spermatozoa* across the peritoneal cavity must take place if pregnancy occurs. The corpus luteum is then found in the ovary of *the same side* as the gravid horn, as shown in Fig. 125. In other

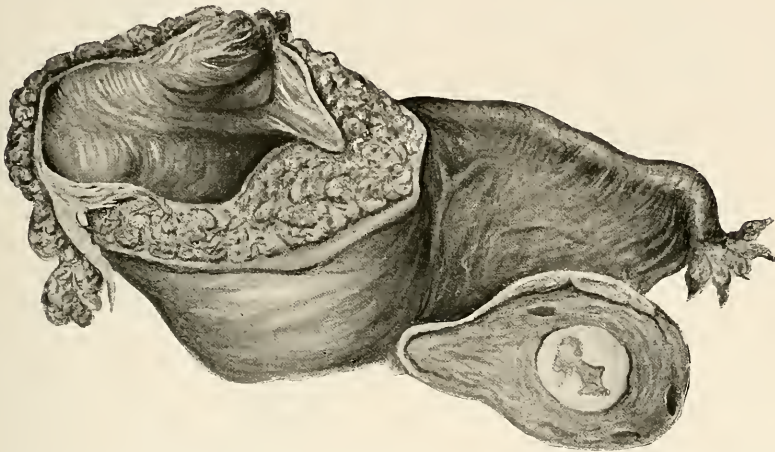

FIG. 125. PREGNANCY IN ACCESSORY HORN OF A BICORNUTE UTERUS SEEN FROM BEHIND. Rupture has occurred through the upper pole of the sac. The ovary contained a corpus luteum of pregnancy (Doran and Lockyer).

instances, where the corpus luteum is in *the opposite ovary*, external migration of the *ovum* must have occurred, either before or after fertilization. In Fig. 125 the accessory horn shows a broad pedicle which was found on microscopic section to be blind. In the majority of cases the pedicle is narrow and long, allowing a considerable amount of mobility to the horn.

Rupture of a gravid horn generally occurs through its upper and inner wall, and is preceded by a gradual process of thinning (see Fig. 125). There is no decidua formation in an imperfectly developed horn (see Fig. 126) so that the eroding power of the trophoblast acts directly on the muscle-fibres in a way similar to that seen in tubal pregnancy, where it is also unchecked by a decidua. Contributing factors in the causation of rupture are found in the cornual contractions and in the increased tension due to the growth of the ovum within the sac. Some accessory horns are sufficiently well developed to allow pregnancy to continue to term. More often the musculature is feebly developed, and then rupture generally occurs at or before

the sixteenth week of pregnancy. If pregnancy goes to term a false labour occurs, the foetus dies and is retained, when it may become

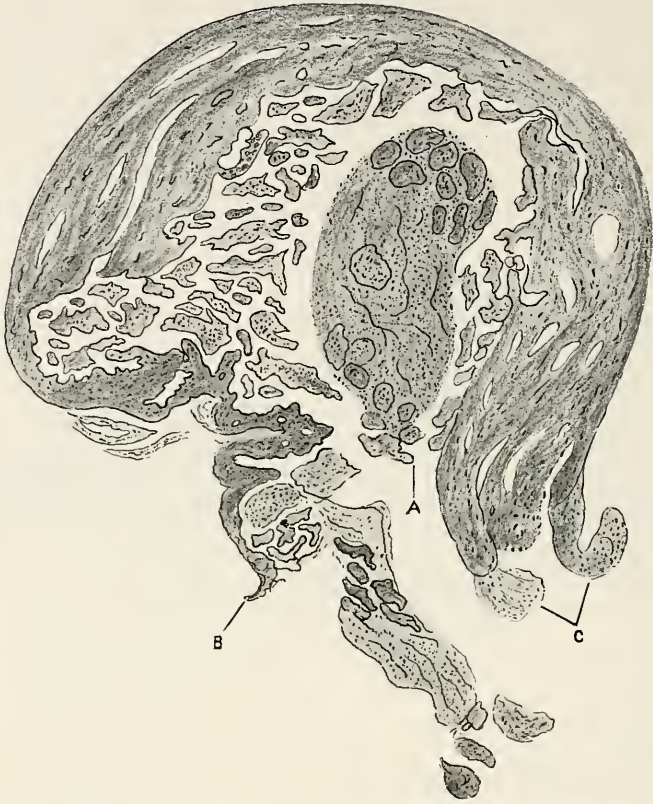


FIG. 126. TRANSVERSE SECTION THROUGH THE SITE OF RUPTURE OF CORNUAL PREGNANCY. Erosion of the muscular layers of the horn is well shown. A, Portion of placenta in lumen of horn ; B, Muscle laminae thinned out and plicated ; C, Thick muscle laminae which have retracted after rupture and expulsion of foetus.

macerated, only the bones remaining, or it may be converted into a lithopædion.

### CLINICAL FEATURES OF TUBAL PREGNANCY

This subject will be considered in relation to three stages : I. Before the occurrence of hæmorrhage ; II. After that occurrence ; III. In secondary abdominal pregnancy.

**I. Before the Occurrence of Internal Hæmorrhage.** At this time tubal pregnancy gives rise to little more local or general disturbance than does an early pregnancy in the uterus. When a healthy adult woman, who is usually regular, goes for several weeks over the expected

date of her period, there is a strong presumption of pregnancy, but at this time there may be nothing to indicate whether pregnancy is uterine or extra-uterine. The general signs and symptoms of pregnancy, such as amenorrhœa, morning sickness, and slight mammary changes are often met with, but in something like 30 per cent. of cases there is no definite interruption of the periods, as irregular bleeding makes its appearance at or before the time when the first period following conception becomes due. The occurrence of uterine bleeding probably indicates that hæmorrhage has occurred either into the gestation-sac or into the tube-lumen; it follows, therefore, that this change may be expected by the end of the first month in about 60 per cent. of cases. In the remainder, amenorrhœa may persist for a period of two to three, or exceptionally, four or five months. During this time the only symptom likely to be met with apart from those of pregnancy is recurrent attacks of spasmodic abdominal pain, which is often referred to the affected side (Blacker). This is probably due to acute distension of the tube, for it is certain that hyperplasia does not occur in the gravid tube comparable to that seen in the gravid uterus; dilatation in the tube is therefore *passive*, not *active*. The occurrence of attacks of abdominal pain in early pregnancy should always arouse the suspicion of an ectopic gestation, and must be regarded as indications for an internal examination.

*Physical Signs.* The presence of signs of mammary activity are of importance only in a woman who has never before been pregnant; the most important point is hypertrophy of some of the lobules of the gland, often those in the upper and outer quadrant. On vaginal examination softening of the lips of the external os may be detected, and this forms one of the most reliable signs of early pregnancy. The body of the uterus may be found to be somewhat enlarged and of softish consistence.

The *unruptured gravid tube* forms an elastic swelling lying as a rule posteriorly or postero-laterally to the uterus (Fig. 107); it may in rare cases be found in the utero-vesical pouch. Pulsating vessels are often to be felt beneath it. Its physical characters do not distinguish it from tubal enlargements due to other causes, and its nature can only be inferred from the accompanying symptoms.

Care is required in distinguishing tubal pregnancy from a *small ovarian cyst associated with early uterine pregnancy*. Before the eighth week the uterine changes characteristic of pregnancy cannot be definitely recognized even under anæsthesia, and herein lies the chief difficulty of the differential diagnosis. Cervical softening will be present in both cases. If slight uterine hæmorrhage is present, this in no way assists the diagnosis, for it often occurs from the gravid uterus. The character and position of the swelling are not essentially different in the two cases, but the presence of definitely pulsating

vessels *on the affected side only* is favourable to a diagnosis of tubal pregnancy. Rapid increase in size, as determined by repeated examination, is the surest differential point, but when in doubt it is always better to operate.

It appears certain, from clinical observation, that symptoms other than those just described do not occur until hæmorrhage has taken place—either into the tube itself, into the peritoneal cavity, or into the broad ligament. In the majority of cases the first sign of disturbance is the occurrence of a little external bleeding from the uterus (metrorrhagia), which may precede, by a few days, any of the more serious symptoms which inevitably follow. These symptoms, which will be described below, are commonly regarded as the symptoms of extra-uterine gestation, but they are in reality *secondary* symptoms, inasmuch as they result not directly from the gestation, but from certain disturbances which either destroy the ovum or greatly modify the course of its development. Naturally the secondary symptoms are not uniform, for they depend upon the nature and extent of the damage which has been sustained by the ovum and the tube. In any case a marked and rapid transformation of the clinical features takes place as soon as the normal course of gestation is disturbed.

**II. After the Occurrence of Internal Hæmorrhage.** The uterine hæmorrhage continues and is usually steady, not irregular, moderate in amount, and dark in colour. Separation and discharge of the decidua may also occur, sometimes in the form of a complete cast of the uterus (*see* Fig. 106), more often in fragments; in some cases the discharge of the decidua is not recognized at all, and it is possible that it may be cast off gradually in the form of *débris*. The characters of the decidua are definite and uniform, and their recognition may be of considerable help in diagnosis.

The decidual membrane is smooth upon its inner and rough upon its outer surface, which is also often beset with small papillary elevations. Microscopically, it is seen to consist of a superficial compact layer, and a deep reticulated or cavernous layer (*see* Fig. 127). The surfacetepithelium is almost entirely lost, and very few glands are to be found in the compact layer, which consists of closely packed masses of oval, round, or polygonal cells with large globular nuclei—the *decidual cells*. Many large venous sinuses and numerous interstitial hæmorrhages, sometimes of large size, are commonly found in this part of the membrane after it has been shed. The deep layer contains many irregularly dilated glands, in most of which the epithelium is fairly well preserved. The presence of decidual cells in small numbers, in tissue passed from the uterus, is not of much importance, but a membrane possessing the characters above described is distinctive of pregnancy. In cases of uterine pregnancy (abortion) traces of chorionic villi, or of chorionic epithelium, will usually be found



attached to the decidual membrane, but naturally this will not be found in extra-uterine pregnancy.

The clinical results of internal bleeding in tubal pregnancy are variable and mainly depend upon two factors, viz. the *amount* and the *rapidity* of the bleeding. If the hæmorrhage is rapid and the amount of blood lost great, the effused blood becomes distributed over the general peritoneal cavity, and tends to accumulate in the

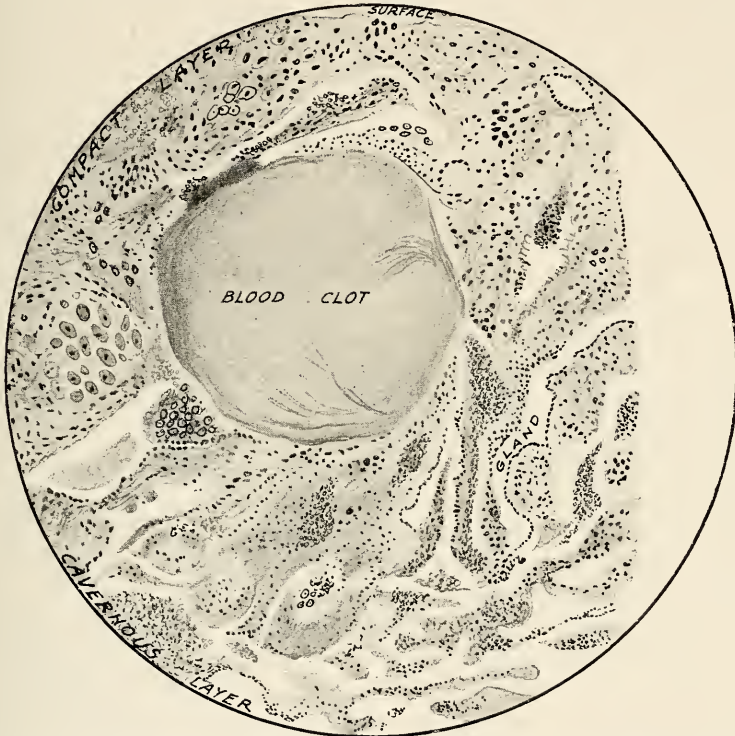


FIG. 127. DECIDUAL CAST FROM A CASE OF EXTRA-UTERINE GESTATION. A large interstitial hæmorrhage is seen in the centre of the membrane; to the left are seen clusters of decidual cells.

most dependent parts, viz. the pouch of Douglas or the renal pouches; this is the *diffuse* type sometimes spoken of as 'intra-peritoneal flooding.' If the hæmorrhage is slow or the amount small, the effused blood becomes quickly shut off from the general peritoneal cavity by the formation of lymph around it; this is the *encysted* type.

*A. Diffuse Type of Intra-peritoneal Bleeding.* Occasionally a single hæmorrhage occurs so rapid and profuse as to cause death in a few hours, before surgical aid can be obtained. Blacker has recorded a case which ended fatally in twenty minutes. It may ensue with this appalling suddenness when there has been no previous warning

of anything abnormal except perhaps the occurrence of attacks of spasmodic pain referred to above. In such a case the hæmorrhage is always intra-peritoneal, and may be due either to tubal rupture or to tubal abortion. More frequently a diffuse hæmorrhage is less severe, ceases spontaneously after a time, and while imperilling the patient's life, is not necessarily fatal. It may, however, recur after an interval and prove ultimately fatal. The initial attack of bleeding may occur without any exciting cause, when the patient is at rest in bed, or even when asleep; more often it appears to have been induced by some slight muscular effort, such as that entailed by ordinary domestic work or by the act of defæcation.

Severe abdominal pain, sudden in onset, situated in one or both iliac regions, is usually the first symptom. It is often quickly followed by vomiting, and may lead to faintness or, less often, to actual loss of consciousness from syncope. Upon these symptoms supervene, in cases of profuse bleeding, the signs and symptoms of concealed hæmorrhage—pallor, rapid and feeble pulse, deep, laboured breathing (air-hunger), restlessness, coldness of the extremities or of the whole skin-surface of the body, sweating, depression of temperature. Slight hæmorrhage from the uterus will also usually occur. It must be recollected that it is only when a *very large amount of blood is rapidly lost* that the classical signs of internal hæmorrhage are met with. An equal amount of blood effused in stages, spread over two or three days, instead of at a single loss, does not occasion symptoms nearly so severe, for the body possesses the power of rapidly adjusting itself to loss of blood. Pallor and quickening of the pulse-rate may then be the only general signs observable.

The presence of a large amount of free blood in the peritoneal cavity can usually be detected by percussion; when the patient is lying down it gravitates into the flanks, which accordingly become dull, and the area of dulness shifts slowly when the position of the patient has been altered.

When a diffuse tubal hæmorrhage, though severe, is not large enough immediately to imperil life, the symptoms resemble those of the condition often called 'peritonism,' and are common, with variations, to many circumstances under which fluid suddenly escapes into the peritoneal cavity. These symptoms are: Acute abdominal pain, at first located to one iliac region, but soon becoming general, with more or less profound shock; the symptoms of shock differ from those of profuse bleeding chiefly *in the absence of restlessness and air-hunger*. The pain may last for many hours, and may be accompanied by abdominal distension and by vomiting, but the latter is not persistent. Gradual improvement supervenes, and in two or three days the symptoms generally subside. There is, however, great risk under these circumstances of renewal of the bleeding, which will manifest itself by recurrence of more or less acute attacks

of pain and of some of the symptoms of shock. Even while the patient is confined to bed, recurrences of bleeding may be met with ; a risk which is sufficiently explained by the anatomical points already referred to.

The *diagnosis* of tubal pregnancy under these conditions is sometimes fairly simple. When there has been a profuse loss of blood the fact that internal bleeding has occurred will be obvious from the signs already described ; a history of a recent short period of amenorrhœa giving place to slight uterine bleeding will suggest the possibility of ectopic pregnancy. Pelvic examination may show softening of the cervix and a swelling behind or to one side of the uterus may be detected, which represents the gravid tube (Fig. 107). These findings together make up a strong presumptive case for the diagnosis of tubal pregnancy with internal bleeding.

More often there is no history of amenorrhœa, and all that can be made out on vaginal examination is the presence of blood in the pouch of Douglas, and particular attention should be directed to this point. Owing to the distension and tenderness, detailed abdominal examination may be impossible without anæsthesia, but the pouch of Douglas can always be examined, for it is easily accessible both *per vaginam* and *per rectum*. The space behind the cervix feels full, and the consistence of the swelling is characteristic ; there is no definite outline, it is soft and doughy when upward pressure is made with the finger, and, felt from the rectum, the swelling may be found to bulge towards the anterior rectal wall. The swelling is not a cyst for its outline is impalpable ; it is not inflammatory fluid, for there is a complete absence of tension ; it can only be blood. Judged in association with the general clinical features, this point is conclusive of the diagnosis of free internal hæmorrhage, and the outstanding cause of this condition is ectopic pregnancy.

When the loss of blood has been less severe than this, the symptoms are less characteristic, and there may be some doubt whether perforation of a hollow viscus, or an acute inflammation, has occurred. The history may be misleading, inasmuch as early uterine pregnancy may be associated with any of these surgical disasters in women in the fertile period of life. If the condition of the patient is not too serious to allow of a few hours delay, the further course of the case will often clear up the diagnosis, for after internal hæmorrhage has ceased the general condition rapidly improves, while with such lesions as perforative peritonitis the general condition as rapidly deteriorates, and characteristic localizing symptoms may appear.

#### *Differential Diagnosis of Diffuse Hæmorrhage.*

(a) *Acute Appendicitis.* Rare cases of so-called *fulminating appendicitis* occur in which the symptoms are mainly those of acute toxæmia, and there is little by which the lesion may be localized. The symptoms more closely resemble those of shock than those of

hæmorrhage. In the case of an *appendix-abscess* however it is not uncommon to find a pelvic swelling (abscess) either on the right side or in the pouch of Douglas, and this is a source of difficulty in the diagnosis. It cannot be too strongly emphasized that indications of *concealed bleeding* are the most important signs of tubal pregnancy in the stage under consideration for the moment. Further, *uterine bleeding* is not met with in association with appendicitis, and due weight should be given to this sign, which is practically invariably seen in extra-uterine pregnancy. The more common type of *acute appendix* in which definite local muscular rigidity and tenderness are often associated with a swelling in the appendix region, need not be confused with tubal pregnancy. Yet even with careful consideration mistakes are not altogether avoidable, and it is the duty of the gynæcologist to fit himself to deal efficiently with cases of acute appendicitis which he may meet with when operating.

(b) *Perforation or Rupture of a Viscus*. In these conditions the predominant features in the early stages are those of shock, followed after some hours by the signs of an 'acute abdomen,' and later by those of general peritonitis. Here also the general indications of pregnancy, and the occurrence of uterine bleeding, will not be met with unless indeed the accident should occur in the early weeks of normal pregnancy, and differential diagnosis is then almost impossible. In any case the indication for an exploratory operation is urgent, and the operator must be prepared to deal with whatever condition he may find.

*B. Encysted Type of Intra-peritoneal Bleeding*. In this form bleeding is more gradual than in the diffuse type, and the signs of internal hæmorrhage are usually inconspicuous. Nevertheless a certain amount of pallor and quickening of the pulse are present from the first, and may become more pronounced as the case proceeds. The prominent symptoms constantly encountered are *fever, pain, and uterine hæmorrhage*; as a rule attacks of pain precede the occurrence of bleeding, increasing in intensity as they recur.

The *pain* which is met with is almost always sudden in onset, and usually spontaneous, although muscular effort may appear to excite it; it is always severe, and may be intense; beginning in one or other iliac region, it soon affects the whole abdomen, but later on may again become localized; it is frequently attended with vomiting and other signs of shock, sometimes with faintness or actual syncope; after lasting acutely for several hours it subsides, and thereafter may recur at varying intervals of a few days or a week, until several attacks have been sustained; sometimes continuous pain without exacerbations follows the first attack.

The *uterine hæmorrhage* rarely begins before the first attack of pain; it shows the characters already mentioned, and may be accompanied by discharge of a decidual cast, either complete or in fragments.

After pain and bleeding have lasted for a few days an *irregular elevation of the temperature* occurs as a rule, which is due in part to the peritonitic reaction which occurs around the effused blood and results in its isolation, and in part to the absorption of fibrin-ferment or other products from the dead blood. The temperature seldom exceeds 100°–102° F. unless infection of the hæmatocele occurs; yet occasionally a sharp rise to 104° or 105° has been observed from an uninfected hæmatocele.

The blood which is slowly poured from the gravid tube tends to accumulate in the most dependent part of the peritoneal cavity—the pouch of Douglas. In some cases, probably when the bleeding is very slow, the effused blood does not reach the pouch of Douglas at all; it becomes rapidly encysted by adhesive peritonitis and is detained in contact with the bleeding part, which may be the abdominal ostium, or a rent in some other part of the tube. An encysted collection of blood in the pelvic peritoneal cavity is called a *pelvic hæmatocele*; when formed around the abdominal ostium it is distinguished as *peritubal* (see Fig. 114), when formed upon the proximal part of the tube it is called *paratubal* (Handley) (see Fig. 115). Around these encysted collections of blood a *false capsule* is rapidly formed by the deposition of layers of lymph externally, and beneath this by organization of the superficial layers of the blood-clot. In this way a membrane  $\frac{1}{16}$  to  $\frac{1}{4}$  inch in thickness, may be formed. In those rare instances where intra-ligamentary rupture occurs, the blood is slowly poured out between the layers of the broad ligament, and this condition is distinguished as a *pelvic hæmatoma*. Hæmatocele of the pouch of Douglas is far commoner than either of the other varieties.

In some instances considerable *intra-tubal* hæmorrhage may occur without any escape of blood from the tube taking place. An acute attack of pain, or it may be recurrent attacks, indistinguishable from those just described, usually accompanies this form of hæmorrhage also.

*Physical Signs.* From the symptoms which have been already described, a presumptive diagnosis of tubal pregnancy with internal bleeding can generally be made. The physical signs met with are mainly those of a pelvic effusion, the nature of the effusion being inferred from the history and the symptoms.

A large pelvic *hæmatocele* forms a swelling extending upwards above the pubes (see Fig. 128). The hypogastric region is prominent, and pressure causes considerable pain. On palpation a dome-shaped swelling, ill-defined in outline and elastic in consistence, can be made out. Its position is usually, but not always, mesial. On percussion the note is subresonant. The surface of the swelling felt in the hypogastrium corresponds to the roof of the hæmatocele, which is formed by omentum and coils of intestine adherent to one another and to the mass of effused blood beneath them.

On vaginal examination, it will be found that the whole uterus, including the cervix, is displaced forwards and pressed close up to the back of the symphysis pubis ; sometimes it is somewhat elevated, and may be displaced a little to one or other side of the middle line. Softening of the lips of the os externum may be recognizable and the body is often somewhat enlarged. The rest of the pelvis is occupied by the effusion, which has crowded the uterus out of its normal position ; sometimes it depresses the floor of the pouch of Douglas

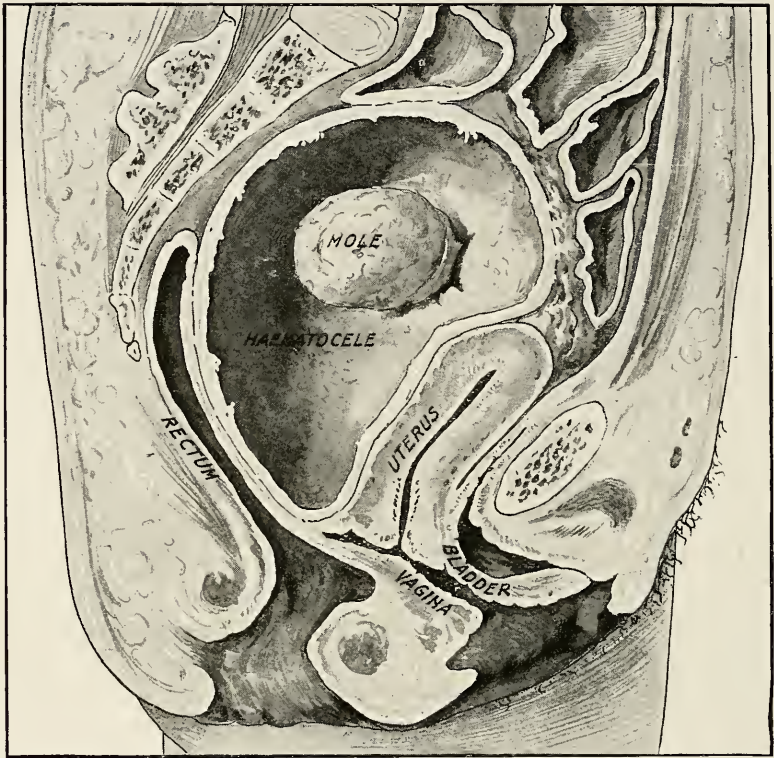


FIG. 128. PELVIC HÆMATOCELE SHOWN IN MESIAL SAGITTAL SECTION (Bumm). The section shows the hæmatocele distending the pouch of Douglas and pushing the uterus forwards. Attached to the left wall of the hæmatocele is a tubal mole.

and causes bulging of the posterior fornix. The consistence of the swelling is generally elastic ; it may be almost doughy in parts or, on the other hand, areas which feel firm and solid may be encountered. These variations are probably due to incomplete or irregular coagulation of blood. The pelvic mass is continuous with that felt above the pubes. On rectal examination it may be found to fill the sacral hollow (Fig. 128) and compress the bowel ; thickening of the utero-sacral folds is also commonly felt and probably results from coagulation taking place upon their surfaces.

*Differential Diagnosis of Pelvic Hæmatocele.* In considering this point it must be recollected that, although the great majority of pelvic hæmatoceles are due to ectopic pregnancy, this is not invariably the case. Thus Jayle has collected seventeen cases due to rupture of a small blood cyst in the ovary, and others have been recorded from rupture of a tubo-ovarian varicocele.

Four conditions may give rise to difficulty in diagnosis, viz. (1) a retroverted gravid uterus; (2) an inflammatory effusion; (3) an ovarian tumour incarcerated in the pelvis; (4) an incomplete uterine abortion.

(1) The differential diagnosis is not always easy from *retroversion* of the *gravid uterus*. It is, however, of practical importance, for if the treatment of a retroverted gravid uterus was applied to a case of pelvic hæmatocele, disaster might follow from rupture of the hæmatocele.

The history usually presents well-defined differences. Thus retention and incontinence of urine, common in retroversion when the uterus has grown large enough to fill the pelvis, are exceptional with hæmatocele, although they sometimes occur. Bleeding from the uterus may occur with either, but the discharge of decidual tissue, apart from abortion, is only met with in extra-uterine cases. Attacks of abdominal pain strongly favour the diagnosis of hæmatocele.

On bimanual examination the gravid uterus is of more uniform consistence than the hæmatocele, and may sometimes be felt to undergo intermittent contractions. The point of chief diagnostic importance, however, is that with a hæmatocele the body of the uterus will be found to lie *in front of the swelling which fills the pouch of Douglas*. If the fundus cannot be felt in front, or to one or other side, it may be concluded that the swelling felt posteriorly is the enlarged uterine body. Owing to the softening of the tissues in pregnancy the cervix of the retroverted uterus may appear under anæsthesia to be movable independently of the retroverted body, and the observer must not be misled by this point. Unless the uterus can be definitely recognized in front of the swelling it is not a hæmatocele.

(2) An *ovarian cyst* which has become incarcerated by adhesions in the pouch of Douglas, and is sufficiently large to occupy the whole pelvic cavity, gives rise to the same displacement of the uterus as a hæmatocele. The consistence of the swelling is, however, uniform, and more tense or resistant than the hæmatocele, and its general outline is better defined. Menstruation may be unaffected; the commonest disturbance, if any, being in the direction of menorrhagia. There is no softening of the cervix and no irregular uterine bleeding.

(3) *Inflammatory* (peritonitic) effusions in the pouch of Douglas and inflammatory enlargements of the Fallopian tubes can best be distinguished by a careful consideration of the history (*see p. 259*), and in this connection it should be borne in mind that while fever is the initial symptom in pelvic peritonitis which is sometimes ushered in with a

rigor, it is a comparatively late and mild one in hæmatocele. In inflammatory cases the general condition of the patient does not suggest hæmorrhage; there is no pallor, and the pulse, though quick, is of high tension. There are none of the general symptoms of pregnancy. The local signs of the two conditions may be very similar, but the local tenderness in the case of the inflammatory effusion is much greater than in the case of the hæmatocele, and there is more abdominal distension.

(4) *Incomplete Abortion.* This diagnostic error usually consists in regarding a case of hæmatocele as an abortion; in many instances the uterus has been explored and curetted before the true nature of the condition has been recognized. The mistake may be followed by serious consequences if the hæmatocele is ruptured, or if septic infection should occur.

Both conditions are attended by the general signs of pregnancy, the occurrence of abdominal pain, uterine bleeding, and the discharge of membrane from the uterus; the cervix is found to be softened, and on perfunctory examination a peritubal hæmatocele may be mistaken for the body of the gravid uterus. Fever also may occur with a prolonged abortion, whether infected or not. No rules for the avoidance of this error need be laid down; care in consideration of symptoms and in pelvic examination is undoubtedly called for, and due attention should be paid (*a*) to the position of the swelling; (*b*) to its correspondence in size to the presumptive period of pregnancy; (*c*) to the severity of the external bleeding, which is hardly ever profuse with hæmatocele, but frequently so with an abortion; (*d*) to the nature of the discharged membrane, chorionic tissue being readily recognizable even to the naked eye.

Peri- and paratubal hæmatoceles cannot be clinically distinguished from a hæmatosalpinx. Effusions of blood into the broad ligament (hæmatoma) closely resemble inflammatory effusions in the same position (cellulitis), and are best distinguished by the clinical history.

**III. Secondary Abdominal Pregnancy.** The clinical diagnosis of this condition presents considerable difficulties, and in the great majority of the recorded cases diagnosis has not been made until, following upon the death of the fœtus, the gestation-sac has become altered by infection or by shrinkage. The history of the pregnancy presents abnormal features, such as attacks of abdominal pain in the early months, usually accompanied by hæmorrhage; but when the ovum survives a tubal rupture, the amount of internal bleeding appears to be inconsiderable, and the accompanying symptoms are less urgent than those described above. In advanced pregnancy the local conditions on abdominal examination may closely resemble those of normal gestation, the position of the body of the fœtus, and of the presenting part, showing little abnormality. The most striking difference is



the condition of the cervix : in an advanced normal pregnancy the degree of softening of the whole of the cervix is extreme and quite characteristic : in the extra-uterine case softening, if apparent at all, is only slight. Careful examination under anæsthesia would, however, show that the uterus was small and was displaced to some extent by the gestation-sac, while the use of the sound would indicate that the uterine cavity was only slightly enlarged and empty. The differential diagnosis of the intra-ligamentary from the intra-peritoneal variety presents even greater difficulties ; in the latter the fœtus usually lies above the pelvic brim and is more freely movable ; while in the former the head may lie unusually low in the pelvis to one or other side, and the mobility of the fœtus may be unusually limited. But absolute reliance cannot be placed upon these points.

The fœtus often perishes before full time is reached ; it may, however, survive until term has been exceeded. A definite attack of pain, such as could be called a ' false labour,' does not in all cases occur, but when met with it is usually synchronous with the death of the fœtus. After this occurrence the abdominal enlargement may gradually decrease from absorption of fluid ; on the other hand it may rapidly increase in size, either from hæmorrhage into the gestation-sac, or from infection reaching it from the bowel. Infection is usually distinguishable from hæmorrhage by being accompanied by fever.

Old cases of secondary abdominal pregnancy, in which the fœtus has been retained for prolonged periods after its death, are almost incapable of being clinically diagnosed. It is curious to note the extraordinary resistance to infection from adherent intestine which this condition exemplifies. Notwithstanding the large masses of dead matter which the gestation-sac contains, and its contiguity to sources of infection, the processes of dry gangrene (mummification) and subsequent encrustation with lime-salts may proceed without apparent interruption, and the presence of the large foreign body thus built up may be tolerated for many years with little apparent inconvenience. Many instances are on record of a lithopædion being found in the body of a woman who died of some independent malady at an advanced age. Thus Kuchenmeister has recorded the case of a woman who died at the age of eighty-seven, and in whose body a lithopædion was found which, it was estimated, had been retained for a period of fifty-seven years. In some cases, however, the lithopædion has proved to be the direct cause of death from intestinal obstruction.

## TREATMENT OF EXTRA-UTERINE PREGNANCY

This subject must be considered in relation to the various clinical phases just described.

I. **Unruptured Extra-Uterine Gestation.** In this case the gravid

tube or ovary should be removed without delay by abdominal section. The great probability that internal hæmorrhage will occur, with its serious risks to life, necessitates this preventive operation being performed in all cases. The operation required is that afterwards described on p. 766 ; in the case of tubal pregnancy the corresponding ovary is as a rule healthy and should not be removed. The gravid tube can be excised by securing the mesosalpinx with two or three ligatures and dividing the tube close to its uterine attachment (salpingectomy). The procedure is simple and the prognosis correspondingly favourable.

**II. Diffuse Internal Hæmorrhage.** In this case operation is again invariably necessary. The conditions may here be very unfavourable for surgical interference, as when the patient has been brought nearly to death by a profuse intra-peritoneal flooding. No unnecessary delay is admissible, but time for efficient preparation is usually available as the hæmorrhage ceases spontaneously after a rapid profuse loss, and gradual improvement in the general condition of the patient at once sets in. If the condition of the patient is, however, deteriorating instead of improving, even a short delay may be fatal ; the abdomen must be immediately opened and the bleeding vessels secured. Success may be obtained in cases apparently desperate, and the responsibility which the operator undoubtedly takes in operating is, under the circumstances, perfectly justifiable. Saline transfusion into the median basilic vein should be practised, in the worst cases, immediately before or during the operation, and is of the greatest assistance to success. Rapid work is necessary when the patient is under the anæsthetic ; the pedicle should therefore be secured in the simplest and most expeditious manner possible. As much of the effused blood as possible should be cleared away, but time must not be consumed in making a complete peritoneal toilet. One or two pints of warm, sterile, saline solution may be poured into the peritoneal cavity and left to be absorbed, before the wound is closed.

**III. Encysted Internal Hæmorrhage.** Here there is no necessity for immediate operation, but in the majority of cases recovery does not take place without surgical interference of some character. *Palliative treatment* has been extensively resorted to in such cases ; it consists in confining the patient strictly to bed, and trusting to absorption of the dead blood taking place by natural processes. This may undoubtedly occur, but the process is very slow and many weeks, running even into months, may elapse before the effusion has disappeared. Little or nothing can be done by medical measures to hasten absorption. In some cases a hæmatocœle may be observed to increase steadily in size, notwithstanding that the patient is confined to bed ; this is generally due to progressive or repeated hæmorrhage into the gestation-sac. Increase in size may, however, be

due to infection of the hæmatocele, and is then usually accompanied by aggravated pain and fever. It follows that when palliative treatment is decided upon, a guarded prognosis should be given, for resort may ultimately be necessary to some operative procedure.

A pelvic hæmatocele may be attacked from the abdomen, or from the vagina by posterior colpotomy. The advantage of the former is that the damaged tube is completely exposed and can be removed; the pelvic peritoneal cavity can be properly cleared out, and the wound closed without drainage. When the vaginal operation is adopted, the hæmatocele is simply evacuated and drained (*see p. 777*); evacuation is necessarily incomplete and, as coagulated blood does not come away freely by drainage, several weeks may elapse before the cavity has completely closed up. The advantage is that the risks attending opening of the general peritoneal cavity are avoided, and in cases of infected hæmatocele this risk is undoubtedly a serious one. Vaginal drainage is therefore the operation of choice in an infected hæmatocele; in other cases the abdominal operation is, as a rule, to be preferred as being more thorough and followed by shorter convalescence.

**IV. Secondary Abdominal Pregnancy.** Whether intra-ligamentary or intra-peritoneal, this condition can be dealt with only by operative measures. The difficulty of distinguishing the two varieties has been already referred to; it practically precludes any attempt to apply different methods of treatment to them. We shall, therefore, consider the method of dealing with such cases, firstly when the *fœtus is alive and viable*, and secondly when the *fœtus has been for some time dead*.

(a) It is but seldom that cases come under observation while the child is alive, and the number of recorded cases operated upon is relatively small. The proper procedure in such cases is to operate at once with the view of securing the survival of the child as well as the mother. The only objection to this procedure is the formidable technical difficulty which may be encountered during the operation, owing to the presence of a quick placenta with its undamaged maternal circulation. Hæmorrhage of the most severe kind may occur when it is separated, and may be very difficult to control. Occasionally, however, surprisingly little difficulty is met with, and the anatomical dispositions in different cases explain it. Sometimes, as in tubo-abdominal cases, the placenta is mainly attached to the broad ligament and the uterus. The vessels which supply it are accordingly, in the main, the uterine and ovarian arteries. An attempt should therefore be made to secure these vessels before the separation of the placenta is begun. The ovarian artery may be secured on the pelvic brim, where it crosses the ureter; in cases of difficulty the uterus may be removed in order to obtain access to the uterine artery of the affected side, the procedure adopted being the transverse method of hysterectomy, commencing on the sound side (*see p. 750*). With these vessels

under control the placenta may be peeled off without much danger. Drainage is usually required, and these cases are specially suitable for the vaginal route.

In other cases the placental attachments are widespread, involving coils of intestine and areas of mesentery. Control by ligature of the feeding arteries is then impossible. The placenta must be rapidly peeled off; such bleeding-points picked up with forceps as can be isolated, and for the remainder, plugging with gauze must be relied upon for controlling the bleeding. It may even be necessary to clamp bleeding areas with forceps and leave them in position for twenty-four hours. The best material for plugging is bismuth gauze, a more potent hæmostatic and antiseptic than iodoform.

The immediate after-treatment of such cases is always an anxious matter. Nothing should be touched for twenty-four hours when the outer part of the gauze plugging should be loosened, and the forceps gently opened and then withdrawn with care. Day by day a portion of the gauze should be removed; until the whole has been got rid of by the fifth day. The plugs should be thoroughly soaked with sterile saline solution to facilitate withdrawal, but the process is necessarily very painful and an anæsthetic may be required.

In opening the gestation-sac it may be practicable, in either variety, to make the incision through a part which is closely incorporated with the abdominal parietes, when the operation may be conducted extra-peritoneally throughout. With this object the incision may be made in the *linea semilunaris* instead of the *linea alba*. After extracting the child and dividing the cord the membranes should be peeled off the wall of the sac and the limits of the placenta thus defined.

(b) The difficulties of dealing with the quick placenta in the past, induced many operators to postpone operative interference until the death of the child has occurred in the natural course of events, no attempt being made to save it. Methods of destroying the unborn child were even advocated as a preliminary to operation, and then to delay operation for several weeks in order to allow time for thrombosis of the placental sinuses to occur and thus facilitate separation of the placenta. Separation of the placenta is not then attended by undue hæmorrhage, and to that extent the operation is rendered safer. There is, however, the added disadvantage that infection of the sac from bowel-organisms may occur, this being more likely with a dead than a living ovum. Infection constitutes one of the most formidable complications of the condition, and the risk of its occurrence may be regarded as a condemnation of the methods of delay. It is better to operate at once, whether the child is dead or alive.

It has been advised that when bleeding is difficult to control, the placenta should be left *in situ*, and the sac marsupialized by stitching

the edges to the skin of the abdominal wound. It may then be removed piecemeal with forceps and scissors after a few days delay, allowing thrombosis to occur. Infection of the placenta is, of course, unavoidable, and there are grave risks of secondary hæmorrhage from sepsis, which quite outweigh the immediate advantages of this method.

PART I: SECTION V  
INFECTIONS OF THE FEMALE PELVIC  
ORGANS

INCLUDING

- (a) MICRO-ORGANISMS OF THE GENITO-URINARY TRACT.
- (b) SEPTIC INFECTIONS.
- (e) SPECIFIC INFECTIONS.

MICRO-ORGANISMS OF THE FEMALE GENITO-  
URINARY TRACT

A LARGE variety of organisms are found in the female genital tract and a lesser number in the urinary organs ; many organisms which occur in the genitalia are not found in the urinary tract.

**Vaginal Flora in the Newborn Child.** For the first twenty-four hours of life the vagina is said to be sterile, but by the third day it always contains micro-organisms. The latter include *staphylococcus pyogenes albus* and *aureus*, and *streptococci*. Maxwell has shown that before bacterial contamination occurs the vaginal secretion of infants is acid. From the second day of infant-life organisms in the vagina increase in numbers, and in addition to those above-mentioned Schmidgall found the *bacillus coli communis* and the vaginal bacillus (see Fig. 129) during the first year of life. This authority considers that the character of the vaginal secretion of the infant is influenced by the vaginal flora of the mother, the explanation being that the genitalia of a female fœtus may become infected during birth in the case of breech presentations. In older children bowel-bacteria form about half the germs present in the vaginal secretion. The finding of organisms so constantly in the vaginæ of young children negatives the existence of a natural vaginal anti-septic function at this age.

**Flora of the Adult Vagina.** In 1892 Döderlein published the results obtained from the examination of the vaginal secretion of 195 pregnant women. The secretions were divided according to macroscopic evidence into (a) normal, (b) pathological or abnormal.

Bacteriological examination showed that the flora were quite different in the two conditions.

(a) *The normal secretions* presented a whitish appearance like curdled milk; there was no mucus present and the reaction was intensely acid. Microscopically it contained epithelial squames and mucous bodies. From this normal secretion a distinctive bacillus was cultivated. It appears as a long thick bacillus, non-motile, anærobic, and it produces lactic acid. In 36 per cent. of cases this organism (Döderlein's bacillus) was accompanied by a yeast fungus. Döderlein's bacillus was found to possess the power of destroying staphylo

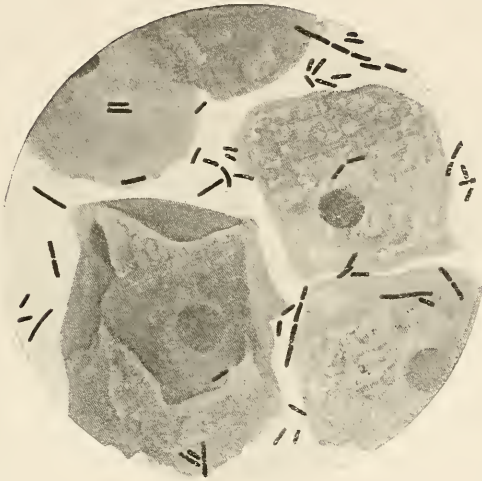


FIG. 129. THE VAGINAL BACILLUS (E. Shaw).

cocci within certain limits. When the latter were introduced into virgin vaginae they disappeared in four days. This germicidal action was attributed by Döderlein to the presence of lactic acid produced by the bacillus which bears his name, and he advanced the following facts in support of this view:

(1) All pathological vaginal secretions, containing saprophytes and many pathogenic germs, are only faintly acid or even alkaline in reaction.

(2) In puerperæ the vaginal bacillus disappears and its place is taken by many kinds of saprophytes; the lochial discharge is alkaline.

(3) When the lochia cease, the saprophytes disappear, the vaginal bacillus reappears, and the vaginal secretion becomes intensely acid.

(b) *The abnormal secretions* were yellowish or greenish in colour, of the consistency of cream, mixed with mucus, and often contained bubbles of gas; their reaction was feebly acid or alkaline and the quantity usually abundant. Bacteriologically they contained cocci and bacilli in great variety. Of the 195 cases examined by Döderlein

eight only showed streptococci, and in these virulency was established in only five cases.

The relative frequency of streptococci in pathological vaginal secretions of pregnant women is variously given by recent investigators, the average being about one case in every five examined. Streptococci are, however, only very rarely found in the vaginal secretions of *non-pregnant* women according to Menge.

The germicidal power of the vaginal secretions has been proved by many other investigators, including Krönig, Menge, Walthard, and Stroganoff. Krönig inoculated the vagina with pure cultures of *streptococci*, *staphylococci*, and *bacillus pyocyaneus*, and found that these germs were destroyed after eleven to twenty hours. Menge summarized the causes of the destruction of pathogenic germs in the vagina as follows: (1) The antagonism of the normal flora of the vagina; (2) the products of the life-activity of the vaginal bacillus; (3) acidity of the secretions; (4) the germicidal power of the anatomical elements of the vagina; (5) the leucocytosis produced either by the vaginal discharge or by the infecting organism; (6) phagocytosis following the leucocytosis and the absence of free oxygen in the vagina.

**Distribution of Organisms in the Genital Tract.** The genital canal is divided practically into two parts, the one *infected* the other *sterile* (see p. 57). According to Walthard, however, there are three divisions of the genital canal: (1) the lower, containing leucocytes and bacteria; (2) the intermediate, containing only leucocytes; (3) the upper, containing neither leucocytes nor bacteria. According to Stroganoff no part of the cervix contains organisms in the majority of cases.

In the region of the vestibule the *smegma bacillus* is found. It is an organism resembling the bacillus of tuberculosis both in its morphology and in its staining capacities, which fact has an important bearing in the diagnosis of tuberculous disease of the urinary tract (see p. 301).

**Summary.** (1) In normal vaginal secretions the vaginal bacillus is the most plentiful of all organisms.

(2) None of the organisms composing the normal vaginal flora are pathogenic. Even streptococci behave as saphophytes in the normal mucous membrane.

(3) Streptococci can become infectious, and if the tissues are injured in any way, these germs attain a virulence quite equal to that of the streptococci of puerperal infection.

(4) The lactic acid found in normal vaginal secretions has been proved by conclusive experiments (carried out by Schlutter) to be the product of the bacillus of Döderlein.

**Micro-organisms of the Urinary Tract.** Infection of this tract is very common, but the variety of organisms found therein is small. The modes of entry of organisms to the urinary tract will be considered under Cystitis and Pyelitis (see pp. 267 and 274). As regards the urethra



Savor found no bacteria in this passage in 36.5 per cent. of the normal cases examined. Kelly and Burnam express the view that more than half of normal individuals show bacteria in the urethra. Hofmeister pointed out that there are fewer bacteria in the deeper parts of the urethra than are found in the more exposed parts near the meatus. The organisms found in the urethra in apparently normal cases include staphylococci, colon bacilli, and, less frequently, streptococci. In the majority of cases of primary infection the bacteria present belong to the *B. coli* group. Bacteriological experience has shown that the *B. coli communis* is the most common organism met



FIG. 130. *BACILLUS COLI* (E. Shaw). Film made from a culture of *B. coli communis*. The bacilli vary in size, and some are in chains.

with in pyuria, and that in the majority of cases it occurs alone. In a certain percentage of cases *streptococcus brevis* is present as a secondary infection, and the same may be said of *staphylococcus albus*, *staphylococcus aureus*, and *bacillus pyocyaneus*.

Next to the *B. coli* as a primary infective agent may be placed the *B. tuberculosis*. This organism is nearly always accompanied by *staphylococcus albus* and sometimes by one or other of the organisms named above. To prove the presence of *B. tuberculosis* in urine the possibility of contamination with the smegma bacillus must be excluded, as these two organisms cannot with certainty be differentiated by their morphology and staining properties (*see p. 307*), therefore, when testing for tubercle, a catheter-specimen should always be used.

The Infective processes which may affect the genito-urinary tract may be classified as follows :

## I. Septic infections (non-specific).

### A. Genital.

#### (1) Uterine sepsis.

##### (a) Sapræmia :

Puerperal.

Non-puerperal.

##### (b) Pyometra.

##### (c) Septicæmia.

##### (d) Retained products and subinvolution.

##### (e) Senile endometritis.

#### (2) Pelvic cellulitis.

#### (3) Pelvic peritonitis.

#### (4) Pyæmia.

### B. Urinary.

#### (a) Cystitis.

#### (b) Pyelitis.

### C. Appendicitis.

## II. Specific infections.

#### (a) Gonorrhœal.

#### (b) Tuberculous.

#### (c) Syphilitic.

#### (d) Parasitic.

## SEPTIC GENITAL INFECTIONS

Under the above heading will be included only those conditions which are due to infection by common pyogenic organisms, infections by certain specific germs being described under their respective headings. We have here to deal with two groups of bacteria: (1) Saprophytic (*non-pathogenic*), which give rise to putrefactive processes and which thrive in dead or passive tissues, and (2) parasitic (*pathogenic*), which subsist on living tissues. Whilst the above division is admissible it must be borne in mind that saprophytes have the faculty of becoming parasites and *vice versa*. The germs which are found in putrefactive processes are very variable, some are bacilli, some are cocci. The best known variety is the *bacillus proteus vulgaris*. Saprophytes flourish in the secretions of wounds, decidual *débris*, placental fragments, retained lochia, necrotic myomata, and in carcinomata. By their growth they destroy the material on which they feed and produce soluble chemical bodies which act as toxins. When such substances are retained in the body under pressure, *e.g.* in a closed sac or cavity, they become absorbed to an extent which causes a general febrile reaction, which subsides directly an outlet is provided for the putrefactive secretions.

To the clinical conditions set up by saprophytes the terms *sapræmia*, *toxæmia*, or *putrid intoxication*, are applied.

There are two specific organisms which resemble saprophytes in their mode of action, viz. the bacilli of diphtheria and tetanus, *i.e.* these organisms do not penetrate deeply into the tissues but produce their effects through the absorption of their toxins. Diphtheria of the genitalia is very rare, and tetanus extremely so, therefore these diseases will not receive further mention.

Parasitic bacteria also act by the liberation of toxins, but the latter are produced in the living tissues of the body on which the germs thrive; the diseases occasioned in this way are much more severe and more dangerous than those produced by the putrefactive (saprophytic) class. Parasitic bacteria produce a true *infection* (in contradistinction to mere *intoxication*), which in its most virulent form is described as general sepsis, bacteræmia, or septicæmia.

The varieties of bacteria which produce a true infection are very few; the commonest and the most dangerous of this class are the streptococci. In the majority of cases streptococci alone are found; less frequently the infection is a mixed one, consisting of a streptococcus with other bacteria. The streptococcus which is usually found in septic infections of the genitalia is the *streptococcus longus seu erysipelatus*. In comparison with the streptococcus other germs play a subordinate part. Those found in addition are *staphylococcus aureus* and *albus*, *bacterium coli communis* (mostly in company with streptococci), the *bacillus aerogenes capsulatus*, the *pneumo-bacillus* of Friedländer, and some anaerobic germs.

As stated above, it is quite impossible to prove that any bacterium is capable of producing *only* infection or *only* intoxication. The gravity of any given case is decided by the virulence of the strain of the bacteria which are present and by the resisting powers of the tissues. In this sense the streptococcus is proved to possess the most exalted virulence, but it is also certain that the *bacillus coli* produces both intoxication and infection.

For the growth of non-specific pathogenic germs the presence of a wound, or of dead tissue or secretion, is generally essential. On the other hand the specific germs of such diseases as diphtheria, noma, tubercle, gonorrhœa, and syphilis seem to be able to colonize in the absence of any local lesion.

Non-specific pyogenic organisms gain access to the genital tract through wounds or abrasions occasioned, in the majority of cases, during labour or abortion. The manifestations of septic infection therefore appear most commonly during the early days of the puerperium. Septic infection may also occur after manipulations and operations upon the uterus, such as curetting and the passage of the uterine sound; it is also seen in cases of cancer and necrotic myomata. The condition therefore admits of classification into (1) puerperal

septic infection and (2) non-puerperal septic infection, and as this classification is clinically convenient it is often followed.

The consideration of puerperal septic infection is included in obstetric text-books, but as a matter of practice its treatment often comes under the purview of the gynæcologist, and it will therefore be included here along with the infections which are non-puerperal, and therefore of a purely gynæcological nature.

## INTOXICATION OR SAPRÆMIA

(*Synonym—Absorption Fever*)

**Puerperal Sapræmia.** This condition is frequent in the puerperium and after abortion. Retention in the uterus of placental tissue, or of membranes, or of lochial discharge, provides a most suitable nidus for the growth of saprophytes. The symptoms produced by a putrefactive process will be proportional in severity to the degree of absorption, and this will vary inversely with the efficiency of drainage: thus putrid tissues in the uterus will result in a higher degree of intoxication than when decomposing material lies in the vagina, since the discharges from the latter escape more freely. The effect on the puerperal uterus of a putrefactive process within it is that involution is delayed, the organ remains bulky and flabby; being soft, it is easily lacerated during intra-uterine manipulations—a point to which particular attention must be drawn. The endometrium is thickened, sloughy, and covered with a foul-smelling discharge. Adherent blood-clot, membranes, or fragments of placenta, in a state of decomposition, may be present. To this condition the term of *putrid puerperal endometritis* has been given. Microscopically are seen, from the cavity outwards (1) a thick layer of necrotic tissue composed of fibrinous material overlying remains of necrotic endometrium, and containing organisms (generally bacilli); (2) a *wide* zone of leucocytic infiltration; (3) œdematous muscle devoid of infiltration and free from organisms. To the wide protective barrier of leucocytes is due the fact that the effects of puerperal sapræmia are frequently transient. Its influence is shown clinically by the fact that after uterine exploration and indiscreet curettage, intensification of the toxæmia is wont to follow, resulting in a rigor; in some cases the character of the disease is altered and true infection (septicæmia) is set up. Such clinical evidence teaches the lesson that to make a sharp distinction between saprophytic and parasitic bacteria is dangerous, and that in every case of intra-uterine sepsis the possibility of a blood-infection must not be overlooked. It must be admitted that there is often great difficulty in coming to a decision whether a given case is one merely of intoxication or of blood-infection.

*Treatment.* When it is established that the uterus is empty, intra-uterine treatment, even douching, is unnecessary, as long as the discharges are escaping freely. Slight cases of sapræmia seldom call for intra-uterine exploration. The further treatment of sapræmia will be considered with the treatment of uterine-sepsis in general (*see pp.* 246–248).

**Non-puerperal Sapræmia.** Whilst sapræmia, in the majority of cases, is due to puerperal processes, it is liable to be met with in certain gynæcological conditions. *Submucous myomata* readily become infected. They are frequently necrotic from impairment of their blood-supply, and after menstruation the local conditions are especially favourable to bacterial invasion of the uterine cavity. These tumours themselves are prone to open up the communication between the *cavum uteri* and the vagina, and during extrusion of the growth the lower pole may become strangulated and may slough. Whether a submucous myoma sloughs or not, depends largely upon the integrity of its capsule. The passage of the uterine sound, or curettage, in such cases may, by causing capsular abrasions, expose a necrotic myoma to the risk of infection. With sloughing uterine growths the degree of intoxication depends upon the drainage, upon the size of the growth, and the extent to which it has sloughed. Enucleation *per vaginam* is the treatment for such cases.

In cases of *carcinoma of the cervix* the canal may be so completely closed by the growth that the intra-uterine secretion cannot escape; this leads to hydrometra, which is speedily infected by the germs which are always found in a necrosing cancerous growth. The result is that a pyometra (*see p.* 240) and signs of septic absorption (sapræmia) follow.

At the risk of repetition it must be stated that the *passage of the uterine sound* has repeatedly led to intoxication by setting up a septic endometritis. Caustics, such as chloride of zinc, fuming nitric acid, and strong antiseptics, when applied to the cavity of the uterus may produce necrosis, which will lead to septic absorption, and the same condition may follow atmocausis by superheated steam.

Finally, intoxication may occur from *collections of blood* in the vagina, uterus, Fallopian tube, and pouch of Douglas becoming infected. As a rule such blood-collections as occur in the genital tract are not exposed to infection from without, but if a hæmatocolpos is treated by an inefficient opening, the latter closes and may lead to a putrid pyocolpos.

Intoxication due to suppuration in a cellulitic exudate will be dealt with under the heading of pelvic cellulitis (*see p.* 252).

*Treatment.* It will be seen that the treatment of non-puerperal sapræmia is mainly surgical and consists in dealing with the cause, for example removal of a necrotic myoma, etc.

**Pyometra.** Pyometra may occur as an *acute* condition during the puerperium due to infection of retained lochia. We have known of two cases in which nearly a pint of purulent fluid had collected in post-partum uteri which were retroflexed. The symptoms were those of sapræmia, and they cleared up after evacuation of the pus and irrigation of the uterus with a weak antiseptic. In non-puerperal

cases pyometra is a *chronic* condition, produced by infection of retained uterine secretion. It may be found in association with senile or tuberculous endometritis, cicatricial contraction of the

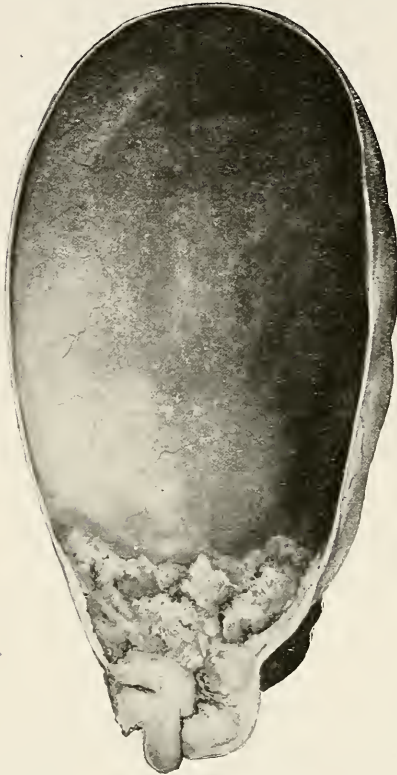

FIG. 131. LARGE PYOMETRA WITH VERY THIN WALLS, in a case of carcinoma of the cervix.

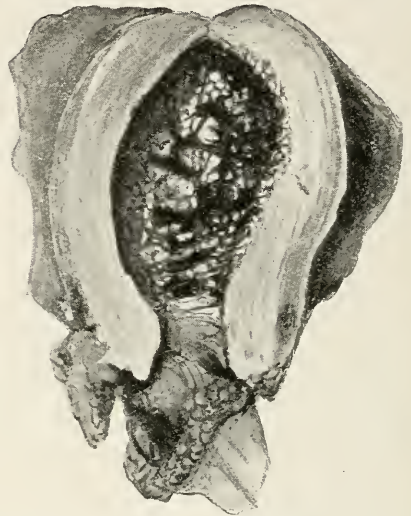

FIG. 132. SENILE ENDOOMETRITIS AND PYOMETRA. Uterus removed by vaginal hysterectomy. Multipara, aged 63. The endometrium is replaced by granulation tissue.

cervical canal, or cancer of the cervix, and Burkle has estimated that it occurs in from 5-6 per cent. of cervical carcinomata. In some cases the cervical canal is patent, the retention of fluid being due to loss of contractile power in the uterine wall. This is sometimes associated with retroflexion, when uterine drainage is still further impeded. On rare occasions pyometra may result from infection of a hæmatometra. Suppurating submucous myomata may also be accompanied by a certain amount of pus retained in the uterus. In *acute pyometra* there is a danger of infection spreading along the tubes to the peritoneum producing pyosalpinx and peritonitis. In one of our cases a peritonic abscess had to be opened subsequent to the drainage of the pyometra.

*Pathology.* The fluid is usually thin, offensive, brown or chocolate-coloured pus, from which various organisms (including the bacillus coli) have been cultivated, but which may prove to be sterile. The condition of the uterine wall varies with the amount of the distension, *i.e.* with the quantity of retained pus; it is often thin and soft, but the muscle may be little reduced in thickness. A case has been

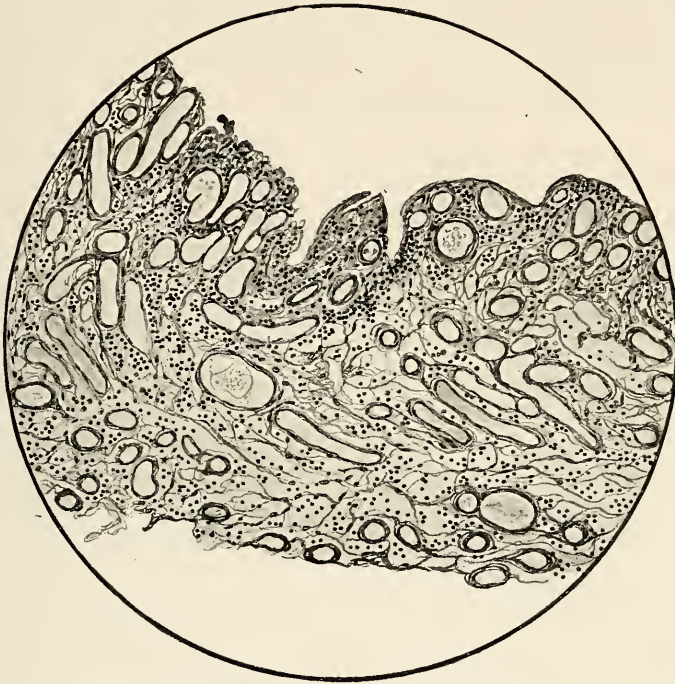

FIG. 133. MICROSCOPIC SECTION OF THE LINING OF THE UTERUS IN A CASE OF PYOMETRA. It consists of very vascular granulation tissue, the mucosa having been destroyed.

recorded by one of us in which the uterine wall was reduced to the thickness of parchment (Fig. 131). The cavity, as a general rule, possesses a smooth surface, but when pyometra has been of long standing the cavity is lined by a rough pyogenic membrane macroscopically resembling diffuse carcinoma, but consisting entirely of granulations, as seen in Figs. 132 and 133. In cases of diffuse tuberculous endometritis which have gone on to suppuration and pyometra the cavity will be lined by the caseous masses characteristic of tubercle.

*Clinical Features and Treatment.* Cases associated with malignant growths are frequently overlooked, as they only occur in an advanced stage of cervical disease; when the cervix remains patent intermittent profuse discharges of pus occur. Pyometra may cause pain, fever, and rigors, or sweating, but these symptoms may be absent. When in cases of *carcinoma cervicis* the uterine body is felt to be soft and

enlarged, the cavity should be explored before hysterectomy is undertaken, as the escape, during operation, of pus from an unsuspected pyometra has led to fatal peritoneal infection.

In cases of *pyometra* due to senile endometritis, the cervix should be dilated, the uterus cleared out and curetted, and then swabbed with pure carbolic acid, and drained with a strip of gauze passed through the cervix and changed daily; vaginal hysterectomy is indicated in cases which resist this treatment. When associated with a malignant growth or tubercle, the treatment is determined solely by the extent and operability of the disease.

### INFECTION OR SEPTICÆMIA

From what has already been stated it will be understood that a sharp clinical distinction between intoxication and blood-infection is often impossible, indeed it would seem that the question is one of a quantitative rather than a qualitative difference, and it is quite certain that a putrefactive process may become a true septicæmia. It is nevertheless certain that the morbid process may be a true blood-infection from the start. Such a condition is nearly always puerperal in origin, but as in sapræmia so in septicæmia, the organisms may gain entrance through abrasions caused by the passage of the sound or through operation-wounds. The gross local lesions which are associated with puerperal infection are here given in anatomical order.

**Vulva.** In severe cases of puerperal infection ulcers are formed on the vulva; they present a dirty greyish-green surface and are bathed in foul purulent discharge. They are surrounded by a zone of redness, and there is often marked œdema, especially of the labium minus. The most common situation for such septic ulcers is the posterior part of the *introitus vaginae*. Such ulcers cause local pain and tenderness, and a 'burning' on passing urine.

**Vagina.** Wounds extending to the vagina from a torn cervix and from perineal lacerations may become septic. Bruising due to prolonged labour may cause necrotic areas on the anterior vaginal wall, leading to sloughing and fistula-formation. Extensive vaginal lacerations extending into the ischio-rectal fossa may sometimes be discovered in cases of puerperal infection. Such lesions require thorough drainage and frequent cleansing. In the case of a perineal laceration which has become septic, the stitches must be removed, the wound laid freely open, and painted with two per cent. iodine-solution and drained with gauze.

**Cervix Uteri.** Lacerations of the cervix may become infected and form sloughing ulcers; such a condition is nearly always an indication that a similar state of sepsis exists in the uterine cavity.



**The Uterus.** This is usually the primary seat of infection. The organ will correspond in size with the date of the puerperium; it is soft and flabby. Its cavity may present nothing unusual to the naked eye, *i.e.* there is no foul clot or placental tissue present, and no sloughing is to be seen on the surface.

Microscopically the changes in the wall of the uterus contrast with those seen in cases of sapræmia, and the condition is called

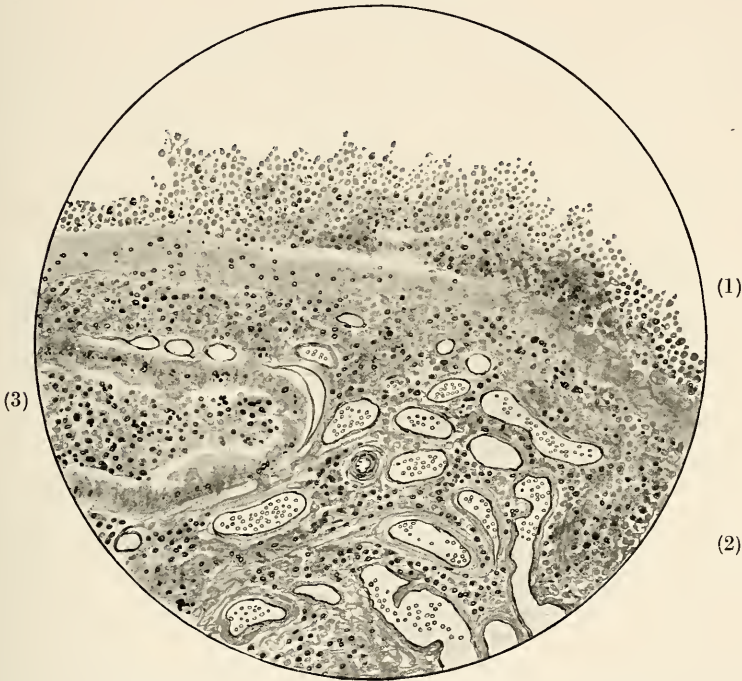

FIG. 134. ENDOMETRIUM IN A CASE OF PUERPERAL SEPTICÆMIA WHICH ENDED FATALLY. It shows (1) a roughened granular surface; (2) a *leucocytic zone* containing dilated capillaries; (3) a uterine gland with its epithelium partially destroyed.

*infective endometritis.* The leucocytic zone which in the *putrid* endometritis of sapræmia is well formed and thick in the case of the infective endometritis of septicæmia is badly formed and thin, too thin in fact to limit effectually the invading organisms. Consequently the latter are not only found in the endometrium, but by suitable staining they can be demonstrated in the œdematous musculature of the uterus (*see* Fig. 135), where they are generally accompanied by a track of leucocytes which leads back to a weak spot in the leucocytic zone, thus indicating the path of invasion. In many cases there is no naked-eye evidence of the muscular invasion, but occasionally multiple or single abscesses may form in the myo-

metrium. In rare instances whole areas of muscle may become gangrenous and be thrown off in small fragments or large pieces. To this condition the name of *metritis desiccans* has been given.

The blood-vessels of the area corresponding to the point of invasion are found to be thrombosed. This applies to the venous sinuses at the placental site and also to the vessels around a tear in the cervix when such exists. The infection of these thrombi explains the

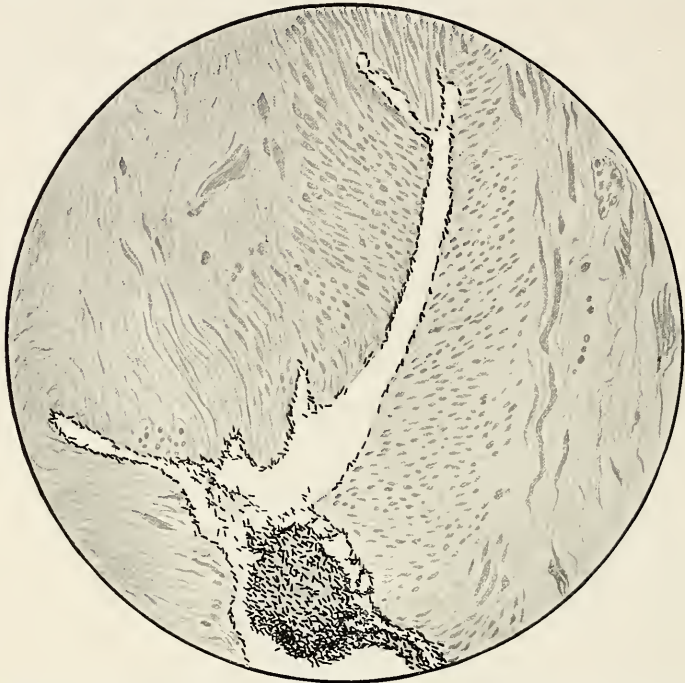

FIG. 135. SECTION THROUGH THE MUSCULAR WALL OF THE SAME UTERUS AS THE PRECEDING FIGURE, showing a dilated lymphatic containing colonies of the *Bacillus perfringens*, a non-motile, Gram-positive, anaerobe, first discovered in 1898 by Veillon and Zuber in conditions of gangrene.

frequency of a spreading septic thrombo-phlebitis in the ovarian, uterine and femoral veins. From the uterus, infection may extend to the pelvic cellular tissue, to the peritoneum, to the Fallopian tubes, and to the ovaries.

### SYMPTOMS OF INFECTION OF THE UTERUS

Under this heading will be included the signs and symptoms of the two pathological conditions to which attention has already been drawn, viz. the *putrid* endometritis of sapræmia and the septic or *infective* endometritis of septicæmia. From the clinical aspect it is customary to speak of both conditions as uterine *infection*, and as

experience shows that sapræmic and septicæmic processes are often combined, there is justification for including both in the common term *infection*, provided the fact that there are two varieties is not overlooked.

*The onset of uterine infection* generally occurs during the first four or five days following labour; cases beginning later than this are probably due to infection subsequent to labour.

In *mild* cases the first symptom is a rise of temperature to 101°–102° F.; this is accompanied by a corresponding rapidity of the pulse-rate, frontal headache, and malaise. In *severe* cases the fever starts earlier and is quickly followed by a rigor and an exaggerated pulse-frequency, whilst other symptoms, such as vomiting and diarrhœa, may supervene. A mild type of onset is more frequently associated with sapræmia, but it does not exclude septicæmia.

The uterus may be abnormally large, and tender to touch, the ochia may be profuse, offensive, and dirty in colour; such signs are characteristic of the *putrid endometritis of sapræmia*. On the other hand, the involution of the uterus may be normal, the organ may not be tender, the lochia may be non-offensive and not profuse, it may even be reduced in amount or absent. All such signs point to a blood-infection, *i.e.* to *septicæmia*, whilst it is common experience to find cases of mixed infection in which the symptoms are so anomalous that a differential diagnosis cannot be made by unaided clinical means. It will be useful here to describe the general features of simple sapræmia and of simple septicæmia.

**Symptoms of Sapræmia.** The main clinical manifestations are *fever*, *putrefactive discharge*, and *sub-involution*. Following infection during labour the temperature will rise on the third or fourth day to 100°–102° F. There is a sense of chill, but as a rule no actual rigor. The pulse-rate is accelerated in proportion to the rise of temperature. The patient does not appear to be seriously ill. The uterus is larger than it should be and may be tender. The lochia are foul and profuse, the vulval pad is widely stained by the blood-pigments which have escaped into the serum from the broken-down red discs. The illness soon subsides after the employment of suitable treatment, but if untreated generalized infection may result.

**Symptoms of Septicæmia.** The onset is generally acute and occurs during the first three days of the puerperium. An initial rigor is the rule with the temperature rising higher day by day. During a rigor the temperature may mount to 105°–106°–107° F. In general the temperature is remittent in type, it does not drop to normal, but suffers remissions of two or three degrees daily. The pulse-rate is invariably rapid, the rapidity being *disproportionate to the temperature*; the volume is small, and the tension is lowered in severe cases. A persistent pulse-rate of over 120 is of grave import. The uterus is neither unduly large nor tender. The lochia are scanty or absent,

the milk is suppressed. Puerperal ulcers may be found on the vulva. Cutaneous rashes may appear, and the skin assume a lemon-yellow colour. Later the tongue is furred and sordes appear on the lips. Diarrhœa may supervene as a late symptom. Sleeplessness may be marked, synovial effusions may appear in various joints. There is a marked leucocytosis, and an increase in the polymorphonuclear leucocytes with a diminution of eosinophile corpuscles.

The *positive* diagnosis of septicæmia consists in finding the organisms in the blood, but a negative result is not conclusive since the germs in circulation may be few and their presence intermittent. The most likely time to demonstrate their existence in the blood is just after a rigor.

### TREATMENT OF UTERINE INFECTION

The consideration of this subject involves details of *prophylaxis* for which a manual of obstetrics must be consulted. After the diagnosis of uterine infection has been made by the exclusion of all other causes of pyrexia, treatment must be begun without waiting to differentiate between sapræmia and septicæmia. The means adopted will vary with the severity of the symptoms.

If the symptoms are mild, vaginal douching and the administration of ergot and aperients is all that is necessary. The patient is put in the Fowler's position (*see* p. 847) as an aid to drainage. If the symptoms do not subside in a day or two, disinfection of the uterine cavity must be undertaken. This, if done thoroughly, involves an exploration under an anæsthetic and must be carried out with rigid aseptic precautions. A swab of the intra-uterine secretion for bacteriological examination should first be taken in the manner described below.

When the infective process is of high virulence, as indicated by the height of the fever or the occurrence of rigors, the detachment of adherent pieces of infected placenta or membrane is not unattended with danger; fresh blood- and lymph-channels outside the protective zone of leucocytic infiltration may be laid open, and through them a large dose of toxic material may be rapidly absorbed; or actively growing bacteria may make their way into the circulation, resulting in generalization of a hitherto localized infection. This risk, however, is one which must be faced, due care being taken by suitable technique to limit the risk as far as may be possible.

*The operation* of clearing out the uterus when it contains the infected placental remains is, therefore, one which calls for special care and some skill; unless the circumstances allow of its being carried out thoroughly, and with adequate surgical precautions, it should not be undertaken at all; for an incomplete attempt is

certain to aggravate the condition and may convert a mild case into one of great severity.

The patient should be anæsthetized, the vulva shaved and disinfected, and the vagina cleansed as far as may be. Before anything is passed into the cavity of the uterus, a specimen of the uterine secretion should be obtained for bacteriological examination, partly for diagnostic purposes, and partly to allow a vaccine to be prepared later if called for. Great care should be exercised in getting the uterine secretion free from vaginal or cervical contamination. To effect this a small sterile glass-tube should be passed through the cervix, and along this the swab may be pushed up to the fundus, and secretion thus got from the upper part of the uterus. Little or no artificial dilatation of the cervix is required as a rule, for during the first week of the puerperium the index finger can be introduced through the internal os with care. Laceration of the cervical tissues should be carefully avoided. The entire cavity should then be explored with the finger; adherent pieces of tissue are, as a rule, readily recognizable and are most commonly met with at the part which corresponds with the implantation site. This part of the uterine wall always feels rough and irregular to the finger, even when there is nothing retained, and the student must not be deceived by this; the remainder of the uterine wall should feel smooth and uniform to the touch, if free from retained tissues.

An attempt should then be made to detach the retained piece of tissue with the finger; the gloved finger forms a very blunt instrument, and will only detach the tissue in the plane of natural separation. If it is morbidly adherent, the finger will not suffice, and it should then be seized with a pair of ovarian-forceps and gently twisted off. The so-called 'blunt' curette will not suffice to do more than the gloved finger can do. The remainder of the uterine wall should not be scraped; and the operation is completed by thoroughly douching the uterus with a mild antiseptic, such as Tr. iodi 1 drachm to water 1 pint, or by douching with hypertonic saline solution, salt 4 drachms to water 1 pint. Finally the uterus should be grasped bimanually between the fingers of the two hands and massaged until it responds by contracting; this will squeeze out blood and arrest the oozing, which is always free; the uterine walls may then be swabbed with pure tincture of iodine.

If no retained tissues are found in the uterus, the walls should simply be swabbed with tincture of iodine and nothing further done.

Indiscriminate curetting in uterine sepsis is definitely to be condemned. The tissues of the uterine wall are so softened in septic inflammation, that the curette may detach strips of a much greater thickness than when the tissues are not inflamed; therefore the protective zone of leucocytes may be actually removed and a fresh raw surface laid bare through which infective material will be rapidly

absorbed. Further, there is nothing to be gained by scraping where foreign tissues are not encountered; the superficial necrotic changes which always attend a septic endometritis are not the chief source of danger, for the open cervix allows of the ready escape of the discharges which these changes produce. Except for the separation of morbidly adherent membranes or placenta the curette should not be made use of.

As a rule no further intra-uterine treatment is required. The patient is kept propped up in the sitting position to promote drainage, and hot vaginal douches are serviceable in exciting uterine contractions. A rigor may occur at any time within twelve hours after the operation. This occurrence does not necessarily indicate generalization of the infection, it may be due to the rapid absorption of a large dose of toxins at the operation site. These toxins will, however, be quickly excreted if their production in the uterus has been arrested, and the recovery of the patient will not be retarded by the rigor.

The *specific* treatment of septicæmia consists in an endeavour to establish an artificial immunity by the use of polyvalent anti-streptococcic serum, followed by an autogenous vaccine as soon as it can be prepared. The actual value of these means cannot as yet be estimated with any degree of certainty. The details of general treatment include the employment of subcutaneous infusion of saline solution, which promotes leucocytosis and stimulates the skin and kidneys, thereby aiding the elimination of toxins. Surgical treatment has been extended to the removal of the uterus *per vaginam* and to ligation of the large pelvic veins at or above the level of the pelvic brim. Neither of these apparently logical procedures has met with the success for which their advocates had hoped.

For fuller details of puerperal uterine infection the student should consult a text-book on obstetrics.

## RETAINED PRODUCTS AND SUB-INVOLUTION

### (*Sub-acute Endometritis*)

This condition is a sequel of a confinement or of an abortion, in which infection plays an undoubted part. The clinical features are largely modified by the presence or absence of retained tissues in the uterus. It is certain that pieces of the ovum may remain in the uterus for weeks without becoming putrid; and if infection is present it may be of so mild a type that its presence is clinically overlooked. The main symptom is then hæmorrhage of irregular type, usually more or less continuous but varying in quantity. The patient soon becomes anæmic, and even when obviously ill, her condition may be attributed to loss of blood alone. A little fever is usually found, however, and there is little doubt that infection of a low degree of

virulence forms an important element in the case. Such cases are easily cured by removing the retained piece of tissue with the precautions set forth in the preceding section.

In many cases of this variety, however, nothing has been retained in the uterus, and hæmorrhage is not then a prominent symptom. Such patients complain of the persistence of a blood-stained discharge since the miscarriage, of internal pain and backache aggravated by exertion, and of more or less general feeling of illness. Women of the hospital-class usually do not consider themselves sufficiently ill to lie up, but come to the out-patient department for relief.

On examination it will be found that the cervix is closed, the uterine body definitely, although not greatly, enlarged; in a considerable proportion of cases the adnexa on one side or on both will be found thickened, tender, and sometimes prolapsed into the pouch of Douglas. Often the uterus is retroverted, but by no means invariably. Speculum-examination shows a muco-purulent discharge issuing from the cervix, which may be covered with an unusually bright red erosion; the vaginal walls are also often deeply reddened, although seldom tender. During the first few weeks after the miscarriage careful observation of such cases will often show a slight, irregular pyrexia.

Such cases as these were formerly designated 'sub-involution,' and it is possible that an arrest of the normal process of puerperal involution is a factor in causing the uterine enlargement in some cases (*vide infra*). A certain number of cases of this type probably pass gradually into the state known as 'chronic metritis,' which is described on p. 420. In others, the tubal and ovarian infection progresses, and its importance from a clinical point of view comes to overshadow completely the uterine infection from which it originally arose. In considering chronic tubal infection the probability that a chronic septic endometritis accompanies it must not be overlooked.

The *treatment* consists in curetting the uterus, and this operation may have to be repeated before a satisfactory result is obtained. The presence of a certain amount of thickening and tenderness of the adnexa does not contra-indicate this operation. A mild tubal infection may subside after the infective focus in the uterus from which it arose has been destroyed. If the adnexal inflammation is advanced, and there is suspicion of the presence of pus, curetting is contra-indicated.

**Sub-involution.** Following upon a confinement or a miscarriage an enlarged condition of the uterus is often met with, to which the name of *sub-involution* is usually applied. This name connotes the view that the enlargement is due to an arrest of the normal process of puerperal involution before the uterus has been reduced to approximately its proper size. To such a change the name of *sub-involution* is, of course, strictly applicable. The enlargement thus produced

may become permanent, and may be associated with severe bleeding and other symptoms. At this stage the condition is classed for clinical purposes as one of the varieties of *chronic metritis*, and its causation and minute histology will be fully discussed in connection with that condition (*see p. 421*).

We are dealing here, however, with *recent cases of sub-involution*, which present quite a different clinical picture. Certain conditions must be recognized as predisposing causes of arrested involution, *e.g.* age and fertility.

*Age.* It has been already pointed out that the relative proportion of muscle and fibrous tissue to the uterus, varies with the age of the

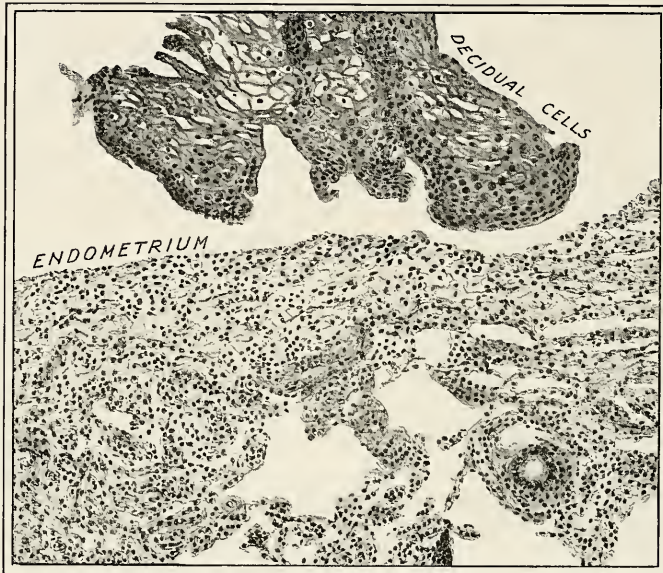

FIG. 136. SCRAPING FROM THE UTERUS IN A CASE OF SUB-INVOLUTION.  
A fragment of decidua is seen upon the surface of the endometrium.

subject. Before puberty the proportion is muscle 2, fibrous tissue 3 ; after puberty it becomes muscle 3, fibrous tissue 2 ; after the menopause the proportion again becomes muscle 2, fibrous tissue 3, or the amount of muscle may be even less than that. The greater the proportion of fibrous tissue in the uterus the more does the process of involution tend to become incomplete.

*Fertility.* Each succeeding pregnancy results in the deposition of an excess of elastic tissue in the uterus, with a loss in the relative proportion of muscle (*see p. 421*). Accordingly a slight and permanent enlargement of the uterus occurs in all women who have had several children.

In the great majority of cases of sub-involution which come under observation, arrest of the process of involution is not the only patho-



logical factor. It is probable that infection and retained tissues are the commonest causes of arrested involution. Another frequent concomitant condition is retroversion, which is directly attributable, partly to the undue size and weight of the uterus, partly to the general relaxation of the uterine supports which results from pregnancy.

The *symptoms* of sub-involution bear a general resemblance to those of subacute endometritis. The more pronounced is the element of infection the more severe are the symptoms, and when a piece of infected tissue remains in the uterus, irregular fever and severe hæmorrhage may occur, as described in connection with acute septic endometritis. In cases accompanied by only a mild infection the main symptoms are menorrhagia and leucorrhœa, with pain especially marked when the uterus is also retroverted.

The *diagnosis* is usually simple, for bimanual examination is easy in women recently confined and the enlargement of the uterus can be readily detected, and its position, forward or backward, readily made out. It may be very tender to palpation if a definite uterine infection is present. It is by no means always easy to determine whether any retained tissue is present without exploring the uterine cavity; if the internal os remains patulous, the presence of a piece of tissue of considerable size may be foretold. A small fragment does not interfere with the closure of the internal os.

The *treatment* consists in the first place in exploring and curetting the uterus. If no retained tissues are found and the condition is of long standing, this operation may fail, and the case then becomes clinically identical with the group of chronic metritis.

### SENILE ENDOMETRITIS

This is a form of true endometritis which occurs in elderly women who have passed the menopause, and it is not usually met with until several years after this event. By this time the changes in the endometrium associated with post-climacteric atrophy (*see* p. 402) are pronounced, and they, no doubt, form a predisposing cause of infection. The special liability of the vagina to infection at this time is marked, and it is highly probable that the vagina is frequently the primary source of the infection which ultimately leads to senile endometritis. The two conditions *senile vaginitis* and *senile endometritis* are accordingly usually associated. The *symptoms* met with are *hæmorrhage*, which is never severe, and *discharge*, which is purulent and sometimes offensive. The endometrium shows true inflammatory changes, *i.e.* foci of suppuration are present and plasma-cells are found in abundance in the altered stroma, whilst such gland-tubules as remain show cystic change and desquamation of their epithelium. The surface-epithelium is likewise destroyed. The uterus is usually small and its walls are thin and atrophied. From suppuration and

destruction of the mucosa two results may ensue : (1) Stenosis of the cervix ; (2) pyometra.

*Stenosis* results from fusion of the partly denuded lips of the os or walls of the cervix ; it leads to the retention of secretion which, in the presence of infection, becomes purulent and often highly offensive (pyometra). As a sequela of senile endometritis *pyometra* is rare, but it occurs in some instances independently of stenosis of the cervix (*see p. 240*).

The *differential diagnosis* of senile endometritis from carcinoma of the uterine body, a disease prone to occur about the same period of life, is discussed on p. 548.

The *treatment* consists, in the first place, in curetting and thorough disinfection of the uterine cavity ; after the operation has been recovered from, application of a strong antiseptic fluid such as pure carbolic acid or iodized phenol should be made to the walls of the uterus once or twice a week, or relapse will probably occur. If a cure cannot be effected by these means, the uterus should be removed by the vaginal route (vaginal hysterectomy, *see Fig. 132, p. 240*).

### PELVIC CELLULITIS

(*Synonyms—Parametritis, Peri-uterine Phlegmon, Lymphangitis*)

This condition is one of the most important local lesions resulting from puerperal infection. As a complication of the puerperium it is an acute infective disease resulting from lacerations of the cervix, lower uterine segment, or vagina. If such lesions become infected a primary lymphangitis is set up in the adjacent cellular tissues, and to this the name of 'parametritis' was applied by Virchow, Matthews Duncan, and others.

Primary acute cellulitis also occurs in the pelvis apart from obstetric injuries. Surgical operations on the cervix, with faulty antiseptic technique, or those undertaken for the removal of infected necrotic myomata, may lead to cellulitis. Occasionally it may be set up by a spread of lymphangitis from a rectal ulcer, which produces a phlegmon in the perirectal connective tissue, and it is not an uncommon accompaniment of extensive cancer of the cervix.

It is to this *primary* form of pelvic cellulitis that this section chiefly applies, but it must be borne in mind that pelvic cellulitis may also occur in varying degrees of intensity as a sequence of pelvic peritonitis, and as an accompaniment to salpingo-öophoritis ; in such cases the cellulitis is a *secondary* condition, and, clinically speaking, it is also of secondary importance, the disease which has caused the cellulitis being the predominant and primary factor.

**Anatomy.** For a description of the distribution of the cellular tissue and lymphatics of the pelvis, reference should be made to pp. 5 and 71. Without a clear understanding of the anatomical

distribution of the cellular tissue it is impossible to obtain an intelligent appreciation of this disease.

The following anatomical points will bear repetition :

(1) The cellular-tissue not only surrounds the blood-vessels, but it forms their sheaths, hence cellulitis starting in the pelvis may spread *viâ* the perivascular lymphatics to those regions outside the pelvis whence the large blood-vessels arise.

(2) The cellular tissue of the pelvis is continuous with that of the rest of the body, therefore a cellulitis of pelvic origin may spread by lymphatic-continuity into other areas adjacent to the pelvis.

(3) The cellular tissue lies immediately underneath the peritoneum, therefore an acute primary cellulitis necessarily sets up a secondary peritonitis, and a primary peritonitis will secondarily implicate the subjacent cellular tissue.

(4) The cellular tissue is related to the ureter in the same way as it is to the blood-vessels, hence cellulitis may track up along this duct to the kidney-region, just as it may course along the large vessels to reach the front of the thigh and the buttock.

(5) The cellular-tissue completely invests the supra-vaginal cervix whilst it is practically non-existent where the peritoneum covers the body of the uterus, therefore primary cellulitis is liable to occur when a cervical injury becomes infected, but it is unlikely to be caused by primary direct infection from lesions confined to the *corpus uteri*.

(6) The cellular tissue, which lies between the vaginal roof and the peritoneum, ordinarily measures one-third of an inch in thickness. In pregnancy, this is enormously increased; for instance at full term the broad ligaments lie above the pelvic brim, and the peritoneum does not dip into the lateral parts of the pelvis at all. This increase in the size of the pelvic cellular space during pregnancy can be realized when it is remembered that it will accommodate a placenta which escapes into it through a rupture in the lower uterine segment, and also that it is possible to perform Cæsarean section through this interval without opening up the peritoneal cavity. This enormous increase of connective-tissue in the pregnant state is of the greatest clinical acute primary importance.

**Etiology.** The commonest infecting agent is the *streptococcus pyogenes*, which may be associated with staphylococci, with gonococci, or with the colon bacillus, or it may be obtained in pure culture. Gonococci alone do not produce acute primary cellulitis.

A *predisposing cause* is to be found in a lessened resistance of the tissues due to bruising during delivery or operation. The commonest point of entry of organisms is through lacerations of the cervix and upper part of the vagina, produced, as a rule, by instrumental delivery or by version, and occasionally also during spontaneous labour. When infection follows abortion, primary acute cellulitis is not likely to occur, because there is less risk of cervical and vaginal laceration,

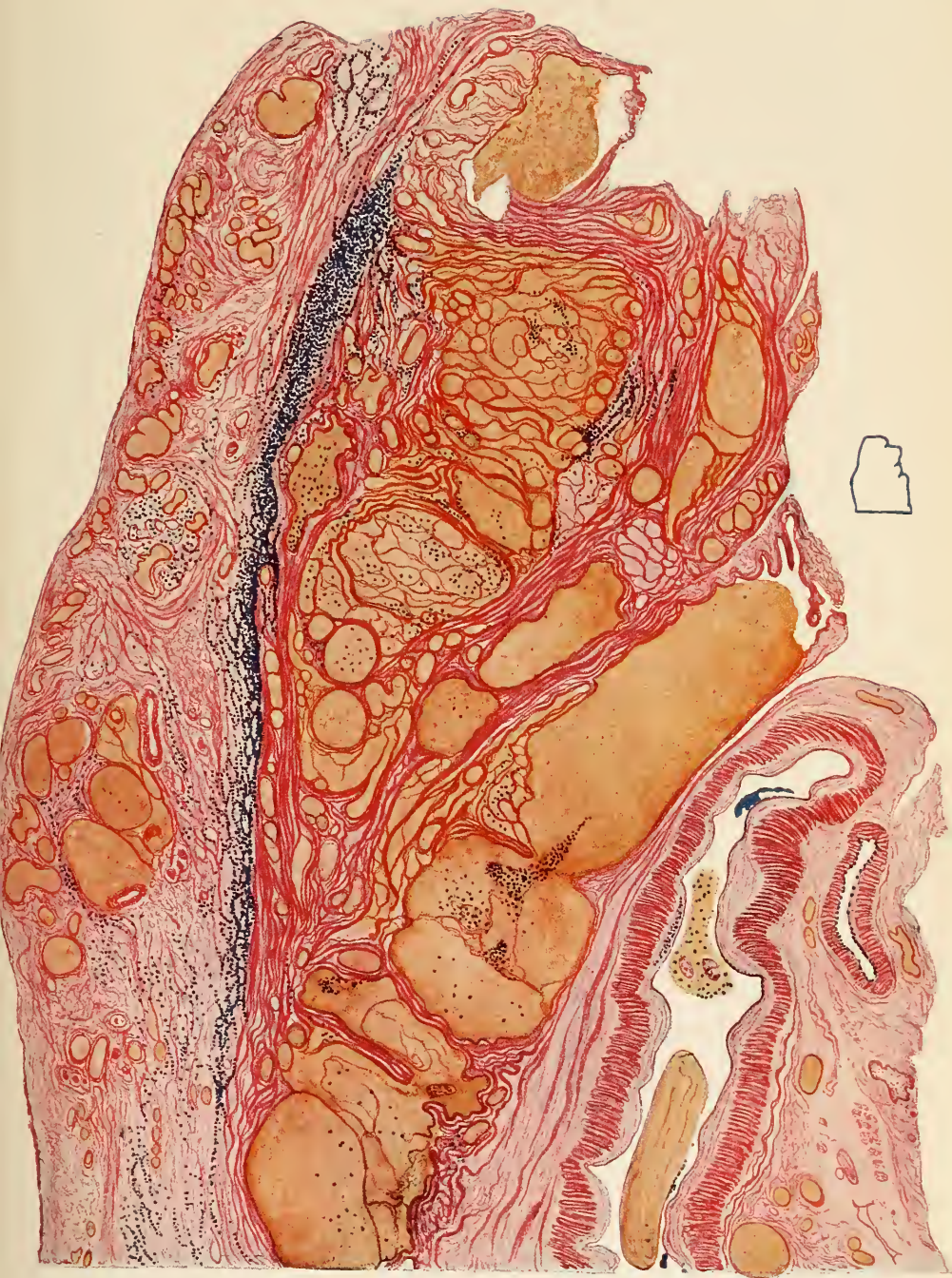and because the amount of cellular tissue is far less than that present at term. Abdominal operations which involve extensive dissection deep in the pelvis, especially when performed for carcinoma, are liable to set up acute cellulitis, and, as already mentioned, vaginal operations necessitating dilatation of the cervix for septic intra-uterine growths, may likewise be followed by the same form of local pelvic inflammation.

In comparison with pelvic peritonitis primary pelvic cellulitis is a very rare affection.

**Pathology.** Following the entrance of organisms into the lymphatic vessels, the tissues become hyperæmic and infiltrated with *blood* (see Plate VI) and leucocytes. This stage is rapidly succeeded by the outpouring of a sero-fibrinous exudation, and by œdema of the infected area. The swelling thus formed is at first soft, but it very soon becomes stiff and indurated, due to clotting of *blood* in the tissues, thrombosis in the veins, and coagulation of lymph. Later on it acquires a hardness which is almost equal to that of cartilage. The fibrinous exudation is first felt in the base of the broad ligament adjacent to a septic cervical or vaginal laceration, where it may form a very extensive unilateral mass. When extension occurs, the exudate usually spreads towards the antero-lateral pelvic walls, and can be felt as an indurated mass anteriorly above Poupart's ligament, and laterally in the iliac fossa. Backward extension along the utero-sacral fold to the pararectal connective-tissue also occurs, and, as already stated, it may follow the track of the ureter to the loin (see Fig. 137), and the course of the blood-vessels through the great sacro-sciatic notch, through the crural canal, and through the obturator foramen. Finally the exudation may spread from the *cavum Retzii* upwards along the course of the obliterated hypogastric vessels and the urachus towards the umbilicus. An extra-pelvic extension of this character is known as *remote parametritis*. Not infrequently suppuration occurs in these extensions (see Fig. 138).

The inflammatory exudation may undergo complete absorption and eventually disappear altogether, leaving no evidence of damage to the tissues. In the most severe cases suppuration occurs, resulting in a pelvic abscess. Usually there is a single abscess-cavity, but there may be multiple foci of suppuration (see Pelvic Abscess, p. 262). In the acute form of primary pelvic cellulitis, thrombophlebitis may occur in the veins of the thigh leading to *phlegmasia alba dolens*.

*Chronic pelvic cellulitis* is never a sequel of the acute primary disease which has just been considered. It is found as a complication of peritonitis and salpingo-öophoritis, and it sometimes happens that an infected tube and ovary may be so surrounded by cellutic exudation, that the primary lesion cannot be made out until the induration in the connective-tissue subsides. Opinions differ as to whether this





secondary cellulitis persists ; some authorities say that it does do so, and that fibrous tissue is formed which produces puckering and contraction of the overlying peritoneum ; others deny the existence of chronic pelvic cellulitis altogether. Some writers draw attention to a chronic form of pelvic cellulitis which is found beneath the pouch of Douglas and which is thought to arise from an infection through the rectal wall. It seldom produces a large exudation, but small hard masses, accompanied by thickening of the folds of Douglas's pouch ; it leads to much scarring and contraction of the pouch of Douglas, and is spoken of as *parametritis chronica atrophicans* and also as *parametritis nodosa posterior*. According to Robert Meyer, processes of epithelium sometimes grow down into the indurated cellular tissue and form pseudo-gland tubules, thus giving rise to an adeno-myoma of the recto-genital space (*see p. 493*). This type of cellulitis rarely leads to suppuration.

**Symptoms.** On the second or third day after infection of the cellular tissues, the patient has a rigor with a rise of temperature and acceleration of pulse. Pain is not a characteristic symptom ; when present it is an indication that the peritoneum is also involved. The skin becomes harsh, dry, and desquamating. When suppuration occurs there is progressive emaciation, and the skin takes on a characteristic earthy sallowness. Anorexia, constipation, dysuria, mental depression, and irritability of temperament are symptoms which may be expected. When extension occurs along the cellular tissues overlying the ilio-psoas muscle, the patient lies with the leg of the affected side drawn up in order to relax the muscles. If allowed to get up before resolution has occurred, she will limp, and attempts at walking will cause pain. This may lead to the discovery of an exudation which had not been suspected, in a case in which the general symptoms were those of a mild form of infection.

**Physical Signs.** When an examination is made, the vagina will be found to be hot and tender, with marked pulsation of the large vessels in the lateral fornices. A tear may be discovered in the vaginal wall or, more often, in the cervix. In the early stages of acute pelvic cellulitis, when the exudate is serous and the tissues are œdematous, a slight feeling of resistance on the affected side is all that can be felt. After a lapse of several days the exudation becomes fibrinous and is then palpable as a hard, unyielding, tender mass around the cervix and upper part of the vagina. The mass spreads out into the base of the broad ligament and causes fixation of the cervix and depression of the lateral fornix. The mass may be large enough slightly to displace the uterus laterally, but Cullingworth has stated that "an exaggerated importance has been attached to lateral displacement of the uterus as a distinctive sign of pelvic cellulitis ; it occurs but rarely, and is of little diagnostic value." A point of importance is, that whilst the exudate spreads all around

the cervix in the form of a thick, tender, indurated collar, it does not, as a rule, extend far into the opposite broad ligament, hence a pelvic cellulitic swelling is mainly *unilateral*.

A very extensive exudation will vary in its physical signs according to the course taken in its unilateral extension. Most frequent of all is to find (1) that it takes the form of a broad, hard band which runs along the inner portion of Poupart's ligament; (2) more rarely the hardness is felt above the pubes, whence it ascends upwards in the midline towards the umbilicus; (3) sometimes the exudate occupies the iliac fossa and can be felt at the level of the anterior iliac spine, and above that point it appears again in the loin, where, when suppuration occurs, a swelling of considerable size may appear (*see* Figs. 137 and 138); (4) in some cases the exudation may be felt in the utero-sacral fold and around the rectum, where on rectal examination it appears as a hard, indurated, semi-circular mass investing the front and lateral aspects of the bowel. Under such conditions the pouch of Douglas is empty unless peritonitis is also present. The iliac fossæ and the renal region should be carefully examined as extensions to these parts may occur (remote parametritis, *see* Fig. 137).

When suppuration does not occur, the exudation gradually becomes absorbed until no trace of it can be found.

*Cellulitic Pelvic Abscess.* Suppuration is not uncommon in acute pelvic cellulitis. As in the majority of cases, the exudation occupies the cellular space of the anterior part of the pelvis, the abscess formed will point externally, and generally over the inner half of Poupart's ligament, more rarely over the outer half. As previously stated, a perinephric abscess may be formed which will point in the loin. Exceptionally, an abscess will point in Scarpa's space or in the gluteal region. A point of importance for the student to note is that only very exceptionally does a cellulitic abscess burst into the bladder, vagina, or rectum. The presence of pus is indicated by œdema and pitting of the skin, by finding a soft spot in the area of induration, and later by definite fluctuation. The usual time for an abscess to point is from the seventh to the twelfth week after delivery (Cullingworth).

**Diagnosis.** One of the earliest signs of cellulitis is fixity of the cervix, accompanied by a tender unilateral swelling. Later on, the swelling spreads laterally and becomes hard; it may obliterate the vaginal fornix, and eventually become evident above Poupart's ligament. If the exudate widely opens up the folds of the broad ligament, the whole uterus will be fixed, and in this case, pushed somewhat towards the opposite side (*see* Fig. 139). When the cellulitis has taken a backward direction, its presence is best made out by rectal examination, when the horseshoe-band of induration investing the bowel, and continuous with an induration in the utero-sacral ligament, will be easily felt.



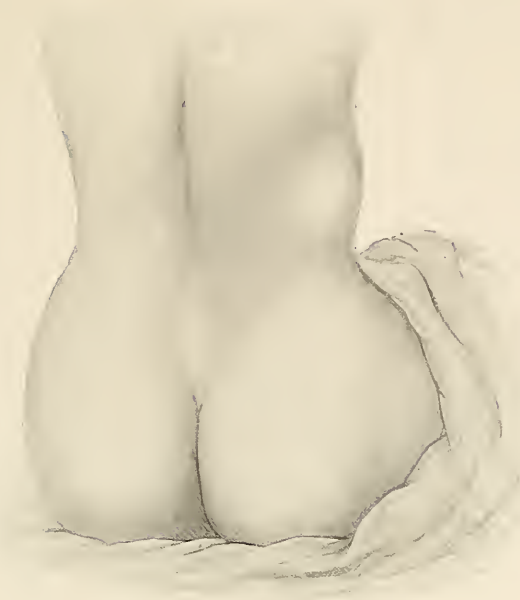

FIG. 137. SWELLING IN RIGHT LOIN CAUSED BY REMOTE PARAMETRITIS. The abscess in the loin appeared ten months after confinement. The cervix had been badly torn and had sloughed off completely.

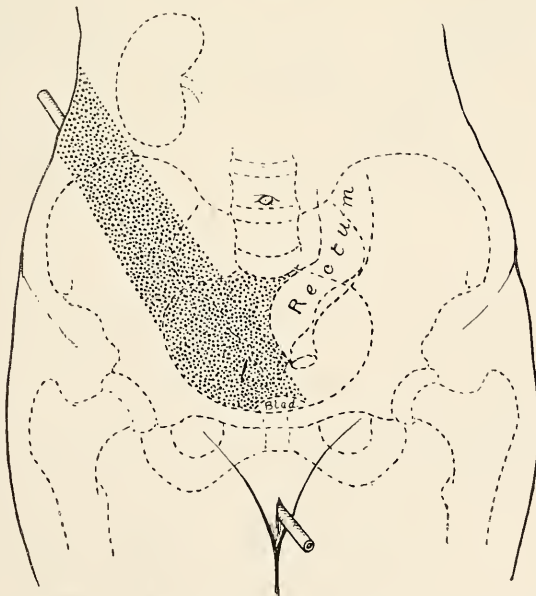


FIG. 138. REMOTE PARAMETRITIS SCHEME OF CASE SEEN IN FIG. 137, showing a drainage tube which was passed through the whole length of the suppurating tract.

There are two conditions which simulate the rarer form of cellulitis which fills up the whole of the mesometrium. (1) Hæmatoma, produced by intra-ligamentary rupture of an ectopic gestation, or by a ruptured varicose vein; (2) a broad ligament myoma. The confusion is chiefly one of physical signs, the clinical history, if carefully gone into, will greatly assist the diagnosis. In the case of pelvic cellulitis there will be a history of puerperal pyrexia or of post-operative fever; with a hæmatoma the history will be that of a sudden pain, faintness, and an attack of vomiting; pyrexia will have been slight and transient, unless the blood-effusion had suppurated. As regards a myoma, Figure 139 shows how,

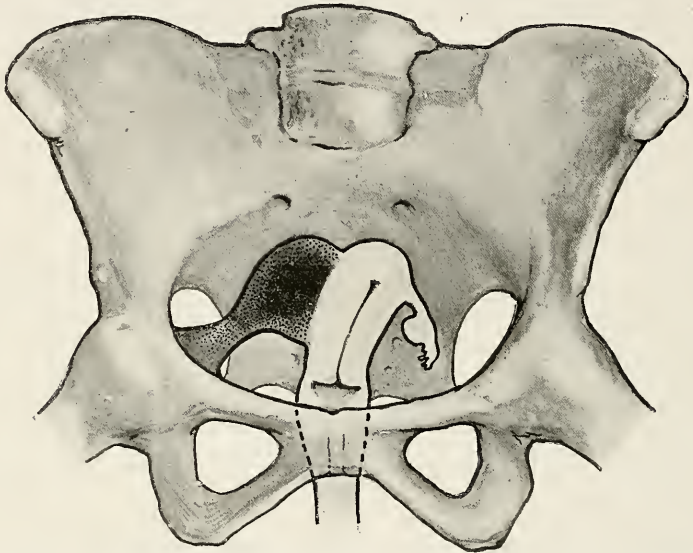


FIG. 139. A PARAMETRIC EXUDATION IN THE RIGHT BROAD LIGAMENT, yielding clinical signs similar to a myoma of the uterus (after Winter and Ruge).

during resolution of a cellulitis, a lump may be felt resembling an intraligamentary uterine growth; but again there will be the history of infection to aid the diagnosis of cellulitis, whilst in the case of a tumour, no such history is obtainable unless it became infected.

Differentiation between pelvic peritonitis and pelvic cellulitis will be deferred until the latter condition is described (pp. 263, 264).

**Prognosis.** Under favourable conditions the exudation completely subsides, recovery is complete, and the attack of cellulitis leaves no barrier to future pregnancy. When suppuration occurs, if the pus pointing externally is evacuated, recovery is rapid. When the pus extends to parts distant from the uterus, or burrows posteriorly, recovery may be prolonged for several months. In

the case illustrated in Fig. 137 the illness had lasted for ten months before the abscess appeared in the loin. After the whole track had been drained the sinus quickly closed and the patient soon recovered.

**Treatment.** Rigid asepsis in midwifery and in surgical manipulations would prevent the occurrence of acute primary pelvic cellulitis. When the disease is established, treatment consists of prolonged rest in bed, the giving of saline aperients, the application of fomentations to the lower abdomen, the use of hot vaginal douches and electric-light baths. The value of glycerine tampons as an aid to absorption is a matter of doubt. Septic wounds of the vaginal vault and of the cervix must receive suitable treatment. When pus forms, the abscess must be opened without delay, and a drainage-tube inserted. Care must be taken to avoid contraction of the knee-joint, by placing the limb on a double inclined splint, which should be taken down daily to exercise the knee-joint.

## PELVIC PERITONITIS

(*Perimetritis*)

Although pelvic peritonitis is an infective process, its function is protective and life-saving, but when the excitant is too virulent the resultant peritonitis may be destructive to tissues and dangerous to life.

**Etiology.** Pelvic peritonitis is the result of some pre-existing intrapelvic disease; the symptoms it produces are often the first indication of the presence of such disease, hence arose the idea that pelvic peritonitis was a primary idiopathic inflammation. This view is now known to be erroneous.

The commonest cause of pelvic peritonitis is an ascending infection of the genital tract which has reached the Fallopian tube (*see* Plate VII, p. 287). The commonest sources of infection are therefore puerperal sepsis and gonorrhœa, whilst tubercle comes third in etiological importance. The morbid anatomy of inflammatory affections of the Fallopian tubes and of the ovaries will be described in detail in a later section (*see* p. 608), but certain points must here be referred to in order to render an account of pelvic peritonitis intelligible.

*Salpingitis.* Pelvic peritonitis in the female usually arises as a complication of salpingitis. By means of the Fallopian tube the peritoneum is placed in direct continuity with the mucous lining of the uterus and of the vagina; thus extension of an infective process in the uterus to the peritoneum is what must be regarded as likely if not inevitable. Once a tube is infected, the lumen, at its uterine end, is speedily closed by turgescence of the mucous membrane, and infective secretions find their way through the more patent abdominal ostium as their only mode of egress. Hence pelvic peritonitis is a

constant sequel to salpingitis. When the abdominal ostium is closed the infected secretion, which becomes pent up, causes an extension of the inflammatory process through the walls of the tube to its peritoneal coat, thus giving rise to *perisalpingitis* and adhesions. With retention of pus in the tube the tendency is to repeated fresh attacks of peritonitis, the spread of inflammation extending over the neighbouring peritoneum on each occasion. The pus may also find its way through the tube, and produce a peritubal abscess in the way explained on p. 618. From close proximity with the ovary, the abdominal ostium is frequently sealed to the surface of this gland, but apart from this change infected material, escaping from the tubes, causes *perioöphoritis* and in many cases infection of the Graäffian follicles, leading to ovarian abscess (see Fig. 351, p. 647). In such cases the ovary provides a fresh source of infection for the peritoneum, and it may happen that the original tubal infection may clear up when the ovarian abscess will appear to be the source of the peritonitis.

*New Growths.* Experience shows that a cystoma of the ovary is much more likely to become the seat of abscess-formation than is the non-cystic ovary, since suppurating ovarian cysts are much more frequently encountered than is the true ovarian abscess. The infection in the case of suppurating cystomata is, however, not necessarily of tubal origin. An ovarian cyst may come in contact with, and press on, the bowel, and becoming infected from the latter may lead to pelvic peritonitis. Ovarian cysts may also lead to inflammation of the serosa by becoming infected after suffering injury, from twisting of their pedicle, or from bruising during labour. Some types of tumour, viz. the papillary cyst and teratoma, are rarely found without evidence of more or less extensive peritonitis, and the same applies to every type of malignant ovarian or tubal growth, and also to lutein hæmatomata. Myomata do not, as a rule, cause peritonitis, but they are very prone to undergo necrosis and are very commonly associated with salpingitis, hence a necrotic myoma may, like an ovary, form an independent source of peritonitis.

*Acute Uterine Infections.* As already mentioned, when a septic infection follows abortion, labour at term, or surgical procedures on the genital tract, it may be followed by a general pelvic peritonitis. In some of these cases the peritonitis may remain localized to the pelvis with the formation of an encysted abscess in the pouch of Douglas. More often diffuse pelvic suppuration of a very virulent type and involving both the peritoneum and the connective tissues ensues. This is rapidly fatal.

*Pelvic Cellulitis.* We have stated that a pelvic cellulitis may be secondary to pelvic peritonitis; the converse holds equally good, especially when the former has gone on to suppuration and abscess-formation.

*Tubercle.* In relative importance tubercle may be regarded as the third bacterial source of infection of the pelvic peritoneum, the other sources of *paramount* importance being sepsis and gonorrhœa. For an account of the relationship between tubercle and pelvic peritonitis the student is referred to the section on tuberculosis of the female genitalia (p. 314).

*Pelvic Hæmatocele.* Peritubal and paratubal hæmatoceles are examples of what peritonitis can accomplish as a protective agent. The false capsule which limits the amount of hæmorrhage, and which shuts off the blood from the general peritoneal cavity, is produced by adhesive peritonitis. In diffuse hæmatocele there is also an associated peritonitis which tends to limit the extravasation of blood by the formation of adhesions between omentum and coils of intestine at the pelvic brim.

*Appendicitis.* The vermiform appendix in woman frequently lies in the pelvis and is intimately concerned with gynæcological affections (*see* p. 277). It is, therefore, necessary, when investigating a case of right-sided pelvic peritonitis, to bear in mind the possibility of a diseased appendix; indeed this organ may not infrequently be found adherent to the right Fallopian tube or to the ovary, and is one of the common causes of right-sided salpingo-oöphoritis (*see* Fig. 324, p. 609). It has also been found adherent to the pregnant uterus, when the risk of uterine infection is very great.

**Pathology.** When inflamed, the peritoneum becomes dull, dry, and slightly roughened; masses of lymph adhere to its surface and lead to the formation of adhesions. After repeated attacks, adhesions showing a varying degree of organization into fibrous tissue are to be seen. Serous effusion is another feature of peritonitis. The serum collects in the pouch of Douglas, where it becomes shut off by adhesions; it is also found between adhesions, forming swellings resembling true cysts. The name of *encysted serous perimetritis* has been given to the latter condition. In the serous effusion it is common to find floating flakes of lymph. Serous effusion is present in every case of *acute* pelvic peritonitis, but where the inflammation passes to a chronic stage the fluid may be absorbed; collections encysted between adhesions may however remain and form pseudo-cysts varying in size from that of a pea to that of a large orange. To such serous pseudo-cysts of inflammatory origin, Targett gave the somewhat incorrect name of *perimetric cystomata*. In some cases these pseudo-cysts are subdivided into loculi by membranous septa.

Inasmuch as pelvic peritonitis usually originates in salpingitis, the densest adhesions are usually met with at the abdominal end of the tube, but in appendical cases, the adhesions are most dense wherever the vermiform appendix happens to be situated.

When the infection is more virulent the secondary peritonitis leads to the formation of intra-peritoneal abscess or, in rarer instances,

such as virulent puerperal sepsis, to general suppurative peritonitis. *Intra-peritoneal abscesses* may be single or multiple. As the tubes, in cases of *salpingitis purulenta*, generally lie with their ostia low in the pouch of Douglas, that cavity becomes the receptacle for pus, and it is here that an intra-peritoneal abscess most commonly forms. From ulceration of a tubal pus-sac an intra-peritoneal abscess may be formed in whatever position the tube may happen to have leaked. Sometimes the ulceration occurs into a loculus of an ovarian cyst and a tubo-ovarian, instead of an intra-peritoneal, abscess is then formed.

Small intra-peritoneal abscesses may dry up and disappear ; larger abscesses will either run an acute course, or remain latent and cause but few symptoms. There is a marked tendency for ulceration of the abscess-wall to occur, and for the contents to escape into the pelvic colon. Less frequently, the pus escapes into the bladder or vagina. In rare instances it will burst into the peritoneal cavity, or through the abdominal wall.

**Symptoms.** Pelvic peritonitis is ushered in by sudden acute local pain accompanied with fever, rapid pulse, and often vomiting. This is followed by abdominal distension, either general or local. The acute pain may last for a few hours, and on subsiding it leaves a tenderness over the affected parts. Except in cases of diffuse septic peritonitis rigors are not frequent ; a rigor may indicate the bursting of a pyosalpinx or of an ovarian abscess. Constipation, dyschesia, and dysuria may be met with. In chronic cases dysmenorrhœa, menorrhagia, sacralgia, and inability to work are the prominent symptoms. *There is always a tendency to recurrent subacute, or even acute attacks*, which form a good indication of the presence of some focus of suppuration, of which, in the intervals, the temperature may give no sign. The grade of severity in the symptoms of pelvic peritonitis varies between those which cause a patient to be bedridden and emaciated, to those where the woman suffers only from occasional attacks of pelvic pain. The patient during an acute attack lies on her back with her knees drawn up ; the lower abdomen is rigid and tender and may be tympanitic from flatus in the distended intestines.

On vaginal examination, if the parts are not too tender, the posterior vaginal fornix may be felt to be depressed by a central, retrouterine swelling, which pushes the uterus forwards. Lateral swellings cannot usually be detected in the acute stage, but when this has subsided elongated swellings, leading to the uterine cornua, may be made out under anæsthesia. Such lateral swellings represent the fused tubes and ovaries. These tubo-ovarian masses are of various shapes and sizes, they may be large enough to depress the lateral fornices or, they may rise above the pelvis and, in the case of large pus-sacs, ascend as high as the umbilicus. When examination is made soon

after an acute attack, the consistence of the adnexal structures is found to be hard and dense owing to a cellulitic exudation around them, and also to the œdematous thickening of the tube-walls. This hardness subsides in time, and the true outlines of the appendages become more easily felt. It may then be possible to obtain distinct fluctuation in a pus-sac. Fuller clinical details will be given in dealing with tubo-ovarian inflammation (*see* p. 629).

**Diagnosis.** The two conditions which are most likely to be mistaken for pelvic peritonitis are pelvic cellulitis and pelvic hæmatocele.

*Pelvic Cellulitis.* There are many points of strong contrast in the etiology, signs, and symptoms of pelvic peritonitis and cellulitis, the most important are summarized in tabular form below :

	PELVIC CELLULITIS	PELVIC PERITONITIS
<i>Frequency</i> .	Rare.	Common.
<i>Cause</i> .	Sepsis.	Sepsis, gonorrhœa, tubercle.
<i>Associated lesion</i> .	Laceration of cervix and vagina.	Salpingitis.
<i>Symptoms</i> .	Pain, none or slight, unless peritoneum is involved.	Pain severe, the initial symptom.
<i>Signs</i> .	Unilateral, hard, smooth swelling.	Bilateral irregular swellings of unequal consistence.
<i>Commonest position of swelling</i> .	Above Poupart's ligament continuous with induration in lateral fornix (pathognomonic).	In pouch of Douglas, continuous with lateral swellings.
<i>Cervix</i> .	Surrounded and fixed by a hard thick collar.	No indurated girdle, therefore usually some mobility of cervix.
<i>Rectum</i> .	Surrounded by a belt of induration narrowing calibre of bowel.	Walls not indurated, not encroached on laterally.
<i>Broad ligament.</i> .	When infiltrated, forms hard, smooth, flattened tumour continuous with uterus can be moved slightly from front to back.	When tumour caused by inflamed tube and ovary, the mass is irregular, not continuous with uterine body, but lies on a plane below and behind it, and is quite fixed.
<i>Course</i> .	Tends to disappear entirely.	Tends to persist and permanently to impair the mobility of the uterus, and even to cause its displacement.

	PELVIC CELLULITIS	PELVIC PERITONITIS
<i>Abscess</i>	. Tends to point externally and to open above Poupart's ligament.	Usual outlet is the bowel or other internal part.
<i>Sinuses</i>	. Never persist.	Often persist and cause much trouble.
<i>Prognosis</i>	. Good. No impairment of prospects of maternity.	Less favourable. Mortality higher, tends to chronic invalidism and to sterility.

*Pelvic Hæmatocele.* Of the three types (peritubal, paratubal, and diffuse), the diffuse hæmatocele, with the pouch of Douglas full of blood, has to be distinguished from effusion of serum and pus due to pelvic peritonitis. The clinical history of ectopic pregnancy and the transient febrile attack will point the way to the diagnosis of hæmatocele, but it must be remembered that when, as may happen, the latter suppurates, the signs and symptoms will resemble those of an intra-peritoneal abscess. Peri- and paratubal hæmatoceles forming definite tubal swellings can only be diagnosed from true inflammatory tubal conditions by a careful study of the clinical history.

**Prognosis.** After an acute attack has passed off there is a liability to recurrence of peritonitis due to the fact that a focus of pus may remain in the tube, or ovary, or amongst peritoneal adhesions. Thus pelvic peritonitis must be regarded as a serious disease which seldom completely clears up, but tends to produce a state of chronic ill-health and incapacity for physical exertion. Interference with the normal action of the bowel is a frequent result, and adhesions which have formed, may be dense enough to produce acute intestinal obstruction. Only in rare instances does pelvic peritonitis clear up completely.

**Treatment.** *Preventive.* The commonest cause of pelvic peritonitis is gonorrhœa, therefore prophylaxis implies the early recognition and vigorous treatment of this common disease (*see p. 288*). Prophylaxis in the non-gonorrhœal cases consists in carrying out strict asepsis in midwifery and in surgery. When the disease has once been established, patients must be cautioned against the risk of a relapse by avoiding exposure to cold, over-fatigue, and constipation, especially during menstruation. Attention to the bowels is of great importance for obvious reasons.

*Medical.* During an acute attack rest in bed is essential, the initial pain will require anodyne treatment. One-sixth of a grain of heroin may be given, abdominal fomentations applied, and the distension relieved by an enema; 1 oz. of castor oil may be given if the enema does not act efficiently. Alcohol may be indicated by a



weak, intermittent pulse. Collapse should be treated by applying hot bottles to the extremities and by giving an injection of strychnine.

*Surgical.* Except in the case of acute appendicitis it is generally wiser to postpone operative interference until an acute attack of pelvic peritonitis has passed off, but this will not apply to serious septic conditions, where "opportunity is fleeting" and where desperate risks must be taken. When a tense cystic swelling forms in the pouch of Douglas it should be at once evacuated by posterior colpotomy (*see p. 777*). The same applies to a rapidly increasing swelling in the lower abdomen, for this may prove to be a suppurating ovarian cyst or an intra-peritoneal abscess. Less acute, and chronic cases must be considered individually, many such are best treated by rest and medical aid, that is to say they will recover without operation.

If, after the first acute attack, nothing be felt except a swelling indicative of chronic salpingo-oöphoritis with no evidence of the presence of pus, operation is not indicated. Recurrent attacks may be regarded differently, and removal of an inflamed tubo-ovarian mass may be necessary for restoration of health, but every endeavour should be made by rest in bed, douches, aperients, and enemata, to reduce the size of the swelling before its removal is considered imperative. Such a conclusion must only be drawn from the fact that the inflammatory mass is not reduced in size by palliative means. In hospital practice the surgeon's hand is often forced by the necessity of restoring the patient to health as soon as possible, because she happens to be a bread-winner. In private practice it is possible to be much more conservative in the treatment of adnexal inflammation. For further details *see pp. 632-634*.

It may be necessary in a certain number of cases to operate for symptoms produced by extensive adhesions, *e.g.* for a fixed retroposed uterus. In such circumstances attempted reposition *per vaginam*, with a view to maintaining the normal position of the uterus by the use of a pessary, is a distinctly dangerous procedure; whereas if the uterus is freed from adhesions and kept in position by ventri-suspension, the relief of symptoms may be expected, and even sterility may be cured by these operative means.

## PYÆMIA

We have seen that following a local infection of the genital tract a general or systemic infection may ensue. This may occur in two ways. (1) The organisms may pass directly into the circulation *viâ* the lymphatics and blood-vessels, and then multiply in the blood-stream without causing any local lesion. To such a spread of infection the name of *septicæmia* or *bacteraemia* is applied; (2) the bacteria may pass from the uterine wall into the veins, setting up septic thrombo-phlebitis. Some of the infected thrombi then break down,

particles are carried off as septic emboli and become lodged in various situations throughout the body, notably in the lungs. At the point of lodgment these emboli form foci of infection, resulting in the formation of serous effusions or abscesses. Thus is set up the condition known as *pyæmia*.

All cases of pyæmia are of grave import. Lea states that this form is responsible for from 30 to 50 per cent. of all deaths from puerperal infection. The prognosis varies with the organism present. Streptococcal pyæmia is usually fatal, but with other organisms there is a better chance of recovery. Pyæmia may result from non-puerperal as well as from puerperal infection. The thrombo-phlebitis, by which it is preceded, may follow directly upon a uterine infection, or be secondary to a local infection, such as pelvic peritonitis or primary cellulitis. The primary source of infection is usually the uterus, and by far the commonest cause is criminal attempts at abortion. Apart from this it may be met with in obstetric practice, where there is a history of intra-uterine manipulations, such as manual delivery of the placenta, or where a sharp curette has been used to remove fragments of infected placenta during the puerperium. The condition indicates a relatively less degree of virulence in the bacteria than that which produces septicæmia. This is indicated by the following facts: (1) bacterial dissemination is for a time confined to the pelvic veins; (2) clinically the disease is later in onset than septicæmia; (3) the organisms can only be found in the blood just before and during a rigor; (4) the disease is not so fatal. According to Opitz the mortality from pyæmia is about 30–40 per cent.

The *symptoms* appear on the fourth or fifth day after infection, with an initial rigor, and the temperature rises to 104° or 105° F. It then rapidly falls to or below normal, the patient meanwhile sweating profusely. The pulse at first is proportionately less rapid than in septicæmia; it is only in the later stages of pyæmia that the pulse-frequency is increased to the extent seen in the latter condition. The course of pyæmia is characterized by repeated rigors, whilst in the intervals the temperature may remain normal or subnormal. In this way the disease may continue for weeks. In the worst examples death usually occurs in the third week, but we have known a fatal issue postponed until the fifty-second day. A case has been recorded in which a pyæmic patient recovered after seventy rigors and an illness lasting five months. A fatal issue depends on the distribution of the emboli; multiple emboli in the lungs, endocardium, and brain being necessarily fatal.

Autopsies on pyæmic cases have revealed extensive thrombosis in the femoral, ovarian, uterine, iliac, and renal veins, and in the vena cava. Also multiple abscesses in the lungs, with areas of pulmonary gangrene, pneumonia, and empyema. Metastatic abscesses have been found in the brain, the eye, the liver, the kidney, in joints, bones,

skin, and muscle. Ulcerative endocarditis is seen to be present in half the fatal cases. The peritoneum generally escapes, excepting for slight local peritonitis around the broken-down thrombi in the local veins.

The *treatment* of pyæmia is the same as that already mentioned for septicæmia. In addition to specific serum-therapy, the injection of chemicals such as collargol (10 c.c. of a 1 per cent. solution) may be given into a vein once daily, or nucleinic acid in doses of 1-2 drachms of a 2 per cent. solution may be given twice daily under the skin. Turpentine in 1 drachm doses has been injected into the tissues of the anterior abdominal wall with a view to forming an *abcès de fixation*. This form of treatment however is of doubtful value. Tuffier has met with some success by employing direct infusion of healthy human blood taken from the radial artery of the donor.

The local treatment consists in trying to prevent the spread of emboli by tying off the ovarian veins on the proximal side of the thrombosed area. This has been recommended by W. A. Freund, by Trendelenberg, and by Burn, but the results have not been encouraging.

## SEPTIC URINARY INFECTIONS

### CYSTITIS

**Etiology.** The causes of cystitis are (*A*) predisposing, (*B*) active. The bladder is more easily infected in women than in men.

(*A*) The *predisposing* causes are chill, foreign bodies in the bladder (*e.g.* stone, hairpins, etc.), introduction of instruments (catheter), vesical new growths, retention of urine due to paralysis, or to obstruction caused by a retroverted gravid uterus or a tumour in the pelvis, and lastly, to traumatism, *e.g.* injury during operation or fracture of the pelvis.

(*B*) The *active* causes are *bacteria*, which may reach the bladder by way of (1) the urethra; (2) neighbouring organs; (3) the bloodstream. Examples of urethral or *ascending* infection are (*a*) bacteria carried from the anal region to the urethral orifice (*B. coli*); (*b*) direct infection of the urethra in gonorrhœa; (*c*) direct infection during catheterisation. The most frequent avenue of infection of the bladder is the urethra. Examples of infection from neighbouring organs are (*a*) fistulous openings from rectum or colon, uterus, or vagina; (*b*) lymphatic spread from the rectum or pelvic cellular tissue (parametritis); (*c*) direct infection from the peritoneum (pelvic peritonitis); (*d*) direct infection from ureter and kidney; the latter is known as *descending* infection.

The kind of organism causing the infection has a marked influence in determining the avenue of infection. Thus, the gonococcus

infects the bladder by ascent from the urethra. Most tuberculous infections of the bladder in women are from urine coming down from a kidney which has become tuberculous through the blood-stream. The colon bacillus may cause both bladder- and kidney-infection by ascent through the urethra, or it may first infect the kidney through the blood, cause a pyelitis, and then descend to the bladder. The same applies to the pyogenic cocci and to the *proteus* group. The relative frequency of the two main routes of infection, the ascending and the descending, cannot be stated, but in hospital practice there is no doubt that the ascending infection is the commoner, for it is common observation that nearly all cases of cystitis in the wards are post-operative and largely due to repeated catheterisation.

The most important organisms which cause infection of the urinary passages are: the colon bacillus, the typhoid bacillus, the *staphylococcus aureus*, the *staphylococcus albus*, the streptococcus, the gonococcus, the proteus bacillus, the tubercle bacillus, the *bacillus pyocyaneus*, and bilharzia. The commonest of all is the *bacillus coli communis*, the next most frequent is the tubercle bacillus. Very common combinations forming mixed infection are (a) *B. coli* and staphylococci; (b) *B. coli* and streptococci; (c) *B. coli*, staphylococci, and streptococci. Another common combination is *bacillus tuberculosus* and staphylococci. Mixed infections usually mean that the secondary organism has been conveyed by instruments.

The identification of gonococci and of tubercle bacilli is made by staining films prepared from the centrifugalized deposit. With other organisms cultural methods are employed. The pathogenicity of the organisms is sometimes determined by animal inoculations, *e.g.* in tuberculosis.

It is generally agreed that two factors must be present in the causation of cystitis—one the *infecting organism*; the other, *injury*, either in the nature of actual trauma or a condition of lowered resistance. Micro-organisms alone will not set up cystitis: this has been proved by injecting large quantities of bacteria into the bladder without any detriment to that organ; and again cystitis is by no means an invariable accompaniment of renal infection. Similarly, traumatism produced during parturition or by surgical instruments will never alone cause cystitis, but if traumatism is severe or repeated, sooner or later micro-organisms from the bowel, or from the urethra, or even from the circulation, will find a nidus, and start an infection. Hence it is that repeated catheterization is so frequently followed by cystitis. The influence of trauma as a predisposing cause of cystitis is brought to the attention of the surgeon in performing hysterectomy, notably for cancer. In cases where there has been much difficulty in dissecting the bladder from a

cancerous cervix, the base of the organ will be contused and indurated by effusion of blood, and it is frequently found that a severe cystitis follows after the catheter has been passed only a few times. Of all the paths of entry for organisms, it must be borne in mind that the *ascending* route is by far the most important.

A thorough bacteriological examination should be made in all cases of cystitis, especially if the infection does not respond promptly to treatment, since, by a recognition of the organism responsible for the infection, it is possible to employ autogenous vaccine therapy.

**Pathology.** The appearances of *acute cystitis* have been studied by cystoscopy. The mucosa is universally reddened and swollen; dilated branching vessels are prominent; ecchymoses may be seen. The lesion starts in the epithelium and reaches to the submucosa, but there is no involvement of the muscle and perivesical tissues. Microscopically, there is dilatation of blood-vessels and the tissues of the mucosa are infiltrated with polymorphonuclear leucocytes, and perhaps with plasma-cells. Later on, the blood-vessels are seen to proliferate and the leucocytes aggregate, forming foci which lead to tiny abscesses. In spite of these changes the mucosa is hardly ever adherent to the submucosa. In acute cystitis there is very little loss of epithelium, and practically never any muscular hypertrophy.

*Chronic cystitis* presents a remarkable variety of lesions. Super-added to the ordinary changes incidental to chronic inflammation of the mucosa, there is a great thickening of the muscular coats and marked trabeculation. In tabetic cystitis the bladder is distended, but in an uncomplicated case of chronic cystitis the capacity of the bladder is diminished. The entire wall is thickened, the mucosa is slate coloured, showing red spots here and there. Instead of a smooth, velvety aspect the surface becomes leathery and granular. It is thrown into coarse folds, and presents ulcers and bosses of granulation tissue. Leucoplakic patches may be present and actual cysts may form between trabeculae.

Microscopically the surface epithelium is in part absent, polymorphonuclear leucocytes and plasma-cells abound. The muscle is largely replaced by fibrous tissue, and the perivesical tissues undergo a fibro-lipomatous change which adds greatly to the thickness of the organ. A leucoplakic area presents many layers of horny epithelium overlying scar-tissue. The behaviour of the epithelium in chronic cystitis is very striking. It dips down into the submucosa as solid buds of transitional epithelium; these buds break down in the centre and form small cysts, which vary in size from a pin's head to a pea. By the breaking down of these cysts small pockets are formed in which phosphatic deposits collect. This goes on to extensive ulceration with further incrustation, resulting in the so-called stalagmite-bladder. An even more striking pathological feature demonstrated by the mucosal epithelium, is the formation in chronic cystitis of

pseudo-glands, resembling Lieberkuhn's follicles in the intestine. The process of branching gland-formation is similar to that seen in the muscular wall of the Fallopian tube in chronic salpingitis, especially in tuberculous cases (see Fig. 150, p. 312). It is also seen in the formation of acquired *erosion* following on cervicitis (see p. 406). The significance of such gland-formation in the walls of the bladder is that these pseudo-follicles are liable to become the site of the development of carcinoma, and their presence affords a rational explanation of the occurrence of adeno-carcinoma of the bladder.

**Symptoms.** The characteristic symptoms of cystitis are increased frequency of micturition, pain, dysuria, local tenderness, a sense of pressure or bearing down in the lower abdomen, and turbidity of the urine.

The onset of *acute cystitis* is ushered in with a severe febrile attack. In the most severe cases there may be a rigor. The temperature may rise to 101°, 102°, or 103° F., and the patient feels very ill, complaining of a severe forcing pain in the hypogastrium which radiates round to the back. The pain is accompanied by tenderness in the hypogastric area. Irritability of the bladder soon becomes very distressing, small quantities of urine are passed with intense pain of a spasmodic character (*strangury*). This goes on day and night, robbing the patient of sleep; the pulse rapidly rises, and the temperature keeps up continuously. Under suitable treatment the severe symptoms gradually subside, but frequent and painful micturition may remain long after the fever has subsided. The urine, during the acute stage of cystitis, is rendered turbid by the presence of pus-cells, epithelial cells, and blood-corpuscles. The latter may be present in sufficient numbers to render the urine smoky, or to be thrown down as a red ring in the deposit which forms when a specimen is allowed to stand in a conical glass. In the majority of cases of cystitis in women, the urine is acid or neutral in reaction; alkaline ammoniacal cystitis is only seen in the female, when, from any cause, there is a sloughing mucosa. The amount of albumen will vary with the quantity of pus and blood which is present. If a large trace persists after the acute symptoms have subsided, it points to involvement of the kidney. The blood-count is normal in acute cystitis, *i.e.* there is no leucocytosis.

An acute cystitis may clear up completely, or it may lapse into the chronic form. The gravity of acute cystitis is due (*a*) to the difficulty of complete cure; (*b*) to the danger that ascending infection along the ureters to the kidney may occur, but this is, fortunately, a very exceptional complication of acute cystitis (see p. 274).

When cystitis lapses into the *chronic stage*, all symptoms subside except the increased frequency of micturition, and even that may be absent; but long after the symptoms have subsided, there may be organisms abounding in the urine. In a recent case which was under

our care in hospital for twelve weeks, an extensive growth of the *bacillus coli communis* was grown from the urine two months after the patient had felt quite well, and in spite of the fact that she had been systematically treated by urotropin irrigations, and autogenous vaccines.

In *subacute* cystitis, as a rule, the frequency of micturition is lessened but still marked, indeed in some instances it may be so troublesome at night as to exhaust the patient from want of sleep. In the most severe cases, a constant spasmodic condition of the bladder occurs, leading to a dribbling of urine indistinguishable at first from the simpler forms of incontinence. The amount of pus may be small at first, so small in fact that it is only to be found in a centrifugalized deposit of a twenty-four hours specimen. With the continuance of the disease the pus increases until there is a heavy deposit of pus, mucus, and epithelial *débris*.

**Diagnosis.** Cases of *acute cystitis* occur during pregnancy, in the puerperium, after operations, and in the subjects of an acute gonorrhœal infection. In the worst cases the question of the kidney being also implicated will arise (pyelonephritis). When acute symptoms supervene after the passage of a catheter in the puerperium, or after an operation, the diagnosis of an inflamed bladder is not difficult. The local pain and tenderness, the frequent and painful micturition, and the altered character of the urine, are clear indications of cystitis. In a gonorrhœal infection, the swollen meatus, and a purulent urethral discharge, together with the discovery of the gonococcus will suffice for diagnosis. It might be said that absolute diagnosis is only to be obtained by direct inspection of the bladder-walls, but in acute cystitis it is not advisable to employ a cystoscope as additional trauma may result therefrom. We must, therefore, be content with such evidence as can be obtained clinically, short of actual inspection of the interior of the organ, and this, when combined with a cytological and bacteriological examination of the urine, suffices for all practical purposes.

In *chronic cystitis* a cystoscopic examination is often essential, it may be made, with or without, the aid of an anæsthetic. The first investigation is best made under anæsthesia; for a description of the technique the student should consult a text-book on the surgery of the urinary tract. Cystoscopic examination has revealed the fact that inflammation of the bladder is not uniformly distributed over the mucous surface, but exists in localized foci or ulcers. Irregular red areas, rounded or crenated in shape, are seen, or sometimes the infection causes petechiæ containing little spots of ulceration. Such lesions may give rise to very troublesome hæmorrhage and they heal very slowly. When an ulcerated area heals, it contracts and leaves a linear or radiating scar. The line of an old ulcer stands up as a falciform ridge, dividing the bladder into deep loculi, and expansion

of the organ is thereby seriously curtailed. When healed, a linear ulcer appears as a yellowish white streak in the centre of a red zone.

*Differential Diagnosis.* It is important to differentiate between cystitis and the condition known as *irritable bladder*, in which there is increased frequency in voiding urine and tenderness at the base of the bladder. These symptoms are found to be associated with hyperæmia of the trigone. There is no inflammatory area to be seen on cystoscopic examination, and there is no pus in the urine. Similarly in *bacilluria* there is no local lesion, for, as was previously stated, micro-organisms are found to abound in the urine long after the symptoms of cystitis have cleared up. If a bladder is examined in a persistent case of bacilluria there will be none of the signs of inflammation mentioned above. In every case of increased frequency of micturition from whatever cause, *e.g.* when it appears in the early and late months of pregnancy, or when it is caused by the pressure of pelvic tumours, a thorough examination of the urine should be made, in order to exclude the possibility of cystitis.

Finally, the diagnosis of cystitis must not be considered complete until the infecting organism has been isolated; a practical guide in this respect may here be mentioned, *viz.* that a persistent acid pyuria with a small quantity of pus, and accompanied by slight fever, is liable to be a tuberculous affection.

**Treatment of Acute Cystitis.** The patient must remain in bed until the acute stage is over. At the onset it may be necessary to give heroin hypodermically to allay the pain. Copious drinks of *alkaline* mineral water should be given, it has a sedative effect. Balsam of copaiba (given in capsules) and sandal-wood oil are said to be of use in gonorrhœal cystitis.

Urotropin given in combination with acid phosphate of soda, and combined in a mixture with the tincture of hyoscyamus and infusion of buchu, will help to cut short the disease. If the bladder is not too tender it may be irrigated with warm boric acid solution or with boroglyceride solution twice a day, and at the end of the irrigation a teaspoonful of melargen, in solution varying from 1 to 10 per cent. (according to tolerance) should be injected. If the cystitis does not clear up, vaccine-therapy should be employed. In a few cases it is necessary to drain the bladder through a vaginal incision.

**Treatment of Chronic Cystitis.** Before beginning the treatment of chronic cystitis, the possibility of a renal source of infection should be thought of, and settled by cystoscopic examination. If a descending infection can be excluded, the treatment of the bladder is preceded with on (*a*) general, (*b*) local lines.

*Internal medication* is employed (*a*) for the relief of pain and (*b*) to destroy the invading bacteria. The preparations of opium (morphia, codein, and heroin) must not be used; the best sedative consists of a mixture containing 20 grs. of citrate of potassium, and  $\frac{1}{2}$  drachm



of the tincture of hyoseyamus in combination with infusion of buchu. To destroy the organisms present there is no drug so efficient as urotropin. Its efficiency depends upon the liberation of formaldehyde in the urine; the reaction being manifested only in acid urine, acid sodium phosphate should be given at the same time. These two drugs are combined together in tablets, and sold under various fancy names by druggists, but we prefer to prescribe them in an ordinary mixture, so as to combine with them other sedative drugs such as hyoseyamus and buchu. The determination of the infecting organism is of assistance; *e.g.* where tubercle bacilli are found, the initial lesion will be in the kidney, and call for the surgical treatment of that organ. Gonococci will indicate the employment of copaiba, and sandal wood, and the administration of large doses of alkalis. The coliform group of bacilli will indicate the need for large doses of urotropin, *i.e.* 10, 15, 20 grs. thrice daily, together with 20 grs. of acid sodium phosphate. The diphtheria bacillus, if present, would indicate the use of antitoxin. The proteus group of bacilli in alkaline urine, necessitates rendering the urine acid by giving benzoic acid in doses of 10–15 grs., and then following this up with urotropin when the urine has been rendered acid. Staphylococcic and streptococci cystitis also indicate the use of the latter drug.

*Local treatment* includes (a) irrigation; (b) instillation; (c) topical applications; and (d) drainage.

(a) If the urine is acid, the bladder should be washed out with a borax-solution, in the strength of one teaspoonful to a pint of warm water at 105° F. In the case of alkaline urine, warm boric acid solution should be used. Care must be taken to admit no air into the bladder, as it causes distress. After the first rinsing, the same solution may be run in and out two or three times by alternately elevating and lowering the funnel. Irrigation should be used twice daily. In very chronic cases the bladder will not hold many ounces of fluid, but with patience the organ can be gradually *distended* to hold ten times as much as it does at first. In order to assist the tolerance of the bladder, a 1 per cent. solution of cocaine may be injected five minutes before irrigation is begun.

(b) Instillation consists in the injection of a fluid and leaving it in the bladder. It should be used immediately after irrigation. The best preparations for this purpose are solutions of silver nitrate 1–1000, argyrol in 30 per cent. solution, protargol in 2–10 per cent. solution. One or two teaspoonfuls are injected by means of a glass-catheter, to which is attached a rubber bulb containing the fluid to be injected. Many cases of chronic cystitis are cured by combined irrigation, distension, and instillation.

(c) Topical treatment consists in the direct application of a drug to the diseased area after such has been well defined (and found to be strictly localized) by means of cystoscopy. It is suitable for small

areas of ulceration above the trigone on the posterior wall of the bladder (Kelly and Burnam).

(d) *Drainage*. The bladder may be kept at rest for a week or longer by drainage *per urethram*, by means of a self-retaining catheter. The viscus must be irrigated once or twice daily during the retention of the catheter.

*Vesico-Vaginal Drainage* is a valuable method of treatment for bad cases. It is indicated when the patient is utterly intolerant of any local form of treatment. Its effect is to put the bladder completely at rest and to keep it clean. The opening is made through the anterior vaginal wall, and must be large enough to allow of a free escape of urine. The edges of the wound must be oversewn to prevent spontaneous closure.

**Urethritis.** This condition is discussed in the section dealing with gonorrhœa (*see p. 290*).

### PYELITIS : PYELONEPHRITIS

It is considered doubtful whether a renal infection is ever strictly localized to the mucous membrane of the pelvis and calices of the kidney, but the term 'pyelitis' is used clinically in describing the milder and non-surgical forms of pyelonephritis, and is in such general use that we shall retain it.

Pyelitis may be caused by chemical irritants and by infective organisms. Only the latter will be considered. Organisms may enter the kidney through the blood-stream, through the lymphatics, or by the ureters in an ascending infection. In cases of *chronic* pyelitis the bacillus coli is usually found in pure culture. The manner in which the bacillus coli obtains access is at present unsettled. There are three possible routes to be considered. The *first* is an ascending infection *per urethram*; as Williamson has pointed out, this may occur either by direct infection of stagnant urine above a ureteral block, or by the peri-ureteral lymphatics. By this route the bladder would first be involved, but clinically the special symptoms of cystitis are seldom observed in the early stages. The *second* is by the circulation, the organisms passing through the kidney and attacking the mucous membrane of the renal pelvis (*descending infection*). The *third* is a direct infection from the bowel, the organisms passing from the colon through the peri-ureteral cellular tissue to gain access to the ureter, or possibly to the kidney. In *acute* pyelitis staphylococci and streptococci, and the proteus bacillus are more frequent. More rarely the gonococcus, pneumococcus, and the bacillus of influenza are found (Kelly and Burnam). Among the conditions which predispose to the occurrence of pyelitis are (a) hydronephrosis; (b) pressure on the ureter (*e.g.* from the gravid uterus); (c) retention of urine with cystitis; (d) infection in other parts of the body.

**Pathology.** There is a great variety in the form and extent of the lesions found in the kidney. In *obstructive* cases, *i.e.* where the flow of urine has been interfered with on one side by a pelvic tumour, or by the pregnant uterus, or by cancer of the cervix involving the ureter, the corresponding kidney is liable to become infected through the blood-stream. At autopsy the kidney may look fairly normal, but there will be marked disease of the pelvis and ureter. Histologically, the renal substance will be found to show various grades of nephritis, enough seriously to impair its secretory power.

In cases where there has been no ureteral obstruction, but where there is a severe infection of the kidney, the parenchyma contains multiple small, or single abscesses in the acute form, whilst in a chronic form the kidney-substance is reduced, being largely converted into fibrous tissue. In such cases the ureter and pelvis may appear normal. The above constitute two types of pyelonephritis, and there is every grade of transition between them.

**Symptoms.** In the *acute* form, the patient is suddenly seized with acute abdominal pain, sometimes attended with shivering, and leading, after a few hours, to abdominal distension and sometimes to vomiting. The pain, diffused at first, usually settles down to the right side, but in a small proportion of cases the left is the affected side. The bowels are usually constipated and the tongue furred. The kidney, when palpable, is tender and may be felt to be enlarged; often there is well-marked rigidity of the rectus muscle over it, and so much tenderness that detailed palpation is impracticable. Sometimes the pain on pressure is felt chiefly in the costo-vertebral angle. In cases occurring in pregnancy, the gravid uterus usually shows no abnormality, but tenderness, with thickening of the terminal portion of the ureter (usually the right) may be detected *per vaginam* on deep palpation at the sides of the cervix anteriorly. The temperature may be raised to 103°–104° F., and the fever continues irregularly for some days unless controlled by treatment. Sometimes rigors occur, and the general condition of the patient is so much affected as to give rise to anxiety. When occurring in the puerperium, it may be mistaken for septic uterine infection.

On examination of a catheter-specimen of the urine, it will usually be found distinctly acid, less often it has been observed to be neutral or alkaline. It is turbid and contains flocculent *débris*. In the great majority of cases culture-methods yield a pure *bacillus coli*; sometimes other pyogenic organisms are also present. There are no renal casts, but the deposit may contain a little blood, and there is always a good deal of pus, shed epithelial cells, and epithelial *débris* from the urinary passages. The quantity of urine is usually small, and there is no offensive odour. A trace of albumen can usually be found. In many cases the onset is less acute than this, but fever and severe pain in the abdomen or flank are invariably met with.

In the *chronic* form the symptoms are, of course, less characteristic. There is often slight irregular fever, but this is not invariable, and the patient complains of backache and sometimes of persistent irritability of the bladder. Large quantities of urine may be passed—a fact which is said to explain partly the increased frequency of micturition. The development of cystitis is the rule, and in some cases the bladder symptoms are liable to mask the primary pyelitis. Dysuria may be taken as a sign that the bladder has become secondarily infected. As a rule the kidneys are not enlarged, nor are they tender on palpation, but pressure on the ureter *per vaginam* elicits pain and a desire to micturate (Kelly and Burnam).

**Diagnosis.** This rests on a careful examination of the urine, and in localizing the lesion to one or other side by cystoscopy. In acute pyelitis the urine contains a quantity of serum-albumen, some red discs, pus-cells, and the invading micro-organisms.

Cystoscopic examination reveals a reddened, pouting, or retracted ureteral orifice on the affected side. Turbid urine may be seen issuing from the corresponding ureter, and clear urine from the other.

In gonorrhœal cases there will be collateral evidence of the disease in the cervix, urethra, and perhaps in the Fallopian tubes. Other primary sources of infection should be sought for.

Acute pyelonephritis is frequently confused with malaria, tuberculosis, appendicitis, cholecystitis, or typhoid fever.

**Prognosis.** Acute cases usually respond readily to appropriate treatment. Chronic cases are very intractable and often resist treatment.

**Pyelitis of Pregnancy and the Puerperium.** This condition seldom occurs earlier in pregnancy than the fourth month; occasionally an acute attack of great severity occurs in the puerperium, when care will be required to distinguish it from acute septicæmia. It may assume either an acute or a chronic form, and as a rule there have been no symptoms of cystitis or of renal disease previous to the pregnancy.

The right kidney shows a marked predisposition to this disease, but not to the extent that was at one time believed. Out of 129 cases collated by Albeck and Lenharz, in 67 the right kidney alone was affected, in 26 the left kidney alone, and in 36 both right and left were affected. It has been shown further by autopsy, and by direct observation upon cases submitted to operation, that the ureter may become dilated, at any rate in its abdominal part, upon the affected side. It is generally agreed that this dilatation does not affect the lower portion of the ureter, *i.e.* that it is only found in the part which lies above the pelvic brim. It will be recollected that ureteral dilatation similar to this has been observed in autopsies on cases of eclampsia.

**Treatment of Pyelonephritis.** In an acute case the patient should be kept in bed, the diet restricted to fluids, chiefly milk, and large doses of an alkaline diuretic, such as citrate or acetate of potash, administered with the object of increasing the amount, and reducing the acidity of the urine. As already stated, an acid urine forms a better culture-medium for the *bacillus coli* than an alkaline urine. The acute symptoms usually subside in a few days if a free flow of urine can be maintained, and it is probable that much of the initial severity of the attack results from dilatation of the renal pelvis and upper part of the ureter. The bowels must be freely moved every day. The urinary infection can directly be attacked in two other ways, viz. by urinary antiseptics and by autogenous vaccines (see Cystitis, p. 271). It has been found best to withhold urinary antiseptics until the acute symptoms have subsided. The results obtained with vaccines are unreliable, but this treatment is worthy of trial. Medicinal measures usually suffice to relieve the symptoms, but the specific organism often persists in the urine after the symptoms have all disappeared. Catheterization of the ureter, either alone, or with irrigation of the renal pelvis, is sometimes practised.

## APPENDICITIS

No excuse is needed for including an account of this condition in a text-book of Gynæcology. It has been already pointed out that both in its anatomical and pathological bearings the vermiform appendix is closely related to the special pelvic organs of the female. Thus the appendix, in a considerable proportion of normal cases, is found to overhang the pelvic brim and to lie in contact, or in close relation, with the right tube and ovary. Again it has been pointed out that inflammation of the tube and ovary is not infrequently due to infection from an appendix, which itself diseased, has become adherent to one or other of those organs. From this close relationship it naturally follows that there is sometimes difficulty in distinguishing clinically between morbid conditions of the appendix, and of the right tube and ovary. Errors in diagnosis are accordingly not uncommon, and the gynæcologist, when operating, is frequently called upon to deal with this organ, either because it is found to be the primary seat of disease, or because it is involved in disease which has spread to it from the tube or ovary. Many gynæcologists, and as we think with justice, make a routine practice of examining the appendix when performing an abdomino-pelvic operation, and of removing it whenever it shows signs of disease either active or latent. From all this it follows that appendicitis is a subject with which the gynæcologist must be familiar, and the technique of the removal of this organ is a part of the training and experience which he must acquire.

**Anatomy and Topography of the Appendix.** The vermiform appendix springs from the inner aspect of the cæcum, about 1 inch below the ileo-cæcal valve. The anterior longitudinal band of the ascending colon, if followed downwards, will be found to terminate at the base of the appendix. It is a cylindrical structure of an average length of  $3\frac{1}{2}$  inches, and provided with its own mesentery, in the free border of which runs the appendicular branch of the posterior ileo-cæcal artery. Usually it is straight, but not infrequently it may be found curved, or acutely bent, when inflammatory changes have occurred. The direction of the appendix from its base is very variable; it may hang down into the true pelvis, or it may run upwards along the inner aspect, behind, or even on the outer side, of the cæcum and ascending colon. When inflamed it may be found adherent in one of the three shallow peritoneal fossæ which are found in the ileo-cæcal region. It may, on occasion, much exceed its normal length, and a specimen measuring 10 inches in length has been removed by Paterson. It has not infrequently been found, when elongated, running upwards to the liver, the tip of the appendix being adherent to the under-surface of this organ.

In structure, the appendix resembles the rest of the intestinal tract in consisting of *peritoneal*, *muscular*, *submucous*, and *mucous* coats. The mucosa has a covering of columnar epithelium, with a fair number of tubular glands similar to Lieberkühn's glands. In addition, there is an abundance of lymphoid tissue, collected in the form of numerous *follicles*, which project on the surfaces and also extend into the submucous layer. They are most numerous in the distal parts of the organ.

Of the *function* of the appendix nothing is definitely known, and by many writers it is regarded as a vestigial structure.

**Etiology of Appendicitis.** In infancy and old age the disease is rare, in young and middle-aged adults it is most common. Of the exciting causes of appendicitis nothing is definitely known, and it is unnecessary in this chapter to examine the many interesting speculations which have been put forward by different writers. The organisms which are found are those normally inhabiting the intestinal tract.

**Morbid Anatomy.** The inflammatory process begins in the mucosa and thence spreads outwards, involving the peritoneal coat last of all. The initial stage is a *catarrhal inflammation* of the mucous membrane, and specimens examined at this stage usually show small petechial spots, and sometimes minute ulcers. When the infection is acute the catarrhal stage passes into one of extensive, or even general, *ulceration* of the mucous membrane, as a result of which perforation of the coats may occur at some point. Occasionally, the infection is so acute that massive *gangrene* affecting all the coats, or even the entire organ occurs. The gangrenous coat soon gives way, allowing the contents to escape. When the infection is less virulent than this,

the stage of catarrhal inflammation passes into one of sub-acute or chronic inflammation affecting all the coats of the organ, and by extension affecting its own mesentery, and the peritoneal surfaces of adjacent organs. In such cases the inflammatory process progresses, not uniformly, but by exacerbations with more or less prolonged intervals, and clinically these cases are characterized by repeated recurrences.

An inflamed appendix tends to form adhesions rapidly with surrounding organs. These are protective, and serve to isolate the diseased organ from the general peritoneal cavity. Occasional exceptions are met with in the case of an acutely inflamed or gangrenous appendix, in which diffuse general peritonitis ensues, and yet the diseased organ may be found entirely free from adhesions. This is to be explained by the sudden flooding of the peritoneal cavity with organisms of great virulence, which being rapidly absorbed produce an acute toxæmia, in the presence of which the protective peritonitic reaction is not developed. That perforation does not invariably result in general peritonitis is explained by the fact that there is usually time for limiting adhesions to be produced.

As a result of the adhesions, localized abscess-formation is frequently seen in cases of appendicitis. This may occur either with an acute initial attack, or with a chronic case which has undergone exacerbations. There are four principal situations in which an appendix-abscess may develop; (*a*) on the inner aspect of the cæcum, the pus-cavity being limited by adherent coils of small intestine; (*b*) on the outer part of the cæcum between it and the anterior abdominal wall; (*c*) in the pelvic cavity, either in the pouch of Douglas, or in the cellular-tissue planes on the right pelvic wall; (*d*) behind the cæcum, tracking upwards towards the kidney, or into the connective-tissue lying upon the iliacus muscle (*retro-cæcal abscess*). These abscesses very rarely burst into the peritoneal cavity; occasionally they become spontaneously evacuated into the intestine, or through the abdominal wall. Sometimes they remain encapsuled and gradually become sterile. Occasionally secondary abscesses may form in such remote situations as the left iliac region and the sub-diaphragmatic space.

## CLINICAL FEATURES OF AN ACUTE ATTACK

The symptoms of an *acute* attack will be first described, and then those of a *chronic* case with exacerbations.

**Symptoms.** The onset is almost invariably sudden and may occur in an individual who has previously shown no sign of ill-health. The first symptom to appear is abdominal pain, followed rapidly by nausea or vomiting, rise of temperature and pulse-rate, and the appearance of certain localizing abdominal changes.

*Pain* is very variable in intensity, and may be extremely severe. At first it is, as a rule, referred to the umbilicus or the epigastrium ; later, in the majority of cases, it is referred to the right iliac region, but this is by no means invariable. Not uncommonly it is referred to the right hypochondrium, sometimes to the left iliac region. It follows that little importance can be attached in diagnosis to the site of the pain.

*Vomiting*, although a common initial symptom, is rarely severe or prolonged, except when general peritonitis rapidly supervenes.

*Temperature* is usually found to be elevated a few hours after the onset of the attack, but the degree of the fever is very variable and is *no guide to the severity of the condition*. If the initial rise is high a partial fall soon occurs, succeeded by a secondary rise on the second or third day. A sudden fall of temperature may occur from perforation, and is apparently due to peritoneal shock from the escape of the contents of the appendix. Absence of fever does not exclude appendicitis, and is occasionally met with in the most acute cases of general peritonitis.

The *pulse-rate* is a more important guide than the temperature. It is almost invariably raised even when there is no elevation of temperature, but as a rule the pulse-rate corresponds roughly with the degree of fever. A steadily rising pulse is to be regarded as a grave sign, even when the temperature does not move in conformity with it. The *quality* of the pulse is not characteristic.

**Abdominal Signs.** In the initial stages there is general tenderness on pressure, even of the gentlest ; this is soon succeeded by general abdominal swelling, and impaired movement on respiration, localized tenderness, rigidity of the right rectus muscle, affecting usually the lower half of the muscle, and in some cases the formation of a swelling in the right iliac region.

The degree of *general enlargement* is not great unless general peritonitis supervenes. When *localized tenderness* appears the general tenderness usually subsides, although the localization may take the form of an exaggerated tenderness at some part. The point of greatest tenderness is usually in the area corresponding to the position of the base of the appendix (*vide supra*), but this is by no means invariable. McBurney's point (obtained by bisecting a line joining the umbilicus with the right anterior superior iliac spine), although the commonest point of greatest tenderness, has not the diagnostic importance which was at one time attributed to it. Not infrequently the most tender spot will be found beneath the right costal arch over the gall-bladder, or in the right renal region. Sometimes the umbilical region, or the left iliac region is the seat of greatest tenderness. In retro-cæcal cases, the tender spot is often to be found posteriorly in the costo-iliac space ; unless this is remembered an important diagnostic sign may be overlooked.



*Muscular rigidity* is a very important sign, and great attention should be paid to it. It is a reflex spasm which is protective in function, the muscle being 'on guard' over the subjacent diseased area. In its lightest form it can best be detected by palpating the two recti muscles simultaneously with the two hands, when the delicate difference can be detected. Later on, the tension and resistance of the muscle can be more readily recognized. This sign is an early one and is therefore of importance, for it may be found at a time when the abdominal respiratory movements are apparently unchecked.

A *swelling* in the right iliac region is formed in most cases where protective adhesions have had time to develop, *i.e.* in all but the most severe cases of perforation, gangrene, or general peritonitis. In the early stages this swelling is obscured by the protective muscular spasm beneath which it is being formed. In character it is ill-defined, subresonant, of variable size, and of variable tenderness and consistence. It consists mostly of adherent coils of intestine, within which may be found a variable amount of pus. In some cases the swelling may be formed in the pelvis, and may then be detected by vaginal or rectal examination, even if nothing can be felt in the appendix-region. It is therefore important to remember the assistance which may be obtained in a difficult case from internal examination.

The majority of cases of acute appendicitis tend to subside spontaneously; recurrence is then almost invariable, although the subsequent attacks are usually less severe. When the original infection is intense, the case goes from bad to worse, and if unrelieved by operation, death ensues from acute toxæmia or from general peritonitis.

**Differential Diagnosis.** We are here only concerned with the diagnosis of certain gynæcological conditions: there are a number of other conditions, common to both sexes, the exclusion of which is of equal importance, but for this the reader must be referred to text-books of Surgery.

*Ectopic Pregnancy.* The symptoms in the early stages of profuse internal bleeding from tubal rupture, or tubal abortion, may closely resemble the initial symptoms of acute appendicitis (*see* p. 221). In both, an acute attack of abdominal pain attended with nausea or vomiting, may occur with entire suddenness. Some general abdominal enlargement and tenderness are seen, and in an ectopic case, the pain and tenderness may become localized to one or other iliac fossa. And further, in both conditions a swelling may be detected in the pouch of Douglas, and although in the one instance it is blood, and in the other inflammatory fluid or pus, the differentiation of these two is not easy. A history of amenorrhœa may be misleading, for appendicitis may occur in early uterine pregnancy.

Three points may be relied upon to distinguish a case of ectopic

pregnancy. (1) There are definite signs of internal bleeding, such as pallor, coldness of the extremities, a subnormal temperature (in the initial stages), and in bad cases restlessness and air-hunger. (2) Slight hæmorrhage from the uterus practically always occurs, and will usually be found to have preceded the acute onset. (3) On vaginal examination, cervical softening, and some enlargement of the body of the uterus may be detected. If these three points can all be made out the diagnosis is certain. Errors in diagnosis of this condition are not attended by serious consequences, if the rule laid down for the treatment of both is followed, viz. *operate immediately*.

*Acute Salpingitis.* The commonest cause of this condition is an ascending infection, consequently it is most likely to be met with in the course of an attack of gonorrhœa or in connection with miscarriage and childbirth. In virgins tubercle is the commonest cause, and, although usually chronic, tuberculous salpingitis sometimes undergoes acute exacerbations. The history of the case is consequently an important point in the differential diagnosis. An attack of acute salpingitis frequently coincides with a menstrual period.

The initial symptoms may closely resemble those of acute appendicitis; when localizing abdominal signs appear, they will be found to affect the lower abdominal zone generally, although tenderness and pain may be much more marked upon one side than the other. This is due to the fact that acute salpingitis is essentially a bilateral condition. In this region a swelling soon develops, which has the characters already described as those of pelvic peritonitis, for except in the most acute cases, a protective roof of adherent coils of intestine is formed above the inflamed tubes.

On pelvic examination the findings are usually definite and clear. Acutely inflamed appendages are recognizable as postero-lateral swellings of characteristic shape, and accompanied by general thickening and extreme tenderness of the region of the pouch of Douglas. Rectal examination will often give better access to the swelling than examination *per vaginam*.

*Acute Axial Rotation of an Ovarian Cyst or a Dilated Tube.* The clinical results of acute twisting of the pedicle will be described on p. 719, to which the reader is referred; it will be seen that they also resemble the initial symptoms of acute appendicitis. The recognition of this condition depends solely upon the discovery of the tumour (cyst or tube) which has become twisted. In the case of an ovarian cyst of moderate size, this presents little or no difficulty, except perhaps in the case of very corpulent women. A dilated tube seldom attains sufficient size to be recognized by abdominal examination alone; but bimanual examination will certainly reveal its presence. It is only in the early stages that diagnostic difficulties

will arise ; when the abdominal swelling and tenderness subside, a complete examination of the abdomen becomes practicable, and the tumour will then be discovered.

*Ovarian Hæmatoma.* Occasionally an acute effusion of blood occurs into the interior of an ovary (*see p. 658*), causing intense pain and many of the signs of peritoneal irritation—such as abdominal enlargement and tenderness. When the right ovary is affected, the localizing signs make the case practically indistinguishable from one of acute appendicitis. The affected ovary may, however, be found, on pelvic examination, to be enlarged and extremely tender. If the case is kept for a time under observation, the ovary may be found to increase rapidly in size.

*Acute Pyelitis.* In this condition a sudden onset attended with acute abdominal pain in the right side and tenderness on pressure, and sometimes with vomiting, may occur. A catheter specimen of urine will show the characteristic changes associated with pyelitis (*see p. 276*), enabling the condition to be recognized.

The differential diagnosis of the above-mentioned conditions from acute appendicitis is not of mere academic interest, but also has its practical importance. In the cases of ectopic pregnancy and axial rotation, immediate operation is indicated, so that the treatment does not differ from that of acute appendicitis. In the cases of acute salpingitis and ovarian hæmatoma the interests of the patient require delay for reasons which are set out in the section dealing with tubo-ovarian inflammation (*see pp. 632–634*).

**Treatment of Acute Appendicitis.** The treatment is to operate as soon as the diagnosis is made ; when in doubt as to the diagnosis, it is better to operate than to wait. The justification for formulating such a rule is, that cases of acute appendicitis practically always recover when operated on in the early stages, while the risk to life increases with every day's delay. When perforation, or gangrene, or diffuse peritonitis has occurred, it is not too much to say that every hour's delay imperils the patient's chances of recovery. Yet there is no clinical method of recognizing the exact condition of the appendix ; the true nature and gravity of the case can only be revealed by operation. If the diagnosis is proved to be wrong, a simple exploration of the abdomen, when properly carried out, is practically devoid of risk, and it is better to operate and be wrong, than from indecision to allow the favourable moment to pass.

*The Operation.* The technique of removal of the appendix is considered in a later section (*see p. 767*). It is, however, important to bear in mind that in dealing with all acute abdominal conditions, the aim of the surgeon should be strictly to limit his interference to what is absolutely necessary. Prolonged manipulations, forcible handling, and hæmorrhage should be most carefully avoided. If an abscess is present, the collection of pus should be evacuated and drained ;

if the appendix lies within the abscess-cavity it can be dealt with, if not, the abscess-wall should not be broken through in order to search for it. It is better to perform a second operation and remove it at a later date. Again, if the appendix is located, but cannot be raised to the surface on account of adhesions, it is better to amputate it and cauterize the base without attempting to bury the stump. The bowel-wall may easily be torn, as acute inflammation renders it extremely friable, and to close the rent may prove impossible for want of free access. It is generally advisable to drain cases of acute appendicitis ; when collections of pus have been met with it is essential.

A case of acute appendicitis with severe toxæmia is not out of danger when the operation has been successfully concluded. Vigorous treatment on the general lines laid down for cases of septicæmia (*see* p. 248) must be begun immediately after the operation, and among the measures advised none is more important than continuous, rectal, saline transfusion.

### CHRONIC APPENDICITIS

After an attack of acute appendicitis has subsided, if an operation is not performed, recurrences are practically certain to occur. These recurrences vary much in severity, and are often sub-acute or even trivial in character. Sometimes cases of chronic appendicitis are met with in which there has been no acute attack at all.

**Morbid Anatomy.** The conditions met with at operation are chiefly peritonitic adhesions, with thickening and induration of the walls of the appendix. As a result of narrowing of the lumen in places, local dilatations may form, the distal end being specially liable to undergo this change. Often the appendix is bent or twisted, and its mesentery thickened. In the earliest stages the vessels on the surface of the appendix are injected, and the whole organ feels abnormally rigid. On opening a 'chronic appendix' faecal matter or faecal concretions are almost invariably found within it. Cases such as these are true instances of primary appendicitis even when the appendix is found, as frequently happens, adherent to the tube, the ovary, or the uterus ; the latter organs then show no other abnormality than the adhesions.

Frequently, however, the appendix becomes involved in the spread of an infective inflammation from the tube, and it is then difficult to know whether it was primarily diseased or not. Thus it may be found densely adherent to the wall of a pyosalpinx, or an infected ovarian cyst. When such a condition has been of long standing, a fistulous communication may be established by ulceration between the lumen of the appendix and the abscess-cavity, as in the case recorded by Bland-Sutton. This occurrence is, however, very rare. In cases where the appendix and the right tube are involved, while the left

tube and ovary are healthy, the presumption is that the appendix is the organ primarily at fault. Unilateral salpingitis from gonorrhœa or sepsis is almost unknown, but it may occur from tubercle, and when the right tube and appendix are the only organs involved, the possibility of tubercle should always be borne in mind.

**Clinical Features.** The symptoms of chronic appendicitis are abdominal pain, not necessarily referred to the site of the appendix at all, and frequently felt in the epigastric or umbilical regions. The most characteristic feature is its marked tendency to recurrence in definite attacks, which may last for a few days, or only for a few hours. As a rule, no exciting cause of the attacks can be recognized. In addition to the attacks of pain, there is often more or less constant abdominal discomfort or actual pain, which may be aggravated by such conditions as menstruation, fatigue, jolting as from a railway journey, etc. In addition there are often marked dyspeptic symptoms, especially of the variety known as 'hyperchlorhydria,' and attributed to an excess of acid in the gastric secretions. It has been shown, of recent years, that gastric and duodenal ulcers frequently occur in company with chronic appendicitis, and the clinical picture is necessarily complex in its details.

When chronic or acute inflammatory pelvic conditions exist in company with chronic appendicitis, the clinical features are modified in a different direction. The tendency to recurrent attacks of abdominal pain is a feature of both conditions, and menorrhagia, dysmenorrhœa, discharges, and sterility are usually present as well. When the symptoms appear more severe than should be expected from the amount of damage sustained by the pelvic organs proper, it is reasonable to suspect that the appendix is also involved.

The *physical signs* met with in chronic appendicitis are few and ill-defined. Tenderness in the 'appendix region' is often met with in cases of pelvic inflammation as well as appendicitis. Sometimes definite thickening can be felt on deep palpation, sufficiently localized to warrant its being attributed to the appendix. If the stomach or duodenum is involved, the tenderness and thickening may be found in the upper abdomen. If pelvic examination shows definite inflammatory enlargement of the tubes and ovaries, the relation of the appendix to the swelling can only be made out by exploratory operation.

**Treatment.** Cases of chronic appendicitis usually resist all medical treatment and come in the end to operation. When removing an appendix of this character the general surgeon must recollect how frequently the tubes and ovaries are also involved, and must carefully examine them. And in the same manner the gynæcologist, when dealing with chronically inflamed adnexa, must never omit to explore the appendix and remove it whenever it shows any abnormality.

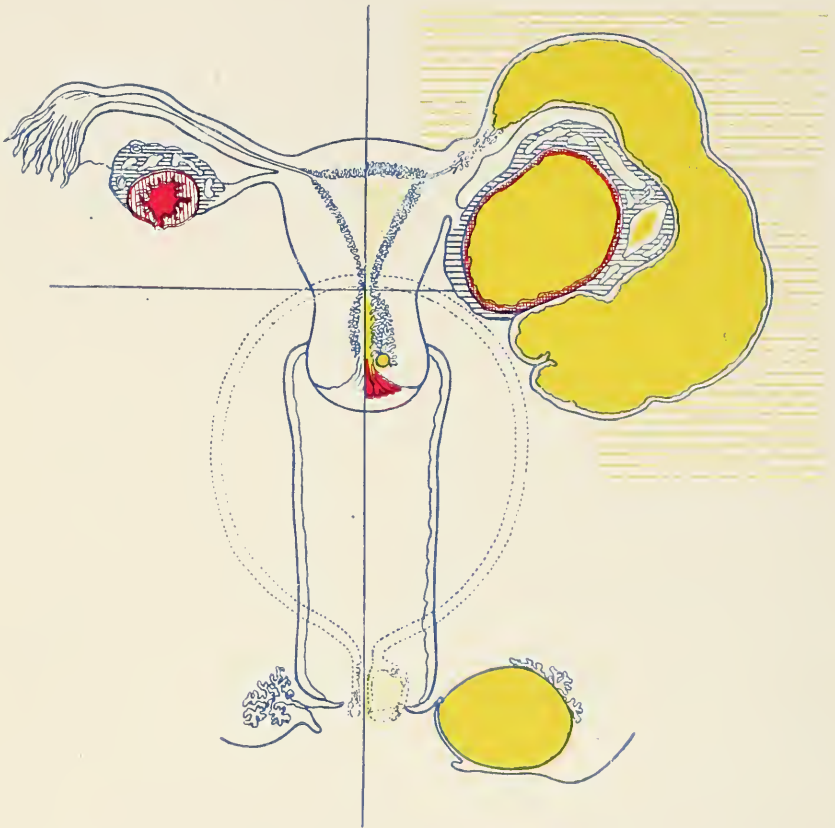
## SPECIFIC INFECTIONS

## GONORRHŒA IN WOMEN

**Historical.** The word gonorrhœa from *γονή* (seed), and *ρῆν* (flow), dates from A.D. 160, and was given by Galen to the flow of pus which escapes from the male urethra in the condition which we now know to be a contagious venereal disease. Galen believed gonorrhœa to be an involuntary flow of semen; etymologically therefore, the term 'gonorrhœa' is inaccurate. In the Book of Leviticus (chap. xv) Moses laid down rules relative to prophylaxis, and in Deuteronomy we find that a man was entitled to a divorce if his wife was found to have gonorrhœa. Thus biblical history takes us back to about B.C. 1471. The disease was also known to the early Japanese, Egyptians, Romans, and Greeks. The early writers gave little attention to gonorrhœa in the female, and intraperitoneal complications were not recognized. About the end of the fourteenth century the infectious and contagious nature of gonorrhœa began to be recognized, and medical supervision of brothels was inaugurated. Towards the end of the fifteenth century the first great epidemic of syphilis swept over Europe. It was a comparatively new disease, and subsequently much confusion arose between syphilis and gonorrhœa. The latter was regarded as a complication of syphilis, and was vigorously treated by mercury and sarsaparilla. John Hunter, wishing to settle the relationship of gonorrhœa to syphilis, inoculated himself in May 1767 by making two punctures in his penis with a lancet dipped in venereal matter taken from a supposed case of gonorrhœa. He developed syphilis, and consequently drew the conclusion that syphilis developed from gonorrhœa. The true explanation of the nature of gonorrhœa thus received a set-back, which was not made good, for over sixty years. Phillippe Ricord (1831-1837) made 667 inoculations of gonorrhœal pus and in no case did syphilis result, thus clearly establishing the non-identity of gonorrhœa and syphilis. Ricord did not believe that gonorrhœa was a specific disease, but regarded it as a 'simple' catarrh produced by the action of various irritants on the mucous membrane. Among these irritants he mentioned uterine catarrhal, lochial and menstrual discharges as peculiarly likely to set up urethritis. In 1868 Salisbury found spores in twos and fours in pus-cells, and in 1872 Hallier found a micrococcus in gonorrhœal pus.

In 1879 Neisser described these micrococci and their method of division and gave them the name *gonococci*. Watson Cheyne discovered the gonococci in the same year as Neisser, but did not publish his discovery until 1880. In 1872 Emil Noeggerath, of New York, drew attention to "latent gonorrhœa of the female sex." Previous to this, gonorrhœa in the female was regarded as a vaginitis.





SCHEME OF GONORRHOEAL INFECTION OF THE FEMALE GENITAL TRACT (after J. A. Amann). Abscess of the duct of Bartholin (yellow). Gonorrhoeal urethritis and paraurethral abscess (dotted yellow); gonorrhoeal cervicitis (yellow); erosion (red); endometritis (dotted yellow); pyosalpinx (yellow) with indrawn fimbriae; lutein abscess (yellow with red wall); perisalpingitis perioöphoritis, pelvic peritonitis (yellow lines).



Noeggerath was the first to insist that inflammation of the uterus, appendages, and peritoneum was the direct result of gonorrhœa. He showed that the disease may remain latent for long periods, and drew attention to the sterilizing effects of gonorrhœa.

*Summary.* Ricord definitely established the identity of gonorrhœa. Noeggerath proved it to be an *ascending* infection capable of producing sterility and puerperal infection, and what is very important he pointed out the long continued contagiousness of the disease. Neisser in 1879 demonstrated the specific diplococcus with which his name has ever since been associated. In 1886 Roux of Paris published the method by which gonococci can be differentiated by the Gram-method of staining.

**Bacteriology.** The gonococcus is most frequently found in pairs, but is not uncommonly seen in tetrads, and occasionally groups of eight cocci exist. In shape they are somewhat reniform, and have been likened to coffee beans; they are arranged with their concave surfaces in close apposition (see Fig. 140). In size a gonococcus measures from  $\cdot 8\mu$  to  $1\cdot 6\mu$  in the long diameter and  $\cdot 6\mu$  to  $\cdot 8\mu$  in its short axis. It is non-motile.

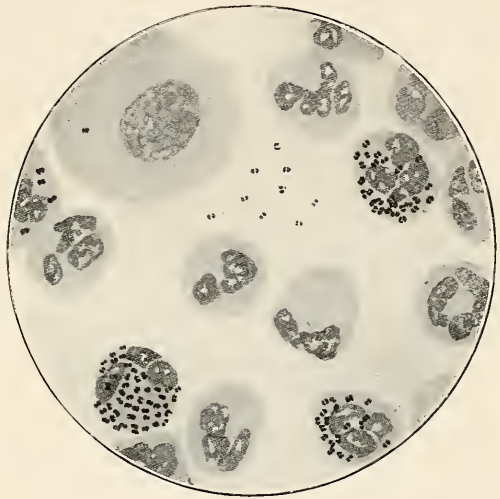


FIG. 140. Gonococci discovered by Neisser and by Watson Cheyne in 1879. The film was prepared from vaginal discharge and stained with Löffler's methylene-blue. The gonococci are seen lying free and also within pus-cells (E. Shaw).

The typical shape and arrangement are best seen in smear-preparations made from pus. When prepared from growths on culture-media, gonococci vary considerably in size and are rounded in shape. A film made from pus shows the organisms *within the pus-cells*—an important feature for purposes of identification. Gonococci are Gram-negative, they are difficult to grow on ordinary culture-media, the best medium being agar covered with a thin film of sterile human blood. There are two other organisms which, like the gonococcus, are left unstained by Gram's method, viz. the meningococcus (*diplococcus intracellularis meningitidis*) and a staphylococcus known as *micrococcus catarrhalis*. The former not only resembles the gonococcus in its characters and staining reaction, but it is likewise to be found in pus-cells. Cultural differences must be relied upon in making a differential diagnosis between these two organisms, and this is provided for by the fact that the meningococcus

grows more readily on artificial media, *e.g.* it will thrive on plain agar, on which the gonococcus will not grow. If Gram-negative diplococci are found in cerebro-spinal fluid it may reasonably be assumed that they are meningococci, and if Gram-negative diplococci are found in the secretion of the genitalia the inference is that they are gonococci; but the meningococcus has occasionally been found in the urethra and in the female genital organs, so that cultures must be made in order to arrive at a correct diagnosis. The *micrococcus catarrhalis* has been found in the urethra. It grows freely on media in common use such as agar, broth and gelatin; it is more oval in form, and is slightly larger than the gonococcus.

Growths of gonococci on blood-agar soon die, so that to keep the growth alive, sub-cultures must be made every other day, and even then they soon lose their power of reproduction (Shaw). In addition to the peculiarities above mentioned, it is to be noted that the gonococcus shows a selective parasitic adaptability for the human race. Even the highest apes cannot be infected.

**Pathology.** *Toxin and Injury.* The gonococcus produces an endotoxin which sets up an active inflammatory reaction. This toxin is said to be set free from the body of the organism at its death. The inflammation spreads along epithelial-lined surfaces without, as a rule, producing necrosis of the epithelium, but this may occur, and then infection quickly extends to the underlying tissue, when necrosis and abscess-formation may follow. The inflammatory exudation consists of serum and polymorphonuclear leucocytes; little or no fibrin is formed. The leucocytes take up the fat and collect in the subepithelial tissues, where they appear to the naked eye as a narrow, opaque, yellowish zone. In the more chronic lesions, lymphocytes often infiltrate the submucous tissues in large numbers, plasma-cells abound and eosinophiles may be fairly numerous.

The gonococcus, although normally an organism which lives on mucous membranes, is able to penetrate into the tissues and into the blood. Thus a *gonococcal septicæmia* may arise, with metastatic infection of joints, heart, serous membranes, and meninges (*see p. 298*). In women the seriousness of gonorrhœa is enhanced by the far-reaching local injuries it produces, and by its persistence in spite of treatment.

Being acute to start with, it tends to become less active and to persist in a chronic form for years. It commonly causes a spread of inflammation through the whole generative tract, as well as along the urethra, and bladder; and sometimes it ascends to the ureters and to the kidneys. The effect of the toxin on the fibroblasts is to cause them to throw out an abundance of collagen which produces scar-tissue and contraction. The toxin is also said to account for the buboes which are seen in acute cases of gonorrhœa.

**Clinical Data.** *The Collection of Material for Investigation.* This requires a knowledge of the lurking-places of the gonococcus, which,

stated briefly, are all the anatomical orifices and crypts appertaining to the external genitalia, and also the cervical canal. These comprise the urethra with the openings of the paraurethral glands in its floor; the openings of Skene's tubules (*see* p. 66), the orifices of Bartholin's ducts; and, finally, the cervical endometrium and Nabothian follicles. From these situations secretion may be obtained. In obtaining a specimen from the cervix, a Ferguson's speculum is passed and the external os exposed; excess of mucus or muco-pus is removed by a saturated solution of sodium bicarbonate, and a wire, with sterile wool wound around it, is passed up the cervical canal and the mucous membrane well rubbed, this will bring away some surface-epithelium with its secretion and a little blood. The swab is then returned to its tube and sent to the laboratory. When the organism cannot be detected in the cervical secretion, it may still be possible to find it in the deeper portions of the glands, if a piece of tissue is excised for microscopic examination.

Urethral secretions are obtained by running the finger along the anterior vaginal wall from within outwards, so as to express the fluid from the meatus. By means of expression, pus may also be made to issue from the ducts of Bartholin. A fine platinum loop may be passed into the more patent of Skene's tubules, and a suppurating Nabothian follicle may be punctured by a sterile scalpel through a speculum. Care must be taken to avoid contamination with vulval or vaginal secretions. If pus from more than one source is examined the tubes must be numbered. The methods of preparing and staining films are described below.<sup>1</sup>

The clinical importance of what has already been stated must be emphasized, viz. that the danger of gonorrhœa is very largely due to the power possessed by gonococci of penetrating uninjured epithelial tissues. Once underneath the surface, these tissues afford them

<sup>1</sup> METHOD OF STAINING FOR GONOCOCCI. From a swab taken in the way indicated, the secretion must be spread upon a clean glass-slide free from grease. It should then be fixed by passing it three times through a Bunsen flame, and stained by Gram's method. Examination is then made under a  $\frac{1}{12}$  inch oil-immersion lens.

*For Films.* (a) Prepare, dry, and fix the secretion as above stated. (b) Stain for at least two minutes in freshly prepared anilin-water-gentian-violet or anilin-water-methyl-blue, to 100 c.c. of which, 1 c.c. of a 1 per cent. solution of NaOH has been added. (c) Wash in fresh anilin-water. (d) Stain in Gram's solution for from thirty seconds to two minutes, according to the thickness of the film. (Gram's solution consists of one part of iodine, two parts of KI, and 300 parts of distilled water.) (e) Decolorize in absolute alcohol until no more colour is given off by two or three washings. At this stage Gram-positive bacteria are stained blue-black, while Gram-negative organisms are unstained. (f) Counterstain with a watery solution of fuchsin for thirty seconds to one minute. (g) Wash in water. (h) Mount in Canada balsam.

*N.B.* The anilin-water solutions are made by dissolving as much of the dye as possible in a saturated aqueous solution of anilin-oil. The anilin-solution should be filtered through moist filter-paper, to secure the exclusion of undissolved droplets of the anilin-oil.

nutrition and protection, whence the chronicity of the disease and its frequently latent characters.

There is no immunity against gonorrhœa. The wife to whom a husband has given the disease may re-infect her husband. Chronic cases are as dangerous as they are common, owing to the fact that gonorrhœa may be present in chronic form without subjective signs to warn the infected person of its presence. Gonorrhœa can be very obstinate, but it can be cured. Many bacteriological investigations are necessary, however, before we are in a position to pronounce upon a cure.

The average incubation-period by the natural mode of conveyance of the organism is about *three days*. Accurate determination of the site of infection in women, is a matter of prime importance for the gynæcologist. This will depend, to some extent, upon the anatomical peculiarities of the genitalia. A highly situated meatus is more likely to escape initial infection than one which opens lower down; a low cervix with a gaping vagina may lead to the former being the first site of inoculation, but a very common occurrence is to get both urethra and cervix infected at the same time.

**Gonorrhœa Urethritis.** This is extremely frequent, and is generally present in fresh infections. In three days the discharge is purulent, the swollen lips of the meatus present as prominent red flaps, owing to the ectropion of the mucous membrane, and between these a drop of greenish-yellow pus exudes. The canal is tender up to the neck of the bladder; on endoscopic examination the swollen mucous membrane is seen to be covered by pus and a croupous exudate, and on removal of the latter a slightly hæmorrhagic red surface is disclosed. The patient's general condition is not much interfered with; subjectively there is tickling or burning after micturition. Then follows a dull, continuous, pressure-sensation above the symphysis, or cramp-like pain during micturition may be complained of. These subjective symptoms soon lessen, in three or four weeks the urethra has its normal appearance, and in from six to twenty weeks it heals. If the general state of the patient is good it may heal spontaneously. In the chronic stage gonorrhœal urethritis is difficult to detect; if the patient has voided urine within an hour of examination, pus may be absent. In this way a woman, who may be regarded as clean by her doctor, may infect her husband. An important point to know is that even when pus is absent from the urethra, the swollen meatal lips present for some time as red or grey jelly-like elevations, very sensitive to the touch, and they bleed on palpation. Later on, the whole tube feels thick and hard, and internally the mucosa looks granular or jelly-like, and upon its surface plaques of grey or glassy appearance may be seen. Chronic gonorrhœal urethritis may, at any time, again become subacute or even acute.

In the lower part of the urethra and near its mouth are found tiny glands, the homologues of the prostate. Their orifices soon become infected in the acute stage of gonorrhœa, and if their ducts get blocked, small miliary abscesses form at the side of the meatus. It is important to remember these glands in the treatment of gonorrhœa in women.

**Gonorrhœal Inflammation of Bartholin's Glands.** This is often double in acute stages of the disease, and generally so in the chronic form. The rule is for one gland to become infected before the other ; it does not always result in abscess-formation, and before it does so the appearances are not very striking. It is detected by the everted swollen mouth of the duct, from which pus can be squeezed ; and a spindle-shaped hardness indicates *adenitis*. Sometimes the duct becomes blocked with a cast swarming with cocci. It is well to give here a word of caution about an over-readiness to diagnose gonorrhœa from undue redness of the orifice of Bartholin's duct. This feature may be due to innocent (non-specific) causes, and although it was designated the *macula gonorrhœica* by Sanger, it is by no means pathognomonic of this disease.

Specific Bartholinitis may last for many months, undergoing exacerbations especially after coitus ; it gives a dull pain on walking or sitting, but subjective signs are not prominent. In chronic cases the duct may be blocked partially or completely, the secretion becomes pent up in either case, but if the block is only partial the secretion escapes, and fills up again, giving what Martineau called *abcès à repetition*. If the block is complete and the secretion great, a large abscess the size of a pigeon's egg forms. This is situated at the hinder part of the labium majus and pushes forward as far as the vestibule (*see* Fig. 176, p. 364) ; it is fluctuant, and the skin over it is red, stretched, and shiny. It ruptures in from one to two weeks, generally on the inner side, seldom above or below ; a suppurating fistula is formed which gradually closes up.

**Condylomata Acuminata**, or venereal warts, are the result of irritation produced by gonorrhœal discharges. They are compound papillomata which may occur on any part of the vulva and surrounding skin of the thighs and natal cleft, and may even extend up the whole length of the vagina. They consist of a central branching stalk of connective-tissue, which is covered by layers of squamous epithelium. In size they vary from that of a pin's head to masses as big as a chestnut or Tangierine orange, and may be so numerous as to cover the vulva and completely to obscure its anatomy (*see* Figs. 141 and 142). Rarely, they extend up the vagina, and may be found upon the vaginal cervix. If the discharge subsides these warts may disappear spontaneously, but in neglected cases they persist and undergo necrosis. They are diagnosed from syphilitic condylomata by being more pointed, and more inclined to become pedunculated.

**Gonorrhœa of the Vagina.** The vagina was formerly regarded

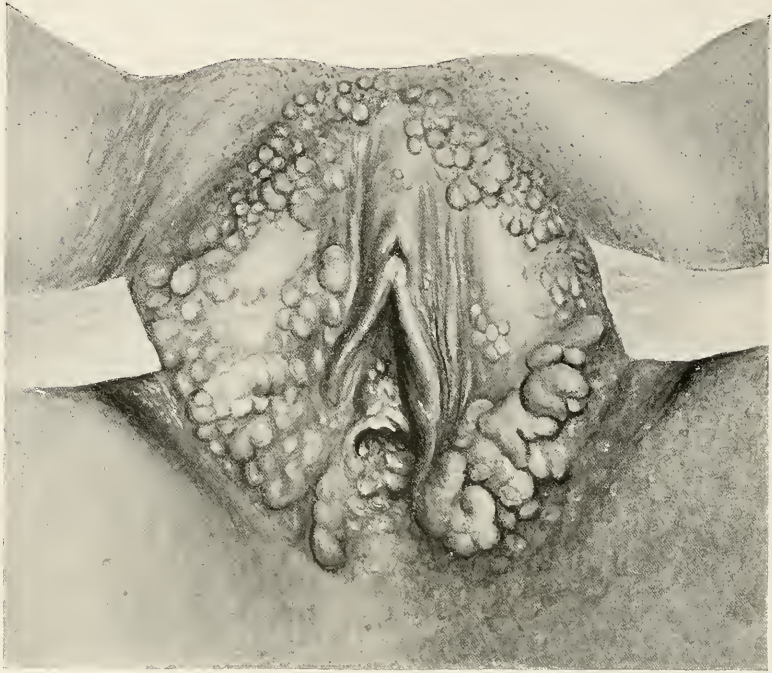


FIG. 141. *CONDYLOMATA ACUMINATA VULVÆ.* Naked eye appearance.

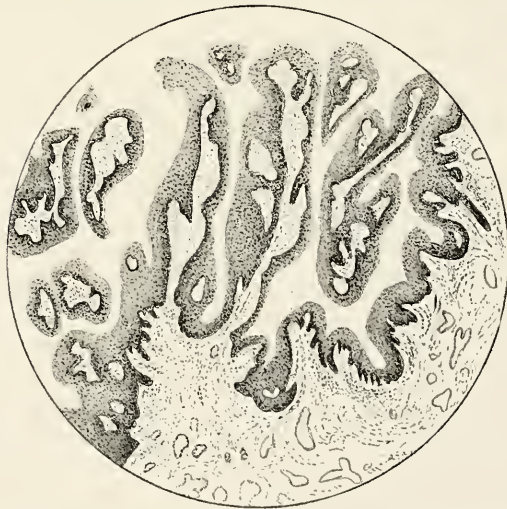

FIG. 142. *CONDYLOMATA ACUMINATA VULVÆ.*  $\times 16$ . (Jolly.) Microscopic appearance.

as the commonest seat of this disease, but this is only true in children. The thick keratoid vaginal epithelium of the adult offers consider-

able resistance to the entry of penetrating diplococci, whereas the latter find it a comparatively easy task to enter through the epithelium of the urethra and of the cervical canal. In children, the vaginal epithelium is thin and soft, and hence more easily penetrated by the cocci.

Acute primary gonorrhœal vaginitis in adults is a most exceptional occurrence. It presents very striking features. There is such an abundance of pus that the outer genitalia are matted by dried secretion; the small labia are red, œdematous, and project beyond the labia majora, and they are eroded on the vaginal surface. The hymen is likewise swollen, tender, and eroded; patches of adherent lymph are seen here and there, whilst every furrow is filled with pus; the whole mucous membrane easily bleeds on touch, and is so exquisitely tender that examination has to be conducted under a general anæsthetic. The symptoms are marked pain, heat, burning, and swelling of the outer parts, tenderness of the whole lower abdomen, inability to walk, even sneezing, coughing, and loud speaking being painful. There is fever with a few rigors. The symptoms subside in about three weeks, if no menstrual period intervene; it may leave behind a chronic cervicitis, but it never leaves a chronic gonorrhœal vaginitis.

Too great stress cannot be laid upon the fact that in chronic gonorrhœa there is nothing in the appearance of the vagina at all suggestive of its presence, simply because the disease is usually not in the vagina, but in the *cervix uteri* and urethra; no importance is to be attached to the appearances of the vaginal walls in the diagnosis of *chronic* gonorrhœa. In young people and nulliparæ, redness and swelling of the vaginal mucous membrane are met with often enough in the *early stages* of infection. This is generally due to secondary invasion by pus from the cervix. In children, vaginitis is the usual result of gonorrhœal infection.

**Gonorrhœa of the Cervix.** Next to the urethra, the cervix is the most common seat of infection, cervicitis being present in 80 per cent. of the acute, and in 95 per cent. of the chronic cases. In the majority of cases the infection originates as an *endocervicitis*, *i.e.* as an inflammation of the cervical endometrium which swells up and projects beyond the external os. The thinned-out squamous epithelium in the region of the external os is thrown off by a hæmorrhagic exudation, presenting a raw, red zone over which the columnar epithelium ultimately grows to form a definite catarrhal or pseudo-adenomatous patch (*erosion*). The gonococcus penetrates as far as the deep epithelium of the compound cervical glands, and the fibromuscular stroma in which the latter are set, becomes infiltrated with polymorphonuclear leucocytes and serum. The exudation produces an œdematous state of the cervix, which is appreciated clinically as softening, and by a livid congested appearance in the acute stages. At first, therefore, in a recent acute infection the cervix is swollen, the

external mucous membrane is stretched, shiny and red, and through it there may appear the suppurating points of infected Nabothian follicles, giving the vaginal surface of the cervix an acneiform appearance. Bumm regards this last condition as a sign of repeated infection. Pain is not a well-marked symptom; movements of the uterus cause a slight tenderness; the patient complains chiefly of the discharge, but in some instances there is pain in the sacral region and over the pubes.

**Gonorrhœa of the Body of the Uterus.** Gonorrhœa of the *corporeal* endometrium and of the submucous and muscular strata, when it occurs, is always a sequel of gonorrhœal endocervicitis. It is, fortunately, not an invariable accompaniment of infection of the cervical endometrium, although its occurrence is favoured by the patency of the cervical canal at a menstrual period, or after the emptying of a pregnant uterus. Whilst gonorrhœal cervicitis is essentially chronic, gonorrhœal endometritis is much more transient, and it is difficult to demonstrate the gonococcus in the endometrium of the body. We have repeatedly found a true endometritis, as evidenced by the presence of plasma-cells and interstitial thickening of the stroma, in cases of gonorrhœal salpingitis, and explain the persistence of the endometritis by repeated infection from the Fallopian tubes. The endometrium in such cases corresponds to the hyperplastic type of endometritis (*see* p. 399), and shows the following evidences of a chronic inflammatory process: (1) proliferation and metaplasia of the surface-epithelium, columnar, giving place to squamous cells; (2) goblet-cells appear in the glandular epithelium in all stages of the menstrual cycle; (3) the gland-lumina at all stages of the cycle may be distended with mucus or serum containing leucocytes, blood, and epithelial *débris*; (4) the stroma contains plasma-cells (Plate VIII). As a rule, no gonococci are found, and the above-mentioned changes are not peculiar to gonorrhœal infection. For other data the student is referred to the chapter dealing with chronic endometritis (p. 392).

*Metritis.* In severe cases of gonorrhœal *corporeal* endometritis the underlying myometrium is involved. In the acute stage the whole muscular wall is softened and boggy, and gives the impression of a subinvolted organ, even in a nullipara. The most marked cases of gonorrhœal metritis are usually associated with adnexal infection and pelvic peritonitis.

*Clinical Features.* In the *acute* form the symptoms are those of acute metritis. In the early stages the cervix cannot be drawn down without pain. Under an anæsthetic, the body is found to be only slightly movable on the cervix; it is stiffly anteflexed or retroflexed.

Subjectively there is a sense of fulness and stretching with a boring or pulsating pain in the pelvis, leading to a cramp-like 'bear-



ing down.' Bodily movements are impossible, and the patient feels very ill. Fever is always present.

Young women, whose first attack reaches the cavity of the uterus, always suffer most, that is, more than those who have suffered from pre-existing chronic cervicitis. It is a notable fact that the severe symptoms rapidly subside. In a week, or sometimes a couple of days, the tenderness is less and the cramps are gone, the patient gets about again, and attaches but little importance to her few days illness. We do not, as a rule, meet with acute uterine gonorrhœa in gynæcological practice. These cases come to us after the acute attack is over, when there is nothing pathognomonic in the symptoms; the secretion is often so slight as to be easily overlooked; this applies especially to chronic infection limited to the cervical canal, the only symptom of which is discharge, which may be quite clear whilst still containing cocci. Pseudo-adenomatous areas (*erosion*) on the cervix may be present, but more suggestive than *erosion* is a bright red inflammatory border to the orifice, with some ectropion. With such local signs exacerbation of symptoms, especially after sexual excess or menstruation, is liable to occur, the flow again becoming purulent, and the pelvic pain may return.

*Chronic* gonorrhœa of the cavity of the uterus, which has not extended to the tube, shows no special symptom of its own, and is only to be diagnosed by finding gonococci in the discharge, taken from the body of the uterus, with special precaution against cervical contamination. In some, especially the more chronic cases, there arise signs of chronic metritis.

**Gonorrhœa of the Fallopian Tubes and Ovaries.** The pathological changes in the tubes and ovaries are not specific to gonorrhœa, and are fully described in the sections on tubal and ovarian inflammation (*see* pp. 608 and 645). There are two mechanical barriers to the ascent of gonorrhœa, the internal os and the uterine end of the Fallopian tubes. The cocci have no power of movement in themselves, their spread is by passive deportation or continuous surface-growth; the small size of the external os, and the minute calibre of the interstitial part of the tube, are not sufficient to obstruct so small a body as a coecus, but are yet small enough to obstruct mechanical deportation. Conditions which favour the spread of the disease are (1) menstruation, (2) labour and the puerperium, (3) coitus, (4) instrumentation. The onset may be sudden and acute. There is an initial rigor followed by pyrexia, which is often maintained for a fortnight. Pain of a continuous and boring character may be complained of. As the condition is often bilateral, tenderness in both groins over the eleventh dorsal segment is generally present. Menstruation is rendered painful, crampy, more frequent, more excessive, and it lasts longer. In *acute* salpingitis the abdominal walls are too rigid to make out more than a tenderness on one or both sides, but

with the aid of an anæsthetic the tubes feel like stiff cords running outward and backward from the uterine cornua; an increase in their size is not at first noticeable. Healing can now set in, and the possibility of a future pregnancy is not yet excluded. If complete healing fails, the tenderness on pressure persists, menstruation continues to be painful, the woman is sterile and liable to periods of relapse. With the climacteric the pain subsides. The usual results of gonorrhœal salpingitis are therefore *sterility and pelvic pain*. But this is not all, for a large pus-sac may develop with involvement of peritoneum, ovaries, and surrounding viscera; this is indicated by a corresponding increase in severity of the general and the local symptoms. It is not usual for a tubal abscess to arise directly on infection, there is generally a history of frequent attacks with improvement in between. In these cases a tumour of variable size is found lying in the pouch of Douglas; it may be slightly mobile, but often quite fixed and tender on pressure; this tumour consists of the enlarged tube, and inflammatory exudation uniting it to omentum, adnexa, and small bowel.

When once a pus-sac has become thoroughly encapsulated in dense adhesions the acute attacks of pain and fever are less frequent, and if the patient will not submit to operation, she may drag out a weary life of ill-health for many years.

**Gonorrhœa of the Peritoneum.** In acute ascending gonorrhœa, even when there is no escape of cocci from the abdominal ostium of the tube, there occurs a fibrinous exudation of the tubal and uterine peritoneal coats. The thin wall of the tube allows the spread of inflammation by continuity of tissue to its own serosa. This kind of inflammation may entirely subside. Of more importance are those cases of peritonitis due to the escape of pus from the tube. A gonorrhœal pus-tube which leaks freely during removal has been known to cause fatal general peritonitis. This is probably due to a mixed infection with staphylococci and streptococci, since gonococci alone do not live very long on the peritoneum. Gonococci may exist, however, long enough to cause a fibro-purulent exudation on the surface, the final results of which are mattings of the neighbouring organs—tubes, ovaries, omentum, rectum, and parietal peritoneum.

The onset of peritonitis is clinically indicated by a rise of temperature and by increased pain; some patients are extremely ill as soon as the peritoneum is involved. The severe pain at the onset and in all future attacks is explained by *peritonitis*.

**Gonorrhœa of the Anus and Rectum.** These are rare conditions. We may find gonorrhœal pus around the anus without the latter being infected. Direct contact of pus with the deeper parts of the anal canal is necessary to cause the disease. It may be set up by coitus *per anum*, unclean instruments, or digital examination. Rectal gonorrhœa is more frequent than is supposed; a perineal tear during

labour may lead to this condition. The symptoms are heat and burning after stool, with the formation of erosions, ulcers, and fistulæ at the anal orifice. The discharge may be mixed with blood; œdematous folds of mucous membrane hang dependent at the anal ring, these are very tender to touch. When the disease has become chronic the swelling subsides, but the mucosa is still red, and on dilatation, erosions can be found above the anal orifice and even above the internal sphincter. It is difficult to get the cocci out of the mucous folds, and hence rectal gonorrhœa is prone to become chronic, and is capable of leading to granulation and stricture. In women, the latter is usually situated below the internal sphincter when due to gonorrhœa. Periproctal abscess and rectal fistula may result from rectal gonorrhœa.

**The Course of Gonorrhœa in Women.** The disease may be slight or severe; its intensity depends largely upon the site of the disease. It is slight so long as it is confined to the urethra and cervix; once beyond the internal os, the disease becomes severe. Many women date the onset of their illness from this moment. The condition, which is often overlooked, is chronic urethritis, with or without cervicitis; the acute stage is soon over and the pain forgotten; a slight discharge is left, which is ignored, the woman becomes tolerant and does not consult a doctor.

**Disturbances of Function.** These vary with the localization. Gonorrhœal disease of childhood does not disturb later functions because the genital apparatus is not yet opened up, and so the uterus and tubes escape; any after-history relates to vulval conditions, the symptoms being itching and burning. The course of gonorrhœa in an otherwise healthy child is favourable, the disease is curable in four to six weeks.

Functional disturbances in adults relate to menstruation and ovulation. Gonorrhœal endometritis and salpingitis disturb menstruation, the interval is reduced, the duration of the flow is prolonged, and the amount is increased, dysmenorrhœa of *secondary* type is produced; pain may commence a week before the flow and last as long afterward. Salpingitis and peritonitis cause exacerbations of menstrual pain. Ovulation is not interfered with until the ovary becomes encapsulated by adhesions and suppurates, or is in a state of fibroid induration throughout. In such cases the periods are postponed, and there is a tendency to amenorrhœa.

**Relation of Gonorrhœa to Fertility.** Gonorrhœa by no means always leads to sterility. It does not do so in the majority of cases. The frequency of *ophthalmia neonatorum* proves this, since in most cases the disease was present in the mother at the time of conception (Bumm). Conception can never occur after bilateral salpingitic closure of the tubes. Many women are rendered sterile, either completely or after the birth of one child. The relation of gonorrhœa to abortion is not definitely settled. Sanger held that gonorrhœa of

the endometrium produced abortion about the fourth or fifth month, from inflammation of the decidua, and gonococci have been found in the decidual fragments which formed part of an abortion. After the ovum has completely filled the uterine cavity, gonorrhœa will not produce abortion, there will be no symptoms as far as the uterus is concerned, but there will be a very profuse discharge both from the cervix and from the urethra.

**Gonococcal Septicæmia.** Under conditions not thoroughly understood, gonococci may enter the blood-stream, and cause a general blood-infection indistinguishable, clinically, from septicæmia due to streptococci or other organisms. Systemic infection by the gonococcus is rare; it is more prone to occur after the local lesion has become chronic than during the acute stage, but it has been known to supervene within seven days of the initial attack. It occurs more frequently in males than in females, and is more often seen in children, and in gravid, than in non-gravid subjects. In women, general gonorrhœal infection usually originates from an intrapelvic lesion, *e.g.* salpingitis, at a time when all the evidences of gonorrhœa may have disappeared from the external genitalia.

The gonococcus has been grown from the blood in pure culture in gonococcal septicæmia, but the infection is frequently a mixed one, the associated organisms most commonly being the colon bacillus, streptococci, and staphylococci.

The prognosis is always serious, but particularly so when gonococci and streptococci are associated. Gonococcal septicæmia may be fatal in itself, but death is more often due to metastases, the most important of these are endocarditis, pericarditis, arthritis, periostitis, pleurisy, pneumonia, and pyelonephritis. From this it will be seen that the serous and synovial membranes form the sites of election of the infective emboli; but metastatic lesions have also been noted, though less frequently, in tendon-sheaths, periosteum, nerves, muscles, the parotid gland, and the skin. The commonest local manifestation of general gonococcal infection is *arthritis*. The gonococcus has been found in the joint-effusion and in granulations on the synovial membranes. When the infection is a mixed one the effusion becomes purulent. The disease is more frequently polyarticular than monoarticular. The commonest joint to be affected is the knee; the wrist is attacked more frequently in women than in men. Gonorrhœal arthritis may follow vulvo-vaginitis and ophthalmia in children and in infants. Holt states that a pyæmic arthritis in a young infant is more frequently due to the gonococcus than to any other micro-organism. The prognosis as regards life is good. Recurrences are frequent; partial ankylosis is common, but is less likely to occur in children than in adults.

For the symptoms, diagnosis, and treatment of gonorrhœal arthritis, a work on Surgery should be consulted.

**Diagnosis.** This is much more difficult in women than in men, vaginal discharge being a symptom of a whole series of pathological conditions which are not infective. If on vaginal examination we see pus on squeezing the urethra, and if at the same time there is redness and ectropion of the urethral and cervical mucous membrane (*see* p. 290), it is safe to diagnose gonorrhœa. In the chronic stages there may be no pus in the urethra until some hours after micturition. Pus or muco-pus from Bartholin's duct points to gonorrhœa, but the redness of the orifice of the duct, which Sanger called the *macula gonorrhœica*, is of no great diagnostic value. Suppuration in Bartholin's gland generally means gonorrhœa, but not always, since it may occur in puerperal women and even in virgins from sepsis.

Gonorrhœa of the vulva, vagina, cervix, body of uterus, and tubes, cannot be diagnosed with certainty without bacteriological examination. In adults a purulent discharge coming from the vaginal walls or from the vulva is generally not gonorrhœal. Granular vaginitis is not generally gonorrhœal; the same applies to pseudo-adenomatous patches (*erosions*) and various inflammations of the cervical mucosa. Even the 'gonorrhœal warts' are not always pathognomonic. All the changes that can arise in the uterus, tubes, and peritoneum from gonorrhœal infection can also arise from sepsis, especially in the puerperal state, therefore we must take full account of all associated conditions, and gauge the history carefully, in order to diagnose gonorrhœa with safety. In cases of young women who are unmarried, tubercle must be considered in the differential diagnosis of tubal swellings.

Scalding micturition with a vaginal discharge arising soon after marriage is probably due to gonorrhœa. Threads in the urine are suggestive, but not pathognomonic.

In all cases of suspected gonorrhœa, the discharge should be collected on a sterile swab from the cervix, or urethra, or from the duct of Bartholin's gland, for microscopic and cultural investigation.

**Prophylaxis and Treatment.** The public must be taught to regard gonorrhœa as a serious disease and not as a trifling accident or a slight misfortune. Doctors must warn their male patients of the serious results of this disease in married life. Marriage during the existence of chronic gonorrhœa should be forbidden. Patients should be warned of the infectiveness of the discharge, sponges should never be used for its removal, cleansing of the genitals must be done with wool, which can immediately be burned.

In the *acute* stages the patient should rest in bed, take a sitz bath, and wash the external genitals with a mild antiseptic such as boric acid lotion. Employ no other local treatment in the acute stage. Smear the external genitals with lanoline to prevent excoriation by discharge. In cervical gonorrhœa, in the acute stages, do not paint the cervix, but keep the vagina clean with douches and baths. After

the fourth week, when the condition will have become subacute, paint the endocervix with a Playfair's probe dipped in 10 per cent. melargen or argyrol.

For urethritis, in subacute cases, frequent daily applications of 1 per cent. protargol, carefully injected by means of a small syringe under low pressure, should be used. In chronic gonorrhœal urethritis use the endoscope and paint any erosion with 20 per cent. silver nitrate, or apply the galvano-cautery. Copaiba balsam does not kill gonococci, but empirically it does good, especially in gonorrhœa of the neck of the bladder. It may act on the cocci indirectly through the tissues. True gonorrhœal vaginitis, which is rare in adults, should be treated by a douche of 1 per cent. melargen and baths. For infected follicles about the vulva and meatus urinarius, use the galvano-cautery, introduce the point cold and gradually turn the current on. Bartholin's duct should be split and cauterized with silver nitrate. Extirpation of the gland and duct, if a retention cyst or an abscess develops, must be carried out (*see Operation*, p. 836).

For chronic gonorrhœal cervicitis, draw down the cervix with a volsella, paint the canal with 10 per cent. solution of melargen, or with nitrate of silver until the surface becomes filmy white, and leave an ichthyol tampon (10 per cent. in glycerine) in the vagina for twelve hours. Treat pseudo-adenomatous areas around the os with lunar caustic, and if they prove intractable remove them by the method described on p. 801. Gonorrhœal warts should be scraped off.

Gonorrhœal endometritis must be treated with great caution. Do not curette, except for severe menorrhagia, which is very rare. Do not drag down the uterus forcibly with a volsella. Apply a 10 per cent. solution of melargen or of silver nitrate on a Playfair's probe; leave it *in utero* a few minutes, then continue the treatment by douching the uterine cavity with 0.5 per cent. silver nitrate, introduced by means of a two-way catheter, the patient of course being kept in bed. If these weak solutions fail, in obstinate cases paint the endometrium with strong iodine solution. In any case, if fever follows from intra-uterine treatment, the latter should certainly be discontinued. Vaccine treatment for gonorrhœal cervicitis and for endometritis is unsatisfactory, but it relieves the pain in arthritis, and has been found useful in ophthalmia.

For salpingitis and peritonitis, absolute rest in bed, cold compresses to the abdomen, and morphine suppositories per rectum, with saline purgation must be employed. Prolonged rest is the most important matter to attend to; it should be continued for two months at least. In the case of a recent attack, the patient should not be allowed to walk until the temperature has been normal for one month.

If pus-sacs develop, they should be removed as soon as the initial febrile attack has subsided; the uterus should also be taken

away at the same time, for, if it is left, the cornual stumps are a source of infection.

In gonorrhœa, coitus should be prohibited.

During the puerperium, prolonged rest is most essential. The patient should be kept in bed four or five weeks, even if there has been no fever, the time of greatest danger for puerperal women, who are the subjects of gonorrhœa, is when they first get out of bed and move about.

## TUBERCULOSIS OF THE GENERATIVE ORGANS

**General Pathology.** The organism responsible for tuberculosis was discovered by Koch in 1882. It is a delicate bacillus  $3\mu$  in length. It can be grown slowly on blood-serum and more rapidly on certain special media.

The diagnosis is made by finding the bacillus in a film made from the pus (see Fig. 143). After fixation of the pus on a slide or cover-slip, hot carbol-fuchsin is poured on the film and left for five minutes. The cover-slip is then immersed in 25 per cent. sulphuric acid until the colour disappears; it is then washed in tap-water, the film is counter-stained with Lœffler's methylene-blue for one minute, then washed and dried. Tubercle bacilli are stained bright red, the other structures in the film appear blue.

The smegma bacillus stains in the same way, but it is more easily decolorized by alcohol, so that in examining for tubercle of the *external genitalia* it is better to employ a 3 per cent. solution of hydrochloric acid in absolute alcohol instead of the 25 per cent. mixture of sulphuric acid and water. By this means the smegma bacillus becomes decolorized and only the tubercle bacilli will remain red (see p. 235).

The lesion produced by the tubercle bacillus is first manifested by a proliferation of the endothelial cells of the lymphatic channels. The cells thus produced are called *epithelioid* from their resemblance to epithelial cells. By nuclear division in an epithelioid



FIG. 143. TUBERCLE BACILLUS (F. Shaw). This organism was discovered by Köch in 1882. In the upper half of the field are seen large numbers of tubercle bacilli obtained by culture. In the lower half of the field are seen tubercle bacilli on a film prepared from sputum.

cell a giant-cell with peripheral nuclei is formed. Around this multinuclear cell other epithelioid cells arrange themselves concentrically to form a *giant-cell system*, which is completed by a widely extending zone of lymphocytes. Such a system is invisible to the naked eye, but when many such fuse together they appear as yellow or grey nodules and are known as *tubercles*. A *tuberculous giant-cell system* is an avascular granuloma which tends to undergo necrosis and to become the site of a secondary infection by true pyogenic cocci. In the human subject a tuberculous lesion shows only a scanty number of bacilli; those which exist are mostly extra-cellular, but occasionally they may be found inside a giant-cell or in an epithelioid cell. An emulsion made by pounding tuberculous tissue in normal saline solution; when injected into the knee-joint of a guinea-pig, causes an ascending infection of the lymphatic glands, which is followed in the course of a few weeks by general tuberculosis. This *physiological test* is slow, but it is the most reliable from the point of view of diagnosis. For diagnostic purposes use is made of the fact that tissues invaded by the tubercle bacillus are hypersensitive to tuberculin. Koch's 'old tuberculin,' the cutaneous inoculation of von Pirquet, and the conjunctival inoculation of Calmette are employed as tests. If a subcutaneous injection of tuberculin is followed by bearing-down pain, tenderness in the vaginal fornices, or metrorrhagia, the coincidence is regarded as suggestive of pelvic tuberculosis. The diagnostic tests for tubercle are therefore (1) microscopic, (2) therapeutic, (3) physiological. The microscopic discovery of the specific bacillus is conclusive; the tuberculin (therapeutic) test is not always reliable, because a reaction may be obtained after tuberculous lesion has healed. The physiological test (inoculation into guinea-pigs) is absolutely positive.

**Frequency.** André Rives has published statistics which show that the frequency of genital tuberculosis found at the autopsies of women dying of general diseases is 1 per cent. In women dying of phthisis and other forms of tuberculosis, pelvic tuberculosis exists in 5 per cent. It has been stated that 10 per cent. of all cases of salpingitis are tuberculous. Genital tuberculosis frequently causes no characteristic symptoms, so that during laparotomy unsuspected tuberculosis is not infrequently discovered.

**Etiology.** Genital tuberculosis is uncommon before puberty and rare after the menopause; the majority of cases occur between the fifteenth and thirty-fifth years. Hypoplasia, or defective development of the genitalia, would seem to predispose to an infection by tubercle. The co-existence of tubercle with other types of infection suggests that a pre-existing inflammation may determine the site of a tuberculous deposit. New growths in like manner are said to favour a tuberculous infection. It has been claimed that adenomyomata of the tube predispose that structure to tuberculous infection



but this is reversing facts. It is the tuberculous lesion that produces a condition which has been confused with adenomyoma (see Fig. 339, p. 624).

**Methods of Infection.** Three paths of infection of the pelvic organs are recognized—the ascending path, the descending path, and the blood- and lymph-streams.

*Ascending Infection via the Mucous Surfaces.* Tuberculosis of the vagina, uterus, and Fallopian tubes occurs most commonly in virgins, which is opposed to the theory held by some, that an ascending infection by spermatic fluid is a common explanation of genital tuberculosis in the female. Gorovitz obtained positive results by injecting tuberculous material into the uterus of guinea-pigs, but when the infective organisms were only introduced into the vagina the results were negative. It is possible that in rare instances tuberculous discharges from the bladder or bowel have caused direct inoculation of the genital tract from below, but speaking generally an ascending tuberculous infection, although possible, must be extremely rare in its occurrence.

*Descending Infection.* Experiments on animals have proved that foreign particles can pass from the peritoneal cavity to the vagina. In like manner, tubercle bacilli may be washed into the Fallopian tubes in cases of tuberculosis of the peritoneum or of the mesenteric glands, but it has been observed that the latter are rarely involved in genital tuberculosis. In cases where the general peritoneum and the pelvic viscera are involved at the same time, it is difficult to decide which is the primary focus, but the possibility that tuberculous peritonitis may produce a descending infection along the mucosa of the tubes must be admitted.

*Infection through the Blood- and Lymph-streams.* Most authorities now regard the blood-stream as the most important route of infection. This mode of infection can never be excluded in any case, and is the only satisfactory explanation in those cases of pelvic tuberculosis where there is an isolated lesion with no evidence of tubercle elsewhere. Moreover, such isolated lesions may be interstitial in situation with no evidence of invasion of the mucous membrane. It is, however, difficult to exclude an older *primary* focus in other parts of the body, so that perhaps it is wise to regard primary tuberculosis of the genitalia as a rare occurrence.

**Distribution.** The order of frequency in which the pelvic viscera are affected is: Fallopian tubes, body of uterus, ovaries, cervix, vagina, and vulva.

**Prognosis.** The coincidence of tuberculosis in other viscera, e.g. pulmonary, alimentary, or urinary tuberculosis, increases the gravity of the prognosis. Sterility is the rule, but when pregnancy does occur the maternal prognosis is grave. Acute miliary tuberculosis has been known to occur after labour or abortion. If fistulæ

form, they are most intractable. Tuberculosis of the female genitalia usually runs a chronic course, and on the whole the prognosis is serious.

**Tuberculosis of the Vulva.** Clifford White states that about one-quarter of all cases occur in children. In adults it is usually secondary to some other lesion. There are two main types—the *ulcerative* and the *proliferative (non-ulcerative)*. The former is the commoner.

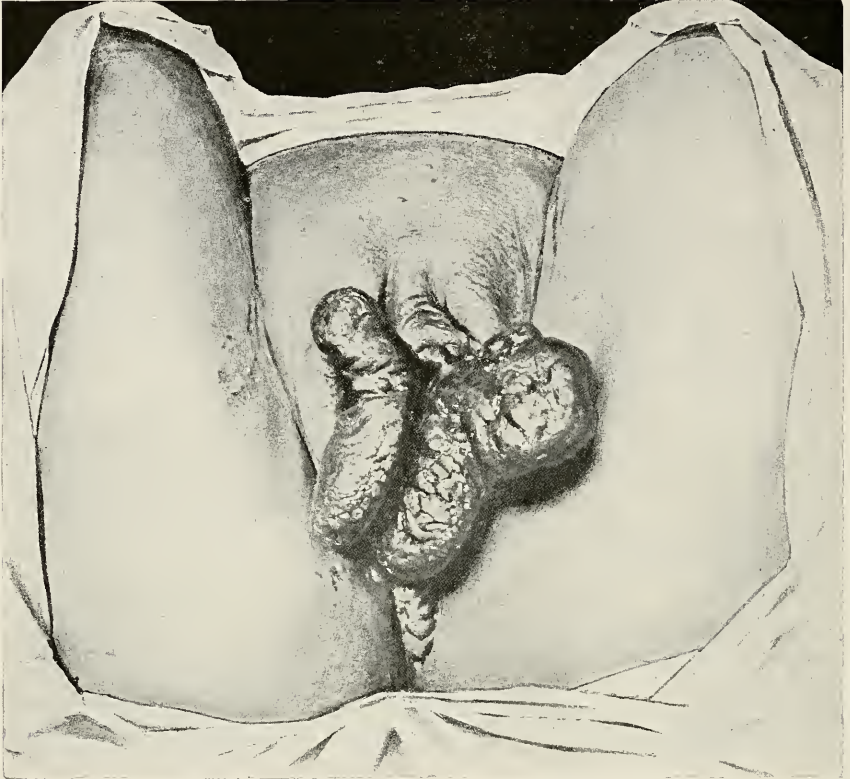


FIG. 144. SHOWING THE PROLIFERATIVE (NON-ULCERATIVE) TYPE OF TUBERCULOSIS OF THE VULVA (Bender). The labia are hypertrophic, the condition simulating elephantiasis.

Tuberculous ulcers occur on either labium majus or minus—they are multiple, with yellowish bases, and with œdematous, purple edges. By the confluence of several ulcers a serpiginous sore is produced, which shows signs of healing in one part while extension is occurring elsewhere. The epithelium at the edges is sodden and raised. The lesion is tender on contact. From a vulval ulcer, sinuses may be found running into the adjacent connective-tissues, which are always œdematous. The inguinal glands are only affected late in the disease. Tuberculous ulceration of the vulva is sometimes associated with hypertrophy of the labia, which may be so extreme as to simulate elephantiasis. The *proliferative* or *non-ulcerative* type has been

described by Bender ; it is rare, both labia are generally involved, and the vulva becomes regularly hypertrophic as seen in elephantiasis (see Fig. 144). It mostly affects adults, and often recurs after operation. Microscopically there is œdema of the sub-epithelial tissues, and round-celled infiltration. Owing to the bulk of tissue present, giant-cell systems are infrequent and therefore difficult to find.

*Symptoms.* Swelling of the vulva, painful micturition, and in some cases pruritus, are the chief symptoms. In an ulcerative lesion there will be some discharge, and cicatrization may lead to urethral stenosis.

*Diagnosis.* A tuberculous ulcer in childhood has to be distinguished from noma and from diphtheritic vulvitis (see p. 339). Tuberculous ulcers of the vulva in adults must be distinguished from *ulcus molle*, chancres, herpes, epithelioma, and (if accompanied by hypertrophy) from lymphangioma and from sarcoma (see pp. 354, 362). Differential diagnosis in the early stages is not difficult, but late in the disease, when the vulva has become altered by hypertrophy, œdema, and ulceration, diagnosis may be impossible by clinical means so that the specific tests described above will be required.

The proliferative or non-ulcerative form to which Bender has drawn attention resembles chronic lymphangitis, and the diagnosis depends upon finding tuberculous systems in the tissues by microscopic examination.

*Prognosis.* In children the disease progresses rapidly and dissemination of tubercle occurs early. In adults progress is slow, but if phthisis is present the outlook is grave. Prognosis is more favourable in the proliferative than in the ulcerative cases.

*Treatment.* If the patient's general condition will admit of a general anæsthetic being given, free excision is indicated. Otherwise X-rays may be employed and ulcers painted with lactic acid ; sinuses should be irrigated with peroxide of hydrogen (5 vols.).

**Tuberculosis of the Vagina.** Tuberculosis of the vagina is infrequent ; it is rarely a primary lesion and is usually seen in association with tuberculous cervicitis. Two forms are described—the *miliary* and *ulcerative*. The commonest sites for ulcers are the posterior fornix and the *introitus vaginæ*, near the urinary meatus in front, or near the perineum behind.

*Symptoms.* Leucorrhœa, blood-stained discharge, dysuria, pruritus, and vulvitis are the symptoms which accompany tuberculous vaginitis.

*Diagnosis and Treatment.* The lesion must be distinguished from a septic ulcer due to a neglected pessary, from epithelioma, and from venereal lesions. The purple œdematous granulations, seen at the edges of the ulcers, and evidence of co-existing tuberculosis in other parts, may be relied on as helping to make a correct diagnosis. The treatment consists of excision where possible, but if the patient is

too ill to tolerate radical measures, douching and radio-therapy may be employed.

**Tuberculosis of the Cervix.** According to Clifford White, the cervix is affected in about 8 per cent. of cases of tuberculosis of the female generative organs. An isolated lesion involving only the cervix is rare, the cervix being usually secondarily implicated by a descending infection from the tubes or uterine body. Clinically two varieties are recognized, the *ulcerative* and *proliferative* forms; of these the former is the more frequent. The disease may be confined to the portio-vaginalis or to the canal, but usually both are affected simultaneously (*see* Figs. 145 and 146). The ulcers occur in the neighbourhood of

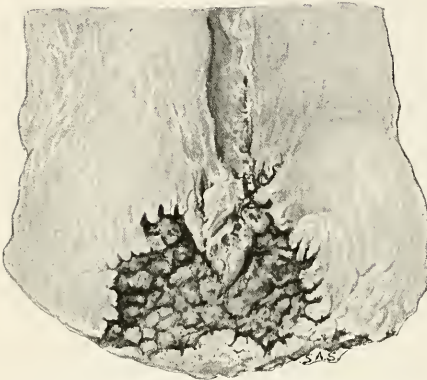


FIG. 145. SHOWING PRIMARY TUBERCULOUS ULCERATION OF THE CERVICAL CANAL. (Clifford White.) The cervix shown is Fig. 146 bisected.

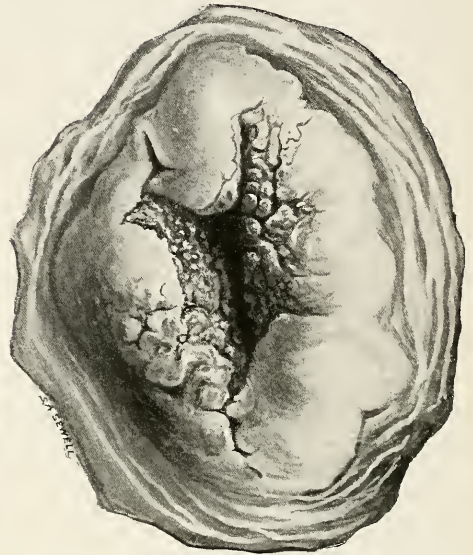


FIG. 146. SHOWING THE ULCERATIVE FORM OF PRIMARY TUBERCULOUS CERVICITIS. (Clifford White.)

the external os, they may be single or multiple; they are serpiginous in outline, with sharp edges and a yellowish base. The proliferative variety appears as fine and coarse papillary processes around the external os and over the adjacent part of the portio vaginalis, to which they give a dark, livid, red appearance, resembling the rare condition of simple adenoma of the cervix (*see* p. 500). These outgrowths may block the cervical canal and give rise to *pyometra*. This form of tuberculosis is also accompanied by ulceration due to the breaking down of tuberculous foci. The cervical glands become hypertrophied and their lumina are filled with serous exudation and round cells. Metaplasia of the epithelium of the glands is often marked, giving a resemblance to squamous-celled epithelioma, which in some cases has actually been associated with tuberculosis of the cervix. Giant-

celled systems exist in the infiltrated muscle-tissue surrounding the glands (see Fig. 147).

*Signs and Symptoms.* The ulcerative condition is often mistaken clinically for carcinoma, and the latter can be satisfactorily excluded only by microscopic examination. A blood-stained leucorrhœal discharge, which may be offensive, is present. There is little or no pain, menorrhagia may be noted, there is no fever, and the patient's general condition remains good unless there is tubercle elsewhere.

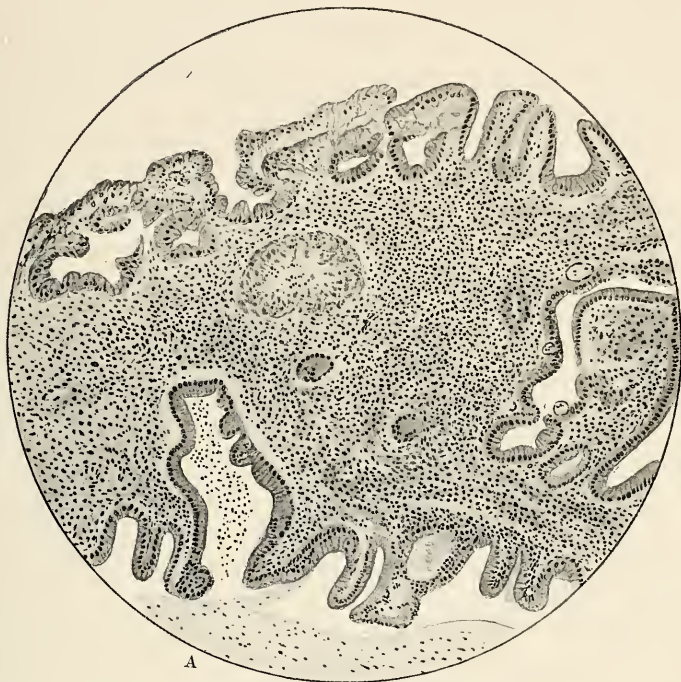

FIG. 147. TUBERCULOSIS OF THE CERVIX UTERI. Showing giant-celled systems. A. Gland filled with serous exudation and round cells. A gland at the top of the Figure showed metaplasia of its epithelium.

The *proliferative type* resembles in appearance a pseudo-adenoma (*erosion*), but it is soft, friable, and very vascular; there is no surrounding infiltration. The tuberculous cervix has been described as “looking like a carcinoma and feeling like a cervicitis.” It is difficult clinically to diagnose a tuberculous ulcer of the cervix from a venereal ulcer; resort must be had to microscopic examination and to Wassermann's test. The prognosis in an isolated cervical lesion is good, but the outlook is often vitiated by the presence of tuberculosis in other parts of the body.

The *treatment* consists of high amputation of the cervix, but if there is also advanced phthisis no operative treatment is indicated.

**Tuberculosis of the Body of the Uterus.** Tuberculosis of the body of the uterus is generally secondary to tuberculous salpingitis, but cases of primary uterine infection have been recorded. It occurs at all ages from infancy to the climacteric. It may be associated with tubercle of the cervix. Of all cases of uterine tuberculosis the cervix *alone* is involved in 2 per cent. and the body of the uterus *alone* in 85 per cent. (C. White); in the remainder both are affected together. The commonest site for the disease is near the cornua; during pregnancy it attacks especially the placental site.

*Varieties.* (1) A miliary form without ulceration; (2) a chronic diffuse or caseous type; (3) a chronic fibroid variety. The second type is the one usually met with clinically, acute miliary tuberculosis of the body is only met with in dying women, whilst the third, or fibroid form, is very rare. The chronic diffuse type is what is generally known as *tuberculous endometritis*, but the invasion is not confined to the mucosa, it spreads into the subjacent muscular tissue. The first macroscopic evidence is the presence of small yellowish areas in the mucosa near one or other cornu, *i.e.* near the entrance of the Fallopian tubes (Cullen). At first, the surface-epithelium is intact, the glands become enlarged, and their epithelium proliferates, whilst the interglandular tissue becomes infiltrated with small round cells, in which giant-cell systems make their appearance. Later the epithelium on the surface gives way, its place is taken by granulations which break down and caseate, so that on section we see a surface-layer of caseous material, then a layer containing polynuclear cells and giant-cells, with here and there the fragment of an endometrial gland remaining, followed deeper down by a zone of round-celled infiltration and hæmorrhage. It is not uncommon for the caseous granulations to obstruct the cervical canal and for pyometra to form (*see p.* 240). We have traced a tuberculous infection from the Fallopian tubes into the musculature of the uterus without the endometrium becoming infected, the infection having travelled along the perivascular lymphatics just as it does in carcinoma; such an observation explains the occurrence of interstitial tuberculous abscesses in the uterine body.

In tuberculous endometritis the muscularis is generally implicated to some extent, being thickened and fibrotic. Tubercle and carcinoma of the endometrium may co-exist, and it is thought that the marked epithelial metaplasia which is found in the glands of a mucous membrane infected by tubercle may, in many instances, be the starting point of a malignant process.

*Symptoms.* These are not characteristic. Leucorrhœa and menorrhagia may be present, followed by amenorrhœa on the destruction of the endometrium, or on the formation of a pyometra. Pain, when present, is due to a complication, such as salpingitis or pyometra. Sterility is the rule.

*Diagnosis and Treatment.* Whilst there are no characteristic symptoms, physical examination shows an enlarged uterus which is usually accompanied by a tubal swelling or swellings. Examination of curettings will reveal the presence of giant-cell systems. In advanced cases caseous material may be extruded.

The *treatment* is either simple curettage or laparotomy. If there is no other evidence of tubercle than that discovered by curettage, nothing further for the moment should be done by way of operative treatment, but the patient should be carefully watched. When there is evidence of other pelvic lesions there can be no alternative but to open the abdomen and remove the infected tissues.

**Tuberculous Disease of the Ovaries.** The ovaries may be secondarily infected from the Fallopian tubes or from the peritoneum. In either of these conditions perioöphoritis is common, but owing perhaps to the density of the cortex, infection of the ovarian stroma is comparatively rare. It is very doubtful whether interstitial tuberculous öophoritis ever occurs primarily, but von Franqué has traced the source of an ovarian infection to an abrasion in the vaginal vault. Schöttlander states that miliary tubercles may exist in apparently healthy ovaries, and Sitzenfrey demonstrated the presence of tubercle bacilli in the ova of the human ovary in the case of a woman with pulmonary and pelvic tuberculosis.

Apart from a few isolated examples of infection *viâ* lymphatics, it may be stated that, clinically, tuberculous öophoritis is associated with infection of the peritoneum and of the Fallopian tubes, both ovaries being commonly affected.

In the early stage of the disease miliary tubercles are found in the connective tissue of the cortex, whilst the Gräafian follicles may be quite normal in appearance, even when surrounded by the inflammatory exudation. Later caseation sets in, the glandular tissue is destroyed, and the ovary enlarges, and ultimately becomes an abscess-sac. Tuberculous öophoritis may subside leaving the ovary in a state of fibrosis. The symptoms and physical signs are similar to those of tuberculous salpingitis.

**Tuberculosis of the Fallopian Tubes.** This is the most frequent of all tuberculous lesions in the female genitalia. The reason for this being that the Fallopian tubes are so constructed and placed as to favour the stagnation of any infective matter (*see* Salpingitis, p. 609). Tuberculous salpingitis therefore is present in 85 per cent. of all cases of tuberculosis of the generative organs in women.

*Frequency.* According to Clifford White adequate investigation by careful observers has shown that about 10 per cent. of all tubes removed for inflammatory disease show old or recent tuberculous lesions. The majority of cases occur between the ages of fifteen and thirty-five years.

*Pathological Anatomy.* The tubes are generally enlarged and bent,

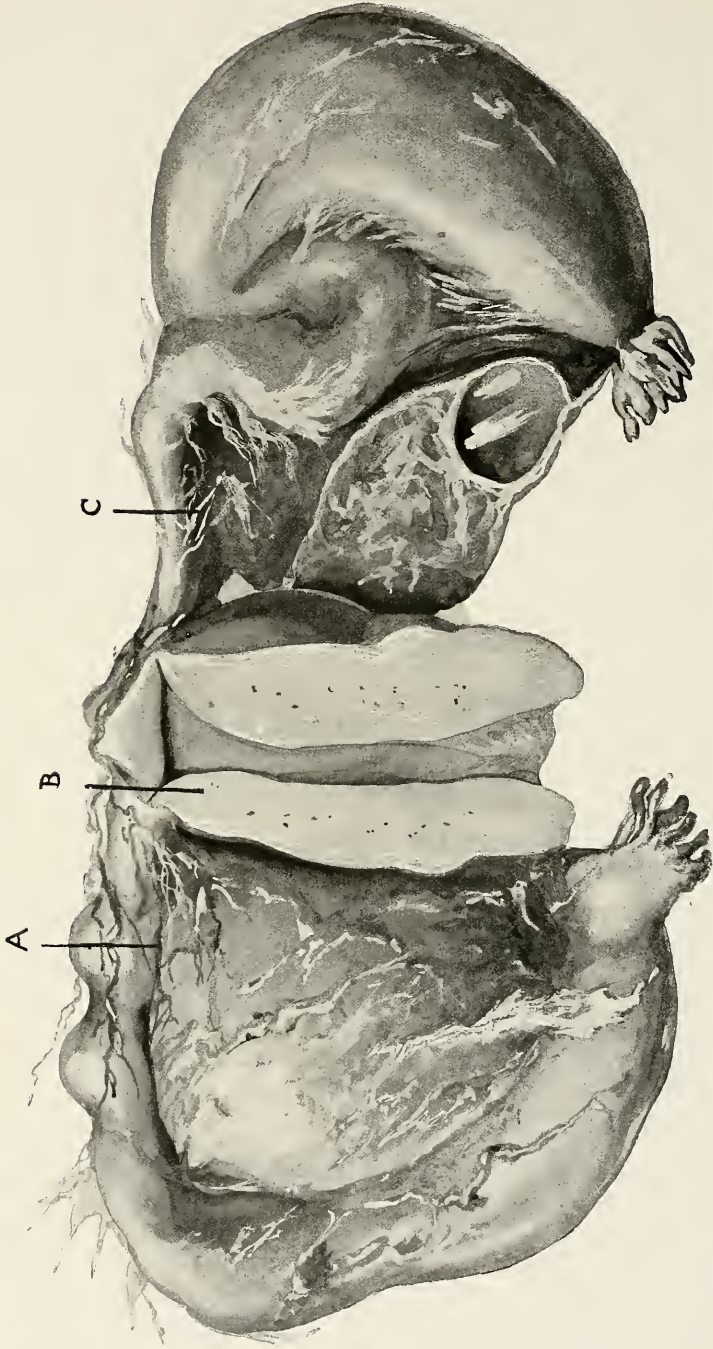


FIG. 148. DOUBLE TUBERCULOUS PYOSALPINX. Note (1) the presence of Nodular Salpingitis; (2) The Fimbriae are not indrawn.

A and C show the points at which sections were taken to prove the presence of tuberculous foci in both tubes. At B a section showed foci of tubercle spreading from the interstitial part of the tube into the uterine muscle.



there may be nodular thickenings, more especially near the isthmus. The fimbriated extremity may be patent and even patulous; when closed the fimbriæ are not, as a rule, indrawn, but remain visible (Fig. 148). Three types of tuberculous salpingitis are met with: (a) perisalpingitis, (b) endosalpingitis, (c) interstitial salpingitis, but all three forms often occur together. In (a) the peritoneum covering the tube is studded with tubercles. In (b) the plicæ are swollen and infiltrated, their tips become denuded of epithelium

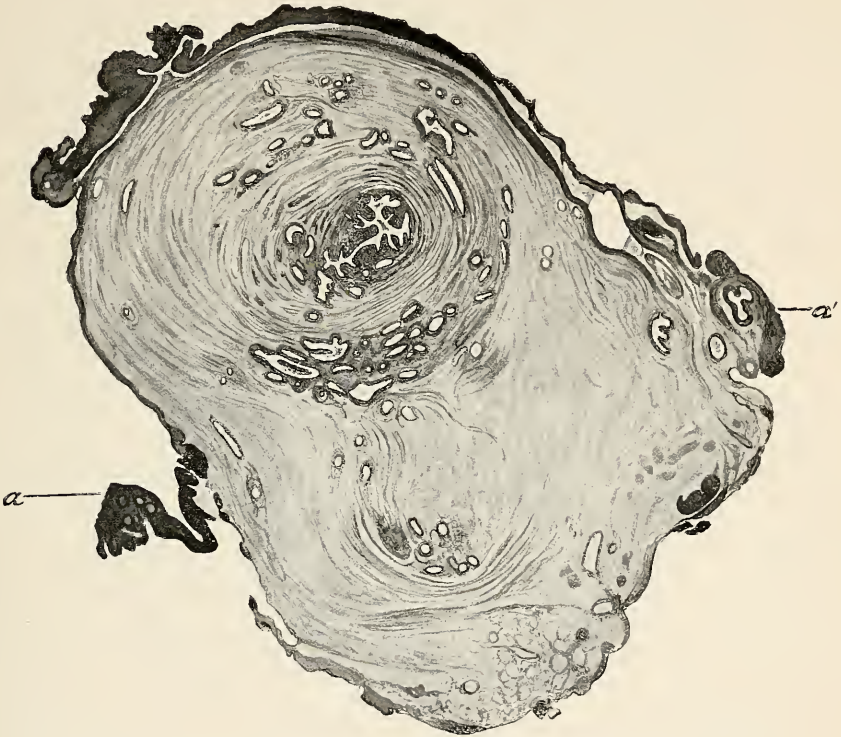


FIG. 149. NODULAR SALPINGITIS (SALPINGITIS ISTHMICA NODOSA (von Franqué). *a a'* extent of peritoneal coat of tube.

and stick together, thus forming pseudo-cysts (*salpingitis pseudo-follicularis*). The epithelium may also undergo metaplasia and keratinization, and instead of a single layer of columnar cells, irregularly shaped cells, in many layers, are formed by proliferation. In some cases these changes are so marked as to resemble malignancy. In other cases the epithelium is totally destroyed and the tube lumen filled by caseous *débris*. A variety of endosalpingitis is the so-called *nodular* salpingitis, in which the epithelium is carried quite deeply into the muscularis, where it proliferates in an adenomatous manner, whilst both the muscle and connective tissue undergo hyperplasia, so that histological resemblance to an adeno-

myoma is produced (see Fig. 150. This trespassing of epithelium, known as *epithelial heterotopy* or epithelial displacement, is not peculiar to tuberculous lesions but also occurs though in a less

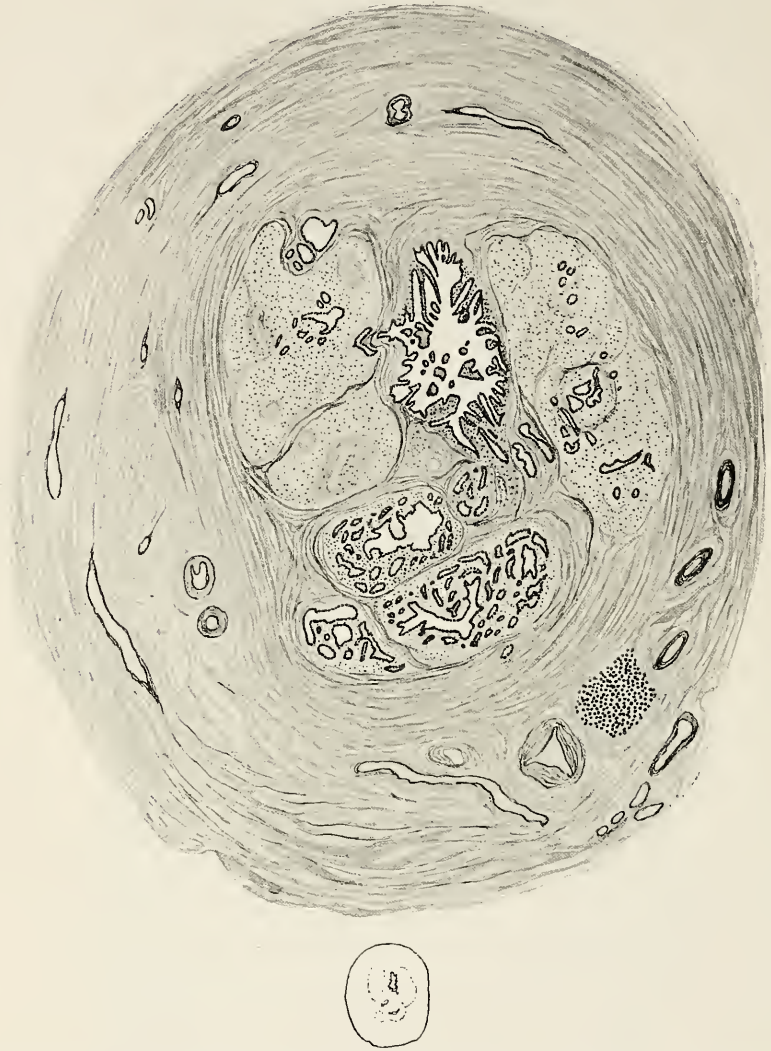

FIG. 150. MICROSCOPIC SECTION OF NODULAR SALPINGITIS (SALPINGITIS ISTHMICA NODOSA). Showing gland-follicles in the muscularis (*salpingitis follicularis*). The inset shows the actual size of the tube. Tuberculous systems were seen under a higher power (see FIG 339, p. 624).

marked degree, in gonorrhœal and septic infections of the tubes. In nodular tuberculous salpingitis the nodules may undergo calcification. In (c) giant-cell systems or caseous foci are found in the muscle-wall; this *interstitial* type is due to a blood- or lymph-infection.

It is impossible in the early stages to tell by macroscopic examination that a case of salpingitis is tuberculous, but if a tube is thickened at its isthmus whilst the abdominal ostium remains patent it suggests the presence of tubercle. In cases due to peritoneal

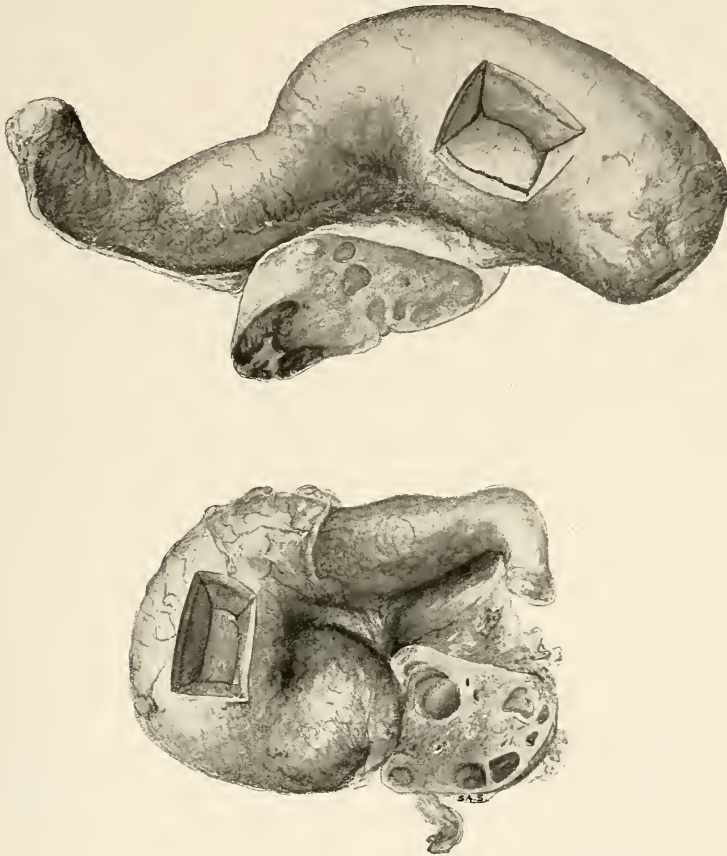


FIG. 151. DOUBLE TUBERCULOUS PYOSALPINX. The upper sac resembles a banana in shape. It was non-adherent. The lower specimen shows the tube bent upon itself and adherent to the ovary. It was also adherent to other adjacent structures. Apertures made in the tubes after hardening show the inspissated caseous contents.

infection, miliary tubercles may be seen on the serous surface, and can often be traced to the subserous coat. The stress of the infection usually falls on the two ends of the tube, the ampullary and the uterine. When the fimbriæ adhere together a pyo-salpinx forms in the ampullary portion; this is said to happen in one-third of all cases. The contents consist of sterile, liquefied caseous material; only in cases of secondary infection will true pus be found. A *cold abscess* of the tube is the name given to a large tuberculous pyosalpinx with thin walls, the result of a mild infection of a previously healthy

tube. Such an abscess may closely resemble an ovarian cyst, the investing peritoneum being generally of normal appearance. In other cases the tubes filled with tuberculous material may form banana-shaped swellings (*see* Fig. 151). In advanced cases of tuberculous salpingitis dense adhesions unite the tube to adjacent structures; fistulous tracts may penetrate the ovary, the bowel, or the bladder. Occasionally the mesenteric glands are found enlarged.

*Clinical Features.* The symptoms are those of ordinary salpingitis. In the miliary form, symptoms referable to the tubes may be absent altogether, whilst if secondary infection of a tuberculous abscess supervenes the symptoms may be very severe. It is a common experience for an operator to be surprised to find that a tubo-ovarian mass is tuberculous, and Whitridge Williams' expression, "unsuspected tuberculosis," covers a large number of cases. There may be a failure in general health with loss of weight. There may be iliac and lumbar pain, aching in character, with exacerbations due to tubal contraction or to perisalpingitis. Dysmenorrhœa of secondary (*congestive*) type may be present. Partial amenorrhœa may be noted; other symptoms referable to endometritis, such as leucorrhœa, may be present, and lastly ascites may cause abdominal enlargement. The onset is usually insidious, and the progress of the disease is slow.

*Physical Signs.* Ascites may or may not be present, a nodular bead-like thickening of the isthmic portion of the tube suggests tubercle; in the absence of these features there are no characteristic signs to point to a salpingitis being tuberculous.

*Diagnosis.* If bilateral salpingitis be present in a virgin who gives no history of appendicitis, tubercle may be regarded as the most likely cause of the trouble. Nocturnal pyrexia, or definite signs of phthisis, will strengthen the suspicion. A ruptured ovarian cyst with ascites will produce physical signs akin to those of tuberculous salpingitis with ascites.

*Treatment.* In cases in which the tubal or tubo-ovarian lesion constitutes the main focus of the disease, laparotomy followed by removal of the affected organs should be carried out. In advanced cases it is surgically sound to remove the uterus as well as the suppurating tubes (*see* Fig. 148). Wherever possible, the whole, or a portion, of one ovary should be left, as most cases which come to operation occur in women under thirty-five years of age. A tuberculous abscess should never be drained *per vaginam*, as an intractable fistula always results.

**Tuberculosis of the Peritoneum.** Tuberculosis of the peritoneum is commoner in women than men. The peritoneum of the pelvis is the part frequently affected most, a fact which has been attributed to the gravitation of tubercle bacilli to the bottom of the peritoneal cavity. Williams attributes peritoneal infection to a pelvic source in from 40 to 50 per cent. of cases. Abbé considers that 66 per

cent. of the cases are infected from the thoracic glands, and 16 per cent. through the mesenteric glands. The intestine and the blood-stream are other sources of infection.

*Varieties.* There are three types to be distinguished: (1) the miliary, (2) the caseous, (3) the fibroplastic.

(1) *The Miliary Form.* This form may exist for a long time without causing symptoms. The peritoneum is covered with minute tubercles (see Fig. 152). There may or may not be adhesions present.

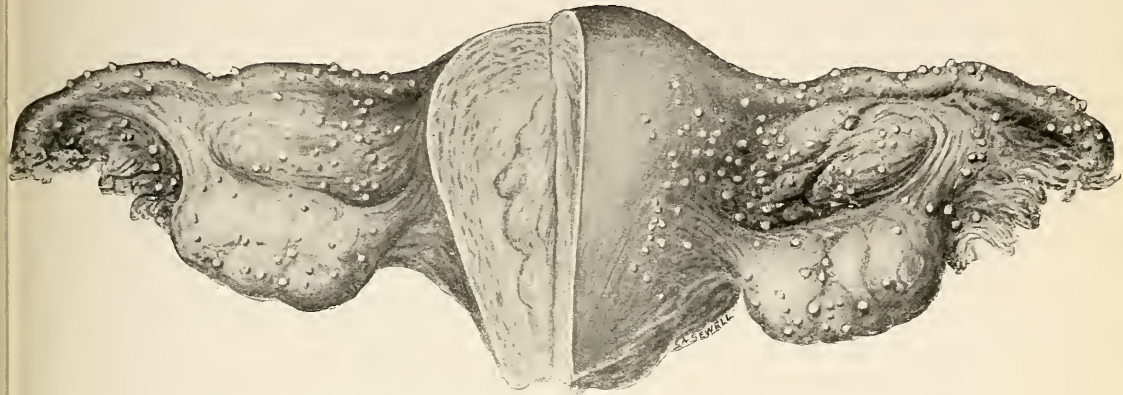


FIG. 152. SHOWING MILIARY TUBERCULOSIS OF THE PELVIC PERITONEUM.  
(Clifford White.)

In the acute form the peritoneum is thickened and lustreless, and flakes of lymph, like opaque curds, adhere to the surface. There is a variable amount of ascites; the fluid is yellow or blood-stained, and may contain masses of floating lymph. In this type adhesions are frail and easily bleed.

(2) *The caseous form* is much more severe; caseous masses and abscesses exist, the intestines and omentum may form an adherent mass which feels like a neoplasm on physical examination. Between coils of adherent bowel encysted collections of yellow, caseous, or purulent fluid may be found. Such a condition may be localized to the pelvis or to the omentum or elsewhere, or a general ascites may exist. There is a danger in the caseous form of *fistulæ* forming and opening into bowel or bladder or at the umbilicus. When localized to the pelvis, tuberculous peritonitis is practically always associated with tuberculosis of the Fallopian tubes, and the whole may form a cystic mass which resembles an adherent ovarian cyst.

(3) *The fibroplastic form* is the outcome of the two other varieties, especially of the first. It is characterized by the disappearance of the tubercles, by the formation of bands uniting intestinal coils to each other and to the parietes. The adhesions may be so dense as to make it difficult to find the true peritoneal cavity. Encysted collections of clear yellow fluid exist. The omentum and mesentery

retract, and may thereby produce kinks and narrowing of the bowel. Bands passing from one point to another endanger the bowel by causing risk of strangulation.

Clinically, all three types of tuberculous peritonitis may be found in combination.

*Symptoms and Signs.* Symptoms may be entirely absent or they may be those of extensive peritonitis associated with intestinal obstruction. The onset may be so acute as to suggest the presence of a twisted ovarian cyst—a condition which the physical signs may also resemble. Certain prodromata may be noted in many cases; they are, anorexia and loss of weight, dyspepsia, and rise of temperature, especially towards evening. In acute cases the temperature may run up to 103° F., and there is acute abdominal pain and a certain amount of tenderness. In the more chronic forms there is often bearing-down pain in the pelvis and tenderness in the lower abdomen. Kelly has drawn attention to dysuria as a frequent symptom. The abdomen is at first tympanitic, but later, signs of ascites are present. A variable percussion-note is obtained, according to whether a distended coil or an encysted collection of fluid is encountered. In the most chronic ascitic form the phenomenon of shifting dulness is easily obtained, because the fluid is not encysted by adhesions. Sometimes an apparently solid tumour will be found which gives a resonant note, and the relations of the tumour may change between two examinations; such puzzling anomalies are always suggestive of tuberculous peritonitis.

*Diagnosis.* The diagnosis may be very difficult. The acute cases have to be differentiated from typhoid fever, and from other forms of acute peritonitis; the *chronic* cases from malignant neoplasms and ovarian cysts, whereas some cases are not even suspected, much less diagnosed. The family history, and the presence of tubercle elsewhere, are of the greatest help in forming an opinion. Cases with free fluid and no pelvic mass resemble cirrhosis of the liver; cases with a pelvic mass and free fluid simulate ovarian carcinoma. Encysted tuberculous fluid in the pelvis may resemble an ovarian cystoma. Other alternative cystic conditions higher up in the abdomen are hydronephrosis, cystic sarcoma, hydatids, and appendix-abscess. When the parietal peritoneum is thickened it gives a characteristic doughy feel to the abdominal wall. With a slowly enlarging abdomen presenting anomalous and variable physical signs, the probability of tuberculous peritonitis should always be borne in mind.

*Prognosis.* The chronic miliary, or ascitic form gives the best chance of recovery. The prognosis in the caseous form, with multiple breaking-down foci, is unfavourable. The prognosis is better in adolescence than in young children and elderly subjects. Associated phthisis or intestinal tuberculosis renders the prognosis grave. High temperature, blood and mucus in the stools, diarrhoea, frequent

vomiting, and emaciation are very unfavourable symptoms, as they indicate that the mucosa of the bowel is involved.

*Treatment.* If recognized in the early stages, sanatorium treatment, combined with X-rays and tuberculin injections, should be tried. Palliative treatment should also be given a full trial in the caseating and adhesive types. In cases of free fluid, where the latter is increasing, the abdomen should be opened, the fluid evacuated, and the Fallopian tubes and appendix removed if they are implicated.

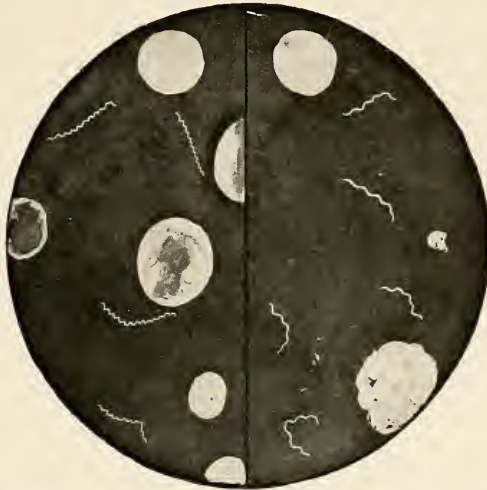


FIG. 153. *TRAPONEMA PALLIDUM*. (E. Shaw.) Films made from the discharge obtained from specific ulcers, prepared by the Indian-ink method. To the left of the Figure is seen the *Treponema pallidum*, it has the form of a closely folded white spiral. To the right of the Figure is shown the *spirocheta refringens*, which presents wide spirals. The latter organism is thicker than is the *treponema pallidum*; it is *non-specific* but it is shown by way of contrast with the true specific organism.

Great care is necessary in dealing with adhesions, because intestinal fistulæ are easily formed but never heal, the same applies to an external fistula, so that great care should be expended upon the closure of the abdominal wall. Treatment at a sanatorium should follow convalescence from operation.

## SYPHILIS IN WOMEN

It is not intended in this section to give a general description of syphilis; works on Surgery can be consulted for this purpose. In many respects, however, the disease as it occurs in women shows well-marked differences from that seen in men, and it is with these points that we are here chiefly concerned.

The specific organism, *treponema pallidum* (or *spirocheta pallida* of Schaudinn), is a small spiral filament with pointed ends (*see* Fig.

153) ; it is actively mobile, being furnished with a flagellum at each end. It is present in primary, secondary, and tertiary lesions. Successful inoculation-experiments upon monkeys have recently been carried out, so that no doubt remains as to its causal relation to the disease.

It has been clearly established that women may become infected in two different ways : (a) by sexual congress with a man in whom the disease is active ; (b) through becoming impregnated by a man in whom the disease is latent. The former differs little from the disease as seen in men, the chief differences being found in the characters of the initial lesion. The latter is distinguished as *conceptional syphilis* ; it is acquired indirectly, *i.e.* through a fertilized ovum which is the seat of active disease, and it differs from the ordinary form in the following respects : (a) there is no primary stage ; (b) the early secondary stage is often absent, and when observed is very mild ; (c) the first manifestations of the late secondaries may not make their appearance until many years have elapsed and the child-bearing period is over.

It is owing to recent advances in the methods of diagnosis and treatment of the disease that the true nature of conceptional syphilis has been made clear. The apparent freedom, in many cases, of the mother of obviously syphilitic children, from all manifestations of the disease, led to the view that she was in some way protected from infection by her child. This view received support from the well-established fact that a woman could suckle a syphilitic child which she had borne herself, and remain free from all signs of the disease, while another woman, not the mother of the child, would become infected by suckling. These observations formed the basis of "Colles's Law of Immunity." Extended clinical observation and the use of the Wassermann test have, however, put the matter in its true light. The disease is present, but in a very mild form ; the Wassermann reaction is often negative, and positive evidence of the existence of syphilis may only be obtained after the age of child-bearing has been passed. It is perhaps to the inactivity of the disease in the infecting husband that the extreme mildness and even latency of the disease in the wife is to be attributed. The developing ovum probably offers the organism a better environment, for the children of such parents often show severe manifestations of the disease.

**The Initial Lesion.** A typical Hunterian chancre is seldom seen in women. It will be recollected that this lesion is a subcuticular granuloma, which shows a marked tendency to superficial erosion or ulceration. The resulting ulcer has a dirty greyish base and a raised edge. In men, the exposed position of the lesion favours the ulcerative process, and as a sequel of secondary infection by cutaneous organisms, a stratum of inflammatory induration is formed at the



base, to which the characteristic features of the *hard sore* are due. In women the primary lesion is less exposed to external sources of injury and infection, and consequently less regularly develops the characteristic induration of the base. It is probable that the original papule is often absorbed completely without ulceration having occurred, and consequently without scarring.

*Site.* The commonest positions are, in the following order of frequency, the labia, the cervix, the vagina, and extra-genitally, the anus and the inner aspects of the thighs. When affecting the vaginal walls or the cervix, the patient will be necessarily unconscious of the presence of a sore. In many cases the labial sore also passes unnoticed, for it is painless and gives rise to no noticeable discharge. When observed, a *labial* chancre appears either as a flat papule, or a shallow ulcer with a greyish unhealthy floor; if the base is picked up between the fingers induration is not noticeable. The *cervical* chancre similarly is non-indurated, and may present either in a papular or an ulcerative form. The stage in which the typical ulcer is seen may be brief, and may pass unnoticed, leaving a clean reddish papular area not unlike a cervical *erosion*. Vaginal chancres are rare: the extra-genital chancres resemble the typical *hard sore* more closely than any of the others.

Labial chancres are often multiple, attacking apposed surfaces; sometimes a free purulent discharge is present, and an indurative œdema may affect a large area of the vulva. In labial chancres the inguinal glands will show the typical enlargement and induration. In cervical chancres the external glands may escape altogether as the lymphatics drain into the deep iliac glands; occasionally, owing to free lymphatic anastomoses, the inguinal glands may be involved as well.

Septic infection, leading to phagædena, is seldom seen in women, as free surface-drainage is permitted from the sore in all positions in which it occurs; the typical situation for a phagædenic sore is the prepuce, where drainage is imperfect and difficult.

It must be recollected that mixed infection with the virus of gonorrhœa and syphilis is not uncommon from impure coitus, and the symptoms referable to the former, inasmuch as they appear earlier, and are more obtrusive, may entirely obscure the existence of the more serious constitutional infection.

**The Secondary Stage.** In women two lesions belonging to this phase of the disease often make an unusually early appearance, viz. condylomata of the vulva, and papilloma of the tongue. Condylomata, or mucous patches, form flat, broad, warty elevations, greyish in colour, moist in appearance, always multiple; they are often very extensive in distribution, affecting not only the labia, but the perineal body, the anus, the folds of the nates, and the inner surfaces of the thighs. They are usually infective like the primary sore. The

*papilloma* of the tongue will be found at the apex of the circumvallate papillæ, *i.e.* on the posterior part of the tongue; it forms a flat, red elevation with an irregular surface. Its presence along with a local lesion of doubtful characters is powerful confirmatory evidence of syphilis; hence examination of the tongue should be part of the routine followed in cases of suspected syphilis.

In only one other respect does this stage differ notably from what occurs in men. This is in the occurrence of a characteristic skin-lesion on the neck—*leucoderma cervicis*. In women it is one of the most frequently observed manifestations of the disease, and according to Shillitoe was present in three-fourths of fifty consecutive cases examined by him. Its situation is the back of the neck, and in order to demonstrate it, the patient's neck and shoulders must be uncovered and her hair drawn upwards on to the top of the head. It occurs in two forms, either as a brownish, patchy discoloration with light desquamation of the skin, or as pale islands of irregular shape surrounded by pigmented skin. From its situation it may be unnoticed by unobservant women. The pigmentation may be very deep, or so slight that it can only be detected when seen through cobalt-blue glasses, and syphilologists advise the routine use of this aid to diagnosis when examining the neck.

Examination of the chains of *lymphatic glands* which are accessible to palpation will generally show the characteristic induration and enlargement without peri-glandular thickening; this is well marked in the superficial and deep cervical glands, and in those of the axilla and the elbow.

*The tertiary stage* presents no distinctive features in woman except as regards the reproductive functions. Here the disturbances met with in conceptional syphilis, and described below, occur to an even more severe degree than in that condition.

**Diagnosis.** It is clear from what has been said that when a woman has been exposed to the contagion of syphilis the greatest care is called for in clinical investigation. Careful inspection of the vulva may reveal traces of a disappearing lesion, which would be overlooked were the observer not aware of its inconspicuous characters. The fact that such a lesion, when found, does not present the characters typical of a syphilitic chancre must be allowed very little weight in diagnosis; and even if it heals rapidly under simple local treatment caution is still called for. In the absence of an external lesion the cervix and vaginal walls should in all cases be *carefully inspected in a good light*: an ordinary digital examination is of course quite useless for the purpose. Next to the local examination the most important points are the examination of the tongue and fauces, and the back of the neck.

Owing to the atypical character of the initial lesion in women diagnosis by detection of the infecting organism is advisable. The

treponema may usually be detected in an initial sore or papule by the following method. First wash the surface of the sore with saline : then squeeze it, or lightly scrape the surface with a knife without causing bleeding ; with a platinum loop take up a drop of the serum expressed and place it on a glass slide : side by side with this place a drop of water and a drop of an emulsion of Indian ink ; mix the three drops and prepare cover slips from the resulting large drop. Examined with an oil-immersion lens the treponema will stand out unstained from the general black background (*see* Fig. 153).

If the organism cannot be detected in the sore the differential diagnosis of certain other conditions will have to be considered, *e.g.* *ulcus molle*® in the case of an external sore, and in the case of a cervical lesion a simple *erosion* and an early carcinoma. In women a soft sore is more difficult to distinguish than in men, owing to the absence of induration from the specific lesion. It can only be diagnosed by the definite exclusion of syphilis. In the case of the two latter excision of a portion of tissue, including the margin of the sore and the healthy tissue outside it for microscopic examination is the only method of positively recognising these conditions. The introduction of a positive test for generalised syphilitic infection has, however, rendered methods of differential diagnosis largely unnecessary, and they need only be resorted to when circumstances do not admit of the Wassermann test being applied. Without it, the examination of any case of suspected syphilis may now be said to be incomplete. A negative result must not be absolutely accepted ; the test should be repeated after an interval of a few days, treatment being in the meantime withheld. Owing to the complexity of the method and the numerous possible sources of error, an experienced bacteriologist should be entrusted with the performance of the test. Until the secondary stage has been entered upon, and there are signs of local glandular enlargement, dissemination of the disease has not occurred, and the test is of no value. It cannot, therefore, be usefully applied at the first appearance of the initial lesion. The detection of the treponema suffices for diagnosis in this stage, and treatment may be at once entered upon.

**Conceptional Syphilis.** Conceptional syphilis is found only in parous women who have borne a child to, or who have at the least become impregnated by, a man suffering from late manifestations of an untreated or imperfectly cured syphilis. Marital relations *per se* do not suffice to infect the wife ; the disease is in some way transmitted to her from the fœtus, and from this it follows that the infecting agent enters her blood through the placenta. At the point of entrance no local lesion is developed, consequently the primary stage is absent. Throughout, the infection is of a particularly mild type, and definite manifestations may be delayed in appearance for many years after the original infection.

The proof that the woman is suffering from syphilis is, however, three-fold. *First*, the long-observed clinical fact that she may suckle an obviously syphilitic child without herself showing any sign of having contracted the disease. This was formerly held to indicate that she was *immune*, *i.e.* protected from the disease; but this term must be accepted in the light of present-day knowledge of the nature of *immunity*, *viz.* that it is only conferred by contracting the disease in a mild form. Viewed in this light the clinical fact correctly observed by Colles becomes an important proof that the mother is herself syphilitic. *Secondly*, the fact that in many cases, though not in all, a positive Wassermann test can be obtained. Opinions differ as to the most favourable time for the application of the test.<sup>9</sup> According to McDonagh it is usually negative during pregnancy, but may be positive after pregnancy has terminated, and is most likely of all times to be positive when the woman has passed the menopause and the child-bearing period of life is over. Others report a large proportion of positive results during pregnancy, and the question must in the meantime be left undecided. It will be recollected that if the Wassermann test is negative this cannot be accepted as certainly excluding syphilis. *Thirdly*, definite syphilitic lesions are often met with eventually in these cases, and according to McDonagh the post-climacteric age is the time at which they are most likely to occur. Gummata and lesions of the central nervous system are not uncommon forms.

Apart from these considerations the most striking feature of conceptional syphilis is to be found in the obstetric history. These women are often highly fertile, *i.e.* conception occurs with relative frequency. The foetal mortality is, however, very high, and miscarriages, or the birth of premature dead children are the *usual results*. Occasionally a child is carried to term, and born alive, and may then show definite signs of the disease at birth; or it may be apparently healthy when born, but sooner or later it is practically certain to develop more or less severe manifestations of the disease. According to the observations of Hochsinger, not more than 9 to 10 per cent. of the children borne by syphilitic mothers are free from signs of the disease at birth, and of these a considerable number develop signs of syphilis during the first six months of life. These observations were not, however, confined to women who were the subjects of conceptional syphilis alone, but included those infected directly, and consequently the conclusions are not applicable, without reserve, to the condition we are now considering. It is certain that syphilis is the commonest of all the causes of foetal mortality, *i.e.* of the death of the *fœtus in utero*. Unless appropriately treated, the effect of the specific virus upon reproduction shows little or no tendency to die out, and miscarriages, premature births, or foetal deaths *in utero* may be spread out over a series of several years. Examination of

the foetal membranes and placenta, or of the foetal viscera, *e.g.* the liver, shows that the treponema is usually present. The organism is therefore probably transmitted in the paternal semen, and develops mainly in the tissues of the ovum ; why infected semen in such cases does not *directly* infect the wife is not clear.

**Treatment of Syphilis.** It is much to be deplored that the general public attitude towards the disease renders it so often necessary to conceal from women the nature of the disease from which they are suffering ; this renders efficient treatment extraordinarily difficult. The introduction by Ehrlich of salvarsan and neo-salvarsan, organic preparations of arsenic, while undoubtedly a great advance in the treatment of the disease, has not accomplished all that was originally claimed for it. Experience has shown that it is not the specific, sovereign remedy that it was at first supposed to be. Its usefulness in controlling the outward manifestations of the disease is beyond question, but it appears that in order to ensure a final cure, and to avoid the risk of late manifestations, a full course of mercurial treatment should be combined with it. It is unnecessary to point out that the treatment both of husband and wife is necessary, not only in their own interest but to safeguard their offspring from the risk of inheritance.

As soon as the diagnosis has been made, either by the detection of the organism or by a positive Wassermann reaction, arrangements should be made for the immediate administration of a dose of salvarsan by intravenous injection. Care is called for in the administration of this potent remedy, and not all persons are suitable for the treatment. The circulatory and urinary systems must be healthy ; the existence of an aneurysm, chronic Bright's disease, or pulmonary phthisis with cavitation are contra-indications. One of the effects of the drug is to produce a sudden sharp rise in blood-pressure, and in the case of an aneurysm a fatal result might follow. The existence of middle ear disease or commencing optic atrophy are also regarded as contra-indications. Careful technique is required for intravenous injections, and the patient should rest in the recumbent position for several hours after the administration of the drug. The dose is about 0.5 gm. ( $7\frac{1}{2}$  grains) and must be given in fresh solution, made with freshly distilled water. The administration should be reserved for those who are specially experienced in the method.

More than one injection is not, as a rule, advised, but it should be followed by the continuous administration of mercury for twelve months, and the interrupted use of the same remedy for a second twelve months. Mercury may be given by the mouth, the rectum, the skin, or by intra-muscular injection ; unless it is badly tolerated by the alimentary canal the more convenient method of mouth-administration may be followed. The other methods have not been shown to possess any definite advantages, except the avoidance of

gastro-intestinal irritation. Convenient forms are the grey powder and Dover's powder pill of Hutchinson, or the more recently introduced salt of salicylate of mercury. The latter may be conveniently given in the form of a suppository in dose of  $\frac{1}{2}$  grain every night (Shillitoe). In all cases mercurial administration should be pushed to the point of producing some of the signs of mercurial poisoning, such as the blue line on the gums; if the dose is gradually increased, it is usually well tolerated. The condition of the teeth has an important bearing upon mercurial treatment. Extensive dental caries or *pyorrhœa alveolaris* are contra-indications, and must be dealt with effectively before the administration is begun.

In some cases, especially those with late manifestations, iodides in full doses may judiciously be combined with mercury.

*Syphilis and Marriage.* The question when it is safe for a man who has had syphilis to marry has always been very difficult to answer satisfactorily; nor has the difficulty been entirely removed by the introduction of Wassermann's test, for a negative result cannot be entirely relied upon. Approximate certainty can be obtained only by a thorough course of treatment, comprising, if possible, at least one preliminary administration of salvarsan and two years treatment with mercury, the first year continuously, the second year intermittently. Should manifestations of the disease appear in spite of treatment, a further six months continuous course of mercury is advisable. Wassermann's test should be repeated at the end of the allotted course of treatment before marriage is sanctioned.

### PARASITIC AFFECTIONS OF THE GENITALIA

The following varieties of parasites may be met with in the genital tract under rare conditions:

- (1) Protozoa.
  - (a) *Trichomonas vaginalis*.
  - (b) *Amœba urogenitalis*.
- (2) Trematode worms.
  - (a) *Distoma hæmatobium*.
- (3) Nematode worms.
  - (a) *Oxyuris vermicularis*.
  - (b) *Ascaris lumbricoides*.

More common and of greater clinical significance are:

- (4) Cestodes.
  - (a) *Tœnia echinococcus*.

And for the sake of convenience may be added an example of the higher class of bacteria:

- (5) Streptothrices.
  - (a) *Actinomycosis*.

(1) **Trichomonas Vaginalis.** This is a flagellated protozoon (see Fig. 154) measuring 0·015–0·025 mm. in length and 0·007–0·012 mm. in breadth. It thrives in the acid vaginal secretion. It occurs at every age of life, but how it finds its way into the vagina is unknown. It cannot live in an alkaline medium, so that menstrual discharges and alkaline douches are inimical to its existence. In the vagina this parasite is harmless, but it may invade the urethra and bladder and set up chronic cystitis.

Another protozoon the *amœba urogenitalis* has been recorded in Japan. It wanders from the vagina into the bladder and sets up tenesmus and hæmaturia.

(2) **Distoma hæmatobium** (*Bilharzia hæmatobia*) occurs less frequently in women than in men. In a few cases it has caused lesions of the labia majora resembling gonorrhœal warts (*condylomata acuminata*). In these cases the ova of this round worm are found in the submucosa of the vagina. The distoma has also been known to produce a papillary condition of the cervix uteri resembling epithelioma.

(3) **Oxyuris vermicularis**, a form of thread-worm frequently found in the large bowel of children, has been discovered in the vulva and vagina, where it produces a vulvitis and colpitis resembling a gonorrhœal infection. This worm has been known to enter the uterus and Fallopian tubes, setting up serious inflammation in the higher genital tract.

**Ascaris lumbricoides.** This is the common round worm of the intestine, it has been found in the vagina in cases of rectovaginal fistulæ.

(4) **Echinococcus.** Cysts due to the *tœnia echinococcus* will be described in the next section.

(5) **Actinomycosis** of the genitalia is described later (see p. 331).

It is very difficult to prove the parasitic nature of vulvitis and colpitis in children, but in cases where the gonococcus cannot be demonstrated, careful search for the oxyuris should be made, and the bowel washed out with infusion of quassia. The vaginitis should at the same time be treated by syringing with a weak antiseptic, such as 1–2 per cent. lysol-solution. Cystitis should be treated by washing out the bladder with 1 per cent. protargol-solution and by giving urotropin *per os*. Papillary growths of parasitic origin should be removed.

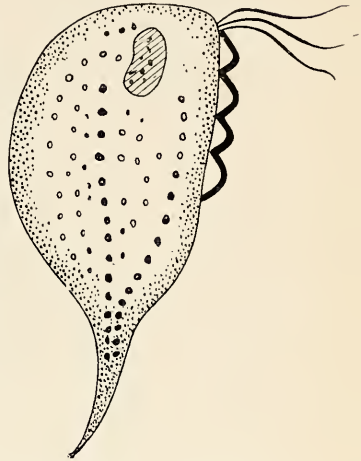

FIG. 154. TRICHOMONAS VAGINALIS  
HIGHLY MAGNIFIED  
(H. Füh).

### HYDATID DISEASE OF THE PELVIS AND PELVIC VISCERA

Hydatid disease is due to a cestode or tapeworm known as the *Tænia echinococcus*. Like other members of the class *cestodes*, this worm passes through two phases of development. The mature sexual form (*enteral phase*) is only found in the intestinal tract of certain canines, *e.g.* the dog, wolf, etc. The immature *encysted* form

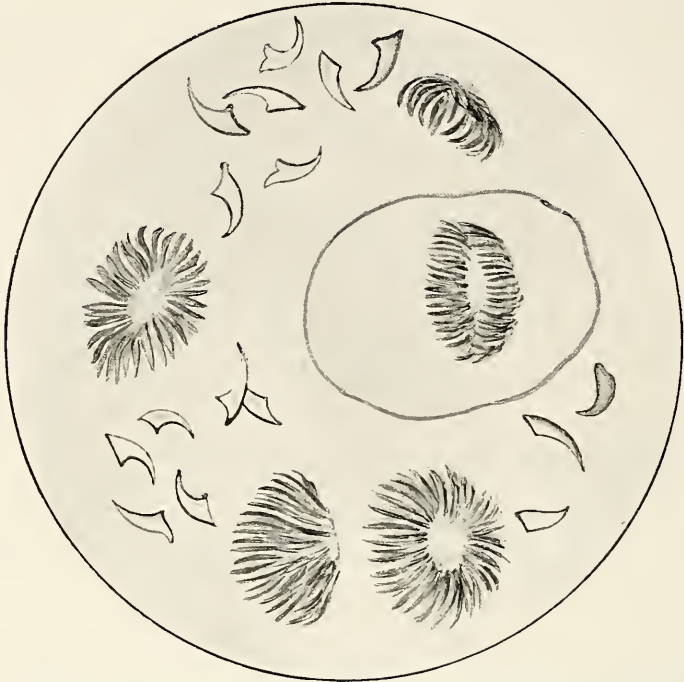


FIG. 155. SCOLICES OF TÆNIA ECHINOCOCCUS (Taylor Young and Welsh).

(*somatic phase*) is passed in the viscera, connective tissues, or serous membranes of various other mammals, notably in the sheep and occasionally in man. For full details of the life-history of the parasite the student is referred to a text-book of Medicine.

Each embryo-worm possesses three pairs of hooklets, and is enclosed in a chitinous shell. It is called an *oncosphere*. The disease in man begins with the ingestion of such oncospheres as have been discharged from the bowel of the dog and have found their way into drinking water or on to vegetables, or which after becoming desiccated, have been inspired in dust by the host (air-borne). In the stomach the chitinous shells are softened and the spicated embryo liberated. The hooklets bore a track for the embryo through the alimentary walls. In 60 per cent. of cases (Thomas) it finds its way to the liver probably by the portal system, and in 12 per cent. the embryo-worm reaches the lungs. Taylor Young points out that as the embryos are



only thrice the size of a red blood-disc and are actively motile, it is possible for them completely to penetrate through the walls of stomach or bowel and migrate into the peritoneal sac and along connective-tissue planes, and he concludes either that it has a selective affinity for certain tissues, or else that some tissues enjoy a greater immunity than others from echinococcal invasion.

A *hydatid cyst* is a monocyst derived from one embryo; it is surrounded by a *pericyst* or adventitious capsule provided by the host and produced by inflammatory reaction. The parasitic part of the cyst is composed of two layers, *ectocyst* and *endocyst*. It contains an abundance of watery fluid. In size it varies from less than an inch to more than a foot. The ectocyst is the cuticular outer layer; it is translucent, like hard-boiled white of egg, and shows a fine lamination which is so characteristic that a small fragment is enough for identification. The endocyst or germinal layer represents the vital tissue of the parasite; from it a multitude of heads or *scolices*, bearing hooklets (see Fig. 155), may develop from numerous small projections known as *brood-capsules*. When the parasite is healthy the cyst-walls are tense and the fluid contents clear. When the parasite dies the cyst-walls collapse and leucocytes may enter in abundance, producing what is called a *suppurating hydatid*, although no bacteria are present. A hydatid cyst may dry up, degenerate, necrose, or calcify.

Secondary, or daughter cysts arise by endogenous or exogenous formation, but there is no further advance in the life-cycle of the worm within the intermediate host.

**Endemic Areas.** The parasite is endemic to Australasia, the Argentine, Iceland, and to portions of the European Continent. In Iceland women are more often affected than men and, according to Taylor Young, this proportion is reversed in Australia. The incidence in man is dependent solely on the opportunity of infection.

**Interaction between the Parasite and its Host.** There is evidence of the passage outwards from the encysted parasite of substances which stimulate a series of reactions on the part of the host, including (1) *immunity reactions* and the appearance of anti-bodies in the blood; (2) *leucoblastic reactions* of a selective type; (3) *toxic reactions*. All these reactions reach their maximum when the cyst is ruptured. The *immunity* (precipitin) reaction provides a scientific test for the diagnosis of hydatid disease within certain limits (Fleig and Lisbonne). The *leucoblastic* reaction is shown by a selective increase of eosinophil-leucocytes in the blood. The *toxic* reactions are insignificant except after rupture of the cyst, when they may include (a) such symptoms as syncope or urticaria; (b) local inflammatory processes from direct contact with hydatid-fluid (peritonitis); (c) chronic toxic effects, e.g. wasting and anæmia. Hydatid cysts are therefore not inert foreign bodies, but must be regarded as living structures which are

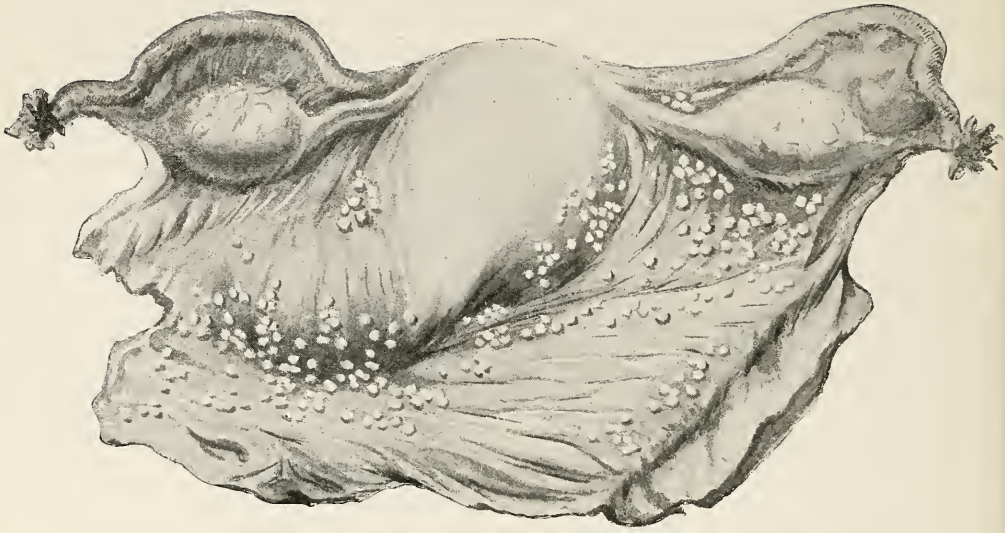


FIG. 156. SECONDARY IMPLANTATION OF SCOLICES ON THE PERITONEUM FOLLOWING RUPTURE OF A HYDATID CYST (Taylor Young and Welsh).

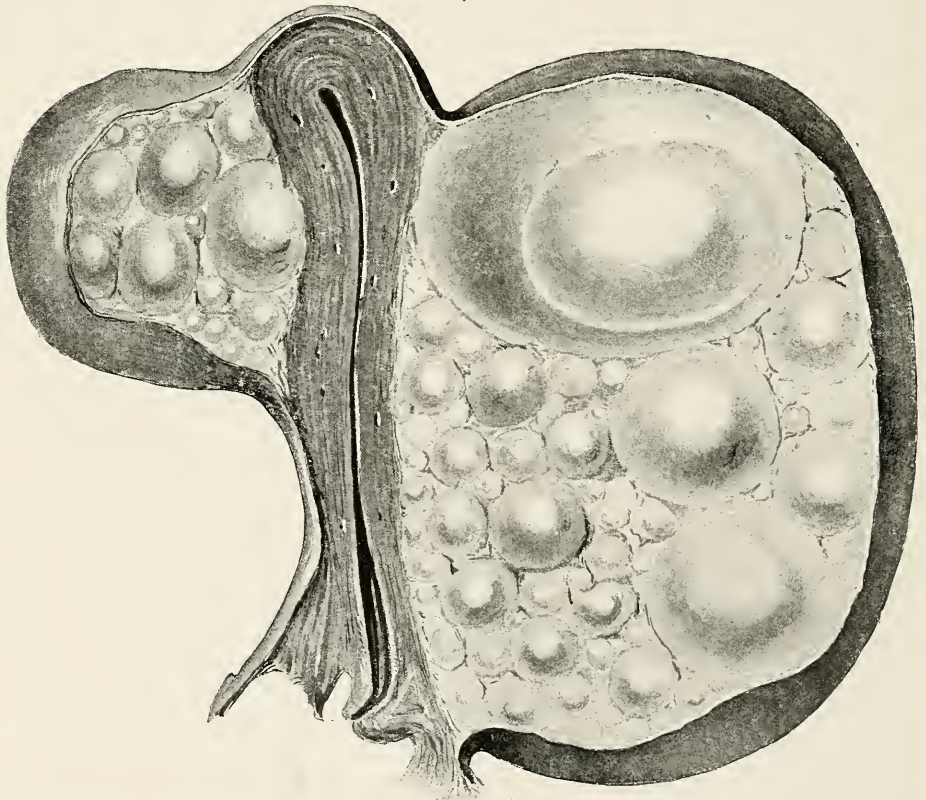


FIG. 157. ECHINOCOCCAL CYST IN UTERINE MUSCLE (Taylor Young and Welsh).

capable of causing a continuous reaction within the tissues of the host.

**Topical Distribution in the Pelvis.** *Secondary implantation* of scolices (heads) on the peritoneum of the pelvis is a frequent occurrence after rupture into the peritoneal cavity (see Fig. 156) of a primary cyst situated higher up.

*Primary pelvic hydatids* generally take origin in the connective tissues immediately beneath the peritoneum of the pouch of Douglas, whence they spread and come into connection with the uterus, ovaries, Fallopian tubes, bladder, and rectum. The parenchyma of the pelvic viscera is only very rarely the seat of primary development of the echinococcus. Nearly all cases described as growing from the ovary or from the Fallopian tube are really invasions of the loose connective tissue of the broad ligament (Taylor Young and Welsh). Subserous invasions of the hollow pelvic viscera may ultimately lead to perforation into the lumina of these structures, and the latter may then become filled with daughter-cysts (lumen of tubes, cavity of uterus).

Primary hydatids of the *uterus* (see Fig. 157) have been observed by Giles and Moloney; of the *Fallopian tubes* by Doléris and Eden (see Fig. 158); of the *ovary* by Péan, Taylor Young and Welsh. Hydatids have also been found primarily to invade the pelvic bones, and when situated in extraperitoneal situations they have been known to obstruct labour.

**Diagnosis.** With a proper control-test, a positive result with the specific immunity-reactions, or the microscopical discovery of hooklets, makes the diagnosis of echinococcal invasion certain. A well-developed eosinophilia is strong presumptive evidence of hydatid invasion in cases where the physical signs are confirmatory but indecisive (Taylor Young and Welsh).

The characters which hydatid cysts of the pelvis present on examination are very variable. A large thin-walled cyst may be indistinguishable from any of the commoner cysts which arise in the pelvis. A thick-walled hydatid cyst may simulate a single myoma or a teratoma, and multiple cysts may give the impression of multiple subserous myomata (see Fig. 157). The site of invasion is difficult to locate clinically, the part of the pelvis in which the mass lies being often the only point which can be determined with certainty. The presence of a mass in the liver, or the history of a previous operation for hydatids of the liver, would afford strong presumptive evidence of a pelvic swelling being echinococcal in origin. After rupture of the cyst there will be a history of sudden disappearance of the swelling, with possibly symptoms of serous peritonitis, marked eosinophilia, and transient urticaria (Barling and Welsh).

**Treatment.** As the pelvic condition is often not the only manifestation of hydatid disease, the surgeon must be prepared to deal with abdominal lesions as well, *e.g.* in the experience of one of us

the cysts had burrowed behind the diaphragm and extended as high as the left axilla, whilst below it depressed the pelvic floor and bulged into the vagina.

The treatment of hydatids consists in the removal of the cyst

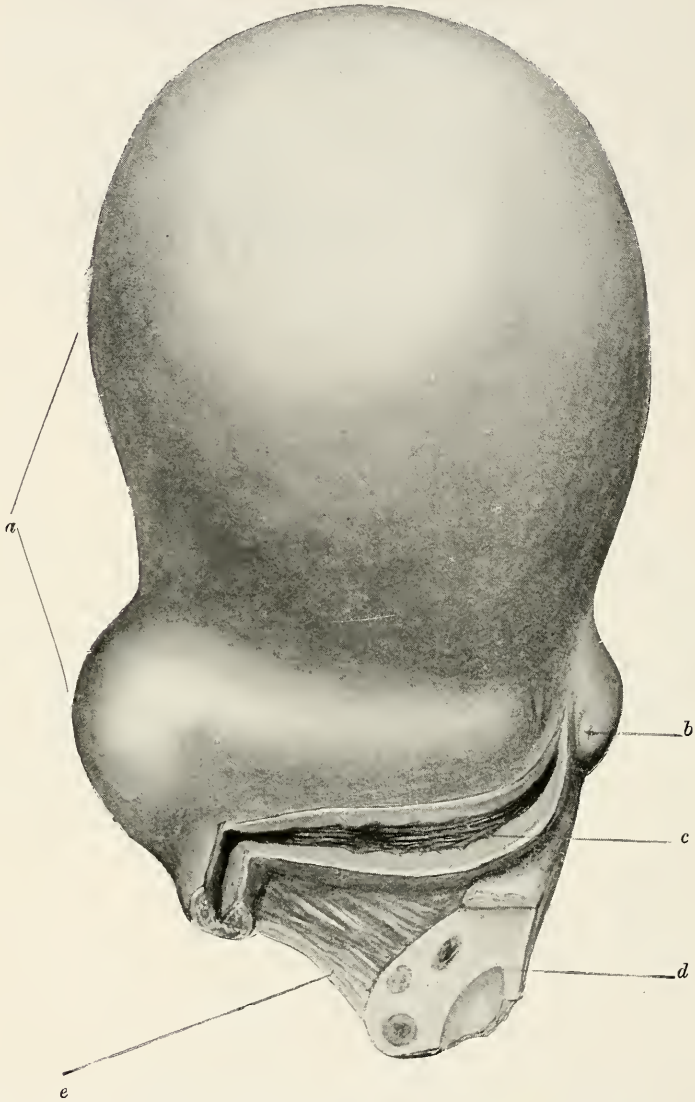


FIG. 158. HYDATID (ECHINOCOCCAL) CYST OF THE FALLOPIAN TUBE. *a*, Cyst. *b*, Closed abdominal ostium. *c*, Lumen of tube laid open. *d*, Ovary. *e*, Mesosalpinx. The cyst has formed in the subperitoneal cellular tissue of the upper wall of the tube.

or cysts. The removal should be *complete* whenever possible. In a certain number of cases only *partial* removal can be carried out, the adventitious pericyst having to be left behind.

(1) *Complete Removal of the Cyst.* Hydatids of the uterus, ovaries, tubes, and broad ligaments are best treated by this method. Simple cysts should be aspirated before incising the pericyst.

(2) *Partial Removal of the Cyst.* This consists in opening the pericyst and scraping away the entire endo- and ecto-cyst in order to destroy the parasite. The operation is concluded in one of two ways: (a) By stitching the cut edges of the pericyst to the parietes and inserting a drain (*marsupialisation*) or (b) by inverting the cut edges of the pericyst and uniting them by sutures, thus closing the cavity.

Sometimes the pericyst may be calcified, or too thick and tough to collapse when empty; it then becomes necessary to drain. In pelvic cases drainage should be carried out *per vaginam*.

In operating for the removal of hydatids the risk of operative implantation must be borne in mind. The edges of the wound should be protected by rubber-sheeting, and the various intra-abdominal structures guarded by gauze-pads.

### STREPTOTHRIX INFECTIONS, INCLUDING ACTINOMYCOSIS

The generic term streptothrix embraces certain *higher* forms of bacteria which are pathogenic in man and other mammals. In certain cases the organisms have a radial grouping which is characteristic in the ray-fungus or *actinomyces*. The lesions produced by streptothrices, in common with those of tubercle, leprosy, and syphilis, belong to the *chronic infective granulomata*.

This group of lesions is characterized by nodules of granulation-tissue around foci invaded by the organisms. The endotoxins of the latter modify the inflammatory reaction in such a way as to produce peculiar cell-formation in the granulations. This gives rise to the development of endothelioid and giant-cells. The latter, which are abundant in tubercle, are however less numerous and less definite in streptothrix-infections. The granulomata produced by streptothrices invariably lead to chronic local suppuration.

**The Organisms.** The streptothriceæ differ from the *lower* forms of bacteria in consisting of a filament which shows true branching and the development of gonidia or spores. The latter arise from specialized hyphæ; thus, both in the tissues and in cultures, the parasite appears as an interlacing network of branching filaments which soon form a densely matted compact mycelium. The following changes occur in the latter: (a) The formation of swellings at the ends of the filaments; (b) necrotic changes in the centre of the mycelial mass; (c) fragmentation of the mycelial threads.

Of the terminal swellings two distinct forms appear: (1) small bulbous expansions of the filaments themselves; (2) larger hyaline swellings of the investing sheaths forming the so-called *clubs*. The latter assume a radial arrangement, and from this fact the name *ray-*

*fungus* or *actinomyces* is derived (see Fig. 159). Clubs are best seen in bovine lesions, in human infections they are very fragile and therefore hard to demonstrate. They occur in a late stage of the growth when the colonies in the tissues are extensive and have begun to show central necrosis.

To demonstrate a streptothrix-infection, the tissues must be stained by Gram's method, the filaments of mycelium and the spores

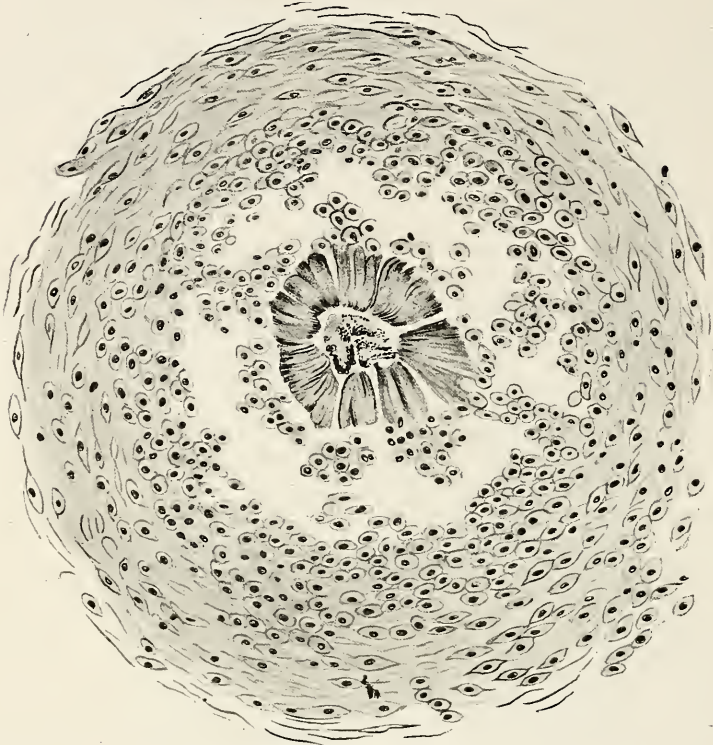


FIG. 159. ACTINOMYCOSIS FROM THE TONGUE OF A COW (Sims Woodhead).

are gram-positive, the hyaline clubs and necrotic areas are gram-negative.

*Distribution.* Some American and Norwegian authorities regard the streptothricæ as essentially pathogenic parasites, which cannot continue to subsist outside the animal body. There is however evidence to show that the pathogenic streptothricæ are capable of a non-pathogenic (saprophytic) existence, *e.g.* that they may be found on straw, grain, and grass, and that they gain access to the body through abrasions made by infected material. A common point of entrance is the mouth and pharynx, but infection may also occur through the alimentary and respiratory tracts, and through the skin.

**Morbid Anatomy.** The lesion is characterized by its progressive extension. By direct local spread, large areas of tissue may become

infected, and there may also be secondary dissemination to distant parts. Each colony becomes the centre of an infective focus, and each focus ultimately forms a small abscess surrounded by indurated tissue. In this way an infected organ may be riddled with multiple foci of suppuration, or may become the seat of an enormous abscess.

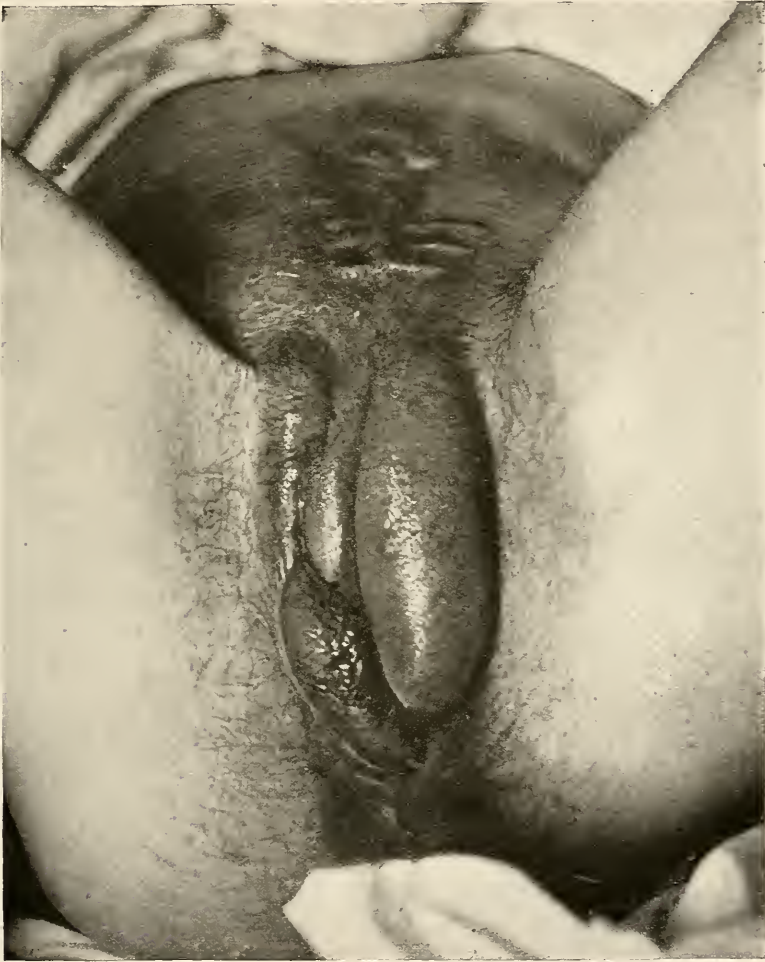

FIG. 160. ACTINOMYCOSIS OF THE EXTERNAL GENITALIA (Taylor Young and Welsh).

The pus is characteristic, in that it contains whitish or sulphur-yellow granules, visible to the naked eye ; these represent the actual parasitic colonies.

**Clinical Features.** General intoxication may be severe, causing fever, sweating, and wasting, but this is not usually the case until late in the disease, and even with extensive chronic infections there

may be but little constitutional disturbance. It may be said that the general intoxication is similar to, but less severe than, that due to tuberculosis. In abdomino-pelvic lesions three stages have been pointed out by Grill: (1) A stage of invasion with vague symptoms suggesting appendicitis; (2) a stage of tumour-formation in the viscera or in the abdominal walls, usually in the ileo-cæcal region, and seldom painful; (3) a stage of suppuration with the formation of deep sinuses and intractable fistulæ.

*Pelvic Infection.* Pelvic infection is rare, it most often occurs *viâ* the appendix, but it may happen through the blood-stream, the organism entering the system through the tonsil.

Actinomycosis of one or both ovaries has several times been recorded. The organs were reduced to fibrous tissue enclosing small abscesses, or were found to be nothing more than a thin abscess-sac.

Actinomycosis of the Fallopian tube has been found to be generally on the right side, suggesting infection from the appendix.

**Treatment.** Free removal of infectious tissues and swabbing the raw surfaces with tincture of iodine is recommended. Large doses of potassium iodide (90 grains thrice daily) should be given for a few days and then withdrawn for a week, then given again for a few days and afterwards repeated once a month (Taylor Young). This authority also favours the administration of nascent iodine by giving 30 grains of potassium iodide every morning, to be followed after four hours by 1 oz. of chlorine-water, repeated at intervals of two hours until 3 ozs. have been taken. This, he says, should be continued for many months. Taylor Young also speaks highly of the value of autogenous vaccination.



**PART II**  
**REGIONAL GYNÆCOLOGY**



## PART II : SECTION I

### DISEASES OF THE VULVA AND URETHRA

#### ACUTE INFLAMMATORY CONDITIONS

COMPARED with the frequency of inflammatory processes in the upper part of the genital tract, acute and chronic inflammation of the vulva are met with relatively seldom. Inflammation of the vulva is nearly always associated with that of the vagina and endometrium. In many of these cases it is produced by infected secretions escaping from above, which, by causing the vulval epithelium to become sodden, allows of its penetration by septic or other infective germs. Thus necrotic uterine tumours may produce successively septic endometritis, colpitis, and vulvitis. Urinary fistulæ are a source of septic discharges, which exert a very excoriating effect upon the vulva. Suppurative urethritis acts in the same way.

Diabetes may be a cause of vulvitis. The sugar-containing urine is frequently infected with the fungi of thrush and a leptothrix, either or both of which may cause vulvitis. Fæcal fistulæ, a complete perineal tear, and hæmorrhoids, may also be indirect causes of acute vulvitis.

As the vulval skin is provided with a thick protective epithelium, it is necessary for the surface-continuity to be destroyed before acute vulvitis can supervene. Irritating discharges will do this, as just stated, but there may be evidence of trauma, *e.g.* masturbation or rape. In the case of children, acute vulvitis is more readily caused by gonorrhœa, since the epithelium, being thin and delicate, is less impervious to organisms than that of adults.

**Gonorrhœal Vulvitis.** The gonococcus is the most frequent cause of *acute vulvitis*, accounting for more than 75 per cent. of cases (Jaschke). It is more frequent in young subjects for the reason given above.

Clinically, acute gonorrhœal vulvitis is associated with urethritis and inflammation of the paraurethral glands, and not infrequently with Bartholinitis as well. The secretion in the acute stage is copious, purulent, and of a yellowish-green colour. From the irritating effect of the pus, 'warts' (*condylomata acuminata*) are formed on the external genitals (*see* Figs. 141 and 142 on p. 292). In acute

cases it is generally easy to find the gonococcus in films prepared from the pus.

Acute vulvitis is seen in its most extreme form in the vulvo-vaginitis of children. The labia, both small and large, are intensely red, swollen (*see* Fig. 161), œdematous, and sore, and may become adherent. A false membrane may form on the labia minora. In

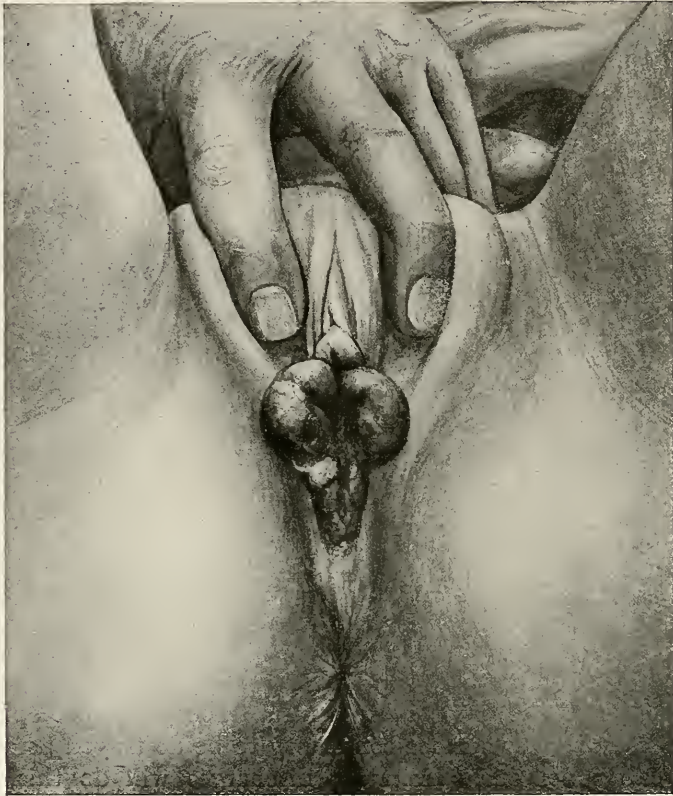

FIG. 161. VULVO-VAGINITIS IN A GIRL OF 14, showing inflammatory œdema of the nymphæ.

this condition the vagina, urethra, and Bartholin's glands may be simultaneously infected; it causes swelling of the inguinal glands and is accompanied with malaise and pyrexia. In cases of assault, gross traumatic lesions may be present, but in young children vulvitis may occur in the absence of a definite lesion, the gonococcus being conveyed to the genitals on a towel or by the fingers. The same applies to the bacillus coli and to parasites (*ascaris* and *oxyuris*).

*Treatment.* Vaginal douches should not be employed, but the patient should be made to sit in a bath two or three times a day for half an hour, and during the intervals boric lint, wrung out in hot sterile

water, should be applied between the labia and over the vulva. When the acute attack has subsided the labia should be painted with a 10 per cent. solution of melargen, and if urethritis be present the canal should be swabbed with melargen solution, 5 per cent., applied on a small probe.

**Syphilitic vulvitis** is a rare accompaniment of specific ulcers and condylomata (*see Syphilis*, p. 319).

**Ulcus molle** is very frequently a cause of acute vulvitis. The labia are swollen and bathed in a copious secretion, and the glands in the groin soon become acutely inflamed and painful.

**Rarer Forms of Vulvitis.** Under this heading may be classed vulvitis seen in acute miliary tuberculosis (*see Infections*, p. 304), gangrenous vulvitis, membranous vulvitis, erysipelatous vulvitis, and thrush.

*Gangrenous Vulvitis.* This is a very rare disease, but it may occur from infection of a vulval wound during the course of puerperal fever. It may also supervene in erysipelas, diphtheria, venereal infection, smallpox, and typhus. There is intense local pain, accompanied by marked general toxæmia.

*Noma* is a form of gangrenous vulvitis which occurs in rare instances during, or after, an attack of measles or one of the specific diseases in childhood. The disease is generally unilateral. The labium of one side swells, a dark spot appears over an area of induration, followed by the formation of vesicles, bullæ, ulceration, and gangrene.

The *local treatment* consists in free removal of the gangrene and in painting the parts with sulphurous acid. This should be followed by hot antiseptic fomentations changed every four hours. The *general treatment* consists in the use of antigenous vaccines and maintaining the patient's strength.

*Membranous Vulvitis.* This is generally due to an infection by the Klebs-Löffler bacillus; it may also be caused by streptococcal infection. The labia are inflamed and swollen, patches of greyish-green membrane appear here and there, and may ultimately cover the whole or a large part of the vulva. The true diphtheritic membrane is thrown off in small pieces, but in streptococcal vulvitis large yellow sloughs are separated. Unless the condition passes into that of gangrenous vulvitis the membrane is formed only of the superficial layers of the integument, whilst in the latter the fibro-fatty tissues are deeply implicated. Membranous vulvitis may lead to superficial atresia of the vulva (p. 166).

*Treatment.* The organism must be isolated, and in the case of infection by the Klebs-Löffler bacillus, antidiphtheritic serum must be injected. Locally, the parts should be treated with strong solutions of phenol or biniodide of mercury.

*Erysipelatous vulvitis* occurs as a rare but deadly affection. It

takes the form of a spreading phlegmon in the cellulo-cutaneous tissues and leads to diffuse suppurative cellulitis or to the formation of an extensive abscess. The treatment consists in maintaining the patient's strength with stimulants, and the administration of iron tonics. Locally, warm antiseptic fomentations should be applied.

*Apthous vulvitis* is sometimes seen in badly nourished children, and in adults during pregnancy, and towards the end of a long and fatal illness. Small white adherent patches, surrounded by a zone of redness, and accompanied by a certain amount of œdema of the vulva, are the signs by which it is recognized. The white patches consist of a surface-growth of the mycelium of *oidium albicans*.

*Treatment.* The local condition responds to mild antiseptic measures, such as the application of lint soaked in perchloride of mercury solution (1-3000). Attention to the general health is important.

**Skin Diseases in the Vulval Region.** *Intertrigo* is the most common skin-lesion in this region. It is seen in fat and dirty subjects as a superficial redness of the labium majus and of the *sulcus genito-femoralis*. It is commonest during the hot season, and causes itching and soreness. Intertrigo indicates the taking of a daily bath, and the parts should be bathed with  $\frac{1}{2}$  per cent. spirituous resorcin-lotion, then dusted with equal parts of oxide of zinc and boric acid.

*Furunculosis* occurs on the labia majora from infection of hair follicles, scratches, and acne-spots. It is sometimes an indication of ill-health. Small pustules should be painted with 2 per cent. spirituous solution of iodine; boils should be opened and treated with an antiseptic dressing.

Rarer skin affections are herpes, psoriasis, and molluscum contagiosum.

*Herpetic Vulvitis.* Groups of vesicles appear on one or other labium majus; they may coalesce to form bullæ. Eventually they become pustular, then rupture and dry up. Before vesicles form the labium is very painful; in the eruptive stage there is intense itching and irritation. An ointment composed of bismuth carbonate (1 dr.) and lanoline (1 oz.) spread on lint should be applied to the affected parts.

### CHRONIC INFLAMMATORY CONDITIONS

Chronic inflammation of the vulva is found as a sequel to the acute processes already described, more especially in gonorrhœa, in which constant vulval irritation may result from infective discharge from the cervix. Under the above heading are included certain well-marked clinical conditions, viz. eczema, leucoplakia, and kraurosis, also esthiomène and the specific ulcers. As chronic vulvitis is in-

variably accompanied by irritation in a more or less severe degree, we shall first consider this symptom.

**Pruritus Vulvæ.** Irritation (itching and burning) at the vulva is, of course, a symptom, not a disease; further, it may be occasioned by a variety of morbid conditions, and may be accompanied by other symptoms besides the above. It is classed as a distinct disease by Sängcr under the name of *vulvitis pruriginosa*, and Veit described a definite pathological condition, *parakeratosis*, as characteristic of pruritus vulvæ. In parakeratosis, processes of keratinized

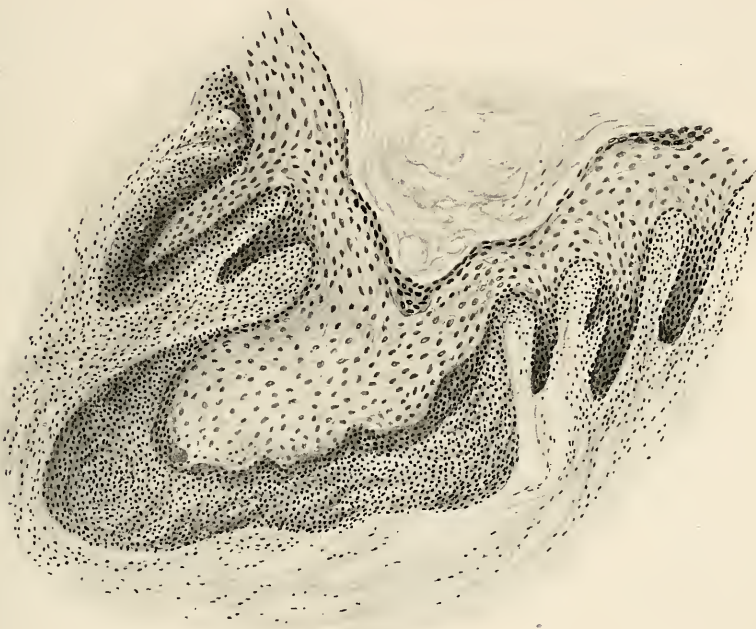

FIG. 162. PARAKERATOSIS OF THE VULVA.  
From a case of pruritus.

epithelium dip down into the corium, where they are surrounded by a zone of leucocytic infiltration (see Fig. 162). This form of dermatitis is probably not a precursor of pruritus, but is more probably the result of rubbing and scratching.

Sometimes in cases of intense itching no local morbid condition can be discovered. In most instances the irritation leads to friction and scratching of the affected parts, which result in changes in the local appearances which may obscure the original affection. The areas most frequently involved correspond to the clitoris and nymphæ; in severe cases the greater labia, the whole of the ostium vaginae, the perineal body, the anus, and the post-anal region all may be affected. It may be met with in children, adults, or old women.

In cases of slight severity, the irritation is felt chiefly or solely at night after retiring to bed ; all gradations of severity may, however, occur, and in the severest cases there is constant and intolerable itching both day and night, the patient becoming haggard and emaciated from loss of sleep and ceaseless annoyance. Such cases have been known to terminate in insanity or suicide.

*Causes.* A great variety of morbid conditions may give rise to pruritus, but they may all be classified in three groups : (1) Chronic discharges which irritate the vulval mucous membrane. (2) Diseases primarily affecting the vulva. (3) Toxic conditions and neuroses.

(1) Discharges coming from the uterus or the vaginal walls do not, as a rule, occasion pruritus, but chronic gonorrhœal discharges, and the septic discharges set up by a neglected pessary, frequently do so ; the constant slight dribble of urine from a small vesico-vaginal fistula may set up intolerable pruritus, and much the same result may follow from incontinence of the bladder-sphincter. In adults of unclean habits pediculi or accumulations of dirt, and in children threadworms which migrate to the vulva from the anal canal, produce much the same results as vaginal discharges. Masturbation, as an occasional cause of pruritus, also belongs to this class.

(2) Chronic forms of ulceration, *e.g.* those due to tubercle or tertiary syphilis, cause itching, but these conditions are rare. There are two skin diseases, which, however, are fairly common and usually set up this disorder in a severe form, *viz.* *eczema* and *leucoplakia* ; whilst an uncommon local disease, known as *kraurosis*, also causes pruritus. The last three conditions will be described (*see pp.* 344 and 347) after the treatment of pruritus in general has been considered.

(3) *Toxic Conditions and Neuroses.* Cases in which pruritus vulvæ is not accompanied by recognizable alterations in the appearance of the affected parts, except those due to scratching, are usually attributable to a neurosis. The subjects of this form of pruritus are usually women of neurotic or hysterical temperament. A common exception is the pruritus of pregnancy, which in its usual form is only a mild affection, but sometimes becomes intolerably severe, expanding into general irritation of the skin of the whole body. This affection is now more properly regarded as due to a form of gravidic toxæmia, although the nature of the toxæmia is unknown. Pruritus vulvæ may also be an accompaniment of glycosuria and diabetes, but whether this is due to the irritant qualities of sugar-laden urine, or to nerve-lesions produced by toxæmia resulting from the disease, is unsettled. In every case of pruritus the urine should be examined for sugar.

*Treatment of Pruritus.* The possibility of an exciting cause, such as glycosuria or leucorrhœa, being present, must first be considered ; if such conditions as these are overlooked, treatment will



necessarily be unsuccessful. The next point to consider is the nature of the local changes in the skin, if such are present ; when none are found it is always very difficult to relieve the irritation. Cases of chronic eczema, and early cases of leucoplakia, can, as a rule, be greatly relieved, and in many cases entirely cured, by appropriate treatment.

In regard to *local treatment* two preliminary points are of great importance, viz. that strict local cleanliness should be observed, and that scratching and rubbing should be avoided as far as possible. In a severe case, the patient often scratches herself unconsciously when asleep, and at other times the irritation is so intense that the impulse to rub or scratch is almost irresistible. A hot alkaline hip-bath (p. 344), taken before retiring to bed, often brings temporary relief, and as a means of local cleansing is a useful preliminary to the application of local remedies.

Of the numerous local remedies which have been made use of none can be recommended with confidence, for what succeeds in one case may fail in the next. In mild or early cases, or when no local changes are found, sedatives such as a 5 per cent. thymol or menthol ointment or lotion may succeed ; or, failing these, a 5 per cent. to 10 per cent. cocaine ointment. Hot compresses wrung out of lead and opium lotion, or sprinkled with *linimentum belladonnæ*, may also prove useful. In other cases strong antiseptic solutions are more successful, such as 1-1000 *biniodide* of mercury, which penetrates skin more readily than the perchloride ; or 5 per cent. carbolic lotion freely applied exerts both an antiseptic and a local anæsthetic action. When the local changes are advanced, caustics strong enough to cause a certain amount of desquamation are often useful, such as pure liquefied carbolic acid painted freely over the affected parts under anæsthesia ; a milder remedy of this class is a solution of nitrate of silver of 40 grains to the oz., the application of which causes very little pain. In some instances the prolonged and careful use of a dilute mercurial ointment, one half of the official strength, or the *unguentum metallorum*\* of hospital pharmacopœias, may be found of great service. Intractable cases may sometimes be relieved by the use of X-rays.

The treatment of cases in which there are well-marked local changes, and which cannot be relieved by the above measures, will be described when dealing with the respective causal conditions.

**Eczema vulvæ** begins as a papular eruption, usually upon the inner surfaces of the greater labia, but may also be found upon the lesser labia, and upon the parts of the vulva covered with hair. The papules become vesicular and desquamate, leaving a moist surface, around which an area of redness is quickly formed. In

\* Ung. Metallorum R̄ Ung. Plumbi Acet. Ung. Hydrarg. Nit dil: Ung. Zinci āā partes æquales.

acute cases this erythematous zone may spread widely to the perineum and the inner aspects of the thighs. In old-standing cases the affected areas become dry and scaly. The acute stages are attended with pain, the chronic stages with itching and burning (pruritus); impelled by the necessity of obtaining relief from the itching, the affected parts are scratched and rubbed, giving rise to abrasions which in time may become infected. Thus the original morbid appearances may be hidden beneath the secondary lesions due to scratching.

*Treatment.* The cause of the eczema, *e.g.* vaginal discharge, should be sought for and treated by suitable means. During the acute stage rest in bed is necessary. The patient should be given a bath at a temperature of 95° F., to which is added bicarbonate of soda and potash, of each 1 oz. This allays the itching. Afterwards soothing applications are applied to the sore parts by a nurse. Lint soaked in Liq. plumbi subacetatis (1 dr.), Acidi salicylatis (5 gr.), dissolved in 1 oz. of milk, is recommended. Or the lint may be smeared with an ointment containing 20 grs. of salicylic acid, 3 dr. of oxide of zinc or of bismuth, to 1 oz. of lanoline.

**Leucoplakic Vulvæ.** Berkeley and Bonney have defined this lesion as "a chronic inflammatory condition characterized in its early stages by marked hyperæmia and cellular activity, and in its later phases by marked epithelial hypertrophy, and a thickened, sclerosed and retracted condition of the subepithelial tissue."

In a well-marked case the whole of the vulva, with the exception of the vestibule and orifice of the urethra, may be implicated, and the disease may even spread laterally to the folds of the thighs, and over the perineum to encircle the anus (*see* Figs. 168, 169). The cause of the disease is unknown. The authors quoted above have been unable to obtain any evidence of syphilis, either clinically or histologically, in the series of twenty-four cases examined by them. They state that in a series of nineteen cases the average age was fifty-one years.

*Signs.* Leucoplakia of the vulva has been divided into four clinical stages. In the *first* stage the parts affected are reddened, swollen, and excoriated; the surface is dry. In the *second* stage the labia minora decrease in size, from retraction of the tissues by subepithelial thickening. The surface has now changed in colour from red to opaque white. This occurs in patches which fuse until the whole area becomes opaque—hence the term leucoplakia. In the *third* stage cracks and ulcers appear, yielding a scanty discharge and sometimes slight hæmorrhage on contact. At this stage malignant epithelial changes may occur in an ulcer or in a fissure (*see* Figs. 168 and 169, p. 355. If carcinomatous changes do not supervene, the leucoplakic condition passes into its *fourth* or final stage, in which the involved area becomes smooth, shiny, and white, the labia minora and clitoris practically disappear, and the disease becomes quiescent.

*Pathology.* The histological appearances are best described by considering the morbid changes in the early, intermediate, and late stages.

In the *early stage* there is thickening of the epithelium and round-celled infiltration of the sub-epithelial connective tissue. This stage corresponds to that shown in Fig. 162 as *parakeratosis*. Reference to this Figure will show that the horny layers are thickened by keratoid degeneration, whilst there is epithelial hyperplasia of the basal layer with the formation of deep processes of epithelial cells between the

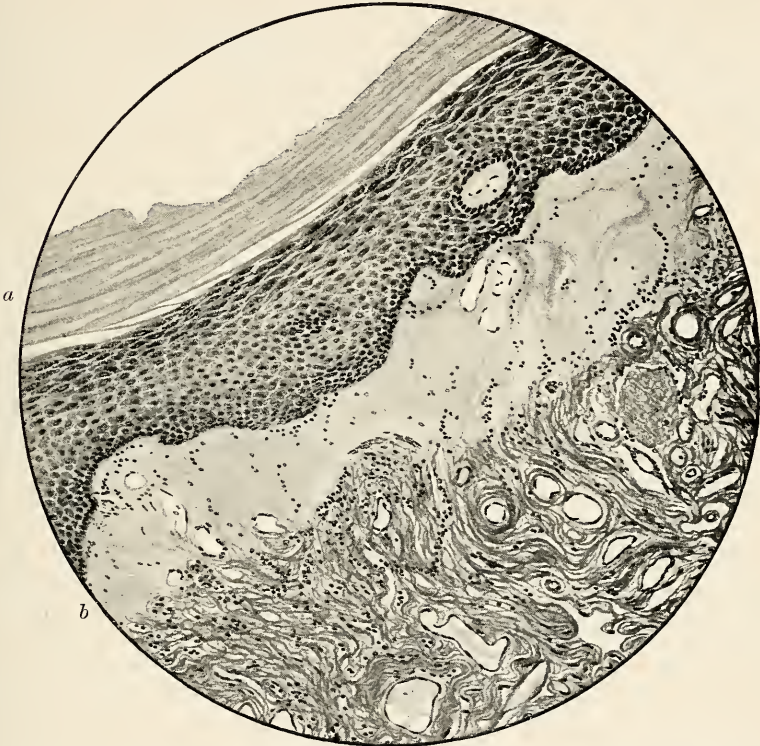

FIG. 163. LEUCOPLAKIA VULVÆ. *a*, The superficial squamous-celled layer shows excessive horny degeneration and desquamation; *b*, the connective tissue of the corium immediately beneath the epidermis shows a wide zone of hyaline degeneration, and appears practically structureless.

papillæ of the corium. It is around these deep epithelial processes that the round-celled infiltration is most marked.

In the *intermediate stage* the keratinized epithelium begins to desquamate, the round-celled infiltration gives place to an exudation of plasma-cells, and hyaline degeneration of the connective tissue in the superficial layers of the corium makes its appearance.

In the *late stage* the horny layer becomes thinned by desquamation, the down-growing epithelial processes disappear, hyaline degeneration

of the corium leads to the disappearance of elastic fibres and of healthy connective tissue; thus a wide zone of hyaline material may be seen immediately beneath the epithelium (see Fig. 163). It is in this stage—in which a desquamating epithelium lies upon a degenerate corium—that cracks and fissures occur and malignancy may supervene. The *final stage* in the late stage is that of fibrosis. Fresh fibrous tissue takes the place of the hyaline material, leaving the corium permanently thickened; by this time the surface-epithelium, devoid of downgrowths, is reduced to a thin, flat layer covering the sclerosed tissues underneath.

*Symptoms.* Often the only symptom is pruritus, which is markedly severe in the first and second stages. The third stage is characterized by pain and acute soreness due to exposure of nerve-endings in the floor of ulcers or fissures. In the fourth stage symptoms disappear.

*Diagnosis.* Leucoplakic vulvitis must be diagnosed from kraurosis. For the points of contrast between these two conditions the student is referred to p. 348. Whether an ulcer or fissure associated with the third stage of leucoplakia is malignant or not is settled by microscopic examination.

*Prognosis.* A certain percentage of cases pass into the fourth stage, in which the disease becomes quiescent, the remainder may develop carcinoma. The percentage of malignancy following leucoplakia has not been ascertained.

*Treatment.* In the first and second stages the treatment is that for pruritus (p. 343). Failing relief, or if the third stage be reached, the treatment is that of free excision (see Operations, p. 839).

*Relationship of Leucoplakic Vulvitis to Carcinoma of the Vulva.* We regard leucoplakia as a precancerous condition, *i.e.* as an antecedent and cause of carcinoma of the vulva. Histologically, it is found that the malignant change begins as an increasing hypertrophy of the interpapillary epithelial processes, whereby they penetrate more and more deeply into the connective tissue. This epithelial activity reaches its maximum in the second stage of leucoplakia. The next stage towards carcinoma is seen in branching of the enlarged interpapillary downgrowths. Bonney lays stress upon the relation between malignant epithelial growth and the altered state of the subepithelial connective tissues in leucoplakia. In the earliest stages of the disease, the subepithelial tissues take on "an accession of cellular energy which anticipates the occurrence of epithelial hypertrophy" (Bonney). In a later stage, *i.e.* that which is accompanied by *hyaline* change (see Fig. 163) and the disappearance of elastic tissue, epithelial growth-activity is favoured by absence of the latter. In the final stage of leucoplakia, which is characterized by dense sclerosis, the white fibrous elements probably check epithelial ingrowth and hence the diminished tendency to malignancy in this stage of leucoplakia.

**Kraurosis Vulvæ.** In 1885 Breisky drew attention to a disease of the vulva, to which he gave the name kraurosis. Until that date the condition had escaped recognition, and since then it has been universally confused with leucoplakia. Berkeley and Bonney describe kraurosis as "an atrophic condition of the vulva associated clinically with stenosis of the vaginal orifice, and pathologically with certain changes in the dermis."

*Distribution.* The labia minora, the vestibule, the orifice of the urethra, and that of the vagina are always, and the hood of the clitoris is sometimes, affected. The skin of the outer surface of the labia majora, the folds of the nates, the perineum, and the post-anal region are never affected.

*Signs.* There are two stages. In the *first* the mucocutaneous surface is red, glistening, and shiny, whilst here and there are tiny discrete patches of a bright red or purple colour. A caruncular condition of the urethral orifice is often present. In the *second* stage the surface becomes pale yellow, glistening, and smooth, all ridges having been obliterated. The vaginal orifice is contracted, making digital examination difficult, the labia minora and clitoris disappear, the mons Veneris atrophies, and the pubic hair becomes brittle, and breaks off or falls out.

*Symptoms.* The patient complains of soreness, pain, dysuria, and dyspareunia, pruritus is not a marked symptom and may be absent; the chief trouble is dyspareunia. Thibierge states that "the functional symptoms of kraurosis vulvæ are of an exclusively mechanical order." In the first stage dysuria is very marked and coitus is painful; in the second stage, owing to contraction of the vaginal orifice, coitus is impossible.

*Pathology.* The epithelium is thinner than usual and the papillæ have mostly disappeared. The subepithelial tissues show patches of inflammatory cells. Under a red surface-area, aggregations of plasma-cells are seen immediately adjacent to the thinned and flattened epithelial layer, and mixed with the plasma-cells, are seen polymorpho-nuclear leucocytes and lymphocytes. The former push their way outwards between the surface-epithelial cells. Elastic tissue is seen everywhere, excepting where accumulations of plasma-cells abound. Whilst the changes are in a large measure inflammatory, it would appear that a deficiency, or absence, of ovarian secretion plays a large part in the causation of the disease (*vide infra*).

*Diagnosis.* As this condition is liable to be confused with leucoplakia, the distinctive differential points are summarized in the table given below (*see p. 348*).

*Treatment.* The palliative treatment mentioned under pruritus (*see p. 343*) should be tried. Red patches may be cauterized or excised, whilst for stenosis of the introitus vaginæ the plastic operation described on p. 511 may be carried out.

### Differential Diagnosis of Leucoplakia and Kraurosis

#### *Leucoplakia*

(A) A chronic inflammatory condition, cause unknown.

(B) Vestibule and orifice of urethra never affected; may spread over remainder of vulva, around the anus and on to genito-femoral sulcus.

(C) Three stages are to be distinguished.

(1) Parts red, *swollen*, excoriated, dry.

(2) Tissues *retracted and thickened*. Colour changes from red to semi-opaque white.

(3) Cracks, ulcers, discharge, bleeding on contact. Carcinoma may appear in a crack or ulcer.

(D) A precancerous condition.

#### *Kraurosis*

(A) An atrophic condition, with patches of dermatitis, found in young sterile subjects, at the menopause, and after double oöphorectomy.

(B) Located to labia minora, vestibule, orifices of urethra and vagina. Rest of vulva and adjacent areas (thighs and perineum) free.

(C) Three stages to be made out.

(1) Diseased area red, with small purplish-red patches seen on remains of hymen, on vestibule, and around urethra.

(2) Tissues *retracted and thinned*. Colour changes to that of yellow elastic cartilage, surface glistening and perfectly smooth.

(3) Labia minora and clitoris disappear. Mons veneris atrophies, pubic hairs disappear. Vaginal orifice contracts.

(D) No tendency to malignancy.

### ULCERATION OF THE VULVA

All septic or infective processes occurring in the vulva may lead to ulceration, also every malignant new growth will ultimately lead to ulceration, and even growths of benign origin may, by becoming infected, cause ulceration of the external genitalia. Hence it follows that all or most of the lesions to be mentioned under the above heading will be more fully described elsewhere; thus tuberculous ulcers, chancre, *ulcus molle*, the tertiary syphilitic ulcer, rodent ulcer, squamous-celled carcinoma, ulceration due to leucoplakia and *esthiomène* will all appear under their respective headings.

**Septic Ulcers.** These may arise on the vulva-during the course of puerperal fever. *Small* septic ulcers may appear in the fossa navi-

cularis or on the hymen following laceration at the first coitus. They should be treated by an antiseptic douche and cocaine ointment (2 per cent.), and if they show signs of delay in healing, the cautery should be applied or the ulcer excised. *Larger* septic ulcers may occur on the labia as the result of infection of a severe wound inflicted by accident, or from a ruptured varicose vein or hæmatoma. They require rest in bed and an antiseptic dressing.

**Fissures.** These occur chiefly in the vestibule and in the fossa navicularis; they are shallow linear ulcers, extremely sensitive and consequently causing great pain on coitus. They are readily curable by one or two applications of solid silver nitrate, or liquefied carbolic acid, the vulva at the same time being kept scrupulously clean.

**Follicular Ulcers.** These may follow on follicular vulvitis, and occur in the hair-bearing skin of the labia majora and sometimes in other parts; they are multiple and occur in crops. They may form part of a general furunculosis, or may occur independently in the vulva. A papule first forms, which becomes vesicular, then pustular, and lastly forms a small round ulcer which may be of considerable depth. Sometimes the pustules dry up, and the scab does not separate until the underlying surface has healed. Considerable induration may form round the affected spots, giving rise to pain and tenderness. Dry boracic dressings externally, and iron internally, will usually arrest their formation.

**Tuberculous Ulcers.** These are rare in the vulva and occur chiefly in children affected by advanced tuberculous disease of the genito-urinary tract. They are indolent in type and show the characters associated with tuberculous ulceration in other parts. Microscopic examination will establish the diagnosis. Local treatment is seldom required owing to the presence of advanced tuberculous disease elsewhere. For further mention see p. 304.

**Syphilis.** For an account of the ulcerative lesion of this disease see pp. 318, 319.

**Esthiomène or Genito-Anal Scleroma.** This is a chronic hypertrophic condition associated with secondary ulceration, it is described on p. 350.

**Leucoplakic Ulcers.** These have already been mentioned. See p. 344.

**Actinomycosis.** Ulceration due to this rare vulval lesion has been referred to on p. 333.

**Rodent Ulcer, Carcinoma, and Sarcoma.** Ulceration due to these conditions will be referred to under their respective headings.

## HYPERTROPHIC AND HYPERPLASTIC CONDITIONS OF THE VULVA

Under this heading we include certain conditions which are usually *acquired*, and are produced by some form of chronic irritation. *Congenital* hypertrophy is rare, and when present it is confined to single parts of the pudenda, *e.g.* to the labia minora and to the clitoris.

(1) **Hypertrophy of the Clitoris.** This condition is generally congenital. It occurs, however, in a minor degree as the result of chronic irritation such as that due to chronic vulvitis; it is usually unconnected with masturbation, although masturbation has been known to produce a certain amount of enlargement of the organ. Marked cases of hyperplasia are always congenital.

*Treatment.* Congenital hypertrophy requires no treatment as a rule, but certain cases occur, with a patent vagina, in which the enlarged clitoris causes either obstruction or dyspareunia; in such as these the organ may be removed wholly or in part. For minor enlargement due to irritation by infective processes or by masturbation, clitoridectomy should not be performed.

(2) **Hypertrophy of the Nymphæ.** The labia minora may be elongated to form long pendulous flaps. This condition may be congenital, or it may be produced by masturbation or, finally, by manipulation carried out with the intent to produce enlargement. The last cause is exemplified by the practices of the South African Hottentots and of certain Circassian races, who, by certain, methods practised on their female children, produce that enormous hypertrophy of the nymphæ described as the "Hottentot apron." Hypertrophic nymphæ may form an impediment in coitus, or may become irritated from the contact of clothes in walking. If, in a virgin, both clitoris and nymphæ are enlarged, so as to project visibly between the labia majora without separation of the thighs, masturbation in childhood may be suspected. The inference is stronger if the right nymphæ is specially elongated. Masturbation does not, however, necessarily produce any physical change whatever. If they appear to be a source of irritation, the hypertrophied nymphæ may be partially or wholly removed.

(3) **Condylomata.** These structures, whether produced in the course of gonorrhœa or in the secondary stage of syphilis, must be regarded as examples of a local hypertrophy secondary to an inflammatory process. They have already been described (*see pp.* 291, 292).

(4) **Esthiomène.** The name of esthiomène (*ἔσθειν*, to eat away) was first applied by Huguier in 1849 to a form of chronic nodular hypertrophy, associated with secondary ulceration, which he had observed in the vulva; he regarded it as probably tuberculous in origin. Some later writers regard it as *syphilitic* (Kurz), others as a form of lupus, others as elephantiasis. It appears probable that



under this designation have been grouped cases of varied kinds, some tuberculous, some syphilitic, others of chronic infective origin.

This disease finds its chief incidence in prostitutes of the lowest class, and is associated with uncleanness, insobriety, and constant local irritation.

*Morbid Anatomy and Histology.* The two main features in this condition are ulceration and hypertrophy, both of which are present in varying degree in all cases. The whole vulva may be greatly deformed and altered in outline. The parts most frequently affected are the clitoris and labia minora. The latter project from the labial sulcus as sessile or pedunculated wattles, with an irregular surface divided up into convolutions by deep fissures. In the fissures, ulceration takes place, and thus fistulæ may form. The skin is yellow or dead-white, dry and hard; the hypertrophied tissues are firm, elastic to touch, and quite painless.

The extent of the ulceration, in a given case, seems to be inversely proportional to the amount of hypertrophy. In the most severe forms of the disease deep burrowing ulceration leads to destruction of tissue, followed by atresia of vagina, urethra, and rectum.

*Histology.* The chief features of the affected tissues are their density, the presence of patches of round-celled infiltration, vascular engorgement, thickened capillaries, endarteritis and mesarteritis of the larger vessels.

*Prognosis.* Early treatment results in recovery. Where the condition has existed for years, response to treatment is slight or *nil*. The tendency is to fistulous formation, and death from exhaustion. Pelvic peritonitis, vomiting, diarrhœa, and pyrexia are the late symptoms of a case of esthiomène. In one of the six cases recorded by Kurz, malignancy (epithelioma) had supervened.

*Treatment.* In cases yielding a positive Wassermann reaction the treatment will consist in the administration of mercury and iodide of potassium, and injections of salvarsan should be given. Locally strict cleanliness is most important, frequent hip baths should be taken. Lotio nigra should be used freely, and ulcers painted with 5 per cent. solution of silver nitrate. The perineum should be kept dry and dusted with boric acid and calomel powder.

When there is no response to medical treatment the hypertrophic area should be removed *en masse*, after which antisyphilitic treatment may be continued.

(5) **Elephantiasis.** Elephantiasis of the vulva is rare in this country, although comparatively common in women of the dark races. A fair number of cases have, however, been recorded, some being referred by the authors to syphilis, others being instances of true *elephantiasis arabum*; in some cases it is congenital (Ballantyne). An interesting example of true elephantiasis has been recorded by Maclean in which the disease affected the right buttock and lower limb as well

as the vulva. The disease appears to begin in the labia minora, and pursues a very chronic course. In process of time large masses of nodular or warty growth, weighing several pounds, may be formed which, becoming pediculated, hang down between the thighs, and show a marked tendency to superficial ulceration (Fig. 164). The warty

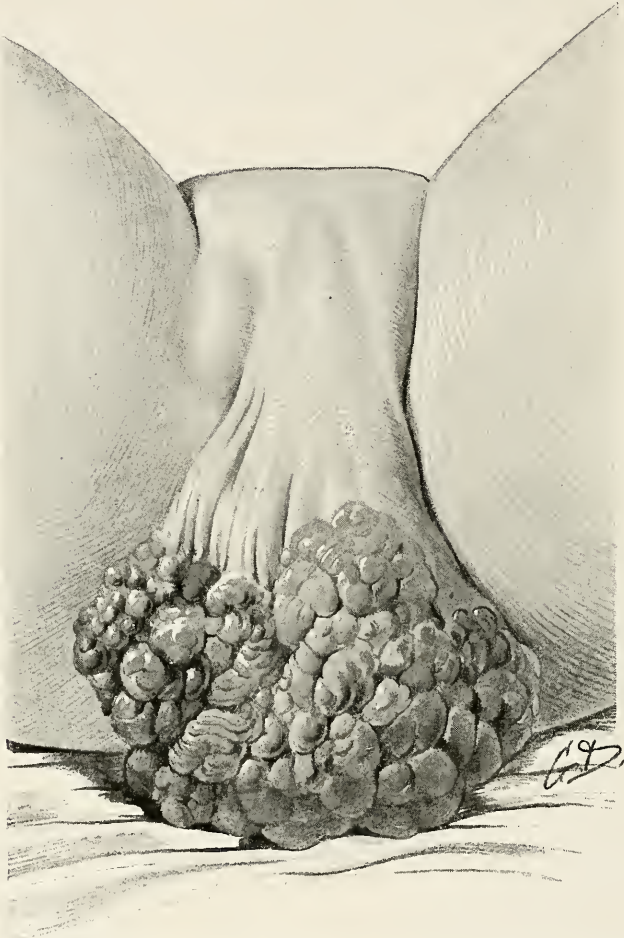


FIG. 164. ELEPHANTIASIS OF THE VULVA, WARTY VARIETY (Maclean). A large pediculated mass of warty growth overhangs the vulva, being attached to the anterior part of the vulva in the neighbourhood of the clitoris.

form (*E. verrucosa*) is commoner than the smooth form. The filaria may be non-existent in the blood even in cases of undoubted elephantiasis like that recorded by Maclean. Histologically, the growth consists of fibrous tissue containing many dilated lymphatic spaces, and often undergoing myxomatous degeneration. Drugs have no effect upon this disease, but as surgical removal of the hypertrophied masses is usually practicable in the vulva, the prognosis is

more favourable than when the disease affects the lower limbs. Elephantiasis of the scrotum is relatively much more frequently observed than elephantiasis of the vulva.

### NEW GROWTHS OF THE VULVA

**Fibroma** is not uncommon. Beginning in the subcutaneous connective tissue, it usually becomes pediculated, but may be sessile and may attain an enormous size. The large tumours often

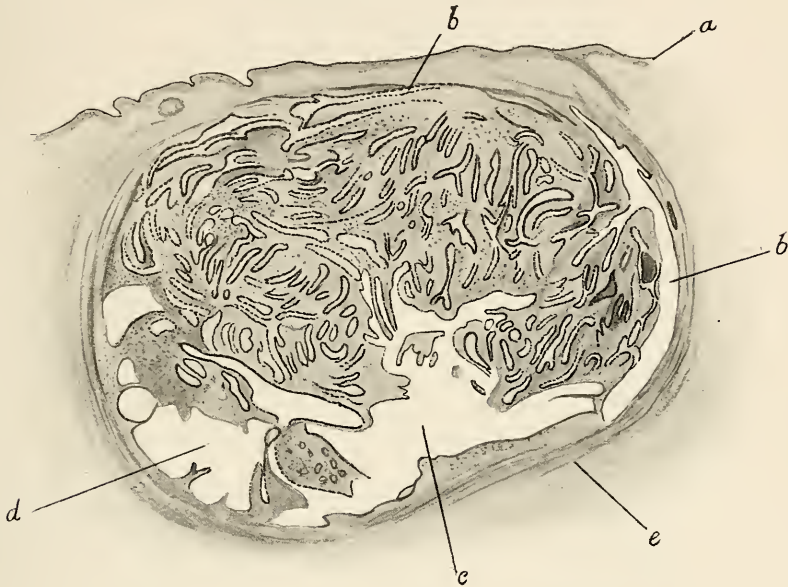


FIG. 165. ADENOMA OF THE UPPER THIRD OF THE RIGHT LABIUM MINUS  $\times 20$  (Schickele), which was situated close to the interlabial sulcus and said by Schickele to be derived from the Wolffian duct. (a) Surface epithelium; (b b) canals derived from Wolffian relics; (c) space filled with round-celled exudation; (d) fatty tissue; (e) connective-tissue capsule of growth.

become the seat of superficial ulcers due to venous stasis and friction. Usually they are firm and hard, but may undergo myxomatous or calcareous degeneration. They cause no symptoms except those due to their bulk, and they are easily removed by dividing the pedicle and tying the vessels it contains.

**Lipoma** is a rarer form of new growth than fibroma. It may occur in the greater labia either as a pediculated, or an encapsuled, or a diffuse growth.

**Papillomata.** These frequently occur upon the skin-surfaces in cases of chronic gonorrhœa (see p. 292).

**Teratomatous Cysts** also occur, though very rarely.

**Adenomata and Adenomyomata.** *Adenomata* of the vulva are found in various situations, they may arise (1) in the upper part of

the labium minus (*see* Figs. 165 and 166). (2) In the neighbourhood of the urethra (vulvo-urethral) in which position they may become malignant and form one variety of urethral cancer (*see* Fig. 182). (3) They may arise in Bartholin's gland (*see* p. 367). (4) Finally small

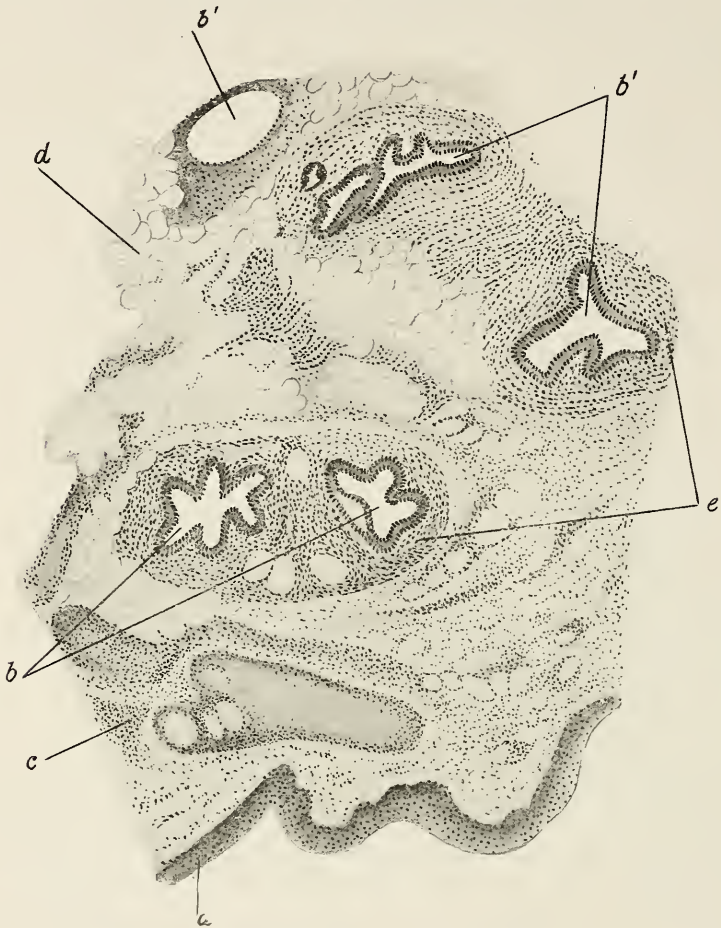


FIG. 166. SECTION OF GROWTH SEEN IN FIG. 165 EXCISED WITH A PORTION OF THE LABIUM MINUS  $\times 68$ . (*a*) Epithelium ; (*b b'*) canals, = relics of the Wolffian duct ; (*c*) round-celled infiltration ; (*d*) fatty tissue ; (*e*) connective-tissue sheath of the canals (after Schickele).

adenomata may occur in the skin of the labium majus, where their origin can be traced to a sebaceous gland (*adenoma sebaceum*).

*Adenomyomata* are found in the upper part of the labium majus and in the region of the external abdominal ring. They are thought to belong to the class of embryonic tumours, and their origin is attributed to portions of mesonephric (Wolffian) tubules carried down through the canal of Nuck by the round ligament. They may be solid throughout, or partly cystic, in the latter case they almost

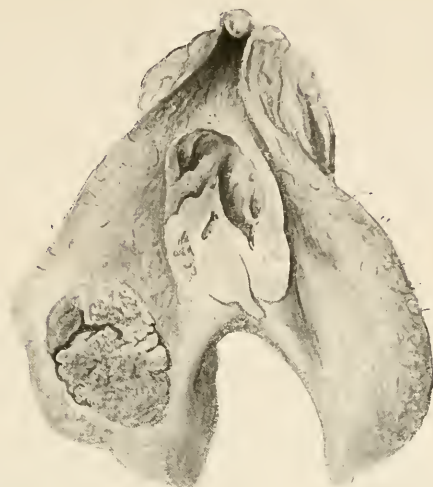


FIG. 167. EPITHELIOMA OF THE CLITORIS WITH A CONTACT-METASTASIS ON THE RIGHT NYMPHA.

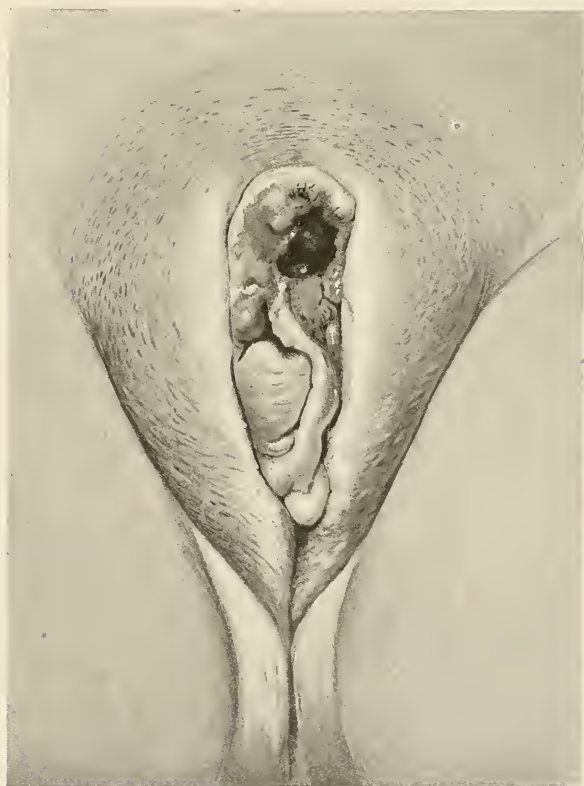

FIG. 168. SHOWING THE ASSOCIATION OF EPITHELIOMA, (SQUAMOUS-CELLED CARCINOMA) OF THE VULVA AND LEUCOPLAKIA ; the latter condition involves the labia and the perineum.

invariably contain altered blood and swell up during menstruation, a fact which leads some authorities to regard these growths as Müllerian. In their histology they resemble adenomyomata which arise in the uterus, for details of which the student is referred to the section dealing with these growths (*see p. 489*).

**Myxomata** have been described, they are probably degenerated pendulous fibromata.

**Sebaceous** and **mucous cysts** occur on the labium minus. They are

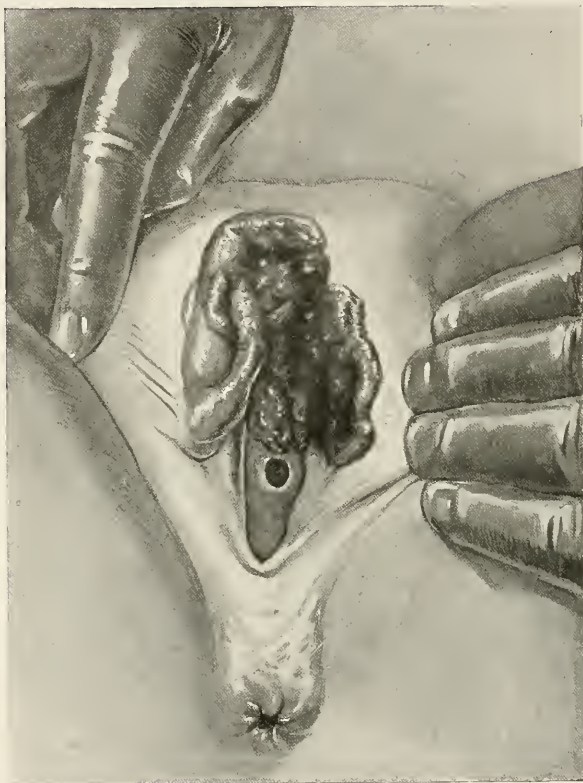

FIG. 169. THE SAME CASE AS IN FIG. 168 WITH THE LABIA RETRACTED TO SHOW THE EXTENT OF THE MALIGNANT PROCESS. It has spread across the vestibule as far down as the orifice of the urethra.

in no sense neoplastic, but are due to retention in the blocked ducts of these glands of sebum and mucus respectively.

**Malignant Growths.** The following malignant growths may arise primarily in the vulva, their relative frequency being in the order stated: *squamous-celled cancer*, *melanoma*, *sarcoma*, *adeno-carcinoma*, and *rodent ulcer*. Secondary growths are very rarely found in the vulva, with the single exception of cases of chorion epithelioma, which in this location has been observed with comparative frequency.

**Epithelioma (Squamous-celled Carcinoma).** The vulva is the rarest site in the female genitalia for cancer to develop. Vulval cancer is a disease of advanced age ; its starting-points are the clitoris, labia majora, labia minora, and the perineum. The growth is characterized by extensive new formation of tissue and by a tendency to early superficial ulceration ; there is a diffuse infiltration of the surrounding tissues, with involvement of the inguinal lymphatic glands.

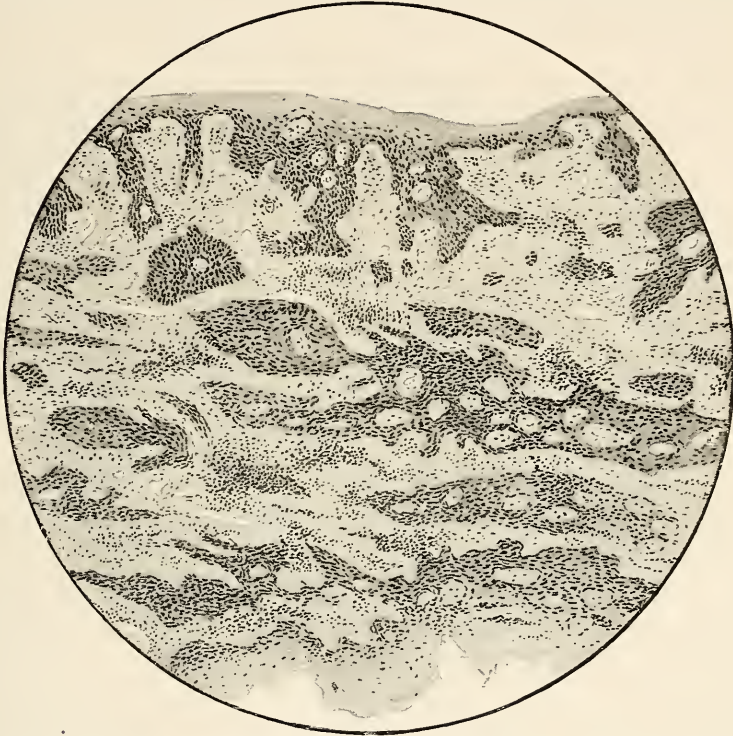

FIG. 170. SQUAMOUS-CELLED CARCINOMA OF THE VULVA. The section is through the base of the labium minus. The subepithelial tissues are seen to be permeated by cancer-processes arising from the deep epithelium.

*Epithelioma of the Clitoris.* There is no uniformity of opinion as to which site, the clitoris or the labia, is the commoner as the starting-point of cancer. Individual experience differs on this point. In our own case we have seen more examples of cancer of the labia than of the clitoris. When the clitoris is primarily affected, the disease is seen to start on the prepuce as a hard nodule which quickly ulcerates ; there is diffuse infiltration of the surrounding tissues and the inguinal glands are early involved, but not in all cases. The course of the disease may be rapid or chronic, but as the clitoris is very sensitive there is a better chance of early detection than when cancer starts in the labia. Fritsch has called attention to the frequency of peri-urethral extension from cancer of the clitoris. When ulceration is established

the surface oozes, becomes moist, and the discharge rapidly becomes septic and offensive. There may be blood in the discharge, but free hæmorrhage is not characteristic even of the late stages. The relationship between cancer of the vulva and leucoplakia has been discussed in another place. The co-existence of these two conditions is well shown in Figs. 168 and 169.

*Epithelioma of the Labia.* The disease most commonly starts on the inner surface of the labium majus, whence it spreads to the labium

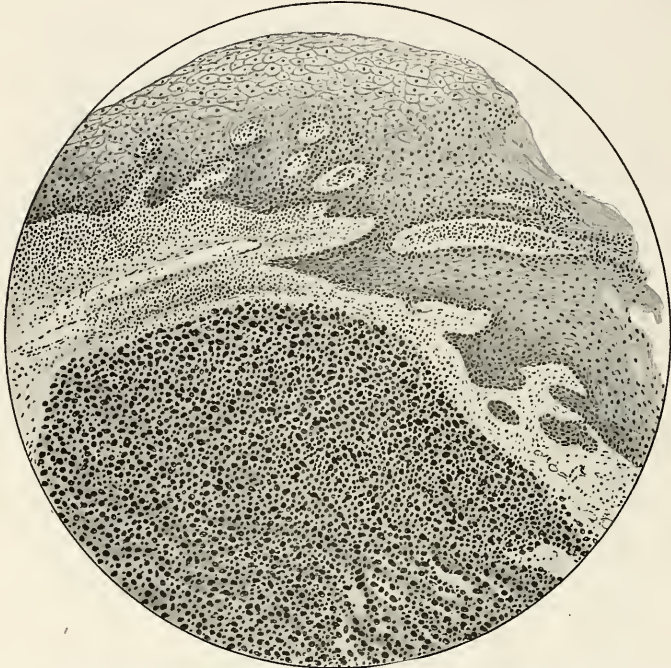

FIG. 171. MELANO-CARCINOMA OF THE VULVA. The cells of the new growth contain an abundance of pigment (melanin).

minus. It may first appear as a hard nodule like that described on the prepuce of the clitoris, but it may attain to the size of a small apple before ulceration commences; or it may first be discovered as a small excavated ulcer with indurated and everted edges, or finally it may present as a deep fissure. Ulceration gradually involves the whole of the labia and leads to a most offensive, thin, sero-purulent discharge. As in cancer of the clitoris, bleeding is not extensive, unless some large vessel becomes eroded by the malignant cells.

An interesting feature of labial cancer is that it may be multiple, a fact due in some cases to implantation (see Fig. 167), whilst in others there is microscopic evidence of deeply seated outrunning processes of cancer-cells connecting surface-growths which are apparently independent.

The histological characters are those common to skin-cancer



in other parts (see Fig. 170), the chief peculiarity being that there is a great abundance of epithelial pearls.

**Adeno-carcinoma** always starts in the gland of Bartholin or in the duct belonging to that structure ; it is described on p. 367.

**Rodent Ulcer.** This type of malignant disease is very rare in the vulva. It arises in the dermis, and not from the surface-epithelium. It may start in the sebaceous glands or in hair-follicles, but has never been proved to originate in the sweat-glands. Arising in the *cutis*

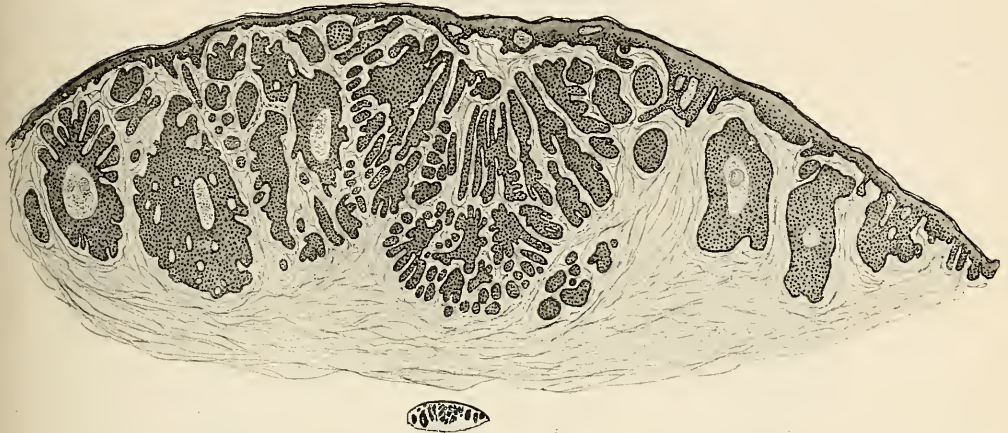

FIG. 172. RODENT ULCER OF THE LABIUM MAJUS SEEN UNDER A LOW POWER. Note the club-like epithelial processes which make up the growth and which have no connection with the surface-epithelium.

*vera* the growth spreads underneath the epidermis which becomes invaded from below, thus contrasting with an epithelioma which invades the dermis from the epidermis. The cell-growth forms flask-shaped masses, from which club-like processes project (see Fig. 172); these run underneath the epidermis which shows no proliferation. The surface-epithelium becomes ultimately thinned out and rubbed off, exposing the subjacent growth, and thus an ulcer is formed.

The individual cells are round in shape and much smaller than those of an epithelioma ; they do not become horny but, on the contrary, show a great tendency to become vacuolated, and thus spaces are formed in the centre of the cell-masses (see Fig. 172).

‘Cell nests’ are seldom seen, and when present they are small and ill-developed.

Rodent ulcer of the vulva is only seen in elderly women and is exceedingly rare. If seen early it appears as a smooth flattened nodule in the skin of the labium majus, it causes no pain, and is not accompanied by a zone of hyperæmia. Later on, the thin epithelium covering the centre of the papulæ ulcerates, after which, growth in the depths and surface-ulceration progress *pari passu*.

The ulcer has a smooth surface which is slightly depressed, and

limited by an irregular, hard rolled-over edge. The discharge is thin watery pus. Lymphatic glands and viscera are never invaded, but by local infiltration the growth may spread to, and erode, the pubic bones. The progress of the growth is very slow indeed, and of all malignant epithelial growths the rodent ulcer is the most benign. The treatment is free removal, bearing in mind the fact that the

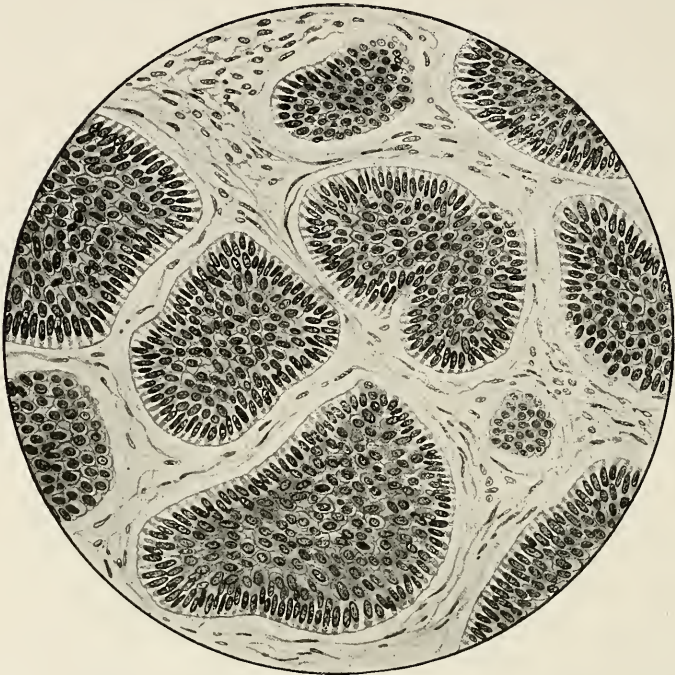


FIG. 173. EPITHELIAL PROCESSES OF RODENT ULCER OF THE LABIUM MAJUS UNDER A HIGH POWER. (The same growth is shown in Fig. 172.)

growth may extend for some distance underneath apparently healthy surface-epithelium.

**Melanoma.** This is a pigmented form of malignant new growth which occurs specially in deeply pigmented situations such as the choroid coat of the retina and certain areas of the skin; but it has also been known to develop in the mucous membrane of the hard palate (Treves), and of the gums, and on the lips. It is a rare disease in any situation, and particularly so in the vulva, although in this situation it has been shown to occur rather more frequently than non-pigmented sarcoma. When occurring on the genitals it especially effects old women, 70 per cent. of the recorded cases having occurred above the age of fifty (Holland).

Melanoma of the vulva may be primary or secondary. In primary melanoma the labium majus alone, or the labium minus and clitoris, are the most common points of origin; but it occurs twice as often

on the labium majus as on the nymphæ and clitoris, a fact which may be due to the excess of pigment in the former situation.

*Pathology.* This disease was originally described as a form of carcinoma but as histological methods became more exact the majority were found to possess the structure of sarcomata. It is now known that some are carcinomata (see Fig. 171) and some sarcomata. Thus, Treacher Collins has proved that some of the melanomata which arise

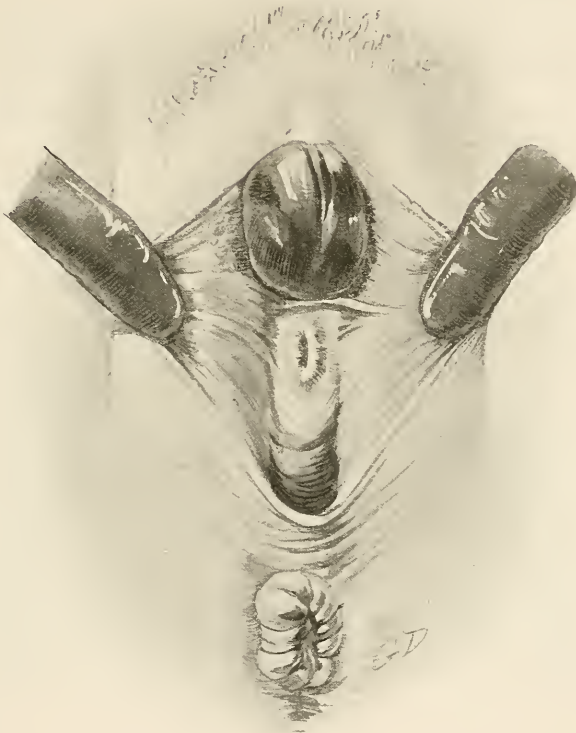


FIG. 174. MALIGNANT MELANOMA OF THE VULVA (Eardley Holland). The growth has arisen in the vestibule, between the clitoris and the urinary meatus.

in the eyeball are carcinomata, and both types are also to be found in the skin. In the latter situation melanomata are more frequently sarcomatous than carcinomatous. From a microscopic examination of thirty-three recorded cases collected by Holland, twenty-six were classed as sarcomata, six as carcinomata and one uncertain. The cancerous type usually develops from a pre-existing pigmented mole. Of thirty-three skin-melanomata recorded by Eve, twenty-six were traced to a pigmented mole.

*Macroscopically* the growth is generally deep purple or black in colour, and usually of quite small dimensions, e.g. about the size of a

filbert nut, but the growth shown in Fig. 174 was said by Holland to be as large as a bantam's egg. It ulcerates early and bleeds readily. Secondary deposits are often more deeply pigmented than the primary growth.

*Microscopically*, whether sarcomatous or cancerous, the pigment in the growth varies greatly in amount. It consists of golden-brown

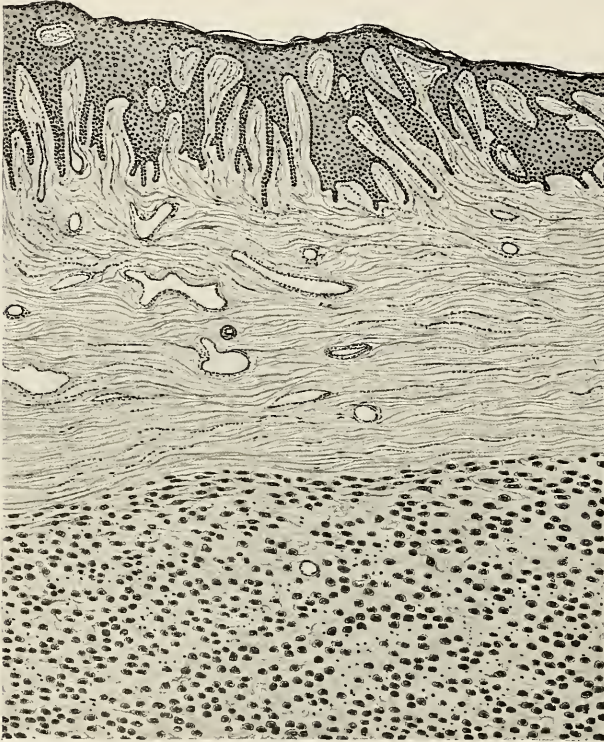


FIG. 175. MYXO-SARCOMA OF VULVA.

granules of melanin of variable size, distributed within the cytoplasm of the cells, in the fibrous connective tissue, and in the walls of the vessels. When aggregated in masses, the granules appear quite black, so that adjacent lymphatics, when choked with pigment, may resemble streaks of ink.

The decision in certain cases as to whether a melanoma is a sarcoma or a carcinoma is often difficult, and the pigmentation may be so abundant as to make it impossible to decide from the characters of the cells. Moles have an alveolar structure which will tend to render the appearances sarcomatous, but Unna and most other pathologists regard the molar variety as carcinomatous. In many cases the true nature must be left in doubt, hence the term *melanoma* must be understood to include both melano-carcinoma and melano-sarcoma.

*Prognosis.* This is grave ; so great is the malignancy that according to Erichsen, if the primary growth is larger than a filbert, local treatment is of little value. Dissemination is rapid. In the case of vulval melanoma early involvement of the inguinal glands occurs. Out of twenty-six after-histories collected by Holland, only one patient was free from recurrence after three years.

*Treatment.* This consists in free excision of the growth and extirpation of the inguinal glands on both sides.

**Sarcoma** appears to be one of the rarest of the malignant tumours of the vulva ; Blair Bell has succeeded in collating twenty-one cases of non-pigmented sarcoma from general literature, and this small number sufficiently indicates its rarity. It attacks the labium majus more frequently than other parts, and occurs at an earlier age than epithelioma and melanoma, 50 per cent. of the recorded cases having occurred between the ages of thirty and fifty. Histologically the growth may consist of spindle-cells, of round cells, or of both kinds ; in other cases a form of myxo-sarcoma (*see* Fig. 175) occurs, as is the case with sarcomata of other parts. Diagnosis is only possible with the help of the microscope, and the treatment is free and early removal. The prognosis as regards recurrence is bad.

**Tumours of the Perineum.** Tumours in the perineum are very rare ; those which have been recorded have not arisen *in situ*, but have pushed their way outwards and distended the perineum as a result of continuous growth. A remarkable case recorded by Malcolm was that of a semi-solid, semi-cystic growth which weighed 39½ pounds. It proved to be a cystic fibromyoma. All the pelvic organs were normal and the growth appeared to have arisen from the parametric or paravaginal tissues. That it was not of fascial origin (fibroma) was proved by Shattock, who demonstrated unstripped muscle-fibres in the tumour.

## MORBID CONDITIONS OF BARTHOLIN'S GLAND

**Cysts.** Both the duct, and the gland itself, may give rise to the formation of a cystic tumour. Cysts of the *duct* are true retention cysts due to stenosis of inflammatory origin, or more rarely to obstruction by a calculus. The resulting tumour is superficial and opens out the posterior third of the labium majus (*see* Fig. 176) ; it is seldom larger than a hen's egg, and is either oval or globular in shape (*see* Fig. 177). The deformity produced by it is fairly characteristic, the introitus vaginæ being encroached upon, and the integumental coverings stretched tightly over the bulging tumour. The line of origin of the labium minus runs over the front of the swelling. Cysts of the *gland* are probably produced in the same manner, but are much less common than those of the duct. They lie deeply beneath the posterior part of the labium majus, and sometimes burrow upwards along the lateral

vaginal wall and backwards into the ischio-rectal fossa. The integumental coverings are lax, and the deformity is less pronounced. The cyst can be grasped between the finger passed into the vagina, and the thumb placed externally, and its size and depth thus estimated.

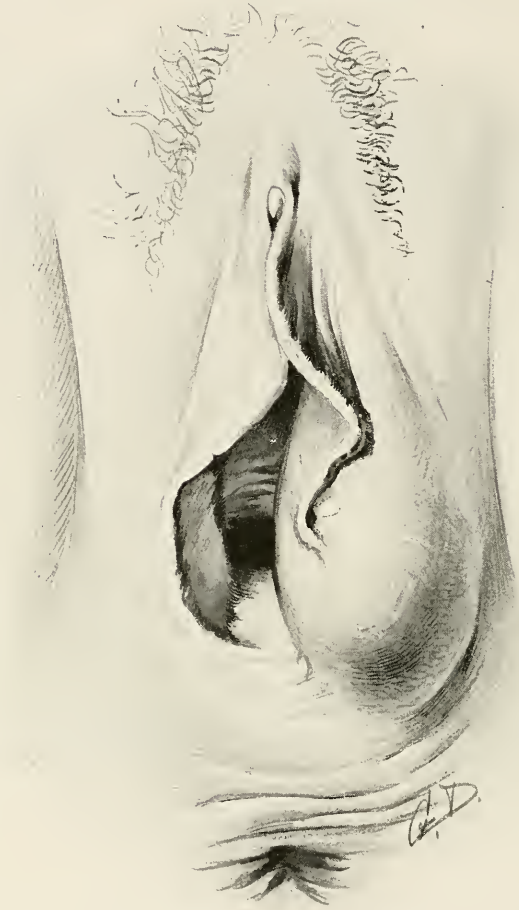

FIG. 176. BARTHOLINIAN CYST, FORMED BY DILATATION OF THE DUCT OF BARTHOLIN'S GLAND.

The fluid these cysts contain is usually thin, and serous, but may be thick and coloured in long-standing cases. Figure 178 shows the characters of the wall of a Bartholin's cyst, and Figure 179 shows dilated (small cystic) spaces in the corresponding gland, produced by the obstruction in the duct.

The only *symptoms* associated with a Bartholinian cyst are mechanical in origin and slight in degree. Unless inflamed it causes no

pain and it is not sensitive when touched. It is, however, somewhat prone to become infected from vaginal discharges, or sometimes as the result of injury, and an *abscess* may then be the result.

The treatment is surgical and may be found described on p. 836.

**Inflammation.** The gland is not palpable when of normal size. When enlarged and indurated by chronic inflammatory processes it may be felt as a firm body of the size of a haricot bean or larger, lying deeply in the tissues beneath the posterior part of the labium majus (see Fig. 41, p. 62). On pressure a turbid fluid may exude from the ducts. In gonorrhœal infection, a definitely purulent discharge can often be demonstrated in the same manner, long after the vulvitis from which it originally arose has disappeared. When thus chronically infected, a dull red zone of

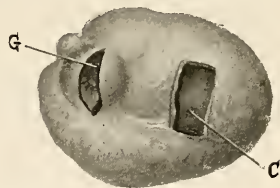


FIG. 177. CYST OF BARTHOLIN'S DUCT (NATURAL SIZE). (G) Gland; (C) Opening made in cyst.

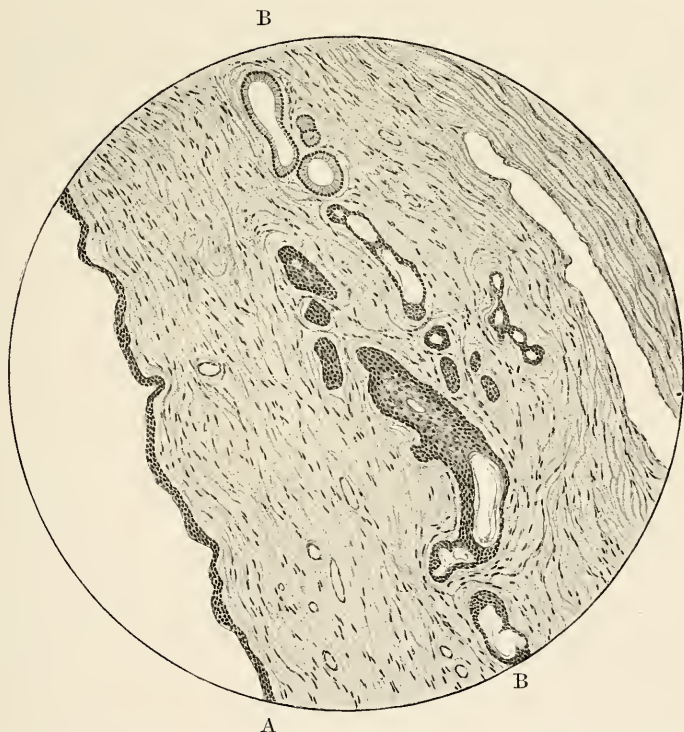

FIG. 178. SECTION THROUGH THE WALL OF A BARTHOLINIAN CYST. (A) Lining composed of cubical epithelium which is becoming squamous; (B) Outlying processes of the gland.

discoloration is usually seen around the mouths of the ducts, where they open on each side just external to the hymen. Cysts

formed by obstructive dilatation of the duct may suppurate, the gland having been often infected before dilatation occurred. The suppuration is usually limited to the cyst, but may spread to the gland or to the surrounding cellular tissue, giving rise to a *labial abscess*.

An *abscess* may occur from acute infection of the gland itself, or of a pre-existing cyst; usually the infection is gonorrhœal; in the case of a cyst, traumatism followed by septic infection from organisms in the

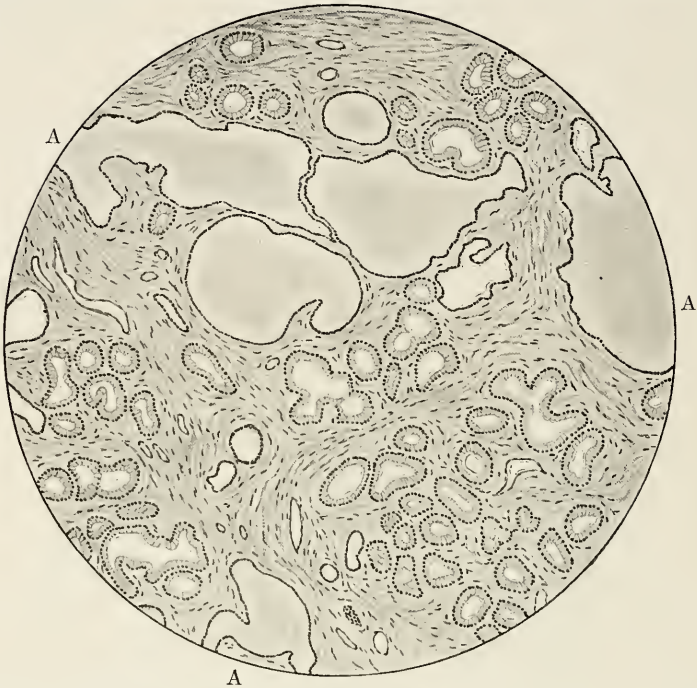


FIG. 179. BARTHOLIN Gland showing cystic spaces produced by obstruction caused through a retention cyst forming in the duct.

skin, or the vaginal secretions, is sometimes the cause. Suppuration is usually limited to the gland or cyst, but widespread inflammatory swelling of the labia may accompany the process. Not infrequently spontaneous rupture of the abscess occurs externally, giving rise to a sinus which may be very persistent. The *symptoms* of suppuration are pain, rapid enlargement of the swelling, redness, œdema and tenderness of the integumentary coverings; a moderate rise of temperature to 100° F. or 101° F. is also usually present. The *treatment* will be described on p. 836.

*Tuberculosis* of Bartholin's gland is very rare. Two cases have been recorded.

**New Growths of Bartholin's Gland.** Solid tumours of Bartholin's gland are rare. Within the limits of our own knowledge they are confined to adenoma, endothelioma and adenocarcinoma.



(a) *Adenoma* has once been met with by one of us. The tumour presented at the vulva in the same way as a Bartholinian cyst. It was of firm consistence, rounded in shape, and the size of a walnut. It caused no discomfort except on coitus. There was no induration around it. The tumour shelled out quite easily. On naked-eye section it had a similar appearance to an adenoma of the breast. It was quite solid except for a small hæmorrhagic spot in the centre.

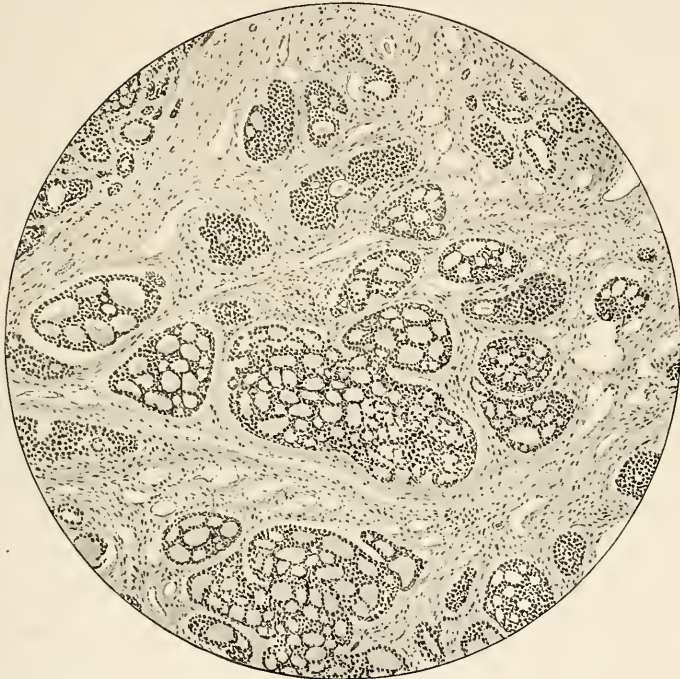


FIG. 180. ENDOTHELIOMA OF BARTHOLIN'S GLAND.

Microscopically it consisted of racemose gland-tissue within fibrous trabeculae.

(b) *Endotheioma*. This tumour is very rare in the Bartholinian gland. It differs in no way from this type of growth when found in other glands such as the parotid (*see* Fig. 180).

(c) *Adenocarcinoma*. This again is a very rare disease. The age at which it occurs is given as between twenty-eight and ninety years, half of the cases occurring after the age of fifty years. Herbert Spencer has recorded one case; in that instance the columnar-celled growth appeared to have started in the deep part of the principal duct.

*Signs*. Its first appearance is that of a tender, hard, nodular swelling in the region of the gland. The skin is sometimes discoloured and there may be local œdema, especially in the region of the hymen. The skin eventually becomes perforated and a large fungating mass

protrudes on the surface. The growth has been found to have eroded the ramus of the pubes. The inguinal glands are affected early.

*Symptoms.* There is severe pain, especially on walking and during menstruation. In the early stages coitus is painful, later, it is of course impossible.

*Prognosis.* The outlook as regards recurrence is unfavourable.

The treatment of these conditions is surgical, free excision of the growth being indicated, including a portion of the pubic bone if necessary.

### LESIONS OF THE BLOOD- AND LYMPH-SYSTEMS

**Hæmatoma Vulvæ.** A hæmatoma of the vulva may result from a blow or a kick, or it may be due to rupture of a varicose vein caused by some violent exertion. It also sometimes results from deep-seated hæmorrhage due to imperfect hæmostasis in operations on these parts.

*Symptoms.* The patient complains of local pain and tenderness, and she may be very anæmic from loss of blood.

*Signs.* There is a dark, tender swelling of one or other labium majus; the skin or mucous surface may have given way leading to free external hæmorrhage, or a thrombus may project through the site of rupture in a varicose vein. The blood may escape into the cellular tissue *external to the pelvic fascia*, in which case it will distend the labium majus, and may track thence to the perineum behind and to the anterior abdominal wall in front. The consistence of the swelling will vary with the period that has elapsed since the injury. At first it is cystic, then doughy, and finally firm. If infection occurs, an abscess results. The blood may escape into the cellular tissues *beneath the pelvic fascia*, i.e. into the pelvic connective tissues, in which retro-peritoneal situation it may form a swelling large enough to occlude the lumen of the vagina and to compress the rectum. This type of hæmatoma may arise from hæmorrhage originating in the cellular tissues, deep to the pelvic fascia, and the blood perforating the fascia finally infiltrates the labium.

A vulval hæmatoma is more likely to be caused during the pregnant than during the non-gravid state, and it may form an obstruction to delivery.

*Treatment.* The patient must be kept in bed, and cold lead lotion applied. If infection occurs, free incision must be made and antiseptic fomentations applied.

**Varicose Veins.** The most marked examples of varicose veins of the vulva are seen as a complication of pregnancy, but the condition may be produced by any cause of obstruction to the pelvic veins.

*Symptoms.* The patient complains of aching pain and swelling of the vulva.

*Signs.* The veins stand out as tortuous dark blue structures in one

or both labia. In severe cases they extend into the inguinal region. Usually they are soft and allow of expression of their contents, but they may appear as a mass of hard knotty cords, each the size of an index-finger, the hardness being due to thrombo-phlebitis. Blood may leak into the subcutaneous tissues, producing a diffuse hardness under an intact, discoloured skin, or, as stated above, the skin may rupture as well as the veins, in which case there may be alarming and even fatal hæmorrhage.

*Treatment.* If the condition becomes extreme during pregnancy the question of inducing labour will have to be considered. If rupture is followed by severe hæmorrhage it may become necessary to expose the vein and tie it.

**Œdema of the Vulva.** The most marked examples of this condition occur in pregnancy complicated with albuminuria. It is also associated with renal disease apart from the gravid state, with cardiac disease, with varicose veins of the vulva, with vulvitis (*see* Fig. 161, p. 338), and with suppuration in the pelvic cellular tissue.

The swelling causes local pain and discomfort. In vulvitis, and in cases of œdema due to a systemic cause, the swelling is bilateral; it may be so extensive as to cause sloughing of the apposed surfaces of the labia majora.

*Treatment.* The patient should be kept at rest, and the foot of the bed tilted. If the œdema is extreme the tissues should be drained with a Southey's tube, and boric acid fomentations applied, meanwhile the cause of the condition must be treated as far as is possible.

### LABIAL HERNIA

Labial hernia in women is much less common than the corresponding affection (inguinal hernia) in the other sex; femoral hernia is the variety most frequently met with in women.

A labial hernia may contain a knuckle of bowel or a piece of omentum; in addition to, or instead of, these structures may be found an ovary, with or without its companion tube, a uterus alone, or a uterus with the adnexa of one or both sides; Figure 83, p. 154, shows an accessory uterine horn and an imperfect tube which were removed from a hernial sac. A few instances have been recorded in which a gravid uterus has been found in an inguinal hernia. It must be remembered that hydrocele of the *processus vaginalis*, or canal of Nuck, may closely simulate a labial hernia.

### PERINEAL INJURIES

The anterior one-third of the perineal body is almost invariably lacerated to a certain extent in labour, the effect being to destroy the posterior commissure and fossa navicularis. In all considerable perineal lacerations the posterior vaginal wall is also involved, the

tear here being usually lateral, and running upwards for an inch or more. In women who have had several children a similar tear is often found on each side. These tears persist in the form of sulci, which can be traced from the anterior edge of the perineum upwards and to one or other side, isolating the median portion of the vaginal wall, which often becomes prolapsed and its tissues thickened. Similar injuries may be found in cases where the perineal body is fairly well preserved. These vaginal lacerations destroy the supporting fibres of the levator ani and the vaginal sphincter, the result being that the ostium vaginae becomes relaxed and so distensible that three or four fingers can be passed into the vagina without inconvenience to the patient (*see* Fig. 217, p. 597). They are consequently important predisposing factors in the causation of *prolapse*. This relaxed condition of the vaginal introitus may exist without any greater injury to the perineal body than that mentioned above.

Frequently, however, damage more extensive than this is sustained by the perineal body, which may be lacerated up to, or even so as to include, the external sphincter ani muscle. Perineal lacerations may therefore be classified in three degrees: *first degree*, involving only the anterior one-third; *second degree*, involving the whole perineal body up to the anal sphincter; *third degree*, involving the anterior portion of the sphincter itself. Lacerations of the second degree greatly enlarge and distort the ostium vaginae, but are not in all cases accompanied by prolapse, although the recto-vaginal septum is greatly attenuated. Those of the third degree produce a characteristic alteration in the appearance of the anus. Under normal conditions the pigmented perianal integument is thrown into shallow radiating folds by the persistent retraction of the circular sphincter muscle (*see* Fig. 318). When this muscle has been lacerated anteriorly the divided ends retract so that the muscle becomes crescentic or horseshoe-shaped instead of circular. A small shallow pit in the skin on each side can often be seen which indicates the position of the retracted end (*see* Fig. 494, p. 819). Further, while the radiating folds persist laterally and posteriorly, they are lost anteriorly. The competence of the sphincter may be so much injured that a portion of the rectal mucosa becomes prolapsed in the form of a bright-red sessile nodule, the size of a pea or even as large as a cherry. The grip of the sphincter upon the finger is always recognizably weakened. In slighter cases the patient may be conscious of weakness only when the bowels are relaxed, or when controlling the passage of flatus. In severe cases complete incompetence of the anus results.

The *treatment* of these injuries consists in repairing the perineum; this operation (perineorrhaphy) is described on p. 812.

## VAGINISMUS

This name was given by Marion Sims to a condition in which there is an abnormal hyperæsthesia of the external genital organs, which, when coitus is attempted, sets up reflex spasm of the muscles of the pelvic floor. The act of coitus is usually quite impossible.

Cases of vaginismus admit of division into two classes: (1) Those in which no apparent cause can be found; (2) those in which some local lesion is discovered.

The extreme hyperæsthesia in the first class must be regarded as a local manifestation of neurosis. The sensitiveness is more than a mere shrinkage from timidity, for the patient may be desirous that marriage should be consummated, and still unable to tolerate the attempt. The trouble is liable to what Matthews Duncan called "spontaneous variations," and may even disappear. Its manifestations, like those of other neuroses, are erratic; thus, as a rule, coitus is unendurable, and attempts at examination cannot be tolerated without an anæsthetic; at other times, a patient can suffer the admission of the examining finger, and allow of an examination being carried out without difficulty. Again, a woman who has suffered coitus without hindrance, may for some unknown reason, develop vaginismus. As a rule, any attempt at investigation will produce painful cramps and nervous excitement, the buttocks will be raised, the back arched, and the thighs pressed tightly together, and an anæsthetic must be given before the examination can proceed. Some cases are recorded in which coitus has commenced before the spasm of the levator ani muscle was set up, and then the spasm proved sufficiently intense to prevent withdrawal (*penis captivus*). Fritsch recorded a case in which he was obliged to chloroform the woman before the penis could be set free.

In the second class of case, local examination may reveal a vascular caruncle or an inflamed hymen, or inflamed *carunculæ myrtiformes*, or a small ulcer or fissure in the fossa navicularis. All these are known causes of dyspareunia, and in a neurotic patient they may set up a painful reflex spasm, sufficient to prevent coitus altogether.

*Prognosis.* In the first class of case the prognosis must be guarded; on the whole it is not very hopeful. Even where pregnancy has followed suitable treatment, the condition may recur. In the second class the prognosis is good, as local causes admit of cure.

*Treatment.* Slight cases may be relieved by the application of a 5 per cent. cocaine ointment some ten minutes before coitus is attempted. If this fails the patient should be given an anæsthetic and the hymeneal ring forcibly dilated by vaginal dilators, leaving one of large size in the vagina for some hours afterwards. Dilators of increasing size should be inserted daily and left *in situ* for some hours. Another plan of

treatment, which no doubt is the best, is to incise the sphincter, an operative procedure which will be found described on p. 841.

Local conditions such as an inflamed hymen or urethral caruncle should be removed. Fissures may be divided, and ulcers excised or cauterized.

### COCCYGODYNIA

The first account of this complaint was published in 1844 by J. C. Nott, who spoke of it as "neuralgia of the coccyx." This surgeon removed the last two coccygeal bones from the patient, who had had a fall four years previously, but had suffered pain in the coccyx for only ten months. Caries had reduced the terminal segment to a mere shell. The symptoms disappeared after operation. The term *coccygodynia*, by which it is now known, was introduced by Simpson of Edinburgh.

From this complaint men are almost immune, the reasons assigned being, that in the male, the tubera ischii are closer together, and the coccyx, being higher up, is afforded a better protection from external violence.

*Etiology.* Hirst states that three-quarters of the cases are due to injuries in labour, but the disease may occur as the result of a fall or a kick; on the other hand, there may be no history or sign of injury; and then rheumatism is usually the assigned cause. There is frequently temporary pain in a coccygeal joint following labour, which is easily understood, since backward displacement of the bone is bound to occur during the passage of the foetal head, and laceration of ligaments, if not dislocation of a joint, may easily happen. There is no doubt that a nervous element is apparent in a large number of cases, even when it is agreed that there has been trauma to call it forth.

*Pathological Anatomy.* Hirst states that in the majority of cases there is a laceration of the ligaments of a coccygeal joint. He says the second coccygeal joint is more often affected than the first. The intervertebral disc is thickened and softened. There may be ankylosis of the whole bone, which then runs in a straight line from the sacrum downwards, so that whenever the patient sits down she feels as though she is sitting on a nail. In one case described by the above author, there was an oblique fracture through the second coccygeal vertebra. In other cases the lower fragment was pulled forward at right angles to the upper, presenting a difficulty to subsequent labour.

*Symptoms and Diagnosis.* Pain is felt at the end of the spine, especially on sitting down. Defæcation and coitus are painful. Pressure over the coccyx causes pain.

On examination with the index finger in the rectum and the thumb in the natal cleft, the fragment below the ruptured joint can be thrown

out of the line of the upper fragment, and the sharp ridge of the upper fragment may be felt when the lower fragment is pushed back. It is impossible to do this with a normal bone (Hirst). In a thin subject a sharp ridge of bone may irritate the skin over it, and the latter may become inflamed.

*Treatment.* Many cases recover spontaneously, and it is well to try palliative treatment for some months. The part should be painted with unguentum iodi, and the patient should rest. If no disease or injury can be demonstrated the patient should be treated as a rheumatic or hysterical subject. If other means fail coccygectomy should be performed (see p. 445).

## DISEASES OF THE URETHRA

**Inflammation.** *Acute urethritis* has already been described (see p. 290); it is probably always of gonorrhœal origin. *Chronic urethritis* may follow an acute attack, or it may be chronic from the first, being set up by the passage of a foreign body from without, or of a calculus from within. It is sometimes accompanied by urethral ulceration. An abscess may result from infection of a urethrocele. It presents as a tender elongated swelling in the anterior vaginal wall, which, on pressure, causes an escape of pus through the urethral orifice.

A suburethral abscess will likewise give rise to a swelling similar to the above, but, unless ulceration into the urethra has occurred, the contents cannot be expressed, and on passing a probe into the urethra the abscess cannot be explored. The treatment is described on p. 835.

**Tumours.** Innocent tumours include caruncles, papilloma, mucous polypi and fibromata. Malignant tumours comprise carcinomata and sarcomata.

*Urethral Caruncles* (see Fig. 181). These small growths from the urinary meatus are of comparatively frequent occurrence. They rarely exceed the size of a pea, and are usually solitary and attached immediately within the posterior lip of the meatus. Some are sessile, rounded, pale red in colour, and only slightly sensitive to the touch; others are pediculated, bright red in colour, often lobulated, and in some cases, but not in all, extremely sensitive to the touch. The paler sessile growths are found on examination to consist of granulation tissue with a covering of stratified squamous epithelium, *i.e.* they are *granulomata*. They are often associated with a chronic urethral discharge, and probably result from chronic infection of the peri-urethral glands, which are especially numerous near the meatus. The bright red pediculated growths, on the other hand, vary considerably in structure; some contain glandular tissue, either in the form of crypts, tubules, or spaces lined with epithelium, which appear to arise directly from the peri-urethral glands, *i.e.* they are *adenomatous*. The stroma consists of a delicate connective tissue often infiltrated with

leucocytes, in which the vessels are always very numerous. Others contain large and numerous cavernous blood spaces in addition to the glandular elements, but these cannot strictly be called angiomatous. Others again are *papillomatous*, and present an irregularly broken surface, consisting of flat elevations with intervening sulci. The latter are lined with a thick layer of stratified epithelium of the transitional

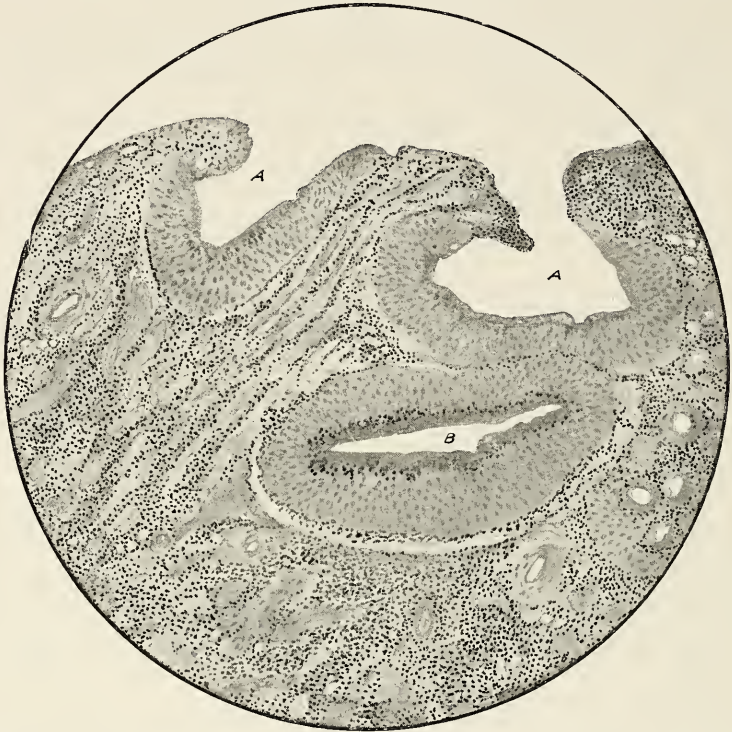

FIG. 181. PAPILOMATOUS FORM OF URETHRAL CARUNCLE. *A*, Surface depression lined with stratified transitional epithelium; *B*, a similar depression or crypt in transverse section. The stroma is very vascular, and infiltrated with leucocytes.

type common to the urinary passages. The epithelial covering is often lost upon the surfaces of the elevations (see Fig. 181). The adenomatous caruncles are sometimes very sensitive, but observers have not succeeded in detecting nerves in them.

The chief *symptom* to which urethral caruncles give rise is painful and frequent micturition. Others cause such severe pain on micturition as to lead to retention of urine. Sometimes slight irregular hæmorrhage occurs from a caruncle, and sometimes the sensitive ones occasion dyspareunia. Many caruncles give rise to no symptoms whatever, and are discovered, if at all, by accident.

The *treatment* is excision (see p. 832). Recurrence after operation



may occur. Occasionally a growth at first regarded as a caruncle recurs, and ultimately reveals the characters of epithelioma.

Compound papillomata have been found growing from the edges of the urethra. Mucous polypi and fibromata are very rare ; their nature has to be proved by microscopic examination.

*Carcinoma of the Urethra.* This disease may be secondary to cancer of the vulva, vagina, cervix or bladder, the urethra becoming

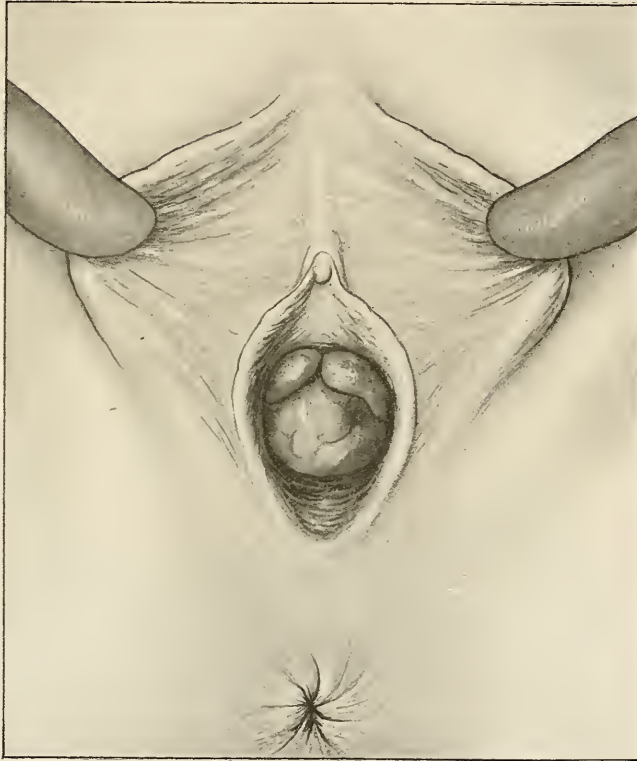


FIG. 182. ADENO-CARCINOMA OF THE PARAURETHRAL GLANDS, FORMING A TUMOUR IN THE FLOOR OF THE URETHRA. In size and colour it resembled a black cherry.

involved by direct continuity. *Primary* cancer is very rare in the female urethra, which may be due to the fact that leucoplakia of the vulva never affects the vestibule or urethral orifice. Chronic inflammation probably plays a part in the etiology of malignant diseases here as elsewhere (Halle).

The symptoms occur late, they are painful micturition, hæmorrhage, and discharge. When ulceration is established pain occurs independently of micturition.

The disease is rare ; Beckwith Whitehouse has collected forty-three

cases, and three others have been reported by one of us. Whitehouse divides cancer of the urethra into *vulvo-urethral* and *urethral* varieties.

The *vulvo-urethral* variety presents three forms, (1) an irregular dark purple papillomatous growth which bleeds on contact, and which has to be diagnosed from a large urethral caruncle, and from an acute prolapse of the mucous membrane (compare Figs. 182 and 183); (2) an ulcerative form, situated in the floor of the urethral orifice; (3) an induration around the meatus leading to stenosis.

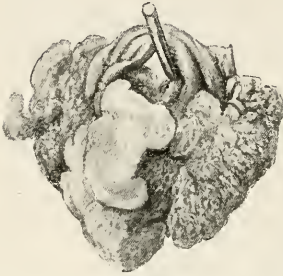


FIG. 183. PRIMARY CARCINOMA OF THE URETHRA: PAPILLIFEROUS TYPE. The pointer is in the urethral canal.

The *urethral* variety presents as (1) an irregular elongated ulcer, seen only by urethroscopic examination; (2) a peri-urethral induration involving, as it extends, the whole length of the urethra.

This disease affects elderly women who have passed the age of the menopause. It begins either in the peri-urethral glands, when its histology is that of an *adenocarcinoma*, or it starts in the surface-epithelium and forms a *squamous-celled cancer*.

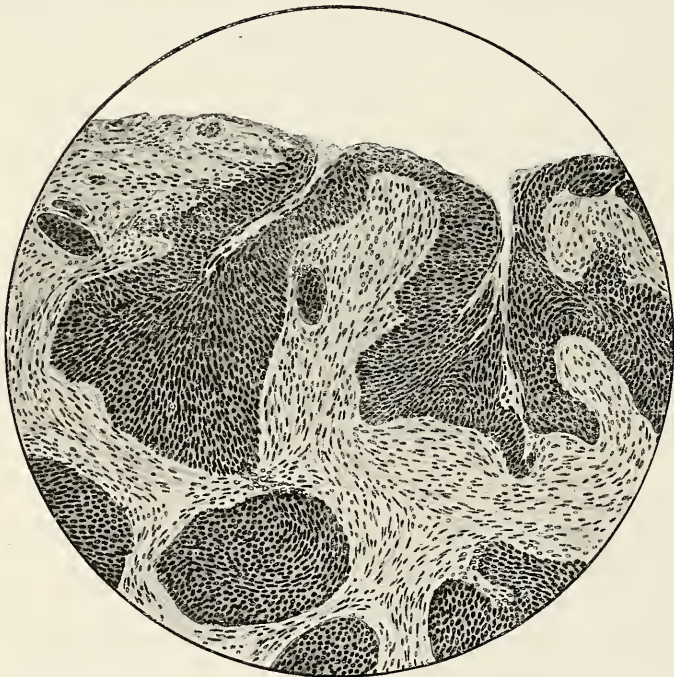


FIG. 184. VULVO-URETHRAL CARCINOMA OF THE SQUAMOUS-CELLED TYPE.

The floor of the urethra is the part first attacked, and the growth spreads thence along the entire canal from the meatus to the bladder.

The inguinal glands are involved in at least 20 per cent. of cases (Karaki). The disease may spread over the vestibule and through the vaginal wall, but shows little tendency to attack the bladder.

The *treatment* consists in free excision of the urethra and the inguinal glands on both sides. If a portion of the proximal end of the urethra can be saved, it should be stitched to the anterior vaginal wall, but in such cases incontinence of urine usually results. If the sphincter of the bladder is injured or partially removed in the operation, the neck of the bladder should be closed and a permanent suprapubic fistula established.

*Sarcoma of the Urethra* is very rare; up to 1911 only fourteen cases had been recorded. Two of these occurred in women over fifty years of age and one in an infant three months old. The growth appears as a livid deeply fissured nodule, which bleeds on contact, and on section has a brain-like greyish appearance. The *treatment* is free removal.

**Urethral Calculus.** In women urethral calculus is rare. It may be due to a deposit of phosphates around a foreign body or around a migrated ligature. A vesical calculus may become arrested in the urethra.

*Signs.* The urethra will be tender to touch. The calculus may be felt through the anterior vaginal wall; on passing a sound the latter will come in contact with the stone.

*Symptoms.* A calculus expelled from the bladder may, by obstructing the urethra, cause retention of urine. The symptoms of cystitis are usually present, and added to these there is increased pain and strangury due to the impaction.

*Treatment.* The calculus may be removed with forceps, or the posterior wall of the urethra may be incised through the vagina, the stone removed, and the wound closed with two layers of catgut sutures.

**Prolapse of the Urethral Mucous Membrane** (see Fig. 185). In its slighter manifestations this condition may be confused with the sessile forms of urethral caruncle. A partial or complete ring of mucous membrane becomes everted through the meatus; its colour is deeper than that of the mucous membrane of the vestibule, and it overhangs the edges of the meatus. Its attachment all round to the margins of this aperture can be readily demonstrated. It is usually accompanied by a certain amount of dilatation of the urethra, the patulous condition of the meatus probably being the determining cause. It may produce symptoms of irritability of the bladder similar to those met with in the non-sensitive urethral caruncles.

An *acute* form is sometimes met with in which a great part of the mucous membrane of the urethral canal becomes suddenly protruded through the meatus; the immediate cause appears to be straining at stool, the predisposing cause, dilatation of the urethra or prolapse of the

anterior vaginal wall. The protruded mucous membrane becomes partially or completely strangulated, and forms a swelling which may be as large as a walnut (*see* Fig. 185). Its colour is deep red or nearly

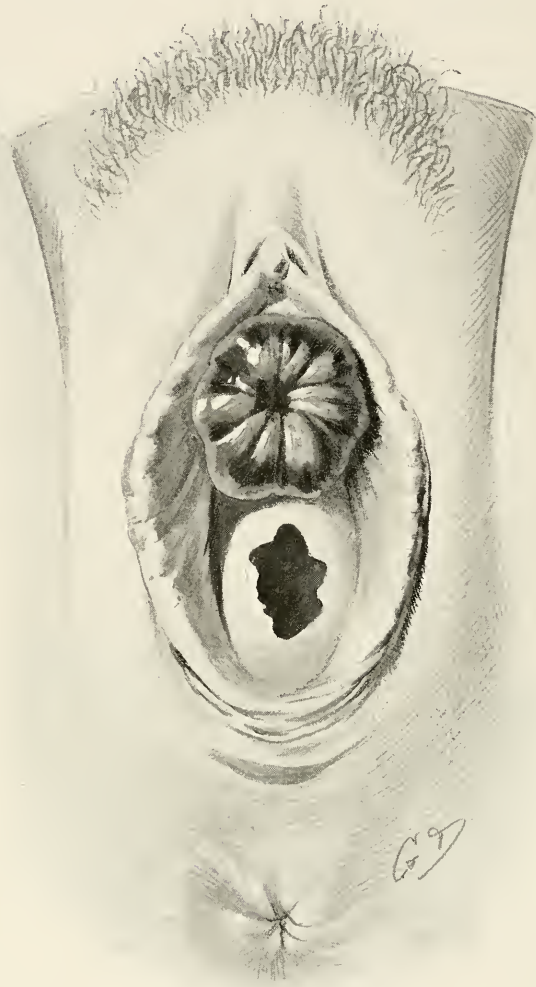


FIG. 185. ACUTE PROLAPSE OF THE URETHRAL MUCOUS MEMBRANE (Arnold Lea).

black, according to the degree of strangulation which has occurred ; at the apex of the swelling a small aperture is to be seen through which urine slowly dribbles. This condition causes severe pain, dysuria, frequency or incontinence, and sometimes vesical tenesmus ; the congested mucosa bleeds a little, either spontaneously, or whenever urine is passed. The condition is distinguished from a dark-coloured

new growth by the fact that the urethral canal passes through its centre, whereas when a growth is present the meatus urinarius is always eccentric.

The *treatment* of the acute form is to reduce it, if possible, under anæsthesia ; this may, however, be impracticable, and if reduced the prolapse sometimes recurs. Excision of the prolapsed portion of the mucous membrane must then be practised, as described on p. 835.

## PART II : SECTION II

### DISEASES OF THE VAGINA

THE vagina may be the seat of inflammation, ulceration, cysts, solid tumours (innocent and malignant). It is also subject to congenital anomalies, acquired defects, and injuries.

#### INFLAMMATION OF THE VAGINA : VAGINITIS : COLPITIS

Inflammation of the vaginal walls is not of frequent occurrence. The acid secretion (p. 233), the many layers of squamous epithelium (p. 55, *see* Fig. 55), and the absence of glands all act together to protect the vagina from infection. When the vaginal secretion is rendered alkaline by purulent discharges coming from above, and when the epithelium is sodden from the same cause, or subjected to the pressure of a neglected or ill-fitting pessary, the natural barriers to infection are broken down.

**Causation.** The commonest causes of vaginitis are gonorrhœal and streptococcal infections, the use of pessaries, excessive coitus, too frequent and too hot vaginal douches, the introduction of foreign bodies, the presence of fistulæ, necrotic and malignant uterine growths and intestinal parasites. Among the rarer causes are specific and tuberculous ulcers, and also malignant disease of the vagina itself.

With regard to gonorrhœa we must repeat that this disease rarely causes primary vaginitis except in young subjects. In chronic cervical gonorrhœa a *secondary* vaginitis may be present, which is due to the septic organisms which have followed in the train of the gonococcus (*see* p. 292).

Primary vaginitis is seen in children, in whom it appears as a vulvo-vaginitis, a condition which may arise from other causes as well as from gonococcal infection (*see* p. 337).

**Acute Vaginitis.** The prominent symptoms are pain, throbbing, and a sense of burning heat. Dysuria and sometimes dyschesia are complained of. On inspection the mucous membrane is red, and roughened by the presence of swollen papillæ. It is covered with a copious purulent or muco-purulent secretion. On swabbing away the pus, the surface is found to be tender, and the tips of the papillæ may bleed. Externally there will be evidence of vulvitis; the labia

may be adherent to one another with inspissated discharge, which later may cause intertrigo of the adjacent skin.

*Vulvo-vaginitis* of children (see Fig. 161, p. 338) is a form of acute colpitis which requires special mention. It begins as an infection of the vulva, whence it spreads to the vagina; it is common in children of all ages. As already stated, a considerable proportion of cases are due to gonorrhœal infection, which may be conveyed by towels or by fingers, or may be the result of indecent assault. In other instances the condition owes its origin to scratching, followed by infection by skin-organisms. Dirt and threadworms are often the cause of the pruritus which leads to scratching. *Vulvo-vaginitis* is present in the rare cases of infection by the Klebs-Löffler bacillus, and also in the ulceration which follows measles and other exanthemata (see *Vulva*, p. 339).

The *treatment* of acute vaginitis is often very unsatisfactory and prolonged. The organism should be sought for by bacteriological examination, and a careful search also made for oxyurides. Mild antiseptic lotions should be used and strict cleanliness is essential. If the gonococcus is detected, treatment with 2 per cent. solution of melargen is best. It may be introduced into the vagina through a small catheter or pipette. In diphtheritic cases, local treatment should be accompanied by use of the diphtheria antitoxin.

**Granular Vaginitis** is a very rare form of colpitis, which is nearly always due to a gonococcal infection in a pregnant woman. The condition is accompanied by pain and an abundant yellow-green discharge. It is termed *granular* because of the presence on the mucous membrane of small indurated nodules of a deep red colour.

**Membranous or Aphthous Vaginitis** may be caused by the presence of the *oidium albicans* in debilitated subjects at the end of a long illness. It is due to an extension of aphthous vulvitis (see p. 340).

Pseudo-membranes may also form after the application of caustics.

Three specific forms of vaginitis must also be mentioned (although their occurrence is rare), viz. diphtheritic, septic, and emphysematous vaginitis.

**Diphtheritic Vaginitis** appears as a form of the membranous variety; it occurs in children as a specific type of vulvo-vaginitis (see above). It may lead to complete or superficial stenosis of the vagina.

**Septic Vaginitis** may occur in the puerperium as a result of the infection of vaginal lacerations, when it may lead to the formation of a false membrane containing streptococci or a mixture of pyogenic organisms. Apart from child-bearing, it may be secondary to ulceration from malignant disease, or from retained pessaries. The foul discharges from cancer of the cervix, or from a sloughing myoma, may likewise set up this condition.

**Emphysematous Vaginitis.** This is a rare disease characterized by the formation of small, hard, purple papules, which become pustular and fill up with gas to form bullæ. As with granular vaginitis, this condition has been most often observed in pregnant and puerperal women who have become infected with the gonococcus.

**Chronic or Catarrhal Vaginitis.** This form of vaginitis is fairly common, being one of the most frequent causes of leucorrhœa. The mucous membrane is reddened, and there is a fairly abundant, yellowish, muco-purulent discharge. On careful inspection of the vaginal wall, numerous small areas of a deeper red than the surrounding mucosa are apparent; sometimes these spots bleed when firmly wiped with cotton wool. The changes are often most marked in the vaginal fornices. Occasionally small vesicles or pustules may be observed on the surface. Microscopically the vaginal wall shows round-celled infiltration of the subepithelial connective tissue, and extensive desquamation of the superficial epithelial layers; at spots corresponding to the deep red areas, the epithelium may be completely shed, laying bare the connective tissue. The discharge is neutral or alkaline in reaction, and contains many pus-cells in addition to shed epithelium.

**Senile Vaginitis.** In women who have passed the climacteric age, or in younger women after an artificial or operative menopause has been produced, a severe form of catarrhal vaginitis is often met with which may be called *senile vaginitis*. In this form the deep red areas already noted are large and numerous, and often especially affect the ostium vaginae. Epithelial desquamation is more extensive, and from the formation of large areas of superficial ulceration two results may follow: (1) Fibrotic thickening and contraction of the connective tissue may occur, leading to irregular puckering of the vaginal wall or to narrowing of the lumen; (2) abraded surfaces which become apposed to one another may adhere, forming transverse septa, or, when affecting the fornices, shutting off small pockets from the main vaginal canal.

This form of vaginitis is accompanied by a profuse, thin, purulent discharge which may be blood-stained. The relative severity of the process is to be attributed to atrophy of the mucosa and loss of the protective vaginal secretion, which render the tissues less able to resist bacterial invasion.

**Diagnosis of the Cause of Vaginitis.** The discharge should always be examined for the exciting organism; in the case of the gonococcus it must be remembered that it quickly disappears from the vagina, so that only the germs of a secondary infection may be found, hence a negative result does not exclude gonorrhœa. The swab should always be taken from the cervix or urethra as the gonococcus persists for a longer period in these situations (*see* p. 289). The associated conditions will help to confirm a suspicion of gonorrhœa, *e.g.* cervicitis,



urethritis, Bartholinitis, may be present as confirmatory evidence. For the bacteriological diagnosis in vulvo-vaginitis of childhood, Sinclair made use of the urethroscope in the investigation of eighty-three cases. This author states that about 22 per cent. of these would have escaped detection without the use of this instrument.

**Treatment of Chronic Vaginitis.** Vaginitis is curable by douching and local applications, supplemented by attention to the general health, and avoidance of local irritation.

Douches are chiefly useful in removing discharges, and thus lessening the irritation which their contact with the mucosa causes, and in preventing the decomposition of retained secretions. The simple saline douche, consisting of a teaspoonful of sodium chloride to a pint of warm water, is the most generally useful, or one of the weak antiseptic douches may be employed instead. It is impossible for the weak solutions used as antiseptic douches to exercise any marked bactericidal action upon organisms which have penetrated the vaginal epithelium.

Local applications are also required and may be made directly through a speculum, or by the use of medicated vaginal pessaries. Surgical disinfection of the vaginal walls under anæsthesia may be necessary in gonorrhœal cases. The most useful applications *per speculum* are solution of nitrate of silver (10 to 20 gr. to 1 oz.) and a 2 per cent. solution of iodine; the vaginal walls may be swabbed with these solutions twice or three times a week, after careful wiping with cotton-wool swabs to remove secretion. Medicated pessaries containing ichthyol, resorcin, thymol, and similar antiseptic substances may be introduced by the patient into the vagina every night; as the medium melts the antiseptic becomes distributed over the vaginal walls. The douche should be used shortly before introducing the medicated pessary.

General treatment consists in the suspension of marital intercourse, avoidance of alcohol and cigarette-smoking, and attention to the daily evacuation of the bowels. If gouty manifestations are also present, treatment should be directed to this condition, which appears to favour the occurrence or the persistence of a mild form of vaginitis.

## ULCERATION OF THE VAGINA

Ulceration occurs under the following conditions :

- (1) From pressure exerted by a neglected or ill-fitting pessary; occasionally also from foreign bodies introduced for purposes of masturbation, or for the prevention of conception, or by insane persons, with no purpose whatever. Fistulous communications with the rectum or with the bladder may result from this form of ulceration.
- (2) From lacerations which have become infected; these may

occur in the puerperium in association with sapræmia or septicæmia, or at other times from traumatism.

(3) From friction in the case of advanced prolapse of the second and third degrees.

(4) From tuberculous or syphilitic deposits, or from malignant growths.

Local or general vaginitis necessarily accompanies ulceration.

## NEW GROWTHS

**Vaginal Cysts.** Small cystic tumours of the vaginal wall are not uncommon, but they very rarely exceed the size of a cricket ball. They are more often met with on the anterior and lateral wall than on the posterior wall. They bulge into the vaginal canal, the covering mucous membrane becoming thin and translucent. Occasionally they become polypoid. In the anterior wall they are often accompanied by prolapse (cystocele); indeed, these two conditions may be readily mistaken for one another, for the cyst may be large enough to protrude through the vulva (*see* Fig. 186). The larger ones may also burrow deeply into the pelvic cellular tissues. The contents are usually thin and colourless, but may be tinted by altered blood. In the smaller cysts, a single layer of columnar epithelium is generally found; in the larger cysts this is often entirely, or almost entirely, lost; they are almost always unilocular.

Cysts of this character are believed to arise from persistent portions of Gartner's duct (*see* p. 77). On two occasions we have met with cysts in the upper part of the posterior vaginal wall, which proceeded from growths of an adenomyomatous nature arising in the recto-vaginal septum. In each case they contained a serous blood-stained fluid. Very rarely multilocular cyst-adenomata occur in the vagina; occasionally, also, small cysts with an endothelial lining are found, which have no doubt arisen from dilated lymphatics. Although the vagina, like the Fallopian tubes, does not normally contain any glands, nevertheless, under the influence of inflammation, cells grow down from the basal layer of the epithelium in the form of solid processes, from which glandular tubules ultimately develop. From these 'glands' small cysts arise, which may be so numerous as to be studded all over the vaginal surface. The condition in this extreme degree is very rare, and has been described by Bonney and Glendining as *adenomatosis vaginæ*. In fewer numbers, or as isolated examples, such cysts are not uncommon.

*Symptoms and Treatment.* Vaginal cysts give rise only to symptoms of mechanical origin; they may protrude at the vulva, causing discomfort and bearing-down pain, or they may occasion difficulty in coitus. They may be dealt with surgically by partial or complete excision (*see* Operations, p. 843).

Vaginal Fibromyomata are much rarer than cysts. In structure




FIG. 186. CYST OF THE ANTERIOR VAGINAL WALL. The cyst protrudes through the vulva when exposed with a speculum.

and appearance they resemble uterine myomata, but the proportion of muscle which they contain is relatively small. They seldom

exceed the size of a cricket ball, and are often pediculated; they are much more frequently met with in the anterior than in the posterior wall. Unlike uterine fibroids, they are generally solitary. They give rise to mechanical symptoms only, and can be readily removed by enucleation.

**Chorion epithelioma.** This rare disease may occur primarily in the vagina, but usually it is secondary to a corresponding growth in the

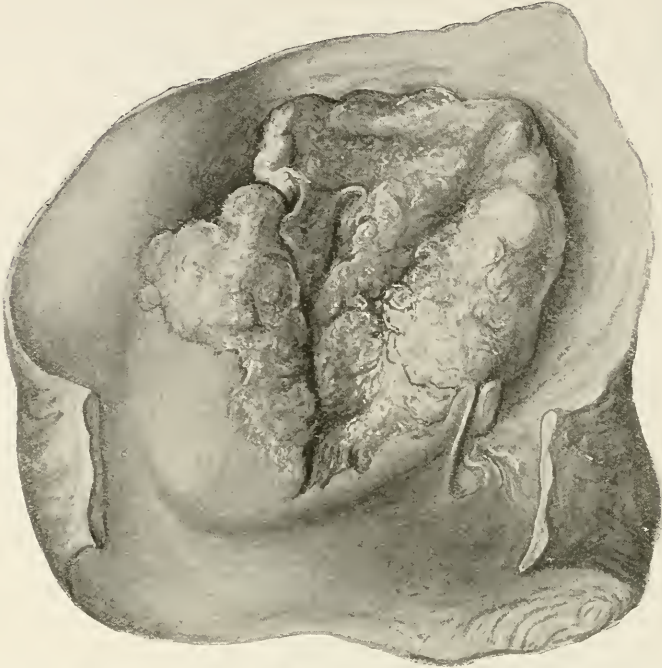

FIG. 187. PRIMARY EPITHELIOMA OF THE VAGINA. The growth occupied mainly the posterior wall, but in its upper part it ran around the lateral wall and reached to the midline anteriorly. In the latter situation the bladder-wall was very adherent.

uterus. A case of primary chorion epithelioma of the vagina has been recorded by Berkeley, and we have seen one such case, where, since removal, the patient has been free from recurrence for some years. The growth appears as a purple nodule not unlike a thrombosed vein; when secondary, there may be more than one of these livid bosses present. In a case at the Samaritan Hospital there were two metastases on the anterior vaginal wall, both of which were visible on separating the labia. These growths are extremely vascular and bleed freely on contact. Primary growths have been known to disappear spontaneously.

**Carcinoma of the Vagina.** Cancer is met with in the vagina as a primary or as a secondary growth.

*Primary cancer* is rare, the subjects of the disease being usually

elderly women, although a few cases have occurred between twenty-five and thirty years of age. In some cases it has supervened upon prolonged irritation from a neglected pessary; occasionally it complicates prolapse of the vaginal walls. In the majority of instances the disease begins in the posterior wall in the form of a circumscribed area of induration; this enlarges in all directions and tends to become ulcerated superficially. Several isolated patches of the disease may be met with, or it may surround the vaginal canal, forming an annular

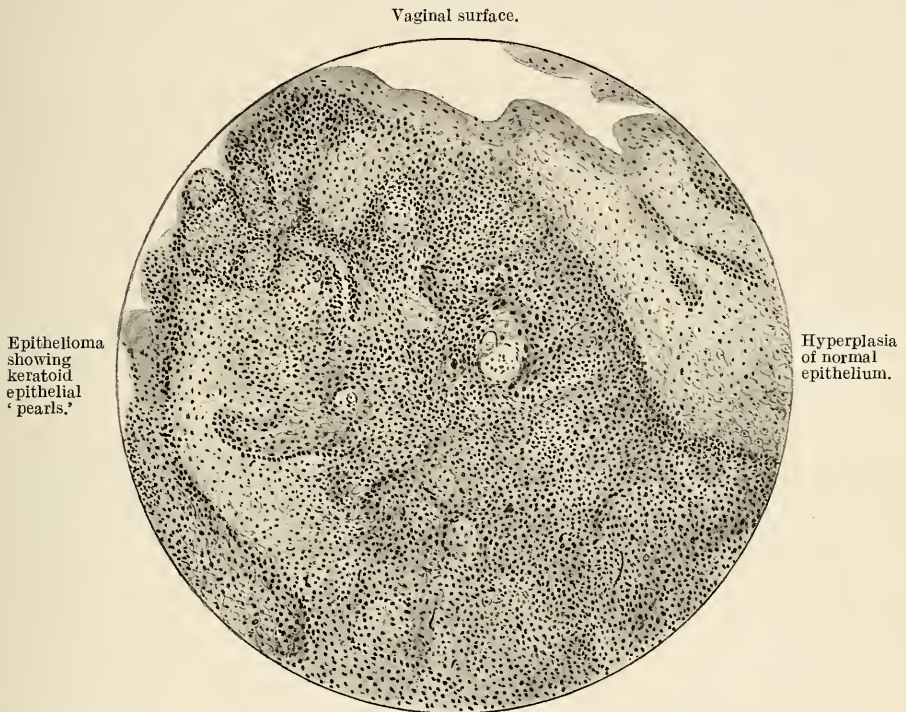

FIG. 188. PRIMARY EPITHELIOMA OF THE VAGINA. Microscopic section of growth shown in Fig. 187.

stricture. The paravaginal cellular tissue is early infiltrated; when the neighbourhood of the ostium vaginae is attacked, the inguinal glands may become indurated; from the remainder of the canal the lymphatics pass, with those of the cervix, to the deep *hypogastric* glands. A rectal fistula is a frequent accompaniment of the later stages; a bladder-fistula may also be formed, but is of much rarer occurrence. Histologically the growth presents the usual appearances of a squamous-celled cancer (*see* Fig. 188).

*Secondary cancer* is more common and may be met with as an extension from cancer of the cervix or of the rectum; more rarely it arises from cancer of the uterine body, the metastases being formed from implantation of living cancer-cells carried down from the uterus

with blood or other discharges. An instance has also been recorded which was secondary to cancer of the Fallopian tube, and Doran recorded a case of malignant hypernephroma of the vagina secondary to a growth in the kidney.

The *symptoms* are indistinguishable from those of cancer of the cervix (see p. 538); the amount of bleeding is, however, small. Digital examination shows the vaginal wall to be the seat of the growth, and the cervix may be found at a higher level than the upper limit of the growth and quite unaffected by it. Fixation of the vagina occurs early from involvement of the perivaginal cellular tissues.

*Treatment.* In the early stages excision of the affected portion of the vaginal canal may be practised or, better still, the entire vagina and uterus may be taken away together *en masse* from below. This severe operation is not practicable if the cellular tissue has become affected. The prognosis as regards recurrence is unfavourable.

**Sarcoma** of the vagina is extremely rare, being much more uncommon even than carcinoma.

In *children* vesicular sarcoma, similar to that met with in the cervix, may occur; infants of one to three years of age have furnished the greater number of cases. The vesicular masses may fill the vagina and protrude at the vulva.

In *adults* sarcoma of the vagina may occur at any time from puberty to extreme old age. It may assume either a circumscribed or a diffused form; in the latter the growth surrounds the whole canal, and considerable constriction of the lumen results.

In 1904 Jellett collected data of thirty-nine cases of primary sarcoma of the vagina. In the majority of cases the growth appeared on the anterior vaginal wall. In Jellett's own case it had spread all around the vaginal orifice. Most of the growths were spindle-celled, and six of these were probably endotheliomata.

A study of the above cases showed that the prognosis of vaginal sarcoma is grave, but in six cases, including Jellett's own, there was no recurrence after several years.

**Endothelioma.** Primary endothelioma occurs in the vagina, but its ambiguous histological features lead sometimes to a diagnosis of sarcoma, at others to that of carcinoma. Jellett recorded a case in 1907 in which the growth appeared in the anterior fornix, in the form of multiple, raised areas which were beginning to ulcerate and which bled on contact. They were regarded clinically as possible extensions from an intra-cervical cancer. Histologically, dilated lymphatics, surrounded by masses of proliferating endothelium, gave a picture resembling gland-formation.

**Diagnosis and Treatment of Malignant Vaginal Growths.** In symptoms and general characters sarcoma and endothelioma resemble carcinoma; histological examination reveals the appearances charac-

teristic of these growths in other parts. The only treatment likely to be useful is free excision of the whole of the vagina with the uterus.

### INJURIES TO THE VAGINA AND THEIR RESULTS

The vagina is frequently *lacerated* in parturition, and from prolonged *compression* during labour, portions of the anterior wall may slough, giving rise to a vesico-vaginal fistula. Sometimes the vaginal wall is *perforated* through violence; the commonest position is the posterior fornix, and septic peritonitis may result from this injury. This may occur in the procuring of an abortion by an unskilled person, or from self-mutilation by the insane. Severe lacerations of the vagina have occasionally occurred during *coitus*; such lacerations usually affect the posterior vaginal wall as an extension from the hymen; in some instances, however, extensive lacerations of the vaginal fornix have occurred, leading to profuse bleeding.

The immediate *treatment* of vaginal lacerations consists in disinfection of the wound, arrest of bleeding, and repair by suture. Injuries involving the wall of the bladder frequently result, later on, in the formation of a vesico-vaginal fistula; this condition may accordingly be conveniently considered here, along with certain other forms of vaginal fistulæ.

**Urinary Vaginal Fistulæ.** The commonest form is that in which direct communication is established between the bladder and the vagina (*vesico-vaginal*); sometimes, in extensive injuries, the anterior lip of the cervix may be destroyed, or so deeply torn that the cervical canal also communicates with the bladder (*vesico-cervical*). Occasionally direct communication is established between the ureter and the lateral vaginal fornix (*uretero-vaginal*); the usual cause is an undiscovered injury to the ureter in the course of such procedures as hysterectomy, resulting in the formation of a fistula.

*Vesico-vaginal fistulæ* are situated in the upper half of the anterior vaginal wall. They are seldom met with of larger size than will admit the tip of the index finger; exceptionally, however, fistulæ of twice this size are seen, while, on the other hand, they may be as small as a pin's head. The larger ones are readily recognized on exposing the anterior vaginal wall with the aid of specula (*see* Fig. 500, p. 826). The vesical mucous membrane becomes prolapsed, and overhangs the edges of the aperture in dark-red folds; the margin of the opening in the vaginal wall is formed by a dense white ring of cicatricial tissue. Urine may be seen escaping through it in small intermittent overflows, as it is delivered into the bladder through the ureters. The smallest fistulæ are more difficult to discover; a probe gives assistance in the search, and if necessary a coloured, sterile fluid can be used to distend the bladder, when the escape into the vagina will be readily seen. The vaginal walls and vulva always

show a good deal of inflammatory change set up by the constant irritation of the urinary overflow. The condition may be complicated by cystitis and decomposition of urine, when extensive excoriation of the mucous membranes and skin may occur, and deposits of ammonia salts collect upon the edges of the fistula.

Vesico-vaginal fistulæ may also be set up in advanced stages of carcinoma of the cervix, or of the vagina, by direct invasion of the bladder-wall, and ulceration of the growth.

*Ureteral fistulæ* are situated in the vaginal fornices ; the aperture is always small, and may be difficult to discover. The local changes in the vagina and vulva are the same as those just described.

Urinary fistulæ, although they cause intense physical discomfort and mental distress, are not attended by serious consequences to the general health, and unless cystitis occurs the risk of ascending infection does not appear to be great. Bladder-fistulæ may be dealt with by the plastic operations described later on (*see* p. 827). Ureteral fistulæ are usually best dealt with by removal of the corresponding kidney, a careful cystoscopic examination being first made to determine which ureter has remained in communication with the bladder. Attempts to effect an anastomosis between the distal end of the divided ureter and bladder have seldom been successful ; but this point is referred to again in a later section (*see* p. 826).



## PART II : SECTION III

### DISEASES OF THE UTERUS

#### A. INFLAMMATION AND ALLIED CONDITIONS

- (a) ACUTE ENDOMETRITIS
- (b) CHRONIC CORPOREAL ENDOMETRITIS
- (c) ALLIED CONDITIONS
- (d) CERVICAL ENDOMETRITIS
- (e) CHRONIC METRITIS

#### ENDOMETRITIS

IN this section will be described the various results of inflammation affecting the uterus and also certain processes which, although allied to inflammation, are not demonstrably inflammatory in their nature. The latter are grouped for convenience along with *Chronic Endometritis* and are spoken of as *allied conditions*; their clinical importance is considerable, and their pathology is still a subject of dispute; it will therefore be necessary to deal with them at some length. The true inflammatory changes, *i.e.* those in which there is histological evidence of inflammation, are probably due in the first instance to *infection*; nevertheless it is not always possible to determine the nature of the infective agent. It will be understood that an inflammatory process attacking the endometrium will tend to spread by continuity of tissue to the uterine muscle; therefore in any case of infective endometritis an element of metritis may also exist. Experience shows, however, that except in cases of acute infection, the muscular tissue is not extensively invaded, and the changes in the endometrium form the important feature. In some cases of chronic infection, however, the whole muscular wall may become affected, giving rise to one variety of the condition known as 'chronic metritis.'

#### ACUTE ENDOMETRITIS

There is only one type of this disease and that is due to infection. The infection of the endometrium occurs in both puerperal and non-puerperal cases. In the former *sapraemia* and *septicemia* will be the

clinical results of the infection (*see pp. 238 and 242*). Of the non-puerperal causes *gonorrhœa* is by far the most important. Other conditions leading to acute endometritis are of an essentially septic nature and include necrotic myomata, degenerating carcinomata, infection of hæmatometra, the passage of a septic instrument, and the results following the use of strong caustics.

Our knowledge of the histology of acute endometritis is, in the main, derived from examination of sapræmic and septicæmic uteri; for it is quite exceptional that opportunity is afforded of examining the endometrium in a case of acute gonorrhœal endometritis, whilst in pyometra the mucosa, as already seen, is reduced to a layer of septic granulation tissue (*see Fig. 132, p. 241*).

Therefore for an account of the morbid anatomy diagnosis and symptoms of acute corporeal endometritis the student is referred to the section dealing with uterine sepsis and pyometra (*see pp. 238 and 243*).

*Subacute Endometritis.* This condition is exemplified in association with retained products of gestation and in sub-involution, conditions which have been fully discussed already (*see p. 248*).

### CHRONIC ENDOMETRITIS

This condition must be separately considered in the body and in the cervix, and may be classified as follows :

(I) *Chronic Corporeal (Interstitial) Endometritis.* The stress of the changes falls upon the stroma, but in some types, glandular increase is also present. Accordingly the main inflammatory changes in all cases are interstitial, and the name of 'interstitial endometritis' adequately describes them all. Certain varieties must, however, be recognized, as follows :

Interstitial Endometritis	{	(a) Atrophic.	{	(1) Diffuse-fungous.
		(b) Hyperplastic		(2) Polypoidal-cystic.

*Allied Conditions.* (a) 'Glandular endometritis' (so-called);  
 (b) Post-climacteric atrophy (so-called 'atrophic endometritis').

(II) *Chronic Cervical Endometritis.*

### CHRONIC CORPOREAL ENDOMETRITIS

#### (Interstitial Endometritis)

**Pathology.** Before proceeding to the study of this subject the student must revise his knowledge of the anatomy of the endometrium (*see p. 16*) and also refer to the description given on pp. 89-97 of the changes which occur in the mucous membrane of the uterus as

the result of menstruation. It will have been gathered from the section on Menstruation that the endometrium varies greatly in its histological characters within purely physiological limits. It is possible to classify these normal variations according to the particular time at which they appear in the menstrual cycle. Thus the endometrium shows (1) post-menstrual, (2) interval, (3) premenstrual, and (4) menstrual changes.

It is evident that these cyclic variations must never be lost sight of in our endeavours to decide, by microscopic examination, between what is normal and what is pathological. The credit of pointing out the importance of considering the menstrual changes in connection with the question of endometritis is due to Hitschmann and Adler (*see p. 89*). The view taken by the above authorities is that there is only one form of chronic endometritis, and that is the *interstitial* variety. If this opinion be correct the classification of chronic endometritis devised by Gebhard and Ruge (*vide infra*), which hitherto has been generally accepted, must be abandoned. All previous classifications of endometritis were made under the impression that between one menstrual period and another, the structure of the endometrium remained fixed and unaltered, whereas it must now be recognized that *the endometrium is never at rest*.

Bearing in mind these fundamental facts, we will now pass on to consider the means at our disposal for arriving at a correct diagnosis of chronic interstitial endometritis. In most organs of the body a chronic inflammatory process does not admit of much controversy, but there are certain special difficulties peculiar to a variable structure like the endometrium which render a correct decision on the question of the presence of chronic inflammation unusually difficult. The recognition of inflammation will depend upon changes in the *stroma* rather than changes in the glands.

(A) *Changes in the Stroma.* (1) *Œdema.* This has been said to be evidence of inflammation, but as it is normally present in the premenstrual stage it cannot be regarded as pathognomonic of inflammation in the endometrium.

(2) *Round-celled Infiltration.* In dense tissue, like muscle for example, the presence of a round-celled exudation is easy of detection, but in a richly cellular structure such as the corporeal endometrium its recognition is more difficult. In the normal stroma we find an abundance of lymphocytes and connective-tissue cells, and just before menstruation a limited number of polymorphonuclear leucocytes are also present. In the subacute, and to a less degree in the chronically inflamed endometrium, there are accumulations of polymorphonuclear leucocytes around the glands and sometimes actually in the lumina. The same cells may also often be found diffused throughout the superficial layers of the stroma underneath the surface-epithelium. The distribution of these cells is often patchy; their diagnostic value

depends upon their aggregate numbers, upon their deep-staining properties, and upon the contrast in shape between their irregular-shaped nuclei and the symmetrical nuclei of the adjacent lymphocytes; moreover, a leucocyte is slightly larger in size than a lymphocyte.

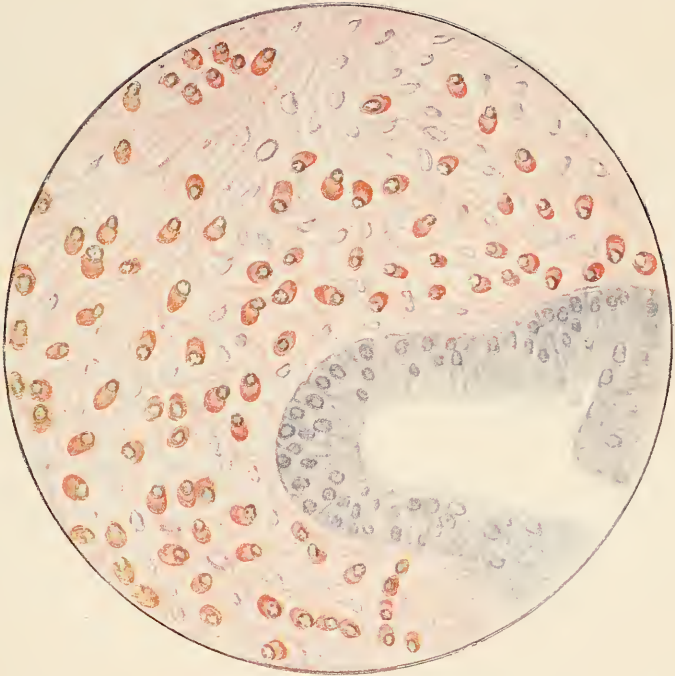
(3) *Plasma-cells* (Plate VII). This is another exudation-cell, which, when present in large numbers, forms the most reliable index we have to the presence of a true *chronic* inflammation. Many authorities dispute the value of the plasma-cell as a diagnostic feature of chronic inflammation, but we agree with Hitschmann and Adler as to its paramount importance. A few plasma-cells may be found in the normal endometrium, just as may a few polymorphonuclear leucocytes, but in the chronically inflamed membrane plasma-cells are abundant (*see* Plate VIII), so that their diagnostic value is dependent on the numbers present. It may be said that during the *subacute* stage of endometritis the inflammatory exudate consists of a diffuse or patchy distribution of polymorphonuclear leucocytes, and that when the inflammation becomes *chronic* the exudation consists of plasma-cells which have replaced the leucocytes.

So important is the plasma-cell in the diagnosis of chronic endometritis, that we must now describe its characters fully.

The plasma-cell is twice the size of a lymphoid cell, it contains a large amount of basophilic cytoplasm, its outline is polyhedral and irregular; there is often a pale area around the nucleus, the latter has a wheel-like appearance; it is eccentric and shows a stellate arrangement of its chromatin bodies. Its origin is variously given. Unna says it is developed from connective tissue; the prevailing idea is, that the plasma-cell is developed from the lymphocytes of the blood or lymph. In chronic endometritis it is found in large numbers, often making up the entire exudate, and it is easily differentiated from the other elements of the endometrium. Plate VIII shows plasma-cells in the endometrial stroma stained by the Unna-Pappenheim method; the chromatin of the nuclei stains green, the cytoplasm red.

The details of the special method of staining for plasma-cells will be found in text-books of Pathology.

At present the diagnosis of subacute and chronic endometritis depends therefore upon the finding of (1) round-celled exudation, and (2) an exudate consisting of plasma-cells distributed in patches or diffused throughout the stroma, but, as in inflammation elsewhere, there are vascular changes to be considered as well. These, in the subacute stage, amount to (3) dilatation of the vessels, and in the chronic stage to (4) the formation of new vessels, and thickening of the vessel-walls. Following on the above changes we get in the stroma (5) the inevitable fibrosis which characterizes all chronic inflammatory lesions. This introduces another difficulty in the case of the endometrium, since in diagnosis we shall be called upon to



ENDOMETRITIS showing Plasma-cells (red) and Lymphocytes (pale blue) stained by the Unna-Pappenheim process.



distinguish between the physiological atrophy of the membrane, which occurs after the menopause, and pathological fibrosis. The latter must also be differentiated from the compressed and relatively dense stroma of the post-menstrual phase.

(B) *Changes in the Glands.* The usual effect of chronic inflammation occurring in the neighbourhood of epithelium is to produce proliferation of the epithelial cells. This appears not to take place in the case of the uterine glands, at any rate it is not constant enough to make it a characteristic feature of chronic endometritis. As a rule, the size and shape of the glands will vary with the phase in the menstrual cycle ; but it would seem that in some cases the inflammatory state of the stroma is capable of *inhibiting the involution which normally occurs in the glands after menstruation*, thus preserving as permanent, the glandular hyperplasia characteristic of the premenstrual stage. It is possible in such cases to find, at all periods of the menstrual cycle, signs of an interstitial inflammation combined with the glandular hypertrophy and hyperplasia, which are *normal* only in the premenstrual phase. In addition to hypertrophy and hyperplasia of the glands, many of the cells lining their lumina retain their secretion and are converted into goblet- or beaker-cells.

We will now enumerate in tabular form the changes in the endometrium which, in our opinion, are due to inflammation and which, therefore, constitute true endometritis.

*The Inflamed Corporeal  
Endometrium shows :*

*The Normal Corporeal  
Endometrium shows :*

- |  |  |
|--|--|
| (1) Mucus <i>within the cells</i> of the glands.                                     | (1) Mucus <i>in the lumina</i> of the tubules only.  |
| (2) Polymorphonuclear leucocytes in large numbers.                                   | (2) Polymorphonuclear leucocytes few in numbers, and present in the premenstrual stage only.   |
| (3) Round-celled exudation in the superficial muscular layers.                       | (3) None.  |
| (4) Plasma-cells in abundance.   | (4) Plasma-cells few, single, or none.   |
| (5) New vessels, many with thick walls.  | (5) Thin - walled blood - vessels only.  |
| (6) Invasion of superficial muscle by some of the tubules of the endometrium.        | (6) Invasion of muscle by glands far less marked.  |
| (7) Fibrosis of stroma, with glands reduced in size, and thick-walled blood-vessels. | (7) Fibrosis of stroma, with shrinkage in size of some glands and cystic distension of others, but no thick-walled vessels (in senile endometrium only). |

Only conditions which fulfil the criteria laid down above can properly be named *chronic endometritis*, and we shall limit this title strictly to them. As already mentioned, two histological varieties of chronic endometritis may be recognized, but, before describing their characters, the question of their causation must briefly be considered.

**Etiology.** In some instances a direct connection with an infection can be established, and most of such cases are gonorrhœal. In others there is a definite history of preceding septic infection to which the condition may reasonably be attributed. In others, however, there is no history of infection from without; the possibility of an infection by the blood cannot, however, be excluded, and consequently even these cases may be due to infection of an unrecognized type. Owing to the multiplicity of organisms present, a bacteriological diagnosis of chronic infective lesions is usually impracticable in all parts of the body.

Chronic endometritis cannot be definitely proved to be gonorrhœal except by demonstrating gonococci in the glands, or in the stroma of the endometrium. Cultures from the corporeal secretion are very difficult to obtain free from contamination by cervical discharge, and, as we shall see later, there is no doubt that cervical endometritis is frequently gonorrhœal. Cases of chronic endometritis associated with definite signs of old gonorrhœal infection may, however, be presumed to be gonorrhœal, and in such, the changes described as interstitial endometritis are frequently met with. There are, however, no histological features specially characteristic of gonorrhœa (*see* p. 294).

Chronic endometritis associated with retained products of conception may be assumed to be septic, and so may cases which immediately follow an infection resulting from miscarriage, labour, or operative interference within the uterus, even if it be of such an inconsiderable character as the passage of the uterine sound. In such cases the lesion is often subacute rather than chronic. In these cases, also, the appearances are not definitely characteristic.

**Varieties.** Two varieties of chronic (interstitial) endometritis may be recognized in which the histological changes are sufficiently distinctive to justify their being regarded as definite varieties. In the *atrophic* variety the stress of the changes falls upon the stroma of the endometrium, the glands being only secondarily affected as a mechanical result of the changes in the surrounding stroma. In the *hyperplastic* variety changes occur in all the elements of the endometrium. As will appear, they are in the main hyperplastic changes, but associated with these are others which can only be regarded as the result of an inflammatory process. It will be recollected that hypertrophy is a common result of chronic inflammation of mucous membranes in all parts of the body.



(a) **Atrophic Form.** In this form there are two stages to be recognized: (1) An acute and subacute stage, and (2) a chronic stage.

In the *first stage* the mucous membrane is reddened and swollen. We have here a true inflammatory process which leads to exudation of serum, red blood-corpuscles, and leucocytes into the stroma. By

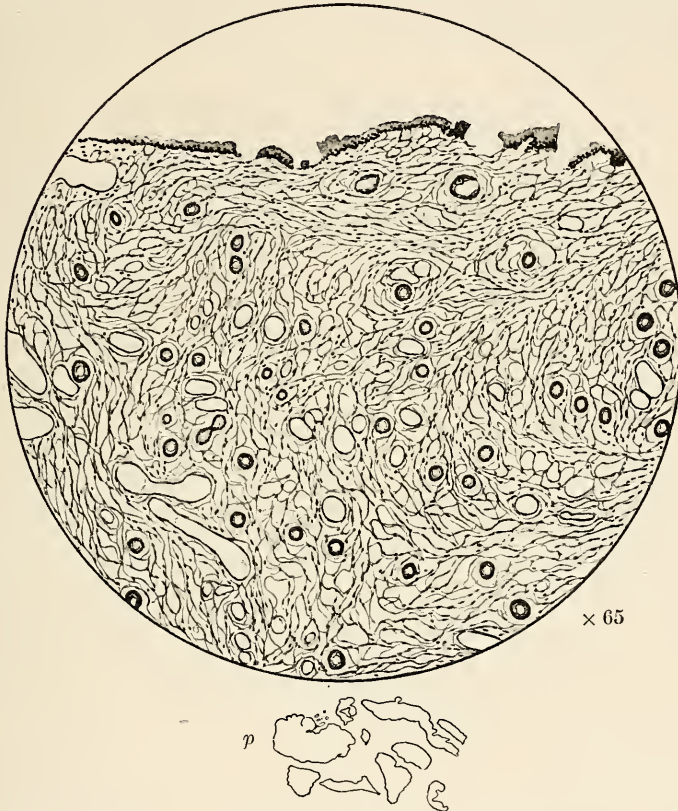

FIG. 189. SHOWING ATROPHIC (INTERSTITIAL) ENDOMETRITIS: CHRONIC STAGE. The fibrotic state of the stroma is apparent. The glands are small and compressed, and many have lost their epithelium. The inset represents the outlines of the tissues on the microscopic slide. It shows a small polypus (*p*), but the other fragments demonstrate the atrophic condition of the mucous membrane.

pressure the glands become smaller, and they are more widely separated from one another by the infiltrated stroma. This stage is met with in ascending gonorrhœa and in sepsis following abortion. In the *second* or *chronic stage* the endometrium is thinner than normal (see Fig. 189). The stroma is denser owing to the presence of fibroblasts and fully formed connective tissue. The glands are small and scanty; many have lost their epithelium and appear as small cysts devoid of a lining. In both the subacute and chronic forms, but especially in the latter, plasma-cells are to be found in abundance. It may therefore

be taken for granted that this is a true endometritis, and always produced by infection. It may be accompanied by *chronic metritis* (see p. 420).

Difficulties in diagnosis may arise in consequence of the resemblance between the large stroma-cells seen in this form of endometritis and the cells of a decidual membrane, or those of a sarcoma. As the differential diagnosis is important, the diagnostic points are here arranged in columns.

*Interstitial Endometritis*

*Decidua*

- |   |   |
|---|---|
| <p>(1) In the acute and subacute stages enlarged stroma-cells are grouped in patches, not uniformly distributed.</p> <p>(2) The stroma-cells are never so large as the decidual cells.</p> <p>(3) The stroma-cells vary in shape and size.</p> <p>(4) The stroma-cells are separated by a loose reticular inter-cellular substance.</p> | <p>(1) The <i>decidua compacta</i> is formed from the whole of the superficial layer of the endometrium, and is therefore uniform and general.</p> <p>(2) The decidual cells are much larger than the stroma-cells in endometritis, and are very rich in protoplasm.</p> <p>(3) The decidual cell is remarkably uniform in shape and size.</p> <p>(4) Decidual cells lie close together, hence the term 'compacta.'</p> |
|---|---|

In the more advanced and chronic stages the young fibrous-tissue cells have to be distinguished from fibro-sarcoma.

*Interstitial Endometritis*

*Fibro-sarcoma*

- |   |   |
|---|---|
| <p>(1) In young fibrous tissue the cells vary slightly in size and shape.</p> <p>(2) The nuclei are quite simple.</p> | <p>(1) In fibro-sarcoma there is much greater variability in size and shape of cells, and in their staining capacity.</p> <p>(2) The nuclei show mitotic figures.</p> |
|---|---|

(b) **Hyperplastic Form.** Two sub-varieties may be distinguished: (1) diffuse-fungous; (2) polypoidal-cystic.

(1) *Diffuse-fungous Form.* In this form of endometritis the mucous membrane is uniformly thickened and tends to the formation of polypoidal masses. Histologically it combines hypertrophy of gland-tissue with extreme hyperplasia of the stroma (see Fig. 190). The glands are as large as those seen in the premenstrual stage, whilst the stroma is as dense as it is in chronic interstitial endometritis. It is probably a true inflammatory condition, and the following features lend support to this view.

In the fibrotic stroma are seen thick-walled blood-vessels which are totally unlike the capillary vessels seen in the normal endometrium at its fullest premenstrual development (compare Fig. 190 with Fig. 62, p. 89). The connective-tissue cells are in every stage of maturity from young fibroblasts (*large stroma cells*) to fully developed strands of fibrous tissue. Many of the columnar cells lining the glands are

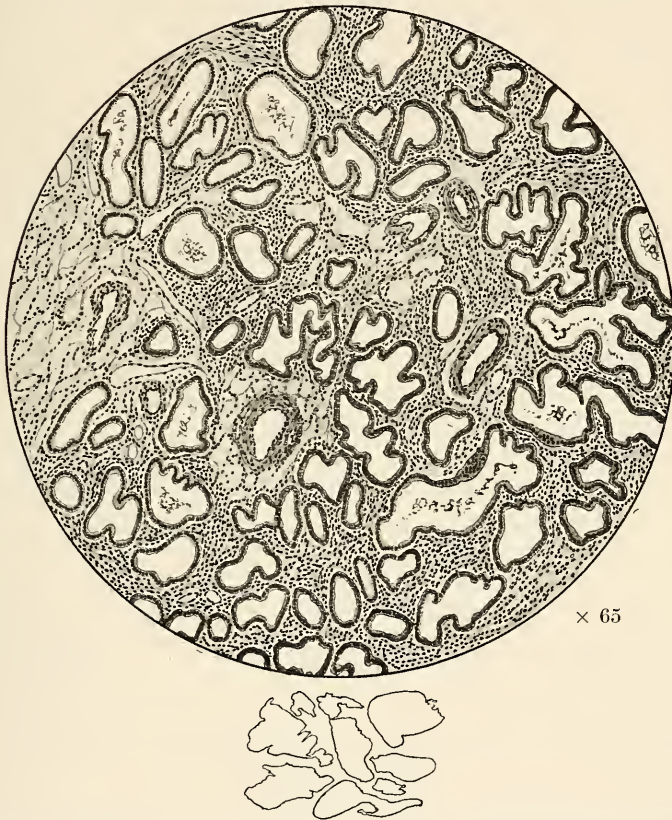


FIG. 190. SHOWING THE CONDITION KNOWN AS ENDOMETRITIS DIFFUSA FUNGOSA. The glands are as large and as complicated as those seen in the premenstrual stage of the healthy endometrium, but the stroma is very dense owing to the presence of young fibrous tissue. The important feature is the presence of thick-walled blood-vessels. Under a high power goblet-cells were seen in the epithelium. The inset shows outline of tissue on slide.

seen to contain goblets of mucus, which is another distinction—as in the normal mucous membrane of the *cavum uteri* there are no goblet-cells, except occasionally during the few days which make up the premenstrual phase (*see p. 18*). Finally, plasma-cells are often found in abundance. There is a tendency to the formation of distension-cysts due to the occlusion of the stomata of the glands on the surface of the endometrium. Indeed, this form merges into the

variety next to be described, *i.e.* *endometritis polyposa cystica* (see Fig. 191).

(2) *Polypoidal-cystic Form.* This variety is probably an advanced stage of fungous endometritis in which the endometrium has become more polypoid and the cystic condition of the gland more marked (see Fig. 191). The condition is comparable to the synovial fringes

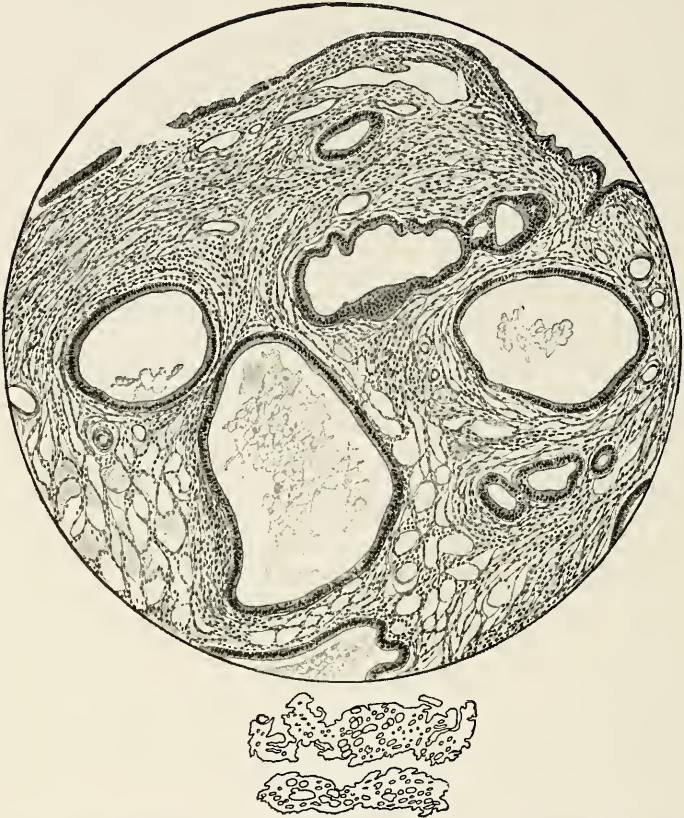


FIG. 191. ENDOMETRITIS POLYPOSA CYSTICA.  $\times 65$ . Note the density of the stroma and the large size of the dilated glands. The inset is a drawing of the scrapings as seen on the microscopic slide by the naked eye.

formed in chronic synovitis of the knee-joint. The polypoidal masses are covered by surface-epithelium except upon their attached side. During curettage a polypoid portion of endometrium may easily be missed by the curette, and if this happens the symptomatic menorrhagia is apt to persist, a fact which renders this form of endometritis more difficult to treat than the other forms above mentioned.

In both diffuse-fungous endometritis and polypoidal-cystic endometritis the deepest lying tubules can be seen to dip down into the muscle-tissue for a considerable distance, and in uteri which have been removed it is found that the muscle-walls are hypertrophied.

There can be little doubt that both conditions are the result of a chronic infective process, as in the case of the atrophic form ; indeed, it is more than likely that fungous and cystic endometritis are later results of an inflammatory process which, starting in the premenstrual phase, *has prevented the normal involution of the glands from taking place*, so that a hyperplasia and hypertrophy of glands, which was originally physiological and transitory, has become pathological and permanent, because the inflamed stroma has *arrested the involution* which is normal to the post-menstrual period.

### ALLIED CONDITIONS

There are a number of conditions which in the past have been wrongly regarded as varieties of 'chronic endometritis' ; none of them, however, fulfil the conditions laid down above as characteristic of a chronic inflammation. One of them, viz. '*glandular endometritis*,' is the condition of the endometrium normal in the premenstrual phase ; another, '*atrophic endometritis*,' is a normal post-climacteric change, which coincides with the general decline of activity in the sexual organs ; a third, *simple adenoma*, is more properly regarded as a new growth ; whilst a fourth, '*exfoliative endometritis*,' is a menstrual disorder which has never been proved to be inflammatory. The first *two* of these conditions, although not instances of endometritis at all, must be briefly referred to here in order fully to explain the present view of the subject, the *third* being dealt with as a new growth of the uterus (*see p. 496*), and the *fourth* as a disorder of menstruation (*see p. 187*).

'**Glandular Endometritis.**' Ruge in 1879, and Gebhard in 1899, described under this name a condition of the endometrium frequently observed in minor gynæcological affections. The condition was pronounced by them to be inflammatory ; the microscopic appearances were definite and readily recognizable ; they were seen with extraordinary frequency under conditions which called for the operation of curetting. The conclusions of Ruge and Gebhard received general acceptance, and thus the belief arose that 'glandular endometritis' was one of the commonest pathological conditions known to the gynæcologist.

It is to Hitschmann and Adler that the credit must be given of first pointing out the error which had been made by Ruge and Gebhard. Their work, published in 1907, upon the cyclical changes in the endometrium, in connection with menstruation, has been described in another place (p. 89), and it suffices here to point out that the changes supposed to be characteristic of 'glandular endometritis' are in reality identical with the changes regularly and normally observed in the pre-menstrual phase. Owing to the special character of the functional changes which the endometrium undergoes, glandular

changes *alone* cannot be accepted as evidence of inflammation. Yet apart from the glands there is no evidence whatever of any inflammatory changes in the condition we are considering. It follows that what has been called 'glandular endometritis' is not a pathological condition at all.

In order to demonstrate the identity of the pre-menstrual changes

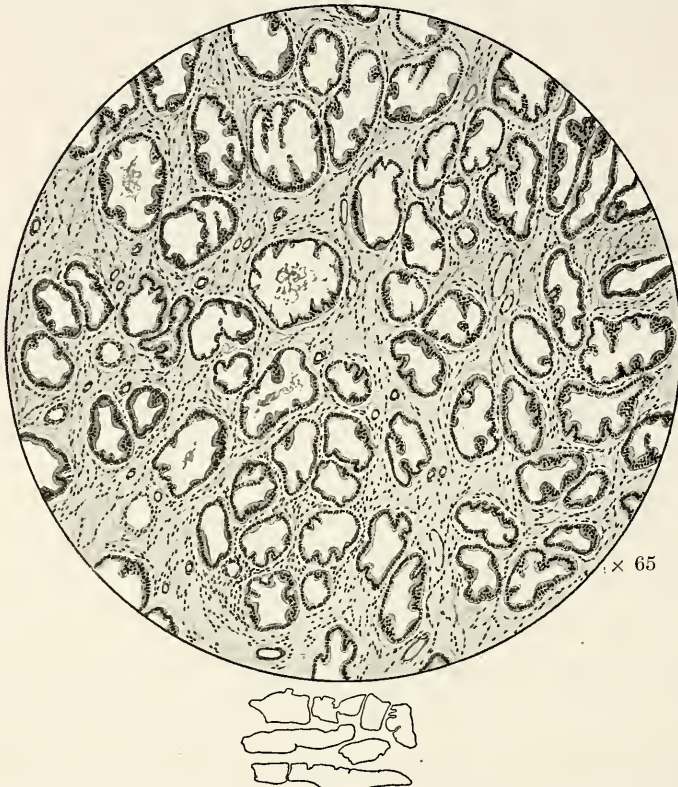

FIG. 192. SHOWING THE SO-CALLED 'ENDOMETRITIS GLANDULARIS.' This is the normal appearance of the endometrium in the premenstrual state. Note the crenated appearance of the tubules, the ingrowing fern-like tufts and the dilated condition of the glands. Contrast also the stroma with that seen in the hyperplastic form of interstitial endometritis (fungous endometritis), Fig. 190.

with so-called glandular endometritis Figs. 192 and 193 are here given; they represent sections which were made from curettings several years ago, and were then regarded as typical of 'glandular endometritis' (compare with Figs. 62 and 63, p. 89).

'**Atrophic Endometritis**' (*Post-climacteric Atrophy*). Hand-in-hand with the shrinkage of the uterus at and after the climacteric, the endometrium becomes atrophic and thin; the glands change their direction in relation to the surface epithelium; originally running at right angles to it, they now take an oblique course (Fig. 194); they are

reduced in size, their orifices become occluded, and they may form small cystic follicles (Fig. 195). The stroma becomes fibrotic, and presents much the same appearances as those seen in the atrophic stage of interstitial endometritis. This is a normal involution-change which occurs

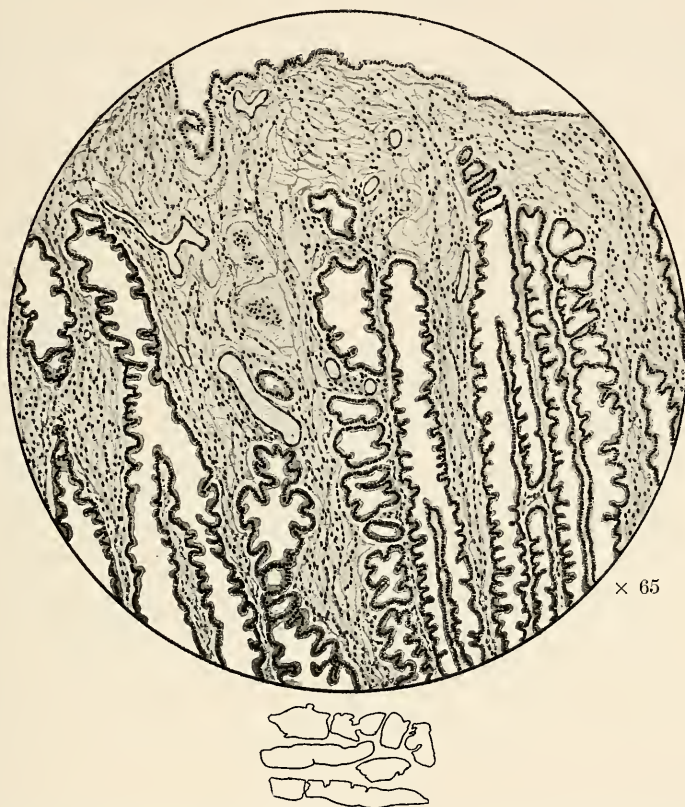

FIG. 193. FROM THE SAME SLIDE AS FIG. 192. The corkscrew-like appearance of the glands is shown, and also the branching. The compact superficial stratum is in process of formation, but no patches of decidua-like cells have formed as yet. Compare Fig. 63, p. 90, which is an advanced stage of the condition shown in this Figure, the formation of the cavernous layer being also more advanced.

after the cessation of the ovarian function. There is nothing pathological in the alteration of structure which the endometrium undergoes as described above. Therefore, like the glandular variety, this so-called 'endometritis atrophicans' must be excluded from the class of true chronic endometritis. It is quite common, however, for infection to be grafted on to this condition, and when it occurs true *senile endometritis* results. The latter has already been described in the section dealing with Infections (p. 251).

Occasionally in this post-climacteric atrophy the surface-epithelium, and that lining the glands, undergoes metaplasia and becomes

squamous ; to this senile change the term *leucoplakia uteri* has been given, and it helps to account for the occasional occurrence of squamous-celled epithelioma in the body of the uterus.

**Simple Adenoma of the Endometrium.** This condition will be described under Benign Epithelial New Growths of the Uterus (*see* p, 496).

**Menstrual Exfoliation** (exfoliative endometritis) has already been described under Disorders of Menstruation (*see* p. 187).

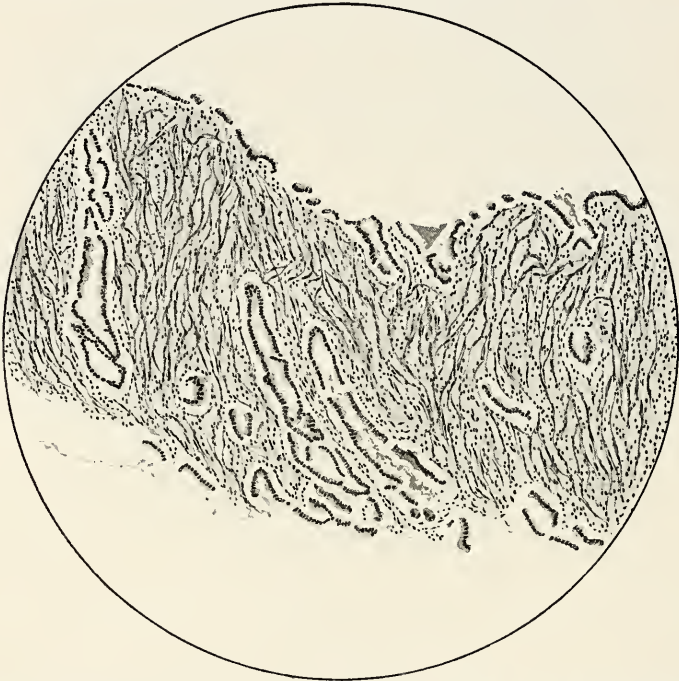

FIG. 194. SHOWING THE CHANGES WHICH OCCUR IN THE ENDOMETRIUM IN OLD AGE.  $\times 65$ . The surface-epithelium is desquamating, the glands are running obliquely to the surface, and their epithelium is degenerated. The stroma is very fibrotic, and the entire endometrium is thin.

### CERVICAL ENDOMETRITIS : EROSION : NABOTH'S FOLLICLES

It has already been shown that the cervical endometrium differs essentially in its anatomical features from the endometrium of the body of the uterus. Pathologically, and clinically also, the cervical part of the endometrium deserves special consideration. In spite of the continuity of the surface-epithelium at the internal os, the spread of inflammation to the cavity of the uterus from the cervix is by no means invariable, and even when both body and cervix are involved, the effects may be much more marked in the latter than in the former.

*Macroscopically*, cervical endometritis is evidenced by redness and swelling of the mucous membrane around a patulous external os, to-



gether with an abundance of muco-purulent secretion from the cervical canal. One or more small mucous polypi are not infrequently seen attached near the margin of the inflamed os, or projecting from the cervical canal. *Histologically*, there is a round-celled infiltration beneath the columnar epithelium and around the glands (Fig. 196). At first the epithelium proliferates, the cells are filled with mucus and are

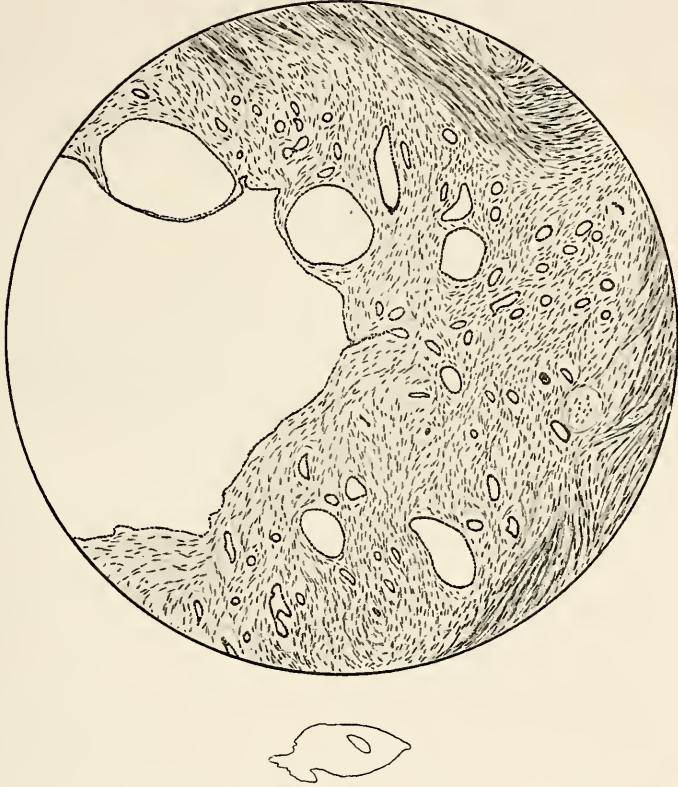

FIG. 195. SHOWING THE ENDOMETRIUM OF A PATIENT IN WHOM THE MENOPAUSE OCCURRED AT THE EARLY AGE OF THIRTY-SIX. Note the fibrotic stroma, the loss of epithelium in the glands and their cystic condition. The inset shows the naked-eye view of a section taken transversely through the cavity of the uterus; the *cavum uteri* being the small oval space seen in the Figure.

rapidly shed. The glands swell up, become cystic, and are filled with their own secretion, in which aggregations of leucocytes are often seen. Proliferation followed by desquamation of the gland-epithelium occurs, leaving cystic spaces devoid of epithelium (*see* Fig. 16, p. 21). During the process of repair, the degenerated glands become invaded by fibroblasts and disappear. The surface-epithelium is renewed by the development of new cells, but the stroma remains chronically thickened by the addition of fibrous tissue, whilst the original tissue shows

hyaline degeneration and marked thickening of the walls of the blood-vessels.

**Pseudo-Adenoma of the Cervix** (*Erosion* or *Catarrhal Patch*). Most intimately associated with inflammation of the cervical endometrium is the common lesion known clinically as *Erosion*, but to which Barbour has given the name of *Catarrhal patch*. The correct patho-

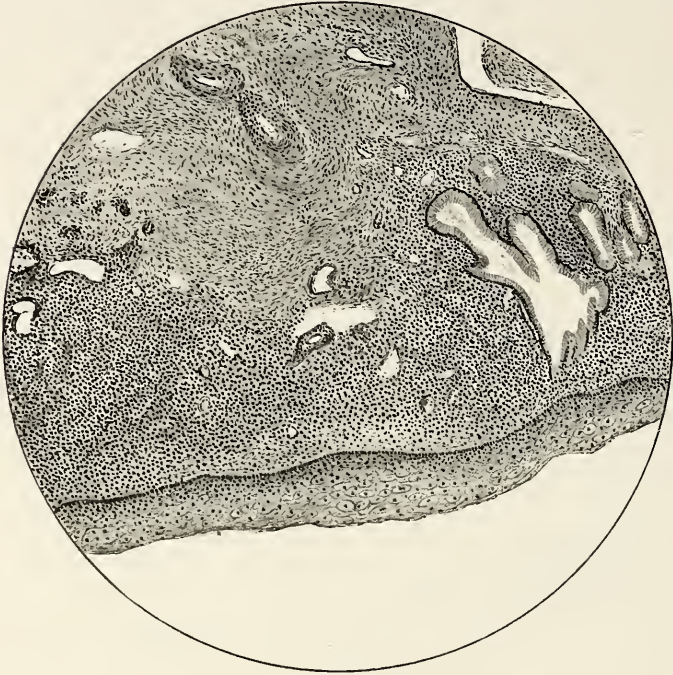

FIG. 196. SECTION THROUGH THE VAGINAL PORTION OF THE CERVIX FROM A CASE OF CERVICAL ENDOMETRITIS.  $\times 105$ . There is an extensive round-celled infiltration of the tissues. This has spread from the cervical canal to the deep aspect of the intact squamous epithelium. At a later stage the squamous epithelium is thrown off, and true ulceration, followed by *erosion*, around the external os is thus produced.

logical name for the condition is *pseudo-adenoma*, glandular proliferation being combined with, and being indeed due to, an inflammatory process. A benign adenoma (a definite neoplasm) also occurs in the cervix and must be carefully distinguished from pseudo-adenoma due to inflammation (*see p. 500*).

*Pathological Anatomy.* In order to understand *erosions* the student must be familiar with the appearances and structure of the normal cervix already described on pp. 19–22.

In the foetus the true mucous membrane extends beyond the external os, so that the lining of the cervical canal, in early life, spreads itself out for a variable distance upon the free vaginal surface of the cervix. When this foetal condition persists it gives rise to what is known as a

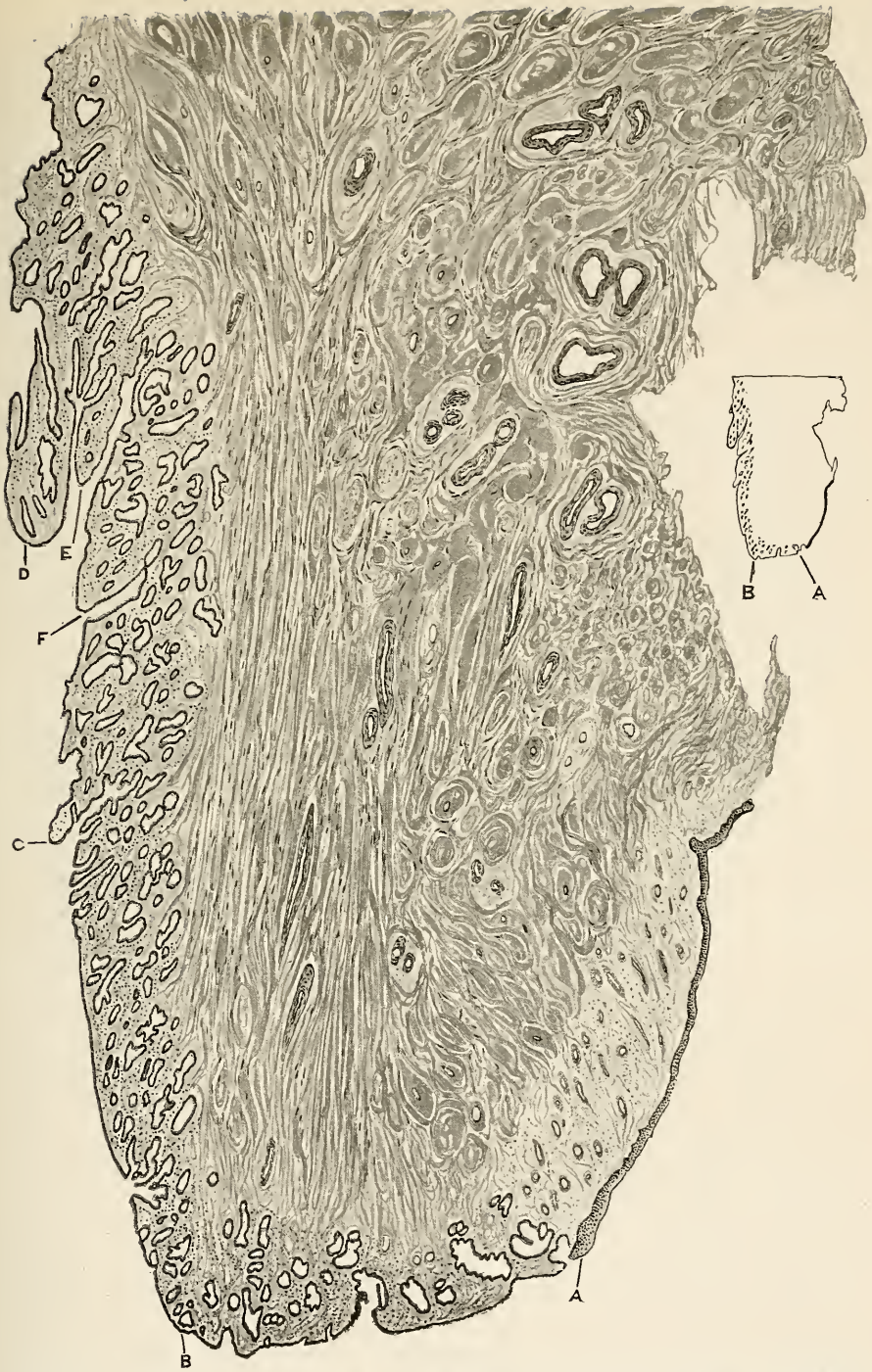

FIG. 197. LONGITUDINAL SECTION OF THE PORTIO VAGINALIS SHOWING THE MICROSCOPICAL CHARACTERS OF AN 'EROSION.' From B to A the squamous epithelium has been replaced by a pseudo-adenoma continuous with the cervical endometrium which it resembles in structure. At C E F are seen the folds of cervical endometrium known as the *arbor vitæ*. At D the endometrium has become polypoidal.

*congenital erosion*. This explains how it is that we find sometimes *erosions* on the cervix in the cases of young virgins, and in the absence of inflammation. Congenital erosions are however uncommon, and with this exception we are convinced that *erosions* are caused by inflammation.

Microscopically, it is quite impossible to distinguish any difference between an *ectropion* produced by laceration of the cervix (*see p. 559*)

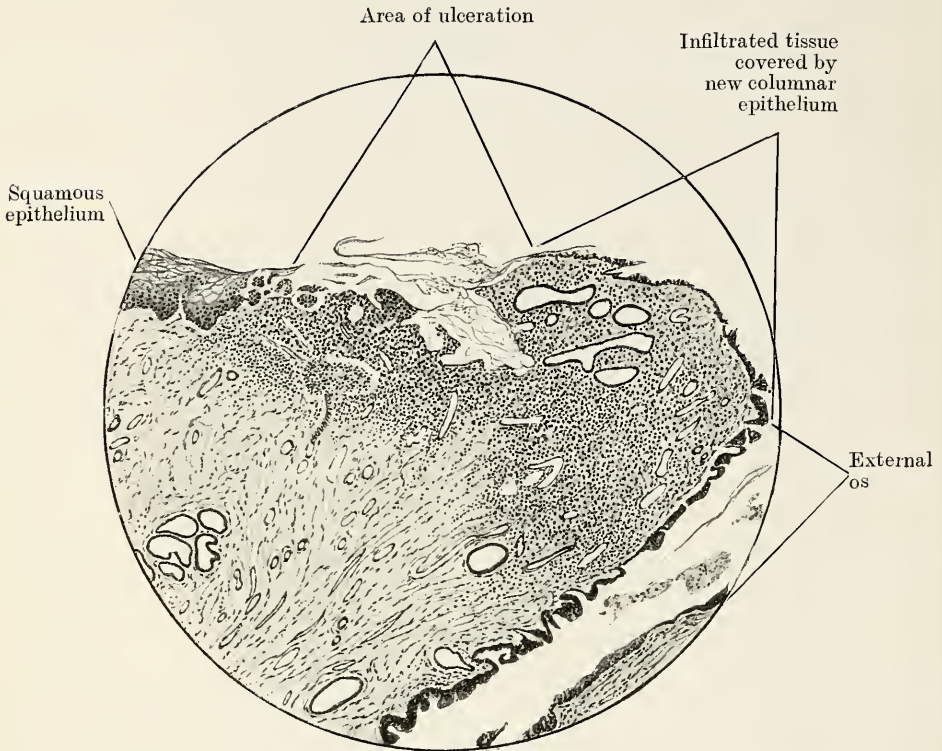


FIG. 198. SHOWING THE INFLAMMATORY ORIGIN OF AN ACQUIRED *Erosion*. An inflammatory exudation has spread from the cervical canal outwards underneath the vaginal surface of the cervix.

and a cervical *erosion*, since the latter presents the same characteristics as everted and inflamed cervical endometrium.

The microscopic characters of a pseudo-adenoma (*erosion*) are those of the cervical endometrium *plus* the signs of inflammation. The result is a *proliferative pseudo-adenomatous* condition consisting of a surface-layer of columnar epithelium through which open the mouths of branching glands which lie immediately beneath (*see Figs. 200G, 201G, 202G*). Under the columnar epithelium and surrounding the glands there are always aggregations of inflammatory round cells, and we have repeatedly found an abundance of plasma-cells in the sub-epithelial exudation. In places, the inflammatory exudation comes to the

surface, and is not covered by epithelium, either squamous, or columnar. Such areas, therefore, are examples of true ulceration (see Fig. 199). They will be covered by the proliferating columnar epithelium at a later stage (see Fig. 198).

We have come to regard an acquired *erosion* therefore, as the result of nature's attempt to heal an ulcer by covering it with epithelium. The columnar character of the latter is due to the fact that, for the most part, it is derived from the epithelium lining the canal, an acquired *erosion* being analogous, so far as the behaviour of the

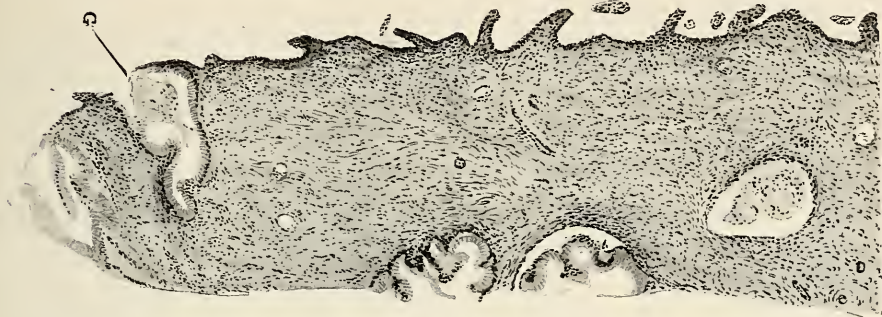


FIG. 199. SHOWING THE SURFACE OF THE PORTIO VAGINALIS.  $\times 80$ . The superficial layers of squamous epithelium have been shed. The basal layer remains and is seen covering the papillae. At G is seen a glandular depression (filled with secretion), which has been formed from the basal layer of the surface-epithelium. The clinical appearances were those of an 'erosion' of papillary type.

epithelium is concerned, to a congenital *erosion*, where the epithelium of the canal does not end abruptly at the internal os, but trespasses on the surface of the vaginal cervix.

We have, however, repeatedly found that the basal layer of the *squamous* epithelium is capable of producing columnar cells, and these, by dipping down into the non-glandular fibro-muscular layers, produce branching glandular crypts. In our opinion, therefore, the glands seen in an *erosion* may be derived from two sources, (1) from proliferation of the true cervical endometrium, (2) from proliferation and metaplasia of the basal cells of the squamous epithelium which covers the vaginal portion of the cervix (see Figs. 200, 201, and 202). When such secondary gland-formation occurs, the glands may open on the surface producing what is sometimes known as a *papillary* form of *erosion* (see Fig. 199); others may present as closed follicles, which become distended by their own secretion to form cysts, producing what is sometimes known as a *follicular erosion* (see Figs. 197 and 200).

When an inflammatory exudate is covered by a *single layer* of columnar epithelium the condition is sometimes spoken of as a *simple erosion* (see Fig. 202). This distinction into *simple*, *papillary*, and

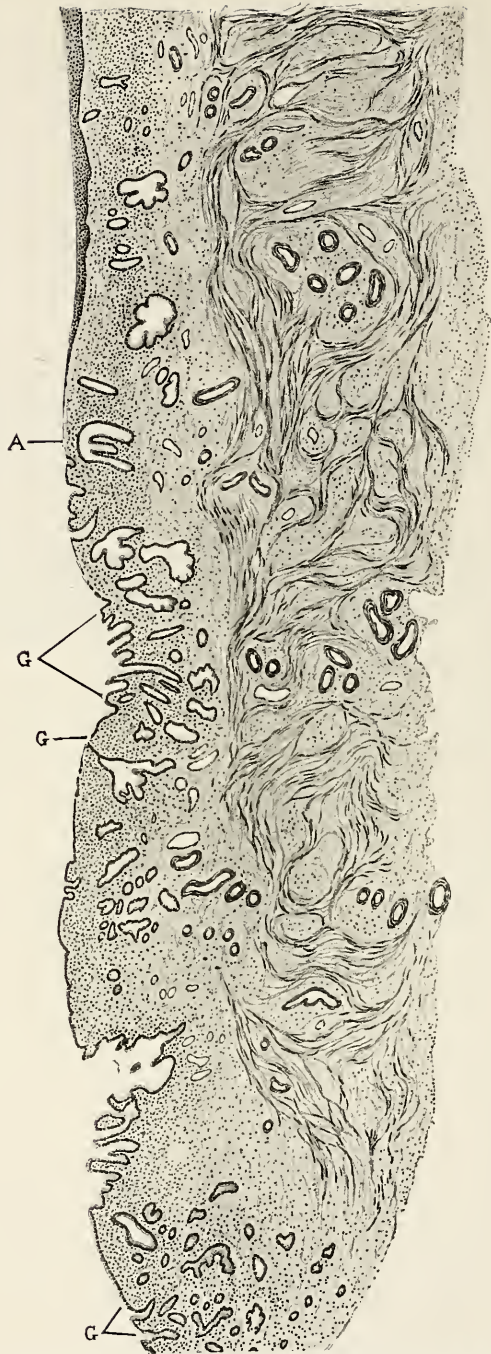


FIG. 200. SHOWING THE SURFACE OF AN *Erosion* ON THE PORTIO VAGINALIS. At A the squamous epithelium has become thinned out, and only the basal layer is left. The basal layer is continued along the remaining surface and sends down gland-like tubules into the stroma at points marked G. The deeper parts of the tubules are seen as epithelial lined spaces (follicular erosion).

*follicular erosions* is highly artificial, because the three varieties are merely phases, or degrees, of one and the same process.

All these types may, however, be produced, not by ulceration and healing, but by a proliferative adenomatous invasion (*congenital*) of the surface of the *portio vaginalis* by the endometrium lining the canal.

Thus an *acquired erosion* is a true inflammatory lesion, while the *congenital* type is due to adenomatous invasion. In *acquired erosion* the inflammatory process has excited epithelial proliferation, with the

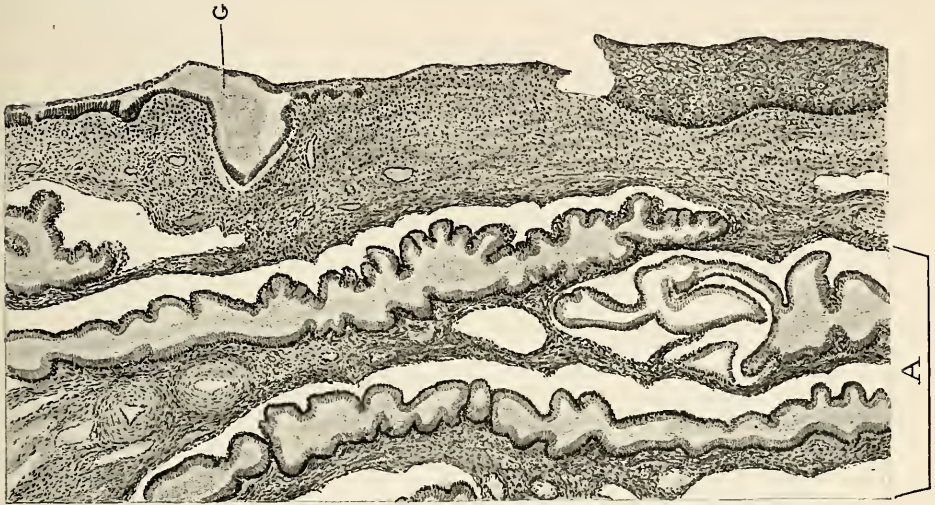


FIG. 201. SHOWING A SECTION OF THE PORTIO VAGINALIS WHICH IS COVERED ONLY BY THE BASAL LAYER OF SQUAMOUS EPITHELIUM.  $\times 105$ . Beneath this there is a gland (G), the columnar epithelium of which is pushing aside the basal layer of the squamous epithelium from which it may have arisen. A shows the tubules of an adenomatous growth. The surface on the right shows squamous epithelium.

object of covering over an ulcer. The process is sometimes discovered when only partially complete; portions of the surface of the ulcer are then apparent, uncovered as yet by epithelium (*see* Fig. 198).

Unfortunately for nature's process, when once epithelial invasion has been started (even when, as here, it is quite benign) it is not easily checked, and instead of normal healing it results in epithelial overgrowth. This is what happens in an *erosion*, so that instead of a healed ulcer, we find a proliferative adenomatous process as the result, and to this we apply the term *pseudo-adenoma of the cervix*.

*Naboth's Follicles.* This is the name given to cystic cervical glands, when they are large enough to be clinically recognized. They push forwards the squamous epithelium, and project as tense shining bluish-looking rounded bodies on the vaginal surface of the cervix. They are frequent enough, apart from any known lesion, to cause anatomists to figure them as a usual characteristic of the normal cervix (*see* Fig. 16, p. 21). These cysts may attain the size of a pea, more rarely they

have been found as large as a grape. When punctured, very thick tenacious mucus escapes. After such a cyst has opened on the surface, if the lining is not destroyed, it may proliferate, and trespass upon the squamous-celled surface and set up an *erosion* in this way.

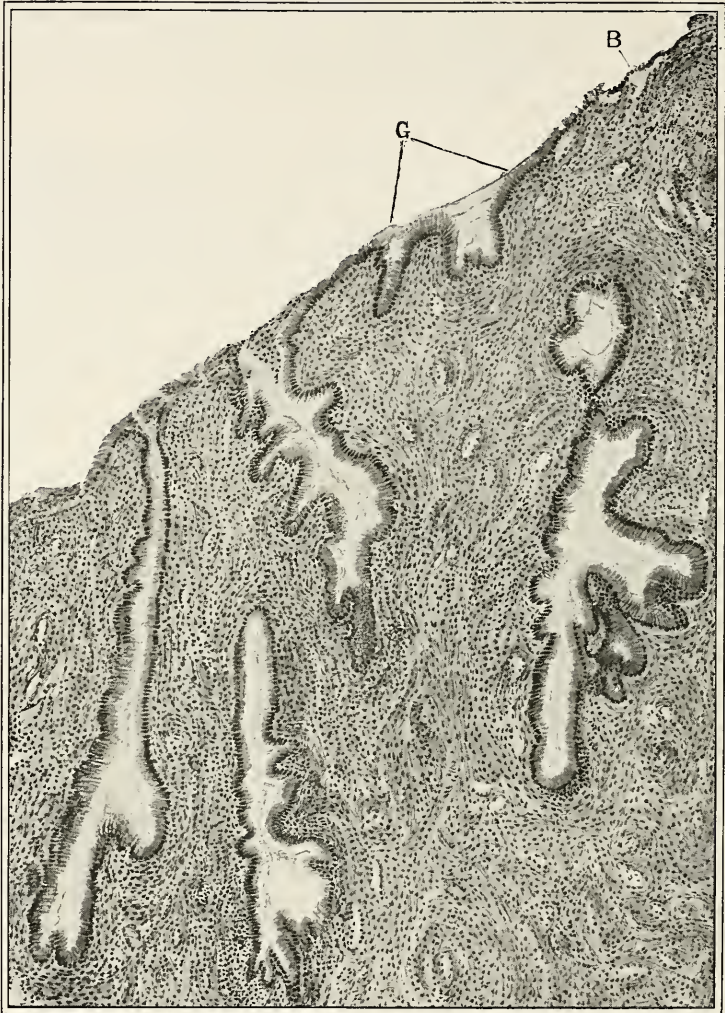

FIG. 202. CERVICAL EROSION (SIMPLE FORM). Vertical section through a patch showing (B) basal layer of surface-epithelium from which glandular depressions (G) have been formed.

It thus happens that the cavity of a previous Naboth's follicle may be seen to open on to an *erosion*. In gonorrhœa, the contents of a Naboth's follicle may become infected, and on puncture muco-pus will then escape.

Naboth's follicles may sometimes appear beneath the surface of



a healed *erosion*. This means that whilst the surface has become normal, some of the deep follicles have not been destroyed, but have become enlarged by distension until they show through the new superficial epithelium ; in other words healing has not occurred in the depths.

### CLINICAL FEATURES OF CHRONIC ENDOMETRITIS

In considering the clinical features it is unnecessary to distinguish between endometritis of the body and of the cervix ; the two conditions almost invariably occur together, although in some instances the chief changes are corporeal, in others cervical. The different conditions of the endometrium described in the preceding pages are not distinguishable clinically from one another ; the same group of symptoms may be present in all. Accordingly, the clinical features of chronic endometritis must be considered generally, without reference to individual varieties.

These conditions are met with in all classes of life, and in all phases of sexual activity. Frequent among married women, both sterile and parous, they are also by no means uncommon in virgins. In the former, the possibility of an infective cause must always be considered ; but in many such cases no clinical evidence of a preceding infection can be discovered. Occasionally occurring soon after puberty, they may be met with at any subsequent age, up to the time when post-climacteric atrophy sets in. They do not occur before puberty or after the menopause.

Chronic endometritis is to be regarded as a minor ailment, and the symptoms to which it gives rise are seldom clinically severe. Four symptoms are so commonly met with in these cases, that their presence in association with one another, suggests at once the nature of the ailment ; they are *leucorrhœa*, *menorrhagia*, *dysmenorrhœa*, and *pelvic pain*. Undoubtedly this syndrome may be met with in other conditions such as fibroid tumours, but chronic endometritis is of commoner occurrence than fibroids, and should be first thought of.

The *leucorrhœa*, which is invariably present, is due to glandular hypertrophy resulting in increased secretion, and the chief source of the discharge is usually the cervix, where more or less extensive *erosions* are nearly always to be found. The discharge is whitish or yellowish-white in colour, and usually non-irritating ; often it contains portions of the viscid, ropy material which is characteristic of the secretion of the cervical endometrium.

*Menorrhagia*, though equally regular in occurrence, is more variable in degree. As a rule the menstrual loss is of moderate severity, distinctly more than is habitual to the patient, but not sufficient to cause marked anæmia and exhaustion. The duration of the period is nearly always definitely prolonged. In rare instances, however,

profuse hæmorrhage occurs which confines the patient to bed, and may even be alarming. The increased menstrual loss is due partly to the increase in thickness of the uterine mucosa, partly to the increased vascularity which attends all new formation of tissue.

*Dysmenorrhœa* is quite as frequently met with as the two preceding symptoms. In nulliparous subjects it is even more frequent, but in parous women it is definitely less common than either leucorrhœa, or menorrhagia (Donald and Shaw). It is seldom really severe, although occasionally, acute cases of dysmenorrhœa are found to be associated with chronic endometritis. The pain can only be referred to the abnormal condition of the endometrium, the abnormally thick and bulky mucosa to some extent interfering with the expulsive power of the uterus, and thus exciting spasmodic contractions.

*Pelvic Pain.* Many patients complain of dull pain, of a chronic character, during the menstrual *interval*. This symptom is, however, absent in something like 60 per cent. of cases (Donald and Shaw). Usually the pain when present is referred to the lower abdomen, more commonly to the left than to the right side; sometimes backache is complained of.

Apart from the characteristic syndrome, other symptoms are occasionally met with. *Irregular bleeding* in the menstrual interval may occur; sometimes this takes the form of an occasional show for a few hours or a day or two; sometimes a quick, sharp spurt of bleeding may occur lasting only a few hours; in rare instances it may occur after coitus. If mucous polypi are found in the cervix (*see* p. 480), bleeding such as this is readily explained, but polypi are not always present in such instances.

*Neurasthenia* and marked derangement of the general health, including dyspepsia, constipation, mental depression, etc., are not infrequently associated with chronic endometritis and its *allied* conditions, especially in cases of long standing. How far these symptoms can be directly referred to the condition of the uterus is doubtful. One thing is clear, however, viz. that neurasthenic symptoms are liable to arise in all cases of long-standing ailments, and when the sexual organs are at fault, the liability to neurasthenia is especially great in both sexes.

In parous women, chronic endometritis may coincide with a period of sterility, and after a successful curetting conception again occurs. And further, nulliparous women, subjects of this affection may remain sterile until relieved by curetting. It is therefore probable that these abnormal conditions of the endometrium are unfavourable to conception.

It must next be borne in mind that chronic endometritis is frequently complicated by other pelvic lesions. What has hitherto been said has reference only to uncomplicated cases. Three other associated conditions are frequently found, however, viz. *backward displacement*,

*prolapse*, and a *small fibroid tumour*. The last-named condition may cause symptoms indistinguishable from those of chronic endometritis, and whenever the clinical features of an individual case are unusually severe, the presence of a fibroid tumour should be suspected. In such cases the growth may be interstitial in position, and of such small size that it is very difficult to recognize it clinically. Well-grown fibroids of considerable size often give rise to symptoms very similar to the syndrome of chronic endometritis, but their presence is readily recognized, and errors of diagnosis should not occur.

Backward displacement, and prolapse, are conditions the symptomatology of which will be considered later.

It is therefore important for the student to bear in mind that pelvic lesions are often multiple, and that the detection of one, probably the most obvious, does not necessarily exhaust the diagnosis; in the case of chronic endometritis, the commoner complications should therefore be borne in mind and care taken not to overlook them.

**Physical Signs.** The uterus in chronic endometritis is always the seat of slight symmetrical enlargement, and the cavity, as measured by the sound, is lengthened for  $\frac{1}{2}$  to  $\frac{3}{4}$  of an inch. The diagnosis, as far as the condition of the corporeal endometrium is concerned, therefore rests upon the association of these physical alterations with the symptoms which have just been described. It has, however, been pointed out that the cervical endometrium is nearly always affected as well, and as this part of the uterus is accessible to visual examination as well as to touch, confirmatory evidence can be usually obtained from it. In cervical endometritis the three following changes may be found on examination *per speculum*: (a) Dilatation of the canal, especially of the external os, associated with eversion when well-marked parturient lacerations are present; (b) the presence of '*erosion*' either in the form of a ring round the os, or on one or other lip, or on both lips, but unequally; (c) an excess of the characteristic clear, or turbid viscid cervical secretion. Only in active infective conditions does the secretion become actually purulent. In parous women the increased size of the canal is often very marked, and the index finger may be passed up to the internal os. In a few cases, one or more small mucous polypi will be seen protruding from the canal, or attached to the lips of the os; they form part of the general overgrowth of the cervical mucosa (see Fig. 238).

When there is no *erosion*, the chief lesion is usually in the uterine body; the secretion then found issuing through the external os is not the characteristic cervical mucus, but a thinner, pale yellowish fluid.

**Treatment.** The majority of cases of chronic endometritis can be cured by curetting, although this operation may sometimes have to be repeated before a satisfactory result is obtained. Cases in which well-marked neurasthenia, or other derangement of the general health is present, do not yield such favourable operative results; these may

either be treated throughout by medical means, or if curetting is performed this should be supplemented by appropriate medical treatment. Curetting will not cure neurasthenia, or chronic dyspepsia, and this should be clearly in the minds of both the doctor and the patient. The details of the operation of curetting will be described in another section (*see* p. 797). If a well-marked *erosion* is present, curetting is not sufficient, for the glands of an *erosion* penetrate the cervical tissues too deeply to be removed by scraping. The eroded areas should therefore at the same time be removed by excision, as described on p. 799.

The benefit derived from curetting is not immediate. The first period may show little improvement. But gradually the conditions improve during the three to six months which follow the operation, until the maximum amount of benefit has been attained.

It must not be concluded that an operation is to be enforced upon all women who are subjects of chronic endometritis. The condition is not in itself serious enough to justify such an attitude. When only the symptoms directly referable to the uterus are met with, and these are well-marked, operation may be advised with confidence. When other symptoms of the neurasthenic type predominate the indication for operation is not so clear.

Such cases may be more successfully treated by medical means. Many are the subjects of chronic toxæmia, usually of intestinal origin, sometimes of some other variety, such as oral sepsis, which is especially common in the 'hospital class.' In such cases the uterine condition is of minor importance, and success cannot be attained by treating it alone. The medical treatment, therefore, embraces many matters quite outside the scope of this work. Direct treatment of the uterine condition by medical means is necessarily symptomatic. The amount and duration of the monthly loss may be checked by the use of drugs, in the manner explained in a previous section (p. 135).

### CHRONIC METRITIS AND ALLIED CONDITIONS

Under this term, are included for convenience, three different pathological conditions, all of which are closely allied in their clinical features although divergent in etiology and structure, only one being a true inflammatory process. As will appear later, the name 'Chronic Metritis' is, from the standpoint of pathology, inexact, but it is convenient to retain it, partly because its use has become general, and partly for the reason that no exact pathological designation for the whole group is practicable. Another name which has been widely applied to the same group of conditions is *uterine fibrosis*; the use of this name we propose to discontinue, for as will be seen, it is even less appropriate than 'chronic metritis.' On account of the intractable bleeding to which it gives rise, Cullingworth called this type of uterus the "clinically malignant uterus." It will be most

convenient, in the case of chronic metritis, to consider the clinical features first, and the pathology afterwards.

**Clinical Features.** These conditions are met with mainly but not exclusively, among parous women. Two series of cases (totalling seventy-four) have been recorded by Fletcher Shaw, and one series of ninety-one by Briggs and Hendy, and in both these series approximately the same proportion of cases is found in which pregnancy occurred, viz. 85 to 86 per cent. The importance of *pregnancy* as a causal factor is clearly indicated by these figures.

As regards *age*, about two-thirds of the cases occur between forty and fifty years, the remainder falling below the age of forty, or at some time subsequent to the menopause. Below thirty years the condition is very rarely met with, but Briggs and Hendy have recorded a case at twenty-eight and Shaw one at twenty-three. Cases of severe hæmorrhage at puberty are occasionally met with which are clinically intractable, and may possibly form a separate group, but opportunities for histological examination of the uterus in these cases must be awaited before a decision can be arrived at.

The characteristic clinical feature of all cases is *severe menstrual bleeding* without evidence of any new growth in the uterus, such as a fibroid tumour or cancer. Other symptoms of minor importance usually met with are *pain* and *leucorrhœa*. The symptoms are but slowly progressive, and the majority of cases do not come under observation until the symptoms have been in existence for several years.

The severity of the hæmorrhage is very variable. Usually its duration much exceeds that of a normal period, and the menstrual interval in a severe case may be reduced to a week or less. Occasionally sharp attacks of profuse bleeding occur, for a few hours, in the course of a prolonged hæmorrhage of moderate severity. The patient may be reduced to a condition of profound anæmia by frequent recurrence of such hæmorrhages. As a rule, however, the amount of bleeding is not alarming, although it greatly exceeds that of normal menstruation. Excessive pain during the period is uncommon. Usually the patient is exhausted by the prolonged period, and requires a week or more to recuperate. Occasionally attacks of slight bleeding occur during the intervals. The usual remedies for uterine hæmorrhage do not control the bleeding at all, and hot douches are also of little use.

In the menstrual intervals a certain amount of more or less constant dragging pain is complained of, which is probably due to the weight of the enlarged uterus (*vide infra*). Unless complications, such as chronic inflammation of the tubes and ovaries, are present, pain is seldom severe.

**Physical Signs.** In a simple case the only abnormal condition found on examination is a symmetrical enlargement of the uterus of moderate extent. In consistence the uterus is unusually hard, and

often it is sensitive or even painful when handled. The sound, if passed, will show that the uterine cavity is elongated, but a measurement of more than  $3\frac{1}{2}$  inches is seldom found. No other abnormality is present in a simple case.

Two complications are, however, of common occurrence, viz. backward displacement of the uterus, and tubo-ovarian inflammation. These conditions of themselves tend to cause the same symptoms, viz. menorrhagia, pain, and discharge, and consequently their presence increases the severity of the case. This is especially true of tubo-ovarian inflammation, and when this condition is present it must be regarded clinically as the predominant lesion, the treatment of which is of more immediate importance than the metritis.

Certain diseases, such as chronic nephritis and general arteriosclerosis, sometimes occur in connection with *chronic metritis*, and they may perhaps be shown in the future to have some causal connection with it. It is important that such conditions when present should not be overlooked.

**Pathology.** However much the histology may vary, there are certain gross changes which are fairly uniform. The uterus is symmetrically enlarged, the thickness of its walls being about twice the normal (*i.e.* 1 inch or more instead of  $\frac{1}{2}$ – $\frac{3}{4}$  inch) (*see* Fig. 203). The cavity is enlarged, being often 1 or 2 inches longer than normal. The uterus as a whole feels abnormally dense and hard. On section the walls appear more fibrous, *i.e.* paler, and the vessels stand out more prominently, than normal (Fig. 203). The characters of the endometrium are by no means constant. The mucous membrane may be thickened or it may be very thin. There may be associated with it salpingo-öophoritis (*see* Fig. 204), but this is not a necessary accompaniment of the disease.

**Classification.** Fletcher Shaw has described three distinct pathological groups, all answering to the above general description and all yielding similar symptoms. We shall best fulfil our purpose by adopting this classification. The etiology of each group is different and the distinction is based on the histological findings, so that the classification is purely pathological. It comprises: (1) Chronic metritis, in the strict and limited sense of the term defined below; (2) chronic sub-involution; (3) hypertrophy.

Fletcher Shaw noted with regard to the relative frequency of the above groups, that in 95 per cent. of cases in which hysterectomy was performed for *chronic metritis* the histological condition was *sub-involution*; in 4 per cent. it was *hypertrophy*; and in 1 per cent. it was true *chronic metritis*, *i.e.* a late result of acute interstitial inflammation. It must be recollected that these three groups may overlap; *e.g.* a sub-involuted uterus may be also the seat of a chronic inflammation.

It will be understood that whilst the term *chronic metritis* is

retained for general application, speaking from the purely pathological standpoint, pure cases of chronic inflammation are but seldom

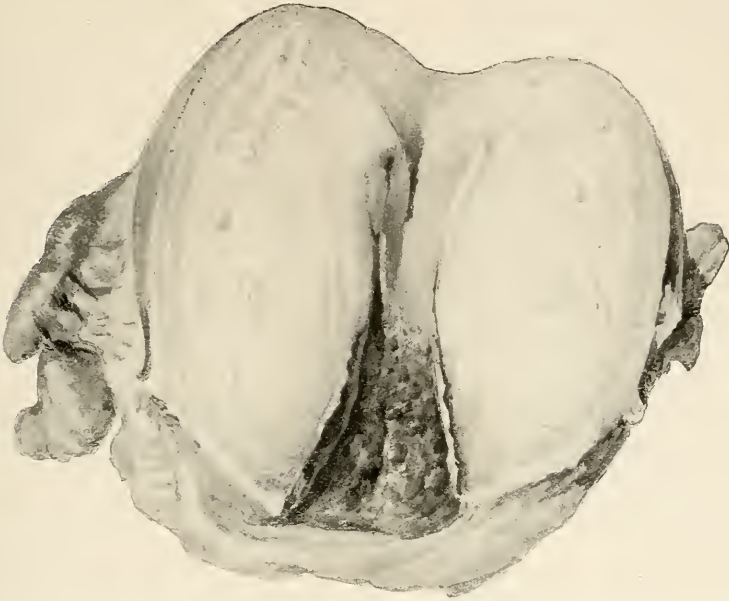


FIG. 203. CHRONIC METRITIS SHOWING GREAT THICKENING OF THE UTERINE WALLS AND THICKENED VESSELS WITH PATENT MOUTHS.

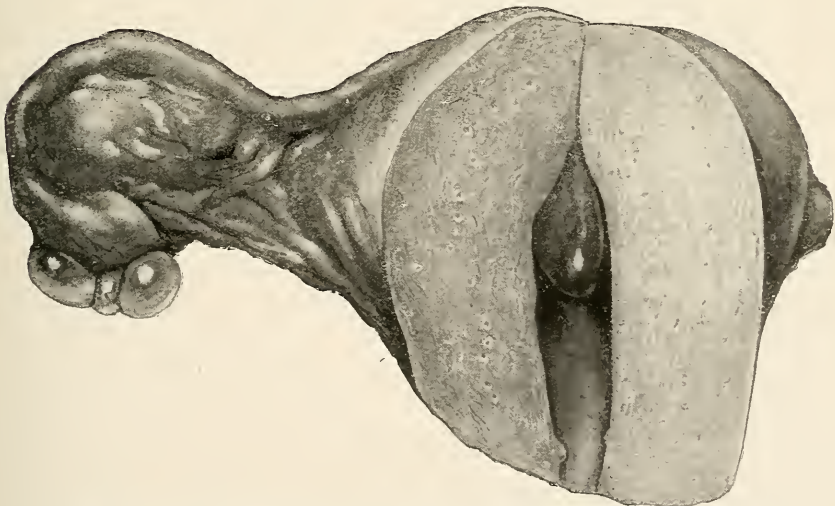


FIG. 204. CHRONIC METRITIS ASSOCIATED WITH CHRONIC SALPINGO-OÖPHORITIS AND AN INTRA-UTERINE MUCOUS POLYPUS. Note the thickening of the arterial walls.

met with, and that most cases described as *chronic metritis* are really examples of sub-involution. We have already expressed the view,

however, that, in spite of the absence of clinical or microscopic evidences of inflammation, sub-involution itself is usually due to a mild form of sepsis (*see* p. 251).

(1) *True Chronic Metritis*. The state of the muscle-wall of the uterus in cases of acute sepsis has already been described in the section dealing with uterine sepsis (*see* p. 244). It is fair to assume that in acute gonorrhœal infection the same inflammatory exudations occur as in puerperal sepsis, but most probably they are not so intense. In the later stages these have disappeared, having given place to fibrous-tissue formation. The fibrous tissue is most marked in the outer third of the muscle wall, but it extends throughout the entire musculature, so that the muscle-bundles, suffering from pressure of the excess of fibrous tissue, become diminished in size and more widely separated than normal (*see* Plate IX). The elastic tissue is not affected, either as regards amount or distribution.

The only histological change in the myometrium in pure chronic metritis is, therefore, an increased amount of fibrous tissue situated mainly in the outer third of the muscle wall; the associated endometrial changes are those described under Chronic Interstitial Endometritis (*see* p. 398).

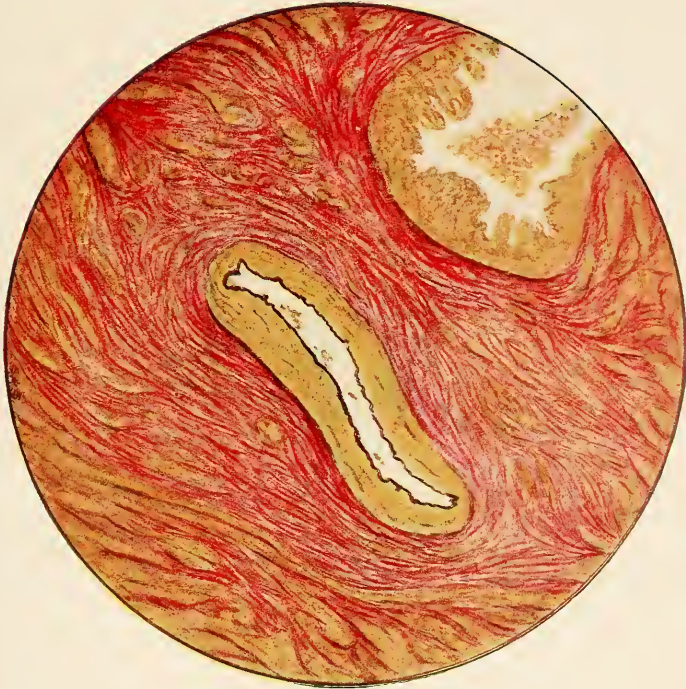(2) *Chronic Sub-involution*. Before describing the changes in the uterus which are produced by sub-involution, we shall mention those by which normal involution is characterized, as described by Goodall.

During *normal involution* there is a rapid diminution in the amount of muscle-tissue, which is probably brought about by atrophy, fatty degeneration, and perhaps peptonization and liquefaction of the muscle-fibres, the waste products being thus rendered soluble and being carried off by the lymph-stream. Changes also occur in the vessel-walls which are of great importance, and for the purpose of understanding the pathology of sub-involution they must be carefully noted. To meet the lessened demand for blood, changes occur, the effect of which is to reduce the size of the lumina of the vessels; this is best seen in those of the retro-placental site. Many of these vessels become completely occluded by thrombosis; in some the blood-clot is seen to become canalized, forming a ring within the tunica interna, leaving a still patent but notably diminished lumen.

In the *arteries*, the fibrous tissue in both tunica media and tunica adventitia swells and undergoes hyaline change, while the elastica interna also becomes swollen and thickened. The staining reactions of this degenerated elastic tissue are profoundly altered, becoming, in the case of young tissues, brick red, and finally, in late stages, yellow (Plate X, A.E.I.), with Weigert's stain, which colours healthy elastic tissue black.

The hyaline tissue of the media next invades the elastica interna, enters the lumen of the thrombosed vessel, and replaces any blood-clot present, the lumen becoming ultimately completely occluded by



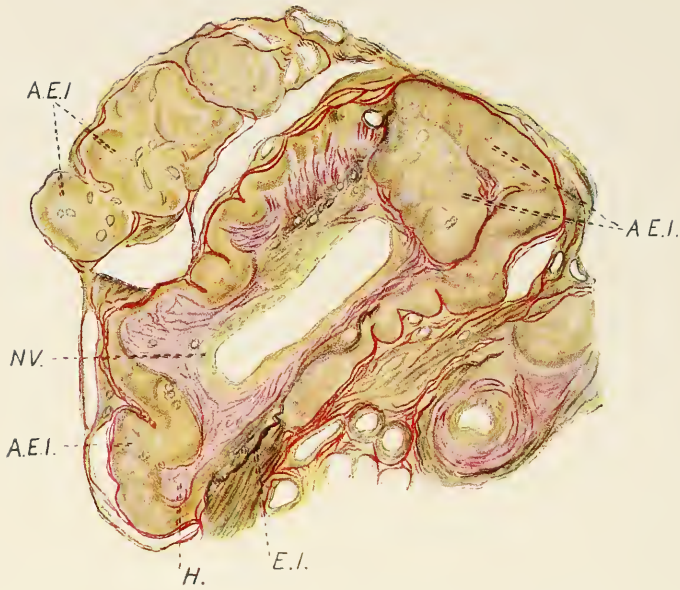


THE UTERINE WALL IN TRUE CHRONIC METRITIS. Note the large amount of red fibrous tissue in the wall of the uterus. The elastic tissue is confined almost entirely to the elastica interna of the vessels.

Stain: Weigert and Van Gieson. (Fletcher Shaw.)



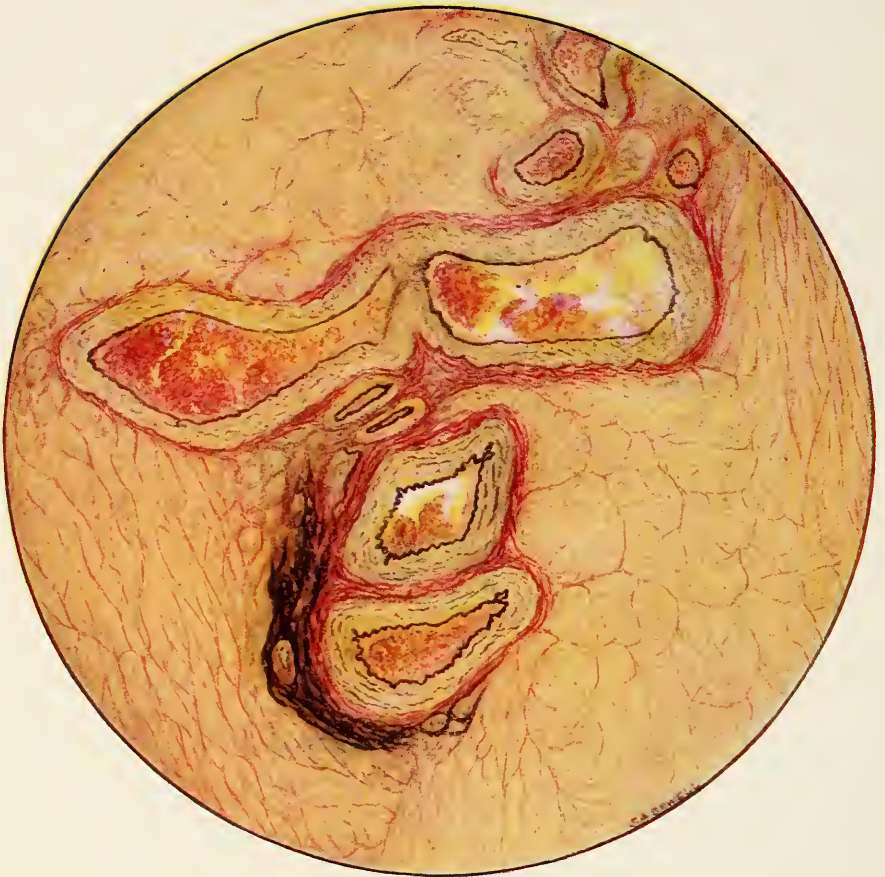



SHOWING HOW AFTER PARTURITION THE NORMAL PROCESS OF INVOLUTION AFFECTS THE ARTERIES IN THE UTERINE WALL (Goodall). Section of a vessel containing a new smaller one. The elastica interna (*A.E.I.*) of the original vessel has undergone colloid change in all its course except at one spot (*E.I.*), where it retains its black stain and where the muscularis of the old tunica media remains, though interspersed with elastic tissue. (*H.*) denotes the interarterial space filled with hyaline substance. At one spot it has become invaded by elastic tissue. (*N.V.*) = the new vessel within the old one. In the upper left corner is shown a large corrugated degenerated elastica interna of a vessel cut more or less parallel with its long axis. It contains in its central part a minimum of red hyaline tissue. In the right lower corner is seen a partially atrophic old vessel of small calibre with a still smaller new vessel in its lumen. A relatively large interarterial space filled with red hyaline tissue is present.

After Goodall.

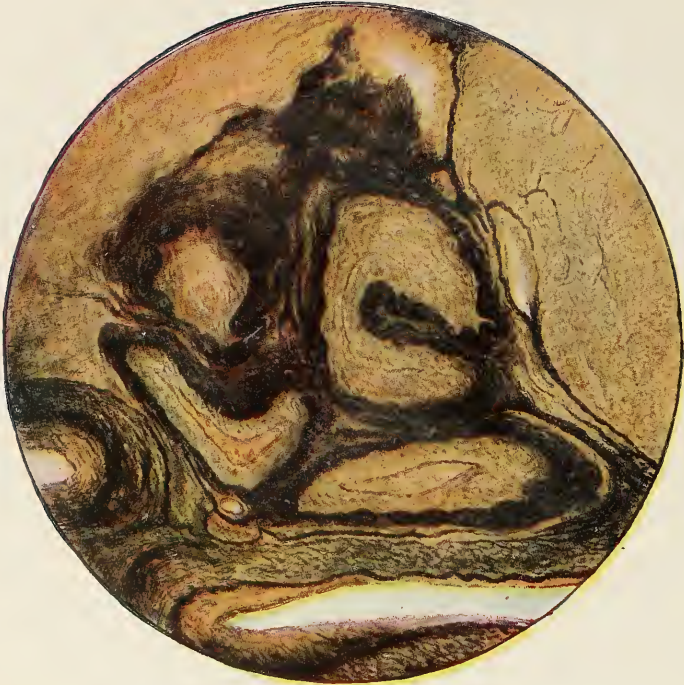



VESSELS IN A NORMAL PAROUS UTERUS. All these vessels are new-formed, the remains of the old vessel-walls having been completely absorbed, except in the left bottom corner of the figure. Here two vessels retain some black elastic tissue outside their wall. This elastic tissue is the remains of the elastica interna of the old large vessel within which the two new ones were formed.

Stain: Weigert and Van Gieson. (Fletcher Shaw.)





VESSELS IN A SPECIMEN OF CHRONIC METRITIS DUE TO SUB-INVOLUTION. These new-formed vessels, each with a narrow elastica interna, are surrounded by masses of black tissue; they are the degenerated remains of the elastica interna of the old vessels which have not been absorbed.

Stain: Weigert and Van Gieson. (Fletcher Shaw.)



the hyaline material. When thrombosis has been partial or absent, the hyaline material which has entered the lumen becomes invested with endothelial cells which form the lining of a new vessel within the old one (Plate X, N.V.). External to this, the hyaline material in turn becomes invaded by muscle-cells and fibroblasts, and a new vessel-wall is produced by these elements arranging themselves in a ring, the muscle-fibres inside (*media*) and the fibroblasts outside (*adventitia*). All this takes place within the old vessel, so that we have a new small artery, surrounded by the remains of the *elastica interna* and *tunica media* of the old one (Plate X, A.E.I. and N.V.). Intervening between the new vessel and the remains of the old one is the *inter-arterial space*, which is occupied by the hyaline material which flowed into the lumen and lined the *elastica interna* (Plate X, H.). The old vessel-wall in complete involution would totally disappear, but involution is seldom complete, so that traces of some of the old vessels usually remain to stamp a normal parous uterus (Plate XI).

In *sub-involution* the most noticeable feature is the persistence of a *large* amount of tissue which belonged to the old vessels. We thus find new vessels surrounded by masses of degenerated *elastic tissue* which belonged to the swollen *elastica interna* of the old vessels. This now regains its normal staining properties, and appears black instead of brick-red, when stained by Wiegert's method (Plate XII). Sometimes this elastic tissue is interspersed with muscle-tissue representing remains of the old *media* (*see* Plate XI).

In the *veins* there is no definite *elastica interna*, but the walls contain a good deal of elastic tissue intermixed with fibrous tissue. During involution the fibrous tissue swells and becomes hyaline; this reduces the lumen of the vein. This hyaline tissue normally becomes converted into muscle, but when involution is impaired (*sub-involution*) it is converted into *elastic tissue* instead of muscle.

During involution the fibrous and elastic tissues of the uterine musculature undergo the same change as in the vessel-walls, *i.e.* they swell and become hyaline, afterwards becoming partly absorbed. In *sub-involution* absorption of the excess is arrested, and this is reconverted into fibrous and elastic tissue, so that more of the latter remains than is seen in a normal nulliparous uterus.

*It will thus be seen that an excess of elastic and fibrous tissues forms the predominant feature of a sub-involuting uterus.* The cause of this imperfect involution is usually, if not always, *sepsis* of a moderate degree (*see* p. 251). The infection may be so slight as to give no other sign of morbidity save the *sub-involution*. On the other hand, the *sepsis* may give rise to peri-uterine infection, and in the case of retained products to *sapremia*. Contributory causes are *age*, *multiparity*, and *general acute and chronic diseases*, which cannot be discussed in this connection.

(3) *Hypertrophy.* According to Fletcher Shaw 4 per cent. of the cases of *chronic metritis* must be classed as chronic non-inflammatory hypertrophy and hyperplasia. The type of patient in which this is to be found is a nullipara, at or near the menopause, suffering from the chain of symptoms of which hæmorrhage is the most marked. The only physical sign is a symmetrically enlarged firm uterus. All signs of inflammation are absent.

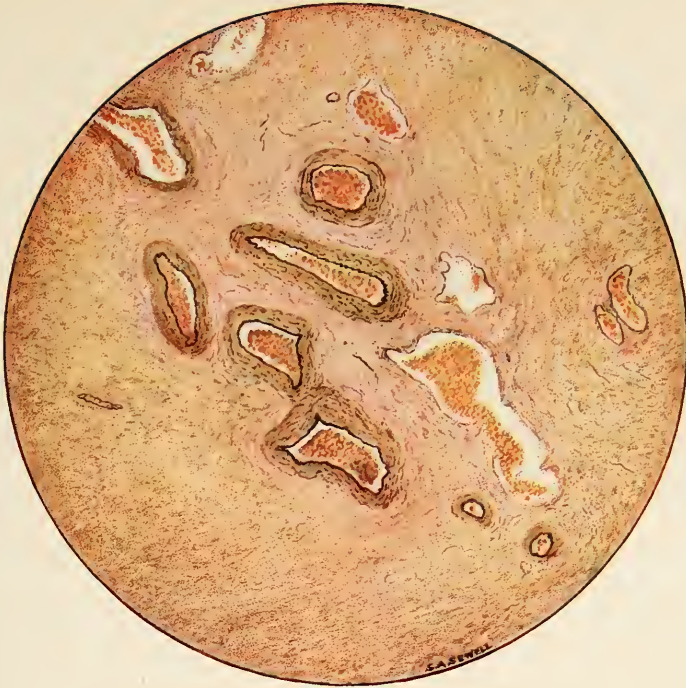The pathology of such a uterus is very different from the preceding varieties. The most marked feature is the great thickening of the endometrium. To this is added an increased thickness of the muscular walls. Muscle and fibrous tissue maintain their normal *relative* proportions (*see* p. 22), only there is a proportional increase of each of these constituents. The amount of elastic tissue and its distribution is similar to that of a normal virgin uterus (*cf.* Plate XIII (*a*) and (*b*)). In fact all the component tissues maintain their virginal proportion (*see* Plate II, p. 22), the changes being purely quantitative, not qualitative. Histologically, no distinction can be made between the hypertrophic and the normal uterus.

The explanation of the enlargement is that there is a primary adenomatous hyperplasia of the endometrium (*see* Fig. 248, p. 497), which causes excessive hæmorrhage. The increased thickness of the muscular wall is regarded as due to a work-hypertrophy produced in the endeavour to expel the swollen endometrium, which is treated as a foreign body.

These three varieties, as described by Fletcher Shaw, undoubtedly include the great majority of cases clinically classed as chronic metritis. It is possible, however, that further observation will lead to the recognition of a fourth variety, *viz.* that due to *uterine arterio-sclerosis*. General blood-vascular diseases may affect the uterine vessels in the same manner as those of other organs. In elderly women they may be atheromatous, and we have in one case found definite sclerotic changes in the arteries in a uterus removed for uncontrollable bleeding (*see* Plate II). This uterus was not enlarged, and structurally it was found that there had been a considerable replacement of muscle by fibrous tissue (Plate II), owing to the patient having passed the age of the climateric.

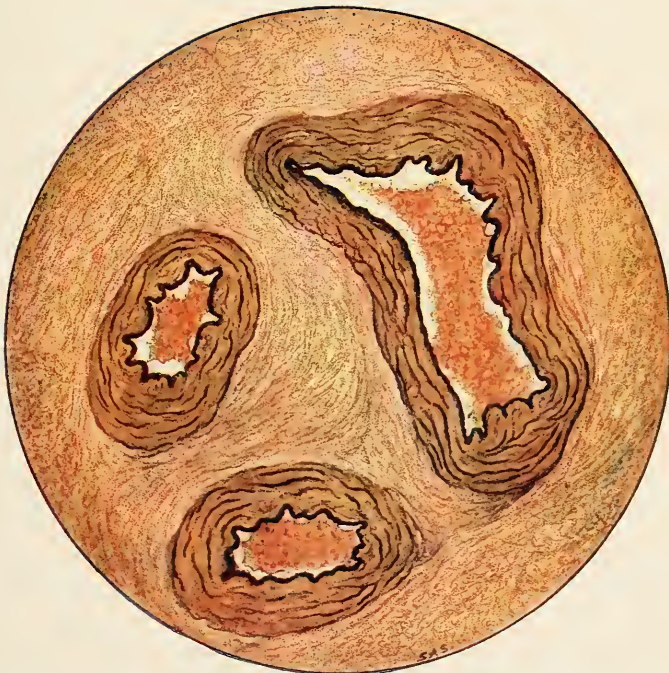Some observers, including Beckwith Whitehouse, have advanced the view that some cases of chronic metritis are due to syphilis, but it has never been proved that syphilis alone can produce any of the changes which have been described as characteristic of the three main varieties.

**Mechanism of the Bleeding.** There are probably two main factors which determine the character and the severity of the bleeding, in cases of chronic metritis. The first is the associated thickening of the endometrium, which is present in a considerable proportion of cases; the second is the mechanical obstacle to efficient retraction



VESSELS IN A SPECIMEN OF CHRONIC METRITIS DUE TO HYPERTROPHY. These vessels are indistinguishable from those found in a virgin uterus (*vide infra*).

Stain: Weigert and Van Gieson. (Fletcher Shaw.)



ARTERIES IN A VIRGIN UTERUS. The elastic tissue is confined chiefly to the internal elastic lamina of the arteries.

Stain: Weigert and Van Gieson. (Fletcher Shaw.)



of the uterine muscle, owing to the presence of a relative excess of elastic tissue or, in some cases, of fibrous tissue. This second factor is obviously not present in cases of simple hypertrophy. The importance of uterine contraction in arresting menstrual bleeding has been already explained (*see* p. 100) and need not be further alluded to. A subsidiary factor, which must not be overlooked, is the frequent association of inflammatory lesions of the adnexa, the effect of which is to favour pelvic congestion during menstruation.

**Treatment.** Experience has conclusively shown that medicinal treatment of *chronic metritis* is useless. Drugs which control uterine hæmorrhage in other conditions are of no benefit, and the same must be said of balneo-therapeutics, douching, and intra-uterine applications. Even the resulting anæmia cannot be successfully treated while the periodic losses of blood continue to recur.

Curetting is sometimes of temporary benefit, but is never permanently curative. From what has been said of the mechanism of bleeding in these cases, it will be clear that removal of the endometrium, when thickened, will not completely restore normal conditions in the uterus, although it removes for a time one of the factors which produce excessive hæmorrhage. In some instances curetting is not even of temporary benefit, and this is especially true of cases in which the endometrium removed by the curette is not obviously thickened. Owing to the difficulty of making the clinical diagnosis between chronic *endometritis* and chronic *metritis* when the case first comes under observation, curetting is, as a rule, first performed, and the non-success of this operation is an important diagnostic aid. The inefficiency of curetting is a clinical point which is firmly established by general experience.

The only other operative measure available is removal of the uterus, the ovaries being both conserved if healthy. This, of course, definitely arrests the bleeding and is accordingly a certain cure. To remove an important organ which shows so few pathological changes as does the uterus in chronic metritis, undoubtedly appears a disproportionately severe surgical procedure. The amount of suffering, ill-health, and physical disability caused by this condition is, however, extraordinarily great, and in this must be sought the real justification of the radical operation. The sudden arrest of menstruation is liable to entail certain disagreeable results which have been already referred to, but these are only slight disadvantages in proportion to the relief which the operation brings.

*Radio-therapeutics.* An alternative to removal of the uterus has been made available during the last few years by developments in the therapeutic uses of X-rays. By repeated external applications of X-rays, it has been conclusively shown that complete arrest of menstruation can be obtained with something akin to certainty, this effect being produced by the direct action of deeply penetrating hard

rays upon the uterus and the ovaries. The technique is the same as that employed for the X-ray treatment of fibroid tumours, and the matter will be more fully dealt with in that connection. Much less experience has been obtained at the moment of writing of the effects of radium and the allied metal mesothorium upon chronic metritis, and no definite conclusions are at present warranted.

## B. NEW GROWTHS AND CASTS OF THE UTERUS

- (a) FIBROID TUMOURS
- (b) POLYPI
- (c) CASTS
- (d) ADENOMYOMA
- (e) ADENOMA
- (f) MALIGNANT GROWTHS

### FIBROID TUMOURS

#### GENERAL PATHOLOGICAL ANATOMY

These tumours occur in great diversity of size, shape, and distribution; they are subject to a variety of secondary changes, and frequently induce secondary changes in neighbouring organs; their description must necessarily be somewhat lengthy.

Fibroids may develop in any part of the uterus, but are much commoner in the body than in the cervix, only 8 per cent. of all uterine fibroids being situated in the cervix. In rare cases they arise also in the round ligament. They are almost invariably multiple, probably not more than 1 to 2 per cent. occurring as single tumours. They may, under certain conditions, attain enormous size, and all gradations may be met with down to small growths of the size of a split pea or a millet seed. They may symmetrically enlarge the organ in which they grow, or they may distort its shape, or, being attached to the uterus only by a pedicle, they may attain a large size without producing any considerable alteration in the bulk or shape of the parent organ. When multiple, one growth frequently attains a size predominant over the others; the number to be found in a single uterus is, as a rule, comparatively small, but occasionally enormous numbers of small growths are met with, none of which attains considerable size.

Fibroid tumours are solid growths arising in the muscular tissue of the uterine wall. In the early stages they are invariably enclosed within a well-formed capsule, from which they receive their blood-supply; their vessels therefore enter at the periphery, and the central

parts of these tumours are less vascular than the peripheral parts. As they increase in size they may either grow outwards beneath the peritoneum or inwards beneath the mucosa, or they may remain surrounded by a definite layer of uterine muscle, *i.e.* completely enclosed with the uterine wall. Three varieties are thus produced which are respectively called *subperitoneal*, *submucous*, and *inter-*

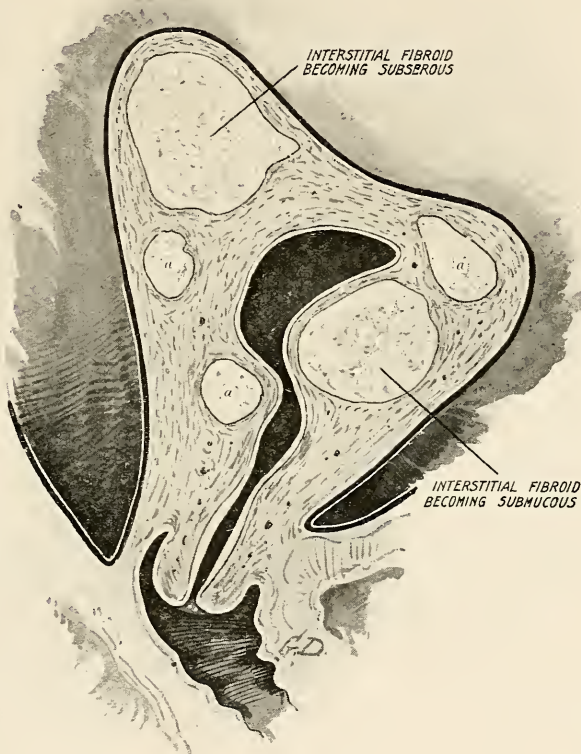


FIG. 205. THE FORMATION OF SUBMUCOUS AND SUBSEROUS FIBROIDS (diagrammatic). *a, a*, Small interstitial fibroids.

*stitial* fibroids. It will be understood that the great majority of fibroids are at first interstitial; the greater number are small, but such tumours may attain a size sufficient to distort the uterus, and protrude upon the mucous or peritoneal surface; being enclosed within their capsule, and surrounded outside this with a complete zone of muscular tissue, they are, however, still interstitial (*see* Fig. 205). As they grow they may pass outwards, being, as it were, extruded from the muscular wall so as to reach and displace the peritoneal coat; or they may pass, in the same manner, inwards into the cavity raising the mucous membrane. As a result of this process the tumour

escapes from its capsule, so that the greater part is covered only by peritoneum or endometrium. Both subperitoneal and submucous fibroids may retain a sessile attachment to the uterine wall, or may become polypoid by the formation of a distinct pedicle, which sometimes attains the length of 2 or 3 inches (*see* Fig. 206). In the case of

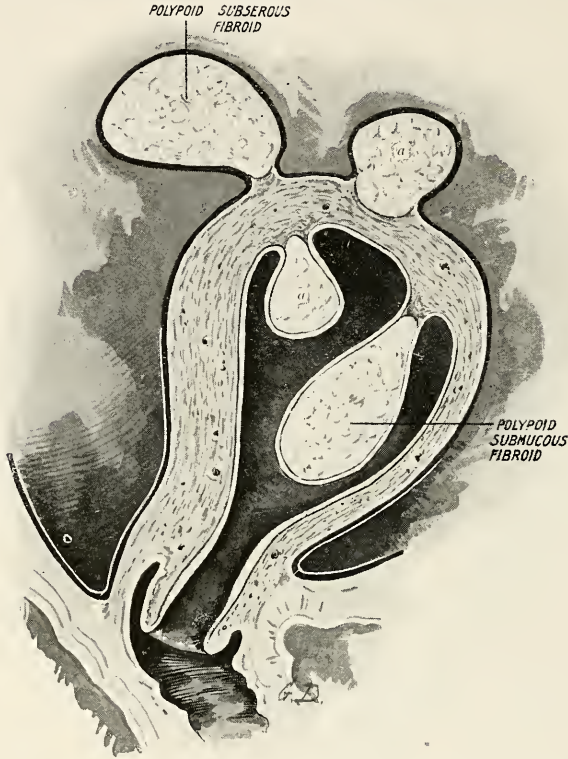

FIG. 206. THE FORMATION OF POLYPOID FIBROIDS (diagrammatic). The growths *a, a*, still retain a sessile attachment to the uterine wall; the other two have been completely pushed out of the muscular layer.

sessile tumours, a portion of the capsule at the base usually persists, allowing the tumour to be readily shelled out of the uterine wall.

Fibroid tumours vary greatly in consistence; the great majority are hard and inelastic in texture; some are of wooden or almost stony hardness; others are soft, and some are cystic. It is probable that all fibroids are originally hard, softening being almost invariably due to degenerative changes; softness, however, in rare cases results from œdema, and more rarely still from extreme vascularity. On section, their colour is usually paler than that of the cut uterine wall; those which are moderately hard show upon their cut surface a whorled arrangement of curved, interlacing fibres, which has been aptly likened to a ball of rolled worsted. The softer growths do not show



this appearance. The capsule consists, like the muscular wall of the uterus, very largely of muscle-fibres; when divided it retracts along with the uterine wall, and tends to extrude the tumour from its bed. If an interstitial fibroid is hemisected *in situ* after operative




FIG. 207. A SECTION OF A HARD FIBROID TUMOUR (low power). The arrangement of the interlacing bundles of fibres is well shown.

removal of the uterus, this phenomenon will usually be observed slowly to take place. A minor result of this process is to make the cut section of the tumour not flat, but slightly convex.

**Microscopic Appearances.** Fibroid tumours consist of plain muscle and white fibrous tissue in varying proportions. The smallest fibroids

consist entirely of muscle-fibres, and these may correctly be termed *myomata*. By the time they reach a diameter of 1 cm. there is a considerable proportion of fibrous tissue present, and accordingly the name *fibro-myoma* or '*fibroid*' may be correctly applied to these growths. The nuclei of plain muscle are short, thick, straight, or slightly curved rods with rounded extremities; the nuclei of fibrous tissue are spindle-shaped, and curved, and are both longer and more delicate than the muscle nuclei (*see* Fig. 208). When seen in cross-section it is not easy to distinguish connective tissue from muscle-fibres except by the differential stain of van Gieson, by which

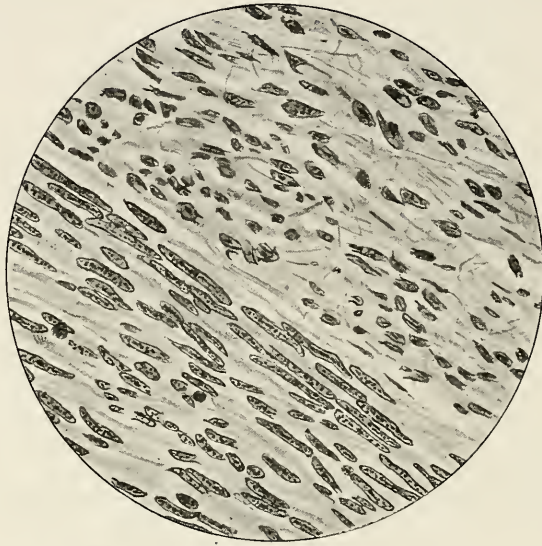


FIG 208. THE ELEMENTS OF A FIBROID TUMOUR (high power). In the lower half of the Figure are seen bundles of the rod-shaped nuclei of plain muscle arranged in parallel planes. Above are seen the spindle-shaped and stellate nuclei of connective tissue.

muscle is stained yellow and fibrous tissue pink (*see* Plate II). The intermingled muscle and connective-tissue fibres are arranged in small bundles which interlace in curves of varying direction, thus producing the whorled arrangement shown in Fig. 207, and often observable with the naked eye. In a hard fibroid the number of vessels seen under a low magnification, in a single field of the microscope, is very small; the majority are of the capillary type, but large vessels with thick walls can also be found. Some fibroid tumours are, however, of softer consistence and much more vascular than this, showing very large numbers of well-formed arteries in the microscopic field. Occasionally the degree of vascularity is extreme, the tumour being permeated with blood-vessels and blood-sinuses; to these the name *telangiectatic fibroid* was applied by Virchow. These soft vascular growths may belong to either of the three varieties just described,

and are often non-capsulated. The capsule of a fibroid tumour differs from the tumour-tissue chiefly in three points: (1) It is of much looser texture, and is composed in the main of parallel bundles of muscular and fibrous tissue; (2) it contains large numbers of vessels, some being arteries, the majority capillaries and veins (*see* Fig. 209); (3) the muscle-laminæ are frequently separated by lymph-spaces.

In a small number of fibroid tumours, gland-tubules may be found on a careful microscopic search, surrounded by a zone of highly

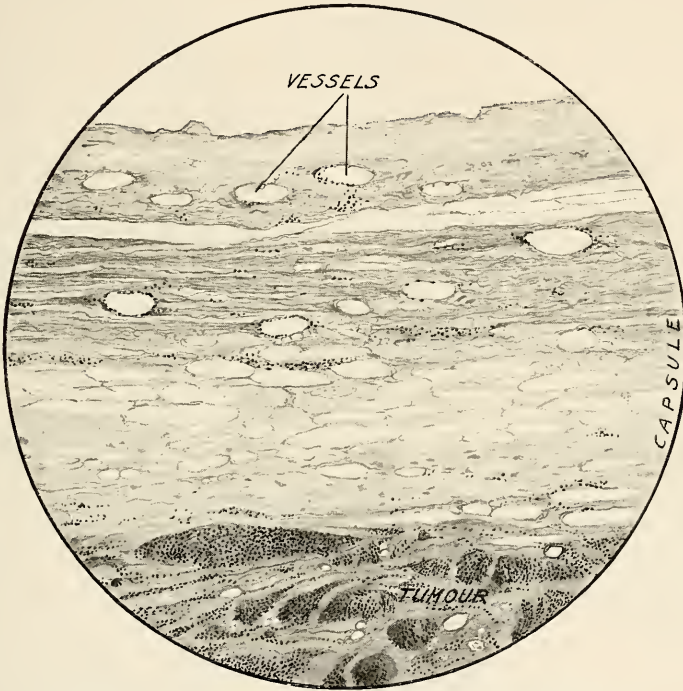


FIG. 209 CAPSULE OF A FIBROID TUMOUR (low power).

cellular tissue, which closely resemble the glands of the endometrium (*see* Fig. 11). All such tumours are to be regarded, not as ordinary fibroids, but as one type of *adenomyomata*, and these will be considered in a later section (*see* p. 489).

It will now be necessary to describe in more detail the characters of the three varieties of fibroid tumour.

**Subperitoneal (Subserous) Fibroids.** These growths are nearly always multiple and may attain enormous size. Since they have greater freedom of growth, subperitoneal fibroids are able to attain a greater size than the other varieties, and apart from degenerative changes, the largest specimens met with are of this description. Fig. 210 is fairly typical of this class. It will be noticed that the

uterus itself is not much enlarged and lies in the centre of the mass formed by the tumours; it is also slightly rotated on its long axis, so that the anterior surface faces to the left. On the right side are two subperitoneal growths, sessile, and smooth on their surface; on the left is a single large pediculated growth showing a well-marked nodular surface quite different from those of the other side. Near

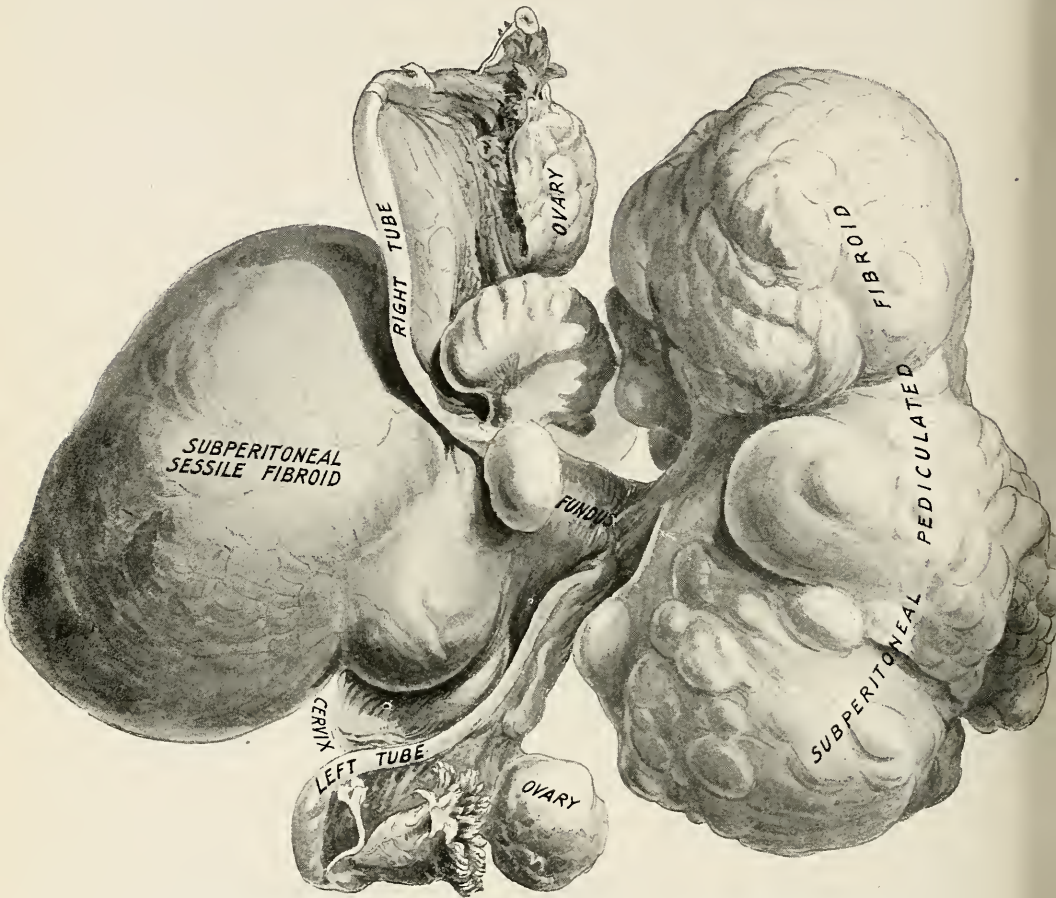


FIG. 210. MULTIPLE FIBROID TUMOUR, weight 7 lbs. Nullipara, aged 49. The large nodular fibroid had a pedicle 2 inches long. The uterus had rotated, bringing the right cornu forwards.

the right cornu are two smaller growths, the anterior sessile and smooth, the posterior pediculated and nodular. It is obvious that the pedicle of the largest growth is long enough to permit of the occurrence of axial rotation of the tumour or torsion of the pedicle (see p. 452).

Unless inflammatory changes have occurred, the peritoneal covering of a subperitoneal fibroid is connected with the tumour only by a

thin layer of the general subserous connective tissue ; accordingly it can be readily stripped off when divided. *The blood-supply* is mainly derived through the uterine attachment and is often scanty, these tumours being as a rule less vascular than either of the other varieties. Sometimes the main blood-supply is derived from a source external to the uterus, the commonest being the omentum. Cullen has described a uterine fibroid lying free in omental tissue, and one of us discovered a similar condition, but in this instance the tumour was attached to the peritoneum of the anterior abdominal wall in addition to omentum, although quite free from the uterus. Cullen has given the name of "parasitic fibroids" to such isolated growths. Sometimes, however, the stalk is thick and fleshy and contains vessels of large size. Histologically, subperitoneal fibroids consist almost entirely of fibrous tissue in which extensive hyaline and cystic formation is common.

Subperitoneal fibroids, when of large size, rise above the pelvic brim into the abdominal cavity ; when of smaller size they remain in the pelvis, and may then occupy, or distend, the pouch of Douglas, or rest upon the fundus of the bladder.

**Retroperitoneal Fibroids.** Fibroids which grow from parts of the uterus which have no peritoneal covering—the lateral walls and the anterior wall below the peritoneal reflection—grow out beneath the peritoneum, and when of large size occasion great alterations of the normal pelvic relations. When in this way they pass between the layers of the broad ligament they first distend that structure (*see* Fig. 211), then, growing laterally, they may raise the peritoneum covering the lateral pelvic wall, and open the mesentery of the pelvic colon or sigmoid flexure, so that this part of the gut comes to lie directly upon the surface of the tumour ; on the right side they may pass in the same way behind the cæcum and the vermiform appendix ; passing backwards they may raise the floor of the pouch of Douglas up to the level of the sacral promontory ; passing forwards they obliterate the utero-vesical pouch, raise the bladder high above the pelvic brim, elongate the urethra and displace the ureters. Fibroids which thus distort the general peritoneal relations of the pelvis are often called *retroperitoneal*. Examples of retroperitoneal fibroids are seen in Figures 211 and 212. In Figure 211 the tumour has opened up the left broad ligament, elongating the Fallopian tube which curves over its surface ; the right broad ligament with its tube and ovary are seen to be unaffected. A great part of this tumour lay beneath the floor of the pouch of Douglas, which was elevated nearly to the level of the sacral promontory. Figure 212 shows a very large growth which occupies the right broad ligament, the peritoneum being intact over the summit of the growth. It thus affords a good illustration of the relations as seen before operation. When the ureters are displaced by these growths, one or other ureter may become compressed,

leading to atrophy of the kidney, or to dilatation of the ureter, and hydronephrosis.

**Interstitial Fibroids.** These tumours are usually small or of only moderate size; they cause less distortion of the uterus and less

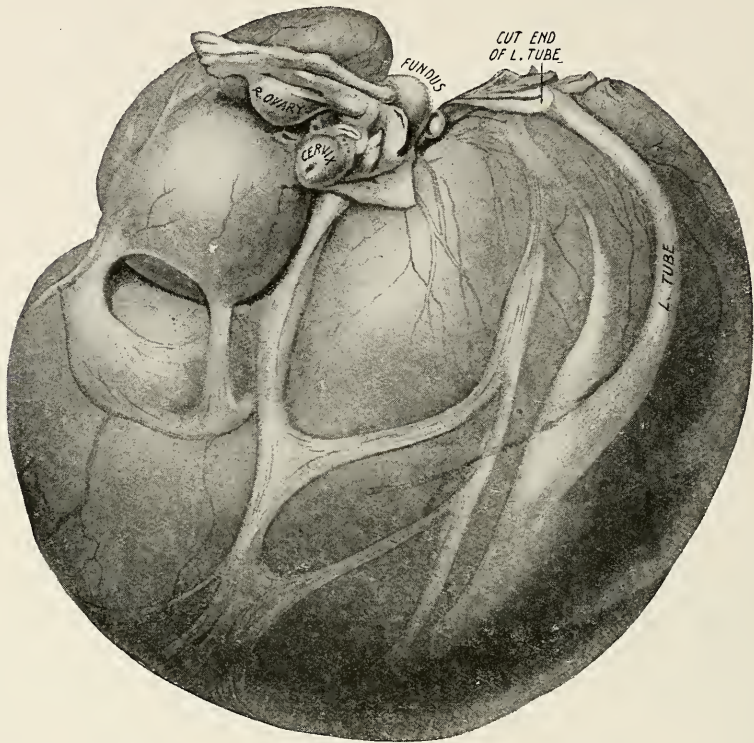


FIG. 211. LARGE RETROPERITONEAL FIBROID TUMOUR, weight 30 lbs. Nullipara, aged 55. The tumour consists of two lobes of unequal size; between them lies the uterus, which is only slightly enlarged. The larger lobe has expanded the left broad ligament, stretching the tube over it; the left tube is divided near the uterus

disturbance of the general pelvic relations than subperitoneal fibroids. The enlargement of the uterus which they produce is sometimes fairly symmetrical (*see* Fig. 213), but more or less distortion is usually met with. They occur in the anterior and posterior walls, and in the fundus. Solitary fibroids are usually of the interstitial variety, and in such cases the capsule is sometimes absent, giving rise to a diffused growth. The general rule that fibroids are multiple also applies, however, to the interstitial variety; there are generally several, and in the great majority of instances they occur in company with subperitoneal or submucous growths, or both.

**Submucous Fibroids.** These tumours are usually of comparatively small size; they are generally globular or ovoid in shape, and tend in

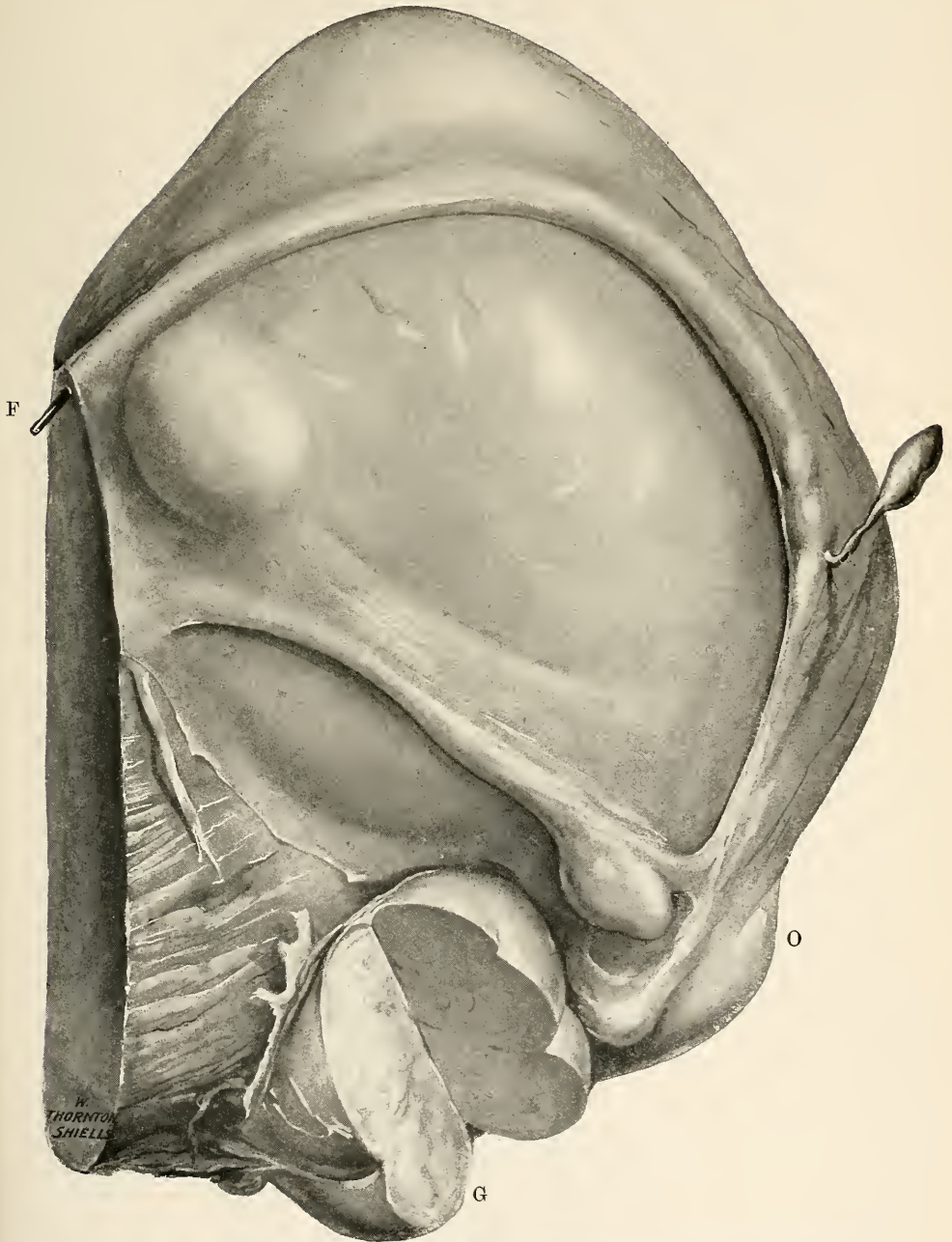


FIG. 212. SHOWING AN INTRALIGAMENTARY (RETROPERITONEAL) FIBROID OF THE RIGHT SIDE. F, Fallopian tube into which a bristle has been passed; the ovary, attached to its elongated ligament, lies one inch internal to the letter O; G, small lobe growing from the large fibroid tumour.

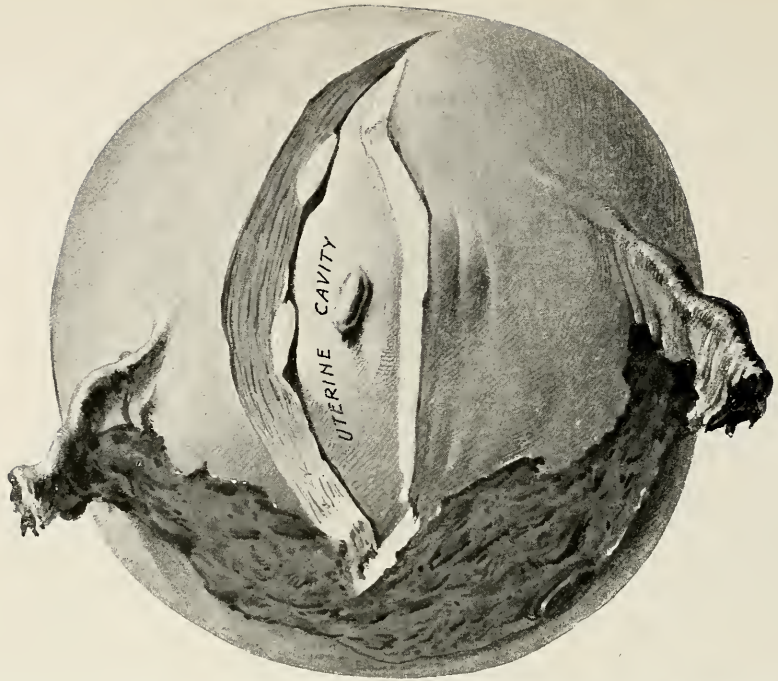


FIG. 213. INTERSTITIAL FIBROID TUMOUR IN THE ANTERIOR WALL OF THE UTERUS. Multipara, aged 62. The uterus and fibroid form a large tumour of globular shape.

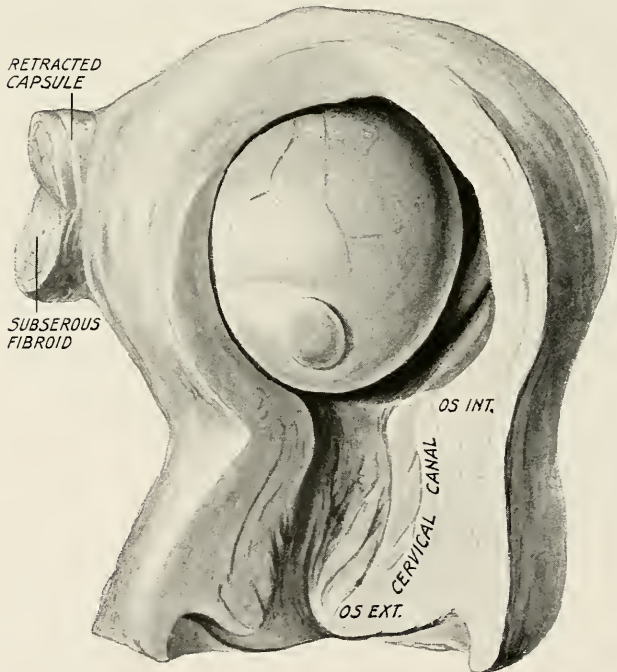


FIG. 214. SESSILE SUBMUCOUS FIBROID TUMOUR (Charing Cross Hospital Museum). Nullipara, aged 51. The tumour is globular in shape and completely fills up the enlarged uterine cavity.



the natural course of events to become polypoid. By encroachment upon the uterine cavity they act as foreign bodies in increasing the normal contractions of menstruation, or actually in exciting contractions in the intermenstrual periods, the effect of which is still further

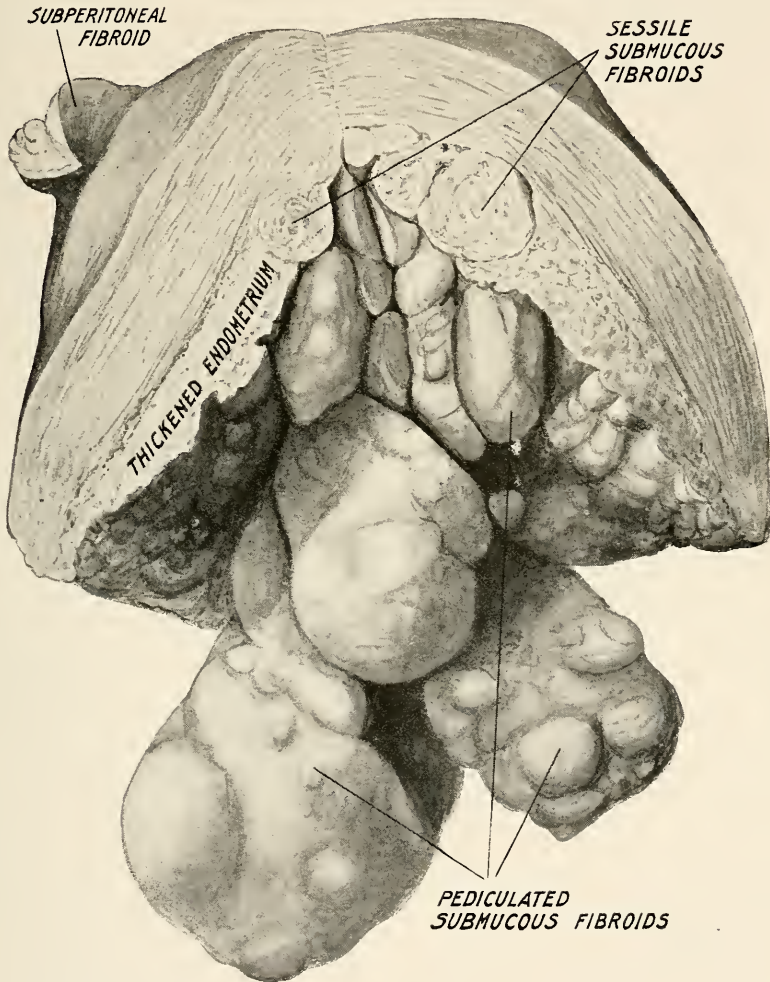


FIG. 215. UTERUS CONTAINING AN UNUSUALLY LARGE NUMBER OF SUBMUCOUS FIBROID TUMOURS, SOME SESSILE, OTHERS POLYPOID. Nullipara, aged 38. The endometrium is seen to be enormously thickened.

to extrude the tumour until it becomes polypoid. Fibroids which protrude upon the peritoneal aspect do not produce this effect. Submucous fibroids are often solitary, when they symmetrically enlarge the uterus and distend its cavity, which they fill up like a cast (so-called 'cup-and-ball' fibroid) (see Fig. 214). They are, however, sometimes multiple, and in such cases various phases of the process of

extrusion may be met with in a single uterus, some being still partly embedded in the musculature, others completely submucous but sessile, others definitely polypoid (*see* Fig. 215). Very occasionally they are so numerous and so crowded together in the uterine cavity as to become polygonal from mutual pressure, like faceted calculi in the gall-bladder (*see* Fig. 216). In this specimen the uterine cavity was

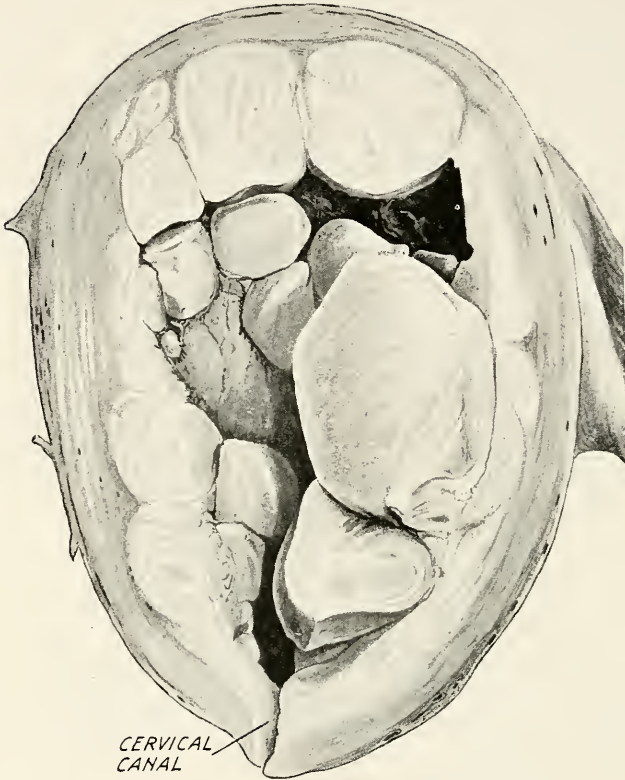


FIG. 216. MULTIPLE SUBMUCOUS FIBROID TUMOURS. Nullipara, aged 31. The uterus contained sixty separate fibroid growths, the greater number of which were submucous. They were closely packed together in the uterine cavity, and some were moulded by pressure of contiguous growths.

packed with small submucous fibroids, which had been compressed by being closely packed together. Like subperitoneal growths, submucous fibroids usually present an even surface, but sometimes they are nodular as in Fig. 215.

In becoming polypoid, submucous fibroids escape from their capsule, and are then covered immediately by the mucosa. The essential steps in the process of pediculation are, a gradual yielding of the capsule, and subsequent extrusion of the growth from its bed by uterine contractions. When the process of pediculation is com-

plete, the pedicle consists of an investment of endometrium, within which is a fibro-muscular core, representing what is left of the base of the capsule. It is seldom more than one-half inch in thickness. Comparatively few vessels enter the polypus through its stalk, the blood-supply being chiefly derived from the covering endometrium. Accordingly, when the pedicle is divided in removing the polypus, there is little or no bleeding from it, for the vessels it contains are small, and are spontaneously closed by retraction of the divided muscular and elastic fibres.

Fibroid polypi not infrequently become expelled through the cervix into the vagina, the cervical canal becoming dilated, as in labour or abortion. Uterine contractions no doubt form the essential factor in this process, the polypus acting as a mechanical dilator; the function known as 'uterine polarity' may aid in producing this result. Elongation of the pedicle occurs during this process, and it is not very uncommon for a stalk 1 or 2 inches long to be produced. Complete detachment of a polypus by separation of its pedicle sometimes occurs in the puerperium, but is extremely rare under other conditions; if of small size, the tumour is then spontaneously expelled from the vagina; if retained it becomes infected, and sloughing results.

Polypi which have been expelled through the cervix are specially liable to injury and to infection. Superficial ulceration of the mucous covering from friction or other injury may occur, and give rise to serious hæmorrhage. Polypi which have occupied this position for some time may, however, acquire by metaplasia, a covering of stratified epithelium similar to that of the vaginal wall; by this they are protected both from injury and infection.

After the polypus has passed through the cervix, the canal retracts upon the pedicle, but though much smaller than the tumour it remains somewhat dilated. Polypi arising from the fundus may, during expulsion, cause *inversion of the uterus*. The inversion is usually partial and subsides after the removal of the growth. On p. 586 is seen a total inversion of both uterus and vagina, produced by a fibroid polypus; this is very rare.

**Cervical Fibroids.** Only 8 per cent. of fibroids arise in the cervix; the remainder are corporeal. They are almost always solitary, differing sharply in this particular from those of the body. They may arise in the cervix above the vaginal reflection, or in the *portio vaginalis* itself. Of the former some are interstitial (true cervical fibroids) (*see* Fig. 217), others are attached to the wall of the cervix by a narrow pedicle or by a broad base, and are, strictly speaking, retroperitoneal tumours (pseudo-cervical fibroids) (*see* Figs. 219 and 220). Either of these varieties, but especially the latter, may attain a large size, and from their anatomical relations they naturally give rise to severe pressure symptoms, and to displacement of neighbouring organs. As will be

readily understood, from its contiguity to the supra-vaginal cervix, the ureter is liable to displacement, and even to compression, by

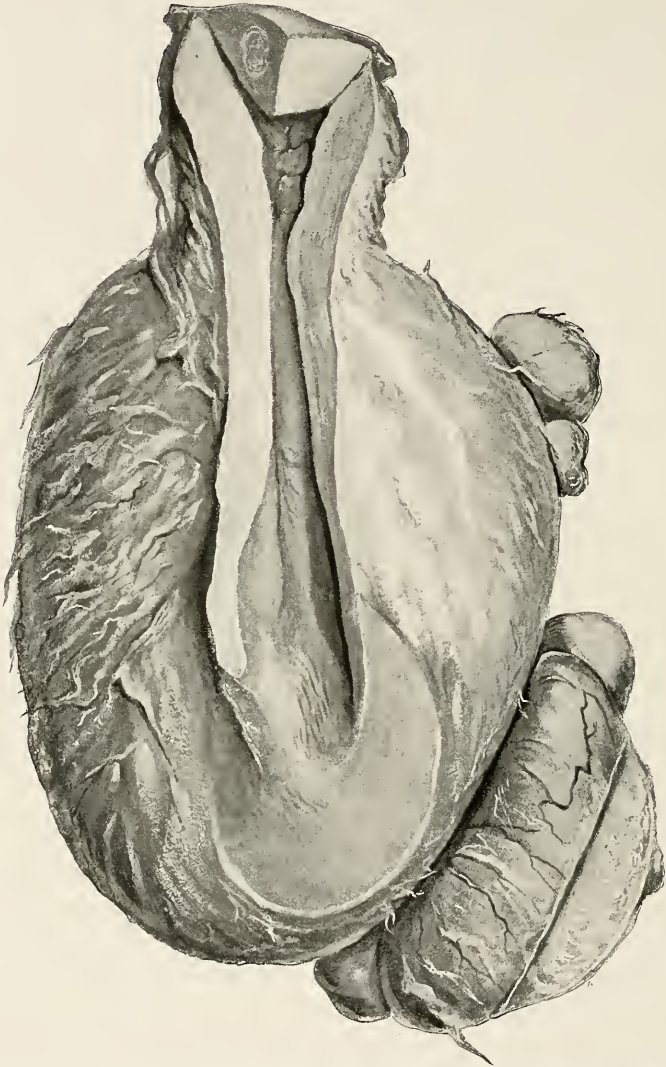


FIG. 217. INTERSTITIAL (TRUE) CERVICAL FIBROID TUMOUR SEEN FROM IN FRONT. Virgin aged 34. The body of the uterus is situated upon the summit of the tumour. The cervical canal is elongated and the external os is opened up. On the left side are seen secondary lobes of the growth. The left ureter lay deeply in the sulcus between the lower lobe and the main tumour.

these tumours. The uterine arteries are also liable to be displaced either anteriorly or posteriorly.

*Interstitial or true* cervical growths usually arise in the posterior

wall; they elongate the cervical canal and they may displace it to one or other side (*see* Fig. 218). They usually form oval or globular tumours with the uterine body placed upon their summit, which,

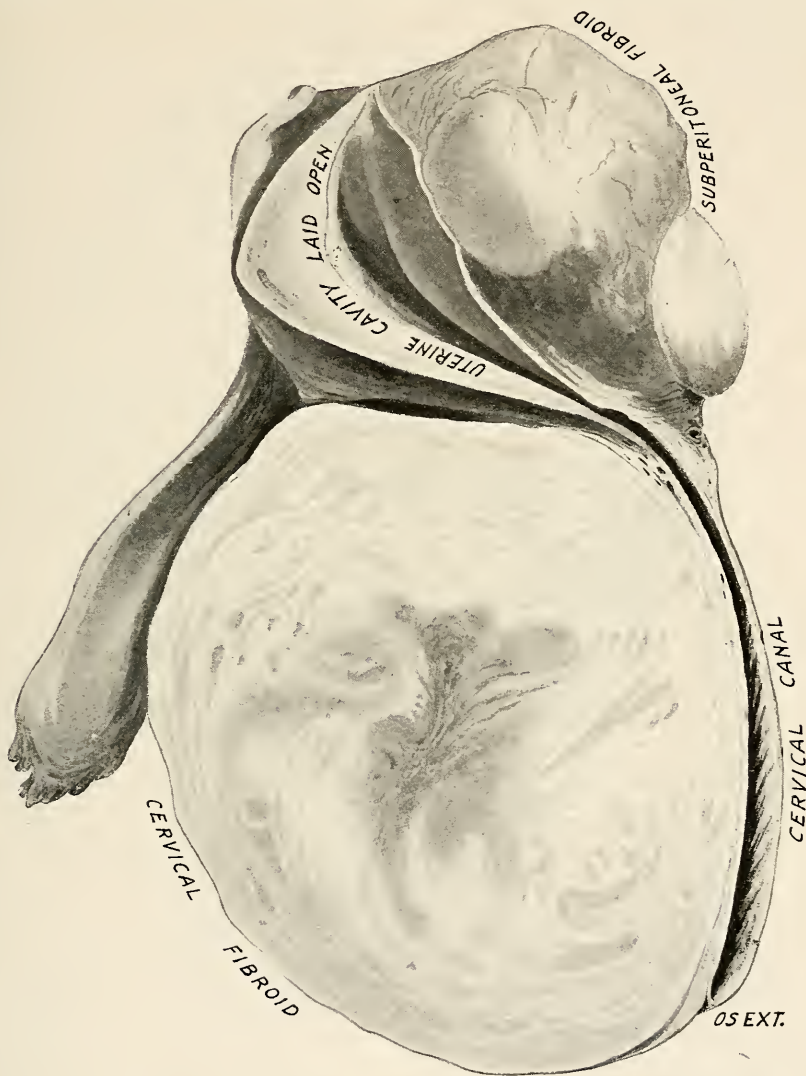


FIG. 218. INTERSTITIAL (TRUE) CERVICAL FIBROID TUMOUR, DIVIDED ANTERO-POSTERIORLY. Nullipara, aged 32. The cervical canal is displaced to one side and elongated ( $3\frac{1}{4}$  inches); the uterine body is elevated above the tumour.

unless it also contains fibroid growths, remains of approximately normal size. *Subperitoneal* or *pseudo-cervical* fibroids usually occupy and distend the broad ligament, retaining an attachment by a narrow neck to the supra-vaginal cervix. They are often completely encapsulated as in Figure 219. They displace the uterus to the opposite

side of the pelvis, and usually elongate it; in the specimen, from which Figure 219 was drawn, the uterus measured 4 inches from fundus to os externum. In the very large tumour represented in

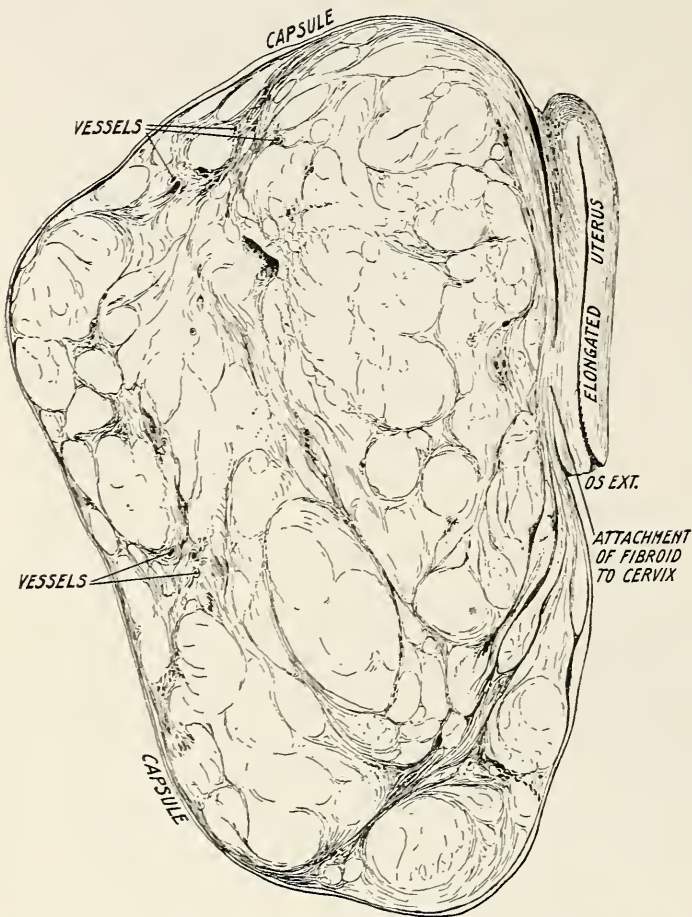


FIG. 219. PSEUDO-CERVICAL FIBROID TUMOUR, INTRA-LIGAMENTARY IN POSITION. Nullipara, aged 47. The tumour is attached to the uterine wall at about the level of the internal os by a narrow pedicle. The uterus is elongated (4 inches) and was displaced laterally by the tumour.

Figure 211 the larger lobes had an attachment by a narrow pedicle to the side of the supra-vaginal cervix.

Fibroids growing from the *portio vaginalis* are usually of small size. They begin as interstitial growths, but may become polypoid as in Figure 221, in the same manner as fibroids of the body, *i.e.* they become extruded beneath the mucous membrane of the cervical canal, and develop a pedicle in the manner already described.

**Coincident Changes.** The growth of fibroid tumours is frequently attended by a number of other changes in the uterus or the other

pelvic organs, which may be called coincident changes, since their etiological relation to these tumours is not settled. The *endometrium* may be entirely unaffected when subperitoneal fibroids alone are

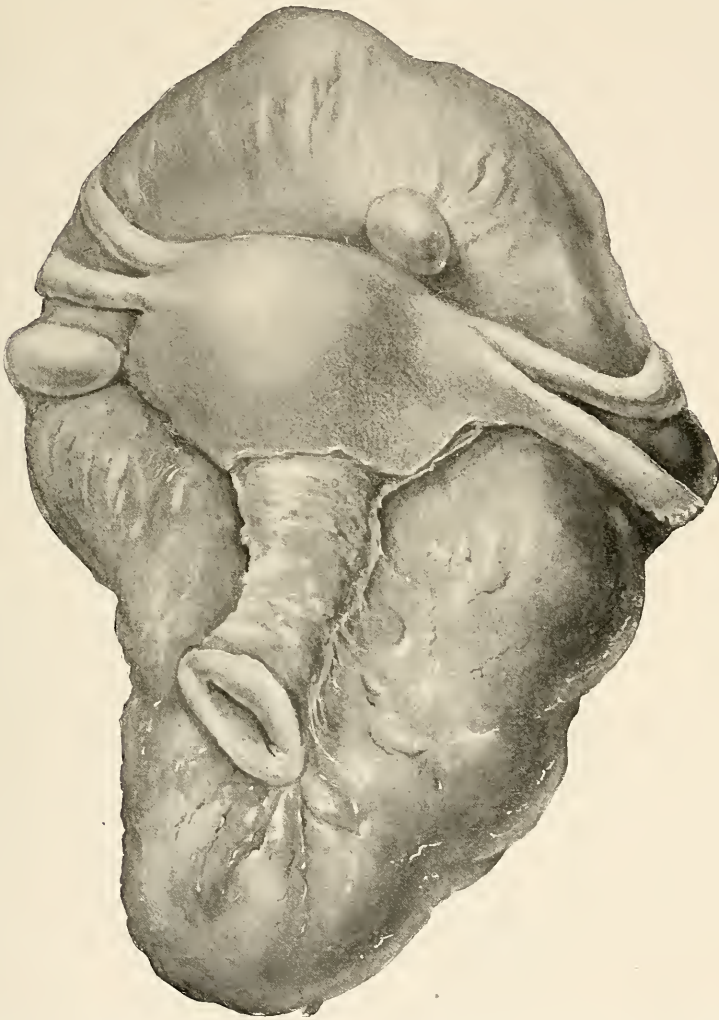


FIG. 220. PSEUDO-CERVICAL FIBROID (*i.e.* a retroperitoneal growth) arising from the front aspect of the cervix by a *broad base*. Cf. Fig. 219, in which the tumour arises by a *narrow pedicle* from the back of the cervix (after Schickele).

present; submucous and interstitial growths are, however, almost always accompanied by marked thickening of the mucous membrane, due to a proliferative glandular hyperplasia, and it is not uncommon to find extensive hæmorrhages in the stroma. The overgrowth of the endometrium and the co-existence of fibromyoma may possibly be due to some common cause, *e.g.* excess of ovarian hormone. To

the endometrial hyperplasia one of the symptoms commonly associated with fibroid tumours is probably due, viz. leucorrhœa, and the increased monthly bleeding, also met with, is probably in part

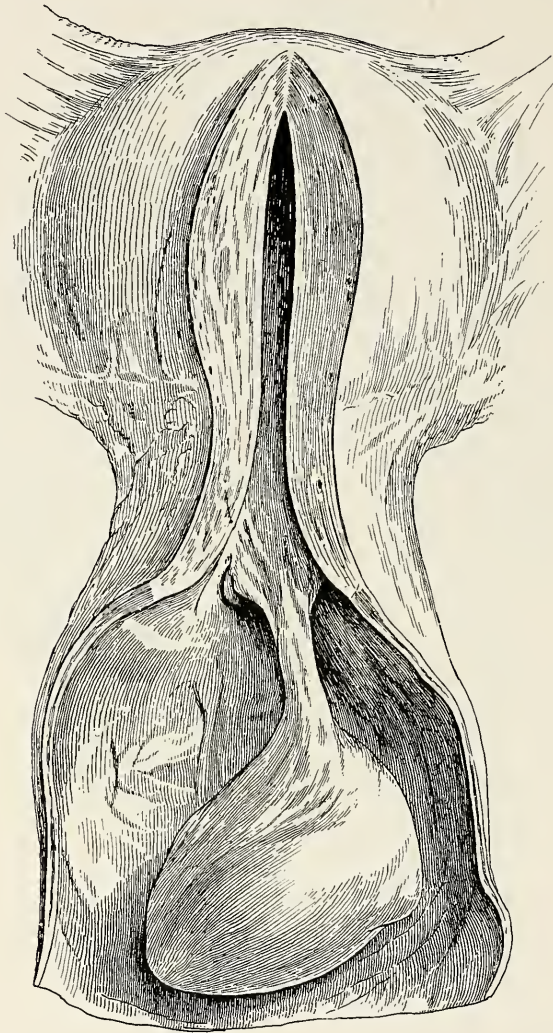


FIG. 221. FIBROID POLYPUS ATTACHED BY A LONG PEDICLE TO THE POSTERIOR LIP OF THE EXTERNAL OS (Charing Cross Hospital Museum).

occasioned by the same condition. Mucous polypi may also be found growing from the endometrium in association with fibroids of the body of the uterus.

The *cavity* of the uterus is, of course, greatly enlarged when there are multiple submucous growths as in Figures 215 and 216. It is also enlarged by single submucous tumours, such as in Figure 214. Interstitial growths distort and displace the cavity without, however, causing



much enlargement. Subperitoneal growths may elongate without dilating the uterus. In large multiple tumours of the interstitial variety, the uterine cavity often occupies an eccentric position, lying in front, behind, or on one side of the tumour (*see* Fig. 218).

*Rotation* of the uterus may occur with fibroids as in Figure 215, where the anterior surface of the uterus was twisted to the left side, and in some cases partial strangulation of the tumour is the result. Large retroperitoneal growths may produce wide displacements of the uterus, elevating it high above the pelvic brim, or displacing it far to one or other side (*see* Fig. 211). Pediculated submucous growths attached to the fundus may cause chronic inversion of the uterus (*see* Fig. 311, p. 586).

*Ovaries and Fallopian Tubes.* Recent observations upon fibroid uteri removed by operation have made it abundantly clear that coincident disease is frequently present in the tubes and ovaries. Tracey has recently collated a large number of cases (3561) recorded by different operators, and in this series it was found that 20 per cent. showed definite disease in the ovaries, and that a somewhat smaller proportion—14·5 per cent.—showed definite morbid changes in the Fallopian tubes. Among the conditions thus met with may be mentioned cystic tumours of the ovaries, chronic inflammation of the ovaries, hydrosalpinx, and pyosalpinx. This high rate of frequency clearly points to something more than coincidence; in all probability there is a causal relationship between these morbid conditions, but which is primary, and which consecutive, we do not at present know.

*Blood-vessels.* The uterine arteries and lymphatics form the main nutritive supply of large fibroid tumours; they may be greatly hypertrophied, and irregularly distributed over the growth, sometimes entering it in front or behind instead of at the side. The ovarian arteries are usually much less hypertrophied than the uterine arteries. Large venous plexuses are usually found in the broad ligaments, and sometimes superficial veins of very large size, covered by peritoneum only, course over the surface of the tumour. These varices may rupture either spontaneously or as the result of traumatism, causing serious internal hæmorrhage. In the case of large tumours the lymphatics of the broad ligaments may be enormously dilated even to the size of a little finger. These subside on the removal of the tumour and cannot be demonstrated without injection.

*Ascites with Fibroids.* This is rare, but it sometimes occurs with large, movable, pedunculated subperitoneal growths, especially those which receive a large blood-supply from the omentum, or those in which partial rotation of the uterine pedicle has taken place.

## SECONDARY CHANGES IN FIBROIDS

Largely owing to the disparity between the size of fibroids and their blood-supply, these tumours are extremely liable to degenerative and other changes, which may be enumerated as follows :

(A) *Degenerative changes.*

- (1) Atrophy.
- (2) Hyaline degeneration.
- (3) Cystic degeneration.
- (4) Fatty degeneration.
- (5) Calcareous degeneration.
- (6) Necrosis, necrobiosis.

(B) *Circulatory changes.*

- (1) Oedema and lymphangiectasis.
- (2) Axial rotation leading to :
  - (a) Congestion.
  - (b) Interstitial hæmorrhage.
  - (c) Necrosis.
  - (d) Detachment of tumour.

(C) *Angiomatous or telangiectatic changes.*

(D) *Infective changes* leading to :

- (1) Inflammation.
- (2) Suppuration (localized abscess).
- (3) Gangrene and sloughing.

(E) *Malignant changes.*

- (1) Sarcoma (malignant leiomyoma).
- (2) Perithelioma.
- (3) Endothelioma.

**Atrophy.** With the cessation of the ovarian function after the climacteric, a certain number of fibroids undergo spontaneous atrophy and consequent reduction in size. Instances are recorded of the total clinical disappearance of these growths after menstruation has ceased. This, however, must be regarded as quite an exceptional sequence of the change of life. Atrophy of fibroids is no doubt brought about by the same causes as those which produce atrophy of the normal uterus at the same period of life.

The employment of X-rays in the treatment of myomata has, during the past few years, been extensive in continental clinics, and it is claimed that atrophic changes are thus artificially produced in myomata similar to the atrophy which is known to occur in some cases after the menopause. There is sufficient clinical evidence on record to show that reduction in size of fibroids does occur after the cross-fire application of X-rays. This result is probably due more to a primary

atrophy of the ovaries than to the direct influence of the rays upon the tumour itself, most observers being agreed that atrophy of the ovaries can be produced by X-rays suitably applied (*see also* p. 478). Atrophy of fibroids may be also artificially produced by total oöphorectomy, and this operation was introduced in 1882 by Lawson Tait for the express purpose of reducing the size of fibromyomata, but has now been abandoned.

**Hyaline Degeneration.** The substance hyalin is one of a group to which also belong glycogen, mucin, amyloid, and fibrin, in that they all have the one common property of appearing opalescent like ground-glass. In chemical composition these substances vary greatly; some have definite chemical reactions, but most have not. Hyalin is perhaps the most indefinite of the entire group; it shows no distinctive chemical reaction, but fortunately it exhibits very marked tinctorial properties, which render its discovery a matter of ease. Hyaline degeneration is a change which occurs in smooth muscle, in connective tissue, and in blood-vessels. In fibroids it most commonly commences in the bundles of collagen and fibroglia-fibrils which make up the connective tissue. The normal structure of the latter disappears and is replaced by colourless homogeneous material, which stains deeply with eosin and fuchsin. Muscle-cells have been shown to demonstrate the same change in their centre, which then stains deeply with eosin. This is regarded by some authorities as a post-mortem change and may be ignored so far as hyaline degeneration in fibroids is concerned, since it is comparatively rare. In fibroid tumours hyaline degeneration of vessels occurs, but it is not common; indeed, the vessels as a rule resist this change to the last, so that it is not unusual to see healthy-looking vessels lying free in spaces where liquefaction of hyaline tissue has occurred. It should be understood, therefore, that practically always, hyaline degeneration starts in the connective tissue which envelops the muscular bundles (*see* Plate XIV, Fig. A). When the blood-vessels of a fibroid are markedly hyaline it is more than likely that the growth shares with other organs in a general blood-vascular degeneration.

The majority of fibroid tumours show some degree of hyaline change, even when quite small in size and when situated in the vascular muscle-wall of the uterus. As the extent of the degeneration varies inversely with the blood-supply, hyaline change is most marked in pedunculated subserous growths, on account of their defective nutrition. It is also seen in submucous polypi, where it favours necrosis. A point of considerable importance is that the investing hyaline material exerts compression on the muscle-cells. The nuclei of the latter resist to the last, but the cell-bodies quickly disappear, leaving only the nuclei, which finally are broken up into granular fragments and disappear likewise (*see* Fig. 222). In some cases the muscle-cells, which are snared by a hyaline trabecular network, take on a malignant

activity and become sarcomatous; this establishes a close association between hyaline degeneration and sarcomatous change in fibroids.

**Cystic Degeneration. Hyaline Liquefaction.** This is the colligative stage of the hyaline change, *i.e.* by the liquefaction of the hyaline deposit, *cysts* or spaces are formed within the tissues of a fibroid. The distribution of the hyaline material will determine the characters of the cavities which are produced by liquefaction. If the hyalin is laid down in uniform plaque-like masses, large cysts will result.

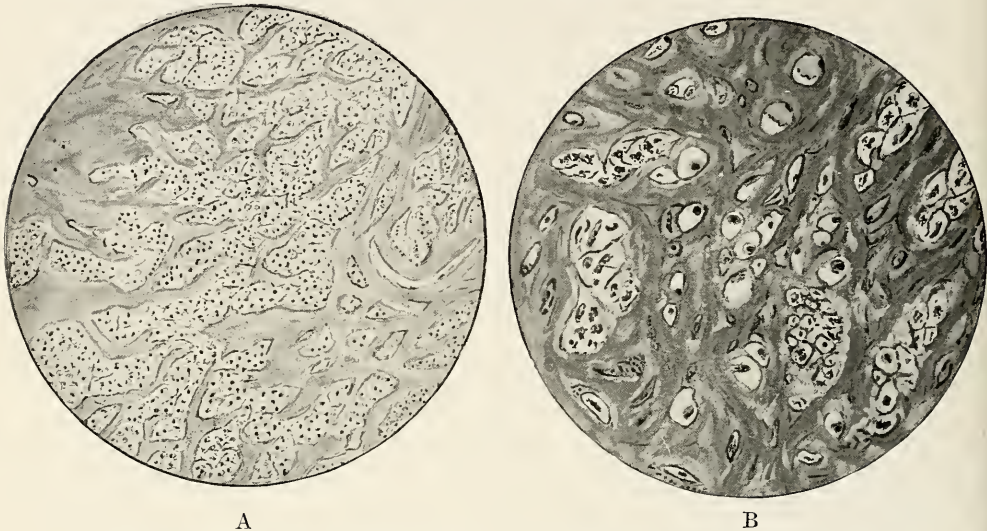



FIG. 222. HYALINE DEGENERATION. A, COLLAGEN REPLACED BY HYALIN. The latter forms branching trabeculae which ramify among the muscle-bundles. B, EFFECT OF HYALIN ON THE MUSCLE-CELLS. The latter are swollen and their nuclei are broken up into granular fragments.

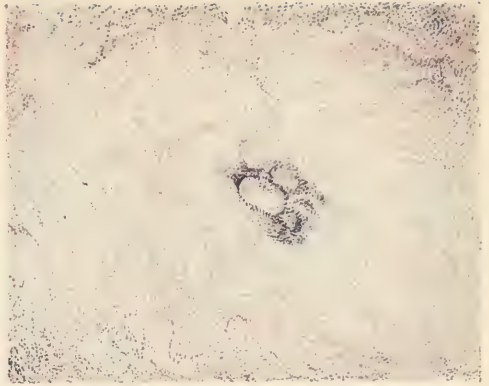When the hyalin is more discrete and trabecular (Fig. 222 A) multiple cysts will result which, by the breaking down of intervening septa, tend to fuse and become unilocular (*see* Fig. 223).

The cavities thus produced are not true cysts, that is to say they have no endothelial lining. Their walls, which may be either ragged (*see* Fig. 225 and Plate XIV, Fig. A) or smooth (*see* Figs. 223 and 224), are composed of hyaline tissue which has not as yet undergone liquefaction. The spaces enlarge by the spread of liquefaction, and, as stated above, by the breaking down of trabeculae between small cysts (*see* Fig. 223).

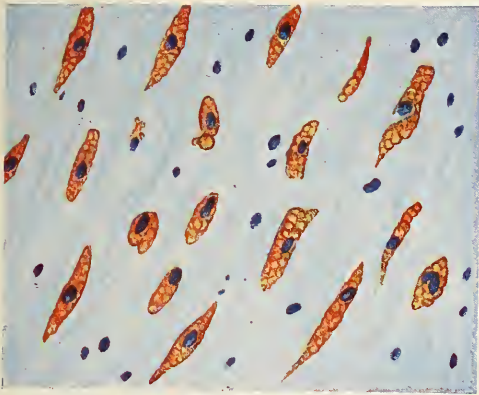
The fluid-contents of cysts produced by liquefaction of hyaline areas varies considerably. It is commonly straw-coloured and highly albuminous; it never contains mucin, or pseudo-mucin. It may coagulate spontaneously, but that which is obtained from the larger cysts remains fluid. It is not uncommon to find the fluid coloured by blood-pigment, so that it may be turbid, greenish-brown, red, or reddish-brown,



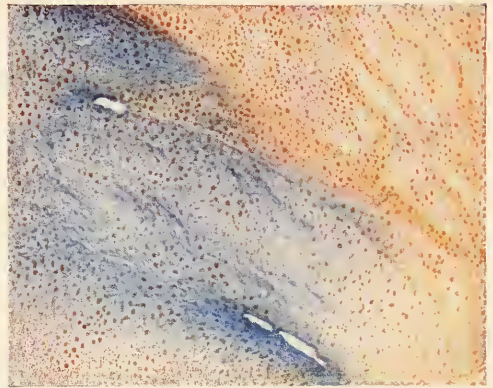
**A**  
**IRREGULAR HYALINE LIQUEFACTION.** A stage in the production of a cyst with ragged walls.




**B**  
**HYALINE DEGENERATION OF COLLAGEN-FIBRES.** The nuclei of muscle-cells are faintly stained.



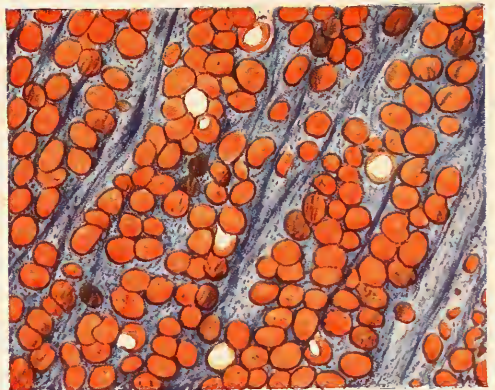
**C**  
**FATTY FIBROID.** Fat droplets are seen in the muscle-cells replacing the normal cytoplasm.



**D**  
**FATTY DEGENERATION AS SEEN IN A RED FIBROID.** The droplets of fat are very small.



**E**  
**OEDEMATOUS FIBROID.** The lymphatics are dilated by stasis and the edema-fluid is seen to be fixed as flocculent granular material (stained pink) in the stroma.



**F**  
**FATTY FIBROID.** The large fat-droplets run in the direction of the muscle-bundles.



Cystic degeneration is not always due solely to liquefaction of hyaline areas. It follows red necrosis, which is a change, probably always preceded by hyaline degeneration (*see* Fig. 225). If red necrosis intervenes between hyaline and cystic degeneration, the contents of the cyst may resemble pure venous blood in appearance, but we have found that the fluid contains no fibrin-ferment and therefore does not coagulate. The muscle-fibres in the walls of such a cyst will contain fatty globules, whereas in the case of cystic hyaline areas, where there

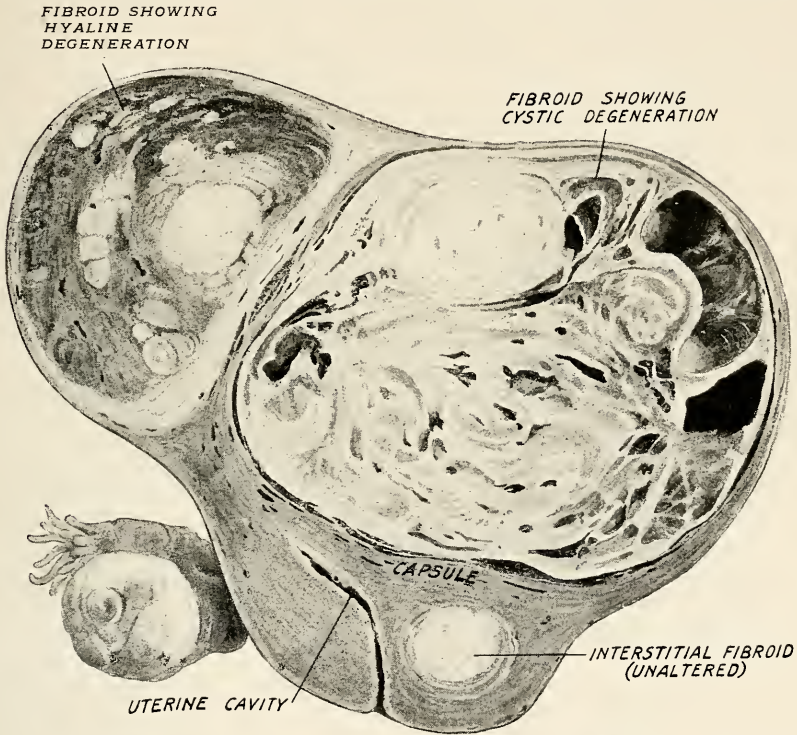


FIG. 223. MULTIPLE FIBROID TUMOUR OF THE UTERUS. Multipara, aged 39. The largest fibroid shows well-marked cystic degeneration; the smaller one on the right shows the earlier stage of hyaline liquefaction.

has been no deposit of red necrosis, or *necrobiosis* as it is called, there will be no fat.

It may be concluded that the majority of cysts found in myomata are pseudo-cysts derived from liquefaction of hyaline deposit. True cysts do exist in fibroids, and these will be referred to under *Lymph-angiectasis*.

**Fatty Degeneration.** This change is far less commonly observed than is hyaline degeneration. It is an essential precursor to calcareous deposition, which is not an infrequent change, especially in fibroids found in elderly subjects. The probability, therefore, is that fatty

degeneration has often in the past escaped detection for want of suitable staining reagents. For the study of the fatty stage in the degeneration of myomata, the fresh tissue should be taken, frozen sections made, and stained with Sudan III. The section is then mounted in Farrant's solution. The fat-droplets are picked out as deep orange or sunset-red globules. They lie inside the muscle-fibres and therefore are arranged

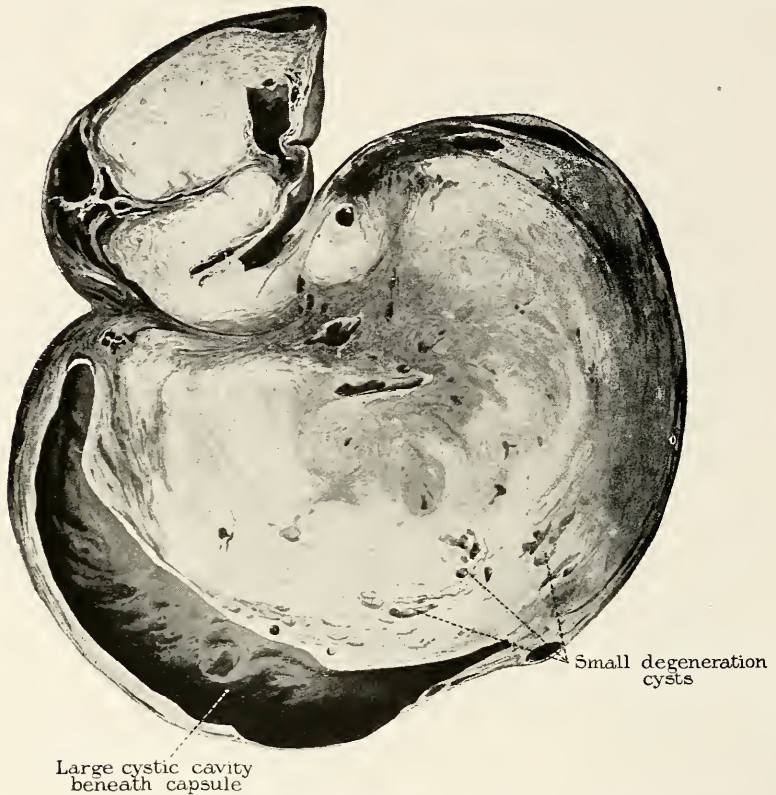


FIG. 224. LARGE RETROPERITONEAL FIBROID TUMOUR. A large subcapsular cystic space has been formed in the lower part of the Figure, and many smaller spaces in other parts. The large cystic space has smooth walls, *cf.* Fig. 225.

in the direction of the muscular bundles. The macroscopic appearance of fat in a myoma is variable, being influenced by associated conditions due to changes in the blood. The cut surface of a fatty myoma may be pale yellowish in colour, but it is often tinted by soluble blood-pigment. The normal whorled appearance is obscured, and the surface is homogeneous.

Microscopically, the changes are those of hyaline degeneration to which the deposition of fat-globules is added. Thus there are seen (1) irregular and scanty nuclear staining; (2) granular and hyaline change; (3) fat-globules running in the original direction of the



muscle-fibres ; (4) fat within wandering phagocytes, both inside and

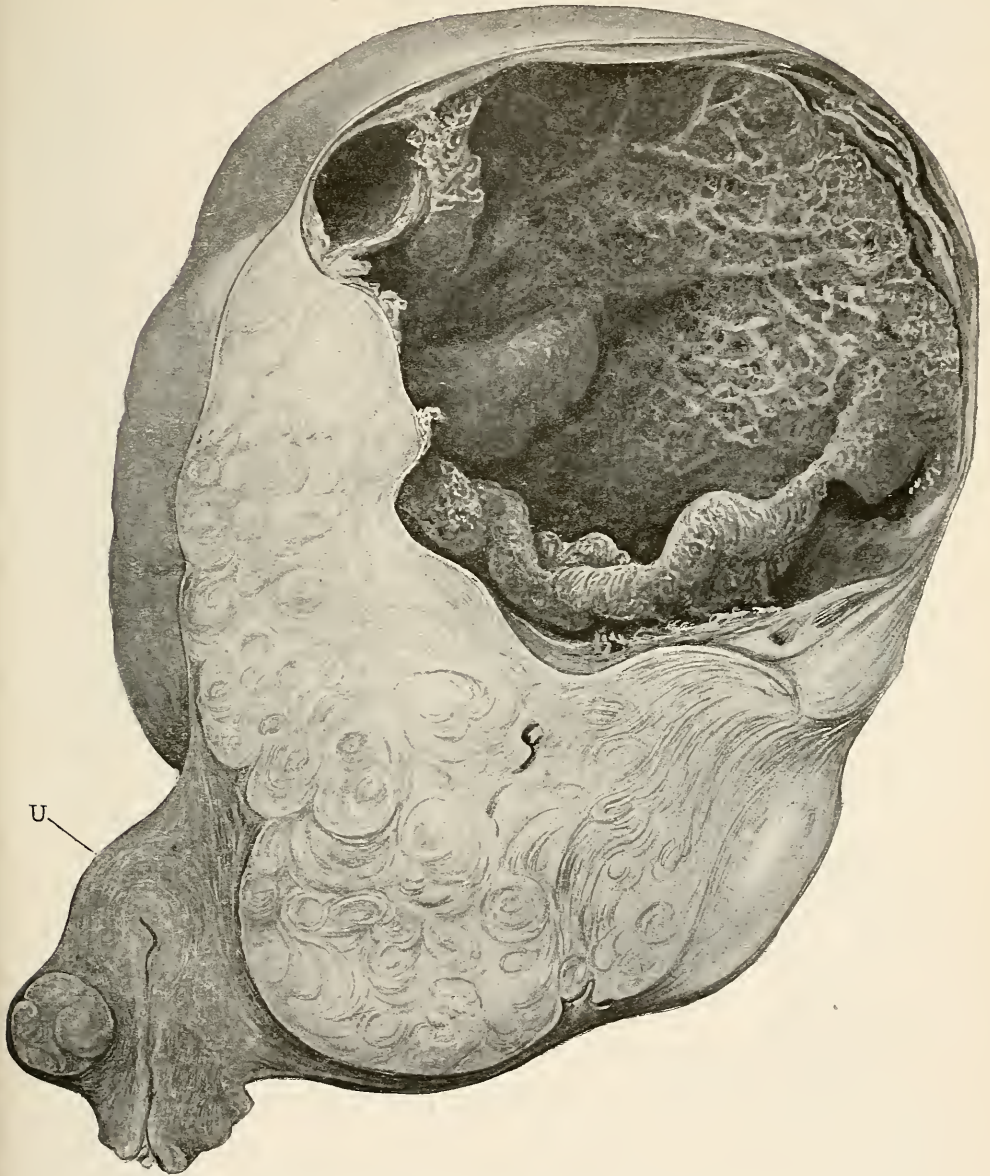


FIG. 225. LARGE SUBSEROUS FIBROID ATTACHED TO THE UTERUS BY A BROAD BASE. The upper half of the tumour is cystic. The cyst shows a convoluted false membrane. The contents were viscid blood-stained fluid and the original change was hyaline degeneration probably followed by red necrosis. U, Uterus.

outside lymphatics ; (5) signs of vascular degeneration, engorgement, thrombosis, and fibrin-deposits in the vessels.

The above description applies to a true degenerative process, which

is, as already stated, a precursor of calcareous degeneration. It also invariably precedes necrosis, a point to which further reference will be made.

The presence of fat in a myoma appears in some rare instances to be due to a *vital* but depraved activity, which is akin to lipoma-formation elsewhere in the body. Such terms therefore as *lipomyoma*, *fibro-lipomyoma*, and *lipomatosis* have been used to describe this pseudo-growth.

Microscopically, the fat-globules in *lipomatosis* are as large as those seen in an ordinary lipoma, whereas in ordinary fatty degeneration the droplets are extremely minute (compare Fig. C and Fig. D, Plate XIV). The naked-eye characters are also totally different. The whorled appearance of the fibrous elements of the tumour may remain. There is no evidence of necrosis nor of thrombosis. Figure C, Plate XIV, shows that even in this condition the fat is formed at the expense of the muscle-fibres, so that how far it is justifiable to regard the change as degenerative, and how far it is neoplastic, must be left undecided.

**Calcareous Degeneration.** The deposition of lime-salts in fibroids is quite commonly observed in elderly subjects. Preceding the deposit of calcium salts, the tissues contain fatty substances known as lipoids, some in the form of lipoid-fat, some as lipoid-soaps; in other words, malnutrition has led to hyaline and fatty degeneration. The fat combines with the albumen of the dead cells to form soap-albumen. The latter forms insoluble double calcium-soaps with calcium derived from the blood; finally by combining with  $\text{CO}_2$  and  $\text{PO}_4$  carbonates and phosphates of lime are deposited as insoluble salts in the dead tissues.

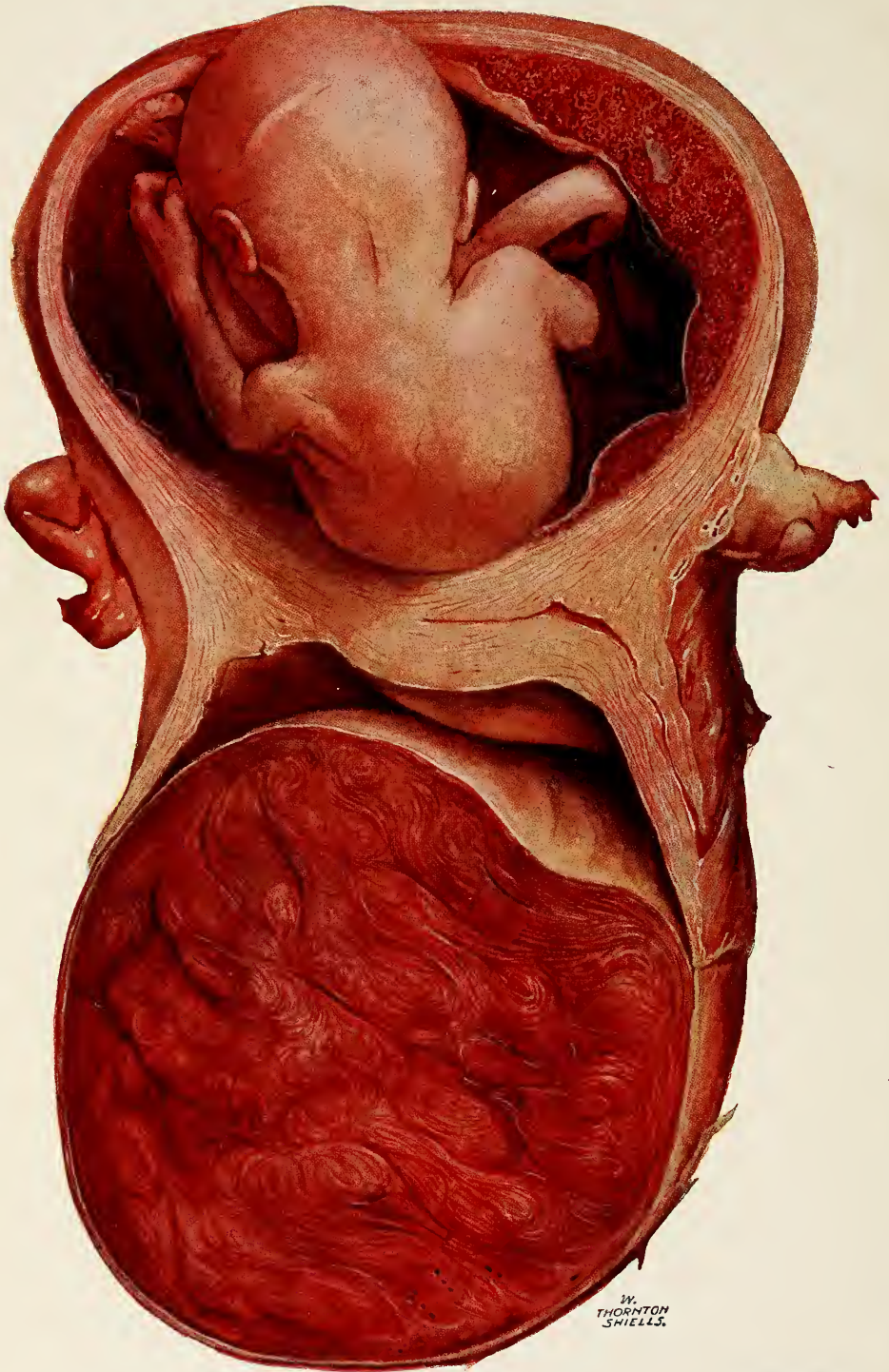
Calcareous degeneration of fibroids may affect the periphery of the growth only, producing a shell-like investment, or the deposit of lime salts may be diffused throughout the whole substance of the tumour, producing the so-called *womb-stone*.

Calcification of a fibro-myoma may be clinically detected by the use of X-rays.

**Necrosis. Necrobiosis.** Necrosis is to be found according to Tracey in 5 per cent. of myomata removed by operation. The central parts of a myoma, being the most remote from its blood-supply, are most prone to undergo necrotic change. The demarcation of a necrotic area may be sharp, or it may be indefinite. The colour of the dead tissue varies with the blood-vascular changes in the neighbourhood; it may be yellow-grey, grey-brown, greyish purple, magenta-red or mahogany-red. Necrotic patches are liable to occur in subserous, interstitial, and submucous fibroids. The change is invariably preceded by hyaline and fatty degeneration.

The term *necrobiosis* is generally used to indicate partial destruction or death of the tissues, in contradistinction to *necrosis* or total





W.  
THORNTON  
SHIELDS.

death ; but the term has received a narrow application, and has been employed to designate a particular form of degeneration of fibroids which is frequent in pregnancy and in the puerperium. From its colour it has also been known as *red degeneration*. A reason for using the term *necrobiosis* is, that there is clinical evidence to support the view, that certain necrobiotic fibroids, or cases of red degeneration, can actually recover their vitality ; that is to say, the clinical signs of tenderness and pain and also the rise of temperature which sometimes occur, may subside after having caused a protracted and tedious puerperium. But it must be pointed out that it is incorrect to regard necrobiosis and red degeneration as synonymous terms, and the question of the colour of the tissue is a side-issue.

Red fibroids are of comparatively soft consistence. On section they resemble raw or partly cooked beef-steak ; they give off a peculiar fishy odour ; dilated and thrombosed vessels may sometimes be seen in the capsule, and more occasionally in the interior of the growths. The colour is due to the tissues being stained by soluble blood-pigments set free by hæmolysis, which Leith Murray attributes to the action of the lipid substances that are always present. The actual chemical nature of the soluble colouring material is undecided, nor is it yet determined what relation, if any, the hæmolysis has with the thrombosis which is so commonly present.

Microscopically, the stage at which the degeneration has arrived is estimated by the number and appearance of the cell-nuclei, and by the behaviour of the cytoplasm to differential stains ; the more necrotic the growth, the less the differentiation, and the more diffuse becomes the staining. Red myomata have no special characteristics in this respect. The microscopical features enumerated under *Fatty Degeneration* (p. 447) hold good for any form of necrosis irrespective of its colour, so that under the microscope it is impossible to tell red necrosis from yellow or any other colour. *Red* degeneration is therefore not a *pathological type*. Nevertheless it has assumed a special clinical significance from its frequent association with the gravid or puerperal uterus. It may, however, be found in the non-pregnant state. Plate XV shows a myoma in a state of total red degeneration in a uterus four and a half months pregnant.

Necrotic areas, whatever their colour may be, are not due to infection. When bacteria are found, the infection is secondary.

**Œdema and Lymphangiectasis.** It is common to speak of a fibroid which is soft and exudes an abundance of fluid on section, as being *œdematous*. The majority of cases so described are really examples of the liquefaction which results from hyaline degeneration. True œdema is uncommon ; liquefaction, however, is frequently observed in fibroids ; it may be accompanied by œdema, but it must be clearly understood that the two processes are separate and distinct.

An œdematous fibroid feels semi-fluctuant, and the consistence

of the uterus is very suggestive of pregnancy. On section much serum escapes. After preservation for many weeks in Kaiserling's solution the cut surface becomes concave, and sulci appear between the lobes of the growth. The fluid contains only a scanty amount of albumen, which contrasts with the highly albuminous fluid found in cases of hyaline liquefaction.

When microscopically examined, an œdematous fibroid shows the muscle-bundles separated by a flocculent or granular material formed of the constituents of the transudation which have become fixed in the hardening process (*see* Fig. E, Plate XIV). The muscle-fibres themselves are swollen from intracellular transudation, so that in transverse section they appear as large clear cells with unstained cytoplasm.

In œdematous fibroids the lymphatic channels are dilated; sometimes this is marked enough to justify the condition being described as *lymphangiectasis*. The dilatation of lymph-channels and the transudation of serum are the results of some mechanical compression, just enough to produce a gradual, partial obstruction in the lymph-circulation. Impaction of the tumour in the pelvis is the commonest cause of true œdema.

**Axial Rotation.** A stalked subperitoneal fibroid lying above the pelvic brim sometimes becomes twisted, *i.e.* rotated upon its axis; when the twist is extreme, the uterus to which the tumour is attached sometimes participates in the rotation. Further, a uterus greatly enlarged by the presence of multiple sessile, or interstitial fibroids sometimes becomes rotated *en masse*, the cervix forming for it a kind of pedicle, capable of being twisted to some extent. Axial rotation is an accident which occurs to ovarian tumours much more frequently than to fibroids, and the general considerations concerning its occurrence will be referred to later on in that connection (*see* p. 702). It may now be said, however, that pregnancy, which exerts a powerful predisposing influence in the case of ovarian tumours, appears to bear no such close relation to the occurrence of rotation in fibroids.

In the case of fibroid tumours rotation is usually partial only, for the thickness of the pedicle prevents the twist from completing more than half a circle. It is equally impossible for the *uterus* to become rotated through a complete circle, but even partial rotation may lead to occlusion of the cervical canal, and the accumulation of menstrual blood in the uterus (*hæmatometra*). Fibroids which have rotated assume a deep plum-colour from congestion, and extensive interstitial hæmorrhage is found on microscopic examination. The tumour also, as a rule, contracts extensive adhesions to neighbouring organs. Occasionally the nutrition of the pedicle beyond the twist is greatly interfered with, atrophy occurs, and the tumour becomes detached from the uterus. It is then generally nourished through vascularization of the adhesions which it has contracted; omental adhesions are

the most important as sources of this alternative blood-supply (*parasitic fibroids*).

Acute symptoms similar to those which will be described in the case of ovarian tumours may be met with when fibroids become suddenly twisted. This is, however, exceptional; as a rule the rotation occurs gradually, and the symptoms referable to the torsion are inconsiderable, or may even be absent.

**Angiomatous or Telangiectatic Changes.** True angiomata, *i.e.* growths composed of a new formation of blood-vessels, are rare in myomata; they are, however, occasionally found, the new vessel-formation being apparently independent of degenerative or necrotic change.

The engorged vessels around necrotic areas, particularly the type known as *red degeneration*, are sometimes so pronounced as to be described as telangiectases. This does not imply that new vessels have formed, but that, owing to stasis and engorgement, every pre-existing vessel has come into prominence. The same change is seen to follow congestion in those submucous fibroids which have suffered from compression during expulsion (*see* Plate XVI, p. 481), and in subperitoneal fibroids which have undergone extreme torsion of their pedicle.

**Infective Changes.** When fibroid tumours become infected the endometrium is usually the channel of infection; from this it follows that submucous growths are the most, and subperitoneal growths the least liable to become affected in this way. Another possible source of infection is the bowel, the fibroid being then attacked from its peritoneal surface. In very rare cases infection appears to occur through the blood.

Sometimes the whole of a large fibroid tumour, consisting of the uterus and several growths, becomes inflamed, resulting in the formation of general adhesions which may involve practically the whole of its peritoneal surface, and attach the tumour firmly to bowel, omentum, the uterine adnexa, and the parietal peritoneum. Coincident salpingo-oöphoritis is also always present. In such cases the uterus is probably attacked from both sides; from the endometrium by an infection which has ascended from the vagina, and from the peritoneum by the pelvic peritonitis, resulting from the tubal infection. In cases such as these, pain and menorrhagia are prominent symptoms, but the existence of peritoneal adhesions alone does not always cause pain, and their presence may remain unsuspected until the abdomen has been opened. Instead of the whole tumour thus becoming infected, individual growths may be attacked, the infective process ending in suppuration or sloughing.

*Suppuration*, or the formation of an abscess in a fibroid growth, is very rare, but instances have been recorded both in interstitial growths (endometrial infection), and in subperitoneal growths (bowel infection). The abscess may be evacuated in the former case into the uterine cavity, in the latter through the bowel.

*Sloughing* occurs almost solely in connection with submucous or polypoid growths, the source of infection being a pre-existing purulent discharge; or in some cases it is accounted for by operative interference or instrumentation, obstetric or gynæcological, of the uterine cavity. While the capsule of the tumour is intact, sloughing probably never occurs; when the capsule has been torn, either in the natural process of extrusion of the tumour, or by operative interference, infection is prone to lead to sloughing. It is most commonly met with in connection with puerperal septic infection of the uterus. The processes of sloughing and extrusion go on together, and profuse irregular hæmorrhage often accompanies them. Fever, as a rule, is of moderate degree, for free drainage can take place through the cervix, rendered patulous by the uterine contractions which accompany the process of extrusion. Histological examination of expelled fragments of the growths is in these cases often inconclusive, for the staining-reactions of the dead tissues are lost.

*Adhesions* are not commonly formed by fibroid tumours, and are much less frequent than is the case with tumours of the ovary. In Tracey's series of 3561 cases the tumour was found adherent in only 3·5 per cent. Adhesions occur under three different conditions: (1) localized adhesions may form over an area which has undergone degeneration, the omentum being as a rule the structure to which the abnormal attachment is contracted; (2) general adhesions of the whole peritoneal surface of the tumour may occur from uterine infection; (3) localized adhesions may be found in the neighbourhood of an extra-uterine source of infection, *e.g.* an inflamed Fallopian tube or ovary, the vermiform appendix, or a coil of intestine.

When adhesions are present the tumour seldom entirely loses its mobility, and their recognition before operation is a matter of difficulty. They do not in all cases cause pain, and except that they increase the operative difficulties of removal, they are not of great moment.

### MALIGNANT CHANGES IN FIBROID

Myomata being exclusively mesenchymal growths, the only type of malignant metaplasia which they can possibly undergo, must be mesoblastic likewise. We may thus have (1) malignant leiomyomata, which are very cellular and capable of producing metastases, although they are not histologically malignant; (2) sarcomata, formed by malignant metaplasia from the muscle-cells (*see* Figs. 227 and 228) and from the connective-tissue cells of a myoma; (3) peri- and endotheliomata, which are types of sarcoma of low malignancy arising from the blood-vessels and lymphatics of a myoma. Epiblastic tissue being absent, it is impossible for epitheliomata and carcinomata to develop from within a myomatous tumour. A myoma may, however, be *invaded* by a co-existing carcinoma or sarcoma.



**Sarcomatous Metaplasia.** The possibility of sarcomatous change occurring in a fibro-myoma was once held to be doubtful, but

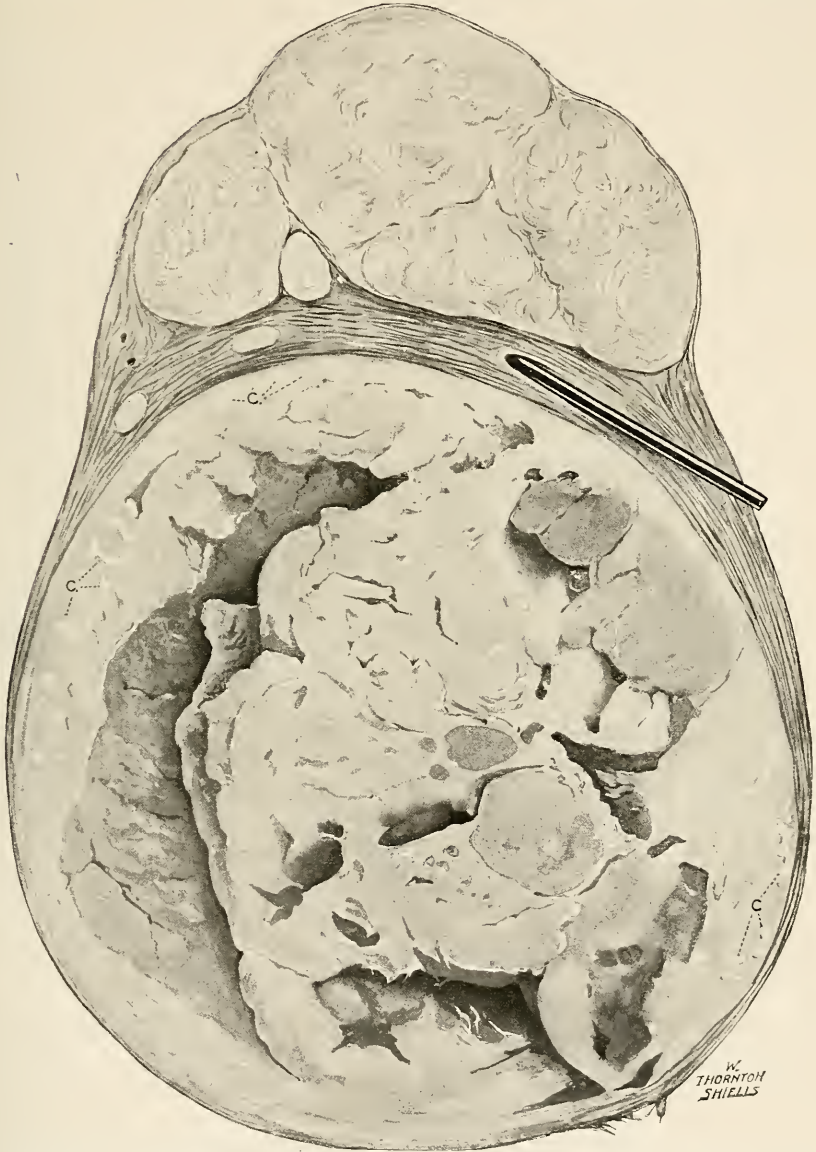


FIG. 226. SARCOMATOUS METAPLASIA IN A FIBROID TUMOUR. The lower and larger growth shows areas of smooth homogeneous sarcoma. The large cystic space was an abscess-cavity. The smaller ones were blood-cysts. The capsule of this growth was calcareous. Compare the whorled appearance of the fibroid seen above with the smooth section of the sarcoma seen below

it is now generally admitted. The natural history of a fibro-myoma, the type-cell of which is the embryonic fibroblast, would not

be complete without this faculty of demonstrating malignant metaplasia.

*Frequency.* Fehling and also Martin found sarcomatous metaplasia in fibroids in about 2 per cent. of cases. Cullen found this change in 1·21 per cent., Noble in 1·8 per cent., and Tracey in 1·5 per cent. of cases.

It is a well-known clinical fact that fibroid polypi, *i.e.* pedunculated submucous myomata, which on section have appeared innocent, may recur again and again, and have ultimately been found to have undergone sarcomatous change. Every variety of fibroid may become affected.

*Naked-Eye Appearances of Sarcomatous Areas.* Early sarcomatous change in a fibroid cannot be recognized macroscopically, but when the condition is well established, the gross features of the malignant area afford a striking contrast to the surrounding unchanged myomatous tissue. The area is often sharply defined, owing to the cut surface being homogeneous and not whorled as it is in the section of a fibroid (*see* Fig. 226). It is yellowish in colour instead of being pearly white, and the malignant tissue is much softer than the unaltered fibro-myomatous tissue by which it is surrounded. The sarcomatous area may become cystic, and encysted collections of blood or blood-stained fluid may be present. These blood-cysts are formed from the giving way of embryonic, thin-walled capillary vessels. Sarcomatous change usually commences in the central part of a myoma (*see* Fig. 226).

*Microscopic Appearances.* To study metaplasia, sections must be taken from the junction between the altered and the unaltered portions of a fibromyoma, *i.e.* at the periphery of the malignant area. There are two possible sources of origin for a sarcoma developing in a fibroid, *viz.*, *connective tissue* and *muscle*. In the former, the intermuscular fibrous tissue becomes abnormally cellular. Between the masses of new (sarcoma) cells the muscle disappears entirely or in part, so that a trabecular appearance is given to the growth. Whilst increasing in size, the cells of the new growth develop processes (*see* Fig. 228), and some of them become angular; the nuclei reach the size of epithelial nuclei and they show mitotic division. The growth contains many thin-walled capillary vessels, which become dilated to form blood-cysts, and often show lacerations which have produced interstitial hæmorrhage. A section taken through the centre of the growth will show it to be composed of an admixture of spindle and round cells. It is possible that both connective tissue and muscle may take part in a malignant metaplasia simultaneously. On the other hand, it has been proved that the change may arise in the muscle-tissue only (*see* Figs. 227 and 228). Sarcomatous metaplasia of muscle leads to a fibrosarcoma, that is, there is a preponderance of spindle cells and cells with processes (*see* Fig. 228); the round cells of lower type seen in malignant metaplasia of connective tissue are less in evidence or altogether absent. Attention has

already been drawn to the close association of hyaline degeneration of connective tissue and malignant metaplasia of muscle.

Fibromyomata of the uterus are sometimes *invaded* by a sarcoma arising in the uterine wall (*see* Figs. 229 and 230), and it is due to this fact that doubt has arisen as to a true malignant change arising *de novo* in the fibromyomatous tissue itself.

A sarcoma starting in the muscle-wall of the uterus is difficult to distinguish from one starting in the muscle of a fibroid tumour, as

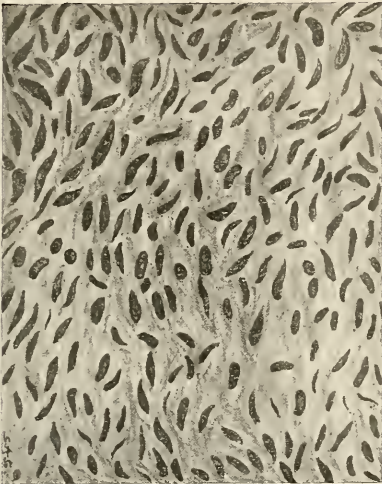

FIG. 227. SARCOMATOUS METAPLASIA OF THE MUSCLE-CELLS OF A UTERINE FIBROID TUMOUR. The short rods are unaltered muscle-cells, the spindle- and oat-shaped cells are malignant.

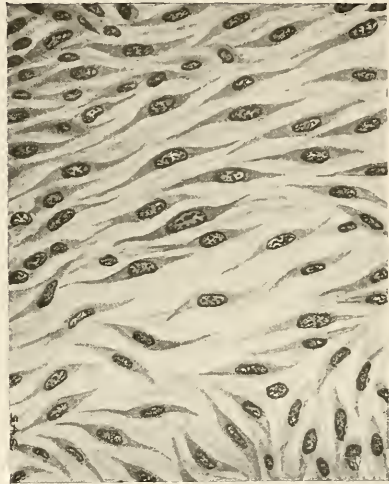

FIG. 228. SARCOMATOUS METAPLASIA OF THE MUSCLE-CELLS OF A FIBROMYOMA OF THE UTERUS. Note the branching processes of the cells.

both may be fibrosa comata, and in certain cases it is impossible to pronounce judgment as to the starting-place of the malignant process. If the malignant change is found in the centre of a large fibroid which is definitely encapsulated, it is fair to assume that it started primarily in the tumour.

**Endotheliomatous Change in Fibroids.** The occurrence of endo- and peri-theliomatous changes in fibromyomata is very rare. They will therefore be referred to under Sarcomata (*see* p. 514).

**Fibroid Tumours and Cancer of the Uterus.** The association of fibroids and malignant uterine growths may occur in two different forms: (1) fibroid tumour with cancer of the cervix (*see* Fig. 231); (2) fibroid tumour with cancer of the body (*see* Fig. 232). In both forms the fibroid and the carcinoma are independent diseases, cancer having attacked a uterus already the seat of a fibroid growth.

With regard to *cancer* it may definitely be stated that in 3 or 4 per cent. of cases of fibroid tumours removed by hysterectomy, carcinoma

has been found, and with somewhat greater frequency in the body than in the cervix. Thus in 1400 cases Kelly and Cullen found cancer of the body in 1·78 per cent., and of the cervix in 1·28 per cent. ; in 1118 cases Noble found cancer of the body in 2·4 per cent., and of the cervix

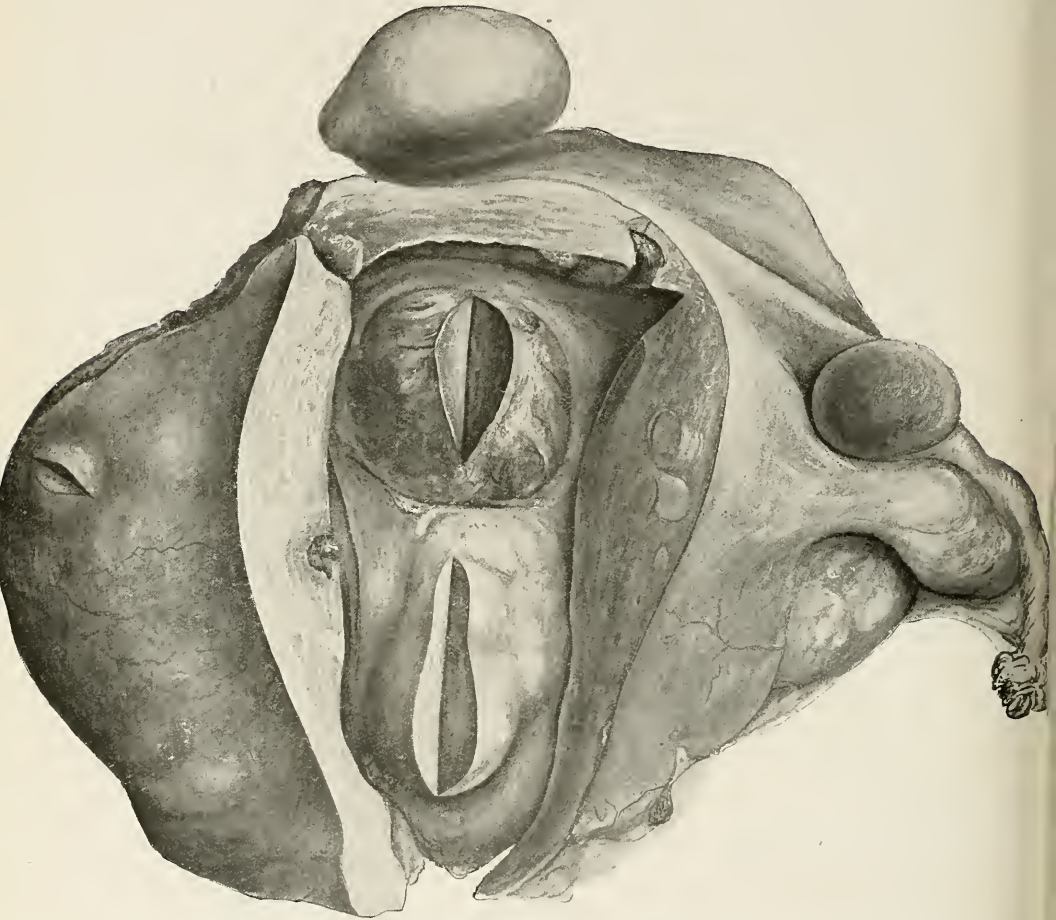


FIG. 229. FIBROID TUMOUR INVADDED BY SARCOMA. Two sarcomatous nodules are seen projecting as submucous growths into the cavity of the uterus. The microscopic appearances are shown in Fig. 230.

in 1 per cent. Tracey in 3561 cases (collated) found cancer of the body in 1·7 per cent., cancer of the cervix in 0·7 per cent. In considering the subject of uterine cancer later on, it will be seen that this disease occurs with much greater relative frequency in the cervix than in the body ; when associated with fibroid tumours the relative proportions are thus reversed.

The subjects of fibroid tumours are more frequently sterile than other women, and this fact in part accounts for the greater frequency

with which, in these women, cancer occurs in the body than in the neck of the uterus.

The association of cancer and fibroids is rarely, if ever, seen before the age of forty. The view has been advanced that the figures already given lead to the conclusion that the subjects of fibroid tumours are more liable than other women to the development of cancer in later middle age. It is doubtful if this conclusion is justified; it must be recollected that the statistics are compiled only from cases submitted to the operation of hysterectomy, *i.e.* from only a proportion of the total number of women in whom fibroids occur. If it were possible to calculate the association of cancer with fibroids generally, and not alone with cases operated upon, the aspect of the matter would probably be greatly changed.

A small number of cases—over thirty in all—have been recorded in which cancer was recognized in the cervical stump left after the operation of supravaginal amputation for a fibroid tumour. In our experience this has occurred as late as  $2\frac{1}{2}$  years after the uterus was amputated for fibroids. This cannot, however, be held to imply any special liability of the cervical stump to become cancerous. In several of the cases it appears that the malignant disease was present at the time of the operation, but was not then recognized.

The *diagnosis* of malignant changes in fibroid tumours, or of the concurrent formation of a malignant growth in the uterine body, can seldom be made before the removal of the tumour. The possibility of malignancy must, however, always be entertained under the following circumstances: (1) When the tumour enlarges after the menopause is over; (2) when bleeding returns after the menopause is over; (3) when ascites, anæmia, or wasting appear; (4) when after the age of forty, the tumour is soft in consistence and grows rapidly; (5) when recurrence takes place, *e.g.* after the removal of a polypus.

Under these circumstances the removal of the tumour should not be delayed.

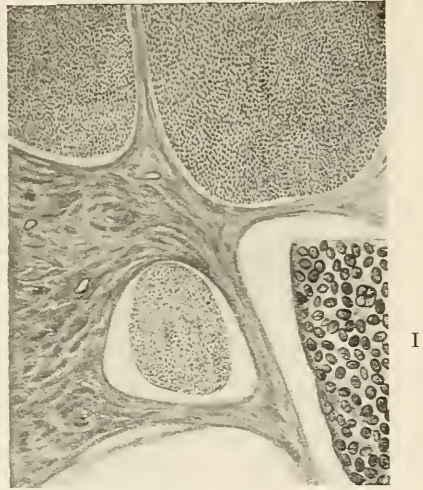


FIG. 230. SARCOMATOUS INVASION OF A FIBROID TUMOUR. The inset (I) shows the sarcoma-cells under  $\frac{1}{8}$  inch objective.

**FIBROIDS AND PREGNANCY**

This subject is fully dealt with in text-books of Midwifery, but

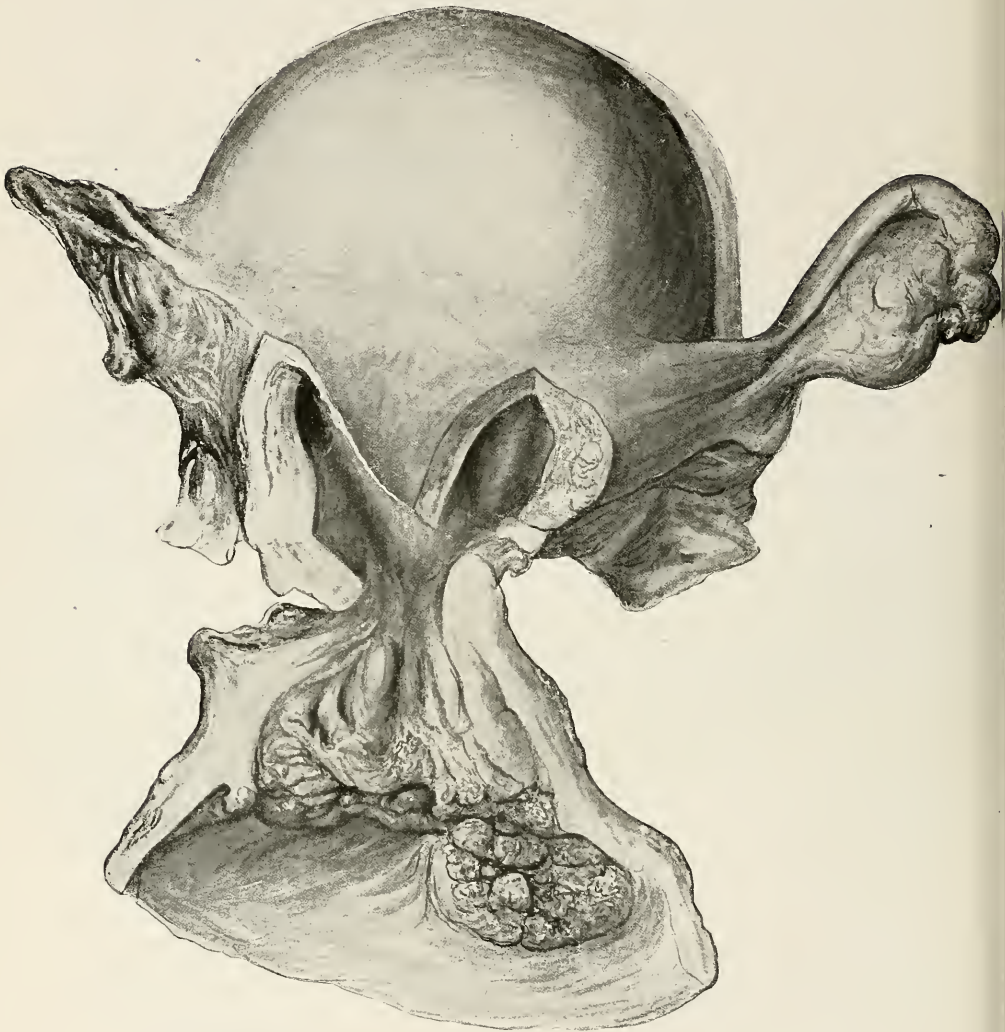


FIG. 231. CANCER OF THE CERVIX ASSOCIATED WITH FIBROID TUMOUR OF THE BODY OF THE UTERUS. Patient *et. 49*.

inasmuch as the treatment frequently comes under the notice of the gynæcologist, a short *résumé* is here given.

*Treatment.* Pregnancy should be allowed to continue until term, unless (1) severe complications due to the tumour arise, or (2) the tumour is so situated as inevitably to cause insuperable obstruction during labour. In the former case the offending tumour should, if

possible, be removed by myomectomy and the uterus allowed to remain. Even with improved modern technique this operation is attended with considerable risk of abortion, for Devine has recently collected 130 cases with an abortion rate of 23 per cent. It is often

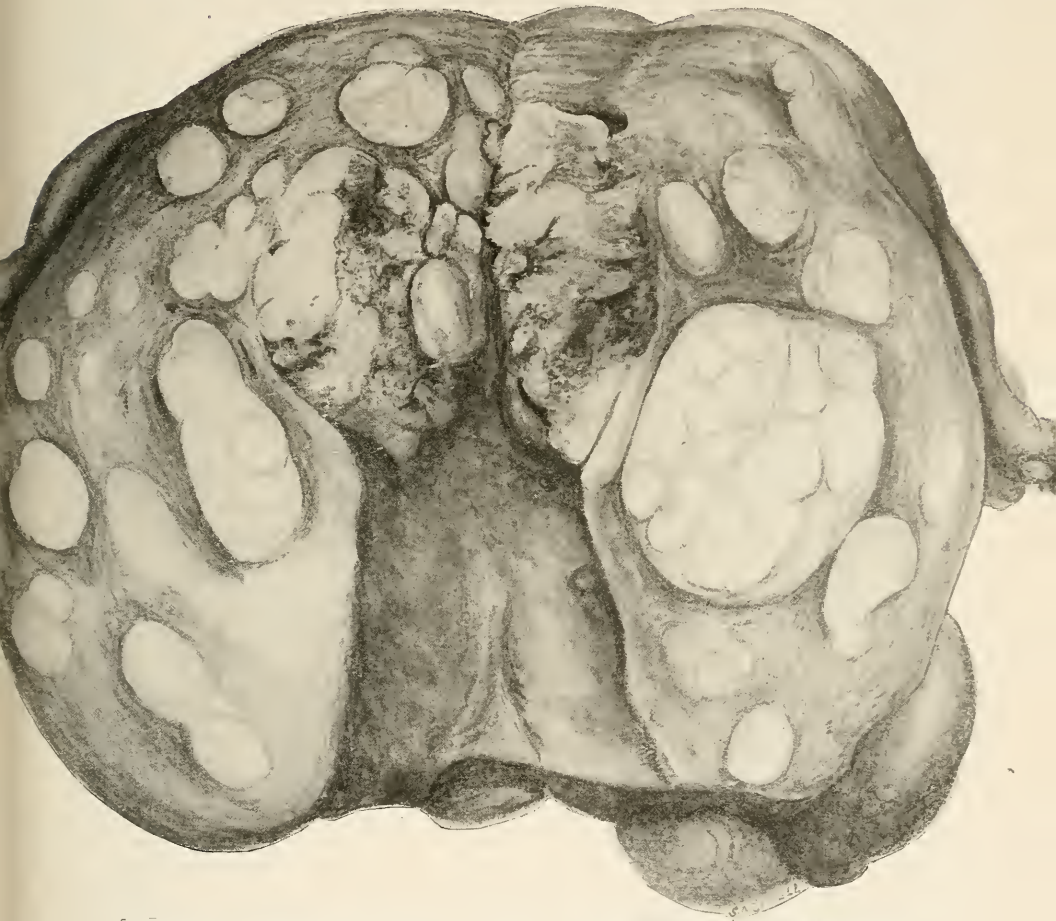

FIG. 232. CANCER OF THE BODY OF THE UTERUS ASSOCIATED WITH MULTIPLE FIBROMYOMATA. The cancerous process had invaded some of the submucous fibroid nodules. Patient *et. 54*.

difficult to decide during pregnancy whether a fibroid tumour will cause obstruction in labour or not. If the fibroid is cervical, serious obstruction cannot be avoided. If it is corporeal and does not involve the lower part of the body, the probability is that it will not. There are many, however, intermediate in position, the effect of which on labour is doubtful. In many instances tumours apparently involving the lower uterine segment will become drawn up during labour, so as to clear the pelvic brim and allow of the passage of the child. When obstruction in labour can be foretold with certainty or even with

probability it is better to deliver by Cæsarean section than to allow the patient to run the serious risk associated with labour. With this operation may be combined (a) myomectomy (*Cæsarean myomectomy*), if the fibroid is solitary and can be easily enucleated, and the patient is under forty; (b) subtotal hysterectomy (*Cæsarean hysterectomy*) with conservation of healthy ovaries under all circumstances. The former, although theoretically preferable, is actually a more difficult and dangerous operation than Cæsarean hysterectomy; on the other hand, Cæsarean hysterectomy at a near term is no more serious than hysterectomy at an earlier period, when the fœtus is non-viable, and is, therefore, on the whole the best method of dealing with such cases. Wherever possible operation should be postponed until the child is fully viable. Induction of abortion or premature labour when fibroids are present cannot be recommended; the position of the fibroid tumour may render dilatation of the cervix difficult, and if interference is necessitated to evacuate the uterus, serious mechanical obstacles may have to be overcome.

### GENERAL CLINICAL FEATURES OF FIBROID TUMOURS

Uterine fibroids are among the commonest tumours to be found in any part of the human body. From post-mortem records the statement has been made that in from 20 to 25 per cent. of all women who reach adult age fibroid tumours can be found in the uterus. No safe conclusions can, however, be drawn from records of autopsies, which only comprise a small percentage of the number of deaths in the community. There appears to be good reason to believe that fibroids occur more frequently in black than in white races. This is certainly true of the negroes of the United States, and Gaillard Thomas stated that some competent observers regarded fibroids as of almost constant occurrence in negroes over thirty years of age.

The relative frequency of occurrence at different ages is a point upon which it is difficult to obtain reliable evidence. They may arise in any part of the sexual period of life, but there is no evidence that they ever occur before puberty, or that they arise *de novo* after the menopause. Many cases come under clinical observation for the first time after the climacteric has been passed, but in such cases the tumour has probably been in existence for some time. Before twenty-five years they are rare, before twenty they are very rare. The earliest authentic case is probably that of Cavaillon, in a girl of thirteen who had suffered severely from menorrhagia for twelve months. The tumour was removed by hysterectomy, and its benign nature was certified in the pathological laboratory of Lyons. The greatest care is required in distinguishing sarcoma from fibroids especially in subjects under twenty years of age.

A point of great practical importance is the age at which fibroid



tumours most frequently give rise to symptoms leading to the discovery of their existence. In many cases these tumours do not cause any disturbance until they have grown to a considerable size, and the time when they come under observation is by no means the time at which they arise. There is general agreement that it is in the decade thirty-five to forty-five that fibroid tumours are most likely to become troublesome, and during these years a greater number of operations for these tumours are performed than in any other decade.

Conflicting statements have been made as to the relative frequency of their occurrence in married and unmarried women ; it appears that while their formation is quite independent of sexual activity, their subsequent growth is accelerated by sexual intercourse and child-bearing. The actual conditions, local or general, to which the formation of uterine fibroids are due are quite unknown.

### SYMPTOMS

The symptoms to which a fibroid tumour may give rise are very variable. In many cases a small tumour gives rise to none whatever ; it is compatible with unimpaired health, and if discovered it is only by accident. Others of larger size attract attention from their bulk, which causes a noticeable abdominal enlargement, and often a loss of symmetry from the nodular character of the growth. This is a point of distinction from the enlargement due to an ovarian cyst which is usually regular and uniform. There is, however, a general tendency for fibroids, which may for years have been innocuous, to give rise in the end to symptoms of greater or less severity. Very few women, subjects of fibroid tumours, escape at some time or other suffering from certain ill-effects, although their appearance may be delayed for many years.

Fibroid tumours may give rise to *abdominal enlargement, hæmorrhage, pain, disturbances of the reproductive functions, pressure-symptoms and leucorrhæa* ; in consequence of prolonged ill-health, certain other indirect or remote symptoms may supervene, *e.g. anæmia, constipation, dyspepsia, and neurasthenia*. And further, in consequence of secondary changes in the tumour, striking developments may occur in the clinical features, consisting sometimes of aggravation of pre-existing symptoms, sometimes of the appearance of acute or subacute abdominal disturbances, sometimes of sudden disturbance of the functions of the bladder (retention of urine).

The subject will be best considered by taking the chief symptoms individually.

**Hæmorrhage.** Excessive monthly bleeding (menorrhagia) is the commonest disturbance produced by fibroid tumours ; yet it is by no means constant in occurrence. Tumours of large size may exist without it, while often excessive or even dangerous hæmorrhage may be pro-

duced by others quite small in size. Bleeding is, in fact, dependent upon the situation rather than the size of the growth. Several other factors in the causation of the hæmorrhage must, however, be recognized: (1) Increased size of the uterine cavity and therefore an increased area covered by endometrium; (2) coincident thickening of the endometrium; (3) mechanical obstacle, caused by the tumour, to muscular contraction of the uterus, an important factor in arresting menstrual bleeding under normal conditions; (4) formation of mucous or fibroid polypi; these may give rise to bleeding of the most serious degree. When degenerative or malignant changes occur, or when the tumour becomes infected, a fresh set of conditions favourable to hæmorrhage are introduced which will be referred to later on. Subserous, intraligamentary, or retroperitoneal fibroids may exist and even attain a large size without greatly affecting the uterine cavity and the endometrium, and therefore without giving rise to hæmorrhage. Small submucous growths on the other hand may suffice to bring about bleeding of a serious character. Sometimes a submucous fibroid with an enlarged uterine cavity may be found in cases where there has been no increase of bleeding at all, but, generally speaking, fibroids of this class are characterized clinically by abnormal bleeding. The interstitial ones occupy an intermediate position as regards their tendency to produce hæmorrhage.

In severe cases monthly periods are prolonged and excessive, with shortening of the menstrual intervals. The regularity of the menstrual rhythm is not well maintained when there is pronounced menorrhagia, variations of several days being not uncommon. When of only moderate severity, menorrhagia may continue for a long time without greatly affecting women who in other respects are healthy. But the capacity of the individual to recover from periodic losses of blood is variable, and many women pass into a condition of chronic anæmia, when, judged by average standards, the amount of bleeding has not been severe. Thus, bleeding must be judged rather by its effects than its amount. When the patient complains that it takes her a week or two to recover energy after her period, it is certain that she is losing more blood than can be made up without ill-effects upon the body generally. Blood-counts should be made, and the condition of the heart and the circulation carefully noted in such cases.

*Intermenstrual bleeding* is relatively uncommon with fibroids which are not undergoing secondary changes. Slight bleeding of this character may occur with submucous or interstitial fibroids, and is to be attributed to the expansion and thickening of the endometrium. This condition of the endometrium is favourable to the formation of mucous polypi, and these structures still further increase the tendency to irregular bleeding. When this form of hæmorrhage is really profuse it will generally be found that a fibroid polypus is present, or is in course of formation. A small polypus of this kind may give rise to

bleeding of the most alarming severity owing to laceration of the vessels in its capsule during the process of extrusion.

Instances of fatal bleeding from fibroids, although very uncommon, have been from time to time recorded—not as the result of a single overwhelming loss of blood, but from the recurrence of severe losses at short intervals. When the body has been largely depleted of blood, an amount of fresh hæmorrhage may prove fatal which would be borne by a normal individual without difficulty.

*Internal bleeding* sometimes occurs from fibroid tumours. Large subperitoneal veins are formed in many instances, and they may become varicose, or a venous aneurysm may be formed as in the case recorded by Spencer. In the exposed position they occupy, crossing the surface of the tumour, they may be ruptured by direct injury giving rise to serious internal hæmorrhage. From compression against the sacral promontory ulceration of the wall of the vein may occur, as in a case recorded by Bruce Clarke. Occasionally a fibroid tumour has been lacerated by a violent blow on the abdomen, and this also gives rise to profuse internal bleeding.

One other point must be noted in regard to the influence exerted by fibroids upon bleeding from the uterus, viz. that the menopause is very commonly delayed for several years beyond the average date of its occurrence. The climacteric age should probably be regarded as from fifty to fifty-five, instead of as from forty-five to fifty. This change is not confined to cases characterized by abnormal bleeding but is a common feature of fibroids of all varieties. Cases in which irregular hæmorrhages continue after the usual climacteric age has been reached, must not be regarded as instances of delay; only cases in which the monthly losses continue to be regular can properly be so regarded.

**Pain.** Pain is not a common symptom of fibroid tumours; when present it is in many cases directly due to complications affecting either the tumour itself, or other structures adjacent to the uterus.

Uncomplicated fibroids may, however, occasion pain in two ways: (a) by making the menstrual process painful; (b) by compressing the vessels and nerves around them (pressure-symptoms).

*Dysmenorrhœa* may be attributed either to mechanical interference with uterine contraction caused by an interstitial or submucous growth, or to excessive muscular contraction induced reflexly by the presence of a fibroid polypus. Severe menstrual pain is quite uncommon with uncomplicated fibroids, and as in the case of hæmorrhage, those which are subserous are the most innocuous in this respect. Many of the complications referred to below as causes of pain may also occasion dysmenorrhœa, so that this symptom cannot be attributed directly to the tumour unless it is met with in an uncomplicated case.

The type of dysmenorrhœa which accompanies fibroids is usually the *secondary* or *congestive* type (see p. 181).

*Pain from pressure* may be caused by fibroids which fill up

completely the pelvic cavity, but in such cases other symptoms, also due to pressure, arise, and the various effects of pressure will therefore be described together later on.

When *severe* pain, whether menstrual or intermenstrual, is complained of, the presence of complications should be suspected. Perhaps that most frequently met with is *co-incident disease of the tubes and ovaries*, the nature of which is referred to on p. 443. Chronic inflammation of these organs may occasion more or less constant abdominal pain or discomfort with resulting physical disability, and also may give rise to recurring attacks of pain of a severe character. Suppurative inflammation, if acute, may give rise to an acute abdominal illness difficult to distinguish, in its initial stages, from acute infection of the appendix or gall-bladder. Further, an ovarian cyst may co-exist with a fibroid tumour, and in such a case the ovarian cyst shows an unusual liability to become adherent in the pelvic cavity. Being held down in the pelvis by the superimposed uterine tumour, its circulation is impeded, and an inflammatory reaction is readily set up around it leading to plastic peritonitis.

In the second place, changes may occur in the tumour itself which give rise to pain. Of these changes the one which most frequently causes pain is *infection*; the sources of this infection and the resulting changes in the tumour are described on p. 453. *Acute* infection leading to sloughing of a submucous or interstitial fibroid gives rise, in the initial stages, to acute pain and fever. *Chronic* infection leads to the formation of peritoneal adhesions around the tumour, and sometimes to thickening and induration of the cellular tissue. Often chronic tubo-ovarian inflammation is also present, the infective process having travelled through the uterus to reach the tubes. Adherent fibroids may be attended by pain of a subacute and more or less constant character, which is usually aggravated before and at the beginning of each monthly period, *i.e.* dysmenorrhœa of the secondary type may be present.

*Red degeneration* or *necrobiosis* is also in many cases, although by no means invariably, associated with pain; rise of temperature, although not by any means a regular concomitant of the pain, may occasionally be found.

*Axial rotation* of a subserous stalked fibroid, or of a uterus containing a fibroid tumour, causes pain at first by interfering with the venous return from the tumour, and later by setting up peritonitic adhesions around it.

When *pregnancy* occurs in a uterus the seat of fibroid tumours, a good deal of pain is often complained of, which may continue throughout pregnancy, and may even be prolonged into the puerperium. This does not in all cases arise from degenerative processes, although pregnancy is one of the conditions specially favourable to the occurrence of red degeneration. Sometimes the fibroids increase rapidly in size, concurrently with the uterus, and the resulting total volume of the

tumour becomes very large, so that the effects of pressure cannot be excluded. Often, however, the fibroids are painful on palpation, while the part of the uterus which contains the ovum is not, suggesting that some change has occurred in the fibroids themselves.

There is no means of distinguishing, from the clinical character of the pain, the nature of the complication to which it is due. Usually the pain is referred to the lower abdomen and is more marked upon one side than the other, and it may extend down the thighs. Lumbar and sacral pain is, generally speaking, characteristic of pressure from a fibroid which has filled up the pelvis. Recurring acute or sub-acute attacks of abdominal pain suggest inflammatory complications involving the tubes and the peritoneum. Fibroids which give rise to pain are also commonly tender to palpation, while unaltered fibroids are not.

**Pressure-Symptoms.** The clearest effects of the pressure exerted by a fibroid tumour are to be found in the case of the bladder; these effects, however, are not seen with so much frequency as might be expected from the anatomical relations of the bladder to the uterus. Heavy fibroids of large size extending from the pelvis into the upper abdomen might be expected seriously to interfere with the diastole of the bladder; in point of fact they do not, except in a comparatively small proportion of cases. The bladder appears to possess a remarkable facility in accommodating itself to altered dispositions; if its dilatation in the usual directions is impeded, it dilates in other directions with little loss of its retentive capacity. So long as a tumour superimposed upon the bladder is not fixed, but retains a fair degree of mobility, the only bladder-symptom is, as a rule, moderate frequency of micturition; in the case of very large tumours this may become severe.

It is in the case of fibroids impacted in the pelvis that the most marked disturbances of the bladder are to be found. These tumours often raise the floor of the bladder high above the level of the symphysis pubis; this will occur when the uterine tumour is retroverted, and is large enough to fill the pelvic cavity tightly, or when the fibroid develops beneath that portion of the base of the bladder which lies in contact with the uterus. The bladder then becomes an abdominal viscus even when empty, and an inevitable consequence is that the urethra becomes lengthened. Probably this lengthening is accompanied by increased tension leading to narrowing of the lumen of the canal. A bladder thus displaced is therefore liable to become the seat of *retention of urine*, which is probably due chiefly to narrowing of the urethra interposing an increased resistance to the expulsion of the bladder-contents. The conditions are of course similar to those found in retroversion of the gravid uterus at the end of the third month. Yet retention occurs more frequently in this case than in the case of fibroids, probably because in the latter the changes are more gradually brought about.

When retention of urine occurs under the conditions just described, the first attack often coincides with menstruation, or with the premenstrual congestive phase. Fibroid tumours can often be observed definitely to increase in size during the week preceding a monthly period, and this may raise the difficulties which the bladder has to encounter to a point at which it is impossible to overcome them. Sudden and complete retention, calling for the use of the catheter, is the usual form, and after a day or two in bed, with regular catheterization, the bladder will often recover its functions, and recurrence of the trouble may be postponed for several weeks or months. The subsidence of the menstrual congestion, favoured by the horizontal position of the body, brings about sufficient reduction in size of the tumour to relieve the difficulty. The degree of congestion occurring at menstruation is probably variable, and therefore recurrence of the trouble does not necessarily occur at the next period.

Actual difficulty in passing urine, frequency and pain during and after micturition, may also be complained of, but only when evidence of urinary infection is absent can these symptoms be attributed to pressure by the fibroid. Dribbling incontinence may occur in neglected cases of retention, when the bladder has been allowed to become over-distended; in rare cases it may be produced by direct pressure on the bladder.

The *ureter* may be displaced by intra-ligamentary or retroperitoneal fibroids, which burrow beneath it, raise it up, and stretch it. In the majority of such cases little injury occurs to the ureter, but occasionally its lumen becomes narrowed, urine ceases to flow freely from the kidney, and hydronephrosis occurs; in still rarer instances the kidney on the affected side atrophies. Compensatory hypertrophy of the remaining kidney may, however, prove adequate to the needs of the body, even in such cases, so that no clinical symptoms of renal disease may appear. Should cystitis occur in a case in which the ureter has been thus injured, the liability to upward spread of the infection to the kidney is greatly increased.

*Blood-vessels* may show signs of direct compression by fibroid tumours, although, even with those of the largest size, the vessels may escape. The external iliac vessels at the pelvic brim are sometimes affected in this way, and the soft muscular floor upon which they lie perhaps accounts for the frequency with which they escape injurious pressure. The usual result of pressure is œdema or varicose veins of the lower extremities; one side may be alone affected. More rarely a true thrombotic phlegmasia is seen from formation of a clot in the external iliac or femoral vein.

The inferior hæmorrhoidal vessels are also liable to pressure, resulting in aggravated forms of piles.

*The Intestine.* Cases of intestinal obstruction due to fibroid tumours occasionally occur. In the majority, the rectum or pelvic

colon has been the seat of obstruction, due to compression by a hard, fixed pelvic fibroid : several of such cases have been recorded in elderly women and the tumour has been found to be calcified. The small intestine is also sometimes affected by a coil becoming nipped between the tumour and some unprotected bony surface on the pelvic brim, such as the sacral promontory or sacral ala (Barris).

The *upper abdominal viscera*—stomach and liver—may be so much compressed by a very large fibroid growing upwards beneath the costal arch that their functions are seriously interfered with. It is only with tumours of quite uncommon size that this will occur, and at the same time, embarrassment of respiration and of cardiac action may be seen.

*Functional disturbances of digestion*, in women who are the subjects of fibroids of moderate size, *i.e.* which do not exceed the level of the umbilicus, are often loosely spoken of as pressure-effects. This is, however, not so ; symptoms of this kind are independent of the tumour, and can usually be relieved by general measures. Constipation is also often so regarded but without justification, as is clearly seen when the constipation continues unabated after the removal of the tumour.

*Nerves* are the least liable of all adjacent structures to be compressed by pelvic tumours. Only fibroids which burrow underneath the pelvic peritoneum can affect them directly, and it is remarkable in how few instances any clinical evidence of nerve-compression can be found. Muscular paresis is practically unknown, and pain when present does not follow the distribution of the nerves. Cases of sciatica, for example, are quite uncommon in association with fibroid tumours which, from their situation, might exert direct pressure upon the sciatic nerve.

**Reproductive Disturbances.** The reproductive functions may be disturbed by fibroids in several directions. *Sterility* is a common, but not an invariable, result ; a considerable proportion of women with fibroids have borne children previous to the discovery of the tumour. During pregnancy there is an increased risk of abortion ; during labour serious difficulties from obstruction may occur. During the puerperium there are risks of sloughing if the uterus should become infected ; a submucous tumour may be extruded with profuse hæmorrhage, or a severe form of degeneration, such as *necrobiosis* may occur. Yet it is quite possible for a woman with a fibroid tumour to bear one child or even several without mishap. Submucous and interstitial growths are more harmful to the reproductive functions than subserous ones ; and those which arise in the cervix or the lower part of the uterine body are most liable to cause obstructed labour.

**Leucorrhœa.** This is a frequent but unimportant symptom. It is due mainly to the coincident thickening of the endometrium, which has been already described. Sources of discharge, which are independent of the tumour, such as cervical 'erosion' or mucous polypi,

may also contribute to it. The discharge is of the common mucous or muco-purulent type which has been already described on p. 138. Departure from this type rarely occurs except from secondary changes in the tumour. From infection, an offensive discharge may occur, which in the case of sloughing fibroids may be extremely putrid. A thin or watery, coloured discharge may occur when cystic degeneration has taken place. The significance of bleeding in the menstrual intervals has been already referred to.

From what has been said it will be seen that the clinical results of the presence of a fibroid tumour are very variable. Under favourable circumstances it is not incompatible with unimpaired general health, and it may remain quiescent for many years, during which its existence is unsuspected. At the same time, in the majority, a certain amount of trouble accompanies a fibroid tumour, the severity of the symptoms being graduated, from what is almost negligible, up to a degree at which the general health is profoundly affected. And further, tumours which have remained quiescent for several years may at any time, from change in their mode of growth (*e.g.* extrusion into the uterine cavity), or from secondary changes, suddenly reveal their presence by symptoms of a more or less serious character.

There are certain risks inseparable from each variety of fibroid ; thus submucous growths may become polypoid or may slough from infection ; interstitial and subserous growths may undergo cystic degeneration or *necrobiosis* ; subserous stalked growths may become twisted ; all varieties may become infected by an ascending infection of the genital tract, or perhaps, in some cases, from the bowel. Recorded instances in which fibroids have directly caused a fatal result are extremely rare, taking into consideration the great frequency of their occurrence. In consequence of the variety of unfavourable influences which they may exert, however, both directly and through the changes they induce in other organs, fibroids occupy a position among histologically benign neoplasms which is unique. No other structurally innocent tumour produces such widespread and unfavourable effects as may, in many cases, be seen with fibroids.

### PHYSICAL DIAGNOSIS OF FIBROIDS

Fibroids usually occur as multiple tumours although occasionally they are solitary ; some grow outwards beneath the peritoneal covering producing a nodular mass ; others remain interstitial or submucous, when their surface is generally smooth ; the great majority are inelastic solid growths, but they may become of stony hardness from calcification ; or they may become softened or definitely cystic in character from degenerative changes. Usually insensitive to touch, they may become tender or even acutely painful from secondary changes.



Further, they vary in size from tiny nodules up to a mass large enough greatly to distend the entire abdominal cavity. It will be clear that the physical diagnosis of tumours so varied in character may present great difficulties. For purposes of note-taking those which do not extend above the pelvic brim may be called *small* fibroids ; those which extend above the pelvis but do not exceed the level of the umbilicus—*medium-sized* ; those which exceed the level of the umbilicus—*large* fibroids.

In the first place certain points applicable to fibromyomata of all sizes should be borne in mind. *Submucous* fibroids tend to produce a symmetrical enlargement or expansion of the uterus similar to that of pregnancy, together with a proportionate elongation of the uterine cavity which, under favourable conditions, can be detected by the sound. A measurement of from four to six inches may be obtained, and under no other conditions except pregnancy is the uterine cavity lengthened to such an extent. It must, however, be recollected that owing to distortion of the uterine cavity (*see* Fig. 218) the sound may fail to pass up to the fundus, so that a short measurement cannot be trusted in all cases. *Interstitial fibroids* tend to produce an asymmetrical tumour, the surface of which is smooth and regular ; elongation of the uterine cavity may be detected as in the former case. *Multiple subserous* fibroids tend to produce a tumour of quite irregular shape and of nodular surface ; individual masses of the tumour may be movable independently of the whole, showing that they are stalked, or loosely attached though sessile ; the uterine body may sometimes be made out among the masses of which the tumour consists, and may not be greatly enlarged nor its cavity greatly, if at all, lengthened. Subserous nodules may vary a good deal in consistence and in the degree of smoothness of their surface. Sometimes a *solitary subserous* fibroid attains a very large size, forming a smooth-walled tumour, the connection of which with the uterus is not always easy to demonstrate.

Lastly, it must be recollected that in multiple fibroids all three classes are often represented, which introduces a further element of complexity into the physical characters of the resulting tumour. It follows from what has been said, that a uterine fibroid tumour may be so large, and of such irregular shape, that it bears no resemblance to the parent organ.

Certain diagnostic points may now be noted which serve to distinguish all *tumours of uterine origin from others*, and which are applicable to all kinds of fibroid.

There are two pelvic organs in which tumour-formation is common, the uterus and the ovary ; uterine tumours are with few exceptions solid growths ; ovarian tumours may be either cystic or solid, but cystic tumours predominate in the proportion of about 9 to 1. A solid tumour occupying the pelvis or the lower half of the abdomen may

therefore be presumptively regarded as uterine in origin ; a cystic tumour in the same position may be presumptively regarded as ovarian.

Under favourable conditions, the distinction between cystic and solid tumours may be made with ease ; a dense inelastic mass is readily recognized by palpation as solid, while a lax cyst, filled with thin fluid, readily yields fluctuation and a fluid thrill. But solid tumours are not all densely hard, nor do all cysts yield a fluid thrill ; by softening of the tissues a solid tumour becomes yielding, and by concentration of the contents and subdivision into small loculi, a cyst may become resistant ; the result is that the distinctive characters of each become obscured.

Another factor which affects facility of diagnosis is the condition of the abdominal walls. When the parietes are thin, the muscles not unduly resistant, and the amount of adipose tissue small, the conditions are favourable. In the case of obese women the difficulty of determining the character of an abdominal tumour is very much increased, for through a thick abdominal wall, solid and cystic growths feel very much alike.

A tumour in the pelvis or lower half of the abdomen which is definitely solid in consistence is therefore probably a uterine fibroid. Confirmatory evidence of its uterine origin may be sought in several directions.

The first point is the *relation of the cervix* to the tumour. In some instances it is easy to demonstrate the continuity of the vaginal cervix with the tumour ; thus in medium-sized fibroids which lie above the pelvic brim and are non-adherent, the cervix can be felt on bimanual examination to pass upwards into the mass, and on gently rocking the tumour from side to side with a hand placed on the abdomen, it will be seen that the least movement is shared by the cervix. This test must not be sought by pressing the tumour down into the pelvis, as this would depress the cervix even if the tumour were only super-imposed upon the uterus. In the case of small pelvic tumours the same test can often be applied, but owing to the more confined space in which they lie, lateral movement of the tumour is necessarily more restricted. In the case of a retroverted uterine fibroid tumour, the continuity of the cervix can be readily felt through the posterior fornix.

The *sound* is an instrument upon which little reliance can be placed in the diagnosis of uterine tumours. As already stated, owing to encroachment of the growth upon the lumen of the uterus, an elongation of the cavity may escape detection by the sound, and further a large uterine tumour may exist without producing any elongation of the cavity. Therefore measurements with the sound, unless definitely increased above the normal, are valueless. Sometimes the *direction* in which the point of the sound passes is a useful indication ; if it passes into the tumour-mass, the probability of the uterus being involved is of course very great ; although even then, it must be

recollected, that the uterus may be adherent to the tumour and not form part of it. Owing to the risks of infection, the use of the sound except under anæsthesia, is not to be recommended (*see* p. 239).

Examination under anæsthesia may demonstrate the *independence of the ovary on each side* from the tumour; but for a definite result the conditions must be favourable, *i.e.* the tumour of moderate size, and the abdominal walls thin.

These general points having been considered, it will be convenient to take up the diagnosis of certain types of fibroid tumour.

**Small Fibroid Tumours.** The simplest diagnostic instance is the small submucous or interstitial fibroid. This gives rise to a smooth walled, solid, pelvic tumour, the continuity of which, with the cervix, is usually easy to determine. In the case of a submucous growth, or an intra-uterine polypus, the enlargement may closely resemble in outline that due to pregnancy, the uterus being expanded so as to become approximately globular. Interstitial growths may cause distortion in shape, when the differentiation from a gravid uterus is much easier. These growths have not, as a rule, the densely hard consistence of the larger tumours, which are mainly subserous. Four points of distinction from a gravid uterus may be sought for :

(1) The *menstrual history* is usually distinctive; in normal pregnancy amenorrhœa is almost invariable; with fibroids amenorrhœa is almost unknown until the climacteric age, with the sole exception that pregnancy may occur in a fibroid uterus with resulting amenorrhœa. From pathological causes, however, pregnancy may give rise to irregular or continuous bleeding, which may equally be caused by a fibroid tumour.

(2) In primigravidæ changes indicative of pregnancy may be found in the *breasts*, such as hypertrophy of breast-lobules, increased pigmentation of the areola, and the presence of secretion which can be expressed through the nipple. Of these changes, one, *viz.* the presence of secretion, may also be met with in fibroid tumours; the other breast-changes just mentioned are, however, only seen in pregnancy.

(3) The *condition of the cervix* is a point of distinction to which great importance must be attached. Softening such as is met with in pregnancy does not occur with fibroids, the cervix being often unusually hard and resistant. If ordinary care is taken the mistake will not be made of confusing an *erosion* with the softening of pregnancy. A certain amount of purplish discoloration of the mucous membrane of the cervix is sometimes seen with fibroids.

(4) *Intermittent contractions* may be detected in a uterus of the third or fourth month of pregnancy; at this period the contractions are feeble and care is necessary to detect them. Often they produce a recognizable alteration in the shape of the uterus rather than a change of consistence. But when recognized they constitute an important sign of pregnancy.

The diagnosis of the occurrence of pregnancy in a fibroid uterus will be referred to later on.

**Medium- and Large-sized Fibroid Tumours.** These tumours are much more diversified in character than the small ones which are fairly uniform. As a rule the growths are multiple, and when a number of subserous nodules or masses are present, the resulting tumour is quite irregular in shape, and does not retain the median position of the parent organ, but extends much further to one side than the other. These tumours are nodular or bossy on the surface, or they may consist of two or more large masses which can be moved independently of one another. The constituent masses are often of diverse degrees of hardness. Sometimes a portion of the tumour may be so freely movable as to suggest that it is pedunculated. Occasionally solitary fibroids attain a very large size, forming smooth-walled tumours, which are approximately median in position, and uniform in consistence.

In the case of fibroids of this size, there is seldom any difficulty in demonstrating their pelvic connections. Even in the case of pedunculated subserous growths the pedicle is very rarely long enough to enable it to ride free above the pelvic brim, as may happen with an ovarian cyst (*see* p. 711). In nearly all cases some portion of the tumour remains pelvic, and on abdominal examination it can be followed downwards into the pelvic brim (*see* p. 116). For this reason they are, generally speaking, less mobile than ovarian tumours, especially as regards movement in a vertical plane, this movement being checked by the cervical attachments.

On auscultation of the surface of a large fibroid tumour a *souffle* can often, but not in all cases, be detected over some part of the tumour. It is similar in character, although seldom so pronounced, as that produced by a gravid uterus. This sign is, strictly speaking, merely an indication that large superficial arterial branches are present on a part of the tumour which is accessible to the stethoscope. The anatomical arrangements of the blood-supply of the uterus favour the formation of such vessels when the organ becomes greatly enlarged either from tumour-formation or from pregnancy. In the case of ovarian tumours, a *souffle* is never heard.

With fibroid tumours of this class, the conditions found on *internal examination* are very variable. In some cases, the tumour lies entirely above the pelvic brim, and can be reached only with difficulty if at all *per vaginam*; the cervix and the lowest part of the uterine body are not involved, and the lower pole of the tumour consequently forms a narrow neck. In other cases, a portion of the tumour may lie in the pelvis, and may be felt as a protuberance springing from the lower part of the uterus. Occasionally a fibroid tumour is seen which not only rises well above the pubes but also fills completely, or nearly so, the pelvic cavity. Sometimes such tumours have arisen in the posterior uterine wall, and have become moulded in their growth so as to fill the

pelvic cavity exactly ; they are practically immovable and are often described as *impacted*. More often they are either *retro-peritoneal* in position, or they arise in the cervix (*cervical fibroids*). The physical characters of these varieties of fibroids deserve special consideration.

*Retro-peritoneal fibroids* (see p. 431) of large size cause more extensive changes in anatomical relations than any other pelvic tumours. On *abdominal* examination, their only striking feature is their immobility ; much less lateral movement is possible than with the ordinary varieties. On *pelvic* examination, two points as a rule attract attention. In the first place the cervix is frequently displaced to a very marked extent, in an upward and forward direction. It may lie above the upper border of the pubes and be almost inaccessible to the finger ; the anterior vaginal wall is at the same time elongated, and its direction has become nearly vertical.

The second point is that the tumour-masses extend downwards into the pelvic cavity to a great depth. The largest part is usually found behind, where it may insinuate itself into the cellular tissue of the recto-vaginal septum until it extends as far as the middle of the posterior vaginal wall. The formation of such a tumour-mass necessarily raises the cervix and pushes it forwards. On *rectal* examination, the size and consistence of such a mass can be better felt than *per vaginam*. Sometimes a large retroverted fibroid tumour, or a tumour with a large subserous outgrowth from the posterior wall, gives rise to similar pelvic conditions.

*Cervical Fibroids*. These tumours rarely extend higher than the level of the umbilicus. They are almost always solitary, and form firm, smooth-walled tumours of oval outline. Occasionally a movable nodule can be felt upon the summit, which represents the upper part of the uterine body (see Fig. 217). On vaginal examination they are found to extend deeply into the pelvis and to be nearly fixed. The vaginal portion of the cervix is always, to a greater or less extent, involved in the tumour. In an extreme case the characteristic finger-shaped process of the portio vaginalis is entirely absent ; in the vaginal vault is felt a smooth oval or conical mass, and upon the surface of this mass careful examination will detect a small aperture surrounded by a slightly raised lip, representing the external os. In a less extreme case the lowest part of the vaginal portion is preserved and may be recognized by touch, while the tumour is felt to expand rapidly above it, forming thus a striking contrast to those cases in which the cervix is not implicated and a well-formed neck remains.

*The largest fibroid tumours* can only be compared with ovarian growths, and their physical diagnosis will be considered in the section on the Diagnosis of Ovarian Tumours (pp. 711 and 717).

**Pathological Diagnosis.**—The exact diagnosis of the histological nature of a uterine tumour cannot be made until it has been removed, carefully inspected throughout, and submitted to expert microscopical

examination. Clinical diagnosis can therefore never be more than the estimation of probabilities, and it calls for no detailed discussion. Three steps in diagnostic reasoning may be mentioned.

(1) A solid tumour is present, which apparently arises within the pelvis. Probably the patient suffers from excessive monthly bleeding, or from irregular hæmorrhages, but these symptoms are sometimes absent. (2) The tumour is recognized as uterine from its relation to the cervix, and possibly from the presence of an unaltered ovary on each side. (3) It is assumed to be innocent in character from (*a*) the long duration of the symptoms, and sometimes the known presence of a tumour for a long period; (*b*) the mild and unprogressive character of the symptoms, and the well-maintained health of the patient.

Diagnosis cannot be carried further than this by the clinician; exact diagnosis is the work of the pathologist. Reference has been made already to the relatively high proportion of cases in which sarcomatous changes have been found in isolated areas of fibroid tumours systematically examined after removal. Again, carcinoma may appear in the endometrium of a fibromyomatous uterus, giving rise to no symptoms at first, or to only slight irregular bleeding. In the early stages of these malignant processes there are no clinical data to warn the clinician of their presence.

It follows from this, that after its removal a fibroid tumour should be carefully examined by the surgeon, and if its naked-eye characters are equivocal, an expert histological diagnosis should be sought.

### TREATMENT OF FIBROID TUMOURS

There are no means known by which the formation of fibroid tumours can be prevented, or their subsequent growth controlled. Medical and therapeutic measures may be successful in palliating the symptoms to which they give rise; cure can be obtained by surgical measures, or in some instances by the use of large doses of Röntgen rays. The former method is symptomatic only, the latter methods are curative.

Not all fibroids require treatment; unless symptoms clearly attributable to their presence are met with no treatment need be adopted, and in many cases it is better that the patient should not be informed of the existence of the tumour. When definite symptoms requiring relief are present, the decision must first be made between palliative (symptomatic) and radical treatment. It must be recognized that considerable difference of opinion exists upon this matter, and no individual view would meet with universal acceptance. The results of palliative treatment are uncertain and on the whole unsatisfactory, although an occasional success may be met with. No harm is done, however, by giving this treatment a trial when the patient is under forty years of age, and the symptoms are not severe. It should

be borne in mind that the remote results of removing the uterus, as regards the general health, are more serious in young women than in those who are approaching the age of the menopause.

Under the following conditions it is better that *surgical treatment should not be delayed* :

- (a) When the tumour exceeds the size of a seven months gravid uterus ; the bulk of the mass is then a sufficient reason for its removal.
- (b) When the tumour is increasing rapidly in size, or is accompanied by pain or by irregular bleeding.
- (c) When a fibroid which has been quiescent, becomes troublesome in any way after the menopause.
- (d) Whenever palliative treatment fails to control bleeding, and there is advancing anæmia.

When *menorrhagia* is the only symptom caused by a fibroid tumour, rest in bed during the monthly period is sometimes sufficient to reduce the flow to moderate limits, within which it does no harm. Over-exertion, or chill during menstruation, may occasion a violent or protracted hæmorrhage.

**Symptomatic Treatment.**—*Hæmorrhage* and *anæmia* are interdependent conditions, and both must be treated if success is to be attained.

The medicinal treatment of uterine hæmorrhage has been already described on p. 135 ; it only remains in this place to indicate that in cases of bleeding from fibroid tumours preparations of ergot are seldom successful, unless given in full doses by deep injection. Ergot was formerly given continuously to women with fibroid tumours, in the belief that by keeping the uterine muscle contracted, it diminished the blood-supply and so arrested the growth of the tumour. It was further claimed that submucous fibroids could be expelled under the influence of ergot. It is very doubtful whether either of these results, when observed, could be attributed to the action of ergot in any given case. Next to ergot, preparations of cotarnine, such as *lodol*, deserve a trial. It must be admitted, however, that the prospects of efficiently controlling hæmorrhage from fibroid tumours with drugs are not good.

Bleeding of the most severe type can usually be temporarily controlled by plugging the vagina. In these cases, the uterine cavity also can sometimes be plugged in an emergency, as the cervical canal is patulous, but the greatest care is required to avoid infection if this method is employed.

After a severe hæmorrhage, the patient should be kept in bed and treatment directed to the resulting anæmia. Iron in some of its milder forms, hæmoglobin, bone-marrow, raw-meat juice, and a liberal supply of milk, are the more important items in the treatment. The ability of different persons to recover from large losses of blood is

variable ; many women appear to suffer little and recover rapidly ; others do not properly recover even when treated in the manner just indicated, and successive hæmorrhages, in already anæmic patients, become more and more difficult to control.

*Pain and Pressure-Symptoms.* Pain may be due to secondary changes in the tumour, such as inflammation, or to pressure upon other viscera or upon nerves. Relief can be obtained by rest in bed, but treatment at a spa in this case gives the best results ; such treatment consists in the consumption of large quantities of mineral water, aided by prolonged hot baths and hot vaginal douches, combined with the use of massage and electricity. In this country Woodhall Spa, in France Plombières and Cauterets, and in Italy Salzo-Maggiore, are suitable for cases of fibroid tumour. A course of this treatment repeated regularly, once or twice a year, may succeed in deferring a resort to surgical measures for a long time, or in fortunate cases permanently. Cases in which hæmorrhage is the prominent symptom are unsuitable for spa-treatment.

Pressure upon the bladder, causing frequency of micturition, incontinence or retention, is most often met with in connection with menstruation—either during or immediately before the period, and is probably due to a slight increase in the size of the tumour from congestion. Under these circumstances, retention requires the regular use of the catheter until in the natural course the tumour diminishes in size, the pressure is relieved, and the bladder recovers. Retention occurring in the menstrual intervals can also be temporarily relieved by rest in bed and the catheter. In a few fortunate cases it may be possible to give more permanent relief by pushing the tumour out of the pelvis and above the pelvic brim, under anæsthesia if necessary. The vagina should then be plugged and the plugging renewed daily for two or three days, to prevent the tumour from returning to its pelvic position. Pessaries in such cases are incapable of keeping up the enlarged and heavy uterus. A small fibroid tumour in a prolapsed uterus causing bladder-symptoms may be successfully treated by a pessary, if the condition of the perineum allows of the instrument being retained.

**Treatment by Röntgen Rays.** It has now been shown conclusively that certain classes of fibroids can be successfully treated with X-rays. The use of X-rays for this purpose was suggested by the observations of Albers-Schonberg (1903) and others who succeeded him, upon the destructive action of the rays upon the genital glands of animals. It was shown that atrophy of the ovaries with more or less destruction of Græafian follicles, and fibrotic changes in the interstitial tissue, occurred in animals, and later observations have shown that similar results are produced in the human ovary. The effect of prolonged and repeated exposures in women, is completely and permanently to arrest menstruation. This implies that all the follicles have been destroyed, functionally if not anatomically, and as a small



amount of active ovarian tissue suffices to keep up menstruation, total destruction is the result aimed at. Recent clinical observations have suggested that in addition, the rays exert a direct effect upon the tissues of the fibroid tumour itself, resulting in atrophic changes. The indirect action through the ovaries is, however, the more important.

These effects are produced by some, but not all, of the rays given out by an X-ray tube. The so-called *hard, penetrating, or  $\gamma$ -rays* alone reach the deep parts of the body; the *soft rays*, and the various *secondary* rays emitted, are absorbed by the skin and are the cause of X-ray burns, and X-ray dermatitis; these must be excluded by special methods of filtration. The technique of X-ray treatment of fibroids is consequently complicated, and special apparatus is required, and also special experience on the part of those using it.

A comparatively large experience of the results of X-ray treatment has now been gained, and it is certain that in properly selected cases complete cessation of both menstrual and irregular hæmorrhages can be obtained, and in addition, in certain cases, diminution in size, or, exceptionally, complete disappearance of the fibroid has been observed. The chief effect, and that most regularly seen, is control of bleeding. The condition produced is, in fact, an artificial menopause due to atrophy of the ovaries, and the general symptoms which occur with the normal menopause, such as *flushings* (see p. 108) are met with.

The cases held to be suitable for X-ray treatment are fibroids of small or medium size, which present no sign of degeneration or inflammatory changes, occurring in women of forty years of age or upwards. Large tumours which exceed the level of the umbilicus should be surgically removed on account of their bulk, for X-rays cannot induce a very marked diminution in size of such growths. Women below the age of forty suffer much from the effects of destruction of the function of the ovaries, and consequently at that age *conservative hysterectomy* (*vide infra*) is the method of choice. Degeneration and inflammatory changes should always be regarded as indications for operative removal of these tumours. The treatment is prolonged, for exposures can only be made at comparatively long intervals, and are usually spread over three or four months. It does not, however, interfere with the patient following her ordinary pursuits, and it involves no risk to life; in these respects it compares favourably with operative treatment.

**Surgical Treatment.** *Curetting.* This operation is sometimes useful in producing a temporary alleviation of hæmorrhage; this result cannot, however, be relied upon, and as a rule the operation is unsuccessful. It is only suitable for tumours of small size; in large tumours the uterine cavity is so frequently distorted in shape that curetting is impossible (see Fig. 218). The cervix should be dilated sufficiently to admit of preliminary exploration with the finger, as

small polypoid or submucous growths may then also be detected and removed. Dilatation is sometimes very difficult, and may be impossible when cervical tumours are present, owing to the density of the tissues.

*Myomectomy.* This procedure (cutting the tumour out of the uterus) is the operation of choice in the case of solitary tumours occurring in young women, when the conservation of the uterus itself is desirable. The operation may also be applied to multiple subserous tumours whether pediculated or sessile. Tumours of large size may be successfully dealt with in this way. In the case of women of forty-five years of age or over, the retention of the uterus is unimportant.

The advantage of myomectomy is that, the uterus being retained, menstruation continues and pregnancy may occur; the disadvantage is that fresh fibroid tumours may subsequently form. In only a small proportion of cases does pregnancy actually occur after this operation, for women who are subjects of these tumours show also a low degree of fertility. It must also be borne in mind that after the abdomen has been opened and the tumour has been carefully inspected, local conditions may be found which preclude myomectomy and necessitate removal of the uterus. When this operation is undertaken, it is accordingly advisable to secure permission to remove the uterus if this should be found necessary.

*Hysterectomy* by the supravaginal (subtotal) or by the total method, with conservation of the ovaries when healthy, is the operation which will be found most generally useful for fibroid tumours. The artificial menopause which follows is not, as a rule, more severe than that which occurs naturally. If both ovaries are removed as well as the tumour, and the patient is under forty years of age, the climacteric symptoms are often severe and prolonged.

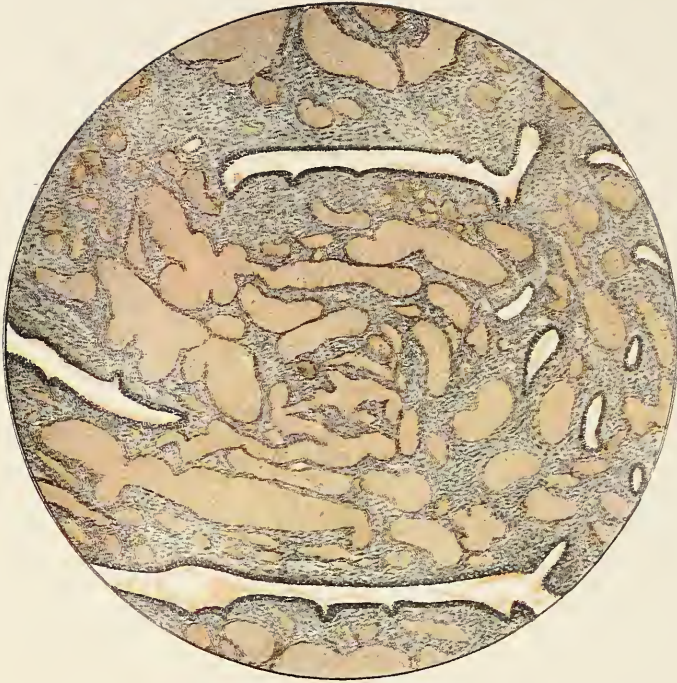These operations are described on pp. 740–756.

## UTERINE POLYPI

Only two kinds of polypi are common in the uterus, *mucous* or *adenomatous* polypi and *fibroid* polypi. The former have their seat of election in the lower part of the cervical canal near the os externum, but may also occur in the uterine body. The latter, on the contrary, have their seat of election in the body, but occasionally occur in the cervix. Polypi which combine the characters of both kinds (*fibro-adenomatous*) are not uncommon in both body and cervix.

**Mucous** or **adenomatous** polypi are small, soft, pediculated structures which are usually multiple, and of the average size of a pea, although they may sometimes attain the size of a cherry or even of a walnut. The variation in size will be appreciated by referring to Fig. 234. As seen at the mouth of the cervical canal they are of a light pinkish or red colour, and are attached either to an area of *erosion*, or to the cervical endometrium within the canal. By their





FIBROADENOMATOUS POLYPUS OF THE CERVIX, showing vascular engorgement due to stasis. This is not an example of telangiectasis, *i.e.* there is no formation of new vessels.

colour they are sharply distinguished from the vaginal mucosa. Though usually solitary, they may occur in groups of two or three. When occurring in the corporeal endometrium they are usually not discovered until removed by the curette (*see* No. 19 in Fig. 234, and Fig. 233). In Fig. 239 is shown a mucous polypus attached to the lateral border of the uterus which escaped removal, although the operation of curetting was twice performed. Hyperplasia, both of the cervical and corporeal endometrium, and cervical *erosion* are common accompaniments of mucous polypi. Polypi may also be met with in cases of chronic metritis (*see* Fig. 238).

On histological examination they are seen to consist of a connective-tissue stroma of loose texture supporting numerous glands, some of which open upon the surface, others have become dilated and form small retention cysts (*see* Fig. 235). These glands are lined with cylindrical epithelium similar to that of the endometrium. The stroma is extremely vascular, the microscopic field showing a large number of vessels, both arterial and venous; the former frequently show also thickening of their outer and middle coats (endarteritis). Some of the thin-walled vessels seen in Fig. 235 may be dilated lymphatics, the majority are veins of large calibre. Sometimes, as the result of stasis due to compression of their pedicle during extrusion, the vessels become engorged with blood (Plate XVI) and the polypus assumes a dark purple colour. The surface of a cervical mucous polypus somewhat resembles that of an *erosion* (compare Fig. 202, p. 412); it has an incomplete epithelial covering of cylindrical cells, chiefly found in the neighbourhood of the mouths of the glands. The firmer fibroid or fibro-adenomatous polypi often have a covering of well-developed stratified squamous epithelium like that of the vaginal mucosa; and sometimes the surface of the same polypus may show cylindrical epithelium in one part and stratified squamous epithelium in another (*see* Figs. 236 and 237). Parts of the surface covered with squamous epithelium are smooth, parts covered with cylindrical epithelium are velvety in texture.

Two *symptoms* are commonly associated with mucous polypi, viz. *hæmorrhage* and *leucorrhœa*; it will be recollected that the same symptoms are often caused by chronic endometritis. Profuse or protracted monthly loss results from intra-uterine (usually fibroid) polypi, and irregular or prolonged slight bleeding from cervical (usually mucous) polypi; often both types of bleeding are met with in severe cases. A mucous polypus of small size sometimes causes hæmorrhage so severe as to endanger life.

The *diagnosis* of cervical polypi is very simple, for they can be felt with the examining finger and inspected with the aid of a speculum (*see* Fig. 238). Intra-uterine polypi can only be detected by exploring the uterus with the finger, or by the use of the curette (*see* Fig. 233). All polypi should be submitted to careful histological

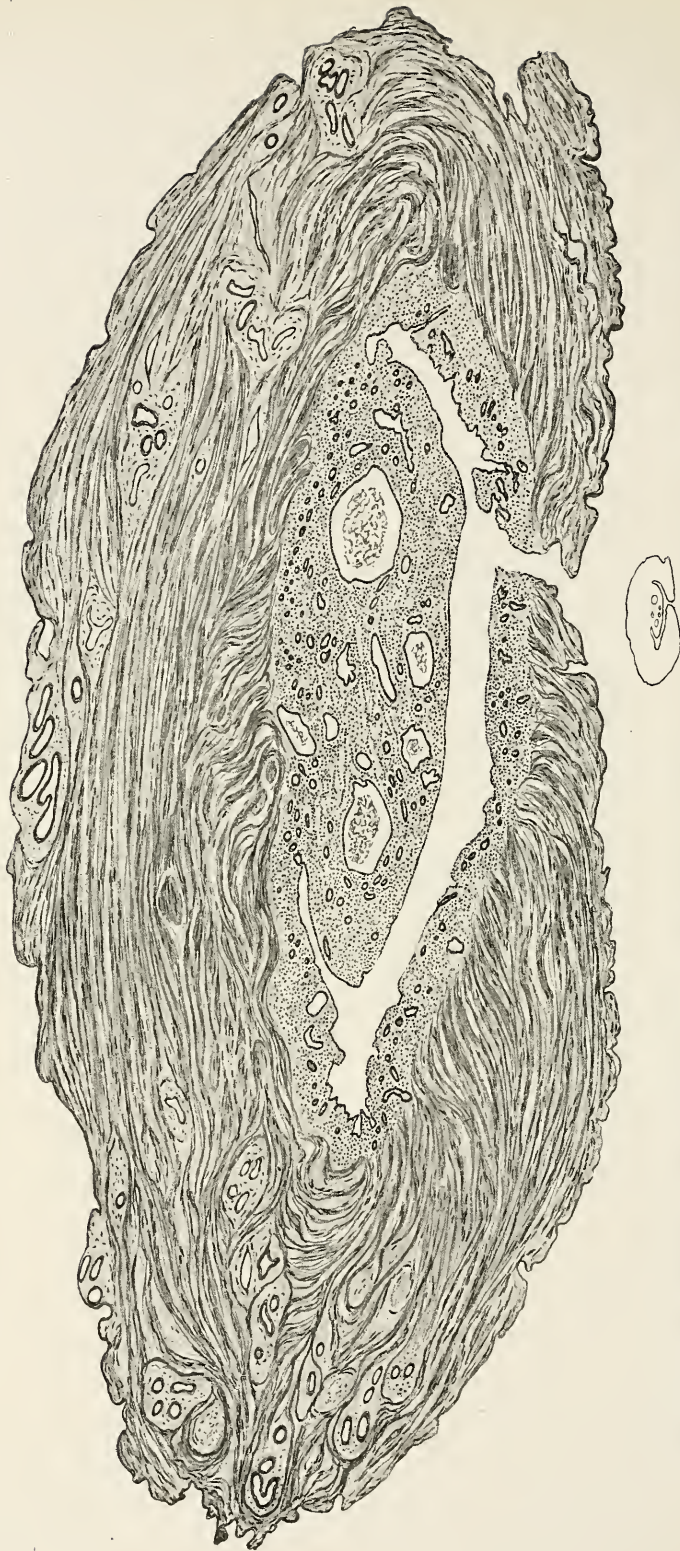


FIG. 233. TRANSVERSE SECTION THROUGH THE UTERINE WALL, showing a cystic polypoidal overgrowth of the endometrium. There is general hyperplasia of the endometrium, which will be appreciated by comparing this Figure with Fig. 17, p. 23.

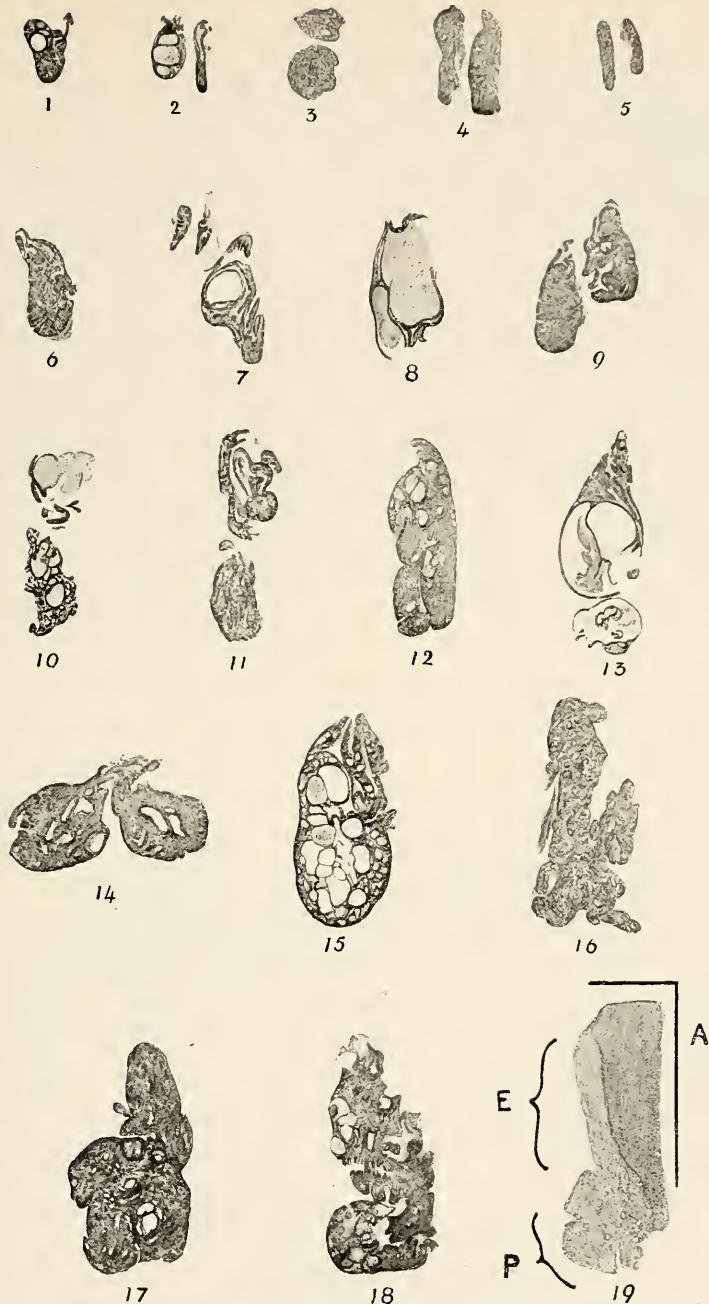


FIG. 234. MUCOUS POLYPI OF THE UTERUS. Nos. 1-18 show cervical polypi. No. 19 shows a corporeal polypus. A, Muscle-wall; E, endometrium; P, polypus. All the figures represent the actual size of sections of the growths prepared for microscopic examination. It will be noticed that the majority of the polypi are cystic.

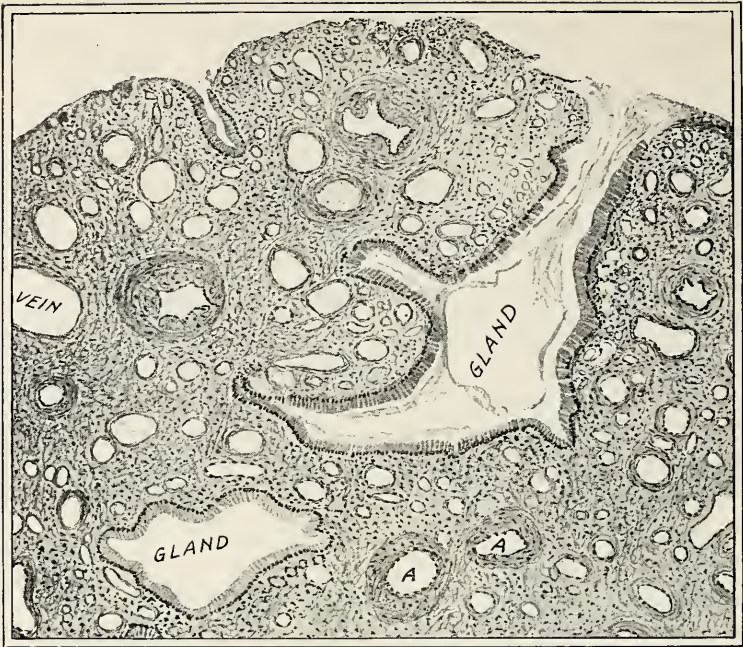

FIG. 235. MUCOUS POLYPUS OF THE CERVIX. The stroma is very vascular and shows numerous large arteries with thickened walls and also many veins and lymphatics.

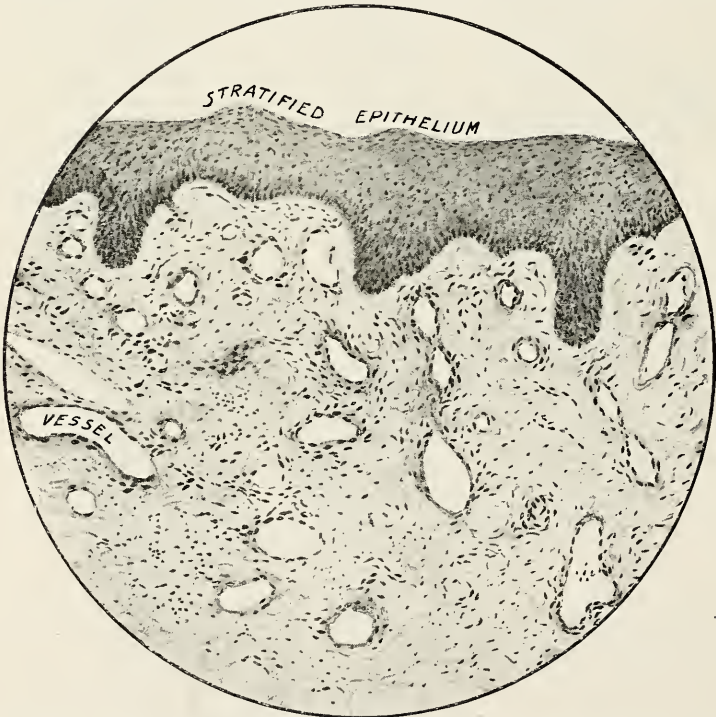

FIG. 236. FIBRO-ADENOMATOUS CERVICAL POLYPUS. The epithelial covering consists of a thick layer of stratified squamous epithelium like that found on the vaginal wall. The stroma consists of very vascular fibrous tissue.



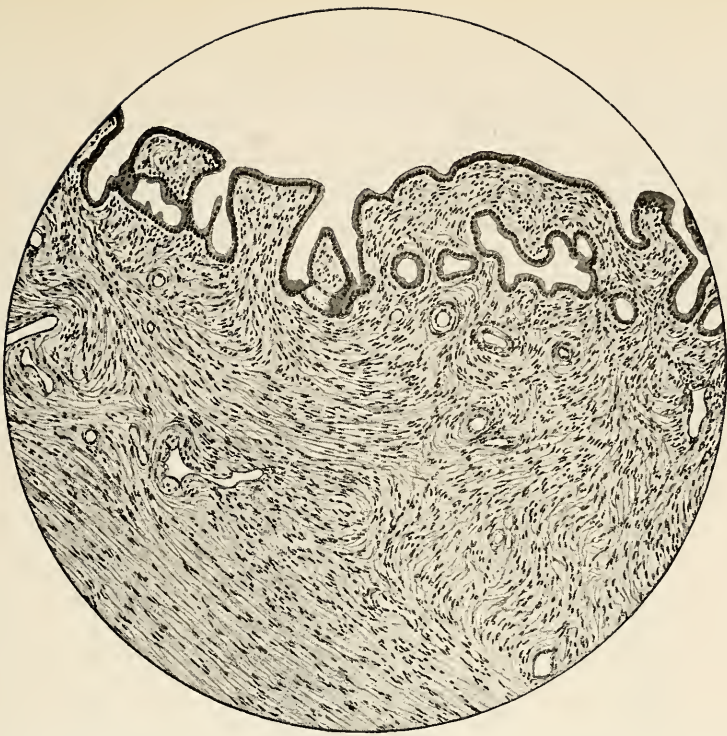

FIG. 237. FIBRO-ADENOMATOUS CERVICAL POLYPUS. From the same specimen as Fig. 236. The surface is papillomatous and covered completely with a single layer of columnar epithelium. The stroma consists of vascular fibrous tissue.

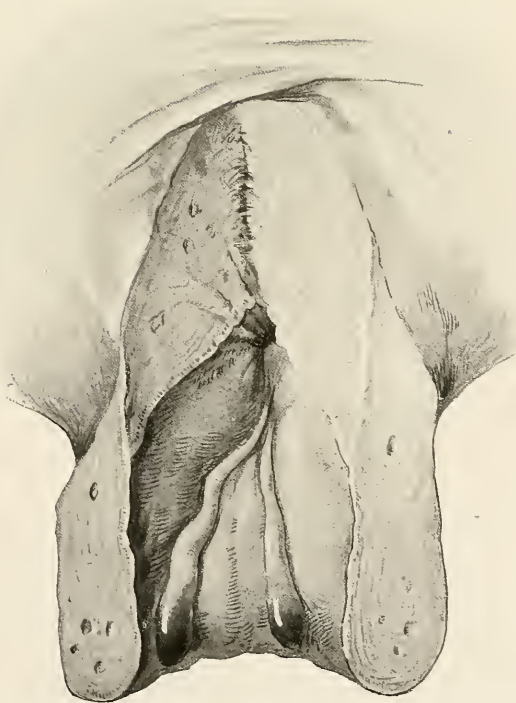


FIG. 238. MUCOUS POLYPI ATTACHED AT THE LEVEL OF THE INTERNAL OS IN A CASE OF CHRONIC METRITIS. The free ends of the long slender polypi have undergone necrotic changes.

examination, for apparently innocent growths may eventually prove to be sarcomata (*see below*).

The *treatment* of cervical polypi is to seize them with forceps, crush, and then twist them off by tearing through the pedicle. Small ones may be destroyed by the actual cautery. It is well at the same time to curette the uterus, as hyperplasia of the endometrium so frequently accompanies mucous polypi.

**Fibroid polypi** have been described in the section dealing with fibroid tumours of the uterus (pp. 432–437).

**Placental polypi** are a sequence of incomplete abortion, or of retention of a piece of placenta after labour. Hæmorrhage occurs

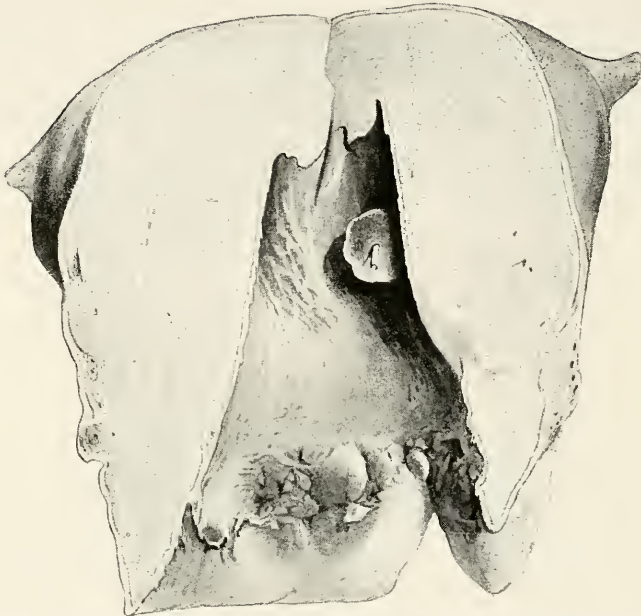


FIG. 239. MUCOUS POLYPUS OF THE ENDOMETRIUM IN A CASE OF CHRONIC METRITIS. The fibro-muscular wall of the uterus is greatly thickened (Charing Cross Hospital Museum).

from partial separation of the retained structures, or from imperfect uterine retraction. Coagulation of effused blood takes place upon the surface, and gradually the mass grows by accretion, until it may fill the uterine cavity, and project at the external os. These polypi are always single.

**Malignant polypi** are usually sarcomatous (*see Fig. 255, p. 505*). In such cases the malignant character of the growth may not at first be apparent, it being regarded as a fibroid polypus. Recurrence takes place after removal, and apparently a change in histological characters may occur, for cases have been described by competent observers in which, while the first polypus removed was fibroid, the

recurrence was definitely sarcomatous. This point will be again referred to in connection with sarcoma of the uterus.

**Diagnosis of an Intra-uterine Polypus.** In all cases of severe hæmorrhage, whether menstrual or irregular, for which there is no obvious cause in the cervix or vagina, the possibility of a polypus in the uterine cavity must be considered. Small mucous polypi occasion only slight enlargement of the uterus, of the same character as that found in chronic endometritis. Fibroid polypi are always large enough to cause considerable increase in the size of the uterus, and in some cases it may be felt to be as large as a cricket ball. Usually the uterus is globular in shape, and its walls are smooth, unless other interstitial or subserous fibroid growths are also present. In consistence the uterus is harder than normal. Bimanual examination may set up considerable hæmorrhage. The sound gives a long measurement in these cases, unless its passage is checked by the polypus; sometimes the tip of the sound may be felt to impinge upon the polypus and then slip past it. Usually, however, the sound fails to elicit definite signs of its presence. If the internal os is open the polypus may be seen, or felt by the finger.

In the great majority of cases, the diagnosis can only be made by dilating the cervix, and then exploring the uterine cavity with the finger. Fibroid polypi feel firm and smooth, and do not bleed severely when touched; mucous polypi are soft and compressible; placental and malignant polypi are soft and friable, and may bleed profusely under examination. The placental polypus can readily be detached with the finger, leaving the uterine wall smooth; further, it is associated with a history of hæmorrhage dating from an antecedent miscarriage or labour.

It is of great practical importance that all uterine polypi removed by operation should be examined histologically. Apparently innocent growths may prove to be malignant, as has been already mentioned.

The *treatment* of an intra-uterine polypus is to remove it and curette the uterus, after first dilating the cervix, unless this has been already effected by the polypus.

## UTERINE CASTS

Cast of the uterine cavity of four distinct kinds are known to occur: (1) Decidual casts; (2) menstrual exfoliations; (3) fibrinous casts; (4) blood-casts.

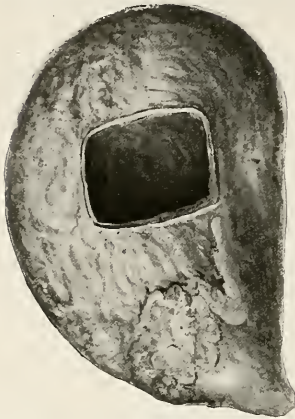(1) *Decidual casts* are passed most commonly in cases of extra-uterine gestation; these have already been described (*see* p. 197). Much the same type of cast is more rarely passed in cases of uterine pregnancy which end in abortion (*see* Fig. 240). The cast in this case is similar to that which is seen in ectopic pregnancy and no trace of an ovum can usually be found. It has been attributed to

inflammation of the endometrium preceding, or subsequent to, implantation of the ovum, but in a series of cases investigated by one of us no history of infection was obtainable, and all evidence of an extra-uterine pregnancy was wanting.

(2) *Menstrual exfoliation* has already been described (p. 187).

(3) *Fibrinous casts* are occasionally passed during the course of one of the specific exanthems (see Fig. 241); they are not a consequence of pregnancy, and contain no recognizable portions of the endometrium in their wall. They appear to be a local phenomenon due to a general blood-infection.

FIG. 240. DECIDUAL CAST, PASSED AS AN ABORTION. The fetus had been absorbed.



(4) *Blood-casts*. These are the rarest of all; an example is shown in Fig. 242. This cast forms a complete mould of the cavity of the uterus, from the fundus to

the external os; its lower end consists of a conical portion about an

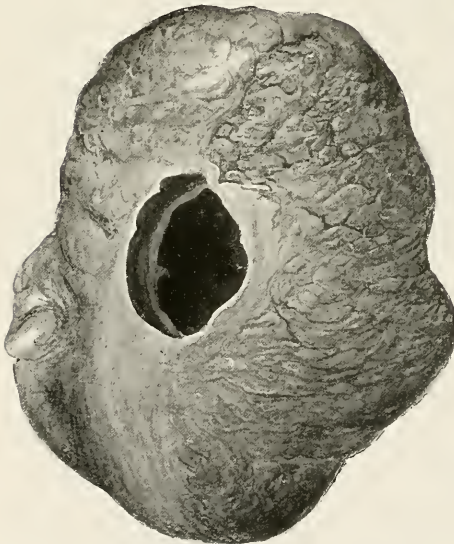


FIG. 241. FIBRINOUS UTERINE CAST. The wall consisted of fibrinous material and contained no endometrial tissue. The contents were fluid blood. From a case of typhoid fever.

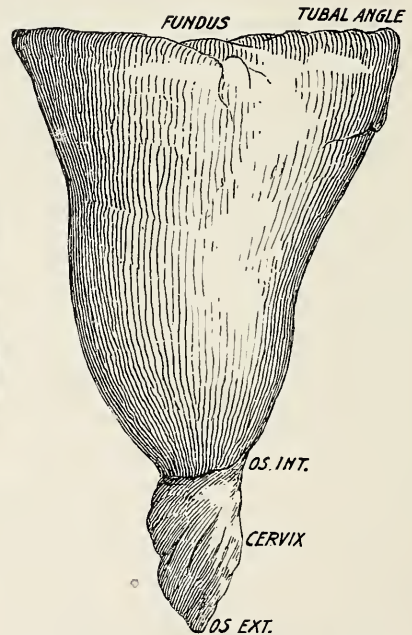


FIG. 242. COMPLETE UTERINE BLOOD-CAST. From a case of tonsillar septicæmia.

inch in length, which is separated from the body of the cast by a shallow sulcus corresponding to the position of the os internum. The specimen

shown in the Figure consisted of a solid mass of coagulated blood, and was passed from the uterus by a woman who died from acute septicæmia of tonsillar origin.

## ADENOMYOMA

An adenomyoma is a new formation consisting of gland-elements and muscle-tissue, to which is added a certain amount of remarkably cellular connective tissue around the glands. The commonest situation in which adenomyomata are found is the female genital tract, and the uterus itself forms the site of election for most of these tumours. They are also met with in extra-uterine situations, notably in the round ligaments, ovarian ligaments, and in the rectogenital (recto-uterine and recto-vaginal) connective tissues.

**Etiology.** The etiology of adenomyoma is very obscure. The following theories have been advanced, and much may be said in support of each of them. (a) *Congenital theory*, i.e. the formation of new 'growths' from relics of the Müllerian and Wolffian ducts. (b) *Diverticular*, i.e. the formation of diverticular outgrowths from the endometrium into the uterine wall. (c) *Inflammatory*; (1) from the tubal mucosa, giving rise to cornual adenomyomata; (2) from the peritoneum (serosal), giving rise, for example, to adenomyomata of the rectogenital space.

The considerations involved in the discussion of these theories are so complex as to be unsuitable for introduction in a work of this scope.

**The Classification of Adenomyomata.** As the etiology of many adenomyomata is debatable it is impossible to classify these tumours on an etiological basis. We shall therefore adopt a topical classification and divide them into *uterine* and *extra-uterine*, as follows:

Uterine adenomyomata	{ (a) Central. (b) Peripheral.
Extra-uterine adenomyomata arising in	{ (a) The round ligament. (b) The ovarian ligament. (c) The rectogenital space.

**Uterine Adenomyomata.** (a) *Central or Diffuse.* The epithelium in this type arises from the mature uterine mucous membrane. It therefore belongs to the *diverticular* variety of Cullen. Some authorities state that the cause of the invasion of the muscular walls by the mucous membrane is a pre-existing endometritis, but, although this is a very probable explanation, it needs further proof. The invasion may occur into the substance of a pre-existing myoma, but more frequently it takes place into the walls of the uterus, and not into a pre-existing growth.

The muscle and connective tissue of the invaded area undergo

hyperplasia, probably in response to an irritation caused by the ingrowing epithelium ; the result is, that a diffuse thickening of the wall of the uterus occurs. The *posterior* wall of the uterus is most commonly affected in this way, but the change may extend to the entire body of the uterus ; it does not spread into the cervix, diffuse

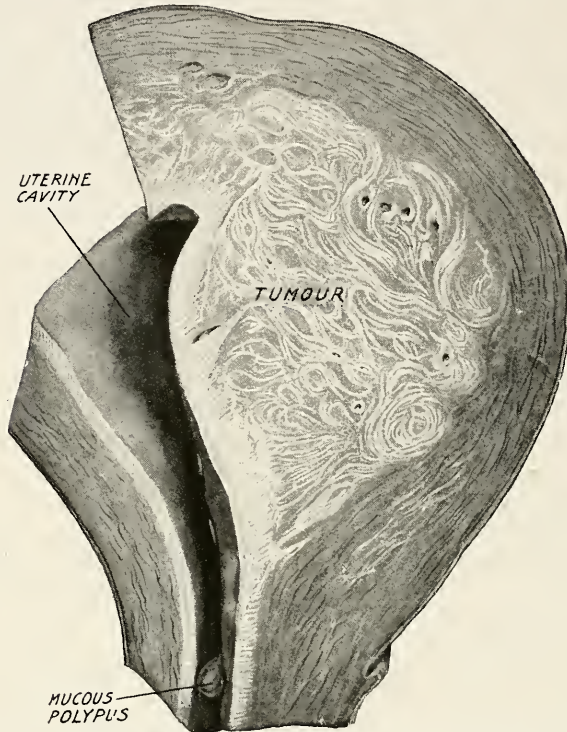


FIG. 243. ADENOMYOMA OF THE UTERUS, DIFFUSE FORM (Cullen).

uterine adenomyoma being confined entirely to the body, and affecting the upper, rather than the lower, part of the organ (*see* Fig. 243).

There is no definitely circumscribed limit to a centrally situated growth ; it is essentially a diffuse condition. The mucous membrane covering the area involved may appear quite normal or it may be thickened. The down-growing crypts can sometimes be seen upon the mucous surface, and may even form small cystic spaces in a late stage of the disease, giving a honeycombed appearance to the surface of the tumour (*see* Figs. 244 and 245).

On section the growth is often found to be extremely hard, but cystic changes may cause it to become softened. The cut raw surface shows a whorled appearance not unlike that seen in fibromyomata (*see* Fig. 243), but the usual pearly white colour is wanting, the surface being of a duller white or even pinkish. It is therefore not so sharply defined as a myoma, either as regards its colour or its limitation. The

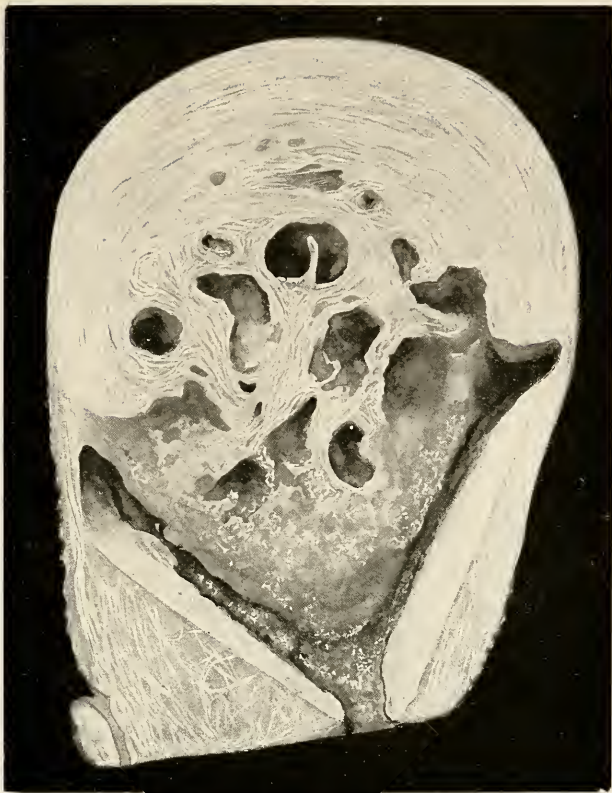


FIG. 244. SHOWING THE HONEY-COMBED APPEARANCE OF THE SUBMUCOUS PORTION OF AN ADENOMYOMA OF THE UTERUS.




FIG. 245. DIFFUSE ADENOMYOMA OF THE UTERINE BODY SHOWING CYSTIC SPACES. From one of the latter, three tiny mucous polypi project.

supporters of the inflammatory theory regard the central diffuse adenomyoma as a diffuse chronic inflammation to which they apply the name *adenomyositis uteri*.

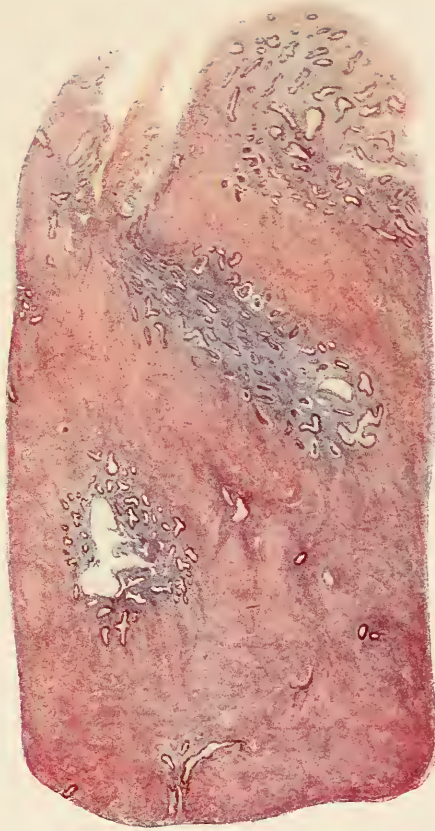
The general effect on the size of the uterus is variable. It may be normal or may reach the size of a three-months gestation. It is common to find small myomata (either single or multiple) present, which render the outline of the uterus nodular or irregular. When no myomata are present the general shape of the organ need not be much impaired. Adhesions to neighbouring structures are common. Adnexal inflammation is very frequent, even more so than is the case with fibromyomata.

*Structure.* The epithelial invasion takes the form of tubules which show repeated branching, and which are lined by ciliated columnar epithelium. Their lumina sometimes contain pigmented bodies, thought to be associated with the function of menstruation and to consist of altered blood. These branching tubules run in connective-tissue spaces between the muscle bundles (Pl. XVII), and a characteristic arrangement is for a number of tubules to run along a connective-tissue space. Such a series of outrunners proceed from a discrete mass of gland-tubules packed more closely together, but whether seen singly or in masses, the tubules are surrounded by hyperplastic connective tissue. The latter is very cellular, and resembles the stroma of the endometrium in its appearance. Moreover this tissue, to which the name of the *cytogenous mantle* is applied, has been shown to undergo decidual reaction during pregnancy. In spite of the histological and physiological resemblance of the *cytogenous tissue* to the stroma of the endometrium, R. Meyer has expressed the opinion that it is not of mucosal origin, but is really the original connective tissue of the invaded area, altered by chronic inflammation. With the formation of cysts from distension of the lumina of the tubules, the *cytogenous mantle* is diminished in amount even to actual extinction, otherwise this peculiar tissue forms one of the most constant and most marked histological features of an adenomyomatous growth.

(b) *Peripheral or Circumscribed.* In comparison with the preceding, this variety is extremely rare. According to Von Recklinghausen it forms a small nodular growth situated near the *cornu uteri*, and generally on the posterior wall of the uterus. It has since been shown that most of these cornual growths are really examples of *salpingitis nodosa* (see p. 623), occurring in the isthmic and interstitial parts of the Fallopian tube. On the other hand, there are a very few cornual tumours which have been shown *not* to have arisen either from the tube or from the uterine mucous membrane, and which must be regarded as arising from embryonic relics.

Quite a different type of peripheral adenomyoma is that to which Cullen has drawn particular attention. It is the outward protrusion of





ADENOMYOMA UTERI, showing gland-tubules invading the muscularis from the endometrium.



a central mucosal growth, which may produce a subperitoneal tumour of considerable size. The outward protrusion of growth may be subperitoneal, or it may project into the layers of the broad ligament. A definite communication between the cavity of the uterus and the gland-tissue of such growths has been proved in several cases. In the case of Döderlein and Herzog, pregnancy occurred within the cavity of an adenomyoma situated in the left broad ligament. There is no doubt therefore that some adenomyomata behave exactly as fibroids, in undergoing partial extrusion from their original interstitial position. This fact seems conclusively to prove that adenomyomata, in certain instances, are myomata which have suffered mucosal invasion.

Just as some adenomyomata by a process of extrusion, become subperitoneal and intra-ligamentary, so others by projecting inwards become submucous; in both instances it is fair to assume that the original growth was a myoma which has been subjected to invasion by the epithelium of the mucous membrane. Such growths are to be distinguished from the diffuse variety previously described in which there is no evidence of a pre-existing myoma.

**Extra-uterine Adenomyomata.** (a) '*Adenomyoma*' of the *Fallopian Tube*. This condition is identical with *salpingitis isthmica nodosa*, for the description of which see pp. 622–626.

(b) *Adenomyoma of the Round Ligament*. Adenomyomata occur on the round ligament in three situations: (1) Between the uterus and the internal abdominal ring (intra-peritoneal); (2) in the canal of Nuck (intra-parietal); and (3) outside the external abdominal ring (extra-peritoneal). The last situation is the commonest site for these growths. When found in the vicinity of the external ring, cystic adenomyomata are difficult to distinguish from hydrocele of the canal of Nuck; in fact, the diagnosis is generally made by microscopic examination after removal. A definite pedicle attaching the cystic growth to the round ligament can be made out, when not densely adherent to all the surrounding structures. The contents of the cyst are often blood-stained and chocolate-coloured. These tumours are usually unilateral, they sometimes extend to the *labium majus* (see p. 354) and they swell up and become painful during menstruation; by these symptoms some few cases have been correctly diagnosed.

The uterine end, and the distal end, of the round ligament form the sites of election of these tumours, and three times as many adenomyomata are found in the latter situation as in the former.

(c) *Adenomyoma of the ovarian ligament* is a rare condition and only of pathological interest.

(d) *Adenomyoma of the Rectogenital Space*. The rectogenital space is the cellular interval between the rectum behind and the cervix uteri and vagina in front. It is one of the sites of election for *extra-uterine* adenomyomata. The majority of the growths which

have been observed in this situation are quite small, but in several instances the tumours have been very extensive, conveying the impression that they were malignant.

The small growths appear as adherent nodules, which are felt by the examining finger to lie above the posterior vaginal fornix, and sometimes to cause a projection into the posterior vaginal vault. In size, these nodes are often not larger than a cherry or small chestnut.

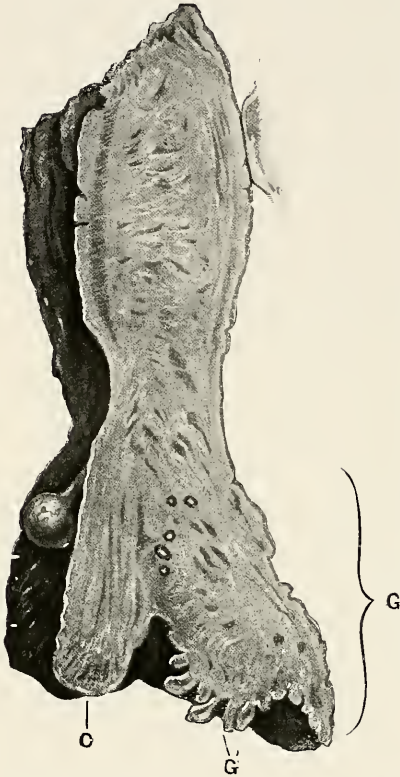

FIG. 246. SAGITTAL SECTION OF THE POSTERIOR WALL OF UTERUS, showing G, adenomyoma adherent to the back of the cervix (C); G' shows the irregular papillary condition of the growth in the posterior vaginal fornix (after Kleinhaus).

They are often painful and are a source of dyspareunia, a fact which leads to their early detection in married women. They are far more adherent to surrounding structures than are the small myomata which are sometimes to be met with in the posterior fornix. They lack the tense elasticity of a vaginal cyst, and sometimes they cause the vaginal mucous membrane to become puckered and even papillary (*see* Fig. 246), whilst the surface of a cyst is always smooth. Small nodes have been found to be adherent to the rectum or to the cervix, and even to the ischial spine. When a fixed hard nodule can be felt above the posterior fornix on vaginal examination, the presence of adenomyoma of the rectogenital space must be thought of, especially if there is a complaint of painful coitus.

If the early nodular stage passes unobserved, the growth may spread in a diffuse manner and invade the surrounding structures. It may invade the muscular and submucous coats of the rectum, the muscular wall of the cervix, and the cellular tissues at the base of the broad ligament. The left broad ligament is generally more affected than the right. As the growth enlarges, it may raise the peritoneum of the pouch of Douglas and even strip up the peritoneum from the posterior uterine wall. The vaginal mucosa becomes fixed to the growth both over the posterior fornix and to a variable part below it. The vaginal mucous membrane itself becomes invaded by the glandular elements which ultimately penetrate and give rise to a bleeding papillary surface (*see* Fig. 246). Usually the tumour

forms a densely hard fixed mass with indefinite outlines, and the cervix, rectum, and vagina are absolutely fixed to it (*see* Fig. 247). During pregnancy, however, it becomes softer and increases in size. *Per rectum*, a hard tumour can be felt in the anterior or antero-lateral wall, the rectal mucous membrane is movable over it, although the

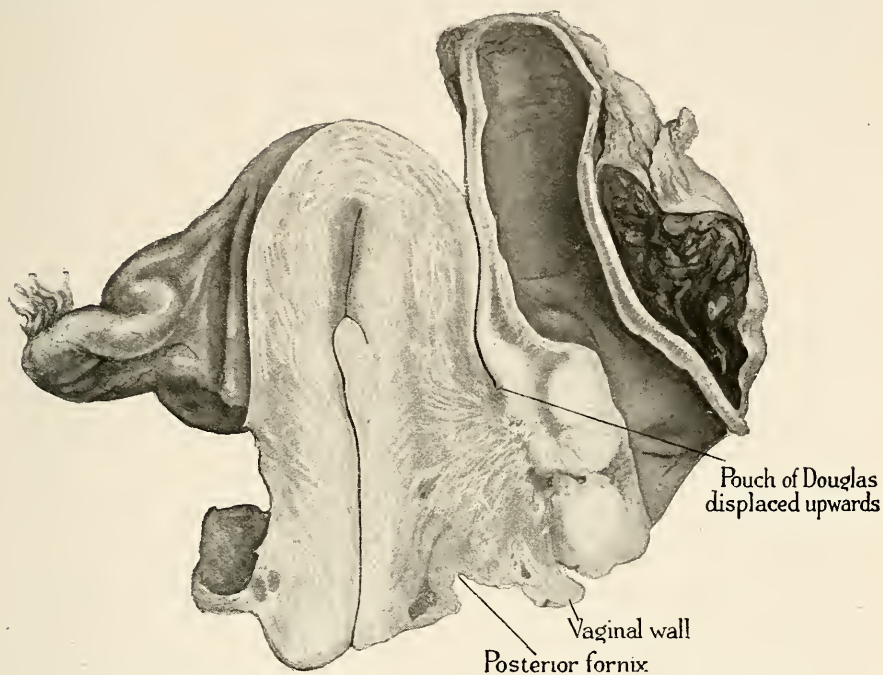


FIG. 247. ADENOMYOMA OF THE RECTO-VAGINAL SEPTUM. The growth is fused to the cervix and to the rectum. It has caused a narrowing of the lumen of the bowel.

mass may be large enough to reduce the lumen to a very small capacity and to give the impression of a malignant tumour.

*Symptoms.* The most notable symptom is obstinate constipation and painful defæcation, more rarely actual obstruction occurs. There is, however, no rectal hæmorrhage. As soon as the growth penetrates and begins to destroy the vaginal mucosa, there is a hæmorrhagic discharge *per vaginam*. The symptoms and signs of an associated myoma and of adnexal disease are sometimes super-added.

**Diagnosis of Adenomyoma in General.** The majority of cases occur in women between the ages of thirty and fifty years. Sterility is said to be twice as common as it is in myomata. Menstruation is excessive in over 60 per cent. and dysmenorrhœa occurs in about 50 per cent. of cases. It is exceptional to meet with infantilism or mal-development. Pelvic peritonitis of varying degree is present in one half of the cases. Polano found adhesions in 89.5 per cent. Fibromyomata of the uterus form a very common association.

Uterine adenomyomata cannot be distinguished clinically from fibroids, nor in all cases from chronic metritis. Rectogenital tumours are liable to be mistaken for cancer of the rectum and for cancer of the vaginal vault, when the latter is ulcerated. The condition has been diagnosed as diffuse hæmatocele and as pelvic abscess. Microscopic examination of an excised portion is the only certain mode of diagnosis.

**Prognosis.** Sloughing and necrosis have never been recorded in adenomyomata, and these tumours rarely become malignant. There is not the same tendency to spontaneous shrinkage, and cessation of menorrhagia and of pain, as is seen in some fibroids, hence it must be admitted that the outlook is worse with adenomyoma than with fibromyoma.

Curetting and medical treatment, which sometimes do good in cases of fibroids, aggravate the symptoms in adenomyomata. The infiltrative faculty of adenomyoma also increases the gravity of the prognosis.

**Treatment.** Small non-encapsulated nodules at the cornua of the uterus have been excised with cessation of symptoms, but enucleation is quite impossible. The removal of a wedge-shaped portion of the uterine wall wide enough to be quite free of the indurated area should be carried out. For the diffuse variety nothing but total hysterectomy should be performed.

For extensive growths in the rectogenital space, it has been shown that total removal or excision of the invaded bowel is unnecessary. These growths do not cause *uterine* hæmorrhage. The indication for operation appertains to the bowel; when left, there is a danger of stenosis and chronic intestinal obstruction. Moreover, ulceration into the vagina is very liable to occur. Some check is therefore required by way of operation. When assured by microscopic proof that the case is one of innocent epithelial invasion and not carcinoma, the removal of the entire uterus together with as much of the growth as possible is the best procedure.

All forms of radiotherapy (radium, X-rays) for adenomyoma are disappointing.

## BENIGN EPITHELIAL GROWTHS OF THE UTERUS

**Simple Adenoma (Adenomatous Hyperplasia).** From what was stated in dealing with the so-called 'glandular endometritis' (*see* p. 401), it will have been gathered that in most cases the hypertrophy and hyperplasia of gland-structures, which are so frequently encountered in the endometrium, are either to be regarded as the results of physiological variations referable to the function of menstruation, or as the results of an inflammatory process. We agree with Hitschmann and Adler, however, in maintaining the view that

there is a *true pathological hyperplasia* of the gland-elements of the endometrium, which is *not* caused by inflammation, but is of the nature of a *true new growth*. The condition is associated with abnormal menstruation and its causation, like that of other neoplasms, is unknown. To this condition the name of *simple adenoma* must be applied.

The growth consists of a glandular hyperplasia in which there is no evidence of inflammation of the stroma. Clinically it is associated with extreme menorrhagia, and sometimes with dysmenorrhœa.

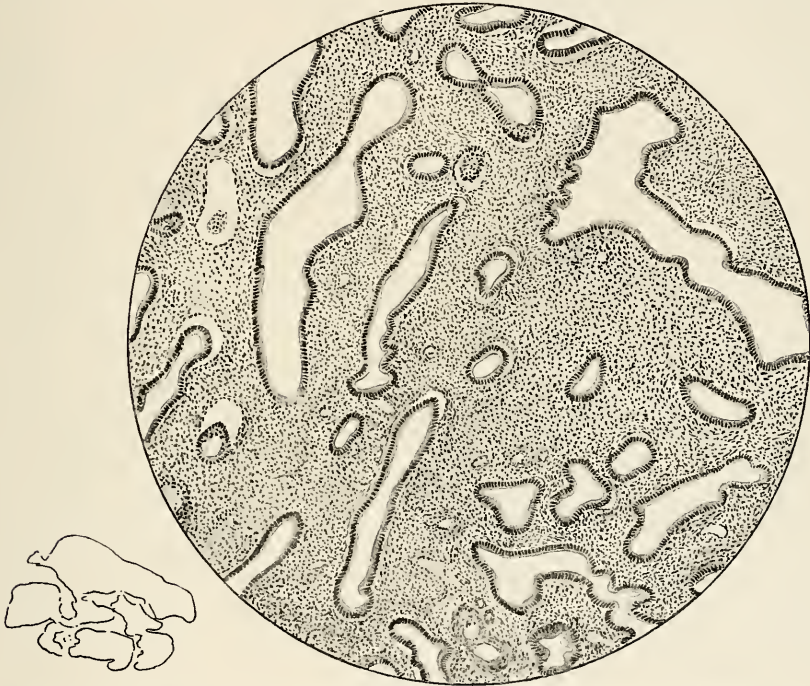


FIG. 248. SIMPLE ADENOMA (ADENOMATOUS HYPERPLASIA) OF THE ENDOMETRIUM REMOVED FROM A VIRGIN. The inset shows the size of some of the portions removed by curettage. Note that although the glands are enlarged they are widely separated by a uniformly hyperplastic stroma (*cp.* Fig. 190, p. 399).

We have seen it in virgins and also in young married women who were childless, and in whom no source of infection could be traced.

The mucous membrane is enormously thickened both by hypertrophy and hyperplasia, affecting glands and stroma alike (*see* Fig. 248). During curettement, large soft masses of adenomatous tissue are brought away. Microscopically, the diagnosis of simple adenoma is the most appropriate; thick-walled blood-vessels and other signs of chronic inflammation in the stroma are wanting (*see* Fig. 248). When this glandular hyperplasia is localized, or when it is more marked over a circumscribed area than over the remainder

of the corporeal endometrium, a true corporeal mucous polypus is the result (*see* Uterine Polypi, Figs. 233 and 234, p. 482).

**Prognosis.** The condition is very liable to recur after curetting, which is a further manifestation of its neoplastic nature. Simple adenoma of the endometrium as seen in young subjects shows no tendency to become malignant, but it causes a secondary work-hypertrophy of the muscular walls of the uterus, so that the organ becomes chronically enlarged and indistinguishable clinically from a case of chronic metritis (hypertrophic form) (*see* p. 422).

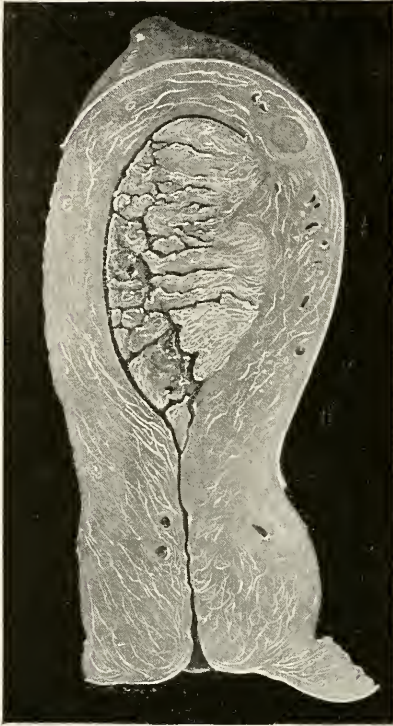


FIG. 249. PAPILLIFEROUS ADENOMA OF THE ENDOMETRIUM. From a specimen in the Royal College of Surgeons (Bland Sutton). The entire uterine cavity is filled with an adenomatous growth composed of villous tufts closely packed together. For the microscopical features of this type of growth *see* Fig. 250.

**Papilliferous Adenoma (Villous Tumour of the Endometrium).**

This is also a rare condition, and histologically it is closely allied to, if not indistinguishable from, that above described. It occurs, however, at a later period of life, *i.e.* after the menopause, the youngest recorded case being fifty-two and the oldest eighty-four. Any influence, therefore, which the ovaries might exercise upon the uterine mucous membrane will have ceased. The symptoms accordingly are different; instead of excessive menstruation there is blood-stained vaginal discharge, which may be continuous and which, coming on in the climacteric period or later, suggests the presence of cancer of the body of the uterus. The term *villous tumour of the body of the uterus* was given to this growth by Bland Sutton, because it resembles a villous papilloma of the bladder, excepting that the investing epithelium is of *columnar* type in the uterine growth (*see* Fig. 250) and *transitional* in that arising from the mucous membrane

of the bladder. The subjects in whom papilliferous adenoma is found are generally nulliparous. The growth may arise from one wall of the uterus or it may be diffused over the endometrium (*see* Fig. 249). It may be the only pathological condition present or it may be associated with a fibroid tumour. Papilliferous adenoma and cancer are not found together, but portions of the former may infiltrate the uterine wall, whilst other parts of the same growth are still benign.



*Diagnosis.* Papilliferous adenoma of the uterus in elderly subjects has to be differentiated from adeno-carcinoma (*see* p. 533). The symptoms and clinical features are similar in each case, therefore the nature of the new growth can only be determined by histological investigation of the scrapings removed by curettage. In some cases this may prove easy, and no doubt will arise as to the simple nature of the case, the

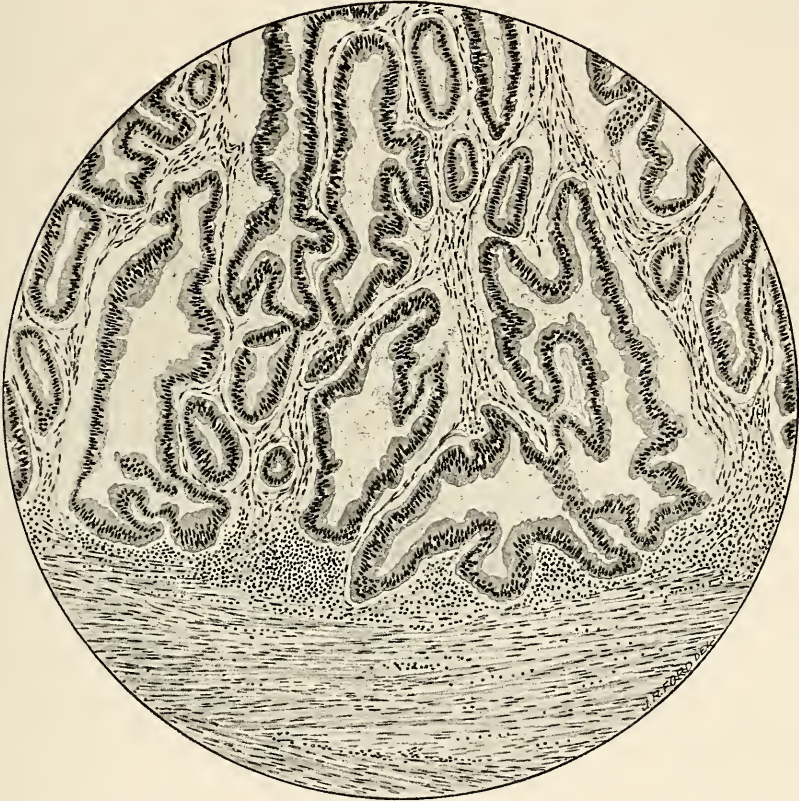

FIG. 250. PAPILLIFEROUS ADENOMA OF THE UTERUS (Malcolm). The growth did not invade the muscular walls of the uterus. The uterus was also the seat of a medium-sized fibroid. Some of the tubules show epithelial proliferation.

tubules being lined by a *single* layer of columnar epithelium, and but little or no invasion of the uterine muscle is present. On the other hand there are cases, *e.g.* that reported by Bland Sutton (*see* Fig. 249), in which considerable difficulty will be found in deciding whether the amount of penetration of the uterine wall by the gland-tubules constitutes malignancy or not.

Curettings obtained from repeated recurrences in some cases have shown a benign structure, but upon removal of the uterus its walls have been found to be invaded by a growth indistinguishable from a tubular carcinoma (Targett).

*Prognosis.* From the above facts it will be seen that a villous papilloma of the uterus, although benign, possesses the power of infiltration and invasion of the muscular walls of the uterus ; in other words, it must be regarded as a clinically malignant growth.

*Treatment.* If curettings obtained from the uterus of an elderly subject reveal the presence of a histologically benign papilliferous adenoma the case should be treated by hysterectomy.

**Simple Adenoma of the Cervix.** True adenoma is an extremely rare condition in the cervix. As will be shown later, when the *columnar*

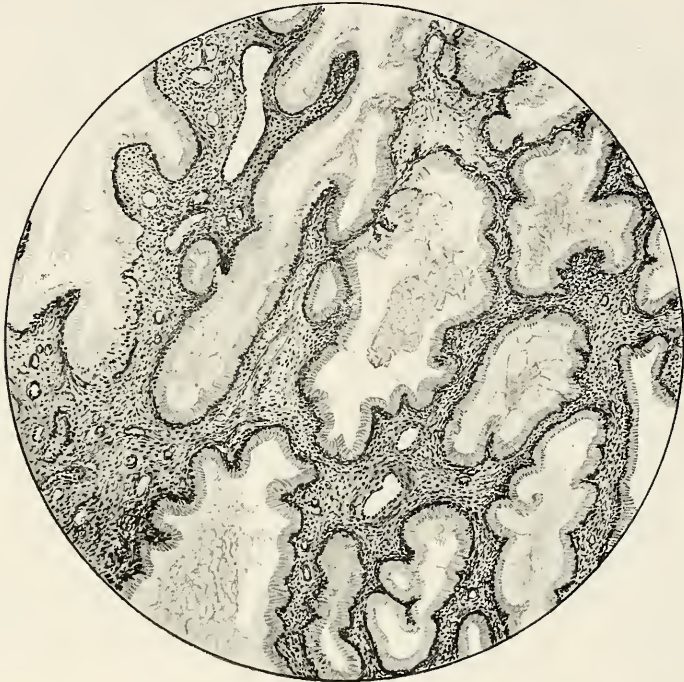

FIG. 251. SIMPLE ADENOMA OF THE CERVIX. From a sterile woman aged thirty-six years.

epithelium of the cervical glands proliferates, the tendency usually is towards the development of cell-metaplasia and malignancy, the resulting neoplasm being a *squamous-celled* carcinoma. Less frequently a true *adeno-carcinoma* of tubular type develops, in which a marked resemblance to gland-tissue is produced. Rarest of all is the formation of a simple adenoma possessing an essentially benign structure. The only case of which we have had experience was that of a woman aged thirty-six years, who had been married eleven years and was sterile. She had suffered from *profuse leucorrhœa* from childhood. Other symptoms were *hæmorrhage on coitus*, *menorrhagia*, *metrorrhagia*, and a constant *dragging pain*. On examination the

surface-epithelium of the vaginal cervix was mostly replaced by a papillary, hæmorrhagic growth, which was deeply fissured as if cut with a knife. In colour the growth was a deep red, it bled freely on contact, but was far more resistant and tougher than a carcinoma. The supra-vaginal cervix was hard and the body of the uterus was spherical and bulky. Curettage brought away very little corporeal mucous membrane. Microscopically, the cervical growth consisted of long straight gland-tubules, some of which gave off secondary branches (*see* Fig. 251 and Fig. 201, p. 411). The tubules were dilated and filled with mucus; their lining epithelium consisted of a single layer of tall columnar cells with basal nuclei. In places the surface-epithelium was intact, whilst elsewhere it was thinned out over the growth, and gradually disappeared where the latter became flush with the surface. Surrounding the growth was a certain amount of inflammatory infiltration, and beneath it the cervix was hard and fibrotic. The condition was unaccompanied by any other pelvic lesion. Vaginal hysterectomy was performed after a portion of the growth had been examined microscopically.

This new growth differs from an *erosion* (*pseudo-adenoma*) by its deeper penetration into the cervical tissue, by the larger size of the gland-tubules, and by the coarser character of its tufted papillary surface-processes; clinically, it is much more hæmorrhagic than is an *erosion*, more closely resembling the appearances seen in tuberculous cervicitis (*see* Figs. 145 and 146, p. 306).

## MALIGNANT GROWTHS OF THE UTERUS

A. MESOBLASTIC—(a) SARCOMA, INCLUDING ENDO-  
THELIOMA AND PERITHELIOMA

B. EPIBLASTIC  $\left\{ \begin{array}{l} (a) \text{ CARCINOMA} \left\{ \begin{array}{l} \text{CERVICAL} \\ \text{CORPOREAL} \end{array} \right. \\ (b) \text{ CHORIONEPITHELIOMA} \end{array} \right.$

## SARCOMA OF THE UTERUS

Sarcoma forms less than 0·5 per cent. of all malignant growths of the uterus and is therefore one of the rarest forms of malignant tumour of this organ. The relative frequency of sarcoma and carcinoma is about 1 to 40–50.

Sarcoma may start primarily in the body or in the cervix uteri, the relative frequency of these two sites being as 5 to 1. Thus in its site of origin uterine sarcoma presents a striking contrast to uterine

carcinoma, which is much commoner in the cervix than in the corpus uteri. Moreover, the epithelial and the mesoblastic components of the uterus present a strong contrast as regards their relation to neoplasms. The mesoblast (muscle and connective tissue) is a common source of origin for benign tumours (fibromyomata), whilst mesoblastic malignant growths (sarcomata) are rare. On the other hand the epithelium is a common site of origin for malignant tumours (carcinomata), whilst benign growths (adenomata, papillomata) are very rare and papillomata should be regarded as clinically malignant when they occur. It is the uterine epithelium, therefore, which is responsible for the extreme proneness to malignancy which is displayed by the uterus.

Another point of contrast is the fact that in the rarer form of carcinoma, *i.e.* the corporeal, the prognosis is relatively good; whilst in sarcoma of the uterine body (as also of the cervix) the prognosis is very bad.

For descriptive purposes sarcomata of the uterus may be classed as follows :

- |                                    |   |   |
|------------------------------------|---|---|
| I. Sarcoma of the uterine wall     | { | (a) Diffuse.<br>(b) Circumscribed.<br>(c) Arising in a fibromyoma.                  |
| II. Sarcoma of the endometrium     | { | (a) Diffuse.<br>(b) Circumscribed — including<br>'grape-like' sarcoma of<br>cervix. |
| III. Special forms of sarcoma.     |   |   |
| IV. Endothelioma and perithelioma. |   |   |

**Sarcoma of the Uterine Wall.** Two types of sarcoma arise from the uterine wall: (a) the diffuse; (b) the circumscribed; a third arises in a pre-existing fibroid.

(a) *Diffuse.* This is the rarest form of all. It causes a uniform enlargement, producing a condition resembling the gravid uterus in shape and consistence. The sarcoma-cells (round and spindle) are diffused throughout the entire thickness of the uterine wall. This form is said to be of connective-tissue origin.

(b) *Circumscribed.* This variety occurs as a solitary globular mass of softish friable consistence, which in its early stage may show a certain amount of encapsulation (*see* Fig. 252). In colour it is dull yellowish, in consistence it is homogeneous, and shows none of the fibrillated appearances characteristic of fibroids. Its surface is often discoloured from patches of necrosis (*see* Fig. 253, p. 504) and interstitial hæmorrhage. These growths may contain cystic spaces filled with straw-coloured or blood-stained fluid. The smaller cysts may be due to œdema, the larger are either definite lymphangiectases,

or else spaces formed by the breaking down of necrotic tissue. Dilated blood-vessels forming large sinuses (telangiectases) may sometimes be met with. The microscopic appearances are variable, the cells being often of mixed type; round, spindle and giant cells may all exist in one and the same sarcoma (*see* Fig. 256).

These growths are interstitial in their origin, and as such they are only of moderate size, but they may become both submucous (*see* Fig. 253)

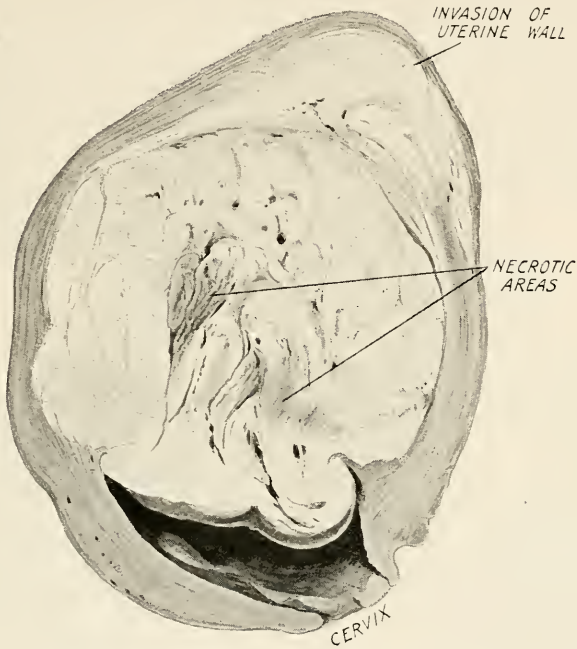


FIG. 252. CIRCUMSCRIBED SARCOMA OF THE UTERINE WALL. Multipara, aged 60. At the fundus the growth has invaded the uterine wall; the lower part projects into the uterine cavity.

and subserous, and under these circumstances they may attain considerable dimensions, the largest on record weighing forty pounds (Piquand). A point of clinical importance is the liability of these growths to become polypoid. Fig. 255 shows such a one from which three polypi were removed prior to hysterectomy. In a number of these polypoid cases inversion of the uterus has occurred, inversion being more common in association with sarcomatous than with myomatous polypi. It has been suggested (A. R. Simpson) that inversion is favoured by malignant infiltration producing a softening and paralyzing effect on the uterine muscle. Circumscribed sarcoma of the *cervical wall* is rare. Figs. 257 and 258 show the naked-eye and microscopic features of such a growth.

(c) *Sarcomatous Metaplasia in a Fibromyoma*. We have already stated that the types of primary malignant changes which are to be

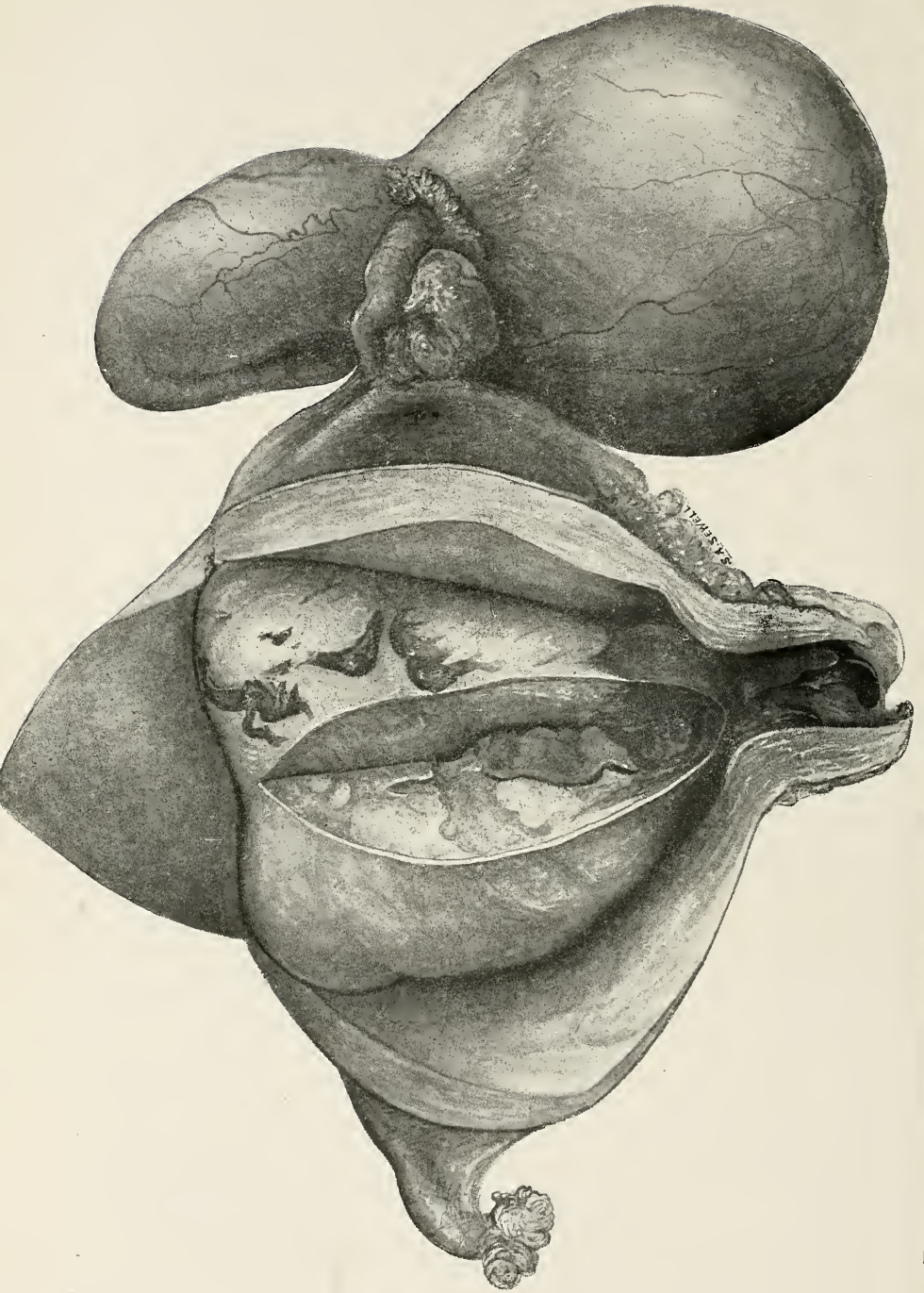


FIG. 253. CIRCUMSCRIBED SARCOMA OF THE UTERUS. The growth forms a circumscribed submucous tumour of the anterior wall of the uterus (the uterus is opened from behind). On the right side there is a teratomatous cyst of the ovary.

met with in a fibromyoma are malignant leioma, sarcoma, peri- and endothelioma. A fibroid may also be invaded by a co-existing sarcoma.

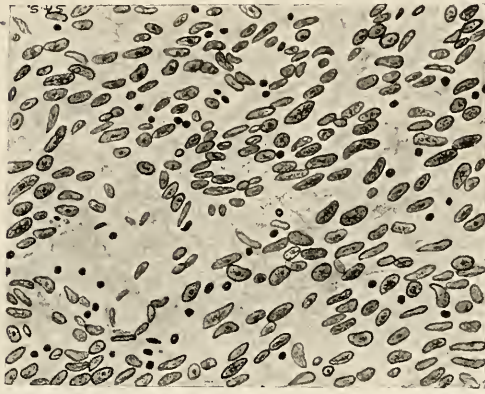


FIG. 254. SARCOMA OF THE UTERUS. Showing the microscopic structure of growth seen in Fig. 253. Mitotic figures are seen in the nuclei of the oval cells.

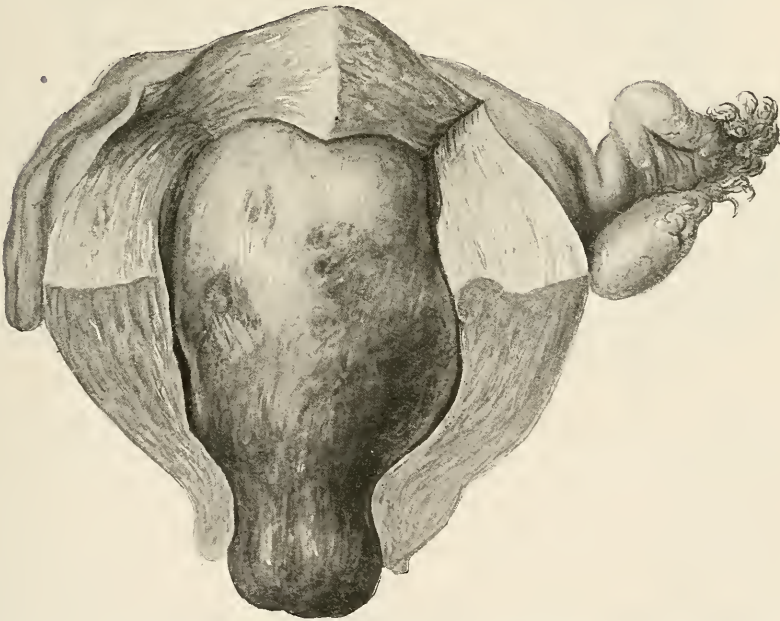


FIG. 255. SARCOMA OF THE UTERUS. The uterus, opened posteriorly, shows a submucous sarcoma. The lower pole of the growth dilated the cervix and presented as a polypus in the vagina. There was a secondary subperitoneal nodule attached to the fundus uteri. The histology of this nodule is seen in Fig. 256.

The frequency with which sarcomatous changes are found in fibroids is about 1.5 to 2 per cent. The malignant change usually takes place in the

centre of the tumour (*see* Fig. 226, p. 455). Often several myomata are present, while only one is affected. The naked-eye appearances are the same as those already described as characterizing a circumscribed sarcoma. Sarcomatous change may occur in all three-of the primary varieties of uterine fibroids, but is relatively more frequent in those which remain intramural. In most cases the sarcoma-cells are thought

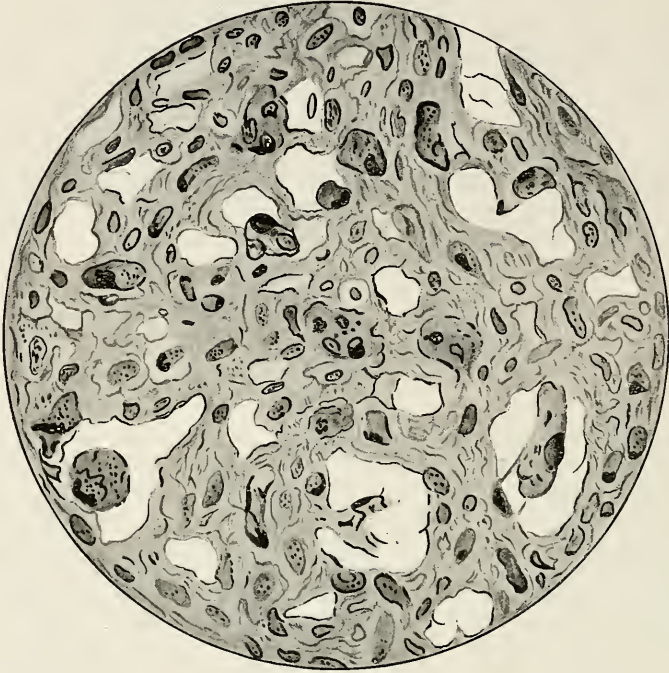

FIG. 256. SARCOMA OF THE UTERUS.  $\frac{1}{6}$  obj. 3 eyepiece. Showing the microscopic characters of a subperitoneal nodule from specimen Fig. 255. Many multi-nucleated giant cells are seen.

to be due to metaplasia of the connective-tissue cells of a fibroid, but many observers, including ourselves, have been able to trace the transformation direct to the muscle-fibres (*see* Figs. 227 and 228, p. 457). It is possible that in some cases the sarcoma-cells arise from both sources simultaneously.

The term *malignant leioma* (leiomyoma) is synonymous with *malignant myoma*, the definition of leioma being a tumour of mesenchymal origin, of which the cells tend to differentiate into smooth muscle-cells. The type-cell is the smooth muscle-cell such as we see it in the uterine wall. *Malignant leioma* is a term reserved for a rare type of myoma consisting solely of young actively growing unstriped muscle-tissue. It therefore gives the microscopic appearance of being benign. Its malignant nature is revealed by the presence of metastases in various parts of the body, such as the lungs, liver, pelvic cellular



tissues and intestines. In a case which one of us examined, there were pulmonary and rectal growths resembling in structure the primary myoma of the uterus. From such cases we learn that young muscle-cells may behave in a malignant manner without undergoing anaplasia or reversion to embryonic type. In a *myosarcoma* the muscle-cell reverts to a more elementary type, and provides microscopic evidence

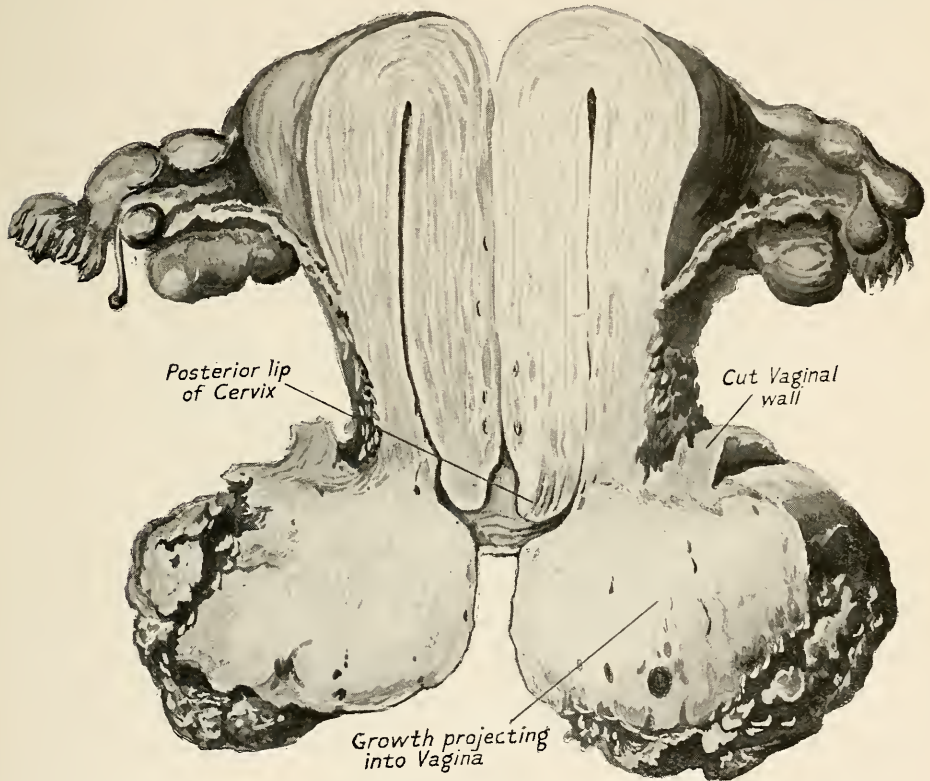


FIG. 257. SARCOMA OF CERVIX UTERI, SINGLE WOMAN ÆT. 29 (T. G. Stevens). The growth appeared to start in the *fibro-muscular* wall of the cervix and not in the cervical endometrium. Cp. Fig. 259, which shows an *endometrial* sarcoma of the cervix.

of malignancy. A malignant *leioma* affords no such histological proof of its malignant capabilities, it shows young myoblasts and fibroblasts causing the myomatous tissue to appear more cellular, and in the absence of metastases, the only histological diagnosis which is possible is that of an actively growing myoma.

**Sarcoma of the Endometrium.** This is a much rarer form than that derived from the muscle-wall; there are two varieties to be considered :

(a) *Diffuse*. Cases where an intramural sarcoma has become sub-mucous and polypoid are difficult to distinguish from those of *endo-*

*metrial* origin. In general appearance the mucosal form corresponds with the intramural, but the tissues are softer and more friable, and loose pieces may be found lying free in the uterus, and perhaps discharged through the cervix. The growth usually arises in the endometrium near the fundus, whence it spreads so as to involve the whole mucous membrane of the body ; generally it stops short at the internal

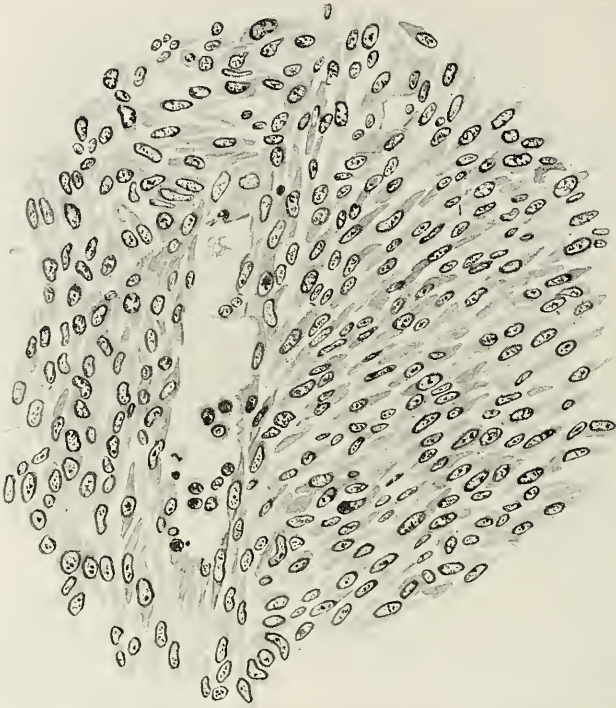

FIG. 258. SARCOMA OF WALL OF CERVIX UTERI (T. G. Stevens). Microscopic features of specimen shown in Fig. 257. They are those of a myosarcoma.

os, but it may involve the cervical endometrium as well. The uterus becomes soft and uniformly enlarged, resembling the pregnant organ. On section the endometrium is seen to be thickened, its inner surface may be shaggy and even polypoid. This type of growth has been known to block the cervix and cause both hæmato- and pyometra. Histologically it may be classed with the round-celled sarcomata.

(b) *Circumscribed* sarcoma of the endometrium begins as a nodule which may grow outwards into the muscular wall, or inwards towards the cavity, the latter being more frequent. In the uterine cavity it tends to become polypoid, dilating the cervix and passing out into the vagina, where, owing to strangulation and infection, it will appear as a dark red, sloughy growth. This type of endometrial sarcoma may

arise in the cervix, when it may be difficult to distinguish from a proliferating epithelioma.

One form of circumscribed sarcoma of the cervical endometrium presents very distinctive clinical features, appearing as a vesicular sarcoma generally referred to as "the grape-like sarcoma of the cervix," or *sarcoma cervicis botryoides*. This is a very malignant

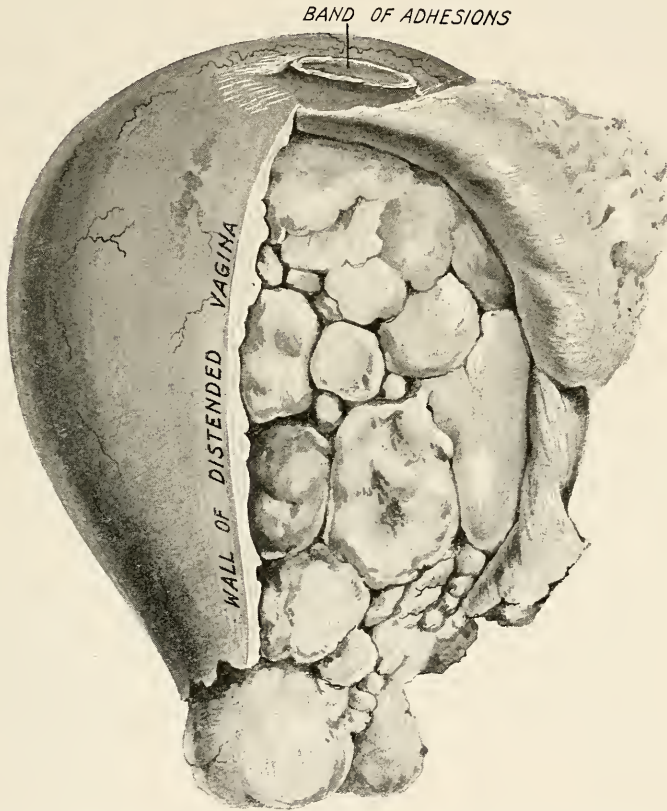


FIG. 259. VESICULAR OR GRAPE-LIKE SARCOMA OF THE CERVIX (Curtis). Infant, 12 months old. The uterus and vagina were removed by an abdominal operation. The vagina is distended with masses of growth, which are shown by reflecting a portion of the vaginal wall. The uterus is not seen.

multiple-polypoid growth characterized by the formation of a collection of globular grape-like vesicles connected in irregular series, or attached to the uterine wall by delicate stalks. Its growth is rapid, and it may fill up and distend the vagina (see Fig. 259). It is met with in infancy, in adolescence, and after the menopause. The cyst-like masses are due to oedematous infiltration occurring in a rapidly growing sarcoma. Microscopic examination reveals a covering of squamous or cylindrical epithelium, and a stroma of mixed large, round

and spindle cells, separated by œdematous spaces. In some specimens striped muscle-fibres and hyaline cartilage have been found.

**Special Forms of Sarcoma.** Sarcomata of the uterus, like those of other organs, show a tendency to the formation of tissues of a higher grade of development, thereby forming tumours of great pathological complexity. Such growths being of great rarity need only be enumerated. The *malignant leioma* already mentioned may be put into this category. *Primary melano-sarcoma* of the uterus with secondary deposits in the brain and other organs has been recorded. *Myxo-sarcoma*, giving the mucin reaction with acetic acid, occurs;

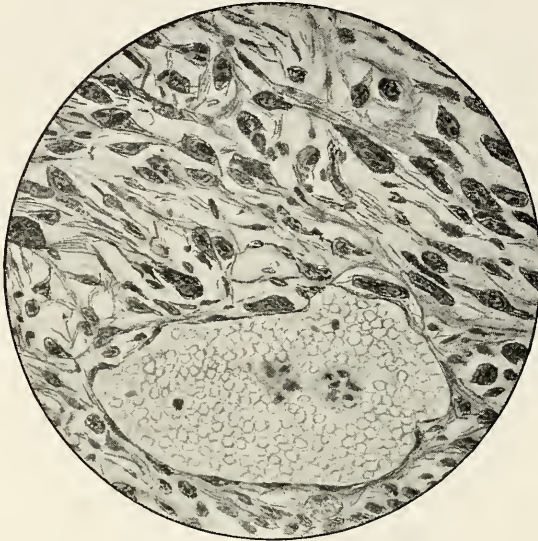


FIG. 260. SARCOMA OF THE UTERUS. The growth consists of round, spindle, and giant cells; the large vein shows a giant cell and a cluster of sarcoma-cells in its lumen, illustrating the mode of dissemination characteristic of sarcoma.

*lympho-sarcoma*, soft growths composed of typical lymphoid tissue, have been reported by Gow and others. *Lipo-myosarcoma* has been described by Sitzenfrey. *Angio-sarcoma*, *chondro-sarcoma*, *adeno-chondro-sarcoma* and *rhabdo-myosarcoma* have all been recorded. Tumours closely allied to endotheliomata have been described as a combination of carcinoma and sarcoma under the title *Carcinoma sarcomatodes*; in this connection it may be mentioned that sarcoma has been produced in a mouse by implantation of cancer-cells.

**Spread of Uterine Sarcoma.** The intramural form is of relatively low malignancy, probably because it remains encapsuled until it has attained considerable size. The channel of dissemination is the blood-stream; the large size and the delicate walls of the new vessels favour the entrance of sarcoma-cells, and their presence can often be demonstrated in the lumina as in Fig. 260. After passing through the uterine

wall the growth invades the bladder, the Fallopian tubes, the ovaries, and the pelvic lymphatics. In fatal cases submitted to autopsy,

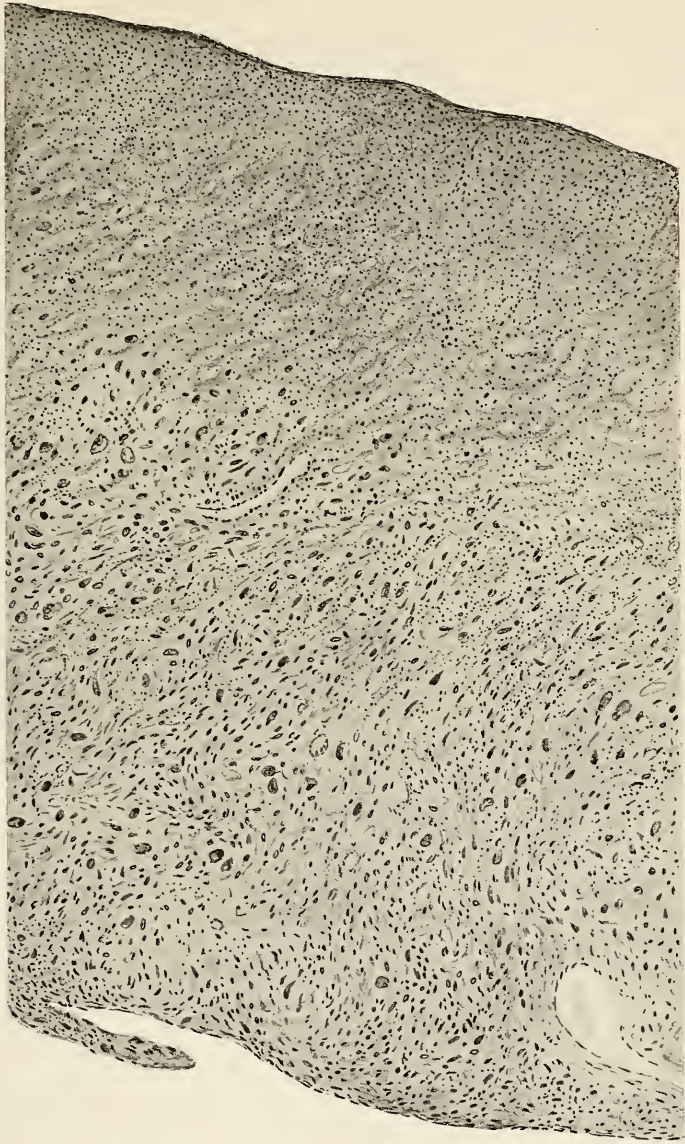

FIG. 261. SARCOMA OF THE UTERUS.  $\times 105$ . Showing a wide zone of necrosis on the surface of the growth. The growth demonstrates a common feature of uterine sarcoma, *i.e.* a mixture of cells comprising spindle, round, oat-shaped and giant cells.

visceral metastases are found in over 70 per cent. (Veit), the organs most frequently affected being the lungs and the liver; metastases also occur, though much less frequently, in the intestines, the spleen, and the kidneys. Urinary and fæcal fistulæ are seldom caused by sarcoma.

**Clinical Features.** Sarcoma of the uterus occurs both in infancy and childhood, and an instance in a fœtus has been recorded by Phillips ; but the great majority of cases occur in women who have passed the menopause. From a study of 438 cases, Veit concludes that from forty-five to sixty years of age represents the time at which

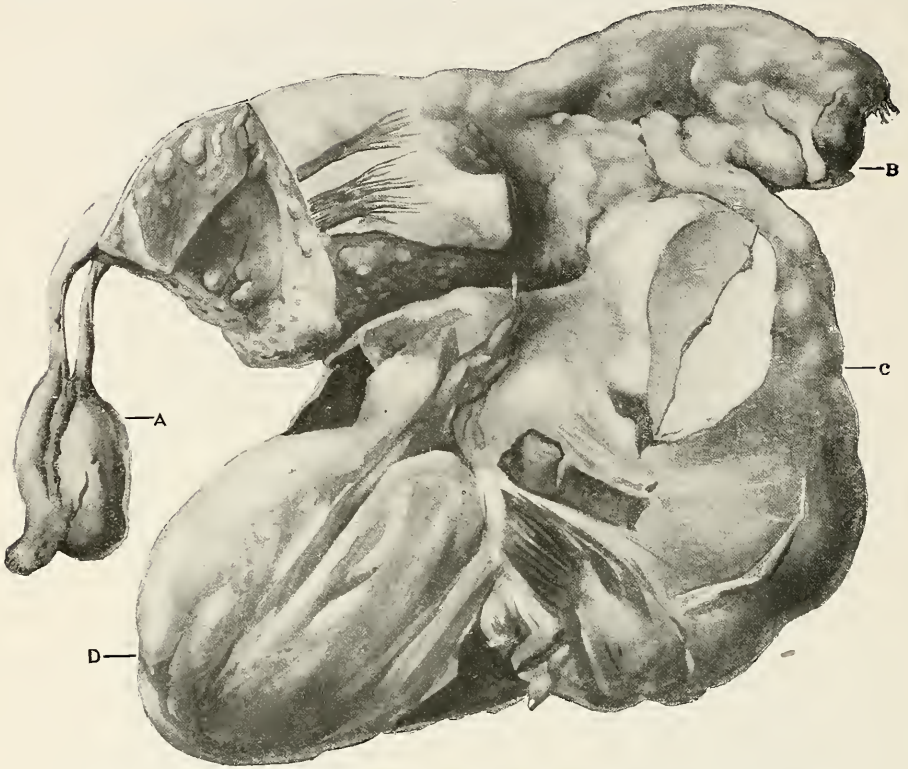


FIG. 262. PERITHELIOMA OF THE UTERUS SEEN FROM THE FRONT (Doran and Lockyer). The cavity of the uterus with small nodules of the growth in the wall is shown on the right side. A, Right ovary. B, Left tube and mesosalpinx infiltrated with new growth. C, Large solid growth in left broad ligament. D, Cystic part of growth in left broad ligament. The patient was free from recurrence five years after operation.

women are most prone to uterine sarcoma. One-fourth of the patients are nulliparous and three-fourths parous.

As previously stated, sarcoma attacks the body of the uterus more often than the cervix, differing sharply in this respect from cancer. It also forms a much larger tumour than cancer, and so occasions much greater enlargement of the uterus. Usually the enlargement is fairly symmetrical, but may be irregular if the growth projects beneath the peritoneal coat, or if fibroids are also present. Vesicular sarcoma, when it occurs in the cervix, is easy of recognition by direct examination.

The *symptoms* to which sarcoma gives rise are *hæmorrhage*, *dis-*

charge and pain ; it will therefore be apparent that the symptoms do not allow of its being distinguished from cancer (see p. 338). The *bleeding* is

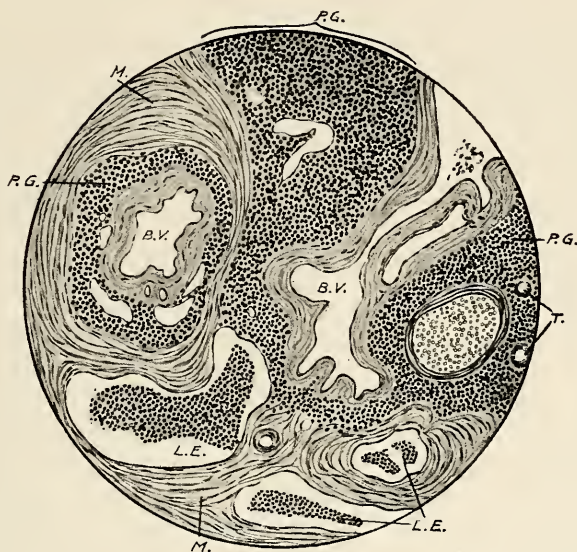

FIG. 263. SECTION OF PERITHELIOMA OF THE UTERUS. (Doran and Lockyer.) showing the microscopic appearances of tumour in Fig. 262. *B.V.*, Blood-vessel ; *L.E.*, Lymphatic Embolus ; *P.G.*, Peritheliomatous Growth ; *M.*, Uterine Muscle ; *T.*, Tubules from Mucosa.

irregular, or continuous, but is seldom profuse. Before the menopause the first indication of hæmorrhage may be progressively increasing menorrhagia. The *discharge* is watery and blood-stained, and becomes

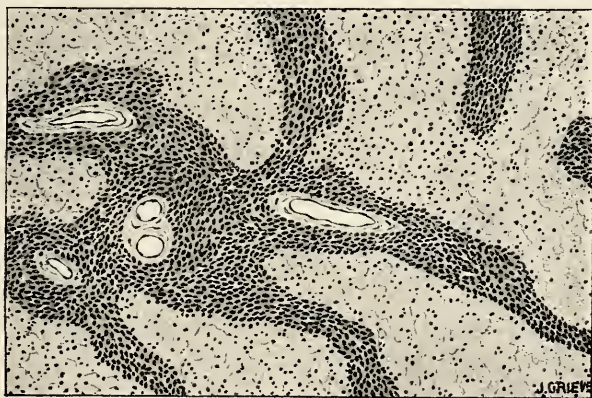

FIG. 264. PERITHELIOMA OF THE UTERUS (LOW POWER) (Johnstone) Whorls of epithelioid cells are arranged around vessels ; the endothelium of the latter is intact.

offensive at an early stage. *Pain* is severe and occurs comparatively early ; this is probably due to the relatively rapid rate of growth. Constitutional symptoms, such as headache, sleeplessness, anæmia,

and loss of flesh sometimes appear early and are out of proportion to the amount of hæmorrhage and discharge ; such symptoms should arouse suspicion of malignancy without reference to the size of the uterine tumour. The marked tendency of all sarcomatous growths to necrose (*see* Fig. 261) and become infected is well known ; this results in septic poisoning and Veit calculates that of the mortality from uterine sarcoma 85 per cent. is to be attributed directly to cachexia and sepsis.

The *treatment* consists in total extirpation of the uterus and its adnexa without delay ; the abdominal operation is preferable to the vaginal as allowing of freer removal of the broad ligaments and inspection of the other pelvic organs. The prospect of recurrence is highest in the round-celled type of growth arising in the endometrium, but it is great in every variety. The least malignant of all is the sarcoma which develops in a myoma.

**Endothelioma and Perithelioma of the Uterus.** These are malignant growths arising from proliferation of the cells of the tunica interna or the tunica externa (respectively) of medium sized blood- or lymph-vessels. They possess no naked-eye characters by which they can be distinguished from other kinds of malignant growth ; careful examination of the tissue by an expert microscopist is required for their recognition. These forms of malignant tumours are regarded as sarcomata possessing a low type of malignancy ; they are commoner in the ovary than in the uterus. The macroscopical and histological characters of uterine perithelioma are well shown in the accompanying illustrations (Figs. 262, 263 and 264), while the appearance of endothelioma will be described later (*see* p. 685). In regard to prognosis peri- and endotheliomata differ markedly from sarcomata, on account of their lower grade of malignancy. The chance of recurrence after removal is decidedly less than it is with sarcoma proper.

## CANCER OF THE UTERUS

Carcinoma is more frequently met with in the uterus than all the other malignant growths taken together. Two organs in the female sex show a greater predisposition to cancer than any others, *viz.* the breast and the uterus, the liability of these two being about equal. From a study of the cancer statistics of large clinics it appears that in women affected by cancer, the organ primarily attacked is the uterus in about 30 per cent. of all cases (Welch, Orth). In the present unsettled state of knowledge of the causation of cancer, little can be said in explanation of this special predisposition of the uterus and mamma.

*Traumatism* and *chronic irritation*, *e.g.* a long-standing inflammation, are generally accepted as predisposing causes of cancer. Both the breast and the uterus are especially exposed to risks of injury ; the former from its exposed situation, the latter from the effects of child-bearing. And further, both organs are frequently the seat of chronic



inflammatory processes. Another predisposing cause of cancer is *senescence*, *i.e.* old-age changes, in tissues ; both these organs are subject

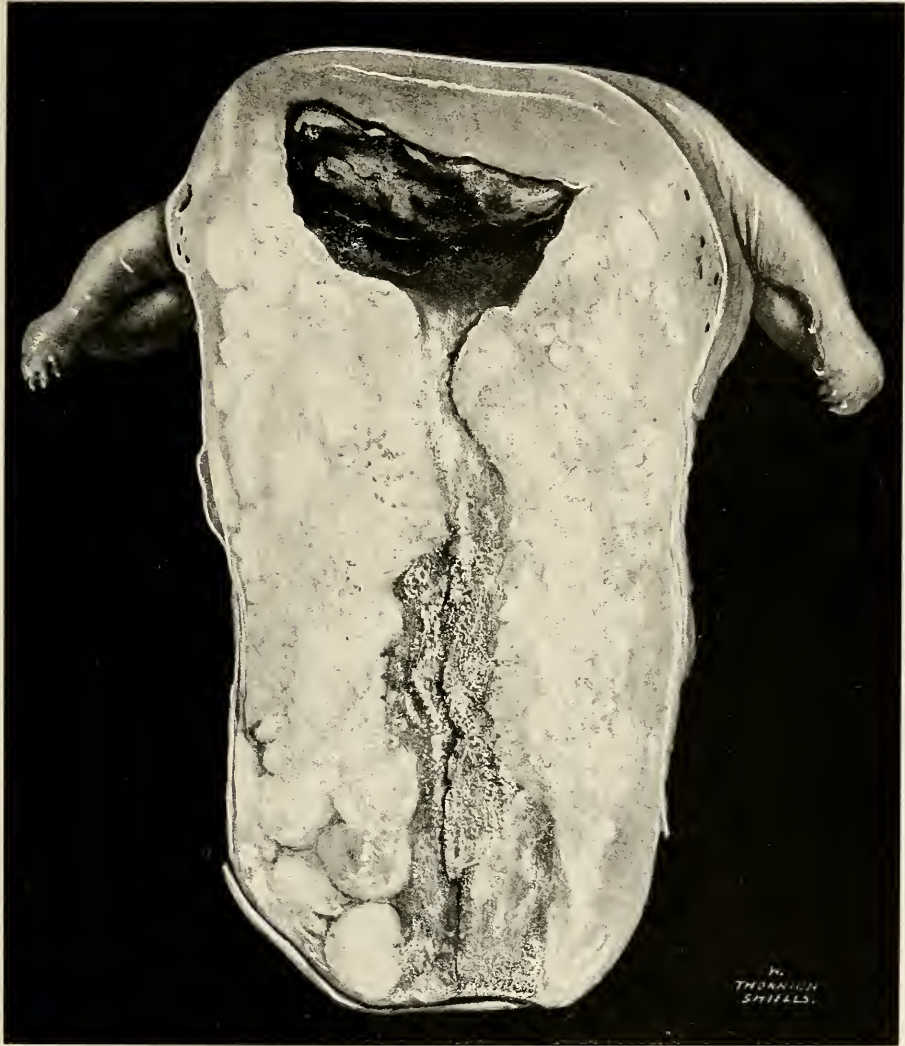


FIG. 265. GENERAL CARCINOMATOSIS OF THE UTERUS, THE DISTINCTION BETWEEN BODY AND CERVIX IS LOST. The cavity was dilated by blood (hæmatometra). Cf. Fig. 131, p. 240.

to such changes as soon as the period of sexual activity has passed, *i.e.* at a much earlier age than the tissues of the body generally.

Cancer may attack either the cervix or the body of the uterus ; in rare instances both divisions are affected in a single case, as seen in Fig. 265. The cervix is much more frequently attacked than the body, but it is very difficult to define with accuracy the relative frequency

of the two. From a study of post-mortem statistics it would appear that 95 per cent. of cases of uterine cancer are cervical, and only 5 per cent. corporeal. Clinical statistics give a higher proportion of cases of corporeal cancer than this. Thus Wilson has recently recorded

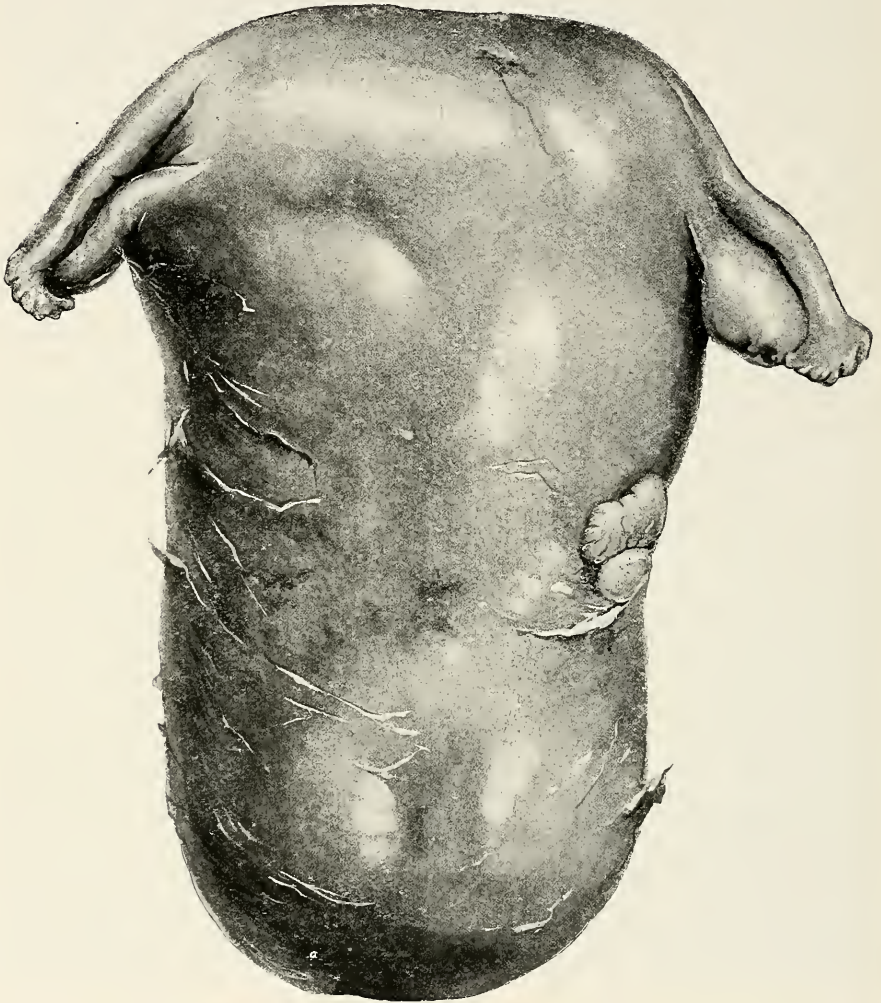


FIG. 266. POSTERIOR VIEW OF THE SAME UTERUS AS SHOWN IN Fig. 265.

a series of 596 consecutive cases of uterine cancer observed by him in Birmingham, and in 11.25 per cent. the primary seat of the disease appeared to be the body. It is not, however, in all cases possible to say in which division of the uterus the disease first appeared.

Cervical and corporeal cancer present so many points of anatomical and clinical difference, that they are entitled to consideration as distinct diseases.

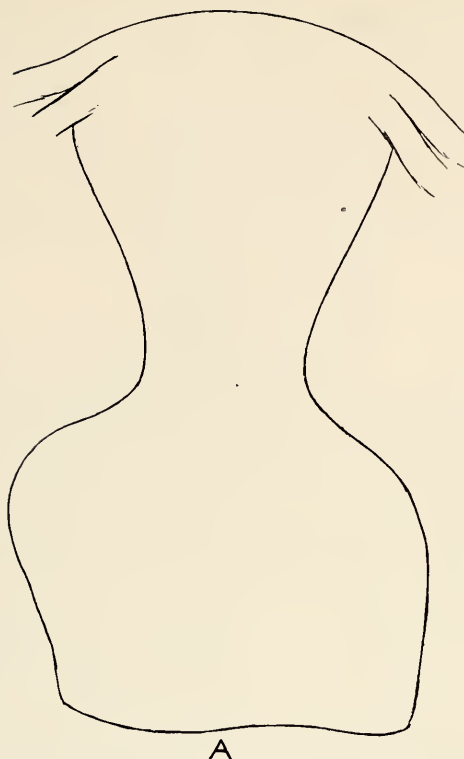


FIG. 267. OUTLINE (DRAWN TO SIZE) OF THE UTERUS AND A PORTION OF THE VAGINA COVERING THE CERVIX IN A CASE OF ENDOCERVICAL CANCER. The uterus was removed by Wertheim's total hysterectomy. The cervix is shown in the following Figures, 268 and 269.

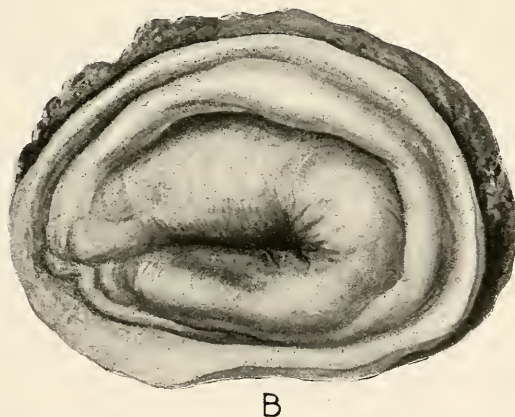


FIG. 268. VAGINAL ASPECT OF THE CERVIX IN THE CASE OF ENDOCERVICAL CANCER seen in Figs. 267 and 269. There is an old laceration present, but the vaginal surface is intact and not involved in the malignant growth. See Fig. 269.

### CANCER OF THE CERVIX

**Pathological Anatomy.** Cancer may arise in the cervix in two different positions: (a) from the deep layers of the epithelium of the portio vaginalis (*cervical cancer*); (b) in the cervical endometrium, i.e. the mucous membrane lining the cervical canal (*endocervical or medullary cancer*). Some pathologists believe that it may arise in the epithelium derived from foetal relics, but this is a hypothesis which it is

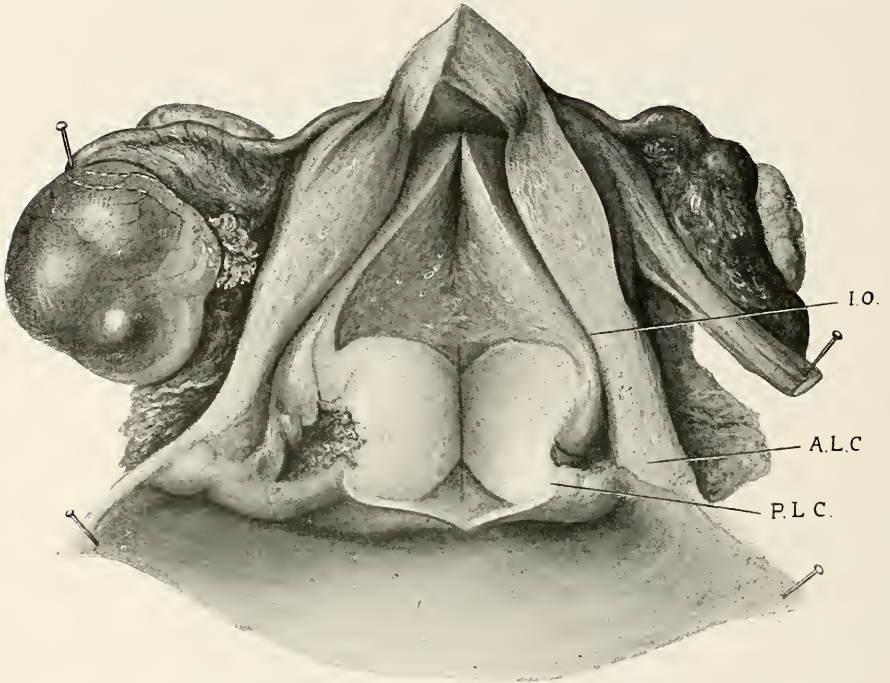


FIG. 269. ENDOCERVICAL CANCER. The specimen has been laid open from the front to show that the growth has started in the cervical endometrium and not in the epithelium covering the *portio vaginalis* (see Fig. 268). I.O., Internal os. A.L.C., Anterior lip of cervix. P.L.C., Posterior lip of cervix. Between these two points lies the cervical canal, which on the right side shows an ulcerated area, the starting-point of the malignant growth. (See Figs. 270, 271, 272.)

equally difficult to prove or refute. It has commonly been taught that cancer of the cervix may be systematically distinguished as (a) cervical cancer, which, arising in the squamous epithelium of the portio is a *squamous epithelioma*, and (b) endocervical cancer, which arising in the columnar epithelium of the cervical endometrium, is therefore an *adenocarcinoma*. Careful examination, however, of a large series of cervical carcinomata has demonstrated that this simple, and apparently logical classification breaks down; in fact; it is often impossible to decide either by naked eye or (in advanced cases) by histological

examination, whether a cancer started in the squamous epithelium of the *portio vaginalis* or in the columnar epithelium of the cervical

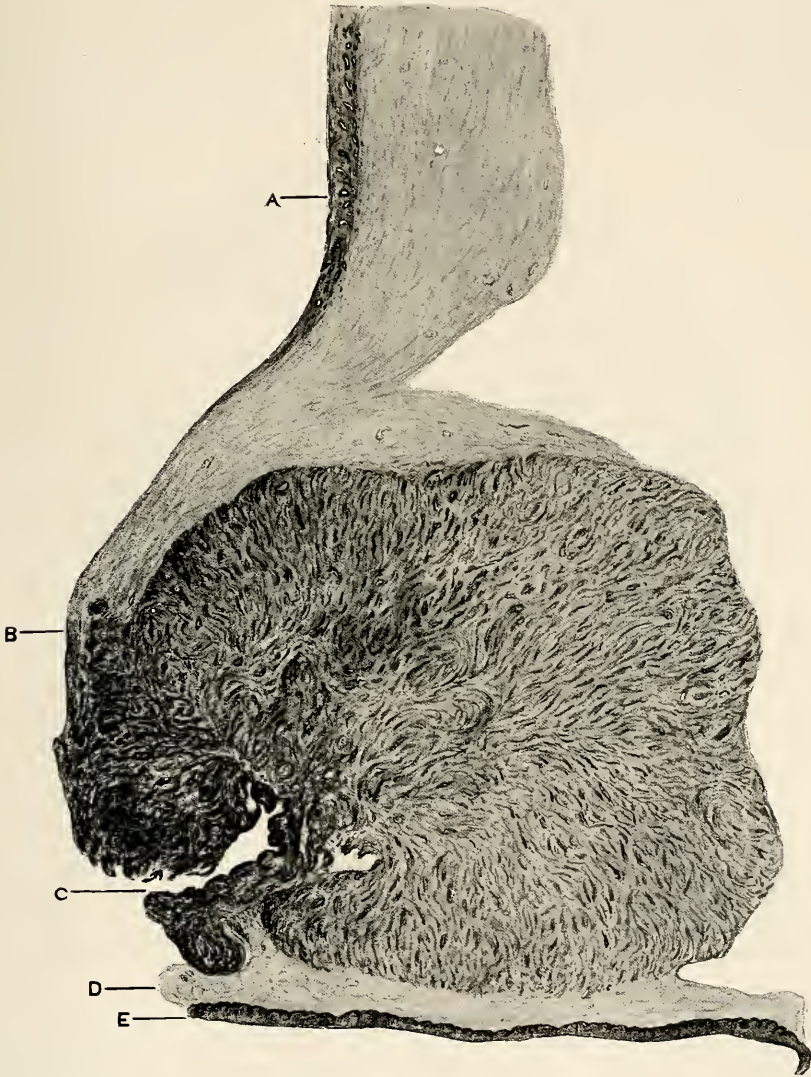


FIG. 270. SAGITTAL SECTION OF SPECIMEN SHOWN IN FIG. 269.  $\times 4$  SHOWING A SQUAMOUS-CELLED CANCER STARTING IN THE CERVICAL ENDOMETRIUM. A, Corporeal endometrium. B, Cervical endometrium. C, Malignant ulceration of cervical endometrium. D, Fibro-muscular tissue of cervix free from growth. E, Healthy surface of *portio vaginalis cervicis*. The microscopic characters of the growth are seen in Figs. 271, 272.

endometrium. The disability to prove the site of origin in cases of cancer of the cervix is due to the marked disposition of the epithelium of the cervix to undergo metaplasia. This change is very liable

to occur in the case of the columnar epithelium, not only in cells already cancerous, but also in what may be called the *pre-cancerous stage*. In cases of cervical catarrh and cervicitis, with or without ectropion of the cervical mucous membrane, the columnar epithelium may be seen assuming the characters of squamous epithelium. In the same manner squamous epitheliomata may be seen to arise from the

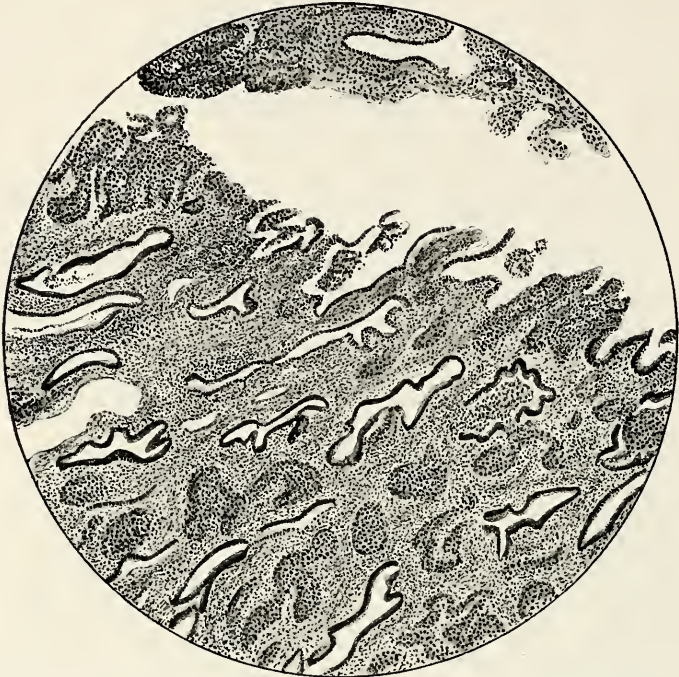

FIG. 271. SECTION OF THE GROWTH SHOWN IN THE PRECEDING FIGURE. It was taken from point C in Fig. 270, *i.e.* through the free edge of the ulcerated area in the cervical canal. The growth is composed of solid, clubbed, branching processes, of squamous epithelial cells. The latter can be seen to arise from the columnar epithelium of the superficial and deep glands of the cervical endometrium. (See also Fig. 272.)

columnar cells of the endometrium, as well as from the squamous epithelial investment of the portio vaginalis. *Almost all carcinomata of the cervix belong to the squamous type.*

**The Squamous-celled Cancer.** From the above remarks it will be seen that this variety may arise from the portio vaginalis (cervical cancer) or from the endometrium of the cervix (endocervical cancer). The growth arising from squamous epithelium starts in the deep layers, from whence proliferating cells form buds and solid processes which dip into the subjacent fibromuscular tissues. Whilst the downgrowth is taking place, the cells in the superficial layers are thrown off, so that between the downgrowing epithelial processes the surface-epithe-

lium is thinned out and may even be absent. The rate of growth may be estimated by the features assumed by the invading solid processes—the more rapid the growth, the larger and thicker are the cancer-masses, and the more diminished becomes the connective tissue framework.

*Microscopic Appearances of a Squamous-celled Cancer.* The characteristic appearances are only to be found at the advancing edges of the

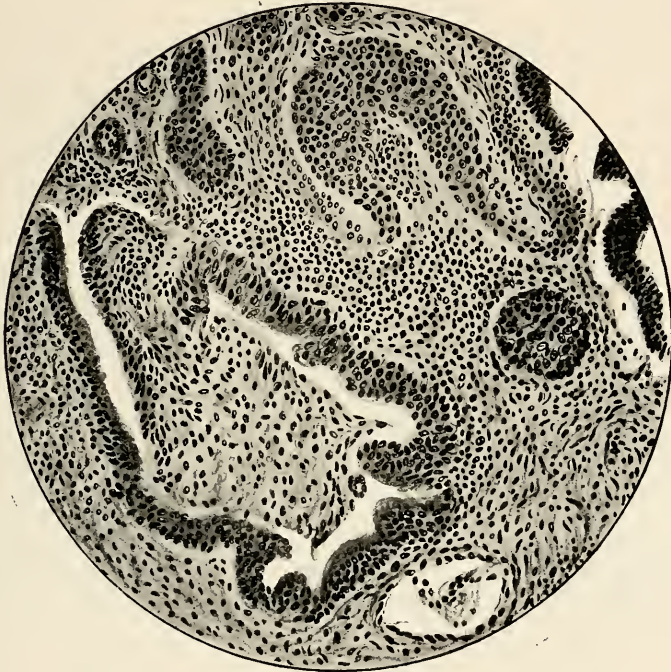


FIG. 272. VIEW UNDER HIGH POWER ( $\times 278$ ) OF SECTION SHOWN IN FIG. 271. Showing the squamous character of the malignant cells and their origin from the columnar epithelium of the cervical endometrium.

growth, and sections required for diagnosis should always be taken from this part. It has been pointed out that from the deep layers of the stratified epithelial covering of the normal cervix, shallow digitate processes project into the subjacent connective-tissue layers (*see* Fig. 273). Cut in transverse section these processes appear under the microscope as small islets of epithelial cells, uniform in character, surrounded by connective tissue from which they are sharply differentiated. In squamous-celled cancer the new growth is formed from the deep layer of cells on such processes as these by the production of large, branching, solid, epithelial offshoots (*see* Fig. 274) which penetrate the healthy tissues deeply, and destroy them in their advance. In transverse section they appear as masses of epithelium of various shapes

and sizes, more or less sharply bounded by a well-defined fibromuscular stroma, representing the normal tissues of the cervical wall. In these masses the peripheral layer of cells is cubical (*see* Fig. 272); passing towards the centre, the cells are more irregular and tend to become polygonal. In the central parts may occasionally be seen small areas of flattened cells arranged concentrically, the so-called *epithelial pearls*,

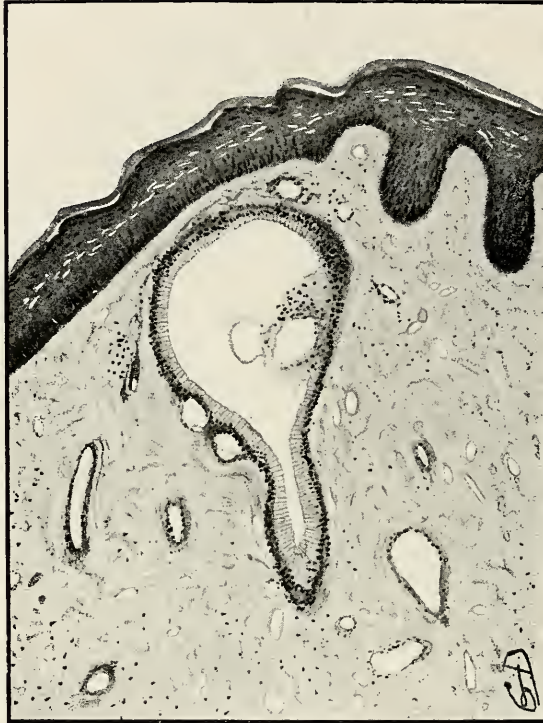


FIG. 273. VERTICAL SECTION THROUGH THE VAGINAL SURFACE OF THE CERVIX UTERI, showing digitate processes of surface-epithelium projecting into the subjacent fibromuscular tissue.

but this is a change which is seldom seen in squamous-celled carcinoma of the cervix, since the majority, arise from columnar and not from squamous epithelium. Instead, the central cells of a cancerous area become softened and degenerated to form a fluid or semi-fluid pulp in which free nuclei and leucocytes, but no cancer-cells, are seen. By this colliquative necrosis, gland-like spaces lined by many layers of epithelium are produced, but the cells lining such spaces always preserve their squamous characters. Such a condition superficially resembles, but should not be regarded as, adeno-carcinoma.

Near the cancer-areas, the stroma often shows a certain amount of round-celled infiltration and oedema, and the cancer-cells may be seen escaping into, and invading, the connective tissues. In the more



advanced portions of the growth the fibromuscular stroma is not seen ; the cancer-cells become more widely disseminated and penetrate the surrounding tissues, destroying them in their advance, so that large areas of the growth consist of little else but masses of cancer-cells. These parts of the tumour are prone to ulceration ; the characteristic appearances are then lost, and an extensive zone of round-celled infiltration is found around them (*see* Fig. 275). The surface of a squamous-

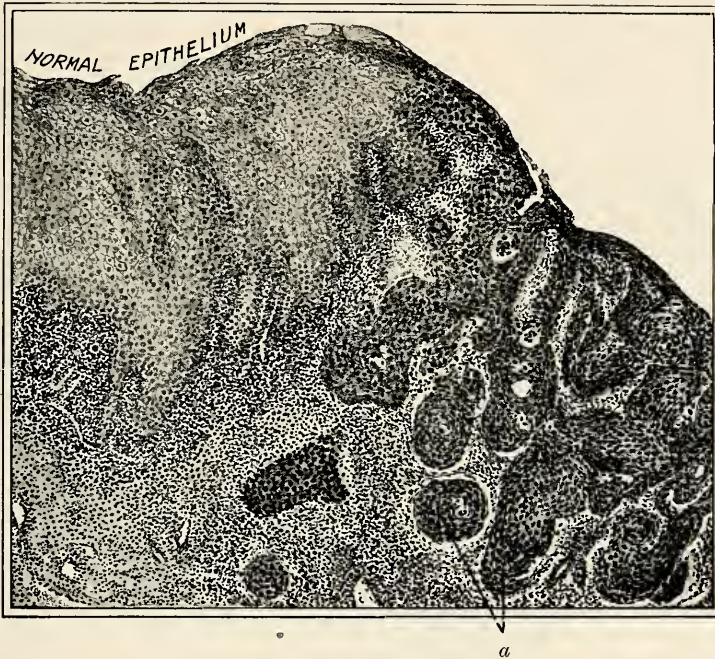

FIG. 274. SQUAMOUS-CELLED CANCER OF THE CERVIX. Multipara, aged 27. The section is made through the edge of the growth. At *a* are seen two epithelial processes, one in cross-section, the other running up to the surface.

celled cancer usually displays these modifications, except at the edges, where the appearances remain characteristic. Here it is often seen that the cancer has penetrated the stroma beyond the apparent edge of the growth, passing into parts which are still covered by normal epithelium (*see* Fig. 275).

Figure 276 illustrates another microscopic feature of a squamous-celled cancer. This change is rarer than the one previously described, in which liquefaction of cancer-cells resulted in a pseudo-glandular appearance. In this instance the cancer has arisen from an *erosion*, and the downgrowths show glandular formation which has led to this type of epithelioma being regarded erroneously as an adenocarcinoma. The epithelium of the surface and that of the deep gland (marked 2) is definitely squamous in character, and it is from the

nature of the epithelium that a cancer is classified. Such spaces as are found in squamous-celled cancer of the cervix never secrete; their contents, as already stated, consist of the solid and fluid products of degeneration.

**Adeno-carcinoma of the Cervix** is rare, and like the squamous-celled growth it arises from the cervical endometrium, either from the columnar epithelium of the surface or from that deeper down in the gland-

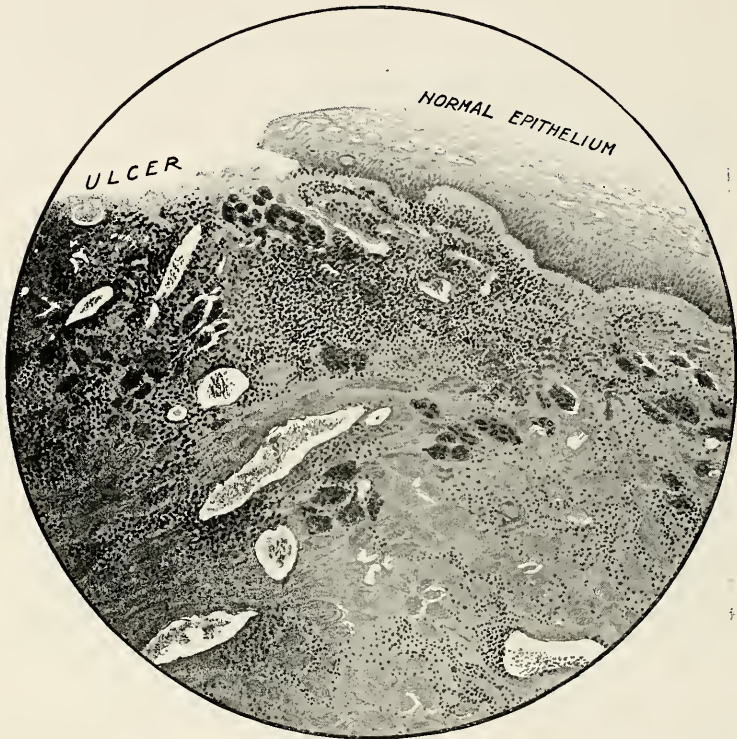

FIG. 275. SQUAMOUS-CELLED CANCER OF THE CERVIX. Nullipara, aged 40. The growth had formed a small ulcer on the posterior lip of the external os. The section is taken through the edge of the ulcer and shows that the growth has penetrated into parts still covered by normal squamous epithelium. A good deal of round-celled infiltration is seen both in the superficial and deep parts.

tubules, the latter source being the commoner site of origin. The cancer starts by the formation of tubular projections from the lumina of the glands. These crypts, communicating with the lumen of an original tubule, begin to branch and elongate, and may join up with others which have arisen from another site; hence a complex adenomatous formation is produced. Some of the secondary tubules may project into the lumina (*inverting type*), but for the most part they spread outwards in the fibromuscular stroma, which becomes gradually diminished by the invasion of these ramifying tubules. There is no marked tendency to multiplication of layers, so that for the most part

the lumina possess only a single layer of cubical epithelium (*see* Fig. 277). This type of cancer is rare in the cervix; it resembles in its histology the so-called *adenoma malignum* (tubular carcinoma) of the uterine body. The histological evidence of malignancy consists, mainly, in the invasion and destruction of the stroma by the proliferating tubules. This growth has, however, but little tendency to

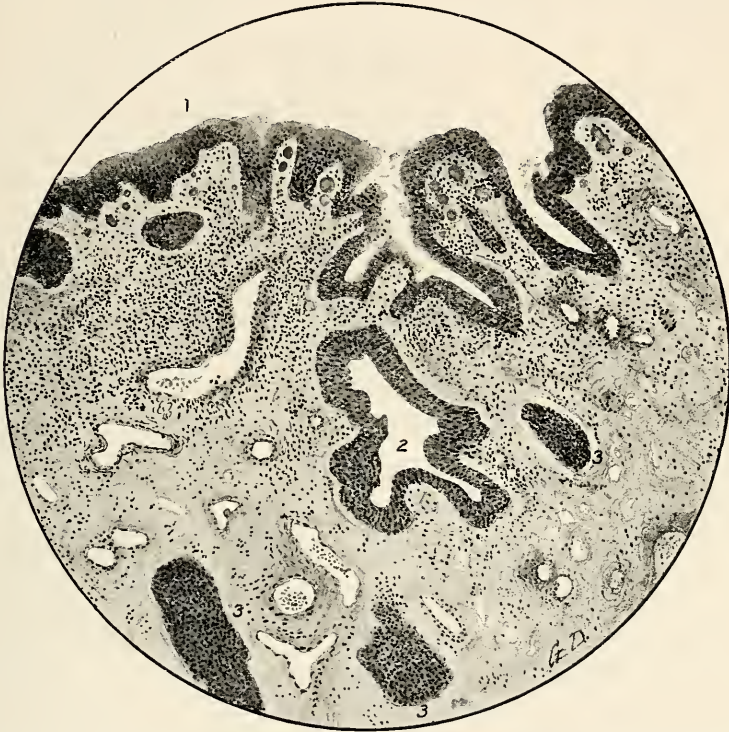

FIG. 276. CARCINOMA OF THE CERVIX. The cancer has arisen in an 'erosion.' The epithelial covering (1) is proliferated and stratified; the deep pseudo-glands (2) show the same characters; alveoli packed with cancer-cells are seen at (3).

invade the parametrium and the adjacent viscera; it is therefore far less malignant than the squamous-celled cancer.

In a few cases adeno-carcinoma of the cervix shows the same colloid degeneration of cells as is seen in cancer of the bowel.

**Macroscopic Appearances of Cancer of the Cervix.** The naked-eye appearances of cancer of the cervix are very variable. The younger the subject, the softer, more brain-like, and more malignant is the growth. Roughly speaking, cancers of the cervix uteri may be divided into those which show, from the first, a tendency to *erode* or *ulcerate*, and those which are characterized by a marked degree of *new formation* or *proliferation*. Such a division into types, (1) ulcerative, and (2) proliferative, is, however, not wholly satisfactory, because the deepest

cervical excavations are those which are caused by the necrosis of a certain type of *proliferative cancer* to which we shall again refer.

(1) *Formative or Proliferative Type*. One of the most frequent forms of this type is the so-called *cauliflower carcinoma* of the portio vaginalis. This type proceeds from one or other lip of the cervix and forms a huge mass of new tissue with a warty or nodular surface (see Fig. 278). This projects into the vagina, but shows a lesser tendency

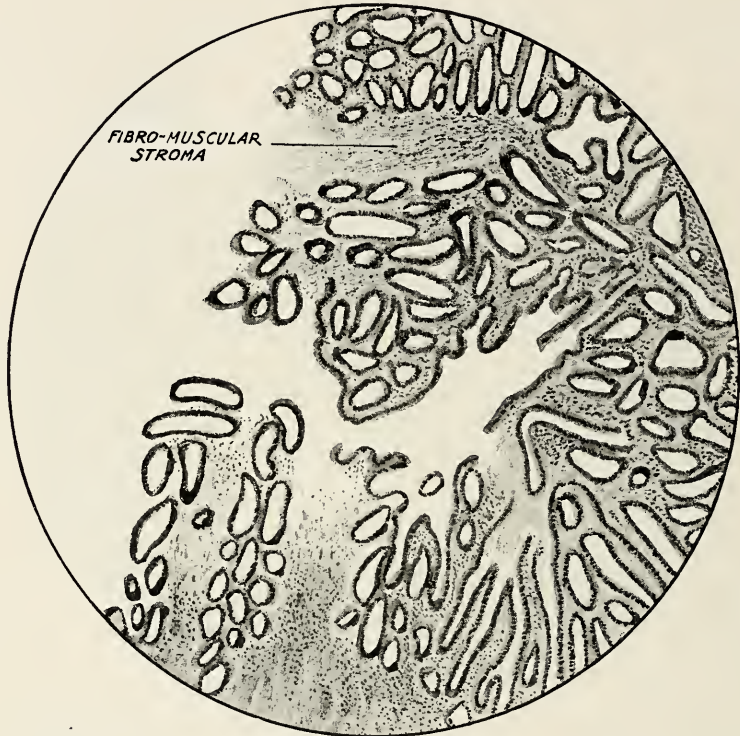


FIG. 277. ADENO-CARCINOMA OF CERVIX, TUBULAR FORM. Multipara, aged 37.

to spread into the deep tissues. Such a growth may reach the size of a fist and appear at the vulva, whilst its attachment to the portio may be by a relatively thin base. The surface may be furrowed and lobulated, and is often deeply fissured (see Fig. 278). The largest growths are extensively degenerated and covered with a greyish-green necrotic layer. Generally such large growths are not formed, because the new tissue rapidly necroses. This kind of growth has a strong tendency to spread along the vagina, by direct continuity or by contact-implantation. In such cases the cancer-cells may penetrate the vaginal mucous membrane and involve the paravaginal tissues; it may then break through into the vaginal wall and appear at another spot.

Another equally if not more frequent form of the proliferative type is the *medullary cancer*, which arises from the deep layers of the

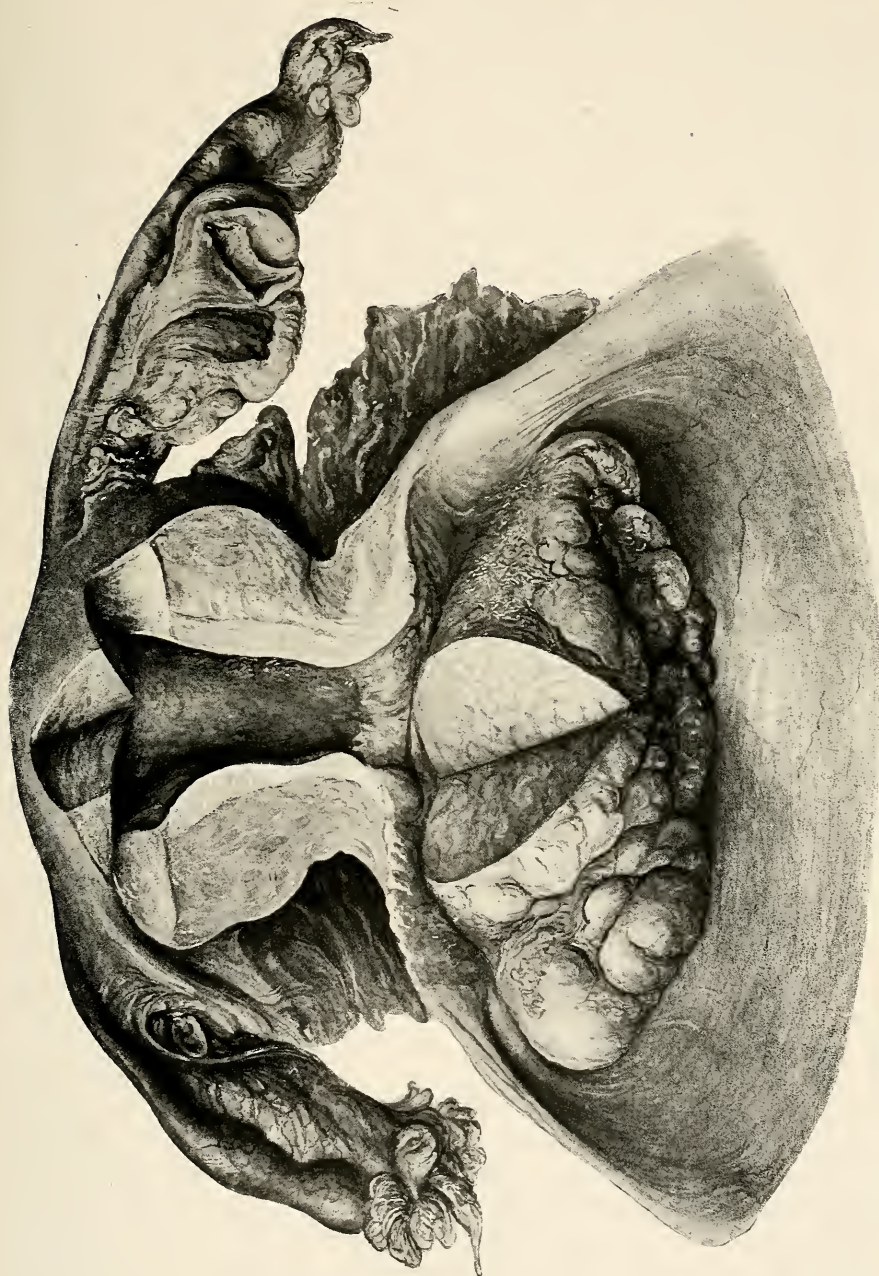

FIG. 278. PROLIFERATIVE TYPE OF SQUAMOUS-CELLED CARCINOMA OF CERVIX LYING IN A PORTION OF THE VAGINA.  
Removed by Wertheim's Method of total hysterectomy.

epithelium of the portio vaginalis or from the epithelium of the cervical endometrium. Even when it arises from the deep layers of the squamous epithelium of the portio, it spreads, from the first, into the depths of the cervix, and is therefore intracervical in position, hence the term *medullary*, which is used in reference to its deep situation, and in no way refers to the structure, or consistence of the growth. These proliferative growths at first form spherical, nodal masses of cancer (see Figs. 269 and 270, p. 518) in the tissues of the portio and supravaginal cervix. The cervix as a whole is much enlarged circumferentially and rendered irregular in shape (see Fig. 267, p. 517). At first the epithelium covering the portio vaginalis is intact (see Fig. 268),

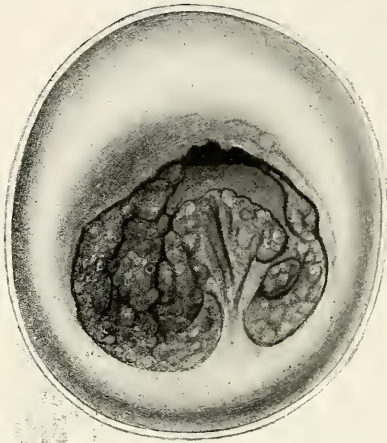


FIG. 279. ENDOCERVICAL (MEDULLARY) CARCINOMA OF CERVIX SHOWING EARLY ULCERATION.

but later on, the growth makes its appearance both externally (Fig. 279), and towards the cervical canal (Fig. 280). By the time ulceration has appeared on the external surface of the portio vaginalis, the proliferation of the growth within the cervix has often extended as far as the internal os in an upward direction, and laterally it may have reduced the cervix to a mere shell and involved the lymphatics in the loose cellular tissues. By the breaking down of an endocervical (medullary) proliferative cancer, a very deep crateriform ulcer is produced. The condition is then that of a somewhat cone-shaped excavation,

with its apex near the internal os, and its base where the external os was originally situated, but often the portio as such has disappeared, and the walls of the ulcer are flush with the vaginal fornices (see Fig. 280). The walls of the conical crateriform ulcer thus formed, consist of sloughy, crumbling, hæmorrhagic masses of growth, which on examination may come away by contact with the examining finger. With this form of cancer, infiltration of the parametrium is most rapid, metastases are most common, and often it establishes fistulous communications with the bladder and rectum. It may safely be said that of all types of cervical cancer, the endocervical (medullary) type is the most destructive.

(2) *The Ulcerative Type.* Far less frequent than either of the preceding, is the cancer which produces a flat sore with a shallow, hard edge. It probably starts in an *erosion*. There is relatively little tendency for this type of growth to penetrate deeply; it spreads very gradually, and somewhat resembles the rodent ulcer of the external skin. It is found especially in elderly subjects, and

at its onset is difficult to diagnose from an *erosion*, or from simple ulceration.

A still rarer form of cancer is met with also in old subjects in which the tendency to ulceration is very slight. It consists of a hard puckered induration of one or other lip of the *portio vaginalis*. It bleeds but slightly on contact and shows little tendency to disintegra-

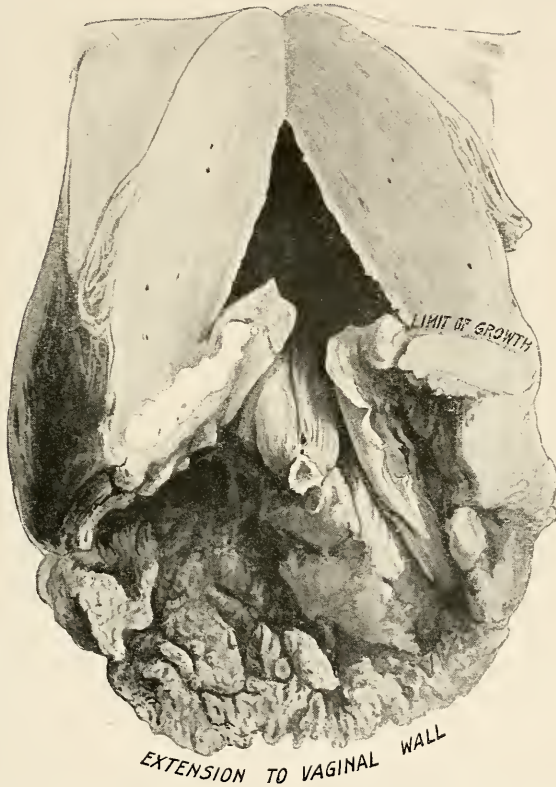


FIG. 280. ADVANCED CARCINOMA OF THE CERVIX: ULCERATIVE TYPE. The vaginal cervix has disappeared, being replaced by an irregular cavity with ragged walls; the growth has extended on to the vaginal wall below, and to the level of the internal os above.

tion. Microscopically the marked feature is the comparatively small size of the cancerous processes, and the relatively large amount of the stroma. The cancer-cells run in small lymph-spaces, almost in single or double file, with a large amount of fibromuscular tissue between them; there is probably an overgrowth of connective tissue taking place simultaneously with the slow cancerous growth. The cancer-cells are small in size but stain deeply. The microscopic appearances are those of a very chronic scirrhous of the breast, or of a rodent ulcer.

In concluding our observations on the pathology of cancer of the

cervix three final points may be mentioned respecting the sites of origin of the disease. (1) A rare form of cervical cancer, the so-called *central node*, has been described as springing from foetal relics. It is said to reach ultimately to the surface, but whilst the cervical canal and the surface of the *portio* remain normal, it will give rise to no symptoms, and it may reach an inoperable stage before being discovered. This may of course be the case with the ordinary medullary type already referred to, and, as we have stated already, the origin of cancer from foetal relics must be very difficult to prove. (2) Cervical polypi may become cancerous and the disease may then secondarily involve the cervix. (3) Lastly, we have attached no importance, as a mode of classification, to a distinction between cancer of the *portio vaginalis* and cancer arising from the cervical endometrium because we find that it is often impossible to be sure of the site of origin of these growths, even after careful macroscopic and microscopic examination. Only the cauliflower excrescence and the flat ulcer can be regarded as surface carcinomata with any degree of probability, and it may be repeated that these types are relatively benign as compared with the intra-cervical cancer, *i.e.* their tendency to invade extra-uterine tissues is less than that shown by the latter variety.

**Spread of Cancer of the Cervix.** The spread of cancer follows certain lines. The chief line of invasion is by connective-tissue spaces and lymph-spaces. Sometimes the lymph-vessels of the cervical wall are injected with cancer-cells. The first invasion is one of continuity, the cells forming solid outrunners which reach the larger vessels. From thence the lymph-stream helps in the distribution of cells, and the latter reach the neighbouring glands and fill up their peripheral sinuses. The usual course is a continuous efferent spread of cancer, whilst metastases in the lymph-glands are relatively uncommon (*vide supra*).

The malignity of cervical cancer is due to the complex lymph-system in and around the cervix. The lymph-channels lead direct to the parametrium, also to the cellular tissue of the utero-sacral ligaments and sides of the rectum. From the cellular tissue, extension anteriorly to the bladder occurs with relative frequency, and in an endo-cervical (medullary) cancer this takes place both earlier and with greater frequency than in the other forms. As a result of necrosis or sloughing of the tissues, a zone of cellulitic inflammation may be formed, which cannot be distinguished *clinically* from malignant infiltration. The terminal portions of the ureters may become obstructed in advanced cases, either by compression from infiltration of the surrounding cellular tissue, or by direct extension of the growth to their walls. Dilatation of the ureter (hydro-ureter) above the obstructed portion may then occur.

The lymphatic glands become involved in a definite order from the cervix as follows. The first is found at the crossing of the ureter by the uterine artery in the base of the broad ligament. Then follow



the iliac set on the external iliac artery, and the hypogastric group in the angle between the external and internal iliac arteries and in front of the internal iliac vein. Then come the sacral glands on the posterior pelvic wall, by the side of the rectum; still more remote are the superficial and deep lumbar glands, the inguinal glands, and also the colic set. Generally speaking the glands nearest to the uterus are the first to be involved, but not infrequently the proximal group escapes whilst the more distant ones become involved.

It is assumed that the earlier the cancer, the less likelihood is there to find lymph-metastases, and conversely the more advanced the cancer, the more likely is it to find glands involved. Investigations of late years have proved this assumption to be wrong. There is no rule as to the lymphatic spread of the disease. All that can be said is, in about one-third of the cases of extensive inoperable cancer, the glands are free from deposit. Also, that in operation-cases one-third show gland metastases. The cancerous glands are often not much enlarged; on the other hand glands are frequently much swollen and inflamed which are as yet free from new growth. Since carcinoma-cells can penetrate blood-vessels they may spread *viâ* the blood-stream, but this is less frequent with cancer than with sarcoma.

Metastases in distant organs occur only in the most advanced stages of the disease, and are relatively rare. According to the statistics of the Middlesex Hospital (MacCormac), in 109 autopsies for cancer of the cervix, visceral metastases were only found in 20 per cent., the organs most prone to these deposits being the liver and the spleen. The upper part of the urinary tract is frequently affected from direct extension of the disease to the bladder and ureters, and MacCormac reports that kidney lesions—usually hydro- or pyonephrosis—were present in 43·5 per cent. of his series of autopsies.

## CANCER OF THE BODY OF THE UTERUS

**Pathological Anatomy.** Cancer of the uterine body arises in the endometrium, from the epithelium of the surface, or from that of the glands. It may attack an otherwise healthy uterus or one which is already the seat of a fibroid tumour. The upper part of the uterine cavity is first affected (*see* Fig. 282 and Fig. 232, p. 461) in the great majority of cases. As the disease advances it tends to overrun the whole of the mucous membrane, and may then appear to naked-eye examination in one of two different forms. In the commoner *tuberos* type large, projecting, sessile masses of new growth are formed which more or less completely fill up the enlarged uterine cavity (*see* Fig. 281). In the rarer *papillary* form the new growth consists of large numbers of delicate polypoid processes, sometimes branching, sometimes divided by sulci on their surface (*see* Fig. 283). In some cases this rapid diffusion of the disease over the whole uterine surface is not seen, but instead, a

mass of growth is found upon a single spot, and the form then assumed by the disease is *polypoidal* (see Fig. 282).

The disease rarely passes through the internal os to attack the cervical endometrium, and invasion of the fibromuscular wall of the

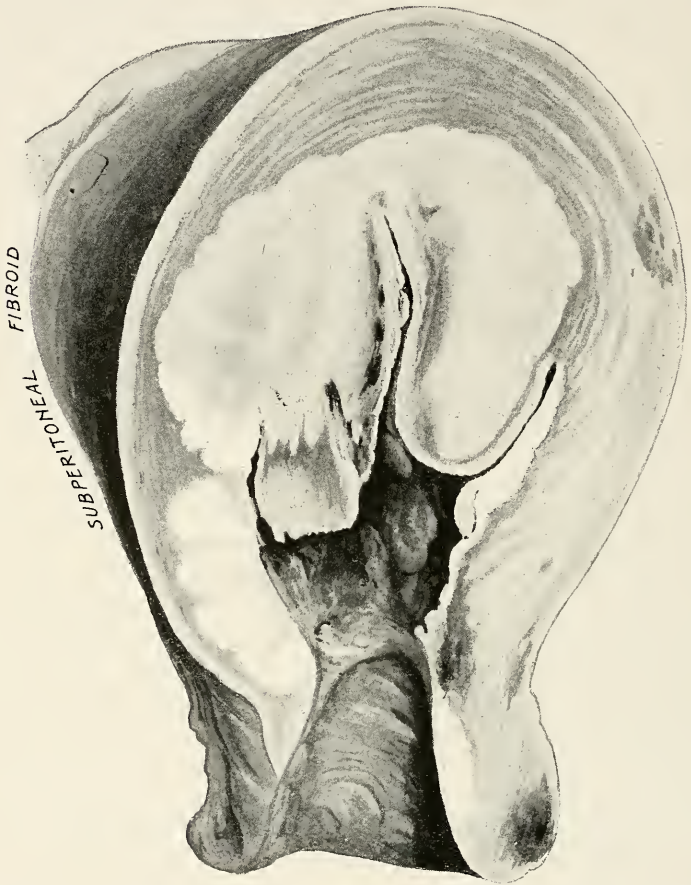


FIG. 281. CARCINOMA OF THE BODY OF THE UTERUS. A small subperitoneal fibroid was also present. Multipara, aged 49. The growth consists of tuberous masses arising at the fundus and projecting into the uterine cavity. The growth has extended over the endometrium to the internal os. Invasion of the fibromuscular tissue is clearly seen.

uterus occurs later than in cancer of the cervix, but can always be seen by the naked eye in advanced cases. Formative processes are commonly in the ascendant, and ulceration of the growth, so common in cancer of the cervix, is much rarer; the greater freedom of the uterine cavity from infection from without perhaps explains this difference. Enlargement of the body of the uterus, as a rule, is only of moderate extent; it is rare for these tumours to attain a large size, but Spencer has recorded an exceptional instance in which the uterus weighed

1 lb.  $1\frac{1}{2}$  oz. and measured  $5\frac{1}{4}$  inches in length. The normal contour of the uterus is, as a rule, preserved, for the growth invades the uterine wall very slowly, and seldom reaches the peritoneal coat except in advanced stages (*see* Fig. 265). From the upper angle of the uterine cavity the growth frequently extends to the interstitial portion of the Fallopian tube.

**Microscopic Appearances.** In contradistinction to cervical cancer, carcinoma of the uterine body is almost always of the glandular

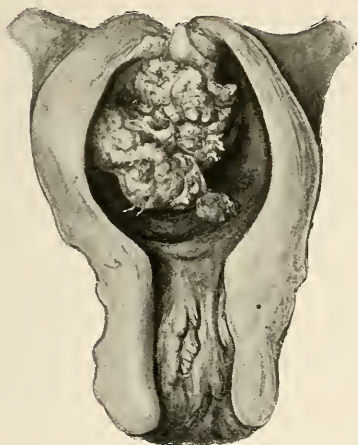


FIG. 282. EARLY CARCINOMA OF THE BODY OF THE UTERUS. Patient aged 53. The growth formed a papillary polypoidal mass which was attached to the right cornu by a comparatively narrow base. The uterine cavity measured  $1\frac{1}{4}$  inch from fundus to external os.

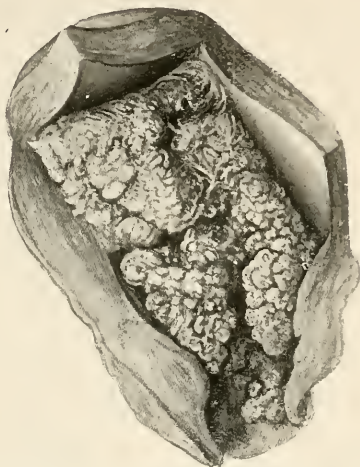

FIG. 283. CARCINOMA OF THE BODY OF A SENILE UTERUS. The growth is composed of papillary or villous masses which have protruded through the internal os and dilated the cervix.

variety, but a few rare instances (including a case published by one of us) of primary squamous-celled cancer of the corporeal endometrium have been described.

*Adeno-carcinoma* may assume two different forms: (1) the tubular, and (2) the alveolar. Opinions differ as to which is the more common.

(1) The *tubular* form consists of an irregular and very free proliferation of gland-tubules of varied shape and size, which lie in contact with one another, the stroma being scanty. The tubules are lined with high columnar epithelium, which differs from that of the normal uterine glands in the situation and character of the cell-nuclei. The latter are placed at irregular levels; they are variable in shape and present karyokinetic figures; and they do not stain with the same uniform intensity as do the nuclei of benign epithelium. The growing tubules may bud outwards (*everting type*) (*see* Figs. 284 and 285), or they may produce a number of papillary processes within their own lumina (*inverting type*)

(see Fig. 286). Both the inverting and everting forms occur together and have no pathognomonic significance. At the growing edge the

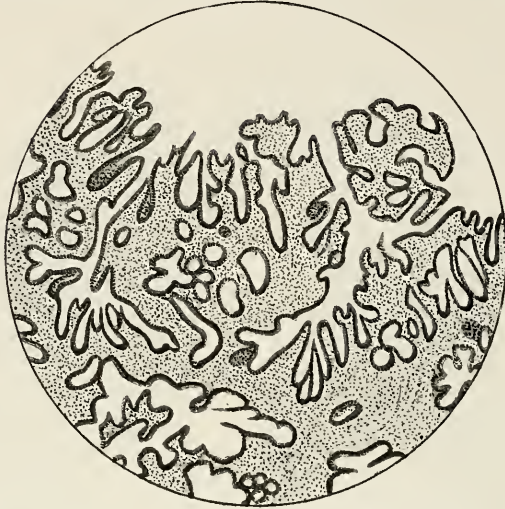

FIG. 284. ADENO-CARCINOMA OF THE BODY OF THE UTERUS.  $\times 30$ . Showing the everting form of tubular carcinoma in its early stage.

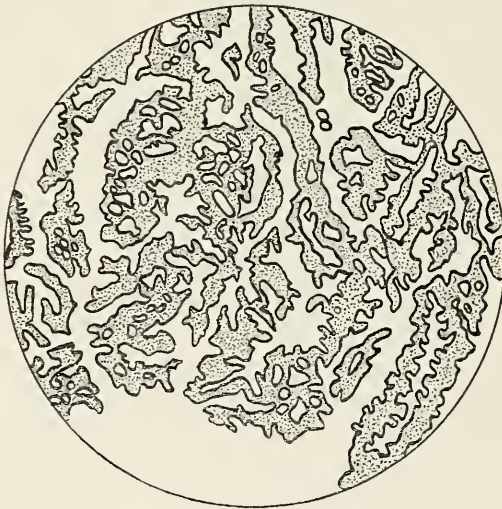

FIG. 285. ADENO-CARCINOMA OF THE BODY OF THE UTERUS.  $\times 30$ . Showing the everting form of tubular carcinoma in its advanced stage. Note that the tubular processes are more complicated than those in the incipient stage seen in Fig. 284.

tubules may be seen to invade and destroy the tissues of the uterine wall. The epithelium of individual tubules does not proliferate so as to fill up the lumen. In some parts the growth often consists of masses

of delicate, compound, branching papillæ, consisting of a slender and very vascular connective-tissue core, covered with two or three layers of columnar epithelium. The surface-cells of the papillæ proliferate freely and irregularly, and islets of cells, detached from the papillæ, are frequently seen in the microscopic field.

In some cases tubular cancer of the uterine body presents somewhat different features ; the growth consists of an aggregation of tubules, of perfectly regular and uniform characters, lined with a single layer of

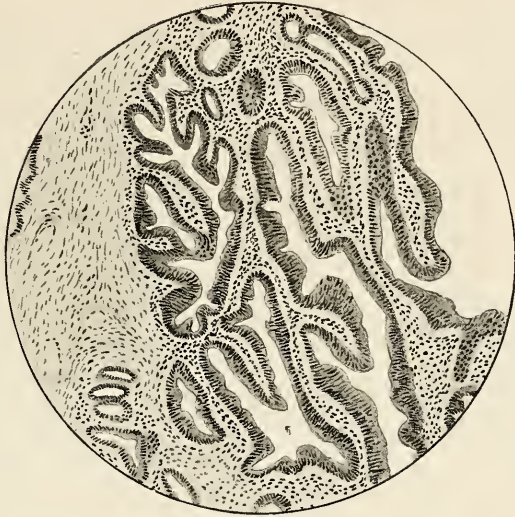

FIG. 286. ADENO-CARCINOMA OF THE BODY OF THE UTERUS.  $\times 30$ . Showing the *inverting* type of tubular carcinoma. The tubules form processes within their own lumina.

regular epithelium. The stroma is scanty, the tubules invade and destroy the fibromuscular wall, and if the growth is removed by scraping it recurs. The name of *adenoma malignum* was applied to this form by C. Ruge, and it deserves special mention because the differentiation of *adenoma malignum* from the benign form of gland proliferation seen in the early decidua may sometimes present difficulties, to overcome which many sections of curettings may have to be made before the signs of malignancy in the cell-nuclei (which have already been enumerated) can be found.

(2) *Alveolar Form.* This form of cancer of the body of the uterus is stated by some observers to be more common than the tubular variety. This is because some pathologists only designate as *tubular* those rare cases in which the epithelium is represented by a single layer of cubical cells, *i.e.* the *adenoma malignum* of Ruge. In alveolar carcinoma the predominant histological feature consists in the glands containing many layers of cells, irregular in shape and size ; gland-lumina are rapidly filled up, so as to form solid branching

columns of cells, which join up with one another to form still larger, solid, epithelial masses (*see* Fig. 287). The central cells of the latter break down, and thus the alveoli are produced from whence the term 'alveolar' carcinoma is derived. This central degeneration is produced in the same way as that seen in the solid masses of an epithelioma of the cervix, and this similitude has led to the error of regarding epitheliomata as adeno-carcinomata. In Figure 287 the free cell-proliferation of adeno-carcinoma is seen to have obliterated and to have

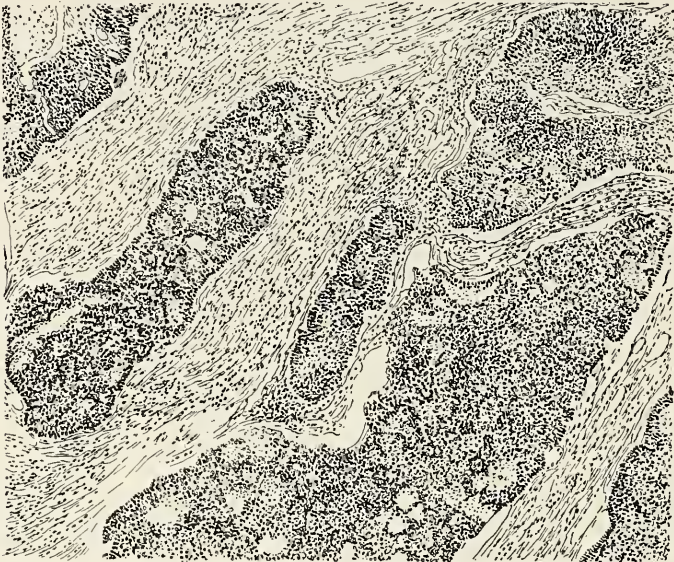


FIG. 287. ADENO-CARCINOMA OF THE BODY OF THE UTERUS: ALVEOLAR FORM. The cancer-cells are arranged in closely packed spaces limited by well-preserved fibromuscular tissue.

filled up the gland spaces, and the central alveolation is well marked. It is obvious that the malignancy of such a growth is of greater degree than that of the tubular form of adeno-carcinoma (*see* Figs. 284 and 286).

The histological differentiation into tubular and alveolar carcinoma is quite independent of, and bears no definite relation to, the macroscopical varieties of cancer of the uterine body, so that in the earlier stages of the disease at any rate, it is impossible to tell by the naked eye which form of cancer is present; it can only be said that the deeper and more extensive the destruction of the muscular wall, the more likely is the case to be one of alveolar cancer.

*Squamous-celled Cancer.* In a small proportion of cases of chronic endometritis it has been observed that the normal columnar epithelium on the surface has been replaced in isolated patches by stratified squamous epithelium, and prolonged irritation resulting in cell-metaplasia, has been assumed to be the cause of this so-called

*leucoplakia*. A very few cases of primary squamous-celled cancer have also been described in the body of the uterus; in some of these the whole of the growth was of this nature, in others, parts were squamous-celled, and parts adenocarcinomatous. It can only be recognized by microscopic examination, when epithelial pearls and the general appearances described in connection with the same type of growth in the cervix will be met with.

**Spread of Cancer of the Uterine Body.** Cancer remains limited to the affected organ much longer when occurring in the body than when arising in the cervix. It tends less rapidly to infiltrate the uterine wall, and lymphatic infection also proceeds more slowly. Glandular enlargements are therefore less often met with in operable cases of cancer of the body than in those of cancer of the cervix. The lymphatics which drain the uterine body run along the upper border of the broad ligament in close relation with the ovary and Fallopian tube (*see* Fig. 47, p. 72), and then accompany the ovarian vessels over the brim of the pelvis to reach the lateral chains of lumbar glands lying at each side of the spinal column. A lymphatic vessel also runs from the fundus to the inguinal chain of glands in company with the round ligament. None of these glands, however, become enlarged except in very advanced stages of the disease. Secondary growths sometimes occur in the vagina from direct implantation of cancer-cells carried down from the uterus in the discharge. Ultimately the peritoneum and pelvic cellular tissue become infiltrated in the same manner as in cancer of the cervix, but not until the disease has advanced much further. The results are, however, much the same, and in fatal cases metastases have been discovered in the liver, omentum, adrenals, etc.

Pyometra is a common complication of the advanced stages of both cancer of the cervix (*see* Fig. 131, p. 240) and cancer of the body. Hematometra may also be met with, although more rarely (*see* Fig. 265, p. 515).

## CLINICAL FEATURES OF CANCER OF THE CERVIX

**Incidence.** Two factors must be considered in relation to the incidence of the disease, viz. age and child-bearing.

*Age.* As is the case with cancer of other organs, the age of appearance of this disease is subject to very wide variations. The extremes are represented by a case in a child of two and a half years, recorded by Adams, and one in a woman of ninety-three recorded by Findley. Under the age of twenty it is extremely rare, although two cases at the age of eighteen have been recorded, one by Cragin, the other by de Rouville, and one by Schauta at seventeen years. The decennium forty-five to fifty-five is that in which the greatest age-predisposition is apparent, about 40 per cent. of all cases coming under observation between those years. This special age-predisposition is, however,

more apparent than real, owing to the fact that the number of women alive at middle age greatly exceeds the number of those who survive to advanced years. As Wilson has pointed out, in proportion to the number of women living at different ages, the liability to cancer of the cervix increases rapidly from thirty-five to seventy-five years, after which it again rapidly declines.

*Child-bearing.* Cancer of the cervix is so rarely seen in childless women that it may almost be regarded as a disease of motherhood. The most careful statistics show that not more than 4 per cent. of recorded cases have occurred in nulliparous women, *i.e.* in women who have not borne children. A certain number of nulliparæ, however, have had miscarriages, but no children, and this point should also be taken into consideration. For a precise estimation the figures should be corrected by comparing the relative numbers of parous (including abortion) to nulliparous women in the general population; but no such statistics are available.

A further interesting point has also been established, *viz.* that the subjects of cancer of the uterus have shown an unusually high degree of fertility. Lewers placed the average number of pregnancies in his series at five; in Wilson's series the average number of pregnancies (including abortion) was six and a half. The latter is of course much above the average productivity-rate in this country. There can be no doubt that parturient lacerations and the chronic inflammatory conditions which so frequently follow them, form the connecting link between child-bearing and the development of cancer. These conditions are described in connection with *lacerations of the cervix* (p. 559) and *cervical erosion* (p. 404), to which the reader may be referred. The direct transition from an 'erosion' to a cancer can be at times observed, and is illustrated in Figure 276. Wilson believes that pre-cancerous conditions may sometimes be found in an 'erosion' similar to those observed in the tongue and in lymphatic glands.

**Diagnosis of the Early Stages of the Disease.** It must be understood that the first observed symptoms of cancer of the cervix represent, not the onset, but a comparatively advanced stage of the disease. *There are no initial signs or symptoms.* Until the growth has attained a considerable size, and until the necrotic changes to which it is so liable have set in, no indication of its presence can be detected, and it will remain undiscovered, except by a chance examination. This only repeats what is almost a constant feature of cancer when it affects parts other than exposed epithelial surfaces, such as the lip and the tongue. Since the first symptoms to be observed do not by any means correspond with the onset of the disease, its duration cannot be reckoned from them. In point of fact the time of actual onset is in almost every case unknown, and therefore the rate at which cancer of the cervix advances in the early stages is also unknown.

The earliest symptom met with is almost invariably *hæmorrhage*,



slight in amount, irregular in occurrence, and as is most characteristic of all—often produced by coitus. Coitional hæmorrhage may, however, sometimes occur from other causes such as an ‘erosion’ or a mucous polypus, so that this symptom cannot be regarded as distinctive of cancer. Sometimes the bleeding is excited by straining at stool, by unaccustomed exertion, or by jolting, as during a railway journey. Menstruation is not necessarily increased in amount or disturbed in rhythm, and there may be no other symptoms whatever at this time. Women who have reached the age at which the disease is most likely to occur, attach little importance to slight bleeding of this kind, which they attribute traditionally to the approach of the change of life. The absence of other symptoms, such as *discharge* or *pain*, is regarded as an indication that nothing can be wrong. Yet the disease may have been in existence for some months before there is even a trace of hæmorrhage, for this symptom does not appear until erosion of superficial vessels has occurred from necrotic changes in the tumour tissues.

The next symptom to appear is a *discharge*; sometimes its appearance precedes the bleeding, but this is not usual. The discharge at this stage is usually thin, yellowish, or brownish in colour, nearly constant, slight in amount, and has no offensive odour. It results from bacterial (saphrophytic) invasion following upon necrotic changes in the tumour tissues. Sometimes it is profuse in amount, and this appears to be especially likely in cases where the predominance of formative processes leads to the production of a large mass of new growth.

No other symptoms than these are to be anticipated until the disease has reached an even more advanced stage; there is no ill-effect upon the general health, and in most cases there is no pain. The hæmorrhage tends, however, in time to appear more frequently and to become more severe in character; this is especially the case when ulcerative processes predominate. In some cases, especially in women of advanced age, the amount of hæmorrhage is trivial throughout the whole course of the disease.

*Pain* is never an early symptom of the disease, but it may be met with in association with hæmorrhage or discharge. This symptom may probably be taken to indicate that the cellular tissue around the cervix is already to some extent involved. The cellular tissues suffer in two ways, as has been already pointed out, (*a*) by cancerous infiltration; (*b*) by inflammation due to infection by organisms which have attacked the necrotic tumour-tissues. Cancerous infiltration probably produces pain at first by blocking the lymphatic circulation in the affected areas. Clinically, the pain associated with cancer of the cervix is felt chiefly in the lower part of the back; it is subject to exacerbations; it is not relieved by lying down, and is often worse at night than during the day time.

An interesting observation has been made by Wilson as to the

character of the first-observed symptoms. In a series of 328 cases he found that hæmorrhage *alone* was the first symptom in 41 per cent. In a number of other cases discharge or pain appeared at about the same time as the hæmorrhage; if these cases are included it appears that hæmorrhage, either alone, or in company with discharge or pain, was the earliest symptom in 65 per cent. of cases.

From what has been said it is obvious that the onset of cancer of the cervix is insidious, and the initial symptoms to which it gives rise are apparently trivial in character and comparatively late in appearance. The disease can be recognized at this stage only by careful physical examination, supplemented in some instances by the aid of the microscope. The urgent necessity of making such an examination at the first moment that the case comes under observation must in all cases be borne in mind. Patients are sometimes unwilling to submit to the necessary examination, but a medical man is not justified in deferring to objections of this kind, and his duty is, first to explain the necessity of an examination, and then to decline absolutely the responsibility of treatment until an examination has been made. To prescribe, for instance, a drug such as ergot, and the use of a vaginal douche, to a middle-aged woman who complains of intermenstrual hæmorrhage even though inconsiderable in amount, is to lose time upon which the patient's chances of relief solely depend, in the event of these symptoms being due, as is quite possible, to cancer.

**Diagnosis of Cancer of the Portio Vaginalis.** On examining the cervix with the finger the conditions found will depend upon the form the disease has assumed. Often extensive changes will be found in a case in which the duration of the symptoms has been brief and their severity inconsiderable. In the rare instances when the earliest stages of the disease can be observed it will be seen that the growth forms a firm, but not densely hard, nodular, elevated patch, or sometimes a shallow ulcer, involving some part of the *os externum* and extending over the surface of the cervix. Almost invariably the growth is sessile, and when of large size it causes well-marked alterations in the contour of the cervix. The position of the external os can be defined by touch, as it is not entirely involved in the disease at the stage under consideration. If the surface of the growth is lightly scraped with the gloved finger-nail, it breaks down, being *friable* in consistence, and portions of it come away with a certain amount of bleeding.

The cervix should next be exposed with a speculum and examined in a good light. The part affected by the growth will be found darker in colour than normal, and dull instead of polished in appearance. Its surface is irregular, and in parts, where ulceration has occurred, it is worm-eaten in appearance; this is usually found at the parts near the *os externum* which represent the oldest portions of the growth. The outlying parts may be smooth and still covered with polished, intact, stratified epithelium. The ulcerated parts bleed when lightly

swabbed with cotton-wool. In cases such as this, the diagnosis of a malignant new growth is not for a moment in doubt, the following points being amply sufficient to decide that the disease is malignant: (1) The area of firm nodular induration; (2) the ulceration of portions of this area; (3) the friability of the tissues as indicated by lightly scraping with the finger-nail; (4) the free bleeding thus excited.

Bimanual examination is useful in estimating the total extent of the swelling formed by the growth and the surrounding induration, and the general mobility of this mass. The latter point will be referred to again below. Lastly, a *rectal* or a *combined rectal and vaginal examination* should be made in every case of cancer of the cervix; thickening of the utero-sacral folds and of the bases of the broad ligaments can be more clearly perceived, and its extent estimated, than by the vagina. The posterior surface of the supra-vaginal portion of the cervix is also accessible from the rectum, and accordingly a more complete impression of the extent of the disease in this position can be obtained.

Occasionally, when the disease comes under observation *before surface-ulceration* has occurred, diagnosis may present considerable difficulty. A small, slightly elevated, dull red patch involving a portion of the external os may then be seen. Spiegelberg has pointed out that while the mucous membrane is slightly movable over the surface of the cervix in health, it becomes adherent at a very early stage to a subjacent malignant growth, imparting to the cervical tissues a firm, slippery consistence like that of wet rubber. This sign is, however, not of much service, except in cases of endocervical (medullary) cancer where the surface of the *portio vaginalis* is not yet enriched. Non-ulcerated patches of cancer bear a certain resemblance to a *cervical 'erosion,'* but this resemblance is not close enough to mislead any but an inexperienced observer. To the touch the 'erosion' feels smooth and soft like velvet, while the cancer is slightly roughened or distinctly nodular; the tissues of the 'erosion' are firm and non-friable to the finger-nail; although an 'erosion' sometimes bleeds *from one or two points* after swabbing with cotton-wool, the amount is small, and the oozing is not general as in the patch of cancer. Actually, 'erosions' show little tendency to become malignant, but in all cases in which the least doubt exists a section should be taken for microscopic examination. This must be done with care, a piece about a third to a half inch in diameter being cut out of the edge so as to include a definite area of outlying healthy tissue, and the excised piece dropped immediately into a weak solution of formalin or 50 per cent. spirit before being sent to the histologist.

The early malignant *ulcer* may be confused with *tuberculous disease* or with a *chancre*. Tuberculous disease of the cervix is rarely primary (see p. 306), and accordingly the presence of signs of tubercle in other organs may direct attention to the possibility of the cervical lesion

being of the same nature. The local appearances are not dissimilar to those of cancer (*see* Fig. 146, p. 306), and numerous cases have occurred in which the uterus has been removed on account of cervical disease, which has been subsequently proved to be tuberculous, not malignant. Tuberculous disease of the cervix gives rise to free muco-purulent discharge, but not usually to spontaneous bleeding, and its tissues are not friable like those of the malignant ulcer. However, microscopic

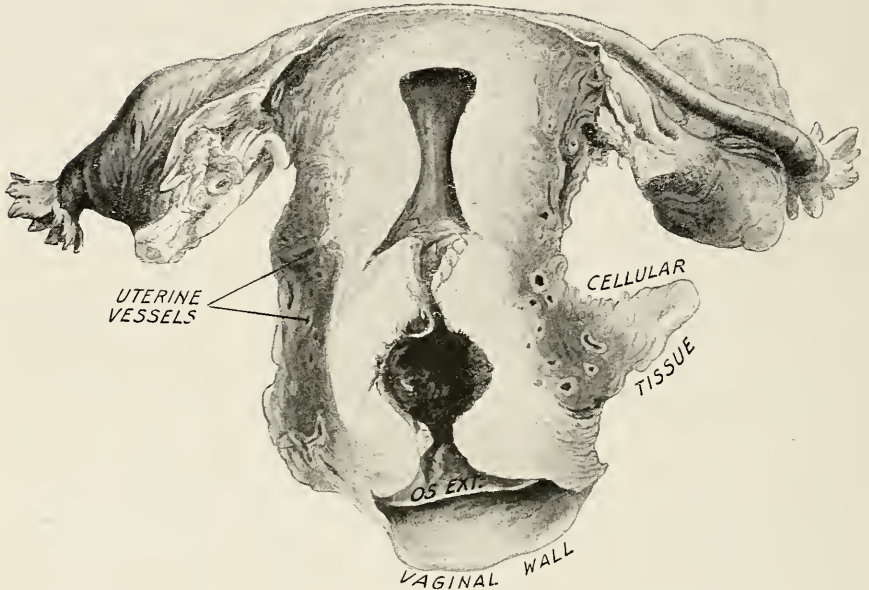


FIG. 288. ENDOCERVICAL CARCINOMA. Multipara aged 54. The vaginal portion of the cervix is atrophied; the supra-vaginal cervix is the seat of the disease, the central cavity representing the oldest part. The disease has not spread visibly beyond the limits of the cervix.

examination must, as a rule, be resorted to before the tuberculous nature of the ulcer can definitely be settled.

*Cervical chancre* is not uncommon, but its nature is soon revealed by the appearance of the early constitutional signs of syphilitic infection. The specific organism may usually be detected by the method described on p. 321. If this is negative, microscopic examination will reveal the absence of malignant changes.

**Diagnosis of Endocervical Cancer.** Cancer in its endocervical form is less easily recognized by physical examination than when the vaginal portion is attacked. Beginning within the cervical canal the growth shows less tendency to spread in the direction of the external os than in other directions (*see* Fig. 269), at any rate until an advanced stage is reached (*see* Fig. 280). The disease first infiltrates the fibromuscular tissues, leading to broadening and induration of the cervix, while the *os externum* and the vaginal surface remain unaffected (*see* Fig. 288).

A general increase in the bulk of the cervix results (*see* Fig. 267), which is densely hard; it may sometimes be located in the supra-vaginal cervix, upon upward pressure with the finger through the vaginal fornices. Sometimes this increase in density and in bulk will be detected better by rectal examination; indeed, only rectal examination can reveal the true extent of the disease when the upper part of the cervix is chiefly attacked. A densely hard enlargement of the deeply lying parts of the cervix, associated with hæmorrhage, and without involvement of the os, should always suggest endocervical cancer. A scraping taken with a small sharp spoon from the interior of the canal will be required for a definite diagnosis. When the disease is fairly advanced it reaches the *os externum*; this becomes enlarged by ulceration (*see* Fig. 279), exposing the lower part of the growth, which then presents as a nodular friable mass. At a still later stage an extensive crateriform cavity continuous with the vagina may be formed by ulceration (*see* Fig. 280).

**Diagnosis in Advanced Stages of the Disease.** The advanced stages of cervical cancer are characterized by free putrid discharges with hæmorrhage, at times constant and slight, at times irregular and profuse, at times quite uncontrollable. In rare cases there is little or no bleeding even in the advanced stages. In the *ulcerating* form the cervix has disappeared, and in its place is found a large crateriform or cup-shaped cavity, with indurated ragged walls, extending upwards to the lower part of the body-cavity, and also involving the vaginal fornices to a greater or less extent (*see* Fig. 280). The disease may indeed advance upon the vaginal walls, especially the anterior wall, nearly as far as the ostium vaginae. In all such cases the pelvic cellular tissue has also been invaded, and this will be perceived much more clearly by rectal than by vaginal examination. By vaginal examination the limits of the growth on its deeper aspects cannot be defined, but only the limits of the cavity formed by ulceration. By rectal or recto-vaginal examination the mass of new growth will often be found surprisingly large, extending forwards and on each side to the bony pelvic walls, and backwards so as to encroach upon the lumen of the bowel. The mass feels densely hard and often tender, and is almost, if not entirely, immovable.

In the advanced stages of the *formative* type a large mass of new growth is formed, occupying the upper part of the vaginal canal (*see* Fig. 278). This mass is attached to, or has replaced, the cervix; sometimes its surface is divided up by sulci into a complex papillary arrangement resembling a cauliflower; sometimes the surface is uniform and rounded. In both cases the growth is dark coloured, and shows superficial sloughing. Sometimes the mass of cancer is so large as to fill the whole of the vagina, and present at the *ostium vaginae*, coming into view when the labia are held apart by the fingers. The position of the external os can seldom be defined in stages so advanced as this. In this

form also, the extent to which the disease has spread deeply can best be defined by rectal examination. Such cases must be carefully distinguished from large sloughing polypi, and this can invariably be done by recognizing, in the case of a fibroid polypus, the stalk which attaches it to the uterus. An anæsthetic will be necessary if the growth is very large, in order to allow the finger to be passed up far enough to reach the pedicle. In both cases the hæmorrhage is often very free during examination. In these advanced stages of the disease putrid discharges are met with which often have an appallingly offensive odour. This may not be observed by the patient herself, but the discharges are very irritating and cause vulvitis with ulceration and extensive intertrigo.

In the advanced stages of cancer of the cervix the *general symptoms* become prominent. Loss of flesh occurs comparatively late, and in elderly women, at any rate, it progresses very slowly. Anæmia is always present as an element in the cancerous cachexia, but sometimes, as the result of profuse losses of blood, profound anæmia occurs at an earlier period than this. In other cases cachexia ensues somewhat rapidly, being in all probability accelerated by absorption of toxic products from large ulcerating or necrotic growths. Loss of appetite, and want of sleep due to nocturnal pain, further aggravate the general ill-health.

As the local disease comes to involve *other pelvic organs*, a fresh train of symptoms appears. The tendency of the disease to spread to the bladder has been already referred to, but a considerable area of the muscular wall of the bladder may be involved without giving rise to hæmaturia, if the mucosa escapes; consequently it is not until ulceration occurs and a vesico-vaginal fistula is about to be formed that the extension is revealed. The urinary incontinence and cystitis which result from this fistula add greatly to the patient's distress, and it is hardly possible to conceive anything more pitiable than the condition of the patient at this stage. Occasionally one of the ureters becomes blocked by new growth which has invaded it, when the proximal part of the ureter becomes dilated and the functional activity of the corresponding kidney impaired. By ulceration, a ureteric fistula in the vaginal roof may be formed. Ascending infection of the kidneys from cystitis, or from ulceration of the pelvic portion of the ureters, may occur, and lead speedily to a fatal termination.

A different train of symptoms may arise from infection of the uterine cavity, which, aided by obstruction to the escape of discharges into the vagina, leads to the formation of a *pyometra* (see p. 240). By direct extension from an infected endometrium a pyosalpinx may be formed on one or both sides, and from this again septic peritonitis may arise, which of necessity proves rapidly fatal. Pyrexia and abdominal distension in the late stages of cancer of the cervix may usually be taken to indicate these complications.

**Diagnosis of Operability.** A case is said to be operable when there appears to be a reasonable chance of removing the *whole of the disease by a radical operation*. Palliative operations in which a part only of the disease is removed have their uses and will be considered later. In the case of the uterus, the difficulties of forming a clinical estimate of the extent of the disease are peculiarly great ; consequently the diagnosis of operability is to be regarded as approximate only, and when an operation is undertaken, the first step in the procedure is to revise the clinical estimate, which has been made by a careful exploration of the disease *in situ*, before its actual removal is begun. The value of this procedure is very great, and in doubtful or border-line cases we need not hesitate to open the abdomen for purposes of diagnostic exploration. Laparotomy *per se* is attended with little or no risk, and whenever the operator is in doubt as to whether a case is operable or not, the hope of removing the disease should not be abandoned until an abdominal exploration has been made. In many cases, however, the clinical findings make it certain that the disease is inoperable, and it is then unnecessary to subject the patient to the discomfort and distress of an abdominal operation. Abdominal exploration has largely taken the place of the preliminary examination under anæsthesia, as being much more exact.

The lymphatic glands which drain the cervix are so situated as usually to be inaccessible to clinical examination, and in consequence the question of operability has to be considered without reference to their condition. The question must be decided mainly by the local conditions, but the general state of the patient must also be taken into consideration. There are two points only, in regard to the *local conditions*, upon which reliance can be placed, viz. the degree of mobility of the uterus, and the extent to which the surrounding structures have been involved. *Mobility* may be tested with the fingers during bimanual examination, the extent to which the cervix can be moved in all directions being carefully observed. Sometimes it may be possible to seize a healthy portion of the cervix with a volsella and gently pull it down towards the vulva ; in the case of a parous woman the normal mobility allows of the os externum being thus drawn down to the vulva. Slight impairment of mobility does not by any means negative the operation. More marked degrees of fixation must be considered in connection with the extent of the surrounding induration. When the mobility of the cervix has been much impaired, the evidence of surrounding infiltration is usually well marked.

A certain amount of caution is, however, necessary in the interpretation of the *condition of the surrounding tissues*. Inflammatory thickening due to chronic infection of the adnexa can only be definitely distinguished when characteristic outlines of a dilated tube can be made out. Sometimes a layer of induration can be felt beneath the upper part of the anterior vaginal wall. In such cases the floor of the

bladder is almost certainly involved, and cystoscopic examination may yield definite indications of this. The condition of the utero-sacral folds, and the bases of the broad ligaments, can be made out much better by recto-vaginal than simply by vaginal examination, so that the importance of an examination *per rectum* must again be insisted upon. In advanced cases the mass of induration can be felt to extend outwards to the bony pelvic wall on one side, or it may be on both. In such a case radical operation is of course impossible.

Along with these local conditions the *general state* of the patient must be considered. The radical operation for cancer of the cervix is one of great severity, and cannot be borne by enfeebled subjects. Women of advanced age, *e.g.* over sixty, are seldom fit to bear it. In addition, if there has been much wasting, if there is great anæmia, or if the temperature shows irregular fever, the operation should be postponed or abandoned.

Cases are *certainly inoperable* when profound anæmia from bleeding, or signs of cachexia are present, when the cervix is completely fixed, and there is a great amount of surrounding induration, or when fistulous communications have been formed with other organs. Cases are *certainly operable* in which the cervix has retained much of its mobility, the ligaments are little if at all thickened, and the general condition of the patient is unaffected, or at any rate little impaired. Between these limits lie a large number of cases which are doubtful, and it must be recollected that the ultimate hopelessness of palliative treatment makes it imperative that the surgeon should sometimes face serious operative risks.

**Duration and Prognosis.** According to MacCormac's series, the average duration of the disease in ninety-two cases not operated upon was 1·6 year from the appearance of the symptoms ; it has been already pointed out that the actual onset of the disease antedates the onset of symptoms by a variable but considerable interval. Cases in which the disease occurs comparatively late in life, after the menopause, run a less rapid course than those which occur at an earlier age, and women of sixty to seventy years of age sometimes survive for five or six years when no surgical treatment has been adopted. Below thirty-five years of age the expectation of life is very short, for the disease often terminates within a year. Pregnancy sometimes occurs in young subjects, and rapid advance of the growth during pregnancy must then be anticipated, probably as a result of the increased vascularity which attends gestation. In such cases there is grave risk of puerperal infection if delivery *per vias naturales* takes place, in consequence of injury and subsequent sloughing of the cancerous tissue. The rate of advance does not appear to be affected by the histological variety of the growth.

The causes of death are frequently to be found in the complications which accompany the later stages of the disease. Those most fre-



quently met with are the spread of septic infection to the peritoneum and to the kidneys.

### CLINICAL FEATURES OF CANCER OF THE BODY

Cancer is of much rarer occurrence in the body than in the neck of the uterus, the proportion being about 1 to 15. Multiparous women do not display the same tendency to suffer from cancer of the uterine body as from cancer of the cervix. Statistics show that about one half of the recorded cases of cancer of the body occur in nulliparous women, and the parous women affected show but a low degree of fertility, averaging one or two children each. It occurs with greatest frequency at a somewhat later age than cancer of the cervix, viz. between fifty and sixty; women are therefore more likely to be attacked by this disease after the climacteric has been passed than before it. Below the age of forty-five it is very uncommon.

**Early Stages.** The *symptoms* of corporeal cancer closely resemble those of cervical cancer; they are, however, even later in appearing and less conspicuous in character. Necrotic changes do not occasion putrid discharges to anything like the same extent, because the corporeal growth is better protected from invasion by bacteria; the uterine cavity in health is sterile, while the vagina always contains numerous saphrophytic organisms. The discharges from corporeal cancer do not become putrid so early, nor are they so extremely offensive as those of cervical cancer. Again, the amount of bleeding is less, indeed it is seldom if ever profuse, and the usual form in which it appears is as a *bloodstained discharge*, which is the first symptom to appear. In many cases this is so slight that it has been present for several months before the patient is led by it to seek advice.

From this it follows that the early recognition of corporeal cancer is even more difficult than that of cervical cancer, and the necessity of insisting upon a complete local examination, whenever irregular bleeding, however trivial, occurs in elderly women, must once more be pointed out. Owing to the fact that the disease is in a situation inaccessible to direct examination, the physical signs are much less definite, even in advanced stages, than those of cancer of the cervix. Before the local examination is made the symptoms, though suggestive of cancer, give no indication of its location, and it may in fact be found in the vaginal wall, the cervix or the uterine body. If the two first-named parts are found to be healthy, attention is next directed to the body. In the great majority of cases of the disease this will be found, on bimanual examination, to be enlarged, although to this rule there are definite exceptions (*see* Fig. 282). And it is important to recollect that enlargement must be considered in relation to the age of the patient; a size which would be normal to a multiparous woman in the sexually active period, will be abnormally large in one who has

passed the climacteric. If the disease should attack the atrophied uterus of a woman long past the climacteric age, an advanced stage may be reached while the organ is still much under the normal size (*see* Fig. 283). The important point to bear in mind is that cancer cannot be excluded because the uterus is atrophied.

The enlargement due to cancer is moderate in extent and uniform in character. The question of enlargement is complicated by the fact that fibroids are found in company with corporeal cancer with exceptional frequency, with the result that the uterus may be of irregular shape as well as of abnormal size (*see* Fig. 232, p. 461). Mobility remains unimpaired until a much more advanced stage than is the case with cervical cancer.

It will be obvious from these findings that something more than a bimanual examination is required for the recognition of the disease, and in fact a definite diagnosis, except in advanced stages, can only be made by exploration of the uterine cavity. This simple procedure is by no means unattended with danger in the case of corporeal cancer. If the disease is advanced, perforation of the uterine wall with the sound, a dilator, or even the curette, may readily occur, an accident which calls for the immediate removal of the uterus. Casual exploration with the sound cannot be too strongly condemned; the exploration should be carried out carefully with all the antiseptic and other precautions set forth in connection with vaginal operations (*see* p. 729) such as curetting. The cervix should, as a rule, be dilated sufficiently to admit the curette freely and allow free uterine drainage, *i.e.* up to No. 8 or 10 dilator. Often during dilatation fragments of tissue detached by the instrument will pour out of the cervix: they consist of pale greyish or discoloured fragments of friable tissue, and the appearance of such tissue may be sufficient to settle the diagnosis. In less advanced cases the curette must be used carefully and gently, and this instrument will bring away more or less of the same friable material. If the use of the curette is negative, the dilatation may be carried further until the cavity can be explored with the *little finger*, or if necessary the *index finger*.

The conditions which have to be distinguished from cancer of the body are *senile endometritis*, *villous papilloma* and an *interstitial fibroid* which is causing hæmorrhage owing to some degenerative change. The distinction from the two former is made by an exploratory curetting; the presence of a fibroid may usually be determined by careful bimanual examination, and curetting will show whether or not endometrial cancer has also developed.

The differential diagnosis by histological examination of senile endometritis and villous papilloma of the body, from corporeal cancer is important.

In *senile endometritis* the endometrium is thin and the surface-epithelium replaced, to a large extent, by granulation tissue (*see*

Fig. 131, p. 241) ; the glands are few and shrunken, and those remaining run a straight or oblique course through the stroma. The latter is fibrotic and dense. No muscle-fibres will be seen in the scrapings.

In *villous papilloma* (see Fig. 250, p. 449) the processes are exuberant and branching, they are lined with fairly regular columnar epithelium with basal nuclei, the stroma consists of fibrous tissue only, no muscle fibres being present in the curettings.

In *cancer of the body* the appearances vary according to whether the growth belongs to the *tubular* or to the *alveolar* type. In the *tubular* form there is a mimicry of gland-tissue, but the tubules are lined by *many* layers of cubical epithelial cells with nuclei at various levels; this helps to distinguish a tubular cancer from a villous papilloma. In the *alveolar* type, there is no attempt at gland-formation, the cells are neither columnar nor cubical, but vary in shape, being often quite atypical; they aggregate in densely packed columns and masses, which by breaking down in the centre give an alveolar appearance to the growth (see Fig. 287, p. 506).

With either of the above forms the curettings will show some portion of the muscular wall of the uterus to be invaded by the cancerous tissue. The stroma will therefore contain both muscle and fibrous tissue, and it will be cedematous and infiltrated with round cells. Masses of cancer-cells or malignant gland-tubules will be found among the muscle-bundles.

**Advanced Stages.** In the advanced stages offensive discharges due to ulceration of the growth are met with; fixation occurs and is often due to direct transperitoneal extension of the growth to the omentum, to the wall of the rectum, pelvic colon or cæcum; the cellular tissue also becomes infiltrated, but this occurs at a much later period than in cancer of the cervix. In other respects the final stages of the disease are similar to those already described in cancer of the cervix.

## TREATMENT OF UTERINE CANCER

**Radical Operation.** When the uterus is attacked by cancer in any part, extirpation of the diseased organ with its appendages, the surrounding cellular tissues, and the lymphatics which have become involved, offers the sole chance of recovery. For the reasons already stated, a large proportion of cases first come under observation when the disease has already reached a stage at which a radical operation is impracticable. A radical operation should be advised and attempted whenever there appears to be a reasonable hope of its performance being possible. The prognosis as regards recurrence after hysterectomy is unusually good in the case of cancer of the body, for the anatomical reasons which have been already mentioned. In cancer of the cervix the prognosis is much less favourable, owing to the tendency to early involvement of the cellular tissue and lymphatics, and of important organs such as

the bladder, and possibly to the greater activity of the cancer-elements. The modern operation introduced by Wertheim (*see* p. 752) may, when it has been fully tested by experience, be found to have considerably improved the prognosis as regards recurrence, but at present, in our opinion, this cannot be definitely stated to be the case. Writers upon cancer statistics usually regard as 'cured' all cases in which five years have elapsed after the operation without recurrence, and on this basis the percentages of 'cures' have been variously estimated at from 5 per cent. to 25 per cent. *of those who survive the operation*. The prognosis as regards recurrence is very much more favourable in corporeal than in cervical cancer.

Even when radical operation is followed after an interval by recurrence, the advantages derived by the patient are considerable. Not only is there a definite prolongation of life and of capacity for work, but the disease when it recurs assumes a much less distressing form. The growth is situated more deeply and is not so liable to ulcerate; the distressing discharges caused by the primary growth are less marked.

The method of hysterectomy suitable for these cases is described in a later section (*see* p. 752).

**Palliative Treatment.** When the hope of curing the disease by a radical operation has been abandoned, much may still be done to delay the progress of the disease, to control the discharges which so greatly aggravate the patient's distress, and to relieve pain. There are three methods by which these objects may be sought: (a) by a partial operation, *i.e.* for the removal of the necrotic portion of the growth; (b) by radiation, *i.e.* treatment with radium and X-rays; (c) by drugs, vaccines and other *medical* measures.

(a) *Partial Operation.* This procedure consists in the removal, with the sharp spoon, curette and scissors, of as much of the friable ulcerating growth as possible. It is chiefly applicable to cases of cervical cancer; the great risk of perforating the uterus and infecting the peritoneal cavity practically prohibits its use in corporeal cancer. Strict antiseptic precautions must be observed; the spoon must be used with care, and the finger constantly employed to gauge the depth to which the scraping has passed. The limits of the friable tissue can be recognized by the finger, and beyond this the scraping should not go; large arterial branches may be laid open by an unrestrained use of the spoon. The vaginal edges of the growth may be clipped with scissors until healthy tissues are reached.

The large cavity thus produced may be treated either with the electro-cautery, or with a strong antiseptic and astringent solution. The objection to the former is that considerable sloughing usually results; the advantage of it is that it completely destroys an additional layer of cancerous tissue. Inasmuch as the operation is at best a partial one, the practical advantage gained by using the cautery is not very

great. The alternative to the cautery is a solution which will arrest oozing, and at the same time act efficiently as an antiseptic. A mixture of acetone and tincture of iodine, in equal parts, or a 1 per cent. solution of formaldehyde are very serviceable. The use of these solutions can be repeated every two or three days while the cavity produced by the scraping is healing up. In past times strong caustics such as chloride of zinc, either solid or in concentrated solution, were employed, with the avowed object of producing an extensive slough. Such methods are now unreservedly condemned, for such destructive agents act equally upon normal and diseased tissues, and it is impossible to limit the scope of their action.

The effect of this procedure is to arrest, or greatly reduce, the amount of bleeding and discharge from the ulcerating new growth ; at the same time absorption of septic products is arrested, and the combined effect is seen in great improvement in the general health and comfort of the patient. The effect is of course only temporary, but the operation may be repeated after an interval.

(b) *Radiation.* Extensive trial has been made during recent years of Röntgen rays and radium in cases of inoperable uterine cancer. In a few instances it has been claimed that the disease has been 'cured' by these means, but in the present state of our knowledge we are not justified in regarding these means as curative ; the only known method of cure is free excision of the whole of the disease.

There is, however, no doubt that radium emanations, and the hard or penetrating variety of Röntgen rays exert a destructive action upon cancerous tissue which is *selective*, *i.e.* it does not act in the same manner upon normal tissues. The effect is best obtained in the case of surface-growths which can be readily exposed to the action of the emanations or the rays ; in the case of an internal growth the conditions are more difficult, and the results less favourable. Into the nature of the tissue-changes, and the manner in which they are produced we cannot enter here, the reader must be referred to works on Radiology for such information. The clinical effects seen in successful cases are shrinkage and desiccation of the accessible parts of the growth, with diminution or actual arrest of the hæmorrhage and discharge ; effects equally important are relief of pain and improvement in the general health. Occasional reports have been made of cases which, originally deemed inoperable, have so far improved under radio-therapeutic treatment, that a radical operation was ultimately practicable.

Radium is applied directly to the cervical growth, or to the interior of the uterus in corporeal cases. A tube containing at least 40 to 50 mg. of radium chloride is employed and an exposure of twelve to twenty-four hours given, and repeated every three weeks until the maximum effect has been produced. The tube requires to be insulated in a special capsule of lead or aluminium, and this capsule must be

protected from actual contact with the tissues by careful packing with gauze or rubber.

The technique of X-ray treatment of uterine cancer is complicated, and cannot be entered into here. The remarks already made with regard to the X-ray treatment of fibroids may be taken as applying to cancer also (*see* p. 478). There is at present much difference of opinion as to whether X-rays or radium are the more useful, and in the meantime the point must be regarded as unsettled.

In cases where a large necrotic cervical growth is present, the palliative operation described above may be followed usefully by a full course of radio-therapeutic treatment. In another way radiation may also be usefully combined with operative treatment. It may happen in the course of an extensive dissection for an advanced cancer (radical operation) that some doubt remains as to whether the whole of the disease has been removed. The *prophylactic* use of radium and X-rays is then advisable, as soon as the patient is convalescent, in the hope of destroying any outlying areas of cancer which may have been left behind.

So far as radio-therapeutics have been adequately tried, the results appear to be unequal and somewhat uncertain : but it is reasonable to hope that by these means much may be done to alleviate the advanced stages of the disease. If local ulceration and sloughing can be arrested, such distressing sequelæ as urinary and fæcal vaginal fistulæ may be largely avoided ; additional advantages may also arise from the control of local sepsis, *e.g.* the arrest of septic absorption and upward spread of infection to the peritoneum.

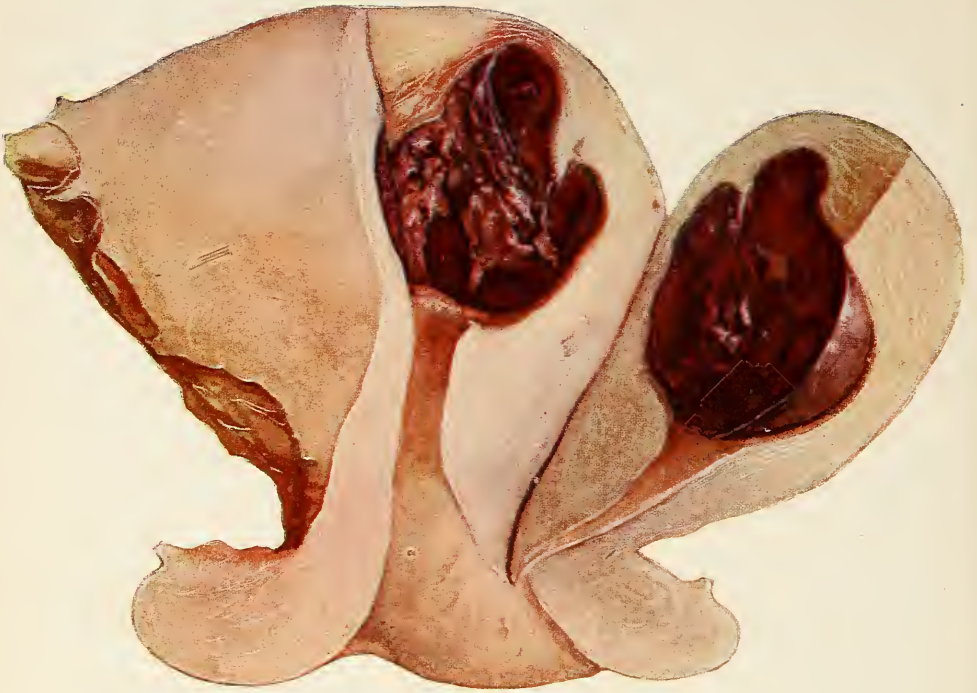(*c*) *Medical treatment* resolves itself into the relief of pain, the alleviation of putrefactive changes by antiseptic douches and vaginal tampons, the arrest of attacks of hæmorrhage, and care of the general health. None of the so-called ' cancer cures ' are of any real service.

For the relief of *pain*, opium in some form becomes ultimately necessary, and that in increasing doses ; in the earlier stages aspirin, pyramidon, or some other synthetic analgesic substance, may prove sufficient. Resort to the use of opium should be delayed as long as possible, in consequence of the rapidity with which tolerance of this drug may become established, and the consequent necessity of continually increasing the dose. Codein is in some respects preferable to morphia, and heroin also forms a useful alternative, as it does not give rise to the after-effects, such as nausea and constipation, which are so often conspicuous when morphia is employed.

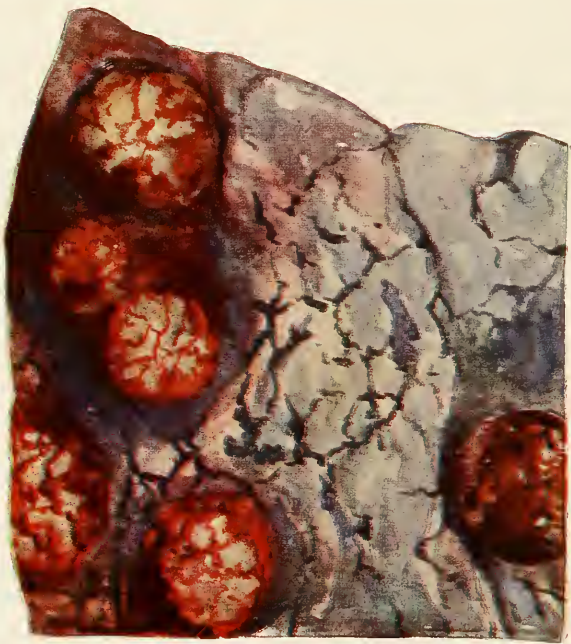Of antiseptic douches the most generally useful as deodorants are formalin and peroxide of hydrogen and hypertonic saline. The former must be used in weak solution of about  $\frac{1}{1000}$  of the 40 per cent. solution, as it is very irritating. Peroxide is non-irritating and may be used in the same strength as for general surgical purposes, *e.g.* 5 volumes solution.

Drugs are of little use in the control of hæmorrhage. Turpentine





A



B



in five-minim doses, given in capsules, sometimes appears to do good. Severe bleeding can be temporarily arrested by plugging the vagina.

## CHORIONEPITHELIOMA

It is convenient to consider this unusually interesting form of malignant tumour in connection with the uterus ; but although, in the great majority of cases, the uterus is the organ primarily attacked, exceptions sometimes occur, the primary growth being found in the vagina, the labium, the Fallopian tube, or the ovary.

Its special histogenetic feature is that it arises from certain embryonic tissues, viz. the epithelial and connective-tissue elements of the chorion. It is accordingly a disease which affects women who have at some time or other been pregnant ; apparent exceptions to this statement will be mentioned later. The connection with pregnancy may be quite remote, several years having elapsed before the appearance of the tumour ; on the other hand, it may make itself manifest during the puerperal period following an abortion or a confinement. In approximately one out of every three cases it has been found that the immediately preceding pregnancy terminated as a hydatidiform mole ; when the rarity of the latter condition is borne in mind the significance of its frequent association with chorionepithelioma will be apparent.

In cases in which the primary growth was found in the Fallopian tube or ovary, it may be presumed that these organs had been the seat of an early ectopic gestation. When the primary growth is vulval or vaginal, it may be supposed that implantation of placental tissue has occurred, perhaps, upon an abrasion, which has subsequently given origin to the malignant growth.

**Pathological Anatomy.** In the uterus the growth usually arises in the fundus and the adjacent parts of the anterior and posterior walls, *i.e.* in the position of the placental site (*see* Fig. 289). Three very early cases examined by one of us all show that the growth starts deeply in the uterine muscle, the mucous membrane being intact and not involved in the malignant process. In these cases it was only by sections made through the musculature of the uteri, that the foci of new growth were discovered (*see* Fig. 291). Later on the tumour present in the uterine cavity causing a symmetrical enlargement of the organ (*see* Plate XVIII) ; more rarely it produces a nodular subserous mass by projecting beneath the peritoneal surface (*see* Fig. 289), and in a case recorded by one of us the peritoneal coat had given way causing fatal peritonitis. The growth itself is soft, dark in colour, and freely hæmorrhagic (*see* Plate XVIII) ; its tissues are of especially low vitality, and therefore very prone to break down ; consequently the older parts are generally found to consist of *débris* and blood-clot, the characteristic elements being found only at the growing edge. These

changes in the base and central parts of the tumour are well seen in Fig. 290. Invasion of the fibromuscular wall is usually visible, and isolated implantation-nodules are often found in the lower part of the uterine cavity. Similar nodules, formed in the same manner, may be

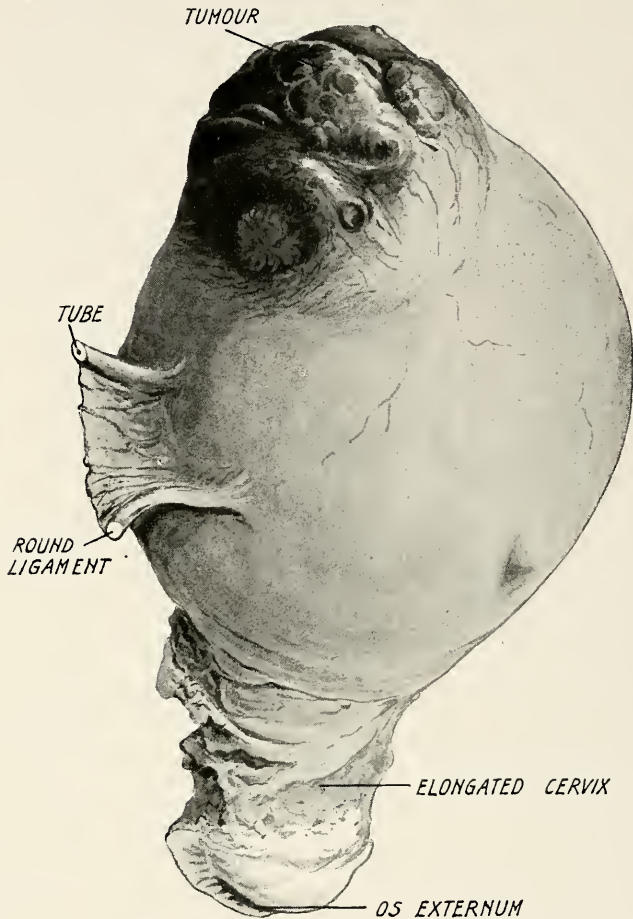


FIG. 289. CHORIONEPITHELIOMA OF THE UTERUS. Multipara, aged 26. The uterus is enlarged, but its surface is smooth, except at the fundus. Here a nodular mass of dark-coloured growth is seen, the peritoneal covering being still intact. There is also well-marked elongation of the supra-vaginal portion of the cervix.

found in the vaginal walls and the vulva. These nodules are of a deep plum colour, soft and friable; they bleed readily when handled. The uterine growth does not attain large size, in this respect resembling corporeal carcinoma. In a few cases grape-like bodies, resembling the vesicles of a hydatidiform mole, have been seen in these tumours. No matter what may be the location of the primary growth, its structure and characters are uniform.

The cell-elements which are typical of this tumour are the following : (see Fig. 293) : (1) large irregular multinucleated masses of protoplasm (plasmodia) in which cell-boundaries cannot be recognized ; these are derived from the outer layer of the chorionic epithelium or syncytium ; (2) small polyhedral cells with large nuclei lying in closely packed masses ; these are derived from the inner or Langhans' layer of the

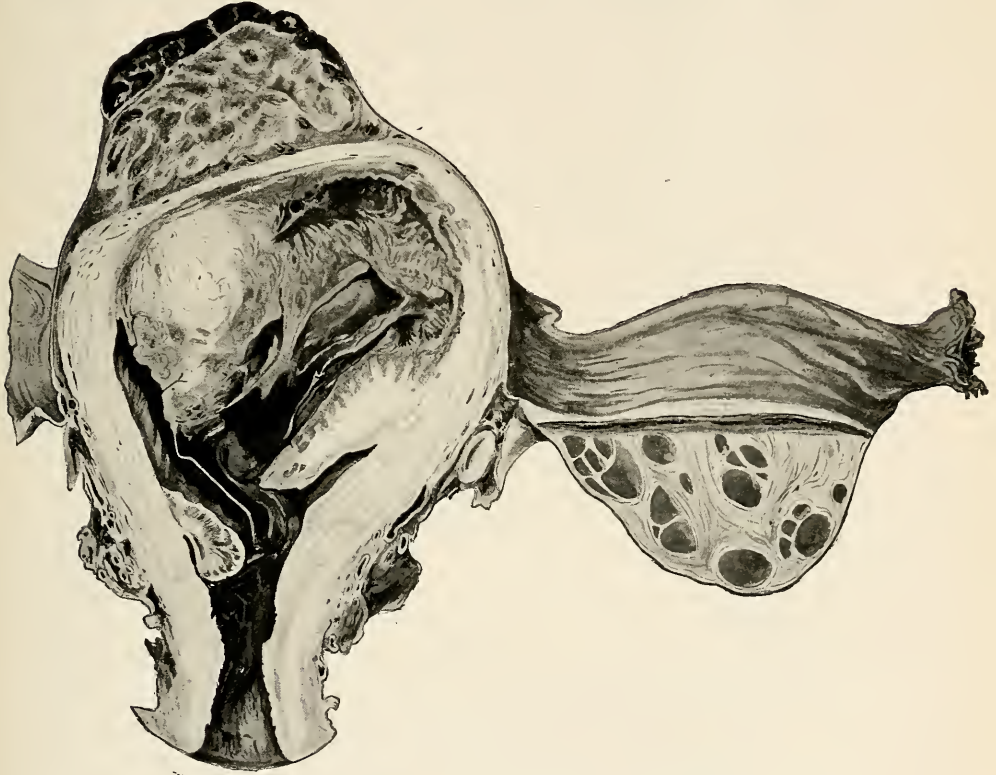


FIG. 290. CHORIONEPITHELIOMA OF THE UTERUS. The same specimen as Fig. 289. The nodular projection on the fundus probably represents an intramural metastasis, being separated from the root of the growth by a layer of fibromuscular tissue. An isolated polypoid metastasis is also seen in the lower part of the uterine cavity.

chorionic epithelium ; (3) large mononucleated cells, and multinucleated giant cells, collected in masses, or invading the stroma of the uterine tissues ; these are probably derived from both (1) and (2). In addition to these elements, definitely recognizable chorionic villi are sometimes present, either of normal appearance or in a condition of vesicular degeneration ; the origin from the epithelium of the villi of the three varieties of cells just described has been traced by a number of different observers.

The tumour-elements show no definite arrangement, but are mingled with one another in irregular clusters and masses, and are sufficiently

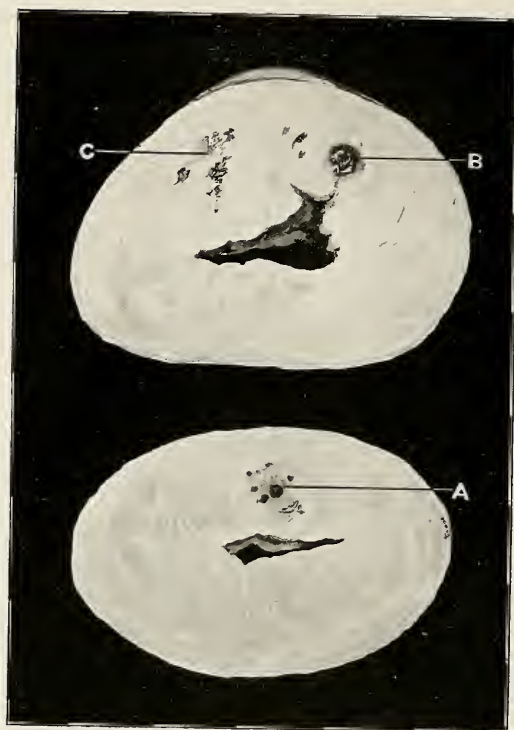


FIG. 291. TRANSVERSE SECTION THROUGH THE UTERINE BODY, showing early chorion-epithelioma arising in the muscularis, *i.e.* beneath the mucous membrane (Malcolm Bell and Lockyer).

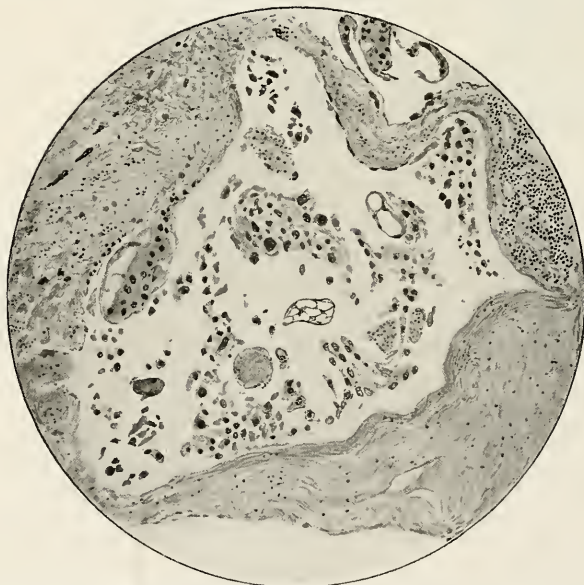

FIG. 292. MICROSCOPIC SECTION OF TISSUE REMOVED FROM THE FOCUS OF GROWTH MARKED A IN FIGURE 291. The intramuscular space contains solid and vacuolated masses of syncytium. *Cf.* Fig. 293. (Malcolm Bell and Lockyer.)

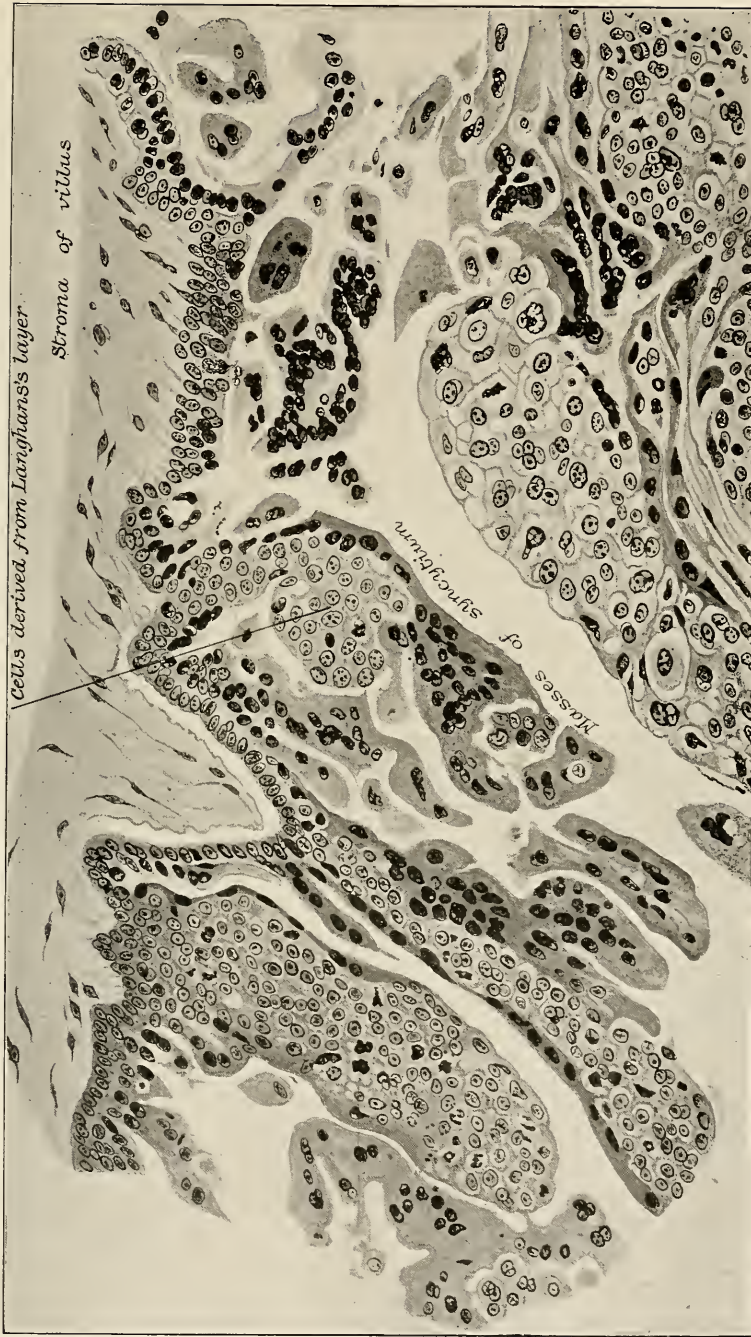

FIG. 293. CHORIONEPITHELIOMA OF THE UTERUS (Teacher). This section, under a high power, shows the characters of the essential cellular elements of the tumour.

characteristic to establish the microscopical diagnosis of chorion-epithelioma.

Chorionepithelioma may occur at any age within the limits of possible pregnancy, a case having been recorded at seventeen and one at fifty-five. A high degree of fertility appears to entail a certain predisposition to the disease, for a relatively large proportion of cases has occurred in women who have had five or more pregnancies. In two out of every three cases, the immediately preceding pregnancy terminated in abortion.

As in the case of all other varieties of malignant disease of the uterus, the earliest symptom is *hæmorrhage*. Usually it is severe from the first, and in this respect differs greatly from that met with in carcinoma. Not infrequently the patient also notices the passage of 'shreds' or 'pieces' in the discharge. In exceptional cases the amount of bleeding is not at any time considerable. More often profound anæmia results from profuse and repeated hæmorrhages. Ulceration of the growth and decomposition of the discharges, indicated by an offensive odour, occur earlier than with carcinoma and form a striking feature of the condition. To this is usually added a certain amount of fever; as a rule it is moderate, but severe rigors and other evidences of acute sepsis sometimes occur.

The degree of malignancy of the growth is variable even more than is the case with other varieties of malignant tumour. Sometimes it destroys life in a few weeks by the formation of widely diffused metastases; at other times its virulence is decidedly moderate, and radical operation has proved successful a year or eighteen months after the appearance of the first symptoms. Dissemination occurs through the blood-vessels, the cell-elements of the growth having been traced into efferent veins, and found in the venous channels of distant parts. The cells of this tumour possess an unusual power of eroding the walls of the vessels and so reaching the blood-stream. One of the commonest positions for metastases is the lung (*see* Plate XVIII), hæmoptysis and sometimes pleural effusion furnishing clinical evidence of the occurrence. The brain, the liver, the spleen, and the pancreas may also be attacked; in the brain metastases are relatively frequent.

*Diagnosis.* Cases of chorionepithelioma may follow quickly upon an abortion, and have been accordingly mistaken for sapræmia with retention of placental tissue, and treated as such. Both conditions are attended with hæmorrhage, a foul uterine discharge, fever, enlargement of the uterus, and the presence within it of decomposing *débris* of tissue or blood-clot. Clearing out the uterus brings a temporary improvement in cases of chorionepithelioma, but after an interval the symptoms all recur with severity, and the uterus is again found to contain considerable masses of *débris* although completely evacuated at the first operation. The rapid reproduction of decomposing tissue in the uterus under such circumstances is strongly suggestive of chorion-

epithelioma. Cases in which the connection with pregnancy is more remote than this may arouse no suspicion of the real nature of the condition. An enlarged uterus, giving rise to hæmorrhage and, possibly, a foul discharge, is naturally treated, in the first place, by exploration and scraping, which will result in free bleeding and in the removal of a quantity of *débris*. The ultimate diagnosis can then only be made by a skilled microscopist, and the whole of the tissue removed from the uterus should be sent to the pathologist with as little delay as possible.

The only possible *treatment* is extirpation of the uterus at the earliest possible moment. Owing to the serious condition in which so many of these cases come first under observation, the primary mortality of the operation has been unusually high. The prognosis as regards recurrence is not so favourable as in corporeal cancer. But in one respect the ultimate prognosis compares favourably with cancer, for in several cases the removal of the primary growth has been followed by complete disappearance of metastases in parts, such as the vaginal wall, where they could be directly observed.

## LACERATIONS AND DISPLACEMENT OF THE UTERUS

### LACERATIONS OF THE CERVIX

Laceration of the cervix is so common in labour that signs of this injury are regarded as the usual indication of partity (*i.e.* of child-bearing). Parturient lacerations rarely heal by first intention, and in consequence they leave, not only visible scarring, but often marked deformity as well. This takes the form of a gap in the continuity of the cervical wall, which may involve only the cervical lip, or may run up into the vaginal roof, or into the base of the broad ligament, according to the extent of the original injury. The left lateral wall of the cervix is the commonest seat of these lacerations (*see* Fig. 294); sometimes there is one on each lateral wall; occasionally there are three or more dividing the cervix up into irregular segments. Considerable puckering may then occur which completely alters the shape and appearance of the cervix. When a deep tear has run up into the vaginal vault, an irregular scar may be traced from the base of the cervical injury across the lateral vaginal fornix.

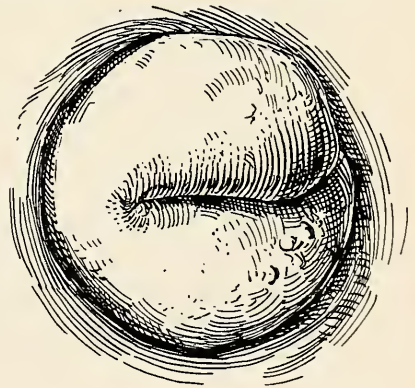

FIG. 294. OBSTETRIC LACERATION OF THE CERVIX WITH EVERSION AND THICKENING OF THE LIPS OF THE OS.

When a deep bilateral laceration has occurred, the cervix is split into two halves, which are roughly anterior and posterior (see Fig. 295). A certain amount of infection of a mild type takes place, resulting in

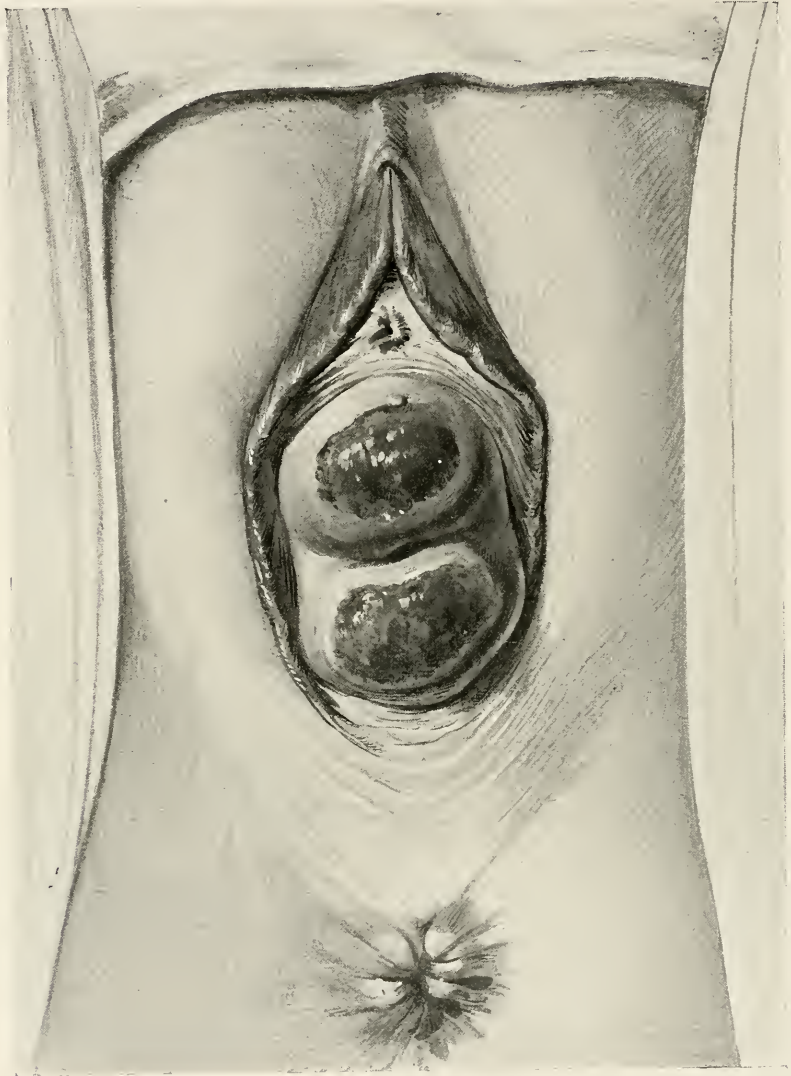


FIG. 295. DEEP BILATERAL LACERATION OF CERVIX WITH ECTROPION (EVERSION) OF THE LIPS, in a case of the second degree of prolapse.

thickening and ultimately in contraction of the cervical tissues. As a consequence each lip becomes *everted*, i.e. rolled outwards upon its vaginal aspect; this exposes a large area of mucosa covering the cervical aspect, which becomes thickened and congested from chronic irritation, a condition often spoken of as 'erosion' (*pseudo-adenoma*)



(see p. 406). This combination of 'eversion' with 'erosion' is frequently seen in multiparæ.

Other morbid conditions attributable originally to the same cause are often present. Thus prolapse from lacerations and over-stretching may occur, or chronic inflammation of the cellular tissue, or of the tubes and ovaries, may result from infection through the lacerations. These patients consequently often present a series of lesions, of which the cervical laceration forms only an item, although an important one.

*Clinical Features.* Cervical lacerations only give rise to symptoms when they have produced 'eversion' and the chronic inflammatory changes in the cervical tissues which accompany it. The symptoms are therefore only the indirect result of the injury. They are identical with those described on p. 413 as the symptoms of 'erosion,' and accordingly they need not be repeated here. Frequently the clinical features are rendered more complex and more severe by the association of prolapsé or chronic pelvic inflammation with the cervical lesions.

It has long been held that cervical lacerations are a powerful predisposing cause of cancer. This view is based *first* upon the general principle that injury predisposes to cancer in all organs, the predisposition being explained by the chronic irritation which scar-tissue is supposed to produce in the healthy tissues around it. *Secondly*, the well-proved fact that cervical cancer is mainly a disease of parous women strongly supports this view. *Thirdly*, as we have seen, an *everted* cervix is also the seat of chronic inflammation, and this condition, it is held, predisposes to cancer in the same way as scar-tissue.

It is difficult to obtain direct proof, for cases of cervical cancer can seldom be shown to have arisen in relation to scar-tissue, although occasionally it may be traced to an erosion, as in Figure 276. At the same time the reasonable probability of these views gives to cervical injuries an importance considerably greater than the comparatively trivial nature of their immediate effects.

Cervical lacerations of unusual depth sometimes do harm in a different direction, viz. they impair the retentive capacity of the uterus in pregnancy and thus lead to abortion. If the laceration has run up into the vaginal fornix, almost the entire length of the cervix from internal os to external os may have been involved, impairing the capacity of the lower uterine segment to support the ovum.

The *diagnosis* of the condition is very simple when the cervix is exposed with a speculum in a good light. By hooking a tenaculum into each cervical lip the eversion can be unrolled and the cervix reconstructed. The depth and position of the lacerations can then be exactly made out. The exposed cervical surfaces are bright red in colour and present the appearances characteristic of an 'erosion' (see p. 406). If traction on the cervix is made it will sometimes be found that there is great loss of mobility, which is generally due to

old-standing cellulitic scar-tissue immobilizing the cervix more or less completely. The condition of the uterine body and the adnexa should always be carefully explored by bimanual examination.

*Treatment.* The only possible treatment of cervical lacerations is operative; the object of the operation is not only to restore the integrity of the cervical wall but also to deal with the associated conditions of 'eversion,' and formation of scar-tissue. It is not necessary to treat all cases of laceration of the cervix. Generally speaking those which are not associated with 'eversion,' and those which do not extend to the vaginal roof, do not require treatment. Partial lacerations do not lead to any great amount of scarring, and it is only bilateral lacerations of some depth which lead to 'eversion' of the cervical lips.

The condition of the other pelvic organs should be carefully examined before an operation is undertaken. On account of the frequency with which multiple lesions are present, other operations such as curetting or perineorrhaphy may be required as well as the operation for repair of the cervix, which will be described on p. 799.

## DISPLACEMENTS OF THE UTERUS

Before entering upon this subject, we must first consider the means by which the normal position of the uterus and of the other pelvic viscera is maintained. It is important to remember that when the uterus is displaced, other organs are often affected as well. In the case of downward displacement (*prolapse*) the alterations induced in the position of other pelvic organs are so extensive that the condition cannot be strictly regarded as a *displacement of the uterus*; it must be viewed as a complex condition affecting many structures besides the uterus. It will therefore be treated separately as an independent condition.

### THE SUPPORTS OF THE UTERUS

The uterus is an organ which, on account of its anatomical relations, and on account of the remarkable enlargement which it undergoes during pregnancy, requires loose attachments and a correspondingly wide range of normal mobility. The frequent changes in volume of the bladder, as this organ undergoes its alternating diastole and systole, produce marked changes in the position of the uterus: the normal degree of anteversion is only possible when the bladder is empty; as this organ fills up, the uterus is gradually pushed backwards, becoming first erect and then displaced upwards and backwards towards the sacral promontory. When in this position retroversion may readily occur from further distension, or from some accidental cause. The influence of the volume of the rectum upon the uterus is less marked;

but distension of the rectal ampulla probably elevates the uterus to some extent. During pregnancy the uterus increases enormously in size, and also produces well-marked alterations in the position and relations of adjacent viscera, notably the tubes and ovaries, the bladder and portions of the pelvic peritoneum. In order to allow of these changes, all of which are physiological, the uterine attachments must allow the organ freedom to accommodate its position to the varying conditions of the adjacent viscera, and also to undergo enlargement without causing undue strain upon its anatomical attachments.

The uterus is structurally continuous with the vagina, the vault of which is reflected over the vaginal portion of the cervix; this is its most unyielding attachment. The peritoneal 'ligaments,' which have been already described, are morphologically of the nature of a *mesentery*; they carry the blood-vessels and nerves of the organ, and offer a certain amount of resistance to any gross displacement while leaving it a wide range of mobility. This is also true of the 'ligaments' of the bladder. When observed from within the abdomen during operative work, the broad ligaments, utero-sacral ligaments and utero-vesical ligaments all appear as lax folds, which under normal conditions will allow of the uterus being drawn up to, or through, the abdominal incision without the use of force (*see* Fig. 20). They can by no means be regarded as *supports* which sustain the uterus at a constant level.

The round ligaments are not, however, homologous with the mesentery. Developmentally the round ligament is the adult form of the structure which corresponds to the gubernaculum testis of the male (*see* Fig. 51, p. 77). The function of this structure is developmental only, and the portion which becomes the round ligament may perhaps be regarded as a vestigial structure which serves no definite purpose in the adult. Its laxity, its variability in size, and its curved course through the pelvis negative the idea that it can exert any notable influence upon the position of the uterus. It is very doubtful whether it can even oppose any effective resistance to forces tending to retrovert the uterus into the pouch of Douglas. It can, however, be made serviceable by the surgeon, who constructs from it a useful artificial uterine support (*see* p. 770).

The chief supports of the uterus, *i.e.* the structures which maintain its horizontal level, are to be found in the muscular and fascial structures which close the pelvis below. They are arranged in two groups, one of which lies at a deeper level than the other. The superficial group forms part of the anatomical *perineum*, and consists of the superficial anal sphincter, the transversus perinei, and sphincter vaginae (bulbo-cavernosus) muscles, with the superficial and deep layers (triangular ligament) of the perineal fascia. The above muscles are solely sphincteric in function. The deep group of musculo-fascial structures constitutes the *pelvic diaphragm*. This is a funnel-shaped structure, oval in shape, with the long axis antero-posterior. It consists of the

levator ani and coccygeus muscles of each side, with the visceral layer of the pelvic fascia, which forms their aponeurosis.

Anatomists now describe the levator ani as comprising two muscles, which have been named from their attachments, the *pubo-coccygeus*, and *ilio-coccygeus* muscles; the former represents what was formerly distinguished as the anterior portion, the latter, as the posterior portion of the levator ani. The *pubo-coccygeus* arises from the back of the pubic symphysis and body, and from the pelvic wall along an oblique line

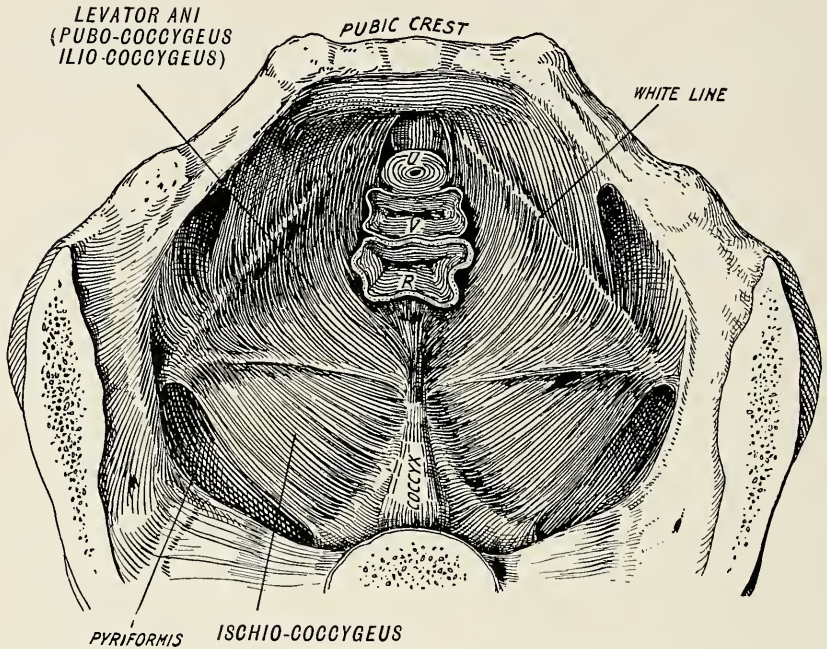


FIG. 296. THE PELVIC DIAPHRAGM AS SEEN FROM ABOVE (Deaver).

which is continued upwards and outwards towards the obturator canal, and also in part from the triangular ligament (*see* Fig. 296). The muscle passes backwards and inwards and is inserted partly into the last sacral vertebra, and partly into a tendinous median raphé situated behind the rectum, where it unites with its fellow from the opposite side (Thompson). These muscles partly ensheath the vagina and rectum, and exert to some extent a supplementary sphincteric function. The *ilio-coccygeus* arises sometimes from the ilio-pectineal line, and sometimes from a fibrous arch passing from the pubes to the ischial spine, the 'white line of the pelvic fascia' (Thompson). It has an aponeurotic insertion into the two last coccygeal vertebræ and into the ano-coccygeal median raphé. The coccygeus, or *ischio-coccygeus* muscle arises from the ischial spine, and is inserted into the lateral aspects of the lower sacral vertebræ and the coccyx.

The fascial structures are the aponeurotic portions of the *pelvic fascia*.

Morphologically the pubo-coccygeus, ilio-coccygeus and ischio-coccygeus muscles represent the powerful tail-muscles of apes and other lower mammals ; the two former are the depressors of the tail ; the last named are the tail-wagging muscles. In man, owing to the disappearance of the tail, these muscles have lost their original function, and are of course much less powerfully developed than in tailed animals. Considerable difference of opinion has been expressed as to their function in man. By some writers they are regarded as vestigial structures which are too feeble to be of much practical value (Fothergill). Others consider that they have an important function which has developed in consequence of the assumption of the erect attitude by man. This function is to oppose sudden increases in intra-abdominal pressure, such as frequently occur from violent muscular effort in coughing, sneezing, and in the act of defæcation (Paramore). But for the presence of structures in the pelvic floor capable of effectively counteracting such increases in pressure from above, hernial protrusion of the pelvic viscera would probably occur with greater frequency. The latter view appears to be the true one, and if this is accepted, it follows that the muscles, closing the pelvic cavity below, which by their contraction are capable of increasing the resistance of the pelvic diaphragm as required, are in reality structures of great physiological importance.

It must be borne in mind, however, that the pelvic diaphragm is weakened by being pierced by the urethra and vagina ; in women who have borne children, the aperture representing the latter is of large size. The rectum should not be regarded as piercing the pelvic diaphragm ; it lies entirely free in a compartment of its own, and has a much wider range of normal mobility than the two other canals. An element of weakness is thus evident in the pelvic diaphragm, which owing to the accidents of child-birth is capable of greatly impairing its functional efficiency.

Certain other arrangements exist which counterbalance this element of weakness to a great extent. In the first place the vagina and urethra are attached to the sloping sides of the pelvic diaphragm by the layer of pelvic fascia which invests them, and which is continuous with the other divisions of the pelvic fascia at the white line. In the second place the cervix and vaginal vault have a specialized attachment of their own. It will be recollected that the uterine vessels reach the uterus at the level of the internal os ; as they cross the pelvis from the neighbourhood of the sacro-iliac joint, they carry with them an investment of strong fibrous tissue (*see* Fig. 297). These vessels with their sheaths form an important lateral attachment, which will oppose descent of the uterus. Further, at this level is to be found a well-formed band of fibrous tissue which has been named the "transverse ligament of the cervix" (Paterson). It follows the line of the uterine

vessels, but at a lower level, and is continuous with their fibrous investment; it is continuous externally with the fibrous sheath of the iliac vessels, and with strong fibrous bands which enter the pelvis through the sciatic notch; internally it is attached to the sides of the uterus, to the sides of the vaginal vault and to the sides of the urethra and bladder. It has been frequently pointed out that in removing the uterus *per vaginam* the cervix cannot be pulled down much below its normal level until the structures at its sides have been divided, when it comes down easily outside the vulva. It is

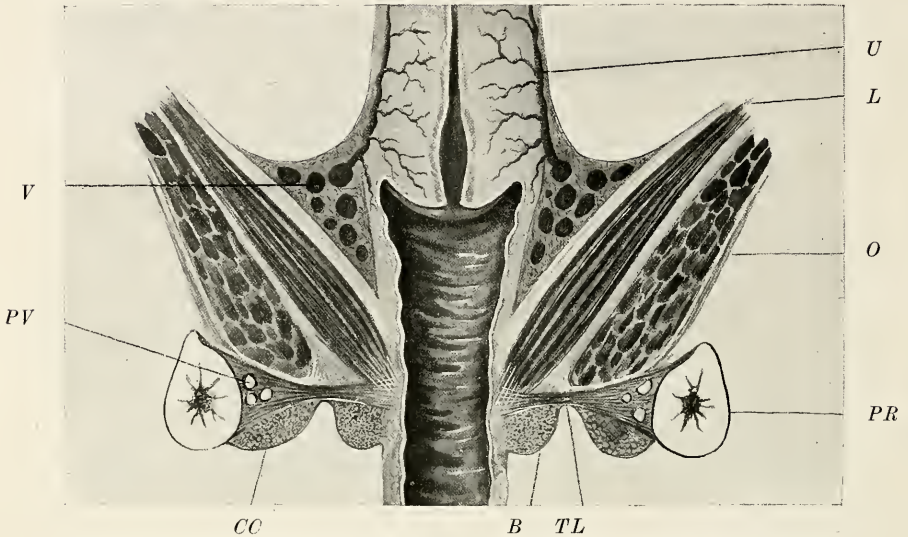


FIG. 297. CORONAL SECTION THROUGH THE PELVIC FLOOR. *L.* Levator ani; *O.* Obturator internus; *PR.* Pubic ramus; *TL.* Triangular ligament; *B.* Bulb of vagina; *CC.* Crus clitoridis; *PV.* Internal pudic vessels and nerve; *U.* Uterine artery; *V.* Veins of the parametrium (after Elliott Smith and Stopford).

the division of the uterine vessels and the transverse ligaments which liberates the cervix.

It appears, therefore, that the uterus is maintained at its normal level by the pelvic diaphragm, and by the supplementary transverse fascial bands attached to the cervix and vaginal vault. The continual changes in intra-abdominal pressure which result from respiration, changes of posture, coughing, sneezing, and general muscular effort are opposed by the contraction of the muscles of the pelvic diaphragm, which are therefore in constant functional activity. It is possible that abnormal increases in intra-abdominal pressure may lead to compensatory hypertrophy of these muscles. On the other hand, injury to these structures or to the transverse fascial bands from overstretching, or from laceration in child-birth, will seriously impair their efficiency, causing them to yield before the forces of intra-abdominal pressure, and thus to allow the occurrence of prolapse.

## DISPLACEMENTS

The following displacements of the uterus may be met with :

- (a) Forward—anteversion, anteflexion.
- (b) Backward—retroversion, retroflexion.
- (c) Inversion—turning inside out.
- (d) Downward—prolapse.

The term displacement of the uterus is understood to include some

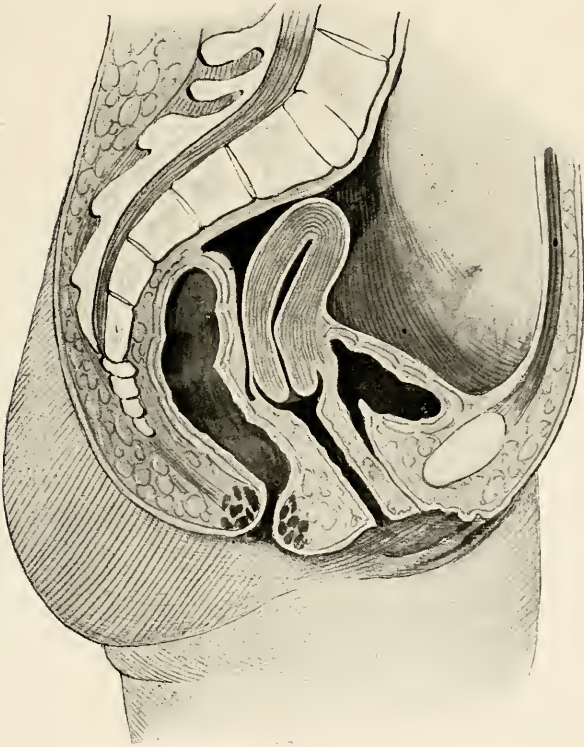


FIG. 298. RETROPOSITION OF THE UTERUS.

departure from the normal *position* of the organ, and also in most cases an alteration in the *curve of its axis*.

The simplest form of displacement is that in which an alteration of position occurs without marked alteration in the uterine axis. Thus the uterus may be pushed bodily forwards against the pubes (*ante-position*) by some tumour or collection of encysted fluid in the pouch of Douglas (see Fig. 128, p. 224) ; a little straightening of the uterine axis may result, but the organ remains anteverted. Similarly the uterus may be pushed back into the sacral hollow (*retro-position*) (see Fig. 298) by tumour in the utero-vesical pouch, or may be drawn there by contraction of old inflammatory adhesions in the pouch of Douglas.

Or it may be pushed over to one side of the pelvis by a laterally situated swelling, *e.g.* a cyst developing between the layers of the broad ligament on the opposite side (*sinistro-* or *dextro-position*—see Fig. 433, p. 760) or drawn over by contraction of the cellular tissue upon the same side. Again, the uterus may be raised above the level of the pelvic brim (*elevation*) by a collection of retained menstrual fluid in the vagina (see Fig. 96, p. 174), or may sink below its normal level, either from failure of its proper supports, or from increase of intra-abdominal pressure above it, produced by abdominal tumours or collections of fluid. Occasionally the uterus undergoes *rotation* on its long axis as is sometimes seen in connection with fibroid tumours (see Fig. 210, p. 430).

It will be obvious that such displacements as these, though of anatomical interest, in reality are only mechanical results of other morbid conditions which are of far greater importance, and are only capable of correction by removal of these conditions. With one exception it is doubtful whether they are of any practical importance whatever unless the displaced uterus becomes gravid, when of course the function of parturition might be seriously interfered with. Displacement downwards is the exception referred to; it induces secondary displacement of other organs and leads to a definite train of clinical results. It is usually known as *Prolapse*, and will be considered separately (see p. 591).

Displacements are usually accompanied by an alteration in the uterine axis, which may be of two kinds—*version* or *flexion*. Instead of the body of the uterus being directed forwards towards the pubes, it may be directed backwards towards the sacral hollow (*retroversion*), or more rarely towards one or other side of the pelvis (*lateriversion*). In such cases (*versions*) the width of the angle between the body and the cervix is not much altered. But in other cases the width of this angle is diminished until it becomes acute, when the uterus is said to be *flexed*; if the uterine body remains directed forwards the condition is called *anteflexion*; if occurring in connection with displacement backwards, *retroflexion*. For practical purposes no distinction need be made between versions and flexions, and they will be considered together in the succeeding paragraphs.

### Forward Displacement

**Anteversion** is the normal position of the uterus; it varies continually with the filling and emptying of the bladder, and is usually exaggerated in early pregnancy. While the width of the corporeo-cervical angle remains normal, the condition is not to be regarded as pathological.

**Anteflexion** occurs under two different conditions; in some cases it is congenital, and is associated with deficiency in size and development



of the whole organ (*see* p. 156), in other cases, which, however, are very rare, the displacement is acquired, being brought about by contraction of the utero-sacral ligaments (chronic utero-sacral cellulitis) pulling the isthmus upwards and backwards, and thus increasing the acuteness of the uterine angle. The same result may ensue from adhesions in the lower part of the pouch of Douglas, pulling back the cervix and posterior vaginal wall. The uterine angle may then be reduced below a right angle, with a consequent abrupt bend in the curve of

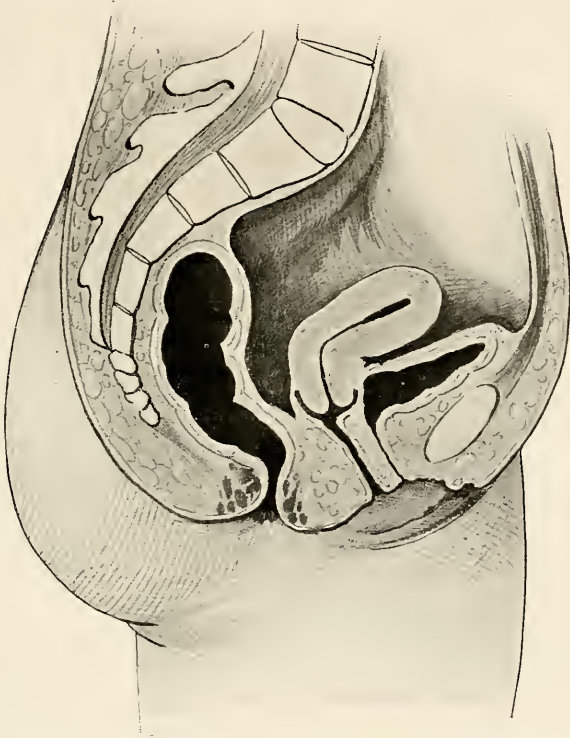


FIG. 299. ANTEFLEXION OF THE UTERUS (Diagrammatic).

the uterine cavity (*see* Fig. 299). Both the congenital and the acquired types are rare, the latter being especially uncommon. The reduction in the width of the corporeo-cervical angle may be due, either to an altered direction of the cervix, the position of the body being nearly normal, or to a forward bending of the body, the direction of the cervix being normal; or in some cases it may be due to both conditions. The first-named is much the commoner form (*see* Fig. 299), the external os being directed downwards and forwards instead of downwards and backwards.

*Diagnosis* is easy by bimanual examination. In the congenital type the uterus is unduly small and freely movable, while in the acquired type it is of normal size and its mobility is necessarily limited by the

adhesions, or by the contracted posterior ligaments. The degree of flexion can be estimated by the index finger placed in the anterior fornix. It must be borne in mind that the uterine angle is subject to considerable variation in size under normal conditions, and slight degrees of ante flexion, therefore, sometimes occur in health. Certainly not all cases are pathological; only those should be so regarded in which either deficiency in the size of the uterus, or chronic inflammatory changes are found in connection with it. Under all other conditions ante flexion is not pathological and does not require treatment.

The two main *symptoms* of pathological ante flexion are *dysmenorrhœa* and *sterility*. The bend in the uterus is not, however, directly responsible for either of these symptoms; in the congenital type both are due to the deficient development of the organ; in the chronic inflammatory type they are due mainly to the associated inflammatory lesions.

It follows from what has previously been said that the *treatment* of these cases is to be directed not solely to the correction of the abnormal uterine angle, but to the alleviation of the causal conditions when practicable. In the congenital type dilatation of the cervix may be performed, but it is of only temporary benefit; in a few fortunate cases pregnancy may follow this operation and a permanent cure may then result. Attempts to stimulate the development of the uterus by the electric current have been made, and have generally proved unsuccessful. In the chronic inflammatory type the treatment is that of chronic pelvic inflammation (*see* p. 265).

### Backward Displacement

Although the usual position of the uterus is one of anteversion, it will be understood from what has been said about the supports of the uterus, that a narrow interpretation of what is normal cannot be attempted in the case of this organ. Instances have been already mentioned of departures from the position of anteversion which are of themselves of no importance, and which are brought about by disease in adjacent parts. Owing to anatomical disposition it is possible for the uterus to be displaced backwards without interfering in any way with the position or function of any other organ. In other cases, the tubes and ovaries are also dragged out of position, but these are the only organs which can in any way be displaced. Clinical experience has indubitably proved that it is possible for a uterus 'displaced' backwards to perform all its functions, including that of gestation, normally. There is, therefore, not the slightest justification for regarding every case of backward displacement as pathological or as requiring treatment. Often the condition is seen in women with perfectly normal health.

There are, however, certain respects in which a backward-lying

uterus is to some extent at a disadvantage, especially in relation to the functions of *insemination and menstruation*. The former may be affected by the coincident displacement of the external os. Coitus in the dorsal position deposits semen in the posterior vaginal fornix ; if the uterus is retroverted, the external os is directed away from the posterior fornix, and the entrance of spermatozoa into the cervical canal is possibly rendered more difficult. That this disadvantage may be readily overcome is shown by the numerous cases in which repeated pregnancy has occurred in women with a retroverted uterus.

With regard to menstruation, it must be recollected that a uterus fully retroverted or retroflexed is so placed that the fundus is on a lower level than the internal os ; consequently the force by which the menstrual fluid is expelled has to overcome a certain amount of resistance from gravity. To a uterus on the border-line of muscular inefficiency, this slight obstacle may be sufficient to induce muscular spasm and its attendant severe menstrual pains. Yet in many cases, as menstruation occurs without any abnormal pain, the obstacle is clearly of no importance.

It is open to question whether backward displacement has any influence upon the *uterine circulation*. Some writers believe that as the broad ligaments become folded over the edges of the utero-sacral ligaments, pressure is exerted upon the walls of the veins of the pampiniform plexus to an extent sufficient to cause stasis. In this way a broad-ligament varix may result, but it is probably very rare, and its clinical significance when present is doubtful.

The foregoing considerations serve to explain the fact that a large number of instances of retroversion are encountered on routine gynaecological examination, where the 'displacement' gives rise to no ill effects. Retroversion has been observed in the foetus, and it is probable that many cases in adults are congenital. Other minor abnormalities may be associated with it in congenital cases, such as a shortness and narrowness of the vaginal canal, or an undersized *portio vaginalis*. In other instances the 'displacement' is fortuitous, and later may be found spontaneously corrected on a second examination.

Great care is accordingly required in deciding what view to take of a case of backward displacement. To treat all cases is clearly improper, and a careful consideration of the associated symptoms, and of the type of the patient, is required. No distinction need be made between retroflexion and retroversion ; the extent to which the uterus bends at the isthmus depends upon the tone of the uterine wall, and except that a marked flexion aggravates the mechanical impediments already referred to, it is of no importance. While retroversion is often congenital, retroflexion is usually an acquired condition.

Apart from the degree of flexion at the isthmus, cases of backward displacement vary in regard to the extent to which the uterus is deflected from its normal position. In its simplest form the uterus is

drawn backwards towards the sacral hollow, occupying much the same position as it would naturally fall into during extreme distension of the bladder (*see* Fig. 4, p. 8, and Fig. 298). This may be conveniently distinguished as *retroposition*. The stages of a true retroversion are represented in Figs. 300, 301, and 302); from these it will be seen that the uterus rotates in a backward direction upon a transverse axis passing through the isthmus, the result being that the fundus describes a wide arc which ends below upon the floor of the pouch of

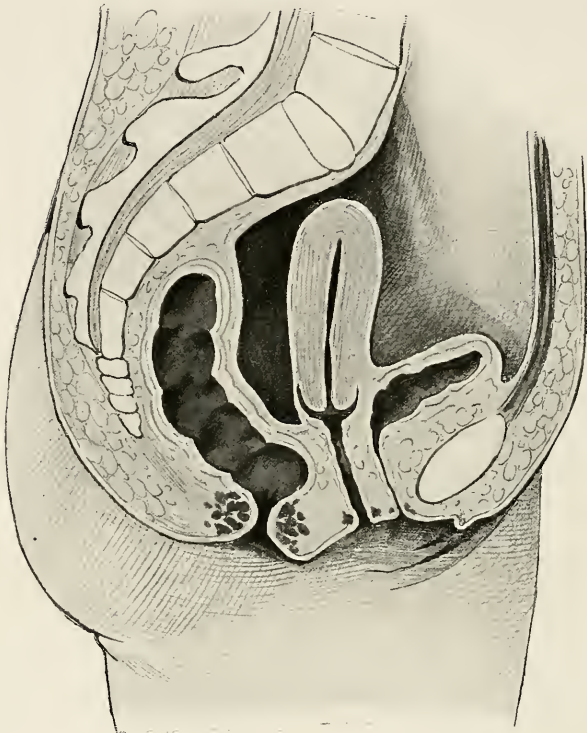


FIG. 300. RETROVERSION OF THE UTERUS (First Stage).

Douglas, while the external os describes a much smaller arc directed towards the pubes. The three stages represented are not definite degrees of retroversion, but it is convenient for clinical description to recognize these stages of the process of displacement.

Apart from the congenital cases the commonest cause of backward displacement is a general lax condition of the uterine supports, due in many cases to child-bearing but often also occurring in nulliparous women. Many cases of retroflexion first come under observation after child-birth, and are no doubt brought about by two factors (*a*) relaxation of the uterine supports, and (*b*) the abnormal size and weight of the uterus. In these circumstances the uterine body may be readily displaced backwards by a fall or by overdistension of the

bladder. Such a result is obviously more likely to occur if the uterus is heavy, as from early pregnancy, or sub-involution, or from enlargement due to a small fibroid tumour. Backward displacement is also an accidental result of the second and third stages of prolapse (*see* Fig. 314, p. 593). Sometimes it occurs in consequence of great increase in intra-abdominal pressure from the presence of a large tumour or a large amount of fluid in the peritoneal cavity. Lastly, it may be brought about by pelvic peritonitis affecting the pouch of

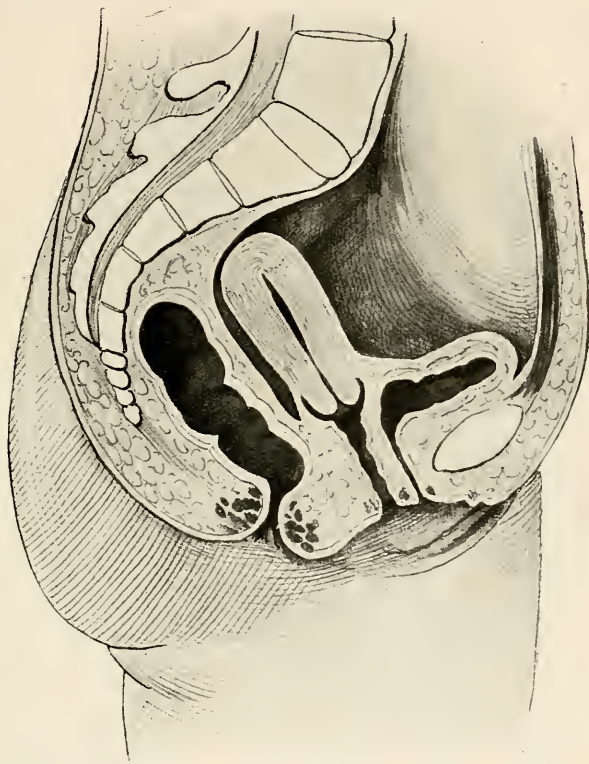


FIG. 301. RETROVERSION OF THE UTERUS (Second Stage).

Douglas, and resulting in the formation of adhesions, the gradual contraction of which draws the uterus down to the floor of the pouch.

Sometimes an enlarged and retroverted uterus, when examined during an abdominal operation, shows signs of having been exposed to excessive friction in its abnormal position. Thus the peritoneal surface may be darker than normal, with irregular areas of pale mottling upon the posterior surface, and in a case seen by one of us there was a distinct shallow ridge upon the fundus where it lay in contact with the rectum.

**Complications.** Simple cases of backward displacement, *i.e.* those in which there is no other morbid condition present, rarely give rise

to symptoms and accordingly seldom require treatment. Only when some other condition is superadded does it give rise to symptoms. Perhaps the commonest complication is sinking of the whole organ below its proper level (*descent*). When multiparæ are affected, the general parturient relaxation of the supporting structures tends to produce both displacements. These cases cannot, however, be considered as instances of prolapse, for they do not show the tendency to progress in the direction of complete procidentia which is char-

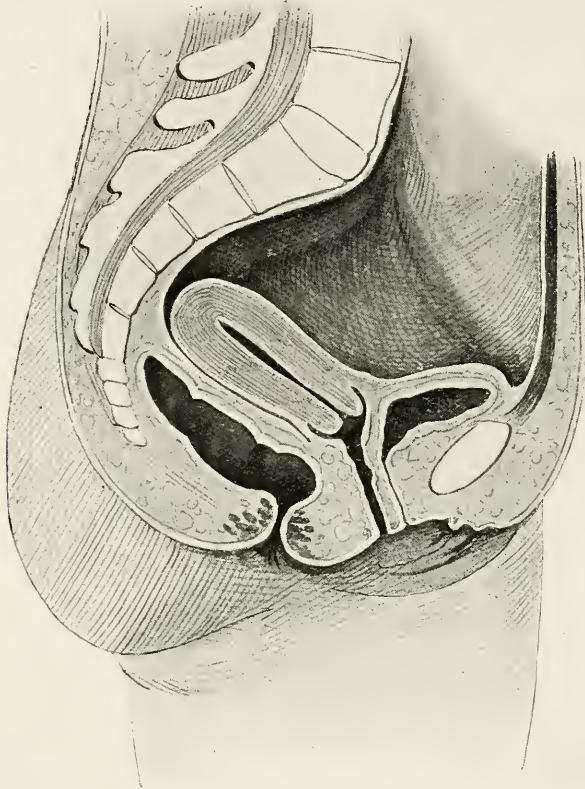


FIG. 302. RETROVERSION OF THE UTERUS (Third Stage).

acteristic of 'falling' of the womb. Retroversion with descent is, however, always more serious than when the normal level is maintained. Next in frequency and importance comes *prolapse of the ovaries*. The tubes and ovaries are frequently dragged downwards and backwards until they lie in the pouch of Douglas; often one or both ovaries may be found upon the floor of the pouch underneath the retroverted fundus. The clinical features of the case are undoubtedly intensified when prolapsed ovaries are also present.

These two conditions are, strictly speaking, the only *complications* of backward displacement.

Three other morbid conditions, although independent in origin, are, however, so frequently found in association with it, that mention must be made of them here. The first of these is *pelvic inflammation*, the commonest form being bilateral salpingitis. With this condition more or less widespread peritonitic adhesions are usually found, the result of which is a complete, or nearly complete, loss of mobility of the uterus. This fixation, it will be observed, affects not only the uterus but the adnexa as well. Reposition of the organ, except by operative measures, is impossible, and the mass of inflamed structures filling the posterior pelvic compartment may be the cause of severe suffering.

The second is an *interstitial fibroid tumour* which has enlarged the uterus to a size sufficient to fill tightly the sacral hollow and crowd the other pelvic organs. In many such cases the fibroid has developed in the posterior uterine wall, and the uterus is not, strictly speaking, retroverted at all. In others, however, the whole organ is distinctly retroverted, and the symptoms to which it gives rise can be relieved by simply correcting the malposition. When the tumour is situated in the posterior wall, the direction of the uterine cavity may not be much affected, and reposition is usually impossible in such cases.

The third is the condition already described as *chronic interstitial endometritis* (see p. 392), which is especially frequent in cases of puerperal backward displacements.

When a fibroid tumour or salpingitis is present, these conditions so much outweigh in importance the position of the uterus, that they are to be regarded as the sole determining factors in treatment, and the principles upon which they are to be dealt with are considered elsewhere.

**Symptoms.** It has been mentioned already that in a certain proportion of cases, backward displacement gives rise to no symptoms and requires no treatment. In the majority, however, the following symptoms, or some of them, will be met with: *pain* in the lower abdomen and sacral region; *menorrhagia*, *dysmenorrhœa* and *leucorrhœa*; and married women may complain, in addition, of *dyspareunia* and *sterility*. It must, however, be borne in mind that a similar symptom-complex, due to other causes, may be met with when the position of the uterus is normal; accordingly, the dependence of the symptoms in a given case on the malposition of the uterus cannot always be postulated with certainty.

*Pain* is never acute, but is more or less constant and of a dull aching or dragging character; it most commonly takes the form of backache, or sometimes of a dragging pain in one or both iliac regions. Pain is usually most severe in cases where the uterus is adherent, or the ovaries are prolapsed. *Menorrhagia* and *leucorrhœa* are the result of accompanying endometritis. *Dysmenorrhœa* may be due in part to congestion, in part to the increased difficulty which the uterus meets

with in expelling the menstrual blood, when the uterine body lies below the level of the internal os, as in cases of extreme backward displacement. *Dyspareunia* is seldom present, except in cases where recent adhesions exist, or where the ovary is completely prolapsed, *i.e.* lies on the floor of the pouch of Douglas. Women with a backward displacement are by no means necessarily *sterile*, but it has been frequently observed that after several years of non-fertile marriage, cure of a backward displacement has been followed by conception. This displacement is therefore a possible factor in the causation of sterility.

These are the only symptoms which can be directly attributed to the displacement, and it will be apparent that they are neither important nor characteristic. Backache is the commonest of all the ailments of which women in indifferent health complain; and especially is this the case in the large class of ailments described as 'functional.' The discovery that a woman complaining of backache has a retroverted uterus is no justification for attributing the pain to the displacement; the greatest harm may be done in individual cases by too readily accepting this apparently easy explanation, and carrying out unsuccessfully the treatment appropriate to the displacement. Another equally unfortunate error is to attribute to the displacement symptoms for which it could *under no circumstances* be responsible. The commonest instance of this misjudgment of a symptom is irritability of the bladder, or incontinence, neither of which can possibly be caused by backward displacement of a uterus of approximately normal size.

A further source of error lies in the fact that retrodisplacement may be found in women who present the well-known picture of complex *functional disturbances* of the pelvic type. The greatest difficulty lies in estimating at their true value the dependence of such symptoms upon the malposition of the uterus. That in some instances such a relationship subsists is undoubted; in the majority, however, this sequence of events is not apparent, and there is room for grave doubt as to the true relationship between them. No clinical problem taxes the patience and the judgment of the conscientious gynæcologist more than this. If the simple rule, followed apparently by some, is observed, of correcting every case of backward displacement, it may be safely said that while a proportion of the patients treated will benefit, an equal or larger proportion will actually be made worse.

**Diagnosis.** The diagnosis of backward displacement can be made only by internal examination. *Per vaginam* the examining finger first notes the forward displacement or inclination of the cervix; this is most marked in cases of retroversion (*see* Fig. 302). Owing to the frequency with which slight degrees of prolapse are associated with backward displacement, the uterus is often found at a lower level in the vagina than normal. The anterior fornix is found empty on bimanual examination, *i.e.* the uterine body cannot be felt there. Exploring the



posterior fornix, a body will be felt there which, in favourable cases, can be at once shown to be the uterus. The following three points suffice for this diagnosis : (a) the structure found in the pouch of Douglas can be felt to be continuous with the cervix, no sulcus or interval being recognizable between them ; (b) on moving the cervix from side to side with the finger, the body in the pouch of Douglas will be felt to move with it ; (c) the characteristic pyriform shape of the uterine body may be recognized, the broad end lying below and behind the cervix. The latter point can often be more readily made out by rectal than by vaginal examination. It is often difficult to make a bimanual examination of a retroverted uterus except under anæsthesia. Confirmation of diagnosis may be made in a difficult case by the passage of the sound, which must be carried out under strict antiseptic precautions (*see* p. 128). The ovaries, if simply prolapsed, will be found at the sides of the uterine body in the pouch of Douglas ; their shape, mobility and sensitiveness assist greatly in recognizing them. Sometimes, however, they may be found adherent either to the back of the uterus or to the floor of the pouch of Douglas. In cases where the retroversion is unaccompanied by prolapse, the normal position of the ovaries may be preserved. Finally, an attempt should be made to push the body of the uterus upwards and forwards in the axis of the pelvic brim, when an estimate of its degree of freedom from adhesions may be formed. Adhesions often, however, permit a considerable degree of mobility, but when stretched they usually cause pain, and can sometimes be felt by the finger as tense bands. The presence of adhesions must not be inferred from a failure to replace the uterus, unless the attempt has been made under anæsthesia.

Difficulty will in some cases be met with from extreme tenderness of the uterus, in others from loading of the rectum with scybala. Detailed diagnosis must then be deferred until the appropriate preparatory treatment has been carried out.

**Treatment.** From what has been already said it will be clear that a difficult preliminary question may have to be decided, viz. is the case one which requires treatment at all ? No absolute rules can be formulated, but the problem can be narrowed down to some extent by defining certain classes of cases as follows : (1) in young unmarried women, and in women who have passed the climacteric, treatment of an *uncomplicated case* is never required ; (2) in sterile married women the displacement may be corrected even if no pelvic symptoms are present at all ; (3) cases occurring in married women in which the ovaries are prolapsed usually require treatment. With regard to all other classes of cases careful judgment and selection are called for.

The object of treatment is to replace the uterus and *maintain it in its normal position*, and to do this in the simplest possible manner. In recent puerperal cases a period of rest in bed, the patient lying in the prone position for several hours each day, and combined with massage

and passive muscular exercises, may both relieve the symptoms and spontaneously restore the uterus to its normal position. The treatment is, however, tedious and seldom applicable except in the well-to-do classes. In all other cases therapeutic reposition is the alternative.

When reposition of the uterus has been decided upon, two methods are available, viz. (a) the operative method, the object of which is to maintain the uterus permanently in a position of anteversion, and (b) the instrumental method, the object of which is to keep the uterus anteverted by means of a mechanical support (pessary) placed in the

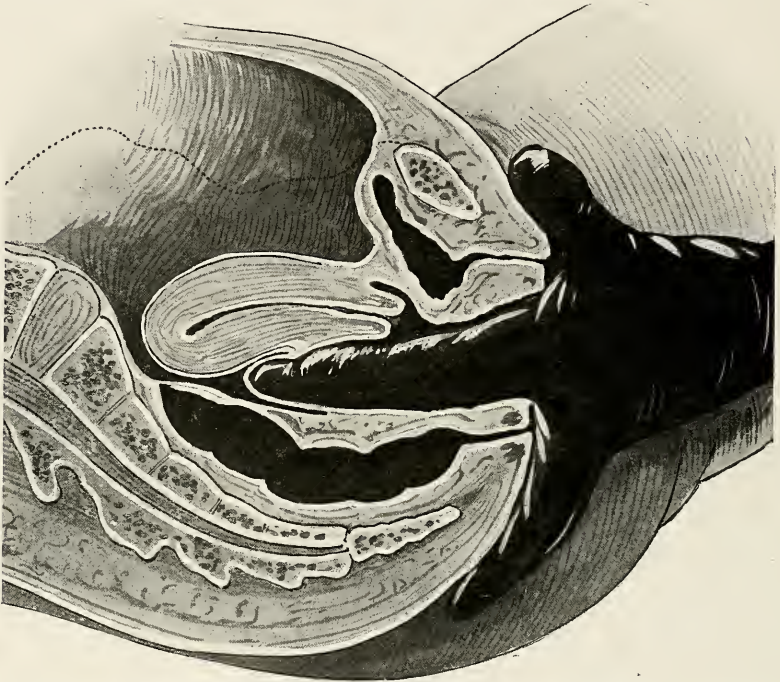


FIG. 303. METHOD OF DIGITAL REPLACEMENT OF A RETROVERTED UTERUS. First step, in which the body is pushed up to the level of the sacral promontory.

vagina. Operative treatment is comparatively recent ; treatment by pessaries has been in vogue for many generations. There is at present no uniformity of opinion as to the special indications for each method, but one or two guiding principles may be stated thus : (1) The use of a pessary should always be regarded as a temporary expedient only ; its prolonged use is objectionable from the point of view of cleanliness, and sometimes causes serious trouble from ulceration. (2) A pessary rarely cures a displacement, *i.e.* its use cannot be discontinued without recurrence taking place. (3) An operation, suitably planned, involves but slight surgical risks, and is almost invariably successful in preventing recurrence. It follows that the field of application of a pessary is limited ; a typical instance in which it may be used is a puerperal back-

ward displacement associated with sub-involution. Here the use of a pessary for three months may permanently cure the displacement, for in that time the uterus may be restored to its normal size and the cause of the displacement thus removed. Other instances are cases of sterility, and cases in which the surgeon is in doubt as to whether the symptoms are due to the malposition or not; here the pessary affords an experimental test of the relation of the symptoms to the lesion.

Pessary-treatment having been decided upon it must be borne in mind that unless the pessary retains the uterus in a satisfactory

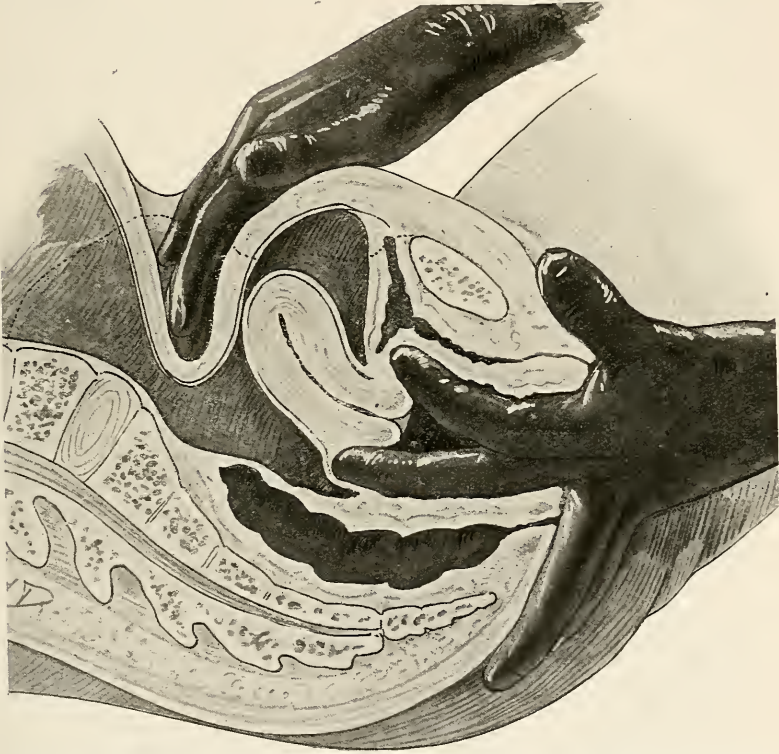

FIG. 304. METHOD OF DIGITAL REPLACEMENT OF A RETROVERTED UTERUS. Second step, in which the fundus is drawn forwards away from the sacrum, and the cervix pushed upwards and backwards.

position, it has failed in its purpose, and must be discontinued. Failure of the pessary to effect this purpose forms one of the strongest indications for operation.

Before attempting to replace the uterus *preparatory treatment* is sometimes necessary. It is essential that the lower bowel should be empty, and in patients habitually constipated a course of aperients may be necessary; if the displaced uterus is very tender, replacement without an anæsthetic cannot be carried out, owing to the pain which the manipulation causes. The patient may then be sent to bed for a

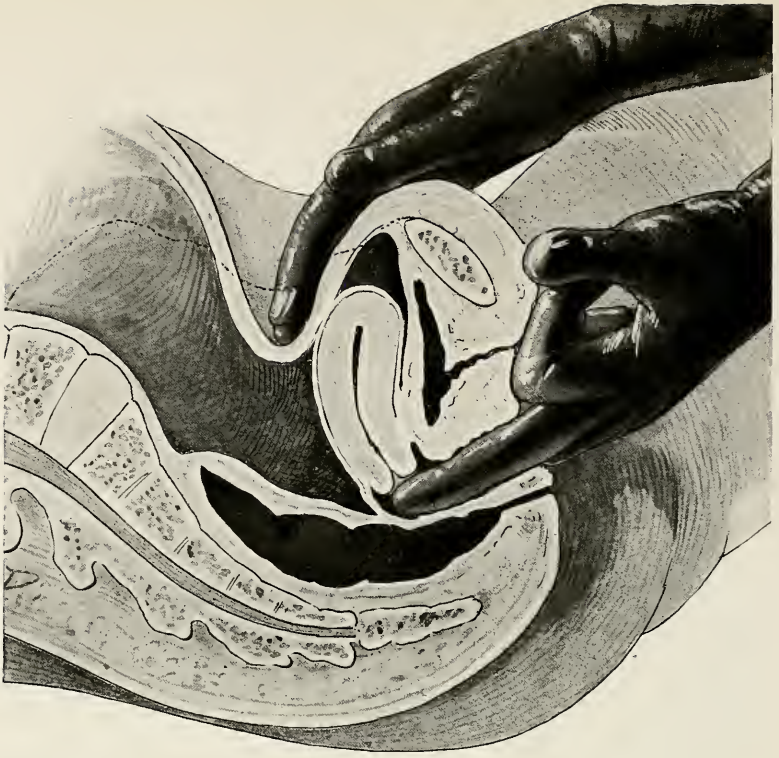


FIG. 305. METHOD OF DIGITAL REPLACEMENT OF A RETROVERTED UTERUS. Third step, in which the fundus is drawn forwards to the pubes, and the whole uterus elevated.

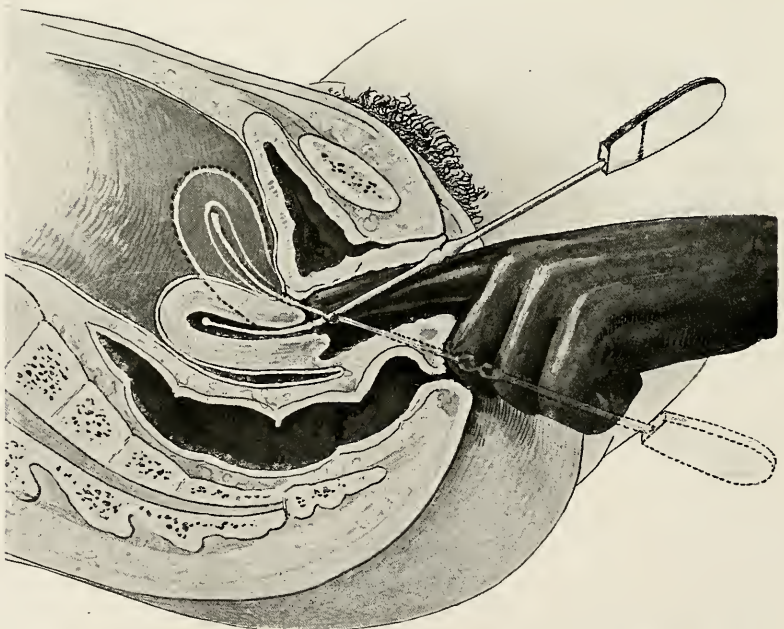


FIG. 306. USE OF THE SOUND IN COMPLETING THE REPLACEMENT OF A RETROVERTED UTERUS UNDER ANÆSTHESIA.

week, and treated with hot vaginal douches twice or three times a day, vaginal pessaries or tampons of glycerine or of glycerine and ichthyol, a daily saline aperient before breakfast, and a light diet without alcohol. The employment of general anæsthesia, although it allows of the uterus being replaced, does not obviate the necessity for these preparatory measures, for a pessary cannot be supported in comfort by the patient when great tenderness of the pelvic organs is present.

The displaced uterus may be reduced with the fingers, either alone or aided by the uterine sound ; if anæsthesia is not employed the Sims's




FIG. 307. PESSARIES FOR BACKWARD DISPLACEMENT. (a) Hodge Pessary ; (b) Albert Smith Pessary. Note that the lower end of (a) is square, and its profile-curve is more pronounced than (b).

position is the most useful (*see* Fig. 80, p. 126). The index and middle fingers of one hand are first passed into the posterior vaginal fornix, and with them pressure is made upon the fundus of the uterus in an upward and forward direction towards the pelvic brim (*see* Fig. 303,

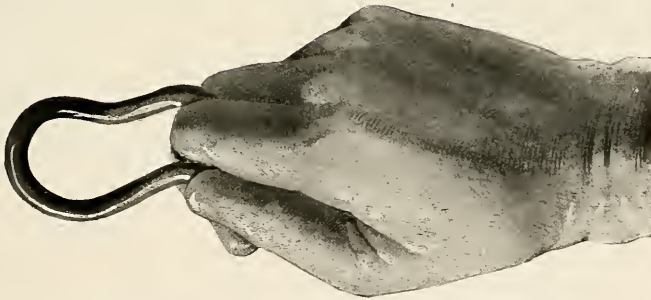


FIG. 308. HOW TO HOLD THE HODGE PESSARY.

p. 578). With the assistance which the Sims's position lends to this manœuvre, the fundus can easily be raised to the level of the sacral promontory ; but the most difficult part of the reduction remains. If the abdominal walls are thin and lax, they can now be depressed by the fingers of the other hand until these pass behind the uterine fundus, which is then gently directed forwards towards the symphysis, while the internal fingers push the cervix upwards and backwards towards the sacral hollow, as shown in Figs. 304 and 305.

The second and third stages can often be best carried out after

getting the patient to turn over on her back, while the operator keeps the uterus in the position to which he has raised it. With the complete muscular relaxation of general anæsthesia, the aid of Sims's position is not required, and the whole procedure can be carried out with the patient on her back. If the uterus cannot be replaced by the finger alone in this manner, an anæsthetic should be given. Digital manipulations may then succeed, and if not, the sound may be employed as well; owing to the importance of observing strict asepsis in the use of this instrument it is better not to use it for this purpose

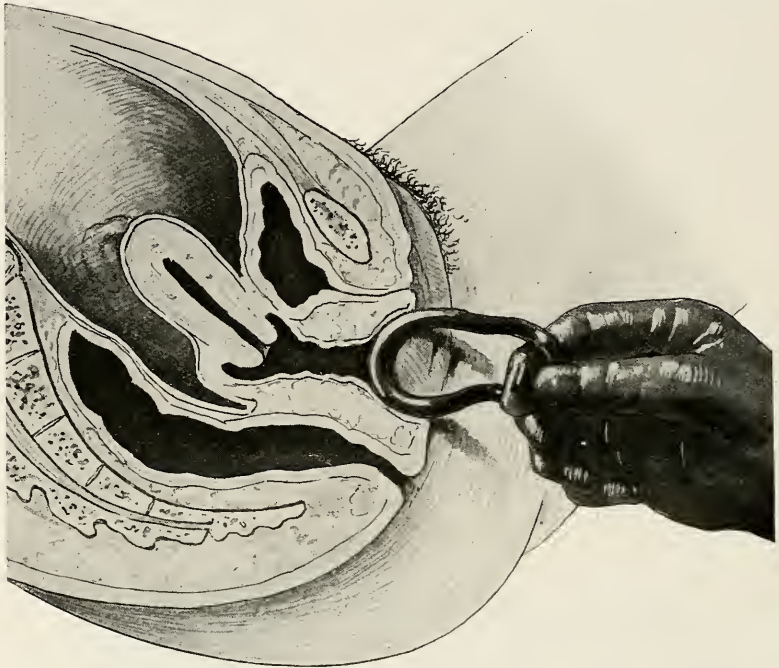


FIG. 309. HOW TO INTRODUCE THE HODGE PESSARY. First step, the instrument passing through the ostium vaginae.

except under anæsthesia when the requisite disinfection of the passages can be properly carried out. In very stout women reposition may be impracticable without the use of the sound. The uterus should first be raised as far as possible with the fingers; then the sound is introduced and passed up to the fundus; by carrying the handle well back over the perineum the fundus will be directed towards the pubes, where it can be pushed still further forwards by the fingers of the external hand (Fig. 306).

The manipulations with the sound must be very gently carried out; in attempting to raise an adherent uterus the sound may be pushed through the uterine wall. Unless the fundus can be readily brought forwards to the pubes, the attempt should be at once discontinued.

In some cases after the uterus has been apparently replaced without much difficulty, the faulty position recurs as soon as the retaining finger or the sound is removed. Lax adhesions are sometimes present in such cases, in others the immediate recurrence of the malposition is probably due to rigidity of the uterine wall which prevents the slight forward bending of the body on the cervix which is necessary to the position of anteversion. In all such cases pessaries will prove unsuccessful. Prolapsed ovaries, if not adherent, will be carried up into an approximately normal position when the uterus is ante-

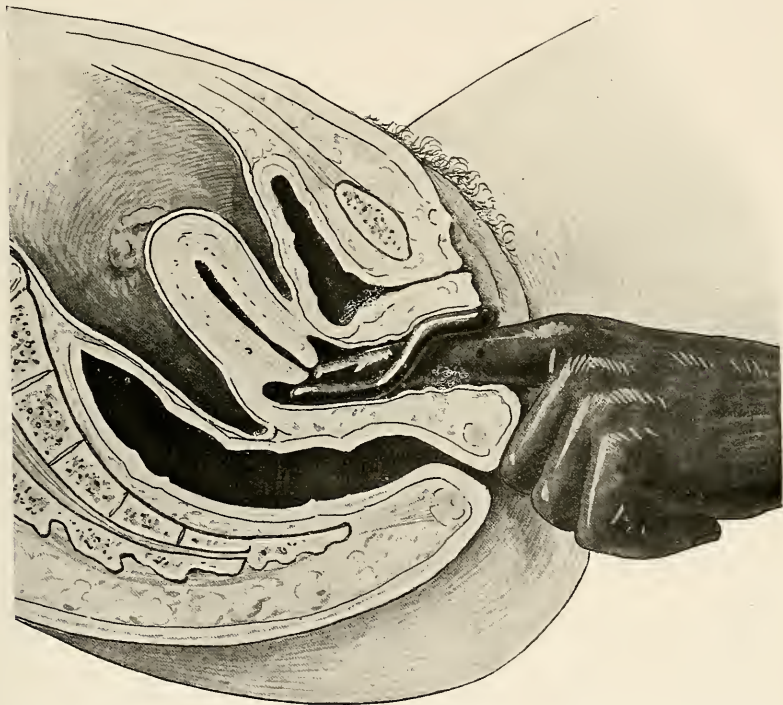


FIG. 310. HOW TO INTRODUCE THE HODGE PESSARY Second step, the instrument being pushed up into the posterior fornix.

verted. Tubo-ovarian adhesions will prevent replacement ; they can often be felt through the posterior fornix when the body of the uterus is elevated or held forwards.

When the uterus has been satisfactorily reduced, a suitable pessary should at once be introduced to retain it in position. The most convenient pessary for general use in these cases is the Hodge or Albert Smith pattern, shown in Fig. 307, or one of the various modifications of these patterns. The surgically clean instrument is held in the fingers of the right hand, as in Figs. 308 and 309, and introduced in the antero-posterior diameter of the vulva, the perineum being held back by the index finger of the left hand. If the uterus has been replaced

with the sound, the pessary may be introduced by passing it over the handle of the sound, the latter keeping the uterus in position. It is then pushed on gently in an upward and backward direction, until about one half of the instrument is within the vagina. The right index finger is then directed along the posterior vaginal wall to the upper bar of the pessary, which can then be carried on until it lies behind the cervix in the posterior fornix (*see* Fig. 310); the pessary will of itself rotate into the transverse diameter of the vagina as this is being done. The lower end of the instrument should now lie just within the ostium vaginae and in contact with the anterior vaginal wall, well above the urinary meatus; it thus rests against, and is supported by, the thick soft tissues which lie behind the lower end of the symphysis pubis, and which serve as its *point d'appui*, the pessary, as a whole, acting as a long vaginal splint. The upper end carries the posterior fornix upwards and backwards, and thus prevents forward displacement of the cervix. If, however, the vaginal walls and uterine supports are very lax, or if the pessary is too short, it is quite possible for the body of the uterus to fall back over the top of the instrument into the pouch of Douglas.

These pessaries are made of vulcanite, celluloid or flexible Britannia metal, rigidity being an important element in their construction. They may, however, be covered with rubber to reduce the risks of pressure. The instrument should be carefully adjusted to the length and capacity of the canal in which it is to lie. It should cause no discomfort to the patient, who should indeed be unconscious of its presence after introduction. If none of the commercial sizes is perfectly satisfactory, Britannia metal and vulcanite instruments can be moulded to the required shape, the latter after immersion in boiling water.

The patient should be directed to use a vaginal douche daily while wearing the pessary, and under no circumstances to allow it to remain longer than three months without being changed. Neglect of these precautions may lead to vaginal infection or ulceration. When changing the pessary a careful inspection with a speculum should be made of the posterior fornix and cervix; after a few months use of a rigid instrument superficial excoriations may be found which bleed when wiped with cotton-wool. If neglected, these may lead to ulceration of serious extent. They are more likely to form in the case of nulliparous women with narrow vaginae, than in parous women in whom the vaginal walls are more lax. The use of the pessary should be discontinued if this occurs and the patient advised to submit to operation.

It is often useful to perform a preliminary curetting of the uterus before pessary-treatment is begun, especially in cases of sub-involution and chronic endometritis.

Cases in which the displacement is irreducible or cannot be corrected by pessaries, can be dealt with only by operation. It must not be



forgotten, however, that tubo-ovarian inflammation, when present takes the case out of the class of displacements altogether, and the treatment should then be considered from a different point of view.

The operation of choice in backward displacements is intra-peritoneal shortening and interposition of the round ligaments, known as Gilliam's operation. Other methods of shortening the round ligaments are practised, or as an alternative, the uterus itself may be stitched to the abdominal parietes. These procedures cannot be usefully discussed without describing them in full, and the reader is here referred to the later section dealing with operations for backward displacements (*see* p. 770).

### CHRONIC INVERSION OF THE UTERUS

This condition is one of great rarity. In something like 90 per cent. of cases it is puerperal in origin and begins as an *acute* inversion. In the remainder it is non-puerperal and associated with the presence of a tumour, most commonly a submucous fibroid, growing from the fundus or upper part of the body of the uterus (*see* Fig. 311). Sarcoma appears to produce this result with relatively greater frequency than a fibroid (*see* p. 503); a small number of cases associated with carcinoma have also been described. The inversion is seldom complete in these cases, but may be so in rare instances, as in that recorded by Schäfer where a fibroid of the fundus produced a puerperal inversion. Puerperal cases, on the other hand, are usually complete; the cervical canal may be partially retained, as in Fig. 312, or the whole of the cervix together with the upper part of the vagina may also be inverted.

The *causation* of puerperal inversion need not be here considered. In non-puerperal cases, due to an intra-uterine tumour, the two factors which predispose to the occurrence of the displacement are, the weight of the tumour and the dilatation of the cervix which an intra-uterine growth usually produces. These two conditions allow of the portion of the uterine wall which forms the base of the tumour dropping into the cavity of the uterus; when this process has once been begun its progress is probably effected by contractions of the surrounding muscular wall; which tend still further to dilate the cervix and expel the mass.

**Anatomy.** In non-puerperal cases the size of the inverted uterus is never very large; cases are not classed as 'chronic inversion' until from four to six weeks have elapsed since delivery, and during this period involution proceeds with approximate regularity. The peritoneal surface of the uterus forms the cavity or *cup* of the inversion, and this seldom exceeds  $2\frac{1}{2}$  inches in depth. Usually the cup is empty, but sometimes contains the Fallopian tubes and ovaries; in acute puerperal cases a coil of the intestine may be contained in it, but this is never found in chronic cases, for persistence of the condition would clearly

result in intestinal obstruction. Not infrequently the cup becomes obliterated by adhesion of the peritoneal surfaces, resulting probably from infection which has gained entrance through the exposed mucous surface. Obliteration of the inversion-cup greatly increases the

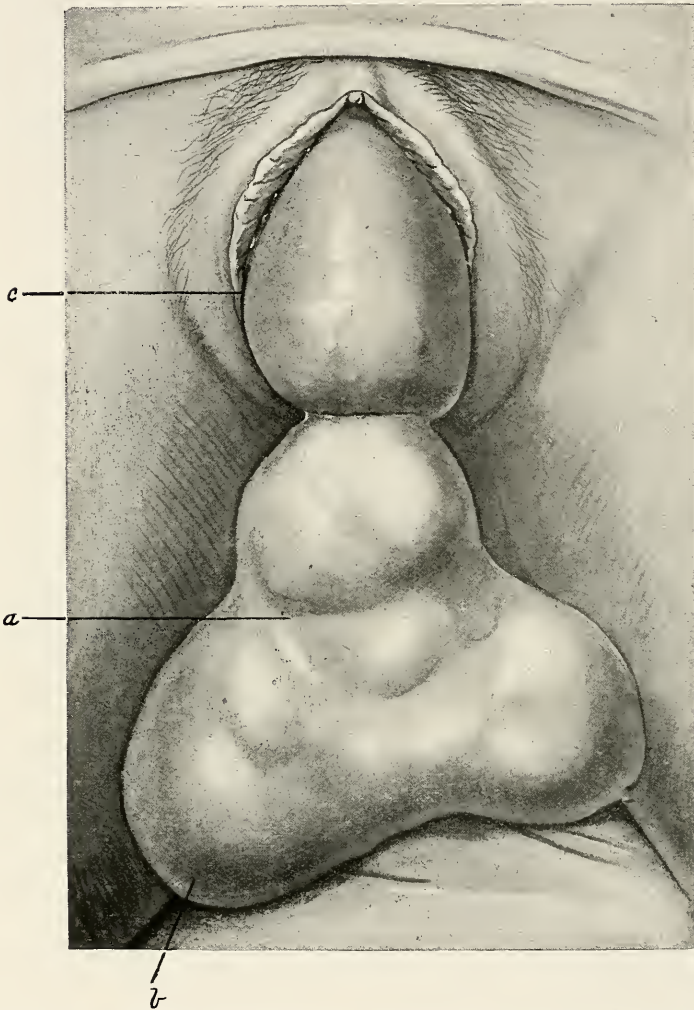


FIG. 311. COMPLETE INVERSION OF THE UTERUS AND VAGINA DUE TO A SUBMUCOUS FIBROID (after Barnes). *a*, Uterine fundus. *b*, Tumour. *c*, Inverted vagina.

difficulty of replacing the uterus. The edges of the cup form a prominent ring which is palpable by abdominal examination and is of great service in the diagnosis of the condition.

The mucous surface in the earlier stages is much altered in appearance by congestion and œdema; the openings of the Fallopian tubes are thus obscured. Later on superficial ulceration from traumatism

or infection may occur. Occasionally, in long-standing cases, cell-metaplasia from friction occurs, and the epithelium becomes stratified, taking on the external characters of vaginal mucous membrane.

While puerperal inversion is nearly always complete, non-puerperal inversion is usually incomplete, and varies in extent from a mere depression corresponding to the base of the tumour, up to the expulsion of the fundus into the vagina. In rare instances (*see* Fig. 311) complete inversion both of the uterus and the vagina may, however, take place.

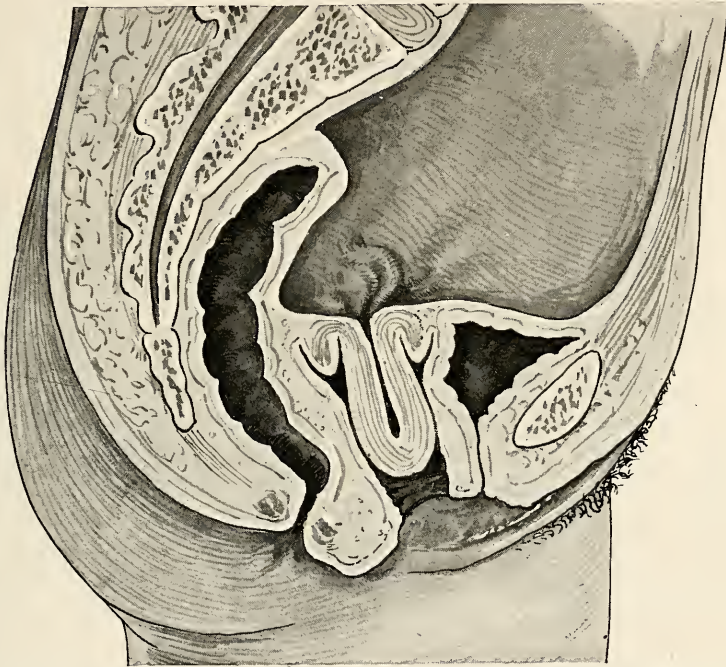


FIG. 312. INCOMPLETE CHRONIC INVERSION OF THE UTERUS (diagrammatic, after Haultain). The tube and ovary are seen lying above the inverted uterus.

The attachment of the tumour is usually fundal, but may be either sessile or polypoid.

**Clinical Features.** The prominent *symptom* of chronic inversion is irregular hæmorrhage, dating in puerperal cases from the last confinement; the bleeding may be very severe and has sometimes proved fatal. In addition, the patient may complain of the presence of a tumour, or of the womb 'coming down.' The diagnosis can only be made by physical examination, and while in complete puerperal cases this is very easy, in partial cases associated with a tumour, great care is required to avoid mistakes.

The completely inverted uterus forms a pyriform swelling, occupying the upper part of the vaginal canal. It is smooth, dark red in colour,

and usually bleeds readily on being handled. The orifices of the Fallopian tubes can seldom be distinguished. On passing the examining finger upwards, a constricting ring may be felt surrounding the neck of the swelling (*see* Fig. 312); this represents the external os, and shows that the cervical canal is not completely inverted. If the cervix has been completely inverted, no constricting ring is felt, and the finger meets the resistance of the vaginal *cul-de-sac* all round. Bimanual examination will reveal the absence of the uterine body from its normal position; the recto-abdominal method is the most suitable, as the vagina is occupied by the inverted uterus. The sound, if used, cannot be passed higher than the top of the vagina. Next to the absence of the uterus, the most important point is the recognition by abdominal examination of the ring of the inversion-cup; under anæsthesia this can always be felt, and its recognition is also an important point in regard to the reduction of the displacement.

**Differential Diagnosis.** There are two other conditions in which a large pyriform, bleeding swelling may be found occupying the vagina, and their differential diagnosis from inversion is a matter of considerable importance. These conditions are: (1) a large fibroid polypus; (2) carcinoma of the cervix. In both of these cases, when a careful bimanual examination is made, if necessary under anæsthesia, the body of the uterus will be found to occupy its normal position. In the case of the *polypus*, its stalk can generally be felt *per vaginam*, but this may conceivably be mistaken for the neck of the inverted uterus; the uterine cavity is, however, open, and a sound may be passed into it along the neck of the polypus. In cases of *carcinoma of the cervix* with formation of large masses of new growth (*see* p. 527), the cervical canal cannot be identified, but a careful bimanual examination will reveal the presence of the body of the uterus lying above the swelling in the vagina.

In incomplete cases, which are usually associated with the presence of a tumour, the diagnosis is less easy; while the tumour is readily recognized, the fact that the uterus is also inverted may escape notice altogether, unless the points just mentioned with regard to a recto-abdominal examination are borne in mind. A mistake of this kind may lead to serious operative mishaps (*vide infra*) and is only to be avoided by remembering its possibility and making, as a matter of routine in all cases of vaginal tumour, a careful examination of the body of the uterus.

**Treatment.** Cases of inversion when recent are to be treated by manual reduction; this procedure is described in text-books of midwifery. After some time has elapsed the inversion is much more difficult to reduce, and continuous elastic pressure is required to overcome the resistance offered by the inversion ring. The best method of applying this pressure is by the *repositor* of Aveling shown in Fig. 313. The vulcanite cup (*a*) fits over the fundus of the uterus;

the cup is continued below into a rigid curved stem (*b*), to which four strong rubber bands are attached; these are in turn fixed by tapes to an abdominal girdle, or preferably to shoulder straps (*c*); the cup is thus held in contact with the fundus, and by stretching the rubber bands, continuous elastic pressure in an upward direction is applied through the stem to the inverted uterus. Considerable discomfort attends the use of the repositer, and the treatment must therefore be applied intermittently, as the patient is able to bear it. The process of replacement must be carefully watched, and the cup may be removed before reduction is quite completed, for the last part of the process will occur spontaneously. If this precaution is not adopted, the cup may be carried inside the replaced uterus, and great difficulty may be encountered in extracting it through the narrow cervix.

Failure may, however, occur from two causes: (1) obliteration of the peritoneal cup by adhesions which form an absolute bar to success; (2) rigidity of the uterine tissues, a certain amount of elasticity being clearly required to allow the uterus to be re-inverted. If the first application of the repositer should fail, an interval of ten days should be allowed during which an attempt may be made to improve the local conditions. Thus the patient may be kept at rest with the foot of the bed raised, and hot vaginal douches alternating with glycerine tampons made use of. The second attempt may then succeed.

When attempts at reposition fail, operative measures must be adopted, and these measures are of course required in all cases of non-puerperal inversion.

*Operative Treatment.* This may be radical or conservative. *Radical* operation consists in removing the uterus by vaginal hysterectomy; it is indicated in most cases of non-puerperal inversion, and in others when the patient has passed or is nearing the end of the child-bearing period. Puerperal cases in young women should if possible be treated by conservative methods only.

When a tumour is present the question of its possible malignancy should first receive consideration. Fibroid tumours are usually encapsulated, and can be shelled out after the capsule has been freely incised. Non-encapsulated growths may be malignant and should be treated as such. In some instances preliminary microscopic examina-

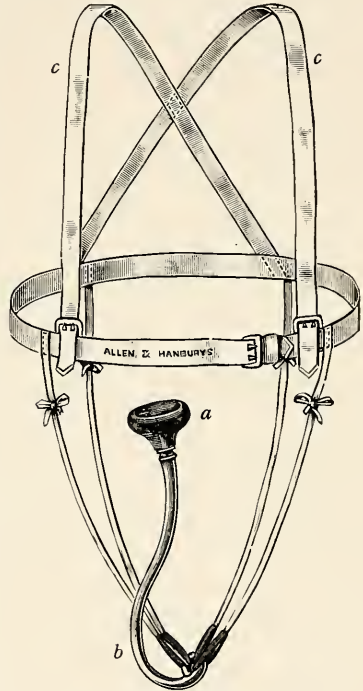


FIG. 313. AVELING'S REPOSITOR FOR CHRONIC INVERSION.

tion of a portion of the growth may be desirable. If the case is regarded as malignant, an extended vaginal hysterectomy, after the method of Schuchardt, should be practised (*see* p. 845).

Of *conservative* methods many varieties have been advocated ; that which has best stood the test of experience is to overcome the difficulty of reposition by means of an incision through the uterine and the vaginal walls (*see* p. 833). By means of these incisions difficulties such as peritonitic obliteration of the inversion-cup can be dealt with, and room obtained for the manipulation of the uterine walls. The mortality of the operation is low, and the permanent results appear to be good.

## PART II: SECTION IV

### PROLAPSE; AND HYPERTROPHIC ELONGATION OF THE CERVIX

As already mentioned prolapse is a complex condition affecting the uterus and many other pelvic organs and structures. It is, strictly speaking, not an affection of the uterus, and in considering it attention should not be concentrated upon the uterus, which in the majority of cases is not the organ which is either primarily or chiefly affected.

There are four common clinical varieties of prolapse, viz. (1) prolapse of the anterior vaginal wall (*cystocele*); (2) prolapse of the anterior vaginal wall and the uterus; (3) prolapse of both anterior and posterior vaginal walls (*cystocele* and *rectocele*); (4) complete prolapse of the uterus with inversion of the vagina, *i.e.* *procidentia*; (5) one other form must be recognized which is much rarer, viz. prolapse of the posterior vaginal wall alone (*rectocele*). With these conditions must be classed another, viz. *hypertrophic elongation of the cervix*. This condition is frequently met with as a complication of prolapse, although in one of its forms (*vide infra*) it is primary and occurs alone.

The frequency with which these different forms are met with is variable; the commonest combination is uterine prolapse with *cystocele*; then, combined *cystocele* and *rectocele*; with uterine prolapse cervical elongation and hypertrophy are frequently combined; the rarest conditions are simple *cystocele* and simple *rectocele*, the latter being the rarest of all.

It is therefore clear that *prolapse* is not a displacement of the uterus alone, the vagina being usually involved as well, and in some cases also, as will be seen later, the bladder and urethra, the rectum, the Fallopian tubes and ovaries, the broad ligaments, and even coils of intestine or a portion of the omentum, may form a part of the prolapsed structures.

Prolapse may be likened to hernia, inasmuch as it consists in the protrusion of a portion of the pelvic contents through an aperture in the supporting structures. *Procidentia* further resembles hernia in the presence of *coverings*, the vagina, a *sac*, consisting of the utero-vesical and utero-rectal pouches, and certain *contents* which may consist of a variety of different structures which have been drawn into it. The hernial aperture through which prolapse occurs is formed

internally by the interval between the *levatoris ani* muscles and externally by the ostium vaginae.

All varieties of prolapse, except that due to elongation of the cervix, are met with much more frequently in parous than in nulliparous women, and there can be no doubt that the obstetric laceration and relaxation of supporting structures are powerful predisposing causes. In a few cases it may be that the walls of the hernial aperture are congenitally weak, and the internal organs indifferently supported; prolapse may then occur without any actual injury having taken place. On the other hand, stretching of the hernial aperture, when once begun, may be continuously increased by abnormal intra-abdominal pressure; as when a large abdominal tumour is present, or when the patient follows some laborious occupation involving muscular effort, or suffers from a chronic cough, or from attacks of violent sneezing as in hay-fever. Constipation, and the straining it entails, may in the same way become a contributory cause.

### ANATOMY OF PROLAPSE

In all but very early cases of prolapse there is a protrusion from the vulva, but the extent of the protrusion is very variable. The protrusion may be only apparent after the patient has been up and about for some hours; when resting it again retreats within the vulva. In all forms of prolapse the degree of protrusion is increased by contraction of the diaphragm and abdominal muscles, *e.g.* in 'straining.'

**Prolapse of the Uterus.** This is described as occurring in three degrees. In the *first*, often called *descent*, the uterus lies below its normal level, but the cervix does not protrude from the vulva; it *may or may not* be accompanied by backward displacement. In the *second* degree the cervix protrudes, in part or wholly, from the vulva, and the body *is always* directed backwards. In the *third* degree, distinguished as *prolapsed*, the whole uterus is expelled through the vulva, and the vagina in consequence is almost completely inverted.

The first stage of the process consists essentially in dropping of the uterus; any backward displacement is only incidental and is explained by the fact that the uterus cannot fall as low as the pelvic outlet unless it lies in the axis of the outlet. The vagina is not affected at this stage to an appreciable extent. The second and third stages consist essentially in inversion of the vagina, and this process usually takes place from below upwards, *i.e.* the vagina is not inverted by the traction exerted upon it by the falling uterus; on the contrary, the latter is drawn out of the pelvic outlet by the inversion of the anterior wall of the vagina. That this is the true sequence may be demonstrated in a case of prolapsed uterus by watching the reappearance of the prolapsed parts after they have been reduced. If the patient is directed to strain, the lower part of the anterior vaginal wall first appears, then the



remainder of this wall bringing with it the cervix, and lastly the posterior wall appears, being inverted in the reverse direction, viz. from above downwards. Procidentia is accordingly a combination of cystocele with *prolapsus uteri*; the inversion of the posterior vaginal wall, as will be seen later, is not a true rectocele, but the mechanical result of the uterus being driven out of the pelvis.

The structure of the hernial protrusion in cases of *procidentia* is

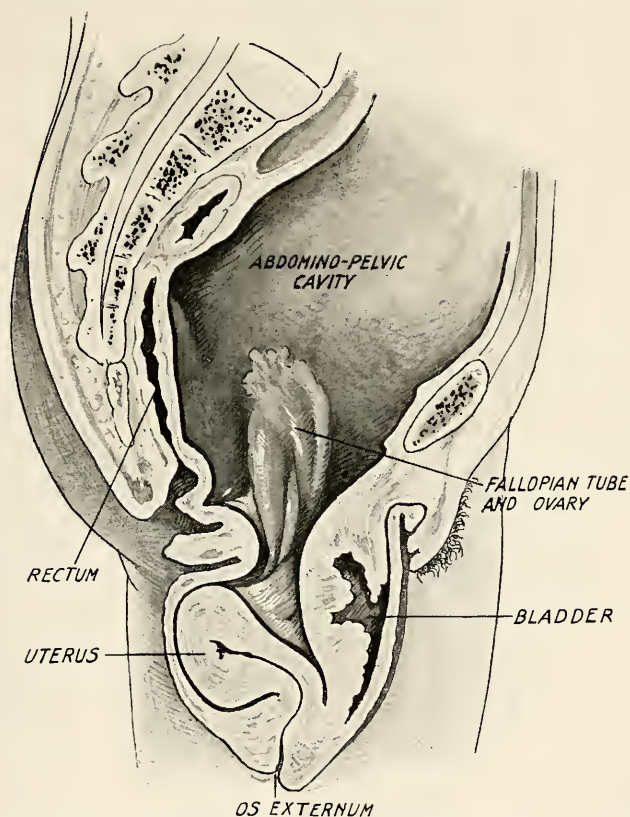


FIG. 314. PROCIDENTIA UTERI, as seen in mesial sagittal section of the pelvis; the cervix is somewhat elongated (Berry Hart).

shown in Figures 314 and 315, in sagittal mesial section. The protrusion forms an inverted cone, the apex of which is formed by the *portio vaginalis* with the external os; the outer coat or covering of the hernia is formed by the wall of the vagina, which is completely inverted, and can be traced forwards to the urinary meatus and backwards to the perineal body. At the base of the hernia lie the mons Veneris in front and the anus behind. The sections show that the whole of the bladder and the whole of the uterus lie within the hernia. The posterior vaginal wall has been completely separated from the rectum; only a small portion of the anterior rectal wall is seen in Figure 315, while in

Figure 314 it is seen that no part of the rectum has been drawn into the protrusion. The urethra runs almost vertically upwards from the bladder to the meatus. The anterior and posterior peritoneal pouches

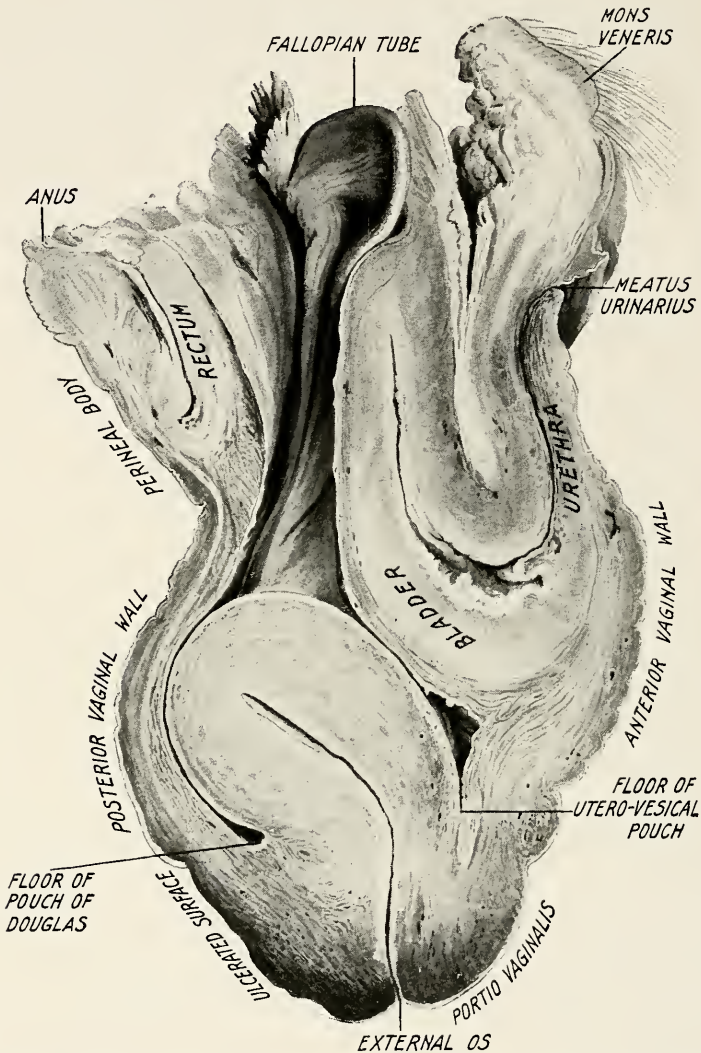


FIG. 315. PROCIDENTIA UTERI FROM A DISSECTION. A sagittal mesial section has been made through the hernial protrusion to show its component parts. The thickening of the bladder wall is probably due to chronic cystitis (Charing Cross Hospital Museum).

lie outside the pelvis; the Fallopian tube and ovary lie at a much higher level than the uterus. It would obviously be possible, during life, for coils of intestine or portions of omentum also to find their way into the peritoneal pouches.

It is not in all cases that the whole of the bladder passes into the

hernia ; in less advanced instances it is the base of the bladder only, the herniated portion forming a sac in which urine is liable to become stagnant. It is obvious from the marked displacement of the urethra that considerable mechanical difficulty must arise in evacuating the bladder.

Cases of total prolapse of the uterus such as those just described are rare ; instances are much more common in which, although almost the whole of the vagina is inverted, a portion of the uterus is retained

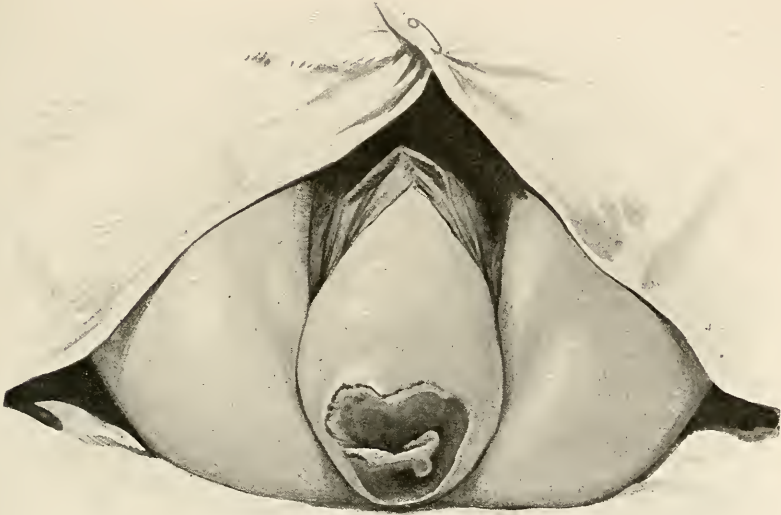


FIG 316. THE CLINICAL APPEARANCES OF PROCIDENTIA AND ALSO OF THE EXTENSIVE DEGREES OF THE SECOND STAGE OF PROLAPSE. Note the anterior vaginal wall is completely inverted and there is extensive ulceration of the cervix.

within the pelvis owing to the accompanying elongation of the supra-vaginal cervix. These are not, strictly speaking, cases of *procidentia*, but are extreme examples of the second degree of prolapse. When the *base* of a true *procidentia* is pinched up with the fingers the uterus is not felt in it at all.

In long-standing cases of the second and third degrees, certain *secondary* changes occur in the prolapsed parts. The anterior vaginal wall loses its transverse folds and becomes smooth from stretching ; next the epithelial covering dries and takes on the appearance of skin. In chronic cases great thickening of the vaginal wall occurs from congestion and œdema, and the tissues lose their pliability and become hard and dense. The anterior wall shows these changes much more markedly than the posterior, and may be found one-third to half an inch thick in chronic cases which have been long unreduced. As a result of these changes, ulceration is not infrequently found on some part of the

prolapsed mass, usually near the external os (*see* Fig. 316). Usually it is callous in type and is due to defective circulation, malnutrition of the tissues, and chronic irritation from friction, urinary contamination, etc. Occasionally infection spreads from the ulcer to the deeper tissues, and may lead to local peritonitis and the formation of adhesions.

Elongation of the cervix is frequently found in cases of procidentia, usually affecting the supra-vaginal portion, but sometimes affecting the vaginal portion also. As a rule this condition results from the prolapse, but sometimes it is a pre-existing abnormality, and possibly a contributory cause. The body of the uterus is always retroverted in procidentia (*see* Figs. 314 and 315), and in old women it may be atrophied from post-climacteric changes. In long-standing cases of *true* procidentia, in which there is no elongation of the cervix, the whole uterus shrinks, and may become abnormally small.

As a rule, the hernia is reducible without difficulty; occasionally it becomes temporarily irreducible from œdematous swelling of the parts; after a few days rest in bed, however, reduction can usually be effected in these cases. Very rarely, cases of completely irreducible procidentia are met with, failure to return the prolapsed parts being due, either to rigidity of the vaginal walls, or to the formation of peritonitic adhesions involving the prolapsed uterine body.

The condition of the *perineal body* is an important clinical point in connection with prolapse, although, as has been already pointed out, it is not an etiological factor of much importance. Three degrees of perineal laceration are usually described. In the first the anterior half of the perineal body is involved; in the second the tear has extended up to, but has not included, the external *sphincter ani* muscle; in the third this muscle has been involved, the anus is wholly or partly incompetent, and a portion of the rectal mucous membrane often protrudes (*see* Fig. 494, p. 819). In rare cases of prolapse, *e.g.* in nulliparæ, the perineal body may be found uninjured. Loss of the tissues of the perineal body does not necessarily cause prolapse of the uterus; but one of its functions is to assist in closing the vaginal orifice, and the destruction of this function is certainly a predisposing cause of prolapse of the vaginal walls. Not infrequently the perineal body is injured on its deep (vaginal) aspect without much external sign of injury. On picking up its tissues between the thumb externally and the finger in the vagina, it will be found that the anterior part of the perineal body has been greatly reduced, often to the thickness of stout paper. If the vaginal orifice is now opened up by the fingers, a deep sulcus will be found in the posterior vaginal wall running upwards and to one side; sometimes there are two sulci of unequal depth, one on each side. On the floor of the sulcus an irregular line of cicatricial tissue will be found. The deep part of the perineal body has been destroyed by a puerperal laceration extending into it from

the posterior vaginal wall, and this internal injury weakens the vaginal orifice as much as, or even more than, an external one. In such cases very marked *relaxation* of the orifice may be present, so that it may be stretched sufficiently to admit three or even four fingers without giving the patient pain (*see* Fig. 317).

Incompetence of the anus is one of the most distressing complications of perineal injuries, and careful attention should always be paid to the condition of the external sphincter. In its normal condition, the

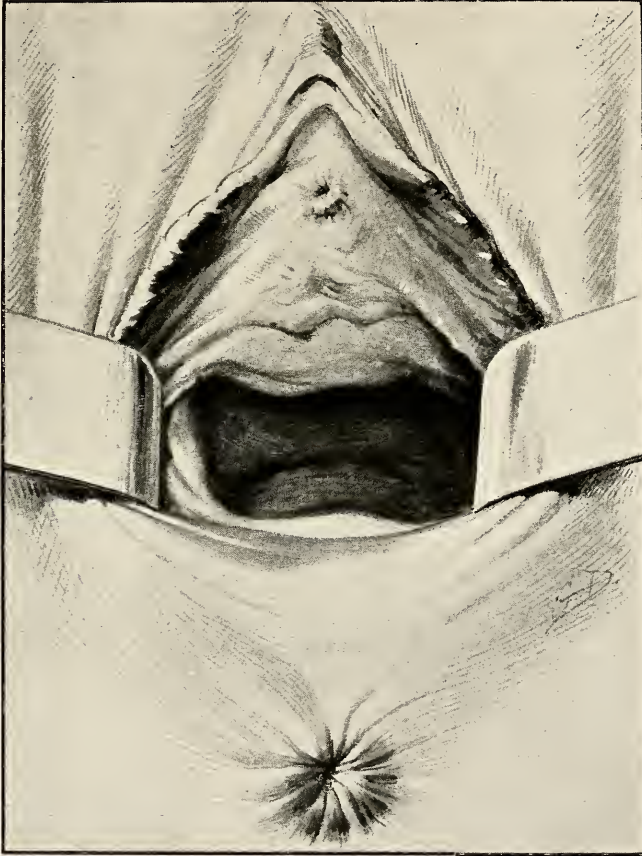


FIG. 317. RELAXATION OF THE OSTIUM VAGINÆ IN A PAROUS WOMAN, due to laceration of the posterior vaginal wall. The skin-surface of the perineal body is uninjured. (From a photograph.)

presence of shallow radial folds of skin around the anus indicates its functional activity (*see* Fig. 317); when the anterior part of the muscle has been involved in a perineal laceration these radial folds, though still seen at the sides and posteriorly, are absent in front, the anterior wall of the anus being represented by a band of smooth cicatricial tissue. The ends of the torn muscle have retracted so that it is now

horseshoe shaped, and the position of the retracted ends is often indicated by a shallow pucker or dimple in the skin on each side. As a rule the retracted ends are not precisely opposite one another (see Fig. 494, p. 819).

**Cystocele.** In this condition the anterior vaginal wall, and with it the base of the bladder and the urethra, protrude from the vulva (see

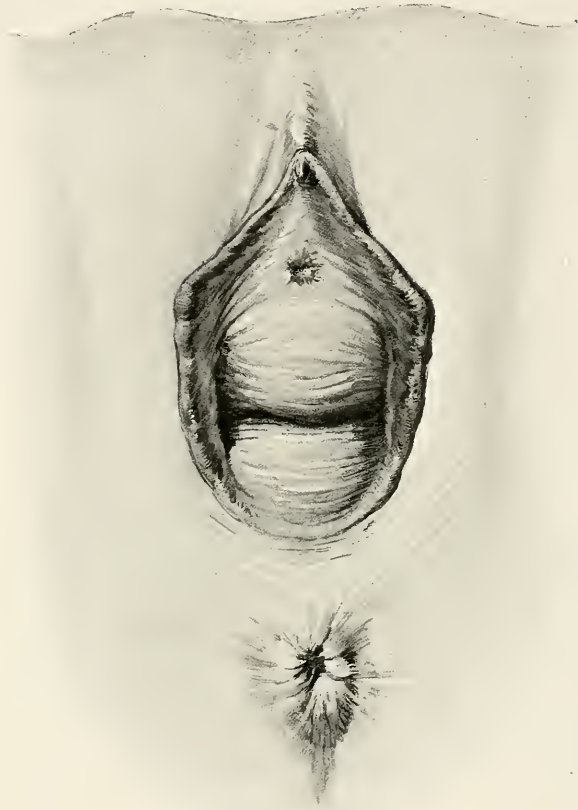


FIG. 318. CYSTOCELE (early stage), with slight prolapse of the posterior vaginal wall.

Fig. 318). The vaginal wall becomes stretched, and loses the characteristic transverse folds which are normally found, except in its lower part, where they persist. The lowest part of the anterior vaginal wall is the part first involved, but in extreme cases the whole of this wall may protrude, dragging the external os down to the vulva. A certain amount of descent of the uterus accompanies it, but well-marked cystocele may exist with only a slight degree of uterine prolapse, and this form may be met with in both parous and nulliparous women. The anterior fibres of the levator ani, which arise

from the back of the pubes, form an important support to the anterior vaginal wall and bladder; cystocele is a protrusion of the bladder through the interval between the two levators; accordingly laceration or overstretching of these muscles, or possibly congenital weakness, predisposes to the occurrence of this form of prolapse.

The protrusion is soft and elastic in consistence owing to the participation of the bladder. At the anterior extremity, underneath the pubes, the orifice of the urethra will be observed; it is displaced forwards and is consequently more prominent than under normal conditions. The vertical course of the urethra may be demonstrated by passing a catheter into the bladder. In the recumbent position cystocele will not be obvious until the patient strains, when the protrusion at the vulva will at once appear. On vaginal examination, with the parts in their natural position, the anterior vaginal wall will be felt to be relaxed and elongated.

**Rectocele** is a protrusion of the lower part of the posterior vaginal wall which has carried with it a corresponding portion of the anterior rectal wall; the swelling, therefore, contains part of the lumen of the rectum. This is the rarest of all the forms of prolapse. When, in procidentia, the posterior vaginal wall becomes inverted, it separates from the rectum so that the latter does not enter into the hernial protrusion at all (*see* Figs. 314 and 315). The loose cellular tissue of the recto-vaginal septum allows the rectal and vaginal walls to be thus separated from one another. In such circumstances a rectocele is not formed, although the posterior vaginal wall is prolapsed. For the production of a rectocele it is necessary that firm union should exist between the rectal and vaginal walls, and inflammation of the cellular-tissue plane following upon a puerperal laceration is the usual antecedent. In such cases the perineal body does not necessarily show traces of injury, the laceration may have been above it. Occasionally, however, rectocele is seen as a primary condition in a nulliparous woman; the mechanism of its production in such cases is not clear.

**Hypertrophic Elongation of the Cervix.** The cervix may become elongated in either its *vaginal* or its *supra-vaginal* portion (*see* Fig. 7, p. 13); the change is not due to stretching, but to new formation of tissue, *i.e.* the elongation is hypertrophic. Elongation of the *vaginal portion* is usually congenital. Elongation of the *supra-vaginal cervix* is frequently, but not always, acquired; in the great majority of cases it is associated with prolapse of the uterus.

(a) *Elongation of the Vaginal Cervix (Portio Vaginalis).* The cervix presents at, or protrudes from the vulva, and the condition may therefore be mistaken for prolapse of the uterus (*see* Fig. 319). It is, however, most commonly seen in virgin or nulliparous women, in whom prolapse is uncommon. On internal examination the fundus of the uterus will be found at its usual level, *i.e.* the organ is not prolapsed; also the vaginal fornices are not depressed; the vaginal canal

is occupied by a long cylindrical body, at the free end of which is found the os externum ; and the length of the uterine cavity as determined by the sound may be increased up to four or four and a half inches. In procidentia the protrusion of the cervix is due to the low level of the organ, in cervical elongation it is pushed out on account of its extreme length. The diagnosis is accordingly a matter of great

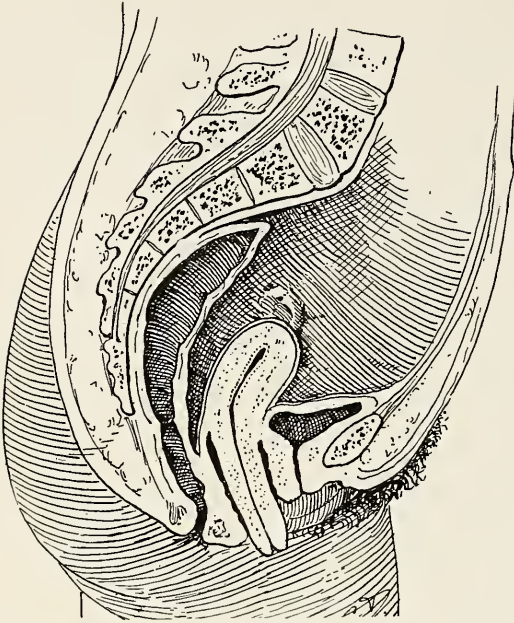


FIG. 319. HYPERTROPHIC ELONGATION OF THE VAGINAL PORTION OF THE CERVIX (diagrammatic).

simplicity, for the clinical resemblance of this condition to prolapse is only superficial.

In *congenital* elongation of the *portio vaginalis* the vaginal cervix presents points of histological interest (see Fig. 320). The hypertrophy affects the fibro-muscular stroma only, the gland-elements of the endometrium and the squamous epithelium of the *portio vaginalis* showing neither hypertrophy nor hyperplasia; in fact, the epithelial structures, both columnar and squamous, appear to be comparatively poorly developed (cf. Fig. 15, p. 20).

(b) *Elongation of the Supra-vaginal Cervix.* This condition is seldom if ever met with apart from uterine descent or prolapse.

Occasionally cases of complete cystocele with elongation of the supra-vaginal cervix are met with, in which little or no change has occurred in the *posterior vaginal wall*. In such cases the elongation presumably affects the intermediate portion of the cervix ; the intermediate portion is described as that comprised between the level of the peritoneal reflection on the anterior and that on the posterior wall (see Fig. 7, p. 13). Combined elongation and hypertrophy of both the vaginal and supra-vaginal portions are also commonly met with in marked cases of prolapse of the uterus. Whether the elongation is a sequence of the prolapse or a cause of it is uncertain.

### SYMPTOMS OF PROLAPSE

The symptoms to which prolapse give rise are variable, and often inconsiderable. In slight cases a feeling of weight or 'bearing down'



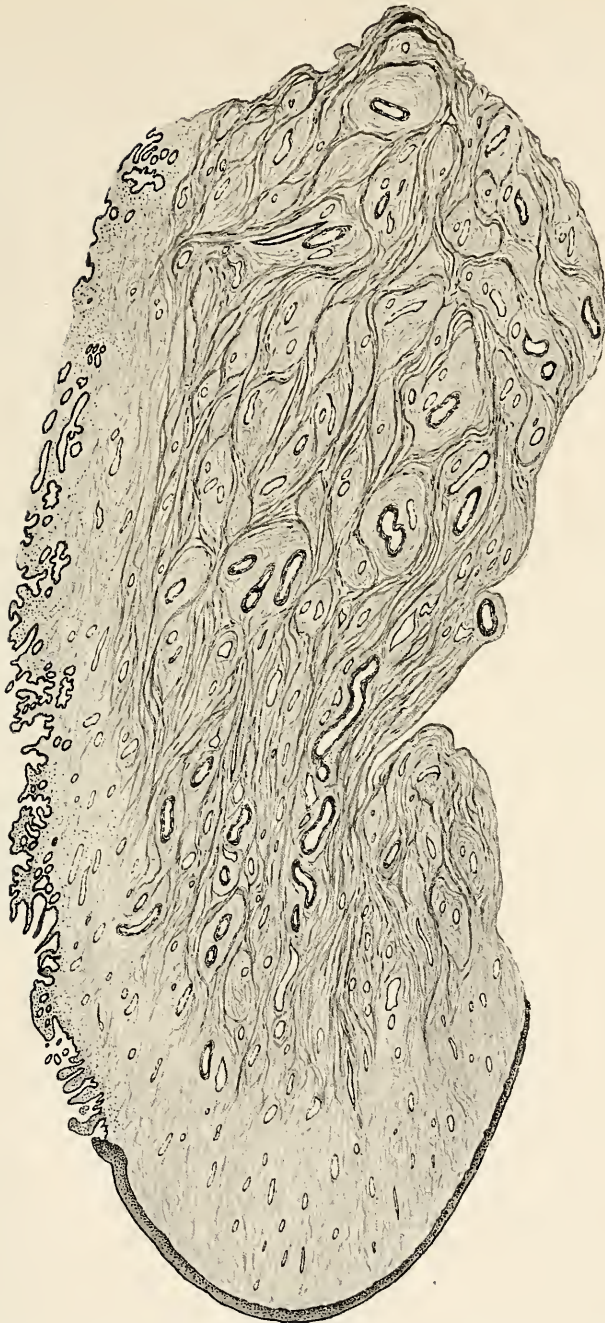

FIG. 320. A SAGITTAL SECTION THROUGH THE CERVIX OF A YOUNG VIRGIN IN A CASE OF HYPERTROPHIC ELONGATION. The os presented nearly at the vulva. There is hypertrophy of the fibro-muscular tissue, but the glands are few and small, and the squamous epithelium is relatively thin.

is usually the only symptom present. In other cases, even moderate degrees of prolapse give rise to constant dragging pain; this is aggravated by standing or walking, or by muscular effort of any other kind, and may become insupportable to women who lead an active life. Rest in the horizontal position will usually relieve this pain by correcting the displacement. Persistent pain is only met with in cases of temporarily or permanently irreducible procidentia. On the other hand, in some cases of complete procidentia, the inconvenience caused by the bulk of the hernial protrusion is the only thing the patient complains of. Hypertrophic elongation of the vaginal cervix causes a certain amount of discomfort from the mechanical effects of the protrusion, and in unmarried women often a good deal of mental distress. It also offers an obstacle to coitus. In other respects it is of little importance.

Prolapse is a displacement of slow and gradual formation; it is during the early stages that pain is most prominent; when the displacement ceases to advance, pain diminishes or disappears. The menstrual function is not affected, nor is the reproductive capacity much impaired, except in cases of procidentia. Leucorrhœal discharge is commonly met with, and slight bleeding may occur from ulceration of the protruding parts. In cases of cystocele, irritability of the bladder and frequency of micturition are often but not always complained of; sometimes the bladder is incompletely evacuated, and cystitis from decomposition of residual urine may then occur. In almost all marked cases of cystocele the sphincter of the bladder is weakened, and slight dribbling incontinence occurs on coughing or muscular exertion.

When the *sphincter ani* muscle has been extensively injured, a greater or lesser degree of rectal incontinence results, and this when present forms the most distressing symptom of all. While control of flatus and liquid contents may be lost, total incontinence is seldom or never seen. The injury does not involve the deep sphincter except in very extensive lacerations, and the competence of this muscle makes up for the loss of the external sphincter.

The most important clinical symptom of prolapse, in the majority of cases, is that it incapacitates the patient from leading an active life, and from most kinds of manual labour.

*Diagnosis.* In all cases of prolapse the condition of the perineal body should be ascertained by careful inspection in a good light, noting the extent of the deficiency, if any, and the condition of the external sphincter ani. The patient should then be asked to strain, gently at first and then strongly. If the protruded parts do not include the cervix, the finger should be passed into the vagina, and the horizontal level of the external os carefully noted during straining and when at rest. Finally, an ordinary bimanual examination should be made, noting the position of the uterus, the fundus, the condition of the tubes and ovaries, and the pelvic contents generally.

It must be recollected that, except in extreme cases, prolapse disappears in the recumbent position, and in that position will only become evident when the patient strains; in order to observe the full extent of the displacement it is in some cases desirable to examine the patient in the standing position. Well-marked instances of cystocele may be observable only when the patient stands up and strains; if the examination is confined to the recumbent position, the condition may be overlooked. In most cases the full extent of the displacement will only appear in the erect position, and allowance must be made for this in estimating the degree of displacement which is apparent when the patient is examined lying down.

Protrusion of the cervix at the vulva is due either to prolapse, or to hypertrophic elongation of the cervix; not infrequently both conditions are present. Elongation of the vaginal portion of the cervix is easily recognized, as it can be both seen and felt. The protruding cervix cannot well be mistaken for any other structure, the presence of the external os at the lower end, and the normal position of the fundus, being distinctive. Elongation of the supra-vaginal cervix can also be recognized by palpation, the long slender cylindrical outline being easily felt through the vaginal walls in a case of proidentia. The use of the uterine sound is usually unnecessary.

The only condition which can be mistaken for cystocele is a *cyst of the anterior vaginal wall* (see Fig. 186, p. 385); such cysts usually become prolapsed and then form a vulval protrusion resembling a cystocele. On replacing the cyst within the vagina, its presence in the anterior wall will be detected by the examining finger on careful bimanual palpation; in cystocele when the vaginal wall has been replaced and the bladder is empty, nothing but the general lax condition of the vaginal wall is observed. The use of a bladder-sound will, of course, clear up any doubt that may remain. Similarly a rectocele may be distinguished from a prolapsed cyst of the posterior vaginal wall by rectal examination.

### TREATMENT OF PROLAPSE

There are three possible lines of treatment for cases of prolapse: (1) Rest and general massage; (2) pessaries; (3) operative measures.

(1) Slight cases of prolapse occurring in young women, detected soon after confinement and associated as they often are with 'subinvolution,' are often curable by putting the patient to bed for three or four weeks, and taking measures to improve the general muscular condition. Daily massage by a skilled person, with muscular exercises, attention to the daily evacuation of the bowels, and the administration of such tonic remedies as strychnine and iron, are the points of greatest importance. As the weight of the uterus diminishes, and the general muscular condition improves, the prolapse may be permanently cured;

or alternatively the advance of the displacement may be arrested, and the symptoms permanently relieved. This method is not applicable to old-standing cases or to those of the second and third degrees.

(2) *Pessaries*. Gynæcologists of an earlier generation devised vaginal pessaries which are capable of keeping the uterus within the body under almost all circumstances, if their presence can be tolerated by the patient. In the case of some of them, the discomfort of the pessary is greater than that of the prolapse, and in addition, their continued use is liable to cause serious ulceration, leading sometimes to perforation of the vaginal walls, opening up the bladder, the rectum, or the peritoneal cavity. No useful purpose would be served by describing these obsolete instruments; the conditions under which they were formerly resorted to are now dealt with more satisfactorily by operative measures.

Prolapse can never be *cured* by wearing a support, as is the case with some instances of backward displacement (*see* p. 570). The pessary is used to relieve symptoms, and to check the natural tendency to increase of the condition. It is in cases of prolapse of the uterus of the first and second degrees that a pessary will be found most useful, and the elastic (watch-spring) rubber-covered ring is the instrument which will be found most generally useful (*see* Fig. 321). It must be recollected that these pessaries are unsuitable for cases in which the retentive power of the vagina has been completely lost through extensive laceration of the perineal body, or through relaxation of the *ostium vaginae*. Unless the structures which close the vaginal aperture retain much of their natural competence, the pessary will be expelled by muscular efforts such as straining at stool, or even when walking. The pessary cannot be worn in comfort if such conditions as inflammation or ulceration of the vaginal walls are present.

In selecting a ring pessary for such a case, it is important to use the largest size which can be retained without discomfort, the action of the pessary being slightly to stretch the vaginal canal in its transverse diameter. While the upper parts of the vaginal walls remain in their normal position only slight descent of the uterus is possible. Its action in supporting the uterus is thus mainly indirect. If the pessary is large enough to exert much tension upon the vaginal walls, its effect will be still further to stretch these already relaxed structures, and thus actually to aggravate the condition.

To introduce the ring pessary, the patient should lie upon her side or on her back with the thighs flexed; the *clean* instrument is then held in the right hand, the index finger being passed through the ring in the manner shown in Figure 322. The ring, thus compressed to an oval shape, is introduced in the antero-posterior diameter of the ostium vaginae, being directed at first backwards towards the sacral hollow. When rather more than one half of the instrument is inside, it may be allowed to expand, and then pushed gently upwards; rotation into the trans-

verse diameter now occurs spontaneously, and the index finger should be slipped up the posterior vaginal wall so as to guide the upper part into position *behind* the cervix. The lower part should now lie behind the lower border of the symphysis pubis, and the instrument should be of



FIG. 321. THE WATCH-SPRING RING PESSARY.



FIG. 322. HOW TO HOLD THE PESSARY FOR INTRODUCTION.

sufficient size to prevent the anterior vaginal wall from sagging through it. This instrument does not interfere with marital intercourse.

In cases of cystocele a ring pessary is seldom successful, for the anterior vaginal wall and bladder will protrude through it if the cystocele is of considerable size. Ring pessaries with a perforated rubber diaphragm are sometimes used for this purpose, but this device is objectionable, as it prevents the free escape of the uterine and vaginal secretions. For slight cases of cystocele a Hodge pessary to the lower end of which a transverse bar has been added is useful; severe cases of cystocele can only be dealt with efficiently by operation (*see* p. 806).

Cases of prolapse in which the retentive power of the vagina has been lost are, generally speaking, unsuitable for treatment by pessaries, and in almost all cases operative measures should be advised. Some-

times, however, in such cases the patient may decline to submit to operation, in others operation may be undesirable on account of advanced age or for some other reason. In these circumstances mechanical support may be afforded by the Napier pessary.

The Napier pessary (*see* Fig. 323) consists of a thick but flexible stem terminating above in a shallow-rubber cup ; when introduced the




FIG. 323. NAPIER'S PESSARY FOR PROLAPSE.

cervix rests upon the cup, which is perforated to allow of the escape of discharges. The stem is of sufficient length to allow the lower end to lie outside the vulva. Through this end are threaded two rubber bands, and to each end of the bands tapes are attached. The tapes are passed, two forwards over the pubes and two backwards over the buttocks, to be fixed to a belt round the waist. By adjusting the tension of the tapes, elastic pressure in an upward direction is exerted upon the instrument through the rubber bands, and in this way the descent of the uterus or the vaginal walls is prevented. This instrument should be worn only in the day, and removed each night and a vaginal douche used ; before re-introducing it the instrument should be thoroughly cleansed by boiling, or by immersion in 5 per cent. carbolic solution. The continued use of this pessary cannot be advised unless these precautions are taken, but its management is readily learned by the patient herself or an attendant. Neglect of these precautions may lead to serious ulceration of the vagina ; and inasmuch as the precautions cannot be enforced, cases in which it is recommended must be carefully selected.

(3) *Operative measures* for prolapse include the following procedures : (1) Perineorrhaphy ; (2) radical cure of cystocele ; (3) amputation of the cervix ; (4) Le Fort's operation ; (5) ventrisuspension and ventrifixation ; (6) vaginal hysterectomy combined with suture of the broad ligaments.

The description of these operations will be given in a later section,

but the indications for each may here be briefly mentioned. *Perineorrhaphy* is indicated when the perineal body has been considerably injured, or when the *ostium vaginae* has become relaxed so that its retentive capacity is diminished or lost. Its object is to restore the vaginal outlet, and in addition, when necessary, to repair the anal sphincter. In cases where the posterior vaginal wall is prolapsed, the dissection may be extended upwards until rectum and vagina have been sufficiently separated from one another, and the redundant vaginal wall then removed; this is sometimes called *colpoperineorrhaphy*. A special operation is practised for the radical cure of cystocele (*see* p. 806). In cases of extensive uterine prolapse it is desirable to perform ventrisuspension or ventrifixation of the uterus as well, and thus support the prolapsed organs from above. Indeed, in such cases an extensive operative procedure may be necessary, including amputation of the elongated cervix, radical cure of cystocele, perineorrhaphy and ventrisuspension. In women who are approaching or who have passed the menopause, an alternative to these measures may be found in Le Fort's operation (*see* p. 824), for the older subjects, or in removing the procident uterus *per vaginam*, and in uniting the broad ligaments so as to form a floor for the bladder for those in whom it is desirable not to impair marital relations. Perineorrhaphy is usually required as well in cases where hysterectomy has been performed. The removal of the uterus does not of itself prevent prolapse of the vaginal walls, and the vagina may subsequently become completely inverted unless the additional procedures just mentioned are carried out. For elongation of the vaginal cervix amputation is all that is required: elongation of the supra-vaginal cervix is dealt with as a constituent feature of prolapse.

The permanent results of these operative measures for prolapse are good, if primary union of the plastic operations is secured. There is, of course, a certain tendency to stretching of the cicatrices, and in anticipation of this the constricting plastic operations should be carried to a point of slight exaggeration. The part most likely to suffer stretching is the anterior vaginal wall; plastic operations on the anterior vaginal wall should therefore in all cases be supplemented by perineorrhaphy in order to afford the repaired anterior wall all possible support from below. Unless this is done the operation is very likely to prove a failure. Ventrisuspension alone is useless for prolapse, but when combined with the plastic operations mentioned it becomes of great service.

## PART II: SECTION V

### MORBID CONDITIONS OF THE FALLOPIAN TUBES

- (1) TUBAL CYSTS      (2) TUBAL INFLAMMATION  
(3) TUBAL NEW GROWTHS

CONGENITAL Abnormalities and Tubal Pregnancy have been already considered ; we have here to deal with (1) Tubal Cysts ; (2) Inflammatory affections ; and (3) New growths.

#### TUBAL CYSTS

*Small irregular bullæ* may form on the tubes as the result of lymphatic obstruction in cases of large pelvic tumours. They are not true cysts. Small *subserous vesicles* the size of shot, pearly white and glistening, are sometimes present ; they are thought to be due to cystic changes in down-growths from the peritoneal coat of the tube produced by a low form of inflammation.

*Hydroparasalpinx*. This name was given by Kossmann to small cysts of the broad ligament which have a blind stalked attachment to the tube ; he regarded these structures as developed from accessory Müllerian relics. Others regard them as Wolffian derivatives.

*Accessory Hydrosalpinx*. Handley has shown that an accessory tube may become cystic by closure of its abdominal ostium and by torsion of its connection to the main tube ; Bell further showed that such a cyst may attain dimensions sufficient to render it clinically important. These structures are probably identical with the *antrum tubæ* described by Røederer and by Montgomery.

*Hydatids of Morgagni* being Müllerian in origin form a variety of tubal cysts.

*Cystic fibromyxoma* of the tubal fimbriæ has been described by Sænger.

*Fimbrial cysts* arising in the tubal fimbria which runs to the ovary are described on p. 698.

*Echinococcal* cysts have been found in the Fallopian tubes on very rare occasions ; they have been already described in the section on Parasites (*see* p. 330).

#### INFLAMMATION OF THE FALLOPIAN TUBE

Owing to their protected situation, the tubes are but rarely the seat of *primary infection*, which can only occur through the bloodstream, but when inflamed, the symptoms are so pronounced that the primary source of the disease becomes of secondary importance



and is often difficult to locate. Infection of the tubes may occur by four routes: (1) By spread of inflammation from the uterine mucosa; (2) From the peritoneal cavity through the *ostium abdominale*; (3) Through the lymphatics, *indirectly* from the parametrium, and less often from the vermiform appendix (*see* Fig. 324) and the sigmoid flexure (*viâ* their mesenteries), or *directly* from any part of the bowel by adhesions of the apposing serous surfaces; (4) By the blood-stream.

The gonococcus of Neisser is the most frequent cause of salpingitis, accounting as it does for about 75 per cent. of all cases. Gonococcal salpingitis is due to an ascending inflammation of the genital tract. The same may be said of streptococcal salpingitis. In tubal infection the streptococcus is of less importance only than the gonococcus, and as both these organisms reach the tube *viâ* the uterus, it is clear that most cases of salpingitis are the result of an ascending infection. Pyogenic bacteria may also enter the tube in the three other ways mentioned above. The tubercle bacillus which stands third in order of importance as a source of salpingitis, probably gains access most often by the blood-stream, but not infrequently it enters by the *ostium abdominale* in cases of tuberculous peritonitis. It is also known that the bacillus of tubercle may reach the tube by a circuitous route, by entering through an abrasion in the vaginal or uterine mucosa; thence it will pass into the lymph-vessels of the parametrium, and from there, directly enter the tube and ovary. As the tubercle bacillus may set up no local irritation at its point of entrance, the above method of invasion is difficult to prove clinically, but it has been demonstrated experimentally. Of other organisms which have occasionally been known to cause salpingitis may be mentioned the *bacterium coli commune*, *actinomyces*, *typhoid bacillus*, *diplococcus pneumoniae*, *pneumobacillus of Friedländer*, and even the *influenza bacillus* (von Franqué).

The transport of non-mobile germs is effected by their power of continuous surface-growth. Want of cleanliness during a menstrual period will allow bacteria to spread from the vulva to the tube by direct surface-infection.

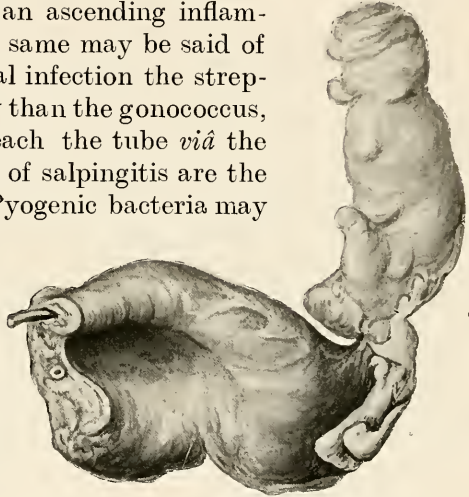


FIG. 324. RIGHT-SIDED SALPINGITIS, with inflamed appendix vermiformis adherent by its tip to the tube. A bristle is placed in the uterine end of the tube.

### Catarrhal Salpingitis

In simple catarrhal inflammation the organisms are of low virulence and are few in numbers. The muscularis is not affected and the mucosa is but little changed. The stroma of the plicæ is not infiltrated, but the folds are separated from one another by exudation, and in this exudation are found many desquamated, swollen epithelial cells, a few leucocytes, and perhaps a little blood. For the most part the epithelium of the mucosa is intact, the ciliæ have in part disappeared, but are often still distinguishable. This stage of slight salpingitis is relatively seldom seen since it quickly subsides. But with repeated attacks permanent changes are wrought, the most important being a closure of the ends of the tube. This results in the retention of secretion and a gradual expansion of the tube, *i.e.*

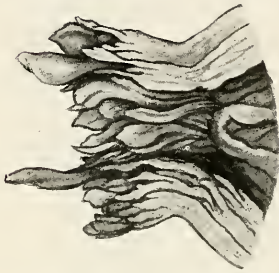


FIG. 325. CLOSURE OF THE ABDOMINAL OSTIUM. First stage, showing retraction (indrawing) and swelling of the fimbriæ. (Sitzenfrey.)

in the formation of a *hydrosalpinx* (*sactosalpinx serosa*). For the formation of a tubal sac, the sole essential is a closure of both extremities.

**Hydrosalpinx.** The usual mode of closure of the abdominal ostium is that the fimbriæ are drawn into the lumen of the tube, and their surfaces then fuse together (*see* Fig. 325). Thus a closure of the outer end of the tube is brought about by a plug, consisting of the swollen fused fimbriæ, which are suffering compression by the unyielding peritoneal investment of the tube.

Previous to this, there has been an epithelial closure of the *uterine* end of the tube, caused by catarrhal swelling of its mucous membrane. When it is remembered that the lumen of the interstitial part of the tube is only 0.5 to 1 mm. in diameter, it will be understood that a slight turgescence is sufficient to effect its occlusion. There is now no chance of escape for the secretion of the tubal mucous membrane, and a collection of fluid in the lumen results. By intratubal fluid-pressure the tube is both elongated and expanded. When the indrawn plicæ are completely welded or fused together, the closure of the tube becomes permanent. It is obvious that in this mode of occlusion the fimbriæ will have disappeared externally, and nothing will remain to mark the site of the ostium but a small cicatrix (*see* Fig. 327).

Another method of closure is that which occurs from without inwards. This arises from peritonitis, and results in adhesion of the ostium to adjacent surfaces. In the absence of catarrh the uterine ostium of the tube may be still open, in which case no hydrosalpinx will result. Such a closure is seen for example in cases of appendicitis in which the serosa of the tube is implicated. This mode of closure

will be again referred to in the description of pyosalpinx and tubo-ovarian cysts.

*Macroscopic Appearances of Hydrosalpinx.* The distension of the tube is first seen, and is always most marked, at the ampulla, whence it extends gradually to the uterine end. The early distal enlargement is accounted for by the fact that the muscle is thinner at the ampullary end of the tube. Thus a hydrosalpinx of typical shape possesses a pedicle, consisting of the relatively small and but little altered uterine

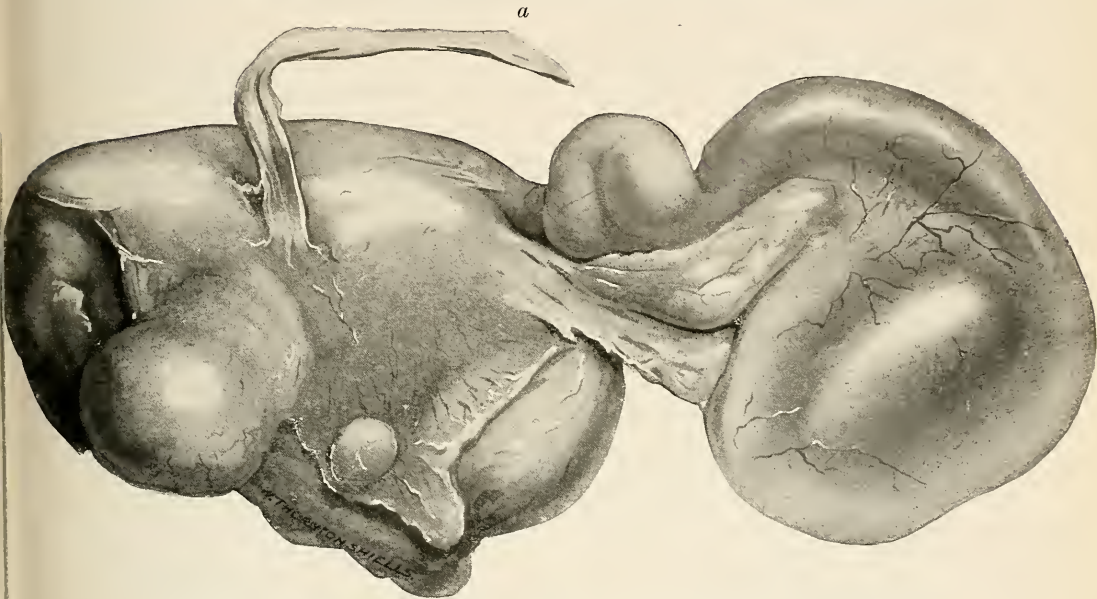


FIG. 326. UTERUS WITH FIBROIDS; RIGHT HYDROSALPINX. *a*, Elongated band of adhesion from an old ventrifixation. The ovary is seen below the inner half of the dilated tube.

end of the tube, which connects the more or less distended ampulla to the cornu. The entire tube may now resemble in shape an Indian club, or a retort, or a post-horn.

Kinking of a hydrosalpinx is apt to occur because the inelastic peritoneal coat cannot share in the elongation of the muscle; coiling or winding of the tube takes place, especially if the peritoneum is adherent (*see* Fig. 326). The kinks produce spurs or projections of the muscle and mucosa, which form false septa in the dilated lumen.

Whatever the shape of a hydrosalpinx may be, its walls are always thin and may be semi-transparent; when opened up, the mucosa may be found to be as flat as a serous membrane, with here and there a slight fold or projection, representing the remains of the original plicæ. As already stated, the fundamental lesion which leads to hydrosalpinx is repeated attacks of *catarrh* of the mucous membrane; this does not lead to thickening of the muscle, so that the latter is not

prepared to cope with the raised intratubal pressure exerted by the accumulation of fluid; this accounts for the thin wall of a hydrosalpinx. There may, or may not be, signs of inflammation externally. In addition to the cicatrix at the site of the abdominal ostium, there may be nothing to show the inflammatory nature of the lesion; on the other hand, extensive peri-salpingitis is not uncommon (see Fig. 327), and the sac may even be invested and fixed by membranous adhesions. The contents of a hydrosalpinx generally consist of a clear or slightly clouded, thin, serous, albuminous, or mucoid fluid.

*Microscopically*, in early cases of hydrosalpinx evidences of inflammation can be traced in the mucosa, e.g. round-celled infiltration

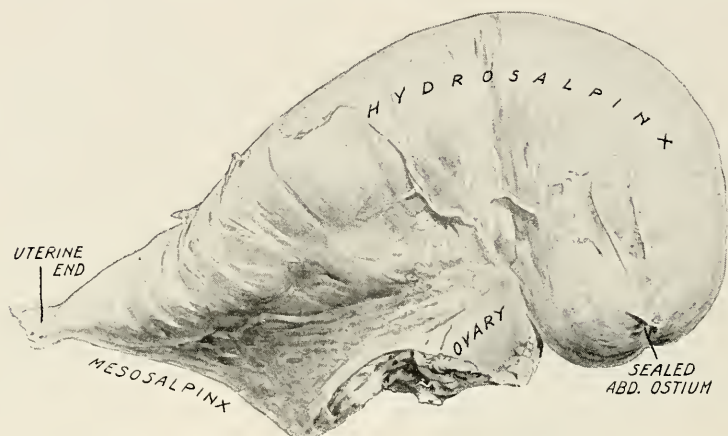


FIG. 327. HYDROSALPINX (Royal College of Surgeons Museum). The specimen shows the characteristic retort-shaped dilatation, and at the outer end a puckered depression indicating the position of the abdominal ostium. The ovary has been partly cut away. There are numerous peri-salpingitic adhesions.

in the folds, fusion of the tips, and resulting pseudo-follicles at the bases, of the plicæ. Even in the otherwise unaltered muscle there may be tracts of round-celled infiltration. In the walls of larger sacs all traces of inflammation are often lost. In the sac itself the flattened epithelium lies immediately upon a fibrous wall, from which the muscle-bundles have often completely disappeared. Microscopic examination of the contents will reveal the presence of leucocytes, epithelial cells, and perhaps a few red discs. In a large sac the contents are always sterile, the causal bacteria being of low virulence are soon destroyed (see also p. 621). Whether a hydro- or a pyosalpinx will form after closure of a tube is solely a question of the number and virulence of the invading organisms. It is stated that the contents of a hydrosalpinx may be ejected into the uterus and escape *per vaginam*. In these cases the terms *hydrops tubæ profluens* and *hydrorrhœa tubæ intermittens* are used to describe this process; its occurrence in cases

of tubal papilloma has been established; with hydrosalpinx it is entirely hypothetical.

Occasionally axial rotation of a hydrosalpinx occurs, resulting in the effusion of blood into the tube. This condition may resemble that next to be described, viz. hæmatosalpinx, but it is more accurately described as a *blood-stained hydrosalpinx*.

**Hæmatosalpinx.** This is a condition in which the tube becomes distended with blood, and is an occasional result of catarrhal sal-

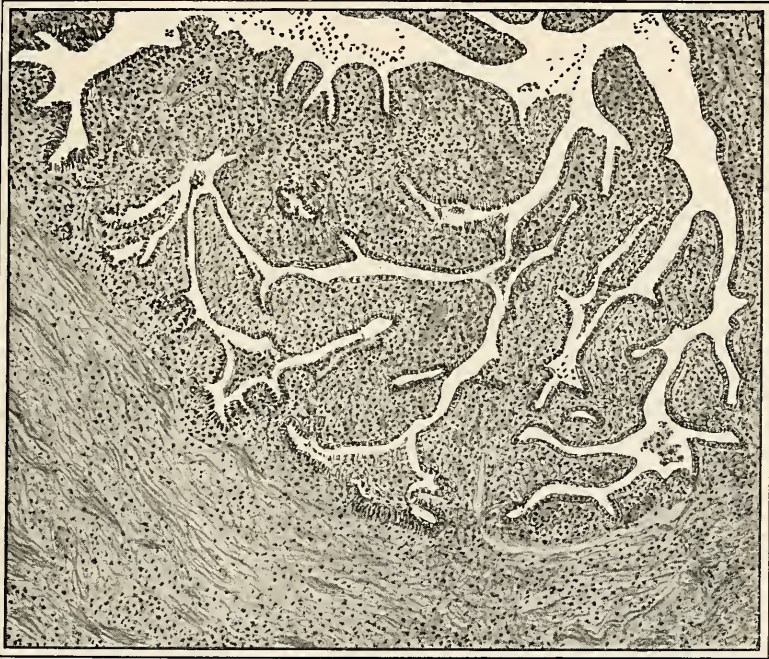

FIG. 328. SUPPURATIVE SALPINGITIS; FROM THE AMPULLA OF THE TUBE. The plicæ of the tubal mucosa are swollen by infiltration of pus-cells and mononuclear round cells. The latter are derived from proliferation of the fixed connective-tissue cells. The above is an early stage of salpingitis purulenta.

pingitis. The infection is more acute than in cases of *hydrosalpinx* and results in an effusion of blood from engorged capillaries. Closure of the abdominal ostium, in this case, is effected by the escape of blood, which sets up perisalpingitis and causes adhesion of the ostium to neighbouring surfaces. Two other varieties, non-inflammatory in character, are met with, viz. that due to tubal pregnancy and that associated with cryptomenorrhœa (*see* p. 172).

It is in ectopic gestation that true hæmatosalpinx is most commonly seen, and this occurs mechanically, not as the result of inflammation. Non-inflammatory hæmatosalpinx is also on rare occasions secondary

to hæmatocolpos and hæmatometra in cases of imperforate hymen (*see* p. 173). Hæmorrhage into the lumen of the tube occasionally occurs in axial rotation of a mobile tubal swelling, and this gives rise to the same type of acute abdominal symptoms as are associated with torsion of the pedicle of an ovarian cyst (*see* p. 702).

### Suppurative Salpingitis

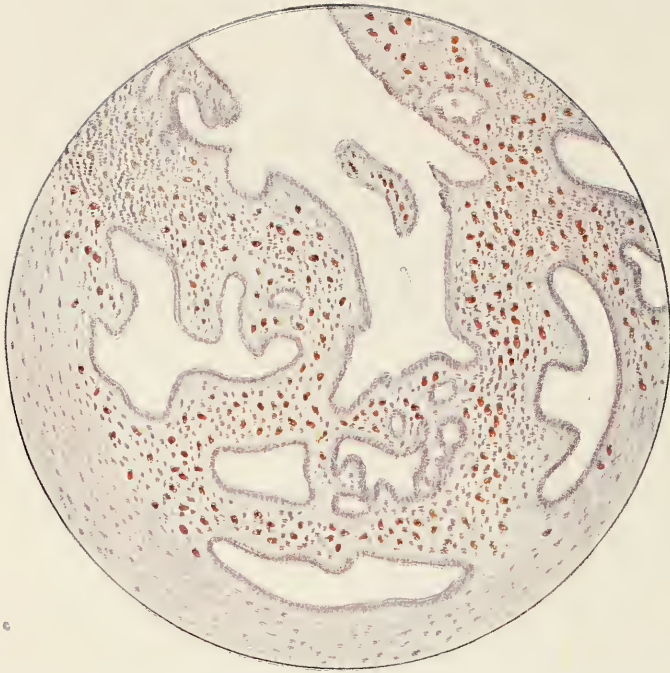
Suppurative inflammation of the tube is usually due to an acute ascending infection which has reached the tube from without. The

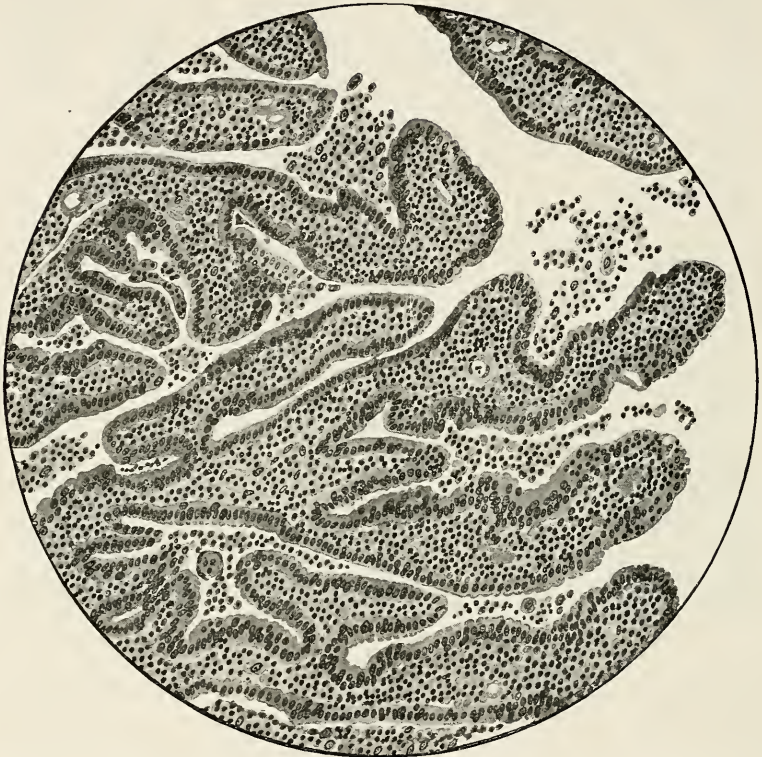

FIG. 329. SUPPURATIVE SALPINGITIS (Early Stage). Under a high power the round-celled infiltration of the stroma is seen; pus-cells and lymphocytes are present in the lumen.

organisms are virulent and invade (1) the connective-tissue elements of the mucosa, and (2) the entire tube-wall as far as its peritoneal coat. There is first seen a very marked thickening of the plicæ (*see* Fig. 328); this is due in part to the dilatation of the blood- and lymph-vessels, and in part to an inflammatory infiltration of the stroma with polymorphonuclear pus-cells and mononuclear round cells, the latter being derived from the proliferation of the fixed connective-tissue cells. Numerous lymphocytes also are seen both in the swollen





PURULENT SALPINGITIS (SUBACUTE), showing an abundance of plasma-cells in the inflammatory infiltration. Note the fusion of the plical tips which has produced *pseudo-follicles*. There is no invasion of the muscularis by the mucosa such as is seen in chronic interstitial salpingitis.



plicæ and in the purulent secretion which occupies the tube-lumen (see Fig. 329). Later on when the condition is subacute the character of the infiltration changes, and plasma-cells take the place of the polymorphonuclear and mononuclear cells (see Plate XIX). In the acute stage of suppurative salpingitis the tube is increased in size, and is soft, this change being due to œdema of the muscularis and of the subserosa. If healing occurs this thickening may subside, and

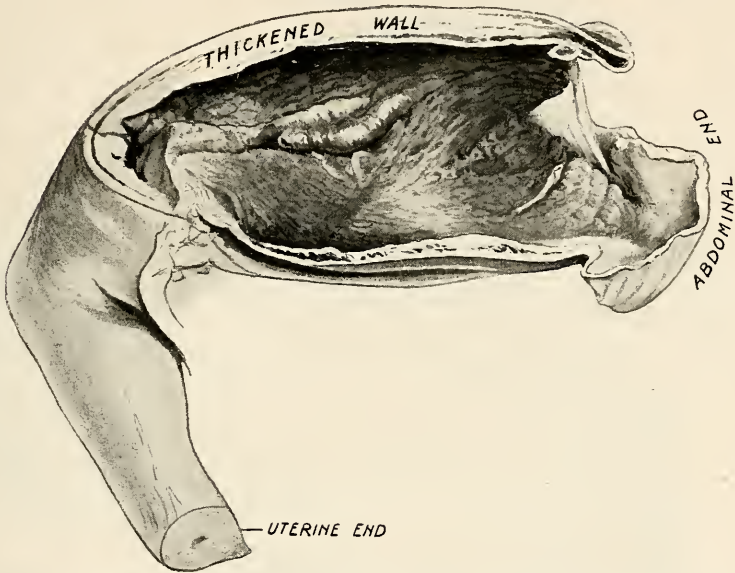


FIG. 330. CHRONIC PYOSALPINX (Charing Cross Hospital Museum). The tube is bent at a right angle, the outer part alone being dilated. The tube-wall is thickened throughout. From the same case as Fig. 334.

the subsidence of a tubal swelling may sometimes be noted clinically. If the acute inflammation does not soon subside, the mouth of the tube becomes closed, pus collects in the lumen, and the muscular and subserous layers, which are already softened and swollen by œdema, yield to the pressure exerted by the contained purulent secretion; thus the tube-wall becomes stretched and relatively thinned out, but never to the same degree as seen in hydrosalpinx. The final result is a *pyosalpinx*. On the other hand, the initial inflammatory attack may be followed by a relapse or by repeated recurrences of subacute and chronic inflammation. Instead of a pus-sac forming, the tube-wall then becomes thickened, and a state of *interstitial suppurative salpingitis* is produced. The result of suppurative salpingitis on the tube is, therefore, twofold. The tube may become chronically thickened forming a pus-tube (*interstitial salpingitis*), or it may become distended and dilated to form a pus-sac (*pyosalpinx*). It is common to find that the inner portion shows interstitial changes while the

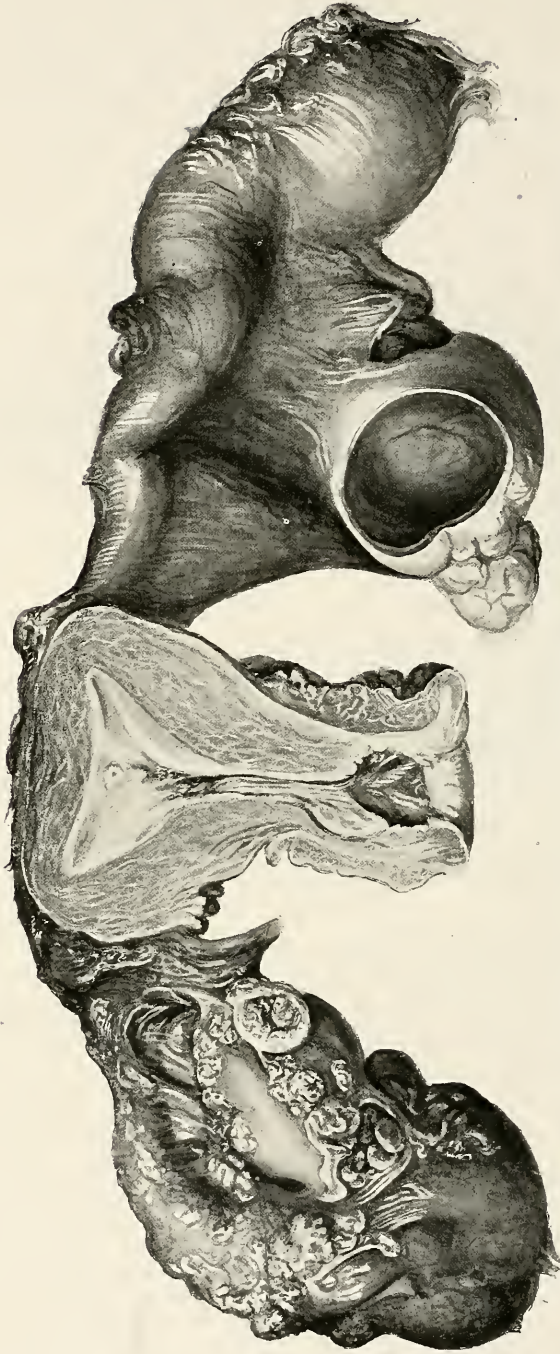


FIG. 331. BILATERAL PYOSALPINX OF GONORRHOEAL ORIGIN. Note the extensive tubal adhesions.

ampullary portion is distended with pus, so that both varieties of suppurative salpingitis may occur in the same tube. The formation of a pyosalpinx will be considered first.

**Pyosalpinx** (*Sactosalpinx Purulenta*). The mechanism by which retention of pus produces a pyosalpinx is in many respects similar to that by which the fluid of a hydrosalpinx is confined within the lumen

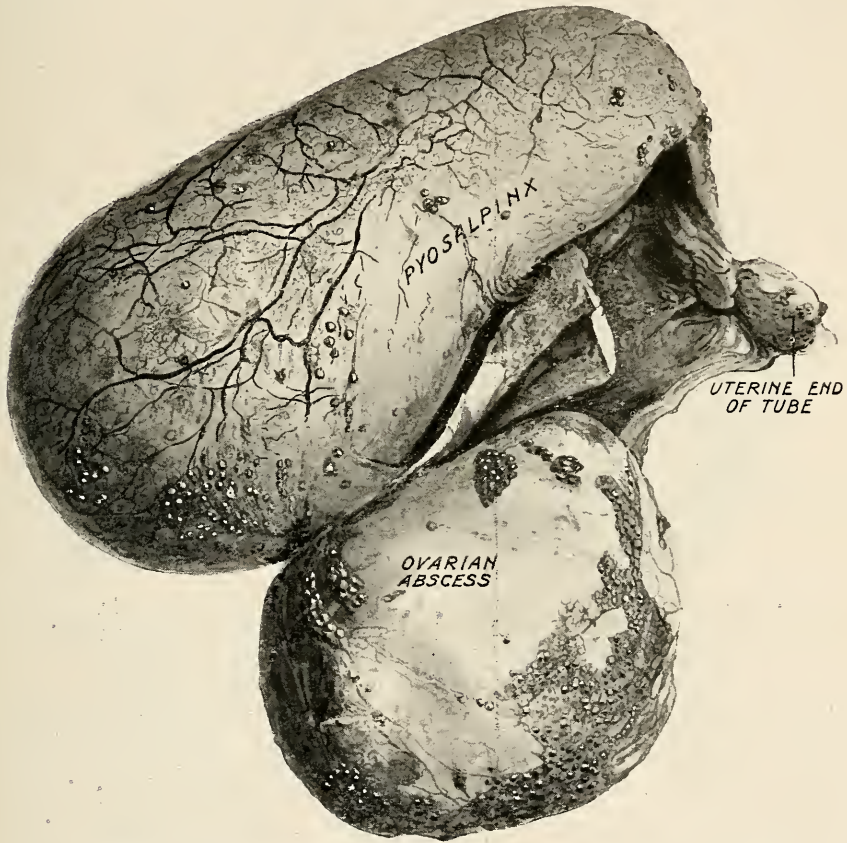


FIG. 332. TUBERCULOUS PYOSALPINX AND OVARIAN ABSCESS. Nullipara, aged 21. The dilated tube shows the characteristic retort shape. Both tube and ovary are studded with tubercles; they are almost entirely free from adhesions.

of the tube. The fimbriæ are indrawn to a certain extent, but closure is aided by more rapid fusion of the fimbriæ owing to destruction of the surface-epithelium. Closure is often effected by the formation of an external pseudomembrane, or through the fusion of the abdominal ostium to neighbouring organs. In such cases, after the separation of the adhesions the abdominal ostium may be found to be still open, and the plicæ still visible, so that indrawing of the plicæ is not so essential to the formation of a pyosalpinx as it is to the

formation of a hydrosalpinx. In fact, retention of pus may occur through the swelling of the mucosa alone. Of importance to operators is the fact that through an open abdominal ostium, a pus-tube may communicate with a collection of pus enclosed in a false membrane around the mouth of the tube (*peritubal pyocele*), just as in tubal pregnancy the lumen of the tube may communicate with a peritubal hæmatocele (see Fig. 114, p. 206). A *peritubal pyocele* is far more liable to rupture during salpingectomy than is a true pyosalpinx, so that there

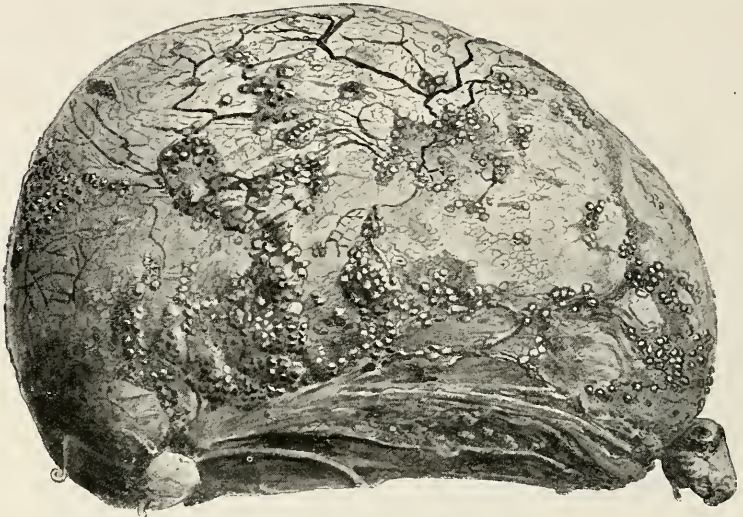

FIG. 333. TUBERCULOUS PYOSALPINX. From the same case as Fig. 332. The dilatation is roughly cylindrical or sausage-shaped and the tube wall is studded with tubercles.

is invariably an escape of pus during its removal, an accident which may be attended with serious consequences (see p. 296).

The formation of a tubal pus-sac may be rapid or slow; in the former case the walls will, as already stated, be relatively thin; in the latter event, the muscularis at first shows signs of a work-hypertrophy, but even here the subsequent deposition of fibrous tissue causes muscular atrophy, and thus an old pus-sac may consist of a thick wall, composed entirely of connective tissue without a trace of muscle. The peritoneum is generally overlain by fibrinous adhesions, granulations, and finally by thick connective-tissue laminae. Generally there is also extensive pelvic peritonitis, with adhesions to the ovary, to the back of the uterus, to the broad ligament, and to the rectum. Tubal pus-sacs may communicate with each other or with an ovarian abscess (see Fig. 332), in fact the adnexal structures may be so welded together by peritonitis as to render it impossible to distinguish tubal from ovarian tissues. When the abdomen is opened in such a case access to the pelvic organs may be entirely prevented by a

roof of densely adherent structures which has been formed by fusion of omentum, coils of small intestine and loops of pelvic colon over the inflamed organs. These adhesions are protective, and serve the

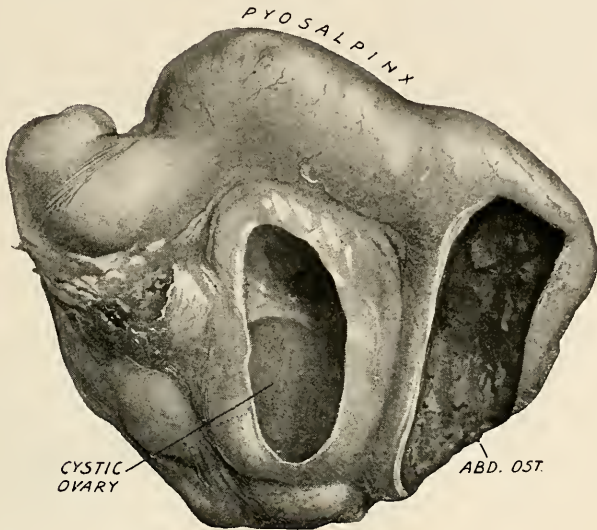


FIG. 334. CHRONIC PYOSALPINX. The tube is not much dilated, its outline is convoluted and its walls are thickened. The ovary is enlarged, cystic, and firmly adherent to the tube.

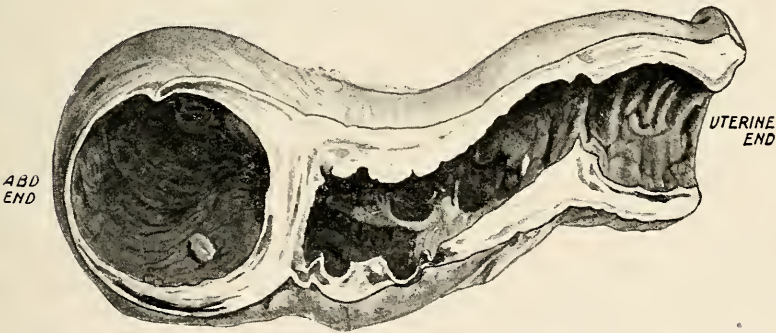


FIG. 335. CHRONIC PYOSALPINX (Charing Cross Hospital Museum). The dilatation is fairly uniform, the tube-wall is thickened, and a septum is formed near the abdominal end.

useful purpose of limiting the infective process to the pelvis. On the other hand, there are exceptions, and a pyosalpinx may be freely mobile and hard, giving the clinical signs of a pedunculated myoma.

On section, the mucous membrane of a pyosalpinx is seen to be bright red, yellow, or grey. Microscopically, there is seen to be much desquamation of the surface-epithelium; it may be shed entirely, but where epithelium persists, it becomes many-layered, and thickened;

the individual cells, instead of being cubical, become round or irregular and may even resemble the squamous or transitional type seen in the urinary tract.

With acute suppuration the epithelium first disappears at the summits of the main plicæ and of their branches. The raw extremities then adhere and organic union occurs producing pseudo-follicles (see Plate XIX), which may persist and can be found in the thicker parts of the wall of a pyosalpinx. In large pus-sacs the entire mucous

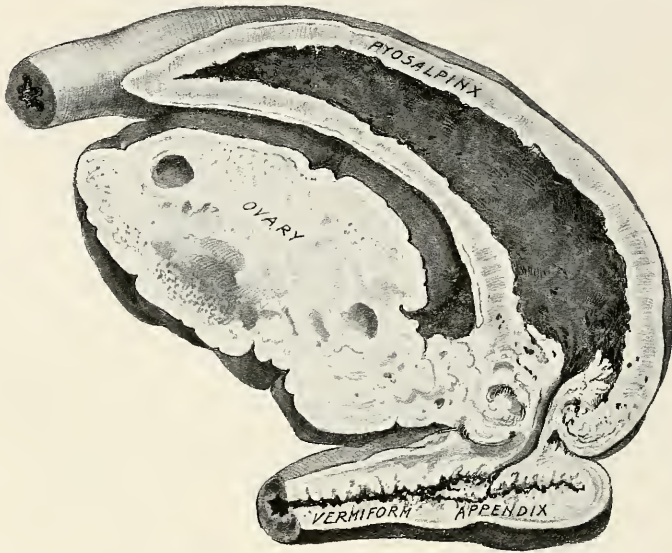


FIG. 336. TUBO-APPENDICULAR FISTULA (Bland-Sutton). The appendix has become adherent by its tip to the abdominal ostium, and a fistulous communication has been formed in that position. Infolded relics of the tubal fimbriæ are seen.

membrane may have disappeared leaving nothing but a lining of granulations; but even here traces of the mucosa, in the form of displaced follicles, may be found in the fibrous tissue of which the sac-wall is composed (*salpingitis follicularis*).

*Contents of a Pyosalpinx.* The contents of a pyosalpinx are very variable. When of *tuberculous* origin the pus may be fluid or semi-solid, consisting of caseous *débris* and devoid of odour unless secondarily infected with the colon bacillus or with saphrophytic organisms. Sometimes the caseous material becomes inspissated, and dry hard nodules are found, and not infrequently calcareous changes occur in the lining of a tuberculous pyosalpinx. It is very rare to find the tubercle bacillus, but it has occasionally been discovered in the sac-wall. In pyosalpinx due to *gonorrhœa* or to *puerperal sepsis*, the pus may be thick or thin, yellow or bloodstained, uniformly creamy, or flocculent from flakes of necrotic lymph. In the absence of *B. coli*

and of saphrophytes there will be no odour, but after the death of the exciting pathogenic bacteria, it is common to find a secondary invasion by putrefactive germs. The character of the contents is then totally changed and offensive pus results.

Bacteriological examination of the pus from forty-three cases of pyosalpinx revealed the fact that in thirty-three instances it was sterile, *i.e.* the organisms had died; in seven the gonococcus was found (Howard Kelly). In one case there was a mixed infection by staphylococci and streptococci. In two, the organisms were undiagnosed. In none was the *B. coli* discovered. Among the rarer organisms found are the *bacillus aerogenes capsulatus*, the *micrococcus lanceolatus*, and the *proteus bacillus*.

From the above we may conclude that there is a tendency for pus in pyosalpinx to become sterile and that mixed infections are rare, but it must also be remembered that infection by an organism of one type paves the way for a secondary invasion by bacteria of another form, and when offensive pus is discovered, in most cases, this is what has happened. It is important to bear in mind that while the contents of a *chronic* pyosalpinx are sterile in three-fourths of the cases, the contents of an *acute* pyosalpinx are highly infective; the same may be said of the peritonitic abscesses which often occur in the neighbourhood of the affected tube.

*Rupture of a Sactosalpinx.* This accident occurs not infrequently with a hæmatosalpinx resulting from tubal pregnancy. It is probable that a hydrosalpinx may rupture spontaneously, without giving rise to any clinical phenomena whatever, and there is accordingly no means of estimating its frequency. Spontaneous rupture of a pyosalpinx into the peritoneal cavity is very rare, owing to the fact that, as a rule, the tube-wall is too much thickened and too densely adherent to surrounding structures to permit of this accident. Nevertheless forty-eight cases have been collated by Bonney (1909), and the grave nature of the occurrence is made clear by the fact that 48 per cent. of these cases terminated fatally.

*Tubal Fistulæ.* In chronic cases of pyosalpinx fistulous communications may be formed between the tube and its fellow or with one of the hollow viscera, by gradual destruction, through ulceration, of the septum formed by the adherent walls. Most commonly the communication is formed with the intestine—the upper part of the rectum, the pelvic colon, or a coil of ileum being the parts usually implicated. In rare cases a fistulous communication may be formed between the vermiform appendix and the tube (*see* Fig. 336). Next in frequency to the intestine comes the vaginal vault; a pyosalpinx commonly occupies the pouch of Douglas and is therefore adjacent to the vagina, but the intervening tissues are thicker and denser than in the case of the intestine. Lastly, and least frequently, the pyosalpinx may discharge into the bladder; the infrequency with which a dilated

tube is found in the utero-vesical pouch explains the rarity of this form of tubal fistula.

The formation of a tubal fistula is a curative process and may be followed, in some cases, by obliteration of the canal of the tube, and permanent cure. More frequently drainage is inadequate, reaccumulation occurs, and the fistula simply persists. Cystitis does not necessarily follow the formation of a tubo-vesical fistula, for the pus may be destitute of living organisms. Tubo-ovarian fistulæ will be referred to under *Tubo-ovarian Cyst and Abscess* (see p. 627).

**Interstitial Salpingitis.** This is the result of repeated attacks of sub-acute inflammation. There is pus-formation in these cases, but not to the same extent as is seen in tubal pus-sacs. The ostium of the tube is sealed and is generally found fused with the ovary, the only notable exception being in tuberculous cases, where extensive interstitial salpingitis may exist with an open abdominal end, the swollen fimbriæ remaining non-adherent and free (see Fig. 148, p. 310).

Although in some cases tubes are found which show interstitial salpingitic changes throughout their whole length, it is more common to find considerable collections of pus in the ampullary segment. In such cases the isthmic portion may be thickened by hypertrophy of muscle, and by young fibrous tissue, so that the transverse diameter of the tube measures 2 cm. or more. Figure 330 illustrates the effect of interstitial salpingitis at the uterine end of the tube produced by chronic inflammation which has allowed sufficient time for the tube-wall to become thickened. Figure 335 shows that with chronic interstitial salpingitis the entire lumen may be distended with pus; the wall is everywhere thickened except that formed of false membrane at the abdominal ostium. This is a rarer type than that seen in Fig. 330.

The thickening of the tube-wall in interstitial salpingitis may be uniform (see Fig. 330), but often it is irregular and definite nodes are produced; this nodular condition is most marked at the isthmic or uterine end, where the tube joins the cornu uteri (*salpingitis isthmica nodosa*). This localized enlargement is generally found in cases of tuberculous salpingitis (see Fig. 148, p. 310), but it is also produced to a less marked degree in gonorrhœal and septic cases. The characteristic behaviour of the mucosa in chronic interstitial salpingitis is best illustrated by the study of these nodes.

The striking feature of *salpingitis nodosa* is the presence in the thickened fibromuscular wall of displaced or ectopic epithelium, which is derived from the mucous membrane of the tube. When, by progress of the infection, the muscularis becomes infiltrated by round cells and softened by œdema, the epithelial cells of the mucosa, or perhaps portions of the entire mucosa, become squeezed (by intratubal pressure) into the substance of the muscular wall, producing true follicles, *i.e.* gland-spaces lined by cubical epithelium. Owing to the presence of these follicles this variety is called by some pathologists *salpingitis*



*follicularis* (see Figs. 337, 338, 339). The displaced epithelium actively proliferates in its new situation, and produces an intramural, complex, glandular structure. Simultaneously, the fibrous and

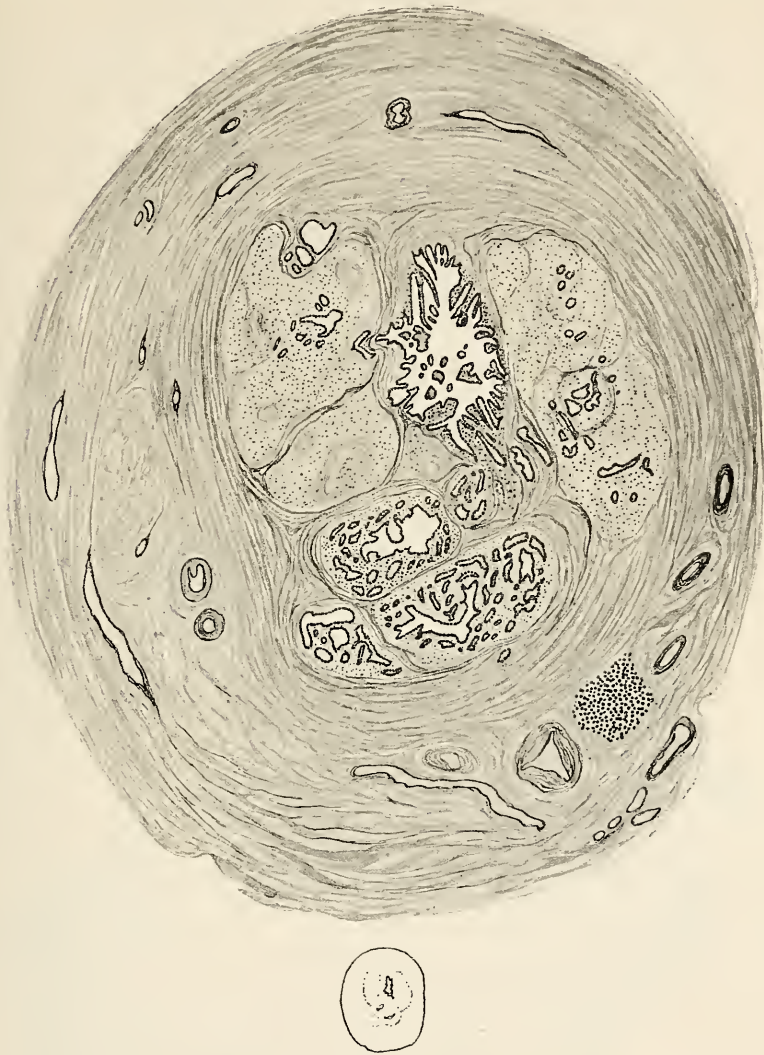

FIG. 337. TRANSVERSE SECTION OF TUBE THROUGH AN AREA OF *salpingitis isthmica nodosa*. Note that the mucosal epithelium has penetrated the muscular strata, and appears as branching adenomatous follicles (*salpingitis follicularis*).

muscular elements take on active hyperplasia in response to the irritation produced by the growing glandular tissue, and the result is a well-defined nodule. This process may spread into the interstitial part of the tube, and may expand the tubal isthmus, so that at the

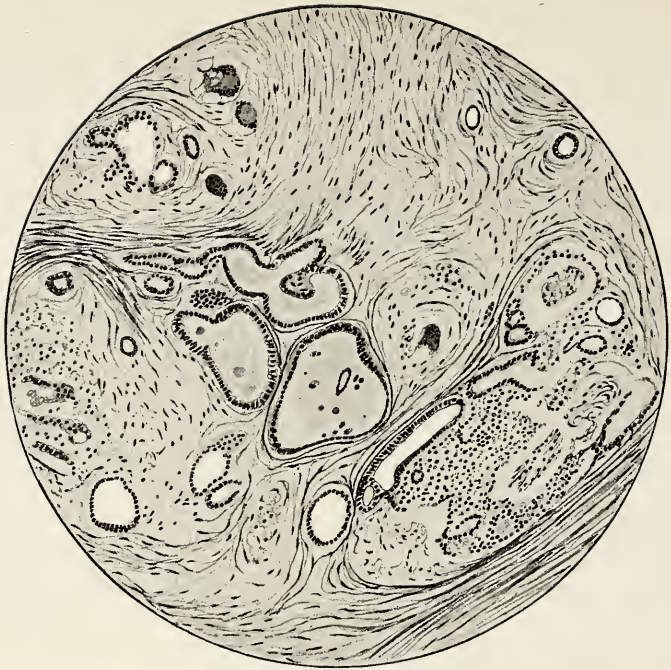

FIG. 338. PORTION OF FIG. 337 UNDER A HIGH POWER. Note the distended follicles and numerous giant cells lying in the muscularis. The lumen of the tube is not seen.

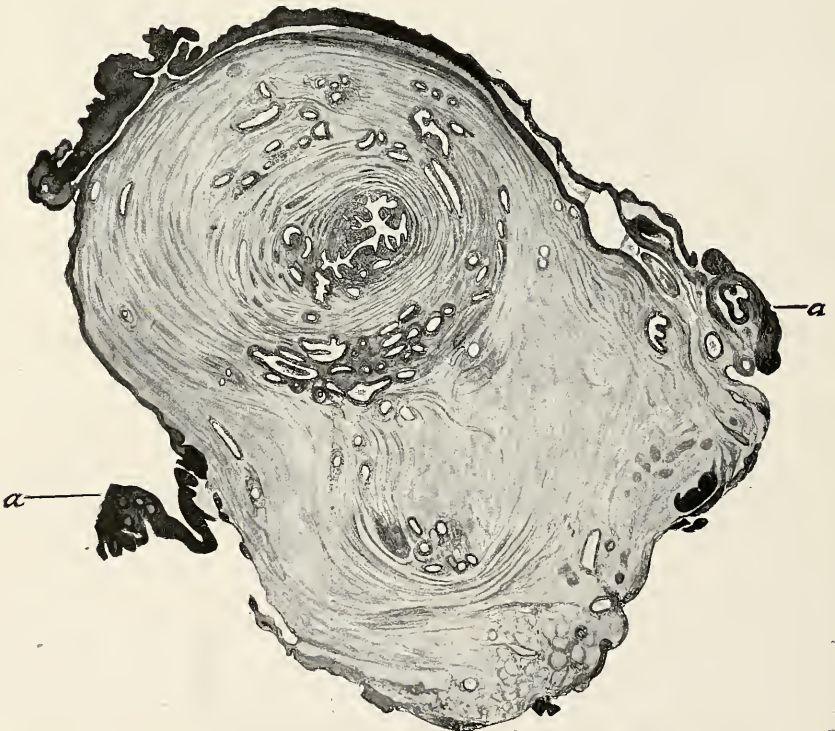


FIG. 339. SALPINGITIS ISTHIMICA NODOSA. Showing extension into the broad ligament (von Franqué), *a-a* = peritoneal coat of tube.

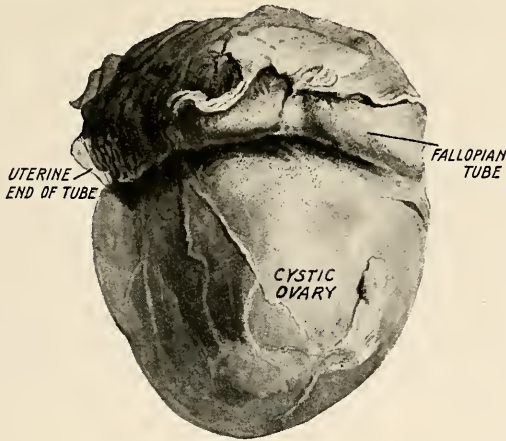


FIG. 340. CHRONIC SALPINGO-OÖPHORITIS. Multipara, aged 43. The ovary is enlarged by cystic formation; the tube is not dilated, but closely adherent to the upper part of the ovary, the mesosalpinx being concealed by the adhesions.

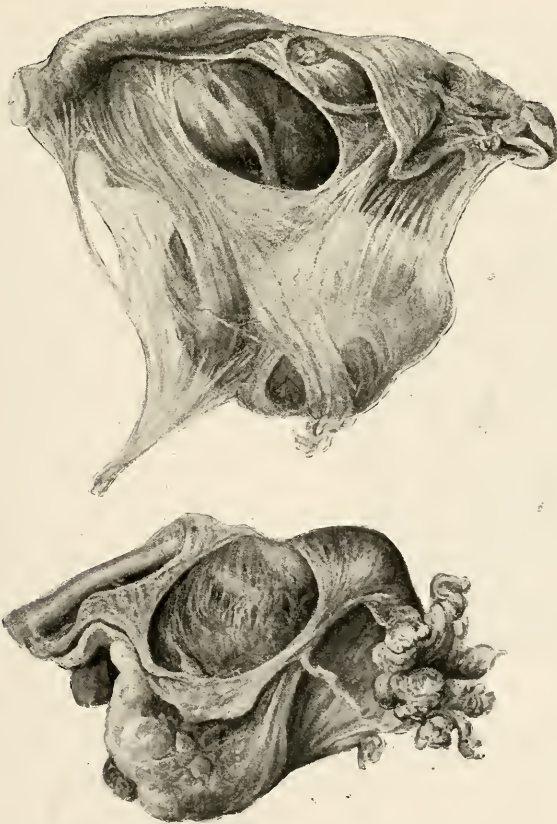

FIG. 341. BILATERAL CHRONIC SALPINGO-OÖPHORITIS. Showing extensive peritonitic adhesions.

cornu, the mesosalpinx becomes opened up by a solid tubal mass the size of a walnut or larger (*see* Fig. 339). The connection between the gland-follicles and the lumen may ultimately be cut off, but often pervious crypts or *culs-de-sac* persist so that the follicles lying in the muscle-wall may be injected from the lumen of the tube. The epithelial lining of the displaced follicles may be composed of columnar, cubical, or flattened cells and their lumina may be filled with secretion, or old blood, or pigment-laden cells. The clinical significance of the mucosal diverticula above referred to is, that they may perhaps become the seat of tubal pregnancy.

The changes described as nodular salpingitis are best seen in tuberculous tubes, but may be found in lesser degree in all cases of chronic salpingitis independent of their etiology.

### Chronic Salpingo-öophoritis

Many cases of chronic salpingitis are non-suppurative and not accompanied by dilatation of the tube. There is marked perisalpingitis accompanied by perioöphoritis, and a moderate degree of thickening of all the layers of the wall of the tube (*see* Fig. 341). From the fact that almost without exception the ovary shares in the inflammatory process, the term *chronic salpingo-öophoritis* is correctly applied to this condition. The abdominal ostium remains patent for much longer than in the other varieties of salpingitis, but ultimately becomes sealed. An extensive pelvic peritonitis may also be present.

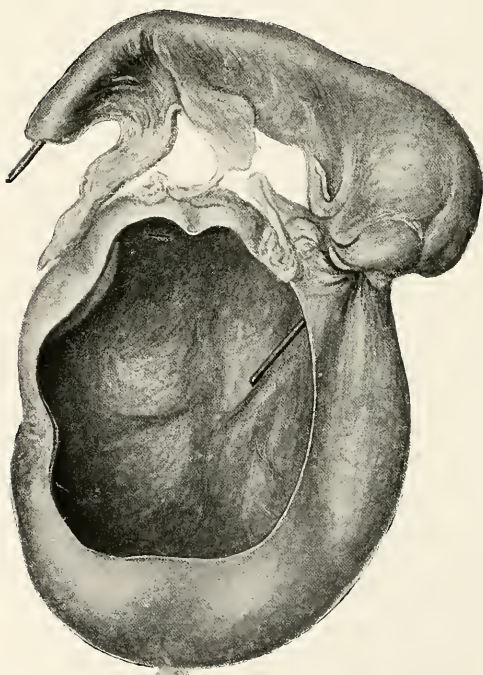


FIG. 342. TUBO-OVARIAN CYST. Showing a bristle passed through the length of the tube and projecting into the cavity of the ovarian cyst.

It must be assumed that in this condition *repeated* catarrhal attacks have led to a certain degree of thickening of the middle coat of the tube. There being no suppuration, the epithelium on the plicæ remains intact and varies exceedingly in character. Marked proliferation and also metaplasia of cells are seen. Papillary

and tufted masses of epithelial elements may abound to such a degree as to give the appearance of papilloma and carcinoma. These mucosal

changes have in fact given rise to the view that cancer of the Fallopian tube is the outcome of chronic salpingitis.

**Tube-ovarian abscess: Tube-ovarian cyst.** The fusion between tube and ovary produced by inflammation may lead to a communication between a pyo- or hydrosalpinx on the one hand, and an ovarian abscess or cyst on the other. This results in the formation of a cyst the wall of which belongs in part to the tube, and in part to the ovary. The point of communication is usually a small aperture, but the latter may be of considerable size. Around this aperture, the spread-out fimbriæ of the tube can be seen, radiating over the adjacent surface of the ovarian portion of the wall of the cavity. This shows that the aperture is a patent tubal ostium.

### Clinical features of Inflammation of the Tubes and Ovaries

The symptoms of inflammation of the tubes and ovaries resemble those of pelvic peritonitis already described (p. 262). Exact diagnosis is much more difficult in acute than in chronic cases, for lapse of time, and the progress of the physical signs of the disease, are often of great service in determining the position and nature of the principal lesions in a given case.

**General Symptoms in Acute Cases.** In acute cases which develop rapidly grave symptoms indistinguishable from those of other forms of the 'acute abdomen' may develop without any localizing signs being discovered in the pelvis. More frequently the onset is less severe and two main symptoms then manifest themselves, viz. fever and pain; vomiting, except during the first few hours, is rare. The fever is usually severe, running up to 103° or 104° F., and may be associated at its onset with a definite rigor, or with attacks of chilliness. Thereafter the temperature runs an irregularly intermittent course, similar to that of septicæmia. The fever in some cases subsides rapidly, and in a few days the temperature becomes normal; this indicates that the inflammatory focus has been isolated by adhesions. In other cases recurrences of high fever occur with intervals of abatement; this is seen when a salpingitic inflammation succeeds in passing the barrier and invading fresh regions of the peritoneum, or when suppuration occurs.

The pulse-rate is quickened, as a rule, proportionately to the temperature. When the pulse-rate is disproportionately rapid, generalized infection is probably occurring.

Abdominal pain and distension, both at first limited to the hypogastric zone, are commonly met with; they are in a special sense indications of peritonitis. Great tenderness on abdominal pressure is also present, and defæcation and micturition may become painful. The general condition of the patient, as indicated by the tongue, and the ability to take nourishment, is fairly good.

The symptoms indicative of pus-formation are not in all cases clear. Rigors may be absent, and the fever is not invariably exacerbated. After a time the general condition of the patient deteriorates, the pulse quickens, and sweating occurs; rapid emaciation, and the appearance of a peculiar earthy tint of the skin, may be seen in prolonged cases. Abscess-formation may occur in a few days in cases of acute infection; in chronic infections its occurrence may be much delayed.

Assistance in the diagnosis of pus-formation may be sometimes obtained by making a differential blood-count, and repeating it on one or more occasions, a single estimation being unreliable. (1) A total of 20,000 to 25,000 leucocytes per cubic millimetre, with from 80 per cent. to 85 per cent. of polymorphonuclear cells, indicates the presence of pus or other infective fluid, which is imperfectly isolated and from which absorption of toxin is occurring rapidly. (2) A total count of from 10,000 to 15,000 leucocytes indicates either the absence of pus, or if pus be present, the loss of its infectivity. A high and increasing leucocyte-count, obtained on several occasions, is the clearest indication of active suppuration (Topley).

**General Symptoms in Chronic Cases.** In the great majority of cases of chronic tubo-ovarian inflammation there is a prolonged history of pain and general ill-health, which can be traced to a confinement or an abortion, or to an attack of gonorrhœal infection. In puerperal cases there may be no definite history of septic infection, but merely a retarded convalescence; or the onset of symptoms may be delayed for a period of several weeks or months after the occurrence of the confinement or abortion. In gonorrhœal cases, an interval even more prolonged may elapse between the original infection and the appearance of symptoms of pelvic inflammation. It will be found on inquiry that during this interval the general health has been unsatisfactory, and that the symptoms of gonorrhœa have not been entirely relieved. Sterility also almost always characterizes this interval.

In women who are virgins, bowel-infection and tubercle are the commonest antecedents, while in parous women any of the possible causes, or a combination of them, may be met with.

An important feature of cases of chronic tubo-ovarian inflammation, and one which is frequently present, is the occurrence of intercurrent acute attacks, or exacerbations, at irregular intervals. These intercurrent attacks reproduce the general features of acute pelvic inflammation, and are usually attended by abdominal pain and fever, slight or moderate in degree. Often they are sufficiently severe to necessitate confinement to bed for several days, but the attacks are not necessarily so severe as this. Their onset is frequently synchronous with a menstrual period. They do not, of necessity, indicate the presence of sup-

uration, but they do imply that the infective agent is still active in the inflammatory focus. In time these relapses cease as the virulence of the infecting agent becomes exhausted.

In the quiet phases, chronic inflammatory lesions give rise to few symptoms, the most troublesome being pain, which is felt chiefly in the lumbar and iliac regions, and is aggravated to so marked an extent by exertion, that the patient becomes disinclined to effort of any description and falls into a state of chronic invalidism. Dysmenorrhœa of the secondary type, menorrhagia, and leucorrhœa, are nearly always present, and probably arise in part from associated chronic infection of the endometrium or the vagina. Dyspareunia and sterility are common, and, sooner or later, a train of hysterical symptoms often becomes superimposed, which may distract attention from the true cause of the illness. Occasionally gross pelvic lesions, such as pyosalpinx, come in time to be tolerated extraordinarily well and give rise to little or no trouble, the probable explanation being that the infective agent has entirely lost its virulence. Thus a tubal abscess of considerable size may be discovered in cases where no indication of its presence was afforded by the temperature or the general condition of the patient; in such cases the organisms have probably all perished and the pus will be found sterile (*see* p. 621).

**Diagnosis of Tubo-ovarian Inflammatory Swellings.** The swelling formed by *inflamed adnexa* almost invariably lies in the posterior compartment of the pelvic cavity (*see* Figs. 343 and 344), although occasional exceptions have been recognized. As a rule the swelling is not mesial but postero-lateral in position, and in something like 75 per cent. of cases both sides can be felt to be involved, either in the form of a single mass of large size, or of two distinct swellings, that on one side being appreciably larger than that on the other. In other cases, while a definite swelling is formed upon one side, only an ill-defined thickening of the tube and ovary is to be felt upon the other. The actual characters of the swelling itself are varied. The outline of the affected tube and ovary is often obscured by the presence of surrounding exudative or plastic peritonitis; the result is the formation of a firm, fixed, tender mass in the position indicated, the nature of which can only be inferred. In other cases more detail can be recognized; thus a pediculated attachment of the swelling to the uterine cornu of the same side may be felt (*see* Fig. 343), or the outline of a curved structure like the crooked finger may be made out representing the tube, and a globular or oval portion representing the ovary. When suppuration has occurred, details of this kind can rarely be recognized owing to the amount of surrounding peritonitic thickening which is present. The rectal-bimanual examination should always be practised in these cases, for it will show the close relation of the swelling, when large, to the anterior rectal wall; the finger in the rectum is able to

reach the lower and posterior surfaces of a swelling in the pouch of

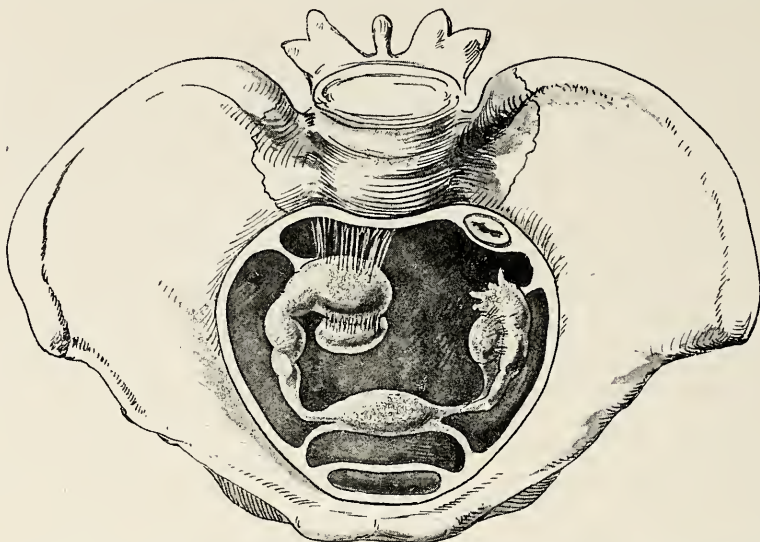


FIG. 343. TUBO-OVARIAN INFLAMMATORY SWELLINGS (Martin). Representing diagrammatically the position and character of the swellings. The right tube is sealed and dilated, and adhesions have been formed with the ovary and the peritoneum of Douglas's pouch. The left tube is thickened but not sealed.

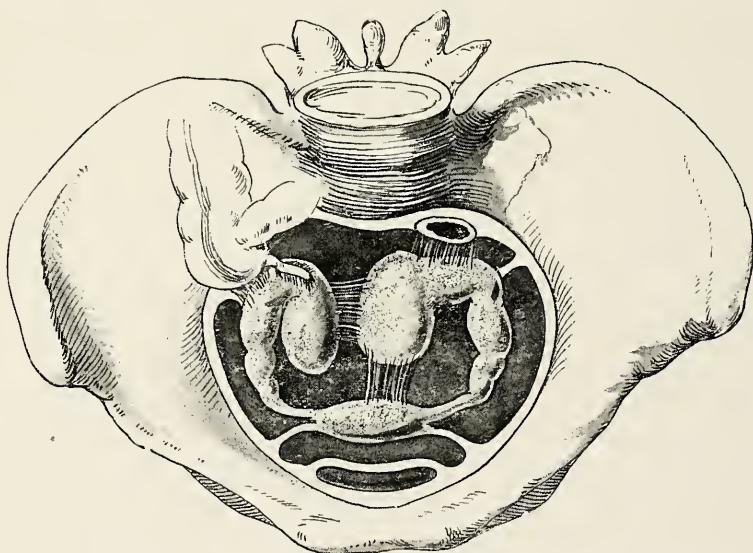


FIG. 344. TUBO-OVARIAN INFLAMMATORY SWELLINGS (Martin). Representing a more advanced stage than Fig. 343. The cæcum and vermiform appendix are adherent to the right tube. Both tubes are sealed and dilated; adhesions are seen to the other tube, to the rectum and to the uterus.

Douglas, while from the vagina, only the anterior surface can be felt.



Rectal examination is therefore of great value in the diagnosis of cases of inflamed adnexa.

Occasionally, swellings of this nature are large enough to extend above the pelvic brim and to be felt on abdominal palpation; more rarely still, cases occur in which a pyosalpinx or hydrosalpinx has been found drawn up into the abdominal cavity proper, so as to lie entirely above the pelvic brim. When a large amount of surrounding thickening and fixation is present suppuration has probably occurred; when there is little thickening, and the affected tube and ovary are comparatively soft and not entirely fixed, the presence of pus is improbable. Even when the appendages of one side appear on examination to be but slightly, if at all, affected, operation may unexpectedly reveal extensive changes in them; prognosis in this respect must therefore be cautious. A general anæsthetic is of course a great aid to accurate diagnosis in all cases, and is indispensable when the conditions are very unfavourable to a satisfactory bimanual examination.

The definite recognition of suppuration in these cases is often a matter of great difficulty. Pointing can rarely be recognized except when it involves the rectum; there it may sometimes be detected by the finger high up in the anterior wall, by the formation of a soft, highly sensitive spot upon the swelling. As a rule, it is unsuspected until a discharge of pus reveals its occurrence. Densely hard, fixed swellings, with much surrounding induration, usually contain a focus of pus, albeit often a small one.

In all chronic cases the condition of the *uterus* must not be overlooked; frequently laceration and erosion of the lips of the cervix will be found, and frequently also, the body of the uterus is enlarged and tender. These conditions indicate the presence of a chronic endometritis, which was probably originally septic, and may still be a focus of infection from which the tubal or ovarian inflammation may from time to time be reinforced. In such cases the uterus requires treatment, as well as the more deeply seated inflammation.

**Differential Diagnosis.** In the *acute* stages the differentiation of pelvic inflammatory swellings from one another is not a matter of great practical importance, for all are as a rule to be treated by palliative methods until suppuration occurs. In *chronic* cases a detailed diagnosis of the parts affected should, however, be attempted.

Of all the varieties of pelvic inflammatory swelling the tubo-ovarian is by far the commonest. Chronic cellulosic deposits are very rare, as the experience gained by the operative treatment of cases of pelvic inflammation has clearly shown. Chronic peritonitic effusions, small in extent and often multiple, are not uncommonly found in association with inflamed tubes and ovaries; they hardly ever occur alone, and their importance is quite secondary to the changes in the adnexa. As has been already mentioned, the commonest result of pelvic peritonitis is the formation of adhesions, leading

subsequently to displacement and loss of mobility of the uterus and its appendages.

Tubo-ovarian swellings large enough to be felt above the pelvic brim are often found to include a small ovarian cyst, which has become infected from the Fallopian tube, and to which the bulk of the swelling is largely due. There are no physical signs by which a large pyosalpinx can be distinguished from an infected ovarian cyst. Small tubo-ovarian swellings, on the other hand, are usually posterior or posterolateral in position, of more elastic consistence, and are, as a rule, very sensitive when touched; they also give rise to pain when the cervix is moved forward by the finger in the vagina. Often the characteristic outline of a convoluted and thickened tube can be made out in some part of the swelling.

Confusion sometimes arises from the presence of an *inflamed and adherent subperitoneal fibroid*. Usually it can be distinguished by the closeness of its relation to the uterus, but in chronic nodular salpingitis, which chiefly affects the isthmus, the swelling closely resembles a nodular fibroid both in its position and relations. Although a tubo-ovarian swelling is often closely adherent to the back of the uterus, a sulcus between them can usually be felt on vaginal or rectal palpation, which indicates the line of cleavage. In the case of the inflamed fibroid, the swelling appears to be completely incorporated with the uterus. Under anæsthesia, it may be possible in the case of the fibroid to recognize the tubes and ovaries in their normal position.

### Treatment of Tubo-Ovarian Inflammation

**Acute Cases.** All acute cases, whether in the initial stage or during a recurrence, are to be treated in the first place by expectant or palliative measures. When, however, in such cases there is evidence of diffused peritonitis, or of the formation of pus, the treatment necessarily becomes surgical.

During the stage of fever, severe pain, and tenderness, all local interference should as far as possible be avoided, the patient being kept in bed, the diet limited to fluids, the bowels kept open, and simple measures for the relief of pain adopted, such as the application of hot fomentations to the abdomen. In all prolonged cases, whether accompanied by much fever or not, a careful watch should be kept for local signs of suppuration, the importance of rectal examination for this purpose being borne in mind.

**Chronic Cases.** In such cases it is often a matter of some difficulty to decide whether medical or surgical treatment will give the patient the better chance of recovery. Generally speaking it may be said that medical treatment may be preferred when there has been only a single acute attack, when the tubo-ovarian enlargement is not great, or when there is no evidence of suppuration. As a general rule it

may also be said that surgical treatment is indicated when there have been repeated acute attacks, when the tube is distinctly dilated, or when there is evidence of suppuration; repeated acute recurrences generally signify the presence of an imperfectly isolated collection of pus.

*Medical or palliative treatment* may often with advantage be preceded by curetting the uterus, when the signs of chronic endometritis are present. This operation not only removes an infected endometrium but allows of the disinfection and drainage of the uterine cavity. This may be followed by a course of local treatment, during which the patient should be confined to bed. Sexual intercourse, and the use of alcohol, must be forbidden during the treatment. Attention should be paid to the condition of the alimentary canal; anæmia, when present, should be energetically treated with suitable preparations of iron, or of hæmoglobin and bone marrow. The local measures consist of vaginal douching, hot hip-baths, and medicated vaginal tampons and pessaries, the usual remedial agent being a 2½ per cent. solution in glycerine of ichthyol or resorcin. Hot-air, or electric-light baths, applied to the whole of the trunk and limbs also promote the absorption of inflammatory exudates. Drugs are of little use, but small doses of mercury and iodide of potassium sometimes appear to do good even in cases not obviously specific. Courses of treatment of ten to fourteen days duration may be repeated at intervals, as long as there is evidence of progressive improvement in the local and general conditions. The value of vaccine treatment in cases where the infecting organism can be isolated must not be forgotten.

Certain watering-places are of special benefit in cases of tubo-ovarian inflammation. The more important are: in this country, Woodhall Spa; in France, Plombières and Chatel Guyon; in Italy, Salzo-Maggiore. The course of treatment usually lasts from three to four weeks, and the details should be carried out under local medical supervision. Repeated visits to these places are usually required, and there is no doubt that great improvement in general health, and marked relief of local symptoms may be thus obtained in chronic non-suppurative cases. Any evidence of local suppuration absolutely contra-indicates palliative treatment.

It is clear that palliative treatment, to be successful, must be prolonged, and from its nature it is beyond the reach of the poorer classes. Accordingly social conditions often form a factor of importance in deciding between palliative and surgical treatment.

*Surgical Treatment: (a) Suppurative Cases.* Collections of pus, wherever they may be formed, must be evacuated as soon as they are recognized. *Peritonitic abscesses* are most conveniently reached, as a rule, through the posterior vaginal fornix, by the procedure known as *posterior colpotomy* (see p. 777). When the pus has been reached, the finger should be passed into the cavity for exploration, and any

septa felt may then be broken down so that free drainage may be obtained, but the limiting wall of the abscess-cavity should not be disturbed. A large, flanged rubber drainage-tube is then introduced and the case treated on ordinary surgical lines.

An *acute pyosalpinx* attended with fever and with abdominal pain and distension should also, if possible, be evacuated and drained by posterior colpotomy. In such cases the pus is certainly infective, and fouling of the general peritoneal cavity is difficult to avoid when the operation is performed by the abdominal route. The disadvantage of the vaginal operation is that secondary peritonitic or ovarian abscesses may remain undetected; when therefore the operation fails to give complete relief, a fuller exploration from above must be undertaken without delay. Dilated tubes, when drained vaginally, may entirely close without any further operation being required, but when other inflammatory foci, not necessarily suppurative, remain, a cure cannot be obtained.

*Chronic pyosalpinx*, whether unilateral or bilateral, is best dealt with by extirpation of the affected tubes by the abdominal route. The ovaries are often infected as well, and the uterus is probably in similar state. When the disease is bilateral a radical operation including complete removal of the tubes and ovaries, and of the uterus by *total hysterectomy*, is therefore the best operation to perform. The removal of the uterus does not appreciably increase the severity of the operation, and allows of more efficient drainage being obtained.

(b) *Non-suppurative Cases*. When an operation is decided upon in these cases radical procedures should, if possible, be avoided. The ovary is not necessarily infected, and should be carefully examined and inspected after the abdomen has been opened, to see if it cannot be wholly or partially conserved upon one side or the other. It may not be necessary to remove both tubes in these cases, and a sealed but only slightly thickened tube may be restored to functional competence by *salpingostomy* (see p. 766). Conservative procedures are clearly to be preferred in young women, whenever the local conditions warrant an attempt being made to save the damaged organs.

Inasmuch as the clinical recognition of the presence of pus is so difficult, it is necessary before operating to secure the patient's consent to whatever procedure the operator may subsequently find it desirable to adopt.

### NEW GROWTHS OF THE TUBES

The majority of new growths of the tube—sarcoma, myoma, lymphangioma, teratoma, papilloma and carcinoma, are very rare and their nature will not be diagnosed before operation. About one hundred and forty primary carcinomata and eighteen cases of chorion-epithelioma have been recorded. Of these papilloma, carcinoma, and chorion-epithelioma are most important clinically.

**Primary Tubal Papilloma.** The term *papilloma* was first applied by Doran in 1879 to an exuberant morbid growth arising from the mucosa of the Fallopian tube. Sixteen cases of benign papilloma have been recorded. It arises in the form of numerous villous processes or papillæ (see Fig. 345). These papillæ possess a central core of connective tissue, from which proceed multiple branches, which in their turn may again divide so that a racemose villous growth (see Fig. 347) is produced which eventually fills and dis-

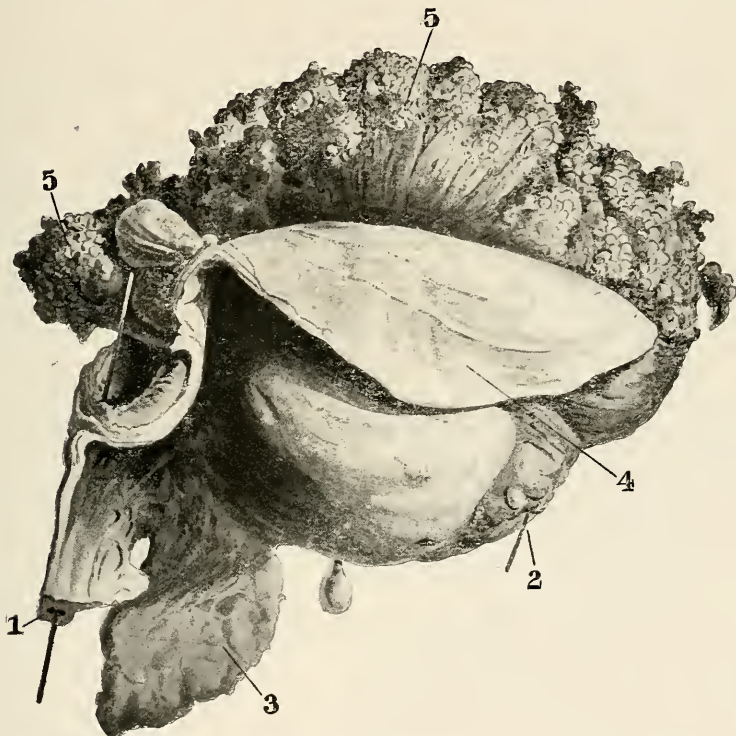


FIG. 345. A FALLOPIAN TUBE ENLARGED AND DILATED BY MASSES OF PAPILOMATOUS GROWTHS, WHICH SPRING FROM THE MUCOUS MEMBRANE (Hubert Roberts). They have not rendered the tube impervious, and a bristle is passed completely through it from the uterine end to the fimbriated extremity. No secondary deposits were found, and the patient was known to be alive twenty-three years after the operation. (1) Uterine end of tube. A bristle is passed through this to the fimbriated extremity. (2) Bristle issuing from fimbriated extremity of tube. (3) Ovary, which is healthy. A small pedunculated cyst below the tube near the ovary. (4) Wall of tube, turned down to show growth is seen inside. (5, 5) Masses of papillomatous growth filling the tube.

tends the tube without invading its walls. As a result of distension by the growth the tube-walls are ultimately thinned (see Fig. 345). The tube may attain a large size without closure of the abdominal ostium taking place. The branching processes are invested by columnar ciliated epithelium and by columnar cells devoid of cilia ;

the latter secrete a thin watery mucoid fluid. In the case shown in Fig. 345 the fluid escaped from the patent abdominal ostium and gave rise to ascitic effusion, but the innocence of the case was proved by the absence of secondary deposits, and by the fact that the patient was known to remain well for twenty-three years after the removal of the growth. On the other hand cases are recorded in which the abdominal ostium was sealed by inflammation whilst the uterine end

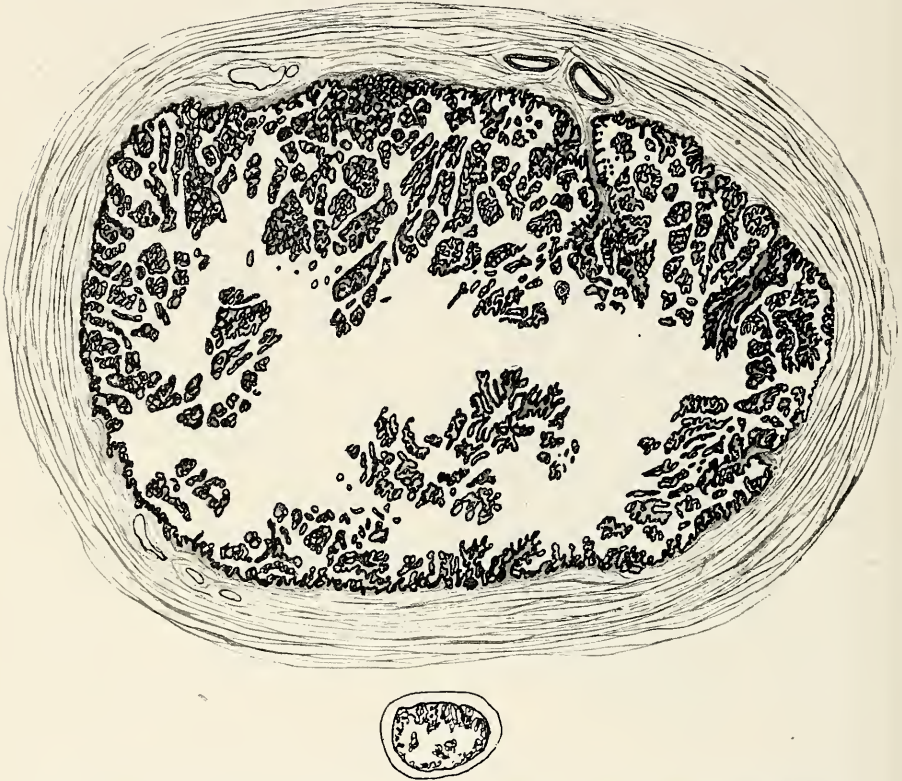

FIG. 346. MALIGNANT PAPILLOMA OF FALLOPIAN TUBE. Inset, natural size. This part of the tube shows no invasion of its walls by the new growths, but sections proved that this had occurred.

remained patent, allowing of the escape of great quantities of sero-sanguineous fluid *per vaginam*.

*Etiology.* In many cases the history of previous inflammation is quite clear; on the other hand it is not always evident that a pre-existing salpingitis was present.

*Signs and Symptoms.* Papilloma of the tube gives rise to a tumour which can be felt on bimanual examination. From the presence of fluid in the tube the swelling may have the consistence of a tense cyst upon one or other side of the uterus. It may be accompanied by free fluid in the peritoneal cavity even in the absence of malignancy.

There may be a history of sudden escape of pink watery discharge which comes away in gushes drenching the patient's clothes (*hydrops tubal profluens*). Such an event may be preceded by pain of a crampy character, caused by tubal contractions.

*Diagnosis.* Recognition of the condition will depend upon the detection of a swelling clinically recognizable as an enlarged tube. The diagnosis of simple, from malignant papilloma and from adenocarcinoma (*vide infra*) in the absence of evidence of metastases cannot be made by clinical means.

*Prognosis.* Simple papilloma may become malignant (*see* Fig. 347), and in this respect it shows a close analogy to the ciliated papilliferous cyst of the ovary (p. 669). The evidence of malignancy rests upon finding deposits of the growth in the muscularis of the tube by microscopical examination and also, to a less certain degree, upon the formation of masses of epithelial cells produced by proliferation and metaplasia of the epithelium investing the papillæ (*see* Fig. 347).

The *treatment* is complete removal of the affected tube, and if the opposite tube shows evidence of disease it should be resected also.

**Secondary Papilloma** occurs as a surface-growth, *i.e.* on the *peritoneal* aspect of the tube. It is met with as an extension from papillomatous growths of the ovary; the symptoms will therefore be referable to the primary growth (*see* p. 718).

**Adenocarcinoma.** As with papilloma, cancer of the Fallopian tube may be primary or secondary. In its *secondary* form the disease may be due to direct extension by continuity of tissues from cancer of the ovary, or more rarely of the body of the uterus. In ovarian cancer microscopic deposits have been observed by one of us in the perivascular lymphatics of the tubes even when the latter showed no

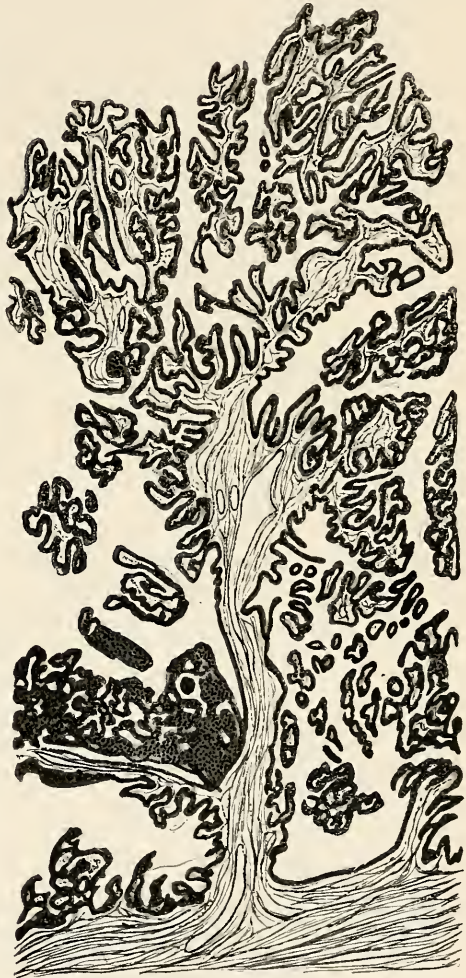

FIG. 347. PORTION OF FIG. 346.  $\times 45$ .  
The malignant metaplasia is well shown.

naked-eye changes. Cancer-cells may also make their way into the lumen of the tube through a patent abdominal ostium. Secondary cancer in the tube may occur with a primary growth situated in the alimentary tract; it is probable therefore that many of the cases presumed to be primarily tubal, are in reality secondary to an undiscovered cancer in some other organ.

*Primary Cancer* of the tube is a rare disease, but not so rare as is simple papilloma, of which, according to Doran, only sixteen

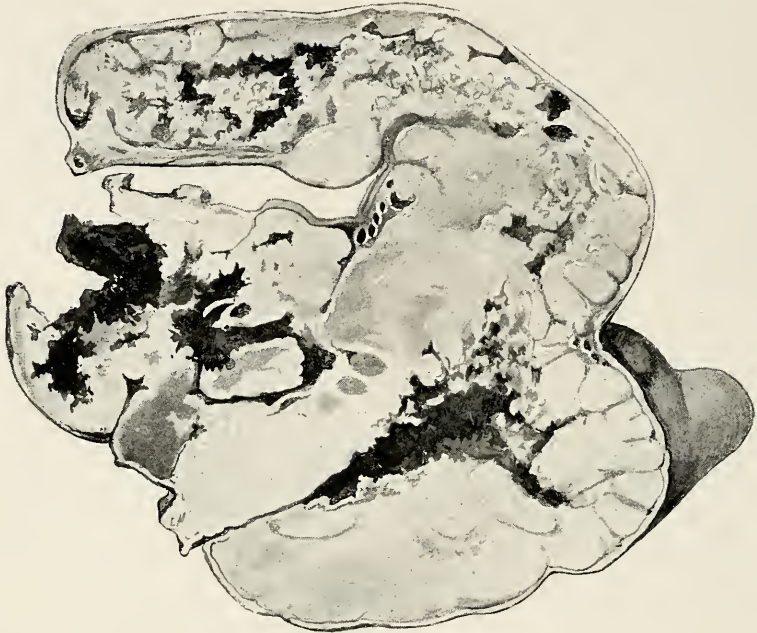


FIG 348. PRIMARY ADENOCARCINOMA OF THE FALLOPIAN TUBE, patient aged 58 (Herbert Spencer). The growth has considerably distended the outer part of the tube, the wall of which is intact except at the abdominal ostium. (From the *Journal of Obstetrics and Gynæcology of the British Empire*, vol. xvii, p. 33.)

cases are recorded. Orthmann reported the first authentic case of cancer of the tube in 1888, and in 1910 Doran brought the number of his collated cases to 100, since when about forty more cases have been recorded.

*Clinical Features.* Adenocarcinoma is more frequently bilateral than is simple papilloma. It especially affects women at or about the time of the climacteric. The age of the patient from whom the specimen shown in Fig. 348 was removed was 58 years. Doran states that parous women are the most subject to this disease.

*Pain* is very common but not an invariable symptom. It appears to be due to increased tension produced by retained secretion and is



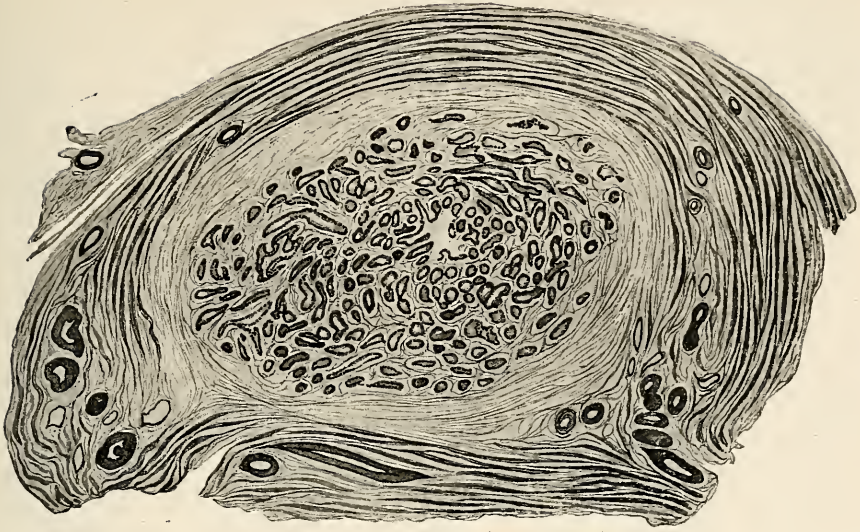

FIG. 349. ADENOCARCINOMA OF THE FALLOPIAN TUBE. Inset, natural size.

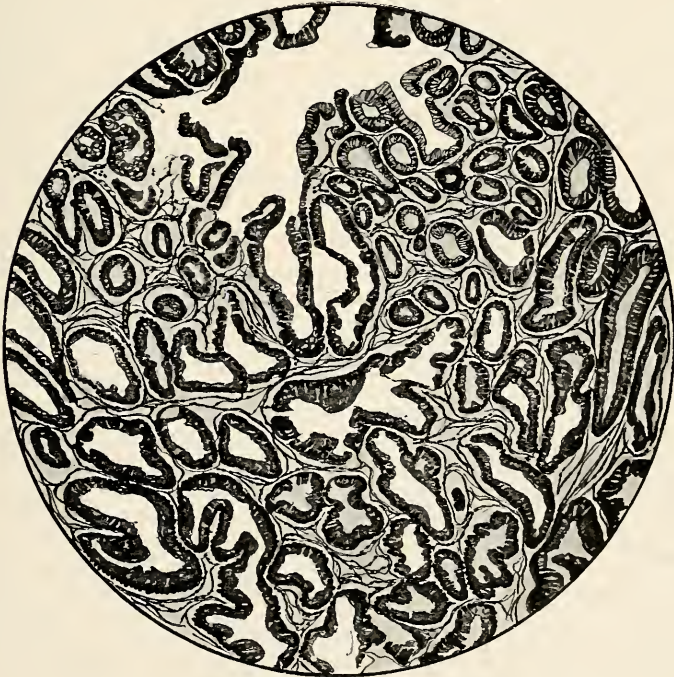

FIG. 350. ADENOCARCINOMA OF THE FALLOPIAN TUBE.  
Portion of Fig. 349.  $\times 65$ .

worse in cases where there is no discharge. The presence of a *swelling* is noticeable in most cases ; in size this may vary from a small mass in the lateral fornix to an abdominal tumour of considerable dimensions. In some cases a uterine or ovarian tumour may be present as well.

*Discharge* is the most important of all the symptoms, being present in more than 27 per cent. of cases ; it is usually thin, watery, and sanious, as in papilloma.

*Ascites* may be present and is an indication of metastatic implantation, and not of patency of the abdominal ostium as in the case of simple papilloma. There is a distinct history of pelvic inflammation, either gonorrhœal or puerperal, in a large number of cases, and in several the tubes have previously undergone gross inflammatory changes, such as hydrosalpinx, pyosalpinx, and tubo-ovarian cystic disease.

*Pathology.* In 36 per cent. of cases the disease is bilateral. The tumours which have been examined after removal have varied in dimensions from the size of a pigeon's egg to that of a mass, examined by one of us, which measured 10 inches in its greatest by 8 inches in its least circumference. The shape of the tube is maintained until the walls are ruptured by the intratubal masses (*see* Fig. 348). On section, the lumen is seen to be occupied by a yellowish-white growth of either soft or firm consistence, which resembles the cut surface of a sarcoma in its central and more compressed parts, whilst externally are seen the coarse papillary masses characteristic of a carcinoma. The thin tube-wall forms a sac for the growth, between which and the latter may be found hæmorrhagic or mucoid fluid pent up in cyst-like spaces. The abdominal ostium is generally closed by pre-existing inflammation, and the outer surface of the delicate sac is often densely adherent to adjacent structures.

Histologically, cancer of the tube varies within wide limits, from adeno-carcinoma of *tubular* type, such as that seen in Figs. 349 and 350, to a diffuse *spheroidal-celled* growth with cells densely packed within large alveolar spaces (*alveolar carcinoma*). It may here be mentioned that the malignant papilloma already referred to is often included in the records of *cancer* of the tube ; this is quite admissible so long as it is remembered that the growth started as a benign tumour and not as a cancer. The histological features assumed by a papilloma after it has undergone malignant epithelial metaplasia have already been described (*see* Fig. 347).

*Diagnosis.* The disease is seldom detected at an early date. " A watery sanious discharge in a woman between 45 and 55, associated with a distinct and usually tender swelling in one lateral fornix, without clear evidence of uterine cancer or of a movable ovarian tumour, are indications of the existence of primary cancer of the Fallopian tube " (Doran).

*Prognosis.* Carcinoma of the tube is extremely malignant. The tube-wall offers but a slight resistance, and there is only the thinnest possible layer left, which easily ruptures. The proximity to large lymphatics, and the possible patency of the abdominal ostium, are among the factors which make dissemination easy. Again, rupture during operation may lead to implantation, or particles may escape through the ostium during operative manipulations. The operation for removal may entail many difficulties so that there is a primary mortality of 7 per cent. More than 25 per cent. of patients die of recurrence between six months and one year after removal of the affected parts (Doran).

*Treatment.* This consists in the free removal of the tube or tubes, and owing to the extreme malignancy of the disease it is better to perform hysterectomy at the same time, so that the tubes, ovaries, and uterus may be extirpated *en masse*.

**Primary Chorionepithelioma.** This disease of the tube has been recorded eighteen times, and, as when found in other situations, the growth is extremely malignant (*see p. 553*).

## PART II: SECTION VI

### MORBID CONDITIONS OF THE OVARIES

- (1) CHRONIC OVARIAN PAIN
- (2) DISPLACEMENTS
- (3) INFLAMMATION
- (4) NEW GROWTHS

#### CHRONIC OVARIAN PAIN

WOMEN not infrequently complain of chronic pain referred to the iliac region on one side or the other, or sometimes on both sides ; this area is often loosely styled the ' ovarian region.' The left side is much more frequently affected than the right, and in the majority of cases the subjects of this pain are women of pronounced nervous temperament. The ovary may be found somewhat enlarged and more sensitive than usual to pressure in the bimanual examination, but without restriction of its mobility. Such ovaries are often said to be ' congested.' In other cases the ovary may be felt to be of abnormally small size. If signs of inflammation, affecting the Fallopian tube and ovary on the same side as the pain, are found, the pain is to be attributed to the inflammatory process or its results.

An *enlarged* painful ovary, when examined after opening the peritoneal cavity, is often found to contain a number of small follicular cysts (*see* p. 649), and, as will be explained later on, this condition is of inflammatory origin. The *small* painful ovary is usually found to be of abnormally dense consistence, with numerous deep puckerings such as are commonly found in the ovaries of women who are approaching the close of the fertile period of life. These ovaries have been called ' cirrhotic,' since they contain few Gräafian follicles and an abnormally large proportion of well-formed fibrous tissue; the pain is attributed in some way to the pressure-effects on nerves of this excess of fibrous tissue. But it must be recollected that analogous changes occur in the ovary under normal conditions in connection with the menopause, and at such times ovarian pain is not a marked or constant symptom.

But while it is doubtful whether premature fibrotic changes in the ovary are a source of pain, there is no doubt that the association of

slight inflammatory changes in the ovarian cortex with the formation of small retention cysts, is a frequent source of pain. Such ovaries are not only enlarged and tender when examined clinically, but are also, in almost all cases, of abnormally large size.

In many cases, however, no definite abnormality can be detected, and such are regarded as instances of ovarian 'neuralgia.' It is therefore necessary to distinguish four groups of cases of chronic ovarian pain: (a) those in which the ovary is enlarged, tender, and limited in mobility; these are *inflammatory*, and often there is also evidence of thickening of the Fallopian tube; not infrequently the changes are bilateral; (b) those in which the ovary is enlarged, and tender but freely movable; these are examples of what will be described later as *small-cystic degeneration*; (c) those in which the ovary is abnormally small; (d) those in which no abnormality can be detected. The last named is probably a neurosis; the others are associated with recognizable changes in the affected organ. Care must be exercised in all these cases, and examination made under anaesthesia, in order to determine the local conditions with as much precision as possible.

*Treatment.* The fact that an ovary is the seat of pain is not a sufficient reason for removing it. An organ of such physiological importance is not to be lightly sacrificed during the years of its functional activity. Ovarian pain without definite organic changes is to be regarded and treated as a neurosis, and all local treatment is to be avoided; removal is never justified, for it is useless inasmuch as it does not relieve the patient, or in some cases is positively harmful. The removal of both ovaries for such a condition is a surgical blunder of the greatest gravity.

When local changes have occurred, the treatment depends upon their nature and extent. When definitely inflammatory, the palliative treatment indicated on p. 633 may be applied with benefit, and often, if persevered in, with complete success. Cystic changes are, however, uninfluenced, so far as we know, by all therapeutic measures. Partial resection, with conservation of as much healthy tissue as possible, is the operation of choice. The limitations of usefulness of ovarian transplantation have been already discussed (p. 552).

## DISPLACEMENTS OF THE OVARY

Congenital *non-descent* of the ovary is a very rare anomaly, but a few cases have been recorded in which the ovary has been detained above the pelvic brim in the neighbourhood of the ureter (Bland-Sutton).

As a result of pelvic peritonitis ovaries may be found displaced and adherent to the fundus or back of the uterus, to the ovary or Fallopian tube of the opposite side, to the abdominal wall, the omentum, or in rare cases even to the floor of the utero-vesical pouch.

**Prolapse of the Ovary.** In this condition one or both of the ovaries lie in the para-rectal pouch or in the pouch of Douglas. This displacement is a common result of backward displacement of the uterus (*see* p. 570), but also often occurs as an independent condition. In the latter case there are two determining causes, *viz.* relaxation of the ovarian supports (usually the result of pregnancy) and enlargement with increase in weight of the ovary. These conditions lead the ovary to sink first into the para-rectal pouch and later, slipping over the edge of the utero-sacral fold, to fall into the pouch of Douglas. At first the ovary, though usually enlarged, is not otherwise abnormal; after a time it may become adherent in its faulty position from the occurrence of plastic peritonitis. Except in cases of backward displacement the condition is usually unilateral, or if bilateral one ovary is affected to a much greater extent than the other.

The main *symptom* of a prolapsed ovary is a dull aching pain felt in the back or in the hypogastric zone of the abdomen, and when the condition is associated with backward displacement of the uterus other symptoms may be present (*see* p. 574).

In its abnormal position in the pouch of Douglas the ovary is subject to disturbance from the filling and emptying of the rectum, from straining during defæcation, or from coitus. In its normal position it is protected almost entirely from disturbances of this kind. These considerations probably account for the fact that the majority of prolapsed ovaries are very sensitive to touch *per vaginam* or *per rectum*, and to this abnormal sensitiveness the pain so often experienced is due. The pain is increased during menstruation, but beyond being unusually painful this function is not otherwise disturbed. Married women sometimes complain of dyspareunia, the pain in some cases being described as severe and sickening in character. Yet cases are not very infrequent in which prolapsed ovaries are not unduly sensitive, and do not give rise to pain, but are discovered, as it were, by accident during clinical examination.

As is the case with many other gynæcological ailments, neurasthenia and hysteria are frequently found in association with prolapsed ovaries. Care must be exercised in avoiding the error of attributing all the patient's alleged sufferings to the displaced ovary.

The *treatment* of a prolapsed ovary is a subject which calls for the exercise of discretion, especially if complicated by obvious neurosis. *Relief* of pain can sometimes be secured by a course of local treatment, such as rest, vaginal douching and vaginal tamponade; rest in such cases should be enforced in the prone position, or on the side to which the affected ovary belongs. These measures may temporarily relieve the embarrassed circulation through the ovary. A ring pessary will limit the descent of the ovary, although it is powerless to restore it to its normal position. Only a certain amount of relief can be anticipated from the use of this instrument. Cure can be obtained by

stitching up the ovary in its proper position by shortening the ovarian ligament (*ligamentum ovarii proprium*).

In cases dependent upon backward displacement, the treatment is that suited to the displacement, and nothing more.

**Hernia of the Ovary.** This condition may be *congenital* when the ovary occupies the canal of Nuck; in many reputed cases, however, the body found in this canal has proved on microscopic examination to be a testis, or a combined gland—ovo-testis (*see p. 167*). The *acquired* form is much commoner than the congenital; the ovary has been found in every variety of hernia, but more commonly in the inguinal, than in any other. It is usually accompanied by its companion Fallopian tube, and sometimes by a knuckle of bowel or a piece of omentum. Ovaries displaced in this way are usually functionally active. The gland often becomes swollen and unusually tender during menstruation, and in rare instances axial rotation has occurred, giving rise to acute symptoms and to a diagnosis of strangulation of the hernia. When the ovary cannot be reduced, the case should be treated surgically upon the lines suited to the variety of hernia which it represents.

## INFLAMMATION OF THE OVARY

Oöphoritis is due to the same causes as inflammation of the tubes, but the ovary is less often infected than the tube. Extension of inflammation from the tube to the ovary occurs in two different ways, (1) by a spread to the *surface of the ovary* directly from the tube or adjacent peritoneal surfaces; this results in the formation of ovarian adhesions and a thickening of the superficial layers of the cortex (*peri-öophoritis*). (2) Bacteria may *penetrate the ovarian tissues* through a ruptured Gräafian follicle, or may be deposited in them by the blood- and lymph-streams (*interstitial öophoritis*).

### Perioöphoritis

Perioöphoritis is of frequent occurrence, the commonest precedent conditions being salpingitis (*see Fig. 341, p. 625*) and pelvic peritonitis. The adhesions may bind the ovary firmly to the tube, to the back of the broad ligament, or to the floor of the pouch of Douglas. In a large proportion of cases the ovary, in addition to being adherent, is also enlarged from the formation of numerous small unilocular cysts, resulting from the non-dehiscence or cystic degeneration of Gräafian follicles. The frequency with which adherent ovaries are cystic, points to the conclusion that inflammatory changes lead directly to this condition, which is known as the 'small-cystic' ovary (*see Fig. 354, p. 649*).

In the acute stage of perioöphoritis the ovary can be easily separated from the adherent tube and neighbouring peritoneum. It is swollen, as a rule, and oedematous. In chronic perioöphoritis it

is usual to find the ovary enveloped by fibrous webs and intimately bound to the tube (*see* Fig. 341), sometimes along the whole length of the latter, sometimes to its abdominal ostium, the fimbriæ of which are obscured by the adhesions. Inflammatory peritoneal cysts often overlie both tube and ovary and the mesosalpinx intervening between tube and ovary may have disappeared, or if present may be thickened by inflammatory new formation (*see* Fig. 340).

### Acute Interstitial Oöphoritis

This condition is usually due to a streptococcal infection spreading from a septic endometrium during the puerperium or after abortion, or it may be caused by a direct blood-infection during one of the acute fevers. Thus acute interstitial oöphoritis is liable to occur in typhoid, cholera, and scarlet fever; it also occurs in poisoning by phosphorus and arsenic. In acute oöphoritis resulting from septic endometritis, the ovary is soft and swollen, in colour it may be yellowish, deep-red, or dirty grey, sometimes it may be nearly black. The surface is covered with thick fibrinous flakes. On section the stroma is œdematous, and small interstitial abscesses are found. The follicles may also contain pus. The condition is accompanied with acute peritonitis, which is often fatal before a clinical diagnosis of acute oöphoritis can be made.

In cases of infection of a lesser degree of intensity (subacute infection) the injury to the ovary (1) may be repaired to some extent, but the follicles invariably suffer permanently (*see* Fig. 354), (2) the subacute stage may pass into a chronic oöphoritis, or (3) abscesses may form which run a subacute or a chronic course.

**Ovarian Abscess.** Abscesses are found in two situations within the ovary: (1) in the stroma, (2) within either a follicle or a corpus luteum. The latter situation is by far the more usual.

In an ovarian abscess the specific organism exists for a longer time than it does in a pyosalpinx. Many months after abortion we were able to grow pure cultures of a streptococcus after twelve hours incubation, from pus aspirated from an ovarian abscess.

(1) An abscess in the stroma is the result of a direct blood-infection and may arise in the course of enteric fever or other specific fever, or of puerperal sepsis. It is therefore an embolic or pyæmic lesion. Many foci of suppuration may be found and they are usually small, with ragged walls, and devoid of a lining of granulations.

(2) *Corpus Luteum Abscess.* The usual site for an ovarian abscess is the mature Gräafian follicle or the corpus luteum, and the usual mode of infection, is not through the blood-stream, but by the progress of an ascending infection along the mucous membrane of the tube. The organisms enter through the tear in the follicle caused by dehiscence in ovulation, the process of infection being analogous to the transfer-



ence of a spermatozoon to a follicle, such as is known to occur in ovarian gestation. This kind of abscess is therefore one of the final

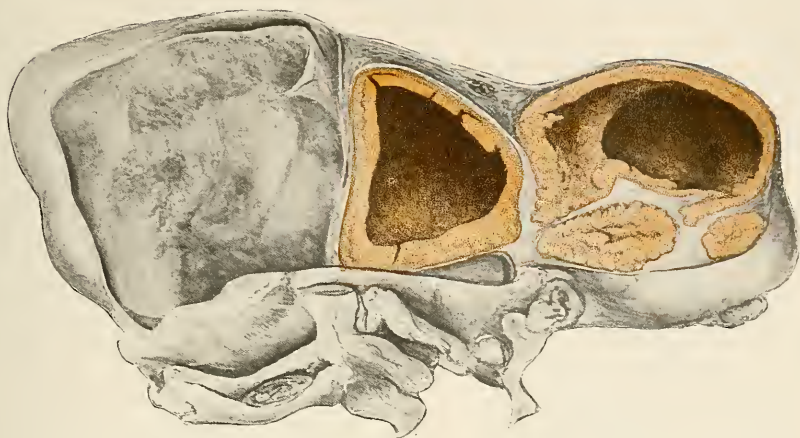


FIG. 351. TWO LUTEIN ABSCESSES IN A CYSTIC OVARY. Note the convoluted yellow lutein tissue.

results of an ascending infection from the lower genital tract, and the commonest cause is gonorrhœa. Since the pus is formed from the

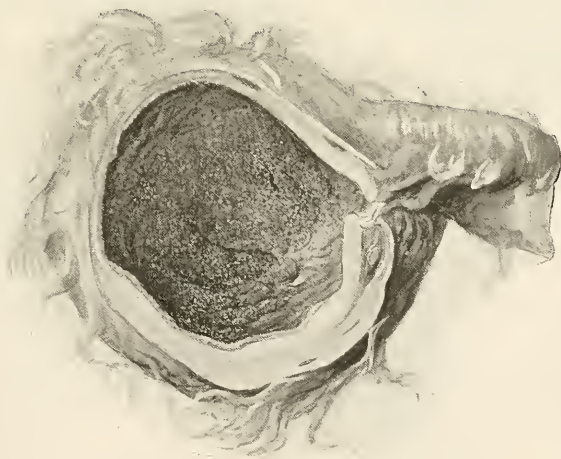

FIG. 352. LUTEIN ABSCESS FROM A CASE OF DOUBLE SALPINGO-OÖPHORITIS. Note the 'frog spawn' lining, and the adhesions on tube and ovary.

infection and breaking down of the blood-clot within a corpus luteum, the lining of the abscess will, in the first instance, be composed of the convolutions of lutein tissue. Later on, when the abscess has become chronic, the lutein cells are in part replaced by granulations, but it is

generally possible to distinguish their presence microscopically. In a recently formed lutein abscess the characteristic yellow lining is very obvious, and its folded appearance is maintained in those of small dimensions. When granulations intermingle with lutein cells, the lining becomes coarsely granular, giving an appearance which has been likened to frog's spawn. Figures 351 and 352 represent the average sizes of lutein abscesses. The largest which we have encountered was the size of a foetal skull, and was densely embedded in the left side of the pelvis. Lutein abscesses run a very chronic course, become densely adherent (see Fig. 352), and as there is frequently no rise of temperature, they are rarely diagnosed before operation, but when opened up after removal, the tufted or papillary character (see Fig. 353), and yellow-ochre colour, of their inner wall is diagnostic.

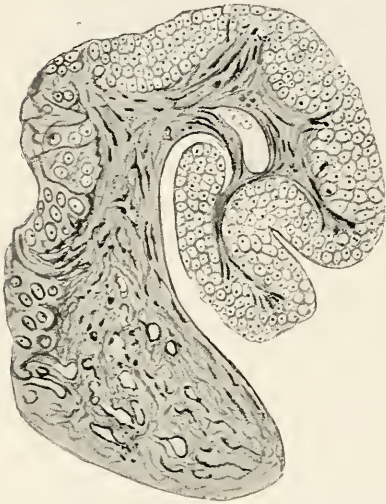


FIG. 353. LUTEIN ABSCESS, showing one of the tufts which give the papilliferous or 'frog-spawn' appearance to the yellow abscess-wall. The section was taken from specimen shown in Fig. 352.

*Follicular Abscess.* An unripe or atresic follicle, or what will later be described as a *theca-lutein cyst*, may become infected *viâ* the blood-stream, as we have already seen in acute oöphoritis. It is quite possible that this may also occur in subacute and chronic oöphoritis. In such cases, we must assume that the infection occurs through actual penetration of the thin walls of such cysts as project on the surface of the ovary. It is a well-known fact that although the gonococcus usually produces a surface-inflammation, it, nevertheless, is capable of penetrating into cellular tissues. In suppuration of unripe

follicles, the theca-lutein cells are often seen as a flattened lamina lining the cavities, but the papillary or tufted appearance of the lining membrane of a corpus-luteum abscess is never seen.

### Chronic Interstitial Oöphoritis

This condition is generally bilateral, but it is not invariably so. There is almost always enlargement of the ovary and fixation of the organ to the pelvic wall, or in the pouch of Douglas, where it is prone to gravitate by reason of increase in weight and size.

*Causation.* *Gonorrhœa* is the most frequent cause of chronic oöphoritis. It is therefore most common in young women between twenty and thirty years of age. In children and virgins a latent

*appendicitis* may be the cause, or an acute *puerperal* oöphoritis may, as already stated, pass into a chronic stage. It may be that *circulatory disturbances*, of a non-inflammatory nature, produce the same histological changes in the ovary as those caused by infection; so that all sources of irritation leading to increased blood-supply to the ovaries must be considered in the etiology of this form of oöphoritis. Notably these are uterine myomata, ovarian tumours of the opposite side, sexual excitement (masturbation, *coitus interruptus*, etc.). The patient herself will often give as a cause, *chill*, e.g. getting wet during a period, and this cannot be excluded, as it may lead to a determination of blood to the inner genital organs sufficient to produce an extension of a pre-existing inflammation.

*Macroscopically*, the ovary is almost always enlarged. The surface is frequently covered by adhesions; it is uneven and lobulated, partly

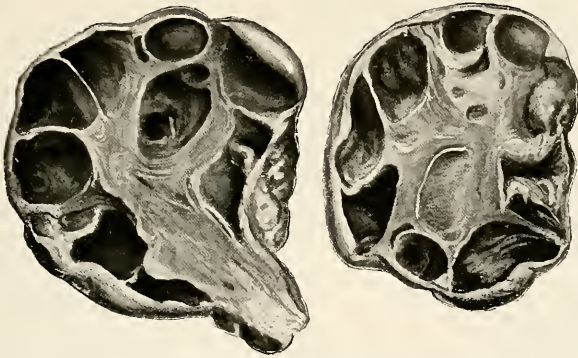


FIG. 354. SMALL CYSTIC DEGENERATION OF THE OVARY (Williamson).  
The cysts are atresic follicles.

from an unusual number of distended follicles, partly in consequence of deep depressions and folds of the cortex itself (*ovarium gyratum*).

*Microscopically*, there is (1) a more or less uniform thickening of the tunica albuginea, visible as white spots similar to the tendinous spots of the cardiac ventricle; (2) an increase of the connective tissue of the stroma accompanied by a marked reduction or total disappearance of the primordial follicles; (3) the corpora albicantia and cystic follicles are increased in numbers, due sometimes to impairment in the retrogression and absorption of the lutein tissue, the latter remaining as compact hyaline masses; (4) in other cases the ovary is converted into a mass of non-nucleated fibrillary connective tissue, and becomes reduced in size and very hard.

**“Small-cystic Degeneration of the Ovary.” Sclerocystic Disease.**

In this condition the number of visible follicles may be increased to twenty or more; they vary in size from that of a pea or bean, to that of a pigeon’s egg, whilst the stroma is diminished in amount (see Fig. 354). In many of the cysts the egg-cell is still visible,

but often it is degenerated or has disappeared, together with the granulosa-layer. These cysts are *atresic follicles*. Some possess a lutein lamina. The failure of these follicles to ripen and rupture is due in part to the thickened tunica albuginea, and may be dependent also upon the fact that the egg-cell has degenerated, which in its turn may be a result of inflammation. When a follicle has lost its egg-cell, one of two alternatives will happen, according to the stage of development which the follicle has reached ; these are (1) the formation of a *hydrops folliculorum*, or (2) the formation of a theca-lutein cyst.

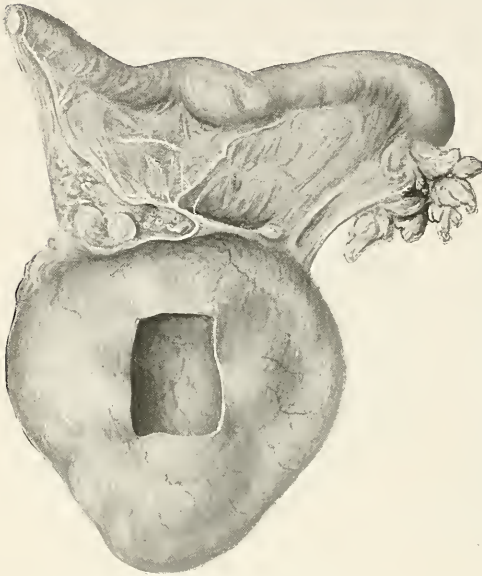


FIG. 355. LARGE HYDROPS FOLLICULORUM OR SIMPLE SEROUS CYST.

**Hydrops Folliculorum.** This condition is not regarded by all writers as inflammatory in origin, but in our opinion this is the correct view to take of its causation.

In small-cystic degeneration, or sclero-cystic disease, we have the initial stages of the formation of dropsical follicles. In a variable structure like a Gräafian follicle, it is difficult to say where physiological enlargement ends and where pathological distension begins. We must therefore take the degenerated condition of the egg-cell and stratum granulosum as evidence that the distension is

pathological, and we must find collateral evidences of chronic oöphoritis, before drawing the conclusion that the latter is the cause of the distension of the follicle.

Round-celled infiltration which appears in the early stages of oöphoritis is not seen in the chronic stage. The signs of chronic inflammation in the ovary are (1) multiple corpora albicantia ; (2) abnormal thickening of vessels ; (3) absence or reduction in numbers of primordial follicles ; (4) sclerosis (fibroid induration) of the cortex ; (5) macroscopic adhesions and enlargement of the ovary. These changes are often met with in association with hydrops folliculorum, and when present they justify the conclusion that the follicular distension is the outcome of chronic oöphoritis.

Macroscopically, these distension-cysts appear as thin-walled translucent vesicles on the surface of the ovary. There may be many such, but generally only one enlarges to a considerable size ; the remainder, succumbing to the pressure of the largest cyst, finally disappear. Very

rarely, a number of cysts enlarge simultaneously, producing a multilocular tumour, the septa of which consist of thinned-out ovarian stroma dividing the individual cysts one from another. This is the so-called 'Rokitansky's tumour,' or *compound hydrops folliculorum*. By the breaking-down of septa between dropsical follicles, a cyst composed of two or three conjoined loculi may be formed, but again this is exceptional, it being usual to find a single unilocular cyst.

Microscopically, the cyst-wall is composed of connective tissue, the outer layer being fibrous, the inner cellular and containing vessels. The innermost layer consists of the basal cells of the stratum granulosum, the more superficial cells, together with

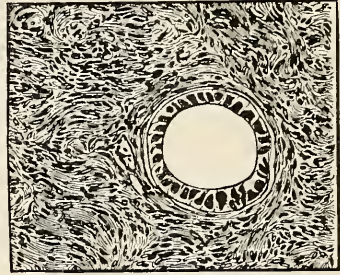


FIG. 356. ATRESIC GRAAFIAN FOLLICLE FROM AN ADULT OVARY (early stage). The egg-cell is lost, only the membrana granulosa remains, and its cells have changed their form and become cubical instead of spherical

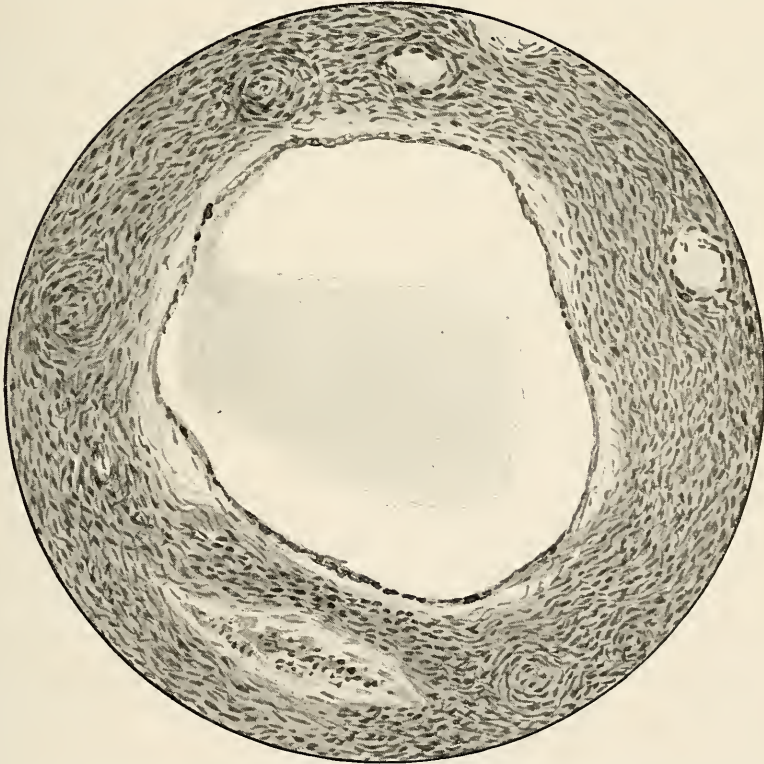


FIG. 357. FOLLICULAR RETENTION CYST (Hydrops Folliculorum). The section shows an irregular dilated follicle with its epithelial lining flattened and atrophied by pressure.

° ovum and discus proligerus having been shed (see Figs. 356 and 357).

The cells of the basal layer are seen to have changed their shape and become cubical. As the cyst enlarges these cells become flattened out, and eventually they are destroyed by the pressure of the cystic fluid. In colour this fluid is pale yellow; it contains albumen, salts, and nitrogenous extractives. It has a low specific gravity.

Hydrops folliculorum *per se* causes no characteristic symptoms. It appears at every period of life up to the menopause. The cysts may rupture and undergo spontaneous cure.

**Simple Serous Cysts.** Some authorities regard the cyst described by this title as the simplest form of an ovarian adenoma, but we consider it to be an exaggerated form of hydrops folliculorum and therefore include its description under inflammatory changes of the ovary and not under the section dealing with new growths.

Simple serous cysts are seldom sufficiently large to cause symptoms, they may attain the size of an orange, and in exceptional cases reach large dimensions. Usually they are unilocular, but one or two septa may be present. They have thin walls, and contain clear albuminous fluid of low specific gravity. They grow slowly, and may rupture, but the contents set up no irritation of the peritoneum; and there is clinical evidence to suggest, that without rupture, the contents may be absorbed and the cyst subside. The fluid is a secretion from the epithelium lining the cyst. As the cyst enlarges the epithelial lining becomes flattened out, and shows a certain tendency to proliferate. The increase of epithelium and the correspondingly large size of the cyst is no reason for regarding a simple serous cyst as a new growth, the same epithelial increase is seen in a large hydrosalpinx; also it is to be remembered that in salpingitis the epithelium (in response to inflammation) behaves in an adenomatous manner, *i.e.* it proliferates and forms cystic follicles in the wall of the tube (*see* Fig. 338, p. 624), but the adenomatous formation thus produced is not regarded as a new growth.

Proliferative processes such as are characteristic of neoplasms are entirely wanting in the walls of a large hydrops folliculorum (simple serous cyst). It is true that small dense wart-like projections are sometimes seen as papillæ upon the otherwise flat surface of the cyst; these however show no epithelial overgrowth, but are generally covered by a flat layer of endothelioid cells. These projections may be explained by regarding them as due to an *inflammatory* hyperplasia of the connective tissue in the wall of the cyst, *i.e.* of the nature of condylomata acuminata (*see* Fig. 141, p. 292), especially as they resemble these structures histologically.

**Theca-lutein cysts** are a very common accompaniment of chronic oöphoritis. The characteristic feature of the cyst is that theca-lutein cells are present in its wall. They are formed from follicles in which the ripening process has begun, that is, after the development of the lutein cells in the theca interna, and sometimes after the dis-

appearance of the membrana granulosa. Many theca-lutein cysts, however, still retain an epithelial lining (membrana granulosa) internal to the lutein lamina, and are consequently termed *epithelial-lined lutein cysts*. Those which are non-epithelial, possess a lamina of fibrinous material covering the lutein layer. This is probably the representative of the unaltered part of the theca interna of the follicle (see Fig. 358); it may be smooth, tufted or wavy in outline. The lutein cells which are found in the theca-lutein cysts are much smaller than those seen in the yellow convoluted lutein-layers of a ripe corpus luteum (cf. Figs. 359 and 360). Many continental authorities regard the latter as having an origin in the granulosa-cells, and thus divide lutein cysts into two varieties, the theca-lutein cyst and the granulosa-lutein cyst. In our opinion this view has never been conclusively proved (see Ovary, p. 44).

It will be seen that while theca-lutein cysts and hydrops folliculorum are both due to chronic oöphoritis, they differ in one essential particular, viz. that the former shows the presence of lutein cells. In the latter condition the cystic changes occur before the lutein cells have developed. There is no evidence to show that once a follicle has become dropsical, it can proceed to the normal development of lutein cells from its theca interna. Absence of the egg-cell, and the gradually increasing intracystic pressure, prevent further progress towards maturity.

Theca-lutein cysts are usually unilocular and single, but many small lutein cysts are to be found in a single ovary which has suffered from chronic interstitial oöphoritis. Occasionally these small cysts may be bilocular (see Fig. 359). The contents consist of an albuminous, clear, straw-coloured fluid, which is derived mainly by transudation from the vascular theca interna. When an epithelial lining persists (see Fig. 359), it will contribute by its secretion to the fluid contained in the cyst.

**Compound Theca-Lutein Cysts** are bilateral, thin-walled, multilocular ovarian cysts found in association with vesicular mole and

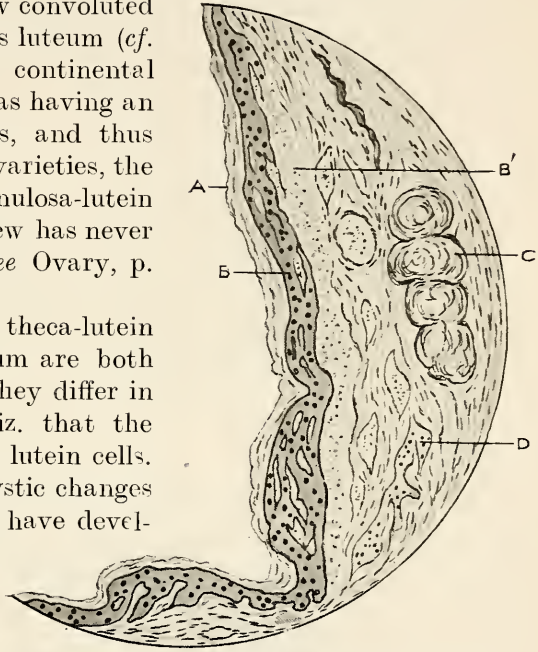


FIG. 358. WALL OF A LARGE THECA-LUTEIN CYST. The lutein cells have become compressed by tension of the cyst contents so that the outline of the cells is lost. A, Internal layer of fibrin; B, Lamellar arrangement of compressed lutein cells. B', Layer of blood-clot within theca interna. C, Corpus albicans. D, Displaced lutein tissue lying in ovarian stroma.

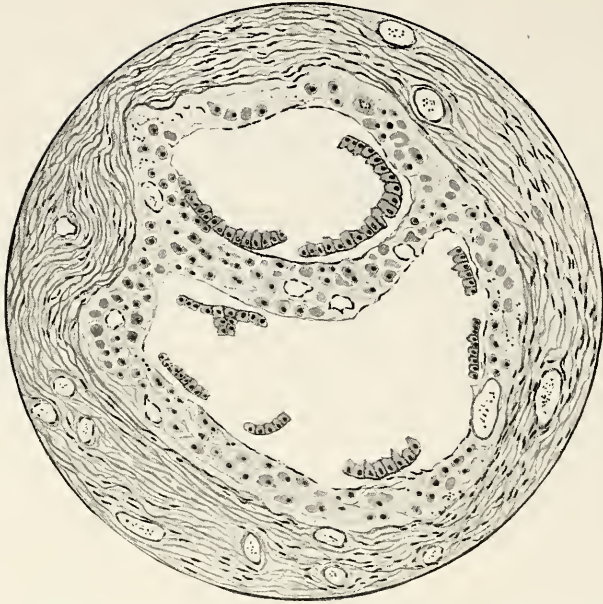


FIG. 359. THECA-LUTEIN CYST, BILOCULAR. The theca-lutein cells are smaller than those seen in the convolutions of a ripe corpus luteum (*cf.* Fig. 360). The granulosa-layer still persists in detached fragments.

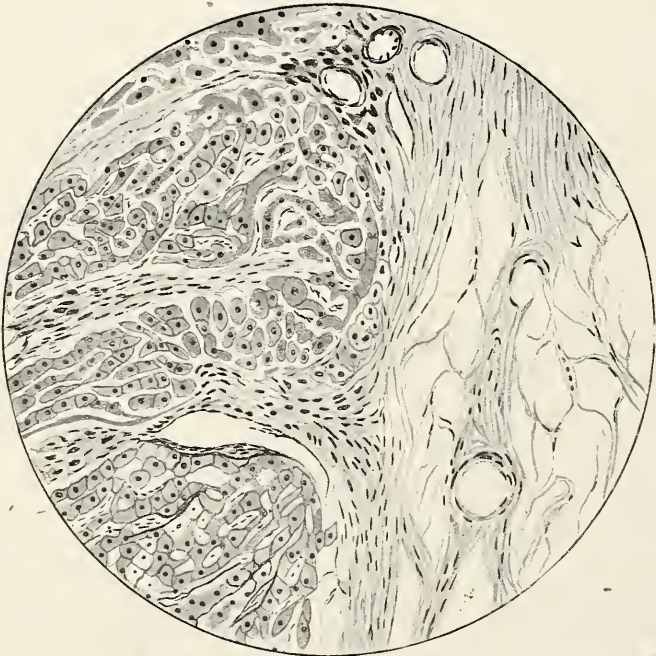

FIG. 360. MICROSCOPIC SECTION OF NORMAL CORPUS LUTEUM, such as those seen in Plates III and V. The large mono-nuclear lutein cells, rich in cytoplasm, make up the yellow convolutions.



with chorionepithelioma. The average size of such cysts is that

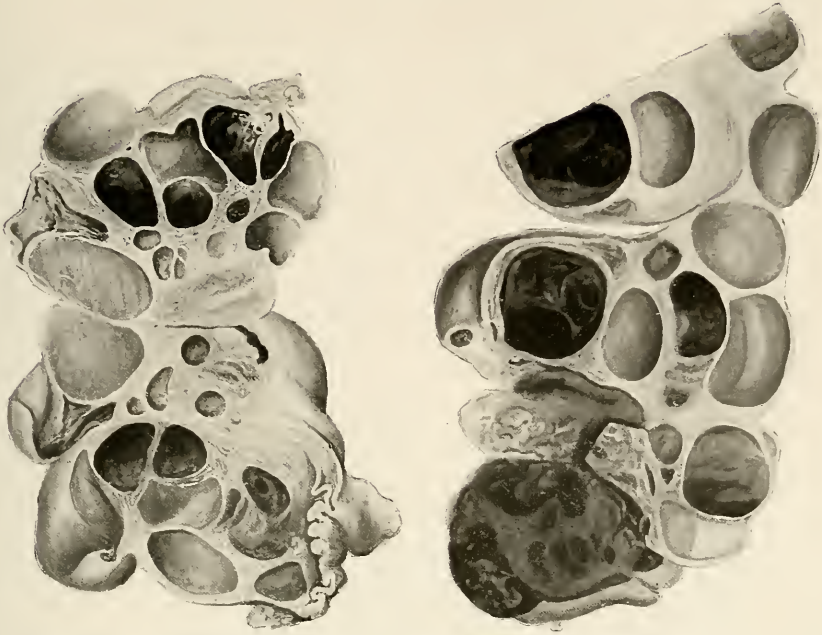

FIG. 361. BILATERAL COMPOUND THECA-LUTEIN CYSTS FROM A CASE OF VESICULAR MOLE, followed by chorionepithelioma.

of a foetal skull. In general appearance a compound theca-lutein cyst

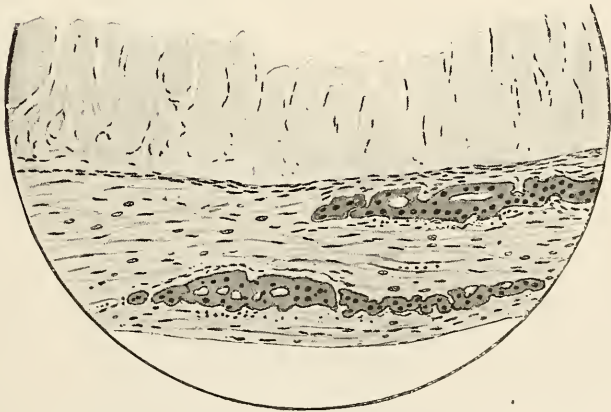


FIG. 362. WALL OF A LOCULUS OF A COMPOUND THECA-LUTEIN CYST, showing the albuminous fluid-contents hardened by formalin solution. The lutein tissue is represented by two laminae which have been displaced from the inner surface and lie in the fibrous tissue composing the cyst-wall.

resembles a compound hydrops folliculorum or large Rokitansky's tumour. The loculi possess extremely thin, tense walls, looking like

bubbles about to burst. Through the thin walls may be seen yellow patches of the lutein lamina which forms the lining of the cysts. On section, the cysts can be seen to arise from the oöphoritic or cortical part of the ovary, the hilum and adjacent medulla being the last part to be invaded (*see* Fig. 361). A ripe corpus luteum may sometimes be detected in the remaining solid portion of the ovary. Even in the largest cysts a considerable part of the ovary may remain intact. The contents of the loculi are a clear, straw-coloured, highly albuminous fluid which solidifies in formalin solution (*see* Fig. 362). Islands of solid lutein tissue may be found in what remains of the solid part of the ovary. In the largest loculi of these compound cysts the lutein lamina is very compressed and flattened out (*see* Fig. 362), it is often found to be displaced within the fibrous tissue composing the thin cyst-wall. The innermost lining is composed of fibrinous material (*see* Fig. 358).

The excess of lutein tissue in a compound theca-lutein cyst was thought to provide a stimulus which resulted in the abnormal trophoblastic proliferation seen in vesicular mole and chorionepithelioma. This hypothesis has, however, never been conclusively proved.

Compound theca-lutein cystomata are of considerable clinical importance, since they are liable to axial torsion of their pedicle (*see* Fig. 363; Malcolm, Bell and Lockyer), and a remarkable fact from the clinical point of view is that they may spontaneously shrink until the ovaries assume their normal size.

**Cysts of the Corpus Luteum.** This term has erroneously been used to describe theca-lutein cysts which arise from atresic follicles. It must be clearly understood that theca-lutein cysts arise from abnormalities (probably the result of inflammation) produced during the *maturation* stage of a Gräafian follicle. Such cysts, therefore, form a variety of atresic follicles, follicles that is, which have received a check in their development, preventing further maturation along normal lines to dehiscence, and to the formation of a corpus luteum. The question arises, Can cysts ever develop from a ripe corpus luteum during its *retrogression* and before its normal disappearance? We have found evidence to show that a few cysts do develop in this way: (1) by liquefaction starting in the central blood-clot and (2) by cystic spaces forming in displaced masses of lutein cells. Such cysts are, however, only interesting from the histological standpoint; they are probably of no clinical importance.

After rupture, the ripe follicle on rare occasions does however provide one pathological condition of great clinical significance, viz. the corpus luteum hæmatoma (*vide infra*). This leads to a continuance of hæmorrhage after ovulation, which is sufficiently excessive to simulate an ectopic pregnancy, and from which it can only be distinguished by microscopic examination of the hæmatoma, proving the absence of chorionic villi in the clot.

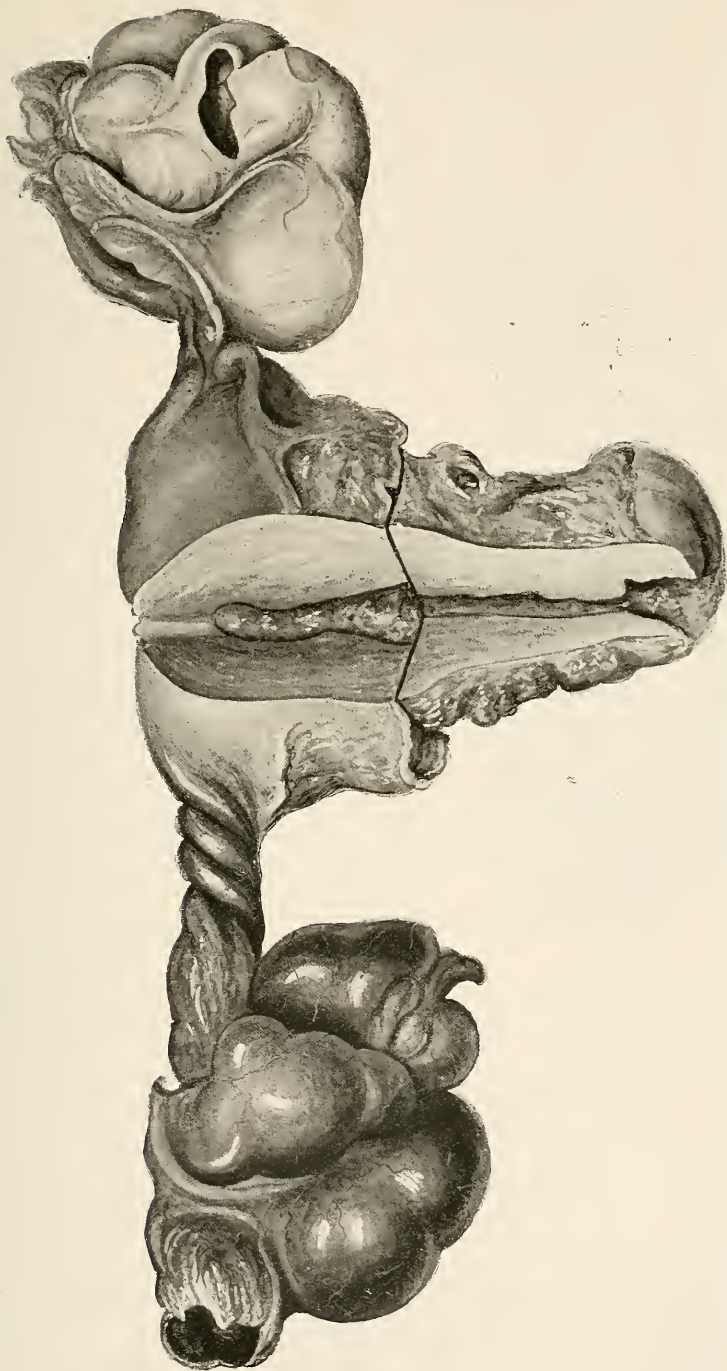

FIG. 363. AXIAL TORSION OF A COMPOUND LUTEIN CYSTOMA, in a case of vesicular mole followed by early chorion epithelioma (Malcolm, Bell and Lockyer).

**Ovarian Hæmatomata.** Synchronous with the formation of lutein cells in the theca interna, there is a great increase in the vascularity of this layer of the follicle. In some cases this results in hæmorrhage which may be so excessive as to invert and rupture the inner lining of the follicle and then the cavity of the latter becomes distended with blood. In the presence of chronic interstitial oöphoritis it is not uncommon to find excessive congestion of the theca interna ;

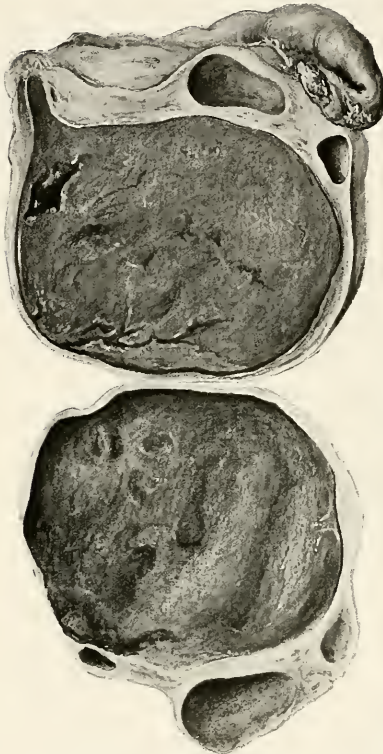

FIG. 364. LUTEIN HÆMATOMA.  
Bisected in its transverse axis.

from this, hæmorrhage into the cavity of the follicle follows. Thus an ovarian hæmatoma is another result of chronic interstitial oöphoritis. The majority of lutein-hæmatomata are formed in this way prior to full maturation of the follicle, and they therefore provide yet another termination to the atresic follicle. From certain causes, of which chronic inflammation may be one, a *mature* follicle (ripe corpus luteum) may become abnormally distended with blood, and after what appears to be a normal dehiscence, may continue to bleed to such an extent as to cause symptoms of internal hæmorrhage. The hæmatoma in the ovary in such cases maintains the appearances of a corpus luteum, in that it has a thick lining of yellow cells which often keeps its convoluted outline. Whilst there is enough blood in its cavity to justify the term 'hæmatoma' the *excess* of blood has escaped, and the convolutions of lutein tissue have not been subjected to enough pressure from contained blood to cause

them to be flattened out. Under normal conditions, as soon as the follicle dehisces and the ovum escapes, the vascularity of the theca interna subsides, and blood escapes only in sufficient amount to take the place of the liquor folliculi. In chronic oöphoritis the congestive state of the theca interna is not thus easily relieved, but may lead to ovulation being accompanied with severe internal hæmorrhage. In such cases, therefore, the blood comes from the periphery of the corpus luteum (theca interna) and not from the ovarian cortex lacerated by dehiscence.

Most hæmatomata of the ovary are lined by lutein tissue; sometimes, however, the hæmorrhage may not be circumscribed, but we find it diffused into the stroma, where blood may collect in sufficient amount to produce a hæmatoma the size of an egg. This *diffuse hæmatoma* is not so commonly met with as are *circumscribed* or *lutein hæmatomata*.

As the latter is caused by chronic oöphoritis it is not surprising to find that hæmatomata are often bilateral, and are often very adherent and accompanied by chronically thickened tubes. They are liable to secondary infection, and form one of the precursors to ovarian abscesses (see Figs. 351 and 352, p. 647).

Hæmatomata derived from theca-lutein cysts have thick walls, they may attain the size of an orange (see Fig. 364), the contained blood may be inspissated and resemble anchovy paste, or may form a thick tarry syrup. Except in the largest cysts, lutein tissue, as a flat lamina, may be made out underneath an inner fibrinous lining. Ovarian hæmatomata have to be diagnosed from ovarian gestation, and this especially applies to the hæmatoma derived from a mature follicle. Microscopic examination for chorionic villi will be necessary to settle the diagnosis.

A summary of the pathological changes which may occur in the Gräafian follicles as the result of chronic inflammation and death of the egg-cell may prove useful.

- |  |                                  |  |   |                   |  |                                  |
|--|----------------------------------|--|---|-------------------|--|----------------------------------|
| Changes in the unripened follicle.               | {                                | <ol style="list-style-type: none"> <li>1. Small cystic disease.</li> <li>2. Hydrops folliculorum.</li> <li>3. Simple serous cysts.</li> <li>4. Theca-lutein cysts. {               <table border="0" style="display: inline-table; vertical-align: middle;"> <tr> <td style="font-size: 2em; padding-right: 5px;">{</td> <td>(a) single small.</td> </tr> <tr> <td></td> <td>(b) compound theca-lutein cysts.</td> </tr> </table> </li> <li>5. Theca-lutein hæmatoma.</li> </ol>               | { | (a) single small. |  | (b) compound theca-lutein cysts. |
| {  | (a) single small.                |  |   |                   |  |                                  |
|  | (b) compound theca-lutein cysts. |  |   |                   |  |                                  |
| Changes in the ripened follicle (corpus luteum). | {                                | <ol style="list-style-type: none"> <li>1. Delayed absorption of the lutein convolutions leading to :           <ol style="list-style-type: none"> <li>(a) Islands of lutein cells being distributed in the ovarian stroma.</li> <li>(b) In these scattered areas of lutein cells small cysts form which have only a pathological interest.</li> </ol> </li> <li>2. Corpus luteum hæmatoma, a rare condition which may cause internal hæmorrhage.</li> <li>3. Corpus luteum abscess.</li> </ol> |   |                   |  |                                  |

It will thus be seen that from the *clinical* point of view all the important changes wrought by chronic inflammation (save two) concern the unripened follicle, and not the corpus luteum.

### NEW GROWTHS OF THE OVARY AND CYSTS OF THE BROAD LIGAMENT

In this section only true neoplasms will be described. Cysts arising as the result of inflammatory changes have been already dealt with in the preceding pages. Owing to their clinical resemblances it is

convenient to consider broad-ligament cysts in conjunction with ovarian tumours although they do not arise in ovarian tissue.

**Etiology.** On the subject of the etiology of ovarian neoplasms nothing is known, and on the question of the histological derivation difficulties arise, because in the case of ovarian growths of epithelial origin the cells do not correspond to any pre-existing type of cell peculiar to the ovary. It may be recalled that in the ovary there are three varieties of epithelium, viz. (1) that of the surface of the organ (*capsular epithelium*); (2) the epithelial lining of the follicles (*membrana granulosa*); (3) the epithelial tubules of Wolffian origin which persist in the hilum. From the fact that cystic structures resembling true Gräafian

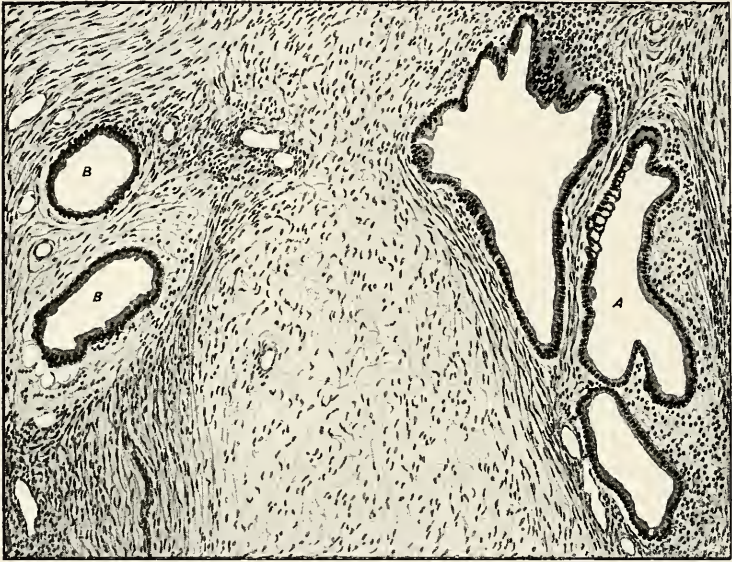


FIG. 365. HEALTHY OVARY OF AN ADULT WOMAN. Multipara, aged 40. The epithelial-lined spaces (A and B) illustrate the origin of the cyst-adenoma; their connection with the capsular epithelium was traced in serial sections. The epithelium is columnar, and in the space marked (A) contains a number of goblet cells.

follicles are found in ovarian cysts it has long been held that the majority of ovarian cysts, and notably the multilocular or pseudomucinous variety, are derived from the oöphoron or Gräafian follicle system. The simpler or unilocular cysts, which may contain small fibrous warty excrescences, were regarded as arising in the non-egg-bearing portion of the ovary, known as the epoöphoron or hilum. Recent work has upset this simple theory. The supposed follicles in multilocular cysts are now believed to arise from cystic degeneration of epithelial downgrowths, and the papillomatous cysts have been shown by Whitridge Williams to arise independently of Wolffian structures. The opinion which is now gaining ground, largely owing to Walthard,

is that the majority of ovarian epithelial new-growths are derived from the surface-epithelium (*see* Fig. 365), and not from the Gräafian follicles or Wolffian relics.

Nevertheless it has been proved that neoplasms may arise from the normal follicle-epithelium. We have repeatedly seen proliferation of the epithelium in a follicle such as might be considered as the starting-point of an adenoma, but the egg-cell is always absent in such cases, which is a proof that the follicle has suffered some kind of injury from oöphoritis or other cause.

On the other hand, as above indicated, the direct development of true proliferating growths from the surface-epithelium has been conclusively proved, and such an origin is very probable for pseudo-mucinous cysts. Epithelial cysts and carcinomata may occasionally be found to arise as *surface*-papillomata; generally, however, a *down-growth* of the epithelium takes place, and it is in this deep process of surface-epithelium that the new growth arises.

**Classification.** The following classification is based upon the histological characters as presented at the time of investigation; it will include all but a very few clinically undiagnosable tumours:

A. Tumours arising in the ovary.

I. *Epithelial Tumours.*

1. Benign: Adenoma.

(a) Cyst-adenoma pseudomucinosum.

(b) Cyst-adenoma serosum (ciliatum, papillare).

2. Malignant: Carcinoma.

(a) Primary.

(b) Secondary.

II. *Connective-tissue Tumours—Desmoids.*

1. Benign: Fibroma. Fibromyoma.

2. Malignant: Sarcoma. Endothelioma. Perithelioma.

III. *Tumours containing products of several embryonic layers.* Teratoma (in the wide sense). Tridermoid embryoma.

1. Innocent: Cystic Teratoma ('Dermoid').

2. Malignant: Teratoma in the narrow sense (blastomatous teratoma).

IV. *Compound Ovarian Tumours.*

B. Cysts arising in the broad ligament.

(a) Fimbrial.

(b) Epoöphoritic (parovarian).

(c) Cysts of Kobelt's tubes.

(d) Cysts of the hydatid of Morgagni.

**BENIGN EPITHELIAL TUMOURS**

Eighty per cent of all ovarian growths are adenomatous, and show a tubular gland-formation. Solid adenomata are rare; the tubules of an adenoma very rapidly develop into cysts. The chief feature of a

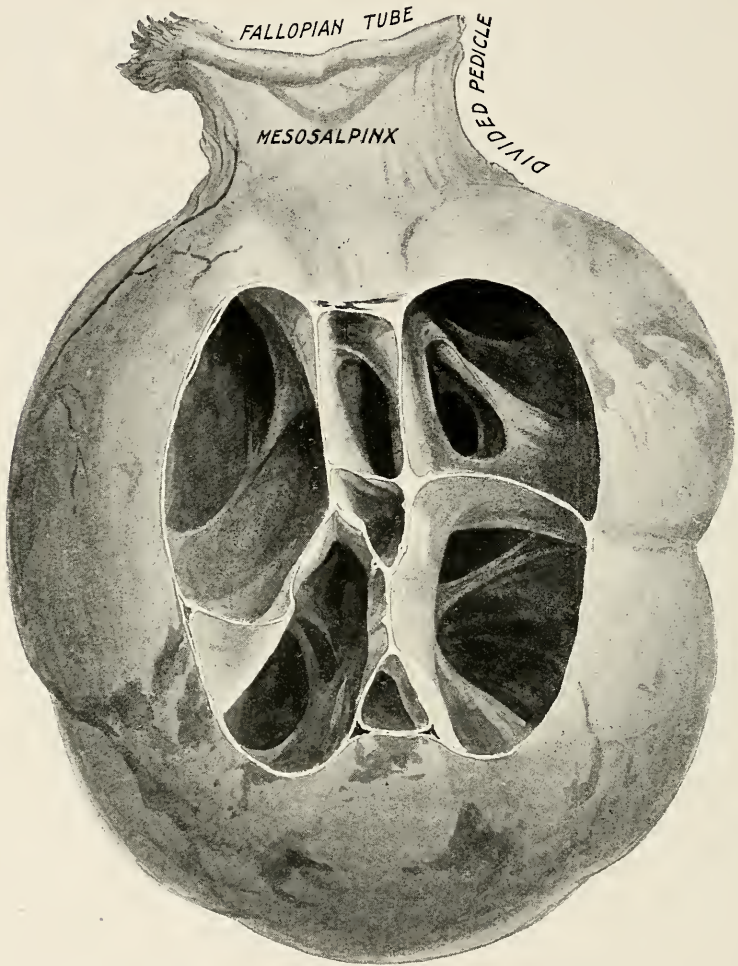


FIG. 366. CYST-ADENOMA PSEUDOMUCINOSUM OF THE OVARY (Charing Cross Hospital Museum). A portion of the cyst-wall has been removed to show the multilocular character of the tumour. The ridges seen in the interior are traces of broken-down septa.

cyst-adenoma is the more or less rapid and unlimited enlargement of the cystic spaces, produced by the continuous secretion and rapid proliferation of their lining-epithelium. The epithelium sends out multiple glandular projections which produce daughter-cysts in the connective tissue of the cyst-wall, which likewise increases. By



proliferation, these cysts in their turn, originate another generation of daughter-cysts, the process continuing until a multilocular cystic tumour is produced. We must imagine this process as taking place simultaneously at many points in an ovary. In further growth, one or more cysts predominate in size; the smaller ones bulge into the walls of the larger, and ultimately fuse with the latter by the rupture of partition-walls. The remainder of the pre-existing septa then appear as bands or elevated rings on the inner surface of the larger cysts. By

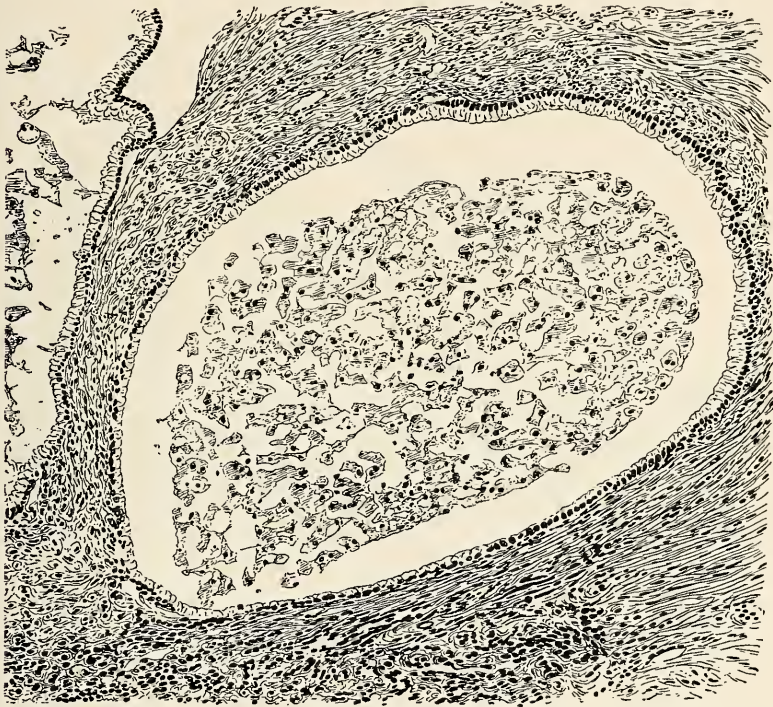

FIG. 367. CYST-ADENOMA PSEUDOMUCINOSUM OF THE OVARY. Showing a loculus with its epithelial lining and the septa composed of well-formed fibrous tissue.

repeated fusion of small cysts a large loculus is produced (see Fig. 366), but it is still possible to find in its wall many 'daughter-cysts,' and also when examined microscopically the glandular remains of tiny cysts. Hence arose the old term *Cystoma proliferans glandulare*.

The epithelium of an ovarian cyst is supported on a richly cellular sub-epithelial connective-tissue basis (see Fig. 367). This cellular connective tissue, in order to accommodate the rapidly growing epithelium, projects into the cyst as a spur (see Figs. 368 and 369); these spurs or processes are very numerous, and they throw out secondary spurs or branches, which in their turn form tertiary twigs, and so on. The whole of this racemose arrangement carries a surface-epithelium composed of tall columnar cells with small basal nuclei. This arrangement

is strikingly similar to the branching of chorionic villi. The proliferation of the epithelium and sub-epithelial connective tissue seen in ovarian cysts is of two types, according to whether the branching of the adenoma takes an outward direction (into the cyst-wall) or an inward direction—into the lumen. The former is called the *everting* and the latter the *inverting* type. The everting type of adenomatous proliferation is present in every ovarian cyst; the inverting type is less common,

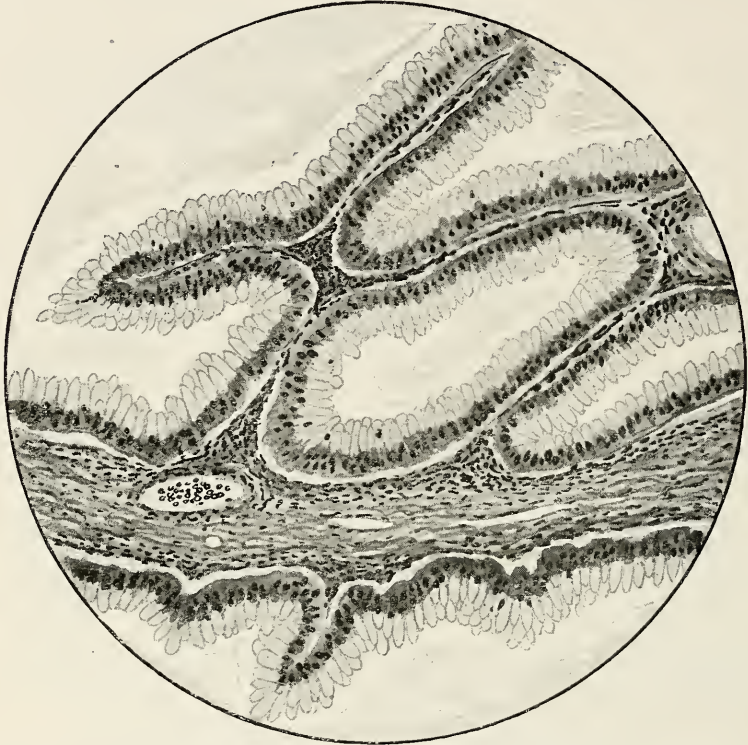


FIG. 368. CYST-ADENOMA PSEUDOMUCINOSUM OF THE OVARY. Showing the high columnar epithelial found in the smallest loculi. Inverting type of proliferation.

but it is a constant feature of the rarer variety known as the *cystoma serosum papillare* to which we shall refer later.

(a) **Cyst-adenoma Pseudomucinosum.** This variety constitutes *two-thirds of all ovarian growths*. It is characterized by the high palisade character of its epithelium. The cytoplasm is strikingly clear, the cell-bodies are full of secretion and are therefore often of the goblet or beaker-variety, the nuclei lie at their base and are very small in comparison to the size of the cell. The cells contain *pseudomucin*, a mucoid substance which is not precipitated by acetic acid and which contains a glycoprotein, *i.e.* a body which on boiling with a mineral acid is split up into albumen and COH. In the pure state pseudomucin

is a stiff jelly; it can be cut by a knife, and is opalescent. As seen in the smaller cysts, the fluid is more or less thick or thin, but is always stringy or *colloidal*. Its specific gravity varies between 1010–1030, according to the degree with which it is mixed with serous exudation, blood, and degenerated thrown-off epithelium. The colour ranges from yellow or

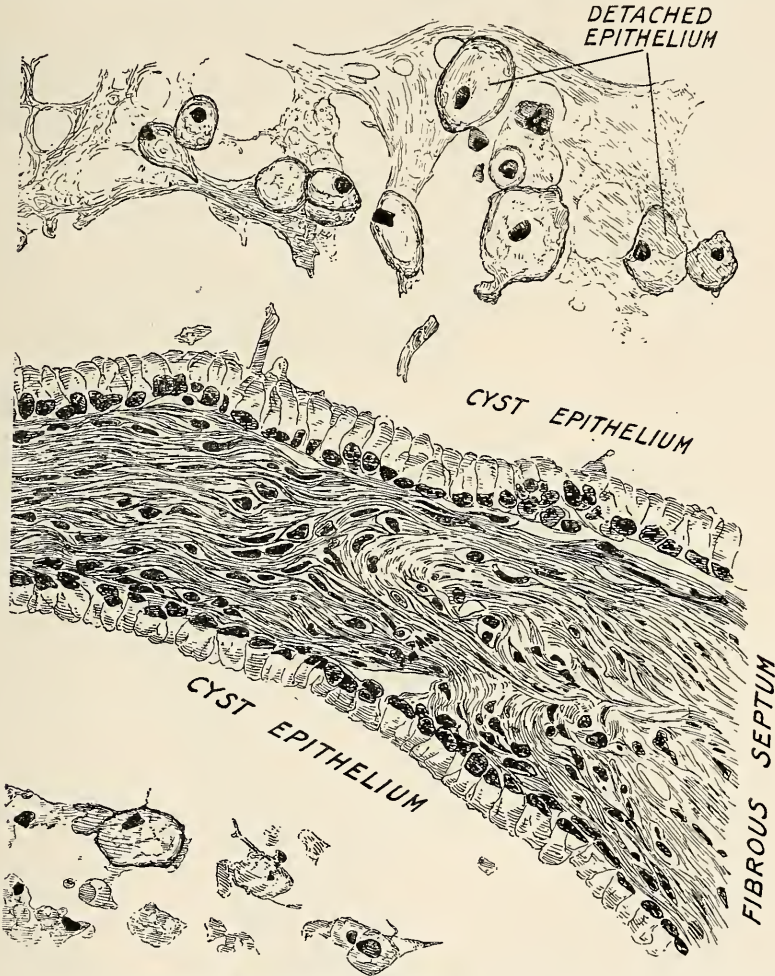


FIG. 369. CYST-ADENOMA PSEUDOMUCINOSUM OF THE OVARY. The section shows a septum between two compartments, both surfaces being covered with a single layer of high columnar epithelium. The detached epithelial cells are swollen and distorted. (A portion of Fig. 367 more highly magnified.)

greenish-grey, to a dirty red-brown or blackish tint; sometimes the presence of cholesterol gives a glistening appearance to pseudomucin. The reaction is alkaline.

Pseudomucinous cysts are, as a rule, unilateral. They are coarsely nodular or lobulated and are multilocular (*see* Fig. 366). The term *multilocular cyst* is therefore the most appropriate for the description

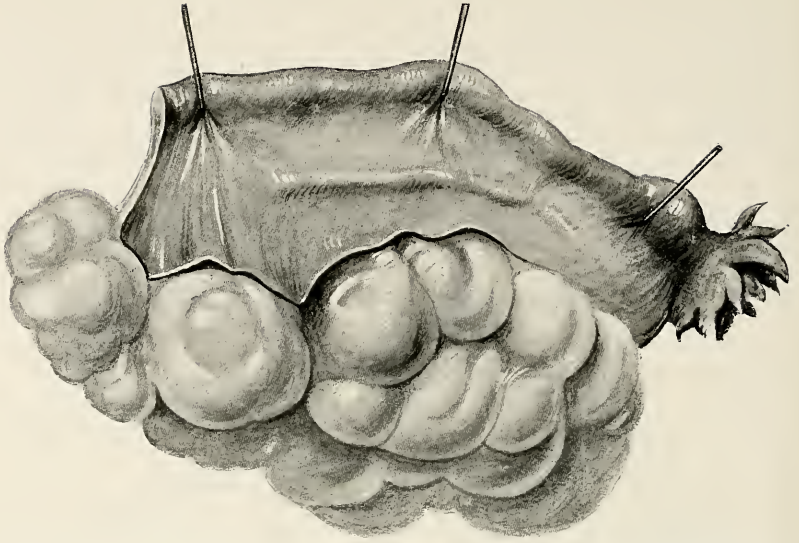


FIG. 370. PSEUDOMYXOMA OVARII. The multiple cysts are distended by jelly-like pure pseudomucin.

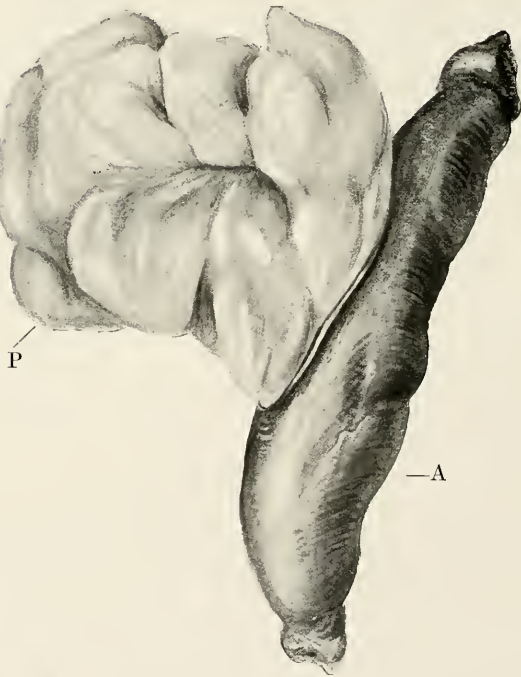


FIG. 371. APPENDIX VERMIFORMIS DISTENDED WITH PSEUDOMUCIN. From the same case as shown in preceding Figure 370. On incising the appendix, A, the viscid, jelly-like pseudomucin, P, escaped and remained adherent.

of its naked-eye characters. They may attain an enormous size, representing the largest tumours ever met with in the body. The amount of fluid which they may contain is sometimes enormous; the tumour from the case shown in Fig. 406 contained  $16\frac{1}{4}$  gallons. As these tumours are now usually removed as soon as they are recognized, they are not allowed time to attain their full size. They may form adhesions to the anterior abdominal wall, to the omentum, to intestines, to the under-surface of the liver, and to the diaphragm.

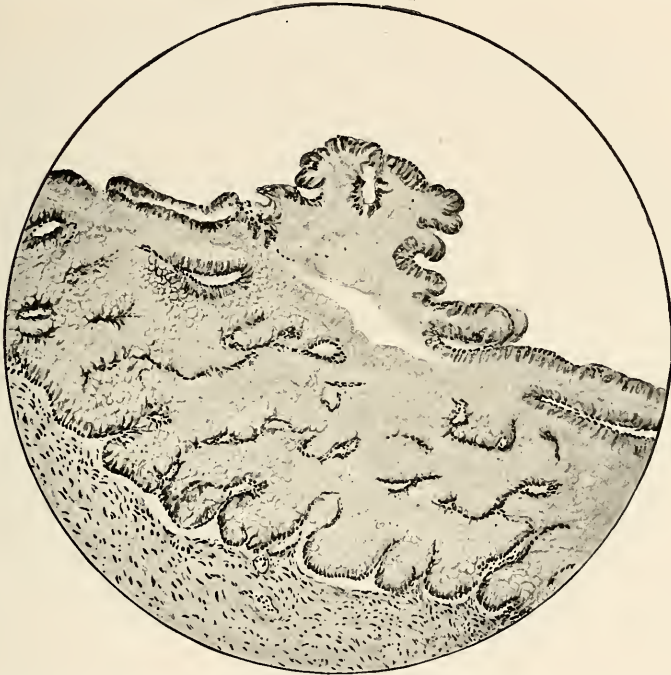

FIG. 372. PSEUDOMYXOMA OVARII. The gland-elements of the cyst are transformed into jelly-like pure pseudomucin. In many places the basal nuclei represent all that remains of the original cells.

Adhesions are especially common if the pedicle undergoes gradual torsion, or if one or more of the surface-cysts become ruptured. The pedicle consists of the infundibulo-pelvic fold containing the ovarian vessels, the *ligamentum proprium ovarii*, the Fallopian tube, and the stretched mesovarium.

*Pseudomyxoma ovarii* (see Figs. 370 and 371). This is the name given to a variety of the pseudomucinous cyst, in which the contents consist of pure pseudomucin and the walls of the cyst are very thin and transparent. On microscopic section the high palisade epithelium, which is so characteristic a feature of the pseudomucinous cyst, is seen to have largely disappeared, often only the basal parts of the cells remaining. The cytoplasm is replaced by a structureless substance which stains very faintly with eosin (see Fig. 372). This material is

pure pseudomucin, a resultant product of cell-degeneration or secretion, or, according to Nagel, a product of degeneration of the cyst-wall. The profound structural alteration produced by its presence is best appreciated by comparing Figure 368 with Figure 372.

Rupture of the cyst-wall frequently occurs and masses of jelly-like pseudomucin (*see* Fig. 371 P) are constantly poured on to the peritoneum,

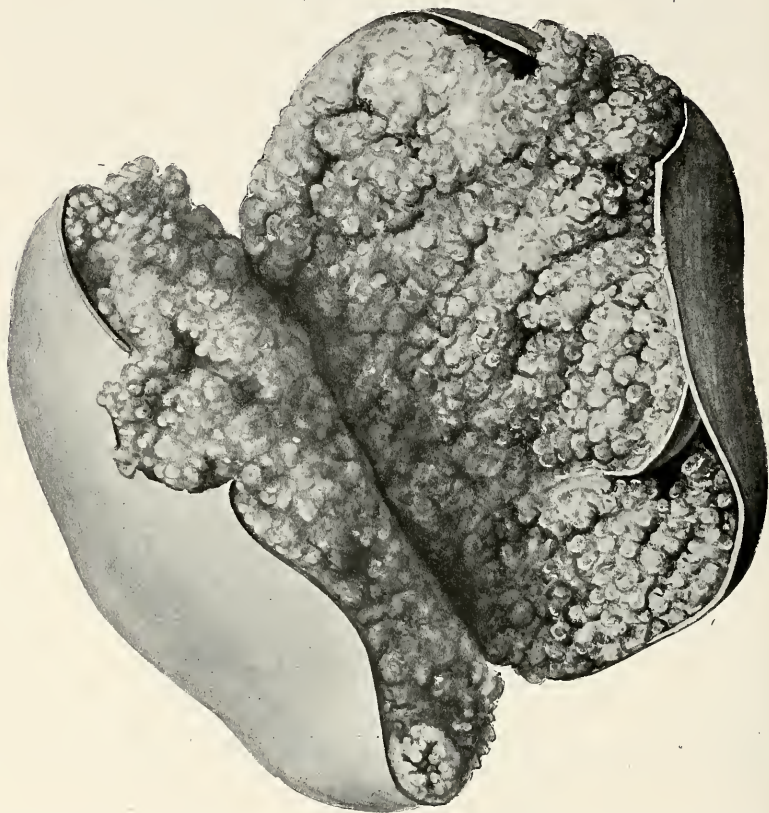


FIG. 373. CYST-ADENOMA SEROSUM PAPILLARE (after von Franqué). The papilliferous processes have broken through the capsule of the growth and have also entirely filled its cavity. A very rare type.

which it is difficult, if not impossible, for the latter to absorb, the result being that the material is distributed over the whole abdomen by the peristalsis of the bowel. Thus an irritative chronic peritonitis is set up, with the development of young connective tissue between adherent peritoneal surfaces; a complete clearance by operation is impossible, and the condition is now described as *pseudomyxoma peritonei*.

This condition is, nearly always, a secondary result of *pseudomyxoma ovarii*, but a similar affection has, in about twelve instances, been recorded as starting in the vermiform appendix, in which the

appendix was involved as well as the ovary. These appendix-cases have mostly occurred in males, but two in women have been noted by Wilson and one by Eden (*see* Fig. 371). Even when the primary source of the disease (ovary or appendix) is removed, it frequently happens that fresh pseudomucinous masses develop. Then, in consequence of the destroyed vitality of the peritoneum, the gland-cells are able to become implanted upon it and to proliferate, and finally

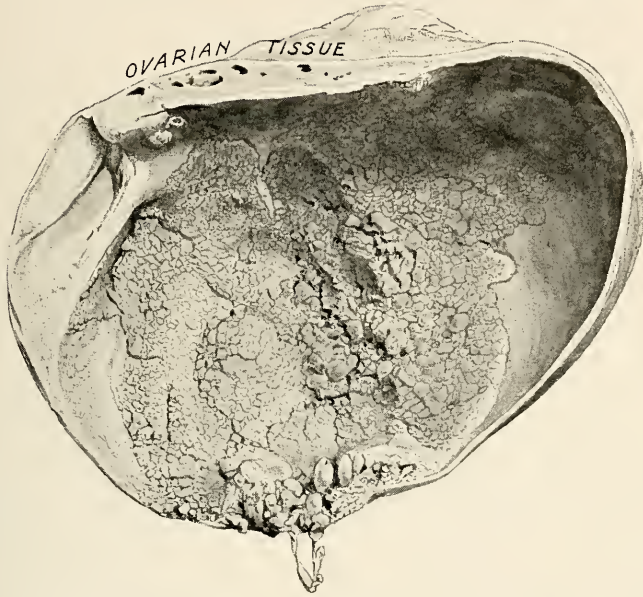

FIG. 374. PAPILLIFEROUS CYST OF THE OVARY (Royal College of Surgeons Museum). The cyst is unilocular, and its inner surface is thickly studded with warty masses. A certain amount of ovarian tissue, bearing Gräafian follicles, has persisted.

to continue their secretion of pseudomucin. Very rarely even true malignancy may supervene.

(b) **Cyst-adenoma Serosum Papillare (Papilliferous Cyst).** This variety of ovarian cyst is nearly always papilliferous and is characterized by its low epithelium, which is mostly ciliated and less actively secreting than is the epithelium in the pseudomucinous cyst; it is sometimes termed *cystoma ciliatum papillare invertens*.

This type of cyst has thin walls (*see* Fig. 373) and the intracystic papillomata consist essentially of a delicate connective-tissue core with an epithelial covering; they are formed by direct outgrowth from the cyst-wall. To the naked eye they appear individually as small wart-like projections with an irregular surface (*see* Fig. 374). They may be diffused widely, in small clusters, over the cyst-wall, or, being collected in larger groups, they may form tuberous masses resembling a cauliflower. Sometimes they thickly cover nearly the whole wall of the

cyst and entirely fill up its cavity (*see* Fig. 373), but this is very rare, the contents of the cyst being usually fluid. Structurally they present two types. In the first type (simple papillæ) the papillæ are inactive ; they form shallow rounded projections, and consist of a delicate fibrous-tissue core, with an epithelial covering showing numerous shallow invaginations, composed of a single layer of cells (*see* Fig. 375). In the second (compound papillæ) the papillæ are very active ; they consist of an aggregation of compound sinuous, branching processes,

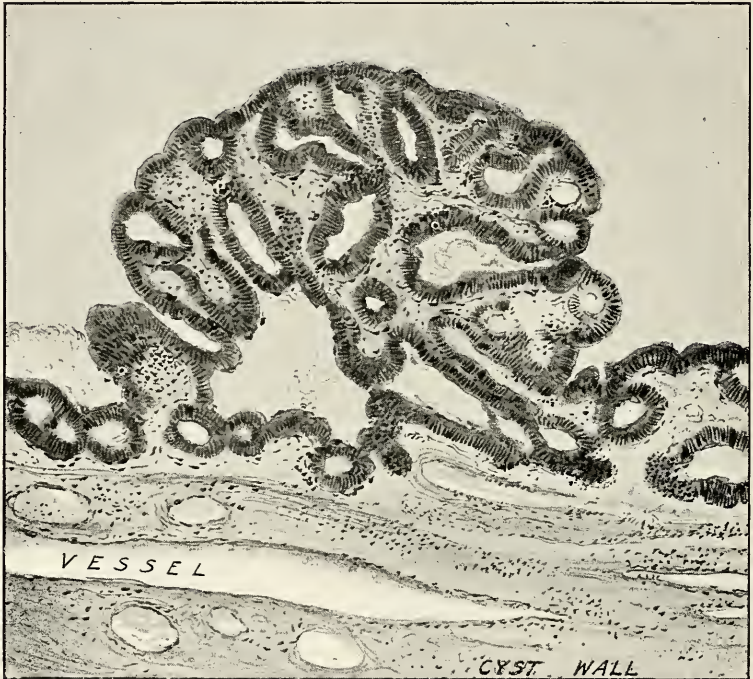

FIG. 375. PAPILLIFEROUS CYST OF THE OVARY. A simple papilla showing the connective-tissue core, the epithelial covering, and the numerous epithelial invaginations.

composed of a core of delicate connective tissue and an epithelial covering of a single layer of low columnar cells (*see* Figs. 376 and 377).

The contents of the cyst are thin and watery, scarcely at all stringy, and contain but little albumen and no pseudomucin. A papilliferous cyst is frequently bilateral and intraligamentary in situation, that is to say, it travels out from the follicle-zone through the medulla and hilum of the ovary into the mesosalpinx, which it opens up. It therefore lies within the folds of the broad ligament and *possesses no pedicle* ; it is only slightly mobile, being far less so than the pseudomucinous variety, which is but rarely found in the intraligamentary situation. It is much slower in its growth than the latter, and is



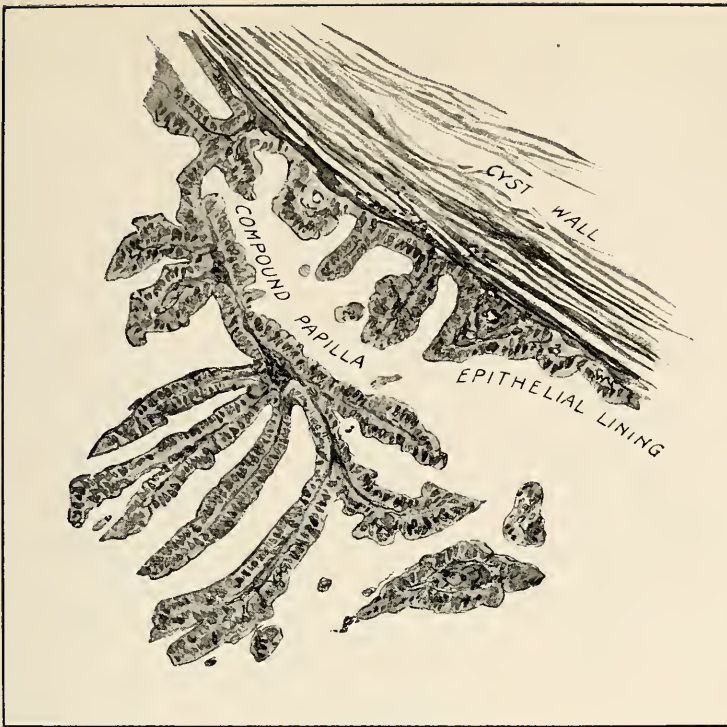


FIG. 376. PAPILLIFEROUS OVARIAN CYST. Showing the origin of the papillæ from the cyst-wall. Numerous buds and processes are thrown out by the epithelium. (Semi-diagrammatic.)

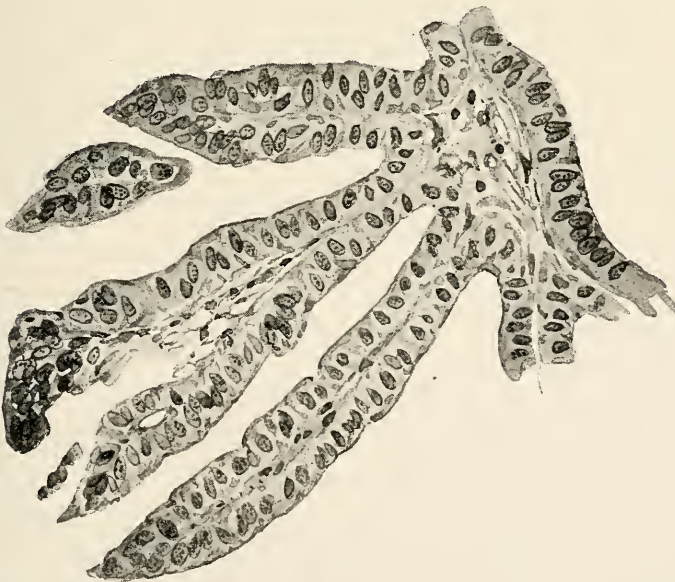

FIG. 377. PAPILLIFEROUS OVARIAN CYST. The section shows the structure of a compound papilla, with its single layer of epithelial cells.

seldom larger in size than a man's head, and it contains but few loculi (see Figs. 373 and 374).

Clinically this variety of ovarian cyst is of extreme importance since it has a great tendency to become malignant, this change being much more marked in the serous (papilliferous) than in the pseudomucinous cyst. Moreover, without becoming structurally malignant, the solid papillary growths are liable to produce rupture of the cyst-wall leading

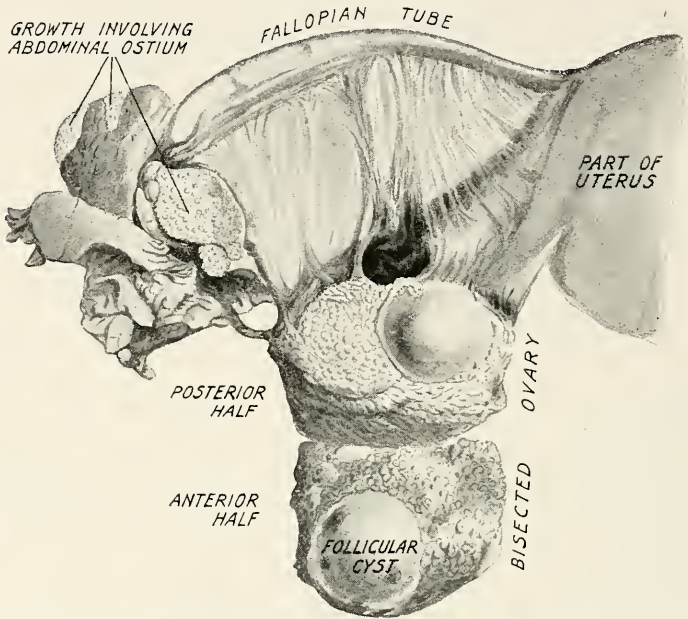


FIG. 378. PAPILLIFEROUS OVARIAN CYST WHICH HAS BECOME MALIGNANT. Multipara, aged 68. The growth has spread from a malignant papilliferous ovarian cyst of the opposite side. The ovary has been bisected so as to show both external surfaces, which are nearly covered with delicate papillary growth. A cluster of similar growth is seen upon the mesosalpinx and upon the abdominal ostium of the tube.

to implantation of tumour-cells upon the surface of the ovary (see Fig. 378) and also upon the peritoneum.

Papillæ, which are structurally malignant, are much softer and more vascular than the benign ones, and on microscopic examination they show remarkably active growth, forming long compound processes branching freely, and showing well-marked and irregular epithelial proliferation (see Figs. 379 and 380). Once the papillæ escape from the cyst-wall there is no limit to their dissemination. Rapid ascites and injury to health follow. Even metastases in lymph-glands and on the pleural aspect of the diaphragm have been noted, in cases of dissemination of microscopically innocent papilliferous serous cysts. The secondary peritoneal growths tend to disappear after the removal

of the principal tumour, but they may remain and subsequently assume a true carcinomatous character.

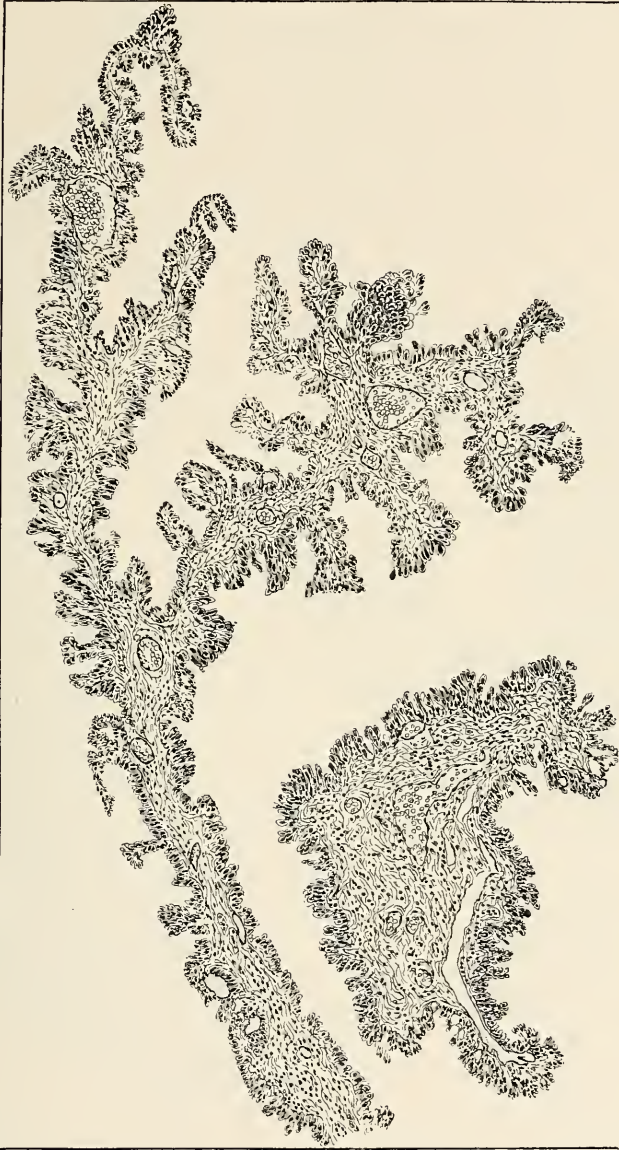

FIG. 379 PAPILLIFEROUS PROCESS, showing malignant proliferation of the epithelium. From the same specimen as Fig. 378.

### MALIGNANT EPITHELIAL TUMOURS

**Carcinoma of the Ovary.** Cancer may occur in the ovary under conditions which may be stated as follows :

I. As a primary growth.

II. As a secondary growth arising either by direct extension, or more often by metastasis.

I. **Primary Ovarian Cancer.** This is a comparatively rare form of tumour; it is generally agreed that among the organs liable to be attacked by primary cancer in women, the ovary stands low in order of frequency; its occurrence is certainly very much less frequent than that of uterine cancer. Its age incidence is wide; about 68 per cent. of cases occur in women between the ages of forty-five and fifty-five (Glendinning), *i.e.* in the climacteric decennium, but it may also occur in adolescents and in children. It is frequently bilateral, but a simultaneous onset of the disease in both ovaries is unlikely; it is more probable that



FIG. 380. PORTION OF PAPILLIFEROUS PROCESS SEEN IN FIG. 379 under a higher power, showing well-marked malignant proliferation of the epithelium.

one ovary is attacked by metastasis or by direct extension. This view receives some support from the fact that, at the somewhat advanced period when these tumours commonly come under observation, one is usually considerably larger than the other. They are frequently, but not invariably, accompanied by ascites.

The growth is usually smooth, of irregular shape, and moderate size, but specimens weighing upwards of fifteen pounds have been described. Its consistence is usually that of a soft solid tumour, but not infrequently some parts are solid and other parts cystic (*see* Fig. 381), and the latter may form irregular protuberances on its

surface. It usually has at first a well-formed fibrous-tissue capsule derived from the tunica albuginea; but this may sometimes be invaded and destroyed in places by the cancer-cells, which then become free to disseminate themselves in the peritoneal cavity. On section its substance is seen to be fairly homogeneous, and of friable consistence; numerous cystic spaces may be seen, some of which represent cavities formed by degeneration, others are lined with epithelium. Not infrequently these cavities are formed in superficial parts of the tumour, forming projecting bosses which render the shape and outline of the tumour very irregular. Areas of interstitial hæmorrhage of reddish, brownish, or yellowish colour, according to their age, are also often seen. A diagnosis can only be made with certainty by means of the microscope.

Carcinoma of the ovary is very variable in its *histological* structure.

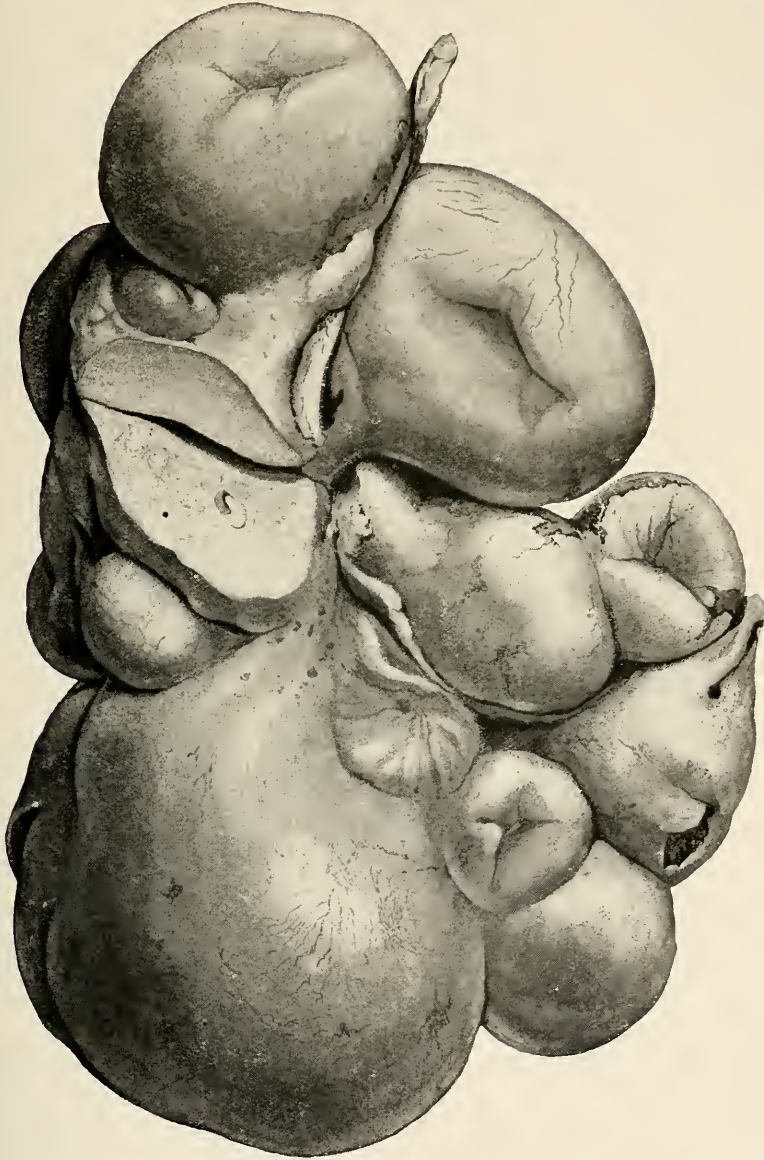


FIG. 381. CYSTIC ADENO-CARCINOMA OF THE OVARY (Charing Cross Hospital Museum). The large tumour is partly cystic, and partly solid; one of the solid portions has been laid open. A similar growth of somewhat smaller size was present in the other ovary. The microscopic appearances were those of the diffused form of carcinoma (*see* Fig. 385).

Macroscopically two principal groups are distinguishable: (1) the cystic adeno-carcinoma, and (2) the solid carcinoma.

(1) *The cystic adeno-carcinoma* corresponds in its naked-eye

characters to a benign cystic adenoma, and it is often necessary to make a most careful histological investigation before its malignancy is discovered. It occurs as a multilocular cystic tumour (*see* Fig. 381), containing, as a rule, inverting or papillary growths and a fluid which varies within very wide limits, but which frequently consists largely of pseudomucin. When apparently solid, very soft, brain-like, white or yellowish areas appear in a multilocular cyst, the latter should be

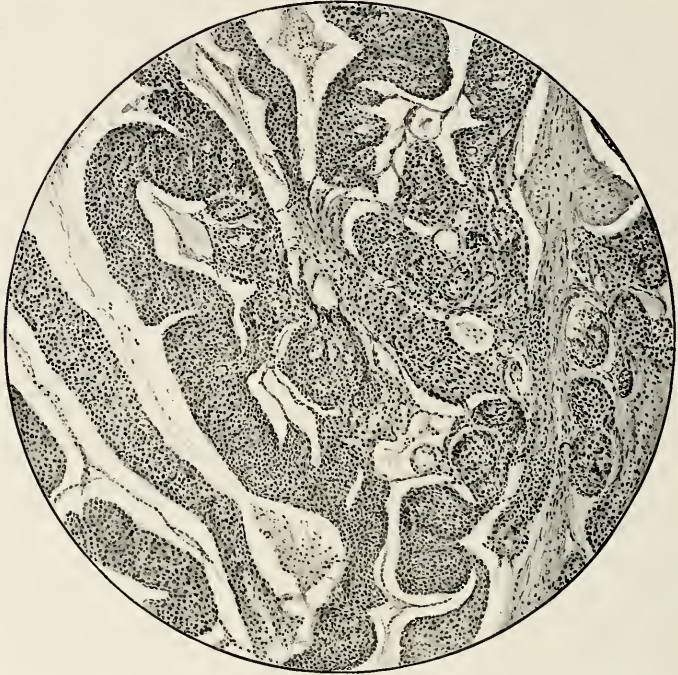

FIG 382 CYSTIC ADENO-CARCINOMA OF OVARY. The single layer of columnar epithelium of benign adenoma is replaced by many layers of cancerous cells.

regarded with suspicion and should be examined microscopically for evidence of malignancy.

Cystic adeno-carcinoma can occur primarily, or may be the result of a malignant change in a hitherto benign cyst. In either case there may be numerous cysts lined by a single layer of columnar epithelium, lying in proximity to other cysts in which are seen many layers of irregularly shaped epithelial cells, filling up the lumina in characteristic malignant fashion (*see* Fig. 382). In the metastases also, simple and malignant glandular structures exist side by side, while the benign elements continue the function of secretion.

The type of *papillary cancer* derived from a papilliferous serous cyst was shown in Figs. 378, 379, 380 (pp. 672-674).

(2) *The solid carcinoma.* In the second group, the carcinomata form solid coarsely lobulated tumours with a well-formed pedicle (*see* Fig.

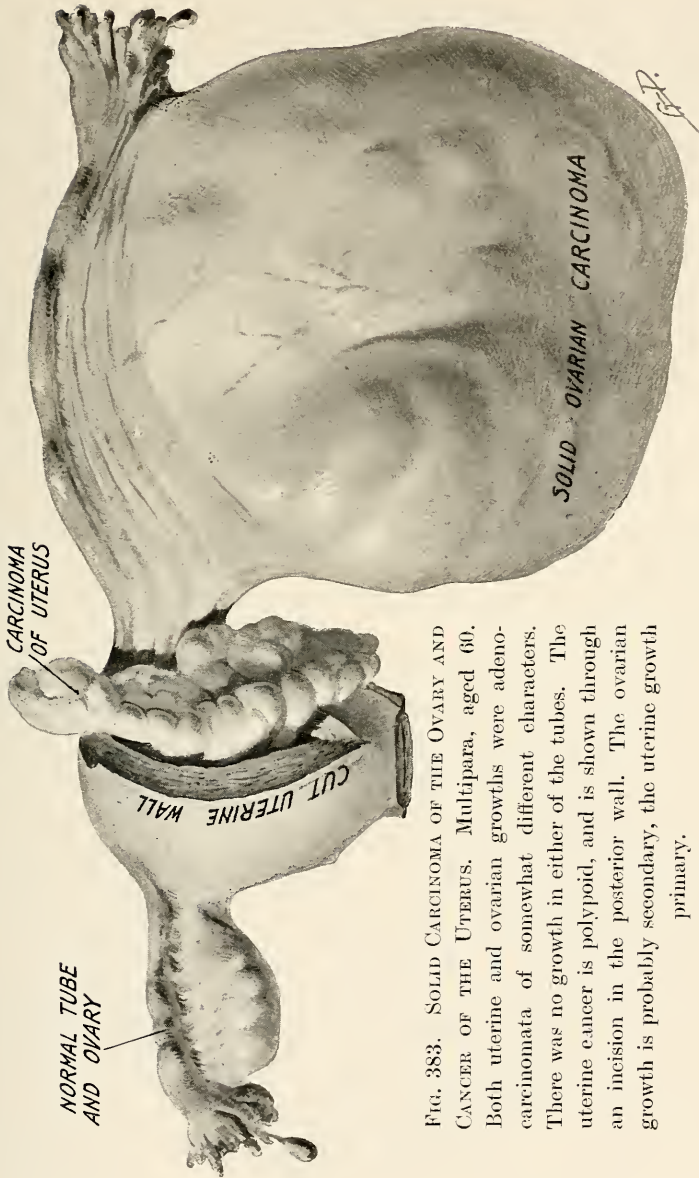


FIG. 383. SOLID CARCINOMA OF THE OVARY AND CANCER OF THE UTERUS. Multipara, aged 60. Both uterine and ovarian growths were adenocarcinomata of somewhat different characters. There was no growth in either of the tubes. The uterine cancer is polypoid, and is shown through an incision in the posterior wall. The ovarian growth is probably secondary, the uterine growth primary.

383). The normal shape of the ovary is more or less preserved. The structure is that of an ordinary carcinoma, *i.e.* the growth is made up

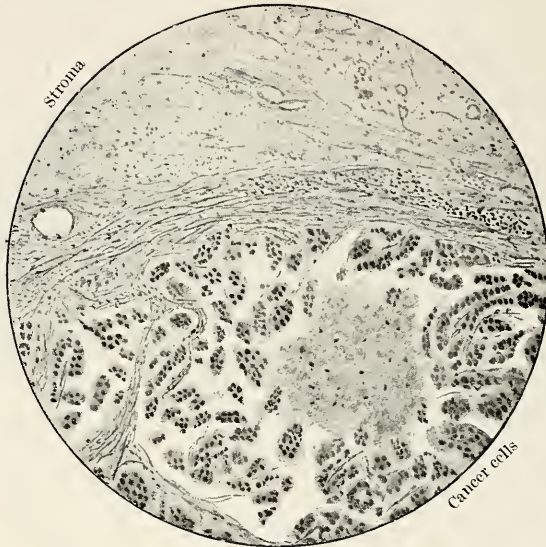

FIG. 384. ALVEOLAR CARCINOMA OF THE OVARY. Multipara, aged 48. The cancer-cells are arranged in irregular columns and masses. The stroma in the upper part of the Figure is abundant and degenerated.

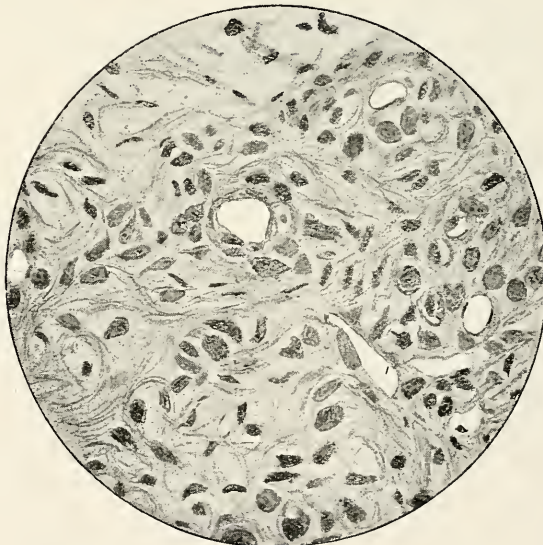


FIG. 385. DIFFUSE CARCINOMA OF THE OVARY. Multipara, aged 30. The cancer-cells are of varied shapes and sizes, and the stroma is relatively abundant.

of solid strands and nests of epithelial cells running in a fibrous stroma (alveolar type) (*see* Fig. 384), or the entire ovarian substance may be



so uniformly invaded by the epithelial cells that the differentiation between carcinoma and sarcoma may be difficult or impossible (diffuse type) (*see* Fig. 385).

Carcinoma of the ovary has a great tendency to break through the tunica albuginea and by proliferation to produce papillary processes or nodes on the peritoneum (*see* Fig. 378) and especially so in Douglas's pouch, where the tiny particles sink by gravity. Hæmorrhagic ascites occurs in consequence of such dissemination. A spread along the tube is common; we have shown that this may occur along the perivascular lymphatics of tubes which have a normal appearance externally; other observers have shown the cancer-cells being carried towards the uterus by the ciliary action of the tubal mucosa. In either case the cancer-cells have been traced into the uterine wall, where we have found deposits lying in the uterine muscle beneath a healthy endometrium. The regional glands, *i.e.* the retroperitoneal, lumbar and prevertebral sets, do not, as a rule, become invaded. As soon as the carcinoma reaches the surface of the ovary, dense adhesions unite the organ to neighbouring viscera especially to bowel, leading not infrequently to the necessity for performing enterectomy during the removal of the growth. Carcinoma of the ovary of whatever variety is usually bilateral, this applies not only to primary, but also to secondary growths.

**II. Secondary Ovarian Cancer.** When the ovary becomes cancerous secondarily the primary growth may be found (*a*) in the pylorus, the colon, or more rarely, some other part of the intestine; (*b*) in the liver; (*c*) in the mamma; (*d*) in the uterine body. Not infrequently secondary growths in the ovary attain a very large size, while the primary growth in another organ remains small and gives rise to no conspicuous symptoms (*see* Figs. 383 and 386). It is the presence of the ovarian tumour, and often of the accompanying ascites, which attracts attention, not the primary disease. Both ovaries are commonly, but not invariably, affected, and usually to an unequal degree; indeed there may be great discrepancy in the size of the two tumours. Microscopically both the alveolar and diffused types of cancer may be met with (*see* Figs. 384, 385), but there is little in their histological features to distinguish the secondary from the primary growth. In some instances the amount of connective-tissue stroma found in secondary growths is abnormally large and ill-formed, and shows an unusually strong tendency to undergo myxomatous degeneration, and to become altered by interstitial hæmorrhage.

There is great difficulty in determining the relative frequency of the varieties of ovarian cancer just described. Cancerous changes in originally benign cysts are much commoner than was formerly supposed, as the results of systematic microscopic examination of these tumours has clearly shown. As a strictly primary disease ovarian cancer is very rare; many instances originally regarded as primary

being shown subsequently to be secondary to cancer of some other

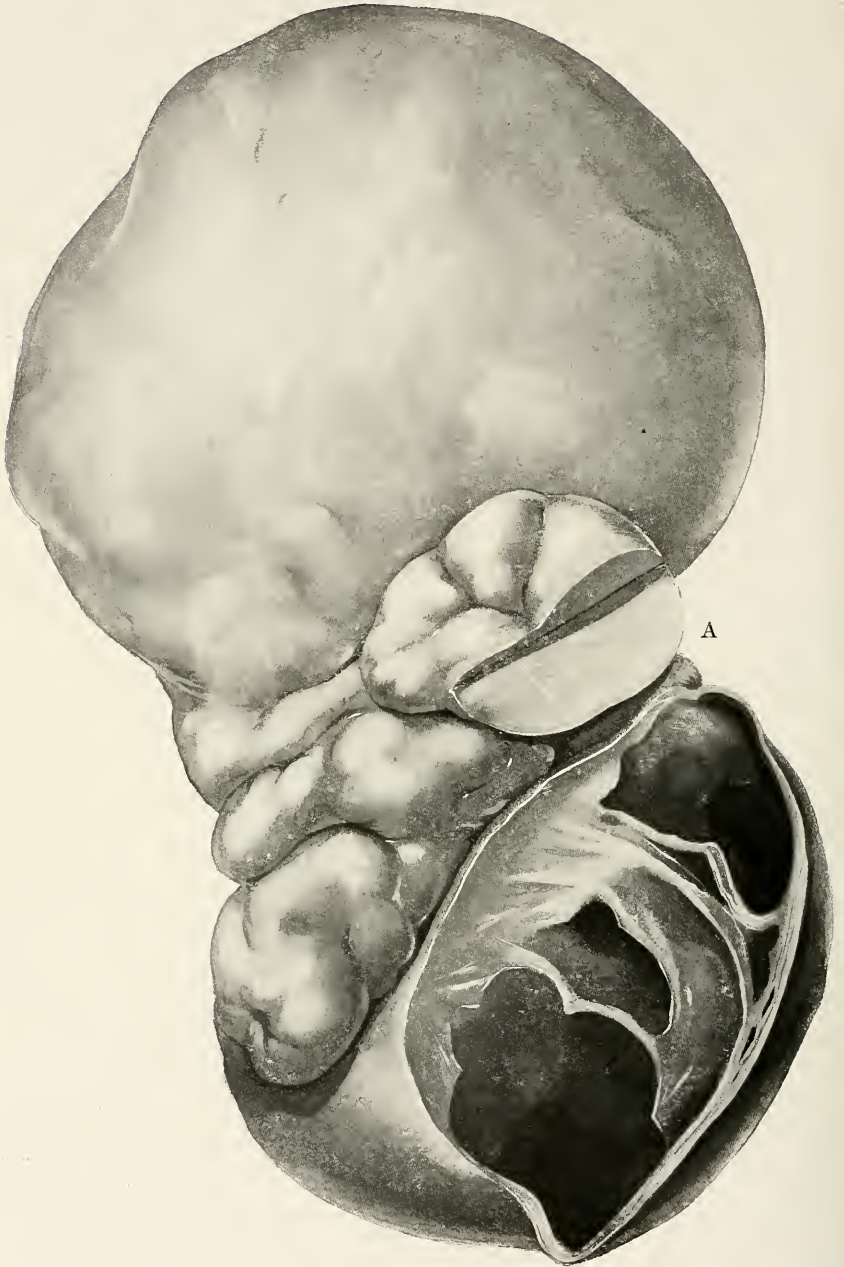


FIG. 386. SECONDARY OVARIAN CARCINOMA. The primary growth was situated in the pelvic colon. The microscopic appearances are shown in Fig. 387. A, Site of section shown in succeeding Figure.

viscus. The obtrusive size of the secondary growth directs attention

to it, while the primary growth being small, and giving rise to no urgent symptoms, remains unrecognized. Post-mortem statistics of cancer show that secondary growths are frequently found in the ovary after death in mammary cancer, in stomach-cancer, and in cancer of the intestine. But it must be recollected that in such cases the affection of the ovary is not recognized during life unless the tumour is of large size ; consequently the frequency of secondary ovarian cancer, as clinically met with, is probably considerably underestimated. It is probable that from a clinical standpoint cancerous changes in an

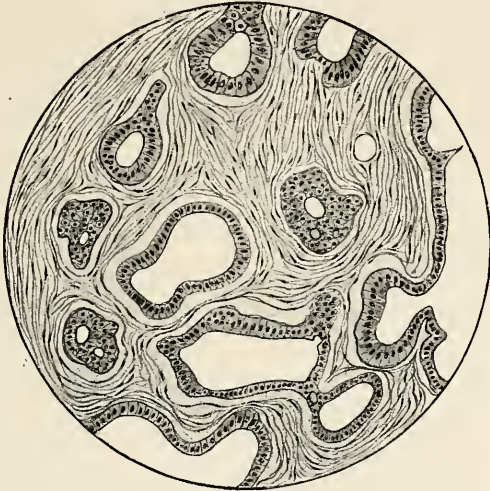

FIG. 387. SECONDARY OVARIAN CARCINOMA. The malignant tubules in a dense fibrous stroma resemble those of the primary growth, which was a columnar-celled carcinoma of the colon (see Fig. 386).

ovarian cyst are the most frequent, secondary cancerous tumours coming next, and the true primary growth last in order of frequency.

The transference of cancer-cells to the ovaries in secondary ovarian carcinoma may be *viâ* the lymphatics, or by an adherent omentum ; or it may occur by direct implantation of cells which can pass through the bowel-wall and, escaping into the peritoneal cavity, gravitate to the ovaries, where they lie in the most dependent part of the peritoneal sac. Such implanted cells have been actually found on the surface of normal ovaries.

Secondary carcinoma of the ovaries appears in both the aforementioned types, *i.e.* the cystic and the solid. The most common form is that of a solid tumour, resembling a fibroma which has been invaded by columns and masses of cancer-cells ; when secondary to a bowel-carcinoma, the growth is a columnar-celled cancer (tubular carcinoma) (see Fig. 387).

Inoperable carcinomata of the ovaries soon become fatal and only 10-20 per cent. of cases operated upon remain free from recurrence.

With bilateral malignant disease only a few isolated cases finally escaped from recurrence.

In order to improve the prognosis in all cases of ovarian cancer, both ovaries, both tubes, and the uterus should be removed *en masse*, together with any palpably enlarged glands.

### BENIGN CONNECTIVE-TISSUE TUMOURS OF THE OVARY

**Fibromata.** Apart from the frequent small fibrous outgrowths (*corpora fibrosa*), which arise from ruptured and unruptured follicles, and which some regard as true surface-fibromata, connective-tissue tumours are uncommon, comprising only about 5 per cent. of all ovarian tumours. Excluding the small debatable surface-fibromata, there still remain two fairly distinct types of fibromata of the ovary to be described. The common variety is that in which the entire organ is replaced by the new growth, but there is a less frequent form (*encapsulated fibroma*) in which the growth is invested by a capsule consisting of the tunica albuginea, and of a variable amount of ovarian cortical tissue, which occasionally permits the tumour to be shelled out in a manner somewhat similar to the enucleation of a myoma from its bed in the uterine wall. This latter class is rare and is invariably benign.

The characters of the commoner variety (*diffused fibromata*) are as follows: they are frequently bilateral with one tumour much larger than the other. In size, they may become as large as a man's head. The general shape of the ovary is usually preserved. The surface is smooth and shiny; shallow sulci, separating large, smooth lobes are present. On section, the colour of the interior is dead white. Adhesions are rare. These tumours do not open up the layers of the broad ligaments; they possess a pedicle which allows of free movement and which, as three examples in the Charing Cross Hospital Museum show, may become twisted, leading to intense congestion of the tumours. In consistence ovarian fibromata are extremely hard, as a rule, but hyaline degenerative changes are common, leading to the formation of liquefactive areas and cystic cavities. Œdema may also occur, but less frequently than hyaline liquefaction. Small hæmorrhages in cyst-like cavities are occasionally observed.

Histologically, an ovarian fibroma is composed of groups of irregular spindle-cells packed into areas separated by bands of coarser fibrous tissue. The cellular areas are by no means of uniform appearance. In some the new cells are seen to have developed into mature fibrillary tissue with scanty nuclei, and in which hyaline degeneration has already set in. In others, the area consists of young fibroblasts of typical spindle shape, the latter frequently giving rise to the impression that the growth is a spindle-celled sarcoma. The clinical history of non-recurrence after many years, proves that such tumours are no more

dangerous than those composed entirely of dense non-nucleated, and perhaps hyaline, fibrous tissue. On the other hand, this type of apparently simple fibroma, with a structure indistinguishable from that of

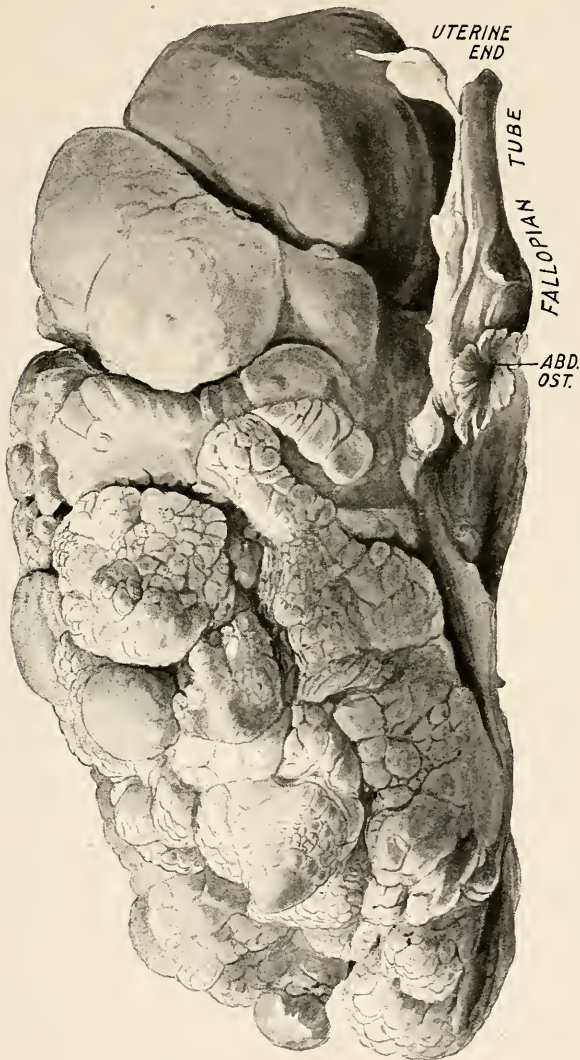


FIG. 388. SARCOMA OF THE OVARY (Charing Cross Hospital Museum).  
Multipara, aged 43.

ovarian stroma, may prove to be extremely malignant and lead to rapid dissemination, so that a prognosis based upon histology alone may prove to be quite misleading (*see* Sarcoma of the Ovary).

One notable clinical feature of these growths, even when quite innocent, is that they are frequently associated with hydroperitoneum and more rarely with hydrothorax. Ovarian fibromata are found at all

periods of life. Our youngest case was in a child of twelve years, and our oldest an adult of seventy. In both the pedicles were twisted.

**Adenofibromata.** Very exceptionally ovarian fibromata contain cystic gland-spaces, lined by cubical or columnar epithelium. Giles has recorded a case of this type; the tumour was larger than an adult's head, and in some of the spaces, the epithelium was thought to show malignant proliferation, but clinically the tumour proved to be benign. Spencer has met with a similar case, but these tumours are very rare. The adenomatous formation leads to pseudomyxomatous degeneration, and these tumours are softer than are pure fibromata. Although they may become cancerous, this is exceptional.

**Myofibromata and myomata** have been described, but are very rare.

All the above connective-tissue tumours grow very slowly, have a well-formed pedicle, and are hence very mobile. Owing to their hardness and free mobility they cause pain on bodily movement, and lead to ascites through mechanical irritation to the peritoneum.

### MALIGNANT CONNECTIVE-TISSUE TUMOURS

**Sarcomata.** These rare tumours occur in every period of life and are often found at *an earlier age than carcinoma*, in fact the majority are found at about the age of puberty, and after the menopause. When found in young girls these growths are usually of the round-celled type and are extremely malignant. In about half the number of recorded cases the growths were bilateral, and as in the case of fibromata, one tumour may be much larger than the other. In size, ovarian sarcomata may attain enormous dimensions; they are usually pediculated, oval in shape, their surface presents a certain degree of lobulation (*see* Fig. 388), and large veins may be seen under the stretched tunica albuginea. Some sarcomata are composed of spindle-cells; these are hard and difficult to distinguish from fibromata. Others are made up of round embryonic cells and have a softer consistence; they may even be brain-like in their softness. Cystic cavities are common and the cysts may be filled with blood (*see* Fig. 389). Finally both the spindle-celled and the soft forms may be found in one and the same tumour. Microscopically the hard variety is found to contain a large amount of innocent-looking fibrous tissue arranged in strands which enclose groups of spindle-cells with large nuclei. The latter show multiple chromatin-granules, and vary in size and shape.

In endeavouring to decide whether a *hard* cellular connective-tissue tumour of the ovary is an innocent fibroma or a malignant sarcoma, stress must be laid upon the characters of the nuclei of the cellular elements; variation in shape and size, a rich supply of chromatin, and evidence of mitosis, are all points in favour of malignancy. But as we have stated in connection with fibroma, there is room for error in

attempting to form an opinion as to malignancy solely from the microscopic examination of these connective-tissue growths.

The microscopic characters of the *soft* or round-celled sarcoma are much more distinctive.

The small round cells have a deeply staining, relatively large nucleus, centrally situated in a clear cytoplasm. Multinucleated giant-

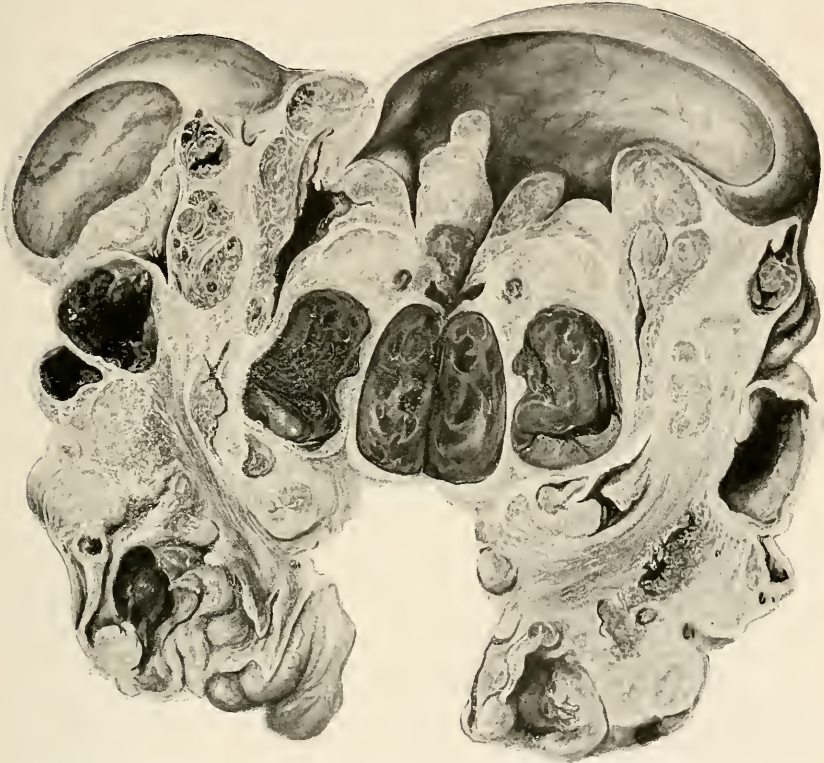

FIG. 389. SARCOMA OF THE OVARY. Both ovaries were the seat of sarcoma, and secondary deposits were removed from the peritoneum of the utero-vesical pouch. The dark areas are cysts filled with blood-coagula. The microscopic characters are seen in Figure 390.

cells are common amidst the small round cells. There is an intercellular stroma which ramifies between the individual cells, and by which the latter are often arranged in an alveolar pattern. The vessels are embryonic, having only an endothelial coat; their lumina may be seen to be filled with sarcoma-cells. Free hæmorrhages are often seen surrounded by areas of degeneration. The round-celled sarcoma is very malignant; metastases are found early, and masses of sarcomatous growth occur on the peritoneum together with ascites.

*Melanosarcoma* occurs both primarily and secondarily in the ovary.

**Endothelioma.** This is a type of sarcoma in which the origin of the proliferating cells can be traced to the *endothelial* lining of lymphatics

and blood-vessels. These growths are frequently bilateral. They resemble carcinomata of the ovary so closely in every clinical detail (occurrence in youth, shape, rapid growth, ascites, dissemination and cachexia) that a differentiation before operation is impossible.

It is often extremely difficult to decide between an endothelioma or a round-celled sarcoma, and a growth of epithelial origin. The case of

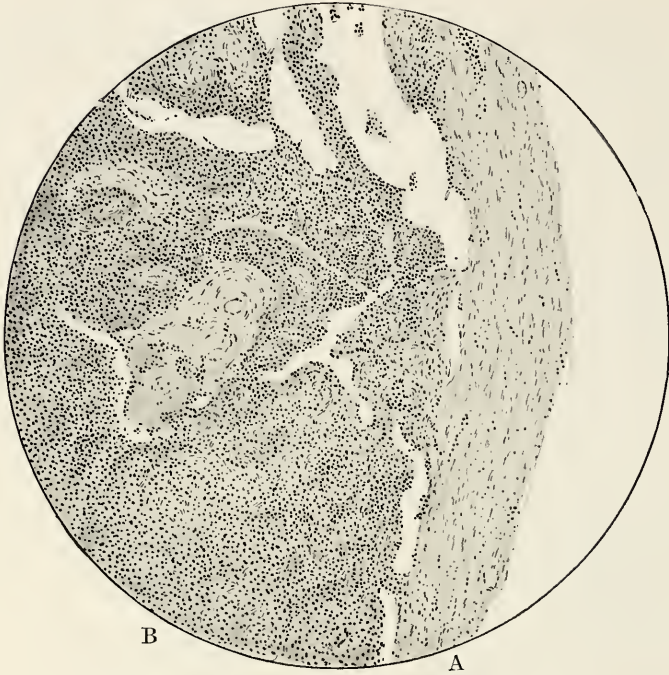


FIG. 390. SMALL ROUND-CELLED SARCOMA OF THE OVARY. Section from specimen shown in Fig. 389.  $\times 105$ . A, Ovarian cortex. B, Sarcomatous growth; the latter was very soft and degenerate.

endothelioma can only be decided by demonstrating the transformation of the normal endothelial cells into the cells of the tumour (*see* Fig. 391), and when cysts are present they are lined by typical flattened endothelium, composed of cells variable in shape and arranged in many layers. Generally speaking, the cells and their nuclei are polymorphic; syncytial masses exist, and wandering cells are present. Hyaline and mucoid degeneration makes its appearance in the stroma, just as in epithelial growths. Sometimes endotheliomata are cystic and papillary, and then they are difficult to distinguish from either primary or secondary adeno-carcinomata.

Macroscopically, sarcoma and endothelioma are softer than fibromata. Their section is brain-like and white; areas of hæmorrhage, fatty degeneration, and necrosis are common. The contents of the cystic endotheliomata are thin and serous, not pseudomucinous.



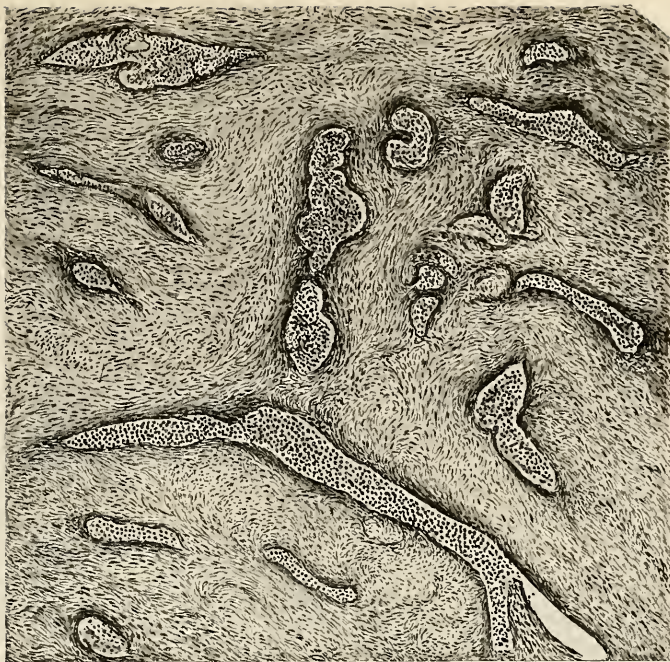

FIG. 391. SOLID ENDOTHELIOMA OF THE OVARY ( $\times 80$ ). The cells filled up the lymphatic channels, from the endothelial linings, of which they arose. There is an abundance of dense fibrous-tissue stroma which is unusual with ovarian endotheliomata.

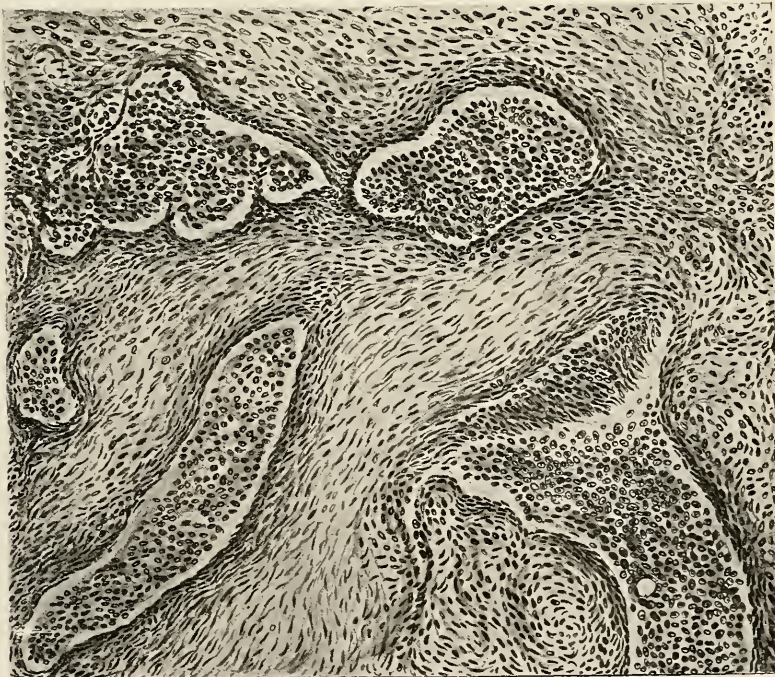

FIG. 392. SOLID ENDOTHELIOMA OF THE OVARY ( $\times 278$ ). Same section as that in preceding Figure under a higher power.

The cystic growths are always solid in parts, and the solid areas are soft and brain-like.

**Perithelioma.** This is another type of sarcoma in which the cells take origin from the *adventitia* of the blood- and lymph-vessels. The new cells are small, round, and epithelioid in appearance (*see Fig. 393*). The collections of epithelioid cells are seen to surround the lumen of

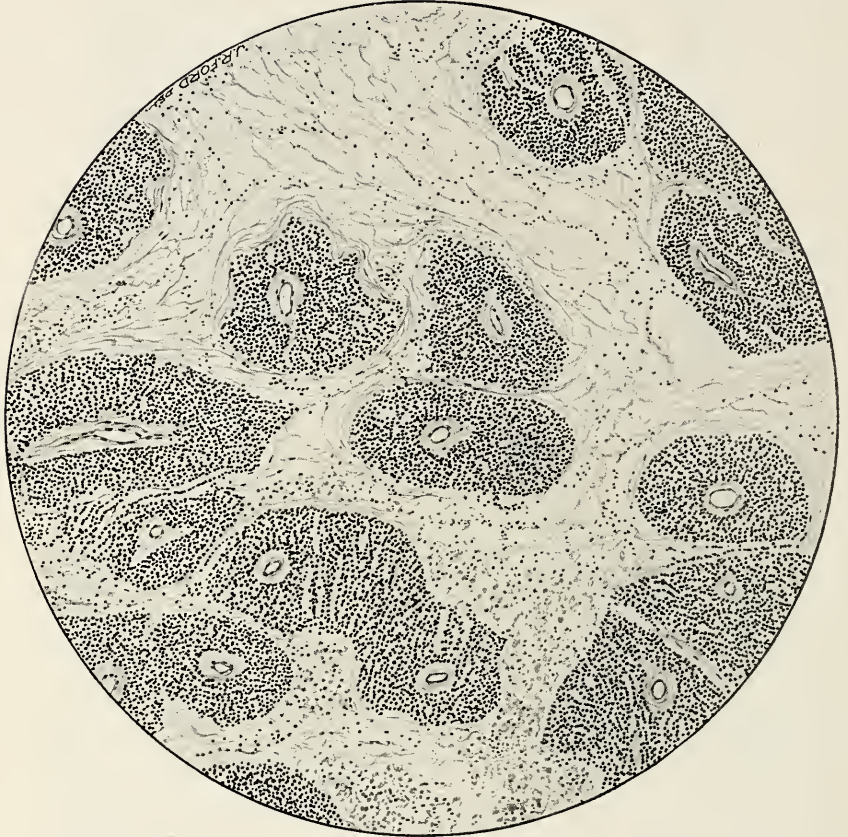

FIG. 393. PERITHELIOMA OF THE OVARY ( $\times 80$ ). The growth consisted of solid masses in the wall of a teratomatous ovarian cyst.

the particular vessel from which they arose, from whence, spreading radially, they invade adjacent tissues for a variable distance. Large strands of fibrous tissue intervene between one cellular area and another, so that perithelioma can be demonstrated as starting from multiple foci. This type of growth is firmer than a round-celled sarcoma, but, like the latter, it has a smooth, homogeneous cut-surface. In our own experience this type of sarcoma is the least malignant of all; in Doran and Lockyer's case of perithelioma of uterus, tube and ovary, the patient was well after five years, although it was reasonably certain that all the growth had not been removed.

## OVARIAN TERATOMATA

**Teratomatous Cysts: Ovarian Dermoids.** Teratomatous ovarian cysts are usually termed *dermoids* of the ovary, but this is not strictly accurate. A *dermoid* is a cyst produced by the inclusion of ectodermal structures only; its cavity is lined with skin and skin-appendages,

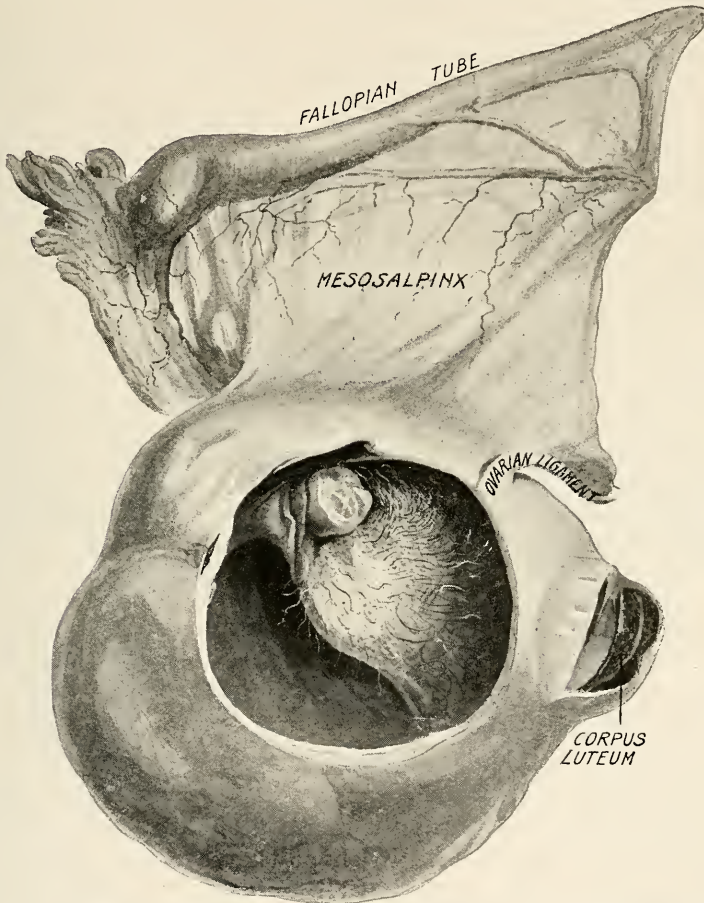


FIG. 394. TERATOMATOUS OVARIAN CYST (DERMOID). In the interior of the cyst are seen a patch of skin furnished with hairs, and a well-formed tooth resembling a premolar. The whole of the ovarian tissue is not destroyed, as is shown by the presence of a recent corpus luteum.

it contains no hypoblastic elements like mucous membrane, and no mesoblastic structures such as muscle, cartilage or bone. On the other hand, we usually find all three embryonic layers, epi-, meso-, and hypoblast, represented in an ovarian *dermoid*. The student should bear in mind, therefore, that an ovarian dermoid is a *teratomatous* growth within an ovarian cyst. Whether the cyst-formation

is secondary to, and caused by, the teratomatous growth is a matter which is unsettled.

Teratomatous ovarian cysts are usually pedunculated (*see* Fig. 394). They make up about 10 per cent. of all ovarian tumours (von Franqué); as a rule they occur singly but are often bilateral (14 per cent. Olshausen). They have been met with at all ages from the eighth month of intra-uterine existence (Reissman) to the eighty-third year of life (Potter). They are slow of growth and when small give rise to no symptoms; they may, therefore, have been in existence for long periods before being clinically recognized. Many teratomatous cysts may

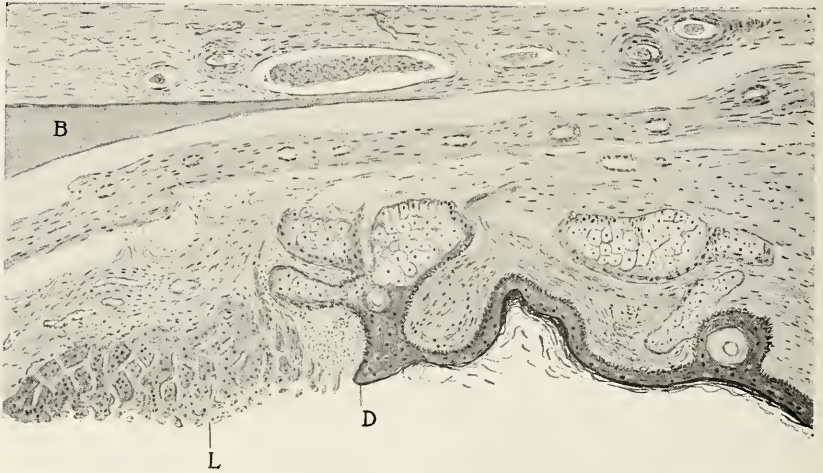


FIG. 395. TERATOMATOUS PROCESS (DERMOID) IN THE WALL OF A LUTEIN CYST. B, Dilated blood-vessels. D, 'Dermoid' process. L, Lutein lamina, which lined the greater part of the cyst-wall.

occur in one and the same ovary. A teratomatous ovarian cyst never reaches the dimensions which can be assumed by a pseudomucinous cyst; it is not often larger than a man's fist, and at the most is not bigger than an adult's head. In shape they are generally spherical (*see* Fig. 394); the surface is smooth, glistening, and the yellow colour of the contents is often seen through the thin membranous cyst-wall.

If the cyst be regarded as an essential part of the tumour we may say that an ovarian dermoid consists (i) of a cyst, and (ii) of a teratomatous prominence projecting from its inner wall into the cavity of the cyst. The relationship of the cyst or cysts to the normal ovarian tissue is of importance. It is usually found that the ovary is flattened and incorporated with one part of the cyst-wall to such a degree as to escape detection by the naked eye; less frequently it may form a projection on the *outer surface* of the cyst-wall. Exceptionally, the cystic teratoma may possess a pedicle of its own which attaches it to the ovary. In many cases ovarian tissue bearing follicles or corpora

lutea can be detected in the neighbourhood of the ovarian ligament. This tissue is functionally active and should be retained if possible, when the cyst is removed by operation. Figure 395 shows the presence of a *dermoid* prominence in a lutein cyst. This is probably the result of fusion of a *dermoid* cyst with a lutein cyst.

The contents of a teratomatous cyst are fluid at body-temperature but become semi-solid and granular on cooling. The teratomatous prominence is covered by epidermis from which long slender hairs grow out. The skin-elements do not line the whole cyst, but are found on the so-called *dermoid processes* and on the adjacent parts of the cyst-wall. The *dermoid process* projects from the wall into the lumen of the cyst. It is a solid mass of tissue, often shaped somewhat like a nipple, invested with hair and containing sebaceous glands and various bony constituents such as teeth (*see* Fig. 398), portions of the lower jaw, flat skull bones, long bones, etc.

After removal, when the cyst-contents have had time to solidify, the cyst-wall looks dry, shrunken, and crackles when handled; it then pits on pressure and has a doughy consistence. The contents consist of sebaceous material, coils of long hair, granular *débris*, fat-globules, and crystals of cholesterin. In this material are sometimes seen small solid balls composed of a fatty substance with a nucleus of hair; more rarely whitish balls of harder consistence are found. These consist of agglomerations of shed epidermal cells (epithelial balls). Sometimes balls consisting entirely of shed intertwined hairs are found loose in the cyst-cavity.

The *dermoid process*, already referred to, represents an attempt at the formation of the cephalic extremity of an embryo, and in a favourable case the following structures, occurring in superimposed layers, may be detected: (1) cutaneous tissues representing the scalp (*see* Fig. 396); (2) bone representing the cranium; (3) an epidermal sulcus in which may be found teeth and bone representing the mouth; (4) neuroglia representing the brain; (5) tubes and depressions, some of which are lined by ciliated epithelium, representing the upper extremities of the respiratory and alimentary tracts. In some teratomatous cysts the nipple-shaped prominences mentioned do not occur at all, so that the arrangement here described is not of universal occurrence in these tumours. The significance of these findings will be referred to again in connection with the histogenesis of ovarian dermoids.

It will thus be seen that a variety of tissues of ectodermal and mesodermal origin occur in these tumours, and some of them deserve more particular mention.

*Skin* only occurs in patches; it resembles its normal prototype in consisting of a cuticle resting upon a *cutis vera*, and in being furnished with hair-follicles and abundant sebaceous glands (*see* Fig. 396), and occasionally with a few ill-developed, spiral sweat-glands. Fatty tissue is often found beneath it, and sometimes striped muscle-fibres.

Imperfectly formed nails are also sometimes found. *Hair* in ovarian dermoids may be either dark or light in colour ; individual hairs may attain the length of many inches, and sometimes they grow through the cyst-wall so that their free ends appear upon the outer surface. The interesting statement is made by Bland-Sutton that as age advances, hair in ovarian dermoids becomes grey, or may be shed, rendering the

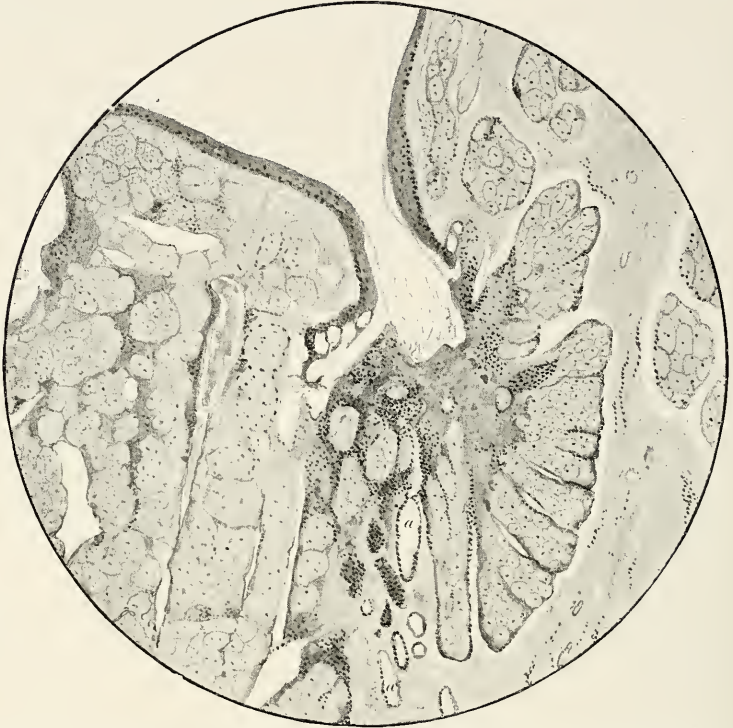

FIG. 396. SECTION THROUGH A DERMOID PROCESS OF A TERATOMATOUS OVARIAN CYST. The section shows a patch of skin with a hair-follicle surrounded by abundant sebaceous glands. The tubules, *a, a*, represent rudimentary sweat-glands.

dermoid tumour "bald." *Sebaceous glands* are active and abundant, and form the source of the characteristic fatty contents of the cyst. *Epithelial balls* have received special attention from Bland-Sutton. They are described as about the size of pills, and are composed of masses of shed epidermal scales, aggregated around a rolled-up hair. They are not often seen, but may occur in very large numbers, so as practically to fill up the cyst-cavity. *Teeth* are found in upwards of 50 per cent. of ovarian dermoids. They are for the most part of the canine or incisor type, and consist of enamel and dentine. They may be very numerous, and as many as three hundred have been found in a single specimen. They are often partly embedded in bone, and in such cases unerupted

teeth may also be found buried in the bony tissue. *Bone* is a frequent constituent. Usually it occurs in plates and masses of quite irregular conformation. Instances have, however, been described of imitations of various normal bones of the skeleton; thus an imperfectly formed digit furnished with a nail has been seen, and bony masses resembling certain bones of the face or cranium have also been met with. *Carti-*

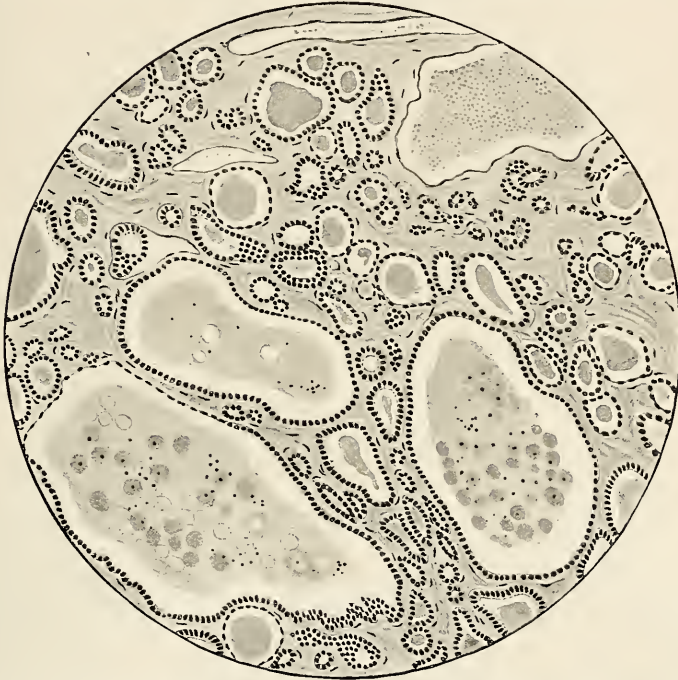

FIG. 397. OVARIAN TUMOUR. Showing a structure similar to that of the thyroid gland; such a structure is sometimes seen in teratomata.  $\times 150$ .

*lage* of the hyaline variety in the form of flat plates is not infrequently found in dermoids.

In a few rare instances certain structures of *entodermal* origin have been found, such as patches of thyroid-gland tissue, portions of intestinal wall consisting of plain muscle and a mucosa furnished with Lieberkühn's glands, and epithelial tubes lined with ciliated cells which have been held to represent the respiratory tract.

The structures found in cystic ovarian teratomata (ovarian dermoids) may accordingly be summarized thus :

1. *Ectodermal* : Skin, hair, sebaceous glands, sweat-glands, teeth, nails, neuroglia.
2. *Mesodermal* : Bone, fatty tissue, fibrous tissue, muscle.
3. *Entodermal* : Thyroid (*see* Fig. 397), mucosa of small intestine and air-passages.
4. *Granulation-tissue* containing phagocytes.

The inner surface of the wall of an ovarian teratomatous cyst is composed for the most part of granulation-tissue, with patches of skin

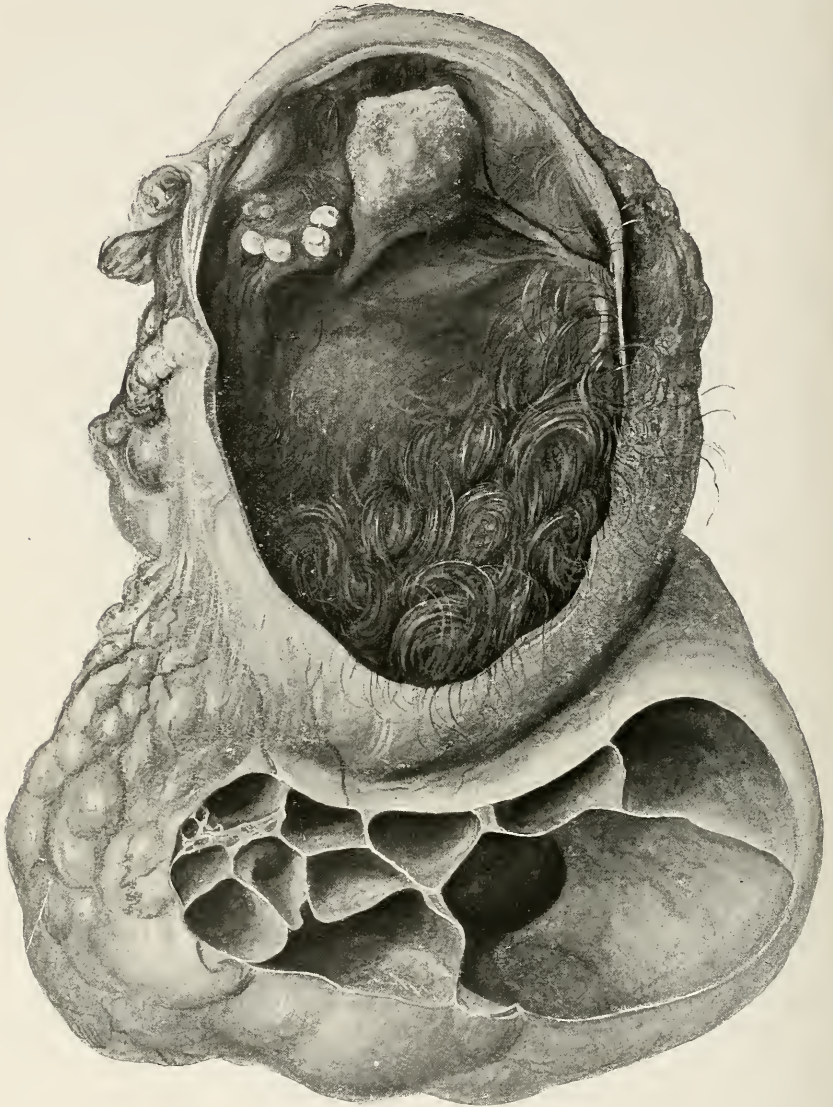


FIG. 398. COMPOUND OVARIAN CYST. The largest loculus shows a *teratomatous process* composed of a tongue-shaped solid epidermal mass and four teeth set in a bony ridge. The loculus was filled with granular sebaceous material and hair. The lower part is an adenoma pseudomucinosum.

or mucous membrane here and there. It is probable that the granulation-tissue results from the chronic irritation caused by the peculiar nature of the cyst-contents. Phagocytes in the act of destroying fragments of hair are to be seen in the granulation-tissue.



Occasionally *teratomatous* cysts unconnected with the ovary have been found in the abdominal or pelvic cavity. They, when pelvic, may arise from accessory ovarian tissue; when abdominal, through the escape of some active elements of an ovarian teratoma.

As stated before, the origin of the *cyst* in which a *dermoid process* or teratoma is found is uncertain; possibly it is the result of distension of the ovarian stroma by the sebaceous contents thrown out by the *dermoid process*; it may represent a follicular cyst, a lutein cyst (see Fig. 395), or even a lymph-space. It is not infrequently a loculus of a pseudomucinous cyst into which a *dermoid process* has penetrated (see Fig. 398). The teratomatous ovarian cyst is not a proliferating tumour but an example of a retention cyst; its enlargement is very slow and is not due to growth of new tissue—but only to gradual distension of the cyst by the sebaceous secretion.

The epithelial elements of a teratomatous cyst may become malignant; this occurs in about 3 per cent. of cases. Most frequently seen is the epithelioma of squamous type, more rarely the sebaceous glands become malignant. We have met with one case of secondary peritheliomatous change occurring in a teratoma (see Fig. 393, p. 688). It may be said that a *dermoid* is essentially an innocent growth, and even when malignant areas appear in it, the prognosis is good, but, on account of its slow growth and duration, it is frequently a source of clinical disturbances, such as pressure, axial torsion, suppuration, and complications during pregnancy, labour, and in the puerperium. Rupture is less frequent than with the proliferating cystomata, and it occurs nearly always as a result of trauma, viz. during labour, but a thin-walled teratomatous cyst will rupture sometimes as the result of the internal pressure of its own contents. After rupture, adhesions and a false capsule form. It is said that local peritonitis around a teratomatous cyst of the ovary may be set up by the penetration of the capsule by hairs.

**Solid Ovarian Teratomata.** These are the rarest of all ovarian tumours. As already indicated, they are clinically malignant, and tend to recur rapidly after removal. They may attain an enormous size, and in this particular they differ considerably from teratomatous cysts. Their incidence falls especially in adolescence, although a case has been reported in a woman of forty-nine. Generally speaking, they form *solid* irregularly lobulated growths, containing more or less numerous cystic spaces, some of degenerative origin, others lined with epithelium. Microscopic examination reveals the presence of an extraordinary variety of embryonic tissues derived from all three layers of the blastoderm, and these occur in confused association, without any attempt at the formation of *fully organized* structures, such as the teeth, skin, and bone which are characteristic of teratomatous cysts. The various elements are, for the most part, in a very embryonic state and are very irregularly arranged. In consequence

of their embryonic character the foetal constituents show a pronounced tendency to active proliferation, tissue-growth is very rapid, and not infrequently it is malignant, metastases being formed in which the embryonic tissue is mostly of sarcomatous type (*see* Fig. 399), carcinomatous metaplasia being less frequent. On macro-

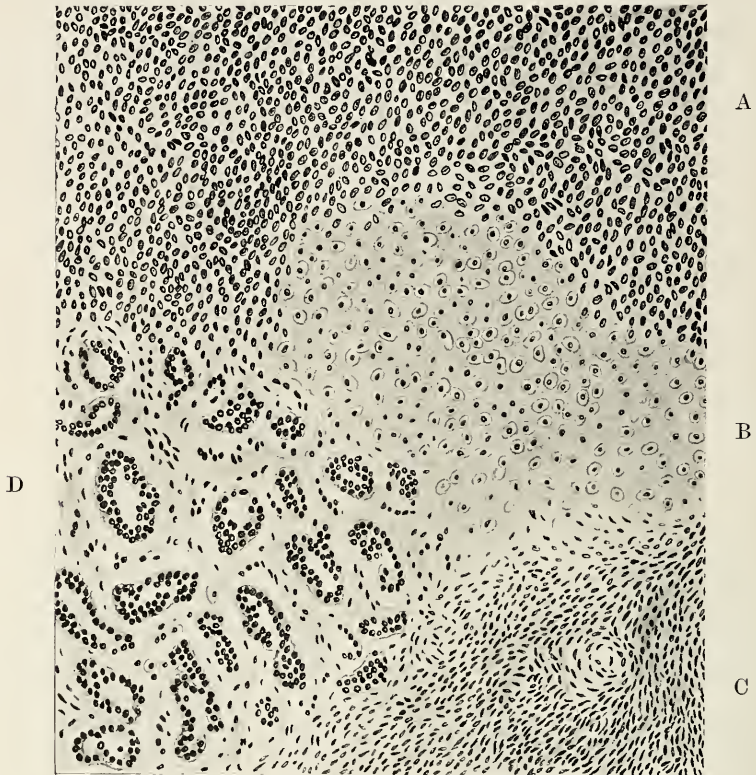


FIG. 399. SOLID OVARIAN TERATOMA.  $\times 278$ . Showing areas of three distinctive types of new growth. A, Sarcoma. B, Cartilage. C, Ovarian stroma. D, Embryonic gland-tubules.

scopic section, soft brain-like tissue predominates, but this is often combined with numerous small and large cysts containing epidermal structures. Microscopically every tissue of the human body can be represented, the different structures being found in varying degrees of development but mostly immature.

**Histogenesis.** The theories that ovarian teratomata might arise from *parthenogenesis* and *sporogeny* (asexual reproduction) are not seriously entertained by modern pathologists. Although this mode of reproduction is seen in certain plants and certain insects, there is no evidence of its occurrence in the higher animals. A later theory, enunciated by Cohnheim, ascribed the inception of tumours generally,

to misplaced embryonic rudiments, cells or aggregations of cells, which became misplaced during the complicated shiftings of the embryonic tissues during the developmental process. In this way epidermal and mesodermal cells may have become 'included' in the ovary at an early period of embryonic development, and such cells, after lying dormant, possibly for many years, may become active and give rise to growths consisting of epidermal and mesodermal structures. This was conveniently spoken of as the theory of *embryonic rests*. Again, many writers have attempted to explain the occurrence of teratomata by associating them with those aberrant forms of pregnancy which result in the production of 'conjoined twins,' or with the duplication or dichotomy of different parts of the body in the foetus.

The latest theory enunciated independently by Waldeyer and Wilms is that both cystic and solid teratomata are the result of some unknown but powerful stimulus applied to the egg-cell; in response to this stimulus proliferation occurs, and the resulting growth may contain cells representative of all the different structures which are normally produced from the egg-cell under the stimulus of fertilization. The egg-cell possesses the potential power of producing all the tissues of the body; by some unknown pathological stimulus this potential power may be partially evoked, and will naturally lead to atypical and incoordinate results. A similar stimulus applied to an epithelial cell may produce carcinoma; to a connective-tissue cell, sarcoma. This *ovular* theory of Wilms affords a satisfactory explanation for the formation of *ovarian* teratomata, but it is less helpful in the elucidation of similar growths in other parts of the body, or those found in the male sex.

### COMPOUND OVARIAN TUMOURS

The varieties of ovarian tumours hitherto described may be regarded as generally recognized types; many individual instances, however, occur of tumours which cannot conveniently be included within these types owing to some peculiarity, usually of the nature of diversity of structure, in different parts. Thus cystic tumours may be in parts pseudomucinous, in other parts papillary; or a pseudomucinous tumour may show a single dermoid loculus (*see* Fig. 398), or a circumscribed fibroma in its wall. Again, an innocent cystic tumour may show malignant metaplasia of its epithelial or connective-tissue elements, giving rise to a cancerous or sarcomatous and peritheliomatous change (*see* Fig. 393). Again, a solid tumour may be in one part fibroma, in another sarcoma (*fibro-sarcoma*); or a fibroma may show collections of epithelial tubules in some part of its mass (*fibro-adenoma*). The occurrence of plain muscle-fibre in an ovarian fibroma has also been described (*fibro-myoma*); rare instances of *fibro-myosarcoma* have also been recorded. These compound types, though of great interest to the pathologist, possess no practical importance

beyond the additional difficulty which they may introduce into the histological determination of the innocence or malignancy of individual growths.

### CYSTS ARISING IN THE BROAD LIGAMENT

Under this heading we may conveniently consider the following varieties of cystic tumours :

Fimbrial cysts.

Epoöphoritic cysts.

Cysts of Kobelt's tubes.

Cysts of the hydatid of Morgagni.

**Fimbrial Cysts.** It has hitherto been commonly accepted that all

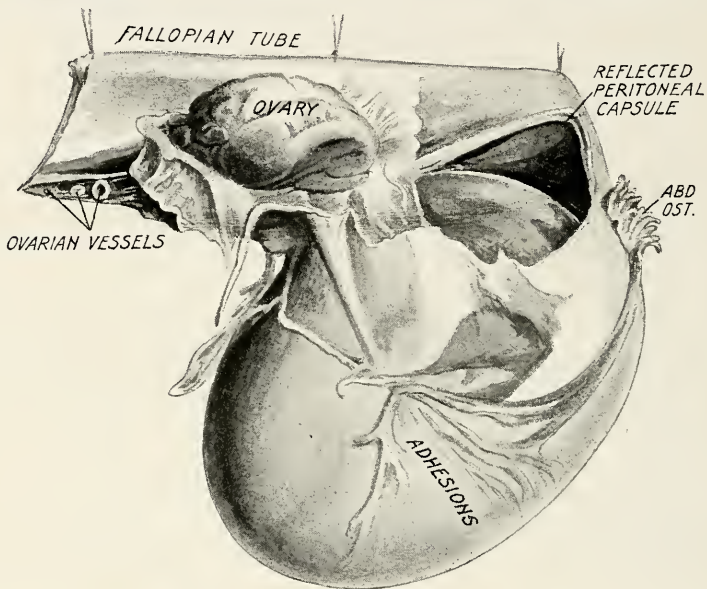


FIG. 400. FIMBRIAL CYST. Multipara, aged 43. The cyst occupies the outer part of the broad ligament; the posterior peritoneal layer has been partly reflected to show its intra-ligamentary position.

broad-ligament cysts which reach a size sufficiently large to render them clinically important are parovarian, *i.e.* that they arise from the epoöphoron, or organ of Rosenmüller. Keith has shown that this view is wrong, and that such cysts have their origin from developmental remains in the ovarian fimbria of the Fallopian tube. The term *fimbrial cyst* is therefore here used as the title of those cysts which have previously been described as *parovarian*.

*Origin.* The ovarian fimbria of the tube has been shown by Keith to be formed in part from the genital ridge, and to contain (in the new-born child) a portion of ovarian tissue continuous with the hilum.

In a large percentage of subjects, a tiny cyst will be found attached to the ovarian fimbria; such structures are developed in the homologues of the *rete testis* of the male (Keith). Keith, in a series of preparations, has shown all the stages of development from these minute fimbrial cysts into large tumours. A similar development from small parovarian cysts into large tumours has never been demonstrated.

*Characters.* Fimbrial cysts vary in size from very minute dimensions to enormous tumours. As they grow they develop between the layers of the broad ligament and open up its peritoneal folds. Thus

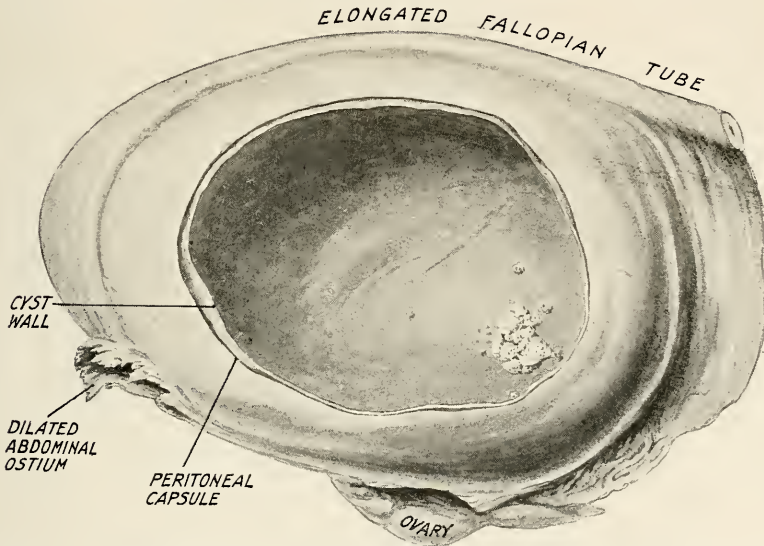


FIG. 401. FIMBRIAL CYST (Royal College of Surgeons Museum). The Fallopian tube is stretched over the summit of the cyst which occupies the mesosalpinx. The ovary is seen on the side opposite to the tube. The ovarian fimbria is much elongated. A cluster of papillomata is seen on the inner surface of the cyst-wall.

the Fallopian tube becomes arched and elongated over the upper surface. The ostium of the tube is attached to the outer surface of the cyst, and the ovarian fimbria runs from the tubal ostium to the ovary. The latter structure is generally quite separate and distinct, but in the case of very large cysts it may become greatly thinned and flattened out, and incorporated in their walls.

The pedicle of a fimbrial cyst is composed of that portion of the broad ligament which is not occupied by the cyst. It follows that only cysts of comparatively small size can be said to possess a pedicle (*see* Fig. 401). When large enough to occupy all the space between the peritoneal folds of the broad ligament the cyst becomes sessile.

The cyst is unilocular and has a very thin, but comparatively strong,

wall which is loosely attached to the investing peritoneum. The inner surface is smooth excepting for the occasional presence of a few warty growths (*see* Fig. 401). Microscopically the wall is seen to contain connective tissue and muscle-fibres, and the lining consists

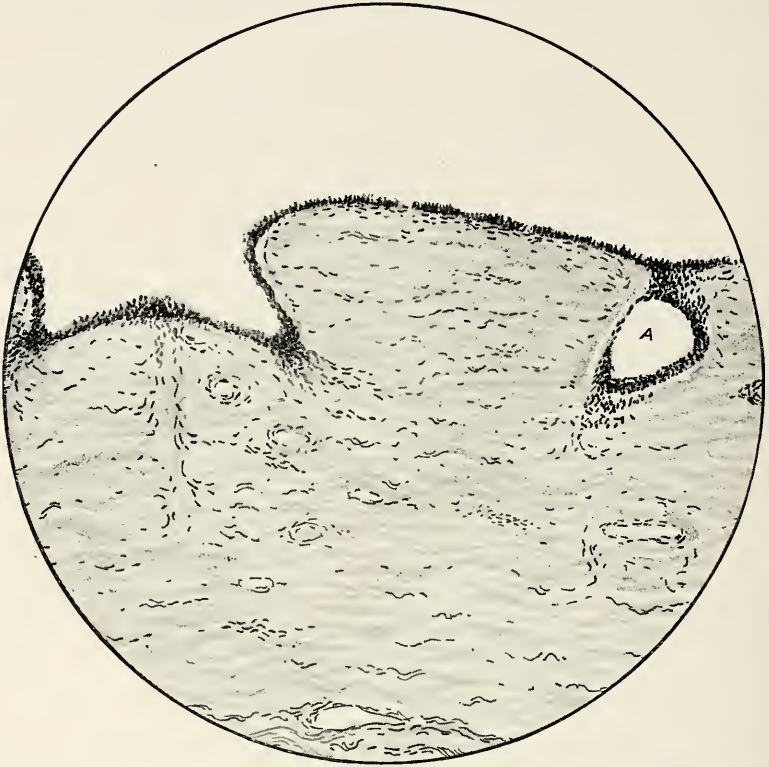

FIG. 402. FIMBRIAL CYST. The section shows the scanty epithelial lining consisting of imperfectly preserved cubical cells. A is merely an inclusion of lining-epithelium due to the fusion of two fibrous papillomata.

of columnar ciliated epithelium. The contents consist of a limpid alkaline fluid, nearly or quite as colourless as water, and having a low specific gravity (1004–1006); it contains a faint trace of albumen and very rarely pseudomucin.

*Clinical Features.* Fimbrial cysts probably never develop before puberty, they grow very slowly, and may exist for many years without causing serious symptoms.

Large cysts, after opening up the broad ligament, may burrow downwards into the paravaginal and pararectal connective tissues, displacing the uterus upwards and forwards or to one or other side. They may also elevate the peritoneum and open up the mesosigmoid or mesocæcum, reaching by this retroperitoneal route high up into the abdomen.

As both fimbrial cysts and papilliferous ovarian cysts are found in the broad ligament these growths may be confused one with the other,

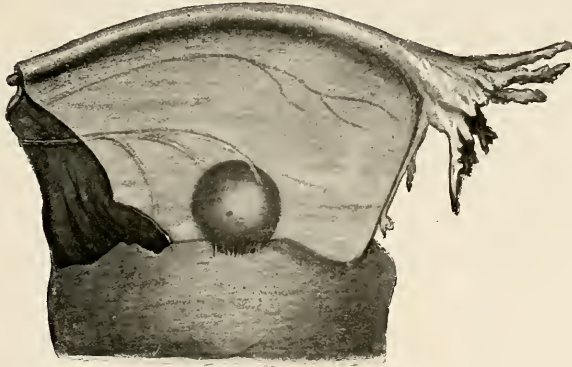

FIG. 403. PAROVARIAN CYST. (Doran.)

especially as fimbrial cysts may contain papillomatous growths (see Fig. 401). Fimbrial cysts with their intracystic papillomata are,

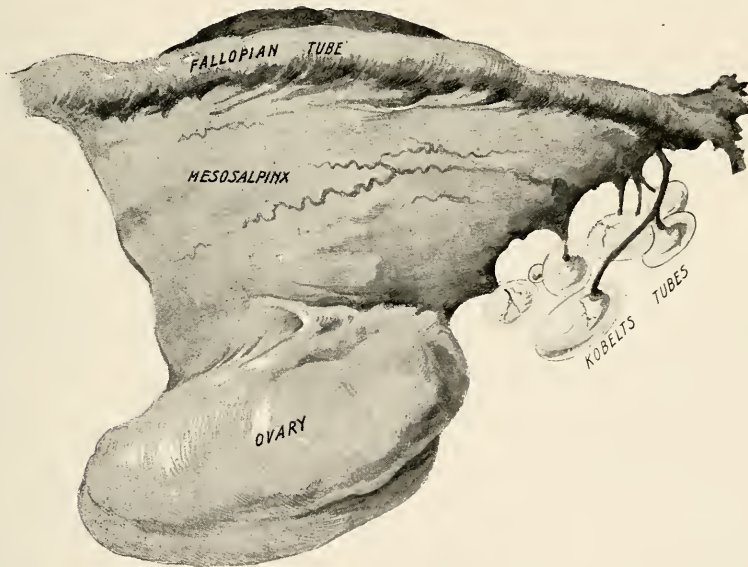


FIG. 404. THE FALLOPIAN TUBE, OVARY, AND MESOSALPINX OF THE LEFT SIDE (Charing Cross Hospital Museum). On the free edge of the mesosalpinx is seen a cluster of small pediculated cysts, probably derived from Kobelt's tubes.

however, essentially innocent, whilst papilliferous ovarian cysts often present malignant characters.

**Epoöphoritic Cysts (Parovarian Cysts).** The canals of the epoöphoron are formed of circular muscle-fibres and an epithelium provided with

cilia (Fig. 35, p. 48). One, or occasionally several, of these develop into cysts, which are generally quite small (*see* Fig. 403), they may however attain a size equal to that of a large fimbrial cyst. Such cysts generally arise in the vertical tubules of the epoöphoron, more rarely they originate in the duct of Gartner. They are small translucent structures with a thin capsule containing connective tissue and muscle-fibres. Their contents consist of colourless fluid of low specific gravity containing salts and a trace of albumen. Cysts arising in the lower segment of Gartner's duct have been described in the section dealing with the vagina, p. 385.

**Cysts of Kobelt's tubes** never attain a large size (*see* Fig. 404) and never cause clinical symptoms. They are probably pronephric in origin.

**Cysts of the Hydatid of Morgagni.** The hydatid of Morgagni is a modified tubal fimbria. Small cysts of this body are quite frequent. They appear as pediculated translucent structures containing watery fluid. If Keith's view as to the origin of the fimbriated end of the Fallopian tube is correct, viz. that it is a derivative of the pronephros, the above cysts must likewise be regarded as pronephric (*see* p. 78).

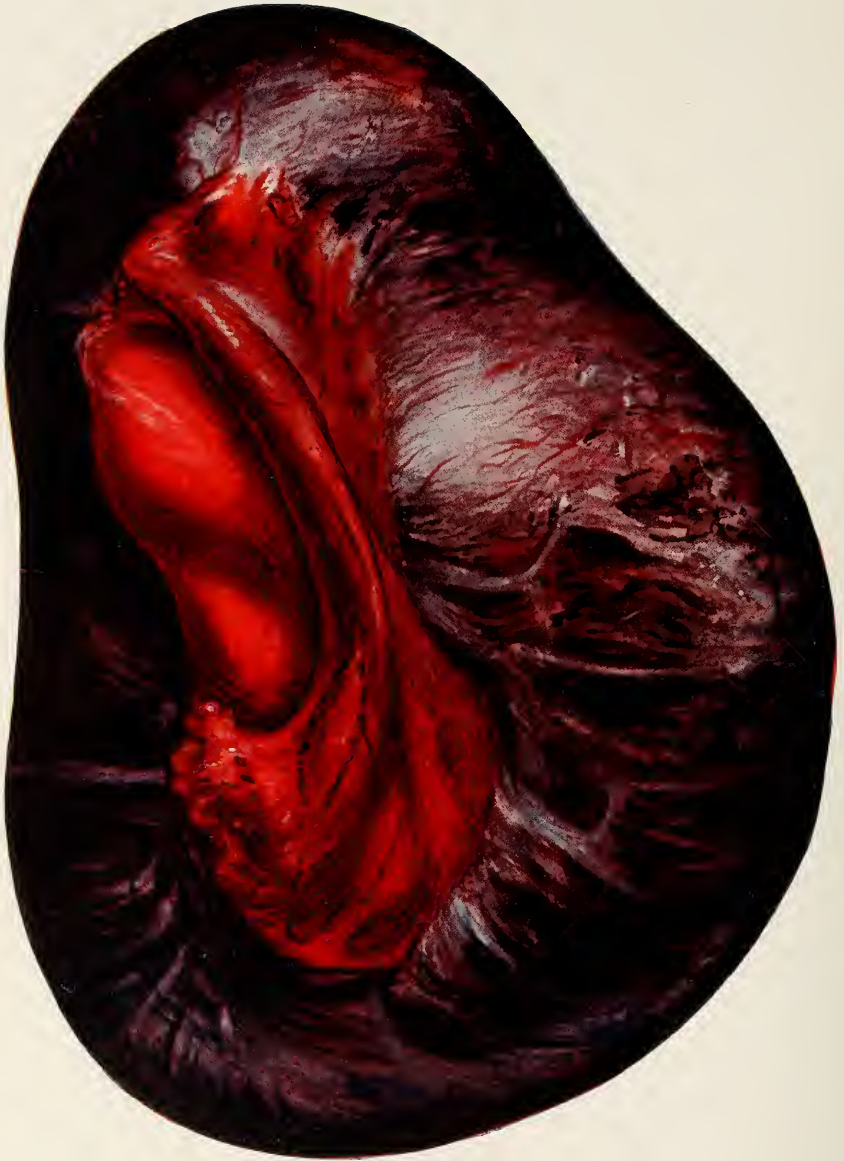## SECONDARY CHANGES IN OVARIAN TUMOURS

(1) **Axial Rotation : Torsion of the Pedicle.** This accident is found to have occurred in about 2 per cent. of cases submitted to operation. The tumours which are most likely to undergo this change are cysts of moderate size with a fairly long, thin pedicle which allows them to rise above the pelvic brim. It occurs more rarely with solid than with cystic tumours, and those of very large size are usually prevented by their bulk from rotating. The extent of the torsion varies from one half-turn to twelve complete turns ; a twist of less than one half-circle probably does not affect the circulation in the tumour at all. The effects produced upon the tumour vary with the extent of the torsion, and probably with the rapidity of its production ; these effects may be described in three stages.

(a) *Congestion.* A moderate twist is sufficient to compress the thin-walled veins of the pedicle, and arrest the venous return from the tumour without greatly reducing its arterial supply. The vessels subjected to compression are the ovarian vessels, which reach the tumour through the infundibulo-pelvic fold. The uterine artery is not affected, but since the uterine veins communicate freely with the pampiniform plexus in the broad ligament, the uterine circulation is also disturbed. On the distal side of the twist it is accordingly found that the Fallopian tube, broad ligament, and cyst-wall are greatly swollen. On the proximal side of the twist swelling also takes place, but to a less marked extent ; this is to be explained by the fact just mentioned that







OVARIAN CYST DRAWN IMMEDIATELY AFTER REMOVAL, showing the effects of acute torsion of the pedicle.

twisting of the broad ligament interferes to some extent with the venous outflow from the uterus itself. Both the pedicle and the tumour become engorged with venous blood, extensive interstitial hæmorrhage occurs, and in addition, bleeding takes place into the loculi of the cyst. As a result, enlargement of the tumour takes place, and in some cases spontaneous rupture, from increased tension due to intracystic effusion of blood, has been observed. Tumours in this condition are usually of a dark plum colour (Plate XX), and dull, having lost the polished appearance characteristic of the unaltered cyst-wall. In this condition the tumour is liable to become infected from the bowel. Adhesive peritonitis is frequently found around it, causing adhesions to neighbouring intestinal coils, to the omentum, and the abdominal wall; adhesions are not, however, invariably present. Extensive thrombosis is often observed in the veins of the pedicle on both sides of the twist, and it may spread far into the large veins of the broad ligament.

(b) *Necrosis* may take place from sudden arrest of the arterial supply or, more gradually, as the result of extreme congestion. The tumour in this condition is very liable to become infected from adherent coils of intestine, giving rise to suppuration or gangrene. But even when the twist is sufficient completely to kink the arteries, necrosis may not occur if the change has been a gradual one and the tumour is small; the omental and other adhesions, which rapidly form, become vascularized and are able to furnish sufficient blood to maintain the vitality of the tumour. If the twist is too rapidly produced to allow time for adhesions to form and become vascularized, this alternative source of blood-supply will not be available and necrosis will then ensue.

(c) *Detachment* may occur, from atrophy of the tissues of the twisted portion of the pedicle. Fresh connections having been formed during the process, the tumour not only maintains its existence but may actually increase in size, and appear to be growing from some other abdominal organ.

*Causation.* Not much is known about the causes of axial rotation. The conditions which predispose to its occurrence are, small size and free mobility of the tumour, and laxity of the abdominal wall. It is therefore not uncommonly met with in pregnancy and the puerperium. Trauma or muscular strain may in some cases actually initiate the rotation, and once started the movement may, perhaps, continue spontaneously. There has been great discussion as to the *direction* of the movement of rotation. It appears that the movement may occur in either of the two possible directions, and that in the majority of cases it follows the direction of the movement of supination of the forearm on the affected side, *i.e.* the tumour rotates towards the side to which it belongs. An instance of axial rotation of an ovarian cyst in the fœtus has been recorded.

(2) **Infection.** Ovarian cysts are much more prone to infection than are uterine fibroids. They may become involved in the spread of septic or gonorrhœal infection from the uterus and the Fallopian tubes, or by the passage of organisms into them from the bowel through adherent coils of intestine. In pre-antiseptic times, infection often followed the operation of tapping a large cyst through the abdominal parietes. Infection is, however, much commoner in the case of small pelvic cysts than in the larger abdominal ones. As already mentioned, axial rotation is a powerful predisposing cause of bowel adhesions, and consequently of infection also. It is stated that dermoid cysts are especially prone to become infected, but the evidence upon which this statement is based is inconclusive; probably, in many cystic teratomata described as containing pus, the characteristic sebaceous contents were mistaken for purulent fluid, owing to the resemblance of their naked-eye characters to pus. It is not uncommon to find certain loculi of an infected cyst containing pus, while the contents of the others are non-purulent. The infective process is clinically found to be much more often chronic than acute; not infrequently, the pus is sterile at the time of operation.

A suppurating ovarian cyst becomes closely adherent to neighbouring viscera, and, after destroying the intervening walls, may discharge spontaneously by perforation into the rectum, the bladder, or the vagina. If the cyst contains a teratomatous (*dermoid*) process, hair and teeth may thus be passed per rectum or through the urinary passages. It would seem that suppurating teratomatous cysts are more liable to perforate the bladder than other varieties of ovarian cysts, a point which is no doubt explained by their being more frequently found in the utero-vesical pouch. It is a possible, but extremely rare, occurrence for a suppurating ovarian cyst to rupture into the peritoneal cavity. When a pyosalpinx is also present a communication may be established between them, forming a tubo-ovarian abscess.

(3) **Rupture.** Three conditions may lead to rupture of an ovarian cyst: (1) traumatism; (2) sudden increase of intracystic tension from hæmorrhage or suppuration; (3) morbid changes in the cyst-wall. Spencer Wells stated that rupture had occurred in 2·4 per cent. of his series of 1000 ovariectomies.

(1) Thin-walled cysts can sometimes be felt to rupture during a bimanual examination; this is especially liable to occur under anæsthesia with complete muscular relaxation. During labour, an ovarian cyst in the pouch of Douglas may rupture from the pressure exerted upon it during the delivery of the fœtus. A large cyst may no doubt be ruptured by direct abdominal violence such as a blow or a fall.

(2) Axial rotation is by far the commonest cause of any considerable hæmorrhage into an ovarian cyst. The spontaneous rupture of suppurating cysts has been already mentioned.

(3) In the colloid or jelly-cysts the wall is unusually friable, and spontaneous rupture may occur from mere inability of the tissues to support the normal amount of intracystic tension. Papillary growths, either innocent or malignant, may actually perforate the cyst-wall, or by weakening it, lead to spontaneous rupture. Cystic carcinomata of the ovary not infrequently undergo spontaneous perforation into the peritoneal cavity, owing to the friability of the cancerous tissues.

*Results of Rupture.* These depend entirely upon the nature of the cyst-contents which are effused into the peritoneal cavity. Serous fluids of low specific gravity and scanty albuminous contents, such as those found in fimbrial and follicular cysts, are readily absorbed by the peritoneum, without any local inflammatory reaction taking place. No serious consequences need therefore be anticipated from such an accident as the bursting of a small cyst during clinical examination. Thick fluids containing large quantities of albuminous material, such as those found in pseudomucinous cysts, or thick fluids containing fat, loose hair, and other solid materials, such as are found in cystic teratomata, do invariably produce a local peritonitic reaction. Small quantities of such fluids sometimes become completely encysted by adhesive peritonitis, but more commonly, the fluid escapes in large amount and becomes diffused over the peritoneal cavity; it then tends to accumulate in certain positions, viz. in the pouch of Douglas and in the renal pouches, as is the case with all free fluids in the peritoneal cavity. It resists absorption, and the adhesive inflammation which is set up is a protective process, which has the effect of isolating and imprisoning the foreign material. Unless the cyst-contents were infected at the time, general peritonitis does not supervene.

In the case of teratomatous and papillary cysts a further result ensues, viz. the active epithelial elements which these tumours contain, become grafted upon the peritoneal membrane and grow there. Thus a crop of peritoneal warts may be found, after rupture of a papillary cyst, not only in the neighbourhood of the tumour but also in distant parts. Cases have been described in which, after rupture of a teratomatous cyst, numbers of small epithelial growths with hairs have formed upon the peritoneal membrane. It is probable also that some instances in non-ovarian abdominal teratomata have been formed by peritoneal implantation from ruptured cystic ovarian teratomata. The rupture of a malignant ovarian cyst is followed by rapid spread of the growth to the surrounding peritoneum. It is now well established that in non-malignant cases of peritoneal implantation, spontaneous disappearance of the peritoneal growths occurs after removal of the primary tumour.

(4) **Adhesions.** Plastic peritonitis may occur around an ovarian tumour in consequence of axial rotation or infection, as has been already mentioned. Many tumours become adherent, however, in which these changes have not occurred. Small growths lying in the pouch of

Douglas are more often found to be adherent than larger ones occupying the abdominal cavity. Coincident disease, such as appendicitis, salpingitis or pelvic peritonitis from uterine infection, is the usual explanation of the formation of the adhesions. In some instances the unaltered tumour may itself cause sufficient peritoneal irritation to produce the same result without the aid of bacterial infection; cystic teratomata are believed to be especially liable to form adhesions in this way. On the other hand, solid tumours, such as fibromata,

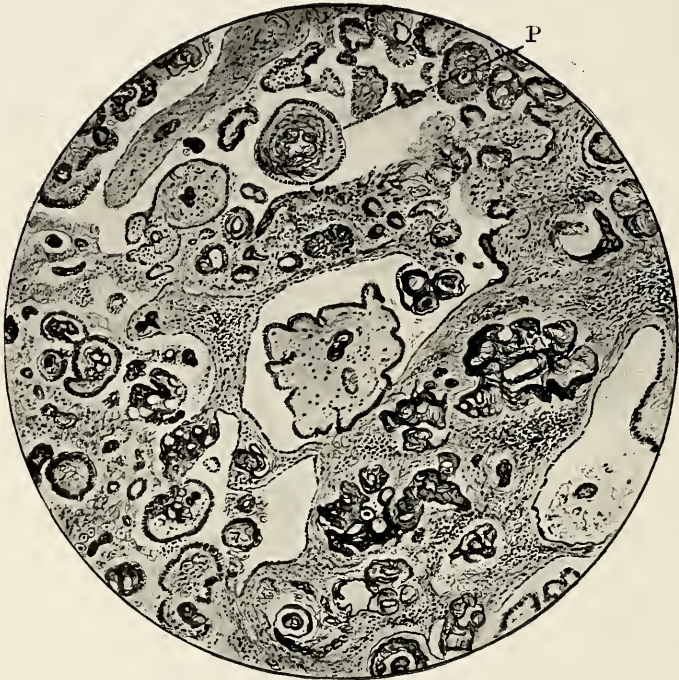


FIG. 405. PAPILLIFEROUS OVARIAN CYST,  $\times 105$ , which has undergone psammomatous change. P, Psammoma-body.

become adherent more rarely than cystic tumours, though the amount of peritoneal irritation which they cause must be greater.

Adhesions result in more or less complete fixation of the tumour; when thus confined in the pouch of Douglas it is often spoken of as 'incarcerated.' Adherent pelvic tumours cause pain and usually menorrhagia; and there can be no doubt that the formation of adhesions increases the urgency of the symptoms to which these tumours give rise. Operative difficulties may also arise from adhesion of coils of intestine to the growth.

(5) **Malignant Degeneration.** The occurrence of carcinomatous or sarcomatous changes in the wall of an innocent ovarian cyst has been described in another place.

(6) **Degeneration-Cysts in Solid Tumours.** Cystic cavities are frequently met with in the interior of both innocent and malignant solid tumours. They result from myxomatous degeneration or coagulation-necrosis; their walls are ragged and irregular, their fluids contain altered blood and tissue-debris, and they possess no epithelial lining. It will be recollected that similar cysts are frequently found in fibroid tumours of the uterus (*see* p. 446).

(7) **Psammomatous Degeneration.** The occurrence of this curious change is rare in ovarian cysts. Globular bodies composed (according to the analysis of Lassaigne) of cholesterin, albuminous matter, and sub-phosphate of lime, are formed in the stroma of papilliferous cysts. These bodies may be hard or soft, according to the amount of earthy deposit they contain. On section they show a laminated structure (*see* Fig. 405).

## CLINICAL FEATURES OF OVARIAN TUMOURS

Exact pathological diagnosis by clinical methods is at present impossible, but careful consideration of each case will usually admit of its being allotted to one of three classes, viz.: (a) *Benign cystic tumours*; (b) *Benign solid tumours*; (c) *Malignant tumours*. The clinical features will therefore be considered in relation to each of these three classes in turn.

The age-incidence of ovarian tumours generally is very wide; they may occur in the foetus, or they may first be recognized in extreme old age. Operations for their removal have been undertaken with comparative frequency in children under twelve years of age, and in a few cases, infants under two years of age have been surgically relieved of these growths. Sir John Williams showed from a study of statistics, now thirty years old, that ovarian tumours occurred with decidedly greater relative frequency in unmarried than in married women.

### Benign Cystic Tumours

**Symptoms.** Uncomplicated, innocent ovarian cysts produce few symptoms, those met with being mainly due to their *size*, their *position*, or to *secondary changes* which have occurred in them. Their presence does not necessarily affect either of the ovarian functions of menstruation or ovulation, as, even when they are bilateral, a certain amount of active ovarian tissue persists. They do not as a rule cause pain, nor do they affect the general health until they have reached a large size. As a rule their rate of growth is comparatively slow, although more rapid than that of fibroids. Teratomatous cysts often remain stationary for long periods. As a result of secondary changes they may rapidly increase in size. An ovarian cyst may accordingly attain a large size before the patient's attention is attracted

to it, and then it may be only the abdominal enlargement of which she complains.

The *position* occupied by the tumour is, however, an important factor in the case. Small tumours not exceeding the size of a cricket-ball are usually found in the pouch of Douglas, into which they sink by gravity. When exceeding this size they generally rise above the pelvic brim into the abdominal cavity, where they ride free among the viscera. If the ascent of such a tumour is prevented by absence of a pedicle, or by any other cause, pain usually supervenes, being due in part to crowding of the pelvic viscera proper, in part to disturbance of the pelvic circulation, and sometimes to direct pressure upon the nerves which pass out through the sacro-sciatic and obturator foramina. It is very uncommon for ovarian cystic tumours in the pelvis to cause retention of urine from pressure on the urethra or the neck of the bladder, but frequency of micturition is commonly observed in such cases. The rectal functions are not disturbed, but menstruation may become more painful and more profuse than usual, probably as a result of obstruction to the venous return from the uterus by pressure on the bases of the broad ligaments. If adhesions are formed, the tumour may become a source of pain, aggravated by menstruation, by exertion, jolting, coitus, and constipation.

Ovarian cysts which have risen into the *abdominal cavity* proper, give rise to far less trouble than those detained in the pelvis. They do not cause pressure-symptoms until they are large enough to fill the greater part of the abdomen and stretch the abdominal walls; in extreme cases they may, however, displace the diaphragm upwards and embarrass the action of the heart and the respiratory movements, and also obstruct the circulation through the great abdominal veins, thus leading to hæmorrhoids, and to œdema of the lower extremities. Even in the case of the largest cysts the amount of œdema is not extreme, owing to the development of a collateral circulation by way of the veins of the abdominal parietes (Fig. 406). In cases such as these, the general health may become profoundly deteriorated; emaciation may be extreme, resembling that found in the late stages of cancer, and clinical observers of fifty years ago were accustomed to describe an 'ovarian facies' in such cases—a peculiar sallow tint of the skin, with an expression of weariness and suffering. Owing to the popularization of the operation for removal of ovarian tumours, cases are now very rarely allowed to reach this advanced stage before surgical relief is obtained.

**Physical Signs.** When *pelvic* in position a small ovarian cyst is inaccessible from the abdomen, but is recognized on bimanual examination as an oval or globular, tense, elastic swelling lying as a rule behind the uterus, which it displaces forwards. When uncomplicated, it is movable and not sensitive to touch. Its position is rarely exactly median, but it does not necessarily lie upon the side from which it



grows. The pedicle may be palpated bimanually when the local conditions are favourable; this is made easier by anæsthesia, or by pulling down the cervix with a volsella to put the pedicle on the stretch. Non-adherent cysts are movable independently of the uterus;



FIG. 406. LARGE OVARIAN CYST IN A COLOURED WOMAN AGED 47 (Hammond). The tumour contained  $16\frac{1}{4}$  gallons of fluid. Dilated subcutaneous veins are seen coursing over the abdomen. There is only slight œdema of the lower extremities.

adherent cysts are not, and care is then required in distinguishing them from uterine fibroids. The posterior surface of the cyst can be felt best from the rectum. Usually cysts of this size are regular in contour and uniform in consistence. Rounded tense projections due to the presence of daughter-cysts on the surface may, however, be found; sometimes a densely hard area may be felt at some part of the surface,

suggesting that the tumour is a teratomatous cyst containing a bony or cartilaginous plate in its wall.

Small ovarian cysts are occasionally found in the utero-vesical pouch instead of in the pouch of Douglas, in which case the uterus becomes partially or entirely retroverted. It is a curious and interesting point that an unusually large proportion of the tumours found in this situation are teratomatous ovarian cysts.

A *medium-sized cyst*, when *abdominal* in position or when extending from the pelvis into the abdomen, forms a well-defined, elastic swelling, with a surface generally smooth, but sometimes broken by rounded projections representing external clusters of daughter-cysts. It usually lies more to one side than the other, but it may be exactly mesial in position. It is freely movable and insensitive to touch; when the pedicle is long, the fingers can be passed below the tumour into the pelvic brim; usually, however, the tumour can be felt to pass deeply into the pelvis, the lower border being inaccessible. On percussion it is dull, except near the borders where the intestine usually overlaps it, giving a subresonant note. Tumours large enough to extend above the umbilicus may yield a fluid thrill, but this is not always the case; the production of a thrill depends upon the presence of a large cavity in the anterior part of the tumour; if no such large cavity is formed, a definite thrill cannot be obtained. Ovarian tumours are all dumb on auscultation. Bimanual examination will show that the uterus is distinct from the tumour; its position may be normal, but frequently it lies retroverted.

The flanks will usually be found resonant in uncomplicated cases, but when present, free fluid in the peritoneal cavity is significant, and the exclusion of ascitic fluid should always receive attention in examining a case of ovarian tumour. It must be recollected that free fluid may occur with papillary or teratomatous cysts, or any malignant tumour, or it may result from rupture of a pseudomucinous cyst.

*Very large cysts* which greatly distend the abdominal cavity are comparatively rare; they may, however, attain a size such as that shown in Figs. 406, 407, and 408. In the first of these three examples the tumour appears to be considerably larger than the patient's body; in such a case as this the entire abdominal wall including the flanks is protuberant, the two sides being usually unequal; the belly is pendulous (*see also* Fig. 407), the umbilicus is everted, the skin tense, and the subcutaneous veins may become distended. A fluid thrill will be readily obtained in all directions; the greater part of the abdomen is quite dull to percussion, the exceptions being the subcostal angle, where stomach resonance persists, and the outlying portions of the flanks, where a muffled colon-note can nearly always be obtained. When the patient lies on her side, the upper flank may become slightly more resonant, owing to sinking of the heavy tumour towards the dependent flank. The peri-umbilical area is always completely dull.

On vaginal examination the uterus is usually found either retroverted or prolapsed; it is very rare to find its position normal in the case of very large tumours. In these cases it is often very difficult to locate the body of the uterus except by introducing the sound, but this matter is not of great practical importance.

The diagnosis of the *side* from which the tumour arises is also a matter of small importance; three points serve as guides, viz. the lateral inclination of the tumour (which, however, is sometimes misleading), the position of the pedicle, and the palpation of a normal ovary upon the unaffected side, which, however, is rarely practicable without anæsthesia.

Sometimes the *intraligamentary situation* of the tumour can be recognized; when, as occasionally happens, such tumours have a pedicle, they cannot be distinguished from others. An intra-ligamentary growth tends to displace the uterus to the opposite side of the pelvis (see Fig. 433, p. 760); this displacement chiefly affects the body, but the cervix is also to some extent affected. Further, intraligamentary tumours are less freely movable than others, and often they tend to burrow, so that their deepest part lies unusually low down, and may pass behind the cervix under the floor of the pouch of Douglas.

**Differential Diagnosis of a Benign Ovarian Cyst.** Differential diagnosis of an abdominal tumour is always a matter of difficulty and uncertainty, and many mistakes are made by the most careful diagnostician. Too many operators in the present day are ready to leave the question entirely until the abdomen has been opened. If a 'lump' can be felt, it is regarded as a sufficient reason for operation, and the nature of the lump can be inquired into by the pathologist after its removal. Such an attitude, if prevalent, would soon be fatal to the art of clinical diagnosis, and would reduce the surgeon to the intellectual level of a skilled artisan. Differential diagnosis is well worthy of careful study, not only because knowledge is an end in itself, but because it is in the patient's interest that the surgeon should fully understand her case. The preparations for an operation, the question of operability, and the prognosis, are points which require as full knowledge as possible of the condition to be dealt with.

(1) *Small cysts*, situated in the pelvis, when freely movable, may be confused on physical examination with (a) a *pediculated subperitoneal fibroid*; (b) an *inflammatory effusion*; (c) a *hydrosalpinx*, or *gravid tube*; (d) a *retroverted gravid uterus*.

(a) Careful examination should, in the case of the *fibroid*, demonstrate the immediate attachment of the tumour to the uterus, its hard, well-defined edges, and its solid consistence. It is very rare, although possible, for a subperitoneal fibroid to possess a pedicle long enough to be clinically recognized. Softening is very rarely met with in small fibroid tumours, except in pregnancy, so that the difference in consistence is a point of great practical importance. As fibroids are

usually multiple, and as interstitial or submucous growths usually accompany subperitoneal ones, menorrhagia may be a prominent symptom. Fibroids may, however, be found along with an ovarian cyst.

(b) A small ovarian cyst, when inflamed and adherent in the pouch of Douglas, may be difficult to differentiate from an effusion in the pouch, or from a swelling formed by inflammation of the tubes and ovaries. The special characters of these latter swellings have already been described (*see* p. 611).

(c) A *hydrosalpinx* can often be distinguished from a small ovarian cyst by its elongated or tortuous shape (*see* Fig. 326, p. 611). It must be recollected that rectal examination is of great value in the detailed examination of swellings occupying the pouch of Douglas.

A *gravid Fallopian tube* has been frequently confused with a small ovarian cyst. The chief guides in distinguishing the former are the coincident signs of pregnancy—amenorrhœa, breast changes, and softening of the cervix; except in a primigravida the two latter are not easy to recognize in the early weeks of pregnancy. The shape and consistence of the swelling is similar in the two cases; usually a pulsating vessel can be felt in the lateral vaginal fornix below a gravid tube, but this is not invariably present, and is sometimes felt under other conditions, especially when inflammatory changes are present.

(d) A *retroverted gravid uterus* is also most readily distinguished by the recognition of the accompanying signs of pregnancy. The consistence of the swelling in the pouch of Douglas is not unlike that of an ovarian cyst, and owing to the softening of the tissues of the isthmus, the cervix may appear to be movable independently of the swelling behind it. Attention should be paid to the position of the cervix, which is always *displaced upwards* and *directed forwards* to a greater or less extent. On the other hand, although a tumour in the pouch of Douglas may displace the whole uterus forwards, it does not alter the direction of the cervix; therefore forward inclination of the cervix indicates that the swelling in the pouch of Douglas is uterine. In all cases of doubt examination under anæsthesia will be helpful in demonstrating the continuity of the cervix with the swelling. This is easier when the swelling can be pushed up out of the pouch of Douglas.

(2) When the ovarian cyst is larger and lies in the *abdominal cavity* it offers an easy diagnostic problem, when the abdominal walls are thin, for the fluid consistence of the swelling, and the independence of the uterus can be easily recognized. In corpulent women it sometimes requires care to decide whether, or not, there is a tumour present, and many mistakes have been made, for an altogether abnormal amount of fat may be deposited in the abdominal wall and in the omentum.

(a) An *obese abdomen* is uniformly enlarged especially below the level of the umbilicus. The navel is depressed, as a rule abnormally so, while all large intra-abdominal tumours tend to evert it. On palpation

the definite outlines of a tumour are missing, and the observer must not be misled by what is called 'increased resistance.' The extreme thickness of the subcutaneous fat-layer can be demonstrated by pinching it up with the fingers of the two hands, and when this is present great care in diagnosis is obviously called for. A certain amount of general loss of resonance results from the thickness of the fat-layers, but on deep percussion a resonant note can be elicited. Examination under anæsthesia greatly assists the deep palpation of an obese abdomen, in a woman who from nervousness fails to relax her muscles.

(b) *Phantom* abdominal tumours are produced partly by a more or less involuntary depression of the diaphragm, and partly by gaseous distension of the intestines. Sometimes it is associated with amenorrhœa and other symptoms suggestive of pregnancy, when the name of *pseudocyesis* is applied to it. Unless associated with corpulency the abdomen remains resonant on percussion, and there is no excuse for the observer being deceived by this condition. Under anæsthesia it wholly or partly subsides, allowing the abdominal organs to be satisfactorily examined. Women of nervous temperament are more likely than others to present this form of abdominal enlargement.

(c) *Pregnancy*. If amenorrhœa from some intercurrent cause is present, the differential diagnosis from *pregnancy* may present difficulties. The chief reliance will then be placed upon the condition of the mammæ and the cervix, and the results of auscultation. Total absence of breast-changes, and of cervical softening, in connection with an abdominal tumour exceeding the height of the umbilicus, will serve to exclude pregnancy with practical certainty. The fœtal heart-sounds, if recognized, offer the most certain diagnostic sign. If any doubt exists a second observation after a fortnight's interval will demonstrate the increase in size of the gravid uterus at the usual rate—about one inch in fourteen days. Such rapid increase is quite unusual with ovarian cysts, except from axial rotation, or from intracystic hæmorrhage.

(d) On the other hand, the presence of menorrhagia from an intercurrent cause may suggest that the tumour is a *fibroid*. As a rule, the dense solid consistence and sharply defined margins of a fibroid tumour are easily distinguished from the elastic resistance and less sharply defined outlines, of an ovarian cyst. Felt through a very thick abdomen they are difficult to distinguish from one another by palpation; it is, however, rare for the mobility of fibroids to be so free as that of uncomplicated ovarian tumours. Chief reliance must be placed in such cases upon recognizing, by the bimanual examination, that in the case of the ovarian cyst the uterus is independent of the tumour. Difficulty may arise in the case of fibroids which have been softened by extensive degenerative changes, for their consistence may approximate to that of an ovarian or other cyst. But even fibro-cystic tumours of the uterus seldom have walls thin enough to allow a fluid

thrill to be felt, and the detection of the thrill in a doubtful case is decidedly in favour of the ovarian origin of the tumour. A *bruit* can often be heard over a fibroid tumour (*see* p. 474), but ovarian tumours are always silent on auscultation. Additional difficulties may arise from the co-existence of ovarian and fibroid tumours. When one or other tumour is of predominant size, the smaller is obscured and is often overlooked; the most important point is the want of uniformity in the consistence and character of the whole tumour, when carefully examined in detail. This should always suggest the possibility of the double nature of the condition.

Certain general considerations may assist the differential diagnosis of fibroid and ovarian tumours. Fibroids are of slower growth, and accordingly present a long clinical history of menorrhagia, and possibly of other symptoms, before they attain large size. Ovarian tumours are of more rapid growth, the duration of the symptoms is relatively short, and menorrhagia is quite an unusual result of their formation.

Many other forms of cystic tumours may occur in the abdomen, although much more rarely than cysts of the ovary; the more important are *mesenteric* cysts, *pancreatic* cysts, *renal* cysts (*see* Fig. 407), including hydronephrosis, *encysted peritonitic accumulations*, and *hydatid* cysts. These tumours are slow of growth and do not give rise to pain, as a rule, until they attain considerable size.

(e) *Mesenteric* and *pancreatic* cysts arise in the umbilical or subcostal zones of the abdomen (*see* Fig. 72, p. 115); when they have attained a large size they may extend downwards to the pelvic brim. They are often freely movable, but usually it is possible to make out that their point of attachment is in the abdomen, not in the pelvis. An ovarian cyst with a long pedicle, although it may be found in the umbilical zone, can be pushed down into the pelvis, unless it has become adherent in its altered position. Mesenteric and pancreatic cysts, even when freely movable, are tethered in the abdomen proper. On percussion, irregularly distributed areas of subresonance are found over these tumours, owing to loops of intestine crossing them.

(f) *Renal* cystic tumours, when of small size, may be found in the pouch of Douglas having been completely dislocated from their normal position, or possibly congenitally misplaced. When of larger size they may extend from the costal margin to the pelvis, and though definitely lateral in position, they may extend across the middle line to the opposite side. Usually large renal tumours pass deeply into the flank, and can be felt posteriorly upon one side or the other between the last two ribs and the iliac crest; this is quite unusual in the case of an ovarian cyst. As a rule the renal tumour is oval in shape, the long axis being usually oblique, and a band of partial resonance, corresponding to the colon, can usually be made out on its anterior surface. The affected kidney may be functionally inactive, secreting no urine,

a point which can be determined by cystoscopic examination of the bladder or catheterization of the ureters.

Occasionally a healthy kidney, or the healthy spleen, may occupy the pouch of Douglas; the nature of such cases can seldom be cleared up except by opening the abdomen.

(g) *Encysted collections of peritonitic fluid* are often tuberculous in origin. Signs of tubercle in other organs may then be present, suggesting that the abdominal condition is also of that nature. The other organs may, however, be free from disease, but irregular fever, wasting, and night-sweats may accompany the abdominal enlargement, when tubercle will naturally be thought of. In some cases, however, the abdominal enlargement is almost the only symptom present; amenorrhœa, however, occurs much more frequently than with ovarian cysts. In other cases the condition is septic in origin and may have followed labour or miscarriage (see p. 262).

The abdominal swelling is usually situated in the umbilical and hypogastric zones. It is ill-defined and only slightly movable, and is not entirely dull on percussion. These points are explained by the fact that the enclosing wall is composed of adherent viscera, of which a considerable part always consists of intestine. If it extends into the pouch of Douglas, the lower pole can be felt *per vaginam*; the body of the uterus has no independent mobility, being involved in the surrounding adhesions.

(h) *Hydatid cysts* may occur in the ovary, or the Fallopian tube, or in any part of the subperitoneal tissue of the pelvis. In the latter position they form fixed, diffused swellings which may attain large size and extend into the abdomen. Their nature may sometimes be surmised from a history of the previous occurrence of hydatids in the same subject; or they may discharge spontaneously through the bladder or bowel, when daughter-cysts and hooklets will be discoverable in the

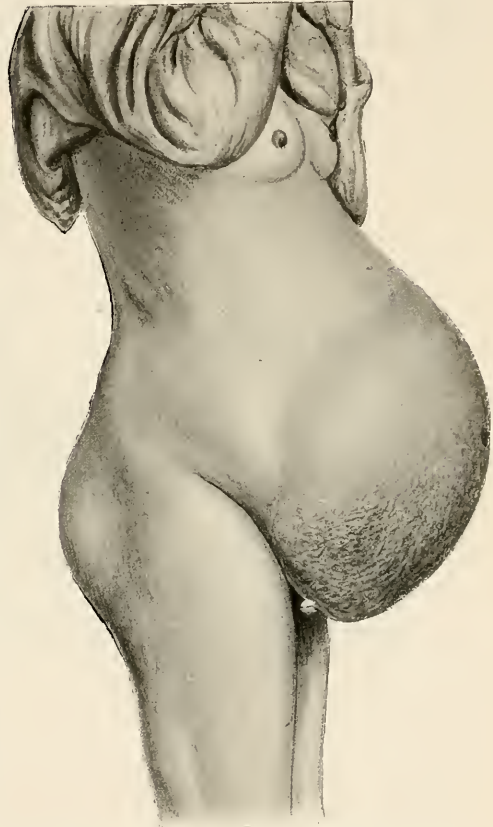

FIG. 407. LARGE CYSTIC KIDNEY SIMULATING AN OVARIAN CYST. Patient erect.

discharges. Apart from this, the specific serum-reaction is the only possible means of pre-operative diagnosis (*see p. 329*).

(3) *Very large abdominal cysts* must be distinguished from extreme degrees of *ascites*, whether simple or associated with intra-abdominal malignant disease, and from *fibro-cystic tumours* of the *uterus*. With the patient lying on her back, in *ascites* the clearest note on percussion is obtained around the umbilicus, the dullest note in the flanks; in ovarian cysts the converse is the case. In cases of *ascites* the distribution of dulness shifts readily with changes of posture, but with ovarian

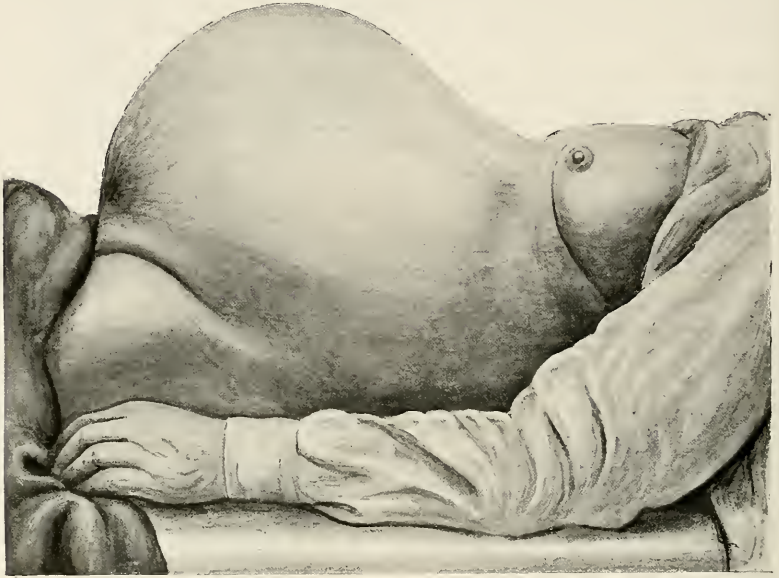


FIG. 408. LARGE FIBRO-CYSTIC TUMOUR OF THE UTERUS. Patient recumbent.

cysts dulness does not shift except to a very slight extent. In *ascites* some causal condition, such as cirrhosis of the liver, may be detected, or the presence of hard nodular masses in the abdomen may suggest advanced malignant disease with secondary deposits.

It is very uncommon for fibro-cystic tumours of the uterus to attain the enormous size of the largest ovarian cysts, and if it has been determined that the fluid is encysted and not free, the probability that it is ovarian is very high. Nevertheless numerous instances have been recorded in which a tumour of this character revealed itself as a fibro-cystic uterine tumour on opening the abdomen (*see Fig. 408*). The differential diagnosis is not of great practical importance, as the treatment in either case is to remove the tumour. Occasionally a renal cystic tumour may attain the size of the largest ovarian cyst, even to the extent of producing 'pendulous belly' (*see Fig. 407*); pre-



operative diagnosis is then very difficult. It may however be possible in the former to demonstrate the presence of a band of resonance crossing the tumour and corresponding to the position of the colon.

### Benign Solid Tumours

Like cysts, the innocent solid tumours of the ovary seldom give rise to direct symptoms until secondary changes occur in them. There is a somewhat greater tendency for bilateral fibromata to cause amenorrhœa by complete destruction of the ovarian substance than is the case with the cysts. They attract attention earlier than the cysts, from the inconvenience caused by their bulk and weight, and the amount of abdominal distension produced is frequently aggravated by the occurrence of ascites. Axial rotation occurs, but with less relative frequency than in the case of cysts.

On examination these tumours form oval, firm, insensitive swellings which have the same relations to the uterus as the cysts. Their dense consistence and sharply defined outlines are usually appreciable without difficulty, except in obese women. But generally speaking, these tumours are not so hard as fibroids of the uterus, and in some cases, from the occurrence in them of cystic degeneration, they may feel elastic or doughy on palpation. Free ascitic fluid can be detected clinically in a considerable proportion—probably one-third to one-half—of all cases; in considerably more than this, fluid is found, on operation, in quantity too small for clinical recognition. The clinical results of axial rotation and infection are much the same as in the case of cysts.

**Differential Diagnosis.** A solitary, pediculated, subperitoneal, fibroid tumour may be difficult to distinguish from an ovarian fibroma. If, however, the uterus is movable independently of the tumour, the latter is in all probability ovarian; and if the presence of ascitic fluid can also be made out, it becomes practically certain that the tumour is ovarian. Menorrhagia is not induced directly by either growth, but since fibroids are often multiple, an interstitial growth may be present along with the subperitoneal one, when the periods may be profuse. An ovarian fibroma may induce amenorrhœa when bilateral, but has no tendency to increase the menstrual flow. It is, however, quite possible in subjects of an ovarian fibroma also to find fibroid tumours in the uterus, when no assistance can be obtained in diagnosis from analysis of the symptoms. In the case of the fibroid tumour it may be possible, with the assistance of general anæsthesia, to recognize that both the ovaries are present and distinct from the tumour, when its ovarian origin can be definitely excluded.

### Malignant Ovarian Tumours

Ovarian tumours are more frequently discovered to be malignant after removal than recognized as such clinically. In the early stages,

malignant disease gives rise to no characteristic symptoms or clinical appearances; a tumour which on naked-eye examination after removal appears to be innocent may be demonstrated by the microscope to be malignant (*see* p. 676).

It is not too much to say that the absolute exclusion of malignancy is impossible before operation, for unilateral cystic growths of small size may be cancerous, and even cysts of large size which readily yield the signs of fluid contents, sometimes show limited areas of malignant change. The frequency with which ovarian tumours, removed by operation, are found to be malignant, therefore, becomes a point of considerable practical importance. It appears from the records of clinics that from *eight to ten per cent. are malignant*, and that in the case of solid or semi-solid growths the proportion is considerably higher than for the whole. In any case this relatively high malignancy-rate justifies the rule, that the removal of all ovarian tumours should be advised, quite independently of their clinical characters. At the same time, certain conditions may be recognized as indicating an increased probability of malignancy, and therefore as constituting *urgent indications for immediate operation*.

A solid ovarian tumour, associated with ascites and giving rise to considerable pain, may justly be suspected of being malignant, but from what has been said above with regard to pain and ascites, it will be seen that these points are by no means characteristic of malignant disease. Free fluid in company with a cyst may, however, be due to leakage of simple cyst-contents, or to the dissemination of a papillary growth over the peritoneum. The latter condition is not necessarily malignant (*see* p. 672). Ascites occurs in only about *fifty per cent.* of cases of ovarian cancer (Glendinning) and probably somewhat less frequently than this in sarcoma. In women over forty years of age, the significance of pain and ascites as indications of malignancy is greatly increased. Amenorrhœa is often, but not always, present, and indicates, in the early stages, that the disease is bilateral. Tumours of large size are, however, not infrequently accompanied by irregular bleeding from the uterus.

In cases of *secondary* ovarian cancer, and in the advanced stages of the *primary* disease, great and rapidly increasing abdominal enlargement is met with due in part to ascites, in part to the size of the ovarian growth, and in part to the formation of numerous visceral metastases. Pain, which is comparatively early in its appearance, grows severe as the enlargement of the abdomen becomes pronounced. Later still, general wasting and swelling of the feet occur, which appear the more striking as they are associated with great abdominal enlargement. These features are, however, common to the advanced stages of other forms of intra-abdominal malignant disease, and are not specially characteristic of ovarian cancer.

It must be recollected that in cases of secondary ovarian cancer

the tumour often greatly exceeds the primary growth in size, and may be met with at a time when few, if any, indications of the existence of the primary growth are to be found. Particular attention should, therefore, be paid, in cases of suspected malignant ovarian tumours, to the possibility of the presence of a primary growth in the stomach or intestine, or in the mamma.

Solid malignant tumours may arise in the omentum, the mesentery, or the pelvic cellular tissue, which closely resemble those of ovarian origin; all are usually secondary, not primary. Owing to their anatomical relations these growths rapidly infiltrate surrounding structures, and therefore tend to become fixed when comparatively small. Ovarian malignant growths, as has been explained, are at first encapsuled, and local infiltration cannot be observed clinically, until the capsule has been broken through; they therefore retain their mobility much longer than those of the mesentery or the omentum.

### The Diagnosis of Secondary Changes in Ovarian Tumours

When an ovarian tumour becomes troublesome by increasing rapidly in size, or by giving rise to pain, or when it first reveals its presence by the sudden onset of acute abdominal symptoms, it is certain that some degenerative change has set in, or that the growth is malignant. The clinical features of secondary changes are therefore of great interest and importance.

**Axial Rotation.** The clinical results of axial rotation depend in the main upon the rapidity with which rotation occurs, and upon its extent. Rotation not exceeding one-half of a circle, found upon operation, has often been unsuspected clinically, and probably gives rise to no symptoms. When exceeding half a circle, severe symptoms are not in all cases produced, but the tumour may increase rapidly in size and become sensitive to touch, and may give rise to pain. These symptoms in the case of a presumptively innocent cyst always suggest axial rotation. It is probable that only an extensive twist, rapidly produced, gives rise to *acute abdominal symptoms*. Sometimes these are sudden in onset, the patient being unexpectedly seized with severe abdominal pain and vomiting; more often the onset is gradual and the symptoms consist of increasing abdominal pain, with distension and tenderness, and usually a moderate amount of fever. The acute symptoms may last for several days, during which the abdominal distension increases, mainly owing to the progressive increase in size of the tumour, which is caused by the rotation (*see p. 703*). In the majority of cases the acute symptoms subside spontaneously, but, as has already been pointed out, very serious results, such as rupture or gangrene of the cyst, may ensue.

The *diagnosis* in acute cases is made by discovering the tumour; owing to the distension and tenderness this may be difficult, and even when a tumour has been known to exist and can be felt, detailed

examination is impracticable. But the association of an abdominal or pelvic tumour with the symptoms just described is, of itself, almost a sufficient warrant for the diagnosis of axial rotation; rotation of a fibroid tumour may also produce acute symptoms of a similar nature, but this accident is very much more frequent with ovarian than with uterine tumours. It will be recollected, also, that ovarian tumours are especially prone to this accident during pregnancy or the puerperium.

*Treatment.* Ovarian tumours which have become twisted should be removed without unnecessary delay. It is not, however, necessary to operate during the stage of acute pain and fever, for these symptoms almost invariably subside spontaneously, and the operation can then be performed with less risk to the patient. If the symptoms do not subside in two or three days, further delay is, however, inadvisable.

**Inflammation and Infection.** Ovarian tumours which become inflamed are usually of small size, and are confined in the pelvic cavity, the two chief sources of infection being the bowel and the uterus. The formation of adhesions around such tumours necessarily follows. They then invariably give rise to pain aggravated by exertion, by jolting, and sometimes by coitus. The adhesions may be gradually produced without any acute attack of pain or illness; sometimes, however, the onset is acute, the patient being confined to bed for a few days, and thereafter complaining more or less constantly of pain. The clinical features accordingly closely resemble those of a case of inflammation of the uterine adnexa (*see p. 627*). On examination, tumours thus affected are sensitive, unusually tense, and their mobility is more or less completely lost.

When small cysts of this kind undergo *suppuration*, a dense inflammatory deposit is thrown out around them, which results in absolute fixation of the swelling, and obscures its outlines and characters. There is no means of distinguishing, in such cases, a pyosalpinx from a small, suppurating ovarian cyst (*see Figs. 354 and 352*). Large cysts are comparatively rarely the seat of suppuration. Well-marked constitutional disturbance, with rise of temperature, results from suppuration when the infective process is acute; this is, however, relatively rare, the infective process being much more often chronic. In cases of the latter class, the tumour is usually so effectually isolated by plastic peritonitis, that absorption from it is more or less completely prevented, and constitutional symptoms are accordingly slight in extent or entirely absent. The pus from such tumours may prove to be sterile on bacteriological examination.

As felt through the abdominal or vaginal wall, the swelling is densely hard and quite fixed; its cystic nature may be by no means evident. It is then difficult to differentiate it from other forms of *pelvic abscess*; this point has already been referred to on p. 632.

**Ovarian Tumours and Pregnancy.** The association of pregnancy with a single ovarian cyst of moderate size is so frequently observed, that the conclusion may be drawn that the presence of such a tumour offers little hindrance to conception. Bilateral tumours form a more serious obstacle to pregnancy, and are therefore seldom observed with it. Solid ovarian tumours being of much rarer occurrence than cysts, are much less frequently met with in pregnancy, but the presence even of a malignant ovarian tumour does not necessarily prevent the occurrence of conception. An interesting and important point in connection with the *character* of the ovarian growth complicating pregnancy is the frequency with which teratomatous cysts are found. Of 862 cases collated by McKerron 204, or nearly 1 in 4, were of this nature. McKerron's estimate has more recently received confirmation by the publication of forty-one cases operated upon by H. R. Spencer. Of these twelve (29·25 per cent.) were teratomatous cysts. This frequency is explained by the fact that this type of cyst is usually small and gives rise to no, or to few, symptoms; they therefore remain long unobserved in the pelvis. When pregnancy occurs they suffer injury which leads to their detection. As a complication of pregnancy teratomatous cysts are more dangerous than simple cystomata for the following reasons: (1) Their greater tendency to remain in the pelvis; (2) their greater liability to cause peritonitis; (3) their proneness to suppuration (McKerron).

Ovarian tumours do not unfavourably affect the course of pregnancy or tend to induce abortion. When of small size their presence may be completely overlooked until labour is over, and even in the puerperium they may not be detected unless some secondary change such as axial rotation occurs in them. When lodged in the pelvis, they cause pressure-symptoms during the later months of gestation, and this leads to their discovery; but not uncommonly it is the obstruction offered by such tumours to delivery, which first reveals their presence.

When a large ovarian cyst lying in the abdomen, is associated with a gravid uterus of similar size, the diagnostic problem is often somewhat difficult of solution. The abdomen is much larger than is appropriate to the period of amenorrhœa; usually the uterus and the tumour lie side by side, and the presence of an oblique sulcus, or depression, indicates that the swelling consists of two parts; in one half of the swelling the signs of pregnancy appropriate to the period of gestation will be found, in the other half these will be absent. When one is much larger than the other, the smaller may escape recognition, and the case is regarded as a simple instance of pregnancy or of ovarian cyst. Great difficulty will be often experienced in distinguishing an ovarian cyst from a subperitoneal fibroid under these circumstances, as the latter may become so much softened during pregnancy as closely to resemble the former in consistence.

Pregnancy does not affect the rate of growth of ovarian tumours,

but definitely increases the risk of occurrence of certain secondary changes in them. Thus *axial rotation* is found to have occurred in about 6 *per cent.* of ovarian tumours removed during pregnancy (Sir John Williams), as compared with a general incidence of 2 *per cent.*; the risk of *rupture* is even more considerably increased, the percentage-occurrence, according to the same observer, being about 10 *per cent.*, the greater number of which occurred during or after labour. In the puerperium there is also the increased risk of suppuration from spread of infection from the uterus.

### TREATMENT OF OVARIAN TUMOURS

Treatment is entirely surgical. No means are known by which the growth of these tumours can be in any way influenced, nor does age in any way affect them, as is the case sometimes with uterine fibroids. Inasmuch as exact diagnosis of the pathological nature of the tumour is impossible, there should be no delay in their removal. Tumours which give rise to no clinical suspicion of malignancy, may prove to be malignant on microscopic examination. Their liability to become twisted, or infected, supplies a further reason for their prompt removal. Ovariectomy is one of the most successful of abdominal operations, and may be undertaken with confidence, even in childhood, or in advanced age; the co-existence of pregnancy scarcely, if at all, affects the prognosis of recovery from the operation. The tapping of any large ovarian cyst is not generally advisable. This procedure may, however, be desirable in cases of extreme cardiac embarrassment, as a means of temporary relief to the circulation, and should be followed as soon as may be by removal of the tumour.

Small non-adherent cystic tumours may be removed by colpotomy (*see p. 777*), but the abdominal operation is to be advised in all cases of large tumours, or of those believed to be extensively adherent, or suspected of being malignant.

Ovarian tumours which cause obstruction during labour by lying below the presenting part of the fœtus, may often be pushed up above the pelvic brim if labour has not advanced too far and the presenting part is not jammed in the pelvis. The attempt should be made under anæsthesia, and great assistance can be obtained by placing the patient in the Trendelenberg position. The child is then delivered as soon as possible with forceps. Bruising of the cyst-wall almost inevitably occurs under these circumstances and the tumours should therefore be removed within forty-eight hours of delivery.

If during labour the ovarian tumour is found to be immovably fixed in the pelvis immediate removal by abdominal operation is indicated. It will be necessary to turn the gravid uterus out of the abdomen in order to obtain access to the tumour in the pouch of Douglas, and accordingly it is best to deliver the child by Cæsarean section before dealing with the tumour.

**PART III**  
**OPERATIVE GYNÆCOLOGY**





## PART III

SECTION I : TECHNIQUE ; SECTION II : OPERATIONS ;  
SECTION III : AFTER-TREATMENT

### TECHNIQUE

OPENING the peritoneal cavity by incision of the abdominal wall (*abdominal section, laparotomy, cœliotomy*) or of the vaginal fornices (*colpotomy*) is the first step in the performance of a number of operations to be described in the succeeding pages. It will be convenient, and will serve to avoid repetition, if certain points in the technique, and in the general management, of all operations which involve a preliminary opening of the peritoneal cavity are considered together.

#### PREPARATION OF THE PATIENT

Except in surgical emergencies, from thirty-six to forty-eight hours rest in bed before operation should be insisted upon ; this interval may be used for the examination of the urine, and of the digestive system, the lungs and circulatory system. The presence of a moderate amount of albumen or sugar does not form a contra-indication to abdominal operation ; advanced Bright's disease or advanced diabetes do so, however, as a rule. Urinary infections should be carefully treated before all pelvic operations ; operative disturbance of the bladder may lead to an outbreak of acute cystitis in such cases.

One of the first requisites is careful preparation of the alimentary canal. In this connection, the importance of oral sepsis must not be overlooked, for this condition increases the severity of post-anæsthetic vomiting by producing chronic irritation of the gastric mucous membrane, and it also increases the difficulty of feeding ; further, it may become the cause of septic pneumonia if infective material is drawn into the air-passages during anæsthesia. Carious teeth, and suppurative conditions of the gums, should therefore be first attended to, if the operative conditions are not urgent. The diet should be simple and non-stimulating in character and restricted in amount. Purgation *immediately before operation* is to be avoided ; it is better to give a mild aperient on two occasions three and two days before the operation ; an enema on the night preceding the operation will then suffice to clear the colon. A drastic purge given the night before the operation produces marked depression, at a moment when the vitality should be conserved. The advantages of these careful preparations are (1) coils

of intestine are found empty at the operation ; (2) stagnant contents are removed which might be a source of danger during convalescence.

In the case of patients of low vitality the administration of strychnine, either hypodermically or by the mouth, for several days before operation is of distinct prophylactic advantage in diminishing post-operative shock. In the case of an operation which it is anticipated may be prolonged or severe, a hypodermic injection of hyoscine and morphine, morphine and atrophine, or of all three, may be given three-quarters of an hour before the operation. The doses given of these combinations are hyoscine gr.  $\frac{1}{100}$ , morphine gr.  $\frac{1}{6}$  to  $\frac{1}{4}$ , and atropine gr.  $\frac{1}{20}$ . A comfortable drowsiness is thereby induced which obviates the extreme apprehension with which many nervous women await the commencement of an operation. Further, it diminishes the amount of anæsthetic which is required, reduces post-operative vomiting and pain, and in our experience has greatly reduced the frequency of post-anæsthetic bronchitis and pneumonia, the latter results being probably explained by the diminution which these drugs produce in the secretions of the respiratory mucous membranes.

The conventional view that abdominal operations upon the pelvic organs should not be performed during a menstrual period is a concession to sentiment, and not the expression of a surgical necessity. The presence of menstruation does not in any way complicate the operative procedure or disturb the convalescence ; it is therefore unnecessary to postpone a proposed operation on account of the unexpected appearance of menstruation.

### GENERAL CONDUCT OF THE OPERATION

The operator is personally responsible for everything connected with the operation, although much of the work is actually delegated to his assistants. Apart from the primary object of the operation, there are certain matters of the highest importance which must always be kept in view : (1) the prevention of infection ; (2) the safe conduct of anæsthesia ; (3) the prevention of post-operative shock. Upon due attention to each of these matters will often depend both the immediate success of the operation, and the favourable progress of convalescence.

**The Prevention of Infection.** This is in many respects the surgeon's chief concern, and that which involves the greatest responsibility, for failure may be attended with fatal consequences. Within the limits of this chapter it is impossible to discuss the general bearings of bacterial infection, and the principles underlying antiseptic and aseptic methods. It is now generally agreed that absolute asepsis, *i.e.* a bacteria-free operative environment, is practically impossible of attainment. Fortunately it is not essential to success, as all healthy tissues have the power of disposing of a certain number of organisms

which may obtain access to them. The peritoneum probably possesses this power to a greater extent than any other tissue.

The atmosphere cannot be excluded, and in a room occupied by living persons it always contains organisms suspended in particles of saliva driven from the mouth and air-passages during breathing, talking, coughing, etc. Further, the skin and all mucous membranes are to be regarded as surgically 'infected' tissues, since in health they harbour organisms capable of setting up infection when transplanted to other parts, *e.g.* the deeper layers of a wound. When, as is often the case, the tissues in the neighbourhood of the operation are infected, the difficulties are much increased.

The practical aim of the surgeon, therefore, is to sterilize the operation-area itself as far as may be, and to prevent as far as practicable any bacteria from being introduced into the wound either directly by instruments and appliances, or indirectly through the air.

**The Operation-Area.** The technique to be followed is somewhat different in the case of abdominal and vaginal operations.

The *abdominal wall* should be prepared twelve hours before operation by shaving the pubes down to the level of the folds of the clitoris, and thoroughly cleansing with spirit-soap and water; special attention must be paid to the umbilicus. The difficulties of sterilizing skin are well recognized, and some surgeons have abandoned the attempt to do so, relying solely upon simple cleansing of the abdominal wall; they regard antiseptic solutions as being ineffective for sterilization, and objectionable from diminishing the vitality of the tissues. The majority of surgeons, however, are of opinion that the risks of skin-suppuratation cannot be met except by the use of antiseptics. Our practice is, after the preliminary cleansing just described, to have the skin firmly rubbed with swabs soaked in ether or acetone in order to remove accumulations of fatty material from the glands, and then to paint the whole abdominal surface freely with a 2 per cent. watery solution of iodine, or with tincture of iodine. The whole abdominal area, including the groins and the flanks, should be dealt with in this way. A sterile dressing is applied and the painting of iodine repeated after the patient has been anæsthetized.

The *vulva* and *vagina* present unusual difficulties to efficient sterilization, owing to the constant presence of secretions, and the proximity of the urinary and anal apertures. The bacterial flora of the vulva are abundant and varied (*see* p. 232); the dense hairy covering, and the abundance of sweat and sebaceous glands, place further difficulties in the way of effective sterilization. If healthy conditions prevail, the bacteria present are probably not of great pathological significance, but if the conditions are diseased, pathogenic organisms of high virulence may be present, the destruction of which will be very difficult.

In the case of abdominal operations preparation of the vulva and vagina is not, as a rule, necessary. In some, *e.g.* in panhysterectomy

when the vagina is laid open from above, and in cases where the vagina is to be opened for drainage, the preparation of the canal is a matter of considerable importance. It is better not to omit the preparation of the vagina in all circumstances in which there is the possibility of having to open the vaginal vault.

When operations upon the cervix, vagina or vulva are to be undertaken, of course the necessity of preparation is sufficiently obvious. Plastic operations such as those for prolapse, and for repair of the cervix, depend largely for a successful result upon careful preparation.

It is of especial importance, in such procedures as perineorrhaphy when the anal canal is involved, to make sure that the rectum is empty

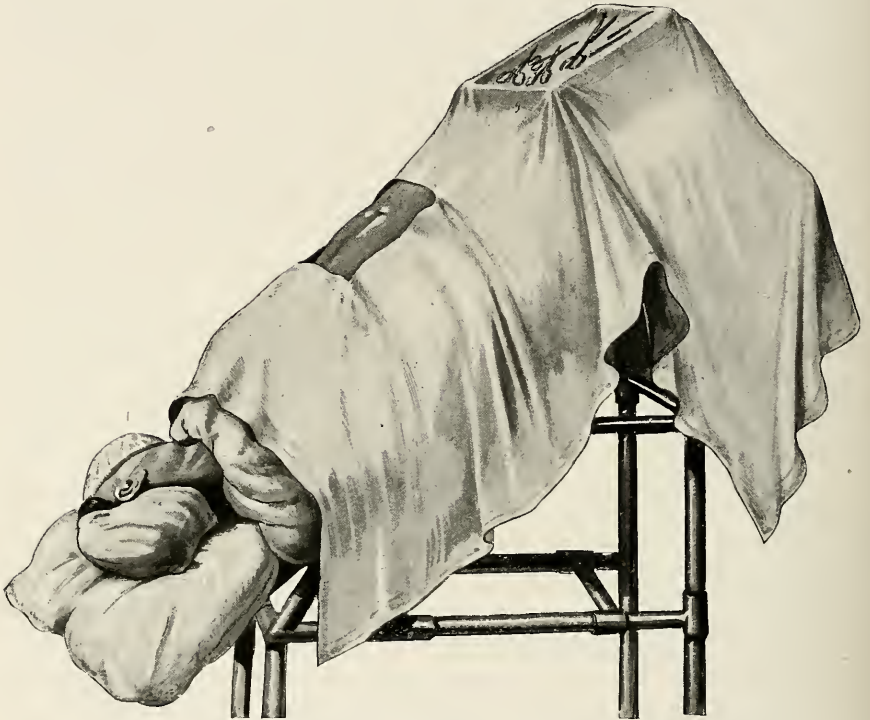


FIG. 409. THE TRENDELENBERG POSITION; patient ready for operation

at the time of operation, and a modification of the usual procedure will be found advisable. This consists in the administration of a quarter of a grain of opium in pill, or a full dose of the *Mist. Catechu*, c. *Opio* B.P. after the enema has been given on the night previous to the operation. This will arrest peristalsis for the time being, and thus prevent the contents of the upper part of the colon from making their way into the rectum. This is much better than repeating the enema an hour or two before the operation, which excites peristalsis in the colon at a time when it is desirable to suppress it. In this manner soiling of the field of operation can best be avoided.

Vulva and pubes should be completely shaved, and the skin prepared with spirit-soap. The vagina cannot be prepared by douching alone, although this is useful in removing secretions. Disinfection must be carried out under anæsthesia immediately before the operation is begun. The iodine method yields good results, the watery or alcoholic



FIG. 410. THE POSITION AND COVERINGS FOR A VAGINAL OPERATION.

solution being rubbed firmly, first into the vaginal walls with the aid of a speculum, and then into the skin of the labia, perineum, and inner aspects of the buttocks and thighs.

It is generally speaking undesirable to perform plastic vaginal operations during menstruation; when the secretions are obviously unhealthy, *e.g.* purulent or offensive, such operations are absolutely contra-indicated until healthy conditions have been restored.

**The Isolation of the Field of Operation.** The operation-area having been thus prepared as far as possible, it is important that, during the

operation, this part of the body should be so surrounded by sterile protective coverings that it is completely shut off from other parts of the body, or of the body-coverings. This is effected by covering up the entire surroundings of the 'field' with sterilized cloths and waterproofs. The general arrangements are sufficiently indicated in Figs. 409 and 410, which show the patient in position for an abdominal and for a vaginal operation. In vaginal operations it is important that the anus should be covered with a waterproof-dressing fixed with stitches or clips to the surrounding skin.

### PREPARATION OF INSTRUMENTS, SWABS AND LIGATURES

*Swabs and compresses* should be made of gauze or Gamagee tissue, which is now almost universally used instead of marine sponges. In abdominal operations two large compresses (ten inches to twelve inches square), or several loosely rolled pieces of gauze six yards long and four to six inches wide, are required for *packing*, *i.e.* for isolating the pelvic area from the upper abdomen and its contents. For taking up blood and for general cleansing, it is best to provide a large number of smaller gauze swabs three to four inches square. All should be used wrung out of warm, sterile, saline solution, and discarded when soiled. They must be carefully counted before and after the operation, and for this duty the operator is responsible. Supplies of swabs, dressings, towels, aprons, etc., sterilized by steam under high pressure, and preserved in hermetically sealed tins, can now be obtained from surgical instrument makers, and may be used with confidence when supplied by firms of repute.

*Instruments and Ligatures.* Instruments should be boiled for at least ten minutes *immediately before* the operation; sharp instruments may be immersed in 1 in 20 carbolic solution or in methylated spirit for a quarter of an hour, instead of boiling, which blunts them. If silk or linen-thread ligatures are employed, they should be *boiled for an hour* before use; a second boiling for ten minutes immediately before the operation is also desirable. It is desirable to work with ligatures as fine as possible consistently with good hæmostasis. Number four silk is quite strong enough, when properly treated, to hold the thickest ovarian pedicle.

The great majority of surgeons prefer to use an *absorbable* material for the general purposes of a ligature, and catgut is the only material of the kind which is available. The sole disadvantage of catgut is that its preparation and sterilization are difficult and complicated. The raw gut obtained from manufacturers may contain living bacteria in its substance, which being liberated when the ligature is absorbed by the tissues, may set up infection. In a few cases post-operative tetanus has in this way been caused. It is well known that the tetanus bacillus is present in the fæces of most animals. As catgut cannot be

boiled in water without destroying it, chemical methods of sterilization have to be employed. Further, for many of the purposes served by a ligature it is desirable that absorption should not be rapid; thus stitches placed in the aponeurosis in closing an abdominal incision should be able to resist absorption, and retain their strength, for fourteen to twenty-one days. Unless specially prepared for this purpose, catgut will not resist so long. It must, therefore, be artificially hardened. The complete process accordingly consists in first permeating the whole substance of the gut with an efficient antiseptic, and for this purpose iodine or carbolic acid is usually employed. The sterile gut is then subjected to the hardening reagent, which is either formaldehyde or bichromate of potash. Finally the prepared gut is stored in sealed packets (dry) or in alcohol.

### ANÆSTHESIA

The anæsthetic most suitable for abdominal work is ether given by the 'open' method. The previous administration of narcotics as advised above is of great advantage for the reason already given (p.726). Post-operative vomiting is probably less severe after this method than any other. In patients suffering from chronic bronchitis, chloroform may be substituted. The important details of administering anæsthetics cannot be discussed in this work; it is advisable always to entrust this part of the operation to the most experienced person available.

Under some conditions it is well to combine local anæsthesia with the general anæsthetic, or to operate by local anæsthesia alone. The combination of the two after the manner which has been popularized by Crile under the name of "anoci-association," is of great advantage: (a) by 'blocking' the efferent nerve-impulses from the operation-area, which are concerned in producing that effect upon the central nervous system which is called *shock*; (b) by diminishing the amount of anæsthetic required, the toxic effects of general anæsthesia, which are so unfavourable in septic conditions, are lessened or avoided. The method consists in the infiltration of the tissues with a weak solution of novocain or quinine-urea-hydrochloride *before they are incised* by the operator. In the process of opening the abdomen, the skin and fat are first infiltrated, then divided; the same procedure is then applied in turn to the musculo-aponeurotic layers, and to the peritoneum. During the internal manipulations, the broad ligaments, for example, may be infiltrated before they are clamped and divided, as is done in hysterectomy.

In certain cases a general anæsthetic, even in reduced amount, is contra-indicated, and then the best method is that of intradural (spinal) anæsthesia, stovaine being the best agent to employ for this purpose. Thus, in cases of cardiac disease with failure of compensation, in acute ileus, and in eclampsia, spinal anæsthesia is the method

of choice. In the case of a limb the anæsthetic may be injected directly into the nerve-trunks, but in abdominal work this is not practicable. For the details of these methods other works must be consulted.

### GENERAL MEASURES FOR THE PREVENTION OF SHOCK

It is of great importance that the atmosphere of the room in which the operation is performed should be well-warmed, the temperature being about 70° F. In addition, the body-heat of the patient should be conserved as far as possible by proper coverings, by avoiding unnecessary soaking of the coverings with fluids, and when possible, by keeping the operating table warm; this may be done by an electric heater, or by cans of warm water placed beneath the surface of the table. In prolonged operations Arbuthnot Lane advises the use of continuous subcutaneous saline transfusion, and in specially debilitated subjects this may be advisable. Finally, the *method of operating* is a factor of great importance from the point of view of shock. Rapidity, gentleness in manipulation, careful protection of exposed viscera, and prompt control of hæmorrhage will often allow of the most formidable operations being carried out without any marked degree of shock.

### THE OPERATOR AND ASSISTANTS

As a general rule the fewer persons concerned in the performance of an operation the better; one experienced assistant is essential, but for rapid work two or three assistants, each knowing exactly what is expected of him, are necessary. The operator is personally responsible, and one of his pre-occupations is to watch the work of his assistants. The same routine of preparation should be followed by all concerned.

*The sterilization of the hands* of all persons actually engaged in the operation is an important detail which demands the personal attention of the operator. The following method, which has been subjected to repeated bacteriological tests by different observers, may be confidently recommended: (1) the nails must be short and the skin of the hands intact; (2) the hands and forearms should be scrubbed with a freshly boiled nail-brush, in hot water and soap, for at least ten minutes; ether-soap or spirit-soap may be employed at this stage as solvents of fatty matter; (3) after removing the soap with fresh water, the hands and forearms should be immersed in a watery solution of 1 in 1000 biniodide of mercury for two or three minutes, and then rubbed over with a swab soaked in another solution of biniodide of mercury in diluted alcohol (75 per cent.), the proportion of biniodide being 1 in 500; (4) the hands thus sterilized should be immediately covered with sterilized rubber gloves. If boiled, the gloves can be most conveniently put on by filling them with boiled water or a weak solution of



biniodide of mercury. It is more convenient to use dry sterilized gloves which can be readily slipped on with the aid of sterilized French chalk. Biniodide is preferred to perchloride of mercury as being a more powerful germicide, and as penetrating the skin more readily owing to its not coagulating albumen, as is the case with the perchloride. The wearing of gloves does not obviate the necessity of careful sterilization of the hands, for gloves are sometimes punctured or torn during the operation.

Sterilized gowns or blouses, and a covering for the head which completely covers the hair, the nose, and the mouth, leaving the eyes alone free, should be worn by the operator and his assistants.

### GENERAL CONDUCT OF THE OPERATION

*Position.* For all operations on the pelvic organs, the inclined, or Trendelenberg position is of great assistance (*see* Fig. 409); it allows of the intestines being withdrawn from the operation-area, and kept out of the way; and further, by raising the pelvis, it brings the contents of this cavity into easier reach. In the case of stout persons it somewhat embarrasses the action of the diaphragm, and so impedes aeration of the blood, with the result that marked cyanosis supervenes, but this condition when carefully watched is not of serious moment.

The *incision* which is most generally useful is the median, or paramedian, supra-pubic incision; this gives better access to the pelvic cavity than any other. The lower end should extend down to the pubic bone, due care being exercised in avoiding the bladder; freer access is thus given to the pelvic cavity than when the incision is placed higher up. Occasionally an incision through the linea semilunaris, or through the rectus muscle will give more convenient access as when, for example, the right adnexa and the vermiform appendix are at fault. The transverse incision of Pfannenstiël may be used when comparatively small space is required, as in operations for ventral suspension of the uterus. This incision divides the integument and the anterior rectal sheath transversely about one and a half inches above the pubes; the cutaneo-aponeurotic flaps are then retracted up and down, and the muscle and peritoneum are divided in the mesial plane (*see* Fig. 440, p. 771). The resulting skin-cicatrix is concealed by the pubic hair, and the fact that the different layers are divided in planes which cross at a right angle greatly reduces the risk of the subsequent formation of a hernia. If more room is required the transverse cutaneous incision may be made higher up, half-way between the pubes and umbilicus.

Short incisions are, as a rule, to be deprecated; the object of the abdominal incision is to provide free and easy access to the operation-area. Insufficient room prevents a proper inspection of the area of

disease, prolongs the operation, often requires the use of a needless amount of force, and makes it difficult to conduct the satisfactory examination of other organs which is often called for. A long incision is no more likely to become the seat of hernia than a short one, and the sole argument which can be urged in favour of the latter is the so-called 'cosmetic' advantage of the more inconspicuous scar.

*Exposure of the Operation-Area.* Operative manipulations are greatly assisted by providing free access to the parts; this is in part provided for by a suitably placed incision of adequate length, in the

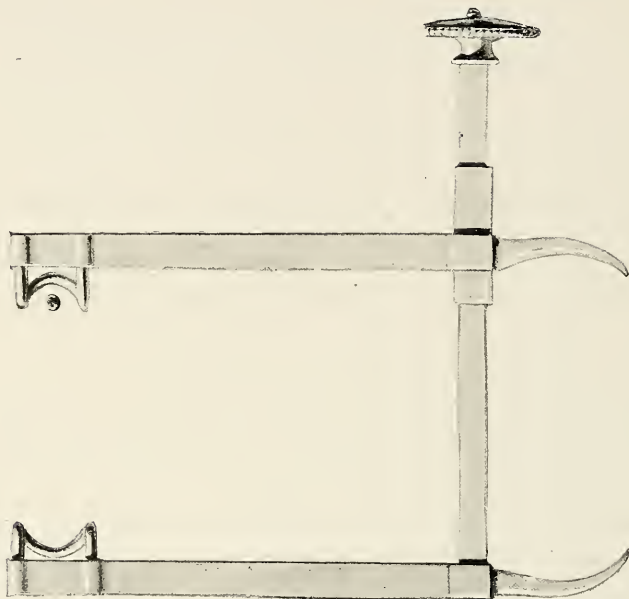


FIG. 411. GOSSET'S ABDOMINAL RETRACTOR.

case of abdominal operations. Great assistance can be further obtained by the use of suitable retractors which hold apart the edges of the abdominal incision, or in the case of the vulva, the margins of the *ostium vaginae* and the vaginal walls. Convenient retractors for abdominal work are those of Gosset and Faure. The former is shown in Fig. 411, and is also seen in position in Fig. 433; the latter is shown in Fig. 412. Gosset's retractor has the merits of simplicity and easy adjustment; Faure's is more complex but allows of wider separation of the edges of the wound. These are both self-retaining retractors and enable the operator to work with fewer assistants. For vaginal operation, necessitating exposure of the cervix and vaginal walls, the arrangement shown in Fig. 413 is the best. The two-bladed vaginal retractor of Jayle (see Fig. 414) separates the lateral vaginal

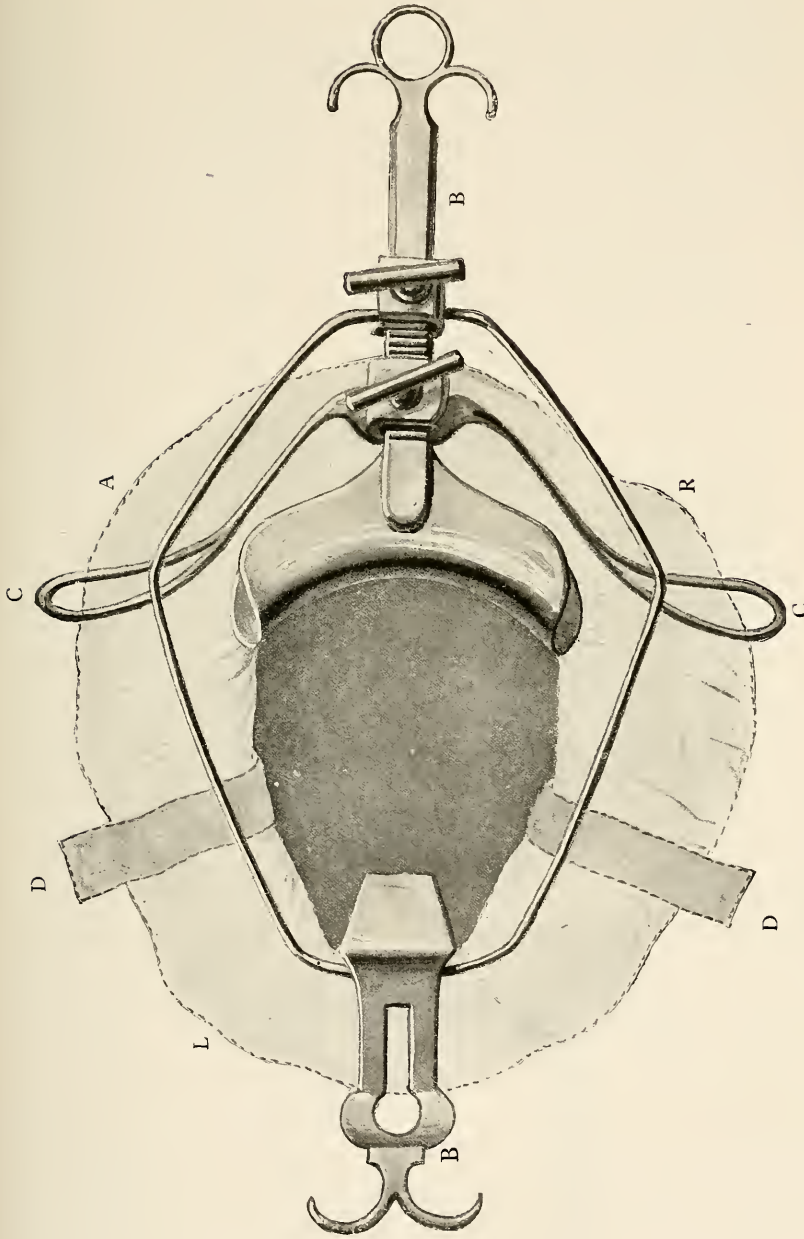


FIG. 412. FAURE'S ABDOMINAL RETRACTOR IN POSITION. A, Rubber sheeting with a broad flange tucked away and covering the deep aspect of the abdominal wall. B B, Retractors fixed in position on frame. C C, Limbs of frame which are placed between and underneath the patient's thighs. D, Pliable lead retractors for clamping rubber sheet in position.




FIG. 413. JAYLE'S VAGINAL RETRACTOR AND AUVARD'S SPECULUM IN POSITION.

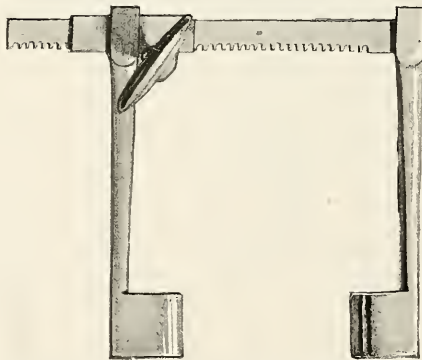


FIG. 414. JAYLE'S VAGINAL RETRACTOR.

walls, while the self-retaining weighted speculum of Auvard (*see* Fig. 415) depresses the posterior vaginal wall and perineum. The exposure of the depths of the vaginal canal which is thus afforded, enables manipulation to be carried out with ease under direct observation, and obviates the risk of infection resulting from contact of instruments, etc., with the skin-surfaces of the vulva which are so difficult to sterilize.

*Intra-abdominal technique.* There are certain general principles to be borne in mind in all internal manipulations of the abdominal viscera. These can only be mentioned without elaboration, and their importance will, it is hoped, be sufficiently apparent. (1) All viscera should be handled as little as possible, and as gently as possible. (2) Hæmorrhage should be reduced to a minimum by securing vessels when possible before dividing them; it is often of advantage to secure the blood-vessels supplying an area before commencing to deal with it. (3) In dealing with infective lesions, or in opening mucous tracts, the operation-area should be carefully isolated by packing, so as to protect the upper abdominal cavity, and parts of the pelvis which may not be involved. (4) Raw areas should not be left in the peritoneal cavity as they may become the seat of adhesions, which later may cause much suffering, or even sometimes give rise to acute intestinal obstruction. Raw areas should be *peritonized*, *i.e.* covered with peritoneum drawn from neighbouring parts, or failing this with an omental graft.

(5) Antiseptics should not be applied to healthy peritoneal surfaces, nor should these surfaces be subjected to damage from friction such as vigorous mopping, or by the use of dry swabs and mattresses. This applies especially in general peritoneal infections, when it is of the greatest importance to avoid traumatism of the already damaged serous membrane. (6) The operator must learn to work rapidly and not to waste time in purposeless manipulations. (7) Whenever possible, the abdomen should be closed without drainage; this point is, however, so important that special consideration must be given to it.

**Drainage.** Abdominal surgery is now carefully feeling its way in the limitation of drainage of the peritoneal cavity. Experience has shown

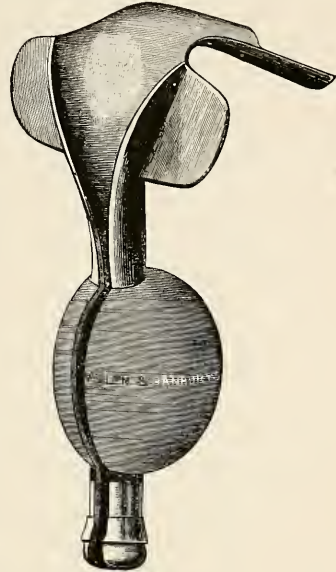


FIG. 415.—AUVARD'S SELF-RETAINING VAGINAL SPECULUM. The shank of the speculum is weighted with a ball of lead, and channelled to allow of the escape of douche fluids from the vagina.

that the peritoneum possesses remarkable powers of dealing with fluids, even those of an infective nature, so long as its vitality is not seriously damaged, and the original focus of infection has been removed. Blood is not easily disposed of by the peritoneum, and owing to its suitability as a nutritive medium, it is specially liable to become the seat of infection either from the bowel, or from bacteria admitted

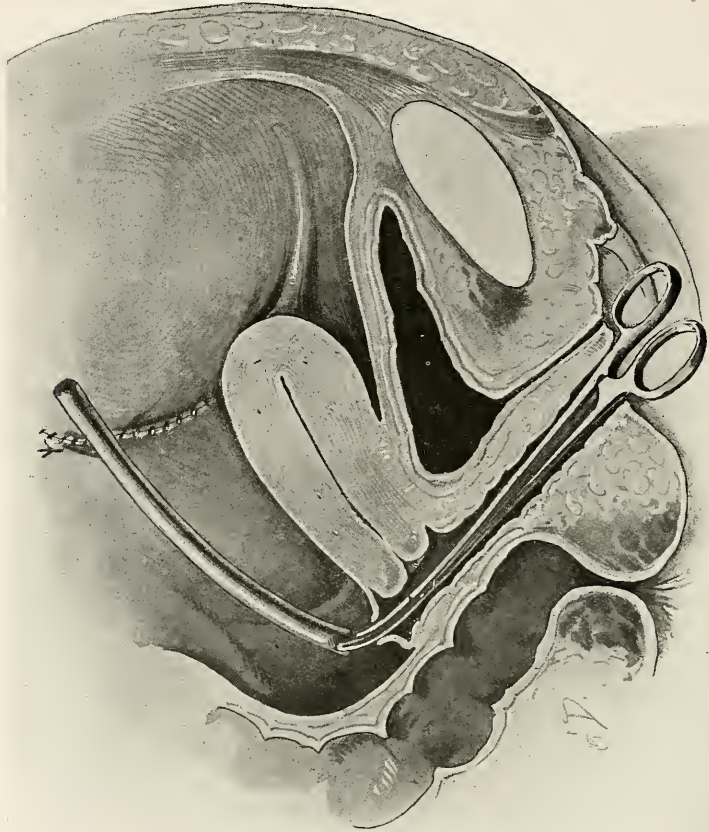


FIG. 416. VAGINAL DRAINAGE.

at the time of operation. The only two conditions which are now generally recognized as indications for drainage are localized collections of pus, and imperfect hæmostasis in the operation-area. It is impracticable to drain the whole peritoneal cavity by any method, because the drain becomes shut off by adhesions in a few hours; it therefore only drains the locality in which it lies. In acute generalized peritonitis, drainage of certain selected areas may be advisable, *e.g.* the great peritoneal pouches such as the pouch of Douglas and the renal pouches. The best material for drainage is rubber-tubing.

In pelvic surgery two *routes* for drainage are available, the vaginal route and the supra-pubic route. The former has certain clear advantages. (1) The drain-tract is the shortest possible, viz. between the pouch of Douglas, or the broad ligament, and the vaginal vault ; (2) it secures the assistance of gravity in the outflow of retained fluids ; (3) it allows of the abdominal wound being completely closed, and thus obviates the later risk of scar-hernia which is inseparable from drainage by the supra-pubic route. The great disadvantage of the vaginal route is that we are draining into an infected canal, and the risks of secondary infection through the drain-tract are much greater than in the case of the abdominal route.

Figure 416 illustrates vaginal drainage being carried out during an abdominal operation. The vagina is opened by cutting down upon a pair of forceps passed into the posterior fornix and with these forceps the drain-tube is then drawn into position.

**Closing the Abdomen.** Before the abdomen is closed the operator must satisfy himself that all swabs, forceps, needles, etc., which have been in use during the operation are accounted for ; foreign bodies such as these have frequently been left in the peritoneal cavity, and no accident more dangerous to the patient during convalescence than this can occur.

The parietal incision should be sewn up in layers ; a fine continuous catgut suture may be used for the peritoneum, and stouter interrupted stitches which should be of hardened catgut for the fascia ; the skin and subcutaneous tissues may then be united by a continuous silk suture, or by interrupted stitches of silk or silkworm gut. When the layer of fat is of more than average thickness, a buried catgut stitch may also be used to bring the deeper parts of this layer together, or two or three deep interrupted stitches may be introduced before stitching the fascia, which will embrace all the tissues between the skin and the peritoneum. Many operators prefer to unite the skin with a fine *subcuticular* ligature which leaves no needle marks, or with Michel's clips. These methods give a less conspicuous cicatrix than when stitches are used.

The wound dressings should be dry, absorbent, and aseptic ; they must be retained firmly in position by a tight binder, the most convenient pattern being the 'many-tail.' When no drain is used, a collodion scab may be applied along the line of stitches which effectively excludes air from the wound.

## ABDOMINAL OPERATIONS

## MYOMECTOMY

**Indications.** This is a conservative operation for the removal of fibroid tumours without sacrificing the uterus. Whilst, theoretically, abdominal myomectomy is an ideal operation, in point of practice it has a limited field of utility. This is due to the fact that fibroids

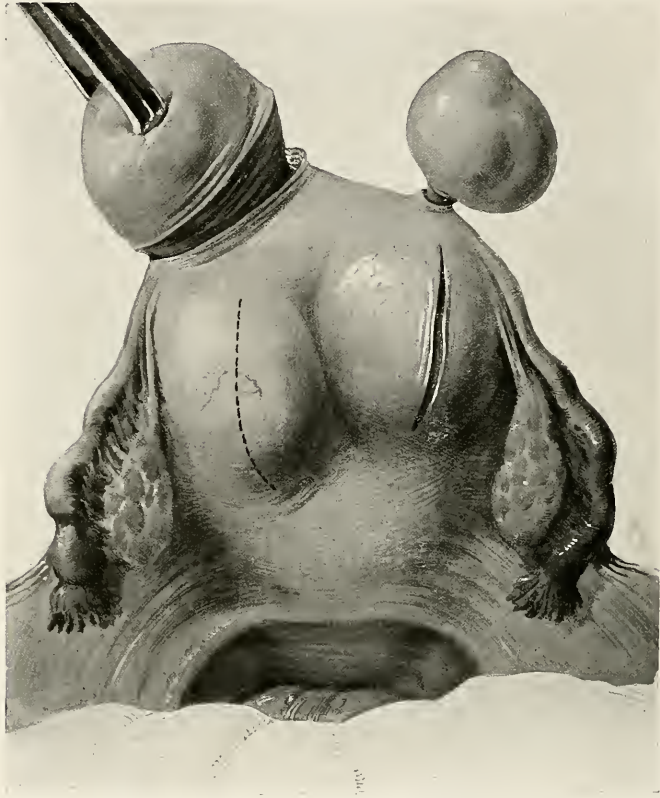


FIG. 417. MYOMECTOMY (diagrammatic), showing the linear and the circumferential incision.

are frequently multiple and when several tumours are removed the uterus is reduced to a useless organ. The clearest indications for this operation are found : (1) In the case of a *pedunculated* subperitoneal fibroid ; (2) pregnancy complicated by one or two fibroids which are causing urgent symptoms ; (3) solitary interstitial fibroids in young women.

The amount of exposure to which the uterus is subjected will depend upon the situation of the myoma or myomata. When the growth is in the lower segment, the uterus may have to be everted. If the uterus has to be drawn outside the abdomen, it should be



covered with a sterile towel which has been dipped in hot saline solution. In dealing with a *sessile* subserous myoma, or with an interstitial growth, a linear incision across the summit of the tumour, or a circumferential incision some distance from its uterine attachment, is made through the entire thickness of its capsule (*see* Fig. 417). Before this is done some operators apply clamps guarded with rubber to both broad ligaments. The growth is then seized with a volsella and the enucleation is commenced (*see* Fig. 417). This is done mainly by blunt dissection. The edge of the capsule is

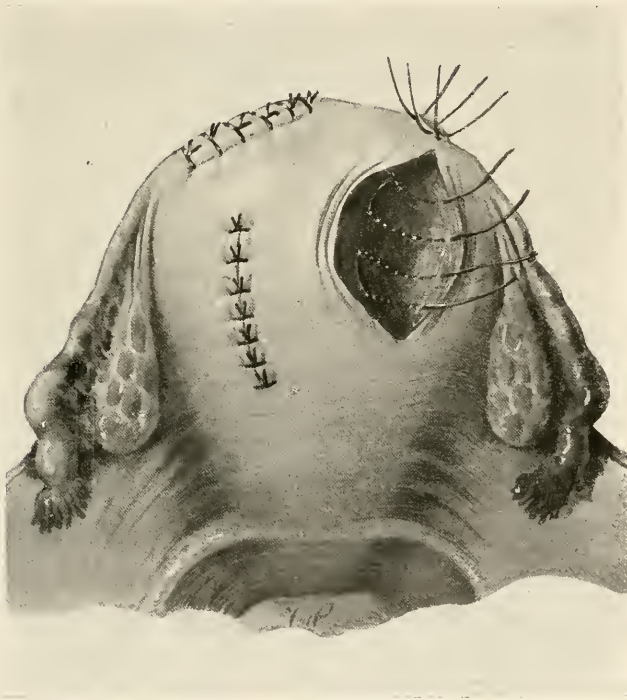


FIG. 418. MYOMECTOMY, showing the method of closure of the cavity.

peeled off the tumour with a gauze swab; by firm pressure on the tumour with the swab, aided by a few snips here and there with scissors, enucleation is easily effected. In the case of a gravid uterus all manipulations must be carried out with the utmost gentleness, undue traction must be avoided, the uterus must be steadied but not squeezed by the assistant, and care must be taken to avoid opening the cavity of the uterus. As soon as the tumour is enucleated, the closure of the cavity previously occupied by it is proceeded with. For this, buried catgut sutures are used (*see* Fig. 418). Beginning at the bottom of the wound many layers of mattress-sutures may be required before the apposition reaches the surface-level. For small cavities purse-string sutures may be used, but when the wound is wide and deep, running

purse-string sutures are liable to cause distortion of the shape of the uterus, and when gestation is present this may set up uterine contractions. The edges of the wound should come together without tension and without puckering. The peritoneum may be made to cover the wound by using interrupted stitches, or a Lembert's suture of fine Pagenstecher's silk. *Pedunculated* myomata are removed by turning back a shallow collar from the pedicle, amputating the latter at the base of the collar, and then uniting the edges by sutures which pass through the tissues of the stump.

### SUBTOTAL HYSTERECTOMY : SUPRA-VAGINAL AMPUTATION

This operation consists in the removal of the uterus (with or without the appendages) by amputation through the cervix. The entire body and the greater part of the isthmus (supra-vaginal cervix) is therefore removed. It is extensively practised by English and American surgeons in the surgical treatment of fibroids of the body of the uterus, and some surgeons adopt this method of hysterectomy for cases of chronic metritis and also for cases of double pyosalpinx. The indications for the removal of one or both ovaries will depend entirely upon the state of those organs. They may be so involved in tubo-ovarian inflammation, or by co-incident new growth, as to necessitate their removal; but it should always be the aim of the surgeon to save as much ovarian tissue as possible, and when both organs are ablated a healthy portion should, if possible, be grafted within the rectal sheath. Opinions differ widely as to the relative value of the two operations, *subtotal* and *total* hysterectomy (*vide infra*). The preparatory steps as far as the laparotomy is concerned have already been mentioned.

With the abdomen opened, and with the operator standing on the right side of the patient, the tumour is drawn up into the wound and the intestines are then packed off with thin rubber sheeting, taken out of sterile saline solution. Large Gamgee mattresses, or a six-yard roll of gauze may also be used, if necessary, to assist in keeping the intestines out of the pelvic cavity. The advantage of applying the rubber sheeting first, is that it does not stick to the intestines. The uterus having been drawn up, the appendages are examined, in order to decide whether it is necessary to remove one or both ovaries. In a case where both ovaries may safely be left *in situ*, the amputation of the uterus through the cervix proceeds as follows :

The operator draws the uterus and tumour to the right side. The left round ligament is divided between two clamps. A second pair of clamps is then applied to the remaining structures arising from the cornu, viz. to the Fallopian tube and to the ligament of the ovary, and these tissues are divided between them. The assistant then raises the peritoneum of the utero-vesical pouch with toothed

dissecting forceps, and the operator inserts one blade of the scissors under the peritoneum, and divides the fold from left to right, close to and across the front of the isthmus of the uterus. After

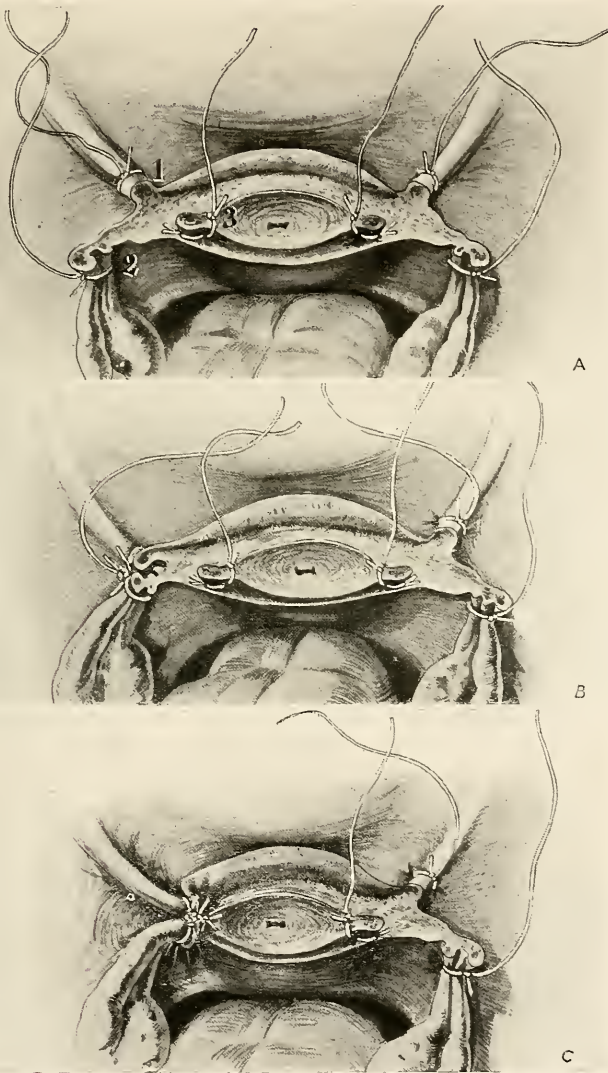


FIG. 419. Fig. A (1) Round ligament; (2) Fallopian tube and ovarian ligament; (3) corner of cervical stump. Fig. B shows (1) and (2) united. Fig. C shows (1), (2), and (3) united on the left-hand side of diagrams.

division, the peritoneal flap is pushed down, together with the upper part of the bladder, by means of a swab in a holder. It will be found necessary to use a few snips with scissors in order to free the bladder in the midline. The left uterine vessels are next exposed, and isolated by passing a dissector between the vessels and the side of the cervix

and running it up and down between the two. The isolated vessels are now clamped in two places about one inch apart with stout artery forceps and then cut across. The appendages and vessels upon the right side are dealt with in the same manner, and when this is done the uterus is attached only by the cervix and by the peritoneum of the posterior uterine wall. The amputation through the cervix is made low down, to effect which, the uterus is drawn well up by the operator, who takes a swab in a holder and with it rolls the bladder downwards and the uterine vessels outwards. Then, with a scalpel, a

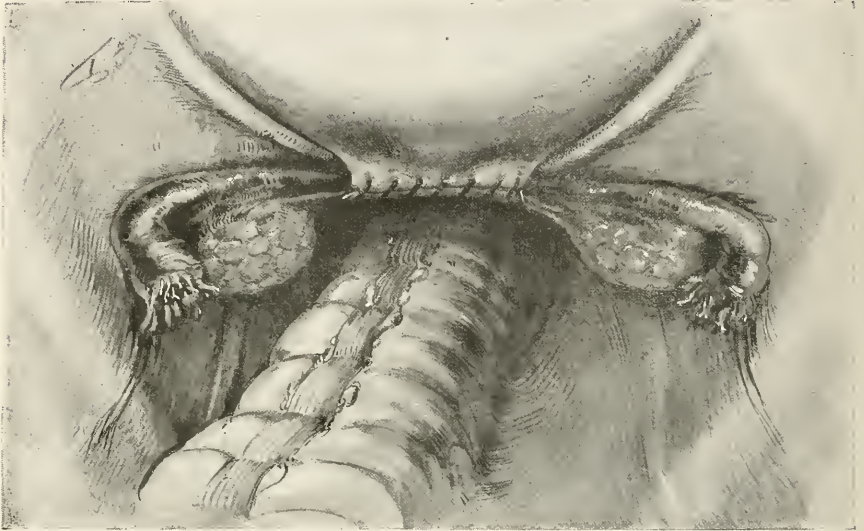


FIG. 420. MODE OF CLOSURE OF THE PERITONEUM IN THE PELVIC FLOOR.

V-shaped incision is made from front to back, the anterior cut running downwards and backwards through the bared cervix, and the posterior cut running downwards and forwards through peritoneum and cervix. Before the amputation is complete, the assistant grasps the cervical stump with a volsella, and when the uterus and tumour are removed, the stump is drawn up and the cervical endometrium painted with iodine. The operator then inserts one or two mattress-sutures of catgut through the shelving cervical flaps. Some surgeons scollop out the core of the cervix leaving only a shell—this is not necessary; other scrape out or cut away the cervical endometrium—this also is superfluous. When the cervical flaps are brought into apposition by suture, the latter are left long and the volsella removed. The uterine vessels are next tied off by inserting a ligature behind the clamp in each case. These ligatures are cut short as soon as they are tied, and an encircling ligature is now passed through the lateral wall of the cervix and made to include the uterine artery, thus bracing the latter to the cervical wall. Subsequently, the round ligament clamp, and those on the tubes and ovarian

ligaments, are replaced by ligatures, which are all left long for the time being. When all clamps are removed there remain three sets or pairs of long ligatures on either side of the pelvis. From above downwards they are those (1) on the tube and ovarian ligament ; (2) on the round ligament ; (3) on the corner of the cervical stump (*see* Fig. 419). One strand of each pair is now cut off, and of the remaining three each is united to the one lying next to it. Thus, the cervical ligature is tied to that on the round ligament, and one of these to the ligature on the tube and ovarian ligament. The latter ligature should be

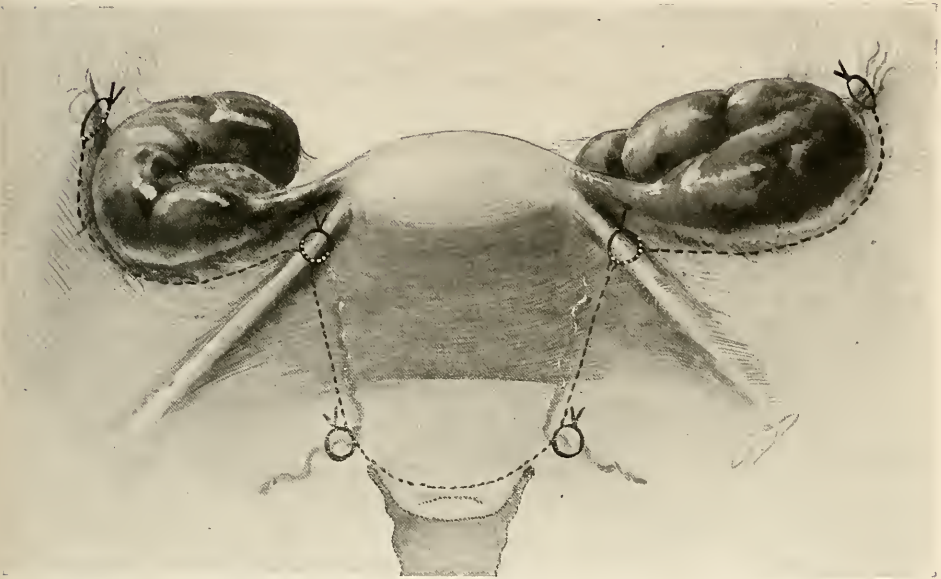


FIG. 421. SCHEME OF SUBTOTAL HYSTERECTOMY. (Supra-vaginal amputation.) In a case where both appendages are being removed.

augmented by a second transfixion-ligature, if there is the slightest degree of tension.

When the ligatures on either side are thus united, the cervix is held up at its corners by all the lateral structures which have thus been brought together. The peritoneal edges are finally apposed over the cervical stump by a running suture from left to right (*see* Fig. 420). The wound must be absolutely dry at the finish. The mattresses and rubber-sheet are now removed, and the abdomen closed as already described on p. 739.

Figure 421 gives a scheme of subtotal hysterectomy in a case where both appendages are to be removed.

### TOTAL ABDOMINAL HYSTERECTOMY ; PANHYSTERECTOMY

In this operation the entire uterus is removed (with or without the appendages) by dividing the vagina close to its attachment to

the cervix. It is definitely indicated in the surgical treatment of interstitial cervical fibroids (*see* Fig. 217, p. 438), where the cervix has been drawn up and expanded by the growth. It is the method of hysterectomy usually adopted when it is necessary to take the uterus away for cancer of the *body*, and in cases of double pyosalpinx. Many surgeons employ the *total* to the entire exclusion of the *subtotal* method of hysterectomy. The advocates of *total* hysterectomy claim that it is the better operation (1) because carcinoma may develop in the portion of cervix where it is left behind, over thirty cases having been recorded (*see* p. 459); (2) hæmorrhage is better secured in the total operation. On the other hand, the total operation takes longer to complete—therefore where speed is a consideration as in Cæsarean hysterectomy, the *subtotal* method is the best procedure. Total abdominal hysterectomy, performed as described below, was formerly employed for carcinoma of the cervix, but it has now given place to a more extensive operation introduced by Wertheim (*vide infra*). Before performing panhysterectomy it is essential that the vagina be systematically cleansed by antiseptic douches during two or three days preceding the operation. This should be supplemented by painting the *portio vaginalis* and vagina with a two per cent. solution of iodine just before the operation is begun, *i.e.* after the patient is anæsthetised.

In the description of supra-vaginal amputation both ovaries were retained. In describing panhysterectomy the removal of the adnexa will be included. The ovaries are not removed unless they are diseased in cases of fibroid tumour, but for carcinoma of the body the tubes and ovaries are systematically removed in the operation of panhysterectomy.

When the ovaries are to be removed, the round ligaments are tied off and divided, and the *infundibulo-pelvic folds* are then clearly defined by gentle traction on the outer half of the Fallopian tube, which can be done by the assistant. If on the left side the sigmoid is found adherent to the free edge of the broad ligament by accessory peritoneal folds, these are carefully divided with scissors and the bowel pushed back. With the left thumb and index finger the ovarian vessels are grasped whilst a ligature is passed from within outwards through the avascular thin portion of the broad ligament, which lies internal to the ovarian vessels. The latter are then tied and the ligatures cut short. This is done on both sides and then the operation proceeds as already described, excepting that it is better to ligate, rather than clamp, the vessels at every stage, because with the increased depth of the wound it may be found that a number of large forceps will get in the way. After ligating the left uterine vessels, the connective tissue and ureter are pushed downwards and outwards by firm pressure applied by a swab in a holder which is pressed against the lateral wall of the cervix. The uterus is now drawn forcibly upwards by means of a stout volsella with a lateral curve (*see* Fig. 422). This instrument should be applied to

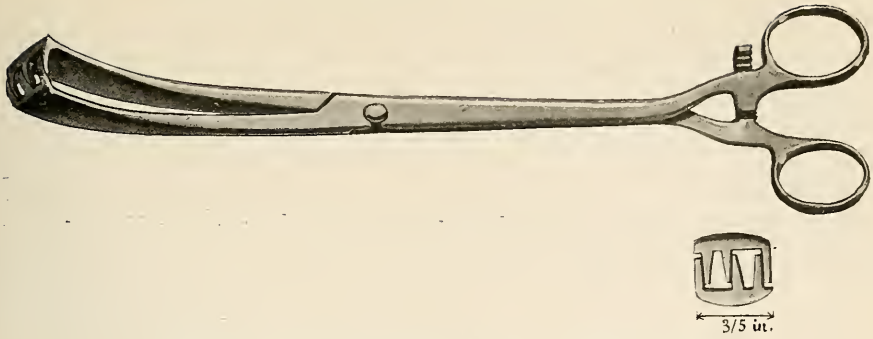


FIG. 422. STOUT VOLSELLA WITH A LATERAL CURVE.

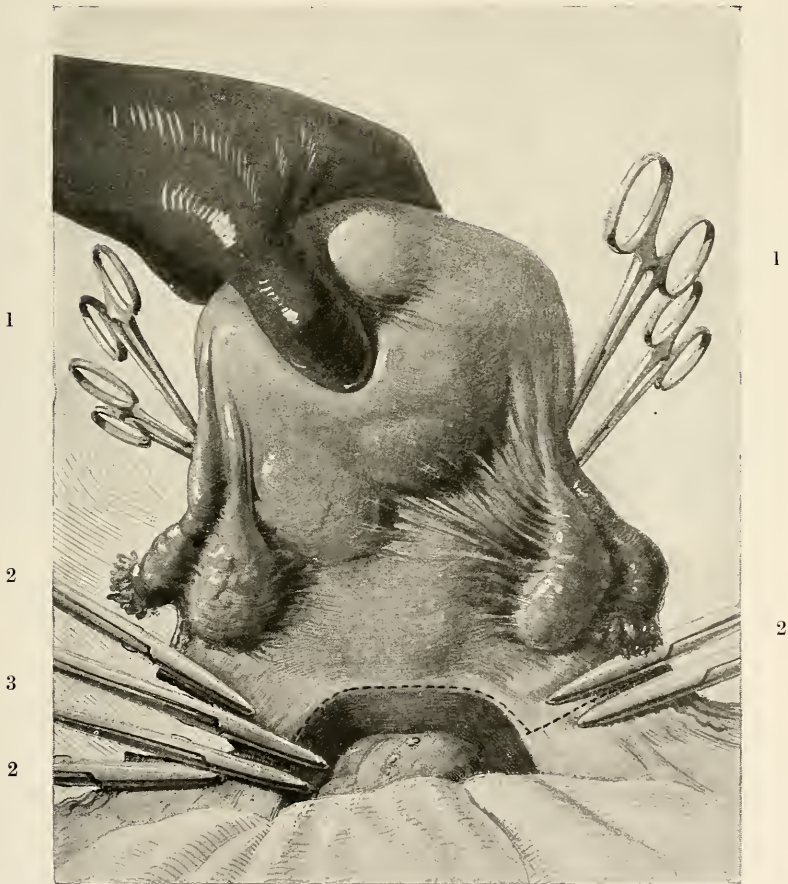


FIG. 423. TOTAL ABDOMINAL HYSTERECTOMY. On the left side the infundibulo-pelvic fold has been divided. The utero-sacral fold is clamped ready for division. 1 = Forceps on round ligament. 2 = Forceps on infundibulo-pelvic fold. 3 = Forceps on utero-sacral fold.

the lateral wall of the isthmus (supra-vaginal cervix). Traction by means of the volsella puts the parametrium on the stretch, and as the uterine vessels and ureter have already been displaced, the parametric tissues may be clamped by forceps. The first pair of forceps grasps the utero-sacral ligament which is divided on the uterine side of the clamp (*see* Fig. 423 [3]) The second pair is applied to the utero-sacral ligament on the opposite side, which is then likewise severed. The scissors are then inserted on the flat under the peritoneum at the back of the uterus and pushed across from

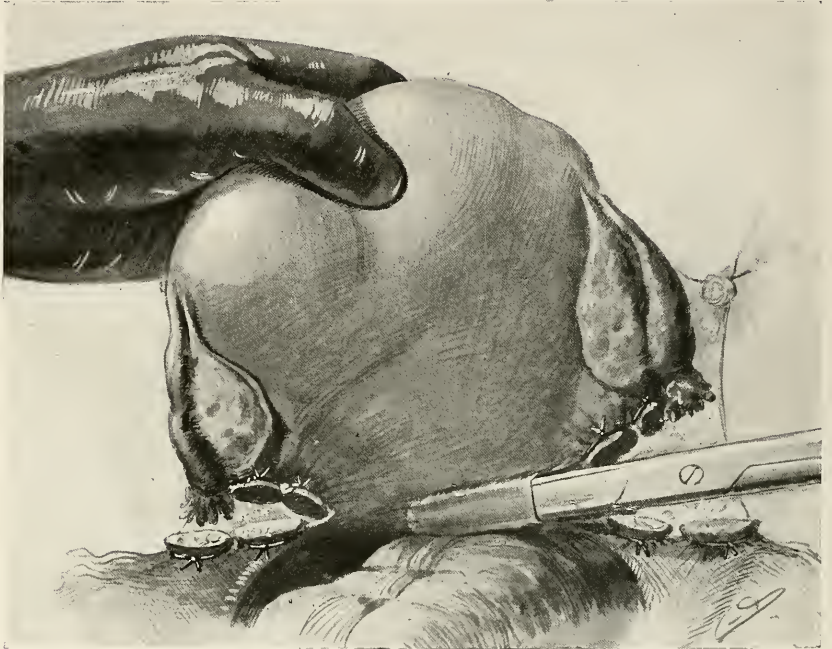


FIG. 424. TOTAL ABDOMINAL HYSTERECTOMY. The infundibulo-pelvic and the utero-sacral ligaments are ligatured on both sides ; the clamps are removed. The peritoneum is being separated from the posterior uterine wall.

right to left, from one cut utero-sacral ligament to the other (*see* dotted line in Figs. 423 and 424). The peritoneum thus freed is then divided, and the rectum, which is thereby exposed, is pushed down by breaking through its loose attachment to the vagina. A third and fourth clamp are now used to grasp the lateral parametric tissues on either side of the cervix. This lateral parametric tissue is then divided by keeping the scalpel close to and by cutting on the cervix. The deep lateral dissection is carried down on either side, until the vagina is reached ; a point which is easy to notice, because the vaginal walls are laxer and less resistant than the cervix. As to where the vagina is to be opened is a matter of choice ; some operators open it in front, others at the side. The latter has the advantage of allowing the lateral incision to proceed



until the vagina is cut into, when its vascular lateral angle can be clamped and drawn up, whilst the remainder of the vagina is divided from left to right first along the anterior, and then along the posterior, walls. When the vagina is divided its edges should be caught by four pairs of clamps, one on the centre of the anterior wall, one on the posterior, and one on each lateral angle. These clamps are immediately replaced by ligatures which are left long and brought together in one pair of forceps. By leaving these ligatures long they may be used as

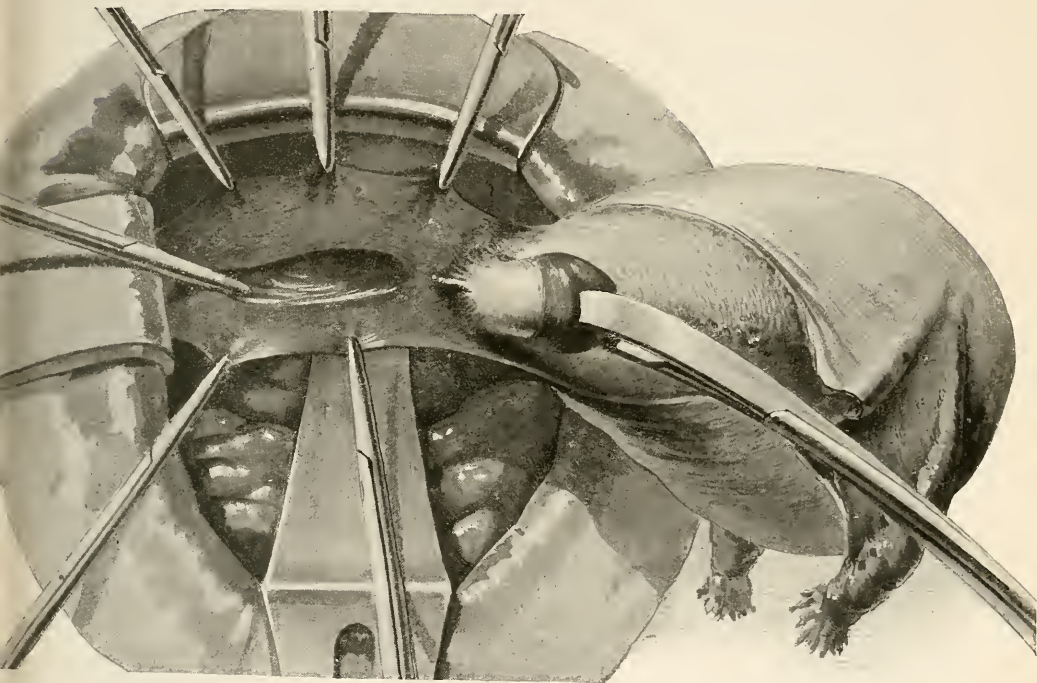


FIG. 425. ABDOMINAL TOTAL HYSTERECTOMY BY THE TRANSVERSE METHOD. The vagina has been opened and the cervix pulled up by a volsella. The clamps are attached to peritoneal flaps; they *should* have been shown applied to the edges of the vagina.

temporary tractors, and serve to keep the walls of the patent vagina in apposition for the time being. It should be noted however that the vaginal canal is not closed by sutures in this operation (*see* Fig. 425). The utero-sacral clamps, and those on the parametrium, are next replaced by ligatures which may be transfixed in the tissues to prevent them from slipping off. The entire deep area is now carefully examined for oozing-points. When the raw surfaces are quite dry, the closure of the pelvic connective tissue is begun. The round ligaments are sewn to the corners of the vagina, and the original vaginal sutures which were in use as tractors are then cut short. The peritoneum is next brought together by a running glover's stitch from left to right.

When there is a good supply of peritoneum in the flaps, this membrane can be easily brought together by means of a purse-string suture, a method adopted by Spencer. It is a very rapid means of restoring the peritoneal floor of the pelvis, but when it is done, the lateral vaginal angle is tied to the parametric suture, instead of to the round ligament, as a means of support. Finally, the omentum

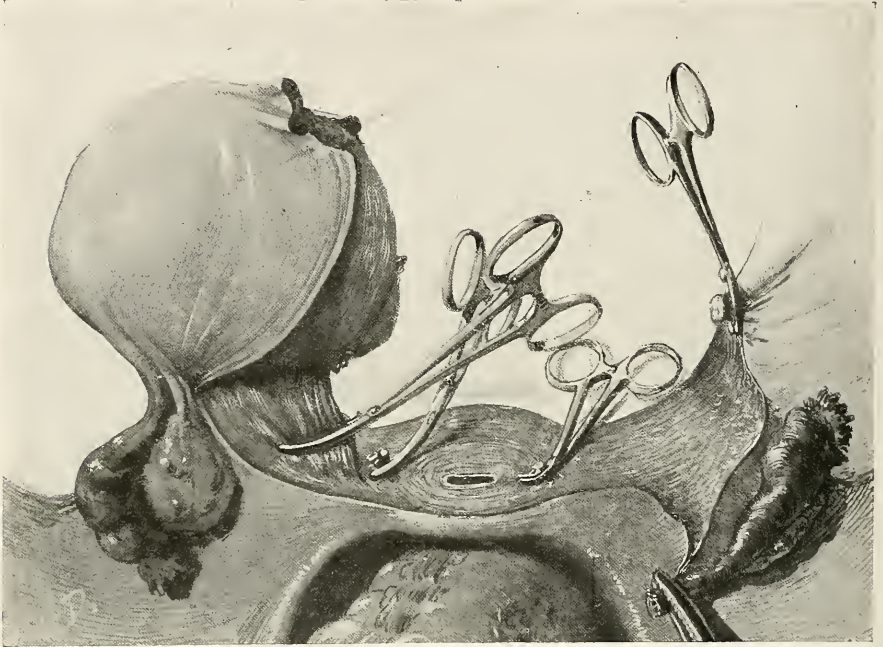


FIG. 426. ABDOMINAL SUBTOTAL HYSTERECTOMY BY KELLY'S METHOD.

is drawn down so as to cover the small intestines ; instruments and swabs are counted, and the abdomen is then closed.

### Special Methods of Hysterectomy

(a) **Kelly's Supra-vaginal Amputation by Continuous Incision from one side to the other.** This is the most rapid method of performing subtotal hysterectomy, and when the ovaries can be saved it can be carried out most expeditiously by the use of clamps to control the vessels, no ligature being applied until the uterus is removed. Forcippresure is not advisable, however, for securing hæmostasis when the ovaries are to be taken away with the uterus, as they may slip off the infundibulo-pelvic fold during subsequent manipulations, especially when applied far back near the pelvic brim. In such cases, before incising the mesosalpinx it is best to tie the ovarian vessels in the manner already described.

Kelly's rapid method of continuous incision may be used for straightforward uncomplicated cases of hysterectomy, *i.e.* where the uterus can be drawn well up into the wound ; it is also better adapted

to meet the difficulties of dealing with a burrowing myoma, than is the form of subtotal hysterectomy already described. Two clamps are applied to the left appendages at the cornu uteri, and these structures are then divided between them with a scalpel, the left round ligament is treated in the same way; the vesical peritoneum is divided and pushed down together with the fundus of the bladder. The left uterine vessels are then divided between forceps and the cervix cut straight across from left to right, until it hangs by the right broad ligament. The latter are seized with a pair of curved museaux or with Moynihan's cholectomy forceps (*see* Fig. 427), whilst the uterus

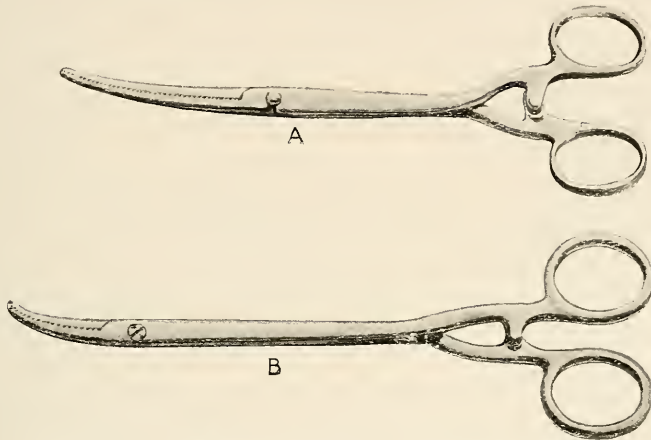


FIG. 427. A, Museaux forceps; B, Cholectomy forceps.

and tumour are rolled still further to the right and dragged up (*see* Fig. 426). Its only attachment then will be the right appendages. These are clamped and divided from below upwards.

(b) **Doyen's Panhysterectomy.** This is a modification of the classical method of performing total hysterectomy. After drawing the uterus well up and packing off the intestines, the tumour and uterus are held forwards to obtain a good view of the lower part of the posterior uterine wall. The *posterior vaginal fornix* is then opened, and the cervix is thus exposed from behind. With a stout volsella the cervix is drawn through the opening in the vagina, and its attachments to the vagina, laterally, and in front, are severed from below upwards. The utero-vesical pouch is divided, the uterine vessels are clamped and divided, and finally the appendages are treated likewise. The operation is carried out entirely from below upwards.

(c) **Pryor's Total Hysterectomy.** By this method the surgeon proceeds as is done in Kelly's continuous left-to-right subtotal hysterectomy, excepting that the lateral dissection passes low enough to allow the line of amputation to pass across the vagina instead of through the substance of the cervix. It is the most expeditious manner of performing panhysterectomy.

### The Radical Abdominal Operation for Carcinoma of the Cervix : Wertheim's Operation

The principle upon which this operation is based consists in the removal of infected cellular tissue and glands, and also of *enough of the vagina to form a capsule for the enclosure of the malignant cervix*. Before removal of the latter, the vaginal covering is hermetically sealed by the application of two strong clamps specially designed for the purpose (see Fig. 428).

Abdominal hysterectomy for cancer of the uterus has been practised since 1878. In 1896 Clark successfully carried out the operation of

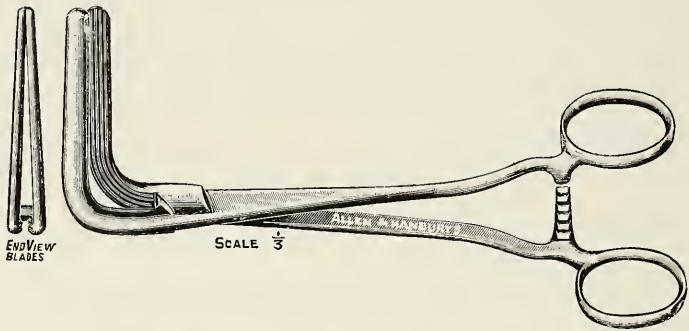


FIG. 428. EDEN'S MODIFICATION OF WERTHEIM'S VAGINAL CLAMP. The blades are forged so that the tips come into contact one with another while the heel of the curve is still open. On locking the blades all the tissues included between the tip and the heel are firmly grasped.

removal of the uterus and its appendages, with the pelvic cellular tissue, and with the lymphatic glands as high as the bifurcation of the common iliac vessels. Wertheim was the first to recognize the necessity of diminishing the *risk of cancer-implantation* on the raw surfaces, and to obviate this danger he devised the plan above mentioned, hence the operation as now performed goes by his name, although many minor details in the technique have been modified from time to time.

The operation is essentially one for the specialist; this is clearly shown by Wertheim's own statistics, which demonstrate that the primary mortality, which in his first thirty cases was 40 per cent., was reduced by experience to such a degree, that in his last thirty published cases it was only 7 per cent. The average primary mortality deaths due to operation, may be put down at the present time as somewhere between 12 and 15 per cent., which is *at least* twice as great as the primary mortality of vaginal hysterectomy, an operation which used to be performed for the same disease. The percentage-operability, *i.e.* the number of cases suitable for radical operation, is

greatly increased by Wertheim's operation, since it enables the operator to deal with cases which are inoperable by the vaginal route. Expressed in figures, it may be said that the percentage-operability in the two procedures is as 65 to 15. As regards permanent cure, which is reckoned on the basis of freedom from recurrence for *five years*, statistics prove the superiority of the more extensive operation, the best results of vaginal hysterectomy showing 12 per cent. as compared with Wertheim's results which gave 62 per cent. of 'absolute cures.' The conclusion may therefore fairly be drawn that many lives are saved by Wertheim's operation which would inevitably have been lost by the employment of any other operative means.

**The Operation.** When the case is advanced the patient is kept in bed for a week or ten days in order to employ means of rendering the cervix and vagina as clean as possible, and also to improve the state of health generally. With a sloughing growth accompanied by offensive discharge it is customary to apply the actual cautery under anæsthesia, and to scrape away as much of the necrotic tissue as possible. This is followed by peroxide of hydrogen (10 vols.) douches, and by the application of acetone and iodine to the raw surface. The wound in the cervix should be quite clean before the major procedure is undertaken. Immediately before the operation, the vagina is swabbed out with 2 per cent. iodine solution, and packed with sterilized gauze, an end of which is left outside the vulva.

With the patient in the Trendelenberg position, and the abdomen opened from above the umbilicus to the pubic bone, a careful exploration of the pelvic cellular tissue and lymphatic glands is first made. Then stout silk ligatures are passed under the adnexal structures close to the cornu uteri; these when knotted serve as tractors (*see Fig. 429*). The uterus is now drawn up and the utero-vesical pouch examined. Here the peritoneum may be found to be puckered and abnormally adherent. The first step in the operation then should be to raise the peritoneum and investigate the relation of the growth to the base of the bladder. If it is found that the growth has deeply implicated that viscus, the peritoneal wound should be closed and the operation should not be proceeded with. If this preliminary investigation proves favourable, the infundibulo-pelvic and round ligaments are tied off, and the ends of the tubes are tied to the cornua so as to keep these structures folded out of the way (*see Fig. 429*). The cut edges of the broad ligament on one side are opened up by the fingers, and the ureter is sought as it runs on the posterior leaf of peritoneum between the pelvic brim and the cervix. This cord-like structure is best found by taking the sheet of peritoneum between finger and thumb, when it will be appreciated as a firm cord the size of a slate-pencil. When the ureter has been identified, it is traced forwards from the brim of the pelvis behind, to the cervix in front, at the side of which it enters the *ureteric canal* beneath the uterine artery. At this stage the bladder is dissected

off the front of the cervix in the manner already described. When this is done, it is also necessary to push it down from the antero-lateral aspect of the cervix in many cases of advanced carcinoma; many venous points have to be caught up during this dissection. When the bladder has been displaced, its peritoneal covering may be stitched

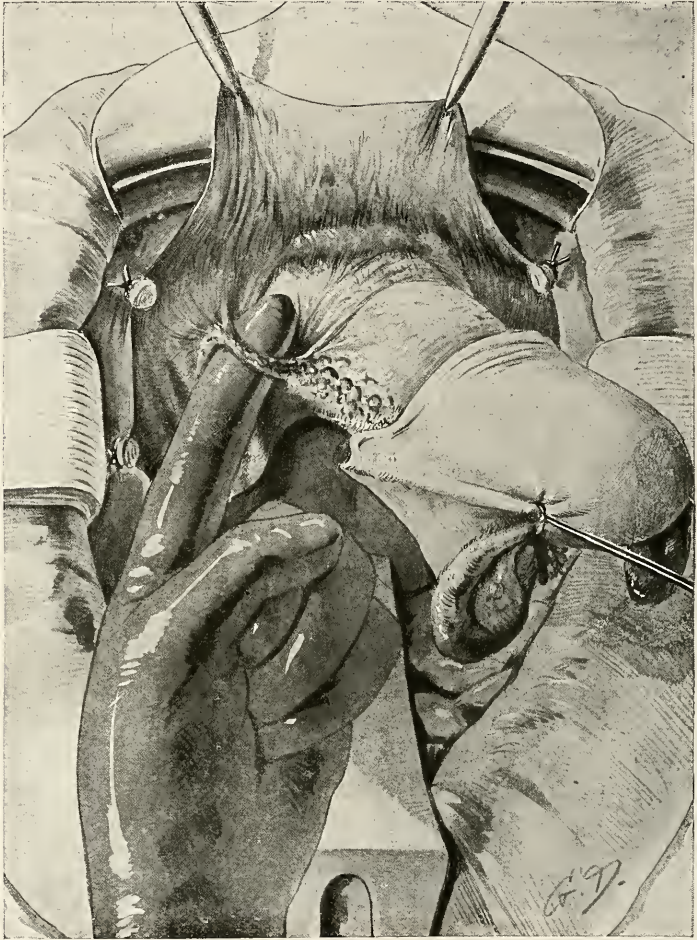


FIG. 429. ABDOMINAL TOTAL HYSTERECTOMY FOR CANCER OF THE CERVIX.  
Method of isolating the uterine artery.

up to the lower angle of the abdominal wound, or held forwards with forceps (*see* Fig. 429). Attention is then again directed to the ureter. The left index finger is passed through the ureteric canal and brought out in front of the uterine artery between it and the bladder (*see* Fig. 429). The finger always carries before it a thin tough sheet of cellular tissue which has to be teased apart on the apex of the finger before the latter is freed. When this is done, a ligature is passed under the uterine

artery and this vessel is tied as far out towards the pelvic wall as possible. Before tying this ligature the ureter must be traced along its whole course to the bladder, in order to make sure that it is completely freed from the artery which is about to be tied. After the ligature is

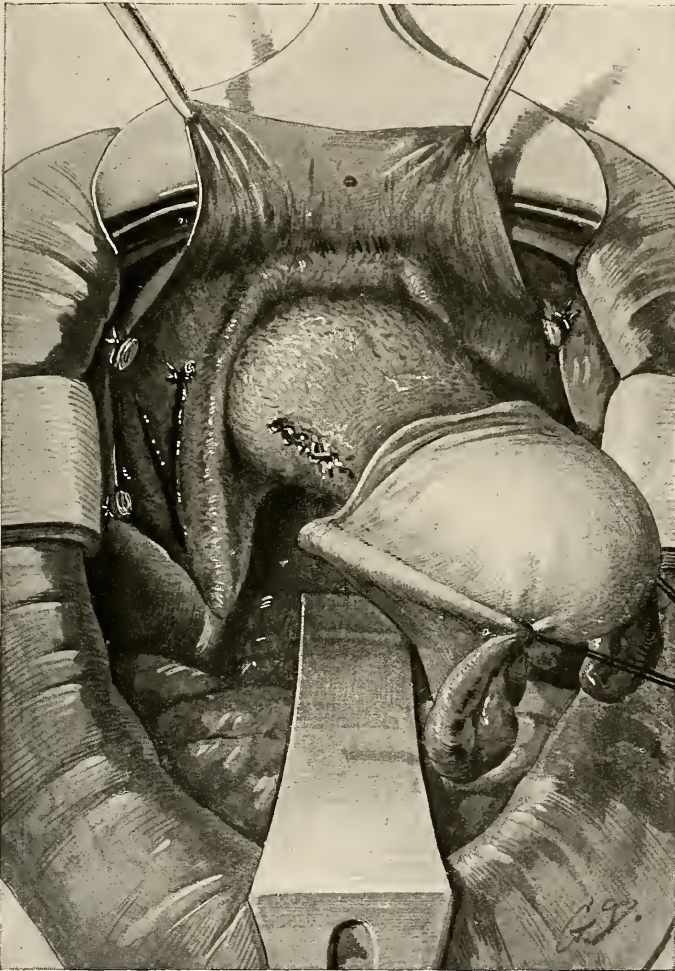


FIG. 430. ABDOMINAL TOTAL HYSTERECTOMY FOR CANCER OF CERVIX.  
Uterine artery divided. Ureter exposed in the whole of its pelvic course.

tied the artery is divided, when a complete view of the exposed ureter can be demonstrated along the whole of its pelvic course (*see* Fig. 430). The ureter is now rolled off the cervix and side of the vagina with a gauze swab. The same procedure is carried out on the opposite side. (Should any glands be met with between, or overlying, the vessels these should be removed. It is often necessary to do so before the ureters can be exposed.) The uterus during the next stage of the operation is

drawn up and carried forwards. The utero-sacral folds are clamped and divided, the peritoneum at the back of the vagina is cut across and the rectum pushed back. Next the parametric tissues on both sides are clamped with specially strong forceps devised by Wertheim for the

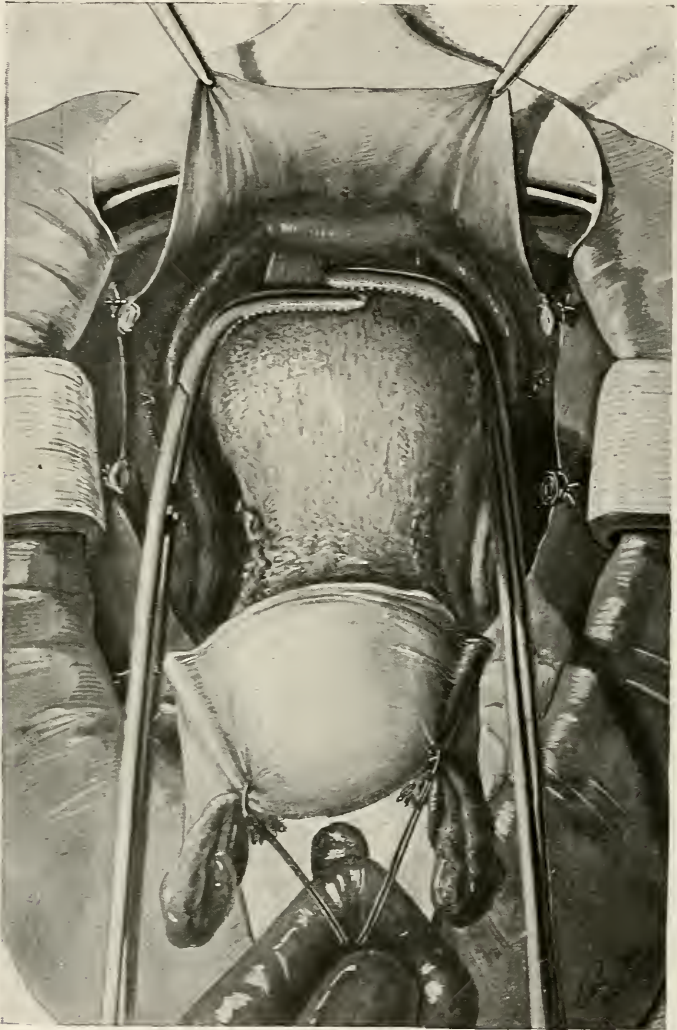


FIG. 431. ABDOMINAL TOTAL HYSTERECTOMY FOR CANCER OF CERVIX. Vaginal clamp applied. (The parametric clamps are omitted for greater clearness.)

purpose (*see* Fig. 432). When the bases of the broad ligaments are divided, the uterus is drawn forcibly upwards in the direction of the upper angle of the wound and the vaginal clamps applied (*see* Fig. 431). Before so doing it is necessary to raise the bladder with a wide flat retractor, and at the same time to define the ureters as they enter that



viscus. They must lie well outside the curve of the clamps. After the vaginal clamps have been tightly closed the vagina is amputated below their grip, and the uterus with the cervix enclosed in a vaginal capsule is thus freed and can be removed. The edges of the vagina are now

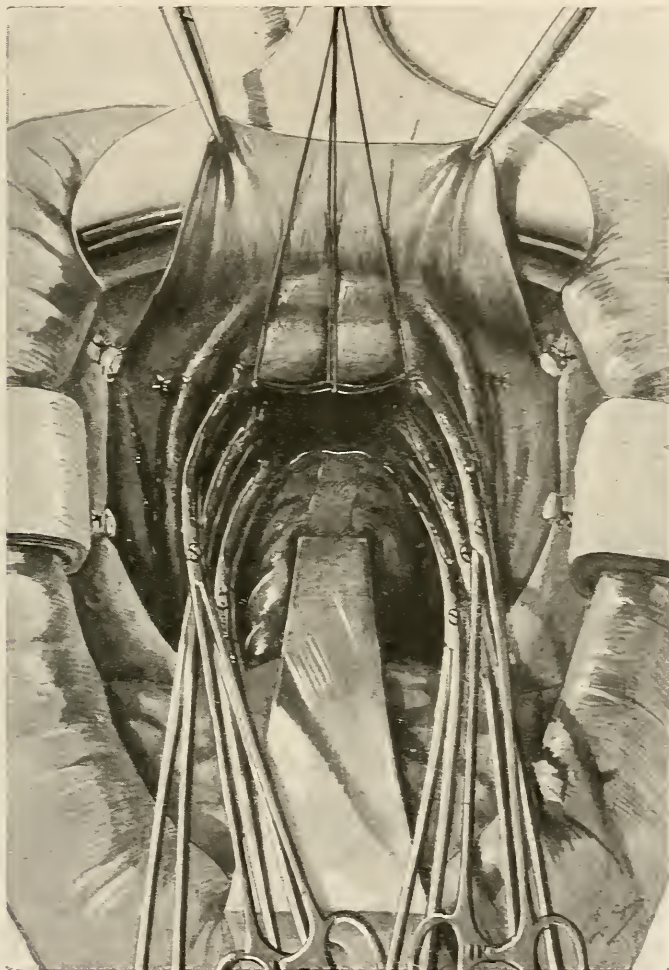


FIG. 432. ABDOMINAL TOTAL HYSTERECTOMY FOR CANCER OF CERVIX. Uterus removed. The vaginal walls are held up and brought into apposition by three long sutures, but the canal is not closed by the sutures. The posterior pair of clamps are on the utero-sacral folds. The two anterior pairs are on the parametrium.

picked up and the two lateral angles which bleed freely are at once tied. The parametric tissues are transfixed and tied behind the clamps, and the latter are then removed: the same is done to the utero-sacral folds.

The wound is now examined for oozing-points, which when found are caught and tied off; a further search is made for glands and then

the raw surfaces are covered by closure of the peritoneum in the way already described. The vagina is left open and no gauze is inserted into the deep cellular tissues or into the vaginal canal.

### OVARIOTOMY

The name *ovariotomy* is applied, by time-honoured custom, to the operation for the removal of an ovarian tumour.

**Indications.** It has been already explained that all ovarian tumours should be removed as soon as the diagnosis of their presence has been made. In the case of bilateral tumours a portion of follicle-bearing ovarian tissue should, if possible, be conserved upon one side or the other.

**Steps.** The essential steps in this simple operation are the delivery of the tumour through the incision, the division of the pedicle, and the control of its vessels. Tumours of small size can be turned out of the abdomen entire through a median incision of four to five inches in length ; the pedicle can then be examined and secured under direct observation. Should the tumour have contracted adhesions to its surroundings, these must be divided and the growth must be completely liberated and brought out of the wound, so that the pedicle may be defined, before anything further is done. Recent adhesions to the parietal peritoneum can be readily and safely separated with the fingers. Adhesions to omentum or intestine must be carefully dealt with under direct observation and not by touch alone. Large vessels may be found in omental adhesion which require ligature ; intestinal adhesions though they may ooze freely when torn through, seldom give rise to troublesome bleeding unless the wall of the bowel has been lacerated. Infected, and suppurating cysts may become so densely adherent to bowel, that separation of the two is impossible. It is then best to cut through the cyst-wall so as to leave a thin layer of it attached to the bowel. Cystic tumours too large to be turned out through a subumbilical incision, may be first reduced in size by tapping, if the following conditions are complied with : (1) there is a large loculus in the cyst containing a considerable amount of fluid ; large tumours composed of an aggregation of small loculi cannot be tapped ; (2) the pedicle is not twisted, nor is the tumour extensively adherent—conditions under which the contents may have been infected ; (3) there is no clinical condition which raises a suspicion of malignancy. If these conditions are not complied with, an incision must be made large enough to allow of the complete eventration of the tumour, for the reason that the escape of ovarian fluid into the peritoneal cavity, which is difficult to avoid completely during tapping, may be followed by serious results. When, however, the conditions are favourable, tapping is desirable as facilitating the removal of the tumour, and avoiding the expenditure of time in closing a very long abdominal incision. For tapping, an ovariectomy-trochar

should be used ; the escaping fluid can be led away through a rubber tube attached to the end of the trochar. When the collapsed tumour has been drawn out of the abdomen, the pedicle is clamped with two or three pairs of artery-forceps, and then divided between the clamps and the tumour.

When long and thin, the pedicle may be transfixed with a blunt needle midway between the uterus and the infundibulo-pelvic fold where the broad ligament contains few if any vessels, and secured with a ligature tied at each side, the outer embracing the ovarian vessels, the inner the ovarian ligament and Fallopian tube. A thick broad pedicle should, however, be secured in sections, which can be transfixed and tied off as the clamps are removed. Special attention should then be paid to the ovarian ligament, which must be understitched separately (*see* Fig. 437) ; it retracts a good deal when divided, and as a vessel of considerable size (the anastomotic branch of the uterine artery) accompanies it, dangerous hæmorrhage may occur from slipping of the ligature. Securing the pedicle in sections is preferable to embracing a considerable thickness of tissue with stout ligatures, for it gives more secure control of hæmorrhage, and does not strangulate the included tissues, or limit the future mobility of the uterus. The ovary of the opposite side should be carefully examined before the abdominal incision is closed, for in many cases a second smaller tumour is found, the existence of which was previously unsuspected.

Finally, the raw surfaces of the pedicle should be sewn over with a running stitch of fine catgut or thread, to prevent the formation of adhesions, which are so apt to result from the exposure of a raw area within the peritoneal cavity. A certain amount of raw surface cannot be entirely avoided, but its extent should be kept within the narrowest possible limits. When dealing with bilateral cystic tumours in young women, it may occasionally be desirable to retain a portion of normal ovarian tissue if such exists. Pseudomucinous cysts and cystic teratomata may thus be dealt with, when no suspicion of infection or of malignancy is present. Follicle-bearing tissue can often be recognized near the attachment of the ovarian ligament, and this may be preserved when dividing the pedicle. All oozing from the raw ovarian tissue must be carefully controlled with fine stitches.

**Removal of Broad Ligament Cysts.** Occasionally these cysts develop in an upward direction and become provided with a definite pedicle, when they can be dealt with in the same manner as an ovarian cyst. Usually, however, they develop in a downward direction, their base resting on the pelvic floor, their sides and summit being covered with the widely separated layers of the broad ligaments. Stretched over the tumour are the round ligament and the Fallopian tube with a wide interval between them (*see* Fig. 433) ; on the posterior aspect the ovary may sometimes be found intact, although oftener it is

unrecognizable. Such a growth is dealt with by enucleating it from its bed.

A transverse incision is made through the peritoneum covering the upper surface of the tumour parallel to, and in front of, or behind, the Fallopian tube. If the cyst is not adherent a loose bed of cellular tissue is at once entered which may be opened up by blunt dissection around

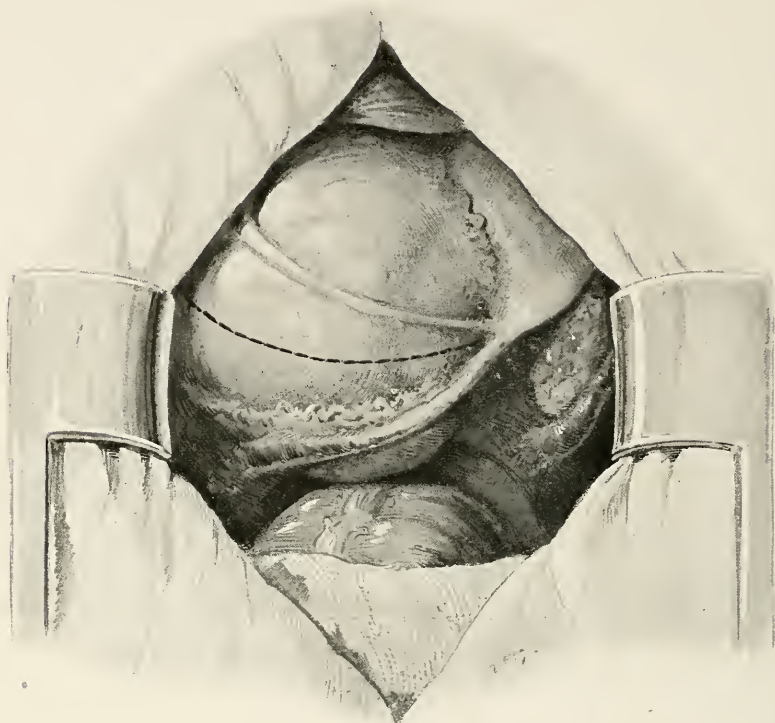

FIG. 433. CYST OF THE LEFT BROAD LIGAMENT EXPOSED *in situ*. The dotted line shows the incision in the peritoneal covering ; in front of it runs the round ligament.

the tumour so as to free it. Usually these cysts have very thin walls and are easily ruptured ; with care, small ones can be enucleated completely and removed intact (*see* Fig. 434). In the case of large ones, it is better to open the cyst after freeing the top and sides and empty it of its contents, or the manipulations will be much hampered by the bulk of the tumour. In freeing the deeper parts, the walls of the detached broad ligament are picked up with ring forceps, and the deeper parts of the cyst can then be peeled off with the fingers or with a swab held on a long pair of forceps. Gentleness is here requisite or the cyst-wall will tear, leaving portions behind. The cyst-wall is most likely to be adherent in relation to its floor, and here fibrous bands may be met

with which must be clamped and divided with scissors, and afterwards ligatured.

The bed of the cyst is next carefully examined and all oozing-points controlled; complete hæmostasis is essential to the success of the final stage. This consists in obliterating the deepest part of the bed with sutures introduced as shown in Fig. 435. The redundant peri-

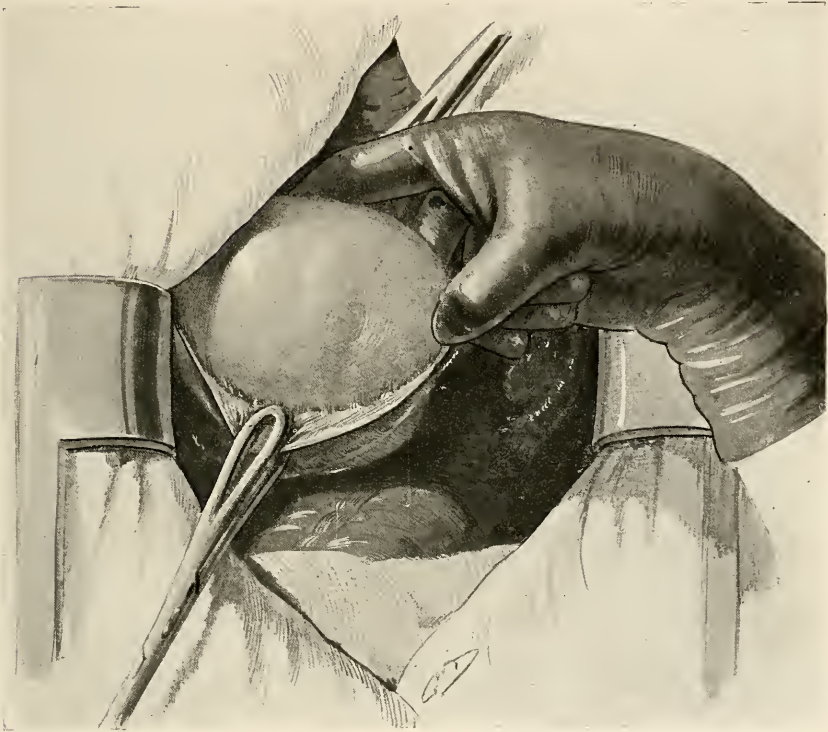


FIG. 434. SHELLING THE BROAD LIGAMENT CYST OUT OF ITS BED WITH THE FINGERS.

toneum which was in relation to the upper part of the tumour is then cut away, care being taken of the tube and ovary, and the peritoneal edges can then be brought together by a continuous suture. If bleeding from the bed of the tumour cannot be completely controlled, an opening should be made into the posterior vaginal fornix (see Fig. 416, p. 738), and a rubber tube passed into the vagina for drainage; it can be removed in forty-eight hours. Finally, the upper part of the broad-ligament cavity is closed over the drain-tube.

*Infected broad ligament cysts* are very difficult to deal with; complete enucleation of the adherent cyst-wall is often impracticable. Here vaginal drainage is invaluable and should be carried out somewhat differently. The infected bed may be swabbed with tincture of iodine and the vaginal fornix opened *freely*. The end of a long length of

bismuth or iodoform gauze is then passed into the vagina, and the remainder used to pack the bed from below upwards. Finally, the peritoneum should, if possible, be closed over the gauze packing; if this is not practicable a second supra-pubic drain must be employed as well.

Vaginal drainage calls for special precautions in after-treatment which will be mentioned later on (*see* p. 863).

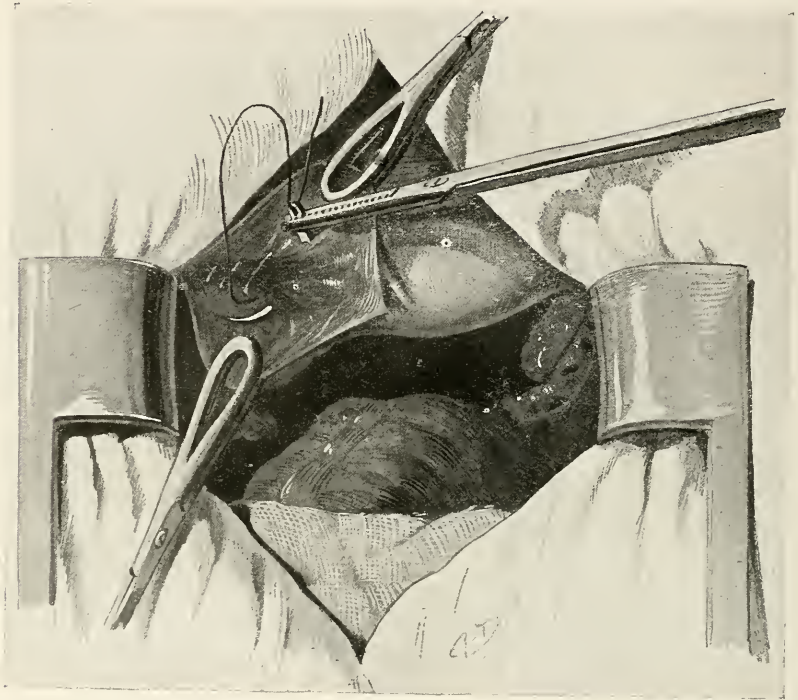


FIG. 435. CLOSING THE BED OF THE BROAD LIGAMENT CYST WITH A RUNNING STITCH.

### OPERATIONS ON THE UTERINE ADNEXA

**Indications.** The following conditions may necessitate the partial or complete removal of one or both the Fallopian tubes, or of the ovaries, or portions of the ovaries, or of both tubes and ovaries: (1) pyosalpinx, or ovarian abscess, or both; (2) non-suppurative inflammation, including hydrosalpinx and cystic disease of the ovaries; (3) new growths of the tubes or ovaries; (4) extra-uterine gestation.

When the tube with its companion ovary is removed, the operation is known as *salpingo-oöphorectomy*; it may be unilateral or bilateral. In removing an ovarian tumour, the corresponding tube is also removed, as it forms a part of the pedicle. There is, further, no advantage in retaining the tube after the ovary has been removed. Removal of

the tube alone, or of the ovary alone, is known as *salpingectomy* or *oöphorectomy* respectively. When a portion only of the ovary is removed the operation is called *resection*. The construction of an artificial abdominal ostium in the outer portion of the tube is called *salpingostomy*.

**In Suppurative Cases.** Tubes or ovaries which are the seat of suppuration cannot be dealt with on conservative lines, but must be entirely removed. After a preliminary inspection of the parts, the pelvic cavity should be isolated by careful packing with swabs and rolls of gauze, to avoid soiling of the upper peritoneal cavity. It is often impossible to avoid opening collections of pus during the manipulations.

The separation of adhesions, in suppurative cases, requires careful and delicate manipulation. Omental adhesions are usually first encountered. Tags may be simply detached, but larger portions of adherent omentum may be cut away and secured with ligatures. Bowel-adhesions should next be dealt with. In the case of the right adnexa the vermiform appendix is frequently involved, and should always be examined (*see* p. 767).

As far as possible each part should be seen as well as felt, and in dealing with adherent structures in the pelvis, the proper exposure of the parts is facilitated by the use of a double-bladed retractor such as that shown in Fig. 411, p. 734, which will mechanically hold the edges of the wound widely apart. Lightly adherent coils of intestine should be gently peeled off with a swab; firm bands of intestinal adhesion may be divided with blunt-pointed scissors, as far as possible away from the wall of the bowel. The peritoneal coat of the adherent intestine is frequently damaged during separation, and in difficult cases the lumen of the bowel may be actually opened. It may even occasionally be necessary to resect a length of small intestine which has become closely involved, and perform an anastomosis.

In dealing with tuberculous cases, injuries to the intestine are especially dangerous; fæcal fistulæ are very apt to result, and tuberculous fistulæ are so intractable that they must be regarded as practically incurable.

The position in which adhesions to bowel are most difficult to deal with is the neighbourhood of the rectum. The parts cannot easily be brought up into the wound or dealt with under direct observation; the sense of touch has to be largely relied upon, aided by such direct illumination of the deeper parts of the pelvic cavity as is possible. In comparatively recent cases the inflamed intestinal wall is unusually friable, and tears with unexpected ease. The injury may not be detected until the adherent structures have been removed, and the bed in which they lay has been carefully inspected. It is therefore obvious that a minute examination of the rectum should always be made when deep adhesions in its neighbourhood have been dealt with.

All injuries to bowel must be at once repaired. If the peritoneal coat only has been torn, a single row of stitches, or a running stitch reuniting the edges, will suffice. If the muscular coat has been torn or the lumen of the bowel laid open, deep stitches embracing all the coats should first be introduced, and then one or two rows of Lembert's stitches superimposed. The stitches should as far as possible be introduced in the transverse axis of the gut to avoid constriction.

Adhesions to other structures such as the uterus, the back of the broad ligament, and the opposite tube and ovary, can be dealt with more freely than those which involve the intestine.

Collections of pus in the tube or ovary may be evacuated by aspiration or with a trochar, or by an incision, before attempting to

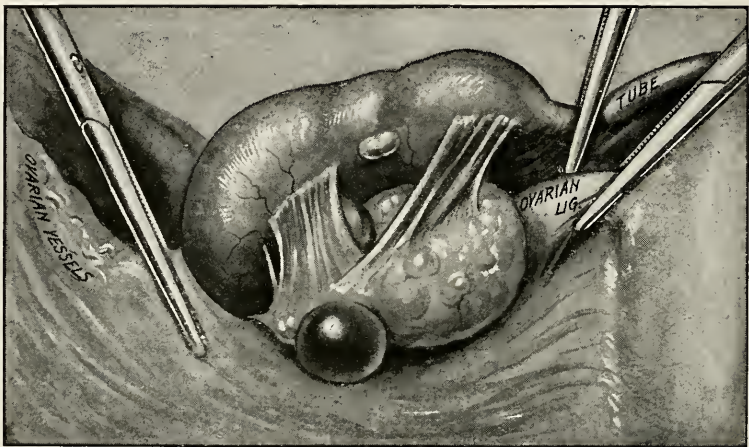


FIG. 436. TREATMENT OF THE PEDICLE IN SALPINGO-OÖPHORECTOMY (modified from Kelly and Noble). Three structures are secured with clamps: (1) the infundibulo-pelvic fold containing the ovarian vessels; (2) the uterine end of the tube; (3) the ovarian ligament. The tube and ovary are then cut away.

draw them out of the wound; in this way the escape of pus can be controlled better than when the abscess bursts during the manipulations.

When after separation of the adhesions the pedicle has been defined, it is often found considerably thickened by inflammatory changes; ligature in bulk of such a pedicle is undesirable; it should be clamped in three or four sections, and the appendages cut away before the ligatures are passed (*see* Fig. 436). The outer ligature includes the ovarian vessels; of the inner ligatures, one embraces the uterine end of the tube, the other the ovarian ligament and its accompanying vessel (*see* Fig. 437). A separate ligature is desirable for the latter structure, as it contains a good deal of muscular tissue which retracts, and it is usually accompanied by an artery of considerable size. The



fourth ligature shown in Figure 437 is not required unless the pedicle is long or thick. If the uterine end of the tube is much thickened it should be excised along with a wedge-shaped piece of the uterine cornu, the gap thus left in the uterus being closed with interrupted stitches. This will obviate the risk of subsequent trouble arising from the stump of the infected tube.

In *bilateral* suppurative cases, both ovaries are frequently so closely involved, that their removal is called for as being probable foci of infection. When this is the case it is better to remove the uterus as well, for the following reasons: (a) the organ is functionless when both ovaries have been removed; (b) it is in many cases infected also, and may give rise to much subsequent trouble if not removed; (c) the

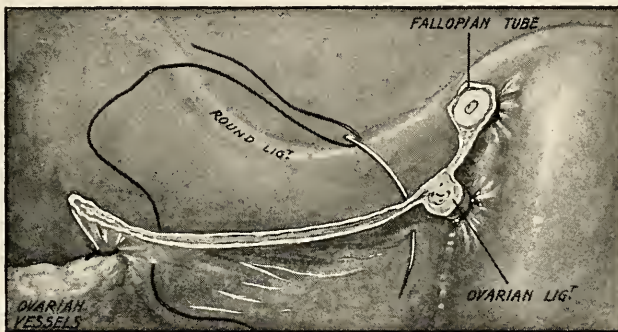


FIG. 437. LIGATING THE PEDICLE IN SECTIONS AFTER THE TUBE AND OVARY HAVE BEEN CUT AWAY (modified from Kelly and Noble).

operation-field can be much more efficiently drained when the uterus has been removed; (d) the severity and duration of the operation are not appreciably increased by this procedure. The method of total hysterectomy has been described on pp. 745-751.

The restoration of the peritoneal covering of the pelvic floor is often a matter of some difficulty after these operations. Usually the peritoneal covering of the bladder can be largely utilized, and raw areas of considerable extent, which cannot be covered, may be shut off from the general abdominal cavity by stitching over them a free loop of the pelvic colon; or a piece of the omentum may be grafted over it.

Drainage is always necessary in difficult cases although no absolute rule need be laid down (see p. 738). The vaginal route is the route of choice, and when the whole of the uterus (panhysterectomy) has been removed it involves no additional incision. If this has not been done, the posterior fornix can be opened by cutting down upon a pair of forceps introduced into the vagina by an assistant. When bowel has been extensively injured, or there has been escape of pus, suprapubic as well as vaginal drainage may be necessary.

**In Non-suppurative Cases.** In non-suppurative conditions an attempt should always be made in the case of women, under forty years of age, to avoid the complete removal of both ovaries. In cases of bilateral hydrosalpinx, the tubes may be removed without the ovaries when the latter are unaffected, except for the presence of peri-öphoritic adhesions; if the ovaries are also the seat of small cysts, as is frequently the case, resection of the diseased portions is usually practicable, leaving sufficient ovarian tissue to maintain the ovarian functions. Multiple small cysts may be destroyed by the actual cautery, and the ovary then dropped back into its place.

**Salpingectomy.** This operation consists in dividing the whole extent of the mesosalpinx, from the infundibulo-pelvic fold to the cornu of the uterus, and then cutting through the isthmus of the tube, or excising the interstitial portion along with the remainder of the tube. The divided mesosalpinx is secured with two or three fine ligatures, the vessels it contains being small and unimportant except near the uterine border (*see* Fig. 44, p. 69). The tissues at the angle of the uterus are very vascular, and in this position bleeding-points must be carefully controlled. This procedure forms also the operation of choice in cases of tubal gestation; the ovary as a rule is healthy, and it is unnecessary to sacrifice it, if this is not necessitated by its relation to the gestation-sac.

**Salpingostomy** consists in constructing an artificial abdominal ostium in the ampullary portion of the tube. It is suitable only for cases of chronic hydrosalpinx in which the contents are thin and serous, the walls of the tube not thickened, and in which the patency of the tube-lumen can be demonstrated by passing a probe up to the uterus. An incision an inch and a half long is made upon the dorsal surface of the tube, which goes through all the coats; the edge of the tubal mucosa is then united to the peritoneal coat with a few fine interrupted stitches. The results of this procedure as regards future pregnancy are not encouraging, as adhesions often form around the new *ostium abdominale*, closing it once more, and in addition the ciliary function of the tubal mucosa may have been destroyed by the inflammatory changes.

**Resection of Follicular Cysts.** Small follicular cysts, not exceeding the size of a pea, are frequently found in healthy ovaries, and do not call for removal. When such cysts exceed the size of a cherry it is better to remove them by resection. A wedge-shaped piece is first cut out, including the greater portion of the cyst-wall; the base of the cyst will then be found to present a definite lining membrane which can be peeled off with forceps. The incision in the ovary is then closed with fine interrupted stitches. All bleeding must be carefully controlled before the ovary is dropped back into the pelvis.

## APPENDECTOMY

**The Incision.** When the abdomen has been opened by a sub-umbilical incision for a pelvic operation, it is easy to explore and remove the appendix at the same time. If the operation is undertaken primarily for the appendix, the lateral incision through the *linea semilunaris* is often most convenient; this also allows of the pelvic organs being explored, and the right appendages can be removed conveniently through it, if the incision is extended downwards towards Poupart's ligament. The gridiron-incision parallel to Poupart's ligament has the disadvantage for the gynæcologist that access to the pelvis cannot be obtained through it.

**Steps.** There are three steps in the operation proper: (a) to find the appendix; (b) to isolate and excise the appendix; (c) to peritonize the stump.

(a) In a chronic case it is not always an easy matter to find the appendix, and a careful search is sometimes required. Cases reported by operators of 'absence of the appendix' represent in reality only failures to find it, for the organ is never absent unless it has been removed by operation. The first step in a difficult case is to expose the *caput cæci* entirely, define the anterior longitudinal band and trace it to its termination; this corresponds with the base of the appendix, as some of the fibres of this band pass into the muscular coat of the appendix. If this fails to disclose the organ, the cæcum should be freed and displaced upwards so that its posterior surface can be examined; this is not an uncommon position in which to find the appendix. If this also fails the inner aspect of the cæcum and ascending colon must be minutely explored upwards as far as the hepatic flexure; it is here that serious difficulties with adherent small gut may be met with. Lastly, the peritoneal pouches behind the ileo-cæcal junction should be explored; these are the most difficult situations in which to find the appendix.

(b) When found, the appendix must be very carefully handled whilst freeing it from its adhesions. Usually it is best to begin with the distal end and work towards the cæcum; if, however, this end is inaccessible, as may be the case when the appendix runs upwards, it is best to define the point of origin in the cæcum, divide this between two pairs of forceps, and then work towards the tip of the organ, securing the mesentery in sections at the same time. Adhesions to small bowel call for very careful management, in order to avoid lacerating the delicate wall. When dense adhesions unite the appendix and the Fallopian tube, these adhesions need not be disturbed, for each organ can be readily removed, beginning with its point of origin and working towards the site of the adhesions.

When the appendix and its mesentery have been defined, the latter is transfixed with a needle near the wall of the cæcum, and the

ligature tied upon the free margin. If the mesentery cannot be properly

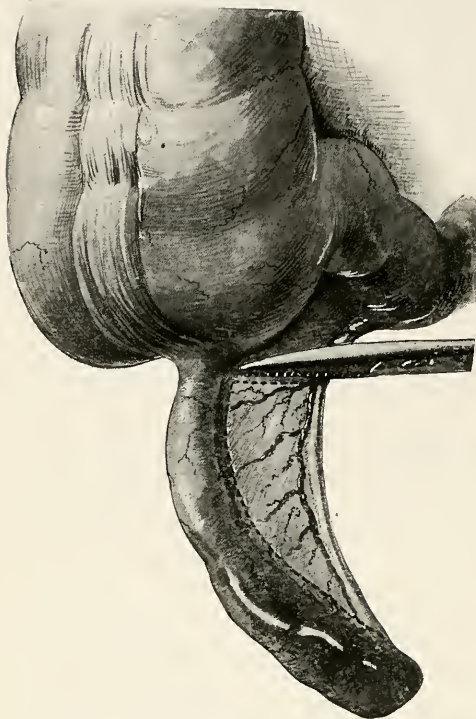


FIG. 438. REMOVAL OF APPENDIX. The organ is separated from its mesentery by an incision corresponding to the dotted line.

freed, it is best to clamp and tie it in sections up to the cæcal wall. When the appendix has been properly cleared, it should be brought up into the wound along with a portion of the cæcum, so that it can be carefully isolated from the peritoneal cavity and the edges of the wound, by packing with gauze. The base of the appendix having been thus cleared is clamped (*see* Fig. 439), and a ligature placed upon the groove left by the clamp (*see* Fig. 439A). Excision is completed by placing another clamp on the distal side of the ligature and cutting between the two; the second clamp prevents escape of fæcal contents from the distal part of the appendix. The appendical mucosa now exposed in the stump is touched with the actual cautery or with a strong antiseptic such as carbolic acid or tincture of iodine.

(c) The stump of the appendix is peritonized by burying it completely

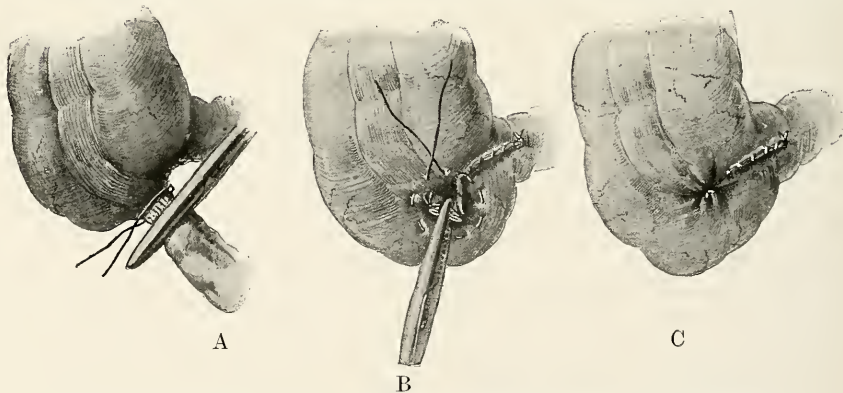


FIG. 439. APPENDECTOMY. A. Ligature applied to crushed base of appendix. B. Invagination of stump, purse-string suture placed in position. Mesentery oversewn. C. Stump peritonized by drawing tight the purse-string suture.

in the wall of the cæcum (*see* Fig. 439B). In a simple case this can

be done with a purse-string stitch, which should be of linen thread or silk of a medium size. This stitch is introduced about one inch outside the base of the appendix; it passes first through the anterior longitudinal band which is firm and comparatively avascular, then takes up the bowel-wall again, and at the opposite point takes up the mesentery of the appendix. It is desirable to introduce this stitch before amputating the appendix, so that the stump can be buried immediately, before any further manipulations are required. When the purse-string is being tied, an assistant pushes the stump inwards towards the lumen of the gut, invaginating the cæcal wall, which is thus brought together over it (*see* Fig. 439c). If inflammatory thickening of the wall of the gut has occurred, the purse-string is unsuitable and the stump must be buried by a double row (superimposed) of Lembert's stitches. In acute cases, when the bowel-wall is often inflamed, no attempt should be made to bury the stump, owing to the risk of lacerating the friable bowel-wall with the stitches. The stump is simply cauterized and then dropped into the abdomen.

When the appendix cannot be freed from adhesions, for example, to a coil of small intestine, without lacerating the bowel, it may be dealt with as follows: First, the base is defined, crushed with forceps, ligatured and divided. Then the appendix is laid open by a longitudinal incision, and the mucosa peeled off with forceps. The fibro-muscular shell remaining is then cauterized *in situ*, and a drainage-tube passed down to it, no attempt being made to remove it.

Drainage is usually necessary in acute cases, seldom necessary in chronic cases. In acute cases with localized suppuration, only the abscess-cavity requires drainage. When a good deal of free purulent, or semi-purulent, fluid is found in the general peritoneal cavity, it is usually advisable, in addition, to drain the pouch of Douglas. This can be done by the supra-pubic route, or by posterior colpotomy after closing the abdominal wound (*see* p. 777).

## VENTRISUSPENSION AND VENTRIFIXATION

**Definition.** These names are given to operations designed to keep the uterus in a position approximating to that of normal anteversion. This may be done in three ways: (a) by stitching the body of the uterus directly to the abdominal parietes (*ventrifixation*; *hysteropexy*); (b) by shortening the extraperitoneal parts of the round ligaments (*Alexander-Adams operation*), or by interposing the intraperitoneal portion of the round ligaments between the layers of the abdominal parietes (*ventrisuspension*); (c) by stitching the body of the uterus to the anterior vaginal fornix (*vaginal fixation*). Of these methods the third has been shown by experience to entail so many disadvantages that it is not to be recommended, and it will therefore not be described. The first is of occasional service, but only under certain special

conditions which will be indicated below. The second method is that generally applicable; there are, however, several different ways in which it may be carried out, not all of which can be described fully in a text-book. The intra-peritoneal operation, fully described below (Gilliam's), is that which in the authors' opinion is the best.

**Indications.** The common indication for these operations is backward displacement of the uterus (*see* p. 570); occasionally they may be useful in prolapse when combined with plastic vaginal operations.

### Ventrisuspension

Operative anteversion of the uterus by means of the round ligaments may be carried out by simply shortening the ligaments, or by interposing them between the layers of the abdominal parietes; the former is an extraperitoneal, the latter an intraperitoneal operation.

**Extraperitoneal Operation. Alexander-Adams Operation.** This operation consists in: (*a*) exposing the external abdominal ring on each side by an incision similar to that for inguinal hernia; (*b*) isolating the round ligament as it leaves the inguinal canal, and pulling out a length of at least two inches on each side; (*c*) cutting off the length and stitching the cut end to the pillars of the external ring. This procedure is practicable only in cases of 'simple' backward displacement; *i.e.* cases in which there are no adhesions, or other conditions which require treatment. Its usefulness is therefore strictly limited, for it has been already explained that very few cases of simple backward displacement require operative treatment (*see* p. 571). The chief objection to it is that the operation is performed, as it were, in the dark, and the exact effects upon the uterus of what is done cannot be observed directly. It was introduced at a time when the fear of opening the peritoneal cavity led surgeons to adopt various devices to attain their ends without doing so. Now that improved technique has rendered this procedure safe, the *raison d'être* of the Alexander-Adams operation has to a great extent passed away. The results obtained in suitable cases were good.

**Intraperitoneal Operation.** When the abdomen has been opened, the round ligaments can be utilized to suspend the uterus in various ways; the two objects aimed at are to shorten the ligaments, and to furnish them with fresh attachments. In the intraperitoneal operations, the part of the round ligament made use of for suspending the uterus is the proximal two or three inches; this is much stronger than the distal part which is made use of in the Alexander-Adams operation. The fresh attachments are usually made to the anterior abdominal wall, but in one method a loop of round ligament on each side is passed backwards through an aperture made in the mesosalpinx, and the two loops are then stitched together and to the posterior uterine wall. As the results of this procedure are unsatisfactory, it will not be further described. The usual method is to pull a loop of each round ligament through the *deep layers* of the abdominal parietes, and stitch them to

the edges of a small opening made in the *anterior sheath of the rectus*

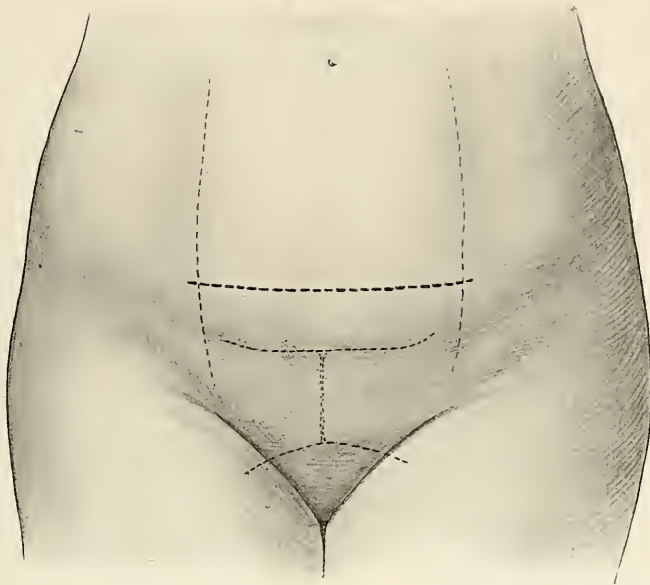


FIG. 440. THE TRANSVERSE ABDOMINAL INCISION.

*abdominis muscle*. The procedure can be carried out by different

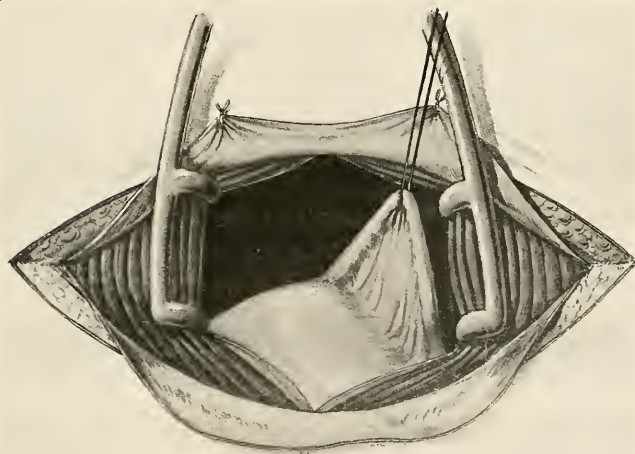


FIG. 441. A LOOP HAS BEEN PASSED UNDER THE ROUND LIGAMENT AND USED TO PULL THE UTERUS UP INTO THE WOUND.

methods, but that introduced by Gilliam is the best, and this alone

will be fully described. The idea underlying Gilliam's operation is that the loop of round ligament should be embedded, as far as possible, in the subperitoneal cellular tissue, instead of being carried across the peritoneal cavity to the parietes.

*Gilliam's Operation.* The operation here described, while it follows the general lines of Gilliam, comprises one or two small modifications which the authors have found serviceable.

The abdominal incision should be transverse, running from the semilunar line on one side to that on the other, at a level of about two fingers' breadth above the symphysis (*see* Fig. 440). Skin, sub-

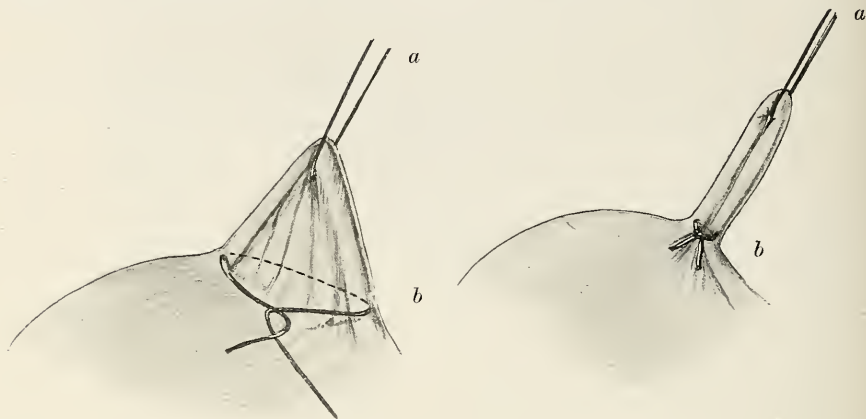


FIG. 442. THE STITCH WHICH LOOPS THE PROXIMAL END OF THE ROUND LIGAMENT. *a*, Traction-ligature. *b*, Loop-ligature.

cutaneous tissues, and rectus sheath are to be divided in the same plane, the incision being carried outwards on each side until the outer edge of the rectus muscle is seen. Careful hæmostasis is required, as many more vessels are divided in the transverse than in the longitudinal incision. The aponeurosis is then stripped carefully off the muscles, downwards to the pubic bones, and upwards for about the same distance. In order to open up the wound the upper aponeurotic flap may be fixed by stitches to the skin as shown in Fig. 441. Next, the recti are separated from one another *in the middle line*, and the peritoneum opened in the same plane. This incision yields a scar which is exceptionally strong, inasmuch as the superficial parietal planes are divided at right angles to the deep ones. Further, it allows the interposition of the loop of round ligament to be carried out more exactly, as will appear later on.

The uterus and its adnexa are then carefully examined. Adhesions may have to be dealt with, and in that case not only the uterus but the tubes and ovaries must be completely liberated before the subsequent steps are begun. A point upon the round ligament about



two inches from the uterine angle is seized and a ligature passed beneath it with which it is pulled upwards ; this is the *traction-ligature* (see Fig. 441) ; the two limbs of the loop are then stitched together as shown in Fig. 442. The first ligature is for temporary use as a tractor in the subsequent stages. The procedure is then repeated on the opposite side. It is best to employ ligatures of unabsorbable material such as silk or thread for this operation. The object of this step is to double the ligament and thus increase its strength as a support, and at

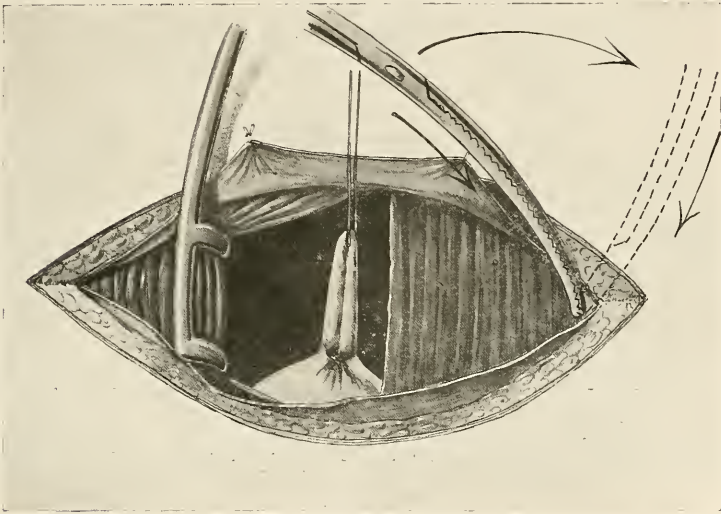


FIG. 443. THE CURVED DRESSING FORCEPS ARE INTRODUCED AT THE OUTER EDGE OF THE RECTUS. The dotted lines and arrows show the direction of the forceps in passing behind the anterior layer of the broad ligament.

the same time to provide that traction made upon the loop shall be effectively exerted *upon the fundus of the uterus*.

The next step is the *interposition* of the round ligament. A slightly curved pair of blunt-pointed forceps (see Fig. 443) is introduced outside the edge of the rectus muscle and pushed downwards in the plane of the extraperitoneal cellular tissue towards the anterior pelvic wall ; the transversalis fascia is the only structure actually pierced by it. Thence it is directed through the internal inguinal ring and thence again beneath the anterior layer of the broad ligament, and as the cellular-tissue planes of the pelvis and the parietes are continuous, no further structure is pierced. It is then pushed on towards the uterine angle, and made to pierce the peritoneum on the anterior surface of the broad ligament just below the base of the loop (see Fig. 444). The ends of the ligature holding the loop are then seized in the forceps and pulled upwards ; the loop follows it and is easily made to appear at the outer border of the rectus (see Fig. 445) ; here it is at once

fixed by thread stitches to the angle of the incision in the rectus sheath

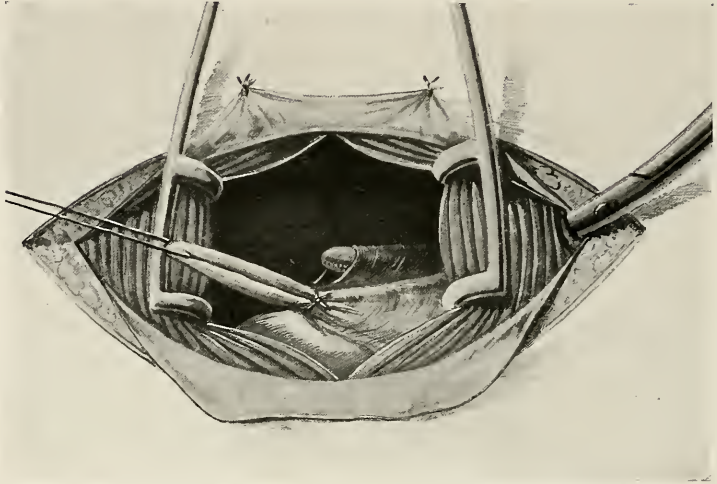


FIG. 444. SHOWS THE POINT OF THE FORCEPS EMERGING BELOW THE LOOP-STITCH ; THE TRACTION-LIGATURE IS SEIZED BY THE FORCEPS AND PULLED THROUGH.

and the traction-ligature is then withdrawn ; the procedure is repeated on the other side.

It will be found that the uterus now lies with the fundus directed

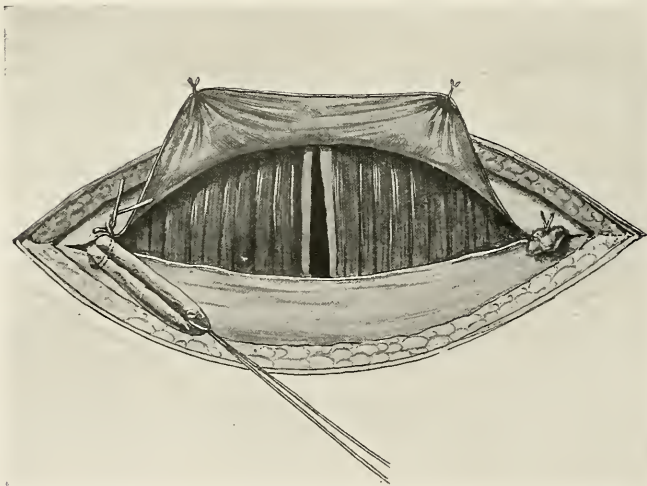


FIG. 445. THE LEFT LIGAMENT HAS BEEN PULLED THROUGH AND STITCHED TO THE ANGLE OF THE INCISION IN THE APONEUROSIS.

forwards but not in actual contact with the parietes. The utero-vesical pouch is *wide and roomy*, and its peritoneal surfaces have not

been injured or disturbed, so that no bands or adhesions can be formed by which loops of gut could conceivably become strangulated.

The abdominal incision is closed in the usual manner in layers, and a fine rubber tube may be sometimes employed to drain the subaponeurotic strata which are often the seat of some serous oozing. The relations of the uterus and the interposed ligaments are shown in Figure 446.

If the longitudinal incision is employed, the loops of round ligament are interposed as follows. The anterior surface of the rectus sheath is cleared outwards from the incision for two or three inches. A small transverse cut is then made in it, and through this the blunt

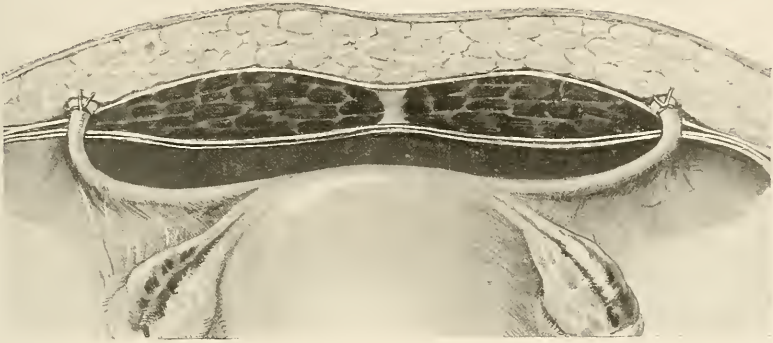


FIG. 446. SHOWING THE RELATION OF THE ROUND LIGAMENTS TO THE PARIETAL STRUCTURES WHEN THE OPERATION HAS BEEN COMPLETED.

forceps are pushed through the rectus muscle, and then directed through the internal inguinal ring and along the anterior pelvic wall, up to the uterine cornu. A simpler plan may be followed by simply pushing the forceps straight through all the parietal layers, including the peritoneum, without attempting to direct it beneath the anterior layer of the broad ligament to the uterine cornu. This has the disadvantage that the utero-vesical pouch is encroached upon laterally.

### Ventrifixation. Hysteropexy

In this operation the uterus is stitched directly to the anterior abdominal parietes. After the abdomen has been opened by a median incision, the uterus and adnexa are carefully and completely freed from adhesions, and then brought up into the wound and examined.

The introduction of the sustaining sutures is a point of great importance. The *upper part of the uterine body* must be left free, and the sutures introduced into the anterior wall as low down as possible; the sutures must, however, in all cases be placed above the level of the peritoneal reflection on to the bladder, which should be carefully identified before they are introduced. In this way the bladder will be

avoided, the fundus will be left free, and the anterior surface of the uterus will be drawn into apposition with the abdominal wall.

The stitches should be of chromicized catgut or fine silk, and should be passed from side to side, first picking up the parietal tissues and then being carried deeply into the muscular layer of the uterus, finally emerging through the parietal tissues of the opposite side. The first stitch may be made to include the parietal peritoneum only, on each side of the incision ; a second pair may be made to include the peritoneum, rectus muscle, and aponeurosis, by which a firmer hold is obtained ; four sutures alternately superficial and deep will suffice in all cases. Catgut ligatures are absorbed in a few weeks, and silk ligatures probably cut their way out of the uterus in time, so that in all cases the retention of the uterus in its new position depends upon the formation of a band of adhesions in the position of the stitches. This band is often thick and strong, but it may stretch to a length of one inch to two inches, when its supporting power is lost to a very great extent (*see* Fig. 326, p. 611). Stitches which include the parietal muscle and fascia approximate the uterus, for the time being, more firmly to the abdominal wall, while the adhesions are being formed and strengthened by organization, for which time is required. These adhesions always allow of a certain range of mobility, and it is probable that this operation seldom if ever results in *fixation*, strictly speaking, of the uterus.

**Comparison of Ventrisuspension and Ventrifixation.** Now that these operations have been described, the question of their relative merits must be considered.

The following advantages over ventrifixation may be claimed for ventrisuspension : (*a*) the position of the uterus is much more nearly that of normal anteversion than is the position after direct fixation ; (*b*) the utero-vesical pouch is not encroached upon, and the bladder is free to expand both upwards and laterally ; (*c*) no adhesions are formed between the uterus and the abdominal wall which might give rise to intestinal obstruction ; (*d*) the entire body of the uterus is free to develop during pregnancy, and in this development it is important to remember the round ligaments participate, so that they become elongated.

It is beyond question that a considerable number of cases of acute intestinal obstruction have occurred, resulting from adhesions following direct fixation (ventrifixation), and also that in many cases serious obstetric complications in pregnancy or labour have been recorded.

In elderly women who have passed the age of child-bearing, and in persons who, as the result of removal of both tubes or both ovaries, have been rendered absolutely sterile, the obstetric objections to direct fixation do not apply.

The only important objection to ventrisuspension is the variability

of the round ligaments in thickness ; sometimes they are so thin that even looping them does not provide a support of adequate strength. It is possible that ligaments as weak as this may subsequently elongate sufficiently to allow of recurrence of the backward displacement. Again, in cases of chronic pelvic inflammation the round ligaments may be adherent and so thickened as to become rigid. They cannot then be utilized for interposition and Gilliam's operation becomes impracticable.

## VAGINAL AND VULVAL OPERATIONS

### COLPOTOMY

This operation consists in making an incision through the anterior fornix so as to open the utero-vesical pouch (anterior colpotomy), or through the posterior fornix so as to open the pouch of Douglas (posterior colpotomy). The object of the operation is to evacuate collections of blood or of inflammatory fluids in these pouches, or sometimes to remove new growths of small size such as ovarian cysts or pedunculated myomata, or to open and drain tubal or ovarian collections of pus in acute suppurative inflammation of the uterine adnexa.

**Posterior Colpotomy.** The cervix is exposed as shown in Figure 447, and the posterior lip seized with a volsella and drawn forwards so as to expose the posterior fornix. A transverse incision an inch and a half long is then made about an inch away from the *os externum* ; this divides the vaginal mucous membrane and opens up the cellular tissue plane in the floor of the pouch of Douglas. The finger is then passed through the incision and the tissues are picked up with forceps close to the posterior wall of the uterus, and carefully divided with scissors. In this manner the peritoneum is reached and opened at a variable depth, but by keeping close to the uterus all risk of injuring the rectum or small bowel will be avoided. The opening into the peritoneum may be enlarged by the fingers or by a pair of blunt forceps until it is as large as the incision in the vaginal wall. There is, as a rule, little hæmorrhage, but the peritoneum should be stitched to the vaginal mucous membrane by a few interrupted sutures, one being placed at each extremity of the incision.

When *collections of fluid* are present in the pouch of Douglas, they may be tapped with the trochar shown in Figure 448 as soon as the vaginal mucous membrane has been divided. This instrument consists of a strong stilette held in a special pair of forceps grooved suitably to hold it. The instrument is pushed through the wall of the collection of fluid, and then upon opening the forceps the stilette is released and can be withdrawn. By separating the blades of the forceps, the opening can

now be enlarged to the desired extent. The finger is then passed into

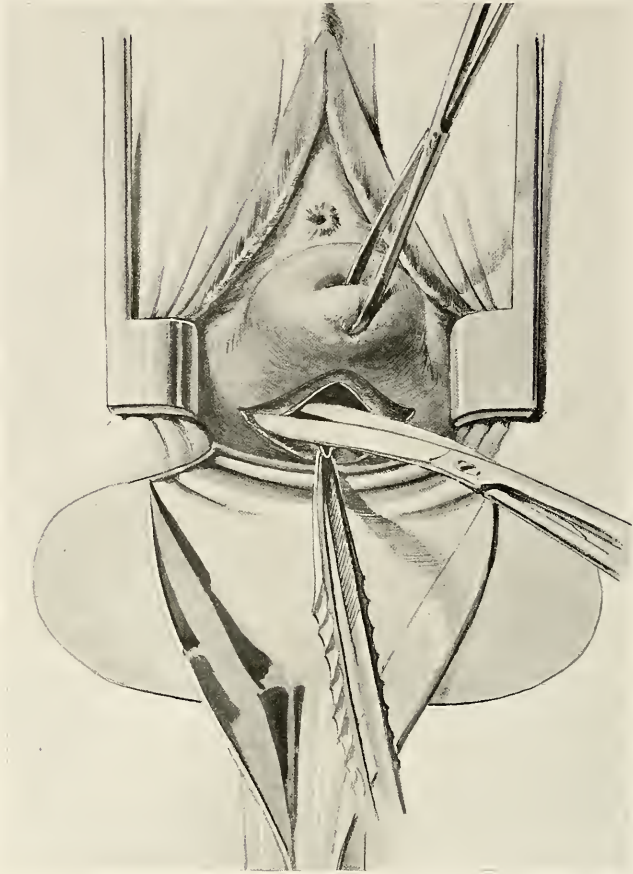


FIG. 447. POSTERIOR COLPOTOMY. The cervix has been drawn down and is being held forwards with a volsella. The mucous membrane of the posterior fornix has been divided by a transverse incision made about one inch above the external os. The peritoneum of the pouch of Douglas is caught up by dissecting forceps and is being divided transversely.

the cavity for exploration of its walls, and in chronic cases, where

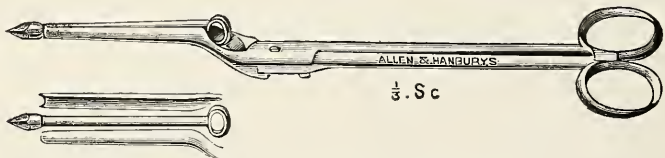


FIG. 448. MARTIN'S PELVIC TROCHAR.

the fluid has been effectively isolated by adhesions, it may be douched with a sterile saline solution to wash away blood-clot or purulent

material. This should not be done in recent or acute cases, lest infective material be carried upwards by the fluid into parts previously unaffected. Drainage may be provided for by loosely packing the cavity with gauze, or by introducing a rubber drainage-tube provided with a flange to keep it in position.

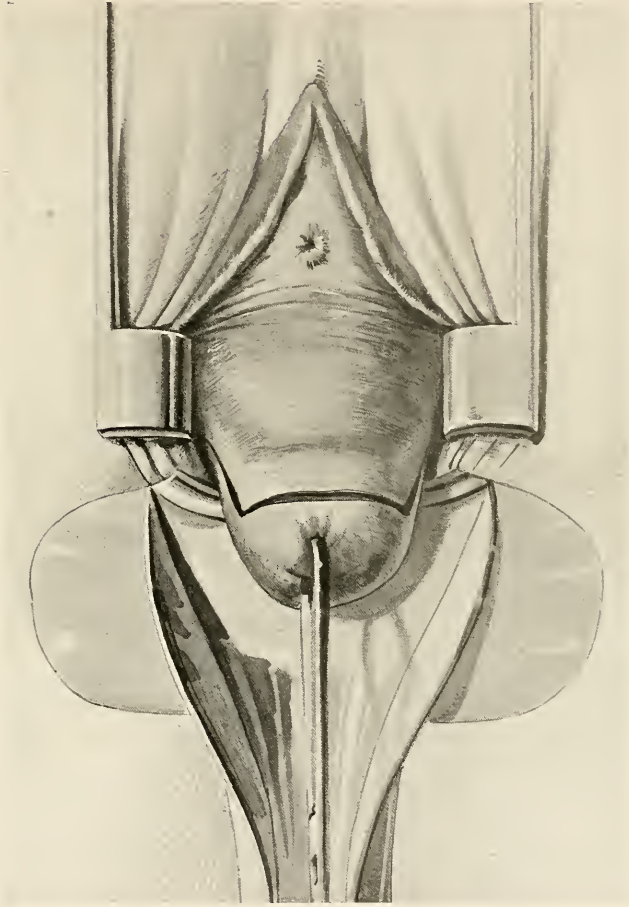


FIG. 449. INCISION PREPARATORY TO ANTERIOR COLPOTOMY AND TO SPLITTING THE CERVIX FOR THE REMOVAL OF SUBMUCOUS FIBROIDS.

**Anterior Colpotomy.** In this procedure, the preliminary steps of which are described on p. 789, a transverse incision is made across the anterior fornix, just below the lower limit of the bladder (*see* Fig. 449), which corresponds to the line where the rugose mucous membrane covering the bladder merges into the smooth mucosa covering the cervix. When there is any doubt in determining this line, the limits of the bladder are defined with a sound. The incision is necessarily made much nearer the external os than in posterior colpotomy.

The bladder is then separated from the cervix by first putting the intervening connective tissue on the stretch and dividing it with blunt-pointed scissors directed towards the cervix (*see* Fig. 450). This is done until the peritoneum is finally reached. It lies at a much deeper level than that of the posterior pouch. With the finger in the wound and directed towards the uterus, the smooth peritoneal surfaces can

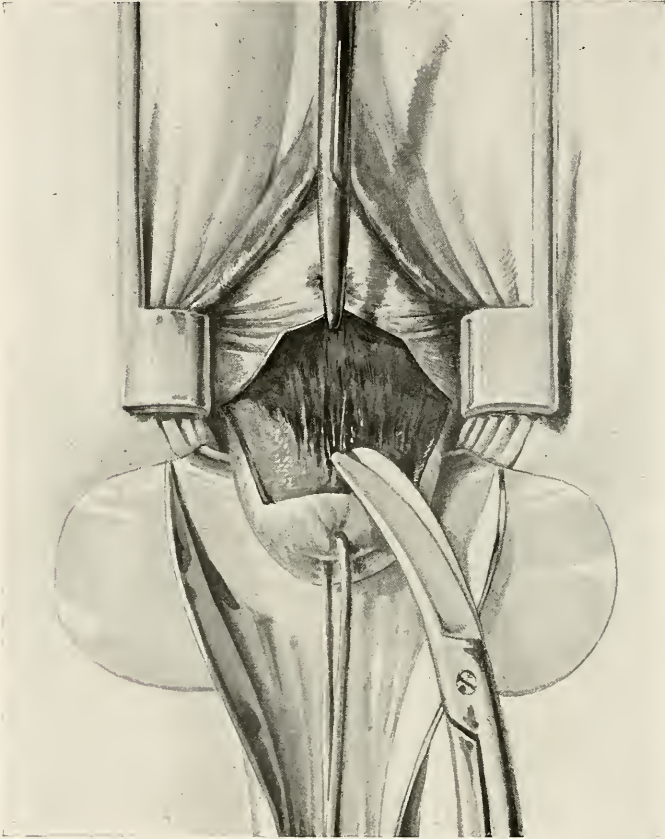


FIG. 450. METHOD OF SEPARATING THE BLADDER FROM ITS CERVICAL ATTACHMENTS.

be felt to slide over one another when the floor of the utero-vesical pouch has been reached (*see* Fig. 451). The peritoneum is now picked up with forceps, and divided close to the uterine wall so as to avoid the bladder.

This operation is much less frequently performed than posterior colpotomy, since collections of blood and of inflammatory fluids are much more commonly found in the posterior than in the anterior peritoneal pouch; nevertheless inflamed adnexa, small pedunculated fibroids, and small ovarian cysts are in some cases more easily removed by this route.



## VAGINAL FIXATION AND INTERPOSITION OF THE UTERUS

*Vaginal fixation* was introduced as a means of correcting backward displacement of the uterus. It consists in opening the utero-vesical pouch as in anterior colpotomy, and then anteverting the uterus and

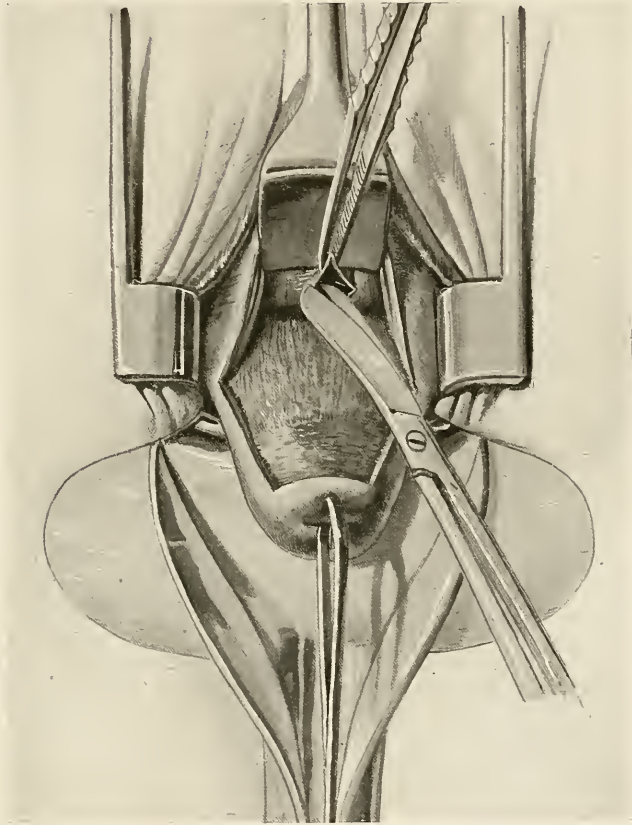


FIG. 451. ANTERIOR COLPOTOMY. The bladder is held up by a flat spatula. The peritoneum of the utero-vesical pouch is drawn down in the interval between the spatula and the uterus, where it is grasped by forceps whilst a transverse opening is made with scissors.

stitching the anterior surface of the body to the edges of the incision in the vagina, the bladder being thus displaced from its normal relation to the cervix. The results do not compare favourably with those obtained by the operations of ventrisuspension and ventrifixation already described (p. 770).

**Interposition of the Uterus.** More recently a modification of the above operation has been introduced by Wertheim, and adapted for cases of severe prolapse. Briefly, the operation consists in separating

the whole of the bladder from the anterior vaginal wall by a long median incision, extending from the cervico-vaginal reflection to a point about one and a half inches above the urinary meatus; the utero-vesical pouch is then opened as in anterior colpotomy. The fundus of the uterus is now drawn through the incision into the vagina, and the peritoneum of the utero-vesical pouch stitched to that covering the posterior wall of the uterus, so as once more to close the peritoneal cavity. The redundant part of the anterior vaginal wall is next cut away, and the edges are then brought together over the front of the uterus, which is finally fixed to the vaginal wall by several strong sutures. The uterine body is thus greatly anteverted, and lies interposed between the anterior vaginal wall and the bladder, which has been displaced upwards.

This operation is the method adopted by some operators for procidentia occurring in women who have passed the menopause; in its strongly anteverted position prolapse of the uterus is impossible, and cystocele is equally incapable of being produced. Supplemented by perineorrhaphy when the vulva is dilated or the perineum deficient, the results are said to be good. In young women this operation is not justifiable, as pregnancy cannot be allowed to occur with the uterus in such an abnormal position.

### VAGINAL HYSTERECTOMY

This operation requires a capacious vaginal outlet so that when the *introitus vaginae* is small it must be enlarged either by episiotomy or by Schuchardt's incision (*see p. 845*). The latter was commonly employed in former years when vaginal hysterectomy was performed for cancer of the cervix. Hysterectomy *per vaginam* is carried out in two ways: (1) by extirpating the uterus from above downwards; (2) by effecting its removal from below upwards. Only the latter, which is the method commonly employed, can here be described.

**Vaginal Hysterectomy from below upwards.** The cervix is seized by a volsella and drawn down. A circular incision is then made through the mucosa around the *portio vaginalis* below the level of the reflection of the bladder. Two additional antero-lateral incisions may be made as shown in Figure 449, in order to provide more room. The bladder is next dissected off the cervix (*see Fig. 450*). When this is done the cervix is drawn to one side, and the ligation and division of the parametric tissues are commenced. These include the sacro-uterine ligament behind, and the vesico-uterine parametric tissue in front, and they make up together a wide attachment of cellular tissue to the sides of the cervix. It is therefore advisable to ligate them separately. The cervix should be drawn forwards during the tying of the sacro-uterine ligament, and backwards whilst ligating the vesico-uterine parametric tissue. In Figure 452 this has been done on the

right side and the ligatures are shown drawn aside. To avoid injury to the ureters, continuous retraction of the bladder is kept up by means of a spatula inserted between the cervix and that viscus (*see*

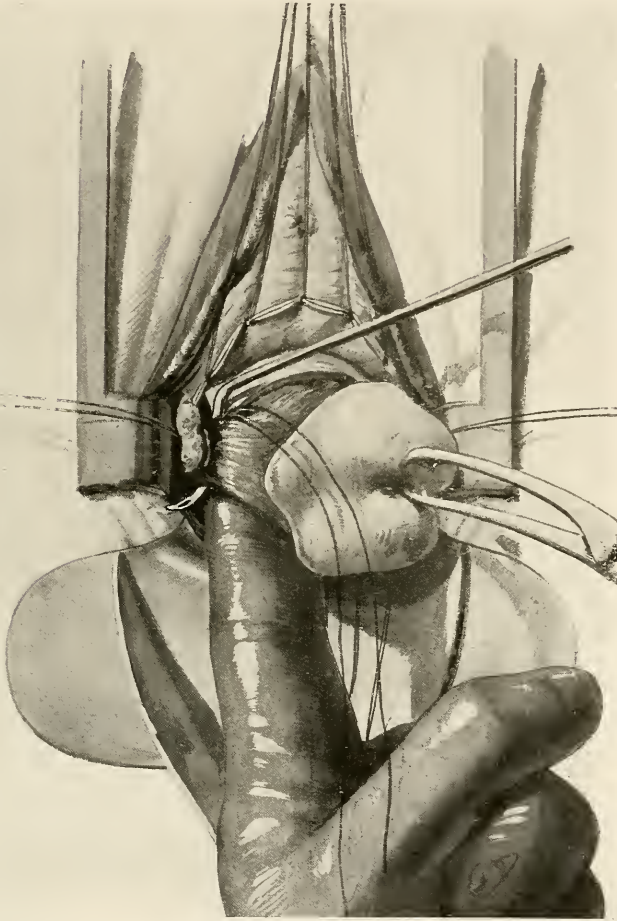


FIG. 452. VAGINAL HYSTERECTOMY. On the right side the sacro-uterine ligament and the vesico-uterine parametric tissue have been divided.

Fig. 457, p. 788); the ureters are drawn up in this way, together with the bladder, whilst the needle carrying the ligature is passed as close to the cervix as possible.

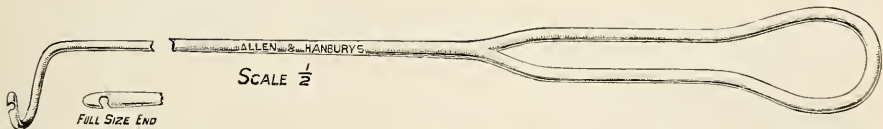

FIG. 453. WORRALL'S BROAD LIGAMENT NEEDLE FOR VAGINAL HYSTERECTOMY.

While tying the ligatures the traction on the cervix must be relaxed. Division of the tied parts is made with scissors close to the cervix and

at right angles to the direction of the tissues, in order to provide a broad flat stump from which the knot will not slip off. Figure 452 shows the method of passing sutures by means of a long curved blunt-pointed needle (*see* Fig. 453), which is shown embracing tissue that

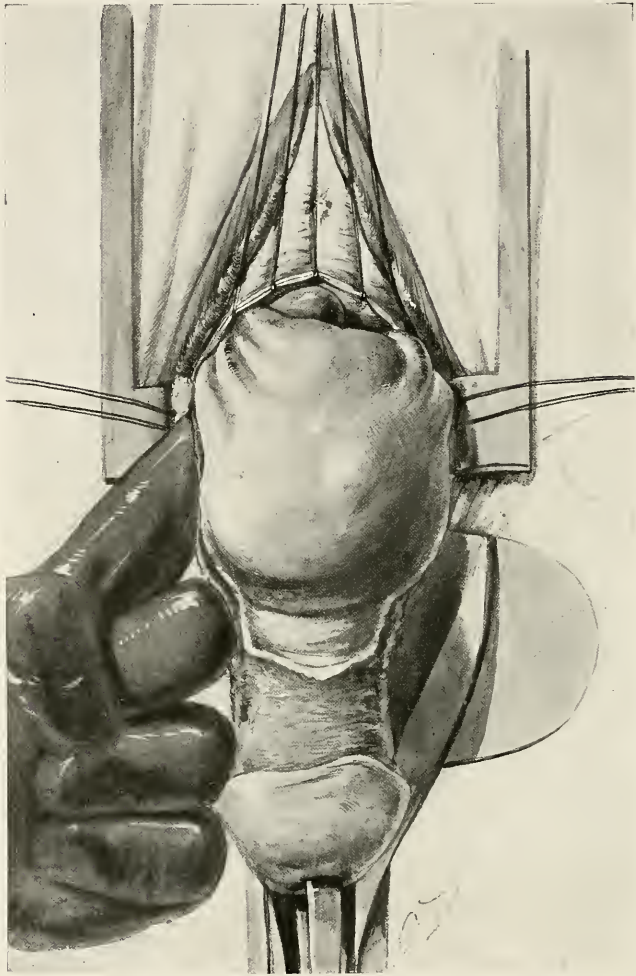


FIG. 454. THE LATER STAGE OF VAGINAL HYSTERECTOMY. The peritoneum of the utero-vesical pouch has been united to the vaginal mucosa by long interrupted sutures. The fundus is drawn outside the vagina by the index-finger of the left hand. The round ligament, Fallopian tube, ovarian ligament, and the ovarian artery lie upon the finger ready for suturing.

includes the uterine artery. The pulsations of this vessel can be felt, but the artery is not usually seen before it is divided; after division its characteristic tortuosity is apparent.

After the parametrium of the one side has been tied and divided as high up as possible, that on the other side is dealt with in like

manner. The uterus may then be drawn lower down and the peritoneal folds of the vesico-uterine pouch and the pouch of Douglas are brought within easy reach. To open the former the cervix is drawn downwards and backwards and the bladder is raised with a spatula. The peritoneal fold is grasped with forceps and divided in

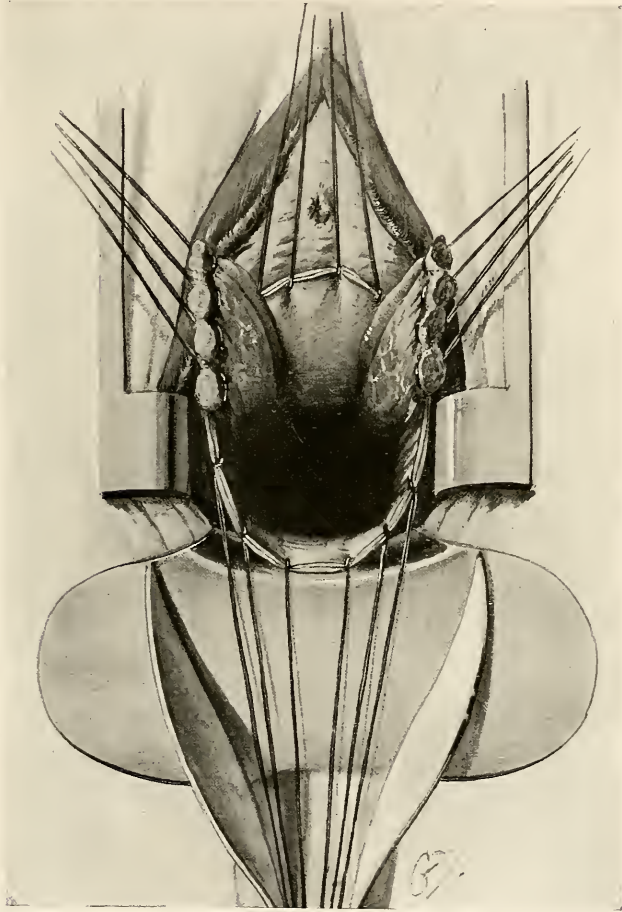


FIG. 455. VAGINAL HYSTERECTOMY, showing the parts after removal of the uterus.

the midline by scissors, as in anterior colpotomy (*see* Fig. 451, p. 781). The opening may be enlarged by cutting, or by stretching it to the required size by the fingers. To open the pouch of Douglas the cervix is drawn upwards and the peritoneum divided as described in posterior colpotomy (*see* Fig. 447, p. 778). The peritoneum of both pouches should now be united to the vaginal mucosa as shown in Figure 454. The remaining parts of the parametrium are now tied and divided on both sides, and when this is completed the uterus can be drawn further

down until it hangs only by its adnexa. In tying the adnexal structures, which are seen lying upon the finger in Figure 454, it is usual to deal with each separately, thus the round ligament is first tied and divided, then by drawing the uterus to one side the ovary and tube can be drawn down and examined. If found to be diseased these structures should be removed; this is done by first defining

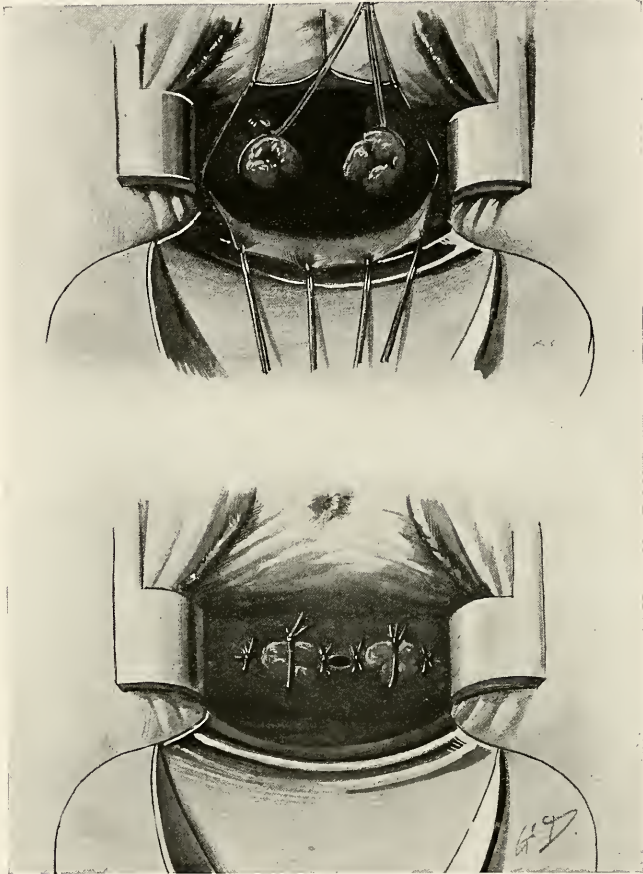


FIG. 456. VAGINAL HYSTERECTOMY. The final stage of the operation showing the method of dealing with the lateral stumps and of closing the vaginal wall. The upper Figure shows the encircling ligatures left long and the former ones cut short. The lower Figure shows the stumps lying in the vagina with the vaginal vault closed.

the infundibulo-pelvic fold which carries the ovarian vessels. When this fold is clearly seen and put on the stretch, it is transfixed by the blunt needle (shown above), tied firmly with a stout ligature, and then divided. When, as is usual, the ovary and tube are left *in situ*, the tube is first transfixed, tied, and divided, and then the ovarian ligament and its vessels are dealt with by a separate ligature in the same manner.

Figure 455 shows the adnexa divided and the uterus removed. The peritoneum of the utero-vesical fold and that of the pouch of Douglas is seen united to the vaginal mucous membrane by interrupted sutures. The final steps of the hysterectomy consist in the fixation of the lateral stumps and the closure of the vaginal vault. Before the original ligatures are cut short, an encircling suture is passed around each stump, and the ends of each encircling ligature are passed through the vaginal flaps as shown in the lower drawing of Figure 456. Lastly, the edges of the vaginal flaps are brought together by interrupted sutures.

### VAGINAL MYOMECTIONY

This operation may be extremely simple, as, for instance, when it only involves the removal of fibroid polypi from the cervix; on the other hand, it may require special skill, for example, in the removal of submucous growths, either sessile or polypoid, which are confined to the body of the uterus. In these cases it may be necessary to raise the bladder off the cervix, to split the anterior cervical wall, and also to remove the fibroid piecemeal. The simpler operation will first be described.

**Cervical Polypi.** Fibroid polypi of the cervix generally have a stalked attachment to the wall of the canal, and the latter is usually dilated to some extent. The operation of removal merely consists in division of the pedicle with scissors, which may be done without fear of bleeding, or, the polypus may be seized with forceps and its removal effected by twisting and snipping the stalk simultaneously.

**Intrauterine Polypi.** Fibroid polypi arising in the uterus may dilate the cervical canal and pass into the vagina, retaining their uterine attachment by a long pedicle, which may run up even to the fundus; as a rule, the attachment is found to be to the lower part of the uterine wall. There is no difficulty in removing growths such as these, if the pedicle is not too thick, by seizing the polypus in strong forceps and forcibly twisting it; or the stalk may be divided with curved blunt-pointed scissors passed along it into the uterus. The division should be made short of its actual base, and only gentle traction made upon the polypus at the time, so as to avoid all risk of cutting into, or perhaps actually button-holing, the uterine wall. Very thick stalks are best dealt with by first partly dividing them with scissors, and then forcibly twisting through the remainder.

Fibroid polypi of considerable size may *remain within the uterine cavity*, and their removal is then more difficult, as the cervix cannot be sufficiently dilated to allow of their being withdrawn through it. The difficulty may be surmounted in either of two ways: (1) by reducing the size of the polypus before attempting its withdrawal; or (2) by enlarging the cervix, by incising it up to the level of the internal os; in the case of large polypi these two methods may be

combined, as the cervix cannot be enlarged sufficiently to allow the polypus to pass. In either case the cervix should be first dilated to the fullest extent, and the preliminary use of a tent is helpful (*see* Fig. 467, p. 796). Then the index finger is passed into the uterus and the size and relations of the polypus are determined. Next, the polypus is detached by division and twisting of its stalk. A sessile

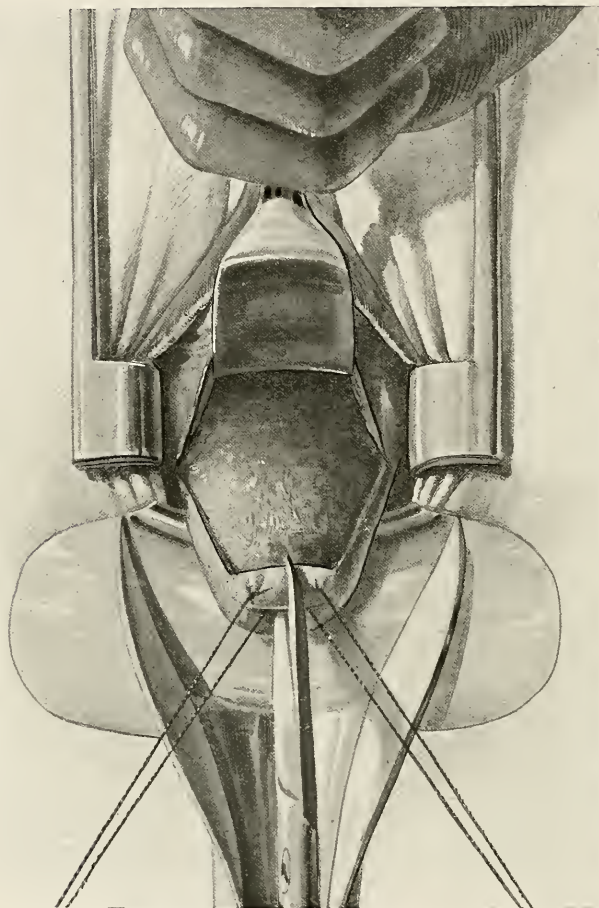


FIG. 457. VAGINAL MYOMECTOMY. The bladder has been dissected off the cervix and is being held up and protected by a flat rectangular spatula (*see* Fig. 459). The anterior lip of the cervix, steadied by long ligatures, is about to be divided in the mid-line with scissors.

submucous fibroid, such as that shown in Fig. 214, p. 434, may be dealt with by the method next to be described.

**Vaginal Myomectomy by Morcellement.** The foregoing description of how to deal with intra-uterine polypi embraces the main principles which underlie the operation of vaginal myomectomy. A fuller description is necessary of the method of dealing with large submucous



myomata by the vaginal route. These tumours frequently slough, and are then accompanied by a putrescent discharge, which renders any attempt to remove the uterus *per abdomen* particularly dangerous. Moreover, the cervix is frequently found to be opened up by such tumours, and their most dependent part may lie in the vagina. Taking a case where the cervix is not dilated, the operation of vaginal myomectomy is carried out in the following way : An Auvard's

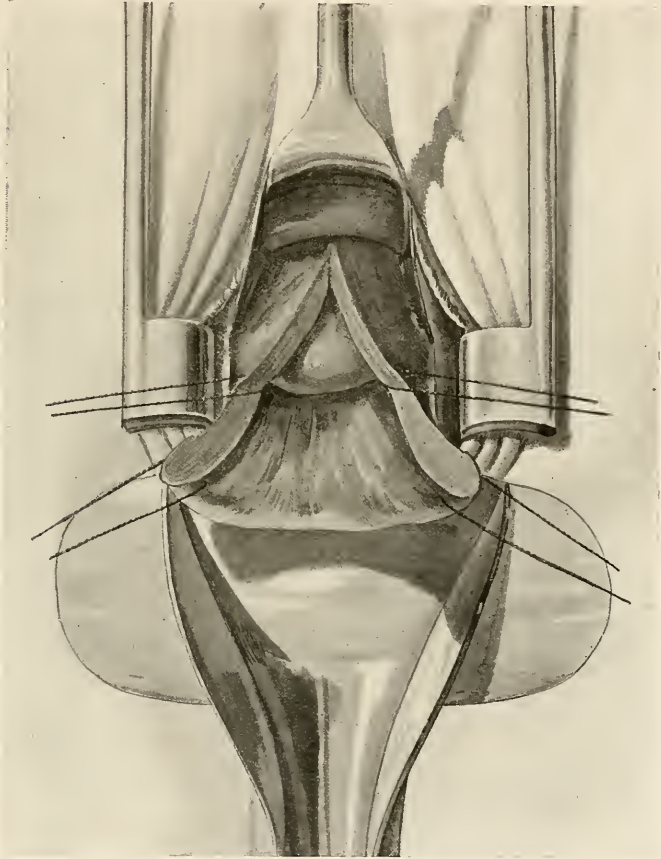


FIG. 458. VAGINAL MYOMECTOMY. The cervix has been split by a median incision in its anterior wall ; the edges of the incision are transfixed and held aside by traction on long stout ligatures. The lower pole of a submucous fibroid is exposed through the upper part of the wound.

speculum is inserted to depress the perineum and the posterior vaginal walls. The vagina is dilated laterally by Jayle's self-retaining dilator (*see* Fig. 414, p. 736). The anterior lip of the cervix is grasped with a volsella and is drawn down. A wide crescentic incision is now made through the vaginal mucosa in front of the reflection of the bladder. When necessary two lateral incisions may also be made, passing upwards and outwards from either angle of the transverse

incision, thus mapping out a tongue-shaped flap of vaginal mucous membrane (*see* Fig. 449, p. 779). The limits of the bladder are indicated by the difference in appearance of the vaginal mucous surface in the anterior fornix, that covering the bladder being rugose, and that part covering the anterior cervical wall below the bladder being smooth. The incision across the front of the cervix should therefore be made through the smooth and not through the rugose mucous membrane. The central point of the upper margin of the incision is grasped with toothed dissecting forceps and pulled vertically upwards, so as to put the connective tissue on the stretch. The vertical bands of tissue uniting bladder to cervix are then cut through with blunt-pointed scissors curved on the flat (Fig. 450, p. 780). When a fold of the

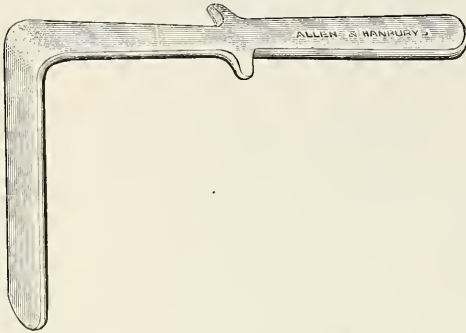


FIG. 459. FLAT VAGINAL RETRACTOR.

bladder has thus been dissected off the cervix, the total separation may be effected by blunt dissection, *i.e.* by pushing the bladder off the cervix with a finger wrapped round with gauze. When the bladder is free it is held up by a flat rectangular retractor (*see* Fig. 459), or by a simple copper spatula, and the anterior wall of the cervix thus displayed is ready for splitting (*see* Fig. 457). Before the in-

cision is made, a stout silk ligature is passed through the lips of the cervix on either side of the volsella which has already been applied to the anterior lip for the purpose of drawing it down. As soon as the ligatures are applied, the volsella is removed. The cervix is now steadied by traction on the ligatures, and its anterior wall is divided in the middle line. A second pair of ligatures may be applied to the flap of cervical tissue higher up near the internal os if required (*see* Fig. 458). With large submucous tumours arising from the fundus it is sometimes necessary to carry the central incision beyond the internal os into the lower uterine segment, in which case the utero-vesical pouch is opened up as well (a thing to avoid if the tumour is sloughing). Where it is necessary to divide a portion of the lower uterine segment the flap incision through the vaginal mucosa (*see* Fig. 449, p. 779) is most useful as it gives a wider approach to the field of operation. With the cervix thus opened up the intra-uterine tumour is grasped with a volsella whilst an incision is made into its capsule. The latter is stripped back, and a portion of the exposed growth is seized with a second volsella and *morcellement* is begun. This consists in cutting up the tumour-substance piecemeal within its capsule. In thus dealing with a large tumour special instruments are desirable, and those of Segond well serve the purpose. They consist of very

strong volsellæ, short-bladed knives on long handles, and stout curved scissors also with long handles (*see* Figs. 460). Successive portions of growth are seized with a volsella, then gouged out and cut away with the knife (*see* Fig. 461). Observance of the following points is essential: (1) The growth must be kept well in view. (2) Before a piece is removed another hold must be made by a second volsella, applied elsewhere to

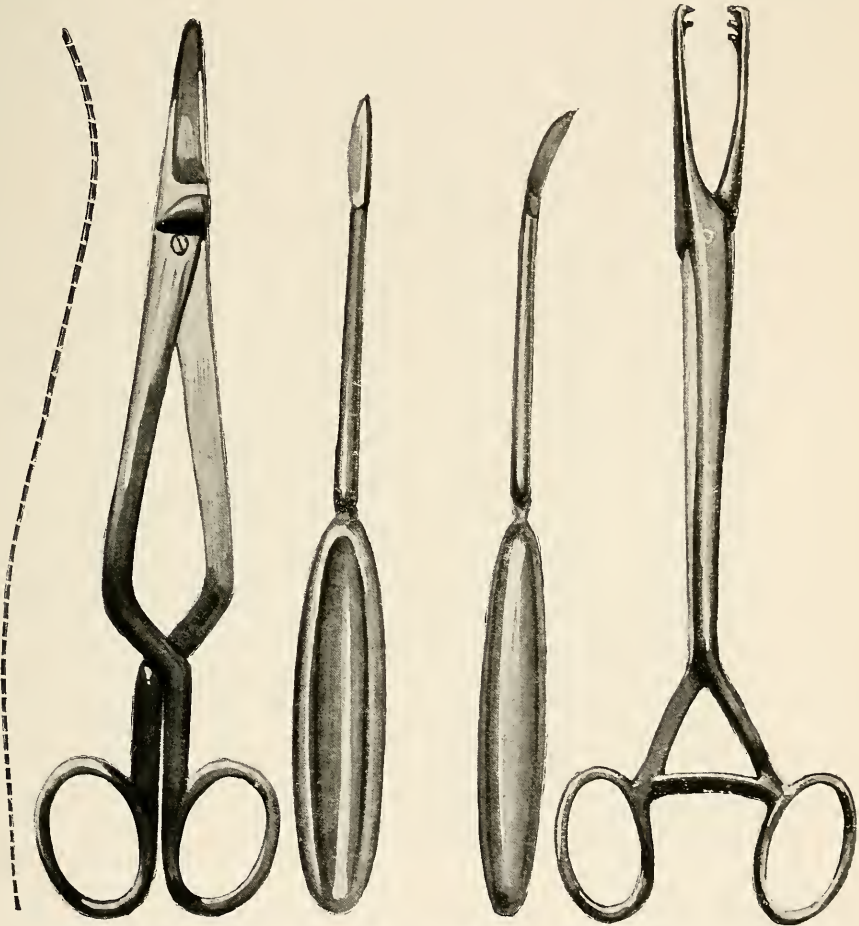


FIG. 460. INSTRUMENTS USED IN THE REMOVAL PIECEMEAL OF A LARGE SUBMUCOUS FIBROID (MORCELLEMENT).

the tumour. (3) The process of cutting up must be carried on within the capsule. (4) The index finger of the right hand should frequently be inserted inside the capsule for the purpose of stripping it off the successively accessible portions of the tumour. (5) The fundus must be grasped by an assistant. By working inside the capsule, and by preserving its integrity, free hæmorrhage is avoided. The uterus contracts *pari passu* with the morcellement and enucleation. When the

growth is removed, the capsule has to be dealt with. It may be found to be intimately adherent to the fundus, in which case it is best to cut away the freed portion, and leave the adherent part to come away during subsequent involution. When the uterine cavity is emptied, 15 m. of ernutin should be injected into the muscles of the buttock, and the edges of the cervical incision are brought together by interrupted sutures of chromic gut, which are passed through the entire thickness

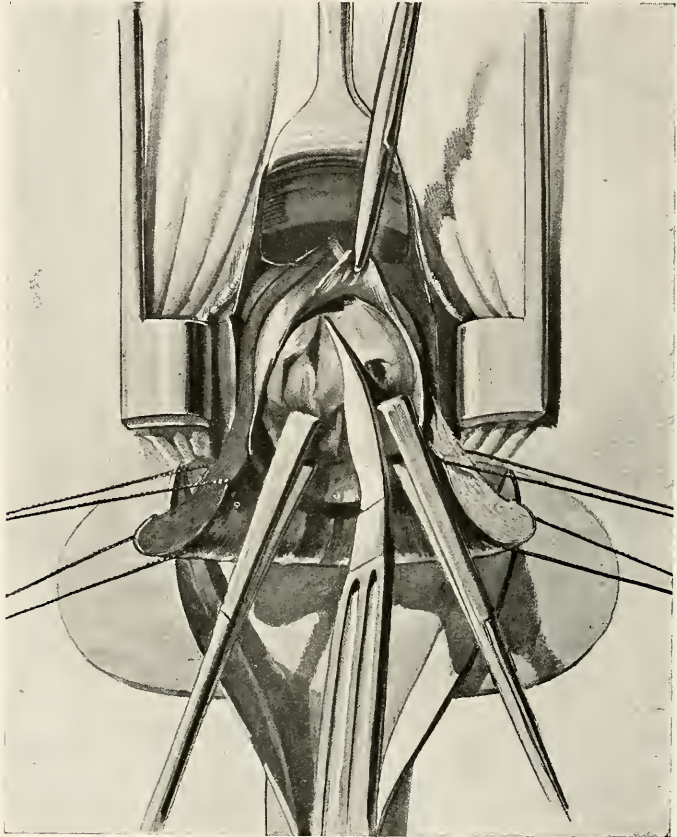


FIG. 461. MYOMECTOMY BY MORCELLEMENT. The tumour is removed piecemeal by seizing and cutting away segments of growth within its capsule.

of each wall. The uppermost stitch is placed just above the upper angle of the incision. The last suture should be so placed as to effect accurate apposition of the lips of the external os. The integrity of the cervix having been restored the bladder retractor is removed, and the crescentic or flap incision in the vaginal mucous membrane is then closed by interrupted catgut stitches (*see* Fig. 462). A drain of bismuth gauze is inserted into the uterine cavity.

## DILATATION OF THE CERVIX AND CURETTING

**Dilatation of the Cervix.** Apart from pregnancy, this operation may be performed in the following conditions : (1) spasmodic dysmenorrhœa ; (2) as a preliminary to curetting or other intra-uterine operations ; (3) to establish drainage in pyometra or purulent endometritis.

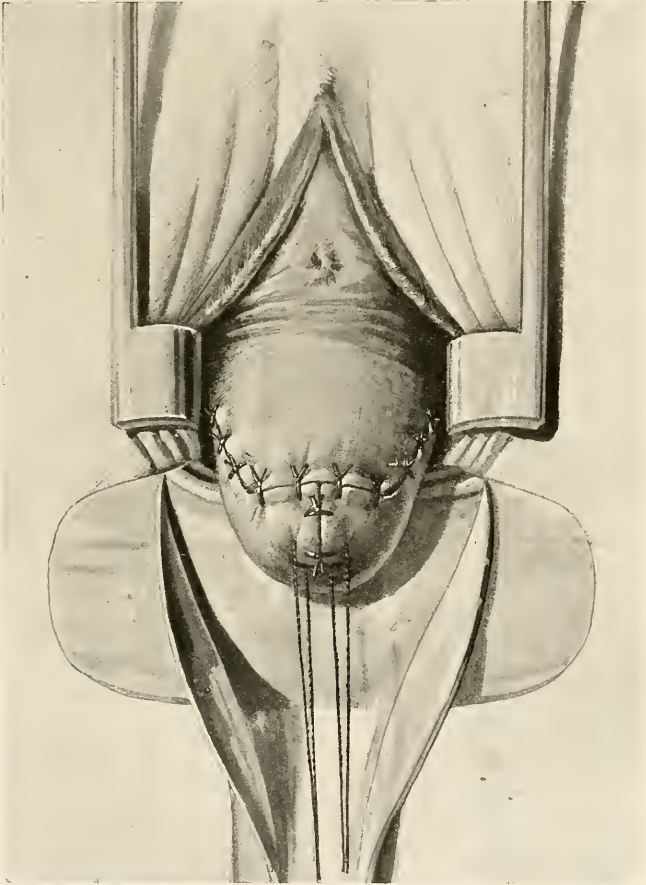


FIG. 462. VAGINAL MYOMECTOMY, showing the final stage of the operation.

The vulva and vagina having been thoroughly swabbed and douched under the anæsthetic, a careful bimanual examination of the pelvic organs should be made, as a routine procedure, before anything else is done. The most convenient speculum to use for depressing the perineum is that of Auvard (*see* Fig. 463), which is self-retaining. The best lateral retractor is that of Jayle, which is also self-retaining (*see* Fig. 414, p. 736). The cervix is then seized with a volsella and its condition noted. Next, the sound is passed to observe the length and capacity of the uterine cavity and the condition of its walls. A firm

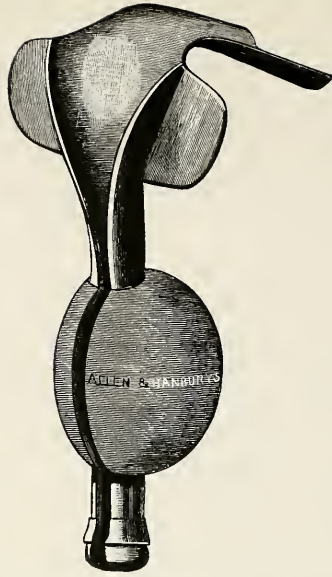


FIG. 463. AUVARD'S SELF-RETAINING VAGINAL SPECULUM. The shank of the speculum is weighted with a ball of lead, and channelled to allow of the escape of douche fluids from the vagina.

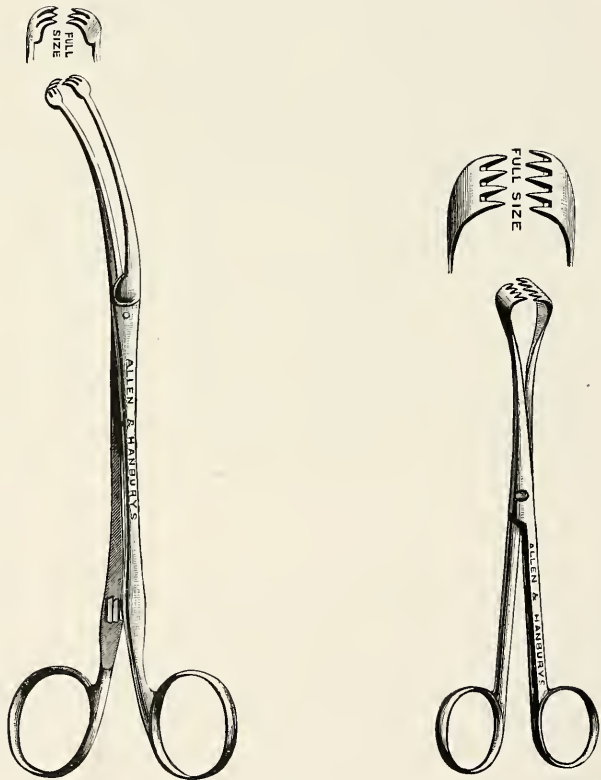


FIG. 464. VOLSELLA FORCEPS. The short pair is stronger and more generally useful for operative work than the long pair.

hold of the cervix is necessary in introducing the dilators, and two pairs of volsellæ such as those shown in Figure 464 may be used, placing one at each side of the anterior lip. Then the cervical canal is dilated with the graduated metal dilators shown in Figure 465, beginning with the

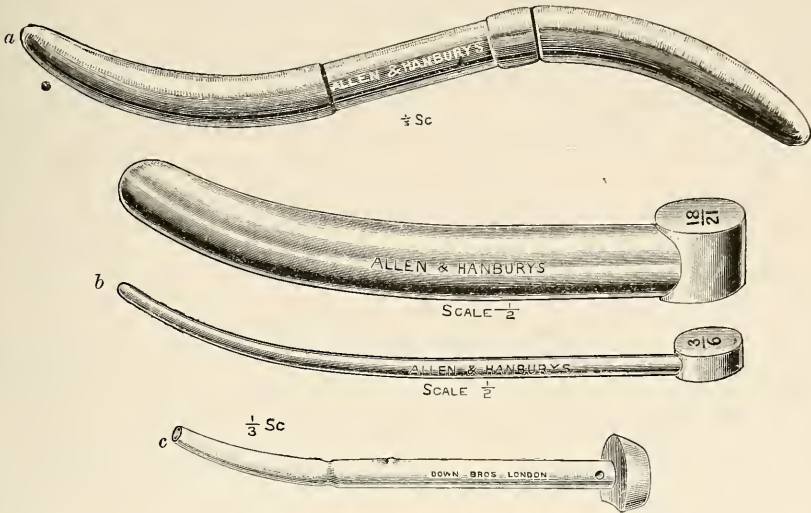


FIG. 465. UTERINE DILATORS: *a*, Fenton's; *b*, Hawkins Ambler's; *c*, Ramsay's (hollow). The instruments are made of metal, and are conical, being narrower at the point than the base. Ramsay's dilator is notched at a point two and a half inches from the tip.

smallest size and passing them in sequence until sufficient dilatation has been obtained. If the patient is a nullipara and the external os unusually small, two lateral incisions may be made into the external os of about one-third of an inch in depth. The chief resistance to the passage of the dilators is found, however, at the internal os, the difficulty being greater in nulliparous than in parous women. The first four or five dilators usually pass easily; the sixth, seventh, and eighth encounter the greatest obstruction, and at this point a certain amount of laceration of the cervical tissues in the upper part of the canal usually occurs. The remaining dilators can then be passed without difficulty. Each should be firmly pushed in and carried right up to the fundus. The hollow dilator of Ramsay is the easiest to work with as it allows blood and secretion contained in the uterus to escape through the central channel. The extent to which the dilatation will be carried is determined by the purpose of the operation; for curetting it is sufficient to dilate to number ten; for spasmodic

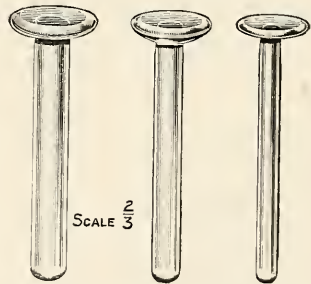


FIG. 466. INTRA-UTERINE GLASS STEMS FOR USE AFTER DILATATION OF THE CERVIX.

dysmenorrhœa dilatation should be carried up to number fourteen; when it is desired to pass the finger into the uterus the largest sizes are generally required.

When full dilatation of the cervix is required the procedure may be rendered easier by the preliminary use of a laminaria tent (*see* Fig. 467), which should be introduced into the cervix at least twelve hours before the operation. The tent swells from imbibition of fluid, and not only starts the process of dilatation, but causes so much softening of the cervical tissues that subsequent dilatation with the graduated bougies is facilitated, and the risk of laceration thus diminished. It is therefore especially useful when it is desired to pass the finger into the uterus in the case of a nulliparous woman. The disadvantages of the tent are

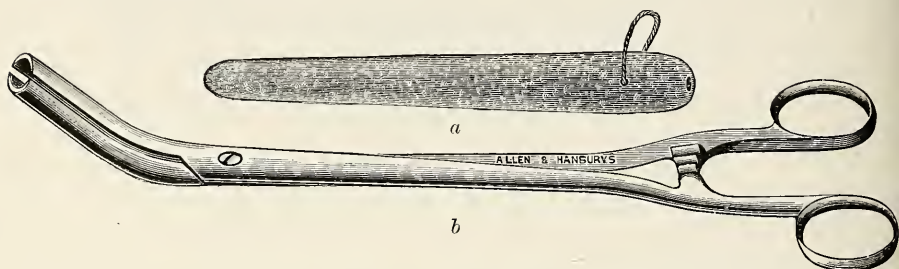


FIG. 467. *a*, LAMINARIA TENT. *b*, TENT-FORCEPS. The tent is made of compressed sea-tangle, which swells considerably from absorption of moisture.

that in an unmarried woman it is difficult to pass it without an anæsthetic, and that while it is in the cervix severe uterine colic (spasmodic contraction) is sometimes set up.

Tents may be sterilized by keeping them for a week or ten days in absolute alcohol. To pass them, a tent-forceps such as is shown in Figure 467 is useful. After preliminary douching of the vagina, the cervix is exposed and seized with a volsella; the tent is then passed until the upper end is well through the internal os. In a nullipara it is best to pass a small size, and if possible introduce a second beside it. In a multipara a single tent of larger size will suffice. The use of a tent is absolutely contra-indicated by the presence of purulent or offensive discharges. A certain amount of preparatory softening of the cervix may be obtained by the insertion into the vagina of a glycerine tampon a few hours before dilatation is commenced.

Dilatation of the cervix is frequently performed as a preliminary step, to be followed by further intra-uterine procedures such as digital exploration, curetting, removal of polypi, etc. The introduction of the finger for exploration is only required in certain cases, and these may be indicated as follows: (1) when a polypus or other intra-uterine new growth is suspected; (2) in cases of hæmorrhage following abortion or child-birth, when retained pieces of placental tissue may be found; (3) when, after curetting, hæmorrhage is profuse and difficult



to control. The index finger is the most convenient one to use, traction is made with the volsella, by an assistant, upon the cervix, and aided by the left hand placed in contact with the fundus, the right index finger is gradually pushed upwards so as to explore the walls of the uterus on both sides, and especially the tubal angles. If the uterus can be well drawn down and is not greatly enlarged, its cavity can be explored with the little finger.

In the case of a nulliparous woman who has passed the menopause it is, however, very difficult to dilate the cervix sufficiently to admit the finger without causing severe laceration, and it is usually preferable to place reliance upon the sound and the curette.

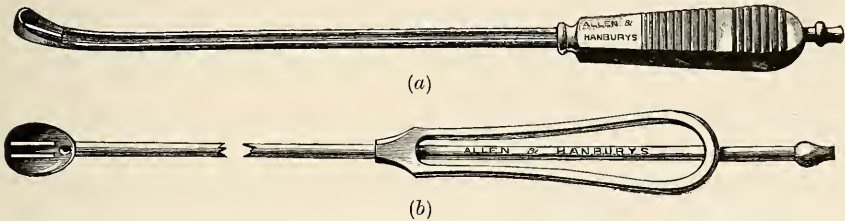


FIG. 468. THE FLUSHING UTERINE CURETTE. The stem is channelled to allow of the uterine cavity being irrigated.

**Curetting.** This operation consists in scraping away the endometrium with a sharp spoon or *curette*, after suitably dilating the cervix, and, in some cases, also exploring the uterine cavity with the finger. The indications for its performance are: (1) General enlargement of the uterus not due to a new growth, and associated with hæmorrhage or discharge, *e.g.* sub-involution, chronic endometritis, and allied conditions; (2) cases of uterine hæmorrhage for which no definite cause can be found; (3) occasionally in hæmorrhage from small interstitial fibroids; (4) suspected malignant disease of the uterine body, for diagnosis; (5) as a preliminary to certain operations for uterine displacements; (6) cases of sterility or repeated abortions, for which no constitutional or local cause can be found.

After suitable dilatation of the cervix, the scraping is most conveniently done with a flushing curette of the patterns shown in Figure 468. The instrument is channelled to allow of sterile saline solution, or of a non-toxic antiseptic—such as iodine or lysol—being run through it, to irrigate the uterine cavity. The spoon-shaped end has a moderately sharp edge capable of removing the soft mucosa. The large size (*b*) has the advantage of being too large and blunt to be inadvertently pushed through the uterine wall; the small one (*a*) can, however, be directed more thoroughly into the uterine angles so that the endometrium of this part does not escape complete removal. The latter is therefore more efficient, and if carefully used it is not a dangerous instrument. The blunt curette made of stout wire may,

however, be employed in exploratory curetting for suspected cancer of the body of the uterus, in which condition the tissues of the uterine wall are unusually friable, and perforation may readily occur.

In scraping the uterus the entire wall should be systematically dealt with, the mucosa being removed in strips by pressing the edge of the curette firmly against the uterine wall and drawing it from the fundus down to the cervix. *The uterine angles require special attention.* The detached pieces can be collected as they are washed away by the solution which pours freely out of the dilated cervix. After completing the scraping, the uterine cavity may be dried with a probe or forceps covered with a thick twist of sterilized wool. Oozing may be free, and can usually be checked by raising the temperature of the flushing solution to 118° F., or by applying upon a uterine probe (see Fig. 469) a strong antiseptic styptic, such as liniment of iodine, or iodised phenol (iodine, grs. 40 ; liquefied carbolic acid, 1 ounce). If

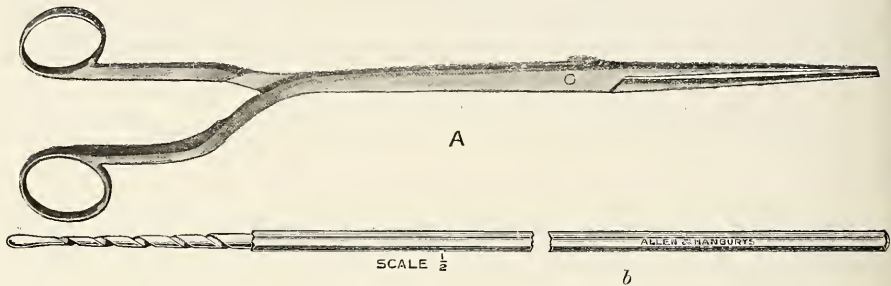


FIG. 469. (A) CERVICAL DRESSING FORCEPS AND (b) PROBE FOR INTRA-CERVICAL APPLICATIONS.

this is not completely successful, a strip of sterile or antiseptic gauze, *e.g.* subgallate of bismuth, may be passed up to the fundus by uterine dressing forceps (see Fig. 469) and a tampon placed in the upper part of the vagina. The application of a strong antiseptic is always desirable in cases of chronic endometritis of infective origin.

The uterine wall may be *perforated* by the curette, or, as is more likely, by the dilators, especially the small sizes. This accident should be at once observed by the absence of resistance to the onward passage of the dilator after the proper limit has been reached. No bleeding results from perforation with a *small* dilator, and, if the operation has been aseptic and the uterus not previously infected, no harm follows. The operation can be completed, for the aperture is spontaneously closed by muscular contraction and by the elasticity of the tissues. This accident must not, however, be considered as of slight importance, since under certain conditions it necessitates sacrificing the uterus. If, for example, the perforation has been caused by a *large* dilator the hæmorrhage may be so severe that it cannot be checked satisfactorily (see Fig. 470), and hysterectomy is then the safest treatment. Again, if a septic uterus is thus perforated, one of two courses may be adopted ;

either the uterus should be at once removed, by the vaginal route if practicable, or the posterior fornix should be opened and free drainage *per vaginam* provided. The perforation is much more likely to occur in the lateral or posterior walls than the anterior; if in the lateral wall, the peritoneal cavity is not necessarily opened, and the risks are consequently less serious. In dilating a rigid cervix a laceration at the internal os may occur so deep as to communicate with the broad ligament. This, again, does not, as a rule, cause severe bleeding, and is usually not observed unless the finger is introduced into the uterus.

Free *bleeding* after curetting is usually found to be the result of incomplete detachment of some new growth, such as a polypus, the presence of which was unrecognized. The finger should always be introduced into the uterus for exploration in such cases, in order that the operation may be properly completed.

## PLASTIC OPERATIONS ON THE UTERUS AND VAGINA

**Trachelorrhaphy.** This operation is designed for the repair of cervical lacerations; and an operation planned upon similar lines may also be done in cases of extensive cervical 'erosion' without laceration, the effect being to excise the 'erosion' and cover the area with the vaginal mucosa.

Cases requiring operation are almost always associated with eversion and 'erosion,' of the walls of the cervix. The complete procedure, therefore, consists of repair of the lacerations, and excision of the areas of 'erosion,' which at the same time corrects eversion. The operation can best be described in steps:

*Step I. Dilatation and curetting.* This is usually advisable, partly because the uterus is unhealthy, partly because dilatation facilitates the subsequent steps of the operation.

*Step II. To outline the flaps.* The cervix is exposed with Jayle's retractor and Auvard's speculum and pulled down as far as possible with two pairs of volsellæ. An incision is then made in the vaginal mucosa which begins on the right side one-eighth of an inch above the apex of the triangular gap left by the laceration, and is continued along the edges of the 'erosion,' around the anterior lip, and up to a

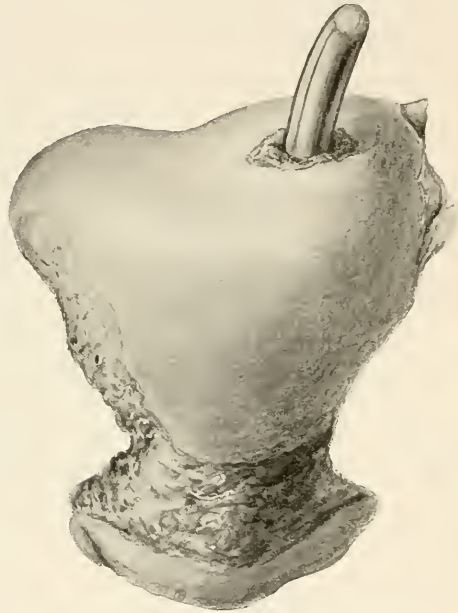


FIG. 470. PERFORATION OF THE FUNDUS UTERI BY A METAL DILATOR.

corresponding point above the apex of the laceration on the left side. This incision is about one-eighth of an inch deep, *i.e.* it divides the vaginal mucosa only (*see* Fig. 471). The cut edge is then seized with Kocher's forceps and the flap dissected upwards to the level of its base (*see* Fig. 472); this flap includes the vaginal mucous membrane

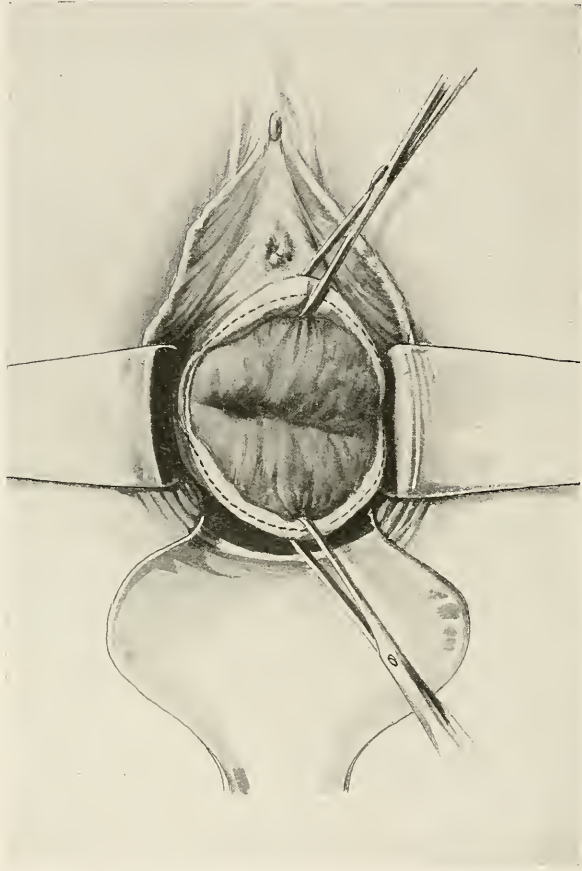


FIG. 471. EXPOSURE OF THE CERVIX FOR TRACHELORRHAPHY. The dotted lines indicate the incisions by which the flaps are raised.

only, which is thus raised from the cervical wall. The posterior lip is then similarly treated, and in joining the incisions at the sides of the cervix, care must be taken to include all the cicatricial tissue which lies in the apex of the laceration.

*Step III. Amputation of the everted Cervical Lips.* The exposed lower part of the cervix, consisting of the everted surfaces, is now cut away, and a ligature placed upon the vessels at each side of the cervix. This is best done by pushing up the vaginal mucosa at the sides; the vessels can then be seized above the line of amputation, and secured

by passing a stitch beneath them. This arrests bleeding generally from the cut surfaces, and is an important step in the operation.

*Step IV. Reconstruction of the External Os (Bonney's Method).* The manner in which the continuity of the surfaces is restored is shown in Figures 473 to 477. The best material to use for the stitches is chromicized or formalin-iodine catgut, which will resist absorption for fourteen days. A suture about 12 inches long is passed through the apex of each flap, and knotted firmly at its middle, so as to leave two ends of equal length. These ligatures can be used for traction while the lateral stitches are introduced.

Then one or two sutures are passed deeply at the sides of the cervix, so as to close the region of the apex of the laceration. These should enter the tissues deeply and are important in the control of oozing (see Fig. 463).

Each of the flap-ligatures is now used to cover over the remaining raw area as shown in Figures 475 and 477. Each end is made to transfix the cervical wall, entering through the canal and emerging upon the vaginal surface at about the level of the base of the flap. In passing these stitches, the curved slot-needle of Bonney (see Fig. 476) will be found very convenient. It is entered on the vaginal surface and made to emerge in the cervical canal; then the ligature is passed into the slot and pulled through. When both ends of the ligature have been made to transfix the cervical wall and are knotted, the effect is to roll in the flap as shown in Figure 475 until its apex is brought up against the edge of the cervical canal. The repetition of this procedure upon the posterior flap completes the external os (see Fig. 477). The cervix and vaginal roof should be swabbed with tincture of iodine, and the vagina packed with sterile gauze, which is removed twenty-four hours later.

It will be observed that the effect of this operation is to shorten slightly the vaginal portion of the cervix as well as to repair the injury.

*Emmett's Trachelorrhaphy.* This is the classical operation for

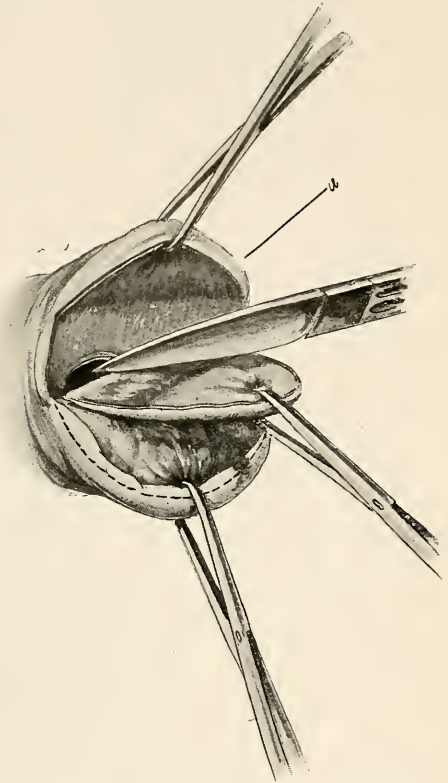


FIG. 472. TRACHELORRHAPHY. Cutting away the everted cervical lips. *a*, The vaginal flap which has been raised from the cervix.

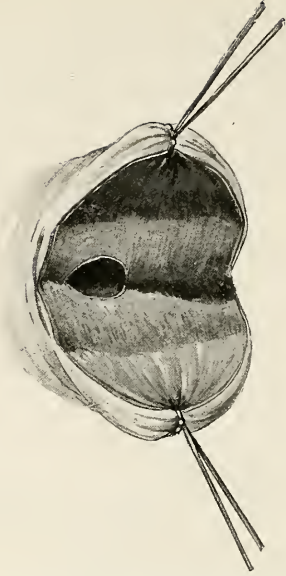


FIG. 473. TRACHELORRHAPHY. The everted lips have been cut away and the vaginal flaps are held with ligatures which transfix the apex.

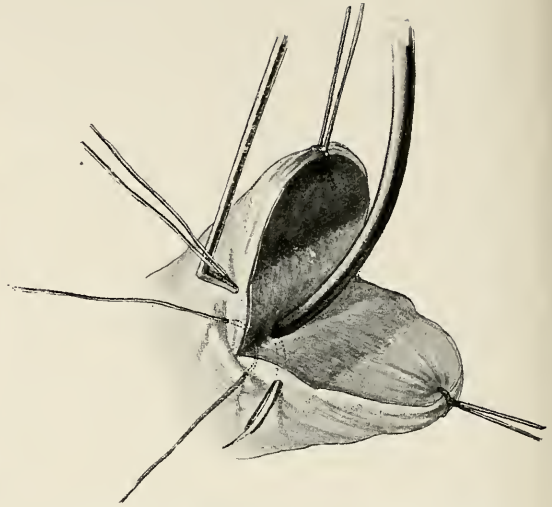


FIG. 474. INTRODUCTION OF THE LATERAL STITCHES. The sound is in the cervical canal.

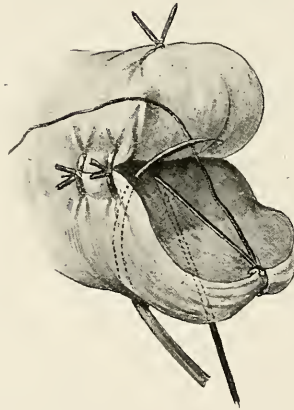

FIG. 475. THE ANTERIOR FLAP HAS BEEN ADJUSTED. One strand of the ligature on the posterior flap has been drawn through the cervical wall.

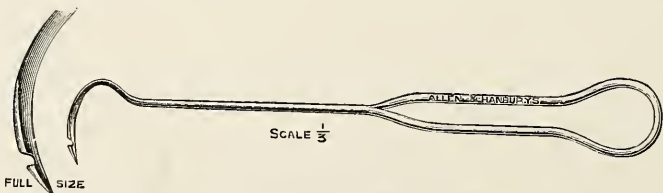


FIG. 476. BONNEY'S CERVICAL NEEDLE.

cervical laceration. It consists in removing a narrow strip of tissue corresponding to the edges of the laceration, and including the apex of the flap in all cases. If the cicatricial tissue in this situation is not removed, primary union of the wound is much impeded. The resulting raw surfaces are then united by stitches passed as follows : the stitch

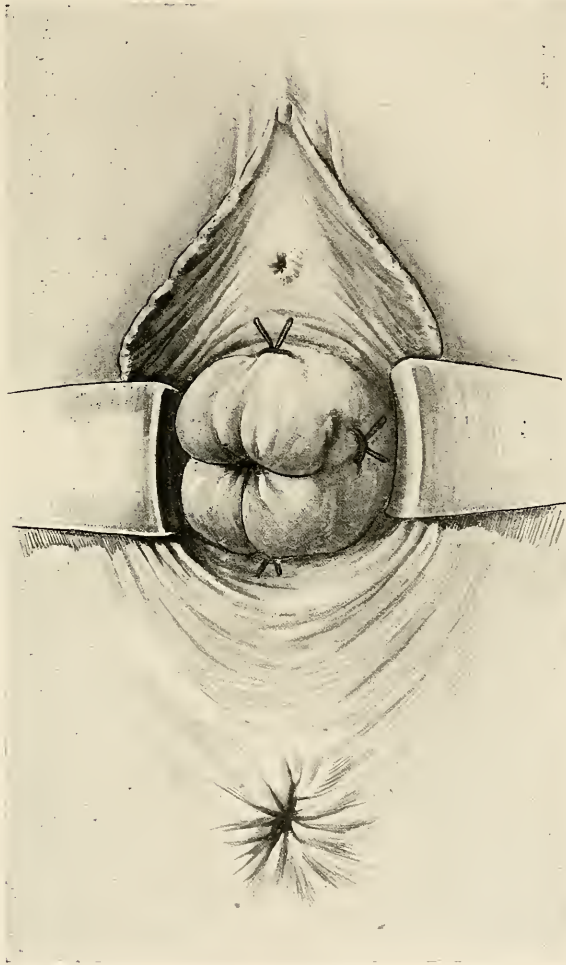


FIG. 477. TRACHELORRHAPHY. The operation completed.

enters on the vaginal aspect of the anterior lip, and emerges upon its cervical aspect ; next it passes through the posterior lip in the reverse direction and is knotted upon the vaginal surface. Three or more ligatures may be required on each side. In excising the strips, care is taken to leave untouched a bridge of tissue at the apex of each lip about one-third of an inch long, which will serve to form the margins of the external os of the reconstructed cervix.

The operation sacrifices less tissue than the procedure first described and does not shorten the cervix. But it leaves the bulk of the 'eroded' area untouched, and does not allow the eversion of the lips to be

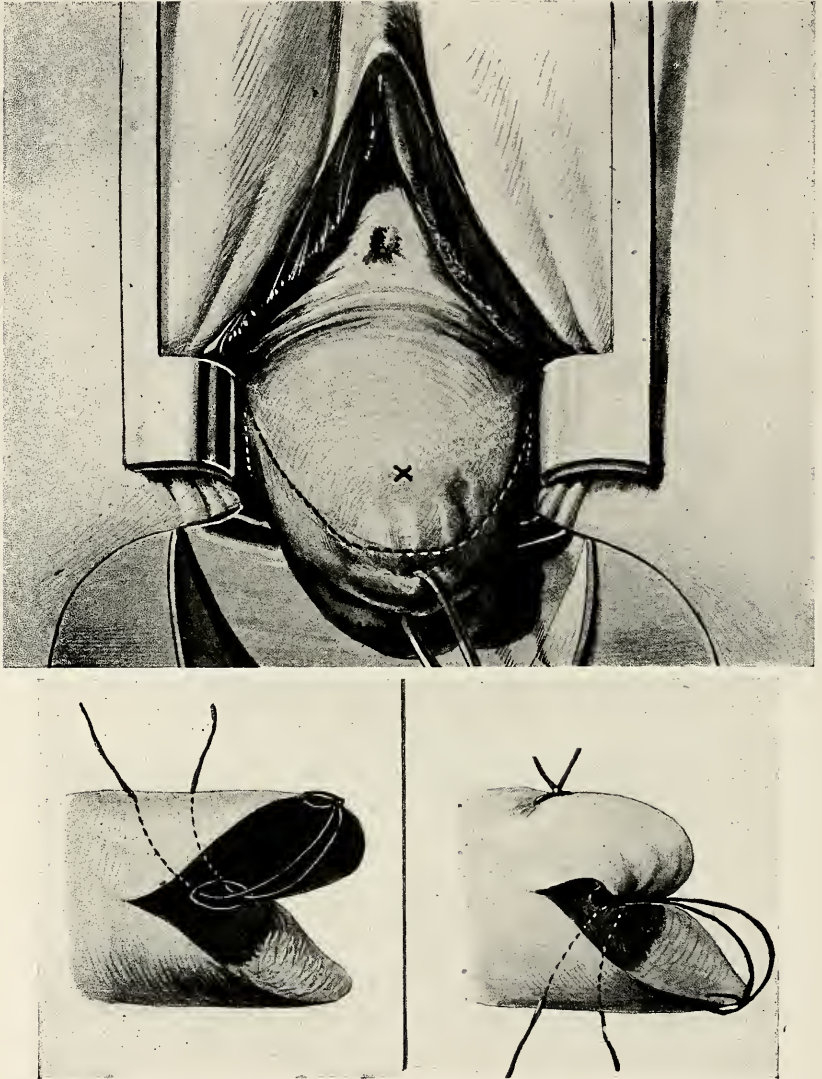


FIG. 478. AMPUTATION OF CERVIX. The dotted line in the upper Figure indicates the extent of the anterior flap. The posterior flap is formed in the same way. The two lower Figures show the shelving character of the flaps and the method of rolling them in.

completely overcome. Except for slight cases the complete operation is therefore to be preferred.

**Amputation of the Cervix (Vaginal Portion).** This operation is performed for hypertrophic elongation of the *portio vaginalis*.



The operation is planned upon the same lines as those just described for trachelorrhaphy. Owing to the elongation of the lower portion of the cervix the anterior flap-incision may be placed higher up without endangering the bladder (*see* Fig. 478). The lower limit of the bladder must be defined by the sound before commencing the incision, and again before passing the deep stitches. The amount of




FIG. 479. POZZI'S OPERATION FOR STERILITY, showing the depth to which the incision is carried.

cervical tissue removed is, however, much greater than in trachelorrhaphy, and in delimiting the flaps due regard must be paid to the extent of tissue which it is proposed to remove. The base of the flap corresponds to the level of the amputation, and the flap should be about three-quarters of an inch long to allow for shrinkage (*see* Fig. 478). The covering of the stump is carried out in the manner described above. The careful *understitching of the vascular areas* at the sides of the cervix is an important operative detail.

**Pozzi's Operation for Sterility.** The cervix is seized with a volsella on either lip and drawn down. It is then divided laterally with

scalpel or scissors, the incisions extend upwards for about three-quarters of an inch to one inch (*see* Fig. 479). The raw surfaces thus produced are hollowed out by removing a small tongue of the intervening fibro-muscular wall. The mucous membrane of the cervical canal is then sutured to the vaginal surface of the cervix by two or three interrupted sutures of chromic catgut (*see* Fig. 480). The

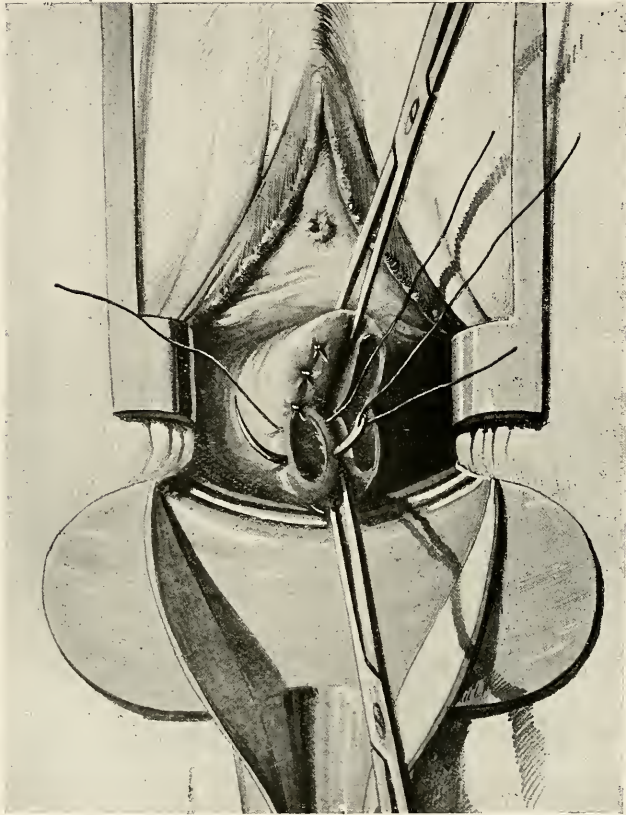


FIG. 480. POZZI'S OPERATION FOR STERILITY, showing the mode of closure of the incisions by apposition of cervical and vaginal surfaces.

union of the mucous membrane and cervical skin prevents adhesion of the cervical lips, by covering in the raw surfaces. The operation is usually begun by curetting the uterus, and concluded by lightly packing the upper part of the vaginal canal with bismuth gauze, which should be removed after twenty-four hours.

**The Radical Cure of Cystocele.** This operation is designed for the radical cure of prolapse of the anterior vaginal wall and bladder. It is therefore performed in cases of simple cystocele, and also in cases of marked uterine prolapse, when it is usually combined with other procedures, such as perineorrhaphy. The aim of the operation

is to restore the structures which normally form the *floor of the bladder*, *i.e.* the structures upon which the base of the bladder rests. This involves a deep dissection as will be seen immediately, and the operation differs so much in character from the procedure generally described as *anterior colpoorrhaphy*, that it is advisable to apply to

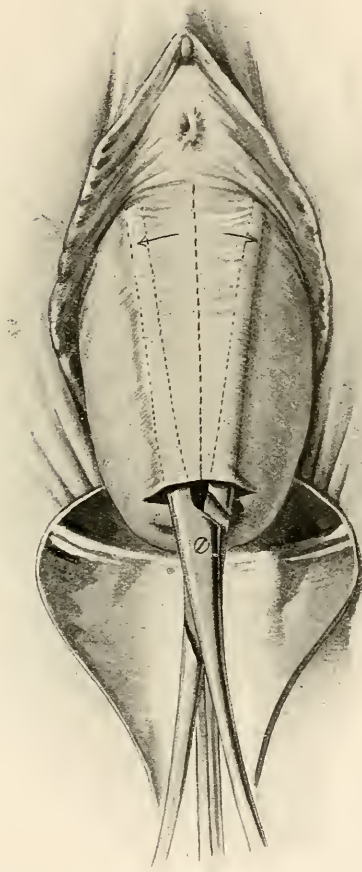


FIG. 481. RADICAL CURE OF CYSTOCELE. *Step I:* The cervix is pulled down with a volsella, which, to simplify the illustration, has not been shown.

it a different name. It may therefore be spoken of as the *radical cure* of cystocele, which brings it into line with the operations, similar in principle, performed for abdominal hernia.

The most careful aseptic technique is required to ensure primary union of the wound. Urinary infection, and the presence of a purulent vaginal discharge, are absolute contra-indications; the operation must be postponed until these conditions have been cured. The full

preparation of the patient and of the field of operation must be carried out in the manner described on p. 728. Stout chromicized or iodine-formalin catgut is the best suture-material.

*Steps of the Operation.* In cases accompanied by prolapse of the uterus, good exposure of the whole length of the anterior vaginal wall can be obtained by traction on the cervix with a strong volsella, pulling

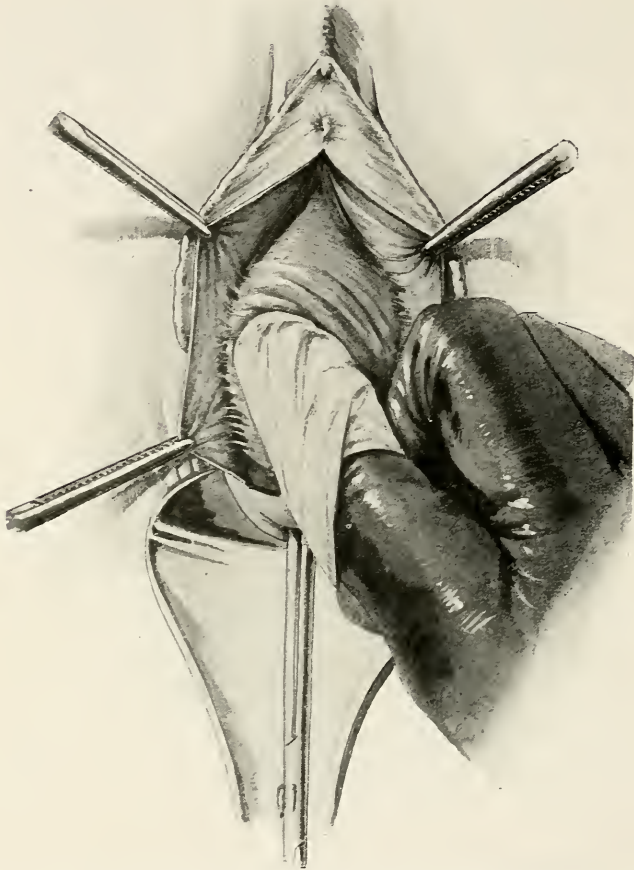


FIG. 482. RADICAL CURE OF CYSTOCELE. *Step II*: Separating the bladder by blunt dissection from the vaginal walls.

the external os as far out of the vulva as possible. In less advanced cases, good exposure can be obtained by the use of Jayle's retractor.

*Step I.* A transverse incision half an inch long is made on the anterior wall of the cervix half an inch above the os externum. A pair of straight blunt-pointed scissors is then entered on the flat immediately beneath the vaginal mucosa and thrust upwards towards the urinary meatus in the manner shown in Figure 481. By opening the blades the loose cellular-tissue plane between bladder and vagina

is opened up, and an extensive separation of these two structures is obtained. The anterior vaginal wall is then slit up with scissors along the mid-line, as marked in the Figure.

*Step II.* The edge of the median incision is picked up on each side with two or three pairs of forceps and the separation of the bladder completed. This is done mainly by blunt dissection, with the finger

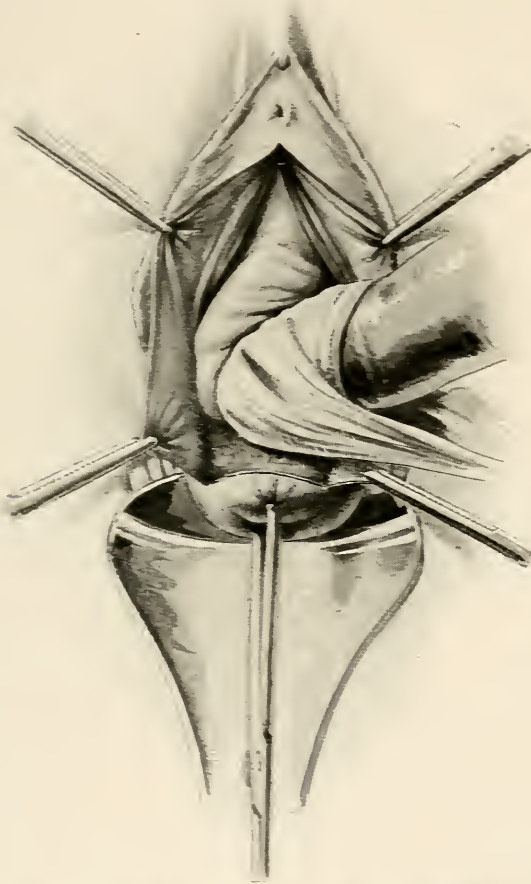


FIG. 483. RADICAL CURE OF CYSTOCELE. *Step II (continued)*: Separating the bladder from the cervix.

and a swab (*see* Fig. 482). but here and there fibrous bands must be divided with scissors. In long-standing cases of prolapse, inflammatory adhesion of the superficial and deep structures may have occurred, to an extent which necessitates a good deal of cutting. The separation is carried out laterally on each side, until the finger defines the edge of the bony pubic arch; large veins may here be met with, which require careful ligation. Next the bladder is dissected off the anterior wall of the cervix in the same manner (*see* Fig. 483), the

separation being carried up as far as the peritoneal reflection, but the peritoneum should not be opened. The whole of the base of the bladder now lies fully exposed in the wound, and all bleeding-points upon it should be carefully controlled. It will be found that, with

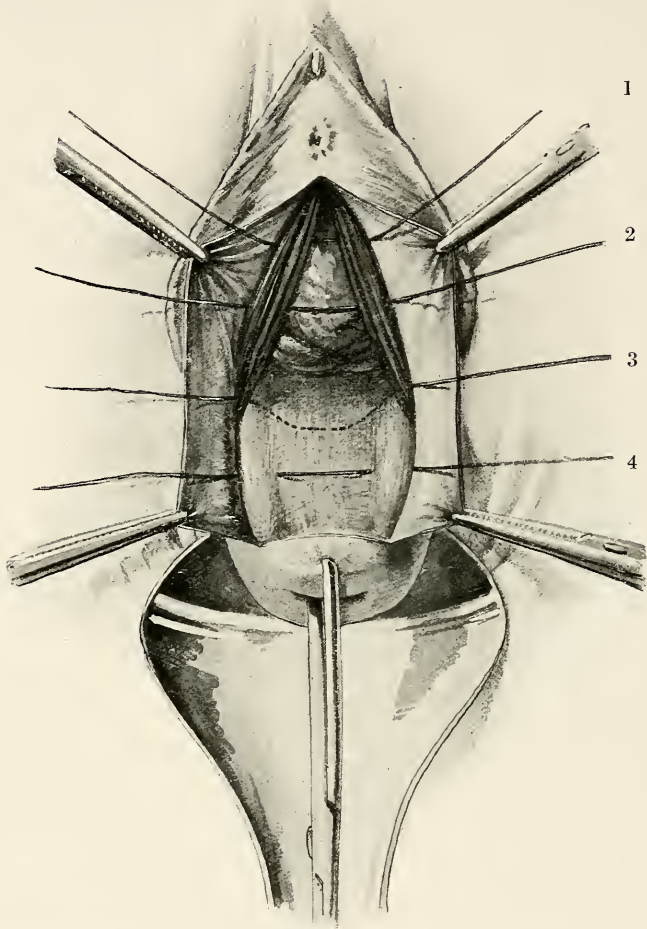


FIG. 484. RADICAL CURE OF CYSTOCELE. *Step III*: Restoring the supports of the bladder. Note that the bladder has been pushed upwards behind the pubes.

the finger, the bladder can be pushed upwards behind the pubes until it is out of sight (*see* Fig. 484).

*Step III.* The *supports of the bladder* are next restored. On inspecting the deep surfaces of the lateral flaps which have been raised, it will be seen that muscular and fascial structures are present, which can be defined with the finger, or at times muscular fibres can actually be seen in the position shown in Figure 484. These represent the anterior

portions of the pubo-coccygeus (levator ani) muscles and the visceral layer of the pelvic fascia. Without further dissection these structures can be brought together in the middle line by interrupted sutures passed deeply through them. In introducing these stitches, the bladder is pushed up out of the way by an assistant, and should be held there until the stitches are tied. Two stitches are passed in this way.

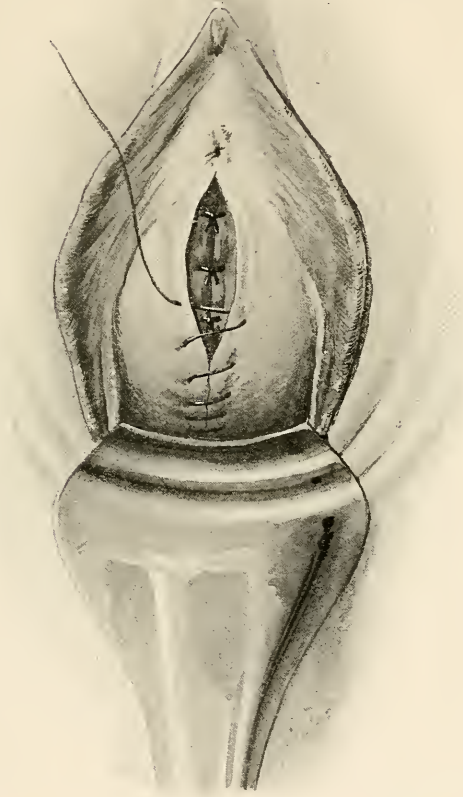


FIG. 485. RADICAL CURE OF CYSTOCELE. *Step IV* : Uniting the edges of the vaginal wall.

A third stitch is passed through the musculo-fascial layer and also made to take a deep hold of the exposed anterior cervical wall, so that when tied the edges of the muscle are held in contact with the cervix, and no interval remains through which the bladder might again become pushed down. The fourth stitch (shown in Fig. 484) is only occasionally required ; it takes up the cellular tissues at the sides of the cervix corresponding to the lowest parts of the broad ligaments and unites them in front of the cervix. When elongation of the cervix is present, the lower portion may at this stage be amputated, and the operation is then completed as follows :

*Step IV.* The redundant portions of the vaginal flaps are now cut away, and the edges united with a running stitch or with interrupted sutures, beginning at the cervix and ending just below the urinary meatus (*see* Fig. 485).

The anterior vaginal wall is then swabbed freely with tincture of iodine, and the vaginal canal loosely packed with sterile gauze. If the

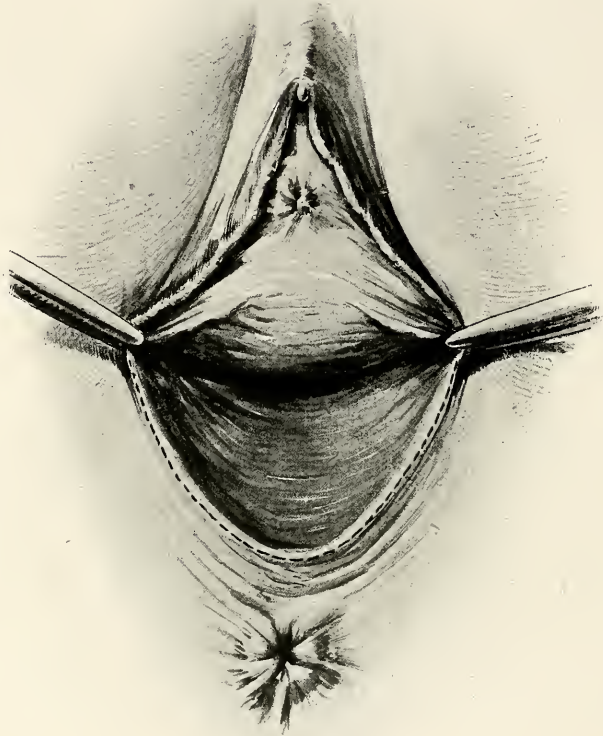


FIG. 486. PERINEORRHAPHY FOR INCOMPLETE LACERATION. The dotted line shows the first incision.

perineum is deficient, perineorrhaphy should also be performed, in order to afford the bladder additional support.

**Perineorrhaphy.** This procedure is a plastic operation for the secondary repair of obstetric injuries of the perineum and of the posterior vaginal wall. The operation required for the primary immediate repair of such injuries is described in textbooks of midwifery. In cases where the primary operation has failed, secondary repair should not be undertaken for at least six weeks, this interval being required to allow the natural processes of involution to be completed, and any local infection which may be present to be cleared up.



The extent of the operation varies according to the local conditions present. An extensive laceration laying open nearly the whole of the anal canal may be seen (*see* Fig. 495, p. 820), or the condition may be merely the *relaxed vaginal outlet* shown in Figure 317, p. 597. Between these extremes many intermediate degrees are met with, such as Figure 494, p. 819, in which the anterior portion of the superficial sphincter has been injured. Two objects may be said to underlie a successful perineorrhaphy: (1) to restore the normal supports of the

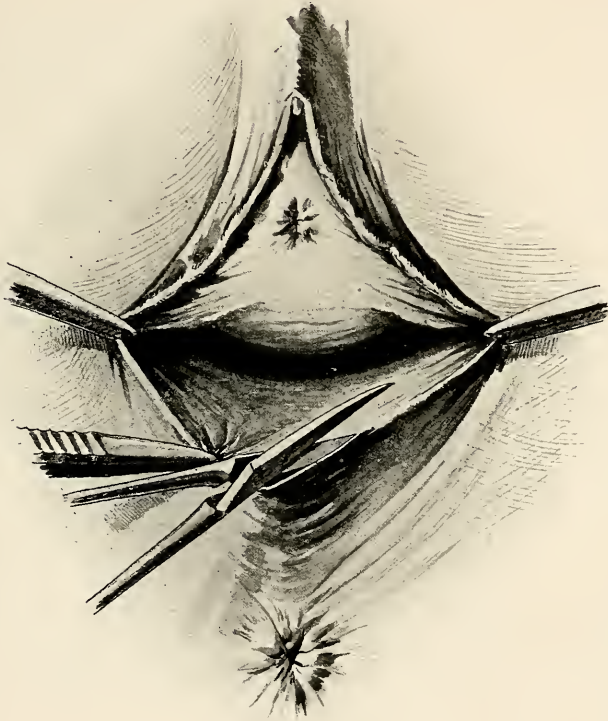


FIG. 487. PERINEORRHAPHY. *Step I: Making the First Incision by Splitting the Tissues with Scissors.*

posterior vaginal wall, viz. the pubo-coccygeus muscles and perineal body; (2) to restore the continuity and competence of the anal canal when necessary.

In the first place the operation will be described as practised for an incomplete laceration, *i.e.* one which does not involve the anal canal, and afterwards the modifications required for a complete laceration will be indicated.

*Perineorrhaphy for incomplete laceration.* The steps of this operation are illustrated in the series of Figures 486 to 493. The surroundings of the vulva, including the anus, should be carefully kept covered with

sterilized coverings fixed in position with clips or with stitches (*see* p. 729). These coverings are not shown in the drawings illustrating the operations in order that the anatomical relations to the rectum may be clearly represented.

*Step I.* The operation is begun by raising a flap from the lower end of the posterior vaginal wall, and the first step consists in outlining the flap to be raised. A clip is placed upon the edge of the

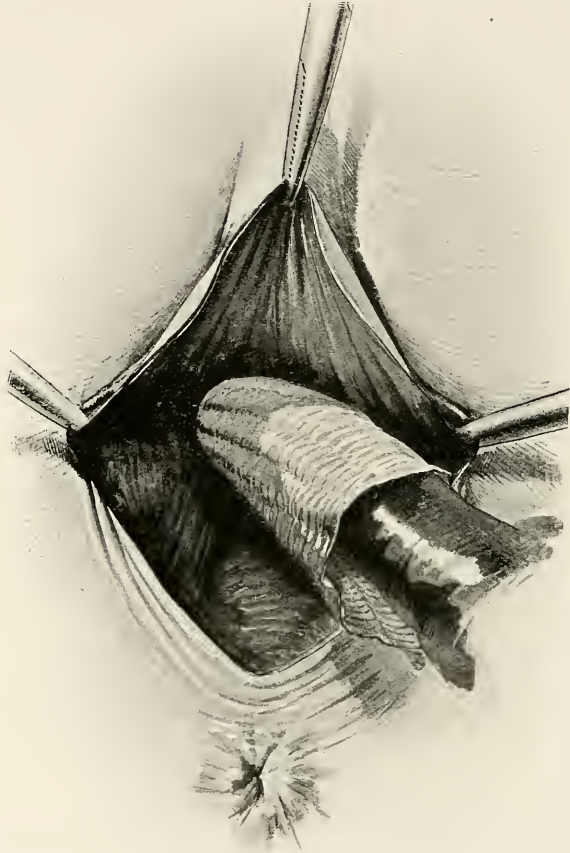

FIG. 488. PERINEORRHAPHY. *Step II: Raising the Vaginal Flap by Blunt Dissection.*

ostium vaginæ at a point roughly corresponding to the posterior extremity of the nympha on each side (*see* Fig. 486). By approximating these clips in the middle line, the size of the new ostium vaginæ will be indicated; it should be large enough to admit two fingers, and the points picked up in the forceps should be so adjusted as to give a space of about this extent. The extremity of the posterior vaginal wall in the mid-line is then seized with toothed dissecting forceps, and a pair of sharp pointed scissors used to split the tissues from this point up to

the lateral forceps on each side, as shown in Figure 487. This outlines the vaginal flap.

*Step II.* This consists in raising the vaginal flap. The free edge of the flap is picked up with two or three pairs of forceps, and the separation begun by snipping with sharp-pointed angled scissors. A

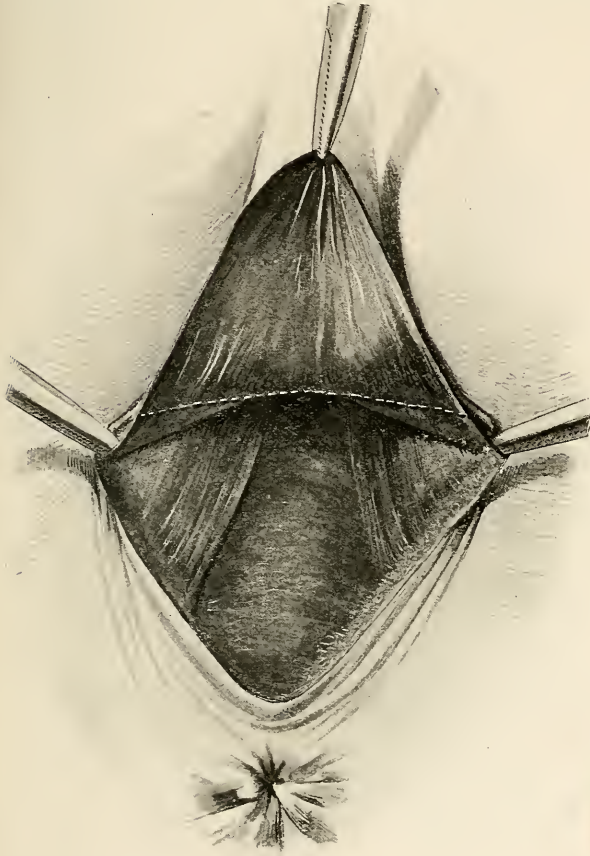


FIG. 489. PERINEORRHAPHY. *Step II*: The Vaginal Flap has been raised; in the Depths of the Wound Lies the Rectum. The dotted line shows where the vaginal flap will be subsequently cut off.

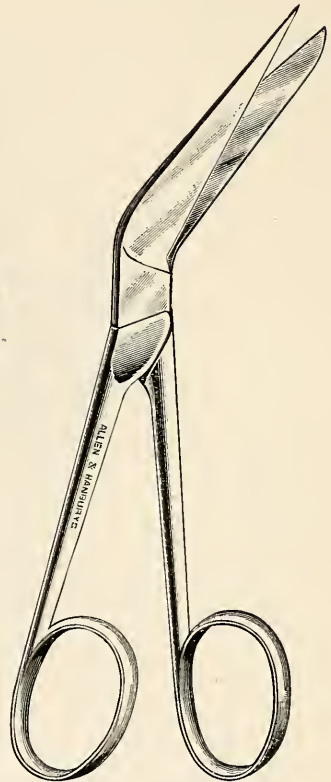


FIG. 489A. ANGLED SCISSORS FOR PERINEORRHAPHY.

good deal of old cicatricial tissue is often encountered at this stage, which must be carefully worked through, keeping as near as possible to the vaginal mucous membrane. The dissection must be carried out on each side, to the full extent defined by the lateral pair of clips. After the cicatricial-tissue zone has been passed, the dissection can be continued upwards through the connective-tissue layer with the finger and a swab, aided by a few snips with scissors (*see* Fig. 488). Many large veins will be seen, but these are almost all connected with the rectum

(*inferior hæmorrhoidal plexus*) and can be peeled off the vaginal wall to a great extent uninjured. The separation of rectum and vagina can be carried upwards in this way to any required extent. A point from two and a half to three inches above the ostium vaginæ will usually suffice. After completing this step it is useful to commence the amputation of the vaginal flap on each side along the line indicated

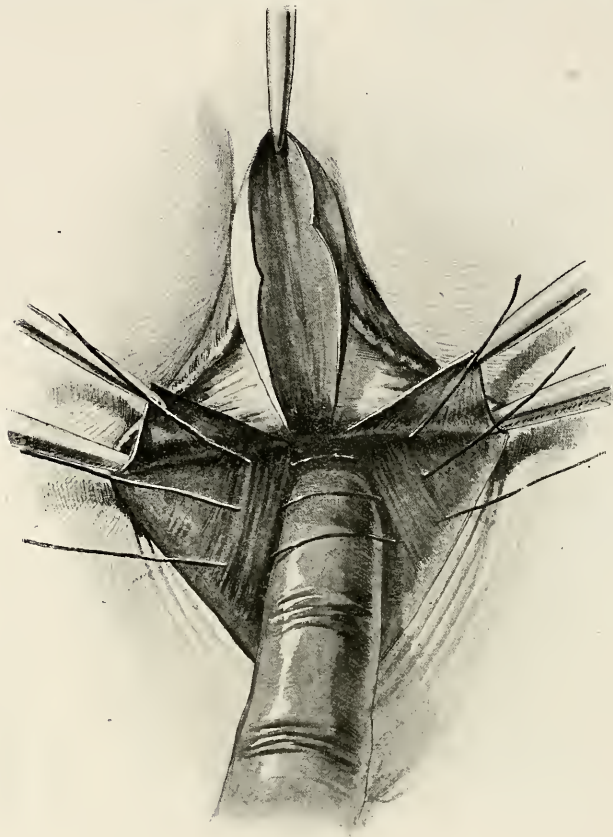


FIG. 490. PERINEORRHAPHY. *Step III*: The rectum has been pressed back by the finger; the deep sutures have been passed through the lateral musculo-fascial tissues but not tied.

in Figure 489; this allows of better access to the highest part of the dissection.

All arterial hæmorrhage must be controlled by ligatures, and the largest veins should be similarly dealt with; it is not necessary, however, to arrest all oozing by ligature, as this will cease spontaneously when the tissues are brought together.

*Step III.* If the deep wound now produced is carefully inspected, it will be seen that the rectum occupies the deepest part, lying in the middle line; if the rectum is pressed back with the finger, it will be seen

that on each side is a mass of tissue, lying in a plane superficial to it, which can be defined with finger and thumb (*see* Fig. 490). Usually these masses are of unequal thickness on the two sides, and their bulk varies in different cases; the more marked the degree of prolapse the less readily can these masses be felt. They represent what remains of the posterior fibres of the pubo-coccygeus muscle, a layer of the pelvic fascia, etc. (*see* Fig. 489). These lateral masses are now to be brought together in the middle line in front of the rectum by interrupted

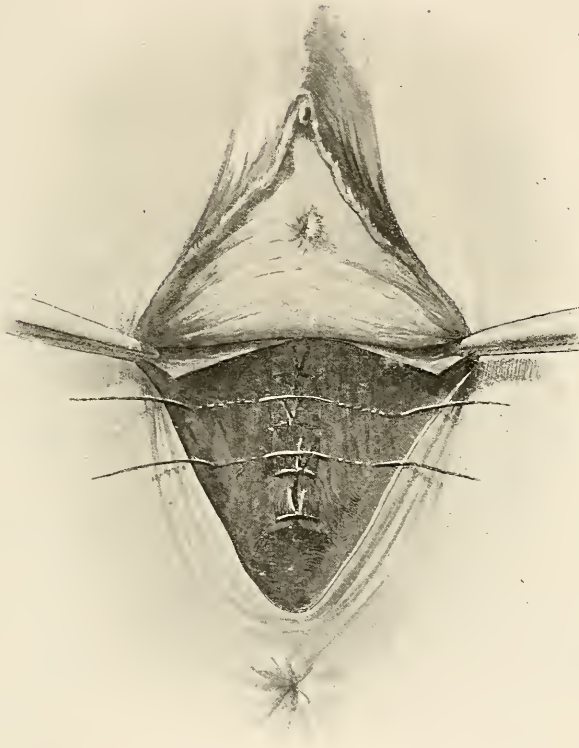


FIG. 491. PERINEORRHAPHY. *Step IV.* The deep stitches have been tied; the intermediate stitches have been introduced.

stitches of stout catgut, the rectum being pushed back with the finger while they are introduced (*see* Fig. 490). The highest of these stitches should be made to include the deep surface of the posterior vaginal wall, so as to leave no dead space in the apex of the dissection-wound. Upon these stitches depends the ultimate success of the operation, for they restore the natural supports of the rectum and posterior vaginal wall.

*Step IV.* The posterior vaginal flap is now entirely cut away, and one or two arterial twigs in the cut edge usually require ligature. A

second row of stout catgut stitches is then introduced, bringing together the middle strata of the wound and covering in those first introduced (see Fig. 491). In this way the perineal body is built up over the pubo-coccygeus muscles.

*Step V.* The edges of the posterior vaginal wall are now brought together by a running stitch of stout catgut; it is important to make sure that this stitch controls the actual upper limit of the incision from which free oozing may occur if it is left open (see Fig. 492). This stitch ends below at the points originally picked up by the lateral forceps.

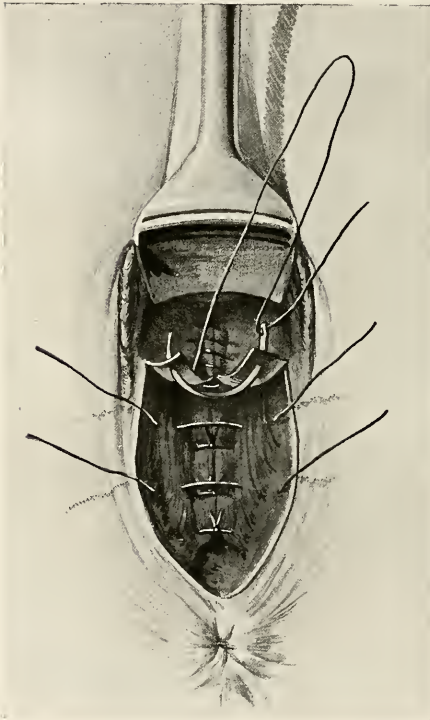


FIG. 492. PERINEORRHAPHY. *Step V.* Uniting the cut edges of the posterior vaginal wall with a running stitch.



FIG. 493. PERINEORRHAPHY. *Step VI.* The skin-edges of the restored perineal body have been united by a subcuticular suture.

*Step VI.* Nothing now remains but to approximate the skin-edges, and thus complete the perineal body. This is best done with a subcuticular stitch of medium sized catgut, as shown in Figure 493. This stitch adjusts the edges without tension, and greatly reduces the discomforts of convalescence. Finally the vaginal walls, the vulva,

and the perineal region are swabbed with iodine and a sterile dressing fixed with a T bandage. This dressing should be bulky and the

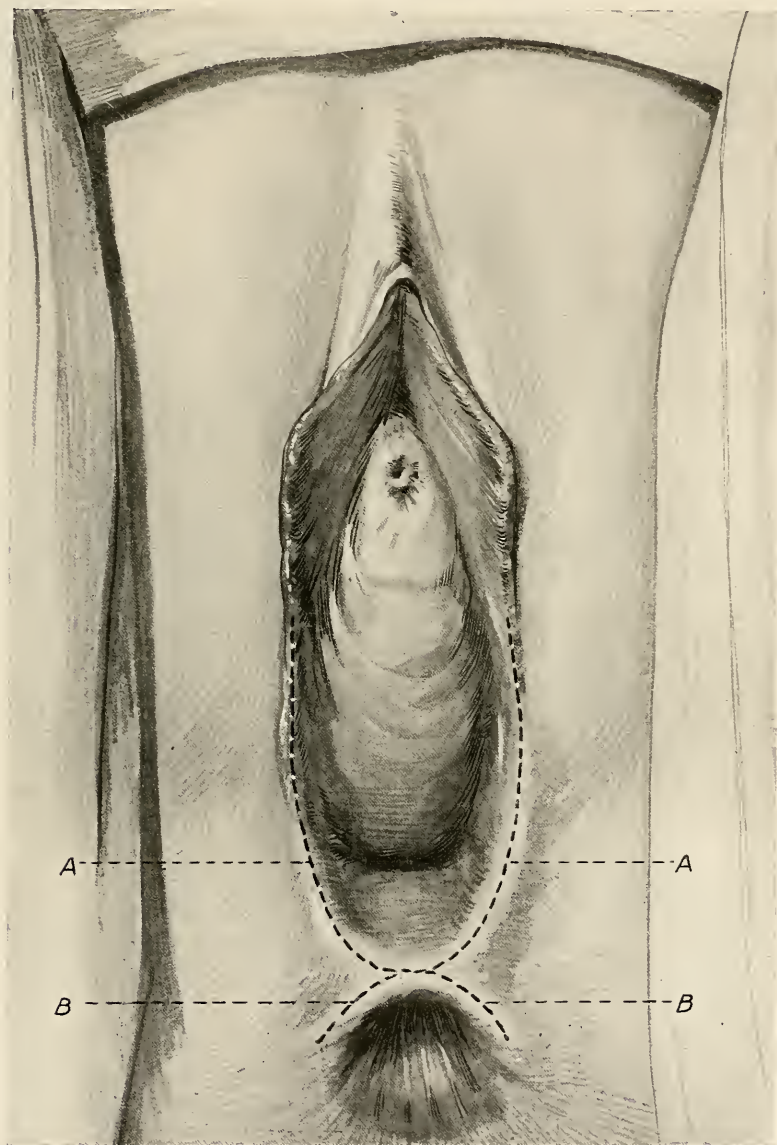


FIG. 494. COMPLETE PERINEAL LACERATION. The perineal body is absent, the vulva patulous, and the anterior vaginal wall prolapsed (cystocele). The anus is gaping, and the radial cutaneous folds are absent anteriorly. The dotted lines represent the incisions by which the vaginal and anal flaps are raised.

bandage firmly applied in order to exert pressure upon the perineum and thus assist in controlling oozing.

*Perineorrhaphy for Complete Laceration.* When the anal canal itself, or any part of the anal sphincter has been involved in an obstetric laceration, the early steps of the operation are necessarily different from those just described. The importance of restoring the functional competence, as well as the actual continuity, of these parts, will be readily appreciated. Figure 495 is drawn from a photograph of an

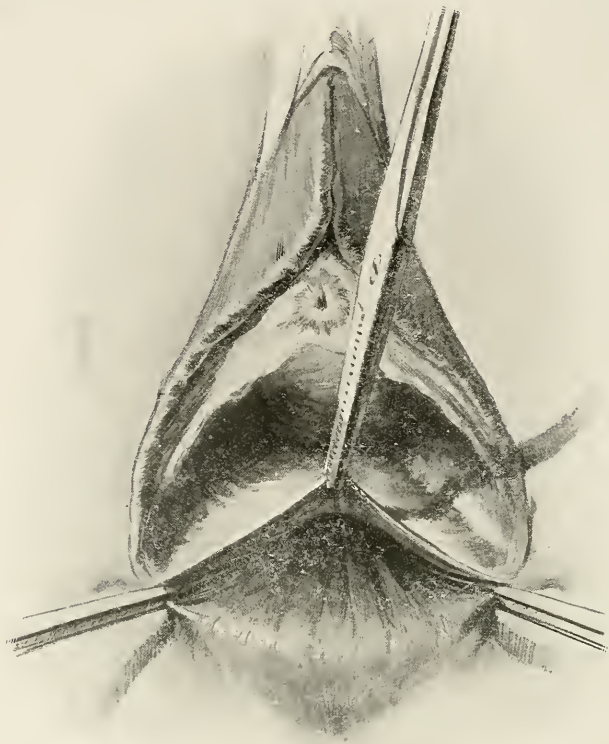


FIG. 495. COMPLETE PERINEAL LACERATION INVOLVING THE LOWER PART OF THE ANAL CANAL. The three pairs of forceps show the limits of the first incision.

extensive degree of injury to the rectum, the retentive capacity of the anal sphincter having been completely destroyed. The lower part of the rectum should be irrigated with boracic lotion before commencing the operation.

*Step I.* The condition shown in Figure 494 represents an incomplete laceration of the anus in which only the anterior part of the sphincter has been involved; the dotted lines indicate the incisions required to map out the flaps which it is necessary to raise. The two short posterior limbs will form the margins of the *anal flaps*, the two long anterior limbs those of the *vaginal flaps*. The end of the posterior limb extends half an inch behind the depression which indicates the



retracted end of the torn superficial sphincter ani muscle. The anterior limbs are carried forwards to the posterior ends of the nymphæ. When the injury has been so extensive as to lay open the anal canal, the first incision is made as in Figure 495, by splitting the V-shaped edge of the thin recto-vaginal septum, taking care to carry back the incision for half an inch beyond the retracted end of the

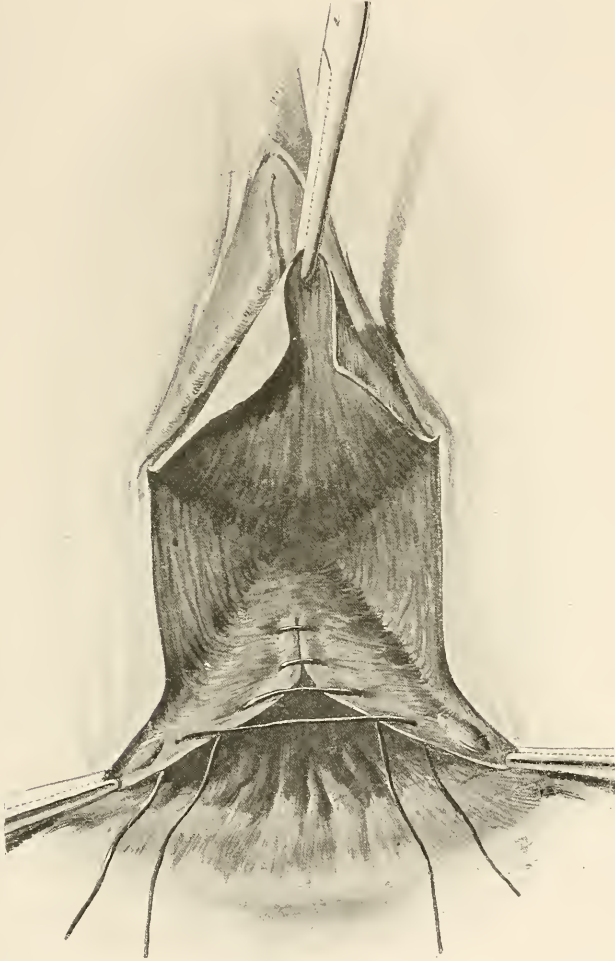


FIG. 496. COMPLETE PERINEAL LACERATION. *Step II.*  
From the same case as Fig. 495.

sphincter on each side. The anterior limbs of the incision are carried forwards as already described.

*Step II.* This step consists in splitting the recto-vaginal septum so as to free the anterior rectal wall not only upwards but laterally on each side as well. This must be done carefully on account of the tenuity of this septum, and it is often necessary to pass the finger into the bowel as a guide. In this case the gloved index finger is covered

with a finger-stall which is thrown away as soon as used. Strict attention must be paid to the lateral dissection, which must be

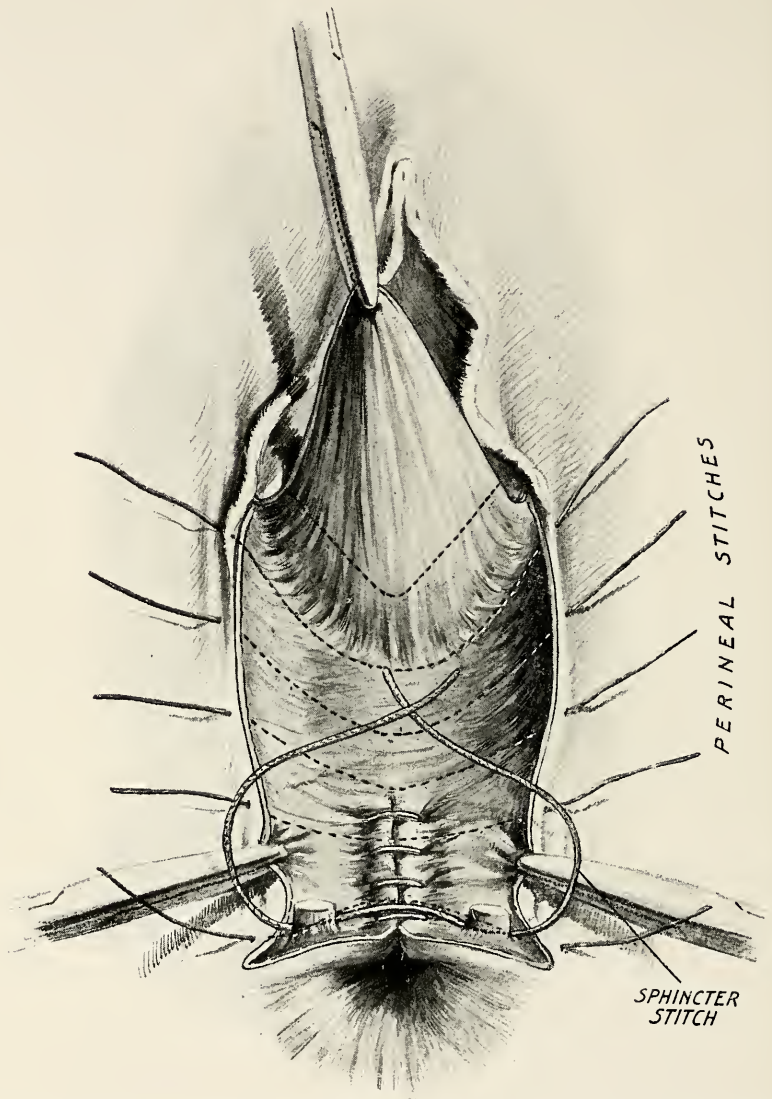


FIG. 497. PERINEORRHAPHY FOR COMPLETE LACERATION. The rectal stitches have been tied, the knots being concealed in the rectum. The sphincter has been introduced, but not tied. The perineal stitches also have been introduced, but not tied. The dotted V-shaped line in the base of the vaginal flap indicates where the flap is to be cut away.

thoroughly carried out in cases such as Figure 496, in order to allow the edges of the V-shaped gap in the anal canal to come together

without tension. If the stitches are tied under tension they will inevitably give way, and the whole wound will become infected and break down. This is the commonest cause of failure with the operation. As soon as this dissection is completed the rectal stitches should be introduced, as shown in Figure 496,<sup>2</sup> and the canal thus closed.

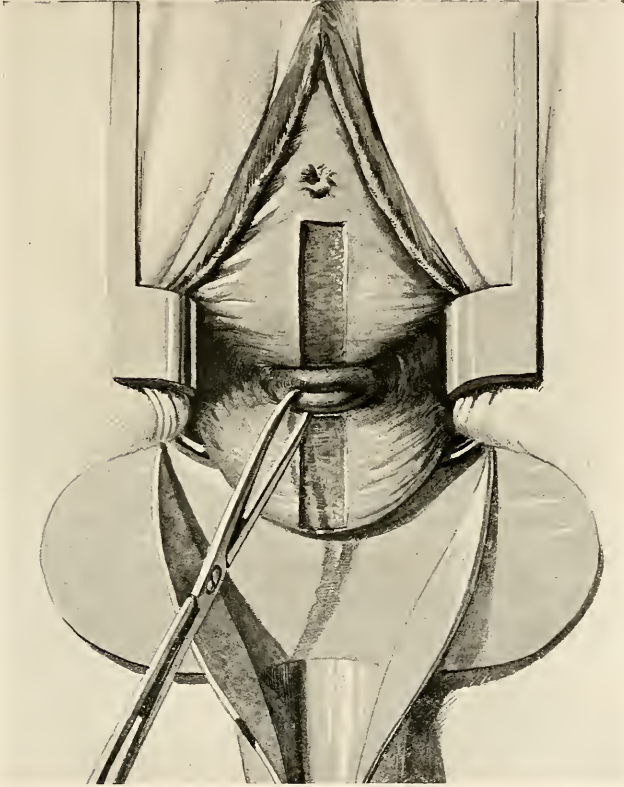


FIG. 498. LE FORT'S OPERATION FOR EXTENSIVE PROLAPSE IN ELDERLY SUBJECTS. The strips of vaginal mucous membrane have been removed.

Interrupted stitches of chromicized or iodine-formalin gut are used, and knotted on the side of the rectum.

The remaining steps of the operation are the same as those described above. A fresh pair of sterilized gloves and fresh instruments should be used as soon as the rectal canal has been closed, and before commencing the deep dissection of the recto-vaginal space. Before closing the skin-edges, an attempt should be made to bring together the retracted ends of the superficial sphincter (*see* Fig. 497). The position of the ends of the muscle can usually be recognized, and although actual muscle-fibres can seldom be seen, a stitch passed deeply beneath them will take up the muscle along with other tissues and approximate its ends with fair accuracy.

**Le Fort's Operation.** In elderly women in whom the question of nubility is of no importance, and who are the subjects of complete procidentia or of advanced prolapse of the second degree, this operation is suitable, and is usually successful. When efficiently performed it forms a barrier to coitus, and establishes an impediment to vaginal

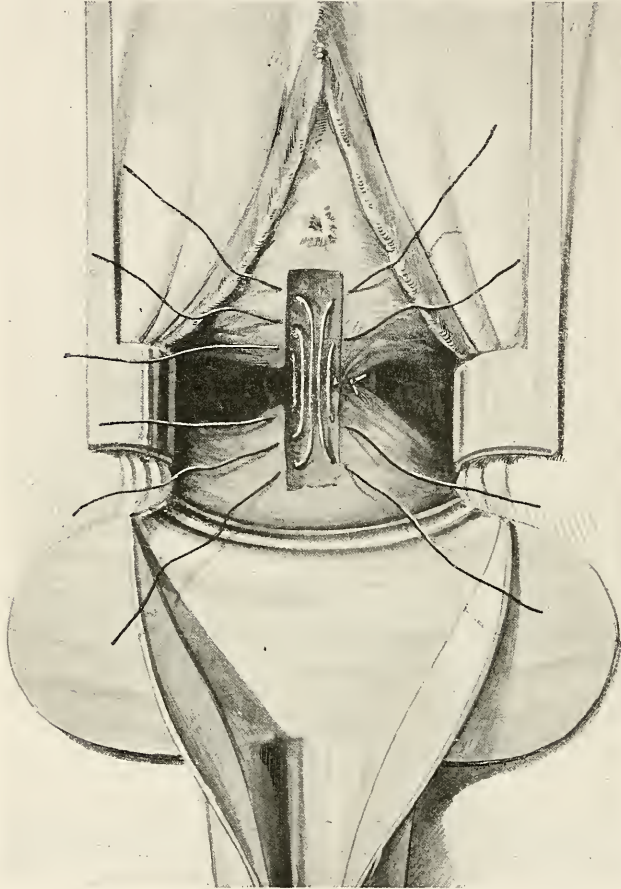


FIG. 499. LE FORT'S OPERATION, showing the method of uniting the anterior and posterior raw surfaces.

drainage. It is therefore limited in its application, and should never be employed until after the fertile period is passed and menstruation has ceased.

The operation consists in establishing a central longitudinal partition by suturing the anterior to the posterior vaginal wall. To do this, the cervix is grasped and drawn out of the vulva by means of a volsella. Four incisions are made on the anterior surface of the vagina, enclosing a rectangular area of mucous membrane measuring some six or seven centimetres in length by two centimetres in width.

The mucous membrane thus mapped out is dissected off, and an area of mucosa similar in all respects to the above is removed from the posterior vaginal wall (*see* Fig. 498). The edges of the raw surfaces on the anterior wall are then united by interrupted chromic catgut sutures to the corresponding edges on the posterior wall (*see* Fig. 499). The effect of this is to bring two raw surfaces (the one anterior and the other posterior) into apposition. Thus a central partition is formed which effectively prevents eversion of the vaginal walls. The median partition should be long enough to reach to the vulva, and should be flush with the perineal margin behind and reach almost to the urethral orifice in front. A drain of bismuth gauze should be inserted in the space left on either side of the median partition, and retained for twenty-four hours. The condition of the uterus should be observed before this operation is undertaken; an unhealthy cervix or any kind of uterine discharge should be cleared up by suitable treatment as a preliminary procedure. Similarly there must be no ulceration of the vaginal mucous membrane. If the parts are healthy and clean, primary union occurs, leaving a partite vagina which cannot prolapse and which thereby prevents descent of the uterus; prolapse of the bladder and the rectum are also impossible.

**Operations for Fistulæ.** The following conditions may call for operative treatment by repair of the fistula or otherwise.

I. *Urinary Fistulæ.* (1) Vesico-vaginal fistula; (2) vesico-cervical fistula; (3) Uretero-vaginal fistula; (4) Vesico-abdominal fistula; (5) Uretero-abdominal fistula. II. *Fæcal Fistulæ.* (6) Ano-perineal fistula; (7) recto-vaginal fistula; (8) abdominal fæcal fistula.

These fistulæ may be met with under three conditions: (*a*) as the result of obstetric injuries; (*b*) as sequelæ of operative procedures involving the urinary or intestinal tract; (*c*) as the result of malignant disease involving these parts. Those due to the last-named cause are of course incapable of operative cure; the others can all be dealt with by suitable methods.

The operations required are in many instances complicated and do not call for detailed description. There are certain general principles of dealing with fistulæ which may, however, be considered.

Fistulous tracts which are lined by mucous membrane show little or no tendency to close spontaneously, while those which are lined only by granulation-tissue show a strong tendency towards repair. Vaginal fistulæ, both urinary and fæcal, belong to the former class; all the abdominal fistulæ and the ano-perineal fistulæ belong to the latter class. While operation is consequently always indicated in the former class, the latter should be left alone as long as they show any tendency towards progressive repair.

In the case of urinary fistulæ the success of operative procedures

depends to a great extent upon the condition of the urine being healthy. Consequently urinary infection must be carefully treated and completely corrected before operation is undertaken. In the case of fæcal fistulæ no such precautions are practicable.

The operations required for *abdominal fæcal fistulæ* are difficult and complicated procedures which cannot be described here. *Ureteral*

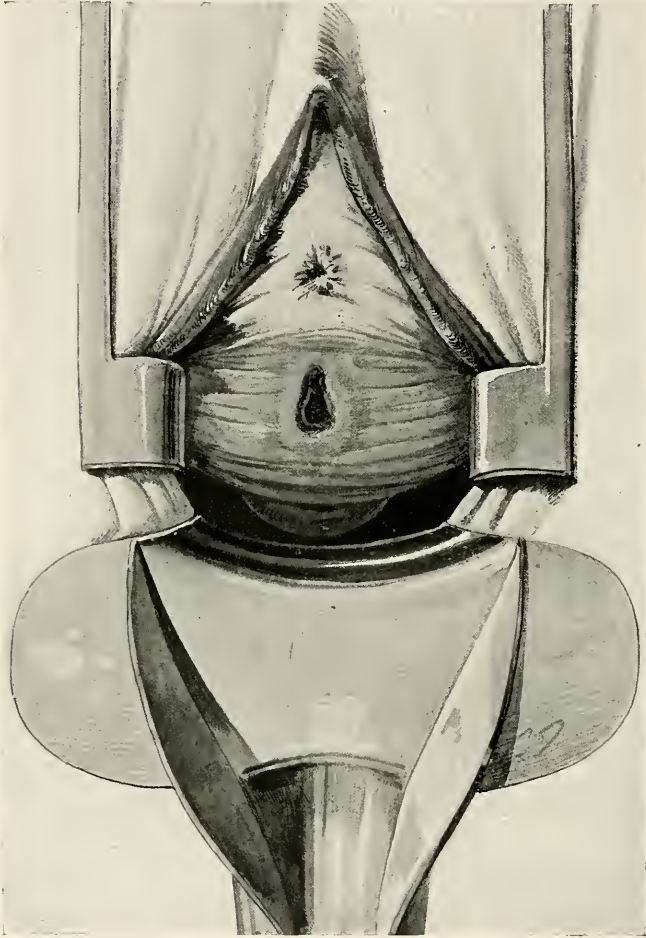


FIG. 500. VESICO-VAGINAL FISTULA EXPOSED FOR OPERATION.

*fistulæ* whether vaginal or abdominal are to be dealt with either (a) by transplantation of the proximal end of the damaged ureter into the bladder—*uretero-vesical anastomosis*, or (b) by the removal of the kidney on the affected side, the other kidney having first been demonstrated to be present and functionally active by catheterization of the ureter and urinary analysis. Only under exceptionally favourable conditions is the former likely to be successful. Vesico-vaginal fistulæ

and recto-vaginal fistulæ can usually be dealt with by plastic operations which may now be described.

**Vesico-Vaginal Fistulæ.** The majority of these fistulæ affect the upper and middle thirds of the anterior vaginal wall, and can be closed by an operation *per vaginam*. A small number are situated higher than this, and are accompanied by more or less destruction of the anterior cervical wall. In these, the hole in the bladder may be situated so high that it can be best reached by an intra-peritoneal supra-pubic operation. This consists in separating the bladder from the uterus and vagina, beginning above and extending well down below the level of the lower

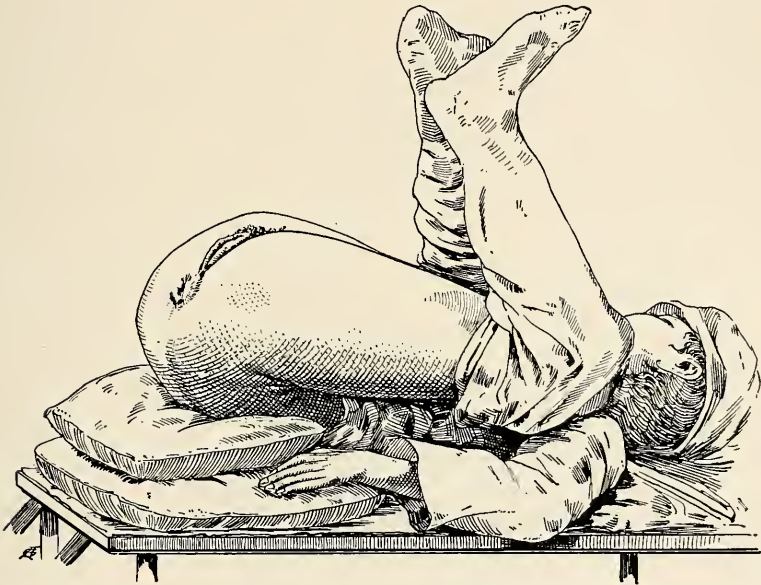


FIG. 501. ELEVATED PELVIC POSITION FOR OPERATION FOR VESICO-VAGINAL FISTULA (after Kelly).

border of the fistula ; the aperture in the bladder is then closed, and afterwards that in the vagina. The operation is formidable owing to the difficulty in obtaining access to the parts.

The procedures which may be practised for those situated in the middle or lower third (*see* Fig. 500) of the vagina are as follows :

The operation suitable for moderate-sized fistulæ, involving only the vaginal wall and bladder, is simple and easy. In order to obtain a good view of the anterior vaginal wall it is advisable to employ the elevated pelvic position shown in Fig. 501. The posterior vaginal wall being then held back by a flat retractor the fistula can be well seen (Fig. 500). Two different methods of closure may be practised : (*a*) in one the edges of the fistula are simply rawed and then stitched together ; (*b*) in the other, a flap-splitting method, the bladder and vaginal walls are first widely detached from one another, and then

separately united by distinct sets of stitches. The former method is only suitable for fistulæ of the smallest size.

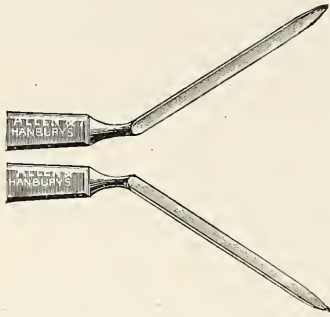


FIG. 502. KNIVES FOR VESICO-VAGINAL FISTULA.

(a) In rawing the edges of the fistula, fine, keen, angled knives like those shown in Figure 502 are employed, and a narrow strip of tissue is removed all round, which includes both bladder and vaginal wall, the latter being rather more freely removed than the former. Three strata of tissue are thus traversed, viz. vaginal wall, perivaginal cellular tissue, and bladder-wall. Stout interrupted stitches are used to close the aperture, and these should be passed through all the tissues except the vesical mucosa, a good hold of the vaginal wall

being required, as there is necessarily considerable tension. All oozing from the edges of the mucosa must be carefully controlled by hot

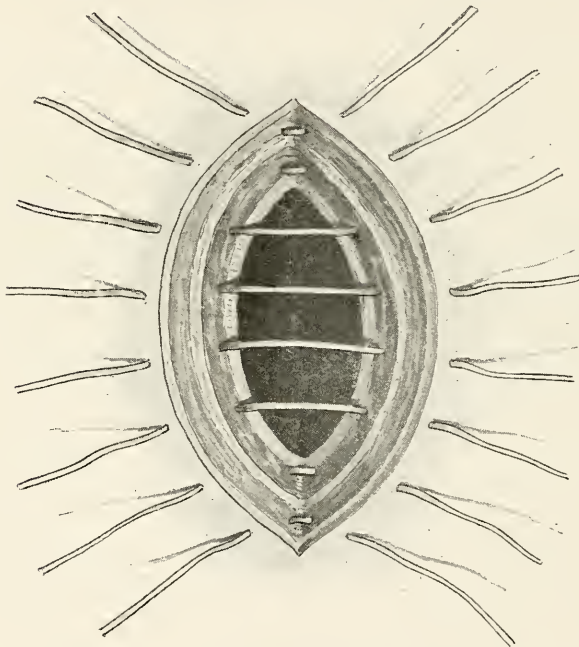


FIG. 503. OPERATION FOR VESICO-VAGINAL FISTULA. The edges have been rawed, and the sutures introduced so as to include all the tissues except the mucous membrane of the bladder.

irrigation, or by forcipressure, before the ligatures are tied. The rawed edges of the bladder-mucosa are thus brought into apposition but are not included in the stitches (see Fig. 503). Chromicized catgut is the best suture-material to employ. The fault of this operation is that the



edges of the fistula are held together under considerable tension, a condition unfavourable for healing by primary union.

(b) In the flap-splitting operation an incision is made all round the fistula, cutting through the vaginal wall alone; from this incision two short longitudinal incisions are carried, one upwards towards the

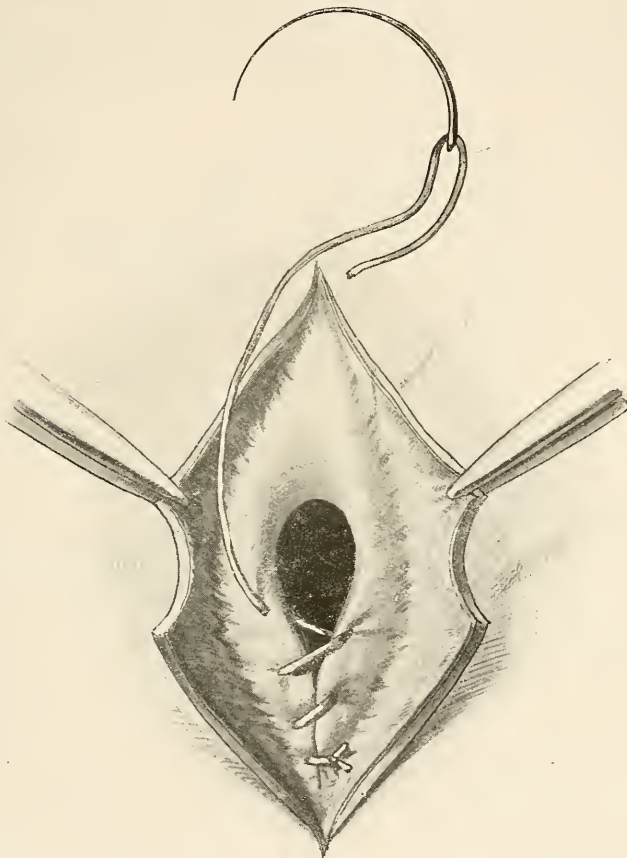


FIG. 504. FLAP-SPLITTING OPERATION FOR VESICO-VAGINAL FISTULA. The vaginal flaps have been raised and are held aside by forceps. A catgut stitch is seen, which inverts the edges of the aperture in the bladder-wall.

cervix and the other downwards towards the *meatus urinarius* (see Fig. 504). By means of these incisions two flaps of vaginal wall are then dissected carefully off the subjacent bladder, until the latter is exposed for half an inch all round the fistula (see Fig. 505). The edges of the opening in the bladder are not incised, but the opening is closed by a continuous catgut stitch passed just outside the edge through the muscular wall alone, on each side of the fistula, so as to bring muscular wall in apposition with muscular wall and invert the mucosa, in the manner of Lembert's peritoneal suture. The

separation of the bladder from the vagina frees the former, and allows the edges of the opening to be drawn together with ease. A second series of interrupted stitches may then be similarly passed from side to side so as to bury the first stitch. The edges of the vaginal flaps are finally trimmed and united accurately by catgut stitches so as completely to cover up the bladder-walls. The advantages of this method are : (1) absence of tension ; (2) strengthening of the bladder-wall by superimposed layers of sutures ; (3) better protection of the bladder-stitches from vaginal infection. It is essential in the after-

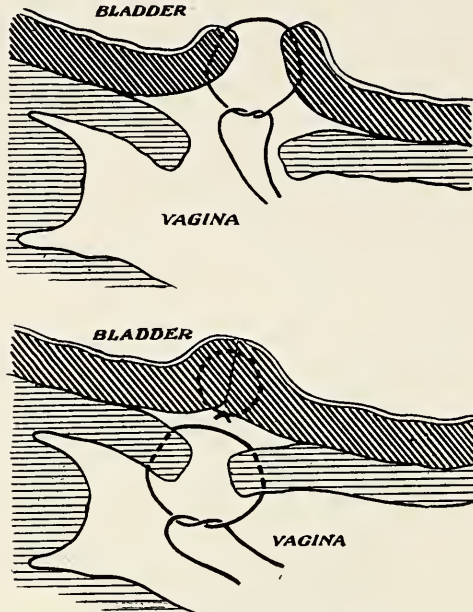


FIG. 505. FLAP-SPLITTING OPERATION FOR VESICO-VAGINAL FISTULA—  
DIAGRAMMATIC.

treatment that the bladder should not be allowed to become even moderately full, and continuous drainage must be provided for.

A self-retaining rubber catheter may be kept in the bladder for five or six days after either operation. It should be removed daily and boiled before it is again inserted. After extensive operations for the closure of large apertures, it is better to drain the bladder by the supra-pubic route with a large rubber tube. The resulting fistula closes spontaneously in six weeks. Diluents should be given freely to prevent over-acidity of the urine, and careful vaginal asepsis must be observed, as primary union of the vaginal stitches is an important element of success. In the presence of urinary infection success is very difficult to achieve.

**Recto-vaginal Fistulæ.** In the *lower third* of the posterior vaginal wall these fistulæ are comparatively common. They result from

irregular healing of obstetric lacerations of the perineum, and are of small size ; in the operation for complete perineal rupture they can be closed without modifying the steps of the operation (*see* Fig. 496).

Those situated in the *middle third* can be dealt with in the manner already described for vesico-vaginal fistulæ by separating the rectum from the posterior vaginal wall, and closing the opening in the former, separately from that in the latter. Or they may be reached by an operation which, commencing as in perineorrhaphy, extends the dissection of the recto-vaginal space upwards, until a point well above the upper limit of the fistulous aperture has been reached. The opening in the rectum can then be closed with interrupted stitches and the vaginal wall united over it.

Fistulæ situated in the *upper third* of the vagina often involve the floor of Douglas's pouch and the posterior wall of the cervix. Considerable sloughing from fæcal infection often follows the injury, and this ultimately results in the formation of much cicatricial tissue, which forms an absolute bar to spontaneous healing, and adds much to the difficulties of operative repair. Cicatrization immobilizes the parts, and as they lie at a considerable depth the mechanical difficulties attending the operative manipulations are formidable. Fistulæ in this situation may often be best reached by an abdominal operation, and in order to obtain proper access from above, it may be necessary to remove the uterus. In exceptionally difficult cases a preliminary left inguinal colotomy may be necessary as in a case recorded by one of us : this is kept open until the fistula has been successfully dealt with, and time has been allowed for firm union to occur. The colotomy-opening is then closed. Healing is greatly aided by cutting off the fæcal stream from the affected segment of the intestine.

### Operation for Restoration of an Inverted Uterus

**Indications.** This operation may be practised in cases of chronic puerperal inversion, in which the uterus is otherwise healthy, and attempts to reduce it by Aveling's repositor (*see* p. 589) have failed. Cases of chronic inversion due to new growths (*see* p. 586) are not suitable for this procedure, as has been already explained. The operation should not be undertaken until all signs of infection, when such have been present, have disappeared. The operation is a conservative procedure, and should be preferred to vaginal hysterectomy in young women whenever the condition is favourable for it.

The technique here described is that of Spinelli, and the operation is known as 'Spinelli's operation'; it will be best understood by describing each step in order. The most careful antiseptic preparations are called for before the operation is begun, and during its performance.

*Step I.* Opening the utero-vesical pouch through the anterior fornix (*see* Figs. 506, *b* and *c*). The condition shown in Figure 506, *a*, is

an incomplete inversion, the cervical lips being well defined. The anterior lip is fixed with a volsella and the procedure already described as 'anterior colpotomy' carried out (*see* p. 779).

*Step II.* The anterior wall of the uterus is split in the middle line from os externum to fundus (*see* Fig. 506, *d* and *e*). Scissors are used, and the uterus is steadied by traction upon each half of the divided cervix.

*Step III.* The uterus is re-inverted by the fingers, in the manner shown in Figure 506, *f* and *g*, the peritoneal surface of the organ being pressed forwards and the cut edges at the same time rolled backwards. This is the most difficult part of the operation, especially in long-standing cases on account of the rigidity of the uterine tissues. When the inversion is corrected the incision lies behind, the fundus still being the lowest part.

*Step IV.* The uterine incision is closed in two layers, the first including mucosa and muscular layer, the second including peritoneum and muscular layer. The fundus of the uterus is carried forwards and upwards to obtain access to the anterior uterine surface (Fig. 506, *h* and *i*).

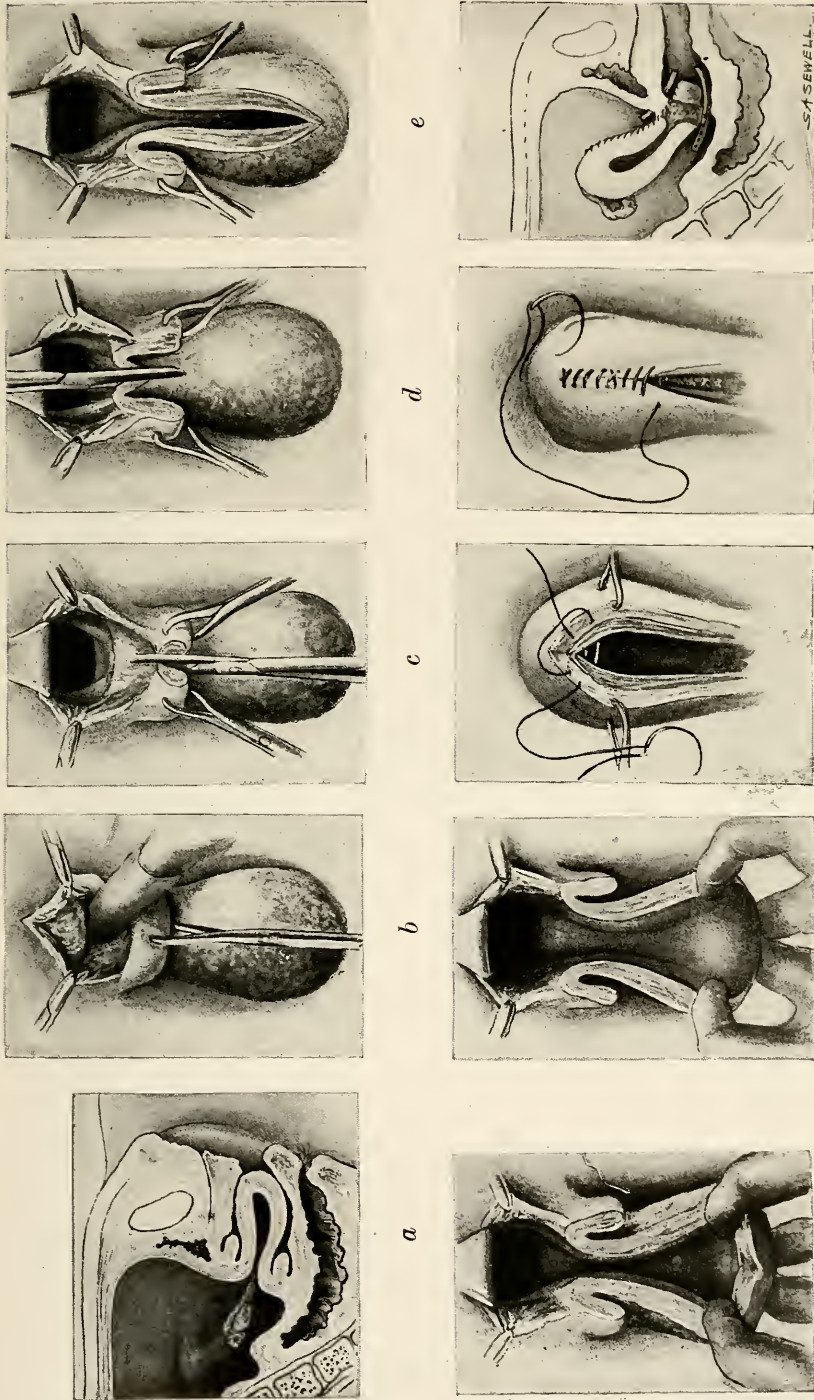
*Step V.* The uterus is next returned to the pelvic cavity by pushing it up through the opening in the utero-vesical pouch; the uterus is thus rotated around a transverse axis passing through the supra-vaginal cervix. The relations are shown in Figure 506, *j*, which also indicates the line of suture in the anterior uterine wall.

*Step VI.* Finally the peritoneal and vaginal incisions in the utero-vesical pouch and the anterior fornix are closed. Spinelli advises that both anterior and posterior pouches should be drained.

## OPERATIONS ON THE VULVA

**Atresia of the Vulva.** This condition has been mentioned on pp. 165 and 339. It is occasionally found in adults and is the result of membranous vulvitis due to diphtheritic or streptococcal infection during childhood. The lesion is superficial and is remedied by the following simple operation. The bridge of scar-tissue shown in Figure 93, p. 166, is divided in the middle line from one end to the other. The flaps thus formed will be seen to have an inner mucous and an outer cutaneous surface; these surfaces are united by sewing over the edges with catgut as shown in Figure 507. The great depth at which the hymen lay in this Figure (photographed immediately after the operation) became rapidly reduced by consolidation and retraction of the divided tissues.

**Urethral Caruncle.** Caruncles are sometimes treated by burning, a Pacquelin's cauterium being used. The result of cauterization is unsatisfactory, recurrence of the growth being common after such procedure. It is far better to remove a caruncle by excision.



*f* *g* *h* *i* *j*  
FIG. 506. SPINELLI'S OPERATION FOR CHRONIC INVERSION OF THE UTERUS. (For description of Figures see text, pp. 831-2.)

*Excision and Suture.* The growth is seized with fine forceps and drawn down until its origin from the mucous membrane of the posterior wall is clearly defined. It is then excised with a scalpel or with fine sharp-pointed scissors. The incision is carried through the entire

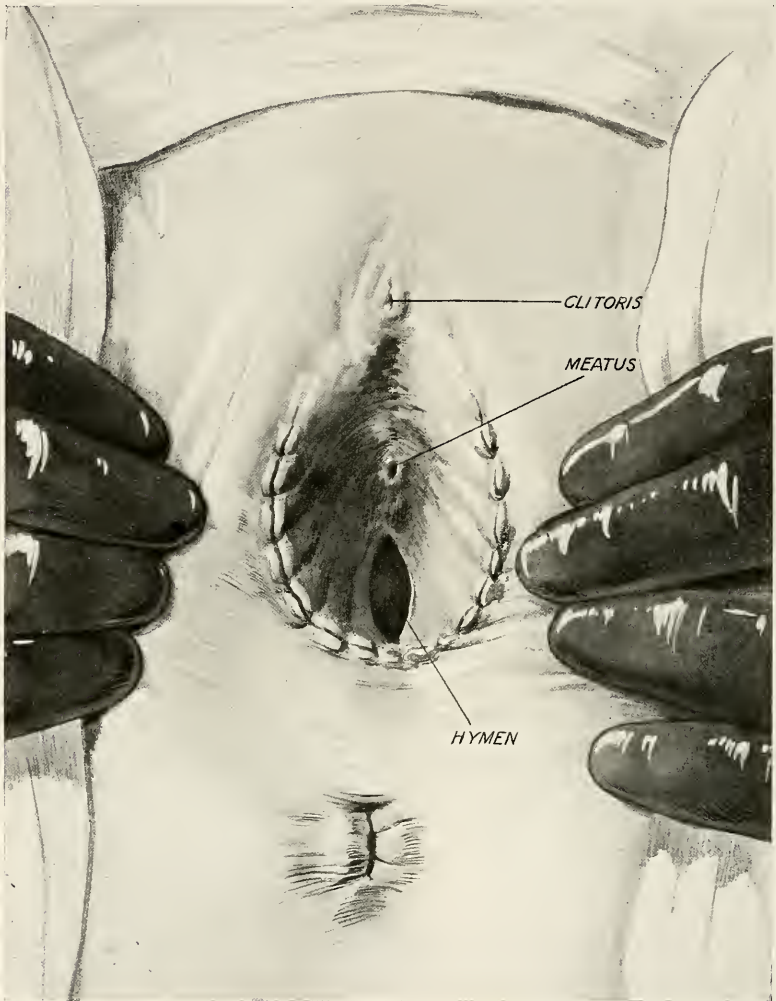


FIG. 507. THE OPERATION FOR VULVAL ATRESIA SHOWN COMPLETED.  
See also Figure 93, p. 166.

thickness of the mucous membrane and it leaves an oval elongated wound on the floor (posterior wall) of the urethra. The edges of this wound are brought together by one or two fine catgut sutures. If the excision is not complete there is a liability to recurrence, hence it may be necessary to dilate a small urethra before removal of the growth, in order to obtain a good view of the extent of its attachment to the urethral floor.

**Prolapse of the Urethra.** The prolapsed portion of the mucous membrane (*see* Fig. 185, p. 378) is grasped with forceps and put on the stretch. At the base of the stretched mucosa two lateral catgut sutures are passed, one on the right and the other on the left side. These sutures are to prevent retraction of the mucosa after the prolapsed portion is removed; the sutures include all the tissues in the urethral wall, being passed (1) through the attachment of the urethra to the vestibule; (2) through the fibro-muscular wall and the mucosa; (3) into the lumen of the urethra and out again through the urethral walls, where, before being tied, they are held aside until the prolapsed mucosa is cut off. This is done by dividing the prolapsed collar from before back through its upper and lower surfaces until the level of the above sutures is reached; then the two resulting lateral flaps of mucous membrane are divided flush with the ligatures. The latter are then tied, when they form the two lateral sutures of the new meatus. Similar sutures are passed above and below to bring the mucosa into union with the vestibular surface all round and thus to form the new *meatus urinarius*. An additional advantage of the method is that the undue patency of the meatus is reduced.

**Urethrocele.** A urethrocele is a sacculated portion of the mucous membrane which projects towards the anterior vaginal wall, where it forms a small rounded reducible swelling.

**Excision.** The treatment of the condition consists in its removal. A sound is passed into the urethra and its tip directed into the urethrocele. A linear incision is then made through the vaginal wall on to the tip of the sound lying in the urethrocele. The vaginal wall is then dissected off the latter, when the stretched mucous membrane forming the sacculus will appear as a thin-walled cyst. The edges of this structure are generally adherent to the urethral wall in the same way that the sac of a ventral hernia is adherent to the parietes; it is therefore safe to cut off the sac close to the aperture through which it has prolapsed, without fear of retraction of the mucous membrane. This is next done and then the floor of the urethra is closed by interrupted catgut sutures. Finally the small vaginal skin-flaps are trimmed with scissors and brought together with catgut sutures. In cases where there is no definite 'sacculus' but a general laxity of the entire length of the urethra, excision of any part of the urethra is unsuitable. It is then better to treat the dilated duct on the same principle as that adopted for the bladder in the radical cure of cystocele (*vide* p. 806).

**Operations for Incontinence of Urine.** In certain cases where there is no abnormality of the bladder or of the urine, but where the only sign to account for the troublesome symptom of incontinence is a dependent position of the urethra, an operation for the *elevation of the meatus* has been devised. A horseshoe-shaped incision is made through the vestibular mucous membrane above and to either side of the meatus. By uniting the edges of the meatus to the outer edges of the vestibular

incision, the mouth of the urethra is drawn up for half an inch, or more, above its former position. Cases of incontinence occur in which an undue patency of the urethra is found, which may, or may not, be accompanied by cystocele. The treatment then consists in making a longitudinal median incision through the vaginal wall along the length of the urethra, raising two lateral vaginal flaps, then invaginating the floor of the urethra, and bringing the margins of the groove into apposition with interrupted catgut sutures. When a lax urethra accompanies a cystocele the above procedure is merely a continuation of the radical cure of cystocele (*see* p. 806), the central vaginal incision being carried as far as the *meatus urinarius*.

**Excision of Bartholin's Cyst.** A vertical linear incision is made over the vulval swelling (*see* Fig. 176, p. 364). Reference to Figure 41, p. 62, will show that the gland of Bartholin lies immediately behind the bulb of the vestibule. Since the latter contains many large vessels, the anterior limit of the incision should not be made so high as to injure this structure. The incision having been made, its edges are picked up with pressure-forceps, and the mucous membrane and skin of the labium are dissected off the cyst, care being taken not to button-hole the delicate mucosa. Strands of connective tissue carrying blood-vessels are divided between clamps, whilst the cyst is being shelled out of its fibro-fatty bed. It is quite possible to remove the cyst and the gland together as Figure 117, p. 365, shows, but in the case of large cysts the gland will have been flattened out and will not be found. After the cyst has been removed entire, all bleeding-points are secured by catgut ligatures, and then the wound is closed by buried sutures of the same material. A pad of gauze is placed between the labia before the external dressing is applied. The patient is kept in bed for a week.

**Bartholin's Abscess.** Whenever possible the abscess-sac should be dissected out without rupture or perforation; the difficulty of so doing lies with the vulval mucous membrane, which soon becomes very adherent and thinned. It is worth while to sacrifice a portion of the mucosa in an attempt to secure primary union of the wound. If, therefore, two curved incisions are made so as to include a lozenge-shaped piece of the mucosa at its most adherent part, it is possible to dissect out the pus-sac entire. The wound may then be completely closed in layers with catgut sutures. The alternative plan is to lay the abscess open freely, scrape away the pyogenic membrane, swab the raw surface with 1-2000 biniodide of mercury solution and pack with bismuth gauze. The cavity then granulates up from the bottom, leaving an area of indurated tissue in the depths of the wound which can be felt for months afterwards.

**Hydrocele of the Canal of Nuck.** Serous peritonitic fluid sometimes collects in the *processus vaginalis peritonei* when the latter remains patent. The result is a cystic swelling at the upper part of the *labium*



*majus* overlying the external abdominal ring. The treatment is removal, which is carried out as follows : An incision is made parallel to Poupart's ligament at a level of 2 cm. above that structure, and extending from the pubic spine to the internal abdominal ring. The skin and superficial fascia are first divided, and superficial vessels are tied off. Then the aponeurosis of the external oblique muscle is slit up along the whole length of the wound, and the canal of Nuck is thus exposed. The peritoneum of the latter may be found to be distended with fluid only at its terminal part, or it may present as a cyst reaching from one end of the wound to the other. The cyst must be completely freed from the round ligament and the adjacent tissues ; it is then opened up and its contents allowed to escape. The peritoneal sac is next seized with pressure-forceps and twisted until the neck is found to yield. A ligature is now applied to the twisted neck and the rest of the sac cut off. The stump is then fixed to the parietes above and external to the internal abdominal ring. In closing the wound the aponeurotic flaps of the external oblique are held aside whilst two mattress-sutures are passed through the muscular fibres of the internal oblique and through the external oblique aponeurosis close to its attachment to Poupart's ligament. As there is no spermatic cord in the female, these buried sutures are passed in the same plane. Finally the external aponeurosis is united. This is best done by drawing down the upper flap over the lower so as to strengthen the wound by providing for a double layer of aponeurosis over the line of the incision. The overlapping aponeurotic flaps are kept in apposition by mattress-sutures. The skin is united by subcuticular suture. Catgut may be used throughout the operation. A collodion scab, a pad of wool, and a spica bandage are applied, and the patient is kept in bed for a fortnight.

**Labial Hernia.** An epiplocele or enterocele may form a swelling in the canal of Nuck or in the *labium majus*. When the hernia has extended into the external genitals the incision described above may have to be prolonged in order to reach the lower end of the sac, or, when not very adherent, the labial part of the sac can be drawn up into the wound without the latter being enlarged. On opening the sac it must be emptied of its contents, bowel must be returned into the abdomen, omentum must be tied and cut off. In other respects the operation is the same as that for hydrocele of the canal of Nuck.

**Warts of the External Genitalia.** Before operating for this condition it is necessary to keep the patient in bed, and to give repeated vaginal douches, also to treat any infective condition of the cervix or urethra which may be present.

Vulval and pudendal hair should be removed as far as is possible and the whole vulva swabbed with acetone and painted with iodine (2 per cent.). The larger warts are then removed by a scalpel and the smaller ones are scraped off with a sharp spoon. It may be necessary

to unite the edges of the wounds with a fine catgut stitch in the case of the larger warts. An aseptic dressing is applied, and the patient is kept in bed until the wounds and abrasions have healed.

**Epithelioma of the Vulva.** In the removal of a malignant growth from the vulva it is essential to extirpate the inguinal glands on

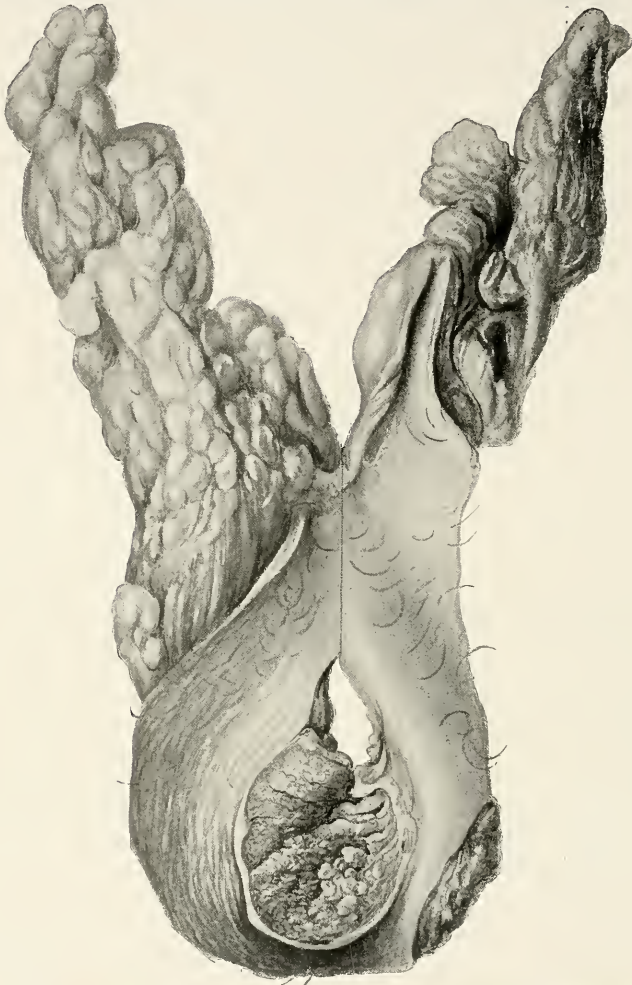


FIG. 508. EXCISION OF VULVA AND INGUINAL GLANDS PERFORMED FOR VULVO-VAGINAL CANCER.

both sides at the same time, whether they are palpable or not. Cancer which involves the vestibule often spreads across the mid-line (*see* Fig. 169, p. 356); it is also not infrequently multiple, appearing on both sides simultaneously (*see* Fig. 167, p. 355); in such cases, therefore, it becomes necessary to remove the glands from *both* groins. The operation proceeds as follows (*see* Figs. 508 and 509):

An incision through skin and superficial fascia is made above and

parallel to Poupart's ligaments, and the fatty tissue of the groin, carrying the glands of both the inguinal and femoral groups, is dissected out *en masse* from without inwards. This is done on both sides, the divided vessels being clamped and ligatured as the operation proceeds. The mass of glands and fat is not removed at this stage,

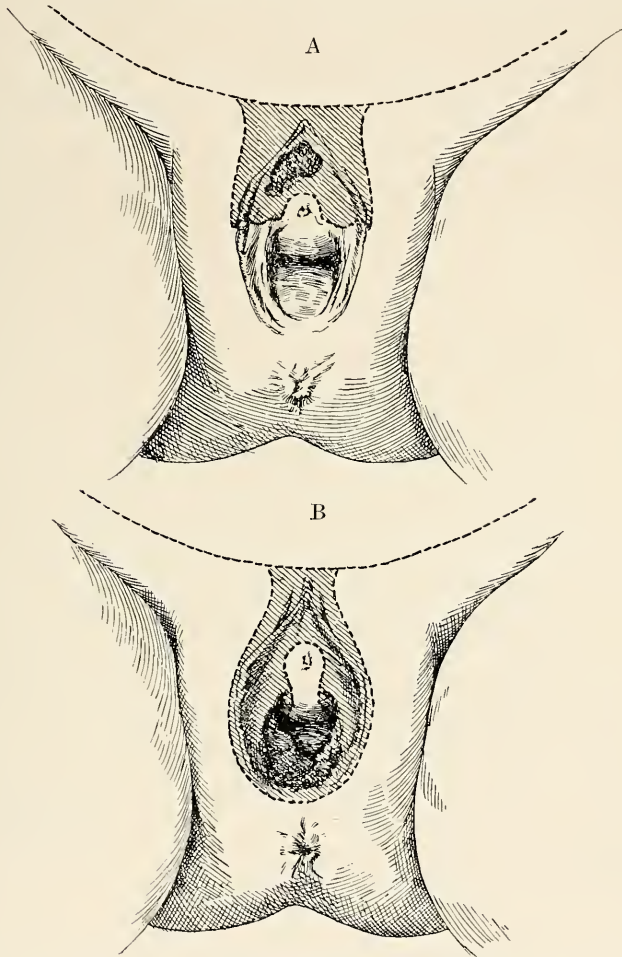


FIG. 509. A. OPERATION FOR CANCER OF THE CLITORIS. Dotted line shows incisions and the shaded area the parts to be removed. B. OPERATION FOR VULVO-VAGINAL CANCER. The incisions are represented by a dotted line. The shaded area shows the parts to be removed.

but is wrapped in sterile gauze and removed in conjunction with the cancerous tissue later in the operation. After dissection of the glands the inguinal wounds are closed with interrupted fishing-gut sutures and covered with a sterilized towel.

The position and extent of the vulval growth will determine the subsequent steps of the operation. If the growth involves the clitoris and adjacent nymphæ, as shown in Figures 167 and 169 (pp.

355 and 356), these structures are removed *en masse*. To do this the lower ends of the inguinal incisions are prolonged downwards by cutting through the substance of the *labia majora* to a point beyond the lower extremity of the growth, keeping well outside the cancerous area. These lateral incisions are now joined by two others running transversely, one through the skin of the *mons Veneris* above the growth and one through mucous membrane below, the latter passing across the vestibule just above the level of the *meatus urinarius* (see Fig. 509A). The tissues thus mapped out are now removed together with the attached inguinal glands. The dissection proceeds from above downwards and in removing the clitoris its crura are divided close to their attachments to the pubic rami and the branches of the pubic arteries which run to the clitoris (see Fig. 41, p. 62) are tied off as soon as divided. Care must be taken to avoid injury to the urethra, a sound being retained in the canal to determine its position. When the disease is confined to the lower part of the vulva as seen in Figure 508 the skin incision is made to encircle the vulva and that through the mucosa encircles the vagina and urethra (see Fig. 509B). The area for removal being thus defined, dissection is continued from the point where it was left off. The fatty tissue from the groin which had been held aside whilst the vulval and vaginal incisions were made, is now grasped by the operator, and whilst the vulval tissues are put on the stretch they are dissected off the pubic rami above, and from the perineal body below. Branches of the internal pudic artery running to the clitoris and to the bulb on either side, are clamped as soon as cut. The closure of the wound requires careful consideration, in order that the normal situation of the urethral orifice be preserved as far as is possible. It is best, therefore, to begin by approximating the skin-edges to the urethra by a few radially placed fishing-gut sutures; then proceed to unite the vaginal mucosa with the external skin, and finally to close the wide upper area in front of the symphysis pubis. Fishing-gut sutures should be used for apposition, and catgut for hæmostasis.

### OPERATIONS ON THE VAGINA

**Operation for Vaginismus.** In some cases hyperæsthesia and spasm often persist in spite of palliative treatment (see p. 371). It then becomes necessary, first to incise the superficial vaginal sphincter muscle, and to follow this up by gradual mechanical dilatation. The incision is best made in the middle line posteriorly, commencing at a point an inch above the hymen, and passing over the *fossa navicularis* and perineal body to a point an inch below the hymen (see Fig. 510). It should be deep enough to divide skin and mucous membranes and also the subjacent muscular fibres. Owing to the lateral pull of the divided tissues the median incision leaves a *transversely* spindle-

shaped raw surface which can be closed by uniting the upper to the lower edge with interrupted sutures (*see* Fig. 511). Two lateral incisions, of the same kind, may be practised instead of the single median one. After the wound has healed the patient should be taught to use a tubular vulval dilator, such as that shown in Fig. 512.

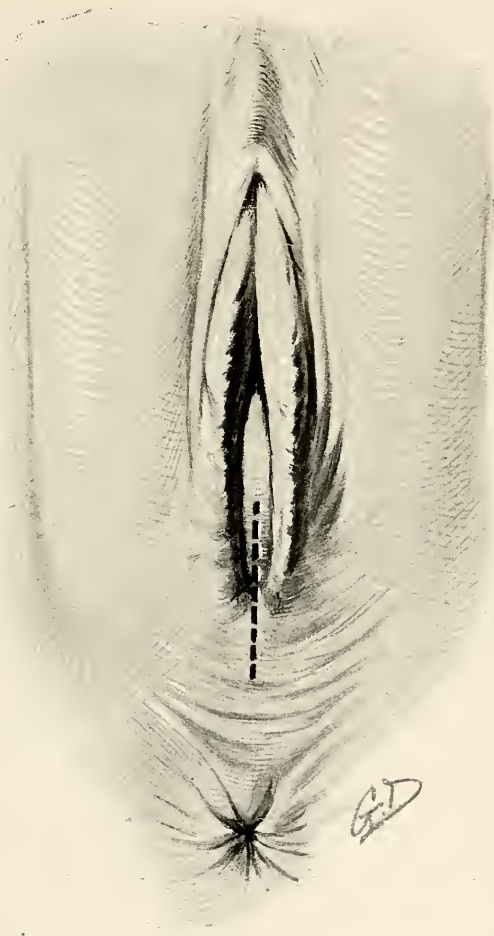

FIG. 510. THE INCISION FOR CASES OF VAGINISMUS.

At first cocaine ointment may be applied to the vulva before passing the dilator, so as to avoid the discouragement occasioned by pain. It should be introduced every night or every second night, and allowed to remain in position for half an hour to one hour. This treatment persisted in, if necessary, for several weeks, will nearly always effect a cure of the condition.

**Partial Absence of the Vagina.** In a few rare instances the vagina is absent in the lower part of its course only, as a congenital defect.

If the uterus and ovaries are normally developed, cryptomenorrhœa will result. It is then possible to effect an opening in the following manner.

A sound is passed into the bladder, and at the same time the grooved

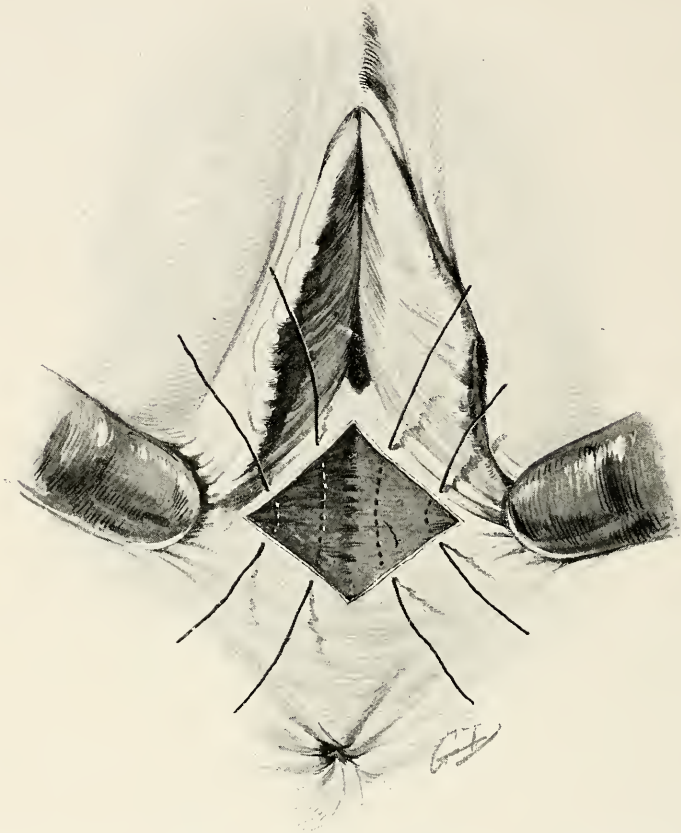


FIG. 511. OPERATION FOR VAGINISMUS. Method of uniting the edges of the diamond-shaped raw area produced by lateral traction with the fingers.

index finger of the left hand is placed in the rectum, the two together acting as a guide.

A transverse incision is made in the position for the vaginal orifice,




FIG. 512. VAGINAL DILATOR. The instrument resembles a tubular speculum, but is closed at one end. It is made of glass or vulcanite.

and as soon as the skin is divided, a septum of connective tissue is

encountered. This has to be teased apart with great care for fear of injuring the bladder or rectum. A pair of sinus-forceps should be inserted, and cautiously opened in the transverse direction, snipping the stretched tissues from time to time with blunt pointed scissors. The lower end of the imperforate vaginal canal is readily recognized, as it is distended with retained menstrual fluid. After opening it and evacuating the contents its edges are joined up with skin-flaps obtained from the vulva. The opening thus obtained is at first packed with gauze and subsequently dilated with graduated vaginal dilators.

**Total Absence of the Vagina.** When the vagina is totally absent, the upper Müllerian structures usually remain undeveloped also. In 1910 Baldwin described an operation for total absence of the vagina, the object of which is to render a woman nubile although she is wanting in the essential organs of generation. In our opinion this operation is unsound ethically and entails unjustifiable risks. Whilst we do not recommend this procedure, its chief points are briefly mentioned.

The operation consists in dissecting through the cellular tissues between bladder and rectum from the vulva to the peritoneum. The abdomen is then opened and a dependent loop of ileum resected, *without disturbance to its mesenteric attachment*, and drawn down through the wound and sewn to the edges of the vulva. The new vagina thus consists for the time being of two parallel portions of small gut. During convalescence the central partition is divided and a single canal is thus produced.

There is great strain upon the mesenteric vessels, enough to cause occlusion of some of them, and sloughing of the intestinal coats may occur. In some cases also it is physically impossible to bring the extremity of the loop down to the vulva.

**Longitudinal Vaginal Septum.** A mesial longitudinal septum sometimes persists as a foetal relic due to incomplete fusion of the two Müllerian ducts to form a common vagina. Sometimes two septa are seen, one on the anterior and one on the posterior vaginal wall; these relics are the result of partial absorption of the mesial septum comprised of the two Müllerian ducts.

No operation is required unless dyspareunia is caused by the presence of such tags or flaps. It then becomes necessary to remove the septum or septa with scissors close to the vaginal walls, and to bring the edges of the linear wounds together with continuous catgut sutures.

**Vaginal Cysts** (*see* Fig. 186, p. 385) may cause discomfort and bearing-down pain, or they may occasion difficulty in coitus. They should be dealt with surgically by complete excision. When the cyst is large, and has stretched a considerable portion of the vaginal wall to form an investment, a good deal of the latter may be sacrificed. Accordingly, instead of making a linear incision over the convexity of the cyst as was advised when dealing with a cyst of Bartholin's duct, a lozenge-shaped or circular incision may be made so as to leave

a portion of the vaginal mucous membrane on the cyst-wall. The outer edges of the incision are then made tense with pressure-forceps and the cyst dissected out of its bed. Care must be taken not to puncture the cyst, as it is more difficult to dissect out the wall of a collapsed cyst than that of one which is tense from fluid-contents. It may be necessary in some cases to dissect deeply into the pelvic cellular tissues at the top of the vagina, or at the sides. When the cyst lies in the anterior vaginal wall, the floor of the urethra and base of the bladder must be dissected off with caution, whilst a sound is retained in the latter. In the case of deeply seated cysts many vessels may have to be tied with catgut, and the cellular bed built up with sutures placed in layers. Finally, after all oozing has ceased, the vaginal mucous membrane is closed with continuous or interrupted sutures.

**Solid Tumours of the Vagina.** Solid tumours in this situation usually prove to be fibromyomata or adenomyomata. Their site of election is the upper part of the posterior vaginal wall, especially the posterior fornix.

*Fibromyomata* are generally single spherical growths with a capsule formed of the surrounding connective tissues. They sometimes attain the size of a large orange, and when discovered should be removed. The growth is thoroughly exposed and a linear incision is made through the vaginal wall and through the capsule of the tumour. The latter then appears as a whitish, glistening, solid mass. This is seized with a volsella and forcibly drawn down. It is then enucleated from its capsule with closed blunt-pointed scissors, any adherent strands of tissue being snipped as occasion may require. In the case of large growths, morcellement of the tumour renders removal more easy, and enables the operator to work through a smaller incision. The capsule-bed is closed with layers of mattress-sutures, and finally the edges of the vaginal mucous membrane are brought together with interrupted sutures. The vagina is then packed with bismuth gauze, and an aseptic dressing applied to the vulva by means of a T binder.

*Adenomyomata* are generally diffuse, adherent nodules, devoid of a capsule. They may occur singly or they may be multiple. Only the smaller nodules can be successfully dealt with by a vaginal operation. Since they are often densely incorporated with the vaginal mucosa it is necessary to remove the latter together with the nodule.

The growth should be well exposed to view, and the adherent vaginal mucosa grasped with a volsella. An incision is then made *around the adherent mucous membrane* through the whole thickness of the vaginal wall, traction being made on the tumour all the while. On the deep aspect the tumour may adhere so intimately with the peritoneum, or with the utero-sacral ligament, as to necessitate cutting through these structures in effecting its removal. This will require ligature of the utero-sacral fold and closure of the opening made in the pouch of Douglas. If there is troublesome oozing, it is well to insert a



small rubber drain, or even to pack the wound with gauze for twenty-four hours. If hæmostasis is satisfactory, the wound in the vaginal wall may be closed by interrupted sutures of chromic gut.

**Carcinoma of the Vagina.** Secondary carcinoma of the upper part of the vagina, due to spread of a cervical cancer, is dealt with by Wertheim's panhysterectomy. If primary cancer is detected in an early stage and is situated near the vulval orifice, it can be removed by extirpating the lower half of the vagina. If the disease lies higher up, the entire vaginal canal must be sacrificed together with the uterus, the latter being removed in order to obviate the risk of uterine discharges being subsequently retained. Figure 187, p. 386, shows the entire vagina removed for epithelioma.

*Removal of the Vagina and Uterus by the Vaginal Route.* A circular incision is made through the vaginal mucosa at its junction with the vulva. The mucous membrane is then dissected as a continuous tube right up to its cervical attachments. The lower free edges of this tube are then inverted, and the canal closed with stout silk which can be used as a tractor. With the vagina completely dissected and only attached to the cervix, the latter can be pulled down by using the former as a tractor. The cellular tissue attached to the cervix will then be found exposed, and if the vaginal orifice is capacious the uterus may be removed by the method described under "Hysterectomy from below upwards" (p. 782). If more room is required a paravaginal incision is made on one side. This begins above at the level of the cervix, passes deeply into the ischio-rectal fossa, and externally through the skin and deep structures between the *tuber ischii* and anus; finally curving around the anus, it divides the sphincter and some of the fibres of the levator ani. This is Schuchardt's incision for providing an efficient approach for vaginal hysterectomy. It is rarely required, bilateral episiotomy, *i.e.* division of the anterior margins of the perineum on either side of the mid-line to a depth of about one inch being usually sufficient. After the uterus and vagina have been removed, the paravaginal or episiotomy wounds are sutured with interrupted stitches. The cavity left by the operation is then packed with bismuth gauze.

## COCCYGECTOMY

The conditions for which this procedure is indicated are discussed on pp. 372, 373. The operation is carried out as follows:

The patient is anaesthetized and then placed in the Sims's position. The natal cleft and adjacent skin is painted with 2 per cent. solution of iodine. A straight incision carried down to the bone is made over the central coccygeal line from its tip to the end of the sacrum. The tissues are separated with hooked retractors and all the soft structures are cut loose from the bone. The forefinger of the left hand is inserted under the tip of the coccyx to act as a guide and to protect the rectum.

The dissection should extend to above the level of the alæ of the first coccygeal segment, so as to make sure of leaving no part of the coccyx behind.

Hirst recommends that at this stage a swab be inserted into the cavity beneath the isolated coccyx to catch fragments of bone-dust and to control hæmorrhage. A Gigli saw is now inserted under the bone and pushed up so as to remove the tip of the sacrum. After the bone has been sawn off, the median sacral artery is tied with catgut. A small drain is inserted and the wound closed with interrupted fishing-gut sutures. The drain is removed after twenty-four hours.

## THE AFTER-TREATMENT OF GYNÆCOLOGICAL OPERATIONS

A great number of points arise for consideration in connection with the after-treatment of operations, and it will be convenient to deal with the subject systematically, considering first the management of simple cases and then the management of severe and complicated cases. Further, the immediate treatment, *i.e.* treatment during the first twenty-four hours, will be considered in each group apart from the later treatment.

### I. AFTER-TREATMENT OF A SIMPLE ABDOMINAL CASE

(A) **The Immediate Treatment.** This begins with the removal of the patient from the operating table to her bed. It should be done in all cases skilfully, gently, and with no unnecessary delay. The bed should be previously warmed with hot-water bottles, *which should be removed when the patient is placed in it.* Burning of the skin is very readily caused during unconsciousness, and accidents with hot-water bottles frequently occur unless the greatest care is taken. If hot-water bottles are specially ordered, they should be put in the bed after the patient has been placed there, and their position carefully arranged. One of the duties of the attendant nurse is to assure herself from time to time that the protective coverings of the bottles are not disturbed by the patient's movements.

*Posture.* The most convenient position for the patient at first is the horizontal, and she should be turned a little on her side with a pillow to support the back. In this position vomiting is easier, and the mouth and throat can be kept clearer than when she lies on her back. When vomiting is over, she may be laid on her back either flat or with the shoulders raised with pillows. Slight changes of posture, from time to time, are very grateful to the patient and do no harm if carefully carried out.

In all cases when infective lesions have been dealt with, whether drainage has been adopted or not, the posture known as 'Fowler's position' is of great advantage. The patient is propped with pillows in a semi-upright, sitting position, and a bolster placed beneath the bent knees and tied to the bed-head prevents her from slipping down again. This posture may be assumed as soon as the reflexes have been re-established. It serves to prevent dissemination of infective fluids from the pelvis or lower abdomen into the dangerous upper abdominal zone, where absorption is more rapid, and its results more serious, than is the case with the pelvic peritoneum. The fluids present find their way into the most dependent part of the peritoneum, *i.e.* the pouch of Douglas, whence they can be withdrawn by drainage, or, if no drain-tubes have been used, isolated by plastic adhesions so that their effects become strictly localized. Shock is no contra-indication to this posture, which involves no strain upon the patient and is very restful.

*Anæsthetic Vomiting.* Inhalation-anæsthesia leads almost invariably to nausea and vomiting. This symptom is however very variable in intensity, and somewhat variable also is the time at which it occurs. Sometimes it is slight and infrequent, and ceases in a few hours. In other cases it is frequent, prolonged, violent, and accompanied by retching of the most distressing kind. Besides exhausting the patient this causes much pain in the abdominal wound.

The ejected fluids are frothy and greenish, and may at first contain large quantities of mucus which have been swallowed. The amount is seldom great when the patient has been properly prepared for the operation.

Usually the vomiting ceases in from twelve to twenty-four hours; occasionally some vomiting persists for two or three days, not changing its type, and being unaccompanied by other symptoms. Everything swallowed is immediately rejected, but the pulse and temperature are not elevated, the abdomen does not become distended, and the vomit still consists only of the gastric secretion. These points serve to distinguish it from the vomiting due to commencing peritonitis (*vide infra*).

*Treatment.* Anæsthetic vomiting can be largely controlled, though not entirely prevented, by careful preparation of the patient, by the use of narcotics before operation, and by supplementing the general anæsthetic with local anæsthesia, as described in the section on Technique (p. 725). The *cause* is mainly to be found in irritation of the gastric mucous membrane by mucus, charged with anæsthetic, which has been swallowed during the operation. No attempt should be made at first to check the vomiting by sedatives; on the contrary, it should be encouraged until the mucus has all been got rid of. Warm water containing a teaspoonful of bicarbonate of soda to four ounces may be freely given; it will be almost certainly rejected, bringing

with it fresh quantities of mucus partially dissolved by the action of the alkali.

‡ If vomiting persists after six hours, attempts to stop it should be made, but these are not always successful. Sips of boiling water often give temporary relief. Three or four ounces of strong coffee with a teaspoonful of bicarbonate of soda, or the same quantity of a 10 per cent. solution of glucose, are sometimes successful. Bromides *per os* or *per rectum* may succeed, and a mustard leaf may be applied to the epigastrium. In obstinate cases all mouth-feeding should be absolutely withheld for six hours, and nutrient or saline enemata given every three hours. If this fails, gastric lavage is the only remaining remedy, and this almost invariably succeeds; it causes so much distress, however, that it should be reserved for cases which have resisted all other measures.

*Thirst.* This is one of the most distressing symptoms of the early convalescence in almost all cases. When vomiting is severe it is greatly aggravated by the further loss of fluid thus entailed, and by inability to take fluids by the mouth. As soon as vomiting has ceased hot water may be given freely in small quantities. When water cannot be given by the mouth, thirst may be partially relieved by administering enemata of normal saline solution; not more than a pint should be given, and the injection may be repeated every four hours for the first twenty-four hours if necessary. Rectal saline is also useful in counteracting the effects of shock and hæmorrhage.

*Pain.* The chief seat of pain is the abdominal wound and, as already stated, vomiting greatly aggravates it. There is no necessity to withhold sedatives, and morphia ( $\frac{1}{8}$  gr.) or heroin ( $\frac{1}{12}$  gr.) may be given hypodermically a few hours after operation, and repeated as may be required. Minor degrees of pain can often be relieved by giving 15 to 20 grs. of aspirin in the rectal saline.

*Bladder.* The renal secretion is scanty for the first twenty-four hours after an abdominal operation, and the first evacuation of the bladder is not as a rule required for eight to ten hours. The patient is not always conscious of necessity, but the natural voiding of the urine should be encouraged. The first urine obtained should be kept for examination; blood may be present, indicating injury to the bladder or ureter. Care must be taken that the bladder does not become gradually over-distended through repeated incomplete evacuation. If less than four to six ounces is voided naturally at a time, or if the patient complains of bladder irritability, the catheter should be passed.

Occasionally complete retention occurs after operation, and this may last for several days, or sometimes, until the patient is allowed to get up. Nervousness is the chief factor in its occurrence. When prolonged use of the catheter is required, prophylactic measures against cystitis should be promptly carried out, urotropin and acid sodium

phosphate being administered, and the bladder washed out daily with weak boracic lotion (*see also* p. 272).

(B) **Treatment after the first Twenty-four Hours.** *Diet.* Fluid food in small quantities may be given as soon as the anæsthetic vomiting has ceased. Milk and barley water, weak tea and milk, soups and jellies, with abundance of water to drink, suffice for the first forty-eight hours. Solid food in the shape of rusks, boiled fish, stewed fruit, baked apples, and custard will be as readily digested as fluids, and indeed often cause less flatulence. After the bowels have been moved a light convalescent diet may be given.

*Bowels.* The chief discomfort of the early convalescence is the colicky pain which arises from flatulent distension of the intestines and, to a less extent, of the stomach. Its severity is proportionate to the duration and extent of the operation, and is most marked in cases which have required actual handling of the intestines. It is probably due to a paresis of reflex origin, and is occasioned by peritoneal irritation, or possibly by plastic peritonitis in the neighbourhood of intra-abdominal ligatures or raw areas. The temperature is often raised to 100° or 101° Fahr. After a free evacuation of the bowels has been obtained it soon disappears in cases which are doing well; its persistence is an indication of the onset of peritonitis. On the second day of convalescence an enema consisting of a pint of soapy water with an ounce of turpentine, well mixed together, should be given; this brings away with it a large quantity of flatus and thus gives great temporary relief. It may be repeated as required. A soft rubber tube may be passed for six inches into the rectum and allowed to remain there for half an hour, and this often aids the passage of flatus. The aperient should be given on the morning of the third day, and nothing is better, or more certain, than castor oil; calomel (3 grs. in divided grain doses), followed after six hours by a saline such as white mixture or a full dose of Epsom salts, is the best substitute for castor oil. A daily mild aperient or enema is usually required during convalescence.

*Dressings and Stitches.* Wounds that have not been drained and that have been made through healthy tissues do not require re-dressing for three or four days. Wounds that have been drained should, however, be re-dressed twice every twenty-four hours, and this must be carried out with full antiseptic precautions, including the use of rubber gloves. Sterilized gauze and cotton-wool are the best materials for receiving discharges, and they must never be allowed to become soaked through. Drainage-tracks which pass into the peritoneal cavity should not be irrigated until the fifth day, for if the track is imperfectly isolated infective material may be forced into neighbouring areas by the irrigation. Abdominal sinuses should be irrigated not with a syringe but with a tube and funnel and only a low pressure employed. Peroxide of hydrogen (five volumes) or hypertonic saline

solution (4 drachms to 1 pint) are the best fluids to use for this purpose.

Superficial stitches, *i.e.* those which include the cutaneous layer only, or Michel's clips can be removed on the eighth day. Deep stitches which have taken up the fascial layer as well as the skin should be allowed to remain for ten days. If suppuration appears the affected stitches should be at once removed.

*Getting up* is fixed for the tenth to the fourteenth day, and in three weeks the patient may again be walking about. In simple cases a week in bed may sometimes suffice; on the other hand, debilitated subjects may require a longer period of rest. When the abdominal incision has healed by first intention it is unnecessary, in most cases, for the patient to wear an abdominal belt. If drainage has been employed through the abdominal incision the scar always has a weak spot, and a belt should be worn for at least six months. This may also be desirable when the abdominal muscles are abnormally weak, as from multiparity, or over-distension by a large abdominal tumour. Breathing exercises, and exercises for the abdominal muscles, are also valuable in such circumstances for the prevention of hernia.

## II. COMPLICATIONS AFTER ABDOMINAL OPERATIONS

**Shock.** The causation of post-operative shock is still the subject of much dispute. Of the many theories which have been advanced three may be selected for mention, inasmuch as they have been supported by serious experimental work. (1) The theory of Crile is that post-operative shock is due to depression of the vasomotor centre, due partly to noxious nerve influences from the site of operation, partly to direct poisoning by the anæsthetic; (2) Boise has advanced the view that it is due to cardiac spasm; while (3) Henderson contends that shock is due to an excess of carbon dioxide in the blood, *i.e.* to a degree of asphyxia. In the present state of our knowledge no practical purpose would be served by examining the relative merits of these theories.

The essential feature of post-operative shock is *profound depression of the circulation*, indicated by cardiac feebleness and low blood-pressure. It is present to a moderate extent after all severe intra-peritoneal operations; in different circumstances many different degrees of severity are observed, and in some cases the patient may die of shock without recovering consciousness. The conditions which may be expected to lead to severe shock are great loss of blood, severe trauma, chilling of viscera by exposure, rough handling of the abdominal organs, prolonged anæsthesia, and a precedent loss of vitality from illness. To a great extent these predisposing causes can be avoided by careful management, but not, of course, in all cases. After severe abdominal operations a pint of normal saline solution may

be poured into the peritoneal cavity and left for absorption; this diminishes shock and relieves thirst. It cannot be used in infective cases owing to the risk of distributing infective material over the general peritoneal cavity.

Shock, when severe, is clearly manifested before the effect of the anæsthetic has passed off, and while the patient is still unconscious. The skin is pale and cold, and the lips and finger-tips are slightly cyanotic; sometimes a cold sweat is found, especially upon the face and palms of the hands. The pulse is rapid, small, and very feeble, but the outline of the artery is distinct; the temperature is sub-normal, the respiration shallow, and usually increased in rapidity. The mental condition is lethargic, and though the patient can be roused she rapidly becomes again somnolent. The renal secretion is more or less completely suspended, and in severe cases of shock suppression of urine, lasting for twenty-four hours or upwards, may occur.

It is, of course, of prime importance to distinguish shock from hæmorrhage, and the following points of contrast must be borne in mind.

<i>Shock</i>	<i>Hæmorrhage</i>
(1) Onset immediate.	Onset after an interval, it may be, of several hours.
(2) Patient lethargic, sleepy or stuporous.	Patient restless, and excited or distressed.
(3) No pain.	Abdominal pain, often severe.
(4) Pulse small, rapid, artery distinct.	Pulse small, rapid, artery flabby.
(5) Respiration shallow and quick.	Respiration deep and laboured.
(6) No attacks of syncope.	Recurrent attacks of syncope.

Shock may continue for many hours in spite of treatment, and sometimes all attempts at restoration fail and the patient dies. Usually, however, a gradual reaction sets in, the pallor diminishes, the surface of the body becomes warmer, the temperature rises, and the pulse becomes stronger and more rapid.

The *treatment* consists in endeavouring to restore the circulation by wrapping the patient in warm blankets, and maintaining heat with hot bottles which, however, must be very carefully shielded from contact with the skin. Burns of a serious nature may be caused during unconsciousness by comparatively low temperatures. In addition, a pint of warm saline should be administered *per rectum*, and the foot of the bed raised to a height of ten to twelve inches. Other means should be employed to raise blood-pressure, and for this purpose nothing is more effectual than pituitary extract, which should be given hypodermically in the doses previously stated (*see*

p. 136). This may be repeated in four hours if necessary. Strychnine in full hypodermic doses ( $\frac{1}{30}$  gr.) is also freely given by some surgeons, although Crile, on theoretical grounds, advises against it. Its stimulant action on nerve-centres is probably of service.

In very severe cases reliance must be placed upon the subcutaneous or intravenous injection of saline solution ; the former is the simpler

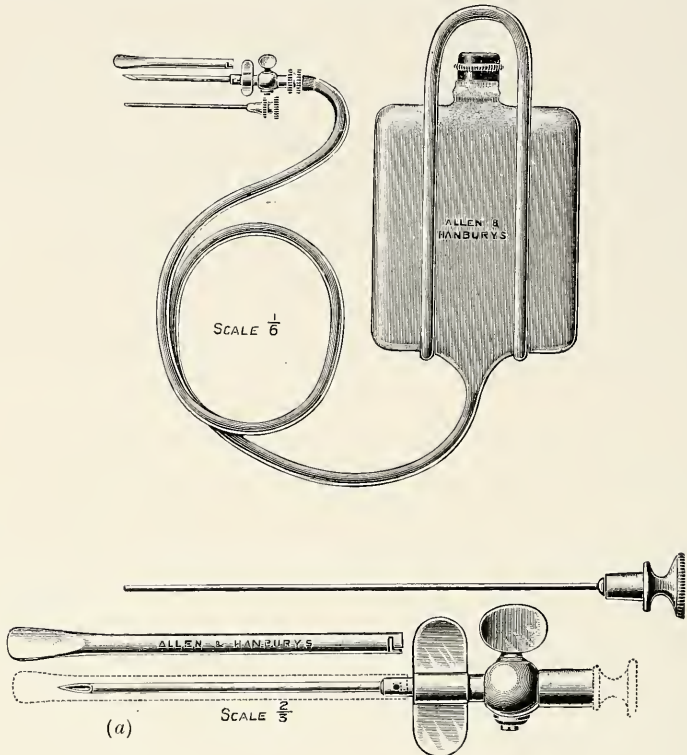


FIG. 513. ARBUTHNOT LANE'S APPARATUS FOR SUBCUTANEOUS SALINE TRANSFUSION. It consists of a rubber bag and rubber tubing, with a needle furnished with a stop-cock, for subcutaneous use, shown at (a).

method and suffices for all but the most urgent cases, for which the intravenous method should be reserved.

A convenient apparatus for subcutaneous transfusion is that shown in Figure 513, which has the great advantage that the whole of it may be readily sterilized by boiling. In the female, the best place for the injection is beneath the mamma or beneath the skin covering the ribs in the axilla ; half a pint can be introduced on each side, and will be rapidly absorbed. The skin must be carefully sterilized before introducing the needle ; air must be completely expelled from the tubing, and the whole procedure conducted with scrupulous antiseptic precautions. Extensive suppuration, or even sloughing of cellular tissue, may result from failure of these precautions. The



temperature of the solution in the bag should be maintained at about 100° Fahr. In some cases shock supervenes during the course of an operation, on account of loss of blood or from prolonged manipulations; this method of subcutaneous transfusion may then with advantage be practised during the completion of the operation.

**Recurrent Hæmorrhage.** Serious hæmorrhage in the first twenty-four hours is almost invariably due to *slipping of a ligature* which has included a large vessel, and the ovarian pedicle is the commonest seat of this accident. Increasing pallor, restlessness, air-hunger, and a rapidly rising pulse-rate, together form an unmistakable picture of concealed bleeding and serve to distinguish it, as has been explained, from shock. The differential diagnosis of shock and internal hæmorrhage is obviously a matter of the greatest practical importance from the standpoint of treatment. In the presence of these symptoms, the abdomen must be reopened without delay, the bleeding-points securely controlled, and the effused blood removed by swabbing from the peritoneal cavity. Occasionally, severe hæmorrhage occurs from vessels in the parietal incision, but as a rule the bleeding is intraperitoneal. Saline transfusion, either intravenous or subcutaneous, should be begun in severe cases immediately before reopening the abdomen, and one to two pints of sterile saline solution may be left in the peritoneal cavity before closing the abdominal wound. The necessity for haste must not excuse slackness in aseptic detail, for after severe hæmorrhage the power of the tissues to resist infection is greatly reduced.

Slight oozing from small bleeding-points, which have escaped notice in the pelvis, may result in the formation of a *pelvic hæmatocele*. The amount of blood thus lost may be insufficient to produce any of the constitutional symptoms just enumerated. A rise of temperature towards the end of the first week usually results, and if the blood becomes infected from the bowel, or from some other source, fever may be high and accompanied by abdominal pain and distension. On vaginal examination a characteristic soft swelling will be found in the pouch of Douglas, and when infected this may burrow deeply between the rectum and the vagina, causing the upper part of the posterior vaginal wall to bulge prominently. The treatment in all cases is to open the posterior fornix by posterior colpotomy and drain the hæmatocele into the vagina.

**Acute Abdominal Distension.** A moderate amount of distension usually occurs after all intraperitoneal operations upon the second and third days. It is accompanied by colicky pains and flatulence, and yields readily when a satisfactory evacuation of the bowels has occurred. *Acute* abdominal distension may supervene rapidly at about the same period, or a little later, and it must be recognized that there are four different causes to which it may be due, viz. (1) peritonitis; (2) intestinal obstruction; (3) intestinal paresis or

pseudo-ileus; (4) acute dilatation of the stomach (gastrectasia). These conditions must be considered with care, for upon their early and correct recognition the success of the treatment largely depends.

**I. Peritonitis.** Acute post-operative peritonitis is always due to infection; the plastic peritonitis which usually occurs in the neighbourhood of ligatures and lines of incision in the peritoneum is part of the natural process of repair and is non-infective. Infective peritonitis may be the result of imperfect asepsis during operation, when it is usually streptococcal; or the infective agent may have been present in the tissues at the time of operation; or it may gain access later from the bowel as the result of traumatism or of circulatory disturbances, when bowel organisms (*B. coli* or *S. faecalis*) are commonly found. From the clinical point of view the results of the infection depend largely upon the extent of peritoneum involved, and it is convenient to divide cases of acute peritonitis into *diffused* and *localized*.

*General or Diffused Peritonitis.* This formidable complication is now seldom seen, owing to the efficiency of modern technique. The clinical features are by no means uniform; sometimes they are so marked as to make the diagnosis obvious at a glance, sometimes they are so unobtrusive that their serious import may be unappreciated. Usually the symptoms occur early; post-anæsthetic vomiting may pass into the vomiting of peritonitis, which is nearly constant, spontaneous, and independent of food or drink; the vomited matters are brownish and ultimately become fæcal. Great thirst usually accompanies continued vomiting. The temperature and pulse rise rapidly in irregular steps, the abdomen becomes rapidly distended and the abdominal walls rigid; constant pain, referred to the abdomen generally, is complained of, and the patient's expression indicates suffering. The leucocyte-count is definitely raised, perhaps to 40,000, in the earlier stages with a corresponding rise in polymorphonuclear leucocytes, but in advanced stages this leucocytosis may subside. Cutaneous rashes often appear. Complete obstruction of the bowels supervenes after a day or two, although at the beginning flatus and fæces may be obtained with enemata. The pulse becomes feebler and thinner as it increases in rapidity, and the outlook is in all cases extremely grave.

In rare cases pain, abdominal distension and rigidity may be absent; there is nausea but no vomiting; the temperature does not rise above 100°; but the pulse-rate is rapid and increasing, and the general condition is unsatisfactory. After two or three days the classical signs of peritonitis appear with extraordinary rapidity, and if the abdomen is immediately opened general suppurative peritonitis may be discovered.

*Treatment.* Attention must once more be drawn to the necessity of scrupulously observing all the precautions detailed in the section

on Technique in order to prevent the occurrence of peritoneal infection during the operation, especially when dealing with infected organs. When once the condition has declared itself, treatment must be promptly applied, and the following methods may be adopted: (a) free drainage; (b) saline transfusion; (c) stimulation; (d) specific vaccines and sera.

*Drainage* of the peritoneum is difficult to carry out under all circumstances, and when extensive adhesions have formed the difficulties of draining the whole peritoneal sac are greatly increased. It is however useful to drain the great pouches, viz. the pouch of Douglas and the renal pouches, and for this purpose small stab-incisions should be made in the selected spots under *local anæsthesia*. The use of a general anæsthetic should be avoided, if possible, in acute septic conditions. Rubber tubes of large size are best for this purpose. It must not be forgotten that peritoneal drainage is greatly facilitated by maintaining Fowler's position, which favours accumulation of fluids in the lower abdominal zone and hinders the upward spread of infection to the dangerous subdiaphragmatic zone.

*Saline* is best administered, in septic conditions, by slow continuous rectal injection—*proctoclysis*. It is essential that the injection should run very slowly—a drip from the end of the tube is all that is required—and the temperature of the solution should be carefully regulated and uniformly maintained. If these precautions are observed intolerance is very seldom met with; when the fluid is rejected by the bowel the explanation usually is either that the temperature of the solution is above or below body heat, or that the flow is too rapid. Several pints may thus be absorbed in twenty-four hours and the treatment may be continued for several days; it is, however, well not to make the injection absolutely continuous, but to suspend it for an hour or two from time to time. Saline acts in three ways: (a) by diluting the dose of toxins absorbed into the blood; (b) by promoting leucocytosis; (c) by stimulating the excretory functions, especially of the liver, the kidneys, and the skin.

*Specific treatment* has proved disappointing in acute septic conditions. Antistreptococcic serum of the polyvalent kind may be given at once, in most instances, without waiting for bacteriological diagnosis to be made. It does no harm, even if some other organism than the streptococcus is concerned. As soon as possible, cultures should be made from the blood and the peritoneal exudate, and an autogenous vaccine prepared. Only small doses of about one million should be given at first until the extent of the reaction has been observed.

*Localized Peritonitis.* This may occur in two forms: (1) Around the site of an infected organ (appendix or pyosalpinx) removed at the operation, or (2) around an effusion of blood (hæmatocele) which has formed as the result of imperfect hæmostasis, and has become

infected by organisms either introduced at the operation or derived from the bowel. The symptoms bear a general resemblance to those just described, but differ as follows : (a) The elevation of temperature and pulse-rate is less marked ; (b) pain and rigidity are localized either in the lower abdominal zone or in one or other iliac fossa ; (c) on vaginal examination a tense and very tender swelling may be found behind the cervix ; (d) the onset is somewhat later and the condition does not, as a rule, become fully developed earlier than the end of the first week ; (e) vomiting is less persistent, and absolute intestinal obstruction rarely occurs, although obstinate constipation is the rule.

The essential sign is the formation, sooner or later, of a definite area of induration, or of a distinct hard mass, which indicates the focus of infection. Around this area a more or less extensive zone of plastic peritonitis occurs, and if the organisms concerned are sufficiently virulent, this barrier may be passed, and the peritonitis may eventually become general or diffused. It is often difficult to decide whether suppuration has occurred or not.

*Treatment.* If suppuration does not occur a localized peritonitis may subside, and the exudate may become in time completely absorbed. Effusions of blood are less likely to become absorbed than serous or plastic exudates, and the process is always very slow. Great care should be exercised in deciding when to operate in cases of localized peritonitis. When a *definite effusion* is present in the pouch of Douglas, no hesitation need be felt in opening it by posterior colpotomy. Thickening or induration in this position is, however, not an indication for operation. If the affected area can only be reached by opening the abdomen, operation is attended by greater risks and should not be undertaken unless the indications are clear. Reasonable suspicion of the presence of pus always justifies operation under such circumstances. It is better, if possible, not to drain through the original incision but through stab-incisions placed immediately over the affected area ; this avoids the risk of the long incision becoming infected.

**II. Intestinal Obstruction. Mechanical Ileus.** This condition may occur during convalescence from an abdominal operation : (a) From kinking of a loop of small gut due to adhesions to a line of sutures or a raw surface ; (b) from strangulation beneath a band of adhesions or in an artificial aperture, *e.g.* a hole in the omentum or mesentery ; (c) from volvulus. The first named is the commonest condition, the apex of a prolapsed loop of small intestine being found adherent to the pelvic floor. Independent conditions such as a hernia or a stricture of the colon, which have been unobserved at the operation, have been found in a few cases.

Intestinal obstruction is attended by symptoms which bear a general resemblance to those of acute peritonitis, *viz.* vomiting,

thirst, pain, abdominal distension, and complete retention of the bowel contents. Certain points of distinction may however be noted : (a) The onset of obstruction is usually later, commonly towards the end of the first week ; (b) pain is paroxysmal and between the spasms the patient is comfortable ; (c) although much distended the abdomen is not markedly rigid ; (d) the temperature is often normal, and when fever is present it is seldom high ; (e) the pulse-rate is quickened out of all proportion to the temperature ; (f) vomiting becomes fæculent earlier than with peritonitis ; (g) visibly distended coils of intestine may be seen through the abdominal wall and may show exaggerated peristaltic contraction (dysperistalsis) ; sometimes parallel coils run across the abdomen like the rungs of a ladder.

When a diagnosis of obstruction has been made operation should be immediately undertaken. As a preliminary measure the stomach should be emptied and thoroughly irrigated through a stomach-tube. Only absolutely necessary intra-abdominal procedures should be undertaken at the moment ; the general condition of the patient usually forbids such operations as resection and anastomosis of bowel. Damaged or gangrenous gut should be brought out at the wound, fixed there and opened, so as to drain the intestine above the seat of obstruction. The resulting fæcal fistula can be closed later.

**III. Intestinal Paresis. Paralytic Ileus.** When met with as a post-operative complication this condition resembles in its general features general peritonitis, already described. Its onset is at approximately the same time ; vomiting and abdominal distension are early symptoms ; a certain amount of fever and of rise in the pulse-rate are met with. When unrelieved the distension of the abdomen may attain an extreme degree in a day or two. There is, however, no rigidity of the abdominal wall, and no marked leucocytosis. It may be possible to distinguish it from mechanical ileus by noting the complete absence of any signs of intestinal peristalsis ; thus the paroxysmal pain characteristic of mechanical obstruction is absent, and no borborygmi are audible even on auscultation of the abdomen ; further absolute arrest of the intestinal contents, both flatus and fæces, is seldom met with : a little flatus or fæces may be obtained by high enemata.

The *treatment* consists in adopting measures to restore the muscular contraction of the intestine, and the effect of the treatment is a valuable aid to diagnosis also. If the obstruction can be overcome by these means, mechanical causes and general peritonitis can usually be excluded. On the other hand, the non-success of these methods, generally speaking, excludes paralytic ileus and constitutes an indication for operation.

Purgatives, colon-irrigation by high enemata, and the use of certain drugs such as pituitrin and eserine, which act powerfully

upon intestinal peristalsis, are the methods of choice. Purgatives will not prove of service unless given in the early stages, and castor-oil or calomel, in full doses, is the most reliable. If unsuccessful, the dose should not be repeated, but instead frequent and copious high enemata consisting of soapy water or saline solution should be given. A long colon tube should be used, and the patient laid on her right side with the buttocks raised; this posture favours the flow of the fluid into the transverse portion of the colon, and so to the descending portion. In all forms of obstruction the first one or two enemata thus given may evacuate fæces and flatus which have entered the colon, or at any rate have passed the seat of obstruction. In all but the paralytic form absolute retention of the bowel-contents is soon developed.

Pituitrin may be given in four-hourly doses of 1 c.c., in combination with  $\frac{1}{100}$  gr. of eserine sulphate; here again it must be said that unless given in the early stages not much help will be obtained from these drugs. But their prophylactic use, in cases in which, from the nature of the operation, intestinal complications are anticipated, is strongly to be recommended. When vomiting interferes with the exhibition of purgatives, these hypodermic remedies form useful substitutes.

When vomiting is persistent the use of the stomach-tube will be useful. After the contents of the organ have been removed, the stomach is washed out with two or three pints of warm alkaline solution, which exerts a solvent action on mucus and thus cleanses the mucous membrane. After emptying the stomach, an ounce of sulphate of magnesia in concentrated solution may be run in and allowed to remain.

**IV. Acute Dilatation of the Stomach** is much rarer than the three above-mentioned conditions. It most resembles paralytic ileus, and is probably due to similar causes. There is acute abdominal distension which is most marked in the upper zone and is accompanied by a rapid pulse, and a temperature not much above normal or even subnormal. There may be periodic attacks of copious vomiting, or if the loss of tone is absolute, there may be no vomiting at all. The stomach-tube will clear up the diagnosis in a doubtful case. Sometimes reverse peristalsis takes place and the stomach-contents become fæcal.

The *treatment* consists mainly in evacuation of the stomach-contents with the stomach-tube, and free lavage; this may have to be repeated several times. Posture is of some service, the patient being encouraged to lie in the position in which the stomach will drain most readily into the duodenum. This is approximately Sims's position, with the patient on the right side instead of the left and the foot of the bed raised a few inches upon blocks. Nothing should be given by the mouth, but small nutrient enemata may be adminis-

tered at regular intervals of four to six hours. The prognosis of this condition is always grave.

**Suppression of Urine.** Severe shock is usually characterized by great diminution of the renal secretion, which, however, becomes re-established after the reaction has set in. In cases of chronic nephritis uræmic suppression may occur, but if the patient is properly prepared for the operation and the condition of the kidneys observed, the surgeon will not be taken by surprise. With this exception, partial or complete suppression persisting after recovery from shock suggests the possibility of one or both ureters having been included in ligatures or injured by clamps. If the injury has been one-sided the small amount of urine passed is usually blood-stained and highly concentrated. It is in the operations of pan-hysterectomy and the removal of broad, ligament tumours, that such injuries to the ureter are liable to occur. Cystoscopic examination and catheterization of the ureters is the surest means of recognizing this serious mishap.

The *treatment* of suppression depends upon its cause. When due to shock the treatment already advised for this condition should be vigorously carried out. In addition, dry-cupping the loins or the application of mustard to the renal regions will be found useful. When due to obstruction of the ureters, the abdomen must be reopened without delay and the obstruction removed. Dilatation of the ureter on the proximal side of the ligature renders this procedure comparatively easy. If the accident is promptly discovered it will be sufficient to release the ureter from the ligature. After prolonged ligation the vitality of the ureter is not well maintained at the site of the ligature, and sloughing may occur. Therefore anastomosis of the proximal end into the bladder may be required in such cases.

**Cystitis.** After certain pelvic operations which involve extensive separation of the bladder from its attachments, such as pan-hysterectomy, cystitis is a frequent complication. The vitality of the vesical mucosa probably suffers in consequence of circulatory disturbances, and bacterial invasion *per urethram* by catheterization or spontaneous ascent is thereby greatly facilitated. Another frequent cause of severe cystitis is the performance of such operations as the above in the presence of pre-existing urinary infection; serious exacerbations may then occur. The introduction of a septic catheter may of course set up an acute cystitis, but even if adequate precautions are taken repeated catheterization is usually followed by a subacute infection of the bladder. This is probably to be explained by slight traumatism plus the introduction of urethral bacteria (*see* p. 234) into the bladder in numbers too great to be dealt with by the natural germicidal force of the acid secretion, and further, some organisms, such as the *B. coli*, appear to flourish best in acid urine.

*Prophylaxis* may be practised by administering urinary anti-septics before operation, or in commencing them at once in cases of

retention of urine where regular catheterization is required. The treatment of the condition when established has been considered in another place (*see* p. 272).

**Urinary Fistulæ.** These fistulæ may form either through the abdominal wound or into the vagina, and may involve either the bladder or the ureter. Injuries to these organs are most likely to occur in abdominal pan-hysterectomy, in vaginal hysterectomy, and in the removal of broad-ligament tumours. If laceration of the bladder or division of a ureter has occurred and has not been detected, the escape of urine is immediate. Usually, however, several days elapse before the leakage of urine manifests itself. Injury has then been sustained by the bladder or ureter which so impairs its vitality that sloughing occurs and the wall gives way. Therefore until the slough has separated there may be no indication of the damage which has occurred. Convalescence is, however, usually febrile from the commencement, and the patient is not "doing well." Urinary infection almost always accompanies the formation of these fistulæ, and in the case of bladder-fistulæ a very acute cystitis may supervene. This adds greatly to the risks and the discomfort of the condition, for the infected urine causes excoriation of the skin of the abdominal wall or of the vaginal and vulval mucosa.

*Treatment* is therefore first directed to the condition of the urine, for not only is spontaneous healing impossible in the presence of infected urine, but also operative procedures for repair of the injury are impracticable while it lasts. Spontaneous closure of a urinary fistula is exceptional; as a rule operation is required on the lines laid down in a previous section (*see* p. 825).

**Fæcal Fistulæ.** Post-operative fæcal fistulæ are usually abdominal; more rarely they occur in the vagina from injury to the rectum. The abdominal fistulæ are met with after operations for acute appendicitis, and after operations in which injury to bowel has occurred, and the subsequent process of repair has been defective. The intestinal leak usually appears towards the end of the first week.

*Abdominal Fæcal Fistulæ*, when carefully treated, show a strong tendency to spontaneous closure. The constant leakage of fæcal matter calls for the most careful nursing, and frequent changes of dressing are required, while the surrounding skin must be protected from the excoriating action of the intestinal juices with a thick layer of boric ointment spread on lint. One of the most troublesome results in the earlier stages is the occurrence of parietal abscesses in the neighbourhood of the fistula from the passage of infective material into the deeper layers. Three important points in management must be insisted upon, viz.: (1) Frequent dressings and careful nursing; (2) daily enemata to ensure that the lower bowel is kept empty, for the amount of intestinal contents which passes into the distal segment, *i.e.* the part beyond the fistula, is promoted by



keeping the segment empty ; (3) keeping the bowel quiet by avoiding aperients, making the diet chiefly fluid, and administering small doses of opium regularly. The process of spontaneous closure is very slow, and several months may elapse before the leakage entirely ceases.

*Vaginal Fæcal Fistulæ* show little tendency to spontaneous closure ; their general management is to be carried out upon the same lines as the above.

**Infection of the Abdominal Wound.** This may take the simple and unimportant form of a *stitch-abscess*, or a diffuse infection may occur resulting in suppuration beneath the aponeurosis, or in the subcutaneous fat-layers, or in both. Suppuration in the deep layers is attended by pain in the wound and considerable fever. The skin-edges may have united, but the skin-surface is tense and shiny, and there is considerable diffused tenderness on pressure. One or two stitches should be removed, and the subcutaneous layers explored with a director or sinus forceps ; next, one or two of the fascial stitches should be divided and removed and the subaponeurotic layer exposed. When the abscess has been struck free drainage must be provided, counter-openings being made where required. Sometimes considerable sloughing occurs from a virulent infection, and then the whole length of the wound should be laid open and freely irrigated with hypertonic saline solution.

**Rupture of the Abdominal Wound.** This accident may occur in two ways, viz. from non-union or from infection. *Non-union* usually results from two factors : (a) Excessive strain upon the wound as from persistent, violent vomiting, or from coughing ; (b) premature absorption of catgut ligatures in the aponeurotic layers. On account of the latter danger specially hardened catgut should be used for the abdominal wound (*see* p. 731). Occasionally, however, rupture occurs when unabsorbable ligatures have been used, the ligatures being apparently torn out of the tissues by the strain to which they are subjected. In cases of virulent infection with sloughing, rupture may occur even when no undue strain is put upon the wound. It occasionally happens that the peritoneal and aponeurotic layers rupture while the skin-stitches still hold ; coils of intestine are then expelled into the subcutaneous layer, and unless the accident is promptly discovered dense adhesions soon form to the edges of the peritoneum and aponeurosis. If a continuous skin-stitch has been used, the detection of this accident is difficult ; if the stitches are interrupted, the edges open up between the sutures and the presence of bowel can then be detected.

The *treatment* is, of course, immediately to re-suture the wound after carefully freeing and returning any structures that have become herniated.

**Post-operative Parotitis and Phlebitis.** These are examples of septic metastasis. *Parotitis* has become very uncommon since

the elaboration of modern methods of aseptic surgery. In some cases it was traced to oral sepsis, and consequently it is advisable that carious teeth should be removed, or pyorrhœa treated before operation, if the necessary time is available. *Phlebitis* is more common and occurs in something like 1 per cent. of cases. Sometimes small superficial or deep veins in the calf of the leg are attacked, but from this no serious consequences follow. When the femoral vein is affected the result is œdema, pain and swelling of the affected limb, with elevation of temperature and general malaise. The treatment is prolonged rest and the avoidance of movement of the limb; this must be continued for a week after all pain has disappeared and the temperature has become normal. A certain amount of swelling of the ankle, and stiffness or pain on movement, may remain for several months, and these are best treated by massage and the use of an elastic bandage.

**Pulmonary Embolism.** This occurrence, although occasionally seen after surgical operations upon all parts of the body, is met with after abdominal operations with greater relative frequency than any others. Operations for the removal of the uterus are stated by some observers to be attended by a mortality of 1 per cent. from pulmonary embolism, and even if this figure is inaccurate there is no doubt that this accident is especially prone to follow hysterectomy. The explanation of this relationship is obscure, and it may be said of post-operative embolism generally, that the age or general conditions of the patient do not appear to influence its occurrence, and it is exceptional to find any clinical evidence of infection. Sudden or undue effort is rarely recorded in these cases, and it is undoubted that the accident may occur when the patient is completely at rest. The majority of cases occur in the second week, but numerous instances have been recorded in the third and fourth weeks of convalescence.

The *symptoms* come on with great suddenness. A sharp or even violent pain in the side is first complained of, and immediately followed by gasping respiration, and a feeling of distress in the region of the heart. The skin becomes cold and moist, cyanosis appears, and the pulse rises to 120 or 140 and becomes very feeble. Death may ensue within a few minutes; on the other hand the symptoms may be less urgent, when the patient may survive a few hours, and in occasional cases may recover. The size of the pulmonary vessel which has been blocked probably determines the result.

The *treatment* consists in the inhalation of oxygen and the hypodermic administration of cardiac stimulants in full doses. Artificial respiration may be practised as long as the heart continues to beat.

## II. AFTER-TREATMENT OF VAGINAL OPERATIONS

**Major Vaginal Operations**, *i.e.* those which involve opening the pelvic peritoneal cavity, are to be managed upon the same lines as an abdominal cœliotomy. They produce less shock than abdominal operations, and the early convalescence is attended by less distress from thirst, pain, and intestinal flatulence. It is however difficult to avoid the occurrence of a mild form of infection of the vaginal wound, which manifests itself by slight fever and an offensive discharge towards the end of the first week. If gauze packing has been used, a certain portion of the gauze should be removed each day until the whole has been got rid of by the fifth day. If unabsorbable ligatures have been used, infection is almost inevitable, but such ligatures usually loosen during the third week and should then be removed, when the discharge quickly clears up. Vaginal douching is inadvisable for the first four days, but after this it is useful and adds to the comfort of the patient. The time to be spent in the recumbent position is about the same as after an abdominal operation.

**Minor Vaginal Operations**, in which are included the plastic procedures such as the radial cure of cystocele and perineorrhaphy, depend for their success to a great extent upon careful treatment during convalescence. Primary union is more difficult to secure in a vaginal or vulval than in an abdominal wound. Not only is the vaginal wall more difficult to disinfect before operation, but also much more difficult to preserve from post-operative infection, owing to the proximity of the urethra and anus. Operations, such as curettage and dilatation of the cervix, which involve no cutting, require no special after-treatment, except a few days rest in bed.

*Plastic Operations.* In such procedures as perineorrhaphy hardened catgut ligatures which will resist absorption for at least ten days should be employed, chromicized gut being the best for the purpose. Unabsorbable ligatures cause considerable œdema, which adds greatly to the discomfort of convalescence and renders their removal often painful and difficult. The inclusion of masses of tissue in such ligatures should always be avoided, as the resulting strangulation interferes with the process of repair.

External wounds should be carefully and simply treated. After evacuation of the bowels or bladder the surfaces should be irrigated with a weak antiseptic solution, and a vaginal douche of similar kind should be given daily after the first forty-eight hours, a soft rubber tube being employed for the purpose. After all oozing from the incision has ceased, *i.e.* about forty-eight hours, the wounds may be covered with strips of lint spread over with a soft boric acid ointment. This serves to protect them to some extent from contamination.

In the opinion of many operators the catheter should be used every eight hours for the first four days, after which the patient may

be allowed to pass water naturally in the sitting position or upon her hands and knees. An aperient should be given on the third morning. In the case of perineorrhaphy for complete rupture involving the anus the first action of the bowels requires careful management. The diet should be fluid only until this time has been passed, in order to limit the bulk of the contents of the bowel. Castor-oil is probably the best aperient to administer, and it may usefully be supplemented by giving a small enema of warm olive oil, which may be retained for a time and will serve to soften the rectal fæces. In this manner the first action is usually rendered easy and painless. Subsequently it is best to secure a daily action in order to avoid the formation of hard masses. Straining at stool is more liable than anything else to do harm in the case of a complete perineorrhaphy.

# INDEX

- ABDOMEN**, acute distension of, after abdominal operations, 853  
 closing of, after operation, 739  
 cystic tumours in, differential diagnosis, 714  
 indications of pus formation within, 627  
 general enlargement of, 115  
 localized enlargement of, 116  
 large ovarian cysts within cavity of, 708, 710  
 obese, simulating ovarian cyst, 712  
 operations on, 740  
     complications after, 850  
     palpation of, 113  
     pendulous, 716  
     regions of, 115  
     rupture of viscus in, 222  
     rupture of wound of, 861  
     tumours of, 116  
**Abdominal examination of patient**, 112  
     ostia, accessory, 154  
     signs of appendicitis, 280  
     wall, preparation of, for operation, 727  
**Abdomino-pelvic cavity**, divisions of, 114  
**Abortion**, criminal, 266  
     decidual cast passed as an, 488  
     incomplete, differential diagnosis of, in pelvic hæmatocele, 226  
     incomplete tubal, *facing* 197  
     tubal with hæmatosalpinx, 198, 204  
**Abscès de fixation**, 267  
**Abscess**, appendicular, 279  
     cellulitic pelvic, 256  
     corpus luteum, 646  
     follicular, 648  
     intra-peritoneal, 262  
     of Bartholin's gland, 365, 366  
     ovarian, situations of, 646  
         and tuberculous pyosalpinx, 617  
     stitch-, 861  
     tuberculous, drainage of, 314  
     tubo-ovarian, 627  
     gonorrhœal, 291  
**Accessory abdominal ostia**, 154  
     ovaries, 153  
     uterus, 156  
**Actinomycosis**, 325, 331  
     clinical features of, 333  
     morbid anatomy, 332  
     of external genitalia, 333  
**Actinomycosis**, pelvic infection, 334  
     treatment of, 334  
**Adenitis**, gonorrhœal, 291  
**Adeno-carcinoma**, cervical, 518, 522, 524, 528  
     cystic, of ovary, 675  
     of Bartholin's gland, 367  
     of body of uterus, 533, 535  
         alveolar, 535, 536  
         tubular, 533, 534  
     of Fallopian tubes, 637  
     of para-urethral glands, 375  
     true, 500  
**Adeno-chondro-sarcoma of uterus**, 510  
**Adenofibromata of ovaries**, 684  
**Adenoma**, malignant, 500, 525, 535  
     of body of uterus, 535  
     of Bartholin's gland, 367  
     of vulva, 353  
     papilliferous, 498  
     simple, 496  
         of endometrium, 401, 404  
         removed from virgin, 497  
     *See also* Cyst-adenoma  
**Adenomata of vulva**, 353  
     urethral, 373  
**Adenomatosis vaginæ**, 384  
**Adenomatous polypi**, 480  
**Adenomyoma uteri**, circumscribed or peripheral, 492  
     extra-uterine, 493  
     of recto-genital space, 493, 495  
     of uterus, 489  
         diagnosis of, 495  
         diffuse form, 490  
         nodular stage, 494  
         prognosis, 496  
         structure of, 492  
         treatment of, 496  
     of vagina, operation for, 844  
     of vulva, 353  
     tuberculosis confused with, 302  
**Adhesions**, and fibroid, 454  
     intestinal, 763  
     of appendix, 279  
**Adipose tissue**, formation after removal of ovaries, 51  
**Adnexa**, inflammation symptoms, 629  
     uterine, operations on, 763  
**Adolescence**, hæmorrhage in, 133  
**Adrenal glands**, preparations of, in treatment of hæmorrhage, 135

- Adrenalin solution in plugging, 137
- After-treatment of gynecological operations, 846
- complications after abdominal operations, 850
  - acute abdominal distension, 853
  - acute dilatation of stomach, 858
  - cystitis, 850
  - faecal fistulae, 860
  - infection of the wound, 861
  - intestinal obstruction, 856
  - intestinal paresis, 857
  - mechanical ileus, 856
  - paralytic ileus, 857
  - parotitis, 861
  - peritonitis, 854
  - phlebitis, 861
  - pulmonary embolism, 862
  - recurrent hæmorrhage, 853
  - rupture of the wound, 861
  - shock, 850
  - suppression of urine, 859
  - urinary fistulae, 860
- vaginal operations, 863
- After-treatment of simple abdominal operations, 846
- immediate treatment, 846
  - anæsthetic vomiting, 847
  - bladder, 848
  - pain, 848
  - posture, 846
  - thirst, 848
  - treatment after twenty-four hours, 849
  - bowels, 849
  - dressings, 849
  - stitches, 849
  - when to get up, 850
- Age, and the menopause, 107
- in cancer of cervix, 537
  - in chronic metritis, 417
  - in sarcoma of uterus, 512
  - in sterility, 148
  - in sub-involution, 250
  - influence of, on structure of ovaries, 46
  - of commencement of menstruation, 87
  - old, changes in endometrium, 403, 404
  - genitals in, 57
  - predisposing cause of cancer, 515
- Alcoholism, cause of amenorrhœa, 179
- Alexander-Adams operation of ventrisuspension, 769
- Alkaline drinks in cystitis, 272
- Amenorrhœa, obesity associated with, 104
- primary, 106
  - clinical features of, 175
  - developmental causes, 171
  - general causes of, 172, 177
  - treatment of, 176, 177
  - secondary, causes of, 178
  - treatment of, 179
  - varieties of, 171
- Ammonia, bromide of, in amenorrhœa, 185
- Amœba urogenitalis, 324
- Anæmia, causing primary amenorrhœa, 177
- effect of, upon menstruation, 131
  - severe, cause of amenorrhœa, 178
  - treatment of, 477
- Anæsthesia, 731
- local, 731
  - Anæsthesia, spinal, 731
- Anæsthetics, vomiting after, 847
- Analgesics, use of, 552
- Anal membrane, 83
- Anatomy of appendix, 278
- of Fallopian tubes, 32
  - of ovaries, 36
  - of uterine supports, 562
  - of vagina, 1, 53
  - of vulva, 57
  - surgical, of pelvic cavity, 11
- Angiomata, true, 453
- Angio-sarcoma of uterus, 510
- Anoci-association, advantages of, 731, 850
- Anteflexion of uterus, 568
- Anteversion of uterus, 568
- Antipyrin in amenorrhœa, 185
- Antiseptic solutions in pruritus, 343
- Antiseptics in operations, 727
- Anus, gonorrhœa of, 296
- hæmorrhage from, 106
  - incompetence of, due to prolapse, 597
- Aphthous vulvitis, 340
- Apiol in amenorrhœa, 179
- Appendages, uterine operations on, *facing* 45, 138, 176, 759, 762
- Appendectomy, incision for, 767
- steps of, 767, 768
- Appendicitis, acute, abdominal signs in, 280
- clinical features of, 279
  - differential diagnosis in, 281
  - symptoms of, 280
  - treatment of, 283
- chronic, clinical features of, 285
- morbid anatomy of, 284
  - treatment of, 285
- differential diagnosis of, from tubal pregnancy, 221
- etiology of, 278
- gangrenous, removal of gravid uterus after, *facing* 45
- morbid anatomy of, 278
  - pelvic peritonitis due to, 261
- Appendix, adhesions of, 279
- anatomy and topography of, 278
  - distension with pseudomucin, 666
  - gangrenous, 278
  - localized abscess formation, 279
  - removal of, 767
- Arteries or artery,
- circular of cervix, 68
  - ovarian, 68
  - pubic, course of, 70
  - uterine, 54, 68, *facing* 421
  - vaginal, 54
  - virgin uterus, *facing* 422
- Arthritis, gonorrhœal, 298
- pyæmic, in children, 298
- Ascaris lumbricoides in genital tract, 325
- Ascites, abdominal enlargement due to, 116
- differential diagnosis of, from large abdominal cysts, 716
  - in cancer of Fallopian tubes, 640
  - with fibroid tumours, 443
- Atresia of cervix, 163
- of genital canal, 163
  - of vagina, 165
  - of vulva, 165
- Atrophy arrested by ovarian grafts, 52
- of fibroids, 444

- Auscultation, abdominal, 117  
 Auvard's self-retaining vaginal speculum, 737, 794  
 Aveling's reposer for treatment of chronic inversion, 589  
 Azygos vaginæ artery, 69
- BACILLURIA, 272  
 Bacillus coli, in infant vagina, 232  
   in urinary tract, 235  
   urinary infection due to, 143, 267  
 Bacillus, Döderlein's, 233  
   perfringens, 244  
   proteus vulgaris, 236  
   pyocyaneus, 235  
   smegma, 234  
   tuberculosis, in urinary tract, 235  
   vaginal, 56, 233  
 Backache in uterine displacements, 576  
 Bacteræmia, 265  
 Bacteria, cystitis due to, 267  
   non-specific pyogenic, 237  
   parasitic, 237  
 Bacteriological examination of discharges, technique for, 129  
 Bacteriology of genito-urinary tract, 232  
   of gonorrhœa, 287  
   of pyelitis, 274  
   of pyosalpinx, 621  
   of salpingitis, 609  
   of vaginal secretion, 56, 57  
 Bacteriuria, 143  
 Bartholin's duct, 63  
 Bartholin's gland, 63  
   abscess of, 365, 366  
   adeno-carcinoma of, 367  
   adenoma of, 367  
   cysts of, 363  
   endothelioma of, 367  
   gonorrhœal inflammation of, 291  
   inflammation of, 365  
   morbid conditions of, 363  
   new growths of, 366  
   secretion of, 65, 138  
   site of, 64  
   structure of, 65  
 Bed-wetting, *See* Enuresis  
 Bilharzia hæmatobia in genital tract, 325  
 Bimanual examination of patient, 119  
 Biniodide and perchloride of mercury, 733  
 Bladder, 54  
   anatomical relationships, 5, 7, 67  
   blood-supply of, 68  
   developmental processes of, 81  
   distension, uterine displacement due to, 15  
   drainage of, 274  
   effects of fibroid tumours of uterus upon, 467  
   gland formation in, 270  
   inflammation of, 267  
     after operations, 848, 859  
   instillation of, 273  
   irrigation of, 273  
   irritable, 272  
   over-distension of, 116  
   position of, 66  
   separation from vaginal attachment in colpotomy, 780  
 Bladder, separation of, in radical cure of cystocele, 808  
   supports of, restoration of, 810  
   structure of, 67  
   topical treatment of, 273  
   ulceration of, in cystitis, 271  
   villous papilloma of, 498  
     *See also* Cystitis, Micturition, etc.  
 Blood, character of, in hæmatoma, 659  
   examination of, in diagnosis, 129  
   menstrual, coagulability of, 98  
 Blood-casts, 488  
 Blood-clot, 99  
 Blood-count, differential, 628  
 Blood-pressure and post-operative shock, 850  
   effect of menstruation upon, 100  
 Blood-supply of fibroids, 431  
 Blood-system of vulva, lesions of, 368  
 Blood-vessels, effects upon, of fibroid tumours, 468  
   in specimen of chronic metritis, *facing* 421  
   of endometrium, 19  
   of pelvic organs, 68  
   of uterus, 24  
     after parturition, *facing* 421  
     effect of fibroid tumours on, 443  
 Boils, vulval, 340  
 Bonney's method in trachelorrhaphy, 801  
   needle for use in trachelorrhaphy, 802  
 Breasts, atrophy after the menopause, 109  
   changes in pregnancy, 473  
 Broad ligaments, 25  
   anatomical relationships of, 27  
   cysts of, 698  
     infection of, 761  
     epoöphoritic, 701  
     fimbrial, 698  
       clinical features of, 700  
     parovarian, 701  
     removal of, 759  
   dissection of, 70  
   infundibulo-pelvic fold, 25  
   myoma, differential, diagnosis of, 25  
   posterior aspect of, 26  
   varix, 571  
 Bromide in amenorrhœa, 185
- CÆSAREAN hysterectomy, 462, 742  
   myomectomy, 462, 740  
 Calcareous degeneration of fibroids, 450  
 Calcium metabolism, 51  
 Calcium salts, 99  
   in menstrual fluid, 98  
   in treatment of hæmorrhage, 135  
 Calculus, renal, pain in, 143  
   urethral, 377  
 Canal of Nuck, hydrocele of, removal of, 836  
 Cancer associated with fibroids, 457, 459, 461  
   " cured " cases of, 550  
   differential diagnosis from papilloma, 499  
   lymph metastases, 530  
 Cancer of body of uterus, 531  
   adeno-carcinoma, 533  
   advanced stages of, 549  
   alveolar form, 535, 549  
   causes of, 514  
   clinical features of, 547

- Cancer of body of uterus—  
 differential diagnosis of, 548  
 early stages, 547  
 microscopic appearance, 533  
 papillary, 531, 533  
 pathological anatomy, 531  
 polypoidal, 532  
 spread of, 537, 544  
 squamous-celled, 537  
 tuberos, 531, 532
- Cancer of cervix, 518  
 adeno-carcinoma, 524, 526  
 causes of, 515  
 child-bearing and, 538  
 clinical features of, 537  
 diagnosis of advanced stages of, 543  
   of early stages of, 543  
   of operability, 545  
 discharge in, 539  
 duration of, 546  
 endocervical, 518  
   diagnosis of, 542  
 formative or proliferative, 526, 527, 543  
 hæmorrhage and, 539  
 influence of age upon, 537  
 inoperable, 546  
 involving other pelvic organs, 544  
 macroscopic appearances of, 525  
 medullary, 526, 528  
 pain and, 539  
 pathological anatomy of, 518  
 portio-vaginalis, 528, 541  
 prognosis of, 546  
 pyometra and, 544  
 radical operation for, 752  
 spread of, 530, 544  
 squamous-celled, 520  
   microscopic appearances of, 519,  
   520, 521  
 symptoms of, 538  
 ulcerative, 528, 529, 543  
 with fibroid tumour of body of uterus,  
 460
- Cancer of Fallopian tube, 640
- Cancer of uterus, 514, 515  
 treatment of, 549  
   by radiation, 551  
   radical operation, 545, 549  
   medical, 552  
   palliative, 550  
   partial operation, 550  
   with fibroid tumour, 457, 458, 461
- Cancer of vagina, operation for, 845  
 primary, 386  
 secondary, 387
- Cancer of vulva, 357, 358  
 relationship to leucoplakia, 346
- Cancer, offensive discharges due to, 139, 544  
 risk of implantation of, 752  
 squamous-celled, 500, 520  
   microscopical appearances, 521  
 urethral, types and varieties of, 376  
 vulvo-vaginal, excision of vulva and  
 inguinal glands, 838
- Cancer. *See also* Carcinoma
- Canceroid. *See* Ulcus molle
- Carcinoma of ovary, 673  
 alveolar, 678  
 diffuse, 678  
 primary, 674
- Carcinoma, urethral, 375  
 of vagina, 386  
 sarcomatodes, 510  
*See also* Cancer
- Carcinomatosis, general, of uterus, 515
- Carunculæ myrtiformes, 62
- Caruncles, urethral, 143, 373  
 urethral operation for, 832, 834
- Casts, blood-, 488  
 decidual, 487  
   from case of extra-uterine gesta-  
   tion, 219  
 fibrinous, 488  
 menstrual exfoliation, 488  
 uterine, 487
- Castration, ovarian grafts after, 52
- Catarrhal patch of cervix, 406  
 salpingitis, 610
- Catheter, risks attending use of, in retention  
 of urine, 144
- Catheterization, infection due to, 267
- Caustics, necrosis caused by, 239  
 sloughs produced by, 551
- Cell-elements of chorion-epithelioma, 555
- Cells, epithelioid, 301  
 exudation in endometritis, 393, 399  
 genital, 76  
 giant-cell system, 302  
 of endometrium, secretion of, 18  
 of mature follicle, 42  
 of vaginal epithelium, 55  
 "theca-lutein," 44
- Cellular tissue, pelvic, 9  
 anatomical points, 253
- Cellulitis, pelvic, 252  
 anatomy of, 252  
 abscess in, 256  
 chronic, 254  
 contrasted with pelvic peritonitis,  
 260, 263  
 diagnosis of, 256  
 etiology of, 253  
 exudation in, 256  
   section through, *facing* 254  
 pathology of, 254  
 prognosis in, 258  
 physical signs of, 255  
 symptoms of, 255  
 treatment of, 258
- Cervicitis, gonorrhœal, treatment of, 300
- Cervico-vaginal insertion of uterus, 29
- Cervix, amputation of, 607, 804  
 atresia of, 163  
 congenital, 176  
 operation for, 163  
 results of, 163  
 treatment of, 163  
 cancer of, 458, 518  
   radical operation for, 753  
   with fibroid tumour of body of  
   uterus, 460  
 catarrhal patch, 406  
 chancre of, 319, 542  
 circular artery of, 68  
 condition in chronic endometritis, 415  
 congenital erosions of, 408  
 conical, 164  
 cystic glands of, 411  
 dilatation of, 185, 793  
 indications for, 793



- Cervix, dilatation of, intra-uterine glass stems for use after, 795  
 in treatment of sterility, 150  
 use of laminaria tent in, 796
- divisions of, 13  
 effect of menstruation on, 99  
 elongation of, 593, 596, 599  
 endometritis of, 404  
 endometrium of, 16, 19  
 erosion of, 22, 406, 541, 560  
   gonorrhœal, 293, 295  
   pathological anatomy of, 406, 419  
   trachelorrhaphy for, 799  
 eversion of, in lacerations, 561  
 exposure of, by Jayle's and Auvard's specula, 127  
 fibroid tumours of, 437, 472  
 glands of, 22  
 gonorrhœa of, 293, 300  
 hæmorrhage from, 130  
   local causes of, 132  
 hypertrophic elongation of, 591, 599  
 microscopic appearance of, 601  
 lacerations of, 559  
   as predisposing cause of cancer, 561  
   clinical features of, 561  
   deep bilateral, 560  
   diagnosis of, 561  
   operations for, 801  
   repair of, 799  
 length of, 30  
 lymphatics of, 73  
 muscle layers of, 24  
 polypi of, 481  
   fibro-adenomatous, *facing* 481, 484, 485  
   mucous, 484  
   removal of, 787  
   treatment of, 486  
 portio vaginalis, 13  
 prolapse of, 591  
   diagnosis of, 602  
   symptoms of, 600  
   treatment of, 603  
     by operation, 606  
     by pessaries, 604  
     by rest and massage, 603  
 pseudo-adenoma of, 406  
 retention cysts of, 119  
 sarcoma of, 507  
   wall of, 508  
 section of vaginal portion of, 20, 601  
 simple adenoma of, 500  
 splitting of, in vaginal myomectomy, 789  
 stenosis of, 252  
 supra-vaginal, 13  
   elongation of, 600  
 trachelorrhaphy operation, 799  
 transverse ligaments of, 28  
 tuberculous disease of, 306, 541  
 ulceration of malignant, 541  
   tuberculous, 306  
 vaginal portion of, 119  
   elongation of, 599, 600  
   inspection of, 119
- Cestodes in genital tract, 324
- Chancere, Hunterian, 318  
 of cervix, 542  
 sites of, 319
- Child-bearing, relationship to cervical cancer, 538
- Childhood, hæmorrhage in, 133
- Children, genitals of, 57  
 gonorrhœal infection of, 298  
 Græafian follicles, development in, 40  
 ripening follicle in, 40  
 structure of ovary in, 46  
 syphilis in, 322
- Chill, effect on menstruation, 105
- Chlorosis, cause of amenorrhœa, 177, 178
- Chondro-sarcoma of uterus, 510
- Chorionc epithelioma, 553  
 cellular elements of, 557  
 diagnosis of, 558  
 formation of, 50  
 of vagina, 386  
 pathological anatomy of, 553, 557  
 secondary deposits, *facing* 553  
 symptoms of, 558  
 treatment of, 559
- Chorionic villi from tubal mole, 203
- Circulation, depression of, after operations, 850
- Clamp, vaginal, Wertheim's, modified, 752
- Climate, influence of, upon menstruation, 87
- Climacteric period, *see* Menopause
- Clitoris, 83  
 epithelioma of, 355, 357  
 hyperplasia of, 350  
 site of, 60
- Cloaca, development of, 80
- Cloacal membrane, of embryo, changes in, 83  
 region of embryo, model of, 80, 82
- Clots intra-uterine, 182
- Coccygeotomy, 845
- Coccygeus muscles, 564
- Coccygodynia, 142, 372
- Codein for relief of pain, 552
- Cœlomic cavity, 74, 80
- Coitus, hæmorrhage following, 131  
 injuries to vagina during, 389  
 interruptus, 649  
 painful, 112, 146, 147, 371, 576  
 prevention by kraurosis, 347  
 sterility due to position in, 571
- Collagen replaced by hyalin in fibroids, 446
- Colles's Law of Immunity, 318
- Colloid increase in pregnancy, 104
- Colon, irrigation of, after operations, 857
- Colpitis, 380  
 in children, 381
- Colporrhaphy, anterior, 607, 807
- Colpotomy, anterior, 606, 779  
 preparatory incision, 779  
 separation of bladder from cervical attachment, 780, 781  
 posterior, 777, 778
- Conceptional syphilis, 318, 321
- Condylomata, 319, 350
- Condylomata acuminata, 291, 337
- Congenital erosion, 408  
 malformations, 152
- Convalescence after operations, 850
- Copaiba balsam in cystitis, 272  
 in gonorrhœa, 300
- Cords of Kœlliker, 38
- Corpora lutea, number of, 46

- Corpus albicans, 44  
 Corpus luteum, 37, 45  
   abscess, 646  
   cysts of, 656  
   formation of, 49  
   function of, 46, 49  
   internal secretion of, 49  
   normal, microscopic section of, 654  
 "Corpus luteum" tablets, 109  
 Costal zone, examination of, 114  
 Cretinism, causing amenorrhoea, 172  
 Crile's method in shock, 731  
   theory of shock, 850  
 Cryptomenorrhoea, 162, 165, 173  
   causes of, 173  
 Curette, uterine, flushing, 797  
 Curetting for placental remains,  
   in chronic endometritis, 415  
   in hæmorrhage, 137  
   in treatment of fibroids, 479  
   of uterus, 797  
     bleeding after, 799  
     dangers of, 798  
 Cyst-adenoma of ovary, 662, 664  
   pseudomucinosum, 664  
   serosum papillare, 669  
 Cystic adeno-carcinoma of ovary, 675  
   degeneration of fibroids, 446  
   disease of ovaries, 643  
   polypoidal overgrowth of endometrium,  
     482  
   tumours, differential diagnosis of, 714  
 Cystitis, acute, 269, 270  
   treatment of, 272  
   after abdominal operations, 859  
   chronic stage, 270, 271  
   condition of urine in, 270  
   diagnosis of, 271  
   differential diagnosis of, 272  
   etiology of, 267  
   gonorrhœal, 272  
   local treatment of bladder, 273  
   pain in, 143, 270  
   painful micturition in, 271  
   pathology of, 269  
   renal complications in, 271  
   subacute, 271  
   symptoms of, 270  
 Cystocele, 598, 603  
   combined with prolapsus uteri, 591, 593  
   pessaries for, 605  
   radical cure of, 806  
 Cystoma ciliatum papillare invertens, 669  
   proliferans glandulare, 663  
   serosum papillare, 664  
 Cystomata, perimetric, 261  
 Cystoscopic examination, 271  
 Cysts, abdominal, 117  
   differential diagnosis from ascites,  
     716  
   cervical retention, 119  
   dermoid, of ovary, 689  
   echinococcal, 608  
     in uterine muscle, 328  
   fimbrial, of broad ligament, 698  
   follicular, resection of, 766  
   hilum, small, 78  
   hydatid, 326, 330  
     differential diagnosis of, from  
       ovarian tumours, 715  
   Cysts, lutein, 656  
     mesenteric, differential diagnosis of,  
       from ovarian tumours, 714  
     multilocular, 662, 665  
     of anterior vaginal wall, simulating  
       cystocele, 603  
     of Bartholin's gland, 363  
       excision of, 836  
     of broad ligament, 659, 698  
       removal of, 759  
     of corpus luteum, 656  
     of ovaries, 649, 689  
       differential diagnosis of, 712  
       in pelvic hæmatocele, 225  
     pancreatic, differential diagnosis of,  
       from ovarian tumours, 714  
     papilliferous, 669  
     parovarian, of broad ligament, 701  
     simple serous, 650, 652  
     subepithelial tubal, 608  
     teratomatous, complicating pregnancy,  
       721  
       ovarian, 689  
     theca-lutein, 648, 652  
     tubal, 608  
     tubo-ovarian, 627  
     vaginal, 384  
       operative treatment of, 843  
 DEBILITY, cause of secondary amenorrhoea,  
   178  
 Decidua compacta, 90  
   ovarian, 193  
   differential diagnosis of, 398  
 Decidual casts, 487  
   -cells, 218  
 Defæcation, painful, in extra-uterine adeno-  
   myoma, 495  
 Degeneration of Græafian follicle, 44  
   fatty and hyaline, of fibroids, 444, 447  
   red, 451, 466  
 Dermoid cysts, contents of, 691, 693  
   of ovary, 689  
 Development and function, disorders of, 152  
   of external genital organs, 84  
   of genito-urinary tract, 74  
 Diagnosis, methods of, 116  
 Diet after operations, 849  
 Dietl's crisis, 142  
 Digestion, disorders due to fibroids, 469  
 Dilatation of cervix, 150, 185, 793, 796  
 Dilators, uterine, 795  
   vaginal, 842  
 Diphtheria, genital, 237  
 Diphtheritic vaginitis, 381  
 Discharges, causing itching of vulva, 342  
   diagnosis of, 140  
   examination of, in clinical examination,  
     129  
   in cervical cancer, 539  
   in sarcoma of uterus, 512  
   in tubal adeno-carcinoma, 640  
   offensive, 139  
   purulent and muco-purulent, 138  
   serous, thin, 139  
   symptomatic, 112  
   tampon-test for, 139  
   treatment in, 140  
   vaginal, types of, 138

- Displacements of ovary, 643  
of uterus. *See* Uterus
- Distoma hæmatobium in genital tract, 325
- Diverticula of Fallopian tube, 155
- Döderlein's bacillus, 233  
in vaginal secretion, 56
- Douching, hot, in treatment of hæmorrhage, 137  
in vaginitis, 383
- Douglas, pouch of. *See under* Pouch
- Doyen's panhysterectomy, 751
- Drainage in abdominal operations, 738  
of bladder, 274  
of peritoneum in treatment of peritonitis, 855  
of wounds, 849  
vaginal, 738  
vesico-vaginal, 274
- Drugs in dysmenorrhœa, 185, 187  
in treatment of hæmorrhage, 135
- Dressings after abdominal operations, 849  
changing of, after abdominal operations, 849
- Dysmenorrhœa, as symptom of chronic endometritis, 414  
as symptom of displacement of uterus, 575  
clinical types of, 183  
congestive, 183  
symptoms of, 186  
drugs in, 185, 187  
due to ante flexion, 569  
in fibroid tumours of uterus, 465  
intra-uterine clotting causing, 182  
membranous, 187  
menstrual exfoliation causing, 187  
treatment of, 189  
obstructive, 182  
primary, 183  
treatment of, 183  
operative, 185  
palliative, 185  
secondary, pain in, 186  
symptoms of, 186  
treatment of, 187  
severe, 154  
sources of pain in, 181  
spasmodic, 183  
dilatation of cervix for, 793  
uterine, contractions causing, 182  
varieties of, 181  
vaso-motor disturbances causing, 183
- Dyspareunia, 112, 371  
as symptom of displacement of uterus, 576  
external causes of, 146  
internal causes of, 146  
treatment of, 147
- Dystrophia adiposo-genitalis, 104
- Dysuria in tuberculosis of peritoneum, 316
- ECHINOCOCCAL infection, 326, 328  
diagnosis of, 329
- Echinococcus in genital tract, 325
- Ectopia ovarii, 153
- Ectopic gestation. *See* Pregnancy. Extra-uterine
- Ectropion, cervical, 408
- Eczema vulvæ, 343
- Egg-cells, 40
- Egg-follicles, 76
- Elephantiasis of vulva, 351, 352  
verrucosa, 352
- Embolism in pyæmia, 266  
pulmonary, after abdominal operations, 862
- Embryo, abdominal region of, section through, 75  
cloacal region of, 80, 81  
development of ligaments in, 84  
genito-urinary development in, 75, 77, 79, 83  
pelvic region of, 83  
section through, 76  
undeveloped genital structures in, 86
- Embryology of genito-urinary tract, 74
- Emmenagogues, 179
- Emmett's trachelorrhaphy, 801
- Endocervical cancer, 517, 519, 542
- Endocervicitis, 293, 300
- Endocrinous glands, defects of, causing amenorrhœa, 172  
functions of, 101, 105
- Endometritis, 391  
acute, 391  
atrophic, 401, 402  
cervical, 404  
chronic, 392, 396  
allied conditions of, 401  
atrophic form of, 397  
clinical features of, 413  
differential diagnosis of, 398  
diffuse-fungous forms of, 398  
etiology of, 396  
hyperplastic form of, 398  
pathology of, 392  
physical signs of, 415  
polyoidal-cystic form, 400  
table, showing changes in endometrium, 395  
treatment of, 415  
varieties of, 396, 401  
diffusa fungosa, 399  
exfoliative, 401  
use of term, 187  
glandular, 401, 402  
gonorrhœal, treatment of, 300  
infective, 243  
of septicæmia, 244  
interstitial, 392  
chronic, associated with displacements of uterus, 575  
differential diagnosis of, 398  
pathology of, 392, 395  
plasma-cells and lymphocytes, *facies* 394  
purulent, drainage in, dilatation of cervix for, 793  
putrid, of supræmia, 244  
puerperal, 238  
senile, 109, 251, 403  
and pyometra, 240, 242  
differential diagnosis from cancer, 548  
sub-acute, 248  
tuberculous, 308
- Endometrium, 12  
adenoma of, simple, 497  
after the climacteric, 31

- Endometrium, before menstruation, 89  
 blood-vessels of, 19  
 cervical, 16, 19  
 changes in, due to fibroid tumours, 441  
 changes in old age, 403, 404  
 changes in stroma, 393  
 cyclic variations of, 393  
 cystic polypoidal overgrowth of, 482  
 effect of menstruation on, 393, 395  
 epithelium of, 17  
 glands of, 17  
 in early stage of involution, 94, 95  
 normal and pathological conditions contrasted, 395  
   premenstrual phase, *facing* 16  
 on third day of menstruation, 96  
 on sixth day of menstruation, 97  
 plasma-cells in, 394, 399  
 round-celled infiltration, 393  
 sarcoma of, 507  
 secretion of cells of, 18  
 stroma of, 18  
 structure of, 16  
 villous papilloma of, 498
- Endosalpingitis, 311
- Endothelioma of Bartholin's gland, 367  
 of ovary, 685, 687  
 of uterus, 514  
 of vagina, 388
- Enuresis, nocturnal, 144  
 causes of, 145  
 treatment of, 145
- Epiblastic growths of uterus, 502
- Epimenorrhœa, 180
- Epistaxis, causes of, 106
- Epithelial growths of uterus, benign, 496  
 heterotopy, 312  
 tumours, malignant, 673  
   ovarian, 661
- Epithelioma of clitoris, 355, 357  
 of labia, 358  
 of vagina, 386  
 of vulva, 357  
   operative treatment of, 838  
 squamous, 518
- Epithelium, capsular of ovary, 76  
 malignant proliferation in papilliferous processes, 673  
 of Bartholin's glands, 65  
 ovarian, varieties of, 660  
 transition point of cervical, 22  
 vaginal, 55
- Epoöphoron, 75
- Ergo-apiol in amenorrhœa, 179
- Ergot, in treatment of hæmorrhage, 136
- Ernutin, 136
- Erosion of cervix, 22, 293, 406, 419, 799
- Erysipelatous vulvitis, 339
- Eserine, action on intestines, 857
- Esthiomène, vulval, 350
- Examination, methods of abdominal, 112, 115  
 bimanual, 119  
 discharges, etc., 129  
 history of illness, 111  
 patient's history, 111  
 rectal, 123  
 specula, 123, 125  
 urinary system, 129  
 uterine sound, 126  
 vaginal, 117
- Examination, methods of abdominal, visual, 123  
 of blood in diagnosis, 129  
 of discharges, tissue, etc., in diagnosis, 129  
 of urinary system, 129
- Extra-uterine adenomyomata, 493
- Extra-uterine gestation. *See* Pregnancy, Extra-uterine
- FACE, "ovarian facies," 708
- Fallopian tubes, 7  
 abdominal ostium, 33, 34  
 absence of, 154  
 accessory abdominal ostium, 78  
 adeno-carcinoma of, 637, 638  
   clinical features of, 638  
   microscopic appearances of, 639  
   pathology of, 640  
   symptoms of, 638  
   treatment of, 641  
 adenomyomata of, 493  
 ampulla of, 33, 35  
 anatomy of, 33  
 ascending infection of, 259  
 cancer of, 640  
 chorionepithelioma of, primary, 641  
 cold abscess of, 313  
 cysts of, 608  
 development of, 79  
 dilatation of, 282  
 diseases of, cause of tubal pregnancy, 195  
 defects of, 154  
 displacements of, 155  
 diverticula of, 34, 155  
 effect of fibroid tumours upon, 443  
 fistulæ of, 621  
 gonorrhœa of, 295  
 gravid, differential diagnosis of, from ovarian cyst, 712  
 hæmorrhage from, 220  
 hydatid disease of, 329, 330  
 hydrosalpinx, 612  
 hypoplasia of, 155  
 identification of, in examinations, 121  
 infection of, channels of, 35  
 inflammation of, 608  
   clinical features of, 627  
   interstitial portion, 33  
   *See also* Pyosalpinx and Salpingitis  
 isthmus of, section through, 34  
 malformation of, 154  
 morbid conditions of, 608  
 new growths, 634  
 operations on, 762  
 pain in diseases of, 466  
 papilloma of primary, 635  
   secondary, 637  
 removal of, 176  
 rudimentary, 154  
 structure of, 33  
 subserosa of, 33  
 suppuration of, 762  
 tuberculosis of, 309, 618  
 tubo-appendicular fistula of, 620  
 tubo-ovarian inflammation, 627, 632  
   *See also* Pregnancy and Tubal Mole, etc.

- Fat, deposition of, at menopause, 107  
 Fatty degeneration of fibroids, 447  
 Faure's abdominal retractor, 735  
 Fenton's uterine dilator, 795  
 Ferguson's speculum, 124  
   method of introducing, 124  
 Fertility, as factor in sub-involution, 250  
   relation of gonorrhœa to, 297  
 Fever, absorption, 238  
   puerperal, 238  
 Fibrin, 99  
 Fibrinogen, 99  
 Fibrinous casts, 488  
 Fibro-adenomatous polypus of cervix, *facing*  
   481  
 Fibroid polypi, removal of, 787  
 Fibroids, angiomatous changes, 453  
   associated with cancer, 457, 459, 461  
   blood-supply of, 431  
   circulatory changes, 451  
   degenerative changes, 444, *facing* 446  
   development of, 424  
   elements of, 428  
   formation of, 426  
   frequency of, 462  
   infective changes, 453  
   interstitial, associated with displace-  
   ment of uterus, 575  
   malignant changes, 454,  
   multiple, 431  
   parasitic, 431  
   polypoid, 435  
   retroperitoneal, 431, 448  
   telangiectatic, 428  
   varieties of, 425  
   *See also* Uterus, tumours of, Fibroid  
 Fibro-lipomyoma, 450  
 Fibroma of vulva, 353  
 Fibromata, diffused, 682  
   encapsulated, 682  
   of ovary, 682  
 Fibromyoma, 428  
   menorrhagia with, 181  
   of vagina, 385  
   operation for, 844  
 Fibrosarcoma, 456  
 Fibrosis, uterine, 416  
 Finger-stall, double, in vaginal examina-  
   tion, 118  
 Fissures, vulval, 349  
 Fistulæ, abdominal, 860  
   fecal, after abdominal operations, 860  
   operations for, 825  
   incontinence of urine due to, 144  
   operations for, 825  
   rectovaginal, operation for, 830  
   tubal, 621  
   tubo-appendicular, 620  
   ureteral, 390, 826  
   urinary, after abdominal operations, 860  
   operations for, 825  
   vaginal, 389  
   vesicovaginal, 389  
   elevated pelvic, position for opera-  
   tion, 827  
   exposure of, for operation, 826  
   flap-splitting operation for, 829  
   knives for operation, 828  
 Flatus after operations, 849  
 Fluid, menstrual, composition of, 98  
 "Flushing" at menopause, 108  
 Fœtus, death of, in secondary abdominal  
   pregnancy, 227  
   *in utero*, 322  
   development of external genitals in, 84  
   genito-urinary development in, 79  
   malformation of, 153  
   ovary of, 40  
   pelvis of, 30  
   retention of, 214  
   syphilis of, 318, 321  
 Follicles, atresic, 650  
   egg-, 76  
   primordial, 39, 77  
   unripened, changes due to inflamma-  
   tion, 659  
   *See also* Græafian follicles  
 Forceps, cervical dressing, 798  
   curved dressing, 773  
   Moynihan's cholectomy, 751  
   tent, for use in dilatation of cervix,  
   796  
   volsellum, 794  
 Fornices, bimanual examination of, 121, 122  
 Fossa navicularis, 62  
   pelvic, 7, 8  
 Fourchette, 59  
 Friedlander's bacillus, 237  
 Function, disorders of, 152  
   disturbances of, due to gonorrhœa, 297  
 Furunculosis, vulval, 340  
  
 GANGRENE, of appendix, 278  
   of vulva, 339  
 Gartner, duct of, 26, 49, 75  
 Genital canal, atresic conditions of, 163  
   cells, 76  
   folds, 78, 83  
   organs, parasitic affections of, 324  
   papilla, 83  
 Genital tract, distribution of micro-  
   organisms in, 234  
   fusion of, with urinary tract, in embryo,  
   79  
 Genitalia, duplication of, 164  
   female, development of, 77  
 Genitals, developed stage, relation to em-  
   bryonic structures, 86  
   development at puberty, 87  
   effect of menopause on, 108  
   embryonic structures, table, 86  
   external, development of, 84  
   inspection of, 118  
   warts of, removal, 837  
   homologues of, 74, 76  
   internal, lymphatics of, 71  
   nerves of, 74  
   tuberculosis of, 301  
   undeveloped stage of, table, 86  
 Genito-urinary tract, development of, 74  
   infective processes of, 235  
   micro-organisms of, 232  
 Germ-epithelium, of ovary, 76  
 Germicides, 732  
 Germinal cords, 76  
 Gestation. *See* Pregnancy  
 Gestation sac, 193  
 Gilliam's operation of ventrisuspension, 772  
 Gland-formation in bladder, 270

- Glands, Bartholin's, 64  
 cervical, 22  
 correlation of functions of, 100  
 effect of menstruation upon, 94, 96  
 endocrinous, defects of, causing amenorrhœa, 172  
     effect of removal of ovaries on, 50  
     functions of, 101, 105  
 of endometrium, 16, 18  
 of pelvic organs, 72  
 urethral, 66  
 uterine, changes in inflammation, 395
- Glans clitoridis, 83
- Glass stems for dilatation of cervix, 795
- Gloves, use of, in abdominal examination, 118
- Glycogen, produced during menstruation, 97
- Glycosuria, pruritus due to, 342
- Goitre in women, 104
- Gonad, 75
- Gonads characteristic of both sexes, 167
- Gonococcal septicæmia, 298
- Gonococci, cultivation of, 287, 288  
     method of staining for, 289  
     septicæmia due to, 288
- Gonococcus, urinary infection due to, 267
- Gonorrhœa, 286  
     bacteriology of, 287  
     cause of chronic interstitial oöphoritis, 648  
     cause of tubal pregnancy, 195  
     chronic, 290  
     clinical data of, 288  
     course of, 297  
     diagnosis of, 299  
     functional disturbance in, 297  
     gonococcal septicæmia, 298  
     historical summary, 286  
     incubation period, 290  
     infection of genital tract, scheme of, *facing* 287  
     "latent," 286  
     method of staining for gonococci, 289  
     mixed infection in, 319  
     of anus, 296  
     of body of uterus, 294  
     of cervix, 293  
     of Fallopian tubes and ovaries, 295  
     of peritoneum, 296  
     of rectum, 296  
     of vagina, 292  
     painful micturition in, 111  
     pathology of, 288  
     relation of, to fertility, 297  
     septicæmia of, 298  
     sterility due to, 296, 297  
     treatment of, 299
- Gonorrhœal cystitis, treatment of, 272
- Inflammation of Bartholin's glands, 291
- urethritis, 290  
 vaginitis, 380  
 vulvitis, 337
- Gosset's abdominal retractor, 734
- Gräafian follicles, absence of, 153  
 atresia of, 44, 650  
 changes in, due to inflammation, 659  
 development of, 39  
 entry of spermatozoa to, 193  
 from ovary of adult, 41  
 liquor of, 41
- Gräafian follicles, maturation of, 36, 37, 42  
 number in ovary, 38  
 ripening, 41, 42, 43, 44  
 rupture of, 44  
 structure of, 39
- Grafting, functional activity after, 52  
     *See also* Ovarian Grafting
- Grafts, autoplasmic, 52  
 heteroplasmic, 52
- Granulomata, chronic, infective, 331
- urethral, 373
- Gubernaculum testis, 28
- HÆMATOCELE, 117  
 diffuse, 206  
 paratubal, 207  
 pelvic, 853  
     differential diagnosis of, 225, 264  
     formation of, in tubal pregnancy, 223, 224, 229  
     peritonitis due to, 261  
     peritubal, 205
- Hæmatocolpos, *facing* 173, 174  
 lateral, 162
- Hæmatocolpos-fluid, composition of, 98
- Hæmatoma, differential diagnosis of, 258  
 lutein, 658  
 of vulva, 368  
 ovarian, diagnosis of, 283
- Hæmatomata, ovarian, 658
- Hæmatometra, causes of, 176  
 result of atresia of cervix, 163
- Hæmatosalpinx, 613  
 with tubal abortion, 198  
 result of atresia of cervix, 163
- Hæmophilia as cause of uterine hæmorrhage, 131
- Hæmorrhage, 130  
 at menopause, 133  
 cervical, local causes of, 132  
 differential diagnosis of, from shock  
     after abdominal operations, 851  
     in tubal pregnancy, 221  
 external capsular, causes of, 199, 206  
 from mucous membranes, periodic, 106  
 from uterus, general causes of, 131  
 in adolescence, 133  
 in childhood, 133  
 in chorionepithelioma, 558  
 in chronic metritis, mechanism of, 422  
 in fibroid tumours, 465, 477  
 in infancy, 133  
 in post-climacteric period, significance of, 133  
 in sarcoma of uterus, 512  
 intermenstrual, in fibroid tumours of uterus, 464  
 internal, clinical results of, in tubal pregnancy, 219  
     due to fibroids, 465  
     from fibroid tumours of uterus, 465  
 internal capsular, causes of, 199  
     results of, 201  
 intra-peritoneal, 219  
 local causes of, 131  
 menstrual, phase of, 91  
 operative treatment of, 137  
 periodic, 106

- Hæmorrhage, recurrent, after abdominal operations, 853  
 severe, significance of, 134  
 symptomatic, 112  
 symptom of cervical cancer, 539  
 symptom of fibroid tumour of uterus, 463  
 treatment of, 135, 477  
   by drugs, 135  
   by hot douching, 137  
   operative, 137  
   by plugging, 137  
   by X-rays, 137  
 tubal, causes of, 132  
 uterine, in tubal pregnancy, 216, 222  
   local causes of, 131  
   vaginal causes, 132  
   vulval causes, 132
- Hair, pubic, 57  
 at the menopause, 109
- Hands, care of, in examinations, 117  
 sterilization of, for operations, 732
- Hawkins Ambler's uterine dilator, 795
- Heredity, influence of, 152
- Hermaphroditism, 87, 167, 168  
 false, 168
- Hernia of ovary, 645  
 labial, 369  
   operative treatment, 837  
   ovarian, 155
- Herpes, vulval, 340
- Hodge pessary, 581
- Hyaline degeneration of fibroids, 445  
 liquefaction of fibroids, 446
- Hydatid cysts, interaction between parasite and its host, 327  
 of Fallopian tube, 330
- Hydatid disease, diagnosis of, 329  
 endemic areas of parasite, 327  
 diagnosis of, 329  
 of pelvic viscera, 326  
   treatment of, 329  
 topical distribution of, in pelvis, 329
- Hydatid of Morgagni, 49
- Hydatids, pelvic, primary, 329
- Hydrastis, 136
- Hydrocele of canal of Nuck, removal of, 836
- Hydroparasalpinx, 608
- Hydrops folliculorum, 650, 651
- Hydros tubæ profluens, 612
- Hydorrhœa tubæ intermittens, 612
- Hydrosalpinx, 610, 612  
 accessory, 608  
 bilateral, 766  
 differential diagnosis from ovarian cyst, 712  
 intermittent, 139  
 macroscopic appearances of, 611  
 microscopic appearances of, 612  
 with fibroids of uterus, 611
- Hymen, 54  
 eribriform, 62  
 defects of, 166  
 development of, 84  
 imperforate, 62  
   causing amenorrhœa, 173  
   treatment, of 176  
 laceration of, 131  
 section of, 60  
 structure of, 61, 62, 173
- Hyoscine administered before operation, 726
- Hyperchlorhydria, 285
- Hypogastric zone, examination of, 114
- Hypospadias, 169
- Hysterectomy, abdominal, subtotal, 746, 750  
 total, 746, 748  
   conservative, in treatment of uterine fibroids, 479  
   Doyen's panhysterectomy, 751  
   in chronic metritis, 418  
   Kelly's method, 750  
   Pryor's method, 751  
   special methods of, 750  
   sub-total, 462, 742  
     closure of peritoneum in pelvic floor, 744  
     supra-vaginal amputation, 742, 745  
 total abdominal, 745, 747  
   Wertheim's operation, 752  
 vaginal, 782  
   final stage of operation, 786  
   from below upwards, 782  
   late stage of operation, 784  
   showing parts after removal of uterus, 785  
   Worrall's needle in, 783
- Hysteria, as cause of retention of urine, 144  
 stigmata of, 113, 116
- Hysteropexy, 769, 775
- ILEUS, mechanical, after operations, 856  
 paralytic, after operations, 857
- Iliac region, swelling in appendicitis, 281
- Immunity, Colles's law of, 318
- Incisions, abdominal in ventrisuspension, 771, 775  
 directions for, 733  
 in appendectomy, 767  
 in myomectomy, 740  
 Kelly's continuous, 750
- Incontinence of urine, causes of, 144  
 treatment of, 145
- Infancy, hæmorrhage in, 133
- Infections of fibroids, 453, 466  
 methods of, in tuberculosis of generative organs, 303  
 mixed, cystitis due to, 268  
 pain due to, 466  
 prevention of, during operation, 726  
 risk of, by use of instruments, 128  
   in examinations, 117  
 of pelvic organs, 232  
 septic, of genito-urinary tract, 236  
 specific, 286  
   of genito-urinary tract, 236  
 streptothrix, 331  
 urinary, septic, 267
- Infectious diseases, acute, effect of, upon menstruation, 131
- Inflammation, abdominal symptoms, 628  
 and allied conditions, 391  
 of Bartholin's gland, 365  
 ovarian, 643
- Inflammatory conditions, acute, 337  
 chronic, 340  
 effusions in pouch of Douglas, 225
- Inguinal glands, superficial, 72
- Insanity at the menopause, 107

- Instruments, preparation of, for operation, 730  
 Second's, used in vaginal myomectomy, 790
- Intertrigo, vulval, 340
- Intermenstrual bleeding in fibroid tumours of uterus, 464  
 pain, 190
- Intestinal complications after operations, 849  
 obstruction after operations, 856
- Intestines, abdominal examination and palpation, 113, 117  
 adhesions of, 763  
 effects upon, of fibroid tumours of uterus, 468  
 reverse peristalsis of, 858  
 treatment of, after abdominal operations, 849
- Intoxication, puerperal. *See* Sapræmia
- Intra-ligamentary pregnancy, 209
- Intra-peritoneal abscesses, 262  
 hæmorrhage, encysted type of, in tubal pregnancy, 222  
 pregnancy, 209
- Intra-uterine clotting, causing dysmenorrhœa, 182  
 menstrual clot, 99
- Introitus vaginae, 60
- Iron in amenorrhœa, 180
- Irritation, chronic, cancer following, 514
- Itching of vulva, 341, 344
- JAYLE'S and Auvard's specula, use of, for exposing cervix, 127  
 Jayle's vaginal retractor, 736
- Joints, gonorrhœal affections of, 298  
 pyæmic, 298
- KELLY'S method of abdominal subtotal hysterectomy, 750  
 supra-vaginal amputation, 750
- Kidney, cystic, simulating ovarian cyst, 715  
 cystic tumours of, diagnosis of, 714  
 infections of, 143  
*See also* Pyelitis  
 movable, 114  
 pain in, 141, 143
- Kobelt's tubes, 49, 74
- Kraurosis, differential diagnosis of, 348  
 vulvæ, 347
- LABIA at menopause, 108  
 chancre of, 319  
 epithelioma of, 358  
 hernia of, 369  
 operative treatment of, 837  
 rodent ulcer of, 359, 360
- Labia majora, 57  
 development of, 84
- Labia minora, 59  
 development of, 84
- Labour, false, in pseudocyesis, 107  
 in extra-uterine pregnancy, 209
- Lacerations of cervix, 559
- Lactic acid, 56  
 in menstrual fluid, 98  
 produced by Döderlein's bacillus, 233
- Laminaria tent for use in dilatation of cervix, 796
- Laue's apparatus for subcutaneous saline transfusion, 852
- Le Fort's operation, 607, 823
- Leioma, malignant, 506
- Lembert's stitches, in inflammatory thickening of gut-wall, 769
- Leucoderma of neck, 320
- Leucocytic zone in endometritis of sapræmia, 243
- Leucoplakia, differential diagnosis of, 348  
 uteri, 403  
 vulvæ, 344, 345  
 pathology of, 345
- Leucorrhœa, 138  
 symptom of chronic endometritis, 413  
 of displacement of uterus, 575  
 of fibroid tumours of uterus, 469
- Levator ani muscles, 564
- Ligaments, broad, cysts of, 659  
 removal of, 759  
 cervical, transverse, 28  
 development of, in embryo, 84  
 of cervix, 28  
 of ovary, 26  
 of uterus, 28  
 utero-sacral, 28  
 which support the uterus, 563  
*See also* Broad, Round, etc.
- Ligamentum latum, 78  
 suspensorium ovarii, 75
- Ligatures, preparation of, for operation, 730  
 traction, 773  
 unabsorbable, œdema due to, 863
- Liniments in pruritus, 343
- Lipoma of vulva, 353
- Lipomatosis, 450
- Lipomyoma, 450
- Lipo-mysarcoma of uterus, 510
- Lithopædion, 214, 227
- Liquefaction in follicle cavity, 43
- Lodal, 136
- Lotions in pruritus, 343
- Lubricants, use of, in examinations, 117
- Lungs, embolism of, after abdominal operations, 862
- Lutein abscess, 647  
 cells, 44, 49  
 cysts, 656  
 teratomatous process in, 690  
 hæmatomata, 658
- Lymphangitis. *See* Cellulitis, pelvic
- Lymphatic glands of uterus, 25, 72  
 of vagina, 73  
 pelvic, 9, 71
- Lymphangiectasis of fibroids, 451
- Lympho-sarcoma of uterus, 510
- Lymph-system of vulva, lesions of, 368
- Lymph-system, relationship to cancer, 530
- MACULA gonorrhœica, 291, 299
- McBurney's point, 280
- Malformations, etiology of, 152  
 of Fallopian tubes, 154  
 of uterus, 156  
 of vagina, 156
- Malignant changes in fibroid, 454  
 disease after menopause, 110



- Malignant growths of vulva, 356  
 Marriage and gonorrhœa, 299  
 Marriage and syphilis, 324  
 Martin's pelvic trochar, 778  
 Massage, in treatment of prolapse, 603  
 Meatus urinarius, formation of new, 835  
 Melanoma of vulva, 360  
 Melanosarcoma of ovary, 685  
   of uterus, primary, 510  
 Melargen, in cystitis, 272  
   in gonorrhœal cervicitis, 300  
   in gonorrhœal endometritis, 300  
   in vulvitis, 339  
 Menopause, age factor in, 107  
   anatomical changes due to, 108  
   artificial, 108  
   atrophic endometritis after, 402, 405  
   commencement of, 107  
   delayed, 465  
   dilatation of cervix after, methods, 797  
   effect of, on uterus, 31  
   grafting experiments and, 52  
   hæmorrhage after, 130, 133  
     significance of, 110  
   hæmorrhage at, 133  
   metabolic changes during, 108  
   musculature of uterus before and after,  
     *faciæ* 22  
   ovarian grafting and, 50  
   premature, 108  
   psychical changes during, 107  
   treatment during, 109  
   vasomotor changes during, 108  
   villous papilloma after, 498  
 Menorrhagia, 180  
   in fibroids of uterus, 463  
   symptom of chronic endometritis, 413  
     of displacement of uterus, 575  
 Menstrual exfoliation, vertical section  
   through, 189  
 Menstrual fluid, clotting of, 182  
   retention of, 165  
     clinical features, 175  
 Menstrual molimina, 179  
 Menstruation, abnormal, 106  
   age of commencement of, 87  
   amount of loss in, 88  
   anatomy of, 89  
   blood-pressure symptoms, 100  
   cause of, 50, 100  
   cessation of. *See* Menopause  
   changes in stroma during, 95  
   character of discharge, 88  
   clinical features of, 99  
   clots and coagulability of fluid, 98  
   commencing, histology of, 92  
   composition of menstrual fluid, 98  
   concealed. *See* Cryptomenorrhœa  
   disorders of, 171  
     *See also* Amenorrhœa, Dysmenor-  
     rhœa, Menorrhagia, Menstrual  
     exfoliation, Pain  
   duration of, 88  
   effect of acute infectious diseases upon,  
     131  
     anæmia upon, 131  
     fibroids on, 463  
   effect on cervix and uterus, 99  
     endometrium, 393, 395  
     epithelium, 94  
   Menstruation, effect on glands, 94, 96  
     mucosa, 96  
     secretion, 95  
   endometrium before, anatomy of, 89  
   exfoliation during, 488  
   first day of, 96  
   general management of, 105  
   glycogen produced during, 97  
   in double uteri, 161  
   influence of climate upon, 87  
   intermenstrual pain, 190  
   interval phase, 92, 96  
   irregular, bleeding in, 414  
   irregularity in rhythm, 184  
   membranous exfoliation during, 187,  
     188, 189  
   operations not delayed by, 726  
   pain in, 100  
   painful. *See* Dysmenorrhœa  
   phase of hæmorrhage, 91  
   phase of involution and repair, 91  
   pre-menstrual phase, 90, 96  
   psychic disturbances of, 100, 107  
   precocious, 88  
   premonitory symptoms, 100  
   profuse. *See* Menorrhagia  
   race factor in, 88  
   rest during, 184, 186  
   severe in chronic metritis, 417  
   sources of pain in, 181  
   stage of premenstrual congestion, 90  
   symptoms of, 100  
   third day of, 97  
   vasomotor changes in, 100  
   use of emmenagogues in, 179  
   vicarious, 105  
 Mental depression and menstruation, 100, 107  
 Mercurial ointment, 343  
 Mercury in syphilis, 323  
 Mesoblastic growths of uterus, 502  
 Mesometrium. *See* Broad Ligaments  
 Mesonephros, 74  
 Mesosalpinx, 26, 47  
 Metabolic changes during menopause, 108  
 Metabolism, effect of removal of ovaries on,  
   51  
 Metanephros, 74  
 Metaplasia, sarcomatous, 455  
 Metritis, chronic, 416  
   age in, 417  
   blood-vessels in, specimen of, *faciæ*  
     421 and 422  
   clinical features of, 417  
   complications of, 418  
   hæmorrhage in, 417  
   hypertrophy of uterus in, 422  
   hysterectomy in, 418  
   mechanism of bleeding in, 422  
   pathology of, 418  
     classification of, 418  
   section from wall of specimen,  
     *faciæ* 420  
   simple, case of, 417  
   sub-involution and, 420  
   thickening of uterine walls, 419  
   treatment of, 423  
   with chronic salpingo-oöphoritis,  
     419  
   desiccans, 244  
   from gonorrhœal infection, 294

- Micro-organisms of genito-urinary tract, 232  
of genital tract, distribution of, 234  
of urinary tract, 234
- Micturition, disturbances of, 142  
frequency of, 142  
painful, 111, 112, 142  
in cystitis, 271  
scalding, 290, 299
- Mineral waters in treatment, 633
- Miscarriage in patient's previous history, 111
- Mole, ovarian pregnancy forming, 192  
tubal, 196  
formation of, 201  
vesicular, theca-lutein cysts in, 655
- Monkeys, menstruation in, 99, 101
- Mons veneris, 57
- Morcellement, instruments for use in, 791  
vaginal myomectomy by, 788, 792
- Morgagni, hydatid of, 74
- Moynihan's cholectomy forceps, 751
- Mucin in hæmatocolpos fluid, 98
- Mucosa, changes in, during menstruation, 96
- Mucous membranes, genital, normal condition of, 118, 138  
periodic hæmorrhage from, 106
- Mucous polypi, 480
- Müllerian ducts, development of, 78, 81, 82, 158
- Müller's prominence, 82, 84
- Muscle layers, submucous, subserous and vascular, 24
- Muscles which support the uterus, 563
- Muscular rigidity in appendicitis, 281
- Muscularis mucosæ, 24
- Musculature of uterus, 22, 24
- Museaux forceps, curved, 751
- Myofibromata of ovaries, 684
- Myoma, malignant, 506  
of uterus, sarcoma arising in, 503
- Myomata of ovaries, 684  
submucous, sapræmia due to, 239  
X-rays in treatment, 444
- Myomectomy, 462, 740  
indications for, 740  
in treatment of uterine fibroids, 480  
linear and circumferential incisions, 740  
method of closure of cavity, 741  
vaginal, 787  
by morcellement, 788  
Segond's instruments used in, 791  
stages of operation, 792, 793
- Myosarcoma, 507
- Myxœdema, as a cause of hæmorrhage, 131
- Myxomata of vulva, 356
- Myxo-sarcoma of uterus, 510  
of vulva, 362
- NABOTH'S follicles, 411  
ovula, 119
- Napier's pessary for prolapse, 606
- Necrobiosis, 450, 466, 469, 470
- Necrosis, caused by caustics, 239  
of fibroids, 450
- Needle, Bonney's, for trachelorrhaphy, 802  
Worrall's broad ligament, 783
- Negresses, menstruation in, 88
- Neisser's gonococcus, causing salpingitis, 609
- Nematodes in genital tract, 324
- Neosalvarsan, treatment by, 323
- Nephritis, uræmic suppression in, 859
- Nephrogenic cord, 74
- Nerves, effect of fibroids on, 469  
of genital organs, 74  
of uterus, 25  
ovarian, 37
- Neuralgia of coeeyx, 372  
ovarian, 643
- Neurasthenia in chronic endometritis, 414  
pain associated with, 141
- Noma. *See* Vulvitis, Gangrenous
- Novocain infiltration, 731
- Nullipara, uterus of, 14
- Nymphæ, hyperplasia of, 350  
*See also* Labia minora
- OBESITY, abdominal enlargement of, 115  
associated with amenorrhœa, 104  
diagnosis of abdominal tumours in, 712  
tendency to, at menopause, 108
- Œdema of endometrium, 393  
of fibroids, 451  
of nymphæ, 338
- Œdematous fibroids, *faciæ* 446
- Ointments in pruritus, 343
- Oncospheres, ingestion of, 326
- Oöphorectomy, 763  
gland-changes after, 104
- Oöphoritis, 645  
interstitial, acute, 646  
chronic, 648  
causes of, 648  
tuberculous, 309
- Operations, abdominal, 740  
complications after, 850  
general conduct of, 726  
area of operation, 727  
closing the abdomen, 739  
drainage, 738  
exposure of operative area, 734  
Faure's retractor, 734  
Gosset's retractor, 734  
incision, 733  
intra-abdominal technique, 737  
isolation of field of, 727  
position, 733  
preparation of abdominal wall, 727  
prevention of infection, 726  
sterilization of vulva and vagina, 727
- Operations, gynæcological, after-treatment of, 846  
isolation of field of, 729  
vaginal, 777  
position and coverings for, 729  
technique of, 725
- Operator, precautions by, 732
- Ophthalmia neonatorum, 297
- Opium for relief of pain, 552
- Opitz-Gebhard's gland, 90, 94
- Organisms, vaginal, 56
- Os, condition of, 119  
externum, 13  
reconstruction of, 801  
internum, 13, 15  
uteri, external, 79  
pin-hole, 163, 182

- Ostia accessory, 154  
 Ostium, vaginal, 60  
 Ovarian artery, 68  
   extracts, 50, 109  
   grafting, 50  
   results of, 52  
 ligament, 8  
   adenomyomata of, 493  
 pregnancy, 192  
 secretion, effect on menopause, 108
- Ovary and ovaries—  
 abnormal situation of, 153  
 abscess of, 647  
 absence of, 153  
 accessory, 153  
 adenofibromata of, 684  
 after the menopause, 109  
 anatomical relationships of, 36  
 atresic, Gräafian follicle of, 651  
 attachments of, 26  
 benign connective-tissue tumours of, 682  
 benign epithelial tumours of, 662  
 bilateral suppuration of, 765  
 blood-supply of, 37  
 carcinoma of, 673  
   cystic adeno-carcinoma of, 675, 676  
   primary, 674  
   secondary, 679, 680  
   solid, 676, 677  
 characters of, 37  
 chronic ovarian pain, 643  
 corpus luteum, abscess, 646  
   cysts of, 656  
 cortex of, histology of, 40  
   in child, 39  
 cyst-adenoma of, 662, 663  
   pseudomucinosa, 664  
 cystic, lutein abscesses in, 647, 648  
 cystic, diseases of, 643  
 cystic tumours of, size and position, 708  
 cysts of, 649, *facing* 702  
   acute axial rotation of, 282  
   appendix distended with pseudo-  
   mucin, 666  
   associated with pregnancy, 217  
   large, 708, 710  
   papilliferous, 668, 669, 670  
   pseudomyxoma ovarii, 666, 667  
   simple serous, 652  
   theca-lutein, 652, 653, 654  
   compound, 653, 655  
     axial torsion, 657  
 decidual reaction in, 193, 194  
 defects of, causing amenorrhœa, 172  
   influence on menstruation, 172  
 dermoid cysts of, 689, 692  
 development of, 75  
   external form, 78  
   in embryo, 78  
 differentiated, 76  
 displacements of, 643  
 endothelioma of, 685, 687  
 enlarged painful, 642  
 fibromata of, 682  
 fetal, 40  
 follicular cysts of, 766  
 functions of, 49  
   correlation of, 100  
 gonorrhœa of, 295
- Ovary, Gräafian follicles present in, 38  
   protruding upon surface of, 43  
   hæmatomata of, 658  
     lutein hæmatoma, 658  
   hernia of, 645  
   histology of, 38  
   hydatid disease of, 329  
   hydrops folliculorum, 650  
   inflammation of, 645  
     clinical features of, 627  
   inflammatory changes, 643  
   in hermaphrodites, 167  
   internal secretion of, 50, 53  
   malformations of, 153  
   malignant connective-tissue tumours  
     of, 684  
   malignant epithelial tumours of, 673  
   melanosarcoma of, 685  
   misplacement of, 86  
   morbid conditions of, 642  
   myofibromata of, 684  
   myomata of, 684  
   pain in diseases of, 466  
   prolapse of, 574  
   nerve supply of, 37  
   new growths of, 659  
   pathological changes in Gräafian follicles  
     due to inflammation, 659  
   perithelioma of, 688  
   pregnancy in. *See* Pregnancy, Ovarian  
   prolapse of, 644  
   resection of, partial, 138  
   removal of, effects of, 51  
   rudimentary, 153  
   sarcoma of, 683, 684, 685  
   size and shape of, 36  
   small-cystic degeneration of, 649  
   small painful, 642  
   supernumerary, 153  
   suppuration of, 763  
   teratomata of, 689  
     histogenesis of, 696  
   tuberculosis of, 309  
   tumours of, benign solid, 717  
     classification of, 661  
     compound, 697  
     malignant, 717  
     secondary changes in, 702  
   teratomata of, solid, 694, 695, 696  
   variation in structure at different periods  
     of life, 46
- Ovariectomy, 722, 758  
   indications for, 758
- Ovula Nabothi, 119
- Ovulation, 41, 49
- Ovum delay in passage of, 195  
   fertilization of, 193  
   fertilized, delay in passage, 195, 196  
   relationship of corpus luteum to, 49
- Oxyuris vermicularis in genital tract, 325
- PAIN, acute, on micturition, causes of, 144  
   after abdominal operations, relief of, 848  
   associated with disturbances of mic-  
   turition, 142  
   “bearing-down,” 141  
   clinical character of, 467  
   coccygeal, 142, 372  
   diagnostic, significance of, 140

- Pain, disturbances of micturition and, 142  
 from pressure, in fibroid tumours of  
 uterus, 465  
 gonorrhœal, 296  
 in appendicitis, 280, 285  
 in cancer, 539  
 in chronic metritis, 417  
 in congestive dysmenorrhœa, 186  
 in fibroid tumours, 465, 478  
 in menstruation, sources of, 181  
 in pyelitis, 275  
 in sarcoma of uterus, 513  
 intermenstrual, 190  
 localized, 142  
 menstrual, 100  
 neurasthenic, 141  
 opium for relief of, 552  
 ovarian, chronic, 642  
 pelvic, 142  
   symptom of chronic endometritis,  
     414  
   regional, 141  
   significance of, in fibroid tumours of  
     uterus, 465  
   spasmodic in dysmenorrhœa, 183  
   symptomatic, 112  
   symptom of displacement of uterus, 575
- Palpation, abdominal, 113
- Pampiniform plexus, 68
- Panhysterectomy, 745
- Papilloma, differential diagnosis from can-  
 cer, 499  
 of Fallopian tube, 635  
 of tongue, 320  
 villous, differential diagnosis from can-  
 cer, 549  
 of endometrium, 498
- Papillomata, urethral, 374
- Parakeratosis of vulva, 341
- Paralysis, intestinal, after operations, 857
- Parametritis nodosa posterior, 255  
 remote, 254, 257  
*See also* Cellulitis, pelvic
- Parametrium of Virchow, 9
- Para-rectal fossæ, 8
- Parasitic affections of genital organs, 324
- Parasitic bacteria, 237
- Parasites, interaction between, and the host,  
 327
- Paratubal hæmatocele, 207
- Para-urethral glands, adeno-carcinoma of,  
 375
- Para-vesical fossæ, 7
- Paroöphoron, 75
- Parotitis, post-operative, 861
- Parous uterus, 15
- Parovarium, 26, 47, 75  
 transverse section of, 48
- Parturition, normal involution after, *facing*  
 421
- Patient, abdominal examination of, 112  
 bimanual examination of, 119, 120, 121  
 methods of examination of, 111  
 position of, for vaginal examination, 118  
 preparation of, 725  
 rectal examination of, 123  
 recto-abdominal examination of, 123  
 recto vagino-abdominal examination  
 of, 123  
 vaginal examination of, 117
- Patient, visual examination of vaginal walls  
 and cervix, 123
- Pelvic cavity, anatomy of, 3  
 surgical anatomy of, 11
- cellulitis, 252, 258, 263  
 congestion in menstruation, 100  
 diaphragm, 564  
 floor, 30  
   coronal section through, 566  
 hæmatocele. *See* Hæmatocele  
 inflammation, associated with displace-  
 ment of uterus, 575  
 organs, blood-vessels supplying, 68  
   infections of, 232  
   lymphatics of, 71  
   nerves of, 74  
   palpation of, 120  
   topical distribution of hydatid  
   disease, 329
- pain, symptom of chronic endometritis,  
 414
- peritoneum, 5  
 peritonitis, 259  
 region of embryo, model of, 83  
 tumours, 116  
 viscera, hydatid disease of, 326
- Pelvis, anatomical relationships, 1
- Pendulous belly, 716
- Percussion, abdominal, 117
- Perimetritis. *See* Peritonitis, pelvic
- Perineal body, 8, 65, 596
- Perineorrhaphy, 606, 812, 864  
 for complete laceration, 819, 822  
 for incomplete laceration, 812, 813  
 steps of operation, 814, 820
- Perineum, injuries of, 369  
 lacerations of, 370, 596  
   complete, 819, 822  
   perineorrhaphy for, 812  
 tumours of, 363
- Perioöphoritis, 260, 645
- Perisalpingitis, 260
- Perithelioma of ovary, 688  
 of uterus, 512
- Peritoneum, anatomical relationships of,  
 5, 7, 25  
 echinocoecal infection of, 328  
 encysted collections of fluid within, 715  
 gonorrhœa of, 296  
 infection of, 13  
 mode of closure of, 744  
 tuberculosis of, 314  
   diagnosis of, 316  
   prognosis of, 316  
   signs and symptoms of, 316  
   treatment of, 317  
   varieties of, 315
- Peritonism, 220
- Peritonitis, diffused, 854  
 encysted, 117  
 general, after abdominal operations, 854  
   treatment of, 854  
 gonorrhœal, 296, 300  
 infective, 854  
 localized, after abdominal operations,  
 855  
 pelvic, 259  
   causing tubal kink, 195  
   contrasted with pelvic cellulitis,  
   260, 263

- Peritonitis, pelvic, diagnosis of, 263  
 etiology of, 259, 261  
 new growths as cause of, 260  
 pathology of, 261  
 prognosis in, 264  
 salpingitis complicating, 259  
 serous, 261  
 symptoms of, 262  
 treatment of, 264  
 symptoms of, 854
- Peritubal hæmatocele, 205, 206
- Peri-uterine phlegmon. *See* Cellulitis, pelvic
- Pessaries, for backward displacement, 581  
 Hodge, 581  
 in treatment of prolapse, 604  
 medicated, 383  
 Napier's, 606  
 ring, 605  
 Smith (A.), 581  
 watch-spring ring, 605
- Phantom abdominal tumour, 107, 113, 116  
 tumours, 713
- Phenazone in amenorrhœa, 185
- Phlebitis, 266  
 post-operative, 861
- Phlegmasia alba dolens, 254
- Phosphorus, excretion of, 51
- Pituitary body, preparations of, in treatment of hæmorrhage, 135  
 extract, administration in shock after abdominal operations, 851  
 action on muscle, 105  
 gland, effect of pregnancy upon, 104  
 effect of removal of ovaries upon, 51
- Pituitrin, action on intestines, 857
- Placenta, after treatment in secondary abdominal pregnancy, 229  
 polypi of, 486  
 quick, 230  
 remains in uterus, clearing of, 246
- Plasma-cells in endometrium, 394, 399
- Plastic operations, 799  
 amputation of cervix, 804  
 for fistulæ, 825  
 for restoration of inverted uterus, 831  
 Le Fort's operation for prolapse, 823  
 on vagina, 840, 863  
 on vulva, 832  
 perineorrhaphy, 812  
 Pozzi's operation for sterility, 805  
 radical cure of cystocele, 806  
 trachelorrhaphy, 799
- Plica diaphragmatica mesonephrica, 75
- Plugging, as a treatment of hæmorrhage, 137
- Poisoning, chronic, cause of amenorrhœa, 179
- Polypi, adenomatous, 480  
 cervical, 481  
 removal of, 787  
 fibroid, 435, 436  
 attached to external os, 442  
 sarcomatous change in, 456  
 intra-uterine, diagnosis of, 487  
 mucous, 419  
 removal of, 787  
 treatment of, 487  
 malignant, 486  
 mucous, 480  
 hæmorrhage due to, 134  
 in chronic metritis, 485
- Polypi, placental, 486  
 sarcomatous, 503  
 uterine, 480
- Portio vaginalis of cervix, cancer of, diagnosis of, 540  
 elongation of, 599
- Positions for operations, 728, 733
- Post-climacteric atrophy, 402  
 period, significance of hæmorrhage at, 133
- Posture of patient after abdominal operation, 846
- Pouch of Douglas, 5, 8, 29  
 cellulitis involving, 255  
 inflammatory effusions in, 225  
 prolapse of ovary into, 644
- Pouch, utero-vesical, 6
- Pouches, peritoneal, 6, 11
- Pozzi's operation for sterility, 805
- Pregnancy, abdominal, secondary, clinical  
 diagnosis of, 210, 226, 229  
 after grafting experiments, 52  
 and fibroid tumours of uterus, 460, 466  
 and ovarian tumours, 721  
 cause of, 50  
 diagnosis of, 117  
 differential diagnosis of, in ovarian cysts, 713  
 ectopic, 191  
 differential diagnosis of, from appendicitis, 281  
 effect, upon pituitary gland, 104  
 upon supra-renal glands, 105  
 upon thyroid gland, 104  
 upon uterus, 31  
 extra-uterine, 191  
 treatment of, 227  
 grafting experiments and, 52  
 in accessory horn of uterus bicornis, 214  
 in anomalous situations, 197  
 in fibromyomatous uterus, *facing* 451  
 intra-ligamentary, 209  
 intra-peritoneal, 209  
 ovarian, 192  
 cyst associated with, 217  
 diagnosis of, 193  
 pain in, 466  
 peritoneal, primary, 191  
 pruritus of, 342  
 pyelitis of, 276  
 relationship to cervical cancer, 538  
 sub-peritoneal, 211  
 spurious at menopause, 107  
 tubal, abortion with hæmatosalpinx, 198, 205  
 anatomical changes due to, 197  
 case of tubo-abdominal, 213  
 causes of, 196  
 clinical features of, 216  
 after internal hæmorrhage, 218  
 before internal hæmorrhage, 216  
 decidual cast from, 197  
 diagnosis of, 221  
 differential diagnosis of diffuse hæmorrhage, 221  
 etiology of, 194  
 implantation of ovum, 199, 202  
 incomplete abortion, *facing* 197

- Pregnancy, tubal, intra-ligamentary rupture of tube, 209  
 intra-peritoneal rupture of tube, 208  
 peritubal hæmatocele, 205  
 physical signs of, 217  
 predisposing factors, 197  
 repeated, 195  
 section through gravid tube, 200  
 showing gravid tube, 196  
 superficial embedding of ovum, 199  
 terminating in abortion, 204, 205  
 termination through external capsular hæmorrhage, 206  
 termination through internal capsular hæmorrhage, 201  
 unruptured, 217  
 tubo-abdominal, 213  
 twin in double uteri, 161  
 Wassermann test during, 322
- Preputium clitoridis, 59, 60
- Pressure-symptoms of fibroids, 467, 478
- Primordial follicles, 77
- Probe for intra-cervical application, 798
- Procidencia uteri, 574, 593, 824
- Proctoclysis in treatment of peritonitis after abdominal operations, 855
- Prolapse of cervix, 591  
 of ovaries, 574, 644  
 of urethra, operations for, 835  
 of uterus, 591  
 symptoms of, 600  
 treatment, 603, 606
- Pronephros, 74
- Proœstrum in animals, 101  
 periodic, 51
- Protargol. *See* Melargen
- Protozoa in genital tract, 324
- Pruritus, causes of, 342  
 of pregnancy, 342  
 treatment of, 342  
 vulvæ, 341
- Pryor's total hysterectomy, 751
- Pseudo-adenoma, 406  
 of cervix, 406, 560  
 proliferative, 408
- Pseudocervical fibroid, 441
- Pseudocycosis, 107
- Pseudohermaphroditism, 87, 167, 168, 170
- Pseudomucin, 664, 666
- Pseudomyxoma ovarii, 667  
 peritonei, 668
- Psychical changes and menstruation, 100, 107  
 due to menopause, 107
- Puberty, delayed, causing primary amenorrhœa, 177  
 hæmorrhage at, 131  
 influence on sexual characteristics, 87  
 mature follicles after, 41  
 secondary sexual development at, 86
- Pudic arteries, course of, 70
- Puerperal sapræmia, 238
- Puerperium, pyelitis of, 276
- Pulse-rate in appendicitis, 280
- Purgatives, after operations, 857
- Purse-string suture in appendectomy, 769
- Pus in vaginal discharges, 138  
 pelvic, evacuation of, 11
- Pus-formation, 628
- Pyæmia, 265  
 symptoms of, 267
- Pyæmia, treatment of, 267
- Pyelitis, acute, 274  
 diagnosis of, 283  
 ascending infection *per urethram*, 274  
 bacteriology of, 274  
 causes of, 274  
 chronic form, 276  
 diagnosis of, 276  
 of pregnancy and puerperium, 276  
 pain in, 275  
 pathology of, 275  
 predisposing causes of, 274  
 symptoms of, 275  
 treatment of, 277
- Pyelonephritis. *See* Pyelitis
- Pyocele, peritubal, 618
- Pyometra and cancer of cervix, 544  
 causes of, 240, 252  
 clinical features, 241  
 drainage in, dilatation of cervix for, 793  
 pathology of, 241  
 senile endometritis and, 240, 242  
 treatment of, 241
- Pyorrhœa alveolaris, 324
- Pyosalpinx, 615, 617  
 bacteriology of, 621  
 bilateral, of gonorrhœal origin, 616  
 cause of tubal pregnancy, 195  
 chronic, 615, 619  
 contents of, 620  
 rupture of, 621  
 treatment of, 763  
 tuberculous, 618  
 double, 310, 313  
 ovarian abscess, 617
- Pyuria, 272
- QUININE-UREA-HYDROCHLORIDE infiltration, 731
- RACE factor in menstruation, 88
- Radio-therapeutics in treatment of chronic metritis, 423
- Radium, in treatment of uterine cancer, 551
- Ramsay's hollow uterine dilator, 795
- Rectal examination of patient, 123, 541
- Recto-abdominal examination of patient, 123
- Rectocele, 599
- Recto-genital space, adenomyoma of, 493, 495
- Recto-vagino-abdominal examination of patient, 123
- Rectum, gonorrhœa of, 296
- Red degeneration of fibroids, 451, 466  
 myomata, 451
- Repositor, Aveling's, 589
- Reproductive functions disturbed by fibroids, 469
- Resection, 763  
 of follicular cysts, 766
- Rest during menstruation, 184, 186
- Retained products, 248
- Reticular cords, 76
- Retractor, abdominal, Faure's, 735  
 Gosset's, 734  
 vaginal flat, 790  
 vaginal, Jayle's, 736
- Retropitoneal fibroids, 431, 448
- Retroposition of uterus, 567, 572

- Retroversion of uterus, 572
- Rhabdo-myosarcoma of uterus, 510
- Rigors, repeated, in pyæmia, 266
- Rokitansky's tumour, 651
- Röntgen rays. *See* X-rays
- Rosenmüller, organ of, 48, 75
- Rotation, axial, of fibroids, 452, 466  
of ovarian tumours, 722
- Round ligaments, 28, 563  
adenomyoma of, 493  
interposition of, 773  
relation to parietal structures, after  
ventrisuspension, 775  
shortening of extra-peritoneal parts,  
769  
suspension of uterus by means of, 770
- Rudimentary development, 153
- Rut in animals, 51, 101
- SACTOSALPINX, rupture of, 621  
purulenta. *See* Pyosalpinx
- Saline injections in treatment of peritonitis  
after abdominal operations, 855  
transfusion in shock after abdominal  
operations, 852
- Salpingectomy, 763, 766
- Salpingitis, 608  
acute, differential diagnosis of, from  
appendicitis, 282  
symptoms of, 627  
bacilli causing, 609  
bacteriology of, 609  
catarrhal, 610  
chronic symptoms of, 628  
complicating pelvic peritonitis, 259  
follicularis, 622  
gonorrhœal, 295, 300  
cause of tubal pregnancy, 195  
interstitial, 615, 622  
isthmica nodosa, 311, 493, 622  
transverse section of tube, 623, 624  
nodular, 311, 492, 622  
pseudo-follicularis, 311  
purulent, *facing* 615  
right sided, with inflamed appendix, 609  
sub-acute, *facing* 615  
suppurative, 614  
from ampulla of tube, 613  
tuberculous, 308, 314  
clinical features, 314  
frequency of, 311  
pathological anatomy of, 309  
types of, 311  
varieties of infection, 609
- Salpingo-oöphorectomy, 762  
treatment of pedicle in, 764
- Salpingo-oöphoritis associated with chronic  
metritis, 419  
chronic, 625, 626  
double, 647
- Salpingostomy, 763, 766
- Salvarsan, injections of, 323  
precautions in use of, 323  
treatment by, 323
- Sapræmia, 237, 391  
non-puerperal, 239  
puerperal, 238  
putrid endometritis of, 244  
symptoms of, 245
- Saprophytes, action of, in vagina, 234, 236  
in vaginal secretions, 56
- Sarcoma cervicis botryoides, 509
- Sarcoma, differential diagnosis of, 398  
grape-like or vesicular, 509  
metastases of, 506, 511  
of cervix, 507, 508, 509  
of endometrium, 507  
circumscribed, 508  
diffuse, 507  
of ovaries, 683  
of urethra, 377
- Sarcoma of uterus, 501  
age in, 512  
classification of, 502  
clinical features of, 512  
of uterine wall, 502  
arising in myoma, 503  
circumscribed, 502, 503, 504, 505  
diffuse, 502  
special forms of, 510  
spread of, 510  
symptoms of, 512  
treatment of, 514
- Sarcoma of vagina, 388  
of vulva, 363  
polypoid, 503
- Sarcomatous metaplasia in fibroid, 455
- Scissors, angled, for perineorrhaphy, 815
- Sclerocystic disease of ovary, 649
- Sclerosis, disseminated, 112
- Secretions, cervical, 22  
effect of menstruation upon, 95  
internal, of corpus luteum, 49  
of ovary, 50, 53  
of Bartholin's gland, 65  
vaginal, 56  
abnormal, 233  
after the menopause, 109  
germicide powers of, 334  
natural, 118, 138  
normal, 233
- Scdatives in dysmenorrhœa, 185
- Second's instruments for use in vaginal  
myomectomy, 790
- Semen, ascending infection from, 303  
syphilis transmitted by, 323
- Senile endometritis. *See* Endometritis
- Senile vaginitis, 109, 251, 332
- Septicæmia, 237, 242, 265, 391  
gonococcal, 298  
infective endometritis of, 244  
puerperal, 238  
symptoms of, 245
- Septic infections of genito-urinary tract,  
236
- Serum-treatment of peritonitis, 855
- Sex-characteristics at puberty, 86  
mistakes in, 170
- Sex-gland, 75
- Sexual changes at the menopause, 107  
characters, secondary, 168, 170  
development, secondary, 86  
excitement, effect on menstruation, 131  
intercourse and syphilis, 321  
*See also* Coitus
- Shock, after abdominal operations, dif-  
ferential diagnosis of, 851  
complicating abdominal operations, 850  
Crile's method of preventing, 731

- Shock, post-operative prophylaxis of, 726  
 prevention of, general measures for, 732
- Silver nitrate in gonorrhœal infections, 300
- Sims's position, 125, 126  
 vaginal speculum, 125
- Sinus urogenitalis, development of, in embryo, 79  
 fusion of, with urinary and genital tracts, in embryo, 79
- Skin, preparation of, for operation, 727
- Sloughing of fibroids, 454
- Smegma bacillus, 234, 301
- Smith, Albert, pessary, 581
- Soft sore, 321, 339  
*See also* Ulcus Mollè
- Sound, uterine, 126, 128  
 dangers attending use of, 128  
 in replacement of retroverted uterus, 580  
 sapræmia set up by passage of, 239  
 value of, in diagnosis of uterine fibroid, 472
- Spa treatment, 633
- Speculum, vaginal, Auvard's, 794  
 Ferguson's, 124  
 introduction of, 124  
 Sims's, 125
- Spermatic fluid, ascending infection from, 303  
 syphilis transmitted by, 323
- Spermatozoa, entry to Græafian follicle, 193
- Sphincter ani, injury to, 602
- Sphincter, vesical, reflex spasm of, 144
- Spinelli's operation for restoration of inverted uterus, 831, 833
- Spirocheta pallida, 317
- Squamous-celled cancer, 520
- Staphylococcus albus, 235  
 in vagina of new-born child, 232  
 aureus, 235  
 in vagina of new-born child, 232  
 infection, cystitis due to, 268
- Sterility, causes of, 147  
 local, 148  
 dilatation of cervix for, intra-uterine glass stems for use after, 795  
 displacement of uterus as factor in, 576  
 due to antelexion, 570  
 fibroid tumours of uterus, 469  
 gonorrhœa, 296  
 influence of age upon, 148  
 menstrual exfoliation and, 188  
 position in coitus affecting, 571  
 Pozzi's operation for, 805  
 treatment of, 149, 571
- Sterilization before operations, 732
- Stitch-abscess, 861
- Stitches in abdominal operations, 849  
 removal of, after abdominal operations, 850
- Stomach, acute dilatation of, after abdominal operations, 858  
 lavage of, after operations, 858
- Stovaine in spinal anæsthesia, 731
- Strangury, 270
- Streptococci in vagina of new-born child, 232
- Streptococcal infection, 237
- Streptococcus brevis, 235  
 pyogenes, cellulitis due to, 253
- Streptothrices in genital tract, 324
- Streptothrix infections, 331
- Stroma, changes in, during menstruation, 95  
 of endometrium, 18
- Stypticine, 136
- Styptol, 136
- Sub-involution after abortion, 248  
 uterine, 249
- Supernumerary ovaries, 153  
 tubes, 154
- Suppuration of fibroids, 453  
 of ovaries and tubes, 763, 765
- Suppurative salpingitis, 614
- Suprarenal glands, effect of pregnancy upon, 105
- Swabs, preparation of, for operation, 730
- Symptoms, investigation of, 112
- Syphilis, 317  
 and marriage, 324  
 Colles's law of immunity, 318  
 conceptional, 318, 321  
 diagnosis of, 320  
 fetal, 322  
 initial lesion of, 318  
 mixed infection in, 319  
 parental, influence of, 152  
 secondary stage of, 319  
 tertiary stage, 320  
 treatment of, 323  
 usual site of, 319
- TENIA ECHINOCOCCUS, hydatid disease due to, 326  
 in genital tract, 324  
 scolices of, 326, 328
- Tampon test for discharges, 139
- Technique for bacteriological examination of discharges, etc., 129  
 intra-abdominal, 737  
 of operations, 725
- Telangiectatic changes of fibroids, 453
- Temperament, changes at menopause, 107
- Temperature of operating theatre, 732  
 (body) in intra-peritoneal bleeding, 223  
 in sapræmia, 245  
 in uterine infection, 245
- Tent, laminaria and forceps, 796
- Teratomata, contents of, 691, 693  
 ovarian, 689
- Teratomatous cysts complicating pregnancy, 721
- Testis in hermaphrodites, 167
- Theca-lutein cysts, 46, 648, 652
- Thirst, after abdominal operations, relief of, 848
- Thrombogen, 99
- Thrombokinase, 99
- Thrombolysin, 99
- Thrombo-phlebitis, 266
- Thymus, atrophy of, 87
- Thyroid gland, effect of pregnancy upon, 104  
 effect of removal of ovaries upon, 51  
 imperfect development of, 172
- Tissues, elastic, uterine, 24  
 examination of, in diagnosis, 129  
*See also* Stroma
- Toxæmia, 237, 245, 391



- Trachelorrhaphy, 799  
 Bonney's method, 801  
 Bonney's needle, 802  
 Emmett's method, 801  
 steps of, 800
- Traction ligature, 773
- Traumatism, cancer following, 514  
 urinary infection due to, 268
- Treatment during menopause, 109  
 of acute appendicitis, 283  
 of actinomycosis, 334  
 of adenomyoma of uterus, 496  
 of anæsthetic vomiting, 847  
 of cancer of uterus, 549  
 of cervical polypi, 486  
 of chorionepithelioma, 559  
 of chronic appendicitis, 285  
 endometritis, 415  
 inversion of uterus, 588  
 metritis, 423  
 ovarian pain, 643  
 vaginitis, 383
- of cystitis, 272  
 of displacements of uterus, 577  
 of dyspareunia, 147  
 of eczema vulvæ, 344  
 of extra-uterine pregnancy, 227  
 of fibroid tumours of uterus, 476  
 of gangrenous vulvitis, 339  
 of general peritonitis after abdominal operations, 854  
 of gonorrhœa, 299  
 of hæmorrhage, 135  
 operative, 138  
 of hydatid disease of pelvic viscera, 329  
 of incontinence of urine, 145  
 of intermenstrual pain, 190  
 of malignant vaginal growths, 388  
 of menstrual exfoliation, 188  
 of nocturnal enuresis, 145  
 of non-puerperal sapræmia, 239  
 of ovarian tumours, 722  
 of painful micturition, 144  
 of pelvic cellulitis, 258  
 of pelvic peritonitis, 265  
 of primary amenorrhœa, 176  
 of primary dysmenorrhœa, 184  
 of prolapse, 603  
 of pruritus vulvæ, 342  
 of puerperal sapræmia, 239  
 of pyæmia, 267  
 of pyelitis, 277  
 of pyometra, 241  
 of sarcoma of uterus, 514  
 of secondary amenorrhœa, 179  
 of secondary dysmenorrhœa, 187  
 of severe hæmorrhage, 135  
 of shock after abdominal operations, 851  
 of sterility, 149  
 of sub-involution, 251  
 of syphilis, 323  
 of tuberculosis of genital organs, 305,  
 307, 309, 314, 317  
 of tuberculosis of peritoneum, 317  
 of tubo-ovarian inflammation, 632  
 of uterine infection, 246  
 of vaginismus, 371  
 of vulvo-vaginitis, 338
- Trematodes in genital tract, 324
- Trendelenberg position for operation, 728
- Treponema pallidum, 317, 321
- Trichomonas vaginalis, 325
- Trochar, pelvic, Martin's, 778
- Tubal abortion, causes of, 204
- Tubal mole, 196  
 chorionic villi from, 203  
 formation of, 201
- Tubal pregnancy. *See* Pregnancy, tubal
- Tubal rupture, 206  
 causes of, 207  
 results of, 208  
*See also* Fallopian tubes
- Tubercle bacillus, 301  
 diagnostic tests for, 302  
 pelvic peritonitis due to, 261  
 urinary infection due to, 268  
 vaginal, 235
- Tuberculin, diagnostic inoculations of, 302  
 Koch's old, 302
- Tuberculosis, causing primary amenorrhœa,  
 177  
 of body of uterus, 308  
 of cervix, 306  
 of Fallopian tubes, 309  
 of generative organs, 301  
 distribution of, 303  
 etiology of, 302  
 frequency of, 302  
 methods of infection, 303  
 pathology of, 301  
 prognosis, 303  
 of ovaries, 309  
 of peritoneum, 314  
 of urinary tract, 235  
 of vagina, 305  
 of vulva, 304  
 visceral and genital, coincidence of, 303
- Tubes. *See* Fallopian tubes
- Tubo-abdominal pregnancy, 213
- Tubo-ovarian abscess, 627  
 cyst, 626, 627  
 inflammation, acute, symptoms of, 627  
 treatment of, 632  
 chronic, symptoms of, 628  
 treatment of, 632  
 in metritis, 418  
 swellings, diagnosis of, 629, 630  
 differential diagnosis of, 631
- Tumours, abdominal, 116
- Tumours of cervix (fibroid), 437, 475  
 interstitial, 438, 439  
 subperitoneal, 439, 440  
*See also* Cervix
- Tumours of Fallopian tubes. *See* Fallopian tubes
- Tumours of ovaries—  
 benign cystic, 707  
 differential diagnosis of, 711  
 larger specimens of, 709, 715, 716  
 physical signs, 708  
 symptoms of, 707  
 benign epithelial, 662  
 benign solid, clinical features of, 717  
 differential diagnosis of, 717  
 classification of, 661  
 clinical features of, 707  
 compound, 697  
 malignant, clinical features of, 717  
 epithelial, 673  
 pregnancy and, 721

- Tumours of ovaries—  
 secondary changes in, 702  
 adhesions, 705  
 axial rotation, 702  
   diagnosis of, 719  
 degeneration cysts in solid tumours, 707  
 diagnosis of, 719  
 infection, 703  
   clinical features of, 720  
 malignant degeneration, 706  
 psammomatous degeneration, 706, 707  
 rupture, 704  
 torsion of pedicle of, 702  
   causation of, 703  
   congestion, 702  
   detachment, 703  
   necrosis, 703  
 treatment of, 722
- Tumours of perineum, 363
- Tumours of uterus—  
 adeno-chondro-sarcoma, 510  
 adenomyoma, *facing* 492  
 angio-sarcoma, 510  
 carcinoma sarcomatodes, 510  
 chondro-sarcoma, 510  
 chorionepithelioma, 553  
 circumscribed, 508  
 endothelioma, 514  
 fibro-cystic, differential diagnosis of, from ovarian cysts, 716  
 lipo-mysarcoma, 510  
 malignant leioma, 506  
 malignant myoma, 506  
 melano-sarcoma, 510  
 lympho-sarcoma, 510  
 myxo-sarcoma, 510  
 perithelioma, 514  
 rhabdo-mysarcoma, 510  
 sarcoma, 501  
 (Fibroid) and pregnancy, *facing* 451, 460  
   treatment of, 460  
 angiomatous changes, 453  
 circulatory changes, 451  
   axial rotation, 452  
   lymphangiectasis, 451  
   oedema, 451  
 clinical features of, 462, 470  
 degenerative changes, 444  
   atrophy, 444  
   calcareous degeneration, 450  
   cystic degeneration, 446  
   fatty degeneration, 447  
   hyaline degeneration, 445  
   hyaline liquefaction, 446  
   necrobiosis, 450, 466  
   necrosis, 450  
 diagnosis of, 472  
 differential diagnosis, from cancer, 548  
   from ovarian cyst, 711  
 dysmenorrhœa in, 465  
 effect upon ovaries and Fallopian tubes, 443  
 hæmorrhage in, 465, 477  
 infective changes, 453, 466  
   adhesions, 454  
   inflammation, 453  
   sloughing, 454
- Tumours of uterus (fibroid)—  
 infection and suppuration, 453  
 inflamed and adherent, 632  
 interstitial, 432, 434, 471  
 malignant changes, 454  
   cancer, 457, 458  
   diagnosis of, 459  
   endothelioma, 457  
   sarcomatous metaplasia, 455  
 medium and large sized, 474  
 microscopic appearances of, 427  
 multiple, 430, 471  
   oedematous, *facing* 446  
 pain in, 465, 478  
 pathological anatomy of, 424  
 pathological diagnosis of, 475  
 physical diagnosis of, 470  
 pregnancy and, 466  
 relation to cervix, 472  
 removal of, by vaginal myomec-  
 tomy, 787  
 retroperitoneal, 431, 432, 475  
 secondary changes in, 444  
 size of, 473  
 small, 473  
 submucous, 432, 434, 435, 471  
 subperitoneal (subserous), 429, 632  
 symptoms of, 463  
   hæmorrhage, 463  
   leucorrhœa, 469  
   pain, 465  
   pressure-symptoms, 467  
   reproduction disturbances, 467  
 telangiectatic changes, 453  
 treatment of, 476  
   by Röntgen Rays, 478  
   surgical, 479  
     curetting, 479  
     hysterectomy, 480  
     myomectomy, 480  
   symptomatic, 477  
 varieties of, 425
- Tumours, pain during growth of, 141  
 pelvic, 116  
 pelvic peritonitis due to, 260  
 phantom abdominal, 107, 113, 116  
 simulating ovarian cysts, 713
- ULCERATION of vagina, 383  
 causing itching of vulva, 342
- Ulcers, follicular, vulval, 349  
 malignant cervical, 541  
 rodent, of vulva, 359  
 septic, vulval, 348  
 tuberculous of cervix, 306  
   of vulva, 304, 349
- Ulcus molle, 321  
 causing acute vulvitis, 339
- Umbilical zone, examination of, 114
- Unguentum metallorum, 343
- Ureters, 54  
 development of, 82  
 displacement of, due to fibroid tumours  
   of uterus, 468  
 pelvic course of, 10  
 obstruction of, 859
- Uretero-vaginal fistula, 389
- Urethra, 54  
 acute inflammatory conditions of, 337

- Urethra, anatomical relationships of, 65  
 ascending infection through, 274  
 bacteria in, 234  
 calculus of, 377  
 carcinoma of, 375  
 caruncles of, 373  
   operation for, 832, 834  
 development of, 84  
 dilatation of, 66  
 diseases of, 337, 373  
 expression of secretion from, 289  
 inflammation of, 373  
 lax, 826  
 mucous membrane of, 66  
 prolapse of mucous membrane, 377  
   operation for, 835  
 sarcoma of, 377  
 submucosa of, 66  
 tumours of, 373
- Urethral or ascending infection, cystitis due to, 267, 269
- Urethritis, 373  
 gonorrhœal, 290, 300  
 pain in, 143
- Urethrocele, excision of, 835
- Urinary antiseptics, 859  
 infections, septic, 267  
 system, examination of, 129
- Urinary tract, fusion of, with genital tract, in embryo, 79  
 micro-organisms of, 234
- Urinary vaginal fistulæ, 389
- Urine, bacteriology of, 143  
 condition of, in cystitis, 270  
 examination of, in disturbances of micturition, 143  
 incontinence of, 139, 142  
   causes of, 144  
   operations for, 835  
   treatment of, 145  
 organisms in, 143  
 pus in, in cystitis, 271, 272  
 retention of, causes of, 144  
   due to fibroid tumours of uterus, 467  
 suppression of, after abdominal operations, 859
- Urogenital fold, 78  
 membrane, 83  
 sinus, 83, 85
- Urorectal septum, 80
- Urotropin in cystitis, 272, 273
- Uterine appendages, bimanual examination of, 121  
 artery, 68  
 fibrosis, 416  
 sound, 126, 128  
   risks attending use of, 128
- Utero-sacral ligaments, 28
- Utero-vesical ligaments, 7  
 pouch, site of, 6
- Uterus, absence of, 156  
 accessory, 156  
 acute infections of, causing pelvic peritonitis, 261  
 adenomyoma of, 489  
 adenomyoma of, central or diffuse, 489, 490, 491  
   classification of, 489  
   etiology of, 489  
   extra-uterine, 493
- Uterus, adenomyoma of, peripheral or circumscribed, 492  
 anatomical relationships, 1, 562  
 angle of, 15  
 arterial blood-supply of, 69  
 at different periods of life, 30  
 attachments of, 25  
 benign epithelial growths of, simple  
   adenoma, 496  
   villous papilloma, 498, 499  
 bicornis unicollis, 158, 159  
 bicornute, pregnancy in accessory horn of, 215  
 blood-clots in, 99  
 blood-vessels of, 24, facing 421  
 body of, cancer of, 531  
   gonorrhœa of, 294  
   inspection of, 120  
   tuberculosis of, 308  
 cancer of, 514, 531  
   with fibroid tumour, 457, 458  
 casts of, 487  
   blood-casts, 488  
   decidual, 487, 488  
   expelled from, 187  
   fibrinous, 488  
 changes in, after menopause, 31  
   due to fibroid tumours, 440  
   during menstruation, 99  
 chorionepithelioma of, 553, 554  
 chronic inversion of, 585  
   anatomy of, 585  
   clinical features of, 587  
   differential diagnosis, 588  
   due to submucous fibroid, 586  
   incomplete, 587  
   treatment of, 588  
 "clinically malignant," 416  
 condition of, in intra-uterine polypus, 487  
 contractions, causing dysmenorrhœa, 182  
   pain due to, 182  
 cornu or angle of, 12  
 coronal section of, 14  
 curetting of, 797  
 "decidual reaction" of, 197  
 development of, in embryo, 79  
 didelphys, 157  
 diseases of, 391  
 displacements of, 562  
   anteflexion, 568  
   ante-position, 567  
   anteversion, 568  
   backward, 570  
   in metritis, 418  
     complications of, 573  
     diagnosis of, 569, 576  
     due to distension of bladder, 15  
   forward, 568  
   pessary treatment of, 578  
   retro-position, 567  
   retroversion, digital replacement of, 578, 579, 580  
   three stages of, 572-574  
 symptoms of, 575  
 treatment of, 577  
   by pessary, 578  
   operative, 578  
 types of, 567

- Uterus, duplication of, 156  
 effect of menopause upon, 109  
   of menstruation on, 99  
   of pregnancy on, 31  
 elastic tissue of, 24  
 endothelioma of, 514  
 enlargement in chronic endometritis, 415  
 fibroid tumours of, 424  
 general anatomy of, 11  
 gravid, 117  
   differential diagnosis of, in pelvic hæmatocele, 225  
   musculature of, 24  
   removal after death from gangrenous appendicitis, *facing* 45  
   *See also* Pregnancy  
 hæmorrhage from, 130  
   general causes of, 131  
   local causes of, 131, 465  
 hydratid disease, 329  
 hypertrophy of, in chronic metritis, 422  
 infantile, causing amenorrhœa, 172  
 infantilis, 152, 156  
 infection of, symptoms of, 244  
   treatment of, 246  
     by operation, 246  
     specific, 248  
 inflammation of, 391  
 innervation of, 182  
 interposition of, 781  
 inversion of, 831  
   Spinelli's operation for restoration of, 831  
 involution after parturition, *facing* 421  
 lacerations of, 559  
 length of, 14  
 ligaments of, 28  
 lymphatics of, 25, 72  
 malformations of, 156  
   influence on menstruation, 172  
 malignant growths of, 501  
 menstrual fluid, accumulation in, 176  
 muscular supports of, 563  
 musculature of, 22, 24  
 muscle and fibrous tissue proportions, 250  
 nerves of, 25  
 new growths of, 424  
 normal, of nullipara, 14  
   parous, 15  
 obstruction in dysmenorrhœa due to, 182  
 perforation of, by dilators or curette, dangers of, 798, 799  
 perithelioma of, 512, 513, 514  
 polarity of, 184, 186  
 polyp of, 480  
   mucous, 480, 483  
   section through uterine wall, 482  
   symptoms of, 481  
 position of, 15  
 prolapse of, anatomy of, 592  
   clinical features of, 596  
   complications, 596  
   degrees of, 592  
   Le Fort's operation, 824  
   secondary changes, 595  
   symptoms, 600  
   treatment, 603  
 pubescens, 152, 156
- Uterus, pus in, 240  
 putrefactive processes in, 238  
 removal of, with vagina, by vaginal route, 845  
 retained products of, 248  
 retroverted gravid, differential diagnosis of, from ovarian cyst, 712  
 rotation of, partial, 442  
   with fibroids, 443  
 rudimentary, 156  
   causing amenorrhœa, 172  
 sagittal section of, 12  
 sarcoma of, 501  
   special forms of, 510  
 scraping of, 798  
 septicæmia of, 243  
 septus, 159, 160  
 structure of, 16  
 sub-involution of, 248  
   chronic, in chronic metritis, 420  
   diagnosis of, 251  
   symptoms of, 251  
   treatment of, 251  
 subseptus, 161  
 supports of, 562  
   pelvic diaphragm, 564  
 supra-vaginal amputation of, 742  
 suspension of, by means of round ligaments, 770  
 tuberculosis of body of, treatment of, 309  
   varieties of, 308  
 tumours of. *See* Tumours  
 unicornis, 159, 162, 163  
 vaginal attachment of, 29  
 villous tumour of body of, 498  
 virgin, arteries in, *facing* 422
- Utriculoplasty, 138
- VAGINA, absence of, partial operation for, 841  
 total, operation for, 843  
 adenomyomata of, operation for, 844  
 anatomical relationships, 1, 53  
 arterial blood-supply of, 69  
 atresia of, 106, 165  
   congenital, causing amenorrhœa, 176  
   treatment of, 165  
 bacillus of, 233  
 carcinoma of, 386  
   operation for, 845  
 chorionepithelioma of, 386  
 connective tissue of, 56  
 cysts of, 384, 603  
   operative treatment of, 843  
 development of, in embryo, 79  
 digital examination of, 118  
 discharges from, types of, 138  
 diseases of, 380  
 duplication of, 156, 160  
 effect of menopause on, 109  
 endothelioma of, 388  
 epithelioma of, primary, 386  
 fibromyomata of, 385  
   operation for, 844  
 flora in, 232  
   in new-born child, 232  
 fornices of, 54  
 glandular structures of, 55

- Vagina, gonorrhœa of, 292  
inflammation of, 380  
injuries to, 389  
in nulliparous woman, 54  
lymphatics of, 73  
malformations of, 156  
malignant growths of, diagnosis of, 388  
treatment of, 388  
muscular layer of, 56  
new growths of, 384  
occlusion of ostium, 173  
operations upon, 777, 840  
after-treatment, 863  
colpotomy, 777  
myomectomy, 787  
operative reconstruction, 165  
pathogenic germs in, destruction of, 234  
relaxation of ostium, 597  
removal of, with uterus, by vaginal route, 845  
results of injuries to, 389  
rugæ of, 54  
sarcoma of, 388  
secretions of, 56  
abnormal, 233  
bacteriology of, 56  
germicidal powers of, 234  
natural, 118, 138  
normal, 233  
septicæmia of, 242  
septum of, longitudinal, 843  
sterilization of, for operation, 727  
structure of, 55  
tuberculosis of, 305  
tumours of, solid, operation for, 844  
ulceration of, 383  
urinary fistulæ, 389  
walls of, 54, 119  
inspection of, 119  
section of, 55
- Vaginal examination of patient, 117  
position in, 118
- Vaginal fixation of uterus, 769
- Vaginal operations, fixation of uterus, 781  
hysterectomy, 782  
interposition of uterus, 781
- Vaginismus, 371  
as cause of dyspareunia, 146  
cause of, 63  
operation for, 840
- Vaginitis, 380  
acute, 381  
chronic, 382  
treatment of, 383  
diagnosis of cause of, 382  
diphtheritic, 381  
emphysematous, 382  
granular, 381  
membranous, 381  
senile, 109, 251, 382  
septic, 381  
vulvo-, 388  
treatment of, 388
- Varicose veins of vulva, 368
- Vasomotor changes during menopause, 108  
disturbances causing dysmenorrhœa, 183
- Veins, pampiniform plexus, 68  
varicose, of vulva, 368
- Veneral warts, 291, 299, 319, 337
- Ventrifixation, 775  
comparison with ventrisuspension, 776  
definition of, 769
- Ventrisuspension, Alexander-Adams, operation, 769  
comparison with ventrifixation, 776  
definition of, 769  
extraperitoneal operation, 770  
Gilliam's operation, 771, 775  
abdominal incision in, 771  
ligatures in, 772  
use of forceps in, 773, 774  
in prolapse, 607  
intraperitoneal operation, 770
- Vesical fold, transverse, of peritoneum, 6
- Vesical pouches, lateral, 7
- Vesico-vaginal drainage, 274  
fistula, 389
- Vestibule, site of, 60
- Vicarious menstruation, 105
- Virgins, examination of, 123
- Viscera, effect of fibroids on, 469  
pelvic, hydatid disease of, 326
- Visual examination of vaginal walls and cervix of patient, 123
- Volsella, use of, 128
- Vomiting after anæsthetic, 847  
treatment of, 847
- Vulva, acute inflammatory conditions of, 337  
adenomata of, 353  
adenomyomata of, 353  
anatomy of, 57  
at menopause, 108  
atresia of, 165, 166  
operation for, 832, 834  
treatment of, 167  
carcinoma of, squamous-celled, 357  
condylomata of, 292  
differential diagnosis of leucoplakia and kraurosis, 348  
diseases of, 337  
eczema of, 343  
elephantiasis of, 351, 352  
epithelioma of, 357  
operative treatment of, 838  
esthiomène of, 350  
fibroma of, 353  
hæmatoma of, 368  
hypertrophic and hyperplastic conditions of, 350  
inflammatory conditions of, chronic, 341  
in multiparous woman, 61  
inspection of, 118  
kraurosis of, 347  
leucoplakia of, 344, 345  
relation to carcinoma of vulva, 346  
lipoma of, 353  
malignant growths of, 356  
melano-carcinoma, 358  
melanoma of, 360  
myxomata of, 356  
myxo-sarcoma of, 362  
new growths of, 353  
occlusion of, 165  
œdema of, 369  
papillomata of, 353  
parakeratosis of, 341  
plastic operations upon, 832

- Vulva, pruritus of, 341  
 causes of, 342  
 treatment of, 342  
 rodent ulcer of, 359  
 sarcoma of, 363  
 septicæmia of, 242  
 skin diseases of vulval region, 340  
 sterilization of, for operation, 727  
 superficial atresia of, 165, 166  
 tuberculosis of, 304  
 ulceration of, 348  
 ulcers of, tuberculous, 304  
 varicose veins, 368  
 virgin, 58, 59
- Vulvitis, acute, 338  
 aphthous, 340  
 causes of, 337  
 erysipelatous, 339  
 gangrenous, 339  
 gonorrhœal, 337  
 leucoplakic, diagnosis of, 346  
 relationship to carcinoma, 346  
 membranous, 339  
 rarer forms of, 339  
 syphilitic, 339
- Vulvo-urethral carcinoma of papilliferous  
 type, 376  
 of squamous-celled type, 376
- Vulvo-vaginitis of children, 293, 298, 381  
 parasitic, 325  
*See also* Vaginitis
- WARTS of external genitalia, removal of,  
 837  
 venereal, 291, 299, 319, 337
- Wassermann reaction, 318, 321  
 test during pregnancy, 322
- Wertheim's operation, 746  
 for carcinoma of cervix, 752  
 vaginal clamp, modified, 752
- Wolffian body, 38, 74  
 Wolffian duct, development of, 78, 80
- Worms in genital tract, 324
- Worrall's broad ligament needle, 783
- Wounds, infection of, 861
- XENOMENIA. *See* Menstruation, vicarious
- X-rays, arrest of uterine hæmorrhage by, 137  
 in treatment of myomata, 444  
 of uterine cancer, 551  
 of uterine fibroid, 478
- ZONA pellucida of follicle, 42

PRINTED BY

SPOTTISWOODE, BALLANTYNE AND CO. LTD.  
LONDON, COLCHESTER AND ETON, ENGLAND







COUNTWAY LIBRARY OF MEDICINE

RG  
101  
E22

RARE BOOKS DEPARTMENT

