

Dana (C. L.)

---

---

*On the Microbic Origin of Choréa.*

*Report of a Case, with Autopsy.*

BY

CHARLES L. DANA, A.M., M.D.,

PROFESSOR OF NERVOUS AND MENTAL DISEASES, NEW YORK POST-GRADUATE  
MEDICAL SCHOOL.

57

FROM

THE AMERICAN JOURNAL OF THE MEDICAL SCIENCES,

JANUARY, 1894.



ON THE MICROBIC ORIGIN OF CHOREA: REPORT OF A  
CASE, WITH AUTOPSY.

BY CHARLES L. DANA, A.M., M.D.,

PROFESSOR OF NERVOUS AND MENTAL DISEASES, NEW YORK POST-GRADUATE MEDICAL SCHOOL.

THE more recent studies of the pathology of chorea have led to a practically unanimous conclusion that the seat of the disease is primarily in the bloodvessels and the blood, with secondary degenerative changes in the parenchyma, and that the cause is either some microbe or toxic substance, or both. The evidence regarding these points was collected by me in an article on the pathological anatomy of chorea published in *Brain*, April, 1890.<sup>1</sup> Since then an article on chorea with a contribution to its germ theory has been published by Dr. Henry J. Berkley in the *Johns Hopkins Hospital Reports*, 1891, vol. ii., No. 6. The examination of Dr. Berkley's cases led to the opinion that they were of infectious origin.


The anatomical seat of the disease probably varies. The principal changes are in the brain, and are sometimes chiefly in the cortical and sub-cortical motor areas, often perhaps in meninges as well as cortex.

The case I present seems especially valuable because it was originally a typical case of Sydenham's chorea; the lesions are distinct, and a very careful bacteriological examination was made with fruitful results.

The case has also a clinical value because it shows the gradual involvement of a motor disorder not strictly like chorea, yet developing upon a perfectly typical attack of that disease.

**SUMMARY OF THE CASE.**—*Male, aged thirty-four years; family history good; acute rheumatism at tenth year, Sydenham's chorea at fourteenth year; repeated attacks of the same disease every two or three years, final attack eight months before examination; general violent choreic movements, affecting face, tongue, neck, especially, but also arms, trunk, and legs; tonic spasms in neck and back at times; rhythmical movements of head and arms at times; no paralysis, no anaesthesias or pains, no endocarditis; general nutrition fair; mental development good; cessation of movements during sleep; death from exhaustion. Autopsy: chronic lepto-meningitis of convexity of brain, hyaline bodies in brain cortex, slight meningitis of the upper part of spinal cord, slight meningo-encephalitis; diplococci found in the proliferating tissue between meninges and brain; heart normal.*

<sup>1</sup> Richter (*Western Lancet*, vol. xii. p. 529) found cocci in the blood in a case of chorea. Donkin (*Brit. Med. Times and Gazette*, 1884, vol. ii. p. 743) found some rod-like bodies in the tissues. Naunyn (*Mitth. a. d. med. Klin. zu Königsberg*, 1888, p. 296) found fungi in the pia.



Bernard E.,<sup>1</sup> aged thirty-four years, merchant; admitted November 3, 1891. Family history good; father and mother still living; one sister and one brother died in infancy. No chorea in family.

*Previous history.* Patient suffered in childhood from chickenpox and measles. At ten years he had a severe attack of rheumatism that kept him in bed for six months; this involved his knees, ankles, hips, and shoulders. Between ten and fourteen years he was well, except for occasional returns of his rheumatism.

*Present disease.* At fourteen his symptoms of chorea began; first with feelings of muscular uneasiness, then followed by irregular, twitching movements, noticed first in left hand and left side of neck. These spread so as to involve the greater part of the body, but continued more marked on left side. Attack resembled the ordinary form of chorea of Sydenham. After a few months there was a remission, but the disease returned every two or three years and was so severe as to keep the patient in bed for five or six months. Between the attacks the symptoms were slight. The present attack began in March, 1891, eight months before I saw him.

*Status præsens.* Patient was a man of average height and fairly well nourished; he was able to walk, but did so with some difficulty. He suffered continually from jerky movements of the face, neck and arms, and the trunk of the body; the legs also were somewhat involved. These movements were in the main choreic in character; the head would be jerked back and sideways, the facial muscles would twitch; the tongue movements were so active that speech was indistinct. There were occasional spasmodic twitchings of the eye muscles, producing conjugate deviation usually. The muscles of the neck, particularly the sterno-mastoid and deep rotators on the left side, were greatly involved. The arm movements were irregular and incoördinate; occasionally there was a marked tremor in them. The movements were especially those of flexion of the wrist, flexion and extension of fingers, pronation and supination of the wrist. The trunk of the body was affected, more particularly the movements of the back; the head would be carried back so that for a moment he would be held in a condition of opisthotonos. In the latter stages of his illness this involvement of the muscles of the back became particularly severe, so that the patient would suffer practically for several days from a condition of opisthotonos, or what might be called clonic opisthotonos, the body being arched back so that he could only lie on his side in bed. The continual movements of the body made it difficult to secure a satisfactory photograph: Fig. 1, however, gives some idea of the nature of the affection. The muscles of the body were well developed, particularly those of the neck and back, and there was nowhere any sign of paralysis. The dynamometer with the right hand registered 50°, left hand 45°.

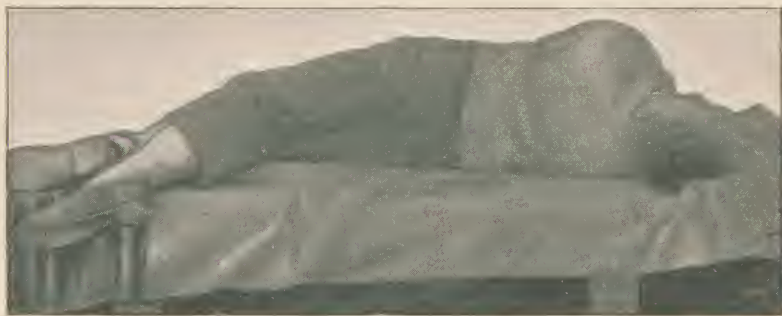
There was no anæsthesia or hyperæsthesia and no tenderness or points of pressure which gave relief from the spasm. The reflexes were normal so far as could be ascertained. There were no trophic or vasomotor disturbances. The patient slept fairly well, and during sleep the movements ceased. He had no headaches that he particularly complained of, and his mind was clear. He was an intelligent man, but very much and very naturally depressed over his malady. He had

<sup>1</sup> This patient was kindly referred to me by Dr. R. H. Sayre, to whom I am also indebted for important notes regarding the history.

later in his disease considerable pain during the more severe spasms which affected his back. The lungs, heart, kidneys, and abdominal viscera were normal. He had no rise of temperature.

Patient was placed upon large doses of chloral together with tonics; these gave him some relief, but produced no permanent benefit. Various other measures, including iodide of potassium, hyoscine and anti-spasmodics, and morphine, were employed without any special benefit. One month after admission, in a fit of depression, the patient attempted suicide by cutting his throat with a safety razor. He was discovered by the nurse before he had accomplished the deed and was

FIG. 1.



Chronic chorea, showing attitudes assumed during the spasmodic movements.

transferred to the surgical side for treatment. He had managed to cut one of the sterno-cleido-mastoids nearly across, and the constant movements of the parts made the healing of the wound very slow. He gradually recovered, however; but shortly afterward, on January 10, 1892, he suddenly and unexpectedly died, a little over two months after admission, and ten months from the beginning of his last severe attack. His disease had lasted with remissions for twenty years.

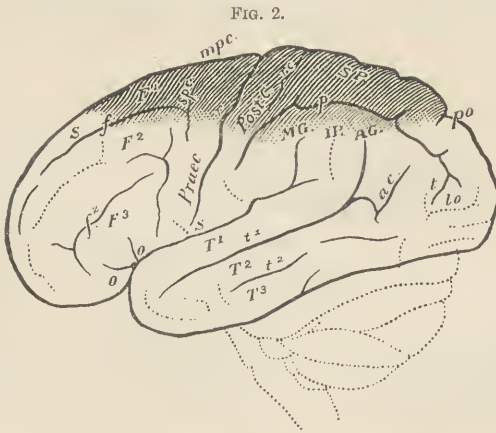
*The autopsy* was made next day by my house physician, Dr. Gwathney, to whom I am much indebted for the details of this case.

Body slightly emaciated; rigor mortis marked. Lungs showed some oedema and hypostatic congestion; calcareous concretion in left pleura



about the size of a chestnut. Kidneys showed cortex diminished, some congestion, markings fairly plain, capsule slightly adherent; they presented the appearance of some diffuse nephritis, chronic in character. Stomach showed increase of interstitial tissue; no marked congestion. Spleen and intestines normal; liver much congested.

The *brain* was large, weighing fifty-four ounces. The dura mater was not adherent and appeared normal. No excess of fluid in the cavities. The brain was considerably congested. The bloodvessels at the base were normal. Over the convexity of the hemispheres on both sides was a granular thickening of the pia mater and arachnoid. This presented the appearance of a chronic proliferative meningitis; it reached from the base of the first frontal convolution back to near the occipital lobe; it extended down nearly half-way on the great convexity of the brain and also about half-way upon the median surface. On cutting through the membrane here it was found to be thickened and slightly attached to the surface beneath. It was impossible to get the spinal cord, but a portion of it, extending to about the fourth cervical, was cut out through the foramen magnum. The pia mater about the cervical cord and medulla seemed somewhat thickened and congested. The brain was hardened in Müller's fluid for about three months, and portions of the cortex were stained in carmine and Weigert's solution of hæmatoxylin. A section of the hemisphere involving the thickened meninges was cut



Showing area of lepto-meningitis.

out and placed at once in alcohol and there hardened. This was subsequently stained and examined for bacteria by Dr. Brooks, of the New York Post-Graduate Laboratory. Dr. Brooks made a very large number of examinations of the membranes, and I am greatly indebted to him for his painstaking investigations.

*Microscopical examination.* The parts examined microscopically were mainly the superior parietal lobule and upper central convolution, as it was these parts that were most severely involved in the process. Examinations were also made of the basal ganglia, the internal capsule, and a series of sections was made extending down through the pons and medulla and upper part of the spinal cord.

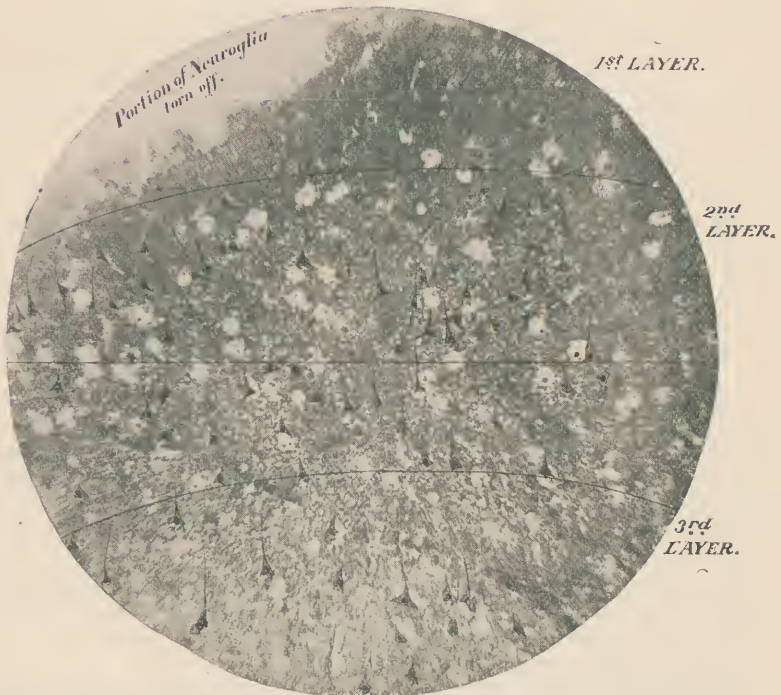
The detailed notes are as follows:

*Superior parietal lobules.* The pia mater is thickened, this being due to a rich connective-tissue proliferation; but there is no exudate or round-cell infiltration. It is simply a chronic proliferative thickening. (See Dr. Brooks's report.) (Fig. 2.)

The superficial or neuroglia layer of the cortex shows, in some areas, distinct softening or degeneration with a rich cellular infiltration, apparently coming from the meninges. This infiltration does not extend beyond the neuroglia layer. The vessel walls are slightly thickened, and there is perivascular dilatation in the outer and small pyramidal layer.

In the specimen which was hardened in alcohol alone, numerous large hyaline masses were seen, both in the pia mater and just below it, ex-

FIG. 3.



Section from superior parietal lobule, stained with carminate of soda and osmic acid. Photographed by Dr. J. H. Smith; bromide enlargement; details added.  $\frac{2}{3}$  objective.

tending in smaller numbers as far as the second layer of the cortex. These masses do not stain; they are irregular in size, but average  $\frac{1}{100}$  inch in diameter. They are evidently *artefacts*, yet indicate a morbid condition of the nervous tissue. They lie sometimes around, but not in, the vessels.

The specimens hardened in Müller's fluid do not show these bodies. In these latter specimens, however, including those hardened in osmic acid and bichromate of potash, a different kind of hyaline bodies is

seen. They are found chiefly in the second (angular cell) and third (small pyramidal) cell layers of the cortex. They are round or nearly so, translucent, and do not stain in carmine, hæmatoxylon, or osmic acid. They are about  $\frac{1}{1000}$  inch in diameter. In the centre of most of these there is a nucleus. They appear to be neuroglia or pyramidal cells undergoing some degenerative change (see Figs. 3 and 4).

There are places where it seems as if one could see a pyramidal cell undergoing a hyaline degeneration (Fig. 4, *a, b*), but of this I cannot feel certain. The bodies do not (like the large hyaline masses) seem to stand in any relation with the bloodvessels.

It was in these regions where these degenerative changes were seen that micro-organisms were found as detailed below. The nerve cells

FIG. 5.



Drawings of hyaline bodies and pyramidal cell as seen by  $\frac{1}{6}$  and  $\frac{1}{12}$  objectives.

proper do not show any decided changes, at least with any stains I was able to use (carmine, logwood, osmic acid, methylene blue). The outlines were sharp and nuclei distinct. Here and there, however, it seems as if the hyaline change was attacking a cell (see Fig. 5). The bloodvessels show no decided change either as regards thickening, dilatation or proliferation.

The changes above described were found to exist in all parts of the cortex where there was meningeal thickening, but were much more pronounced in the superior parietal and upper central convolutions. Other parts of the cortex were normal.

*Sections of the lenticular nucleus*, and particularly of the putamen, show considerable vascularity, and a few of the *small hyaline bodies* such as are seen in the cortex. These bodies are still more numerous in the claustrum, however, and the external capsule. The substance of the pons and medulla is nearly normal. There is some congestion of the nerve nuclei, but the fibres and cells are normal and no hyaline bodies are seen here.

*At the exit of several of the cranial nerves*, particularly the seventh and sixth, the meninges are much thickened; the arteries show a peri-arterial proliferation of rather active character; their walls are thick, and small hemorrhages can be seen in them. One root of the vagus seems much more congested than the other and contains a few degenerated fibres.



FIG. 4.



Chorea. Bacteriological examination.

Section of parietal lobule, stained with carminate of soda and osmic acid. Drawn from  $1/5$ th objective. *a.* Hyaline bodies. *b.* Small pyramids. *c.* Large pyramids. *d.* Bloodvessel.



The anterior cornua at the level of the first cervical are congested and the cells much pigmented, but not seriously injured. At the decussation of the anterior pyramids there is an artery lying in the posterior median groove having very thick walls and showing a *proliferation of the intima cells*, also a peri-arteritis. Other arteries in this neighborhood show a very striking peri-arteritis.

The *hypoglossal nerve* in this neighborhood is normal in its course through the medulla, but after its exit shows much vascularization. Section shows thickened sheath with some proliferation of endoneurium cells.

The *spinal branch of the spinal accessory* shows the same condition even more strikingly. There are inflamed vessels, a perineuritis, and interstitial neuritis of a slight degree. These meningeal and vascular changes seem much less high up in the pons.

*Bacteriological examination.* Portions from the cortex of the upper central convolutions were placed at once in alcohol and hardened. These were submitted to Dr. H. T. Brooks, bacteriologist of the Post-Graduate laboratory, who made the following report:

Sections were stained in logwood, Bismarck-brown, carmine, and the Weigert stain for micro-organisms. Sections showed small, irregularly circumscribed areas of disintegration of brain substance, of varying size, extending over greater part of section and reaching to within a short distance of peripheral layer. These areas are composed of finely reticulated basement substance enclosing a more or less homogeneous material. Some areas are composed wholly of this tissue, while others (generally the smaller) include rounded, vesicular and granular nuclei, which take on intense staining. No bacteria could be demonstrated here.

The meninges showed some thickening and in certain portions slight evidence of proliferation; there were no exudative elements in this part, though rarely a small diplococcus could be made out, and when seen was invariably isolated. These organisms were confined to inner surface (portion) of membrane.

In that portion of the cortex immediately below the junction with the meninges a few small diplococci, resembling in every detail those present in brain covering, were seen, never more than two occurring in a field of  $\frac{1}{2}$  oil-immersion (Leitz).

The micro-organisms were about half the diameter of a red blood-cell, and resembled very closely the *diplococcus lanceolatus*. Though not in large numbers, they were found in all the sections, and always in the deeper layer of the pia and superficial part of the cortex.

RÉSUMÉ.—There is a meningitis of the cortex which extends into and in large numbers involves the cortex. It is characterized by an active connective-tissue proliferation and the presence of diplococci in the meninges and cortex. In the cortex are small hyaline bodies which indicate a degenerative change of the brain substance. This degenerative change affects the deeper parts of the brain to a less extent, extending down into the capsule and lenticular nucleus, but not the optic thalamus. There is a meningitis with active vascular changes in the upper part of the cord which seems particularly to surround and affect the roots of the nerves as they leave the medulla and the cord.

It seems to me that the teachings of this case are very important in many ways. First of all, it shows us that there is a close relationship between many of the chronic spasmodic disorders of irregular type and the chorea of Sydenham. Secondly, it confirms the view already generally accepted, that chorea is a vascular and humoral disease. Third, it gives weight to the belief held by many that there is, in some cases at least, a microbe which produces this disease. Fourth, it shows that in these cases the seat of the lesion is either meningeal or superficially cortical so far as the brain is concerned, and that as regards the spinal cord the seat of the lesion is mainly in the meninges and bloodvessels, where it apparently surrounds and irritates the roots of the nerves.

Finally, we cannot explain chorea by finding any particular *seat* of the disease, though the voluntary motor tract in the brain must at some point be involved.

Neither has chorea any special form of anatomical change invariably associated with it, though degenerative hyaline change and evidences of vascular irritation are most common.

There must be, in order to produce chorea, a specific kind of irritation of the cells. This need not be of one kind; it may be a rheumatic poison or a diplococcus toxin. But the specific irritants are not numerous, for though the motor fields undergo innumerable forms of injury and disease, chorea occurs but rarely, and only when the proper regions are properly irritated. There is nothing which would explain the phenomena of the disease so well as to suppose that the specific agent producing chorea is a microbe, and perhaps some form of the diplococcus.

The various types of chronic chorea would be explained by the changes in the intensity of the irritation, its special localization, and the degree of organic change which it eventually induced.





# The American Journal OF THE MEDICAL SCIENCES.

MONTHLY, \$4.00 PER ANNUM.

WITH 1893 THE AMERICAN JOURNAL OF THE MEDICAL SCIENCES enters upon its seventy-fourth year, still the leader of American medical magazines. In its long career it has developed to perfection the features of usefulness in its department of literature, and presents them in unrivalled attractiveness. It is the medium chosen by the leading minds of the profession on both sides of the Atlantic for the presentation of elaborate Original Articles; its Reviews are noted for discernment and absolute candor, and its Classified Summaries of Progress each month present an epitome of medical advances gleaned by specialists in the various departments. According to unquestionable authority, "It contains many original papers of the highest value; nearly all the real criticisms and reviews which we possess, and such carefully prepared summaries of the progress of medical science and notices of foreign works that from this file alone, were all other publications of the press for the last fifty years destroyed, it would be possible to reproduce the great majority of the real contributions of the world to medical science during that period."

## The Medical News.

WEEKLY, \$4.00 PER ANNUM.

BY KEEPING closely in touch with the needs of the active practitioner, THE NEWS has achieved a reputation for utility so extensive as to render practicable its reduction in price from five to **Four Dollars** per annum. It is now by far the cheapest as well as the best large weekly medical journal published in America. Employing all the recognized resources of modern journalism, such as the cable, telegraph, resident correspondents, special reporters, etc., THE NEWS furnishes in the 28 quarto pages of each issue the latest and best information on subjects of importance and value to practitioners in all branches of medicine. Its numerous departments are designed to subdivide and present its material in the most attractive and convenient manner.

In a word THE MEDICAL NEWS is a crisp, fresh, weekly newspaper, and as such occupies a well-marked sphere of usefulness, distinct and complementary to the ideal monthly magazine, THE AMERICAN JOURNAL OF THE MEDICAL SCIENCES.

### The Year-Book of Treatment for 1893

Gives a classified summary and review of the real advances in treatment made during 1892 in all departments of the science of medicine. Price, \$1.50; or in combination with either or both the above journals, 75 cents.

### The Medical News Visiting List for 1893

Published in four styles: Weekly, dated, for 30 patients; Monthly, undated, for 120 patients per month; Perpetual, undated, for 30 patients weekly per year; Perpetual, for 60 patients weekly per year. The first three styles contain 32 pages of important data and 176 pages of assorted blanks; the 60-patient perpetual consists of 256 pages of blanks. Price, each, \$1.25. In combination with either or both above periodicals, 75 cents. Or, JOURNAL, NEWS, VISITING LIST and YEAR-BOOK, \$8.50. Thumb-letter index for VISITING LIST, 25 cents extra.

LEA BROTHERS & CO., PUBLISHERS, PHILADELPHIA, 706 & 708 SANSOM STREET.