



Digitized by the Internet Archive
in 2018 with funding from
Wellcome Library

https://archive.org/details/b30456290_0003

M. A. A. Radini

A
S Y S T E M
OF THE
A N A T O M Y
OF THE
H U M A N B O D Y.

[Faint, illegible text at the top of the page, possibly a title or header.]

2 Y 3 F B M

1787

THE END OF THE WORLD

A
S Y S T E M
OF THE
ANATOMY
OF THE
H U M A N B O D Y ;

ILLUSTRATED BY
UPWARDS OF TWO HUNDRED TABLES, CONTAINING NEAR A THOUSAND
FIGURES,

COPIED FROM
THE MOST CELEBRATED AUTHORS,
AND
FROM NATURE.

By ANDREW FYFE.

IN THREE VOLUMES.

SECOND EDITION, WITH ALTERATIONS AND IMPROVEMENTS.

V O L. III.

EDINBURGH:

PRINTED BY J. PILLANS & SONS.

SOLD BY THE AUTHOR, EDINBURGH ;
BY LONGMAN, HURST, REES, & ORME ; AND BY T. KAY, T. COX,
AND J. MURRAY, LONDON.

1806.

SYSTEM

THEORY

HUMAN BODY

THEORY OF THE HUMAN BODY

THE HUMAN BODY

THE HUMAN BODY

THE HUMAN BODY

THE HUMAN BODY

THE HUMAN BODY

THE HUMAN BODY

THE HUMAN BODY

THE HUMAN BODY

THE HUMAN BODY

CONTENTS

OF THE

THIRD VOLUME.

PART V.

	<i>Pag.</i>		<i>Pag.</i>
OF THE BLOOD-VESSELS IN GENERAL,	3	<i>Blood-Vessels of the Diaphragm,</i>	42
DISTRIBUTION OF THE BLOOD-VESSELS,	5	————— <i>of the Chylopoietic and Assistant</i>	
<i>Of the Pulmonary Artery and Veins,</i>	<i>ib.</i>	<i>Chylopoietic Viscera,</i>	47
<i>General Course of the Aorta and Vena Cava,</i>	<i>ib.</i>	————— <i>of the Organs of Urine and Ge-</i>	
<i>Blood-Vessels of the Head, and part of those of</i>		<i>neration,</i>	54
<i>the Neck,</i>	6	————— <i>of the Containing Parts of the</i>	
<i>The Remaining Blood-Vessels of the Neck, with</i>		<i>Abdomen, and of the Pelvis</i>	
<i>those of the Superior Extremity in General,</i>	27	<i>and Inferior Extremity,</i>	71
<i>Blood-Vessels within the Thorax,</i>	41		

PART VI.

OF THE ABSORBENT SYSTEM.

OF THE ABSORBENTS IN GENERAL,	81	OF THE PARTICULAR ABSORBENTS,	82
---	----	---	----

PART VII.

OF THE NERVES.

OF THE NERVES IN GENERAL,	117	<i>Nerves within the Thorax,</i>	152
DISTRIBUTION OF THE NERVES,	118	————— <i>of the Chylopoietic and Assistant Chy-</i>	
<i>Nerves which pass through the Base of the Cra-</i>		<i>lopoietic Viscera,</i>	163
<i>nium,</i>	<i>ib.</i>	————— <i>of the Organs of Urine and Generation,</i>	167
<i>Spinal Marrow, and Origin of the Spinal</i>		————— <i>of the Loins, Pelvis, and Inferior Extre-</i>	
<i>Nerves,</i>	139	<i>mity,</i>	172
<i>Nerves of the Neck and Superior Extremity,</i>	143	GLOSSARY,	184

PART V.
OF THE
BLOOD-VESSELS.

VOL. III.

A

OF THE BLOOD-VESSELS IN GENERAL.

THE BLOOD-VESSELS are divided into ARTERIES and VEINS.

ARTERIES.

The *Arteries* are Elastic Canals, which convey the Blood from the Heart to the different parts of the Body, and are distinguished from the *Veins* by their *Pulsation*.

The Original Trunks of the Arteries, or those which arise from the Heart, are Two in number,—the *Pulmonary Artery* and *Aorta*. From these all the other Arteries are derived.

The Arteries are dispersed over the whole body, and are every where surrounded with Cellular Substance.

The Principal Trunks run in the *Centre* or deepest parts of the Body and Extremities, where they are least exposed to danger, deriving support or defence from the Bones along which they pass.

The largest Arteries go to the *Viscera*, within the Great Cavities, the smaller ones to the *Skin* and *Muscles*, and those still smaller to the *Bones*, and, in certain places, become so extremely minute as altogether to exclude the Red Blood, carrying a Colourless Fluid only.

The Arteries are distinguished from the *Veins*, by the *whiteness* of their Colour, and *thickness* of their Coats.

They are composed of different *Layers* or *Coats*, which are readily separated by Dissection.

In several parts of the Body, as in the *Posterior Mediastinum*, they are surrounded by a *Membrane*, common to them and to the neighbouring *Viscera*.

In other parts of the Body, especially in Young Subjects, they are surrounded with so much Cellular Substance, as to give them the appearance of being inclosed in *Sheaths*.

The first of the proper Coats is the *External Membranous*, or *Cellular*, called also by some Authors the *Nervous Coat*.

In the Large Arteries, this Coat is frequently furnished with *Fat*, and is of a very *elastic* nature. Owing to this Elasticity, the Arteries, in receiving the Blood from the Heart, become dilated and elongated, and start from their place, which forms the *Pulse*, called also the *Dia-stole* of the Arteries.

The *Second*, or *Middle Coat*, is composed of Fibres

running in a Transverse direction,—of a pale red colour;—each Fibre appearing to form only the Segment of a Circle, although the whole constitutes a Cylinder round the Artery.

By the contractility of this, and the Elastic nature of the former Coat, the Arteries are enabled to drive the Blood to the *Veins*, in proportion as they receive it from the Heart;—and this Contraction is called the *Systole* of the Arteries.

The *Third*, or *Inner Coat*, is formed of a transparent Membrane, remarkably thin, smooth, and dense, by which the Blood is prevented from transuding.

The different Coats of the Arteries are connected to each other by fine Cellular Substance, which some Authors have considered as forming so many *Lamellæ*.

The Arteries are supplied with their own Blood-vessels, termed *Vasa Vasorum*, which come from the nearest small Branches, and are every where dispersed upon their external Surface.

They have also their *Lymphatics*, which, on the Large Arteries, as the *Aorta*, are so numerous as sometimes to cover them.

They are likewise furnished with *small Nerves*, forming, in some parts of the Body, a *Plexus*, which vanishes in their external Coat.

There are no *Valves* belonging to the Arteries, excepting those which are placed at the Mouths of the *Pulmonary Artery* and *Aorta*.

Where the Arteries run a certain way without sending off Branches, they are observed to be of a *Cylindrical* form; but where Branches come off, their Capacity is diminished, and this is in proportion to the number of their Ramifications.

Wherever an Artery divides into two Branches, the *Area* of these two Branches, taken conjunctly, are found to be nearly one half larger than the *Area* of the Trunk from which they issue.

When the Trunk and Branches of an Artery are regarded collectively, they appear evidently of a *Conical* figure; the point of the Cone being formed by the Trunk, and the Basis by the Branches of the Artery.

The Section of the Arteries is Circular;—when empty, they become Flat, but recover their round form upon being distended by Injection.

OF THE BLOOD-VESSELS IN GENERAL.

The Angles at which the Branches go off from their Trunks are in general more obtuse or acute, in proportion to their vicinity to the Heart, and are such as are most favourable to the Parts they have to supply.

In the Trunk of the Body, or where they belong to tender and delicate Viscera, the Angles are more obtuse, —in the Extremities they are more acute; the former circumstance tending to diminish, and the latter to increase the force of the Blood.

The Arteries form many Divisions and Subdivisions before they reach their Terminations, and at last become invisible to the naked Eye.

The Divisions formed by any single Artery have been variously enumerated by different Authors,—one, in particular, reckoning them at forty, and another, of equal respectability, only at twenty; their number, however, is such as to allow them to supply the most minute parts of the Body.

The Strength of the Arteries depends upon the thickness of their Coats, which is found to vary in different Arteries.—In the Aorta, the Coats are thick and strong; —in the Arteries of the Brain and Spleen, they are thin and tender;—but the Thickness and consequent Strength are proportionally greater in the small Branches than in the large Trunks.

The Arteries run more or less in a waving direction, which breaks the force of the Blood in them, and prevents them from being strained by the motions of the parts to which they belong.

The Flexions are most frequent in Arteries belonging to parts, the size and situation of which are changeable.

The Windings of many of the Arteries are in proportion to the degree in which they are distended, those which are nearly straight in their natural state, frequently becoming serpentine when their distension is increased.

Several of the Large Arteries form Communications with each other, termed by Anatomists *Anastomoses*; but the Anastomoses are more frequent among the small Branches, where they form a Plexus which lessens the danger of Obstruction.

The Anastomoses are more frequent in the Skin and Membranous Parts. In the Solid Viscera, the Arteries run in a different manner, being in some crowded together in the form of Trees or Bulbes, in others having a Serpentine appearance, and in several forming Penicilli, according to the disposition of the part.

The Arteries obtain their particular names from their Situations, Place of Destination, &c. and the term *Capillary*, as expressive of their smallness, is applied to their Minute Branches.

The Diameters of the different Trunks and Branches of the Arteries, vary much in different parts of the Body; but those of the Capillaries are more nearly equal to each other.

The Arteries terminate in the following manner, viz.

In Red Veins, as is observed by the assistance of the Microscope and by Injections:

In Glands or Follicles, by Secretory Ducts, which separate a Fluid from the general Mass of Blood:

In Exhalent Vessels, which discharge their Contents into the Internal Cavities, or upon the External Surface of the Body:

In Colourless or Lymphatic Branches, which are afterwards continued to the Circulating Veins, as in the Cartilages and Cornea.

The Arteries convey Blood from the Heart to the different parts of the Body:

To assist in converting the Chyle into Blood:

To nourish the Body, and promote its Growth:

To assist in preserving the Fluidity of the Blood, and the Heat and Life of the Body:

To form the different Secretions; and,

To renew the Growth of Parts destroyed by Accident or Disease.

VEINS.

The *Veins* are Elastic Flexible Tubes, returning the Blood from the different parts of the Body to the Heart, and having no Pulsation.

The *Coats* of the Veins are the same in number with those of the Arteries, but are thinner, denser, and less elastic.

In the Large Veins, as the Vena Cava, the Coats can be separated from each other; but in the small Branches their separation is difficult.

The *Muscular Coat* of the Veins being loose like Cellular Substance, much thinner, and more indistinct than that of the Arteries, has occasioned its existence to be denied by many Authors.

The Veins are also furnished with their *Vasa Vasorum*, similar to, and from the same source with those of the Arteries.

The *Colour* of the Veins is bluish, and when full of Blood, in consequence of their thinness, they appear of a purple tinge.

Their *Size* is more than double that of the Arteries to which they belong; excepting the Pulmonary Veins, the size of which scarcely surpasses that of their corresponding Arteries.

In the Flethy parts of the Body, particularly in the Extremities, they consist of *Two Sets*; one *Deep-seated*, accompanying the Arteries, the other running immediately under the Skin, and termed *Subcutaneous*.

The Veins of the Thoracic and Abdominal Viscera generally accompany their Arteries; and the same is observable in the small Branches belonging to Membranous parts.

The *Figure* of the Veins is similar to that of the Arteries; and, upon comparing the Area of their Trunks with the collective Area of their Branches, like them too, they are perceived to be Conical; the Base of the Cone being formed by the Branches, and the Apex by the Trunks.

The

The Size and Number of the Veins is so much greater than that of their corresponding Arteries, that when the Vessels of a Membranous part are distended by an Injection of different colours, the Veins are observed in a great measure to conceal the Arteries: In the Intestines, however, the number of the Arteries and Veins is nearly equal.

There is much greater Variety among the Trunks of Veins, with respect to Situation and Division into Branches, than is observable among the Arteries.

The Variety in Nature, in this respect, is such, that the Veins of every Subject differ a little from those of another.

The Veins are capable of suffering greater Distension than the Arteries, yet are more frequently ruptured.

The Anastomoses are greater and more frequent in Veins than in Arteries; those of the former being often by large Trunks, whereas those of the latter, excepting in a few places, are by small Branches only.

Where the Veins are exposed to Muscular action, they are furnished with *Valves*, which are Semilunar Folds continued from the inner side of the Vessels, and placed

in Pairs at irregular distances; their nature being similar to those of the Absorbents.

The Valves are Concave towards the Heart, and, when closed or applied to each other, represent a figure somewhat like that of the shut end of a Thimble.

Between the Valves and Sides of the Veins next the Heart, the Blood insinuates, and Cavities are formed, termed *Sinuses* of the Valves, which appear externally in the form of Varices.

The Valves are generally found in the Fleishy parts of the Body, but are chiefly situated in the Veins of the Extremities.

They are wanting in the Veins of the Deep-seated Viscera, viz. in those of the Cranium, Thorax, and Abdomen, excepting the Spermatic Veins, and sometimes the Internal Mammary Veins, and the Branches of the *Vena Azygos*.

The Valves direct the Blood towards the Heart, and prevent Regurgitation.

The Veins convey the Blood from the extremities of the Arteries, with the Chyle and Lymph from the Absorbents to the Heart.

DISTRIBUTION OF THE BLOOD-VESSELS.

Of the PULMONARY ARTERY and VEINS.

THE *Pulmonary Artery* arises from the Right Ventricle of the Heart, and ascends behind the Sternum, and within the Pericardium, inclining a little to the left side. Tab. LXXXV. *e, f*.

Having run as high as the concave side of the Arch of the Aorta, it divides into Right and Left Lateral Branches, which terminate in the corresponding sides of the Lungs. Tab. LXXXIII. Fig. 1. *f, f*.

The Right Branch, which is the largest, passes behind the Curvature of the Aorta and the Superior Vena Cava, and is of course also the longer of the two. Tab. LXXXV. Tab. LXXXIII. Fig. 1.

The two Branches are dispersed throughout the Substance of the Lungs, by Ramifications which accompany those of the Bronchi, and, becoming gradually smaller, terminate upon the Pulmonary Cells.

From the extreme Branches of the Pulmonary Artery, the Blood is returned by corresponding Veins.

The *Pulmonary Veins* run contiguous to the Arteries, and, unlike the other veins in general, are nearly of the same size with their Arteries.

In their course they unite into larger Branches, which at length form Four Principal Trunks,—two from the Right, and two from the Left Lung,—which, after perforating the Pericardium, terminate in the Left Auricle of the Heart.

General Course of the AORTA and VENA CAVA.

The *Aorta* arises from the upper and back part of the Left Ventricle of the Heart, and sends off, at its Origin, the *Coronary Arteries* formerly described. Tab. LXXXIII. *r, s*.

Where it takes its Origin, it turns a little to the right, and is afterwards directed upwards, backwards, and towards the left side.

It ascends as far as the top of the Thorax, under the name of *Aorta Ascendens*, and is afterwards reflected obliquely backwards over the root of the left Branch of the Trachea, forming what is termed *Curvature* or *Arch* of the Aorta. Tab. LXXXV. *s, t*.

It then commences *Aorta Descendens*, which runs down close upon the Spine, till it reaches the Fourth Vertebra of the Loins, where it divides into the *Two Iliac Arteries*. Tab. CLXXIV.

The Thoracic portion of the *Aorta Descendens* is situated on the fore and left part of the Spine, between the Layers of the Posterior Mediastinum.

Where it passes from the Thorax to the Abdomen, it goes between the long Crura of the Diaphragm, after which it descends more immediately upon the fore part of the Vertebrae.

The Aorta sends off Arteries which carry Blood to the different parts of the Body, from whence it is returned
by

OF THE BLOOD-VESSELS

by Veins to the Inferior and Superior Venæ Cavæ, excepting what passes to the Coronary Vessels.

The *Inferior Cava* is formed by the union of the two Venæ Iliacæ, upon the last Vertebra of the Loins, a little below the Termination of the Descending Aorta.

It is situated upon the fore-part of the Spine, and at the Right side of the Aorta, which it accompanies for a considerable way through the Abdomen. Tab. CLIX.

Near the upper end of the Abdomen, it recedes from the Aorta, and passes behind the large Lobe of the Liver.

It perforates the Diaphragm in its Tendinous part, and having entered the Pericardium, it goes immediately into the Right Auricle of the Heart.

The Inferior Cava receives the Blood from the Inferior Extremities, from the Pelvis and Abdomen, and carries it to the Heart.

The *Superior Cava*, Tab. LXXXV. Tab. CLIX. formed by the union of the two Great Venæ Subclaviæ, with the addition of the Vena Azygos,—is situated in the upper part of the Thorax, upon the right side of, and a little more anteriorly than, the Ascending Aorta.

It begins behind the Cartilage of the first Rib, somewhat higher than the Arch of the Aorta, and has at first a small inclination towards the right side.

After descending about an inch, it perforates the Pericardium, and having run nearly twice this space, it enters the Right Auricle, opposite to the termination of the Inferior Cava.

The Superior Cava receives the Blood from the Head, Neck, Arms, and Containing Parts of the Thorax, and also carries it to the Heart.

BLOOD-VESSELS OF THE HEAD, AND PART OF THOSE OF THE NECK.

ARTERIES.

FROM the upper side of the Arch of the Aorta, *Three Large Arteries* arise, which supply the Head, Neck, and Superior Extremities.

Of these Three Arteries, one on the right side, termed *Innominata*, soon divides into the *Right Carotid*, and *Right Subclavian Artery*. Tab. LXXXV. *x*.

The other two are the *Left Carotid*, and *Left Subclavian*, which come off in separate Trunks. Tab. CLVIII. Fig. 1. O, P.

CAROTID ARTERIES.—The Carotid Arteries, Tab. CLIX. after emerging from the Thorax, ascend upon the fore-part of the Vertebrae, on each side of the Neck, between the Trachea and Internal Jugular Veins, and behind the Sterno-mastoidei, gradually receding from each other.

In the Neck, they do not send off any Branches till they reach the top of the Larynx, where each, opposite

to the Os Hyoides, divides into *External* and *Internal Carotid Arteries*, Tab. CXXXI. the former supplying the outer parts of the Head, the latter the Brain.

The EXTERNAL CAROTID, Tab. CXXXI. is placed more anteriorly, and nearer the Larynx, than the *Internal*, which lies deeper, and is, at its Root, the larger of the two.

The External, though smaller than the other, appears as a continuation of the common Trunk.

It runs up behind the Angle of the Lower Jaw, towards the Temple, and in its passage before the Ear is sunk deep in the substance of the Parotid Gland, which it supplies in its course, and is divided into the following principal Branches, viz.

The ARTERIA LARYNGEA SUPERIOR, GUTTURALIS SUPERIOR, vel THYROIDEA SUPERIOR, which comes off from the Root of the External Carotid, and sometimes from the Top of the Common Carotid. Tab. CXXXI. *l*.

It passes downwards and forwards in a winding direction, and sends

Branches to the Muscles under the Os Hyoides :

Branches to the Sterno-mastoideus, Platysma Myoides, Jugular Glands, and Skin near the Larynx :

The *Laryngeal Branch* to the small Muscles and other parts peculiar to the Larynx.

The *Thyroid Branch*, which is the continuation of the Trunk, dispersed upon the Substance of the Thyroid Gland : The Branches of the Laryngeal Artery communicate with their fellows on the opposite side : The Anastomoses of the Thyroid Branches, however, are small compared with the rest :

The ARTERIA LINGUALIS, Tab. CXXXI. *u*. Tab. CXXXIII.—which is sent off immediately above the former :—It goes forwards and upwards over the corresponding Cornu of the Os Hyoides, and under the Hyo-glossus, in a direction towards the under and fore part of the Tongue :—It gives

A *Small Branch* to the Pharynx :

A Branch, termed *Ramus Hyoideus*, to the Muscles placed between the Tongue and Larynx :

The *Dorsalis Linguae* to the Fauces, Amygdala, Epiglottis, and Pharynx :

The *Ramus Sublingualis*, which comes off under the middle of the Tongue, and is dispersed upon the Sublingual Gland and adjacent Muscles :—and

The *Ramus Raninus*, which is the principal Branch of the Lingual Artery, running at the under and lateral part of the Tongue, and terminating near its point :

The ARTERIA FACIALIS, MAXILLARIS EXTERNA, LABIALIS, vel ANGULARIS, Tab. CXXXI. *y*. Tab. CXXXIV. which also runs forwards, and goes under the Stylo-hyoideus, and Tendon of the Digastricus. It perforates the Submaxillary Gland, mounts suddenly over the Angle of the Lower Jaw, at the under and fore part of the Masseter, from whence it proceeds in a tortuous

tuous manner by the side of the Nose, towards the inner Corner of the Eye.

In this Course, it sends the following Branches to the adjacent parts :

The *Palatina Inferior*, vel *Ascendens*, which runs upwards upon the side of the Pharynx, covered by the Styloideus, to be dispersed, by a Superficial and Deep Palatine Branch, upon the Velum Palati and parts near it :

A *Branch* spread out by many Twigs upon the Tonfil, and reaching as far as the Tongue :

Branches to the Inferior Maxillary Gland :

Small Branches to the Root of the Tongue, to the Skin, Muscles, &c. near the Angle of the Jaw :

The *Arteria Submentalis*, which advances between the anterior Belly of the Digastricus, the Mylo-hyoideus, and Base of the Lower Jaw, furnishing Branches to the Submaxillary Gland, the Skin, Mylo-hyoideus, Chin, and Under Lip :

A *Branch*, upon the outside of the Jaw, to the Masseter :

The *Inferior Labial Artery*, which arises a little higher than the former, and goes to the lower part of the Under Lip, inosculating with the corresponding Branch on the opposite side :

Small Branches dispersed upon the Buccinator, and communicating with others dispersed upon the Substance of the Cheek :

The *Coronaria Inferior*, which comes off near the Corner of the Mouth, sometimes from the Labialis Inferior ; —and,

The *Coronary Superior*, larger than the former, to the Upper Lip, from whence Branches run to the under part of the Partition and Point of the Nose. Tab. CXXXIV.

The Coronary Arteries run near the edges of the Lips, where, meeting with their fellows of the opposite side, they form an *Arteria Coronaria Labiorum*.

Frequently one or both Coronary Arteries are larger than ordinary, in which case those on the opposite are proportionally smaller.

After sending off the Coronary Branches, the Facial Artery runs near the Wing and Side of the Nose.

From this part of the Artery, Branches are sent inwards to the Nose, and outwards to the Cheek.

The Facial Artery is at last lost upon the parts about the inner Corner of the Eye, and middle of the Forehead.

The PHARYNGEA INFERIOR, vel ASCENDENS, which is a small Artery arising near the Lingual Artery, and frequently from the root of the Occipitalis. Tab. CXXXI. *γ*.

After ascending some way, it divides into Branches, which are dispersed upon the Pharynx, Fauces, and Base of the Skull, where some of them enter the large Foramina, and supply part of the Dura Mater.—From this Artery, Twigs are also sent to the Sterno mastoideus, Nerves, and Conglobate Glands near it.

The ARTERIA OCCIPITALIS, Tab. CXXXI. No. 8. which arises from the back-part of the External Carotid, and at its Origin is concealed by the other original Branches sent off from that Artery.

It runs over the beginning of the Internal Jugular Vein, and afterwards passes between the Atlas and Mastoid Process, and posterior Belly of the Digastricus.

It goes likewise under the upper ends of the Trachelo-mastoideus, Splenius, and Complexus; after which, it becomes more superficial, where it runs near the middle of the Occiput.

In its course, it is very tortuous, and gives off different Branches to the surrounding Muscles, viz.

Branches to the Digastricus, Stylo-hyoideus, Sterno-mastoideus, and Glands of the Neck, and communicates with Branches of the Cervical Arteries.

Another Branch, which passes, with the Jugular Vein, to the under and back part of the Dura Mater.

A *small Branch*, which is sometimes from the Posterior Auricular, and is distributed on the Lobe and outer edge of the Ear.

The *Auricularis Posterior*, which comes frequently off from the Trunk of the Carotid.—It sends Branches to the Parotid Gland, Digastricus, and Sterno-mastoideus, —a Branch to the Meatus Externus and Membrana Tympani,—the *Stylo-mastoid Branch*, which passes through the Foramen Stylo-mastoideum, giving Twigs to the Meatus Externus, Membrana Tympani, and Internal Ear.

The Auricular Artery passes afterwards behind the Ear, gives Branches to the Integuments, Muscles, and Bones there, and, creeping upon the back-part of the Concha, sends Twigs to it, and terminates upon the side of the Head.

The Occipital Artery gives next a Branch, of considerable size, which descends between the Trachelo-mastoideus and Complexus, and afterwards gives Branches to most of the Muscles on this part of the Neck.

The Trunk of the Artery afterwards ascends upon the Occiput, dividing into several Branches, which are dispersed upon the Integuments and Occipito-frontalis, communicating with the Occipital Artery of the opposite side, one Twig passing occasionally through the Foramen Mastoideum to the Dura Mater. Tab. CXXXIII. T.

The ARTERIA MAXILLARIS INTERNA, Tab. CXXXIII. Y,—which goes off from that part of the Trunk which is covered by the Parotid Gland, and at its origin lies behind the middle of the upright Plate which divides into the Condylod and Coronoid Processes of the Lower Jaw.

It passes first between the Jaw and Pterygoideus Externus, and afterwards ascends, in a tortuous manner, towards the back-part of the Antrum Maxillare, sending numerous Branches to the Parts belonging to both Jaws.

At its Origin, it furnishes Twigs to the fore-side and adjacent parts of the Outer Ear.

It then sends off the *Arteria Dura Matris Media Maxima*, *Meningea*, vel *Spheno-spinalis*, which runs between the

the External and Internal Carotids, passes through the Foramen Spinale of the Sphenoid Bone, and spreads, like the Branching of a Tree, Tab. LVIII. G, over the surface of the Dura Mater and inside of the Parietal Bone.

Before entering the Foramen Spinale, it sometimes gives Twigs to the Muscles and other parts near it, and within the Cranium; besides the Branches mentioned above, it furnishes Twigs to the Substance of the Bones, and to the Inner Ear.

The *Inferior Maxillary Branch*, which runs in the Inferior Maxillary Canal, sending Branches to the substance of the Bone, and to the Teeth; the remainder of it passing out at the Anterior Maxillary Foramen, communicating upon the Chin with Branches of the Facial Artery.

Branches to the Pterygoideus, Masseter, and inner part of the Temporalis, under the names of *Arteriae Pterygoideæ, Massetericæ, and Temporales Profundæ*:

The *Arteria Buccalis* to the Buccinator and other soft parts of the Cheek.

The *Arteria Alveolaris*, which runs behind the Antrum, and sends Branches to the soft parts surrounding the Upper Jaw.—It sends other Branches which enter by small Holes to the Antrum, and to the Substance and Back-teeth of the Jaw; one of which is larger than the rest, and is the *Proper Alveolaris*.

The *Infra-orbital*, which passes in the Canal under the Orbit, giving, at its entrance, Twigs to the soft parts in the bottom of the Orbit, and, in its progress, other Twigs to the Antrum, Substance of the Jaw, and Fore-Teeth; after which it goes out at the Foramen Infra-orbitarium, and terminates on the Cheek by small Branches which communicate with those of the Facial Artery.

The *Palatina Descendens*, or *Palato-Maxillary Branch*, which passes through the Foramen Palatinum Posterius, and runs between the Osseous and Fleishy parts of the Palate, supplying these with Branches; communicating with the Palatina Inferior, and frequently proceeding through the Foramen Incisivum to the inner part of the Nose.

The *Superior Pharyngeal*, which is a small Branch terminating in and about the upper part of the Pharynx.

The *Large Lateral Nasal*, which enters the Foramen Spheno-palatinum, and divides, at the upper and back part of the Nose, into many Branches, which supply the greater part of the inside of the Nose, viz. a Branch to the Posterior Ethmoid Cells,—a larger Branch to the Septum Narium,—a conspicuous Branch passing through the Spongy Bones to the bottom of the Nose, furnishing Twigs to the Membrana Schneideriana and Antrum Maxillare, and communicating with the Palato-maxillary passing through the Foramen Incisivum.

ARTERIA TEMPORALIS.—The Trunk of the External Carotid, having given off the Arteries already mentioned, passes up between the Meatus Auditorius and root of the

Zygoma, and forms the *Temporal Artery*, named also *Temporalis Externa, vel Superficialis*;—from the root of which are sent off several Branches, of unequal size, to the Parotid Gland.

The *Transversalis-Faciei*, which arises nearly opposite to the Internal Maxillary. It proceeds transversely under the Zygoma, over the Masseter, and near the Parotid Duct. After giving Branches to the Parotid Gland, it supplies a large portion of the Cheek, communicating with the Facial and Internal Maxillary Arteries. Tab. CXXXIV. i, i.

The Articular Artery, which sends Branches to the Articulation of the Jaw, the External Meatus and Membrana Tympani, and penetrates as far as the Inner Ear, communicating with the Arteria Stylo-mastoidea.

The Deep *Temporal Branch*, sent off behind the condyle of the Jaw, which ascends obliquely forwards under the Aponeurosis of the Temporal Muscle to the outer part of the Orbit.

Anterior Auricular Branches, which come off near the Origin of the former Branch, and are ramified upon the fore-part of the Ear, inosculating there with the Posterior Auricular Artery.

Branches to the Masseter, which communicate in the Cheek with the Facial and Internal Maxillary Arteries.

The Temporal Artery, having detached the Branches mentioned above, forms one or two sharp Turns before the Ear, and a little above the root of the Zygoma, where the Pulsation of the Artery can be felt, and frequently even seen, it divides into Two Large Branches, an *Anterior* and *Posterior*, which are placed superficially between the Integuments of the Head and Aponeurosis of the Temporal Muscle.

The *Anterior, Internal Anterior, or Temporo-frontal Branch*, advances in a Serpentine direction, spreading out its Ramifications upon the side and upper part of the Fore-head, some of which reach as far as the Orbit.

It supplies the Integuments and Muscles near it, communicates, about the Orbit, with the Facial Artery, and at the upper part of the Head, with the corresponding Branch of the other side.

It occasionally gives a Branch from near its Root, termed *Ramus Orbicularis*, which runs towards the outer Corner of the Eye, to be distributed upon the Orbicularis.

The *Posterior, or External Posterior, or Temporo-occipital Branch*, which appears as the continuation of the Trunk, ascends obliquely backwards, and is distributed extensively on the Integuments and Muscles upon the lateral parts and Crown of the Head, communicating with the Anterior Branch, and with the Occipitalis on the same side of the Head, and also with the Posterior Temporal Branch of the opposite side,—from which, and from the other Branches on the Head, numerous Twigs go to the Pericranium, and to the Substance of the Bone.

INTERNAL.

INTERNAL CAROTID ARTERY.

The INTERNAL CAROTID, Tab. CXXXI. *b*,—sometimes termed *Arteria Cerebralis*,—is arched back at its Origin, and then ascends in a waving direction on the fore-part of the *Rectus Capitis Anterior Major*, as far as the *Foramen Caroticum*, without giving off any Branches.

At the Base of the Cranium, it makes a sudden turn forwards, and enters the Carotic Canal of the Temporal Bone, Tab. CXXXII.—While in the Canal, it passes upwards and forwards like the Canal itself, and is surrounded by a considerable quantity of Cellular Substance, and by the *Dura Mater*, which form a Cushion between it and the Bone.

After leaving the Canal, it again bends upwards and then forwards, by the side of the *Sella Turcica*; and perforating the *Dura Mater*, at the root of the Anterior Clinoid Process, it is suddenly reflected obliquely backwards and upwards; after which it divides into Branches. Tab. CLXXXVI.

Through the whole of its course, it runs in a Serpentine manner, which prevents the Blood in it from rushing too quickly and forcibly upon the tender Substance of the Brain, and,—contrary to the nature of other Arteries,—it is of a Conical form, though it does not send off any Branches till it enters the Cranium.

While at the side of the *Sella Turcica*, it furnishes small Twigs to the *Dura Mater* and parts adjacent, as—A Branch which passes through the *Pars Petrosa* to the *Tympanum*,—a Branch termed *Posterior*,—and another termed *Anterior Artery* of the *Cavernous Sinus*, to the *Dura Mater*, *Glandula Pituitaria*, and Nerves at the side of it.

As soon as the Carotid perforates the *Dura Mater*, at the root of the Clinoid Process, it transmits

The ARTERIA OPHTHALMICA, Tab. LXXIII. Fig. 16. *m*. Tab. LXXVI. Fig. 1. 2. which is the Principal Artery belonging to the Eye and its Appendages.

The Ophthalmic, or Ocular Artery, immediately after it comes off from the Carotid, enters the *Foramen Opticum*, and creeps under the Optic Nerve, included in the *Dura Mater*, towards the outer part of the Orbit. Tab. CLXXXVI. *a, a*.

After proceeding some way through the Orbit, it traverses its Cavity, taking a Spiral direction towards the Nose, between the Optic Nerve and *Depressor Oculi Muscle*.

In this course, it first transmits Filaments to the *Dura Mater* and Substance of the Optic Nerve, and to the beginning of the Muscles in the bottom of the Orbit; after which it gives off the following Branches, viz.

The *Arteria Lacrymalis*, Tab. CLXXXVI. *b*, which runs at the outside of the Orbit, and is chiefly dispersed upon the Lacrymal Gland; some Threads advancing to the Eye-lids. One Twig to the Periosteum of the Orbit, and another through the Cheek-Bone.

VOL. III.

The *Arteria Centralis Retinae*, Tab. LXXIII. Fig. 7. *b*,—which penetrates the Optic Nerve a little behind the Ball of the Eye,—runs in the centre of the Nerve, and spreads out into many small Branches upon the inside of the Retina.

When the Nerve is cut across, the orifice of the divided Artery is observable, which, before its nature was understood, was long known by the name of *Porus Opticus*.

In the Adult, the Central Artery appears to terminate entirely upon the Retina; but in the Fœtus, after furnishing, at the bottom of the Orbit, the Branches proper to the Retina, the Trunk is continued forwards through the Axis of the Vitreous Humour, supplying its Cells and Membrane with delicate Filaments, and afterwards spreading out upon the back-part of the Capsule of the Lens. Tab. LXXIV. Fig. 11.

Its Branches are dispersed upon the Lens in a radiated manner, and, after surrounding it, some of them are sent forwards to the *Membrana Pupillaris*.

The *Arteriæ Ciliares*, Tab. LXXIII. Fig. 4. *e, e*,—three or sometimes more in number,—which divide into Branches running in a Serpentine direction along the opposite sides of the Optic Nerve, and dividing into the *Ciliares Breves*, and *Ciliares Longæ*.

The *Ciliares Breves*, vel *Posteriores*, Tab. LXXIII. Fig. 4. *b, b*,—formed not only of Branches from the original Ciliary Trunks, but also of Twigs from the Muscular Branches,—are numerous. They perforate the Sclerotica, near the Insertion of the Optic Nerve, give Twigs to that Coat, and dividing into still smaller Branches, creep forwards upon the *Tunica Choroides*;—forming many Communications with each other as they advance, and retiring gradually from the convex to the concave surface of this Coat, to supply the Iris and Ciliary Processes.

The *Ciliares Longæ*, Tab. LXXIII. Fig. 5. *a, a*,—which seldom consist of more than two Trunks,—perforate the Sclerotica a little farther forwards than the former, pass along the Choroid Coat to its anterior part, and then each separates into two Branches, and these into others which inosculate round the outer edge of the Iris.

Besides the *Ciliares Breves et Longæ*, there is another Set, termed *Ciliares Anteriores*, which are a few Arterious Filaments from the Muscular Branches, entering the Eye where the Straight Muscles are inserted.

At the root of the Iris, different Sets of Ciliary Arteries unite into Arches, which form an irregular Circle, called *Circulus Iridis*.

From this Circle, many Arteries run upon the Iris, in a radiated serpentine manner, towards the Pupil, near which several of them also unite into Arches; and from these, Twigs are sent, along with the rest of the radiated Branches, to the inner edge of the Iris.—In the Fœtus, they are continued to the *Membrana Pupillaris*.

The *Muscularis Superior*, et *Muscularis Inferior*, which are

B

are dispersed upon the Muscles, Membranes, and Fat of the Eye; giving Twigs also to the Sclerotic Coat.

The *Ethmoidalis Anterior*, et *Posterior*, two extremely small Twigs, especially the latter, which pass through the Foramina Orbitaria Interna,—Anterior, et Posterior,—to the Bones and Membranes of the Nose, particularly to the Frontal, Ethmoid, and Sphenoid Sinuses, where they communicate with the Nasal branches of the Internal Maxillary Artery.

The *Supra-orbitalis*, vel *Frontalis*, which, after giving Branches to the Muscles and Periosteum at the upper and fore part of the Orbit, emerges from the Socket, passes through the Foramen Supra-orbitarium, and is divided into two parts;—one dispersed upon the Periosteum of the Fore-head, the other running to the Skin and Muscles on the Fore-head and upper Eye-lid, and communicating with the anterior Branch of the Temporal Artery.

ARTERIES OF THE BRAIN.

The Arteries of the Brain consist of the two *Internal Carotids*, Tab. CXXVII. *a, a*, and the two *Vertebrials*. Tab. CXXVII. *d*.—Tab. CXXVIII.

Each Internal Carotid, after sending forwards the Ocular Artery, gives a number of separate Twigs to the Optic Nerve, the Infundibulum, and the Choroid Plexus, and sends a particular Branch backwards to the Vertebral, termed *Arteria Communicans*, and then divides into the *Arteria Anterior*, and *Arteria Media Cerebri*.

The *ARTERIA ANTERIOR CEREBRI*, Tab. CXXVII. *g, g*, turns towards its fellow of the opposite side, and commonly sends Filaments to the First and Second Pair of Nerves.

A little before the union of the Optic Nerves, the right and left Anterior Cerebral Arteries become almost contiguous, and anastomose by means of a short, but large transverse Branch, which forms part of that Communication of Vessels termed *Circus Arteriosus WIL- LISII*.

From this transverse Branch, but more frequently from the Anterior Cerebral artery near it, a Branch is sent off, which passes into the Third Ventricle, and furnishes Twigs to the Septum Lucidum, and fore-part of the Fornix.

The Anterior Cerebral Artery ascends upon the inner side of the Anterior Lobe of the Brain, and sends off a principal Branch, and commonly another soon after; both of which arch backwards upon the inner flat Surface of the Hemisphere.

The continuation of the Anterior Cerebral Artery is termed *Arteria Corporis Callosi*, and is reflected back upon the union of the Corpus Callosum and Hemisphere as far as the Posterior Lobe of the Brain.

The Branches of the Anterior Cerebral Artery are divided into minute Ramifications, which are first spread out upon the flat Surface of the Hemisphere, and afterwards upon its upper part.

The Ramifications form numberless Anastomoses with each other upon the Surface of the Brain, and afterwards pass, by minute Filaments, into its Cortical and Medullary Substance.

Besides the Anastomoses of the different Branches of this Artery on the Surface of the Hemisphere, small Branches run across the Corpus Callosum, and inosculate with those of the opposite side.

The *ARTERIA MEDIA CEREBRI*, termed also *ARTERIA FOSSÆ SYLVII*, Tab. CXXVII. CXXVIII.—which is larger than the former,—runs outwards in a lateral direction through the *Fossa* of SYLVIIUS, to the outer part of the Brain.

It gives first Filaments to the Glandula Pituitaria and parts adjacent to it, and then divides into principal Branches; of which one Set go to the Anterior, and the other to the Lateral and part of the Posterior Lobe of the Brain.

From this Artery, one or two Twigs run up into the Anterior Cornu of the Lateral Ventricle, and assist in forming the Choroid Plexus of that Cavity.

Upon the outer Surface of the Brain, the Branches of this Artery inosculate with each other, and with those of the Anterior Cerebral Artery, and then plunge into the substance of the Brain, where they meet with the Deep Branches of that Artery.

VERTEBRAL ARTERIES.

The two *Vertebral Arteries*,—which are only a little smaller than the Internal Carotids,—arise from the Subclavian Arteries at the bottom of the Neck.

Each of them, at a small distance from its origin, enters the Canal formed for its reception by the six uppermost Cervical Vertebrae. Tab. LIII. Fig. 3. *b, b*.—Tab. CXXXII. CXXVIII.

It ascends through the Neck, nearly in a straight direction, sending Twigs outwards, between the Vertebrae to the deep Muscles of the Neck, and others which pass inwards by the Holes which transmit the Spinal Nerves, to the Spinal Marrow and its Membranes; communicating with the Spinal Arteries. Tab. CXCI. Fig. 3. F.

Immediately below the Head, it gives out more considerable Branches to the Deep Muscles at the back part of the Neck, particularly to the Recti and Obliqui Postici, the Trachelo-mastoideus, and Complexus; inosculating with Branches of the Occipital Artery.

At the upper part of the Neck, it forms Contortions somewhat similar to, and answering the same purpose with those of the Internal Carotid Artery.

One turn is formed upwards and outwards, in passing from

from the third to the second Vertebra; and another outwards and forwards, in going between the Vertebra Dentata and Atlas.

After perforating the Atlas, it bends suddenly back, and runs in an horizontal direction in a Notch upon that Bone.

Having reached the Foramen Magnum Occipitis, it turns upwards, perforates the Dura Mater, and enters the Cavity of the Cranium.

After entering the Cranium, it passes with the Medulla Oblongata, upon the Cuneiform Process of the Occipital Bone, inclining towards its fellow on the other side, and at the beginning of the Medulla, the two Vertebrae unite into the Trunk called *Basilar Artery*.

Upon entering the Skull, each Vertebral Artery sends a small Branch, termed *Arteria Meningea Posterior*, to the posterior part of the Dura Mater.

It then disperses Twigs to the Medulla Oblongata, and frequently gives off the small Branch which forms the *Posterior Artery* of the Spinal Marrow.

Near the part where it unites with its fellow, it sends down the *Anterior Artery* of the Spinal Marrow.

From the Vertebral, or from the Basilar, or sometimes from each, a principal Branch is sent off, named *Arteria Cerebelli Posterior*, or *Inferior*, which passes between the Cerebellum and Medulla Oblongata, and furnishes Branches to the under part of the Cerebellum, to the back part of the Medulla Oblongata and Tuber Annulare, and forms the Choroid Plexus of the Fourth Ventricle.

The *BASILAR ARTERY*, Tab. CXXVII. *e, e*, runs along the middle of the Tuber Annulare, which it slightly impresses, and lies upon the Cuneiform Process of the Occipital Bone.

From the sides of this Artery, numerous Filaments run transversely, to be dispersed upon the Tuber and adjacent parts.

One Branch, larger than the rest, called *Auditoria Interna*, passes between the two portions of the Seventh Pair of Nerves to the Internal Organ of Hearing.

At the extremity of the Cuneiform Process of the Occipital Bone, and at the upper and fore part of the Tuber Annulare, the Basilar Artery divides into four principal Branches, two to each side; and these go off almost at right angles from the Trunk, viz.

The *Arteria Superior*, or *Superior Cerebelli*, Tab. CXXVIII. which turns round the Crura Cerebri, expands its Branches upon the upper part of the Cerebellum, and sinks into its Substance, supplying also the Nates, Testes, and Parts near them.

The *Arteria Posterior*, or *Profunda Cerebri*, Tab. CXXVIII. which sends Twigs to the Tuber and to the Crura Cerebri, and unites with the Internal Carotid by the *Arteria Communicans*.

It supplies also parts lying near the Third Ventricle,

and afterwards turning round the Crura Cerebri, passes back between the Cerebrum and Cerebellum.

It distributes its numerous Branches chiefly to the Posterior Lobe of the Brain, one Branch in particular penetrating into the Posterior Cornu of the Lateral Ventricle, and with Branches of the Internal Carotid, forming the Arterious part of the Choroid Plexus.

The Branches of this Artery anastomose with those of the anterior part of the Internal Carotid, at the inside of the Hemisphere,—and with those of the lateral part of that Artery, at the outside of the Hemisphere, in the manner these do with each other in the other parts of the Brain.

The *Arteria Communicans*, Tab. CXXVII. *c, c*.—Tab. CXXVIII. which unites the posterior Cerebral Branch of the Vertebral Artery to the Trunk of the Internal Carotid, and is nearly of the same diameter, but longer than that transverse Artery which connects the anterior Branches of the Internal Carotid.

It sends minute Threads to the Crura Cerebri, &c. and contributes to the formation of the *Circle of WILLIS*,—or that kind of communication by which the Blood or Injected Matter can pass readily across from one Internal Carotid to the other,—or from these backwards to the Basilar Artery.

VEINS OF THE HEAD AND PART OF THE NECK.

The Veins which return the Blood from the Arteries of the Head and Neck, unite into the following Trunks, viz.

The *Facial Vein*, which, formed by the Frontal Vein, and by an intricate Plexus of Branches upon the Face, winds obliquely downwards and outwards, at a distance from the Artery; but, in crossing the Jaw, it goes close by the outside of it, and terminates in the External Jugular Vein. Tab. CXXXV. *d*.

The *Temporal Vein*, Tab. CXXXV. *e, f, g, b*, formed by Superficial and Deep Branches from the sides and upper part of the Head, and running down upon the Temple at some distance from the Artery.

The Branches of the Temporal Vein form large Anastomoses; before, with those of the Frontal Vein; above, with their Fellows on the other side; and behind, with the Branches of the Occipital Vein.

The Trunk descends at the fore-part of the Ear, and, along with the Artery, sinks in the Substance of the Parotid Gland. Tab. CXXXIV. CXXXV.

In its descent before the Meatus Auditorius Externus, it receives Branches from the Ear, Parotid Gland, and Cheek, corresponding with those sent to these parts from the Carotid, or Temporal Artery.

At the under part of the Lower Jaw, the Facial and Temporal

Temporal Veins commonly unite and form the External Jugular.

The *External Jugular Vein*, Tab. CXXXV. No. 9, receives the following Branches at the upper part of the Neck, viz.

Branches of the Internal Maxillary Vein, the principal part terminating in the Internal Jugular.

The *Lingual Vein*, one Branch of which, termed *Ramina* from its complexion, is seen under the Tongue, and is that Vein which is opened in Venesection.

Some *Branches* from the Occipital Vein, Tab. CXXXV. No. 4. the rest passing to the Internal Jugular and Vertebral Veins, and sometimes also communicating by a Foramen Mastoideum with the Lateral Sinus.

The Trunk of the External Jugular Vein descends in the Neck, between the Platysma Myoides and Sternomastoideus, receives in its course Branches from the adjacent parts, and terminates in the Subclavian Vein.

In the formation and termination of this Vein, there is great Variety in different Subjects.

It frequently happens that most of the Ramifications, which commonly run from the Face and Throat into this Vein, go to the Internal Jugular.

Often the Facial Vein goes into the Internal Jugular, and the Temporal continued forms the External Jugular.

Sometimes one of the External Jugulars terminates in the usual way, and the other in the Internal Jugular.

In some rare Cases, the External Jugulars have both been found terminating in one side of the Neck.

Besides the Vein commonly called External Jugular, a small Subcutaneous Vein, termed *Anterior External Jugular*, Tab. CXXXV. *p.*, descends in the fore-part of the Neck, receiving Branches from the adjacent parts, and terminating in the Subclavian Vein.

VEINS OF THE EYE AND ITS APPENDAGES.

The Blood sent to the Contents of the Orbit is returned partly to the Facial Vein at the inner Corner of the Eye, but chiefly to the proper Ocular Vein, Tab. LXXVI. Fig. 3. 4. which terminates in the Cavernous Sinus by the following Veins, viz.

The *Vena Centralis Retinae*, Tab. LXXIV. Fig. 13. which is formed by many small Branches expanded upon the inner surface of the Retina along with those of the corresponding Artery.

The *Vena Centralis* enters the Optic Nerve, where the Artery leaves it; and a little behind the Ball of the Eye, it emerges from the Nerve, and runs between it and the Sheath which covers it; receiving many Twigs from the Nerve and its Membranes.

It passes afterwards under the Fasciculus of Nerves, which belongs to the Eye, and terminates, sometimes in the Ocular Vein, but, in general, directly in the Cavernous Sinus.

From the Iris and Choroid Coat, the Blood is returned by the *Short* or *Anterior Ciliary Veins*, and by the *Long* or *Posterior Ciliary Veins*, and also by a principal Set of Ciliary Veins, termed *Vasa Vorticosa*.

Small Veins return from the Iris, which go under the Arterious Circle to the Veins of the Choroid Coat, and communicate with each other;—but without forming any Circle, such as is found in the Eyes of Oxen, and which corresponds, in them, with the Arterious Circle.

The *Short Ciliary Veins* pass from the Iris through the Sclerotic Coat, near the same part where the Anterior Ciliary Arteries enter.

The *Long Ciliary Veins*, like the Arteries, are commonly two in number, and of a smaller size than the Vorticose Veins.

They run from the Iris backwards along the Choroid Coat, communicate in their passage by minute Branches with the Vorticose Veins, and afterwards perforate the Tunica Sclerotica behind.

The *Venæ Vorticosae*, Tab. LXXIII. Fig. 9. B, B, Fig. 14.—Tab. LXXV. are numerous, and obtain their name from the Whirls composed by their Branches: the course of which has been compared to a *Jet d'eau*, or to the Spiral Ridges upon the points of the Fingers, &c.

Of these Veins, four, or sometimes five, are by much the most conspicuous; the rest being smaller, and having less of the Vorticose appearance.

The Branches of each of the four principal *Venæ Vorticosae* run in a close Congeries, unite at acute angles into larger Branches which have a curved direction, and these proceeding from all sides, meet in a point, and form the Trunk of the Vein.

The Trunks of these *Venæ Vorticosae*, thus placed in the centre of their respective Whirls, are situated at the opposite sides of the Eye, and perforate the Sclerotic Coat obliquely near its middle.

The rest of the *Venæ Vorticosae*, or smaller Ciliary Veins, communicate with the adjacent larger Vorticose Veins upon the surface of the Choroid coat, and also perforate the Sclerotica near its middle.

After piercing the Sclerotica, the different Vorticose Veins unite into four or five small Ciliary Trunks, receiving a number of minute Twigs, which paint the Cellular Substance covering the Surface of the Sclerotica.

The Ciliary Veins run in a serpentine direction at the opposite sides of the Eye, and pass, either separately, or united with other small Veins in the Orbit, into the Trunk of the Ocular Vein.

The other Venous Branches within the Orbit, correspond in a great measure with their respective Arteries. They consist of—

Branches from the Palpebrae and inner Corner of the Eye:

The *Lacrymal Branch*:

The *Ethmoidal Branches*:

Muscular

Muscular Branches,—and *Branches* from the Fat in the Orbit, and from the Membranes lining it.

The different Branches from the Eye and its Appendages form, by their union, the *Ocular Vein*, which greatly exceeds the size of the corresponding Artery.

The *Ocular Vein* forms large Anastomoses with the Facial Vein, at the inner Corner of the Eye, and afterwards passes back at the inner side of the Orbit.

From the inner, it goes across to the outer side of the Orbit, under the Attollens; and, after running back through the Superior Orbital Fissure, covered by the Third and Sixth Pair of Nerves, it terminates in the Cavernous Sinus.

VEINS OF THE DURA MATER CORRESPONDING WITH ITS ARTERIES.

The *Veins of the Dura Mater*, Tab. CXXVI. accompany their Arteries, and go partly through Perforations in the Base of the Cranium, to terminate in Branches of the External or Internal Jugular Veins.—The rest go into the nearest Sinuses of the Brain.

VEINS OF THE BRAIN.

The smaller Veins of the Brain accompany the Arteries. Their Trunks run chiefly between the Circumvolutions of the Brain, at a distance from the Trunks of the Arteries.

They terminate in the different *Sinuses* of the Dura Mater, and generally in an oblique direction, which prevents the Blood from returning into them.

The Sinuses most commonly found are the following:

The *Superior Longitudinal Sinus*, Tab. LX. *b, i, i, k*,—Tab. LIX. *E, E*, which begins at the under part of the Spine of the Frontal Bone,—runs along the upper edge of the Falx,—and becoming gradually wider, terminates upon the middle of the Occipital Bone, in the two Lateral Sinuses.

It receives the Blood from the upper part of the Brain, by several large Venous Trunks, which enter it obliquely forwards.

The *Torcular Herophili*, Tab. LX. *u, w, x*, or *Fourth Sinus* of the Ancients, chiefly formed by the Vena Galeni, which returns the Blood from the Choroid Plexus, Corpora Striata, Septum Lucidum, and other Internal Parts of the Brain.

The Torcular passes back in the joining of the Falx and Tentorium, and terminates, along with the Superior Longitudinal Sinus, in the beginning of the Lateral Sinuses.

The *Inferior Longitudinal Sinus*, Tab. LXVIII. *w, x*. a remarkably small one, situated in the under edge of the Falx.—It receives Branches from that Membrane,

and from the Corpus Callosum and parts of the Brain near it, and terminates in the beginning of the Torcular Herophili.

The *Two Lateral Sinuses*, Tab. LX. *y*,—Tab. LIX. *H, H*, or *Second* and *Third Sinuses* of the Ancients, formed by the Longitudinal and Torcular Sinuses.

They run at the posterior edge of the Tentorium, along the Lateral Ridges of the Os Occipitis, as far as the Base of the Petrosal Processes of the Temporal Bones, from whence they wind downwards, pass through the Foramina Lacera common to the Occipital and Temporal Bones, and terminate in the Internal Jugular Veins.

Frequently one of the Lateral Sinuses is formed by the Longitudinal, and the other by the Torcular Sinus; in which case, the one is found larger than the other.

The Lateral Sinuses receive Veins from the Cerebellum, and from the under and back part of the Cerebrum. They likewise receive the following small Sinuses, situated under the Brain, viz.

The *Circular Sinus of RIDLEY*, which is placed about the Glandula Pituitaria, and frequently surrounds it completely; receiving the Blood from it, and from the adjacent Bones and Membranes, and terminating in the Cavernous Sinuses. Tab. CXXVI. Fig. 2. *b, b*.

The *Cavernous Sinuses*, which are situated at the sides of the Sella Turcica, and receive Blood from Veins lying near the lateral Branches of the Internal Carotid Arteries, from the Ocular Veins, and from the Circular Sinus of RIDLEY. Tab. CXXVI. Fig. 2. *c*.

The Cavernous Sinuses surround the Carotid Arteries and Sixth Pair of Nerves, and have a Cavernous structure within, somewhat resembling that of the Penis.

The *Superior Petrosal Sinuses*, situated upon the Ridges of the Partes Petrofæ. Tab. CLXXXVI. No. 15. 15.

They receive some small Veins from the Dura Mater and Base of the Brain, and communicate backwards with the Lateral, and forwards with the Cavernous Sinuses.

The *Inferior Petrosal Sinuses*, placed at the roots of the Partes Petrofæ.—They receive the Blood from the Cavernous, and discharge it into the ends of the Lateral Sinuses. Tab. CLXXXVI. No. 14. 14.

Besides the Sinuses mentioned above, the following also are frequently met with, viz.

A *Perpendicular Occipital Sinus*, situated in the Falx Cerebelli, which is sometimes single, sometimes double, and terminates in the Lateral Sinuses.—It receives Veins from the Dura Mater, and communicates with the Vertebral Veins. Tab. CLXXXVI. No. 12.

Anterior Superior, and *Anterior Inferior Occipital Sinuses*, placed over the Cuneiform Process of the Occipital Bone, and communicating with the Inferior Petrosal and Lateral Sinuses, and with the Vertebral Veins. Tab. CLXXXVI. No. 18. 17.

INTERNAL

INTERNAL JUGULAR VEIN.

The Lateral Sinuses, having received the Blood sent to the Brain from the Carotid and Vertebral Arteries, pass out of the Cranium, and form the *Internal Jugular Veins*, Tab. CXXXV. *q, q*; each of which, at its Origin, is bulged back in form of a Varix, which is termed *Diverticulum*; and this is lodged in a Fossa at the root of the Pars Petrosa of the Temporal Bone.

The INTERNAL JUGULAR VEIN descends behind the Sterno-mastoideus, upon the fore and outer part of the Common Carotid Artery, with which it is included in a Sheath of Cellular Substance; and is frequently a good deal dilated towards its under extremity, especially in advanced life.

In its course in the Neck, it receives *Branches* from the Pharynx and Muscles adjacent to it:

The *Internal Maxillary Vein*:


One or more *Branches* from the Occiput:

The *Lingual Vein*, which sometimes terminates in the External Jugular:

The *Superior Laryngeal*, and now and then the *Inferior Laryngeal*, which more frequently goes into the Subclavian, or to the top of the Cava.

The Internal Jugular also receives *Branches* from the Muscles of the Neck, and at length terminates in the Subclavian Vein.

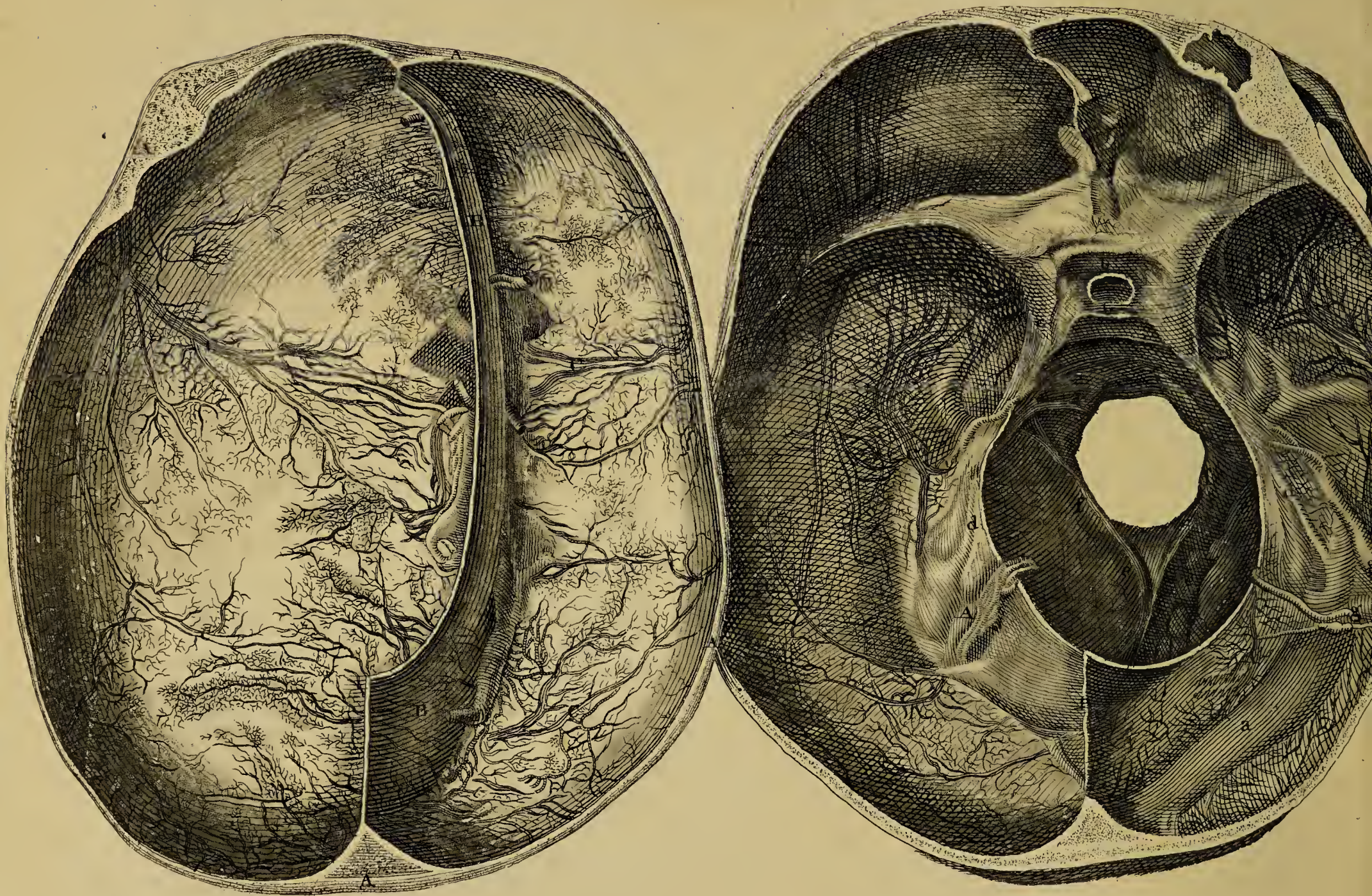TABLE



TAB. 88.

Fig. 1.

Fig. 2.



T A B L E CXXVI.

Represents the Inside of the CRANIUM of a CHILD, with the DURA MATER adhering to it, the VEINS of which are minutely injected.

FIG. 1.

Represents the Concave Surface of the Upper Part of the CRANIUM, with the DURA MATER and its VEINS.

- A, A, &c. The cut edge of the cranium.
- B, B, The large falciform process of the dura mater, with the termination of the veins of the upper part of the brain in the superior longitudinal sinus.
- C, C, C, The veins of the dura mater, the anterior trunks of which are the Venæ Meningeæ Mediæ: The others are seen terminating, either in the superior longitudinal sinus, or running towards the holes in the base of the cranium.

FIG. 2.

Represents the VEINS and SINUSES of the DURA MATER and BASE of the CRANIUM.

- A, The tentorium, with the termination of cerebral veins in the left lateral sinus.
- B, The cut edge of the large falciform process.
- C, C, Trunks of the venæ meningeæ mediæ.
- a, The right lateral sinus.
- b, b, The *Circular Sinus* of RIDLEY.
- c, The left cavernous sinus.
- d, d, The superior petrosal sinuses.
- e, e, The posterior occipital sinuses.
- f, f, The sinuses of the great occipital foramen.
- g, g, Cerebral veins, terminating in the right lateral sinus.

T A B L E.

T A B L E CXXVII.

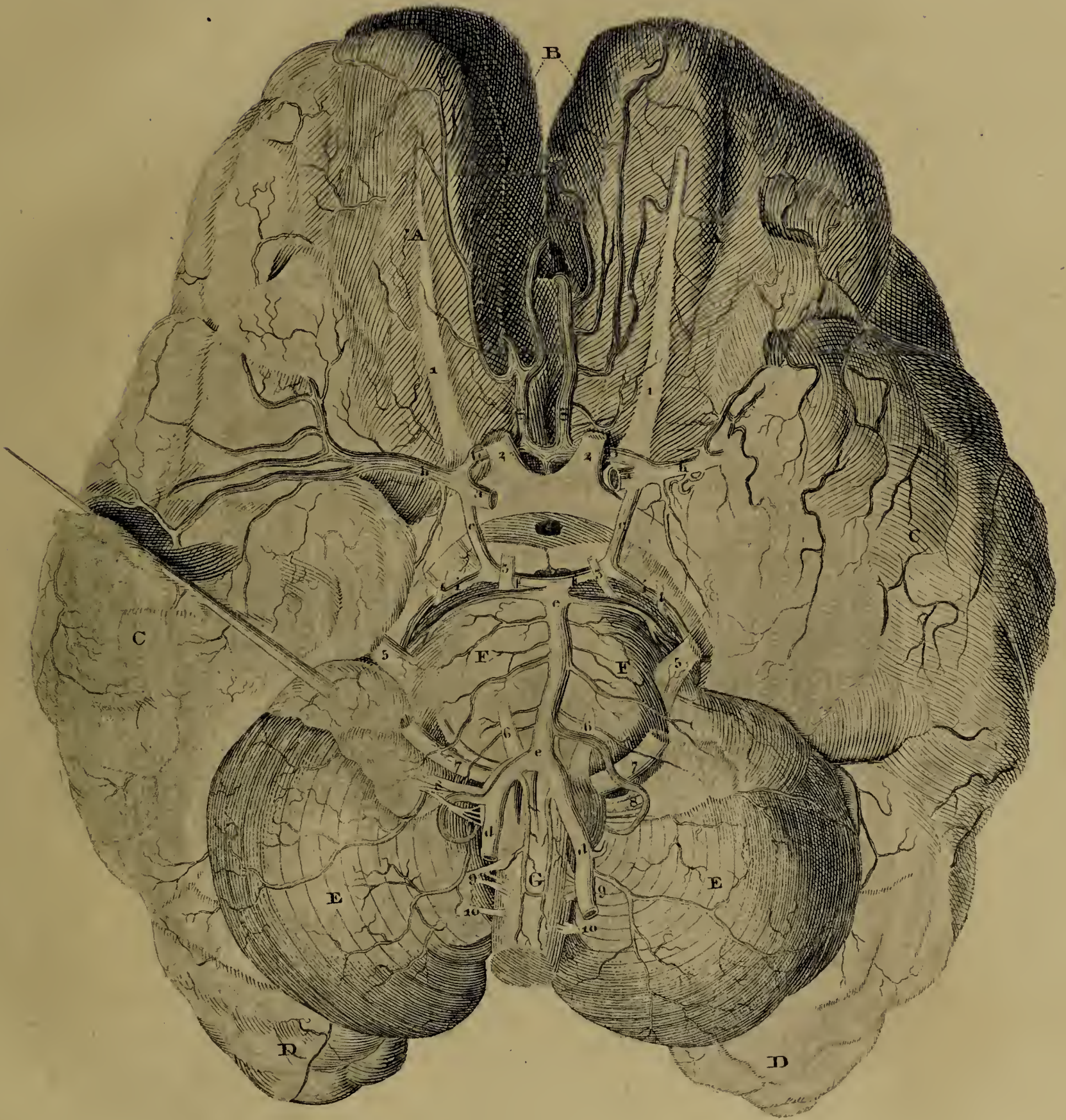A VIEW of the BASE of the BRAIN, with the TRUNKS of its ARTERIES
and NERVES.

A, A, The anterior lobes of the brain.
 B, The anterior lobes separated a little from each other.
 C, The lateral lobes.
 D, D, The posterior lobes.
 E, E, The cerebellum.
 F, F, The tuber annulare.
 G, The medulla oblongata.
 a, a, The trunks of the internal carotid arteries.
 b, b, g, g, Their anterior branches running between the anterior lobes of the brain, and turning over the corpus callosum to reach the inner side of the hemispheres.
 b, b, Their middle branches running in the *Fossæ* of SYLVIVS, to the lateral parts of the brain.
 A little behind g, g, is seen the cross branch by which the anterior cerebral arteries communicate.
 c, c, The branches by which the carotids communicate with the vertebral arteries.
 d, d, The vertebral arteries, with the anterior spinal arteries sent down from them.
 e, e, The basilar artery formed by the union of the vertebrals.
 f, f, The division of the basilar artery into the posterior arteries of the cerebrum, and the superior arteries of

the cerebellum ;—the right one is seen, in this figure, passing from the vertebral, and the left from the basilar artery.
 i, i, The posterior cerebral arteries ; the superior arteries of the cerebellum being seen immediately behind them.
 a, b, b, a, c, f, f, c, The *Circus Arteriosus WILLISII*, formed by the communications of the internal carotids with each other, and with the vertebral arteries.
 1. 1. The first pair, or olfactory nerves, advancing under the anterior lobes of the brain.
 2. 2. The second pair, or optic nerves, behind which are seen their union, and the tractus optici.
 3. 3. The third pair, or motores oculorum.
 4. 4. The fourth pair, or nervi pathetici.
 5. 5. The fifth pair, or nervi trigemini.
 6. 6. The sixth pair, or nervi abducentes.
 7. 7. The seventh pair, composed of the portio dura and portio mollis, the former of which is placed anteriorly.
 8. 8. The eighth pair, composed of the glosso-pharyngeus and par vagum.
 9. 9. The ninth pair, or lingualis, composed of small fasciculi.
 10. 10. The tenth pair, or sub-occipital nerves.

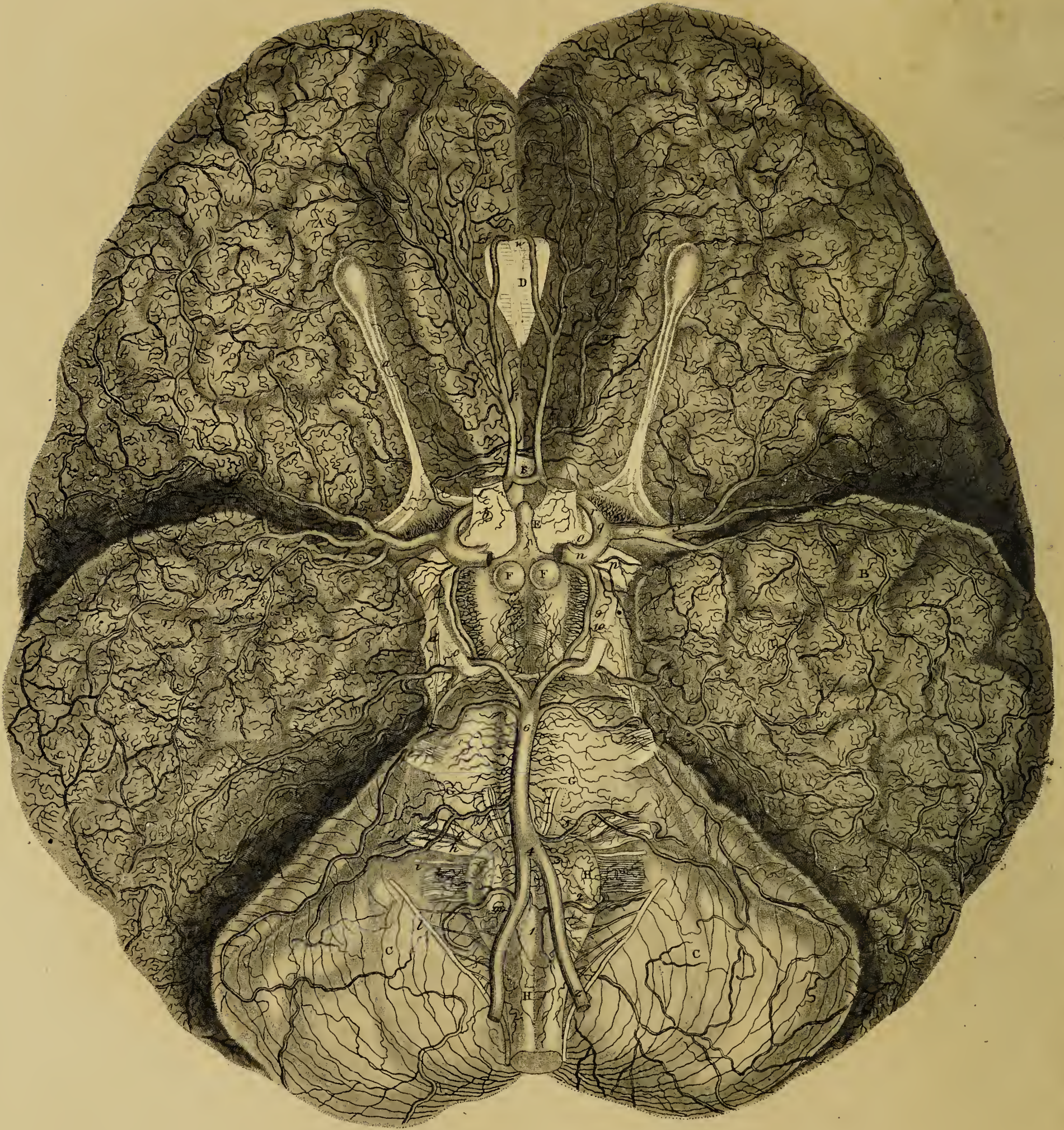
TABLE

TAB. 127.





TAB. 128.




T A B L E CXXVIII.

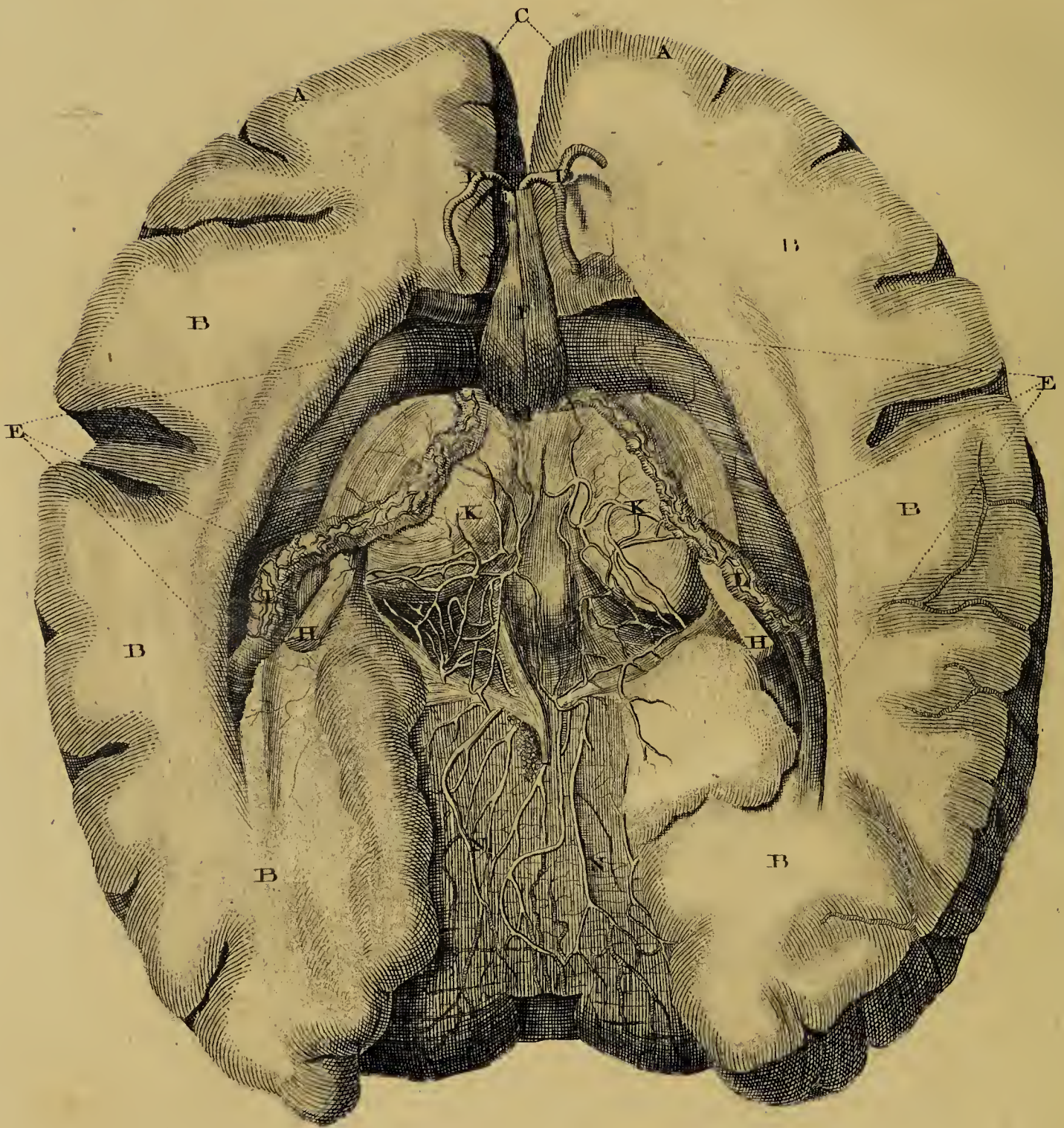The ARTERIES of the BASE of the BRAIN shewn more fully than in the preceding Table. A slight VIEW is likewise given of the Origin of the NERVES. The BRAIN is flattened, the different LOBES are separated a little from each other, and the CEREBELLUM is drawn back, to shew as many Arteries as possible in one View. To save the multiplying of Letters, the NERVES are marked on one side of the BRAIN, and the ARTERIES on the other.

-
- A, A, The anterior lobes of the cerebrum.
 B, B, The middle lobes.
 C, C, The cerebellum.
 D, The corpus callosum, shewn by separating the under side of the anterior lobes of the cerebrum from each other.
 E, The infundibulum.
 F, F, The eminentiæ mamillares.
 G, G, The tuber annulare.
 H, H, The medulla oblongata.
a, The first or olfactory nerve, with its roots behind, and bulb before.
b, The second or optic nerve.
c, The third or oculo-muscular nerve.
d, The fourth or pathetic nerve.
e, The two parts of the fifth nerve.
f, The sixth or abductor nerve.
g, The portio dura, and,
h, The portio mollis of the seventh nerve, with their intermediate branches.
i, The glosso-pharyngeal part, and,
k, The filaments which form the pars vaga of the eighth nerve.
l, The accessory or spinal nerve, formed of numerous roots.
m, The ninth or lingual nerve.
n, The trunk of the internal carotid artery.
o, The root of the ocular artery.
p, Two small branches from the carotid; the anterior distributed upon the tractus opticus, and adjacent convolutions of the brain; the one behind is the anterior inferior choroid artery, being continued to the inferior extremity of the choroid plexus in the lateral ventricle.
q, The division of the carotid into the anterior, and the external, middle, or posterior cerebral branch.
r, The arteria anterior cerebri.
s, The transverse artery, by which the anterior cerebral branches of the opposite sides communicate.
- t*, The continuation of the anterior cerebral artery, termed *Arteria Corporis Callosi*. Near its root it sends branches to the optic and beginning of the olfactory nerve.
u, Inferior cerebral branches of the arteria callosa, giving twigs to the olfactory nerve, and externally communicating with the extremities of the external cerebral artery.
v, Anterior and internal cerebral branches of the arteria callosa, distributed to the internal surface of the anterior lobes.
w, The arteria callosa turning to the upper part of the corpus callosum, which it follows almost its whole length, dispersing itself upon the internal surface of the hemisphere, upon the dura mater near it, and giving twigs to the third and upper fore-part of the lateral ventricles.
x, The arteria media cerebri, termed also SYLVIAN branch of the internal carotid, somewhat larger than the arteria anterior. It sends first delicate branches to the substance of the brain at the root of the olfactory nerve.
y, The division of this artery into three branches, of which one goes to the anterior lobe of the cerebrum, the second goes deep in the fossa of SYLVIVS to the anterior and lateral lobes, the third passes to the lateral and posterior lobes; the branches communicating on the surface, then in the substance of the brain, with the branches of the anterior cerebral artery.
z, The vertebral artery at its entry into the cranium.
 1. The anterior artery of the spinal marrow, which, at its beginning, is seen communicating with its fellow.
 2. The arteria magna, posterior, inferior, vel profunda cerebelli, turning between the cerebellum and medulla oblongata, to be dispersed upon these and upon the tuber annulare.
 3. Numerous little arteries to the tuber and to the neighbouring nerves.
 4. The

4. The union of the vertebrales to form the basilar artery, which is placed over the middle of the tuber annulare, and sends many twigs to the tuber, and to the adjacent nerves.
5. The arteria minor, inferior, vel profunda cerebelli, the origin of which, as commonly happens, is not opposite to the one of the other side. About a finger's-breadth from its origin, it is seen sending off the arteria auditiva, which is cut across; it afterwards anastomoses with the arteria magna posterior cerebelli.
6. The division of the basilar artery into the arteria superior cerebelli, and the arteria posterior, vel profunda cerebri, on each side.
7. The arteria superior cerebelli, turning over the tuber, furnishing branches to the upper part of the cerebellum, and communicating with the branches of the arteria minor cerebelli.
8. The arteria posterior cerebri, passing outwards to the posterior lobe of the cerebrum, and communicating with the external cerebral artery, and with the superior artery of the cerebellum. Between the trunk of this artery, the tuber, and the fourth nerve, twigs are seen going off, which penetrate to the choroid plexus in the inferior cornu of the lateral ventricle.
9. The arteria communicans, joining the internal carotid and vertebral arteries, and furnishing a large share of the circle of WILLIS.
10. Twigs sent from the arteria communicans to the inferior extremity of the choroid plexus in the lateral ventricle.



TAB. 129



T A B L E CXXIX.

Represents the ARTERIES of the BRAIN, as seen after an Horizontal Section of the CEREBRUM,
at the Depth of the LATERAL VENTRICLES.

-
- | | |
|--|--|
| <p>A, A, The cortical, and,
B, B, &c. The medullary part of the cerebrum.
C, The anterior lobes of the cerebrum, separated a little from each other.
D, D, The arteriæ corporis callosi.
E, E, The cavities of the lateral ventricles.
F, G, The medullary part of the brain, between the corpora striata.
H, H, A section of the posterior crura of the fornix.</p> | <p>I, I, The corpora striata.
K, K, The thalami optici.
L, L, The choroid plexuses, between which are seen the vascular web, termed <i>Tela Choroidea</i>, which covers part of the thalami, and unites the plexuses to each other.
M, The passage by which the lateral ventricles communicate with each other and with the third ventricle.
N, N, The branches of the arteriæ cerebelli superiores, dispersed over the upper surface of the cerebellum.</p> |
|--|--|

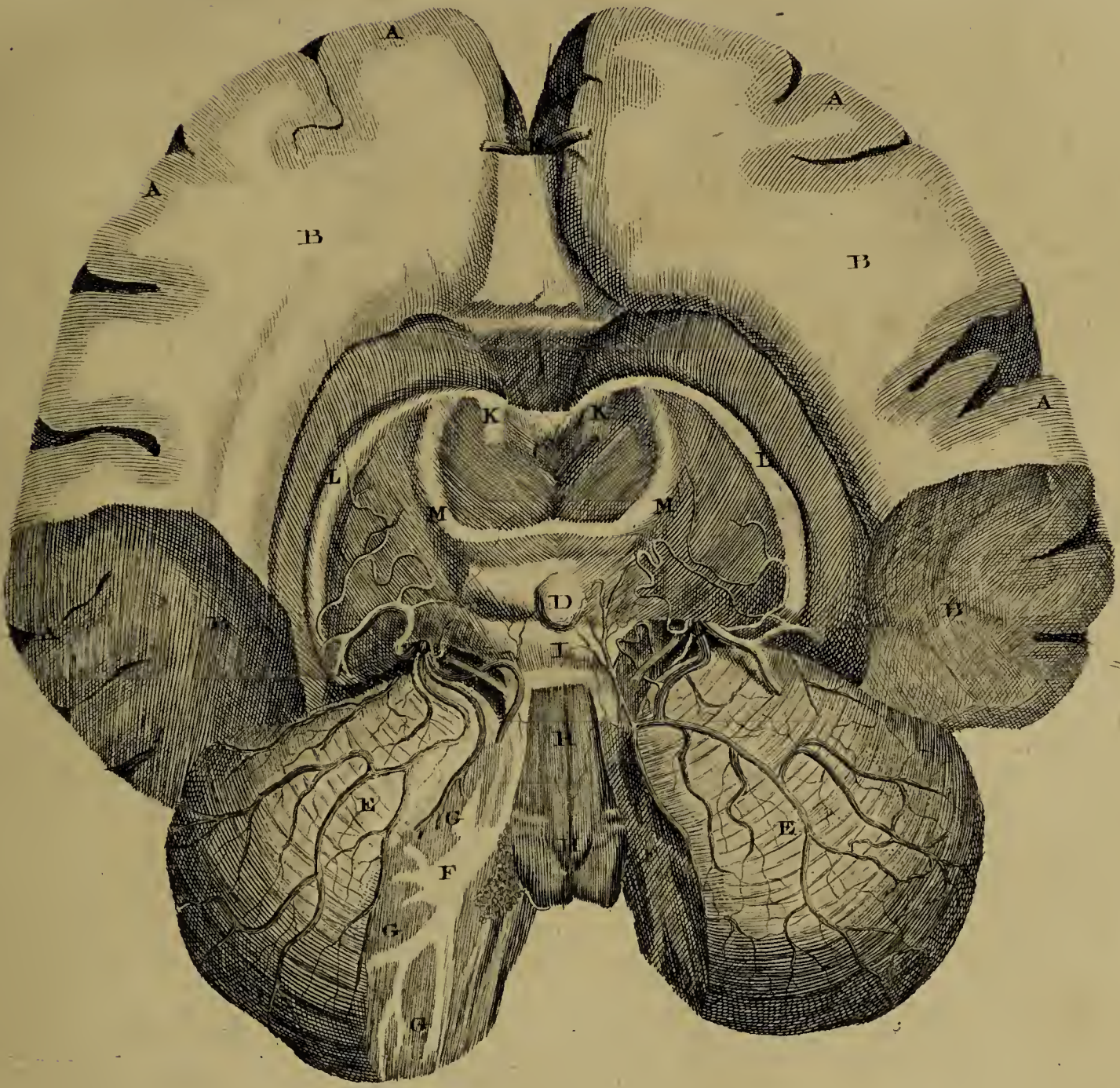
T A B L E CXXX.

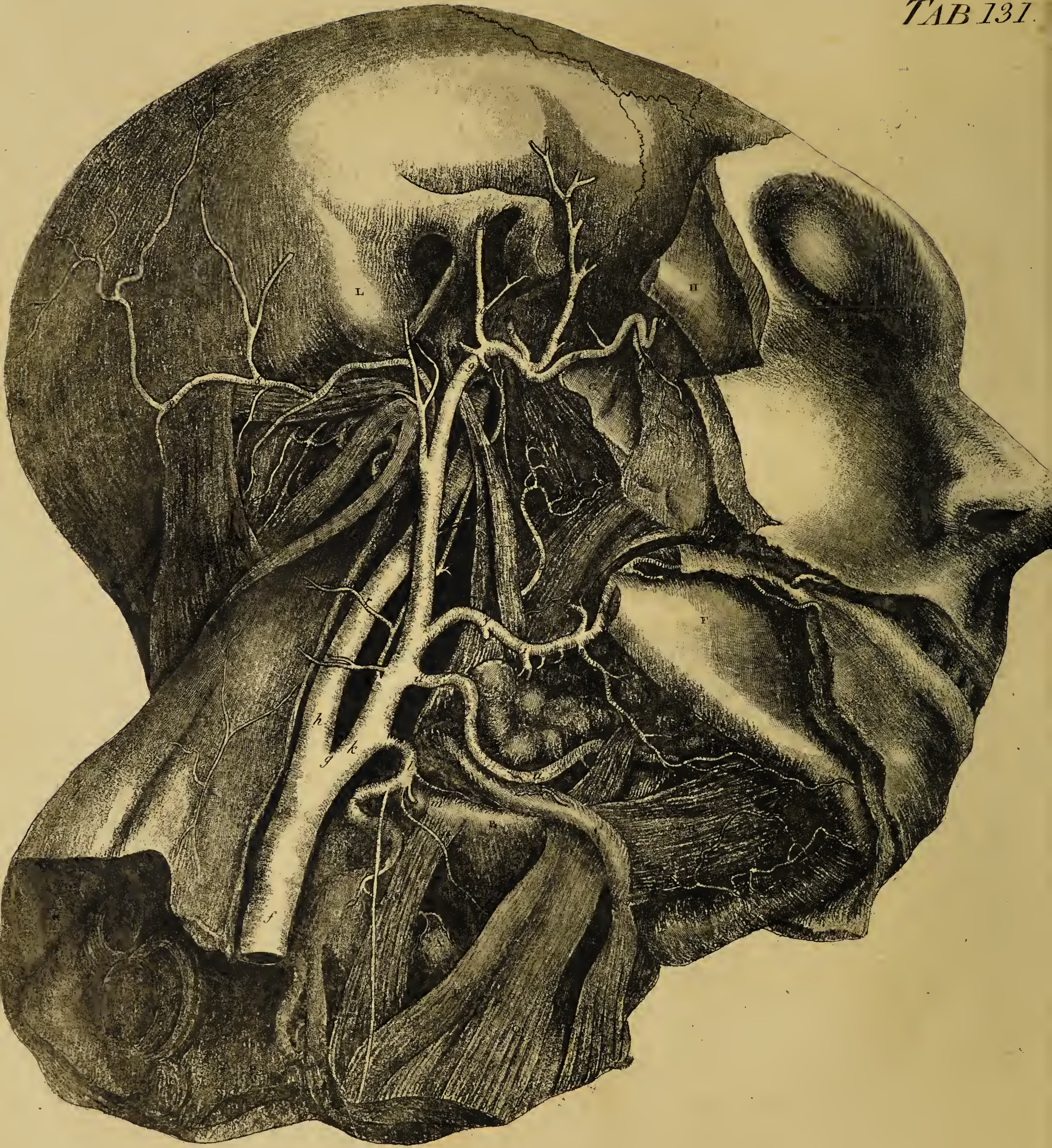
In this Table, the CHOROID PLEXUS and TELA CHOROIDEA, represented in Table CXXIX. are removed, and the THALAMI OPTICI, with the PINEAL GLAND, NATES, and TESTES, exposed; together with the FOURTH VENTRICLE, ARTERIÆ CEREBRI PROFUNDÆ, and ARTERIÆ CEREBELLI SUPERIORES.

A, The cortical substance of the brain.
 B, B, &c. The medullary substance.—The two posterior B's placed upon an oblique section of the posterior lobes of the brain.
 C, Part of the corpus callosum.
 D, The pineal gland, placed over the nates.
 E, E, The upper surface of the cerebellum.
 F, F, The medullary part of the cerebellum, termed *Arbor Vitæ*.
 G, G, The cineritious part of the cerebellum.
 H, H, The fourth ventricle, forming the calamus scriptorius.

I, The testes.
 K, K, A section of the anterior crura of the fornix.
 L, L, The tænia semicircularis.
 M, M, Medullary lines continued from the commissura cerebri posterior, inserted into the tænia.
 N, The arteriæ corporis callosi.
 O, O, Branches of the vertebral arteries, termed *Arteriæ Cerebri Profundæ*, which supply the back-part of the cerebrum, and *Arteriæ Cerebelli Superiores*, which are distributed upon the upper part of the cerebellum.

TAB. 130.





T A B L E CXXXI.

Represents the COMMON CAROTID ARTERY; its Division into INTERNAL and EXTERNAL CAROTIDS; the Course of the former in the NECK, and the Principal BRANCHES of the latter.

-
- A, The inferior margin of the thyroid cartilage.
 B, The superior margin.
 C, The os hyoides.
 D, The inferior maxillary gland.
 E, The sublingual gland.
 F, The extremity of the lower jaw, the branch of which is removed.
 G, The external pterygoid wing.
 H, The outer part of the zygoma broken off.
 I, The inner part of the zygoma.
 K, The meatus auditorius.
 L, The mastoid process.
 M, The foramen for the third branch of the fifth pair of nerves.
 N, The seat of the transverse process of the atlas.
 O, The sterno-thyroideus muscle.
 P, The omo-hyoideus.
 Q, Q, The sterno-hyoidei.
 R, The mylo-hyoideus.
 S, Part of the hyo-glossus, the most of which is destroyed.
 T, The pharynx descending from the uncus pterygoideus.
 U, The musculus stylo-glossus.
 V, The stylo-pharyngeus.
 W, The levator palati.
 X, The circumflexus palati.
 Y, The obliquus capitis superior:
 Z, ————— inferior.
 a, The levator scapulæ.
 b, The complexus.
 c, The eighth nerve.
 d, d, The vertebral artery;
 e, Its muscular branch to the obliqui capitis, rectus major, complexus, and rectus minor.
 f, The common carotid artery.
 g, The end of the common carotid.
 h, h, The cerebral trunk, a little curved in this place.
 i, The artery entering the cranium.
 k, The external carotid.
 l, The superior thyroid artery.
 m, A branch to the hyo-thyroideus, hyo-glossus, and sterno-hyoideus.
 n, A branch to the sterno-hyoidei muscles.
 o, A branch descending a great way under the skin to the omo-hyoideus.
 p, To the crico-thyroideus and thyroid gland.
 q, A branch from the arteria pharyngea.
 r, A superficial branch to the parotid gland.
 s, The first branch to the pharynx, divided upwards and downwards.
 t, A branch to the eighth nerve, intercostal ganglion, scalenus, rectus internus, and longus colli.
 u, u, The lingual artery.
 v, A branch to the hyo-glossus.
 w, The truncus lingualis profundus, or arteria ranina.
 x, The superficial, or sublingual branch to the mylo-hyoideus.
 y, The facial artery.
 z, The palate-branch of this artery.
 1. A large branch of the facial artery to the inferior maxillary gland.
 2. 3. A branch termed Arteria Submentalis, to the sublingual gland and mylo-hyoideus.
 4. The facial trunk in its way to the face.
 5. The occipital artery.
 6. The stylo-mastoid artery.
 7. The posterior auricular artery.
 8. 8. Branches of the occipital artery to the occiput, finciput, and splenius.
 9. The winding of the carotid, where it begins to degenerate into the temporal artery.
 10. The temporal artery:
 11. The meningeal artery, passing through its foramen.
 12. The external deep temporal artery.
 13. The internal deep temporal artery.
 14. The internal maxillary artery, passing by the root of the pterygoid process.
 15. The alveolar artery.
 16. The infra-orbital artery.
 17. The nasalis and palatina descendens, appearing obscurely in the sphenomaxillary fissure.

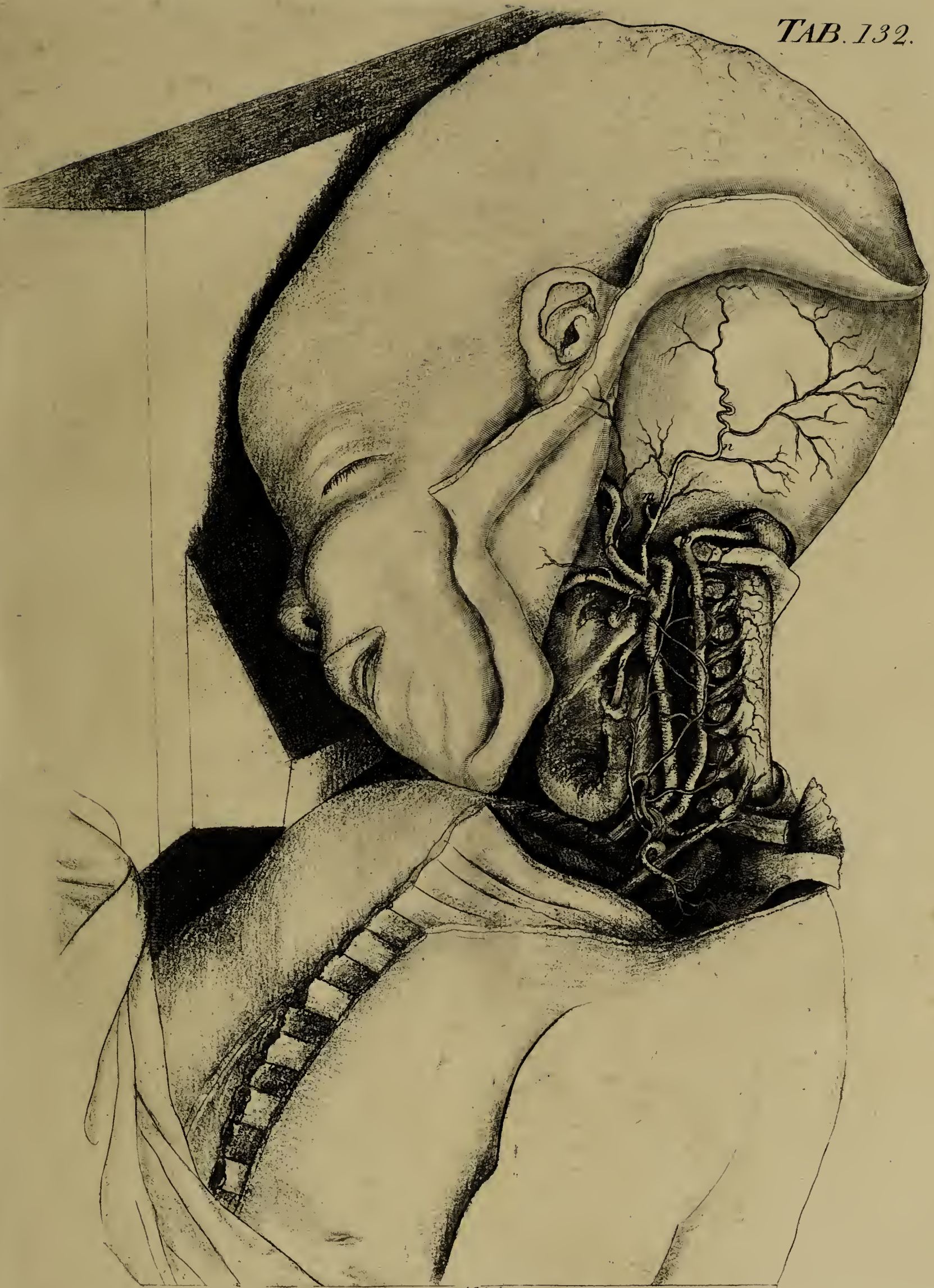
TABLE

T A B L E CXXXII.

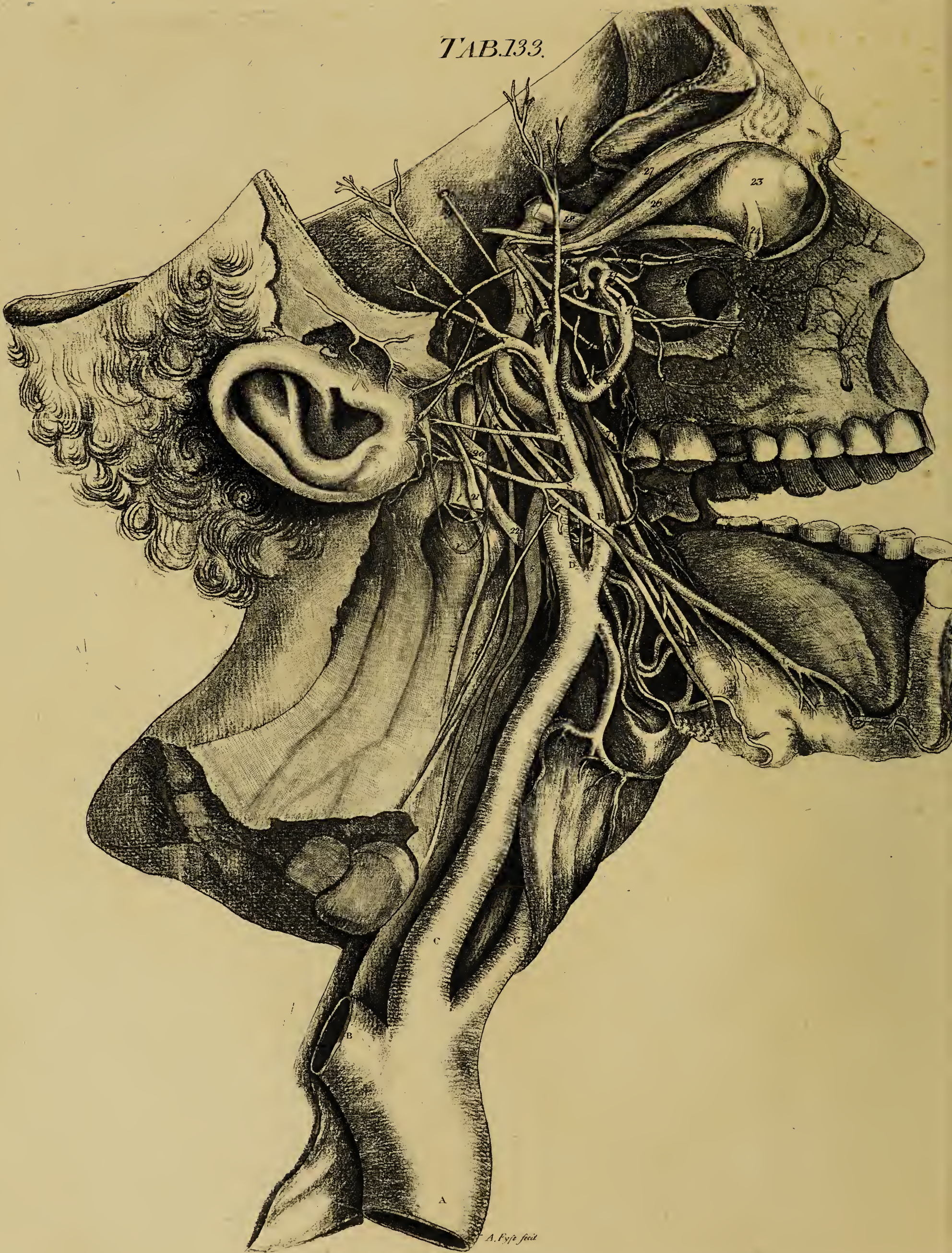A VIEW of the VERTEBRAL and CAROTID ARTERIES, with some of the BRANCHES of the EXTERNAL CAROTID, in a CHILD.

- | | |
|--|---|
| <i>a</i> , The subclavian artery. | <i>k</i> , The facial artery. |
| <i>b</i> , The course of the subclavian. | <i>l</i> , The occipital artery. |
| <i>c</i> , The superior dorsal artery of the scapula. | <i>m</i> , The mastoid branch. |
| <i>d</i> , The inferior laryngeal artery, in its way to the thyroid gland, with an anterior cervical branch. | <i>n</i> , The ramifications of the occipital artery. |
| <i>e</i> , The anterior cervical artery. | <i>o</i> , The vertebral artery, with numerous branches from it to the spinal marrow and its membranes,—and other branches which communicate with the deep cervical arteries. |
| <i>f</i> , The common carotid artery. | <i>p</i> , Its arch near the atlas. |
| <i>g</i> , The external carotid. | <i>q</i> , A branch of the cervicalis anterior to the vertebræ. |
| <i>h</i> , The superior laryngeal artery. | |
| <i>i</i> , The lingual artery. | |

TABLE



TAB. 133.



A. Fyfe fecit

T A B L E CXXXIII.

Represents the Upper Part of the AORTA, the CAROTID ARTERIES, and particularly the INTERNAL MAXILLARY BRANCH, and Serpentine Course of the INTERNAL CAROTID.

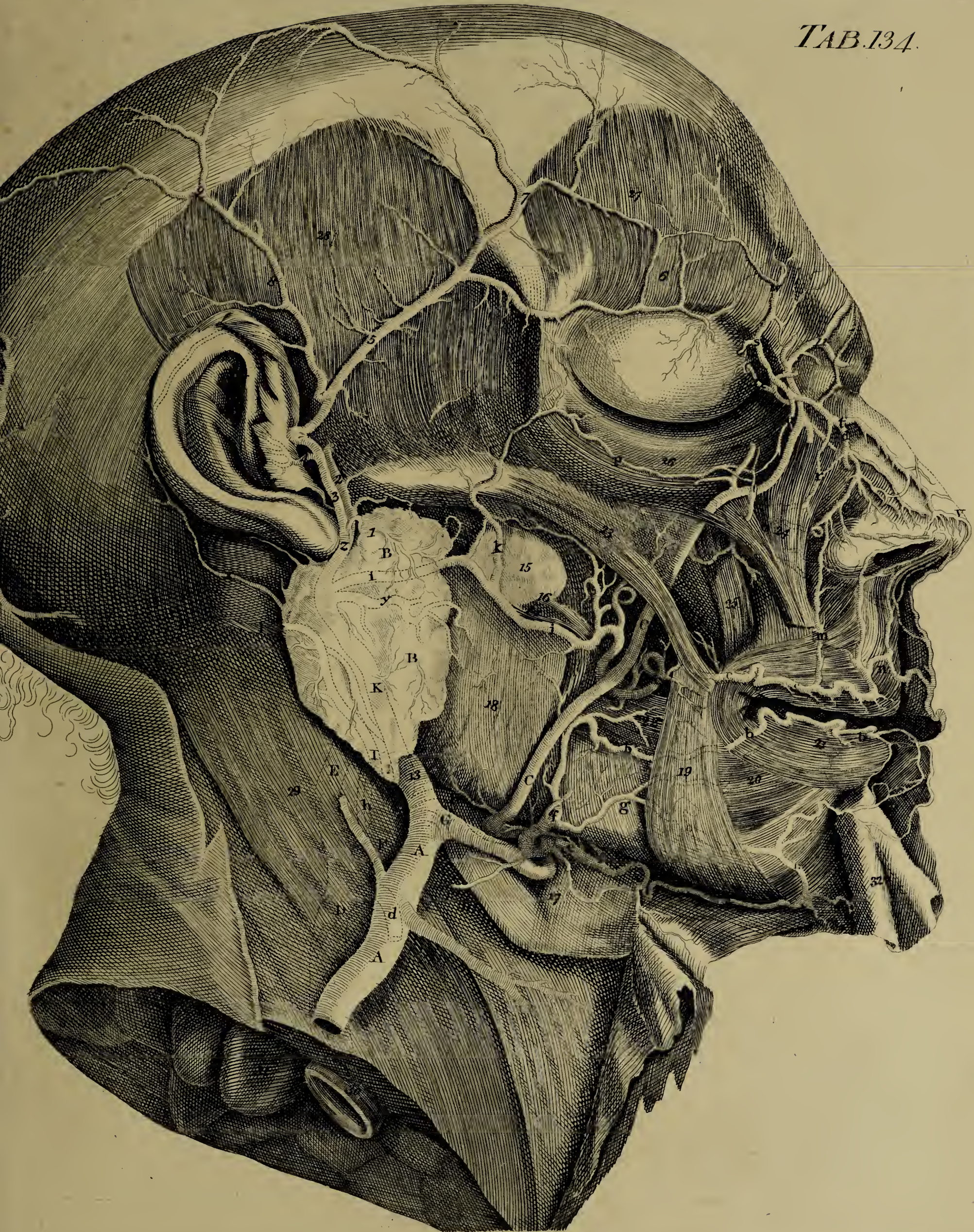
-
- | | |
|--|--|
| <p>A, The aorta, uncommonly large.
 B, The right subclavian artery.
 C, C, The common carotids.
 D, The internal,
 E, The external carotid.
 F, F, The superior thyroid artery, removed from its place, and drawn downwards.
 G, The windings of the internal carotid without the cranium;
 H, Its curvature within the os petrosum.
 I, A section of the internal carotid, where it perforates the dura mater, and goes to the brain.
 K, The lingual artery.
 L, The facial artery, slightly expressed;
 M, N, O, Its palatine branch to the palate and uvula.
 P, Branches of the lingual artery, which go to the chin and under lip.
 Q, The part where the infra-orbital and alveolar branches of the internal maxillary anastomose.
 R, R, The temporal artery.
 S, The occipital artery.
 T, The posterior auricular artery.
 U, The anterior branch of the temporal artery.
 V, The posterior branch of the same.
 W, Its auricular branch.
 X, A branch to the masseter and temporal muscles.
 Y, The trunk of the internal maxillary artery.
 Z, The meningeal branch of this artery.
 <i>a</i>, The inferior maxillary branch.
 <i>b</i>, The pterygoid branch of the meningeal artery.
 <i>c</i>, Two pterygoid branches of the maxillary artery.
 <i>d</i>, The deep posterior temporal branch.
 <i>e</i>, ——— anterior temporal branch.
 <i>f</i>, The ramus buccalis, companion of the buccinator muscle.
 <i>g</i>, The alveolar branch of the maxillary artery.
 <i>h</i>, The infra-orbital branch of the maxillary artery.
 <i>k, k</i>, A branch to the palate.
 <i>l</i>, The uppermost pharyngeal branch.
 <i>m</i>, A branch to the nose.
 <i>n</i>, Branches to the periosteum of the orbital fissure.
 <i>p</i>, The arteria pharyngea ascendens;</p> | <p><i>q</i>, Its branch to the tongue.
 <i>r</i>, A branch to the muscles of the neck.
 <i>s</i>, Branches to the pharynx and muscles of the uvula.
 <i>t</i>, The internal jugular vein.
 <i>u</i>, The nervus durus of the seventh pair;
 <i>v</i>, Its anastomosis with the nerve of the eighth pair.
 <i>w</i>, The ninth pair of nerves.
 <i>x</i>, The ramus descendens of this nerve, to the muscles of the neck.
 <i>y</i>, The trunk of the eighth pair.
 <i>z</i>, The accessory nerve.
 1. 1. A nerve from the eighth pair to the basis of the tongue and plexus pharyngeus.
 2. 3. The two roots of the intercostal nerve.
 4. The small common trunk of the intercostal nerve;
 5. 5. Its large ganglion.
 6. The continuation of the intercostal nerve.
 7. The inferior maxillary nerve from the third of the fifth.
 8. The lingual branch from the same.
 9. The temporal branch of the same.
 10. The ramus buccalis.
 11. The infra-orbital branch from the second of the fifth nerve.
 12. The superior laryngeal branch of the eighth nerve.
 13. The ramus palatinus of the second of the fifth nerve.
 14. A branch from the infra-orbital of the fifth nerve to the sinus Highmori.
 15. The fourth nerve.
 16. The sixth nerve.
 17. The third nerve.
 18. The optic nerve.
 19. The duct over the alæ pterygoideæ.
 20. 21. 22. Muscles arising from the styloform process.
 23. The ball of the eye.
 24. The trochlea.
 25. The musculus trochlearis.
 26. The rectus superior.
 27. The levator palpebræ superioris.
 28. Part of the sinus Highmori.
 29. 29. A probe introduced into the Eustachian tube.</p> |
|--|--|

TABLE

T A B L E CXXXIV.

A VIEW of the ARTERIES, and some of the Principal VEINS on the Outside of the HEAD.

-
- D, The situation of the common carotid artery, marked by dotted lines.
- E, The situation of the internal carotid artery, marked by dotted lines.
- F, The situation of the external carotid artery, also marked by dotted lines.
- d, The superior thyroid artery.
- G, The sublingual artery, covered with veins and with the hyo-glossus muscle.
- H, The facial artery, also covered at its beginning.
- e, The pterygoid branches.
- a, The submental artery.
- f, Superficial branches.
- g, The muscular artery of the under lip, communicating with the submentalis, a.
- b, b, b, The coronary artery of the under lip, sending branches to the masseter, buccinator, and depressor anguli oris, and terminating in the lip.
- I, I, The occipital artery covered by the parotid gland and by muscles, and becoming superficial on the occiput.
- b, The pharyngeal artery concealed.
- K, The trunk of the temporal artery covered by the parotid gland.
- i, i, The transversalis faciei arising from the external carotid artery,—uncommonly large in this figure.
- k, A branch to the temple and under eye-lid.
- l, Branches to the muscles of the cheek.
- c, c, c, The continuation of the transversalis faciei, forming, in this figure, the coronary artery of the upper lip.
- m, The lateral nasal artery communicating with the ophthalmic.
- n, The continuation of the superior coronary artery, sending branches to the nose, and communicating with its fellow on the opposite side.
- o, The seat of the infra-orbital artery covered with muscles.
- p, The anastomosis of the infra-orbital and transversalis faciei.
- q, The anastomosis of the infra-orbital and superior labial artery.
- r, The anastomosis with the ophthalmic artery. Besides these anastomoses, the dotted lines point out several other branches which pass to the side of the nose and upper lip.
- s, The ophthalmic artery coming from the orbit.
- t, A branch of the ophthalmic artery to the side of the nose.
- u, A branch which communicates with one from the transversalis faciei.
- v, Anastomoses with the nasal coronary branches.
- w, A branch to the fore-head.
- x, The posterior auricular artery.
- y, A branch of the external carotid to the parotid gland.
- z, The external carotid forming the temporal artery.
1. A branch from the temporal artery to the masseter muscle and parotid gland.
 2. The deep branch of the temporal artery.
 3. The trunk of the temporal artery.
 4. The anterior auricular branch.
 5. The anterior temporal branch.
 6. The communications of the anterior temporal with the ophthalmic artery.
 7. Branches to the fore-head, upper part of the head, and temple.
 8. The posterior temporal branch.
 9. The arteriæ fincipitales.
 10. Anastomosis with the occipital artery.
 11. The frontal vein.
 12. The ophthalmic vein.
- C, C, The facial vein.
13. The temporal vein.
 - A, A, The external jugular vein.
 - B, B, The parotid gland.
 14. The duct of the parotid gland.
 15. The

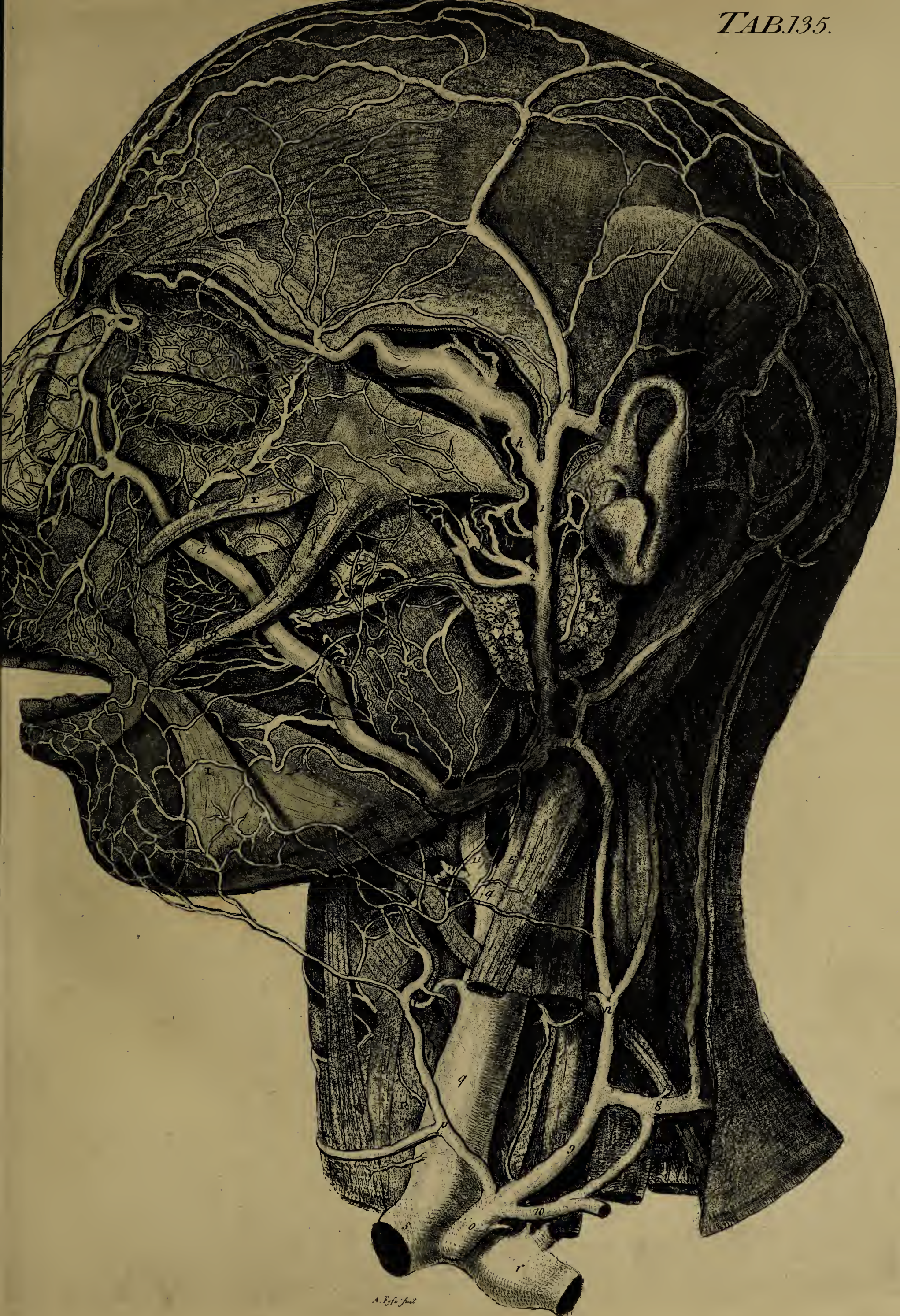

15. The accessory parotid gland.
16. The duct of the accessory parotid gland.
17. The submaxillary gland.
18. The masseter muscle.
19. The depressor anguli oris.
20. ----- labii inferioris.
21. The orbicularis oris.
22. The buccinator.
23. The zygomaticus.
24. The levator labii superioris alæque nasi.
25. ----- anguli oris.
26. The orbicularis palpebrarum.
27. The frontalis.
28. The temporalis.
29. The sterno-cleido-mastoideus.
30. A section of the trachea.
31. The spinal marrow.
32. The integuments cut and turned back.

T A B L E CXXXV.

A VIEW of the VEINS, &c. of the HEAD and NECK.

- A**, The frontal muscle.
B, The tendon of the occipito-frontalis.
C, The attollens aurem.
D, The retrahentes aurem.
E, E, The aponeurosis of the temporal muscle, cut to show the vein it concealed.
F, The zygomaticus minor.
G, ————— major.
H, The levator anguli oris.
I, The depressor anguli oris.
K, The upper end of the platysma myoides.
L, The masseter.
M, M, The parotid gland divided, to obtain a view of the vein which it covers.
N, The duct of the parotid gland.
O, The small, or accessory parotid gland, with its duct opening into that of the parotid.
P, The sterno-hyoideus.
Q, ————— thyroideus.
R, The thyroid gland.
S, The omo-hyoideus.
T, A section of the sterno-cleido-mastoideus.
U, The splenius.
V, The trapezius.
W, The common carotid artery.
X, The superior thyroid artery.
a, Numerous communications between the frontal and temporal veins.
b, The trunk of one of the frontal veins.
c, The ocular-angular vein, formed by the frontal vein of this side, and by numerous branches which communicate with the temporal veins, and with veins upon the eye-lids and nose.
d, The facial vein receiving branches from the face in general.
e, f, The anterior superficial temporal vein, communicating with the frontal, with the posterior superficial vein, and with its fellow upon the opposite side.
g, The posterior superficial temporal vein communicating with the occipital veins.
h, The deep temporal vein communicating with the frontal, facial, and superficial temporal veins.
1. The superficial temporal vein.
2. The transversalis faciei.
3. The continuation of the temporal vein.
4. The occipital branch of the external jugular vein.
k, k, The superficial occipital vein.
l, The posterior branch of the facial vein.
m, The communication between the temporal and facial veins.
5. The trunk formed by the facial and temporal veins, represented in this Figure going into,
6. The internal jugular vein.
n, n, **9.** The external jugular vein, strictly so called.
o, The termination of the external jugular in the subclavian vein.
7. A large branch of this vein.
8. 10. The posterior cervical vein.
11. The superior laryngeal vein.
p, The anterior external jugular vein.
q, q, The continuation of the internal jugular vein.
r, The subclavian vein.
s, The great subclavian vein.



THE REMAINING BLOOD-VESSELS OF THE NECK, WITH THOSE OF THE SUPERIOR
EXTREMITY IN GENERAL.

ARTERIES.

SUBCLAVIAN ARTERY.

THE Subclavian Artery has been already observed to arise, on the right side, in common with the Carotid, by a Trunk called *Arteria Innominata*; and on the left, to come off directly from the Aorta. Tab. LXXXV.

ARTERIA INNOMINATA.—The *Arteria Innominata*, named also *Right Subclavian*, which is scarcely two inches in length, ascends obliquely over the Trachea, at the right side of which it divides into the *Right Proper Subclavian*, and the *Right Common Carotid*. Tab. CXCVI.

The *Left Subclavian* arises from the Arch of the Aorta, at the outside of the Carotid, and ascends to the upper part of the Thorax, forming there a sharper or more extensive Curvature than the Subclavian of the right side.

After the two Subclavians have emerged from the Thorax, each passes transversely outwards at the under part of the Neck, behind the Origin of the *Sterno-mastoideus*, and continues its course outwards between the Anterior and Middle *Scaleni*, and between the Subclavian Muscle and first Rib. Tab. CXXI. *b*.

After crossing the first Rib, it goes under the Pectoral Muscles to the Axilla, where it obtains the name of *Axillary Artery*.—In this course, it sends off the following Branches, viz.

The *Vertebral*;—the *Internal Mammary*; and—the *Superior Intercostal Artery*.—The first of these has been already described: The two others belong to the inner part of the Thorax.—It also gives off—

The *THYROIDEA*, vel *GUTTURALIS INFERIOR*, Tab. CXLV. *p*, which arises at the outer side of the Vertebral Artery, previous to the passage of the Subclavian under the *Scalenus*. It ascends obliquely inwards in a winding manner behind the Carotid Artery, gives Branches to the Trachea, which descend in the Thorax, and inosculate with the Bronchial Arteries, also Twigs to the Larynx, Pharynx, and Esophagus; while the most considerable part of the Artery is dispersed upon the Thyroid Gland, inosculating with the Superior Laryngeal Artery.

The *CERVICALIS ANTERIOR*, Tab. CV. *o*, which frequently comes off from the root of the Inferior Thyroid, and ascends in the Neck, furnishing Superficial Branches to the Muscles which go from the Trunk of the Body to the Neck, and Deep Branches to the Glands, Nerves,

&c. lying on the fore and lateral parts of the Cervical Vertebrae.

The Deep Branches anastomose with the Vertebral and Occipital Arteries; and some passing through the Intervertebral Holes where the Nerves come out, communicate with the Spinal Arteries.

The *CERVICALIS POSTERIOR*, Tab. CV. *l*, which arises in common with the Anterior Cervical, or with the Inferior Thyroid.—This is larger than the former, lies farther out, and runs in a winding direction outwards and upwards.

It supplies the Skin and Muscles at the lateral and back part of the Neck, communicates with Branches of the Occipital and Vertebral Arteries, and sends a principal Branch downwards to the parts about the top of the Shoulder, and the upper and lateral parts of the Thorax.

The *DORSALIS SUPERIOR SCAPULÆ*, Tab. CXXXVII. *p*. Tab. CV. *k*, which comes frequently from the root of the Thyroid, and runs transversely behind the Origin of the *Sterno-mastoideus*, near the Clavicle. It afterwards perforates the Notch in the superior Costa of the Scapula, and, expanding its Branches upon the Dorsum of that Bone, supplies the Spinati and other Muscles situated there, and likewise furnishes Branches to the Joint of the Shoulder.

Besides the Branches of the Subclavian Artery mentioned above, others are frequently found, which are more variable in their Origin, and in their Distribution in the Neck.

AXILLARY ARTERY.

The AXILLARY ARTERY, Tab. CXCIV. *a*. Tab. CXCVIII. lying in the Axilla, between the Subscapularis and Serratus Major, is surrounded by the Lymphatic Glands and Fat, by the Veins, and also by the large Nerves which form the Brachial Plexus. It gives some small Branches to the adjacent Muscles and Nerves;—but its principal Branches are,

The *THORACICÆ*, vel *MAMMARIE EXTERNÆ*, Tab. CXXI. right side, *f, g, h, i*,—three or four in number,—which by some Authors are described under particular names; as,

The *Thoracica Superior*, which arises opposite the First or Second Rib, gives Branches to the Serratus and Intercostales; and to the Pectorales and Skin:

The *Thoracica Longa*, which sends Twigs to the Axillary Glands; but goes chiefly to the Serratus, Pectoralis, Mamma, and Integuments, and inosculates with Branches of the *Thoracica Superior*;

The *Thoracica Humeralis*, vel *Acromialis*, which goes off opposite the *Thoracica Superior*, and divides suddenly into Branches, which run to the upper parts of the Thorax near it, and to the Integuments, Muscles, and Ligaments, surrounding the Articulation; inosculating with Branches of the Scapular Arteries:

The *Thoracica Axillaris*, vel *Alaris*, which, when present, goes off from or near to the *Thoracica Humeralis*, and is bestowed upon the Axillary Glands, Fat, &c. frequently dispersing Branches upon the under edge of the Subscapularis, and upon the Pectoralis and Serratus:

The SCAPULARIS INTERNA, vel SUBSCAPULARIS, Tab. CXXXVI. Fig. 1. O, which arises, at the under edge of the Subscapularis, and soon divides into the Proper *Scapularis Interna*, and the *Dorsalis Scapulae Inferior*:

The SCAPULARIS INTERNA runs near the inferior edge of the Scapula, and sends off many large Branches, the principal part of which are dispersed upon the Latissimus Dorsi, Teres Major, and Subscapularis. It sends Branches also to the Muscles arising from the Coracoid Process, to the Capsular Ligament, and to the Axillary Glands, which have large Anastomoses with each other, and with the Superior Dorsal Artery of the Scapula:

The DORSALIS SCAPULÆ INFERIOR, Tab. CXXXVI. Fig. 2. a, g, &c. immediately after leaving the Internal Scapular Artery, turns round near the Cervix of the Scapula, between the Inferior Costa of the Bone and Teres Major, to the Fossa Infra-spinata:

Upon the Posterior Surface of the Scapula, it spreads out into Branches of considerable size, which are dispersed upon the Muscles covering the under and back part of the Bone, and extend also to the Capsular Ligament; while the Trunk, ascending, inosculates with that of the Superior Dorsal Artery of the Scapula, whereby an Arch common to the two Arteries is formed at the root of the Acromion:

The CIRCUMFLEXA, vel ARTICULARIS ANTERIOR, Tab. CXXXVII. Z, which is sent off between the Subscapularis and Teres Major. It passes in a transverse direction between the Heads of the Coraco-brachialis and Biceps, and Body of the Os Humeri, immediately below the Joint of the Humerus. It is dispersed upon the Muscles which cover it, and upon the Periosteum and Capsular Ligament of the Joint.

The CIRCUMFLEXA, vel ARTICULARIS POSTERIOR, Tab. CXXXVII. u, which arises directly opposite to the former, or by a common root with it, and is by much the larger of the two.

It passes first between the Subscapularis and Teres Major, and then turns round between the back part of the Os Humeri, and Long Head of the Triceps, and the Deltoides. It sends Branches to the Periosteum and

Joint, to the Short Head of the Biceps and Coraco-brachialis, to the Triceps and Subscapularis, and runs in a circular manner to the Deltoides. Its extreme Branches anastomose with those of the Anterior Circumflex Artery, so as completely to encompass the Body of the Bone.

After giving off these different Branches, the Axillary Artery emerges from behind the edge of the Pectoralis Major, and runs along the Os Humeri, where it is termed *Humeral*, or *Brachial Artery*.

HUMERAL ARTERY.

The HUMERAL ARTERY, Tab. CXXXVII. CXXXIX. descends behind the inner edge of the Biceps, covered by the Tendinous Aponeurosis of the Arm, and having the Triceps Extensor Cubiti behind. In this course, it bestows Branches to the Muscles and Integuments, and to the Periosteum and Bone, viz.

A Branch under the Coraco-brachialis to the Capsule of the Joint and parts adjacent to it.

Branches to the Triceps and Coraco-brachialis.

Various Branches to the Biceps, Brachialis Internus, and Bone.

The PROFUNDA HUMERI, vel SPIRALIS, Tab. CXL. which arises near the upper part of the Arm, at the insertion of the Latissimus Dorsi and Teres Major, taking a Spiral direction downwards and outwards, between the Triceps and Bone, and terminating at the outer Condyle of the Os Humeri, by a *Large communicating Radial*, or *Profundo-radial* Branch.

The Arteria Profunda sends Branches upwards, which inosculate with others from the Humeral and Scapular Arteries. The principal Branches run to the Coraco-brachialis and Triceps, and to the Muscles at the outer part of the Elbow;—and one of them, termed *Large communicating Ulnar*, or *Profundo-radial*, descending at the inner side of the Arm, is sometimes so considerable as to form—

The PROFUNDA INFERIOR, or MINOR, Tab. CXXXVII. No. 4. This Artery is frequently a Branch of the Profunda Superior, but more commonly an original Branch sent off from the Trunk of the Artery, near the middle of the Arm.

It gives Branches to the Muscles and other parts at the inside of the Arm, and terminates about the inner part of the Os Humeri.

The RAMUS ANASTOMOTICUS MAGNUS, Tab. CXXXVII. which comes off a little above the Elbow, and bestows Branches to the Brachialis Internus, to the under end of the Triceps, and to the Muscles, Ligaments, and Parts in general about the Elbow-Joint.

Besides these, there are several other Branches sent in succession from the Trunk of the Humeral Artery into the Muscles and other parts adjacent, which are shorter than the rest, and run more in a transverse direction, especially those to the Biceps. One small Branch, termed

Nutritia,

Nutritia, or *Medullaris*, goes into the Substance of the Bone by the Passage near its middle, and supplies the Marrow, and parts which contain it.

The Trunk of the Humeral Artery having sent off the different Branches which belong to the Arm, passes to the middle of the Bending of the Elbow, between the Aponeurosis and Round Tendon of the Biceps.

About an inch below the Elbow, it commonly divides into two principal Arteries, the *Radial* and *Ulnar*. Tab. CXXXVII. CXL. It happens, however, now and then, that this Division takes place about the middle of the Arm; and in certain instances as high as the Axilla.

The *RADIALIS* passes over the Pronator Teres, and follows the course of the Radius through the whole length of that Bone. It descends between the Supinator Longus and Flexor Radialis, resting on the Flexor Longus Pollicis.

At the upper part of the Fore-arm, it is covered by the Supinator Longus: In its descent, it becomes more superficial, and, at the under part of the Fore-arm, it lies close upon the Radius, and immediately under the Skin, in consequence of which, the Pulse is commonly felt in this place. Its principal Branches are,

The *Recurrans Radialis*, which is reflected to the Muscles and Parts of the Joint near it, and anastomoses freely with the Profundo-radial, and Profundo-minor of the Humeral Artery, at the outer part of the Elbow.

Numerous *Lateral Branches*, in the descent of the Artery, to the Muscles and Integuments, and parts in general situated about the Radius.

The *Superficialis Volæ*, which goes off at the Wrist, and passes over or through the Abductor Pollicis to the Palm. It is sometimes so small as scarcely to reach the Palm. More frequently it is a considerable Artery, sending Branches to the Ball of the Thumb and superficial parts of the Palm near it,—a Branch along the outer side of the Thumb,—and an Anastomosing Branch, which unites with the Arch of the Ulnar Artery.

Small Branches to the Ligaments, Bones, and other parts about the Wrist.

One, or sometimes two Branches, termed *Dorsal*, to the back part of the Metacarpus and Fingers.

At the under end of the Fore-arm, the Radial Artery turns back under the Tendons of the Extensors of the Thumb;—then getting between the roots of the Metacarpal Bones of the Thumb and Fore-finger, Tab. CXXXVII. CLVII. and, perforating the Abductor Indicis, it divides into Three Principal Branches, viz.

The *Arteria Magna Pollicis*, which runs along the side of the Thumb next the Fingers, and sometimes divides at its root into two Branches, which supply both sides of it.

The *Radialis Indicis*, which runs along the side of the Fore-finger next the Thumb.

The *Palmaris Profunda*, which crosses the Hand between the roots of the Metacarpal Bones and Flexors of the Fingers, and forms an *Arcus Profundus*, from which Branches go off to the Interossei and other deep parts of the Palm.

The *ULNARIS*, somewhat larger than the Radialis, appears at first as the continuation of the Trunk of the Humeral Artery.

At its upper part, it sinks deep behind the Flexor Muscles of the Hand, and passes afterwards, for some way, between the Flexor Sublimis and Profundus Digitorum.

Near the Wrist, it becomes more superficial, and runs between the Tendons of the Flexor Carpi Ulnaris and Flexor Digitorum Profundus, to the Hand.

In this course, it sends off many Branches to the Fore-arm, among which the following are the most considerable.

The *Recurrans Ulnaris*, Tab. CXXXVII. No. 13. which runs deep among the Flexor Muscles, and soon divides into Branches, which ascend and supply the Parts about the posterior and inner side of the Elbow and Capsule of the Joint.—In the Groove behind the inner Condyle of the Os Humeri, it communicates by distinct Anastomoses with the Profunda Inferior, or with the Ramus Anastomoticus, sent down from the Humeral Artery.

The *Interossea Posterior*, Tab. CXXXVIII. No. 8. which comes off at the upper end of the Interosseous Ligament, perforating it immediately at its Origin, and going to the back-part of the Fore-arm.

From this place, it sends upwards a *Recurrent Branch*, which communicates, upon the back part of the Elbow, with the other Recurrent Arteries, and with the Branches sent down from the Humeral Artery, and forms along with these a Plexus of Vessels upon the back part of the Joint.

The Interossea is afterwards continued downwards, and is chiefly dispersed upon the Bellies of the External Muscles of the Hand and Fingers, being commonly exhausted before it reach the Wrist.

The *Interossea Anterior*, Tab. CXXXVII. No. 22. which comes off sometimes immediately below the former, and at other times in common with it. It is considerably the larger of the two; but only about half the size of the Ulnar Artery from which it springs.

It runs close upon the Interosseous Ligament, and furnishes Branches to the Muscles and Deep Parts upon the anterior side of the Fore-arm, and the Nutritious Arteries of the Radius and Ulna.

Near the Wrist, the principal part of the Artery perforates the Ligament, and goes to the posterior side of the Carpus and back of the Hand, dividing into Branches which anastomose with others of the Posterior Interosseous and Radial Arteries. The other part of the Artery is spent about the Ligaments on the fore-side of the Wrist.

The Ulnar Artery, having given off its Recurrent Branch, and the Arteriæ Interossee, with many Lateral Branches to the inner side of the Fore-arm, passes by the radial side of the Os Pisiforme, and then over the Annular Ligament into the Palm, where it forms the *Arcus Volaris Superficialis*.

At the under end of the Fore-arm, it sends off a *Dorsal Branch*, which passes behind the Tendon of the Flexor Carpi

Carpi Ulnaris to the back of the Hand, where, joining with Branches of the Anterior Interosseous and Radial Arteries, it assists in forming a Plexus, which supplies the back part of the Wrist, Hand, and Fingers, with a number of Branches, which are small when compared with those in the Palm.

The *Arcus Volaris Sublimis*, vel *Superficialis*, is placed with its convex side downwards, and extends obliquely from the root of the Metacarpal Bone of the Little Finger towards that of the First Bone of the Thumb; being covered by the Expansion termed *Aponeurosis Palmaris*.

From the *Arcus Volaris*, Branches are sent off in the following order, viz.

Several *Small Branches* to the Integuments and other Superficial parts of the Palm;

A considerable Branch, termed *Ulnaris Profunda* of the Palm, which sinks near the root of the Metacarpal Bone of the Little Finger, and, inosculating with the Palmar Branch of the Radial Artery, assists in forming the *Arcus Profundus*:

A *Branch* to the inner side of the Little Finger:

Three large Digital Branches, which run opposite to the Interstices of the Metacarpal Bones, to the Roots of, or Clefts between the Fingers.

At these Clefts, each of the Three Digital Arteries is divided into two Branches, one of which Branches of each Division runs along the anterior Radial margin of one Finger, and the other along the anterior Ulnar margin of the Finger next it;—the Three Digital Arteries thus supplying the margins of all the Fingers, excepting the inner margin of the Little Finger, and the outer margin of the Index.

At the roots of the Fingers, each of the Digital Arteries receives a small Branch from the *Arcus Profundus*.

At the Roots and Joints, but more particularly at the Points of the Fingers, the Arteries communicate by cross Arches, and send Branches to the parts adjacent.

The Superficial Arch of the Palm commonly sends off one of the Arteries of the Thumb, and ultimately communicates by a large Anastomosis with the Root of the *Arteria Magna Pollicis*.

VEINS OF THE SUPERIOR EXTREMITY, AND OF PART OF THE NECK.

The Veins of the Superior Extremities have numerous *Valves*, and are divided into a *Superficial* and a *Deep Set*; the former lying immediately under the Integuments, the latter accompanying the Arteries, and taking their names from them. Tab. CXL.

The Subcutaneous Veins have many large Anastomoses with each other, particularly on the Fore-arm, where they unite, separate, and re-unite several times, thus forming a Plexus by which it is surrounded.

The Superficial Veins from the back of the Hand,

(one of which, belonging to the Little Finger, was termed *Salvatella* by the Ancients), go chiefly to the *Superficial Radial*, and partly also to the *Ulnar Veins*.

The Superficial Radial Veins go to the *Vena Cephalica*, Tab. CLIX. B, and the Superficial Ulnar Veins to the *Vena Basilica*, Tab. CLIX. D, at the Joint of the Elbow.

The Superficial Veins on the anterior part of the Fore-arm form a Plexus which communicates laterally with the Radial and Ulnar Veins, and, particularly with a Trunk termed *Mediana Longa*. Tab. CLIX. C.

From this Plexus an *Internal Median Trunk* is commonly formed, which terminates in the Basilica.

The *MEDIANA LONGA*, arises by numerous Branches from the back of the Hand and root of the Thumb, and communicates with the *Vena Salvatella*.

It crosses over the Radius, and has a slanting direction, and a little below the Bending of the Elbow, is divided into *Mediana Cephalica*, Tab. CLIX. E, and *Mediana Basilica*, Tab. CLIX. F, which, running obliquely upwards, terminate a little above the Elbow, the former in the Cephalic, and the latter, crossing over the Humeral Artery, in the Basilic Vein.

Though this description corresponds with the general distribution of the Fore-arm; yet, so great is the Variety among them, that they are scarcely found to agree exactly in any two Subjects.

The *BASILICA*, in its ascent, forms the principal Humeral Vein, which passes along the side of the *Os Humeri*, a little to the inside of the Humeral Artery; and, receiving Branches from the corresponding side of the Arm, and communicating with the deep Veins, it runs into the Arm-pit, and forms the *Vena Axillaris*.

The *CEPHALICA* ascends at the outside of the Biceps, receives Branches from the adjacent parts of the Arm, and communicates in several places with the Basilic; and, passing in the Groove between the *Pectoralis Major* and the *Deltoides*, terminates in the Axillary Vein.

The *Deep Veins*, termed also *Vena Satellites*, or *Concomites*, run close by the sides of their respective Arteries, one lying commonly on each side of the Artery, and receiving the Blood from the adjacent parts. Tab. CXXXIX. Tab. CLIX.

In various places they anastomose with each other by short Branches, which cross over the Arteries.

Near the Joint of the Elbow, the *Deep Radial*, *Ulnar*, and *Interosseous Veins*, form a Plexus over the Bifurcation of the Humeral Artery.

From this Plexus, a short but large Branch passes outwards, and forms a Communication with one of the Subcutaneous Veins, and, in general, the Communication is with one of the Median Veins.

The *Vena Axillaris*, Tab. CXXXIX. No. 17. formed by the Trunks of the Superficial and Deep Humeral Veins, receives the Veins corresponding with the *Circumflex Arteries*, and the *Internal*, and the *Inferior Dorsal Veins* of the *Scapula*.

A little higher, it is joined by the *Vena Thoracica Externa*

terne, and about this place changes its name for that of *Subclavian Vein*.

The *VENA SUBCLAVIA*, Tab. CXXXIX. No. 19. Tab. CLIX. A, passes between the Clavicle and first Rib, at the inner side of the Trunk of the Artery, and afterwards goes over the fore-part of the *Scalenus Anterior*, at the under end of the Neck.

After crossing the first Rib, it receives the *Vein* corresponding with the Superior Dorsal Artery of the Scapula, other *Veins* which belong to the Cervical Arteries, and also *small Veins* from the Skin and Muscles on the back-part of the Neck.

While situated in the Neck, it likewise receives the *External*, and then the *Internal Jugular Veins*; and near this last, a *Vein* of considerable size, which corresponds with the Trunk of the *Vertebral Artery*.

The *Vertebral Vein* communicates within the Cranium, by small Branches, with the Inferior Petrosal Sinuses, or with the Occipital Sinuses; but is chiefly formed by Branches arising from the Spinal Marrow and its Membranes, and from the Bones and Deep-seated Muscles of the Neck.

Behind the top of the Sternum, the *Subclavian Vein* frequently receives the *Inferior Laryngeal Vein*, the *Anterior External Jugular*, and the *Internal Mammary Vein*. — Besides these, the *Left Subclavian* receives also the *Left Superior Intercostal Vein*; after which, it goes across the Root of the Great Arteries sent up from the Arch of the Aorta, and joins its Fellow of the opposite side, to form the *Cava Superior*.

TABLE

T A B L E CXXXVI.

Represents the ARTERIES of the SHOULDER.

FIG. 1.

The Hollow Part of the RIGHT SCAPULA laid bare.

BONES and MUSCLES.

- A, Part of the coracoid process.
- B, The head of the os humeri.
- C, The upper, and,
- D, The under edge of the scapula.
- E, E, E, Muscular prints upon the hollow surface of the scapula.
- F, A section of the subscapularis muscle.
- G, The deltoïdes.
- H, The tendon of the latissimus dorsi.
- I, The teres major.
- K, The long head of the triceps extensor cubiti.
- L, L, L, The termination of the ferratus magnus.
- M, The lymphatic glands, termed *Glandulæ Alares*.

VESSELS.

- a, The subclavian artery.
- b, The vertebral artery.
- c, c, The external thoracic arteries divided.
- d, A branch to the deltoïdes.
- e, The origin of the internal scapular artery.
- g, The posterior circumflex artery of the humerus, which, in this figure, arises in common with the internal scapular.
- h, The internal scapular artery.
- i, A branch to the latissimus.
- k, Large branches to the latissimus and ferratus magnus.
- l, l, A branch forming a circle with the dorsal artery, q, and proceeding to ascend along the base of the scapula.
- m, The anastomatic branch.
- n, Branches forming a communication between the superior and inferior dorsal arteries of the scapula.
- o, A deep branch of the scapular artery.
- p, A branch to the teres major.
- q, The posterior branch following the inferior margin of the scapula.
- r, A branch to the anterior hollow part of the scapula, also following its inferior margin.
- s, s, s, Branches of the cavity of the scapula.
- t, The nutritious artery of the scapula.

- u, A branch which passes through the fissure, at C, along with the superior scapular arteries.
- v, The trunk of the superior artery of the scapula;
- w, Its supra-spinal branch.
- x, The anterior circumflex artery of the humerus.
- y, A branch to the deltoïdes.
- z, ————— glandulæ alares.

FIG. 2.

The Back of the same SCAPULA.

BONES and MUSCLES.

- A, The spine of the scapula.
- B, The acromion.
- C, Part of the clavicle.
- D, The basis of the scapula.
- E, The inferior margin of the scapula.
- F, The feat of articulation with the os humeri.
- G, The fossa supra-spinata.
- H, The dorsum scapulæ.
- I, A section of the os humeri.
- K, The infra-spinatus muscle turned forwards.
- L, The teres minor also turned forwards.
- M, The long head of the triceps extensor cubiti.
- N, The teres major.
- O, The remains of the ferratus magnus and rhomboides.
- P, The trapezius.

VESSELS.

- a, The inferior dorsal artery of the scapula, Fig. 1. o.
- b, A branch to the teres major.
- c, Another branch from the trunk, l, Fig. 1.
- d, A branch descending to the back of the scapula, Fig. 1. q.
- e, Anastomosis with k.
- f, Branch o, Fig. 1.
- g, An ascending branch covered with the acromion.
- h, Anastomosis between the trunks of the superior and inferior dorsal arteries of the scapula, under the acromion.
- i, A twig following the spine of the scapula.
- k, Another dorsal branch of the scapula.
- l, An ascending anastomatic branch.
- m, Branches to the infra-scapularis.
- n, The superior dorsal artery of the scapula.
- o, A branch to the supra-spinatus, anastomatic with b.
- p, The exterior branch.

TABLE

Fig. 1.

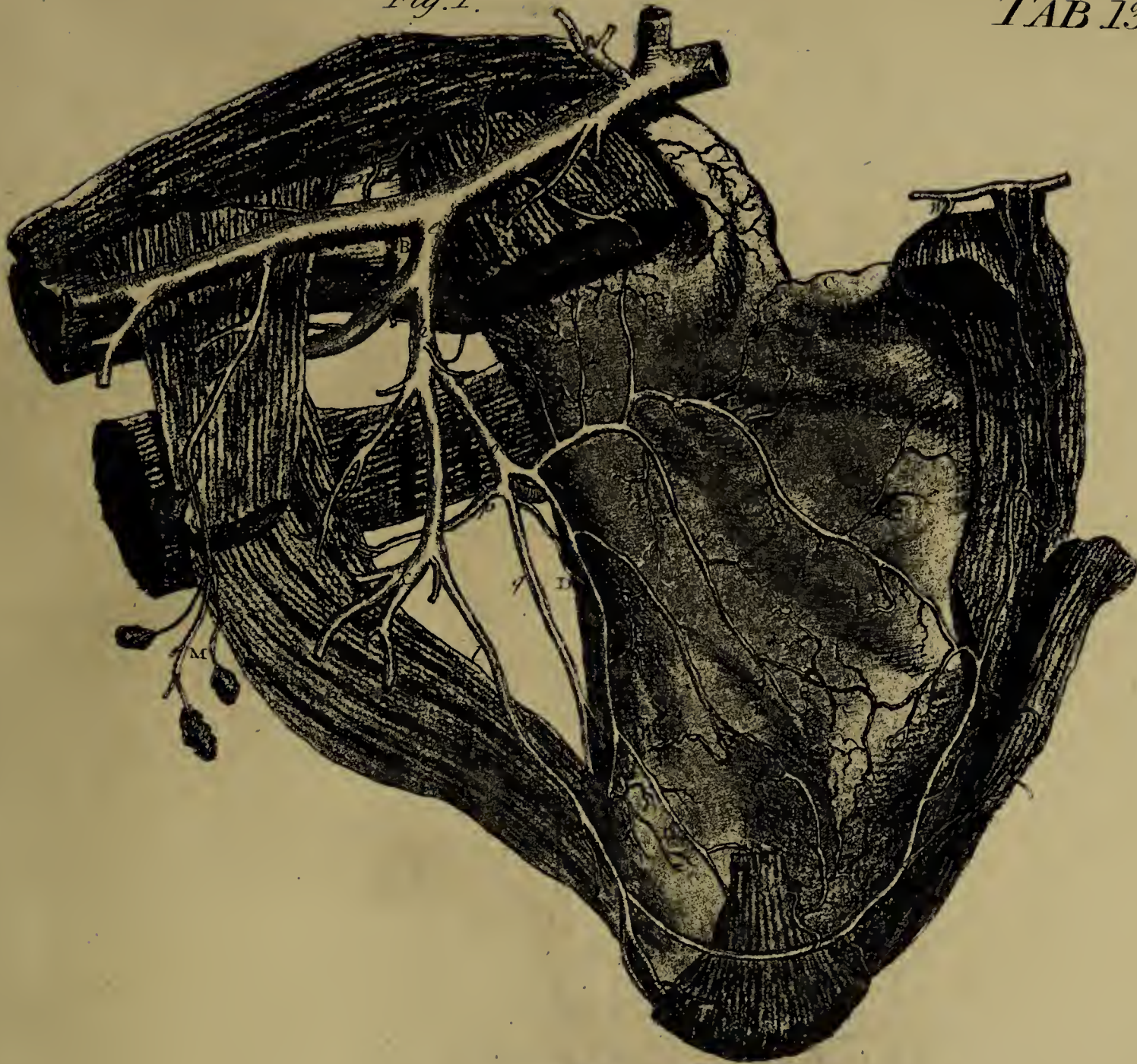


Fig. 2.

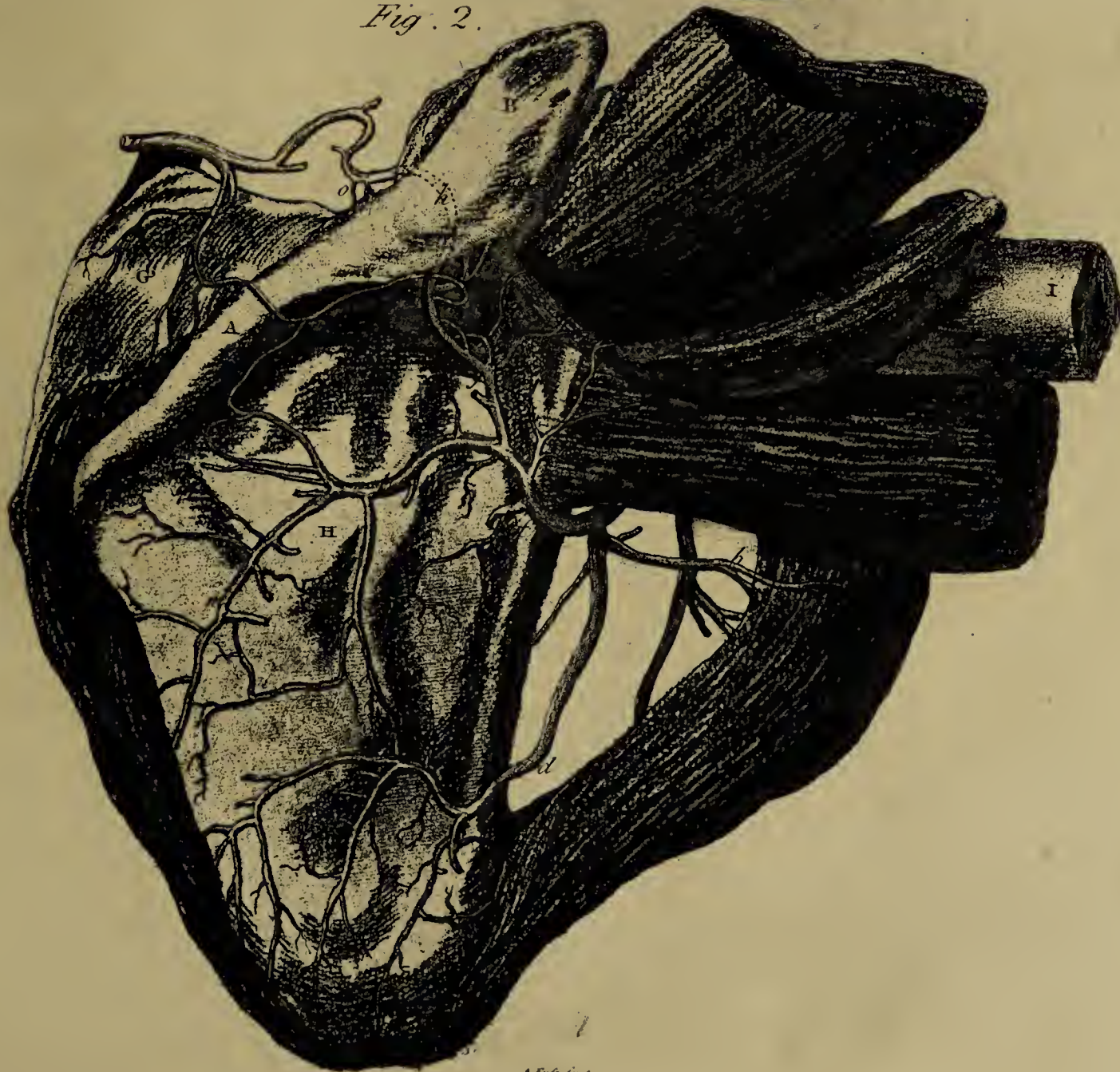

Fig. 1.

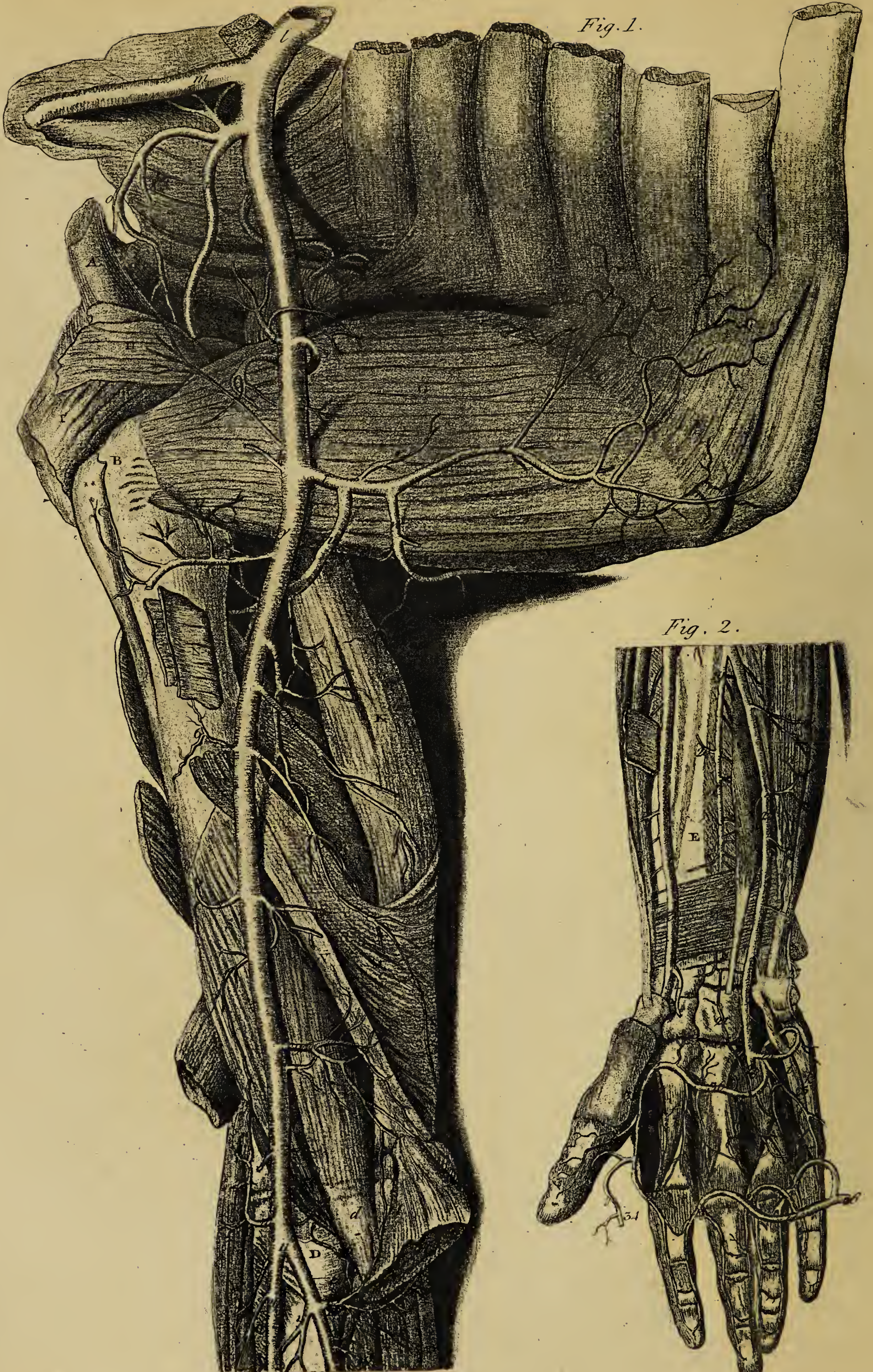

Fig. 2.

T A B L E CXXXVII.

The ARTERIES of the RIGHT ARM, seen Anteriorly; the First Order of MUSCLES being removed.

MUSCLES and BONES.

- A, Part of the clavicle.
 B, The head of the os humeri.
 C, The groove of the biceps.
 D, The tubercle of the radius into which the biceps is inserted.
 E, The radius laid bare.
 F, A portion of the serratus magnus.
 G, The subscapularis.
 H, The end of the pectoralis minor.
 I, Part of the deltoïdes.
 K, The long head of the triceps extensor cubiti.
 L, The short head of the same.
 M, The third head, termed *Brachialis Externus*.
 N, The insertion of the teres major.
 O, ————— latissimus dorsi,
 P, ————— pectoralis major.
 Q, ————— the deltoïdes.
 R, ————— coraco brachialis.
 S, The brachialis internus.
 T, The origin of the supinator longus.
 U, The common head of the flexors which go to the hand.
 V, The aponeurotic expansion separating the brachialis externus from the internus.
 W, The head of the extensores carpi radiales.
 X, The flexor longus pollicis.
 Y, The pronator teres.
 Z, ————— quadratus.
 a, Part of the flexor profundus.
 b, The flexor carpi ulnaris.
 c, The supinator brevis.
 d, The tendon of the biceps.
 e, The abductor indicis. See Fig. 2.
 f, g, The interossei.
 h, The abductor minimi digiti.
 i, The flexor brevis minimi digiti.
 k, The adductor minimi digiti.

VESSELS.

- l, The trunk of the right subclavian artery. See Fig. 1.
 m, The right carotid.
 n, The inferior thyroid artery.

VOL. III.

- o, The posterior cervical.
 p, The superior dorsal artery of the scapula.
 q, The dorsal branch.
 r, The acromial branch.
 s, The large branch to the subscapularis.
 t, The internal scapular artery.
 u, The posterior circumflex branch of the humerus.
 v, Branches to the humerus and extensor brevis.
 w, The inferior dorsal artery of the scapula.
 x, Branches to the serratus magnus.
 y, The place where the trunk of the artery of the superior extremity has its name changed from axillary to that of humeral.
 z, The anterior circumflex artery of the humerus, giving off branches to the subscapularis, head of the os humeri, and groove of the biceps.
 1. A branch anastomotic with the posterior circumflex artery.
 2. The profunda humeri.
 3. A branch to the long head of the triceps.
 4. The profunda inferior to the triceps.
 5. The ramus descendens forming anastomoses in the brachialis externus.
 6. A branch to the surface of the os humeri.
 7. ————— brachialis, from whence the arteria nutritia.
 8. ————— brachialis internus and biceps.
 9. The ramus anastomoticus magnus of the brachial artery.
 10. The radialis recurrens, arising above the division of the recurrens.
 11. The division of the humeral trunk.
 12. The ulnar artery.
 13. The recurrent ulnar branch.
 14. Anastomosis with the ramus anastomoticus of the humeral artery.
 15. The posterior anastomotic artery.
 16. The anterior artery of the joint.
 17. A branch to the supinator brevis and radius.
 18. The nutritia ulnæ.
 19. The anterior interosseous artery. See Tab. CXXXVIII. Fig. 2. No. 11.
 20. The nutritia radii.
 21. The

E

- | | |
|---|--|
| <p>21. The artery to the two interosseous muscles of the fourth finger.</p> <p>22. The ulnar artery.</p> <p>23. A branch to the back of the hand.</p> <p>24. The deep palmar artery.</p> <p>25. The ulnar branch of the little finger.</p> <p>26. 26. The corresponding parts of the ulnar artery.</p> <p>27. The superficial arch of the palm.</p> <p>28. 28. 28. Bifurcations from which the digital arteries go off.</p> | <p>29. 30. The radial artery.</p> <p>31. The radial artery passing between the metacarpal bones of the thumb and fore-finger.</p> <p>32. The artery of the thumb ;</p> <p>33. Its radial branch.</p> <p>34. A branch cut from the superficial branch which goes off from the radial artery at 31.</p> <p>35. The radial indicis.</p> <p>36. The deep arch of the palm.</p> |
|---|--|

TABLE

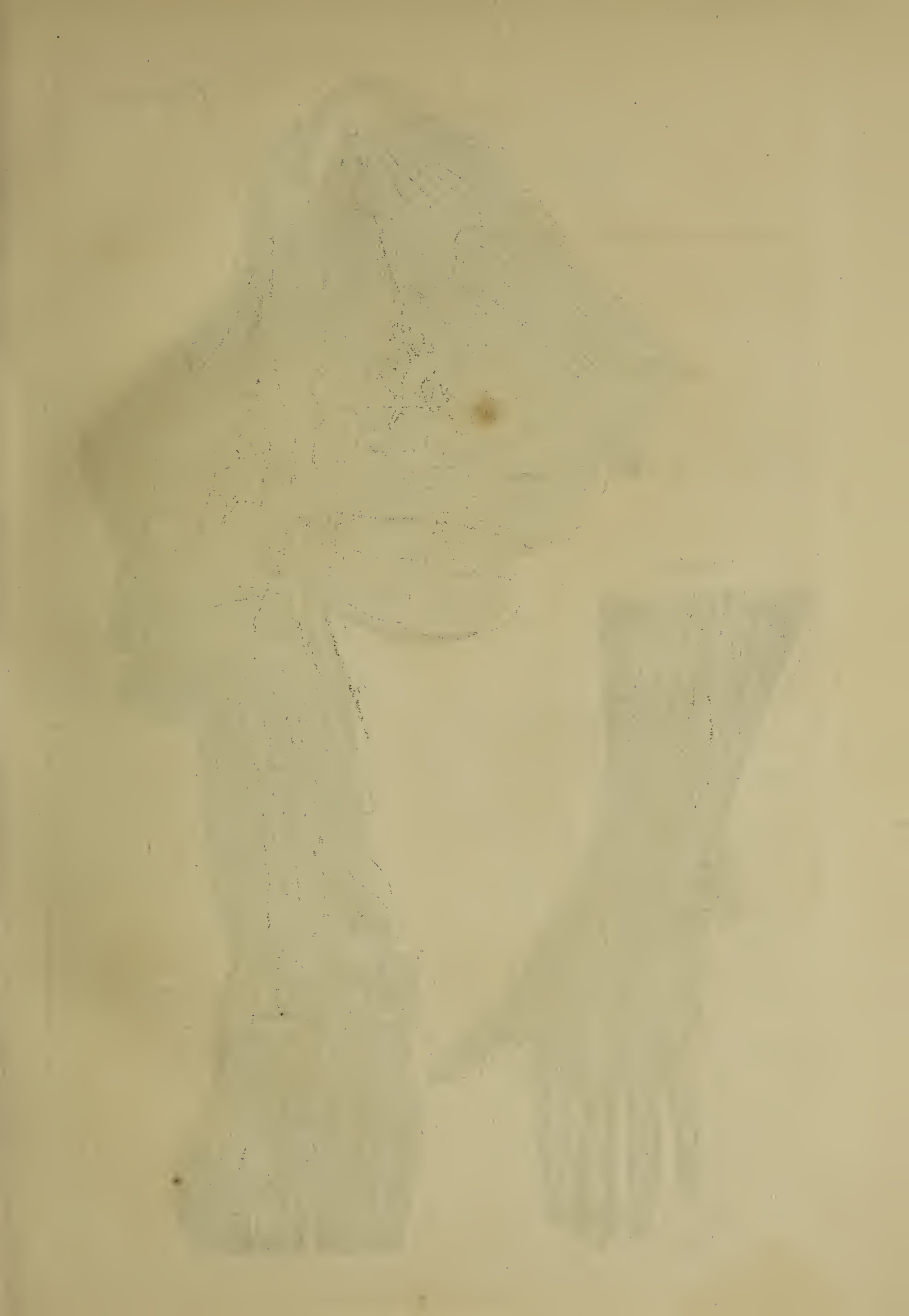
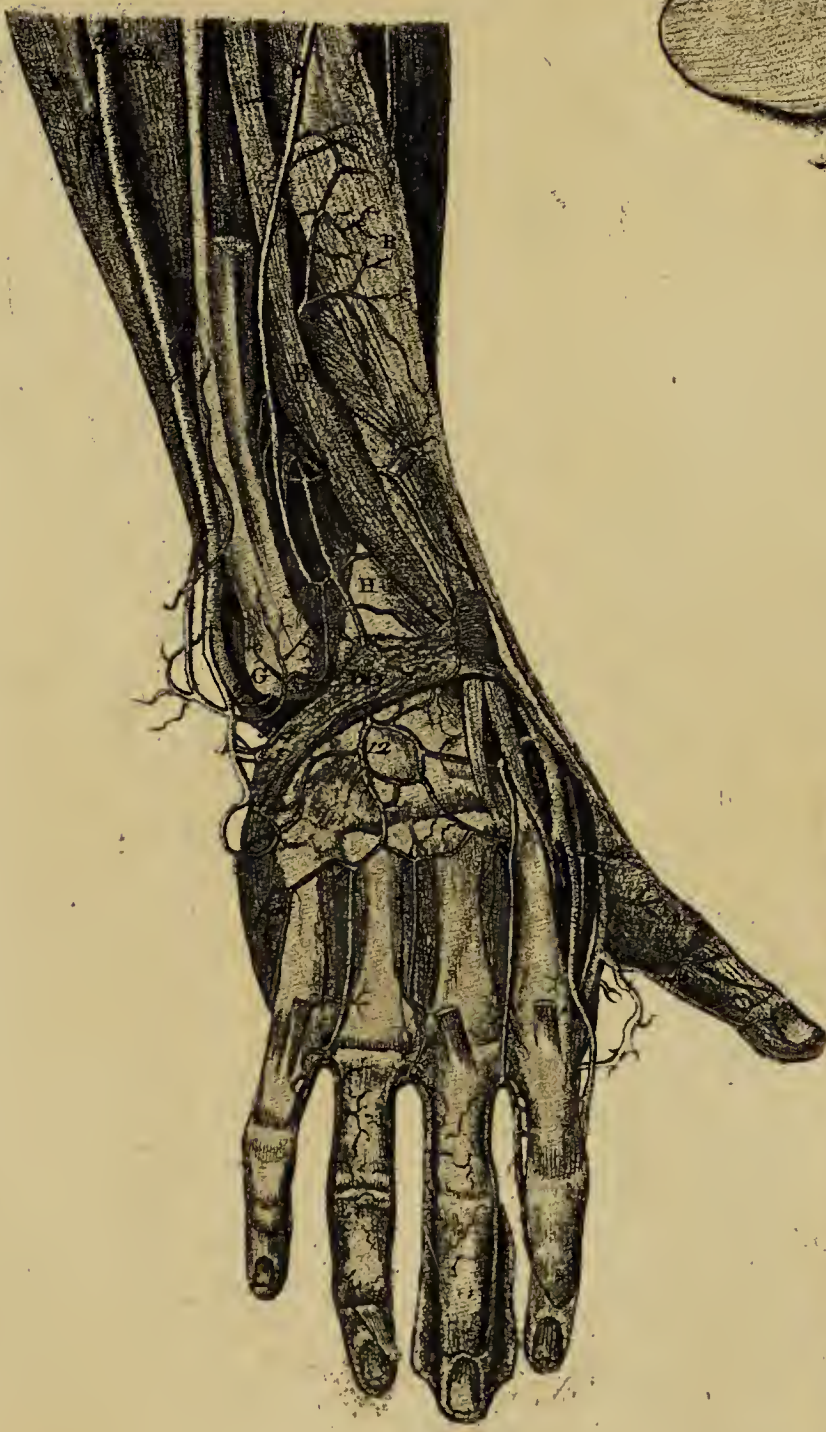


Fig. 1.

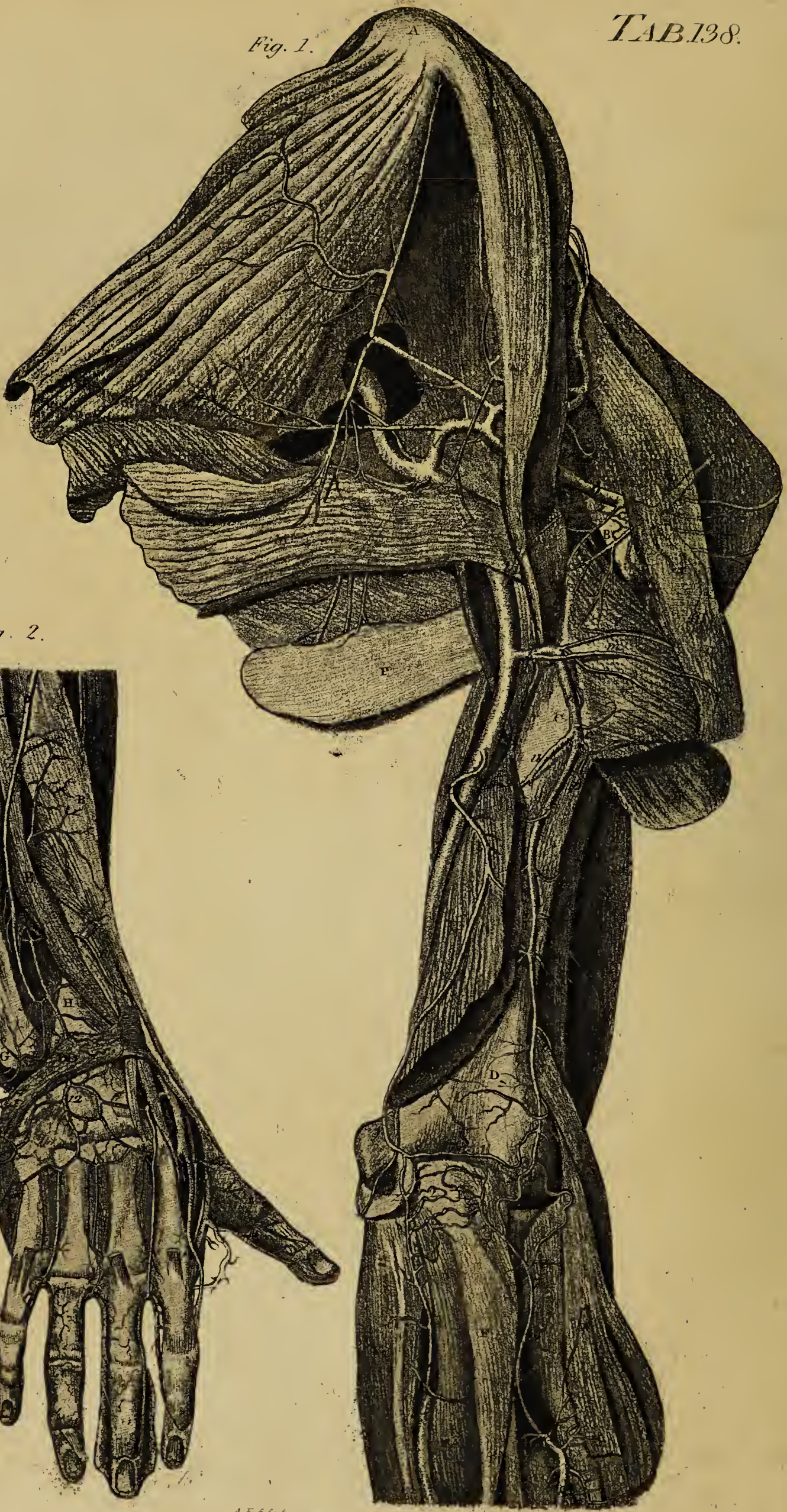

Fig. 2.



T A B L E CXXXVIII.

A BACK VIEW of the RIGHT ARM;—the greater part of the MUSCLES of the FIRST STRATUM removed, to shew the ARTERIES.

BONES and MUSCLES.

- A, The inferior point of the scapula.
 B, C, A portion of the os humeri, near its head B, and under its head C.
 D, The posterior part of the under end of the os humeri.
 E, The olecranon.
 F, The upper part of the ulna.
 G, The styloform process of the ulna.
 H, Part of the radius.
 I, The ferratus magnus muscle.
 K, The subscapularis.
 L, L, The deltoides.
 M, The latissimus dorsi.
 N, The teres minor.
 O, The teres major.
 P, The pectoralis.
 Q, The ferratus minor.
 R, The coraco-brachialis.
 S, The biceps.
 T, The brachialis internus.
 U, ————— externus.
 V, The long head of the triceps.
 W, The head of the extensor on the fore-arm.
 X, The supinator longus.
 Y, Y, The flexor carpi ulnaris.
 Z, The supinator brevis.
 AA, AA, The extensor carpi ulnaris.
 BB, The extensor secundi internodii pollicis.
 CC, The extensores carpi radiales.
 DD, The ligamentum armillare dorsale, or posterior ligament of the wrist.

VESSELS.

- a*, The axillary artery.
b, The scapular artery.
c, A twig to the ferratus magnus.
d, The scapular branch.

- e, f*, A twig to the scapula, ferratus, teres major, and latissimus dorsi.
g, g, The trunk of the scapular artery following the margin of the scapula.
h, The posterior circumflex artery of the humerus.
bb, A branch to the ferratus, pectoralis, and latissimus.
i, The anterior circumflex artery to the head of the humerus.
k, The profunda humeri.
l, A branch to the extensor longus.
m, A branch to the deltoid muscle.
n, o, p, Branches to the extensor longus.
q, r, s, ————— brachialis internus.
t, A branch anastomotic with the posterior interosseous artery.
u, A branch to the brachialis externus, skin, and flexors of the cubit.
v, The posterior articular arch.
w, A branch anastomotic with the posterior interosseous artery.
x, Another posterior branch of the humerus.
y, A branch anastomotic with *v*.
z, Anastomosis with the recurrent branch of the ulna.
 1. The recurrent branch of the ulna.
 2. The rete of the olecranon with the interosseous artery.
 3. The ulnar artery.
 4. The dorsal branch.
 5. Branches to the ulna.
 6. The recurrent branch of the posterior interosseous artery.
 7. To the extensors.
 8. 8. The trunk of the posterior interosseous artery.
 9. Anastomoses between the anterior and posterior interosseous arteries.
 10. A branch to the tendons of the extensores carpi radiales.
 11. The anterior interosseous artery, after it has perforated the interosseous ligament.
 12. The dorsal branch of the carpus.

T A B L E CXXXIX.

The Anterior Part of the RIGHT ARM, with the SUBCUTANEOUS BLOOD-VESSELS.

MUSCLES.

- A, The omo-hyoideus.
 B, The trapezius.
 C, The deltoides.
 D, The latissimus dorfi.
 E, The teres major.
 F, The coraco-brachialis.
 G, The biceps ;
 H, Its round tendon.
 I, The aponeurosis of the biceps.
 K, K, The triceps extensor cubiti.—The upper K is placed upon the brachialis externus, and the under K upon the long head of the triceps.
 L, M, The supinator longus.
 N, The pronator teres.
 O, The flexor radialis.
 P, P, The flexor sublimis.
 Q, The flexor ulnaris.
 R, Part of the extensor ulnaris.
 S, Part of the flexor profundus.
 T, T, The palmaris longus.
 U, The armillary, or annular ligament of the carpus.

VESSELS.

- a, The trunk of the right subclavian artery.
 b, The right carotid.
 c, The right subclavian.
 d, The inferior thyroid artery.
 e, The deep cervical artery.
 f, The artery of the top of the shoulder.
 g, The first thoracic,
 h, The second thoracic artery.
 i, The internal scapular artery.
 k, The anterior circumflex artery.
 l, The progress of the subclavian artery.
 m, The seat of the artery liable to injury in venesection.
 n, n, The origin and progress of the ulnar artery.
 o, o, The radial artery.
 p, A large branch covered by the pronator teres.
 q, A twig of the volar branch of the radial artery, to the abductor and short flexors of the thumb.
 r, The radial,
 s, The ulnar artery.

- t, A deep branch from the ulnar artery.
 u, A branch from the ulnar to the little finger.
 v, The superficial arch of the palm.
 w, x, y, The three large digital arteries.
 z, z, z, Bifurcations of the digital arteries.
 1. The radial branch of the index.
 2. The inosculation of the ulnar with a superficial branch of the radial artery.
 3. The communication between the ends of the trunks of the radial and ulnar arteries.
 4. The radial artery emerging into the palm.

VEINS.

5. The superficial radial vein, which, in this figure, corresponds above with the mediana longa.
 6. The division of the mediana longa into,
 7. The mediana basilica, and, 15. the mediana cephalica.
 8. The superficial ulnar veins.
 9. The beginning of the basilic vein.
 10. The basilic vein receiving the median basilic.
 11. One of the venæ profundæ, which accompanies the humeral artery.
 12. The termination of that vein in the vena axillaris.
 13. The other vena profunda.
 14. The termination of that vein in the axillaris.
 15. The median cephalic, the figure being a little below the part where it forms the cephalic.
 16. The cephalic vein passing between the large pectoral and the deltoid muscle.
 17. The termination of the cephalic in the axillary vein.
 18. The external jugular vein.
 19. The subclavian vein.
 20. The internal jugular vein.
 21. The vena cava.

NERVES.

22. 23. The roots of the superior plexus.
 24. The prior trunk of the radial nerve.
 25. A root from the inferior plexus.
 26. The nervus musculo-cutaneus.
 27. The radial nerve.
 28. A part subject to danger in venesection.

TAB. 139.

Fig. 1.

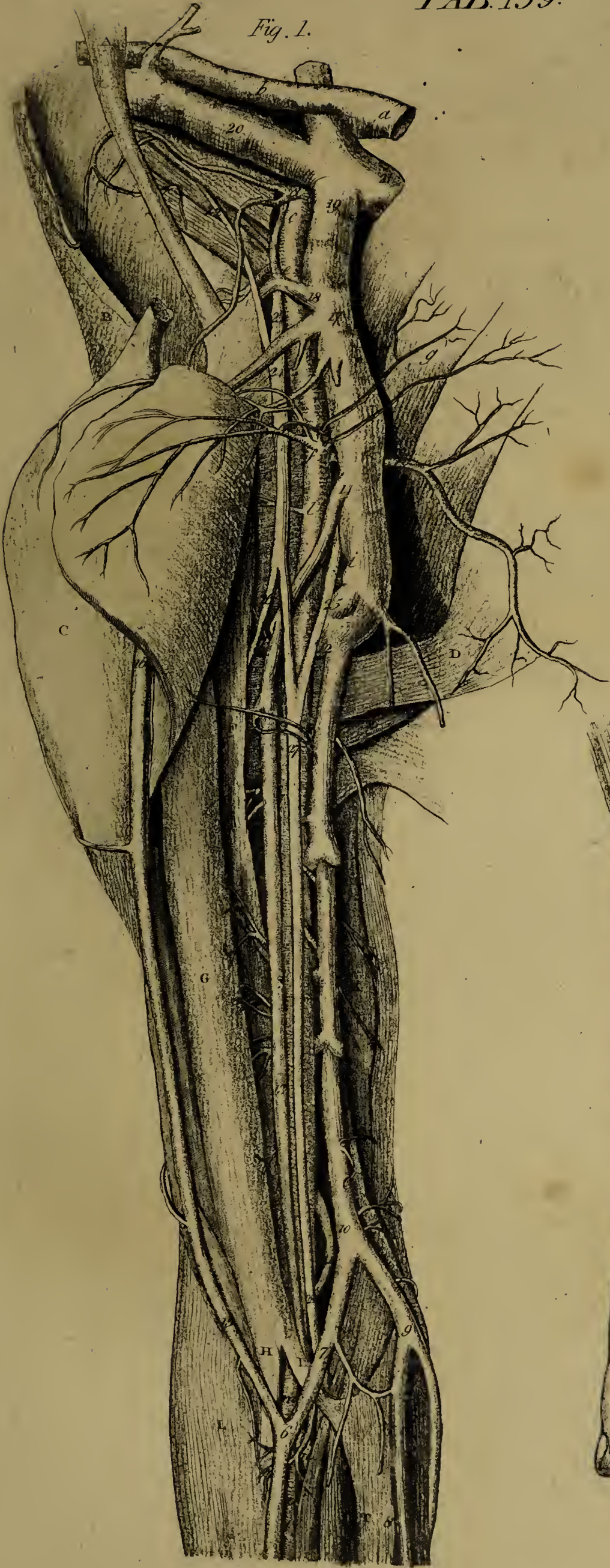


Fig. 2.

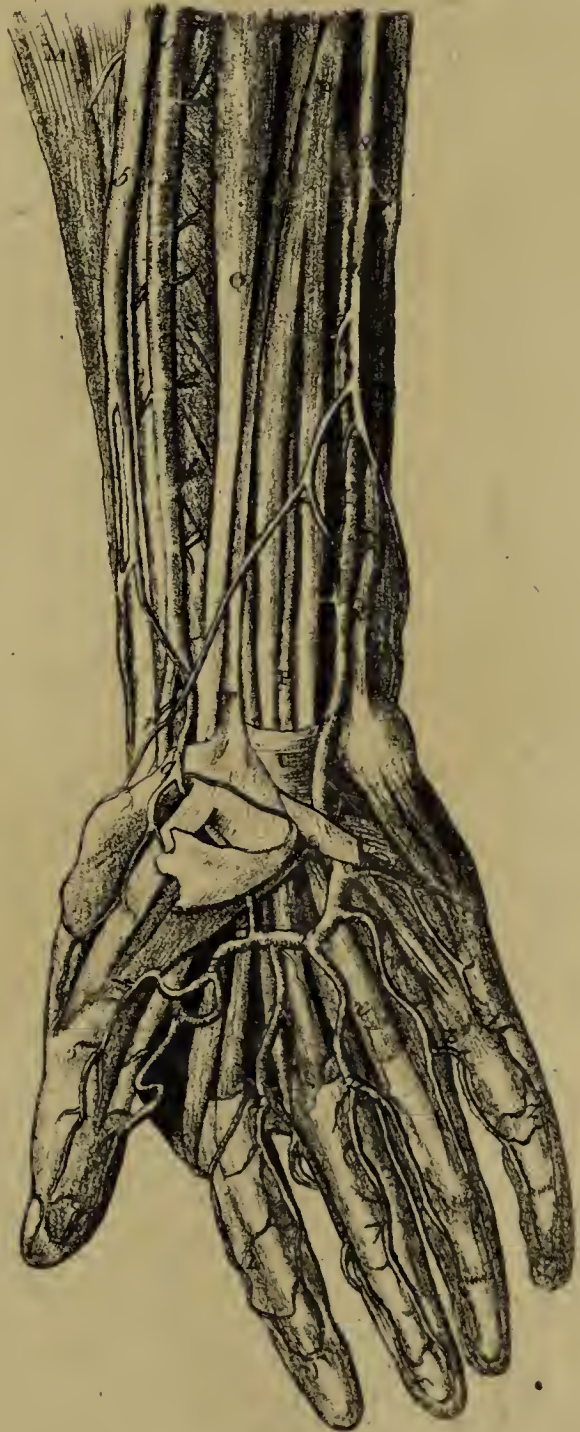


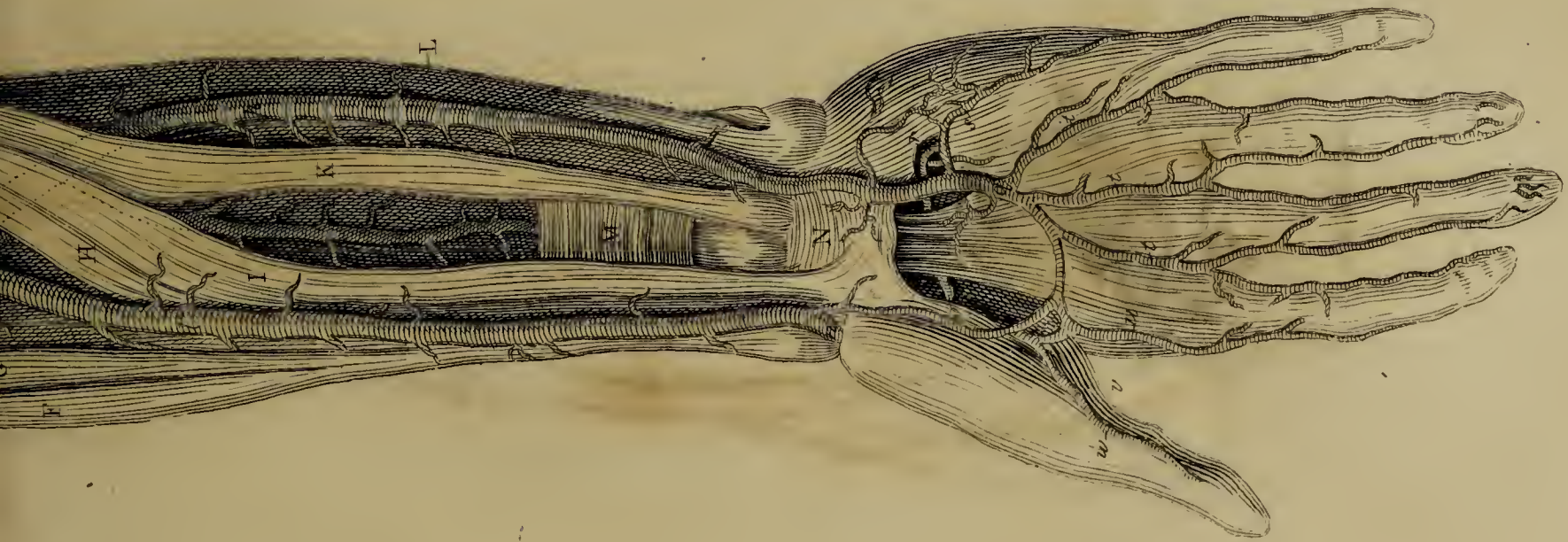
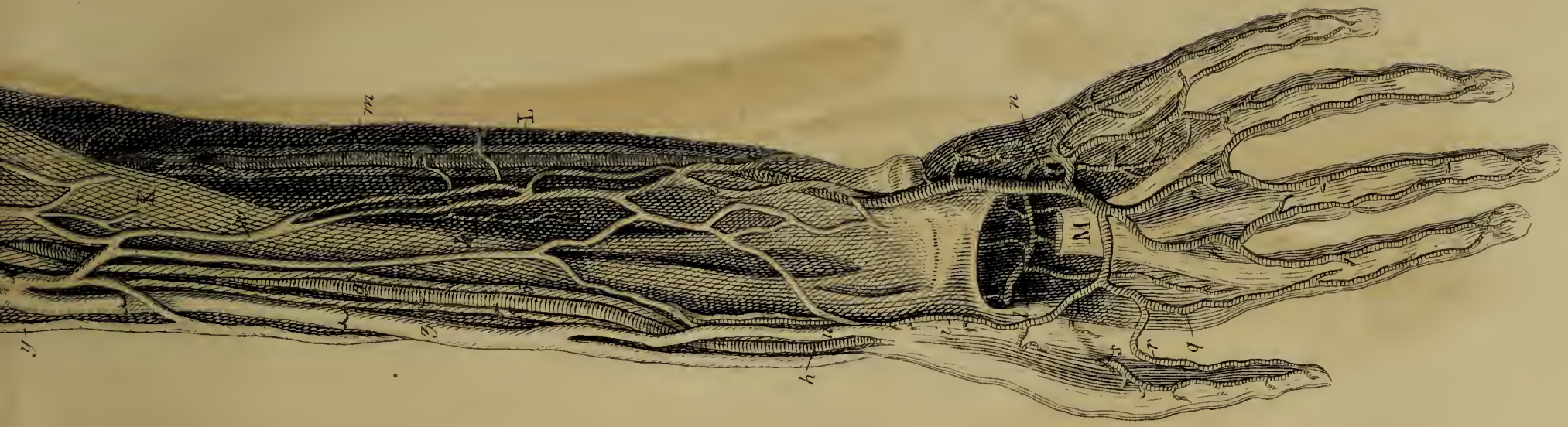


Fig. 1.

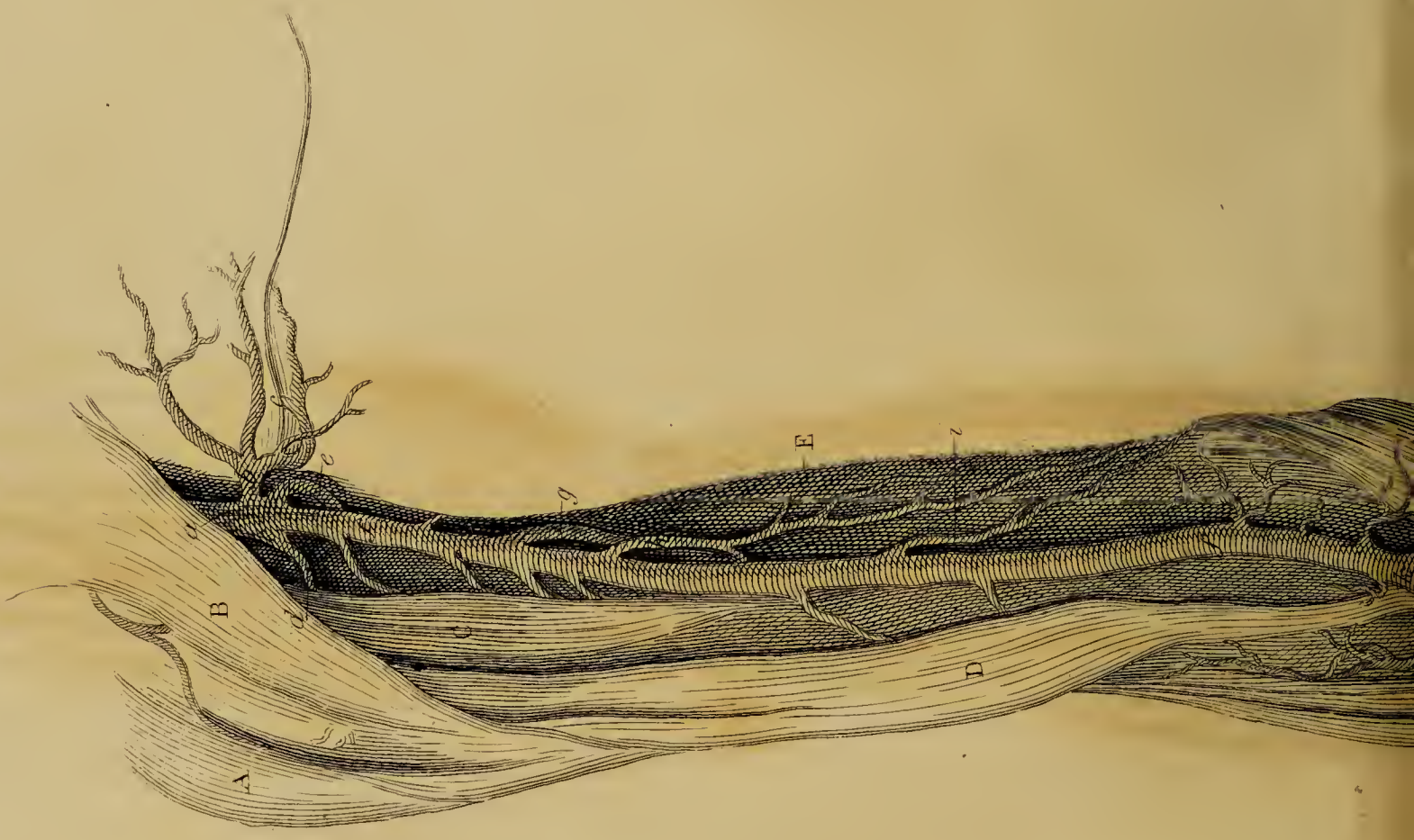
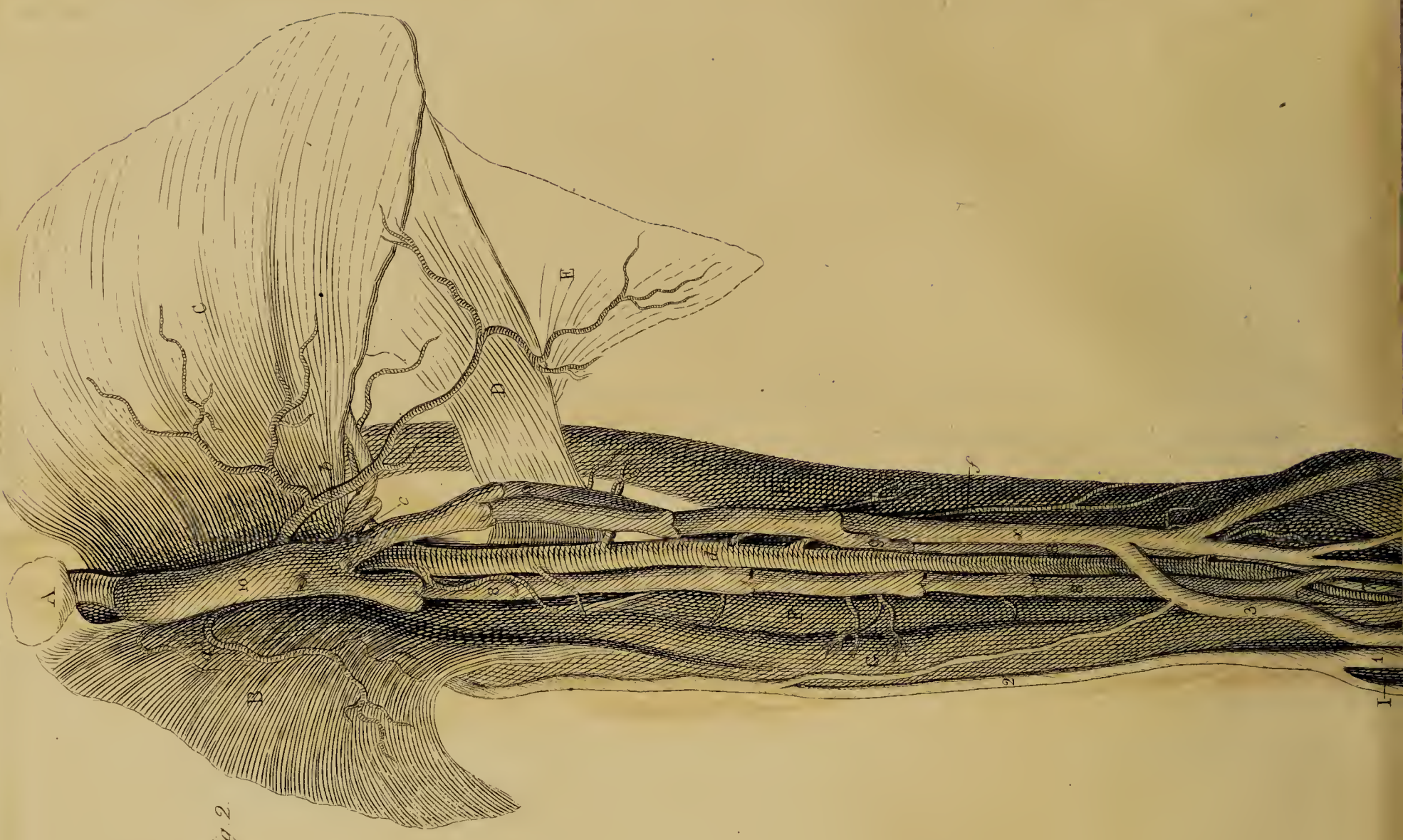
Fig. 2.





A. F. del.

T A B L E CXL.

Represents the BLOOD-VESSELS seen on the Fore-Part of the SUPERIOR EXTREMITY.

FIG. 1.

The ARM of a Young Subject, with the ARTERIES injected, and the MUSCLES dried.

- A, The deltoid.
- B, The pectoralis major.
- C, The coraco-brachialis.
- D, The biceps.
- E, The triceps.
- F, The supinator longus.
- G, The extensores carpi radiales.
- H, The pronator teres.
- I, The flexor carpi radialis and palmaris longus, pulled towards the radius.
- K, The flexor digitorum sublimis and the profundus, drawn towards the ulna.
- L, The flexor carpi ulnaris.
- M, The pronator radii quadratus.
- N, The ligamentum carpi annulare.

ARTERIES.

- a, The axillary artery.
- b, The scapularis interna.
- c, The dorsalis scapulæ inferior, turning round the under edge of the scapula.
- d, The circumflexa anterior.
- e, ————— posterior.
- f, f, The trunk of the humeral artery, sending branches to the biceps and other muscles on the arm.
- g, The profunda or spiralis.
- h, ————— minor.
- i, The ramus anastomoticus magnus.
- k, The division of the humeral artery into the radial and ulnar arteries.
- l, The radial artery, sending numerous branches to the muscles next the radius.
- m, The recurrent branch of the radial artery.
- n, The under end of the radial artery, after giving off the superficial volar branch, turning between the metacarpal bones of the thumb and fore-finger, to form,
- o, The deep arch of the palm.
- p, The ulnar artery, pulled a little towards the inner side of the arm, to shew the branches it sends to the corresponding muscles.

- q, The superficial palmar arch, formed by the ulnar artery.
- r, The deep palmar branch of the ulnar artery anastomosing with the arcus profundus of the radial artery, behind the tendons of the flexors of the fingers.
- s, A branch to the inner side of the little finger.
- t, t, t, The three large digital branches of the ulnar artery, sending branches to the fingers.
- w, A branch from the conjoined radial and ulnar arteries to the radial side of the fore-finger.
- v, A similar branch from these arteries to the thumb.
- w, Another branch to the thumb from the ulnar artery.

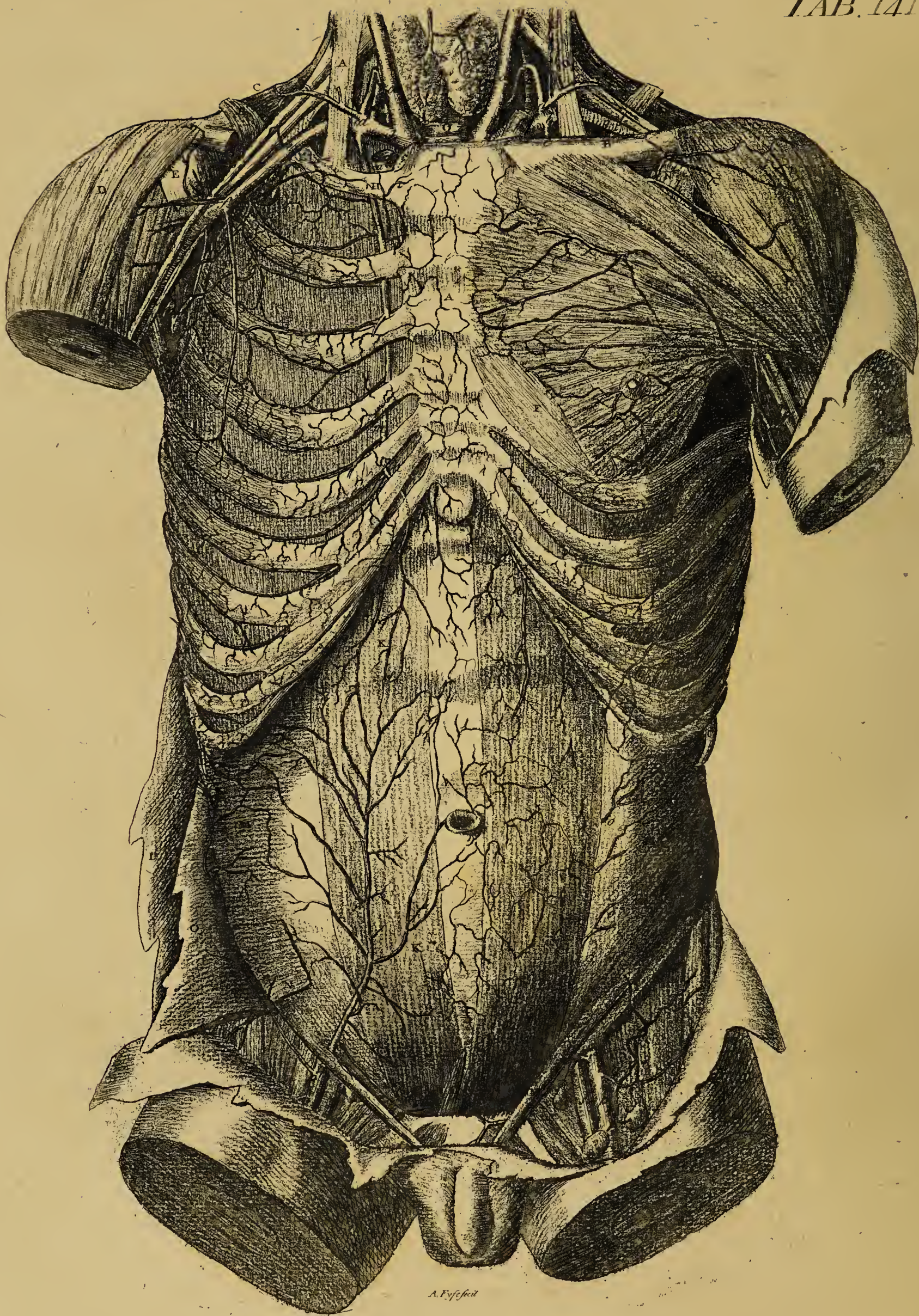
FIG. 2.

The ARM of an ADULT, the ARTERIES and VEINS injected, and the MUSCLES dried. In the Larger VEINS, the VALVES are seen.

- A, The clavicle.
- B, The pectoralis major raised.
- C, The scapula covered with the subscapularis.
- D, The teres major.
- E, Part of the latissimus dorsi.
- F, The body of the os humeri.
- G, The biceps flexor cubiti raised from the body of the bone.
- H, The triceps.
- I, The supinator radii longus.
- K, The flexor carpi radialis and flexor digitorum sublimis, raised and drawn a little towards the radius.
- L, The flexor carpi ulnaris.
- M, The tendons of the flexores digitorum cut and raised.
- a, Branches of the external mammary arteries to the pectoralis major.
- b, The scapularis interna dispersed upon the subscapularis, teres major, and latissimus dorsi.
- c, Part of the dorsalis scapulæ inferior.
- d, The humeral artery sending branches to the muscles.
- e, The profunda minor.
- f, The ramus anastomoticus magnus.
- g, The radial artery.
- h, The course of this artery towards the space between the metacarpal bones of the thumb and fore-finger.
- i, The superficial volar branch of the radial artery.
- k, The anterior interosseous artery.

l, The

- l*, The deep palmar arch of the radial, sending branches to the deep parts of the palm.
m, The ulnar artery.
n, The superficial palmar arch of this artery anastomosing with the volar branch of the radial artery.
o, A branch to the inner side of the deep arch, one to the inside of the hand, and one to the little finger.
p, p, p, The three large digital branches of the ulnar artery, sending branches to the fingers.
q, A branch from the superficial palmar arch to the radial side of the fore-finger.
r, A similar branch from the ulnar artery to the thumb.
s, Another branch to the thumb from the radial artery.
t, A plexus of superficial ulnar veins communicating with the radial and ulnar superficial and deep veins.
u, A superficial vein arising from the thumb, and joining the mediana longa.
v, The small superficial median vein, or mediana interna, communicating with the mediana longa, and with the ulnar and basilic veins.
- w*, A superficial ulnar trunk, forming,
x, The humeral basilic vein.
y, A superficial radial trunk running into the humeral cephalic vein.
z, The mediana longa.
1. The mediana cephalica, forming,
 2. The cephalic vein.
 3. The mediana basilica, terminating in the basilic vein.
 4. 4. The venæ comites of the ulnar artery.
 5. 5. ————— radial artery.
 6. A large vein, forming a communication between the deep radial veins, and beginning of the mediana cephalica.
 7. A plexus of veins, surrounding the humeral artery.
 8. 8. The deep humeral veins, or venæ comites of the humeral artery.
 9. 9. Communications between the deep humeral veins and the vena basilica.
 10. The axillary vein, receiving the basilic, humeral, and inferior scapular veins.



A. F. fecit

T A B L E C X L I .

The ARTERIES of the Fore-Part of the THORAX and ABDOMEN of a CHILD.—The SKIN of the Left Side, and that Part of the OBLIQUUS EXTERNUS which covers the RIBS, are removed.—On the Right Side the CLAVICLE and all the MUSCLES are removed, to obtain a View of the PLEURA and TRANSVERSUS ABDOMINIS.

LEFT SIDE.

BONES and MUSCLES.

- A, The sternum.
- B, The clavicle.
- C, C, The ribs, from the fifth to the twelfth inclusive.
- D, The deltoides.
- E, The pectoralis major.
- F, A muscular slip, found in the subject from which this figure was taken, passing from the sternum to the fifth rib.
- G, The external intercostal muscles.
- H, Part of the serratus magnus.
- I, I, The part of the rectus abdominis, covered with the aponeurotic sheath.
- K, The obliquus descendens.
- L, The posterior column of the abdominal ring.
- M, The spermatic cord.
- N, Part of the pectoralis minor.
- O, The scalenus anticus.
- Q, The aspera arteria.

VESSELS.

- a, The left carotid artery.
- b, The subclavian artery.
- c, The vertebral artery.
- d, The inferior thyroid artery, with the trunk to the gland, and the cervical arteries to the muscles, &c. of the neck.
- e, The internal mammary artery.
- f, The internal jugular vein.
- g, The subclavian artery, after it is freed from the scalenus primus.
- h, Branches to the deltoides.

- i, A branch to the mamma, from the branch of the mammary artery of the first interval.
- k, A branch to the mamma, from the branch of the second interval.
- l, The humeral artery.
- m, The nervus radialis.
- n, That part of the internal mammary artery which belongs to the upper end of the rectus abdominis muscle.
- o, o, Branches which have perforated the linea femilunaris.
- p, The crural artery.
- q, A branch to the inguinal glands.
- r, The origin of the epigastric artery.
- s, The femoral vein.

RIGHT SIDE.

BONES and MUSCLES.

- A, The scalenus anticus.
- B, ————— medius.
- C, The trapezius.
- D, The deltoides.
- E, The pectoralis minor.
- F, The subscapularis.
- G, The latissimus dorsi.
- H, I, The eleven upper ribs.
- K, K, The rectus abdominis muscle slightly expressed, that the vessels which are situated behind it might, as it were, shine through it.
- L, The pyramidalis.
- M, The transversus.
- N, The inferior part of the transversus cut off, to obtain a view of the epigastric vessels.
- O, The obliquus descendens.
- P, ————— ascendens.

VESSEL

VESSELS.

- a, a*, The internal jugular vein.
a, The right carotid artery.
b, ————— subclavian.
c, The vertebral artery.
d, The inferior thyroid artery, with the anterior and posterior cervical arteries.
e, The subclavian emerging beyond the scalenus.
f, The arteria acromialis, or thoracica humeraria.
g, h, The thoracica superior, or prima, inosculating in different places with other thoracic arteries, with the intercostals, and with the mammaria interna.
i, i, The thoracica longa, with numerous anastomoses between it and the adjacent arteries.
 A little below *f*, is seen the thoracic axillary artery descending to the axilla.
k, The internal scapular artery.

- l, m*, The trunk of the mammary artery descending behind the cartilages of the ribs, with the branches cut which it sends to the pectoral muscles, mamma, &c. and others passing outwards to communicate with the intercostal and external mammary artery.
n, The parts where the mammary artery sends off the branch, termed *Musculo-phrenica*, to the diaphragm. — The course of the branch is obscurely marked by dotted lines.
o, The abdominal part of the mammary artery behind the upper part of the rectus abdominis muscle.
p, The circumflex artery of the os ilium, arising from the end of the iliaca externa.
q, The origin of the epigastric artery from the external iliac.
r, Branches to the transversus, rectus, and umbilicus.
s, An anastomosis with the branches of the mammary artery.

BLOOD-

BLOOD-VESSELS WITHIN THE THORAX.

Of the Blood-vessels within the Thorax, the *Pulmonary Arteries* and *Veins*, the *Aorta*, the *Coronary Vessels*, and the other Vessels connected with the Heart, have been already described.

The following are those which remain to be described.

ARTERIES.

The *MAMMARIA INTERNA*, Tab. CXLI. which arises from the Subclavian, opposite to the Inferior Laryngeal, and descends between the Pleura and Cartilages of the True Ribs, and between the *Intercostales Interni* and *Sterno-costalis*, at the edge of the Sternum; sending off,

A *Small Reflected Branch* to the Integuments and Muscles adjacent to the Clavicle:

One or two small Branches, termed *Thymicæ*, to the Thymus Gland, and which, like the Gland itself, are most considerable in the Young Subject:

A minute Branch, termed *Comes Nervi Phrenici*, which accompanies the Phrenic Nerve, and, after giving Twigs to the neighbouring Membranes, is distributed upon the Diaphragm:

Some small Branches, called *Mediastinæ*, and *Pericardiæ*, to the Mediastinum and Pericardium:

Several Branches, outwards, to the *Intercostales*, and others between the Cartilages of the True Ribs at the edge of the Sternum, to the *Pectorales*, *Mamma*, and Integuments, which communicate with those of the *Thoracicæ Externæ*:

A *Large Branch*, at the under end of the Thorax, termed *Musculo-phrenica*, which is dispersed upon the Diaphragm.

The *Mammary Artery* afterwards emerges from the Thorax, commonly under the Cartilage of the Seventh True Rib, and forms an *Epigastric Branch*, which runs upon the back part of the *Rectus Abdominis*, upon the upper end of which it is dispersed, after sending a Branch to the *Obliqui Abdominis*.

The *ARTERIE BRONCHIALES*, Tab. CXLIII. Tab. CXLIV. which come off from the fore-part of the descending Aorta, and are distributed to the Lungs. They consist of,

The *BRONCHIALIS DEXTRA*, which arises sometimes from the Aorta, more frequently, however, from the uppermost Aortic Intercostal, and runs to the corresponding Lungs.

The *BRONCHIALIS COMMUNIS*, which is only sometimes present. It arises from the upper and fore part of the descending Aorta, divides into two Branches; one to the Left side of the Lungs, the other to the Right side, and also to the Esophagus.

VOL. III.

The *BRONCHIALES SINISTRÆ*, Superior and Inferior, which are of unequal size, from the fore-part of the Aorta, at a little distance from each other; the Inferior occasionally coming off from those of the Esophageals.

The *Bronchial Arteries* send small Branches to the Esophagus, to the posterior Mediastinum and Pericardium, and afterwards accompany the Branches of the Trachea through the Substance of the Lungs, where they communicate by minute Branches with the *Pulmonary Artery*.

The *ARTERIE ESOPHAGEÆ*, which are minute Branches, arising from the different parts of the Aorta, or from the Bronchials, and dispersed upon the Esophagus, also sending Twigs to the Posterior Mediastinum and Pericardium.

The *INTERCOSTALIS SUPERIOR*, Tab. CXLV. *f*, which comes off from the Subclavian, a little farther out than the *Mammary*, and, after sending a Branch upwards to the Deep Muscles and Nerves at the under and fore part of the Neck, descends near the Spine, and divides into two or three Branches, which supply an equal number of Intercostal Spaces.

The *INTERCOSTALES INFERIORES*, Tab. CXLIII. CXLIV. CXLIX. which are nine or ten Pairs in number, arising from the back part of the Aorta, and running in the Grooves at the under edges of the Ribs, between the *Intercostalis Externus et Internus*.

They furnish Branches to the Spine, to the Spinal Marrow and its Membranes, to the *Intercostales*, *Pleura*, &c. also numerous Branches to the Muscles on the outside of the Thorax, and communicate with those of the Internal and External *Mammary Arteries*.

The first of the Aortic Intercostals inosculates with the Superior Intercostal of the Subclavian;—the last passing behind the Crus of the Diaphragm, goes over the *Quadratus Lumborum*, and follows the margin of the twelfth Rib, to be distributed upon the Tendon of the *Transversalis Abdominis*.

The *PERICARDIACA, SUPERIOR* and *POSTERIOR*, a small Branch arising sometimes from the concave side of the Arch of the Aorta, although more frequently from the Subclavian or Internal *Mammary*, and sending Twigs to the Pericardium and adjoining parts of the Lungs and Esophagus.

VEINS.

The Blood sent to the Thorax by the *Arteriæ Mammariæ Internæ*, *Bronchiales*, *Esophageæ*, and *Intercostales*, is returned to the Heart by the following Veins, viz. The *MAMMARIÆ INTERNÆ*, which accompany their corresponding

corresponding Arteries, and terminate, the Left in the Subclavian, and the Right in the Subclavian, or in the top of the Vena Cava. Tab. CXLII. *y, m.*—Tab. LXXXV.

Some small Veins, as the *Pericardiac-Diaphragmatic*, the *Thymic*, and *Pericardiac*, which, in place of joining the Mammary Trunk, commonly terminate, the Right in the Subclavian, or top of the Cava, and the Left in the corresponding Subclavian Vein.

The *VENÆ INTERCOSTALES*, which are the same in number with their Arteries, and accompany them along the edges of the Ribs.

Several of the Lower Left Intercostals unite into a Trunk, termed *Vena Azygos*, which crosses over the Spine, about the middle of the Thorax,—behind, but sometimes before the Trunk of the Aorta,—to the right side. Tab. CXLIII. *p, q, t.*

The *VENA AZYGOS*, or *Vena sine Pari*, thus originally formed by the Lower Left Intercostals, ascends on the fore-part of the Spine over the Intercostal Arteries, at the right side of the Aorta. Tab. CLXXIX.

At its lower extremity, it generally communicates with one of the Lumbar Veins, or with the *Vena Renalis*; and not unfrequently with the Trunk of the Inferior Cava.

Upon the Spine, it receives the *Right Intercostals* and the *Right Bronchial Vein*: and turning forwards over the Root of the Great Pulmonary Vessels of that side, it terminates in the Superior Cava.

The *UPPER LEFT INTERCOSTAL VEINS*, or such as are not received by the *Vena Azygos*, terminate in a Trunk on the left side, improperly called *Left Vena Azygos*. Tab. CXLIII. No. 1. 2.—Tab. CLXXIX.

The *LEFT VENA AZYGOS*, *LEFT BRONCHIAL*, or *LEFT SUPERIOR INTERCOSTAL VEIN*, besides the Superior Intercostal Branches, receives the *Left Bronchial Veins*

and Branches from the Esophagus and other parts near it, and terminates in the Subclavian Vein.

The *VENA CAVA SUPERIOR*, Tab. LXXXV. P, R, S, formed by the union of the Subclavian Veins, with the addition of the *Vena Azygos*, passes down at the right side of the ascending Aorta, perforates the Pericardium, and terminates in the upper part of the Right Auricle.

BLOOD-VESSELS of the DIAPHRAGM.

The Diaphragm is supplied with *Arteries* from various sources, viz. those entering its upper part from the Internal Mammary, already described; also small Branches from the Intercostal and Lumbar Arteries. Its principal Branches, however, are the *Phrenic*, or *Diaphragmatic*.

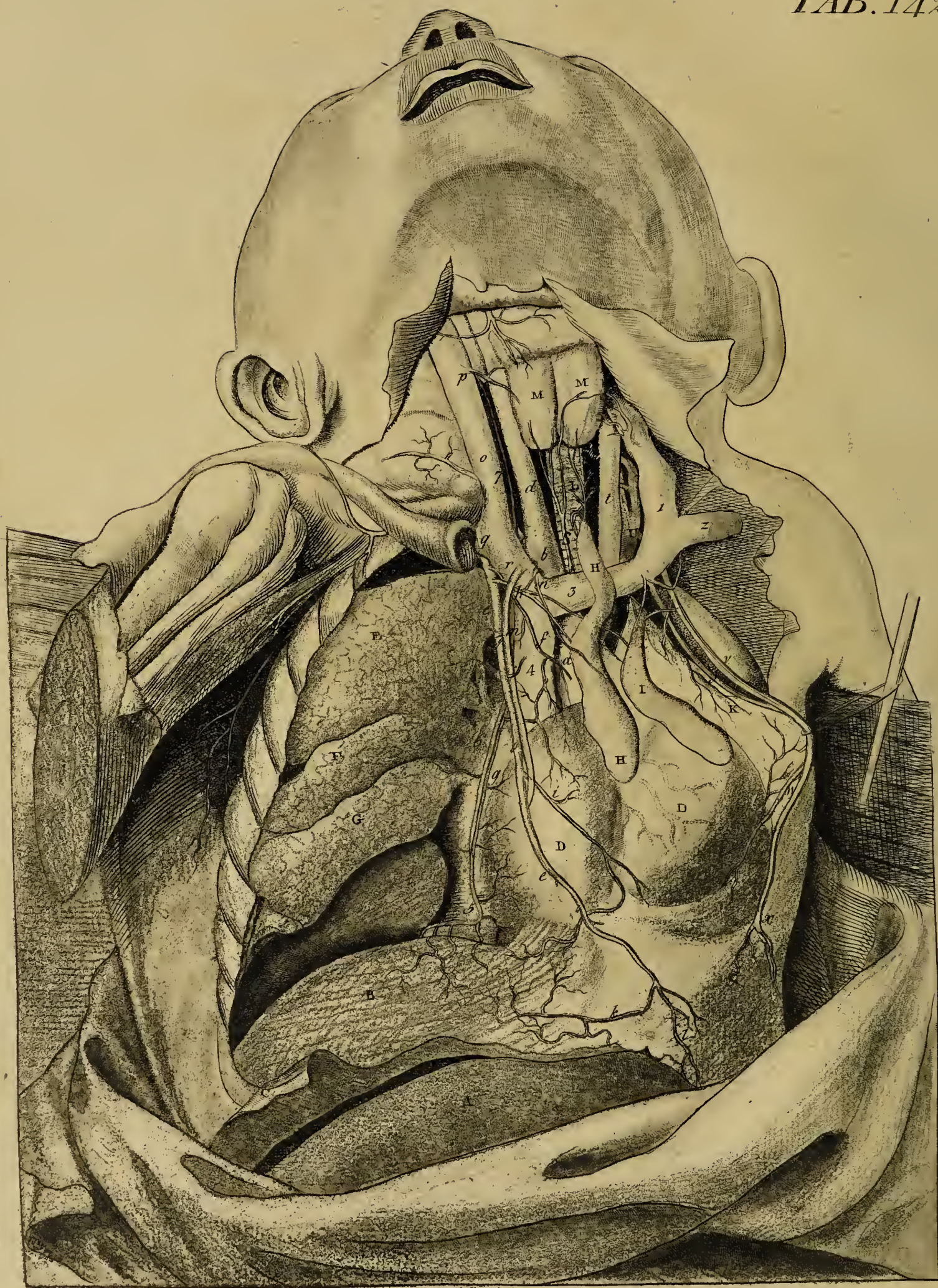
The *ARTERIE DIAPHRAGMATICÆ*, Tab. CXLIX. Tab. CLXXIX. are two in number, one on each side, which arise from the fore-part of the Aorta as soon as it enters the Abdomen.

In general, their origin is distinct from each other, but sometimes they arise by a common Trunk; and now and then, one or both originate from the root of the *Cœliaca*.

They afterwards go obliquely upwards and outwards over the Crura of the Diaphragm, spread out into many Branches, which are chiefly dispersed upon its fleshy sides, and anastomose with those which enter at its upper surface.

They likewise give small Branches to the *Glandulæ Renales*, to the *Cardia*, and parts in general which lie near them.

The *VENÆ DIAPHRAGMATICÆ*, like their corresponding Arteries, run upon the under part of the Diaphragm, and terminate in the Inferior Cava, behind the Liver,—the right being commonly a little lower than the left.



T A B L E CXLII.

The BLOOD-VESSELS of the Anterior Part of the THORAX.

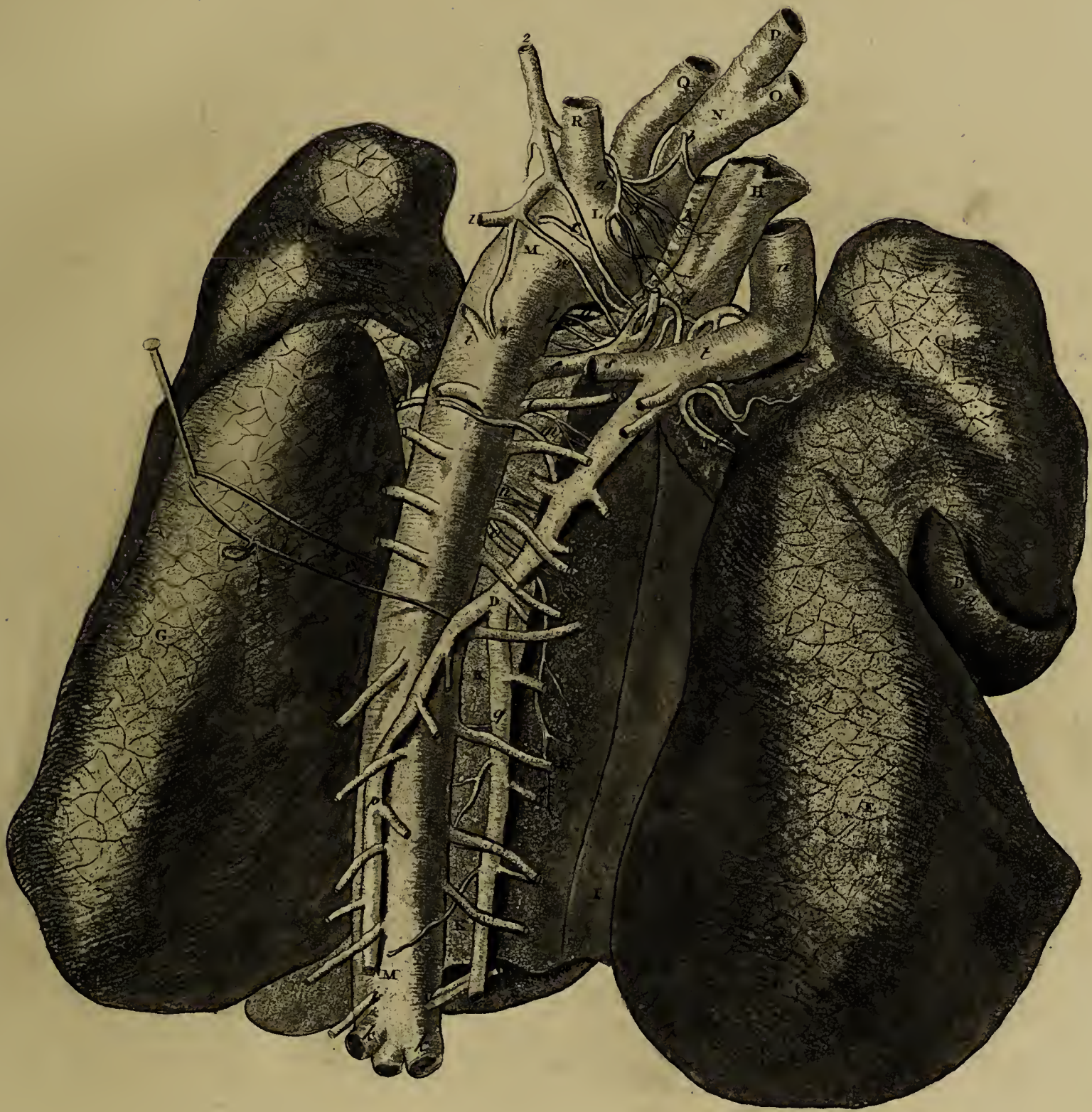-
- | | |
|---|--|
| <p>A, The liver.
 B, The right part of the diaphragm.
 C, A portion of the abdominal muscles.
 D, D, The heart appearing through the pericardium.
 E, F, G, The three lobes of the right lung.
 H, H, The right lobe of the thymus.
 I, The left lobe of the thymus.
 K, The left lamina of the mediastinum joined to the pericardium.
 L, The aspera arteria.
 M, M, The thyroid gland.
 <i>a</i>, Part of the aorta.
 <i>b</i>, The common trunk of the right subclavian and right carotid.
 <i>c</i>, The right subclavian.
 <i>d</i>, ----- carotid.
 <i>e</i>, ----- mammary artery.
 <i>f</i>, The pericardiaco-diaphragmatic branch of the right mammary artery.
 <i>g</i>, A branch, companion of the diaphragmatic nerve.
 <i>h</i>, Small branches to the pericardium.
 <i>i</i>, The internal branch of the mammary artery, or ramus phrenico-pericardiacus.</p> | <p><i>l</i>, The exterior, or musculo-phrenic artery.
 <i>l</i>, The abdominal, or epigastric branch.
 <i>m</i>, The right mammary vein.
 <i>n</i>, ----- thymic vein.
 <i>o</i>, ----- internal jugular vein.
 <i>p</i>, The superior thyroid vein.
 <i>q</i>, The termination of the right subclavian vein.
 <i>r</i>, The common trunk of the right subclavian and jugular vein.
 <i>s</i>, The left inferior thyroid vein terminating in the great subclavian.
 <i>t</i>, The left carotid artery.
 <i>U</i>, ----- vertebral artery.
 <i>v, w, x, y</i>, The left internal mammary artery and vein.
 <i>z</i>, The left subclavian vein.
 1. ----- jugular vein.
 2. ----- bronchial vein.
 3. The trunk of the great subclavian vein.
 4. The superior vena cava.
 5. The inferior vena cava.
 6. The pulmonary veins of the right side.
 7. The right nerve of the eighth pair.</p> |
|---|--|

T A B L E CXLIII.

The Posterior Surface of the LUNGS.—The AORTA is turned towards the Left, to obtain a more distinct VIEW of the VENA AZYGOS, and the BRONCHIAL VESSELS of the Right Side.

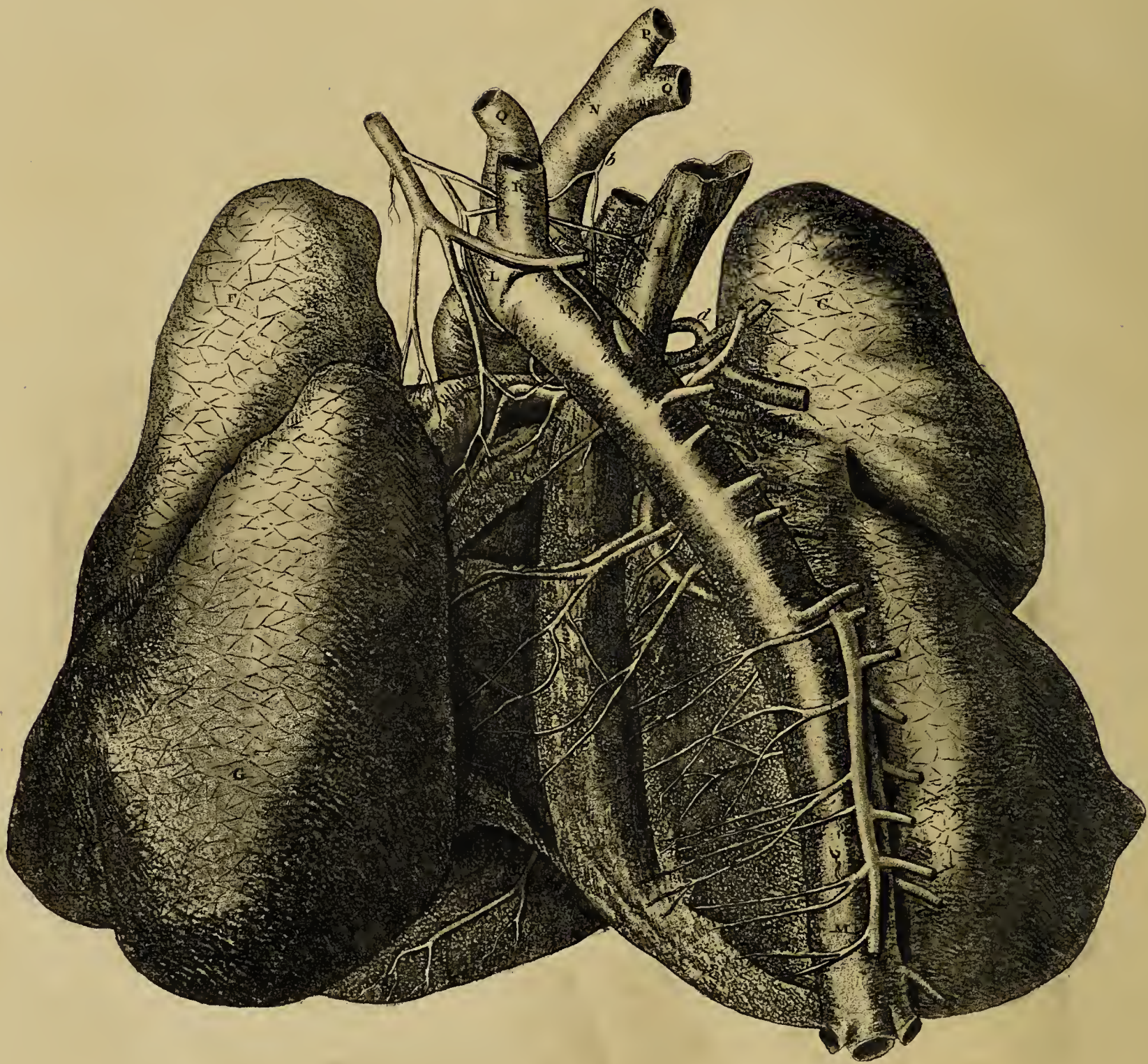
-
- | | |
|--|--|
| <p>A, The trachea.</p> <p>B, The right branch of the trachea.</p> <p>C, Da, E, The right lung; C, the upper, Da, the middle, E, the under lobe.</p> <p>F, G, The left lung; F, the upper, G, the under lobe.</p> <p>H, H, The esophagus.</p> <p>I, I, The pericardium covered posteriorly by the pleura.</p> <p>K, K, The mediastinum posterius.</p> <p>L, The arch of the aorta.</p> <p>M, M, The aorta descendens.</p> <p>N, The common trunk of the right subclavian and carotid.</p> <p>O, The right subclavian.</p> <p>P, ——— carotid.</p> <p>Q, The left carotid.</p> <p>R, ——— subclavian.</p> <p>a, The posterior and superior pericardiac artery, from the left subclavian to the esophagus and trachea.</p> <p>b, The pericardiac artery from the right subclavian to the trunk of the aorta and trachea.</p> <p>c, The arteria broncho-esophagea from the aorta.</p> <p>d, The esophageal artery and vein from the right bronchial.</p> <p>e, The right bronchial artery.</p> | <p>f, The superior intercostal arising from the right bronchial, going to the second interval.</p> <p>g, The bronchial arteries in their way to the lungs.</p> <p>h, One of the left bronchial arteries.</p> <p>ii, ii, The intercostal arteries.</p> <p>k, k, The celiac and mesenteric branches of the aorta in the abdomen.</p> <p>l, m, n, o, The esophageal arteries.</p> <p>p, The left portion of the azygos.</p> <p>q, The right portion.</p> <p>D, The union of the two portions of the azygos.</p> <p>s, The superior intercostal branch from the second and third interval.</p> <p>t, The vena azygos, near its termination in the vena cava.</p> <p>u, The vena cava.</p> <p>v, A branch of the left bronchial vein from the coats of the aorta.</p> <p>w, x, Branches from the esophagus.</p> <p>y, Branches from the aspera arteria.</p> <p>z, Other branches from the esophagus.</p> <p>1. A vein which receives branches from the superior intercostal spaces.</p> <p>2. The left superior intercostal vein.</p> |
|--|--|

TAB. 143.



A. F. J. sculp.

TAB. 144.



A. F. de font

T A B L E CXLIV.

The AORTA turned to the right, to obtain a more distinct VIEW of the VESSELS of the Left Side.

A, The arteria aspera.
B, The left bronchus, above which is the branch of the pulmonary artery.
C, D, E, The three lobes of the right lung; C, the upper, D, the middle, E, the under lobe.
F, G, The two lobes of the left lung.
H, H, The esophagus.
I, The pericardium covered posteriorly by the pleura.
K, The posterior mediastinum.
L, The arch of the aorta.
M, M, The descending aorta.
N, The common trunk of the right subclavian and carotid.
O, The right subclavian.

P, The right carotid.
Q, The left carotid.
R, The left subclavian.

At the upper part of the Root of the Right Lung, the Right Bronchial Artery appears, immediately under which is the Great Branch of the Vena Azygos. Tab. CIII. s.

In the upper half of the opposite side of the Figure, three Left Bronchial Arteries appear, with a Bronchial Vein going into the Azygos, and others passing into the Trunk of the Left Superior Intercostal Vein.

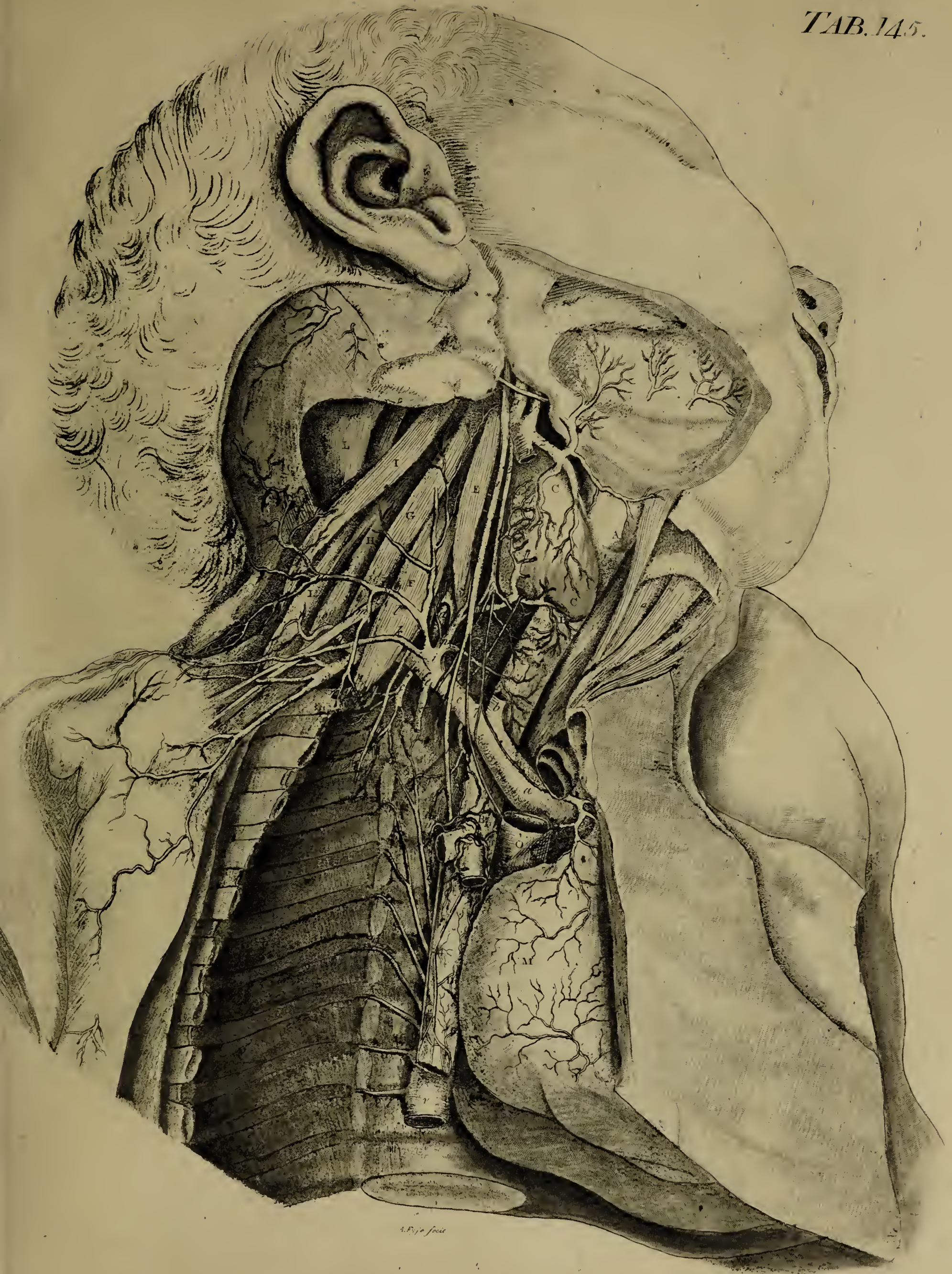
The Arterious Branches observed in the under half of the Figure, are the Arteriæ Esophageæ; their corresponding Veins are seen running to the Trunk of the Azygos.

TABLE

T A B L E CXLV.

A VIEW of the THYROID, CERVICAL, and INTERCOSTAL VESSELS.

-
- | | |
|--|--|
| <p>A, The larynx, slightly shewn.
 B, B, The aspera arteria.
 C, C, The right part of the thyroid gland.
 D, Part of the esophagus.
 E, The rectus anterior major capitis.
 F, The scalenus anticus.
 G, H, The scaleni laterales.
 I, I, The levator scapulae.
 K, The complexus.
 L, The splenius capitis.
 M, The heart turned aside.
 N, The coronary artery.
 O, The vena cava.
 a, The trunk of the right carotid and subclavian.
 b, The right carotid.
 c, ——— subclavian.
 d, The vertebral artery.
 e, The internal mammary artery.
 f, The superior intercostal artery.
 g, An inconstant branch from the subclavian artery, termed <i>Superficial Cervical Artery</i>.
 h, One of the external thoracics.
 i, The trunk of the posterior thyroid.
 k, The posterior cervical artery.
 l, The posterior transverse cervical artery.</p> | <p>m, A superficial branch to the skin of the breast.
 n, Branches to the levator, complexus, splenius, and trapezius.
 o, The anterior cervical artery.
 p, The thyroid branch of the thyroid artery.
 q, The thoracic branch.
 r, Anastomosis with the superior intercostal.
 s, The left bronchial artery.
 t, t, The aortic intercostal arteries.
 u, The uppermost of the inferior intercostals, from which the right bronchial goes off.
 v, The aorta descendens.
 w, The right carotid.
 x, The cerebral trunk.
 y, The external carotid.
 z, The superior thyroid artery, with branches to the gland, and one to the skin of the chin, and muscles of the larynx.</p> <ol style="list-style-type: none"> 1. 1. The eighth pair of nerves. 2. 2. The recurrent nerve. 3. The cardiac nerve from the par vagum. 4. The rete esophageum from the eighth pair. 5. The intercostal nerve. 6. The middle cervical ganglion. 7. The cardiac branches: |
|--|--|



BLOOD-VESSELS OF THE CHYLOPOIETIC, AND ASSISTANT CHYLOPOIETIC
VISCERA.

ARTERIES.

THE Arteries of these Viscera, consist of the *Cæliac*, and the *Superior* and *Inferior Mesenterics*; all of which are *Azygous*, or single Arteries arising from the fore-part of the Aorta.

ARTERIA CÆLIACA.

The *Arteria Cæliaca*, Tab. CLXXIX. arises from the Aorta, immediately after it emerges from between the Crura of the Diaphragm into the Abdomen, or nearly opposite the Eleventh Dorsal Vertebra, and is situated at the upper edge of the Pancreas.

The Trunk of the Cæliac Artery is remarkably short, being little more than half an inch in length, before it divides into its Three Principal Branches, called, from their destination, *Superior Gastric*, *Hepatic*, and *Splenic*. Tab. CLXXIX.

The GASTRICA SUPERIOR, or CORONARIA VENTRICULI SUPERIOR, Tab. XCI. *a, a*. Tab. CXLVI. Tab. CCI. is the smallest of the three. It goes upwards, and a little towards the left, to reach the right side of the upper orifice of the Stomach.

Here it sends Branches to the Cardia, which encircle it, and, ascending some way upon the Esophagus, communicate with the Arteriæ Esophageæ.

The Trunk of the Artery afterwards divides, upon the small Curvature of the Stomach, into principal Branches, some of which run across the upper and under Surfaces, and others obliquely towards the right side; supplying a large portion of the Stomach, and sending Twigs to the Omentum Minus,—while the Trunk is frequently extended as far as the Pylorus.

The ARTERIA HEPATICA, Tab. XCIII. Fig. 2. Y, Tab. XCI. K, the largest of the three great Branches, is concealed at its root by the Pancreas, and passes obliquely forwards, upwards, and to the right side, behind the Pylorus,—before and a little to the right side of the *Lobulus SPIGELII*,—till it arrives at the Cavity of the Liver called *Porta*.

Where it approaches the *Porta*, it divides into the *Gastrica Inferior Dextra*, and the *Proper Hepatic Artery*.

The GASTRICA DEXTRA, Tab. XCII. Fig. 3. Tab. CXLVI. Tab. CCI. or GASTRICA INFERIOR DEXTRA, or GASTRO-EPIPLOICA DEXTRA, sends out—

The *Arteria Pylorica*, which, however, is frequently produced immediately from the Hepatic Artery. It gives Branches to the Pylorus and other parts about the small end of the Stomach, and afterwards runs some way along its small Curvature, inosculating with the Superior Gastric Artery.

Besides this principal Branch, there are a few smaller ones sent from the Gastrica Inferior to the Pylorus.

The *Duodenalis*, which is dispersed upon the beginning and right portion of the Duodenum, along with other Branches coming from the same source, but of inferior size.

Rami Pancreatici, distributed to the right end of the Pancreas.

After furnishing the Branches already mentioned, the Inferior Gastric Artery passes under the Pylorus to the great Curvature of the Stomach, along which it runs; being included, to near its large extremity, in the Layers of the Anterior Portion of the Omentum.

In this course, it sends off—

The *Rami Epiploici*, which are long and slender Branches dispersed upon the Epiploon or Omentum.

The *Rami Gastrici*, which, plunging suddenly into both sides of the Stomach, communicate with the Pyloric and Superior Gastric Arteries.

The Hepatic Artery, having given out the Inferior Gastric, and frequently the Pyloric Artery, soon divides into two principal Branches, a right and left, of unequal size, which run into the *Porta*;—the one,—under the Hepatic Duct,—to supply the great,—and the other the small Lobe of the Liver.

From the Right Branch, before it plunges into the Liver, is sent off the *Arteria Cystica*, afterwards dividing into two smaller Branches, termed *Gemellæ*, which are dispersed upon the Gall-bladder.

Frequently, besides the Hepatic Artery sent off from the Cæliac, there is another, coming sometimes from the Superior Gastric, at other times from the Superior Mesenteric Artery, to be sent into the Liver. In such cases, the Trunk which gives origin to this additional Artery is greater than usual, and the Hepatic Branch, which it accompanies is proportionally smaller. Tab. CXLVI. Tab. CCI.

The ARTERIA SPLENICA, Tab. CXLVII. *g*. Tab. CXCIX. *r, r*, nearly equal in size to the Trunk of the Hepatica, takes a long and serpentine course across the left side of the Body; running first behind, then at the upper

upper part of the Pancreas in its way to the Spleen.—Its Branches are,—

The *Rami Pancreatici*, which are few in number, and small. They run from the Splenic Artery nearly at right angles, and supply the greater part of the Pancreas.

The *Gastrica Sinistra*, *Gastrica Inferior Sinistra*, or *Gastro-Epiploica Sinistra*, which is considerably inferior in length and size to the *Gastrica Dextra*, communicates by its Branches with the *Gastrica Superior*, and *Inferior*, while its Trunk runs a little way towards the right side along the great Curvature of the Stomach.

It sends some *Rami Pancreatici* and *Gastro-Epiploici*, and *Meso-colici Sinistri*, to the Pancreas, to the left portions of the Omentum and Meso-colon; while its Trunk frequently forms a common Arch with the *Gastrica Dextra*.

Three or four considerable Branches, termed *Vasa Brevia*, or *Arteriae Breves*, which run to the left part of the great Curvature of the Stomach, to be distributed upon its large extremity; their Ramifications anastomosing with those of the Superior and of the Left Inferior Gastric Arteries.

The *Rami Splenici*, which are also contorted, are several in number, and of considerable size. They go at the concave side of the Spleen, to be distributed throughout the whole of its substance.

MESENTERICA SUPERIOR.

The MESENTERICA SUPERIOR, Tab. CXLVIII. *b*, arises from the Aorta, immediately below the Cœliac Artery, which it equals in size; and, running under the Pancreas, and then over the Duodenum, it passes between the Layers of the Mesentery, towards the under side of the Abdomen.

In its descent, it is bent a little to the left side, its lower extremity turning towards the beginning of the Colon.

From the convex side of the Artery, many large Branches are sent off to the Small Intestines; while others proceed from the right side to the right portion of the Colon.

The *First Arteries* sent off from the Trunk are very inconsiderable, running to the Pancreas and to the left portion of the Duodenum, and communicating there with Branches of the Cœliac Artery.

The principal Branches from the left side of the Trunk are dispersed upon the Jejunum and Ilium, supplying, in their course, the Layers of the Mesentery with the parts it contains.

The first of these Branches are short and small; those which succeed gradually increase in length and size to the middle of the Arch, after which they diminish again

somewhat in the same proportion towards the lower part of the Ilium.

In their course through the Mesentery, the principal Branches communicate, first by reciprocal Arches, then by Areolæ of different figures, which increase in number, but diminish in size as they approach the Intestines.

From these Areolæ, many Branches are detached, which take a straight course to the Intestines, and are afterwards ramified through their substance, forming numberless Anastomoses with each other.

The Branches produced from the right or concave side of the Trunk are situated between the Layers of the Meso-colon,—their length being almost equal to the breadth of that Membrane.

Near the Intestines, they communicate by large, and then by smaller Arches:—These last, however, are less frequent than those which belong to the small Intestines.

The principal Branches are the following:—

The *Ileo-colica*, which arises near the under part of the Trunk, supplies the end of the Ilium and beginning of the Colon, and communicates with the Branches sent from the extremity of the Trunk of the Artery.

A *Short Trunk*, which divides into—

The *Colica Dextra*, for supplying the right side of the Colon,—its Branches communicating with those of the *Ileo-colica*: And—

The *Colica Media*, or *Media Anastomotica*, which proceeds to the great Arch of the Colon.

Near the Colon, the *Colica Media* divides into two large Branches; one forming an arch with the *Dextra*, the other with a Branch of the *Mesenterica Inferior*.

From the opposite side of the Colon, Branches of this Artery run to the Omentum, and communicate with the *Gastro-Epiploic* Arteries.

Besides the Colic Branches already described, there is frequently an additional one, which arises from the beginning of the Superior Mesenteric Artery, and in its ascent splits into two others; one of which, uniting with the *Colica Media*, forms the large Meso-colic Arch, and the other a similar Arch with the ascending Branch of the *Inferior Mesenteric Artery*.

MESENTERICA INFERIOR.

The MESENTERICA INFERIOR, Tab. CC. *Q*, arises from the Anterior and left side of the Aorta, somewhat lower than half-way between the Superior Mesenteric and the Bifurcation of the Aorta.

It descends obliquely behind the Peritoneum upon the left Psoas Muscle, and soon divides into principal Branches.

These near the Intestine join with each other, and form Arches, from which others go off, composing Areolæ in some

some measure similar to those which belong to the right side of the Colon.—The principal Branches are:—

The *Ramus Ascendens*, which divides near the Intestine, into two Branches; one of which joins the Colica Media, to form the great Meso-colic Arch, the other is reflected upon the left portion of the Colon.

The *Colica Sinistra*, which is frequently double from its origin, or at other times splitting into two Branches, one joining the Ramus Ascendens, the other passing down by the Sigmoid Flexure of the Colon.

The *Hæmorrhoidalis Interna*, which is of great size, being the Trunk continued, anastomoses with the Colica Sinistra, and afterwards descends upon the back part of the Rectum to its under extremity.

VEINS.

The VEINS which return the Blood from the Chylopoietic and Assistant Chylopoietic Viscera accompany their respective Arteries; the Hepatic Branch excepted. They have, like their Arteries, large and frequent Communications with each other, are much superior in size, and, as well as the other Veins of the Viscera situated in the great Cavities, are destitute of Valves.

The following are the principal Trunks:

The MESENTERICA, or MESARAICA MINOR, or HÆMORRHOIDALIS INTERNA.

The MESENTERICA MINOR, running up at the left side of the Spine, receives—

The *Proper VENA HÆMORRHOIDALIS INTERNA*, which returns the Blood from the Intestinum Rectum.

The *Venæ Colicæ Sinistræ*, which return the Blood from the left portion or side of the Colon.

The *Vena Duodenalis*, which returns the Blood from the left portion of the Duodenum.

The Mesenterica Minor commonly terminates in the Vena Splenica, though not unfrequently in the Mesenterica Superior.

The *Vena Splenica*, situated at the under side of its Artery and immediately behind the Pancreas, receives—

The *Rami Splenici*, which return the Blood from the Spleen:—

The *Rami Pancreatici*, which pass from the under side of the Pancreas:—

The *Venæ Breves*, or *Vasa Brevia*, which come from the left or great end of the Stomach:—

The *Vena Gastrica Sinistra*, or *Epiploica Sinistra*, which comes from part of the great Arch of the Stomach, and corresponding portion of the Omentum:—

The *Gastrica Superior*, which comes from the small Curvature of the Stomach, and Omentum Minus, and goes into the Splenic near its termination, or into the beginning of the Vena Portæ.

The Splenic and Inferior Mesenteric Veins, after re-

ceiving their respective Branches, form a short Trunk which joins the Superior Mesenteric.

The VENA MESENTERICA SUPERIOR, or MAJOR. Tab. CXLVII. Tab. CXLVIII. The Great Mesenteric Vein, situated at the under side of the Artery, receives—

The *Rami Mesenterici*, which are very large and numerous, returning the Blood from the Jejunum and Ilium,—the Branches going into the left side of the general Trunk.

The *Ileo Colica*, which comes from the end of the Ilium and beginning of the Colon.

The *Colica Dextra*, which belongs to the right side of the Colon, and terminates in the right or concave side of the Mesenteric Trunk.

The *Colica Media Anastomotica*, which comes from the right portion of the great Arch of the Colon, forming, with the descending Branch of the Mesenterica Minor, a large Arch similar to that of the corresponding Artery, and terminating also in the right side of the Trunk.

The *Gastro-epiploica Dextra*, which belongs to the right portions of the Stomach and Omentum, and frequently unites with the Veins from the side of the Colon, forming a short common Trunk, which has the term of *Gastro-Colica* applied to it.

The *Pylorica* and *Duodenalis*, which sometimes terminate in the Superior Mesenteric, at other times in the Gastrica Dextra.

The Great Mesenteric Vein, formed by the Branches mentioned above, passes over the beginning of the corresponding Artery, and joins the Vena Splenica.

The Trunk formed by these Veins, runs under the head of the Pancreas, and here obtains the name of *Vena Portæ*, or *Vena Portarum*.

VENA PORTÆ.

The VENA PORTÆ, Tab. XCIII. Fig. 2. Z, formed by the two Mesenterics, and by the Splenic Vein, returns the Blood from the Stomach and Intestines, and from the Spleen, Pancreas, and Omenta.

The under part of the Vena Portæ is termed by some Authors *Vena Portæ Abdominalis*, or *Ventralis*; while the upper part,—being of great size, but without having any particular dilatation in it,—is called *Sinus* of the Vena Portæ.

The Vena Portæ, at its beginning, frequently receives the Vena Gastrica Dextra, the Gastrica Superior, the Pylorica, and the Duodenalis, which at other times terminate in one of the great Trunks which form it.

It passes upwards, inclining a little to the right in its course to the Liver, having the Trunks of the Biliary Ducts before, and the Hepatic Artery on the left side of it,—and is about three or four inches in length.

When it reaches the Porta of the Liver, it receives the

Venæ

Venæ Cysticæ into its Trunk, or into its right division, either by two separate Branches, or these united into a single Vein.

In the Porta, it divides into two great Branches, a right and left, sometimes termed *Venæ Portæ Hepaticæ*, which go off nearly at right angles; to be dispersed, through the substance of the Liver, after the manner of an Artery; the subordinate Branches accompanying those of the *Arteria Hepatica*.

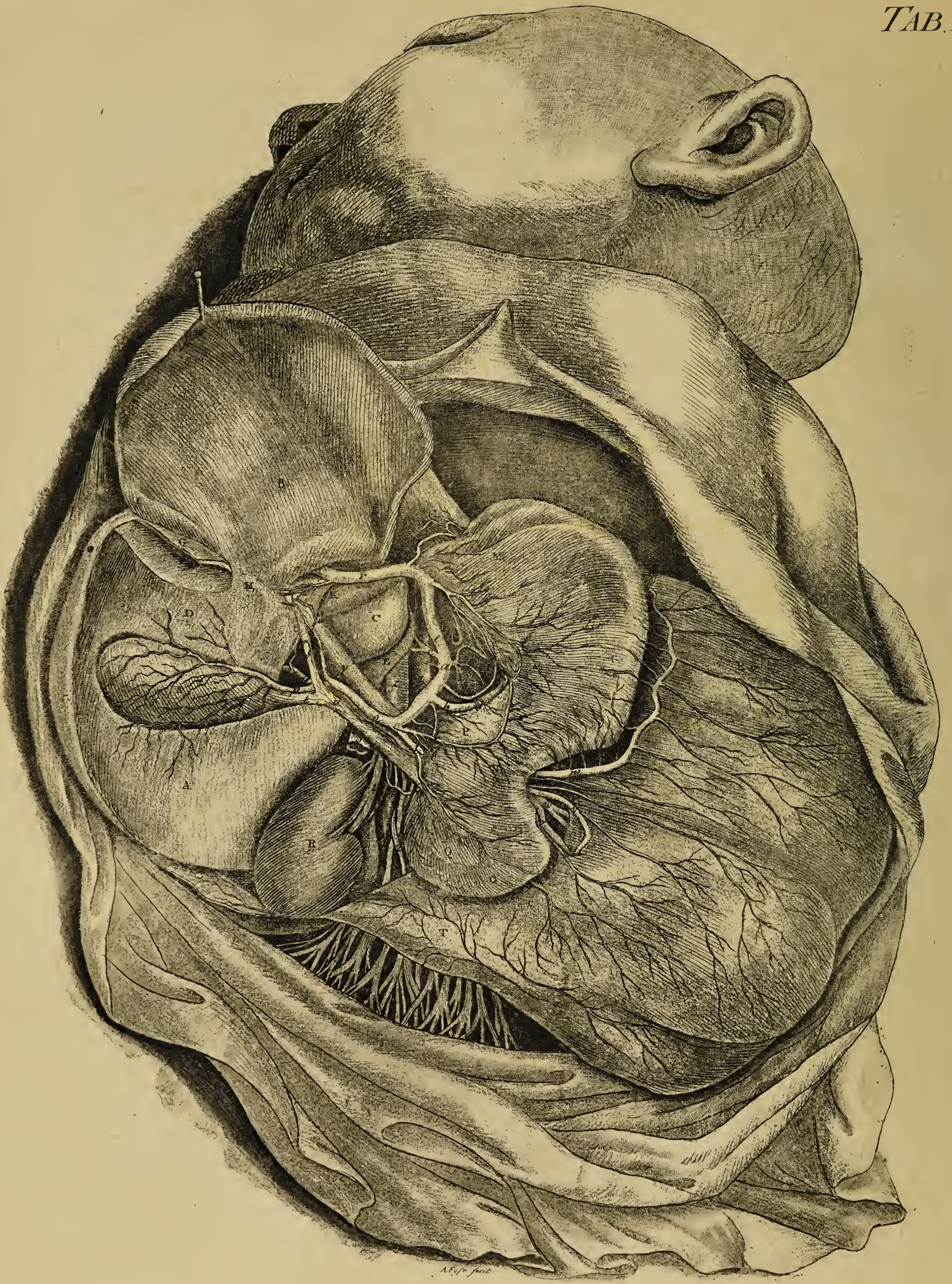
From the Extremities of the *Vena Portæ*, and likewise from the Extremities of the Hepatic Artery, a set of Veins arise, termed *Venæ Hepaticæ*, and sometimes

Venæ Cavæ Hepaticæ, which accompany the Branches of the Hepatic Artery and *Vena Portarum*.

The Branches of the *Venæ Hepaticæ* afterwards unite into large Trunks, which recede from the Hepatic Artery and *Vena Portæ*, and terminate in the Inferior Cava.

Their termination in the Cava is by two, and frequently by three Trunks, at the place where it perforates the Diaphragm; but commonly below this, a few small Hepatic Branches go into the cava, where it is situated behind the Liver.

TABLE



T A B L E CXLVI.

Gives a VIEW of several of the ARTERIES of the CHYLOPOIETIC and ASSISTANT CHYLOPOIETIC
VISCERA.

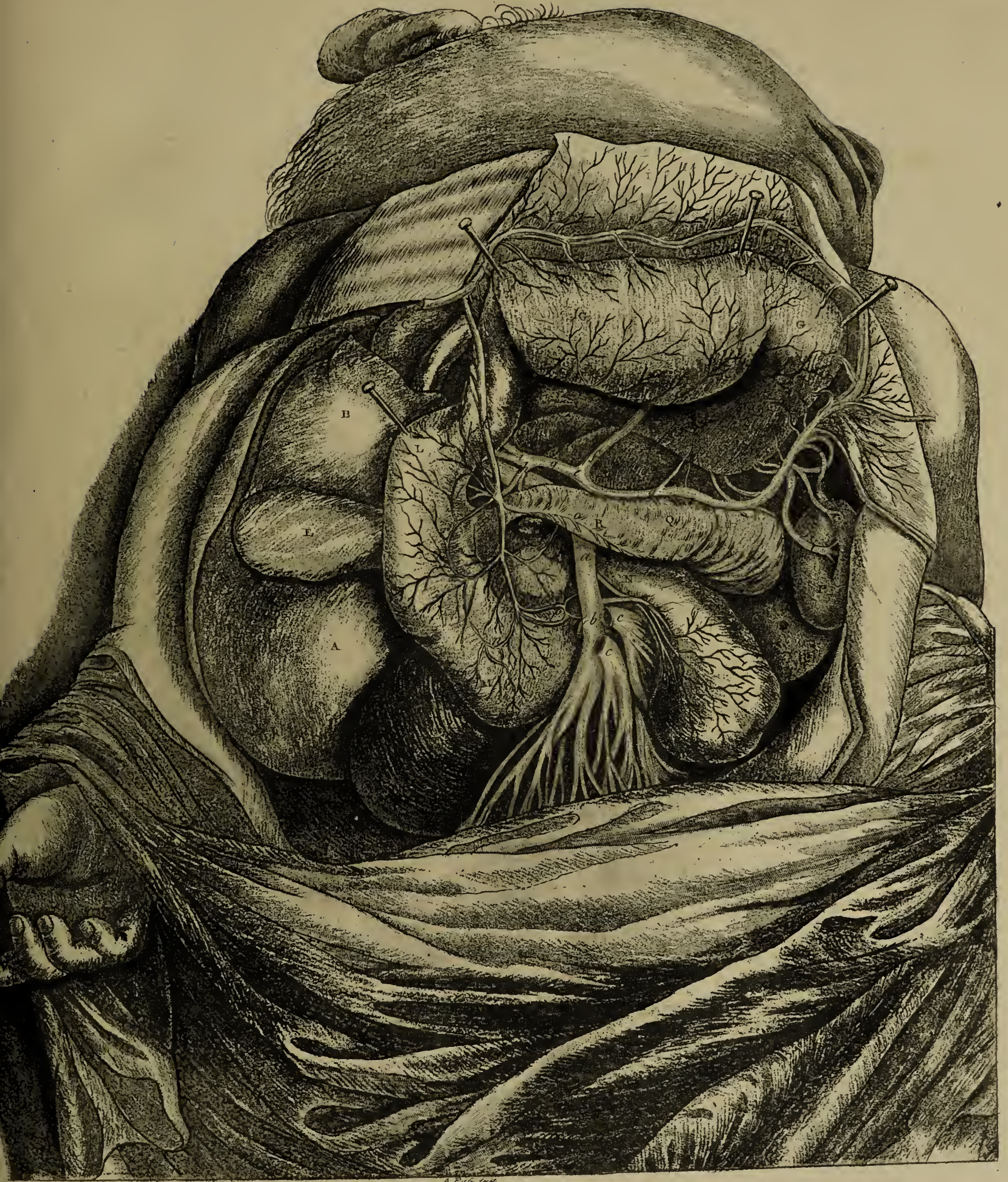-
- | | |
|--|---|
| <p>A, B, C, D, E, The hollow surface of the liver, turned to the right side ;</p> <p>A, The right lobe ;</p> <p>B, The left lobe stretched and pinned out ;</p> <p>C, The lobulus SPIGELII ;</p> <p>D, The lobulus anonymus, between the umbilical vein and vesicula fellis ;</p> <p>E, A fossa at the root of the left lobe, which gives passage to the large hepatic vessels.</p> <p>F, The vesicula fellis.</p> <p>G, The fossa umbilicalis.</p> <p>H, The pons, almost constant, which covers part of this fossa.</p> <p>I, The umbilical vein.</p> <p>K, The fossa ductus venosi.</p> <p>L, The left ligament of the liver.</p> <p>M, N, The stomach taken out of its natural situation, and removed from the liver, to obtain a view of part of the pancreas.</p> <p>M, The part next the esophagus.</p> <p>N, The pylorus.</p> <p>O, The curvature of the duodenum, turned in such a manner, that the posterior part of the descending and transverse portions becomes the anterior.</p> <p>P, A portion of the pancreas.</p> <p>Q, Another part of the pancreas, between the descending and transverse portions of the duodenum.</p> <p>R, The right kidney.</p> <p>Ra, S, The omentum gastro-colicum.</p> | <p>E, Part of the peritoneum covering the mesenteric vessels.</p> <p>a, The trunk of the cœliac artery.</p> <p>b, The right appendix of the diaphragm separating the vena cava from the aorta.</p> <p>c, The right phrenic artery, arising from the cœliac.</p> <p>d, The left phrenic, from the superior gastric artery.</p> <p>e, The superior coronary artery.</p> <p>f, The capsular artery.</p> <p>g, The peculiar splenic artery,</p> <p>h, The splenic artery.</p> <p>i, Superior pyloric arteries.</p> <p>k, The proper pyloric artery.</p> <p>l, The arteria duodenalis.</p> <p>m, n, The right gastric artery.</p> <p>o, The right hepatic artery.</p> <p>p, q, The cystic arteries.</p> <p>r, The left hepatic artery.</p> <p>s, The hepatic duct.</p> <p>t, The cystic duct.</p> <p>u, The ductus choledochus.</p> <p>v, The middle colic artery.</p> <p>w, The mesenteric arteries.</p> <p>x, The right epiploic arteries.</p> <p>y, The vena portarum.</p> <p>z, ----- cava.</p> <p>1. The renal arteries.</p> <p>2. The spermatic vessels.</p> <p>3. The left emulgent vein.</p> |
|--|---|

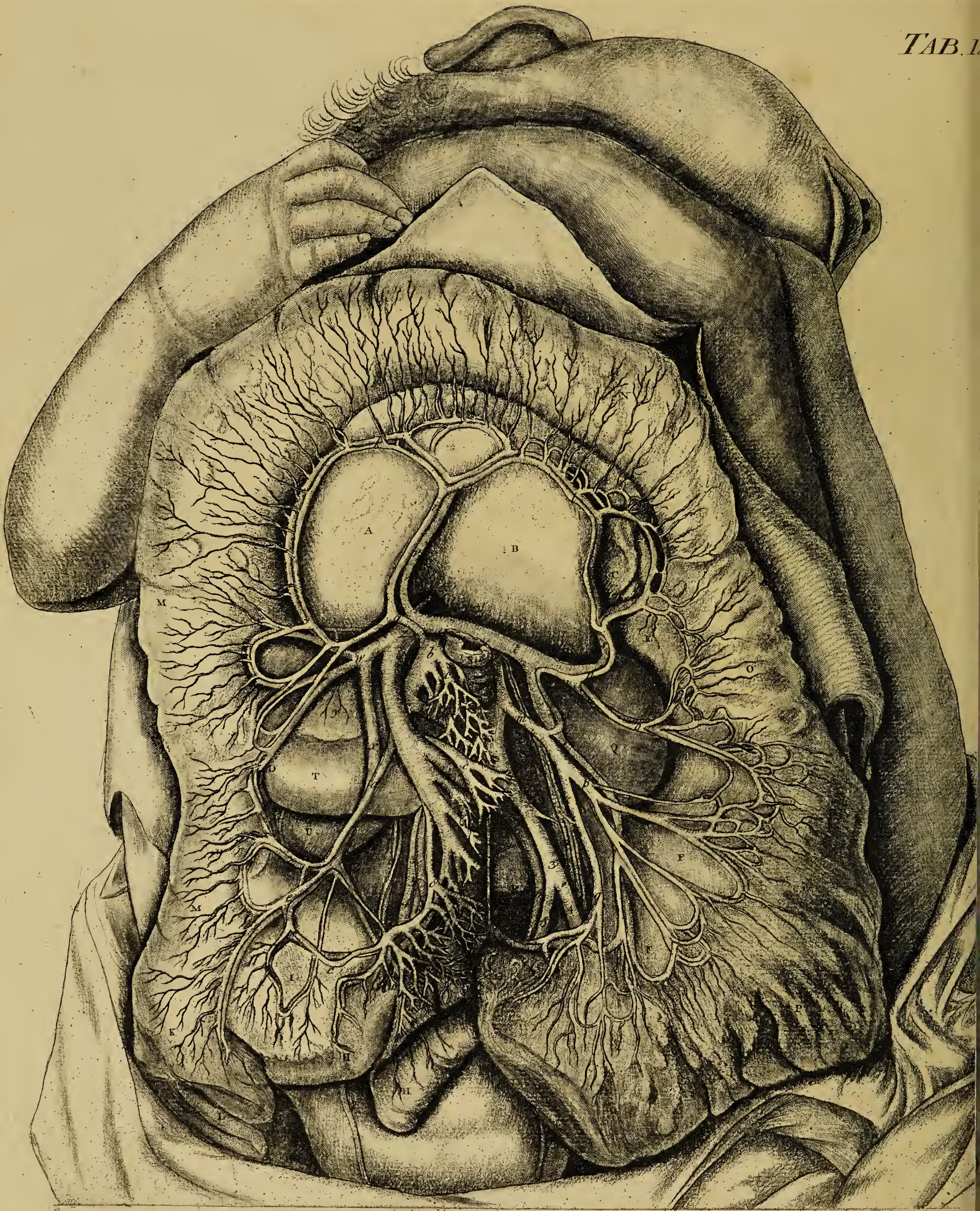
T A B L E CXLVII.

BRANCHES of the CÆLIAC ARTERY, and of the SUPERIOR MESENTERIC ARTERY and VEIN.

-
- | | |
|--|--|
| <p>A, B, The great lobe of the liver turned to the right side.
 CC, the left lobe.
 D, The lobulus SPIGELII.
 E, The vesicula fellis.
 F, The right kidney.
 GGG, The stomach, in such a direction that each orifice looks backwards, nearly as when quite full.
 H, The œsophagus.
 I, A portion of the omentum gastro-colicum.
 K, The pylorus.
 L, The descending portion of the duodenum.
 M, The transverse portion of the duodenum.
 N, The left portion of the same, and beginning of the mesentery.
 O, The left kidney.
 P, The spleen <i>in situ</i>.
 Q, The anterior surface of the pancreas.
 R, The posterior surface of the pancreas turned forwards.
 a, The mesenteric artery passing under the pancreas and over the duodenum.
 b, The middle colic artery.
 c, c, The mesenteric branches of the vena portarum.</p> | <p>d, The vena portarum, pulled a little to the right side.
 e, The trunk of the cœliac artery.
 f, The superior coronary.
 g, The hepatic branch of the cœliac artery.
 h, The gastrica dextra.
 i, The proper hepatic artery.
 k, The right gastro-epiploic artery, following the large curvature of the stomach.
 l, Two inferior pyloric arteries.
 m, The duodenal artery, following the hollow part of the curvature of the duodenum.
 n, Branches to the duodenum;—a little higher are seen, anastomoses between these and the pyloric arteries, and also branches to the pancreas.
 o, The pancreatic artery extending a long way transversely to the left.
 p, A branch from the mesenteric anastomosing with the same.
 q, The splenic artery.
 r, ———— branches.
 s, The left gastro-epiploic artery.
 t, Its anastomosis with the right.
 u, u, The vasa brevia.</p> |
|--|--|

TABLE





T A B L E CXLVIII.

MESENTERIC BLOOD-VESSELS.

- A, B, C, The middle meso-colon entire, and turned up, that its root may be seen.
- A, The feat corresponding to the liver, and,
B, To the stomach, and,
C, To the spleen.
- D, The right part of the meso-colon.
- E, Part of the left meso-colon between the spleen and kidney.
- F, F, The very large left iliac winding of the meso-colon.
- G, That part of it which descends to the intestinum rectum.
- H, H, Part of the intestinum ileum.
- I, The end of the mesentery, where it is continued with the right meso-colon.
- K, The intestinum cæcum.
- L, The appendix vermiformis.
- M, M, The colon dextrum.
- N, N, ——— transversum.
- O, The finistrum.
- P, The left iliac winding, or sigmoid flexure of the colon.
- Q, The left kidney.
- R, The last intervertebral cartilage of the loins.
- S, The first part of the jejunum, which emerges under the transverse meso-colon.
- T, The inferior transverse part of the duodenum.
- U, Part of the right kidney.
- W, The pfoas.
- y, The head of the pancreas.
- b, The superior mesenteric artery.
- c, c, c, c, The branches of the superior mesenteric artery to the small intestines.
- d, The ileo-colic artery.
- e, The ramus cæcalis, anastomotic with the mesenteric artery.
- f, The secondary, or double arches of the colica dextra.
- g, The middle colic artery.
- h, The right colic artery forming an arch with k.
- i, A branch to the middle of the transverse meso-colon.
- l, The union of the ascending branch of the left colic artery, with the middle colic, or large mesenteric arch.
- m, The left colic, or inferior mesenteric artery.
- n, The ascending branch.
- o, Branches of the same to the left portion of the colon.
- p, The middle trunk of the left colic artery.
- q, The inferior trunk, or arteria hæmorrhoidalis interna.
- r, The ascending branch of the internal hæmorrhoidal, or left colic vein.
- s, The descending branch of this vein.
- t, The trunk of the internal hæmorrhoidal, or left colic vein.
- u, The left coronary vein.
- v, The middle colic vein.
- w, The right colic vein.
- x, The ileo-colic vein.
- z, The mesenteric vein.
1. 1. The spermatic artery and vein.
 2. The arteria sacra.
 3. 3. The common iliac arteries.
 4. 4. The external,
 5. 5. The internal iliac arteries.
 6. 6. Their associate veins.

BLOOD.

BLOOD-VESSELS OF THE ORGANS OF URINE AND GENERATION.

ARTERIA RENALIS., Tab. CXLIX. Tab. CLXXIX.

—The Arteria Renalis, called also *Arteria Emulgens*, arises from the side of the Aorta, a little below the root of the Superior Mesenteric Artery.

It commonly comes off by one large Trunk, though frequently by two, and sometimes more; in which case, each of these is smaller than when the Artery is single.

It runs across the Spine and Psoas Muscle, nearly in a transverse direction, descending, however, a little in its course towards the Kidney. The Artery of the right side goes behind the Vena Cava, and is longer than the left, in consequence of the Cava being situated between the Aorta and the Right Kidney.

At the concave edge of the Kidney, the Artery divides into three or four Branches, which sometimes send Twigs to the Glandula Renalis and Tunica Adiposa of the Kidney.

The Renal Branches then plunge into the substance of the Kidney, surround its Pelvis, and afterwards ramify chiefly in its Cortical Substance;—forming Arches with each other, but few in number, at the roots of the Papillæ.

The VENA RENALIS, or EMULGENS, Tab. CLXXIX. terminates in the Inferior Cava; and is more superficial than its corresponding Artery. It is the largest Vein received by the Cava from its origin to the part where it reaches the Liver.

The Left Renal Vein is longer than the Right, in consequence of the Aorta lying between the Left Kidney and the Cava, and is situated first behind, but is afterwards anterior to the corresponding Artery.

The Right Vein is short, covers the Artery, and passes directly into the Cava.

ARTERIE CAPSULARES.—The Arteriæ Capsulares, or *Arteries of the Renal Capsules or Glands*, are small but numerous.

They are derived from the Renal and Diaphragmatic Arteries; and, in general, the Renal Gland, especially the Left, receives additional Branches from the Trunk of the Aorta.

The VENÆ CAPSULARES commonly unite into a large Trunk, which, in the left side, terminates in that of the Kidney, while in the right it frequently goes into the Cava.

ARTERIE ADIPOSÆ.—The Arteries which supply the Tunica Adiposa of the Kidney are numerous Twigs proceeding from the Diaphragmatic, Capsular, and Renal Arteries, or from others near it.

The Veins which return from the extremities of these Arteries pass into the Trunks adjacent.

ARTERIA SPERMATICA, Tab. LXXXVI. Tab. CLXXIX.—The Spermatic Artery, the diameter of which is small when compared with its great length, arises opposite to its fellow, from the fore-part of the Aorta, a little below the Renal Arteries.

Sometimes it arises from the Arteria Renalis, at other times a little higher from the Aorta, and in rarer instances from the Diaphragmatic Artery.

It descends, in a waving direction, on the surface of the Psoas, behind the Peritoneum; the right passing obliquely over the Cava; the left behind the Colic Arteries of the same side, and both before the Ureters, to the under part of the Abdomen.

After this, it perforates the Ring of the Obliquus Externus, and runs in the Spermatic Cord, where it divides into Branches, which are dispersed, some upon the Epididymis, while others larger, and much convoluted, run across the Surface of the Testicle, plunge into its Substance, and are distributed upon the Seminal Ducts.

In the descent of the Artery, it imparts Twigs—

To the Tunica Adiposa of the Kidney:

To the Peritoneum and Cellular Substance near it;—and,

To the Ureters,—which are also supplied with other Arteries from the adjacent Vessels, viz. from the Renal and Capsular Arteries, from the Aorta, the Iliacæ, and Vesicales.

The VENA SPERMATICA, Tab. CLXXIX. is much larger than its corresponding Artery, and is furnished with Valves within, but more particularly without the Abdomen.

It forms a Plexus which accompanies the Artery, and about the place where it recedes from it, which is nearly opposite the under end of the Kidney; it forms a single Trunk, which in the right side goes into the Cava a little below the Emulgent Vein, and in the left into the corresponding Vena Renalis.

Besides the Artery commonly called *Spermatic*, the Testicle generally receives a *Minute Branch*, which arises from the Hypogastric, and accompanies the Vas Deferens to the Body of the Testicle upon which it is dispersed,—communicating there with the Branches of the Spermatic Artery.

The Vein proper to this Artery, terminates in the Vena Hypogastrica.

The *Spermatic Artery*, in the Female, has the same kind of Origin, and the same course through the Abdomen, as in the Male, but is frequently more tortuous;—and, in place of perforating the Abdominal Ring, as it does in the latter, it descends into the Pelvis, between the

Lamina

Lamina of the Ligamentum Latum, to be dispersed first upon the Ovarium and Uterine Tube, and then upon the Body of the Uterus itself,—passing in at its corner, and communicating with the Artery of the opposite side.

The Spermatic Vein has the same termination in the Female as in the Male,—but is considerably larger.

ARTERIÆ ILIACÆ, Tab. CL. a.—The Iliac Arteries consist of the *Two Common Iliacs*, which are formed by the Bifurcation of the Aorta; and of the *External* and *Internal Iliacs* of each side, which are formed by the Bifurcation of the Iliacæ Communes.

The *External Iliac* passes out of the Abdomen behind the *Ligament of POUPART*; the *Internal*, termed also *Arteria Hypogastrica*, descends obliquely into the Pelvis.

At the side of the Pelvis, the Internal divides into many Branches, some of which belong to the Organs of Urine and Generation, the rest to other parts of the Pelvis and adjacent parts of the Thigh.

The following are the Branches sent from the Hypogastric Artery to the Organs of Urine and Generation.

ARTERIA UMBILICALIS, Tab. CL.—The Arteria Umbilicalis appears in the Fœtus, as the continued Trunk of the Internal Iliac; but in the Adult, is shrivelled in the form of a Ligament, excepting at its beginning or under part.

The beginning of the Umbilical Artery gives off—

One or more *Arteriæ Vesicales*, which run to the under part of the Bladder, and extend along its sides as far as the Fundus Vesicæ. At their origin, they furnish Twigs to the Vesiculæ Seminales, Prostate Gland, and Rectum.

In the Female, the Umbilical Artery sends minute Branches to the Bladder, Uterus, Vagina, and Rectum.

ARTERIA UTERINA, Tab. CLI. x.—The Arteria Uterina, termed also *Uterina Hypogastrica*, is much larger than the Spermatic Artery.

It arises from the Hypogastric, near the origin of the Pudic, Hæmorrhoidal, or Umbilical Arteries, and runs into the Uterus at its under extremity.

It is afterwards reflected upwards along the edge of the Uterus, towards its Fundus or upper part, where it meets with the Spermatic Artery, with which it forms frequent Anastomoses. It runs under the outer Coat of the Uterus, and sends out many Serpentine Branches which plunge into its Substance; frequently communicating with the Artery of the opposite side.

The Uterine Artery sends Branches downwards to be distributed extensively upon the Substance of the Vagina, and others forwards, to be dispersed upon the Bladder.

ARTERIA VAGINALIS, Tab. CLI.—The Arteria Vaginalis is frequently a-wanting; in that case the Vagina is supplied by Branches from the adjacent Arteries.—When present, it arises from the Hypogastric, or from some of its Branches,—as that common to the Ischiatic and Pudic,—or from the Hæmorrhoidalis Media; and is distributed upon the under part of the Vagina.

Besides this, there are other Vaginal Branches from the neighbouring Arteries; as from the *Vesicales*, *Uteri-*

na, and *Pudica*, which communicate with each other, and with the proper Vaginalis, upon the substance of the Vagina.

ARTERIA PUDICA, or PUDENDA COMMUNIS, Tab. CL. l, Tab. CLII. d.—The Arteria Pudica, named from its belonging to the Parts of Generation in both sexes, comes off either immediately from the Trunk of the Hypogastric, or from the Arteria Ischiatica.

It passes out of the Pelvis, through the under part of the Notch of the Os Ilium, at the lower edge of the Pyriformis.

It then turns between the Sacro-sciatic Ligaments, to get to the inner side of the Tuber Ischii, where it is lodged deep in the Cellular Substance.

From the Tuber, it proceeds along the inner side of the Crus of the Os Ischium and of the Os Pubis, and behind the Crus Penis, till it approaches the symphysis Pubis.

In its course, it sends off many Branches, of which the following are the principal, viz.

Branches to the Vesiculæ Seminales, Prostate Gland, Neck of the Bladder, and Rectum.

Branches to the Muscles and parts adjacent to the Sacro-sciatic Ligaments; some of them extending as far as the Joint of the Thigh-bone.

Branches to the Muscles, Membranes, and Fat about the Tuber of the Os Ischium.

The *Arteria Hæmorrhoidalis Externa*, which soon divides into Branches, to supply the Muscles and Integuments about the verge of the Anus.

The *Arteria Perinei*, which passes under the Transversalis Perinei, in the space between the Crus Penis and Bulb of the Urethra, and gives Branches to the Skin and Muscles at the fore-part of the Anus and root of the Penis, and to the Scrotum; while the Artery itself terminates on the under side of the Penis.

After dispersing the Branches already mentioned, the Pudic Artery divides, at the root of the Penis, into three principal Branches, viz.

The *First Branch*, which passes into the Bulb of the Urethra, and is continued forwards in the Corpus Spongiosum Urethræ, into the Cells of which many of its Branches open.

The *Second Branch*, termed *Profunda Penis*, which goes into the Crus Penis of the corresponding side, and directs its course in the Corpus Cavernosum, through which it passes, in nearly a straight line, to its other extremity; its Branches communicating with the Artery of the opposite side, and with the Cells of the Penis.

The *Third Branch*, called *Dorsalis Penis*, which turns between the Symphysis Pubis and root of the Penis, and proceeds along the Dorsum, as far as the Glans, adhering closely to the Ligamentous Substance which incloses the Corpora Cavernosa, and sending Branches to it and to the Integuments.

In the Female, the Pudic Artery has the same general course as in the Male.

After reaching the inner side of the Tuber of the Os Ischium,

Ischium, it is extended forwards, and sends Branches to the Anus, Perineum, end of the Vagina, and Labia Externa, and terminates in the Clitoris, somewhat in a similar manner as in the Penis. The Branch, which, in the Male, goes to the Bulb of the Urethra; in the Female, passing to the outer end of the Vagina.

The Blood is returned from the Branches of the Hypogastric Artery dispersed upon the Organs of Urine and Generation, by the following Veins, viz.

The *VENA VESICALIS*, which returns the Blood from the Bladder.

The *VENA UTERINA HYPOGASTRICA*, which comes from the Uterus.

The *VENA MAGNA IPSIUS PENIS*, which runs along the middle of the Dorsum, and is often double to near

the root of the Penis; after which it passes between this and the Arch of the Pubes, forming a Plexus which surrounds the Neck of the Bladder, and sending out Branches which terminate in others at the sides of this Viscus.

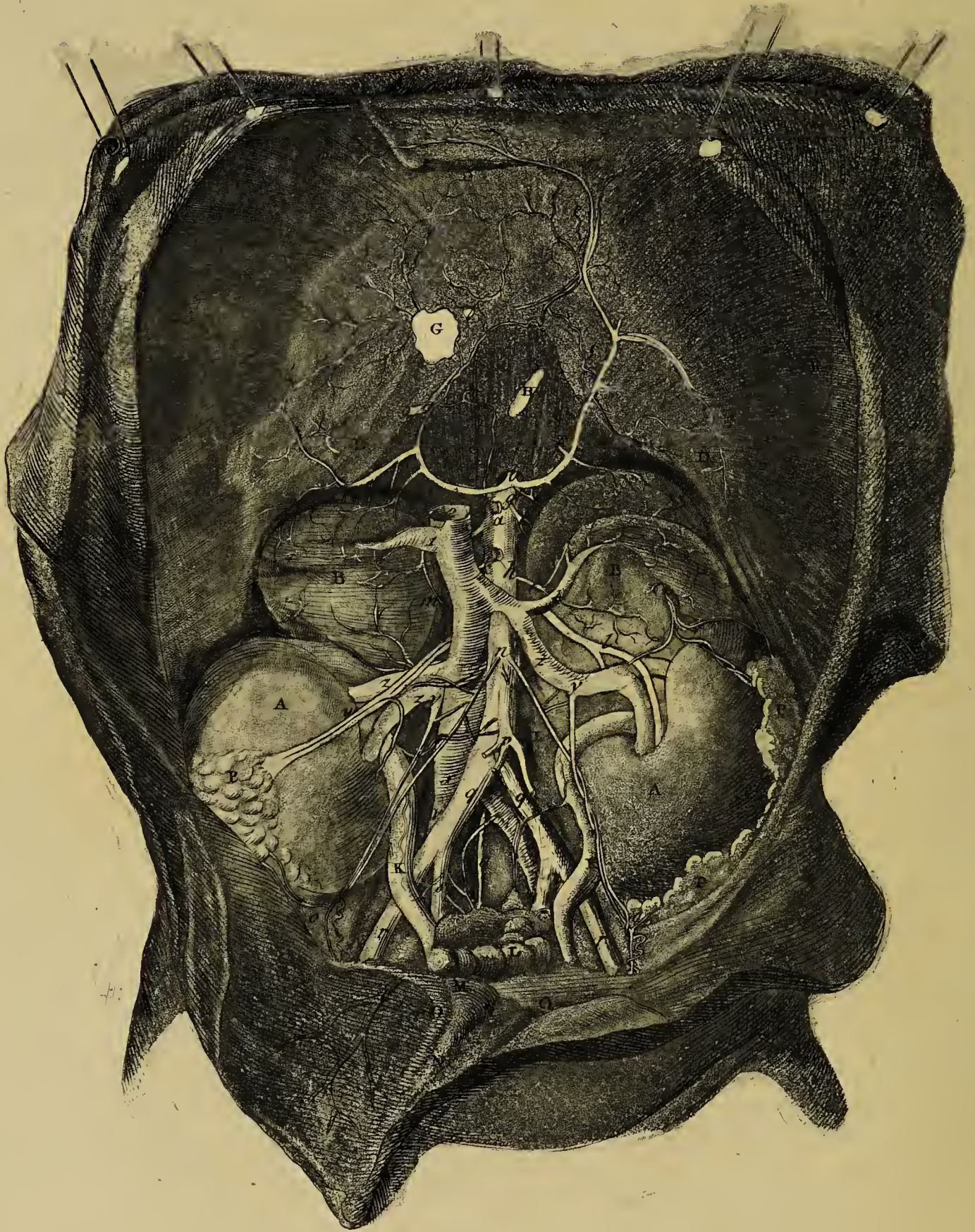
The *VENA PUDICA*, which communicates anteriorly with the Branches of the Vena Magna at the root of the Penis, and afterwards passes back with the corresponding Artery.

The *VENA TEGMENTORUM PENIS*, which is formed by small Subcutaneous Branches, and ends in the top of the Femoral Vein.

The Veins above mentioned, the last excepted, terminate in the *HYPOGASTRICA*, along with other Veins belonging to the Pelvis, to be afterwards described.

TABLE.

TAB. 149.



T A B L E CXLIX.

The DIAPHRAGMATIC and RENAL BLOOD-VESSELS.

-
- A, A, The kidneys.
 B, B, The capsulæ renales.
 C, C, The appendages of the diaphragm.
 D, D, D, The tendinous centre of the diaphragm.
 E, E, The fleshy parts of the septum arising from the ribs.
 F, The ligamentum suspensorium hepatis.
 G, The foramen for the transmission of the vena cava.
 H, ————— passage of the œsophagus.
 I, The psoas of the left side.
 K, K, The ureters.
 L, The intestinum rectum.
 M, The apex of the bladder.
 N, The urachus.
 O, O, The umbilical arteries.
 P, P, P, The remains of the fat of the kidney.
 a, The aorta.
 b, The phrenic artery, arising from a single root in this subject.
 c, c, Branches to the diaphragm.
 d, d, Capsular branches.
 e, The appendical branch of the right branch of the phrenic artery, anastomotic with the left.
 f, A branch to the œsophagus.
 g, The cœliac artery.
 h, The superior mesenteric artery.
 i, i, Appendical branches from the aorta.
 k, k, k, k, Capsular branches from the aorta.
 l, l, The right and left renal arteries.
 m, The right anterior capsular artery from the renal artery.
 n, o, o, The spermatic arteries.
 p, The inferior mesenteric artery.
 q, q, The common iliac arteries.
 r, r, The external,
 s, s, The internal iliac arteries.
 u, The arteria sacra media.
 w, The right adipose artery from the renal.
 y, y, Spermatic branches terminating in the renal veins.
 z, z, The renal veins of the right side.
 1. The right capsular terminating in the cava.
 t, The left capsular ending in the renal vein.
 2. The vena cava where it goes under the liver.

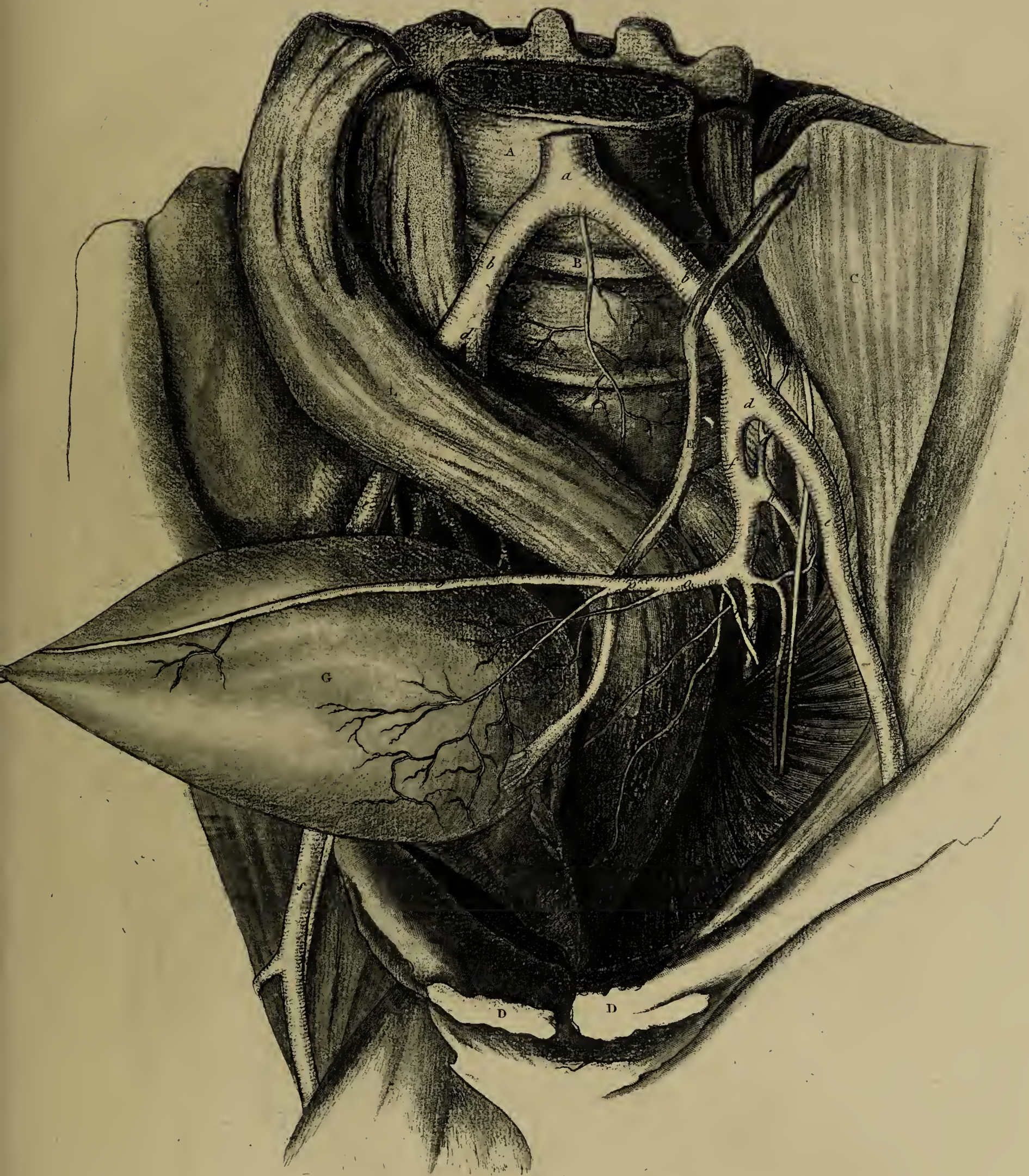T A B L E CL.

ARTERIES of the PELVIS of a Boy of Twelve Years of Age.

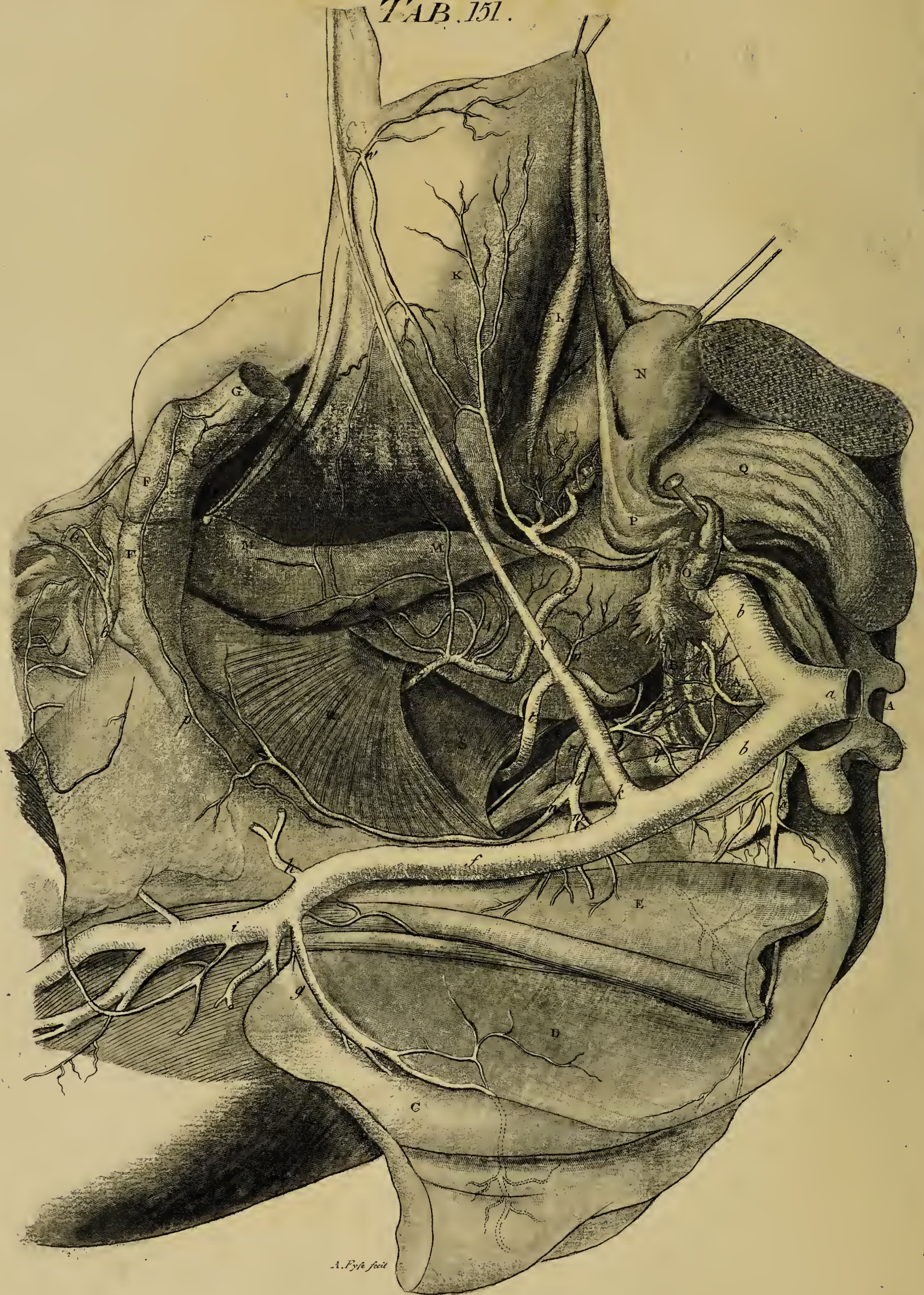
A, The fourth lumbar vertebra.
 B, The intervertebral substance.
 C, The iliacus internus.
 D, D, The ossa pubis.
 E, F, The ureter.
 G, The vesica urinaria.
 H, The prostate gland.
 I, The vas deferens.
 K, The vesicula feminalis, very small.
 L, L, The intestinum rectum.
 M, M, The levator ani.
 N, The musculus pyramidalis.
 a, The termination of the aorta.
 b, b, The common iliac arteries.
 c, The middle sacral artery.

d, d, The division of the common iliac arteries.
 e, e, The external iliac arteries.
 f, The internal iliac artery.
 g, The ileo-lumbar artery.
 h, The arteria glutea.
 i, The pudica communis.
 k, The ischiatica.
 l, The obturator artery.
 m, A branch from the pudica, termed by HALLER *Arteria Vesicalis Ima*.
 n, The hæmorrhoidalis media.
 o, o, The umbilical artery.
 p, The vesical branches.
 q, q, Some roots of the large ischiatic nerve.
 r, The nervus obturator.

TAB. 150.



TAB. 151.



T A B L E C L I.

ARTERIES of the FEMALE PELVIS.

-
- | | |
|--|--|
| <p>A, A, The last lumbar vertebra.
 B, The cartilage between it and the os sacrum.
 C, The left os ilium.
 D, The musculus iliacus internus.
 E, The psoas muscle.
 F, F, The symphysis of the ossa pubis.
 G, H, A section of the right os pubis and os ilium.
 I, The ureter.
 K, The vesica urinaria.
 L, L, Part of the peritoneum which goes from the bladder to the uterus.
 M, M, The vagina.
 N, The uterus.
 O, P, Its left tube, with part of the ligamentum latum.
 Q, The intestinum rectum.
 R, The levator ani spread over the obturator.
 S, The posterior part of it, nearer the os coccygis, proceeding in a somewhat different direction.
 <i>a</i>, The termination of the aorta.
 <i>b, b</i>, The common iliac arteries.
 <i>c</i>, The last lumbar artery.
 <i>d</i>, The middle sacral artery.
 <i>e</i>, The second lateral sacral artery.
 <i>f</i>, The external iliac artery.
 <i>g</i>, The circumflex artery of the os ilium.
 <i>h</i>, The trunk of the epigastric.</p> | <p><i>i</i>, The femoral artery.
 <i>k</i>, The hypogastric artery.
 <i>l</i>, A trunk common to,
 <i>m</i>, The ileo-lumbaris, and,
 <i>n</i>, The obturatoria.
 <i>o</i>, The continuation of the obturatoria through the foramen thyroideum.
 <i>p</i>, The superficial branch of the obturatoria to the os pubis.
 <i>q</i>, The ascending branch of the ileo-lumbar artery, anastomotic with the last lumbar artery.
 <i>r</i>, The arteria glutea.
 <i>s</i>, The ischiatic artery.
 <i>t</i>, The pudenda communis.
 <i>u</i>, A branch to the rectum.
 <i>v</i>, The umbilical artery.
 <i>w</i>, The vesical artery, partly hid in the umbilical artery now changed into ligament.
 <i>x</i>, The arteria uterina.
 <i>y</i>, A branch to the bladder of urine.
 <i>z</i>, The serpentine uterine branches.
 1. Another vesical artery from the artery of the clitoris.
 2. The middle hæmorrhoidal artery.
 3. A branch going out of the pelvis.
 4. Branches to the rectum.
 5. The vaginal artery from the hæmorrhoidæ media.
 6. 6. Arteries of the clitoris.</p> |
|--|--|

T A B L E CLII.

VIEW of the PUDIC and SACRAL ARTERIES.

FIG. 1.

Represents the ARTERIA PUDENDA COMMUNIS of the
MALE.

- A, The os sacrum.
B, Part of the os coccygis.
C, The tuber ischii ;
D, The musculus triceps arising from it.
E, The erector penis.
F, The transversus perinei.
G, The accelerator urinæ.
H, The sphincter ani.
I, K, The levator ani.
L, The obturator internus.
a, The posterior iliac artery.
b, The sciatica.
c, The coccygea.
d, The pudenda communis.
e, A large adipose branch.
f, g, Others to the levator and fat.
h, h, Branches to the obturator internus.
i, The division of the artery into the superficial and deep branches, the former termed *A. Perinei*, the latter *A. Penis*.
k, The arteria perinei.
l, l, Branches to the sphincter and levator.
m, A branch to the erector penis.
n, Branches to the accelerator.
o, ———— skin of the perineum.

- p, The deep branch, or artery of the penis.
q, Branches to the bulb of the urethra.
r, ———— erector.
s, A continuation of the artery of the penis.

FIG. 2.

ARTERIES of the PELVIS of a CHILD of two years of Age,
to shew the SACRAL BRANCHES.

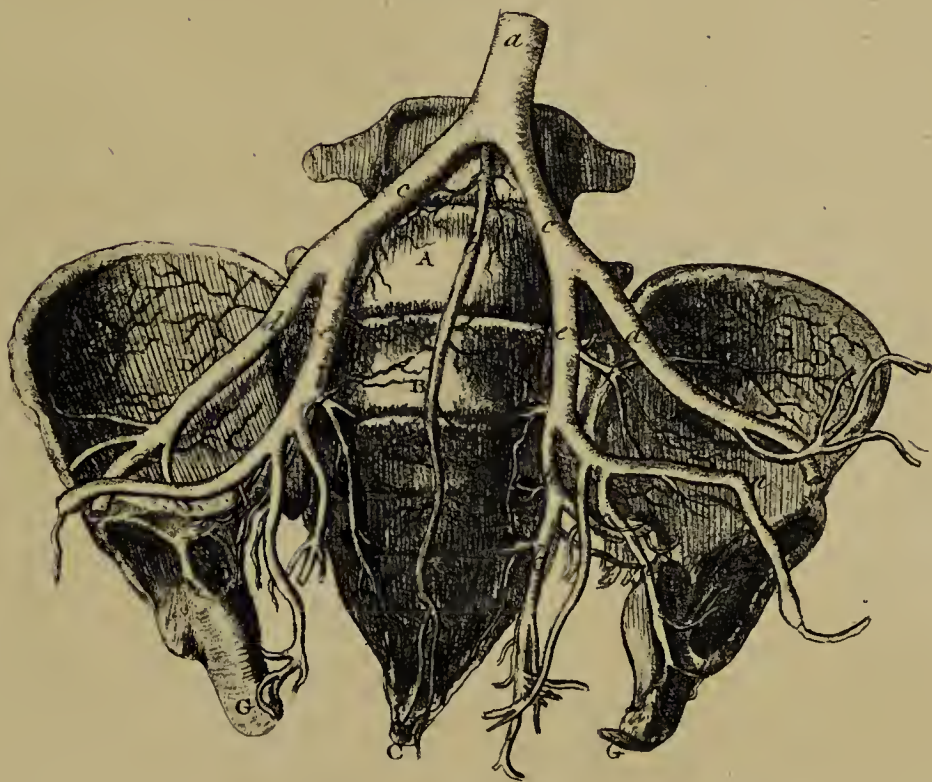
- A, The fifth lumbar vertebra.
B, C, The vertebræ of the os sacrum.
D, D, The ossa ilia.
E, E, The acetabula.
F, F, A section of the os pubis.
G, G, Part of the os ischium.
a, The aorta.
b, The sacra media.
c, c, The common iliac arteries.
d, d, The external iliacs.
e, e, The hypogastricæ.
f, The ileo-lumbalis.
g, The right lateral sacral artery,—single.
h, The ischiatic artery.
i, The trunk of the iliaca going out of the pelvis.
k, The continuation of the ischiatica.
l, The hemorrhoidæ externa, or pudenda communis.
m, The obturatoria.
n, The umbilicalis.

TAB. 152.

Fig. 1.

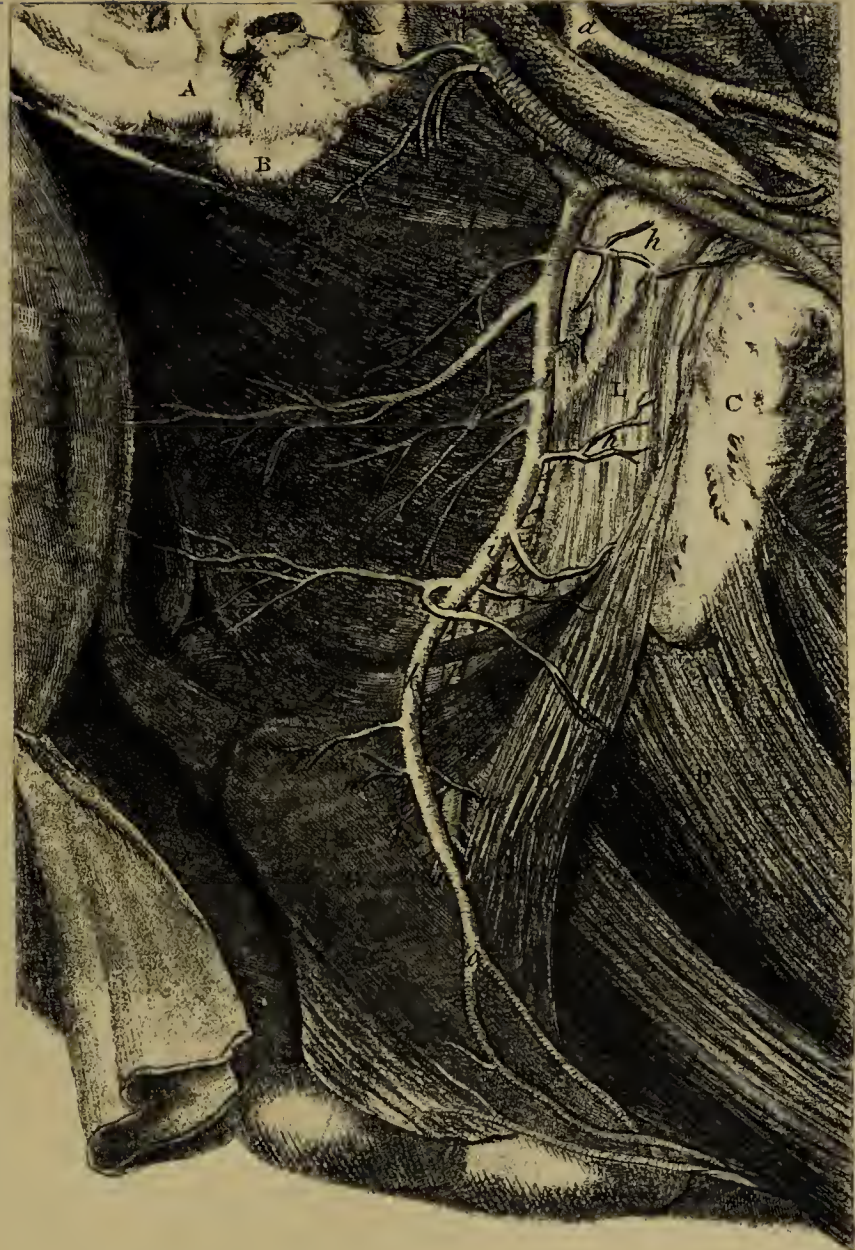

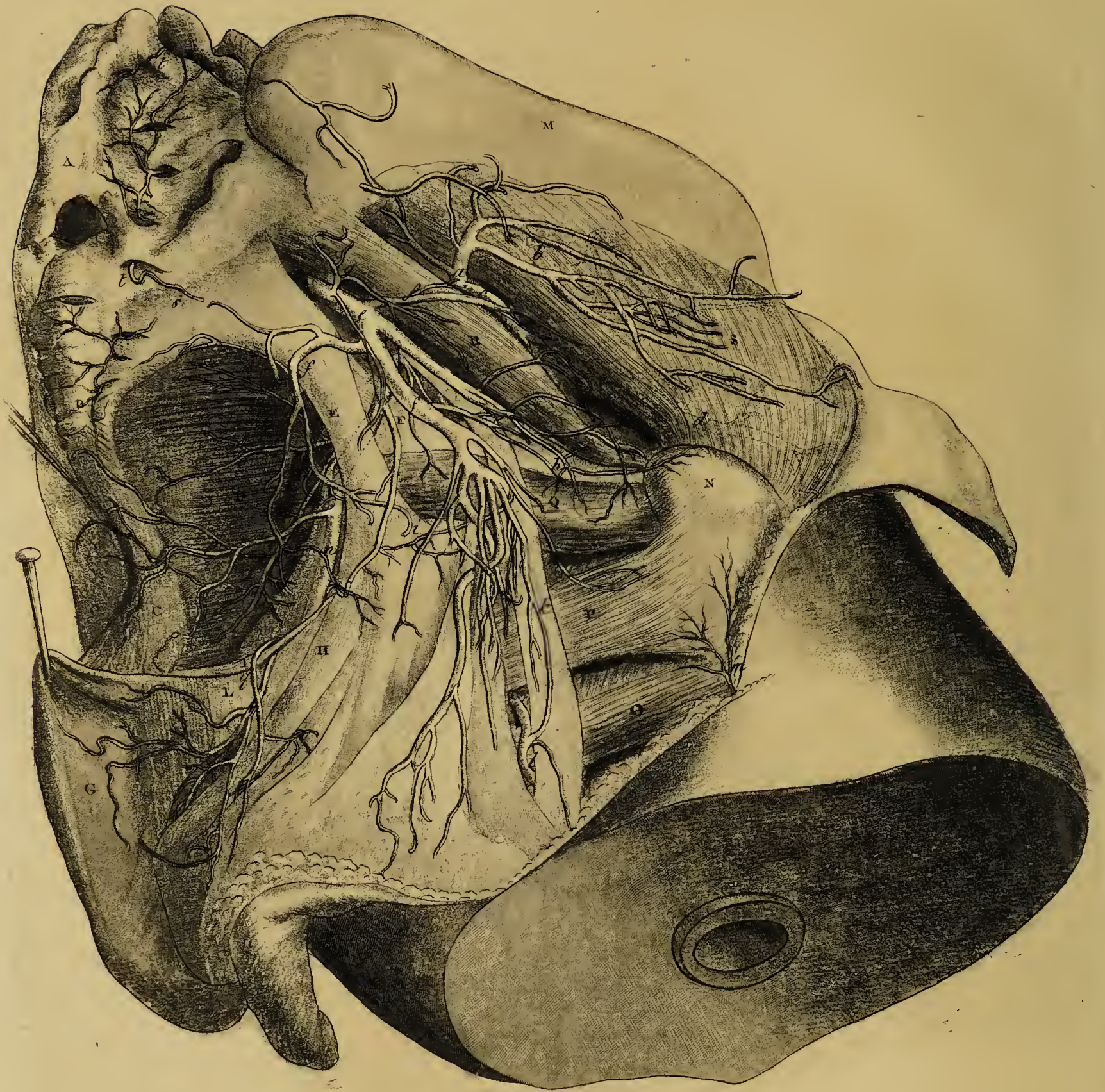Fig. 2.



A. F. J. f. f. f.

TAB. 153.



T A B L E CLIII.

ARTERIES of the Posterior Part of the FEMALE PELVIS.

A, The posterior part of the os sacrum.
 B, The os coccygis.
 C, C, The sphincter ani.
 D, The levator ani.
 E, The ligamentum tuberofo-sacrum.
 F, ----- spinofo-sacrum.
 G, The labium pudendi.
 H, The musculus clitoridis.
 I, The musculus transversalis perinei.
 L, The tuber ischii.
 M, The os ilium laid bare.
 N, The trochanter major.
 O, Part of the triceps magnus,
 P, The quadratus.
 Q, The obturator internus, with the gemelli.
 R, The pyramidalis.
 S, The gluteus medius.
a, The gluteal artery.
b, Superficial branches.
c, The deep trunk.

d, The deep branches.
e, The ischiatic artery.
f, f, f, f, Branches to the gluteus maximus.
g, Branches to the pyriformis.
h, Deep communicating branches to the pyriformis and trochanter.
i, Another deep branch, communicating with the pudica communis, to the tuber ischii.
k, Another communicating with the internal circumflex artery, in the nerve itself.
l, The branch of the internal circumflex artery.
m, ----- obturatoria.
n, The arteria pudica.
o, Branches to the levator ani and coccygeus.
p, Hæmorrhoidæ veræ to the skin and fat of the anus.
q, The superficial artery of the perineum.
r, The arteria labialis pudendi.
s, ----- coccygea.
t, t, ----- sacra.

TABLE

T A B L E CLIV.

Represents the ARTERIES of the Fore and Inner Part of the THIGH.

FIG. 1.

A View of the ARTERIES of the Fore and Inner Part of the LEFT THIGH.

BONES.

- A, Part of the os pubis.
B, The superior anterior spine of the os ilium.
C, The patella.

MUSCLES.

- D, The sartorius.
E, The tensor vaginae femoris.
F, The common end of the iliacus internus and psoas magnus.
G, The rectus femoris.
H, The vastus externus.
I, ——— internus.
K, The pectineus.
L, The triceps anterior, or longus.
M, Part of the triceps medius, or brevis.
N, N, The triceps magnus.
O, The gracilis.
P, The femimembranosus.
Q, Q, Q, The inguinal glands.

VESSELS.

- a, The trunk of the femoral artery.
b, A superficial branch to the sartorius, skin, and inguinal glands.
c, The profunda femoris.
d, The circumflexa externa.
e, Branches to the vastus externus and internus.
f, The circumflexa interna.
g, The superior external pudenda to the skin and labia pudendi.

- b, Branches to the triceps anterior medius and magnus, and gracilis, and femimembranosus.
i, A branch of the profunda to the triceps magnus, and gracilis.
k, l, Large perforating branches of the profunda.
m, The branch of the femoralis to the triceps anterior.
n, The trunk of the femoral artery.
o, The superior branch of the patella, emerging from the vastus internus.
p, The inferior branch of the patella and epiphysis of the os femoris.
q, The inferior articular branch of the tibia.

FIG. 2.

Gives a View of the ARTERIA OBTURATORIA, and CIRCUMFLEXA INTERNA of the LEFT THIGH.

BONES.

- A, The anterior superior spine of the os ilium.
B, The head of the os femoris.
C, The os pubis.

MUSCLES.

- D, The tensor vaginae femoris.
E, E, E, The sartorius.
F, F, The rectus.
G, The vastus internus.
H, The crureus.
I, The iliaco-psoas.
K, A section of the pectineus.
L, The remains of the triceps primus.
M, The obturator internus.
N, The inferior origin of the triceps magnus.
O, The end of the triceps primus.
P, The femi-membranosus.

Q, The

Fig. 1.

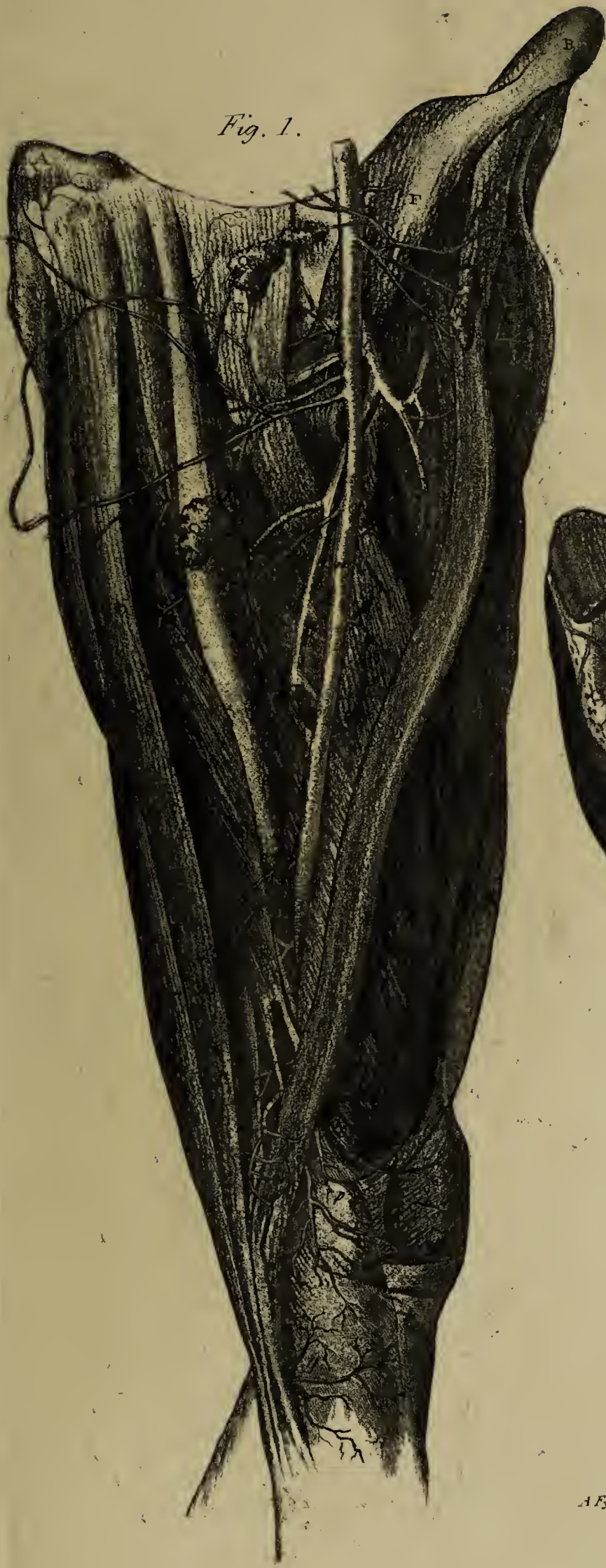
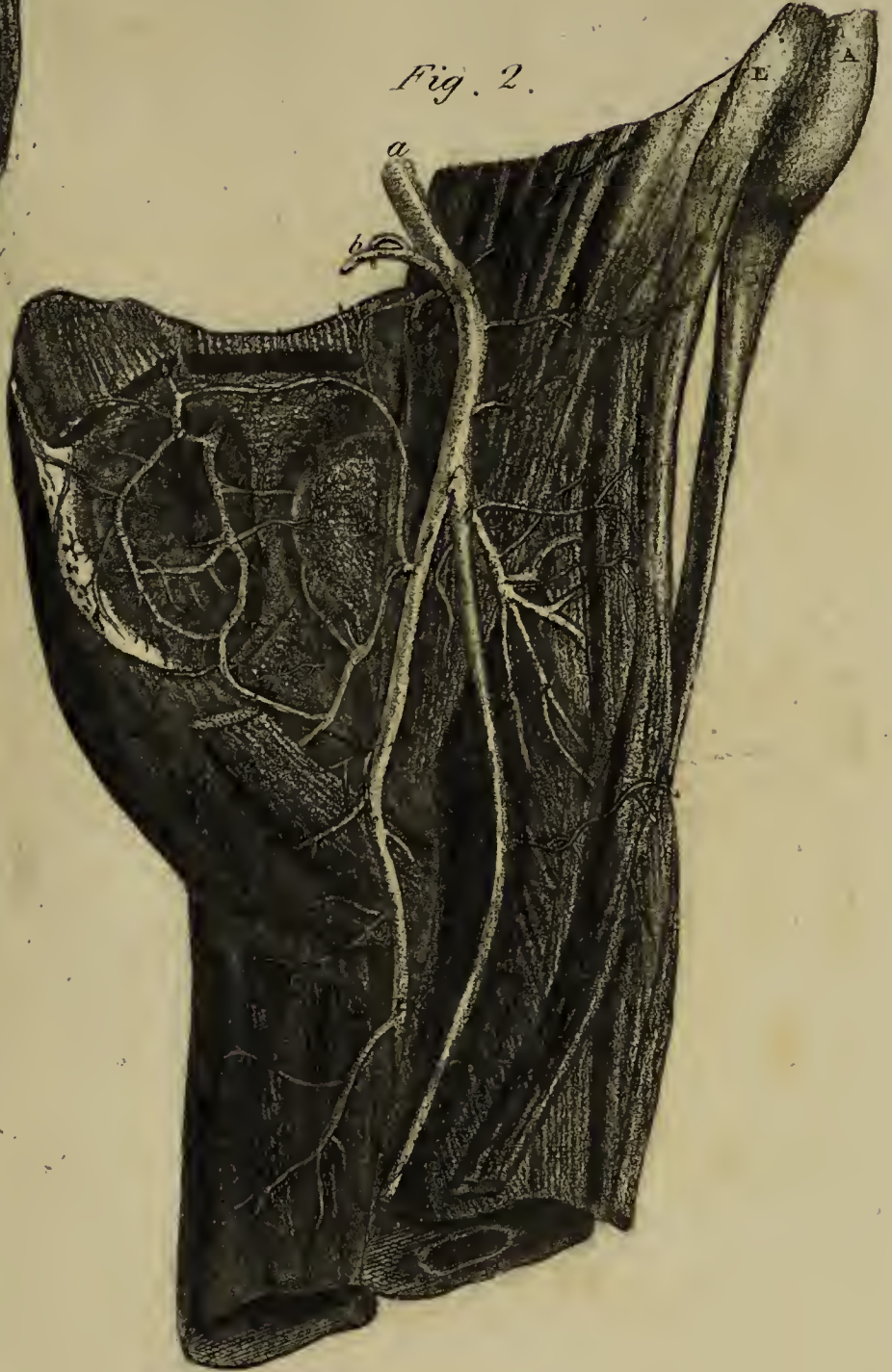
Fig. 2.



Q, The femi-tendinosus.
R, The biceps.

VESSELS.

a, The femoral artery.
b, The epigastric artery.
c, The cutaneous branch of the femoral artery.
d, A branch to the iliacus.
e, A branch to the fertorius and inguinal glands.
f, The division of the femoral artery.
g, g, The crural trunk.
h, The external circumflex artery.
i, i, k, Large branches to the rectus, fartorius, vastus in-
ternus, and skin.

l, The arteria profunda.
m, The branch of the internal circumflex artery to the
pfoas and acetabulum, forming an arch with *r*.
n, The internal circumflex artery.
o, A branch into the joint.
p, The arch of the circumflex artery with the obturatoria.
q, The obturatoria.
r, The superficial branch of the obturatoria.
s, A branch to the capfule of the joint.
t, A branch to the obturator internus.
u, Another branch to the fame, and into the pelvis.
v, The superficial branch of the profunda femoris.
x, The branch of the profunda, where it disappears, to
the femi-membranosus, femi-tendinosus, and biceps
longus.

TABLE

T A B L E C L V .

The Posterior Part of the RIGHT THIGH, with a Portion of the OS ILIUM and PUBIS.—The two GLUTEI MUSCLES, MAJOR and MEDIUS, have been removed from the OS ILIUM:—The SKIN and FAT only from the THIGH.

BONES.

- A, PART of the os sacrum.
 B, The ligamentum tuberofo-sacrum.
 C, A part of the dorsum ilii.
 D, The tuber ischii.
 E, The trochanter major.
 F, Part of the os femoris laid bare in the ham.
 G, The internal condyle of the os femoris.

MUSCLES.

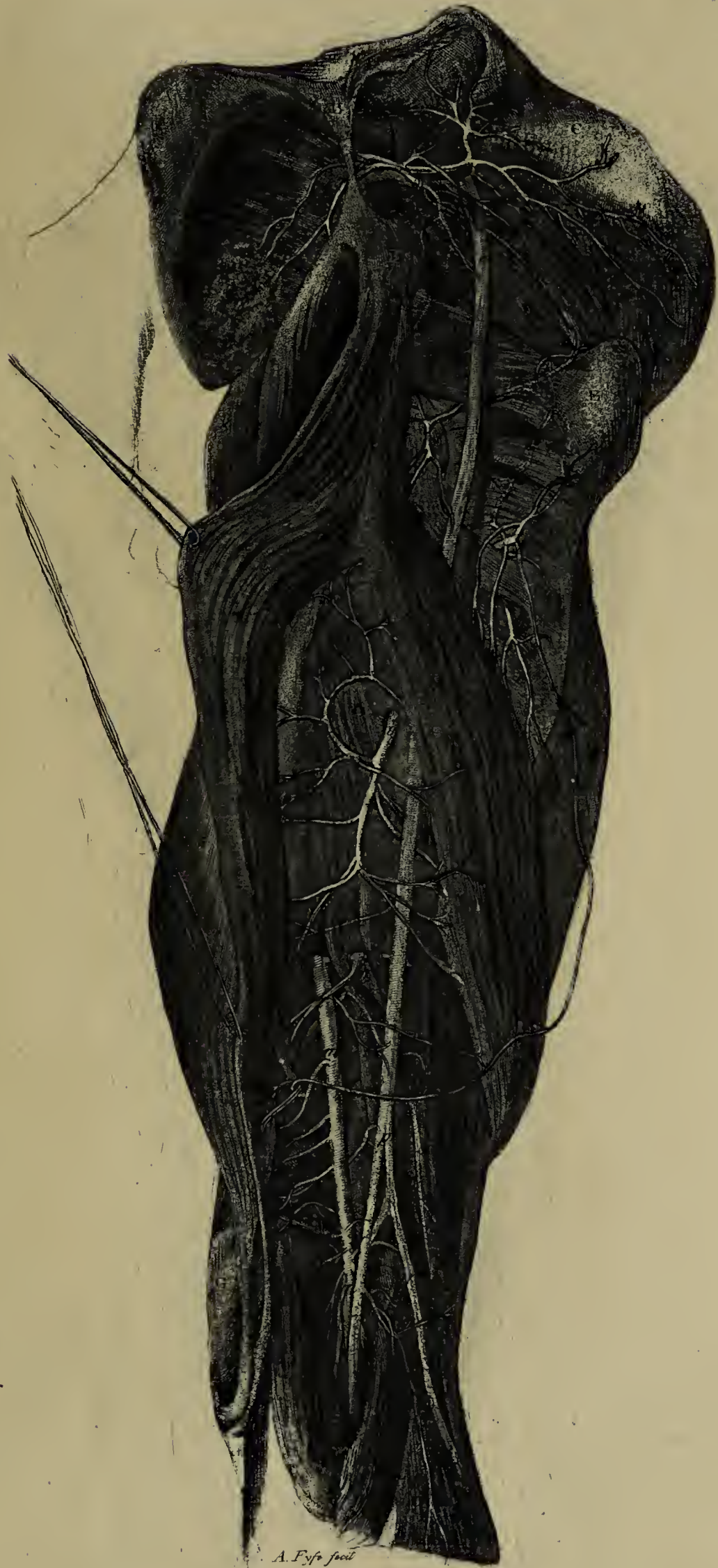- H, The levator ani.
 I, The gluteus minimus.
 K, The pyramidalis.
 L, L, The gemelli and obturator internus.
 M, The quadratus.
 N, N, The triceps brevis.
 O, P, The triceps magnus.
 Q, The vastus externus.
 R, The long head of the biceps.
 S, Its short head.
 Ss, The femimembranosus.
 T, The femitendinosus removed.

- U, U, The gastrocnemius externus.
 V, Part of the vastus internus.

VESSELS.

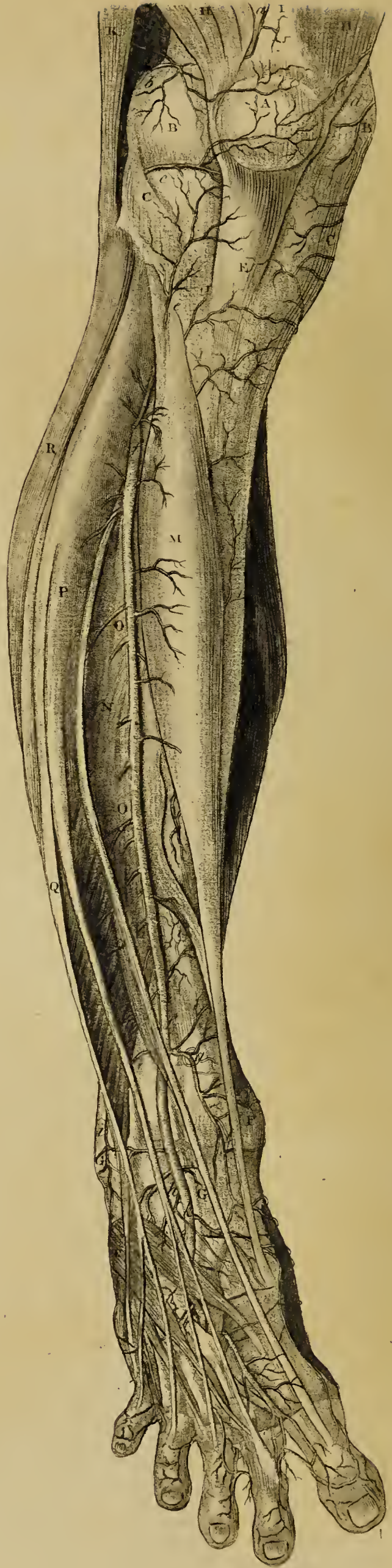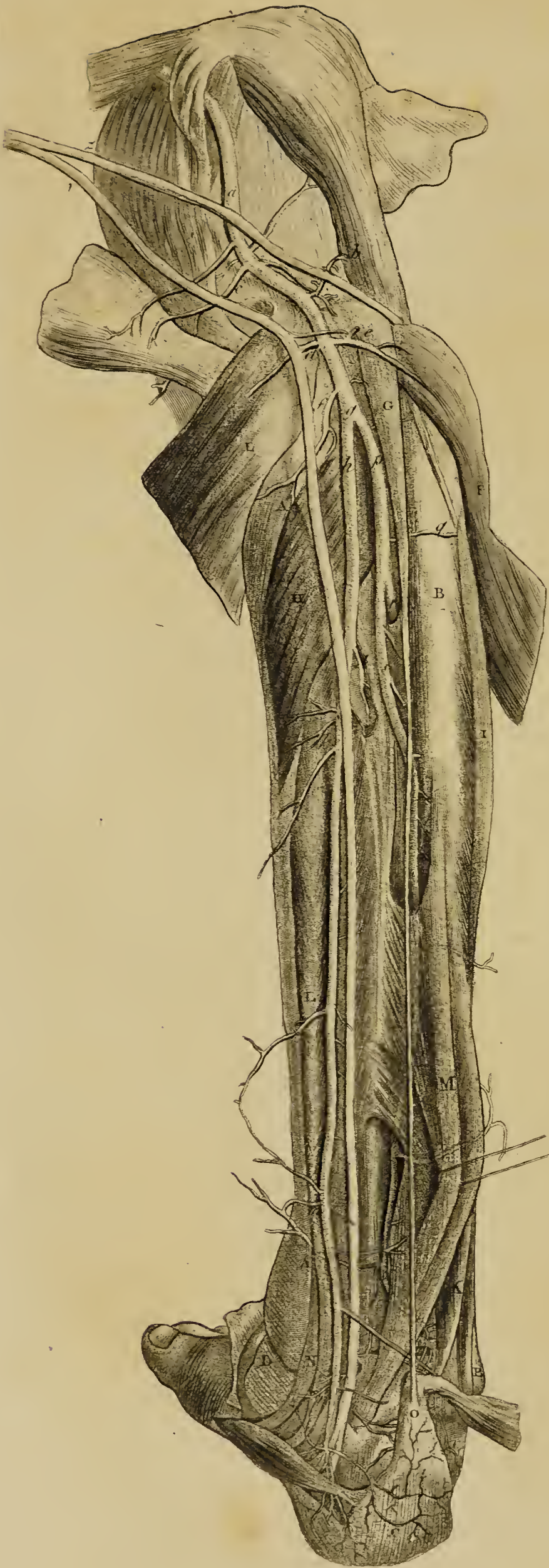- a, The arteria pudica.
 b, Branches going to the penis.
 c, Branches to the gluteus maximus and sciatic nerve.
 d, The branch of the internal circumflex.
 e, The deep branch.
 f, The branch of the first perforating artery arising from the profunda, anastomotic with e, and giving branches to the triceps posticus, os femoris, vastus externus, &c.
 g, An anastomosis in the fascia lata.
 h, Another branch of the profunda, or second perforating artery, going to the vastus externus.
 i, The branch of the second perforating artery.
 k, The perforating branch of the femoral artery to the biceps brevis.
 l, The nutritia femoris.
 m, n, The trunk of the poplitea.
 o, The sciatic nerve.
 p, The popliteal nerve splitting into,
 q, The posterior tibial, and,
 r, The fibular nerve.

TAB. 155.



A. Fyfe fecit

Fig. 1.



T A B L E CLVI.

ARTERIES of the LEG.

FIG. 1.

ARTERIES of the Posterior Part of the LEG.

BONES.

- A, A, The tibia laid bare.
 B, B, The fibula.
 C, The calcaneum.
 D, The astragalus.

MUSCLES.

- E, The gastrocnemius internus and part of the soleus.
 F, ————— externus.
 G, The plantaris.
 H, The popliteus.
 I, The peroneus longus.
 K, ————— brevis.
 L, The flexor longus digitorum pedis.
 M, ————— pollicis.
 N, The tibialis posticus.
 O, The tendo Achillis.

VESSELS.

- a, The popliteal artery, with some branches above the knee, slightly expressed.
 b, The superior external articular artery.
 c, ————— internal articular artery.
 d, A branch to the gastrocnemius internus and soleus.
 e, ————— externus and skin.
 f, The inferior internal articular branch.
 g, The division of the arteria poplitea.
 h, The tibialis postica.
 i, The nutritive artery of the tibia, which gives a branch to the tibialis posticus.
 k, Branches to the tibia, skin, and gastrocnemius internus.
 l, The cutaneous anastomatic branch.
 m, A branch partly cutaneous, partly anastomatic with the fibularis.
 n, o, The posterior tibial artery passing to the sole.
 p, A trunk, in this figure, common to the tibialis antica and fibularis.
 q, A branch passing over the fibula to the peroneus longus.
 r, The tibialis antica perforating the interosseous ligament lower than usual.
 s, The fibularis.
 t, The nutritive artery of the fibula.
 u, The fibularis covered by the fibres of the flexor pollicis.

VOL. III.

- v, A branch of the fibularis to the flexor pollicis and integuments.
 w, The perforating branch of the fibularis.
 x, The posterior termination of the fibularis having anastomoses with the tibialis postica, and terminating in the periosteum of the os calcis.
 y, The posterior tibial nerve.
 z, The anterior tibial nerve.

FIG. 2.

ARTERIES of the Anterior Part of the LEG, and Outer Part of the FOOT.

BONES.

- A, The patella.
 B, B, The condyle of the os femoris.
 C, C, The head of the tibia.
 E, The ligament of the patella.
 F, The epiphysis of the tibia.
 G, G, The malleolus externus, and talus.

MUSCLES.

- H, H, The vastus externus and internus.
 I, The pectinalis.
 K, The biceps.
 L, The gastrocnemii.
 M, The tibialis anticus.
 N, The extensor pollicis.
 O, O, The interosseous ligament.
 P, The extensor digitorum longus.
 Q, The peroneus tertius.
 R, ————— longus.

VESSELS.

- a, The superior artery of the patella.
 b, ————— external articular artery.
 c, The inferior external articular artery.
 d, The superior internal articular artery.
 e, The branches of the anterior tibial artery to the joint and ligaments of the knee.
 f, f, The anterior tibial artery.
 g, The malleoli interna.
 h, The tarsal branches of the tibialis antica.
 i, The branch of the fibularis inosculated with a branch of the tibialis antica.
 k, The trunk of the tibialis antica descending to the sole.

TABLE

T A B L E CLVII.

Different VIEWS of the ARTERIES of the HAND and FOOT.

FIG. 1.

The SUBCUTANEOUS VESSELS of the Inferior Part of the FORE-ARM and PALM of the LEFT HAND.

- A, The arteria radialis.
 B, ——— ulnaris.
 C, C, The superficial palmar arch.
 D, D, D, D, The large digital arteries.
a, a, The volar branch of the radial artery.
b, The dorsal branch of the radial artery.
c, The first deep branch of the ulnar artery.
d, d, The branches running along the sides of the fingers.
e, The radial artery emerging from the palm.
 1. The supinator longus.
 2. The flexor radialis.
 3. The palmaris longus.
 4. The sublimis.
 5. The flexor ulnaris.
 6. The annular ligament of the carpus.
 7. The flexor metacarpi pollicis.
 8. The abductor pollicis.
 9. Part of the flexor brevis pollicis.
 10. The flexor pollicis longus.
 11. The adductor pollicis.
 12. The abductor indicis.
 13. The lumbricalis primus.
 14. The flexors of the index inclosed in their sheaths.
 15. The adductor minimi digiti.
 16. The abductor minimi digiti.
 17. Part of the palmaris brevis.
 18. The aponeurosis of the palm, turned back.

FIG. 2.

VESSELS of the Under Part of the FORE-ARM and PALM of the LEFT HAND,—the SUPERFICIAL MUSCLES being removed.

- A, The radial artery.
 B, The ulnar artery.
 C, C, The superficial palmar arch, from which the digital branches are separated and drawn downwards, to show the deep-seated branches.
 1. The branch of the radial artery which assists in forming the superficial palmar arch.
 2. The trunk from the radial artery to the palm.
 3. The arteria pollicaris.
 4. Branch which belongs to 1.

5. The radial branch of the index.
 6. A branch to the back of the hand.
 7. The deep palmar artery.
 8. The ulnaris minimi digiti.
 9. 9. Parts of the ulnar artery which correspond to each other.
 10. The superficial palmar arch.
 11. &c. The three diverging branches, each divided into two forks, 12. &c. which run down along the sides of the fingers.

FIG. 3.

ARTERIES of the Inferior Part of the FORE-ARM and BACK of the HAND,—the greater part of the MUSCLES of the First Order being removed.

- A, The under end of the posterior interosseous artery anastomosing with the anterior.
 B, The continuation of the radial artery.
 C, The ulnar artery.
 1. The posterior interosseous artery.
 2. A branch to the tendon of one of the extensores carpi radiales.
 3. The anterior interosseous artery, forming various anastomoses on the dorsal side of the carpus.
 4. Part of the radial artery appearing.
 5. The dorsal branch.
 6. The branch of the index.
 7. 7. 7. 7. The dorsal arteries of the hand:
 8. 8. 8. Anastomoses between the dorsal arteries and forkings of the digital arteries.
 9. The dorsal branch of the ulnar artery.

FIG. 4.

ARTERIES of the Upper Part of the FOOT.

- A, The arteria tibialis antica.
a, The musculus tibialis anticus.
b, The extensor pollicis longus.
c, The peroneus tertius, or *Nonus VESALII*.
d, The tendon of the peroneus tertius.
e, The extensor brevis digitorum pedis.
f, The malleoli interna.
g, An ascending branch.
h, Various inosculating branches to the abductor pollicis and sole of the foot.

i, The

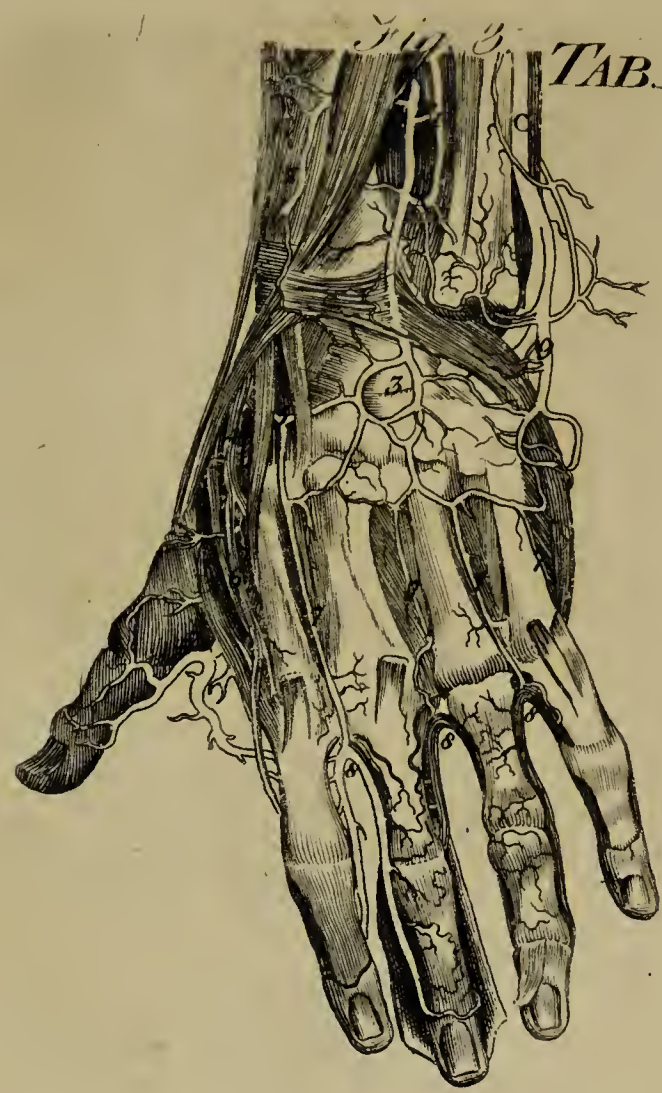
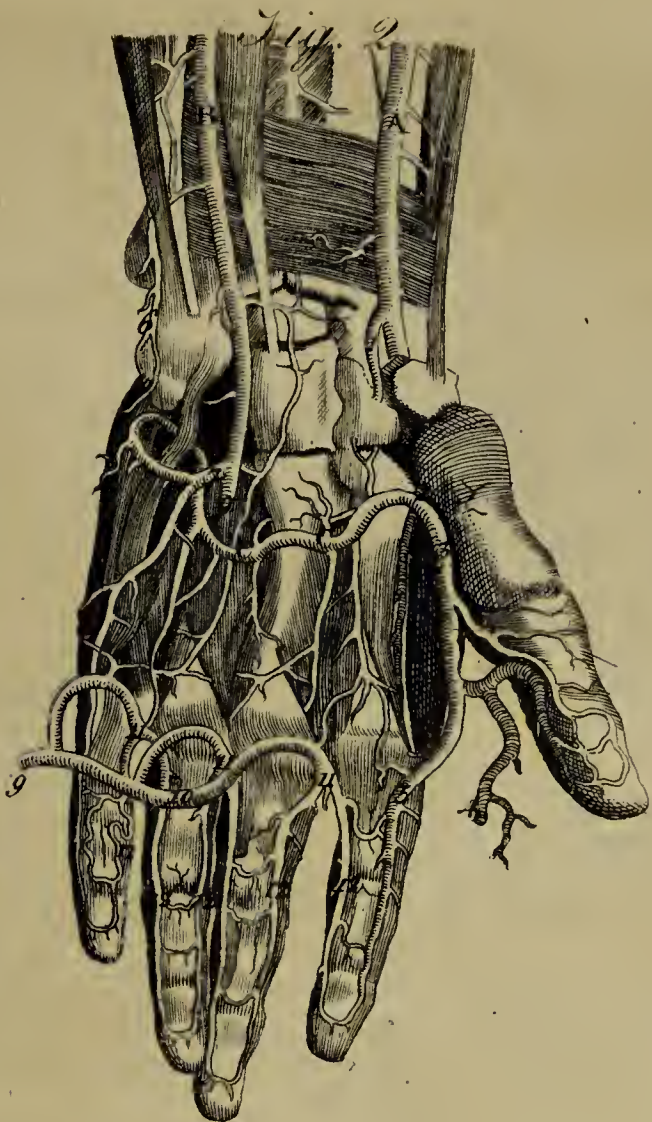
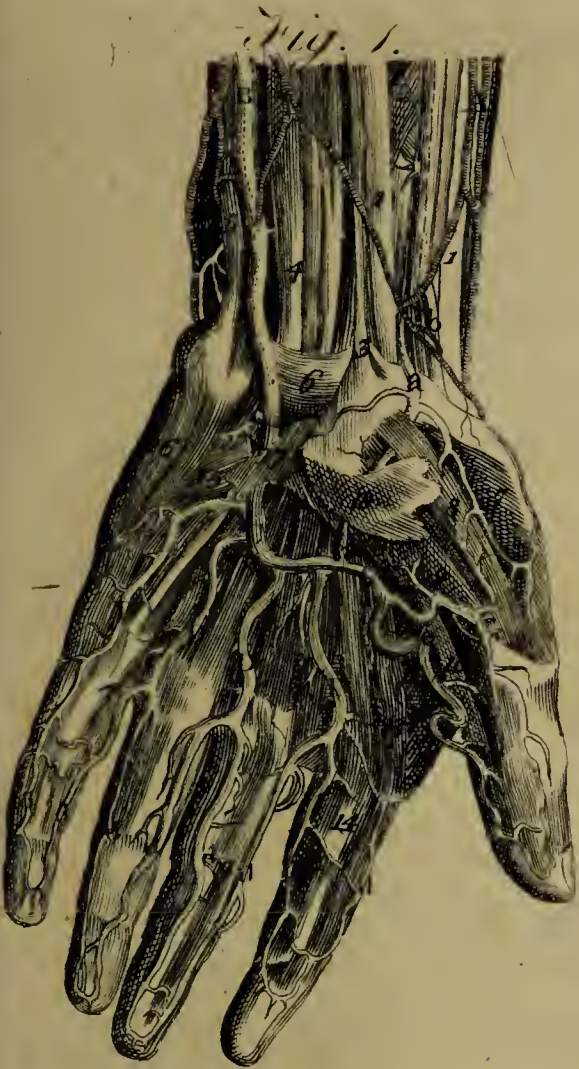

Fig. 4.

Fig. 5.

Fig. 6.

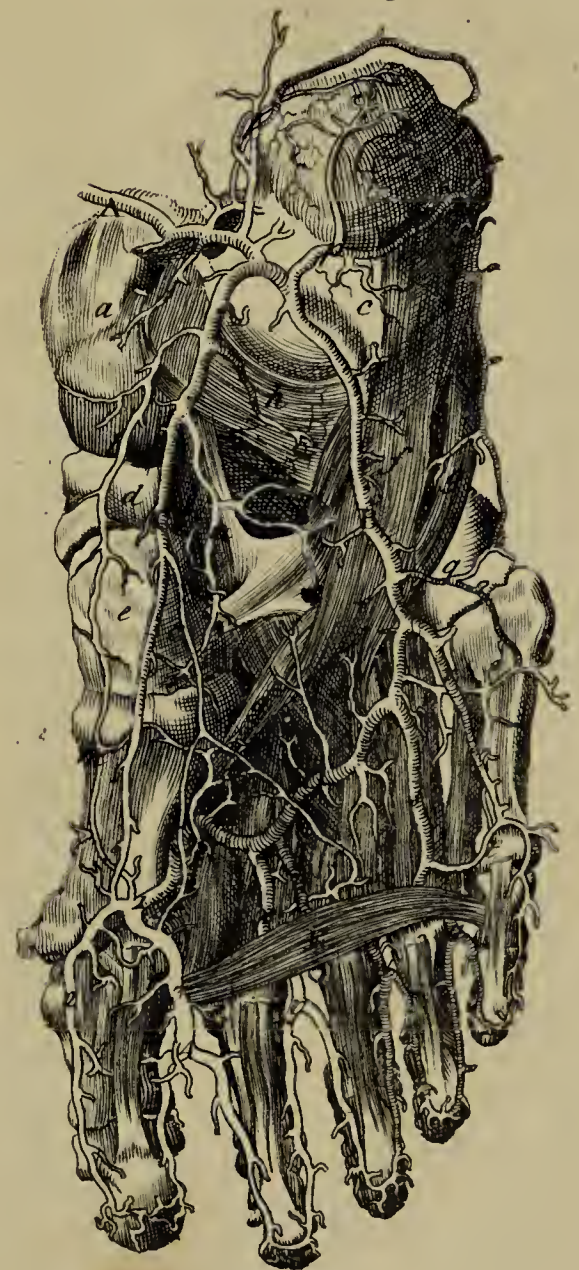
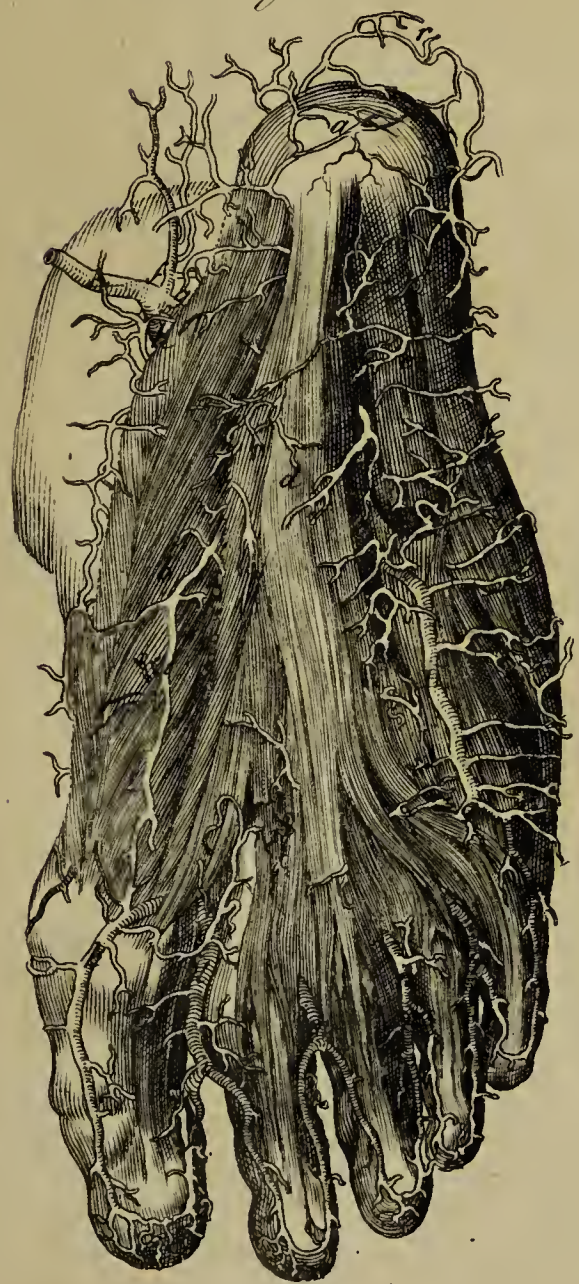
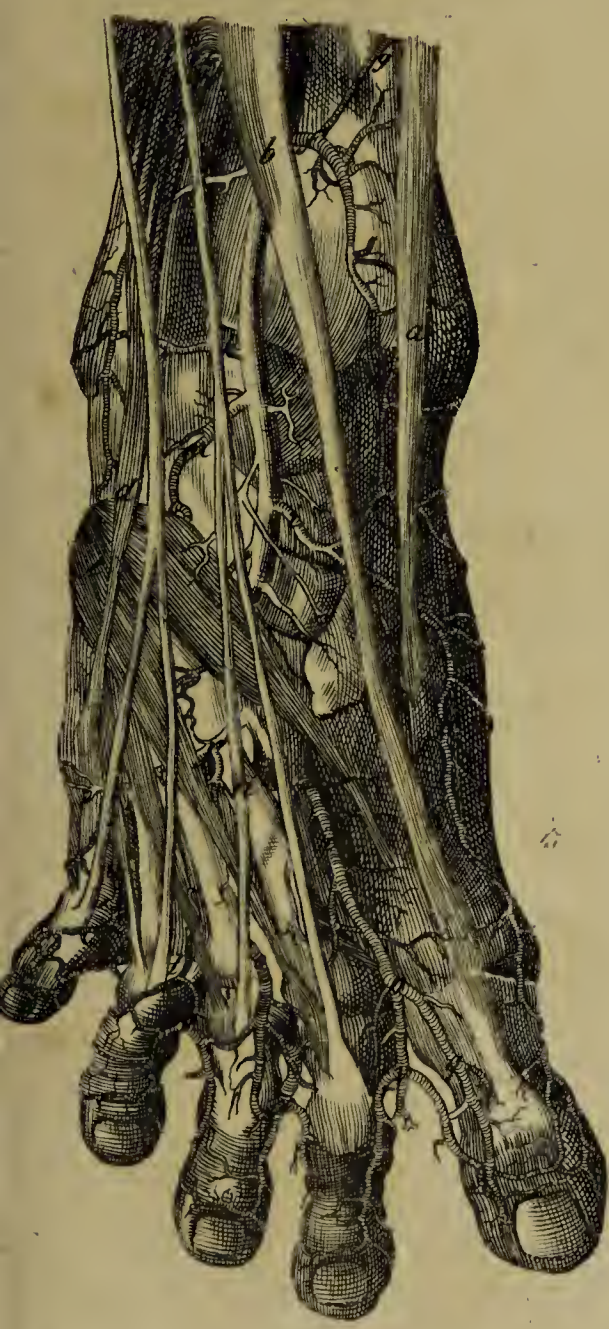
TABLE CLVII. CONTINUED.

61

- i*, The branch of the tibialis antica arising in the ankle.
- k*, The branch anastomotic with the fibularis.
- l*, A branch of the fibularis inosculated with a branch of the tibialis antica.
- m*, The tarsal branch of the tibialis antica.
- n*, The trunk of the tibialis antica descending to the sole.
- o*, The dorsalis pedis.
- p to z*, The dorsal arteries of the other toes, and their communications with the plantar branches at the root of the toes.

FIG. 5.

ARTERIES of the SOLE.

- A, The tibialis postica.
- B, The plantaris externa.
- a*, Branches of the tibialis postica to the heel.
- b*, The plantaris interna.
- c*, The superficial branches of the plantaris externa to the skin and fat.
- d*, The aponeurosis plantaris.
- e*, The trunk of the tibialis postica.
- f*, The superficial branch of the tibialis to the skin and fat.
- g*, The plantaris externa.
- h*, ————— interna.
- i*, The principal superficial branch of the plantaris interna.
- k*, The deep, emerging, internal branch of the great toe, arising from the union of the tibialis antica with the plantar arteries.
- l*, A branch of the deep arch, which is bifurcated at the great toe, and that next it.
- m*, The second fork from the trunk of the external plantar artery to the first and second toe.
- n*, The third fork to the second and third toe.
- o*, The digital artery of the fourth and fifth toe.
- p*, The external digital artery of the fifth toe.
- q*, ————— plantar artery passing under the flexor muscles of the toes.

FIG. 6.

The Deep ARTERIES of the SOLE, after removing the INTEGUMENTS and FLEXOR MUSCLES.

- A, The arteria tibialis postica.
- B, The trunk of the plantaris externa.

- C, The deep branch of the plantaris interna.
- D, The plantar arch.
- E, The transversalis pedis muscle.
- a*, The astragalus.
- b*, The tuber of the os calcis.
- c*, A small plain surface before the tuber.
- d*, The os naviculare.
- e*, The first cuneiform bone.
- f*, The large ligament from the os calcis to the cuboides and fourth metatarsal bone.
- g, g*, The tendon of the peroneus longus.
- h*, The ligament from the anterior tuber of the os calcis to the cuboides.
- i*, The ligament from the astragalus to the middle cuneiform bone.
- k*, The cutaneous branch of the tibialis postica, forming an arch with a branch of the fibularis.
- l*, The interior deep branch of the plantaris interna.
- m*, The anastomosis with the deep branch of the tibialis antica.
- n*, A deep branch to the sole.
- o*, The external branch from the plantaris interna.
- p*, A branch of the external plantar artery to the fat.
- q*, A branch anastomotic with the fibularis.
- r*, The trunk of the external plantar artery, forming the plantar arch.
- s*, The fourth digital artery.
- t*, Anastomosis between the fourth digital artery and the external artery of the little toe.
- u*, The interior branch of the fifth, and exterior branch of the fourth toe.
- v*, The origin of the third digital branch.
- w*, The internal artery of the fourth, and external artery of the third toe.
- x*, The second digital artery.
- y*, The internal branch of the middle toe, and external of the index.
- z*, The trunk of the tibialis antica, a very small part of which is here seen.
 1. A branch of it to the great toe and index.
 2. The arteria pollicis interna.
 3. ————— externa;
 4. Its exterior branch to the great toe, and interior branch to the index.

T A B L E CLVIII.

A GENERAL VIEW of the ARTERIOUS SYSTEM.

FIG. 1.

The Anterior Portions of the THORAX and ABDOMEN cut off, and the contained ORGANS removed as far as is necessary.

TRUNK.

- A, The heart pulled downwards.
a, a, a, The coronary arteries.
 B, C, The right and left auricles.
c, c, The trunks of the left pulmonary vessels.
 D, The trunk of the pulmonary artery.
 E, The aorta.
 F, The arch of the aorta.
f, The ductus arteriosus, peculiar to the foetus.
 G, The arteria innominata.
 I, The right subclavian, and,
 K, The right carotid.
 L, ——— vertebral artery.
 M, The scalenus anticus muscle.
 O, The left carotid artery.
 P, ——— subclavian artery.
 Q, Q, &c. The intercostal arteries, from the fifth to the tenth inclusive.
 R, R, &c. The lumbar arteries.
 S, The trunk of the cœliac artery, from which, *a*, The hepatic, *b*, The superior gastric, and, *c*, The coronary arteries, are sent off.
d, The left phrenic artery.
 T, The superior mesenteric artery.
 U, U, The kidneys.
 V, V, The renal glands.
 W, W, ——— arteries, of which there are two in this figure, in the right side.
e, Small branches from the aorta and renal arteries to the renal glands.
 X, The spermatic arteries.
 Y, The inferior mesenteric artery.
a, a, The common iliac arteries.
b, b, The external iliac arteries.
c, c, The circumflex arteries of the ossa ilii.
d, The right epigastric artery.

- e, e*, The bottom of the bladder of urine, with the ureters behind it.
f, The intestinum rectum.
g, g, The internal iliac arteries, dividing into their principal branches.
b, The ileo-lumbar arteries.
i, The hæmorrhoidalis interna.
k, The sacra media.

NECK AND FACE.

- A, The trachea.
 B, The larynx.
 C, C, The thyroid gland.
 D, D, Branches from the inferior laryngeal artery to the trachea.
 E, E, The internal carotids.
 F, F, The external carotids.
 G, G, The superior thyroid arteries.
 H, The inferior maxillary gland.
 I, I, The facial arteries.
 K, The parotid gland.
 L, The temporal artery.
a, The arteria submentalis.
b, The facial artery dividing into the coronary arteries of the lips.
c, The inferior, and,
d, The superior coronary arteries.
e, The nasal arteries.
f, The ocular angular artery.
g, The superior branch of the ophthalmic artery.
b, The infra orbitalis.
i, The transversalis faciei.
k, The temporal artery.
l, The communication between the temporal and ophthalmic artery.
m, The vertebral artery.
n, A branch termed by HALLER *Thyroidea Inferior Minor*, above which is seen the trunk of the thyroidea inferior, and that sending up the cervicalis anterior.
o, The cervicalis posterior.

SUPERIOR.

Fig. 1.

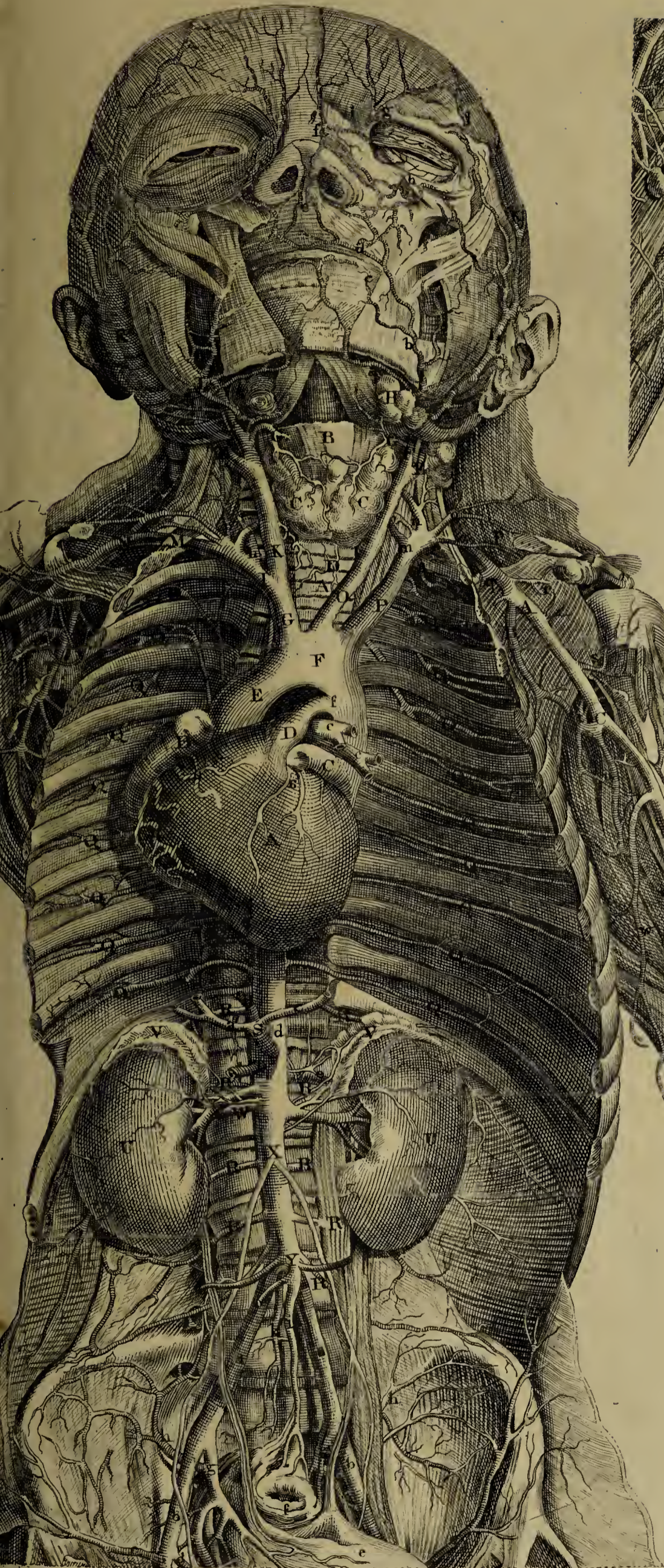


Fig. 2.

TAB. 158.

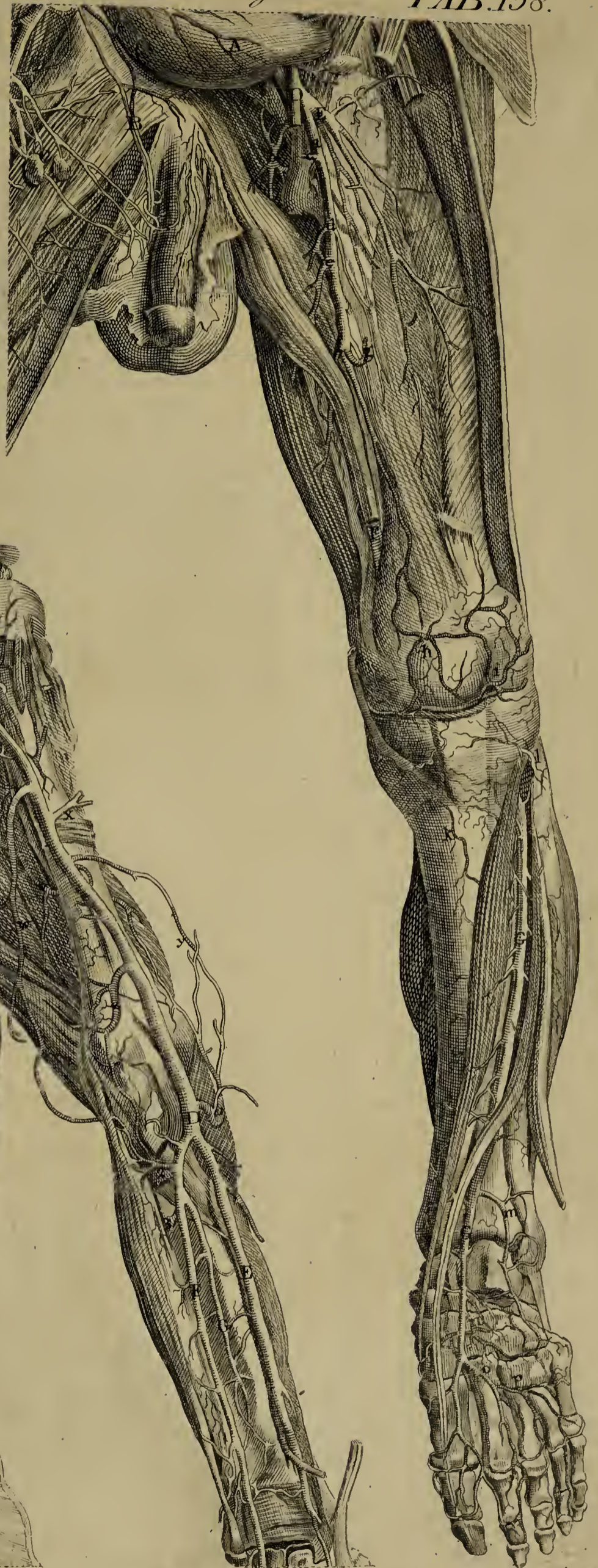



TABLE CLVIII. CONTINUED.

SUPERIOR EXTREMITY.

- p*, The superior dorsal artery of the scapula.
- q*, A branch to the *m. subscapularis*.
- r*, The *acromialis*, cut.
- A*, The axillary artery.
- B*, The *scapularis interna*.
- s*, The *circumflexa anterior*.
- t*, ————— posterior.
- C, u*, The *profunda humeri*.—Lower than the *profunda humeri*, is seen the *profunda minor*.
- v*, A circumflex branch to the dorsum of the humerus.
- w*, A branch anastomosing with the ulnar recurrent.
- x*, A branch to the biceps and *brachialis internus*, cut.
- y*, ————— anastomosing with the radial recurrent.
- z*, The *ramus anastomoticus magnus*.
- D*, The division of the humeral artery into the radial and ulnar arteries.
- E*, The ulnar artery.
- F*, The radial artery.
- G*, The *interossea anterior*.
- 1. The radial recurrent artery.
- 2. The ulnar recurrent anastomosing with the *profunda minor* and *ramus anastomoticus major*.
- 3. The *interossea posterior*.

FIG. 2.

ARTERIES of the Lower Part of the TRUNK, and Fore-

Part of the INFERIOR EXTREMITY, the Anterior Layer of MUSCLES of which are cut off.

- A*, Part of the bladder of urine.
- B*, The spermatic artery, with an associate branch at its inner side from the epigastric artery.—Upon the penis is seen the *A. dorsalis penis*.
- C*, The inguinal glands.
- D*, A section of the femoral artery.
- a*, The *profunda femoris*.
- E*, The *circumflexa externa*.
- b*, ————— *interna*.
- d*, The *perforans prima*.
- e*, ————— *altera*.
- f*, ————— *tertia*.
- g*, The *nutritia femoris*.
- F*, The femoral artery, where it perforates the *abductor magnus*.
- b, i*, The superior and inferior circumflex arteries, forming large anastomoses upon the knee.
- k*, Anastomosis between the inferior articular and tibial arteries.
- l*, The recurrent branches of the *tibialis antica*.
- G, G*, The anterior tibial artery.
- m*, The *arteria malleoli externa*.
- n*, The tarsal branches.
- o*, The metatarsal branch.
- p*, The *arcus metatarsus*.

TABLE

T A B L E CLIX.

A VIEW of the ARTERIAL and VENOUS SYSTEMS.

FIG. 1.

HEAD AND NECK.

- a*, The frontal vein.
b, The facial vein.
c, The temporal veins.
d, The trunk of the temporal vein, where it lies behind the parotid gland, and receives the transversalis faciei.
e, The common trunk formed by the facial and temporal veins, opening into the internal jugular.
f, The occipital veins.
g, The external jugular, arising from the temporal vein.
h, The anterior external vein.
A, A, The external jugular veins, descending, and communicating by,
i, A cross branch at the bottom of the neck.
k, k, The termination of the external jugular in the subclavian veins.

SUPERIOR EXTREMITY.

1. The trunk common to the right carotid and subclavian arteries.
 2. The left carotid.
 3. 3. The left subclavians.
 4. The radial, and,
 5. The ulnar artery.
 6. The superficial palmar arch;—the radial part of it, in this Figure, larger than usual.
a, b, d, The median veins.
c, The superficial radial vein.
B, The cephalic vein.
D, The basilic vein.
C, The mediana longa, dividing into,
E, The mediana cephalica, and,
F, ———— basilica.
e, e, The cephalic vein ascending, and getting between the pectoral and deltoid muscles.
G, The basilic vein passing along the inner side of the arm, and terminating in the axillary vein.
f, g, The venæ concomites of the humeral artery.
h, The axillary vein.
i, The termination of the cephalic.
A, The subclavian vein.

TRUNK.

- A*, The heart, with the coronary vessels.
B, The right, and,

- C*, The left auricle.
D, E, The pulmonary blood-vessels.
F, The arch of the aorta.
G, The aorta descendens
 7. The origin of the diaphragmatic.
 8. ———— cœliac,
 9. ———— superior mesenteric,
 10. ———— spermatic, and,
 11. ———— inferior mesenteric arteries.
 12. The division of the aorta into the two common iliacs.
 13. The sacra media, passing behind the intestinum rectum.
 14. 14. The common iliac arteries.
H, H, The external iliacs.
 15. 15. The internal iliacs.
I, The vena cava superior.
K, ———— inferior.
L, M, The great subclavian veins, the left longer than the right.
N, The termination of the hepatic veins.
O, O, The renal veins, with their corresponding arteries.
P, P, The spermatic veins.
Q, Q, The common iliac veins.
Qa, Qa, The external iliac veins.
R, R, The internal iliac veins.
 19. The vena magna penis, forming a plexus of veins at the neck of the bladder.—At the sides of the vein the arteries appear.
S, S, &c. The intercostal vessels.

INFERIOR EXTREMITY.

- A, A*, The femoral arteries, the left one cut.
 16. The circumflexa externa.
 17. The profunda femoris.
 18. The circumflexa interna.
a, The vena saphena major.
b, The femoral vein.

FIG. 2.

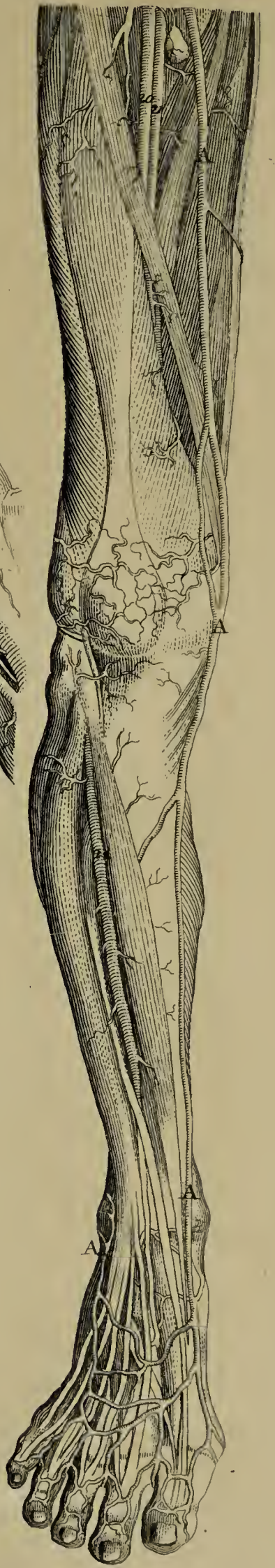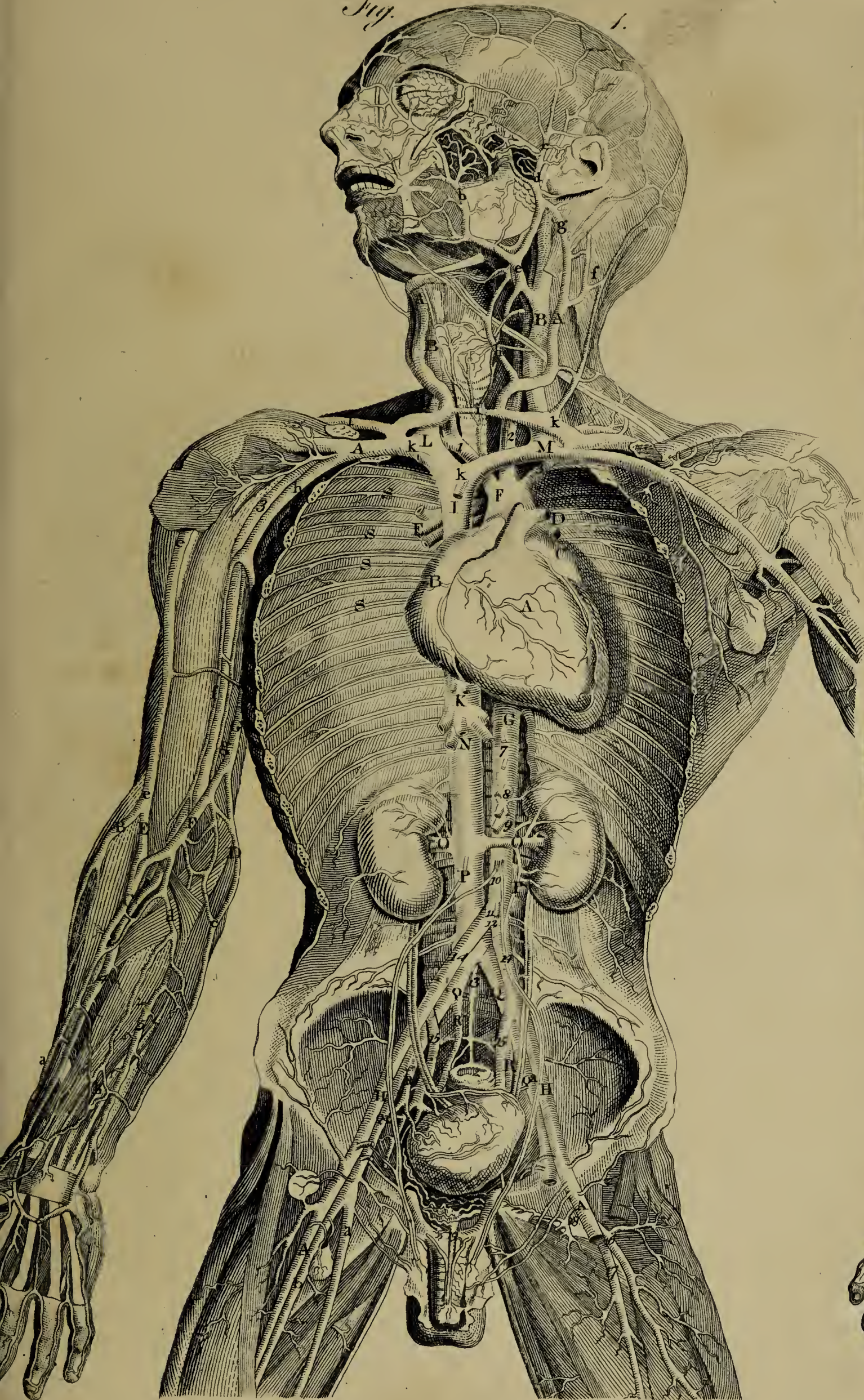
20. The continuation of the femoral artery.
 21. The corresponding vein.
 22. The anterior tibial artery.
A, A, A, The vena saphena major.
Aa, The beginning of the saphena minor.

Upon the Foot and Toes a Plexus of Veins appears, which terminates in both the Saphenæ.

Fig.

1.

TAB. 159.
Fig. 2.



BLOOD-VESSELS OF THE CONTAINING PARTS OF THE ABDOMEN, AND OF THE PELVIS AND INFERIOR EXTREMITY.

ARTERIES.

ARTERIE LUMBARES.—The Lumbar Arteries, Tab. CLVIII. R, R, &c. which are commonly four in number on each side, arise in pairs from the back part of the Abdominal Aorta, in the same manner as the Intercostrals do from the Aorta in the Thorax. The Left are a little shorter than the Right, which pass under the Vena Cava to their place of destination.

They run first over the fore-part of the Bodies of the four uppermost Lumbar Vertebrae, and afterwards go between them and the Psoæ Muscles, in their way towards the sides of the Abdomen.

They give Branches to the Spine, to the Spinal Marrow and its Membranes; are particularly dispersed upon the Lumbar Muscles, and upon the Transversus and Obliqui Abdominis; and, perforating these, they also furnish Branches to the large Muscles and the Integuments in the back part of the Loins.

Superiorly, they communicate with the lower Intercostrals, Diaphragmatic, and Epigastric Arteries.

The first Lumbar passes behind the corresponding Crus of the Diaphragm, to which it gives Branches in its course outwards. The fourth winds round the Crest of the Ilium, to be dispersed upon the Iliacus Internus and Abdominal Muscles.

SACRA MEDIA.—The Sacra Media, Tab. CL. c, is a small Azygous Artery, which arises from the under and back part of the Aorta, immediately at its Bifurcation.

It generally sends off a Branch over each side of the last Vertebra of the Loins, which supplies the place of a fifth Lumbar Artery. This Branch gives off others behind, in common with the Lumbars, while its outer Ramifications are exhausted upon the Iliacus Internus.

The Sacral Artery afterwards descends along the middle of the Sacrum, as far as the Os Coccygis, sending Branches to the Membranes and Substance of these Bones, and to the back part of the Rectum.

ILIACÆ COMMUNES.

After giving off the Arteries of the Contents and of the containing parts of the Abdomen, the Aorta, upon the under part of the Fourth Lumbar Vertebra, divides into the Two Common Iliac Arteries, which are of equal size, and take a similar course upon the right and left sides. Tab. CLI. bb.

They pass obliquely downwards and outwards; and at the under and lateral parts of the last Vertebra of the Loins, *i. e.* opposite to the posterior Symphysis of the

Pelvis, each divides into two others, a Posterior, termed *Iliaca Interna*, or *Hypogastrica*, and an Anterior, termed *Iliaca Externa*.

ILIACA INTERNA.

The Iliaca Interna, or Hypogastrica, Tab. CL. d, Tab. CLI. k, passes downwards and backwards in the posterior and lateral part of the Cavity of the Pelvis, for about a couple of Fingers-breadth, after which it generally divides into a Posterior and Anterior Set of Branches; the former supplying the parts nearest the Sacrum and Ilium, the latter belonging more immediately to the parts about the Anterior region of the Pelvis.

POSTERIOR BRANCHES.

ILEO-LUMBARIS, or **ILIACA INTERNA MINOR.** Tab. CL. g. The Ileo-lumbar is a small Artery, arising sometimes from the end of the Hypogastric, at other times from the beginning of the Glutea.

It passes outwards under the Psoas, and divides suddenly into Branches; one of which frequently forms a kind of *Lumbalis Ima*, or Fifth Lumbar Artery.

The other Branches go to the Psoas and Iliacus Internus, communicating there with the Lumbar Arteries and Circumflex Branches of the Ilium;—a particular Twig constituting an *Arteria Nutritia*, or *Medullaris* of the Os Ilium.

SACRÆ LATERALES, Tab. CLII. Fig. 2.—These are generally two or three, arising from the common Trunk, or the Ileo-lumbar, or frequently from the Gluteal Artery;—though sometimes there is only a single Artery, which descends by the sides of the Sacral Holes, giving Branches, which supply the place of the Sacrae Laterales, and sometimes also, though seldom, of the Sacra Media.

They furnish Branches to the Muscles, Membranes, and Nerves, on the surface of the Os Sacrum, and inosculate by cross Branches with the Sacra Media.

Their principal Trunks enter the Anterior Sacral Holes, to be distributed upon the Cauda Equina and the Membranes and Bones inclosing it.

ARTERIA GLUTEA, Tab. CLI. r. Tab. CLIII. a.—This is sometimes termed *Iliaca Posterior*, and is the largest Branch of the Hypogastric Artery.

Soon after it arises, it passes through the upper part of the great Notch of the Os Ilium, and is reflected over the edge of the Bone, after the manner of the Inferior Scapular Artery.

Upon emerging from the Cavity of the Pelvis, and, after

after giving Twigs to the Iliacus Internus, and Pyriformis, it is divided into two great Branches; one more superficial, the other deep-seated.

The *Superficial Branch* bends round between the Origin of the Gluteus Maximus and Medius, giving many Branches to each, but chiefly to the former, and inosculating, by means of the Posterior Sacral Holes, with the Sacral Arteries.

The *Deep Branch*, situated under the middle of the Gluteus Medius, is subdivided into Two Principal Branches.—a Superior and Inferior.

The *Superior* crosses the Origin of the Gluteus Minor, extends as far as the Spine of the Ilium, and gives Branches to the Gluteus Medius, and others passing downwards between the Gluteus Minimus and Ilium to the Joint of the Thigh;—one Branch forming a Nutritious Artery of the Ilium.

The *Inferior*, or Transverse Branch, ascends over the Gluteus Minimus, and gives many large Branches to the Gluteus Medius and Minimus; some of which extend to the Joint of the Thigh and parts adjacent.

At the under edge of the Gluteus Medius, it is divided into two Sets of Branches, one of which runs in a radiated direction close upon the Bone, and is chiefly dispersed upon the two smaller Glutei, while Branches of inferior size run some of them downwards to the Muscles and Ligaments about the Joint of the Thigh, and others backwards to the parts about the Sacrum, communicating with the Lateral Sacral Arteries through the Posterior Foramina of the Os Sacrum.

The other Set of Branches of the Gluteal Artery creeps in between the Gluteus Medius and Maximus, upon the latter of which it is chiefly dispersed.

ANTERIOR BRANCHES.

ARTERIA OBTURATORIA, or OBTURATRIX, Tab. CL. i. Tab. CLI. n.—The Obturator Artery has its origin from the Trunk of the Hypogastric, or from the Ileo-lumbar, or from the Ischiatic, and sometimes from the end of the Iliaca Externa.

It descends in the Pelvis by the under side of the Psoas Muscle, and afterwards passes through the Hole at the upper part of the Obturator Ligament.

While in the Pelvis, it frequently gives Twigs to the Bladder and other parts near it, and sends a Branch to the Obturator Internus in its passage through the Foramen Thyroideum.

After perforating the Ligament, it divides into Branches, one Set of which are dispersed upon the parts about the Hip-joint, while another belong to the Obturator Externus, and to the Muscles which are situated at the upper and inner part of the Thigh;—the two Sets of Branches inosculating with each other.

ARTERIA UMBILICALIS.—The Umbilical Artery sends off Rami Vesicales from its under part or beginning;

the rest of it in the Adult, being shrivelled into Ligament, as already observed. Tab. CL. CLI.

VESICALIS IMA of Haller, Tab. CL. m.—This is a long and slender Branch which frequently comes off from the root of the Pudic, at other times from the Hypogastric near the Umbilical, and runs to the under part of the Bladder, and to the Prostate Gland.

ARTERIA UTERINA.—The Uterine, or Uterine Hypogastric Artery, is dispersed upon the Uterus, as has been already described.

HÆMORRHOIDALIS MEDIA, Tab. CL. n.—The middle Hæmorrhoidal and small Artery is sometimes sent off from the original Trunk, and at other times from some of its Branches, as the Pudic in the Male, or Umbilical in the Female.

It runs upon the Anterior Surface of the Rectum, and is chiefly distributed upon its Under Extremity, where it anastomoses with the Hæmorrhoidalis Interna. It frequently sends Branches to the under part of the Bladder;—to the Vesiculæ Seminales and Prostate of the Male; and in the Female, to the Vagina and Bladder, by a Vaginal Trunk which supplies the place of the Vaginal Artery sent off from the Uterine.

PUDICA COMMUNIS.—The Pudica Communis, termed by some Authors *Hæmorrhoidalis Externa*, belongs to the Parts of Generation and Anus, as was formerly taken notice of.

ARTERIA SCIATICA.—The Sciatic, or Ischiatic Artery, Tab. CL. b. Tab. CLIII. e, is the largest of the Iliac Branches; except the Glutea.

It goes through the under part of the Sciatic Notch, accompanied by the Nerve of that name, having the Pyriformis between it and the Gluteal Artery.

It afterwards descends some way down the Thigh, in company with the Sciatic Nerve, in the hollow between the great Trochanter of the Thigh-bone and Tuber of the Ischium,—covered by the Gluteus Maximus.

Within the Pelvis, it sends Twigs to the Rectum, Obturator Internus and Pyriformis. Without the Pelvis, it sends an Artery backwards, termed *Coccygea*, which creeps along the Posterior Sacro Sciatic Ligament; some of its Branches perforating the Fibres of the Ligament. It is distributed upon the Coccygeus, the Levator Ani, the Fat and Bones of the Coccyx, and sends Branches upwards which anastomose with some of the lateral Sacral Arteries, through the Holes in the back part of the Os Sacrum.

It gives next off a *Concomitant Branch* which ascends along the Surface of the Sciatic Nerve.

It sends Branches to the Gluteus Medius and Minimus, to the Pyriformis and other Rotator Muscles of the Thigh, and to the Capsule of the Joint.

The principal Branches of the Sciatic Artery, however, are dispersed upon the under part of the Gluteus Maximus, some Twigs being sent to the Muscles arising from the Tuberosity of the Os Ischium, which communicate with the Obturator and Pudic Arteries.

ILIIACA EXTERNA.

The Iliaca Externa, Tab. CLI. *f*, which appears in the Adult as the continuation of the common Trunk, descends along the Brim of the Pelvis, behind the Peritoneum, taking a curved direction by the side of the Psoas Muscle, and afterwards passes over it, and under the *Ligament of POUPART*, to form the Femoral Artery.

In this course, it does not send off any Branches, excepting sometimes a Twig or two to the Peritoneum, Psoas Muscle, Lymphatic Glands, &c. till it is about to leave the Abdomen, where it gives rise to two principal Arteries,—the *Epigastrica*, and *Circumflexa Ossis Ilii*.

The ARTERIA EPIGASTRICA, Tab. CLI. *b*, Tab. CXLI. *r*, goes off from the inner side of the Femoral Artery, immediately before that Vessel gets under the *Ligament of POUPART*.

At its origin, it is a little bent downwards; and about half an inch from the place where it first comes off, it crosses obliquely upwards and inwards, at the upper and outer end of the Abdominal Ring, behind the Spermatic Cord in the Male, and round Ligament in the Female.

It proceeds in this oblique manner, under the inferior part of the Transversus, till it reaches as high as the point of the Pyramidalis, after which it takes a perpendicular direction along the back part, and near the middle of the Rectus Abdominis.

Near its origin, it sends Branches to the adjacent parts of the Pubes, one of which, in the Male, runs to the Spermatic Cord, and in the Female to the Round Ligament of the Uterus.

Under the Umbilicus, it generally divides into two Branches, variable in their size; one directed towards the Umbilicus, the other continued in the line of the Rectus.

It furnishes Branches to the Muscles, Integuments, and Membranes of the fore-part of the Abdomen, communicates in several places with the Lumbar Arteries, and terminates a little above the Umbilicus, where it forms several distinct though small Anastomoses with the under end of the Mammaria Interna.

CIRCUMFLEXA OSSIS ILII, Tab. CLI. *g*.—The Circumflex Artery of the Ilium, almost as large as the Epigastric Artery, arises nearly opposite to it, though frequently a little lower,—immediately behind the under end of the Fallopian Ligament.

It runs at the inner edge of the Crest or Spine of the Os Ilium, between the Transversalis and Obliquus Internus, till it arrives near the Vertebrae of the Loins.

It gives Branches to the Psoas, Iliacus, and Sartorius, to the under end of the Obliqui and Transversus Abdominis, and at length communicates with the Epigastric, and with the Inferior Intercostal and the Lumbar Arteries.

ARTERIA FEMORALIS.

The FEMORAL, or CRURAL, or COMMON FEMORAL
VOL. III. K

ARTERY, Tab. CLI. *i*,—the continuation of the External Iliac,—passes out of the Abdomen between the Ligament of POUPART and Brim of the Pelvis.

At its first exit, it is situated superficially over the Ball of the Os Femoris, having the inner edge of the common end of the Psoas and Iliacus Internus between it and the Joint.

Farther down, it is lodged deep in a hollow at the upper and inner part of the Thigh, with the Rectus and Sartorius upon the outer, and the Adductores Femoris upon the inner side of it.

Here, it is covered by the Glands of the Groin, and by the general Aponeurosis and Fat; and from this part it descends at the inside of the Thigh, turning gradually backwards, till it reaches the Ham.

From the top of the Femoral Artery, a few small Branches are sent off to the Skin of the Abdomen, to the Superficial Muscles and Inguinal Glands, and to the common Integuments at the upper part of the Thigh; also one or two others, termed *Pudica Externæ*, to the Pubes and the Integuments of the External Parts of Generation and inside of the Thigh. Tab. CLVIII. Fig. 2.

About two Fingers-breadth below the Ligament of POUPART, the Femoral Artery divides, somewhat like the Common Iliac, into Anterior and Posterior parts:—The former is the Femoral Artery strictly so called, the latter is termed *Profunda Femoris*. Tab. CLI. CLIV. CLVIII. CLIX.

PROFUNDA FEMORIS.

The ARTERIA PROFUNDA, also called VASTA, POSTERIOR, or MUSCULARIS FEMORIS, concealed at first by the proper Femoral Trunk, gives off at its Origin from that Artery small Branches, arising separately or in a common Trunk, and dispersed upon the Integuments, Muscles, and Capsular Ligament, at the upper and fore part of the Thigh.

It gives next, from its Origin also, two large Branches,—the *Circumflexa Interna*, and *Circumflexa Externa*,—which run in opposite directions at the upper part of the Thigh.

The CIRCUMFLEXA INTERNA, Tab. CLIV. *f*, though most frequently coming off from the beginning of the Profunda, often arises higher than it, from the top of the Femoral; and there are now and then two of them; one a little lower than the other.

It passes between the under end of the Psoas and the Pectinalis, and afterwards turns round the inner part of the Neck of the Thigh-bone.

It sends off—

Branches to the Pectinalis, Triceps, and Capsule of the Joint.

A Superior or Anterior Ascending Branch, to the Triceps and Obturator, having a considerable anastomosis with the Obturator Artery at the external margin of the Foramen Thyroideum. From this Branch a Twig is detached

detached which enters the Breach at the under and fore part of the Acetabulum, to be dispersed upon the Ligamentum Rotundum and the substance called *Gland of the Joint*.

An *Inferior*, or *Inferior Posterior Circumflex Branch*, which is the continuation of the Trunk.

It bends round the Neck of the Thigh-bone, sending small Branches to the Capsule of the Joint, to the Obturator, Quadratus, and Adductor Femoris; communicating with the Obturator and Sciatic Arteries.

CIRCUMFLEXA EXTERNA, Tab. CLVIII. E.—The Circumflexa Externa arises for the most part nearly opposite the former, but frequently a little lower.—Now and then it has a double Origin; one of the Trunks coming off higher than the other.

It passes outwards between the upper ends of the Rectus, Tensor Vaginae Femoris, and Vastus Externus, and over the root of the Trochanter Major of the Os Femoris.

It sends Branches upwards to the under part of the Glutei, and to other Muscles placed at the inferior and back part of the Pelvis, which anastomose with those running down from the Arteria Glutea.

Others which have more of a lateral direction, and are distributed upon the Muscles at the upper and back part of the Thigh, and upon those more immediately about the Joint,—communicating with the Branches of the Circumflexa Interna.

The largest Branches descend between the Rectus Femoris and Vastus Externus; one, longer than the rest, reaching almost as far as the outer part of the Knee.

The Profunda Femoris, having detached the Circumflex Arteries, sinks deep behind the Trunk of the Femoralis, and, passing between the Adductor Muscles and Vastus Internus, descends near to the middle of the Thigh.

In its descent, it sends off, or is divided into principal Branches, termed *Rami Perforantes*, Tab. CLV. which, after sending off small Branches to the Triceps, perforate it, to be dispersed upon the Flexors and other Muscles on the back part of the Thigh.

The Perforantes come off in the following succession, viz.

The *Perforans Prima*, which arises near the Trochanter Minor, perforates the Triceps a little farther down, and furnishes Branches to the Muscles in the upper and back part of the Thigh.

It forms numerous Communications with the Circumflex Arteries, about the root of the Trochanter Major, and anastomoses in particular with the under end of the Sciatica.

The *Perforans Secunda* or *Magna*, which comes off some way below the former, and is the largest of the perforating Arteries.

It gives Branches to the Muscles in general about the middle of the back part of the Thigh, particularly to the Adductors, Vasti, and to the Flexors of the Leg; and

communicates above with Arteries of the Perforans Prima, and with the Circumflex Arteries.

Besides these, there is one, and sometimes two other perforating Branches, which are greatly inferior in size to the two former, and are lost upon the Flexors at the under and back part of the Thigh; one Twig sent off from these sometimes forming a *Nutritia* or *Medullaris* of the Os Femoris.

The Femoral Artery, after giving off the Profunda Femoris, passes down, still covered by the Fascia of the Thigh, between the Vastus Internus and insertion of the Triceps, giving only small Branches to the Muscles and Integuments, at the fore and inner side of the Thigh.

One Branch, termed *Ramus Anastomoticus Magnus*, more conspicuous than the rest, is sent off previous to the passage of the Artery through the Tendon of the Triceps. It descends with many Ramifications upon the Vastus Internus, upon which it is chiefly dispersed; inosculating with the Descending Branch of the Circumflexa Externa; and below, with Branches about the Knee.

About the middle of the inside of the Thigh, it is situated behind the Sartorius; and, nearly two thirds down upon the Os Femoris, it perforates the Triceps, passing between that Muscle and the Bone, in its way to the Leg.

Having perforated the Triceps, it is found in the back part of the Thigh, where it sends *Rami Perforantes*, to the Muscles and Integuments on the back part of the Thigh.

Of the *Rami Perforantes* two are more constant and considerable than the rest, and called by some Authors *Perforans Superior*, and *Perforans Inferior*; the former distributed to the Muscles at the back and inner, and the latter, after sending off the *Principal Medullaris*, going to those of the back and outer part of the Thigh; and both communicating above with the descending Branches already described.

In this part of the Thigh the Artery lies close upon the Bone, and adheres firmly to it, till it reaches the Ham, where it is termed *Poplitea*.

ARTERIA POPLITEA.

The ARTERIA POPLITEA, Tab. CLV. CLVI. strictly so called, is that part of the Femoral Artery which lies over the Joint of the Knee; the name, however, is generally applied to all that part of it which extends between the Posterior part of the Tendon of the Triceps and under edge of the Popliteus, or where the Artery is divided into two Great Branches.

It is lodged deep in the Hollow between the Hamstrings, Condyles of the Os Femoris, and Heads of the Gastrocnemius Externus.

Where it passes over the Joint it lies close upon the Capsule, in the Hollow between the Hamstrings, and between the Condyles of the Os Femoris, covered by its
associate

associate Vein and Nerve, and generally by a large quantity of Fat.

It gives off several Branches, termed *Articulares Superiores* and *Inferiores*, to the Joint of the Knee.

Four of these, situated, two above and two below the Joint, are more regular and constant than the rest, viz.

The *Articularis Superior Interna*, which turns round the Os Femoris, above the Inner Condyle, passes under the Semimembranosus and Semitendinosus, and, after perforating the Tendon of the Triceps, is dispersed upon the upper and inner part of the Knee, anastomosing above with Branches sent down from the Femoral Artery.

The *Articularis Superior Externa*, which arises nearly opposite to the former, passes outwards between the Tendon of the Biceps and Body of the Os Femoris, immediately above its outer Condyle, and is lost upon the Vastus Externus, and upon the upper and outer part of the Knee; its Branches anastomosing with those of its fellow, and particularly with the long descending Branch of the Circumflexa Externa.

The *Articularis Inferior Interna*, which arises opposite the bending of the Joint, passes downwards, and then turns round the Tibia, immediately below its Inner Condyle.

It sends Branches first to the back part, then to the inner side of the Knee; some of them insinuating by the Semilunar Cartilages into the internal part of the Joint.

It communicates above with the Branches of the *Articularis Superior Interna*.

The *Articularis Inferior Externa*, which comes off near the former, and passes first downwards, then outwards, between the External Lateral and the Capsular Ligament, to be dispersed upon the under and outer part of the Knee and inner part of the Joint; communicating with its fellow of the opposite side, and above, with the Branches of the *Articularis Superior Externa*.

Besides the Superior and Inferior Articulating Arteries, another Branch is frequently found, termed *Articularis Media*, or *Azygos*, which is irregular in its origin, arising sometimes from the Trunk of the Poplitea, at other times from one of the Superior Articular Branches. It is situated between the Condyles, and is exhausted upon the Ligaments, Fat, and Bones, at the back part of the Joint; inosculating with all the adjoining Branches.

The other less constant Articular Branches are dispersed upon the Muscles a little above the Joint.

The Arteria Poplitea, having furnished Branches to the Joint of the Knee, gives others to the Muscles at the upper and back part of the Leg; two of which, termed *Surales*, more considerable than the rest, pass into the heads of the Gastrocnemius Externus.

The trunk of the Artery passes afterwards between the heads of the Gastrocnemius Externus, and commonly from two to three inches below the bending of the Knee, and at the under and outer edge of the Popliteus,

or upper end of the Soleus, divides into two large Arteries, the *Tibialis Antica*, and *Tibialis Postica*.

TIBIALIS ANTICA, Tab. CLVI.—The *Tibialis Antica* arises from the fore-part of the Poplitea, and passes directly through the upper end of the Interosseous Ligament to the fore-part of the Leg.

In its descent in the Leg, it adheres closely to the anterior surface of the Interosseous Ligament; lying at first between the *Tibialis Anticus* and *Extensor Digitorum*, and then between the *Tibialis* and *Extensor Pollicis*.

A little above the Ankle, it passes upon the outer and fore part of the Tibia, and, getting under the Annular Ligament and *Extensor Pollicis*, advances in a waving direction upon the convex surface of the Foot.

It supplies, in general, the Muscles and Integuments which belong to the outer and fore part of the Leg and upper part of the Foot, and is ultimately spent upon the Deep Muscles of the Sole.

Its Branches come off in the following order, viz.

A *Small Branch* sent off before the Trunk perforates the Interosseous Ligament, to be dispersed upon the Muscles, Bones, &c. near the Joint; the superior Twigs running in a retrograde direction, and inosculating with the Inferior Articular Branches.

The *Recurrent Anterior*, which arises from the Artery after it has perforated the Ligament, and is distributed upon the Muscles at the upper part of the Leg, and upon the Ligaments at the under part of the Knee; anastomosing there with the Inferior Articular Arteries.

Numerous Branches sent off in a lateral direction to the Muscles and Integuments on the outer and fore part of the Leg.

The *Malleoli Interna*, which comes off near the lower end of the Tibia, and is dispersed on the parts about the Inner Ankle.

The *Malleoli Externa*, which arises a little lower than the former, and is distributed to the parts near the outer Ankle.

The *Arteria Tarsæ*, Tab. CLVII. CLVIII. which takes its origin a little before the bending of the Ankle-joint, and is more considerable in size than the Malleolar Branches.

It passes obliquely outwards and forwards under the *Extensor Brevis Digitorum*, and sends Branches to the Joint of the Ankle, where it communicates with the Malleolar Arteries.

It supplies the greater part of the Muscles, Integuments, &c. on the upper and outer part of the Foot, and sends Branches, termed *Interossei*, to the Muscles between the Metatarsal Bones of the small Toes,—which, however, are frequently derived from the Metatarsal Artery.

Branches from the Artery upon the Dorsum Pedis, distributed to the Integuments, Muscles, Membranes, and Bones, at the upper and inner side of the Foot.

The *Arteria Metatarsæ*, Tab. CLVII. CLVIII. which goes off about the middle of the *Dorsum Pedis*, and passes obliquely towards the root of the Little Toe, assisting the former Artery in furnishing Branches to the upper side of the Foot and Toes, and sometimes, in part or entirely, supplying the place of that Artery.

The remaining portion of the Anterior Tibial Artery afterwards advances between the Extensor of the great, and long Extensor of the small Toes, sending Twigs to the adjacent parts, and dividing, between the Metatarsal Bones of the Great Toe, and that next it, into a *Large Posterior* and a *Small Anterior Branch*. Tab. CLVII. CLVIII.

The *Posterior Branch*, termed *Anastomotica Profunda*, which may be considered as the continuation of the Trunk, sinks between the Metatarsal Bones of the two first Toes, and anastomoses with a deep Artery in the Sole.

The *Anterior Branch* runs forwards, under the name of *Dorso-metatarsæ*, or *Dorsalis Pollicis*, to be dispersed upon the Great and second Toes.

TIBIALIS POSTICA.—The Tibialis Postica, somewhat larger than the Antica, divides about a *finger's-breadth* under the origin of the Tibialis Antica, into the Fibularis, and Tibialis Posticus strictly so called.

The FIBULARIS, termed also *Peronea*, which is smaller than either of the Tibial Arteries, runs down at the inner side of the Fibula, for a considerable way along the Leg, and is situated, first between the Tibialis Posticus and Flexor Longus Pollicis, and is afterwards covered by the last-named Muscle.

Its Branches are distributed to the Muscles at the outer part of the Leg in the neighbourhood of the Fibula,—a small Medullary Branch also penetrating the Substance of that Bone.

A little above the inferior Articulation of the Tibia and Fibula, it sends a Branch forwards, termed *Fibularis* or *Peronea Anterior*, which perforates the Interosseous Ligament, and is dispersed upon the fore-part of the Ankle, where it anastomoses with the External Branch of the Tibialis Antica.

The continuation of the Trunk, sometimes termed *Fibularis* or *Peronea Posterior*, descends behind the Malleolus Externus, to the outer and back part of the Foot, anastomosing with the External Malleolar and Tarsal Branches of the Tibialis Antica.

The TIBIALIS POSTICA, properly so called, Tab. CLVI. passes down at the back part of the Tibia, and runs over the Tibialis Posticus and Flexor Digitorum, and under the Gastrocnemius Internus, in its descent through the Leg.

At the under part of the Leg, it becomes more superficial, running between the Tendo Achillis and Malleolus Internus; having the Tibialis Posticus and Flexor Digitorum Longus on the inner, and the Flexor Longus Pollicis on the outer side of it.

From the Ankle, it runs in the Hollow of the Os

Calcis, and behind the Abductor Pollicis, to the Sole of the Foot.

Its Branches supply the Muscles at the back and inner part of the Leg, and the different parts of the Sole; forming many Inosculations with the Branches of the Anterior Tibial, and the Fibular Artery.

In its course along the Leg, it gives off—

Numerous Branches, similar to those of the Tibialis Antica, to the surrounding Muscles:

The *Arteria Nutritiva Tibiæ*, which begins a little below the upper end of the Trunk, descends for some way in the Leg, and gives Branches to the deep Muscles and Membranes near it, and one Branch termed *Arteria Medullaris*, which enters the Hole near the middle of the Bone:

Several Branches to the parts behind, and at the inner side of the Ankle and Heel, which communicate with others of the Anterior Tibial Artery.

The Trunk of the Artery divides in the Hollow of the Os Calcis, at the place where it is about to go behind the Abductor Pollicis, into two principal Plantar Branches,—the *Interna* and *Externa*.

The Plantar Arteries run forwards under the Aponeurosis Plantaris, having the Flexors of the Toes between them.

The PLANTARIS INTERNA, Tab. CLVII. Fig. 6. C., passes near the inner side of the Sole, between the Aponeurosis Plantaris and Abductor Pollicis.

It gives Branches which run in a retrograde direction to the back part of the Ankle and adjacent parts of the Heel:

Several Branches from each side, which go forwards to the Muscles and Integuments, and other parts at the concave edge of the Sole.

At the root of the Great Toe, it sends a *Principal Branch* to its inner side; it then passes under the Flexor Longus Pollicis, and, after anastomosing with the Arcus Plantaris, gives off a *Large Branch* which splits into two,—one to the outer side of the Great Toe, and the other to the adjacent side of the Toe next it.

The PLANTARIS EXTERNA, Tab. CLVII. Fig. 6. B., which may be considered as the continuation of the Trunk, being in general much larger than the Interna,—passes obliquely outwards between the Flexor Brevis Digitorum and Flexor Accessorius, till it reaches the Base of the Metatarsal Bone of the Little Toe.

It is afterwards arched forwards, between the Flexors and Metatarsal Bones of the small Toes, the Trunk being continued to the root of the Great Toe, under the name of *Arcus Plantaris*.

The External Plantar Artery sends off—

A *Considerable Branch*, first to the under, then to the outer part of the Heel, which communicates externally with Branches of the anterior Tibial and the Fibular Arteries:

Several Branches to the Flexors of the Toes, and to other parts in the outer portion of the Sole, which communicate,

municate, on the inner side, with the Branches of the Plantaris Interna; and at the outer, with those of the anterior Tibial Artery.

The ARCUS PLANTARIS, Tab. CLVII. Fig. 6. D, gives out—

Several Branches to the deep Muscles of the Sole, particularly,

Rami Interossei to the Muscles between the Metatarsal Bones:

A *Branch* to the outer side of the Little Toe:

Three Large Digital Arteries, which are forked at the roots of the Toes, and run along the edges of these in the manner the Digital Arteries do along the Fingers.

Between the Metatarsal Bones of the Great Toe and the one next it, the Plantar Arch anastomoses with the Posterior or perforating Branch of the Anterior Tibial Artery, forming a free communication between the Arteries of the upper and under side of the Foot. Frequently it sends off here a Digital Artery, which forks and runs along the outer side of the Great Toe, and inner side of the Toe next it, so as to supply the place of one of the Branches of the Internal Plantar Artery.

At the roots of the Toes, the Interosseous Arteries of the upper part of the Foot, also form distinct Anastomoses with the anterior extremities of the Trunks of the Digital Arteries.

VEINS.

The VEINS of the INFERIOR EXTREMITY, like those of the SUPERIOR, consist of a *Subcutaneous* and a *Deep* Set, and, like them also, are furnished with numerous Valves.

SUBCUTANEOUS VEINS.—The Subcutaneous Veins are situated between the Common Integuments and General Aponeurosis, and, in many parts, are entirely concealed by the Fat. They anastomose frequently with each other by large Branches, and have several communications also with the deep-seated Veins.

They form two principal Trunks, called *Saphæna Major* and *Saphæna Minor*.

The SAPHÆNA MAJOR, Tab. CLIX. begins upon the upper side of the Foot, runs over the fore-part of the inner Ankle, and ascends in the Leg at the inner edge of the Tibia.

From the Leg, it passes up by the inside of the Knee, and afterwards, from the inner to the upper and fore part of the Thigh.

It is at first composed of Veins, derived from the upper and inner part of the Dorsum Pedis, which have frequent Anastomoses with each other, and are of considerable size.

In its ascent, it is joined by Branches from the Superficial parts of the Leg, and, some way below the Knee, is frequently split into a Plexus.

It receives Branches from the superficial parts of the Thigh, and small Twigs from the Inguinal Glands.

It terminates in the top of the Femoral Vein, nearly opposite to, or a little higher than, the origin of the Arteria Profunda.

The SAPHÆNA MINOR arises upon the outer side of the Foot, and afterwards passes behind the Malleolus Externus.

From this, it ascends, in the back part of the Leg, upon the surface of the Gastrocnemius Externus, and goes into the Ham.

It is formed by the Veins of the upper and outer part of the Foot, and is joined to the Saphæna Major, over the Metatarsal Bones, by one or more Arches, which receive a Plexus of Branches into their lower or convex part.

It is joined by the Superficial Veins of the outer and back part of the Leg, which have frequent Anastomoses with each other, and with the Branches of the Saphæna Major.

It terminates in the Vena Poplitea, and, a little above the Knee, communicates constantly by a small Branch with the Saphæna Major.

DEEP VEINS.—The Deep Veins of the Leg, like those of the Fore-Arm, run close at each side of their Arteries, and are double their number, but differ a little from the Radial and Ulnar Veins, in being proportionally larger.

The TIBIAL and FIBULAR VEINS anastomose in some places with each other, and also communicate with the Subcutaneous Veins.

At the upper part of the Leg, they are united together, to form the Vena Poplitea, and the union is nearly at the same place where the corresponding Arteries come off.

The VENA POPLITEA adheres closely to the upper or posterior surface of the Artery, which it in a great measure conceals, and is commonly single, excepting a small Vein which sometimes accompanies it, and communicates with it.

The Popliteal Vein receives the Venæ Surales and Articulares, and the Saphæna Minor; after which it forms the Femoral Vein.

The VENA FEMORALIS, Tab. CLIX. receives the Veins which correspond with the perforating Branches of the Femoral Artery, and passes in through the Triceps, where the Artery comes out.

In the middle of the Thigh, it lies deeper than the Artery, afterwards turning gradually to its inner side; and, at the upper part of the Thigh, is joined by the Vena Profunda.

The VENA PROFUNDA receives the Veins corresponding with the Branches of the Artery of that name, and is sometimes of a large size, being then in a great measure the continuation of the Vena Poplitea,—a small Vein only in such cases accompanying the Trunk of the Femoral Artery.

Besides the Vena Profunda, the Femoral Vein takes in small Veins from the External Parts of Generation,
from

from the Inguinal Glands, and from the other superficial parts of the Groin;—and, in particular, it receives a Branch of considerable size, which descends from the Integuments of the fore-side of the Abdomen.

The Trunk of the Femoralis, having received the different Veins of the Inferior Extremity, passes into the Abdomen, behind *POUPART'S* Ligament, being still situated at the inner side of the Artery,—after which it forms the *Iliaca Externa*.

The *ILIIACA EXTERNA* receives into its beginning the Epigastric and Circumflex Vein of the *Os Ilium*, and sometimes the *Vena Obturatrix*.

It is situated at the inside of the External Iliac Artery, and afterwards crosses behind it on the right, and behind the Internal Iliac Artery on the left side of the Pelvis, to join the Trunk of the Hypogastric Vein.

The *VENA HYPOGASTRICA*, or *ILIIACA INTERNA*, *Tab. CLIX.* is situated at the outer side of the Concomitant Artery, and receives the different Veins which correspond with the Branches of that Artery, and which are furnished with Valves where they are situated among the fleshy parts of the Pelvis.

The External and Internal Iliacs unite, and form the Common Iliacs, a little below the division of the corresponding Arteries.

The *ILIIACÆ COMMUNES* ascend by the right side of their respective Arteries, and a little below the Bifurcation of the Aorta,—or upon the fore-part of the Fifth Lumbar Vertebra,—unite to form the Inferior Cava, situated, as formerly mentioned, at the right side of the Aorta.

The *VENA CAVA INFERIOR*, *Tab. CLXXIX.* which is much larger than the Cava Superior, and greatly exceeds in size the descending *Aorta*,—receives, at its beginning, the *Vena Sacra*, and, higher, the *Venæ Lumbares*, which, in the left side, pass behind the Trunk of the Aorta.

It likewise receives the *Venæ Renales*, and the *Spermatica* of the right side.

At length it takes in the *Venæ Hepaticæ* and *Diaphragmaticæ*, and, perforating the Diaphragm at the root of the Liver, it terminates in the Right Auricle of the Heart.

PART VI.

OF THE

ABSORBENT SYSTEM.

OF THE ABSORBENTS IN GENERAL.

THE *Absorbent System* consists of the *Absorbent Vessels* and *Conglobate Glands*; the former of which are divided into *Lymphatic* and *Lacteal Vessels*.

The *Absorbents* are small *Pellucid Tubes*, which have been discovered in most parts of the Body, and are supposed to exist in all.

They begin by numberless open *Mouths*, too minute to be visible to the naked Eye: By the assistance of Glasses, however, the Orifices of the *Lacteals* have been seen in the Human Body;—and those of the *Lymphatics* in certain kinds of Fishes;—See *Monro's and Cruikshank's Treatises on this Subject*.

They arise from the External Surface of the Body, from the Cellular Substance, from the Surfaces of the large Cavities, and from the Surface and Substance of the different Viscera; but have not yet been observed in the Cavity of the Cranium, nor in the Placenta and its Membranes.

In the different parts of the Body, they generally run in two Sets; one Superficial and very numerous, the other accompanying the Arteries, and at least double their number.

The *Lacteals* are of the same nature with the other Absorbents. They begin from the inside of the Intestines; and when these contain Alimentary Matter, they carry a white Fluid, called *Chyle*, and at other times a Clear Fluid or *Lymph*, to be mixed with the contents of the *Lymphatics*.

Most of the *Lymphatics*, and all the *Lacteals*, terminate in the Thoracic Duct, by which the *Lymph* and *Chyle* are conveyed to the Red Veins, and mixed with the Blood.

The large Veins in the bottom of the Neck are the common place of termination; no facts or observations having been yet established of their terminating in any other part of the Venous System.

The *Coats* of the Absorbents are thinner and more transparent, but stronger than those of the Red Veins, being able to support a Column of Mercury of considerable weight;—but from their thinness they cannot be enumerated.

The Absorbents are generally supposed, however, to be formed of different *Membranous Layers*, like the Blood-vessels.—Fibres can be seen in them, and their

Muscularity is rendered probable by the Contractile power which they are observed to possess in a living or moribund Animal.

By this Contractility they convey their contents from their origins towards their terminations, in which they are assisted by the motions of the surrounding parts, independent of such a *Vis a Lergo* as contributes to propel the Blood through the Veins.

They are furnished with *Blood-Vessels* for their nourishment, as is sometimes observed by penetrating injections; and this is rendered still more evident by their being susceptible of Inflammation and Pain.

The presence of *Nerves* also appears probable from the acuteness of their feeling when in a state of Inflammation.

In general, they form an irregular *Net-work*, having frequent communications with each other; and these are most numerous in the vicinity of their Glands.

Through their whole extent, they are intercepted by *Valves*, which are placed in Pairs, and are of a Semicircular form; having one edge of each Valve fixed to the side of the Vessel, and the other edge loose across its Cavity, but turned towards the general Terminations.

In some parts, the Valves are found to be situated at equal distances; in others, more irregularly.—Their number also is very uncertain, amounting in some parts to three or four, and in others to seven or eight, or upwards, in the length of an inch;—but varying still more with respect to number in different Bodies, and in different parts of the same Body.

When the Absorbents are distended, they appear largest on the side of the Valves towards their general Termination, and the Enlargements are such as to give the *Lymphatics* a jointed, and the *Lacteals* frequently a Vesicular appearance.

In the Termination of the Absorbents, whether in the Thoracic Duct, or in the Red Veins, there is always one, and commonly two Valves, to prevent the Contents of the Duct or of the Veins from passing into them.

The Valves promote the general course of the *Lymph* and *Chyle*, and prevent the retrograde motion of these Fluids within their Vessels.

The *Lymphatics* take in the Fluids applied to their Orifices by Capillary Attraction, and by a power inhe-

rent in themselves, and by their Contractile nature conduct them into the Mass of Blood, whereby they prevent Morbid Accumulations.—The Lacteals, in like manner, receive the Chyle from the Intestines for the nourishment of the Body.

The *Conglobate Glands*, or Glands of the Absorbent Vessels, are found in various parts of the Body, and are situated in the Cellular Substance under the Skin, or over the Trunks of the Blood-vessels belonging to the different Viscera:—They are of a round or oval Form, and frequently a little flattened.

They are of different Sizes, from that of a Millet-feed to that of a Substance near an inch in diameter; and sometimes several are collected into one Mass.

Their Colour also varies in different parts of the Body, and at different times of life.

In young Subjects, they are generally largest, and of a reddish or brown colour, but become smaller and paler with increasing age; and immediately under the Skin, they are redder and firmer than within the large Cavities.

They have a smooth, dense, *Membranous Covering*, which gives them a shining appearance, and are connected to the surrounding parts by loose Cellular Substance.

Their Coat is connected to the Glandular part by a Cellular Membrane, which, according to DR HALLER, is pervaded by a *Succus Proprius* full of Globules, which, MR HEWSON supposed, afterwards form the Red Globules of the Blood.

Like other Glands, they are supplied with Arteries, Veins, and Nerves.

They are described by some Anatomists, as being composed of *Cells internally*, while others consider them as being a *Congeries of convoluted Absorbent Vessels*.—Most of the Glands have much of the former, but many of them of the latter appearance.

The Absorbents entering into the Glands, are called *Vasa Inferentia*. When they approach, or come in contact with the Gland, they split into radiated Branches, which, after spreading out upon it, penetrate into its Substance.

The greater part of the Absorbents, approaching a Gland, terminate in it in this manner, while others turn aside, or go over it, and terminate in other Absorbents, or in other Glands.

From the opposite side of the Glands, Vessels go out in the manner they entered them, and are termed *Vasa Efferentia*. They are frequently, though by no means always, fewer in number, but larger than the *Vasa Inferentia*.

Most of the Absorbents go through several Glands, but in some parts through one only, before they reach their General Terminations.

The Lymph and Chyle are strained through the Glands, by which they are supposed to undergo certain Changes,—but the Nature of these Changes has not yet been ascertained.

PARTICULAR ABSORBENTS.

THE *Superficial Absorbents of the Lower Extremities* consist of numerous Vessels, which lie between the Skin and Muscles.

They belong to the Integuments in general, and are much more numerous than the Subcutaneous Red Veins.

They can be traced from the Toes, round which they form a Plexus.

From the Toes, several Branches, likewise forming a Plexus, run over the top of the Foot, to the inner part of the Leg, and from that along the corresponding part of the Knee. Tab. CLXI. Fig. 1.—Tab. CLXXVII. Fig. 2.

From the outer part of the Foot, another Plexus arises, which runs along the outside of the Leg, where it splits into two Divisions, one of which crosses obliquely over the fore-part of the Tibia, to the Lymphatics at the inner side of the Knee. Tab. CLXI. Fig. 3.

The other division passes partly to the Popliteal Glands, some ascending upon the outer and back part of the Thigh. Tab. CLXI. Fig. 3.—Tab. CLXXVII. Fig. 2.

The Popliteal Glands, Tab. CLX. Fig. 3. Tab. CLXXVII. Fig. 2. are commonly two or three in number, and are situated near the Artery of the same name, but frequently they are so small and so much buried in Fat, as to be discovered with difficulty.

From the Sole another Plexus of Lymphatics arises, and joins those upon the Leg already described.

From the inside of the Knee a Plexus runs up, consisting of from twelve to twenty Trunks, which pass afterwards on the fore and inner part of the Thigh to the Groin. Tab. CLXI. Fig. 2. Tab. CLXXVII. Fig. 2. Fig. 1.

The greater part of the Trunks of the last Plexus, accompany the *Vena Saphæna Major*, and, in their passage, they receive many small Branches from the outer and back part of the Thigh.

In the Groin, they split into Branches, which penetrate the Inguinal Glands. Tab. CLXI. Fig. 2.

The *Inguinal Glands* are generally from six or eight to a dozen in number, and are of very different sizes; but sometimes

sometimes the number is smaller, from two or more of them being united into one large Gland. Tab. CLXXVII. Fig. 1.

Of the Inguinal Glands, some lie in the Angle between the Thigh and Abdomen, and others a few inches farther down on the fore-part of the Thigh. Tab. CLXII.

The greater number are placed upon the outer part of the Tendinous Aponeurosis, the rest deeper, being in contact with the great Blood-vessels.

The *Superficial Lymphatics of the Thigh* enter the lowest of these Glands; one or more of them, however, frequently pass the first Glands they meet with, and penetrate others higher in the Groin, and sometimes a few do not enter any Glands till they go into the Abdomen. Tab. CLXII. The superficial Lymphatics of the upper and back part of the Thigh, with those of the Nates, Abdomen, and Loins, also enter into the Inguinal Glands. Tab. CLXII.

The *Deep-seated Lymphatics of the Lower Extremity* are situated among the Muscles.—They accompany the Blood-vessels, and are few when compared with the Subcutaneous Set.

In several places, one only has been yet observed on each side of the Trunks of the Arteries, though, in others, they are somewhat more numerous, forming a Plexus over the Blood-vessels.

They arise from the sides of the Toes; and from the deep parts of the Sole, accompanying the Plantar Arteries; and, after reaching the Leg, they run up with the Posterior Tibial Artery to the Ham.

In the Ham, they lie close upon the Trunk of the Artery, and enter the Popliteal Glands.

Besides these, there are similar but smaller Lymphatics, which begin upon the upper part of the Foot, and afterwards accompany the Anterior Tibial, and the Fibular Arteries, receiving Branches from the deep parts of the fore and outer side of the Leg.

The *Anterior Tibial* and the *Fibular Lymphatics*, terminate with the posterior Tibial in the Glands of the Ham.

From the Popliteal Glands, two and sometimes more Trunks of considerable size are sent out, which accompany the Femoral Artery, and, at different distances, communicate with each other, by Branches which pass obliquely across the Artery.

At the upper part of the Thigh, they enter the undermost of the Inguinal Glands, where the Lymph of the Superficial and deep-seated Absorbents of the Limb is mixed and incorporated. Tab. CLXII.—Tab. CLXXVII.

The *Superficial Lymphatics of the Scrotum* enter the upper and inner Inguinal Glands; those deeper seated passing with the Lymphatics of the Testicle into the Abdomen. Tab. CLXII.—Tab. CLXXVII.

The *Superficial Lymphatics of the Penis* begin at the Prepuce, and form a few Trunks which run principally

upon the Dorsum Penis, receiving in their passage Branches which turn round from its Inferior Surface. Tab. CLXII.—Tab. CLXXVII.

In some Subjects, they unite into Trunks in the middle of the Dorsum Penis, which afterwards separate into right and left parts.

In others, they are more unconnected; and in all, they appear to divide at the root of the Penis into right and left Branches, passing into the corresponding Inguinal Glands, which lie next the Symphysis Pubis. Tab. CLXII.—Tab. CLXXVII.

The *Deep-seated Lymphatics of the Penis* arise from the Glans, and from the Body of the Penis, and accompany the Arteries into the under part of the Pelvis.

The *Lymphatics of the Testicle* are numerous, and are among the largest of the whole Body; some of them exceeding the size of a Crow-quill.

They arise from the Coats and Substance of the Testicle, and from the Epididymis, and run with the Spermatic Cord through the Ring of the Abdominal Muscle, to terminate in the Lumbar Glands.—In their passage, they have few Communications with each other. Tab. CLXXVIII.

The *Lymphatics of the External Parts of Generation in Women*, go partly to the Inguinal Glands of each side, and partly through the Rings of the External Oblique Muscles, in company with the Round Ligaments of the Uterus, and terminate in the Iliac and in the Lumbar Glands.

The *Superficial Lymphatics of the under part of the Abdomen*, those of the *Loins, Nates, and Verge of the Anus*, pass into the Inguinal Glands; each set terminating in such of the Glands as lie nearest the parts to which the Vessels belong. Tab. CLXII.

The Inguinal Glands, having received the Lymphatics of the Inferior Extremity, and likewise the Superficial Lymphatics of the External Parts of Generation, send out Trunks fewer in number, but considerably larger than those which enter the Glands.

The *Vasa Efferentia* of these Inguinal Glands enter the Abdomen under *POUPART'S* Ligament, in company with the Inguinal and Iliac Artery.

Some of them go into the Glands situated about the Iliac or the Lumbar Blood-vessels. The *Iliac Glands*, Tab. CLXIII. are frequently almost as numerous as the Glands of the Groin, and one of them is generally found larger than the rest, and placed at the inner edge of *POUPART'S* Ligament. The *Lumbar Glands* are more numerous than any of the Classes already described, and are placed over the Abdominal Aorta, Inferior Cava, and Bodies of the Lumbar Vertebrae.

The rest of the Lymphatics from the Lower Extremity descend at the side of the Pelvis, near the Internal Iliac Blood-vessels, and pass through some of the Glands which are situated there.

The last-mentioned Lymphatics are joined by Absorbents from the Viscera of the Pelvis in general, especially

cially by those of the Bladder and Vesiculæ Seminales in the Male, and by a portion of those of the Uterus and of the Vagina in the Female.

The *Lymphatics of the Bladder*, in both Sexes, accompany its principal Blood-vessels, pass through some small Glands upon the side of it, and, at the under part of the Pelvis, go into the Glands which surround the Internal Iliac Artery and Vein.

The *Lymphatics of the Uterus* run in two Sets. One, which is the largest, goes with the Hypogastric, the other with the Spermatic Blood-vessels.

The *Hypogastric Lymphatics* form a Plexus which runs from above downwards, into Glands situated on the sides of the Vagina.

From these Glands they pass to others which surround the Internal Iliac Vessels, and then, intermixing with the Trunks from the Extremities, they terminate in the Thoracic Duct.

The Lymphatics of the Uterus, like its Blood-vessels, are much enlarged, and of course easily discovered, in the Gravid state.

The *Lymphatics of the Rectum* go first into small Glands which lie between it and the Os Sacrum, and afterwards terminate in the Lumbar Plexus of Glands and Vessels.

Besides the Lymphatics which lie on the inside of the External Iliac Artery, there are others situated on the outside of it, upon the Psoas.

Of these, one part passes up to the Lumbar Plexus, and goes under the Aorta, in different Branches which terminate in the Thoracic Duct.

Another part passes under the Iliac Arteries, and appears upon the Os Sacrum, forming a remarkable Plexus, which goes through many Glands, and is chiefly situated behind the Aorta and Vena Cava. Tab. CLXIII.

The *Lacteal Vessels*, so called from conveying a Fluid like Milk, which is termed *Chyle*, begin upon the inner Surface of the Intestines. Each Lacteal takes its origin upon one of the Villi, by numerous short radiated Branches, and each Branch is furnished with an Orifice for imbibing the Chyle.

From the Villi, the Lacteals run a considerable way under the Muscular Coat of the Intestines, and then pass obliquely through them, uniting in their course into larger Branches.

They follow the direction of the Blood-vessels, and their Trunks are double the number of the Arteries,—one being situated on each side of them.

Upon the outside of the Intestines an External Set appear. They run between the Peritoneal and Muscular Coats, and commonly proceed some way in the direction of the Intestine, and with few Ramifications. Tab. CLXIV.

The Superficial and Deep-seated Lacteals communicate in the Substance of the Intestines, and, after leaving them, commonly form a Plexus, which runs between the Plies of the Mesentery and Meso-colon, without fol-

lowing the course of the Blood-vessels. Tab. CLXIV. CLXV.

The *Lacteals of the Jejunum* are larger and more numerous than those of the *Ilium*; the principal part of the Chyle being contained in this Intestine.

In their course, they pass through a great number of Lacteal or Mesenteric Glands, which, like the Lacteals themselves, are largest and most numerous in that part of the Mesentery which belongs to the Jejunum. Tab. CLXIV. to CLXVIII.

The *Mesenteric Glands* are seated in the Fat, between the Layers of the Mesentery, near the Branches of the Blood-vessels.

They are commonly scattered over the Mesentery, at a little distance from each other; but there are seldom any observed within two or three inches of the Intestines.

They are of different sizes in different parts of the Mesentery, some being about a half or two thirds of an inch in diameter, while others are so small as to be traced with difficulty.

Their Structure is the same with that of the Absorbent Glands in other parts of the Body, but they are generally flatter, and are of a white colour when filled with the Chyle.

They are considered by some Authors as dividing the Lacteals into different Orders.

From the Intestines to the Glands, the Lacteals are called *Vasa Lactea Primi Generis*, and from the Glands to the Thoracic Duct, *Vasa Lactea Secundi Generis*. Tab. CLXIV.

Some divide them into Three Orders;—the first consisting of those which go from the Intestines to the Glands,—the second, of those which run from one Set of Glands to another,—and the third, of those which pass from the Glands to the Thoracic Duct.

The *Lacteals of the Small Intestines*, after passing through the different Glands in the Mesentery, form at last one, and frequently two, three, or more Trunks, which accompany the Trunks of the Superior Mesenteric Artery, till they arrive at the right side of the Aorta, where they sometimes pass into the beginning of the Thoracic Duct, Tab. CLXIV.—At other times they descend a little, and join the Trunks from the Inferior Extremities, to form that Duct.

The Absorbents of the *Great* are of an inferior size in proportion to those of the *Small Intestines*, and have seldom, though sometimes, been observed to be filled with Chyle. Tab. CLXVIII.

In their course, they go through the Meso-colic Glands, which are situated between the Layers of the Meso-colon, but are generally much less numerous and considerably smaller than those of the Mesentery, or of most other parts of the Body.

The Absorbents of the *Cæcum*, and of the *Right Portion of the Colon*, join those of the small Intestines, about the root of the Mesentery.

Those

Those of the *Left Portion of the Colon* accompany the Inferior Mesenteric Artery, and communicate with large Lymphatics near its root.

They terminate at last in the Lumbar Glands, or go directly into the lower part of the Thoracic Duct.

Of the Absorbents of the *Stomach*, one Set runs upon its Small, and another upon its Great Curvature, but neither the one nor the other are found to carry Chyle, though a few Absorbents have been observed filled with it in other Animals,—as the Dog.

The first Set, composed of Branches from the upper and under Surfaces of the Stomach, accompany the Superior Coronary Artery.

In their passage, they go through a few small Glands situated at the junction of the Omentum Minus to the Stomach, and, after becoming larger, they enter other Glands in company with the Deep-seated Lymphatics of the Liver, along with which they terminate in the Thoracic Duct.

The other Set passes from the Great Curvature of the Stomach, partly to the right, and partly to the left side, and, as on the Small Curvature, are formed of Branches from its opposite Surfaces. Tab. CLXXVII.

Those on the left side receive the Lymphatics of the middle and corresponding half of the Omentum Majus: Running to the left side of the Large Curvature of the Stomach, and passing through one or two small Glands on it, they go with the Lymphatics of the Spleen and Pancreas to the Thoracic Duct.

Those of the right side receive the Lymphatics of the corresponding half of the Great Omentum, and also pass through one or two small Glands which lie close to the Right Gastric Artery.

In their descent by the Pylorus, they meet the Plexus which accompanies the Superior Coronary Artery, and runs with them and with the Deep Lymphatics of the Liver to the Thoracic Duct.

The *Lymphatics of the Liver*, like those of other Viscera, run in two Sets; the Superficial of which are numerous, and unite into Trunks just as Roots unite to form the Trunk of a Tree. Tab. CLXXVII.

The Superficial and Deep Sets communicate so freely, that upon injecting the Lymphatics of the External Surface, the Deep-seated Absorbents are readily filled from them.

The principal part of the Lymphatics upon the Convex Surface of the Liver go by a Right and Left Plexus towards the Suspensory Ligament. Tab. CLXXVII.

Running along this Ligament, they directly perforate the Diaphragm, after which they pass through Glands situated upon the anterior part of the Pericardium.

Other Lymphatics from the Convex part of the Liver run towards the Lateral Ligaments, where they form on each side, one or more Trunks of considerable size.

From the Lateral Ligaments they pass through the Substance of the Diaphragm, and afterwards run forwards on its Convex surface, following the direction of

the Ribs.—Not unfrequently, these Vessels, instead of perforating the Diaphragm, run downwards, and terminate in the Thoracic Duct, within the Abdomen.

In their course upon the Diaphragm, they often send Branches backwards, which terminate in Glands upon the Esophagus.—In other instances, these Branches are observed to go directly into the Thoracic Duct.

They receive Branches from the Substance of the Diaphragm, and, after perforating two or three Glands upon its Surface, they join the Trunks from the Ligamentum Suspensorium.

The Lymphatics from the Lateral Ligaments, joined by those from the Ligamentum Suspensorium, form either a Principal Trunk, or a Plexus, which runs up, sometimes between the Layers of the Anterior Mediastinum, and, at other times, in company with the Internal Mammary Blood-vessels on each side.

When they run in the Anterior Mediastinum, they most frequently terminate in the upper end of the Thoracic Duct;—sometimes, however, they communicate with the General Termination in the Right Side of the Neck.

When they accompany the Internal Mammary Vessels, they are observed to terminate, the left in the Thoracic Duct, and the right in the General Termination of that side.

The Lymphatics on the Concave Surface of the Liver, run towards the Porta, and join the Deep-seated Set.—One part of them goes over the under Surface of the Gall-bladder, from which they receive numerous small Branches.

The Deep-seated Lymphatics accompany the Blood and Biliary Vessels, and, communicating with the Superficial Absorbents already mentioned, they pass through several Glands situated about the Trunk of the Vena Portæ, and terminate in the Thoracic Duct, near the Root of the Superior Mesenteric Artery.

The Superficial Lymphatics of the *Spleen* are remarkably small. They pass from its Convex to its Concave Surface, where they join the Deep-seated Lymphatics, which are very considerable in size and number.

The *Splenic Plexus* of Lymphatics accompany the Splenic Artery, and go through several Glands of a dark colour, scattered along the Surface of that Vessel.

The Lymphatics of the Spleen receive those of the Pancreas, which run into them in a transverse direction.

In their course, they unite with the Lymphatics of the Stomach and those descending from the under part of the Liver; and the whole of them, near the Head of the Pancreas, form a considerable Plexus. From this Plexus, Branches are sent off, some passing over the Duodenum, and others under it, and all of them going into the Thoracic Duct, near the termination of the Lacteals.

The *Lymphatics of the Kidney* are seldom seen, excepting when it is enlarged or ulcerated; in which case they may sometimes be distinctly observed. Tab. CLXXVII.

The Superficial Absorbents run from its outer towards its

its inner edge, where, meeting with those deep seated, they commonly unite with them, and form a Plexus which accompanies the Renal Blood-vessels, after which they pass through some of the Lumbar Glands, and terminate in large Lymphatics near the Aorta.

The *Lymphatics of the Capsula Renales*, which are numerous in proportion to its size, terminate in the Renal Plexus.

All the Absorbents already described, excepting those from the Convex Surface of the Liver, terminate in the Thoracic Duct near its beginning.

The *Thoracic Duct*, at its under extremity, is formed by the union of three, or sometimes of more principal Trunks; the first of which is composed of the Lymphatics of the right, and the second of those of the left Inferior Extremity;—the third Trunk, or set of Trunks, belongs chiefly to the Lacteals. Tab. CLXIII. Tab. CLXIV. Tab. CLXXIV. Tab. CLXXVII.

These large Absorbents unite so as to form the Duct over the third Vertebra of the Loins.

Sometimes they unite upon the second Vertebra of the Loins, where the Duct formed by them is twice or thrice as large in diameter as it is higher up.

Commonly it enlarges again upon the first Vertebra of the Loins, where it has generally been called the *Receptacle of the Chyle*, and considered as the beginning of the Duct; being often found forming an oval, or Pyriform Bag, about the third of an inch in diameter.

These large Trunks which form the Thoracic Duct lie close upon the Spine, those of the Right side being placed below the Right Crus of the Diaphragm, and those of the left between the Aorta and Spine, while the Thoracic Duct itself lies at first behind the Aorta, but afterwards passes from it upwards, and a little to the right side, till it gets before the first Vertebra of the Loins.

Here it is situated behind the Right Crus of the Diaphragm, a little higher than the Right Renal Artery, from whence it passes upwards, and afterwards appears in the Thorax, upon the fore and right side of the Spine, between the Aorta and Vein Azygos, Tab. CLXXIV. Fig. 1. U, where it is supposed to be considerably assisted by the strokes of the Aorta in impelling its Fluids.

In the middle of the Thorax, it is smaller than elsewhere; being only about a line in diameter. After this it gradually enlarges, and, near its Termination, is about an eighth or tenth of an inch over.

In the Thorax, it receives the Lymphatics of the Spatia Intercostalia, one or two of which accompanies each of the Intercostal Arteries, and the whole go through small Glands placed near these Arteries, but most numerous about the sides of the Dorsal Vertebrae, where they form a sort of Chain.

Here, likewise, it receives Branches from the Esophagus and Lungs; the former of which is surrounded with a number of Glands, and with a remarkable and intricate Plexus of Lymphatic Vessels.

The *Superficial Lymphatics of the Lungs* form large

Areolæ, which have smaller Areolæ within them, the larger running chiefly between the Lobules, and the smaller passing over them in such a manner as to cover almost the whole Surface of the Lungs. Tab. CLXXVII. Fig. 1.

From the Surface they go to the root of the Lungs, where they pass through the Bronchial Glands, which have already been taken notice of in the description of the Lungs.

At this place they are joined by the Deep-seated Lymphatics, which creep along the Branches of the Trachea and of the Pulmonary Blood-vessels.

Through the medium of the Bronchial Glands, the Lymphatics of the two sides of the Lungs communicate freely with each other.

Having left the Glands, the principal part of those from the left Lung form a Trunk of considerable size, which terminates in the Thoracic Duct, behind the Bifurcation of the Trachea.

The rest of the Absorbents of the left Lung pass through Glands behind the Arch of the Aorta, which are likewise common to those of the Heart. They run at last by a Principal Trunk into the Thoracic Duct near its Termination.

After leaving the Bronchial Glands, the Absorbents of the Right Lung form a few principal Trunks, one of which commonly ascends on the fore-part of the Vena Cava Superior, and, running in a convoluted manner, opens into the Trunk which terminates in the Veins in the right side of the Neck.

The rest of these Trunks go into the Thoracic Duct, near the Bifurcation of the Trachea.

The *Absorbents of the Heart* are small, but numerous, and form principal Trunks which accompany the Coronary Arteries, and, like them, the largest belong to the Left Ventricle.

From the side of the Right Coronary Artery, an Absorbent Trunk which corresponds with it, passes over the Arch of the Aorta to a Gland commonly found behind the Origin of the Carotid Arteries. Tab. CLXXVII. Fig. 1. x.

From this Gland it goes afterwards to the General Termination in the right side of the Neck.

The Lymphatic Trunk accompanying the Left Coronary Artery is formed of two principal Branches.—One of these runs in the Groove between the Ventricles on the superior Surface of the Heart: the other runs in a similar Groove on the under side of the Heart, and having reached the space between the Auricles and Ventricles, turns round to join the former Branch near its corresponding Artery. Tab. CLXXVII. Fig. 1. g.

The Trunk runs next to a Gland placed behind the Pulmonary Artery, between the Arch of the Aorta and Root of the Trachea, which, with the others here situated, is common to the Absorbents of the Heart and Lungs.

This

This Trunk terminates at length in the upper end of the Thoracic Duct.

The Thoracic Duct, after receiving numerous Lymphatics within the Thorax, and having reached as high as the third or fourth Dorsal Vertebra, passes obliquely over to the left side of the Spine, behind the Esophagus, and end of the Arch of the Aorta, or beginning of the Aorta Descendens, till it reaches the Left Carotid Artery.

After this, it emerges from the Thorax, and runs between the Longus Colli, and Internal Jugular Vein, to about the sixth Vertebra of the Neck. Tab. CLXXVI. Fig. 1. I.

It now makes a turn downwards, and, after descending near an inch, terminates in the upper and back part of the Angle formed by the left Internal Jugular and Subclavian Vein. Tab. CLXXIV. Fig. 2. A. Tab. CLXXVI. Fig. 1. K. Tab. CLXXVII. Fig. 1. No. 13. 14.

Throughout its whole course, it has a waving appearance, and this becomes more conspicuous in proportion as it is distended by Injection. Tab. CLXXIV. Fig. 1. U, U. Near the middle of the Thorax, it not unfrequently splits into two or more Branches, and sometimes forms a Plexus, the Branches of which, again, unite into a Common Trunk a little higher up.

After emerging from the Thorax, it commonly divides into two parts, which unite again previous to the Termination of the Duct in the Red Veins, Tab. CLXXVII. Fig. 1. No. 13. 14.; and where there is no Division, there is generally a Dilatation or Sac at the Termination.

Sometimes there is one Termination in the Angle formed by the Red Veins, and one or two in the Subclavian Veins, and now and then, though more seldom, in the Internal Jugular, near the Angle.

In a few instances, it has been found double through its whole length; one Duct going to the common place of Termination in the Left side of the Neck, and the other in the corresponding part in the Right.

It has also, in a few rare instances, been observed to terminate in the Veins in the right side of the Neck, while a Short Trunk, similar to that commonly found there, has terminated in the Left side.

The *Superior*, in a similar manner with the *Inferior* Extremities, have Two Sets of Lymphatics, one lying immediately under the Integuments, and belonging to the Skin and Cellular Substance under it, the other accompanying the principal Blood-vessels, and belonging to the deep-seated Parts.

The Superficial Lymphatics of the Superior Extremities are numerous, and are readily seen in emaciated Subjects.

They arise from the fore and back parts of the Fingers and Hand, by a considerable number of Branches, and form an extensive Plexus upon the corresponding sides of the Fore-arm. Tab. CLXXV. Fig. 3.

Those upon the anterior part of the Fore-arm run directly upwards to the Arm, while the Lymphatics on its back part separate into two Sets; one of which passes obliquely over the Muscles on the Radius, and the other over those on the Ulna, to join the Lymphatics on the anterior part of the Fore-arm. Tab. CLXXV. Fig. 1. 2.

The Lymphatics of the Fore-arm run over the bending of the Elbow, and afterwards ascend upon the fore and inner part of the Arm; the greater number of them running near the Basilic Vein. Tab. CLXXV. Fig. 2.

Some of them frequently pass through small Glands placed along the Humeral Artery, one of which is commonly found a little above the inner Condyle of the Os Humeri; others do not appear to enter any Glands till they reach those of the Axilla. Tab. CLXXV. Fig. 2.

A few Lymphatics accompany the Cephalic Vein, and receive Branches from the outer part of the Arm; and, after passing between the Pectoralis and Deltoideus, penetrate Glands at the under side of the Clavicle.

Of the Deep-seated Lymphatics, two commonly accompany each principal Artery in the Fore-arm, and these, uniting at the Elbow, form two principal Lymphatics, which accompany the trunk of the Humeral Artery. Tab. CLXXVI. Fig. 2. 3. 4.

Having reached the upper part of the Arm, they enter the Axillary Glands, where they are joined by Lymphatics which come from the Mamma and lateral parts of the Thorax, after passing through small Glands placed upon the under edge of the Mamma and of the Pectoralis Major. Tab. CLXXVI. Fig. 3.

The *Axillary Glands* vary in number and size in different Persons: They are somewhat smaller, and fewer in number, than those of the Groin: They are generally surrounded by a considerable quantity of Fat, and are situated in the Hollow between the Pectoralis Major and Latissimus Dorsi; adhering closely to the Trunks of the Axillary Blood-vessels and Nerves. Tab. CLXXV. Fig. 2. Tab. CLXXVI. Fig. 3. Tab. CLXXVII. Fig. 1.

From the Axillary Glands large Branches go under the Clavicle, and form a Trunk, which, in the Left side, commonly joins the Thoracic Duct near its Termination, Tab. CLXXVI. Fig. 1. Tab. CLXXVII. Fig. 1. In the Right side, it joins the short Trunk which forms the Second General Termination of the Absorbent System. Tab. CLXXVI. Fig. 1. Tab. CLXXVII. Fig. 1. Sometimes this Trunk, proceeding from the Superior Extremity, terminates in the Subclavian Vein, at a little distance from the General Termination.

The Axillary Glands receive also the Subcutaneous Lymphatics from the back part of the Thorax, together with the Lymphatics from the Integuments and Muscles of the Scapula.

The Lymphatics on the *Outside of the Head* accompany the Blood-vessels, and pass through Glands in their way to the Neck.

Those passing down with the Temporal Artery go through small Glands connected with the Parotid Gland, and

and also through others situated immediately under the Root of the Zygoma. Tab. CLXXVII. Fig. 1.

The Lymphatics which accompany the Occipital Blood-vessels penetrate one or two minute Glands placed a little behind the root of the Ear, and over the Mastoid Process of the Temporal Bone.

The Lymphatics proceeding from the different parts of the *Face* accompany the Branches and Trunk of the Facial Artery.

Some of them pass through Glands situated upon the outside of the Buccinator, while the principal Trunks go through a number of large Glands placed upon the outer, and also at the under part of the lower Jaw, at the anterior edge of the Masseter, and about the Inferior Maxillary Gland.

The Lymphatics from the *inner Part of the Nose* run principally with the Internal Maxillary Artery, and pass through Glands situated behind the Angle of the Lower Jaw, where they are joined by those which belong to the inner parts of the Mouth.

The Lymphatics of the *Tongue*, and likewise of the *Muscles* and other parts about the Os Hyoides, enter the Glands placed behind the Angle of the Lower Jaw.

Lymphatics have been frequently searched for in the *Brain*, but their existence in that Organ is not yet fully ascertained; though rendered highly probable, from an appearance of Lymphatics having been now and then observed upon the Surface of the Dura Mater, and between the Tunica Arachnoides and Pia Mater,—from Lymphatics and Glands being occasionally found in, or immediately on the outside of the Passages of the Blood-vessels of the Brain,—from Swellings in the Lymphatic Glands of the Neck, following Diseases of the Brain,—from the Absorption of Water, which has sometimes happened in Hydrocephalous cases, and—from their having been found on the Brains of Fishes.

From the Superficial and Deep parts of the Head in general, the Lymphatics accompany the External and Internal Jugular Veins and the Carotid Arteries; receiving at the same time Branches from the Muscles and other parts of the Neck.

The principal part of these Lymphatics go along with the Internal Jugular Vein and Carotid Artery, and, in their passage, form a remarkable Plexus, which goes through the numerous Glands seated near the Blood-vessels, composing a Chain, from which they are termed *Concatenatæ*. Tab. CLXXVII. Fig. 1.

The *Glandulæ Concatenatæ* are more numerous than any other Set of Glands in the Body, excepting those which belong to the Mesentery.

The *Cervical Plexus* of Lymphatics having passed through the *Glandulæ Concatenatæ*, unite at the bottom of the Neck into a Trunk, which, in the Left side, enters the Thoracic Duct near its Termination, and, in the Right, goes into the Trunk, which forms the General Termination of that side. Tab. CLXXVII. Fig. 1.

The Trunk which forms this General Termination is only from a quarter of an inch to half an inch in length, but its size not much less than that of the Thoracic Duct.

It is formed by Lymphatics from the right side of the Liver, Diaphragm, Heart, and the right Lobe of the Lungs, by those of the right Arm, right side of the Head, Neck, and Thyroid Gland; the Lymphatics of the left side of the Thyroid Gland forming a Trunk which ends in the Thoracic Duct.

Besides this Common Termination, some of these Lymphatics occasionally open into the Internal Jugular, or into the Subclavian Vein, at a little distance from the Angle formed by these two Veins.

TABLE



Fig. 1.

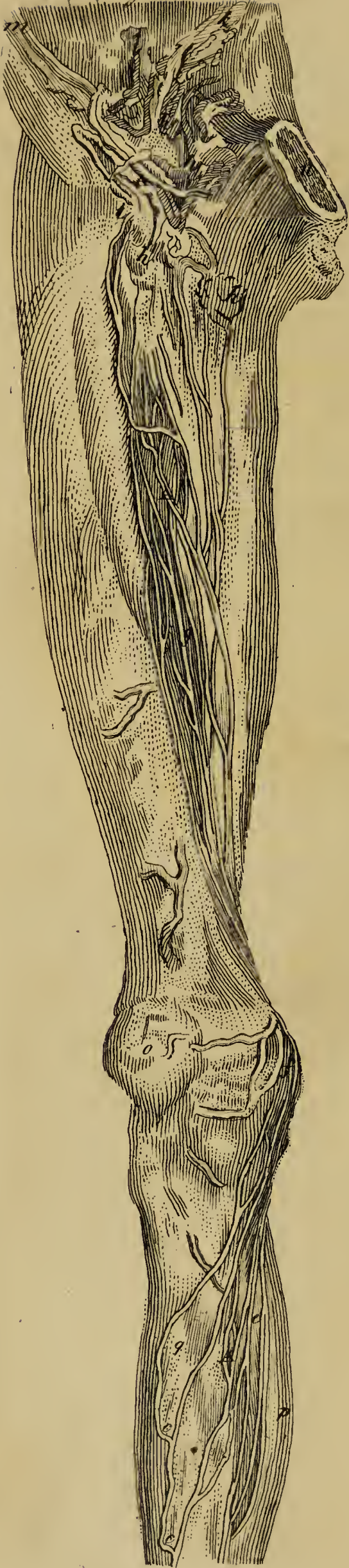

Fig. 2.

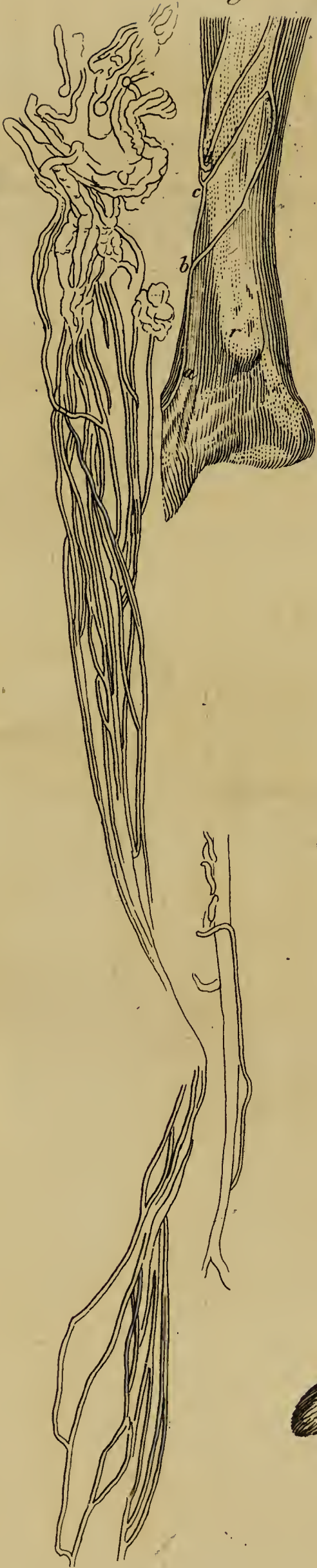


Fig. 3.

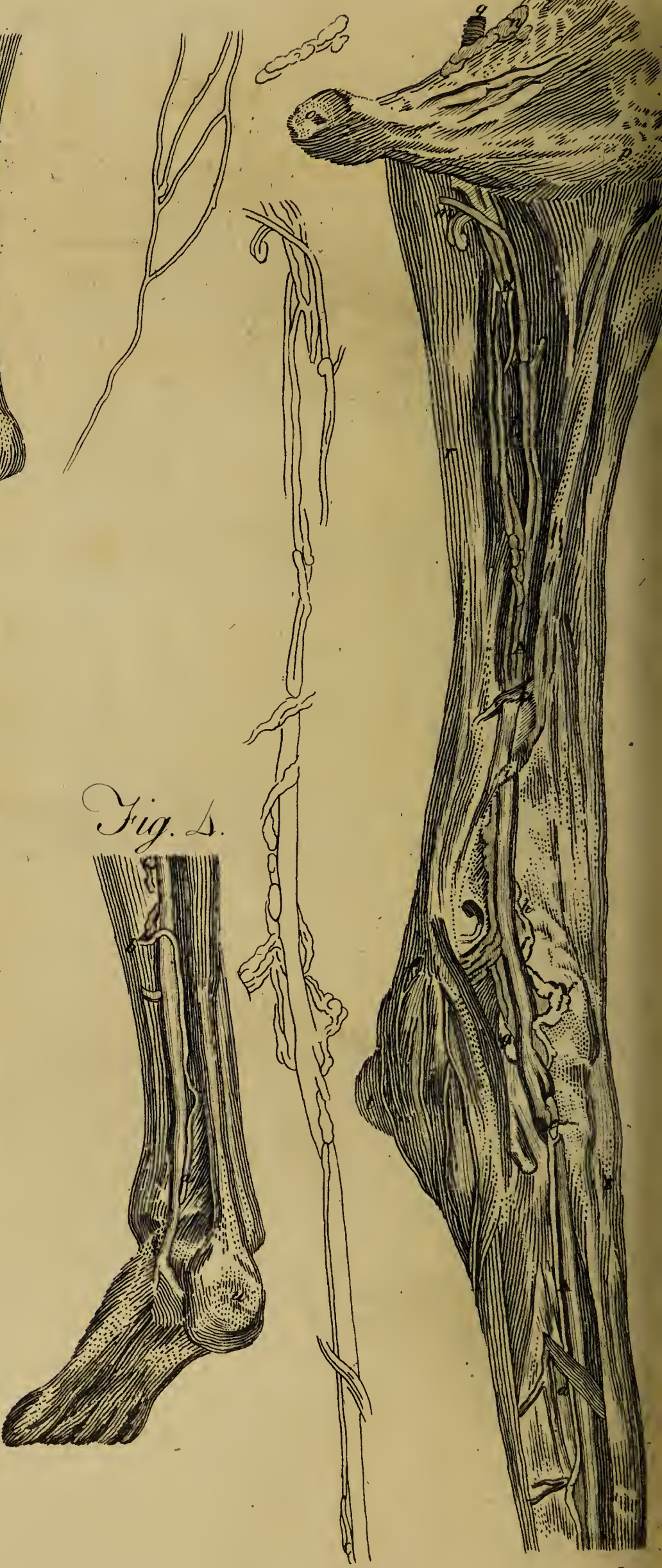
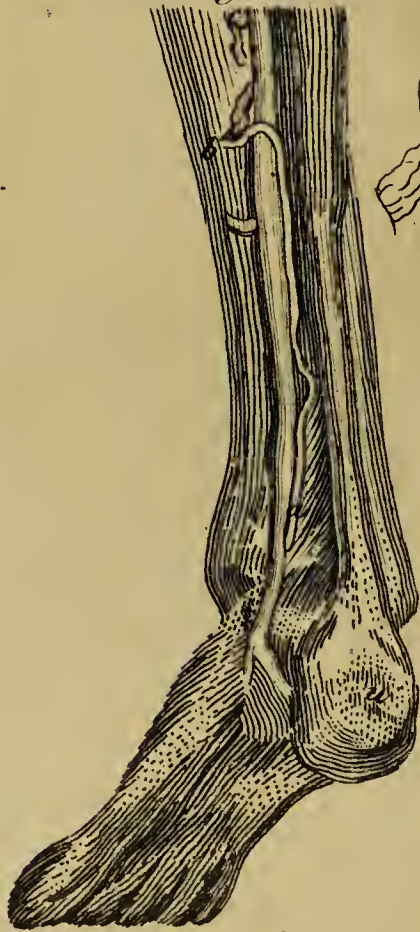
Fig. 4.



T A B L E CLX.

Represents some of the Principal TRUNKS of the LYMPHATICS of the INFERIOR EXTREMITY.

FIG. 1. & 2.

The SUPERFICIAL or SUBCUTANEOUS LYMPHATICS of the Inner and Fore-part of the RIGHT INFERIOR EXTREMITY.

- A, A, A, The general course of the lymphatics upon this part of the extremity.
a, A lymphatic upon the top of the foot;
b, Its division into branches.
c, c, c, Other divisions of this lymphatic.
d, A small lymphatic gland observed in the subject from which this figure was taken.
e, A plexus from these divisions.
f, The part where the injection had stopped in some of the lymphatics.—See the corresponding outlines.
g, The lymphatic vessels from the inner side of the knee, forming a plexus upon the thigh.
h, h, h, The lymphatic glands of the groin.
i, A lymphatic which passes the lowest glands, and enters a gland higher situated.
k, A plexus of lymphatics at the inside of,
l, The iliac artery.
m, The spine of the os ilium.
n, The os pubis.
o, The patella.
p, The gastrocnemius muscle.
q, The tibia.
r, The malleolus internus.

FIG. 3. & 4.

A View of the Deep-seated LYMPHATICS which accompany

the ARTERIES on the Inner and Back part of the INFERIOR EXTREMITY.

- A, A, A, The general course of the lymphatics.
a, A lymphatic vessel accompanying the posterior tibial artery.
b, That vessel crossing the artery.
c, A small lymphatic gland through which the vessel passes.
d, The lymphatic passing under a small part of the soleus which is left attached to the bone.
e, The lymphatic crossing the popliteal artery.
f, g, h, The popliteal gland through which the lymphatic vessel passes.
i, The lymphatic vessel passing with the crural artery through the perforation of the triceps magnus muscle.
k, The lymphatic vessel now dividing into branches, which embrace,
l, The crural artery.
m, A lymphatic gland belonging to the deep-seated lymphatic vessels.—Here the deep-seated vessels pass to the groin, where they communicate with the superficial lymphatics.
n, A superficial lymphatic upon the brim of the pelvis.
o, The os pubis.
p, The tuberosity of the os ischium.
q, The iliac artery.
r, The gracilis muscle.
s, The gastrocnemius and soleus, much shrunk by being dried.
t, The patella.
u, The os calcis.

T A B L E CLXI.

Gives a VIEW of the SUPERFICIAL LYMPHATICS of the INFERIOR EXTREMITY, the INTEGUMENTS being dissected and turned to each side.

FIG. 1.

A View of the LYMPHATICS on the Inside of the FOOT and LEG.

A, A, The vena SAPHENA major.

FIG. 2.

A View of the LYMPHATICS on the Inside of the KNEE and

THIGH;—*the whole tending upwards to the Inguinal Glands, A, A, A, A, through which they pass.*

B, B, The continuation of the vena SAPHENA major.

FIG. 3.

The Lymphatics on the outside of the Leg, one part of them passing over the Tibia to the inside of the Knee, the other going outwards to the Glandula Poplitea.

TABLE



Fig. 2.

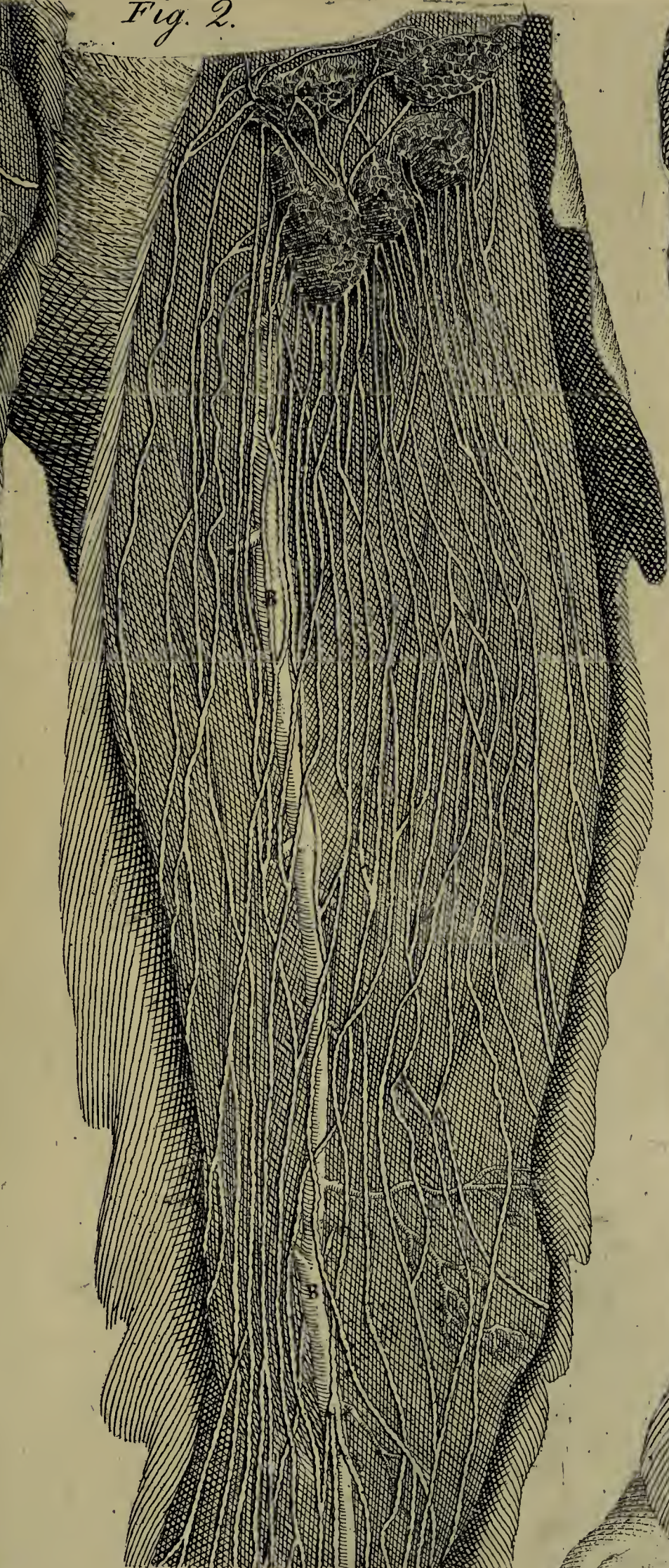
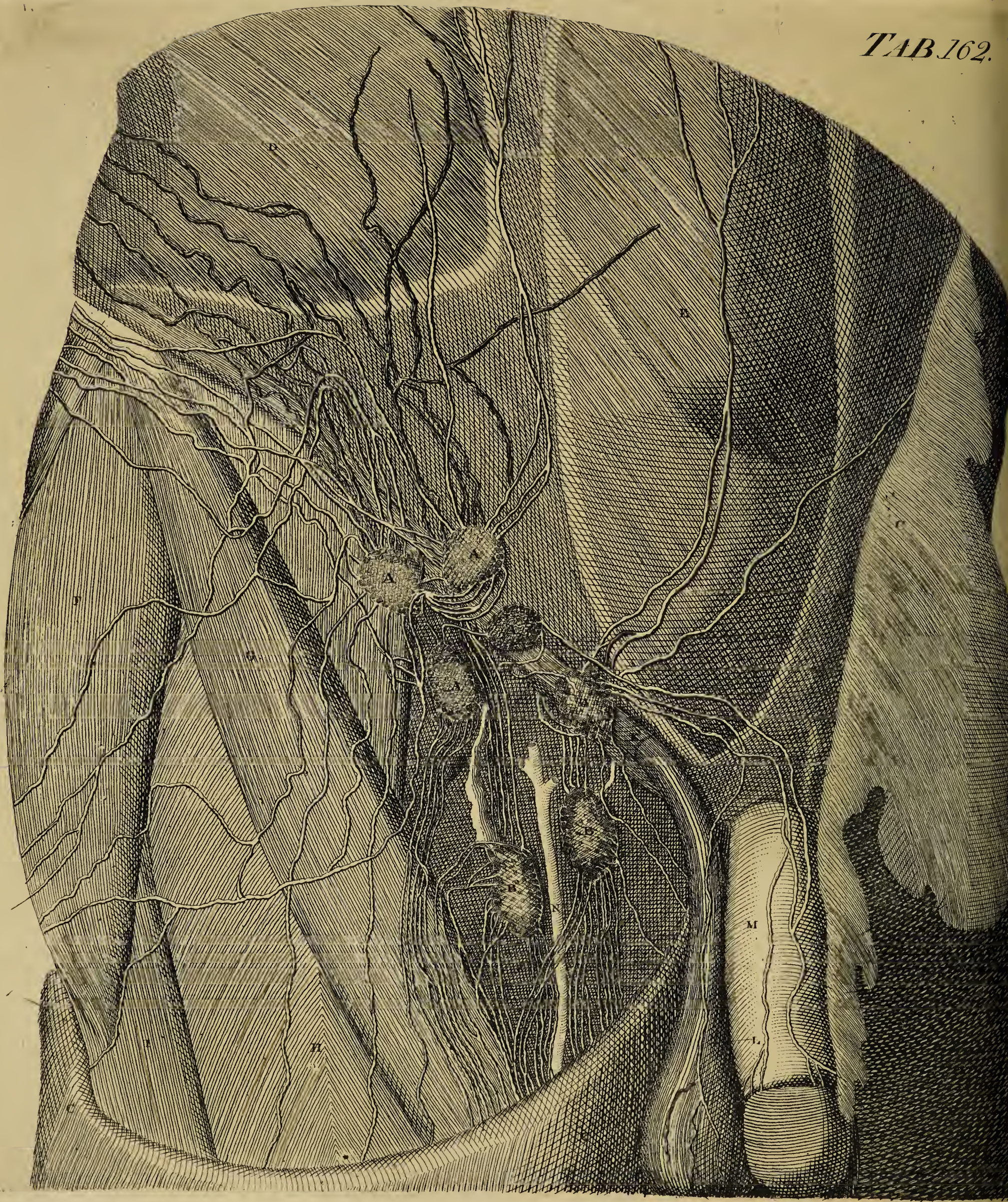


Fig. 3.



TAB.
161.



T A B L E CLXII.

Exhibits the GROIN and adjacent PARTS, with the INTEGUMENTS turned aside, to shew the
SUPERFICIAL LYMPHATICS.

- A, A, &c. The superior inguinal glands.
 B, B, The inferior inguinal, or femoral glands.
 C, C, The integuments turned back.
 D, The external oblique muscle of the abdomen.
 E, The tendon of the external oblique over the rectus muscle.
 F, The tensor vaginae femoris.
 G, The sartorius.
 H, The rectus femoris.
 I, The vastus externus.
 K, The ring of the external oblique muscle.
 L, The cremaster muscle.
 M, The penis.
 N, A subcutaneous vein.

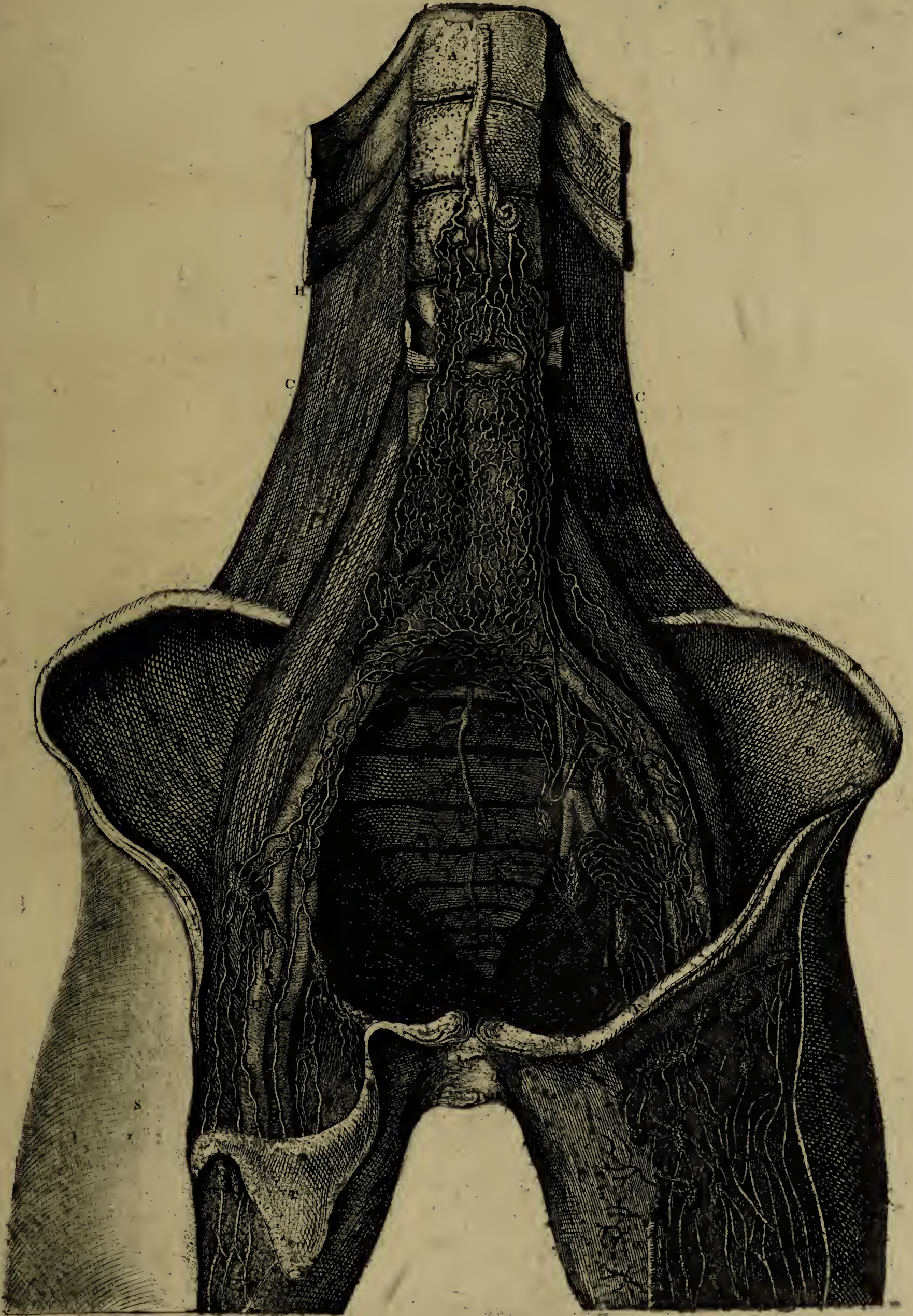The Lymphatics, in this Figure, are seen running from the Penis to the Superior Inguinal Glands;—from the Tunica Vaginalis Testis to the same Glands;—from the fore and inner part of the Thigh, partly to the superior, but chiefly to the inferior Inguinal Glands; some of the vessels passing the first set of Glands, and entering the second. From the Inferior they pass to the Superior Glands. From the outer and lateral parts of the Pelvis, the Absorbents are seen running into the Superior Inguinal Glands. From the superficial and lower parts of the Abdomen, they go to the superior Glands. From the different Inguinal Glands they pass behind *POUPART'S Ligament*, in their way to the Loins.

T A B L E CLXIII.

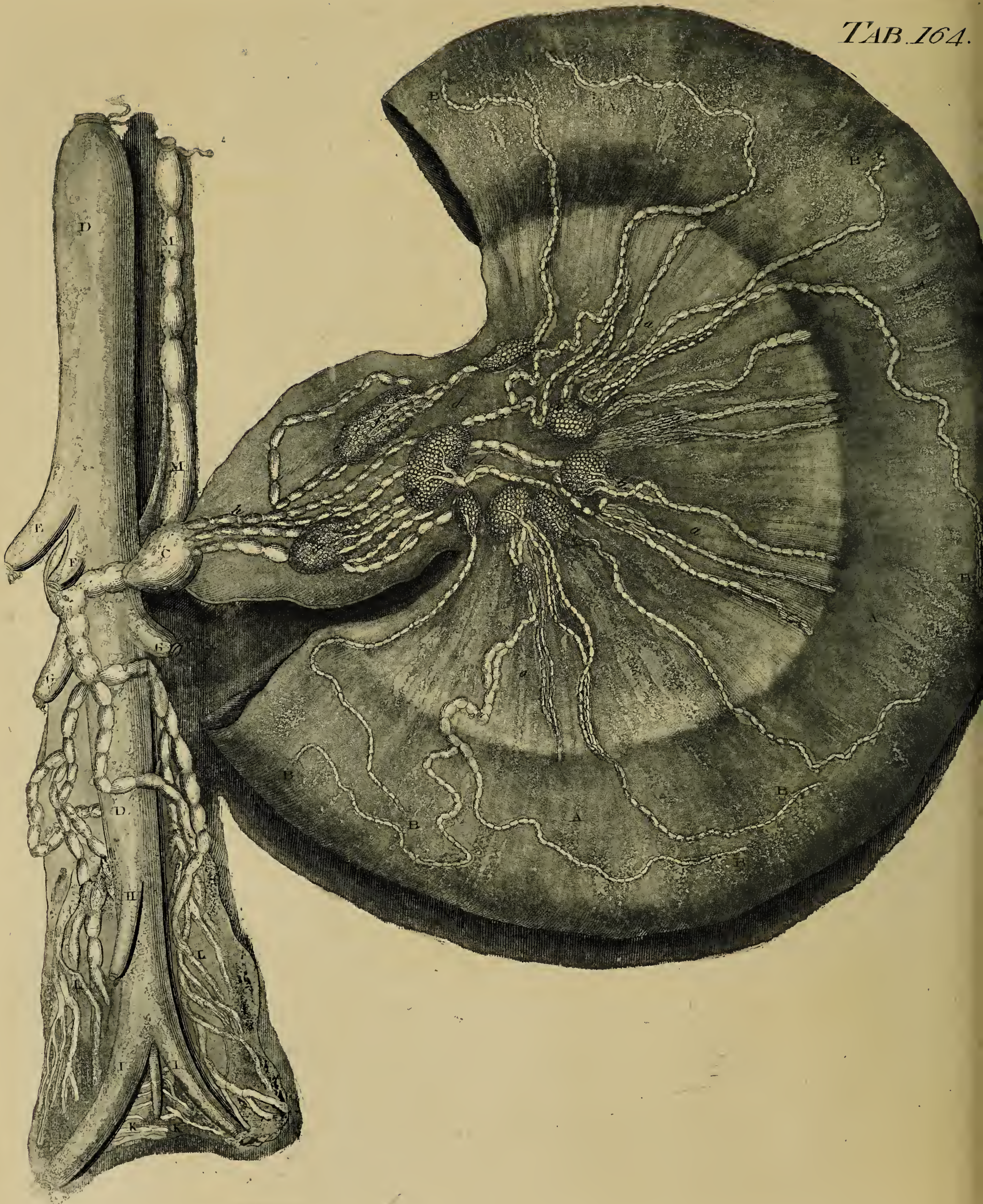
A PORTION of the Under Part of the TRUNK, and the Upper Part of the INFERIOR EXTREMITIES, on which are shewn the Ascent of the LYMPHATIC VESSELS, and their Termination in the beginning of the THORACIC DUCT.

- A, The eleventh dorsal vertebra.
 B, ————— rib of the left side.
 C, C, The muscoli quadrati lumborum.
 D, D, The psoas muscle of each side.
 E, E, The iliaci interni.
 F, A section of the aorta, below the superior mesenteric artery.
 G, ————— vena cava, a little above its origin.
 H, H, The crura of the diaphragm turned outwards.
 I, K, The os sacrum.
 L, L, The left common iliac artery.
 M, The left iliac vein.
 N, The left external iliac artery, pulled a little outwards, to obtain a view of the parts behind it.
 O, The left internal iliac artery.
 P, The nervus obturatorius.
 Q, The right external iliac, or beginning of the femoral artery.
 R, The corresponding vein.
 S, S, The skin of the right and left thigh.
 T, Part of the aponeurosis, with *POUPART'S Ligament* dissected and turned aside, to obtain a view of the lymphatic vessels which enter the pelvis under the fascia lata on the side of the crural vessels.
 U, U, The fascia lata.
 V, *POUPART'S Ligament*.
 W, The vena saphæna.
 a, a, The inferior inguinal glands, which receive the ascending lymphatic vessels.
 b, b, The superior inguinal glands, contiguous to *POUPART'S Ligament*, of which some are anterior, others exterior.
 c, c, The superficial lymphatic vessels ascending from the anterior and inner region of the thigh.
 d, d, The deep-seated lymphatics of the right thigh filled by anastomosis of the superficial ones.
 e, The internal lymphatic trunks.
 f, The external trunks.
 g, The internal lymphatic vessels, or those which descend from the interior inguinal glands to the pelvis.
 h, The external lymphatic vessels, or those which ascend through the pelvis from the exterior glands, according to the length of the external iliac artery.
 i, i, i, Glands which both the internal and external lymphatics penetrate.
 k, The plexus lymphaticus obturatorius.
 l, The plexus ischiaticus.
 m, The lymphatic vessels arising from the exterior trunks and glands, and inserted, on the other side of the external iliac artery and vein, into the internal iliac plexus.
 n, The plexus hypogastricus.
 o, The plexus lumbaris, partly glandular, partly vascular.
 p, The beginning of the thoracic duct, situated before the bodies of the first and second lumbar vertebræ.
 q, q, Two trunks which ascend from the lumbar plexus to increase the thoracic duct.
 r, The thoracic duct ascending before the bodies of the twelfth and eleventh dorsal vertebræ.

TAB. 163.







T A B L E CLXIV.

Gives a VIEW of the LACTEAL VESSELS, and of their Termination in the THORACIC DUCT.

-
- A, A, &c. A portion of the intestine, with its mesentery.
 B, B, &c. The beginnings of the lacteal trunks, tied at the points into which the injected tube had been inserted.
 a, a, a, The continuation of these trunks, before they reach any glands.
 b, b, The vasa inferentia, passing to,
 c, c, The first set of mesenteric glands.
 d, d, The vasa efferentia, passing from the first to,
 e, e, The second set of mesenteric glands.
 f, An oblong mesenteric gland, with a single lacteal passing into it.
 g, A gland, with several lacteals entering it.
 h, Lacteal trunks passing from the mesenteric glands to,
 C, The receptaculum chyli, in which the lacteals terminate.
 D, D, The trunk of the aorta,
 E, The trunk of the cœliac artery, immediately below the diaphragm.
 F, The trunk of the superior mesenteric artery.
 G, G, The trunks of the emulgent or renal arteries, near which the lacteals fall into the receptaculum chyli.
 H, The trunk of the inferior mesenteric artery.
 I, I, The common iliac arteries, which divide nearly opposite to the last lumbar vertebra.
 K, K, A plexus of lymphatics.
 L, L, Lymphatics ascending from the inferior extremities, in their way to the receptaculum chyli.
 M, M, The thoracic duct ascending in the course of the spine.
- N. B. *This Figure, owing to the inadvertency of the Engraver, is reversed.*

TABLE

T A B L E CLXV. AND CLXVI.

Represent PORTIONS of the SMALL INTESTINES and MESENTERY, with the LACTEAL VESSELS and MESENTERIC GLANDS injected with Quick-silver and Wax.—They were considerably dilated, probably by having been included within a Herniary Sac.

T A B L E CLXV.

FIG. 1.

A considerable Portion of the SMALL INTESTINES and MESENTERY, with the LACTEAL VESSELS and MESENTERIC GLANDS injected with Quick-silver, nearly to the part where they terminate in the THORACIC DUCT.

- A, A, A, Sections of the small intestines.
- B, B, B, The mesentery.
- C, C, The root of the mesentery, or that part of it which is joined to the spine.
- D, D, D, The lacteal vessels in their way from the intestines to,
- E, E, &c. The first set of glands.
- F, F, The second set of glands.

Between D, D, D, E, E, &c. and F, F, are seen the numberless valves and communications of the lacteal ves-

sels with each other, their minute subdivisions, entrance into, passage through, and exit from, the different mesenteric glands.

FIG. 2. 3. 4. 5.

Other Small Portions of the Intestines and Mesentery, with their Lacteals also injected with Quick-silver.

FIG. 6.

A SECTION of the SMALL INTESTINES, with its BLOOD-VESSELS injected with Wax, and LACTEALS with Quick-silver.

- A, A branch of an artery.
- B, ————— a red vein.
- C, A lacteal vessel.

Fig. 2.

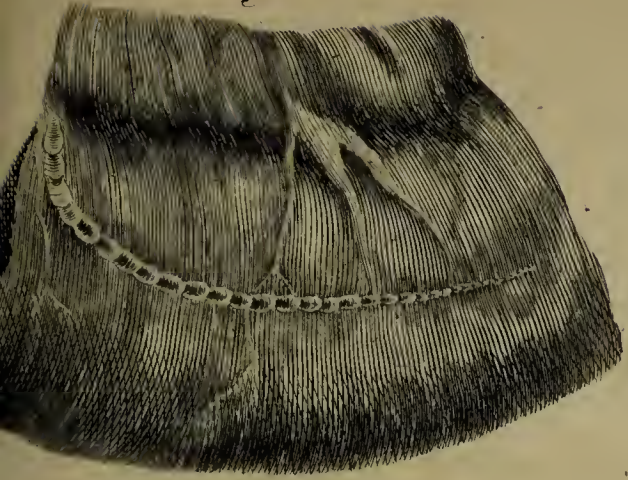

Fig. 3.



TAB 165.

Fig. 6.



Fig. 1.

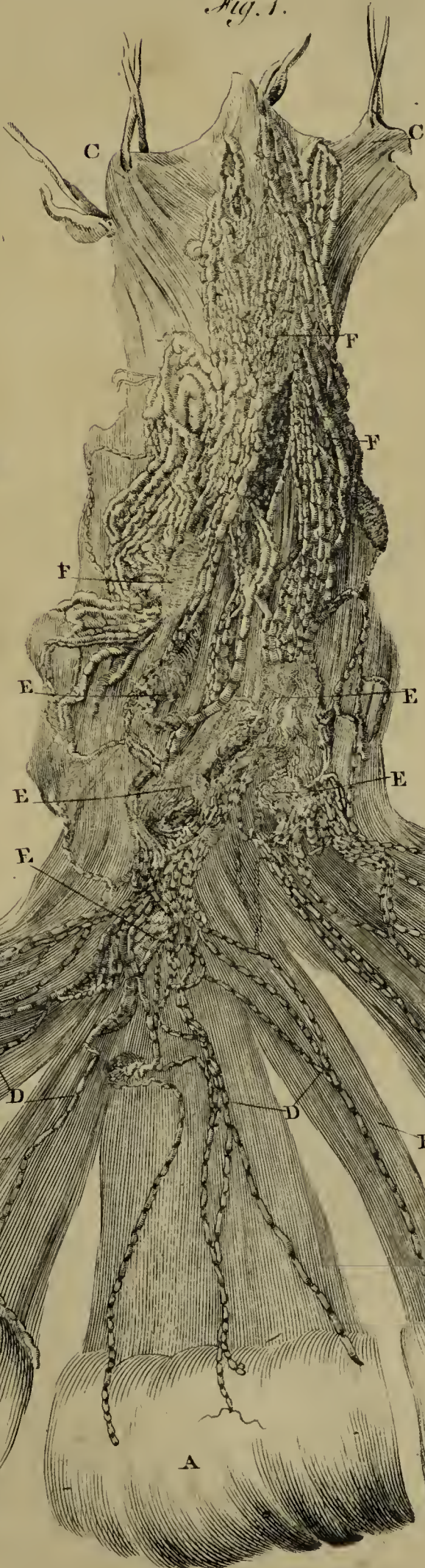
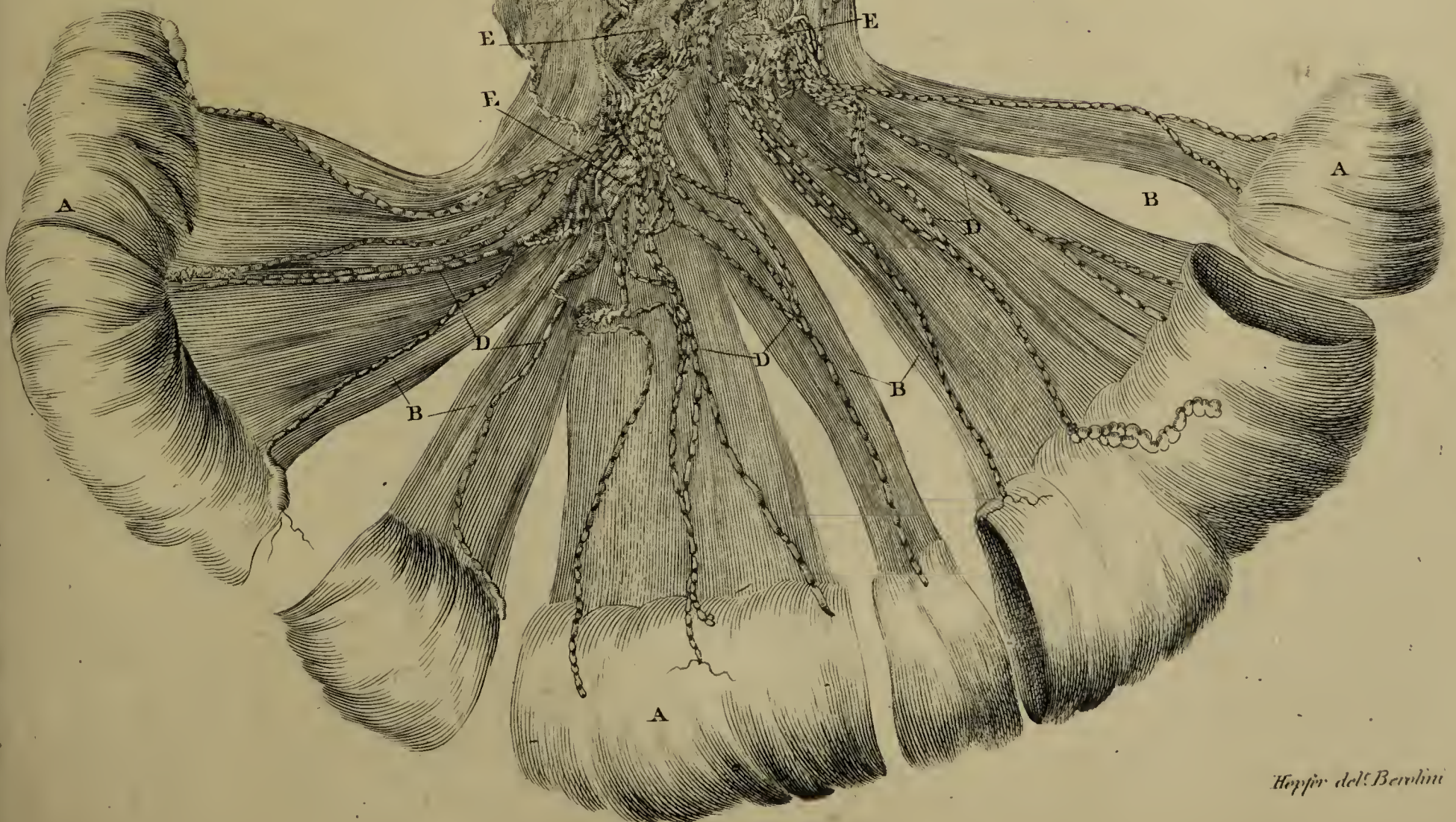
Fig. 4.




Fig. 5.



TAB. 766.

Fig. 6.

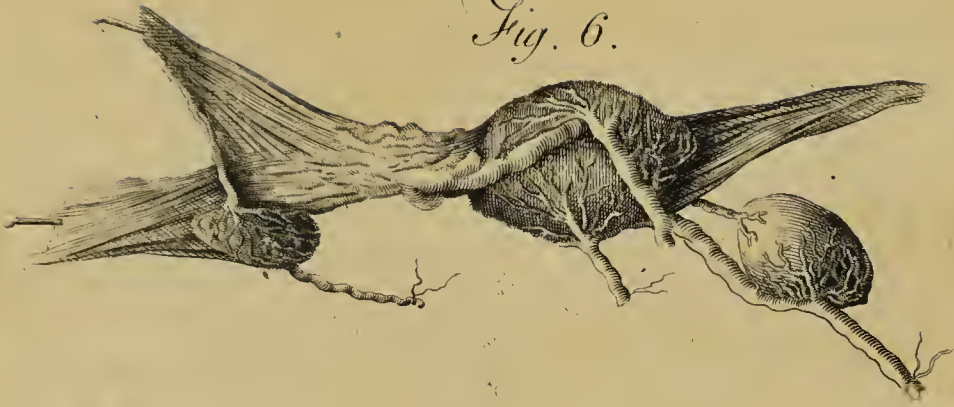

Fig. 1.

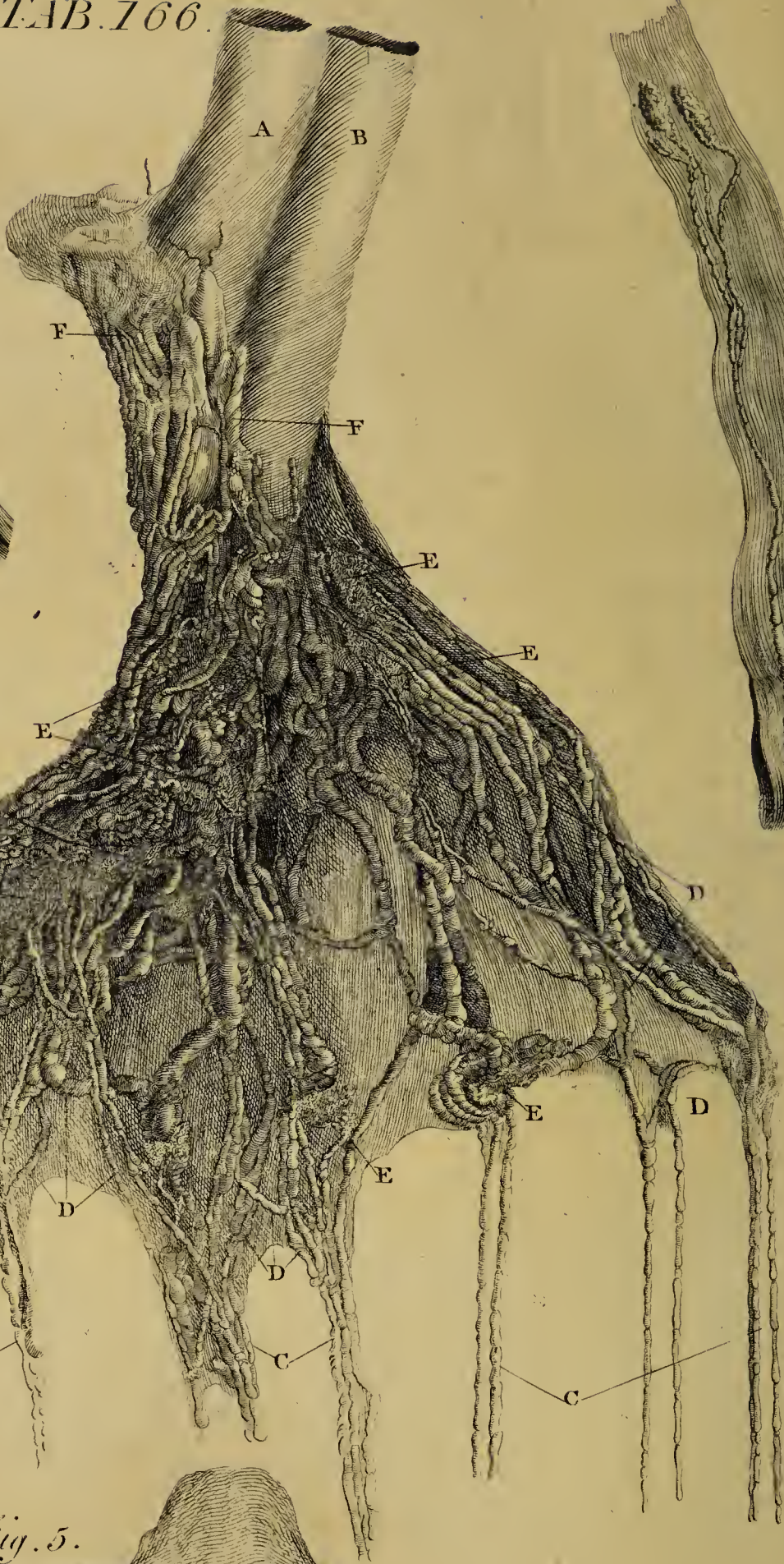


Fig. 3.

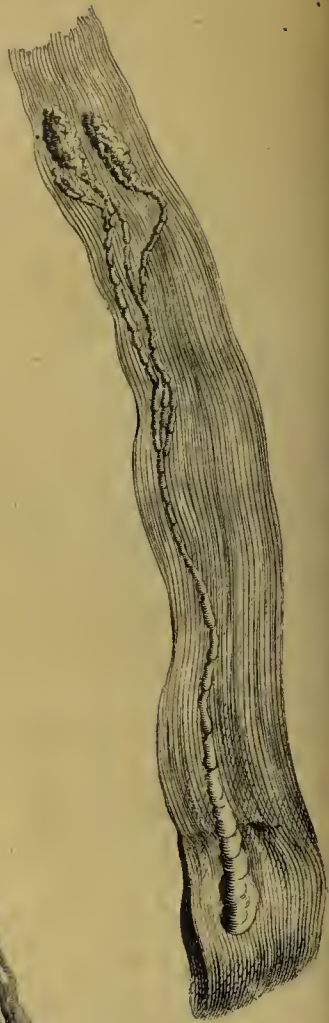

Fig. 2.

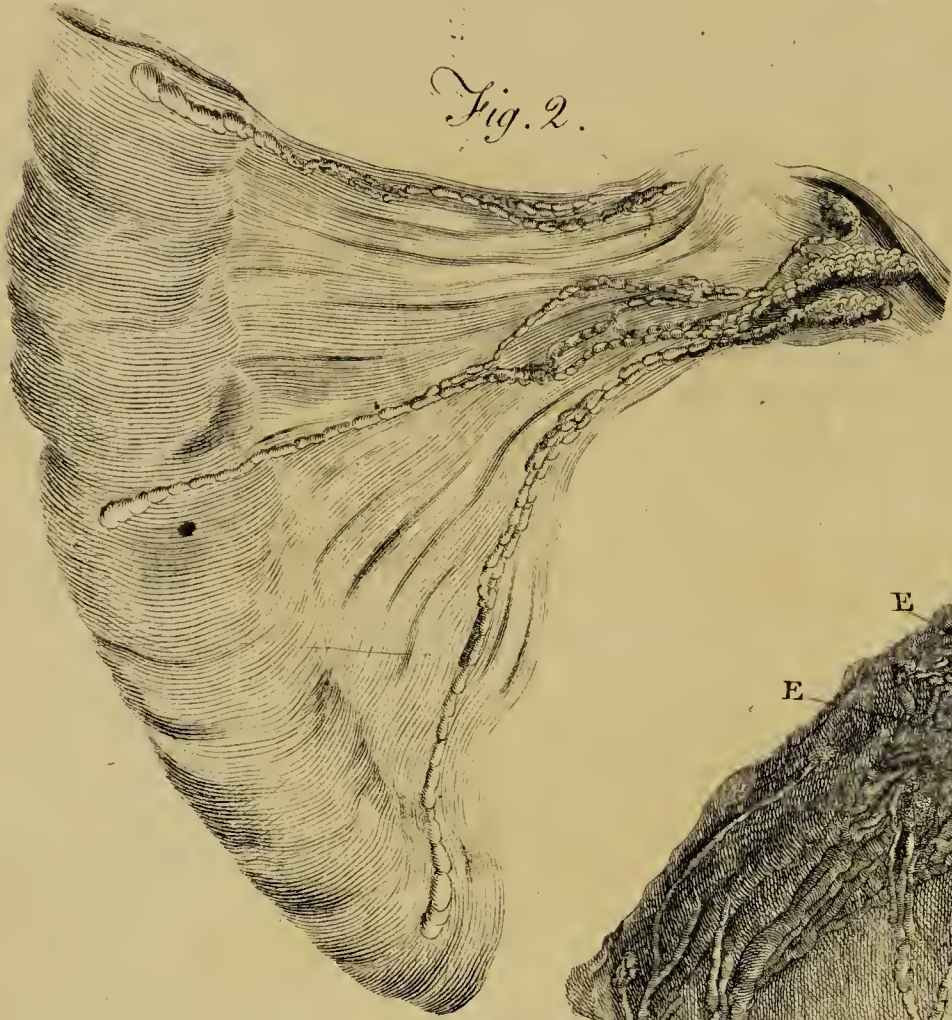

Fig. 4.

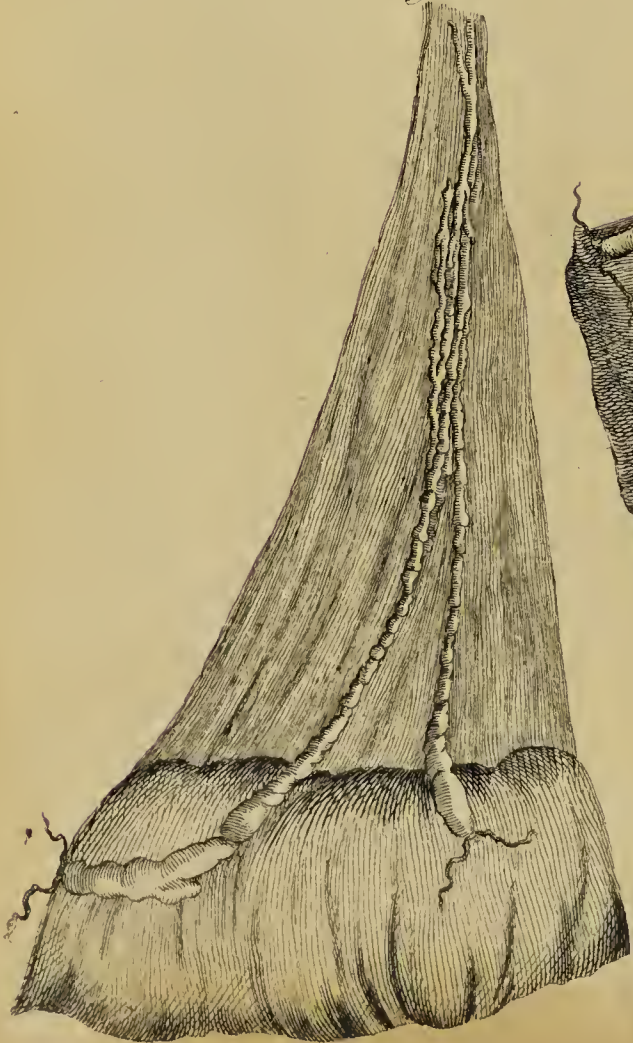
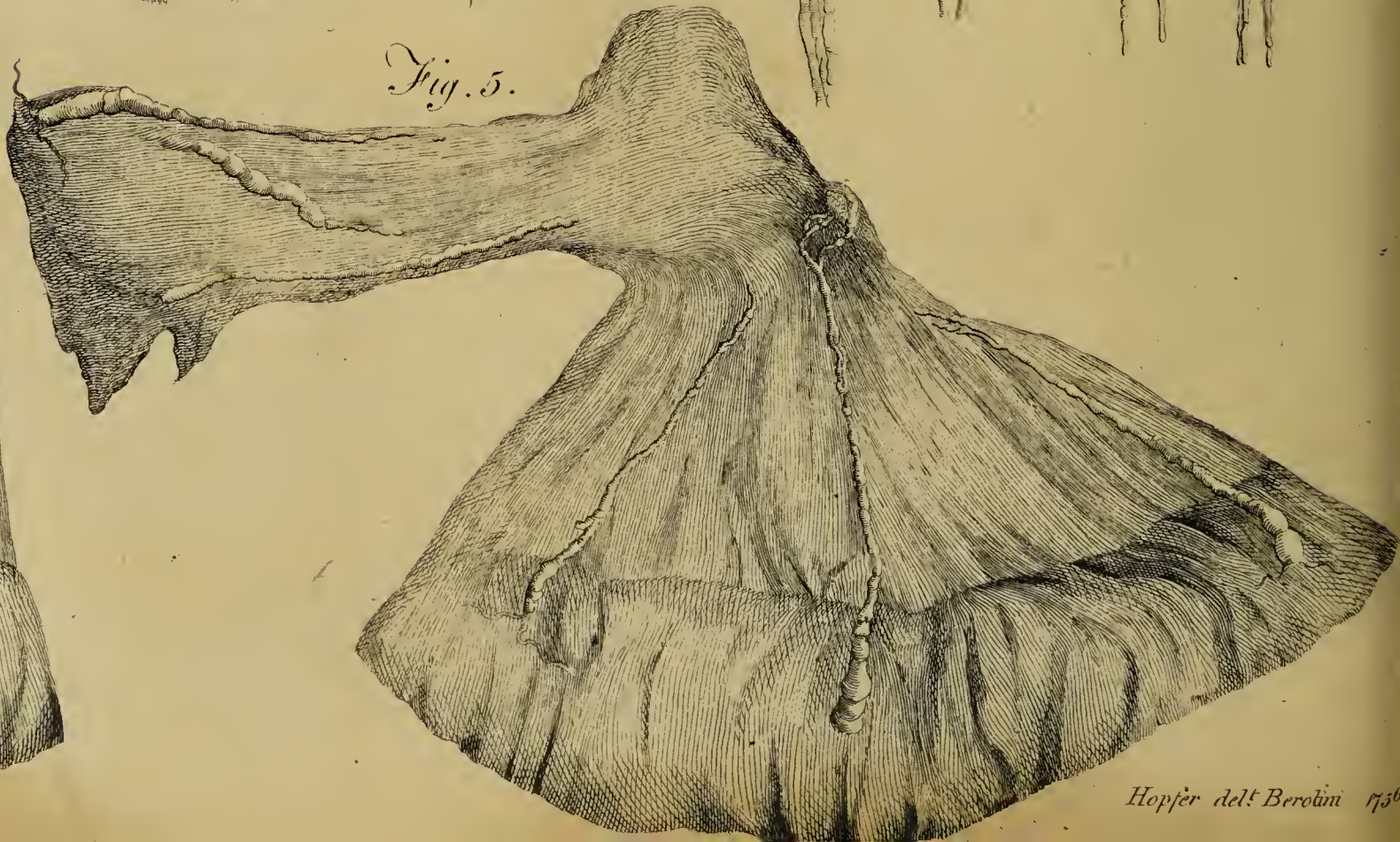

Fig. 5.



T A B L E CLXVI.

Gives VIEWS somewhat similar to those exhibited in the former TABLE.

FIG. 1.

Represents a large Portion of the MESENTERY, with the LACTEAL VESSELS and MESENTERIC GLANDS, after an Injection with Quick-silver.

A, The mesenteric artery.

B, ———— vein.

C, C, &c. Lacteals broken off from the intestine and mesentery, in consequence of having been long kept and frequently agitated in spirits.

D, D, D, Numberless anastomoses of the lacteals with each other, in their course upon the mesentery.

E, E, &c. Their entrance into, and passage through the mesenteric glands.

F, F, Their continuation along the trunks of the mesenteric artery and vein.

FIG. 2. 3. 4. & 5.

Portions of the SMALL INTESTINE and MESENTERY, with some LACTEAL VESSELS and GLANDS injected with Wax.

FIG. 6.

ABSORBENT LYMPHATIC VESSELS and GLANDS injected with Wax and Quick-silver.

T A B L E

T A B L E CLXVII.

FIG. 1.

Represents Part of the **INTESTINUM JEJUNUM**, *with its* **BLOOD-VESSELS, LACTEALS, and MESENTERIC GLANDS.**

- a, a,* The mesentery, the superior lamina of which is removed, and the inferior left, on which appear the mesenteric glands,—distinguished by some into glands of the first, second, and third order,—with the blood-vessels and lacteals.
- b, b,* Glands of the first,
- c, c,* ————— second,
- d, d,* ————— third order.
- e,* The superior mesenteric artery, with the mesenteric branches, and those which are distributed to the coats of the intestines.
- f,* The superior mesenteric vein.
- g, g,* A somewhat long and oval arch of the lacteal vessels.
- h, h,* Lacteal vessels beginning from the intestine. Their course differs from that of the blood-vessels, which run in a more transverse direction. They are divided into trunks, which enter, some of them, the mesenteric glands of the first, some those of the second, and others those of the third order.
- i, i,* Trunks which unite and form the beginning of the thoracic duct.

FIG. 2.

Represents the **EXTERNAL ILIAC ARTERY and VEIN**, *of the*

Natural Size, with the **LYMPHATICS** *situated between these* **VESSELS** *and the* **PSOAS MUSCLE.**

- a,* The external iliac artery.
- b,* ————— vein, drawn somewhat outwards.
- c,* ————— plexus.
- d, d,* The lumbar glands which receive the vessels of the external iliac plexus.
- e,* One of the lymphatic trunks, which ascends from the exterior inguinal glands, in a direct line with the external iliac artery, to the lumbar plexus.
- f,* Lymphatic trunks receiving various branches, inserted into the lumbar plexus.

FIG. 3.

The Course of the **THORACIC DUCT.**

- a,* The first, and,
- b,* The tenth dorsal vertebra.
- c, c,* Portions of the ten superior ribs joined to the vertebræ.
- d, d,* The internal intercostal muscles.
- e,* The ascent of the thoracic duct, in which various divisions and rejoinings appear.
- f, f,* The axillary glands.
- g,* Two large lymphatic trunks, inserted into the arch of the thoracic duct.
- h,* The termination of the duct in the left subclavian vein.

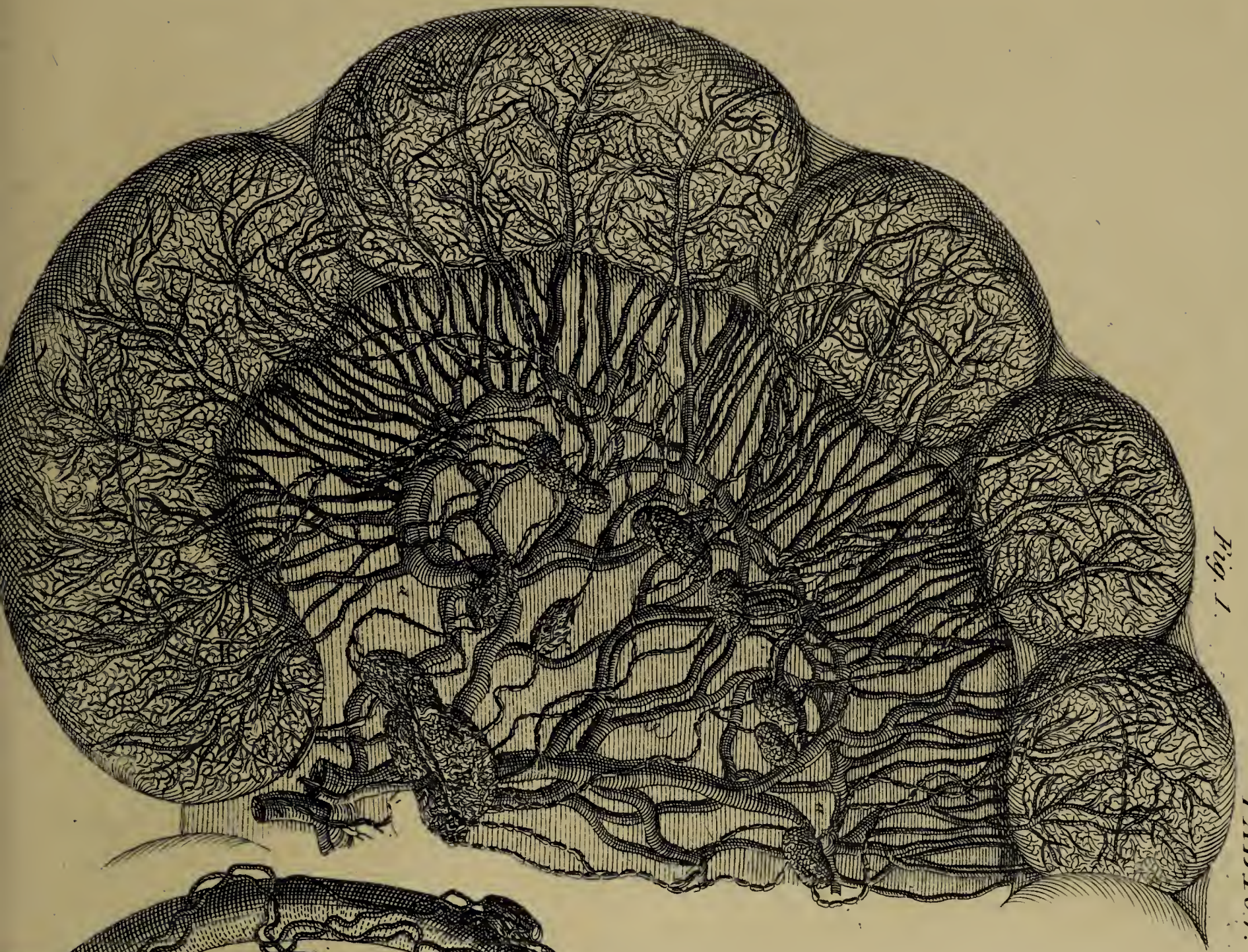

Fig. 1.

TAB. 167.

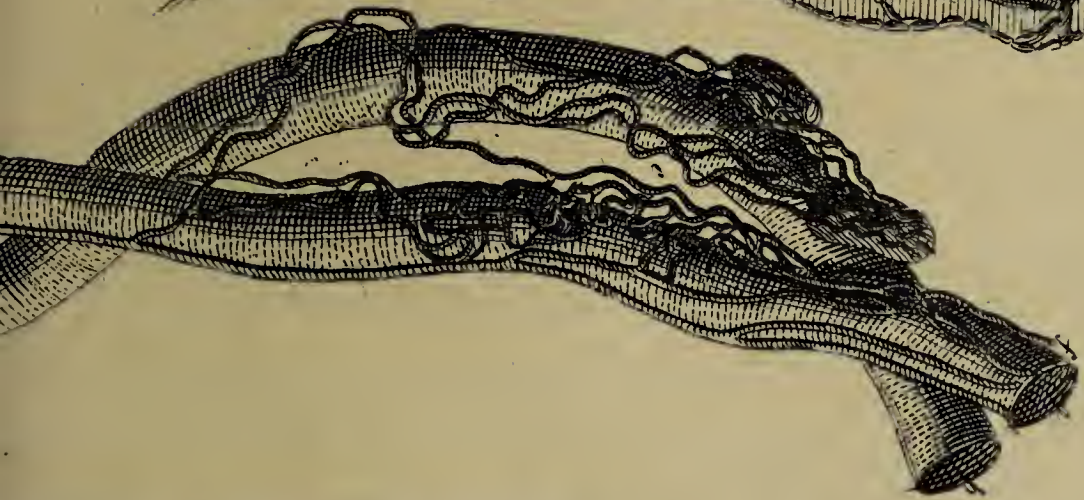

Fig. 2.

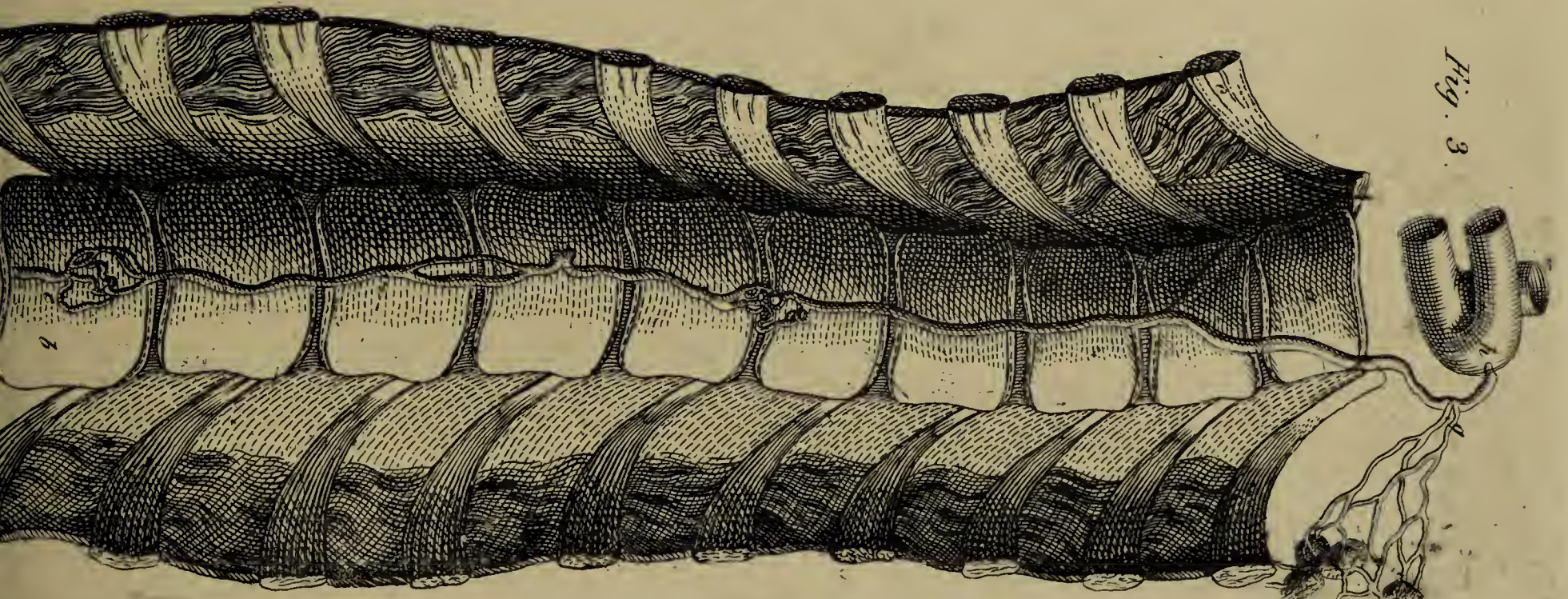


Fig. 3.



Fig. 2.

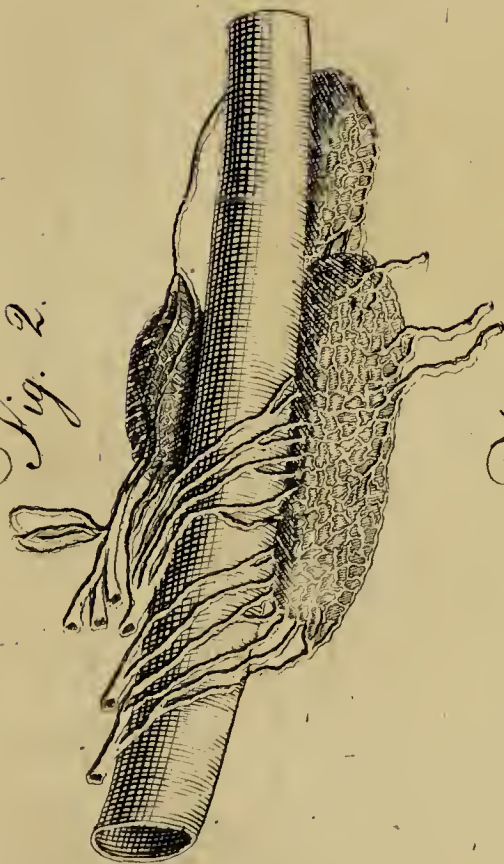
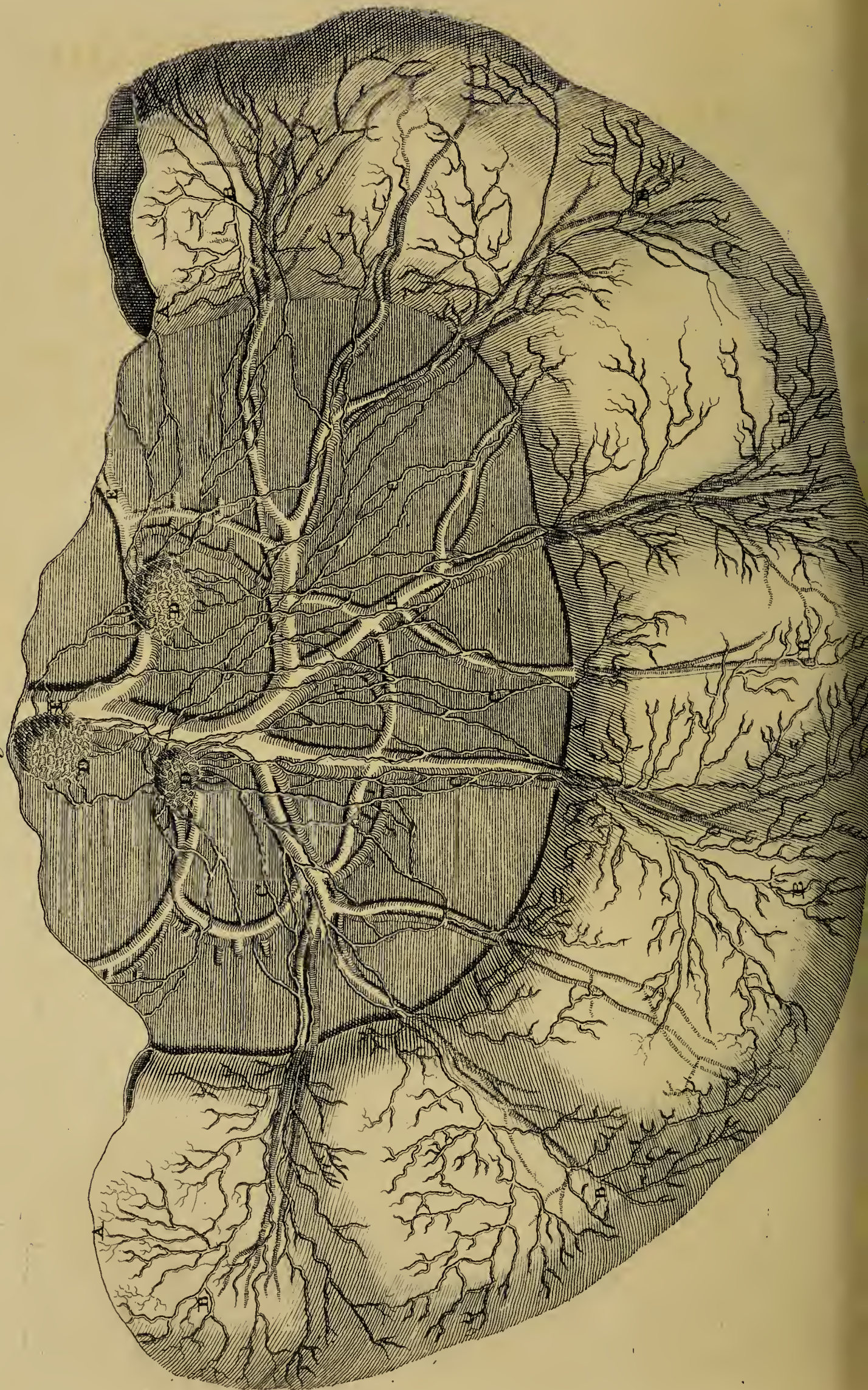

Fig. 1.



T A B L E CLXVIII.

A VIEW of some of the LACTEAL and LYMPHATIC ABSORBENT VESSELS and GLANDS.

FIG. 1.

Shews the LACTEALS of Part of the SMALL INTESTINE.

- A, A, A, A, A portion of the small intestine.
- B, B, &c. The origin of the lacteals from the coats of the intestine.
- C, C, &c. Trunks of the lacteals, variously connecting and separating in their way to the mesenteric glands.

D, D, D, The mesenteric glands, into which the vessels penetrate.

FIG. 2.

Shews Three CONGLOBATE GLANDS, with their VASA INFERENTIA and EFFERENTIA.

T A B L E CLXIX.

FIG. 1.

Represents the LACTEALS at the root of the MESENTERY, and their joining with the LYMPHATICS from the LOWER EXTREMITIES, PELVIS, and ABDOMEN, previous to their Termination in the THORACIC DUCT.

- A, A, A, The root of the mesentery.
- B, The trunk of the superior mesenteric artery.
- C, _____ vein.
- D, D, The kidneys, shrunk in the drying.
- E, The descending aorta, injected with wax.
- F, The inferior vena cava, also injected with wax.
- G, G, The renal veins, the left one passing over the fore-part of the aorta.
- H, The vein of the left renal gland.
- I, The left spermatic vein.
- K, K, The renal arteries.
- L, L, The lacteal vessels of the small and great intestines uniting at the root of the mesentery, and forming a considerable plexus over the trunks of the superior mesenteric artery and vein.
- M, M, Communications between the lacteals and lymphatics of the loins.
- N, N, A plexus of lacteals and lymphatics crossing over the left renal vein, and then passing between the aorta and vena cava inferior, towards the receptacle of the chyle.

O, The union of the absorbents from the inferior extremities, pelvis, and abdomen, previous to their termination in the thoracic duct.

FIG. 2.

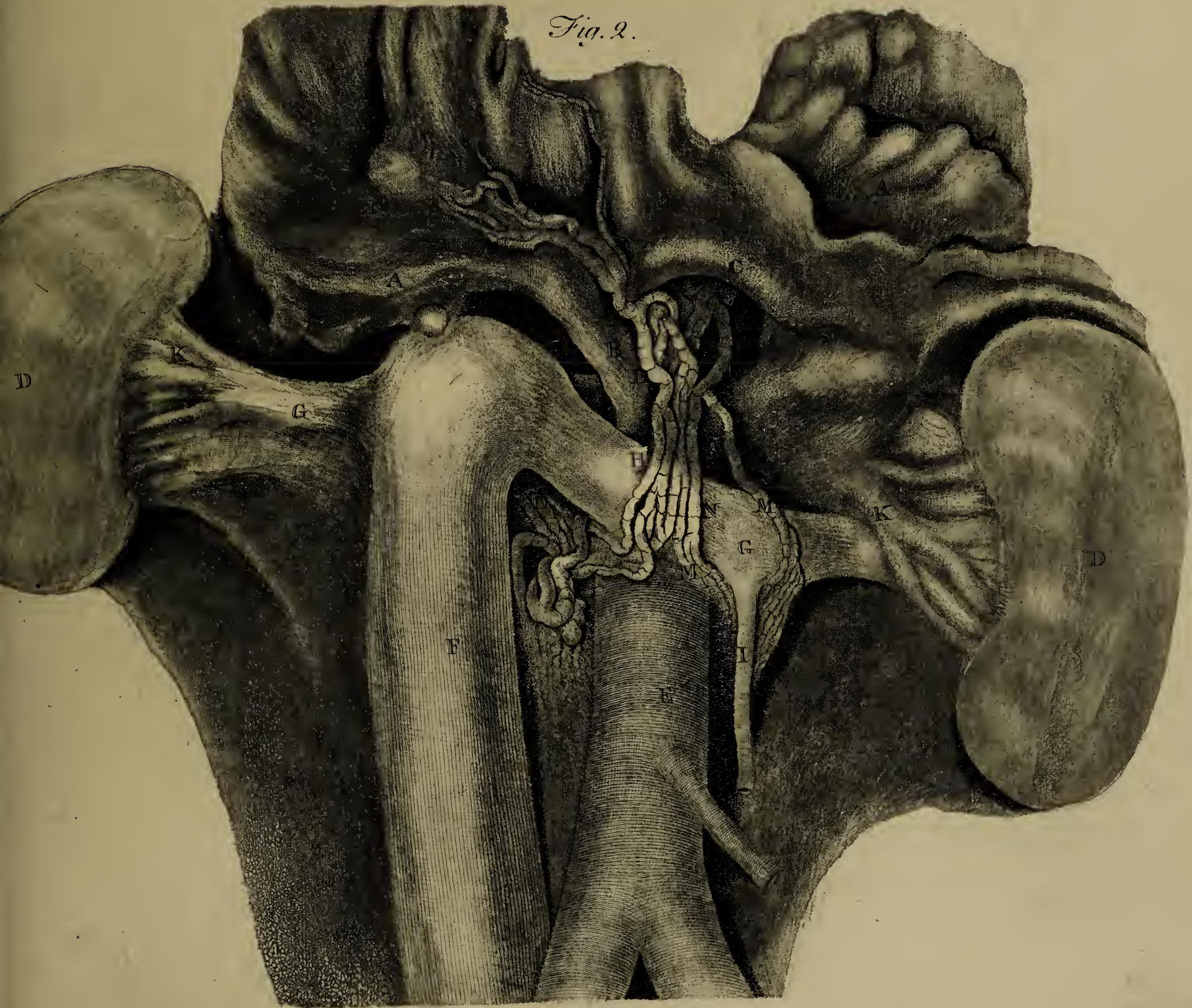
Gives a Posterior View of the joining of the LACTEALS and LYMPHATICS shewn in the preceding Figure, to form the beginning of the THORACIC DUCT, commonly called RECEPTACULUM CHYLI, which is larger than ordinary in this Subject.

- A, The aorta, and,
- B, The vena cava,—obscurely seen in this view, in consequence of being partially covered with cellular substance.
- C, C, The common iliac veins.
- D, The left common iliac artery.
- E, Part of the left iliac plexus of lymphatic vessels and glands.
- F, The principal trunk receiving lymphatic vessels from the inferior extremities, pelvis, and abdomen, terminating in the receptaculum chyli.
- G, A trunk formed by the lacteal vessels, N, N, Fig. 1. also terminating in the receptaculum chyli.
- H, The receptaculum chyli, uncommonly large.

Fig. 1.

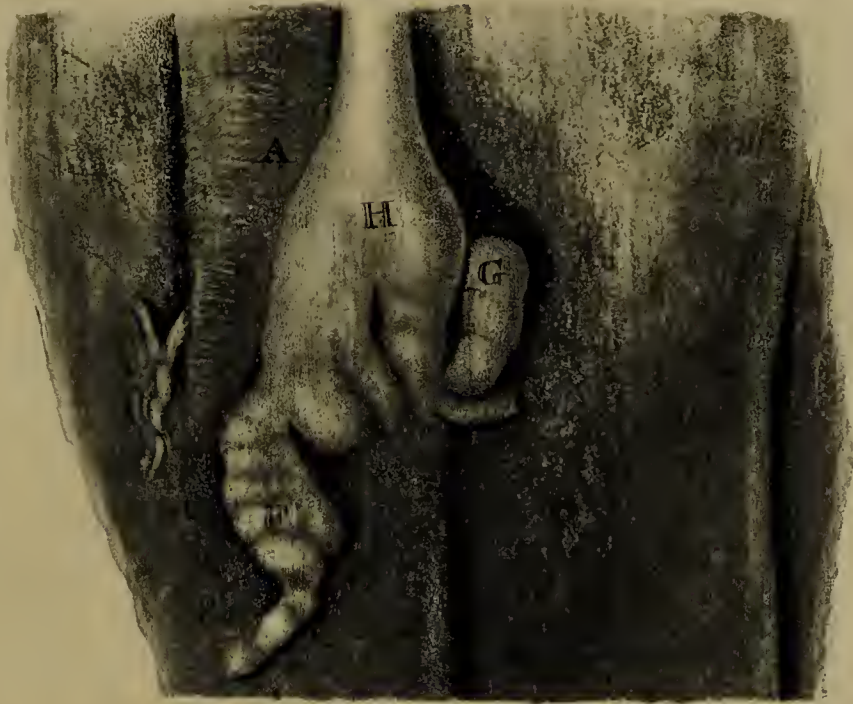

Fig. 2.



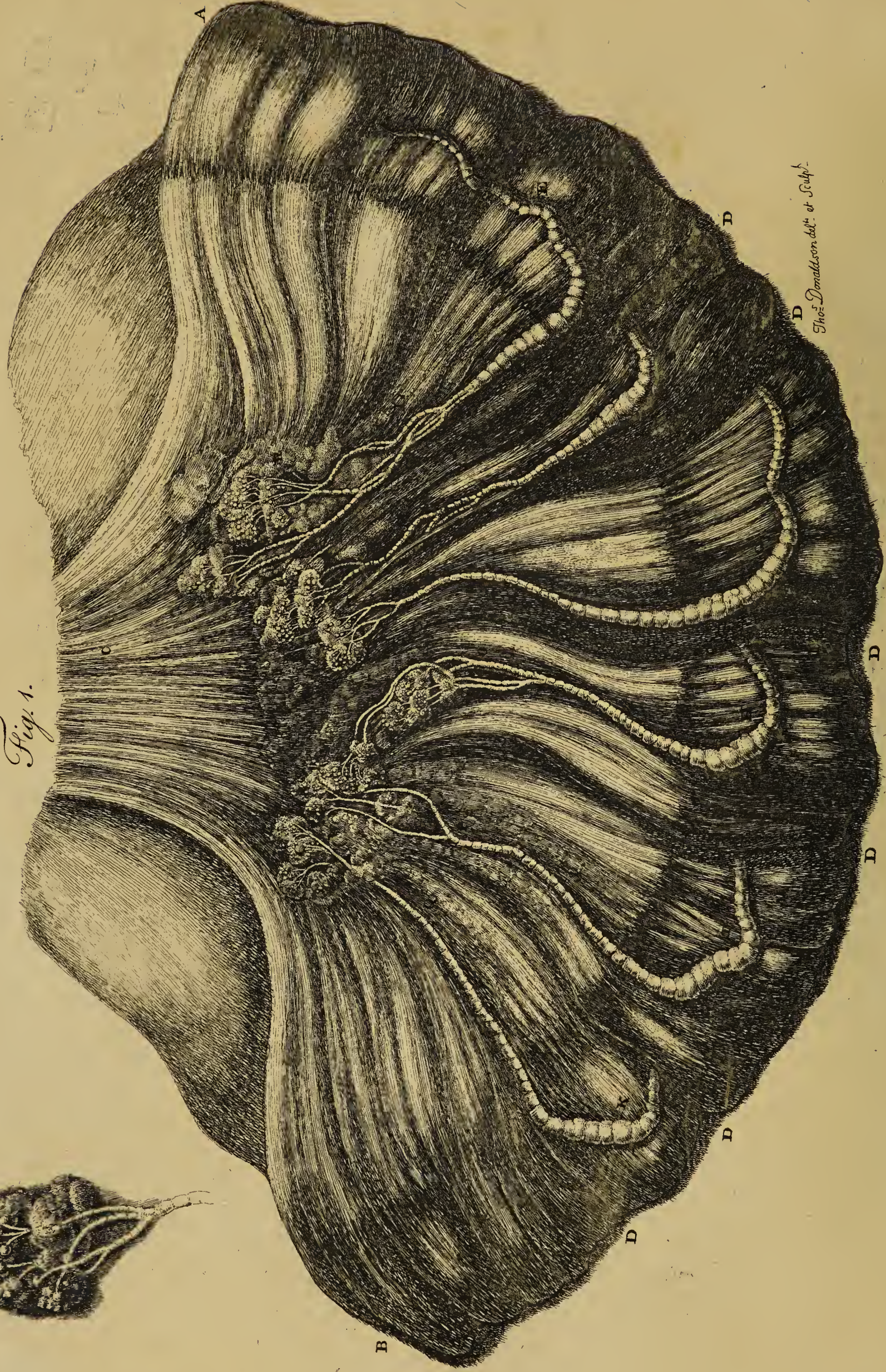


TAB. 172.

Fig. 1.



Fig. 2.



Tho: Donaldson del. et Sculp.

T A B L E CLXX.

FIG. 1.

Gives a View of the JEJUNUM and MESENTERY, in which the LACTEALS, injected with Quick-silver, are seen dilated, or in a Varicose State.—Their VALVES were observed to be thickened, and the Passages between them greatly obstructed.

A, B, The intestinum jejunum collected into folds.

C, The root of the mesentery.

D, D, &c. The great curvature of the intestine.

E, F, G, H, I, K, Varicose lacteals, with numerous joints or pairs of valves.

L, M, N, O, P, Q, The division of the lacteals into branches.

R, S, T, U, V, W, The mesenteric glands, with their lacteals dividing into subordinate branches, previous to their entrance into the glands.—In some places, the lacteals are seen passing into the nearest glands; in others they are observed to go over the nearest, and to terminate upon those more remote from the intestine.

FIG. 2.

One of the MESENTERIC GLANDS, with the LACTEALS entering it, magnified.—The Gland has, in part, a Cellular appearance.

T A B L E CLXXI.

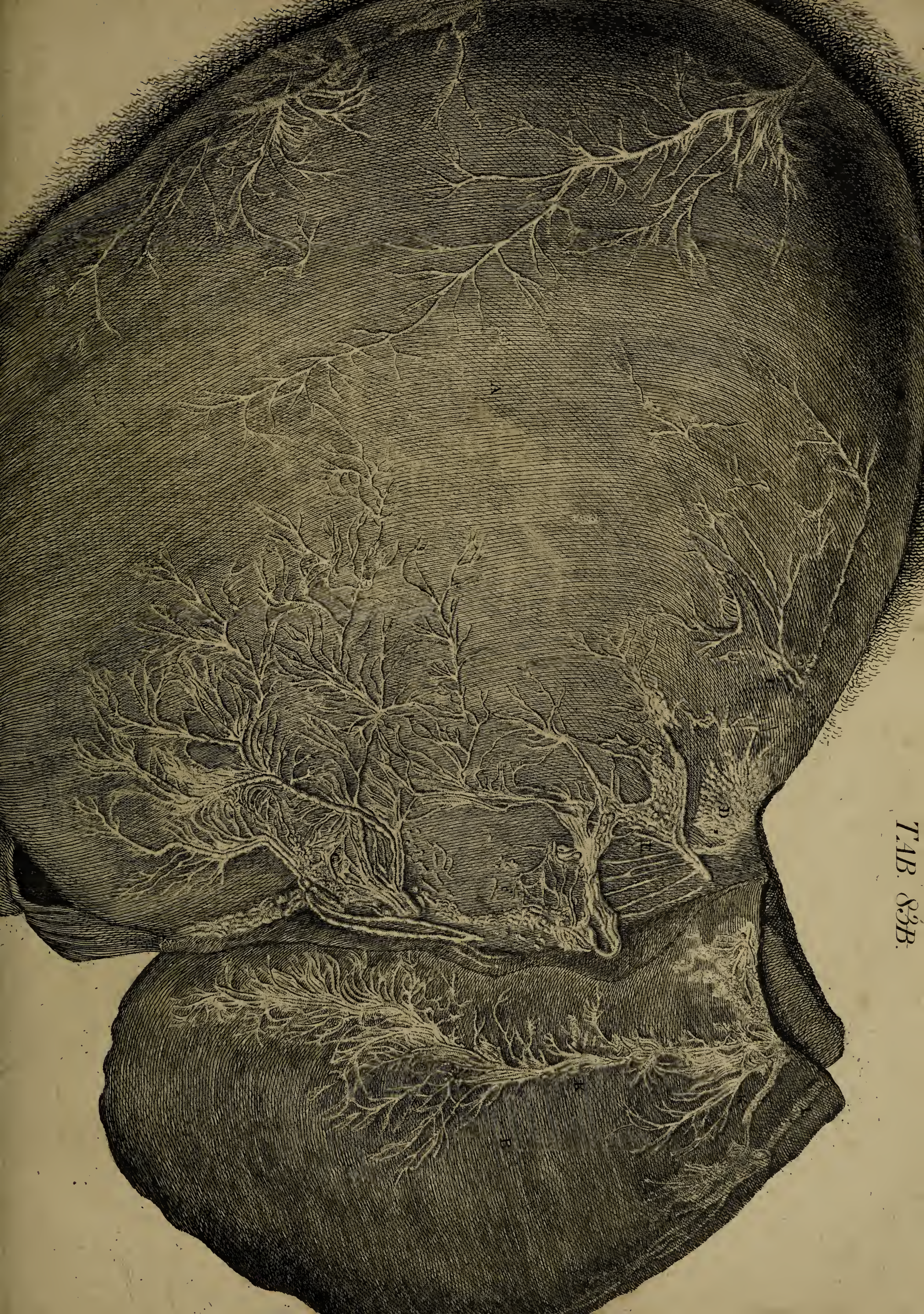LYMPHATICS of the Upper, or CONVEX SURFACE of the LIVER.

- A, The right,
 B, The left lobe of the liver.
 C, D, E, F, G, The lymphatics of the middle of the convex surface of the liver, formed of numerous ramifications, resembling the branchings of a tree, running upon the ligamentum hepatis latum, previous to their termination in the anterior thoracic plexus.
 H, I, Lymphatics in their way towards the right lateral ligament of the liver, to perforate the diaphragm, and assist in forming the anterior thoracic plexus.
 K, K, L, Lymphatics tending towards the left lateral

ligament, also to perforate the diaphragm, and, along with the two other sets, to form the anterior thoracic plexus.

The Lymphatics, in the Preparation from which this Figure was taken, were injected with Quick-silver, from their Trunks towards their Branches.—Immediately after the Injection, the Surface of the Liver was observed to be nearly covered with Lymphatic Vessels, but, in the course of drying the Preparation, many of them disappeared, the injected matter having escaped into the Deep-seated Absorbents.

TABLE



TAB. 83B.



TAB. 172.

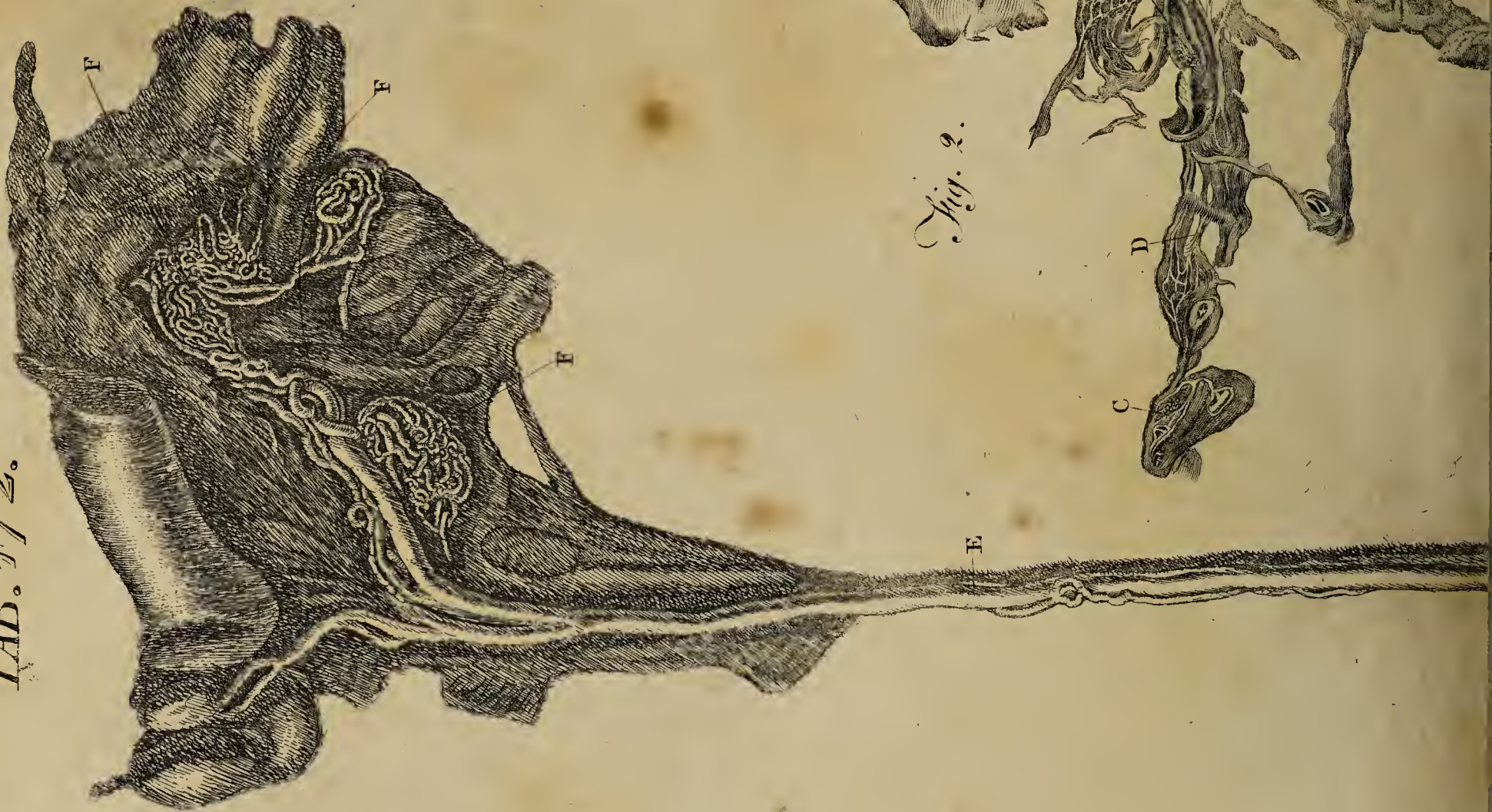
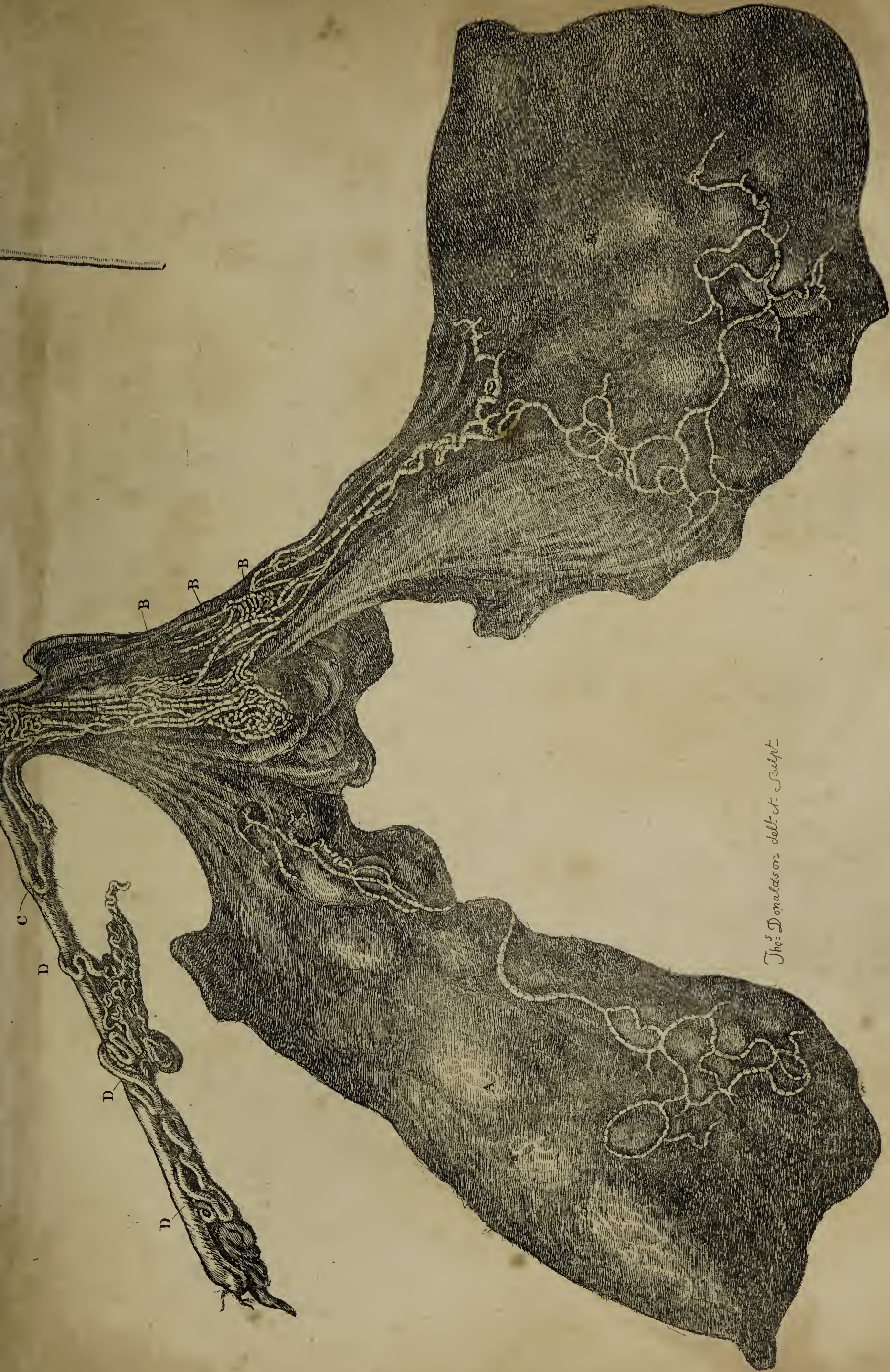

Fig. 1.



Fig. 2.



Tho: Donaldson del: H. Sculpt:

T A B L E CLXXII.

FIG. 1.

Shows some of the LYMPHATIC VESSELS from both sides of the LUNGS, terminating in the THORACIC DUCT;—after they were injected with Quick-silver, and the Parts dried.

- A, A, Sections of the right and left lungs, with their lymphatics forming areolæ, and afterwards proceeding to the lymphatic glands which are contiguous to the esophagus.
- B, B, &c. Lymphatic glands, with their lymphatics filled with the injection.
- C, C, Lymphatic trunks proceeding from these glands, and terminating in the thoracic duct.
- D, D, D, Other lymphatics terminating in the thoracic duct.
- E, The continuation of the thoracic duct.
- F, F, F, Lymphatic vessels and glands which belong to the under and left side of the neck, running towards the upper part of the thoracic duct.

The Preparation from which this Figure was taken, did not afford an accurate view of the termination of the Duct.

FIG. 2.

Represents LYMPHATIC ABSORBENT VESSELS injected, running upwards from the BRONCHIAL GLANDS, to be inserted, by two Branches, into the THORACIC DUCT, not far from its Termination.

- A, The thoracic duct ;
- B, Its termination.
- C, C, &c. The bronchial glands.
- D, D, &c. Lymphatics injected, passing into, or along the bronchial glands.
- E, E, The lymphatics from the bronchial glands, terminating by two branches in the thoracic duct.

T A B L E CLXXIII.

Represents LYMPHATICS from the LUNGS of the Left Side, terminating in the BRONCHIAL GLANDS, near to the division of the TRACHEA into its two Branches.

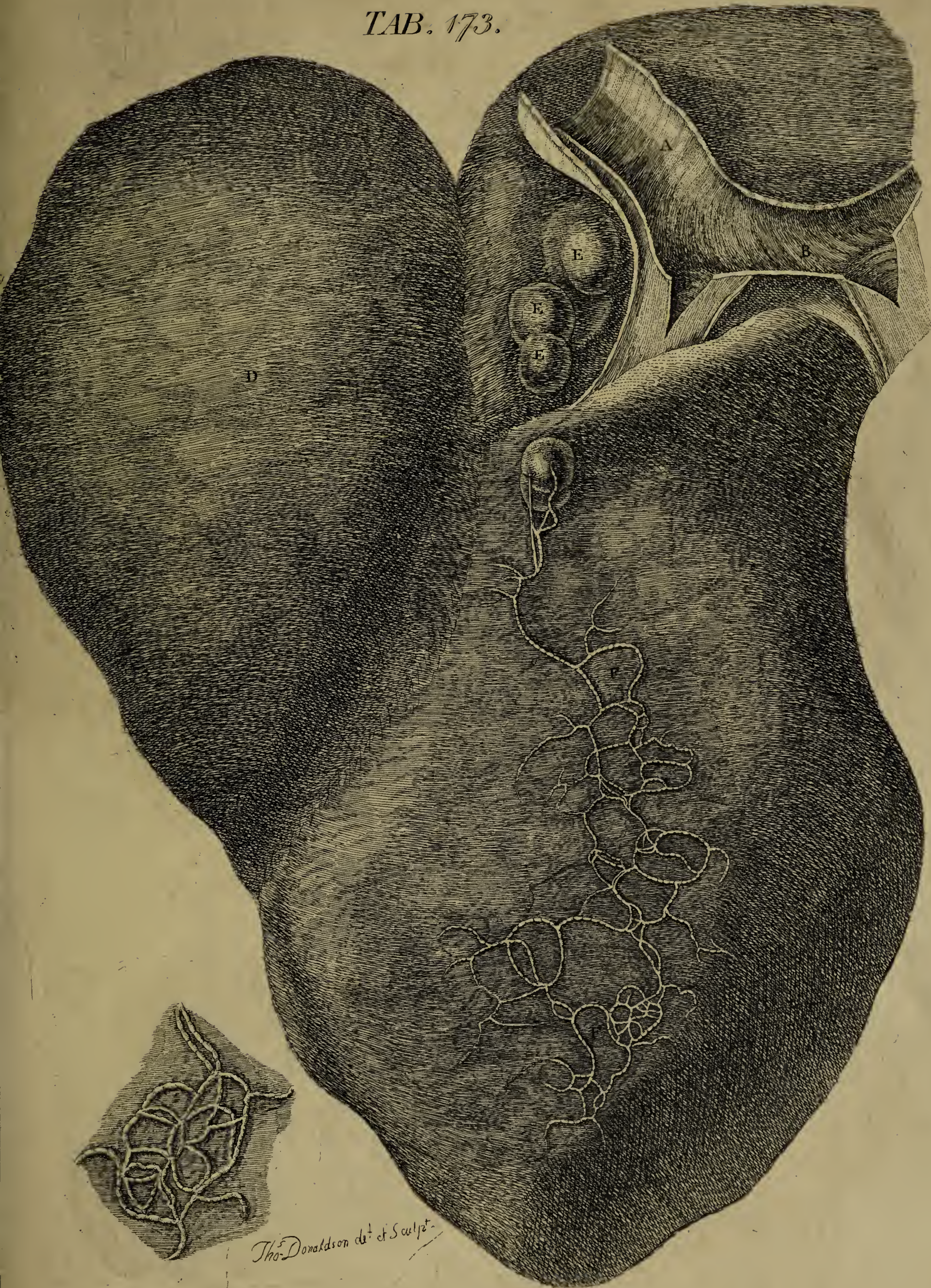-
- A, The trachea, laid open from behind ;
 - B, Its right branch, also opened from behind ;
 - C, Its left branch, part of which is opened.
 - D, D, The left lung.
 - E, E, &c. Bronchial glands at the root of the left lung.

F, F, Lymphatics forming areolæ upon the surface of the lung, and afterwards entering the bronchial glands.

—The annexed Figure shews some of the Lymphatics F, F, magnified.

TABLE

TAB. 173.



Tho^s Donaldson del^t et Sculpt.

TAB. 174.

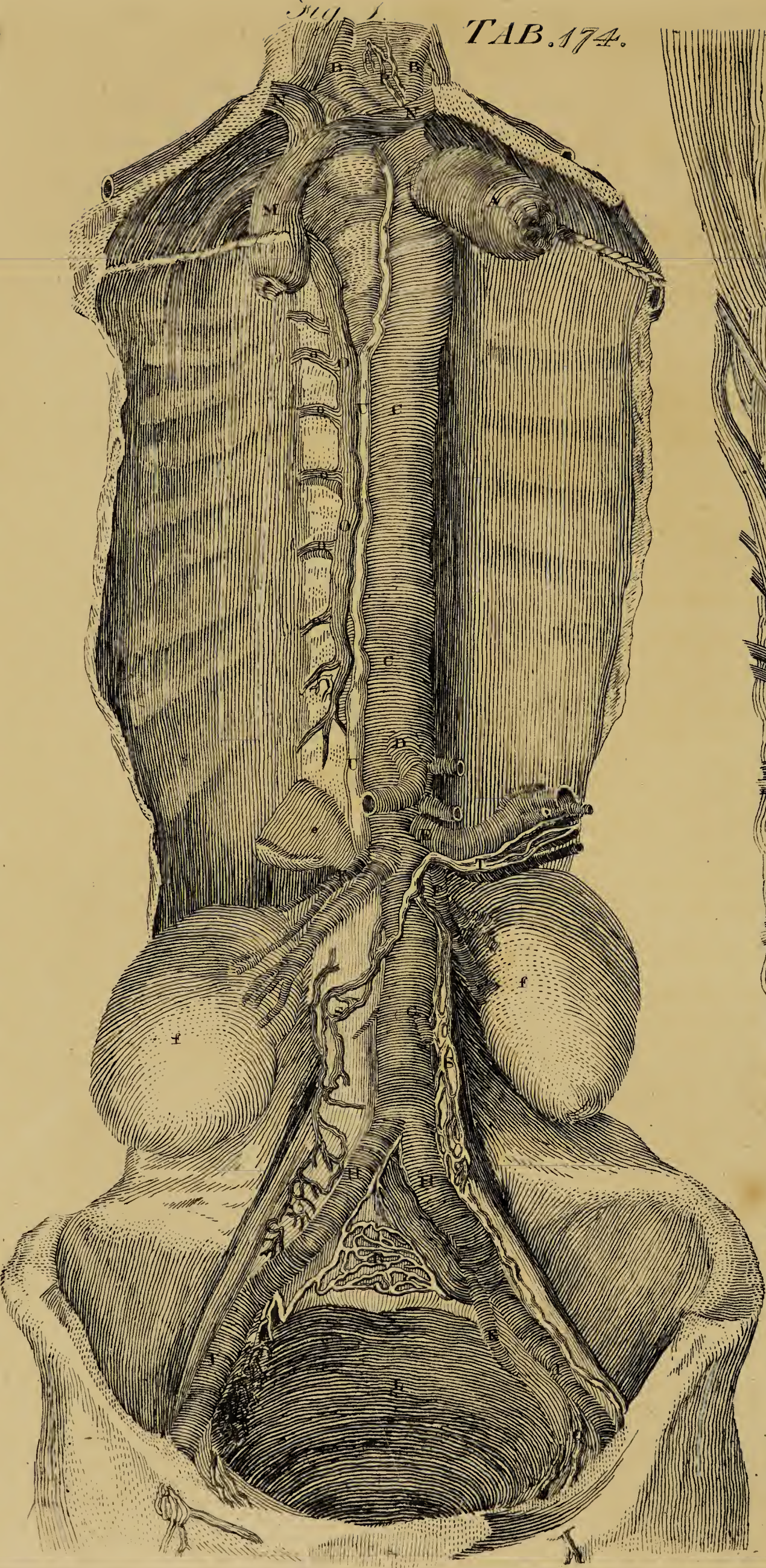


Fig. 2.

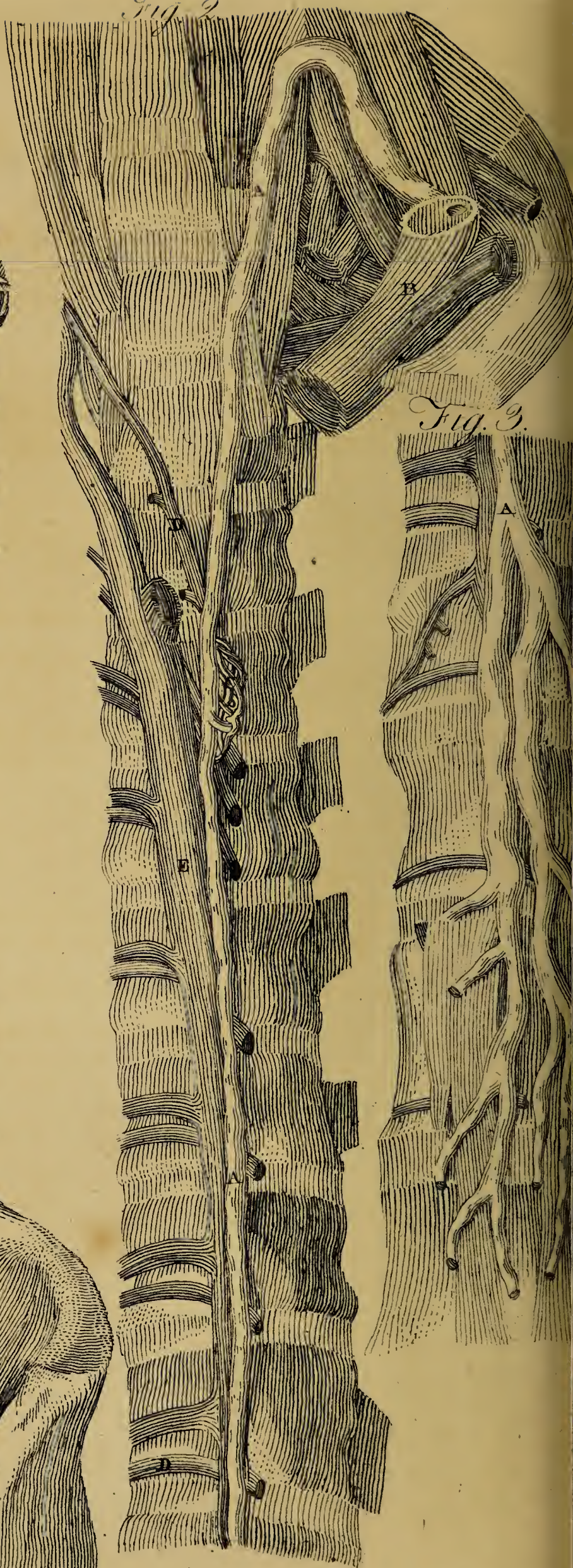
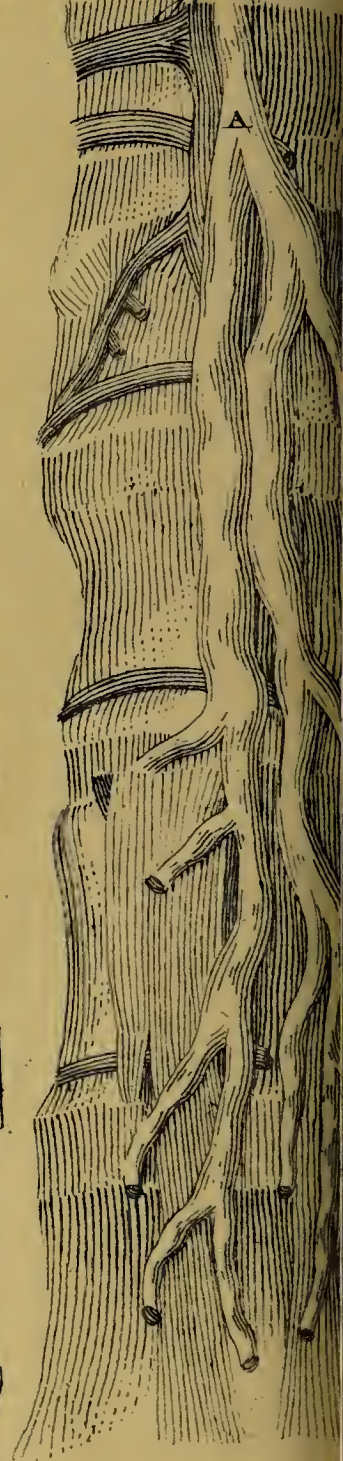
Fig. 3.



T A B L E CLXXIV.

FIG. 1.

An Anterior View of the Back Part of the TRUNK of the BODY, with the THORACIC DUCT and Principal ABSORBENT VESSELS which enter it;—the Anterior Part of the THORAX and ABDOMEN, and all the VISCERA, excepting the KIDNEYS, being removed.

- A, The trunk of the aorta cut off where it emerges from the left ventricle of the heart, and tied to the left side.
- B, B, The common carotid arteries.
- C, C, The aorta descending along the spine.
- D, The trunk of the cœliac artery going off from the aorta immediately below the diaphragm.
- E, The trunk of the superior mesenteric artery, with the beginning of some of its branches.
- e, The right crus of the diaphragm.
- F, F, The emulgent arteries going obliquely to the kidneys, *f, f*, of which the right is somewhat lower than the other.
- G, The trunk of the inferior mesenteric artery.
- H, H, The common iliac arteries.
- I, I, The external iliac arteries.
- K, The internal iliac artery of the left side.
- L, The fundus vesicæ urinariæ.
- M, The superior vena cava, cut from the right auricle of the heart, and drawn a little to the right side by the cord *m*.
- N, N, The subclavian veins, that of the left side longer than the other.
- O, O, The vena azygos, ascending along the right side of the spine to the vena cava superior, in which it terminates; receiving the intercostal veins, *o, o, o*, in its way.
- P, Lymphatics descending from the neck and superior parts.

- Q, Q, Lymphatics from the inferior extremities, seen on each side of the bladder.
- R, A plexus of lymphatics at the lower part of the lumbar region.
- S, S, Lymphatic trunks forming various anastomoses.
- T, Laeteals running along the superior mesenteric artery, in their way to the receptaculum chyli, behind the right emulgent artery, where they fall in with the lymphatics of the inferior parts.
- U, The thoracic duct, or common lymphatic trunk, ascending to the left subclavian vein, which it enters near the termination of the internal jugular vein.

The upper part of this Duct inclines to the Left. This deflection is behind the Heart, after which it passes behind the Arch of the Aorta, which is here drawn aside to shew the top of the Duct.

FIG. 2.

A View of the THORACIC DUCT, from the DIAPHRAGM, nearly to its Termination in the LEFT SUBCLAVIAN VEIN.

- A, A, The trunk of the duct, the upper part of it forming a curvature before it terminates in the left subclavian vein.
- B, The trunk of the subclavian vein.
- C, Subdivisions of the duct sometimes observed, especially where the thoracic lymphatics fall into it.
- D, D, The intercostal arteries.
- E, The vena azygos.

FIG. 3.

A View of the Inferior Part of the THORACIC DUCT, and its Formation.

- A, The beginning of the duct.

TABLE

T A B L E CLXXV.

The SUPERFICIAL LYMPHATICS of the SUPERIOR EXTREMITY,—the INTEGUMENTS being removed.

FIG. 1.

The SUPERFICIAL LYMPHATICS of the Anterior Side of the FORE-ARM and ELBOW, tending upwards.

- A, A, Two small conglobate glands, near the internal condyle of the os humeri.
- B, The radial artery.
- C, The ulnar artery.
- D, The superficial radial vein forming the *mediana longa*.
- E, The superficial ulnar vein.
- F, The cephalic vein.
- G, The basilic vein.
- H, The median basilic vein.

FIG. 2.

LYMPHATICS of the Anterior Surface of the FORE-ARM, proceeding to the AXILLARY CONGLOBATE GLANDS, A, A, A, through which they pass.


- B, The trunk of the humeral artery.
- C,  vein.
- D, The cephalic vein.
- F, The basilic vein.
- G, The deltoid muscle.
- H, The sub-scapular muscle.

FIG. 3.

The SUPERFICIAL LYMPHATICS on the Back Part of the HAND and ARM.

T A B L E

Fig. 2.

TAB. 175.

Fig. 3

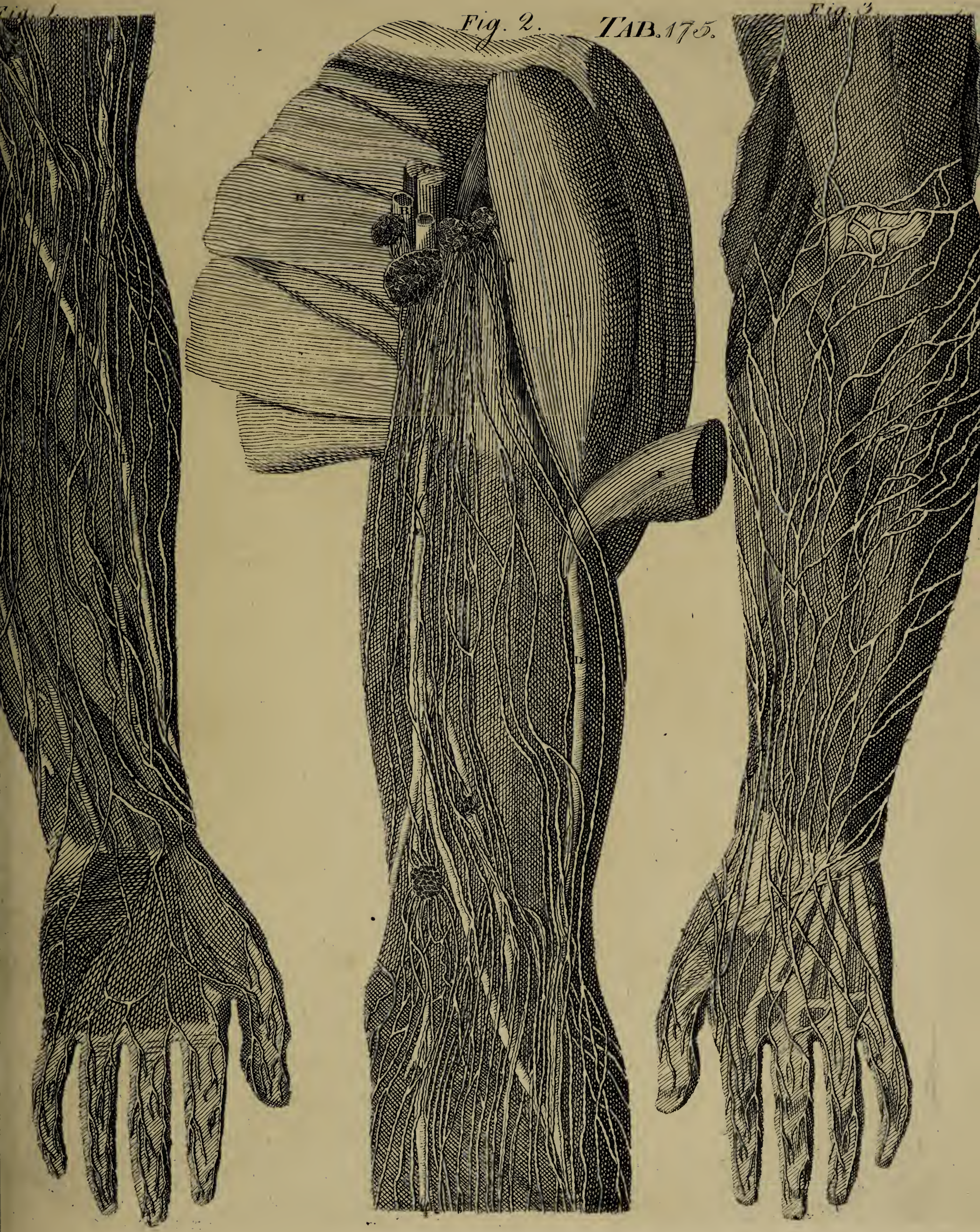

Fig. 1.

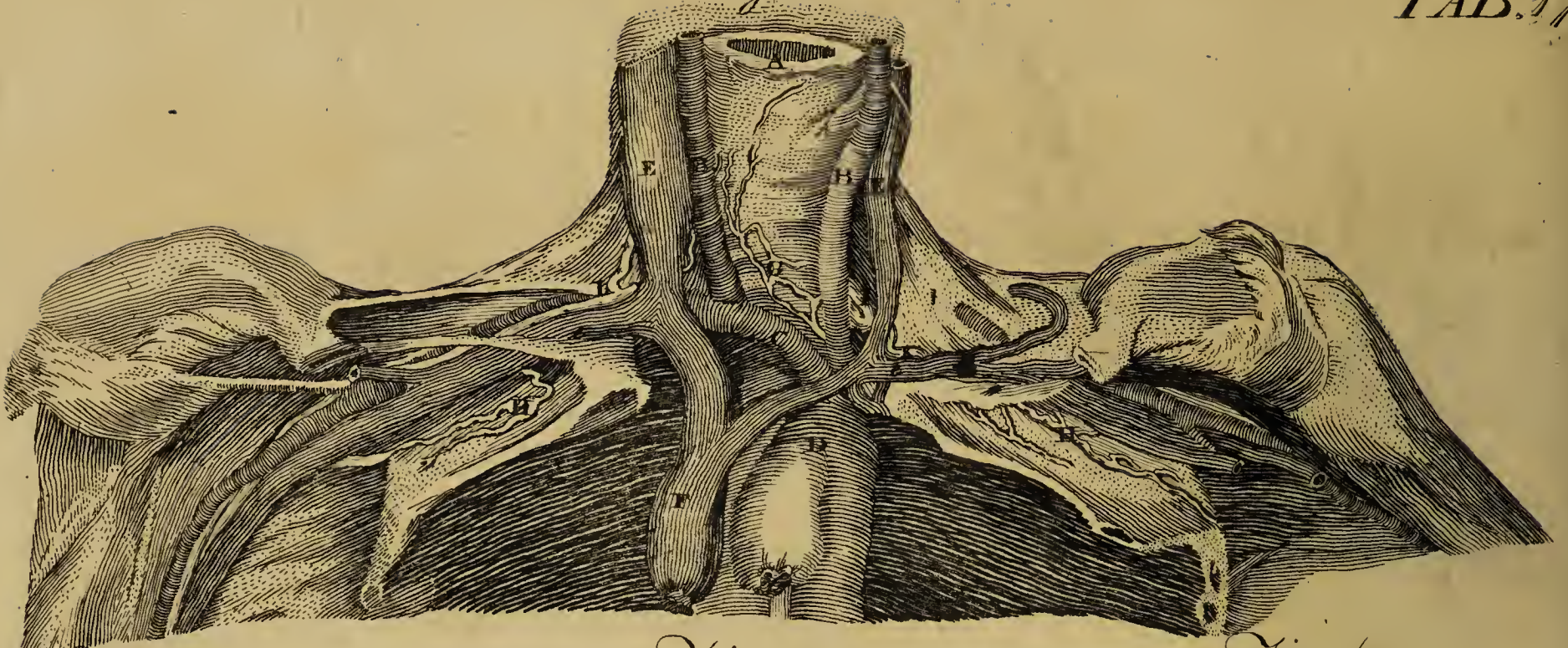


Fig. 2.

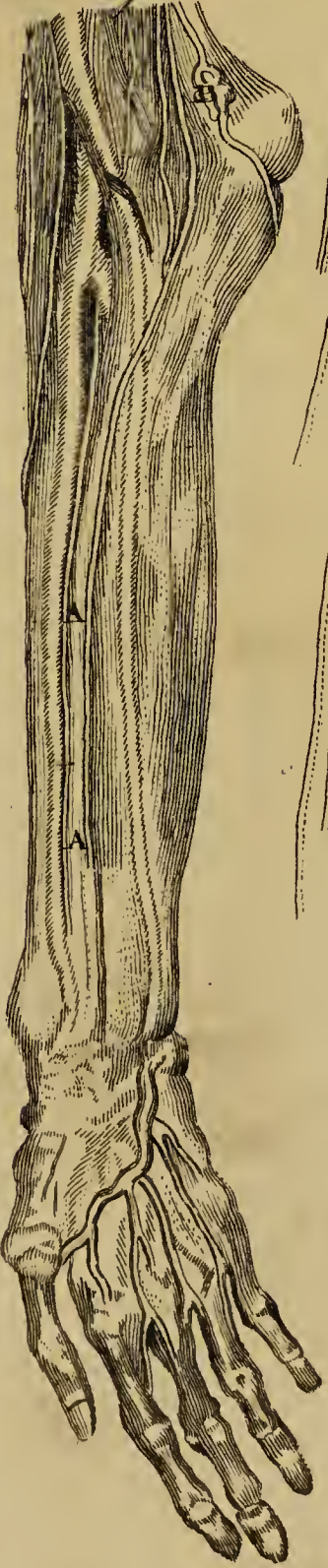

Fig. 3.

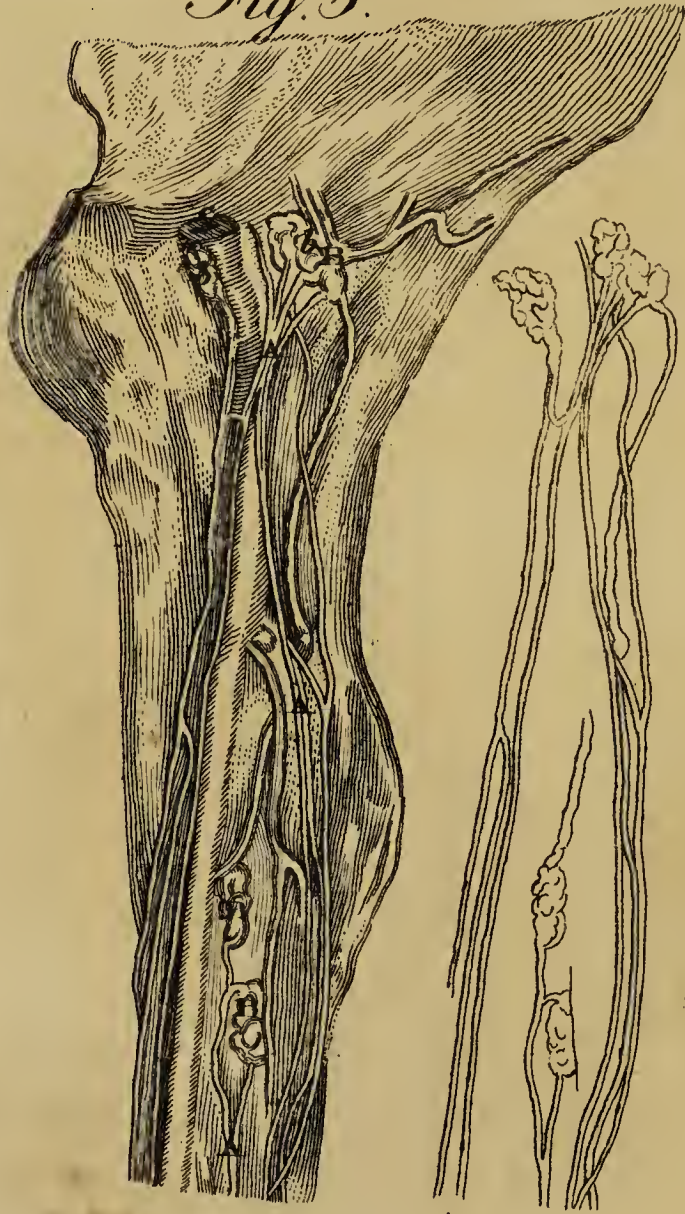
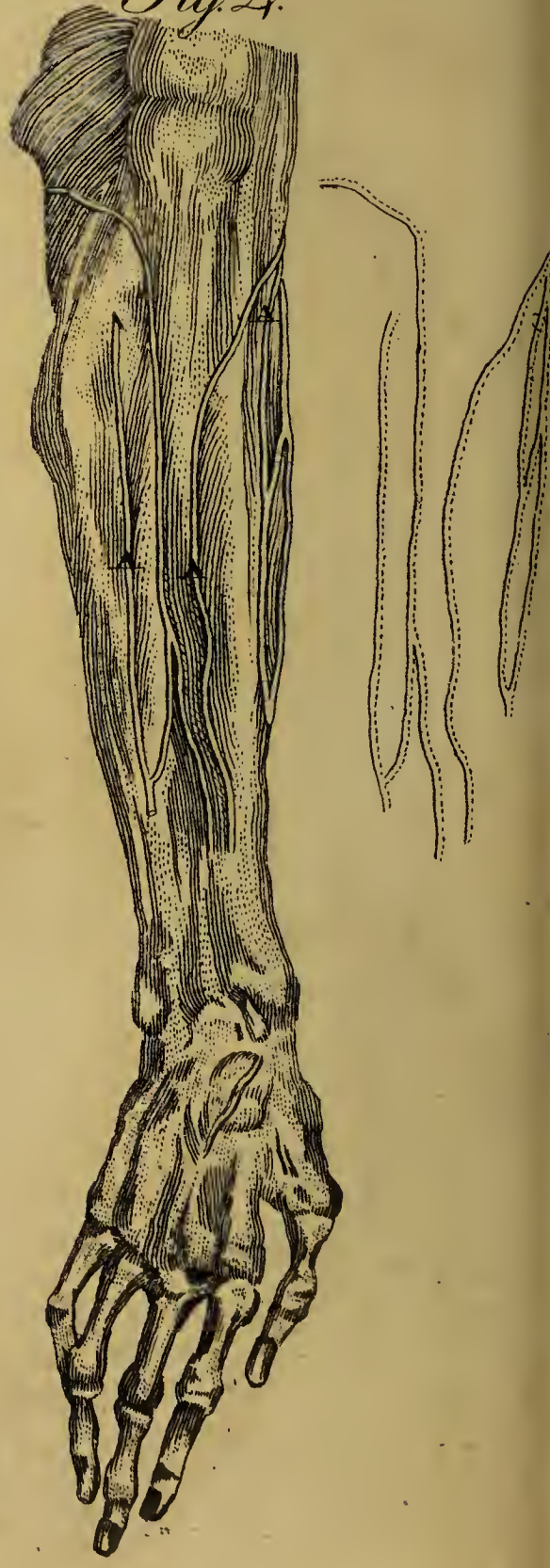
Fig. 4.



T A B L E CLXXVI.

A VIEW of the LYMPHATICS of the SUPERIOR EXTREMITY, and their Termination in the RED VEINS.

FIG. 1.

A View of the Termination of the LYMPHATICS in the RED VEINS.

- A, A section of the trachea immediately below the larynx.
- B, B, The common carotid arteries.
- C, The common trunk of the right carotid and subclavian arteries.
- D, The arch of the aorta.
- E, E, The internal jugular veins.
- e, e, The subclavian veins.
- F, The vena cava superior.
- G, Lymphatics descending upon the fore-part of the neck.
- H, H, Lymphatics of the superior extremities.
- I, The upper part of the thoracic duct, bending downwards to,
- K, The angle formed by the meeting of the left internal jugular and left subclavian veins.
- L, The termination of the lymphatic vessels in the angle between the right internal jugular and right subclavian veins.

FIG. 2.

A View of the SUPERFICIAL or SUBCUTANEOUS LYMPHATICS of the Anterior Part of the RIGHT FORE-ARM.

- A, A, Lymphatic vessels passing upwards.
- B, A lymphatic gland a little above the inner part of the elbow, with a lymphatic vessel passing into it from the back part of the arm.
- C, Lymphatics coming from the back part of the fore-arm.

FIG. 3.

A View of the LYMPHATICS of the Anterior Part of the ARM.

- A, A, A principal lymphatic forming frequent anastomoses.
- B, B, Lymphatic glands placed a little below the middle of the arm.
- B, b, b, The axillary glands through which the lymphatics, A, A, pass.
- C, The cut end of the humeral artery.—The continuation of that artery, with its large branches, are seen obscurely along the whole length of the arm.

FIG. 4.

A View of the LYMPHATICS on the Back Part of the FORE-ARM and HAND.

- A, A, A, Principal lymphatic vessels, most of which pass over the radius to the fore-part of the arm;—one is seen crossing by the inner condyle of the os humeri.

T A B L E CLXXVII.

Gives a General View of the ABSORBENT SYSTEM.

FIG. 1. & 2.

The HUMAN BODY, supposed to be to such a degree transparent, as to shew the General Course of the ABSORBENT VESSELS and GLANDS.—The dotted Lines represent the Deep-seated ABSORBENTS.

FIG. 1.

- A, A, The subclavian veins.
- B, The vena cava superior.
- C, The right auricle of the heart.
- E, ———— ventricle.
- F, The aorta.
- G, The lungs.
- I, The right,
- K, The left lobe of the liver.
- L, The stomach.
- M, N, The kidneys.

FIG. 2.

- a*, The lymphatics of the foot.
- b*, A lymphatic gland represented by MR HEWSON, in Tab. CLX. Fig. 1. *d*, but not met with by later Anatomists.
- c*, The lymphatics of the outside of the leg.
- d*, A lymphatic plexus which follows the course of the vena saphæna major.
- e*, The lymphatics from the outside of the leg, joining those upon the inside of the knee.
- f*, The glandulæ popliteæ, through which the lymphatics which accompany the deep arteries, and part of the superficial lymphatics upon the back of the leg pass.
- g*, The large lymphatic plexus of the inside of the thigh.

FIG. 1.

- b, i, b, i*, The large lymphatic plexus of the thighs passing into the different inguinal glands.
- The *b* on the left groin points out the greater part of the lymphatics of the thigh entering a single gland, which MR CRUICKSHANK found to be the case in a particular subject.

- k, k*, Inguinal glands belonging chiefly to the lymphatics of the scrotum and penis.
- l*, The lymphatics of the scrotum.
- m*, A lymphatic trunk upon the dorsum penis, formed of three branches.—The trunk afterwards divides into two parts; one passing to the right, and the other to the left inguinal glands, *k, k*.
- n, n*, The external iliac plexus of vessels and glands.
- o*, The absorbents of a portion of the great intestines.
- p, q*, The lymphatic vessels of the kidneys passing to the lumbar plexus.
- r*, The lymphatic trunks from the inferior extremities, joining with other lymphatics, and with the lacteals, to form,
- s*, The thoracic duct.
- t*, The absorbents of the large curvature of the stomach, which pass to the thoracic duct.
- u, u, v, v, w*, Lymphatics of the upper surface of the liver, perforating the diaphragm in their way to the anterior thoracic plexus.—Between *v, v*, several glands are seen, through which the lymphatics at this part pass.
- x*, The right coronary lymphatic trunk of the heart, terminating in a gland between the common carotid arteries.
- y*, The left coronary lymphatic trunk, formed of two principal branches.—It afterwards enters a gland between the arch of the aorta and root of the trachea.
- z, z, z, z*, The lymphatic plexus of the lungs.
- 1. Superficial lymphatics which come up from the anterior parts of the hand and fore-arm.
- 2. Lymphatics from the posterior parts of the hand and fore-arm, next the little finger, joining the superficial vessels No. 1 and, along with them, forming a plexus.
- 3. A superficial lymphatic plexus accompanying the basilic vein, and passing through glands upon the fore and inner part of the arm.
- 4. The axillary glands through which the superficial and deep-seated lymphatics of the arm pass.
- 5. A lymphatic trunk not appearing to pass into any gland, till it reaches the neck.
- 6. Lymphatics on the back part of the fore-arm and outer part of the arm, following the course of the cephalic

Fig. 1.

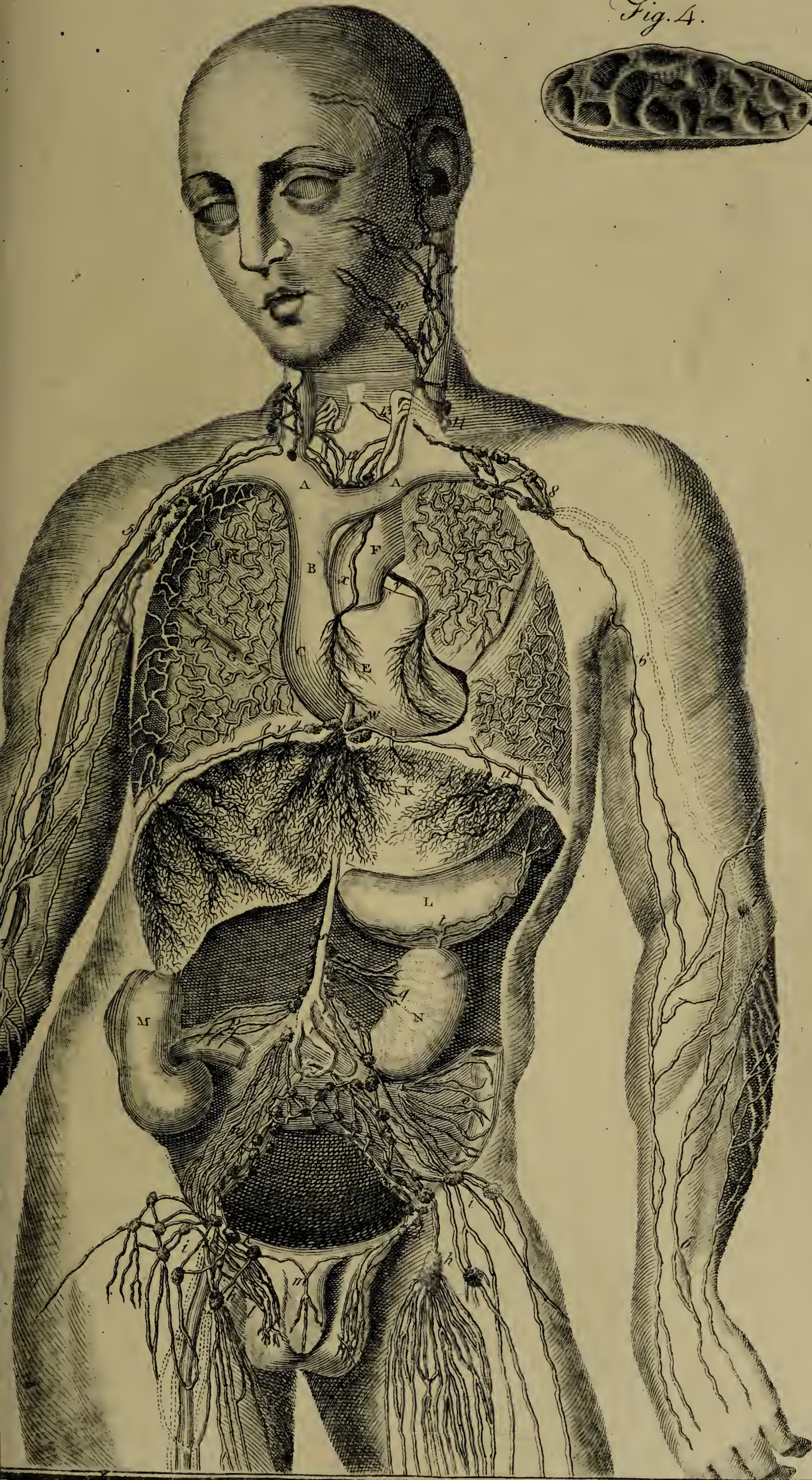
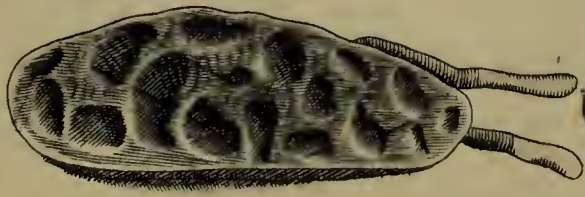

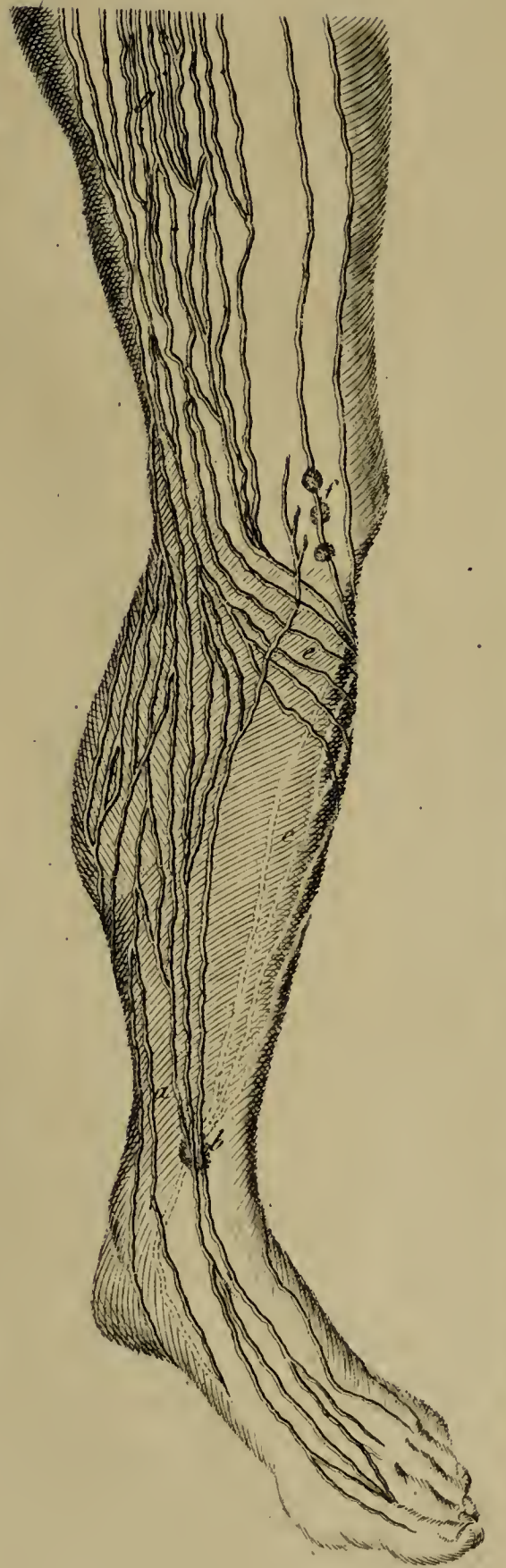
Fig. 4.



TAB. 177.
Fig. 3.



Fig. 2.



phalic vein. The dotted lines represent the deep-seated lymphatics of the arm

7. A gland supposed to be seen upon the opposite side of the arm, through which some of the lymphatics pass.
 8. The axillary cluster of glands blended with some others placed under the clavicle.
 9. The lymphatic trunks which accompany the temporal blood-vessels.
 10. 10. The lymphatics of the face.
 11. The lymphatics of the head and neck passing through the glandulæ concatenatæ.
 12. The lymphatic trunks from the liver, diaphragm, heart, and lungs, emerging from the cavity of the thorax, and ending in the right and left general terminations of the absorbent system.
- A little above 12. are seen the right and left trunks from the thyroid gland.

13. The upper end of the thoracic duct splitting into two parts, before it terminates at 14. in the angle formed by the left subclavian and internal jugular veins.

FIG. 3.

A Gland taken from near the Spleen of a Horse, partially injected with Quick-silver from the Lymphatic Vessels, and dried.

FIG. 4.

The same Gland cut longitudinally, and the Mercury allowed to escape; exhibiting a Cellular appearance, and Communications between the Cells, into which Bristles were introduced, which are here represented.

T A B L E C L X X V I I I .

A General VIEW of the ABSORBENT SYSTEM ; after the LYMPHATICS and LACTEALS had been injected with Quick-silver, the BLOOD-VESSELS with Wax, and the PREPARATION dried.

- A, A section of the upper end of the sternum, and of the inner end of the clavicles which are turned up.
- B, B, The internal jugular veins, between which are seen the muscles, fat, &c. which cover the trachea.
- C, The cavity of the right side of the thorax.
- D, D, The pericardium cut.
- E, The heart.
- F, F, The convex surface of the diaphragm.
- G, G, A flap formed by the integuments and abdominal muscles, turned up.
- H, Part of the liver.
- I, The stomach, and part of the colon shrivelled.
- K, K, The descending aorta.
- L, The right common iliac artery.
- M, M, The inferior vena cava.
- N, N, The mesentery and small intestines collected into folds, and turned to the left side.
- O, The cavity of the pelvis.
- P, The pubes.
- Q, R, The spermatic cord and testicle.
- S, S, S, The inguinal glands distended with quick-silver, and, in part, assuming a cellular appearance.
- T, T, T, Branches of the vena saphæna major.

A B S O R B E N T S .

The course of many of the Absorbents represented in this Figure is so obvious, as to supersede the necessity of Letters, viz.

Those upon the upper part of the Feet, which take their origin from the Toes.

Trunks, behind the inner Ankles, which ascend from the Soles.

Lymphatics, from the outside of the Feet and Ankles, running across the Tibiæ to the inside of the Legs.

The principal Lymphatics of the Legs, running near the great Vena Saphæna.

Lymphatic Trunks, going obliquely across the Tibiæ to the inside of the Legs.

The Course of the principal Lymphatics of the Legs running at the inner sides of the Knees.

A Trunk from the inside of the right Knee.

The principal Lymphatics from the Legs, passing along the inside of the Thighs.

An irregular Plexus formed by the Lymphatics in their course along the inside of the Limbs in general.

The Inguinal Glands, receiving the Lymphatics from the inside of the Thighs, &c.

In the right side :—The Inguinal Glands, receiving Lymphatics which run in a radiated manner from the fore-part of the Thigh upwards and inwards,—from the outer part of the Pelvis inwards, and—from the under end of the superficial parts of the Abdomen downwards.

Upon the right side of the Dorsum Penis :—Two Lymphatic Trunks, one of which, at the Pubes, splits into Branches, which terminate, partly in the uppermost, and partly in the innermost Inguinal Glands.

A few of many Lymphatics injected from the Testicle, passing along the Spermatic Cord.

At the right side of the Pelvis :—The Iliac Plexus of Lymphatics, formed by Trunks which ascend, some of them from the Inguinal Glands, behind POUPART'S Ligament, others from the Spermatic Cord, through the Abdominal Ring, and some from the Contents of the Pelvis, along with the Iliac Blood-vessels.

At the Bifurcation of the Aorta :—Lymphatics which come up from the Surface of the Os Sacrum.

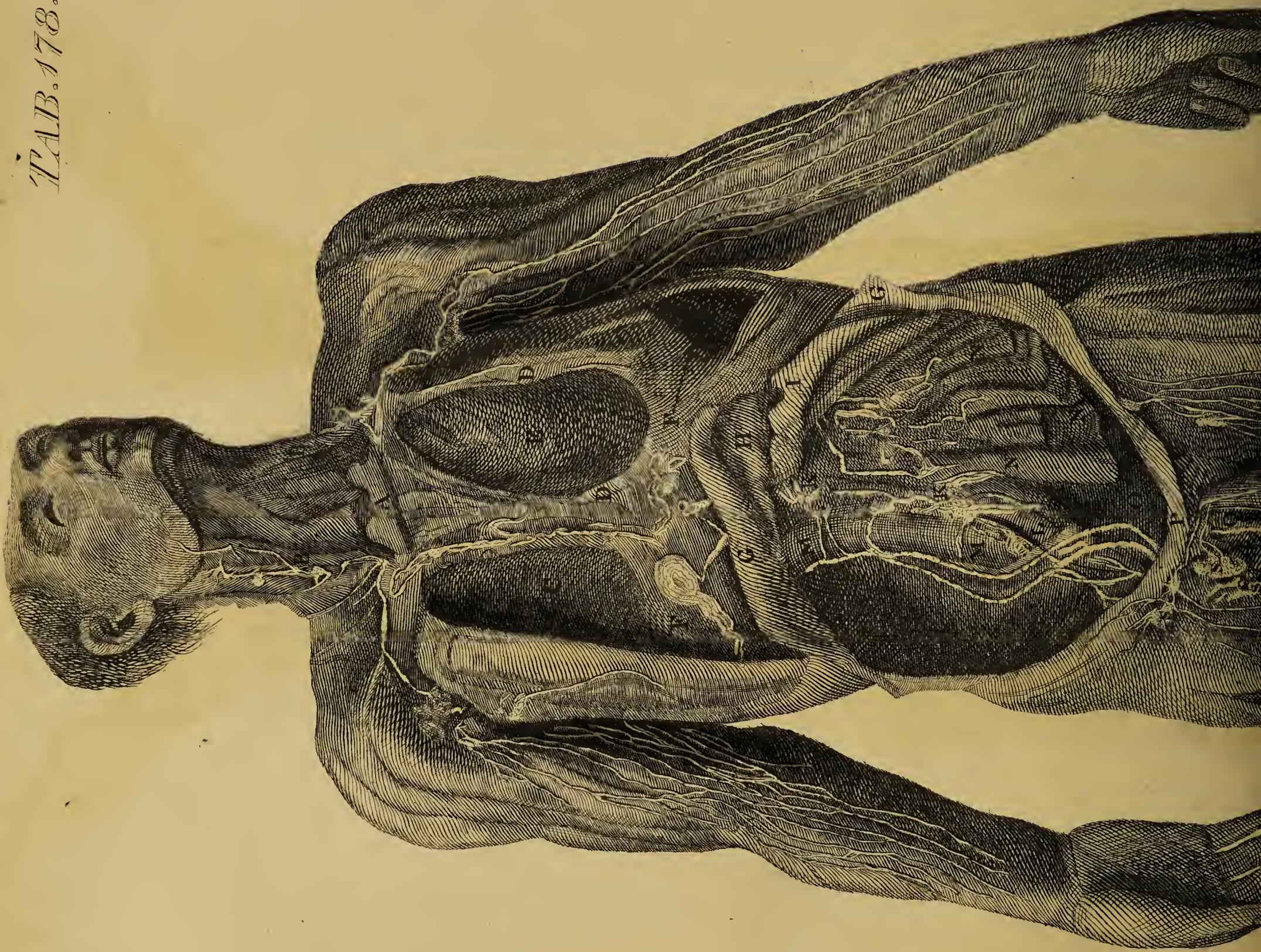At the sides of the Inferior Cava, and over the Aorta :—The Vessels and Glands which form the Lumbar Plexus.

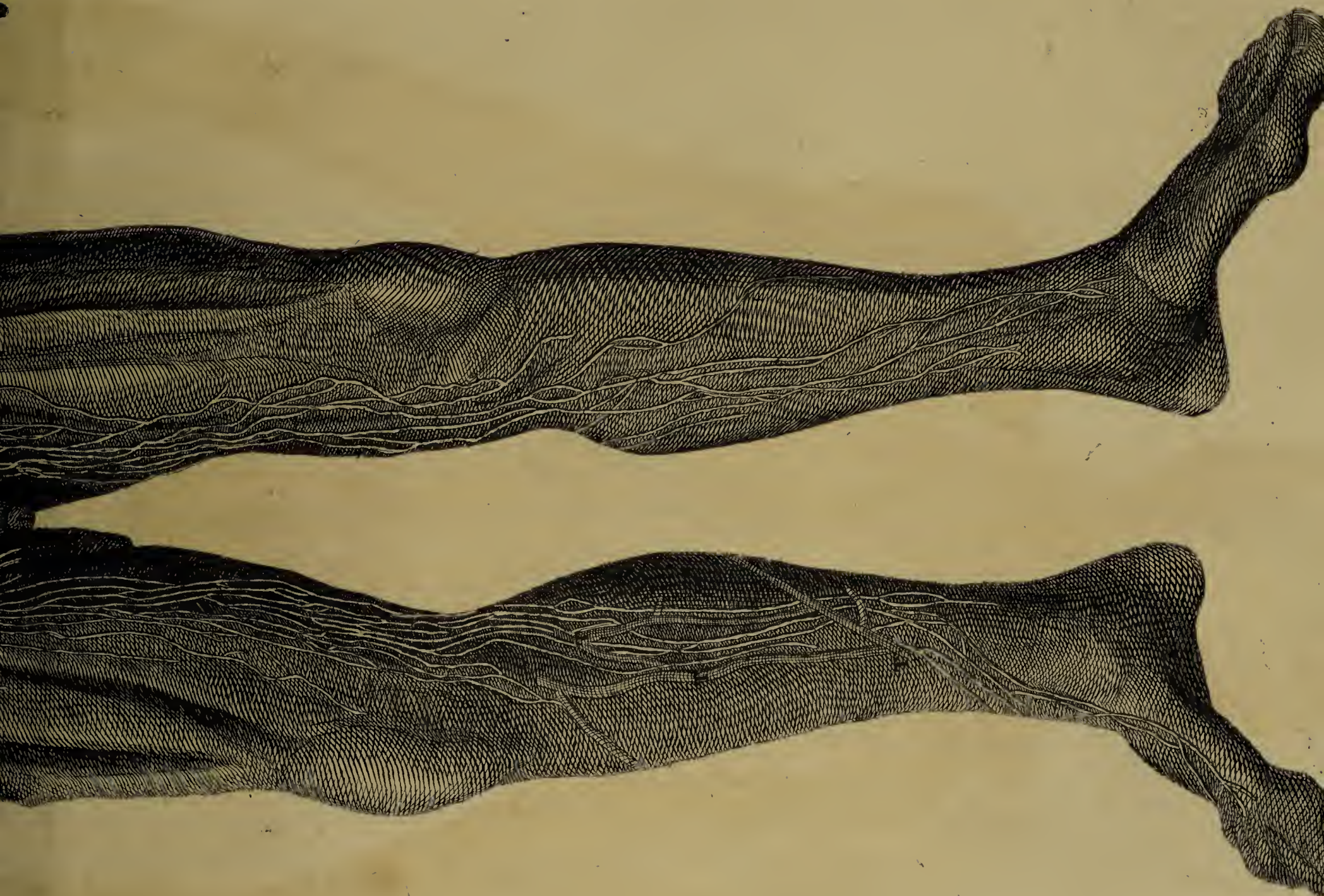Upon the Mesentery :—A few of many injected Lacteals directing their course towards the beginning of the Thoracic Duct.

U, Trunks descending from the under part of the liver, and from other viscera situated at the upper part of the abdomen, meeting with the lacteals and lumbar plexus, and terminating at this place in the thoracic duct.

V, A

TAB. 178.





V, A very large lymphatic gland upon the convex surface of the diaphragm, appearing as if formed of convoluted branches.

Large Lymphatic Vessels entering this Gland, which perforate the Diaphragm from the right side of the Liver.

W, W, Lymphatics and glands placed at the under end of the anterior mediastinum; the vessels passing from the ligamentum hepatis latum, through the fore and middle part of the diaphragm.

X, X, X, X, The anterior thoracic plexus of lymphatic vessels and glands which accompany the internal mammary blood-vessels, receiving the lymphatics from the convex part of the liver and diaphragm, the lymphatics of the right plexus running to the right general termination of the absorbent system, and those of the left plexus to the upper end of the thoracic duct.

Y, A lymphatic trunk from the mamma and other parts on the outer and lateral parts of the thorax, entering glands near the axilla.

Upon the Superior Extremities:—An extensive Plexus formed by the Superficial Lymphatics, which pass from the anterior side of the Extremity upwards, and receive many Branches which ascend in an oblique direction from the opposite sides of the Arm.

At the Axillæ:—The Lymphatics of the Superior Extremities entering the Axillary Glands.

a, a, Principal trunks proceeding from the glands of the axillæ.

b, The termination of the principal trunk of the left arm, along with the thoracic duct.

c, The thoracic duct receiving a lymphatic belonging to the neck, and terminating in the angle formed by the left internal jugular and left subclavian veins.

In the right side of the Neck:—Some of the Lymphatic Vessels and Glands which form the Jugular Plexus.

d, The general termination of the lymphatic vessels of the right side of the head and neck, right arm, &c. in the angle formed by the right internal jugular and right subclavian veins.

N. B. *A much greater number of Absorbents were injected in the Preparation from which this Figure was taken, than are here represented;—none having been painted excepting what could be distinctly seen, after the Preparation had been kept a considerable time in the dried state, and of course many Lymphatics so shrivelled, as not to admit of accurate delineation.*

TABLE

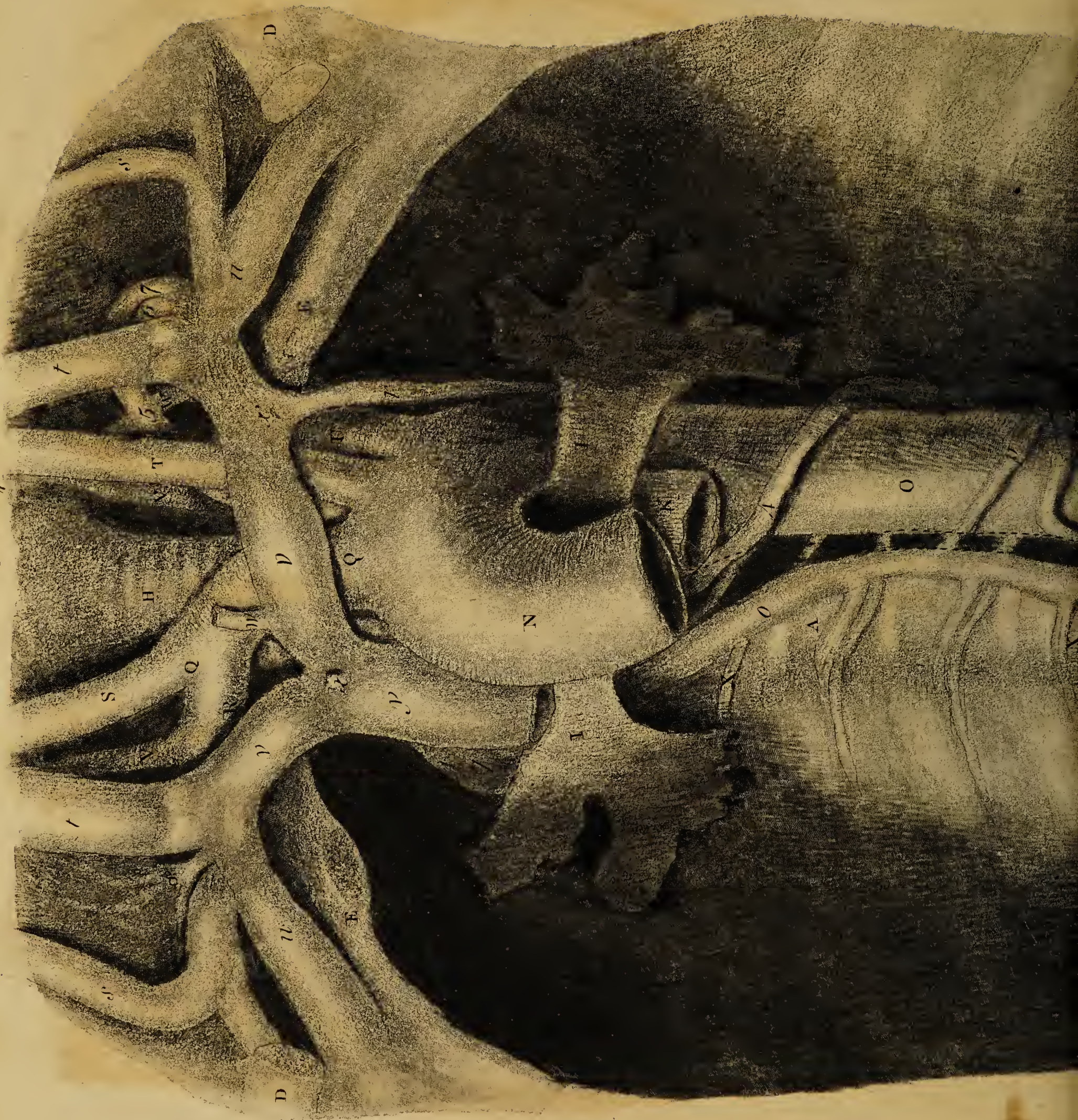
T A B L E CLXXIX.

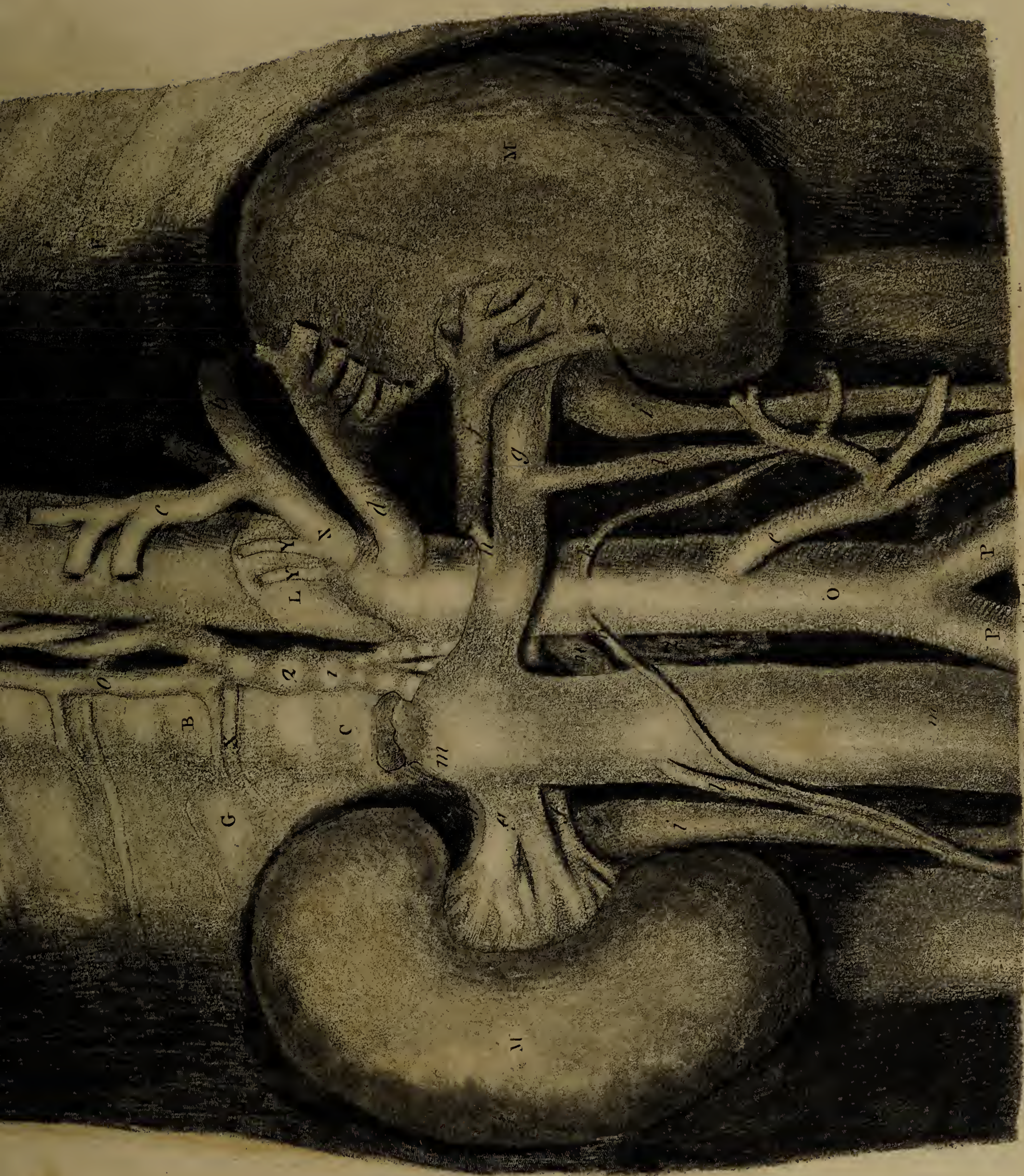
A VIEW of the THORACIC DUCT, and of the usual Terminations of the ABSORBENT SYSTEM in the RED VEINS.—The different VESSELS in the Preparation from which this Figure was taken, were injected with Wax.

-
- | | |
|--|---|
| <p>A, The seventh, and,
 B, The twelfth dorsal vertebra.
 C, The last vertebra of the loins.
 D, D, A section of the clavicles.
 E, E, ————— first ribs.
 F, The eleventh rib of the left, and,
 G, The twelfth rib of the right side.
 H, The trachea.
 I, I, The bronchi.
 K, The esophagus.
 L, Part of the diaphragm.
 M, M, The kidneys.
 N, The ascending, and,
 O, The descending aorta.
 P, The beginning of the common iliacs.
 Q, The arteria innominata.
 R, The right subclavian artery.
 S, The right carotid.
 T, The left carotid, and,
 U, The left subclavian artery.
 V, V, The vertebral arteries.
 W, The left inferior laryngeal artery.
 X, X, The intercostal arteries of the right side.
 Y, Y, The diaphragmatic arteries.
 Z, The celiac artery, sending off,
 <i>a</i>, The superior gastric,
 <i>b</i>, The splenic, and,
 <i>c</i>, The hepatic artery.
 <i>d</i>, The superior mesenteric artery.
 <i>e</i>, The inferior mesenteric artery.
 <i>f, f</i>, The renal arteries, which were double in each side in this subject.
 <i>g, g</i>, The renal veins.
 <i>h</i>, The vein of the left renal gland.
 <i>i, i</i>, The ureters.
 <i>k, k</i>, The spermatic arteries.
 <i>l, l</i>, ————— veins.</p> | <p><i>m, m</i>, The vena cava inferior.
 <i>n</i>, The vena azygos, communicating with the inferior cava, in this subject.
 <i>o, o</i>, The continuation of the azygos, receiving the intercostal veins.
 <i>p</i>, Part of the azygos, which belongs to the under and left portion of the thorax, passing, in this subject, before the aorta.
 <i>q</i>, The termination of the azygos in the superior cava.
 <i>r</i>, The trunk of the left superior intercostal vein.
 <i>s, s</i>, The external jugular veins.
 <i>t, t</i>, The internal jugulars.
 <i>u, u</i>, The subclavian veins.
 <i>v, v</i>, The great subclavians.
 <i>w</i>, The inferior laryngeal vein.
 <i>x, x</i>, The termination of the internal mammary veins.
 <i>y</i>, The vena cava superior.
 <i>z</i>, The lumbar plexus of absorbents, obscurely seen.
 1. 1. The thoracic duct receiving the great trunks formed by the lacteals and the lymphatics of the inferior parts of the body.
 2. The receptaculum chyli.
 3. 3. The thoracic duct, forming an unusual turn across the aorta, and afterwards recovering its ordinary situation.—The dotted lines point out the common course of the duct.
 4. The duct passing behind the aorta.
 5. Its passage behind the left carotid artery.
 6. The duct splitting into two parts, which re-unite previous to,
 7. The termination in the angle formed by the left internal jugular and subclavian veins.
 8. The lymphatic trunk, receiving the absorbents of the right side of the head and neck, right arm, &c. and terminating in the angle formed by the right internal jugular and right subclavian veins.</p> |
|--|---|

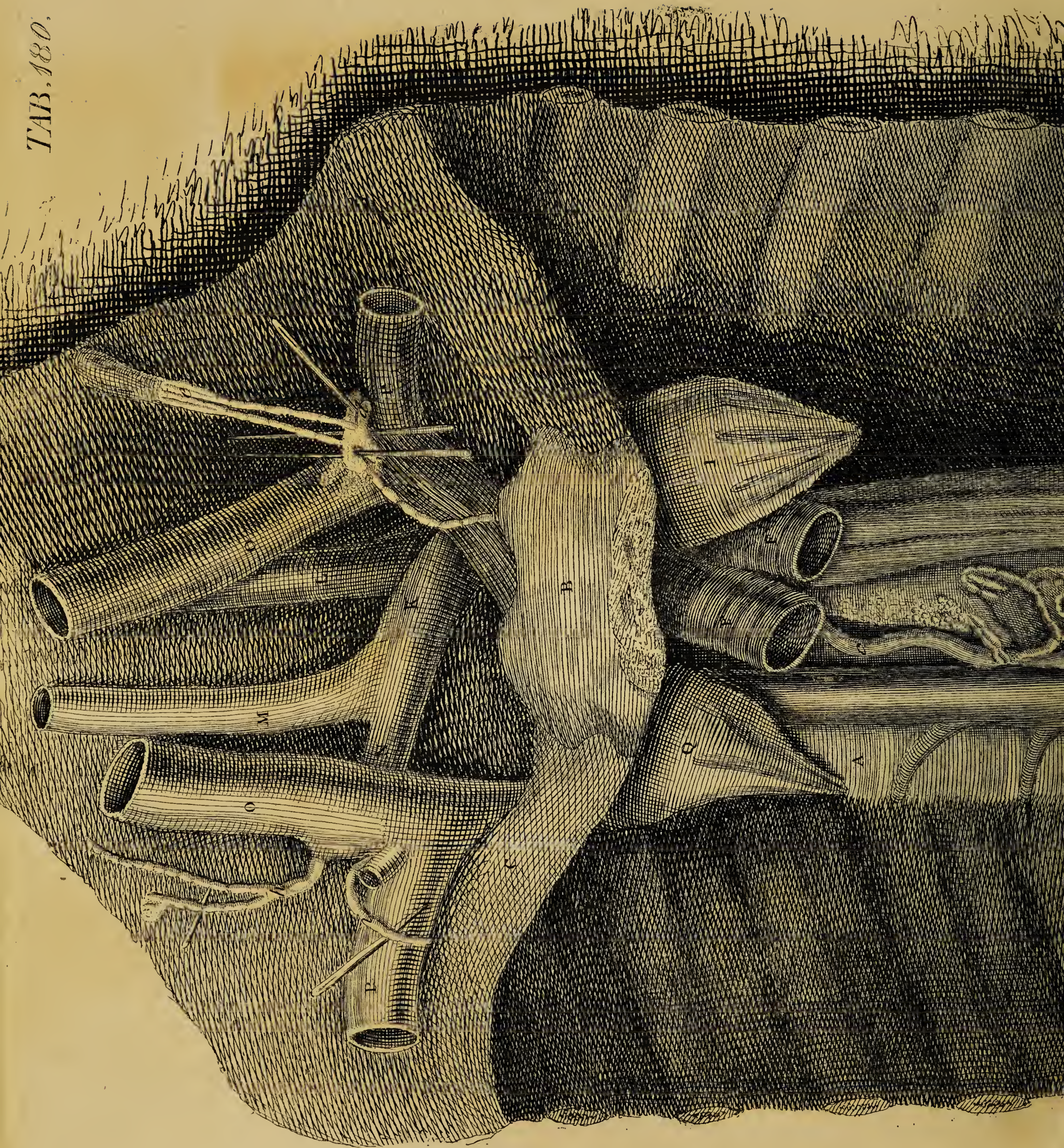


TAB. 17^D.





Altera fecit





T A B L E CLXXX.

Represents the LACTEALS and the LYMPHATICS, from the Lower Parts of the BODY, filled with Wax, terminating in the THORACIC DUCT; the Course of the DUCT in the THORAX, and some unusual Terminations of the ABSORBENT SYSTEM in the RED VEINS.

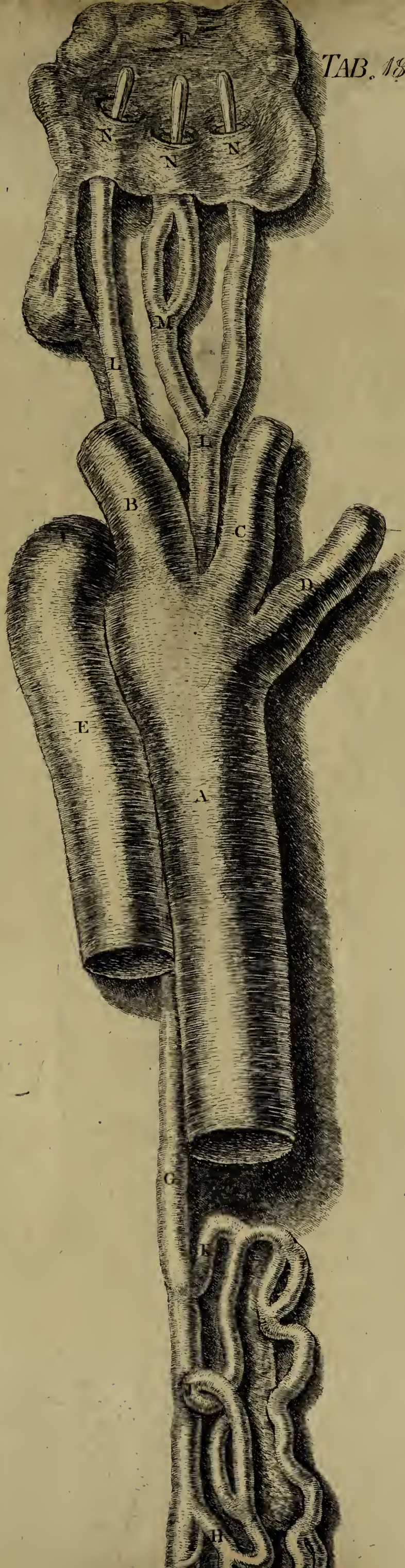
-
- A, A, The spine.
 B, The top of the sternum.
 C, C, The first pair of ribs.
 D, D, The eleventh pair of ribs.
 E, The cut edge of the back part of the diaphragm.
 F, F, The bronchi.
 G, The esophagus.
 H, The cardia.
 I, The ascending aorta, turned a little to the left side.
 K, The trunk common to the right carotid and right subclavian, concealing the root of,
 L, The left carotid artery.
 M, The right carotid, and,
 N, The right subclavian artery.
 O, O, The internal jugular veins.
 P, P, The subclavian veins.
 Q, The superior vena cava.
 R, The vena azygos, with the termination of the intercostal veins of the right side.
 S, The inferior vena cava with the terminations of the renal veins, cut and turned down.
 T, The descending aorta.
 U, The root of the cœliac artery.
 V, The root of the superior mesenteric artery.
 W, W, Lymphatic trunks which receive the absorbents of the inferior extremities, pelvis, &c. terminating in the beginning of the thoracic duct.
 X, X, Lacteal vessels at the root of the mesentery, near to the origin of the superior mesenteric artery, uniting together and forming trunks of great size, which are seen in their progress over the aorta towards the thoracic duct
 Y, The termination of the lacteal vessels in the beginning of the thoracic duct.
 Z, Z, That part of the thoracic duct commonly called *Receptaculum Chyli*.
a, The division of the duct into two parts, which immediately afterwards re-unite.
b, The trunks of that part of the lymphatics of the lungs which terminate in the thoracic duct, about the middle of the posterior part of the cavity of the thorax.
c, The thoracic duct, where it passes behind the arch of the aorta.
d, The splitting of the duct into two parts, which afterwards re-unite, and split again, previous to its termination.
e, The lymphatics of the left side of the head and neck, terminating in the thoracic duct.
f, The termination of the thoracic duct in the end of the left internal jugular vein.
g, A lymphatic trunk from the inner side of the thorax, terminating in the left internal jugular vein.
h, A trunk formed by the lymphatics of the right side of the head and neck, terminating in the right internal jugular vein.
i, A trunk formed by the lymphatics of the right arm, &c. terminating in the angle formed by the right internal jugular and right subclavian veins.

TABLE

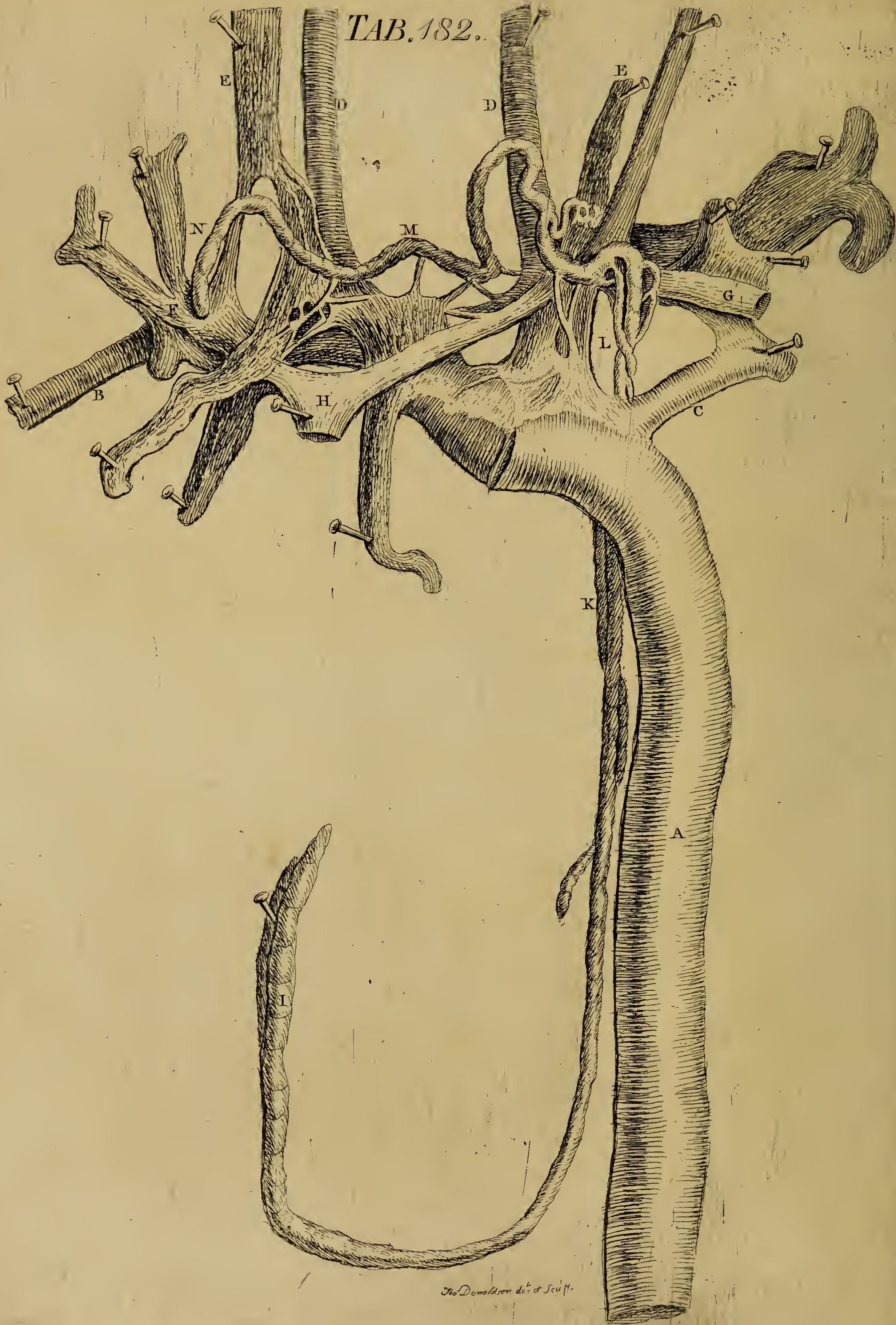
T A B L E CLXXXI.

A VIEW of the THORACIC DUCT, with unufual Divifions and with three Terminations in the RED VEINS.

- | | |
|---|---|
| <p>A, The defcending aorta.
B, The trunk common to the right carotid and fubclavian arteries.
C, The left carotid, and,
D, The left fubclavian artery.
E, The fuperior vena cava, drawn a little afide.
F, The left fubclavian vein laid open.
G, The thoracic duct.
H, I, K, Lymphatic veffels of unufual fize, communica-</p> | <p>ting with each other, and afterwards terminating in the thoracic duct.
L, L, An uncommon divifion of the thoracic duct into two trunks, one of which is again fubdivided, previous to its termination in the red veins.
M, A fplitting of one of the divifions of the thoracic duct into two parts, which afterwards re-unite.
N, N, N, Three terminations of the thoracic duct in the left fubclavian vein.</p> |
|---|---|



TAB. 182.



T A B L E CLXXXII.

A LUSUS NATURÆ of the THORACIC DUCT, which, after running in the usual way to the Left Side of the NECK, turns over to the Right Side, and terminates in the Joining of the Right Internal JUGULAR VEIN with the Right SUBCLAVIAN; thus receiving the ABSORBENTS of the whole BODY.

The DUCT itself was injected with Wax: the other Parts of the PREPARATION from which the Figure is made, shrivelled in the drying;—the Proportion of these Parts is therefore not to be attended to.

A, The aorta.
 B, The right, and,
 C, The left subclavian artery.
 D, D, The common carotids.
 E, E, The internal jugular veins.
 F, The right, and,
 G, The left subclavian vein.
 H, The vena cava superior.
 I, The under end of the thoracic duct turned up.

K, The thoracic duct passing behind the aorta.
 L, A lymphatic trunk passing into the thoracic duct, near that part where it commonly terminates.
 M, The thoracic duct passing across the neck, and receiving lymphatics from the adjacent parts.
 N, The unusual termination of the thoracic duct in the angle formed by the right internal jugular and right subclavian vein.

END OF THE SIXTH PART.



PART VII.

OF

THE NERVES.

OF THE NERVES IN GENERAL.

THE NERVES are firm, white Cords, which are generally considered as being directly continued from the Medullary Substance of the Brain and Spinal Marrow;—although Instances have been frequently met with, where the Brain, and even the Spinal Marrow, have been found nearly obliterated in the Fœtus, and yet the Nerves retained their usual appearance.

They are composed of *Funiculi* closely connected, and each of these again of smaller *Fibrillæ*, which may be subdivided into parts so extremely minute, as almost to elude the naked Eye, but which may be readily seen by the assistance of the Microscope:—No cavity, however, has been yet observed in them.

The *Medullary Part* of the *Fibrillæ* appears to be furnished with Cineritious Substance derived from their *Pia Mater*; in proof of which, they are observed to be in general of a browner colour than the Medullary Substance of the Brain, and larger in their course than at their supposed origin.—MONRO'S *Obs. on Nerv. Syst.*

The Medullary Substance of the *Fibrillæ* is *pulpy* and tender, but rendered thicker and stronger by the coverings they receive from the *Tunica Arachnoidea* and *Pia Mater*, while within the Bones; and more particularly by the additional covering given them by the *Dura Mater* upon their exit.

The *Dura Mater*, in its passage through the Base of the Cranium, and between the different *Vertebræ*, is connected by its External Surface to the *Pericranium* and *Periosteum*; while the inner part of it, together with the *Tunica Arachnoidea* and *Pia Mater*, is continued along the Nerves.

The *Involucra*, or *Coverings*, inclose each of the Nerves in general, and likewise the several *Fibrillæ* of which they are composed, whereby their size, as well as strength, is greatly increased.

The Nerves, soon after leaving the Bones, have the *Dura Mater* so intimately connected with them, that it has been considered, by some Authors, as degenerating into condensed Cellular Substance, notwithstanding it still retains the general appearance of the *Dura Mater*.

Upon examining the Nerves, especially the small ones, in a living or recently dead animal, they are observed to have numerous *White Lines* placed transversely, or in a serpentine direction.—*Obs. on Nerv. Syst.* Tab. XIII.

When the Nerves are moderately stretched, this appearance becomes less evident; and when extended considerably, or when macerated in water, it vanishes entirely.

PROCHASKA (*De Carne Musculari*) supposes these serpentine Lines to be owing to a decussation of Vessels and Fibres of Cellular Substance straitening the Nerves.

Dr MONRO considers them as Folds or Joints allowing the Nerves to accommodate themselves to the various states of Flexion and Extension.

The Nerves are supplied with *Arteries* from the neighbouring Blood-vessels, to which they return corresponding Veins.

The Arteries, however, are small, and are injected with difficulty, excepting in the large Nerves, where they are more considerable, and where, after a minute injection, the Nerve receives the colour of the matter injected.

Upon dividing the Nerves, they are not found to possess much *contractility*; while the Arteries, upon being cut, are observed to retract very considerably.

They are generally lodged in the common Cellular Substance and Fat, and in the Interstices of the Viscera and Muscles, where they are protected from compression; though in several parts they are exposed to the hardness of Bones, or to the action of Muscles, over or through which they pass.

In their course through the different parts of the Body, they generally run as straight as is consistent with the nature of the particular part over which they pass, and their own safety.

In their progress, they divide into *Branches*, which become gradually smaller, and which, though taken collectively, are inferior in size to the Trunks from which they issue.

The Branches generally go off at acute angles; but in several places they have a retrograde direction.

They have commonly the same kind of distribution in the opposite sides of the same Subject, and vary little in this respect in different Subjects.

In some parts of the Body, several Nerves unite together, and form a *Plexus*; in others, they unite into a *Common Trunk*; and in many, by such an union, a hard Knot, termed *Ganglion*, is formed.

When

When the *Plexuses*, or the *Common Trunks*, are minutely examined by flitting open their Coverings, it is found, that their Fibrillæ are intermixed in such a manner, that each of the Nerves passing out from the Plexus, or from the Common Trunk, is composed of Fibrillæ from several, or from all the Nerves which entered it, in consequence of which, the Organs in general are furnished with Nerves from various sources.—*Obs. on Nerv. Syst.*

The *Ganglia* differ from each other in size and figure: They have thicker Coats, and are more Vascular than the Nerves; and are larger than the whole of the Nerves, taken conjunctly, which enter into or go out from them.—They are supposed to serve as fresh Sources of Nervous Influence.

They are composed of Nervous Fibrillæ, covered by something like a Cineritious Matter, and are so divided, multiplied, and intermixed, that each of the Nerves passing out from a Ganglion is found to be composed of Fibrillæ derived from the greater part of the Nerves which enter it.—*Obs. on Nerv. Syst.*

Where Nerves pass out from the side of a Ganglion, they are composed of Fibrillæ which come off in contrary directions;—the one set from the beginning, the other from the opposite extremity of the Ganglion.

The Nerves which go out from the different Ganglia have the same structure with those which enter

them, but are found, with only a few exceptions, to be rather larger.

In the Trunk of a Nerve, the Cords appear to run parallel to each other; but when macerated in water, so as to dissolve the Cellular Substance, or when otherwise accurately examined, they are seen evidently to intermix somewhat after the same manner of the Fibrillæ in the Plexus, or in the Glangia.—*Obs. on Nerv. Syst.*

The Termination of the Nerves is soft, pulpy, and pellucid, as is distinctly seen in the Retina of the Eye or Ear; the external Covering being entirely laid aside, while the Pia Mater, in particular, accompanies them throughout.

The Nerves preserve the motion of the Muscular Fibres.

They constitute the immediate Organs of Sensation, and convey impressions made upon them to the Mind.

The manner in which these Impressions are produced, —whether by a Vibration communicated to the Nerves; —or by a Liquid called *Nervous Fluid*, contained and moving in them; —or by an Electric Matter common to them and many other Substances; —or in what manner that Power acts, termed *Animal Electricity*, which has been lately discovered to take place in the Animal kingdom, upon the application of certain Metals; —is not yet understood.

DISTRIBUTION OF THE NERVES.

THE NERVES are distinguished into two Classes; one arising from the Brain, termed *Cerebral*; the other from the Spinal Marrow, termed *Spinal Nerves*.

The Cerebral Nerves are generally reckoned *Nine* or *Ten Pairs*, besides a particular Pair, which has the name of *Sympathetic*.

They pass through the Holes in the Base of the Cranium, and receive their respective names according to their Order; or from their Functions; or from the Parts on which they are dispersed, &c.

The Spinal Nerves consist of *Twenty-nine* or *Thirty Pairs*, which pass out between the different Vertebrae, besides a Pair called *Accessory*, which enter the Cranium from the top of the Spinal Marrow, and afterwards pass out with one of the Cerebral Nerves.

NERVES WHICH PASS THROUGH THE BASE OF THE CRANIUM.

The FIRST PAIR, or OLFACTORY NERVES, Tab. LXIX. *a, a*, Tab. CLXXXIII. arise, on each side of the Brain, by three separate Striæ, from the Corpora Striata, at the under and back part of the Anterior Lobes,

near where the Carotid Arteries enter the *Fissures of SYLVIVS*.

They are more tender than the other Nerves, and also differ from them in not being composed of Fasciculi.

They run each in a Furrow, upon the under Surface of the Anterior Lobes of the Brain, converging a little; and becoming somewhat larger, till they reach the Cribriform Plate of the Ethmoid Bone.

Upon this Plate, each forms an *Oblong Bulb*, which, in colour and consistence, resembles the Cortical part of the Brain, but is mixed with streaks of Medullary Matter.

From this Bulb, numerous Nervous Filaments are sent off, which pass through the Holes of the Cribriform Plate, and now become firm and strong like the other Nerves, by receiving a covering from the Dura Mater.

After entering the Nose, they divide into two Portions or Planes, Tab. CLXXXIV. Fig. 2. 3. Tab. CLXXXV. Fig. 1. 2.; one passing on the Septum, the other upon the Ossa Turbinata, and other parts opposite to the Septum, and both running at first in Grooves of the Bones.

They form a beautiful Plexus, which is spread out upon

upon that side of the Membrane of the Nose which is contiguous to the Bones, and may be traced a considerable way upon it in distinct Threads, which, becoming gradually smaller, sink into the Membrane, and are supposed to terminate on the surface next the Cavity of the Nose, there constituting the Organ of Smell.

The SECOND PAIR, or OPTIC NERVES, Tab. LXIX. *f, f*, Tab. CLXXXIII. which are of great size,—arise from the Thalami Optici, and are connected in their passage to Tubercles at the root of the Infundibulum, which furnish them with an addition of Medullary Substance.

They are of a purer white than other Nerves, having less Cineritious Matter entering their composition, and differ also in the Pia Mater furnishing them with a general Covering, before it invests the several Fasciculi of which they are formed.

At the fore-part of the Sella Turcica, they unite, and have their Medullary Parts intimately intermixed.

From this union, they go obliquely outwards and forwards through the Foramina Optica into the Orbits; and advancing in the Orbits in a waving direction, to prevent them from being over-stretched in the motions of the Eye,—they perforate the Balls, to be expanded into the Retinæ, which have been already described.

The THIRD PAIR, or MOTORES OCULORUM, Tab. LXXIII. Fig. 16. *p*, Tab. LXXVI. smaller than the Optic Nerves,—arise at the under, inner, and back part of the Crura Cerebri, or between the Corpora Albicantia and Tuber Annulare, by numerous Threads which are soon collected into their respective Trunks.

They pass outwards, perforate the Dura Mater at the sides of the Posterior Clinoid Process, and running along the upper part of the Cavernous Sinuses, at the outside of the Carotid Arteries, they get through the Foramina Lacera into the Orbits.

Upon entering the Orbits, they divide into several Branches, which supply the greater number of the Muscles of the Eye, in consequence of which the Nerves have obtained their particular name.

A Branch runs to each of the Muscles within the Orbits, excepting the Trochlearis and Abductor; and the Nerve likewise assists in forming a small Ganglion, termed *Ophthalmic*, from which Twigs are sent off to supply the Ball of the Eye.

The FOURTH PAIR, or PATHETIC, Tab. LXXIII. *w*, Tab. LXXVI. have their origin the highest of the Cerebral Nerves, and are the most slender of the Body, being generally formed of one Fasciculus only on each side.

They arise by a single, and sometimes by a double root, behind the Testes, from the Medullary Expansion which lies over the passage to the Fourth Ventricle, and which unites the *Processus ad Testes* to each other.

They afterwards turn round the Crura Cerebri, and some way behind the entrance of the Third Pair, perforate the Dura Mater at the edges of the Tentorium.

They run afterwards along the Cavernous Sinuses, at

the outer side of the Third Pair, then cross over that Pair, and passing out of the Cranium through the Foramina Lacera, they go obliquely over the Muscles at the upper part of the Orbits, to be entirely dispersed upon the Patheticus or Trochlearis.

The FIFTH PAIR, or PAR TRIGEMINUM, Tab. CLXXXVI. No. 5. Tab. LXIX. Tab. CLXXXIII. which are the largest Nerves of the Brain, arise, each by an anterior small, and a posterior large Portion, from the side of the Tuber Annulare, where the Crura Cerebelli join it.

They enter the Dura Mater a little below the Tentorium, over the points of the Partes Petrofæ of the Temporal Bones, and form a Plexus on each side, in which upwards of fifty Fasciculi have frequently been enumerated. Tab. CLXXXVI. No. 5.

The Plexus sinks close by the outside of the Cavernous Sinus, concealed by a doubling of the Dura Mater, and forms a Ganglion sometimes called GASSERIAN.

The Ganglion is of a semilunar form, and placed transversely with respect to the Trunk of the Nerve.

From the opposite and curved edge of the Ganglion, three large Branches come out; the first and Anterior, termed *Ophthalmic*,—the second and Middle, the *Superior Maxillary*,—and the Third and Posterior, the *Inferior Maxillary*. Tab. LXVI.

The FIRST BRANCH of the FIFTH PAIR, Tab. LXXIII. Fig. 16. *y*. Tab. LXXVI. at the side of the Sella Turcica, is situated lower than the Third Pair, and afterwards crosses over it, being previously connected by Nervous Matter to the Trunk of the Fourth Pair.

It goes through the Foramen Lacera into the Orbit, and is there divided into the following Branches, viz.

The *Supra-Orbital*, which is the largest of the whole, being a continuation of the Ophthalmic.

It passes immediately under the Membrane which lines the upper part of the Orbit, and splits into two Branches of unequal size.

The smaller Branch, termed *Supra-trochlearis*, runs under the Superciliary Ridge to the Upper Eye-lid and Fore-head.

The larger passes through the Foramen Supra-Orbitarium,—or over the Superciliary Ridge when the Foramen is wanting,—sends Branches to the Upper Eye-lid, and divides into several others, which run back, partly above, but chiefly under the Frontalis, to supply the fore and upper part of the Head in general, while minute Fibres appear to penetrate the Bones.

The *Nasal Branch*, which runs obliquely over the Optic Nerve, where it detaches a Filament or two to the Eye, then under the Levator Palpebræ et Oculi; and, getting between the Abductor Oculi and Trochlearis, passes to the inside of the Orbit.

It sends a Branch, which, after entering the Foramen Orbitarium Internum Anterius, re-enters the Cavity of the Cranium, and gets upon the Cribriform Plate of the Ethmoid Bone.

From

From thence it passes down through one of the anterior Holes of this Plate, and sends Twigs to the Membrane at the anterior part of the Nostril, while the Nerve, descending at the fore-part of the Septum Narium, is dispersed upon the Point and Wing of the Nose.

The continuation of the Nasal Branch, now called *Infra-trochlearis*, passes forwards to the inner Corner of the Eye, and is distributed upon the Lacrymal Sac and parts adjacent.

The *Lacrymal Branch*, which runs along the Abductor Oculi, sends Twigs to the Membranes and Fat near it, likewise one or two through the Substance of the Cheek-bone, and one in particular to the Substance of the Lacrymal Gland; while another passes over the Gland, and vanishes in the neighbouring parts.

A *Branch* to the Ophthalmic Ganglion, which is sometimes sent off from the Nasal, at other times from the Ophthalmic Trunk.

The *Ophthalmic Ganglion*, Tab. LXXIII. Fig. 16. v. Tab. CLXXXVI. Tab. LXXVI. termed also *Lenticular*, from its shape, is formed by this Branch from the Fifth, and by another from the Third Pair, and is commonly the smallest in the Body.

It is of an oblong form, and compressed; is situated at the outside of the Optic Nerve a little before the Foramen Opticum, and is concealed in Fat. Sometimes, though rarely, the Filaments which form it take their origin entirely from the Third Pair.

From the Ganglion, about a dozen of Filaments arise, termed *Ciliary Nerves*, collected into two Portions, which creep along the opposite sides of the Optic Nerve, separated a little from each other, and running in company with the Ciliary Arteries.

Besides the Ciliary Nerves from the Ganglion, one and sometimes two Filaments arise from the Ramus Nasalis, and pass along with the other Ciliary Branches.

The Ciliary Nerves, running with scarcely any division, reach the back part of the Eye, and, a little before the Insertion of the Optic Nerve, enter the Sclerotic Coat, pass obliquely through it, and, about the middle of the Ball, appear upon the Surface of the Tunica Choroides.

Upon this Coat, they run flat, and in a parallel direction, sending very few evident Branches, either to it or to each other, till they reach the Ciliary Circle, where they divide into numerous minute Filaments.

Upon the Choroides, five or six are larger than the rest; some being so minute as almost to escape the naked Eye.

At the Ciliary Circle, each commonly divides into two Branches, which are covered by the Cellular Substance of the Circle; and these, at the root of the Iris, are subdivided into still smaller Branches, which run in a radiated and waving direction; the Ciliary Vessels being interposed.

Near the Pupil, they are united into Aches, from

which very minute Twigs run to the interior margin of the Iris.

The **SECOND BRANCH**, or **SUPERIOR MAXILLARY NERVE**, Tab. CLXXXVI. No. 28. Tab. CLXXXVIII. is larger than the Ophthalmic, and is principally dispersed upon the Parts belonging to the Upper Jaw, from which it has its name.

It goes through the Foramen Rotundum of the Sphenoid Bone, and at its exit divides into numerous Branches, viz.

The *Spheno-Palatine*, or *Lateral Nasal Nerve*, which sends a reflected Branch through the Foramen Pterygoideum of the Sphenoid Bone, to join the Sympathetic Nerve in the Canalis Caroticus, and a Branch which enters the Foramen Innomiatum of the Pars Petrofa, to join the Portio Dura of the Seventh Pair.

The Lateral Nasal Nerve goes afterward into the Spheno-palatine Hole, to be dispersed upon the under and back part of the Septum, and opposite side of the Nose, and upon the Membrane of the Sphenoidal Sinus and Eustachian Tube: One Branch, in particular, after passing along the Septum, goes through the Foramen Incisivum to the Roof of the Mouth.

The *Palato Maxillary*, or *Palatine Branch*, which descends through the Canal leading to the Foramen Palatinum Posteriorem, and, running near the Alveoli with considerable Blood-vessels, sends Branches to the Velum Palati and Roof of the Mouth, and minute Filaments which penetrate into the Palate-plate of the Superior Maxillary Bone.

Small Branches, which pass round the Upper Jaw, and vanish in the Cheek.

A *Twig*, which goes through the Hole in the Os Malaræ, along with a Branch of the Ocular Artery to the Face.

Small Filaments, which run down into the back part of the Superior Maxillary Bone, and supply the Substance of the Upper Jaw, the large Dentes Molares, and Membrane lining the Antrum Maxillare.

The Second Part of the Fifth Pair, after sending off these different Branches, goes into the Canal under the Orbit, and forms the Infra-orbital Nerve, which, while in the Canal, gives off Filaments passing through minute Conduits in the Upper Jaw, to the Antrum, to the Substance of the Bone, to the small Molares, Caninus, and Incisores; and sometimes a Twig, the companion of a small Branch of the Internal Maxillary Artery, to the Membrane lining the Orbit.

The Infra-orbital Nerve passes afterwards out of the Foramen Infra-orbitarium, and divides into many large Branches, to be distributed upon the Cheek, Under Eyelid, Upper Lip, and side of the Nose.

The **THIRD BRANCH**, or **INFERIOR MAXILLARY NERVE**, Tab. CLXXXVI. No. 19. Tab. CLXXXVIII. goes through the Foramen Ovale of the Sphenoid Bone, and supplies the parts belonging to the Under Jaw, and the

the Muscles situated between it and the Os Hyoides, by the following Branches, viz.

One or sometimes two *Deep Temporal Branches*, to the inner part of the Temporal Muscle.

Branches, to the Masseter, Pterygoideus, and Buccinator.

A *Branch*, which passes behind the Cervix of the Lower Jaw, and gives off Filaments to the fore-part of the Ear, and afterwards accompanies the Temporal Artery upon the side of the Head, where it terminates.

A *Branch* to the Buccinator, and other parts of the Cheek.

A Nerve of considerable size, termed *Lingual*, or *Gustatorius*, which passes between the Pterygoidei, to the inner of which it gives some Filaments. It then sends off, from its under side, a Ganglion which transmits Nerves to the Inferior Maxillary Gland.

The Lingual Nerve also transmits several Branches to the Sublingual Gland, and to the Muscles of the Tongue.

It terminates, at length, near the Point of the Tongue, by many Branches which belong chiefly to the Papillæ; in consequence of which, this Branch is considered as the principal Nerve of the Organ of Taste.

The Trunk of the Inferior Maxillary Nerve, having parted with the Lingual Nerve, directs its course between the Pterygoid Muscles to the Posterior Foramen of the Inferior Maxillary Canal.

Before entering the Canal, it sends off a long and slender Branch, which is lodged at first in a Furrow of the Bone, and goes afterwards to be dispersed chiefly upon the Mylo-hyoideus and Sublingual Gland.

The Trunk of the Nerve is afterwards conducted along the Canal of the Jaw under the Alveoli, where it distributes Filaments to the different Teeth of the corresponding side, and to the substance of the Bone; and coming out of the Canal by the Anterior Maxillary Foramen, Tab. CLXXXVII. *y*, somewhat diminished in size, it scatters its remaining Branches upon the Chin and Under Lip.

The SIXTH PAIR, or ABDUCENTES, Tab. LXIX. *k, k*. Tab. CLXXXIII. arise from the beginning of the Medulla Oblongata, at the part common to the Tuber Annulare and Corpora Pyramidalia, and are the smallest of the Cerebral Nerves; the Fourth Pair excepted.

They perforate the Dura Mater at the inner side of the entrance of the Fifth Pair, and run forwards within the Cells of the Cavernous Sinus; but so surrounded by Cellular Substance, as to seem to be protected from the Blood of that Receptacle.

While in the Sinus Cavernosi, they are situated between the Ophthalmic Nerves and Carotid Arteries, upon the surface of the latter of which they send off two or three Filaments on each side of the Head, to assist in forming the Great Sympathetic Nerves.

The Trunks of the Sixth Pair afterwards go through

the Foramina Lacera, to be dispersed entirely upon the Abductores Oculorum.

The SEVENTH PAIR is composed, on each side, of two portions,—the *Nervus Auditorius*, *Nervus Acusticus*, or *Portio Mollis*; and the *Communicans Faciei*, or *Portio Dura*.

The PORTIO MOLLIS, Tab. LXIX. *l, m*. Tab. CLXXXIII. is the softest of the Nerves; excepting the Olfactory.

It arises by transverse Medullary Striæ from the anterior part of the Fourth Ventricle, and is separated from its fellow of the opposite side only by the *Crena* of the Calamus Scriptorius. Tab. CXCI. Fig. 2. *f, f*.

The Striæ, turning round the Medulla Oblongata, apply themselves to the Tuber Annulare, from which they receive an addition of substance, and then get to the side of the Portio Dura.

The PORTIO DURA, sometimes also called *Sympatheticus Minor*, arises from that part of the Brain which is common to the Pons VAROLII, Crura Cerebelli, and Medulla Oblongata; and, at its Origin, is situated upon the inner side of the Portio Mollis. Tab. LXIX. Tab. CLXXXIII.

Between the origin of the Portio Dura and Trunk of the Portio Mollis, a small Nerve arises, termed by WRISBERG, *Portio Media inter Portionem Duram et Portionem Mollem*. Tab. LXIX. Tab. CLXXXIII.

It comes off by minute Fibrillæ, which soon unite into a Trunk, from the posterior part of the Pons VAROLII, or from the adjoining part of the Medulla Oblongata, and is an Accessory Nerve of the Portio Dura.

The Portio Dura, considerably smaller than the Portio Mollis, gets into the Meatus Auditorius Internus, and is there lodged in a kind of half-sheath, formed by that Nerve, to which it is connected by fine Cellular Substance; the Dura Mater, which lines the Passage, giving here a general Covering to both Nerves.

PORTIO MOLLIS.—The Portio Mollis is formed of two Fasciculi, nearly of equal size, one of which belongs to the Cochlea, the other to the Vestible and Semicircular Canals. Tab. LXXVIII. Fig. 14. *f, n*. Tab. LXXIX. A.

Each of these Fasciculi passes by numberless Fibrillæ through the Cribriform Plate in the bottom of the Meatus Auditorius Internus, to the inner parts of the Labyrinth.

The Fibrillæ destined for the Cochlea go through the Holes in the sides of the Modiolus.

Some pass between the Plates which form the Septa of the Gyri; others go through Holes between the Osseous Plates of the Lamina Spiralis; but by much the greatest number perforate the sides of the Modiolus, between the Septum of the Gyri and the Lamina Spiralis.

The larger Fibrillæ run upon the Membrane covering the Lamina Spiralis; while the smaller go from the Modiolus, between the Osseous Septa and on the inner sides

of

way, to the Eighth Pair, by Cellular Substance. Tab. CXCII. No. 77.

A little below the Cranium, each of the Trunks of this Pair of Nerves is conjoined by a cross Branch with the Sub-occipital Nerve, or with an Arch which connects that Nerve and the First Cervical together.

The Trunk then descends between the Internal Jugular Vein and Internal Carotid Artery, and at the root of the Occipital Artery crosses over both Carotids to its place of destination.

Where it begins to cross over the Carotids, it sends down a Branch of considerable size, termed *Descendens Noni*.

The *Descendens Noni*, Tab. CXCII. No. 78. passes down a certain length along with the common Carotid Artery, and, in its course, furnishes Branches to the upper ends of the Omo-hyoideus and Sterno-thyroideus, after which it unites with Branches from the First and Second, and with small Filaments from the Second and Third Cervical Nerves, forming an Arch, from which long and slender Twigs go to the under portions of the Sterno-thyroideus, and to the Omo-hyoideus and Sterno-hyoideus.

The Ninth Nerve passes afterwards behind the Facial and Temporal Veins, or the Trunk formed by these, and over the root of the Facial Artery,—sending a Twig to the Hyo-thyroideus.

Upon the Hyo-glossus, the Trunk of the Nerve is spread into many Branches, which go to the middle of the Tongue, and terminate chiefly in its fleshy parts; a Twig extending as far as the Genio-hyoideus, and two, or sometimes only one Filament anastomosing with the Lingual Branch of the Fifth Pair.

The GREAT SYMPATHETIC NERVE,—obtaining its name from its numerous connections with most of the other Nerves of the Body,—is either formed originally by the reflected Branch from the second of the Fifth Pair, and by one or two, and sometimes three small Filaments sent down from the Sixth Pair while in the Cavernous Sinus; or, according to the opinion of some Authors, the Sympathetic sends off these small Nerves to join the Fifth and Sixth Pairs.

Upon the Surface of the Internal Carotid Artery, while in the Carotid Canal, the Branches of the Fifth and Sixth Nerves and Great Sympathetic making this connection, are pulpy and tender, and form a Plexus which surrounds the Carotid; from which the Trunk of the Sympathetic is most frequently considered as being sent out.

After escaping from the Carotid Canal, the Trunk, which is of small size, is closely connected, for a short space, with the Trunks of the Eighth and Ninth Nerves; and, separating from these, it expands into a large Ganglion, termed *Ganglion Cervicale Superius*, of a long oval form, and situated opposite to the Second Cervical Vertebra. Tab. CXCII. x.

From this Ganglion, the Nerve comes out very little

increased in size, Tab. CXCII. No. 8. and descends on the Anterior Vertebral Muscles of the Neck, behind the Eighth Pair of Nerves, with which, and with the Carotid Artery, it is connected by a Sheath of Cellular Substance.

At the under part of the Neck, and nearly where the Inferior Laryngeal Artery turns towards the Larynx, the Sympathetic forms another Ganglion, termed by some Authors *Cervicale Medium*, and by others *Cervicale Inferius*.

The Ganglion Medium, Tab. CXCII. No. 11. 17. is somewhat similar in shape and size to the Ganglion Superius; though it varies considerably in these respects in different Subjects.

From this Ganglion, principal Branches are sent down, one of which, larger than the rest, and considered as the continuation of the Trunk, turns outwards between the Inferior Laryngeal and Vertebral Arteries to another Ganglion.

This third Ganglion, Tab. CXCII. No. 31. is placed at the Head of the first Rib, and is termed by some Authors *Ganglion Cervicale Inferius*, vel *Imum*, while others consider it as the first of the Thoracic Ganglia.

The Cervical part of the Great Sympathetic is connected with other nerves, and dispersed upon different parts, by the following Branches, viz.

One or two short but thick Branches, which connect the beginning of the Superior Ganglion with the root of the Sub-occipital Nerve:

One or two Pulpy Nerves, which run forwards behind the Internal Carotid Artery, and divide into many others. These, together with the Filaments from the Glossopharyngeus, form a Plexus which sends Branches to the Gangliform Expansion of the Pharyngeus, and afterwards embraces the External Carotid Artery, sending Plexuses of Filaments along its different Branches:

One or two other soft Nerves, going behind the Internal Carotid, and with a Branch of the Laryngeus Internus of the Eighth Pair, forming the Laryngeus Internus:

Thick short Roots connecting the First, or Conjugation of the First and Second Cervicals, with the Superior Ganglion of the Sympathetic Nerve.

From the Superior Ganglion, also, are sent off small Branches, which, uniting with Filaments from the Laryngeus Superior, form the *Ramus Cardiacus Supremus*, vel *Superficialis Cordis*. Tab. CXCII. No. 3. 4. 6.

The *Superficial Cardiac Nerve* of the Sympathetic, in the Right Side, divides into Branches at the bottom of the Neck, which send a Filament or two along the Inferior Laryngeal Artery to the Thyroid Gland, and afterwards unite with the Superficial Cardiac Nerve of the Eighth Pair before the Subclavian Artery, and with the Laryngeal Nerve behind it.—In the Left Side, it terminates in the Cardiac Plexus of Nerves.

From the Second, Third, and Fourth Cervical Nerves, an equal number of Cords descend behind the Scaleni and

and Rectus Major, to the middle Ganglion of the Great Sympathetic.

From the opposite side of the Ganglion, Branches are sent down, which join and form the *Nervus Magnus Profundus*; others are fixed to the Superficial Cardiac and to the Recurrent of the Eighth Pair. The rest go partly over and partly behind the Subclavian Artery, to the Inferior Cervical, and to the first Thoracic Ganglion.

NERVI ACCESSORII AD PAR OCTAVUM.—The Accessory Nerves arise by small Filaments from the Lateral Parts of the Medulla Oblongata and upper portion of the Spinal Marrow.

The Filaments from the Spinal Marrow come off between the Anterior and Posterior Bundles of the Cervical Nerves,—the first of them frequently extending as far as the space between the Sixth and Seventh Pairs.

The different Filaments unite by degrees into their respective Trunks, and often have connections while within the Dura Mater with one or two of the Bundles of the uppermost Spinal Nerves.

The Trunk of the Nerve passes out, in each side of the Cranium, in company with the Nerve of the Eighth Pair; but forms no part of that Nerve, being included in its own peculiar Sheath received from the Dura Mater.

After perforating the Cranium, it separates from the Eighth, and descends obliquely outwards through the Sterno-mastoideus to the Shoulder.

At its exit, it sends off a Branch, termed by some *Ramus Minor*, (the Trunk itself being then called *Ramus Major*), which assists in forming the Pharyngeal Nerve; and gives another, smaller than the former, to be connected to the Pars Vaga of the Eighth Pair.

At the fore-part of the Sterno-mastoideus, it is joined by an Arch to the Sub-occipital, and frequently by another to the First Cervical Nerve.

In its passage through the Sterno-mastoideus, it sends several Branches to the Substance of that Muscle, and terminates at length in the Trapezius.

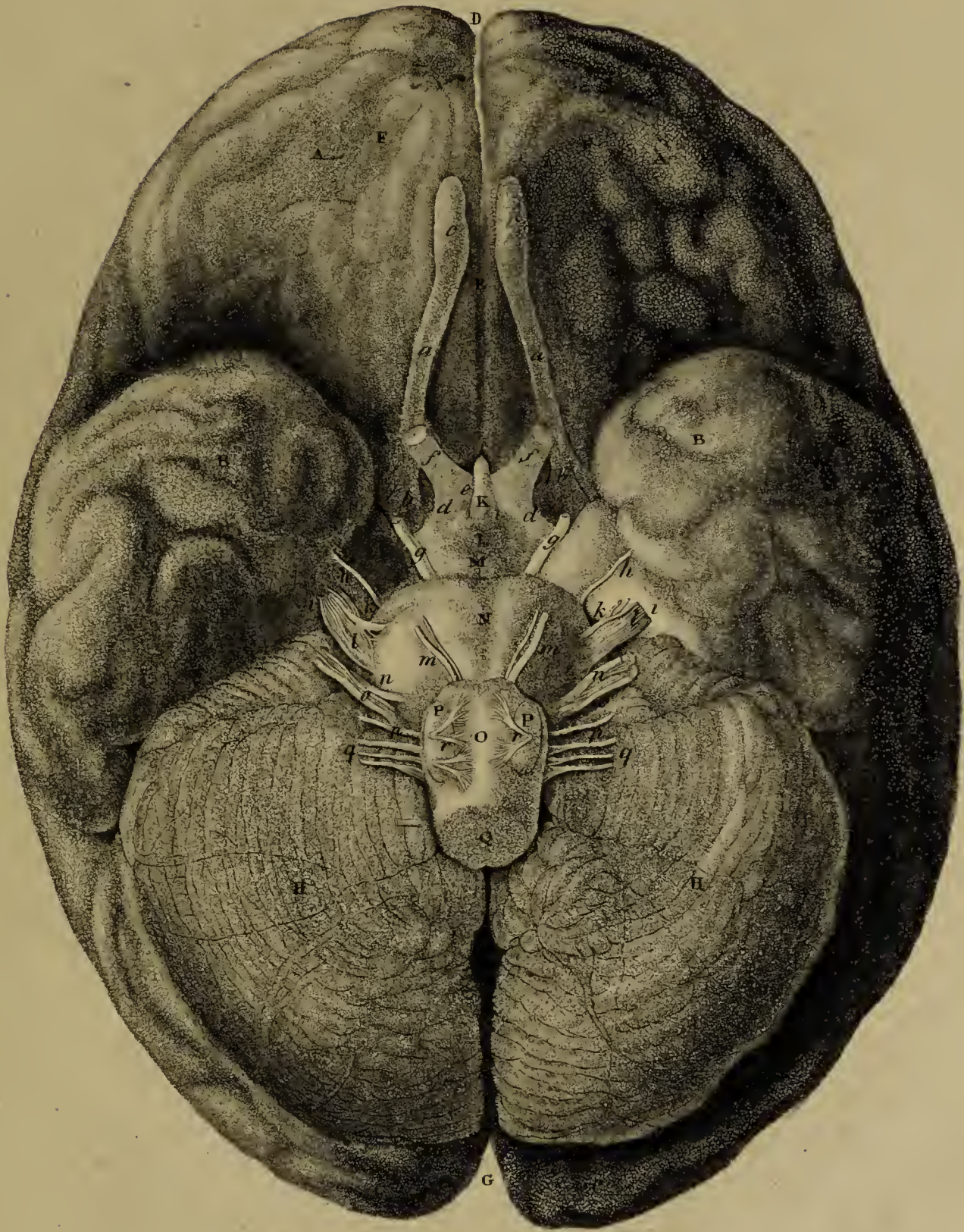
TABLE

T A B L E CLXXXIII.

Represents the BASE of the BRAIN, with the Origin of its NERVES, from a CHILD of three Years of Age, in which the size of the BRAIN is observed to be little inferior to that of an ADULT; but the GYRI are rounder, the cohesion of the LAMINA of the CEREBELLUM flighter, and the CEREBELLUM a little larger in proportion to the CEREBRUM. The NERVES are rounder, and more distinctly Fibrous.

-
- | | |
|---|--|
| A, A, The anterior lobes of the cerebrum. | ber cinereus, with a fibra medullaris interna and a fibra medullaris externa. |
| B, B, The lateral lobes. | <i>c, c,</i> The bulbus cinereus of each of these nerves. |
| C, C, The posterior lobes. | <i>d, d,</i> The tractus optici. |
| D, The distance between the anterior lobes. | <i>e,</i> The union of the optic nerves. |
| E, The space where the anterior lobes are contiguous. | <i>f, f,</i> The trunks of the optic nerves. |
| F, The sinuosities of the anterior lobes corresponding with the orbits. | <i>g, g,</i> The third pair. |
| G, The distance between the posterior lobes. | <i>b, b,</i> The fourth pair. |
| H, H, The right and left portions of the cerebellum, with some branches of arteries and veins dispersed upon them. | <i>i, i,</i> The fifth pair. |
| I, The middle of the cerebellum uniting its right and left portions. | <i>k, k,</i> Their smaller anterior portions; |
| K, The infundibulum. | <i>l, l,</i> Their larger posterior portions. |
| L, The pars cinerea, from which the infundibulum depends. | <i>m, m,</i> The sixth pair, each composed of a smaller internal, and a larger external portion. |
| M, The corpora albicantia. | <i>n, n,</i> The portio dura of the seventh pair in each side, or nervus facialis. |
| N, The nodus encephali, sponis Varolii. | <i>o, o,</i> The portio mollis, or auditory portion of the seventh pair, fulcated for receiving the facial nerve, and nearly as large as in the adult. |
| O, The upper part of the spinal marrow, termed <i>Medulla Oblongata.</i> | Between the facial and auditory nerves, the filaments are seen which join the facial nerves. |
| P, The corpora olivaria. | <i>p, p,</i> The glosso-pharyngei of the eighth pair. |
| Q, A section of the spinal marrow. | <i>q, q,</i> The nervi vagi of the eighth pair composed of three fasciculi. |
| <i>a, a,</i> The olfactory nerves fulcated, becoming broader in their progress forwards, and considerably larger than in the adult. | <i>r, r,</i> The ninth pair, or nervi hypo-glossi, which in the right side consists of two trunks. |
| <i>b, b,</i> The roots of these nerves, each composed of a tu- | |

TAB. 183.



Engraved by A. Fyfe.

Fig. 1.

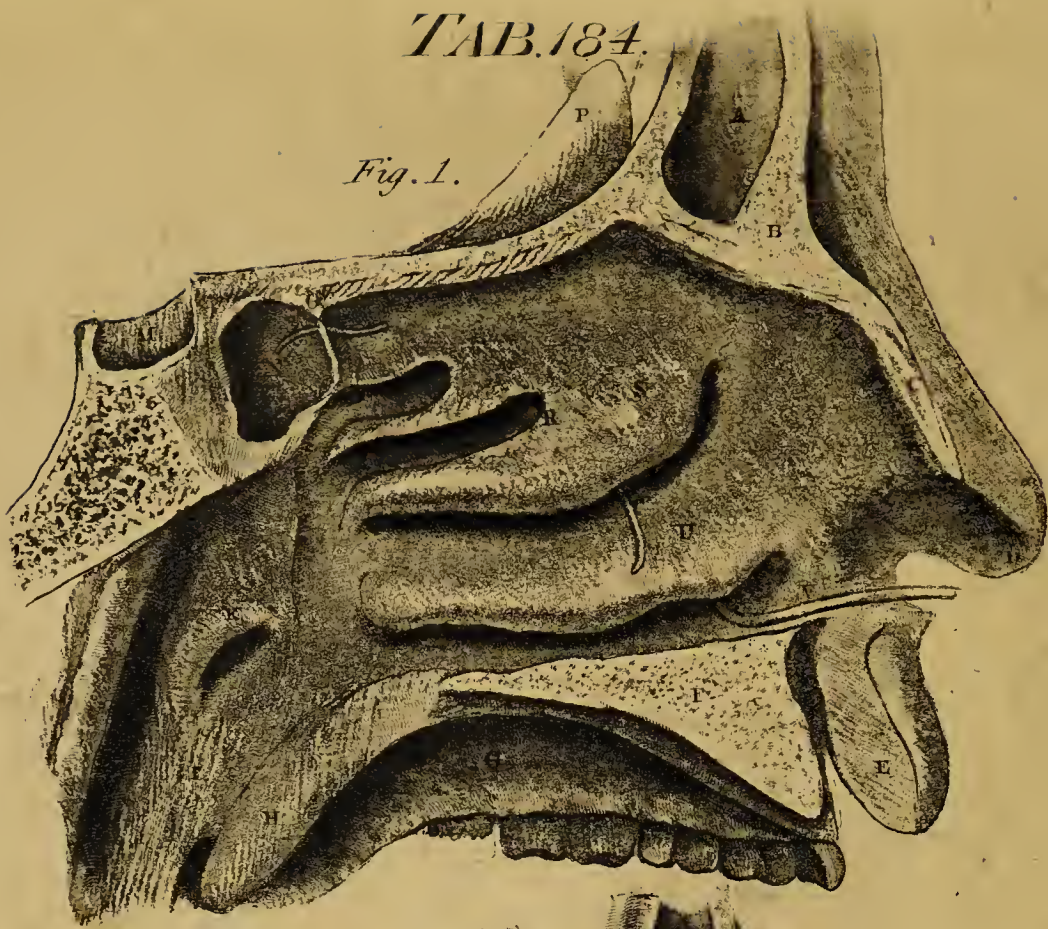

Fig. 2.

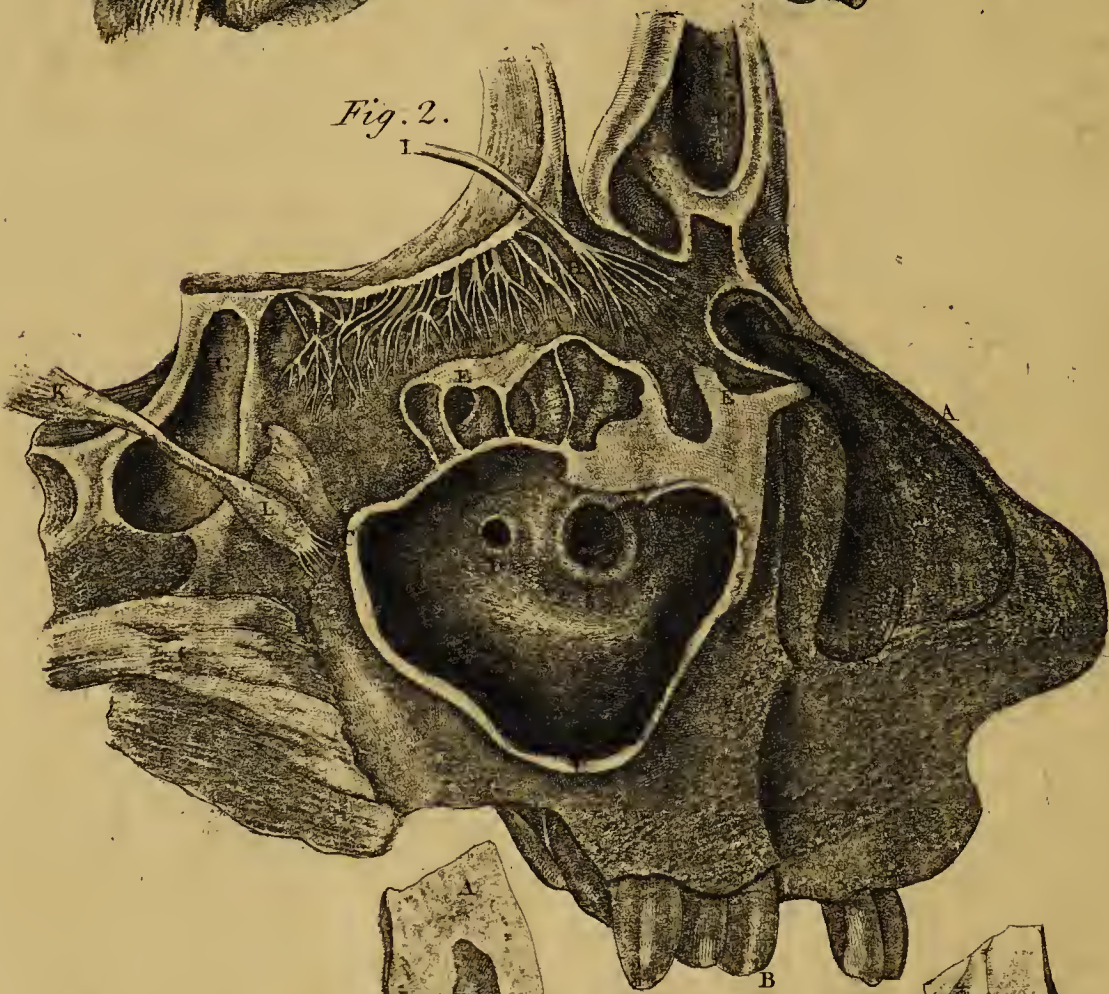


Fig. 3.

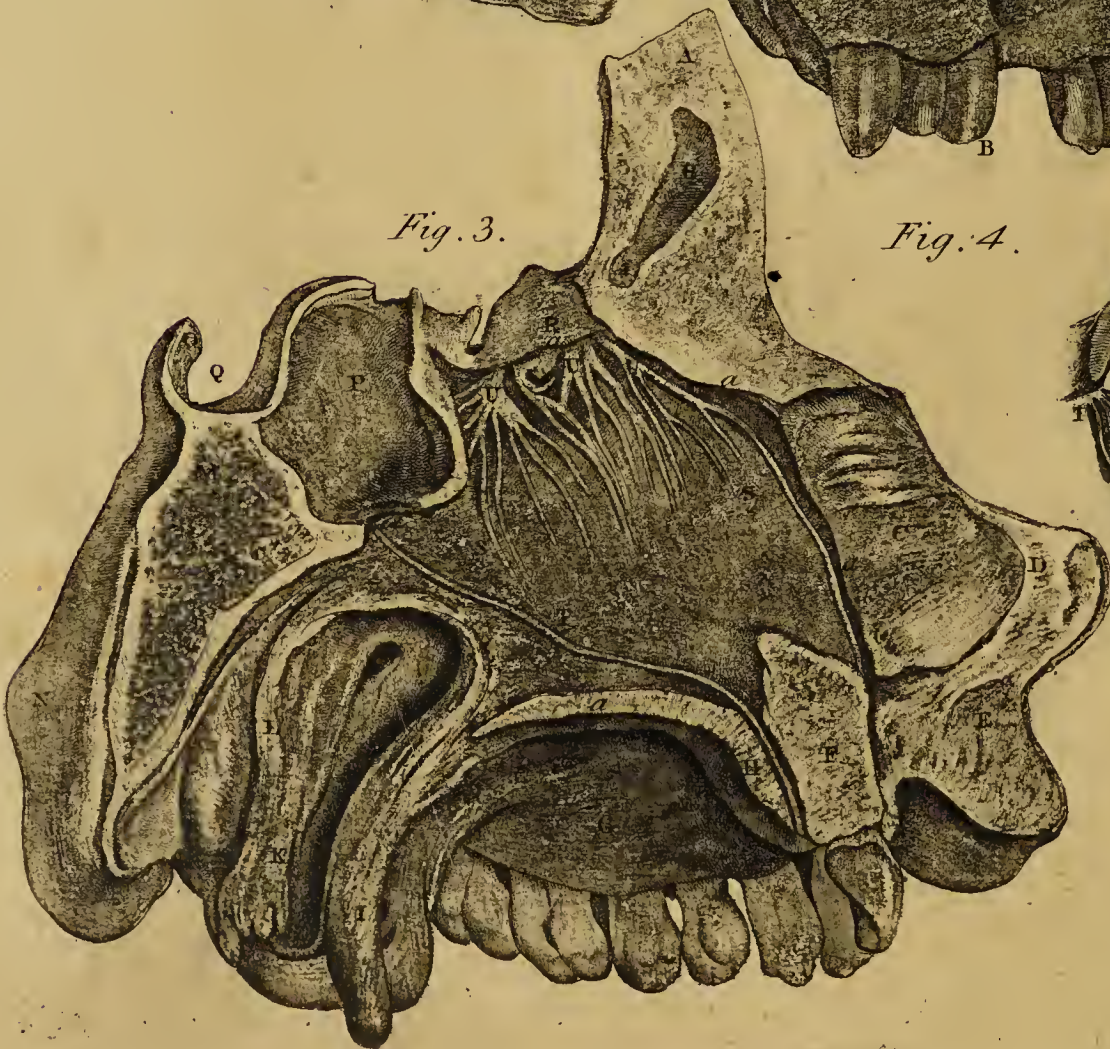
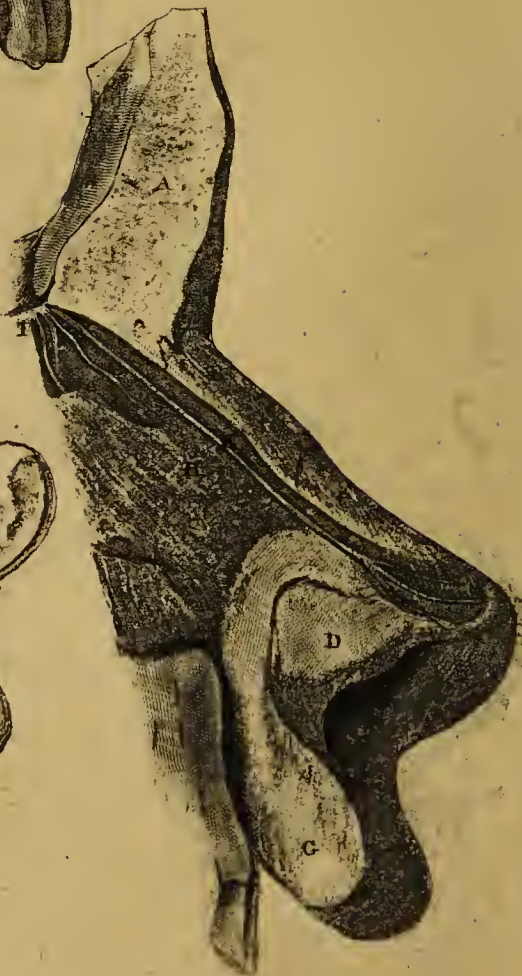
Fig. 4.



T A B L E CLXXXIV.

Represents the NERVES of the Inside of the Nose.

FIG. 1.

A Section of the Left Side of the NOSE, the SEPTUM NARIUM being removed.

- A, The frontal sinus.
- B, ————— bone.
- C, The os nasi.
- D, The point of the nose.
- E, The upper lip.
- F, The palate-plate of the superior maxillary bone.
- G, The roof of the mouth.
- H, The uvula.
- I, The fauces.
- K, The mouth of the Eustachian tube.
- L, The body of the sphenoid bone.
- M, The fella turcica.
- N, The sphenoid sinus.
- O, The opening of the sinus into the nose.
- P, The Crista Galli of the ethmoid bone.
- Q, R, Openings from the ethmoid cells into the nose.
- S, The superior spongy bone.
- T, A probe introduced into the opening of the antrum maxillare.
- U, The inferior spongy bone.
- V, A probe in the lacrymal duct.

FIG. 2.

Represents the Distribution of the BRANCHES of the FIRST, or OLFACTORY PAIR of NERVES, and of the NASAL BRANCH of the FIFTH PAIR upon the MEMBRANE of the NOSE.

- A, The ridge of the nose.
- B, The teeth of the right side.
- C, C, C, A section of the antrum maxillare.
- D, Its openings into the nose.

- E, E, The cells of the ethmoid bone.
- F, The right frontal sinus cut open.
- G, ————— sphenoidal sinus cut open.
- H, H, Branches of the first, or olfactory nerves.
- I, The nasal branch of the first branch of the fifth pair of nerves, ending partly in the septum narium, and partly in the membrane which lines the outer side of the nose.—The branch represented too large.
- K, The nasal branch of the second branch of the fifth pair of nerves.
- L, Its division into branches, which are dispersed on the membrane which lines the outer side of the nose.

FIG. 3.

The OLFACTORY, or FIRST PAIR of NERVES, as they are seen upon the MEMBRANE of the SEPTUM NARIUM.—The OSSEOUS SEPTUM is removed, to obtain a View of the NERVES of the LEFT NOSTRIL, as they pass at first between the MEMBRANE and BONE.

- A, The os frontis.
- B, The frontal sinus.
- C, The cartilaginous part of the septum narium.
- a, a, a, a, The cut edge from which the septum has been separated all round.
- D, The surface of the common skin, where it is lost in the membrane of the nose.
- E, The upper lip.
- F, Part of the alveolar process of the os maxillare, next the symphyfis.
- G, The roof of the mouth.
- H, The bony palate.
- I, The uvula and palatum molle.
- K, The upper part of the fauces.
- L, The opening of the Eustachian tube.
- M, The cuneiform process of the os occipitis.
- N, The inside of the cuneiform process, near the foramen magnum.

O, The

- O, The posterior clinoid process.
 P, The sphenoid sinus, with its septum.
 Q, The sella turcica.
 R, The Crista Galli.
 S, S, The membrane of the left nostril, which lined the septum,—the septum being removed.
 T, A branch of the fifth pair of nerves, which comes through the foramen commune, or sphenopalatinum.
 U, U, U, The first pair of nerves ramifying on the membrane of the septum, after having passed through the cribriform plate of the ethmoid bone.

FIG. 4.

The OLFATORY, or FIRST PAIR of NERVES, as they are

seen upon the MEMBRANE of the NOSE which covers the Turbinated BONE.

- A, The os frontis.
 B, The os nasi.
 C, The cartilaginous and membranous part of the nose.
 D, The ala nasi, with the skin left on it.
 E, The septum narium.
 F, The upper lip.
 G, Part of the alveolar process of the os maxillare next the symphysis.
 H, The membrane of the nose.
 I, A portion of the first pair of nerves, which is afterwards lost upon that part of Schneider's membrane which covers the turbinated bones, Fig. 3. U, U, U.
 K, The branch of the fifth pair of nerves, which is supposed to be lost on the membrane of the nose.

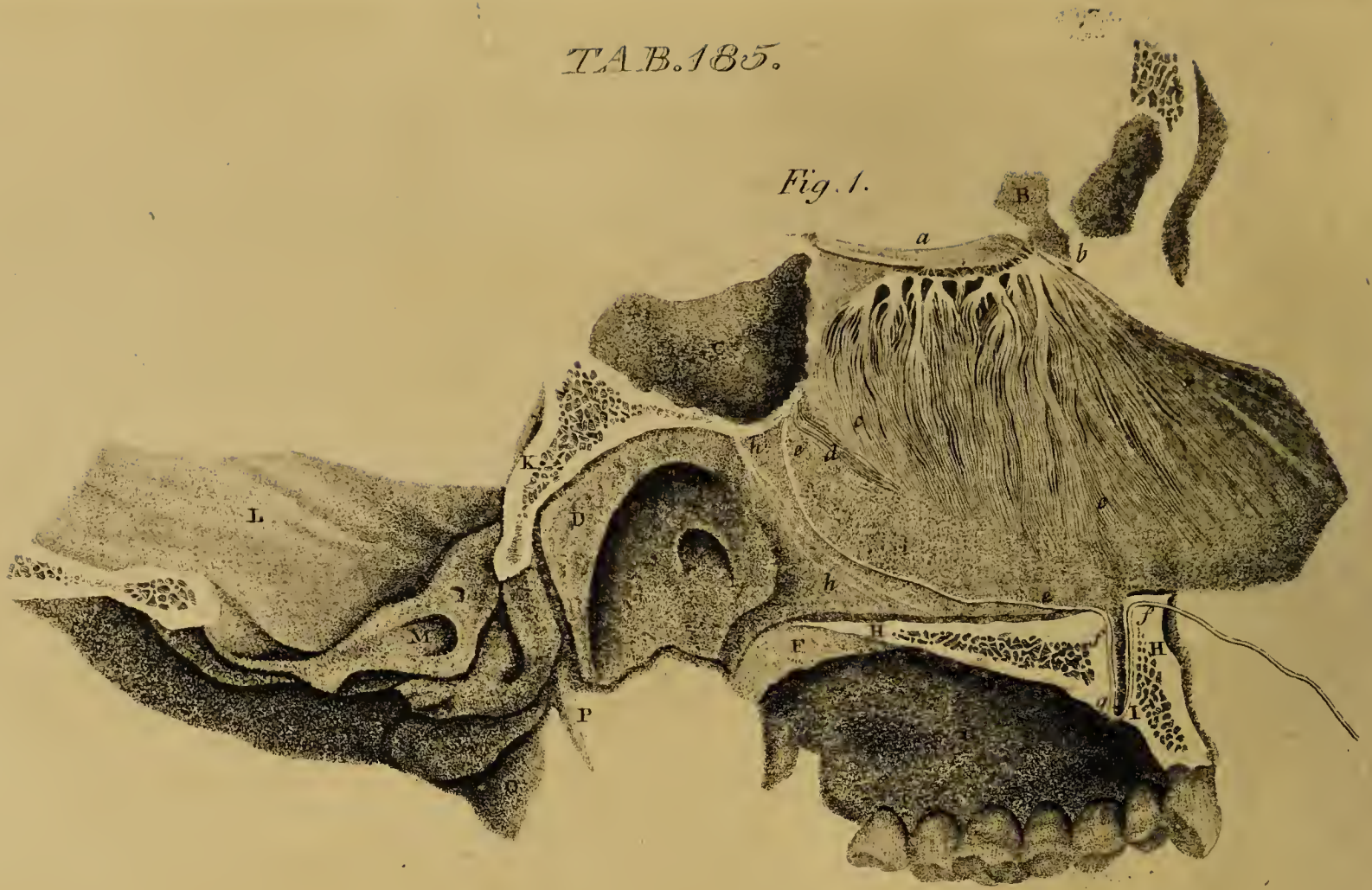


Fig. 2.

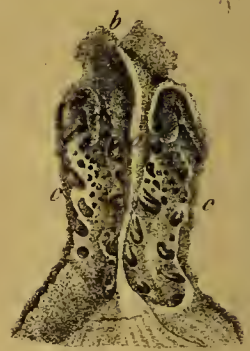

Fig. 3.

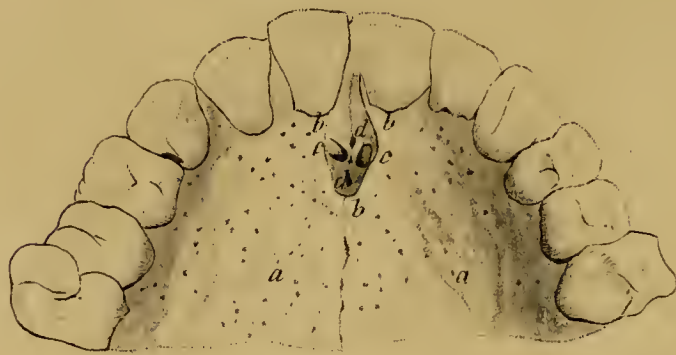
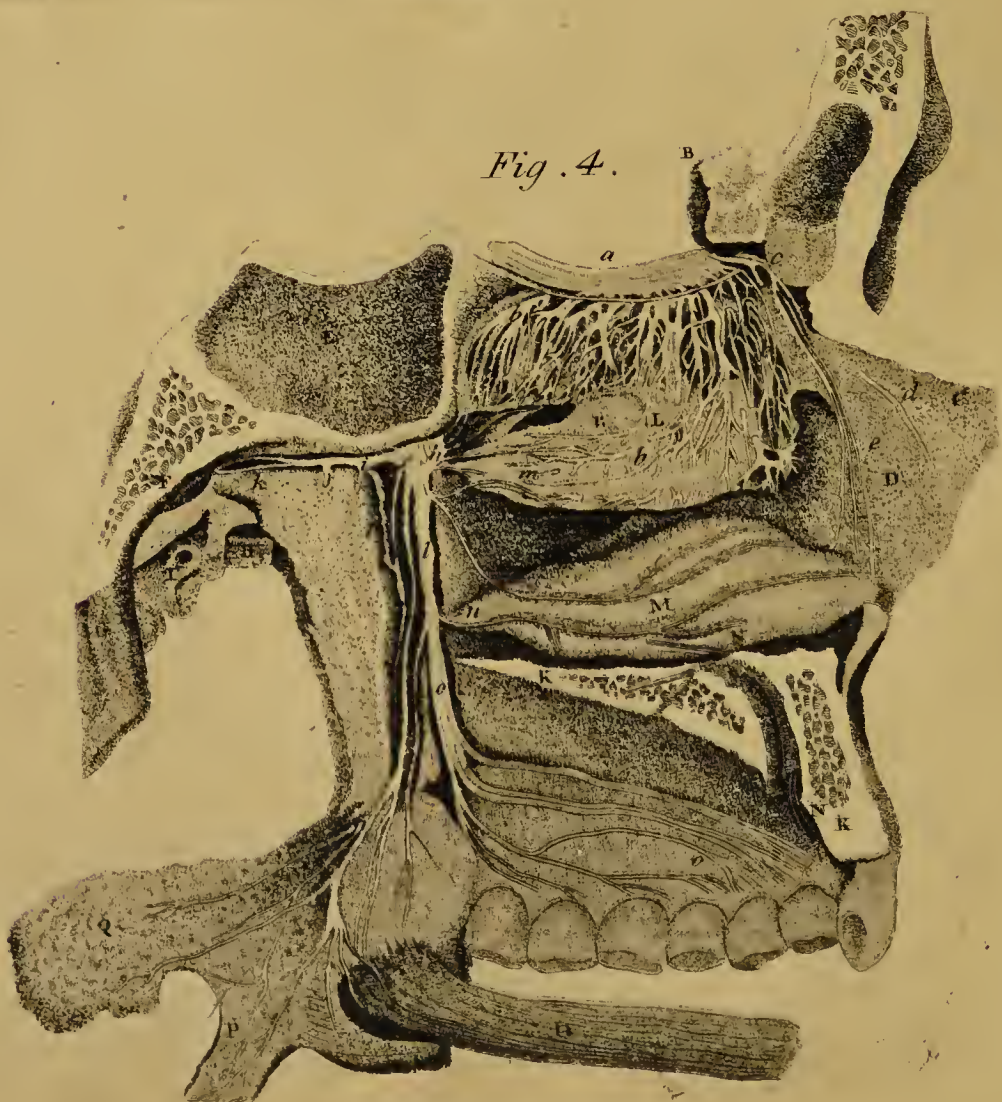
Fig. 4.



T A B L E CLXXXV.

Additional VIEWS of the NERVES of the NOSE.

FIG. 1.

The Left Portion of the BASE of the HEAD divided by a Perpendicular Section proceeding from before backwards, and the Osseous and Cartilaginous Portion of the SEPTUM NARIUM separated from their investing Membrane.—The NERVES upon the Membrane of the SEPTUM are drawn by the assistance of a Magnifying Glass.

- A, The frontal sinus.
 B, Part of the Crista Galli.
 C, The sphenoid sinus.
 D, The membrane of the arch of the fauces perforated by many mucous follicles.
 E, The mouth of the EUSTACHIAN tube.
 F, Part of the palatum molle.
 G, The membrane lining the roof of the mouth.
 H, H, A section of the superior maxillary and palate bones.
 I, The canalis incisivus of the left side.
 K, A section of the cuneiform process of the occipital bone.
 L, Part of the occipital bone in the cavity of the cranium.
 M, The passage of the ninth nerve.
 N, The occipital condyloid process.
 O, The mastoid process.
 P, The styloid process.
a, a, The olfactory nerve, a little raised at its outside. In it are seen, its cut end behind, of a triangular form, its anterior bulbous extremity; the division of this into medullary striæ; and the nervous fibrillæ sent from it, through the lamina cribrosa of the cranium.
b, The nasal nerve of the ophthalmic of the fifth pair, divided into an exterior and interior branch, the latter of which is seen advancing towards the point of the nose.
c, c, c, The nervous filaments of the first pair, descending upon the side of the membrane which is opposed to the osseous and cartilaginous parts of the septum narium. At their entrance into the nose, they are of considerable size; near the lower part of the membrane, they become extremely small, and are seen forming a zonula of nervous fibrillæ.
d, Nasal twigs from the spheno-palatine ganglion.
e, e, The naso-palatine nerve.

VOL. III.

- f, f*, The naso-palatine nerve of the right and left sides descending to the palate.
g, A coalition of the two naso-palatine nerves, and their distribution upon the glandular membrane of the palate.
b, b, The nasal branch to the septum from the VIDIAN hole.

FIG. 2.

Represents the LAMINA ETHMOIDIS, seen from the Cavity of the CRANIUM in a dry SKULL.

- a*, The Crista Galli.
b, The process which joins the nasal apophysis of the frontal bone.
c, c, The lamina ethmoidis, perforated by two series of larger foramina; an internal next the Crista Galli, and an external at the outer part of the lamina. Between the two larger series, a set of smaller holes are observed.
d, A sulcus for the nasal nerve from the ophthalmic of the fifth pair.
e, A rima in the lamina cribrosa, opening into the nose, and separated from the above-named sulcus by an osseous spine.

FIG. 3.

Shews the Orifices of two CANALS for the Passages of the NASO-PALATINE NERVES to the Glandular Membrane of the PALATE.

- a, a*, The osseous palate.
b, b, b, A sinus in the osseous palate behind the anterior dentes incisores.
c, c, The orifices of the ductus incisivi, termed also STENO'S ducts, to the palate.
d, The exit of the posterior, or left canal, for the naso-palatine nerve of that side.
e, The orifice of the anterior, or right canal, for the naso-palatine nerve of the right side.

FIG. 4.

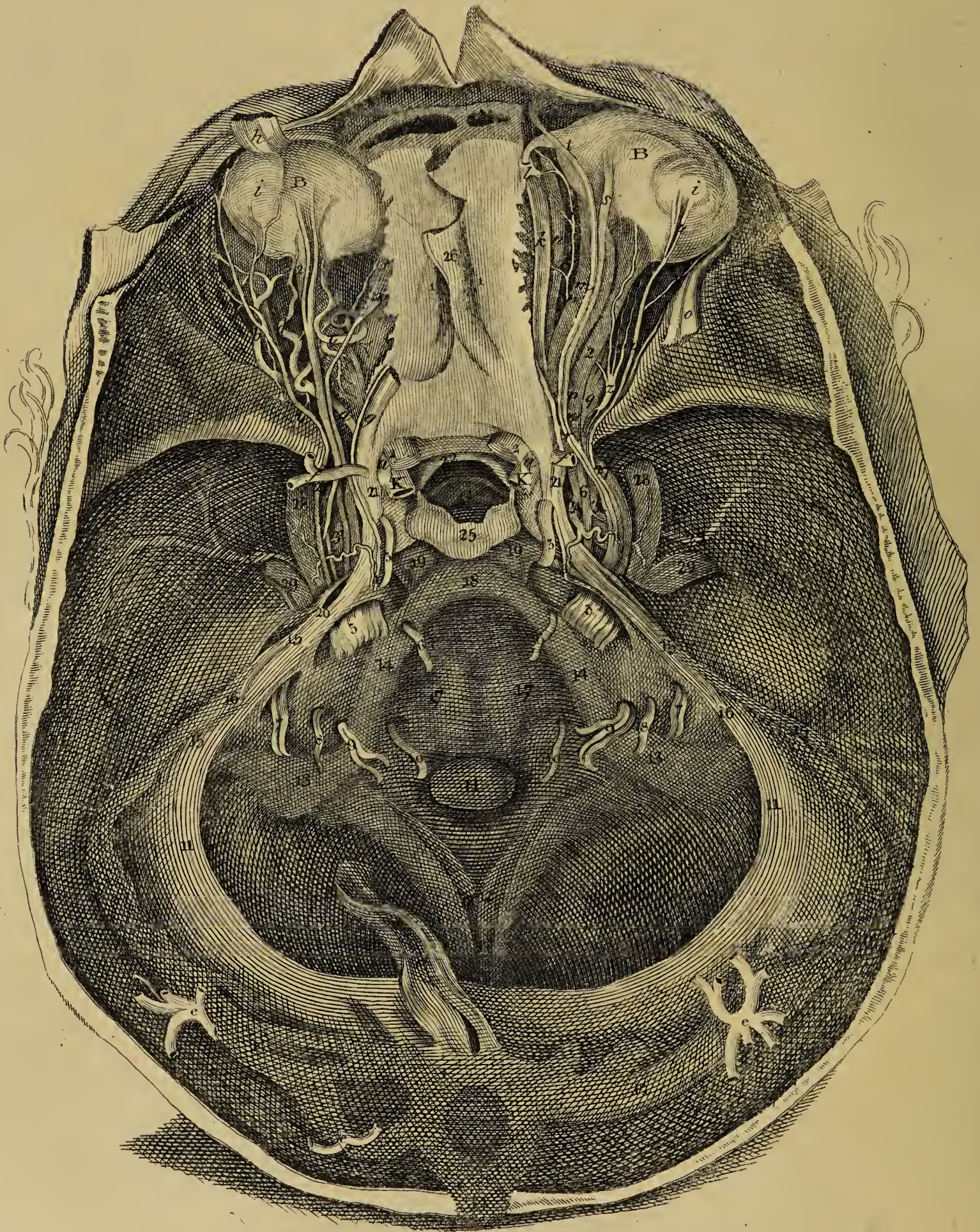
An Outer Perpendicular Section of the NOSTRIL and PALATE, to shew the Distribution of the OLFACTORY NERVE

R

- NERVE upon the OS SPONGIOSUM SUPERIUS, and of the NASAL and PALATINE BRANCHES of the FIFTH PAIR upon the OSSA SPONGIOSA and PALATE. In the NOSE, the NERVES run under the PITUITARY MEMBRANE. The PERIOSTEUM is partly saved, and partly destroyed. The BONES are cut to shew the ETHMOID CANALS.
- A, The frontal sinus.
 B, The Crista Galli.
 C, The left os nasi.
 D, The nasal process of the superior maxillary bone.
 E, The sphenoid sinus.
 F, The external orifice of the carotic canal.
 G, Part of the occipital bone.
 H, The foramen ovale for the third branch of the fifth pair of nerves.
 I, The passage for the principal artery of the dura mater.
 K, K, A section of the superior maxillary and palate bones.
 L, The os spongiosum superius.
 M, _____ inferius.
 N, N, Two bristles introduced into the passages for the naso-palatine nerves.
 O, The levator palati.
 P, The uvula.
 Q, The tonsil.
 a, The olfactory nerve turned a little outwards, to shew the external series of fibrillæ issuing from its trunk. The anterior bulbous extremity of the nerve, and a section of its trunk behind, are seen as in Fig. 1.
 b, b, b, The filaments of the olfactory nerve, after passing through the cribriform plate of the ethmoid bone, distributed upon the os spongiosum superius and adjacent parts of the nose.
 c, The nasal nerve from the ophthalmic of the fifth pair, dividing into external and internal branches.
 d, A filament of the external branch, after going through an osseous canal, passing towards the integuments of the nostrils.
 e, Filaments of the external branch of the nasal nerve, which run between the pituitary membrane and the periosteum of the nostril.
 f, The spheno-palatine ganglion.
 g, Superior anterior nasal nerves from the fifth pair.
 h, The origin of the naso-palatine nerve.
 i, The VIDIAN nerve, sending upwards, near its origin, two twigs to the membrane of the sphenoid sinus, and downwards two branches to the membrane of the fauces and EUSTACHIAN tube.
 k, The division of the VIDIAN nerve into a superficial and a deep branch.
 l, The larger anterior palatine nerve.
 m, The origin of the anterior inferior nasal nerve, and its division into a smaller ascending, and a larger descending branch, both dispersed upon the ossa spongiosa.
 n, The lowest of the nasal nerves spent upon the os spongiosum inferius.
 o, o, The egress of the larger palatine nerve to the arch of the palate; its distribution on the palate, and termination upon the gums.
 p, p, The external palatine nerve.
 q, The smaller posterior palatine nerve, dispersed upon the levator palati, palatum molle, uvula, and tonsil.



TAB 186



T A B L E CLXXXVI.

A VIEW of the Inside of the BASE of the CRANIUM, covered by the DURA MATER; containing SINUSES, NERVES, &c.—The Upper Parts of the ORBITS are removed.

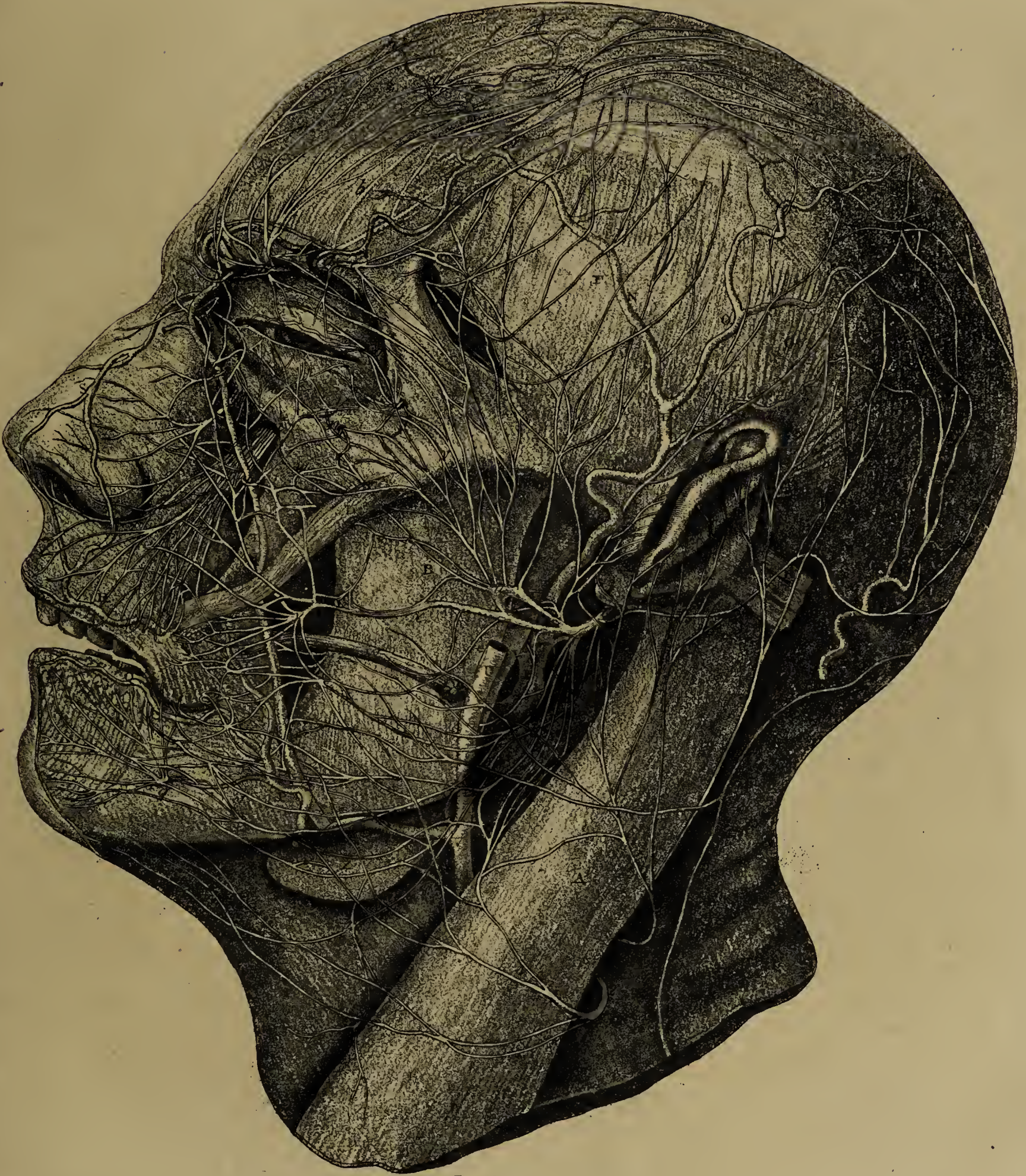-
- A, A, The frontal sinuses.
 B, B, The balls of the eyes.
a, a, The ocular artery.
b, The external branch, sending a branch to the lacrymal gland.
c, The internal branch, sending a branch to the nose.
d, Branches to the eye.
f, Veins from the anterior lobes of the brain, ending in the cavernous sinus.
g, A section of the levatores palpebræ et oculi.
h, The end of the levator palpebræ.
i, The lacrymal gland.
k, The musculus trochlearis.
l, The trochlea.
m, The levator oculi.
n, The adductor oculi.
o, A section of the abductor oculi.
 1. 1. The cribriform plate of the ethmoid bone, lined with the dura mater, through which the first pair of nerves pass to the nose.
 2. 2. The optic nerves.
 3. 3. The third pair.
 4. 4. The fourth pair.
p, A branch of the third pair to the levatores oculi et palpebræ.
q, A trunk of the third pair.
r, The first, or ophthalmic branch of the fifth pair.
s, The external branch which passes through the foramen supra-orbitarium.
t, The internal branch.
u, The branch to the lacrymal gland, &c.
v, A branch which passes through the os malæ to the face.
w, The nasal branch.
x, The proper nasal twig of that branch.
z, The continuation of the nasal branch to the parts at the inner corner of the orbit.
 5. 5. The fifth pair.
 6. 6. The sixth pair.
 7. 7. The seventh pair, composed of the portio mollis and portio dura of each side.
 8. 8. The eighth pair.
 9. 9. The ninth pair.
 10. 10. The tenth pair.
 C, Part of the falx, with the termination of the torcular Herophili, which is bifurcated in this Figure, one part going to the right, and the other to the left lateral sinus.
 D, The end of the superior longitudinal sinus, which, in this Figure, is also bifurcated.
 E, E, The lateral sinuses.
e, e, e, The cerebral veins terminating in the lateral sinuses.
 F, F, The cavernous sinuses cut open.
 G, The Sella Turcica.
 H, The top of the spinal marrow.
 I, The falx cerebelli.
 K, K, Sections of the carotid arteries.
 L, L, The lateral sinuses, where they turn down behind the petrosal parts of the temporal bones.
 11. 11. The inner edge of the tentorium.
 12. 12. The falx cerebelli.
 13. 13. The jugular fossæ.
 14. 14. The inferior petrosal sinuses.
 15. 15. The superior petrosal sinuses.
 16. 16. The veins of the cerebellum, terminating in these sinuses.
 17. 17. The anterior inferior occipital sinuses.
 18. 18. ————— superior occipital sinuses.
 19. 19. The communication of that sinus with the cavernous and circular sinuses.
 20. The termination of the superior petrosal sinus in the cavernous sinus.
 21. 21. The situation of the cavernous sinuses.
 22. The circular sinus of RIDLEY.
 23. 23. The middle and principal arteries of the dura mater.
 24. Small arteries arising from the carotid in the cavernous sinus, dispersed upon the fifth pair of nerves.
 25. The posterior clinoid process.
 26. The Crista Galli.
 27. The first branch of the fifth pair of nerves.
 28. The second branch of that nerve.
 29. The third branch of the same.

T A B L E CLXXXVII.


The NERVES of the FACE.

-
- A, The sterno-mastoid muscle.
 B, The masseter.
 C, The digastric muscle of the under jaw.
 D, The zygomaticus major.
 E, E, The occipito-frontalis.
 F, The aponeurosis of the temporal muscle.
 G, The attolens aurem.
 H, The retrahentes aurem.
 I, The external carotid artery.
 K, The occipital artery.
 L, M, Anastomoses of the occipital and temporal arteries.
 N, The anterior branch of the temporal, communicating with the frontal artery.
 O, The posterior branch of the temporal artery.
 P, The facial artery.
 Q, The coronary artery of the under lip.
 R, ————— upper lip.
 S, The continuation of the facial artery.
 T, The facial vein.
 U, The temporal vein.
 V, The external jugular vein.
 W, The duct of the parotid gland.
 X, The inferior maxillary gland.
 a, The great frontal branch of the ophthalmic nerve.
 b, c, d, e, The deep branches of that nerve, which, after sending twigs to the upper eye-lid, run backwards, chiefly under, and partly over the frontal muscles, to be dispersed upon the muscles and integuments of the fore and upper part of the head.
 f, The small frontal branch, or ramus supra-trochlearis of the ophthalmic nerve, sending branches to the upper eye-lid.
 g, h, The continuation of that nerve dispersed upon the fore-head, and having some connections with the great frontal nerve, and with the nasal branch, or infra-trochlearis, which is seen at the root of the nose, and ascending some way upon the fore-head.
 i, The infra-orbital branch of the superior maxillary nerve, passing through the infra-orbital hole, to be dispersed upon the nose, upper lip, and cheek.
 k, A cutaneous branch of that nerve, which, in this head, goes through a separate hole to the side of the nose.
- l, A reflected branch going also through a separate hole in this head, to the under part of the orbit.
 m, Branches of the infra-orbital nerve, anastomosing with,
 n, The inferior cutaneous nerve of the os malæ.
 o, The superior cutaneous nerve of the os malæ, which is also joined to the nerve n.
 p, An incision in the aponeurosis of the temporal muscle, to shew the anterior cutaneous nerves of the temple.
 q, The mental nerve, or continuation of the inferior maxillary nerve, passing through the anterior maxillary foramen, to be distributed upon the chin and under lip.
 r, The portio dura of the seventh pair of nerves.
- From the root of the Portio Dura is seen an Occipital Branch passing backwards, which gives some Twigs to the back-part of the Ear.
 A Branch is sent up from the Portio Dura, termed *Auricularis Anterior*, which runs behind the Temporal Artery, sends Twigs to the fore-part of the Ear, and afterwards ascends upon the side of the Head.
- s, A middle temporal branch, from the portio dura, ascending at the fore-part of the trunk, and afterwards going deeper than the anterior branch of the temporal artery.
 t, Another temporal branch, forming different connections with the nerves at each side of it.
 u, An arch formed between the superior and middle facial branches of the portio dura.
 v, The superior facial branches, sending branches to the muscles and integuments at the outer angle of the eye, and forming many connections with each other, and with the supra and infra orbital branches of the fifth pair.
 w, A ramus mollis of the great sympathetic nerve, extending along the external carotid artery.
 x, The great facial nerve, or middle facial of the portio dura.
 y, The facialis medius, continued to the space between the masseter and buccinator muscles, forming numerous joinings, separations, and rejoinings, with the superior and inferior maxillary nerves, and with deep branches

TAB. 187.



A. Ryfe fecit



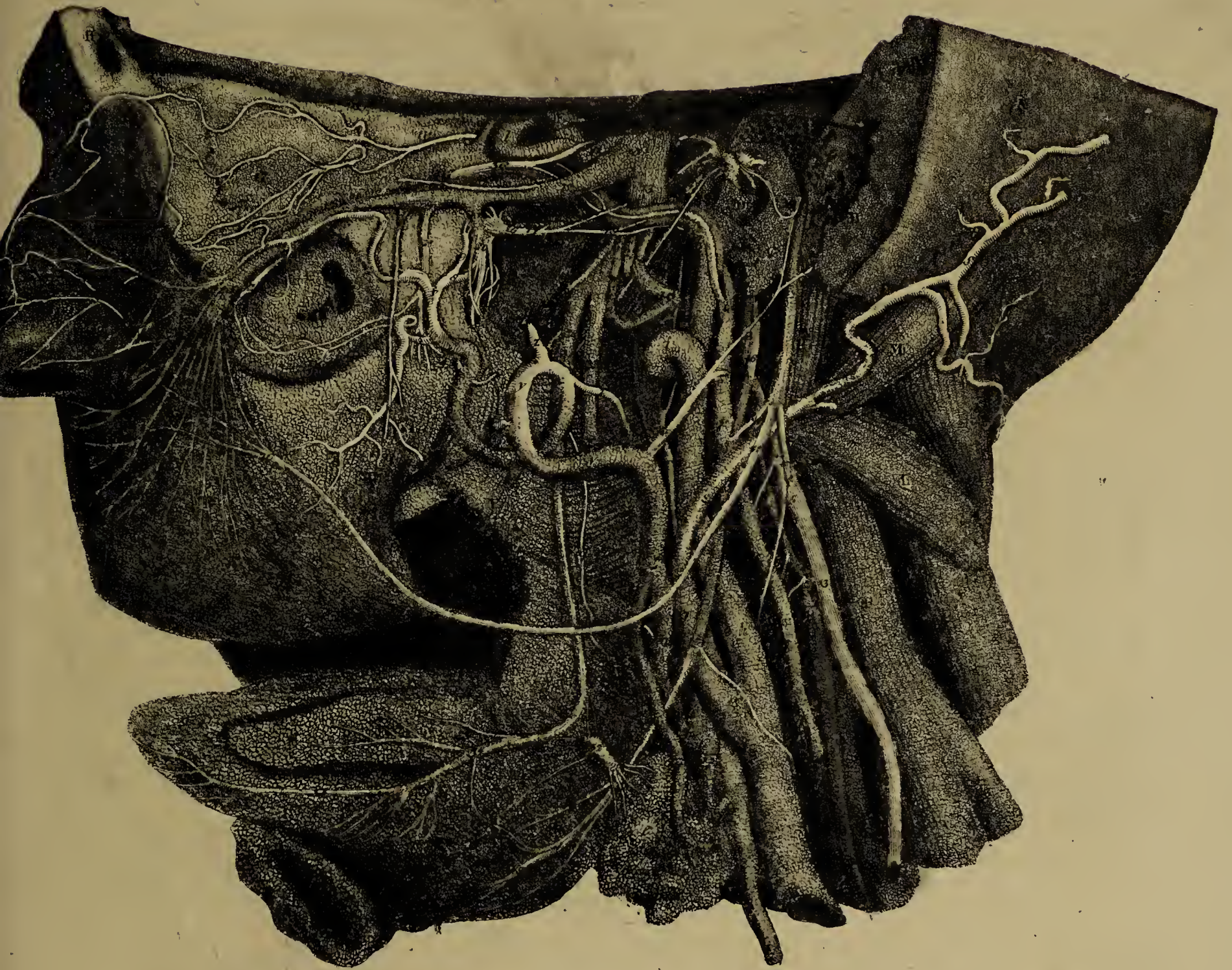- branches which pass out between the two muscles from the superior and inferior maxillary trunks.
- z, The inferior facial branches of the portio dura, giving filaments to the digastric and stylo-hyoid muscles, sending some down upon the neck which commonly run near the external jugular vein, others forwards to the superficial parts of the throat, while the rest of them pass along the lower jaw, and have connections with the branches of the facialis medius.
1. The continuation of the inferior facial nerves, with some connections to the branches of the maxillaris inferior.
 2. The middle cutaneous nerve of the neck.
 3. The inferior cutaneous nerve of the neck, which is often a branch of the third cervical.
 4. Branches of the middle cutaneous nerve of the neck, which have connections with the inferior branches of the portio dura, and with the inferior maxillary nerve.
 5. The posterior auricular nerve, which is a branch of the second cervical nerve.
 6. The anterior branch of the auricularis posterior to the under part of the ear.
 7. A cutaneous nerve, not constant, from the first cervical, running across, to be dispersed upon the skin which covers the under part of the parotid gland.
 8. 9. The posterior branches of the auricularis posterior, distributed upon the back-parts of the ear and temple.

TABLE

T A B L E CLXXXVIII.

In this FIGURE, the SKULL-CAP is removed, and the Base of the CRANIUM separated from the TEMPORAL BONE forwards to the OS MAXILLARE SUPERIUS, and inwards to the Body of the SPHENOID BONE, chiefly to shew the First and Second BRANCHES of the Fifth Pair of NERVES.

- | | |
|---|--|
| <p>A, The joining of the parietal, temporal, and occipital bones.</p> <p>B, The cut edge of the skull at the middle of the pars petrosa.</p> <p>C, A section of the styloid process.</p> <p>D, The inferior part of the membrana tympani, at the upper edge of which are seen the malleus joined to the incus, and that by its inferior extremity to the stapes.</p> <p>E, The posterior clinoid process.</p> <p>F, The pituitary membrane lining the outer part of the maxillary sinus; the bone being removed.</p> <p>G, The inner side of the orbit.</p> <p>H, Part of the os frontis, with the frontal sinus and Crista Galli.</p> <p>I, A section of the lower jaw, near the symphysis.</p> <p>K, The rectus capitis posterior major.</p> <p>L, The obliquus inferior capitis.</p> <p>M, ————— superior.</p> <p>N, The rectus lateralis capitis.</p> <p>O, The origin of the spinalis cervicis.</p> <p>P, The levator scapulae and scalenus cut.</p> <p>Q, The rectus anterior capitis.</p> <p>R, The levator palati.</p> <p>S, The circumflexus palati.</p> <p>T, T, The three constrictores pharyngis.</p> <p>U, U, Fibres which go from the buccinator to the constrictor pharyngis superior, and the origin of the buccinator from the tuberosity of the superior maxillary bone.</p> <p>V, The levator anguli oris.</p> <p>W, The orbicularis oris, with the nasalis labii superioris.</p> <p>X, The depressor alae nasi.</p> <p>Y, The compressor nasi.</p> <p>Z, The tongue inverted, that its lateral and inferior part may appear.</p> <p>a, The sublingual gland.</p> <p>b, The genio-glossus.</p> | <p>c, One of the cornua of the os hyoides, which is here turned towards the neck.</p> <p>d, The hyo-glossus.</p> <p>e, The submaxillary gland.</p> <p>f, The tensor tympani cut from its origin.</p> <p>g, The common carotid artery.</p> <p>h, The internal or cerebral carotid.</p> <p>i, A flexure of this artery under the cranium, sometimes called COWPERIAN;</p> <p>k, Its first curvature within the carotic canal;</p> <p>l, Its fourth curvature.</p> <p>m, The ocular artery.</p> <p>n, The external or facial carotid.</p> <p>o, The thyroidea superior descending and cut across.</p> <p>p, The lingualis passing under the hyo-glossus muscle.</p> <p>q, The arteria palatina sent off from the lingualis to the pharynx and palatum molle.</p> <p>r, The pharyngea ascendens, giving a branch off behind, which goes by the side of the internal jugular vein to the dura mater; a branch forwards to the pharynx; and a branch upwards, to the circumflexus palati and EUSTACHIAN tube.</p> <p>s, The occipitalis;</p> <p>t, A branch from this artery passing through the lambdoid suture to the dura mater.</p> <p>u, The facialis turned down and cut across.</p> <p>v, The continuation of the external carotid.</p> <p>w, The auricularis posterior, at its superior extremity sending upwards the stylo-mastoidea, and backwards a twig to the origin of the digastric muscle.</p> <p>x, The superficial temporal artery cut over.</p> <p>y, z, 1. 2. 3. 4. The internal maxillary artery, which at its beginning is bent round, and in its course sends off, z, the meningeal media; 1. the maxillaris inferior; 2. the temporalis profunda exterior; 3. the buccalis; 4. the temporalis profunda interior; all of which are cut over.</p> <p>5. The alveolaris s. dentalis posterior, which sends a branch downwards to the buccinator and gums, and one forwards through the maxillary sinus, to the pituitary membrane of that cavity; its continuation anastomosing with the infra-orbital artery.</p> <p>6. A branch which sends twigs through the substance of the bone to the roots of the teeth.</p> <p>7. The infra-orbitalis, which passes forwards with the infra-orbital nerve, and sends a branch downwards to the</p> |
|---|--|



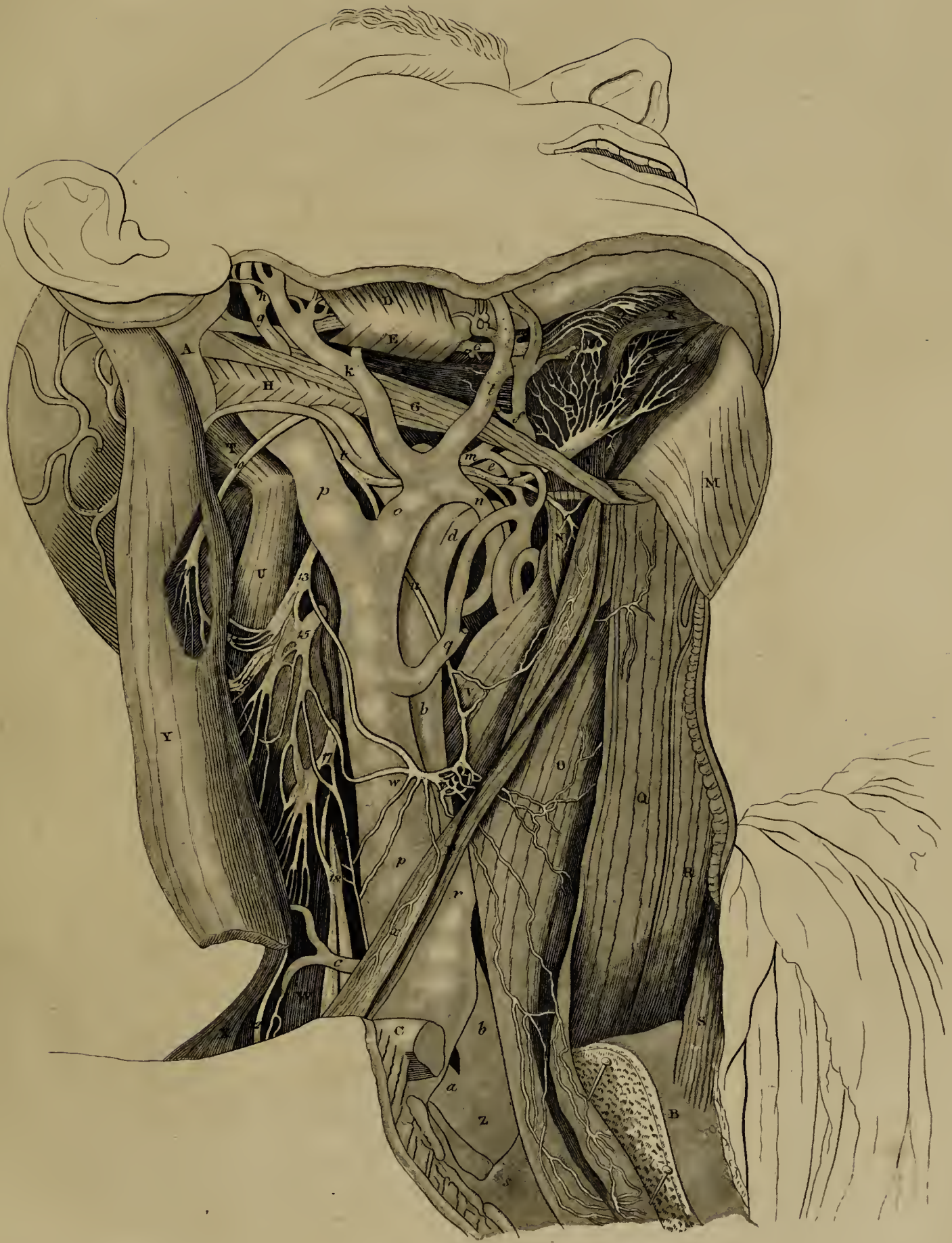- the membrane of the maxillary sinus, and afterwards the ramus dentalis anterior, which communicates with the dentalis posterior.
8. The palatina superior, from which three pterygo-palatine branches descend.
 9. The sphenopalatina, divided into two branches.
 10. The fifth pair of nerves.
 11. The ophthalmic or first branch cut over.
 12. The second or superior maxillary branch.
 13. The third or inferior maxillary branch.
 14. A subcutaneous nerve of the cheek, from the second of the fifth, cut across.
 15. A descending branch from the second of the fifth.
 16. The VIDIAN nerve from that branch.
 17. The superior and superior-posterior nasal nerves.
 18. A superficial branch of the VIDIAN nerve, passing under the third branch of the fifth pair, to join the portio dura.
 19. The deep branch of the VIDIAN nerve dividing into two, the superior joining the filaments from the sixth nerve, and forming the root of the sympathetic nerve, the other branch passing behind the internal carotid to join the sympathetic.
 20. The pterygo-palatine nerves descending through the pterygo-palatine canal to the palate and nose.
 21. The nervus dentalis, s. alveolaris posterior, sending a branch forwards which communicates with the infra-orbital nerve, and branches downwards through the substance of the superior maxillary bone to the root of the dentes molares.
 22. A branch to the buccinator muscle.
 23. The infra-orbital branch.
 24. The ramus dentalis anterior, which joins the dentalis posterior.
 25. The division of the infra-orbital nerve into the *nasalis superficialis superior*, to the nose and under eye-lid; the *nasalis inferior*, which anastomoses with the former branch; the *labialis superior*, which sends branches to the upper lip, and twigs to the under eye-lid.
 26. A remarkable connection between branches of this nerve and the portio dura.
 27. Four cut branches of the third branch of the fifth pair, the anterior is the buccinatorius, behind it are two temporales profundi, and backmost is the massetericus.
 28. The ramus pterygoideus.
 29. The proper inferior maxillary nerve cut.
 30. The superficial temporal nerve formed in this subject of two roots.
 31. The lingual branch.
 32. The maxillary ganglion formed by branches from the lingual nerve, and sending filaments to the submaxillary gland, and a branch forwards to join the ninth nerve.
 33. Branches from the lingual nerve to the sublingual gland and lining of the mouth.
 34. A branch to the substance of the tongue, and connected by a filament with the ninth nerve.
 35. The continuation of the lingual nerve to the substance and point of the tongue.
 36. The sixth nerve, from which two branches are seen descending to form or join the great sympathetic nerve.
 37. The portio dura of the seventh nerve in the Fallopian canal.
 38. A branch of this to the tensor tympani.
 39. The chorda tympani reflected from the portio dura, then passing across the tympanum, and afterwards descending to join the lingual branch of the fifth pair.
 40. A branch which sends nerves to the temple and orbit.
 41. The facial branch.
 42. A descending branch.
 43. The nervus vagus cut over.
 44. A branch from it to the upper ganglion of the sympathetic nerve.
 45. The laryngeal branch of this nerve.
 46. The ninth nerve, or hypo-glossus.
 47. Its descending branch.
 48. A connection between a branch of the ninth, and one from the maxillary ganglion, and farther forwards the connection between the ninth and lingual branch of the fifth nerve.
 49. The termination of the ninth nerve in the genio-glossus muscle.
 50. The sympathetic nerve arising by two roots.
 51. The upper ganglion of the sympathetic nerve, uncommonly long in the subject of this Figure.
 52. The continuation of this nerve.
 53. A branch of the first cervical nerve over the transverse process of the atlas, and descending upon the rectus capitis anterior major.
 54. A connection between this and the sympathetic.
 55. The second cervical nerve, and a connection between it and the sympathetic.

T A B L E CLXXXIX.

Gives a VIEW of the NINTH CEREBRAL NERVE, or the HYPO-GLOSSUS, of the Right Side.

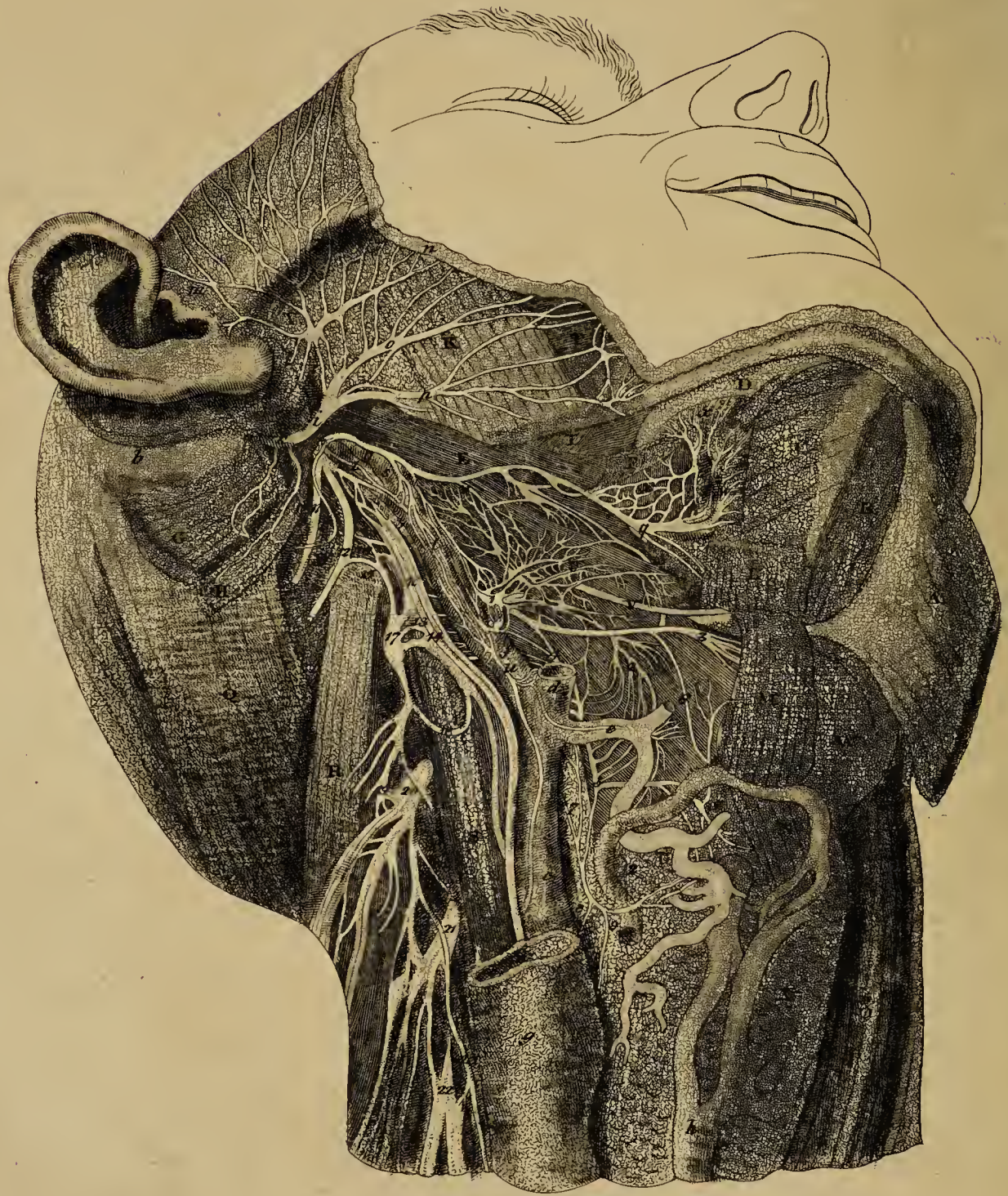-
- A, The styloid process.
 B, The upper part of the sternum divided.
 C, The clavicle.
 D, The masseter muscle.
 E, The pterygoideus internus.
 F, The stylo-glossus.
 G, ———— hyoideus.
 H, The posterior belly of the digastricus.
 I, The hyo-glossus.
 K, The genio-glossus.
 L, ———— hyoideus.
 M, The mylo-hyoideus cut and turned down.
 N, The hyo-thyroideus.
 O, The sterno-thyroideus.
 P, The omo-hyoideus, with one edge turned back.
 Q, The sterno-hyoideus.
 R, Part of the left sterno-hyoideus.
 S, The origin of the left sterno-mastoideus.
 T, The obliquus superior capitis.
 U, The levator scapulae.
 V, Part of the scalenus anticus.
 W, ————— posticus.
 X, ————— cucullaris.
 Y, The sterno-mastoideus.
 Z, The trunk common to the right carotid and subclavian arteries.
 a, The right subclavian.
 b, b, The right carotid.
 c, A transverse cervical branch.
 d, The thyroidea superior.
 e, The lingual arising in this specimen, in common with,
 f, The facial artery.
 g, The temporal artery.
 h, The internal maxillary.
 i, The occipital.
 k, The temporal vein.
 l, The facial.
 m, The lingual.
 n, The thyroidea superior.
 o, The external jugular.
 p, p, The internal jugular.
 q, The gutturalis communicating above with the lingualis.
 r, The thyroidea inferior.
 s, The vena cava superior.
 t, The *nervus hypo-glossus* s. lingualis medius, or ninth of the brain.
 u, The *ramus descendens* NONI, passing over the common carotid artery.
 v, Two branches which unite into one, from which branches are sent to the upper part of the omo and sterno hyoid muscles.
 w, Connections between this nerve and the second, third, fourth, and fifth cervicals.
 x, A branch to the upper end of the omo-hyoideus.
 y, A plexus of nerves formed by the union of the cervicals with the trunk of the ninth. From this coalition of cerebral and spinal nerves, the nerves arise which supply the muscles between the os hyoides and larynx, viz. the sterno-hyoid, the sterno-thyroid, and the omo-hyoid.
 z, The trunk of the ninth nerve advancing between the great arteries and veins of the neck.
 1. A branch to the hyo-thyroideus.
 2. A series of small nerves spread over the hyo-glossus, and giving filaments to this muscle and to the stylo-glossus.
 3. A double anastomosis between this nerve and the lingual branch of the fifth pair.
 4. The extreme branches of this nerve going to the genio-glossus. Filaments from these accompanying the lingual artery to the point of the tongue;
 5. Branches of this nerve to the genio-hyoideus.
 6. The *lingual branch* of the third of the fifth pair;
 7. Branches of this nerve cut, which go to the submaxillary gland;
 8. A branch of this nerve to the sublingual gland.
 9. Nervous penicilli which go to the point of the tongue, and at length terminate in the papillae.
 10. The *nervus accessorius*.
 11. Filaments of the *nervus accessorius* to the sterno-mastoideus, which is cut to shew them.
 12. The *nervus accessorius* at the scapula going to the cucullaris.
 13. The *second cervical nerve*.
 14. Anastomoses between this nerve and the accessory one.
 15. The *third cervical nerve*.
 16. Anastomoses between this and the *nervus accessorius*.
 17. The *fourth cervical nerve*.
 18. The *fifth cervical nerve*, the upper part of the brachial plexus.
 19. The *phrenic nerve*; the third root in this subject arising double from the fifth cervical nerve.

TAB. 189.



Aquatinted by A. Fyfe

TAB. 190.



Aquainted by A. Ryse.

T A B L E CXC.

Shews the NERVUS GLOSSO-PHARYNGEUS, and the RAMUS PHARYNGEUS of the NERVUS VAGUS.

-
- A, The mylo-hyoideus.
 B, The genio-hyoideus.
 C, ———— glossus.
 D, The tongue.
 E, The stylo-pharyngeus.
 F, ———— glossus.
 G, The posterior belly of the digastricus, and,
 H, The stylo-hyoideus cut and turned back.
 I, The pterygoideus internus.
 K, The masseter.
 L, Part of the hyo-glossus cut.
 M, The hyo-thyroideus.
 N, The crico-thyroideus.
 O, The sterno-hyoideus and sterno-thyroideus of the left side.
 P, The obliquus superior capitis.
 Q, The splenius.
 R, The levator scapulae.
 S, The rectus anterior major capitis.
 T, Part of the buccinator.
 U, U, The constrictores pharyngis.
 V, One of the cornua of the os hyoides.
 W, The thyroid cartilage.
 X, ———— gland.
 Y, Part of the parotid gland.
 Z, The zygomatic process.
 a, The cartilage of the meatus auditorius.
 b, The mastoid process.
 c, The common carotid artery.
 d, The external carotid cut off at its origin.
 e, The thyroidea superior.
 f, The internal carotid.
 g, The internal jugular vein.
 h, The vena thyroidea inferior.
 i, The *nervus durus*, or *communicans faciei*.
 k, One branch to the digastricus, and another to the stylo-hyoideus.
 l, An auricular branch from the third of the fifth, anastomotic with the *nervus durus*.
 m, The temporal branch of this nerve,
 n, The superior facial branch,
 o, The middle facial branch,
 p, The inferior facial branch, with numerous anastomoses.
 q, The trunk of the *glosso-pharyngeus*.
 r, A branch of this connected with a branch of the *portio dura*, which goes to the digastric muscle.
 s, A branch joined to the pharyngeal nerve.
 t, Numerous branches sent from the *glosso-pharyngeus*, upon the internal carotid artery, along which they run with soft nerves from the superior cervical ganglion.
 u, A nerve formed of numerous filaments of the *glosso-pharyngeus*, to which are added, some fibrillae from the soft nerves of the uppermost cervical ganglion. A branch of this runs upon the common carotid artery, to the superficial cardiac nerve.
 v, A branch to the pharyngeal nerve.
 w, Branches to the stylo-pharyngeus.
 x, The lingual branches of this nerve, to the side of the root of the tongue, and to the tonsil.
 y, Two filaments dispersed upon the parts about the fauces.
 z, The *nervus pharyngeus* of the *pars vaga*, formed by a branch from the *accessorius*, added to fibrillae from the *pars vaga*.
 1. A gangliform plexus over the constrictor pharyngis medius. From this plexus, branches go to the constrictores pharyngis superior et inferior.
 2. Descending branches to the constrictores pharyngis medius and inferior.
 3. The *laryngeus internus* of the *pars vaga*, and a communication at its root with the pharyngeus.
 4. The *laryngeus externus*, arising by a branch from the *laryngeus internus*, joined to one from the uppermost cervical ganglion.
 5. Branches dividing into others, to the constrictores pharyngis medius et inferior, to the inner part of the larynx, and to the thyroid gland.

6. An anastomosis, not constant, between the external and internal laryngeals.
7. Anastomoses between the laryngeus externus and soft nerves from the uppermost cervical ganglion.
8. A nerve to the superficial cardiac nerve.
9. Nerves to the thyroid gland.
10. The gangliform trunk of the nervus vagus.
11. The *nervus accessorius*, and,
12. The *ninth nerve*, or hypoglossus, cut across.
13. The *ganglion cervicale superius* of the great sympathetic nerve.
14. *Nervi molles* sent off from this ganglion, some of them connected with filaments of the glosso-pharyngeus upon the internal carotid artery.
15. A connection between the first and second cervical nerves, viz. the tenth of the head and first of the neck, of former Authors, and between the first cervical and hypo-glossus.
16. Two nerves passing between the first cervical nerve and uppermost cervical ganglion.
17. A connection by thick short roots, between the second cervical nerve, and uppermost cervical ganglion.
18. A connection between the second and third cervicals, and inferior extremity of the uppermost cervical ganglion.
19. An anastomosis between the second and third cervicals.
20. The *third cervical*.
21. The *fourth cervical*.
22. The *fifth cervical*, and beginning of the brachial plexus.
23. The *nervus phrenicus*.

SPINAL

SPINAL MARROW, AND ORIGIN OF THE SPINAL NERVES.

THE SPINAL MARROW, Tab. XCVI. Tab. CXCI. is the continuation of the Medulla Oblongata, and obtains its name from being contained in the Osseous Canal of the Spine.

It is invested by the same Membranes which cover the Brain, and has an additional partial Involucrum from the Ligamentous Membrane which lines the Bodies of the Vertebrae, and which has been already taken notice of in the description of the Ligaments.

On the inner side of the Ligamentous Lining, the Dura Mater is situated, which passes out of the Cranium by the Foramen Magnum Occipitis, and forms a Cylindrical Sheath, which loosely envelopes the Spinal Marrow, and extends as far as the Os Sacrum.

It is more elastic than the Dura Mater of the Brain, and thereby admits more readily of the different motions of the Spine.

At its egress from the Cranium, it is intimately connected to the beginning of the above-mentioned common Ligamentous Lining, and is also united with the Pericranium at the edge of the Foramen Magnum of the Occipital Bone.

Below the First Vertebra of the Neck, this intimate connection between the Dura Mater and inner Ligament of the Vertebrae is discontinued; a Cellular, Fatty, and Slimy Substance, which surrounds the Dura Mater throughout the rest of the Canal, being interposed between that Membrane and the Ligament.

The Dura Mater is only in contact with the Tunica Arachnoidea, and this also only in contact with the Pia Mater, and lying so loosely over it as to be separated from it with facility through the whole length of the Spine.

The Spinal Marrow, like the Brain, consists of a Cortical and Medullary substance, but differs in this respect, that the Cineritious Matter is placed within the other.

Upon the Surface of the Spinal Marrow, while lying in its natural situation, many transverse Wrinkles or Folds are observed, which allow it to be extended in the motions of the Vertebrae.

It is a little flattened on its anterior and posterior Surfaces, and is larger near the under part of the Neck, and at the top of the Loins, where the great Nerves of the Extremities are sent off, than in the other parts of the Spine.

It is divided into two lateral Portions or Cords, which are separated from each other externally by an anterior

and posterior Fissure continued from the Medulla Oblongata; and each of the lateral Portions is in some measure subdivided by a superficial Furrow into a large anterior and small posterior Cord.

The lateral Portions are firmly united together by fine Cellular Substance, but, without lacerating either, may be separated from each other, before as well as behind, to near their middle, where they are connected by a Layer of Cineritious Matter, which passes from the one Cord into the other.

When the Medulla Spinalis is divided transversely, the Cineritious Substance is observed to have a Cruciform appearance, corresponding with the Cords of which it is composed.

The Body of the Spinal Marrow descends in the Child to the twelfth Dorsal, and in the Adult as far as the second Lumbar Vertebra, and terminates there by a Conical point, which is concealed by Fasciculi of Nerves.

Each of the lateral Portions of the Spinal Marrow sends off from its anterior and posterior parts, flat Fasciculi of Nervous Filaments, which are placed opposite their Fellows on the other side.

Several of the Fasciculi of the Cervical Nerves detach Filaments to those immediately above or below them; and the same thing is occasionally observed of some of the Bundles of Dorsal Nerves.

The anterior and posterior Fasciculi perforate the Dura Mater, from the inner part of which each Fasciculus is furnished with a proper Sheath, and is continued within it, and the Sheaths are connected by Cellular Substance only, till they get between the Vertebrae.

Between the anterior and posterior Fasciculi of Spinal Nerves, and between the Tunica Arachnoidea and Pia Mater, a small Ligamentous Cord, termed *Ligamentum Denticulatum*, is situated, which is attached to the Dura Mater, where that Membrane comes out from the Cranium, and accompanies the Spinal Marrow to its inferior extremity.

It adheres by Cellular Substance to the Pia Mater, and sends off from its opposite side slender Cords, in the form of *Denticuli*, which carry the Tunica Arachnoidea along with them, and, running more or less in a transverse direction, are fixed, each by minute Fibres, to the Dura Mater, in the interstices of the Fasciculi.

The Ligamenta Denticulata of the right and left sides incorporate with the Pia Mater at the inferior extremity or Conical point of the Spinal Marrow, and form a Ligamentous Filament which perforates the under end of the

the Dura Mater, and is fixed by small Fibres to the Membranes covering the Os Coccygis, in the manner the Denticuli are fixed to the Dura Mater.

It is termed by some Authors *Ligamentum Piæ Matris*, and it was considered by the Ancients as the *Fortieth Pair* of Nerves.

It assists in preventing the Spinal Marrow and the tender origin of the Nerves from being overstretched.

Having got between the Vertebrae, each of the posterior Bundles forms a Ganglion, from the opposite end of which a Nerve comes out, and is immediately joined by the anterior Bundle, thus constituting the beginnings of the Trunks of the Spinal Nerves.

The Nervous Cords sent out from the Spinal Marrow, after receiving their Coverings from the Dura Mater, become considerably larger than the Fasciculi which form them; as has been already observed in the general description of the Nerves.

As soon as the Spinal Nerves emerge from between the Vertebrae, each sends Branches backwards to the Muscles near the Spine, and others forwards, to join the Great Sympathetic Nerve; while the Trunk is continued outwards to its place of destination.

The Spinal Nerves are distinguished on each side by numbers, according to the Bones under which they pass: *Thirty Pairs* are most commonly enumerated;—one going under the Head, and termed *Sub-occipital*;—Seven passing under the Cervical,—twelve under the Dorsal,—five under the Lumbar Vertebrae,—and five under the pieces which originally composed the Os Sacrum.

The Fasciculi which form the Cervical Nerves are short, running nearly in a straight direction from their origin to the Inter-vertebral Holes. Those which form the Dorsal Nerves are longer than the former, and run more obliquely downwards; and those which form the Lumbar and Sacral Nerves are very long, and run still more obliquely downwards, till at length the undermost of them become nearly longitudinal.

The size of the Fasciculi corresponds with that of the Nerves which they go to form.—The Fasciculi of the four lowest Cervical and first Dorsal, are large and broad, giving origin to the Great Nerves which supply the Superior Extremity.—Those of the Back are much more slender, while the Fasciculi of the Loins and the two upper Sacral ones are of great size, to form the very large Nerves which run to the Lower Extremity.

The Lumbar and Sacral Fasciculi, while included in the Dura Mater, form a Bundle of Cords, termed *Cauda Equina*, from the resemblance it has to the Tail of a Horse; especially when the Fibrillæ of the Nerves are unravelled by separating them from each other.

The Fasciculi perforate the Dura Mater, nearly opposite to the parts where they pass through the Vertebrae,—of course the Nerves of the inferior parts of the Spinal Marrow emerge from the Spine, considerably lower than their different origins.

BLOOD-VESSELS OF THE SPINAL MARROW.—The Arteries of the Spinal Marrow consist of Anterior and

Posterior Spinal Arteries, and of many additional Branches communicating with others from the adjacent vessels.

The *Anterior Spinal Arteries* arise, one on each side, from the Vertebrals, near where these join to form the Basilar Artery.

Upon the beginning of the Spinal Marrow, they generally unite into a common Trunk, which descends in that depression on the Anterior Surface of the Medulla, whereby it is distinguished into two Lateral Portions, Tab. LXX. Fig. 14. A, and the Artery continues nearly of the same size throughout, in consequence of additions it receives from the neighbouring Arteries.

In the Neck, it communicates with the Vertebral, Thyroid, and Cervical Arteries, by Branches which pass through the same Holes with the Nerves.

In the Back, it receives Branches from the Intercostal, and in the Loins from the Lumbar Arteries; all of which also go through the Inter-vertebral Holes.

It terminates at the under end of the Spinal Marrow; the Cauda Equina being supplied by Branches from the Internal Iliac Artery, which enter through the anterior and posterior Holes of the Os Sacrum.

The *Posterior Spinal Arteries*, Tab. CXCI. Fig. 3. arise commonly from the Inferior Arteries of the Cerebellum, and frequently from the Trunks of the Vertebral Arteries within the Cranium.

They are equal in length to the former Arteries, but considerably inferior to it in size, and continue separate through the whole of their course.

They have constantly a Serpentine appearance, and form frequent Anastomoses with each other, and with Arteries, the Branches of which communicate with the Anterior Spinal Artery.

The Arteries of the Spinal Marrow are divided into minute Branches, which are dispersed upon its substance, upon the Membranes which inclose it, and also upon the substance of the Vertebrae and origins of the Nerves.

The *Veins* of the Spinal Marrow accompany their Arteries, and afterwards terminate in the Sinus Venosi of the Spine.

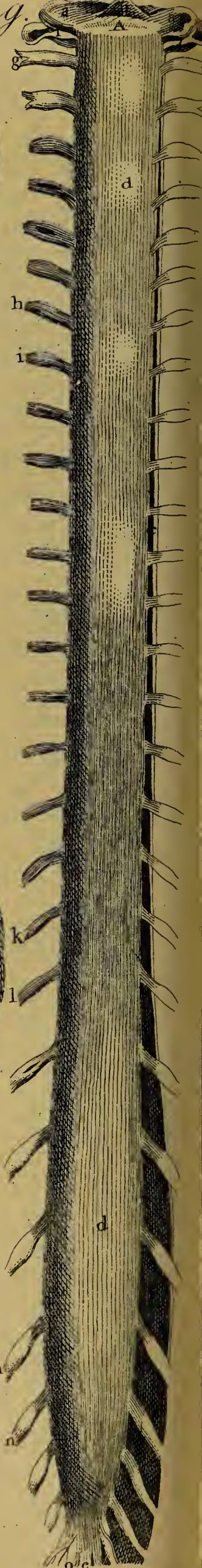
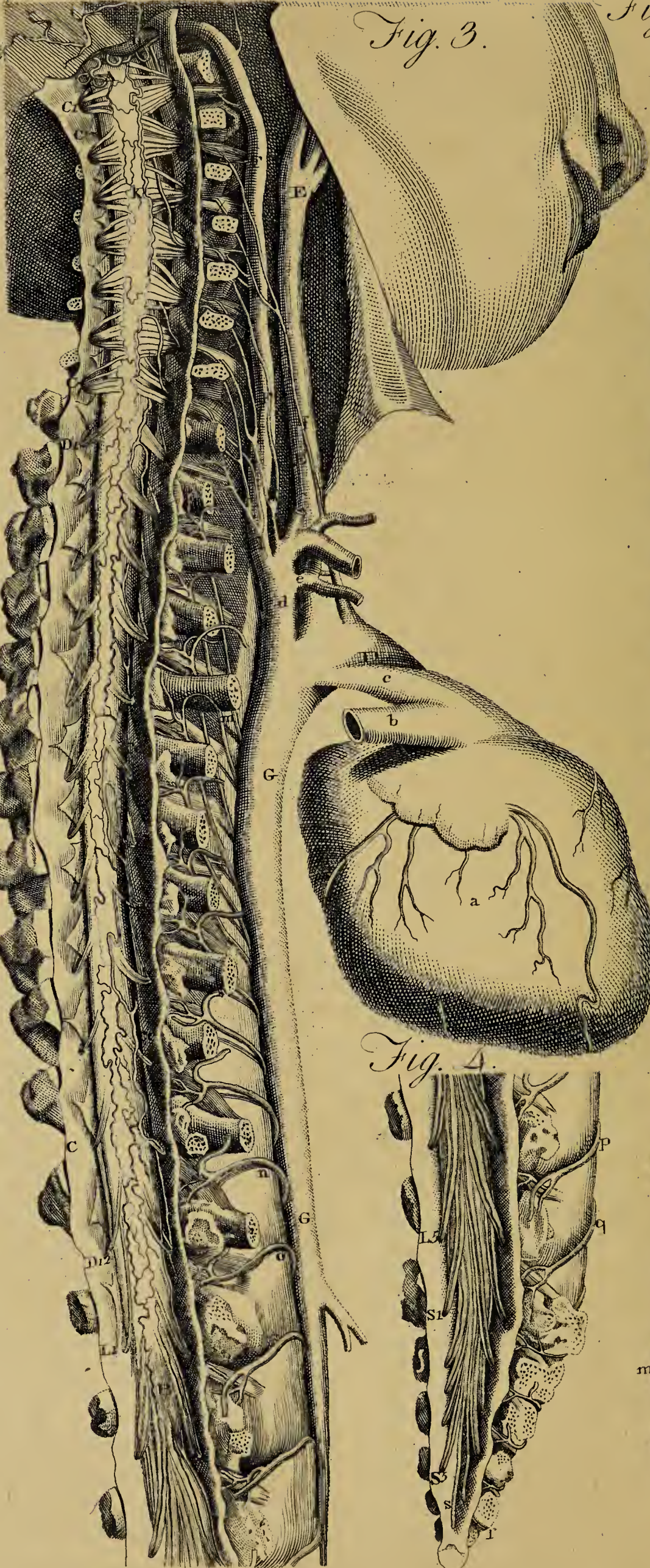
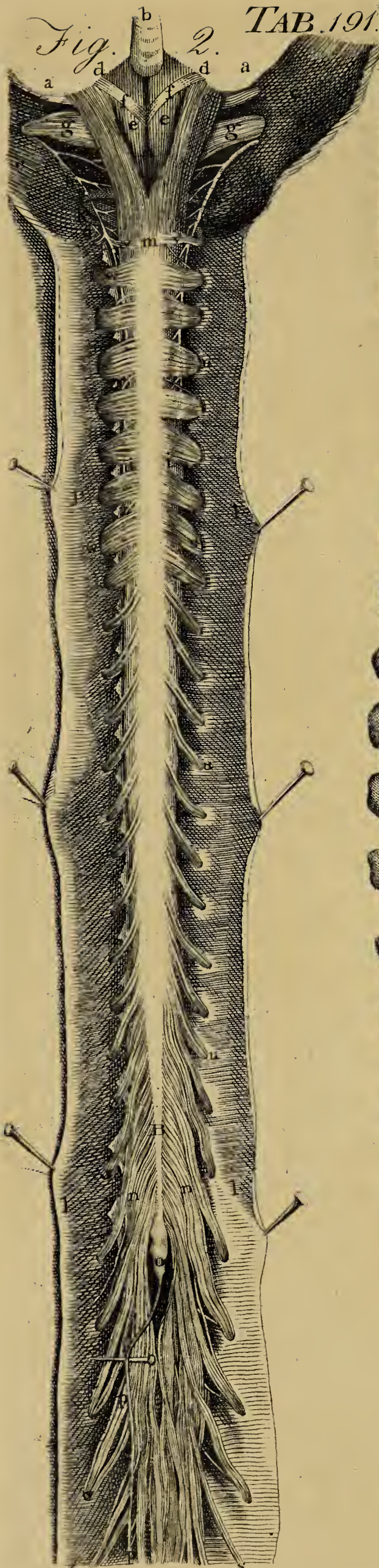
The *Sinus Venosi* consist of one on each side, which runs exterior to the Dura Mater; being chiefly lodged in the Ligamentous Membrane which lines the fore and lateral parts of the Vertebral Canal.

They extend from the Foramen Magnum of the Occipital Bone to the under end of the Os Sacrum, and are so irregular on their Surface, and so much divided and subdivided within by the openings of Veins, as in many parts to have the appearance of Cells.

At the different Vertebrae, they are conjoined by cross Branches, which have a Semilunar form, like the surface of the Bones which surround them.

They communicate at their Superior Extremity with the Occipital and Lateral Sinuses, and send numberless Branches outwards, which open into the Veins, the Arteries of which anastomose with those of the Spinal Marrow.

TABLE



T A B L E C X C I .

VIEWS of the SPINAL MARROW—in a Child.

FIG. 1.

Presents a Posterior View of a Production of the DURA MATER investing the SPINAL MARROW and its NERVES, as in its Natural Situation; together with the whole VERTEBRAL NERVES, their Direction, Situation, and Natural Size in the SPECUS of the VERTEBRÆ.

- a, a*, The superior oblique processes of the first vertebra.
b, b, The processus dentatus of the second vertebra.
c, c, The specus of the vertebræ.
A, A section of the spinal marrow at its origin.
d, d, The coverings of the spinal marrow produced from the dura mater, continued from the os occipitis to the middle of the os sacrum.
e, A ligament continued from the os coccygis.
 On the right side are seen all the Spinal Nerves with their Ganglia, also covered with the Dura Mater.
f, The uppermost spinal nerve, commonly called *Tenth of the Head*
g, —b, The seven cervical nerves of the left side.
i, —k, The twelve dorsal nerves.
l, —m, The five lumbar nerves.
n, —o, The five nerves of the os sacrum.

FIG. 2.

Gives a Posterior View of the MEDULLA OBLONGATA, and the whole of the SPINAL MARROW produced from it, lying in its Natural Situation within the Sheath of the VERTEBRÆ, which is concealed by the DURA MATER being laid open longitudinally, and pinned back.

- a, a*, The space which the lobes of the cerebellum occupied.
b, The vermiform process of the cerebellum.
c, c, Portions of the os petrosum and os occipitis, covered with the dura mater.
d, d, Part of the medulla oblongata from which the spinal marrow descends.
e, e, The fourth ventricle.
A, Its longitudinal furrow, called *Calamus Scriptorius*.
f, f, The seventh pair of nerves.

- g, g*, The eighth pair.
h, h, The nervi accessorii, arising by different roots from the upper end of spinal marrow.
i, i, The lowest roots of these nerves.
k, k, The ninth pair of nerves.
l, l, The dura mater cut longitudinally, and turned back.
m, The beginning of the spinal marrow.
B, The under part of the spinal marrow sending off the nerves *n, n*, which form the cauda equina.
o, The under end of the spinal marrow terminating in two small eminences.
p, A ligament, mistaken by the ancients for a fortieth pair of nerves, running through the dura mater, to be fixed to the os coccygis.
q, The upper end of the ligamentum denticulatum of the left side, adhering to the dura mater. In the interstices of the spinal nerves, the teeth of this ligament are seen inserted into the dura mater, as far as the under end of the spinal marrow.
r, r, Nervous filaments which join the bundles of spinal nerves to each other.
s, s, Posterior bundles of twenty-six of the thirty pairs of spinal nerves.
t, t, Portions of the anterior bundles of the spinal nerves, contiguous to the posterior bundles, but going through separate holes from them in the dura mater.
u, u, u, Holes in the dura mater through which the posterior bundles of spinal nerves pass.
v, The uppermost spinal nerve.
w, w, The seven cervical nerves.
x, x, The twelve dorsal nerves.
y, y, The five lumbar nerves.
z, The first sacral nerve.

FIG. 3. & 4.

Gives a View of the ARTERIES which belong to the VERTEBRÆ and SPINAL MARROW; the SPINE being cut open at its lateral and back part.—These Figures, through the inadvertency of the Engraver, are reversed.

- a*, The heart.
b, The left pulmonary artery.

c, The

- c*, The ductus arteriosus.
D, The arch of the aorta.
E, E, The left carotid artery.
d, The left subclavian artery.
e, The inferior thyroid artery.
f, Its ascending cervical branch, sending an inferior and a superior branch between the vertebræ to the spinal marrow.
g, The arteria cervicalis profunda, also sending branches to the spinal marrow and its membranes.
F, F, The trunk of the left vertebral artery sending branches to the bodies of the vertebræ, to the spinal marrow and its membranes.
h, The trunk of the vertebral artery within the dura mater, and where it is about to enter the foramen magnum occipitis.
i, The inferior artery of the cerebellum.
h, The left posterior spinal artery anastomosing with the right.
l, The superior intercostal arising from the subclavian, and sending branches to the vertebræ and spinal marrow.
G, G, The aorta descendens.
- m*, The first aortic intercostal artery.
n, The tenth aortic intercostal artery. From the intercostal arteries, numerous branches are sent off to the vertebræ, dura mater, and spinal marrow.
o, The first lumbar artery.
p, The fifth lumbar artery.
q, The first sacral artery.
r, The sixth sacral artery.
s, The arteria azygos, arising from the anterior spinal artery.
- A*, The upper end of the spinal marrow.
B, The under end, forming the cauda equina.
C, C, The dura mater, cut and turned back.
Cc, Cc, The teeth of the ligamentum denticulatum fixed to the dura mater.
C, 1. The first cervical nerve.
C, 7. The seventh cervical nerve.
D, 1. The first dorsal nerve.
D, 12. The twelfth dorsal nerve.
L, 1. The first lumbar nerve.
L, 5. The fifth lumbar nerve.
S, 1. The first sacral nerve.
S, 5. The fifth sacral nerve.

NERVES OF THE NECK AND SUPERIOR EXTREMITY.

NERVUS ACCESSORIUS.—The Accessory Nerve belongs in some respects to this Class of Nerves; but having part of its origin within the Head, and from its passing out with one of the Cerebral Nerves, it has been already described along with these.

SUB-OCCIPITAL NERVES, Tab. CXCI. Fig. 2. v, v.—These were formerly called *Tenth Pair of the Head*, and by many at present are termed *First of the Neck*.

They arise, on each side, from the beginning of the Spinal Marrow, by an Anterior and Posterior Fasciculus, like the rest of the Spinal Nerves; and, like these also, they have their Ganglia where they pass out between the Bones.

They perforate the Dura Mater immediately under the entrance of the Vertebral Arteries, and go forwards under them, and over the transverse Processes of the Atlas.

They afterwards appear in the fore-part of the Neck, and are each connected above by an *Arch* to the root of the Ninth Pair, and below by a similar Arch to the first Cervical Nerve.

Anteriorly, they are joined by one or two short Branches to the upper Ganglia of the Great Sympathetic Nerve.

They afterwards divide into Branches, which are distributed upon the Recti et Obliqui Capitis, and upon some of the Deep Extensors of the Head.

The **FIRST CERVICAL NERVE,** Tab. CXCII. No. 45. comes out, on each side, between the Atlas and Vertebra Dentata, and immediately splits into two parts; the first of which passes forwards under the transverse Process of the Atlas, and is joined by an Arch with the Nervus Accessorius, and by Branches with the Ninth Pair: It is also connected by a soft Gangliform Pellucid Root with the upper Ganglion of the Sympathetic Nerve, sending a Branch downwards, to be fixed to the second Cervical Nerve, and also small Branches to the Muscles connected with the fore-part of the Vertebrae.

The other, which is the principal part, goes backwards, and, after sending Branches to the Extensors of the Head and Neck, perforates these, and forms the *Proper Occipital Nerve*.

The *Occipital Nerve* ascends upon the Head with the Artery of that name, and terminates upon the Muscles and Integuments on the upper and back part of the Head; some of its Filaments anastomosing with others belonging to the First Branch of the Fifth, and Portio Dura of the Seventh Pair.

The **SECOND CERVICAL NERVE,** Tab. CXCII. No.

46. after escaping from between the Bones, gives off a Branch, which perforates the Muscles connected to the fore and lateral parts of the Vertebrae, and joins the middle Ganglion of the Sympathetic Nerve.

It sends another *Branch* of considerable size downwards to the Trunk of the Third Pair.

It sends several Branches to the Sterno-mastoideus, behind which it is connected by an *Arch*, and still farther out by a *Filament*, with the Nervus Accessorius.

It is afterwards divided into several Branches; one of which passes downwards some way upon the External Jugular Vein, and, together with a Branch from the First Cervical, forms an Arch within the Descendens of the Ninth Pair.

It gives off a small Root, which is united with others in the formation of the Diaphragmatic Nerve.

A *Large Branch* comes out from it behind the Sterno-mastoideus, which, turning over this Muscle, sends off the following Nerves, viz.

The *Inferior Cutaneous Nerve of the Neck*, which passes forwards to the parts under the Lower Jaw:

The *Middle Cutaneous Nerve*, which runs towards the Angle of the Jaw:

The *Great Posterior Auricular Nerve*, which furnishes an anterior Branch to the under part of the Ear, and a posterior Branch dividing into many others which go to the back part of the Ear and Temple.

The Cutaneous and Auricular Nerves are dispersed upon the Platysma Myoides, Integuments of the side of the Neck and Head, the Parotid Gland, and External Ear; and have several Communications with the Portio Dura of the Seventh Pair.

The remainder of the Second Cervical is distributed upon the Levator Scapulae, and the Extensors of the Neck and Head.

The **THIRD CERVICAL NERVE,** Tab. CXCII. No. 52. after emerging from between the Vertebrae, sends down a Branch to the Trunk of the Fourth Cervical, and another Branch, which forms the principal root of the Diaphragmatic Nerve.

A *Third Branch* perforates the Muscles on the side of the Vertebrae, and joins the middle Ganglion of the Sympathetic Nerve.

A *Small Filament* connects the Third Cervical with the Descendens of the Ninth Pair.

The Nerve is afterwards divided into External and Internal Branches.

The *External Branches* form Anastomoses with the Nervus Accessorius, near the upper part of the Scapula, while

while the Internal, after furnishing Twigs to the Jugular Glands, are dispersed by several large Branches upon the Muscles and Integuments at the under part of the Neck, and upper part of the Shoulder.

The FOURTH CERVICAL, Tab. CXCII. No. 62. sends a Branch behind the Muscles situated on the fore and lateral parts of the Cervical Vertebrae, to the middle Ganglion of the Sympathetic Nerve.

It is connected by one, and sometimes by two Filaments, to the Diaphragmatic Nerve.

It gives Twigs to the Jugular Glands and deep Muscles of the Neck, and, at the outer edge of the anterior Scalenus, joins the Fifth Cervical Nerve. Tab. CXCII.

The FIFTH CERVICAL, Tab. CXCII. No. 65. is united with the Fourth into a Common Trunk, which, after running a little farther out, joins the Sixth Cervical Nerve.

The SIXTH CERVICAL, Tab. CXCII. No. 68. 71. 72. joins the Seventh behind the Clavicle; and to the Seventh, the First Dorsal Nerve is added over the First Rib.

The Four Inferior Cervicals and First Dorsal Nerves are of great size,—especially the three intermediate Nerves.

They pass out between the Scalenus Anticus and Medius, Tab. CXCII. CXCIV. and afterwards run between the Subclavius and First Rib, at the outer side of the Subclavian Artery, to the Axilla.

In the Axilla they separate, unite, and separate again, forming an irregular Plexus, termed *Axillary* or *Brachial*, Tab. CXCII. CXCIV. which surrounds the Axillary Artery.

The *Axillary Plexus* sends Branches to the Subscapularis, Teres Major, and Latissimus Dorsi, and furnishes the External Thoracic Nerves which accompany the Blood-vessels of that name to the Pectoralis and Integuments.

The Plexus afterwards divides into Nerves, most of which are of great size, to supply the Superior Extremity.—They are as follow:

The SCAPULARIS, Tab. CXCIV. Fig. 1. No. 2. which commonly arises from the combination of the Fourth and Fifth Pairs, and, extending outwards, runs through the Semilunar Arch in the upper edge of the Scapula, afterwards descending between the root of the Spine and Head of the Scapula.

It furnishes Branches to the Supra-Spinatus, and is ultimately spent upon the Infra-Spinatus.

The ARTICULARIS, Tab. CXCIV. Fig. 1. No. 3. which arises, like the former Nerve, from the Trunk common to the Fourth and Fifth Cervicals.

It sinks deep in the Axilla, and getting between the under edge of the Subscapularis, and Insertions of the Teres Major and Latissimus Dorsi, it follows the course of the Posterior Circumflex Artery, round the Body of the Os Humeri, immediately below the Articulation.

It sends Branches to the Teres Minor, and some Twigs to the Ligament of the Joint; but is chiefly dispersed upon the Deltoides.

The NERVUS CUTANEUS, Tab. CXCIII. Fig. 1. o, p. which arises from the Trunk common to the last Cervical and First Dorsal Nerve; but is principally formed by Fibrillae from the latter.

It runs down at the inner and fore part of the Arm, near the Radial Nerve.

It sometimes gives a *small Branch* to the upper part of the Coraco-brachialis and Biceps; and, farther down, it gives others to the Integuments and Coats of the Blood-vessels.

About the middle of the Arm, it splits into two Branches,—an Internal and External.

The *Internal Branch*, which is rather the smaller of the two, passes before the Basilic Vein to the inner part of the Elbow, where it divides into Branches; two of which, larger than the rest, turns obliquely over the Heads of the Flexors of the Hand, to be dispersed upon the inner and back part of the Fore-arm.

The *External Branch* divides into several others, behind the Median Basilic Vein, which descend on the anterior and Ulnar side of the Fore-arm, as far as the Wrist.

They pass partly over and partly under the Subcutaneous Vessels; furnishing Twigs to these, and vanishing in the Integuments.

Besides the Nervus Cutaneus, there is another, termed *Cutaneus Minor Internus* of WRISBERG, which, like the rest of the Nerves of the Superior Extremity, takes its origin from the Axillary Plexus; but is more particularly connected with the Ulnar Nerve. It is considerably smaller than the Nervus Cutaneus.

It soon separates from the Ulnar, running afterwards between it and the inner side of the Arm.

A little below the Axilla, it splits into two Branches:

The smaller, turning to the posterior part of the Arm, is divided into Filaments, which are chiefly dispersed upon the Triceps and its Integuments.

The larger Branch descends at the inner edge of the Triceps, and vanishes upon the under end of that Muscle and Skin of the Elbow.

The MUSCULO-CUTANEUS, called also *Perforans*. CASERII, Tab. CXCIV. Fig. 1. No. 4. which consists of Fibrillae from almost all the Nerves entering the Plexus.

The Cord formed by these perforates, obliquely, the upper part of the Coraco-brachialis, to which it gives Branches.

It afterwards passes between the Biceps and Brachialis Internus, furnishing Branches to both.

At the Elbow, it gets to the outside of the Tendon of the Biceps, and runs behind the Median Cephalic Vein.

From thence it descends in the Fore-arm, between the Supinator Longus and Integuments; furnishing Branches to the latter, as far as the root of the Thumb and back of the Hand.

The SPIRAL, or SPIRAL-MUSCULAR NERVE, Tab. CXCIV.

CXCV. Fig. 1. e, which is apparently formed by all the Nerves entering into the Axillary Plexus, and when the Sheaths of the Nerves are slit open, is found to be composed of Fibrillæ from each of the Trunks, excepting from that of the First Dorsal.

It is rather larger than any other Nerve of the Superior Extremity, and is distinguished by its Spiral direction.

It is at first situated between the Axillary Artery and the Ulnar Nerve, and passes obliquely downwards between the two Heads of the Triceps Extensor Cubiti, and afterwards behind the Os Humeri, to the outside of the Elbow.

From thence it proceeds among the Muscles of the Radial side of the Fore-arm, as far as the Hand.

While passing behind the Os Humeri, it gives several Branches of considerable size to the different Heads of the Triceps; some of them accompanying the Branches of the Arteria Spiralis, and terminating on the Heads of the Extensors of the Hand.

Immediately behind the Body of the Os Humeri, it transmits a *Subcutaneous Branch*, which is distributed upon the Muscles and Integuments on the posterior part of the Fore-arm, anastomosing at last with the Nerves on the back part of the Hand.

The Trunk of the Nerve having arrived at the Elbow, is lodged in a Fissure between the Brachialis Internus and Radial Extensors of the Carpus, and there gives off other Branches to the Extensors and to the Supinators of the Hand.

At the Head of the Radius, the Trunk of the Nerve divides into two nearly equal Branches,—the *Superficialis* and *Profundus*.

The *Superficialis*, continued almost straight from the Trunk, immediately transmits a Branch to the Extensores Radiales and Supinator Longus, and then descends at the inner edge of this Muscle along with the Radial Artery.

A little below the middle of the Radius, it crosses between the Tendons of the Supinator and Extensores Radiales, and is divided into a Volar and Dorsal Branch.

The *Volar Branch*, after sending Twigs to the Annular Ligament, is distributed to the Muscles and Integuments of the Thumb.

The *Dorsal Branch* is again subdivided into numerous other Branches, some of which go to the Muscles in the interval of the Metacarpal Bones of the Thumb and Fore-finger, a few Filaments being distributed to the Annular Ligament, while principal Branches run one along each side of the Fore and Mid-finger, and likewise along the Radial side of the Ring-finger.

The *Ramus Profundus*, after sending several Branches to the Extensores Radiales and Supinator Brevis, perforates the latter, and gets to the back part of the Fore-arm.

After quitting the Supinator, it descends under the Extensor Primi Internodii Pollicis and Extensor Digitorum to the back of the Hand.

VOL. III.

In this course, it sends Branches to the different Extensores of the Thumb and Fingers, and at length degenerates into a slender Branch, which, at the Wrist, adheres closely to the Annular Ligament, where it has a Gangliform appearance, and is dispersed, partly upon this Ligament, and partly on the Membranes and Muscles on the back of the Metacarpus.

The *MEDIAN OR RADIAL NERVE*, which comes from the middle and lower part of the Plexus, is formed by Fasciculi from all the Nerves which enter the Plexus, and is nearly of a similar size with the Spiral Nerve.

It descends in the Arm along the anterior surface of the Humeral Artery, to which, and to the Deep Veins, it adheres closely by Cellular Substance.

In this course, it does not give off any considerable Branches;—Twigs, however, are sent from it to the Coats of the adjacent Vessels.

At the bending of the Elbow, it slips over the Tendon of the Brachialis Internus, and perforates the back part of the Pronator Teres.

It afterwards descends between the Flexor Radialis and Musculus Sublimis, and goes in the middle of the interval of the Radial and Ulnar Artery in its way to the Hand.

When it approaches the Fore-arm, it transmits Branches to the Pronator Teres and Integuments near that Muscle.

In the Flexure of the Arm, it furnishes Branches to the Pronator, Flexor Radialis, and Flexor Sublimis, and an Interosseous Branch, which, in some Subjects, receives an addition from the Spiral Nerve.

The *Interosseous Nerve* gives Branches to the Flexor Longus Pollicis, and to the Flexor Profundus Digitorum, descends upon the Interosseous Ligament with the Vessels of that name, and terminates in the Pronator Quadratus.

Near the Hand, it sends a Branch, dividing into others which supply the Muscles and Integuments forming the Ball of the Thumb.

The Trunk of the Nerve, having given Branches to the Fore-arm, passes under the Annular Ligament of the Wrist, where it divides into Branches which are situated behind the Aponeurosis Palmaris, and Superficial Arch of the Arteries.

The principal Branches in the Palm come off in three divisions, from which seven Nerves of considerable size are distributed to the Thumb and Fingers. Of these, two go to the Thumb, and one to the Radial side of the Fore-finger; the rest come off from two forked Trunks, near the Heads of the Metacarpal Bones, and supply the adjacent sides of the Fore and Middle, and of the Middle and Ring Finger.

These Branches send Twigs through the Aponeurosis to the Integuments of the Palm, and others to the Fasciculi Lumbricales; after which they accompany the Arteries sent out from the Superficial Palmar Arch, bestowing Twigs to the adjacent parts of the Fingers, at the points of which they terminate, by numerous Fibres.

T

The

The ULNAR NERVE, Tab. CXCH. Fig. 1. X, Fig. 2. r, which, like the former, is of great size, comes off chiefly from the last Cervical and First Dorsal Nerve.

It extends along the inside of the Triceps, frequently perforating some of its Flethy Fibres, and, near the Elbow, flants a little backwards, to get into a Groove between the inner Condyle of the Os Humeri and Olecranon of the Ulna.

From thence it passes to the Fore-arm, where, after perforating the Heads of the Flexor Muscles, it joins the Ulnar Artery a little below its Origin, and accompanies that Vessel,—running behind it all the way to the Hand.

Under the Axilla, it sometimes receives a Branch from the Spiral Nerve; and from this connection, or from the Trunk of the Ulnar Nerve itself, a Subcutaneous Branch is sent off, which runs between the Triceps and Integuments; furnishing Branches to the latter for a considerable way along the Fore-arm.

Near the under end of the Os Humeri, a Twig or two commonly go to the inner edge of the Triceps.

Under the bending of the Elbow, a Branch is given out to be distributed upon the Belly of the Flexor Ulnaris.

Immediately below the former, another Branch is produced, which is dispersed upon the Flexor Profundus Digitorum.

About the middle of the Fore-arm, a Filament is transmitted which adheres to the Ulnar Artery, furnishing small Twigs to the Coats and Sheath of the Artery, and terminating in the corresponding parts of the Wrist, and Integuments of the Palm.

Near the end of the Ulna, a considerable Branch, termed *Dorsalis*, is sent out, which, turning between the Flexor Ulnaris and Ulna, is directed to the back part of the Hand.

The *Dorsal Nerve* sends Branches to the Integuments of the Wrist and Metacarpus, which have various anastomoses with others of the Spiral Nerve.

It sends off a Branch, which proceeds along the Ulnar side of the Little Finger; and at the Heads of the Metacarpal Bones, another splitting into two Branches, which run along the adjacent sides of the Auricular and Ring-fingers.

The Trunk of the Nerve passes with the corresponding Artery over the Annular Ligament into the Palm, where, like the Radial Nerve, it is covered with the Aponeurosis Palmaris.

In the Palm, it divides into Superficial and Deep Branches; the former destined chiefly for the Fingers, the latter for the deep region of the Hand.

The *Superficial Palmar Nerve* sends—

Branches to the short Muscles of the Little Finger:

A Branch to the Volar-ulnar side of the Little Finger: and—

Another, which is soon split into two smaller Branches; one to the Radial side of the Little Finger, the other to the Ulnar side of the Ring-finger.

The *Deep Palmar Nerve* sinks in between the Abductor and Flexor Parvus Digiti Minimi, or perforates the Head of the latter, and forms an Arch which accompanies the Deep Arch of the Arteries, under the Tendons of the Flexors, and the Lumbricales.

The Deep Nerve gives—

A Branch to the Abductor Minimi Digiti, and one to each of the Interossei.

A Twig to each of the Lumbricales, which enters from behind.

Branches to the Flexor Brevis and Adductor Pollicis.

The Nerve terminates at length by several short Branches upon the Abductor Indicis.

The Nerves on the Palm and corresponding part of the Fingers, like the Arteries, are much larger than those of the opposite side of the Hand.

The Digital Nerves send off many lateral Branches to the Integuments and other parts of the Fingers, and terminate, each, by a Brush of Fibres, at the Apices of the Fingers.

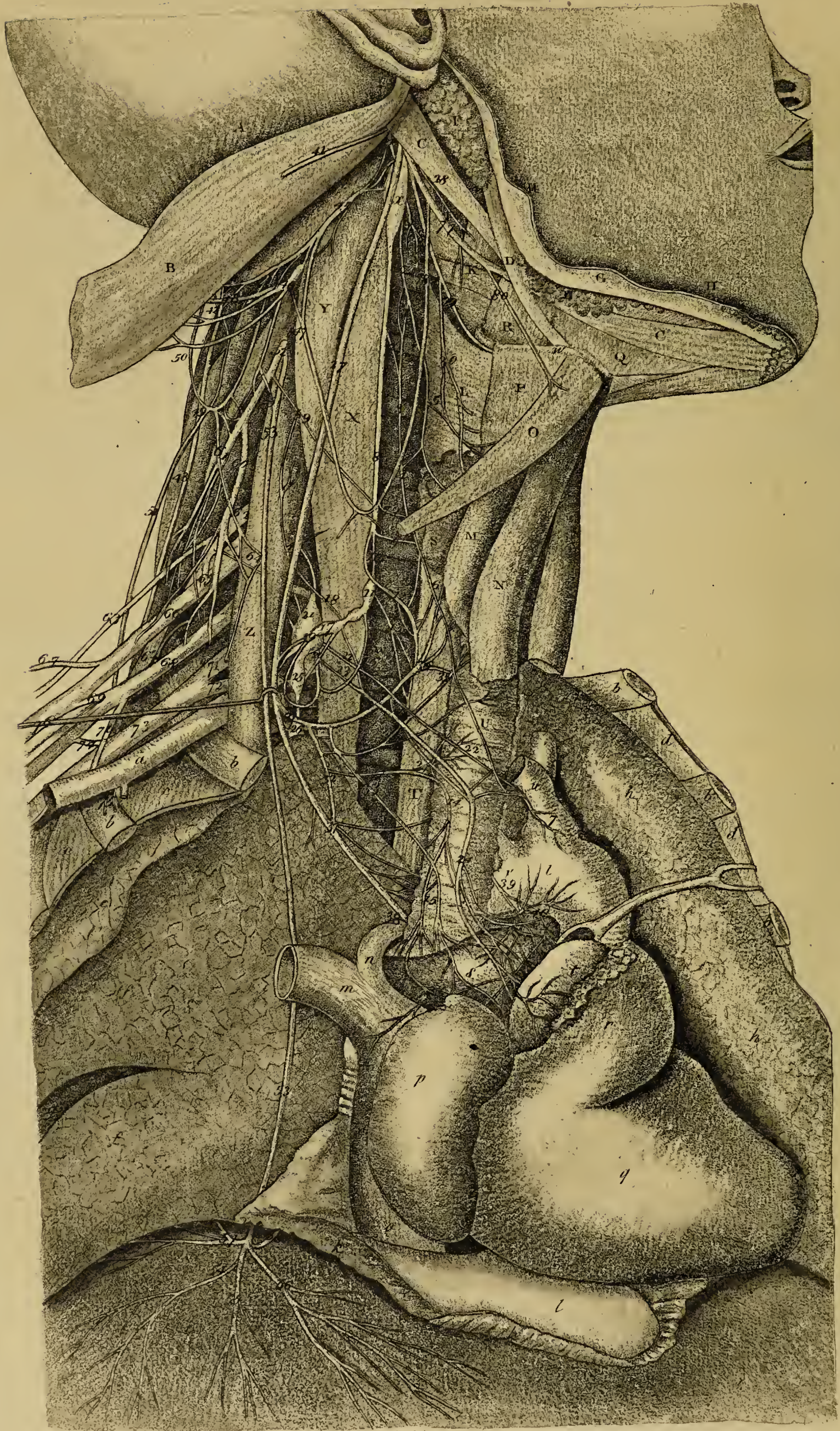
Between the Branches of the Radial and Ulnar Nerve, different Anastomoses are frequently found; and the same may be observed between the Nerves of the Palmar and Dorsal side of the Fingers.

INTERCOSTO-HUMERALES.—Besides the Nerves of the Superior Extremity sent from the Brachial Plexus, there are others belonging to it, which take their origin from the Intercostal Nerves, and which may therefore be termed *Intercosto-Humerales*.

The *Intercosto-Humeral Nerves*, Tab. CXCH. Fig. 1. i, k, l, consist of a Branch from the Second, and of another from the Third Intercostal Nerves; both of which pass out at the fore and lateral parts of the Thorax, the one under the Second, and the other under the Third Rib.

The First Nerve is joined by a small Branch with the Cutaneous Nerve, or with the *Cutaneus Internus* of WRISBERG, and is afterwards dispersed by numerous Filaments upon the Axillary Glands, and upon the Integuments of the Axilla and of the inner part of the Arm.

The Second Nerve is connected by one or more Branches with the First, and sends some Twigs to the Axillary Glands; but is chiefly distributed upon the Integuments of the back part of the Arm, which it supplies with many Branches,—some of them extending as far as the Elbow.

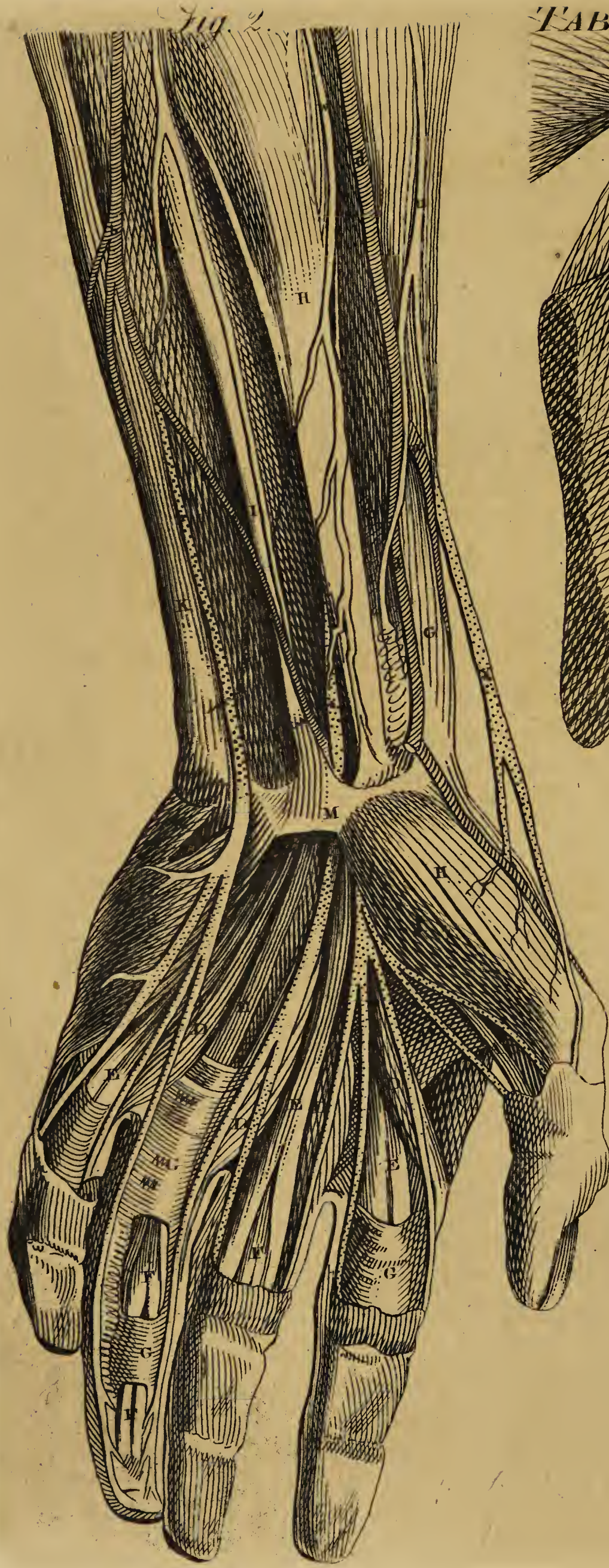


T A B L E CXCII.

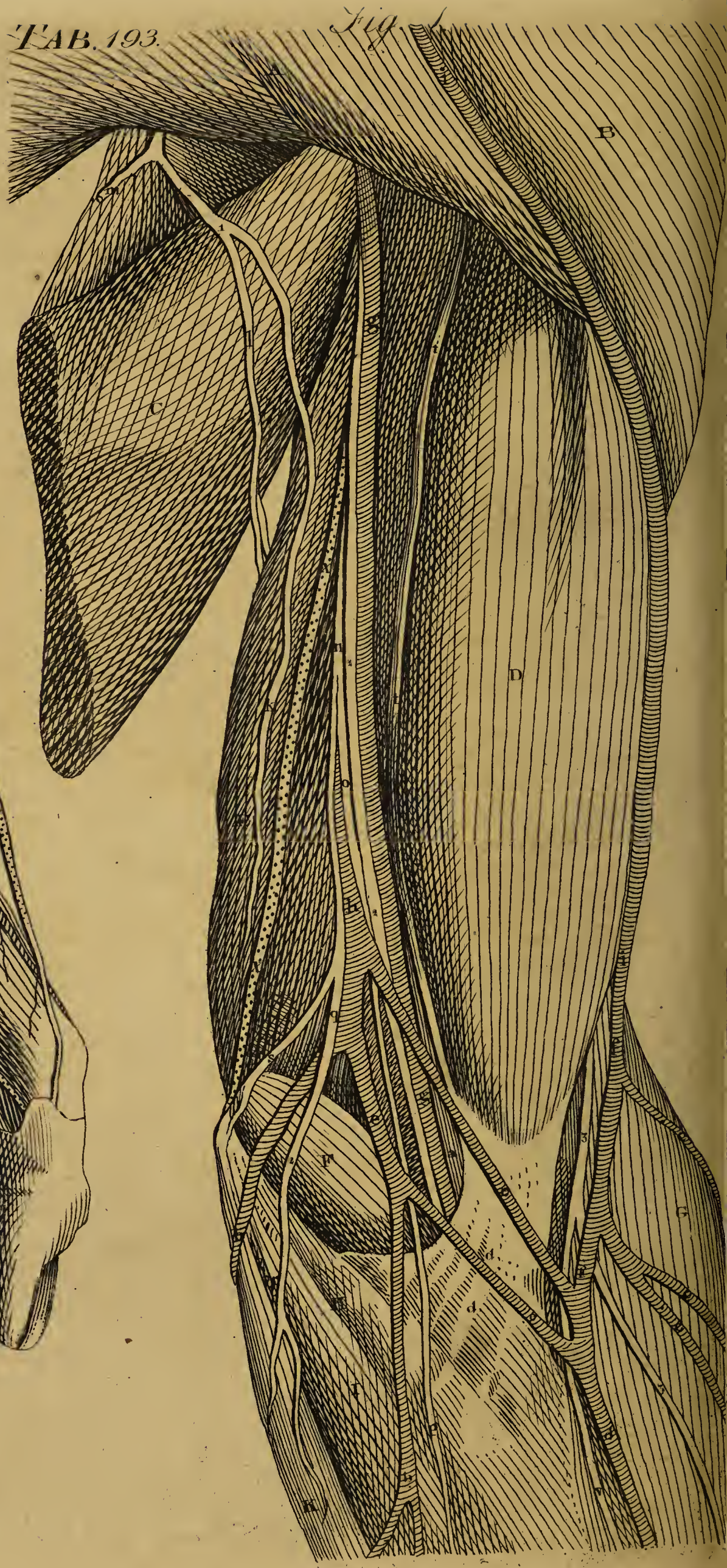A VIEW of the NERVES of the NECK ; and of the GREAT SYMPATHETIC, EIGHTH PAIR, and DIAPHRAGMATIC NERVES in the THORAX.

-
- A, The infertion of the splenius muscle.
 B, The sterno-mastoideus cut and turned back.
 C, The digastricus.
 D, The stylo-hyoideus.
 E, The inferior maxillary gland.
 F, The parotid gland.
 G, The lower jaw.
 H, H, The cut edge of the integuments.
 I, The constrictor pharyngis superior.
 K, ————— medius.
 L, ————— inferior.
 M, The sterno-thyroideus.
 N, ————— hyoideus.
 O, The omo-hyoideus.
 P, The hyo-thyroideus.
 Q, The mylo-hyoideus.
 R, The hyo-glossus.
 S, Part of the thyroid gland.
 T, The esophagus.
 U, The trachea.
 V, V, The cervical vertebræ.
 W, The first dorsal vertebra.
 X, The longus colli.
 Y, The rectus capitis major.
 Z, The scalenus anticus.
 a, The axillary artery.
 b, b, b, The three upper ribs.
 c, c, The external intercostal muscles.
 d, d, The internal intercostals.
 e, The external surface of the right lung.
 f, f, The internal plane surface of the same.
 g, The fissure between the upper and middle lobes.
 h, h, The convex surface of the left lung.
 i, i, The upper convex surface of the diaphragm.
 k, k, The outer surface of the pericardium.
 l, The under part of the pericardium, where it is connected with the tendinous centre of the diaphragm.
 m, The vena cava superior.
 n, ————— azygos.
 o, ————— cava inferior, terminating in the right sinus venosus.
 p, The right auricle.
 q, ————— ventricle.
- r, The pulmonary artery.
 s, The right branch of that artery.
 t, t, The arch of the aorta pulled aside by the assistance of a hook.
 u, The right subclavian, and,
 v, The left carotid artery.
 w, The os hyoides.
 x, The superior ganglion of the great sympathetic nerve.
 y, A ramus mollis from this ganglion, sending off two ramuli which creep along the internal carotid artery.
 z, A branch which forms the beginning of the nervus cardiacus supremus, or superficialis.
 5. A branch from this nerve, which joins the external branch of the laryngeal nerve.
 1. 2. Branches uniting with,
 3. 4. 6. The continuation of the superficial cardiac nerve.
 7. Branches of the superficial cardiac nerve, at the right side of the aorta.
 8. The trunk of the great sympathetic nerve.
 9. A branch which goes along the inferior laryngeal artery to the thyroid gland.
 10. The great sympathetic nerve, forming,
 11. The ganglion cervicale medium.
 12. 13. Branches from the trunk of the sympathetic and the ganglion medium, which, with other branches of the sympathetic and of the eighth pair, from the cardiac plexus.
 14. 15. A nerve formed by a branch from the recurrent, and another from the great sympathetic nerve passing along the trachea, and splitting into other branches, which go to the anterior and posterior surfaces of the heart.
 16. A branch forming an arch between the ganglion medium and the ganglion inferius.
 17. The under part of the ganglion medium.
 18. An arch between the middle ganglion and the fourth and fifth cervical nerves.
 19. 20. Branches passing between the ganglion medium and ganglion inferius of the great sympathetic nerve.
 21. 22. A branch from the inferior cervical ganglion, running to the root of the arteria innominata.
 23. 24. The trunk of the great cardiac nerve, descending

- ing chiefly from the middle cervical ganglion to the cardiac plexus.
25. The first dorsal ganglion.
 26. The second dorsal ganglion.
 27. The pars vaga of the eighth pair.
 28. The pharyngeal branch of the eighth pair.
 29. The superior laryngeal nerve of the eighth pair.
 30. The external branch of the superior laryngeal nerve.
 31. The recurrent nerve of the eighth pair.
 32. 33. 34. Branches from the recurrent nerve to the heart.
 35. 36. Branches of the recurrent, anastomosing, and afterwards passing to the larynx.
 37. Connections between the recurrent and pars vaga.
 38. The pars vaga passing behind the lungs.
 39. A branch from the middle cervical ganglion of the left side, which descends behind the subclavian artery and arch of the aorta, and divides into branches which go on each side of the aorta to the heart.
 40. A branch of the former, which turns to the left side of the aorta in its way to the heart.
 41. The accessory nerve of the eighth pair, perforating the sterno-mastoid muscle.
 42. 43. The continuation of that nerve in its way to the trapezius muscle.
 44. The sub-occipital nerve, with its connections to the great sympathetic and first cervical nerve.
 45. The first, and,
 46. The second cervical nerve.
 47. A branch formed by one from the first, and another from the second cervical nerves, forming an arch with the descendens noni.
 48. The principal part of the second cervical nerve, which, after being increased by branches from the first, forms the great posterior auricular nerve.
 49. Branches of the second and third pair, uniting and sending off,
 50. The small posterior auricular nerve.
 51. A branch from No. 49. which accompanies the nervus accessorius.
 52. The third cervical nerve.
 53. 53. The phrenic nerve.
 - 54.—58. The branches of that nerve upon the diaphragm.
 59. A branch of the third pair to the trunk of the sympathetic nerve.
 60. 61. The principal branches of the third pair, which belong to the muscles and integuments at the under part of the neck, and upper part of the thorax and shoulder.
 62. 62. The fourth cervical nerve.
 63. The scapular nerve, which, in this figure, arises entirely from the fourth cervical.
 64. A plexus formed by branches from the second, third, and fourth pairs, and a branch from the fourth pair to the phrenic nerve.
 65. The fifth cervical nerve.
 66. A trunk formed by the fourth and fifth cervical nerves.
 67. A branch to the pectoral muscle, turned back.
 68. The sixth cervical nerve.
 69. Connection between the fifth and sixth cervical nerves.
 70. A branch from the sixth cervical nerve to the small pectoral and serratus magnus muscles.
 71. The last cervical, and,
 72. The first dorsal nerve.
 73. A trunk common to these two nerves.
 74. A branch ascending from the trunk 73. to join the fourth cervical nerve.
 75. Branches from the trunk 73. to the pectorales and serratus magnus.
 76. A hook pulling the pars vaga outwards.



TAB. 193.



T A B L E CXCIII.

Represents the Primary Order of MUSCLES, with the SUBCUTANEOUS VESSELS and NERVES of the LEFT SUPERIOR EXTREMITY.

FIG. 1.

MUSCLES.

- A, The pectoralis major.
- B, The deltoides.
- C, The latissimus dorsi.
- D, The biceps flexor cubiti.
- d, d*, The round tendon of the biceps, with its aponeurosis extended to the inside of the fore-arm.
- E, The triceps extensor cubiti.
- F, The pronator teres.
- G, The supinator radii longus.

ARTERY and VEINS.

- a*, The brachial artery appearing near the inner edge of the tendon of the biceps, where it may always be felt.
- b*, The basilic vein, near the internal condyle.
- c*, The cephalic vein, near the external condyle.
- d*, The median vein, near the middle of the arm.
- e*, The median-basilic vein. Here there is a second median-basilic vein immediately above *e*.
- f*, The median-cephalic vein.
- g*, The deep-seated vein accompanying the artery, and closely attached to it.

NERVES.

- 1. The axillary branch from the brachial plexus.
- 2. 2. 2. The cutaneous nerve.
- 3. 3. 3. The musculo-cutaneous nerve.

FIG. 2.

MUSCLES.

- A, The tendon of the flexor pollicis longus, passing through the flexor pollicis brevis.
- B, The adductor pollicis.
- C, The abductor indicis.
- D, D, D, D, The muscoli lumbricales, lying in the interstices of the flexor tendons.
- E, E, E, E, The tendons of the flexor digitorum sublimis, or perforatus.
- F, F, F, The tendons of the extensor digitorum profundus, or perforans, appearing through the flits of the perforatus.
- G, G, G, The mucous sheaths, containing the above-mentioned tendons in the grooves of the finger-bones.

VEINS.

- a, a, a*, Branches forming the median vein.
- b*, _____ basilic vein.

NERVES.

The Continuation and Progress of the Cutaneous and Musculo-cutaneous Nerves may be easily traced.

- 1. The ulnar nerve, which, after passing behind the annular ligament and palmar aponeurosis, is distributed to the little and ring-finger.
- 2. The radial nerve, separating in the palm into branches which go to the third, second, and first fingers, and to the thumb.

T A B L E CXCIV.

Represents the BLOOD-VESSELS and NERVES in a deeper Dissection than in the former TABLE.

FIG. 1.	NERVES.
MUSCLES.	
A, The pectoralis minor.	1. Part of the axillary plexus.
A <i>a</i> , The subclavian muscle.	2. The nervus scapularis.
A <i>b</i> , The serratus magnus.	3. The articularis.
A <i>c</i> , The latissimus dorsi.	4. The musculo-cutaneus.
A <i>d</i> , The ball of the os humeri.	5. The spiralis.
B, The coraco-brachialis.	6. 6. The radialis.
C, The biceps muscle.	7. 7. The ulnaris.
C <i>e</i> , The long,	
C <i>f</i> , The short head, and,	FIG. 2.
C <i>g</i> , The tendon of the biceps.	MUSCLES.
D, The brachialis internus.	A, The flexor carpi ulnaris.
E, The triceps extensor cubiti.	B, The palmaris longus.
F, The supinator longus.	C, The flexor carpi radialis.
G, The pronator teres.	D, The supinator longus.
H, The flexor carpi radialis.	E, The palmaris brevis.
I, The palmaris longus.	F, The opponens pollicis.
K, The flexor carpi ulnaris.	G, The flexor pollicis brevis.
ARTERIES.	H, The ligamentum carpi annulare.
<i>a, a</i> , The axillary artery.	ARTERIES.
<i>b, b, b</i> , The humeral artery sending off the ramus anastomoticus magnus.	<i>a, a</i> , The ulnar artery.
<i>c</i> , The division of the humeral artery.	<i>b, b</i> , The radial artery.
<i>d</i> , The radial, and,	<i>c, c, c</i> , The superficial palmar arch, formed by the ulnar and radial arteries.
<i>e</i> , The ulnar artery.	<i>d, d, &c.</i> The digital arteries, with their forkings, and the branches sent along the sides of the fingers.
<i>f</i> , The trunk of the axillary vein.	
<i>g, g</i> , The cut trunks of the superficial veins.	NERVES.
<i>h, h</i> , ----- deep humeral veins.	1. 1. 1. The ulnar nerve.
<i>i, i</i> , Arteries and veins of the axillary glands.	2. 2. 2. The radial nerve.

TABLE

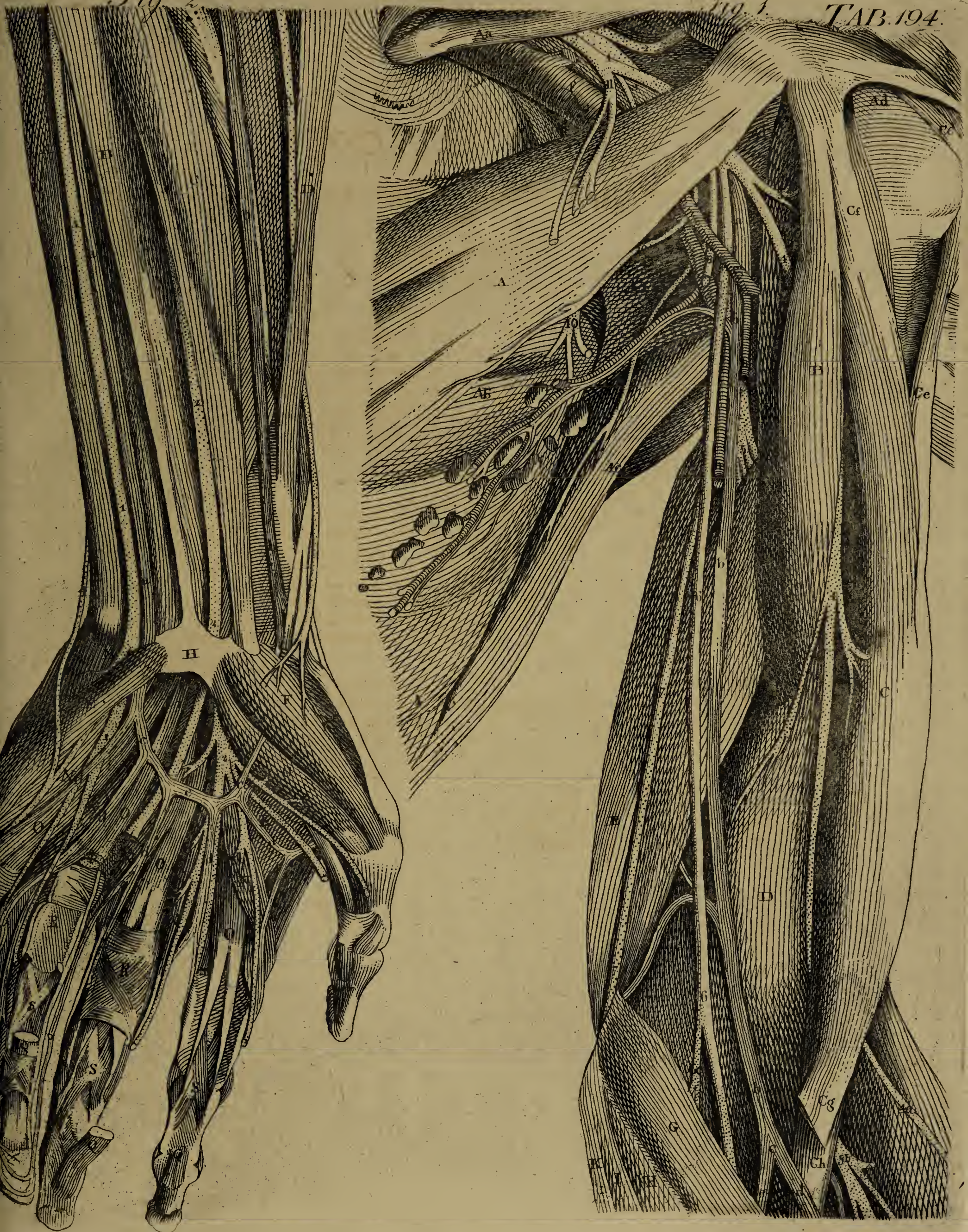
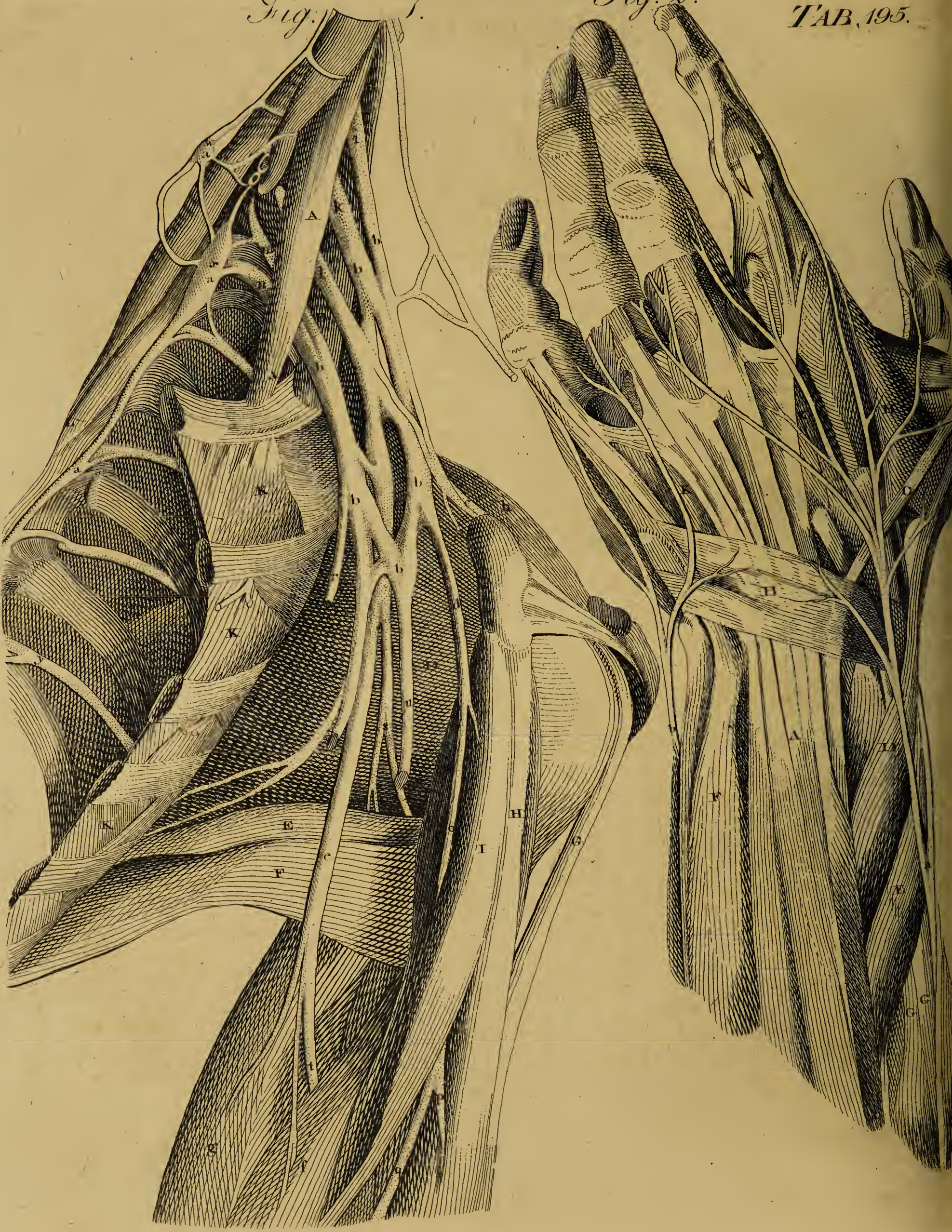
Fig. 1.

Fig. 2.



T A B L E C X C V .

A VIEW of the AXILLARY PLEXUS, and NERVES of the SUPERIOR EXTREMITY of the Left Side,

FIG. 1.

MUSCLES.

- A, A, The scalenus anticus.
 B, B, ————— medius.
 C, ————— posticus.
 K, K, K, The intercostales.
 L, L, The longus colli.
 D, D, The subscapularis.
 E, The teres major.
 F, The latissimus dorsi.
 b, The supra-spinatus.
 G, The tendon of the long head of the triceps.
 H, The short head of the biceps.
 I, The coraco-brachialis.
 f, The second, and,
 g, The first head of the triceps.

NERVES.

- wa, xa, a, The great sympathetic nerves, with connections to the cervical and intercostal nerves.
 wa, The middle cervical ganglion of the great sympathetic nerve.
 xa, The inferior cervical, and first dorsal ganglia, conjoined in this figure.
 a, The third dorsal ganglion.
 y, The fifth intercostal nerve.
 i, The fourth cervical nerve.
 k, The fifth cervical.
 l, The sixth cervical.
 m, The seventh cervical.
 n, The first dorsal nerve.
 b, b, &c. The axillary plexus.
 c, The nervus scapularis.
 s, The articularis.
 v, The cutaneus.

- d, o, p, q, The musculo-cutaneus,—o, the trunk perforating the coraco-brachialis muscle,—p, a branch to the short head of the biceps,—q, the continuation of the trunk.
 e, The spiralis, from which a branch is seen passing to the latissimus dorsi;—t, the trunk of the nerve going between the first and second heads of the triceps, after transmitting branches to these.
 u, The radialis cut.
 Between r, and e, The ulnaris cut.

FIG. 2.

NERVES of the Back of the FORE-ARM and HAND.

MUSCLES.

- A, The tendons of the extensor digitorum passing under,
 B, The posterior annular ligament of the wrist.
 C, The extensor secundi internodii pollicis.
 D, ————— primi internodii pollicis.
 e, ————— ossis metacarpi pollicis.
 F, ————— carpi ulnaris.
 G, G, The extensores carpi radiales.
 H, The abductor indicis.
 I, The adductor pollicis.
 K, K, The interossei.

NERVES.

- a, The trunk of the spiral nerve dividing into volar and dorsal branches, the latter of which is seen subdividing into smaller branches, to be dispersed upon the carpus, back of the hand, thumb, and fingers, as far as the radial side of the ring-finger.
 b, The dorsal branch of the ulnar nerves supplying the remaining part of the wrist, and of the back of the hand and fingers.

NERVES

NERVES WITHIN THE THORAX.

THE NERVES, in each side of the Thorax, consist of the *Phrenic*, the *Pars Vaga* of the Eighth Pair, the *Great Sympathetic*, and the *Intercostals*; all of which are concealed by the Pleura, till they are exposed by dissection.

THE PHRENIC or DIAPHRAGMATIC NERVE, Tab. CXCII. No. 53. has a small Filament from the second Cervical; but is chiefly formed by a Branch from the Third, and by one, and sometimes by two, from the Fourth Cervical Nerve.

It descends in the Neck, along the outer and fore part of the *Scalenus Anticus*, and enters the Thorax behind the anterior extremity of the First Rib, between the *Subclavian Artery* and corresponding Vein.

In the Thorax, it passes over the root of the lungs, and then proceeds along the *Pericardium*, to which it adheres closely in its way to the *Diaphragm*.

The Right Phrenic has nearly a straight direction opposite to the *Superior Cava* and *Right Auricle*; while the left makes a considerable Curve near its under end, corresponding with that part of the *Pericardium* which covers the point of the Heart.

Upon the Surface of the *Diaphragm*, the Trunk is divided into several Branches, which are distributed in a radiated form upon the fleshy sides of that Muscle.

PARS VAGA.—The *Pars Vaga*, Tab. CXCII. No. 53. upon approaching the Thorax, sends a Filament, and sometimes two, termed *Cardiac Nerves*, which join the *Cardiac Branch* of the *Great Sympathetic*, as already observed.

It enters the Thorax between the *Subclavian Vein* and *Artery*, and, after giving off the *Recurrent Nerve*, passes behind the root of the Lungs.

RECURRENT NERVE, Tab. CXCII. No. 31. 36.—The *Recurrent* is reflected upwards, behind the *Subclavian Artery* in the right, and behind the *Arch of the Aorta* in the left side of the Thorax;—in consequence of which, the left Nerve is the longer of the two. It afterwards ascends in the Neck, adhering to the posterior and lateral parts of the *Trachea* in its way to the *Larynx*.

It is connected, near its Origin, by one or two Branches of considerable size, with the adjacent *Ganglia* of the *Great Sympathetic Nerve*; and from the opposite side of its Root it sends other considerable Branches to join those of the Eighth Pair, in the formation of the *Anterior Pulmonary Plexus of Nerves*.

Near the *Subclavian Artery*, it is connected by different Filaments to the *Superficial* and *Deep Cardiac Branches* of the *Sympathetic Nerve*.

In its ascent in the Neck, it transmits *Pencils of Filaments*, which penetrate the *Trachea*, and are dispersed upon its *Internal Membrane*.

Behind the *Thyroid Gland*, it sends off minute Fibres to the beginning of the *Esophagus* and bottom of the *Pharynx*, and small Twigs to the *Gland* itself.

Upon the inner side of the *Thyroid Cartilage*, it furnishes a Branch which constitutes a remarkable *Anastomosis* with another from the *Internal Laryngeal Nerve*.

At the back part of the *Larynx*, it is divided into many *Fibrillæ*, which are distributed to the different Muscles fixed to the *Arytenoid Cartilage* of the corresponding side.

It has also some connections, smaller than the one already mentioned, with Branches of the *Internal Laryngeal Nerve*, and sends minute *Fibrillæ* to the *Internal Membrane* of the *Larynx*; from which circumstance, the *Recurrent Nerves* are considered as the principal Instruments of the Organ of Voice.

The *Pars Vaga*, having transmitted the *Recurrent Nerve*, gives off Filaments which form connections with Branches arising from the Root of the *Recurrent* of the same and of the opposite side.

They anastomose also by small *Fibrillæ* with the *Cardiac Branch* of the *Sympathetic*, and then pass to the fore-part of the *Bronchi*, where they constitute what is termed the *Anterior Pulmonary Plexus of Nerves*.

The *Anterior Pulmonary Plexus*, Tab. CXCVI. thus formed by Branches from the Trunk of the Eighth Pair, with the assistance of others from the *Recurrent* and *Sympathetic Nerves*, extends across the great Branches of the *Pulmonary Artery*, and, after transmitting small Filaments to the *Pericardium* and to the *Great Cardiac Nerve*, furnishes many minute *Fibrillæ*, which accompany the Ramifications of the *Bronchi* and *Pulmonary Blood-vessels* in the Substance of the Lungs.

From the *Pars Vaga*, a little below the origin of the *Recurrent*, and likewise from the root of the *Recurrent* itself, Nerves are sent off, which form a *Plexus*, to be dispersed, partly upon the fleshy-glandular Substance of the *Trachea*, and partly embracing the *Esophagus*, and forming upon it the *small Esophageal Plexus*.

Behind the root of the Lungs, about six or seven Nerves of different sizes are sent off in a transverse direction, which are termed *Posterior Pulmonary Plexus*, although they have few connections with each other. Tab. CXCVIII.

The *Posterior Pulmonary Nerves*, like the *Anterior*, follow the Branches of the *Bronchi* and *Blood-vessels* in the

the Substance of the Lungs, and, becoming gradually smaller, send off minute Twigs, which penetrate the Air-vessels, and are ultimately dispersed upon their Internal Membrane.

After giving out the Pulmonary Nerves, the Pars Vaga is split into Cords, termed *Great Esophageal Plexus*, which surrounds the Esophagus, sends Filaments into its Substance, and is joined by Funiculi of the Pars Vaga of the opposite side.—It goes afterwards through the Diaphragm, to be distributed upon the Viscera of the Abdomen.

From the Ganglia of the Great Sympathetic Nerve, at the bottom of the Neck, and top of the Thorax, the principal *Cardiac Nerves* are produced, which are dispersed upon the Heart; while the continuation of the Trunk of the Sympathetic descends in the Thorax at the side of the Vertebrae.

The **CARDIAC NERVES** of the **RIGHT SIDE** consist of the *Cardiacus Magnus Profundus*, and *Cardiacus Minor*; the latter of which is termed by SCARPA *Cardiacus Aortae Superficialis*.

The **CARDIACUS MAGNUS PROFUNDUS**, Tab. CXCII. CXCVI. is principally formed by Branches from the Second Cervical Ganglion of the Sympathetic, and afterwards receives one or two Filaments from the *Cardiacus Supremus*, together with the *Superficial Cardiac* and other Branches of the Eighth Pair, as formerly described.

The Trunk, arising in this manner from different sources, passes between the Superior Cava and ascending Aorta, to the posterior Surface of the latter, and joins the *Cardiac Branches* of the Left Side.

By the addition of the Left Cardiac Nerves, a Plexus is formed, termed *Plexus Cardiacus Magnus of HALLER*, from which is sent out a long Ganglion of a soft consistence, described by WRISBERG under the name of *Ganglion Cardiacum*.

From the Cardiac Ganglion, the following Branches are given off, viz.

A Branch which, after transmitting Filaments to the Anterior Pulmonary Plexus of the Eighth Pair, passes behind the Right Division of the Pulmonary Artery to the Left Coronary Plexus of the Heart:

One or two Filaments, which unite with others sent from the Anterior Pulmonary Plexus of the Eighth Pair, and go before the Right Branch of the Pulmonary Artery to the Base of the Heart:

Branches of considerable size, passing partly over the right side of the Aorta, and partly between it and the Pulmonary Artery to the Anterior Coronary Plexus:

Small Branches which unite with others coming from the Trunk of the Great Cardiac Nerve, and pass over the Aorta to the Anterior Coronary Plexus.

The **NERVUS CARDIACUS MINOR**, Tab. CXCVI. arises from the undermost Cervical Ganglion, creeps over the Arteria Innominata and Aorta, and terminates in a Plexus formed by the Cardiac Nerves on the left side of the Aorta Ascendens.

VOL. III.

The **LEFT CARDIAC NERVES** are, the *Cardiacus Superficialis*, and the *Cardiacus Magnus Profundus*.

The **CARDIACUS SUPERFICIALIS**, Tab. CXCVII. arises from the upper part of the Sympathetic Nerve, as formerly noticed, and passes behind the Arch of the Aorta to the Plexus Cardiacus Magnus.

The **CARDIACUS MAGNUS PROFUNDUS SINISTER**, Tab. CXCVII. the upper portion of which is smaller than that of the right side, arises by numerous roots from the middle, and from the lowest Ganglion of the Sympathetic Nerve.

It passes across the Arch of the Aorta, and, after receiving the Cardiac Branch of the Eighth Pair, joins the Great Cardiac of the right side, to assist in forming the Cardiac Plexus.

From the Cardiac Plexus, a *Reticulum* of Nerves extends upon the left side of the ascending Aorta, which receives the Cardiacus Minor, and a Filament or two from the Cardiacus Magnus of the right side, going over the Aorta.

From this Reticulum, the *Anterior* or *Right Coronary Plexus* is produced, which passes between the Pulmonary Artery and Aorta, and afterwards follows the course of the Trunk and Branches of the Right Coronary Artery, along with which it is dispersed upon the corresponding side of the Heart.

The Great Cardiac Plexus, after sending a Filament or two to the Lungs, gives off Nerves which unite and form the *Trunk* of the Great Deep Cardiac Nerve of the left side, Tab. CXCVII. which has a soft Gangliiform appearance, and passes along the corresponding side of the Pulmonary Artery.

Upon the Surface of this Artery, the Trunk soon divides into Branches, which, after sending Filaments across it to the right Coronary Plexus, give origin to the *Coronary Plexus* of the *left side*, Tab. CXCVII. which attends the Trunk and Branches of the Left Coronary Artery.

In the Left or Posterior Coronary Plexus, the Nerves are larger than in the Right, corresponding with the parts they have to supply; and, in both, they have repeated connections with each other on the Surface of the Heart.

In general, the Nerves run close to the Arteries; some of them being continued as far as the Apex, while others penetrate the Substance of the Heart.

The Great Sympathetic, having produced the Principal Cardiac Nerves, consists of an anterior and a posterior part,—the former going over, and the latter under the Subclavian Artery.

Behind this Artery, the two parts unite into a Trunk, which descends in the Thorax over the Heads of the Ribs. Tab. CXCIX.

At the Head of each Rib, it forms a small Ganglion of an irregular shape, which unites behind with each of the Intercostal Nerves, generally by two, and sometimes by three short Branches.

From several of the Dorsal Ganglia of this Nerve, Filaments

Filaments are detached obliquely over the Vertebrae to the Coats of the Aorta.

From the Sixth, Seventh, and Eighth Dorsal Ganglia, —and frequently from a Ganglion above or below these, —Branches arise, which descend obliquely upon the sides of the Vertebrae, and unite into a Trunk, termed *Nervus Splanchnicus*, Tab. CCII. which perforates the Appendix of the Diaphragm, and goes to the Viscera of the Abdomen; from which circumstance the Nerve obtains its name.

Besides the *Nervus Splanchnicus*, another, termed *Splanchnicus Secundarius*, or *Accessorius*, is generally observed, which arises from one or two of the Dorsal Ganglia, below the origins of the *Splanchnicus*, —near its termination, —or runs separate from it into the Abdomen.

The INTERCOSTAL, or COSTAL, or DORSAL NERVES, Tab. CXCIX. CCII. after escaping from the Vertebrae, run in the Furrows at the lower edges of the Ribs, in company with the Intercostal Blood-vessels, and proceed to the anterior part of the Thorax, between the two Layers of the Intercostales.

Immediately after getting out from between the Vertebrae, each is connected, as already taken notice of, by short Branches to the Sympathetic Nerve. Tab. CCII.

Opposite to this connection, they give principal Branches backwards to the Muscles lying near the Spine, and serving for the erection of the Trunk of the Body.

Through the rest of their course, they give Branches to the Intercostales, to the Muscles and Integuments of

the Thorax, and also to those of the Abdomen, and, becoming gradually smaller, they at last vanish in the fore-part of the Body.

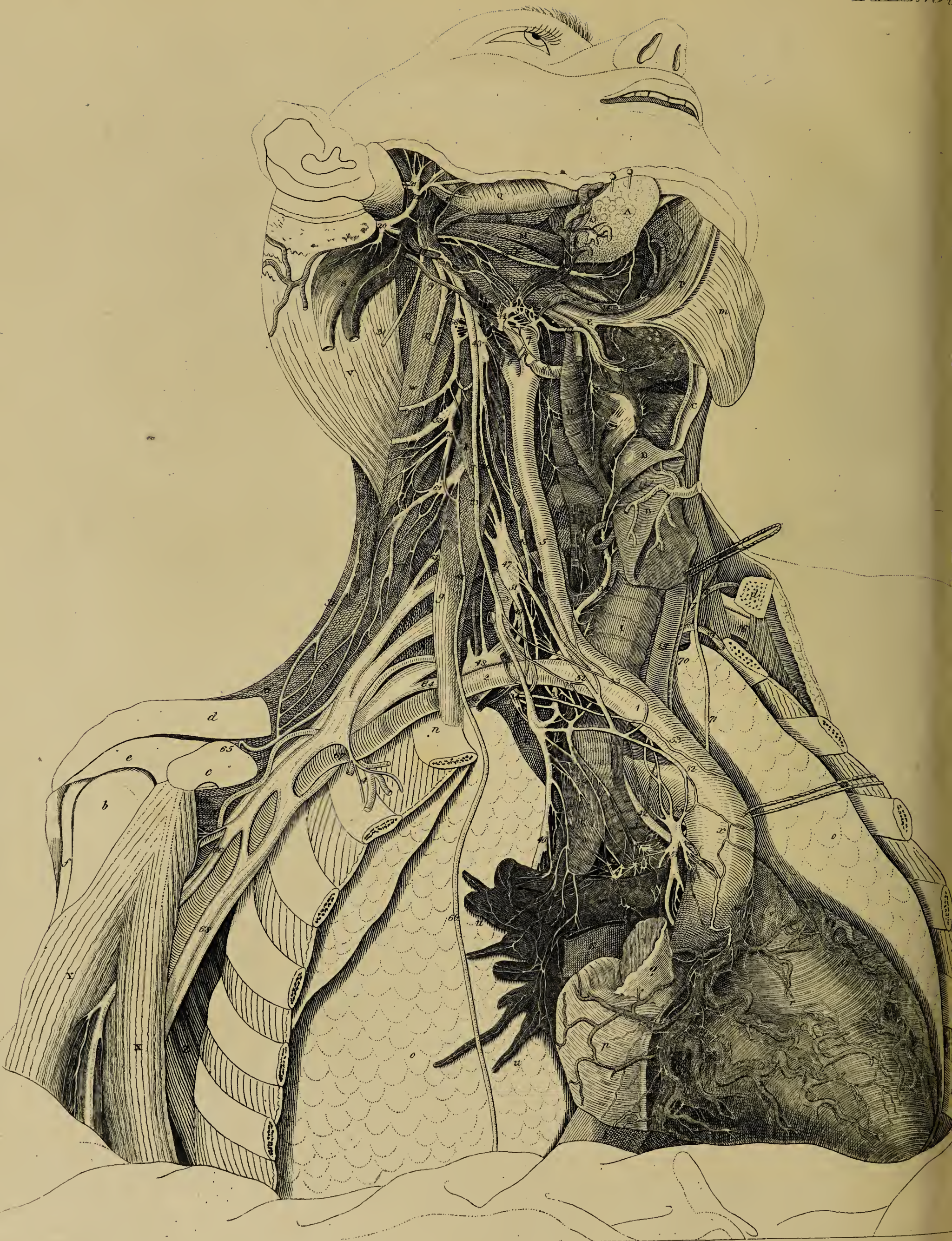
The six upper Intercostals send Branches to the numerous Muscles, and to the Integuments, covering the back part of the Thorax, to the *Serratus Magnus*, and to the upper part of the Abdominal Muscles; while the remains of them, passing out between the Ribs at the edge of the Sternum, are reflected along with Branches of the Internal Mammary Blood-vessels, to be dispersed by small Filaments upon the Mamma, and likewise upon the Muscles and Integuments next the edge of the Sternum.

The Trunk of the First Intercostal enters the composition of the Axillary Plexus; a Branch of it, however, runs along the edge of the first Rib, in the manner the other Intercostals run along their respective Ribs.

Two Principal Branches, one from the Second, and the other from the Third Intercostal, are occupied in forming the Intercosto-humeral Nerves, already described; while a considerable Branch from the Fourth is reflected over the edge of the *Latissimus Dorsi* to the Integuments of the back part of the Thorax.

The Six Lower Intercostals, after supplying the adjacent Muscles and Integuments of the Thorax, continue their course obliquely forwards, and are dispersed upon the different Muscles and Integuments of the Abdomen; —the Twelfth, running from the last Rib along the under end of the Abdomen, sends Filaments, which extend as far as the Skin of the Pelvis and Thigh.

TABLE



T A B L E C X C V I .

Exhibits the CARDIAC NERVES of the Right Side.

-
- A, The submaxillary gland.
 B, The right portion of the thyroid gland turned forwards.
 C, A section of the right portion of the thyroid cartilage.
 D, The cricoid cartilage.
 E, The right cornu of the os hyoides.
 F, The body of the fourth cervical vertebra.
 G, ———— first dorsal vertebra.
 H, The pharynx raised from its insertion, and turned back.
 I, The trachea, with the pharynx pulled towards the left side.
 K, L, The right and left bronchi.
 M, The stylo-glossus.
 N, The stylo-pharyngeus.
 O, The genio-glossus.
 P, The genio-hyoideus.
 Q, R, The insertions of the masseter and pterygoideus internus.
 S, The digastricus, and,
 T, The stylo-hyoideus cut and turned back.
 U, The cucullaris.
 V, The splenius.
 W, The levator scapulæ.
 X, The coraco-brachialis.
 Y, The short head of the biceps.
 Z, The teretes major et minor.
a, Part of the sub-scapularis.
b, The head of the os humeri.
c, The coracoid process of the scapula.
d, d, The clavicles, the left cut across, and the acromion joined to the end of the right.
e, The proper anterior ligament of the scapula.
f, The tendon of the long head of the biceps.
g, The scalenus anticus.
h, ———— posticus.
i, The longus colli.
k, l, The rectus capitis anterior major pulled outwards.
m, The mylo-hyoideus of the right side turned down.
n, n, A section of the ribs and intercostal muscles.
o, o, The lungs.
p, The right sinus venosus, and,
q, The right appendix, or proper auricle of the heart.
r, The right, and part of the left ventricle.
s, The vena cava superior cut across.
t, The vena cava inferior.
u, u, The pulmonary veins of the right side.
v, The trunk of the pulmonary artery.
w, The right branch of that artery.
x, The aorta drawn to the left side.
y, The right coronary artery, ramifying on the corresponding side of the heart.
z, The left coronary artery.
 1. The trunk common to the right subclavian and right carotid.
 2. The right subclavian.
 3. 3. The thyroidea inferior, near the beginning of which the vertebral, cut across, arises in this subject.
 4. The thoracica major.
 5. The common carotid.
 6. The internal carotid.
 7. The external carotid.
 8. The thyroidea superior.
 9. The occipital.
 10. The auricularis posterior.
 11. The transversalis faciei.
 12. The external carotid, sending inwards the maxillaris interna, and before the ear the superficial temporal.
 13. The facial, from which branches are sent off to the submaxillary gland.
 14. The lingualis, with its sublingual branches.
 15. The left carotid.
 16. ———— subclavian.
 17. The thyroidea inferior.
 18. The common origin of the transversa colli et scapulæ.
 19. The mammaria interna divided.
 20. The *nervus durus*, s. *communicans faciei*.
 21. The auricularis, formed by a branch of the third of the fifth, united to one from the *nervus durus*. From the *nervus durus*, filaments are seen descending to the digastricus, to the stylo-hyoideus, and along the external carotid artery.
 22. The

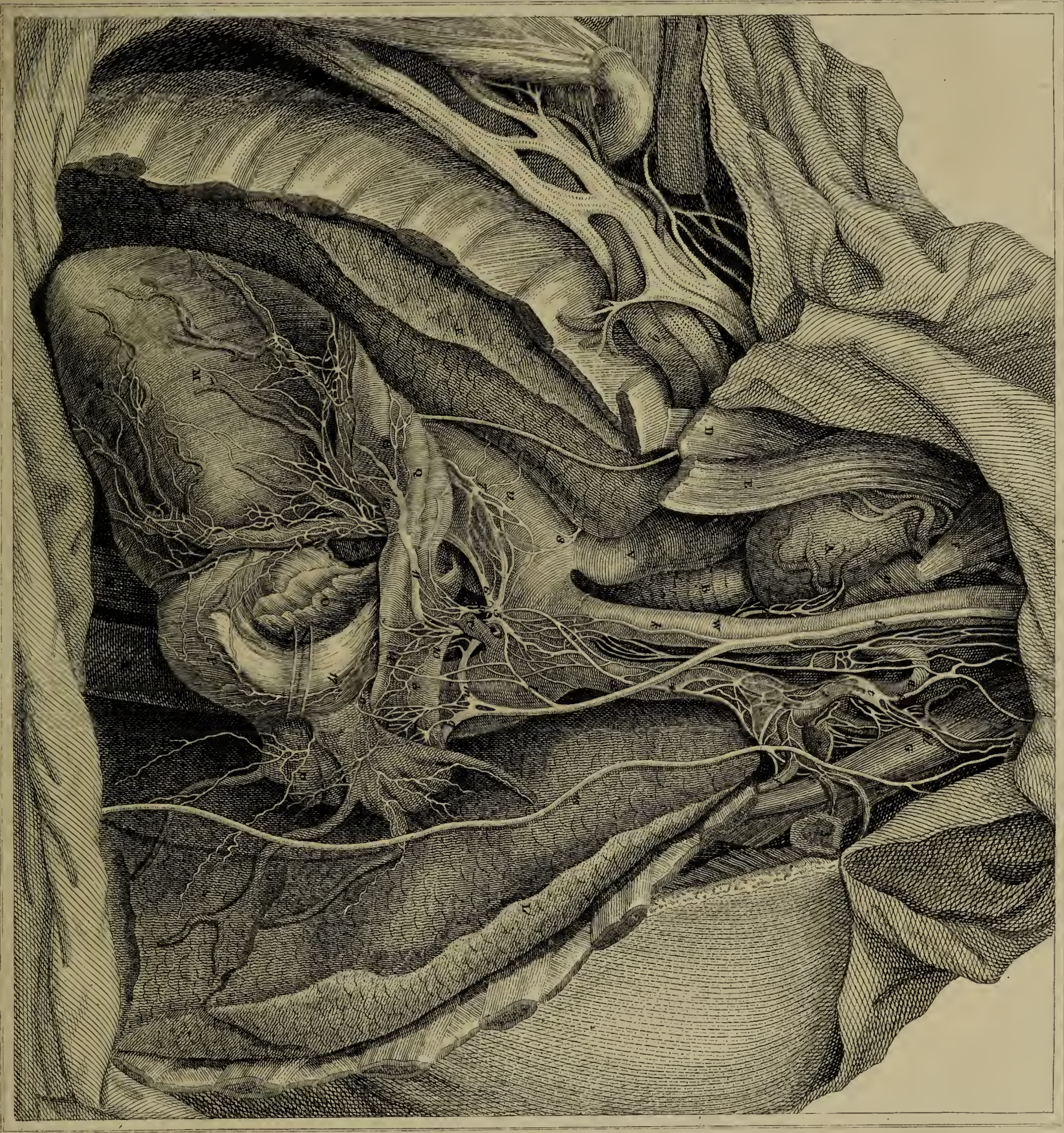22. The temporal and facial branches of this nerve.
23. The *pars vaga* of the eighth pair drawn a little outwards.
24. The *glosso-pharyngeus*.
25. A plexus of nervous filaments from the glosso-pharyngeus, the pharyngeus, and from the superior cervical ganglion going along the internal carotid artery.
26. Branches from the pharyngeus to the pharynx.
27. The *laryngeus internus* of the *pars vaga*, passing from behind the internal carotid to the larynx.
28. A branch from this, which, with others from the pulpy nerves of the superior cervical ganglion, forms the *laryngeus externus*.
29. Branches of the *laryngeus externus* to the pharynx, and to the inner parts of the larynx; and, a little below this, branches to the under part of the pharynx, and to the larynx and thyroid gland.
30. The *laryngeus internus* terminating by numerous branches upon the epiglottis, and other parts about the upper and inner side of the larynx.
31. 31. The *nervus accessorius* divided.
32. The trunk of the *ninth nerve*, or hypo-glossus, cut and turned back.
33. The superficial cardiac branch of the *pars vaga*, and, a little below this, another superficial cardiac branch, which is not constant.
34. Nerves from the middle and inferior cervical ganglion to the trunk of the *pars vaga*.
35. The *recurrent branch* of the *pars vaga*. Near its origin, it is connected by two branches with the middle and inferior cervical ganglia, and by others with the adjacent nerves.
36. The trunk of the recurrent nerve ascending by the side of the trachea, and giving branches along the inferior thyroid artery to the gland of that name; numerous branches which terminate upon the inner membrane of the trachea, and branches to the esophagus, to the bottom of the pharynx, and to the thyroid gland.
37. A remarkable anastomosis between this nerve and the *laryngeus internus*. From this union filaments are sent to the arytenoid gland, to the oblique and transverse arytenoid muscles, and to the inner membrane of the larynx.
38. Numerous filaments to the cricoid and arytenoid muscles, to the inner membrane of the larynx, and various connections with the *laryngeus internus*.
39. Nervous funiculi from the recurrent and *pars vaga*, along the fore-part of the trachea and bronchi to the small anterior pulmonary plexus.
40. The trunk of the *pars vaga* near the right bronchus, sending filaments to the esophagus, and numerous branches to the superficial pulmonary plexus situated over the blood-vessels of that side.
41. A small anterior pulmonary plexus, formed by branches from the *pars vaga* and recurrent. From this, filaments go to the right lung; some join branches of the sympathetic, and go behind the pulmonary artery to the posterior surface of the heart.
42. A conspicuous anastomosis between the left recurrent and the small anterior pulmonary plexus.
43. The *ganglion cervicale superius* of the great sympathetic nerve, from which pulpy branches pass inwards to join the principal branches of the eighth pair.
44. A plexus of pulpy nerves from the sympathetic, interspersed with little ganglia embracing the external carotid, and sending up branches with some minute ganglia along the principal branches of the carotid.
45. The *nervus cardiacus superficialis, s. supremus*, formed by different roots from the superior cervical ganglion, and from the trunk of the sympathetic nerve. Immediately above the number, two branches of this nerve are connected with the *laryngeus externus*, and below filaments run from it, partly along the inferior thyroid artery to the gland of that name, and partly to the cardiac branch of the *pars vaga*; still lower is seen the connection of this nerve to a branch sent off from the inferior cervical ganglion, and by another to the recurrent nerve.
46. The trunk of the *sympathetic nerve*.
47. The *ganglion cervicale medium*, into which three nerves, descending from the second, third, and fourth cervicals, enter.
48. The *ganglion cervicale inferius*, with branches, some before, others behind the subclavian artery, connecting this ganglion with the former one, and with the first thoracic ganglion, one of which, larger than the rest,
49. Is considered as the continuation of the trunk of the sympathetic nerve. Into the upper part of the ganglion cervicale inferius, three nerves are seen passing from an equal number of inferior cervicals.
50. The beginning of the *first*, or what some reckon the *second thoracic ganglion*.
51. Two conspicuous nerves from the middle cervical ganglion, one of which anastomoses with the superficial cardiac branch of the *pars vaga*, and afterwards passes behind the subclavian artery, to connect itself to the recurrent nerve; the other goes over this artery, and connects itself with the subjacent ganglia.
52. The *cardiacus magnus profundus* of the great sympathetic nerve.
53. The *cardiacus minor, s. cardiacus aortæ superficialis*.
54. The *ganglion molle, s. cardiacum* of the great cardiac nerve.
55. Anastomoses between the cardiac nerves of the right and left sides, forming the *great cardiac plexus* of HALLER.
56. The *right* or *anterior coronary plexus*, formed of branches from the cardiac nerves of each side, passing between the aorta and pulmonary artery, and afterwards following the course of the right coronary artery and its branches to the corresponding sides of the heart. Over the trunk of the pulmonary artery, filaments are seen

- seen passing from the left cardiac nerves to the right coronary plexus.
57. The left coronary plexus running along the artery of that name.
58. A connection by short threads between the superior cervical ganglion, tenth of the head, and first of the neck. A little lower, a gangliform connection appears between the under end of the superior cervical ganglion and the second cervical nerve. Near the same place, a branch descends to the rectus capitis major.
59. The posterior auricular nerve arising from the second of the neck.
60. The second cervical nerve, and a connection between it and the third cervical.
61. The third cervical, with its connections to the accessory, and to the fourth cervical.
62. The phrenic nerve arising by three origins.
63. 64. The four inferior cervical nerves and first dorsal.
65. A nerve to the supra-spinatus.
66. The musculo-cutaneous, and a branch from it above, to the coraco-brachialis, and others below, to the biceps and brachialis internus.
67. Branches from the brachial plexus to the pectoralis major and minor, and to the serratus magnus.
68. The radial and ulnar nerves.
69. The phrenic nerve within the thorax.
70. The pars vaga, and,
71. The phrenic of the left side,

T A B L E CXCVII.

The CARDIAC NERVES of the Left Side.

-
- A, The left portion of the thyroid gland.
 B, The trachea.
 C, Part of the pharynx.
 D, The left portion of the sterno-thyroideus.
 E, ————— hyoideus.
 F, The left omo-hyoideus cut.
 G, The scalenus anticus.
 H, Part of the scalenus posticus.
 I, A section of the left clavicle.
 K, L, The right and left lungs.
 M, The heart drawn strongly over to the right side.
 N, Part of the plain surface of the heart.
 O, The left auricle suspended, that the coronary artery and nerves of that side may appear.
 P, The pulmonary sinus.
 Q, The pulmonary artery so twisted as to shew the left cardiac nerves.
 R, The beginning of the right branch of the pulmonary artery.
 S, The left branch of the pulmonary artery.
 T, The ductus arteriosus changed into ligament.
 U, The aorta.
 V, The common trunk of the right carotid and subclavian arteries.
 W, The left carotid.
 X, ——— subclavian.
 Y, The descending aorta.
 Z, The esophagus.
 a, The inferior, and,
 b, The superior thyroid arteries, with their branches to the thyroid gland.
 c, The vertebral artery.
 d, The anterior cervical artery arising from the thyroidea inferior.
 e, The posterior cervical artery.
 f, The internal mammary.
 g, The right axillary.
 h, The profunda scapulæ.
 i, The *pars vaga* of the left side.
 k, The *superficial cardiac branch* of this nerve, and its anastomosis with the small deep cardiacs of the great sympathetic.
 l, Another cardiac branch of this nerve, going partly to the sympathetic nerve near the termination of the former branch, and partly by two filaments to the left auricle.
 m, The left *recurrent nerve*, which at its beginning sends filaments that unite with others from the *pars vaga*, and follow the pulmonary vessels of that side. A little farther on, two filaments are sent off to the great pulmonary plexus.
 n, The distribution of the recurrent nerve at the left side of the trachea and thyroid gland.
 o, A nerve from the *pars vaga* going behind the left branch of the pulmonary artery to the auricles.
 p, A nerve from one of those sent off at *m*, passing between the two left pulmonary veins, to the anterior surface of the lungs.
 q, The trunk of the *pars vaga* turning behind the left bronchus to the esophagus.
 r, The *trunk* of the *left sympathetic nerve*.
 s, The continuation of the trunk after receiving two branches from the second cervical nerve.
 t, The *ganglion cervicale medium*.
 u, The third cervical nerve, sending branches to the middle cervical ganglion.
 v, Small nerves from the third and fourth cervicals to this ganglion.
 w, The *ganglion cervicale inferius*, with nerves passing into it from the middle ganglion.
 x, Branches of considerable size from several of the inferior cervicals and first dorsal, to the inferior cervical ganglion.
 y, Nervous fibrillæ from the superior cervical ganglion, which, uniting with others, form,
 z, The *left superficial cardiac nerve*.
 1. The superficial cardiac nerve, separating into threads, which pass on the opposite side of the aorta to the cardiac branch of the *pars vaga*, and the great cardiac plexus of the sympathetic nerve.
 2. Nerves from the middle cervical ganglion creeping along the inferior thyroid, the vertebral, and the subclavian arteries.
 3. A plexus of nerves from the middle cervical ganglion to the inferior one and to the first dorsal ganglion, and embracing the subclavian artery.
 4. The *nervus cardiacus profundus minor*, arising by numerous filaments from the middle and lowest cervical



TAB. 197.

Amboon sculp.

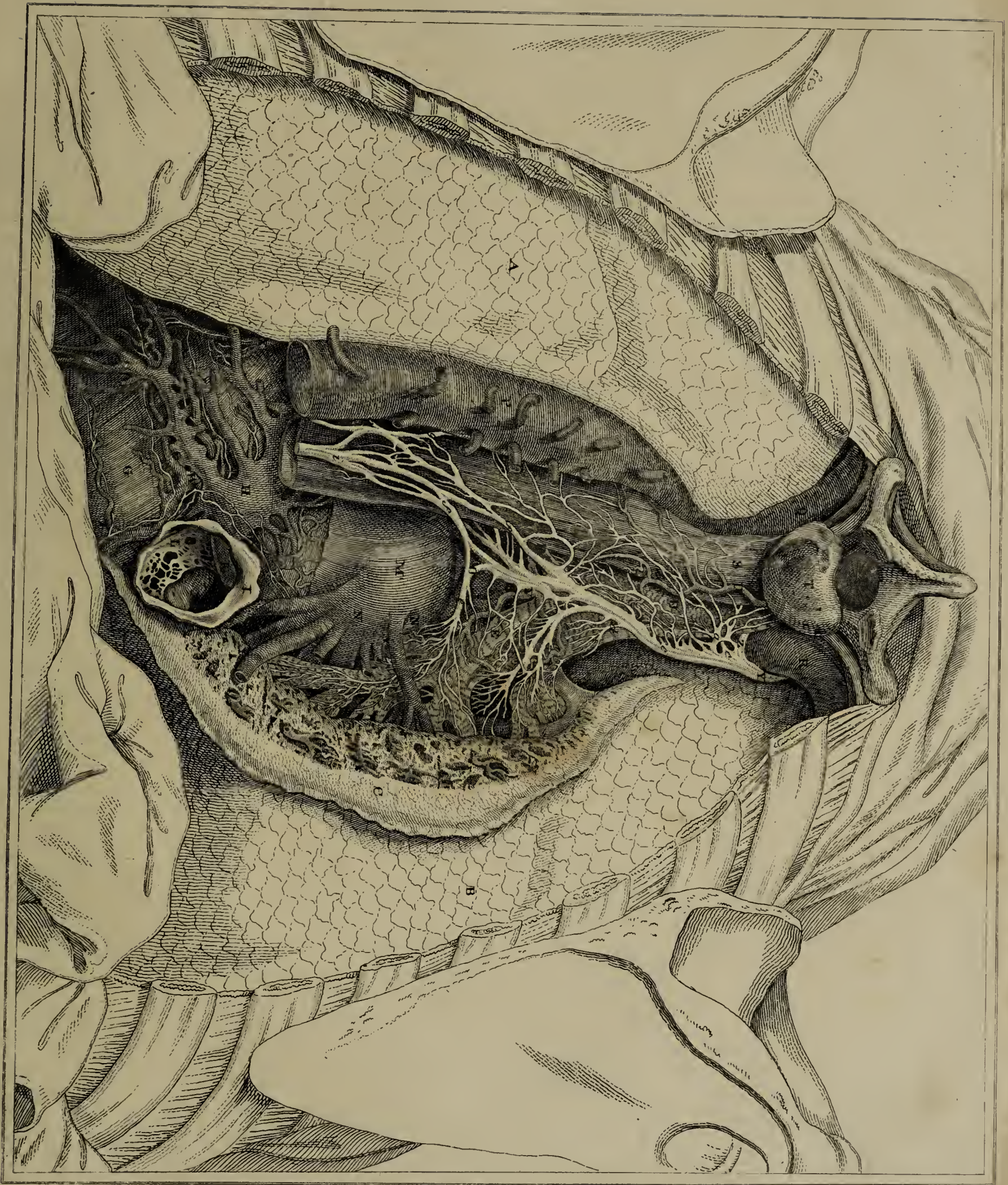
- cal ganglia, with a gangliform appearance at its inferior extremity, where it runs into the great deep cardiac plexus.
5. The *plexus cardiacus magnus profundus*, arising from the concurrence of the nerves of the opposite side.
 6. The *ganglion cardiacum*.
 7. A plexus of nerves from the cardiacus profundus and cardiac ganglion, running between the aorta and pulmonary artery, to form the right coronary plexus.
 8. Nerves from the cardiacus minor of the right side, and farther down other nerves from the cardiacus profundus of that side passing over the aorta to join the plexus No. 7.
 9. A gangliform nerve from the great deep cardiac plexus, dividing into filaments which assist in forming both coronary plexus.
 10. A fasciculus of nerves from the great deep cardiac plexus, running under the shrivelled ductus arteriosus, and forming,
 11. The *nervus cardiacus magnus profundus* of the left side, formed by a fasciculus of nerves.
 12. The division of the great cardiac nerve, at the back part of the pulmonary artery, into branches, which, meeting with others from the cardiac ganglion, form the left coronary plexus.
 13. Branches from the great cardiac nerve, running over the pulmonary artery to the right coronary plexus.
 14. Branches running over the pulmonary artery, and going partly to the left coronary plexus, and partly with the pulmonary artery to the left lung.
 15. The *left, or posterior coronary plexus*, formed of branches from the deep cardiac nerves of each side, which follow the branches of the left coronary to the anterior and posterior regions of the heart.
 16. The origin of nerves which follow a branch of the left coronary artery, seen in Tab. CXCVI. to the fore-side of the heart.
 17. Minute branches which form the great cardiac plexus, which are sent off behind the pulmonary artery, and take a long course upon the pulmonary sinus.
 18. 19. The right and left phrenic nerves.

T A B L E CXCVIII.


The POSTERIOR PULMONARY PLEXUS of the PARS VAGA of the EIGHTH PAIR of NERVES, and the NERVES of the Plain Surface of the HEART.

-
- A, The posterior convex surface of the left lung.
 B, _____ right lung.
 C, The substance of the right lung dissected and turned back, to shew the bronchial vessels and nerves.
 D, The posterior surface of the trachea beset with many mucous glands.
 E, F, The right and left bronchi, the former dividing into branches.
 G, The plain surface of the heart.
 H, The trunk of the great coronary vein, with its branches.
 I, The vena cava inferior cut across.
 K, A membrane occupying the place of the foramen ovale.
 , The valvula EUSTACHII, cribriform in the subject of this Figure.
 M, The pulmonary sinus.
 N, N, Two principal pulmonary veins of the right side.
 O, The pulmonary artery.
 P, The thoracic aorta.
 Q, The left subclavian artery.
 R, The trunk common to the right carotid and subclavian.
 S, The esophagus.
 T, The first dorsal vertebra.
 U, The superior esophageal artery.
 V, The bronchialis dextra, with its branches upon the bronchi of that side.
 W, The coronaria dextra with its branches.
 X, A branch of the coronaria sinistra.
 Y, The *pars vaga* or *nervus vagus* of the right side.
 Z, The *right recurrent nerve* of the *pars vaga*.
 a, The rami *adscendentes et descendentes* from the *pars vaga* and the recurrent near the trachea.
 b, The *plexus esophageus minor posterior* of the *pars vaga*.
 From the Trunk of the Nerve other Branches are seen, going partly to the Trachea and partly to the Esophagus.
 c, c, Branches from the *pars vaga* and recurrent, which belong to the anterior pulmonary plexus.
 d, A fasciculus of nerves from the *pars vaga*, inserted into the beginning of the right bronchus.
 e, e, The *plexus pulmonalis posterior* of the *pars vaga*, formed of branches of various sizes, which go some before, others behind the bronchi, to be inserted into them. In their course they form some anastomoses with each other, and terminate with the aerial tubes.
 f, f, f, The *pars vaga* dividing into branches, which surround the esophagus.
 g, b, i, The *plexus esophageus magnus* of the *pars vaga*, composed of funiculi of the *pars vaga* of each side. From this plexus filaments are sent into the substance of the esophagus.
 k, Two filaments of the cardiac nerves, which accompany the right coronary artery to the plain surface of the heart.
 l, A connection between these and nerves from the great cardiac plexus, between the vena cava inferior, and the left auricle. From the nerves k and l, filaments are sent off which accompany branches of the right coronary artery upon the plain surface of the heart.

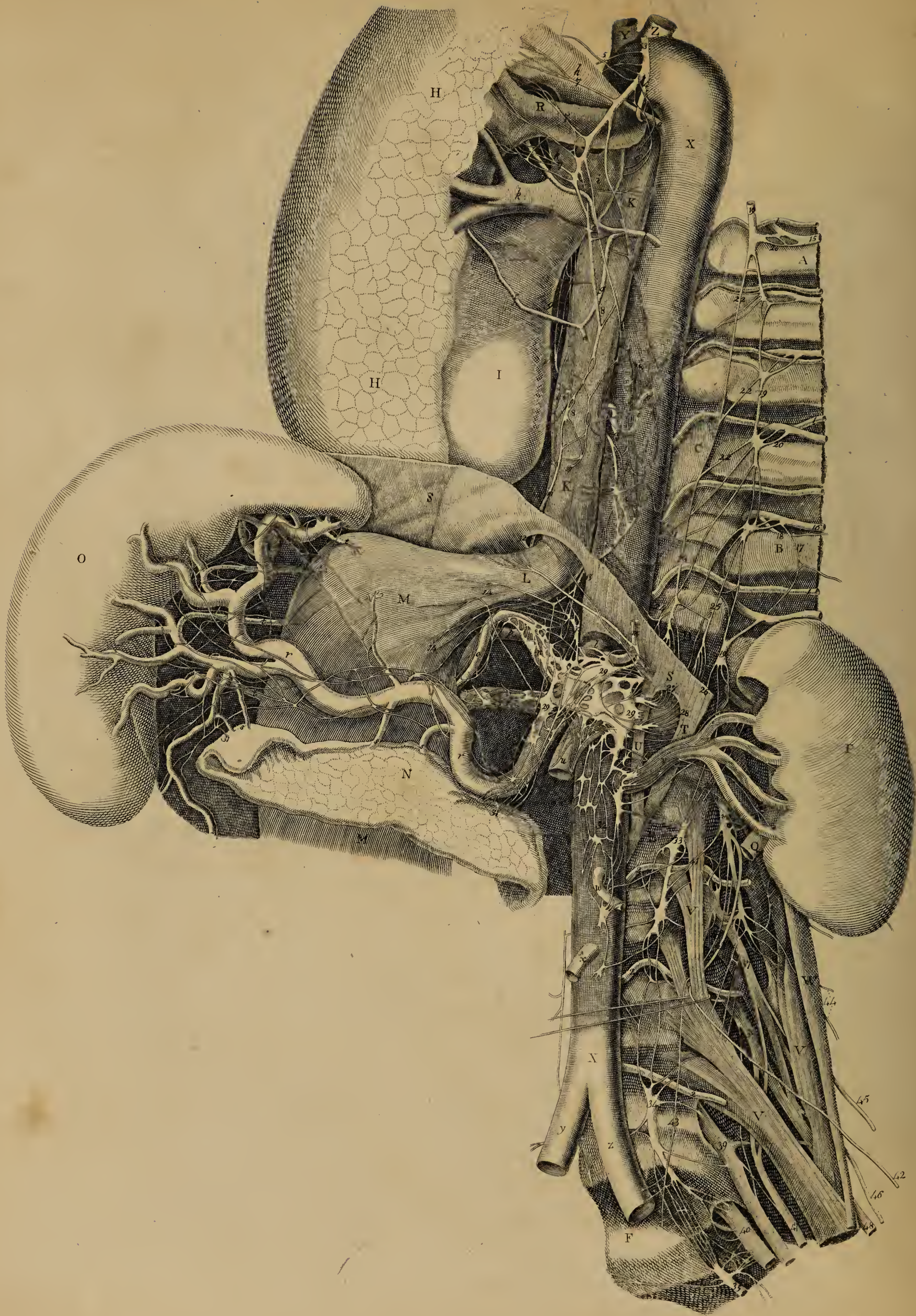
TABLE



TAB. 108.



TAB. 199.



T A B L E CXCIX.

A VIEW of the GREAT SYMPATHETIC and EIGHTH PAIR of NERVES, in the Left Side of the BODY; the LUNGS, Part of the STOMACH, the SPLEEN and PANCREAS, being turned over to the Right Side.

-
- A, The seventh rib.
 B, The eleventh rib.
 C, The ninth dorsal vertebra.
 D, The twelfth dorsal vertebra.
 E, The second lumbar vertebra.
 F, The fifth lumbar vertebra.
 G, The first vertebra of the os sacrum.
 H, H, The left lung.
 I, The pericardium inclosing the heart.
 K, K, The esophagus.
 L, The cardia.
 M, M, The stomach.
 N, The pancreas.
 O, The spleen.
 P, The left kidney.
 Q, The ureter.
 R, The left bronchus.
 S, The lumbar part of the diaphragm.
 T, U, The left crus of the diaphragm.
 V, V, The psoas magnus split and separated, to give a view of the lumbar plexus of nerves and ganglia.
 W, The psoas minor.
 X, The aorta.
 Y, The left subclavian artery.
 Z, ——— carotid artery.
a, The ligamentum arteriosum.
b, The left superior bronchial artery.
c, The arteria esophagea, from whence arises the inferior bronchial artery, cut at *d*.
e, The continuation of the esophageal artery, sending off,
f, The inferior bronchial artery.
g, A communication between the superior and inferior bronchial artery.
h, The left pulmonary artery.
i, ——— sinus venosus.
k, k, The left pulmonary veins.
l, The celiac artery
m, The left diaphragmatic artery.
n, A trunk common to,
o, The superior coronary artery of the stomach, and,
p, A left hepatic artery.
q, The right hepatic artery.
r, r, The splenic artery.
s, s, s, The pancreatic branches from the splenic artery.
t, t, t, The arteriæ breves of the stomach.
u, The superior mesenteric artery.
v, The left renal artery.
w, ——— spermatic artery.
x, The inferior mesenteric artery.
y, The right iliac artery.
z, The left iliac artery.
 1. 1. The intercostal arteries.
 2. 2. 2. The third, fourth, and fifth lumbar arteries.
 3. The trunk of the eighth pair of nerves.
 4. The left recurrent nerve passing round the ligamentum arteriosum and curvature of the aorta.
 5. The cardiac branches from the eighth pair.
 6. 6. &c. The esophageal nerves of the eighth pair.
 7. 7. The pulmonary branches of the eighth pair.
 6. &c. 8. A plexus of nerves of the eighth pair upon the esophagus and aorta, sending branches to both of these.
 9. Branches of the right portion of the eighth pair.
 10. A trunk, formed chiefly by the right portion of the eighth pair, passing to the posterior surface of the stomach, and giving branches to the celiac ganglion and liver.
 11. A trunk, formed by the branches of the eighth pair, running to the anterior part of the stomach, and to the liver.
 12. The anterior or left trunk, passing with the esophagus through the diaphragm.
 13. The posterior or right trunk, passing likewise through the diaphragm.
 14. 14. Branches of the right trunk dispersed upon the posterior surface of the stomach.
 15. The sixth, and,
 16. The tenth intercostal nerve.
 17. A communicating branch between two intercostal nerves.
 18. A posterior branch to the muscles of the back.
 19. 19. The trunk and ganglia of the great sympathetic nerve.

20. 20. Connections between the intercostal and sympathetic nerves.
21. Branches from the great sympathetic nerve to the coats of the aorta.
22. 22. 22. Branches from the ganglia of the great sympathetic nerve, forming,
23. The ramus splanchnicus.
24. Branches from the great sympathetic nerve to the aorta and celiac ganglia.
25. The nervus splanchnicus secundarius, arising from the tenth thoracic ganglion.
26. A branch from the eleventh thoracic ganglion to the celiac ganglion.
27. Branches from the ramus splanchnicus to the diaphragm.
28. Branches of the ramus splanchnicus passing through the diaphragm.
29. &c. The celiac ganglia, from which plexuses of nerves are sent off, which accompany the branches of the celiac and superior mesenteric arteries to the place of their destination.
30. Joinings of the eighth pair with the celiac ganglia.
31. Branches from the splenic plexus to the pancreas.
32. Aortic plexus of nerves and ganglia, proceeding from the celiac ganglia.
33. 34. The lumbar ganglia of the sympathetic nerve.
35. Anastomoses of the last lumbar and first sacral ganglion of the sympathetic nerve, or the trunk of the sympathetic nerve divided.
36. &c.—40. The five lumbar nerves, with their different joinings to each other in the formation of the lumbar plexus of spinal nerves.
41. &c. Anastomoses of the sympathetic with the lumbar nerves.
42. A branch of the first lumbar nerve which belongs to the upper and outer part of the thigh.
43. The nervus spermaticus externus, which goes partly with the ligamentum rotundum to the uterus, and partly through the abdominal ring to the mons veneris.
44. Two branches from the second lumbar nerve, the upper belonging to the quadratus lumborum, the other to the skin of the groin.
45. A branch from the second lumbar to the outside of the thigh and knee.
46. A branch of the crural nerve to the internal iliac muscle.
47. The obturator nerve.
48. The anterior crural nerve.

NERVES OF THE CHYLOPOIETIC AND ASSISTANT CHYLOPOIETIC VISCERA.

THE NERVES of the Chylopoietic and Assistant Chylopoietic Viscera are formed by *Branches* of the *Par Vagum*, and the *Rami Splanchnici* of the *Great Sympathetic Pair*; all which, like the Blood-vessels, are covered by the Peritoneum, in their course towards the Viscera.

The PARS VAGA of the *Left Side*, Tab. CXCIX. Tab. CXCVIII. descending from the great Esophageal Plexus of the Eighth Pair, creeps along the fore-part of the Cardia, detaches Filaments to the Left Hepatic Plexus, and divides into many branches which are distributed to the Upper and Left Portion of the Stomach.

The RIGHT PARS VAGA passes upon the posterior part of the Cardia, and splits into two Fasciculi; one of which goes to the root of the Hepatic Plexus, and to the Cœliac Ganglion, while the other, which is the principal one, is dispersed by numerous Branches upon the under and left portion of the Stomach.

The Nerves of the two Fasciculi have several connections with each other, about the Cardia, and along the small Curvature of the Stomach, and form a Plexus, by some Authors termed *Coronary*, from which Branches extend along the small Curvature, as far as the Pylorus.

The RAMUS SPLANCHNICUS and SPLANCHNICUS SECUNDARIUS, Tab. CXCIX. Tab. CCII. have their origins from the Sympathetics, and perforate the upper and lateral part of the inferior Muscle of the Diaphragm, —as already mentioned in the Description of the Nerves of the Thorax.

After entering the Abdomen, they expand their Fibres, and incorporate with the lateral part of the Great Semilunar Ganglion.

The SEMILUNAR GANGLION, Tab. CC. *d, d, d*, is formed by the Rami Splanchnici of the Right and Left Sympathetics, with the addition of the Branches of the Eighth Pair.

It is of a long curved shape, with the convex edge undermost, and is composed of many smaller Ganglia, termed *Cœliac*, which are of different size and of irregular forms.

The CœLIAC GANGLIA are placed over the Aorta, about the roots of the Cœliac and Superior Mesenteric Arteries, and extend some way upon the Flethy Pillars of the Diaphragm.

From the Cœliac Ganglia innumerable Nerves issue on all sides, forming a Plexus, termed by some Authors

Solar, which extends along the Trunks and Branches of the Cœliac and Superior Mesenteric Arteries.

The Nerves upon these Arteries are so intermixed with each other, and with Cellular Substance, as to form confused Webs; the name of *Plexus*, however, is still retained, and the particular name of each Plexus is derived from the Artery which it surrounds, or the Viscus to which it belongs.

The HEPATIC PLEXUS, Tab. CCI. after giving Twigs to the Renal Glands, sends Filaments to the Diaphragm, which accompany the Diaphragmatic Arteries, and anastomose with Branches of the Phrenic Nerves.

It afterwards divides into Right and Left Plexuses, corresponding with the Right and Left Branches of the Hepatic Artery, or with the Right and Left Trunks when such are present.

The Left Hepatic Plexus furnishes several Branches to the Stomach, which intermix with those of the Eighth Pair, upon the small curvature.

The Right Hepatic Plexus imparts Branches to the corresponding parts of the Pancreas, to the small end of the Stomach and beginning of the Duodenum, and gives origin to the Right Gastro-epiploic Plexus, which attends the Artery of the same name, distributing its Filaments to the Great Curvature of the Stomach, and to the Omentum Majus.

The Hepatic Plexuses surround the Hepatic Artery and Vena Portæ, and, after sending several Filaments to the Biliary Ducts and Gall-bladder, follow the Branches of the Blood-vessels through the Substance of the Liver.

The SPLENIC PLEXUS, Tab. CXCIX. composed of several small Filaments, surrounds the Splenic Artery, gives Twigs to the Pancreas, and then accompanies the Vessels into the Spleen.

The SUPERIOR MESENTERIC PLEXUS, Tab. CC. forms a Vagina, which surrounds, and in a great part conceals, the Trunk of the corresponding Artery.

From this Plexus, numberless Filaments, many of them extremely minute, are produced, which run through the Mesentery, partly with the Blood-vessels, and partly at a distance from them; and which, after supplying the Coats of the Vessels and Mesenteric Glands, are distributed to the small Intestines in general, and to the Right Portion of the Colon.

The Nerves of the Colon are, in proportion to the part they have to supply, larger than those of the Small Intestines,

Intestines, and in several places form Arches, which are situated at the sides of the Arteries.

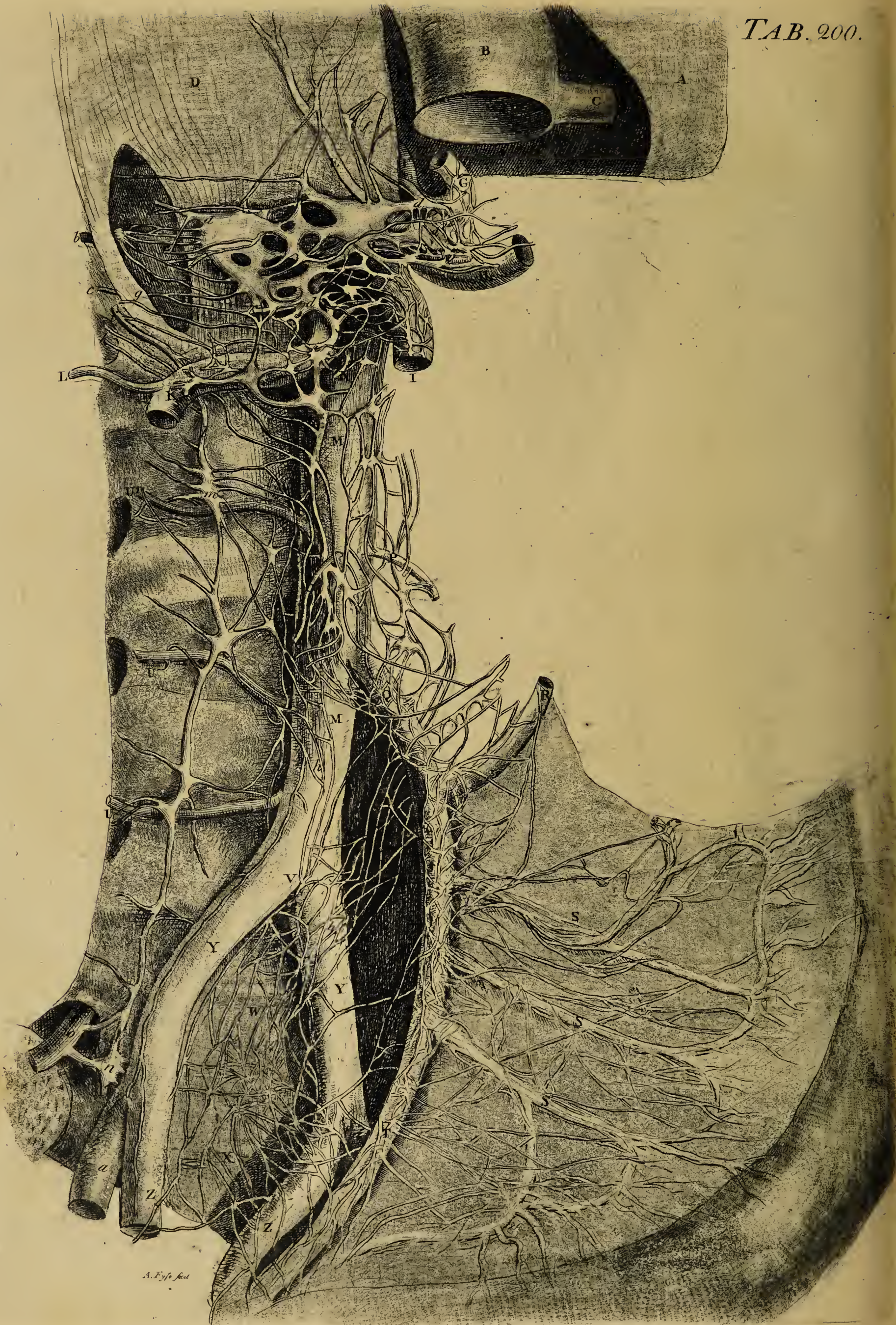The Cœliac Ganglia send down, along the Aorta, a Vagina similar to that surrounding the Superior Mesenteric Artery, which is joined by other Nerves from the Trunk of the Sympathetic continued along the Lumbar Vertebrae.

From the Aortic Vagina or Plexus, Tab. CC. a Process is sent off, termed INFERIOR MESENTERIC PLEXUS, which surrounds the Trunk of the Inferior Mesenteric

Artery, and follows it to the Left Portion of the Colon, and to the Rectum;—the Nervous Filaments forming Arches in several places, as in the Superior Mesenteric Plexus. Tab. CXCIX. Tab. CC.

The Aortic Plexus, receiving fresh supplies from the Trunks of the Sympathetics, sends down a Plexus, commonly termed *Hypogastric*, which passes over the end of the Aorta, and, upon the last Lumbar Vertebra, splits into right and left portions, which descend to the Viscera contained in the Pelvis.

TABLE



T A B L E . C C .

Shews the Principal NERVES which supply the VISCERA of the ABDOMEN ; their GANGLIA, and the frequent Connections which the NERVES, in this place, have with each other.

-
- A, The inferior surface of the right lobe of the liver turned aside.
 B, The vena cava inferior.
 C, A vein of the liver terminating in the cava.
 D, Part of the diaphragm.
 Dd, A cut made in the diaphragm, to shew the passage of nerves through it.
 E, The right diaphragmatic artery.
 F, The left coronary artery.
 G, The right hepatic artery.
 H, The splenic artery.
 I, The superior mesenteric.
 K, The right renal artery.
 L, The artery of the right renal gland.
 M, M, The abdominal aorta.
 N, A right superior spermatic artery.
 O, ——— inferior spermatic artery.
 P, A left spermatic artery.
 Q, The inferior mesenteric artery.
 R, The ascending branch of that artery.
 S, S, S, Branches of that artery to the colon.
 T, A branch to the rectum.
 U, U, U, The lumbar arteries.
 V, Bifurcation of the aorta.
 W, W, The first and last lumbar vertebræ.
 X, The first piece of the os sacrum.
 Y, Y, The common iliac arteries.
 Z, Z, The external iliac arteries.
 a, a, The internal iliac arteries.
- d, d, d, d, The right part of the great femilunar ganglion, or cluster of ganglia, formed chiefly by the branches of the great splanchnic nerve.
 e, e, Nerves of the renal glands.
 f, f, Diaphragmatic nerves from the femilunar ganglion.
 G, The hepatic plexus of nerves.
 H, The splenic plexus.
 I, The superior mesenteric arteries.
 K, The anterior renal plexus of the right side.
 g, Part of the posterior renal plexus.
- Upon the fore-part of the Aorta, a Plexus is formed by Branches of the right and left parts of the Sympathetic Nerves, and numerous Ganglia are likewise observed here.
- N, O, P, The spermatic nerves.
 Q, T, The inferior mesenteric plexus passing along the blood-vessels and mesocolon to the left part of the colon and to the rectum.
 b, b, b, The hypogastric plexus passing down to the pelvis.
 i, The trunk of the great sympathetic nerve.
 k, Branches passing between the great sympathetic nerve and last dorsal one.
 l, l, The trunk of the great sympathetic nerve continued along the side of the lumbar vertebræ.
 m, The second, and,
 n, The fifth lumbar ganglia of the great sympathetic nerve.

From the inner side of the Great Sympathetic Nerve, numerous Branches appear, which make a connection between it and the Superior Mesenteric, Aortic, and Inferior Mesenteric Plexuses:—The outer side of the Nerve gives off Branches to the Lumbar Nerves.

- b, The trunk of the nervus splanchnicus magnus.
 c, ————— secundarius, or accessorius.
 o, The fifth or last lumbar nerve, and its connections with the great sympathetic.

T A B L E C C I.

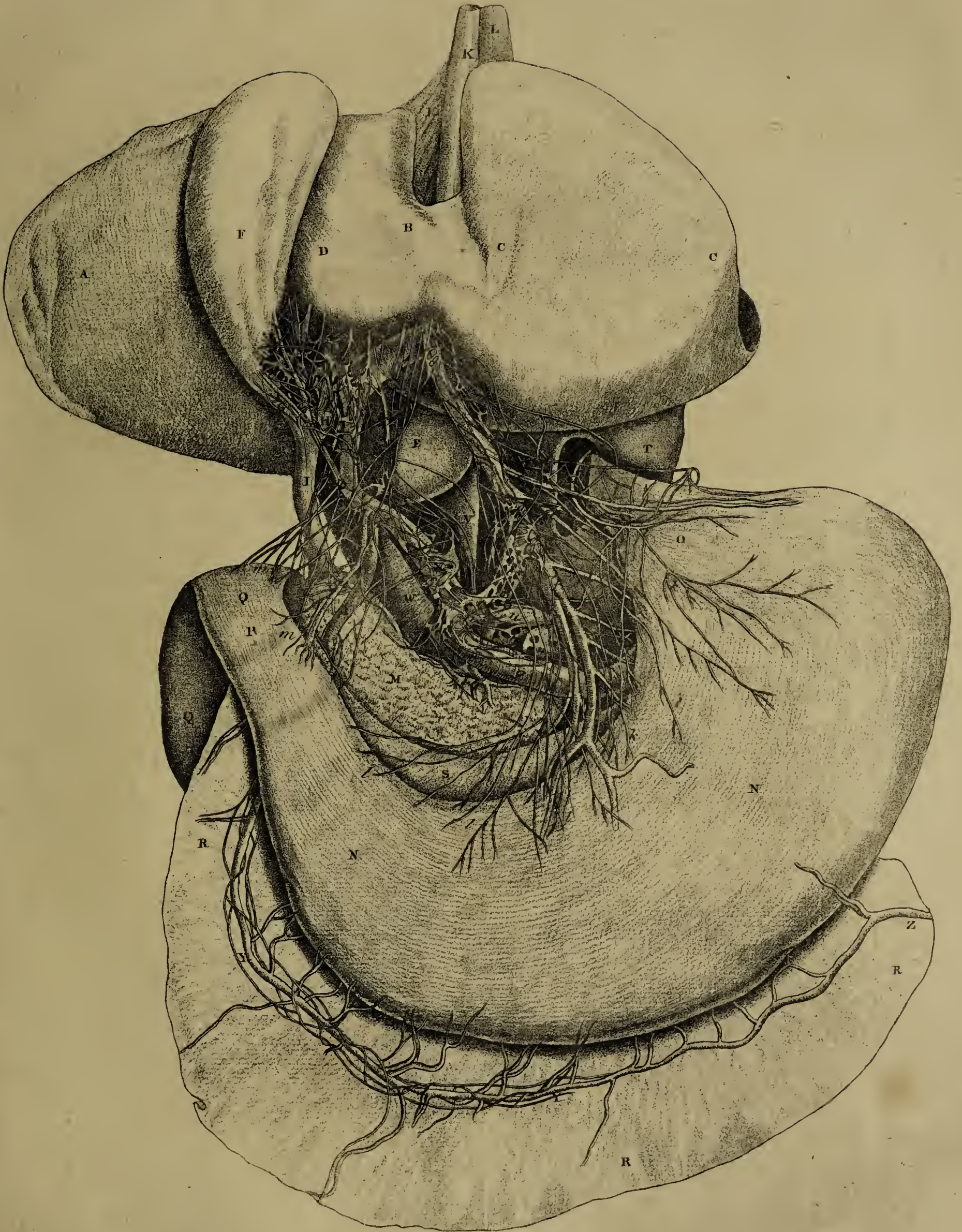Represents the NERVES of the LIVER, and part of the NERVES of the STOMACH, SPLEEN, PANCREAS, and OMENTUM.

A, B, The right, and,
 C, C, The left lobe of the liver, turned up.
 B, D, The lobulus quadratus.
 E, The lobulus SPIGELII, or posterior.
 F, The gall-bladder.
 G, The cystic duct.
 H, The hepatic duct.
 I, The common biliary duct.
 K, The round, and,
 L, L, The broad ligament of the liver.
 M, The pancreas.
 N, N, The upper surface of the stomach turned down.
 O, The cardia.
 P, The pylorus.
 Q, Q, The duodenum.
 R, R, The omentum majus.
 S, A portion of the omentum minus.
 T, T, Part of the diaphragm.
 U, The esophageal sphincter of the diaphragm.
 V, The inferior cava.
 W, The vena portæ.
 X, The right hepatic artery.
 Y, Y, The right gastro-epiploic artery.
 Z, The left gastro-epiploic artery.
 a, The pyloric artery.
 b, The cystic artery.
 c, The trunk common to a left hepatic, and the superior coronary artery of the stomach.
 d, The left hepatic artery.
 e, The cardiac branch, and below that a stomachic branch from the left hepatic artery.

f, The superior coronary artery, with its branches to the upper and under surfaces of the stomach.
 g, The splenic artery.
 h, A pancreatic branch from the splenic.
 n, n, The cœliac ganglia.

From the Cœliac Ganglia the numerous Plexus of Nerves represented in this Table issue, and these in general following the course of the Blood-vessels, the same letters of reference are made to serve for both.

V, W, X, The right hepatic plexus giving nerves to the right lobe of the liver, the biliary ducts and gall-bladder.
 Y, Y, The gastro-epiploic plexus furnishing branches to the great curvature of the stomach, and to the omentum.
 d, The left hepatic plexus supplying the left lobe of the liver.
 d, f, The hepatico-gastric plexus, furnishing nerves to the liver and stomach, and below f, the gastric plexus which is proper to the stomach.
 g, The splenic plexus.
 h, The pancreatic nerves.
 i, The left nerve of the eighth pair, giving off,
 k, k, Nerves to the upper region of the stomach.
 l, l, Branches of the gastric plexus to the small curvature of the stomach.
 m, m, Branches from the right hepatic plexus to the small end of the stomach, and to the beginning of the duodenum.



NERVES OF THE ORGANS OF URINE AND GENERATION.

THE NERVES of the Organs of Urine and Generation consist of the *Renal* and *Hypogastric Plexus*, and of the *Spermatic* and *Pudic Branches*.

The **RENAL PLEXUS**, Tab. CCII. No. 42.—44. is composed of Nerves sent from the Cœliac Ganglia, joined by some others derived from one or two of the Ganglia of the Sympathetic Nerve in the bottom of the Thorax.

It is interspersed, at its beginning, with small Ganglia, termed *Renal*, and is afterwards divided into Anterior and Posterior Plexuses, which extend along the corresponding Surfaces of the Renal Artery, accompanying its Branches in the Substance of the Kidney.

From the Renal Plexus, small Nervous Twigs ascend to the Renal Gland, which is furnished with others from the Cœliac Ganglia and root of the Hepatic Plexus.

The Renal Plexus also sends down Filaments to supply the upper portion of the Ureter,—the under receiving Nerves from the Hypogastric Plexus.

The **HYPOGASTRIC PLEXUS**, Tab. CC. *b, b, b.* Tab. CCII. No. 22. the origin and course of which have been already mentioned, is connected by different Nerves to the adjacent Trunks of the Great Sympathetic and Sacral Nerves, and sends many Branches to the Rectum, Bladder, and Spermatic Vessels in the Male; and to the Rectum, Bladder, Uterus, and Vagina in the Female.—The Nerves of the Uterus are proportionally small.—They pass into its substance at the Cervix, and follow the course of the Blood-vessels.

SPERMATIC NERVES, Tab. CC. N, O, P.—The Spermatic Nerves are very minute;—they consist of a Superior or Internal, and of an Inferior or External Set of Capillary Branches.

The former, Tab. CCII. No. 45. are derived from the Renal and Aortic Plexus, and accompany the Spermatic Blood-vessels in their course through the Abdomen, and afterwards to the Testicle.

The latter, Tab. CXCIX. No. 43. Tab. CCII. No. 10. are sent off from a Branch of the Second Lumbar Nerve, which, running near the Spermatic Vessels, detaches a Filament, which, in the Male, goes in the Spermatic Cord towards the Testicle, but is more particularly dispersed upon the Cremaster. In the Female, Filaments are reflected from it along the Ligamentum Rotundum to the Uterus.

NERVI PUDICI, Tab. CCII. No. 23. Tab. CCIII. No. 3. Tab. CCIV. Fig. 1. No. 14. Fig. 3. G. The Nervi Pudici arise in two Fasciculi,—a *Superior* and *Inferior*,—which are formed by Fibrillæ from all the Cords entering the composition of the Sciatic Nerve.

The Superior Fasciculus is formed, more particularly, by Threads from the two under Lumbar and two upper Sacral Nerves;—the Inferior is composed of a small Cord from the Second, and a large one from the Third Sacral.

The Fasciculi pass through the under part of the Notch of the Os Ilium, and afterwards between the Sacro-sciatic Ligaments, and follow the Pudic Blood-vessels, anastomosing in some places with each other by oblique Branches.

They send many Branches to the Muscles and other parts about the Anus and Perinæum, and then pass forwards to supply the different parts of the Penis.

On the Penis, the Nerves follow the course of the Arteries; the Superior Fasciculus constituting the *Nervus Dorsalis*, and the Inferior giving Branches to the under part of the Penis.

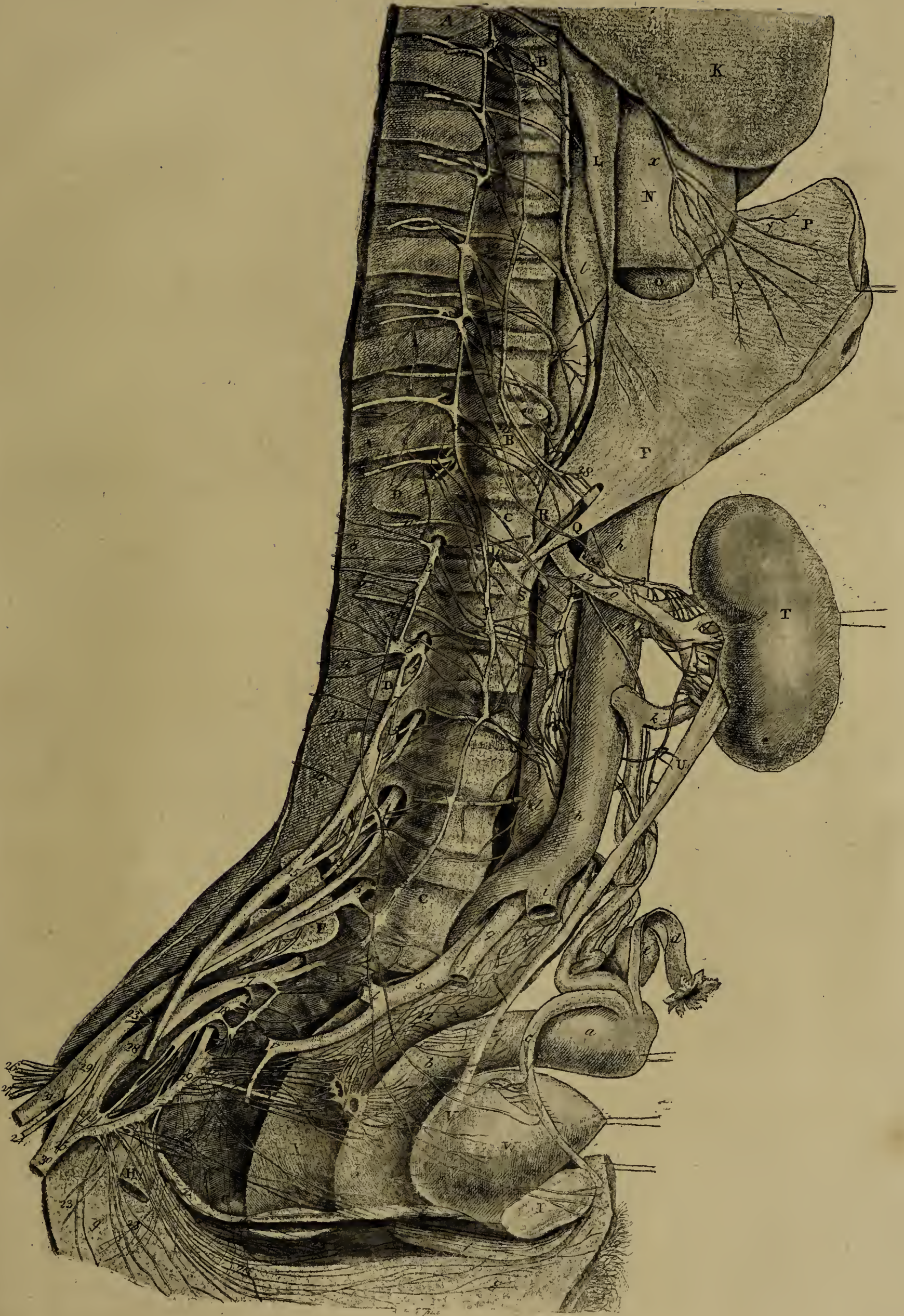
The *Nervus Dorsalis*, which is the most considerable Nerve of the Penis; runs forwards between the corresponding Artery and Vena Magna, expanding into many Branches, which, after supplying the Corpus Cavernosum and Teguments of the corresponding side, terminate in the Substance of the Glans.

T A B L E C C I I .

Exhibits the GREAT SYMPATHETIC NERVE of the Right Side, from the SIXTH RIB to the THIRD VERTEBRA of the OS SACRUM, and likewise the SIX INFERIOR INTERCOSTALS, with the LUMBAR and SACRAL NERVES.—The Right OS INNOMINATUM is removed, that the VISCERA of the PELVIS and their NERVES may be more distinctly seen.

-
- | | |
|---|--|
| A, A, The seven inferior ribs. | <i>l, l,</i> The aorta. |
| B, B, The seven inferior dorsal vertebræ. | <i>m, m,</i> The intercostal arteries. |
| C, C, The lumbar vertebræ. | <i>n, n,</i> The lumbar arteries. |
| D, D, The transverse processes of the lumbar vertebræ. | <i>o,</i> The renal artery. |
| E, The upper part of the os sacrum. | <i>p, p,</i> The superior and inferior spermatic arteries, in this subject. |
| F, The side which was joined by the os ilium. | <i>q,</i> The common iliac artery of the right side. |
| G, The upper part of the os coccygis. | <i>r,</i> The external, |
| H, The internal sacro-sciatic ligament. | <i>s,</i> The internal iliac artery. |
| I, The cartilage of the left os pubis. | <i>t,</i> The trunk common to the ilco-lumbalis and glutea. |
| K, The inferior lobe of the right lung. | <i>u,</i> The trunk common to, |
| L, Part of the posterior mediastinum. | <i>v,</i> The ischiatica, and, |
| M, M, The thoracic duct drawn a little out of its natural situation. | <i>w,</i> The pudenda communis. |
| N, The pericardium, including the heart. | <i>x,</i> The trunk of the phrenic nerve. |
| O, The vena cava inferior, passing through the diaphragm into the thorax. | <i>y, y,</i> Branches of the phrenic nerve dispersed upon the diaphragm. |
| P, P, The diaphragm separated from the ribs, and turned to the left side. | <i>z, z,</i> Seven lower intercostal nerves. |
| Q, The external crus of the diaphragm. | 1. 1. Branches from the intercostals to the muscles of the back. |
| R, The middle crus. | 2. 2. Branches connecting the intercostal nerves to each other. |
| S, The inner crus. | 3. 3. The five lumbar nerves. |
| T, The right kidney turned to the left side. | 4. Connection between the first lumbar and last dorsal nerve. |
| U, The ureter. | 5. 5. Posterior branches to the muscles of the loins. |
| V, Its termination in, | 6. The first lumbar nerve connected to the second by the intervention of a ganglion. |
| W, The bladder of urine. | 7. Connection between the second and third lumbar nerves. |
| X, X, The intestinum rectum. | 8. Branches from the first lumbar nerve to the abdominal muscles. |
| Y, Part of the sigmoid flexure of the colon. | 9. A subcutaneous branch of the groin. |
| Z, Z, The levator ani. | 10. The external spermatic nerve, going partly with the ligamentum rotundum to the uterus, and partly with the same ligament to the pubis. |
| <i>a,</i> The uterus drawn upwards. | 11. Branches from the ganglion of the first and second lumbar nerves, to the muscles of the loins and abdomen. |
| <i>b, b,</i> The vagina. | 12. Branches |
| <i>c,</i> The ligamentum rotundum. | |
| <i>d,</i> The Fallopian tube. | |
| <i>e,</i> The ovarium. | |
| <i>f,</i> The corpus cavernosum and erector clitoridis. | |
| <i>g, g,</i> The integuments turned back. | |
| <i>h, h,</i> The vena cava raised and turned towards the left side. | |
| <i>i,</i> The right iliac vein cut; the left is entire. | |
| <i>k, k,</i> The renal veins of the right side. | |

TAB. 202.



12. Branches to the psoas magnus muscle.
13. The nervus obturatorius.
14. A gluteal nerve from the two last lumbar nerves, to the deep muscles on the outside of the pelvis.
15. 15. The anterior crural nerve.
16. The cutaneous branch of the crural nerve.
17. 18. 19. The three uppermost sacral nerves.
20. The fourth sacral nerve.
21. The fifth sacral nerve sending branches to the coccygeus muscle, and to the sacro-sciatic ligament, &c.
22. 22. 22. The hypogastric plexus of sacral nerves dispersed upon the contents of the pelvis in general.
23. A plexus from the sacral nerves to the anus, perineum, and external parts of generation.
24. A nerve to the pyriformis and gluteus medius.
25. A cutaneous branch which descends as far as the knee.
26. A branch to the rotator muscles of the thigh.
27. Branches to the large gluteus muscle and integuments.
28. 29. The trunk, or plexus, as it is called, of the sciatic nerve.
30. The larger portion of the sciatic nerve.
31. The smaller portion of the sciatic nerve,
32. &c. The trunk and ganglia of the great sympathetic nerve.

Each of the Intercostal, Lumbar, and Sacral Nerves,

is connected with the Ganglia of the Great Sympathetic Nerve, by one, two, or more Branches.

33. A branch of the great sympathetic nerve sent off, at the head of the sixth rib, to the ligaments of the vertebræ and to the aorta.
34. 35. 36. The beginnings of the ramus splanchnicus from the great sympathetic nerve.
37. The continuation of the ramus splanchnicus.
38. The passage of the branches of the ramus splanchnicus, between the external and middle crura of the diaphragm, into the abdomen.
39. Branches from the great sympathetic nerve into the abdomen.
40. 40. 40. Branches to the aorta.
41. The ramus splanchnicus accessorius.
42. The trunk of the superior and posterior renal nerve.
43. ————— anterior renal nerves.
44. 44. The ganglia of the renal nerves.
45. The internal spermatic nerves.—From the spermatic and hypogastric nerves, several branches are sent to the ureter.
46. Connection between the renal and spermatic ganglia.
47. The inferior mesenteric plexus.—Between the great sympathetic nerve, and the renal, spermatic, and inferior mesenteric nerves, numerous branches are seen connecting them together.

T A B L E C C I I I .

VIEWS of the NERVES, &c. of the Inner and Lateral Part of the PELVIS, and of the PENIS.

FIG. 1.

A LATERAL VIEW of the MUSCLES, BLOOD-VESSELS, and NERVES of the Inner and Left Side of the PELVIS; —the Right Side being removed.

- A, A, &c.* The last lumbar vertebra, os sacrum, and os coccygis.—The two first are cut vertically, the latter is entire.
B, The cartilago-ligamentous substance, which forms the symphysis of the ossa pubis.
C, C, The right corpus cavernosum penis and bulb of the urethra, the former of which is cut transversely.
D, The gluteus maximus.
E, The coccygeus muscle covering part of the sacro-sciatic ligament.
F, F, The pyriformis.
G, H, The obturator internus.
a, The left common iliac artery.
b, The external iliac artery.
c, The epigastric artery, with its associate vein.
d, The internal iliac artery.
da, The root of the umbilical artery.
e, The obturator artery.
f, The gluteal artery.
g, g, The pudic artery.
eb, gc, Cut branches which belong to the bladder, rectum, and adjacent parts.
gd, The continuation of the pudic artery, in its way to the penis.
ge, The division of the pudic artery, near the root of the penis.
gf, The arteria dorsalis penis.
gb, ——— perinei.
gi, A branch of the pudic artery entering the bulb of the urethra.
h, A section of the common iliac vein.
i, The external iliac vein.

- k*, The spermatic vessels, with the cut end of the vas deferens.
l, The internal circumflex vein of the os ilium.
m, ——— iliac vein.
n, o, The trunk common to the vena pudica, sciatica, &c.
p, The sacra lateralis.
q, ——— media.
r, The vena pudica, communicating with other branches of the internal iliac vein.
s, A vein forming a communication between the vena pudica and obturatoria, which last is also joined by a cross branch to the epigastrica.
 1. The obturator nerve, with some branches to the muscle of that name.
 2. 2. The four upper sacral nerves, joined above by the last lumbar nerves.
 3. 3. The pudic nerve sending branches to the obturator muscle, and muscles of the anus, and afterwards extending along the upper and under sides of the penis.

FIG. 2.

A VIEW of the MUSCLES, VESSELS, and NERVES, about the ANUS and PERINEUM.

- A*, The anus.
B, B, The under side of the penis.
C, C, The large glutei muscle.
D, D, The sphincter ani.
E, E, The levatores ani.
F, F, The erectores penis covering its crura.
G, G, The transversalis perinei.
H, H, The acceleratores urinæ, covering the bulb of the urethra.
a, The perineal branch of the pudic artery.
b, ——— vein, a section of which is seen on the right side.
c, c, c, The perineal nerve.

TABLE

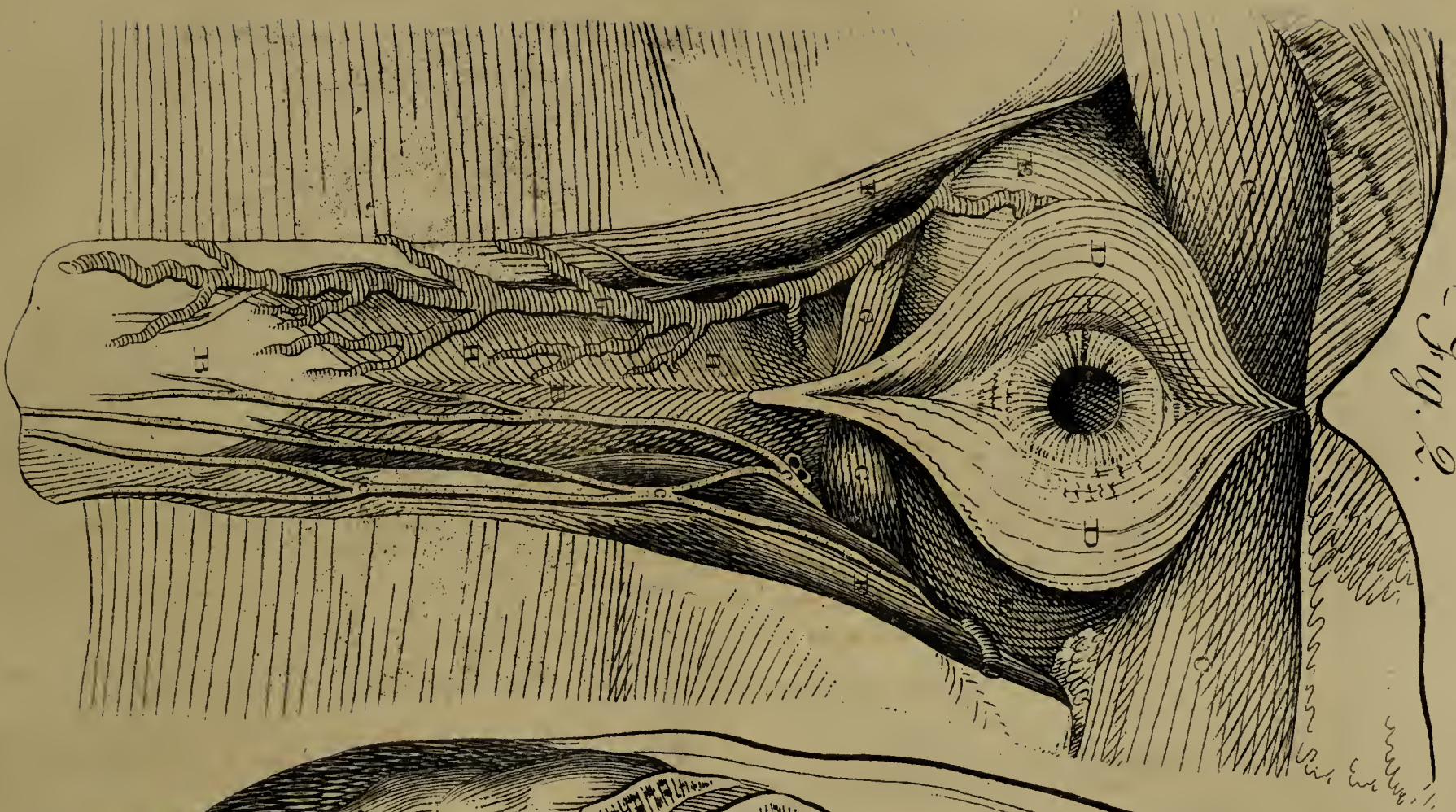

Fig. 2.

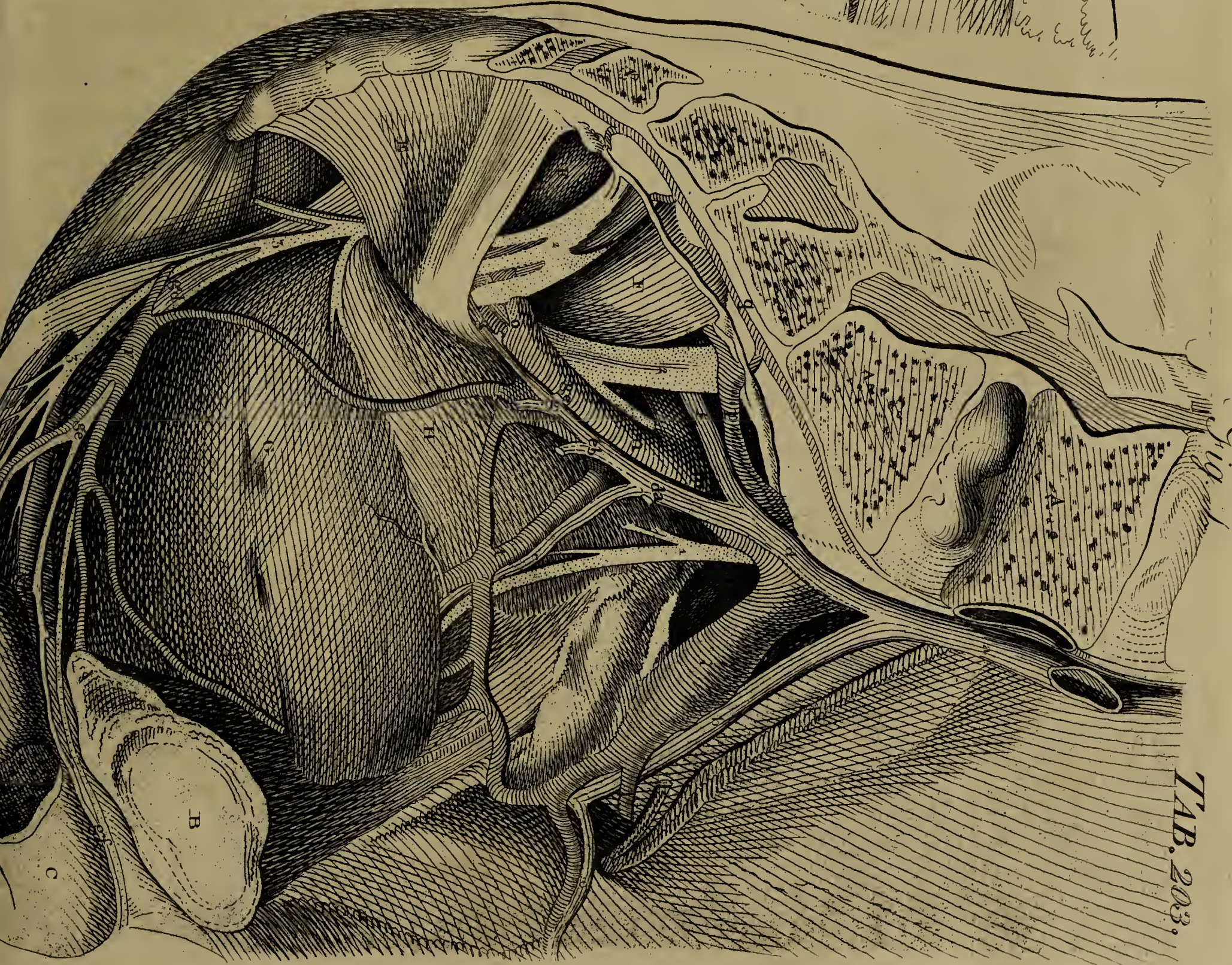


Fig. 1.

Fig. 1.

Fig.

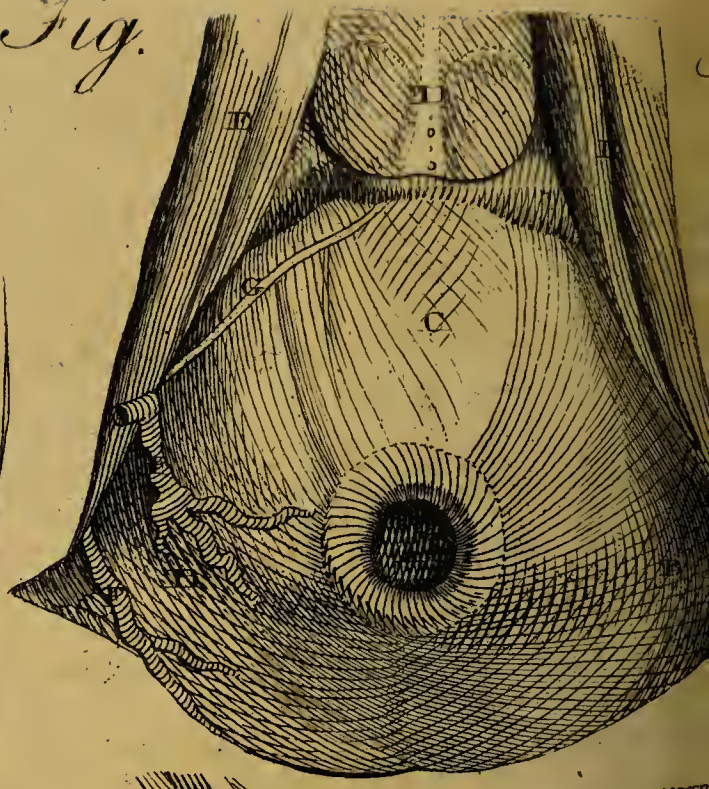
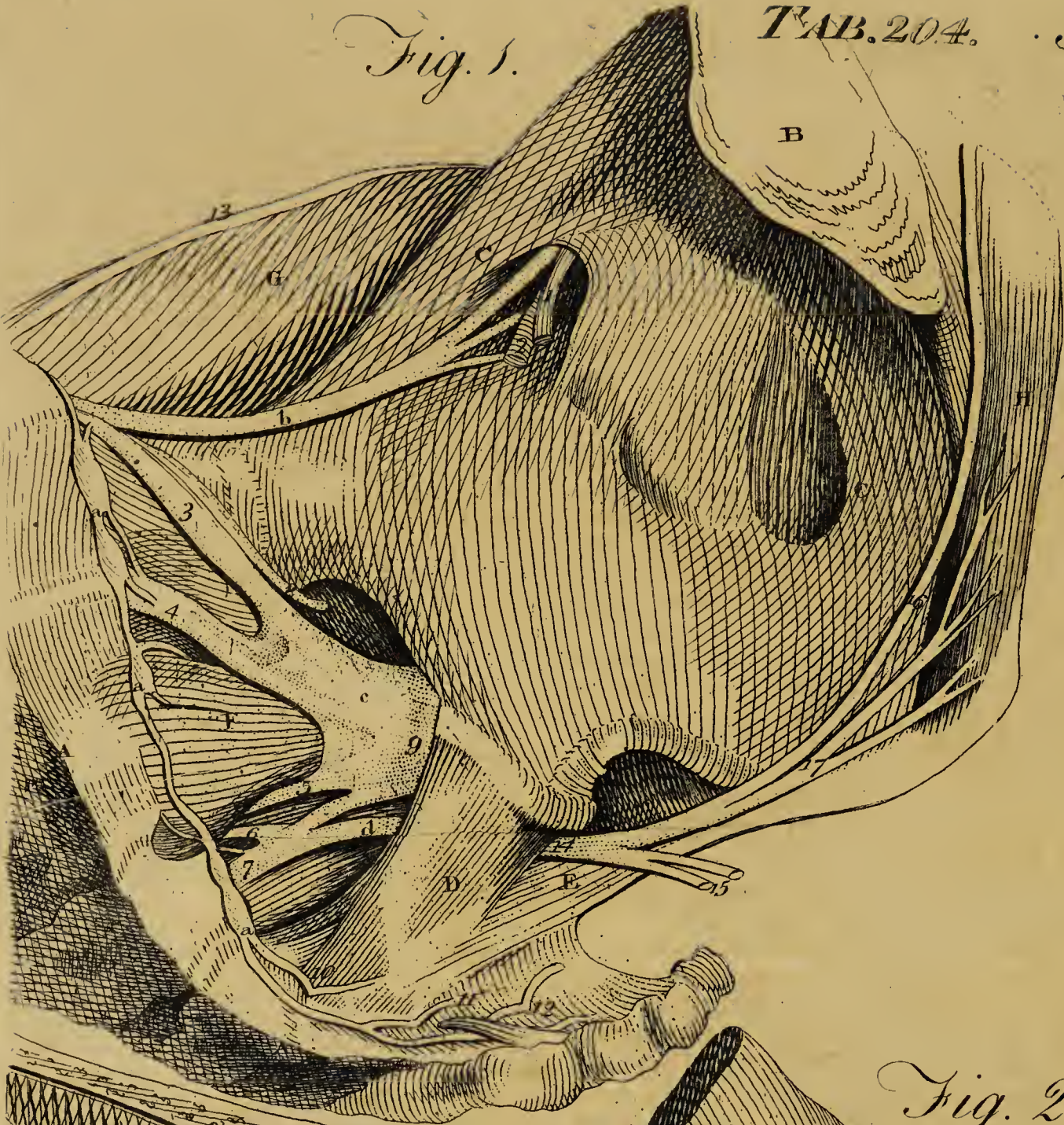
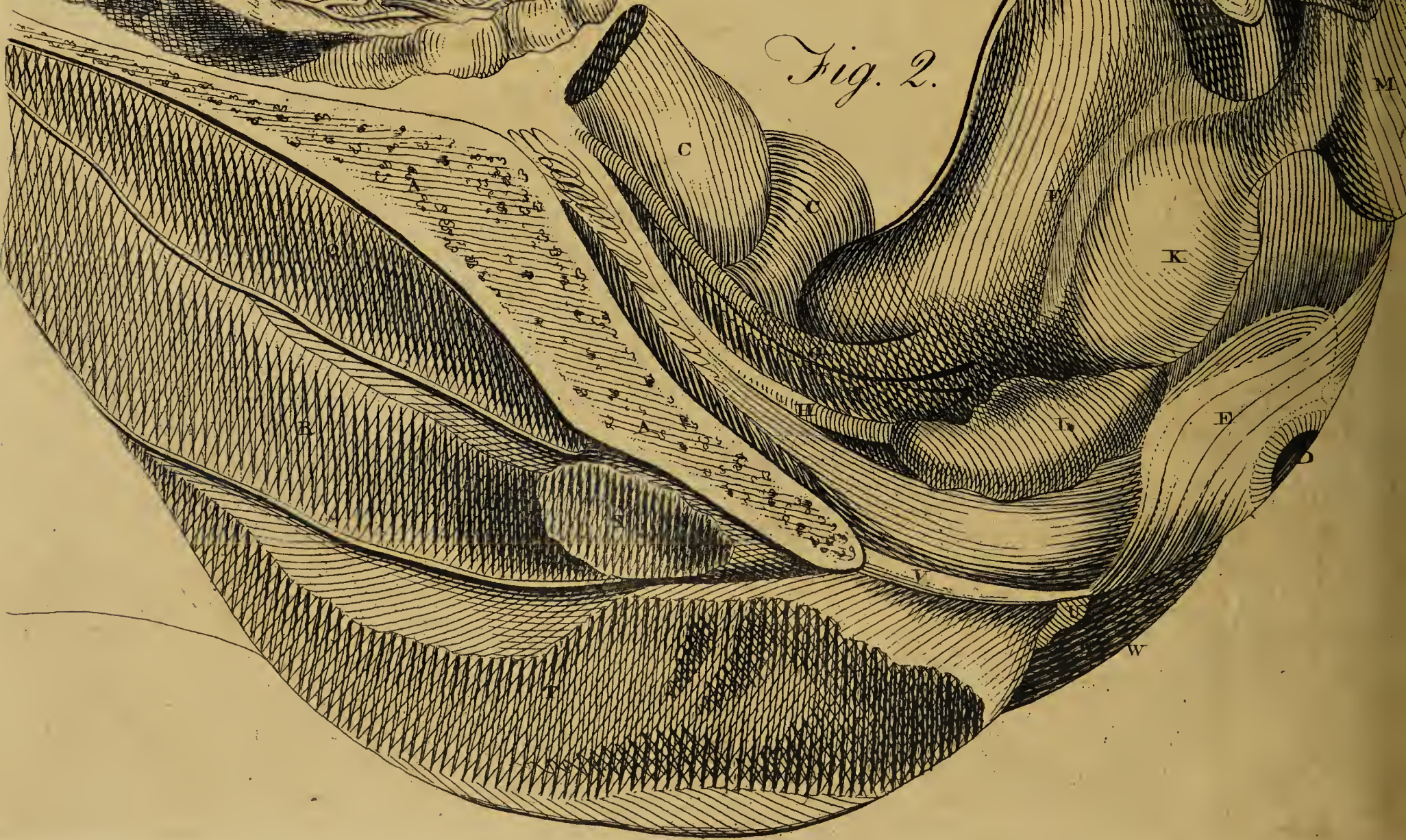

Fig. 2.



T A B L E CCIV.

Gives a VIEW of the Situation of the VISCERA, and of some of the VESSELS and NERVES of the PELVIS.

FIG. 1.

Represents the Inner Side of the Left Portion of the PELVIS;—the Right Os INNOMINATUM, and part of the Os SACRUM being removed.

- A, A, A section of the os sacrum.
 B, A section of the symphysis of the pubes.
 C, C, The ligamentum obturatorium.
 D, The internal, and,
 E, The external sacro-sciatic ligament.
 F, The pyriform muscle.
 G, The psoas magnus.
 H, The erector penis.
 a, The inferior part of the great sympathetic nerve, with its ganglia, and connections to the sacral nerves.
 b, The obturator nerve.
 1. ———— artery.
 2. ———— vein.
 3. A trunk formed by the two inferior lumbar nerves.
 4. The first sacral nerve.
 5. The second sacral nerve.
 6. A branch from the second sacral, which joins the pudic nerve.
 7. The third sacral.
 8. A branch from the lumbar nerves to the glutei muscles.
 9. c, The continuation of the trunk of the sciatic nerve.
 10. The fourth sacral nerve.
 11. The fifth sacral nerve.
 12. The under end of the great sympathetic nerve.
 13. The inguinal nerve.
 14. The pudic nerve passing out between the sacro-sciatic ligaments and joint.
 15. Branches of the pudic nerve to the parts about the anus.
 16. The nervus dorsalis penis.
 17. A branch of the pudic nerve subdivided into two others, the inferior of which is the perineal nerve, and the superior the nervus pudicus inferior.

FIG. 2.

The VISCERA of the PELVIS, seen from the Right Side, the greater Part of the Right Os ILIUM being removed.

- A, A, A section of the os ilium, near the articulation with the os sacrum.

- B, A section of the symphysis of the pubes.
 C, C, The sigmoid flexure of the colon.
 D, The anus.
 E, The sphincter ani.
 F, The bladder of urine, empty and collapsed.
 G, The right ureter.
 H, ———— vas deferens.
 I, ———— vesicula feminalis.
 K, The prostate gland,
 L, The membranous part of the urethra.
 M, The bulb of the urethra.
 N, A section of the right corpus cavernosum penis.
 O, P, p, A section of the penis.—O, P, The corpora cavernosa, with their elastic ligamentous covering and partition;—p, The urethra inclosed in its corpus spongiosum.
 Q, The gluteus minor.
 R, ———— medius.
 S, The pyriformis.
 T, The gluteus maximus.
 U, The point of the os coccygis.
 V, The musculus coccygeus, with the rectum above it.
 W, The gluteus maximus of the left side.
 b, The left musculus pyramidalis.
 c, The ligamentum suspensorium penis.
 d, The peritoneum continued from the bladder of urine to the inner side of the abdominal muscles.

FIG. 3.

The ANUS and Parts about the PERINEUM.

- A, The anus.
 B, B, The levatores ani.
 C, Fibres of the levators intermixing with each other, and with the sphincter vesicæ.
 D, The bulb of the urethra.
 E, E, The erector penis and transversalis perinei alter on each side, the former placed outermost.
 F, The hæmorrhoidal veins.
 G, A branch of the nervus pudicus inferior, inserted into the sphincter vesicæ and bulb of the urethra.

NERVES OF THE LOINS, PELVIS, AND INFERIOR EXTREMITY.

THE NERVES of the Loins, Pelvis, and Inferior Extremity, consist of the continuation or inferior portion of the Sympathetic, and of the Trunks and Branches of the *Lumbar* and *Sacral* Nerves.

The SYMPATHETIC NERVE, Tab. CXCIX. No. 19. Tab. CCII. No. 32. after reaching the Abdomen, makes a sweep forwards upon the anterior and lateral part of the Lumbar Vertebrae, between the Tendinous Crura of the Diaphragm and the Pfoas.

It afterwards descends into the Pelvis, nearly of the same size as in the superior parts of the Body, and passes over the anterior Surface of the Os Sacrum, at the inner side of the Great Sacral Foramina.

Towards the lower part of the Pelvis, it becomes considerably smaller, and at last finishes its course upon the Surface of the Os Coccygis, where it unites into an Arch with its fellow of the opposite side.

In the Loins, it forms Ganglia similar to those in the Thorax, each of which is connected behind by two or three long slender Branches to the roots of the Lumbar Nerves, and before, by other slender Nerves, to the Aortic Plexus.

In the Pelvis also, it forms Ganglia which are connected to the Sacral Nerves on one side, and to the Great Sympathetic on the other, by cross Branches.

Filaments are sent off, in the Pelvis, from the Sympathetic to the Muscles and Membranes about the Os Coccygis, and to the Intestinum Rectum.

LUMBAR NERVES.

The FIVE LUMBAR NERVES, Tab. CXCIX. No. 36. —40. Tab. CCII. immediately after emerging from the Bones, communicate with each other, and are connected with the Sympathetic Nerve by Branches which run over the sides of the Vertebrae, and send large Branches backwards to the Muscles and Integuments on the posterior part of the Loins.

By their connections with each other, they compose a Plexus termed *Lumbar*, which is situated behind the Pfoas, and sends Branches outwards to the *Quadratus Lumborum*, and to the Flexors of the Thigh.

The FIRST LUMBAR NERVE is connected by a small Branch to the Twelfth Dorsal, and by its Trunk to the Second Lumbar.

After giving Twigs to the Muscles of the Loins, it detaches a principal Branch which passes over the *Quadratus*

Lumborum towards the Spine of the Os Ilium, where it sends Branches to the Integuments of the Pelvis, to the upper and outer part of the Thigh, to the under end of the Abdominal Muscles, to the Integuments of the Groin; and to the Pubes and Scrotum.

The SECOND LUMBAR perforates the Pfoas, to which it gives Branches, and afterwards runs into the Third.

From the Second Lumbar, and partly also from the First, the *Spermaticus Externus* is sent off, which perforates the upper end of the Pfoas, and descends near the Spermatic Vessels to the under part of the Abdomen. Near *POUPART'S* Ligament, and sometimes much higher, it splits into two Branches: One goes through the Abdominal Ring, to be dispersed upon the Pubes, Spermatic Cord, Scrotum, and Testis, in the Male; and upon the Round Ligament, the Uterus, the Mons Veneris, and Labia Externa, in the Female.

The other Branch passes out with the Femoral Vessels, and sends Branches to the Inguinal Glands, and to the Integuments of the fore-part of the Thigh.

Another Branch is sent from the Second, or from the Second and Third Lumbar, termed *Cutaneus Externus*, which passes behind the Pfoas, and across the Iliacus Internus, to the Superior Anterior Spinous Process of the Os Ilium. It afterwards bends over the outer end of *POUPART'S* Ligament, and descends in the Anterior and External part of the Thigh; dividing into Branches, which are chiefly dispersed upon the Integuments covering the *Vastus Externus*; some Twigs extending as far as the Joint of the Knee.

Branches of the Second, Third, and Fourth Lumbar, form a Nerve of considerable size, called *Obturator*, which passes between the External and Internal Iliac Blood-vessels, and along the side of the Pelvis.

The OBTURATOR NERVE, Tab. CXCIX. No. 47. Tab. CCII. No. 13. accompanies the Blood-vessels of the same name, through the upper part of the Obturator Muscles and Ligament, and having furnished Branches to the Obturator and Pectineus, it divides into an Anterior and a Posterior Fasciculus; the former dispersed upon the two small Adductors and Gracilis, the latter upon the Adductor Magnus Femoris.

The principal parts of the Trunks of the four upper Lumbar Nerves, especially of the Third and Fourth, unite and form a Nerve of great size, termed *Crural*, or *Anterior Crural*.

The CRURAL NERVE, Tab. CXCIX. No. 48. after bestowing

bestowing Branches upon the Iliacus Internus and Pfoas, passes behind, then at the outside of the Pfoas, to get to the Thigh.

In its course from the Abdomen, and at the upper part of the Thigh, it is situated at the outside of the Femoral Artery, which lies between it and the corresponding Vein.

Behind POUPART'S Ligament, it is divided into many Branches, which are distributed to the Muscles and Integuments on the fore and lateral parts of the Thigh,—one Branch in particular, termed *Saphænus*, descending upon the Leg.

The Branches are as follow :

The *Cutaneus Medius*, Tab. CCV. Fig. 1. *m*, which descends in the fore-part of the Thigh, opposite to the inner edge of the Rectus, and supplies the Integuments near it, as far as the Knee,—one Branch of it connecting itself with another of the Cutaneus Anterior.

The *Cutaneus Anterior*, Tab. CCVI. Fig. 1. *m*, more internal than the Cutaneus Medius,—which crosses over the middle of the Sartorius, and, after supplying the adjacent Integuments, terminates in the Skin and Cellular Substance, at the fore and inner part of the Knee.

The *Cutaneus Internus*, Tab. CCVI. *o*, Tab. CCV. *p, q, r*, still more internal than the former, which passes between the Sartorius and Triceps, and, after giving Filaments to the Integuments at the inside of the Thigh, terminates in the Skin at the under and fore part of the Knee.

The Deep Branches of the Crural Nerve, which are considerably larger than the Superficial, go to the Pectineus and Triceps, to the Sartorius and Gracilis, and to the four Extensors of the Leg, and also furnish Twigs to the Femoral Blood-vessels.

The *Nervus Saphænus*, Tab. CCVI. Fig. 1. *r*, Tab. CCVII. descends between the Sartorius and Triceps, and afterwards behind the Tendon of the former, to the inner side of the Tibia.

Under the Knee it gives off a Branch, named by FISCHER *Saphænus Minor*, Tab. CCVI. Fig. 1. *q*, which goes down a little behind the Saphænus, and, furnishing Filaments to the Integuments of the inner and back part of the Leg, terminates behind the Malleolus Internus, on the Integuments of the Foot.

The Trunk of the Saphænus attends the Vena Saphæna Major, sending many Nervous Threads obliquely forwards to the Integuments on the inner and fore part of the Leg, and is at length consumed upon the Skin and Cellular Substance of the upper and inner part of the Foot.

The remaining part of the Fourth Lumbar Nerve unites with the Fifth into a Trunk which descends into the Pelvis.

SACRAL NERVES.

THE SACRAL NERVES consist of small *Posterior*, and large *Anterior* Trunks. Tab. CCII. CCIII. CCIV.

The POSTERIOR SACRAL NERVES pass out by the Holes in the back part of the Os Sacrum, and anastomose with each other, and with some of the Branches of the Gluteal Nerves.

They send out a few tender Fibrillæ, which are dispersed upon the Muscles covering the back part of the Os Sacrum, and upon the Glutei and their Integuments.

ANTERIOR SACRAL NERVES, Tab. CCII. CCIII. CCIV. Of the Anterior Sacrals, the two uppermost are the largest; the rest suddenly diminish in size, the last being the smallest of the Spinal Nerves.

They go through the Holes in the fore-part of the Os Sacrum, and, soon after their exit, are united with each other, and with Branches of the Sympathetic Nerve.

The FIRST, SECOND, and THIRD SACRALS, join into a Trunk, which receives the common one sent down from the Fourth and Fifth Lumbar, and forms a Plexus which sends out the SCIATIC, the largest Nerve of the Body.

The roots of the Sciatic Nerve give origin to the Fasciculi which compose the Pudic Nerve, formerly described, and also the Gluteal Nerves which are dispersed upon the Muscles of the Hips.

The GLUTEAL NERVES, Tab. CCII. run in two Fasciculi, a Superior, arising immediately from the Trunk formed by the two last Lumbar, and an Inferior, coming off from the two last Lumbar and first Sacral.

The *Superior Fasciculus* goes through the upper part of the Notch of the Os Ilium, to be dispersed upon the two smaller Glutei.

The *Inferior Fasciculus* passes through the under part of the same notch, and below the Pyriformis, to be distributed upon the Gluteus Maximus and Integuments.

The FOURTH SACRAL sends Filaments to the Hypogastric Plexus, others to the Muscles and Ligaments of the Os Coccygis; the rest pass outwards to the Muscles and Integuments about the Anus.

SCIATIC NERVE, Tab. CCVII. Fig. 2. *b*.—The Sciatic or Ischiatic Nerve passes obliquely through the Notch of the Ilium, under the Pyriformis. It goes afterwards over the other short Rotator Muscles, and is placed between the Tuber Ischii and Trochanter Major, where it is covered by the Gluteus Maximus.

After leaving the Pelvis, it descends in the back part of the Thigh, first between the Long Flexors and Adductor Magnus, and then between the latter and Os Femoris, to the Ham, where it obtains the name of *Popliteus*.

In this course, it gives out the following Branches, which supply the Muscles and Integuments on the back part of the Thigh, viz.

Twigs to the Rotators of the Thigh, which come off from it after its passage through the Sciatic Notch.

The *Cutaneus Posterior Superior*, Tab. CCVI. Fig. 2. 4. which arises within the Pelvis, and, passing out with the Sciatic, is divided into Branches, some of which are reflected

reflected to the Scrotum in the Male, and to the posterior parts of the Labia in the Female; and in both, to the Skin about the Anus and Perineum.—The principal Branches of this Nerve pass downwards, supplying the Integuments of the back part of the Thigh, as far as the bending of the Knee.

A *Branch* to the long Head of the Biceps.

Two small Nerves, the one termed *Cutaneus Internus Superior*, which comes off near the upper part of the Thigh, and vanishes in the Skin, a little farther down; the other, termed *Cutaneus Internus Inferior*, which arises near the former, goes down the posterior part of the Thigh, and then, descending upon the inner Head of the Gastrocnemius Externus, terminates in the Integuments of the Calf of the Leg.

A *Large Common Trunk*, and sometimes, instead of it, *separate Branches*, which arise near the middle of the Thigh, and are distributed to the Adductor Magnus, Semi-membranosus, Biceps, and Semi-tendinosus.

NERVUS POPLITEUS, Tab. CCVII. Fig. 2.—The Popliteal Nerve is situated between the Ham-strings, and between the Skin and Popliteal Blood-vessels.

A little above the bending of the Knee, it is divided into a Small External, and a Large Internal Branch; the former named *Fibular*, and the latter *Tibial Nerve*.

The Tibial and Fibular Nerves adhere, for some way, by Cellular Substance; and even the Trunk of the Sciatic may be split into these two Nerves for a considerable way up the Thigh.

The FIBULAR, Tab. CCVII. Fig. 2. *n*, termed also PERONEAL NERVE, sends off, at its beginning, the *Cutaneus Externus*, which is a small Branch giving Twigs to the under end of the Biceps, and which, after running down on the outer Head of the Gastrocnemius, disappears in the Integuments of the same side of the Leg.

Over the outer Condyle of the Os Femoris, it gives off another *Cutaneous Branch*, which goes over the Gastrocnemius, and, after anastomosing with a Branch of the Tibialis, goes along the outer part of the Leg, and terminates in the Integuments of that side of the Foot.

The Fibular Nerve afterwards passes over the Head of the Fibula, and divides into *Superficial* and *Deep Branches*, which supply the Muscles and Integuments of the outer and fore part of the Leg.

The *Superficial Fibular* crosses over the Fibula, immediately under its articulation, and, perforating the Peroneus Longus, and going over the Brevis, it gives Branches to both, and afterwards becomes Subcutaneous, about the middle of the outer part of the Leg.

It sends Branches to the Metatarsus, and to the Extensor Digitorum Brevis; and others, which, after anastomosing upon the upper part of the Foot, furnish Dorsal Branches to the larger Toes.

The *Deep Fibular Nerve* crosses over the Fibula, immediately above the former, and divides into several Branches, viz.

A *Reflected Branch* to the soft parts of the Joint:

A *Branch* to the Peroneus Longus:

A *Branch* to the Tibialis Anticus:

Branches to the Extensor Pollicis, and Extensor Digitorum Longus:

Filaments which creep along the Periosteum of the Tibia, and *others* which adhere to the Coats of the Tibial Artery.

The longest Branch of the Nerve accompanies the Anterior Tibial Artery, and divides upon the Foot into Branches, which have some connections with each other, and supply the Extensor Digitorum Brevis.—Some Filaments continued from these Branches run to the Interossei, while others of more considerable size go to some of the innermost Toes; one Twig sinking with a Branch of the Anterior Tibial Artery to the Deep Muscles of the Sole.

The TIBIAL NERVE, Tab. CCVII. Fig. 2. passes between the Heads of the Gastrocnemius, and, perforating the origin of the Soleus, descends between it and the Flexor Digitorum Longus, upon the Posterior Tibial Artery, to the under part of the Leg; in which course, it sends off the following Nerves, viz.

The *Communicans Tibia*, Tab. CCVI. Fig. 2. *r*, which accompanies the Vena Saphæna Minor in the back part of the Leg, and to the outer part of the Foot.

Behind the Belly of the Gastrocnemius, the Communicans sends a Branch to be consumed in the Fat; and a little lower, it anastomoses with the communicating Branch of the Fibular Nerve.

The under part of this Nerve is dispersed upon the Integuments of the outer Ankle and adjacent side of the Foot, some Branches passing as far as the Dorsal side of two or three of the smaller Toes.

Branches to both Heads of the Gastrocnemius, to the Plantaris, and to the Soleus.

Near the middle of the Leg, it sends *Branches* to the Tibialis Posticus, to the Flexor Digitorum, and Flexor Pollicis.

One or two *Cutaneous Branches*, dispersed upon the Skin at the under and inner part of the Leg.

Near the Ankle, a *Branch* which passes behind the Tendo Achillis; principally to the Integuments of the outer and back part of the Foot.

The Tibial Nerve passes afterwards between the Arteries and Os Calcis into the Sole.

In the hollow of the Os Calcis, after detaching Branches to the parts adjacent, it divides into *Internal* and *External Plantar Nerves*, which are nearly of equal size. Tab. CCVII. Fig. 3.

The INTERNAL PLANTAR NERVE runs near the inner side of the Sole, sends Filaments to the Abductor Pollicis, Flexor Digitorum Brevis, and Flexor Digitorum Accessorius, and Twigs to the Lumbricales.

It afterwards gives out four large Branches, splitting into others, which run with the Arteries along the Plan-

tar

tar sides of the three first Toes, and inner side of the fourth Toe,—in the manner the Radial Nerve runs along the corresponding Fingers.

The EXTERNAL PLANTAR NERVE sends Branches to the Heel, and passes with the Artery of the same name to near the outer edge of the Sole, where it splits into three principal Branches.

The two first run to the adjacent sides of the Fourth and Fifth Toes, and outer side of the Little Toe; the inner one often anastomosing with a corresponding Branch of the Internal Plantar.

The third forms an Arch corresponding with that of the External Plantar Artery, furnishes Branches to the short Muscles of the Little Toe, to the Interossei, Lumbricales, and Transversalis, and terminates in the short Muscles of the Great Toe.

The Plantar Digital Nerves send Filaments to the Integuments, and upon the Toes anastomose with each other, and with the Dorsal-digital Nerves,—as the Palmar-digital Nerves do in the Hand.

TABLE

T A B L E C C V .

Represents the CUTANEOUS and SUBCUTANEOUS NERVES of the LEFT INFERIOR EXTREMITY.

FIG. 1.

Besides some NERVES and MUSCLES situated in the PELVIS, this Figure represents the Anterior CUTANEOUS and SUBCUTANEOUS NERVES, and some BLOOD-VESSELS of the INFERIOR EXTREMITY, as they are seen upon the FACIA LATA, after the SKIN is turned aside, and the FAT carefully removed.

- A, The iliacus internus.
- B, The psoas magnus.
- C, ——— parvus.
- D, The quadratus lumborum.
- E, The Fallopian ligament.
- F, F, F, F, The skin turned back.
- G, The patella.
- H, The symphyfis of the ossa pubis.
- I, The crest of the os ilium.
- a, A branch of the first lumbar nerve.
- b, ——— second lumbar nerve.
- c, Anastomosis with a twig of the first lumbar nerve.
- d, A twig of the second lumbar nerve to the groin.
- e, The external cutaneous nerve, which is a branch of the lumbar.
- f, The posterior branch of the external cutaneous nerve, going to the posterior part of the thigh.
- g, g, The anterior branch of the external cutaneous nerve, to the anterior and external part of the thigh.
- h, i, The root of the crural nerve arising from the fourth lumbar nerve.
- k, The crural, or large anterior femoral nerve.
- l, The division of this nerve into various branches.
- m, The middle cutaneous nerve.
- n, An anastomosis between a branch of the cutaneus medius and cutaneus anterior.
- o, The continuation of the inguinal nerve.
- p, The second branch of the internal cutaneous nerve.
- q, A small branch of the third branch of the internal cutaneous nerve, dividing into twigs which terminate in the fat, filaments, and skin in the inner part of the thigh.
- r, The fifth branch of the internal cutaneous nerve, the twigs of which pass over the ligament of the patella, and terminate in the fat around the knee.

- s, A continuation of the second large branch of the nervus saphænus, the twigs of which terminate in the capsular ligament, skin, and cellular substance.
- t, A small branch to the skin of the interior part of the leg.
- u, u, A continuation of the nervus saphænus.
- v, The largest branch of the nervus saphænus, or nervus saphænus minor.—Immediately below v, it forms a ganglion, from which various small branches are sent off.

FIG. 2.

Represents the CUTANEOUS and SUBCUTANEOUS NERVES, and some of the ARTERIES of the Back Part of the THIGH and LEG.

- A, The gluteus magnus muscle.
- B, ——— medius.
- C, C, The gastrocnemii, covered by the fascia lata.
- D, D, D, D, The skin turned aside.
- E, The os pubis and its synchondrosis.
- a, Small branches of the first lumbar nerve.
- b, A small branch of the second lumbar nerve.
- c, The posterior branch of the external cutaneous nerve.
- d, A branch of the second posterior sacral nerve to the gluteus magnus.
- e, A branch of the third posterior sacral nerve.
- f, ——— fourth posterior sacral nerve.
- g, ——— fifth posterior sacral nerve, to the inferior and inner part of the gluteus maximus.
- h, The trunk of the superior posterior cutaneous nerve, perforating the fascia lata.
- i, The third lateral branch of the superior posterior cutaneous nerve, perforating the fascia lata.
- k, The second lateral branch of the superior posterior cutaneous nerve.
- l, The superior internal cutaneous nerve.
- m, The first lateral branch of the superior posterior lateral nerve.
- n, The external cutaneous nerve.
- o, The inferior internal cutaneous nerve, descending on the back of the gastrocnemius internus muscle, and sending off various twigs.
- p, The nervus cutaneus subfuralis externus superior.

TABLE

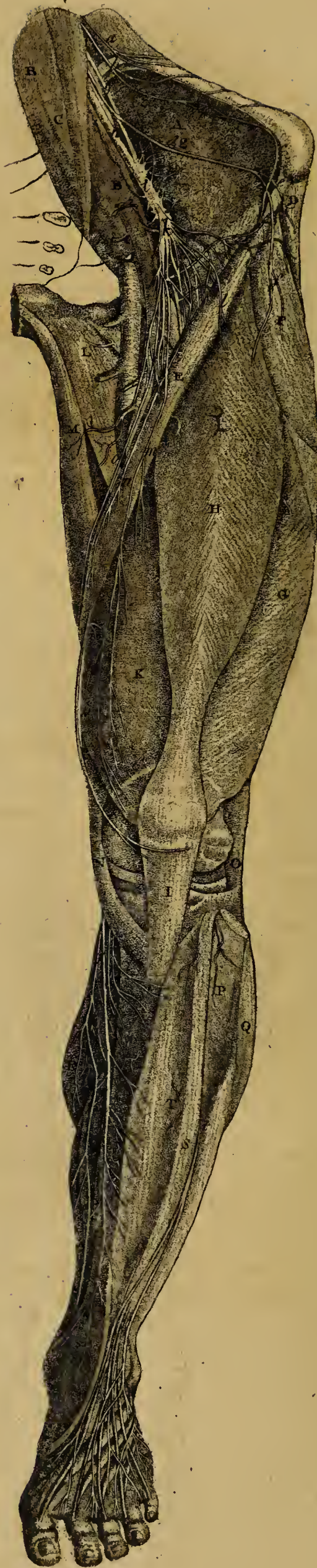
Fig. 2.

Fig. 1.

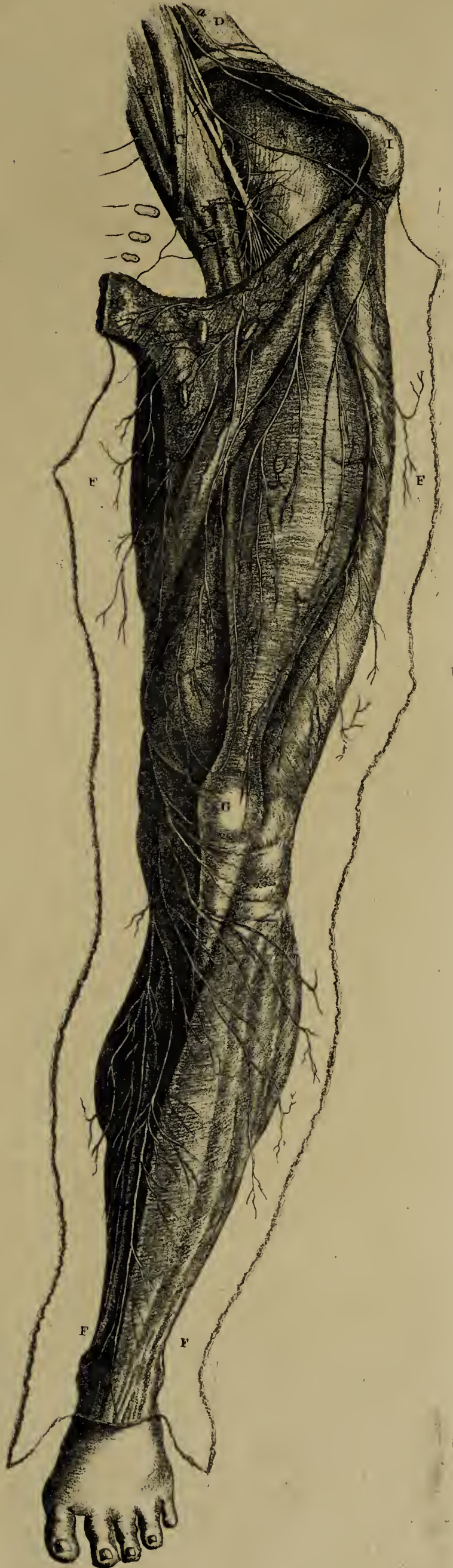
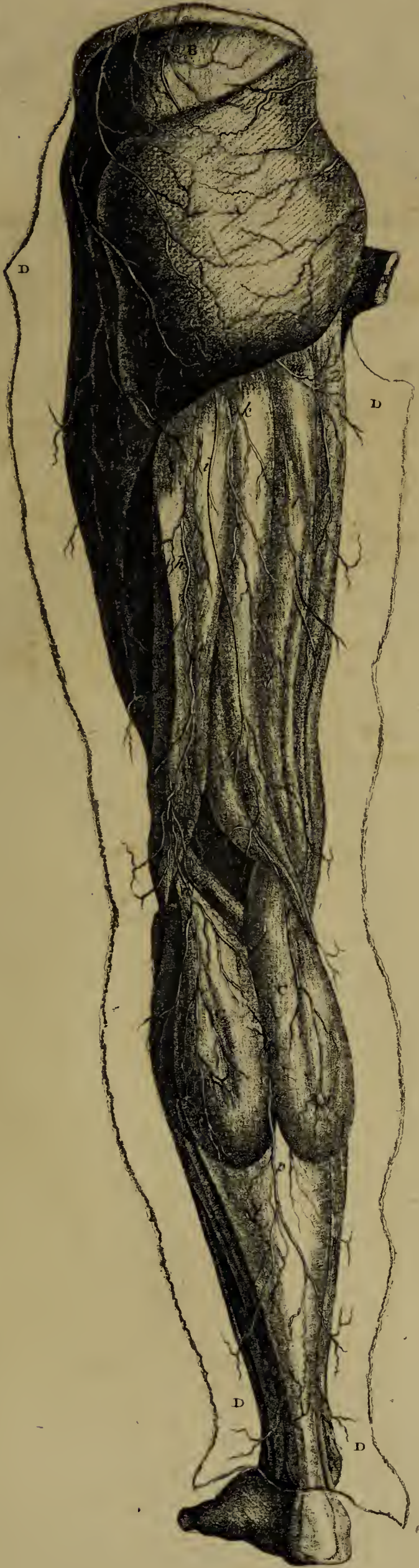
Fig. 2.

Fig. 1.



T A B L E C C V I.

The SUBCUTANEOUS, and some of the MUSCULAR NERVES of the INFERIOR EXTREMITY.

FIG. 1.

Represents the NERVES on the Anterior Part of the LEFT INFERIOR EXTREMITY, with some BLOOD-VESSELS and FIRST LAYER of MUSCLES situated behind the INTEGUMENTS and TENDINOUS SHEATHS; and particularly the descent and distribution of the BRANCHES of the CRURAL or LARGE FEMORAL NERVE. The ARTERIOUS BRANCHES which go to the MUSCLES are left in situ, but the CUTANEOUS BRANCHES are removed, to obtain a more accurate VIEW of the other Parts.

- A, The iliacus externus muscle.
 - B, The pfoas magnus.
 - C, The pfoas parvus.
 - D, The margin or crest of the os ilium.
 - E, The musculus fartorius.
 - F, The tenor of the fascia lata or vagina femoris.
 - G, The vastus externus.
 - H, The rectus cruris muscle.
 - I, A ligament arising from the patella, and inserted into the tibia.
 - K, The vastus internus muscle.
 - L, The pectineus.
 - M, The gracilis.
 - N, The fartorius.
 - O, The biceps cruris.
 - P, The peroneus longus.
 - Q, The soleus.
 - R, The gemelli, or musculus gastrocnemius.
 - S, The extensor longus digitorum pedis, joined with the third peroneus muscle.
 - T, The tibialis anticus.
 - a, A branch of the first lumbar nerve.
 - b, ----- second lumbar nerve.
 - c, Anastomosis of a twig of the second with a twig of the first lumbar nerve.
 - d, A twig of the second lumbar nerve separating and reuniting so as to form an infula.
 - d2. The external cutaneous nerve.
 - e, The posterior branch of the external cutaneous nerve.
 - f, The anterior branch of that nerve.
- VOL. III.

- g, The root of the crural nerve arising from the second and third lumbar nerve.
- h, The root of the crural nerve arising from the fourth lumbar nerve.
- i, The trunk of the crural nerve.
- k, The division of the crural nerve into branches.
- l, The middle cutaneous nerve.
- m, The anterior cutaneous nerve;—its branches are seen as far down as the inner side of the patella.
- n, The long nerve of the fartorius muscle, descending on the inner side of the muscle, and proceeding somewhat anteriorly.
- o, The internal cutaneous nerve.
- p, The fifth branch of the internal cutaneous nerve, perforating the fartorius muscle near the tendon.
- q, The division of the nervus saphænus into saphænus and saphænus minor.
- r, The nervus saphænus.
- s, The continuation of the saphænus minor.

FIG. 2.

Shews some of the NERVES, BLOOD-VESSELS, and FIRST LAYER of MUSCLES of the Back Part of the same INFERIOR EXTREMITY, the SKIN being removed, and the TENDINOUS VAGINÆ turned aside.

- A, The gluteus magnus, or externus.
 - B, The gluteus medius.
 - C, The vastus externus.
 - D, The biceps cruris.
 - E, The femi-tendinosus.
 - F, The femi-membranosus.
 - G, The gracilis.
 - H, The fartorius.
 - I, I, The gastrocnemii.
 - K, The insertion of the tendons of the gastrocnemii muscles into the os calcaneum, properly called Tendo Achillis.
 - a, Small branches of the first lumbar nerve.
 - b, A small branch of the second lumbar nerve.
- Z

c, The

- c*, The posterior branch of the external cutaneous nerve, *d2*. Fig. 1.
- d*, A branch of the second posterior sacral nerve.
- e*, ————— third posterior sacral nerve.
- f*, ————— fourth posterior sacral nerve.
- g*, ————— fifth posterior sacral nerve, going to the under and inner part of the gluteus magnus.
- b*, The trunk of the posterior-superior cutaneous nerve.
- i*, The third lateral branch of the posterior-superior cutaneous nerve.—Between *b*, and *i*, is seen the fourth lateral branch of the same nerve.
- k*, A continuation of the small branch *b*, of the second lumbar nerve, perforating the fascia lata.—Between *i*, and *k*, is seen the second lateral branch of the posterior-superior cutaneous nerve.
- l*, The superior internal cutaneous nerve.
- m*, The first lateral branch of the posterior-superior cutaneous nerve.
- n, n*, The external cutaneous nerve.
- o*, The fifth branch of the internal cutaneous nerve.
- p*, Branches of the inferior internal cutaneous nerve, terminating in the skin and back of the internal gastrocnemius muscle.
- q*, The nervus tibialis.
- r*, ————— communicans tibialis.
- s*, ————— supra-malleolaris.
- t*, ————— peroneus.
- u*, The deep truncated branch of the peroneal nerve.
- v*, The communicating branch of the peroneus, and posterior-inferior cutaneous nerve.
- w*, The nervus cutaneus furialis.

TABLE

Fig. 2.

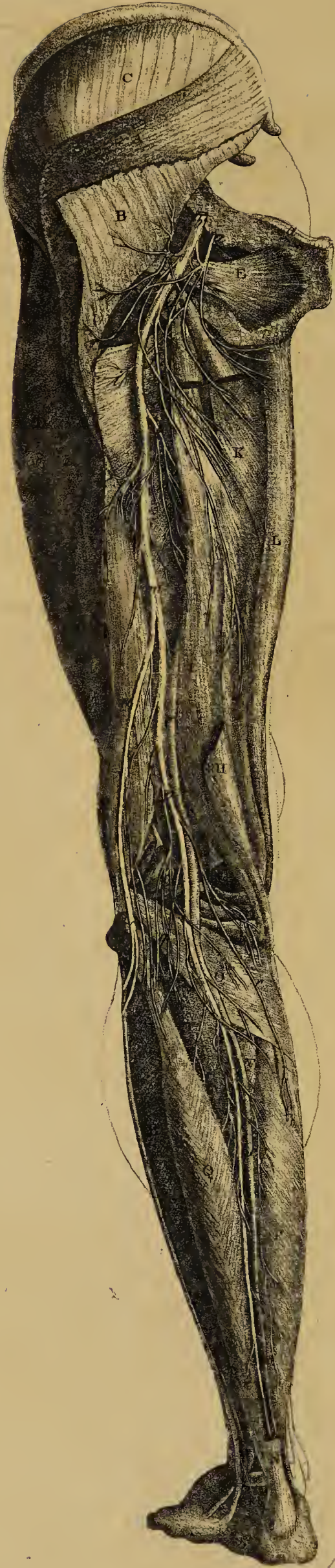

Fig. 1.

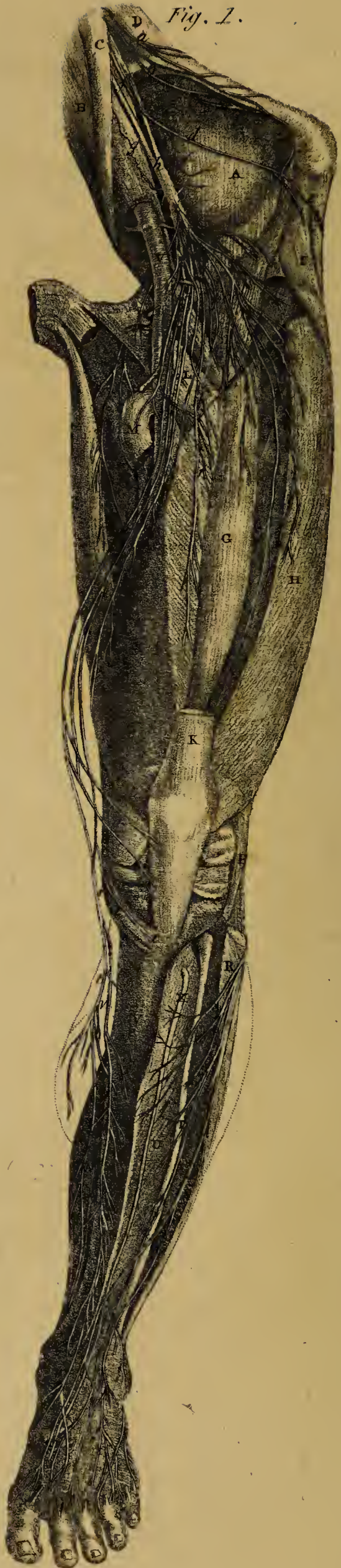
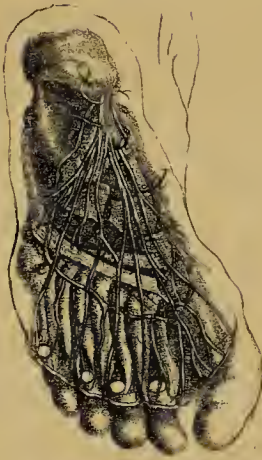
Fig. 3.



T A B L E CCVII.

The MUSCULAR NERVES of the INFERIOR EXTREMITY.

FIG. 1.

An Anterior View of the Second and Third Series of Nerves, Vessels, and Muscles of the Left Inferior Extremity, with the principal Branches of the Nervus Obturatorius, or Femoralis Minor.

- A, The musculus iliacus internus.
 B, The psoas magnus.
 C, ——— parvus.
 D, The quadratus lumborum cut off.
 E, The anterior and lateral part of the gluteus medius.
 F, The greater part of the gluteus minor.
 G, The musculus cruralis.
 H, The vastus externus.
 I, ——— internus.
 K, The tendon of the rectus cruris inserted into the patella.
 L, The pectineus.
 M, The adductor longus femoris dissected, to obtain a more distinct view of the nervus obturatorius.
 N, The gracilis.
 O, O, The adductor magnus femoris.
 P, The biceps cruris.
 Q, The tendon of the gracilis muscle inserted into the tibia.
 R, The peroneus longus.
 S, ——— brevis.
 T, Part of the fibula.
 U, The tibialis posticus.
 V, The tibia.
 W, The soleus.
 X, The anterior tibial artery.
 a, A branch of the first lumbar nerve.
 b, ——— second lumbar nerve.
 c, An anastomosis with a twig of the first lumbar nerve.
 d, The external cutaneous nerve.
 e, The posterior branch of the external cutaneous nerve.
 f, The root of the crural nerve arising from the second and third lumbar nerves.
 g, The root of the crural nerve arising from the third and fourth lumbar nerves.
 h, The crural, or large anterior femoral nerve.
 i, The division of the trunk into branches.
 k, Branches to the vastus externus.

- l, A long or inferior nerve to the crural muscle: It descends almost in the middle of the thigh towards the knee.
 m, The nervus saphænus.
 n, The anterior branch of the nervus obturatorius.
 o, A small anastomotic branch of branch n, which joins this nerve with the nervus saphænus m.
 p, A long or inferior nerve to the vastus internus.
 q, Branches of the internal cutaneous nerve, terminating in the inferior region of the knee.
 r, Small branches of a large twig of the first branch of the nervus saphænus.
 s, A continuation of the nervus saphænus.
 t, The nervus saphænus secundus, or minor.
 u, A continuation of the nervus saphænus minor.
 v, ———.
 w, A small external metatarsal branch.

FIG. 2.

The Posterior Surface of the same Inferior Extremity.—The First Layer of Muscles, the Aponeurotic and Ligamentous Parts, with the Cutaneous and Subcutaneous Nerves, are dissected or turned back;—and the Second and Third Order of Muscles, Vessels, and Nerves, with the descent of the Great Ischiatic or Posterior Femoral Nerve along the Thigh, are shewn.

- A, B, The gluteus maximus or externus, cut off from the upper part of its adhesion, and turned aside, in order that the descent of the ischiatic nerve from the pelvis, and the origin and distribution of the nervi glutei may be more distinctly seen.
 C, The gluteus medius.
 D, The vastus externus.
 E, The obturator internus.
 F, The biceps cruris.
 G, H, The semi-tendinosus; G, its head cut off; H, its tendon cut off.—Contiguous to G, is the long head of the biceps cruris cut off.
 I, The musculus semi-membranosus.
 K, The adductor magnus femoris.
 L, The gracilis.
 M, M, The external and internal heads of the gemelli.
 N, Their tendon, called Tendo Achillis.

O, The

- O, The musculus popliteus.
 P, The flexor longus digitorum pedis.
 Q, ————— pollicis pedis.
 R, The musculus peroneus longus.
 S, ————— brevis.
 T, The tibialis posticus.
 U, The arteria cruralis.
 V, The arteria tibialis postica.
 a, The posterior-superior cutaneous nerve, passing out of the cavity of the pelvis.
 b, The ischiatic, or posterior femoral nerve, passing out of the cavity of the pelvis.
 c, The lateral branches of the posterior-superior cutaneous nerve.
 d, A continuation of the posterior-superior cutaneous nerve.
 e, f, The inferior internal cutaneous branch of the ischiatic nerve.
 g, A branch of the ischiatic nerve going with various small branches and twigs to the gluteus magnus.
 h, The superior internal cutaneous branch of the ischiatic nerve.
 k, A trunk for the nerves of the adductor magnus muscle of the thigh, for the nerve of the semi-membranosus, biceps, and semi-tendinosus muscles, which are frequently found to have a separate origin, but which here go off and are distributed from a common nerve.
- l, A nervous branch, arising from the ischiatic nerve, which descends to the short head of the biceps muscle, and terminates in various small branches.
 m, The division of the ischiatic nerve into the tibial and peroneal nerves.
 n, The nervus peroneus.
 o, ————— profundus.
 p, The nervus tibialis.
 q, The small branch of the nerve common to the soleus, popliteus, and gastrocnemius muscles.
 r, The nervus communicans tibialis.
 s, A continuation of the arteria tibialis postica.
 t, The end of the trunk of the tibial nerve.

FIG. 3.

The Second and Third Order of Nerves and Vessels in the Sole of the same Foot.

- a, The division of the tibial nerve into internal and external plantar nerves, and these again into several branches.
 c, An anastomosis between two branches of the plantar nerves.
 b, The external plantar artery.
 e, The arch of the external plantar artery.
 d, The internal plantar artery.

NAMES OF THE AUTHORS FROM WHOM THE TABLES IN THIS WORK HAVE BEEN TAKEN.

VOLUME I.

TABLE	NAMES OF THE AUTHORS.
1.	<i>Albinus.</i>
2.	<i>Albinus.</i>
3.	<i>Sue.</i>
4.	<i>Sue.</i>
5.	<i>Sue.</i>
6.	<i>Sue.</i>
7.	Fig. 1. <i>Sue</i> ,—2. 3. from Nature.
8.	Fig. 1. 2. from Nature,—3. 4. from <i>Sue</i> .
9.	<i>Sue.</i>
10.	<i>Sue.</i>
11.	Fig. 1. to 8. <i>Sue</i> ,—9. 10. from Nature.
12.	<i>Sue.</i>
13.	<i>Haller.</i>
14.	<i>Hunter, Ruysch, Sue.</i>
15.	<i>Sue.</i>
16.	<i>Sue.</i>
17.	<i>Sue.</i>
18.	<i>Sue.</i>
19.	<i>Sue</i> , and Nature.
20.	<i>Smellie.</i>
21.	<i>Sue.</i>
22.	<i>Sue.</i>
23.	
24.	<i>Sue.</i>
25.	<i>Sue.</i>
26.	<i>Sue.</i>
27.	<i>Sue.</i>
28.	<i>Soemmerring.</i>
29.	Fig. 1. 2. <i>Albinus</i> ,—3. <i>Nesbet</i> ,—4. <i>Gagliardi</i> ,—5. from Nature,—6. <i>Havers</i> ,—7. 8. 10. <i>Cbeselden</i> ,—9. <i>Ruysch</i> .
30.	<i>Cbeselden</i> , excepting Fig. 14. <i>Malpighius</i> .
31.	<i>Cbeselden</i> , excepting Fig. 1. 2. 6. from Nature,—Fig. 16. from <i>Ruysch</i> .

TABLE	NAMES OF THE AUTHORS.
32.	Fig. 1. <i>Weitbrecht</i> ,—3. 14. 16. Nature,—The rest from <i>Cbeselden</i> .
33.	From Nature.
34.	<i>Albinus.</i>
35.	<i>Albinus.</i>
36.	<i>Albinus.</i>
37.	<i>Albinus.</i>
38.	Fig. 1. <i>Bidloo</i> ,—2. to 7. <i>Ruysch</i> ,—8. <i>Cowper</i> ,—9. 10. <i>Albinus</i> .
39.	Fig. 1. <i>Albinus</i> ,—Fig. 2. <i>Le Cat</i> ,—3. <i>Morgagni</i> ,—4. <i>Ruysch</i> ,—5. to 8. <i>Eustachius</i> ,—9. <i>Cowper</i> .
40.	<i>Albinus.</i>
41.	<i>Albinus.</i>
42.	<i>Albinus.</i>
43.	<i>Albinus.</i>
44.	Fig. 1. <i>Albinus</i> ,—2. from Nature,—3. <i>Eustachius</i> .
45.	<i>Albinus</i> , excepting Fig. 3. 4. from <i>Cowper</i> .
46.	<i>Albinus.</i>
47.	<i>Albinus.</i>
48.	Fig. 1. principally from <i>Albinus</i> ,—2. <i>Haller</i> ,—3. to 8. <i>Albinus</i> ,—9. from Nature.
49.	Fig. 1. to 3. from Nature,—4. 6. 7. <i>Cowper</i> ,—5. <i>Cowper</i> , with additions from Nature,—8. <i>Eustachius</i> ,—9. <i>Albinus</i> ,—10. from Nature.
50.	<i>Albinus.</i>
51.	<i>Monro.</i>
52.	<i>Monro.</i>
53.	<i>Weitbrecht</i> , excepting 13. 14. <i>Monro</i> .
54.	<i>Weitbrecht</i> , excepting 7. <i>Monro</i> .
55.	<i>Weitbrecht</i> , excepting 13. <i>Monro</i> .

VOLUME II.

56.	Fig. 1. 2. 5. 12. <i>Loder</i> ,—3. 4. 6. 13. Nature,—7. to 11. <i>Albinus</i> .
57.	Fig. 1. 3. 6. 8. 13. 14. <i>Loder</i> ,—2. 7. 11. 12. Nature,—4. <i>Haase</i> ,—5. <i>Albinus</i> ,—9. <i>Ludwig</i> ,—10. <i>Leidermuller</i> ,—15. 16. <i>Monro</i> .
58.	<i>Vic D'Azyr.</i>
59.	Nature.

60.	Nature.
61.	<i>Vic D'Azyr.</i>
62.	<i>Vic D'Azyr.</i>
63.	<i>Vic D'Azyr</i> , and Nature.
64.	<i>Vic D'Azyr.</i>
65.	<i>Monro.</i>
66.	<i>Monro.</i>
67.	From Nature, for Dr <i>Monro</i> .

TABLE	NAMES OF THE AUTHORS.
68.	The Parisian Artists, with additions.
69.	<i>Vic D' Azyr</i> , and Nature.
70.	Fig. 1. Nature,—2. to 4. <i>Ruysch</i> ,—5. to 7. <i>Eustachius</i> ,—8. 11. <i>Ridley</i> ,—9. 10. <i>Lieutaud</i> ,—12. to 14. <i>Haller</i> .
71.	Fig. 1. <i>Ridley</i> ,—2. 3. 5. <i>Drake</i> ,—4. 6. 10. 11. 13. 17. <i>Ruysch</i> ,—7. <i>Palfin</i> ,—8. 9. 12. 14. 15. 16. 18. to 23. <i>Eustachius</i> ,—24. Nature.
72.	Fig. 1. to 6. <i>Zinn</i> ,—7. <i>Monro</i> ,—8. <i>Morgagni</i> ,—9. <i>Lieutaud</i> .
73.	Fig. 1. to 8. <i>Haller</i> ,—9. <i>Meyers</i> ,—10. to 12. <i>Albinus</i> ,—13. to 16. <i>Zinn</i> .
74.	Fig. 2. 4. 14. from Nature, for Dr <i>Monro</i> , 3. 5. 6. <i>Loder</i> ,—7. <i>Zinn</i> ,—8. 9. <i>Reil</i> ,—10. 12. <i>Wrisberg</i> ,—11. 13. <i>Walter</i> ,—1. 15. to 18. <i>Soemmerring</i> .
75.	<i>Soemmerring</i> .
76.	<i>Soemmerring</i> .
77.	Fig. 1. 2. 5. <i>Valsalva</i> ,—3. 4. 9. 10. <i>Albinus</i> ,—6. 7. 8. 11. 12. <i>Duverney</i> .
78.	Fig. 1. to 6. <i>Valsalva</i> ,—7. to 9. <i>Cotunnius</i> , 10. to 14. <i>Scarpa</i> .
79.	Fig. 2. <i>Loder</i> ,—3. <i>Ruysch</i> ,—4. to 14. <i>Cassebohm</i> ,—1. 15. to 23. <i>Albinus</i> ,—24. to 27. Nature.
79A.	Fig. 1. to 6. From Nature, for Dr <i>Monro</i> ,.... 7. <i>Cotunnius</i> .
79B.	Fig. 1. 2. 34. 35. <i>Valsalva</i> ,—3. 4. 7. and 9. to 26. and 33. <i>Duverney</i> ,—5. <i>Ephemerid. Germ.</i> —8. 27. to 32. <i>Cassebohm</i> .
79BB.	<i>J. Hunter</i> ,— <i>Blake</i> ,— <i>Fox</i> ,—and Nature.
79C.	<i>Blake</i> ,— <i>Fox</i> ,—and Nature.
79D.	<i>Blake</i> ,— <i>Fox</i> ,—and Nature.
80.	Fig. 1. <i>Cbeselden</i> ,—2. Part of a figure from <i>Haller</i> ,—3. 4. 6. Nature,—5. 8. 9. <i>Morgagni</i> ,—7. <i>Weitbrecht</i> .
81.	<i>Jenty</i> .
82.	Fig. 1. to 4. 11. 13. to 15. <i>Eustachius</i> ,—5. to 10. 12. <i>Cowper</i> ,—16. to 19. <i>Morgagni</i> ,—20. <i>Loder</i> .
83.	<i>Senac</i> .
84.	Nature.
85.	Nature.
86.	Fig. 1. <i>Eustachius</i> , with some alterations, —2. 4. <i>Cbeselden</i> ,—3. <i>Monro</i> .
87.	Nature.
88.	<i>Sandifort</i> .
89.	<i>Sandifort</i> .
90.	<i>Haller</i> .
91.	<i>Aitken</i> .

TABLE	NAMES OF AUTHORS.
92.	Fig. 1. 2. 19. <i>Eustachius</i> ,—3. 6. 7. 8. 14. 15. <i>Ruysch</i> ,—4. 5. 12. <i>Mem. de l' Acad. Sc. a' Paris</i> ,—9. 18. 20. <i>Heister</i> ,—10. 11. 21. Nature,—13. <i>Cbeselden</i> ,—16. 17. <i>Morgagni</i> .
93.	Fig. 1. <i>Cbeselden</i> ,—2. <i>Aitken</i> .
94.	Fig. 1. <i>Bidloo</i> ,—3. Nature,—2. 5. 12. <i>Ruysch</i> ,—4. 9. to 11. <i>Eustachius</i> ,—6. <i>Heister</i> ,—7. <i>De Graaf</i> ,—8. <i>Cbeselden</i> ,—13. <i>Le Dran</i> ,—14. to 16. <i>Parsons</i> ,—17. <i>Cowper</i> .
95.	<i>Ludwig</i> .
96.	<i>Ludwig</i> .
97.	Nature.
98.	Fig. 1. <i>Ruysch</i> ,—2. 3. 8. 10. <i>De Graaf</i> ,—4. 5. 7. <i>Eustachius</i> ,—6. <i>Monro</i> ,—9. 12. 13. <i>Cbeselden</i> ,—11. <i>Morgagni</i> .
99.	<i>Monro</i> .
100.	<i>Smellie</i> .
101.	Fig. 1. 2. Nature,—3. <i>Cbeselden</i> .
102.	<i>Ruysch</i> .
103.	<i>Haller</i> .
104.	Nature.
105.	<i>Smellie</i> , with additions from Nature.
106.	Fig. 1. 2. <i>Cbeselden</i> ,—3. From the collection of Mr <i>Burns</i> of Glasgow.
107.	Fig. 1. 6. <i>Parsons</i> ,—2. 7. to 14. 16. to 18. <i>Ruysch</i> ,—3. <i>Morgagni</i> ,—4. 5. <i>De Graaf</i> ,—15. <i>Heister</i> .
108.	<i>Smellie</i> .
109.	<i>Soemmerring</i> .
110.	<i>Soemmerring</i> .
111.	<i>Hunter</i> .
112.	<i>Hunter</i> .
113.	<i>Bidloo</i> .
114.	<i>Hunter</i> .
115.	<i>Hunter</i> .
116.	<i>Hunter</i> .
117.	<i>Hunter</i> .
118.	<i>Hunter</i> .
119.	<i>Albinus</i> .
120.	<i>Wrisberg</i> .
121.	Fig. 1. 2. <i>Bidloo</i> ,—3. to 11. <i>Trew</i> ,—12. <i>Morgagni</i> ,—13. 14. <i>Ephemerid. Germ.</i>
122.	Nature.
123.	Nature.
123a.	Nature.
124.	Fig. 1. <i>Cbeselden</i> ,—2. <i>Haller</i> ,—3. <i>Cbeselden</i> ,—4. Nature,—5. <i>Camper</i> ,—6. <i>J. Hunter</i> .
125.	Fig. 1. 2. <i>J. Hunter</i> ,—3. to 5. <i>Camper</i> .

VOLUME III.

126.	<i>Wrisberg</i> .	131.	<i>Haller</i> .
127.	<i>Haller</i> .	132.	<i>Haller</i> .
128.	<i>Vic D' Azyr</i> .	133.	<i>Haller</i> .
129.	<i>Haller</i> .	134.	<i>Haller</i> .
130.	<i>Haller</i> .	135.	<i>Walter</i> .

TABLE	NAMES OF THE AUTHORS.
136.	<i>Haller.</i>
137.	<i>Haller.</i>
138.	<i>Haller.</i>
139.	<i>Haller.</i>
140.	<i>Nature.</i>
141.	<i>Haller.</i>
142.	<i>Haller.</i>
143.	<i>Haller.</i>
144.	<i>Haller.</i>
145.	<i>Haller.</i>
146.	<i>Haller.</i>
147.	<i>Haller.</i>
148.	<i>Haller.</i>
149.	<i>Haller.</i>
150.	<i>Haller.</i>
151.	<i>Haller.</i>
152.	<i>Haller.</i>
153.	<i>Haller.</i>
154.	<i>Haller.</i>
155.	<i>Haller.</i>
156.	<i>Haller.</i>
157.	<i>Haller.</i>
158.	<i>Haller.</i>
159.	<i>Meyers.</i>
160.	<i>Hewson.</i>
161.	<i>Mascagni.</i>
162.	<i>Mascagni.</i>
163.	<i>Haase.</i>
164.	<i>Sheldon.</i>
165.	} Presented by Dr Monroe, for whom the en- gravings were originally executed, from Preparations still in his possession.
166.	
170.	
171.	
172.	
173.	
178.	
180.	
181.	
182.	

TABLE	NAMES OF THE AUTHORS.
167.	<i>Mascagni.</i>
168.	<i>Mascagni.</i>
169.	<i>Nature.</i>
174.	<i>Hewson.</i>
175.	<i>Mascagni.</i>
176.	<i>Hewson.</i>
177.	<i>Cruicksbank.</i>
179.	<i>Nature.</i>
183.	<i>Soemmerring.</i>
184.	<i>Fig. 1. Nature,—2. Monroe,—3. 4. J. Hunter.</i>
185.	<i>Scarpa.</i>
186.	<i>Haller.</i>
187.	<i>Meckel.</i>
188.	<i>Meckel.</i>
189.	<i>Scarpa.</i>
190.	<i>Scarpa.</i>
191.	<i>Haller.</i>
192.	<i>Neubauer.</i>
193.	<i>Camper.</i>
194.	<i>Camper.</i>
195.	<i>Camper.</i>
196.	<i>Scarpa.</i>
197.	<i>Scarpa.</i>
198.	<i>Scarpa.</i>
199.	<i>Walter.</i>
200.	<i>Walter.</i>
201.	<i>Walter.</i>
202.	<i>Walter.</i>
203.	<i>Camper.</i>
204.	<i>Camper.</i>
205.	<i>Fischer.</i>
206.	<i>Fischer.</i>
207.	<i>Fischer.</i>

G L O S S A R Y.

- ABDOMEN**, (*abdere*, to hide), the lower venter or belly, containing or hiding the intestines, &c.
- ACANTHA**, (*ακάνθα*, to sharpen), sometimes used for the spine.
- ACETABULUM**, (*acetum*, vinegar), the socket for the head of the thigh-bone, resembling an ancient vinegar-cruet.
- ACINI**, (*acinus*, a grape), the internal structure of several glands.
- ACROMION**, (*ακρος*, the extremity, and *ώμος*, the shoulder), a process of the scapula.
- ADENOLOGY**, (*αδην*, a gland, and *λογος*, a discourse), the doctrine of the glands.
- ADNATA**, (*adnascor*, to grow to), the external coat of the eye.
- ALLANTOIS**, (*αλλανξ*, a gut, and *ειδος*, shape), a membrane which envelopes the foetal quadruped.
- ALVEOLI**, (*alveus*, a conduit-pipe), the sockets for the teeth.
- AMNIOS**, (*αιμα*, blood, *αμνιον*, a vessel used by the ancients to receive the blood in sacrifices, *αμνος*, a lamb's skin), the soft membrane immediately surrounding the foetus.
- AMPHYARTHROSIS**, (*αμφω*, both, and *αρθρον*, articulation), an articulation admitting of an obscure motion.
- ANASTOMOSIS**, (*ανα*, through, and *στομα*, a mouth), the communication of vessels with one another.
- ANATOMY**, (*ανα*, through, and *τομω*, to cut), dissection, or that knowledge of animal bodies acquired by dissection.
- ANCON**, the elbow, (from *ασπασθωμαι*, to embrace), because the bones, being there united, are folded one into another. Hence also,
- ANCONIUS**, a muscle situated there, and,
- ANCONOID**, a process of the cubit, from *αγκων*, the elbow, and *ειδος*, shape.
- ANGIOLOGY**, (*αγγειον*, a vessel, and *λογος*, a discourse), a description of the vessels.
- ANTAGONIS Γ**, (*αντι*, against, and *αγων*, a struggle), an epithet of a muscle acting contrary to another.
- ANTIHELIX**, (*αντι*, against, and *ειλω*, to turn about), the external part of the ear opposite to the helix.
- ANTITHENOR**, (*αντι*, against, and *θεναρ*, the palm of the hand), one of the muscles extending the thumb.
- ANTITRAGUS**, (*αντι*, against, and *τραγος*, a goat), a prominence of the ear opposite to the tragus.
- ANUS**, (a contraction of *Annulus*, a little ring), the extremity of the rectum, so called from its circular fibres.
- AORTA**, (*αορτη*, a vessel), the great artery of the heart.
- APONEUROSIS**, (*απο*, from, and *νευρον*, a nerve), a tendinous expansion, supposed by the ancients to be that of a nerve.
- APOPHYSIS**, (*αποφυω*, to spring from), the process of a bone, and a part of the same bone. **EPIPHYSIS**, a process attached to a bone, and not a part of the same bone.
- ARACHNOIDES**, (*αραχνη*, a spider, and *ειδος*, likeness), a cob-web like membrane, one of the coats of the brain and eye.
- ARTERIA**, (*αερα*, air, and *τηρω*, to keep), because the ancients thought that only air was contained in the arteries.
- ARTHRODIA**, (*αρθρον*, a joint), that kind of articulation which is shallow.
- ARYTENOIDES**, (*αρυταναι*, an ever, and *ειδος*, shape), two cartilages of the larynx.
- ASPERA ARTERIA**, (*asper*, rough, and *arteria*, an artery or duct), the trachea or wind-pipe.
- ASTRAGALUS**, (*αστραγαλος*, a die), a bone of the tarsus resembling an ancient die.
- ATLAS**, (*ατλαω*, to sustain), the first of the cervical vertebrae, so named from supporting the head, as Atlas was supposed to support the world.
- AZYGOS**, (*α*, priv. and *ζυγος*, a yoke), a term applied to any part, not having a corresponding part.

B.

- BASILICA**, (*βασιλευς*, a king), an epithet, by way of eminence, given to one of the veins of the arm.
- BRACHIUM**, (*βραχιυς*, short), because, in general, from the shoulder to the hand is shorter than from the hip to the foot.
- BREGMA**, (*βρεγω*, to moisten), the opening of the head

in the course of the sagittal suture, found in the heads of new-born children.

BRONCHIA, (*βρογχος*, the throat), the ramifications of the trachea.

BUCCINATOR, (a trumpeter), a muscle of the cheek, much used by trumpeters.

BURSALOGY, (*Βυρσα*, a purse, and *λογος*, a discourse), a description of the bursa mucosa.

C.

CALCEANUS, (*calx*, the heel), a name of the os calcis.

CALVARIA, or CALVA, (*calvus*, bald), the upper part of the cranium, which turns first bald.

CANCELLI, (lattice-work), the reticular substance in bones.

CAPILLARY VESSELS, (*capillus*, a little hair), the small ramifications of the arteries.

CAPUT GALLINAGINIS, (a wood-cock's head), a little eminence at the termination of the femoral vessels in the penis.

CARDIA, (*καρδια*, the heart), the superior opening of the stomach, so called from being situated near the heart.

CAROTID, (*καρσω*, to induce sleep), arteries of the head and neck, which, if tied, the animal becomes comatose, or are said to cause the appearance of being asleep.

CARPUS, (*καρπος*), the wrist.

CARTILAGE, a matter softer than bone, but harder than ligament.

CEPHALIC VEIN, (*κεφαλη*, the head), the ancients being accustomed to open this vein in disorders of the head.

CERATOGLOSSUS, (*κερας*, a horn, and *γλωττα*, a tongue), a muscle running from one of the cornua of the os hyoides to the tongue.

CEREBELLUM, dim. of CEREBRUM, the brain, (*καρη*, the head).

CERVIX, the hinder part of the neck, the fore-part being called COLLUM.

CHIRURGERY, (*χειρ*, the hand, and *εργον*, work), the profession of a surgeon.

CHOLEDOCHUS DUCTUS, (*χολη*, bile, and *δεχομαι*, to receive), the common bile-duct.

CHORION, (*χωριον*, domicile), the outer membrane involving the fœtus; or *χορος*, a chorus, this membrane being supplied with many blood-vessels in the quadruped.

CHOROIDES, so called on account of its many blood-vessels, resembling the chorion.

CLAVICULA, (dim. of *clavis*, a key), the clavicle or collar-bone; so called from its resemblance to an ancient key.

CLINOID, (*κλινη*, a bed, and *ειδος*, shape), processes of

the sella Turcica of the sphenoid bone, so called from their resemblance to a couch.

CLITORIS, (*κλειω*, to conceal), a part of the female pudendum concealed by the labia majora.

COCCYX, (*κοκκυξ*, a cuckoo), the lower end of the spina dorsa, so called from its resemblance to the beak of that bird.

CŒLIACA, (*κοιλια*, the belly), the name of an artery in the abdomen.

COLON, (*κοιλος*, hollow), the first of the large intestines.

CONDYLE, (*κονδυλος*, a joint, a knuckle, a knot), an eminence in several of the joints.

CONGLOBATE, (*conglobatus*, gathered together in a circle), a gland subsisting by itself, like those of the absorbent system.

CONGLOMERATE, (*conglomeratus*, heaped together), a gland composed of various glands.

CORACO, names compounded with this word belong to muscles which are attached to the coracoid process of the scapula.

CORACOID, (*κοραξ*, a crow, and *ειδος*, resemblance), like the beak of a crow.

CORONARY, (*corona*, a crown), vessels so called from surrounding the parts like a crown.

CORONOID, (*κορωνη*, a crow, and *ειδος*, shape), a process shaped like a crow's beak.

CORPUS CALLOSUM, (*corpus*, a body, and *callus*, hard), part of the medullary substance of the brain, supposed to be firmer than the rest.

CORTICALIS SUBSTANTIA, (*cortex*, bark), the cortical substance of the brain.

COSTÆ, (*custodio*, to guard), the ribs, because they guard the heart, &c.

COTYLOID, (*κοτυλη*, an old measure, and *ειδος*, shape), the cavity for receiving the head of the thigh-bone, resembling the rotuli.

CRANIUM, (*κρανιον*, the skull, quasi *κρανιον*, from *κραν*, the head).

CREMASTER, (*κρεμωω*, to suspend), a muscle so called, because it suspends the testicle.

CRIBRIFORM, (*cribrum*, a sieve), perforated like a sieve.

CRICOID, (*κρικος*, a ring, and *ειδος*, shape), annular.

CRISTA GALLI, a portion of the ethmoid bone, so called from its resemblance to a cock's comb.

CROTAPHICE, (*κροταφος*, the temple), the temporal muscle.

CRURA, (*crus*, a leg), applied to some parts, from their resemblance to a leg or root.

CUBITUS, (a *cubando*), that part of the arm from the elbow to the wrist; because the ancients, during meals, used to recline upon it.

CUBOIDES, (*κυβος*, a cube, and *ειδος*, shape), a bone of the foot resembling a cube.

CUCULLARIS, (*cucullus*, a cowl or hood), the first muscle of the scapula, so named from its shape.

CUNEIFORM,

CUNEIFORM, (*cuneus*, a wedge), wedge-shaped.
CUTICULA, (the dim. of *cutis*, the skin), the scarf-skin.
CUTIS, the skin.
CYSTICUS DUCTUS, (*κυστις*, a bladder, *ductus*, a duct), the duct leading from the gall-bladder.

D.

DARTOS, (*δερω*, to excoriate), an imaginary muscle of the scrotum.
DELTOID, (*Δελτα*, the fourth letter of the Greek alphabet, and *ειδος*, shape), resembling the Greek letter Δ.
DIAPHRAGM, (*διαφρασσω*, to divide), the transverse muscle which separates the thorax from the abdomen.
DIASTOLE, (*διαστελλω*, to fend through), the dilatation of the heart, auricles, and arteries, opposed to **SYSTOLE**, the contraction of the same parts.
DIARTHROSIS, (*διαρθρωω*, to articulate), a moveable connection of bones.
DIGASTRIC, (*δισ*, twice, and *γαστηρ*, a belly), having two bellies.
DIPLOE, (*διπλωω*, to double), the spongy substance between the two tables of the skull.
DODECADACTYLON, (*δωδεκα*, twelve, and *δακτολοι*, fingers), a name of the
DUODENUM, (*duodenus*, consisting of twelve, viz. inches), the first portion of the small intestines, so called from its general length.
DURA MATER, (*durus*, hard, and *mater*, a mother), the outermost membrane of the brain; the ancients finding this harder than, and supposing it to give origin to, the other membranes of the body.

E.

EMBRYO, (*εμβρυω*, to sprout out), the child in the womb, before the fourth month, after which it is called foetus.
EMULGENTS, (*emulgo*, to milk out), the arteries and veins of the kidneys, so called because, according to the ancients, they strained, and, as it were, milked the serum through the kidneys.
EMUNCTORES, (*emungo*, to wipe away), glands which, according to the ancients, received the excrementitious matter from the noble parts, as the parotids from the brain, the axillary glands from the heart, and inguinal glands from the liver.
ENARTHROSIS, (*εν*, in, and *αρθρον*, a joint), an articulation of bones, the same as *Arthrosis*.
ENCEPHALON, (*εγκεφαλος*), the brain.
ENTERIC, (*εντερον*, an intestine), belonging to the intestines.
EPIDERMIS, (*επι*, upon, and *δερμα*, the skin), the scarf-skin.

EPIDIDYMIS, (*επι*, upon, and *διδυμος*, twins, the testicles), the small oblong body which lies above the testicle.
EPIGASTRIC, (*επι*, upon, and *γαστηρ*, the belly), the superior part of the abdomen.
EPIGLOTTIS, (*επι*, upon, and *γλωττα*, the tongue), one of the five cartilages of the larynx, situated upon the glottis.
EPIPHIPIUM, (*επι*, upon, and *ιππος*, a horse), part of the os splenoides, so called from its resemblance to a saddle.
EPIPHYSIS, (*επι*, upon, and *φωω*, to grow), see **APOPHYSIS**.
EPIPLOON, (*επι*, upon, and *πλωω*, to fail), the omentum, or that membranous viscus of the abdomen, which covers the intestines, and hangs from the bottom of the stomach.
EPISTROPHÆUS, (*επιστροφωω*, to turn about), the second cervical vertebra,—the head is turned upon it.
ESOPHAGUS, (*ειω*, to carry, *φαγωω*, to eat), the canal leading from the pharynx to the stomach, carrying what is swallowed into the stomach.
ETHMOID, (*εθμος*, a sieve), so called, because it is perforated like a sieve.

F.

FALCIFORM, (*falx*, a scythe), shaped like a scythe.
FASCIA, (*fascis*, a bundle), an expansion of a muscle, inclosing others like a band.
FAUCES, (the plural of *faux*), the top of the throat.
FIBULA, (a clasp), the lesser bone of the leg, which is thus named from being placed opposite to the part where the knee-buckle or clasp was formerly used.
FCETUS, the child in the womb past the third month, and fully formed.

G.

GALACTOPHEROUS, (*γαλα*, milk, and *φωω*, to carry), conveying the milk.
GANGLION, a knot in the course of a nerve.
GASTROCNEMIUS, (*γαστηρ*, the belly, and *κνημη*, the leg), the muscle forming the thick of the leg.
GASTRO-EPIPLOIC, (*γαστηρ*, the stomach, and *επιπλοον*, the caul), belonging to the stomach and omentum.
GENIO, (*γενειον*, the chin), names compounded with this word belong to muscles attached to the chin.
GINGLYMUS, (*γυγγλυμος*, a hinge), articulation admitting flexion and extension.
GLENOID, (*γληνη*, a cavity), a part having a shallow cavity.
GLOMER, a convoluted bundle of glands.
GLOSSO, (*γλωσσα*, the tongue), names compounded with this word are applied to muscles attached to the tongue.

GLOTTIS,

GLOTTIS, (*γλωττα*, the tongue), the superior opening of the larynx at the root of the tongue.
GLUTEUS, (*γλυτος*, the buttock), muscles forming part of the buttocks.
GOMPHOSIS, (*γομφω*, to drive in a nail), an articulation of bones, like a nail in a piece of wood.

H.

HARMONIA, (*αρμονια*, to fit together), a species of immoveable articulation.
HELIX, (*ελω*, to turn about), the outer bar or margin of the external ear.
HYALOID (*υαλος*, glass), the capsule of the vitreous humour of the eye, so called from its glassy appearance.
HYMEN, (the god of marriage), the membrane situated at the entrance of the virgin vagina.
HYO, names compounded with this word belong to muscles which are attached to the
HYOIDES OS, (*υ*, and *ειδος*, shape), a bone of the tongue resembling the Greek *υ* (upsilon).
HYPOCHONDRIUM, (*υπο*, under, and *χονδρος*, a cartilage), the upper region of the abdomen, next the cartilages of the ribs.
HYPOGASTRIC, (*υπο*, under, and *γαστηρ*, the belly), the lower region of the fore-part of the abdomen.
HYPOGLOSSIS, (*υπο*, under, and *γλωσσα*, the tongue), parts which lie under the tongue, called also *Ranularis*.
HYPOTHENAR, (*υπο*, under, and *θιναρ*, the palm of the hand), one of the muscles contracting the thumb.

I.

JEJUNUM, (empty), one of the intestines, so called from being generally found empty.
ILEUM, (*ελω*, to turn), a portion of the small intestines, so called from being found convoluted.
INCISORES, (*incidere*, to cut), the fore-teeth.
INCUS, (an anvil), a small bone of the internal ear, with which the malleus is articulated.
INDEX, (*indico*, to point out), the fore-finger.
INNOMINATUM, parts which have no proper name.
INTERFEMINEUM, *vide* **PERINEUM**.
IRIS, (the rain-bow), the circle round the pupil of the eye, deriving its name from its various colours.
ISCHIUM, (*ισχυω*, to support), that part of the os innominatum upon which we sit.
JUGALE OS, the zygoma.

L.

LACUNÆ, (little cavities), the excretory ducts of the urethra and vagina, &c.

LAMBDOIDAL, resembling the Greek Λ (lambda).
LAMINA, a scale or plate. It is used for the tables of the skull.
LARYNX, the superior part of the trachea.
LINEA ALBA, a white line formed by the meeting of the tendons of the abdominal muscles.
LUMBRICALES, (*lumbricus*, a worm), four muscles of the hand and foot.

M.

MASSETER, (*μασσαιμαι*, to chew), a muscle which assists in chewing.
MASTOID, (*μασος*, a breast), shaped like a nipple or breast.
MAXILLA, (*μασσω*, to chew), the jaw.
MEDIANA VENA, the middle vein of the arm, between the basilic and the cephalic.
MEDIASTINUM, (*medium*, the middle), the production of the pleura, which divides the thorax into two cavities. **MEDIASTINUM CEREBRI**, a process of the dura mater, which lies between the two hemispheres of the brain.
MENINGES, the dura and pia mater.
MESENTERY, (*μεσος*, the middle, and *εντερον*, the intestine), the membrane in the middle of the intestines, by which they are attached.
MESERAIC, (*μεσος*, the middle, and *αραια*, the belly), the same as the last article.
MESO-COLON, (*μεσος*, the middle, and *κολον*, the colon), that part of the mesentery in the middle of the colon.
METACARPUS, (*μετα*, after, and *καρπος*, the wrist), that part of the hand between the carpus and fingers.
METATARSUS, (*μετα*, after, and *ταρσος*, the tarsus), that part of the foot between the tarsus and toes.
MITRALIS VALVULA, (*mitra*, a mitre), valves at the left ventricle of the heart, like a mitre.
MYLO, (*μολη*, a grinder-tooth), names compounded of this word belong to muscles that are attached near the grinders.
MYOIDES PLATYSMA, a muscular expansion on the neck. *See* **PLATYSMA**.
MYOLOGY, the doctrine of the muscles.

N.

NAVICULARE, (*navicula*, a little boat), a bone of the carpus, and also of the tarsus.
NEUROLOGY, the doctrine of the nerves.
NYMPHÆ, a semicircular glandular membrane in the *puddendum muliebre*, so called because it directs the course of the urine.

O.

O.

- ODONTOIDES, (ὄδους, a tooth, and εἶδος, shape), tooth-like.
 OLECRANON, (ὠλενή, the cubit, and κρανον, the head), the elbow, or head of the ulna.
 OMENTUM, (ομεν, a guess), an abdominal viscus, so called because the ancient priests pretended to reveal the secrets of heaven, by inspecting this viscus.
 OMO, (ωμος, the shoulder), names compounded of this word belong to muscles attached to the scapula.
 OMO-PLATA, (ωμος, the shoulder, and πλατυς, broad), the scapula or shoulder-blade.
 OSTEOLOGY, the doctrine of the bones.

P.

- PANCREAS, (παν, all, and κρεας, flesh), a gland of the abdomen.
 PARENCHYMA, (παρεγγεω, to pour through), a substance connecting the vessels, &c. of the lungs, liver, &c.
 PARIETALIA, (paries, a wall), bones of the cranium serving as a wall to the encephalon.
 PAROTID, (παρα, near, and ωτος, the gen. of ος, the ear), a gland situated near the ear.
 PATELLA, (dim. of patina, a pan), the knee-pan.
 PATHETICA, (παθος, passion), the fourth pair of nerves, because, by means of these, the eyes express certain passions of the mind.
 PELVIS, (πελυξ, a basin), the basin of the kidneys, or the lower part of the abdomen, in which the bladder (and in women the uterus) and rectum are contained.
 PERICARDIUM, (περι, around, and καρδια, the heart), the membrane surrounding the heart.
 PERICRANIUM, (περι, around, and κρανιον, the cranium), the membrane covering the bones of the cranium.
 PERINEUM, (περινεω, to flow round, because that part is generally moist), the space between the external parts of generation and the anus. It is sometimes called INTERFEMINEUM, (inter, between, and femem, the inside of the thigh).
 PERIOSTEUM, (περι, around, and οστεον, a bone), the membrane surrounding the bones.
 PERISTALTIC, (περισειλλω, to contract), the motion of the intestines.
 PERITONEUM, (περιτεινω, to extend around), the membrane lining the abdomen, and covering its viscera.
 PETROSUM OS, (πετρα, a rock), part of the temporal bone.
 PHALANX, (an army), the bones of the fingers and toes are called phalanges from their regularity.
 PHARYNX, (φειν, to convey, because it conveys the food into the stomach), a membranous bag at the end of the mouth.
 PHRENIC, (φρενες, the diaphragm, a φρην, the mind,

- because the diaphragm was supposed to be the seat of the mind), the name of a nerve.
 PHYSIOLOGY, (φυσις, nature), an account of the actions and functions of an animated body.
 PIA MATER, the innermost membrane around the brain.
 PLACENTA, (πλακως, a cake), the after-birth.
 PLANTARIS, (planta, the sole), parts situated in the sole.
 PLATYSMA-MYOIDES, (πλατυς, broad, μυων, a muscle, and εἶδος, shape), a muscle of the neck.
 PLEURA, (πλευρα, the side), the membrane lining the cavity of the thorax.
 PLEXUS, (plecto, to weave together), a kind of network of blood-vessels or nerves.
 POPLITEUS, (poples, the ham), a muscle of the leg.
 PREPUCE, (πραπυτο, to cut off before), the fore-skin of the penis, which the eastern nations generally cut off.
 PROCESSUS, (procedo, to start out), a protuberance of a bone.
 PROSTATÆ, (προ, before, and ιστιμι, to stand), glands situated before the vesiculae seminales.
 PSOAS, (ψοα, the loin), a muscle so named from its situation.
 PTERYGOID, (πτερα, a wing), a process resembling a wing.
 PTERYGO-STAPHALINI, (πτερυξ, a wing, and σταφυλα, the palate), muscles arising from the pterygoid process of the os sphenoides, and inserted into the uvula.
 PUDENDA, (pudor, shame), the parts of generation.
 PUPILLA, (a little puppet), the round aperture in the tunica uvea of the eye.
 PYLORUS, (πυλωρος, the keeper of a gate), the lower orifice of the stomach, guarding the entrance of the bowels.
 PYRAMIDALIS, shaped like a pyramid.

R.

- RADIUS, (the spoke of a wheel), the small bone of the fore-arm.
 RANULAR, like a frog or toad.
 RAPHE, (ραπτω, to sew), a suture.
 RECTUM, the straight gut, the last of the intestines.
 RENES, (ρειω, to flow), the kidneys, through which the urine flows.
 RETINA, (rete, a net), the net like expansion of the optic nerve on the inner surface of the eye.
 RHOMBOIDES, a muscle so called from resembling a geometrical figure (ρομβος), whose sides are equal, but not right angled.
 ROTULA, (dim. of rota, a wheel), the knee-pan.

S.

- SACRUM, (sacred), a bone so called, because it was offered in sacrifice,

SAGITTALIS,

SAGITTALIS, (*sagitta*, an arrow), a suture in the cranium.

SALVATELLA, (*salvo*, to preserve), a vein of the foot, the opening of which was said to preserve health, and to cure melancholy.

SANGUIS, (*σαιν*, to preserve), the blood.

SAPHENA, (*σαφος*, manifest), a vein of the leg.

SARTORIUS, (*sartor*, a tailor), the muscle by means of which the tailor lays his leg across.

SCALENI, (*σκαληνος*, a geometrical figure with three unequal sides), muscles of the neck.

SCAPHA, (a little boat), the depression of the outer ear before the antihelix.

SCAPHOIDES, (resembling a boat), a bone of the carpus, and also of the tarsus.

SCAPULA, the shoulder-blade.

SCELETUS, (*σκελλω*, to dry), a skeleton.

SCLEROTIC, (*σκληρος*, hard), the outermost or hardest membrane of the eye.

SCUTIFORM, shaped like a shield.

SELLA TURCICA, SELLA EQUINA, SELLA SPHENOIDES, are various names for a part of the sphenoid bone resembling a Turkish saddle.

SEPTUM CORDIS, (*sepes*, a hedge), the fleshy substance which divides the right and left ventricles of the heart.

SESAMOID, (*σεσαμμη*, an Indian bean), small bones in the hands and feet resembling the *semen sesami*.

SIGMOID, resembling the Greek Σ (sigma).

SPHENOID, (*σφην*, a wedge), shaped like a wedge.

SPHINCTER, (*σφιγγω*, to shut up), the name of several muscles, whose office it is to shut up the apertures around which they are placed.

SPLANCHNOLOGY, (*σπλαχνον*, an entrail), the doctrine of the viscera.

SQUAMOUS, (*squama*, a scale), covering as the scales of fishes do each other.

STAPES, (a stirrup), one of the small bones of the internal ear.

STOMACHUS, (*στομα*, a mouth, and *χειω*, to pour), the stomach, or upper orifice of the ventricle.

STYLOID, (*stylus*, a pencil), a process like a pencil on the temporal bone.

SYMPHYSIS, (*συμφυω*, to draw together), the connection of bones which have no manifest motion.

SYNARTHROSIS, (*συν*, with, and *αρθρον*, a joint), articulation without manifest motion.

SYNCHONDROSIS, (*συν*, with, and *χονδρος*, a cartilage), articulation by means of intervening cartilage.

SYNDESMOLOGY, (*συνδεσμος*, a ligament), the doctrine of ligaments.

SYNDESMOSIS, the connection of bones by ligaments.

SYNEUROSI, (*συν*, with, and *νευρον*, a nerve), the connection of bones by tendon, formerly mistaken for nerve.

VOL. III.

SYNTHESIS, (*συντιθημι*, to put together), the anatomical connection of the bones of the skeleton.

SYSSARCOSIS, (*συν*, with, and *σαρξ*, flesh), the connection of bones by muscle.

SYSTOLE, (*συστελλω*, to contract), *vide* DIASTOLE.

T.

TALUS, (a die), a bone of the heel.

TARSUS, the space between the bones of the leg and the metatarsus.

TENDON, (*τεινω*, to extend), the extremity of a muscle.

TERES, (round), the name of a muscle.

TESTIS, (a witness, *quia est quasi testis virilitatis*), the testicle.

THECA, (*τιθημι*, to put), the spinal canal is sometimes called Theca Vertebralis.

THENAR, (the palm of the hand), a muscle extending the thumb.

THORAX, (*θοραξ*, to leap), the chest in which the heart leaps or beats.

THYMUS, (*thymus*, thyme), a gland in the thorax.

THYRO, names compounded with this word belong to muscles which are attached to the

THYROID, (*θυρος*, a shield), cartilage, shaped like a shield.

TIBIA, (a pipe), the great bone of the leg.

TONSIL, the round glands placed between the arches of the palate.

TRACHEA, (*τραχος*, rough), the wind-pipe.

TRAGUS, (a goat), a small eminence of the external ear, upon which hair often grows like the beard of a goat.

TRAPEZOID, (*τραπεζιον*, a four-sided figure), like a trapezium.

TROCHANTER, (*τριχαιω*, to run or to roll), a process of the thigh-bone, the muscles inserted into which perform the office of running.

TROCHLEA, (*τροχος*, a wheel), a kind of cartilaginous pulley.

TROCHLEARIS, an articulation where one part moves round another like a pulley.

TUBÆ FALLOPIANÆ, two passages in the womb like trumpets, described by FALLOPIUS.

TYMPANUM, the drum of the ear.

U.

ULNA, (*ωληνη*, the cubit), the large bone of the arm.

UMBILICUS, (*umbo ilium*, the middle of the loins), the navel.

URACHUS, (*ουρον*, urine, and *χειω*, to pour), a ligament of the bladder, occupying the place of the urinary passage of the foetal quadruped, which goes into the allantois.

URETER,

URETER, (*ουρον*, urine), the canal that carries the urine off from the kidney into the bladder.

URETHRA, the passage for the urine from the bladder.

UVEA, (*uva*, a grape), the posterior lamina of the iris.

UVULA, the glandular substance which hangs down from the middle of the soft palate.

VALVES, (*valvæ*, folding doors), little membranes preventing the return of the fluids in the blood-vessels and absorbents.

VERTEBRÆ, (*verto*, to turn), the bones of the spine.

VOMER, (a plough-share), a bone of the nose.

X.

XIPHOID, (*ξιφος*, a sword), like a sword.

Z.

ZYGOMA, (*ζυγος*, a yoke), the cavity under the zygomatic process of the temporal bone.

INDEX.

I N D E X.

	<i>Pag.</i>		<i>Pag.</i>
ABDOMEN, of the, vol. II.	125	Anterior auris,	102
————, muscles on the anterior and lateral parts of the, vol. I.	108	Antihelix, vol. II.	59
————, ——— within the cavity of the,	112	Antitragicus,	59
————, blood-vessels of the containing parts of the, vol. III.	71	Antitragus,	59
————, lymphatics of the under part of the,	83	Anus, muscles of the, vol. I.	111
Abducentes, or sixth pair of nerves,	121	Aorta, general course of the, vol. III.	7
Abductor oculi,	39	Aponeurosis of the superior extremity, vol. I.	120
Abductor { indicis { minimi digiti } manus, vol. I.	124	———— inferior extremity,	125
{ pollicis		———— palmaris,	121
{ or prior indicis		———— plantaris,	130
{ ——— medii digiti		———— temporalis,	104
{ ——— tertii digiti } pedis, 131.132		Appendages of the skin, vol. II.	4
{ minimi digiti		Appendices vermiformes cerebelli,	15
{ pollicis		Appendix vermiformis intestini cæci,	128
ABSORBENT SYSTEM, of the, vol. III.	81	Aqua labyrinthi,	84
Accelerator urinæ, vol. I.	111	Aquæductus FALLOPII,	64
Accessory nerve to the eighth pair, vol. III.	129	———— SYLVII,	14
Acervulus cerebri, vol. II.	15	Aqueous humour of the eye,	36
Acusticus, nervus, vol. III.	121	Aranea tunica,	37
Adductor { minimi digiti } manus, vol. I. 124.125		Arbor vitæ,	15
{ pollicis		Arch of the aorta, vol. III.	7
{ or posterior indicis		Arches of the palate, vol. II.	97
{ ——— medii digiti		Arcus plantaris arteriosus, vol. III.	76
{ ——— tertii digiti } pedis, 131.132		———— arteriosus volaris profundus,	29
{ — prior minimi digiti		———— superficialis,	30
{ pollicis	131	ARTERIES, of the, vol. III.	3
———— femoris triceps,	125	Articular nerve of the shoulder,	144
———— oculi, vol. II.	38	Aryteno-epiglottideus, vol. I.	108
Adeps,	5	Arytenoid- { cartilages, } vol. II. 98.99	
Adipose arteries, vol. III.	54	{ glands, }	
Alæ vesperilionis, vol. II.	104	Arytenoideus { obliquus, } vol. I. 108	
Albuginea tunica, testis,	154	{ transversus, }	
———— oculi,	34	Astragalus,	77
Almonds of the ear,	97	Attollens aurem,	102
Alveolar artery, vol. III.	8	Auditorius, nervus, vol. III.	121
Amnios, vol. II.	177	Aurem retrahentes, vol. I.	102
Amygdalæ,	97	Auricles of the heart, vol. II.	106 et seq.
Anconeus, vol. I.	121	Auricularis posterior arteria, vol. III.	7
VOL. III.		Auris internus, vol. II.	102
		———— transversus,	59
		Axillary artery, vol. III.	27
		———— glands,	87

INDEX.

	Pag.		Pag.
Axillary plexus, - - - - -	144		
Azygos uvulæ, vol. I. - - - - -	107		
----- vena, vol. III. - - - - -	42		
B.			
Ball of the eye, vol. II. - - - - -	33		
-----, coats of the, - - - - -	33		
-----, humours of the, - - - - -	36		
-----, muscles of the, - - - - -	38		
-----, vessels of the, { vol. II. - - - - -	39		
-----, vessels of the, { vol. III. - - - - -	7.12		
-----, nerves of the, { vol. II. - - - - -	39		
-----, nerves of the, { vol. III. - - - - -	119.121		
Basilar artery, vol. III. - - - - -	10		
Basilic vein, - - - - -	30		
Biceps flexor cubiti, vol. I. - - - - -	120		
----- cruris, - - - - -	128		
Biventer cervicis, - - - - -	117		
----- maxillæ inferioris, - - - - -	105		
BLADDER OF URINE, vol. II. - - - - -	153		
-----, blood-vessels of the, vol. III. - - - - -	55.56		
-----, lymphatics of the, - - - - -	84		
BLOOD-VESSELS in general, of the, - - - - -	3		
BONES in general, of the, vol. I. - - - - -	3		
Bones of the cranium, - - - - -	18		
----- face, - - - - -	33		
----- trunk, - - - - -	45		
----- pelvis, - - - - -	52		
----- thorax, - - - - -	58		
----- superior extremity, - - - - -	62		
----- inferior extremity, - - - - -	74		
BONES, of the formation of, - - - - -	5		
----- different kinds of connection and motion of, - - - - -	7		
Brachial artery, vol. III. - - - - -	28		
Brachialis internus, vol. I. - - - - -	120		
BRAIN, of the, vol. II. - - - - -	10		
-----, arteries of the, vol. III. - - - - -	10		
-----, veins of the, - - - - -	13		
-----, nerves which arise from the, { vol. II. - - - - -	16		
-----, nerves which arise from the, { vol. III. - - - - -	118		
Breast-bone, or sternum, vol. I. - - - - -	59		
Bregma, - - - - -	21		
Bronchi, vol. II. - - - - -	111		
Bronchial arteries and veins, { vol. II. - - - - -	112		
Bronchial arteries and veins, { vol. III. - - - - -	41		
----- glands, vol. II. - - - - -	111		
Buccalis arteria, vol. III. - - - - -	8		
Buccinator, vol. I. - - - - -	103		
Bulb of the urethra, vol. II. - - - - -	157		
BURSÆ MUCOSÆ, of the, vol. I. - - - - -	163		
Bursæ mucosæ of the superior extremity, - - - - -	164		
----- inferior extremity, - - - - -	166		
C.			
Cæcum intestinum, vol. II. - - - - -	128		
Cæcum, absorbents of the, vol. III. - - - - -	84		
Calamus scriptorius, vol. II. - - - - -	15		
Calcis os, vol. I. - - - - -	77		
Canals of the cochlea, vol. II. - - - - -	63		
Cancelli, - - - - -	3		
Capitatum, or magnum, os, vol. I. - - - - -	66		
Capitis rectus anterior, { major, } - - - - -	115		
-----, { minor, } - - - - -	115		
----- lateralis, - - - - -	115		
----- posticus { major, } - - - - -	118		
-----, { minor, } - - - - -	118		
CAPSULÆ RENALES, vol. II. - - - - -	152		
-----, blood-vessels of the, vol. III. - - - - -	54		
-----, lymphatics of the, - - - - -	86		
Cardia, vol. II. - - - - -	116		
Cardiac nerves, vol. III. - - - - -	124.153		
Carotid arteries, - - - - -	6		
----- artery, external, - - - - -	6		
----- internal, - - - - -	9		
Carpal bones, vol. I. - - - - -	65		
CARTILAGES, - - - - -	5		
Cartilago enfiformis, - - - - -	59		
Caruncula lacrymalis, vol. II. - - - - -	33		
Cauda equina, vol. III. - - - - -	140		
Cava vena, general course of the, } - - - - -	6		
----- superior, - - - - -	6		
----- inferior, - - - - -	6		
Cawl, vol. II. - - - - -	119		
Cellular substance, - - - - -	5		
Centralis retinae arteria, vol. III. - - - - -	9		
----- vena, - - - - -	12		
Centrum ovale of VIEUSSENS, vol. II. - - - - -	12		
----- femicirculare geminum, - - - - -	13		
Cephalic vein, vol. III. - - - - -	30		
Cerebellum, vol. II. - - - - -	15		
Cerebrum, - - - - -	11		
Cervical nerves, vol. III. - - - - -	143		
----- arteries, - - - - -	27		
----- vertebrae, vol. I. - - - - -	46		
Cervicalis descendens, - - - - -	117		
Cheek, vol. II. - - - - -	78		
Cheek-bones, vol. I. - - - - -	33		
Chest, bones of the, - - - - -	58		
Chorda tympani, { vol. II. - - - - -	65		
Chorda tympani, { vol. III. - - - - -	122		
Chorion, vol. II. - - - - -	177		
Choroid coat, - - - - -	34		
----- plexus, - - - - -	13		
CHYLOPOIETIC and ASSISTANT CHYLOPOIETIC VIS- CERA, of the, - - - - -	125		
----- blood-vessels of the, vol. III. - - - - -	47		
		Chylopoietic	

INDEX.

	<i>Pag.</i>		<i>Pag.</i>
Chylopoietic and assistant chylopoietic viscera, lacteals and lymphatics of the,	84.85	Cornua of the ventricles of the brain,	12
_____ nerves of the,	163	Coronary arteries of the lips, vol. III.	7
Cilia, vol. II.	32	_____ artery of the stomach,	47
Ciliary arteries, vol. III.	9	_____ vessels of the heart, vol. II.	109
_____ veins,	12	Corpora albicantia, vol. II.	15
_____ circle, vol. II.	34	_____ cavernosa penis,	157
_____ glands,	32	_____ fimbriata, vel tænia Hippocampi,	13
_____ processes,	35	_____ olivaria,	16
Cineritious substance of the brain,	12	_____ pyramidalia,	16
Circulus Iridis arteriosus, vol. III.	9	Corpus adiposum,	5
Circumflexa femoris arteria, { interna,	73	_____ callosum,	12
_____ humeri arteria, { externa,	74	_____ ciliare,	35
_____ { anterior,	28	_____ mucosum,	3
_____ { posterior,	28	_____ spongiosum urethræ,	157
Circumflexus palati, vol. I.	106	Corrugator supercillii, vol. I.	102
Circumvolutions of the brain, vol. II.	12	Cortical substance of the brain, vol. II.	12
_____ cerebellum,	15	Costæ, vol. I.	58
Circus arteriosus WILLISII, vol. III.	10.11	Costal nerves, vol. III.	154
Clavicle, vol. I.	62	CRANIUM, bones of the, vol. I.	8
Claviculi of bones,	3	_____ muscles of the integuments of the,	101
Clitoridis erector,	113	_____ nerves which pass through the base of	
Clitoris, vol. II.	116	_____ the, vol. III.	118
Coats of the eye,	33	Cremaster, vol. I.	111
Coccygeus, vol. I.	112	Crico-arytenoideus { lateralis,	108
Coccygis, os,	51	_____ { posticus,	107
Cochlea, vol. II.	62	Cricoid cartilage, vol. II.	98
Cœliac artery, vol. III.	47	Crico-thyroideus, vol. I.	105
Colic arteries,	48.49	Crura cerebri, vol. II.	15
_____ veins,	49	_____ cerebelli,	16
Collar bone, vol. I.	62	Crural artery, vol. III.	73
Colli interspinales,	118	_____ vein,	77
_____ intertransversales,	118	_____ nerve,	172
_____ longus,	115	Cruralis, vol. I.	127
_____ femispinalis,	117	CrySTALLINE lens, vol. II.	36
_____ transversalis,	118	Cuboides, os, vol. I.	78
Colon, vol. II.	128	Cucullaris,	127
_____, absorbents of the, vol. III.	84	Cuneiforme, os,	78
Columnæ carneæ cordis, vol. II. See HEART.		Cuneiformia, ossa,	78
_____ valvulæ VIEUSSENII,	15	Cutaneous nerve of the superior extremity, vol. III.	144
Commissura cerebri { anterior,	14	Cuticle, vol. II.	3
_____ { posterior,	14	Cutis vera,	3
_____ mollis of the optic thalami,	14	Cystic artery, vol. III.	47
Communicans faciei, nervus, vol. III.	121	_____ duct, vol. II.	142
Complexus, vol. I.	117	Cystis fellis,	142
Compressor naris,	102		
Connection of bones, different kinds of,	7	D.	
Constrictor isthmi faucium,	107	Dartos,	154
_____ pharyngis, { inferior,	107	Deltoides, vol. I.	119
_____ { medius,	107	Depressor { anguli oris,	103
_____ { superior,	107	_____ { labii inferioris,	103
Coraco-brachialis,	120	_____ { labii superioris alæque nasi,	103
Cord, umbilical, vol. II.	176	_____ oculi, vol. II.	38
Cornea,	33	Diaphragm, vol. I.	112
Cornua Ammonis,	13	_____, blood-vessels of the, vol. III.	42
		_____, nerves of the,	152.163
		Didymi,	

INDEX.

	<i>Pag.</i>		<i>Pag.</i>
Fifth pair of nerves, or par trigemium, vol. III.	119	Generation and urine, blood-vessels of the organs of,	
First pair of nerves, or olfactory,	118	vol. III.	54
Flexor accessorius digitorum pedis, vol. I.	130	, lymphatics of the organs of,	83.85
biceps cruris,	128	, muscles of the organs of,	
cubiti,	120	vol. I.	III.112
brevis digitorum pedis,	130	, nerves of the organs of, vol. III.	167
pollicis manus,	123	Genio-hyo-glossus, vol. I.	106
pedis,	131	Genio-hyoideus,	106
minimi digiti pedis,	131	Gland, lacrymal, vol. II.	33
carpi radialis,	121	parotid,	83
ulnaris,	121	pineal,	14
digitorum manus { profundus, } -	122	pituitary,	14
sublimis, }		prostate,	156
longus digitorum pedis,	130	sublingual,	84
longus pollicis manus,	123	submaxillary,	84
pedis,	131	Glands, arytenoid,	99
parvus minimi digiti manus,	124	axillary, vol. III.	87
FOETUS, peculiarities of the, vol. II.	178	bronchial, vol. II.	112
, position of the, <i>in utero</i> ,	180	conglobate, vol. III.	82
, circulation of blood in the,	180	iliac,	83
Follicles, sebaceous,	5	inguinal,	82
Foot, bones of the, vol. I.	77	of COWPER, vol. II.	158
, muscles of the,	128	of the joints, vol. I.	169
, ligaments of the,	177	mesenteric, vol. III.	84
, absorbents of the, vol. III.	82	miliary, vol. II.	5
, blood-vessels of the,	76.77	popliteal, vol. III.	82
, nerves of the,	174	renal, vol. II.	152
Fontanella,	21	salivary,	83
Formation of bone, vol. I.	5	sebaceous,	5
Fornix, vol. II.	13	tracheal,	112
Fossa, vel rima magna,	166	Glandulæ ceruminosæ,	60
navicularis,	166	concatenatæ, vol. III.	88
SYLVII,	13	Meibomianæ, vol. II.	32
Fourth pair of nerves, or pathetic, vol. III.	119	odoriferæ,	157
Frænum linguæ, vol. II.	83	Glans penis,	157
labiorum pudendi,	166	clitoridis,	167
preputii,	157	Glossopharyngeus, nervus, vol. III.	123
Frontal sinuses, { vol. I. -	18	Glottis, vol. II.	98
vol. II. -	58	, ligaments of the,	98
Frontalis, vol. I.	101	, muscles of the, vol. I.	107
Frontis, os,	18	Gluteal artery, vol. III.	71
G.		nerves,	173
Gall-bladder, vol. II.	142	Gluteus { maximus, } vol. I.	126
Ganglia, vol. III.	118	medius, }	
Ganglion femilunare magnum,	163	minimus, }	
Gastric arteries,	47.48	Gracilis,	127
veins,	49	GRAVID UTERUS, of the, vol. II.	175
juice, vol. II.	127	Great hippocampus,	13
Gastrocnemius { externus, } vol. I.	128	Great sympathetic nerve, vol. III.	124.153.172
internus, }		Gula, or gullet, vol. II.	113
Gemellus,	128	Gums,	82
Gemini,	127	Gustatorius nervus, vol. III.	121
GENERATION and URINE, ORGANS of, vol. II.	151.164	Gutturalis arteria, { superior, -	6
VOL. III.		inferior, -	27
B		Gyri of the cochlea, vol. II.	62
		Hæmorrhoidalis	

INDEX.

	Pag.		Pag.
H.			
Hæmorrhoidalis arteria, { interna, vol. III.	49	Incus, - - - - -	61
{ media, - - - - -	72	Indicator, vol. I. - - - - -	144
{ externa, - - - - -	55	INFERIOR EXTREMITY, aponeurosis of the, - - - - -	125
- vena, - - - - -	49	, bones of the, - - - - -	74
Hairs, vol. II. - - - - -	4	, blood-vessels of the, vol. III. - - - - -	71
Ham-muscle, or popliteus, vol. I. - - - - -	128	, ligaments of the, vol. I. - - - - -	175
HAND, bones of the, - - - - -	65	, lymphatics of the, vol. III. - - - - -	82
, blood-vessels of the, vol. III. - - - - -	29.30	, muscles of the, vol. I. - - - - -	125
, ligaments of the, vol. I. - - - - -	173	, nerves of the, vol. III. - - - - -	172
, lymphatics of the, vol. III. - - - - -	87	Infra-orbital artery, - - - - -	8
, muscles of the, vol. I. - - - - -	121	Infra-spinatus, vol. I. - - - - -	119
, nerves of the, vol. III. - - - - -	145.146	Infundibulum of the brain, vol. II. - - - - -	15
HEAD, bones of the, vol. I. - - - - -	8	of the cochlea, - - - - -	83
, blood-vessels of the, vol. III. - - - - -	6	of the kidneys, - - - - -	151
, ligaments of the, vol. I. - - - - -	169	Inguinal glands, vol. III. - - - - -	82
, lymphatics on the, vol. III. - - - - -	87	Innominate, os, vol. I. - - - - -	52
, muscles on the, vol. I. - - - - -	121	Integuments, common, of the, vol. II. - - - - -	3
, nerves of the, vol. III. - - - - -	118	Intercostal arteries and veins, vol. III. - - - - -	41.42
HEART, of the, vol. II. - - - - -	105	nerves, - - - - -	154
Helicis { major, } - - - - -	59	Intercostales { externi, } vol. I. - - - - -	114
{ minor, } - - - - -	59	Interossei manus, - - - - -	124
Helix, - - - - -	59	pedis, - - - - -	131
Hepatic artery, vol. III. - - - - -	47	Interosseus auricularis, - - - - -	125
veins, - - - - -	48.49	Inter-spinales et inter-transversales colli, - - - - -	118
nerves, - - - - -	163	dorsi, - - - - -	119
Hippocampus major, vol. II. - - - - -	13	lumborum, - - - - -	119
minor, - - - - -	13	INTESTINES, vol. II. - - - - -	127
Humeral artery, vol. III. - - - - -	28	, small, - - - - -	127
veins, - - - - -	30	, great, - - - - -	128
Humeri, os, vol. I. - - - - -	63	, absorbents of the, vol. III. - - - - -	84
Humours of the eye, vol. II. - - - - -	36	Iris, vol. II. - - - - -	34
Hymen, - - - - -	167	Ischiatic artery, vol. III. - - - - -	72
Hyo-glossus, vol. I. - - - - -	106	nerve, - - - - -	173
Hyooides, os, - - - - -	45	Ischio-cavernosus, vol. I. - - - - -	111
Hyo-thyroideus, - - - - -	105	Ischium, os, - - - - -	53
Hypogastric artery, vol. III. - - - - -	71	Isthmus hepatis, vol. II. - - - - -	140
vein, - - - - -	78	faucium, - - - - -	97
lymphatics, - - - - -	84	VIEUSSENII, - - - - -	107
nerves, - - - - -	164	Iter a palato ad aurem, - - - - -	25
I.			
Jaw-bone, lower, vol. I. - - - - -	39	Iter ad tertium ventriculum, - - - - -	15
, ligaments of the, - - - - -	169	quartum ventriculum, - - - - -	14
, muscles of the, - - - - -	104	Jugular vein, external, vol. III. - - - - -	13
, muscles between the, and os hyo-		, internal, - - - - -	14
oides, - - - - -	105	K.	
Jejunum, vol. II. - - - - -	128	KIDNEYS, vol. II. - - - - -	151
, lacteals of the, vol. III. - - - - -	84	, blood-vessels of the, { vol. II. - - - - -	151
Ileo-lumbalis arteria, - - - - -	71	{ vol. III. - - - - -	54
Iliac arteries and veins, - - - - -	71.73.78	, lymphatics of the, - - - - -	85
Iliacus internus, vol. I. - - - - -	113	, nerves of the, - - - - -	167
Ilium, intestinum, vol. II. - - - - -	128	Knee-joint, ligaments of the, vol. I. - - - - -	175
, os, vol. I. - - - - -	52	L.	
IMPREGNATION, changes produced in the uterine		Labia pudendi, vol. II. - - - - -	166
system by, vol. II. - - - - -	175	Labial	

INDEX.

	Pag.		Pag.
Labial arteries, vol. III.	7	Ligaments of the inferior extremity,	175
Labyrinth of the ear, vol. II.	62	connecting the os femoris with the os	
Lacrimal artery, vol. III.	9	innominatum,	175
gland, vol. II.	33	of the joint of the knee,	175
nerve, vol. III.	120	connecting the fibula to the tibia,	176
Lacrymalia, vel unguis, ossa, vol. I.	33	connecting the bones of the tarsus with	
LACTEALS, vol. III.	84	those of the leg,	176
Lactiferous ducts, vol. II.	103	of the tarsus,	177
Lamellæ of bones,	3	between the bones of the tarsus and those	
Lamina spiralis,	62	of the metatarsus,	177
LARYNX,	97	connecting the metatarsal bones to each	
Laryngea, arteria, vol. III.	6.27	other,	177
Laryngeus, nervus,	123	of the phalanges of the toes,	177
Latissimus dorsi, vol. I.	115	and sheaths retaining the tendons of the	
Laxator tympani, vol. II.	62	muscles of the foot <i>in situ</i> ,	177
LEG, bones of the, vol. I.	75	of the liver, vol. II.	140
Levator anguli oris,	103	Ligamentum suspensorium penis,	157
ani,	111.112	Lingualis, vol. I.	106
labii inferioris,	103	Lingual artery, vol. III.	6
superioris alæque nasi,	103	vein,	12
menti,	103	nerve,	123
oculi, vol. II.	38	Lips, vol. II.	82
palati, vol. I.	106	Liquor amnii,	178
palpebræ superioris,	102	pericardii,	105
scapulæ,	117	LIVER,	140
Ligamenta { lata, } uteri, vol. II.	164.165	blood-vessels of the, vol. III.	47.49
rotunda, }		lymphatics of the,	85
LIGAMENTS, of the, vol. I.	168	nerves of the,	163
of the lower jaw,	169	Lobes of the brain, vol. II.	12
connecting the head with the first and		of the liver,	140
second vertebra of the neck, and		of the lungs,	110
these vertebræ to each other,	169	Locus niger crurum cerebri,	10
of the other vertebræ,	169	Longus colli, vol. I.	115
of the ribs,	170	Longissimus dorsi,	116
of the bones of the pelvis,	171	Lumbar arteries, vol. III.	72
of the superior extremity,	172	glands,	84
of the clavicle,	172	nerves,	172
proper to the scapula,	172	plexus of nerves,	172
of the joint of the shoulder,	172	vertebræ, vol. I.	47
of the joint of the elbow,	173	Lumbricales manus,	122
between the bodies, and between the		pedis,	130
under ends of the radius and ulna,	173	Lunare, os,	66
between the fore-arm and wrist,	173	LUNGS, vol. II.	110
of the carpus,	172	blood-vessels of the, { vol. II.	112
between the carpal and metacarpal		vol. III.	41.42
bones,	172	lymphatics of the,	86
between the extremities of the meta-		nerves of the,	152
carpal bones,	174	LYMPHATICS,	81
at the base of the metacarpal bone of		Lyra fornicis, vol. II.	13
the thumb, and at the first joint of			
the fingers,	174		
of the first and second joints of the			
thumb, and second and third joints			
of the fingers,	174		
retaining the tendons of the muscles of			
the hand and fingers <i>in situ</i> ,	174		

M.

Magna pollicis arteria, vol. III.	29
Magnum, vel capitatum, os, vol. I.	66
Malarum, ossa,	33
Malleolus	

INDEX.

	<i>Pag.</i>		<i>Pag.</i>
Malleolus { externus, - - - - -	56	MUSCLES in general, of the, - - - - -	101
{ internus, - - - - -	75	Musculo-cutaneous nerve of the superior extremity,	144
Malleus, vol. II. - - - - -	61	vol. III. - - - - -	105
MAMMÆ, - - - - -	103	Mylo-hyoideus, vol. I. - - - - -	105
Mammary arteries, vol. III. - - - - -	27.41		
veins, - - - - -	30.41	N.	
nerves, vol. II. - - - - -	144.154	NAILS, vol. II. - - - - -	4
MARROW, vol. I. - - - - -	5	Naris compressor, vol. I. - - - - -	102
Marfupialis, - - - - -	127	Nafalis labii superioris, - - - - -	104
Massa carnea <i>Jacobi Sylvii</i> , - - - - -	130	Nafi alæ depressor, - - - - -	103
Maffeter, - - - - -	104	levator, - - - - -	103
Maffeteric arteries, vol. III. - - - - -	8	offa, - - - - -	33
Mater, { dura, vol. II. - - - - -	10	Nates cerebri, vol. II. - - - - -	24
{ pia, - - - - -	11	Naviculare, os, vol. I. - - - - -	77
MATRIX, - - - - -	164	NECK, blood-vessels of the, vol. III. - - - - -	6.27
Maxilla inferior, vol. I. - - - - -	39	, lymphatics of the, - - - - -	88
Maxillaria superiora, offa, - - - - -	34	, muscles on the fore and lateral part of the,	
Maxillary artery, external, vol. III. - - - - -	7	vol. I. - - - - -	104.115
, internal, - - - - -	7	, nerves of the, vol. III. - - - - -	143
vein, - - - - -	12	, vertebræ of the, vol. I. - - - - -	46
nerves, - - - - -	120	NERVES, of the, vol. III. - - - - -	118
Meatus auditorius externus, { vol. I. - - - - -	25	, cerebral, - - - - -	118
{ vol. II. - - - - -	59	, fpinal, - - - - -	139
internus, { vol. I. - - - - -	26	Ninth pair of nerves, - - - - -	123
{ vol. II. - - - - -	63	Nipple, vol. II. - - - - -	103
Median vein, vol. III. - - - - -	30	Noni descendens, nervus, vol. III. - - - - -	124
nerve, - - - - -	145	Nose, of the, vol. II. - - - - -	57
MEDIASTINUM, vol. II. - - - - -	105	, bones of the, { vol. I. - - - - -	33
Medulla oblongata, - - - - -	16	{ vol. II. - - - - -	57
fpinalis, vol. III. - - - - -	139	, blood-vessels of the, vol. II. - - - - -	58
Medullary substance of the brain, vol. II. - - - - -	12	, lymphatics of the, vol. III. - - - - -	88
<i>Meibomian</i> glands, - - - - -	32	, muscles of the, vol. I. - - - - -	102
MEMBRANA CELLULARIS, - - - - -	5	, nerves of the, vol. II. - - - - -	58
medullaris, vol. I. - - - - -	4	Nymphæ, vol. II. - - - - -	167
pupillaris, vol. II. - - - - -	34.178		
Schneideriana, - - - - -	57	O.	
tympani, - - - - -	60	Obliquus ascendens internus, vol. I. - - - - -	109
secundarii, - - - - -	63	capitis { inferior, - - - - -	118
Meningeal artery, vol. III. - - - - -	7	{ superior, - - - - -	118
Mefenteric blood-vessels, - - - - -	48	descendens abdominis, - - - - -	108
glands, - - - - -	84	oculi { inferior, } vol. II. - - - - -	39
nerves, - - - - -	163	{ superior, } - - - - -	
MESENTERY, vol. II. - - - - -	129	Obturator artery, vol. III. - - - - -	72
Mefo-colon, - - - - -	129	externus, vol. I. - - - - -	126
Mefo-rectum, - - - - -	129	internus, - - - - -	127
Metacarpal bones, vol. I. - - - - -	67	nerve, vol. III. - - - - -	172
Metacarpeus, - - - - -	124	Occipital artery, - - - - -	7
Metatarfal bones, - - - - -	78	vein, - - - - -	12
artery, vol. III. - - - - -	76	nerve, - - - - -	172
Miliary glands, vol. II. - - - - -	5	Occipitis, os, vol. I. - - - - -	22
Modiolus, - - - - -	63	Occipito-frontalis, - - - - -	101
Motion of bones, different kinds of, vol. I. - - - - -	7	Œsophageal arteries and veins, vol. III. - - - - -	41.42
Motores oculorum, or third pair of nerves, vol. III. - - - - -	119	nerves, - - - - -	152.153
MOUTH, of the, vol. II. - - - - -	78	ŒSOPHAGUS, vol. II. - - - - -	113
, muscles of the, vol. I. - - - - -	102	Olfactory,	
Multifidus spinæ, - - - - -	117		

INDEX.

	Pag.		Pag.
Olfactory, or first pair of nerves, vol. III.	118	Parvæ vasa of the eighth pair of nerves, vol. III.	123.152.163
OMENTUM, vol. II.	129	Patella, vol. I.	76
— minus,	130	Pathetic, or fourth pair of nerves, vol. III.	119
Omo-hyoideus, vol. I.	105	Patientiæ musculus, vol. I.	117
Ophthalmic artery, vol. III.	9	Pectinalis,	125
— vein,	12	Pectoralis { major,	113
— nerves,	120	{ minor,	114
Opponens pollicis, vol. I.	123	Pedes hippocampi, vol. II.	13
Optici, or second pair of nerves, { vol. II.	35	Pedis, interossei, vol. I.	131
{ vol. III.	119	Pedunculi { cerebri, } vol. II.	15.16
Orbiculare, os, vol. II.	61	{ cerebelli, }	
Orbicularis oculi, vol. I.	102	PELVIS, blood-vessels of the, vol. III.	71
— oris,	103	—, bones of the, vol. I.	52
— palpebrarum,	102	—, ligaments of the bones of the,	171
Orbits, vol. II.	32	—, lymphatics of the, vol. III.	83
Organs of the senses,	3	—, muscles of the, vol. I.	125
Organs of urine and generation in the male,	151	—, nerves of the, vol. III.	172
— in the female,	164	PENIS, vol. II.	157
—, lymphatics of the,		—, blood-vessels of the, { vol. II.	158
vol. III.	83	{ vol. III.	55.56
—, blood-vessels of the,	54	—, muscles of the, vol. I.	111
—, nerves of the,	167	—, ligamentum suspensorium of the, vol. II.	157
Oris anguli, { depressor, } vol. I.	103	—, lymphatics of the, { vol. II.	159
{ levator, }		{ vol. III.	83
Os tinæ, vol. II.	165	—, nerves of the, { vol. II.	159
Ova,	165	{ vol. III.	167
Ovaria,	165	Perforans, vol. I.	122
P.		Perforatus,	122
Palate,	82	PERICARDIUM, vol. II.	105
—, arches of the,	97	Perichondrium,	5
Palati { circumflexus, } vol. I.	106	Perinei transversus, vol. I.	111.112
{ levator, }		Perineum, vol. II.	167
—, ossa,	35	Periosteum, vol. I.	4
Palatina inferior arteria, vol. III.	7	Peritoneum, vol. II.	125
Palato-maxillary nerve,	121	Peroneal artery, vol. III.	76
Palato-pharyngeus, vol. I.	107	— nerve,	174
Palmaris arteria profunda, vol. III.	29	Peroneus brevis, vol. I.	129
— arcus arteriosus profundus,	29	— longus,	129
— superficialis,	30	— tertius,	130
— nervus,	145.146	Pharyngeal artery, vol. III.	7
— musculus { longus, } vol. I.	121	— nerve,	123
{ brevis, }		PHARYNX, vol. II.	97
Palpebræ, vol. II.	32	—, muscles on the back part of the, vol. I.	107
Palpebræ superioris levator, vol. I.	102	Phrenic arteries and veins, vol. III.	42
Palpebrarum orbicularis,	102	— nerve,	152
PANCREAS, vol. II.	144	Pia mater, vol. II.	11
Panniculus carnosus,	5	Pigmentum nigrum,	35
Pap of the throat,	82	Pineal gland,	14
Papilla, or nipple,	103	Pinguedo,	5
Papillæ of the tongue,	83	Pisiforme, os, vol. I.	66
Par trigeminum, or fifth pair of nerves, vol. III.	119	Placenta, vol. II.	177
Parietalia ossa, vol. I.	21	Plantar artery and arch, vol. III.	76.77
Parotid { duct, } vol. II.	84	Plantaris, vol. I.	129
{ gland, }		Plates of bones,	3
VOL. III.		Platysma myoides,	104
	G	PLEURA,	

INDEX.

	<i>Pag.</i>			<i>Pag.</i>
PLEURA, vol. II.	104		R.	
Pomum Adami,	97			
Pons { TARINI, } { VAROLII, }	16			
Popliteal artery, vol. III.	74	Radial artery, vol. III.		29
glands,	83	nerve,		145
vein,	77	Radialis externus { brevior, vol. I. } { longior, } internus,		122 121 121
Popliteus, vol. I.	128	Radius,		64
Portæ, vena, vol. III.	49	Ranina, arteria, vol. III.		6
Portio mollis of the seventh pair of nerves, vol. II.	64	, vena,		12
dura of the seventh pair of nerves, vol. III.	121	Receptaculum chyli, { vol. II. } { vol. III. }		113 86
Posterior, or adductor { indicis, } { medii digiti } { tertii digiti } pedis, vol. I.	132	Rectum, vol. II.		129
annularis,	125	, lymphatics of the,		84
auris,	102	Rectus abdominis, vol. I.		110
{ indicis } { medii digiti } manus,	125	capitis anterior { major, } { minor, }		115
Prepuce of the penis, vol. II.	157	lateralis,		115
of the clitoris,	167	posticus major,		118
Prior { annularis } { indicis } manus, vol. I.	124	minor,		118
medii digiti manus,	125	femoris,		127
, or abductor indicis pedis,	132	Recurrent nerve of the eighth pair, vol. III.		152
, or { abductor medii digiti } { tertii digiti } { adductor minimi digiti } pedis,	131	Recurrent radial artery,		29
Profunda femoris arteria, vol. III.	73	ulnar artery,		29
vena,	77	Renal artery and vein,		54
penis arteria,	55	glands, vol. II.		152
Pronator radii { quadratus, } { teres, } vol. I.	123	nerves, vol. III.		167
Prostate gland, vol. II.	156	Retina, vol. II.		35
Pfalterium fornicis,	13	Retractor anguli oris, vol. I.		103
Psoas { magnus, } { parvus, } vol. I.	113	Retrahentes aurem,		102
Pterygoideæ arteriæ, vol. III.	8	Rhomboideus,		116
Pterygoideus { externus, } { internus, } vol. I.	104	Ribs,		59
Pubis, os,	53	Rotula,		76
Pudendum, vol. II.	166			
Pudic artery, vol. III.	55		S.	
vein,	56	Sacral artery, vol. III.		71
nerves,	167	lateral arteries,		71
Pulmonary artery and veins,	5	nerves,		173
Puncta lacrymalia, vol. II.	33	Sacro-lumbalis, vol. I.		116
Pupil of the eye,	34	Sacrum, os,		51
Pylorus,	126	Salivary glands, vol. II.		83
Pyramidalis, vol. I.	110	Salpingo-pharyngeus, vol. I.		107
Pyriformis,	126	Saphenæ, -venæ, vol. III.		77
		Saphenus, nervus,		173
		Sartorius, vol. I.		127
		Scala { tympani, } { vestibuli, } vol. II.		63
		Scalenus anticus,		
		medius, } posticus, } vol. I.		118
		Scaphoides, os,		65
		Scapula,		62
		Scapulæ levator,		117
		Scapular arteries, vol. III.		27.28
		nerve,		144
				Sciatic

Sciatic

INDEX.

	<i>Pag.</i>		<i>Pag.</i>
Tarsus of the eye-lids, vol. II.	32	Tragicus,	59
TEETH, { vol. I.	40	Tragus,	59
{ vol. II.	85	Transversalis abdominis, vol. I.	110
Tela choroidea,	13	" colli,	118
Temporal artery, vol. III.	8	" pedis,	131
vein,	11	" urethrae,	111.112
Temporalis, vol. I.	104	Transverso-spinalis { colli, } { dorsi, }	117
Temporum, ossa,	25	Transversus auris, vol. II.	59
Tensor tympani, vol. II.	62	" perinei, vol. I.	111.112
vaginae femoris, vol. I.	127	Trapezium, os,	66
palati,	106	Trapezius,	115
Tentorium cerebelli, vol. II.	10	Trapezoides, os,	66
Teres { major, } vol. I.	119	Triangulari, ossa,	35
{ minor, }	154	Triangularis oris,	103
TESTES, vol. II.	54	" sterni,	115
blood-vessels of the, vol. III.	83	Triceps adductor femoris,	125
lymphatics of the,	167.172	" extensor cubiti,	121
nerves of the,	14	Tricuspid valve, vol. II.	107
cerebri, vol. II.	13	Trochlearis,	39
Thalami nervorum opticorum,	74	TRUNK, bones of the, vol. I.	45
Thigh-bone, vol. I.	119	" muscles situated on the posterior part of	114
Third pair of nerves, or motores oculorum, vol. III.	113	" the,	16
THORACIC DUCT, { vol. II.	86	Tuber annulare, vol. II.	14
{ vol. III.	103	Tubercula quadrigemina,	106
THORAX, of the, vol. II.	41	Tuberculum LOWERI;	61
blood-vessels within the, vol. III.	58	Tube, <i>Eustachian</i> ,	165
bones of the, vol. I.	113	" <i>Fallopian</i> ,	33
muscles situated upon the anterior part of	152	Tunica adnata,	154
the,	97	" albuginea,	11
nerves within the, vol. III.	108	" arachnoidea,	37
THROAT, of the, vol. II.	108	" aranea, or vitrea,	34
Thyro-arytenoideus, vol. I.	105	" choroides,	34
Thyro-epiglottideus,	97	" sclerotica,	154
Thyro-hyoideus,	112	" vaginalis,	35
Thyroid cartilage, vol. II.	6	Turbinata inferiora, ossa, vol. I.	122
gland,	27	Tympani chorda, vol. II.	62
Thyroidea, arteria, superior, vol. III.	75	" laxator,	60
" inferior,	75.76	" membrana,	60
Tibia, vol. I.	77	Tympanum,	60
Tibial arteries, vol. III.	174		V.
veins,	129	Vagina,	165
nerve,	129	Vaginae sphincter, vol. I.	112
Tibialis anticus, vol. I.	12	Vaginal artery, vol. III.	55
posticus,	78	Valves of the absorbents,	81
Tomentum cerebri, vol. II.	6	" of the veins,	5
TONGUE, of the,	88	" of the heart and arteries, vol. II.— <i>See Heart.</i>	
artery of the, vol. III.	106	Valvula coli,	
lymphatics of the,	121.123	" femi-circularis oculi,	33
muscles of the, vol. I.	97	Vasa brevia, vol. III.	48
nerves of the, vol. II.	11	" efferentia testis, vol. II.	156
Tonfils,	13	" of the absorbents, vol. III.	82
Torcular HEROPHILI, { vol. II.	111	" inferentia of the absorbents,	82
{ vol. III.	117	" lactea primi et secundi generis,	84
Trachea, vol. II.	13		Vasa
Trachelo-mastoideus, vol. I.			
Tractus optici, vol. II.			

INDEX.

	<i>Pag.</i>		<i>Pag.</i>
Vasa vaforum, - - -	3	Ulna, vol. I. - - -	64
Vastus { externus, vol. I. - - -	127	Ulnar artery, vol. III. - - -	29
{ internus, - - -	128	----- nerve, - - -	146
VEINS, of the, vol. III. - - -	4	Ulnaris { externus, vol. I. - - -	122
Velum <i>Vieussenii</i> , vol. II. - - -	15	{ internus, - - -	121
VENA CAVA, general course of the, } vol. III. - - -	5	Umbilical cord, vol. II. - - -	176
-----, superior, - - -		----- artery, vol. III. - - -	55
-----, inferior, - - -		Unciforme, os, vol. I. - - -	66
Vena magna ipsius penis, { vol. II. - - -	158	Unguis, ossa, - - -	33
{ vol. III. - - -	56	Voice, vol. II. - - -	99
----- portæ, - - -	49	Volar arches, vol. III. - - -	29.30
Ventricles of the brain, vol. II. - - -	12	Vomer, vol. I. - - -	36
----- of the heart, - - -	107.108	Vorticose veins, vol. III. - - -	12
----- of the larynx, - - -	99	Ureters, vol. II. - - -	164
Vermiform appendix of the cæcum, - - -	128	Urethra, - - -	158.164
----- appendages of the cerebellum, - - -	15	Urethræ transversalis, vol. I. - - -	III
Vertebræ, true, vol. I. - - -	45	Urinæ accelerator, - - -	III
-----, false, - - -	51	UTERUS, of the, vol. II. - - -	164
Vertebral arteries, vol. III. - - -	10	-----, appendages of the, - - -	164
Vesica urinaria, vol. II. - - -	153	-----, gravid, of the, - - -	175
Vesicalis ima, arteria, vol. III. - - -	72	Uvula, - - -	82
Vesicula fellis, vol. II. - - -	142	Uvulæ, azygos, vol. I. - - -	106
Vesiculæ feminales, - - -	156	Z.	
Vestible of the labyrinth, - - -	62	Zonula ciliaris, vol. II. - - -	38
----- of the pudendum, - - -	167	Zygomaticus { major, } vol. I. - - -	103
VISCERA, of the, - - -	3	{ minor, }	
Vitreous humour, - - -	37		



EDINBURGH:
 PRINTED BY J. PILLANS & SONS,
 LAWNMARKET.

Year	Month	Day	Particulars	Debit	Credit	Balance
1843	Jan	1	To Balance			100.00
			By Cash		50.00	150.00
			To Cash	50.00		100.00
			By Cash		25.00	125.00
			To Cash	25.00		100.00
			By Cash		10.00	110.00
			To Cash	10.00		100.00
			By Cash		5.00	105.00
			To Cash	5.00		100.00
			By Cash		2.50	102.50
			To Cash	2.50		100.00
			By Cash		1.25	101.25
			To Cash	1.25		100.00
			By Cash		0.62	100.62
			To Cash	0.62		100.00
			By Cash		0.31	100.31
			To Cash	0.31		100.00
			By Cash		0.15	100.15
			To Cash	0.15		100.00
			By Cash		0.07	100.07
			To Cash	0.07		100.00
			By Cash		0.03	100.03
			To Cash	0.03		100.00
			By Cash		0.01	100.01
			To Cash	0.01		100.00
			By Cash		0.00	100.00



1843

