

Kelly (H. A.)

CANCER OF THE CERVIX UTERI IN THE NEGRESS;

WITH PYO-PHYSOMETRA.

BY

HOWARD A. KELLY, M.D.,

PROFESSOR OF GYNECOLOGY IN THE JOHNS HOPKINS UNIVERSITY; GYNECOLOGIST AND  
OBSTETRICIAN TO THE JOHNS HOPKINS HOSPITAL.

---

441

REPRINTED FROM THE TRANSACTIONS  
OF THE SOUTHERN SURGICAL AND GYNECOLOGICAL ASSOCIATION,  
NOVEMBER, 1890.



# CANCER OF THE CERVIX UTERI IN THE NEGRESS;

WITH PYO-PHYSOMETRA.

BY

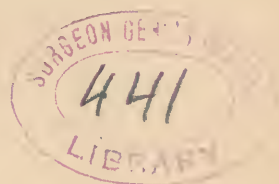
HOWARD A. KELLY, M.D.,

PROFESSOR OF GYNECOLOGY IN THE JOHNS HOPKINS UNIVERSITY; GYNECOLOGIST AND  
OBSTETRICIAN TO THE JOHNS HOPKINS HOSPITAL.

---

REPRINTED FROM THE TRANSACTIONS  
OF THE SOUTHERN SURGICAL AND GYNECOLOGICAL ASSOCIATION,  
NOVEMBER, 1890.

---



PHILADELPHIA:  
WM. J. DORNAN, PRINTER.  
1891.



CANCER OF THE CERVIX UTERI IN THE  
NEGRESS.

PHYSOMETRA IN THE NEGRESS, DUE TO CANCER; MANIA  
FOLLOWING OPERATION; RECOVERY.

BY HOWARD A. KELLY, M.D.,  
*Baltimore, Md.*

---

It is the prevailing opinion among surgeons who have had a wide experience with diseases of the negro race, that cancerous affections are extremely rare. Attention has oftentimes been drawn to this point, and Dr. Tiffany, of Baltimore, has carefully investigated the grounds for such conviction, and, speaking as well from his own wide personal experience, sustains the prevailing impression that cancer in the negro is rare.

If there were not good grounds for this statement it is certain, also, that many of the brilliant clinicians throughout the Southern United States, who are consulted by thousands of negroes yearly in dispensaries and hospitals, would long since have come forward with abundant proofs refuting an assertion so often made.

If we are warranted from these short premises in drawing so broad a conclusion, here is clearly to be found one of those broad racial distinctions between black and white, similar to that which furnishes the black with the immunity from the malarial germ, and that which renders the Indian race more susceptible than the Caucasian to the smallpox germ—traits in some mysterious way transmitted from generation to generation, from adult to embryo. Valuable material for the investigation of this important question is also afforded by the

frequent miscegenation, yielding all grades of color from white, through yellow and brown, to black.

Up to the present time I am not aware that any case of cancer of the uterus in the negress has ever been reported.<sup>1</sup>

My recent observations among the colored population of Baltimore, have, however, tended to shake my conviction as to the extreme rarity of cancer, inasmuch as six cases have presented themselves for treatment at my clinic at the Johns Hopkins Hospital.

Two of these cases were reported by Dr. J. W. Williams, gynecological assistant, in the first gynecological fasciculus of the Johns Hopkins Hospital, Art. XI., p. 96, while two others form the material for this paper.

The first woman was of a brown color, but stated that she was the only child not of a pure black color in a large family, in which she was sure there was no admixture of white blood.

The second patient stated that her maternal grandmother was said to have had some white blood in her.

CASE I. *Epithelioma of the cervix, vaginal wall, and broad ligament; curetting and cauterization. Discharged improved.*—S. V. J., æt. thirty-four, married fifteen years, V.-para, eldest fifteen years, youngest eight years old. She has had four or five miscarriages at about two months—the most recent, five years ago.

She states positively that there is no mixed blood in her family. She is of a dark brown-black color, looking lighter from pallor due to her long-continued illness. Her miscarriages were brought on by pushing the nozzle of a syringe into the cervix and injecting hot water within the uterus. She continued this practice at times for three days before succeeding in inducing the abortion. She did not go to bed while miscarrying, as she wished to conceal the fact from her husband. The type of her early menstruation was a free flow for three days with considerable pain; lately there has been no pain. Leucorrhœa she has had ever since the birth of the first child.

<sup>1</sup> Since writing this a case has been reported in the Boston Medical and Surgical Journal.

The bowels are regular. Urination is frequent and painful. Two years ago she felt unusual pains in the lower abdomen, which have been much worse since the summer of 1889. The distress was at times like "a gathering" in the lower part of the abdomen. Latterly there has been a fetid yellow discharge from the vagina. A doctor told her that there was "a sore on the womb," which he treated with applications.

There has been a bloody flow about twice monthly for many months past. In April, 1890, she had a hemorrhage from the vagina, passing large clots, confining her to bed for three weeks.

A vaginal examination reveals the cervix, lower part of the corpus uteri, broad ligaments, and anterior and posterior vaginal walls, involved in a large, rough, nodular, not exuberant cancerous mass; a microscopic examination of some scrapings confirms the diagnosis of epithelioma.

On June 24, 1890, Dr. Robb, resident gynecologist, operated under chloroform narcosis, curetting the vaginal and cervical surfaces down to a hard resisting base, following this by thoroughly cauterizing the freshened surfaces with a Paquelin cautery.

The hemorrhage, profuse at first, ceased upon cauterization. The vagina was thoroughly douched out with a mercuric bichloride solution (1 to 2000) both before and after operation, and finally packed with iodoform gauze, which was renewed every day until her departure. She reacted well from the operation, leaving the hospital a week later rapidly improving.

CASE II. *Cancer of the cervix complicated by physometra; operation; recovery.*—H. C., widow, æt. sixty-one, sent to the hospital by Dr. Cheston, of West River, Md., July 10, 1890. All her family were pure-blooded negroes, with the exception of her maternal great-grandmother, who was said to have some white blood in her.

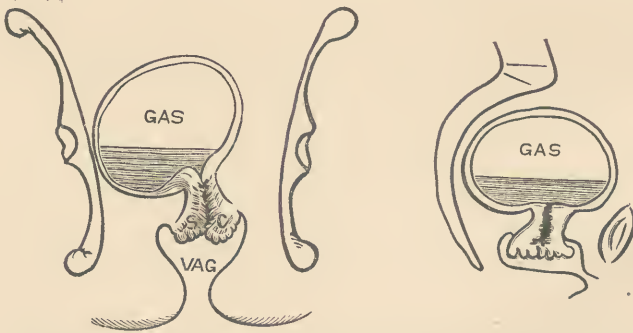
*History.*—She ceased to menstruate more than ten years ago. She has had seven children, all born before the war, 1861. She has had no miscarriages. Two years ago she began to have hemorrhages from the vagina, which ceased for some months, but since Christmas, 1889, she has had some very severe hemorrhages, sometimes lasting a week. There has been no leucorrhœa. There is no urinary trouble. Her bowels are very costive. Her appetite is very good. She has several times been insane.

She complains of a frequent bleeding from the vagina, followed by a watery flow, which continues for one or two days, at times thin, at other times thick and sticky. She occasionally has a burning feeling in the small of the back, extending down the right side and across the abdomen, often very severe. She also suffers from dizziness. Examination and operation by the writer, July 14, 1890. Chloroform, followed by ether narcosis.

*Examination per vaginam:* Cervix high up, fixed against the left pelvic wall. On the right side, continuous with the cervix, is a globular fluctuant mass about ten centimetres in diameter. The cervix is the seat of cancerous degeneration, occupying an area about three centimetres in diameter. Numerous shreds of broken down tissue hang into the vaginal vault, and between them are excavated areas which bleed freely on touch.

*Operation.*—About twelve cubic centimetres of cancerous tissue scraped out with the fingers, followed by a sharp curette, and the base thoroughly cauterized. The growth appeared to be limited to the cervix, and to be very superficial in its extent.

Upon making a bimanual examination to determine the position of the corpus uteri, the vaginal finger suddenly penetrated



Epithelioma in the negress with pyo-physometra. Coronal and sagittal sections.

a large smooth cavity; this was immediately followed by a loud explosion of fetid gas, with a discharge of three fluidounces of thick, grumous, intensely fetid fluid. The sac thus opened proved to be a pyo-physometra—the body of the uterus being distended to the size of a four months' pregnancy with gas and pus. The



walls were thin and peculiarly smooth, and collapsed without contractile efforts. The retention was due to the obliteration of the cervical canal by the cancerous process infiltrating the cervical walls, choking the canal, discharging a part of its secretions upward as well as down into the vagina, thus causing the collection of fluid contents with its gases of decomposition.

After the operation the flabby uterus was douched out with a weak bichloride solution, and the vagina was packed with iodoform gauze.

The patient reacted well from the operation, and had no drawback until July 17th, when, in reply to the question, "How do you feel?" she answered by asking about each member of the doctor's family. Her temperature, which had been about 99°, rose that evening to 101°, and for the next four days rose from 98.5°, or 99° in the morning, to 100° in the evening. The pulse varied from 100 to 120. The dressings were changed every other day and the wound remained aseptic throughout, with very little bloody discharge. The iodoform gauze in the pack was changed to simple aseptic gauze as soon as she exhibited a disturbed mental condition. She apparently secreted a normal quantity of urine, although it could not be measured. On the night of the 18th she was very delirious, and on the 21st had to be tied in bed. She left the hospital on the 26th to return home, quiet and more rational. At no time was there any evidence of any septic or toxic disturbance outside of her mental state.

[NOTE—April, 1891 : She recovered perfectly at home, and has since remained well.]





