

COLUMBIA LIBRARIES OFFSITE
HEALTH SCIENCES STANDARD

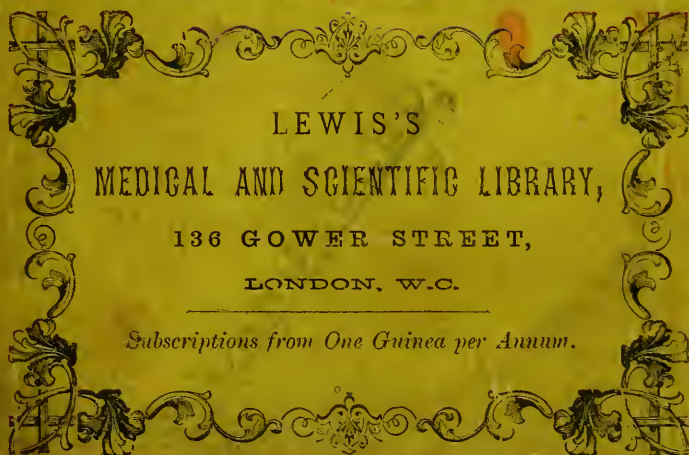


HX64084760

QM416 .L81

Hunterian lectures o

RECAP



LEWIS'S
MEDICAL AND SCIENTIFIC LIBRARY,
136 GOWER STREET,
LONDON, W.C.

Subscriptions from One Guinea per Annum.

QM416
187
L81



COLUMBIA UNIVERSITY
EDWARD G. JANEWAY
MEMORIAL LIBRARY

10/6

HUNTERIAN LECTURES

ON THE

DEVELOPMENT AND TRANSITION OF THE TESTIS.

HUNTERIAN LECTURES

ON THE

DEVELOPMENT & TRANSITION OF THE TESTIS

NORMAL AND ABNORMAL

BY

CHARLES BARRETT LOCKWOOD, F.R.C.S.,

SURGEON TO THE GREAT NORTHERN CENTRAL HOSPITAL; DEMONSTRATOR OF ANATOMY AND OPERATIVE SURGERY IN ST BARTHOLOMEW'S HOSPITAL; HUNTERIAN PROFESSOR OF ANATOMY, ROYAL COLLEGE OF SURGEONS OF ENGLAND; SECRETARY (in England) OF THE ANATOMICAL SOCIETY OF GREAT BRITAIN AND IRELAND, &c. &c.

WILLIAMS & NORGATE,
14 HENRIETTA STREET, COVENT GARDEN, LONDON;
AND 20 SOUTH FREDERICK STREET, EDINBURGH.

1888.

Price Five Shillings.

Jane way
48-825-10131 c

QM41G
L81

SEP 21 1948 576

PREFACE.


THIS book is a reprint of Lectures which have already appeared in the *Journal of Anatomy and Physiology*, and which, as Hunterian Professor, I had the honour to deliver in March 1887 at the Royal College of Surgeons of England. No alteration has been made in them, except that a few clerical errors have been corrected. I have to tender my thanks to the Editors of the *Journal of Anatomy and Physiology* for their liberality in publishing and illustrating these investigations.

C. B. LOCKWOOD.

19 UPPER BERKELEY STREET,
PORTMAN SQUARE,
July 1888.

AP-1031C January

Low 9/15/48



Digitized by the Internet Archive
in 2010 with funding from
Columbia University Libraries

CONTENTS.

LECTURE I.

Method of Investigation, 1—Wolffian Body in Human Embryos, 1—Wolffian Duct of Chick, 5—Epiblastic Origin of Wolffian Duct, 8—Prolongation of Body Cavity into Somite in Rabbit, 11—Wolffian Tubules, 15—The Pronephros, 21.

LECTURE II.

Glomeruli of Wolffian Body, 29—Parenchyma of Wolffian Body, 36—Development of the Body of the Testis, 37—Permanent Kidneys, 45—Human Genital Mass, 48—Fusion of Wolffian Bodies—Synorchis, 49—Mesorchium and Mesovarium, 51—Development of Tubuli Seminiferi, 53.

LECTURE III.

Oviducts, 67—Genital Cord, 69—Transition of Ovary or Testis, 70—Earliest Relations of the Reproductive and Urinary Organs of the Rabbit to each other and to the Skeleton, 71—Earliest Relations of the Human Reproductive Glands and Urinary Organs to each other and to the Skeleton, 74—Relation of the Mesonephros to the Suprarenal Bodies, 76—The Development of the Scrotum and Inguinal Canal, including the Ascending and Descending Cremaster, 85—Processus Vaginalis, 93—The Transition of Sub-peritoneal Fat and Lipoma of the Spermatic Cord, 96—The Gubernaculum Testis, 96—The Cremaster, 107—The Superior Attachments of the Gubernaculum, the Mesorchium, and Plica Vascularis, 109—Relation of the Vas Deferens and Spermatic Vessels to Processus Vaginalis. The Recurrent Branches of the Spermatic Artery, 116—The Closure of the Processus Vaginalis, 118.

THE DEVELOPMENT AND TRANSITION OF THE TESTIS, NORMAL AND ABNORMAL.¹

LECTURE I.

Method of Investigation.

SINCE our ultimate aim is to elucidate human anatomy and pathology, it would seem an ideal plan to trace the development of the testicles and their appendages in the human embryo; but unfortunately this is not entirely possible. A sufficient supply of such material is hard to obtain, and that which is procurable is seldom quite fresh and undamaged. The kindness of numerous friends has, however, enabled me to investigate many interesting points in human embryos, but not the very earliest, as these can only be traced in the lower animals. Before attempting this branch of the inquiry it may be best to glance for a moment at the end which is achieved, and afterwards inquire how it has been accomplished. The fact that the body of the testis and the epididymis have different origins is too well known to call for comment. The epididymis arises from a part of the Wolffian body, the testis from a separate group of cells. The Wolffian body has a prior claim upon our attention, for it has attained a certain degree of perfection before the rudiments of the body of the testis have appeared.

Wolffian Body in Human Embryos.

The smallest human embryo in which I have examined the Wolffian body was seven thirty-seconds of an inch long²—about the size of a small house fly. It is hard to estimate the age of such an embryo as this, but it looks exactly like one which His

¹ This paper consists of three lectures delivered to the Royal College of Surgeons of England in February 1887.

² I am indebted to Mr D'Arcy Power for this embryo.

considers to have been twenty-three days old.¹ The most palpable of its external characteristics were a considerable flexure of the body and neck, an absence of limbs, and the presence of a very obvious tail. Longitudinal sections show that the body is divided into two compartments—a superior, containing the heart; and an inferior, containing the liver, lungs, alimentary canal, and Wolffian bodies.

A glance at the accompanying figure (fig. 1) shows that, owing to the absence of the diaphragm, there is no separate pleural sac, but that the lungs lie in the upper part of a pleuro-peritoneal cavity. The large size and the appearance of its glomeruli render the Wolffian body a conspicuous object. Occupying nearly all the back part of the pleuro-peritoneal cavity, it reaches nearly as far forwards as the heart and pericardium. Its front extremity is tapering and situated behind the lungs, whilst the posterior is larger and extends towards the hinder end of the pleuro-peritoneal cavity.

This brief description can hardly convey an adequate idea of the enormous proportionate size of this part of the embryonic excretory system. Perhaps it would not be incorrect to say that at this period (the 23rd day) the length of the Wolffian bodies is a third of that of the embryo, and that they constitute a sixth part of its bulk. Another most interesting feature is their extension towards the heart and pericardium, for it betrays their close resemblance to the permanent kidneys of the lower vertebrates, *e.g.*, fishes.

Although this particular embryo serves admirably to display the size and importance of the Wolffian body, yet it affords but little information concerning its minute structure. In the section drawn in fig. 1, the organ consists of a groundwork of embryonic connective tissue, throughout which are numerous round and oval spaces. These spaces are lined with minute cubical cells, and a glomerulus protrudes from some part of the wall into the interior. This arrangement holds good throughout the whole length of the Wolffian body; but it may be noticed that anteriorly the glomeruli and the spaces which contain them are smaller than elsewhere. Besides these glomeruli various

¹ His, *Anatomie Menschlicher Embryonen*, Leipzig, 1885, iii.; *Zur Geschichte der Organe*, p. 238; *Atlas*, iii. Tafel x. fig. 7.

tubules lined with epithelium may be made out in the other sections, but, as these will soon be considered in detail, it is unnecessary to do anything more than merely mention them.

Having now obtained a general idea of the Wolffian bodies of

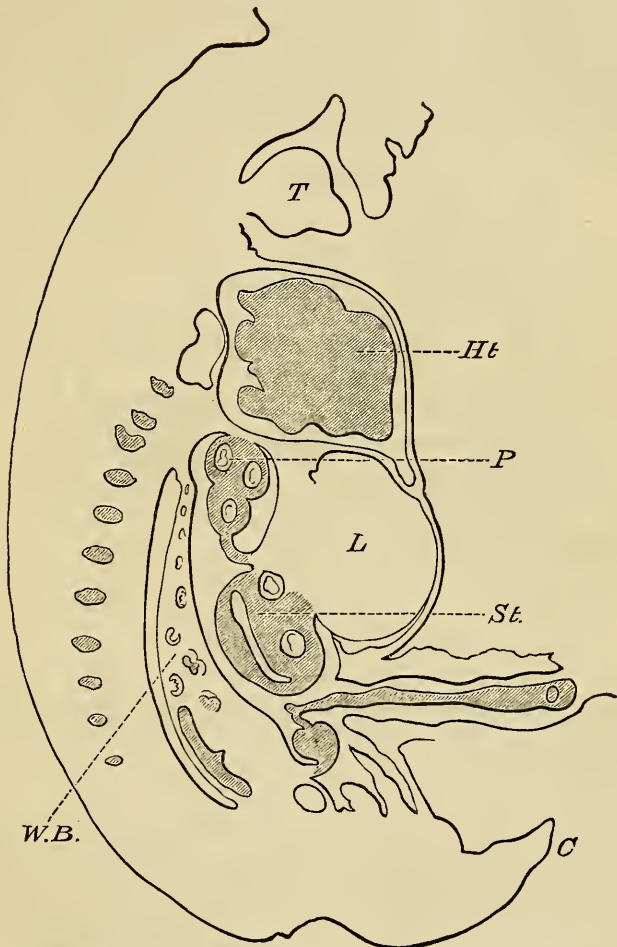


FIG. 1.—*Ht.*, heart; *P*, lungs; *L.*, liver; *St.*, stomach; *W.B.*, Wolffian body; *C*, tail; *T*, tongue. $\times 25$.

the human embryo, we may proceed to examine them in greater detail. For this purpose transverse as well as longitudinal sections are requisite, and a commencement may be made with

specimens which have been made from a human embryo a little larger and more advanced than the last, and perhaps at about the 26th day of intrauterine life.¹ The length of this specimen was nearly half an inch, and the fore and hind limbs had just begun to appear. The section which has been chosen (fig. 2) is through about the middle of the embryo, and the organs divided by it are the stomach, duodenum, liver, and Wolffian bodies. The last named occupy no inconsiderable portion of the back of the pleuro-peritoneal cavity, and their triangular shape is very

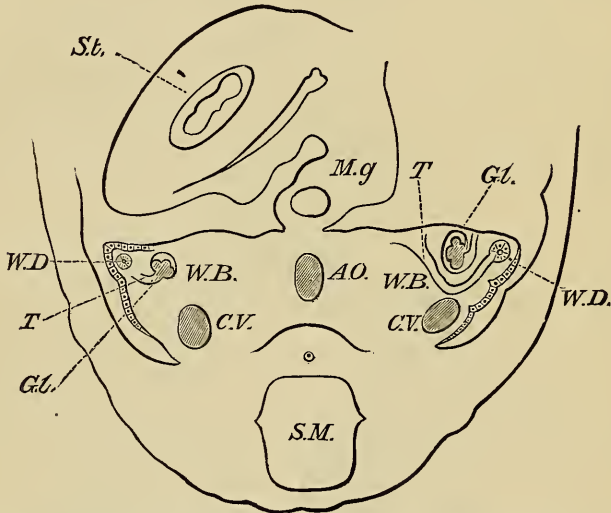


FIG. 2.—*St.*, stomach; *Mg.*, mesogastrium; *W.D.*, Wolffian duct; *T.*, Wolffian tubule; *Gl.*, glomerulus; *C.V.*, cardinal vein; *AO.*, Aorta; *S.M.*, spinal medulla. $\times 25$.

unmistakable. The base of the triangle is towards the aorta and vertebral column, and is continuous with the tissues which surround those parts; the sides are free, and look into the peritoneal cavity. The bulk of the Wolffian body consists of embryonic connective tissue, and its surface is covered with a layer of cells, which are thickest and most columnar round the most prominent part of the organ. Beneath this covering and near the apex of the triangle is a ring of concentrically arranged cells, surrounding a small lumen, and this represents the

¹ This embryo was very like one depicted by His, *Atlas*, iii. Tafel x. fig. 9.

Wolffian duct. On either side coiled tubules, the Wolffian tubules, are apparent; and on one side, the spectator's right, the tubule seems to open into the duct. Moreover, in all probability the tubule is connected with a large glomerulus, for on either side these structures are prominent objects. Since all the things which have been mentioned—duct, tubule, and glomerulus—can be described better hereafter, a detailed account of them will be deferred, and instead we will proceed to trace their mode of origin. Before attempting to do this the large veins in the back part of the Wolffian body may be noted; they are the cardinal veins, and are the channels by which the blood from the primitive kidneys is returned to the heart.

It is clear that it is impossible to pursue this branch of the inquiry upon human embryos, for it may have been noticed that the organs in question had already, in the youngest embryos at my disposal, attained a certain degree of perfection. The important *rôle* which the Wolffian duct is destined to play is betokened by the early age at which it appears. This point, the origin of the Wolffian duct, is, as a preliminary, conveniently studied in chicks, and although knowledge gleaned from them is most valuable, yet perhaps it would be rash to assume its applicability to the human subject without supplementing it with information gathered from other sources.

A great many reasons might be adduced to show that in the rabbit the process of development approximates very closely that which has been observed in man. Moreover, that animal has many advantages, which need not be mentioned, rendering it suitable for these investigations. Therefore I have availed myself of the embryos of this animal, and whatever they have taught will be mentioned in due course.

Wolffian Duct of Chick.

The phenomena which attend the development of the Wolffian duct in the chick are difficult to observe, and authorities are not entirely agreed upon their interpretation.¹ In

¹ Foster and Balfour (*Elements of Embryology*, 2nd ed., edited by Adam Sedgwick and Walter Heape, 1883, p. 94) say that the Wolffian duct may be seen during the first half of the 2nd day. Mr Sedgwick ("The Early Development of the Anterior Part of the Wolffian Duct and Body in the Chick, &c.,")

order to obtain satisfactory information an embryo at about the 48th hour of incubation may be chosen.¹

In a transverse section through the middle of such an one it is easy to recognise the various rudiments. It is unnecessary to describe such well-known objects as the medullary canal and the notochord, nor need particular stress be laid upon those important membranes, the epiblast and hypoblast, for the arrangement of the mesoblast, which lies between them, demands all our attention (Plate I. fig. 1). Close to the medullary canal the mesoblast is thicker than elsewhere, and forms the mesoblastic somites or protovertebræ; beyond these it divides into two layers, the somatopleure and splanchnopleure, separated by an intervening space, the body cavity. It is important to note that the somatopleure and splanchnopleure are united to the somites by a neck of uncleft mesoblast, which is called the intermediate cell mass, and which is said by many observers to give origin to the Wolffian ducts. So far, the presence of the latter in the section has not been mentioned, but nevertheless they are quite clear and distinct. Upon one side, the spectator's right, the Wolffian duct consists of a ring of cells surrounding a small lumen. This ring is situated above the intermediate cell mass,² with which it has no connection, and lies in a bay made by the somite on the inner side, and externally by the somatopleure, the epiblast completing it above (Plate I. fig. 1, *W.D.*). On the opposite side, although the position of the collection of cells, which afterwards forms the duct, is the same, it is questionable whether it has any lumen, and, moreover, it is, in the clearest way possible, united to the outer side of the adjacent somite. Perhaps we may pause for a moment to comment upon these facts. It is so clearly recognised that the Wolffian duct is at first a solid column of cells, which afterwards becomes hollow, that nothing more requires to be said upon that point, but its *Quarterly Journal of Micros. Sci.*, 1881, vol. xxi.) says that "the first trace of the Wolffian duct is visible in an embryo with eight protovertebræ as a slight projection from the intermediate cell mass towards the epiblast in the region of the 7th and 8th protovertebræ."

¹ I am indebted to my friend Mr Ogle for the very beautiful specimens from which these conclusions were drawn.

² Until the later stages of development are treated, all relations will be described as though the embryo was placed with its ventral aspect towards the ground.

connection with the somite is another affair; because, according to some embryologists, the latter would be its normal origin, but others are of opinion that it arises from the intermediate cell mass. Under these circumstances it is interesting to note its connections in this particular embryo. Anteriorly the duct is united to the side of the somite (fig. 1), and, traced towards the head, gradually ends upon it, disappearing by degrees; traced backwards, it first of all separates from the somite and becomes distinct, but further back it joins the intermediate cell mass, and terminates by mingling with it (Plate I. figs. 2 and 3, *W.D.*). My own experience is insufficient to permit me to say whether there is a moment in the development of the Wolffian duct at which it always conforms to this description, but it does not seem unlikely, and the observation has the merit of reconciling conflicting views. However this may be, an important principle underlies these matters of detail, and it is that the Wolffian duct arises from mesoblast. As far as the chick is concerned, this principle seems to be supported by ample histological proofs. Nevertheless, we must not hastily assume that it is true, because, after a little consideration, it will be acknowledged that there are *à priori* reasons with which the observation does not readily conform. For instance, in the case of other glands it is possible to trace the origin of their epithelia either to the epiblast or hypoblast, so that in the case of the Wolffian duct of the chick there seems to be an exception to what ought to be the rule. The difficulty would disappear if credence could be given to the statements of Hensen and His, that in the chick the Wolffian duct commences as a longitudinal involution of epiblast.¹ But the evidence to the contrary seems so weighty, and the mesoblastic origin so clear, that the very

¹ Foster and Balfour, in their excellent manual, give a *resumé* of the views of embryologists on this point (Foster and Balfour, *Elements of Embryology*, 1st ed., p. 82, 1874). They say that Remak and Kölliker described the Wolffian duct as taking origin from the mesoblast of the somatopleure. Dursy regarded it as being derived from the protovertebræ. Hensen, and for some time His, believed that the duct began as a longitudinal involution of the epiblast external to the protovertebræ. Subsequently His took the view that it was a product of the protovertebræ. Waldeyer says the Wolffian duct originates from the intermediate cell mass. But Waldeyer seems to think that the cells lining the duct are originally derived from the epiblast. Quite recently Romiti has described the Wolffian duct as being an involution of the epithelium of the pleuro-peritoneal cavity.

strongest confirmatory evidence must be forthcoming before the epiblastic parentage can be accepted. In truth, His, who at one time advocated it, has greatly modified his opinion.¹

Epiblastic Origin of Wolffian Duct.

The origin of the Wolffian duct is a problem so interesting to the embryologist, and so important to the pathologist, that it has not been allowed to slumber. Quite recently observations have been published with the intention of proving its epiblastic origin in the guinea pig and in the rabbit. So far as the former is concerned, I am unable to adduce any evidence for or against, but as regards the latter, specimens are at hand suitable for investigating its truth.

A recent writer² has endeavoured to show that in the rabbit's embryo certain thickenings of the epiblast separate and become the Wolffian duct. Embryos of the 9th day were used, and it may be stated that transverse sections through the region of the duct closely resemble the transverse sections of the chick (Plate I. figs. 1 and 2). They are, however, much more advanced as regards the folding in of the splanchnopleure, and in the development of the aortæ and body cavity. The epiblastic thickenings in question are situated just above the intermediate cell mass and external to the somite (Plate I. fig. 5), and after examining many embryos, I find that it is impossible to doubt that they actually exist. Nothing could be clearer than the diagrams which Flemming gives to show how the cells which constitute these epiblastic enlargements become detached, and form the Wolffian duct; but, to my mind, the most important evidence, that afforded by actual drawings, is inconclusive. The matter is too important for summary dismissal, and perhaps the actual specimens are inadequately represented by the figures.

¹ Graf Ferdinand Spee, in his paper "Ueber directe Betheiligung des Ektoderms an der Bildung der Urnierenanlage des Meerschweinchens," *Arch. f. Anat. und Phys.*, 1884, p. 89, gives a number of references to the literature of the subject. The epiblastic thickenings which he delineates are singularly like some which occur in both the rabbit and chick, and which will be referred to again presently.

² "Die Ektoblastische Anlage des urogenital Systems beim Kaninchen," Von V. Flemming, *Archiv für Anatomie und Physiologie*, 1886, p. 236, Tafel xi.

Now, although in the rabbit the existence of these thickenings is indubitable, it cannot be without significance to observe that they are by no means confined to one position. The cells of the epiblast seem to accumulate wherever the underlying mesoblast presents an inequality of its surface, and in a specimen which had been taken from a nine days' rabbit embryo (Plate I. fig. 5) there were distinct thickenings at each side of the somites, and an additional one far away from the side of the Wolffian duct in the bend which the somatopleure makes as it turns backwards, and in fig. 9 there is an epiblastic thickening exactly over the dorsum of the somite. It seems pertinent to ask whether we are to assume that all of these thickenings are destined to become Wolffian ducts. But however this may be, it seems quite clear that in the rabbit embryos which I have examined the Wolffian duct is in reality formed from a portion of the cells of the intermediate cell mass.¹ Those cells are at first a solid column (Plate I. fig. 10, *W.D.*), but this in a little while becomes hollowed out to form a real canal (Plate I. figs. 5 and 9, *W.D.*). Of course this does not invalidate the idea that the epiblastic enlargement which overlies the intermediate cell mass may not participate in the production of the duct, but assuming that was so, it seems natural to infer that after producing the duct the swelling would alter. It is true that the figures and diagrams which have been mentioned show that this is supposed to be the course of events, but nevertheless the specimens which I have examined cast doubt upon the matter, because in them both the duct and epiblastic swelling coexist (Plate I. fig. 5, *T.*). Not only may this be seen in rabbits, but in sections through the hinder part of the forty-eight hours' chick, which has been mentioned before (Plate I. figs. 3 and 4), it is clear that the epiblast has thickenings analogous to those of the rabbit's embryo, and, moreover, that the Wolffian duct arises

The specimens from which these observations were made are chromic acid preparations stained with picocarmine, and obtained in the summer of 1886. Others have been prepared this summer (1887), which clearly bear out the views which have been stated in this lecture. The last embryos were hardened in corrosive sublimate and stained with borax carmine.

independently of them from the somite and intermediate cell mass.¹

It must be acknowledged that it is not an easy task to observe the origin of the Wolffian duct in the rabbit's embryo, because early embryos of that animal are exceedingly brittle and hard to prepare. But Kölliker² depicts the duct originating from the intermediate cell mass, and, as may be seen, my own observations are confirmatory of the correctness of that view. Fig. 6 shows the intermediate cell mass of an early rabbit's embryo, and it may be seen how strikingly it resembles the analogous structure belonging to the chick; and I have little doubt but that it is the origin of the cell group from which the Wolffian duct, and, as will be seen presently, the Wolffian tubules originate.

Before proceeding further, a summary of the preceding considerations may conduce to clearness, and they may be tabulated as follows:—(a) In rabbit's embryos the epiblast has thickenings, not only near the intermediate cell mass, but elsewhere; (b) none of these thickenings are altered by the advent of the Wolffian duct; (c) the chick has similar thickenings, although in it the Wolffian duct arises from the mesoblast.

Whatever may be the truth about the Wolffian duct, the preceding observations tend to invalidate the idea that its origin is from epiblast, but, without doubt, many will be reluctant to admit their cogency. Such an admission is particularly hard for the scientific pathologist, who is tempted to assume that the epiblastic origin is true because it accords with *à priori* conceptions. For instance, in the case of the testicle the assumption that the Wolffian duct arises from epiblast has suggested a plausible explanation of the origin of testicular carcinomas, but under the circumstances such an inference seems premature.³ However clearly the epiblastic origin of the Wolffian duct is

¹ Janošik, *Sitzungsberichte der K. Akad. der Wissenschaften*, Band xci. Heft i. and ii., Wien, 1885, p. 113, repudiates Spee's observations, and says he has not seen epiblastic thickenings which he could consider the origin of the Wolffian duct. Janošik's monograph is clear, and gives a very good account of the bibliography.

² Kölliker, *Entwicklungsgeschichte des Menschen und der Höheren Thiere*, Leipzig, 1879, p. 277, figs. 197 and 198.

³ John Bland Sutton, *An Introduction to General Pathology*, 1886, p. 344.

demonstrated, an obvious fallacy has to be guarded against. It is superfluous to point out that nothing but a very simple conclusion ought logically to be drawn from that demonstration—namely, that it may explain the origin of carcinomata from the parts developed from the Wolffian duct and tubules. Presently it will be seen what these are, but I may say at once that it is doubtful whether any part of the body of the testicle ought to be included.

Prolongation of Body Cavity into Somite in Rabbit.

This seems a favourable place to mention an interesting peculiarity of one of the specimens. It is usual in rabbits' embryos, at the end of the 6th or beginning of the 7th day, for the two divisions of the mesoblast to be continuous with one another at the intermediate cell mass, so that there the walls of the body cavity are quite unbroken. Moreover, the intermediate cell mass intervenes between the cells which bound the body cavity and those of the somite. The latter consists of a central area of round cells, surrounded by a wall of others of a columnar type (*e.g.*, v. Plate I. fig. 5 or 6). The meaning of this central area is not at a first glance particularly obvious, but the following observation throws considerable light upon its meaning. In a transverse section through a rabbit's embryo (fig. 7) the walls of more columnar cells surrounding the central part of the somite are particularly distinct and continuous with the somatopleure and splanchnopleure. In consequence the central area of the somite is a part of the general body cavity, to which it is joined by a narrow passage which lies in the centre of the isthmus, representing the intermediate cell mass.¹

Doubtless an observation founded upon the appearances of a single embryo would not deserve to be recorded, if it was not in accordance with our previous knowledge. As far as I am aware, the body cavity is not known to be prolonged in mammalian

¹ George Renson, *Archiv für Mik. Anat.*, 1883, p. 600, "Recherches sur le rein céphalique et le corps de Wolff chez les Oiseaux et les Mammifères." In this paper the author says he has seen this appearance in the chick, and calls the canal the "canal de communication." He likewise quotes Kowalewsky (*Die Bildung der Urogenitalanlage bei Hühnembryonen*, Warschau., 1875, *Jahresbericht*, Hofmann und Schwalbe, 1875, p. 448), who first discovered this canal in the chick.

embryos into the somites, but the appearances which have just been described are very significant, and when we read what Professor F. M. Balfour has written about elasmobranchs it must be acknowledged that a summary dismissal of the subject would be unmerited. This author points out that in some of those fishes the body cavity extends into the somite, and proceeds:— “The vertebral plate comes to consist of a series of rectangular bodies, the mesoblastic somites, each composed of two layers, a somatic and a splanchnic, between which is the cavity originally continuous with the body cavity. . . . Between the vertebral and lateral plates there is left a connecting isthmus, with a narrow prolongation of the body cavity, which gives rise to the segmental tubes, and to other parts of the excretory system.”¹ This quotation shows that there is a strong resemblance between the development of the rabbit and of this particular fish, and it may help to explain the origin of the Wolffian duct. It may be remembered that the Wolffian duct, both in the rabbit and the chick, has been said to begin as a column of cells which afterwards became hollow. In seeking to explain the formation of this canal, it is suggestive to find that in some animals it is merely a shut-off portion of the body cavity, and further light is thrown upon the question by observing that, even in the rabbit, a part of the body cavity may once have occupied the place where the Wolffian duct and tubules afterwards appear. Supposing for a moment that we may assume that in rabbits, as in some elasmobranchs, the lumen of the Wolffian duct is a shut-off part of the body cavity, another objection remains to be dealt with; for if the assumption is admissible, why does the duct, in most specimens, look like a solid column of cells? We should expect it to retain the lumen when once it has been acquired. Although this is a weighty objection, it may lose some of its force if we consider a thing which is often overlooked. It is the custom to ascribe such preponderance to cells that the matrix in which they lie is forgotten. Properly prepared embryos may be seen to consist of cells embedded in a homogeneous matrix, and I am inclined to think that in it are foreshadowed many changes which occur in the arrangement of the cell elements. Therefore

¹ Francis M. Balfour, *A Treatise on Comparative Embryology*, 1885, vol. ii. p. 48 *et seq.*, also fig. 21.

it is not impossible but that in the midst of cell groups apparently solid many unsuspected matrix changes are hidden by the cells themselves. However all this may be, it seems possible that the force which hollows the Wolffian duct and tubules is actually the same as that which makes the body cavity, and that it is a part of the same process of cleavage.¹

After this I need not continue to discuss the actual origin of the Wolffian duct, but will proceed with its subsequent history. First of all, it is necessary to describe the way in which it alters its position. It may be remembered that at the 9th day, in the rabbit's embryo, the duct lay beneath the epiblast, just external to the somite and near the place where the somatopleure and splanchnopleure diverge to form the body cavity. However, owing to changes in contiguous structures, it speedily comes to lie beneath the cells which line the body cavity, and even from the first a slight elevation denotes its situation (Plate I. fig. 5). For reasons which will be clear afterwards, this elevation may be called the urogenital ridge, and the important events which occur in it will, for a time, monopolise all our attention. Perhaps it may be said in anticipation that the development of the Wolffian tubules and of the body of the testis are included in those events, but before beginning this part of the subject it may be as well to say how the Wolffian duct acquires its proximity to the body cavity. This is brought about very simply in rabbits, for it seems to be accounted for by an abrupt bending of the somatopleure backwards, and a downward shifting of the splanchnopleure (figs. 5 and 9). This is hardly the place to discuss the cause of these changes, but it may be explained that when the embryo first appears it forms part of a blastodermic membrane, which is closely applied to the uterine wall, with which the dorsal surface of the embryo is in close contact. A little while after the advent of the Wolffian tube, the axial part of the embryo shifts away from the uterus, and consequently away from the plane of the peripheral part of the blastoderm. Now, both the body and gut walls of the embryo are continuous with the blastoderm, so that after

¹ Kölliker, *loc. cit.*, fig. 198, p. 279, portrays in the rabbit the Wolffian duct as a fissure, such as might be expected had it been originally part of the body cavity.

the embryo has moved they are necessarily bent backwards towards the uterus. In the case of the body wall the bending is very abrupt, and when its relation to the duct is noticed it is easy to see how it makes the canal look more in relation with the lining of the body cavity than it did previously (fig. 5).

Whilst the urogenital ridge has been appearing, other events have happened. It may be remembered that originally the Wolffian duct was represented by a solid column of cells (fig. 10); but these after a time arrange themselves in a ring (Plate I. figs. 9 and 12), and a lumen appears in their midst. When the canalisation is accomplished, the cells provide the duct with a lining of columnar epithelium, which ultimately becomes ciliated and surrounded by various coverings which will be mentioned hereafter. During the progress of these changes the duct has come to lie in the outer part of the urogenital ridge close to the posterior recess of the body cavity (fig. 12, *W.D.*), but another event of the greatest importance has occurred, for the Wolffian tubules have appeared towards its inner and ventral side. When this stage of development is reached, the situation of the urogenital ridge is at the back of the pleuroperitoneal cavity, and at either side of the newly formed mesentery. Traced forwards, the ridge gradually dwindles, and terminates near the heart, and backwards it may be followed as far as the hinder part of the body cavity, but not quite to its end. It is therefore evident that the urogenital ridge of the rabbit has limits which correspond to those of the Wolffian body of the human embryo (Plate I. fig. 1), and it clearly represents an early stage in the development of that structure.

The shifting of the splanchnopleure towards the ventral aspect of the embryo, which is seen in embryos of the 9th day, permits the urogenital ridge to protrude into a comparatively wide body cavity (fig. 12), and there is nothing to interfere with its growth, which goes on apace. By the 10th day it has grown considerably, and the embryo has begun to assume its more permanent characteristics. For instance, both the somatopleure and splanchnopleure have bent inwards towards the ventral aspect,—the latter to form the gut and its mesentery, the former the body wall. At this stage (fig. 12) a large part of the urogenital ridge consists of mesoblast, in the midst of

which the Wolffian duct and tubules are conspicuous. The former lies in the back part of the ridge almost in contact with the lining of the posterior recess of the body cavity, whilst the tubules lie towards its inner side. It is important to note that the epithelium which covers the ridge is slightly larger and a little more columnar than elsewhere. It is called the germinal epithelium. After these preliminaries, we have naturally arrived at a point where the question of the origin of the Wolffian tubules may be raised, and for a while that matter will occupy our attention.

Wolffian Tubules.

Since it is unnecessary to comment upon the importance of this part of the subject, I will proceed at once to discuss the origin of the Wolffian tubules. Nearly all we know about this question has been learnt from the chick, so that it will be best to give a brief account of the phenomena seen in that animal, and afterwards describe those which I have observed in rabbits and in the human embryo.

What follows concerning the development of the Wolffian tubules of the chick is in accordance with the statements made in Foster and Balfour's well-known work on "Embryology."¹ Since the early development of the Wolffian duct of the chick has already been briefly described, perhaps it is hardly necessary to mention the changes by which it arrives beneath the lining of the pleuroperitoneal cavity. The process is very similar to that which has been seen in the rabbit, and the result is that, finally, the duct lies beneath the peritoneal epithelium. The tubules from their earliest appearance are very numerous, and, in a sense, developed independently of the duct. In its formation the latter does not monopolise all the intermediate cell mass, but merely a part, and the remainder becomes converted into the tubule. The process of conversion is not the same everywhere, and, without doubt, the following quotation will make the difference quite clear:—

"In front of about the sixteenth segment special parts of the

¹ *Loc. cit.*, 2nd ed., edited by Adam Sedgwick and Walter Heape, p. 190; also Mr Sedgwick's very able paper upon the subject has been consulted (*Quart. Jour. of Micros. Sci.*, vol. xxi., 1881).

intermediate cell mass remain attached to the peritoneal epithelium on this layer becoming differentiated, there being several such parts to each segment. The parts of the intermediate cell mass attached to the peritoneal epithelium become converted into S-shaped cords, which soon unite with the Wolffian duct, and constitute the primitive Wolffian tubules. Into the commencement of each of these cords the lumen of the body cavity is for a short distance prolonged, so that this part constitutes a rudimentary peritoneal funnel, leading from the body cavity into the lumen of the Wolffian tubule.

In the foremost Wolffian tubules, which never reach a very complete development, the peritoneal funnels widen considerably. The section of the tube adjoining the wide peritoneal funnel becomes partially invaginated by the formation of a vascular ingrowth known as a glomerulus, and this glomerulus soon grows to such an extent as to project through the peritoneal funnel, the neck of which it completely fills, into the body cavity. There is thus formed a series of glomeruli belonging to the anterior Wolffian tubuli projecting freely into the body cavity. These glomeruli with their tubuli become, however, early aborted.”¹

Before going any further it may be wise to pause and deal with the questions which are raised by this quotation, and, following its order the Wolffian tubules may be considered first.

Theoretically speaking the simplest way in which the Wolffian tubules could develop would be as outgrowths from the duct, but the statement in the first sentence, that they arise independently, disposes of this idea, and a little further on it is said that they proceed from the intermediate cell mass. In these particulars the rabbit's embryo resembles the chick, for its Wolffian tubules are not protrusions from the duct, but are developed from a group of cells which is derived from the intermediate cell mass. The meaning of this will be clearer if we turn again to the rabbit's embryo at the beginning of the 9th day. In such an one there is, in the position which the intermediate cell mass would naturally occupy, a collection of cells more or less surrounded by a delicate line of delimitation, and

¹ Foster and Balfour, 2nd ed., p. 191.

lying between the external surface of the somite and the body cavity (fig. 8). Before the end of the 9th day this group alters, and the cells of it, which are near the epiblast, become concentrically arranged to form the Wolffian duct, whilst the others remain as a mass which is ultimately converted into the tubules (fig. 9). At this stage the rudiments of the tubules lie towards the ventral side of the duct, and in close contact with the lining of the body cavity, but for the present the question of their continuity with the latter may be deferred.

Before describing how the Wolffian tubules grow and acquire a lumen, an interesting topic may be discussed. Apparently the group of cells from which the duct and tubules are developed extend without a breach from the posterior end of the body cavity to within a short distance of the head. Now it is not difficult to understand how a part of this column may become converted into a continuous thing like the Wolffian duct, but it is harder to appreciate the development of the tubules from the remainder. Possibly comparative embryology may throw a little light upon the point, and the researches of the late Professor F. M. Balfour show that in the elasmobranchs "one segmental tube (or Wolffian tube) makes its appearance for each somite, commencing with that immediately behind the abdominal opening of the segmental duct, the last tube being situated a few segments behind the anus."¹ Although this segmental arrangement is not so obvious in the embryos of other types,² yet it doubtless foreshadows the principle which determines the grouping of the cells which become the Wolffian tubules.

I regret to have been unable to obtain satisfactory evidence upon this point in rabbits' embryos; but the appearances at the 11th day³ were not uninteresting. At this time, owing to the spiral form of the embryo, it is hardly possible to procure good longitudinal sections, but occasionally a view of twelve

¹ *Comparative Embryology*, vol. ii. p. 692.

² Adam Sedgwick on "The Early Development of the Anterior Part of the Wolffian Duct and Body in the Chick, &c.," *Quart. Jour. of Mic. Sci.*, vol. xxi., 1881; also *Studies from Morphological Laboratory in the University of Cambridge*, part ii., 1882, p. 13 *et seq.*

³ Kölliker, *loc. cit.*, fig. 293, p. 476, depicts a ten days' rabbit's embryo, which corresponds to those which are here called eleven days'. The difference is accounted for by obvious considerations, which need not be mentioned.

somites and their adjacent tubules was obtained. In a section of this sort it was quite clear that, as a rule, two tubules belonged to each somite; but, here and there, it was hard to say whether this number might not be exceeded; at all events, there were many more tubules than somites. Of course this merely indicates the arrangement at that particular moment, the 11th day. At earlier stages the conditions may resemble the more primitive type, but this is perhaps unlikely in an animal so high in the scale as the rabbit.

It has been said before that the Wolffian tubules are developed from a group of cells which lies in contact with the inner and ventral side of the Wolffian duct, and we may now endeavour to see how these acquire a lumen. In highly magnified longitudinal sections (fig. 11), the elements which form the tubules differ but little from those of the duct, and where both come together there is no line of demarcation. Afterwards, by a simple separation of the central cells, the lumen of the tubule appears; but at first the newly formed canal is without any opening into the duct. A junction is obtained by a continuation of the process which has just been described, for by a slight severance of the cells of the duct-wall the lumen of the Wolffian tubule becomes connected with the canal (Plate I. fig. 12).

Before leaving this part of the subject, perhaps I may mention a circumstance which is shown in the drawing of the longitudinal section. It may be noticed that although the tubules are quite apart near the duct, nevertheless a little further off they are united by a string of cells. Assuming that this appearance is not due to any peculiarity of the sections, it seems reasonable to suppose that it is the last trace of a junction which, at one time, was much greater, perhaps complete. However, the appearance is but temporary, and at later stages there is no vestige of any union between the various tubules.

If the preceding description of the development of the rabbit's Wolffian tubules be compared with the account which Foster and Balfour give of the same process in the chick it will be manifest that a very important question still remains to be discussed. It may be remembered that those authors write, that in the chick the anterior tubules are, from their earliest

beginning, in continuity with the peritoneal epithelium; as for the other tubules, they say "in the posterior part of the Wolffian body of the chick the intermediate cell mass becomes very early detached from the peritoneal epithelium, and at a considerably later period breaks into oval vesicles, which elongate into Wolffian tubules."¹

Evidence has already been adduced to show that in the rabbit the body cavity conforms with the conditions determined in elasmobranchs (fig. 7). Perhaps it is unnecessary to repeat how such an arrangement influences the relations of the Wolffian duct and tubules of that animal to the peritoneal epithelium and body cavity. Of course, if similar principles of development obtain in the higher vertebrates as in the elasmobranchs, we should expect to find intimate relations between the developing Wolffian tubules and the body cavity.

So far as concerns the chick nothing more need be said upon this point, but as regards rabbits' and human embryos no apology is called for before the matter is fully discussed.

Clearly the question now is to tell whether the Wolffian tubules of the rabbit are, like the anterior tubules of the chick, continuous with the peritoneal epithelium. In order to ascertain this the nine days' rabbits' embryos, which have been mentioned before, are available.² It may be remembered that one of these (fig. 8) showed a group of cells (the intermediate cell mass) lying between the somite and the body cavity, and from these the Wolffian duct and tubules originated. In a moment the basis for this assumption will be more clearly indicated, but our present object is to ascertain whether the cells are continuous with the peritoneal epithelium. It has been said already that they are clearly delimited everywhere else except near the peritoneal side, but, for the sake of simplicity, the point in question was not referred to. However, it may now be stated that, owing to the physical resemblances of the cells, it is impossible to say where the cells of the tubule end or where those of the peritoneum begin (figs. 8 and 9). In this particular embryo the intermediate cell mass reaches as a

¹ Foster and Balfour, 2nd ed., p. 192.

² These embryos were a little more advanced than those which Kölliker depicts, fig. 218, p. 298, and which are said to be of nine days and two hours.

distinct group of cells only a little way along either side of the axis of the embryo; but, doubtless, this need not be taken to imply that the intermediate cell mass is of limited extent, but merely that the cells which compose it may not differ from their neighbours until about to undergo conversion into duct and tubules.

It is a matter of some importance to follow this part of our subject step by step. As the peculiarities of the tubules are brought into view, fresh light will be thrown upon the question of the origin of the Wolffian duct; and this will further tend to invalidate the idea of its epiblastic origin. An embryo belonging to the same litter as the last is suitable for the purpose in view, and, curiously enough, this second embryo seems in every way more grown and developed than its fellows. In this case, instead of finding an uniform mass of cells (intermediate cell mass) between the somite and peritoneal epithelium, this situation is occupied by the Wolffian duct and rudimentary tubule (fig. 9). The duct is quite isolated from the surrounding structures, and no doubt as to its identity need be entertained. The rudimentary tubules lie towards the ventral side of the duct, and it is quite certain that where they are in contact with the peritoneal epithelium no line of separation can be discerned. Not only is this the case, but there is a distinct resemblance between the cells of the tubules and the epithelium which overlies them. In fact, observers are wont to say that the epithelium grows in to form the tubule; but, although such an expression would afford an accurate idea of the appearances in the rabbit, nevertheless it would convey a misleading impression of the process. It would be more correct to say, that as the cells of the intermediate cell mass differentiated into the Wolffian tubules they assumed a greater resemblance to the peritoneal epithelium. It must not be understood that the preceding statements apply to all the tubules seen in this nine days' embryo, for some of those near the tail end are certainly not connected with the epithelium (fig. 10). Perhaps they are developed independently in the intermediate cell mass; and, if this be so, it would show that there is a striking similarity between the development of the rabbit and the chick, so far as their Wolffian tubules are concerned.

It is important to tell how many of the tubules are connected with the epithelium, but the endeavour has not yielded satisfactory information. Proceeding, therefore, with other questions, we notice that in embryos of the 11th day the junction between the front tubules and the peritoneal epithelium is very clearly marked, and on the 13th day not only is this the case, but fresh peculiarities have appeared. Before these are mentioned it may be as well to comment upon the significance of some of the preceding statements, and in doing so advance another step. First of all, a very simple inference may be drawn from the fact that in the second embryo the situation of the intermediate cell mass is occupied by the Wolffian duct and rudimentary tubules, viz., that the mass has actually separated into those two structures; or the matter might be put differently by saying that the cells of the intermediate cell mass nearest the epiblast simply became the duct, and that the others remained as the tubule. Since, therefore, the Wolffian tubules of the rabbit are continuous with the peritoneal epithelium, we may now proceed to ascertain whether their lumens communicate with the body cavity.

The Pronephros.

The comparative embryology of the vertebrate excretory system is so abstruse that it would be out of place, under such circumstances as these, to attempt its explanation. Those who have paid attention to the subject know that the Wolffian body, which so far is the only organ that has been mentioned, represents but a portion of the entire system. Sedgwick¹ in his able monograph, says, "The most peculiar feature of the excretory system of the vertebrate is the presence of three more or less distinct parts—the pronephros, the mesonephros, and the metanephros, or kidney proper." The mesonephros is the organ which in these pages has been described under the name of the Wolffian body, but nothing whatever has been said concerning the pronephros. Obviously, before it is possible to say whether

¹ "On the Early Development of the Anterior Part of the Wolffian Duct and Body of the Chick," &c., *Quart. Jour. Micros. Sci.*, vol. xxi., 1881; also Gegenbaur, *Elements of Comparative Anatomy*, translated, &c., by Bell and Lankester, London, 1878, p. 603.

this organ is represented in the rabbit, it is necessary to ascertain by what characteristics it may be recognised, and for this purpose Sedgwick may be quoted. First of all, it is stated that "the pronephros when present always develops in continuity with the anterior end of the segmental duct." The initial step in the inquiry is therefore exceedingly simple, for, since the Wolffian and segmental ducts may be considered the same, all that is requisite is to examine the front end of that canal. Next, it is said¹ that—

"In the Amphibian the segmental duct arises as a groove of the parietal peritoneum, just ventral to the place where the body cavity is connected with the cavities of the muscle plates. This groove, which arises first of all anteriorly just behind the branchial region, is continued for a certain distance backward. It soon, however, becomes constricted into a canal lying between the ectoderm (epiblast) and parietal peritoneum. This constriction has been described as taking place in the following manner:—It first appears in the middle region of the groove, giving rise to a canal opening into the body cavity in front and behind. It then is continued backwards until the groove is completely converted into a canal behind, which soon acquires an opening into the cloaca. Anteriorly the wide opening meanwhile is divided up into two (urodela), three (anura), or four openings (cæcilia), according to the species.

"The canal immediately behind the last of these openings becomes coiled, and placed on the same level, but ventral to the openings. The part of the body cavity into which the openings of the segmental duct pass widens out, a vascular projection—the glomerulus—from the dorsal inner wall is formed, extending uninterruptedly from opposite the anterior opening of the segmental duct to as far back as the posterior. The dilated section of the body cavity in which the glomerulus lies, and into which the openings of the segmental duct opens, is partially separated from the rest of the body cavity. The whole structure, including openings of duct, ventral coiled part of duct, glomerulus, and dilated part of body cavity, is known as the pronephros."²

Although the question only refers to Amphibians, the matter has been carried a step further by the discovery of similar organs

¹ Gegenbaur (*Elements of Comparative Anatomy*, translated by J. Bell, 1878, pp. 601, &c.) calls the duct which belongs to the pronephros and mesonephros the "archinephric duct," and says that it originates from the mesoderm.

² Upon this subject Balfour's monograph "On the Nature of the Organ in Adult Teleosteans and Ganoids, which is usually regarded as the Head Kidney or Pronephros," *Studies from Morphological Laboratory in the University of Cambridge*, 1882, p. 69, may be consulted; also Messrs Balfour and Sedgwick's joint monograph "On the Existence of a Head Kidney in the Embryo Chick," &c., *Quart. Jour. Micros. Sci.*, vol. xix., 1878.

in the chick and other birds.¹ Not only are the above-mentioned openings represented in that animal, but glomerular structures protrude from them into the body cavity. However, in rabbits and human embryos similar protrusions cannot be found,² although passages leading from the body cavity into the Wolffian duct or tubules undoubtedly exist, and attention may now be given to them.

It may be remembered that the development of the Wolffian bodies has been traced step by step until the organs were found to consist of a duct, with rudimentary tubules towards their inner sides. These structures, together with their surrounding mesoblastic tissue, lay in a fairly prominent ridge (the urogenital ridge), situated at either side of the mesentery. Moreover, it was said that the urogenital ridge extended towards the front of the body cavity, dwindling gradually, and ended behind the lungs, and close to the sinus venosus. The great blood-vessel of the Wolffian body (the cardinal vein) courses along immediately behind the duct, for which it is a convenient landmark.

After this recapitulation the peculiarities of the front part of the Wolffian body and duct may be followed with greater ease, and first of all its termination may be discussed. It has been found that embryo rabbits at the beginning of the 13th day afford the most satisfactory information. To give an idea of the development of such specimens they may be compared to chicks at the end of the 3rd day of incubation, and the comparison is borne out by the fact that the limbs of the rabbit have budded, and its crystalline lens has appeared.³ However, it is necessary to say that a mere statement of the number of days which may have elapsed since impregnation seldom conveys a correct notion of the degree of development any particular embryo may have attained; so that it may be asserted that is not possible to foretell what embryos will be like any particular time after impregnation, nor can any one be sure that the individual

¹ Janošík says he has seen the fore kidney in the chick, quail, pigeon, and duck, *ibid.*, p. 125.

² Janošík is of the same opinion as regards rabbits, *loc. cit.*, p. 128.

³ Foster and Balfour, 2nd ed., chap. vi. fig. 65, p. 188, give a diagram of a 3rd day's chick, which is comparable to the rabbit's embryo at the beginning of the 13th day.

members of a litter will be alike ; indeed, in the earlier stages they vary exceedingly. If now we return to the rabbit's embryo at the beginning of the 13th day, and investigate the most anterior portion of its Wolffian duct, it is found that a short length of it is detached and separate from the main canal.¹ This isolated front part consists of a solid column of cells (fig. 13) wedged in between the cardinal vein and the peritoneal epithelium, but before it ends posteriorly it has a lumen which is probably connected by two apertures—nephrostomata—with the body cavity (fig. 14). The histology of these communications is quite simple, for, where they are found, the outer side of the duct seems simply blended with the neighbouring epithelium, and through the midst of this connection there is apparently a narrow channel.² A very little way further back than this curious organ the Wolffian duct recommences, and, almost directly after its new beginning, it is united to the body cavity by a process of cells almost the same as those belonging to the detached portion of the duct (fig. 15). But, in addition, the urogenital ridge in this region has a peculiarity, for its most convex part is slightly grooved (fig. 16). Some thickened epithelium which lines the groove reaches towards the Wolffian duct. The succeeding sections show that this epithelial thickening is continuous with a somewhat tortuous Wolffian tubule, which opens in the usual way into the duct.³ From this point the Wolffian duct and tubules, traced backwards, conform to the description which has been given in previous pages.

Assuming the correctness of the foregoing account, it is clear that at the beginning of the 13th day the front part of the rabbit's Wolffian body resembles in some respects the organ which, in the chick, has been called the pronephros. It is true that there is a difference, for the presence of glomeruli has not been determined. An observer⁴ has stated that in twelve days'

¹ Sedgwick (*On the Early Development of the Anterior Part of the Wolffian Duct and Body in the Chick*, p. 16) mentions similar appearances in chicks.

² Upon this point Janošik and Rensen may be consulted. They describe very similar appearances. Janošik says that he has seen four nephrostomata. The specimen I have described had but three.

³ I have never seen the Wolffian tubules of the rabbit open into the body cavity with the exception of the tubules which have been described, and which seem to possess nephrostomata.

⁴ Rensen, *loc. cit.*, p. 607.

rabbits he has seen "from place to place the pleuroperitoneal epithelium adjacent to this canal (Wolffian) present traces of a cellular proliferation, in which can be seen the last vestiges of external glomeruli." Now, in the chick, the external glomeruli are very distinct structures, and not only have other observers¹ failed to discover their analogues in rabbits, but, judging from the specimens I have examined, the vestiges mentioned in the quotation are exceedingly dubious. Nevertheless, the absence of an external glomerulus is not an insuperable objection to the hypothesis that rudiments of a head kidney or pronephros exist in the rabbit, because, as Sedgwick seems to point out,² they are not an essential feature of the organ. Before taking leave of this interesting question, the nephrostomata demand further notice. It is possible that those apertures represent Wolffian tubules in a less complete state of development than elsewhere, but if this is the case they must have become considerably modified.³ For instance, they are joined to the outer side of the duct, and not to its inner and ventral side like the true tubules; secondly, a section sometimes shows a nephrostoma opening by itself into the duct, whilst there may be, in the same section, a tubule to the inner side (fig. 15); finally, the Wolffian tubules blend with the epithelium of the body cavity at the most convex part of the urogenital ridge, and not at its outer side, like the nephrostomata. Concerning the groove that has been mentioned (fig. 16), it would be improper to say more than that it has a certain resemblance to the grooves seen at the fore end of the chick's excretory apparatus, and which are considered to be an important part of its pronephros.

The foregoing observations cannot be considered complete until it has been ascertained whether they are applicable to the human embryo. It may have been inferred, from what has been said, and from the figures which have been given, that the human embryo has a Wolffian body which closely resembles that of the rabbit. A glance shows that in either case its configuration is the same, and no difference can be detected in its con-

¹ Janošik, *loc. cit.*

² Sedgwick, *Early Development of the Anterior Part of the Wolffian Duct and Body in the Chick*, &c., p. 25 *et seq.*

³ If we may judge from Mr Sedgwick's (*loc. cit.*, figs. 13 and 14) figures the nephrostomata of the chick and rabbit are not dissimilar.

tents. Human embryos which, according to His's data,¹ are somewhere about the 30th day of intrauterine life, betray the likeness in a striking degree. Specimens at this age are nearly comparable to thirteen days' rabbits, or to chicks at the end of the 3rd day. Their newly budded limbs have none of the bends they ultimately attain, nor can digits be discerned; moreover, the crystalline lens is incompletely formed and still united to its parent epiblast. A transverse section through such an embryo as this has already been figured and described (p. 4, fig. 2), so nothing further need be said before dealing with the details of the various structures. The way in which the Wolffian duct ends anteriorly, and the relation of the tubules to the peritoneum may be ascertained, but the earlier stages of their development can only be inferred. For the sake of clearness, the description of the posterior termination of the Wolffian duct may be deferred, and for the present only its course and anterior termination considered. After all that has been said, it suffices to say that it runs forward in the urogenital ridge lying beneath its epithelium. Of course, in these respects it resembles the Wolffian duct of the rabbit and chick, and it in no way differs from them, unless, perhaps, in being situated a little nearer the front of the ridge (Plate I. fig. 2).

So far, little has been said about the germinal epithelium which covers the urogenital ridge, because rabbits' embryos have chiefly been described, and in that animal its characters are not very distinctive. However, in the chick the germinal epithelium is represented by a semilune of columnar and large ovoid cells, which surrounds the most convex part of the ridge, and is continuous by its tapering ends with the rest of the lining of the body cavity. The human embryo has germinal epithelium arranged like that of the chick, and its appearance is shown in the accompanying figure, which has been drawn from the front part of the Wolffian body of an embryo at about the 30th day of intrauterine life (fig. 17).²

In human embryos the front ending of the Wolffian duct is the same as in the rabbit or chick, and is found in the same

¹ *Loc. cit.*, part iii. p. 238; *Atlas*, part iii. plate x. figs. 9 to 12.

² The germinal epithelium of the human embryo and of the rabbit is described in Lecture II.

position, behind the lungs, and close to the venous end of the heart. In this region the urogenital ridge and germinal epithelium have almost dwindled away, but the cardinal vein shows where the duct may be found, or rather where the column of cells which represent it may be found, because it is very questionable whether the terminal part has any lumen. However, the ending is independent of the peritoneal epithelium, and lies between the latter and the cardinal vein (fig. 18). The next question is, whether the epithelium of the human Wolffian tubules is connected with the peritoneal epithelium? and a section from the same embryo, but taken a little further back, allows an affirmative answer (fig. 19). At the level of the section the urogenital ridge and germinal epithelium are both very distinct, and the Wolffian duct may be seen lying beneath the latter. But the most striking and interesting feature is a Wolffian tubule which is united by one end to the germinal epithelium, whilst the other dilates and encloses a large glomerulus. Between these points the tubule is narrow, but has a distinct lumen, which, in this specimen, can hardly be said to open into the body cavity. Nevertheless, the histological arrangement suggests very strongly that there may have been an opening, and likewise betokens a distinct resemblance to the anterior Wolffian tubules of the chick and rabbit.

This part of our subject has enough importance to warrant the production of more evidence concerning it. With this object the fore part of the Wolffian body of another human embryo has been delineated (fig. 20). The specimen from which this was taken was very like the last, which had, it may be remembered, budding limbs and a commencing crystalline lens, and was compared to a thirty days' embryo figured by His.¹ In this case there is a very distinct inturning of the peritoneal epithelium, and the nephrostoma which it forms has the appearance of opening into the Wolffian duct.² A third human embryo, a little more advanced than the last two, afforded valuable confirmatory evidence of the junction of the

¹ His, *loc. cit.*, p. 239; *Atlas*, pt. 3, pl. x. fig. 9.

² Since the genital eminence of this human embryo has probably appeared, this epithelial ingrowth might possibly be the opening for the oviduct (Müller's duct), but this supposition will prove unlikely when the development of that canal is discussed in Lecture II.

peritoneal epithelium with that of the tubules, and perhaps with the duct of the Wolffian body. So far, nothing but the knowledge gained from transverse sections has been brought forward, but the longitudinal sections of another human embryo are so interesting, that a brief allusion to them may not seem out of place. After so much repetition, it is needless to describe in detail the excretory organs of this embryo. Its head had been broken off before it came into my possession, but as its limbs had just budded I judged it had attained about the 30th day of intrauterine life, and of course the histological features assisted me in arriving at this conclusion. The interest of the specimen centred in the forepart of the Wolffian body, where three vascular bulbous projections jutted into the body cavity. The free end of each of these (fig. 21) is covered with a layer of cylindrical cells, longer than those which cover the adjacent surfaces. The characters of these projections are very definite, but their size varies. The hindermost is the largest and most vascular, and then comes its next door neighbour; but the foremost prominence, that nearest the head, is quite short, and by no means so obvious as the others. Between the largest of these protrusions, or, in other words, between the middle and posterior, there is a deep recess which, in some sections, seems to open into a neighbouring Wolffian tubule (fig. 22). Unfortunately it is impossible to make an unqualified statement upon this point, but at all events the epithelial lining of the recess is continuous with that of the tubule. Human embryos seldom afford very perfect material, so that, as in this instance, although the outstanding processes are quite clear and distinct, yet the communication between the tubule and body cavity is not so certain. However, the appearances seen in these longitudinal sections acquire fresh significance when they are considered by aid of the information obtained from those which are transverse. Without doubt, after a while the human Wolffian tubules will be demonstrated as clearly in continuity with the peritoneal epithelium in longitudinal as they have been in transverse sections.

The actual nature of these villous-looking protrusions is hard to determine. It is impossible to ignore their likeness to the external glomeruli of the pronephros of the chick, and it is by no means impossible that a similar organ is in question. On

à priori grounds such an assumption is tenable, and I am inclined to think that the human embryo may have a rudimentary pronephros. Speaking relatively, the human embryo, that in which the protrusions into the body cavity were seen, was not more developed than a chick of the third day, and, as far as could be ascertained from longitudinal sections, it did not possess a genital eminence. In the next lecture reasons will be adduced to show that it is unlikely that the projections have anything to do with the oviduct.

LECTURE II.

Glomeruli of Wolffian Body.

The glomeruli of the Wolffian body have been frequently referred to in the first lecture, but, so far, nothing has been said concerning their histology or development. This omission may now be repaired, and, fortunately, suitable human embryos are available for the purpose. This happens because the glomeruli have just appeared in the youngest human embryo at my disposal, and are still in their most primitive condition. In order of development the glomeruli are not manifest until after the Wolffian duct and tubules are well established; and, roughly speaking, their appearance coincides with the earliest budding of the limbs; but, preparatory to their development the Wolffian tubules grow and alter. It may be best to glance for a moment at that phenomenon, and then proceed with the development of the glomeruli.

In Lecture I. the development of the Wolffian tubules was traced until they looked as if they were hollow outgrowths from the duct, and in this early stage their length was insignificant, and they only reached from the inner side of the duct as far as the peritoneal epithelium. But afterwards the tubule elongates, and, by the time the glomerulus has appeared, is slightly bent. A typical tubule would consist of the following parts:—(1) a section carrying the peritoneal opening, and known as the peritoneal funnel,¹ (2) a dilated vesicle into which this opens, (3) a coiled

¹ Foster and Balfour, 2nd edit., p. 193.

tubulus proceeding from (2), and terminating in (4) a wider portion opening into the Wolffian duct.¹ Evidence has been adduced to show that the human embryo, as well as the rabbit, has at the fore end of its Wolffian body peritoneal openings or nephrostomata, but these will not be mentioned again, because this portion of the organ totally disappears, and has nothing whatever to do with the events which follow. But the tubules do not present, either in the rabbit or in the human embryo, any peculiarity at their opening into the Wolffian duct; but towards its other extremity there is a dilatation, into which a bunch of capillaries grows to form a glomerulus. It therefore follows that all the human embryo ultimately possesses of the four divisions of a typical tubule is (1) a coiled canal and (2) its dilated glomerulus-containing part. But we must not forget that in one of the transverse sections of a human embryo of the thirtieth day of intrauterine life a very strong resemblance to the typical arrangement can be traced (fig. 19, Pl. I.). In this case the tubule running from the peritoneal epithelium and ending at a large glomerulus is of the greatest significance, and seems to represent a "peritoneal funnel." Before describing the development of the glomeruli, the manner of growth of the tubule calls for inquiry, and at the outset it is clear that it can hardly take place by additions made at either end. As far as can be judged, the cells which form its walls divide and multiply, and in so doing increase both the length and calibre of the canal they surround.

Taking both the pronephros and mesonephros into consideration, two sorts of glomeruli may be developed in connection with them. The first variety are called external glomeruli, because they protrude into the pleuro-peritoneal cavity instead of into the tubules. Their presence is undoubted in the chick, but it is very questionable whether they exist in the rabbit, and in man their development has hardly been established, although I have described a specimen in which it is possible that they have been imitated. However, in the absence of confirmatory evidence, it would be rash to aver their existence upon such

¹ Since the first lecture was written, I have seen an exceedingly wide opening between a Wolffian tubule and the pleuro-peritoneal cavity in a rabbit's embryo of 9 days and 18 hours.

grounds as these, and therefore, under the circumstances, only the other kind of glomeruli remain for examination. In contradistinction to those which have just been mentioned these are named "internal glomeruli," and they protrude into the Wolffian tubules. A perusal of Mr Sedgwick's¹ monograph shows that the distinction is rather one of detail than of principle, because that author satisfactorily shows that the external glomeruli are simply internal glomeruli which have protruded into the peritoneal cavity through greatly widened-out nephrostomata. However, the names are very convenient, and deserve to be retained. In future, for reasons which have just been given, only internal glomeruli are in question. The accompanying figure, made from a section of a human embryo at about the thirtieth day, affords an idea of the appearance of one of these structures shortly after its appearance. The canal of the Wolffian tubule is at this time about $\frac{1}{600}$ th of an inch in diameter, but is dilated at the end which is furthest from the Wolffian duct to contain the glomerulus. The latter consists of capillaries surrounded by round mesoblastic cells (Pl. II. fig. 23), and covered, where it protrudes into the tubules, by a reflexion of the lining epithelium, which consists of a single layer of cubical cells. In this specimen there is no histological difference between the cells which line the tubule and its dilatation and those which cover the glomerulus. At this early stage the glomerulus bulges prominently into the expanded tubule, and is continuous by a wide base with the rest of the mesoblast of the Wolffian body. However, a trace of a constriction has begun to form at the base, and this by its increase will afterwards form the "neck of the glomerulus." The mesoblast, which in a great measure composes the Wolffian body and glomeruli, is embryonic in type and consists of round nucleated cells, which are about $\frac{1}{1500}$ th of an inch in diameter. These elements have indistinct margins, and in some parts protoplasmic processes unite adjoining cells. The blood-vessels of the Wolffian body at this stage are not very numerous, and are bounded by spindle-shaped cells; they run as loops into the glomeruli (fig. 23). Whatever histological changes take

¹ Adam Sedgwick, *On Early Development of the Anterior Part of the Wolffian Duct and Body in the Chick* &c., p. 24.

place after this, and they are many, the anatomical arrangement which has been described, a glomerulus protruding into the dilatation of a tubule, does not alter, except that the glomerulus, owing to a narrowing of its neck, becomes more pendent into the cavity which contains it (figs. 24 and 25). As regards the place at which the glomerulus protrudes into the tubule, it may be noted that the invagination is not exactly at the end of the tubule, but usually at one side. Of course such a trivial circumstance as this hardly alters the anatomical arrangement.

After it has been established in this way, the glomerulus grows larger, and the tissues of which it is made assume new and altered characters. For instance, both in human embryos and in rabbits, the epithelium which covers its surface changes its cubical shape and becomes flattened. The cell nuclei do not participate in the change but remain round and plump, and bulge in a striking manner and clearly mark the margin of the glomerulus (fig. 25). The layer of epithelium which lines the interior of the glomerulus-containing sac, that which corresponds to Bowman's capsule in the kidney, also becomes flattened, except where it joins the cubical epithelium of the tubule; here it retains its original form (fig. 24). Accompanying these changes in the epithelium are others in the substance of the glomerulus. It has been seen that at its first appearance the latter consisted of small round cells, a few of which were elongated and bounded the capillary loop. The human embryo which yielded this information was somewhere near the thirtieth day of intrauterine life and had but a slight degree of perfection. In another human embryo, $\frac{5}{8}$ ths of an inch long and about the seventh week of intrauterine life (fig. 24, also fig. 39, p. 52), and in which the limbs and fingers and toes were clearly formed, the development of the glomeruli had advanced a step. During the early phases the epithelial covering was easy to recognise because of its cubical shape and deep staining, but in the seven weeks' embryo its identity is by no means so clear, although, without doubt, it is represented by some slightly flattened cells which cover the surface. Moreover, the elements which form the bulk of the glomerulus are bigger than they were at the thirtieth day, and this seems due to an increase in the amount of the protoplasm which surrounds the nucleus. But, besides increasing in

amount, it is perceptible that the protoplasm, especially that which belongs to the cells near the neck of the glomerulus, has sent out branches which, by joining with corresponding processes from other cells, are beginning to form a reticulated network; this reticulum is of the greatest interest and importance, and will be mentioned again presently. However, the bulk of the glomerulus consists at this stage of rounded nucleated cells interpenetrated by a few capillaries, which seem to originate as follows:—Along certain routes the embryonic cells, both of the glomerulus and of the Wolffian body in general, elongate and arrange themselves in parallel lines, separated by a narrow interval into which blood from the neighbouring great vessel enters. Nothing could be simpler than this process, and after originating like this the vessels consist of an afferent set, running from the aorta to the glomerulus, and an efferent set, opening into the great vein of the Wolffian body, the posterior cardinal vein.

If such a glomerulus as that which has been described be compared with those of the kidney, with which every one is familiar, their want of perfection is manifest. We are therefore impelled to carry our inquiries further, and a human embryo whose body and head together measured $1\frac{2}{16}$ inch long, and which had arrived somewhere near the tenth week of intrauterine life (fig. 40, p. 56), afforded a suitable opportunity. In this embryo some of the glomeruli were as large as, if not larger than, those of the adult kidney, and their vascularity was remarkable (fig. 25). The whole glomerulus is composed of a complicated interlacement of tortuous capillaries, amongst which a few cells are intermingled; and, moreover, the epithelial elements have deviated from their early cubical shape, so that both the surface of the glomerulus and the interior of its capsule are lined with flattened nucleated cells. By the time the glomeruli of the Wolffian body have reached this stage of development their resemblance to their fellows of the kidney is very obvious and needs no comment. However, the comparison has an additional interest, because it enables us to infer that the Wolffian glomerulus has reached the period of its greatest perfection. It will be shown presently that this is a stage at which few glomeruli are destined to arrive. Many of those which appear during the earliest and greatest development of the Wolffian body participate in the

atrophy which overtakes the foremost part of the organ, but this is a point which may be reserved for a little while.

Whilst the glomeruli have been passing through these phases of development the tubules and matrix have not remained quiescent. But, before speaking of these, it is important and interesting to ascertain how many tubules and glomeruli the human embryo may possess. Of course an exact determination is hardly possible, but in longitudinal sections of the youngest human embryo that has been mentioned in these pages (fig. 1, p. 3), and which was estimated to have arrived at the twenty-third day of intrauterine life, I calculate that from fifteen to sixteen tubules, and a like number of glomeruli, were present. In the longitudinal sections of another human embryo, also spoken of before, and estimated to have arrived somewhere near the thirtieth day (Pl. I. figs. 21 and 22), there seemed to be from eighteen to twenty tubules and glomeruli. The difference in these two cases is so small that it is evident that, assuming the ages are right, an inconsiderable, or possibly no new development of extra tubules or glomeruli takes place between the twentieth and the thirtieth day of intrauterine life. In a third human embryo which has been mentioned already (p. 32), and which was estimated to have reached nearly the seventh week of intrauterine life, it is hard to say whether the number of glomeruli and tubules has increased; although, on the contrary, some of the foremost, as will be described hereafter, have begun to atrophy (fig. 39, p. 52). The same holds good for a larger human embryo, previously mentioned (fig. 40, p. 56), and whose length was $1\frac{3}{16}$ inch, and whose age was thought to be about the tenth week of intrauterine life; in this specimen there is no increase in the numbers of the glomeruli, but a greater perfection of some, and an atrophy of others. If these inferences are correct, it is clear that they establish a difference between the human embryo and that of the chick, for in the latter, as Foster and Balfour¹ point out,

“In addition to the primary tubules, secondary and tertiary tubules are formed on the dorsal side of the primary tubules. They are differentiated out of the mesoblast of the intermediate cell mass and open independently into the Wolffian duct.”

¹ Foster and Balfour, 2nd edit., p. 192.

Judging from the number of openings into the Wolffian duct, it seems exceedingly doubtful whether in the human embryo any tubules are developed after those which have been described.

It follows, therefore, from what has gone before, that in the human embryo the glomeruli of the Wolffian body reach perfection at a comparatively early period, probably about the tenth week of intrauterine life, but even then some of those which are anterior have begun to atrophy, and it may be said in anticipation that this is the ultimate destiny of all of these structures. But before this interesting topic is touched, if the natural consequence of events is kept in view, other circumstances claim attention, and foremost may be mentioned the relative positions of the various structures which compose the Wolffian body. The situation of the duct, tubule, and glomerulus are portrayed in fig. 2, p. 4, which represents a human embryo at about the twenty-eighth day, or in fig. 37, p. 39, which represents the Wolffian body and genital mass, or sexual eminence as the latter is sometimes called, of a rabbit of thirteen and a half days of intrauterine life. These drawings clearly show that the duct lies towards the extreme outer limit of the organ, that is to say, as far as possible away from the mesentery and aorta; the glomerulus, on the other hand, lies more towards the inner side and in front, so that it is quite near the base of the mesentery. It therefore follows that the duct and glomerulus are some distance apart, and this interval is occupied by the tortuous tubules. That part of the Wolffian body which is nearest the spine contains, as was said before, the vein (posterior cardinal) which carries away its effluent blood. It is desirable to make a careful note of these relations, because they help the interpretation of many subsequent events. A word may be said in this place concerning the lining epithelium of the various canals. In rabbits and in human embryos the Wolffian duct is lined with columnar ciliated epithelium during the later stages. The Wolffian tubules have also a lining of regularly arranged columnar cells, and the inner edge of the cells (fig. 37, p. 39) has large and irregular protoplasmic protrusions. After the seventeenth day in rabbits the cell lining of the tubules of the Wolffian body becomes less

columnar and particularly like the epithelium which lines the convoluted tubules of the kidney.

Parenchyma of Wolffian Body.

The only portions of the Wolffian body which have not been particularly mentioned are its epithelial covering and the mesoblast which surrounds and imbeds the other elements. The latter has already been mentioned indirectly in connection with the connective tissue portion of the glomeruli, so that it is natural to complete the account of its development. Doubtless it is unnecessary to begin anew the description of the mesoblast which composes the human Wolffian body. At first it consists of round protoplasmic cells, each of which possesses a central nucleus. The process by which a very definite reticulated stroma is developed from the round nucleated cells is quite simple: their protoplasm sends out branches which unite with those of adjoining cells so that at last a nucleated meshwork is established. The various stages by which these alterations are brought about are shown in the accompanying figures (figs. 23, 24, and 25), which also indicate that, besides forming the reticulum, some of the cells are converted, in the manner which has been described, into the walls of the various capillaries and blood-vessels. Mere pictorial representations convey but a poor idea of the perfection and beauty of the tissue which forms the parenchyma of the Wolffian body, nor does comparison afford much assistance. Its resemblance to the so-called mucoïd or gelatinous connective tissue,¹ so far as the meshwork is concerned, is palpable; but here the likeness ends. To complete the analogy it would be necessary to demonstrate the presence of mucin in the meshwork, and it is hard to tell how this could be accomplished. But, whatever the nature of the parenchyma of the Wolffian body may be, the tissue which constitutes it is not solely confined to that organ. The last embryo which has been described, that which was supposed to have attained the tenth week of intrauterine life, possesses kidneys of some perfection, and the various glomeruli and tubules which go to form the organ lie in an identical matrix. This observation is so much in accord-

¹ *Vide Klein, Atlas of Histology, 1880, p. 33.*

ance with the views usually entertained of the relationship which exists between the permanent kidneys and Wolffian bodies that there is no difficulty in its acceptance; but in a little while it will be demonstrated that, by the time it has reached a certain stage of development, the body of the testis has a reticulum which differs in no material degree from the parenchyma of the organs which have just been mentioned, namely, of the kidney and of the Wolffian body. The importance of this statement, both from a developmental and from a pathological point of view, will be admitted when we consider that branch of our subject which treats of the development of the body of the testis, and the time has now arrived at which this task may be profitably and conveniently undertaken.

Development of the Body of the Testis.

The mere origin of the body of the testis is a matter of general agreement. This point has been clearly determined in the chick and in many of the smaller mammals, and therefore, so far as they are concerned, the question does not call for lengthened notice. Under the circumstances it is proposed, as a preliminary, to endeavour to ascertain how the gland appears in rabbits and afterwards in human embryos. When once the *origin* of the testicle has been illustrated the development of its various constituents will call for attention, and upon this branch of the subject the widest differences of opinion exist. It would be easy to verify this statement by reference to the well-known writings of Foster, Allen Thomson, or Balfour, or to the admirable epitome which Janošík gives in his recent memoir. As we proceed, the different views will be indicated, but at present let us confine ourselves to the question of the origin of the body of the testicle. At present it is a matter of common acceptation that, at their commencement, no one can discriminate between the rudiments of the ovary and those of the testicle, for I am not aware that Waldeyer's views upon this point have met with acceptance.¹ That author thinks that in chicks a thick germinal epithelium is indicative of female sex, whilst in males it is thin.² Therefore, although at last these

¹ *Eierstock und Ei*, pp. 133 and 135.

² *Ibid.*, p. 137.

glands differ so widely, yet at first they originate from a cell mass which is identical for the male or female; and which in its early stages betrays no evidence of its ultimate fate, whether destined to become an ovary or a testicle. Under these circumstances a suitable name has to be found for this indifferent rudiment, and it is usually called the sexual eminence. The sexual eminence of the rabbit's embryo may be clearly seen during the thirteenth day of intrauterine life. Before describing the manner of its appearance it is desirable, for reasons stated before, viz., the general untrustworthiness of time reckonings, to try to give an idea of the perfection of these embryos. Therefore, it may be said that the head and trunk together, although still curved upon each other, may be estimated to be about two centimetres long. The fore and hind limbs have incipient flexures; as yet they are deficient in digits, but the latter are already foreshadowed by dark parallel lines in the somewhat spatulate ends of the limbs. Finally, the head and face are well formed, and the eye has a well-marked lens and choroid. The internal organs—the heart, lungs, liver, and intestines—are noticeable objects, but the permanent kidneys have not appeared. A transverse section through the middle of the abdomen of such a rabbit's embryo, that is to say, one of thirteen and a half days (fig. 37, p. 39), shows that the Wolffian bodies are large and elaborate organs. The enlargement is in a great measure due to an increase in the growth of the tubules, which, besides having a larger calibre, are more tortuous; moreover, it is obvious that the gland has larger glomeruli and is more vascular. The length of the Wolffian body is still very great compared with that of the embryo. It reaches from the diaphragm, which by this time has almost completed its development, nearly as far as the hind end of the peritoneal sac; in fact, it stretches nearly the whole length of the back of the abdominal cavity. In the specimen from which the drawing was made (fig. 37, p. 39) it happens that the genital eminence is already prominent, and consists of a collection of cells which are heaped up towards the front and inner side of the urogenital ridge, and very near the place where the latter abuts upon the base of the mesentery. At this time the bulk of the urogenital ridge consists of the Wolffian body and its various

constituents. The relation of the genital eminence to the urogenital ridge may be illustrated by saying that, if the length of the ridge be divided into thirds, the genital mass would occupy rather more than the middle third.¹ This is only an approximate estimate, because the eminence tapers at either end, and therefore it is hard to determine its exact limits.²

The histology of the genital eminence in its earliest stages is

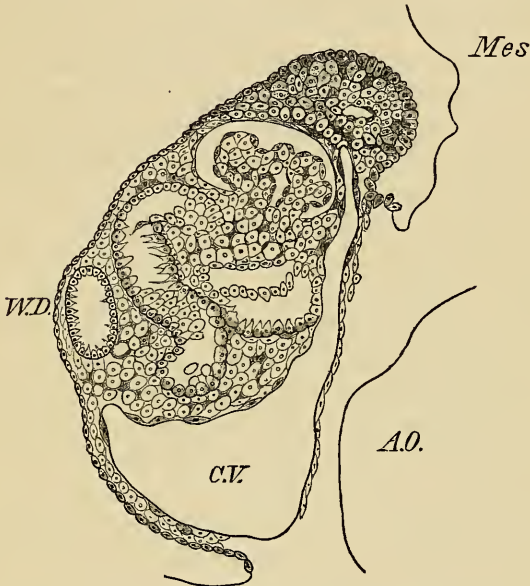


FIG. 37.—Wolffian body and sexual eminence of rabbit, 13½ days. *W.D.*, Wolffian duct; *C.V.*, cardiac vein; *Mes.*, mesentery; *A.O.*, aorta; *G.M.*, genital mass.

of great interest and importance. In order to see the appearances which are described below, sections of extreme thinness are essential, and a high power, such as Zeiss, $\frac{1}{12}$ th oil immersion, should be used. If the section should happen to be at all thick, or the power low, the genital eminence looks like a homogeneous mass of cells. However, it consists of two sorts of

¹ These remarks are also applicable to rats, corresponding in their development to thirteen days' rabbits.

² Foster and Balfour, *loc. cit.*, p. 221, say that at its first commencement in the chick the genital eminence extends the whole length of the Wolffian body and genital ridge, but subsequently is restricted to its anterior part. See also Waldeyer, p. 136, who makes a similar statement.

elements, viz., of a stroma of large branched anastomosing cells, and of unbranched cells (fig. 26) contained in the meshes of the stroma. The relative proportions of branched and of unbranched elements is not the same throughout. Where the eminence abuts upon the Wolffian body the network of branched cells predominates, and is very easy to see. It is continuous with the stroma of the Wolffian body, and the description which has been given to the latter applies to it in nearly every particular. The protoplasm of the branched cells is here and there collected into masses of some size, and where this happens large granular oval nuclei, which have one or more nucleoli, are usually seen (fig. 26). As the cells of the stroma approach the peritoneal surface of the genital eminence they, and their nuclei, become a little smaller, and there is a corresponding diminution in the size of their meshes. At the same time the stroma cells stain more deeply, and their nuclei are irregular in outline. In this and other specimens (fig. 32) some of the processes of the stroma are prolonged between the cells of the germinal epithelium as far as its peritoneal surface. As the genital eminence nears the Wolffian body its stroma becomes more palpable, but near the germinal epithelium it is partially obscured by a number of unbranched cell elements, whose nature is to be determined by an examination of the germinal epithelium. It is convenient to do this by simply tracing the lining epithelium of the abdominal cavity over the genital eminence (fig. 26). It has been said before that the peritoneal epithelium, at the thirteenth day, consists of a single layer of more or less cubical epithelial cells. Supposing that we look at this investment as it reaches the edge of the genital eminence, it may be seen that the individual cells have undergone considerable alteration. First of all, their size is no longer uniform, some being large and oval, others columnar, and not a few quite small and insignificant. So far as size is concerned, a very simple explanation is at hand, for a very active process of multiplication by fission is going on, and the smallest cells are simply those which have just been formed (fig. 26). But, returning again to the margin of the genital eminence and tracing the peritoneal epithelium over it, a marked alteration in the disposition of the epithelium is to be observed. Instead

of being arranged in an uniform layer their depth varies, and their deep surface has an irregularly festooned appearance. This appearance is caused by some of the cells of the germinal epithelium invading the stroma. These cells are recognisable because they stain more deeply than the larger oval cells which belong to the stroma, and because they have no protoplasmic branches. Whether the meshes of the stroma contain any other unbranched cells except these is hard to decide, but, after a great deal of study, I think that if thin sections are examined this question will be answered in the negative. It is exceedingly hard to give an adequate idea of this tissue either by description or by delineation, and although I think it is possible, even from early stages, to recognise the germinal cells, yet it is to be feared that only a very inadequate impression of their peculiarities has been conveyed.

It is obvious that the preceding account does not apply to the very earliest beginning of the genital eminence. But before attempting that topic, a few spindle-shaped cells near the base of the genital eminence (fig. 37, p. 39) may be mentioned. They merely bound blood-vessels which, even at the thirteenth day, have entered the base of the eminence; and they belong to the stroma.

Further knowledge of the genital eminence may be gained from younger embryos, and is confirmatory of the preceding. However, this part of the subject is so important that perhaps it may be well to introduce it here, more especially as by so doing the study of the human embryo is facilitated. In a rabbit's embryo at the beginning of the thirteenth day, and in which the limbs were merely short protrusions, the lining of the peritoneal sac consisted of a layer of cubical cells, each containing a nucleus. These cubical cells were continued over the urogenital ridge without exhibiting any alteration except towards its inner aspect. In this situation, the spot which the genital eminence afterwards occupies, the cells are slightly more columnar (fig. 27) and lie at least three cells deep. Although the various structures, such as tubules and glomeruli, contained in this rabbit's urogenital ridge are not so perfect as they are in the chick at the fourth day—the period at which Waldeyer depicts the germinal epithelium¹—yet it may be assumed that

¹ Waldeyer, *Eierstock und Ei*, p. 120, assigns a much greater distribution to

the thickening of the epithelium seen towards the inner side of the urogenital ridge of this rabbit is the beginning of its germinal epithelium. The section from which the drawing (fig. 27) was made came from about the middle of the ridge, and it was only in this neighbourhood that the thickening was seen.¹ With regard to the characters of the cells of the germinal epithelium, it is to be noted that they stain freely and that those next to the peritoneal sac are columnar, whilst the deeper ones are more or less oval and have a conspicuous nucleus.

The tissue upon which the rabbit's germinal epithelium rests, and which, of course, belongs to the urogenital ridge, consists of a network of branched anastomosing cells, many of which possess a large nucleus and nucleolus. The relation of this tissue to the germinal epithelium is most important. Where the two structures are in contact the basement line of the epithelium is not apparent, more particularly where the epithelium is thickest; and the union is so close that the processes of some of the branched cells are prolonged between the cells of the germinal epithelium.

The conclusions which it seems reasonable to draw from this account of the genital eminence of the rabbit is that that structure from its commencement consists of—A, Stroma; B, Germinal Cells; C, Blood-vessels.

Since it is quite clear from what has gone before that the human embryo has a urogenital ridge and germinal epithelium almost the same as in the chick or rabbit, it seems reasonable to suppose that it might also possess a genital eminence, and that the latter would originate in the same way as in the animals that have just been mentioned. A human embryo two-thirds of an inch long, and whose arms and legs were short and devoid of flexures, seems to place this question beyond the stage of hypothesis. A section through the middle of the urogenital ridge of this specimen shows that there is a distinct elevation towards its front and inner side, and not very far from the base of the mesentery. This elevation mainly consists of mesoblast, and it seems reasonable to assume that it represents an early

the germinal epithelium of the chick than can be seen in rabbits, or, I think, in human embryos.

¹ Compare Waldeyer, *loc. cit.*, pl. v. fig. 50.

stage of the genital eminence. The arrangement of the neighbouring epithelium bears out this assumption. Near the place where the Wolffian duct lies in the urogenital ridge (fig. 28) the peritoneal epithelium is nearly flat, but as it nears the eminence which has just been mentioned its cells become larger and more columnar, and have many of the characters of germinal epithelium. In addition, the depth of the epithelium over the convexity of the eminence is greater than anywhere else. This thickening is due to an actual increase in the thickness of the germinal epithelium, and, besides, a number of its cells are mingled with those of the underlying mesoblast. These deeper cells are somewhat irregularly disposed, and indistinguishable from those which cover the surface. Making every allowance for the nature of the material which has afforded the foregoing information, I think that it would not be rash to conclude that the human embryo has a genital eminence almost identical in character and origin with that of the rabbit. Before taking leave of the human genital eminence a word may be spoken about the mesoblast which helps to form it. This tissue consists of quantities of small mesoblastic cells not much larger than lymph corpuscles. These elements are of various shapes—round, oblong, or spindle-shaped, and each possesses a nucleus. Whether any of them are branched at this early stage is hard to tell, because they are all so closely crowded together, much denser than in rabbits.

This point having been arrived at, the next question refers to certain peculiarities which are attributed to the cells of the germinal epithelium. Perhaps the point at issue may be made clearer by the following quotation:¹—

“This ‘sexual eminence’ is present in the early stages of both sexes. In both the epithelium consists of several layers of short cylindrical cells, a few of which are conspicuous on account of their size and their possessing a highly refractive oval nucleus of considerable bulk; in both the underlying thickened mesoblast consists—as indeed at this epoch it does generally in all parts of the body—of spindle-shaped cells. The larger conspicuous cells of the epithelium, which appear to have quite a common origin with their fellow cells, and to arise from them by direct differentiation, and which are seen at the first in male as well as in female embryos, are primordial ova or primitive germinal cells. Thus in quite early stages it is impossible to detect the one sex from the other.”

¹ Foster and Balfour, 2nd edit., p. 221.

Assuming that, so far as the chick is concerned, these observations are correct, we will now endeavour to see whether they can be applied to either the rabbit's or human embryo.

After the description which has been given of the rabbit's germinal epithelium it is unnecessary to institute tedious comparisons. Although that animal does not possess primitive germinal cells which conform exactly to the description of those of the chick, nevertheless the deeper ovoid cells of its germinal epithelium may be their representatives. It is true that it can hardly be said that "they are conspicuous on account of their size," or that they "possess a highly refractive nucleus of considerable bulk"; but that some of the deeper cells of the rabbit's germinal epithelium betray a distinct resemblance to the primordial ova of the chick, and that they appear to become an integral part of the genital eminence cannot be denied. Moreover, speaking more particularly of ova, when it is considered how, at maturity, the avian ovum differs from that of the mammal, ought we to wonder that their early stages are not quite the same. It seems as though the ovum of the bird began to assume its peculiar characters, especially largeness, from its very beginning; but that in the rabbit and human embryo the germinal cells hardly acquire such a definite individuality.

The quotation raises another question, viz., the characters of the mesoblastic tissue which helps to form the genital eminence. It is said that in chicks at the fourth day of incubation the mesoblast which underlies the germinal epithelium consists of spindle-shaped cells; but Waldeyer,¹ also speaking of chicks at the fourteenth day of incubation, says that the tissue in question consists of ordinary small round or flattened cells joined to one another by branches, and that they are the same as the connective-tissue cells which at this period are found throughout the embryo. In addition, he mentions that a slight augmentation of this tissue causes the elevation which constitutes the genital eminence, and in his figure a colony of nucleated cells is indicated in this position. The whole of this description, of the correctness of which I have assured myself, might be applied to the rabbit's embryo, with the exception that in them there is hardly any increase in the density of the

¹ *Loc. cit.*, p. 136.

stroma which underlies the germinal epithelium. It is to be understood that this statement applies to very thin and highly magnified sections. In human embryos which show the earliest stages of the genital eminence, the tissue subjacent to the germinal epithelium is rich in cells of various shapes and sizes, but, owing perhaps to the nature of the material, the network of branched anastomosing cells is not perceptible; however, it is very obvious in the later stages of the development of the human testicle.

It has been deemed expedient to describe the genital eminence of the rabbit at some length, because, although its histogenesis is most probably the same in the human embryo, yet, as I have often said, the material they afford is seldom good enough to serve as the basis for independent conclusions. Nevertheless, it is easy to understand that, although this be the case, human embryos may furnish a great deal of information which is reliable when supported with evidence derived from examination of other mammals.

When once the genital eminence has become established, its growth proceeds apace. By the seventh week, in human embryos, it is almost equal in bulk to the Wolffian body, and by the tenth week is larger than that structure; a superiority which it ever afterwards maintains. But before passing to these later stages it is desirable to mention some of the steps by which they are reached. So far the Wolffian body, both in rabbits and in human embryos, has been the main representative of the excretory system. However, the definite establishment of the genital mass determines an important alteration.

Permanent Kidneys.

Before this event the Wolffian body throughout its whole extent seems qualified to perform the duties of a great excretory organ. But a time has arrived when the genital mass originates and grows in its proximity, and henceforth the Wolffian body, instead of fulfilling its manifest destiny—to function as an excretory organ—becomes a mere appendage of the newly arisen sexual gland, and eventually is the epididymis. No immediate alteration in the appearance of the Wolffian body denotes this

change in its destiny, but nevertheless the organism has to make provision for the performance of the functions for which the Wolffian body has presumably become incompetent. Under these circumstances, the permanent kidneys begin to originate. In a rabbit's embryo at about the middle of the thirteenth day of intra-uterine life, and in which the genital eminence is comparatively small, and whose Wolffian body is still large, the ureter is the only part of the permanent excretory apparatus which has appeared. This canal springs from quite the hinder end of the Wolffian duct, and running towards the head and behind the posterior part of the Wolffian body, ultimately terminates in the kidney. The latter organ is, as far as I have been able to ascertain from the examination of numerous human embryos and many rabbits, even from its earliest beginning, quite separate and distinct from the Wolffian body (fig. 29). When the kidneys appear the limits of the Wolffian body are very definite, and there is no admixture of its canals with those of the kidney. As for pretending to distinguish the canals of the one organ from those of the other, it would, in my opinion, be exceedingly difficult, or perhaps impossible. If these points are conceded it would seem superfluous to invoke the existence of misplaced Wolffian tubules for the purpose of explaining congenital cystic conditions of the kidneys. Some malformation of the kidney tubules themselves, or of the glomeruli, would afford an equally plausible explanation, and would not necessitate a demonstration of the passage of Wolffian tubules into places where they do not normally exist.¹

The permanent kidneys seem to me to originate in the rabbit and rat in the manner described by Kölliker.² Sections through rabbits at the commencement of the fourteenth day, in my opinion, confirm the statements of that author. After the Wolffian duct has received the whole of the Wolffian tubules it runs a little distance towards the tail end, and terminates in the urogenital sinus. Just before its ending the Wolffian duct receives a canal which closely resembles it in appearance and size. This canal extends forward towards the head, pursuing a course parallel to, but behind, the Wolffian duct, and when it

¹ J. Bland Sutton, "Erasmus Wilson Lectures on Evolution in Pathology," *Lancet*, 1887, vol. i. p. 355.

² Kölliker, *loc. cit.*, p. 946, figs. 579 and 580.

has arrived behind (*i.e.*, dorsal to) the hinder extremity of the Wolffian body, terminates in two or three caecal prolongations (fig. 29). These latter represent the commencement of the kidney, and they are lined with a single layer of columnar epithelium. This lining differs from that of the ureter, with which it is continuous, merely in the length of its cells: instead of being short columnar like those of the ureter, they are exceedingly long. Although these remarks are founded upon observations made upon rabbits, I have also found that they are applicable to the rat. Before leaving the subject an aggregation of mesoblastic cells (kidney blastema) which surrounds the rudimentary kidney tubules calls for remark. It is present both in rabbits and rats, and gives origin to the parenchyma of the organ. It is not proposed to pursue this question any further at present, but perhaps enough has been said to establish the independence of the permanent kidneys and Wolffian bodies. By the end of the fourteenth day the original prolongations from the ureter have been reinforced by many others, and the permanent kidneys are well established. A transverse section through an embryo rabbit, of the fourteenth day after impregnation, shows the relation of the comparatively well-developed kidney to the hinder part of the Wolffian body and to the genital mass (fig. 30). The genital mass may be seen lying to the front and inner side of the Wolffian body, and immediately behind the latter is the rudimentary kidney. Longitudinal sections show that by this time (fourteenth day) there is in rabbits a close correspondence between the antero-posterior limits of the genital mass and those of the kidney, the former, of course, lying in front of the Wolffian body, the latter occupying a corresponding position behind it. Moreover, by this time the Wolffian body has become slightly curved, the concavity of bend being towards the middle line, and embracing the genital mass. For this reason it is impossible in a single longitudinal sagittal section to demonstrate all the foregoing points; a series must be examined. If, for a moment, attention be given to the section of the fourteen-day embryo (fig. 30), the elaborate structure of the Wolffian body is evident; tubules and glomeruli may be seen in great profusion. The sexual gland adheres to its inner side by a broad base, and its substance is

continuous with that of the matrix of the Wolffian body. Under low powers the genital mass looks not unlike ordinary lymphoid tissue, but highly magnified it consists of a very delicate stroma of branched anastomosing cells with a great abundance of round, unbranched, nucleated elements entangled in the meshes (fig. 32). A glance at the kidney is sufficient to prove its rudimentary nature, for it consists of a collection of nucleated cells, contained in a meshwork of branched, nucleated, anastomosing cells, penetrated by a few tubules, offshoots from the ureter. The entire independence of the kidney substance from that of the Wolffian body is very obvious.

Human Genital Mass.

In the rabbit at the fourteenth day the Wolffian body still reaches from the diaphragm to the pelvis, and, roughly speaking, the middle third of its posterior surface is in contact with, but distinct from, the developing kidney; further, it is apparent that the side of the Wolffian body away from the kidney is in relation with the genital gland (fig. 31).¹ The next step is to see how far these observations are applicable to the human embryo.

In a human embryo at about the fifth week of intrauterine life the genital mass, or sexual gland, was a prominent object (fig. 32). It lay rather nearer the outer side of the Wolffian body than is the case in the rabbit, and the section which passes through its midst also divides the lower part of the kidney. As far as I can judge, the Wolffian body of this embryo is normal so far as its histology is concerned, but in a little while a most interesting abnormality of its hinder end will be referred to. However, our present object is to ascertain the relation of the genital gland and Wolffian body to the kidney. It may be said at once that these relations are the same as those which have just been noted in the fourteen-days' rabbit, the only difference being that the sexual organs are not quite so much in front of the kidney as they are in that animal, but more to the outer side. The sexual gland also betrays in its structure another divergence. Even when examined under low powers it

¹ This is more apparent in sections nearer the head than that drawn in Plate II., fig. 30.

is clear that many of the cells which compose it are arranged in columns which radiate from the centre towards the periphery. This feature was not visible in the rabbit, but in this and other human embryos it is very obvious, and may indicate, I think, the commencement of the seminal tubules.¹ Some of the sections obtained from this specimen show that a layer of cubical epithelial cells covers the surface of the genital mass, but, with the exception of the point which has just been mentioned, and which relates to the disposition of the cell elements, the histology is not quite so definite as in the rabbit. The material is hardly good enough to justify very positive statements, but it is quite clear the genital mass consists of two sorts of cell elements; the most conspicuous are those which have been said to have a tendency to arrange themselves in columns, and these are fairly large, deeply stained, unbranched, nucleated cells; the others are situated between and amongst the latter; they are nucleated, but do not stain so well, and are irregular in outline, perhaps branched. It is important to notice that, although the Wolffian tubules are very close to the genital mass, yet they do not penetrate into its substance.

Following onwards the natural sequence of events, two changes which take place at the same time would naturally call for notice. One of these changes is histological, and has to do with the development of the seminal tubes and those of the epididymis; the other is anatomical, and produces the mesentery of the Wolffian body and testis, a structure by means of which those organs become more free and mobile in the abdominal cavity.

Before raising these questions it seems appropriate to mention the abnormality which, as was said before, affected the hinder part of the Wolffian body and genital mass of the embryo which has just been described.

Fusion of Wolffian Bodies—Synorchis.

This is the earliest abnormality which has been met with in these researches, and the embryo in which it was found was about two-thirds of an inch long, and its arms and legs

¹ The expression "tubules" is, of course, incorrect, because these structures are solid columns of cells and possess no lumen.

were already beginning to exhibit incipient flexures. In all respects this specimen seemed to be normal and in good condition, but, at its pelvic end, the Wolffian bodies of opposite sides were fused for a few sections. This part of the organ, viewed in section (fig. 38, p. 50), was exactly like a horse-shoe kidney. The upper part of the Wolffian body, as I have said before, seemed quite ordinary, and a normal genital mass grew in relation with it (fig. 31).

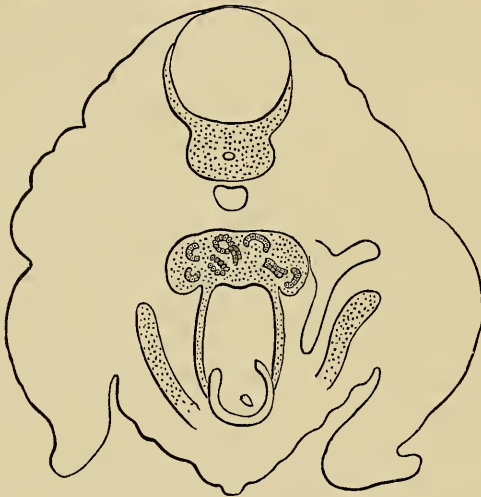

FIG. 38.—Human embryo sixth to seventh week. The Wolffian bodies are blended towards their hinder ends.

It is interesting to speculate upon the condition which might have been found in this case had the embryo ever grown to maturity. Without doubt the testes must have been united to one another. Such occurrences are not unknown, but must be infinitely rare.

Although systematic writers are accustomed to speak of union of the testis, I am not aware of more than one really authentic instance. This rare case is narrated by Geoffroy Saint Hilaire,¹ who was indebted for the details to Breton and Charvet, both of whom seem to have been very competent observers. Perhaps I may quote Mr Curling's² translation of the paragraph, because he

¹ Geoffroy Saint Hilaire, *Histoire des Anomalies*, 1832, t. i. p. 542. The doubtful case is by Acrell, in the *Schwed. Abhandl.*, t. xii. p. 19.

² Curling, *On Diseases of the Testis*, 4th edit., 1878, p. 6.

has alluded to the circumstance and adds that he believes the case to be unique. "An infant was born at Vizille in 1812: several physicians consulted respecting the child's sex and were of different opinions; they decided, however, to inscribe it in the registers as a girl. It died at the age of eighteen months, and was dissected by Breton, who recognised a complete hypospadias. The scrotum was bifid and empty; and the two suprarenal capsules, as well as the two kidneys and the two testicles, were joined together in the middle line. The spermatic arteries and veins, vesiculæ seminales and vasa deferentia exhibited nothing remarkable, each half of the double testicle receiving its particular vessels." Curling proceeds to mention a case of synorchis which Sedillot found whilst examining a recruit, but there is no evidence beyond the mere surmise. Saint Hilaire also alludes in doubtful terms to another case. It is evident that the account which has just been quoted is wanting in many important particulars. For instance, it is not said whether the bodies of the testes were fused or their epididymes, or what relation the abnormal gland had to the other abdominal contents. Under ordinary conditions the mesentery separates the testes, but in such circumstances as are being discussed, it must have become modified. In the case depicted (fig. 38, p. 50) it is clear that the Wolffian bodies fuse just behind the posterior end of the alimentary canal. Curiously enough, in this embryo the kidneys themselves blended for a little way at their hinder extremities, but none of the other paired organs were united.

Mesorchium and Mesovarium.

As far as we have at present traced the development of the genital system, either in rabbits or in human embryos, the determination of the sex, in spite of that which Egli¹ and Waldeyer have said, seems with our present knowledge an impossibility. Whether the radiating arrangement of the unbranched cells of the genital mass, which is seen in some human embryos, may be an indication of the male sex, is of course a matter of doubt, and incapable of direct proof. However, the events which now occur speedily set all doubts at rest. Whether the embryo is destined

¹ Egli, Th., *Beiträge zur Anat. und Entwicklungsgeschichte der Geschlechtsorgane*, Zürich, 1876.

to belong to the male or female sex has no influence upon the alterations which take place in the relations of the Wolffian body to the dorsal wall of the abdomen, or in the alterations which take place in the relations of the genital mass to the Wolffian body. Important modifications take place in these particulars, either in males or females, and since they are far advanced long before the histological details of the sexual organs are perfected, I will consider them first.

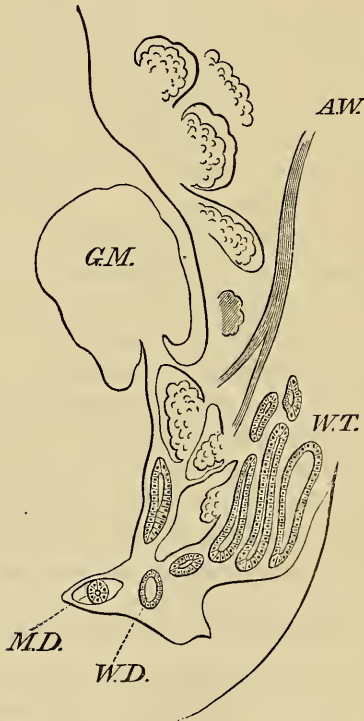


FIG. 39.—Human embryo (seventh week); section towards middle line. *A.W.*, portion of Wolffian body which atrophies; *G.M.*, genital mass; *W.T.*, Wolffian tubules; *W.D.*, Wolffian duct; *M.D.*, Müllerian duct.

The process by which the genital mass is constricted from the Wolffian body, and by which the latter is freed from the dorsal wall of the abdomen, takes place almost directly after the genital mass has appeared. A glance at fig. 37, p. 39, which was made from a transverse section through the genital eminence of a rabbit during the thirteenth day of intrauterine life, shows a faint

constriction at the junction of the genital mass with the Wolffian body; and, moreover, the latter, in proportion to its size, possesses a narrower dorsal attachment. Although these particulars are not so obvious in fig. 31, which was made from a transverse section through a human embryo of about the fifth week, yet indications of their presence are not wanting. However, on the fourteenth day the Wolffian body of the rabbit possesses a broad but distinct mesentery of its own (fig. 30), and the same statement holds good for human embryos which have reached somewhere near the sixth week of intrauterine life. In transverse sections made through human embryos at that period the Wolffian body has a well-marked mesentery, which is attached to the dorsal wall of the abdomen just external to the kidney, and in addition there is an obvious constriction between the Wolffian body and genital mass. Both in human embryos and in rabbits the processes which have commenced in this manner continue to progress, until at last the Wolffian body has a distinct mesentery, which becomes the mesorchium or mesovarium, and the genital mass is merely fastened to the Wolffian body by a narrow neck (fig. 39, p. 52).

The changes by which a mesentery is formed for the Wolffian body and genital mass occur in exactly the same way in either the male or female sex, but whilst they are taking place the histology of the genital mass has undergone great alterations, and moreover the Wolffian body has been profoundly modified.

Development of Tubuli Seminiferi.

Perhaps it will make that which follows clearer if I begin by pointing out the order in which the process of development will be followed. It is quite unnecessary to premise that the genital mass, although at first seemingly indifferent and suitable for conversion into either ovary or testicle, becomes transformed either into a highly complicated tubular organ or into a cell-laden mass. It is not proposed in this place to discuss the conversion of the genital mass into an ovary, but to endeavour to show how it gives origin to the connective tissue and tubules of the testicle, and how the latter acquire their needful efferent channels. Although human

embryos are obtainable suitable for showing the larger details, nevertheless they are rarely good enough to demonstrate the more minute histological changes. It is not necessary on this account to repudiate them altogether, but it makes it desirable to check all conclusions drawn from them by the examination of more reliable material. Under these circumstances the histology of the developing testicle of the rabbit will, first of all, be mentioned, and afterwards the development of the human testicle will be illustrated. But, as we proceed, it will be found that rabbits need only be used in the earliest stages, and that for the final ones human embryos of a satisfactory character are at hand.

We have already described the formation of the genital eminence of the rabbit in its earliest stages. It is unnecessary to recapitulate either its mode of origin or its relation to the Wolffian body. It will suffice to recommence the consideration of its histological structure by referring to the appearance which it presents during the first half of the thirteenth day. Since these have been described in detail, they only call for brief allusion. It may be remembered that from its earliest commencement the genital eminence consisted of a network of branched anastomosing cells, which was continuous with the stroma of the Wolffian body. The meshes of this network contained numerous nucleated unbranched cells, which were in continuity with, and the same as, the germinal epithelium (fig. 26).

The part of this account around which a great deal of controversy turns is the exact relation of the cells of the germinal epithelium to the rest of the genital eminence. Kölliker¹ states his belief that the germinal epithelium only gives origin to the ova and to Müller's duct; but, at the same time, he says that many authors think that it has a much greater rôle to play. The preparations from which the preceding account was written were exceedingly successful, and, in my opinion, showed that the germinal cells penetrated almost half-way towards the base of the genital mass. The embryos had been stained in picrocarmine, by which the germinal cells were deeply coloured—much more deeply than those of the stroma. Janošik gives a description very similar to that which I have endeavoured to

¹ P. 959.

² P. 147 *et seq.*

set forth; but that author does not, in my opinion, lay sufficient stress upon the stroma of the genital mass. He has compiled an excellent epitome of the opinions held by many recent authors.

Although at the beginning of the thirteenth day the germinal epithelium of the rabbit has those appearances, nevertheless at the fourteenth day it still looks almost uniform in structure. Transverse sections made through the genital eminence during the latter period show that its surface is covered with a layer of small cubical cells, and that its bulk consists of a network of branched anastomosing cells, with a number of unbranched nucleated cells in the meshes (fig. 32). There is no feature about the histological appearance of these unbranched elements to positively identify them with the germinal cells; we can only assume, from the preceding observations, that they have been derived from that source. Whilst in this indifferent stage the genital mass, when looked at with a low power, is very like lymphoid tissue. Even high powers do not dissipate this impression, more particularly as regards the stroma; but the cells in the meshes do not at all resemble lymph cells; they are larger, and have a more clearly defined nucleus, and a larger quantity of protoplasm.

Although human embryos are seldom good enough to demonstrate such minute histology as that which has been described, nevertheless the genital mass of a human embryo (fig. 39, p. 52) of about the seventh week was almost the same as that of the rabbit at the beginning of the fourteenth or end of the thirteenth day. Both as regards stroma and unbranched cells the similarity is quite clear.

Remembering that the genital mass consists of a network of branched anastomosing cells, in the meshes of which are numbers of round nucleated elements, we may now proceed to observe how the seminal tubules originate in this tissue. The commencement of the process may be seen in the rabbit's embryo during the fourteenth day. About this time an alteration may be noticed in the tissue which underlies the surface layer of cubical epithelium. This change consists in a more or less complete disappearance of unbranched cells from the stroma in this situation, and in the stroma itself forming a narrow peri-

peral zone, which differs from the central part in the smaller and more elongated character of its meshes (fig. 32). This layer, which represents the commencement of the tunica albuginea testis, is arranged with the long axis of its meshes parallel to the surface epithelium. Towards the centre of the sexual gland other alterations may be seen in the stroma, for its meshes

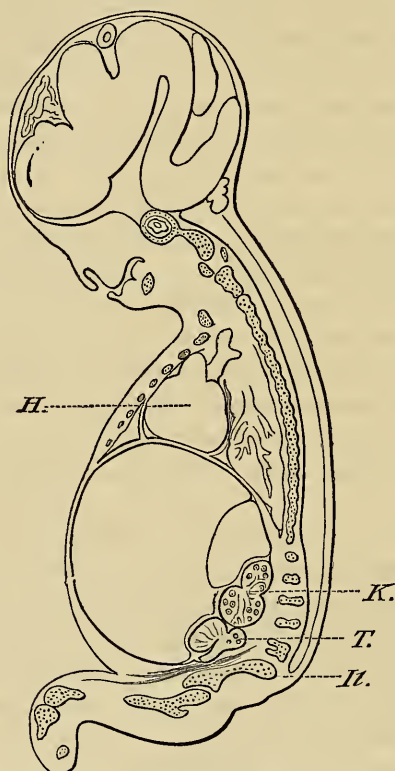


FIG. 40.—Relation of testis *T.* and Wolffian body to kidney *K.*, ilium *Il.*, and to the front wall of abdomen; *H.*, heart.

have in places become exceedingly large, so that aggregations of the unbranched cells are observable. That this betokens the beginning of the seminal tubules will, I think, be conceded after the testicle of a human embryo of about the tenth week has been described. Before entering upon these particulars it may be as well, for reasons which have frequently been stated, to give a brief account of that specimen (fig. 40). The length of a

longitudinal section through the body and trunk was one inch and three-sixteenths, the limbs were well formed, and possessed, besides proper joints, well-marked fingers and toes. The testes and Wolffian bodies lay in contact with, but posterior to (*i.e.*, below, in the erect posture), the kidneys; and as this is a point which will be discussed further on, we may now proceed to examine the histological structure of the testes.

At this stage of development the sexual gland has the general contour of the perfect organ and the Wolffian body has begun to have a likeness to the epididymis. The surface of the testicle is covered with a layer of cubical epithelium, and its interior is made of a stroma of large branched anastomosing cells and of numerous unbranched nucleated elements. The epithelial covering has no peculiarity, and may therefore be passed over;

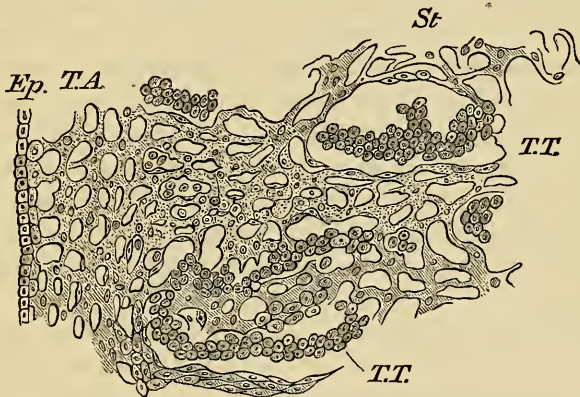


FIG. 41.—Section through testis at tenth week to show developing seminal tubules and stroma. *Ep.*, epithelium; *T.A.*, tunica albuginea; *St.*, stroma; *T.T.*, tubuli testis. $\times 250$.

but the arrangement of the other constituents, more particularly of the unbranched cells, is very interesting. If the microscopical examination is begun with a low power, such as a third of an inch, it is easy to see a rudimentary tunica albuginea beneath the surface, and this is developed, as in the rabbit, by the meshes of the stroma becoming parallel to the surface epithelium, and by the disappearance of unbranched cells from its meshes. Throughout the rest of the gland the stroma, under low powers, has no peculiar feature. If now we pass on to the unbranched

cells, or, as in future they may be called, spermatic cells, it will be found that, instead of being uniformly scattered throughout the testicular stroma, they have disposed themselves along certain paths. The irregular columns which have thus originated have an arborescent appearance, which indicates that they are the commencement of the seminal tubes (fig. 41, p. 57). As these rudimentary tubules approach the tunica albuginea they loop backwards again towards the centre of the testicle. Moreover, near the junction of the testicle with the Wolffian body, or, as in future it may be called, the *isthmus testis*, the converging tubules are joined to one another by numbers of spermatic cells, which are irregularly arranged along the long axis of the testicle, and represent the rete testis (see also fig. 33).

Placing aside, for the moment, the development of the efferent channels of these newly developed tubules, we may proceed to consider the more minute histological characters. For this purpose an amplification of about 250 diameters is enough, and what follows relates to the testicle of a human embryo at about the tenth week of intrauterine life seen with such a power (fig. 41, p. 57). So far as its general arrangement is concerned the stroma is the same as that which has been described already in the developing testicle of the rabbit. But it is to be noted that the strands which form the meshes of the stroma are a great deal thicker.

Moreover, the thickness of the strands of the stroma is not the same everywhere; they are thinnest towards the periphery, but become thicker towards the isthmus testis. Near the tunica albuginea it is easy to see that any particular portion of the testicular stroma is made of branched anastomosing cells, which possess large, granular, oval nuclei and nucleoli; but as the strands of the stroma approach the isthmus it is clear that, although its individual cell elements are the same, yet their relations to one another have altered. The alteration is in the shape of the cells, which, instead of being provided with long and tenuous branches, have either none at all, or, in their place, thick and short protrusions of their substance, and these are continuous with other cells. Owing to these modifications there are places near the isthmus testis and near the rete where the stroma is made of strands of cells which seem to possess no

branches, and which, lying side by side, closely resemble endothelial plates. Where this is the case it would be easy to mistake the unbranched stroma cells for endothelial plates, but, even where the likeness is strongest, traces of a meshwork are here and there discoverable. These appearances have been particularly mentioned because of their importance when taken in relation with certain columns of cells which have been observed in hilum of the mature testicle. Dr Klein¹ describes and figures certain "interstitial epithelial cells" in the hilum of the mature testicle of the cat, and attributes them to the tubules of the Wolffian body, of some of which he considers them to be the remains. Judging from Dr Klein's very beautiful figure, and from specimens of cats' testicles, the structures in question look to me much more like the cells of the developing stroma, such as I have just described. This is not intended to imply that no tubules from the Wolffian body enter the hilum of the testicle (or ovary), and in that which follows evidence will be forthcoming upon this point.

Before taking leave of the stroma of this testicle, it is hardly necessary to do more than mention that it is continuous at the isthmus testis with the stroma of the Wolffian body. The latter has already been depicted and described (fig. 25), and calls for no further mention. It only differs from the stroma of the body of the testicle in not forming strands, and in an absence of collections of endothelial-looking stroma cells, such as have just been alluded to.

The next question that demands attention is the histology of the developing seminal tubules, and of the spermatocells which compose them. If a clear idea has been conveyed of the rudimentary testicular stroma this should prove an easy task. The spermatocells stain more deeply than those of the stroma, and each one has a central nucleus and nucleolus. Their shape is round or oval, and they have no branches whatever. It has been said that the spermatocells are arranged in irregular arborescent columns, and now, under high powers, it is seen that these columns lie in irregular spaces in the stroma (fig. 41, p. 57). These latter are not anything special, and merely look like enlargements of the meshes of the stroma; but the outline of their

¹ Klein, *Atlas of Histology*, p. 269 and 286, pl. xxxix. fig. 3.

walls is more regular and definite, and the cells which form their boundaries are usually flat or spindle shaped (fig. 41, p. 57).

The columns of spermatic cells which lie in these spaces have no particular arrangement, but their tendency seems to be to occupy the centre, and not to lie in contact with its walls. However, it is most interesting to observe that, whilst in this rudimentary state, the spermatic tubules are solid, and composed of small round or oval cells arranged without any particular order.

Owing to the kindness of Mr Hy. Butlin and Mr A. Bowlby I have had the opportunity of examining histological sections of sixteen malignant tumours of the testicle. It was impossible to ignore the great likeness of their tissues to those of developing testis. A stroma of branched anastomosing cells was visible in portions of many of them, and their unbranched elements were practically indistinguishable from the unbranched spermatic elements which have just been described. In none of these malignant tumours could I discover, even after several careful examinations, any elements to which I myself should apply the term "epithelium." On the contrary, specimens which would accord with the definition of a cancer seem to do so because their unbranched elements were collected into irregular columns, like developing seminal tubules.¹ With regard to the existence of epithelium in tumours of the testicle the foregoing statement requires to be qualified to this extent, namely, that I have more than once seen in them tubules or loculi lined with a single layer of columnar epithelium. However, in those cases there was no real resemblance to any ordinary form of carcinoma, and the tumours usually contained cartilage and other mesoblastic elements.

If the order of development was strictly followed the Wolffian body would again claim attention. That organ has, whilst the body of the testicle has been developing, undergone great changes, and is in course of being converted into the epididymis. But to avoid leaping from one branch of the subject to another it is more convenient to carry the development of the body of

¹ E. Rindfleisch, *Lehrbuch der Patholog. Gewebelehre*, Leipzig, 1886, p. 579, quotes from Birch-Hirschfeld, "that the cells, as in cancers of kidney, liver, breast, and testicles, come from the epithelium of the gland canals."

the testicle a stage further, and then return to the Wolffian body.

We have just seen that the seminal tubules of the human embryo, and also the rete testis, are laid down as early as the ninth or tenth week of intrauterine life, so that it only remains to trace their future modifications.

The appearance of the human testicle at the third month has been figured in the accompanying sketch (fig. 33). The seminal tubules are more numerous and thicker, and the rete testis is very much better marked than in the younger embryo. This is due to an increase in the numbers and in the size of the spermatic cells. Both the seminal tubules and the rete testis are solid columns of unbranched, deeply staining, nucleated cells. Evidently the term "tubule" ought not to be applied to these structures until they have acquired a lumen. At the sixth month of intrauterine life the arrangement of the spermatic cells has not altered, but the seminal tubules are larger, and have begun to be exceedingly tortuous. I have no exact information as to when the centre of the seminal columns begins to clear, but in the testicle of a young goat, six months old, there was a very slight indication of a clearing towards the axis of the column.

The phases through which the connective-tissue stroma of the developing testicle passes are comparatively simple. Although up to the tenth week the stroma of the human testicle consists of branched elements, yet by the twelfth week the cells are in places elongated and beginning to be spindle shaped (fig. 33); by the fifth month they have advanced a long way towards being fibrous tissue, and, of course, this is its ultimate destiny (fig. 35). As for the interstitial cells, which may be seen in the stroma of well-prepared sections of adult testicle, it has been said that they are formed from remains of the Wolffian body. The time has now arrived at which we may conveniently endeavour to ascertain the relation of the tubules of the Wolffian body to those of the testicle; and as this important branch of the subject is followed, light will be thrown upon this important and interesting question.

As suitable material is at hand, I propose to confine the rest of this description to human embryos. But, before entering upon

particulars, it is desirable to endeavour to convey an idea of the general appearance and relations of the genital mass at the time when the changes which are about to be mentioned begin. In a human embryo five-eighths of an inch long, and at about the seventh week of intrauterine life, the Wolffian body and genital mass lay near the lower end of the kidney, and just overlapped that organ. The genital mass was in the indifferent stage, and it is impossible to be sure of its ultimate fate; it is attached to the middle third Wolffian body by a narrow isthmus (fig. 39, p. 61). The Wolffian bodies themselves are not by any means so parallel to one another as when first developed, and lie obliquely, with their lower ends converging. There is no difficulty in observing that its structure has undergone great alterations. If we begin with a section near the middle line, and therefore dividing its lower part, it is evident that the foremost glomeruli, although larger, are faintly stained, and their tissues granular,—appearances which indicate that they have begun to degenerate and atrophy. The tubules, on the other hand (fig. 39, p. 52), are exceedingly perfect; their lumens are capacious, and their lining membrane of short columnar epithelium is very distinct (see also figs. 24 and 25). Turning now to a section which divides the upper and outer part of the Wolffian body, quite a different sort of tubule comes into view (fig. 34). These may be said to begin in a collecting tube, which is a continuation forwards of the Wolffian duct. I have purposely refrained from calling this the Wolffian duct, to mark that its characters are decidedly dissimilar, being smaller, and having hardly any lumen. The tubules, which extend from the collecting tube into the hilum of the genital mass, are still more remarkable. In this and other specimens about twenty tubules leave the collecting tube at right angles, and extend into the hilum of the genital mass. At their beginnings these canals have hardly any lumen, but they expand as they run onwards, and gradually acquire one. Their epithelium is peculiar in that it stains exceedingly dark, and in being smaller and more cubical than that of ordinary Wolffian tubules¹ (fig. 34). When we consider the course and the relation of these peculiar

¹ The sexual canals of the human Wolffian body require to be studied in suitable transverse sections, and this would, I am sure, throw light upon their origin.

tubules to the genital mass, it does not seem unreasonable to suspect that they are the commencement of the tubuli efferentia. Waldeyer has given semi-diagrammatic representations of these tubules;¹ the human embryo which he used was 9 cm. long, and therefore much older than that which I have been describing. Waldeyer divides the Wolffian body into two parts: a sexual, consisting of these tubuli efferentia; and a urinary, consisting of the more capacious tubules and glomeruli. At present we are not concerned with the female type, but it may not be out of place to note in it the destination of the genital mass, and of the sexual and urinary parts of the Wolffian body: the genital mass becomes converted into the ovary; the sexual part of the Wolffian body remains as the structure which Waldeyer calls the "Epoophoron"; and the urinary part also persists, and is called by the same author the "Paroophoron." The terminology of these remains is exceedingly confused. Authors have not always drawn a clear distinction between the sexual and urinary portions of the Wolffian body. The former, as we have seen, are smaller, straighter, and less canalised than the others, and have apparently no glomeruli; moreover, they penetrate into the genital mass. The urinary tubules are larger, have a wider lumen, and end in glomeruli, and do not penetrate the genital mass (fig. 39, p. 52). In order to avoid ambiguity, a provisional list of the various names which are commonly applied to these various structures is appended, and has been compiled from the books of Henle, Kölliker, Quain, Waldeyer, &c.

PROVISIONAL LIST OF NAMES.

	In Female.	In Male.
Genital mass becomes	Ovary.	Testicle.
Wolffian body becomes		
A. Sexual part	= { Epoophoron of Waldeyer. Parovarium of Kobelt. Organ of Rosenmüller.	} = { Epididymis and its Vasa efferentia or Coni vasculosi.
B. Urinary part	= Paroophoron of Waldeyer.	= { A. Paradidymis of Waldeyer, or Organ of Giraldès. B. Vasa aberrantia.

Before I endeavour to trace the process by which, in the

¹ *Eierstock und Ei*, p. 142, also plate vi. figs. 60 and 61.

male, the sexual tubules of the Wolffian body become vasa efferentia, a peculiarity which they betray during the indifferent stage may be noticed (fig. 34). Where these tubules open into the collecting tube they are small, and have hardly any lumen, but as they run towards the hilum of the ovary they expand, and have at last a considerable dilatation (fig. 40).

The meaning of this seems obscure, and, as far as I am aware, has not been noticed before. However, Waldeyer made his semi-diagrammatic figures from older human embryos, and I have reason to think that in them the dilatation is not discernible.

The sex of the embryo from which the foregoing observations were made could not be distinguished. Its genital mass was in the indifferent stage, and had neither tunica albuginea nor the rudiments of seminal tubules, and therefore it affords no clear evidence of the way in which a communication is effected between the tubules of the Wolffian body and those of the testicle. The human embryo of about the tenth week may carry us a step further (fig. 40, p. 56). This embryo has already been mentioned, and the development of the body of its testicle has been traced up to the point at which it consisted of solid arborescent columns of cells converging to a rete testis all imbedded in a stroma of branched anastomosing cells, and surrounded, except at the isthmus, by a tunica albuginea. The Wolffian body of the embryo, like the last, consisted of two portions distinguished by the dissimilarity of their tubules; these parts being, of course, those which have been called the sexual and the urinary. The urinary part of the Wolffian body, if we may judge from the perfection of its structure (fig. 25), is at the height of its development, and in size far exceeds the sexual part. This latter contains the curious tubules which have just been described and identified with the vasa efferentia. They are a quarter the size of the urinary tubules, and their epithelium stains darkly; they run nearly at right angles from the collecting tube, and extend into the hilum of the testicle, where they are slightly dilated, and have a lumen. With regard to this last point it is interesting to note that it is exceedingly hard to say whether either the foremost part of the collecting tube, or the portions of the tubules (*tubuli efferentia*) nearest to them have a real lumen. However, in the hilum of the

testicle the latter are canalised, and some of them contain a structureless substance, which stains faintly, and is doubtless some form of secretion. This embryo is, without question, of the male sex, and it shows, at least, that the sexual tubules reach the body of the testicle.

But, before it is possible to form any conception of the way in which the sexual tubules of the Wolffian body become continuous with the rete testis, perhaps it may be desirable to call to mind the anatomical arrangements at this particular moment. Both in the ten weeks' embryo, and in one of twelve weeks (fig. 23), there is, at the isthmus of the testicle, no line of demarcation whatever between the parenchyma of the testicle and that of the Wolffian body. The aggregation of spermatic cells which constitutes the rete testis is in the stroma, and has no distinct limits (fig. 23). Moreover, the tubules of the sexual part of the Wolffian body or vasa efferentia extend into the hilum of the testis, and gradually lose their identity, owing to their cells having become disseminated in the meshes of the stroma. But those meshes are full of rounded unbranched seminal cells, so that there is a continuity of cell elements between the rete testis and vasa efferentia. As cell arrangement proceeds in the body of the testicle, these intermediate cells form the last link in the chain which unites the sexual tubules of the Wolffian body to the rete testis. The actual arrangement of these indifferently disposed intermediate elements does not begin in the human embryo until about the sixth month of intrauterine life. The accompanying drawing has been made from the testicle of a human embryo at about the eighth month of intrauterine life (fig. 35), and although it does not demonstrate an absolute physical continuity of cell elements between tubules of epididymis and those of the testicular lobules, yet, in my opinion, such an union does exist. The elements are arranged in irregular and crooked strings, so that no single section could give adequate evidence upon this point.

This account of the process by which an egress is provided for the seminiferous tubes is, allowing for differences in the mode of expression, very like that which Janošik describes for the rabbit and cat. However, the examination of testicles of various animals—dog, cat, goat, and rabbit—inclines me to

believe that the process is not the same in every type, but that the tubules of the Wolffian body may participate in different animals to a varying extent in forming the rete testis. If this surmise be correct, it would tend to explain the various and contradictory accounts which may be read in the voluminous literature of the subject. Under these circumstances, it has been deemed advisable to adhere to one type, and human embryos seem as suitable as any others, and have, therefore, been used. It is not proposed to follow the histological differentiation of the tubules of the testicle and epididymis beyond the process of establishment. But before leaving the subject, a word may be spoken upon the fate of the glomeruli of the urinary portion of the Wolffian body. These have been seen at the height of their perfection in male human embryos of the tenth week (fig. 25). At the twelfth week it was still quite easy to ascertain their persistence; but in the male none could be found at the sixth month, nor at the eighth month.

But, in a specimen of the ovary and broad ligament of a child eight months old, lent to me by Dr Walter Griffith, there were structures near the hilum of the ovary which had the usual characters of glomeruli, except that Wolffian tubules were not traced to them.

It may be gathered from the foregoing that I have not been able, either in rabbits' or human embryos, to confirm Balfour's assertion that the glomeruli receive the testicular tubules.

We are now in a position to mark what becomes, in the male, of the sexual and urinary portions of the Wolffian body. The sexual tubules become the vasa efferentia, whilst the urinary tubules may persist, and constitute the well-known organ of Giraldès. Some of them may even grow, and persist as the vasa aberrantia. These tubules, when present, vary in number, and one of our pupils, Mr Stanley, has dissected a testicle for me, in which four can easily be made out. This is such an unusual circumstance that I have made a sketch of the specimen (fig. 36).

LECTURE III.

Oviducts.

Before proceeding with the transition of the testicles, the history of the oviducts, or, as they are usually called, the Müllerian ducts, may be briefly mentioned. Before referring to the development of these canals in rabbits' embryos (the type which has been mainly used in these investigations) it is convenient to describe their appearances in certain pigs' embryos, whose Wolffian bodies and ducts were exceedingly large, and in which the characters of the oviducts could be ascertained with some degree of certainty. These embryos, after hardening, were 1·8 c. long, and had fore and hind limbs of same length, but devoid of flexures or digits, and with the faintest trace of cartilage in their interior. The permanent kidneys had just developed, and the Wolffian bodies were exceedingly large, being 6 mm. long, and nearly at the period of their greatest development; dorsalwards they were suspended in the pleuro-peritoneal sac by a broad mesentery; whilst ventralwards, along their middle third, the genital mass was united to them by a slightly constricted neck; the genital mass was in the indifferent stage, and afforded no indication of its ultimate fate. The Wolffian ducts were exceedingly capacious, and lined throughout with a single layer of very short cubical epithelium. But, although the capacity of these ducts was so great, they caused no prominence upon the surface of the Wolffian body, except towards its hindermost end; there they gradually separated off and ran, in the midst of a cord of mesoblast, to empty into the urogenital sinus.

The portions of the oviducts which had developed were A, their abdominal openings, and B, a short length of their epithelial lining. The abdominal opening (fig. 42) was situated towards the inner and ventral aspect of the Wolffian body and a short distance (twenty thin sections) from its foremost end; it was lined with short columnar epithelium, continuous with that which clothed the Wolffian body and lined the rest of the pleuro-peritoneal sac; however, it is to be noticed that its cells

were both larger and longer than those of the peritoneum. The inner and outer boundaries of the ostium were formed by two jutting processes, and the recess behind the outermost was continuous with the lumen of the oviduct. This continuity was effected very simply by the epithelial recesses becoming deeper, and extending further outwards, until at last (fig. 43) it became a distinct canal, lying between the Wolffian duct and the peritoneal epithelium. Followed tailwards, this canal speedily lost its lumen (fig. 44), and ended in a solid column of cells, which was wedged in between the Wolffian duct and the peritoneal epithelium. The ostium of the oviduct is situated immediately in front of the foremost end of the genital mass (fig. 44), whilst its hinder impervious extremity reaches but a short distance tailwards. Thus, although the oviduct is still exceedingly rudimentary, it already affords evidence of its final disposition; for, whilst its ostium is in front of the genital mass, its canal courses round its outer margin to accompany, at last, the Wolffian duct.

This specimen enables us to infer that, in some respects, the oviduct resembles the Wolffian duct. For instance, it is obvious that its foremost end develops sooner than its hinder part, and that the latter is at its first development like the Wolffian duct, in that it consists of a solid column of cells. However, the specimen affords no definite information as to the origin of the oviduct. Although the Wolffian and Müllerian ducts are so near to one another, yet the epithelium of the oviduct is so unlike that of the Wolffian duct, and so distinct from it, that it seems unlikely that it originated thence. On the other hand, there is no doubt whatever that the epithelium of the oviduct is continuous with the epithelium of the surface of the Wolffian body, and the weight of evidence seems in favour of the view of Egli, Kölliker, and Janošik, that that is its source in the Mammalia. The researches of Balfour and Sedgwick, which were referred to in the first lecture, tend to show that in Aves the ostium of the oviduct is formed from the hinder groove of the pronephros. Therefore, before leaving this pig's embryo, we might endeavour to ascertain whether it affords any information upon that point. Although I am unable to adduce any evidence of the actual existence of a

pronephros in the pig, nevertheless, assuming that that organ had been present, it would be improbable for it to have helped in the formation of the oviduct, because the foremost part of that canal is some distance from the situation which the pronephros might be supposed to have occupied had it ever existed, being situated at least twenty sections beyond the foremost end of the mesonephros; this is borne out by longitudinal sections made from other members of the same litter.

The Wolffian body and its duct, and the rudiments of the oviduct, were so large and easy to observe in these pigs' embryos that I regret to have been unable to obtain similar material for investigating the earlier stages. In rabbits' embryos the early stage of the oviduct seems hard to observe; but the specimens in my possession bear out the statement made in the first lecture, to the effect that the structures which had been supposed to represent the pronephros entirely disappear, and therefore take no part in the formation of the oviduct. In other respects they countenance the view that the oviduct begins by an ingrowth of the epithelium of the urogenital ridge, and, finally, they fully bear out Kölliker's observations upon its later stages.¹

Genital Cord.

Although in the male the oviduct is functionless, and only represented by some interesting remains, nevertheless this circumstance has no particular influence upon the early stage of its development. This is exemplified by a human embryo which was mentioned in a previous lecture (Lect. II. p. 32), and which was $\frac{5}{8}$ ths of an inch long, and estimated to have arrived at about the seventh week of intrauterine life. In this specimen the genital mass was in the indifferent stage, and towards its upper end² there were several villous projections, the commencement, presumably, of the fimbriæ of the oviduct, or, as later it is called, the Fallopian tube. The oviduct itself skirts round the outer margin of the genital mass, and after gradually approaching

¹ *Entwicklungsgeschichte*, p. 977.

² So far specimens have been described as though the venter of the embryo was towards the ground. In this lecture the terms ordinarily adopted in human anatomy will be used, and the relations of structures spoken of as though the body was erect.

the Wolffian duct runs in company with that canal towards the lower end of the Wolffian body, where they together enter a thick mesoblastic cord, which is seen in a previous drawing (fig. 39, p. 52). At this period, the seventh week, the cord which contains the Wolffian and Müllerian ducts is very short, and runs gradually inwards to unite with its fellow of the opposite side, and fuse with the mesoblast in which the urinary bladder is embedded. It is convenient to assign their names to these cords, and they should be called respectively the right and left genital cords and the common genital cord. As is well known, after the oviducts have entered the common genital cord they coalesce into a single canal, which ends in the urogenital sinus; the Wolffian ducts, on the other hand, remain apart, and open separately into the same space. In fœtuses at full term it is usual to find the rudimentary oviduct, with a fimbriated end, lying in the digital fossa close to the globus major (*v.*, fig. 45); this structure sometimes possesses a distinct canal. In the specimen which has been figured there are also two large spatulate and pedunculated bodies attached to the globus major; there is usually but one of these bodies, and their meaning seems still very obscure.¹

Transition of the Ovary or Testis.

Method of Investigation.—Apparently the reproductive organs of the seven weeks' human embryo which has just been referred to have, with reference to the other viscera; begun to occupy a lower position in the abdomen, or, in other words, the transition of the ovary or testis, whichever it may be about to become, has commenced.

The transition of the ovary and testicle has been mainly studied by dissection, and, perhaps, there is not much left to be ascertained by that method. For the earliest stages, however, it is desirable to use properly prepared series of histological sections, and since, as yet, this method has been but little used, I propose in that which follows to give the main facts learnt by its employment. By the paraffin method consecutive sections can be obtained in which the relations of the various organs

¹ Wertheimer, art. "Testicule," *Dic. Encyclopédique des Sciences Médicales*, p. 533.

to one another, and to the skeleton, can be studied without fear of disturbance. As the supply of reliable human embryos is necessarily limited, some of the earlier stages will, as a preliminary, be studied by means of rabbits' embryos.

The transition of the reproductive gland has two stages; the first comprises alterations in its position within the abdominal cavity; the second its passage through the abdominal wall into the scrotum.

Before discussing these two phases, it is desirable to endeavour to determine upon what evidence movements of the ovary or testis may be judged to have taken place. It will be readily agreed that the relations of the gland to the skeleton, more particularly to the pelvis, are likely to yield the safest information upon this question. Therefore, for the present, I propose to consider the matter from this standpoint.

Earliest Relations of the Reproductive and Urinary Organs of the Rabbit to each other and to the Skeleton.

It is customary for authors to describe the position of the genital mass and Wolffian body with special reference to their relation to the kidney. This is calculated, I believe, to lead to erroneous conclusions, unless particular care is taken to observe their mutual relations to the skeleton. When, during the thirteenth day, the permanent kidneys of the rabbit appear, they are situated, as we have seen (p. 45, fig. 29, Pl. II.), behind the lower end of the Wolffian body and a little lower in the abdomen than the genital eminence. However, on the fourteenth day, the permanent kidneys have grown forwards (fig. 30, Pl. II.) until they lie behind the middle third of the Wolffian body, and consequently opposite the genital mass. This marks the point from which observers consider the transition of the testis or ovary begins. However, it is clearly wrong to speak of the testicle developing in front of the kidney, for the contrary is the case; and, as we have seen, the kidney develops after the Wolffian body and genital mass, and behind *them*. In these rabbits' embryos it would be wrong, so far, to say that the genital mass and Wolffian body had begun to migrate, although, judging from their relations to the kidney,

and assuming that the latter were immobile, it would be easy to imagine that movement had occurred. Another circumstance which might strengthen that impression is, that whilst the kidneys are developing, the lower end of the Wolffian body grows, as may be seen in the figure of the Wolffian body already described (fig. 39, p. 52), and tends towards the lower part of the abdomen. In consequence of this growth the Wolffian body appears lower in the abdomen, both as regards the kidney and as regards the skeleton. This point will be clearer as we proceed with the description of the transition in human embryos.

Thus, in the rabbit, the earliest changes in the mutual relations of the reproductive organs and kidneys are mainly due to growth and development in the organs themselves. The next step is to consider the early relations of the kidneys and reproductive organs to the cartilaginous skeleton.

Since the lower part of the vertebral column and pelvis are the portions of the skeleton with which the reproductive organs and kidneys are principally in relation, we will proceed with their early development. The Wolffian body and genital mass have attained considerable dimensions prior to the appearance of the cartilaginous vertebræ. For instance, in the embryo of thirteen and a half days, whose Wolffian body and genital mass was described in the second lecture (p. 39, fig. 37), the cartilaginous bodies of the vertebræ could just be discerned. There was, however, no trace of the pelvic cartilages, and the hind limb consisted of nothing but mesoblast, blood-vessels, and nerves, together with a covering of epiblast. In this embryo the ureter had appeared, and ended in an irregular dilation a few sections nearer the tail than the hinder end of the Wolffian body.

The pelvic cartilages appear towards the end of the thirteenth day close to the tail end of the Wolffian body. They originate in a quantity of mesoblast which there is in that region, and an idea of the position of this mesoblast in the human embryo may be gathered from the drawing of a very early specimen given in the first lecture (fig. 1, p. 3). The acetabular portion of the pelvis develops first, and the iliac cartilages extend from it behind the Wolffian body and towards the kidney. By the middle of the fourteenth day the iliac cartilage

reaches well behind the Wolffian body; and the lower part of that organ is quite close to the lower part of the abdomen, and about opposite the head of the femur. Thus the Wolffian body of the rabbit acquires relations with the ventral surface of the pelvis, owing to the manner in which that part of the skeleton is developed, and not on account of any active movements which it (*i.e.*, the Wolffian body) may be supposed to have undergone. Moreover, after the growth of the iliac cartilages the position of these organs seems, by contrast, lower in the abdomen; though, without doubt, the growth of the so-called urinary part of the Wolffian body conduces to this impression.

The influence of these processes of growth upon the apparent position of the genital mass may, perhaps, have been inferred. The first trace of the kidney develops behind the Wolffian body, opposite the lower end of the genital mass; the organ speedily grows, and by the fourteenth day reaches as far as the level of the upper end of the genital mass. At this stage I propose to leave this question, to be resumed by means of human embryos suitable for the investigation of the subsequent stages.

It is hard to ascertain the exact relation of the kidneys and reproductive organs to the spine, because no single longitudinal section divides sufficient of each to these organs to permit of a correct estimate. The most that can be safely affirmed is, that both kidney and genital mass lie opposite the lumbar spine, whilst the Wolffian body extends a little beyond above, and a great deal beyond below.

The acetabular portion of the pelvis develops almost opposite the lowest end of the Wolffian body, and therefore at some distance from either the kidney or genital mass; and although the iliac cartilage grows upwards behind the lower extremity of the Wolffian body, it has hardly, by the fourteenth day, reached as far as either the kidney or genital mass. If anything, it is nearer the lower extremity of the latter.

The foregoing account of the course of events in rabbits' embryos has been given because those animals afford material of a fairly trustworthy character, and useful for checking that derived from human embryos. In endeavouring to ascertain how far that which they have taught is applicable to human embryos, the following points will be kept in view, namely, to

ascertain the relations of the genital mass and Wolffian body to the kidney, and the relations of the genital mass, Wolffian bodies, and kidneys to the skeleton.

Earliest Relations of the Human Reproductive Glands and Urinary Organs to each other and to the Skeleton.

Although I have been unable to obtain human embryos suitable for showing each stage in the development of the permanent kidneys, yet there is little doubt but that those organs begin the same as in the rabbit. For instance, in a human embryo whose hind limbs had just budded, and whose development was almost equivalent to that of a rabbit's embryo of the thirteenth day, the permanent kidneys lay behind the lower end of the Wolffian body and genital mass, and it was evident from their rudimentary structure that they had just appeared. Moreover, in sections through the lower end of the Wolffian body, the acetabular portion of the cartilaginous pelvis and the cartilaginous femur could be seen.

The observation that the human pelvis is developed in a solid mass of mesoblast opposite the lower end of the Wolffian body is borne out by other specimens, and they also show that the iliac cartilage grows upwards behind the end of that organ. In these respects the human embryo resembles the rabbit, and there can be no question but that its Wolffian body is likewise in relation with the venter of the pelvic cartilage, because of the manner in which the cartilage develops and grows, and not on account of movements which the excretory organ may have undergone.

Another human embryo a little more advanced, and which was estimated to have reached about the fifth week of intra-uterine life, has been mentioned in which the kidney lay behind the genital mass and Wolffian body, much in the same way as it did in the rabbit (fig. 31, Pl. II.). So that, up to this point, there seems to be no difference between rabbits and human embryos.

In a human embryo of the seventh week, which has been frequently mentioned, and whose reproductive organs have been figured (fig. 39, p. 52; also fig. 34, Pl. II.), the various features

are shown so clearly that it is proposed to describe them in greater detail.

The section which has been figured (fig. 46) is to the left of the vertebral column, and in its lower part divides the cartilaginous ilium and ischium, and a portion of the femur; in its upper part, amongst other things, the twelfth rib and diaphragm are in view. The histological structure of the kidney is very rudimentary, and that organ lies betwixt the last rib and the crest of the ilium, and almost equidistant from either of those landmarks. Only the lower end of the Wolffian body has been divided in this section, but, as in the case of the rabbit, it lies upon the venter of the ilium, and reaches as low as the head of the femur.

In sections near the mesial plane the main part of the genital mass is just below the kidney, and on a level with the crest of the ilium (fig. 46), whilst its upper part, together with the sexual portion of the Wolffian body, extends along the convex margin of the kidney almost as far as the twelfth rib. It might easily be supposed that these appearances indicated that the genital mass had actually moved to a lower place in the abdomen, and this would be the more easily inferred if nothing but its relation to the kidney were taken into consideration. In a moment we shall see that its relations to the Wolffian body and to the skeleton have undergone no alterations which ought to be attributed to any process of locomotion, although it is probable that its relations to the kidney have become modified owing to the manner in which either organ develops. For instance, it seems possible that the part of the genital mass which is nearest the lower end of the kidney takes a greater share in the formation of the reproductive gland than the upper part. This seems to be so in rabbits of the latter part of the thirteenth day, and also in rats of a similar degree of development. In both of these the lower portion of the genital mass is much more bulky than the upper, and if the same holds good for human embryos, as it seems to do in the one we are discussing, it would naturally help to explain the relative positions of the organs to one another. Before mentioning the growth of the permanent kidneys, it is convenient to ascertain whether the Wolffian bodies have altered their relations to the

newly formed cartilaginous skeleton; for it seems safe to assume that, if those organs have kept their position, the genital mass must have done the same.

I have already pointed out that the relation of the Wolffian body to the pelvis is determined by the manner in which that part of the skeleton develops behind its lower end. In the human embryo of the seventh week, which is being described, the acetabular portion of the pelvis occupies its original position at the lower end of the Wolffian body, although, as in the rabbit, the upward growth of the iliac cartilage makes the sexual organs look lower than they might otherwise do. Judging from its relations to the kidneys, the urinary portion of the Wolffian body seems decidedly lower in the abdomen. This, however, may be partially accounted for by the way in which the temporary and permanent urinary organs grow in relation to each other. Although the kidneys first appear behind the lower end of the Wolffian body, yet their growth seems to be upwards towards the head rather than downwards. Moreover, as we have seen, before the kidneys have attained much size or perfection, this so-called urinary portion of the Wolffian body increases, and tends towards the pelvis. These factors, taken together, seem almost sufficient to account for the relative positions which the kidneys and Wolffian bodies have assumed.

If we recall the early history of the Wolffian body, it is clear that its sexual portion still remains to be accounted for. This, in the specimen which is being described, is applied to the uppermost part of the genital mass (fig. 34, Pl. II.), and lies outside the kidney, and above the level of the iliac crests. Therefore, it may be concluded that although the sexual portion of the mesonephros is undergoing changes, it has not altered its original position, but that various parts of the skeleton and the kidneys themselves have developed and grown in its proximity.

Relation of the Mesonephros to the Suprarenal Bodies.

Should this line of argument be thought wanting in cogency, another circumstance may be mentioned which seems to show that neither the temporary kidneys nor their adjuncts, the geni-

tal masses, have altered their positions. In speaking of the sections through the inner part of the Wolffian body of this seven weeks' embryo (p. 62), it was said that "the foremost glomeruli, although larger, are faintly stained, and their tissues granular,—appearances which indicate that they have begun to degenerate and atrophy." When this was written I felt uncertain whether this portion of the Wolffian body was continuous with the lower and inner part of the suprarenal body. It is so easy in histological specimens to fancy structures are continuous which merely overlap, that I refrained from making any statement upon the subject. However, after studying the specimens over and over again during many months, I am of opinion that a portion of the mesonephros of this human embryo is in actual continuity with the suprarenal bodies. The part in question is that which is nearest the mesentery, and which, as has been repeatedly said, is mainly composed of glomeruli. It reaches the lower and inner part of the suprarenal along the course of the ureter, and towards the upper part of the hilum of the kidney, but quite separate and distinct from the substance of that organ. Not only am I unable to discover any line of demarcation between the glomerular part of the mesonephros and the suprarenal body, but those organs seem to merge gradually into one another; this is seen best by observing the glomeruli, which, whilst being quite distinct below, become fainter and more finely granular as they merge into the suprarenal (fig. 47). The main bulk of the latter is composed of small nucleated cells, arranged in the well-known radiate columns seen in the adult organ. Between these columns there is a supporting stroma, which is directly continuous with that of the Wolffian body, which, it may be remembered, has already been depicted and described (Pl. II., fig. 24, and also p. 36). Towards the centre of the suprarenal body the radiate arrangement of its elements ceases, and instead are loculi of cells more loosely aggregated, and of larger size and oval.

The cortical portion of the suprarenal body of this seven weeks' human embryo has an exceedingly strong likeness to the neighbouring genital mass in the following respects, namely, in the radiate arrangement of its cell elements, their size, shape, and staining, and also in the character of its stroma; although

the last can only be considered a minor and perhaps unimportant point of resemblance.

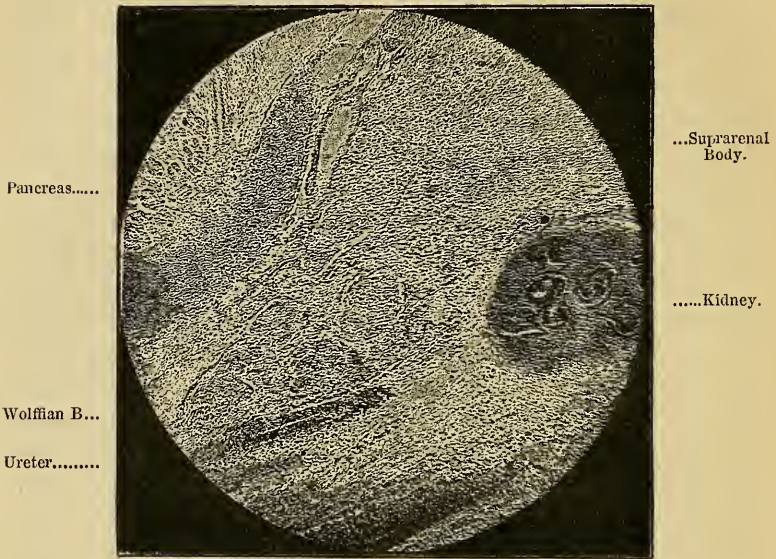

FIG. 47.—Continuity of Wolffian and Suprarenal Bodies in a Human Embryo of the seventh week.—(Electrotype from photograph of section.)¹

In due course I propose to discuss the position and relations of the sexual apparatus of another human embryo, which has been mentioned before, and which was estimated to have attained the tenth week of intrauterine life (fig. 40, p. 56). But, before commencing this topic, it is convenient to inquire whether it in any way confirms the statements which have just been made concerning the relation of the mesonephros to the suprarenal bodies.

In this embryo the kidneys lie opposite the lumbar spine, and their position is the same as in the younger specimen (fig. 40, p. 56). The suprarenal bodies are much larger than the kidneys, and occupy their usual position above those organs. Their lowest part reaches downwards a little beyond the hilum of the kidney. The testicle (for in this case the

¹ I am indebted to my friend Mr Cosens for the micro-photograph from which this electrotype was made.

tunica albuginea and tubuli seminiferi have appeared (fig. 41, p. 57)) and the Wolffian body, or, as it has almost become, the epididymis, lies just below the kidney and upon the venter of the iliac cartilage. In the section which has been figured there is not the slightest connection between the Wolffian body and the suprarenal body, but it may be remembered that in the younger embryo the junction between those organs was effected near the hilum of the kidney by a process of glomerulus containing tissue which lay along the course of the ureter. Now, in the sections which divided that canal, there were in its neighbourhood structures which had all the appearances of those granular and altered glomeruli seen in the previous instance. Moreover, the lowest part of the suprarenal body extends so far into the hilum of the kidney, that although it is hard to tell whether in any particular section it is continuous with the peri-uretral glomerular tissue, nevertheless there is little doubt but that such is the case. But, in addition, the appearances of the lowest part of the suprarenal body are exceedingly significant. In every part of its circumference that organ has a very definite fibrous capsule, which delimits it from surrounding structures, except below, where its continuity is broken. In that region it is, I think, certain that some of the glomerular structures, such as lie along the course of the ureter, are imbedded in the cortex of the suprarenal body. In this older embryo the difficulty of arriving at a correct opinion upon this point is increased owing to the large size of the renal veins; but, nevertheless, the suprarenal body seems still connected with the Wolffian body, although the passage of the renal veins through the peri-uretral tissue renders their continuity harder to determine. I may add that there is not the slightest trace of any mixing of the renal tissues with those of the Wolffian body; on the contrary, the kidney has a definite capsule. Supposing these observations are correct, it is quite unnecessary to comment upon their importance. The recent observations of Mr Weldon¹ seem to show that there is in some types a close relationship between the early development of the suprarenal bodies and the glomeruli of the mesonephros.

¹ "On the Suprarenal Bodies of the Vertebrata," W. F. R. Weldon, *Quart. Jour. Micr. Sci.*, vol. xxv. p. 137, 1885.

Also Janošík¹ has found that the suprarenals develop in connection with the foremost part of the urogenital ridge.

The human embryos of the seventh and tenth weeks, which have just been described, seem to indicate that the human suprarenal body has a developmental relation to the inner and upper part of the mesonephros. Doubtless the appearances of the glomeruli of that organ in the younger embryo indicate that an atrophic process has begun by which the mesonephros becomes eventually disconnected from the suprarenal; and it seems as if, in the older specimens, that dissection was almost accomplished; and to this consummation the growth of the permanent kidneys and of their veins seems to have conduced.

The bearing of the foregoing upon the question whether the Wolffian body and genital mass of the seven weeks' human embryo has descended in the abdomen, or not, can easily be inferred. Judging from their relations to the skeleton, it has already been decided that the sexual and urinary portions of its Wolffian body have undergone no actual alteration in position; and now it may, with plausibility, be urged that the connection of its inner and upper part with the suprarenal body would render such movements exceedingly improbable.

The human embryo of the tenth week is the earliest I have obtained in which the sex is not doubtful. It is hardly requisite to recapitulate the grounds upon which it has been decided that it is a male; the existence of the tunica albuginea testis, and unquestionable tubuli seminiferi are perhaps the most important. Therefore it is of especial interest to endeavour to ascertain whether, in this instance, the testicle and epididymis have undergone any active process of transition towards the lower part of the abdomen, or whether these organs have maintained the position which was determined for them by the development in their proximity of the kidneys and pelvis.

As regards the relation of the Wolffian body to the pelvis, some of the sections show that its urinary part is opposite the acetabular portion of the pelvis, and therefore has undergone no change since that part of the skeleton was developed in its

¹ "Bemerkungen über die Entwicklung der Nebenniere," *Archiv für Micros. Anatomie*, Band xxii., 1883, p. 738 *et seq.*

vicinity. Also, it may be mentioned that the hypogastric arteries have attained considerable size, and project so far into the peritoneal sac that they almost touch the right and left genital strings, just after the latter have left the Wolffian bodies. Later in embryonic life it is probable that those vessels have an influence in determining the point at which, in the male, the sexual glands pass through the abdominal wall.

Although, therefore, the testicle and epididymis of this ten weeks' embryo have maintained their original relations to the pelvis, yet, apparently, their relations to the kidneys have altered. This is due, as in previous instances, to (*a*) changes in the reproductive organs themselves, and (*b*) to changes in their surroundings, including the kidneys. It is convenient to begin with the last mentioned; and, in the first place, it seems improbable that the appearances can be due to any movements of the kidneys. In the seven weeks' embryo those organs were situated opposite the lumbar spine, and now, at the tenth week, they still occupy the same position. In the interval, however, they have grown, and instead of being subordinate to the sexual organs they now surpass them. This circumstance has clearly an influence in determining the relation of the genital glands to the kidney.

The growth of the lumbar spine is also a factor which must be taken into consideration in speaking of the influence which the growth of their surroundings may have upon the apparent position of the reproductive glands. Although, at the tenth week, the lumbar spine has grown a great deal, yet it has only kept pace with the growth of its contents and surroundings. The spinal medulla still extends the whole length of its canal (fig. 40, p. 56), and the cauda equina and filum terminale are non-existent. In older embryos the growth of the spinal column is so rapid that it far outstrips that of the spinal medulla, and, as is well known, leads to the formation of the last-named structures. Now, it is significant to observe that whilst the spinal column, especially of its lumbar part, is growing, the genital gland, either ovary or testis, separates from the kidney. During this separation the kidney remains immobile in front of the lumbar spine, and the sexual gland maintains its original relation to the pelvis, so that one important cause of the separation is

not far to seek, and is, in my opinion, the growth of the lumbar spine.

We may now return to the human embryo of the tenth week, with a view of ascertaining whether any changes in the sexual gland and Wolffian body may have helped to bring them into position below the kidney.

It cannot be considered to have been proved that, in the human embryo, the lower part of the sexual eminence is actually converted into the testicle, but, nevertheless, that is possibly the case; and I have already argued that the circumstance may partially account for the position of the genital mass in the embryo of the seventh week. In the present instance the genital mass has become the body of the testicle, and that organ is decidedly globose, and has ceased to extend around the outer convex border of the kidney, as it did at the earlier stage. Also, the sexual portion of the Wolffian body has become more closely applied to it, to form the epididymis. These circumstances, together with the incorporation of the upper and inner part of the Wolffian body in the adrenals and its partial atrophy, help to determine the position of the sexual glands below the kidneys.

The development of the ovary is not at present in question, but perhaps I may mention that the foregoing observations are, in all probability, applicable to either sex. An exception to this statement must be made in respect to the shape of the ovary, for that organ does not become globular like the testicle, but retains to a certain degree the primitive elongated form of the sexual eminence.

In the human embryo of the twelfth week, and whose testicle has been figured (fig. 33, Pl. II.), that organ, as usual, lay in front of the ilium, and upon the brim of the pelvis; its lower part almost touched the hypogastric arteries, whilst its upper end is just in contact with the kidney. At this age the body of the testicle seems longer than the epididymis, and the latter has on upward prolongation. So far as concerns its relation to the pelvis, the sexual gland is almost in the same position as it was in embryos of the seventh and tenth week; but its mesentery is much longer than it was in them, and it is altogether more separate and distinct. Judging

from the length of the spinal cord, the vertebral column has not grown very much, and has, so far, merely kept pace with the growth of the organs in its vicinity.

At the third month the position and connections of the testicle may be observed by ordinary dissection and with the naked eye. The sex of the embryo may also be ascertained in the same way by the shape of the sexual gland, and, more especially, by the direction of its long axis. In males the long axis of the testicle is vertical and its shape globular; whilst in females the long axis of the ovary is oblique, and the gland is decidedly spindle-shaped. It is hardly necessary to add that the external organs of generation are at this period the same in either sex, and therefore of no value for determining the sex.

Before proceeding, it may be advisable to enumerate the events which seem to participate in leaving the testicle or ovary upon the brim of the pelvis. I will endeavour to give them in their proper sequence. 1. Development of mesonephros. 2. Development of genital eminence. 3. Development and growth of kidney behind mesonephros and genital eminence. 4. Development and growth of pelvis behind lower end of mesonephros. 5. Alterations in upper part of mesonephros; its partial atrophy and probable incorporation in suprarenal capsule. 6. Growth of lumbar spine.

If the observations recorded in the earlier part (p. 70) of this Lecture be correct, the testicle has attained its position upon the brim of the pelvis, and almost in contact with the hypogastric arteries and the abdominal walls, by a gradual process of development and growth. But already, at the third month, preparations are being made for the active transition of the gland through the abdominal wall, and its final deposition in the scrotum. Amongst these preparations are comprised the further development of the mesorchium and of its ascending and descending processes, namely, the plica vascularis and the plica gubernatrix, the development of the gubernaculum itself, the development of the inguinal canal, and, finally, the development of the scrotum.

It is convenient to refer briefly to such of these as can be seen with the naked eye, and then proceed with those which require to be studied by means of histological sections.

The Mesorchium, Plica Gubernatrix, and Plica Vasularis.

The mesorchium has frequently been mentioned before, and is the fold of peritoneum which unites the mesonephros, and afterwards the epididymis, to the back of the abdomen; the word is not, perhaps, quite free from ambiguity, for the mesentery belongs more especially to the mesonephros, but as the name is established by custom, it is desirable to continue its use. At the third month the mesorchium is but a slender support, and is prolonged upwards from the epididymis in a small triangular fold; and, as this subsequently contains the spermatic vessels, I have, in a paper on "Encysted and Infantile Hernia,"¹ ventured to call it the plica vasularis. Without doubt the plica vasularis is the same as the fold which at an early age unites the upper end of the Wolffian body to the diaphragm, and is called by Kölliker² the diaphragmatic ligament of the mesonephros (Zwerchfellsband der Urniere). However, in the later stages these relations of this fold are quite subordinate; whilst, as will be seen, its relations to the spermatic vessels are of practical and pathological importance. The mesorchium is shown in the accompanying drawing, made from a human embryo of the third month, and in this specimen the testicle and kidney are a little way apart, the separation being caused, I believe, by the growth of the lumbar spine and pelvis, including the sacrum in the pelvis. The plica vasularis does not reach quite as far as the kidney, but is, nevertheless, an obvious feature (Pl. III. fig. 48). The lower part of the mesorchium is, on either side, continued along the right and left genital strings, to become continuous with a cord which passes down to the outer side of the hypogastric arteries, and ends in the abdominal wall. This cord is an early stage of the gubernaculum testis, and the downward prolongation of the mesorchium³ is the plica gubernatrix. It is hardly requisite, perhaps, to trace minutely the gradual growth of the mesorchium. It does not, perhaps, develop luxuriantly in every fœtus, but at about the

¹ "The Morbid Anatomy and Pathology of Encysted and Infantile Hernia," by C. B. Lockwood, *Med. Chir. Trans.*, vol. lxi., 1886.

² Kölliker, *Entwicklungsgeschichte*, p. 959.

³ The mesorchium is sometimes called "Seiler's fold."

end of the seventh month it usually has the appearance seen in the accompanying sketch (fig. 49). The base of the mesorchium was loosely fastened along the psoas muscle, and its free edge ended upon the epididymis and testicle; its lower fold contains the gubernaculum, and the upper the spermatic vessels. However, at this age (seventh month) the chief interest of the upper process centres in its relation, on the right side, to the cæcum, vermiform appendix, ilium, and mesentery, to which it is now (towards the end of intrauterine life) adherent; and later it will be seen that this may have an important bearing upon the pathology of congenital cæcocele; on the left side it passes

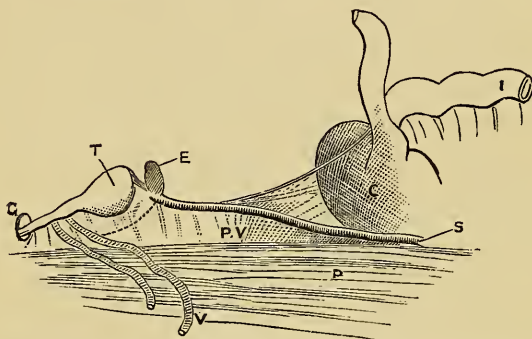


FIG. 49.¹—Drawing made from a seven or eight months' fœtus to show the fold (plica vascularis) which connects the testis with the cæcum. T, testicles; E, epididymis; P, psoas; V, vas deferens; G, plica gubernatrix, disappearing into processus vaginalis; P.V., plica vascularis; C, cæcum; S, spermatic artery; I, ilium.

upwards to the sigmoid flexure. The plica gubernatrix, moreover, disappears below in a peritoneal pouch, which is the beginning of the processus vaginalis. The formation of this protrusion may be considered after the development of the scrotum and inguinal canal.

The Development of the Scrotum and Inguinal Canal, including the Ascending and Descending Cremaster.

It is proposed as far as possible to pursue this branch of the subject by means of histological sections. As far as can be

¹ I am indebted to the Council of the Royal Medico-Chirurgical Society for permission to use this and another block.

ascertained, most of our knowledge of it has been learnt by dissection;¹ yet, although a great deal of information has been gained in this manner, nevertheless, the embryonic tissues are so delicate and hard to manipulate that there seems to be still room for further inquiry. This refers more particularly to the histology of the earlier stages, and I now propose to describe them as briefly as possible, using for the purpose human embryos, which may be supposed to have attained the seventh, tenth, twelfth, and twentieth weeks of intrauterine life.

At the seventh week the structure of the abdominal wall is very rudimentary, and it contains but a trace of muscle in its substance. Its exterior is covered with a layer of epiblast, whilst it is lined within by a clearly defined but tenuous membrane, which is the beginning of the peritoneum. Where the peritoneum lines the front abdominal wall there is no trace of subperitoneal areolar tissue, but towards the back and lower part of the abdomen that tissue is abundant, even at this early age. The main bulk of the abdominal wall is composed of ordinary mesoblastic tissue of considerable density, but towards the middle line a quantity of fine deeply stained fibres betoken the advent of the rectus abdominis. The appearances in this embryo seem to indicate that, so far as concerns the muscles of the trunk, the degree of their development is determined by their size more than by other considerations; and, in consequence, such muscles as the gluteus maximus, erector spinæ, and ilio-psoas are the furthest advanced. In this embryo, also, the pubic cartilages were still some distance apart, and the mesoblast of the abdominal wall continued over their surface into the perinæum, making a decided bulge on either side below the pubes, in the situation of the future scrotum or labia majora, as the case may be; for it has been repeatedly said that the genital mass of this embryo is in the indifferent stage. The scrotal mesoblast is exactly the same as that which forms the abdominal wall, with the exception that it cannot be said with any degree of confidence that there is any indication of the conversion of any part of it into muscle.

¹ F. Bramann, in his "Beitrag zur Lehre von dem Descensus testicularum und dem Gubernaculum Hunteri des Menschen," *Archiv für Anat. und Entwickl.*, 1884, p. 310 *et seq.*, gives an exhaustive account of the literature of the subject, and his investigations will be mentioned again.

Before leaving this embryo, I may mention that the bladder and hypogastric arteries are of some size, and are closely related to the lower third of the wall of the abdomen, behind the developing rectus abdominis; their width, taken together, is considerable, and they make the middle part of the lower front wall of the abdomen look very solid and impervious.

In the human embryo of the tenth week of intrauterine life (fig. 40, p. 56) the development of the abdominal walls has made further progress. Not only the rectus abdominis, but also the external oblique and transversalis, are clearly marked. The fibres of the various muscles are imbedded in embryonic connective tissue, which is most abundant beneath the cutaneous surface and almost absent where the peritoneum lines the transversalis and rectus muscles. The sections which divide the abdominal wall near the site of the future internal abdominal ring show that preparations have commenced which may be supposed to be capable of facilitating the transition of the testicle into the scrotum. Before proceeding to detail them, it may be desirable to indicate the point at which they are seen. As regards the cartilaginous skeleton, it is situated almost vertically above the outer margin of the thyroid foramen, and consequently just internal to the head of the femur. In the next place they are immediately above the inner side of the external iliac vein, which is very large, and external to the hypogastric arteries. As in the younger embryo, these vessels, together with the bladder, occupy a large part of the lower middle part of the abdominal wall. Therefore I am about to describe the abdominal wall at the point at which the internal abdominal ring afterwards appears. The abdominal wall has the following layers:—externally, of course, a cutaneous covering, which has beneath it a thick layer of undifferentiated mesoblastic tissue; next comes a thin and deeply staining lamella which merges above in muscular fibres, and, I take it, represents the external oblique; a third muscular layer forms the next stratum, and upon its inner surface the peritoneum is closely applied, except at a point which will be mentioned directly; the last muscular layer constitutes without doubt the internal oblique and transversalis. Of these various strata, the cutaneous one may be dismissed without further comment. The sub-

cutaneous mesoblastic tissue, as in the younger embryo, extends over the pubes and is continuous with the scrotal eminence. Towards the inner side of the iliac vein, and in the position of the internal abdominal ring, the external oblique layer makes a decided bend into the subcutaneous mesoblastic tissue and towards the scrotum. The concavity of this projection, which, I believe, is an early stage of the external spermatic fascia, is thinly lined with a layer of muscular fibres derived from the succeeding layer; these represent the beginning of the descending portion of the cremaster muscle, and their hollow is filled with embryonic connective tissue. Presently, ascending cremasteric fibres will be mentioned, which are derived from the muscular fibres of the abdominal wall which are nearest to the peritoneum and which ascend with the gubernaculum testis.

In this embryo, moreover, the inguinal canal has begun. The muscular layer of the lower abdominal wall (*i.e.*, of the internal oblique and transversalis) may be said to have below three portions, namely, the descending cremasteric fibres, the ascending cremasteric fibres, and a middle set which descend no farther than the point at which the previous two are given off. In consequence, an interval is left in the situation of the inguinal canal which has the ascending and descending cremaster for its front and back boundaries, and the middle fibres for its roof. The contents of this rudimentary inguinal canal are a quantity of embryonic connective tissue, and some gubernacular fibres which will be mentioned directly.

The peritoneum has been said to be closely united to the inner surface of the transversalis muscle, and I have now to add that it has nothing which corresponds to the bulging of the external spermatic fascia and cremaster. Its surface is quite even, with the exception of a short process which runs upwards from the abdominal wall to either genital string, and which is the beginning of the plica gubernatrix. There is a leash of fibres within the plica like those of areolar tissue, and these fibres pass upwards to the genital string and to the peritoneum; below they spread out and pass beneath the edge of the muscular layer of the abdominal wall (internal oblique and transversalis), and mingle with the walls of the projection formed by the external spermatic fascia and cremaster. The muscular

fibres of the abdominal wall, which are nearest the peritoneum, instead of terminating, as the others did, to form an inguinal canal, are, as I have already said, continued into the base of the plica gubernatrix, and will be mentioned again in speaking of the structure of the gubernaculum testis.

Finally, the testicle itself lies upon the ilium, and a very little way from the front abdominal wall. The peritoneum in the neighbourhood of the testicles and of the back wall of the abdomen has beneath it an abundance of loose embryonic connective tissue.

Assuming that these observations and inferences are correct, it is clear that the scrotum, and some of its layers, is formed long before the transition of the testicle, and quite independently of that event. There is nothing new or novel in this, but it is interesting to record the earliest stages of the process. Carus's theory, that the testicle, in its descent, carried down its own investments from the abdominal wall, has been so abundantly falsified that it is quite unnecessary to argue that the foregoing is also antagonistic to the views of that authority.¹ This is a convenient point to mention that the hypogastric arteries seem to have an influence in determining the point in the abdominal wall at which the processus vaginalis begins to appear. It has been stated in an earlier part of this lecture that those vessels, together with the bladder, render the lower median part of the abdominal wall exceedingly thick and impervious; whilst the lower and external part is comparatively weak and unprotected. From this it follows that after the testicle and vas deferens have passed into the scrotum the ostium of the processus has the hypogastric artery upon its inner side, and it is only after that vessel has dwindled that the epigastric artery takes its place, and becomes the inner boundary of the ostium. Moreover, at first the vas deferens in its course to the migrated testicle turns round the hypogastric artery, and receives a small branch from it—the deferential artery.

The next embryo, that of the twelfth week, was, of course, much larger and better developed than that which has just been described. It was cut into a series of transverse sections, which con-

¹ Sappey, *Traité d'Anatomie Descriptive*, vol. iv. p. 581, 1874, adduces several cogent reasons against Carus's theory.

firmed the inferences drawn from the previous embryo, which, it may be remembered, was cut longitudinally. The testicle of this twelve-weeks' embryo has already been figured (fig. 33, Pl. II.), and lay upon the brim of the pelvis and very close to the abdominal wall and hypogastric arteries. The genital strings, right and left, were united to the lower part of the abdominal wall by the plica gubernatrix. This fold was narrower at either end than in its middle part, where it bulged somewhat. Its substance consisted of round and spindle-shaped cells; the latter had a decided likeness to unstriped-muscle cells, and were continued into the substance of the abdominal wall, in the situation of the inguinal canal. Moreover, the muscular fibres, which have been called the ascending cremaster, entered the base of the plica gubernatrix, and were, without question, continued upwards beneath the peritoneum, which formed the plica, as far as the genital string, or, as it might now be called, the vas deferens. At the point at which the plica gubernatrix was continuous with the peritoneum of the abdominal wall there was no irregularity or trace of the processus vaginalis. Both the external spermatic fascia and the descending cremaster bulge towards the scrotum, which consisted of embryonic connective tissue, whose stellate cells were very clear and unmistakable, and without any admixture of muscular fibres except those which have just been mentioned. The two halves of the scrotum had almost united, although in the perinæum there was still a wide opening between the urethra and the exterior.

The main difference, therefore, between this embryo of the twelfth week and that of the tenth, assuming that their ages have been rightly calculated, seems to consist in a greater development of the muscular constituents of the gubernaculum testis, and of a further fusion of the halves of the scrotum.

It has been said that the testicle of this twelve weeks' embryo was upon the brim of the pelvis and quite close to the abdominal wall, and this position, it will be perceived, is the same as that which the Wolffian body and genital mass or testicle occupied in embryos of the seventh and tenth weeks; moreover, it may be added that, allowing for the growth of surroundings, its position in relation to the acetabular portion of the pelvis is practically the same.

The next stage, in which the development of the scrotum, and of the coverings of the testicle, and of the inguinal canal were investigated by means of histological sections, was probably the fifth month. In this case the processus vaginalis and gubernaculum testis had, as will be presently described, definitely appeared; but, before mentioning them, the scrotum and inguinal canal may be referred to. Perhaps it is to be regretted that there is such an interval between this and the previous embryos, but as development proceeds it becomes more and more difficult to obtain a reliable series of histological sections, and practically it will be found that the hiatus is not likely to lead to erroneous conclusions.

The fœtus from which the following conclusions were drawn was in all respects well formed, and had probably attained the fifth month of intrauterine life; its fingers and toes had fairly well-developed nails. Of course the sex was quite unmistakable, and the penis and scrotum were, so far as regards their naked-eye characters, clearly and definitely established. A series of longitudinal sections of the pelvic region, and of the abdomen below the umbilical cord, were prepared by the paraffin method, after the bones had been decalcified. In this, as in nearly all the other specimens, the stain used was picro-carmin.

The testicles lay in contact with the abdominal wall, just external to the hypogastric arteries, and apparently in front of the acetabular portion of the pelvis. But at this stage it is harder to determine this point, because, owing to the growth of the muscles and other tissues, the gland is separated some distance from any bony landmark. Moreover, the testicle has grown so little in comparison with its surroundings, that it has become quite subordinate.

As may have been inferred, the testicle is separated from the kidney by an interval of more than a quarter of an inch. It would be easy to imagine that this separation might be due to an actual locomotion of the testicle itself, but the foregoing observations show, I think, that the gland and its epididymis have still the same relation to the pelvis as their precursors, the Wolffian body and genital mass, had. The various parts of the pelvis, ilium, ischium, pubes, and sacrum have grown enormously, and also the lumbar spine. Indeed

the latter has grown so much that the spinal medulla only reaches as far as a point which may be judged to be the junction of the sacrum with the lumbar spine.

However, in this foetus the preparations for the actual transition of the testicle through the abdominal wall have made considerable progress, and, as we shall see, the processus vaginalis and gubernaculum testis are definitely established. But before these are described, the structure of the scrotum may be mentioned.

The surface of the scrotum was covered with a layer of epithelium exceedingly like that which covers the cornea, and this likeness was heightened by the absence of papillæ. In other regions the deeper layers of the epidermis were decidedly irregular, and rudimentary papillæ could be discerned. Beneath the epidermis there was a dense layer of spindle-shaped nucleated cells, the unstriped muscle fibre cells of the dartos. The bulk of the scrotum consisted of ordinary embryonic connective tissue, but its irregular cells looked more fibrillar than in the embryo of twelve weeks. Imbedded in this tissue was a denser layer of fibres, prolonged downwards from the external oblique muscle; these looped towards the perinæum, where they became gradually fainter, and finally disappeared. This layer, it may be assumed, was a further stage of the external spermatic fascia. The superficial part of the muscular layer of the abdominal wall also sent numerous fibres into the scrotum, where they spread out, and seemed to terminate; these are the fibres which have been called the descending cremaster. In the vicinity of the pubic cartilage the muscular fibres made smaller loops, and are attached to that part of the skeleton.

It may be mentioned that as yet the fibres of the various skeletal muscles, although well developed, had no appearance of striation; except perhaps in the case of the gluteus maximus and other large muscles, in which it was in places faintly indicated, but of course the mode of preparation may have made the striations indistinct. The internal spermatic fascia is a covering of the testicle which has not been mentioned. But it is questionable whether the transversalis fascia, of which the tunic in question is a part, is itself definitely formed. As in the case of the younger embryos, the peritoneum is closely applied to the transversalis muscle, although there is, even in

this position, a small quantity of tissue suitable for conversion into a fascial layer. However, even this can hardly be discerned in the neighbourhood of the processus vaginalis.

There is a striking difference in the amount of subperitoneal tissue at the front and back of the abdomen. As I have just said, there is hardly any in front, whilst behind it is exceedingly abundant, and loose in texture.

It is hardly necessary to point out that in almost every particular the histology of this five months' embryo confirms and extends the conclusions drawn from those of the tenth and twelfth weeks. Nor is it necessary to add that the external spermatic fascia and the descending cremaster seem to have reached the scrotum by some process of growth and development, and not by any manner of traction.

Processus vaginalis.

It is so well known that a peritoneal pouch precedes the testicle into the scrotum, that without further premise, we may proceed to discuss the manner of its formation. Presently it will be seen that the processus vaginalis has attained a fair degree of development in the five months' fœtus which has just been described, and without doubt it appears a little earlier in intrauterine life. Care has been taken to point out that there was no trace of it in the series of sections made from either the ten weeks' embryo or that of twelve. Unfortunately, I have been unsuccessful in preparing histological specimens from embryos of between the twelfth and twentieth weeks of intrauterine life. But in dissected specimens of embryos of an intermediate size and development, and which might be assumed to have reached the sixteenth week of intrauterine life, there was a dimple in the peritoneum at the lower end of the plica gubernatrix, and this doubtless was the early stage of the processus. This accords with Bramann's¹ observations, but Kölliker² says the processus begins at the third month, and Weil³ at the end of the second.

Reverting to the fœtus of the fifth month, I would direct

¹ *Ibid.*, p. 320.

² *Entwicklungsgeschichte*, p. 994.

³ Weil, "Ueber den descensus testicularum," &c., *Zeitschrift für Heilkunde*, Bd. V., Prag. 1884, p. 226 *et seq.* See also footnote, p. 102.

attention, first of all, to the processus vaginalis at its opening into the abdomen. The first section which has been drawn (Pl. III. fig. 50) shows very clearly the lumen of the processus vaginalis and its relation to the abdominal wall. In front of it are fibres of the internal oblique and transversalis and of the external oblique muscles. The abdominal opening has not been divided at its widest part, and in sections a little farther from the middle line the projecting lips seen in the drawing are absent,

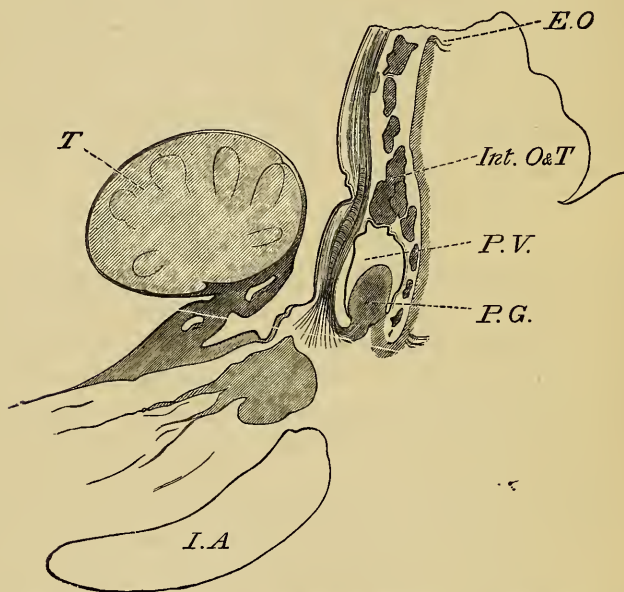


FIG. 51.¹—Processus vaginalis in transverse section. *T*, testicle; *I.A.*, iliac vessel; *P.G.*, plica gubernatrix and gubernaculum; *P.V.*, processus vaginalis; *Int. O and T*, internal oblique and transversalis; *E.O.*, external oblique.

and the aperture involves not less than half the circumference of the canal. The plica gubernatrix projects from the floor of the processus and half fills its lumen; traced upwards it passes through the ostium and unites with the epididymis, but before doing so receives muscular fibres, the ascending cremaster, from the innermost layer of the abdominal muscles. The testicle lies quite close to the ostium of the processus vaginalis, and is at

¹ I am indebted to the managers of the *British Medical Journal* for the use of this and other blocks.

least twice the size of that aperture. If next the lumen of the processus vaginalis be traced in its course through the abdominal walls it is found to diminish gradually (fig. 51), and end in the midst of the muscular fibres of the internal oblique and transversalis. The plica gubernatrix also dwindles in its downward course, and ceases to project into the lumen of the canal. From these appearances it may be inferred that at the fifth month the processus vaginalis is a funnel-shaped canal, wide above and pointed below; moreover, they do not favour the supposition that it has been produced by a force acting from within the abdomen, but rather by traction applied to its pointed extremity.

In older fetuses, such as those of the sixth, seventh, and eighth months of intrauterine life, the gradual progression of the processus vaginalis into the scrotum can be traced by dissection, and the mechanism of the process has been fully described by numerous distinguished observers. It is sufficient for the present to say that it always precedes the testicle towards the scrotum, and it must be admitted that, as it nears its completion, it ceases to possess a pointed extremity, and even becomes more capacious towards its lower part. As we proceed arguments will be advanced to show that, after its muscular structure has become definitely established, the gubernaculum is capable of exerting a certain degree of traction upon the structures to which it is attached. The processus vaginalis is one of these structures, and the weight of evidence seems to favour the theory which attributes its production to the action of the gubernaculum. Perhaps it is unnecessary in the beginning to imagine an active contractive effort, and it may be urged that, at the time the processus vaginalis appears, the gubernaculum is structurally incapable of contraction. It is difficult to say at what moment tissues become capable of contraction. The heart beats before its walls show traces of conversion into muscle, and therefore the above is at least a doubtful argument. But when the phenomena of the infantile hernia and of congenital cæcocele are considered, it will, I think, be evident that the gubernaculum has great capabilities of moving the peritoneum, and can also produce from it hernial sacs—sacs in every way analogous to the processus vaginalis. This question, together with an account of the relations which

the processus vaginalis ultimately acquires to the testicle, the vas deferens, the spermatic vessels, and also to the gubernaculum and cremaster, may be conveniently deferred for a while.

The Transition of Sub-peritoneal Fat and Lipoma of the Spermatic Cord.

It is of interest to remark that the processus vaginalis is accompanied towards the scrotum by a quantity of sub-peritoneal tissue and fat. In two full-grown fœtuses which I have examined, the fatty prolongation was very obvious, and in one caused a slight projection at the external abdominal ring. The sub-peritoneal fat of the fœtus is quite unmistakable, and disposed in small greyish lobules, quite unlike the fine granular fat of other regions. The import of this observation is that there is every reason to believe that the fat which migrates into the scrotum is the source of lipomata of the spermatic cord. Specimens of this rather common affection¹ which I have dissected are in the museum of St Bartholomew's Hospital,² and they show that the tumour is in intimate relation with the spermatic vessels, and therefore in the position which sub-peritoneal fat might be expected to occupy. In these cases the lobes of fat were not continuous with that inside the abdomen, but, as Mr Hutchinson shows, this circumstance has been observed in cases of the same description.

The Gubernaculum Testis.

This structure has already been mentioned several times, and the first trace of it was noted in the histological sections of the human embryo of the tenth week of intrauterine life; and at the twelfth week it could easily be seen with the naked eye. Few things have given rise to so much controversy, and those who are interested in the matter will find the views of the various authorities, both ancient and modern, summarized in the

¹ For cases of the same sort see Curling, *On the Testicle*, p. 556; also *Path. Trans.*, vol. xxxvii., 1886, shown by Mr C. Stonham; also a paper by Mr J. Hutchinson, jun., p. 451 of the same volume, in which the subject is fully discussed.

² Sp. 2812a.

memoirs of Cleland,¹ Godard,² Bramann,³ in the joint memoir of Debierre and Pravaz,⁴ and elsewhere.⁵

It would not, I think, serve any useful purpose to recapitulate the literary researches of these authors, and in what follows it is proposed to lay stress upon points which seem more particularly worthy of notice, and which have not had the attention they may be thought to deserve.

At the third month a distinction can hardly be drawn between the plica gubernatrix and its contents, the gubernaculum. The two together are a delicate band about $\frac{1}{12}$ th inch long, continuous below with the abdominal wall, a little external to the hypogastric arteries, and attached above to the genital string (Pl. III. fig. 48), right or left, as the case may be. A proper appreciation of the early upper attachment of the gubernaculum is of some importance, because, as Bramann⁶ says, authors are not very explicit in their statements concerning it.⁷ For instance, if, as some would have us to suppose, it were thought that the gubernaculum was, from the beginning, inserted into the lower end of the Wolffian body or testicle, a difficulty would arise as soon as an attempt was made to trace corresponding parts in the male or female. Every one would admit that the round ligament of the uterus is analogous to the gubernaculum testis, and yet the round ligament does not accord with current descriptions of the gubernaculum, inasmuch as it is attached neither to the parovarium nor to the ovary itself, but to the uterus. The cause of the dilemma and its explanation are alike obvious, if the earliest insertion of the gubernaculum into the genital string be recognised; later, it will be seen that in the male the gubernaculum acquires, during the 3rd, 4th, 5th, and 6th months, attachments to the epididymis, to the testicle,

¹ *Mechanism of Gubernaculum Testis*, 1856.

² M. E. Godard, "Études sur la Menorchidie et la Cryptorchidie chez l'homme," *Comptes Rendus de la Soc. de Biologie*, Paris, 1857, p. 315 *et seq.*

³ Bramann, *Archiv für Anat. und Phys.*, 1884, p. 310 *et seq.*

⁴ Ch. Debierre et J. Pravaz, Contribution à l'étude du Musele Cremaster, du Gubernaculum Testis et de la Migration Testiculaire, *Lyon Medical*, 1886, p. 101 *et seq.*

⁵ Tourneaux et Herrmann, *Dictionnaire Ency. des Sciences Médicales*, 1886, p. 525 *et seq.*; and Weil, quoted before.

⁶ *Ibid.*, p. 320.

⁷ Quain's *Anatomy*, 9th ed., vol. ii. p. 898; also fig. 805; also Henle, *Handbuch der Eingeweidelhere des Menschen*, 1886, p. 340, fig. 255.

and to the peritoneum of the back of the abdomen. As it acquires these new attachments it comes to lie behind the vas deferens, which, as Bramann points out, crosses over its uppermost part.

A correct appreciation of the way in which the gubernaculum attaches itself first to the vas, then to the vas and epididymis, and afterwards to the testicle as well, explains several anomalies. For instance, it occasionally happens that whilst the testicle and epididymis is retained within the abdomen by adhesions or other causes, nothing but the vas deferens, together with a processus vaginalis, reach the scrotum.¹ Or, as Cloquet,² Curling, Follin, and Godard have shown, the vas and epididymis may proceed towards the scrotum, whilst the body of the testicle remains within the abdomen. A specimen in Guy's Hospital Museum³ illustrates this fairly well. My note of the specimen says, that on the right side the testicle is within the scrotum, but that the tunica vaginalis is patent, forming the sac of a congenital hernia. On the left side the testicle is undescended, and just within the internal ring. The epididymis is apparently pulled away from the testis, and lies within the neck of a process of peritoneum which occupies the inguinal canal. The peritoneum in the vicinity of the testicle is drawn into folds and pleats as if by dragging. The account which has been given of the superior attachments of the gubernaculum would explain these anomalies if two assumptions be allowed: first, that the upper attachments of the gubernaculum sometimes fail to develop properly; and, secondly, that the gubernaculum is capable of dragging the testicle through the abdominal wall, and finally depositing it in the scrotum, or elsewhere. With regard to the first point, I think it will be allowed that if it can be shown that the upper end of the gubernaculum may have no attachment at all, either to the vas deferens, the epididymis, or to the testicle, it will be admitted that they may be sometimes deficient in a less degree. In a very large and full-term anencephalic monster, the scrotum had exactly the appearance

¹ There is a specimen which illustrates this in the museum of University College, Sp. 1137.

² Cloquet, *Recherches Anatomiques sur les Hernies de l'Abdomen*, Paris, 1817, p. 23 et seq.

³ Sp. 2339³⁰.

which it presents in cryptorchids, very small and curiously pinched together. When the abdomen was opened there was only a trace of a processus vaginalis on either side, but the gubernaculum was large and well developed. On the left side, however, the gubernaculum, instead of having its ordinary connections, spread out in a thin and wide leash of fibres, contained within a fold of peritoneum (fig. 52). On the right side of

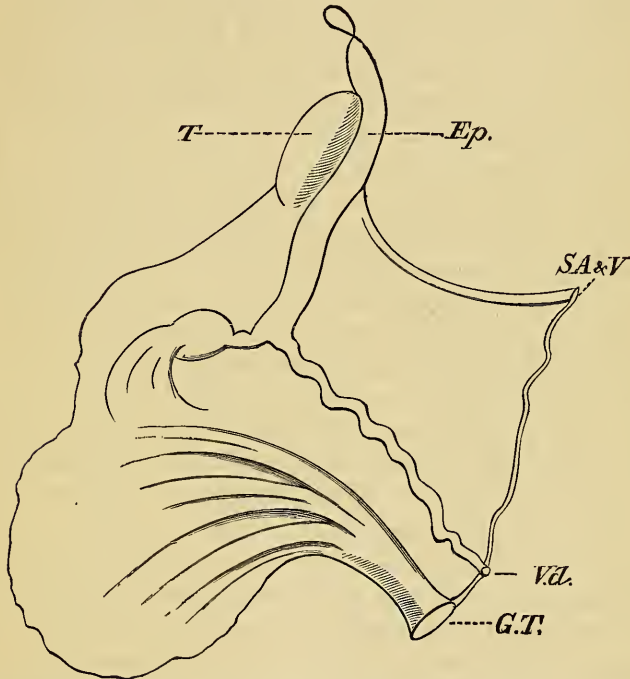


FIG. 52.—*T*, testicle; *Ep.*, epididymis; *SA* and *V*, spermatic artery and vein; *V.d.*, vas deferens; *G.T.*, gubernaculum testis.

the body the attachments of the gubernaculum seemed to be normal.¹ It is also not without interest to note the condition of the scrotum; it looks as though the testicles had sent word to say they were not coming, and, in consequence, it had not developed. Perhaps I may mention here an embryo between the 3rd and 4th months,² in which, had it arrived at maturity, the state of affairs would have been exactly the reverse. In

¹ This specimen is in the museum of St Bartholomew's Hospital, No. 3607*a*.

² Also in the museum of St Bartholomew's Hospital, Sp. 3670*b*.

this specimen the testicles and gubernacula seemed as well developed as they usually are at that age, but no trace of a penis or scrotum or anus could be found, although there were one or two indistinct pores in the perinæum. Obviously, in this case, the testicles could never have accomplished their transition.

The second assumption, that the gubernaculum is capable of traction, has been maintained by some authors and denied by others. Up to this point the present inquiry has favoured the views of Cleland,¹ Sappey,² and Kölliker,³ who seem to believe that in the transition of the testicle the gubernaculum is passive, but that, whilst the testes themselves do not move, their surroundings grow, and, at the same time, the gubernaculum shortens but does not retract—a process analogous to those which produce the relations of the spine and its contents. However, these hypotheses fail to account for certain interesting phenomena which sometimes attend the transition of the testes. The muscular structure of the gubernaculum is, I think, unquestionable, and it seems irrational to deny its tissues the exercise of their function, namely, that of contraction. Moreover, in a moment we shall see that the lower muscular fibres of the gubernaculum are found to be attached—in addition to the pubes, root of penis, and scrotum—in the perinæum and in Scarpa's triangle. Is it not significant that the testicle sometimes migrates into either of the last-named regions? Sometimes it lies close to the anus; in case mentioned in the *Lancet*⁴ it was two centimetres from that orifice and immovably fixed, and presently other instances will be forthcoming. Now it seems hard to conceive how the testicle could have arrived in this position by any process of growth and development. Moreover, during the last stages of the transition, the pyriform portion of the gubernaculum shortens. In a fœtus, 12 inches long, from crown to sole of foot (the legs outstretched), and which had a mesorchium and gubernaculum the same as that figured in an earlier part of this lecture (fig. 49), the plica gubernatrix and the portion of the

¹ Cleland, *Mechanism of the Gubernaculum Testis*, Edinburgh, 1856.

² Sappey, *Traité d'Anatomie Descriptive*, vol. iv. p. 581.

³ Kölliker, *Entwicklungsgeschichte*, p. 997.

⁴ Baudry, *Lancet*, Sept. 1882, p. 454.

gubernaculum between its layers measured $\frac{3}{8}$ inch long; whilst in a fully-developed fœtus, $15\frac{1}{2}$ inches long, and in which the testicle was descended and the processus vaginalis capacious, on looking within that pouch there was no plica gubernatrix or trace of the part of the gubernaculum which lies within that fold of serous membrane. Perhaps these fœtuses place the matter in too favourable a light, and therefore a few more measurements ought to be tabulated. It seems as though the pyriform portion of the gubernaculum does not bear a very constant proportion to the size of the fœtus. It was always measured from within the peritoneum and as it lay in the plica gubernatrix; the extra-peritoneal portion, that which spreads out to the pubes, scrotum, and perinæum, could not always, for obvious reasons, be measured.

No.	Size of Fœtus.	Position of Testis.	Length of Gubernaculum.
1	7 in.	Within abdomen.	Pyriform $\frac{1}{16}$ in.; leash $\frac{1}{16}$ in.
2	$8\frac{1}{4}$ in.	Within abdomen.	Pyriform $\frac{3}{16}$ in.
3	$8\frac{1}{2}$ in.	Within abdomen.	Pyriform $\frac{1}{16}$ in.; leash. $\frac{5}{16}$ ends on tuber ischii.
4	12 in.	Within abdomen.	Pyriform $\frac{1}{16}$ in.
5	$15\frac{1}{2}$ in.	Fully descended.	None.
6	16 in.	On crest of pubes; processus $\frac{3}{16}$ in. further.	Pyriform $\frac{3}{16}$ in.
7	$17\frac{1}{2}$ in.	Bottom of scrotum.	Barely $\frac{2}{16}$ in.
8	19 in.	Bottom of scrotum.	$\frac{3}{16}$ in.

For the present, instead of pursuing this line of argument any further, the lower attachments of the gubernaculum may be mentioned. This branch of the subject has been rendered clear and familiar by the writings of Curling,¹ and therefore a brief description will suffice. Since, however, that author based his observations mainly upon dissected specimens, it is proposed, where necessary, to mention the appearances seen in histological sections, prepared as usual by the paraffin method. At the third month of intrauterine life, the lower end of the gubernaculum looks to the naked eye as if it ended at the peritoneum; but, as we have seen, its tissues can be followed in the histological sections into the

¹ T. B. Curling, *A Practical Treatise on the Diseases of the Testicles*, 4th ed., 1878, p. 17 et seq.

substance of the abdominal wall. Here they enter the hollow of the descending cremaster and external spermatic fascia, interlacing and interpenetrating the fibres. At this age, moreover, the gubernaculum consists of two sorts of tissues. Its main bulk is made up of round and spindle-shaped cells, each with a deeply-stained, round or oval nucleus. Many of the elongated cells seem to run from the abdominal wall towards the genital string, and they have a decided likeness to unstriated muscular tissue, and, as that substance is afterwards found in abundance in the place they occupy, it is probable that they are of that nature. The other tissue of which the gubernaculum is composed is that which I have previously spoken of as the ascending cremaster. This consists of a few of the innermost muscular fibres of the abdominal wall, which runs a short distance along the gubernaculum, lying immediately beneath its peritoneal investment. At the third month their presence can just be recognised, at the fifth they are no longer doubtful, and at the seventh or eighth are abundant and distinctly striated. These ascending fibres have been recognised from the time of John Hunter, and since then most authors have acknowledged their existence.¹ They are better marked in some animals than in man; for instance, in the hedgehog they are very easily seen, and Hunter seems to have derived his ideas from that animal. Their presence is also clearly shown in various series of histological sections of rabbits' embryos, ranging from the 15th to the 17th day after impregnation.²

¹ *Observations on Certain Parts of the Animal Oeconomy*, by John Hunter, 1786.

² Quite recently (Jan. 1888), Dr Klein has kindly sent me a memoir by Professor Weil ("Ueber den Descensus Testicularum nebst Bemerkungen ueber die Entwicklung der Scheidenheute und des Scrotums," *Zeitschrift für Heilkunde*, Bd. v., 1884, p. 225 *et seq.*). In this memoir a full historical *resumé* is given of the gubernaculum and processus vaginalis. Moreover, the subject is studied by means of histological sections, and it is not without interest to compare the results with those which I have from an independent standpoint given. This author (p. 248) describes and depicts the gubernaculum and processus as being clearly established at the end of the second month. As regards the processus this seems too early, and, judging from his sketch, the embryo in which the appearances were seen was as old, or even older than, those which I have considered to have been of the third month. However, the determination of the age of embryos is always a doubtful point. Weil recognises in the gubernaculum both spindle-shaped cells and striped fibres, together with some blood-vessels, which arise from the spermatic and epigastric arteries (p. 254).

The gubernaculum grows rapidly after the third month, and the part of it immediately below the testicle assumes a bulbous shape, and, when quite fresh, looks dense and greyish-white. Below this bulbous part its lower end spreads out in a leash of unstriped muscle fibres, which seem both to blend with and pierce the abdominal wall, and which can be seen quite plainly by dissection. At about the fifth month these fibres spread out fan-like in their main directions, namely, into Scarpa's triangle, upon the pubes and root of penis, and towards the scrotum (Pl. III. fig. 53). By the sixth month, in a fœtus which measured $8\frac{1}{2}$ inches long with its legs extended, a thick fasciculus passed onwards into the perinæum, where it ended in the tissues about the anus and over the tuber ischii. In larger fœtuses the perinæal band of the gubernaculum is oftentimes better developed. In speaking of either the perinæal prolongation of the gubernaculum or that into Scarpa's triangle, which from its position and direction may be called its saphenous prolongation, it is necessary to use guarded language, for although they are both met with very frequently, yet their presence cannot always be affirmed. However, it is difficult to trace fibres of this description amongst fœtal tissues, and at some period before the end of fœtal life the perinæal band would probably exist. It is otherwise with the saphenous band, for although I have found it in most fœtuses which had reached the fifth or sixth month, yet in those which were older it was unrecognisable, and therefore it may be concluded that it is transitory. The fact that it does exist helps to explain that variety of malposition of the testicle which is called crural inclusion. Medical literature contains the records of a great many cases of this, and I have to thank Mr Page of Newcastle for having sent me a portrait of a typical example.¹

In a series of sections of the scrotum and perinæum of a mature fœtus, and in which the testes were fully descended (Pl. III. fig. 54), these perinæal fibres were present, and also others, which united the processus vaginalis to the bottom of the scrotum. There are other circumstances which would render the existence of these perinæal fibres highly probable, even if

¹ Kocher, *Die Krankheiten der Männlichen Geschlechtsorgane*, 1887, p. 570 *et seq.*, collates a number of cases of malposition.

the foregoing evidence was wanting. A little while ago it was remarked that the testicle occasionally lay in the perinæum, and I have before me a sketch, which Mr J. H. Morgan kindly sent me, of a case of a child in which the right half of the scrotum was smaller than the other, and the corresponding testis in the perinæum. But the most significant point in the case was the presence of a band of fibres which held the right testis in the perinæum near the anus. This band, as Mr Morgan's note says, was attached near the anus, and caused the skin to pucker when the testicle was pushed forwards. It seems as though it were a common thing in these cases for the testicle to be held in the perinæum by some sort of a band. Mr Treves has also informed me of a similar case, and in which when the band had been divided with a tenotomy knife, the testicle was replaced in the scrotum. Mr M'Carthy¹ mentions a case, and Cloquet, in another, actually had an opportunity of dissecting out the band.² The perinæal attachments of this band may be either the tuberosity of the ischium, the external sphincter, or the skin. In Cloquet's case it was attached to the tuber ischii. Perhaps it may not be out of place to mention that great caution is requisite in dealing with these cases. There is reason to think that the processus vaginalis may accompany the testicle in its abnormal excursion, and remain in communication with the general peritoneal sac. The consequences which may ensue, if, in the course of operations for the replacement of the testicle, the processus vaginalis was opened without special precautions, are familiar to every surgeon. Mr M'Carthy in his article mentions two deaths from peritonitis after operations upon cases of this kind.

A last reference to the scrotal fibres of the gubernaculum may be permitted, more especially as doubt has been cast upon their existence.³ Their presence is usually affirmed, because an attempt to draw the newly-descended testis upwards out of the scrotum causes the end of that sac to invert, and, moreover, because they can be seen by dissection.⁴ Both of these state-

¹ Quain's *Dic. of Medicine*, 1882, p. 1606.

² *Recherches sur les Causes et l'Anatomie des Hernies Abdominales*, Paris, 1819 pp. 24, 25.

³ Bramann, *ibid.*, p. 334.

⁴ Curling, *Diseases of the Testis*, 4th ed., 1878, p. 17 *et seq.*

ments are, I think, correct; and, in addition, the presence of scrotal fibres is shown in the series of sections of a fully developed scrotum (Pl. III. fig. 54). Nevertheless, those who have attempted to trace smooth muscle fibres with the scalpel will readily understand why opinions vary.

It may be advantageous to enumerate the attachments of the gubernaculum in the order in which they seem to develop, viz., (1) abdominal; (2) pubic and saphenous; (3) perinæal and scrotal. Placing the saphenous upon one side as being, perhaps, inconstant, the functions attributed to the abdominal, pubic, and scrotal are as follows:—The testicle is brought by the abdominal into the ostium of the processus vaginalis, through the canal by pubic, and deposited in its resting place by the scrotal. With regard to the first of these actions, it may be said that the process is not quite so simple as at first glance it seems to be. If we compare the position of the testicle of a five months' fœtus (figs. 50 and 51) with its position in one of the seventh month (fig. 49), it is evident that in the younger embryo the gland lies close to the ostium of the processus vaginalis, whilst in the older embryo it seems to have re-ascended a little way into the abdomen.¹ This re-ascent, which seems a constant occurrence, has been permitted by a luxuriant growth of the mesorchium and by an elongation of the intra-abdominal portion of the gubernaculum. The occurrence is unexpected, and seems to indicate a peculiarity in the action of the gubernaculum, and, in a sense, to detract from the importance given to its abdominal attachment. By its abdominal attachment the gubernaculum can only for a time hold the vas deferens, and afterwards the epididymis and testicle, near ostium of the processus vaginalis. The actual passage of the testicle through the inguinal canal begins during the seventh month, and by that time the vaginalis is ready for its reception, and the gubernaculum has acquired other attachments to the pubes, which may be supposed to afford it a fixed point from which to act and draw the gland, first into the ostium, and afterwards into the canal. The scrotal band, however, seems deficient in firm attachments and unfitted for the duty it is supposed to perform. Various circumstances indicate that, in bringing the testicle

¹ Bramann, p. 620.

through the abdominal wall, the gubernaculum must exert a certain amount of force. For instance, if a foetus be chosen in which the testicle is about to pass through the abdominal wall, and traction be made upon the gubernaculum, it is clear that as the testicle travels towards the scrotum, not only the mesorchium and its contents and the processus vaginalis, but also the peritonæum of the back of the abdomen, moves with it. In consequence of this locomotion of the serous membrane, the cæcum and ilium on the right side, and the sigmoid flexure upon the left, become lower in the abdomen, a circumstance upon which both Scarpa and Wrisberg have commented,¹ and as I proceed other reasons for this belief will be forthcoming. Now, it is obvious that the scrotal attachments of the gubernaculum are ill fitted to afford resistance to the action of the muscle, and I conceive that it is by means of its well-attached perinæal fibres that the gubernaculum is enabled to effect its purpose, the scrotal band merely influencing the final position of the gland.

In attributing the final passage of the testicle through the abdominal wall into the scrotum to the traction of the gubernaculum, I have not thought it necessary to parade the various theories which have been offered as an explanation of the phenomenon. The weight of the organ has been invoked, also certain suppositious respiratory efforts, and, finally, a sort of hernial protrusion.² The first of these theories has been demolished by Sappey, who remarks that during the period of transition the foetus usually lies in the uterus with its head downwards. The second theory calls for no comment, for there is nothing to show that the foetus breathes before birth; rather the contrary. The last theory is more plausible, and has recently been revived,³ but seems to rest upon an obvious ambiguity. The term hernia is used in two different senses. Sometimes it implies merely an anatomical condition, namely, the escape of organs from their containing cavities; at other times the word hernia is used to connote a pathological change; but, used in its pathological and not in its anatomical sense, it

¹ See paper by author, *Roy. Med. Chir. Trans.*, vol. lxix. p. 505.

² Sappey, *Traité d'Anatomie Descriptive*, vol. iv. p. 606.

³ J. Bland Sutton, *An Introduction to General Pathology*, 1886.

is clear that the word hernia ought not to be used in explaining the transition of the testicle, for the simple reason that the pathology of hernia is quite undecided. The question still remains to be settled whether inguinal hernia is due to (a) a defect in the abdominal walls; (b) an elongation of the mesentery; or (c) a general defect of the peritoneum. However this may be, I hope presently to adduce evidence to show that the gubernaculum testis may have something to do with the pathology of congenital cæcocele and of infantile hernia.

The Cremaster.

The anatomy of the cremaster is well known, and does not call for lengthy notice. Where its fibres are attached to Poupart's ligament, they are also continuous with the internal oblique muscle. Its inner tendinous attachment is into the pubes, close to the insertion of the internal oblique muscle.¹ Its loops descend in front of the spermatic cord, and become larger and longer as they descend, and some of them may invest the testicle. Upon these points there is perhaps no dispute, but a variety of opinions prevail as to the parentage of the muscle. It would not be inaccurate to say that there are two main views upon this question. Some think that the cremaster is created out of those striped muscular fibres which ascend the gubernaculum from the abdominal wall, and which I have called the ascending cremaster. Others believe that it is derived from the lower fibres of the internal oblique, and which have accompanied the testis in its transition. The first of these opinions originated with Hunter, who saw that the fibres of the ascending cremaster of the ram became inverted when the gubernaculum was pulled downwards beyond the abdominal wall.² Judging from its characters in the human embryos which have been described above, it is probable that this same thing would happen to them. I have assumed in the foregoing that the chief labour of transition falls upon the smooth muscular elements of the

¹ Quain, 9th ed., 1882, vol. i. p. 327.

² A very clear and correct account of the cremaster is given by Debierre and Pravaz (*Lyon Medicale*, 1886), so far as the muscle can be studied by dissection. They also give an excellent epitome of the views of the various authors.

cremaster. It cannot be denied, however, that the striped fibres may also assist and help to draw the testicle as far as their own lower attachments, but obviously not beyond, as some have supposed. The ascending cremaster of the human embryo is so trivial, that perhaps it ought to be looked upon as a mere survival of a muscle which, in some of the lower animals, is more active and better developed.

We now come to the second theory, that the cremaster is an appendage of the internal oblique muscle, displaced towards the scrotum by the testicle in its transition. From what has gone before it will be seen that this proposition is only true in a very limited sense, namely, so far as it may be taken to imply that the *descending* cremaster is developed in connection with the oblique muscle. The histological specimens which have been described in the earlier part of this lecture seemed to show that the muscular fibres, which were called the *ascending* cremaster, developed in close connection with the internal oblique; perhaps it would not be incorrect to say that they developed as an outgrowth of that muscle. But it must not be ignored that, at first, no distinction can be drawn between the internal oblique and transversalis muscles, so that the latter might claim a share in the process. However, the part of the proposition which attributes the origin of the cremaster to the transition of the testicle is not borne out by the specimens. They show that the external cremaster develops long before that event, and indeed before the processus vaginalis has appeared. Towards the end of the seventh month of intrauterine life the processus vaginalis is so far ahead of the testicle that it must have anticipated the testicle in any action that organ might have had in carrying down the cremaster. It would be more rational to attribute the formation of the muscle to the gradual advance of the peritoneal pouch, rather than to that of the sexual gland. In the later stages, towards the eighth month of intrauterine life, the processus vaginalis is so voluminous that it would be rash to deny it a part in at least modifying the cremaster; but it is so difficult, perhaps impossible, to dissect the muscle in the fœtus, that I have been unable to obtain definite information upon this point.

The Superior Attachments of the Gubernaculum, the Mesorchium, and Plica Vascularis.

The superior attachments of the gubernaculum have already been described, with the exception of the peritoneal prolongation. It may be remembered that they varied according to the stage of development, the gubernaculum being attached first to the genital cord, then to the cord and epididymis, and finally to both of those structures, and also to the body of the testicle. The prolongation which the gubernaculum sends upwards behind the testicle to the peritoneum is chiefly confined to the plica vascularis, but it has sometimes a wider distribution. It was well marked in a fœtus $8\frac{1}{2}$ inches long (legs extended), and presumably of about the sixth month; and in others, 12 inches long, and presumably towards the end of the seventh month, the plica vascularis contained its fibres in great abundance, and they probably reached the organs with which the fold is at various times connected, namely, on the right side with the cæcum, vermiform appendix, or the ilium and mesentery, and on the left side with the sigmoid flexure. Without doubt, the main portion passes to the mesentery, which, at the eighth month, is common to the cæcum and ilium, or to the mesentery of the sigmoid flexure. Both the plica vascularis and its contents, especially the muscular fibres, are of physiological and pathological importance. When the lower end of the right gubernaculum of the fœtus of the seventh or eighth month, whose mesorchium has been figured in an earlier part of this lecture (fig. 49), was pulled downwards, the processus vaginalis, vas deferens, epididymis, testicle, mesorchium, with its plica gubernatrix and plica vascularis, the cæcum and vermiform appendix, the ilium and mesentery, and peritoneum of the back of the abdomen, all glided downwards towards the inguinal canal and scrotum, and traction on the left gubernaculum had the same effect upon the sigmoid flexure. The attachment of the gubernaculum to the various parts of the sexual apparatus is sufficient to account for their displacement, and the other viscera follow, because they are connected with the epididymis by the plica vascularis. Doubtless, the serous membrane of

that fold may be sufficiently inelastic to bear whatever strain there may be, but presently it will be seen that due regard must be paid to the upward prolongation of the gubernaculum. These muscular fibres have an extensive connection with the peritoneum, which lines the back of the abdomen, and doubtless bring about the locomotion of that membrane, which is seen in the transition of the testicle, and in many cases of hernia. That the serous membrane of the back wall of the abdomen is much looser than the rest has been repeatedly pointed out in the earlier part of this lecture; it is underlaid by abundant loose areolar tissue and fat, and is easily displaced and thrown in folds. The peritoneum, which lines the front wall of the abdomen, is, except near the epigastric and hypogastric arteries, intimately bound to the abdominal wall. In adult subjects the union of transversalis muscle, transversalis fascia, and peritoneum is so close, that sometimes it would hardly be incorrect to say that the muscular fibres of the transversalis were inserted into the peritoneum. For these reasons the peritoneum of the front wall of the abdomen is incapable of much displacement, and probably takes but a small share in the formation of large hernial sacs.

Before discussing the other attributes of the muscular fibres, the history of the plica vascularis, considered as a serous fold, may be mentioned. When the testicle glides down the processus vaginalis—which has preceded it—into the scrotum, it retains in a greater or less degree its peritoneal folds. For instance, at its lower end may still be seen in most fœtuses the plica gubernatrix, and from the head of the epididymis another fold, the plica vascularis, runs upwards upon the back of the processus vaginalis towards the abdomen. Owing to its connection with the globus major the plica vascularis is easy to recognise, and it not uncommonly persists throughout life. For instance, Camper,¹ in his *Icones Herniarum*, gives excellent representations of it; Sir Astley Cooper also depicts it;² and Sappey³ says that the visceral layer of the tunica vaginalis

¹ Camper, *Icones Herniarum*, ed. by S. J. Sæmmerring, 1801, Tab. III. figs. 3 and 4.

² Cooper, *Anatomy and Surgical Treatment of Abdominal Hernia*, pl. v. fig. 6, and elsewhere.

³ *Traité d'Anatomie Descriptive*, vol. iv. p. 602.

forms a sort of small mesentery, which contains the testicular vessels; but none of these authors seem to have recognised the developmental significance of this fold. The plica vascularis is usually distinct in a fœtus in which the testicles have just reached the scrotum, and it extends upwards along the back of the processus vaginalis into the abdomen (fig. 45); or, if that passage has been obliterated, a fold, which occupies its position, extends from the internal abdominal ring towards the mesentery either of the cæcum and ilium, or of the sigmoid flexure. The main interest of the plica vascularis depends upon its relation to undescended testis and various forms of congenital hernia.

That the transition of the testis may have an influence upon the last stages of the migration of the cæcum I have elsewhere endeavoured to show,¹ and have published cases in which, when the testicle was undescended and lay within the abdomen, the cæcum remained at or near the liver. On the other hand, I have met with a case in which the right testicle was fully descended, although the cæcum was firmly adherent to the liver.² This abnormality occurred in an anencephalic monster, and I am accustomed always to examine these creatures with care, because they seem particularly liable to intrauterine peritonitis and other complaints, and therefore afford most interesting material. The foregoing case has been mentioned, because it tends to place the matter in a light not very favourable to my hypothesis, but not, however, in an absolutely unfavourable light. In the first place, it has merely been claimed that the testicle in its transition *influenced* the *last* stages of the migration of the cæcum, and in the case which has been mentioned the cæcum must have become adherent to the liver at such an early age, that it could neither have been influenced by the movements of the testicle, nor by its own adherence have impeded that organ. Continuing the pathological bearings of the plica vascularis, there is reason to believe that that fold may in another way be a factor in the pathology of undescended testicle. In reading of cases of abdominal inclusion of the testicle, it is impossible not to be struck by the repeated

¹ "Abnormalities of the Cæcum and Colon, with Reference to Development," *British Medical Journal*, September 1882, p. 575.

² The specimen is described in *Path. Soc. Trans.*, vol. xxxvii. p. 250, and is in the museum of St Bartholomew's Hospital.

references to the presence of adhesions. Without doubt some of these are simply inflammatory,¹ due to intrauterine peritonitis;² but in others it seems safe to infer that the so-called adhesion was in reality the plica vascularis which had persisted in an unusual degree. Such a case as the following is not without significance:—Cloquet found in an aged man the left testicle an inch inside the ring, and fastened to the sigmoid flexure by a band—fibrous, white, round, and very strong.³ Curling mentions another case of imperfect transition, in which the testicle was adherent to the gut, but his observation is based upon clinical evidence,⁴ and I am unable to ascertain that he clearly appreciated that the so-called adhesion was of the nature of the plica vascularis. However, he agrees with Cloquet in believing that congenital bands, which seem to possess the characters of the plica vascularis, may impede the transition of the testicle.

The plica vascularis seems at times to play a different part. It occasionally happens that the cæcum, vermiform appendix, ilium, or sigmoid flexure may accompany the testicle into the scrotum, and give rise to various forms of congenital hernia. In cases of this sort a peritoneal band is very often found passing upward from the head of the epididymis to the herniated gut. The spermatic vessels usually lie in this fold, and it has the characters of the plica vascularis. Wrisberg,⁵ Lobstein,⁶ Sandifort,⁷ and others⁸ have mentioned this circumstance, and the first and last named authors seemed to appreciate clearly

¹ Testicle retained in the abdomen by adhesion to the sigmoid flexure of the colon. John Wood, "Adhesions due to Inflammation from Mesenteric Disease in Fœtal Life," *Path. Trans.*, vol. viii., 1856, p. 265.

² Simpson, *Ed. Med. Jour.*, vol. lii. p. 17 *et seq.* We have also to note the possibility that the retained testicle may in some rare cases set up inflammation in its vicinity.

³ *Recherches sur les Causes et l'Anatomie des Hernies Abdominales*, Paris, 1819, p. 23.

⁴ *Ibid.*, p. 24.

⁵ Wrisberg, "Observationes Anatomicæ de Testiculorum ex Abdominæ in Scrotum descensu," &c., *Comment. Soc. Reg. Scient.*, Gotting., 1800, p. 173 *et seq.*

⁶ Quoted by Wrisberg.

⁷ Sandifort, *Icones Herniæ Inguinales Congenitæ*, 1781, p. 12 *et seq.*

⁸ Scarpa, *On Hernia*, Wishart, Edinburgh, 1814, p. 194, art. on the "Natural Fleshy Adhesion"; also F. Treves, "Hernia of the Cæcum," *Brit. Med. Jour.*, Feb. 19, 1887, p. 385.

the meaning of the connection between the gut and the testicle. They assumed that, owing to persistence of the plica, the gut had been dragged down by the testicle in its transition. However, although there is an element of truth in this assumption, there is reason to doubt whether it is the whole truth. I have mentioned elsewhere¹ a congenital cæcocele, which I was so fortunate as to find in an infant, and in which there was no fold extending from the testicle to the gut, but in its place a quantity of unstriped muscular fibres, which turned upwards from the perinæum and back of the testicle towards the cæcum and peritoneum of the back of the abdomen. These muscular fibres are clearly the upward prolongation of the gubernaculum, which has already been mentioned, and which has been claimed to aid in the locomotion of the peritoneum of the back of the abdomen which accompanies the transition of the testicle. In this respect they seem to have had a share in causing the cæcocele. In another cæcocele sent to me by my friend, Mr Maud, the muscular band was also present; and Professor Cunningham has very kindly written to inform me of a case in which there was a band of fibres so strong "that it does not fall far short of the platysma," and which he considers "as having been the active agent in producing the hernia (of the cæcum), and as having become hypertrophied in the process." In this case there was also a second isolated peritoneal pouch, which I will mention again in speaking of infantile hernia.

The upward prolongation of the gubernaculum is also met with under other circumstances. Normally it persists as the muscular fibres which Henle and Cruveilhier call the internal cremaster;² and presently it will be seen to have an important bearing upon the pathology of infantile hernia. But before mentioning this, perhaps I may point out that the plica vascularis is found very commonly in congenital and funicular herniæ, and is an important guide to the position of the spermatic vessels. It is unnecessary to point out what serious results ensue when these vessels are injured in the performance of operations.

¹ *Med. Chir. Trans.*, vol. lxxix, p. 505.

² Since my paper upon Encysted and Infantile Hernia, and in which this view was put forth, a similar observation has been made quite independently by Debierre and Pravaz (*ibid.*, p. 143), but without reference to hernia.

The peritoneal prolongation of the gubernaculum is, I think, an important factor in producing certain sorts of hernial sacs, especially the sacs of infantile hernia. This opinion is based upon evidence derived from such specimens as the following:—There is a specimen in the museum of St Bartholomew's Hospital,¹ which I have had the opportunity of dissecting, in which the processus vaginalis is represented by a long tube, which extends from the internal abdominal ring to just above the epididymis. This tube communicates with the general cavity of the peritoneum by a small aperture, a quarter of an inch in diameter, which occupies the usual position of the internal abdominal ring external to the epigastric artery. A probe introduced into this opening showed that the processus vaginalis was occluded an inch from the upper end, but in the remainder of its extent its cavity was almost half an inch in diameter above and one and a half below. Behind the superior part of this serous tube a hernial sac protruded from the peritoneum in such a way that the anterior wall bulged slightly into the cavity of the processus vaginalis. Attached to the lower extremity of this protrusion and to its posterior wall were strong bands of unstriped muscle fibre intimately related to the spermatic vessels. The end of the sac to which these were attached was conical and sharply-pointed. This specimen I have described elsewhere, and considered it to have been a variety of infantile hernia.² It is perhaps unnecessary to argue that the origin of the pointed hernial sac was due to the action of the muscular fibres, and, further, that these fibres were a part of the peritoneal prolongation of the gubernaculum. The isolated peritoneal pouch seen in Professor Cunningham's specimen lay towards the outer side of the true sac of the congenital cœcocele; and although it had no connection with the abdominal peritoneum, "was drawn out above into a fine point and has doubtless been dragged down by some stray fibres" (of the gubernaculum). In other cases of infantile hernia the band is also clearly marked, and it may perhaps suffice to mention a single well-marked instance. By an infantile hernia is meant a variety of congenital hernia, in which the processus vaginalis is not obliterated, but remains in the

¹ Sp. 2140B.

² *Med. Chir. Trans.*, vol. lxxix. p. 513.

condition in which it is found in congenital hernia, except that it may be occluded to a greater or less degree near the internal abdominal ring. However, occlusion is probably the exception, and when it does take place the manner of its occurrence can be traced. In addition to this non-obliteration of the processus vaginalis there is, in infantile hernia, a second pouch of peritoneum, which descends behind the other and bulges into it. Sometimes the projection is slight, but at others is so great

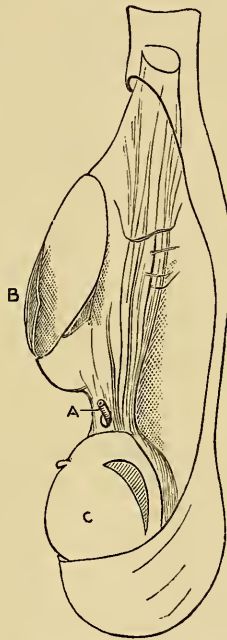


FIG. 55.—Infantile Hernia. A, upward prolongation of gubernaculum with spermatic artery in its midst; B, true spinal sac with double walls; C, body of testicle.

that the true hernial sac—*i.e.*, that which contains the herniated viscus—almost seems to hang from near the ostium of the processus vaginalis, like a sac pendent from the ring. It may render this brief description clearer if I add that, to gain an entrance into the true hernial sac from in front, it would be necessary, first of all, to cut the front and back walls of the non-obliterated processus vaginalis, and then the wall of the true

hernial sac, as Hey¹ calls it. There is reason, however, to believe that the pathology of infantile hernia is in some way connected with the plica vascularis, because in some specimens the remains of that fold can be seen extending from the epididymis to the lower end of the true hernial sac.² In other cases, in which the serous membrane has probably been dissected away, instead of the plica a strong band of smooth muscle fibres unites the back of the epididymis to the extremity of the true hernial sac (see fig. 55). This band represents the peritoneal prolongation of the gubernaculum, and, besides being intimately related to the spermatic vessels, runs upwards along the back of the true hernial sac towards the abdomen. When we recall the influence which the gubernaculum has in forming the processus vaginalis itself, or, as Cloquet has maintained, hernial sacs of various sorts, it seems reasonable to argue that it is an important factor in the pathology of infantile hernia.

Relation of the Vas Deferens and Spermatic Vessels to Processus Vaginalis. The Recurrent Branches of the Spermatic Artery.

It is unnecessary to premise, that as the testicles migrate down the processus vaginalis, the spermatic vessels and vas deferens accompany them, and acquire certain definite relations which it is important to recognise. If a fœtus be chosen in which the testicles have completed their migration, but in which the processus vaginalis is capacious and still in communication with the peritoneum, the relations of the vas deferens and spermatic vessels are usually as follows:—The artery and vein run from the upper part of the abdomen to the outer side of the ostium of the processus vaginalis, and then along the back of that sac, lying in the plica vascularis, as far as the epididymis, where they divide into their two main divisions, one going to the body of the testicle and the other to epididymis; the vein usually lies to the inner side of the artery. The vas

¹ It is interesting to note that in Hey's case of infantile hernia the sac contained the cæcum.

² *E.g.*, Sp. R. 24, St Thomas's Hos. Museum, *Med. Chir. Trans.*, fig. 4, p. 493.

deferens, on the other hand, runs upwards from the neck of the bladder round the hypogastric arteries towards the inner and lower part of the ostium of the processus vaginalis, and thence along the posterior wall of that sac, to reach the globus minor. In the last part of its course the vas deferens lies internal to the vessels, and sometimes quite apart from them (fig. 56). These relations are interesting, because they help to explain the separation of the vas deferens from spermatic vessels seen in many cases of hernia. The London museums contain so many examples of this condition, and it seems such a common and well-known occurrence, that it is perhaps unnecessary to adduce instances; but in nearly all of them the vas deferens lies well to the inner side of the vein and artery. Lawrence¹ mentions numerous instances of this occurrence, and attributes the separation to the distensile force of the hernia. Later, he says the same condition may be found in a small hernial tumour,² and the specimens in museums fully bear out this statement; and they further suggest that mere distension could not have been the sole cause of the separation of the vas from the vessels, but that the predisposing developmental factor which has just been mentioned must also be taken into consideration; indeed, in some instances of congenital hernia, it seems as if the structures in question can never have been together. I hope to deal with this question more fully at another time, and will therefore not endeavour at present to discuss other varieties of the condition.

In endeavouring to ascertain whether the spermatic artery accompanies the transition of the testicle *pari passu* with the peritoneum and processus vaginalis, or whether it was drawn in a greater degree towards the scrotum, several interesting circumstances came to light. Text-books on anatomy usually state that the spermatic artery gives branches to the peritoneum, and on the left side others are frequently supplied to the sigmoid flexure.³ It suggests itself that these branches may afford information bearing upon the question of the relative move-

¹ Lawrence, *On Hernia*, p. 212.

² *Ibid.*, p. 213.

³ See more particularly Turner on the existence of an anastomosing system of arteries between the visceral and parietal branches of the abdominal aorta, *Brit. and For. Med. Chir. Review*, July 1863.

ments of the artery and of the peritoneum; and in numerous dissections I have found the spermatic arteries give off recurrent branches to the peritoneum. The largest of these begin near the internal abdominal ring, and run 4 or 5 inches upwards, giving off branches and gradually dwindling (Pl. III. fig. 56). The inference to be drawn from their presence seems obvious, namely, that the spermatic artery is displaced more than the peritoneum. But, in addition, the recurrent branches of the spermatic artery seem to have a pathological bearing, and it is not improbable that they have something to do with the formation of these secondary pouches, which are found upon the hinder wall of the sacs of some congenital hernia. That these recurrent branches may be also found at the back of the processus vaginalis is shown by various specimens. For instance, there is a dried hydrocele in St Bartholomew's Hospital Museum whose vessels have been injected, and in which the recurrent branches are quite clear;¹ also, there is in the Dupuytren Museum a hernial sac, which has been treated in the same way, and which has the same recurrent arteries upon its hinder wall.² Now, the principle seems established that vessels which are related as these recurrent branches are to the peritoneum may throw that membrane into folds,³ and it is not without significance to note that I have found a large obliterated vessel running in the fold of serous membrane, which formed a supplementary sac upon the back wall of a funicular hernia.⁴

The Closure of the Processus Vaginalis.

A number of foetuses have been examined to see how the processus vaginalis becomes occluded after it has transmitted the testicle. There seems to be, as others have remarked, a strong tendency for it to close in two places, which are some distance apart, namely, just above the testicle and near the internal

¹ 2753.

² Sp. 295.

³ Treves, *The Anatomy of the Intestinal Canal and Peritoneum in Man*, London, 1885.

⁴ This specimen, and another which is of exactly the same nature, are in the museum of St Bartholomew's Hospital, Nos. 2090 and 2140e.

abdominal ring. This statement is founded upon ordinary anatomical evidence, the processus having been merely slit open with scissors. In some fœtuses the serous canal was so attenuated that it was hard to discern, and it would have been rash to make any positive statement as to its patency or occlusion. But there was no evidence in any case to show that the processus vaginalis closed by adhesion. Its interior was always smooth and shining, like the rest of the peritoneum. Importance attaches to this point, because it has been thought that the processus vaginalis sometimes became closed by adhesions which afterwards became stretched into the sac of an encysted hernia. I have elsewhere endeavoured to combat this view upon various grounds, amongst which, perhaps, the most cogent are, first, that such adhesions have never been seen; and second, that the specimens which have been called encysted herniæ belong to the infantile variety.

In bringing these lectures to a close, I wish to thank Mr D'Arcy Power and numerous other friends for the valuable material they have placed at my disposal. And I am especially indebted to Dr Vincent D. Harris for many acts of kindness, and for his assistance and advice.

EXPLANATION OF PLATES AND OF WOODCUTS.

EXPLANATION OF PLATE I.

<i>Ao.</i>	Aorta.	<i>S.</i>	Somite.
<i>Co.</i>	Cardinal vein.	<i>I.c.m.</i>	Intermediate cell mass.
<i>So.</i>	Somatopleure.	<i>W.d.</i>	Wolffian duct.
<i>Sp.</i>	Splanchnopleure.	<i>W.t.</i>	Wolffian tubule.
<i>Ep.</i>	Epiblast.	<i>N.s.</i>	Nephrostomata.
<i>H.y.</i>	Hypoblast.	<i>Gl.</i>	Glomerulus.
<i>B.w.</i>	Body wall.	<i>Nc.</i>	Notochord.
<i>M.s.</i>	Medulla spinalis.	<i>L.</i>	Liver.
<i>M.</i>	Mesentery.	<i>P.</i>	Projection.
<i>I.m.</i>	Intermediate cell mass.	<i>R.</i>	Recess.
<i>T.</i>	Epiblastic thickenings.	<i>Sp.c.</i>	Spinal canal.

Figs. 1 to 4. Embryo chick, 48 hours.—Fig. 1. Connection of Wolffian duct with somite. Fig. 2. Connection of Wolffian duct with intermediate cell mass. Figs. 3 and 4. Epiblastic thickenings. \times about 120.

Fig. 5. Nine days' rabbit's embryo. Epiblastic thickenings and Wolffian duct and tubules coexist. $\times 80$.

Fig. 6. Rabbit's embryo, 8th day. Intermediate cell mass. \times about 50.

Fig. 7. Rabbit's embryo, 8th day. Communication between body cavity and interior of somite.

Figs. 8, 9, and 10. Rabbit's embryo, 9th day. $\times 180$.—Fig. 8. Intermediate cell mass and its connection with lining of the body cavity. Fig. 9. Origin of Wolffian duct and tubule. Connection of tubule with the peritoneum. Epiblastic thickening over somite. Fig. 10. Hinder tubule ununited to peritoneum.

Figs. 11 and 12. Urogenital ridge of a rabbit's embryo of 10th day. $\times 250$.—Fig. 11. Longitudinal section of Wolffian duct and tubules. Fig. 12. Transverse sections. To show the formation of lumen in tubules.

Figs. 13, 14, 15, and 16. $\times 120$. Urogenital ridge of rabbit's embryo at commencement of 13th day. Termination of Wolffian duct and structures supposed to represent a pronephros.

Figs. 17, 18, and 19. Urogenital ridge of human embryos. \times about 100.—Fig. 17. Germinal epithelium. Fig. 18. End of Wolffian duct—Solid column of cells. Fig. 19. Wolffian tubule united to peritoneal epithelium.

Fig. 20. Urogenital ridge of human embryo about 30th day. Connection of epithelium of the body cavity and that of the Wolffian duct.

Figs. 21 and 22. Human embryo of about 30 days. Fore-part of Wolffian body. Projections into body cavity, and joining of peritoneal epithelium with those of the Wolffian tubules.

EXPLANATION OF PLATE II.

Fig. 23. Glomerulus of human Wolffian body. *Gl*, glomerulus; *T*, Wolffian tubule; *V*, afferent and efferent vessels. 7 Hartnack. 4 Eye p.

Fig. 24. Glomerulus of human Wolffian body, seventh week, showing the commencement of the development of capillaries in the glomerulus, the formation of the parenchyma and the tubules. *P*, parenchyma; *T*, tubule; *Gl*, glomerulus; *C*, capillaries; *E*, epithelium of a commencing tubule. 7 Hartnack. 4 Eye p.

Fig. 25. Glomerulus of human Wolffian body at tenth week, showing vascularity of glomerulus and stroma of Wolffian body. *Pr*, parenchyma; *Gl*, glomerulus; *WT*, Wolffian tubule. 7 Hartnack. 4 Eye p.

Fig. 26. Sexual eminence of rabbit, $\frac{1}{2}$ in oil immersion, to show relation of surface epithelium to meshes of stroma. This drawing was from a section close to that shown in fig. 37, p. 39.

Fig. 27. Urogenital ridge of rabbit, beginning of thirteenth day. *M*, mesentery; *GE*, germinal epithelium; *WT*, Wolffian tubule; *WD*, Wolffian duct; *AO*, aorta. 7 Hartnack. 4 Eye p.

Fig. 28. Human embryo, sexual eminence. *GE*, germinal epithelium; *CV*, cardinal vein; *WD*, Wolffian duct; *Gl*, glomerulus. The bulk of the urogenital ridge and its genital eminence consists of mesoblastic cells of various shapes—round, branched, and elongated; these have not been delineated. 7 Hartnack. 4 Eye p.

Fig. 29. Kidney and hinder part of the Wolffian body of a rabbit of thirteenth day. *KB*, kidney blastema; *U*, ureter; *LCT*, loose tissue, which surrounds kidney blastema; *WD*, Wolffian duct; *WT*, Wolffian tubules; *PC*, peritoneal cavity. × 70.

Fig. 30. Rabbit, fourteenth day, to show relation of hinder part of the Wolffian body and genital mass to one another, and to the kidney which has just appeared. *GM*, genital mass; *AO*, aorta; *K*, kidney; *HL*, hind limb; *M*, mesentery. × 25.

Fig. 31. Human embryo, thirty-five days. *GM*, genital mass; *K*, kidney, lower end; *AO*, aorta; *CV*, cardinal vein; *WT*, Wolffian tubules; *Gl*, glomerulus. × 45.

Fig. 32. Genital mass of rabbit, commencement of fourteenth day, to show stroma of branched anastomosing cells, and large, pale, granular cells in its meshes. 7 Hartnack. 4 Eye p.

Fig. 33. Testicle and epididymis of human embryo, at about the twelfth week of intrauterine life. The section is not quite longitudinal. × 25. *ST*, seminal tubules; *RT*, rete testes; *Mesor.*, mesorchium; *Vas. Def.*, vasa deferens; *VE*, vasa efferentia; *IT*, indifferent tissue; *TA*, tunica albuginea.

Fig. 34. Outermost and front part of the same human Wolffian body as that which has been drawn in fig. 39, p. 52. *WD*, Wolffian duct; *CT*, collecting tube; *TE*, tubuli efferentia; *GM*, genital mass. × 45.

Fig. 35. Human foetus, eight months, to show the cell strings of the mediastinum testes which unite tubules of epididymis to seminiferous tubules. *TE*, tubules of epididymis; *MT*, mediastinum testes; *ST*, seminal tubules; *V*, blood-vessels. × 45.

Fig. 36. Human testicle showing four vasa aberrantia. *T*, testicle; *Hy*, hydatid of Morgagni; *VD*, vas deferens; *Ep*, epididymis; 1, 2, 3, and 4, vasa aberrantia.

EXPLANATION OF PLATE III.

Fig. 42. Opening of oviduct of embryo pig into peritoneal cavity. *Ov.*, oviduct; *W.B.*, Wolffian body; *Lng.*, lung; *M.*, mesentery.

Fig. 43. Oviduct, where its lumen begins. Letters the same as fig. 42. *I.P.*, inner process; *W.G.*, Wolffian glomeruli.

Fig. 44. Oviduct near its hinder end. Letters the same as figs. 42 and 43. *O.D.*, oviduct; *G.M.*, genital mass.

Fig. 45. *A*, *B*, and *C*, testicles of human foetuses; *P.V.*, plica vascularis; *O.D.*, remains of oviduct; *S.Hy.*, spatulate hydatid. *Hy.*, hydatid of oviduct.

Fig. 46. Pelvic and lumbar regions of a human embryo of seventh week; *R.*, ribs 11th and 12th; *Sup. R.*, suprarenal body; *K.*, kidney; *G.M.*, genital mass; *W.B.*, Wolffian body; *Il.*, ilium; *Isch.*, ischium; *Fem.*, femur; *Glut.*, gluteus maximus; *St.*, stomach.

Fig. 48. Human embryo of three months to show plica gubernatrix and position of testis; $\times 3$. *T.*, testicles; *K.*, kidney; *I.*, intestine; *P.V.*, plica vascularis; *G.C.*, right and left genital cords; *C.G.C.*, common genital cords; *B.*, bladder; *Gub.*, plica gubernatrix and gubernaculum.

Fig. 50. Ostium of processus vaginalis at fifth month. *Tes.*, testicle; *V.D.*, vas deferens; *Gub.*, gubernaculum; *P.G.*, plica gubernatrix; *P.V.*, processus vaginalis; *C.*, loose cellular tissue; *Il. Ves.*, iliac vessel; *Int. Ob. and Trans.*, internal oblique and transversalis muscles; *Ex. Ob.*, external oblique.

Fig. 53. Gubernaculum of six months' fœtus. The peritoneum has been dissected from psoas and iliacus, and turned over the bladder in order to show the gubernaculum upon its outer surface; *P.*, peritoneum; *Ant. S.I.*, anterior superior spine of ilium; *B.*, bladder; *Hy. A.*, hypogastric arteries; *T.*, testicle; *G.*, gubernaculum; *Ps.*, psoas; *Il.*, iliacus; *Int. Ob.*, internal oblique.

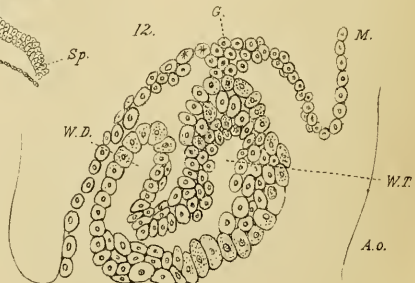
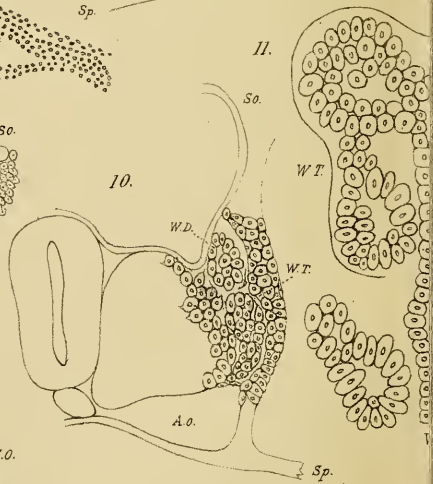
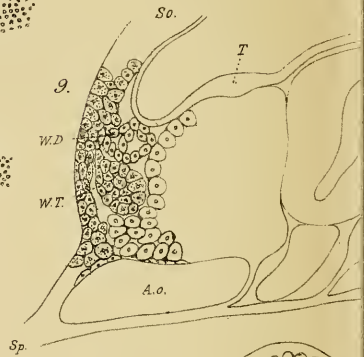
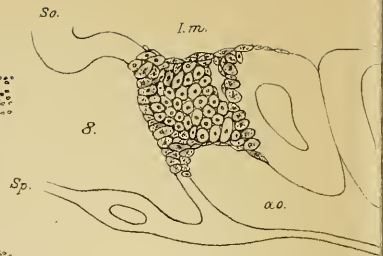
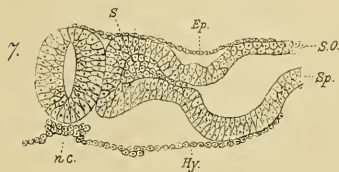
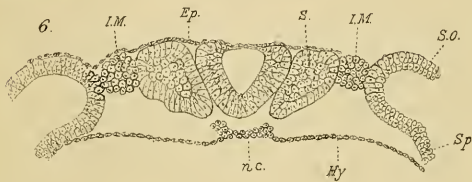
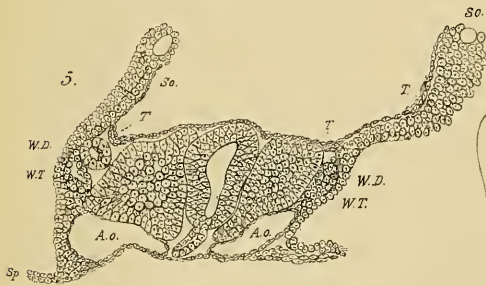
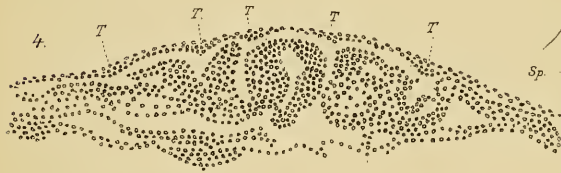
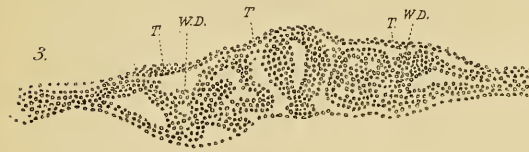
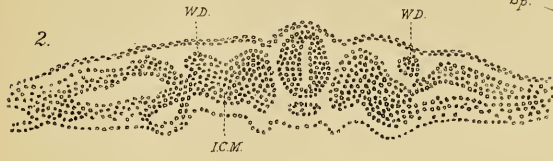
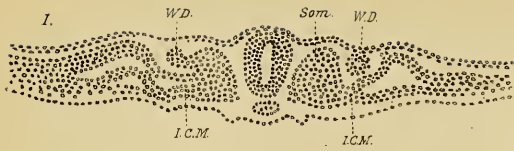
Fig. 54. Diagram constructed from sections and dissections of human fœtuses at full time. To show peritoneal, scrotal, and perineal prolongations of the gubernaculum testis; *Cæ.*, cæcum; *P. Vag.*, processus vaginalis; *P.*, pubic bone; *Pl. Vas.*, plica vascularis; *Ep.*, epididymis; *Tes.*, testicle; *Pl. Gub.*, plica gubernatrix; *Gub.*, gubernaculum; *Per.*, perineal fibres of the gubernaculum testis.

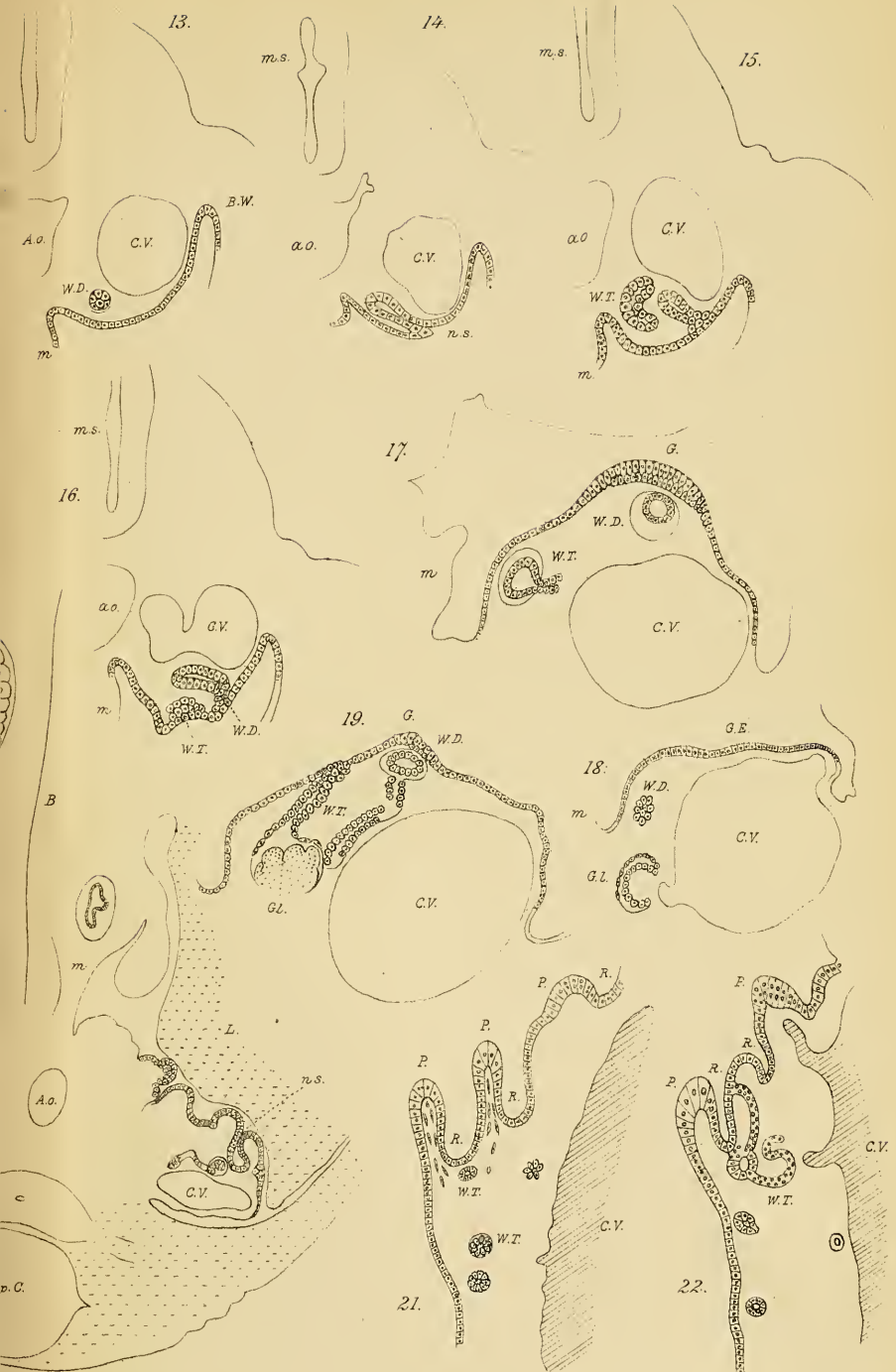
Fig. 56. Processus vaginalis at eighth month of intrauterine life to show the relations of the vas deferens and spermatic vessels to its posterior wall; *S.V.*, spermatic vessels; *V.D.*, vas deferens; *Ep.*, epididymis; *Tes.*, testicle; *Gb.*, gubernaculum.

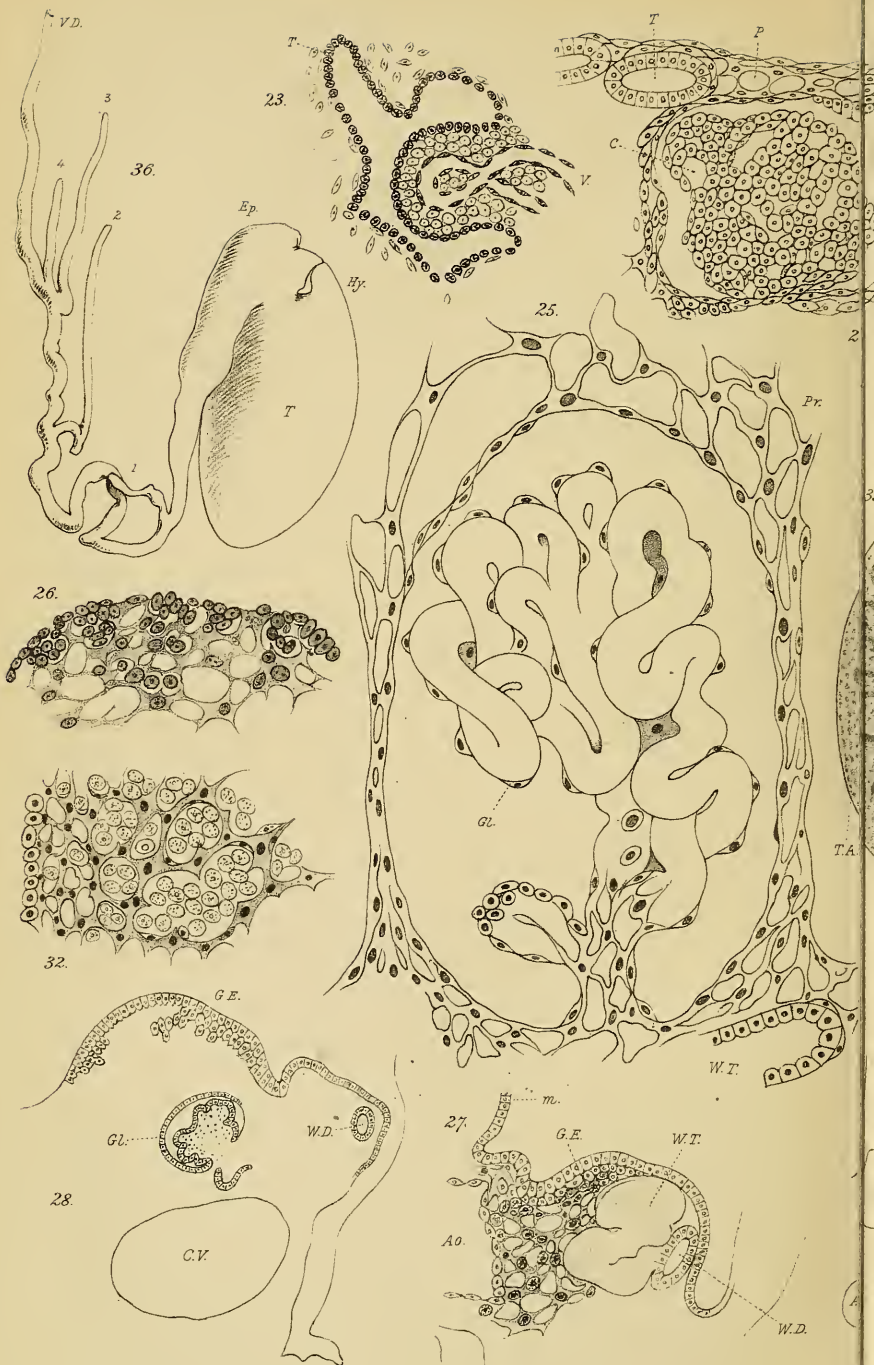
Fig. 57. Recurring branches of spermatic artery; *S. A. and V.*, spermatic artery and vein; *S.*, sigmoid flexure.

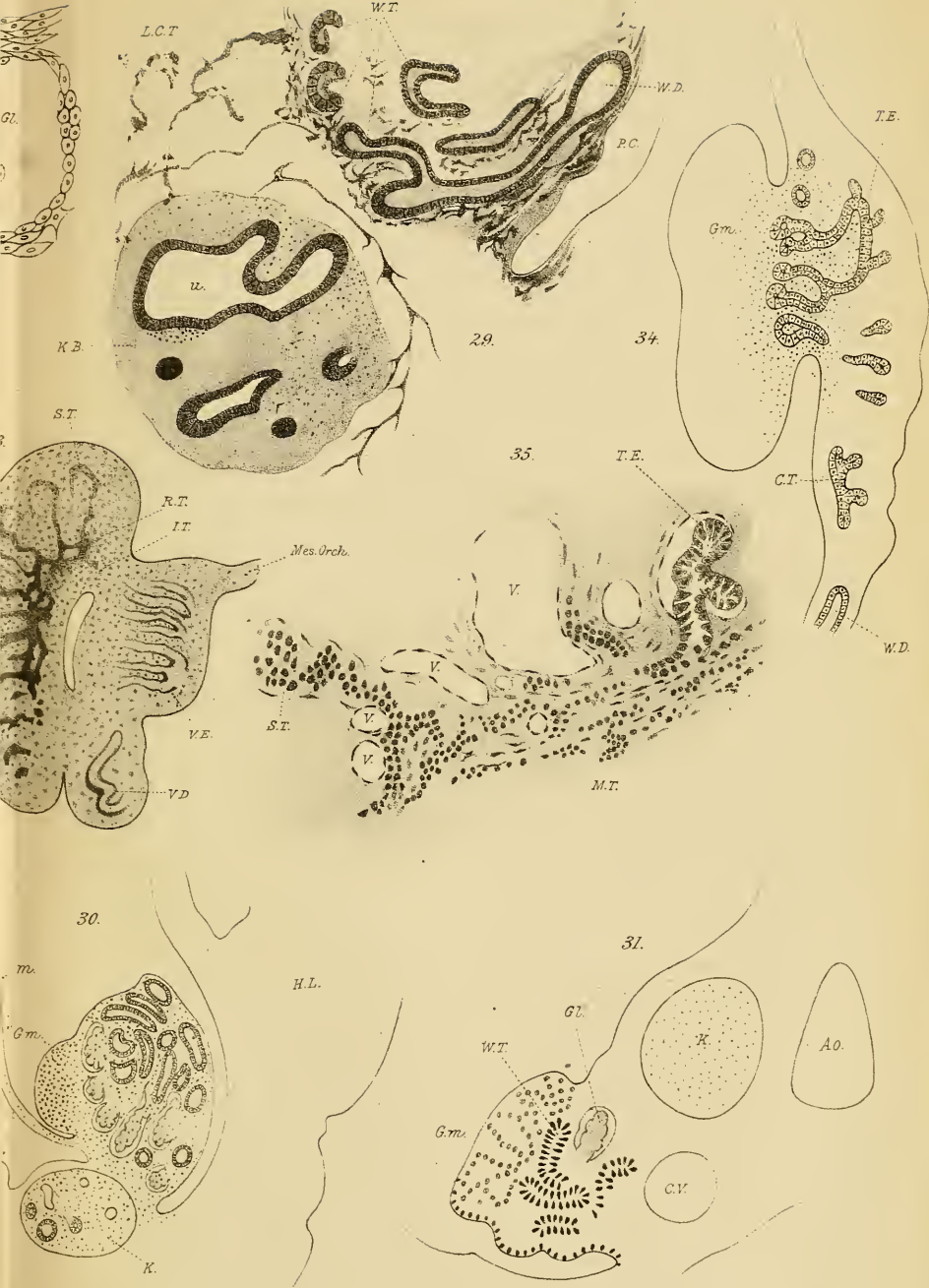
ERRATA.

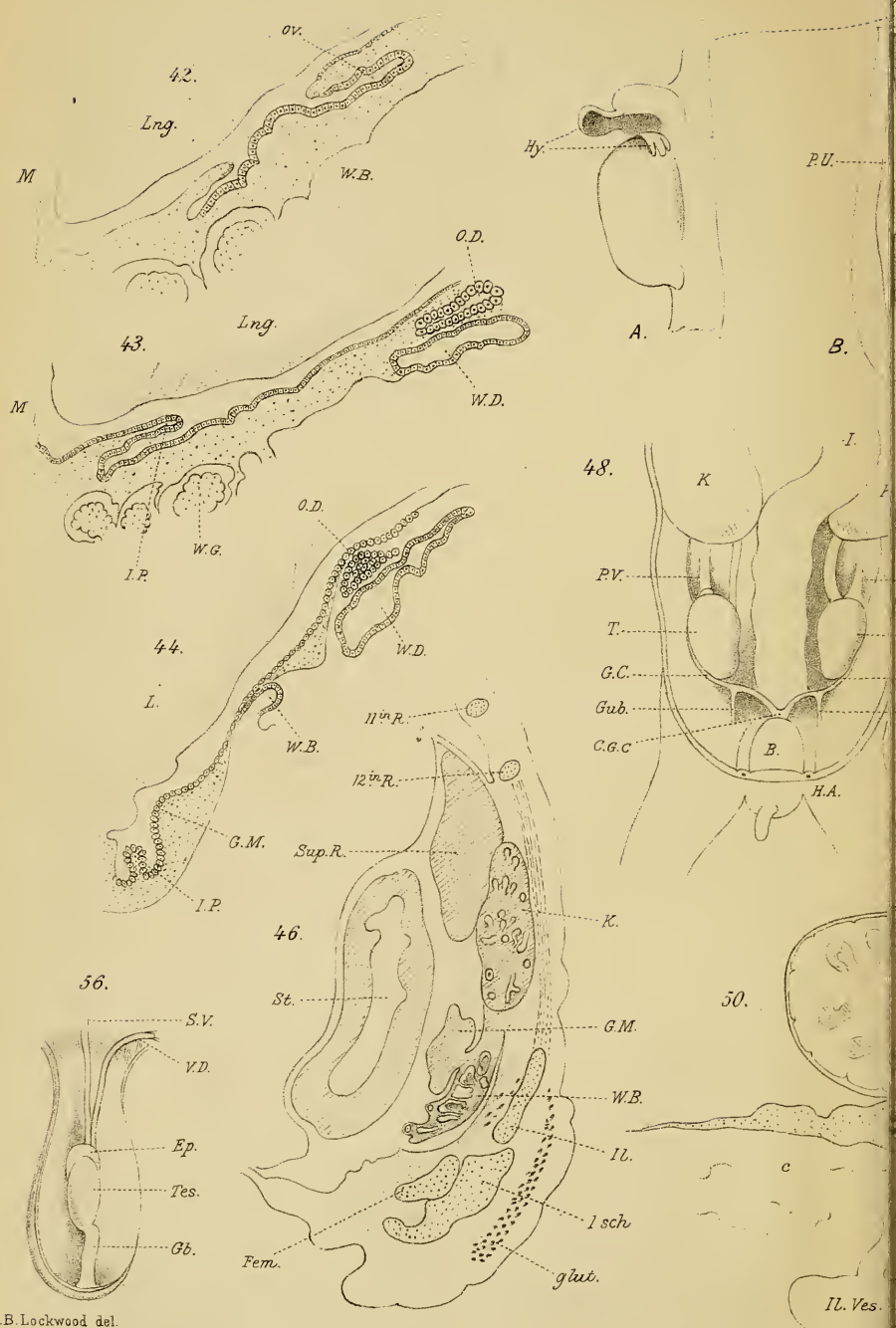
- Page 48, line 23, for 32 read 31.
 „ 65, „ 10, for 23 read 33.
 „ 65, „ 15, for 23 read 33.



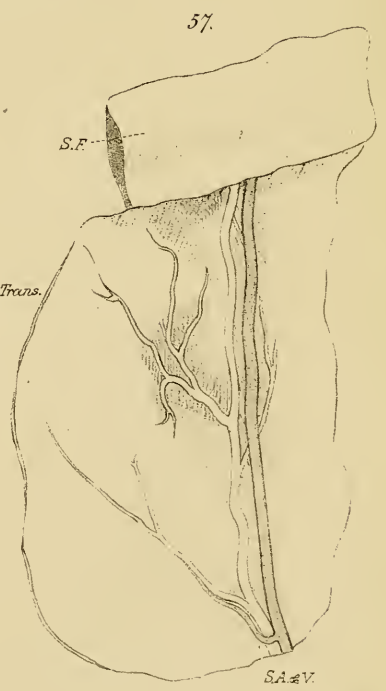
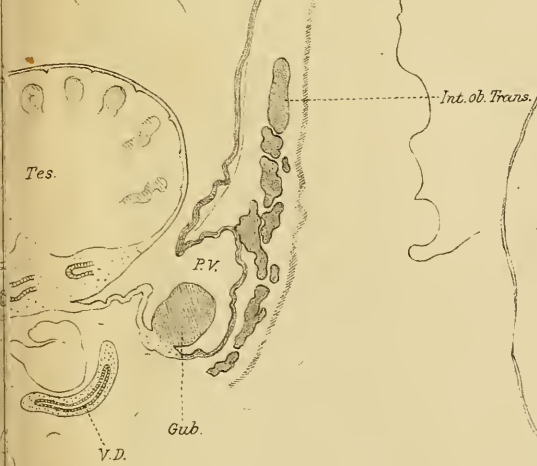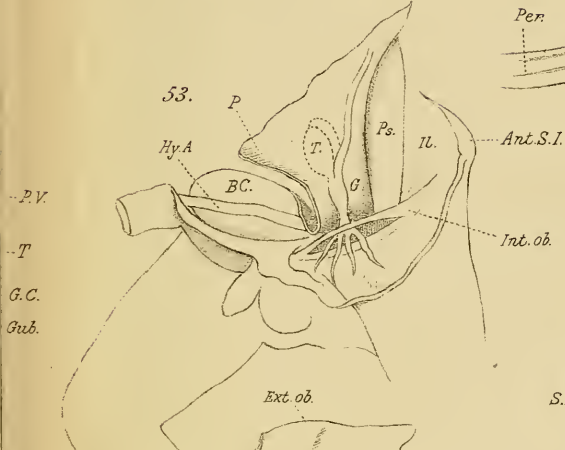
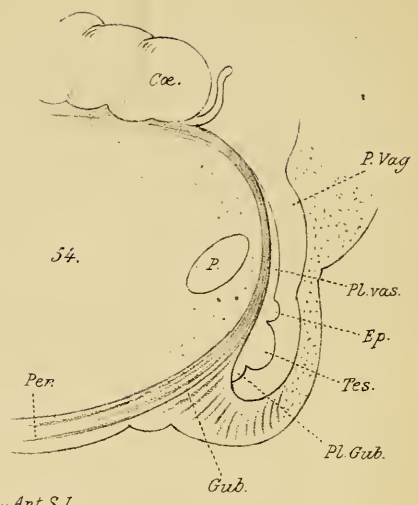
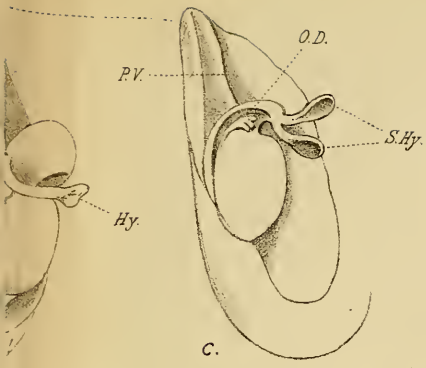








C.B. Lockwood del.



QM416

L81

Lockwood

Hunterian lectures on the development & transition of the testis, normal and abnormal.

QM 416

L 81

