

RF
399
C6



UC-NRLF



B 3 238 634



ADENOIDS
AND TONSILS
COOLIDGE



HARVARD HEALTH TALKS

**THE CARE AND FEEDING OF
CHILDREN**

BY JOHN LOVETT MORSE

**PRESERVATIVES AND OTHER
CHEMICALS IN FOODS: THEIR USE
AND ABUSE**

BY OTTO FOLIN

**THE CARE OF THE SKIN
BY CHARLES JAMES WHITE**

**THE CARE OF THE SICK ROOM
BY ELBRIDGE GERRY CUTLER**

**THE CARE OF THE TEETH
BY CHARLES ALBERT BRACKETT**

**ADENOIDS AND TONSILS
BY ALGERNON COOLIDGE**

**AN ADEQUATE DIET
BY PERCY GOLDTHWAIT STILES**

HARVARD HEALTH TALKS



Digitized by the Internet Archive
in 2008 with funding from
Microsoft Corporation

HARVARD HEALTH TALKS

ADENOIDS AND TONSILS

BY

ALGERNON COOLIDGE, M.D.

PROFESSOR OF LARYNGOLOGY IN HARVARD UNIVERSITY



CAMBRIDGE
HARVARD UNIVERSITY PRESS
1916

RF399

C6

COPYRIGHT, 1916
HARVARD UNIVERSITY PRESS

TO THE
LIBRARY OF THE
HARVARD-YENCHING INSTITUTE
OF CHINESE STUDIES
HARVARD UNIVERSITY

HARVARD HEALTH TALKS

PRESENTING the substance of some of the public lectures delivered at the Medical School of Harvard University, this series aims to provide in easily accessible form modern and authoritative information on medical subjects of general importance. The following committee, composed of members of the Faculty of Medicine, has editorial supervision of the volumes published:

EDWARD HICKLING BRADFORD,
A.M., M.D., Dean of the Faculty of
Medicine, and Professor of Orthopedic
Surgery, Emeritus.

HAROLD CLARENCE ERNST, A.M.,
M.D., Professor of Bacteriology.

WALTER BRADFORD CANNON, A.M.,
M.D., George Higginson Professor of
Physiology.

ADENOIDS AND TONSILS

ADENOIDS AND TONSILS

IN order to follow a description of adenoids and tonsils, it is well to bear in mind that the meaning of neither of these words is perfectly definite nor always the same. The word "adenoids" is generally used to mean an abnormal condition of an organ called the adenoid, or third tonsil, which is always present in childhood and is a normal part of the body. The word "tonsils" is frequently limited to two structures, one on each side of the throat, whereas in strict medical nomenclature there are several tonsils, of which the adenoid is one. These tonsils are all in the throat, or more technically in the pharynx; therefore a brief review of the anatomy of this part of the body is necessary.

HARVARD HEALTH TALKS

THE PHARYNX

The pharynx is a cavity which lies directly in front of the upper segments of the back bone, and extends from the base of the skull downwards to a point midway in the neck. (See Fig. 1.) There are several openings into or out of this cavity, connecting it with the nose, the ears, the mouth, the lungs, and the stomach.

The *palate* is a horizontal shelf extending from the upper front teeth in front to the pharynx behind. It is divided into two parts, the hard palate in front and the soft palate behind. The hard palate is a plate of bone separating the cavity of the mouth from the two nasal cavities, thus forming the roof of the mouth and the floor of the nose. The soft palate is a curtain composed of muscles, its anterior margin united with the hard palate, its posterior margin hanging free in the cavity of the pharynx, and its

ADENOIDS AND TONSILS

lower surface a continuation backwards of the roof of the mouth, terminating in

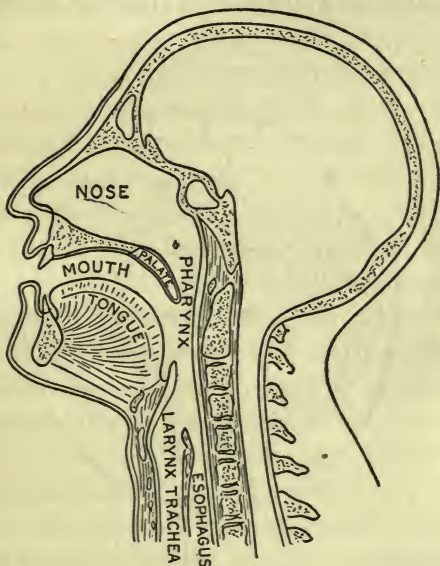


FIG 1.

Diagram of a section of the head and neck, showing the upper part of the passages for air and food.

a tag called the *uvula*, easily seen on looking into a person's throat. (Fig. 2.)

HARVARD HEALTH TALKS

When the soft palate is relaxed or hanging downward, the whole pharynx is one cavity, and air passes through it freely

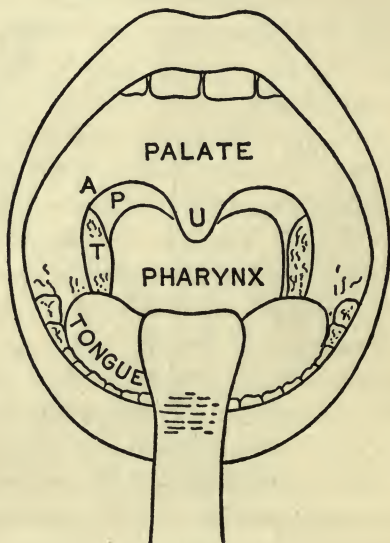


FIG 2.

Diagram of the view presented in looking into a person's throat.

- A = anterior pillar of the palate.
- P = posterior pillar of the palate.
- U = uvula.
- T = one of the faucial tonsils.

ADENOIDS AND TONSILS

between the nose and the lungs. When the soft palate is contracted, it is drawn up into a horizontal position and cuts off the upper from the lower part of the cavity of the pharynx, preventing food from getting into the back of the nose during the act of swallowing.

The upper part of the pharynx, called the *naso-pharynx* is a passage for air only, the lower part for both food and air. Above the soft palate the two nasal passages open directly into the nasopharynx. On each side is the opening of the Eustachian tube which connects the pharynx with the middle ear.

At the bottom of the pharynx there are two openings, one into the larynx for the air, and behind it one into the esophagus, which is the passage for food.

On looking into the throat (Fig. 2) through the mouth, the margin of the soft palate may be seen to split on each side into two folds, which run from the

HARVARD HEALTH TALKS

margin of the uvula, one to the base of the tongue, and the other to the side wall of the pharynx. These are called the *pillars* of the palate.

The cavity of the pharynx is lined with mucous membrane, in the same way that the outside of the body is covered with skin. Although mucous membrane differs from skin in many details, they are in some respects similar. Both of them protect the underlying tissues against injury, dirt, and infections. They are both made up of different layers, the outer being impervious and resistant, the inner ones fibrous, containing blood vessels, nerves, and other structures. These other structures are developed in the skin or mucous membrane for special purposes. Thus in the skin we find finger nails, hair follicles and sweat glands. In the mucous membrane there are glands to secrete water and mucus and we also find structures which resemble glands and are therefore

ADENOIDS AND TONSILS

called adenoid tissue. Adenoid means "like a gland." This adenoid tissue is made from, and is a part of the mucous membrane, in the same way that sweat glands are part of the skin.

THE TONSILLAR RING

This adenoid or gland-like tissue develops in the mucous membrane of certain parts of the pharynx only, forming an irregular ring, which runs obliquely around the cavity. (Fig. 3.) The upper part of this ring is at the top of the back wall of the naso-pharynx behind the openings into the nose. The sides of the ring are in the space between the pillars of the palate, and the lower part is on the front wall at the base of the tongue. The ring is not of equal size all the way round. There are four principal masses of this tissue, one at the top, one on each side, and one at the bottom. These masses are called tonsils and the ring is known as the tonsillar ring. All of this

HARVARD HEALTH TALKS

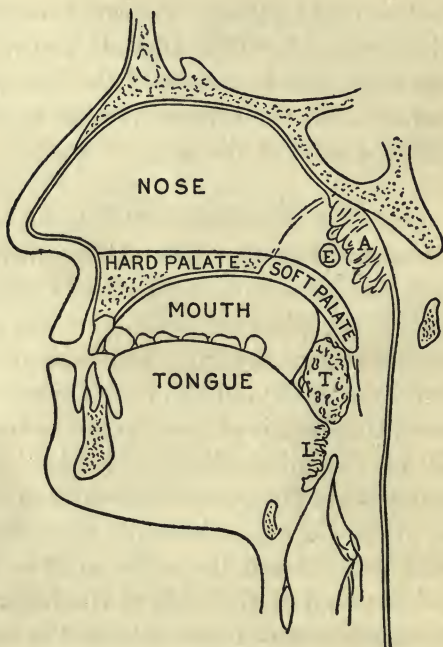


FIG. 3.

Diagram showing the position of the tonsillar ring.

A = the adenoid or third tonsil.

T = one of the faucial tonsils.

L = the lingual tonsil.

E = Eustachian tube, connecting the naso-pharynx with the ear.

ADENOIDS AND TONSILS

tonsillar ring is made of adenoid tissue and in medical books all four principal masses of this tissue are called tonsils. They are normal parts of the body, and are always present at certain periods of life.

Adenoid or tonsillar tissue is formed by a special development of the mucous



FIG. 4.

Diagram of a section of adenoid or tonsillar tissue developing from the mucous membrane, showing the outer layer, or epithelium folding inwards to form the crypts, the inner layers sending up projections between the crypts, and the follicles of the gland tissue surrounding the crypts.

membrane in these areas. This development begins before birth, and continues during childhood. The outer, or epithelial layer of the mucous membrane becomes folded in such a way that pockets are formed lined with epithelium, but extending into the deeper layers of the mucous membrane. (Fig. 4.) These

HARVARD HEALTH TALKS

pockets may be shallow and simple, or they may become deep and branching, while the lower portions of the mucous membrane in the neighborhood of these pockets become much thickened and modified, forming the mass of the tonsil. The pockets are called *crypts*. Between the crypts the deeper structures of the original mucous membrane, fibrous tissue, blood vessels, and lymph channels extend upwards to the surface of the tonsil. Between this network and the crypts are developed a large number of round bodies, called the *follicles* of the tonsil, the function of which is not known.

These tonsillar masses vary very much in size. They may be no larger than the head of a pin or half of a small pea, imbedded in the mucous membrane of the side or the back of the pharynx. On the other hand the four principal tonsils may occasionally grow to the size of an English walnut, with the crypts an inch deep.

ADENOIDS AND TONSILS

Of these four principal tonsillar masses the upper one is the third or pharyngeal tonsil or adenoid, the two on the sides are the faucial tonsils, and the lower one the lingual tonsil. But in order to avoid confusion of names and to use words as they are commonly understood, I shall hereafter call the upper tonsil the *adenoid*, and the two on the sides simply the *tonsils*, and say nothing more about the lingual or lower tonsil because it is of no practical importance for our purposes here.

The adenoid is situated in the upper part of the pharynx, out of sight, above the palate, and opposite the openings into the nose. It is present at birth and increases in size with the growth of the child up to about seven years of age. It remains at about the same size for a few years and then diminishes, so that it is usually small at fifteen and has nearly disappeared at twenty. In childhood it is normally about the size of a pecan

HARVARD HEALTH TALKS

nut. It varies in size and in its time of disappearance in different cases, but it is a normal structure in childhood and should not give rise to any disturbance. But it often does cause trouble, as we shall see when we speak of the harm that it may do.

The tonsils are situated on the sides of the throat in the cleft formed by the separation of the soft palate into the anterior and posterior pillars. (Fig. 2.) The relation of the tonsils to the palate and pillars varies much in different persons. Sometimes they stand out boldly into the throat so that they appear to be very large when the throat is examined. In other cases they are buried or submerged into the palate so that on inspection they are only partially seen, or they may be entirely out of sight. On this account mistakes are often made in judging whether they are enlarged. The tonsils are always present at birth, and like the adenoid they increase in size

ADENOIDS AND TONSILS

with the growth of the child. But unlike the adenoid they do not rapidly disappear as the child grows up. They generally remain through life, gradually becoming smaller, but they may grow large and remain large for years. Although the size varies in different children, it varies much more in adults. In early childhood they are about the same size as the adenoid; later they are larger.

Of what use to the body is this adenoid or tonsillar tissue? We might even ask whether it does any good at all, and if not why it is there. The medical profession must confess that it cannot give definite answers to these questions and consequently there are different opinions about them. When we find so definite and so constant an organ in the body, the presumption is that it is there for some good purpose. There are several other gland-like structures in the body which are of vital importance, but whose

HARVARD HEALTH TALKS

functions have not yet or have only recently been discovered, such as the spleen and the thyroid, thymus, pituitary, and adrenal glands. There are also, to be sure, other parts of the body, of which the appendix is a good example, which are supposed to be remnants of organs that were useful to our remote ancestors, and which although no longer of any use to us have not yet disappeared. But these tonsillar masses do not look like remnants. They are structures which one would expect soon to disappear if they were not needed — in fact they do tend to disappear after childhood. We are almost forced to assume that they have a function, at least during childhood, although we cannot tell what that function is and although we do not discover that any harm comes to a child from removing a large part of the tissue as is often done by operation.

Many theories have been suggested to explain the function of the tonsils. Most

ADENOIDS AND TONSILS

of them conclude that these gland-like structures protect the body in some way against certain infectious diseases.

A plausible theory to explain the function of the tonsillar ring may be outlined as follows. The mouth and nose are the only open portals through which the germs of infectious diseases find an easy entrance into the body. Surrounding these open passages we find the adenoid or tonsillar tissue standing ready to receive these germs into its crypts, and holding them there and not allowing them to go any farther. We know that the presence of a germ of disease in the body, stimulates the body to make an antidote for that particular disease. This is the principle used in vaccination, as against smallpox, or typhoid fever, or lockjaw, or in the manufacture of diphtheria antitoxin. Now it is possible that the tonsils use the germs which find their way into them to prepare antitoxin against those diseases with which the

HARVARD HEALTH TALKS

person is surrounded and to which children are especially liable. Of course they sometimes do not succeed in preventing infection, but we cannot say that they may not often prevent it, or at least make the disease less severe when it comes. This is only a theory, which has not yet been proved, but it offers an interesting explanation of the value of the tonsils in the economy of the body.

We may assume that these structures are of some use, even if not a vital one, and as long as they do no harm they should be let alone.

ADENOIDS

The adenoid and the tonsils up to this point have been described together because they are of the same structure and have evidently a similar function. But in speaking of their diseases they must be taken up separately, because their diseases are different and have to be differently treated.

ADENOIDS AND TONSILS

What is meant when we ask whether a child has "adenoids"? The expression is an unfortunate one because it confuses a normal structure which all children have, with an abnormal condition or disease. What we really mean is this: "Is that gland which is in the upper part of the throat and which is called the adenoid or third tonsil, enlarged or otherwise abnormal so that it is doing the child harm?" If it is, the child may be said to have "adenoids." If it is not it should not be said to have them. In other words, a child may be said to have adenoids if its adenoid or third tonsil is causing any symptoms. The question is generally one of childhood because in adults the conditions are entirely different. Normally the adenoid disappears during adolescence and therefore adenoids are impossible. If it persists it may be looked upon as abnormal, but it practically never in an adult grows large enough to cause the typical symptoms

HARVARD HEALTH TALKS

which occur in childhood. In most cases of adenoids the primary cause of trouble is that the structure has grown too large for the space allotted to it. (Fig. 3.) It may in itself be entirely normal tissue, but there is not room for it in the rather restricted upper section of the pharynx. It is possible for one to reason out the disturbances which this would cause. The first is obstruction of the passage for air between the nose and the throat. This may be so slight that the child has no difficulty in breathing through its nose except at night when the palate is relaxed, or during a cold when the mucous membrane is swollen. If the obstruction is greater, the child will have to breathe through its mouth at all times. The passages into the ears may be blocked, causing periodic deafness or favoring inflammation there. The secretions may be prevented from getting out and may thus cause infection. As a consequence of mouth breathing or re-

ADENOIDS AND TONSILS

tained secretions the child may suffer in many ways, as from dyspepsia or anemia or lack of proper sleep. There are a few cases in which adenoids cause some of these symptoms without being enlarged enough to obstruct breathing.

The principal symptom of adenoids is disturbance to easy breathing through the nose in children. But adenoids are not the only thing that stop up children's noses. A cold may do it, but that should pass off in a few days. Nasal obstruction of a few day's duration only, unless frequently repeated, need not lead to a suspicion of adenoids. The cause of mouth breathing may be an obstruction entirely inside of the nose. The partition between the two nasal cavities is sometimes bent or deformed in such a way that the passage is blocked. There may be a chronic inflammation or some abnormal growth of the mucous membrane of the cavities which obstructs the breathing. Nasal polypi, soft pendulous

HARVARD HEALTH TALKS

growths from the upper regions of the nasal chambers, may occlude the passage, but these are rare in children. Of course if the nose is blocked by any of these, nasal breathing cannot be restored by removing adenoids, and it is the duty of the physician to consider all of these things when examining for adenoids.

If a child persistently breathes either entirely or frequently through the mouth, it should be examined. Persistent mouth breathing cannot fail to do a child harm, compared to which the removal of an adenoid is of slight importance. A child is not necessarily breathing through its mouth because it holds it open. A little observation should show whether the air is going through an open mouth or through the nose. Persistent snoring at night in childhood is as a rule due to obstruction by adenoids.

Another symptom which should lead to a suspicion of adenoids is deafness,

ADENOIDS AND TONSILS

either periodic or persistent. If there is any question of the hearing, an obstructing adenoid should be removed.

A child may become listless or nervous or dyspeptic as a result of adenoids or suffer in other ways. As a rule there will be also trouble in breathing through the nose if adenoids are the cause, but not always. There is still much difference of opinion among physicians as to the extent to which such symptoms as mental dullness, poor development of the palate, asthma, dyspepsia, anemia, or general lack of health may be due to adenoids in children whose nasal breathing is not obstructed. In such cases it may not be easy to say whether the source of the trouble is here or in some other part of the body. Even careful examination will not necessarily show it. If there is a suspicion in the mind of the physician that serious symptoms may be caused by a diseased adenoid, it is better to remove a possible source of trouble even

HARVARD HEALTH TALKS

though the child may be no better off after the operation than he was before.

If an examination shows that the adenoid is preventing proper breathing through the nose, or if there is suspicion that it is causing trouble in the ears or in other parts of the body, it should be removed. No local applications or internal medicines are capable of materially changing the conditions in the adenoid, and they may do harm in other ways. The operation is a simple one, it takes but little time and the child generally recovers speedily. As this part of the throat is sensitive it is advisable to give ether. The more common way of operating is to use an instrument, the end of which resembles a box, open at the back. This is passed into the upper part of the pharynx and pressed against the upper and back wall, so that the adenoid and nothing else enters the opening in the instrument. The opening is then closed by passing a knife upwards, cutting the

ADENOIDS AND TONSILS

adenoid from its attachment. The instrument is then removed, with most of the growth in the box. Any of the adenoid which is left behind is then removed by another instrument, or as it is quite friable, it is often scraped away.

It frequently happens that a child suspected of having adenoids has also diseased tonsils which require removal. In these cases the examination and removal of the adenoid is done as part of the operation for removal of the tonsils, which will be described later.

To summarize: "adenoids" means a disturbance of the adenoid gland, generally an enlargement of it, but sometimes a disease of the tissue. The most frequent harm that it does is to prevent a child from getting the proper amount of air through the nose, and this may cause the child to suffer in many ways. If a child is suffering from adenoids they should be removed.

HARVARD HEALTH TALKS

THE TONSILS

The tonsils are situated on the sides of the throat, between the pillars of the palate (Fig. 2). They sometimes stand out into the cavity of the pharynx, so

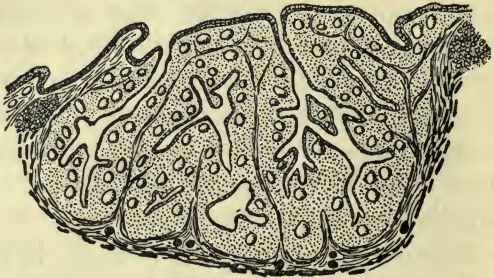

FIG. 5.

Diagram of a section of a submerged faucial tonsil, showing dilated crypts, follicles and capsule. (BARNES.)

that a large part of them can be seen on looking into the throat. Generally they are more or less buried or submerged in the palate.

The surface towards the throat shows numerous openings — the outlets of the crypts, which penetrate through the

ADENOIDS AND TONSILS

body of the tonsil. (Fig. 5.) These crypts may become dilated in places, and contain a considerable amount of retained secretion, which is ultimately discharged into the pharynx.

The tonsil is separated from the underlying structures of the side of the pharynx by a tough membrane, called the *capsule*, which is formed by the deeper layers of the original mucous membrane during the development of the organ. This capsule is pierced by the blood vessels, lymph channels, and nerves which supply the tonsil.

Tonsils vary considerably in size within normal limits. It has already been said that it is difficult without much practice to judge of the actual size of the tonsils by casual inspection, because they may be more or less hidden from sight in the palate. A tonsil which sticks out into the throat may look large and still be no larger than is normal for a person of that age, and it is no

HARVARD HEALTH TALKS

more likely to do harm than one that is out of sight. Both in children and adults the tonsils are sometimes very large, in which case they are a constant source of trouble both from obstruction and because they may lead to very sore throats when they become inflamed. But the more we study the tonsils the more we appreciate that their actual size is in most cases less important than the question whether they are healthy or not. Tonsils are more liable to become diseased than the adenoid, and as they do not disappear after childhood they may be the source of trouble at any time during life.

All throats contain myriads of bacteria of different kinds, some of them capable of causing trouble and even serious disease if they find their way into the inner tissues of the body. The mucous membrane lining the throat and other parts of the digestive and air passages prevents the numerous bacteria in

ADENOIDS AND TONSILS

these passages from getting through, under conditions of health. This local resistance of the mucous membrane is aided by a constitutional or chemical resistance to germs of infection by substances circulating in the blood. If any of these protective aids are weak or if the enemy is unusually strong, the resistance may be overcome, and local or constitutional infection may begin, the course of which will be determined by the relative virulence of the infection to the resisting power of the body.

The tonsils are so situated that different forms of bacteria from the mouth and throat are constantly in contact with them and penetrate into the tonsillar crypts. The presence of the germs of different diseases in the crypts does not necessarily mean that the tonsil is diseased. In fact as previously explained it is possible that the crypts collect these organisms for a beneficial purpose. Although the surface of the tonsil is in

HARVARD HEALTH TALKS

constant contact with bacteria and the crypts contain many of them, they cannot in a healthy tonsil penetrate any farther.

But the crypts may become dilated, and secretion and debris may accumulate in them, making pockets in which vicious bacteria may grow. In such a case the resistance of the tonsil is weakened, and may break down. There is then danger that germs of disease, or the poisons which they produce, may get into the blood current and be carried through the protecting capsule into the general circulation; or they may get into the lymph channels and be carried to the lymphatic glands of the neck, causing swollen glands or even abscesses. The seriousness of the infection caused by what might be called a leaking tonsil, would depend upon the virulence of the bacteria and the resistance of the body to them. It has long been known that enlarged and diseased lymphatic glands

ADENOIDS AND TONSILS

of the neck may be due to infection which has got in through the tonsil. It is now recognized that local infections in other parts of the body, the joints, the heart, or the kidneys may be due to bacteria which have got into the blood current through this portal. Of course the tonsils are not the only part of the body which may present an open door through which the bacteria of infections reach either the blood stream or the lymphatic vessels and glands. They may get in through diseased tooth sockets, or nasal cavities or through abrasions or wounds in any part of the body.

It is often impossible to find the open door through which some constitutional infection has found its way into the system, and consequently suspicious looking tonsils may be unjustly suspected. If the open door can be found it should be closed, and even if it is only suspected to be in the tonsils it is often good judgment to remove these structures rather

HARVARD HEALTH TALKS

than to run a risk of their being a source of danger which out-weighs any good that they may do.

Tonsils which are unhealthy often show it by repeated attacks of tonsillitis, and these attacks may be accompanied by symptoms of bacterial poisoning in other parts of the body. But it must not be thought that an attack of acute tonsillitis necessarily means that there is some chronic disease of the tonsil which requires its removal. A healthy tonsil may become acutely inflamed, and after the attack has passed off be as normal as before. For instance, in epidemics of so-called septic sore throat, caused by a polluted milk supply, perfectly normal tonsils show acute tonsillitis and entirely recover. An acute inflammation of the tonsils may be part of an acute infectious disease originating in some other part of the body.

Some persons are subject to a form of abscess called *peritonsillar abscess* or

ADENOIDS AND TONSILS

quinsy, which is a collection of pus in the region just behind the capsule of the tonsil. The throat becomes sore and swollen on one side, there is pain on swallowing and even on opening the jaws. This gets worse for a few days, and then the abscess either breaks or is opened, allowing the pus to escape. The recovery is rapid, but the trouble is apt to be recurrent. The source of this abscess is to be sought in the tonsil, where a localized infection has succeeded in penetrating through the capsule. Such a tonsil should be removed.

When a person's tonsils are a menace to health the only sure and satisfactory treatment is to remove them. If for any good reason the operation is not at the time advisable, a limited amount of good may be accomplished by local treatment, cleaning out dilated crypts, and keeping the throat as clean as possible by washes and gargles. Applications to the surface of the tonsils only, can seldom do much

HARVARD HEALTH TALKS

good. As the source of the trouble is generally deep seated, the only effective treatment is to remove the whole tonsil. There are two or three methods and several differing details employed by different operators, making a full description of the operation impossible here, but they all aim at dissecting the tonsil with its capsule out of its bed in the side of the throat. Formerly the mass was crudely chopped out, generally leaving the deeper parts behind, but for the last few years improved methods of operating have made it possible to get out the whole structure. The patient as a rule recovers quickly and without serious discomfort or danger, but there are occasionally complications for which it is necessary to be prepared and which delay convalescence.

ADENOIDS AND TONSILS

CONCLUSIONS

I have tried to make clear that an adenoid in children and tonsils through life are a normal part of the body, but that sometimes they go wrong in one way or another and cause trouble which may be slight or may be serious.

The only effective way to deal with adenoids or diseased tonsils is to remove them. Washes, sprays, and different applications to them accomplish very little good. The trouble is not on the surface but deep, and can be effectively reached only by operation. The question arises several hundred times a year in a large city, "Does this child or this grown person need to have his adenoids or his tonsils removed?" Often we are asked, "Is an operation necessary?" Sometimes it is easy to say yes or no; but often we cannot tell whether any harm will come if they are let alone. No one wants to do an unnecessary oper-

HARVARD HEALTH TALKS

ation but on the other hand no one wants to leave in the throat a constant danger to health.

An operation is unpleasant and sometimes exhausting but seldom serious, whereas certain diseases which might be avoided by operation may be all three. The important factor in deciding whether an operation should be done in these cases is the seriousness of the trouble with which we are dealing. If the patient is threatened with a serious disease or an impairment to health by the presence of his adenoids or tonsils, it is gross neglect not to take advantage of surgery. But if the symptoms are trivial, the fact that the adenoids or tonsils look somewhat large is not sufficient reason for taking them out. Some physicians advise an operation for adenoids or tonsils in a large proportion of the children that they examine, others in a much smaller proportion. This difference of opinion is unavoidable because the dan-

ADENOIDS AND TONSILS

gers which they hope to avoid by operation are often such indefinite ones. The good results of an operation are so striking in some cases that there is a temptation to try it frequently, especially as the dangers of the operation are slight. The removal of adenoids is generally a very slight affair. Taking out the tonsils is more likely to be a severe operation although generally it is not.

To go a little into the past history of these operations.

Adenoids may be said to have been discovered in Denmark about thirty years ago, and the operation for their removal then began. The results of the operation are so striking, and the dangers so slight that it very naturally soon became common and has been so since. It is seldom that so much good can be done so easily as in taking out adenoids when a child is suffering from them. Whenever a child is more comfortable or gains in health after the operation, it shows

HARVARD HEALTH TALKS

that the operation was advisable. When the child is no better after it, it may show that he did not need it.

A child should be operated upon if the adenoid is causing him persistently to breathe through his mouth, or if any other serious symptoms may be caused by it.

The removal of the tonsils has been done more or less frequently for a century. The operation appears to have become popular at times and then to have gone out of fashion. But in the last ten or fifteen years the harm which diseased tonsils may cause has been appreciated so that at present the operation is performed much more frequently than ever before. Also in the past ten years the operation has been improved so that the whole tonsil is taken out instead of only a part of it. The operation is a much more severe one than the removal of adenoids. In what cases then should the tonsils be removed? No one wants

ADENOIDS AND TONSILS

to risk an unnecessary operation, but on the other hand, a source of disease should be removed. Opinions about the necessity of operation will be influenced by the benefit or the lack of benefit, or possibly sometimes the harm that has come in other cases, but there is no doubt that certain conditions make operation advisable.

Authorities agree that tonsils should be removed for recurring abscess of the throat, for persistent enlarged glands of the neck that cannot be accounted for by some other cause, for frequent attacks of tonsillitis, for very large tonsils, and in those cases in which it is suspected that serious constitutional disease is caused by a diseased focus in the tonsil.

They should not be removed for trivial reasons such as because they look ragged, because they appear rather large, because they contain a moderate amount of foreign matter, for occasional sore throat

HARVARD HEALTH TALKS

or attacks of simple tonsillitis. It is not justifiable to remove normal tonsils simply because a child is going to have his adenoids out. It is better to do a second operation if this should become necessary. In short, with both adenoids and tonsils we are dealing with structures which are normal parts of the body, and probably serve a useful purpose, and we should therefore spare them unless we have reason to suspect that they are doing harm which out-weighs their usefulness, and which warrants the slight dangers which must always be present in any operation.



